

Christian de Virgilio  
*Editor*

Areg Grigorian *Associate Editor*  
Paul N. Frank *Assistant Editor*

# Surgery

A Case Based Clinical Review

 Springer

---

# Surgery



---

Christian de Virgilio  
Editor

# Surgery

A Case Based Clinical Review

Areg Grigorian  
Associate Editor

Paul N. Frank  
Assistant Editor

 Springer



*Editor*

Christian de Virgilio  
Department of Surgery  
Harbor-UCLA Medical Center  
Torrance, CA, USA

*Assistant Editor*

Paul N. Frank  
Department of Surgery  
Harbor-UCLA Medical Center  
Torrance, CA, USA

*Associate Editor*

Areg Grigorian  
Department of Surgery  
University of California, Irvine  
Orange, CA, USA

ISBN 978-1-4939-1725-9      ISBN 978-1-4939-1726-6 (eBook)  
DOI 10.1007/978-1-4939-1726-6  
Springer New York Heidelberg Dordrecht London

Library of Congress Control Number: 2014958665

© Springer Science+Business Media New York 2015

This work is subject to copyright. All rights are reserved by the Publisher, whether the whole or part of the material is concerned, specifically the rights of translation, reprinting, reuse of illustrations, recitation, broadcasting, reproduction on microfilms or in any other physical way, and transmission or information storage and retrieval, electronic adaptation, computer software, or by similar or dissimilar methodology now known or hereafter developed. Exempted from this legal reservation are brief excerpts in connection with reviews or scholarly analysis or material supplied specifically for the purpose of being entered and executed on a computer system, for exclusive use by the purchaser of the work. Duplication of this publication or parts thereof is permitted only under the provisions of the Copyright Law of the Publisher's location, in its current version, and permission for use must always be obtained from Springer. Permissions for use may be obtained through RightsLink at the Copyright Clearance Center. Violations are liable to prosecution under the respective Copyright Law.

The use of general descriptive names, registered names, trademarks, service marks, etc. in this publication does not imply, even in the absence of a specific statement, that such names are exempt from the relevant protective laws and regulations and therefore free for general use.

While the advice and information in this book are believed to be true and accurate at the date of publication, neither the authors nor the editors nor the publisher can accept any legal responsibility for any errors or omissions that may be made. The publisher makes no warranty, express or implied, with respect to the material contained herein.

Printed on acid-free paper

Springer is part of Springer Science+Business Media ([www.springer.com](http://www.springer.com))

*To my wonderful wife and fellow surgeon Kelly, my five kiddos, Nick (my soccer buddy), Michael (my aspiring protégé), Emma and Sophia (my twin philotherians), and Andrew (my ninja turtle pal), who have always made coming home a pleasure, and to all the UCLA students over the last two decades who have inspired me to teach.*

Christian de Virgilio

*To my mentors – thank you for introducing me to the wonderful world of surgery. To my family: Jores, Ani, and Rebecca – thank you for your continued love and support. And to my biggest inspiration, my mom, Dr. Vehanoush Zarifian, who has helped instill in me compassion for my fellow man and the resilience to conquer life's biggest challenges.*

Areg Grigorian

*To my Mom and Dad, my first mentors and biggest supporters.*

Paul N. Frank



---

## Foreword

Christian de Virgilio MD was a third year medical student at UCLA when I was a general surgery resident on the Pediatric Surgery service. I remember him clearly as he was such an interested student and was at my side throughout the day and night. Those were different times-goals and objectives for learning did not formally exist. We used our patients primarily as our teaching tool. Our quest for data had to be done by using text books and journals in the library as electronic devices full of fingertip information did not exist yet. Dr. de Virgilio was one of best presenters- he could synthesize information and present it in a manner which all could understand and remember. Many of the assignments I used to give to the medical students were on topics that I needed more information on – little did they know that they were my human Google or Safari!

In this wonderful medical student textbook which Dr. de Virgilio has created, he has taken all of those patients who we met and made teaching stories about them so our contemporary medical students can learn prior to meeting such a patient and review once they have met that patient to reinforce the information. In each chapter, the patient story includes the history, physical examination, pathophysiology, diagnosis, and management. In addition, teaching points concerning where one can get in trouble and where there are controversies are outlined to help the student understand the complexity of some of the surgical problems that the patient has. Finally, the essential take home points are summarized allowing the student to feel like they have mastered the topic and are ready to analyze the next patient they meet with such a diagnosis.

The student is then challenged with Surgery Shelf type questions which are very believable patient vignettes, and the answers are given with appropriate explanations of the correct answer. This type of exercise prepares the student for future examinations that they will need to take to complete medical school, residency, fellowship and board certification and re-certification.

Dr. de Virgilio enlisted the help of 2 fourth year medical students to be his assistant editors – what a great way to teach students how to teach!

I could not be more proud of my previous medical student! He has championed the role of the teacher his entire academic life and serves as Vice Chair for Education and Director of the General Surgery training program as well as the Co-chair of the College of Applied Anatomy at the Harbor-UCLA School of Medicine campus.

He remembers that teaching is a natural behavior of all of us who have the privilege to teach medical students – we need to always remember that someone taught us – so we need to teach with all our energy. Our students leave us with their diploma and their dreams.

The future belongs to those who believe in their dreams, Eleanor Roosevelt

Human Health Services, School of Medicine  
University of California, Davis  
Sacramento, CA, USA

Julie Ann Freischlag, MD



---

## Preface

When starting my third year clerkship (last century), I was terrified. I figured the only way to succeed was to do something spectacular. It was quickly apparent (within minutes) that I was never going to come up with an obscure diagnosis that had stumped my chief resident and there was no way I would impress the team with my bumbling attempts at knot tying. In my dreams, I imagined rescuing my attending by deftly stepping in to suture an exsanguinating aortic injury, but of course it never happened (don't try it). I learned that the best way to make a great impression was by coming to the hospital each day as fully prepared as possible. From experience, a great way to do that is by reading.

The goal of our book is to help you make a great impression on your surgery clerkship and to help you to prepare for the shelf examination. To help you reach that goal, we've assembled a team of collaborators that include numerous surgery program directors, surgery clerkship directors, and various award winning surgical educators. We've also included several medical students who were handpicked for their outstanding performance. In fact my two co-editors (Areg Grigorian and Paul Frank) are starting their surgical internship this year. The intent is to assure that the content of the book is comprehensive, and relevant to what a medical student needs to know. Additionally, we feel our book is an excellent adjunct to the curriculum offered to nursing students, physician assistant students, and surgical interns.

Before discussing how to use our book, let me share a few pearls about the surgery clerkship. First the "do's". Surgery is a team based discipline. Always look for ways to help your team. Take an active role. Strive to make yourself irreplaceable, but do so with an air of humility. Treat others like you would your family (assuming you get along with them). Be an effective communicator. Ask a lot of questions (but make it clear from your questions that you've been reading). Ask how you can help. Now the "don'ts". Don't be arrogant. Don't try to upstage your co-student or intern. And finally...don't worry! If you work hard, display enthusiasm, and take an active role, people will notice! You'll also be surprised to discover that most surgeons enjoy teaching (and aren't as mean as portrayed on TV). And you may even get bit by the surgery bug!

Now let's move on to how to use this book. The book is case based and is in a short question and answer format. A risk of a case based book is that you only learn that one specific case. To prevent falling into such a pitfall, we've also included pertinent differential diagnoses for each case, and discuss how to distinguish them. We've tried to limit anatomy and pathophysiology to those that are clinically relevant. We've tried to exclude most cancer staging systems, as these constantly change, are hard to memorize, and are infrequently tested. We've tried to arrange the management in a "what's the next step" format, as such questions are frequently asked. We've purposely avoided too many details about specific aspects of surgical procedures as those are beyond the scope of a student. For those that want a bit more, we've added "areas where you can get in trouble" which are pitfalls in the diagnosis or management, and "areas of controversy". At the end of each chapter there is a Summary of Essentials that permits a quick review. Finally, we've created questions and answers (with an emphasis on why the wrong answers are wrong). It's important to realize that the questions are *not* intended to test your understanding of the reading. Rather, many of the questions are

meant to supplement the reading by testing important topics that couldn't be covered (so don't be discouraged if you miss a lot of them!).

Our advice is to strive to read the whole book during your rotation. Read all the chapters in one section, then do the supplement questions for that section. We've purposely made each chapter relatively short, so that you should be able to read each one in 20–30 min (or less). And you should be able to read 4–5 chapters per week.

We're confident our book will help you during your surgery clerkship as well as for the shelf exam. We also realize that no single resource can do it all (including this book).

We hope you enjoy our book as much as we enjoyed writing it! We'd love to get your feedback. Feel free to email me [cdevirgilio@labiomed.org](mailto:cdevirgilio@labiomed.org). Best of luck on your rotation and in your (surgical) career!

Torrance, USA

Christian de Virgilio

---

## Acknowledgements

Our book project could never have come to fruition without the assistance of several individuals. We would like to acknowledge Richard Hruska, Senior Editor at Springer, who demonstrated belief in our book project and quickly embraced it; Nadina Persaud, Associate Editor at Springer who assisted in finalizing the project; and Connie Walsh, Developmental Editor at Springer who patiently put up with our constant emails, phone calls and numerous revisions. We would also like to acknowledge Simin Bahrami, Taylor J. Choy, and Kathleen Brown, our radiology colleagues at UCLA who have graciously offered numerous images throughout the book to help supplement the chapters. And last but not least, we would like to acknowledge Rebecca Barros, Eric Tamrazian, Hamid Alipour, and Nariman Nassiri for helping review our chapters and questions.

Christian de Virgilio  
Areg Grigorian  
Paul N. Frank





---

# Contents

## Part I Acute Care Surgery

- 1 Nausea, Vomiting, and Left Groin Mass** ..... 3  
Areg Grigorian, Christian de Virgilio, and David C. Chen
- 2 Abdominal Pain, Nausea, and Vomiting** ..... 15  
Jill Q. Klausner and David C. Chen

## Part II Breast

- 3 New Palpable Mass in Right Breast** ..... 25  
Christopher M. Reid, Areg Grigorian, Christian de Virgilio, and Danielle M. Hari
- 4 Abnormal Screening Mammogram** ..... 37  
Areg Grigorian, Christian de Virgilio, and Danielle M. Hari

## Part III Cardiothoracic

- 5 Chest Pain, Diaphoresis, and Nausea** ..... 47  
Areg Grigorian, Paul N. Frank, and Peyman Benharash
- 6 Chest Pain and Syncope** ..... 57  
Paul N. Frank and Peyman Benharash
- 7 Chest and Back Pain** ..... 65  
Paul N. Frank, Simin Bahrami, and Peyman Benharash

## Part IV Endocrine

- 8 Incidentally Discovered Adrenal Mass on CT Scan** ..... 77  
Masha J. Livhits, Christopher M. Reid, and Michael W. Yeh
- 9 Fatigue, Constipation, and Depressed Mood** ..... 87  
Paul N. Frank, James X. Wu, and Michael W. Yeh
- 10 Intermittent Episodes of Sweating, Palpitations, and Hypertension** ..... 101  
Masha J. Livhits, Michael W. Yeh, and Areg Grigorian
- 11 Neck Mass that Moves with Swallowing** ..... 111  
James X. Wu and Michael W. Yeh

## Part V Head and Neck

- 12 Progressively Hoarse Voice** ..... 127  
Kevin A. Peng, Irene A. Kim, and Vishad Nabili

<b>13 Lump on Neck Increasing in Size</b> .....	133
Jon Mallen-St. Clair, Aaron J. Feinstein, and Vishad Nabili	
<b>14 Aural Fullness, Hearing Loss, and Tinnitus</b> .....	143
Andrew M. Vahabzadeh-Hagh, Edward C. Kuan, and Vishad Nabili	
<b>Part VI Hepatopancreaticobiliary</b>	
<b>15 Postprandial RUQ Pain</b> .....	153
Anne Elizabeth Falor, Taylor Choy, and Christian de Virgilio	
<b>16 Right Upper Quadrant Pain, Fever, Nausea, and Vomiting</b> .....	167
Paul N. Frank and Christian de Virgilio	
<b>17 Severe Epigastric Pain with Nausea and Vomiting</b> .....	175
Areg Grigorian and Christian de Virgilio	
<b>18 New Onset of Painless Jaundice</b> .....	191
James X. Wu, Christian de Virgilio, and Danielle M. Hari	
<b>Part VII Lower Gastrointestinal</b>	
<b>19 Bright Red Blood per Rectum</b> .....	203
Blake E.S. Taylor and Tracey D. Arnell	
<b>20 Right Lower Quadrant Abdominal Pain</b> .....	213
Wendy Liu, Christian de Virgilio, Areg Grigorian, and Tracey D. Arnell	
<b>21 Pencil-Thin Stools and Intermittent Constipation</b> .....	225
Areg Grigorian, Christian de Virgilio, and Tracey D. Arnell	
<b>22 Chronic Constipation Presenting With Severe Abdominal Pain</b> .....	237
Vivek Sant and Tracey D. Arnell	
<b>23 Left Lower Quadrant Pain and Fever</b> .....	245
Paul N. Frank, Christian de Virgilio, and Tracey D. Arnell	
<b>Part VIII Neurosurgery</b>	
<b>24 Neck Pain and Paralysis Following Trauma</b> .....	255
Jose Manuel Sarmiento, Debraj Mukherjee, and Chirag G. Patil	
<b>25 Loss of Consciousness Following Head Trauma</b> .....	265
Ardavan Ariel Saadat, Brian Cristiano, and David S. Plurad	
<b>Part IX Orthopedic</b>	
<b>26 Multiple Extremity Injuries After Motorcycle Accident</b> .....	277
Areg Grigorian and Kevin W. Rolfe	
<b>27 Immediate Swelling After Trauma to the Knee</b> .....	287
John F. Fleming III, Aaron Beck, and Kevin W. Rolfe	
<b>28 Right Groin Pain and Limp</b> .....	299
Aaron Beck, John F. Fleming III, and Kevin W. Rolfe	
<b>29 Chronic Right Hand Pain</b> .....	309
Arezou Tory Yaghoubian and Kevin W. Rolfe	

**Part X Pediatric**

- 30 Full-Term Male Infant with Respiratory Distress** ..... 321  
Veronica F. Sullins and Steven L. Lee
- 31 Newborn with Bilious Emesis** ..... 329  
Ziyad Jabaji, Veronica F. Sullins, and Steven L. Lee
- 32 Infant with Bilious Emesis**..... 335  
Veronica F. Sullins and Steven L. Lee
- 33 Infant with Nonbilious Emesis**..... 343  
Ziyad Jabaji, Veronica F. Sullins, and Steven L. Lee
- 34 Infant Born with Abdominal Wall Defect** ..... 349  
Justin P. Wagner and Steven L. Lee
- 35 Excessive Drooling in a Newborn** ..... 357  
Veronica F. Sullins and Steven L. Lee

**Part XI Skin**

- 36 Recently Changed Skin Lesion** ..... 367  
Arezou Tory Yaghoubian and Junko Ozao-Choy
- 37 Right Leg Pain, Swelling, and Erythema for Two Days** ..... 377  
Paul N. Frank and Christian de Virgilio

**Part XII Surgical Complications**

- 38 Postoperative Bleeding** ..... 385  
Areg Grigorian, Paul N. Frank, Christian de Virgilio, and Dennis Y. Kim
- 39 Postoperative Decreased Urine Output**..... 395  
Christy Anthony, Dennis Y. Kim, Christian de Virgilio, and Areg Grigorian
- 40 Shortness of Breath Five Days After Surgery** ..... 403  
Paul N. Frank, Kathleen Brown, and Christian de Virgilio

**Part XIII Trauma**

- 41 Abdominal Pain Following Motor Vehicle Accident**..... 415  
Areg Grigorian, Christian de Virgilio, and Dennis Y. Kim
- 42 Penetrating Abdominal Trauma** ..... 425  
Dennis Y. Kim and Areg Grigorian
- 43 Pedestrian Struck by Motor Vehicle**..... 435  
Zane W. Ashman, Areg Grigorian, Christian de Virgilio, and Dennis Y. Kim
- 44 Gunshot Wound to the Left Neck** ..... 443  
Erik Akopian, Christian de Virgilio, and Dennis Y. Kim
- 45 Stab Wound to the Chest**..... 451  
Omid Yousefian, Christian de Virgilio, Areg Grigorian, and Dennis Y. Kim
- 46 Burns to the Face, Trunk, and Extremities**..... 463  
Arezou Tory Yaghoubian, Areg Grigorian, Christian de Virgilio,  
and Dennis Y. Kim

<b>47 Severe Right Leg Pain After Tibia Fracture</b> .....	473
Andrew Nguyen, Areg Grigorian, and Christian de Virgilio	
<b>Part XIV Upper Gastrointestinal</b>	
<b>48 Bloody Emesis</b> .....	481
Areg Grigorian, Christian de Virgilio, Michael D. Sgroi, and Brian R. Smith	
<b>49 Severe Epigastric Abdominal Pain</b> .....	493
Michael D. Sgroi and Brian R. Smith	
<b>50 Weight Loss and Early Satiety</b> .....	501
Michael D. Sgroi and Brian R. Smith	
<b>51 Chest Pain After Vomiting</b> .....	511
Michael D. Sgroi and Brian R. Smith	
<b>Part XV Urology</b>	
<b>52 Scrotal Pain</b> .....	519
Areg Grigorian and Jeremy M. Blumberg	
<b>53 Scrotal Mass</b> .....	525
Areg Grigorian and Jeremy M. Blumberg	
<b>54 Blood in Urine</b> .....	533
Jeremy M. Blumberg and Kiran Gollapudi	
<b>Part XVI Vascular</b>	
<b>55 Transient Loss of Vision in the Right Eye</b> .....	547
Christian de Virgilio, Jessica Beth O’Connell, and Areg Grigorian	
<b>56 Right Calf Pain with Walking</b> .....	559
Christian de Virgilio	
<b>57 Sudden Onset of Severe Left-Sided Abdominal Pain</b> .....	571
Edward D. Gifford and Michael de Virgilio	
<b>58 Cold, Painful Right Lower Extremity</b> .....	581
Zachary D.C. Burke, Ziyad Jabaji, and Christian de Virgilio	
<b>59 Question Sets and Answers</b> .....	591
<b>Index</b> .....	701

---

## Contributors

**Erik Akopian, MD** Emergency Medicine, Los Angeles County – University of Southern California (LAC+USC), Los Angeles, CA, USA

**Christy Anthony, MD, BS** Department of Surgery, University of California Los Angeles, Torrance, CA, USA

**Tracey D. Arnell, MD** Surgery Department, New York Presbyterian Columbia University, New York, NY, USA

**Zane W. Ashman, MD** Department of Surgery, Los Angeles County Harbor-UCLA Medical Center, Torrance, CA, USA

**Simin Bahrami, MD** Department of Radiology, Ronald Reagan UCLA Medical Center, Santa Monica-UCLA Medical Center, Santa Monica, CA, USA

**Aaron Beck, MD** Orthopaedic Surgery, Harbor-UCLA Medical Center, Torrance, CA, USA

**Peyman Benharash, MD** Division of Cardiac Surgery, University of California, Los Angeles, Los Angeles, CA, USA

**Jeremy M. Blumberg, MD** Urology, Renal Transplantation, Department of Surgery, Harbor-UCLA Medical Center, Torrance, CA, USA

**Kathleen Brown, MD** Department of Radiological Sciences, David Geffen School of Medicine at UCLA, Los Angeles, CA, USA

**Zachary D.C. Burke, BA** David Geffen School of Medicine at UCLA, Los Angeles, CA, USA

**David C. Chen, MD** Department of Surgery, University of California at Los Angeles, Santa Monica, CA, USA

**Taylor Choy, MD** Department of Radiology, UCLA Medical Center, Los Angeles, CA, USA

**Brian Cristiano, MD** Department of Surgery, Harbor UCLA, Huntington Beach, CA, USA

**Christian de Virgilio, MD** Department of Surgery, Harbor-UCLA Medical Center, Torrance, CA, USA

**Michael de Virgilio** University of California Los Angeles, Los Angeles, CA, USA

**Ann Elizabeth Falor, MD** Department of Surgery, Harbor-UCLA Medical Center, Torrance, CA, USA

**Aaron J. Feinstein, MD, MHS** Head and Neck Surgery, University of California, Los Angeles, Los Angeles, CA, USA

**John F. Fleming III, MD** Orthopaedic Surgery, Harbor-UCLA Medical Center, Torrance, CA, USA

**Paul N. Frank, MD** Department of Surgery, Harbor-UCLA Medical Center, Torrance, CA, USA

**Julie Ann Freischlag, MD** Human Health Services, School of Medicine, University of California Davis, Sacramento, CA, USA

**Edward D. Gifford, MD** Department of Surgery, Harbor UCLA Medical Center, Torrance, CA, USA

**Kiran Gollapudi, MD** Department of Urology, David Geffen School of Medicine at UCLA, Los Angeles, CA, USA

**Areg Grigorian, MD** Department of Surgery, University of California, Irvine, Orange, CA, USA

**Danielle M. Hari, MD** Division of Surgical Oncology, Department of Surgery, Harbor-UCLA Medical Center, Torrance, CA, USA

**Ziyad Jabaji, MD** Department of Surgery, UCLA Medical Center, Los Angeles, CA, USA

**Dennis Y. Kim, MD** Department of Surgery, Harbor-UCLA Medical Center, Torrance, CA, USA

**Irene A. Kim, MD** Department of Head and Neck Surgery, David Geffen School of Medicine University of California Los Angeles, Los Angeles, CA, USA

**Jill Q. Klausner** Department of Surgery, David Geffen School of Medicine at UCLA, Los Angeles, CA, USA

**Edward C. Kuan, MD, MBA** Department of Head and Neck Surgery, David Geffen School of Medicine at UCLA, Los Angeles, CA, USA

**Steven L. Lee, MD** Department of Surgery, Division of Pediatric Surgery, Harbor-UCLA Medical Center, Torrance, CA, USA

**Wendy Liu, MD** Department of Surgery, Harbor-UCLA Medical Center, Torrance, CA, USA

**Masha J. Livhits, MD** Surgery and Medicine, Section of Endocrine Surgery, UCLA David Geffen School of Medicine, Los Angeles, CA, USA

**Jon Mallen-St. Clair, MD, PhD** Otolaryngology – Head and Neck Surgery, David Geffen School of Medicine, University of California, Los Angeles, Los Angeles, CA, USA

**Debraj Mukherjee, MD, MPH** Department of Neurosurgery, Cedars-Sinai Medical Center, Maxine Dunitz Neurosurgical Institute, Los Angeles, CA, USA

**Vishad Nabili, MD, FACS**, Department of Head and Neck Surgery, David Geffen School of Medicine at UCLA, Los Angeles, CA, USA

**Andrew Nguyen, MD** Department of Surgery, Harbor-UCLA Medical Center, Torrance, CA, USA

**Jessica Beth O'Connell, MD, FACS** UCLA Department of Surgery, Greater Los Angeles VA Healthcare System, Gonda (Goldschmied) Vascular Center, Los Angeles, CA, USA

**Junko Ozao-Choy, MD** Division of Surgical Oncology, Harbor-UCLA Medical Center, Torrance, CA, USA

**Sung Yul Park, MD** Urology Department, Hanyang University Hospital, Seoul, Korea

**Chirag G. Patil, MD, MS** Department of Neurosurgery, Cedars-Sinai Medical Center, Maxine Dunitz Neurosurgical Institute, Los Angeles, CA, USA

**Kevin A. Peng, MD** Department of Head and Neck Surgery, David Geffen School of Medicine at UCLA, Los Angeles, CA, USA

**David S. Plurad, MD** Department of Surgery, Harbor-UCLA Medical Center, Torrance, CA, USA

**Christopher M. Reid, BS, MD** Department of Surgery, UC San Diego, San Diego, CA, USA

**Kevin W. Rolfe, MD, MPH** Orthopaedic Surgery, Harbor-UCLA Medical Center & Rancho Los Amigos Rehabilitation Center, Torrance, CA, USA

**Ardavan Ariel Saadat, BS** Baylor College of Medicine, Houston, TX, USA

**Vivek Sant, BA** Columbia University College of Physicians & Surgeons, New York, NY, USA

**Jose Manuel Sarmiento, MD, MPH** Department of Neurosurgery, Cedars-Sinai Medical Center, Maxine Dunitz Neurosurgical Institute, Los Angeles, CA, USA

**Michael D. Sgroi, MD** Surgery Department, University of California, Irvine, Wd Orange, CA, USA

**Brian R. Smith, MD** Surgery Department, UC Irvine Medical Center, VA Healthcare System Long Beach, Orange, CA, USA

**Veronica F. Sullins, MD** Department of Surgery, Harbor-UCLA Medical Center, Torrance, CA, USA

**Blake E.S. Taylor, BA** Columbia University, College of Physicians and Surgeons, New York, NY, USA

**Andrew M. Vahabzadeh-Hagh, MD** Head and Neck Surgery, David Geffen School of Medicine at UCLA, Los Angeles, CA, USA

**Justin P. Wagner, MD** Department of Surgery, David Geffen School of Medicine at UCLA, Los Angeles, CA, USA

**James X. Wu, MD** Department of Surgery, UCLA, Los Angeles, CA, USA

**Arezou Tory Yaghoubian, MD** Plastic and Reconstructive Surgery, UCLA, Los Angeles, CA, USA

**Michael W. Yeh, MD** Surgery and Medicine, Section of Endocrine Surgery, UCLA David Geffen School of Medicine, Los Angeles, CA, USA

**Omid Yousefian, BS** Medicine Department, UCSD, La Jolla, CA, USA



---

**Part I**

**Acute Care Surgery**

David C. Chen, Section Editor

Areg Grigorian, Christian de Virgilio, and David C. Chen

A 65-year-old obese woman presents to the emergency department with nausea and vomiting for the past day. The frequency of vomiting has increased despite the fact that she has not eaten for the past 12 hours. For the last few months, she has noticed a painful “lump” in her left groin that would protrude upon straining (i.e., coughing, bowel movements) but would quickly disappear after lying down. She says that the lump appeared a few days ago and has not gone away even after lying down. She has had no bowel movement and no flatus per rectum for the past 24 hours. On examination, the patient has a low-grade fever (100.2 °F), blood pressure of 120/80 mmHg, and heart rate of 120/min. She appears ill and uncomfortable with dry mucous membranes. Lung sounds are clear bilaterally. Her abdomen is mildly distended. Bowel sounds are high pitched with tinkles and rushes. Her abdomen is non-tender to palpation, but there is a 2×2 cm mass in the left groin, inferior to the inguinal ligament that is very painful to palpation. The overlying skin is slightly erythematous. The bulge is just medial to her femoral pulse extending towards her thigh compartment. Laboratory studies are significant for white blood count of  $14.7 \times 10^3$  (normal  $4.1-10.9 \times 10^3/\mu\text{L}$ ).

---

## Diagnosis

### What Is the Differential Diagnosis for a Groin Mass? How Is This Differential Different in Men and Women?

Table 1.1 summarizes the most common differential for a groin mass. This broadly includes congenital and structural malformations, infection, neoplasm, and trauma and may be remembered with the mnemonic *MINT*. Most often, a mass in the inguinal region in men and women represents enlarged lymph nodes. Lymph nodes enlarge either due to autoimmune disease, malignancy, or as a response to a localized or systemic infection. It is relatively common for adults to have small “shotty” lymph nodes in the inguinal region. They pathologically represent “reactive” lymph nodes with follicular hyperplasia in response to minor infections, cuts, or scrapes in the groin, perineum, or lower extremity. Reactive nodes are usually sub-centimeter, mobile, tender, and firm. If nodes are large, tender, and limited to the inguinal region, one must consider syphilis, chancroid, and lymphogranuloma venereum. Large non-tender inguinal lymphadenopathy limited to the inguinal

---

A. Grigorian, MD

Department of Surgery, University of California, Irvine, 333 City Blvd West, Suite 1600, Route. 81, Orange, CA 92868, USA  
e-mail: [agrigori@uci.edu](mailto:agrigori@uci.edu)

C. de Virgilio, MD

Department of Surgery, Harbor-UCLA Medical Center, 1000 W. Carson Street, Torrance, CA 90509, USA  
e-mail: [cdevirgilio@labiomed.org](mailto:cdevirgilio@labiomed.org)

D.C. Chen, MD (✉)

Department of Surgery, University of California at Los Angeles, 1304 15th St., Suite 102, Santa Monica CA 90404, USA  
e-mail: [dcchen@mednet.ucla.edu](mailto:dcchen@mednet.ucla.edu)

**Table 1.1** MINT masses represent the common groin masses

Type	Examples	Comments
Malformation	Undescended testicle, varicocele, hydrocele, hernias	Hernias will protrude with straining and may reduce with pressure
Infectious/inflammatory	Lymphadenopathy (reactive), mononucleosis (EBV), abscess, sarcoidosis, lymphogranuloma venereum	“Shotty,” tender nodes are typically reactive lymph nodes that represent minor infections, scrapes, or cuts
Neoplastic	Lymphoma, lipoma, lymphadenopathy, metastatic cancer (anal, skin, genital)	Large non-tender lymph nodes limited to the inguinal region suggest metastatic cancer (melanoma, anal or genital cancer) (testicular cancer does not usually metastasize to the groin; it more commonly travels to the retroperitoneum)
Traumatic	Hematoma, femoral aneurysm, or pseudoaneurysm	Inquire about a history of recent trauma or intervention

*EBV* Epstein-Barr virus

region suggests metastatic cancer from a local source (melanoma, anal or genital cancer). Large non-tender inguinal lymph nodes that are associated with diffuse lymphadenopathy suggest a systemic process (infectious, malignant, or autoimmune) such as tuberculosis, lymphoma, leukemia, HIV, or sarcoidosis.

Abscesses are also common in the differential of groin masses. These may be due to boils (infected hair follicles), also called furuncles, or carbuncles (a collection of boils). Infections of the apocrine sweat glands (hidradenitis suppurativa) can also cause groin abscesses.

Femoral aneurysms are a rare cause of groin masses. Always ask about a history of trauma or prior interventions, and palpate the mass to assure it is not pulsatile.

In men, it is important to differentiate scrotal masses and pathologies from those of inguinal origin. A scrotal mass may represent an inguinal hernia versus other pathologies which will be discussed in further detail in another chapter.

## What Is the Diagnosis for This Patient?

The diagnosis for this patient is small bowel obstruction (SBO) secondary to a strangulated femoral hernia. The presence of abdominal distention, a groin mass, and high-pitched bowel sounds in a patient with progressive nausea with vomiting is highly suggestive of acute intestinal obstruction. The addition of signs of systemic inflammatory response syndrome (SIRS) (fever, tachycardia, elevated WBC count, pain, redness of the skin overlying the hernia) strongly suggests that the bowel within the hernia sac is ischemic or gangrenous. In this setting, surgery is urgent and one must anticipate the need to perform a bowel resection.

## History and Physical

### Why Is It Important to Ask If a Groin Mass Protrudes with Straining?

The history that the groin mass protrudes with straining (Valsalva) and reduces in the supine position is highly suggestive of a hernia. Hernias develop as a result of structural weakness of the abdominal wall in conjunction with increased intra-abdominal pressure. Contributing factors include prior incisions, heredity, multiple pregnancies, obesity, or liver disease with ascites. History should include conditions that lead to chronic straining, as these may provide clues to underlying untreated conditions such as a chronic cough (chronic bronchitis, lung cancer), constipation (colon cancer), or urinary straining (benign prostatic hypertrophy, prostate cancer). It is also important to inquire about work- and activity-related issues such as heavy lifting and physical exertion.

## Pathology/Pathophysiology

### What Is a Hernia?

A hernia is a protrusion of tissue or organ(s) through a defect, most commonly in the abdominal wall. In abdominal hernias, peritoneal contents, such as the omentum and/or bowel, protrude through a defect or weakness in the muscle/fascia. Hernias have three components: the abdominal wall defect, the hernia sac which protrudes through the defect, and the contents within the sac. The neck of a hernia is the part of the hernia sac adjacent to the abdominal wall defect. If the neck is narrow, bowel may herniate less frequently, but once it does enter, it has a higher chance of becoming constricted by the narrow neck and incarcerating.

### What Is the Difference Between a Reducible and an Incarcerated Hernia? Between an Incarcerated and a Strangulated One?

A hernia can be described as *reducible* if the contents within the sac can be pushed back through the defect into the peritoneal cavity, whereas with an *incarcerated* hernia, the contents are stuck in the hernia sac. A *strangulated* hernia is a type of incarcerated hernia in which there is compromised blood flow to the herniated organ (usually the small intestine, but can also be the omentum, large bowel, or ovary). Strangulation more frequently occurs when the hernia defect is narrow. A loop of bowel protrudes through the hernia and becomes entrapped by the narrow neck. This may lead to a closed-loop bowel obstruction whereby both ends of the bowel are blocked with nowhere for fluid and gas to egress. As the bowel continues to produce gas and secrete fluid, the progressive distention leads to a compromise of the blood flow. Strangulation requires prompt surgical intervention since it can lead to intestinal ischemia, sepsis, bowel infarction, and death. The overall incidence of strangulation in inguinal hernias is less than 1 %. This risk is increased in symptomatic patients and those with significant comorbidities. Predisposing risk factors include older age, duration of hernia (shorter is worse), type (femoral), and comorbidities. Some incarcerated hernias (particularly those with large defects) can remain irreducible for years without causing major symptoms. Others (particularly with narrow necks) are at higher risk of progressing to strangulation.

### What Clues on History and Physical Examination Indicate Whether a Patient with an Incarcerated Has Progressed to a Strangulated Hernia?

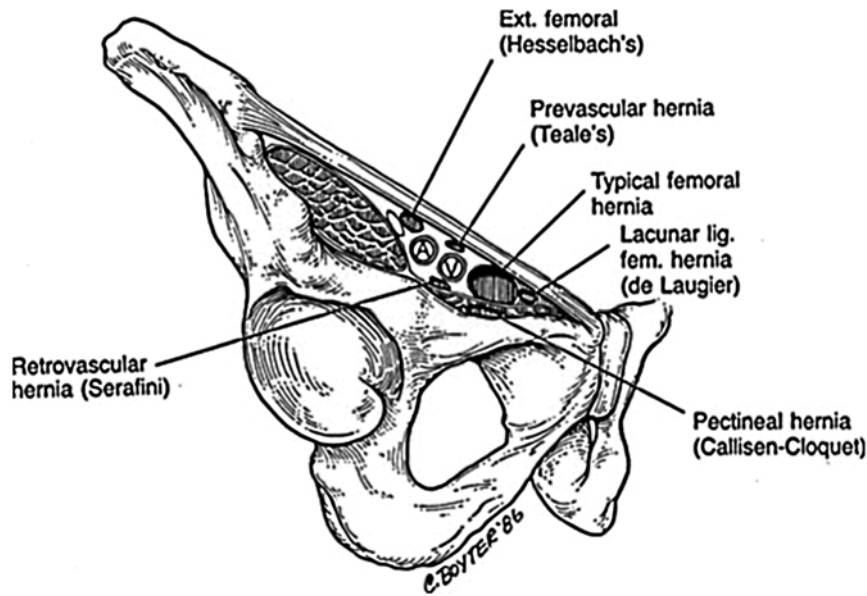
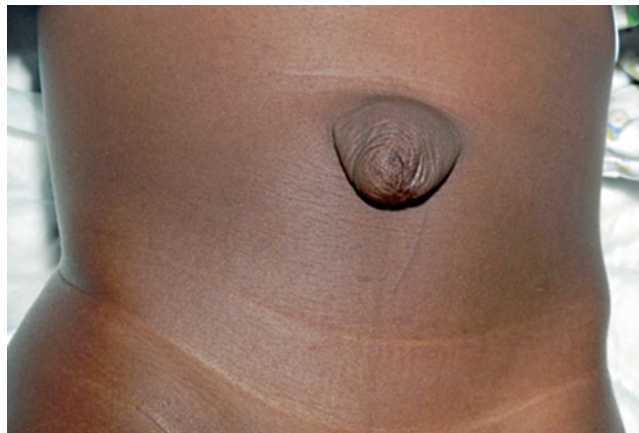A strangulated hernia leads to a compromise of the blood supply of the bowel and subsequent irreversible ischemia and necrosis. Ischemic bowel typically triggers SIRS. Thus the cardinal signs of a strangulated hernia include fever, tachycardia, and an elevated WBC count, as well as redness of the skin overlying the hernia and pain. The patient described presented with all of these signs. A strangulated hernia is a surgical emergency.

### What Are the Different Types of Hernias?

*Inguinal hernias* are divided into direct and indirect types based upon etiology (Table 1.2) and anatomic location. *Femoral hernias* occur in the femoral canal (Fig. 1.1), inferior to the inguinal ligament traversing the empty space medial to the femoral vein (recall the mnemonic “NAVEL” {from lateral to medial: femoral nerve, artery, vein, empty space, lymphatic}). Although they appear infrequently in patients (10 % of all hernias), they are much more common in women and have the highest rate of strangulation. *Umbilical hernias* (Fig. 1.2) are prevalent in the pediatric population and common with congenital hypothyroidism. In children, most are asymptomatic and close spontaneously with no intervention. In adults, umbilical hernias are associated with increased intra-abdominal pressure (pregnancy, ascites, weight gain). Surgery is recommended if symptomatic. *Ventral or incisional hernias* appear at the site of a previous surgery and can occur weeks, months, or even years after the procedure.

**Table 1.2** Inguinal hernia

Type	Anatomy	Pathophysiology	Hernia sac lining	Other
<i>Direct inguinal hernia</i>	Protrudes through the abdominal wall (Hesselbach's triangle), medial to the inferior epigastric artery	Acquired weakness in the abdominal floor, chronic straining	Peritoneum	Least likely to incarcerate, more common in men
<i>Indirect inguinal hernia</i>	Protrudes through the internal inguinal ring lateral to the inferior epigastric artery	Congenital	Patent processus vaginalis	The most common hernia in men, women, and children
<i>Femoral hernia</i>	Passes through the femoral canal, into empty space medial to femoral vein (NAVEL)	Multiple pregnancies dilate femoral veins and widen the femoral canal	Peritoneum	More common in women, most likely to incarcerate/strangulate

**Fig. 1.1** Femoral hernia (With kind permission from Springer Science + Business Media: Hernia, First laparoscopic totally extraperitoneal repair of Laugier's hernia: A Case Report, 2013, p. 122, Ates M, Fig. 1)**Fig. 1.2** Umbilical hernia (With kind permission from Springer Science + Business Media: Management of Abdominal Hernias, Umbilical Hernia in Babies and Children, 2013, p. 202, Khakar A & Clarke S, Fig. 12.1)

## What Is the Pathophysiology of an Indirect Inguinal Hernia? A Direct Inguinal Hernia?

In general, indirect inguinal hernias are congenital, whereas direct hernias are acquired. *Indirect inguinal hernias* are caused by a persistent (patent) processus vaginalis. During embryologic development, the processus vaginalis, an out-pouching of the peritoneum, descends into the scrotum, bringing along the testicle with it. It subsequently closes prior to birth. If the processus remains patent (open), peritoneal fluid can fill the scrotum (communicating hydrocele) or bowel can pass through the patent processus vaginalis into the scrotum (indirect hernia). In men, the indirect hernia sac travels along with the spermatic cord through the internal ring, and into the scrotum. In women, it follows the tract of the round ligament towards the pubic tubercle. *Direct inguinal hernias* are due to a weakness in the floor (transversalis fascia) of the inguinal canal, directly through Hesselbach's triangle. They typically manifest after years of chronic straining, causing wear and tear to the abdominal wall musculature. Since they are acquired, it is unusual to find a direct inguinal hernia in a young person. The neck of an indirect inguinal hernia is relatively narrow as it passes through a relatively rigid and inflexible space (the internal ring), whereas direct inguinal hernias typically have a more broad-based neck, making strangulation less likely to occur.

### Watch Out

Indirect inguinal hernias traverse the deep ring and the superficial ring, while direct inguinal hernias only pass through the superficial ring.

## Why Are Femoral Hernias More Prone to Incarceration?

Bowel entering a femoral hernia passes down the narrow femoral canal. This is because the femoral ring, which serves as the entrance for the femoral canal, is very rigid and unyielding. Thus the fixed neck of a femoral hernia is prone to pinching off the bowel, putting the patient at risk for incarceration.

## What Is the Significance of a Suspected Hernia Being Below as Opposed to Above the Inguinal Ligament?

A hernia below the inguinal ligament indicates that it is a femoral hernia, which passes under (posterior to) the inguinal ligament.

## What Are the Borders of Hesselbach's Triangle?

The lateral border is formed by the inferior epigastric vessels, the medial border by the rectus sheath, and the base by the posterior wall of the inguinal ligament.

## What Is the Significance of Nausea, Vomiting, and High-Pitched Bowel Sounds in the Patient Presented?

These findings suggest that the patient has a small bowel obstruction. The hernia sac likely contains a section of the small intestine that is incarcerated, causing a closed-loop (obstructed both proximally and distally) obstruction. Early in the course of a small bowel obstruction, high-pitched, hyperactive bowel sounds are heard. These sounds are the result of hyperperistalsis, as the intestines try to push the luminal contents past the obstruction. Incarcerated hernias can compromise the vascular supply of a segment of the intestine which can progress to ischemic necrosis and gangrene of the bowel. In a patient with bowel obstruction, a change in bowel sounds from hyperactive to absent, in association with increased pain, suggests progression to bowel ischemia.

## **What Is a Richter's Hernia?**

It is a type of hernia that occurs when only part of the circumference of the bowel wall is trapped within the hernia sac. The herniated segment can become strangulated and result in ischemic changes (see below for more information).

## **What Is a Sliding Hernia?**

A sliding hernia is a type of indirect hernia that occurs when a retroperitoneal organ (usually colon or bladder) typically herniates with the sac and essentially makes up the posterior wall of the sac. It usually occurs in males and more often on the left side.

---

## **Workup**

### **How Do You Diagnose a Hernia in an Adult?**

Hernias are considered a clinical diagnosis. A good history (of a reducible mass that protrudes with straining) and a good physical exam are typically all that is needed. For both men and women, the patient is asked to stand. In men, the examiner's index finger is inserted in a cephalad direction through the scrotum, inverting it, and placed at the level of the external ring. The patient is asked to Valsalva or cough. If a hernia is present, a bulge will be palpated.

### **How Do You Diagnose a Hernia in an Infant?**

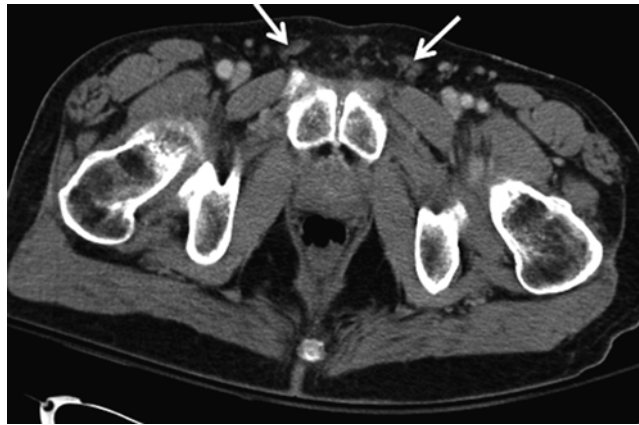Both indirect inguinal hernias and umbilical hernias are common in infants. The physical exam may be challenging as the infant cannot cough or strain on command. Thus the history from the parent of a noticeable bulge with crying is important. Raising the infant's arms will make the infant struggle, increasing intra-abdominal pressure, often permitting visualization of the hernia bulge.

### **How Do You Distinguish Between a Direct and an Indirect Inguinal Hernia Intraoperatively?**

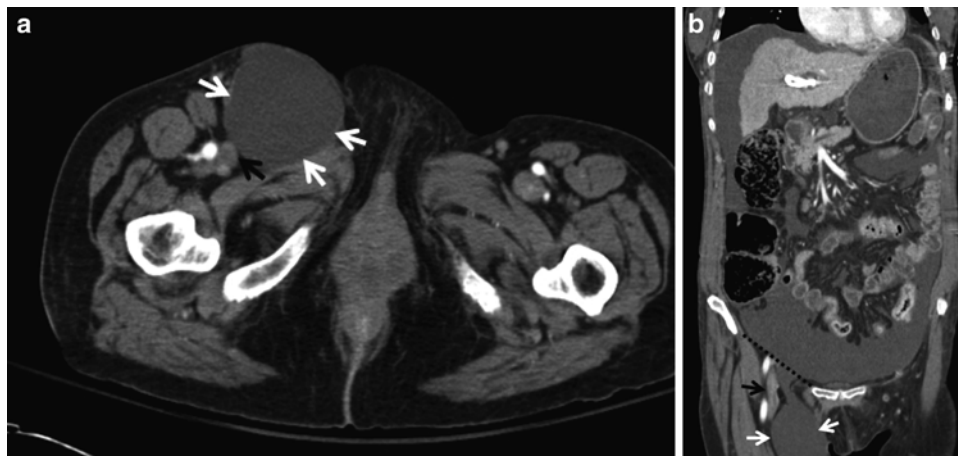
Indirect inguinal hernias originate lateral to the inferior epigastric vessels, while direct inguinal hernias pass medial. Indirect inguinal hernias travel through the internal ring along with the spermatic cord.

### **What Is the Role of Imaging Studies (Ultrasound, CT Scan, MRI) in the Diagnosis of Hernia?**

Abdominal hernias are typically diagnosed on the basis of a history and physical. However, at times, physical exam will be nondiagnostic despite a history that is strongly suggestive of a hernia. In particular, hernias may be difficult to appreciate in the morbidly obese, due to abundant subcutaneous fat. In these circumstances, adjunctive imaging studies may aid in the diagnosis. Ultrasound with Valsalva is cost effective and will often demonstrate an inguinal hernia. But even ultrasound has limited efficacy in the obese patient. Cross-sectional imaging including CT scan or MRI is most helpful. CT scan and MRI are also useful for Spigelian hernia as they lie between two layers of the abdominal wall, making these difficult if not impossible to palpate. CT is more cost effective and convenient than MRI but both provide similar information. In addition, a CT scan is an important diagnostic tool in the setting of a bowel obstruction, as it may demonstrate an undiagnosed hernia as the cause (Figs. 1.3 and 1.4).



**Fig. 1.3** Normal pelvic CT without hernia. *White arrows: normal inguinal canals*



**Fig. 1.4** Axial (a) and coronal (b) CT scans showing a right-sided femoral hernia. Note that it is medial to the femoral vein and inferior to the inguinal ligament. *White arrows: hernia sac. Black arrows: femoral vein. Black dotted line: location of inguinal ligament*

## Management

### What Is the Principle Component of the Operative Management of an Indirect Inguinal Hernia in an Adult? How About a Direct Inguinal Hernia?

For an indirect hernia, the main goal is to open the sac (anteriorly), assess viability of the intestine, reduce any contents, and then perform a high ligation (at the internal ring) of the hernia sac. This eliminates the patent processus vaginalis. The distal sac can be excised if small or left in situ if large. In addition, in adults, the long-standing protrusion of the hernia through the internal ring weakens the surrounding muscle. As such, the floor of inguinal canal is reinforced with a tension-free mesh repair. With a direct hernia, since there is no patent processus vaginalis, the sac is not opened nor ligated. Since the sac consists of peritoneum, and protrudes through the weakened floor of the inguinal canal, the sac is just reduced, and the floor of the inguinal canal is reinforced with a tension-free mesh placement (Lichtenstein repair). Laparoscopic inguinal hernia repair can be used to repair indirect, direct, and femoral hernias utilizing a posterior approach to the myopectineal orifice with mesh reinforcement. An alternative to using mesh is to strengthen the floor by sewing the conjoint tendon to the inguinal ligament (tissue-based repair). Such a repair (without mesh) has the disadvantage of being under tension, and as such the hernia recurrence rate is significantly higher. As such, it is reserved for situations where mesh is unavailable or contraindicated (in association with gangrenous bowel).



## What Are the Principles of the Management of an Incarcerated Hernia?

Acutely incarcerated hernias are at risk of progressing to strangulation; thus they need prompt attention. Provided there is no evidence of strangulation already, an attempt should be made to reduce the incarcerated hernia. If this is successful, hernia repair can be performed semi-electively. If it is not reducible, urgent surgical intervention is required.

## What Is the Recommendation for Inguinal Hernia Repair in Older Infants/Children?

The vast majority of hernias in infants are indirect hernias. Thus high ligation of the hernia sac adequately corrects this defect. Since the hernias are not usually long-standing, the internal ring and the floor of the inguinal canal do not need reinforcement. Approximately 5–10 % of infants will have bilateral indirect inguinal hernias, so an attempt should be made to assess for a contralateral hernia during the initial exam. Many pediatric surgeons will insert a laparoscope during hernia repair into the peritoneum (through the hernia sac) to visualize if a contralateral patent processus vaginalis is present and, if so, will perform simultaneous bilateral hernia repair.

## What Is the Recommended Management for an Umbilical Hernia in an Infant?

Umbilical hernias are very common in newborns. They rarely incarcerate and most close spontaneously by age 2. Indications for surgery are persistence beyond age 4, hernia defect larger than 2 cm in diameter (unlikely to close spontaneously), strangulation, or progressive enlargement after 1–2 years of age.

## Complications

### What Nerves Can Be Injured During Hernia Repair? What Is the Mechanism of Injury? What Are the Consequences?

Nerve injury (Table 1.3) during inguinal hernia repair is common. The nerves can either be transected, stretched, and cauterized or become entrapped by sutures or by scar tissue around the mesh. The result is either temporary or permanent numbness in the areas described above. Overall, as many as 20 % of patients have numbness and/or some degree of chronic burning (neuropathic) pain. Meralgia paresthetica describes burning pain associated with lateral femoral cutaneous nerve injury.

## Areas Where You Can Get in Trouble

### Attempting to Reduce a Strangulated Hernia

Strangulated hernias imply that the bowel is compromised. Although the goal is to quickly restore blood flow to avoid dead bowel, this is not always possible and the bowel may already be gangrenous upon presentation. If such a hernia is reduced, the dead bowel will be pushed back into the peritoneal cavity, leading to sepsis and peritonitis. The only acceptable approach to reducing a strangulated hernia is in the operating room after confirming the bowel is not dead.

**Table 1.3** Nerve injury during hernia repair

Injury	Deficit
<i>Genital branch of the genitofemoral nerve</i>	Loss of cremaster reflex and loss of sensation in the anterior scrotum/labia majora (genital branch)
<i>Ilioinguinal nerve</i>	Loss of sensation at the base of the penis, mons pubis, and inner thigh
<i>Iliohypogastric nerve</i>	Loss of sensation in the suprapubic region
<i>Lateral femoral cutaneous nerve (meralgia paresthetica)</i>	Loss of sensation in the lateral side of the thigh, commonly extending to the knee; more common during laparoscopic repair

### **Failing to Recognize a Richter's Hernia**

Since only part of the wall of the small intestine is herniated, patients do not have signs or symptoms suggestive of bowel obstruction. The absence of obstruction may mislead the clinician into thinking that the bowel is not at risk for strangulation.

### **Failure to Recognize a Sliding Hernia**

A sliding hernia should be suspected when the posterior wall of the hernia sac feels thickened. It is particularly dangerous because if it is not recognized, the bowel can easily be injured or transected when dividing the hernia sac. An indirect hernia sac should always be opened anteriorly as this will prevent making a hole in the bowel or bladder if a sliding hernia is present.

### **Not Separating the Vas Deferens and Testicular Vessels from the Hernia Sac All the Way to the Internal Ring**

Since the indirect hernia sac travels with the spermatic cord, the sac needs to be completely separated from the vas deferens and the testicular vessels. Failure to do so may result in injury to these structures. Of note, transection of the testicular artery rarely leads to testicular ischemia. The testicle also gets blood supply from the cremasteric artery and the artery of the vas deferens. In fact the testicular artery is sometimes purposely divided during surgery for undescended testis in order to mobilize the testicle into the scrotum.

### **Dissecting and Excising the Distal End of a Large Indirect Hernia Sac**

The primary goal of indirect hernia repair is division of the hernia sac with proximal ligation near the internal ring. The distal sac, if small, is typically excised. However, if the indirect hernia sac is large, it will extend into and be adherent to the scrotum. In this situation the distal hernia sac should be left in situ. Attempting to remove the entire sac will require extensive dissection without benefit. Such dissection carries an increased risk of disrupting the venous drainage of the testicle and is the leading cause of testicular ischemia.

---

## **Areas of Controversy**

### **Do You Repair or Observe Asymptomatic Inguinal Hernias?**

There is ongoing debate as to whether asymptomatic inguinal (direct and indirect) hernias should be repaired or whether one should wait for symptoms to develop. A large prospective randomized controlled trial supports the premise of “watchful waiting,” provided no symptoms develop. More recent studies confirm the safety of watchful waiting but suggest that the majority of asymptomatic patients eventually do become symptomatic. Most surgeons offer elective repair of asymptomatic inguinal hernias. Since femoral hernias are at higher risk of incarceration, repair is routinely recommended.

### **What Is the Recommended Management for an Inguinal Hernia in a Premature Infant?**

Premature infants are at higher risk of incarceration. However, premature infants are also at much higher risk of complications from surgery (pulmonary from general anesthesia, injury to the vas deferens due to small size). Data regarding optimal timing of repair are conflicting. Most surgeons agree that optimal management is to delay surgery until infant is out of the ICU.

## Do You Repair Asymptomatic Ventral/Incisional Hernias? Is Mesh Needed for Repair?

Incisional or ventral hernias typically develop after prior abdominal surgery. Most surgeons do not repair asymptomatic incisional/ventral hernias. The procedures are reoperative, so there is more risk of adhesions and thus of bowel injury during surgery. Depending upon the size of the hernia defect, mesh is generally used for repair. Mesh decreases the chances of hernia recurrence compared to sutures alone. However, there are several potential mesh-related complications that arise including mesh infection, adhesion, pain, and erosion into the bowel with fistula formation. Preferred techniques involve placing the mesh in a preperitoneal position, to avoid contact with the bowel. Coated, synthetic, and biologic meshes have been developed to decrease these complications.

## Do You Repair Inguinal Hernias Laparoscopically or Open?

Laparoscopic inguinal hernia repair has a slightly higher recurrence rate than open. However, most of these are due to a steeper learning curve with excellent outcomes with experienced surgeons. Conversely, open repair is associated with slightly more postoperative pain. Both are considered acceptable alternatives with similar results. Currently recommendations define a clear benefit for laparoscopic hernia repair in cases of bilateral inguinal hernias (less pain) and for recurrent inguinal hernias after prior open repair (less pain, similar results) and towards open hernia for first time unilateral hernias.

---

## Summary of Essentials

### History and Physical

- Must differentiate between inguinal and scrotal masses
- With hernias, look for factors that increase intra-abdominal pressure (straining with urination, cough, constipation, ascites, pregnancy)

### Differential Diagnosis

- MINT: *m*alformation, *i*nfectious/inflammatory, *n*eoplastic, *t*raumatic
  - The most common inguinal mass: enlarged lymph nodes, or Cloquet's nodes (femoral triangle)
  - Autoimmune disease, malignancy, or as a response to a localized or systemic infection

### Pathology/Pathophysiology

- Reducible hernia: contents can be pushed back through the defect into the peritoneal cavity
- Incarcerated hernia: contents are stuck in the hernia sac
- Strangulated hernia: a subset of incarcerated hernia with compromised blood flow to the bowel may lead to ischemic bowel (look for SIRS)
- Ventral or incisional hernia: at the site of a previous surgery
- Femoral hernias:
  - Rare, more common in multiparous women, and highly prone to incarceration/strangulation
  - Posterior and inferior to the inguinal ligament and medial to the femoral vein
- Indirect inguinal hernia:
  - The most common hernia in men, women, and children
  - Congenital (patent processus vaginalis), lateral to inferior epigastric vessels, and through the deep and superficial ring
- Direct inguinal hernia:
  - More common in older men
  - Acquired weakness in Hesselbach's triangle, medial to inferior epigastric vessels, and only through the superficial ring

## Workup

- Inquire about sources of increased straining/intra-abdominal pressure:
  - Urinary retention, constipation, heavy lifting, chronic cough, ascites, weight gain
- A hernia is considered a clinical diagnosis:
  - No imaging usually needed
- In morbidly obese, diagnosis can be difficult:
  - CT scan when diagnosis unclear

## Management

- Asymptomatic hernias can be observed:
  - Exception: femoral hernias
  - Exception: inguinal hernias in infancy:
    - Wait until preemie is out of the ICU
- Most eventually become symptomatic
- Indirect hernia (most common):
  - Open the sac (anteriorly), reduce any contents, and perform a high ligation (at the internal ring) of the hernia sac
- Direct hernia (older men):
  - Do not open sac (no patent processus vaginalis), and reinforce floor with mesh (Lichtenstein) repair
- Femoral hernia (women):
  - Medial to the femoral vein
  - Inferior to the inguinal ligament
  - High incarceration risk
- Incarcerated hernia:
  - Attempt reduction, then repair semi-electively
- Strangulated hernia:
  - Urgent surgery
- Umbilical hernia in children:
  - Repair if persists > age 4, defect > 2 cm, and progressive enlargement after age 2
- In adults, definitive treatment of inguinal and femoral hernias also includes strengthening the floor of the inguinal canal with mesh

## Complications

- Persistent pain from nerve injury is common
- Recurrence
- Testicular ischemia:
  - Swollen painful testicle following surgery

---

## Suggested Reading

- Abi-Haidar Y, Sanchez V, Itani KM. Risk factors and outcomes of acute versus elective groin hernia surgery. *J Am Coll Surg.* 2011;213:363.
- Eklund A, Rudberg C, Leijonmarck CE, et al. Recurrent inguinal hernia: randomized multicenter trial comparing laparoscopic and Lichtenstein repair. *Surg Endosc.* 2007;21:634.
- SSAT patient care guidelines. Surgical repair of groin hernias. *J Gastrointest Surg.* 2007;11:1228.
- Wijsmuller AR, van Veen RN, Bosch JL, et al. Nerve management during open hernia repair. *Br J Surg.* 2007;94:17.

Jill Q. Klausner and David C. Chen

A 38-year-old woman presents to the emergency department with colicky abdominal pain, nausea, and vomiting for the past day. She has had at least 10 episodes of green, bilious emesis without blood. She has had no passage of stool or flatus per rectum since yesterday morning and has not eaten in 24 hours due to the vomiting and abdominal pain. She denies a history of similar symptoms and has no other medical problems. Past surgical history is significant for a C-section 2 years ago. On physical examination, her temperature is 99.3 °F, heart rate is 122/min, blood pressure is 124/78 mmHg, and respiratory rate is 14/min. Her mucous membranes are dry and her abdomen is distended, with a well-healed low transverse abdominal incision. Auscultation reveals high-pitched tinkling bowel sounds. She has mild tenderness throughout the abdomen, but there is no rebound, guarding, or rigidity. No masses or hernias are identified. Rectal examination reveals normal tone, no gross blood, no masses, and no stool in the rectal vault. Laboratory examination is significant for a white blood cell count of  $8.2 \times 10^3/\mu\text{L}$  (normal  $4.1\text{--}10.9 \times 10^3/\mu\text{L}$ ), hemoglobin 17 g/dL (12.3–15.7 g/dL), hematocrit 51 % (37–46 %), sodium 141 mEq/L (135–145 mEq/L), potassium 2.9 mEq/L (3.5–5.0 mEq/L), chloride 93 mmol/L (98–106 mEq/L), bicarbonate 31 mEq/L (24–30 mEq/L), BUN 30 mg/dL (7–22 mg/dL), and creatinine 1.2 mg/dL (0.56–1.0 mg/dL). Abdominal x-ray is provided in Fig. 2.1.

## Diagnosis

### What Is the Differential Diagnosis and What Clues on History and Physical Exam Might Direct you toward a Specific Diagnosis?

Diagnosis	History and physical
<i>Small bowel obstruction</i>	Colicky abdominal pain, nausea, bilious vomiting, obstipation, abdominal distention, hyperactive bowel sounds (early) or hypoactive bowel sounds (late), prior abdominal surgery
<i>Gastroenteritis</i>	Cramping abdominal pain, fever, nausea, vomiting, diarrhea, hyperactive bowel sounds
<i>Paralytic ileus</i>	Diffuse abdominal discomfort but no sharp colicky pain, hypoactive bowel sounds, stool in the rectum, may pass flatus and diarrhea, associated with recent surgery, narcotic use
<i>Large bowel obstruction</i>	Gradually increasing abdominal pain with longer intervals between episodes of pain, abdominal distention, obstipation, less vomiting (feculent), more common in the elderly
<i>Colonic pseudo-obstruction (Ogilvie's syndrome)</i>	Debilitated hospitalized medical or surgical patients; abdominal pain, nausea, vomiting, may continue to pass flatus, massive abdominal distention; idiopathic
<i>Mesenteric ischemia</i>	Pain disproportionate to physical findings, nausea, vomiting, anorexia, bloody diarrhea

J.Q. Klausner (✉)

Department of Surgery, David Geffen School of Medicine at UCLA, 757 Westwood Plaza, Los Angeles, CA 90095, USA

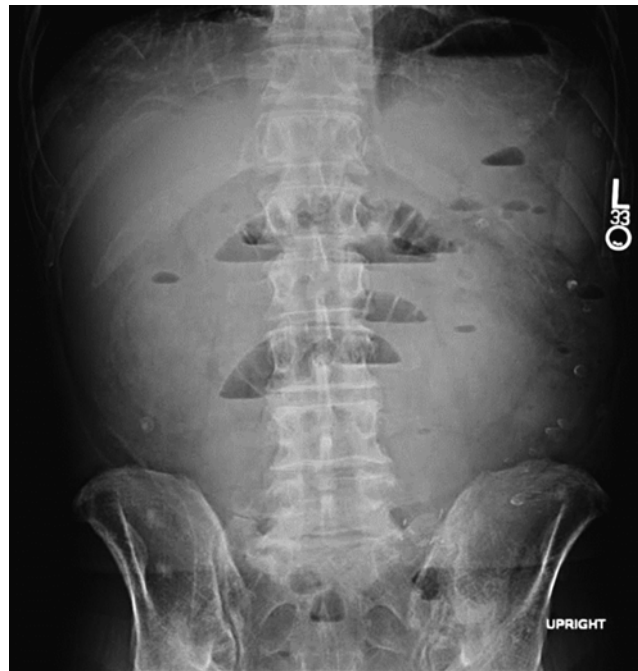e-mail: [JKlausner@mednet.ucla.edu](mailto:JKlausner@mednet.ucla.edu)

D.C. Chen, MD

Department of Surgery, University of California at Los Angeles, 1304 15th St., Suite 102,

Santa Monica CA 90404, USA

e-mail: [dcchen@mednet.ucla.edu](mailto:dcchen@mednet.ucla.edu)



**Fig. 2.1** Upright abdominal x-ray showing air-fluid levels consistent with small bowel obstruction

### What Is the Most Likely Diagnosis?

The history of acute onset of colicky abdominal pain, nausea, vomiting, and obstipation in a young patient with prior abdominal or pelvic surgery is highly suggestive of simple mechanical *small bowel obstruction* (SBO) due to adhesions from prior surgery. This patient presents with uncomplicated, or *simple* SBO, but treatment is necessary in order to avoid progression and potential complications such as strangulation, bowel necrosis, sepsis, and death. This patient also presents with dehydration as evidenced by dry mucous membranes, prerenal azotemia (high BUN-to-creatinine ratio), and hypochloremic, hypokalemic, metabolic acidosis as a result of volume losses from recurrent emesis secondary to her SBO.

---

### History and Physical Exam

#### What Is the Significance of an SBO in the Absence of an Abdominal Scar?

The absence of an abdominal scar suggests that the patient has had no previous surgeries and removes the most common benign etiology of SBO. Since adhesions result from prior surgeries, intra-abdominal adhesions are less likely to be the cause of SBO in a patient without an abdominal scar. This is important because while the majority of SBOs due to intra-abdominal adhesions will resolve with conservative treatment, the other causes of SBO are less likely to resolve without intervention and may need emergent surgical treatment. Additionally, nonadhesive SBOs require further diagnostic evaluation or intervention to assess for malignancy, hernia, or inflammatory bowel disease.

#### Watch Out

Hernias are the most common cause of SBO worldwide.

#### What Is the Howship-Romberg Sign?

This is suggestive of an obturator hernia and consists of pain in the medial aspect of the thigh with abduction, extension, or internal rotation of the hip due to compression of the obturator nerve by an obturator hernia (pelvic hernias seen mostly in elderly multiparous females and in those with significant weight loss).

## What Is the Significance of Severe Abdominal Pain and Localized Tenderness in Association with an SBO?

Severe abdominal pain and localized tenderness in association with SBO are suggestive of complicated or *strangulated* SBO. In contrast to a simple SBO where blood flow to the bowel remains intact, strangulated obstruction occurs when vascular perfusion is impaired, leading to intestinal ischemia and ultimately necrosis. Strangulation accounts for almost half of all deaths due to SBO and increases the morbidity rate significantly. Early surgical intervention is essential to avoid morbidity and poor outcomes. Strangulated obstruction typically presents with continuous (as opposed to colicky) abdominal pain, signs of systemic inflammatory response syndrome (fever, tachycardia, leukocytosis), peritoneal signs, acidosis, absence of bowel sounds, localized abdominal tenderness, and occasionally a painful mass or blood in the stool. Unfortunately, these signs are not particularly sensitive or specific for early strangulation, but they should alert one to the possibility of strangulation and the need for early surgical intervention.

### Watch Out

The 4 cardinal signs of strangulated bowel: fever, tachycardia, leukocytosis, and localized abdominal tenderness.

## Pathophysiology

### What Is a Closed Loop Obstruction?

A *closed loop obstruction* is a particularly dangerous form of bowel obstruction in which a segment of intestine is obstructed both proximally and distally. Gas and fluid accumulates within this segment of bowel and cannot escape. This progresses rapidly to strangulation with risk of ischemia and perforation.

### What Is the Pathophysiology of SBO?

In SBO, gas and fluid accumulate proximal to the site of obstruction, causing dilation of the bowel followed by increased motility in attempt to overcome the obstruction. The dilation results in progressive nausea and colicky, visceral pain with subsequent episodes of emesis. The increased peristaltic activity that attempts to overcome the obstruction in the early course of SBO causes the characteristic colicky pain. Initially, bowel sounds are increased and have a high-pitched, tinkling sound, but as the bowel distends and intramural pressures rise, intestinal motility decreases and bowel sounds diminish. Failure to pass gas or stool per rectum is typically due to a complete mechanical obstruction of the small intestine.

### What are the Most Common Causes of an SBO?

Cause of SBO	Distinguishing features
<i>Crohn's disease</i>	Terminal ileitis, strictures, perianal fistula, abscess, fissures; aphthous ulcers
<i>Gallstone ileus</i>	History of gallstones; pneumobilia (air within biliary tree) seen on CT, possible gallstone on plain film in RLQ at the ileocecal valve
<i>Hernia</i>	Bulge in groin or abdominal wall
<i>Intra-abdominal adhesions</i>	Prior abdominal or pelvic surgery
<i>Intussusception</i>	Target sign seen on CT with proximal lead point in the bowel wall
<i>Neoplasm</i>	History of neoplasm; mass seen on CT
<i>Volvulus</i>	Whirl or omega sign seen on CT

The most common cause of SBO in industrialized countries is intra-abdominal adhesions related to prior abdominal surgery. Historically, hernias were responsible for more than half of mechanical SBOs, but with routine elective repair, the incidence of hernias causing SBO has drastically decreased.

## What Is the Risk of Developing SBO After Different Operations?

Adhesions after pelvic operations are responsible for more than 60 % of all SBO in the USA, with appendectomy being the most common cause, followed by colorectal resection, and then gynecologic procedures. Inflammatory processes such as appendicitis and diverticulitis create adhesions as the omentum and surrounding intestinal loops attempt to contain the source of inflammation and infection. Disruption of the visceral and parietal peritoneum with pelvic operations leads to adhesions, especially in the dependent positions where the loops of small intestine rest. Another possible explanation for this is that the bowel is more mobile in the pelvis than in the upper abdomen, and thus more likely to produce an obstructing torsion.

## What Are the Mechanisms of Fluid Loss in SBO?

Dehydration is a common finding in SBO, but the mechanisms of fluid loss differ depending on the site and degree of obstruction. With proximal obstructions, repeated episodes of emesis as well as refusal of oral intake due to anorexia contribute to dehydration and electrolyte abnormalities. Additionally, in any complete obstruction, there is a transudative loss of fluid into the peritoneal cavity. The intestine proximal to the site of obstruction becomes distended due to the accumulation of gastrointestinal secretions and gas. Stasis in the intestinal lumen results in bacterial overgrowth, which causes even more dilation due to bacterial fermentation. As the hydrostatic pressure within the intestinal lumen increases, fluid accumulates in the bowel wall, altering the Starling forces of capillary fluid exchange such that there is a net filtration of fluid, electrolytes, and protein into the bowel wall and lumen. This loss of fluid from the intravascular space is termed *third spacing* and contributes to dehydration in both proximal and distal SBO.

## Work-Up

### What Laboratory Tests Should Be Obtained in the Initial Work-Up for SBO?

When working up SBO, it is important to obtain a CBC, chemistry panel, and serum lactate. While laboratory values do not play a significant role in the diagnosis of SBO, they are essential in assessing the degree of dehydration and the possibility of bowel ischemia or compromise. Dehydrated patients may exhibit hemoconcentration, as evidenced by elevated hemoglobin and hematocrit. A ratio of BUN/creatinine of greater than 20 is suggestive of prerenal azotemia, which can be caused by decreased blood flow to the kidneys. A chemistry panel can also assess for hypochloremic hypokalemic metabolic alkalosis, which often results from repeated bouts of emesis. Leukocytosis raises the possibility of an infectious etiology or bowel compromise, changing the management algorithm of a simple SBO. An elevated serum lactate, particularly associated with a non-anion gap metabolic acidosis, may indicate an ischemic bowel.

### What Imaging Is Recommended for an SBO?

When SBO is suspected, initial imaging should include an abdominal series (Table 2.1), generally followed by an abdominal and pelvic CT with oral and intravenous contrast.

**Table 2.1** Abdominal series

Films	Purpose
Upright chest radiograph	Rule out free air
Upright abdominal radiograph	Look for air-fluid levels
Supine abdominal radiograph	Estimate amount of distention (width of small bowel)



## How Do You Differentiate Large and Small Bowel on Radiographs?

The small bowel has lines (plicae circulares) going all the way through the bowel, while the large bowel has lines (haustra) only halfway through the bowel.

## What are the Different Radiologic Findings Associated with SBO?

Radiologic finding	Radiologic appearance	Associated pathology in context of SBO
SBO (abdominal series)	Dilated loops of small intestine (plicae circulares), air-fluid levels, bowel stacking	Classic radiographic findings of SBO
Target sign (CT)	Three concentric circles, with hyperdense inner and outer rings and a hypodense middle ring	Intussusception
Whirl sign (CT)	Twist of bowel wrapped around a single constrictive focus of mesentery	Small bowel volvulus
Pneumatosis (CT)	Presence of gas within the wall of the intestine	Strangulated obstruction leading to intestinal ischemia and necrosis
Portal venous gas (CT)	Air in the periphery of the liver due to centrifugal portal flow	Late presentation of pneumatosis with air passing via portal venous circulation

## How Is a Complete SBO Different from a Partial SBO? Why Is It Important to Distinguish Between the Two?

In a *complete* SBO, the intestinal lumen is entirely occluded and there is no passage of gas or fluid. In a *partial* SBO, gas and fluid are able to pass. Patients with complete SBO present with colicky abdominal pain, nausea, vomiting, and obstipation. Those with partial SBO develop similar symptoms, but more slowly, and continue to pass gas and stool beyond 6–12 hours after symptom onset. While plain films of a patient with complete SBO show dilated loops of bowel with air-fluid levels and no gas in the rectum, those with partial SBO will show residual colonic gas. Sometimes plain films will be equivocal, and CT will be necessary in order to visualize the amount of residual air and fluid in the distal intestine. It is important to distinguish between a complete and partial SBO because the management of these two conditions is different. The risk of strangulation is minimal for patients with partial obstruction, whereas the risk is substantial for those with complete obstruction. Thus a partial SBO can typically be managed nonoperatively, while complete SBO may require surgical intervention.

## How Do You Distinguish SBO from LBO?

The clinical presentation of large bowel obstruction (LBO) is dependent upon location and etiology of obstruction. If the proximal colon is involved, it is more likely to be mistaken for SBO as the luminal contents are similar to the small intestine, causing a similar clinical presentation. If a tumor is the cause of LBO, the course is progressive and symptoms are chronic, so it is less likely to be confused with SBO. In general, LBO causes gradually increasing abdominal pain, progressive distention, constipation, and occasionally feculent vomiting. There are longer intervals between episodes of cramping pain, and there is more pain in the suprapubic area with LBO than with SBO. Common causes of LBO include colon cancer, diverticular disease, and volvulus. On imaging, an “apple-core” lesion is characteristic of colon cancer, and a “bird-beak” tapering down toward the lower left quadrant is characteristic of sigmoid volvulus.

## How Do You Distinguish Between Postoperative Ileus and SBO?

In the early postoperative period, it is important to distinguish an obstruction, which occurs in less than 1 % of those undergoing laparotomy, from an ileus. After abdominal surgery, GI motility is reduced due to a number of factors including a stress-induced sympathetic response, the release of inflammatory mediators, and the use of anesthetic and analgesic agents. The small intestine usually regains normal motility within the first 24 hours after surgery, the stomach takes 48 hours, and

the colon can take as long as 3–5 days. This phenomenon is physiologic and is referred to as *postoperative ileus*. It can be difficult to distinguish postoperative ileus from early SBO, since postoperative ileus also presents with abdominal pain, nausea, vomiting, and abdominal distention. However, ileus usually presents with hypoactive bowel sounds and the pain is described as dull and constant. One should suspect SBO if bowel function initially returned and subsequently the patient developed obstructive symptoms or if bowel function has not returned 3–5 days after surgery. Plain films should reveal dilated loops of bowel but no air-fluid levels in ileus. If these are non-diagnostic, CT is very effective in differentiating SBO from postoperative ileus and will often reveal the etiology of postoperative SBO in many cases.

---

## Management

### What Are the Initial Steps in the Management of an SBO?

Patients with SBO are often significantly dehydrated. Aggressive fluid resuscitation (with an isotonic intravenous fluid such as normal saline) and electrolyte repletion are critical initial steps in the management. Additionally, early placement of a nasogastric tube to evacuate air and fluid is important because gastric decompression will decrease nausea, vomiting, distention, and the risk of aspiration. Almost all patients will need an indwelling bladder catheter to monitor hourly urine output.

### Operative Versus Nonoperative Management of SBO

In the absence of peritonitis or evidence of bowel ischemia, patients should first undergo an initial period of nasogastric tube decompression and fluid and electrolyte resuscitation. If the patient develops symptoms or signs of bowel compromise (increasing abdominal pain and tenderness on exam), the patient should then promptly be taken to the operating room. In the absence of such signs, it should be determined whether the SBO is partial or complete. The management of partial SBO is an initial trial of nonoperative management due to the fact that progression to strangulation is unlikely. Studies have shown that 60–85 % of patients with partial obstruction will have resolution of symptoms without the need for surgery. However, if a patient with partial SBO begins to clinically deteriorate, prompt operative intervention may be necessary. The management of complete SBO is more controversial. Some of these patients may progress to the point of strangulation and irreversible ischemia, in which case early operation would be favored. However, some will never progress to this point and will resolve completely with conservative management. Unfortunately, clinical signs and symptoms cannot definitively place a patient into one group or the other. Traditionally, early surgical intervention was the standard therapy, but recent studies have shown that many patients with complete SBO may be managed conservatively, if closely observed and if there are no signs of bowel ischemia. Most agree that it is safe to delay surgery for an additional 12–24 hours after the initial period of resuscitation, but that beyond that time, the risk of complications increases significantly.

### What Should You Do If You Suspect Nonviable Bowel During Laparotomy for SBO?

Necrotic bowel generally does not occur in association with an SBO unless there is a closed loop obstruction. Any bowel that is obviously nonviable needs to be resected. If there are segments of bowel of questionable viability, there are several means to assess its viability. These methods include looking at the color (pink versus pale or bluish), peristalsis versus no peristalsis, and presence/absence of arterial pulsations in the mesentery. In addition, the bowel can be interrogated using a hand-held Doppler to detect audible arterial signals on the antimesenteric border of the questionable bowel. Finally, intravenous fluorescein dye can be administered. Viable bowel will take up the dye, which can then be seen using an ultraviolet (Woods's) lamp. If the viability remains in question, and it is a small segment, the bowel should be resected. If the area of questionable viability is extensive, the bowel is left, and a second look operation is performed the following day after the patient has been warmed and further resuscitated.

### What Is the Management of Early Postoperative SBO?

If the diagnosis of acute postoperative SBO is made, an attempt to classify it as partial or complete is needed. Although most early postoperative SBO are partial obstructions, one must be able to detect complete obstruction to prevent serious complication or bowel compromise. Partial obstruction should be managed conservatively, and in the postoperative

setting, as long as 2–3 weeks of nonoperative therapy may be acceptable. If there is a complete obstruction, one may initiate a trial of conservative management, only proceeding to the operating room for cases of suspected strangulation or lack of improvement after 24 hours of conservative management. Unique to the management of the postoperative SBO is the issue of timing. Traditionally, unless there is clear evidence of peritonitis or bowel compromise, re-operation is avoided after 10–14 days postoperatively because at this time, new adhesions, which are dense and vascularized, can make re-operation difficult and dangerous. Successful conservative management in these cases will ideally push elective intervention out 4–6 weeks when adhesions will remodel, making re-operation less morbid or allowing for avoidance of re-operation altogether.

---

## Summary of Essentials

### History and Physical Exam

- Acute onset of colicky abdominal pain, nausea, vomiting, and obstipation
- History of previous pelvic or abdominal operations
- Examine for hernias

### Pathophysiology

- Most common cause of SBO is intra-abdominal adhesions from prior surgery
- Gas and fluid accumulate proximal to the site of obstruction
- Ongoing emesis and third spacing lead to dehydration, prerenal azotemia, and hypochloremic hypokalemic metabolic acidosis

### Diagnosis

- Classic radiographic findings of SBO: dilated loops of small intestine, air-fluid levels, bowel stacking
- CT can distinguish between postoperative ileus and SBO and can reveal the etiology of SBO

### Management

- Initial treatment includes fluid resuscitation, electrolyte repletion, and placement of a nasogastric tube
- Majority of patients with partial obstruction will not need surgery
- In patients with complete obstruction, may manage conservatively for 12–24 h, but if no clinical improvement, surgical intervention is warranted
- Immediately proceed to operating room if any signs or symptoms of peritonitis or bowel ischemia
- Nonviable bowel must be resected
- Avoid re-operation on early postoperative SBO unless clear evidence of peritonitis or bowel compromise

---

## Suggested Reading

- Cheadle WG, Garr EE, Richardson JD. The importance of early diagnosis of small bowel obstruction. *Am Surg.* 1988;54:565.
- Kozol R. Mechanical bowel obstruction: a tale of 2 eras. *Arch Surg.* 2012;147:180.
- Markogiannakis H, Messaris E, Dardamanis D, et al. Acute mechanical bowel obstruction: clinical presentation, etiology, management and outcome. *World J Gastroenterol.* 2007;13:432.
- Miller G, Boman J, Shrier I, Gordon PH. Natural history of patients with adhesive small bowel obstruction. *Br J Surg.* 2000; 87:1240.
- Taylor MR, Lalani N. Adult small bowel obstruction. *Acad Emerg Med.* 2013;20:528.

---

**Part II**

**Breast**

Danielle M. Hari, Section Editor

Christopher M. Reid, Areg Grigorian, Christian de Virgilio,  
and Danielle M. Hari

A 55-year-old postmenopausal female presents with a new mass in her right breast. She states that the mass has been there for about 3 months and has slowly grown in size. She first noticed it when she was taking a shower. The mass is not painful. She reports no nipple discharge, no nipple inversion, and no skin changes. She had her first menstrual period at age 11. Her only pregnancy was at age 35. Her mother and sister both had breast cancer. On physical examination, she has a 2 cm palpable, hard, ill-defined, immobile, non-tender mass in the upper outer quadrant of her right breast. There is no palpable axillary or supraclavicular adenopathy.

## Diagnosis

### What Benign Conditions Are in the Differential Diagnosis of a Palpable Breast Mass?

Condition	History and physical	Features
<i>Fibrocystic change</i>	Vague irregularity of breast tissue (lumpy breast), often in upper quadrants, cysts have a blue-dome appearance on exam	Most common breast mass in women; found in 60–90 % of breasts during routine autopsy; normal variant of premenopausal breast, some subtypes associated with increased cancer risk
<i>Fibroadenoma</i>	Well-circumscribed, mobile, rubbery, encapsulated mass	Most common benign tumor; typically affects women <30 years old; most common tumor in premenopausal women, estrogen sensitive causing it to grow during pregnancy (most are identified during pregnancy)
<i>Intraductal papilloma</i>	Classically presents as unilateral bloody nipple discharge in premenopausal women	Most common cause of bloody nipple discharge in women aged 20–40; usually do not show up on mammogram; papilloma is lined by epithelial (luminal) and myoepithelial cells in contrast to cancer cells which are only lined by luminal cells
<i>Fat necrosis</i>	Following trauma or recent breast surgery; may be accompanied by pain	Abnormal calcification on mammogram secondary to saponification
<i>Abscess</i>	Painful mass typically in lactating breast, erythematous and warm, fevers, purulent drainage from mass or nipple discharge	Postpartum mastitis: localized cellulitis caused by bacterial invasion through an irritated or fissured nipple
<i>Galactocele</i>	Painful or painless aseptic mass in lactating breast that is not warm or erythematous	Typically occurs on cessation of lactation; can be managed by massaging breast or aspiration

C.M. Reid, BS, MD  
Department of Surgery, UC San Diego, 200 West Arbor Drive, San Diego, CA 92103, USA  
e-mail: [chreid@ucsd.edu](mailto:chreid@ucsd.edu)

A. Grigorian, MD (✉)  
Department of Surgery, University of California, Irvine, 333 City Blvd West, Suite 1600, Route. 81, Orange, CA 92868, USA  
e-mail: [agrigori@uci.edu](mailto:agrigori@uci.edu)

C. de Virgilio, MD  
Department of Surgery, Harbor-UCLA Medical Center, 1000 W. Carson Street, Torrance, CA 90509, USA  
e-mail: [cdevirgilio@labiomed.org](mailto:cdevirgilio@labiomed.org)

D.M. Hari, MD  
Division of Surgical Oncology, Department of Surgery, Harbor-UCLA Medical Center, 1000 W. Carson Street, Box 25, Torrance, CA 90509, USA  
e-mail: [dhari@dhs.lacounty.gov](mailto:dhari@dhs.lacounty.gov)

## What Malignant Lesions Are in The Differential Diagnosis of a Palpable Breast Mass?

Type	History and physical	Features	Prognosis
<i>Ductal carcinoma in situ (DCIS)</i>	Does not usually present as a palpable mass	Malignant cells in ducts with no invasion of the basement membrane; incidental microcalcifications on mammogram; if presents as a mass higher chance of concurrent invasive carcinoma	Majority do well
<i>Invasive ductal carcinoma (IDC)</i>	Firm, immobile, discrete mass, nipple retraction, painless	Malignant cells in ducts with stromal invasion and microcalcifications, most common form of invasive breast cancer	Dependent on stage
<i>Invasive lobular carcinoma (ILC)</i>	Firm, immobile, discrete mass, nipple retraction, painless, frequently bilateral	Malignant cells in breast lobules with insidious infiltration, more responsive to hormonal therapy; higher risk of bilateral disease	Dependent on stage
<i>Mucinous carcinoma</i>	Gelatinous well-circumscribed mass	Well-circumscribed mass, slow growth, more common in elderly	Poor
<i>Inflammatory carcinoma</i>	Inflamed, tender, warm, erythematous breast, peau d'orange	Carcinoma that has infiltrated the subdermal lymphatics, rapid progression, angioinvasive behavior	Poor
<i>Phyllodes tumor</i>	Mobile, slow-growing, firm, rubbery, and large; patients often transient or immigrants	Overgrowth of the fibrous component of the tumor pushes the tumor out ("Fibrous outgrowth in Phyllodes"); tissue diagnosis needed; can be benign but postmenopausal women have an increased potential for progressing to a malignant form	Poor

## What Is the Most Likely Diagnosis for This Patient?

Invasive breast cancer is the most likely diagnosis in a postmenopausal woman with a new palpable breast mass that is non-tender, hard, ill defined, immobile, and in the upper outer quadrant. In addition, she has other risk factors for breast cancer including family history in a first-degree relative and early menarche. Most women detect breast masses in the shower or after trauma to the chest, which brings attention to a palpable mass.

## History and Physical

### What Features on Physical Examination Are Suggestive of Breast Cancer?

Physical exam findings of benign breast masses can be hard to differentiate from cancer, since a normal variant of breast tissue can feel to be nodular. A careful inspection for asymmetry, skin changes, and nipple discharge (or crusting) should be done for each patient reporting a newly found breast mass. A bimanual examination of the breasts should then be performed with the patient in a supine position, with the ipsilateral arm raised above her head, palpating for any obvious masses. A single dominant lesion that is hard, immobile, and with irregular borders is suspicious for breast cancer. The cervical, supraclavicular, infraclavicular, and axillary nodes should also be examined. Enlarged, firm, immobile, and/or matted lymph nodes suggest disseminated cancer.

### What Are the Risk Factors for Breast Cancer?

The most important risk factors for breast cancer are female gender, increasing age, and a family history of premenopausal breast cancer. In particular, a family history of breast cancer in males or premenopausal women, bilateral breast cancer, a history of ovarian cancer, and multiple relatives with cancer should prompt investigation for the presence of a gene mutation. The majority of inherited breast cancers are associated with BRCA1 or BRCA2 gene mutations. Other important risk factors associated with a slightly higher risk of developing breast cancer include diethylstilbestrol (DES) exposure, early menarche, nulliparity or childbirth after age 30, and/or late menopause. Table 3.1 shows the relative risk of developing breast cancer for certain risk factors.

**Watch Out**

Increased lifetime exposure to estrogen is a common theme shared by most of the risk factors for breast cancer.

**Table 3.1** Relative risk (RR) for breast cancer

Low (<2 RR)	Moderate (2–4 RR)	High risk (>4 RR)
Age at menarche < 12	Age at first birth > 30	BRCA1/BRCA2 mutation
Age at menopause > 55	Mother or sister with breast cancer	Age > 70
Nulliparity	Previous breast cancer	
Obesity	Radiation exposure	
Hormone replacement therapy		

### What Are the Different Types of Nipple Discharge and What Is the Differential Diagnosis for Each?

Nipple discharge is categorized as normal milk production (lactation), physiologic nipple discharge, or pathologic nipple discharge. Benign nipple discharge tends to be clear, bilateral, and multiductal. Physiologic discharge can be related to post-lactation (up to 2 years following birth), fluctuating hormone levels (puberty and menopause), or nipple stimulation. Pathologic nipple discharge can be due to medical conditions such as prolactinoma, hypothyroidism (thyroid-releasing hormone stimulates prolactin), Cushing's disease, or medications (e.g., antipsychotics, cimetidine, spironolactone). A common cause of pathologic nipple discharge (unilateral, bloody) is a papilloma, which is a tumor growing from the lining of the breast duct. Nevertheless, malignancy can be found in up to 15 % of patients that present with nipple discharge. Cancer is more likely if the discharge is bloody, spontaneous, unilateral, uniductal, associated with a breast mass, or occurs in women over 40.

## Pathology/Pathophysiology

### What Histologic Features of Fibrocystic Changes Are Associated with Increased Risk for Cancer?

Most cases of fibrocystic-related changes are benign, but certain features place patients at an increased risk for invasive carcinoma in both breasts. Apocrine metaplasia has no increased risk for cancer. Ductal hyperplasia or sclerosing adenosis doubles the risk of cancer development. Atypical hyperplasia has the highest risk for cancer.

### What Is the Pathophysiology of "Peau d' Orange"?

Peau d'orange is derived from French translation (orange skin). When lymph drainage in the breast is compromised by a tumor, it can result in edema expanding the interfollicular dermis, producing characteristic dimples which resemble the texture and appearance of orange peels. When deeper subcutaneous layers are involved, it can also cause pitting. This finding is most commonly seen in inflammatory carcinoma. A full-thickness, punch biopsy of the dermis is essential for definitive diagnosis.

## **What Is the Pathophysiology of Nipple Retraction?**

The suspensory ligaments of the breasts are called Cooper's ligaments. When a breast tumor infiltrates these ligaments, it can retract the skin, often at or around the nipples.

---

## **Workup**

### **What Is the Triple Test for a New Breast Mass?**

The "triple test" is a clinical tool that should be applied to all newly detected breast masses. This includes careful physical examination, imaging, and tissue sampling, with each test classified as benign (1 point), suspicious (2 points), or malignant (3 points). A range from 3 to 9 can help stratify patients into groups that are likely benign to a high likelihood of malignancy.

### **How Does the Age of the Patient Affect the Workup of a New, Palpable Breast Mass?**

The recommended imaging depends on the age of the patient. The breasts of younger women consist of dense, fibrous tissue, and as such, mammography is not as useful in detecting abnormalities. In addition, most breast masses in women under 30 are benign, so it is best to avoid unnecessary radiation. Therefore, ultrasound is the first line of imaging in a woman who is pregnant or less than 30 years old with focal breast findings. Ultrasound can differentiate a cystic mass from a solid mass and can be used for needle-guided aspiration if indicated. If the mass is a simple cyst, it can be observed. If the cyst is painful or enlarging, it should be aspirated. If the fluid is bloody, it should be sent for cytology. If the mass is solid, a biopsy should be performed. The diagnostic procedure of choice is core needle biopsy rather than surgical biopsy. Breast magnetic resonance imaging (MRI) is not indicated for the workup of a new breast mass, but is reserved for diagnostic dilemmas. Note that breast MRI has a high false-positive rate.

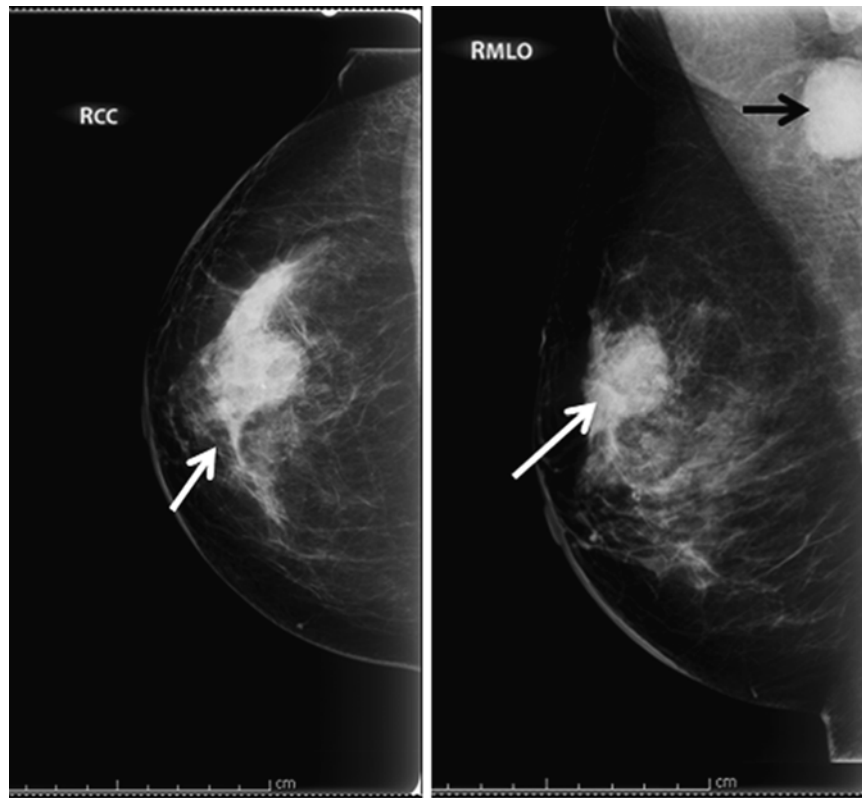
### **What Imaging Is Recommended for Working Up a New Breast Mass in Women Over 30?**

A diagnostic mammogram should be the first test ordered in a woman over the age of 30 with a new breast mass to better characterize the mass, identify other non-palpable lesions in the affected breast, as well as examine the contralateral breast. Certain mammographic features such as asymmetry, clustered pleomorphic calcification, increasing density, or a new mass with irregular borders or spiculation are suggestive of malignancy. Once a mass is identified, a core needle biopsy (ultrasound-guided, if necessary) should be performed to exclude cancer, regardless of mammogram results (Fig. 3.1).

### **What Metastatic Work up Is Recommended Following a Diagnosis of Breast Cancer?**

For clinically early stage breast cancer, an extensive metastatic work up is not needed. Laboratory tests are obtained to search for evidence of liver (liver chemistries) or bone (alkaline phosphatase, serum calcium) metastasis. A chest X-ray is obtained to determine the presence of pulmonary metastasis. Routine abdominal and chest CT are not recommended (unless symptomatic or laboratory values or plain chest X-ray are abnormal). Similarly, bone scintigraphy is only obtained if driven by abnormal lab values or the presence of suspicious bone pain. Likewise, the use of brain CT or MRI is symptom-driven (new onset headaches, vision changes, or seizures). PET scan is also not routinely ordered. For those who on physical exam have a clinically advanced breast cancer (stage 3), a more extensive metastatic workup is recommended, including CT of the chest, abdomen, and pelvis, as well as a bone scan.





**Fig. 3.1** Diagnostic mammogram with craniocaudal (CC) view (*left*) and mediolateral oblique (MLO) view (*right*). *White arrows: mass suspicious for malignancy. Black arrow: enlarged axillary lymph node suspicious for malignant involvement*

**Table 3.2** AJCC staging of breast cancer (7th edition)

Stage	T	N	M	5-year survival (%)
0	In situ	N0	M0	100
I	T1N0	N0	M0	100
II	T2, T3	N0	M0	93
	T1 or T2	N1	M0	
III	Any T	N2-N3	M0	72
	T4	Any N	M0	
IV	Any T	Any N	M1	22

Used with permission of the American Joint Committee on Cancer (AJCC), Chicago, Illinois. The original and primary source for this information is the AJCC Cancer Staging Manual, Seventh Edition (2010) published by Springer Science + Business Media

### How Is Breast Cancer Staged Clinically?

The most commonly used staging system (Table 3.2) is the one described by the American Joint Committee on Cancer (AJCC). *T* (tumor) describes the size of the tumor and/or its depth of invasion. *N* (node) describes spread to regional lymph nodes. *M* (metastasis) indicates if the tumor has metastasized remotely.

## **What Are the Different Tumor Markers for Breast Cancer and How Are They Utilized?**

Though tumor markers for breast cancer exist (CA-15-3, CA 27.29, and CEA), they are not used routinely as not all patients with breast cancer have elevated levels. Additionally, these tumor markers have poor sensitivity and specificity making them poor choices for screening tools.

## **What Is a Triple-Negative Breast Cancer?**

This refers to breast cancer that is negative for estrogen (ER), progesterone (PR), and human epidermal growth factor 2 (HER-2) receptors. The fact that these breast cancers do not express the genes for these receptors makes them more difficult to treat with conventional therapy. Tumors that express the genes for ER/PR receptors are favorable because it allows for the option to employ hormonal drugs as adjuvant therapy to treat breast cancer. HER-2 is a protein that is found in approximately 20 % of breast cancer, and anti-HER-2 therapy can help stop proliferation of cancer cells. However, HER-2 positive cancers tend to be more aggressive. Additionally, triple-negative tumors typically are the most common subtype in BRCA 1 carriers, demonstrate high histological grade, occur at a younger age (<40), and are found more commonly in African-American women. Prognosis for triple-negative breast cancer is typically worse, requiring more aggressive therapy.

---

## **Management**

### **What Surgical Options Are Available for Patients with Stage I and II Breast Cancers?**

The two basic options are breast-conserving therapy (BCT), which consists of a lumpectomy (partial mastectomy) and sentinel lymph node biopsy (SLNB), followed by radiation therapy (to decrease the risk of local recurrence) versus simple mastectomy with SLNB only. BCT is typically reserved for stage I and II cancers. Studies have shown that BCT leads to survival rates that are equivalent to that of simple mastectomy, while providing a more cosmetically appealing option for women. It should be noted, however, that although survival is equivalent, BCT carries an increased risk of local recurrence despite the radiation therapy. Following simple mastectomy, radiation therapy to the chest wall is not necessary in the majority of patients.

### **What Are Contraindications to BCT?**

Absolute contraindications are multiple primary tumors in 2 or more quadrants, diffuse malignant-appearing microcalcifications throughout the breast, previous history of chest wall radiation, positive surgical margins despite repeat excision, and early pregnancy (as radiation cannot be given during pregnancy). However, it is possible to perform BCT in the third trimester of pregnancy and then receive radiation therapy after childbirth. Relative contraindications are a history of collagen vascular disease and large tumors in a small breast in which adequate margins would result in a cosmetically undesired appearance.

### **Can the Nipple and Breast Skin Be Spared During a Simple Mastectomy?**

Yes, two other options for tumor resection are skin-sparing and nipple-sparing mastectomy. These approaches lead to less scarring and a more cosmetically appealing breast reconstruction. There are concerns that leaving behind the nipple areolar complex may increase the risk of developing a new breast cancer or recurrence. This is particularly worrisome in high-risk patients such as those with the BRCA gene. Recent studies suggest that at least in the short term, outcomes are similar to standard mastectomy even in BRCA carriers.

### **What Are the Management Options for Clinically Advanced Stage 3 Breast Cancers?**

Clinically advanced breast cancer (stage 3) includes very large tumors (>5 cm), tumors that have invaded the skin (such as inflammatory breast cancer), or the presence of large matted clinically positive axillary lymph nodes. For these patients,

management must be tailored. If the primary tumor is large, breast conservation is not an option, and the patient will require a simple mastectomy. If there are obvious clinically enlarged and matted lymph nodes, then SLNB is not an option, and the patient will require an ALND. If the patient has both a very large tumor and obvious clinically enlarged axillary nodes, then the patient will require a modified radical mastectomy (mastectomy combined with ALND). If there is diffuse skin invasion such as with inflammatory breast cancer, neoadjuvant (before surgery) chemotherapy is given in order to try to shrink the tumor so as to subsequently be able to attain negative surgical margins.

### **What Is the Premise Behind SLNB?**

A sentinel lymph node is the hypothetical first node or group of nodes from which the lymphatics of the breast drain. The premise behind SLNB is that if the sentinel node(s) is(are) free of metastasis, then other lymph nodes in the axilla will also be disease free, and therefore, there is no need to remove the remaining lymph nodes in the axilla. SLNB is used for staging breast cancers. SLNB is done intraoperatively by identifying, removing, and histologically examining the lymph node to determine if the cancer has spread to the lymph system. A radioactive tracer and/or a blue dye (taken up by lymphatics) are first injected subareolarly. The lymph nodes that are radioactive and/or blue are then considered the sentinel nodes and are removed.

### **Why Does SLNB Need to Be Performed at the Same Time as a Mastectomy and Not Later?**

If a mastectomy is planned, the SLNB needs to be performed at the same time. Once the breast is removed, SLNB is no longer possible as the breast tissue with accompanying lymphatics have been removed.

### **Can There Be More Than One Sentinel Node?**

Yes, in most cases there are 2–4 sentinel nodes.

### **What Do You Do If During SLNB, No Sentinel Lymph Node Lights Up?**

In most cases, the surgeon would proceed to ALND (removing level I and II lymph nodes). Whether to proceed with ALND depends on several factors, including the tumor status (for a low-grade hormone-positive tumor one may forgo ALND) and patient comorbidities (a very elderly patient may also forgo ALND).

### **When Do You Perform Axillary Lymph Node Dissection (ALND)?**

If the sentinel lymph node(s) is (are) positive for metastatic cancer, complete ALND is not necessarily needed. Recent studies have showed the safety of excluding ALND in patients with only 1–2 positive nodes who had undergone breast conservation therapy. Such patients receive radiation to the remaining breast and low axilla, which may obviate the need for ALND. ALND is performed if there are more than two positive sentinel lymph nodes or in patients who underwent mastectomy (as they do not generally receive radiation therapy postoperatively).

### **What Are the Boundaries in the Axilla for Breast Dissection?**

There are 4 boundaries: axillary vein (superior), floor of the axilla (posterior), latissimus dorsi muscle (lateral), and pectoral minor muscle (medial).

## What Are the Boundaries for Lymph Node Levels I–III Dissection?

LN level	Medial	Lateral	Anterior	Posterior
<i>I</i>	Axillary vessels crossing lateral border of pectoralis minor	Medial border of latissimus dorsi	Anterior surface of pectoralis major and latissimus dorsi	Subscapularis
<i>II</i>	Medial border of pectoralis minor	Lateral border of pectoralis minor	Anterior surface of pectoralis minor	Ribs and intercostal muscles
<i>III (Rotter's)</i>	Thoracic inlet	Medial border of pectoralis minor	Posterior surface of pectoralis major	Ribs and intercostal muscles

## What Is the Purpose of Axillary Lymph Node Dissection? Does It Affect Survival?

Axillary lymph node dissection is used for staging of breast cancer; removing the lymph nodes per se has not been shown to improve survival.

## What Are the Options for Hormonal Therapy, and What Is the Premise Behind It?

Cancers that are ER+ or PR+ are candidates for hormonal therapy (Table 3.3). These drugs work by either decreasing the levels of steroid hormones in the body or antagonizing the receptors that promote growth of cancer cells. They are most often used as adjuvant therapy to prevent recurrence.

## What Study Must Be Done Prior to Starting Trastuzumab?

Since there is a high risk of cardiomyopathy in patients receiving trastuzumab, it is recommended that all patients receive an echocardiogram or a MUGA scan to determine their ejection fraction.

## Why Are Aromatase Inhibitors (AI) Only Effective in Postmenopausal Women?

AI work by inhibiting the aromatase enzyme, located in fat tissue, which is responsible for making small amounts of estrogen in postmenopausal women. AI are only effective in women with ovaries that have stopped producing estrogen, which occurs after menopause. The primary source of estrogen for these women is that which is produced in fat cells.

**Table 3.3** Hormonal therapy in breast cancer

Drug	Mechanism	Features
<i>Tamoxifen</i>	Blocks estrogen receptors	Acts like estrogen in some tissues (endometrial) but antiestrogen in others (selective estrogen receptor modulator or SERM), can be used to decrease incidence in high-risk women, increases risk for endometrial cancer and blood clots, taken for 5–10 years following surgery, can cause fatigue, hot flashes, and vaginal dryness
<i>Raloxifene</i>	Blocks estrogen receptors	Decreased risk of endometrial cancer when compared to tamoxifen, as effective as tamoxifen in reducing incidence of invasive breast cancer in high-risk postmenopausal women but does not reduce incidence of DCIS or LCIS
<i>Fulvestrant</i>	Blocks estrogen receptors	Works systemically (not a SERM), severe osteoporosis risk, only approved for postmenopausal women that have failed therapy with tamoxifen
<i>Anastrozole</i>	Aromatase inhibitor	Decreases estrogen levels, only effective in postmenopausal women, can be used in addition to tamoxifen, no risk of endometrial cancer, lesser risk of blood clots when compared to SERMs
<i>Trastuzumab</i>	Monoclonal antibody blocking HER-2 receptors	Reduces recurrence, improved overall survival in late-stage breast cancers, expensive, risk of cardiomyopathy

**Table 3.4** Chemotherapeutic regimens for breast cancer

Class	Representatives	Mechanism	Risks
<i>Anthracyclines</i>	Doxorubicin, epirubicin, and idarubicin	Inhibits DNA/RNA synthesis, inhibits topoisomerase II, halting cell growth and division	Hair loss, vomiting, cardiomyopathy
<i>Alkylating agent</i>	Cyclophosphamide	Promotes DNA damage by alkylating guanine bases	Risk of leukemia, cystitis, and bladder cancer
<i>Antimetabolites</i>	Methotrexate and 5-FU	Interferes with DNA synthesis, halting cell growth and division	Hair loss, vomiting, bone marrow suppression
<i>Taxanes</i>	Paclitaxel and docetaxel	Inhibits mitotic phase in cell cycle	Neuropathy

### Does Everyone with Breast Cancer Require Chemotherapy?

Most patients with breast cancer receive chemotherapy, but there are exceptions. Patients with noninvasive breast cancers (carcinoma in situ) do not benefit from systemic chemotherapy because the cancer cells have little risk for dissemination. In addition, certain very small invasive cancers (<1 cm) with favorable tumor markers and a negative SLNB may not benefit from chemotherapy. In these patients with favorable tumor characteristics, the Oncotype DX breast cancer test is performed. This test examines the individual patient's tumor characteristics at the molecular level, enabling the clinician to predict the likelihood of chemotherapy benefit as well as recurrence in early stage breast cancer.

### What Are the Most Common Chemotherapy Regimens?

Many options are available and should be tailored to the patient's type of breast cancer and personal medical history. The most commonly used drugs fall into four categories (Table 3.4).

### What Are the Options for Breast Reconstruction? What Is the Timing?

Women undergoing a mastectomy may choose to have additional breast reconstruction surgery to retain their breast shape. The options are to perform an immediate or delayed reconstruction. Immediate reconstruction can be done with an autologous tissue flap (transverse rectus abdominal muscle or latissimus dorsi) or with a temporary tissue expander. The tissue expander is later replaced by a permanent implant once the skin is sufficiently stretched. If the patient desires an autogenous reconstruction but requires postoperative radiation therapy, then the reconstruction is delayed (as the radiation may compromise the flap). On the other hand, tissue expanders can be placed immediately, regardless of whether radiation therapy is needed. The decision to perform a delayed reconstruction is based on several factors including patient preference, surgeon availability, and patient risk factors.

## Complications

### What Nerves Are at Risk for Damage During Dissection?

Nerve	Location	Muscle innervated	Deficit if damaged
<i>Long thoracic</i>	Travels along midaxillary line	Serratus anterior	Upward rotation, abduction, and weak elevation of the scapula (winged scapula)
<i>Thoracodorsal</i>	Travels lateral to long thoracic nerve	Latissimus dorsi	Weak extension, adduction, and internal rotation of shoulder joint
<i>Medial pectoral</i>	Travels lateral to or through the pectoral minor muscle and lateral to the lateral pectoral nerve	Pectoral minor and major	Weak internal rotation of humerus
<i>Lateral pectoral</i>	Travels medial to the medial pectoral nerve	Pectoral major	Weak flexion, adduction, and internal rotation of humerus

## What Is the Most Morbid Complication of Lymph Node Dissection?

Lymphedema is the most morbid complication, resulting from the disruption of the normal flow within the lymph system. ALND is associated with a greater risk of lymphedema than SLNB. Lymphedema can lead to significant pain and disability in the affected arm. Patients with lymphedema also have an increased risk of infection owing to the inability to properly mobilize the immune system. In chronic cases, patients may develop lymphangiosarcoma (*Stuart Treves syndrome*), which has a poor prognosis even after limb amputation. For these reasons, SLNB is useful as it prevents unnecessary ALND.

---

## Areas You Can Get in Trouble

### Confusing Inflammatory Breast Carcinoma with Cellulitis

Inflammatory breast carcinoma is characterized by carcinoma in subdermal lymphatics producing an inflamed, swollen breast with no discrete mass. These patients are often initially misdiagnosed as having acute mastitis or cellulitis and treated with a course of antibiotics. The prognosis is poor because cancer cells have already infiltrated the lymphatics. Patients are initially treated with chemotherapy which is followed by mastectomy and then radiation.

### Ignoring a Breast Mass During Pregnancy

Traditionally, breast cancer in pregnancy has been rare. However, it is expected to become more common since the population of women choosing to have children later in life is increasing and the risk of breast cancer increases with age. Pregnant women with breast cancer are often diagnosed at later stages. This is a result of denser breast tissue which can make breast masses harder to visualize on mammogram. In addition, the hormonal changes that take place during pregnancy can obscure any signs or symptoms that may have otherwise prompted a patient to seek a doctor's advice. A pregnant patient's breast is larger, more tender, and lumpier. Delayed diagnosis remains to be the biggest challenge in dealing with breast cancer in pregnancy. In general, women can safely be given chemotherapy during the second trimester. If a patient is diagnosed during the 3rd trimester and requires chemotherapy, it is delayed until after she gives birth. Radiation and hormonal therapy are never recommended during pregnancy.

### Ignoring a Breast Mass in an Elderly Male

Men have breast tissue and as such can also get breast cancer. Breast cancer in males is rare (1 % of all breast cancers) with most cases identified as invasive ductal carcinoma. DCIS is less common as most men present late, with a palpable mass. Since lobules are not fully formed in men, LCIS and lobular breast cancer are extremely rare. The biggest risk factor is age, with most men diagnosed between 65 and 70 years of age. High estrogen levels promote breast cell growth which can lead to cancer. Hormonal medications, obesity, alcohol abuse, cirrhosis, and Klinefelter syndrome can all lead to high serum estrogen levels. Additional risk factors include family history of breast cancer, genetic defects (BRCA-2 is a stronger risk factor in men), and radiation therapy to the chest wall (e.g., Hodgkin's disease). The impression that breast cancer in males has a worse prognosis when compared to women may be a result of diagnosing men at later stages of the disease. However, the overall survival is similar to that of women with the same stage of breast cancer.

#### Watch Out

Gynecomastia is not a risk factor for male breast cancer.

## Areas of Controversy

### Should Mastectomy Be Performed in Patients with Stage 4 Breast Cancer?

The prognosis for stage 4 breast cancer is poor. Given that the tumor has already spread to other organs, the benefit of removing the primary tumor is questionable. Nevertheless, several studies suggest that mastectomy in select patients with stage 4 breast cancer provides some survival benefit.

---

## Summary of Essentials

### History and Physical

- A new breast mass in postmenopausal women is cancer until proven otherwise
- Breast cancer: firm with irregular borders
- Nipple discharge that is bloody, spontaneous, unilateral, uniductal, associated with a breast mass, or occur in women over 40 are more suspicious for cancer
- Risk factors: family history, genetic defects (BRCA1-2), obesity, early menarche, late menopause, nulliparity or child-birth after age 30, alcohol, and radiation to the chest before age 30

### Etiology/Pathophysiology

- Fibrocystic disease is the most common cause of a palpable breast mass
- 1 in 8 women in the United States will develop breast cancer
- The most common malignant neoplasm of the breast is invasive ductal carcinoma
- The most common breast neoplasm in premenopausal women is fibroadenoma
- Triple-negative breast cancer is one that is negative for estrogen, progesterone, and HER-2 receptors

### Diagnosis

- Apply triple test (physical exam, imaging, tissue sample) to all new breast masses
- Imaging
  - $\leq 30$  years old ultrasound
  - $> 30$  years old mammogram plus ultrasound
- Tissue diagnosis is indicated for any clinically suspicious mass regardless of imaging findings
- FNA cannot accurately differentiate in situ from carcinoma thus core needle biopsy is better
- Metastatic workup for clinically early stage breast cancer: CXR, liver chemistries, and alkaline phosphatase
  - Bone scan, CT abdomen, chest, and brain only if suspicion for metastasis is high based on lab tests or clinical Stage 3 disease or symptoms

### Management

- For early stage
  - Lumpectomy, SLNB, and radiation (BCT)
    - Equal in terms of survival
    - Higher local recurrence rate
  - Simple mastectomy with SLND
    - No radiation if early stage, but will need radiation if more advanced
- SLNB
  - Average 2–4 sentinel nodes
  - Less lymphedema than ALND

- If positive for metastasis may need ALND
  - Level 1 and 2 nodes
- For Stage III cancers, treatment must be individualized
  - For inflammatory breast cancer, neoadjuvant chemotherapy followed by modified radical mastectomy, then radiation therapy
  - For large tumors, BCT not an option
  - For clinically positive axillary lymph nodes, SLNB not an option, proceed to ALND
- Drugs
  - Trastuzumab for HER-2 positive
  - Tamoxifen for premenopausal estrogen receptor positive
  - Anastrozole (aromatase inhibitor) for postmenopausal estrogen receptor positive
  - Most patients receive chemotherapy
    - Exception: small (<1 cm) tumors with favorable hormonal and molecular characteristics and SLNB negative

## Complications

- Axillary lymph node dissection can lead to significant morbidity
  - Lymphedema
  - Nerve injury (long thoracic, thoracodorsal, medial, and lateral pectoral nerves)

## Watch Out

- Men can get breast cancer (usually invasive ductal carcinoma)
- Do not confuse inflammatory breast cancer with cellulitis
- Do not ignore breast masses during pregnancy or in younger women
- Always obtain a tissue diagnosis if there is a palpable breast mass
  - Do not let a normal mammogram fool you

---

## Suggested Reading

- Anderson WF, Althuis MD, Brinton LA, Devesa SS. Is male breast cancer similar or different than female breast cancer? *Breast Cancer Res Treat.* 2004;83:77.
- Bauer K, Brown M, Cress RD, Parise CA, Caggiano V. Descriptive analysis of estrogen receptor (ER)-negative, progesterone receptor (PR)-negative, and HER2-negative invasive breast cancer, the so-called triple-negative phenotype: a population-based study from the California cancer Registry. *Cancer.* 2007;109(9):1721–8.
- Edge SB, Byrd DR, Compton CC, et al., editors. *AJCC (American Joint Committee on Cancer). Cancer staging manual.* 7th ed. New York: Springer; 2010. p. 347.
- Giuliano AE, McCall L, Beitsch P, et al. Locoregional recurrence after sentinel lymph node dissection with or without axillary dissection in patients with sentinel lymph node metastases: the American College of Surgeons Oncology Group Z0011 randomized trial. *Ann Surg.* 2010;252:426.
- Giuliano AE, Hunt KK, Ballman KV, et al. Axillary dissection vs no axillary dissection in women with invasive breast cancer and sentinel node metastasis: a randomized clinical trial. *JAMA.* 2011;305:569.
- Kalager M, Zelen M, Langmark F, Adami HO. Effect of screening mammography on breast-cancer mortality in Norway. *N Engl J Med.* 2010;363:1203.
- Lucci A, McCall LM, Beitsch PD, et al. Surgical complications associated with sentinel lymph node dissection (SLND) plus axillary lymph node dissection compared with SLND alone in the American College of Surgeons Oncology Group Trial Z0011. *J Clin Oncol.* 2007;25:3657.
- Nelson HD, Tyne K, Naik A, et al. Screening for breast cancer: an update for the U.S. Preventive Services Task Force. *Ann Intern Med.* 2009;151:727.
- Sullivan T, Raad RA, Goldberg S, et al. Tubular carcinoma of the breast: a retrospective analysis and review of the literature. *Breast Cancer Res Treat.* 2005;93:199.



Areg Grigorian, Christian de Virgilio, and Danielle M. Hari

A 40-year-old woman sees her doctor for an annual physical exam. She is healthy and does not take any medications. She has a family history of breast cancer. Her physical examination is normal with no palpable breast masses. Her doctor recommends that she gets a screening mammography as part of her routine health maintenance screening, which she agrees to do. A week later, she gets a call from her doctor to inform her that she had an abnormal mammogram (BI-RADS 4). Her left breast was found to have multiple clusters of fine linear microcalcifications, with the largest cluster measuring 2 mm in diameter.

---

A. Grigorian, MD (✉)

Department of Surgery, University of California, Irvine, 333 City Blvd West, Suite 1600, Route. 81, Orange, CA 92868, USA  
e-mail: [agrigori@uci.edu](mailto:agrigori@uci.edu)

C. de Virgilio, MD

Department of Surgery, Harbor-UCLA Medical Center, 1000 W. Carson Street, Torrance, CA 90509, USA  
e-mail: [cdevirgilio@labiomed.org](mailto:cdevirgilio@labiomed.org)

D.M. Hari, MD

Division of Surgical Oncology, Department of Surgery, Harbor-UCLA Medical Center, 1000 W. Carson Street, Box 25, Torrance, CA 90509, USA  
e-mail: [dhari@dhs.lacounty.gov](mailto:dhari@dhs.lacounty.gov)

## Diagnosis

### What is the Differential Diagnosis for an Abnormal Mammogram in the Absence of a Palpable Breast Mass?

#### Select benign calcifications

<i>Skin calcifications</i>	May be secondary to dermatitis or hygiene products (e.g., deodorants, ointments)
<i>Vascular calcifications</i>	Linear or parallel tracks; may be associated with underlying vascular disease
<i>Coarse or “popcorn” like</i>	Dystrophic in origin and usually associated with underlying fibroadenoma
<i>Round and punctate calcifications</i>	Associated with fibrocystic changes of the breast, adenosis, and skin calcifications
<i>Eggshell or rim calcifications</i>	Calcifications that appear to be deposited on the surface of a sphere; can be seen in fat necrosis or fibrocystic changes of the breast
<i>Dystrophic calcifications</i>	Coarse, irregular shaped; seen in irradiated breast or following trauma

#### Suspicious calcifications

<i>Amorphous calcifications</i>	Without a clearly defined shape or form; small and hazy appearance
<i>Coarse heterogeneous</i>	Irregular, conspicuous calcifications typically larger than 0.5 mm; associated with benign (e.g., fibroadenoma, fibrosis) and malignant conditions (e.g., DCIS)

#### High probability of malignancy

<i>Fine pleomorphic</i>	Classified as BI-RADS 5; typically associated with DCIS
<i>Fine linear/linear branching</i>	Represent casts of the ducts (“casting” type) in which they lie; often associated with comedo subtype of intraductal carcinoma, typically high grade or poorly differentiated

### What Is the Most Likely Diagnosis?

Fine, linear calcifications on mammogram is highly suggestive of malignancy. Such calcifications form in areas of necrosis and in a linear pattern. This is likely from dead cancer cells lining the ducts that outgrow their blood supply. Thus the most likely diagnosis is malignancy. Since the lesion is small and there is no palpable mass, it most likely represents DCIS as opposed to invasive ductal carcinoma. In addition, she has a family history of breast cancer which increases her risk.

## Screening

### What Are the Recommendations for Breast Cancer Screening?

The age and frequency of screening is controversial. Some cancer societies recommend screening at age 40, whereas others recommend screening starting at age 50 in normal-risk patients. Similarly, the ideal interval is controversial, with some recommending annual screenings and others biennially. At what age screening should stop is also unclear. Some agencies recommend that screening end at age 74 (US Preventive Services Task Force). Others recommend “continuing for as long as a woman is in good health” (American Cancer Society). In addition to mammography, the American Cancer Society recommends clinical breast examination every 3 years from age 20–39 and annually thereafter. The US Preventive Services Task Force sites insufficient evidence to recommend clinical breast examination.

### What Are the Risks of Mammography?

Mammograms utilize small doses of radiation, which over time, can place patients at an increased risk for cancer. However, for most women over 50, the benefits of regular mammograms outweigh any potential radiation risks. Additionally, mammograms can miss up to 20 % of cancers if they are too small or in areas that are difficult to view. On the other end of the spectrum, it may detect cancers that would have otherwise never led to symptoms, subjecting the patient to the adverse effects of intervention or additional testing (e.g., biopsy). Lastly, mammograms are not always accurate. Mammographic

findings are heavily dependent on the technique used in attaining the images, the experience of the radiologist evaluating the images, and the breast density of the patient.

### Why Is Mammography Not Useful in Young Women (<30 Years Old)?

Younger women tend to have denser breast tissue due to a decreased level of fat. Dense breasts make it difficult to detect abnormal calcifications or masses. Nevertheless, masses may still be detected with mammograms.

## History and Physical

### What Is the Gail Risk Model?

The most commonly implemented risk assessment model is the Breast Cancer Risk Assessment Tool (BCRAT), also known as the Gail model. The BCRAT is a mathematical model used to calculate the risk of developing breast cancer. The model considers factors such as age, age at menarche, reproductive history, family history in first-degree relatives, and prior biopsies. One disadvantage of the model is that it can underestimate breast cancer risk in women with a strong family history of breast or ovarian cancer that does not involve first-degree relatives; if this is the case, alternative risk models should be implemented.

## Pathophysiology

### What Is One Quick Feature to Help Differentiate Between Benign and Malignant Conditions on Mammography?

Larger calcifications (macrocalcifications) are almost always benign, while smaller calcifications (microcalcifications) are more frequently seen in patients with breast cancer.

### Compare and Contrast DCIS and LCIS

Ductal carcinoma in situ (DCIS) is characterized by malignant epithelial cells within the mammary ductal system, without invasion into the surrounding stroma (Table 4.1). DCIS has several histological patterns, including comedo with prominent central necrosis, cribriform with back to back glands, and papillary. Comedo-type DCIS is typically high grade and associated

**Table 4.1** DCIS versus LCIS

	DCIS	LCIS
<i>Presentation</i>	Incidental microcalcifications on mammography	Incidental finding on histopathology
<i>Location</i>	Ducts, multifocal	Lobules
<i>Pattern</i>	Comedo (prominent necrosis in the center of the involved spaces), micropapillary, cribriform (back to back glands)	Solid
<i>Axillary metastasis</i>	Present in 1–13 % of patients	Usually absent
<i>Incidence of concurrent invasive carcinoma</i>	Higher	Very low
<i>Risk of subsequent invasive carcinoma</i>	Higher	Lower
<i>Treatment</i>	Excision to negative margin; consider sentinel lymph node biopsy in select group	If found on excisional biopsy, then close observation; if found on core needle biopsy, excise area to rule out adjacent cancer; possibly tamoxifen

with a worse prognosis. DCIS is often multifocal and can be associated with a concurrent invasive carcinoma. DCIS lesions have a high risk of subsequent invasive carcinoma at the site of the DCIS.

LCIS is characterized by malignant epithelial cells that arise from the lobules and terminal ducts of the breast. Unlike DCIS, it is not a premalignant lesion, but rather is a marker for the development of future ipsilateral as well as contralateral invasive breast cancer (ductal or lobular). It is almost always incidentally found on a breast biopsy that is performed for some other reason. LCIS itself is not thought to progress to invasive lobular carcinoma so there is no role for resecting it to attain clear margins. Two forms of LCIS have been associated with microcalcifications on mammography: classic form with small uniform cells versus the pleomorphic form with larger cells. The relative risk of developing an invasive cancer in women with LCIS is approximately 2× higher compared to women without LCIS.

---

## Workup

### How Are Mammograms Used in Staging Breast Lesions?

Mammogram abnormalities include masses, microcalcifications, and asymmetry. The radiologist summarizes the mammographic findings using the American College of Radiology's Breast Imaging Reporting and Data System (BI-RADS) final assessment (Table 4.2), which standardizes the reporting of mammographic findings and indicates the relative likelihood of a normal, benign, or malignant diagnosis. It is important to note that the BI-RADS category only refers to the imaging findings and does not take clinical information into account. Clinically suspicious masses in a patient with a low BI-RADS score still require biopsy (Figs. 4.1 and 4.2).

### What Is the Next Step in Management for the Above Patient?

An abnormal mammogram requires further workup, particularly in BI-RADS 4 or 5. Further workup could include additional diagnostic mammographic views, ultrasonography, and stereotactic core biopsy. This technique is used for non-palpable breast lesions and uses a needle guided by a computer with imaging in two planes.

---

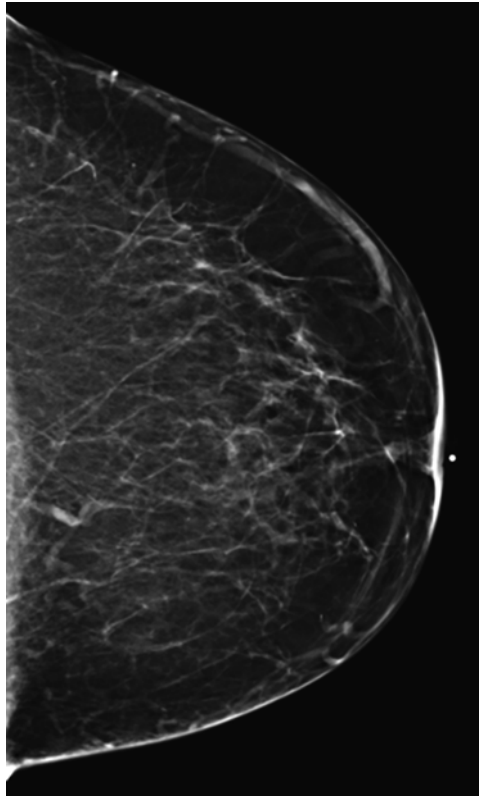
## Management

### What Is the Next Step If the Stereotactic Biopsy Demonstrates DCIS?

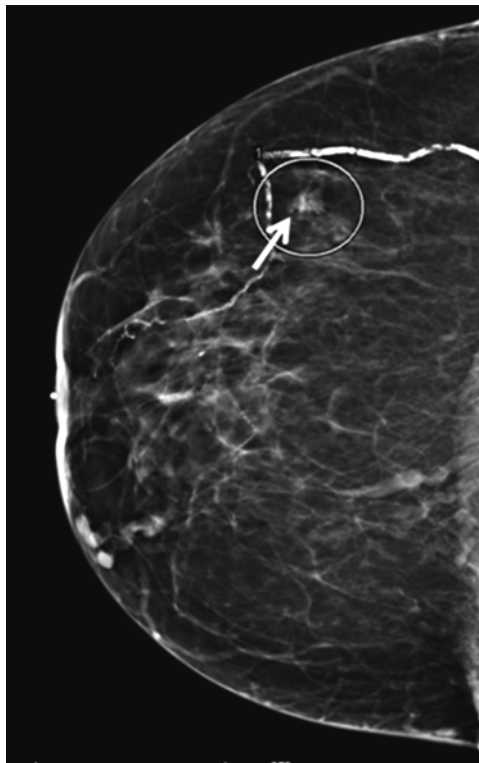
DCIS, if left unresected, will often progress to invasive ductal cancer. Thus the mainstay of DCIS treatment is lumpectomy (excision of entire lesion with negative margins). After excision, the margins of the specimen are inked, and the pathologist must confirm that there is no tumor on the ink. If there is tumor on the ink, then the area must be re-excised. If after re-excision the margin is again positive, a re-excision if possible or a mastectomy is recommended. The goal is to reduce the risk of invasive ductal cancer in that breast.

**Table 4.2** BI-RADS

BI-RADS category	Interpretation
0	Incomplete assessment; needs additional imaging and/or old imaging comparison
1	Negative; continue screening based on current screening guidelines
2	Benign findings; continue screening based on current screening guidelines
3	Probably benign; recommend shorter interval follow-up (e.g., diagnostic mammography and/or ultrasound at 6-month intervals for 1 year)
4	Suspicious abnormalities; biopsy should be considered
5	Highly suggestive of malignancy; biopsy recommended



**Fig. 4.1** Normal screening mammogram, craniocaudal (CC) view



**Fig. 4.2** Abnormal screening mammogram (CC view) showing 1 cm foci of microcalcifications in the upper outer quadrant BI-RADS (category 0)

## What Is the Next Step If the Stereotactic Biopsy Demonstrates LCIS?

Unlike DCIS, LCIS is a risk factor for developing invasive cancer in either breast. However, if LCIS is found on core biopsy, an excisional biopsy is still recommended to rule out the presence of adjacent cancers that are sometimes found. This differs from lumpectomy in that only a conservative amount of tissue is removed to get a better sample of the area (unlike the larger portion removed during lumpectomy). The goal is not to obtain “clear margins” (as you would in DCIS), but to make sure there is not a nearby cancer. If the excisional biopsy removes the mammographically suspicious area and the final path shows only LCIS, then no further surgery is recommended (even if LCIS is found at the margins). This is because LCIS is a marker for an increased risk of breast cancer (lobular or ductal) in *either* breast. Treatment planning for LCIS involves carefully monitoring the patient for the development of invasive cancer with serial mammograms and physical exam (most common). The National Surgical Adjuvant Breast and Bowel Project - Prevention-1 (NSABP-P-1) trial demonstrated that the use of tamoxifen in women with LCIS decreased the risk of developing invasive breast cancer by 49 %. Bilateral prophylactic mastectomy is sometimes considered as an alternative for high-risk women.

## What If the Stereotactic Biopsy Shows Invasive Ductal Carcinoma?

The options are then to perform lumpectomy (to negative margins) with sentinel lymph node biopsy (SLNB) generally followed by radiation therapy to the remainder of the breast or mastectomy with SLNB (without radiation).

## Can You Get Lymph Node Metastasis with DCIS?

DCIS, is by definition, confined within the mammary duct and has not breached the basement membrane allowing it to enter surrounding tissue or the lymph system. However, when DCIS is multifocal, comedo subtype, or high grade, it may have an invasive component that is missed and subsequently result in lymph node metastasis. This occurs in a small number of DCIS cases. As such, SLNB is generally not recommended for DCIS. However, for certain high-risk lesions such as extensive microcalcifications on mammogram or DCIS associated with a palpable mass, SLNB is considered. It is also recommended if the patient chooses a mastectomy for treatment.

---

## Areas of Controversy

### Does Screening Mammography Actually Reduce Mortality from Breast Cancer?

A recent (though highly controversial) study suggests that screening mammography may not be effective in reducing mortality from breast cancer. A 25-year longitudinal randomized screening trial showed that mortality rates were similar in women that received a mammogram every 5 years and those that did not. The long held belief that mammography is beneficial can be attributed to lead-time bias in which early recognition of breast cancer increases the perceived survival time without affecting the course of the disease.

### Prophylactic Bilateral Mastectomy

Women with strong family histories for breast cancer, genetic mutations (BRCA 1 or 2), radiation therapy to the chest before age 30, or conditions that place them at increased risk for developing invasive cancer may consider prophylactic surgery to remove both breasts. LCIS is a marker for increased risk of developing cancer in either breast. Patients with LCIS and a family history of breast cancer could be considered suitable candidates for prophylactic bilateral mastectomy. Patients without a family history may not benefit from such aggressive intervention because of such a low risk of progression to cancer.

---

## Summary of Essentials

### Diagnosis

- DCIS and LCIS do not typically present as palpable masses
- Benign calcifications: skin, vascular, popcorn-like, plasma cell mastitis, lucent-centered, eggshell or rim, milk of calcium, suture, or dystrophic
- Suspicious calcifications: fine, linear, branching, pleomorphic microcalcifications

### Screening

- Age and frequency of screening is controversial
- Some cancer societies recommend screening in normal-risk women starting at age 40, while others recommend starting at age 50
- ACS recommends clinical breast examination every 3 years from age 20–39 and annually thereafter

### History and Physical

- GAIL risk model to help calculate risk of developing breast cancer

### Etiology/Pathophysiology

- Macrocalcifications are almost always benign while microcalcifications are more concerning for cancer
- DCIS can progress to invasive cancer if left unresected
  - Can be multifocal
  - Can be associated with a concurrent invasive carcinoma
- LCIS is only a marker for the development of future ipsilateral as well as contralateral invasive breast cancer (either lobular or ductal)

### Workup

- BI-RADS (0–5) is a standardized summary of mammographic findings
- BI-RADS 3 is probably benign (2 % chance of cancer); BI-RADS 4 is suspicious (15–30 %)
- Stereotactic biopsy for 4 or 5

### Management

- DCIS: lumpectomy to negative margin
- LCIS (found on excisional biopsy): depends on risk factors; low risk treat with observation or tamoxifen, while high risk can be offered prophylactic bilateral mastectomy
- LCIS found on core biopsy requires excisional biopsy to rule out adjacent or associated ductal or lobular cancer

---

## Suggested Reading

- Chala LF, de Barros N, de Camargo MP, et al. Fat necrosis of the breast: mammographic, sonographic, computed tomography, and magnetic resonance imaging findings. *Curr Probl Diagn Radiol.* 2004;33:106–12.
- Demetri-Lewis A, et al. Breast calcifications: the focal group. *Am J Roentgenol.* 2012;198:W325.

- Fisher B, Costantino JP, Wickerham DL, Redmond CK, Kavanah M, Cronin WM, Vogel V, Robidoux A, Dimitrov N, Atkins J, Daly M, Wieand S, Tan-Chiu E, Ford L, Wolmark N, other NSABP investigators. Tamoxifen for prevention of breast cancer: Report of the National Surgical Adjuvant Breast and Bowel Project P-1 Study. *J Natl Cancer Inst.* 1998;90(18):1371–88.
- Kuerer HM, Albarracin CT, Yang WT, et al. Ductal carcinoma in situ: state of the science and roadmap to advance the field. *J Clin Oncol.* 2009;27:279.
- Miller AB, et al. Twenty five year follow-up for breast cancer incidence and mortality of the Canadian National Breast Screening Study: randomised screening trial. *BMJ.* 2014;348:g366.
- Muttarak M, et al. Breast calcifications: which are malignant? *Singapore Med J.* 2009;50:907.



---

**Part III**

**Cardiothoracic**

Peyman Benharash, Section Editor

Areg Grigorian, Paul N. Frank, and Peyman Benharash

A 68-year-old male presents to the emergency room with a 4 hour history of severe chest discomfort, cold sweats, and nausea. The pain is described as heavy pressure over the entire chest and is 9/10 in intensity. He is mildly short of breath and states that the pain is radiating to his neck. He denies any back pain at this time. He has noted reduced exercise tolerance over the past few months, however, only being able to walk for ½ block before having to stop to catch his breath. He is able to lie flat without any shortness of breath. He smokes about one pack of cigarettes per day and was recently diagnosed with diabetes mellitus and hypertension. He denies a history of cardiac events and stroke. Physical examination reveals a blood pressure of 144/78 mmHg, heart rate of 97/min, and a respiratory rate of 28/min. Breath sounds are equal without crackles. Cardiac examination reveals a regular rate without murmurs and an S4. An ECG was obtained which shows sinus rhythm with ST segment elevation in V2, V3, and V4. A troponin is ordered and returns above normal range. Chest x-ray is normal.

---

A. Grigorian, MD  
Department of Surgery, University of California, Irvine, 333 City Blvd West, Suite 1600, Route. 81, Orange, CA 92868, USA  
e-mail: [agrigori@uci.edu](mailto:agrigori@uci.edu)

P.N. Frank, MD (✉)  
Department of Surgery, Harbor-UCLA Medical Center, 1000 W. Carson Street, Torrance, CA 90509, USA  
e-mail: [PaulFrank521@gmail.com](mailto:PaulFrank521@gmail.com)

P. Benharash, MD  
Division of Cardiac Surgery, University of California, 10833 Le Conte Ave., 62-249 Center for Health Sciences, Los Angeles, CA 90095, USA  
e-mail: [Pbenharash@mednet.ucla.edu](mailto:Pbenharash@mednet.ucla.edu)

## Diagnosis

### What is in the Differential Diagnosis?

Diagnosis	Comments
<i>Aortic dissection</i>	Acute, tearing chest pain radiating to the back, associated with hypertension and Marfan's syndrome, can present with stroke, MI, tamponade, acute aortic insufficiency, CXR: widened mediastinum
<i>Acute coronary syndrome</i>	Includes STEMI, NSTEMI, and unstable angina; chest pain described as an "elephant on chest," shortness of breath, diaphoresis, nausea, vomiting, tachycardia, hypotension
<i>Coronary vasospasm</i>	Common in younger patients, cocaine users, and women; coronary narrowing caused by autonomic dysfunction and mimics typical angina associated with a true myocardial infarction
<i>Pericarditis</i>	Pleuritic chest pain that improves with leaning forward, dyspnea, cough, fever, friction rub, pulsus paradoxus (drop in blood pressure on inspiration) if tamponade present
<i>Pulmonary embolism</i>	Pleuritic chest pain (i.e., worse with inspiration), marked dyspnea, hypoxia, hypotension if embolus is massive; right heart strain and abnormal ECG findings may be present
<i>Diffuse esophageal spasm</i>	Esophageal motility disorder presenting with chest pain, dysphagia, and food regurgitation; may be triggered by reflux, caffeine, and spicy foods
<i>Esophageal perforation</i>	Most commonly after invasive procedures such as endoscopy; also in alcoholics with forceful vomiting (i.e., Boerhaave syndrome)
<i>Pneumothorax</i>	Collapsed lung may present as acute pain

MI myocardial infarction; STEMI ST elevated myocardial infarction; NSTEMI non-ST elevated myocardial infarction

### What Is the Most Likely Diagnosis?

Given the patient's history of severe chest pain with radiation to the neck, reduced exercise tolerance, and ST elevation in leads V2, V3, and V4, the patient is likely suffering from an acute coronary syndrome, specifically a STEMI secondary to an occluded left anterior descending coronary artery.

#### Watch Out

Aortic dissection can cause acute coronary artery occlusion and can present in a similar fashion; however, we might also expect a diastolic murmur from aortic regurgitation and a widened mediastinum on chest x-ray.

## History and Physical

### What Are the Risk Factors for Myocardial Infarction (MI)?

Increased age, male, hypertension, hypercholesterolemia, diabetes, smoking, and family history of coronary artery disease are the risk factors for myocardial infarction.

### What Elements on the History and Physical Exam Make MI Less Likely in a Patient Presenting with Chest Pain?

Patients under the age of 40 with no cardiovascular risk factors and older healthy patients (e.g., 60-year-old swimmer) with no cardiovascular risk factors are highly unlikely to be having an MI. Pain that is reproducible by palpation is more suggestive of musculoskeletal pain. Localized pain that is described as being sharp is also less likely to be related to heart disease, as is chest pain related to certain foods or eating.

## What Are the Classic History and Physical Exam Findings Seen in MI?

Chest pain, diaphoresis, anxiety, tachycardia, tachypnea, and nausea/vomiting are classic findings. If there is a large area of ischemic damage to the heart, the patient may have heart failure presenting with bilateral rales (pulmonary edema), jugular venous distention, new S3 or S4 heart sounds, new murmurs, and hemodynamic instability (i.e., cardiogenic shock).

## What Group of Women Is at Highest Risk for MI? Why?

Postmenopausal women are at higher risk for MI. In fact, heart disease is the leading cause of death in women over the age of 40. The decline in estrogen levels is believed to contribute to a higher cardiovascular disease risk profile. Estrogen promotes growth and maintenance of the intimal layer of the arterial wall, maintaining its ability to expand and accommodate blood flow.

### Watch Out

Women presenting with MI are more likely than men to have atypical, vague symptoms.

## Pathophysiology

### What Is Meant by Acute Coronary Syndrome?

Acute coronary syndrome entails varying degrees of acute myocardial ischemia, the end result of coronary artery disease. There are three types of acute coronary syndrome: unstable angina (UA), non-ST segment elevation myocardial infarction (NSTEMI), and ST segment elevation myocardial infarction (STEMI).

### What is the Difference Between UA, NSTEMI, and STEMI?

Condition	Comments
UA	Nonocclusive thrombosis causes reduced myocardial perfusion, but no myonecrosis (death of cardiac myocytes), hence no elevation in cardiac enzymes
NSTEMI	Occlusive thrombosis eliminates perfusion to only partial thickness of the myocardial wall and (affects the subendocardial side) causes myonecrosis leading to elevation in cardiac enzymes and possibly ECG findings suggestive of ischemia (but not ST segment elevation)
STEMI	Occlusive thrombosis eliminates perfusion to full thickness of the myocardial wall and causes myonecrosis leading to elevation in cardiac enzymes and characteristic elevation of ST segment on ECG

### What Are the Series of Events That Take Place During an Acute Myocardial Infarction?

Thrombus formation following plaque rupture is the primary mechanism involved in coronary vessel obstruction leading to ischemia and, eventually, myocyte necrosis and tissue death.

### What Coronary Vessel Is Most Often Affected?

The left anterior descending (LAD) artery is the most commonly affected coronary vessel.

## Are There Different Mechanisms of Myocardial Infarction?

Yes. MIs are classified based on whether or not there is a primary coronary event, such as a plaque rupture with subsequent thrombosis. Causes of MI not associated with a primary cardiac event include decreased oxygen supply (e.g., hypoxia, hypotension, anemia) and increased myocardial oxygen demand (e.g., sepsis, tachyarrhythmias). Postoperative MIs often result from a combination of factors other than primary coronary events. Primary coronary events require urgent intervention, while MIs resulting from non-primary coronary events will often resolve as the underlying cause is addressed.

## What Is Suggested by Episodic Chest Pain Unrelated to Exertion in a Young Person?

Prinzmetal angina is characterized by episodic chest pain unrelated to exertion. Coronary artery vasospasms are responsible for transient decreased perfusion to the heart which causes reversible injury to myocytes. ECG shows ST segment elevation secondary to transmural ischemia, similar to what is seen in unstable angina. However, Prinzmetal angina is not due to coronary artery disease.

---

## Workup

### What Are the Initial Diagnostic Steps for Suspected Myocardial Infarction?

In addition to a relevant history (i.e., prior MI, chest pain) and physical exam, the patient should have a 12-lead ECG and a blood test for cardiac enzymes. A chest radiograph will help rule out other diagnoses like pneumothorax and aortic dissection.

### What Is the Role of Measurement of Cardiac Enzyme Levels in the Blood?

Cardiac enzymes, including troponin-I and creatine phosphokinase myocardial fraction (CKMB), are measured every 8 hours in the first 24 hours of a suspected MI. CKMB is the first to rise but it has a low specificity. Troponin-I has the highest sensitivity for MI and increases in 3 hours, peaks in 6 hours, and gradually decreases over 7 days.

#### Watch Out

Ischemia causing death of cardiac myocytes can cause elevation in cardiac enzymes in both NSTEMI and STEMI, but not in unstable angina.

### What Is the Best Cardiac Enzyme to Diagnose a Second MI on Top of a Recent MI?

CKMB is the best marker to look for secondary MI following a recent MI. Its levels peak within 12–40 hours following MI and decreases after 2–3 days. Therefore, in a subsequent MI, there will be a new increase in CKMB.

#### Watch Out

Both CKMB and troponin are cleared through the kidneys and may have a much longer half-life in the presence of kidney disease.

## What Is the Role of ECG?

ECG will help determine whether there is actually ischemia or infarction and, if so, the location of the ischemia or infarction (Table 5.1). ECG may potentially identify nonischemic causes of the patient's symptoms, such as pericarditis, pulmonary embolism, and arrhythmia.

**Table 5.1** Coronary anatomy and ECG changes

Coronary artery	Branches of	Supplies	ECG leads changes
<i>Left anterior descending (LAD) artery</i>	Left coronary artery	Anterior wall of left ventricle, anterior 2/3 of intraventricular septum	V2, V3, V4
<i>Circumflex branch</i>	Left coronary artery	Lateral and posterior wall of left ventricle, left atrium	aVL, V5, V6
<i>Posterior descending artery</i>	Right coronary artery (80 % of patients)	Inferior wall of left ventricle, posterior 1/3 of intraventricular septum	II, III, aVF

## Management

### What is the Initial Management of STEMI?

Intervention	Rationale
Aspirin	Inhibits platelet aggregation; given before PCI or fibrinolysis
Clopidogrel	Inhibits platelet aggregation; given before PCI or fibrinolysis
Platelet glycoprotein IIb/IIIa antagonist	Inhibits platelet aggregation; given before PCI
Heparin	Prevent clot formation; given before PCI or fibrinolysis
$\beta$ -blocker	Alleviates chest pain by heart rate and contractility (reduces oxygen demand); may also prevent reinfarction and ventricular fibrillation; not given to patients with evidence of cardiogenic shock
Nitroglycerin	Alleviates chest pain by causing vasodilation, thereby reducing preload and afterload (reduces oxygen demand), and improving myocardial perfusion (increases oxygen supply); may cause hypotension
Morphine	Alleviates chest pain by stimulating opioid receptors; only given if chest pain persists despite 3 doses of sublingual nitroglycerin; may cause hypotension or heart block
ACE inhibitor	Especially for patients with anterior MI and EF < 40 %; reduces fatal and nonfatal cardiac events; also prevents cardiac remodeling
Angiotensin receptor blocker (ARB)	For Patients who cannot tolerate ACE inhibitor (e.g. cough)
Atorvastatin	Reduces ischemic complications and expedites resolution of ST segment elevation in patients undergoing PCI; reduces LDL level; recommended for all patients with STEMI without contraindication to statin therapy (e.g., liver disease)
Supplemental oxygen	Only in patients whose oxygen saturation is low

### What Options for Reperfusion Are Available for STEMI?

The preferred treatment is clot removal and stenting in the catheterization lab, known as percutaneous coronary intervention (PCI), within 90 min of symptom onset. In the catheterization lab, the clot can be extracted and the lesion stented with either bare metal or drug-eluting stents. If the patient cannot undergo catheterization within 90 min, systemic thrombolysis via intravenous tPA should be given.

### What If PCI Is Unsuccessful?

If adequate flow cannot be established using percutaneous techniques in the catheterization laboratory, the patient may be referred for emergency coronary artery bypass grafting (CABG). Emergency operations for STEMI continue to have a high mortality despite many technological advances in myocardial protection.

## Does the Timing of Intervention Matter?

Yes. Classically, revascularization of the myocardium within 90 min is recommended for optimal recovery. Some studies have shown that revascularization can be effective for up to 6 hours, but with diminishing benefits.

## What Is the Initial Management of NSTEMI?

As with STEMI, patients with NSTEMI should receive aspirin,  $\beta$ -blocker, nitroglycerin, heparin, platelet glycoprotein IIb/IIIa receptor antagonist (e.g., eptifibatide), supplemental oxygen (for hypoxic patients), morphine (if nitroglycerin does not relieve pain), and ACE inhibitor.

## What Are the Next Options in the Management of NSTEMI?

Patients with an NSTEMI do not need urgent coronary intervention (PCI) unless one of the following conditions are met:

- Recurrent angina at rest or with minimal exertion
- Evidence of CHF (e.g., S3 gallop, pulmonary edema)
- High-risk findings on stress testing
- LV ejection fraction < 40 %
- Hemodynamic instability (i.e., hypotension)
- Sustained ventricular tachycardia
- PCI within the past 6 months
- Prior CABG

Patients without the above conditions may be treated medically and observed, with follow-up echocardiogram and stress test.

## What Is the Most Important Determinant of Long-Term Outcome After STEMI? What Is the Role of CABG in These Patients?

The most important determinant in this patient population is the speed at which blood flow is restored to the ischemic myocardium. In most cases, fibrinolysis or percutaneous intervention would be able to accomplish this at a much faster rate than CABG, largely attributable to delays in getting the patient to the operating room. However, CABG is the recommended intervention in those patients with cardiogenic shock, recurrent ischemia secondary to failed PCI, mechanical complications, or those presenting > 12 hours of the initial insult.

## What Are the Indications for CABG in the Elective Setting?

CABG is rarely performed in the emergent setting (< 5 % of cases). In the elective setting, this procedure is reserved for stable patients with the following conditions:

- > 50 % stenosis of the left main coronary artery
- > 70 % stenosis in all other coronary arteries
- Stenosis of the proximal left anterior descending artery and one other artery
- Stenosis of three coronary arteries
- Obstructions not amenable to stenting (e.g., at bifurcations)

## What Does the Traditional Coronary Artery Bypass Grafting (CABG) Entail?

Traditional CABG involves performing a median sternotomy and placing the patient on a heart-lung machine (pump) to deliver oxygenated blood while the heart is temporarily arrested. The ascending aorta is clamped, and then a cold solution

high in potassium is administered into the aortic root to induce cardiac arrest and help protect the heart while vascular grafts are placed. Surgical revascularization of the heart involves delivering blood flow from the aorta to the coronary arteries distal to the area of stenosis using a graft. Various grafts such as the internal mammary artery, greater saphenous vein, radial artery, and even the gastroepiploic arteries have been used. Once this is completed, the heart is reactivated by warming and potassium washout. This technique is the most commonly performed approach to CABG (as compared to off-pump CABG, see below).

### **What Is an Off-Pump CABG? What Benefit Does It Have When Compared to a Traditional CABG?**

In this procedure, a median sternotomy is also performed. However, the anastomoses are created on a beating heart without the use of the heart-lung machine. Some of the theoretical advantages of not using the heart-lung machine include a reduction of systemic inflammatory response and a decreased incidence of bleeding, renal dysfunction, stroke, and need for blood transfusion. However, many large trials have shown that off-pump CABG has a higher rate of graft closure (i.e., the conduit does not remain patent) and does not improve outcomes significantly in most patients. However, patients with atherosclerosis of the ascending aorta or those with cerebrovascular disease are at greater risk of postoperative stroke during CABG, and they may benefit from off-pump CABG, as this approach is associated with less neurological injury.

### **What Is the Best Conduit for CABG?**

The internal mammary artery coming off the subclavian artery is the best conduit for CABG. Greater than 95 % of these arteries are patent at 10 years when attached to the LAD. This is referred to as a left internal mammary artery (LIMA) to LAD.

### **Should More Than One Coronary Artery Be Bypassed During CABG?**

Several studies have suggested that long-term survival is superior in patients receiving two or more coronary bypass grafts, compared to patients receiving only one. In addition, the rates of postoperative cardiac events (e.g., angina, MI, graft occlusion, or PCI) and death are also lower in patients receiving multiple grafts.

### **How Does CABG Compare to Coronary Artery Stenting in Patients with Multivessel Coronary Artery Disease?**

Despite the improvement in stent technology (drug-eluting stents), CABG continues to be superior to stenting in terms of lower rates of mortality, MI, and revascularization.

### **What Medical Interventions Are Associated with Improved CABG Outcomes in the Perioperative Period?**

Aspirin, beta-blockers, statin therapy, and antibacterial prophylaxis for postoperative infections are associated with improved CABG outcomes in the perioperative period.

#### **Watch Out**

Clopidogrel or other similar thienopyridine category drugs should be discontinued before CABG.



## What Are the Predictors of Mortality Following CABG?

Preoperative cardiogenic shock, emergent surgery, age > 65, and depressed left ventricular ejection fraction.

## How Is Prinzmetal Angina Managed?

Since the etiology of the chest pain is due to transient coronary vasospasms, calcium channel blockers are typically used to treat the underlying cause while nitroglycerin is used to rapidly decrease the chest pain.

## Complications

### What are the Complications of MI?

Complication	Characteristics	Post-MI timing
<i>Cardiogenic shock</i>	Large ischemic areas and tissue death may compromise the contractility of the heart preventing adequate cardiac output; most common cause of death while hospitalized	Immediate
<i>Congestive heart failure</i>	Characterized by a decreased ejection fraction, can progress to cardiogenic shock	Immediate
<i>Arrhythmia</i>	90 % of patients develop some form of arrhythmia in the post-MI state with ventricular fibrillation being the most deadly; most common cause of death outside the hospital	First 2 days
<i>Pericarditis</i>	Pleuritic chest pain that decreases with leaning forward, dyspnea, cough, fever, friction rub	48–72 hours
<i>Cardiac tamponade</i>	Rupture of the ventricular wall may lead to tamponade; may present with Beck's triad of hypotension, distended neck veins, and muffled heart sounds on auscultation	2–10 days
<i>Rupture</i>	Immune cells have removed debris of dead cells, thereby weakening the affected region; interventricular septal rupture can cause right to left shunt; free wall rupture can cause pericardial tamponade; papillary muscle rupture can cause acute mitral regurgitation	3–7 days
<i>Ventricular aneurysm</i>	Occur as a result of a weakened ventricular wall; can lead to stroke (mural thrombus forms which can embolize), heart failure, arrhythmias	5–90 days
<i>Dressler's syndrome</i>	Autoimmune condition where antibodies form against the pericardium and results in an inflammatory pericarditis	1 month

## Areas You Can Get in Trouble

### Silent MI

In up to 25 % of cases, patients may experience silent or atypical MIs in which they do not present with the classic symptoms associated with MI including chest pain. This most often occurs in women, elderly, and diabetic patients.

### Misdiagnosing Aortic Dissection as Acute MI

An aortic dissection may cause severe chest pain mimicking an MI. Patients are often evaluated for a heart attack only to be subsequently found to have an aortic dissection. A Stanford type A aortic dissection (i.e., involving the ascending aorta) can cause coronary artery occlusion and acute MI, as well as heart failure due to acute aortic regurgitation.

## Areas of Controversy

### Is the Radial Artery Useful as a Graft in CABG?

There has been an increased use of the radial artery in recent years, particularly for patients that do not have a viable IMA or saphenous vein available. The long-term survival rates are significantly lower for patients with radial artery bypass when compared to patients with IMA grafts. In addition, postoperative cardiac events including MI, stroke, and repeat

vascularization are higher. Many radial arteries do not dilate well due to the muscular nature of this vessel and are found to be atretic (very narrow) on repeat angiography.

---

## Summary of Essentials

### History and Physical

- Increased age, male gender, cardiovascular disease, diabetes, and smoking are all risk factors for MI
- Chest pain, diaphoresis, anxiety, tachycardia, tachypnea, and nausea/vomiting

### Pathophysiology

- Acute coronary syndrome
  - UA, NSTEMI, and STEMI
- Thrombus formation following plaque rupture is the primary mechanism involved in coronary vessel obstruction leading to ischemia
- LAD most commonly affected
  - Supplies anterior wall of left ventricle, anterior 2/3 of intraventricular septum
  - ECG changes in leads V2, V3, and V4

### Workup

- Workup of MI must be quick
- Timing of revascularization is critical
  - Ideally within 90 min of symptom onset
  - Some benefit up to 6 hours after onset
- ECG
- Cardiac enzymes q8 hours × 24 hours
  - Troponin-I
  - CKMB
- CXR
  - Rule out aortic dissection
- Echocardiogram (if definitive management not delayed) for wall motion abnormalities, ejection fraction
- Determine if STEMI or NSTEMI

### Management

- Initial management
  - Combination of aspirin, clopidogrel, platelet glycoprotein IIb/IIIa antagonist, heparin,  $\beta$ -blocker, nitroglycerin, statin, and morphine
- STEMI
  - Catheterization suite within 90 min for PCI
  - Systemic thrombolysis if PCI not immediately available
- NSTEMI
  - Most do not require PCI
  - Limited subendocardial oxygen supply-demand mismatch allows for more conservative management
  - Elective cardiac catheterization on a selective basis

- CABG
  - Urgent/emergent (rare)
    - Cardiogenic shock
    - Failed PCI
    - Presenting > 12 hours after of the initial insult
  - Elective
    - Left main coronary artery disease
    - Multivessel disease of other coronaries
    - Failed PCI or not amenable to PCI
  - IMA preferred conduit combined with RSVG
  - Most performed with heart-lung machine
  - Better long-term survival than stenting for multivessel disease

---

## Suggested Reading

- Anderson JL, Adams CD, Antman EM. 2012 ACCF/AHA focused update incorporated into the ACCF/AHA 2007 guidelines for the management of patients with unstable angina/non-ST-elevation myocardial infarction. *Circulation*. 2013;127:e000.
- Hannan EL, Wu C, Walford G, et al. Drug-eluting stents vs coronary-artery bypass grafting in multivessel coronary disease. *N Engl J Med*. 2008;358:331–41.
- Hillis LD, Smith PK, Anderson JL, et al. 2011 ACCF/AHA guideline for coronary artery bypass graft surgery. *Circulation*. 2011;124:e652–735.
- Medvedofsky D, Goldenberg I, Fefer P, et al. Statins loading before PCI on STEMI. *J Am Coll Cardiol*. 2013;61(10):E65.
- Muneretto C, Negri A, Manfredi J, et al. Safety and usefulness of composite grafts for total arterial myocardial revascularization: a prospective randomized evaluation. *J Thorac Cardiovasc Surg*. 2003;125:826.
- O’Gara PT, Kushner FG, Ascheim DD, et al. 2013 ACCF/AHA guideline for the management of ST-elevation myocardial infarction. *Circulation*. 2013;127:e362–425.
- Ruttmann E, Fischler N, Sakic A, et al. Second internal thoracic artery versus radial artery in coronary artery bypass grafting: a long-term, propensity score-matched follow-up study. *Circulation*. 2011;124:1321.

Paul N. Frank and Peyman Benharash

A 60-year-old male presents to the emergency department complaining of chest pain when he exercises for the last 2 weeks. He states that the pain feels like heavy pressure over the left side of his chest and rates it a 6 out of 10. He feels short of breath and dizzy upon minimal exertion. He denies any back pain. However, he does note over the past 2 months when he rides a stationary bicycle at the gym he feels some chest pressure, and one time felt fainting, as if he was going to pass out. He is able to sleep flat on his bed at night and does not wake up with a sense that he is suffocating. The patient states that he was told years ago that he had a slight murmur but that it was nothing to worry about. He has not had any follow-up since. He denies a history of cardiac events, stroke, or hypertension. He denies IV drug abuse. He reports no fever or chills. Physical examination reveals a blood pressure of 120/70, heart rate of 88 bpm, and he is afebrile. Breath sounds are normal bilaterally, without rales. Cardiac examination reveals a regular heart rate, a IV/VI crescendo-decrescendo systolic murmur at the second intercostal space at the right upper sternal border that radiates to the neck, and an S4. EKG demonstrates sinus rhythm with left ventricular hypertrophy, without ST segment changes. Troponin and CK-MB are both within the normal ranges.

---

P.N. Frank, MD

Department of Surgery, Harbor-UCLA Medical Center, 1000 W. Carson Street, Torrance, CA 90509, USA

e-mail: [PaulFrank521@gmail.com](mailto:PaulFrank521@gmail.com)

P. Benharash, MD (✉)

Division of Cardiac Surgery, University of California, Los Angeles, 10833 Le Conte Avenue, 62-249 Center for Health Sciences,

Los Angeles, CA 90095, USA

e-mail: [Pbenharash@mednet.ucla.edu](mailto:Pbenharash@mednet.ucla.edu)

## Diagnosis

### What Is in the Differential Diagnosis?

Condition	Comments
<i>Aortic dissection</i>	Acute, tearing chest pain radiating to the back, associated with hypertension, Marfan's; can present with stroke, MI, tamponade, acute aortic insufficiency; CXR-wide mediastinum
<i>Aortic regurgitation</i>	Diastolic murmur loudest at the upper right sternal border, may occur with aortic dissection, may also occur in congenital diseases such as bicuspid aortic valve and Marfan's syndrome
<i>Aortic stenosis</i>	Systolic crescendo-decrescendo murmur loudest at the upper right sternal border, weak and delayed peripheral pulses ( <i>parvus et tardus</i> ), poor prognostic indicators include angina, syncope, and CHF
<i>Pulmonic stenosis</i>	Systolic murmur that does not radiate into the neck, heard loudest along the left sternal border, murmur increases with inspiration, RV heave on palpation
<i>Endocarditis</i>	Classically found in IV drug users, but also look for a history of rheumatic valve disease or congenital anomalies; fever, new murmur, positive blood cultures, and echocardiographic evidence of vegetations on valves; new conduction abnormalities raise concern for intracardiac abscess
<i>Cardiac arrhythmia</i>	Diagnosed by ECG, stable patients may be treated with antiarrhythmics, unstable patients should be electrically shocked
<i>Hypertrophic cardiomyopathy</i>	Younger patients, sudden death in the family, brisk bifid carotid upstrokes, murmur does not radiate into the neck
<i>Mitral regurgitation</i>	Murmur is holosystolic and radiates to the axilla and not the carotids, carotid upstroke may be normal, patients with mitral valve prolapse are at increased risk, as are patients with a history of rheumatic valve disease
<i>Acute pericarditis</i>	One systolic rub and two diastolic rubs may present with diffuse ST segment elevation on ECG, and patients with h/o of MI weeks ago and patients with renal failure are at increased risk; can lead to tamponade
<i>Unstable angina</i>	Episodic chest pain of cardiac origin that is progressively increased in intensity or is brought about by decreasing amounts of physical exertion; this is a type of acute coronary syndrome (ACS)
<i>Noncardiac causes of chest pain</i>	Pulmonary (e.g., PE, pneumonia, pneumothorax), GI (e.g., esophageal spasm, GERD), biliary (e.g., gallstones), pancreatic (e.g., pancreatitis)

### What Is the Most Likely Diagnosis?

Given the presence of a crescendo-decrescendo murmur loudest at the upper right sternal border and the history of a murmur, the patient likely has aortic stenosis. The concerning signs that portend a worse prognosis in this patient are chest pain (i.e., angina) and near syncope.

## History and Physical Exam

### What Is the Significance of an S4?

This extra heart sound is most frequently heard in patients that have left ventricular hypertrophy. Although it is common in patients with aortic stenosis, it can also be heard in patients with hypertensive heart disease and hypertrophic cardiomyopathy, as these conditions also cause left ventricular hypertrophy and decreased left ventricular distensibility.

### What Other Valvar Disease Can Be Mistaken for Aortic Stenosis?

Pulmonic stenosis may present with a similar crescendo-decrescendo murmur at the upper regions of the sternum. Hypertrophic obstructive cardiomyopathy (HOCM) also creates a similar murmur. This may be differentiated from aortic stenosis by asking the patient to perform a Valsalva maneuver, which would increase the murmur in HOCM but decrease its intensity in aortic stenosis. The Valsalva maneuver is done by asking the patient to exhale with force against a closed airway/glottis.

## Does the Intensity of the Murmur Correlate with the Severity of the Valvar Disease? What About the Duration?

As the degree of valvar stenosis increases, the murmur usually decreases in intensity and duration. It also occurs later in systole. However, with all murmurs and bruits, the intensity should not serve as a marker of severity of disease.

## What Are the Three Classic Symptoms of Aortic Stenosis? And How Do the Presence of Those Symptoms Affect Prognosis?

The three classic symptoms of aortic stenosis are angina, syncope, and congestive heart failure (CHF). These three symptoms are associated with a 50 % mortality rate at 5, 3, and 2 years, respectively.

### Watch Out

The most concerning symptom in patients with aortic stenosis is dyspnea, since half of these patients with evidence of CHF will succumb to the disease within 2 years without surgical valve replacement.

## What Are the Differentiating Features of the Various Cardiac Murmurs?

Murmur	Description	Location
<i>Aortic stenosis</i>	Midsystolic crescendo-decrescendo	Upper right sternal border
<i>Aortic regurgitation</i>	Decrescendo diastolic murmur	Lower left sternal border
<i>Mitral stenosis</i>	Diastolic opening snap, low-pitched diastolic murmur, as stenosis worsens, the opening snap occurs later in diastole	Apex
<i>Mitral regurgitation</i>	Holosystolic murmur, decreased or absent S1	Apex, radiating to axilla
<i>Mitral valve prolapse (MVP)</i>	Mid-/late systolic click, possibly followed by late systolic crescendo-decrescendo murmur	Apex
<i>Hypertrophic obstructive cardiomyopathy (HOCM)</i>	Systolic crescendo-decrescendo murmur	Upper left sternal border

## What Changes Do You See in the Systolic Murmurs With Various Maneuvers?

	Valsalva (decreases preload)	Handgrip (increases afterload)	Leg raise (increases preload)
<i>Aortic stenosis</i>	↓	↓	↑
<i>Hypertrophic cardiomyopathy</i>	↑	↓	↓
<i>Mitral regurgitation</i>	↓	↑	↑
<i>Ventricular septal defect</i>	↓	↑	↑

## What Is Pulsus Alternans?

Pulsus alternans is physical exam finding wherein the amplitude of a peripheral pulse changes from beat to beat associated with changing systolic blood pressure. It is most commonly caused by left ventricular failure.

## What Is Pulsus Bisferiens?

Pulsus bisferiens, also known as a biphasic pulse, refers to two strong systolic pulses with a midsystolic dip, in other words, two pulses during systole. It can be seen in aortic regurgitation with or without aortic stenosis and hypertrophic cardiomyopathy.

## What Is the Importance of a History of Intravenous Drug Abuse (IVDA)?

Patients with IV drug use are at risk of endocarditis due to introduction of bacteria into the blood stream. Endocarditis presents with fever and valvar regurgitation rather than stenosis, unless the vegetation is extremely large and causes outflow tract obstruction.

## What Are the Classic Physical Findings Associated with Endocarditis?

Finding	Pathophysiology
<i>Petechiae</i>	Septic emboli or vasculitic processes
<i>Splinter hemorrhages</i>	Microscopic blood clots underneath the nail
<i>Osler nodes</i>	Septic emboli to microvessels in the skin causing <i>tender</i> microabscesses
<i>Janeway lesions</i>	Small erythematous or hemorrhagic <i>nontender</i> lesions on the palms, soles, or distal finger pads
<i>Roth spots (retinitis septica)</i>	Retinal hemorrhages, white spot close to the optic disk surrounded by hemorrhage

### Watch Out

Antibiotics for endocarditis prophylaxis are not indicated in patients with aortic stenosis or sclerosis.

## Pathophysiology

### What Are the Differentiating Features Between Aortic Valve Sclerosis and Aortic Valve Stenosis?

Both aortic sclerosis and stenosis are caused by calcification of the aortic valve. In aortic sclerosis, there is minimal or no restriction of the motion of the aortic valve leaflets and this condition is therefore asymptomatic. In aortic stenosis, there is significant restriction of the motion of the aortic valve leaflets, and this condition can be symptomatic. It should be noted, however, that aortic sclerosis may progress to aortic stenosis (Table 6.1).

### What Are Three Possible Etiologies for the Development of Aortic Stenosis?

Etiology	Population	Features
<i>Senile</i>	Older patients; often after sixth decade of life	Calcification of an otherwise normal valve, <i>most common cause</i>
<i>Congenital</i>	Middle aged; often fourth or fifth decade of life	Calcification and fibrosis of a congenitally bicuspid aortic valve
<i>Rheumatic valvar disease</i>	Immigrants from countries with poor healthcare	Rheumatic fever can affect the aortic valve or mitral valve

**Table 6.1** Differentiating features of aortic sclerosis and stenosis

	Murmur	Carotid upstroke	EKG	Echocardiogram	Aortic valve pressure gradient
<i>Aortic sclerosis</i>	Midsystolic ejection murmur, brief, not very loud	Not delayed	Normal	Visualization of excursion of valve leaflets usually normal or mildly reduced	Normal
<i>Aortic stenosis</i>	Systolic ejection murmur in aortic area, usually with thrill, harsh quality	Delayed	Shows evidence of left ventricular hypertrophy	Thick aortic valve leaflets with decreased excursion	Increased

### Is Stroke Volume Maintained Early in the Course of the Disease? If So, What Maintains It?

Yes. The smaller lumen of the aortic valve results in an elevated left ventricular systolic pressure, and the resultant left ventricular hypertrophy maintains cardiac output without significant dilation of the ventricular cavity. This allows for the stroke volume to be maintained early in the course of the disease.

### What Contributes to the Chest Pain That Is Commonly Seen in Patients with Aortic Stenosis?

High myocardial wall tension coupled with left ventricular hypertrophy increases myocardial oxygen demand which is further compromised by decreased diastolic coronary blood flow. This combination of events can result in angina later in the course of the disease.

### What Causes the Dyspnea in Aortic Stenosis?

The thickened ventricular cavity that may also be somewhat ischemic leads to a stiff ventricle that requires higher filling pressures to maintain end-diastolic volume. This in turn leads to increased pulmonary venous pressures and sensation of dyspnea.

### Why Is AS a Particularly Dangerous Valvar Problem?

Patients with aortic stenosis are at increased risk of sudden death. This risk is about 2 % in asymptomatic individuals and up to 34 % of symptomatic individuals. While the mechanism is not agreed upon, it has been hypothesized that ventricular arrhythmias or an abnormal baroreceptor reflex may be contributing factors.

---

## Workup

### What Laboratory Tests Are Recommended in the Workup for a Patient with Acute Chest Pain?

The initial workup includes serum electrolytes, coagulation panel, cardiac biomarkers (e.g., troponin, CK-MB), and ECG.

### What are the Relevant Biomarkers that may be Tested for in this Setting?

Biomarker	Interpretation
<i>Troponin</i>	Elevated levels of troponin correlate with increased risk of death and other adverse outcomes; indicates death of cardiac myocytes; cardiac troponin is more sensitive than CK-MB
<i>CK-MB</i>	Elevated level indicates death of cardiac myocytes
<i>BNP</i>	Released by ventricular myocytes in response to increased stretch, as in CHF
<i>D-dimer</i>	Byproduct of fibrin breakdown; elevated levels very nonspecific, but may indicate blood clot formation

### What Imaging Is Recommended?

*Chest x-ray* is recommended to look for evidence of CHF, widened mediastinum (suggestive of aortic dissection), and to rule out noncardiac causes of chest pain (e.g., broken ribs, pneumothorax). *Echocardiography* is used to look for ventricular dysfunction such as decreased (hypokinesis) or total absence (akinesis) of movement of the ventricular wall, suggestive of ischemia. Findings consistent with aortic stenosis include thickened aortic valve leaflets with decreased movement. Echocardiography can also demonstrate sequelae of acute coronary syndrome, such as papillary muscle rupture, pericardial effusion, and ventricular dilation. *CT angiography* is indicated if pulmonary embolism or aortic dissection is suspected.



**Watch Out**

Diastolic and continuous murmurs, as well as loud systolic murmurs should always be investigated with echocardiography. Midsystolic soft murmurs in an asymptomatic young patient are typically benign and need no further workup.

---

**Management****What Is the Treatment for Mild Aortic Stenosis?**

For most patients with asymptomatic mild aortic stenosis, medical treatment of hypertension and other cardiac risk factors is appropriate. They may undergo aortic valve replacement if they need to undergo heart surgery for another reason (such as CABG). These patients may undergo echocardiogram every 3–5 years to monitor the progression of aortic stenosis.

**What Is the Treatment for Aortic Stenosis with Heart Failure?**

Patients with CHF and aortic stenosis represent a special subgroup of patients with high mortality. The left ventricle of these patients is dilated (burned out) rather than thick and hypercontractile. On echocardiography, these patients will exhibit a lower gradient than expected based on valve area and may be thought not to have severe aortic stenosis. However, with proper adjunct studies and perioperative ventricular support, these patients may benefit from aortic valve replacement, as this immediately reduces the afterload. Over time, left ventricular hypertrophy may reverse. It is important to note that even the elderly are candidates for surgical aortic valve replacement.

**What Are the Indications for Surgery for Aortic Stenosis?**

Surgical aortic valve replacement should be considered in all patients with symptomatic aortic stenosis. Some of the patients who are poor surgical candidates due to comorbidities may be candidates for transcatheter aortic valve replacement. Asymptomatic patients may undergo aortic valve replacement if they are to undergo cardiac surgery for another reason (such as coronary artery bypass grafting), if they have a left ventricular ejection fraction <50 % or if they have decreased exercise tolerance.

**Do Statins Slow Progression of AS?**

Statins reduce the risk of ischemic cardiac events but they do not slow the progression of aortic stenosis. Calcification of the aortic valve is not atherosclerotic in nature and therefore, statins are not expected to mitigate this process.

---

**Areas You Can Get in Trouble****Drugs to Avoid with Aortic Stenosis**

Drugs that reduce blood pressure place patients with aortic stenosis at risk for hypotension. Classically diuretics,  $\beta$ -blockers, and vasodilators should be used with caution or avoided entirely in patients with severe aortic stenosis. However, these medications are now used commonly at lower doses with caution.

---

## **Elective Noncardiac Surgery with Unrecognized Severe AS**

Surgery carries risks of hypotension related to volume loss and autonomic dysregulation. Induction of anesthesia blunts sympathetic tone and causes vasodilation. Patients with aortic stenosis are very preload sensitive and may be unable to compensate for hypotension (that is often seen at anesthetic induction) by increasing cardiac output to maintain adequate perfusion. Since severe AS places patients at high cardiac risk during elective surgery, it is important to identify the classic murmur preoperatively.

---

## **Areas of Controversy**

### **Bioprosthetic Valve Versus Mechanical Valve?**

Both bioprosthetic and mechanical valves are used in aortic valve replacement. Bioprosthetic valves made from treated animal tissues are degraded by dystrophic calcification as well as possible chronic antigenicity and do not last as long as mechanical valves. Patients with mechanical valves require lifetime anticoagulation, which increases the risk of bleeding. Patients who do not have a contraindication to anticoagulation, especially younger patients, should receive a mechanical valve.

### **Pulmonary Autograft (Ross Procedure)?**

The Ross procedure entails replacing the patient's aortic valve with his or her native pulmonary valve and then replacing the pulmonary valve with a homograft prosthesis (from a deceased individual). Although very technically demanding, this may be beneficial in children because the pulmonic valve can grow as the child grows. Additionally, these patients do not require anticoagulation.

### **Percutaneous Balloon Valvuloplasty?**

Patients with aortic stenosis who are poor surgical candidates may undergo percutaneous balloon valvuloplasty, wherein a balloon is placed across the aortic valve and inflated. This procedure offers a smaller hemodynamic benefit than surgical valve replacement. Additionally, the benefits of the valvuloplasty are only transient. It has been recommended that balloon valvuloplasty may be used as a bridge to surgery in hemodynamically unstable patients. Valvuloplasty can cause regurgitation by tearing the valve and is not performed in patients that have both stenosis and regurgitation.

### **Percutaneous Aortic Valve Replacement?**

More recently, stented collapsible valves have been approved for delivery into the aortic root using minimally invasive catheters. Although the criteria for percutaneous aortic valve replacement are changing, this procedure is only applicable to those who are too high risk for conventional surgical aortic valve replacement. While surgery has a proven record of success, percutaneous valves may not be durable and have a much increased risk of stroke in the perioperative period.

---

## **Summary of Essentials**

### **History**

- Symptomatic aortic stenosis, angina, syncope or near syncope, and dyspnea on lying down
- It may also be asymptomatic

## Physical Exam

- Systolic crescendo-decrescendo murmur loudest at the upper right sternal border and an S4
- As stenosis worsens, flow across the aortic valve decreases, and the murmur will become quieter and be heard later

## Pathophysiology

- Calcification of the valve
- Symptoms due to the mechanical obstruction

## Differential Diagnosis

- Symptomatic aortic stenosis, acute coronary syndrome, aortic dissection, pericarditis, and noncardiac conditions
- Asymptomatic aortic stenosis should be differentiated from other causes of heart murmur

## Diagnosis

- Aortic stenosis may be diagnosed by physical exam and echocardiography

## Management

- The definitive treatment for aortic stenosis is surgical valve replacement. Patients who are poor surgical candidates may undergo balloon valvuloplasty or transcatheter valve replacement

## Watch Out

- Severe AS places patients at high cardiac risk for elective noncardiac surgery
  - Patients with AS are at risk of sudden death

---

## Suggested Reading

Carabello BA. Evaluation and management of patients with aortic stenosis. *Circulation*. 2002;105(15):1746–50.

Nishimura RA, Otto CM, Bonow RO. 2014 AHA/ACC guideline for the management of patients with valvular heart disease: executive summary: a report of the American College of Cardiology/American Heart Association Task Force on Practice Guidelines. *Circulation*. 2014 March 3; <http://circ.ahajournals.org/content/early/2014/02/27/CIR.0000000000000029.full.pdf>

Rossebo AB, Pedersen TR, Boman K, et al. Intensive lipid lowering with simvastatin and ezetimibe in aortic stenosis. *N Engl J Med*. 2008;359(13):1343–56.

Paul N. Frank, Simin Bahrami, and Peyman Benharash

A 26-year-old male presents to the ED complaining of sudden onset severe chest pain radiating to the upper back for the past 3 hours. He describes it as a tearing sensation in his back. He denies any fevers or chills but reports an episode of syncope prior to arriving to the hospital. He is unable to remain still secondary to pain. His past medical history is negative. On initial exam, his blood pressure is 140/50 mmHg and heart rate is 102/min. He appears to be tall and thin, with long arms, long thin fingers, and hypermobile joints. His sternum has a concave deformity. Cardiac examination reveals a regular rhythm with an early diastolic murmur at the left upper sternal border and muffled heart sounds. Breath sounds are equal bilaterally without crackles. ECG demonstrates nonspecific ST segment changes. Troponin and CK-MB are within normal ranges. A chest x-ray demonstrates a widened mediastinum (Fig. 7.1).

## Diagnosis

### What is the Differential Diagnosis?

Condition	History and physical
<i>Aortic dissection</i>	Sudden onset of tearing chest pain radiating to the back or scapula, syncope, hypertension, connective tissue disorders (e.g., Marfan's syndrome)
<i>Aortic regurgitation</i>	Diastolic murmur loudest at upper right sternal border with increased pulse pressure; may occur acutely with aortic dissection or endocarditis
<i>Endocarditis</i>	History of rheumatic heart disease, congenital anomalies (e.g., mitral valve prolapse) or IV drug use; fever, new murmur, positive blood cultures, Janeway lesions (nontender lesions on palms and soles), and Osler nodes (tender lesions on digits)
<i>Cardiac arrhythmia</i>	Unprovoked syncope, dizziness, and hypotension
<i>Acute pericarditis</i>	Substernal, pleuritic chest pain, worse supine, better leaning forward, fever, tachycardia, friction rub, pulsus paradoxus
<i>Unstable angina</i>	Episodic chest pain of cardiac origin that occurs at rest; may be relieved with nitroglycerin
<i>Non-cardiac causes of chest pain</i>	Pulmonary (e.g., pulmonary embolus, pneumonia, pneumothorax), GI (e.g., esophageal spasm, GERD, Boerhaave syndrome), pancreatitis

*GERD* Gastroesophageal reflux disease

P.N. Frank, MD (✉)

Department of Surgery, Harbor-UCLA Medical Center, 1000 W. Carson Street, Torrance, CA 90509, USA

e-mail: [PaulFrank521@gmail.com](mailto:PaulFrank521@gmail.com)

S. Bahrami, MD

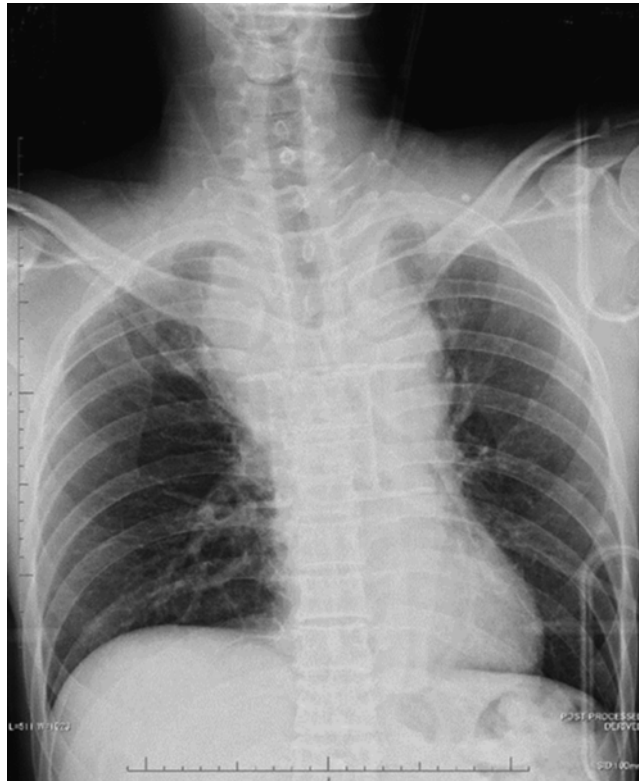
Department of Radiology, Ronald Reagan UCLA Medical Center, Santa Monica-UCLA Medical Center, Santa Monica, CA, USA

P. Benharash, MD

Division of Cardiac Surgery, University of California, Los Angeles, 10833 Le Conte Avenue, 62-249 Center for Health Sciences,

Los Angeles, CA 90095, USA

e-mail: [Pbenharash@mednet.ucla.edu](mailto:Pbenharash@mednet.ucla.edu)



**Fig. 7.1** Chest radiograph on admission showing widening of the upper mediastinum

### What Is the Most Likely Diagnosis?

Ascending aortic dissection secondary to Marfan's syndrome. The history is classic for an aortic dissection. Additionally, the history and physical exam suggest the patient has suffered complications secondary to the aortic dissection including acute aortic insufficiency (early diastolic murmur and increased pulse pressure) and pericardial effusion (muffled heart sounds). It is also suggestive from the presentation that this patient has Marfan's syndrome. Patients with Marfan's syndrome are typically tall, thin, and can have cardiac, skeletal (pectus excavatum, arachnodactyly, hyperflexible joints), and/or ocular (ectopic lentis: displacement of the crystalline lens) abnormalities. It is important to rapidly establish the diagnosis of aortic dissection and to determine the dissection type (A or B), as the management of a dissection is dramatically different from other diagnoses and the management of type A and B also greatly differs (discussed further below).

---

## History and Physical Exam

### What Are the Risk Factors for Aortic Dissection?

The risk factors for aortic dissection are hypertension, connective tissue disease (e.g., Marfan's, Ehlers-Danlos), advanced age, atherosclerosis, pregnancy, cocaine use, aortic injury (e.g., trauma, cardiac catheterization), bicuspid aortic valve), and aortic coarctation.

#### Watch Out

Systemic hypertension is the most commonly identified risk factor for aortic dissection.

## **What Is the Significance of Uneven Pulses in the Upper and Lower Extremities in Patients with Aortic Dissection?**

Uneven pulses suggest that the blood supply to one of those extremities is adversely affected and therefore provides a clue as to the location of the dissection. An upper extremity pulse discrepancy is consistent with a dissection involving the aortic arch, whereas a lower extremity pulse discrepancy suggests involvement of the descending aorta all the way down to the iliac arteries.

## **What Is the Significance of an Increased Pulse Pressure?**

Patients with aortic insufficiency will present with a widened pulse pressure (as in this patient). Diastolic pressure decreases due to regurgitation, while systolic pressure increases secondary to the increased stroke volume as a result of the backflow of blood from the aorta (increased preload).

---

## **Pathophysiology**

### **What Is the Initial Event Leading to an Aortic Dissection?**

An aortic dissection is a progressive separation of the aortic wall that results from a tear in the intima that progresses into the media, essentially splitting the aorta into an inner layer of intima and inner media and an outer layer of outer media and adventitia. This produces two lumens: a true lumen and a false lumen. The true lumen is where the blood usually flows, while the false lumen is the blind sac that is formed between the intimal flap and the outer media. As blood flows into the false lumen, the tear propagates and the false lumen enlarges. Eventually secondary tears may develop, which allow the blood to reenter the true lumen. The tear is a direct consequence of aortic wall shear stress and most often happens in areas exposed to high mechanical forces (such as the aortic arch and proximal descending aorta just distal to the left subclavian artery).

### **Why Are Patients with Marfan's Syndrome at Increased Risk for Aortic Dissection?**

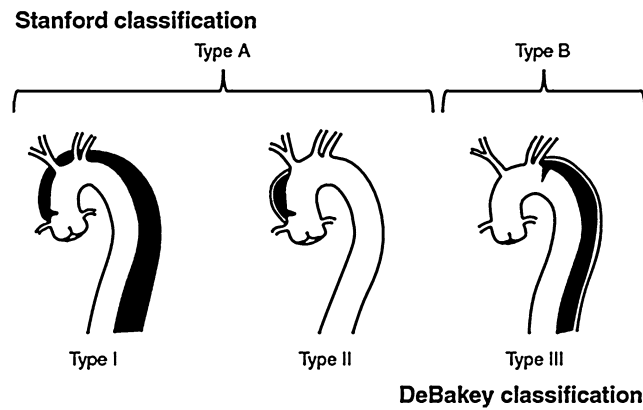
Marfan's is a connective tissue disease that has an autosomal dominant mode of transmission. Its primary defect involves the misfolding of fibrillin proteins, which can result in cystic medial necrosis of large vessels such as the aorta. The subsequently weakened medial wall is left susceptible to dissection.

### **Are Dissections and Aneurysms in the Same Spectrum of Disease?**

No. An aneurysm is dilation (mostly fusiform) of all three layers of an artery that progressively enlarges. Patients with Marfan's are at risk for both aneurysm (mainly in the aortic root) and dissection. Confusion arises in that dissection weakens the arterial wall, such that the lumens (both true and false) dilate over time.

### **How Are Aortic Dissections Classified?**

Two traditional classification schemes exist (DeBakey and Stanford), both of which describe dissections based on the segments of the aorta involved (Fig. 7.2). A Stanford type A dissection involves the ascending aorta/aortic arch, whereas a type B does not. A Stanford type B dissection begins in the descending aorta, distal to the takeoff of the left subclavian artery. The main disadvantage of the Stanford classification is that it does not distinguish between patients with isolated ascending aorta/aortic arch dissection and patients with dissection involving the entire aorta. However, since the most important determinant of therapy is whether the ascending aorta/aortic arch is (Stanford A) or is not (Stanford B) involved, the Stanford classification is more commonly used.



**Fig. 7.2** Aortic dissection classification scheme diagram (With kind permission from Springer Science + Business Media: Vascular Surgery, New Techniques in Surgery Series, Aortic Dissection, 2012, p 112, Pandey VA & Hamady M., Fig. 8.1)

#### Watch Out

Stanford type B aortic dissections are the most common type overall. However, Marfan's patients more often present with type A aortic dissections.

### How Do Aortic Dissections Cause Complications?

The complications and subsequent clinical presentation are highly dependent on the anatomic location of the dissection and whether the dissection affects major arterial branches (Table 7.1). The expanding false lumen can interfere with blood flow in the true lumen and compromise perfusion to the branching vessels, such as those supplying the liver, mesentery, the kidneys, or limbs. This is known as malperfusion syndrome.

### What Life-Threatening Complications Are Specific to Dissections That Involve the Ascending Aorta/ Aortic Arch (Stanford Type A)(Table 7.1)

Type A dissections may dissect into and obstruct blood flow in the coronary arteries, causing myocardial infarction (MI). They may also disrupt blood flow in the carotid arteries, which can cause ischemic stroke. They may also dissect into the pericardial sac, causing acute tamponade, and dissect the aortic valve, leading to acute aortic insufficiency.

### What Major Complications Are Specific to Dissections That Only Involve the Descending Aorta (Stanford Type B)

Type B dissections are much less likely to cause acute complications since the ascending aorta/aortic arch is not involved. Since they begin distal to the left subclavian artery and since the descending thoracic aorta does not have any major arterial branches (other than sometimes to the spinal cord), the dissection can extend for a long distance without causing malperfusion. Note that type A dissections can extend into the descending aorta, so they can also present with these manifestations.

**Table 7.1** Malperfusion syndrome: complications during aortic dissection

Complication	Branching artery	Comments
<b>Type A dissection</b>		
<i>Cardiac ischemia</i>	Coronary	Angina, nausea, vomiting, elevated cardiac enzymes; often involving the RCA
<i>Cerebral ischemia</i>	Brachiocephalic or carotid	May lead to stroke
<b>Type A or type B dissection</b>		
<i>Paraplegia</i>	Intercostal or lumbar (Artery of Adamkiewicz)	Ischemia of the spinal cord can result in loss of motor function in the extremities
<i>Mesenteric ischemia</i>	SMA	Abdominal pain “out of proportion” to physical exam, nausea, bloody diarrhea in severe cases
<i>Kidney failure</i>	Renal	Oliguria, elevated BUN, creatinine
<i>Limb ischemia</i>	Subclavian or iliac	Pain, pallor, and pulselessness in the extremities

SMA superior mesenteric artery, RCA right coronary artery

## Workup

### What Laboratory Tests Should Be Ordered Immediately?

Although laboratory studies are of little value in working up aortic dissection, most clinicians will order blood typing and crossmatching, cardiac biomarkers (e.g., troponin, CK-MB), and ECG. Note that elevated cardiac markers and ST changes on ECG cannot rule out an aortic dissection since acute coronary syndrome is one of the possible sequelae of aortic dissection.

### What Is the First Imaging Modality Recommended in a Patient Who Presents with Acute Chest Pain?

Chest x-ray should be obtained as it will demonstrate a widened mediastinum in most patients with dissection. However, 15–20 % of patients will have a normal chest x-ray. If the CXR shows a widened mediastinum or if suspicion for dissection remains high based on history and physical exam, then a chest CT with intravenous contrast should be obtained next. Although magnetic resonance arteriography (MRA) is another option for visualizing the dissection, a contrast CT is still preferred because it is more readily available in the emergency setting (Figs. 7.3 and 7.4).

### What Imaging Is Recommended If the Patient Is Hemodynamically Unstable and an Aortic Dissection Is Highly Suspected?

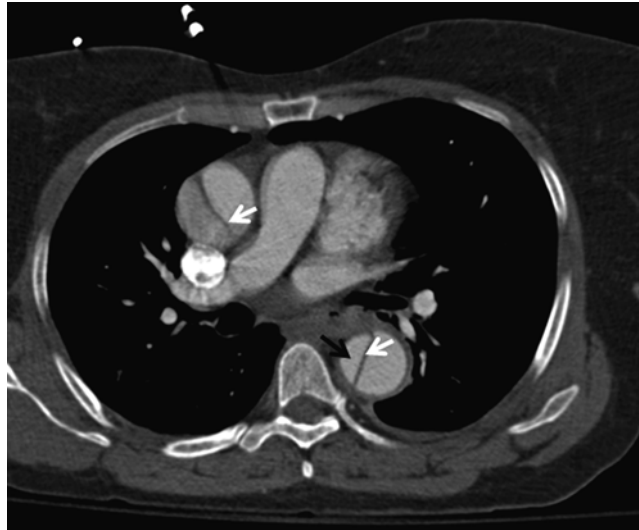
Hemodynamically unstable patients suspected of having a type A aortic dissection should be taken to the OR immediately, without chest CT scan, for surgical intervention. Transesophageal echocardiography (TEE) can be performed in the operating room while the patient is under general anesthesia and if confirmatory, surgery can begin immediately.

## Management

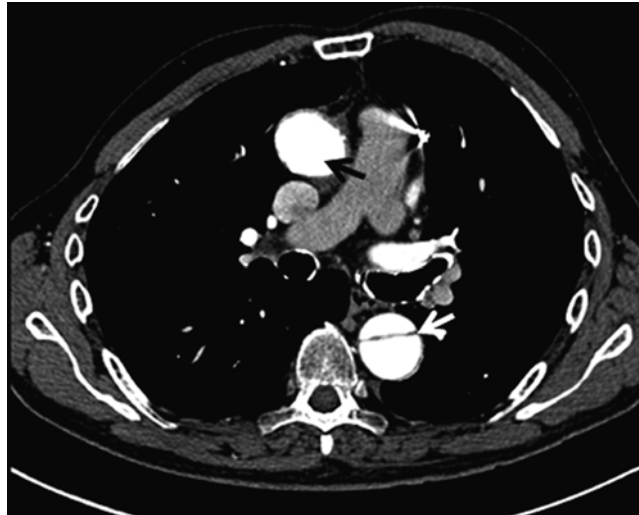
### What Is the First Step in Management of an Aortic Dissection?

Since high blood pressure will propagate the tear, it is critically important to maintain a low blood pressure, usually between 100 and 110 mmHg systolic. This same management principle applies to all types of aortic dissection, regardless of location, and should be initiated as soon as the diagnosis is suspected. This is best done with intravenous beta-blockers. Beta-blockers decrease the shear forces on the aorta by decreasing the dp/dt (change in pressure/change in time).





**Fig. 7.3** Axial CT showing a Stanford type A aortic dissection involving the ascending and descending aorta. *White arrows: intimal flap. Black arrow: true lumen*



**Fig. 7.4** Axial CT showing a Stanford type B aortic dissection involving the descending aorta. *White arrow: intimal flap. Black arrow: normal ascending aorta*

#### Watch Out

Patients with significant aortic regurgitation or tamponade should not receive beta-blockers.

### What Is the Next Step (After Starting Antihypertensives) Once the Diagnosis of Type A Dissection Is Established?

The patient should be taken urgently to the operating room for repair via median sternotomy.

Depending on the exact location of the dissection, part of the ascending aorta may need to be replaced with a synthetic graft, a new aortic valve may need to be placed, and the coronary arteries may need to be reimplemented into the new graft.

## What Is the Next Step (After Starting Antihypertensives) Once a Diagnosis of Type B Dissection Is Established?

The patient should be admitted to an ICU and the blood pressure closely monitored.

## When Should Patients with Type B Dissection Undergo Surgical Repair?

Surgery is reserved for patients that develop complications (e.g., malperfusion syndrome) secondary to compromised perfusion to branches of the descending thoracic or abdominal aorta. This would include evidence of limb ischemia or visceral (bowel, kidneys) ischemia. Other indications include rapidly expanding aortic diameter or ongoing pain despite medical therapy.

## What Are the Surgical Options for a Type B Dissection?

Open repair via thoracotomy and endovascular repair with placement of a stent graft are options for repair of type B dissection. Spinal cord ischemia is a complication specific to repair of dissections involving the thoracic aorta, as the blood supply to the spinal cord (via the artery of Adamkiewicz) may be interrupted.

## What Are the Differences in Prognosis and Definitive Management Between Type A and Type B Aortic Dissections?

	Type A dissection	Type B dissection
<i>Prognosis</i>	50 % of patients die within 48 hours without surgical intervention, < 10 % will live beyond 1 month, MI and stroke portend an even worse prognosis	80 % of patients survive with appropriate medical therapy
<i>Management</i>	Begin with medical therapy (e.g., $\beta$ -blocker) and urgent surgical intervention	Begin with medical therapy <i>only</i> : $\beta$ -blocker (first line), nitroprusside, calcium channel blockers, morphine for analgesia (surgical repair is indicated if there is malperfusion)

## Areas Where You Can Get in Trouble

### Giving Beta-Blockers to a Patient with Aortic Dissection Complicated by Cardiac Tamponade or Severe Aortic Regurgitation

Beta-blockade in these patients will worsen hypotension and may precipitate cardiac arrest.

### Confusing Type A Aortic Dissection with Acute MI

Patients with type A aortic dissection can present with coronary artery malperfusion and thus have a similar presentation as an acute MI. In patients with acute MI not secondary to aortic dissection, MI is generally due to rupture of an atherosclerotic coronary plaque. Treatment consists of antiplatelet agents, heparin, possibly fibrinolytic drugs, and emergent coronary catheterization to relieve the obstruction and possibly place a stent. Patients with type A aortic dissection, on the other hand, should not receive these drugs and need urgent median sternotomy.

## Areas of Controversy

### Endovascular Repair of a Stable Asymptomatic Type B Aortic Dissection

With time, the descending in patient with type B dissections can progressively dilate, eventually requiring surgery if the diameter of the aneurysm exceeds 6 cm. Since endovascular repair of type B dissections is less invasive and is associated with fewer complications, some centers advocate early repair of the stable type B dissections in order to prevent a chronic enlargement of the aorta. However, most surgeons recommend only medical therapy for stable, asymptomatic type B dissections.

---

## Summary of Essentials

### History and Physical Exam

- Sudden onset of severe tearing chest pain radiating to upper back
- Risk factors: severe hypertension, atherosclerosis, advanced age, connective tissue disorders (Marfan's, Ehlers-Danlos), pregnancy, and cocaine abuse
- Look for evidence of acute aortic insufficiency, cardiac tamponade
- Look for evidence of malperfusion
  - Stroke
  - Diminished pulses in an extremity or difference in blood pressure in each arm
  - Severe abdominal pain
  - Oliguria/anuria

### Watch Out

- Aortic dissection can easily be missed
  - Acute MI can be caused by a type A dissection

### Pathophysiology

- High shear stress and pulsatile blood flow can cause a tear that begins in the intima and splits the media, creating a true and a false lumen
- Expansion of the false lumen may occlude branch vessels and cause ischemia to the brain, viscera, or extremities

### Classification

- Stanford A: involves ascending aorta/aortic arch
  - Can also involve descending aorta
- Stanford B: descending aorta (distal to left subclavian) only

### Diagnosis

- CXR: widened mediastinum
  - Not present in 15–20 %
- CT chest with IV contrast: if mediastinum is wide or suspicion for dissection is high
- Unstable patient: directly to OR with transesophageal echo

---

**Management**

- Immediate control of blood pressure: Beta-blocker preferred unless there is suspected tamponade or severe aortic regurgitation
- Type A dissection: immediate operative repair
  - Median sternotomy (replace ascending aorta with graft)
  - Possible aortic valve replacement
  - Possible reimplantation of coronary arteries
- Type B dissection: admit to ICU for blood pressure control
  - Surgery only if evidence of malperfusion or ongoing pain
    - Open thoracotomy or endovascular stent graft

---

**Suggested Reading**

Braverman AC. Acute aortic dissection clinician update. *Circulation*. 2010;122:184–8.

---

**Part IV**

**Endocrine**

Michael W. Yeh, Section Editor

# Incidentally Discovered Adrenal Mass on CT Scan

Masha J. Livhits, Christopher M. Reid, and Michael W. Yeh

A 55-year-old female was involved in a motor vehicle accident several weeks ago after which she underwent an abdominal CT scan which was negative for any injury. However, a 1.7-cm right adrenal nodule was incidentally noted. The patient complains of difficulty losing weight but denies any recent weight gain, abnormal hair growth, or muscle weakness. She has a long-standing history of diabetes and hypertension. She denies headache, palpitations, and flushing. Physical exam is significant for central obesity, but she does not have supraclavicular fat accumulation or purple striae. Workup for the adrenal mass revealed an elevated 24-hour urine cortisol level (170 mcg/24 hours; normal <45). This was followed by a low-dose dexamethasone suppression test, which resulted in lack of cortisol suppression (AM cortisol 14.2 mcg/dl, normal <2). Further biochemical workup including catecholamines and metanephrines as well as plasma aldosterone and renin levels was normal.

## Diagnosis

### What is the differential diagnosis for an adrenal nodule?

Diagnosis	Clinical presentation
<i>Hypercortisolism (Cushing's syndrome)</i>	Weight gain, central obesity, muscle weakness, poor wound healing, hirsutism, amenorrhea, depression, hypertension, diabetes mellitus
<i>Hyperaldosteronism (Conn's syndrome)</i>	Muscle cramps, weakness, hypertension
<i>Catecholamine hypersecretion (pheochromocytoma)</i>	Episodic tachycardia, sustained or episodic hypertension, headache, flushing, palpitations
<i>Androgen hypersecretion</i>	Virilization, hirsutism, menstrual abnormalities
<i>Benign, nonfunctional mass (myelolipoma, adenoma, cyst, hematoma, granuloma/infection)</i>	Often asymptomatic May have specific history related to trauma or infection (e.g., tuberculosis)
<i>Adrenocortical carcinoma</i>	Abdominal pain (mass effect); symptoms related to functional tumor, large >6 cm
<i>Metastasis</i>	History of extra-adrenal tumor (most commonly lung or breast tumor; also melanoma, lymphoma, and kidney and ovary tumors)

M.J. Livhits, MD  
Surgery and Medicine, Section of Endocrine Surgery, UCLA David Geffen School of Medicine, 10833 Le Conte Ave, Los Angeles, CA 90095, USA  
e-mail: [mlivhits@mednet.ucla.edu](mailto:mlivhits@mednet.ucla.edu)

C.M. Reid, BS, MD  
Department of Surgery, UC San Diego Medical Center, 200 West Arbor Drive, San Diego, CA 92103-8890, USA  
e-mail: [chreid@ucsd.edu](mailto:chreid@ucsd.edu)

M.W. Yeh, MD (✉)  
Surgery and Medicine, Section of Endocrine Surgery, UCLA David Geffen School of Medicine, 10833 Le Conte Ave, Los Angeles, CA 90095, USA  
e-mail: [myeh@mednet.ucla.edu](mailto:myeh@mednet.ucla.edu)

The differential for an adrenal mass is broad, given the variety of cell types present in the adrenal gland. The two key defining characteristics are whether the nodule is associated with hormone hypersecretion (functional tumor) and whether it is malignant (has potential to recur and metastasize). Benign, nonfunctional lesions include nonfunctional adenomas, myelolipomas, and cysts. These make up the majority of incidentally discovered asymptomatic adrenal nodules. Functional tumors typically secrete one of three hormone types: cortisol, aldosterone, or catecholamines (epinephrine and norepinephrine). Adrenocortical carcinoma is a malignant cancer defined by the presence of local invasion into adjacent organs, blood vessels or lymph nodes, or distant metastasis. Adrenocortical carcinomas may also be associated with hormonal hypersecretion. Finally, the adrenal glands are a frequent site for metastasis from other primary tumors, most commonly the lung and breast.

### What Is the Most Likely Diagnosis?

Given the small size of the mass, and the evidence of cortisol hypersecretion, it is most likely a benign cortisol-secreting adrenal adenoma.

---

## History and Physical

### What Are the Findings on History and Physical Examination in a Patient that Hypersecretates Cortisol?

Physical exam findings include truncal obesity and fat accumulation around the head (moon facies) and neck (buffalo hump). Proximal muscle wasting can make it difficult for patients to stand from a seated position or climb stairs. The skin thins out, resulting in purple striae on the abdomen and extremities, easy bruising, and a reddish coloration of the face (plethora). Women may present with amenorrhea and hirsutism. Patients often have associated metabolic conditions, i.e., obesity, type 2 diabetes mellitus, elevated cholesterol or lipid levels, and hypertension. Hypercortisolism is also associated with osteoporosis, poor wound healing, and psychiatric symptoms.

### What is the differential diagnosis of hypercortisolism?

Condition	Comments
<i>Exogenous (iatrogenic)</i>	Immunosuppression for organ transplantation
<i>Adrenal</i>	Adenoma, carcinoma, bilateral hyperplasia
<i>Pituitary</i>	ACTH hypersecretion
<i>Lung</i>	Non-small cell lung cancer (ectopic ACTH), bronchial carcinoid

Most hypercortisolism is iatrogenic or exogenous. Pharmacologic glucocorticoids are administered for a spectrum of inflammatory conditions and for as immunosuppression following organ transplantation. *Cushing's syndrome* describes the cluster of clinical findings (signs and symptoms) associated with glucocorticoid excess (described above), regardless of the underlying cause. In other words, patients with Cushing's syndrome may be receiving exogenous glucocorticoids, or they may have a cortisol-producing adrenal tumor, or they may have a tumor producing adrenocorticotropic hormone (ACTH). The latter two circumstances represent endogenous causes of hypercortisolism. The majority of endogenous cases arise from ACTH hypersecretion, which is almost always caused by a pituitary tumor (*Cushing's disease*=hypercortisolism due to an ACTH-producing pituitary adenoma). A second, much rarer cause of ACTH-dependent Cushing's syndrome is an ectopic source of ACTH production (e.g., non-small cell lung cancer and bronchial carcinoids). Up to 25 % of patients with endogenous hypercortisolism have a primary adrenal cause, most commonly a single adrenal adenoma (80 % of cases). A minority of patients have bilateral adrenal hyperplasia or multiple adrenal nodules.

### What Is the Clinical Presentation of an Adrenal Nodule that Hypersecretes Aldosterone?

The hallmark of hyperaldosteronism is hypertension with hypokalemia. Patients with hyperaldosteronism often have refractory hypertension requiring management with three or more antihypertensive agents. Many of them show an excellent response to spironolactone, an aldosterone antagonist. Hypokalemia, a sign of biochemically severe disease, is less prevalent among patients with hyperaldosteronism today than reported historically, due to earlier detection of the disease. Currently the proportion of hypokalemic patients is less than 50%. Hypokalemia may present with muscle cramping, muscle weakness, or rarely paralysis.

### What Is the Clinical Presentation of a Pheochromocytoma?

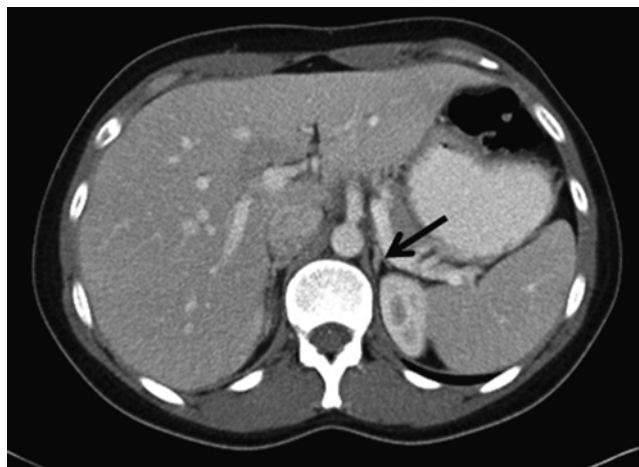Patients with pheochromocytoma most often present with sustained or episodic hypertension. Though only a minority present with the classic triad of headache, flushing, and palpitations, more than 90% complain of at least one of these symptoms.

### What Signs and Symptoms Should Raise Suspicion for an Adrenocortical Carcinoma?

Adrenocortical carcinomas are highly lethal malignancies (5-year survival <25%) which often present at an advanced stage after having grown in a quiescent fashion. Approximately 60% are functional. The most common hormone hypersecretion associated with adrenocortical carcinoma is Cushing's syndrome, with virilization being a distant second and feminization a very distant third. Patients with nonfunctional tumors may present with an abdominal mass, abdominal pain, nausea, anorexia, early satiety, or weight loss. Approximately 75% of adrenocortical carcinomas are >6 cm at the time of presentation (Figs. 8.1 and 8.2).

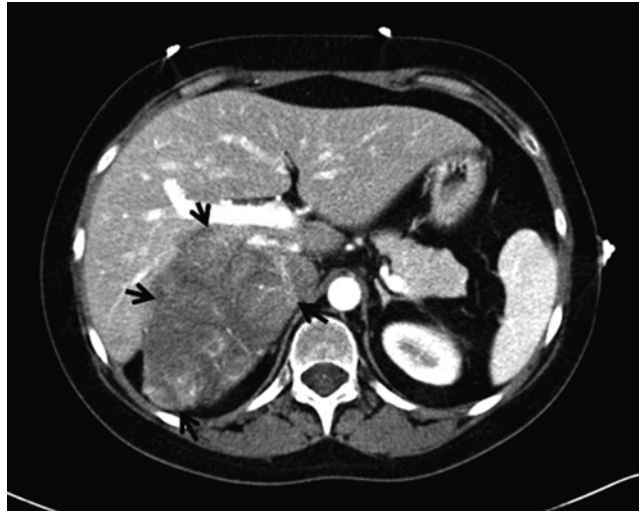### What Is Meant by the Term Adrenal Incidentaloma?

An incidentaloma is an incidentally discovered mass seen on imaging performed for an unrelated reason. Approximately 5% of patients who undergo an abdominal CT scan will have an incidentally discovered adrenal mass. The incidence increases with patient age, with up to 10% of patients having adrenal nodules on autopsy studies (Fig. 8.3).

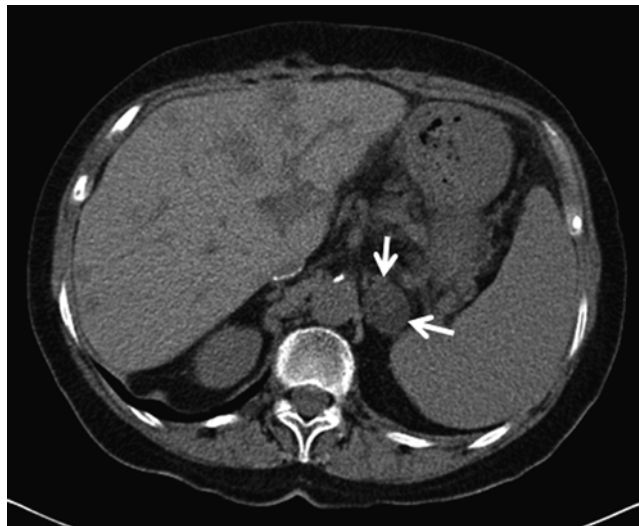


**Fig. 8.1** Axial CT of the normal left adrenal gland





**Fig. 8.2** Axial CT showing a large adrenal mass consistent with malignant adrenal cortical carcinoma



**Fig. 8.3** Axial noncontrast CT showing a small incidentaloma—an asymptomatic adrenal nodule that was discovered incidentally

---

## Pathophysiology

### What Is the Most Common Adrenal Mass?

The most common adrenal mass is a nonfunctional benign adrenocortical adenoma. Only 15 % of adrenal adenomas are associated with hormone hypersecretion. The most common functional lesion discovered incidentally is an adenoma associated with cortisol hypersecretion.

### What Are the Zones of the Adrenal Gland and What Hormones Do They Produce?

Each adrenal gland has an outer cortex and an inner medulla. The cortex is composed of three zones (from outer to inner): glomerulosa, fasciculata, and reticularis. The outer zona glomerulosa is the site of mineralocorticoid (aldosterone) production. The middle zona fasciculata is the site of glucocorticoid (cortisol) production. The inner zona reticularis is the site of

adrenal androgen (dehydroxyepiandrosterone, dehydroxyepiandrosterone-sulfate, and androstenedione) synthesis. The adrenal medulla is the location for catecholamine synthesis.

### **What Are the Systemic Effects of Normal and Excessive Cortisol Secretion?**

Cortisol binds to intracellular cytoplasmic receptors and influences transcriptional activation of genes, specifically affecting glucose metabolism, intravascular volume, and immune modulation. The primary action of cortisol is to increase blood glucose levels via inhibition of insulin-mediated cellular glucose uptake, stimulation of glycogenolysis, stimulation of hepatic gluconeogenesis, and stimulation of peripheral proteolysis and lipolysis. Excessive cortisol secretion therefore causes hyperglycemia, muscle wasting, and fat redistribution which presents as central obesity. Cortisol also regulates intravascular volume and blood pressure by increasing renal reabsorption of sodium, raising peripheral vascular resistance, and having direct chronotropic and inotropic effects on the heart. Excessive secretion results in hypertension. Cortisol impairs cellular immunity by inhibiting cytokine production, inhibiting T-cell activation, and impairing monocyte and neutrophil chemotaxis. Hypercortisolism impairs wound healing and increases the risk of infection.

### **What Is the Cause of Hypertension and Hypokalemia in Hyperaldosteronism?**

Aldosterone acts on the distal convoluted tubule of the kidney to increase sodium reabsorption. This causes passive reabsorption of water and increases extracellular volume and blood pressure. To balance the positively charged sodium ions, potassium is excreted in the urine.

---

## **Workup**

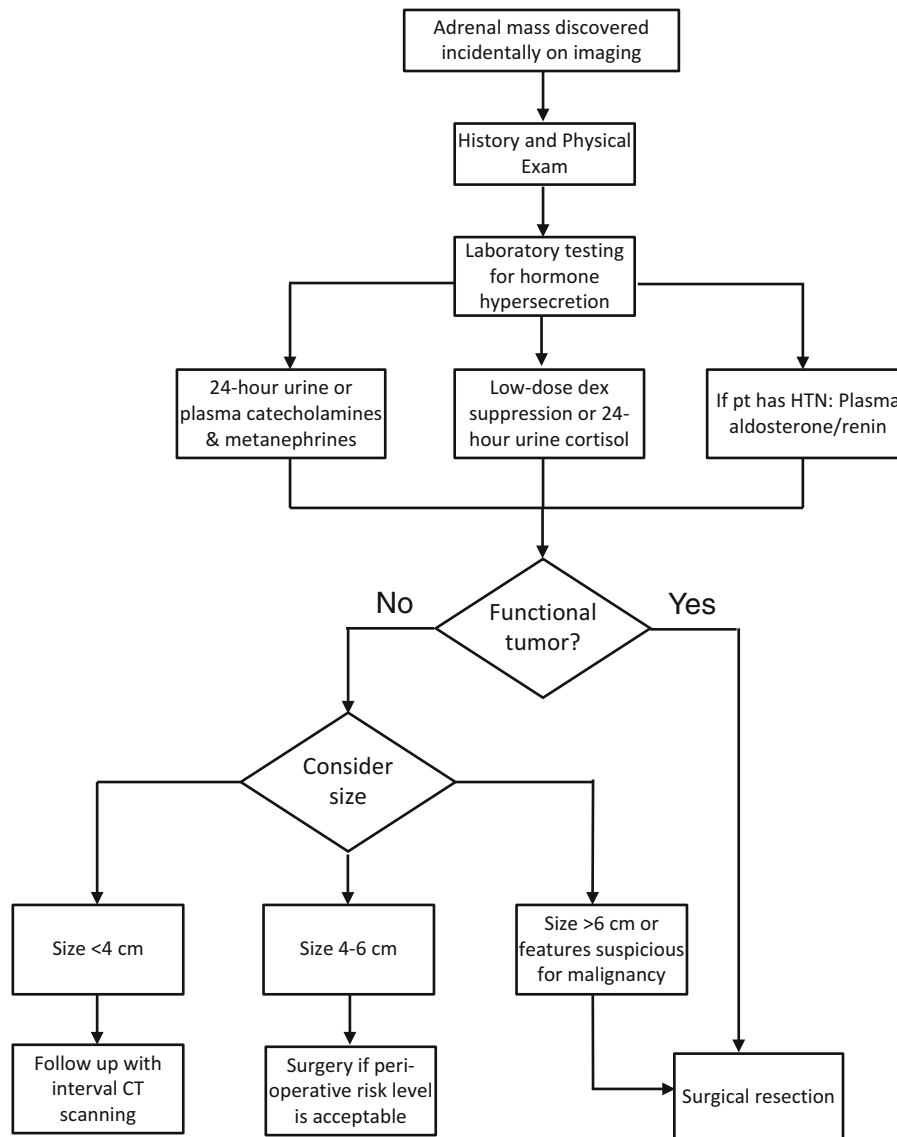
### **What Is the Next Step in Workup when an Adrenal Adenoma Is Suspected or Seen on Imaging?**

An evaluation (Fig. 8.4) must be performed for a functional adrenal tumor that is associated with hormone hypersecretion. A thorough history and physical should be performed, followed by biochemical analysis. Laboratory testing is performed to identify inappropriately high levels of cortisol and catecholamines, as well as aldosterone if the patient has hypertension (Table 8.1).

### **What Laboratory Testing Should Be Performed to Evaluate for Hypercortisolism?**

If Cushing's syndrome is suspected clinically, a careful medication history should be performed to examine for exogenous sources of glucocorticoids, including those contained in herbal or "alternative" formulations, supplements, inhaled agents, and epidural or intra-articular injections. Once those have been excluded, endogenous cases of Cushing's syndrome may be investigated. Due to the wide circadian variability of plasma cortisol levels (highest at 8:00 a.m., lowest at midnight), a single random cortisol level is not helpful. Measurement of the 24-h urine-free cortisol level is commonly used as the first test to screen for Cushing's syndrome; a level in excess of threefold the upper limit of normal ( $>150 \mu\text{g}$ ) is diagnostic of hypercortisolism. The most sensitive test is the low-dose dexamethasone suppression test, a provocative test which involves administering 1 mg of dexamethasone (a potent, synthetic glucocorticoid that does not interfere with cortisol measurement) orally in the evening and measuring plasma cortisol the following morning. In normal physiology, dexamethasone suppresses ACTH production by the anterior pituitary via negative feedback, thereby shutting down normal endogenous cortisol production by the adrenal glands. Hence, the serum cortisol level on the morning after dexamethasone administration should normally be suppressed to below  $5 \mu\text{g/dL}$ . A level above this indicates non-suppression (disruption of negative feedback) and points toward endogenous Cushing's syndrome. A third method of diagnostic testing involves the detection of an elevated serum or salivary cortisol level at midnight, when normal cortisol levels are close to zero (disruption of circadian rhythm).

Once the diagnosis of hypercortisolism is confirmed, further laboratory testing is performed to identify the cause. When normal negative feedback is intact, elevated cortisol levels should suppress ACTH production from the pituitary gland. A low plasma ACTH level ( $<5 \text{ pg/mL}$ ) establishes the diagnosis of ACTH-independent Cushing's syndrome due to an adrenal



**Fig. 8.4** Algorithm for workup and management of incidental adrenal mass

**Table 8.1** Summary of laboratory testing

Diagnosis	Laboratory testing
<i>Hypercortisolism (Cushing's syndrome)</i>	24-h urine cortisol OR Low-dose dexamethasone suppression OR Midnight salivary cortisol <i>If necessary:</i> Plasma ACTH level
<i>Hyperaldosteronism (Conn's syndrome)</i>	High-dose dexamethasone suppression Plasma aldosterone to renin ratio Serum potassium <i>If necessary:</i> Oral or IV salt loading
<i>Catecholamine hypersecretion (pheochromocytoma)</i>	24-h urine metanephrines and catecholamines OR Plasma metanephrines and catecholamines

tumor. A normal or high plasma ACTH level establishes the diagnosis of ACTH-dependent Cushing's syndrome due to either a pituitary adenoma or an ectopic source of ACTH. A subsequent high-dose dexamethasone suppression test may differentiate between a pituitary source of ACTH, which usually suppresses, and an ectopic source of ACTH, which usually does not.

### **What Laboratory Testing Can Identify Hyperaldosteronism?**

Patients with hyperaldosteronism generally have increased aldosterone levels ( $>20$  ng/dL), but the most sensitive screening test is to calculate the ratio between the serum aldosterone level and the plasma renin activity (measured in ng/mL/h). Normal ratios are in the 4–10 range, while patients with hyperaldosteronism have ratios  $>30$ . An elevated ratio in a hypertensive patient indicates autonomous aldosterone secretion and normal feedback inhibition of renin release. Serum hypokalemia and increased urinary potassium excretion may also be observed. To confirm the diagnosis, inappropriate aldosterone secretion should be seen after salt loading, which can be accomplished either with oral salt tablets or intravenous infusion of normal saline. Under normal physiology, the delivery of high quantities of sodium and chloride to the distal convoluted tubule should suppress renin secretion, thereby reducing aldosterone secretion. The presence of high levels of aldosterone following salt loading demonstrates non-suppression and confirms the diagnosis of hyperaldosteronism with high specificity.

### **What Laboratory Testing Can Identify a Pheochromocytoma?**

Levels of catecholamines and their metabolites (metanephrines) can be measured either as a 24 h urine collection or as a plasma test. The 24-h urine collection is a good screening test (very high specificity, slightly lower sensitivity). The plasma test is very sensitive but less specific and should be used when there is a high index of suspicion for pheochromocytoma.

### **What Is the Best Imaging Modality to Evaluate an Adrenal Nodule? What Is Another Option?**

Contrast-enhanced CT scan with fine cuts is generally the preferred imaging modality. It is fast, is widely available, and has excellent spatial resolution to evaluate the adrenal gland. MRI is an alternative that is comparable to CT and based on specific characteristics can help to narrow down the diagnosis.

### **What Imaging Characteristics Help to Differentiate a Benign from Malignant Lesion?**

The following characteristics are suggestive of a benign lesion on CT scan: size  $<4$  cm, homogeneous appearance, well-defined borders, high levels of intracellular lipid (identified as low Hounsfield units (HU) on noncontrast CT scan), rapid washout of contrast, and low amount of vascularity. Features that are more concerning for malignancy include size  $>6$  cm, irregular borders with necrosis, calcification and/or hemorrhage within the mass, ill-defined borders with possible invasion into adjacent structures, low levels of intracellular lipid, and high vascularity.

---

## **Management**

### **What Is the Treatment for a Nonfunctional Adrenal Mass? How Does the Size Impact Management?**

The management of a nonfunctional adrenal adenoma is based on the likelihood of malignancy. Lesions smaller than 4 cm with benign imaging features have a very low risk of malignancy ( $<5\%$ ); these should be observed with interval CT scanning. Lesions greater than 6 cm or those with concerning imaging features should be resected (adrenalectomy). For lesions between 4 cm and 6 cm, either observation or resection is acceptable and should be decided based on patient-specific factors such as the level of perioperative risk.

---

### **What Is the Surveillance Protocol for an Adrenal Nodule that Will Not Be Resected?**

Follow-up should consist of repeat imaging at 6, 12, and 24 months, as well as repeat biochemical evaluation for hormone levels yearly for 4 years.

### **What Is the Treatment for a Functional Adrenal Mass?**

Any functional adrenal mass should be surgically resected, as long as the patient is medically fit to undergo an operation.

### **What Are Important Perioperative Management Principles?**

Patients with Cushing's syndrome require perioperative and postoperative glucocorticoid replacement, as ACTH secretion from the pituitary can remain suppressed for months and sometimes years after surgery. These patients are therefore at risk for adrenal insufficiency. Patients with an aldosterone-secreting mass are treated with spironolactone and potassium preoperatively. Pheochromocytoma patients require preoperative alpha-blockade for 10–14 days prior to surgery and close intraoperative hemodynamic monitoring.

#### **Watch Out**

Beta-blockers should only be used after adequate alpha-blockade in patients with pheochromocytoma because unopposed alpha-receptor stimulation may result in severe vasoconstriction and hypertension.

### **What Are the Key Surgical Principles During an Adrenalectomy?**

Laparoscopic adrenalectomy is now the standard surgical treatment for most adrenal tumors, excluding those suspicious for carcinoma. The operation can be performed either transabdominally or retroperitoneally. The arterial supply of the adrenal gland is derived from branches of the inferior phrenic artery (superiorly), aorta (medially), and renal artery (inferiorly). Venous drainage from the left adrenal vein empties into the left renal vein, while the right adrenal vein empties directly into the inferior vena cava (IVC). Control of the right adrenal vein is the critical step during right adrenalectomy. Open adrenalectomy is preferable in cases of suspected malignancy. Though there is no specific size limitation for laparoscopic adrenalectomy, many surgeons choose an open approach in tumors >8 cm.

---

## **Prognosis**

### **What Is the Prognosis of an Adrenal Adenoma?**

For patients with benign lesions, the prognosis is excellent. Surgery usually brings about biochemical cure in patients with functional adenomas. Adrenalectomy for an aldosterone-secreting adenoma results in durable improvement of hypertension in 70–90 % of patients.

---

## **Key Areas Where You Can Get in Trouble**

### **What Is the Role of Percutaneous Biopsy in the Workup of an Adrenal Mass?**

Percutaneous biopsy is seldom performed during the workup of an adrenal nodule. Its primary role is in determining the presence of metastatic disease in the setting of a known extra-adrenal primary malignancy. Functional tumors that have been confirmed by biochemical analysis do not require biopsy, as it would not affect management. Percutaneous biopsy should

not be performed until pheochromocytoma has been excluded, as there is a risk of precipitating a massive release of catecholamines. Lesions that are suspicious for adrenocortical carcinoma should not be biopsied as histopathologic examination cannot reliably diagnose malignancy and there is a small risk of seeding the biopsy tract.

## What Is Subclinical Cushing's Syndrome and How Should It Be Managed?

Subclinical Cushing's syndrome is defined as autonomous (ACTH-independent) glucocorticoid production from the adrenal gland, without obvious clinical signs of hypercortisolism. It is more common than overt Cushing's syndrome. These patients have a high prevalence of metabolic conditions (obesity, diabetes, and hypertension), which may be ameliorated by resection of the involved adrenal gland. Adrenalectomy is recommended in younger patients and those with biochemical evidence of hypercortisolism or patients with significant comorbid conditions that can be attributed to glucocorticoid excess.

---

## Summary of Essentials

### History and Physical

- Look for evidence of hormonal hypersecretion

### Etiology/Pathophysiology

- Most common adrenal mass is a nonfunctional benign adrenocortical adenoma

### Diagnosis

- Hypercortisolism
  - 24-h urine free cortisol level
  - Low-dose dexamethasone suppression test
- Hyperaldosteronism
  - Serum aldosterone/plasma renin ratio > 30
- Pheochromocytoma
  - Urine or plasma catecholamine or metanephrine levels
- CT scan

### Management

- Functional adenoma—adrenalectomy
- Nonfunctional adenoma
  - < 4cm: observation
  - 4–6 cm: adrenalectomy if good surgical risk
  - > 6 cm: adrenalectomy

### Watch Out

- Do not biopsy adrenal masses
  - Beware of short posterior adrenal vein entering IVC with right adrenalectomy

## Suggested Reading

- Lockhart ME, Smith JK, Kenney PJ. Imaging of adrenal masses. *Eur J Radiol.* 2002;41(2):95–112.
- Mansmann G, Lau J, Balk E, Rothberg M, Miyachi Y, Bornstein SR. The clinically inapparent adrenal mass: update in diagnosis and management. *Endocr Rev.* 2004;25(2):309–40.
- Newell-Price J, Bertagna X, Grossman AB, Nieman LK. Cushing's syndrome. *Lancet.* 2006;367(9522):1605–17.
- Nieman LK. Approach to the patient with an adrenal incidentaloma. *J Clin Endocrinol Metab.* 2010;95(9):4106–13.
- Ogilvie JB, Duh QY. New approaches to the minimally invasive treatment of adrenal lesions. *Cancer J.* 2005;11(1):64–72.
- Terzolo M, Bovio S, Pia A, Reimondo G, Angeli A. Management of adrenal incidentaloma. *Best Pract Res Clin Endocrinol Metab.* 2009;23(2):233–43.
- Young WF. Clinical practice. The incidentally discovered adrenal mass. *N Engl J Med.* 2007;356(6):601–10.
- Zeiger MA, Thompson GB, Duh QY, Hamrahian AH, Angelos P, Elaraj D, et al. American Association of Clinical Endocrinologists and American Association of Endocrine Surgeons Medical Guidelines for the Management of Adrenal Incidentalomas: executive summary of recommendations. *Endocr Pract.* 2009a;15(5):450–3.
- Zeiger MA, Thompson GB, Duh QY, Hamrahian AH, Angelos P, Elaraj D, et al. The American Association of Clinical Endocrinologists and American Association of Endocrine Surgeons medical guidelines for the management of adrenal incidentalomas. *Endocr Pract.* 2009b;15 Suppl 1:1–20.

Paul N. Frank, James X. Wu, and Michael W. Yeh

A 62-year-old woman presents to your office after being diagnosed with osteoporosis by her primary care physician. Her T-score is  $-4.2$  at the lumbar spine. Further testing reveals a serum calcium level of  $11$  mg/dl (normal  $8.5$ – $10.5$  mg/dl), phosphate level of  $1.7$  mg/dL ( $2.5$ – $4.8$  mg/dl), intact parathyroid hormone (PTH) level of  $83$  pg/mL ( $15$ – $75$  pg/mL), and elevated urinary calcium levels. She denies any previous fractures. Her husband reports that she appears more fatigued and has more difficulty concentrating than before. She denies any history of neck irradiation or family history of thyroid or parathyroid disease. She has no significant past medical or surgical history. She has no known allergies. She occasionally takes ibuprofen for joint pain in her hands. She is a retired schoolteacher who is physically active and enjoys traveling. On review of systems, the patient reports constipation and occasional depressed mood. Physical examination demonstrates a healthy adult female; her neck is supple without masses or adenopathy.

---

P.N. Frank, MD

Department of Surgery, Harbor-UCLA Medical Center, 941 W. Carson Street, Torrance, CA 90509, USA  
e-mail: [PaulFrank521@gmail.com](mailto:PaulFrank521@gmail.com)

J.X. Wu, MD (✉)

Department of Surgery, UCLA, 757 Westwood Plaza Mail room B711, Los Angeles, CA 90095, USA  
e-mail: [jameswu@mednet.ucla.edu](mailto:jameswu@mednet.ucla.edu)

M.W. Yeh, MD

Surgery and Medicine, Section of Endocrine Surgery, UCLA David Geffen School of Medicine, 10833 Le Conte Ave, 72-228 CHS, Los Angeles, CA 90095, USA  
e-mail: [myeh@mednet.ucla.edu](mailto:myeh@mednet.ucla.edu)



## Diagnosis

### What Is the Differential Diagnosis of Hypercalcemia?

See the below table for the differential diagnosis of hypercalcemia. A commonly used mnemonic is Chimpanzees.

Etiology	Lab findings	Comment
Calcium supplementation	None	
Hyperparathyroidism	↑ or high-normal PTH	Primary hyperparathyroidism is the most common <i>outpatient</i> cause of hypercalcemia
Hyperthyroidism	↓ TSH	Hyperthyroidism: increased bone reabsorption
Immobility	None	Immobility: rapid bone turnover, usually young patients following trauma
Iatrogenic	None	Thiazide diuretics: increase calcium absorption at distal tubule
Milk-alkali syndrome	↑ HCO <sub>3</sub>	Excess ingestion of Ca <sup>++</sup> from antacids
Paget's disease	↑ Alkaline phosphatase, ↑ serum and urine hydroxyproline	Excessive, disorganized bone remodeling
Addison's disease	↑ ACTH	Unclear, glucocorticoid deficiency may increase bone resorption
Acromegaly	↑ IGF1	
Neoplasm	↑ PTHrP	Can be due to cytokines or PTHrP; most common cause of <i>inpatient</i> hypercalcemia
Zollinger-Ellison syndrome (MEN-1)	↑ Gastrin	
Excessive vitamin D	↑ Increased vitamin D	Excess GI calcium absorption, increased bone reabsorption
Excessive vitamin A	↑ increased vitamin A	Unclear etiology
Sarcoidosis/granulomatous disease	↑ Vitamin D	Granuloma macrophages activate 25-OH vitamin D

PTH parathyroid hormone  
 TSH thyroid stimulating hormone  
 ACTH Adrenocorticotrophic hormone  
 IGF1 Insulin-like growth factor 1  
 PTHrP parathyroid hormone - related protein

#### Watch Out

The most common cause of hypercalcemia in hospitalized patients is malignancy, while primary hyperparathyroidism is responsible for the majority of hypercalcemia in the outpatient setting.

#### Watch Out

Humoral hypercalcemia of malignancy is caused by parathyroid hormone-related peptide (PTHrP) in 80 % of cases (squamous cell cancers), while 20 % is caused by cytokines/chemokines (breast cancer).

#### Watch Out

Familial hypocalciuric hypercalcemia (FHH) causes mild increase in serum calcium. It can be confused with primary hyperparathyroidism, but FHH has low urine calcium. It is a benign condition due to mutations in CASR, which encodes a calcium receptor. The lack of calcium signal increases PTH level, which increases renal calcium reabsorption.

## What Is This Patient's Diagnosis?

An elevation of serum calcium combined with an elevated PTH level confirms the diagnosis of primary hyperparathyroidism. In addition, this patient endorsed fatigue, constipation, and depressed mood, which are all symptoms associated with hypercalcemia.

## History and Physical

### How Do Patients with Hypercalcemia Typically Present with Hypercalcemia?

The classic mnemonic is *stones, bones, groans, and moans*: kidney stones, aching bones, abdominal groans (pain), and neuropsychiatric moans. The most common presenting symptoms prior to routine lab testing were nephrolithiasis and pathologic fractures or bone pain. Due to current routine laboratory testing, most patients diagnosed with hypercalcemia are asymptomatic or mildly symptomatic.

### What Are the Renal Manifestations of Hypercalcemia?

*Nephrolithiasis* in about 8 % of cases (most commonly men under age 60), *nephrocalcinosis* in <5 % of cases, polyuria, polydipsia, and hypertension related to renal disease.

### What Are the Gastrointestinal Manifestations of Hypercalcemia?

Constipation, nausea, vomiting, heartburn, and abdominal pain.

### What Are the Neurological Manifestations of Hypercalcemia?

Fatigue, depressed mood, difficulty concentrating, impaired memory, anxiety, sleep disturbance, proximal muscle weakness, and psychomotor symptoms. Stupor and coma may be found in cases of extreme hypercalcemia (serum calcium >14 mg/dL) or in the elderly.

### What Patient Demographic Most Commonly Presents with Hyperparathyroidism?

Postmenopausal women.

### What Are the Risk Factors for Primary Hyperparathyroidism?

Exposure to low-dose therapeutic ionizing radiation, family history of hyperparathyroidism, and lithium therapy for bipolar disorder.

#### Watch Out

MEN-1 consists of hyperparathyroidism, pituitary adenomas, and pancreatic neuroendocrine tumors. MEN-2A is characterized by hyperparathyroidism, medullary thyroid cancer, and pheochromocytoma. MEN-2B is characterized by marfanoid habitus, oral neuromas, medullary thyroid cancer, and pheochromocytoma.

## **Why Is Family History Important?**

Hyperparathyroidism occurs in a number of inherited diseases, such as MEN-1, MEN-2A, familial isolated hyperparathyroidism, and hyperparathyroidism-jaw tumor syndrome.

## **What Is a Hypercalcemic Crisis?**

Patients with severe hypercalcemia may present with nausea, vomiting, confusion, and mental status changes. This is a medical emergency, as severe hypercalcemia can lead to cardiac arrhythmias and coma.

## **What Are the Physical Exam Findings of Hyperparathyroidism? What Is the Significance of an Anterior Neck Mass Palpated in a Patient with Hyperparathyroidism?**

Physical exam findings are typically not useful in hyperparathyroidism, as the great majority of enlarged parathyroid glands are soft, less than 2 cm in diameter, and non-palpable. An anterior neck mass in a patient with hyperparathyroidism is most commonly a thyroid nodule but can represent a parathyroid carcinoma.

## **What Is Chvostek's Sign?**

Facial twitch in response to tapping on the facial nerve, anterior to the external auditory canal. This reflects early tetany and is a sign of hypocalcemia that may arise after parathyroidectomy.

## **What Is Trousseau's Sign?**

The combination of flexion of the wrist and metacarpophalangeal joints and extension of the digits following inflation of a blood pressure cuff around the arm to greater than systolic blood pressure. Similar to Chvostek's sign, this marks early tetany due to hypocalcemia.

## **What Is T-score?**

The T-score is a test of bone density. The T-score refers to the number of standard deviations below the average for a young adult at peak bone density. Normal bone has a T-score better than  $-1$ . Patients with osteopenia have scores between  $-1$  and  $-2.5$ , whereas those with osteoporosis have a score less than  $-2.5$ .

## **Anatomy**

### **Describe the Location of the Parathyroid Glands. What Is Their Embryological Development?**

There are four parathyroid glands, two superior and two inferior. The superior parathyroids develop from the 4th pharyngeal pouch and migrate in conjunction with the lateral anlage of the thyroid, which form the tubercle of Zuckerkandl on the posterolateral aspect of the thyroid. The superior parathyroid glands are very consistent in their location, with approximately 95 % being located adjacent to the tubercle of Zuckerkandl, posterior to the terminus of the recurrent laryngeal nerve. The inferior parathyroid glands develop from the 3rd pharyngeal pouch and migrate inferiorly in conjunction with the thymus. The inferior parathyroid glands are more variable in their location. About 65 % are located on the surface of the inferior aspect of the thyroid gland, with most of the remainder being found within the thyrothymic ligament or the thymus.

**Watch Out**

The inferior parathyroid glands can sometimes be hidden in the mediastinum (within the thymus), within the carotid sheath, or behind the esophagus.

**Where Are Ectopic Parathyroid Glands Located?**

Ectopic superior parathyroid glands are most commonly found in posterior locations along the esophagus or prevertebral fascia and less commonly in undescended locations near the superior thyroid artery. Ectopic inferior glands may be located in the mediastinum or in the carotid sheath. Intrathyroidal parathyroid glands may be found in 1–4 % of humans. These are classically superior glands, though inferior glands may be partially intrathyroidal. Intrathyroidal parathyroid adenomas may be detected as hypoechoic nodules on ultrasound, and needle aspiration with cytology and/or PTH measurement within the aspirate may aid in the diagnosis. Up to 15 % of people may have more than four parathyroid glands.

**Pathology/Pathophysiology****What are the Key Differences in the Types of Hyperparathyroidism?**

Condition	Ca <sup>++</sup>	PO <sub>4</sub>	PTH <sup>a</sup>	Comments
Primary HPT	↑	↓	↑	Most often found incidentally on routine lab studies in <i>otherwise healthy</i> patients who are <i>asymptomatic</i> CI: PO <sub>4</sub> >33:1
Secondary HPT	↓ or nl	↑	↑	Hypocalcemic stimulus due to poor calcium reabsorption, lack of vitamin D activation Renal transplant usually curative
Tertiary HPT	↑	↓	↓	History of corrected renal failure with transplant Adenoma formed in setting of chronic hypocalcemia with persistent PTH stimulation Hypercalcemia can harm graft function

<sup>a</sup>PTH – intact PTH

**What Pathology Causes Primary Hyperparathyroidism? Is There a Genetic Component?**

Enlargement and hypersecretion by a single (80 %) adenoma or multiple (20 %) parathyroid glands (either four gland hyperplasia or multiple adenomas). Primary hyperparathyroidism is more common than secondary or tertiary hyperparathyroidism, affecting 1 in 400 women and 1 in 1,200 men. The cell population within parathyroid adenomas is monoclonal or oligoclonal. The cause is not well understood. Sporadic mutations in the *menin* tumor suppressor gene (that are responsible for MEN-1) have been found in parathyroid adenomas. An oncogene, *PRAD1*, has also been noted to be overexpressed in a fraction of parathyroid adenomas.

**What Is the Typical Pathology in Primary Hyperparathyroidism Associated with the MEN Disorders?**

Unlike sporadic primary hyperparathyroidism, which is usually due to a single adenoma, with MEN disorders, the gene is expressed in all glands and is thus characterized by four-gland hyperplasia.

**Table 9.1** Calcium metabolism

Hormone	Stimulus	Effect on the kidney	Effect on the bone	Effect on the intestine
<i>Parathyroid hormone</i>	↓Ca, ↑PO <sub>4</sub> , ↓1,25-OH vitamin D, mildly ↓Mg	↑1,25-OH vitamin D production, ↓tubular reabsorption of PO <sub>4</sub> and HCO <sub>3</sub>	↑Bone reabsorption	–
<i>1,25-OH vitamin D</i>	PTH	↓Tubular reabsorption of Ca	↑Ca uptake	↑Absorption of Ca and PO <sub>4</sub>
<i>Calcitonin</i>	↑Ca, gastrin	–	↓Bone resorption	–

### What Is the Pathophysiology of Secondary Hyperparathyroidism?

It is usually an adaptive response to prolonged hypocalcemia from chronic kidney disease or vitamin D deficiency which leads to parathyroid hyperplasia (polyclonal expansion) with excessive PTH secretion. Serum calcium levels can be low or normal. Secondary hyperparathyroidism requiring surgery is uncommon, affecting about 1 % of the US dialysis population each year.

### What Causes Tertiary Hyperparathyroidism?

Persistent excess secretion of PTH following renal transplantation. Renal transplantation restores normal vitamin D homeostasis and reverses secondary hyperparathyroidism in >95 % of cases within 1 year. Patients with tertiary hyperparathyroidism generally manifest with hypercalcemia, inappropriate PTH level excess, and parathyroid hyperplasia. Tertiary hyperparathyroidism is rare.

### What Are the End Organs Affected by hypocalciuric hypercalcemia, and What Are the Effects?

PTH affects the skeleton and kidneys. In the skeleton, PTH increases serum calcium by inhibiting osteoblasts from creating new bone and stimulating osteoclasts to break down the bony matrix to release additional calcium. In the kidneys, PTH increases calcium absorption and phosphate excretion. PTH also drives hydroxylation of 25-OH vitamin D to the active 1,25-OH vitamin D via the upregulation of renal 1-alpha-hydroxylase. Active vitamin D acts as a second messenger to increase calcium absorption from the gut.

### What Is the Basic Physiology of Calcium Metabolism?

Calcium homeostasis in humans is principally regulated by PTH. Calcitonin, a counter-regulatory hormone that lowers the serum calcium, is very weak and has a negligible effect in humans (Table 9.1).

---

## Work-Up

### What Laboratory Tests Are Used for the Diagnosis of Primary Hyperparathyroidism?

Serum calcium, phosphate, chloride, bicarbonate, magnesium, serum creatinine, parathyroid hormone (PTH) level, and 24-h urinary calcium.

### **Does an Elevated PTH Level Combined with an Elevated Serum Calcium Level Establish the Diagnosis of Primary Hyperparathyroidism?**

Not entirely. Urinary calcium is needed to rule out hypocalciuric hypercalcemia (FHH). FHH is rare (prevalence approximately 1 in 78,000). A high urine calcium level (hypercalciuria), with a high PTH level and high serum calcium level, confirms primary hyperparathyroidism. A low urine calcium level suggests FHH.

### **What Is the Difference Between Total Serum Calcium Level and Ionized Calcium Level?**

Total serum calcium is the sum of protein-bound calcium and free calcium. Ionized calcium reflects free (nonprotein bound) calcium.

### **If the Serum Calcium Is High, but the PTH Level Is Normal, Does That Rule Out Primary Hyperparathyroidism?**

No. In the setting of high serum calcium, the PTH level should be low. An *inappropriately normal* (non-suppressed) PTH level in the setting of hypercalcemia would strongly suggest primary hyperparathyroidism. Impaired negative feedback of this kind is often diagnostic of endocrine disease.

### **How Can the Serum Chloride to Phosphate Ratio Suggest Primary Hyperparathyroidism?**

A serum chloride to phosphate ratio  $>33$  is highly suggestive of hyperparathyroidism. PTH acts on the kidney and increases calcium reabsorption as well as excretion of bicarbonate and phosphate. Excretion of bicarbonate results in a rise in serum chloride to balance ion charges, resulting in hyperchloremic metabolic acidosis.

### **What Other Tests Should Be Ordered in a New Diagnosis of Hyperparathyroidism?**

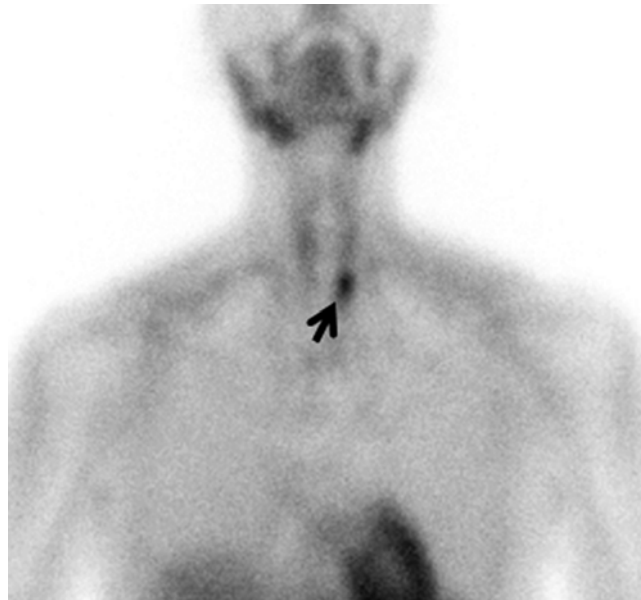Bone mineral density testing via dual-energy X-ray absorptiometry (DEXA) is indicated in asymptomatic patients, all postmenopausal women, and patients with a history of fragility fractures. A T-score is calculated. Patients with hyperparathyroidism often have osteopenia or osteoporosis. Renal ultrasound or abdominal plain films may be used in patients with symptoms suggestive of nephrolithiasis.

### **What Radiologic Findings Are Suggestive of Bony Involvement in Hyperparathyroidism?**

Plain films of the hands can reveal subperiosteal cortical bone resorption, most commonly in the distal phalanges. In rare cases of advanced disease, osteitis fibrosa cystica may be found on plain films, as manifested by brown tumors – lucent areas left by overactive bone breakdown and subsequent fibrosis.

### **What Tests Help Localize the Involved Gland in Hyperparathyroidism?**

<sup>99m</sup>Tc sestamibi scanning (Fig. 9.1) and ultrasound are the most frequently used imaging tests to localize the involved gland(s) in primary hyperparathyroidism. Dynamic parathyroid CT, sometimes termed 4D-CT, is also used by some centers. Localizing studies are generally not indicated in secondary or tertiary hyperparathyroidism, since multiple-gland hyperplasia is the expected underlying pathology.



**Fig. 9.1** Sestamibi scan showing a hyperactive parathyroid adenoma

#### **Watch Out**

Sestamibi is also taken up by the thyroid tissue. Hence, a thyroid nodule can mimic the appearance of a parathyroid adenoma.

### **What if All Localizing Scans Fail to Localize the Abnormal Parathyroid Gland(s)?**

In about 85 % of patients, imaging will localize the abnormal parathyroid gland, and a great majority will have a single parathyroid adenoma. If localizing scans are negative, yet the diagnosis of primary hyperparathyroidism is clearly established, surgery should still be considered but will be technically more challenging. Hence, patients with negative imaging should be referred to an experienced surgeon for treatment.

---

## **Management**

### **What Are the Indications for Parathyroidectomy in Primary Hyperparathyroidism?**

Parathyroidectomy is indicated in patients with symptomatic hypercalcemia (kidney stone, bone, gastrointestinal, and neuropsychiatric symptoms). For patients with asymptomatic hyperparathyroidism diagnosed through a laboratory screening, a 2008 consensus statement recommended the following indications for surgery:

1. Serum calcium level of 1.0 mg/dL greater than the upper limit of normal
2. Creatinine clearance reduced to <60 mL/min
3. Bone mineral density with T-score less than -2.5 at any site
4. Age <50
5. Patients that do not desire or cannot undergo routine surveillance

### **What Are the Indications for Parathyroidectomy in Secondary Hyperparathyroidism?**

High PTH levels (usually in excess of 800 pg/mL) despite best medical management, bone pain, pruritus, progressive renal disease, fragility fractures, or calciphylaxis (calcification of soft tissues) should undergo parathyroidectomy.

### **What Is the Nonoperative Management of Patients with Hyperparathyroidism?**

Patients not selected for surgical therapy require biochemical monitoring of serum calcium and serum creatinine annually. Bone mineral density should be measured every 1–2 years. Bisphosphonates may stabilize or improve bone mineral density. Cinacalcet, a calcimimetic, may be used to reduce the serum calcium, though it has no benefit with regard to bone density.

### **What Is the Role of Intraoperative PTH Monitoring?**

Because of the short half-life of PTH (about 4 min), intraoperative rapid PTH testing may aid in determining the completeness of parathyroid resection. The most commonly used protocol involves drawing PTH levels at the time of gland excision and again 10 min post-excision. A fall of >50 % in the PTH level is associated with a 98 % long-term cure rate.

### **What Are the Surgical Options for Hyperparathyroidism?**

If the patient has a single enlarged parathyroid adenoma, the treatment is to remove that one enlarged gland. If the patient has hyperplasia of all four glands, most surgeons recommend either removing 3½ of the glands or all four glands and reimplanting ½ (about 40 g) of one of the glands into the forearm muscle or into the sternocleidomastoid. The reason all four glands are not removed is that it usually results in permanent hypocalcemia that is very difficult to control. The reimplantation preserves some parathyroid tissue. If the patient then develops recurrent hyperparathyroidism, an incision can be made in the forearm muscle under local anesthesia, and additional tissue can be removed. This avoids a reoperation in the neck.

The tricky part of the operation is that it is not always obvious whether the patient has a single adenoma, multiple adenomas, or four-gland hyperplasia. Thus, four different operative approaches are utilized with advocates for each one:

1. Unilateral neck exploration with excision of a solitary parathyroid adenoma (commonly performed for primary hyperparathyroidism with positive localization)
2. Four-gland exploration with excision of abnormal parathyroid gland(s) and possible biopsy of normal glands (commonly performed for all cases of primary hyperparathyroidism, both localized and non-localized, depending on the surgeon's preference)
3. Subtotal parathyroidectomy: resection of 3½ parathyroid glands, with a marking clip placed on the remnant ½ gland (most appropriate for parathyroid hyperplasia)
4. Total parathyroidectomy with autotransplantation into the sternocleidomastoid or brachioradialis muscle (most appropriate for patients with a high likelihood of recurrent disease, such as MEN-1)

### **What Is the Postoperative Management Following Parathyroidectomy?**

Monitor for neck hematoma, voice changes (injury to recurrent laryngeal nerve), perioral numbness, or tingling in fingers (hypocalcemia). Bone hunger, acute postoperative hypocalcemia attributed to prior PTH-driven bone demineralization, may be observed in patients with biochemically severe disease. Routine postoperative oral calcium supplementation may alleviate minor symptoms of relative hypocalcemia and is used routinely by many expert centers. Intravenous calcium supplementation is not commonly needed.

### **What Is the Treatment for a Neck Hematoma with Stridor?**

Immediate bedside decompression followed by evacuation of hematoma and hemostasis in the operating room.



---

## What Are the Benefits of Parathyroidectomy?

Successful parathyroidectomy results in sustained increases in bone mineral density at multiple sites. Risk of new kidney stone formation falls rapidly after surgery. Approximately 70 % of patients experience improvements in quality of life attributed to relief of constitutional, musculoskeletal, and neuropsychiatric.

## Postoperative Hypocalcemia

In hyperparathyroidism, high levels of parathyroid hormone cause bone to be chronically starved of calcium. Once the hyperparathyroidism has been surgically corrected, bone may voraciously absorb calcium, causing postoperative hypocalcemia. Bone hunger may be pronounced in cases of secondary hyperparathyroidism, particularly in patients who have been on dialysis for many years. Such patients may require prolonged hospitalization for 1 week or more postoperatively for calcium supplementation.

---

## Areas of Controversy

### Surgery Versus Observation in Asymptomatic Hyperparathyroidism

Two competing consensus statements regarding surgical treatment of asymptomatic/minimally symptomatic patients have been published. The more commonly accepted international consensus guidelines, updated in 2008, recommend surgery for select patients meeting certain criteria (see *Management*, above). Approximately 40 % of patients with primary hyperparathyroidism meet one or more criteria, less than half of whom undergo surgery in community practice. The second set of guidelines, published jointly by the American Association of Endocrinologists and the American Association of Endocrine Surgeons, recommends surgery for all patients with primary hyperparathyroidism who have reasonable life expectancy and acceptable perioperative risk profiles.

### Focused/Unilateral Exploration Versus Four-Gland Exploration, Use of Intraoperative PTH Testing

Prior to the advent of localizing studies, four-gland exploration was routinely undertaken after the biochemical diagnosis of primary hyperparathyroidism was made. Starting in the mid-1980s, accurate localization with sestamibi scanning and ultrasound drove the increasing application of focused or unilateral exploration over three decades, yielding high cure rates >95 % in expert hands. Recently, long-term follow-up of large patient populations treated in expert centers has raised the question of whether focused/unilateral exploration results in a higher late recurrence rate compared with four-gland exploration.

---

## Areas Where You Can Get in Trouble

### Assuming Normal Calcium Rules Out Hyperparathyroidism

Total calcium levels can be affected by serum albumin. A malnourished patient with low serum albumin can have a falsely low total calcium level. The formula for correction is corrected Ca = serum Ca + [(0.8) (4.0 g/dL – serum albumin)]. Alternatively, serum ionized calcium can be measured, which is unaffected by albumin. However, ionized calcium is affected by blood pH. When pH is low (acidosis), there is a decreased protein binding, increasing serum ionized calcium.

### Hypocalcemia That Does Not Respond to Calcium Replacement

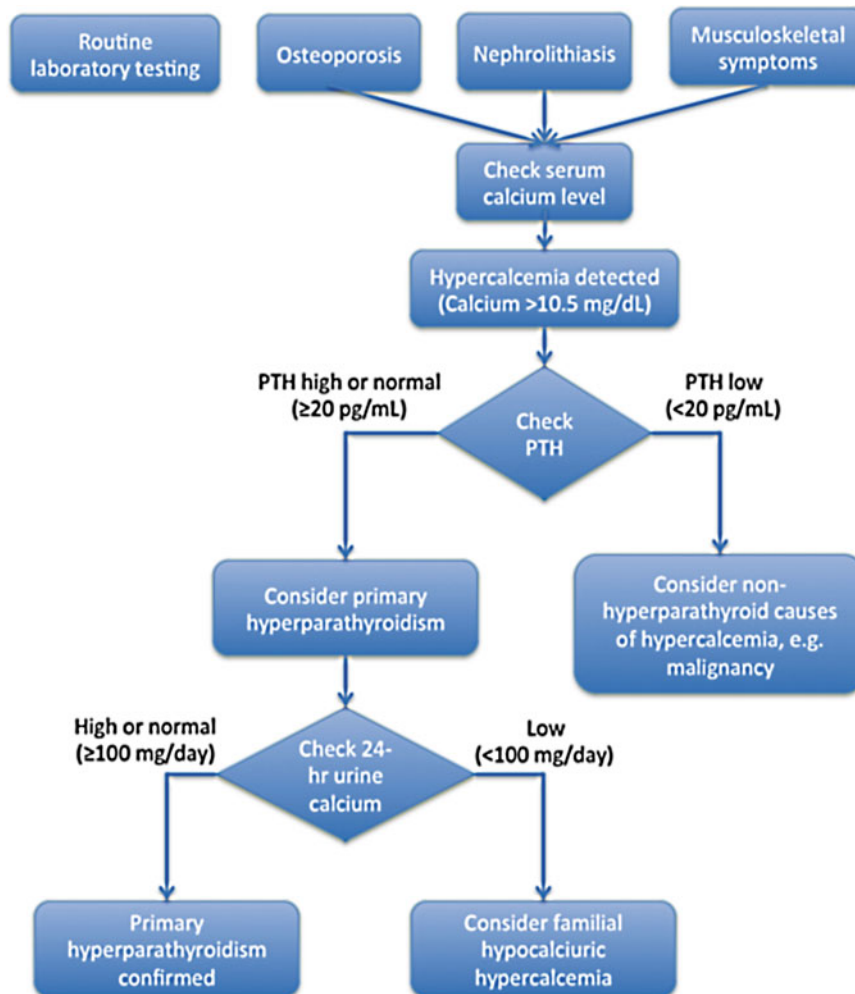
If a patient with hypocalcemia does not respond to calcium repletion, check the magnesium level. Hypomagnesemia can cause refractory hypocalcemia by inhibiting the bioactivity of PTH.

## Special Situations

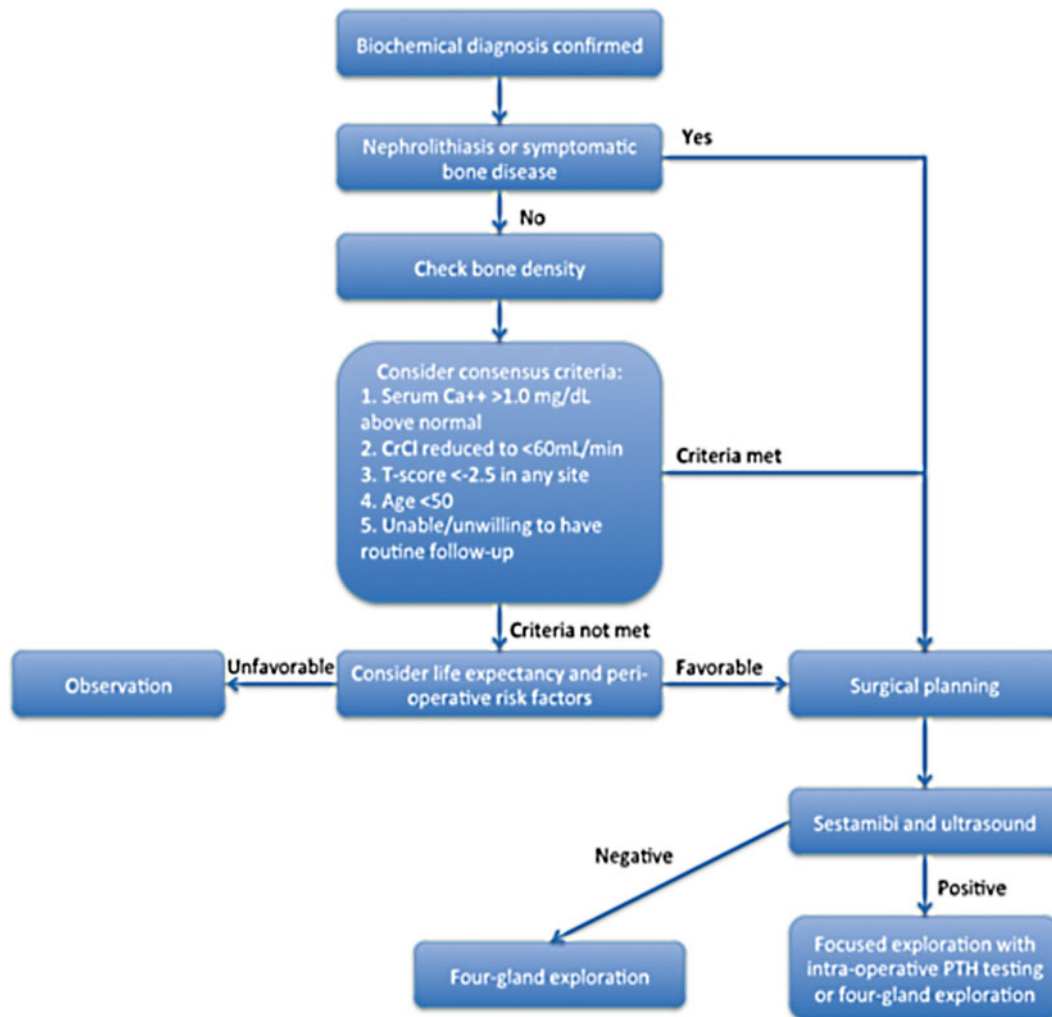
### How Do You Treat Hypercalcemic Crisis?

*Aggressive infusion of normal saline* is the first line of therapy. Hypercalcemic patients are often dehydrated, since the hypercalcemic state impairs the kidney's ability to concentrate urine. Normal saline infusion replaces this lost volume and reduces the serum calcium through dilution. After the patient has been rendered euvoemic, *loop diuretics*, which cause calciuresis, may be added. Hemodialysis may be used in rare cases in the presence of renal failure or to acutely lower the serum calcium level. *Bisphosphonates*, such as pamidronate or the more potent zoledronate, can also help by binding hydroxyapatite in bone and blocking osteoclast activity. Any drugs that may worsen hypercalcemia (e.g., thiazide diuretics) or exacerbate symptoms of hypercalcemia (digoxin potentiates arrhythmias in hypercalcemia) should be immediately discontinued. If the etiology is determined to be primary hyperparathyroidism, patients should undergo urgent parathyroidectomy.

### Algorithm for the Work-Up and Management of Hyperparathyroidism (Figs. 9.2 and 9.3)



**Fig. 9.2** Diagnostic algorithm for primary hyperparathyroidism



**Fig. 9.3** Management algorithm for primary hyperparathyroidism

## Summary of Essentials

### History and Physical

- Symptoms of HPT: stones, bones, groans, and moans
- Differential of hypercalcemia: CHIMPANZEES
- Primary hyperparathyroidism is caused by excess PTH secretion, leading to hypercalcemia and osteopenia
- The majority of patients are asymptomatic and discovered after incidental hypercalcemia is found during routine chemical panels
- The most common outpatient cause of hypercalcemia is primary HPT; the most common inpatient cause is malignancy

### Diagnosis

- Primary hyperparathyroidism: elevated calcium with high or inappropriately normal PTH level
- Secondary hyperparathyroidism: decreased serum calcium with increased intact PTH most often seen with renal disease (also vitamin D deficiency)
- Obtain bone densitometry in asymptomatic patients

## Pathophysiology

- PTH affects the bones and kidneys directly, increasing bone breakdown and calcium absorption and vitamin D activation in the kidneys
- Vitamin D increases calcium absorption in the gut

## Management

- Indication for parathyroidectomy in asymptomatic patients with primary HPT:
  - Serum calcium level 1.0 mg/dL greater than the upper limit of normal
  - Creatinine clearance reduced to <60 mL/min
  - Bone mineral density with T-score less than –2.5 at any site
  - Age <50
  - Patients that do not desire or cannot undergo routine surveillance
- Indication for parathyroidectomy in secondary HPT: high PTH level despite medical management, bone pain, pruritus, progressive renal disease, osteopenic fractures, and calciphylaxis
- Localize PTH adenoma with sestamibi scan and ultrasound

## Watch Out

- Primary HPT is most commonly caused by single parathyroid adenoma, but multiple-gland parathyroid disease is present in 10–15 % of patients
  - The parathyroid glands are variable in their location. Successful surgery depends on the knowledge of the anatomy and embryology of the parathyroids

---

## Suggested Reading

- AACE/AAES Task Force on Primary Hyperparathyroidism. The American Association of Clinical Endocrinologists and the American Association of Endocrine Surgeons position statement on the diagnosis and management of primary hyperparathyroidism. *Endocr Pract.* 2005; 11(1):49–54.
- Bilezikian JP, et al. Guidelines for the management of asymptomatic primary hyperparathyroidism: summary statement from the third international workshop. *J Clin Endocrinol Metab.* 2009;94(2):335–9.
- Li S, et al. Trends in parathyroidectomy rates in US hemodialysis patients from 1992 to 2007. *Am J Kidney Dis.* 2011;57(4):602–11.
- Schneider DF, et al. Predictors of recurrence in primary hyperparathyroidism: an analysis of 1386 cases. *Ann Surg.* 2014;259(3):563–8.
- Stewart AF. Clinical practice. Hypercalcemia associated with cancer. *N Engl J Med.* 2005;352(4):373–9.
- Yeh MW, et al. Surgery for primary hyperparathyroidism: are the consensus guidelines being followed? *Ann Surg.* 2012;255(6):1179–83.
- Yeh MW, et al. Incidence and prevalence of primary hyperparathyroidism in a racially mixed population. *J Clin Endocrinol Metab.* 2013;98(3):1122–9.

---

## Intermittent Episodes of Sweating, Palpitations, and Hypertension

# 10

Masha J. Livhits, Michael W. Yeh, and Areg Grigorian

A 34-year-old woman presents with a chief complaint of what she calls “rushes,” intermittent episodes of sweating, headaches, and palpitations lasting for a few minutes and occurring sporadically every few days. These episodes can occur at any time of day and have sometimes awakened her from sleep. She notes that exercise may provoke her symptoms. She has no significant past medical history. Her physical exam is remarkable only for newly discovered hypertension, with a blood pressure of 165/100 mmHg. Her biochemical workup reveals an elevated 24 hour urine metanephrine (1,163 mcg/day; normal <400). A dedicated adrenal-protocol CT scan shows a 4-cm mass in the right adrenal gland with central cystic change.

---

M.J. Livhits, MD (✉)

Surgery and Medicine, Section of Endocrine Surgery, UCLA David Geffen School of Medicine, 10833 Le Conte Ave.,  
Los Angeles, CA 90095, USA

e-mail: [mlivhits@mednet.ucla.edu](mailto:mlivhits@mednet.ucla.edu)

M.W. Yeh, MD

Surgery and Medicine, Section of Endocrine Surgery, UCLA David Geffen School of Medicine, 10833 Le Conte Ave, 72-228 CHS,  
Los Angeles, CA 90095, USA

e-mail: [myeh@mednet.ucla.edu](mailto:myeh@mednet.ucla.edu)

A. Grigorian, MD

Department of Surgery, University of California, Irvine, 333 City Blvd West Suite 1600, Route. 81, Orange,  
CA 92868, USA

e-mail: [agrigori@uci.edu](mailto:agrigori@uci.edu)

## Diagnosis

### What is the Differential Diagnosis and What Clues on History and Physical Examination Might Direct you Towards a Specific Diagnosis?

Diagnosis	History and physical	Comments
<i>Pheochromocytoma</i>	Episodic hyperadrenergic symptoms (5 P's): pressure (hypertension), pain (headache), perspiration, palpitation, pallor	Associated with MEN 2, neurofibromatosis-1, and von Hippel-Lindau disease (VHL)
<i>Carcinoid syndrome</i>	Bronchospasm, diarrhea, flushing of skin, and right-sided heart disease; symptoms triggered by alcohol or emotional stress	Excess serotonin release, malignant proliferation of neuroendocrine cells, most commonly arise from the small bowel, need liver metastasis or extra-GI tumor for syndrome
<i>Fibromuscular dysplasia</i>	Severe hypertension in a young female	Renal artery has "string-of-beads" appearance due to medial thinning alternating with stenosis; also affects carotid, superior mesenteric, and external iliac arteries
<i>Panic attack</i>	Intense fear or feeling of impending doom, palpitations, perspiration, and hyperventilation	Associated with mitral valve prolapse
<i>Hyperthyroidism</i>	Anxiety, emotional lability, weakness, tremor, palpitations, heat intolerance, perspiration, and weight loss despite increased appetite	Decreased TSH, increased TH
<i>Migraine</i>	Pulsatile, unilateral headache, with nausea/vomiting; some associated with aura (photopsia, paresthesia, numbness)	Can mimic stroke
<i>Coarctation of the aorta</i>	Hypertension in the arms but not the legs, weak femoral and pedal pulses	Turner syndrome, aortic valve pathology
<i>Insulinoma</i>	<i>Whipple's triad</i> : hypoglycemia, symptoms of hypoglycemia (tremulousness, palpitations, perspiration, and anxiety), and improvement after carbohydrate load	Tumor of pancreatic beta cells; MEN 1; 90 % benign
<i>Drug induced</i>	Combination of MAOI (monoamine oxidase inhibitors) with decongestants, sympathomimetics Illicit drugs including phencyclidine (PCP), lysergic acid diethylamide (LSD), and cocaine	Never give $\beta$ -blockers to patients using cocaine (can lead to vasoconstrictive angina due to unopposed alpha-receptor stimulation)

### What Is the Most Likely Diagnosis?

In a patient with newly discovered hypertension coupled with reports of episodes where she experiences sweating, flushing, and palpitations lasting for a few minutes, the most likely diagnosis is a catecholamine surge secondary to pheochromocytoma. This is further supported by her biochemical workup confirming elevated urine metanephrine levels and a CT scan showing a mass in her right adrenal gland. Additionally, she has orthostatic hypotension and elevated hematocrit and serum glucose, all of which support the diagnosis.

## History and Physical

### What Is the Differential Diagnosis for Surgically Correctable Hypertension (HTN)?

Ninety-five percent of HTN cases are due to essential or primary HTN. It is important that the clinician be aware that 5 % are due to surgically correctable causes. These include pheochromocytoma, adrenal adenomas that produce cortisol or aldosterone, renal artery fibromuscular dysplasia, and aortic coarctation.

### What Is the Classic Triad of Symptoms in Pheochromocytoma?

The symptoms of pheochromocytoma derive from the systemic effects of excess catecholamines (Table 10.1). The classic triad of symptoms includes headache, flushing, and palpitations. Though only a minority of patients have all three of these symptoms, 90 % have at least one. It is important to remember that these symptoms are nonspecific and may reflect a number of other underlying diagnoses.

**Table 10.1** Effects of normal and excessive amounts of catecholamine

Receptor	Normal function	Excessive function
$\alpha_1$	Smooth muscle contraction, gluconeogenesis, glycogenolysis	Hypertension, hyperglycemia
$\alpha_2$	Smooth muscle contraction, platelet aggregation	Pallor
$\beta_1$	Chronotropic, inotropic, sweat glands	Tachycardia, sweating
$\beta_2$	Smooth muscle relaxation	Hypotension

### What Are the Other Symptoms of Pheochromocytoma?

The vast majority of patients with pheochromocytoma have either sustained or episodic hypertension, often resistant to standard medical therapy. Other symptoms include anxiety and impaired gastrointestinal motility. Cardiovascular sequelae consist of myocardial infarction, arrhythmias, stroke, and less commonly heart failure.

#### Watch Out

Hypertension associated with pheochromocytoma can be paroxysmal or can have fluctuations superimposed on *constantly* elevated blood pressure. This is dependent on whether catecholamines are released continuously or in shorter bursts.

### Why Do Some Patients Have Orthostatic Hypotension?

Orthostatic hypotension may reflect a low intravascular volume. In addition, patients with pheochromocytoma have adrenergic receptors that are exposed to large amounts of catecholamine and can become desensitized over time. The normal baroreceptor reflex which causes vasoconstriction upon standing from a supine position may be compromised, resulting in orthostatic hypotension.

### Can Patients with Pheochromocytoma Be Asymptomatic?

With the increasing use of CT scans, upwards of 25 % of patients are now diagnosed incidentally during imaging for unrelated disorders. About 5–10 % of incidentally discovered adrenal nodules are pheochromocytomas.

### What Is the Average Age of Diagnosis? Is There a Gender Predisposition?

Patients are usually diagnosed at age 40–50 years. There is an equal incidence of cases in males and females.

### What Is the “Rule of Tens” and Is It Still True?

The “rule of tens” regarding pheochromocytoma (10 % bilateral, 10 % extra-adrenal, 10 % familial, 10 % multifocal, 10 % malignant) was taught to generations of medical students. It was ultimately disproved in the year 2000 after a series of reports described novel germline mutations causing pheochromocytoma. We now recognize that 20–40 % of pheochromocytomas arise as a result of an underlying familial syndrome and that clear genotype-phenotype correlations exist (Table 10.2).

### In a Young Patient with Hypertension, Why Is It Important to Check Blood Pressure in Both the Arms and Legs?

If arm pressures are 20 mmHg greater than the legs, this is concerning for coarctation of the aorta or narrowing of the aorta. The infantile form is associated with patent ductus arteriosus (PDA) while the adult form is not. Patients present with hypertension in the upper extremities and hypotension with weak pulses in the lower extremities. It occurs more frequently in patients with Turner syndrome and bicuspid aortic valves.

**Table 10.2** Hereditary syndromes associated with pheochromocytoma

Syndrome	Gene mutation (function)	Clinical phenotype	Pheo characteristics	Risk <sup>a</sup> (%)
<i>MEN 2A</i>	RET (proto-oncogene)	Medullary thyroid cancer, primary hyperparathyroidism	Benign, bilateral or multicentric; intra-adrenal	50
<i>MEN 2B</i>	RET (proto-oncogene)	Medullary thyroid cancer, marfanoid habitus, mucosal neuromas	Benign, bilateral or multicentric; intra-adrenal	50
<i>Neurofibromatosis (NF) type 1 (von Recklinghausen's disease)</i>	NF1 (negative regulator of ras oncogene pathway)	Neurofibromas, café au lait spots, Lisch nodules (benign iris hamartomas)	15 % malignant; intra-adrenal	1–5
<i>von Hippel-Lindau (VHL)</i>	VHL (tumor suppressor)	Retinal angioma, CNS hemangioblastoma, renal cell cancer, PNET, pancreatic and renal cysts	Benign, bilateral; younger age at diagnosis	10–20

*Pheo* pheochromocytoma, *PG* paraganglioma, *MEN* multiple endocrine neoplasia, *CNS* central nervous system, *PNET* pancreatic neuroendocrine tumor

<sup>a</sup>lifetime risk of pheochromocytoma

## Pathophysiology

### What Is a Pheochromocytoma?

A pheochromocytoma is a catecholamine-producing tumor that is derived from chromaffin cells in the adrenal medulla or sympathetic ganglia.

### What Are the Predominant Catecholamines in Adrenal and Extra-adrenal Tumors?

Most adrenal pheochromocytomas produce a combination of epinephrine and norepinephrine, with norepinephrine being the predominant catecholamine. About 30 % produce only norepinephrine. Dopamine-secreting tumors are rare and usually found in paragangliomas (extra-adrenal). Phenylethanolamine N-methyltransferase, the enzyme that converts norepinephrine to epinephrine, is primarily present in the adrenal medulla and organ of Zuckerkandl. Therefore, pheochromocytomas outside of these locations produce little or no epinephrine. The predominant catecholamine produced is also dependent on local expression of particular catecholamine synthetic enzymes. For example, enzymes that produce epinephrine require high local concentrations of glucocorticoids, making the adrenals a good place to make epinephrine-secreting tumors.

#### Watch Out

Dopamine-secreting tumors usually do not present with hypertension. Instead, these patients have watery diarrhea which reflects the effects that dopamine has on the gastrointestinal tract. Additionally, these tumors can have co-secretions with vasointestinal peptide which can exacerbate watery diarrhea.

### Where Do Pheochromocytomas Develop?

The vast majority arise in the adrenal medulla. However, they can develop anywhere along the sympathetic nervous system between the base of the skull and the bladder. The most common extra-adrenal locations are in the abdomen (75 %), bladder/prostate (10 %), thorax (10 %), and head/neck (5 %). Of those in the abdomen, the majority are located in the para-aortic organ of Zuckerkandl. Extra-adrenal pheochromocytomas are also referred to as paragangliomas.

#### Watch Out

The adrenal medulla is composed of neural crest-derived chromaffin cells.



## **What Can Trigger a Hypertensive Crisis in Pheochromocytoma?**

Catecholamine release may be caused by changes in blood flow, physical stimulation, tumor necrosis, and certain drugs including sympathomimetics (both legal and illegal) and anesthetic agents. Intubation, foods containing tyramine, abdominal trauma, surgical manipulation, emotional stress, micturition (with bladder paragangliomas), and attempts at biopsy are all known to stimulate catecholamine release from pheochromocytomas. Biopsies are generally not advised.

## **Why Do Patients with Pheochromocytoma Have Elevated Hematocrit Levels?**

The chronic alpha constriction in patients with pheochromocytoma leads to volume depletion and hemoconcentration. Additionally, paraneoplastic production of erythropoietin (EPO) leading to high hematocrit levels may be associated with pheochromocytoma.

## **Why Do Patients with Pheochromocytoma Have Hyperglycemia?**

Catecholamines are potent stimulators of hepatic glucose production and inhibitors of insulin secretion and action, leading to elevated serum glucose.

## **What Defines a Malignant Pheochromocytoma?**

The presence of local invasion into adjacent organs (e.g., kidney, liver, vessels) or distant metastases to nonchromaffin sites (liver, lungs, bone) defines a malignant tumor. This occurs in 5–10 % of sporadic cases and upwards of 30 % of inherited cases (most notably those attributed to succinate dehydrogenase subunit B (SDHB) mutations). In contrast to most other tumor types, the determination of malignancy cannot be made by histopathologic analysis of the primary tumor, as cytologic atypia, high mitotic count, presence of necrosis, and even microscopic vascular invasion can occur in tumors with benign clinical behavior. Hence, the diagnosis of malignant pheochromocytoma rests on surgical assessment of invasion and often radiologic identification of metastases.

---

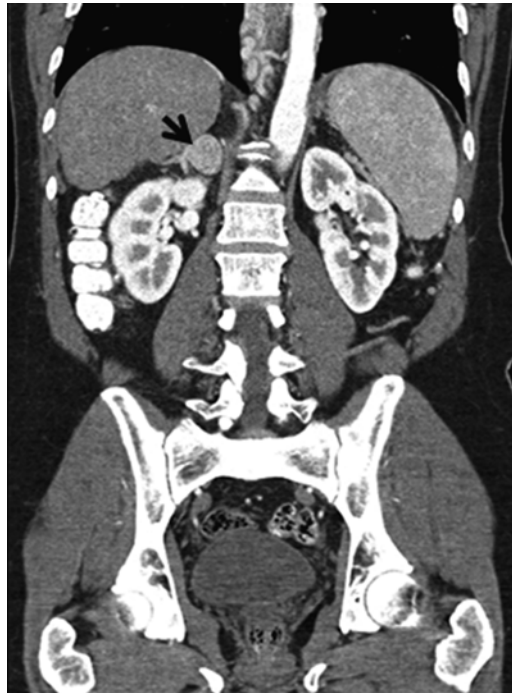
## **Workup**

### **What Laboratory Tests Can Help Make the Diagnosis of Pheochromocytoma?**

Levels of catecholamines (epinephrine, norepinephrine, dopamine) and their metabolites (metanephrine, normetanephrine, vanillylmandelic acid) can be measured in the urine or blood. Twenty-four-hour urine testing is the gold standard, and a result that exceeds twice the upper limit of normal is considered positive. Many patients with hypertension will have slightly elevated levels of catecholamines that are not indicative of pheochromocytoma. Plasma-free metanephrine testing is highly sensitive for pheochromocytoma but is more prone to false-positive results. Plasma chromogranin A is released from neuroendocrine cells and is elevated in the majority of patients with pheochromocytoma. It is nonspecific (i.e., it can be elevated in other conditions) but can help confirm the diagnosis.

### **Is Urine or Plasma Testing More Reliable?**

Establishing the diagnosis of pheochromocytoma can be challenging, since it is a rare diagnosis with a very large screening potential population (hypertensive patients with suggestive symptoms). Therefore, unless a highly specific test is used, false-positive test results will greatly outnumber true-positive test results. A 24-hour urine collection for catecholamines and fractionated metanephrines has a very high specificity (98 %) but slightly lower sensitivity (90 %). This is generally performed twice. Plasma-free metanephrine testing is slightly more sensitive (97 %) but less specific (85 %); hence it can be used to rule out pheochromocytoma when negative but must be confirmed by urine testing when positive results are noted.



**Fig. 10.1** Coronal CT with an enhancing adrenal nodule consistent with pheochromocytoma

### What Medications Can Interfere with Urine or Plasma Testing?

The following medications can cause false elevations of catecholamines: beta-blockers, decongestants, antidepressants (notably tricyclics, monoamine oxidase inhibitors, and venlafaxine), and antipsychotics (notably clozapine). Whenever possible, interfering medications should be discontinued for 2 weeks prior to biochemical testing for pheochromocytoma.

### What Imaging Studies Are Helpful in Making the Diagnosis?

First-line imaging consists of CT (Fig. 10.1) or MRI with contrast, which have high sensitivity and can detect tumors as small as 1 cm. Nuclear imaging with iodine-metaiodobenzylguanidine (I-MIBG), a catecholamine precursor that is taken up by chromaffin cells, is highly specific for pheochromocytoma and may be useful in cases of suspected multifocal or extra-adrenal disease. Co-registered imaging with  $^{18}\text{F}$ -DOPA PET/CT, a novel modality, provides both functional and cross-sectional data simultaneously.  $^{18}\text{F}$ -DOPA PET/CT is likely the optimal imaging study for pheochromocytoma at this time, though its availability is quite limited.

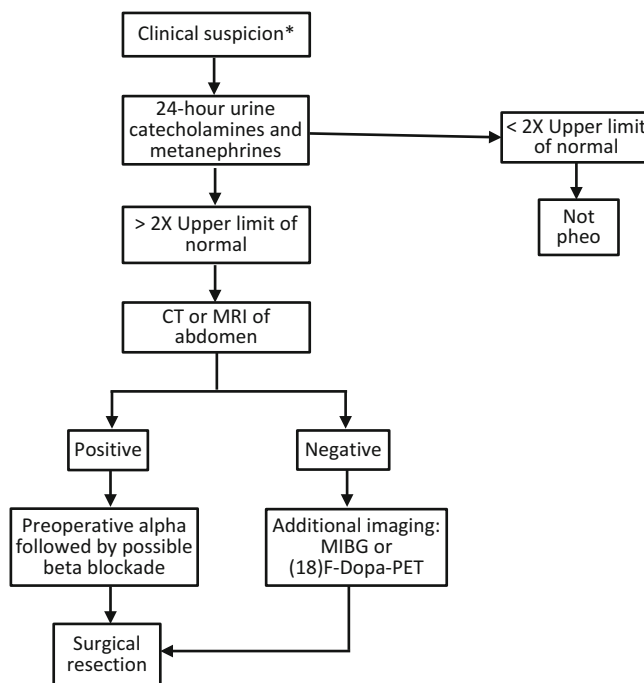
## Management

### What Is the Treatment for Pheochromocytoma?

Treatment (Fig. 10.2) consists of medical conditioning with alpha-blockade and sometimes beta-blockade for at least 2 weeks, followed by surgical resection (adrenalectomy). Surgery is usually curative, except in malignant cases.

#### Watch Out

Pheochromocytoma tumors need to be corrected first before addressing other simultaneous tumors in patients with MEN 2.



**Fig. 10.2** Algorithm for diagnosis and treatment of pheochromocytoma (\*Paroxysmal symptoms, intermittent or sustained hypertension, family history, or adrenal mass seen on imaging)

### What Are the Important Surgical Principles?

The laparoscopic approach is preferred for patients with adrenal pheochromocytomas that are less than 8 cm in size and have no malignant features on imaging. The operation can be performed either transabdominally or retroperitoneally. The arterial supply of the adrenal gland comes from the aorta, renal artery, and inferior phrenic artery. Venous drainage is generally from a single adrenal vein, which drains into the renal vein on the left side. On the right side, a short adrenal vein drains directly into the posterior aspect of the inferior vena cava (IVC). As such, ligation of the right adrenal vein is more difficult. The operation should be completed with minimal and very gentle handling of the tumor, so as to avoid intraoperative catecholamine surges. Effective communication between the surgical team and the anesthesia team is essential, and involvement of an anesthesiologist with experience in pheochromocytoma management is highly recommended. Well-conditioned patients are generally straightforward to manage hemodynamically. Ligation of the adrenal vein should be performed *early* to prevent spillage of catecholamines during tumor manipulation and provide prompt resolution of hypertension. However, vein ligation may, in some cases, bring about some degree of hypotension, requiring isotonic fluids and/or vasopressin for blood pressure support.

### How Do You Prepare a Patient for Surgery?

Alpha-blockade with phenoxybenzamine is initiated 2 weeks prior to surgery. It is titrated up until blood pressure is optimally controlled, resulting in mild orthostatic hypotension. This allows time for patients to restore their previously contracted plasma volume, ensuring that patients are not dehydrated going into surgery. A beta-blocker can be added for patients who develop tachycardia after adequate alpha-blockade.

### What Can Happen If a Beta-Blocker Is Given Prior to Adequate Alpha-Blockade?

The unopposed alpha-adrenergic stimulation from the pheochromocytoma can cause vasoconstriction and precipitate a hypertensive crisis. For this reason, alpha-blockers are always administered first.

## When Is Genetic Testing Indicated?

Genetic testing is currently recommended for all patients with pheochromocytoma or paraganglioma. This can generally be performed after surgical treatment, through referral to a genetic counselor.

### Watch Out

If a patient that has undergone bilateral adrenalectomy develops severe postoperative hypotension and/or hypoglycemia, suspect Addisonian crisis and check plasma ACTH.

## What Are the Main Complications Specifically Associated with Adrenalectomy for Pheochromocytoma?

Complication	Features
<i>Hypertension</i>	May be due to residual tumor, metastatic disease, or underlying essential hypertension
<i>Hypotension</i>	Loss of catecholamine-induced peripheral vasoconstriction, +/- residual effects of preoperative alpha-blockade; may require vigorous fluid hydration postoperatively
<i>Hypoglycemia</i>	Rebound hyperinsulinemia; symptoms may be masked by beta-blockade; monitor serum glucose closely
<i>Arrhythmia</i>	Can result from hypertensive crisis

## How Often Should Plasma and Urinary Catecholamines Be Measured Postoperatively?

These should first be measured 2 weeks after surgery. If they remain high, the patient may have a residual or metastatic tumor present. Monitoring should be continued every 3 months for the first year and then annually afterwards. This applies to normotensive and hypertensive patients.

## Prognosis

### What Is the Overall Prognosis for Pheochromocytoma?

Surgical resection is usually curative and results in normalization of blood pressure. The likelihood of malignant, multifocal, or recurrent disease varies largely as a function of the underlying genotype, since a large fraction of cases are syndromic.

### What Is the Treatment for Malignant Pheochromocytoma?

There is currently no cure, and treatment is mainly directed towards palliation of symptoms. Blood pressure is controlled with alpha-blockers. Surgical debulking is often performed and can help to ameliorate symptoms and reduce the toxic effects of high circulating catecholamines on the heart and other organs. High-dose <sup>131</sup>I-MIBG radionuclide therapy is available through clinical trials and may reduce tumor burden and symptoms in patients whose tumors take up the agent. Multidrug chemotherapy provides a partial response in up to 50 % of patients but has more associated toxicity.

## Key Areas Where You Can Get in Trouble

### Do Not Biopsy a Pheochromocytoma

The discovery of an adrenal mass on cross-sectional imaging may tempt physicians to biopsy the mass. This is ill-advised, as biopsies of the adrenal gland are generally non-informative and may be dangerous. Biopsy of an undiagnosed pheochromocytoma may result in a hypertensive crisis. The first step when an adrenal mass is found or pheochromocytoma is suspected is to perform a biochemical workup.

### Pheochromocytoma and Pregnancy

Pheochromocytoma is a rare cause of hypertension in pregnancy and has a similar clinical presentation to that of the general population. This may be difficult to distinguish from preeclampsia or pregnancy-induced hypertension. The diagnosis is made with laboratory testing, and the imaging of choice is MRI to prevent fetal radiation exposure. Medical management includes alpha-blockade followed by beta-blockade if necessary. The optimal timing of surgery is controversial. Laparoscopic adrenalectomy is considered when the diagnosis is made early in gestation, preferably during the second trimester. If discovered later in pregnancy, delivery should be by cesarean section once the fetus is viable and may be accompanied by tumor resection.

### Hypertensive Crisis During Surgery Due to Undiagnosed Pheochromocytoma

It is mandatory to work up any known adrenal nodule prior to elective surgery to rule out pheochromocytoma. If a patient has unexplained severe hypertension and tachycardia intraoperatively, the diagnosis of pheochromocytoma should be considered. Blood pressure should be managed with intravenous antihypertensive drips and volume repletion. In elective cases, the operation should be terminated after stabilizing the patient.

---

## Summary of Essentials

### History and Physical

- Look for episodic hyperadrenergic symptoms (5 P's): pressure (hypertension), pain (headache), perspiration, palpitation, and pallor
- Associated with the MEN 2 disorders, neurofibromatosis-1, and von Hippel-Lindau disease (VHL)

### Etiology/Pathophysiology

- Tumor derived from chromaffin cells in the adrenal medulla or sympathetic ganglia
- Norepinephrine-predominant catecholamine (followed by epinephrine)
- Triggers of hypertensive crisis include changes in blood flow, physical stimulation, tumor necrosis, anesthetic agents, foods containing tyramine, and surgical manipulation
- Malignancy based on local invasion, not cellular features

## Diagnosis

- Urine and/or blood levels of catecholamines (epinephrine, norepinephrine, dopamine) and their metabolites
  - Plasma-free metanephrine is most sensitive but has higher false positives
- First-line imaging consists of CT or MRI with contrast
- Nuclear imaging with iodine-metaiodobenzylguanidine (I-MIBG) is highly specific for pheochromocytoma and may be useful in cases of suspected multifocal or extra-adrenal disease

## Management

- Medical conditioning with alpha-blockade for at least 2 weeks
- Add beta-blockade for tachycardia and/or arrhythmia
- Surgical resection (adrenalectomy) is curative
  - Laparoscopic approach is preferred for patients with adrenal pheochromocytomas that are less than 8 cm in size and have no malignant features on imaging

## Watch Out

- Don't biopsy adrenal masses
- Never give beta-blocker first (unopposed alpha constriction)
  - If a patient has unexplained severe hypertension and tachycardia intraoperatively, think undiagnosed pheochromocytoma

---

## Suggested Reading

- Brink I, Hoegerle S, Klisch J, Bley TA. Imaging of pheochromocytoma and paraganglioma. *Fam Cancer*. 2005;4(1):61–8. PubMed PMID: 15883712. eng.
- Dluhy RG. Pheochromocytoma – death of an axiom. *N Engl J Med*. 2002;346(19):1486–8. PubMed PMID: 12000821. eng.
- Imani F, Agopian VG, Auerbach MS, Walter MA, Benz MR, Dumont RA, et al. 18F-FDOPA PET and PET/CT accurately localize pheochromocytomas. *J Nucl Med*. 2009;50(4):513–9. PubMed PMID: 19289420. eng.
- Karasek D, Frysak Z, Pacak K. Genetic testing for pheochromocytoma. *Curr Hypertens Rep*. 2010;12(6):456–64. PubMed PMID: 20938758. Pubmed Central PMCID: PMC3061287. eng.
- Kopetschke R, Slisko M, Kilisli A, Tuschy U, Wallaschofski H, Fassnacht M, et al. Frequent incidental discovery of pheochromocytoma: data from a German cohort of 201 pheochromocytoma. *Eur J Endocrinol*. 2009;161(2):355–61. PubMed PMID: 19497985. eng.
- Neary NM, King KS, Pacak K. Drugs and pheochromocytoma – don't be fooled by every elevated metanephrine. *N Engl J Med*. 2011;364(23):2268–70. PubMed PMID: 21651412. eng.
- Sawka AM, Jaeschke R, Singh RJ, Young WF. A comparison of biochemical tests for pheochromocytoma: measurement of fractionated plasma metanephrines compared with the combination of 24-hour urinary metanephrines and catecholamines. *J Clin Endocrinol Metab*. 2003;88(2):553–8. PubMed PMID: 12574179. eng.
- Scholz T, Eisenhofer G, Pacak K, Dralle H, Lehnert H. Clinical review: current treatment of malignant pheochromocytoma. *J Clin Endocrinol Metab*. 2007;92(4):1217–25. PubMed PMID: 17284633. eng.

---

## Neck Mass that Moves with Swallowing

11

James X. Wu and Michael W. Yeh

A 53-year-old woman is referred to your clinic with a chief complaint of a neck mass. She sought care after feeling a lump in the lower anterior neck, just right of the midline. She complains of a sensation of neck tightness, especially when lying supine. She denies any voice changes, difficulty swallowing, or pain. She denies exposure to ionizing radiation. She takes no medications and has no known drug allergies. Her social history is negative for tobacco and alcohol use. She does not have a family history of neck tumors or thyroid problems. On physical exam, she is a well-nourished normal adult female with a solitary, 2-cm nodule in the right lobe of the thyroid that moves with swallowing. There is no associated cervical adenopathy. Her laboratory tests demonstrate a Thyroid stimulating hormone (TSH) of 2 mIU/L (normal 0.4–4) and normal serum free thyroxine (T4) and free triiodothyronine (T3) levels. An ultrasound confirms the presence of a roughly spherical, well-demarcated 2-cm nodule in the right lobe of the thyroid and normal cervical lymph nodes.

---

J.X. Wu (✉)

Department of Surgery, UCLA, 757 Westwood Plaza, Mail room B711, Los Angeles, CA 90095, USA  
e-mail: [jameswu@mednet.ucla.edu](mailto:jameswu@mednet.ucla.edu)

M.W. Yeh, MD

Surgery and Medicine, Section of Endocrine Surgery, UCLA David Geffen School of Medicine, 10833 Le Conte Ave, 72-228 CHS, Los Angeles, CA 90095, USA

## Diagnosis

### What is the differential diagnosis for a thyroid mass?

Diagnosis	Description	Characteristics
<i>Thyroglossal duct cyst</i>	Congenital persistence of thyroglossal duct	Well-defined, smooth neck mass located in the midline, above the cricoid cartilage; elevates with tongue protrusion (swallowing)
<i>Multi-nodular goiter</i> • <i>Nontoxic</i> • <i>Toxic</i>	Multiple nodules distributed throughout the thyroid	Usually benign, may arise from iodine deficiency in childhood
<i>Benign follicular nodule</i>	Solitary nodule of follicular origin, may be solid or cystic ( <i>colloid nodule</i> )	Common in the general population. Prevalence increases with age, women > men
<i>Toxic adenoma</i>	Solitary nodule overproducing thyroid hormone	Almost always benign, appears as a “hot nodule” on thyroid scintigraphy; patient hyperthyroid
<i>Graves’ Disease</i>	Auto-antibodies that stimulate TSH receptor causing hyperthyroidism, diffuse enlargement, and hypervascularity of the thyroid	Ophthalmopathy (lid retraction, exophthalmos, extraocular muscle restriction, optic neuropathy) is present in half of patients and severe in 5 %
<i>Hashimoto’s thyroiditis</i>	Chronic lymphocytic infiltration and autoimmune destruction of the thyroid. Usually painless. Thyroid may be shrunken and fibrotic at the end stage	Positive serum thyroid peroxidase (TPO) antibodies; patient euthyroid in early stage, progressing to hypothyroid over years
<i>Postpartum thyroiditis</i>	Painless goiter, due to autoimmune thyroid disease following pregnancy	Patient initially hyperthyroid, followed by euthyroid state, and then hypothyroidism
<i>Subacute thyroiditis</i>	Painful, transient goiter. Cause unknown, possibly viral	Typically preceded by URI; patient hyperthyroid, followed by hypothyroidism
<i>Suppurative thyroiditis</i>	Transient, painful goiter due to bacterial infection. Most commonly due to <i>Staph. aureus</i> or <i>Strep. pyogenes</i>	Often preceded by URI; patient euthyroid
<i>Riedel’s thyroiditis</i>	Painless, progressive, firm, or “woody” goiter. Cause unknown, results in extensive fibrosis	Mainly affects women, may have positive thyroid antibodies; patient hypothyroid or euthyroid
<i>Thyroid cancer</i> ( <i>Papillary, Medullary, Follicular, Anaplastic Lymphoma, Metastases</i> )	Typically nonfunctional, painless thyroid nodules. Occurring more often in females and extremes of age	Patient usually euthyroid; prognosis varies widely from extremely indolent (papillary) to highly lethal (anaplastic)

### What Is This Patient’s Diagnosis?

With an isolated nodule in the thyroid gland, there is concern for thyroid cancer. However, there is insufficient information to make the diagnosis. The above table demonstrates the differential diagnosis for a thyroid mass.

## History and Physical

### What Are the Common Symptoms of a Patient With a Thyroid Nodule?

Patients often appreciate a lump in the anterior neck. Some may complain of shortness of breath, sensation of neck tightness, voice changes, and/or dysphagia. It is important to also assess for symptoms of hyperthyroidism or hypothyroidism (discussed below).



## How Common Are Thyroid Nodules and How Often Are They Cancerous?

Palpable thyroid nodules can be found in approximately 5 % of the population, and sonographically detectable thyroid nodules can be found in about half of the adult population. The great majority (95 %) of thyroid nodules are benign. Thyroid cancer affects 0.2 % of adults in the United States. The incidence of thyroid cancer has increased by threefold over the past 40 years. Table 11.2 indicates different types of thyroid cancers.

## What Are the Risk Factors for Thyroid Cancer?

Female gender, exposure to ionizing radiation, and family history of thyroid cancer. MEN-2A, MEN-2B, and familial medullary thyroid carcinoma (FMTC) account for 25 % of medullary thyroid cancer cases and are all related to activating mutations in the RET proto-oncogene, a cell membrane tyrosine kinase. Papillary thyroid cancer is associated with Cowden syndrome, Gardner syndrome, and familial adenomatous polyposis. One-fifth of papillary thyroid cancers are due to RET/papillary thyroid carcinoma (PTC) rearrangements, which create a fusion gene comprised of PTC promoters and the RET tyrosine kinase. An estimated one-third or more are due to mutations in BRAF, a gene encoding a signal transduction protein kinase. Thyroid cancer occurs more frequently in women than men. However, nodules occurring in men and in children or the elderly are more likely to be malignant.

### Watch Out

The developing thyroid gland is vulnerable to mutagenesis from low to moderate doses of ionizing radiation. The greatest increase in relative risk of thyroid cancer is associated with exposure before the age of 15. Today, the most common causes are childhood radiation exposure, treatment for lymphoma, and nuclear fallout.

### Watch Out

RET/PTC rearrangements can occur in Hashimoto's thyroiditis and benign adenomas as well.

### Watch Out

Most patients with thyroid carcinoma are euthyroid.

## What Are the Symptoms of Hyperthyroidism?

Nervousness, weight loss, heat intolerance, thirst, palpitations, pressured speech, and tremors. Women may have irregular or absent menses. Thyroid storm, a severe type of hyperthyroidism, causes high-grade fever, arrhythmia, GI upset, and can be fatal.

### Watch Out

The most common cause of death in patients with thyroid storm is high-output cardiac failure. It typically occurs in post-operative patients with undiagnosed Graves' disease. First-line therapy includes beta-blockers and propylthiouracil (PTU).

## **What Are the Symptoms of Hypothyroidism?**

Fatigue, weight gain, lethargy, hair changes, cold intolerance, constipation, difficulty with memory/cognition, impaired libido, and impaired fertility.

## **How Should the Thyroid Be Examined?**

To examine the thyroid, stand behind the patient, reach both hands around the patient's neck, and find the cricoid cartilage with the fingertips of both hands. The cricoid cartilage is the first complete cartilaginous ring below the thyroid cartilage (*Adam's apple*). The isthmus of the thyroid is located just a few millimeters below the cricoid. From there, move your fingers laterally to assess the thyroid lobes, checking for symmetry. Asymmetry is often the first clue to the presence of a thyroid nodule. Depress one side of the thyroid to rotate the contralateral lobe forward for a better feel. Do the same on the other side. Then ask the patient to swallow (it can be helpful to offer the patient some water to sip and hold in the mouth until you are ready). Swallowing elevates the thyroid gland. The movement will often reveal a nodule that you did not appreciate before and may reveal an inferiorly located nodule that was previously hidden behind the clavicles. Lastly, run your fingertips with a crawling motion along the sternocleidomastoid muscle bilaterally, to examine for adenopathy.

## **What Is the Significance of the Mass Moving Up and Down with Swallowing?**

The thyroid gland moves cranially when a patient swallows, due to its attachment to the trachea via the ligament of Berry. A mass that moves with the thyroid is more likely to originate within the thyroid gland as opposed to some other part of the anatomy (lymph nodes, for instance). In rare circumstances, an aggressive thyroid cancer will become fixed due to local invasion of surrounding structures. This is a worrisome sign.

## **What Is the Appearance of a Patient with Severe or Long-Standing Hyperthyroidism?**

Flushed face, warm skin, tremor, weight loss with possible muscle wasting, tachycardia, widened pulse pressure, and hyperactive reflexes.

## **What Is the Appearance of a Patient with Severe or Long-Standing Hypothyroidism?**

Periorbital swelling with puffy face and extremities, fine hair, loss of the outer aspects of the eyebrows, waxy or clammy skin, and weight gain.

---

## **Pathophysiology**

### **What Is the Function of the Thyroid Gland?**

The thyroid contains follicular cells and parafollicular C cells. Follicular cells of the thyroid produce, store, and secrete the thyroid hormones thyroxine (T4) and triiodothyronine (T3). Synthesis of T4 and T3 requires iodide, which the thyroid takes up and stores. T4 is a precursor to T3, which is ten times more potent. The thyroid normally produces 20 % of circulating T3; the rest is converted from T4 in peripheral tissues. These remain protein bound in the circulation, and only the free fraction is active. The parafollicular C cells of the thyroid secrete calcitonin.

## What Is Thyroglobulin?

Thyroglobulin (Tg) is a glycoprotein housed within thyroid follicles that is a storage form/precursor of T4 and T3. Serum thyroglobulin levels correlate positively with the amount of thyroid tissue, thyroid injury/inflammation, and the TSH level. Thus, serum Tg can be used as a tumor marker during surveillance after initial treatment of papillary and follicular thyroid cancer. Anti-Tg autoantibodies are present in about 20 % of thyroid cancer patients and can interfere with Tg testing.

### Watch Out

Tg antibodies can spuriously decrease serum Tg levels, leading to falsely negative test results. In the follow-up of thyroid cancer patients, Tg antibody levels and TSH should always be measured in conjunction with Tg, so that the Tg value can be interpreted in the appropriate context.

## What Are the Actions of Thyroid Hormones?

In general, T4 and T3 regulate basal metabolic rate, growth and development, and sensitivity to catecholamines with effects on many organ systems.

## What Is the Embryologic Origin of the Thyroid?

The primitive thyroid gland arises from the medial pharynx, part of the embryologic endoderm. This tissue descends along the thyroglossal duct into the neck and ultimately gives rise to thyroid follicles and colloid. The rostral-most aspect of the thyroglossal duct is the foramen cecum. C cells, which produce calcitonin, arise from the fourth pharyngeal pouch and migrate from the neural crest into the thyroid gland.

### Watch Out

Ectopic thyroid tissue may be found anywhere along the thyroglossal duct as well as in the anterior mediastinum. Additionally, the thyroglossal duct may not completely obliterate and leave behind thyroglossal duct cysts.

### Watch Out

Ectopic thyroid tissue in the lateral position of the neck is usually a well-differentiated thyroid cancer that has metastasized to cervical lymph nodes.

### Watch Out

Although papillary thyroid carcinoma is known to first spread to the lymphatic system, the prognosis is based on the presence of local invasion.

### Watch Out

Metastatic medullary carcinoma frequently causes diarrhea and flushing, thought to be due to the high *calcitonin* levels.

**Table 11.1** Describe the different types of thyroid cancer

Type	Description	% of thyroid cancer	Characteristics
<i>Papillary adenocarcinoma</i>	Arises from follicular cells; presents as single nodule, often with internal calcifications, usually in early adulthood	~80 %	<i>Slow growing, excellent prognosis</i> with overall survival rates ~95 %; propensity to spread to regional lymph nodes; diagnosis established by characteristic nuclear features found on FNA
<i>Follicular adenocarcinoma</i>	Arises from follicular cells; occurs later in life than papillary; forms soft, rubbery, encapsulated tumors	10–20 %	Good prognosis with overall survival rates ~85 %; propensity to spread <i>hematogenously</i> to distant sites (most common is bone); <i>cannot be diagnosed on FNA</i> or frozen section; diagnosis rests on demonstration of capsular and/or vascular invasion on permanent section
<i>Hurthle cell carcinoma</i>	Subtype of follicular carcinoma; composed of Hurthle cells: large eosinophilic epithelial cells	5 %	Similar to follicular carcinoma but with slightly worse prognosis (overall survival ~75 %); most do not take up RAI
<i>Medullary carcinoma</i>	Arises from C (parafollicular) cells, secretes calcitonin; hard, solid, tumors containing amyloid	5–7 %	Overall survival ~75 %; commonly spreads to regional lymph nodes; miliary liver metastases also common; underlying germ line mutation exists in 25 % of cases; associated with MEN-2A or MEN-2B
<i>Anaplastic carcinoma</i>	Extremely aggressive cancer, likely dedifferentiated papillary or follicular thyroid cancer	1–2 %	Median survival 6 months; uniformly lethal
<i>Thyroid lymphoma</i>	Typically B-cell non-Hodgkin lymphoma	<5 %	Commonly develops in the setting of Hashimoto's thyroiditis
<i>Metastases to the thyroid</i>	Metastases from distant primary malignancy	<1 %	Primary malignancy usually arises from the kidney, breast, lung, or skin (melanoma)

FNA, fine needle aspiration; RAI, radioactive iodine

### Why Cannot Fine Needle Aspiration (FNA) Be Used to Diagnose Follicular Thyroid Carcinoma?

The determination of whether a follicular neoplasm is malignant is a histologic one, not a cytologic one (this differs from papillary cancer). In other words, it rests on whether the proliferation of follicles breaches the capsule and *invades* it. There are no distinguishing cellular features that mark it as malignant. Thus, fine FNA (which only aspirates cells) is not able to determine malignancy since it cannot assess for capsular invasion.

### What Is Considered Well-Differentiated Thyroid Cancer?

Tumors arising from follicular cells are categorized as well differentiated. This category includes papillary, follicular, and Hurthle cell carcinomas. See Table 11.1 for summary of types of thyroid cancer.

#### Watch Out

Thyroid cancer is considered the most common endocrine malignancy in the United States.

### What Are Psammoma Bodies?

Microscopic finding of round, laminar collections of calcified tissue. Seen in papillary thyroid cancer but also found in a number of malignant and benign lesions.

#### Watch Out

The cancers associated with psammoma bodies can be remembered by **psammoma**: papillary carcinoma of the thyroid, serous cystadenocarcinoma of the ovary, meningioma, mesothelioma

## Work-Up

### What Laboratory Tests Are Recommended for a Thyroid Mass?

The first test is a *thyroid-stimulating hormone (TSH)* level. This is the most sensitive measure of thyroid dysfunction and the only test indicated in screening or in the absence of symptoms of hyper- or hypothyroidism. T4 and T3 testing may be indicated if the TSH is abnormal.

### What Are the Appropriate Imaging Studies for a Thyroid Nodule?

Bedside neck ultrasound performed by the surgeon is ideal and increasingly applied nationally. Ultrasound can detect nodules and lymphadenopathy, characterize masses as solid or cystic, and guide FNA. Hypochoic nodules and those with irregular margins or microcalcifications are more likely to be malignant. Patients with clinical or sonographic evidence of locally advanced thyroid cancer that may extend into the aerodigestive tract or substernal region should undergo further cross-sectional imaging with CT or MRI.

### Is Routine Use of Nuclear Imaging Useful for an Isolated Thyroid Nodule?

Thyroid scintigraphy, performed with  $I^{123}$ , is rarely used today. Although iodine-avid (hyperfunctional or “hot”) nodules are virtually all benign, “cold” nodules (with low or no uptake, meaning they are nonfunctional) are only malignant in about 5 % of cases. As such, whether a nodule is hot or cold is not that discriminating and has largely been replaced by FNA. The rare situation where scintigraphy is useful is in the setting where repeat FNA is indeterminate for malignancy. Rather than proceeding to open surgery, some advocate scintigraphy as it may obviate the need for biopsy if the nodule is hot.

### What Nodules Should Undergo FNA?

Thyroid nodules greater than 1 cm in size, nodules with ultrasound characteristics suggestive of malignancy (e.g., internal microcalcifications), or those with a history of growth. Suspicious cervical lymph nodes should also undergo FNA during the same encounter. Nodules less than 1 cm, purely cystic nodules, and those with clearly benign sonographic features as determined by an experienced practitioner do not warrant FNA.

### How Are FNA Results Reported?

A comprehensive reporting system was established by a National Cancer Institute consensus conference in 2009, named the Bethesda System for Reporting Thyroid Cytopathology (Table 11.2).

**Table 11.2** Bethesda reporting system for FNA of thyroid nodules

FNA result	Risk of malignancy (%)
<i>Benign</i>	0–3
<i>Atypia of undetermined significance or follicular lesion of undetermined significance (AUS/FLUS)</i>	5–15
<i>Suspicious of follicular neoplasm</i>	15–30
<i>Suspicious for malignancy</i>	60–75
<i>Malignant</i>	97–99
<i>Inadequate/nondiagnostic</i>	1–4

## Management

### What Is the Next Step in a Patient With an Inadequate/Nondiagnostic FNA?

An *inadequate* FNA is a technically failed biopsy which does not yield sufficient cells to establish a diagnosis. This must be distinguished from an *indeterminate* FNA, which is a technically successful biopsy with adequate cellular yield in which no definite diagnosis of a benign or malignant process can be made (corresponding to Bethesda categories AUS/FLUS and suspicious for follicular neoplasm). *Inadequate* biopsies should generally be repeated.

### What Is the Next Step for a Benign FNA Result?

Annual follow-up with ultrasonography. Nodules that enlarge and/or develop suspicious sonographic features warrant repeat FNA or surgical excision.

### What Is the Next Step for an FNA Which Reports AUS or FLUS?

Management is controversial. The current accepted standard of care is to repeat FNA, since only 20 % demonstrate FLUS a second time, with many nodules found to be benign on the second biopsy.

### What Is the Next Step for an FNA Result of Suspected Follicular Neoplasm?

Remove one lobe of the thyroid. Open biopsies of a thyroid nodule require removal of the entire lobe (meaning the right or left lobe of the thyroid gland, called a thyroid lobectomy). A simple biopsy is not done due to: (a) the thyroid gland being extremely vascular so trying to remove part of the lobe would be very bloody, (b) tumor cells may be spilled in the process, and (c) removing a lobe of the thyroid does not adversely affect thyroid function. Approximately 25 % of these lesions are ultimately found to be malignant. Follicular thyroid carcinoma is indistinguishable from follicular adenoma on FNA and can only be diagnosed on permanent surgical histopathology. Frozen section is generally not helpful for these lesions (see below).

### What Is the Next Step If the Thyroid Lobectomy Reveals Follicular Cancer?

Patients found to have follicular carcinoma on lobectomy should return to the OR for completion (total) thyroidectomy at a later date.

### What Are the Advantages of Total Thyroidectomy in Thyroid Cancer Versus Lobectomy?

Removing the remainder of the thyroid allows for removal of any missed contralateral foci of thyroid cancer (present in up to 70 % of cases). It also allows for using a radioactive iodine scan to detect/treat recurrence or metastases (if half the thyroid is left, such a scan would only light up the remaining thyroid). Finally, total thyroidectomy allows the use of serum thyroglobulin as a marker for recurrence.

### What Thyroid Malignancy Is Amenable to Thyroid Lobectomy Alone? When Is Total Thyroidectomy Appropriate?

Small (<1 cm), unifocal, papillary thyroid carcinomas have such a favorable prognosis and low recurrence rates that total thyroidectomy is of little or no value. In addition to follicular cancer, total thyroidectomy is recommended for larger (>1 cm) papillary and medullary carcinomas.

## **Is It Ever Appropriate to Proceed Directly to Total Thyroidectomy Without Performing a Lobectomy First?**

Surgeons will proceed directly to total thyroidectomy when the FNA returns suspected follicular neoplasm in the following scenarios: bilateral nodules, index nodule >4 cm (higher rate of malignancy), preexisting hypothyroidism, family history of thyroid cancer, or history of exposure to ionizing radiation (the latter two increase the risk of multicentric cancer).

## **What Is the Management of Anaplastic Thyroid Cancer?**

Given the rarity and heterogeneity of presentation, therapy is not standardized. Initial surgical resection or debulking may be considered if preoperative imaging suggests feasibility. If not, chemotherapy and external beam radiation may be performed as first-line therapy, possibly followed by surgery in responsive cases. Treatment is generally palliative (given its aggressive nature) and may include early tracheostomy for airway protection.

## **When Should Central Lymph Node Dissection Be Done? Lateral Neck Dissection?**

For medullary and some papillary cancers. All patients with medullary thyroid carcinoma >1 cm should undergo initial central neck dissection. The indications for central neck dissection in papillary thyroid carcinoma are controversial and discussed below. Lateral neck dissection (modified radical neck dissection) is generally performed when palpable or sonographically abnormal lymph nodes are found in the lateral compartment (jugular chain, deep to the sternocleidomastoid muscle). Follicular cancer spreads hematogenously so there is no role for lymph node dissection.

## **What Is the Role of Intraoperative Frozen Section Pathology?**

Frozen section is generally not useful in the diagnosis of follicular thyroid lesions, and its use should therefore be highly selective. Frozen section only evaluates one or two small sections of the tumor, so capsular invasion will easily be missed. Frozen section can usually diagnose papillary thyroid carcinoma (though recall that almost all of these can be readily diagnosed preoperatively on FNA) but is unable to confirm follicular carcinoma. Frozen section may be used to confirm the presence of thyroid cancer within the lymph nodes.

## **Which Thyroid Cancers Concentrate Radioactive Iodine?**

Most papillary thyroid cancers (70 %) and follicular thyroid cancers (80 %) concentrate radioactive iodine. This has important implications in the use of postoperative radioactive iodine ablation. Only a minority of Hurthle cell carcinomas (5 %) concentrate iodine. Medullary thyroid cancers do not.

## **What Are the Important Elements of Postoperative Management of Thyroid Cancer?**

### **Radioactive Iodine Ablation**

Radioactive iodine (RAI) ablation with  $I^{131}$  may improve survival and reduce recurrences in a follicular thyroid carcinoma and a subset of high-risk papillary thyroid carcinomas.

### **Suppressive Thyroxine Therapy**

TSH stimulates growth of target tissues. Thus, all thyroid cancers should undergo suppression of TSH with exogenous levothyroxine following surgery.

## Follow-Up

Baseline measurement of thyroglobulin and anti-thyroglobulin antibodies should be measured twice annually and then annually when stable. After total thyroidectomy, thyroglobulin (made in the follicle) should become undetectable. Detectable levels should arouse suspicion of recurrence. Neck ultrasound should also be performed annually. Medullary thyroid carcinomas should be followed with serum calcitonin.

### If You Suspect Recurrence, What Study Do You Perform?

If serum Tg levels increase on postoperative monitoring and there is concern for cancer recurrence, patients should first undergo neck ultrasound with a full lymph node survey by an experienced practitioner. This often demonstrates a target lesion that is amenable to FNA. Foci of thyroid cancer outside the neck may be detected by diagnostic I<sub>131</sub> radionuclide scan or thin cut (non-contrast) chest CT.

### Does External Beam Radiation Play a Role in Thyroid Cancer?

Yes, though it is used in <5 % of cases. External beam radiation is used for locally invasive tumors following incomplete resection (positive margins) or for palliation of bony metastases.

### What Nonoperative Management Is Available for Thyroid Nodules?

Radioactive ablation with I<sup>131</sup> can treat hyperfunctioning nodules, reducing tumor size and rendering patients euthyroid in 75 % of cases. For nonfunctioning thyroid nodules, which are the great majority, the alternative is observation.

---

## Complications

### What Are the Major Structures That Can Be Injured During Thyroidectomy?

The recurrent laryngeal nerve, the external branch of superior laryngeal nerve, and the parathyroid glands. The recurrent laryngeal nerve, a branch off the vagus nerve, innervates all of the muscles of the larynx except the cricothyroid muscle. It also provides sensory innervation to the larynx below the vocal cords and parasympathetic innervation to the mucosa in this region. Damage to the recurrent laryngeal nerve on one side results in a paralyzed vocal cord in a median or paramedian position. This manifests as hoarseness and sometimes aspiration. The rate of permanent unilateral recurrent laryngeal nerve injury during thyroidectomy should be less than 2 % in expert hands. Bilateral recurrent laryngeal nerve injury causes airway obstruction and may necessitate urgent tracheostomy. The external branch of the superior laryngeal nerve permits speaking or singing in a high pitch. This nerve may be injured in up to 25 % of cases but is usually asymptomatic unless the patient is a singer or voice professional. Permanent hypoparathyroidism usually results from devascularization of the parathyroids and should occur in less than 2 % of cases in expert hands. Permanent hypoparathyroidism is treated with calcium and calcitriol supplementation.

### Postoperatively, the Patient Develops Stridor in the Recovery Room: The Neck Wound Appears to Be Tense. What Is the Next Step?

Emergent bedside decompression of the hematoma – cut the sutures and open the wound. This usually relieves the airway obstruction immediately. The patient should then return to the operating room for evacuation of the hematoma, irrigation, and careful hemostasis.



## Key Areas Where You Can Get in Trouble

### Incomplete Family History in Patient with Thyroid Mass

Family history should not be overlooked. As mentioned above, 25 % of patients with medullary thyroid cancer have an underlying germ line mutation: MEN-2A, MEN-2B, or FMTC. If medullary thyroid carcinoma is diagnosed on FNA, the immediate next steps are to review the family history and check 24 hour urine catecholamines and metanephrines to exclude pheochromocytoma. Even if there is no family history of endocrine disease, the patient at hand may carry a de novo germ line mutation. Taking a patient to surgery for medullary thyroid carcinoma without first excluding pheochromocytoma biochemically is a potentially lethal error, as induction of anesthesia may trigger sudden release of catecholamines, resulting in stroke, acute myocardial infarction, or heart failure. Discovery of medullary thyroid cancer mandates genetic screening of the patient for RET mutations and, if positive, first-degree relatives. Children with known MEN-2A, MEN-2B, or FMTC should undergo prophylactic thyroidectomy; the recommended age for intervention varies by genotype. MEN-2B mutations are associated with the most aggressive medullary thyroid cancers, and known carriers should undergo thyroidectomy during the first year of life.

### Obtaining CT with Iodinated IV Contrast in Patients with Thyroid Cancer

Prior to radionuclide imaging and ablation, patients are depleted of iodine by maintaining a low iodine diet for several weeks. This, combined with an elevated TSH (achieved by either thyroid hormone withdrawal or injection of recombinant human TSH), optimizes RAI uptake by thyroid cells. Iodinated contrast carries a large load of iodine and may suppress RAI uptake for up to 1 month.

### Missing Postoperative Hypocalcemia

Postoperative hypoparathyroidism must be promptly recognized and treated in order to avoid hypocalcemic emergencies and near emergencies. Oral calcium supplementation is the preferred method of treatment. Because of the delayed action of oral calcium, an anticipatory rather than reactive protocol of managing postoperative hypoparathyroidism, aided by PTH measurement, is most effective.

### Not Recognizing a “Lateral Aberrant” Thyroid Gland

Thyroid tissue present in the lateral compartment of the neck most often represents metastatic papillary thyroid carcinoma within a lymph node.

---

## Areas of Controversy

### Role of Prophylactic Central Neck Dissection (CND) for Papillary Thyroid Cancer

Reoperation for lymphadenectomy is difficult, and pathology reveals central lymph node involvement in 40–60 % of patients with papillary thyroid cancer with clinically negative nodes. Some surgeons advocate prophylactic central lymphadenectomy, citing the following benefits: improved staging, lower postoperative thyroglobulin levels, and a reduced need for reoperation. The effect of prophylactic CND on overall survival is unclear at this time. CND theoretically increases the risk of injury to the recurrent laryngeal nerve and the parathyroid glands; however, recent studies have shown no increase in the permanent complication rate within expert centers rate.

## Management of FNA Biopsy Showing AUS/ FLUS

Per the original description of the Bethesda System for Reporting Thyroid Cytology, AUS/FLUS should undergo repeat FNA given the low risk of malignancy (5–15 %). However, given the subjective nature of thyroid FNA interpretation, the malignancy rate for lesions categorized as AUS/FLUS may be higher depending on the individual institution. As a consequence, some authors advocate diagnostic thyroid lobectomy when an FNA reveals AUS/FLUS. Currently, intense research is being conducted on the role of molecular markers in the diagnosis of thyroid nodules classified as AUS/FLUS or suspicious for follicular neoplasm, and this field is evolving rapidly.

### Management Algorithm (Fig. 11.1)

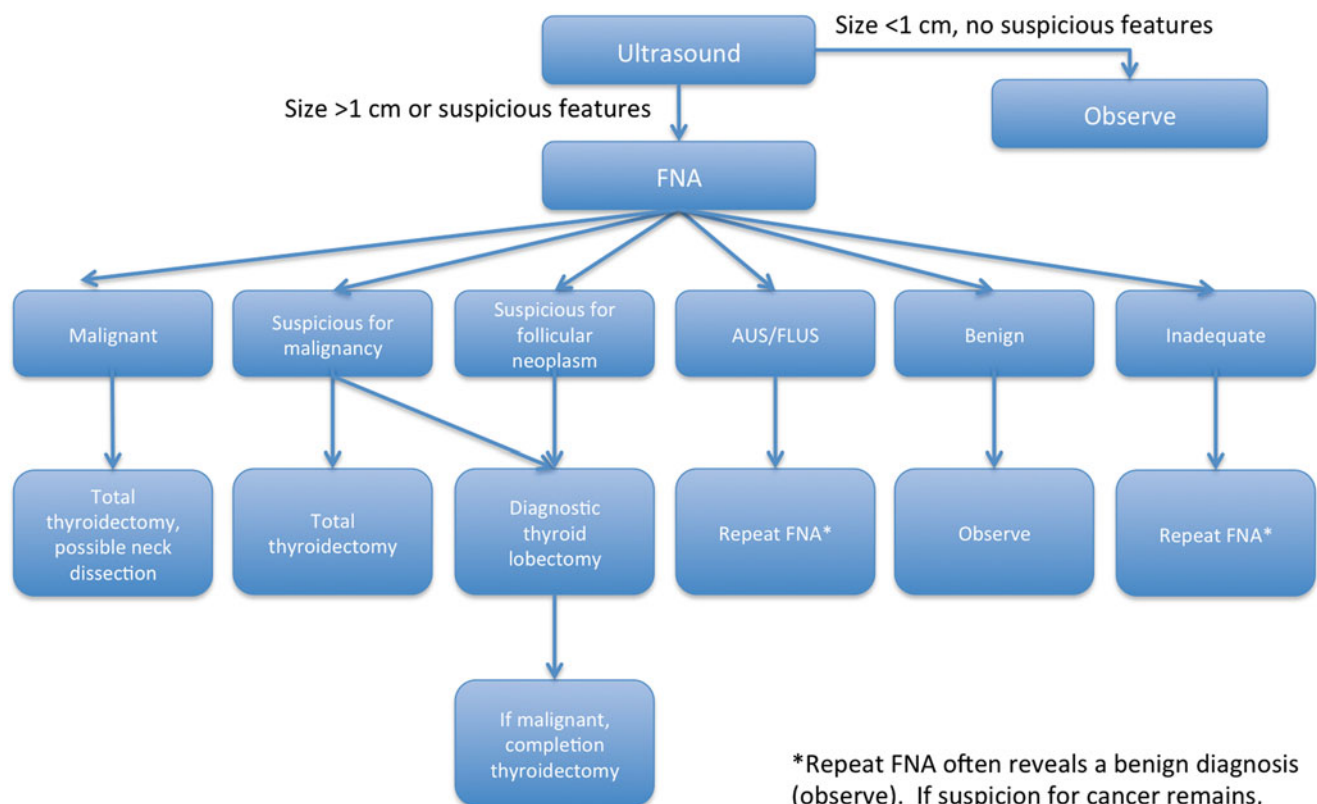
#### Summary of Essentials

#### History and Physical

- Thyroid nodules are common; thyroid cancer is relatively rare
- Risk factors for thyroid cancer are ionizing radiation exposure and family history of thyroid cancer
- Hyperthyroidism: nervousness, fatigue, weight loss, thirst, palpitations
- Hypothyroidism: fatigue, weight gain, constipation, impaired cognition/libido

#### Diagnosis

- The most important initial test is TSH
- Thyroid nodules should be evaluated with ultrasound. If TSH is elevated, get a radioactive iodine scan
- Iodine-avid, “hot” nodules have low risk of malignancy
- Thyroid nodules >1 cm, suspicious ultrasound findings, or increasing in size should undergo FNA



**Fig. 11.1** Diagnostic algorithm for nonfunctioning solitary thyroid nodule found on examination or imaging

## Pathophysiology

- The thyroid gland is comprised mostly of follicular cells that produce thyroid hormones T4 and T3 from thyroglobulin. There is a small population of parafollicular C cells that secrete calcitonin
- Papillary and follicular thyroid cancers arise from follicular cells. They are considered “well differentiated” and a majority take up iodine
- Medullary thyroid cancer arise from parafollicular “C” cells

## Management

- FNA is the most important part of the initial work-up of the solitary thyroid nodule
- Inadequate: repeat FNA
- Benign: observe
- AUS/FLUS: repeat FNA
- Suspicious for follicular neoplasm: diagnostic thyroid lobectomy
- Suspicious for malignancy: consider total thyroidectomy
- Malignant: total thyroidectomy and consider neck dissection

## Watch Out

- Twenty five percent of patients with medullary thyroid carcinoma have an underlying germ line mutation. Pheochromocytoma must be excluded biochemically prior to surgery in all patients with an FNA diagnosis of medullary thyroid carcinoma
- “Ectopic thyroid tissue” in the lateral neck usually metastasize to cervical lymph nodes
- Numbness and tingling in the lips and fingers after total thyroidectomy usually represents hypoparathyroidism and should be promptly treated with oral calcium
- Postoperative neck swelling accompanied by stridor is a hematoma compressing the airway. This is a surgical emergency requiring bedside decompression

---

## Suggested Reading

- Alexander EK, et al. Preoperative diagnosis of benign thyroid nodules with indeterminate cytology. *N Engl J Med.* 2012;367(8):705–15.
- American Thyroid Association Guidelines Task Force, et al. Medullary thyroid cancer: management guidelines of the American Thyroid Association. *Thyroid.* 2009;19(6):565–612.
- Barczynski M, et al. Prophylactic central neck dissection for papillary thyroid cancer. *Br J Surg.* 2013;100(3):410–8.
- Bonnet S, et al. Prophylactic lymph node dissection for papillary thyroid cancer less than 2 cm: implications for radioiodine treatment. *J Clin Endocrinol Metab.* 2009;94(4):1162–7.
- Broome JT, Solorzano CC. The impact of atypia/follicular lesion of undetermined significance on the rate of malignancy in thyroid fine-needle aspiration: evaluation of the Bethesda System for Reporting Thyroid Cytopathology. *Surgery.* 2011;150(6):1234–41.
- Chen JC, et al. Yield of repeat fine-needle aspiration biopsy and rate of malignancy in patients with atypia or follicular lesion of undetermined significance: the impact of the Bethesda System for Reporting Thyroid Cytopathology. *Surgery.* 2012;152(6):1037–44.
- Cibas ES, Ali SZ, N.C.I.T.F.S.o.t.S. Conference. The Bethesda System for Reporting Thyroid Cytopathology. *Am J Clin Pathol.* 2009;132(5):658–65.
- Harvey AM, Mody DR, Amrikachi M. Thyroid fine-needle aspiration reporting rates and outcomes before and after Bethesda implementation within a combined academic and community hospital system. *Arch Pathol Lab Med.* 2013;137(11):1664–8.
- Kouvaraki MA, et al. RET proto-oncogene: a review and update of genotype-phenotype correlations in hereditary medullary thyroid cancer and associated endocrine tumors. *Thyroid.* 2005;15(6):531–44.
- Marotta V, et al. RET/PTC rearrangement in benign and malignant thyroid diseases: a clinical standpoint. *Eur J Endocrinol.* 2011;165(4):499–507.
- Nikiforov YE, et al. Impact of mutational testing on the diagnosis and management of patients with cytologically indeterminate thyroid nodules: a prospective analysis of 1056 FNA samples. *J Clin Endocrinol Metab.* 2011;96(11):3390–7.
- Nygaard B, et al. Long-term effect of radioactive iodine on thyroid function and size in patients with solitary autonomously functioning toxic thyroid nodules. *Clin Endocrinol (Oxf).* 1999;50(2):197–202.
- Popadich A, et al. A multicenter cohort study of total thyroidectomy and routine central lymph node dissection for cN0 papillary thyroid cancer. *Surgery.* 2011;150(6):1048–57.
- Raffaelli M, et al. Prospective evaluation of total thyroidectomy versus ipsilateral versus bilateral central neck dissection in patients with clinically node-negative papillary thyroid carcinoma. *Surgery.* 2012;152(6):957–64.
- VanderLaan PA, Marqusee E, Krane JF. Clinical outcome for atypia of undetermined significance in thyroid fine-needle aspirations: should repeated fna be the preferred initial approach? *Am J Clin Pathol.* 2011;135(5):770–5.
- Wiseman JE, et al. An algorithm informed by the parathyroid hormone level reduces hypocalcemic complications of thyroidectomy. *World J Surg.* 2010;34(3):532–7.

---

**Part V**

**Head and Neck**

Vishad Nabili, Section Editor

Kevin A. Peng, Irene A. Kim, and Vishad Nabili

A 62-year-old male presents with a 2-month history of a progressively hoarse voice. Initially, his voice was only slightly raspy, but over time, he has lost the ability to project his voice and is only able to speak in a loud whisper. He endorses blood-tinged sputum with coughing, which has occurred approximately twice a week for the past month. The social history is remarkable for a 40-pack-year smoking history; he continues to smoke one pack per day. On review of systems, he denies dyspnea, dysphagia, and odynophagia. On physical examination, his voice is breathy and raspy. His oral cavity and oropharynx are remarkable only for caries, and his neck is supple, without lymphadenopathy. Flexible laryngoscopy performed in clinic reveals friable masses on both vocal cords, with a widely patent airway but with impaired mobility of the left vocal cord.

## Diagnosis

### What is the Differential Diagnosis for Hoarseness?

Diagnosis	History and Physical
<i>Viral laryngitis</i>	Acute onset of fever, sore throat, cough, and/or other symptoms consistent with upper respiratory tract infection
<i>Vocal cord paralysis</i>	Breathy voice, most commonly idiopathic or iatrogenic (e.g., injury to recurrent laryngeal nerve during thyroid or thoracic surgery)
<i>Vocal cord nodules, polyps, cysts, or granulomas</i>	Unilateral or bilateral lesions usually resulting from trauma to the vocal cord (voice abuse, endotracheal intubation)
<i>Recurrent respiratory papillomatosis</i>	Benign, occasionally aggressive growths caused by human papillomavirus (HPV)
<i>Spasmodic dysphonia, Parkinson's disease, or other neurological disorder</i>	Vocal tremors or an intermittently breathy or strained voice
<i>Laryngeal cancer</i>	Subacute to chronic onset of dysphonia, possibly with cervical lymphadenopathy (signifying cancer metastasis to regional lymph nodes); smoking is the single largest risk factor

K.A. Peng, MD (✉)

Department of Head and Neck Surgery, David Geffen School of Medicine, University of California, Los Angeles, 10833 Le Conte Ave. CHS 62-132, Los Angeles, CA 90095, USA

e-mail: [kap@ucla.edu](mailto:kap@ucla.edu)

I.A. Kim, MD

Department of Head and Neck Surgery, David Geffen School of Medicine, University of California, Los Angeles, 10833 Le Conte Ave. CHS 62-132, Los Angeles, CA 90095, USA

e-mail: [iakim@mednet.ucla.edu](mailto:iakim@mednet.ucla.edu)

V. Nabili, MD

Department of Head and Neck Surgery, David Geffen School of Medicine, University of California, Los Angeles, 10833 Le Conte Ave. CHS 62-132, Los Angeles, CA 90095, USA

e-mail: [vnabili@mednet.ucla.edu](mailto:vnabili@mednet.ucla.edu)

**Watch Out**

Many lesions that cause hoarseness concomitantly narrow the airway. Be on the lookout, and remember the ABCs: airway comes first!

**What Is the Most Likely Diagnosis in This Patient?**

Taken together, the patient's age, male gender, history of smoking, subacute onset and progression of symptoms, hemoptysis, and appearance of vocal cords on examination are concerning for malignancy (most likely squamous cell carcinoma of the larynx). The absence of cervical lymphadenopathy does not rule out the possibility of laryngeal cancer.

**History and Physical Examination****What Information Can the Nature of Hoarseness Provide?**

Hoarseness, more strictly termed dysphonia, can be qualified specifically. In order to phonate, produce a sound, the vocal cords must move and oppose at the midline (adduction). To breathe, the vocal cords must open (abduction). A *breathy* voice is caused by incomplete closure, as seen with a unilateral vocal cord paralysis. *Aphonia*, the inability to create any vocal sound, is usually due to vocal cords that remain far abducted during attempted phonation, but can be due to mucosal swelling or irregularities precluding any vibration from occurring along the vocal cord. A *strained* voice usually implies a narrowing at the level of the vocal cords, as with a laryngeal mass such as papillomatosis or carcinoma. A *tremulous* voice may indicate a neurological disorder, such as spasmodic dysphonia or Parkinson's disease.

**At What Point Should Hoarseness Warrant Consultation with an Otolaryngologist?**

The most common cause of hoarseness, viral laryngitis, is self-limited and usually resolves after 1–2 weeks. Any hoarseness persisting for longer than 3 or 4 weeks necessitates timely otolaryngic referral.

**Does the Patient Have Any Significant History of Smoking, Chewing Tobacco, or Drinking Alcohol?**

Tobacco use, in both smoked and chewed forms, is the single greatest risk factor for squamous cell carcinoma of the upper aerodigestive tract. Alcohol, while not independently a risk factor for development of cancer, has a compounded effect in the presence of tobacco use.

**Would You Expect Bloody Sputum?**

The vast majority of noncancerous causes of hoarseness are not associated with bloody sputum. Hemoptysis or bloody oral secretions are a red flag for malignancy in the upper aerodigestive tract or the lungs.

**What Is the Most Common Type of Laryngeal Cancer?**

The most common type of cancer found in the larynx, as well as in the entire upper aerodigestive tract, is *squamous cell carcinoma*. The pathogenesis is closely linked to tobacco use in any form and is likely related to chronic inflammation and increased cellular turnover causing metaplasia, dysplasia, and eventual carcinoma.

**Watch Out**

The most common site of malignant lesions of the larynx is the glottis.

## Pathophysiology

### What is the Innervation of the Larynx?

Nerve	Branch	Sensory	Motor
<i>Superior laryngeal nerve</i>	Vagus	Supraglottis	Inferior constrictor, cricothyroid muscles
<i>Recurrent laryngeal nerve</i>	Vagus	Glottis and subglottis	All intrinsic laryngeal muscles except cricothyroid

### Why Is Tobacco Use a Risk Factor for the Development of Squamous Cell Carcinoma of the Head and Neck?

Chemicals contained in tobacco cause chronic inflammation of the mucous membranes of the upper aerodigestive tract. In turn, chronic inflammation and increased cell turnover lead to metaplasia and dysplasia. As the dysplasia becomes severe, it is termed carcinoma in situ. Invasion of these dysplastic cells past the basement membrane of the involved mucosa classifies a lesion as invasive squamous cell carcinoma.

### What Are the Potential Consequences of Unrecognized Squamous Cell Carcinoma of the Upper Aerodigestive Tract?

Squamous cell carcinoma of the larynx, if caught early, portends a favorable prognosis. However, other mucosal sites of the head and neck carry a graver prognosis, and if the diagnosis is made late, the cancer is often the cause of the patient's demise.

### Do Laryngeal Papillomas Cause Cancer?

Laryngeal papilloma, also known as recurrent respiratory papillomatosis, is a condition caused by human papillomavirus (HPV) 6 and 11. Infection with the virus can lead to benign papillary tumors of the larynx and presents primarily with hoarseness. Adults tend to have a single papilloma, while children develop multiple lesions. Though possible, papillomas rarely give rise to laryngeal carcinoma.

## Work-Ups

### What Examination Should Be Performed to Evaluate the Vocal Cords? (Fig. 12.1)

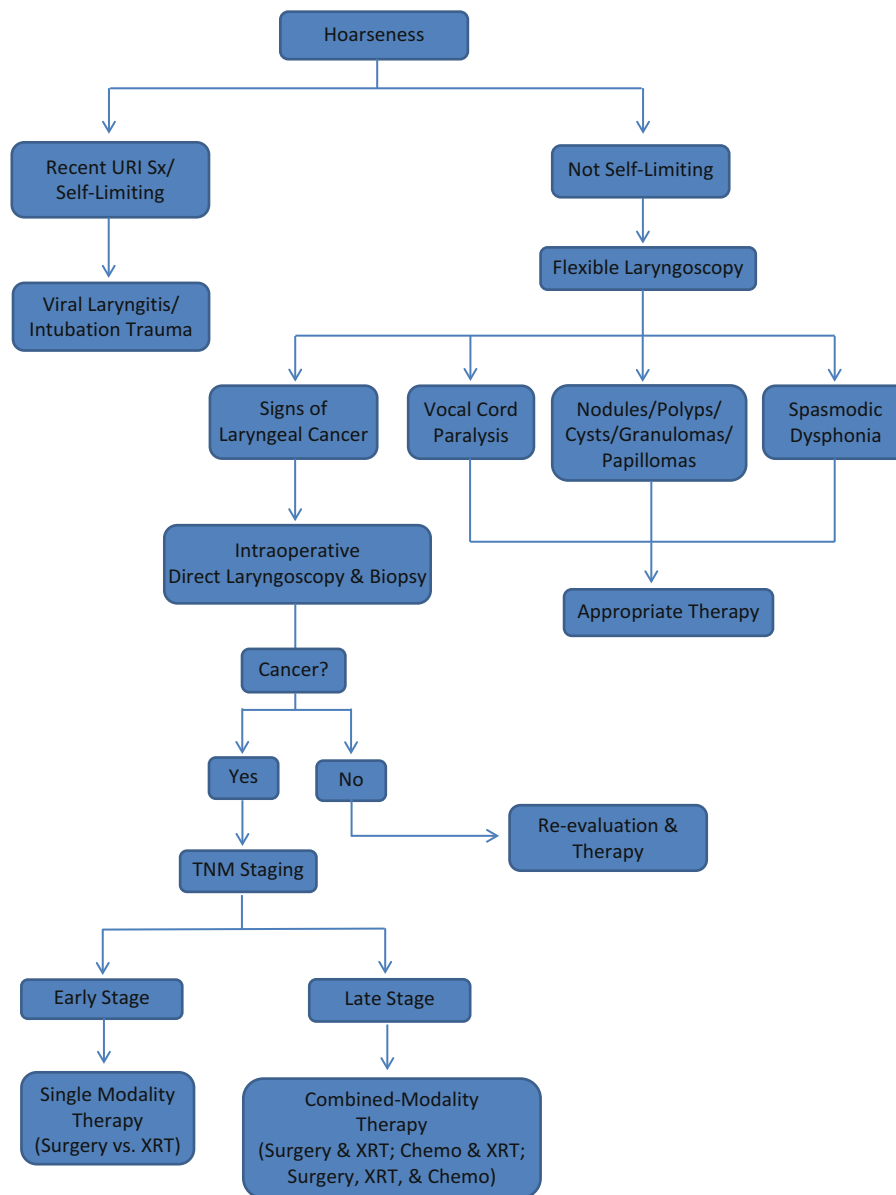
The otolaryngologist will perform a laryngoscopy in the office setting. This may be achieved with a mirror introduced via the mouth (mirror laryngoscopy) or with an endoscope passed through the nasal cavities (flexible fiberoptic laryngoscopy). Structural abnormalities, such as masses, ulcers, or mucosal irregularities, may be noted. Functionally, the otolaryngologist will be able to assess motion of the vocal cords, which are innervated by the recurrent laryngeal nerve.

These maneuvers, grouped under *indirect laryngoscopy*, are differentiated from *direct laryngoscopy*. Direct laryngoscopy is typically performed under general anesthesia. A metal *laryngoscope* is passed into the patient's mouth, and dedicated examination of the patient's oral cavity, pharynx, and larynx is performed. The otolaryngologist may perform biopsies of any suspicious lesions, which will be sent for histopathological analysis.

### If Laryngeal Cancer Is Suspected, What Additional Tests Are Warranted?

A *chest X-ray* is routinely performed to rule out a concurrent primary lung cancer or pulmonary metastases. This is important as a majority of laryngeal and lung cancers are attributed to smoking. In addition, the most common location for distant metastasis of head and neck squamous cell carcinoma is the lungs.

*Computed tomography (CT)* of the neck can reveal metastases to cervical lymph nodes, although CT is not routinely obtained for early-stage laryngeal cancer (see below).



**Fig. 12.1** Algorithm for diagnosis and management of hoarseness

## What Is the Staging for Laryngeal Cancer?

As with a majority of human cancer, laryngeal cancer is staged by the *tumor, node, metastases (TNM)* system established by the American Joint Committee on Cancer (AJCC). This takes into account the location, size, and extent of the primary tumor; the presence and degree of metastasis to cervical lymph nodes; and the presence of distant metastases.

## Management

### What Treatments Are Available?

In *early-stage laryngeal cancer* (TNM stage groups I and II), single-modality therapy—either surgery or radiation—is usually effective in eradicating the disease (Table 12.1). *Surgical resection* of this patient’s laryngeal tumor is usually performed through



**Table 12.1** Treatment options for early-stage laryngeal cancer

	Pros	Cons
Surgery	Performed in a single operation	May have increased vocal breathiness following surgery
Radiation	Excellent vocal outcome	Requires weeks of daily therapy

**Table 12.2** Five-year survival for laryngeal cancer, stratified by TNM stage group at presentation

Stage	5-year survival rate (%)
I	90
II	74
III	56
IV	44

an endoscopic approach via direct laryngoscopy. However, this may lead to permanent atrophy of the vocal cords and a breathy voice in the long term. *Radiation therapy* consists of ionizing radiation given daily over a several-week period.

In *late-stage head and neck cancer*, combined-modality therapy (surgery and radiation, chemotherapy and radiation, or a combination of all three) is often required to eradicate the disease. In patients with suspected or confirmed metastases to cervical lymph nodes, a *neck dissection (cervical lymphadenectomy)* may be required to remove the lymph nodes of the neck. This accomplishes two purposes: cancer-containing lymph nodes are removed as part of an oncologic resection and the number of lymph nodes containing cancer may be counted to guide further management and dictate prognosis.

**Watch Out**

The goal in treating laryngeal cancer is to try to preserve the larynx.

**What Variables Affect Prognosis for Laryngeal Cancer?**

The TNM stage group is the single most important prognostic indicator (Table 12.2). The 5-year relative survival of stage II laryngeal cancer is approximately 75 %.

**Areas Where You Can Get in Trouble****Chronic Laryngitis as a Red Flag**

“Laryngitis” is a term commonly used by primary care physicians to denote any laryngeal derangement causing hoarseness. The most common cause of dysphonia, or a hoarse voice, is a viral infection leading to edema of the vocal cords, resulting in a raspy or breathy voice. This should resolve over the course of 1–2 weeks; persistent hoarseness beyond that time necessitates timely otolaryngologic referral.

**Airway Compromise**

The larynx is the narrowest segment of the human airway. An exophytic mass, such as a squamous cell carcinoma, can cause life-threatening airway obstruction. This may present in a chronic fashion, where a patient with known squamous cell carcinoma becomes increasingly short of breath, or it may present more acutely. In a patient with advanced laryngeal cancer, a tracheostomy may very likely be necessary prior to initiating any treatment.

## Summary of Essentials

### History and Physical Examination

- Duration, progression, and quality of hoarseness
- Tobacco use, including smoking as well as chewing tobacco
- Alcohol use

### Etiology/Pathophysiology

- Chronic inflammation and increased cellular turnover from toxic insults, such as tobacco smoke, lead to dysplasia and invasive squamous cell carcinoma

### Diagnosis

- Indirect laryngoscopy in the office, or direct laryngoscopy in the operating room setting, to visualize the larynx and to obtain biopsies
- Chest X-ray
- Computed tomography (CT) of the neck
- TNM staging

### Management

- Early stage
  - Radiation
  - Surgical resection
- Late stage
  - Chemotherapy with radiation
  - Surgery followed by radiation
  - Tracheostomy may be necessary to secure airway

### Watch Out

- Hoarseness that persists > 3–4 weeks merits immediate referral to an otolaryngologist

---

### Suggested Reading

Forastiere AA, Goepfert H, Maor M, et al. Concurrent chemotherapy and radiotherapy for organ preservation in advanced laryngeal cancer. *N Engl J Med.* 2003;349(22):2091–8.

Hoffman HT, Porter K, Karnell LH, et al. Laryngeal cancer in the United States: changes in demographics, patterns of care, and survival. *Laryngoscope.* 2006;116(9 Pt 2 Suppl 111):1–13.

The Department of Veterans Affairs Laryngeal Cancer Study Group. Induction chemotherapy plus radiation compared with surgery plus radiation in patients with advanced laryngeal cancer. *N Engl J Med.* 1991;324(24):1685–90.

Jon Mallen-St. Clair, Aaron J. Feinstein, and Vishad Nabili

A 58-year-old man presents with a right-sided neck mass that has been increasing in size over the past 3 months. He denies fever, chills, or recent weight loss. He also denies sore throat, difficulty swallowing, changes in his voice, or difficulty breathing. Past medical history is significant for hypertension and gastroesophageal reflux (GERD). Social history is significant for 20 pack-years of smoking. He averages two alcoholic drinks every day. Physical exam of the oral cavity/oropharynx including close visualization and palpation of the tongue, base of tongue, tonsil, and floor of mouth for masses or firmness reveals no obvious lesions that are suspicious for malignancy. Examination of the neck reveals a 2×3-cm firm right-sided neck mass that is poorly mobile, non-erythematous, and not tender to palpation.

---

J. Mallen-St. Clair, MD, PhD (✉)

Otolaryngology – Head and Neck Surgery, David Geffen School of Medicine, UCLA, 10833 Le Conte Ave., RM 62-132 CHS, Los Angeles, CA 90095, USA

e-mail: [jmallenstclair@mednet.ucla.edu](mailto:jmallenstclair@mednet.ucla.edu)

A.J. Feinstein, MD, MHS

Head and Neck Surgery, University of California, Los Angeles, 10833 Le Conte Ave., CHS 62-132, Los Angeles, CA 90095-1624, USA

e-mail: [afeinstein@mednet.ucla.edu](mailto:afeinstein@mednet.ucla.edu)

V. Nabili, MD, FACS

Department of Head and Neck Surgery, David Geffen School of Medicine at UCLA, 10833 Le Conte Ave., CHS 62-132, Los Angeles, CA 90095-3075, USA

e-mail: [vnabili@mednet.ucla.edu](mailto:vnabili@mednet.ucla.edu)

## Diagnosis

### What is the Differential Diagnosis? Apply the “KITTENS” Mnemonic

Condition	Comments
<b>K – congenital</b>	
Thyroglossal duct cyst	Midline mass, moves with tongue protrusion; may become infected; most common congenital neck anomaly
Branchial cleft cyst	Lateral to midline; at risk for infection
Dermoid cyst	Arises from entrapment of epithelium during fetal midline closure
Laryngocele	Intermittent lateral neck swelling caused by herniation of a laryngeal diverticulum through the thyrohyoid membrane; may arise from chronic severe cough or sustained blowing into a musical instrument
Sebaceous cyst	Arises from obstruction of sebaceous gland duct; may become infected
Lymphangioma	Lymphatic ducts that do not communicate with the internal jugular lymphatic system resulting in impaired drainage; also known as cystic hygroma
Thymic cyst	Only requires excision if causing compression of other structures; may occasionally be ectopic parathyroid tissue
<b>I – infectious/inflammatory</b>	
Lymphadenitis	Viral, bacterial, or fungal infection causing lymph node enlargement
Tuberculosis	Lymph nodes may be matted together and form draining sinus tract; also known as scrofula
Toxoplasmosis	May cause lymphadenitis
Cat scratch disease	May cause lymphadenitis
Actinomycosis	Suppurative lymph nodes form sinuses with a bright-red color; pus contains sulfur granules
Deep neck abscess	Present with fever, pain, stiffness, odynophagia, purulent oral secretions; retropharyngeal infection may spread to the mediastinum
<b>T – toxin</b>	
Metals/drugs	Exposure to industrial fumes, nickel, cigarette smoke, and wood dust has been associated with head and neck cancers, which can metastasize to lymph nodes and present as a neck mass
<b>T – trauma</b>	
Hematoma	Contusion or vascular injury; may compromise airway, may require surgical exploration
Foreign body	For example, shrapnel, bullet
Aneurysm	Blunt or penetrating injury may cause pseudoaneurysm of the carotid artery
<b>E – endocrine</b>	
Thyroid hyperplasia	Graves’ disease, goiter
Ectopic thyroid gland	May be found anywhere along the thyroglossal duct; beware of lateral ectopic thyroid tissue as this may be metastatic spread of malignancy
<b>N – neoplastic</b>	
Benign growths	Lipoma, neuroma, fibroma
Malignant growths	Thyroid carcinoma, lymphoma, salivary gland carcinoma, carotid body (paraganglioma)
Metastatic	Unknown primary, mucoepidermoid, adenoid cystic, lung, breast, kidney, GI
<b>S - systemic</b>	
AIDS	Increased susceptibility to infections
Kawasaki disease	Autoimmune disease associated with coronary artery abnormalities

Adapted from Stackler RJ, Shibuya TY, Golub JS, Pasha R. General Otolaryngology. In: Raza Pasha, Justin S. Golub, ed. Otolaryngology-Head and Neck Surgery: Clinical Reference Guide. 4th ed. San Diego: Plural Publishing. 2014: 275–278 and Eustermann VD. Tumors of the Oral Cavity and Pharynx. In: Bruce W. Jafek, Bruce W. Murrow, ed. ENT Secrets. 3rd ed. Philadelphia: Mosby Elsevier. 2005: 221–222

### What Is the Most Likely Diagnosis for This Patient?

A neck mass in a patient over the age of 40 should be considered malignant until proven otherwise. The “rule of 80s” should be applied. A neck mass in an adult has an 80 % chance of being neoplastic and 80 % chance of being malignant. In contrast, 90 % of pediatric neck masses are benign. History of alcohol and tobacco use also increases the risk of cancer. The progressive increase in size of the mass is also consistent with malignancy. The absence of “B” symptoms (fever, chills, weight loss) and the unilateral nature of the mass argue against lymphoma. Furthermore, there is no history of exposure to infection (TB, cat scratch, recent travel) which would suggest an infectious etiology. In addition, infectious neck masses are typically tender, with overlying erythema. The most likely diagnosis is a metastatic lymph node (most likely squamous cell) from an unknown primary. Further work-up is needed to confirm that the neck mass is a metastatic lymph node and, if so, to find the source of the primary tumor.

## What Risk Factors are Associated with Head and Neck Cancer in General?

<b>Alcohol and tobacco<sup>a</sup></b>
Male
Age > 40
Poor dental hygiene
Radiation exposure
African American
<sup>a</sup> In combination, they confer a greater risk

## What Risk Factors are Associated with Specific Head and Neck Cancers?

Risk factor	Type of cancer
Human papillomavirus (HPV)	Oropharyngeal cancer
Epstein-Barr virus (EBV)	Nasopharyngeal cancer, Burkitt's lymphoma
Chinese	Nasopharyngeal cancer
GERD	Laryngeal cancer
Plummer-Vinson syndrome <sup>a</sup>	Pharyngeal and upper esophageal cancer

<sup>a</sup>Symptoms include glossitis, cervical dysphagia, iron deficiency anemia, and esophageal webs

## What Premalignant Lesions Should be Looked for on Physical Examination?

	Comments
Leukoplakia (white patch or plaque)	Buccal mucosa, alveolar mucosa, and lower lip
Erythroplakia (red patch or lesion)	Floor of the mouth, tongue, and soft palate

## What Symptoms can be Associated with Head and Neck cancer and What are the Likely Sources?

Symptom	Definition	Pathophysiology/possible malignant sources
Otalgia	Pain in the ear	Cranial nerves IX and X supply sensory innervation to both the tongue and floor of mouth and also supply sensory innervation to the ear. Pain can be referred to the ear from CN IX via Jacobson's nerve and CN X via Arnold's nerve. In addition, the lingual nerve (V3) supplies sensation to the tongue and floor of mouth as well as the external auditory canal and tympanic membrane via the auriculotemporal nerve
Dysphagia	Difficulty in swallowing	Mass effect of tumor obstructing the path of food bolus (hypopharynx) vs. interference with swallowing mechanism (common in pharynx/tongue/hypopharynx)
Odynophagia	Pain in swallowing	Tumor-related inflammation can cause pain
Dysphonia	Impairment in producing voice sounds	Lesion on vocal cords blocking efficient phonation or vocal cord paralysis from neural involvement
Dyspnea	Difficulty in breathing	Upper airway obstruction
Trismus	Limited opening of the jaw	Tumor invasion into pterygoid muscles
Stridor	High-pitched sound resulting from a narrowed or obstructed airway	Upper airway obstruction
Hemoptysis	Expectoration of blood-stained sputum	Ulceration of tumor into blood vessel in upper airway vs. secondary pulmonary lesion

**Table 13.1**

Tumor	Comment
Pleomorphic adenomas (mixed tumor)	Most common benign salivary gland tumor
Papillary cystadenoma (Warthin's tumor)	Second most common benign salivary gland tumor
Mucoepidermoid carcinoma	Most common malignant salivary gland tumor
Adenoid cystic carcinoma	Second most common malignant salivary gland tumor

## What Types of Abscess are in the Differential of a Neck Mass?

Type of abscess	History and physical	Treatment
Peritonsillar	Older children (> 10 years old), fever, odynophagia, trismus, does not typically cause airway obstruction	Aspirate and drain through tonsillar bed
Retropharyngeal	Younger children (< 10 years old), fever, odynophagia, drooling, can lead to airway obstruction	Calm the patient, intubate, drain through posterior pharyngeal wall
Parapharyngeal	All age groups, associated with dental infections and tonsillitis	Drain through lateral neck (to avoid damaging the carotid artery)

## What Are the Key Aspects of the Head and Neck Exam in the Evaluation of a Solitary Neck Mass?

Though it is tempting to focus completely on examination of the neck, it is imperative that a full head and neck exam be performed. This should include careful inspection and palpation of the scalp, skin, parotid, ears, ear canals, nose, nasal cavity, oral cavity, and oropharynx. In particular, the base of the tongue and tonsillar fossa should be palpated for any evidence of firmness. Full characterization of the neck mass should be performed, with assessment of the size, location, mobility, consistency, fluctuance, overlying skin changes, and associated pain. A full cranial nerve exam should be performed to assess for deficits, which are often associated with advanced head and neck cancer.

## Etiology

### What Is the Differential Diagnosis for Salivary Glands Tumors? What Is Their Malignant Potential?

The salivary glands include the parotid, submandibular, sublingual, and minor salivary glands. Masses in large salivary glands are more likely to be benign while masses in smaller salivary glands are more likely to be malignant. However, the parotid glands (the largest salivary glands) are the most frequent site of malignant tumor.

### What Is Virchow's Node? Why Is It Concerning?

Virchow's node is an enlarged left supraclavicular node. It occurs on the left as this is where the cisterna chyli (dilated lymph sac at the end of the thoracic duct) empties into the subclavian vein. Virchow's node is suggestive of metastatic lung or gastrointestinal malignancy.

### What Are the Most Common Sites of Head and Neck Cancer?

Oral cavity, larynx, and pharynx represent 44 %, 31 %, and 25 % of head and neck cancers, respectively.

### What Is Meant by the Term "Primary Tumor"? What Is Meant by "Unknown Primary"?

A primary tumor refers to the original anatomic site of a tumor growth. An unknown primary tumor refers to a situation where a metastatic tumor such as a cancerous lymph node is discovered and the site of the original cancer is not evident.

### What "Primary Tumors" Arise in the Neck?

Primary tumors of the neck include: lymphoma, thyroid neoplasms, salivary neoplasms, schwannomas, paragangliomas, lipomas, among others.

---

## **What Does a Newly Discovered Malignant Neck Mass Most Likely Represent?**

Malignant neck masses represent spread of cancer via the lymphatic system until proven otherwise. In these cases, the primary site of cancer is unknown and thus represents an “unknown primary.” The primary site is most frequently in the upper aerodigestive tract and must be found in order to appropriately treat the cancer. The unknown primary can also more rarely represent a distant metastasis from breast, lung, or renal cancer. There is a less than a 15% chance that a malignancy that is found in the neck represents a primary neck tumor.

---

## **Etiology/Pathophysiology**

### **What Is the Pathophysiology of Head and Neck Cancer? What Is Field Cancerization?**

Mucosa in the upper aerodigestive tract when continuously exposed to carcinogens appears grossly normal but on a histologic level will demonstrate features of dysplasia. This “field of dysplastic cells” is the bed in which malignancy develops and is referred to as field cancerization. It is thought that these dysplastic cells acquire progressive mutations and genetic alterations that result in progression to cancer; this process is termed multistage carcinogenesis.

### **What Is the Most Common Pathology of Head and Neck Cancer?**

Squamous cell carcinoma (SCC) is identified in 90 % of cases.

---

## **Work-Up**

### **Is Observation an Acceptable Strategy for a Newly Discovered, Isolated, and Enlarged Cervical Lymph Node?**

Observation is only appropriate for patients that do not present with any red-flag symptoms (e.g., dysphagia, odynophagia, dysphonia, hoarseness, weight loss) and if the lymph node has been present for less than 3 weeks. Patients should be reexamined in 3 weeks. If the node disappears, it most likely was inflammatory in nature.

### **In Addition to the Physical Exam Mentioned in the Vignette, What Procedure Is Performed in the Office by the Head and Neck Surgeon When a Metastatic Neck Lymph Node Is Suspected?**

Flexible nasopharyngoscopy is used to evaluate the nasal cavities, nasopharynx, oropharynx, hypopharynx, and glottis to look for a site of primary tumor.

### **Following This Procedure, What Are the Next Steps in the Work-Up of a Neck Mass?**

Radiologic imaging, laboratory studies, and tissue biopsy are typically performed concurrently and in an expedited fashion.

### **What Laboratory Tests Should Be Obtained?**

CBC, coagulation profile, liver enzymes, chemistry panel with renal function, and TSH level.

### **What Initial Imaging Modality Is the Diagnostic Test of Choice to Search for the Primary Tumor?**

CT scan of the head and neck with contrast is the initial preferred imaging modality to look for the primary tumor in the presence of a solitary neck mass that is concerning for metastatic malignancy. A chest X-ray is also recommended. MRI is an acceptable alternative. Ultrasound would not be useful in this setting; however, it is particularly useful in the diagnosis of congenital neck masses.

### **What if the Initial Head and Neck CT Scan Fails to Demonstrate the Primary Tumor, What Additional Imaging Is Recommended?**

A CT scan of the chest is the next step to look for a primary lung source of the metastatic neck node. Whole body PET scan can be helpful to identify primary site and assess for metastasis. The use of the whole body PET as a diagnostic tool in head and neck cancer is controversial.

### **What Is the Best Way to Obtain a Tissue Sample to Determine if the Neck Mass Is a Metastatic Lymph Node?**

FNA is the procedure of choice for a solitary neck mass that is suspicious for being a metastatic lymph node. FNA is highly sensitive and specific and is diagnostic in the majority of cases with minimal morbidity. FNA is 97 % sensitive and specific when diagnostic material is obtained. FNA can yield fluid for cytology to assess for malignancy. In addition, it can facilitate, gram stain, acid fast stain, and cultures. A non-diagnostic FNA should often be repeated, with or without ultrasound guidance prior to proceeding to an open biopsy.

### **Once FNA Confirms That the Neck Mass Is a Metastasis, What Is the Next Step in Determining the Location of the Primary Tumor?**

Panendoscopy is performed in the OR under general anesthesia.

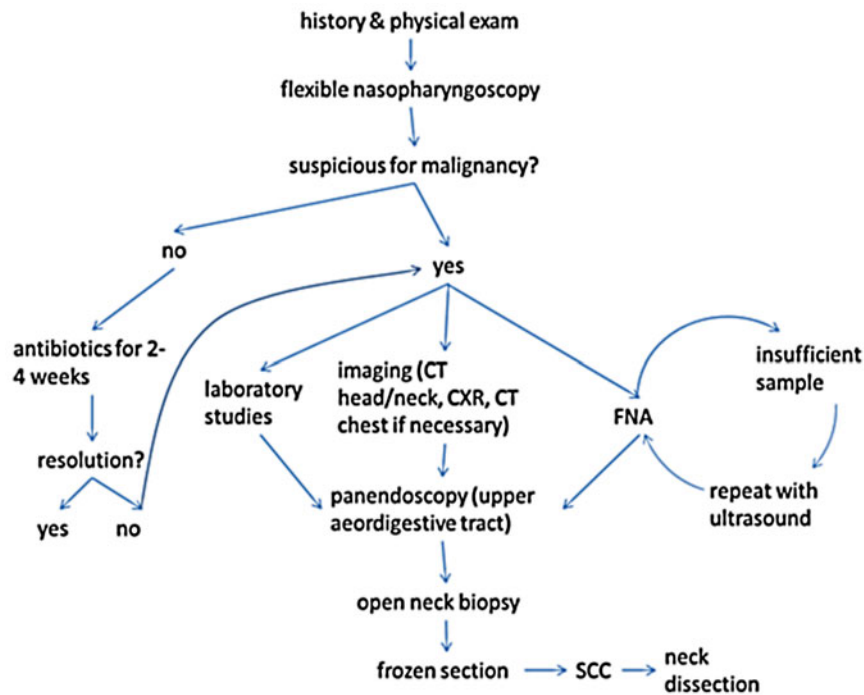
### **What Is a Panendoscopy (Triple Endoscopy)?**

Also termed triple endoscopy, it involves a complete endoscopic evaluation of the upper aerodigestive track, including laryngoscopy, esophagoscopy, and bronchoscopy. This is performed after other less invasive imaging modalities if no primary site can be identified. Panendoscopy allows for biopsy of the upper aerodigestive tract, including the nasopharynx, tonsils, tongue base, valleculae, post-cricoid region, and pyriform sinuses.

### **What Is the Role of an Open Neck Biopsy in the Evaluation of Solitary Neck Mass?**

Open neck biopsies are only considered after a complete work-up has been performed with appropriate history and physical examination, imaging studies (CT vs. MRI, +/- CT PET), FNA (at least once), and panendoscopy. If the neck biopsy is positive for squamous cell carcinoma (SCC) on frozen section performed at the time of the biopsy, then it is imperative to proceed with a neck dissection. The reason being that open neck biopsies have been shown to be associated with increased morbidity and increased rates of local and distant recurrences, possibly from seeding tumor cells at the time of biopsy (although this dogma has been questioned in recent studies as discussed in Areas of Controversy section).





**Fig. 13.1** Work-up of neck mass suspicious for malignancy: If at any point in the work-up the primary tumor is identified, treatment should be tailored to the specific site and type of the tumor. If at the end of the diagnostic work-up no primary tumor has been identified, all sites in the head and neck should be treated

### What Laboratory Studies Can Be Utilized to Assess for Infectious and Inflammatory Causes of Neck Masses?

If the history and physical examination suggest an infectious etiology, laboratory tests are obtained that include complete blood count (CBC), purified protein derivative (PPD), rapid plasma regain (RPR), toxoplasma, HIV, monospot, EBV, and bartonella antibody.

### Management

The management of head and neck cancer is dependent on the subsite and the extent of neck disease at the time of presentation. The management of head and neck malignancy is outside the scope of this chapter.

### Areas Where You Can Get into Trouble

#### Missing a Cancer Diagnosis

Tip-offs that move malignancy higher on the differential diagnosis include a unilateral neck mass that is progressive in size and age over 40 years. Other danger signs include unilateral otalgia, dysphagia, odynophagia, dysphonia, dyspnea, trismus, stridor, and hemoptysis concerning for advanced head and neck cancer. Pain can be associated with neural spread.

## Not Recognizing Potentially Life-Threatening Signs in Advanced Stages of Cancer

Any sign of dyspnea or stridorous breathing should prompt an immediate evaluation of the airway by an otolaryngologist. Similarly, any bleeding from the mouth or hemoptysis should prompt an evaluation of the airway, as erosion into large vessels in the neck can result in airway compromise and exsanguinating hemorrhage. The patient should also be evaluated for signs that would indicate difficulty obtaining an oropharyngeal airway including trismus and obstructing lesions in the oropharynx.

## Inappropriate Biopsy

It is difficult to control bleeding in the oropharynx, so biopsies in clinic should be performed with caution. Inappropriately performing an open biopsy of the neck can be problematic and is thought to potentially seed cancer cells and increase morbidity and decrease survival, although there is now some debate regarding the dangers of open biopsy (see Areas of Controversy section). Open biopsy without ruling out tuberculosis (scrofula) can also lead to chronic draining fistulas to the skin.

---

## Areas of Controversy

### The Role of Whole Body PET in the Management of Head and Neck Cancer

The use of PET/CT is widely accepted for staging head and neck cancer and in assessing for recurrence following treatment. However, the use of PET scans in evaluating the head and neck for occult primaries has been called into question, given the high rate of false-positive results. Current guidelines suggest that a PET/CT should only be considered after all other imaging studies and a full head and neck examination are negative. The PET/CT should be done prior to panendoscopy, as manipulation of the upper aerodigestive tract can result in false positives as well.

### The Role of Open Biopsy

The use of open neck biopsies has been discouraged since a study demonstrated increased morbidity, recurrence and higher rates of distant metastasis in patients who received open neck biopsy in the work-up of neck mass. However, recent studies have not replicated these results. Current recommendations advise at least one FNA prior to open neck biopsy. Given the high sensitivity and specificity and minimal morbidity of FNA and the possible risks of open neck biopsy, it is also reasonable to perform an image-guided repeat FNA if the first FNA is nondiagnostic. If an open biopsy is truly necessary for diagnosis, completion of neck dissection in the event of the biopsy being positive for SCC is recommended to avoid morbidity.

---

## Summary of Essentials

### History and Physical

- Red flags for malignancy include otalgia, dysphagia, odynophagia, dysphonia, dyspnea, trismus, stridor, and hemoptysis
- Palpate the base of the tongue and the tonsillar fossa for firmness
- Always perform a complete cranial nerve exam
  - Look out for danger signs

### Etiology/Pathophysiology

- Risk factors for head and neck cancer include smoking, alcohol, age over 40 years, HPV, infection, EBV infection, GERD, Chinese ethnicity, and Plummer-Vinson syndrome
- Primary tumors of the neck include lymphoma, thyroid carcinoma, salivary gland neoplasms, schwannoma, paragangliomas, and lipomas
- Beware of deep neck abscesses: peritonsillar, retropharyngeal, and parapharyngeal

## Diagnosis

- The first step in work-up is a thorough head and neck exam, including testing all cranial nerves
- Flexible endoscopy should be performed after physical exam to evaluate for a primary tumor
- FNA biopsy and CT with contrast should be performed after flexible laryngoscopy
- Further imaging such as chest CT scan, PET scan, or chest X-ray may be performed for further staging
- If indicated, panendoscopy will be performed to identify the site of primary tumor

## Watch Out

- Missing diagnosis or failing to expedite work-up
- Missing danger signals of advanced head and neck cancer
- Referring for open biopsy without full work-up

## Suggested Reading

- Amedee RG, Dhurandhar NR. Fine-needle aspiration biopsy. *Laryngoscope*. 2001;111(9):1551–7.
- Ang KK, Harris J, Wheeler R, Weber R, et al. Human papillomavirus and survival of patients with oropharyngeal cancer. *N Engl J Med*. 2010;363:24–35.
- Blot WJ, McLaughlin JK, Winn DM, et al. Smoking and drinking in relation to oral and pharyngeal cancer. *Cancer Res*. 1988;48:3282.
- Califano J, van der Riet P, Westra W, et al. Genetic progression model for head and neck cancer: implications for field cancerization. *Cancer Res*. 1996;56:2488.
- Chen A, Otto KJ. Differential diagnosis of neck masses. In: Flint P, Haughey B, Lund V, Niparko J, editors. *Cummings otolaryngology – head and neck surgery*. 5th ed. Philadelphia: Mosby Elsevier; 2010. p. 1636–42.
- Ellis ER, Mendenhall WM, Rao PV, et al. Incisional or excisional neck node biopsy before definitive radiotherapy, alone or followed by neck dissection. *Head Neck*. 1991;13:177–83.
- Eustermann VD. Tumors of the oral cavity and pharynx. In: Jafek BW, Murrow BW, editors. *ENT secrets*. 3rd ed. Philadelphia: Mosby Elsevier; 2005. p. 221–2.
- Greven KM, Keyes Jr JW, Williams 3rd DW, McGuirt WF, Joyce 3rd WT. Occult primary tumors of the head and neck: lack of benefit from positron emission tomography imaging with 2-[F-18]fluoro-2-deoxy-D-glucose. *Cancer*. 1999;86(1):114–8.
- Jungehulsing M, Scheidhauer K, Damm M, et al. 2[F]-fluoro-2-deoxy-D-glucose positron emission tomography is a sensitive tool for the detection of occult primary cancer (carcinoma of unknown primary syndrome) with head and neck lymph node manifestation. *Otolaryngol Head Neck Surg*. 2000;123(3):294–301.
- Liu ES, Bernstein JM, Sculerati N, Wu HC. Fine needle aspiration biopsy of pediatric head and neck masses. *Int J Pediatr Otorhinolaryngol*. 2001;60(2):135–40.
- McGuirt WF, McCabe BF, et al. Significance of node biopsy before definitive treatment of cervical metastatic carcinoma. *Laryngoscope*. 1978;88:594–7.
- Mendenhall WM, et al. Squamous cell carcinoma metastatic to the neck from an unknown head and neck primary site. *Am J Otolaryngol*. 2000;22(4):261–7.
- Miller FR, Hussey D, Beeram M, Eng T, McGuff HS, Otto RA. Positron emission tomography in the management of unknown primary head and neck carcinoma. *Arch Otolaryngol Head Neck Surg*. 2005;131(7):626–9.
- Park R, Nabili V, Yoo GH, Golub JS, Pasha R. Head and neck cancer. In: Pasha R, Golub JS, editors. *Otolaryngology-head and neck surgery: clinical reference guide*. 4th ed. San Diego: Plural Publishing; 2014. p. 230–6.
- Ridge et al. Head and neck cancer. *Cancer Management* 13ed.
- Schwarz R, Chan NH, MacFarlane JK. Fine needle aspiration cytology in the evaluation of head and neck masses. *Am J Surg*. 1990;159(5):482–5.
- Spitz MR. Epidemiology and risk factors for head and neck cancer. *Semin Oncol*. 1994;21:281.
- Stackler RJ, Shibuya TY, Golub JS, Pasha R. General otolaryngology. In: Pasha R, Golub JS, editors. *Otolaryngology-head and neck surgery: clinical reference guide*. 4th ed. San Diego: Plural Publishing; 2014. p. 275–8.
- Zanation AM, Sutton DK, Couch ME, Weissler MC, Shockley WW, Shores CG. Use, accuracy, and implications for patient management of [18F]-2-fluorodeoxyglucose-positron emission/computerized tomography for head and neck tumors. *Laryngoscope*. 2005;115(7):1186–90.

Andrew M. Vahabzadeh-Hagh, Edward C. Kuan,  
and Vishad Nabili

A 5-year-old boy is brought to the doctor by his mother because she is concerned that he may be experiencing hearing loss. Over the past several weeks, he has been turning the volume of his favorite television program louder and has been sitting closer to the television. He has reached all his developmental milestones and is up to date with his immunizations. When asked, the child states that he feels that his ears are always “plugged up.” His medical history includes recurrent episodes of acute otitis media. On exam, he is afebrile. His nasopharynx is clear and he has no cervical lymphadenopathy. On otoscopic examination, his left tympanic membrane (TM) is immobile with an air-fluid level behind it and partial opacification dependently. It does not appear to be erythematous. A vibrating tuning fork placed on the middle of his forehead is appreciated as louder on the left side when compared to the right. The same tuning fork, when placed on the left mastoid bone, is appreciated as louder on the left, while softer when it is placed near the left external auditory meatus.

---

A.M. Vahabzadeh-Hagh, MD (✉)  
Department of Head and Neck Surgery, David Geffen School of Medicine at UCLA, 10833 Le Conte Ave., CHS 62-132,  
Los Angeles, CA 90095-3075, USA  
e-mail: [avahabzadehagh@mednet.ucla.edu](mailto:avahabzadehagh@mednet.ucla.edu)

E.C. Kuan, MD, MBA  
Department of Head and Neck Surgery, David Geffen School of Medicine at UCLA, 10833 Le Conte Ave., CHS 62-132,  
Los Angeles, CA 90095-3075, USA  
e-mail: [ewu@mednet.ucla.edu](mailto:ewu@mednet.ucla.edu);

V. Nabili, MD, FACS  
Department of Head and Neck Surgery, David Geffen School of Medicine at UCLA, 10833 Le Conte Ave., CHS 62-132,  
Los Angeles, CA 90095-3075, USA  
e-mail: [vnabili@mednet.ucla.edu](mailto:vnabili@mednet.ucla.edu)

## Diagnosis

### What is the differential diagnosis for hearing loss in a child?

Diagnosis	History and physical
<i>Acute otitis media (AOM)</i>	Otalgia, fever, bulging and erythematous TM with decreased mobility, poor light reflex; duration <3 weeks
<i>Otitis media with effusion (OME)</i>	Middle ear effusion without signs of acute infection; commonly follows episode of AOM but may develop in isolation; children with OME may present with parental concerns about hearing, language development, behavior, or school performance; immobile TM with air-fluid levels
<i>Chronic otitis media (COM)</i>	Recurrent or chronic ear infections that result in perforation of the TM +/- otorrhea; higher incidence in children with cleft palates, Down's syndrome
<i>Cholesteatoma</i>	Often preceded by Eustachian tube dysfunction and COM; expansile collection of keratinized, desquamated epithelium in the middle ear
<i>Labyrinthitis</i>	Often preceded by a viral infection; acute onset of vertigo, gait instability, nausea, vomiting, and hearing loss; physical exam demonstrates nystagmus
<i>Otitis externa or swimmer's ear</i>	Recent contact with warm water; presents with a tender, swollen pinna and erythematous ear canal with possible discharge
<i>Congenital</i>	Hearing loss since birth that may be hereditary or acquired; intrauterine (TORCH) infections
<i>Miscellaneous</i>	Cerumen impaction, foreign body, trauma

*TORCH* toxoplasmosis, other (syphilis, varicella-zoster, parvovirus B19), rubella, cytomegalovirus (CMV), and herpes infections

#### Watch Out

Cholesteatoma is a misnomer in that it does not contain fat or cholesterol but instead is secondary to desquamated keratinized epithelium.

### What other diagnoses need to be considered in an adult with hearing loss?

Diagnosis	History and physical
<i>Exposure</i>	Work related (e.g., construction worker, sound grip), prolonged or intense exposure to loud noises
<i>Drugs</i>	Exposure to aminoglycosides, aspirin, loop diuretics, cisplatin
<i>Tumor</i>	The most common is a vestibular schwannoma of the cerebellopontine angle; may present with trigeminal (paresthesias) and/or facial (paresis) nerve involvement; rarely, the only presenting symptom may be unilateral tinnitus or ringing in the ears
<i>Ménière's disease</i>	Triad of hearing loss, episodic vertigo, and tinnitus; vertigo may last for several hours (vs. seconds in BPPV); often with aural fullness

*BPPV* benign paroxysmal positional vertigo

### What Is the Most Likely Diagnosis?

Otitis media with effusion (OME). Although this often occurs after an episode of acute otitis media (AOM), it may also develop in isolation (discussed in *Pathophysiology*). The predominant symptom is hearing loss and is typically discovered during school audiology screening exams or after behavioral patterns concerning for hearing loss (e.g., turning television volume louder, sitting closer to the television, replying often with "what?"). Otoscopic findings typically include an immobile TM and air-fluid levels with partial opacification. However, the patient should not have any signs of acute infection (more consistent with AOM). Additionally, the physical exam should be consistent with a conductive hearing loss.

#### Watch Out

Note that the term otitis media (middle ear infection) is often a general diagnostic term but does include 3 different subsets of pathologies involving the middle ear (AOM, OME, and COM, all of which may have very different etiologies). When describing middle ear disease, careful attention should be paid to using the most appropriate term.

## History and Physical

### What Is the Peak Age for OME?

The prevalence peaks at age two and sharply declines after age 6.

### What Are the Risk Factors for OME?

Male, African American, cigarette smoke exposure, low birth weight, younger maternal age, lower socioeconomic index, shorter duration or absence of breastfeeding, and supine feeding position.

### What Is the Implication of Regression in Language?

Hearing loss should be suspected in all children that present with regression or delay in language milestones. In toddlers, the typical history involves a child that could babble but stops suddenly. All such children should be evaluated for hearing loss with an audiology consult. Older children may also have poor scholastic performance from being hard of hearing with poor speech; they may benefit from sitting near the front of the class. Some persistent deficits include impairments in reading ability, hyperactive and inattentive behavior, and a lower intelligence quotient (IQ).

### What Is the Implication of the Presence or Absence of Otagia?

Otagia, along with other acute signs or symptoms of infection (e.g., bulging and erythematous TM, fever, leukocytosis), is more consistent with AOM and less so with OME. Pain with manipulation of the outer ear suggests external canal inflammation (otitis externa).

#### Watch Out

Any pediatric patient with a *unilateral* aural fullness or otagia should be suspected of having a foreign body obstruction. In fact, any unilateral ENT lesion in a pediatric patient (e.g., unilateral rhinorrhea, unilateral wheezing) should be appropriately evaluated for a foreign body.

### What Is the Importance of Otorrhea?

Otorrhea is concerning for middle ear disease with TM perforation. Careful attention should be paid to the characteristics of the drainage which varies from appearing thin/clear/serous, mucoid, bloody, to purulent, all of which suggest different etiologies. Some patients with otagia will report resolution of pain followed by new-onset otorrhea. This sequence of symptoms is highly suggestive of a TM perforation. Failure to resolve drainage after conservative management may require surgical intervention.

### How Does One Distinguish on History and Physical Exam Between External Otitis and Otitis Media?

Otitis externa (“swimmers ear”) typically occurs in patients following exposure to warm water but may also appear after recent ear instrumentation. The most common symptoms include otagia upon manipulation of the external ear, pruritus, and hearing loss. On otoscopic examination, a patient with otitis externa will appear to have an edematous and erythematous external ear canal. The TM is typically intact and freely mobile with no evidence of air-fluid levels (i.e., normal).

## What are some abnormal features found in otoscopic examination that may signify AOM and/or OME?

Feature	AOM	OME
<i>Immobility</i>	Yes	Yes
<i>Air-fluid level</i>	Rare	Yes
<i>Opacification</i>	Yes	Yes
<i>Bulging/fullness</i>	Yes	No
<i>Erythematous</i>	Yes	No

## What Is the Main Symptom Seen with OME?

Conductive hearing loss secondary to fluid within the middle ear space. The presence of an air-fluid level or visible bubbles within the middle ear space is associated with less hearing loss. Aside from hearing loss, patients with OME may also have sleep disturbance, ear fullness, tinnitus, or even balance problems.

## The Majority of OME Cases Spontaneously Resolve Within What Period of Time?

Over 50 % of OME cases spontaneously resolve within 3 months. Those that continue for longer are less likely to resolve promptly.

## Etiology/Pathophysiology

### What Is the Most Likely Etiology for Sudden Deafness?

Sudden deafness is most often due to viral infections and leads to sensorineural hearing loss. The most common viruses are herpes simplex and herpes zoster. Although hearing loss may be permanent, the majority of patients regain normal hearing in 2 weeks. High-dose empiric steroids are the mainstay of treatment often coupled with antiviral therapy.

### What Are the Two Main Causes of OME?

AOM or isolated eustachian tube dysfunction (ETD). Residual fluid from suppurative AOM can lead to OME in 50 % of patients after 1 month and 10 % of patients after 3 months. The fluid is believed to result from chronic inflammation triggered by the presence of bacterial components already present in the middle ear. This inflammatory state leads to upregulation of mucin-rich secretions with impairment of effluent clearance. OME may also be secondary to isolated ETD. This can occur as a result of anatomic blockage from inflammation secondary to allergies, upper respiratory infection (URI), and trauma. The impaired clearance of secretions and lack of pressure equalization between the middle ear and external environment in ETD leads to the production of transudate from the mucosa with the accumulation of a serous and essentially sterile effusion.

#### Watch Out

Regardless of the cause of acute otitis media, Eustachian tube dysfunction is nearly universal in OME.

### What Other Diagnoses Need to Be Considered in an Adult with OME?

OME is rare in adults. In the absence of a history of recurrent ear infections, OME in an adult should be considered cancer obstructing the Eustachian tube until proven otherwise and should prompt consultation with an otolaryngologist.

**Watch Out**

Nasopharyngeal carcinoma, though rare, often presents with OME. It is associated with Epstein-Barr virus (EBV) and has a high incidence in certain regions of China.

**What Is the Role of the Eustachian Tube (ET) and How Does It Differ Between Adolescents and Adults?**

The ET serves to (1) maintain gas pressure homeostasis within the middle ear by equalizing the pressure across the TM, (2) helps prevent infection of the middle ear and reflux of contents from the nasopharynx, and (3) clears middle ear secretions. It fulfills this role by maintaining the capacity to open and close appropriately. Children <6 years of age have shorter, more horizontal ET, lined by more floppy elastic cartilage. Children with Down's syndrome and cleft palate are also more prone to ETD. Additionally, the presence of adjacent adenoid tissue, which tends to enlarge during childhood and regress in puberty, predisposes a child to obstruction of the ET and reflux of nasopharyngeal contents. The ET becomes more adult-like around 6 years of age.

**Which Pathogens Are Most Commonly Found in OME?**

The same bacterial organisms found in patients with AOM can be isolated in patients with OME. These include *Streptococcus pneumoniae*, nontypable *Haemophilus influenzae*, and *Moraxella catarrhalis*. Other microbes may include *Pseudomonas aeruginosa* (more common with otitis externa), *Streptococcus pyogenes*, and other anaerobes.

**Watch Out**

The HiB conjugated vaccine does not cover nontypable *Haemophilus*, so it does not prevent otitis media.

**What Is the Most Significant Complication that May Result from OME?**

Conductive hearing loss. Frequent recurrence of middle ear infections may also result in TM scarring and damage, known as tympanosclerosis, which becomes problematic when the ossicular chain is involved. With persistence of ETD and a negative middle ear pressure, a retracted TM overtime may result in erosion of the middle ear ossicles, TM perforation, and even cholesteatoma formation (e.g., accumulation of epithelium/keratin within the middle ear).

**Watch Out**

Tympanosclerosis is hyaline and calcium deposition within the TM and middle ear mucosa secondary to infection or trauma.

---

**Work-Up****What Does a Pneumatic Otoscopy Allow the Clinician to Do? How Is It Used?**

The finding of a middle ear effusion is key in establishing the diagnosis of OME. Yet middle ear effusion is not always obvious on otoscopy. Traditionally, the determination of an effusion in equivocal cases has required the performance of a myringotomy (the surgical creation of a small hole in the<sup>TM</sup>). Pneumatic otoscopy allows for direct, dynamic assessment of TM mobility in response to pressure changes. Immobility of the TM is most often caused by an effusion. In the hands of a validated otoscope



user, pneumatic otoscopy is 94 % sensitive and 80 % specific for OME when comparing it to the diagnostic gold standard of myringotomy and has the advantage of being cheaper and less resource intensive, requires less training, and is more comfortable for the patient.

### **What Two Tests Will Help Differentiate a Conductive Hearing Loss from a Sensorineural Hearing Loss? How Are They Performed?**

Weber and Rinne tests. Both these tests utilize a tuning fork to distinguish between sensorineural (SNHL) and conductive hearing losses (CHL). Prior to performing, ensure that the ear canals are free of cerumen. The Weber test places the vibrating tuning fork on the forehead or bridge of the nose. The vibrations transmit through the skull and should be heard equally among both ears. Unilateral SNHL lateralizes to the unaffected ear, while unilateral CHL lateralizes to the affected ear. The Rinne test compares air and bone conduction. The 512-Hz tuning fork is placed by the ear canal and then on the mastoid process. The patient is then asked which is louder, the canal (air conduction) or mastoid (bone conduction). A positive or normal Rinne test demonstrates air greater than bone conduction. A negative test demonstrates bone greater than air conduction as is seen with CHL. For example, with a right CHL, one would observe Weber right and Rinne negative on the right. Of course, one can and should also obtain a formal audiogram, upon which a CHL, typically of less than 30 dB, would be observed for OME.

---

## **Management**

### **In Children, What Is the Management for the Majority of Cases of OME?**

The majority of cases of OME spontaneously resolve within 3 months, without medical or surgical intervention. Additionally, up to another 30 % will resolve after 6–12 months. As such, for children not at risk for speech, language, and learning difficulties, it is recommended to wait and observe for a 3-month period. In children with mild hearing loss, the clinician should instruct the family on methods to optimize the listening and learning environment until OME resolution. This includes preferential classroom seating, speaking close and clearly to the patient, and repeating oneself when needed.

### **What Is Autoinflation? Is There a Role for It in OME?**

Autoinflation is a simple method that can be employed to raise pressure within the nose in order to reopen the ET and may be useful in cases of ETD. It can be performed by holding the nose and mouth closed while forcibly exhaling. The idea is to open the ET to introduce air into the under-aerated middle ear to equalize pressures across the TM and promote drainage of middle ear fluid. Autoinflation is a low-cost method with rare adverse effects that can be trialed while awaiting spontaneous resolution.

### **Are Antihistamines and/or Decongestants Recommended for OME in Children? How About Steroids or Antibiotics?**

No. Use of antihistamines, decongestants, and/or combination therapies has not been shown to demonstrate any benefit in children with OME. Oral steroids used alone or in combination with antibiotics appear to accelerate the short-term resolution of OME, but no long-term evidence exists in regard to lasting benefits or hearing improvement for either oral or intranasal steroid use.

### **Should Antibiotics Be Used Routinely for Patients with OME?**

Although a bacterial pathogen can be isolated in the middle ear fluid in roughly one-third of children with OME, the routine use of antibiotics is not recommended because the potential side effects from extraneous antibiotic exposure (i.e., antibiotic resistance) outweigh any benefit gained by a small subset of patients.

**Table 14.1** Indications for tympanostomy tube

Bilateral OME with hearing impairment
OME with symptoms such as vestibular problems, poor school performance, behavioral problems, otalgia, or reduced quality of life
Recurrent AOM with OME
At-risk children with OME (baseline sensory, physical, cognitive, or behavioral factors)

### What Are the Indications for Tympanostomy Tube Insertion?

Tympanostomy tubes, also referred to as ventilation tubes, pressure equalization (PE) tubes, and grommets, are placed through a myringotomy (incision in the TM). They provide for middle ear ventilation and may last for several months to years. Indications for which PE tubes should be placed are listed in Table 14.1.

### How Does the Management of OME Differ in Adults?

Although OME is well documented in the pediatric population and is fairly benign, its presence in adults is more ominous, particularly when it is unilateral in nature. Similar to their pediatric counterparts, OME in adults ultimately result from ETD. This may be secondary to obstruction from a tumor near the openings of the Eustachian tubes (e.g., nasopharyngeal carcinoma), enlarged tonsils/adenoids, or a rapid change in air pressure (barotrauma) after a plane flight or scuba dive. As such, management should be guided by a careful history and physical exam with close attention paid to any lesions that may be obstructing the ET. Nasopharyngoscopy can help visualize the nasopharynx and openings of the ET. Additionally, any unilateral effusion developing in an adult without a history of ear problem should be immediately referred to a head and neck surgeon, as the implications may be serious.

### What Are the Long-Term Complications from Untreated Otitis Media?

Permanent hearing loss, ruptured TM, mastoiditis, temporal bone osteomyelitis, meningitis, sigmoid sinus thrombosis, or brain abscess.

## Summary of Essentials

### History and Physical

- AOM: Otalgia, fever, hearing loss, tinnitus, bulging and erythematous TM with decreased mobility, and poor light reflex; < 3 weeks
- OME: Middle ear effusion without signs of acute infection; commonly follows episode of AOM but may develop in isolation; predominant symptom is hearing loss
- COM: Recurrent or chronic ear infections that result in perforation of the TM +/- otorrhea; higher incidence in children with cleft palates
- Otitis externa: Recent contact with warm water; presents with a tender, swollen pinna and erythematous ear canal +/- discharge; normal TM
- Regression in language may be sign of early hearing loss

### Pathophysiology

- Eustachian tube has three roles
  - Maintain gas pressure homeostasis within the middle ear
  - Prevent infection of the middle ear and reflux of contents from the nasopharynx
  - Clears middle ear secretions
- AOM: Acute infection typically caused by *Streptococcus pneumoniae*, nontypeable *Haemophilus influenzae*, and *Moraxella catarrhalis*

- OME: Two main causes
  - Results from residual fluid from suppurative AOM
  - Isolated ETD
- Nasopharyngeal carcinoma, though rare, often presents with unilateral OME in adults
  - Associated with EBV
  - Higher incidence in China

## Work-Up

- AOM and Otitis externa best diagnosed with history and physical
  - Otoscopy to characterize ear canal contents and TM
- OME
  - Pneumatic otoscopy less invasive than myringotomy
  - In adults, nasopharyngoscopy to evaluate for tumors obstructing ET
- Weber and Rinne tests help differentiated conductive vs. sensorineural hearing loss

## Management

- AOM: antibiotics
- OME: majority of cases do not need any medical or surgical intervention
  - PE tubes are indicated for symptomatic OME lasting at least 3 months
  - PE tubes for recurrent AOM with OME
  - PE tubes if bilateral OME with hearing impairment
  - PE tubes if any OME with vestibular problems, poor school performance, behavioral problems, otalgia, or reduced quality of life

## Complications

- The most significant complication of OME is conductive hearing loss
- Long-term complications of untreated OME include permanent hearing loss, ruptured TM, mastoiditis, temporal bone osteomyelitis, meningitis, sigmoid sinus thrombosis, or brain abscess

## Watch Out

- Any pediatric patient with a unilateral aural fullness or otalgia should be suspected of having a foreign body obstruction
- Any delay in language milestones or regression should be properly evaluated for hearing loss with an audiology consult

---

## Suggested Reading

- Karma PH, Penttila MA, Sipila MM, Kataja MJ. Otoscopic diagnosis of middle ear effusion in acute and non-acute otitis media I. The value of different otoscopic findings. *Int J Pediatr Otorhinolaryngol.* 1989;17:37–49.
- American Academy of Family Physicians, American Academy of Otolaryngology-Head and Neck Surgery and American Academy of Pediatrics Subcommittee on Otitis Media with Effusion. Otitis media with effusion. *Pediatrics.* 2004;113:1412–29.
- Shekelle P, Takata G, Chan LS, Mangione-Smith R, Corley PM, Morpew T, et al. Diagnosis, natural history, and late effects of otitis media with effusion. *Evid Rep Technol Assess (Summ).* 2002;55:1–5.
- Tos M. Epidemiology and natural history of secretory otitis. *Am J Otol.* 1984;5:459–62.

---

**Part VI**

**Hepatopancreaticobiliary**

Christian de Virgilio, Section Editor

Ann Elizabeth Falor, Taylor Choy,  
and Christian de Virgilio

A 40-year-old moderately obese Hispanic female presents to the emergency department with a 1-day history of constant epigastric and right upper quadrant (RUQ) pain. She describes the severity of the pain as a 7 out of 10. The pain began after eating fried pork. She reports that the pain also seems to affect the right side of her back near her scapula. She feels nauseated and has vomited twice. She has had similar pain, but of lesser severity, about once a month for the past year. The pain comes on after eating fried or spicy foods, but previously it has resolved after an hour. She is gravida six and para six. On physical examination, her temperature is 100 °F, heart rate is 110/min, and her blood pressure is 120/80 mmHg. She has marked tenderness in the RUQ of the abdomen to palpation. When the RUQ is palpated while she is taking a deep breath, she abruptly ceases inspiration secondary to pain. The remainder of the abdominal examination is benign. Laboratory values are significant for WBC count of  $14 \times 10^3/\mu\text{L}$  (normal  $4.1\text{--}10.9 \times 10^3/\mu\text{L}$ ), total bilirubin 1.0 mg/dL (0.1–1.2 mg/dl), alkaline phosphatase 70 units/L (33–131 u/L), amylase 60 units/L (30–110 u/L), and lipase 30 units/L (7–60 u/L).

---

A.E. Falor, MD (✉)

Department of Surgery, Harbor-UCLA Medical Center, 1000 W. Carson Street, Torrance, CA 90509, USA  
e-mail: [anniefalor@gmail.com](mailto:anniefalor@gmail.com)

T. Choy, MD

Department of Radiology, UCLA Medical Center, 757 Westwood Plaza, Los Angeles, CA 90095, USA  
e-mail: [tchoy@mednet.ucla.edu](mailto:tchoy@mednet.ucla.edu)

C. de Virgilio, MD

Department of Surgery, Harbor-UCLA Medical Center, 1000 W. Carson Street, Torrance, CA 90509, USA  
e-mail: [cdevirgilio@labiomed.org](mailto:cdevirgilio@labiomed.org)

## Diagnosis

### What is the Differential Diagnosis?

Diagnosis	History and physical
<i>Symptomatic cholelithiasis</i>	RUQ pain radiating around right back after fatty meals, resolves after a few hours, female, multigravida, obese
<i>Acute cholangitis</i>	Persistent RUQ pain, fever, jaundice ( <i>Charcot's triad</i> )
<i>Acute cholecystitis</i>	Persistent (>4 h), severe RUQ pain, fever, <i>Murphy's sign</i>
<i>Acute pancreatitis</i>	Severe epigastric pain radiating straight through to back (2° cholelithiasis, alcohol abuse)
<i>Acute gastritis</i>	Aspirin, NSAID <sup>a</sup> use, steroid use, gnawing epigastric pain
<i>Peptic ulcer disease</i>	Intermittent burning epigastric pain that improves (duodenal ulcer) or worsens (gastric ulcer) with food intake (2° <i>H. pylori infection</i> , NSAID, steroid use)
<i>Malignancy (gastric, pancreatic, biliary)</i>	Chronic pain, weight loss, fatigue
<i>Fitz-Hugh-Curtis syndrome</i>	RUQ pain, history of recent pelvic inflammatory disease (either <i>Chlamydia trachomatis</i> or <i>Neisseria gonorrhoeae</i> ), fever, “violin string” adhesions between liver and diaphragm
<i>Myocardial infarction</i>	Epigastric pain (referred pain), diabetes, cardiovascular disease, hypercholesterolemia
<i>Acute hepatitis</i>	Hepatitis A (recent foreign travel, IVDA, raw shellfish, fecal-oral)
<i>Hepatic abscess</i>	RUQ pain, high fever, hepatomegaly (bacterial or amoebic)
<i>Acute pyelonephritis</i>	Costovertebral angle tenderness, dysuria, hematuria

<sup>a</sup>NSAID Nonsteroidal Antiinflammatory Drugs

### What Is the Most Likely Diagnosis?

With her current history of severe persistent abdominal pain following ingestion of fatty foods, nausea and vomiting, and associated right upper quadrant tenderness to palpation, the etiology is most likely of biliary origin. The patient's prior history is consistent with symptomatic cholelithiasis. With a positive Murphy's sign, fever, tachycardia, and elevated WBC count, the most likely current diagnosis is acute cholecystitis. With a normal total bilirubin and alkaline phosphatase, acute cholangitis and choledocholithiasis are less likely. Similarly, a normal amylase and lipase rule out gallstone pancreatitis.

## History and Physical

### Why Is the Term Biliary Colic a Misnomer? What Is a Better Term?

Colicky pain typically waxes and wanes, with periods of intense pain (such as from a ureter intermittently contracting in the presence of a stone) followed by relief. The pain from gallstones is constant, may last from minutes to hours, and then dissipates. A better term is symptomatic cholelithiasis.

### What Are the Main Risk Factors for Developing Cholesterol Gallstones?

Female gender, pregnancy, oral contraceptive use (excess estrogen leads to higher cholesterol in bile and decreased gallbladder motility) as opposed to obesity (decreases bile salts), high-fat diet (increases bile cholesterol), hereditary (higher incidence in Hispanics, Pima Indians), Crohn's disease and terminal ileal resection (loss of bile salts), and rapid weight loss after gastric surgery (impaired gallbladder emptying).

- Patients with biliary disease often have the 4 “Fs” (female, fat, forty, fertile)

### Why Is It Important to Distinguish Between Symptomatic Cholelithiasis and Acute Cholecystitis?

Symptomatic cholelithiasis is usually managed as an outpatient, with eventual elective laparoscopic cholecystectomy. Acute cholecystitis requires hospital admission, intravenous (IV) antibiotics, and urgent cholecystectomy.

## What Is the Difference Between an Urgent and Emergent Case?

An urgent case can be booked during the next available operating room (OR) time slot, while an emergent case requires a patient to be rushed to the OR immediately.

## How does one Clinically distinguish between Symptomatic Cholelithiasis and Acute Cholecystitis?

	Symptomatic cholelithiasis	Acute cholecystitis
<i>History</i>	RUQ pain usually resolves within minutes to 3–4 h	Unremitting RUQ pain >6 h, associated nausea/vomiting
<i>Physical exam</i>	Mild RUQ tenderness to palpation	Murphy's sign
<i>Vital signs</i>	Normal	Fever, tachycardia
<i>Laboratory values</i>	Normal WBC	Elevated WBC with left shift
<i>Ultrasound findings</i>	Gallstones	Gallstones, gallbladder wall thickening >4 mm, pericholecystic fluid, sonographic Murphy's sign

## Pathophysiology

### What Is the Significance of Abdominal Pain After Eating Fatty Foods?

It suggests a biliary origin of the pain. Fatty food ingestion triggers the release of cholecystokinin, which leads to contraction of the gallbladder. Gallstones may obstruct the cystic duct so that the gallbladder is unable to empty bile as it attempts to contract after fatty food ingestion. The ensuing distention of the gallbladder stretches the visceral peritoneum that surrounds it, leading to RUQ and/or epigastric pain that is vague and mild to moderate in severity (symptomatic cholelithiasis).

### What Is the Significance of RUQ Pain Combined with Scapular Pain?

The gallbladder and the scapula share the same cutaneous dermatome from the same spinal cord levels. The scapula receives cutaneous innervation from the supraclavicular nerves. Since the same spinothalamic pathways (pain and temperature) are activated, gallbladder distention/inflammation triggers scapular pain via the phrenic nerve.

### What Is the Significance of the Patient's Inspiration Stopping with RUQ Palpation?

This physical examination finding is called *Murphy's sign* and is thought to be specific to acute cholecystitis. It represents focal peritonitis of the anterior abdominal wall parietal peritoneum due to inflammation of the adjacent gallbladder. When the patient inspires, the diaphragm moves caudad, as does the gallbladder. Palpating deep in the RUQ causes the gallbladder to then come into contact with the parietal peritoneum, further irritating the inflamed parietal peritoneum and causing cessation of inspiration secondary to pain.

#### Watch Out

Do not confuse Murphy's sign with McMurray's sign, which is a palpable or audible snap occurring when extending a fully flexed knee while applying tibial torsion. A positive McMurray's sign indicates a medial meniscal tear.

### What Is the Difference Between Somatic and Visceral Pain?

Somatic pain is well localized and typically secondary to peritoneal irritation. Patients can often point to where it hurts. In contrast, visceral pain is more difficult to localize and results from mechanical stretching of the abdominal (visceral) organs.

## What Is the Clinical Significance of the Patient's Low-Grade Fever and Tachycardia?

The presence of systemic signs of infection, such as fever and tachycardia, suggests a more severe biliary disease such as acute cholecystitis or acute cholangitis. Symptomatic cholelithiasis (biliary colic) does not present with systemic symptoms.

## What Is Chronic Cholecystitis?

Recurrent bouts of symptomatic cholelithiasis often lead to chronic inflammation of the gallbladder with fibrotic changes seen on histologic examination. As such, biliary colic, symptomatic cholelithiasis, and chronic cholecystitis are interchangeable terms.

## What Exactly Causes Acute Cholecystitis?

Acute cholecystitis is caused by sustained obstruction (impaction) of the cystic duct, most often by a gallstone. This obstruction leads to inflammation and edema of the gallbladder wall and then eventually bacterial overgrowth and invasion of the gallbladder wall. This can progress to ischemia and necrosis (gangrenous cholecystitis) and rarely gallbladder perforation.

## What Are the Typical Organisms in the Bile?

The most common organisms found in biliary cultures from patients with acute cholecystitis are *Escherichia coli*, *Bacteroides fragilis*, *Klebsiella*, *Enterobacter*, *Enterococcus*, and *Pseudomonas* species.

## What Are the Components of Bile?

The three main components of bile are bile salts, cholesterol, and lecithin (a phospholipid). Bile also contains water, electrolytes, proteins, and bile pigments.

## What Are the Two Main Types of Gallstones?

The two main types of gallstones are cholesterol (70–80 % of gallstones in the USA) and pigment.

## How Do Cholesterol Gallstones Form?

Cholesterol gallstones form when the concentration of cholesterol in the bile exceeds its solubility, which causes precipitation of cholesterol crystals. The solubility of cholesterol is dependent on the concentration of cholesterol, bile salts, and lecithin in the bile. Lower concentrations of bile salts or lecithin favor precipitation of cholesterol, as does high levels of cholesterol.

## How Do Pigmented Gallstones Form?

These stones comprise the remaining 20–30 % of gallstones seen in the USA. Pigmented stones are classified as black or brown and contain less than 30 % cholesterol. The dark coloration is a result of the presence of calcium bilirubinate within the stones. *Black stones* are often associated with hemolytic disease such as hereditary spherocytosis or sickle cell disease. As a result of the breakdown of red blood cells, the amount of unconjugated bilirubin increases, leading to the formation of black stones. Black stones are most often found within the gallbladder. *Brown stones*, in comparison, most often form within the bile ducts. They are larger and softer than black stones and usually are associated with bacterial infection and parasites. They are more common in Asian countries.



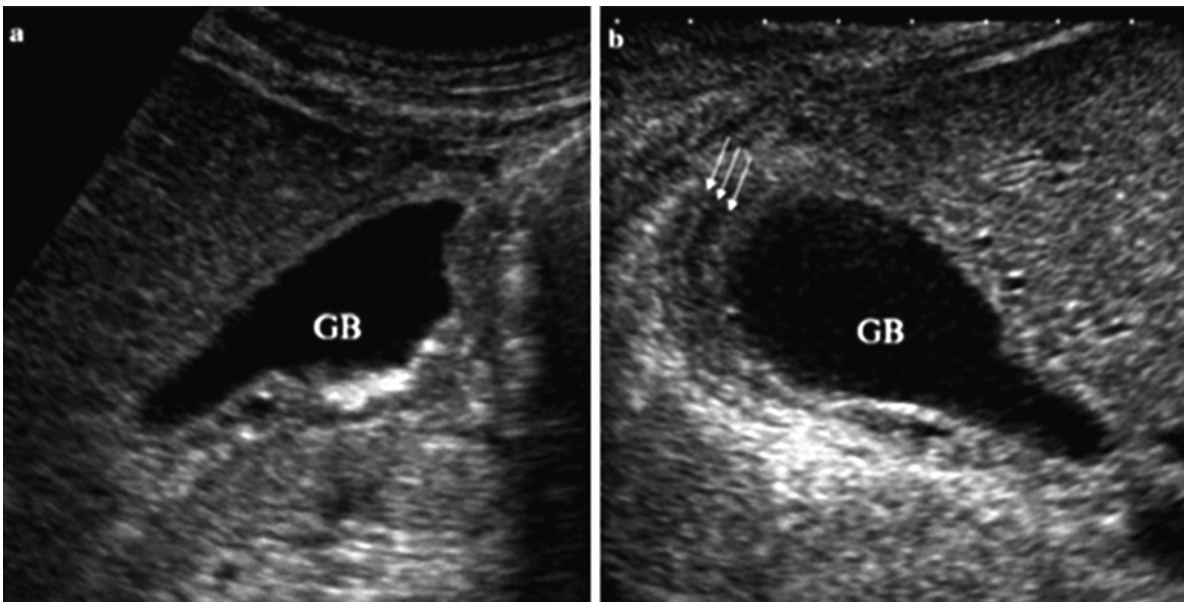
## What are the Different Manifestations of Gallstone Disease?

Condition	Mechanism
<i>Symptomatic cholelithiasis</i>	Transient obstruction of the cystic duct → visceral peritoneal stretch → RUQ pain
<i>Acute cholecystitis</i>	Persistent obstruction of the cystic duct → visceral peritoneal stretch → inflammation of the gallbladder → bacterial overgrowth → infection of the gallbladder → parietal peritoneum inflammation
<i>Choledocholithiasis</i>	Obstruction of the common bile duct
<i>Cholangitis</i>	Obstruction of the common bile duct → bacterial overgrowth → infection of the entire biliary tree → ascends into the liver
<i>Acute gallstone pancreatitis</i>	Obstruction of the common bile duct and pancreatic duct → pancreatic enzyme release
<i>Gallstone ileus</i>	Very large stone erodes into the duodenum → gallbladder-duodenal fistula → stone travels down the GI tract and gets trapped at the ileocecal valve (narrowest part of GI tract) → small bowel obstruction (not ileus!)
<i>Mirizzi's syndrome</i>	Large gallstone impacted in the cystic duct → compresses the common hepatic duct

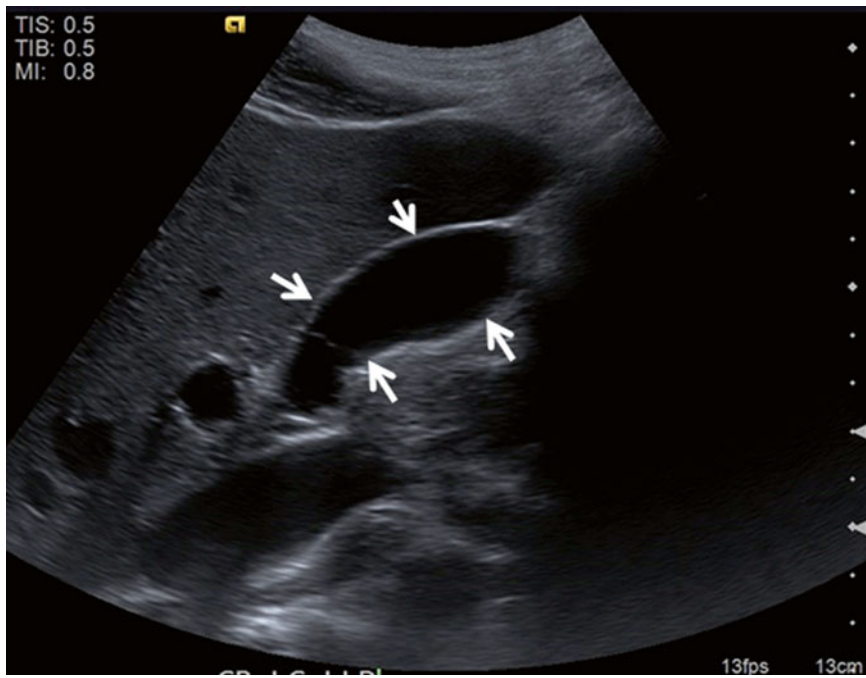## Work-Up

### What Is the Next Step in the Work-Up? What Are the Specific Findings That Would Confirm the Diagnosis?

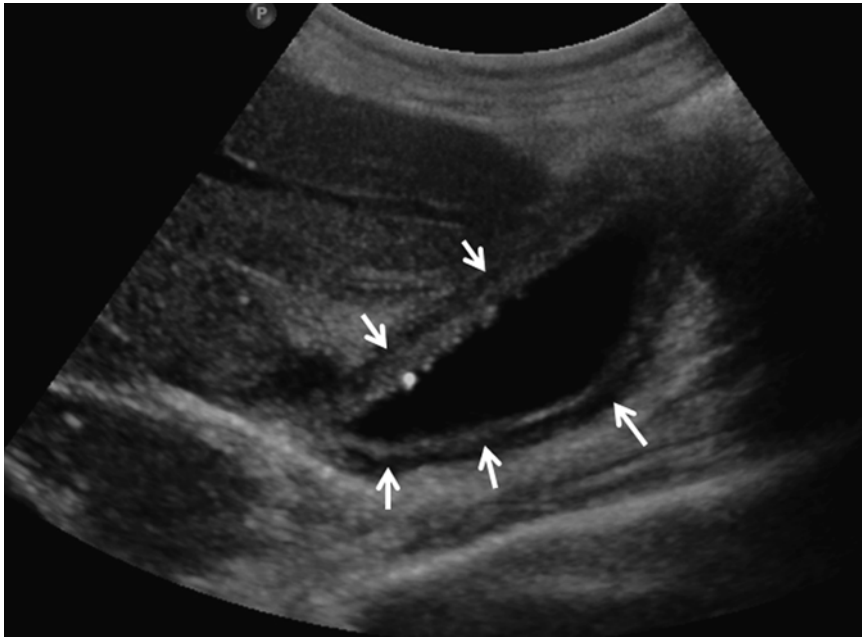
A RUQ ultrasound is the diagnostic test of choice. Gallstones appear as highly echogenic areas with acoustic shadows. The ultrasound should also note the thickness of the gallbladder wall (Fig. 15.1, 15.2, and 15.3) and whether there is any fluid surrounding the gallbladder. These two findings, gallbladder wall thickening (>4 mm) and pericholecystic fluid, are diagnostic for acute cholecystitis. The ultrasound should make note of the diameter of the common bile duct (CBD) as well as whether a stone is visualized within it.



**Fig. 15.1** Thickened gallbladder wall on ultrasound (With kind permission from Springer Science + Business Media: J Hepatobiliary Pancreat Sci, TG13 current terminology, etiology, and epidemiology of acute cholangitis and cholecystitis, 20, 2013, p12, Kimura Y et al., Fig. 3)



**Fig. 15.2** RUQ abdominal ultrasound of a normal thin-walled gallbladder



**Fig. 15.3** RUQ ultrasound showing thickened, edematous gallbladder wall consistent with acute cholecystitis

### What Is a Sonographic Murphy's Sign?

Instead of using the examiner's hand, direct pressure to the RUQ is applied by the ultrasound probe, under ultrasound guidance, while the patient inspires. The pain causes cessation of inspiration. This is thought to be more specific than a clinical Murphy's sign because the gallbladder can be directly visualized as coming in contact with the abdominal wall.

### What Is the Normal CBD Diameter, and What Is the Implication of a Dilated CBD?

A normal CBD ranges from 4 to 5 mm. The normal diameter increases slightly with age (approximately 1 mm per decade after age 40). In most patients a CBD > 6 mm is considered abnormally dilated. This suggests obstruction from either a gallstone or a tumor.

### How Accurate Is Ultrasonography in Detecting Gallstones Within the Gallbladder? Within the CBD?

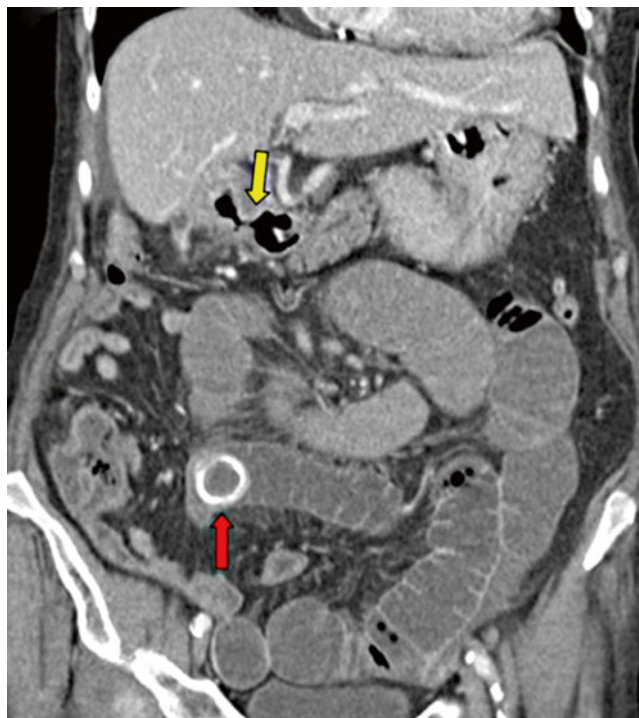Ultrasound is very sensitive (95 %) and specific (97 %) for gallstones (even as small as 1–2 mm) within the gallbladder. Conversely, it is very poor for detecting gallstones within the CBD (sensitivity of about 50 %) as bowel gas interferes with the ultrasound waves.

### What If the Ultrasound Demonstrates Gas Bubbles in the Gallbladder Wall?

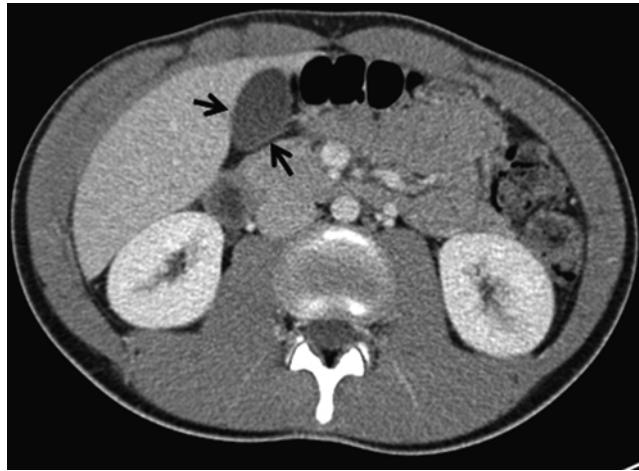
This would be concerning for emphysematous cholecystitis. This occurs when the gallbladder becomes infected with gas-forming organisms (e.g., clostridium) and represents a clinical scenario much like a necrotizing soft tissue infection. This diagnosis is common in older men, often with diabetes mellitus. This can progress to gallbladder perforation, intra-abdominal abscess, sepsis, and death if cholecystectomy is not performed emergently.

#### Watch Out

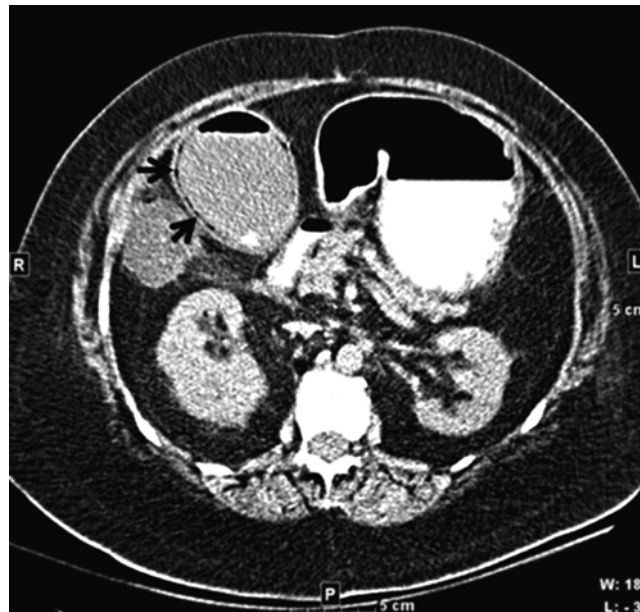
Do not confuse pneumobilia (Fig. 15.4) which is air in the biliary tree secondary to gallstone ileus (due to a fistula between the gallbladder and duodenum) with air in the gallbladder wall (due to gas-forming bacteria) seen in patients with emphysematous cholecystitis (Figs. 15.5 and 15.6).



**Fig. 15.4** Gallstone ileus (With kind permission from Springer Science+Business Media: Clinical Journal of Gastroenterology, A case of gallstone-induced small bowel necrosis masquerading as clinical appendicitis, 2, 2009, p239, Liau et al., Fig. 1)



**Fig. 15.5** Axial CT of a normal thin-walled gallbladder



**Fig. 15.6** Axial CT showing air in the gallbladder wall, known as emphysematous cholecystitis

### **Why Should Liver Tests, Amylase, and Lipase Always Be Sent in the Presence of RUQ and Epigastric Pain? What Is the Significance of Abnormalities?**

A liver panel should include total and direct bilirubin, aspartate (AST) and alanine (ALT) aminotransferase, alkaline phosphatase (AP), and gamma-glutamyltransferase (GGT). In a patient who only had symptomatic cholelithiasis, all of these should be normal. Mild elevations can be seen in acute cholecystitis. Significantly elevated AP and GGT in proportion to AST and ALT suggest cholestasis or biliary obstruction and are often related to choledocholithiasis. Marked elevations in AST or ALT, out of proportion to the AP and GGT, indicate hepatocellular damage, and a primary hepatic pathology such as viral or alcoholic hepatitis, or any other condition in which hepatocyte necrosis is occurring. Amylase and lipase should be sent to rule out gallstone pancreatitis. A normal amylase and/or lipase rules out this diagnosis. Lipase has a much higher specificity for pancreatitis than amylase.

- Liver tests such as AST, ALT, and AP do not actually reflect the synthetic function of the liver (thus the term “liver function test” is a misnomer). Better tests of the liver’s synthetic function include serum albumin, prothrombin time (PT), and international normalized ratio (INR), as the liver synthesizes albumin and clotting factors. Even these tests, however, can be affected by extrahepatic disease.

---

**What If Acute Cholecystitis Is Suspected but the Ultrasound Does Not Demonstrate Gallstones?**

One possible explanation is the rare false-negative ultrasound (<5 %). This may occur if gallstones are very small ( $\leq 1$  mm) or if there are very few gallstones. Another possibility is acalculous cholecystitis. This most often occurs in critically ill patients. It is thought to be secondary to a combination of biliary stasis and gallbladder ischemia in the presence of severe systemic illness. Long-term total parenteral nutrition (TPN) use has also been known to cause acalculous cholecystitis secondary to biliary sludging. Gallstones are not implicated in this condition. If gallstones are not seen on an ultrasound and biliary disease is suspected, the next diagnostic test would be cholescintigraphy (HIDA scan). In this test, radiolabeled hepatic iminodiacetic acid is given intravenously, and then imaging is performed. This compound is absorbed by hepatocytes and then excreted into bile and seen within 30–60 min in the gallbladder, bile ducts, and small bowel in a normal patient. If the cystic duct is obstructed, as in acute cholecystitis, no contrast will be seen within the gallbladder, and the HIDA scan is positive. This test has a sensitivity of 97 % and a specificity of 90 %. Acalculous cholecystitis is uncommon, representing only 5–10 % of cases of cholecystitis. This diagnosis must be addressed emergently with either cholecystectomy or a cholecystostomy tube to decompress the gallbladder. It is associated with high morbidity and mortality. Finally, non-biliary causes need to be considered (see above).

---

**Management****The Patient Presented Has an Ultrasound Demonstrating Gallstones, Pericholecystic Fluid, Gallbladder Wall Thickening of 5 mm, and a Positive Sonographic Murphy's Sign. What Is the Next Step in the Management of This Patient?**

Patients with acute cholecystitis should be admitted to the hospital, made NPO, and given IV fluids and IV antibiotics with gram-negative and anaerobic coverage. Laparoscopic cholecystectomy should be performed, ideally within 48 hours.

**What Is the Ideal Choice of Antibiotics?**

Antibiotics must be tailored to the most likely organisms. Second-generation cephalosporins (e.g., cefoxitin) are considered first line. An alternative would be broad-spectrum penicillin/ $\beta$ -lactamase inhibitors such as piperacillin/tazobactam or ampicillin/sulbactam. In severe cases, third- and fourth-generation cephalosporins may be used.

**What If Gallstones Are Discovered Incidentally? Do They Require a Cholecystectomy?**

There is no benefit for cholecystectomy for asymptomatic gallstones.

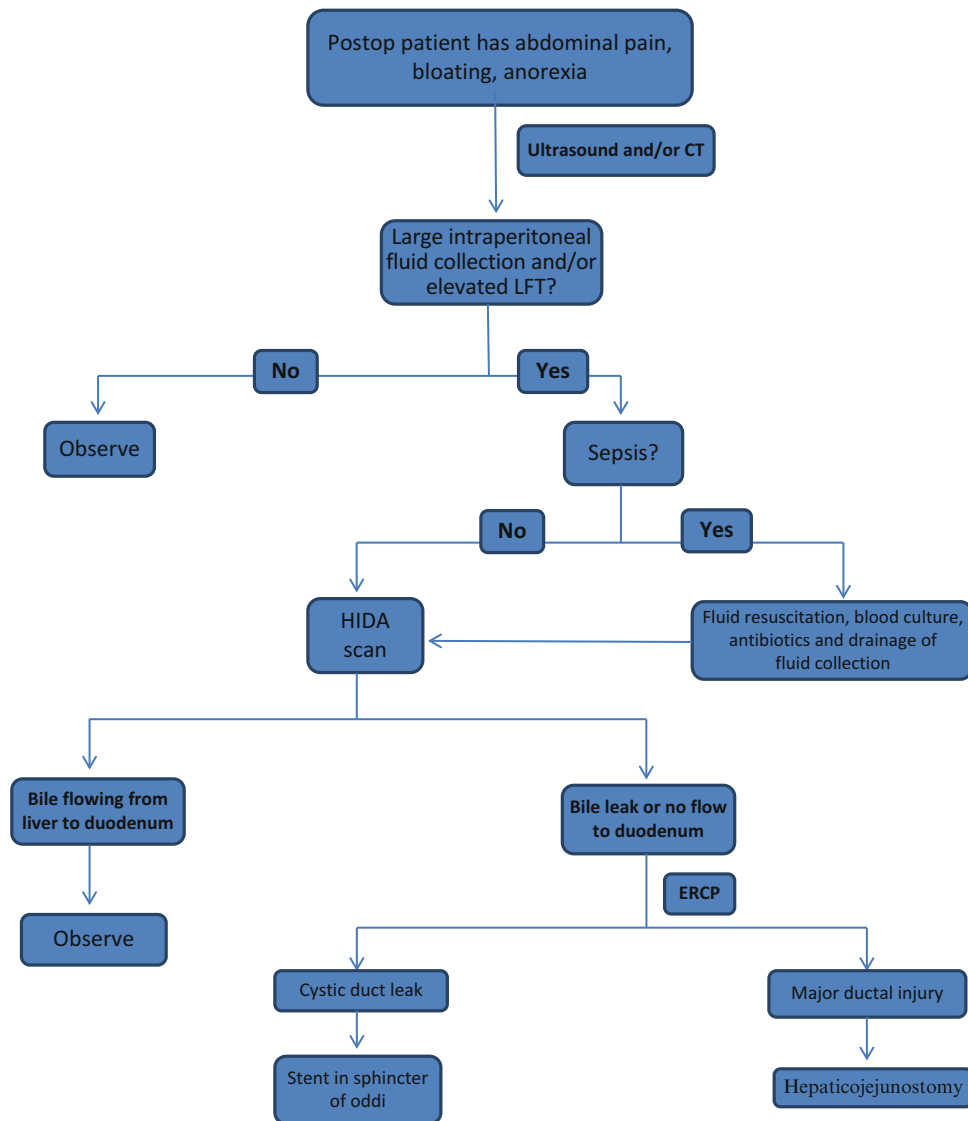
---

**Postoperative****What Is a Major Complication of Laparoscopic Cholecystectomy That Is More Common in the Setting of Acute Cholecystitis?**

CBD injury is one of the most feared complications of laparoscopic cholecystectomy. There is a higher risk of CBD injury in men and during surgery for acute cholecystitis as compared to symptomatic cholelithiasis. The injury is often made when the CBD is mistaken for the cystic duct, and thus the CBD is inadvertently divided.

**How Are These Injuries Managed When Recognized Intraoperatively?**

It depends on the severity of the injury. The blood supply to the common duct is dual (right hepatic artery and proper hepatic artery) and comes in at 9 o'clock and 3 o'clock. As such, if an injury involves less than 50 % of the circumference of the bile



**Fig. 15.7** Work-up for delayed recognition of CBD injuries

duct wall (and is not secondary to cautery), it can be primarily repaired (over a T-tube which acts like a temporary stent). If the injury involves greater than 50 % of the circumference of the bile duct, then a loop of jejunum has to be brought up and anastomosed to the proximal end of the bile duct (a procedure called a Roux-en-Y hepaticojejunostomy). If primary repair is attempted, it will inevitably form an ischemic stricture. Bile duct injuries leading to strictures can cause recurrent cholangitis and eventually cirrhosis and liver failure requiring transplantation.

### How Does the Injury Manifest If There Is Delayed Recognition? How Should It Be Worked Up?

Patients with delayed recognition of CBD injuries present postoperatively with abdominal pain, bloating, anorexia, and elevated liver function tests. Work-up (Fig. 15.7) involves an ultrasound and/or a CT scan of the abdomen/pelvis to look for a large intraperitoneal fluid collection. Such a fluid collection after cholecystectomy represents either blood (from a liver injury or cystic artery bleed) or bile leaking (termed a biloma, emanating from either a liver injury, cystic duct stump leak, or common bile duct injury). If the patient demonstrates evidence of sepsis, a drain should be placed. A HIDA scan should be obtained to see if bile is flowing from the liver to the duodenum and to see if bile is leaking. If bile is leaking, or if no bile

**Table 15.1** Postcholecystectomy syndrome (PCS)

<b>Etiology</b>	<b>Features</b>
<i>Residual stone in CBD</i>	This can lead to pancreatitis, cholangitis, or biliary obstruction
<i>Gallstone in cystic duct stump</i>	Patients with anatomically longer cystic ducts are at risk for retained gallstones
<i>Dysfunction of the biliary tree</i>	Increased pressure at the sphincter of Oddi can lead to impaired function of the biliary tree
<i>Other</i>	Gastritis, peptic ulcer disease

is entering the GI tract, an endoscopic retrograde cholangiopancreatography (ERCP) should be performed to determine whether a major ductal injury exists. If the cystic duct stump is leaking, a stent is placed in the sphincter of Oddi to create a path of least resistance for the bile to flow. A cystic duct leak generally resolves with this treatment. If on the other hand, a common bile or common hepatic duct injury is seen, the patient will need an operation and most likely will require the aforementioned hepaticojejunostomy.

### **What Is the Differential Diagnosis If the Patient Develops RUQ Pain Several Weeks After Cholecystectomy?**

Recurrent RUQ/epigastric pain that develops weeks after cholecystectomy is referred to as postcholecystectomy syndrome (PCS) and is detailed in Table 15.1. Work-up should begin with a complete blood count (CBC) and liver function tests, followed by a RUQ ultrasound. If ongoing pathology in the biliary tree is suspected, an ERCP would be the next test of choice.

## **Areas of Controversy**

### **Timing of Cholecystectomy with Acute Cholecystitis**

Most patients with acute cholecystitis are managed with laparoscopic cholecystectomy (LC), ideally performed within 48 hours of admission. Historically, patients with acute cholecystitis were admitted and underwent a “cooldown” period with intravenous antibiotics for several days prior to surgery. Current opinion on timing of cholecystectomy recognizes that a lengthy waiting period prior to operating on acute cholecystitis is unnecessary. It prolongs hospital stay and makes the LC more difficult, as the gallbladder becomes more scarred, distorting the anatomy, increasing the risk of CBD injury, as well as the likelihood that conversion to open cholecystectomy will be necessary.

### **When Should Acute Cholecystitis Be Managed Nonoperatively?**

Critically ill patients with acute cholecystitis may have an unacceptable amount of operative risk. In a high-risk surgical patient, occasionally acute cholecystitis can be managed initially with antibiotics alone. Some will resolve with this approach. If the patient does not improve, and is a prohibitive operative risk, a percutaneously placed cholecystostomy tube is used to decompress the infected gallbladder. This approach is often used for acute acalculous cholecystitis. This can represent a permanent solution to acute cholecystitis or can be followed with interval cholecystectomy depending on the patient’s clinical status.

## **Areas Where You Can Get in Trouble**

### **Failure to Recognize Gangrenous Cholecystitis**

Acute cholecystitis is thought to be part of a clinical spectrum that can progress to gangrenous cholecystitis in which the gallbladder wall becomes necrotic. Gangrenous cholecystitis is associated with increased morbidity and mortality including severe sepsis and gallbladder perforation. Gangrenous cholecystitis should be suspected in patients who present with severe

unrelenting abdominal pain, high fever, persistent tachycardia, markedly elevated WBC, and/or hyponatremia. It is more common in men and in diabetic patients. If gangrenous cholecystitis is suspected, patient should undergo laparoscopic cholecystectomy urgently to prevent the increased morbidity associated with delay.

### **Failure to Recognize Cholangitis**

Cholangitis occurs in the setting of obstruction of the CBD leading to ascending infection of the biliary tract. This most often occurs secondary to choledocholithiasis, or gallstones within the common bile duct. Combined acute cholecystitis and cholangitis is uncommon but can occur. The two diagnoses can be confused. Cholangitis is associated with *Charcot's triad* (right upper quadrant pain, jaundice, and fever), and *Reynolds pentad* (Charcot's triad with the addition of hypotension and altered mental status). Cholangitis necessitates immediate decompression of the biliary tract, most often with ERCP, although percutaneous transhepatic cholangiography with drainage is an option if ERCP is not available.

---

## **Summary of Essentials**

### **History**

- RUQ pain in obese, multiparous female

### **Physical Exam**

- Murphy's sign for acute cholecystitis

### **Pathology/Pathophysiology**

- Acute cholecystitis triggered by persistent cystic duct obstruction by gallstone

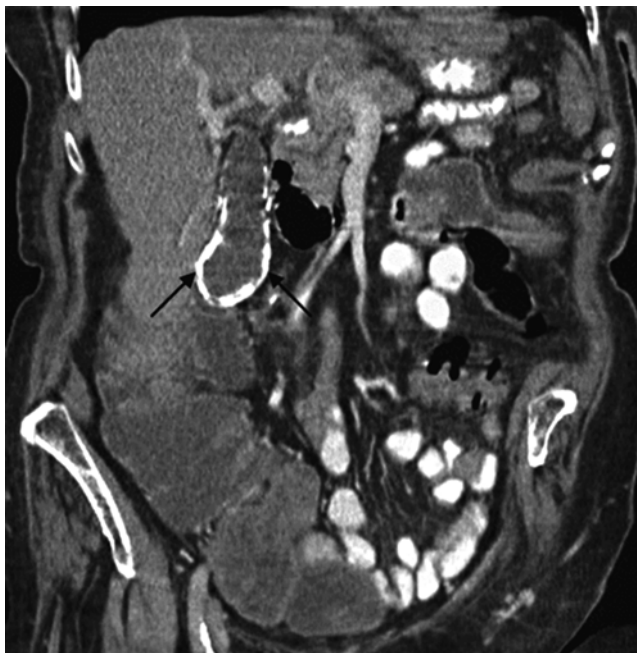
### **Diagnosis**

- RUQ US: gallstones, pericholecystic fluid, thickened gallbladder wall, and sonographic Murphy's sign
- HIDA scan if RUQ ultrasound is nondiagnostic
- KUB not helpful: only 10 % of gallstones are radio-opaque
- 90 % of acute cholecystitis is superimposed on chronic

### **Management**

- Asymptomatic gallstones: cholecystectomy not indicated
- Symptomatic cholelithiasis (biliary colic): elective lap cholecystectomy
- Acute cholecystitis: urgent (within 48 h) lap cholecystectomy
- Acute acalculous cholecystitis: cholecystostomy tube if critically ill
- Emphysematous cholecystitis: emergent cholecystectomy
- Gallstone ileus: remove large impacted gallstone from terminal ileum (leave gallbladder alone)





**Fig. 15.8** Porcelain gallbladder on coronal CT (With kind permission from Springer Science+Business Media: Geriatric Gastroenterology, Gastrointestinal Radiology, 2012, p238, Amorosa JK et al., Fig. 25.27)

### Postoperative

- If a patient presents within the first week after cholecystectomy with abdominal pain, distention, and anorexia, consider a biloma (cystic duct stump leak, CBD injury)
- Cystic duct stump leak readily treated with ERCP and stenting of the sphincter of Oddi
- CBD injury may require hepaticojejunostomy

### Additional Important Facts

- Ursodeoxycholic acid could be employed as conservative management for patients with cholelithiasis
- Calcified gallbladder (porcelain) (Fig. 15.8): increased risk of malignancy, perform cholecystectomy
- Choledochal cysts are congenital dilations of the biliary tree; prone to cholangitis, risk of associated malignancy, need to excise (if intrahepatic ducts are involved (Caroli's disease)), and may need liver transplantation
- Hemolytic anemia in childhood: high risk of black pigment gallstones
- Gallbladder cancer: associated with gallstones (always check final path)
- Gallbladder polyps: > 1 cm suspicious for cancer; >2 cm high likelihood of cancer

---

### Suggested Reading

Falor AE, Zobel M, Kaji A, Neville A, De Virgilio C. Admission variables predictive of gangrenous cholecystitis. *Am Surg.* 2012;78(10):1075–8.  
Gutt CN, Encke J, Köninger J, Harnoss JC, Weigand K, Kipfmüller K, Büchler MW. Acute cholecystitis: early versus delayed cholecystectomy, a multicenter randomized trial (ACDC Study, NCT00447304). *Ann Surg.* 2013;258(3):385–93.

Paul N. Frank and Christian de Virgilio

A 40-year-old female presents with a 24 hour history of right upper quadrant (RUQ) and epigastric pain, associated with nausea and vomiting. She has had similar pain in the past, particularly after eating greasy foods. According to her family, over the last few hours, the patient has become slightly confused. Past medical history is negative. Physical examination reveals a temperature of 102.5 °F, a heart rate of 110 beats/min, respiratory rate of 16/min, and a blood pressure of 90/60 mmHg. She is moderately tender in the RUQ to deep palpation. She has slight scleral icterus. She has noted dark-colored urine. The remainder of her abdominal exam is negative. Laboratory examination is significant for a white blood count of  $15 \times 10^3/\mu\text{L}$  (normal  $4.1\text{--}10.9 \times 10^3/\mu\text{L}$ ), a total bilirubin of 4.0 mg/dl (0.1–1.2 mg/dl), alkaline phosphatase (AP) of 350  $\mu\text{L}$  (33–131  $\mu\text{L}$ ), aspartate aminotransferase (AST) of 300  $\mu\text{L}$  (5–35  $\mu\text{L}$ ) and alanine aminotransferase (ALT) of 280  $\mu\text{L}$  (7–56  $\mu\text{L}$ ), gamma-glutamyl transpeptidase (GGT) of 330  $\mu\text{L}$  (8–88  $\mu\text{L}$ ), and an amylase of 100  $\mu\text{L}$  (30–110  $\mu\text{L}$ ). Urine is positive for bilirubin.

## Diagnosis

### What is the Differential Diagnosis?

Disease	Pathophysiology
<i>Acute calculous cholecystitis</i>	Obstruction of cystic duct by gallstone
<i>Choledocholithiasis</i>	Common bile duct (CBD) obstruction by gallstone
<i>Gallstone pancreatitis</i>	Transient obstruction of the distal CBD (and pancreatic duct)
<i>Cholangitis</i>	Ascending bacterial infection of the biliary system associated with CBD obstruction
<i>Viral hepatitis</i>	Viral infection of the liver, can be acute or chronic
<i>Mirizzi's syndrome</i>	Large stone lodged in the neck of the gallbladder causing external compression of the common hepatic duct
<i>Pyogenic (bacterial) liver abscess</i>	Hematogenous infection (e.g., endocarditis, IV drugs), or local spread from biliary disease
<i>Amoebic liver abscess</i>	Entamoeba histolytica enters portal system from colon via ulceration

P.N. Frank, MD (✉)

Department of Surgery, Harbor-UCLA Medical Center, 1000 W. Carson Street, Torrance, CA 90509, USA  
e-mail: [PaulFrank521@gmail.com](mailto:PaulFrank521@gmail.com)

C. de Virgilio, MD

Department of Surgery, Harbor-UCLA Medical Center, 1000 W. Carson Street, Torrance, CA 90509, USA  
e-mail: [cdevirgilio@labiomed.org](mailto:cdevirgilio@labiomed.org)

## Does the Patient Manifest Systemic Inflammatory Response Syndrome (SIRS)? What Is the Definition of SIRS?

Yes she does. SIRS may be diagnosed when at least two of the following criteria are met:

- $T > 100.4\text{ }^{\circ}\text{F}$  or  $< 96.8\text{ }^{\circ}\text{F}$
- $\text{HR} > 90\text{ bpm}$
- Respiratory rate  $> 20$  breaths per minute or  $\text{PaCO}_2 < 32\text{ mmHg}$  or patient is mechanically ventilated
- $\text{WBC} > 12 \times 10^3/\mu\text{L}$  or  $4 \times 10^3/\mu\text{L}$  or  $> 10\%$  band forms

It is important to note that SIRS may or may not be due to infection. If a patient meets the criteria for SIRS and has an identifiable source of infection (e.g., pneumonia, cholangitis), the patient has *sepsis*.

## What Is the Diagnosis for This Patient?

The most likely diagnosis in a patient with a 1-day history of RUQ pain worsened with greasy foods, nausea, altered mental status, jaundice, and fever is acute cholangitis secondary to gallstone impaction. Additionally, she has leukocytosis, hypotension, elevated bilirubin, and liver function tests, all of which are consistent with the diagnosis.

## What Are the Diagnostic Criteria for Cholangitis?

The Tokyo guidelines have been proposed as diagnostic criteria for acute cholangitis. Patients should have evidence of systemic inflammation (fever and/or leukocytosis), cholestasis (jaundice and/or abnormal liver enzymes), and biliary obstruction (dilated bile ducts on ultrasound).

---

## History and Physical

### What Are the Causes of Obstructive Jaundice That Lead to Cholangitis?

Gallstones are the most common cause. Other causes of obstruction include bile duct strictures, parasites (such as *Ascaris lumbricoides* and Chinese liver fluke, *Clonorchis sinensis*), instrumentation of the biliary system (such as during ERCP), and indwelling biliary stents.

### Would You Expect Pale Stools?

Pale or acholic stools are a result of prolonged biliary obstruction, so this would not be expected in patients with gallstone cholangitis.

### At What Level of Bilirubin Will Jaundice First Be Visible?

Jaundice will be visible at total bilirubin level  $> 2.5\text{ mg/dL}$ . Normal total bilirubin level is up to  $1.0\text{ mg/dL}$ .

### Where Do You Look for Jaundice?

Jaundice will manifest first in the sclerae of the eyes and under the tongue, as blood vessels here are more superficial. It will then descend down toward the chest, abdomen, and legs.

## What Is Charcot's Triad?

Charcot's triad consists of fever, right upper quadrant pain, and jaundice. This cluster of symptoms is classically associated with cholangitis.

## What Percent of Patients with Cholangitis Have All 3 of the Triad?

This presentation is found in only about 40–50 % of patients with cholangitis. Thus in actuality Charcot's triad is not very sensitive. Jaundice is not always clinically obvious.

## What Is Reynold's Pentad? What Percent of Patients with Cholangitis Have All Components?

Reynold's pentad implies cholangitis with septic shock. It includes Charcot's triad plus hypotension and mental status changes. It is present in the minority of patients with cholangitis (5 %). An altered mental status is indicative of severe disease and associated with a poor prognosis.

### Watch Out

Elderly patients with cholangitis may remain asymptomatic until they develop septic shock.

## What Is the Mortality Associated with Cholangitis?

The overall mortality rate is 5 %. This increases in patients with hepatic abscesses or if the original biliary obstruction is secondary to malignancy.

---

## Pathophysiology

### Why Are Gallstones the Most Common Cause of Obstructive Jaundice with Cholangitis?

To get cholangitis, one needs a combination of biliary obstruction and bacteria in the bile. Gallstones are the most common cause because they are the perfect vehicles to harbor bacteria in the biliary tree. As the stone passes from the gallbladder, it may get trapped at the narrowest portion of the biliary tree, the distal common bile duct.

### What Are Potential Consequences of Unrecognized Acute Cholangitis?

Severe untreated cholangitis can give rise to severe sepsis, hepatic microabscesses, and death. If the patient with acute cholangitis develops hepatic microabscesses, AST and ALT will markedly increase as a result of direct hepatocyte damage.

---

## Work-Up

### Why Is It Important to Distinguish Between Hepatic and Posthepatic Causes of Jaundice? How Do You Utilize the LFTs to Do So?

Hepatic causes of jaundice (such as hepatocellular injury from hepatitis) are usually nonsurgical problems, whereas posthepatic causes (such as biliary obstruction from acute cholangitis) are typically surgical. Distinguishing between the two is not always straightforward. Both will have some degree of elevation in total bilirubin, aspartate aminotransferase (AST), alanine aminotransferase (ALT), gamma-glutamyl transpeptidase (GGT), and alkaline phosphatase (ALP). AST and ALT are

enzymes within the liver cells (though AST is also found in the muscle and other cells). With hepatic cellular injury, these enzymes are released. As such with hepatic causes, the AST and ALT (transaminases) can sometimes reach into the thousands and rise out of proportion to the ALP. Such a disproportionate rise in the transaminases is indicative of hepatocellular damage, as seen in acute viral hepatitis, ischemic liver injury, or toxic insult. ALP is present in the cells that line the bile ducts. A marked rise in ALP, out of proportion to the AST and ALT, is therefore more indicative of posthepatic (biliary obstruction) pathology such as choledocholithiasis or cholangitis. Since ALP levels increase with many other diseases (such as bone pathology), a concomitant and proportionate rise in GGT is helpful, as it is more specific to liver disease.

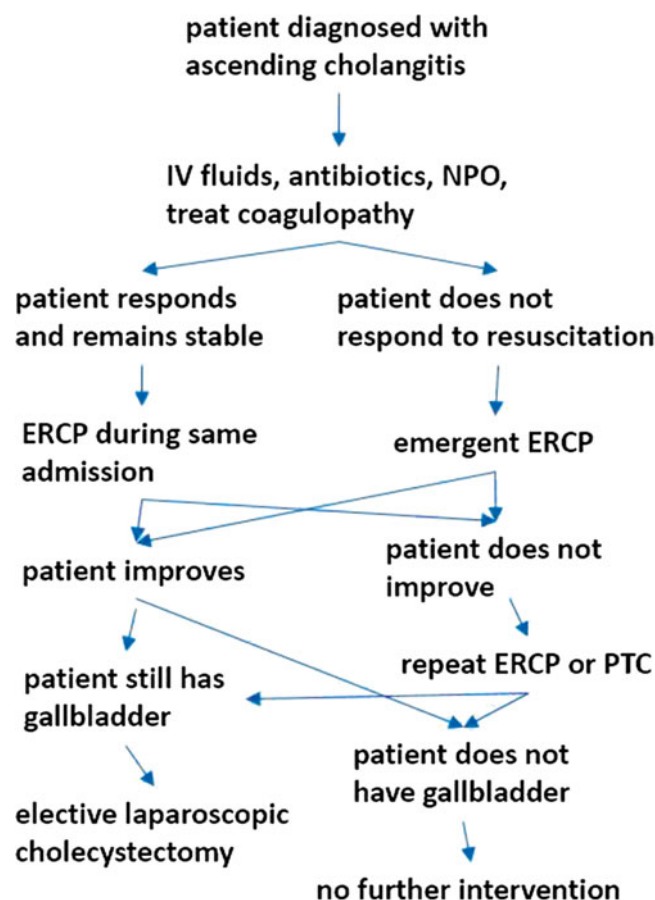
### What Imaging Is the Diagnostic Test of Choice? Does the Test Provide Direct or Indirect Evidence for the Diagnosis?

The first-line diagnostic test is RUQ ultrasound (US). RUQ US is excellent in terms of visualizing gallstones within the gallbladder and in demonstrating dilation of the common bile duct due to obstruction. However, US is poor at detecting stones within the common bile duct. Thus, RUQ ultrasound provides only indirect evidence (dilated common bile duct) for cholangitis. Normal common bile duct diameter is <4 mm until age 40 and then an additional 1 mm for every 10 years over age 40.

## Management

### What Are the Most Important Immediate Management Steps Once SIRS Is Recognized?

Once a patient is diagnosed with SIRS, several things should promptly occur (Fig. 16.1). First, the patient should receive targeted *aggressive intravenous fluid resuscitation* with normal saline or lactated Ringer's. Central venous access should be considered in order to guide resuscitation. Intravenous fluid administration should be titrated such that the patient's central



**Fig. 16.1** Overall treatment algorithm

venous pressure is 8–12 mmHg, the mean arterial pressure is at least 65 mmHg, and the patient's urine output is at least 0.5 mL/kg/h. It has been shown that delays in fluid resuscitation of as little as 3 hours cause increased mortality. Second, *broad-spectrum empiric antibiotics* should be started within 1 hour. In the case of suspected cholangitis, antibiotics should cover enteric organisms (gram-negative rods, enterococcus, and anaerobes). Additionally, at least two sets of *blood cultures* should be obtained, ideally before the administration of antibiotics, but only if this does not cause delay. Additionally, these patients may be at elevated risk of bleeding due to liver dysfunction and/or sepsis. Coagulation studies should be sent, and coagulopathy should be treated accordingly.

### **Does the Patient Need Admission to the ICU?**

Yes. These patients may require invasive hemodynamic monitoring, vasopressor support (in the event of severe sepsis or septic shock), and intravenous antibiotics.

### **Once the Patient Is Resuscitated, Antibiotics Given, and the Diagnosis Is Established, What Intervention Is Recommended? What Is the Goal of That Intervention?**

The next step in treatment is to drain the infected bile, termed biliary decompression. This is best accomplished by endoscopic retrograde cholangiopancreatography (ERCP). During ERCP, a scope is inserted through the mouth to the ampulla of Vater. The ampulla is cannulated, the stone can be extracted, the sphincter of Oddi is cut (sphincterotomy) to allow drainage of the bile into the duodenum, and a stent is often placed. If ERCP is unsuccessful, percutaneous transhepatic drainage (PTC) is the next choice. In this procedure, the bile is drained via a needle inserted directly into the liver. If both of these options fail, the bile may need to be decompressed operatively by placing a drain (called a T-tube) directly into the common bile duct.

### **Following Successful ERCP, What Is the Next Management Step?**

Once the patient's sepsis has completely resolved, they should undergo laparoscopic cholecystectomy (LC) so as to prevent future episodes.

### **Why Not Proceed to Surgery Initially?**

In the past, patients with acute cholangitis were taken directly to the OR for a combination of open cholecystectomy and T-tube drainage of the biliary tree. However, this approach led to high morbidity and mortality rates, as a septic patient was subjected to general anesthesia and an open operation. Biliary drainage via ERCP first has proven to be a safer option.

---

## **Areas Where You Can Get in Trouble**

### **Missing Cholangitis in an Asymptomatic Elderly Patient**

Cholangitis can easily be missed, particularly in the elderly who might present with altered mental status alone, or hypothermia, so always send LFTs in a septic patient, altered patient, and anyone with unexplained abdominal pain.

### **A History of Bloody Diarrhea in a Patient Who Presents with Cholangitis**

A history of bloody diarrhea in a patient who presents with cholangitis is suggestive of inflammatory bowel disease (IBD) with primary sclerosing cholangitis (PSC). PSC occurs more commonly in patients with ulcerative colitis (than Crohn's) and is characterized by inflammation and fibrosis of the intrahepatic and extrahepatic bile ducts. Uninvolved regions of the biliary tree are dilated, resulting in a beaded appearance on imaging. ERCP shows "pearls on a string."

## Areas of Controversy

### Do Patients Always Need Cholecystectomy After Biliary Decompression?

The justification for cholecystectomy after cholangitis in a patient with gallstones is that it will prevent additional complications from gallstones, such as recurrent choledocholithiasis and cholangitis. Several randomized controlled trials have confirmed this by demonstrating significantly lower risk of biliary complications in patients who undergo elective laparoscopic cholecystectomy after bile duct clearance.

---

## Summary of Essentials

### History and Physical

- Charcot's triad
- Reynold's pentad
- Look for evidence of SIRS
- Elderly patients may be hypothermic and leukopenic (are relatively immunosuppressed)

### Etiology/Pathophysiology

- Biliary obstruction with bacterial infection
- Bacteria enter bile either via bloodstream from the portal vein or retrograde from the duodenum
- Most commonly caused by gallstone obstruction of the distal CBD
- Other causes: biliary stricture, cancer, parasites
- Suppurative cholangitis: acute cholangitis complicated by septic shock

### Diagnosis

- Elevated WBC
- AP, ALT, AST, GGT rise proportion
- US: dilated CBD

### Management

- Aggressive IV fluids, blood cultures, broad-spectrum antibiotics
- Admit to ICU
- Urgent biliary decompression via ERCP
- PTC if ERCP fails
- Open surgery (insert T-tube into CBD) if PTC fails
- Cholecystectomy after sepsis resolves to prevent further biliary complications

### Watch Out

- The diagnosis of acute cholangitis may be missed in the elderly and immunosuppressed (e.g. steroids)
- Think sclerosing cholangitis if also having symptoms of IBD

---

## Suggested Reading

- Rosing DK, De Virgilio C, Nguyen AT, El Masry M, Kaji AH, Stabile BE. Cholangitis: analysis of admission prognostic indicators and outcomes. *Am Surg.* 2007;73(10):949–54.
- Wada K, Takada T, Kawarada Y, et al. Diagnostic criteria and severity assessment of acute cholangitis: Tokyo Guidelines. *J Hepatobiliary Pancreat Surg.* 2007;14(1):52–8.



Areg Grigorian and Christian de Virgilio

A 41-year-old woman presents to the emergency department complaining of severe and continuous epigastric pain for the past 24 hours. The pain radiates straight through to her back. She has had progressive nausea with vomiting. The vomitus is bile stained without blood. She has had similar but less severe episodes in the past, usually after eating heavy meals, but they always resolved within a few hours. She is married, with two children, and does not consume any alcohol. On exam, she is afebrile, heart rate is 115/min, blood pressure is 128/86 mmHg, and she has a normal respiratory rate. Her abdomen is not distended. She has no surgical scars on her abdomen and no obvious masses visible. She has no bruising around her umbilicus or along her flank. Bowel sounds are hypoactive. She has marked tenderness to palpation in her epigastrium, without guarding or rebound. The remainder of her abdomen is soft and non-tender to palpation. No masses or organomegaly are appreciated. Laboratory examination reveals a WBC count of  $17.2 \times 10^3$  cells/ $\mu$ L (normal 4.1–10.9  $\times 10^3$  cells/uL), amylase of 1,545 u/L (normal 30–110 u/L), lipase of 1,134 u/L (normal 7–60 u/L), ALT of 245 u/L (7–56 u/L), AST of 263 u/L (5–35 u/L), serum glucose of 156 mg/dl (65–110 mg/dL), and LDH 180 u/L (0–250 u/L). An abdominal series demonstrates gas throughout the small and large bowel, and a focal dilated loop of proximal small bowel without air fluid levels. There is no free air under the diaphragm.

---

A. Grigorian, MD (✉)

Department of Surgery, University of California, Irvine, 333 City Blvd West, Suite 1600, Route. 81, Orange, CA 92868, USA  
e-mail: [agrigori@uci.edu](mailto:agrigori@uci.edu)

C. de Virgilio, MD

Department of Surgery, Harbor-UCLA Medical Center, 1000 W. Carson Street, Torrance, CA 90509, USA  
e-mail: [cdevirgilio@labiomed.org](mailto:cdevirgilio@labiomed.org)

## Diagnosis

### What is the Differential Diagnosis for Epigastric Abdominal Pain? What Clues on History and Physical Examination Might Direct you Towards a Specific Diagnosis?

Condition	History and physical
<i>Gastroenteritis</i>	Nausea, extensive vomiting, diarrhea, myalgia, fever, mild abdominal tenderness
<i>Acute gastritis</i>	Burning/gnawing epigastric pain, NSAID <sup>a</sup> use, mild abdominal tenderness
<i>Acute cholecystitis</i>	Right upper quadrant/epigastric pain radiating to around the right back, nausea, vomiting, fever, <i>Murphy's sign</i>
<i>Peptic ulcer disease (PUD)</i>	Intermittent burning epigastric pain that is better (duodenal ulcer) or worse (gastric ulcer) with food intake, nausea, <i>Helicobacter pylori infection</i> , NSAID use, steroids
<i>Perforated ulcer</i>	Initial epigastric pain, followed by diffuse tenderness, abdominal rigidity, rebound tenderness
<i>Pancreatitis</i>	Epigastric pain radiating to the back, nausea, vomiting, anorexia, fever, tachycardia, cholelithiasis, alcohol abuse
<i>Appendicitis</i>	Periumbilical pain migrating towards right lower quadrant ( <i>McBurney's point</i> ), associated with nausea, vomiting, anorexia, fever, Rovsing's sign, psoas sign
<i>Small bowel obstruction</i>	<i>Adhesions</i> , hernia, neoplasms, dilated loops of bowel with air fluid levels, absence of distal colonic gas on plain X-ray
<i>Mesenteric ischemia</i>	"Severe abdominal pain out of proportion to physical exam," nausea, most often cardiac embolus to superior mesenteric artery from atrial fibrillation, bloody diarrhea in severe cases
<i>Ruptured AAA</i>	Severe abdominal/back/flank pain, pulsatile abdominal mass, hypotension, in elderly male smoker
<i>Referred pain from myocardial infarction</i>	Atypical presentation more common in women and diabetics, cardiovascular disease, obesity, hypercholesterolemia

<sup>a</sup>NSAID nonsteroidal anti-inflammatory drugs

### What Is the Diagnosis for This Patient?

Acute pancreatitis, most likely secondary to cholelithiasis. This patient has the classic presentation which consists of epigastric abdominal pain radiating straight through to the back with nausea and vomiting. She has had prior episodes of pain, which have resolved within a few hours, after eating heavy meals, which is characteristic of symptomatic gallstones. Since the vast majority of pancreatitis cases are due to gallstones or alcohol and this patient does not consume alcohol, we can conclude that her symptoms are most likely related to gallstones. Finally, the amylase and lipase are elevated.

### How Do You Diagnose Acute Pancreatitis?

Acute pancreatitis is considered a clinical diagnosis. The Atlanta criteria were created for the diagnosis of acute pancreatitis. They require two of the following three:

1. Sudden, severe, persistent epigastric pain radiating to the back
  2. Elevated lipase or amylase to 3x greater than the upper limit of normal
  3. Characteristic findings of acute pancreatitis on imaging (i.e., enlarged pancreas, sentinel loops, colon cutoff sign, etc)
- The patient described has all three criteria (the dilated small bowel represents sentinel loops {discussed further below}).

## History and Physical

### What Nonsurgical Conditions Can Mimic an Acute Abdomen?

Gastroenteritis, acute adrenal insufficiency, sickle cell crisis, diabetic ketoacidosis, acute porphyria, pelvic inflammatory disease, kidney stones, and pyelonephritis.

## What Is the Significance of Bruising Around the Umbilicus and Flank?

*Grey Turner's sign* refers to a blue-black discoloration in the flanks. It is considered a sign of retroperitoneal hemorrhage due to acute pancreatitis. *Cullen's sign* is a blue-red discoloration at the umbilicus, and the appearance is a result of digested blood products in the retroperitoneum, forming methemalbumin, that then travel towards the anterior abdominal wall.

### Watch Out

Only about 10 % of gallstones are radiopaque (visible on plain X-ray) versus 90 % of kidney stones. An abdominal ultrasound is the first step in the evaluation for gallstones.

## What Are the Signs, Symptoms, and Findings of Acute Pancreatitis?

Epigastric pain radiating to the back, worsened with food, nausea/vomiting (90 % of cases), anorexia, or decreased oral intake. Physical exam frequently reveals fever, tachycardia, epigastric tenderness with localized guarding, and hypoactive bowel sounds secondary to reactive ileus.

## What Structures Are in the Retroperitoneum?

One can remember these structures with the following mnemonic, “*DID KAPA* (the kangaroo) go retro”: *D*escending colon, *I*VC, *D*uodenum (2nd & 3rd segments), *K*idney, *A*orta, *P*ancreas, *A*scending colon.

## Pathophysiology

### What Is the Pathophysiology of Pancreatitis?

It initially occurs as a result of inappropriate activation of pancreatic enzymes leading to peripancreatic inflammation. Intraparenchymal extravasation of enzymes causes autodigestion of pancreatic parenchyma but primarily damages the peripancreatic tissues and vasculature. The inflammatory response is out of proportion to the insult and, with time, potentiates further damage leading to fluid sequestration, fat necrosis, vasculitis, and hemorrhage.

### What Are the Etiologies for Pancreatitis?

“*GET SMASHED*” will help you remember the causes of acute pancreatitis

*G* – gallstones (40 %)

*E* – ethanol (30 %)

*T* – tumors

*S* – scorpion stings

*M* – mycoplasma or mumps

*A* – autoimmune (SLE or polyarteritis nodosa)

*S* – surgery or trauma

*H* – hyperlipidemia/hypercalcemia

*E* – embolic or ischemia

*D* – drugs or toxins

### Watch Out

The 4 “*F*’s” for gallbladder disease are female, fat, forty, and fertile. Almost 40 % of acute pancreatitis cases are caused by gallstones. However, only about 3–7 % of patients with gallstones develop acute pancreatitis.

## What Medications can cause Pancreatitis?

Disease treated	Medications
Cardiovascular disease	Furosemide, thiazides
Inflammatory bowel disease	Sulfasalazine, 5-ASA
Immunosuppression	Azathioprine
Seizures	Valproic acid
Diabetes	Exenatide
HIV	Didanosine, pentamidine

## How Do Gallstones Cause Acute Pancreatitis?

The exact mechanism is not entirely clear. The most prevailing theory is the Opie's common channel theory (in which the pancreatic and common bile ducts end in a common channel at the ampulla of Vater). A gallstone passes from the gallbladder down into the common bile duct. The theory attributes the inflammation to a transient impaction at the ampulla which not only causes increased pancreatic duct pressure but results in reflux of duodenal juices and bile into the pancreatic duct. Whether it is the increased pressure or the stasis of duct contents that leads to acute pancreatitis is undetermined.

## In Patients with Gallstone Pancreatitis, How Often Does the Gallstone Remain Impacted in the Distal Common Duct?

The gallstones that cause pancreatitis are usually small, and as such, in the majority of cases, the stone remains impacted very briefly, only transiently obstructing the ampulla of Vater, and soon after passes into the duodenum. As such, persistence of a common bile duct (CBD) stone is uncommon and therefore Endoscopic retrograde cholangiopancreatography (ERCP) is not usually needed. This differs from gallstones that cause acute cholangitis, where the stones are usually large and usually need ERCP for removal.

## How Does Alcohol Cause Acute Pancreatitis?

The mechanism whereby alcohol causes acute pancreatitis is unclear. Interestingly, it usually occurs only after many years of alcohol abuse and not after single episodes of binge drinking in an alcohol-naïve pancreas. Intra-acinar activation of proteolytic enzymes seems to be one of the central requirements in all cases of pancreatitis. It has been proposed that the products of ethanol metabolism results in pancreatic hypoxia and oxidative damage, leading to an excessive increase in the calcium ion concentration in pancreatic cells (explaining low serum calcium that develops). Over time, this sensitizes the cells to respond to cholecystokinin (CCK) prematurely, leading to the inappropriate activation of zymogens in the cells.

## What are the Differences Between Acute and Chronic Pancreatitis?

	Acute pancreatitis	Chronic pancreatitis
Onset	Severe and sudden	Recurrent episodes
Etiology	Gallstone (40 %), alcohol (30 %)	Alcohol (90 %), anatomic defects (pancreas divisum)
Presentation	Epigastric pain radiating to back, nausea, vomiting anorexia	Recurrent epigastric pain, weight loss, diabetes, steatorrhea
Labs	High amylase and lipase (more specific)	Low fecal elastase levels
Radiology	Dilated loops of bowel near pancreas ( <i>sentinel loop</i> ) on plain films	<i>Pancreatic calcifications</i> on plain films

## How Many Phases Are There in Acute Pancreatitis?

There are three phases in acute pancreatitis, though not every patient goes through all three. Phase one consists of premature activation of trypsin within the pancreatic acinar cells. The second phase involves intrapancreatic inflammation, whereas phase three consists of extrapancreatic inflammation (affecting multiple organ systems).

## How Is the Severity of Pancreatitis Classified?

The severity of pancreatitis is classified as *mild* and *severe*. Most patients (80–90 %) have mild pancreatitis, which is characterized by the absence of multiorgan failure and local/systemic complications. It usually resolves in 2–5 days. Severe pancreatitis is defined by the development of systemic complications (organ failure) and/or local (pancreatic) complications such as pancreatic pseudocyst, abscess, and necrosis (worst prognosis).

## What Organ Systems Can Be Affected by Acute Pancreatitis?

Cardiac, pulmonary, renal, and gastrointestinal

## How Is Organ Failure Defined?

Organ failure, as defined by the Atlanta Symposium, includes:

- Shock – systolic pressure <90 mmHg
- PaO<sub>2</sub> ≤ 60 mmHg
- Creatinine >2.0 mg/L after rehydration
- Gastrointestinal bleeding >500 cc/24 hours

## What Is the Mechanism for Hypotension in Pancreatitis?

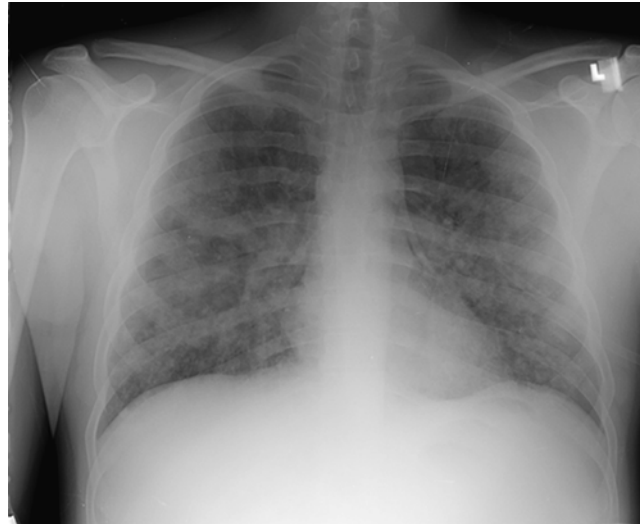
Inflammation and cytokine storm cause endothelial injury and increased permeability in the peripancreatic vasculature, leading to fluid leaking into the retroperitoneal space. The cytokine storm also causes massive vasodilation, which along with a shrunken intravascular volume can cause severe hypotension.

## What Are the Main Pulmonary Complications of Acute Pancreatitis?

Pleural effusions (the majority on the left side) and Acute Respiratory Distress Syndrome (ARDS) (Fig. 17.1). Severe pancreatic inflammation can obstruct lymph drainage around the diaphragm, resulting in a collection of lymph fluid, which subsequently travels across the diaphragm pores and into the ipsilateral base of the lung. These diaphragm pores are the same conduits involved in cirrhotic hydrothorax. In addition, severe inflammation can contribute to fistula formation between the pancreas and the thoracic cavity, permitting free flow of pancreatic enzymes into the lungs.

## What Are the Different Histopathologic Types of Acute Pancreatitis? What Are the Important Differences?

The majority of patients (>80 %) develop *acute interstitial edematous pancreatitis*, characterized by an enlargement of the pancreas due to inflammatory edema. Such patients have no inflammation or destruction of pancreatic cells. Less than 20 % develop *necrotizing pancreatitis* characterized by necrotic pancreatic parenchyma which can lead to sepsis in over half the cases. *Central gland necrosis* is a subtype of necrotizing pancreatitis characterized by necrosis within the body of the pancreas, along with disruption of the pancreatic duct, leaving enzymatic juices to accumulate in the tail of the pancreas. Percutaneous or



**Fig. 17.1** Chest X-ray showing diffuse bilateral pulmonary infiltrates characteristic of ARDS

endoscopic drainage is usually unsuccessful, and most patients will need a distal pancreatectomy. *Hemorrhagic pancreatitis* is a type of necrotizing pancreatitis in which there is extensive bleeding into the pancreatic parenchyma and surrounding tissues. The type of pancreatitis is important because it determines both prognosis and management. The mortality for interstitial edematous pancreatitis and necrotizing pancreatitis is 3 % and 17 %, respectively.

---

## Prognosis

### How Is the Severity of Pancreatitis Determined?

Severity is determined by using one of various scoring systems: Ranson (Table 17.1), APACHE II, BISAP (bedside index of severity of acute pancreatitis), Imrie, or based on clinical evidence of local or systemic complications.

The Ranson criteria are the most commonly used tool and include 5 admission variables and 6 criteria that are assessed after 48 hours. Use “GA (Georgia) LAW” to remember the parameters used in determining prognosis on admission. Use “C. Hobbs” to remember the latter parameters (from Calvin & Hobbes, the comic strip from the 1980s). Each variable gets one point.

#### Watch Out

The degree of amylase and lipase elevation do not correlate with the severity of acute pancreatitis and should not be used to influence management.

### How Are These Criteria/Scoring Systems Used to Determine Whether Someone Has Severe Pancreatitis?

Severe pancreatitis is defined as Ranson scores  $\geq 3$ , APACHE II score  $\geq 8$ , presence of organ failure, and/or local (pancreatic) complications (necrosis, abscess, or pseudocyst). Recently, the BISAP score has been found to be simpler and as accurate as APACHE II. BISAP score is determined by adding one point for each of the following: BUN  $>25$  mg/dL, impaired mental status, systemic inflammatory response syndrome (SIRS), age  $>60$  years, and pleural effusion. Mortality is  $< 1$  % if the score is 0–1, and  $>20$  % if the score = 5.

**Table 17.1** Ranson Criteria

<b>Admission</b>			
Glucose > 200 mg/dL			
Age > 55 years			
LDH > 350 IU/L			
AST > 250 IU/L			
WBC count > 16000 cells/mm			
<b>After 48 hrs</b>			
Calcium < 8.0 mg/dL			
Hematocrit decrease > 10%			
Oxygen PaO <sub>2</sub> < 60 mmHg			
BUN increased by 5 mg/dL or more despite fluid resuscitation			
Base deficit > 4 mEq/L			
Sequestration of fluids > 6 L			
Score 0 to 2	2% mortality		
Score 3 to 4	15% mortality		
Score 5 to 6	40% mortality		
Score 7 to 8	100% mortality		

### What Is the Main Drawback of Ranson Criteria?

It takes 48 hours to measure all variables, and by then, the majority of patients have already declared themselves as to whether their course will be mild or severe and whether they need to be in a monitored bed. In addition, the variables cannot be repeatedly measured on an hourly or daily basis to monitor improvement or deterioration.

### Why Does One Get Hypocalcemia with Severe Pancreatitis?

With severe pancreatitis, free fatty acids are generated by the action of pancreatic lipase. The free fatty acids chelate calcium salts that are present in the pancreas, leading to saponification (the deposition of calcium soaps in the retroperitoneum).

### What Is the Natural Disease Course of Acute Pancreatitis?

The majority of patients with acute pancreatitis recover in less than 5 days without any complications. Close to 20 % of patients have a severe presentation with local or systemic complications (including organ failure).

## What Is the Most Common Cause of Mortality in the First Week of Acute Pancreatitis? Beyond the First Week?

In the first week, death is most often due to multiorgan failure as a result of severe systemic inflammatory response. After the first week, mortality is most commonly due to sepsis secondary to pancreatic necrosis and peripancreatic abscesses (these most often develop in the third and fourth week of hospitalization). If a pancreatic abscess is not drained, mortality approaches 100 %.

### Watch Out

Systemic Inflammatory Response Syndrome (SIRS) is defined by two or more of the following:

Pulse >90 bpm, respiratory rate >20/min, WBC < 4 × 10<sup>3</sup>/μL or > 12 × 10<sup>3</sup>/μL, and < 36 or >38 ° C.

## Workup

### What Are the Most Important Laboratory Tests to Order When Suspecting Acute Pancreatitis?

Serum amylase, lipase, liver function tests (AST, ALT, ALP), electrolytes, CBC, and a lipid panel. Amylase and lipase are typically elevated. In patients with no history of alcohol abuse, elevated ALT greater than three times the upper limit of normal has a 95 % positive predictive value for gallstone pancreatitis. However, close to 20 % of patients will have normal LFTs. A lipid panel is important to rule out hyperlipidemic pancreatitis, usually due to hypertriglyceridemia.

### Which Laboratory Test Is Most Specific for Acute Pancreatitis?

Lipase is most specific. Numerous other diseases can cause hyperamylasemia (Table 17.2).

### Watch Out

In patients with hemorrhagic pancreatitis, the initial hematocrit is *not* a good indicator of blood loss. The hematocrit may take 1 or 2 days to equilibrate. In addition, the patient is severely dehydrated, leading to hemoconcentration, giving a falsely elevated or normal hematocrit.

### What Is the Diagnostic Imaging of Choice on Admission for Acute Pancreatitis?

Right upper quadrant ultrasound. Since the most common cause of acute pancreatitis is gallstones, this is the first etiology that should be ruled out.

**Table 17.2** Hyperamylasemia

Conditions	Specific diseases
<i>Pancreatic disease</i>	Pancreatitis, pancreatic pseudocyst, trauma, ERCP*, pancreatic carcinoma, cystic fibrosis
<i>Salivary disease</i>	<i>Parotitis</i> , radiation, ductal obstruction
<i>Gastrointestinal disease</i>	Peptic ulcer disease, perforated bowel, mesenteric ischemia, appendicitis, cholecystitis, celiac disease
<i>Gynecologic disease</i>	Ectopic pregnancy, ovarian cysts, pelvic inflammatory disease
<i>Neoplasms</i>	Multiple myeloma, pheochromocytoma
<i>Other</i>	Alcohol abuse, <i>renal failure</i> (amylase is renally cleared)

\*ERCP endoscopic retrograde cholangiopancreatography



### What Are the Classic Abdominal X-Ray Findings in Acute Pancreatitis?

A sentinel loop (dilated loops of proximal small bowel in the left upper quadrant near the pancreas) and colon cutoff sign (distended proximal colon with abrupt collapse in the left upper quadrant at the splenic flexure). Both are due to local ileus (paralyzed, nonmotile bowel) as a result of the pancreatic inflammation.

### What Is the Classic Chest X-Ray Finding in Acute Pancreatitis? How Does This Finding Influence Prognosis?

A pleural effusion, classically on the left side. In patients with severe pancreatitis, nearly 85 % have evidence of pleural effusion on admission. In contrast, only 15 % of patients with mild pancreatitis have a pleural effusion on plain films upon admission. This finding is strongly associated with severe pancreatitis.

### What Is the Role of Abdominal CT Scan on Admission?

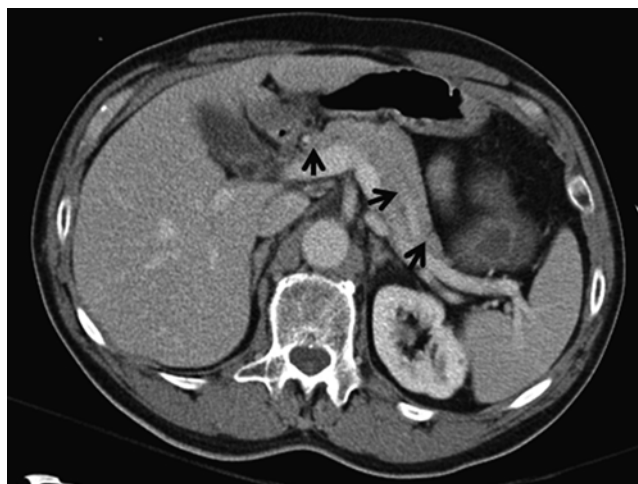CT scan should not be routinely ordered on admission, as it does not change management in the vast majority of cases. Though CT scan can help distinguish between mild and severe pancreatitis, clinical criteria are equally useful in making this distinction. As such, CT should only be ordered in the rare case when the diagnosis of acute pancreatitis is in doubt.

### What Is the Role of Abdominal CT Scan During Subsequent Hospitalization?

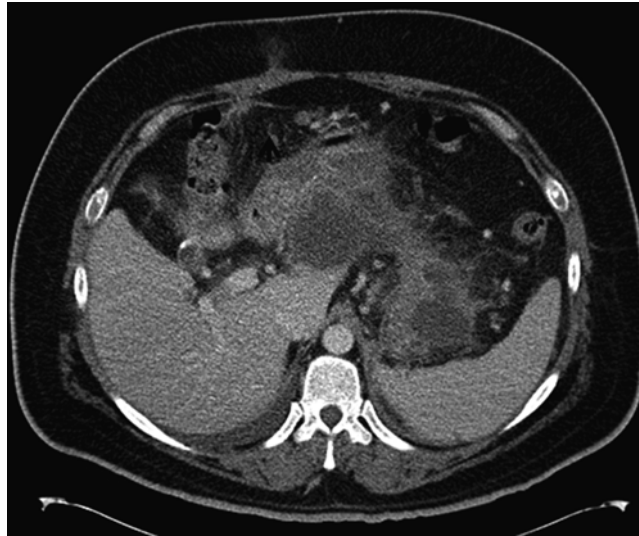
If the patient is not clinically improving after several days of conservative management, CT scan is helpful as it would explain the lack of improvement (such as whether there is pancreatic necrosis). Beyond the first week, CT scan is helpful in the situation where a patient develops worsening abdominal pain, fever, and sepsis, as it may demonstrate a pseudocyst or a pancreatic abscess (these local complications do not manifest on admission) (Figs. 17.2, 17.3, and 17.4).

### What Is the Role of Urgent ERCP in Gallstone Pancreatitis?

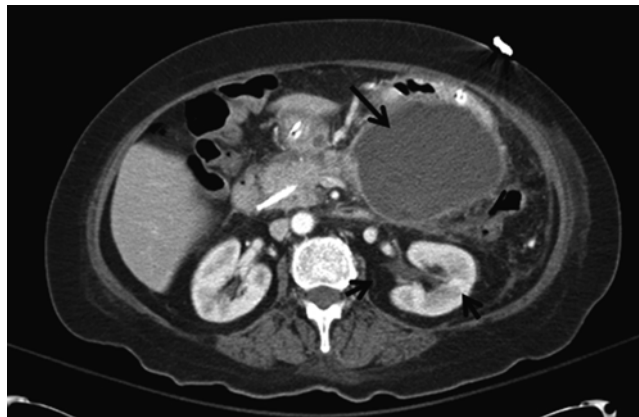
It is rarely needed, and only if there is a suspected concomitant acute cholangitis.



**Fig. 17.2** Axial CT with a normal-appearing pancreas. *Black arrows: normal pancreas*



**Fig. 17.3** Axial CT scan with peripancreatic fluid collections exhibiting thick irregular walls and marked fat stranding, consistent with abscesses



**Fig. 17.4** Axial CT scan showing a thin-walled peripancreatic fluid collection consistent with pancreatic pseudocyst

### **How Would Concomitant Acute Cholangitis and Acute Pancreatitis Be Recognized?**

Diagnosing the presence of both simultaneously can be tricky, as acute pancreatitis can also cause similar derangements as acute cholangitis (though to a lesser degree). Look for evidence of infection (high fever, markedly elevated WBC with left shift) and biliary obstruction (markedly elevated total bilirubin  $\{>4 \text{ mg/dl}\}$  and alkaline phosphatase, dilated CBD on ultrasound).

---

## **Management**

### **What Is the Initial Treatment for Acute Pancreatitis?**

Treatment is supportive and patients are managed conservatively with vigorous intravenous fluid hydration, NPO, analgesics, and nasogastric decompression only if vomiting. The majority of patient's symptoms resolve within 3–5 days with this management.

**Watch Out**

Some clinicians prefer meperidine over morphine for pain control because in theory, meperidine does not cause contraction of the sphincter of Oddi (whereas morphine does), and may allow for quicker resolution of symptoms. However, meperidine increases the risk of seizures.

**What Is the Subsequent Management Plan? And How Does This Differ Between Gallstone and Alcoholic Pancreatitis?**

If gallstones were found on presentation (and there is no history of heaving alcohol abuse), a cholecystectomy should be performed during the same hospitalization because recurrent episodes are high. The timing of cholecystectomy is explored at the end of the case. If alcohol is the etiology, counsel the patient on alcohol cessation and provide referral for support groups.

**How Does the Severity of Acute Pancreatitis Affect Management?**

It is important for several reasons. It assists in triage to a ward (mild pancreatitis) or monitored (step down or ICU) bed (severe pancreatitis). If severe pancreatitis is predicted, it raises awareness to monitor the patient closely for local and/or systemic complications. For gallstone pancreatitis, it assists in determining timing of cholecystectomy: early (within 48–72 h) for mild pancreatitis versus delayed (weeks later after complete resolution) for severe pancreatitis.

**What Is the Management Algorithm for Acute Pancreatitis? (Fig. 17.5)**

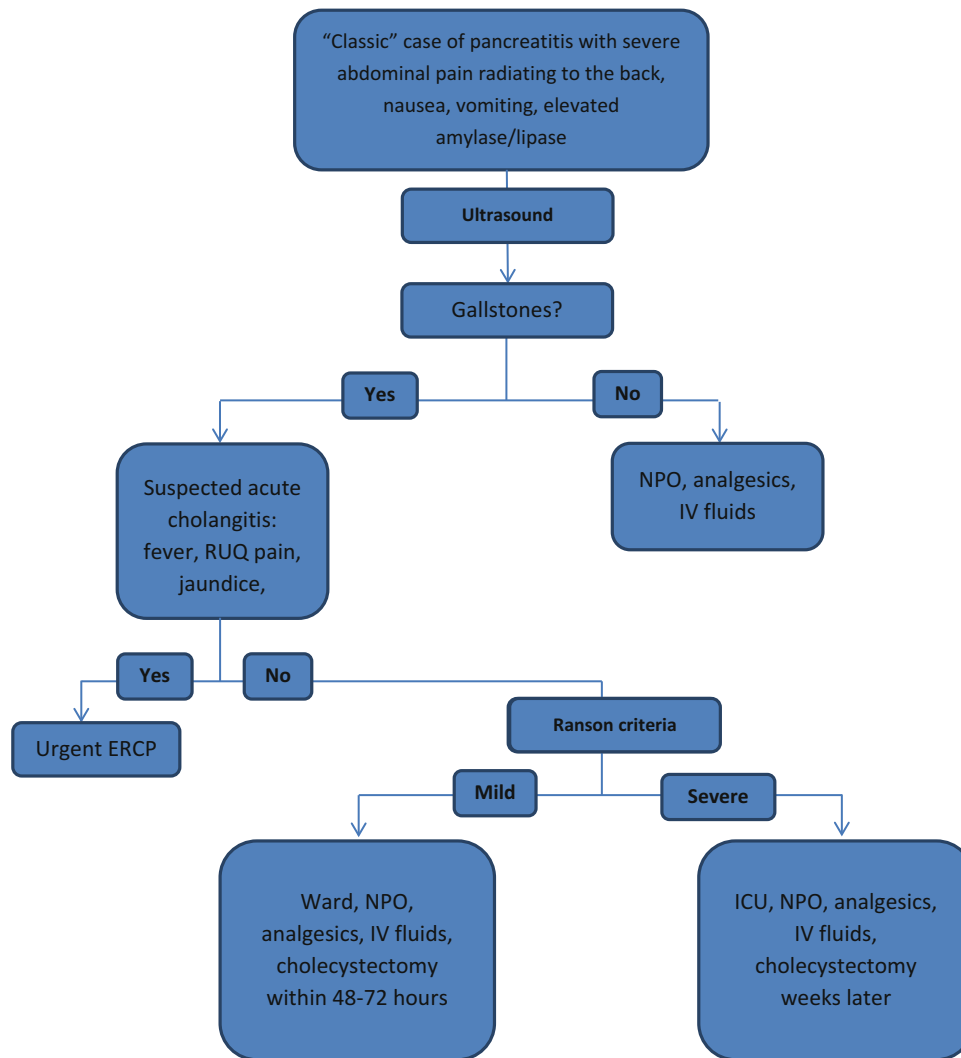
Management algorithm for acute pancreatitis. Based on the practice guidelines from the American College of Gastroenterology

**Special Situations****What Should You Suspect If a Patient with Severe Acute Pancreatitis, Develops a Fever and Leukocytosis 3 Weeks into the Hospitalization?**

This presentation is concerning for a pancreatic abscess. The first step is to order a CT scan with contrast looking for necrotic tissue (i.e., areas that do not enhance) or a pancreatic abscess. If you find evidence of either, a CT or ultrasound-guided aspiration should be performed and sent for culture. If infection is present, antibiotics are administered. Infected pancreatic necrosis and pancreatic abscesses require surgical debridement using a step up approach, which consists of percutaneous drainage followed, if needed, by minimally invasive retroperitoneal removal of infected/necrotic pancreatic tissue (known as a necrosectomy).

**What Should You Suspect If a Patient with a Recent Hospitalization for Pancreatitis Comes in 4 Weeks Later with Persistent Abdominal Pain, a Palpable Epigastric Mass, and Persistently Elevated Serum Amylase?**

A pancreatic pseudocyst. A pseudocyst is a collection of pancreatic fluid surrounded by a wall without epithelium. It results from pancreatic injury such as pancreatitis or trauma, which essentially disrupts a pancreatic duct. The pancreatic enzymatic fluid that leaks out is contained by surrounding fibrotic tissue. Although this most commonly appears in patients with chronic pancreatitis, it can also occur in the weeks following resolution of an acute pancreatitis. The diagnostic test of choice is a CT scan. In the majority of patients, the pseudocyst resolves spontaneously in 6 weeks with supportive treatment only. If the pseudocyst is small (<6 cm) and asymptomatic, observation with serial CT scans is indicated. If it persists beyond 6 weeks, or is >6 cm, or symptomatic (pain, bloating, poor digestion of food), surgical intervention may be



**Fig. 17.5** Management algorithm for acute pancreatitis. Based on the practice guidelines from the American College of Gastroenterology

needed. This is usually done via *internal drainage*, by creating a connection between the cyst and the adjacent intestinal organ, usually the stomach (cystogastrostomy). External drainage is not recommended as this may create a pancreaticocutaneous fistula.

#### Watch Out

The most common cause of death from a pancreatic pseudocyst is excessive hemorrhaging into the pseudocyst due to erosion into adjacent artery.

### What Are the Complications from Chronic Pancreatitis?

Patients may develop *diabetes mellitus* secondary to the destruction of beta-islet insulin-producing cells in the pancreas caused by chronic inflammation. This type of diabetes is very difficult to treat and most patients require insulin. Patients may also develop *steatorrhea* due to poor absorption from the digestive tract. These patients require pancreatic enzyme supplementation. Most patients also complain of severe and persistent *chronic pain*.

## What Is the Most Common Indication for Surgical Management in Chronic Pancreatitis?

The most common indication for surgical intervention is *persistent and severe pain*. The reason why chronic inflammation leads to constant pain is not fully understood, but the mechanism proposed includes nerve injury in the pancreatic head. Nonoperative management, providing temporary pain relief, includes placement of a stent in the pancreatic duct, allowing for improved anterograde flow of pancreatic juices. For definitive treatment, the Puestow procedure (lateral pancreaticojejunostomy) is performed, in which the pancreatic duct is opened all the way from the head to the tail and sutured into the jejunum, allowing the free flow of pancreatic juices into the small intestine.

## Areas of Controversy

### Is Urgent ERCP Beneficial for Severe Pancreatitis?

Only if there is suspicion of concomitant cholangitis. In the absence of cholangitis, the theoretical benefit of urgent ERCP is to remove a gallstone impacted in the distal common duct that might cause ongoing pancreatic inflammation. However, studies have failed to consistently show benefit in using urgent ERCP in the absence of cholangitis. This may be a result of ERCP having a 5 % risk of causing pancreatitis, related to over-injection of contrast medium into pancreatic ducts, and due to the fact that the majority of gallstones pass into the duodenum spontaneously. There is evidence to support endoscopic removal of common bile duct stones with ERCP and papillotomy if cholangitis is also present. Some clinicians also choose to use ERCP in the setting of obstructive jaundice as suggested by increased liver function tests.

### Should Prophylactic Antibiotics Be Administered for Severe Acute Pancreatitis?

Most experts would say no. There is no role for antibiotics for mild pancreatitis, as the disease is due to inflammation, not infection. There is some data to support the use of prophylactic antibiotics for severe pancreatitis. Patients with severe pancreatitis have increased mortality as a result of subsequent infections, justifying a possible role for prophylactic antibiotics, and anecdotally supported by its use in clinical practice over the past several decades. However, its role has been scrutinized by multiple studies in recent years, with most concluding that there is no decrease in mortality for patients receiving antibiotics upon admission.

### Timing of Elective Cholecystectomy After Gallstone Pancreatitis

Cholecystectomy is considered the standard of care in patients with gallstone pancreatitis because there is a high risk of recurrent pancreatitis (as high as 30 % within a month). Whether cholecystectomy is done on an urgent or elective basis is dependent on the presentation. Many centers wait, even with mild pancreatitis, until all laboratory values have normalized which may take 5–7 days. In patients with mild disease, recent randomized studies indicate that cholecystectomy can be performed within 48 hours of admission regardless of whether laboratory values have normalized. With severe pancreatitis, such as necrotizing pancreatitis, delaying gallbladder removal until complete resolution of the pancreatitis is recommended.

---

## Areas Where You Can Get in Trouble

### Missing Hypercalcemia as the Cause of Pancreatitis

In the absence of gallstones and alcohol abuse, the etiology of acute pancreatitis may be unclear. In a patient with hypertension controlled with hydrochlorothiazide, consider hypercalcemia as the etiology. Hydrochlorothiazide increases calcium reabsorption in the distal convoluted tubule. Hypercalcemia leads to a secretory block in the pancreatic duct. While hypercalcemia can cause pancreatitis, pancreatitis can cause hypocalcemia. Inflammation generates free fatty acids that avidly chelate insoluble calcium salts in the pancreatic bed, resulting in hypocalcemia. Thus the predisposing hypercalcemia may be missed.

## Pseudohyponatremia in Pancreatitis

Be aware of pseudohyponatremia in patients with hyperlipidemic pancreatitis. This is often due to a lab error in measuring sodium concentration. True sodium levels are normal.

## Nutritional Support

If patients require being NPO greater than 7 days, nutritional support is needed. *Enteral nutrition* (not parenteral) is preferred, with the feeding tube placed past the ligament of Treitz to avoid activation of the pancreas

---

## Summary of Essentials

### History and Physical

- Nonsurgical conditions that mimic an acute abdomen: gastroenteritis, acute adrenal insufficiency, sickle cell crisis, diabetic ketoacidosis, acute porphyria, pelvic inflammatory disease, kidney stones, and pyelonephritis
- Patients with pancreatitis typically present with epigastric pain radiating to the back, nausea, vomiting, anorexia, fever, tachycardia, cholelithiasis, and alcohol abuse

### Pathophysiology

- The initial event in pancreatitis is the inappropriate activation of pancreatic enzymes
- Gallstones and alcohol are the most common causes of acute pancreatitis

### Diagnosis

- Most cases can be diagnosed with just a history, physical, and abnormal amylase/lipase
- Ranson criteria are used to predict severity based on parameters during initial admission and at 48 hours after

### Workup

- Amylase/lipase levels do not correlate with severity of pancreatitis
- In the absence of a history of alcohol abuse, start with a RUQ ultrasound to look for gallstones

### Management

- Patients should initially be managed conservatively with IV fluids, NPO, and narcotic analgesia
- Gallstones
  - urgent ERCP if concomitant cholangitis
  - early cholecystectomy if mild pancreatitis
  - late cholecystectomy if severe pancreatitis
- If patients do not clinically improve after 3 days of conservative management, get a CT scan with contrast to look for any underlying complications (i.e., necrosis)
- Begin enteral nutrition in patients with prolonged NPO status or in severe acute pancreatitis
- Refractory persistent abdominal pain is the main indication for surgery in chronic pancreatitis

---

## Complications

- Systemic
  - Early (1st week)
  - Multi-organ failure
- Local
  - Late (3 weeks)
  - Pancreatic abscess
  - Pancreatic pseudocyst
  - Pancreatic necrosis

---

## Suggested Reading

- Aboulian A, Chan T, Yaghoubian A, Kaji AH, Putnam B, Neville A, de Virgilio C. Early cholecystectomy safely decreases hospital stay in patients with mild gallstone pancreatitis: a randomized prospective study. *Ann Surg.* 2010;251(4):615–9.
- Bradley III EL. A clinically based classification system for acute pancreatitis: summary of the international symposium on acute pancreatitis, Atlanta, Ga, September 11 through 13, 1992. *Arch Surg.* 1993;128(5):586.
- Chang L, Lo S, Stabile BE, Lewis RJ, Toosie K, de Virgilio C. Preoperative versus postoperative endoscopic retrograde cholangiopancreatography in mild to moderate gallstone pancreatitis: a prospective randomized trial. *Ann Surg.* 2000;231(1):82.
- Uhl W, Warshaw A, Imrie C, Bassi C, McKay CJ, Lankisch PG, Carter R, Di Magno E, Banks PA, Whitcomb DC, Dervenis C, Ulrich CD, Satake K, Ghaneh P, Hartwig W, Werner J, McEntee G, Neoptolemos JP, Büchler MW. IAP guidelines for the surgical management of acute pancreatitis. *Pancreatol.* 2003;3(2):565–73.

James X. Wu, Christian de Virgilio, and Danielle M. Hari

A 68-year-old man presents to the emergency department complaining of fatigue and intermittent vague abdominal pain. He denies nausea or vomiting, but “does not have much of an appetite these days.” He reports having lost almost 20 pounds in the past 2 months. He was recently diagnosed with type 2 diabetes, but has no other medical problems and no previous surgeries. His stools have become lighter in color and his urine is much darker than before. His social history is negative for alcohol use, but he has a 50+ pack-year smoking history before quitting last year. He has no significant family history. On exam, he has a yellow hue to his eyes and tongue, along with scratch marks on his skin. A non-tender mass is palpated in the right upper quadrant (RUQ) of the abdomen. Laboratory testing reveals total and direct bilirubin of 18 mg/dL (normal 0.2–1.3 mg/dL) and 17.2 mg/dL (<0.3 mg/dL), respectively, and alkaline phosphatase (ALP) elevated at 215  $\mu$ /L (33–131  $\mu$ /L). Liver transaminases are mildly elevated. CA 19-9 and CEA levels are normal.

---

J.X. Wu, MD (✉)

Department of Surgery, UCLA, 757 Westwood Plaza, Mail room B711, Los Angeles, CA 90095, USA  
e-mail: [jameswu@mednet.ucla.edu](mailto:jameswu@mednet.ucla.edu)

C. de Virgilio, MD

Department of Surgery, Harbor-UCLA Medical Center, 1000 W. Carson Street, Torrance, CA 90509, USA  
e-mail: [cdevirgilio@labiomed.org](mailto:cdevirgilio@labiomed.org)

D.M. Hari, MD

Division of Surgical Oncology, Department of Surgery, Harbor-UCLA Medical Center, 1000 W. Carson Street, Box 25, Torrance, CA 90509, USA  
e-mail: [dhari@dhs.lacounty.gov](mailto:dhari@dhs.lacounty.gov)



## Diagnosis

### What is the Differential Diagnosis of Jaundice?

Condition		Comments
<i>Prehepatic (hemolytic)</i>	Hemolytic anemia	Pallor, fatigue, shortness of breath
	Gilbert's syndrome	Benign condition triggered by overexertion, dehydration, menstruation, concurrent illness; decreased activity of the enzyme UDP-glucuronyl transferase
<i>Hepatic (hepatocellular)</i>	Ischemic liver injury	May result from transient hypotension and hypoxia or in transplanted donor liver
	Viral	Viral infection of hepatocytes; may progress to acute liver failure, become a chronic infection, or completely resolve
	Toxic ingestion	Acetaminophen, alcohol; can cause acute liver failure
	Primary biliary cirrhosis	Skin xanthomas, associated with rheumatoid arthritis or Sjogren's syndrome
	Primary sclerosing cholangitis	Associated with ulcerative colitis, fatigue, pruritus
	Hepatolenticular degeneration (Wilson's disease)	Autosomal recessive disorder causing retention of copper, Kayser-Fleischer ring (brown ring on edge of iris), cirrhosis, and neurologic manifestations including parkinsonism
<i>Posthepatic</i>	Cholelithiasis	Gallstone (usually formed in the gallbladder) in the common bile duct (CBD) causing obstruction, RUQ pain, nausea
	Acute cholangitis	Ascending infection of the CBD often caused by obstruction; fever, jaundice, RUQ pain, $\pm$ hypotension, $\pm$ altered mental status
	Chronic pancreatitis	May cause biliary stricture, recurrent epigastric pain, malabsorption
	Mirizzi syndrome	External compression of the common hepatic duct by a gallstone in the gallbladder or cystic duct
	Pancreatic carcinoma	Painless jaundice is more common in carcinomas arising from the head of the pancreas; new-onset diabetes if carcinoma in body of pancreas; poor prognosis
	Ampullary carcinoma	Malignancy arising from the ampulla of Vater, most common presenting symptom is obstructive jaundice
	Cholangiocarcinoma	Associated with sclerosing cholangitis, chronic parasitic infections, malignancy of the bile ducts usually present at advanced stage, highly lethal

### What Is the Most Likely Diagnosis?

In a former smoker presenting with a new onset of painless jaundice accompanied by the constitutional symptoms of malignancy (e.g., weight loss), pancreatic cancer is the most likely diagnosis (more common than ampullary or cholangiocarcinoma). This is further supported by a Courvoisier's sign. New onset of type 2 diabetes in an older patient is more associated with tumor of the pancreatic body. Additionally, elevated levels of direct bilirubin and alkaline phosphatase further support the diagnosis.

## History and Physical

### What Is Courvoisier's Sign?

It is the presence of a palpable RUQ mass, which represents a non-tender, enlarged gallbladder. It signifies obstruction, most often of the distal common bile duct, causing the biliary tree and the gallbladder to markedly distend, and is most commonly seen with malignancy (pancreatic, ampullary, or bile duct). Gallstone disease would result in RUQ pain and marked RUQ tenderness to palpation.

### What Is the Implication of Painful Versus Painless Jaundice?

Painful jaundice implies an acute biliary obstruction, usually due to a gallstone, and is usually associated with inflammation/infection, such as acute cholangitis. Painless jaundice suggests a more insidious obstruction as seen with malignancy. The absence of pain also suggests an absence of infection. However, cancers can also be accompanied by mild, vague RUQ or epigastric pain as well.

## **What Are the Risk Factors for Pancreatic Cancer? Cholangiocarcinoma? Gallbladder Carcinoma?**

Risk factors for pancreatic cancer include chronic pancreatitis (strongest risk factor), tobacco, high-fat diet, male gender, and family history. While recent onset of type 2 diabetes is also associated with pancreatic cancer, it is difficult to discern whether it is a risk factor or early symptom of disease. Patients with ulcerative colitis, especially with primary sclerosing cholangitis, are at increased risk for developing bile duct malignancy. Choledocholithiasis, particularly when associated with parasites, is considered a risk factor for bile duct cancer. Long-standing gallstone disease is associated with carcinomas of the gallbladder.

## **Where Is Jaundice Best Detected?**

Examination of the skin should include the mucous membranes of the mouth (under the tongue), palms, soles, and sclerae. Areas that are not exposed to sunlight have more bilirubin due to lack of photodegradation. Rarely, excess consumption of carrots and other carotenoid-containing vegetables can cause yellowing of skin pigment, mimicking jaundice, without a change in the sclera or other mucous membranes.

## **What Is a Sister Mary Joseph Nodule? And What Is the Implication?**

Periumbilical mass (or nodule) signifying possible metastatic abdominal (or pelvic) malignancy. It is most often seen with GI malignancies (e.g., stomach, pancreatic).

## **What Is Blumer's Shelf?**

A step-off felt during rectal exam suggesting metastatic disease to the pouch of Douglas. It is usually a site of metastasis of cancers of the lung, pancreas, and stomach.

---

## **Pathophysiology**

### **What Causes Jaundice?**

Jaundice can be caused by excess serum bilirubin due to hemolysis or impaired metabolism/excretion from the liver into the intestines. Jaundice becomes apparent at approximately bilirubin  $>2.5$  mg/dl.

### **Describe the Metabolism of Bilirubin**

Bilirubin is the product of heme degradation. Breakdown of red blood cells occurs in the spleen, liver, and intravascular space. Initially, bilirubin is unconjugated, not water soluble, and bound to albumin. Bilirubin is conjugated in the liver, becoming water soluble, and excreted into the intestine. Intestinal bacteria convert conjugated bilirubin into urobilinogen, which can be reabsorbed into the systemic circulation, converted to urobilin, and excreted in the urine. Urobilin gives urine its yellow color. The remaining intestinal urobilinogen is converted to stercobilin and excreted in the stool.

### **What Is the Mechanism Behind "Clay-Colored" Stools?**

Stool derives its brown color from stercobilin, a final product of bilirubin metabolism in the intestine. Biliary obstruction decreases bilirubin in the intestines, decreasing stercobilin and resulting in the "clay-colored" stool.

## Workup

### **In a Patient with Obstructive Jaundice, What Would the Typical Laboratory Findings Be?**

Conjugated/direct bilirubin, and consequently total bilirubin, will be increased in all cases of obstructive jaundice. Direct bilirubin accumulates in the circulation and is excreted in the urine, which becomes much darker or “tea colored.” Urine urobilinogen is decreased. ALP levels will also be elevated indicating bile duct obstruction.

### **How Do You Distinguish Between Jaundice from Biliary Obstruction (Posthepatic) and Hepatocellular Damage?**

Hepatic causes of jaundice (such as hepatocellular injury from hepatitis) are usually nonsurgical problems, whereas posthepatic causes (such as biliary obstruction from acute cholangitis) are typically surgical. Distinguishing between the two is not always straightforward. Both will have some degree of elevation in total bilirubin, aspartate aminotransferase (AST), alanine aminotransferase (ALT), gamma-glutamyl transpeptidase (GGT), and ALP. AST and ALT are enzymes within the liver cells (though AST is also found in muscle and other cells). With hepatic cellular injury, these enzymes are released. As such with hepatic causes, the AST and ALT (transaminases) can sometimes reach into thousands and rise out of proportion to the ALP. Such a disproportionate rise in the transaminases is indicative of hepatocellular damage, as seen in acute viral hepatitis, ischemic liver injury, or toxic insult. ALP is present in the cells that line the bile ducts. A marked rise in ALP, out of proportion to the AST and ALT, is therefore more indicative of posthepatic (biliary obstruction) pathology such as choledocholithiasis or cholangitis. Since ALP levels increase with many other diseases (such as bone pathology), a concomitant and proportionate rise in GGT is helpful, as it is more specific to liver disease.

### **What Initial Imaging Is Recommended for Painful Jaundice?**

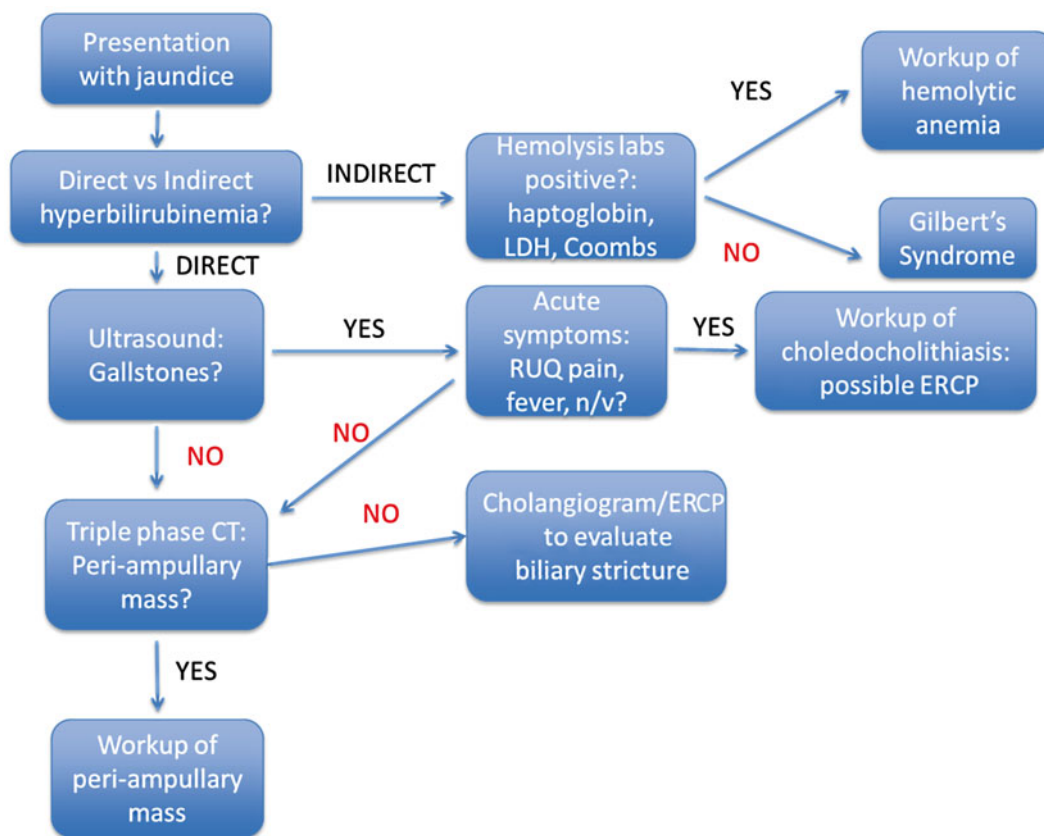
The initial test (Fig. 18.1) should be a RUQ ultrasound. Ultrasound is useful to detect gallstones and dilation of the biliary tree consistent with obstruction. Ultrasound is more likely to be the definitive study when the presentation is painful jaundice since gallstones are usually the cause.

### **What Is the Recommended Imaging Choice for Painless Jaundice?**

For painless jaundice, since the suspicion for malignancy is high, the next study of choice is a “triple-phase” abdominal CT scan as ultrasound cannot rule out pancreatic lesions. Triple-phase CT captures images during 3 phases of contrast: (1) arterial phase, (2) early venous phase, and (3) late venous phase. Triple-phase CT can detect pancreatic and periampullary masses and provide vital information regarding the resectability of the mass. Endoscopic ultrasound (EUS) is a useful adjunct that is utilized in some centers. EUS helps to better delineate the mass, detect smaller masses, detect vascular invasion, and identify enlarged lymph nodes. It can also identify other causes of biliary obstruction, such as a biliary stricture. In this latter case, brush cytology (of the bile duct) is useful to help determine if a stricture is benign or malignant. If CT/EUS does show a pancreatic mass suspicious for malignancy, FNA/biopsy is not necessary if patient is a surgical candidate.

### **What Is the Role for Magnetic Resonance Cholangiopancreatography (MRCP) and/or Endoscopic Retrograde Cholangiopancreatography (ERCP)?**

MRCP and ERCP are not routinely needed. They are used to further delineate the biliary tree especially if no mass is seen and as such the cause of biliary obstruction is unclear. ERCP also permits stent placement or decompression if indicated.



**Fig. 18.1** Algorithm for presentation of jaundice

### What Is the Role of Tumor Markers CA 19-9 and Carcinoembryonic Antigen (CEA)?

Currently, there is insufficient data to use CA 19-9 for screening or diagnostic purposes. CA 19-9 can be elevated in nonpancreatic gastrointestinal malignancies as well as with benign diseases such as cholecystitis, cholangitis, hepatic cirrhosis, and acute and chronic pancreatitis. There is some data to indicate that CA 19-9 can be used for prognostication and for monitoring of therapy, though it is not recommended for such by the American Society of Clinical Oncologists. There is a subpopulation of patients who may have metastatic pancreatic adenocarcinoma yet normal levels of CA 19-9. CEA is used to monitor and prognosticate colorectal cancer but is also elevated in breast, lung, ovarian, prostate, and pancreatic cancer. There is no established role for its use in pancreatic cancer.

## Management

### What Criteria Make a Pancreatic Cancer Unresectable (Not a Surgical Candidate)?

Tumor invasion into the superior mesenteric, celiac, or hepatic arteries would make it unresectable. Metastatic disease also precludes resection. Encasement of superior mesenteric or portal veins is a relative contraindication, although more surgeons are electing to resect tumors involving the portal vein with subsequent vascular reconstruction. Resectability is primarily determined by careful review of a triple-phase CT scan. Some surgeons combine CT with endoscopic ultrasound (EUS). Neoadjuvant chemotherapy is recommended for borderline resectable patients for possible downstaging (tumor shrinkage). For symptomatic patients with unresectable disease, palliative procedures may be performed to alleviate symptoms.

## Should Patients Who Present with Obstructive Jaundice and a Resectable Pancreatic Mass Undergo Biopsy Confirmation?

No. For patients with a resectable mass and no signs of metastatic disease, a biopsy is unnecessary. Given that the patient presents with obstructive jaundice, the mass needs to be resected regardless, and attempts at biopsy can create problems with sampling error and false negatives.

## What Is the Role of Preoperative Stenting in the Presence of a Pancreatic Mass with Obstructive Jaundice?

There is no benefit to prophylactically decompressing (via ERCP and stenting) an obstructed biliary tree in the presence of pancreatic and periampullary cancers. In fact, decompression prior to pancreatic resection is associated with a higher postoperative infectious complication rate. Decompression should only be done to relieve severe symptoms of obstructive jaundice (such as pruritus) or if there is evidence of sepsis from cholangitis.

## What Is the Role of Neoadjuvant Therapy for Pancreatic Adenocarcinoma?

In patients with resectable pancreatic cancer, there is no difference in survival between neoadjuvant chemoradiation with surgery and resection followed by adjuvant therapy. Neoadjuvant chemoradiation can make as many as 1/3 of initially “borderline resectable” pancreatic cancers resectable, with the same expected survival as patients with initially resectable disease. There is a paucity of data regarding neoadjuvant therapy for nonpancreatic, periampullary cancers.

## What Is the Surgical Management of Pancreatic (or Periampullary) Cancer?

The traditional surgical intervention for pancreatic cancer has been a pancreaticoduodenectomy, also known as the Whipple procedure. This has multiple components including removal of the head of the pancreas (pancreatectomy), duodenum (duodenectomy), proximal jejunum (jejunectomy), distal stomach (partial gastrectomy), gallbladder (cholecystectomy), and common bile duct. Modifications including pylorus-preserving pancreaticoduodenectomy and subtotal stomach-preserving pancreaticoduodenectomy have been developed in an attempt to improve outcomes and minimize morbidity.

## In Addition to Pancreatic Cancer, for What Other Conditions Is a Whipple Performed?

Cancer of the duodenum, cholangiocarcinoma, and ampullary carcinoma.

## In Patients who are not Candidates for Pancreatic Resection, What Conditions may Warrant Palliative Procedures? What are the Options?

Condition	Options
<i>Chronic abdominal pain</i>	Celiac axis block, palliative external beam radiation
<i>Gastric outlet obstruction</i>	Gastrojejunostomy (allows oral feeding), open gastrostomy tube placement, or percutaneous gastrostomy tube
<i>Symptomatic biliary obstruction</i>	ERCP with biliary stenting (preferable), percutaneous cholecystostomy (may not adequately drain biliary tree), or hepaticojejunostomy (most invasive)

---

## **What Is the Most Common Complication That Is Specific to a Whipple/Pancreatectomy? What Are Some Other Pancreas Surgery Specific Complications?**

The most common complication is a delayed gastric emptying (gastroparesis) and is best treated with metoclopramide. Other postoperative complications include pancreatic leak/fistula, biliary leak/fistula, hemorrhage, malabsorption (loss of pancreatic enzymes), weight loss, and marginal ulceration.

## **Is There a High Risk of Diabetes After a Whipple Procedure?**

The risk of postoperative diabetes is related to preoperative glucose levels. If the patient does not have diabetes preoperatively and has normal glucose levels, the risk of postoperative diabetes is low, as only the pancreatic head is removed.

## **How Do You Suspect/Diagnose a Postoperative Pancreatic or Biliary Leak?**

Patients that undergo resection of the pancreatic head commonly have postoperative drains left in place. Normal drainage is serosanguinous or straw yellow-red in color. High hourly outputs of sanguinous drainage is concerning for hemorrhage. Green fluid suggests biliary leak. Milky gray-white fluid with a “sheen” on the bulb drain suggests pancreatic leak. To confirm the diagnosis of a pancreatic leak, drain fluid can be sent for fluid amylase, which should be significantly higher than serum levels. Unexplained persistent tachycardia can often be a nonspecific clinical sign.

---

## **Areas Where You Can Get in Trouble**

### **Increased INR (PT) with Pancreatic Cancer**

Bile is necessary for the absorption of vitamin K in the GI tract. Any disease process that leads to prolonged biliary obstruction (such as pancreatic cancer) will cause vitamin K deficiency and therefore a prolonged INR. This can be treated with parenteral vitamin K (if the patient is not actively bleeding) or fresh frozen plasma (if the patient is actively bleeding or needs immediate correction).

---

## **Areas of Controversy**

### **Role of Adjuvant Therapy in Pancreatic or Periapillary Cancer**

The benefit of adjuvant therapy is currently under debate. The two main therapies are 5-FU +/- radiation and gemcitabine. Earlier studies found that adjuvant 5-FU chemoradiation does not have a significant survival benefit, but 5-FU alone added 5 months of median survival compared to observation. Gemcitabine increased disease-free survival by approximately 6 months without an improvement in median survival and has better outcomes than 5-FU but cannot be given with radiation due to toxicity. More recent studies have conflicting data: some demonstrate that resectable pancreatic and periapillary cancers treated with adjuvant chemoradiation demonstrated increased median survival compared to observation after multivariate analysis, whereas others show no benefit.

---

## **Summary of Essentials**

### **History and Physical**

- Malignant biliary obstruction suggested by:
  - Insidious onset of jaundice
  - Painless jaundice

- Tea-colored urine
- Clay-colored stool

## Etiology/Pathophysiology

- 3 categories of jaundice:
  - Prehepatic
    - Hemolytic anemia
    - Gilbert's syndrome
  - Hepatic
    - Ischemic liver injury
    - Hepatic viral infection
    - Toxic ingestion
    - Primary biliary cirrhosis
    - Primary sclerosing cholangitis (mixed hepatic and posthepatic)
    - Hepatolenticular degeneration (Wilson's disease)
  - Posthepatic
    - Choledocholithiasis
    - Acute cholangitis
    - Chronic pancreatitis
    - Mirizzi syndrome
    - Malignant biliary obstruction
- Most common causes of malignant biliary obstruction:
  - Pancreatic cancer
  - Cholangiocarcinoma
  - Ampullary carcinoma

## Diagnosis

- LFTs (total bilirubin [direct/indirect], AST, ALT, ALP)
  - Amylase/lipase to rule out pancreatitis
- Imaging to evaluate for mass/stricture:
  - RUQ ultrasound
  - Triple-phase abdominal CT
  - MRCP
  - EUS
  - ERCP
- Routine stenting not recommended for malignancy prior to resection
- Biopsy not needed in presence of mass causing obstructive jaundice
- +/- FNA, biopsy, brushings if stricture is seen and no mass
- CEA/CA 19-9 if malignancy is suspected; role is controversial for periampullary and biliary malignancies

## Management

- Periampullary masses:
  - Resectable: pancreaticoduodenectomy (pylorus sparing versus traditional)
  - Borderline resectable: consider neoadjuvant chemotherapy and repeat imaging to assess for surgical intervention
  - Unresectable:
    - Biliary stent and palliative chemotherapy
    - Surgical bypass (biliary and intestinal)

---

## Watch Out

- Biliary obstruction associated with fever and pain may require urgent/emergent biliary decompression due to concern for cholangitis

---

## Suggested Reading

- Gillen S et al. Preoperative/neoadjuvant therapy in pancreatic cancer: a systematic review and meta-analysis of response and resection percentages. *PLoS Med.* 2010;7(4):e1000267.
- Kimura Y et al. Definitions, pathophysiology, and epidemiology of acute cholangitis and cholecystitis: Tokyo guidelines. *J Hepatobiliary Pancreat Surg.* 2007;14(1):15–26.
- Maithel SK et al. Preoperative CA 19–9 and the yield of staging laparoscopy in patients with radiographically resectable pancreatic adenocarcinoma. *Ann Surg Oncol.* 2008;15(12):3512–20.
- Narang AK et al. Evaluation of adjuvant chemoradiation therapy for ampullary adenocarcinoma: the Johns Hopkins Hospital-Mayo Clinic collaborative study. *Radiat Oncol.* 2011;6:126.
- Neoptolemos JP et al. Adjuvant chemoradiotherapy and chemotherapy in resectable pancreatic cancer: a randomised controlled trial. *Lancet.* 2001;358(9293):1576–85.
- Neoptolemos JP et al. Effect of adjuvant chemotherapy with fluorouracil plus folinic acid or gemcitabine vs observation on survival in patients with resected periampullary adenocarcinoma: the ESPAC-3 periampullary cancer randomized trial. *JAMA.* 2012;308(2):147–56.
- Oettle H et al. Adjuvant chemotherapy with gemcitabine vs observation in patients undergoing curative-intent resection of pancreatic cancer: a randomized controlled trial. *JAMA.* 2007;297(3):267–77.
- Smeenk HG et al. Long-term survival and metastatic pattern of pancreatic and periampullary cancer after adjuvant chemoradiation or observation: long-term results of EORTC trial 40891. *Ann Surg.* 2007;246(5):734–40.



---

**Part VII**

**Lower Gastrointestinal**

Tracey D. Arnell, Section Editor

Blake E.S. Taylor and Tracey D. Arnell

A 72-year-old female presents to the emergency department reporting an episode of a large volume of bright red blood per rectum 4 h earlier. She states that the toilet was filled with blood. The patient reports that the bleed was painless and was not associated with a bowel movement, and she thinks it stopped about 2 h ago. She has never had rectal bleeding before. She denies fevers and chills. A colonoscopy 2 years ago showed no abnormalities. She has not lost weight recently. Her past medical history is significant for hypertension, and chronic constipation. She has had no prior surgery. On physical examination, her blood pressure is 135/88 mmHg and heart rate is 80 min. She is afebrile and has a normal respiratory rate. She appears to be pale and anxious. Cardiac and lung exams are normal. Abdominal exam reveals no surgical scars and no masses. Her abdomen is non-distended, has normal bowel sounds, and is nontender to palpation, without rebound tenderness or guarding. Digital rectal exam reveals gross blood in the rectal vault but no masses. Anorectal exam shows no enlarged hemorrhoids and no fissures. Laboratory values reveal hemoglobin of 8 g/dL (normal 12–15.2 g/dL), hematocrit of 24 % (37–46 %), and normal mean corpuscular volume (MCV).

---

B.E.S. Taylor, BA (✉)

Columbia University, College of Physicians and Surgeons, 630 W 168th St., New York, NY 10032, USA  
e-mail: [bet2110@cumc.columbia.edu](mailto:bet2110@cumc.columbia.edu)

T.D. Arnell, MD

Department of Surgery, New York Presbyterian Columbia University, 177 Fort Washington, Suite 7-133, New York, NY 10032, USA  
e-mail: [ta2107@columbia.edu](mailto:ta2107@columbia.edu)

## What is the Differential Diagnosis of a Lower GI Bleed?

Disease	Etiologies	Risk factors	Clinical presentation	
Diverticulosis (30–50 %)	Arterial bleed from vasa recta at base of diverticula 90 % of diverticula in sigmoid colon, but 60 % of diverticular bleeds from right colon	Advanced age, lack of fiber, obesity	Painless bright red blood per rectum (hematochezia) in the absence of stool	
Neoplastic (10–20 %)	Colorectal adenocarcinoma may erode or ulcerate	Age >50, African-American race, inflammatory bowel disease, family history, sedentary lifestyle, smoking, obesity, diabetes mellitus type 2	Large LGIB rare Iron-deficiency anemia and/or change in bowel habits	
Iatrogenic	Up to 2 weeks post-polypectomy or biopsy	History of recent colonoscopy	Variable amount of bleeding occurring either immediately or days to weeks after the procedure (likely due to sloughing off of eschar)	
Colitis (10–20 %)	Infectious	CMV, Kaposi's Enteroinvasive organisms: <i>Salmonella</i> , <i>Campylobacter</i> , <i>Shigella</i> , EHEC, <i>E. histolytica</i>	History of eating undercooked or contaminated foods or drinks Immunosuppression Travel history	Bloating Crampy abdominal pain and tenderness Fever and chills Bloody diarrhea
	Ischemic	Nonocclusive mesenteric ischemia secondary to low-flow state Post-op complication of aortic surgery	Hypoperfusion secondary to hypotension, pressors, extreme exercise Dialysis History of aortoiliac procedures	Acute abdominal pain and tenderness Bloody diarrhea Chronic ischemia can result in stricture formation
	Inflammatory	Ulcerative colitis or Crohn's	Family history of IBD	Bloody diarrhea and mucus in stool Abdominal pain and cramping Previous episodes
	Radiation	Direct mucosal damage from radiation exposure resulting in arteriolitis	History of pelvic radiation	Bloody diarrhea, tenesmus (feeling of incomplete defecation), mucus discharge
Angiodysplasia (5–10 %)	Aberrant blood vessels in the GI tract Venous in origin Usually right sided (cecum or ascending colon)	Advanced age Associated with von Willebrand's disease, CKD, aortic stenosis	Painless Often present with iron-deficiency anemia	
Anorectal (5–10 %)	Hemorrhoids—bleeding from the hemorrhoidal venous plexus within the anus	Pregnancy, constipation, straining 4.4 % of US population	Painless bright red blood with straining at bowel movement	
	Anal fissures	Constipation Trauma, IBD, malignancies	Minimal blood usually on toilet paper Tear most commonly posterior midline Severe, tearing pain with defecation	
	Rectal varices—bleeding is more proximal (within the rectum)	Portal hypertension	Painless bright red blood per rectum	
	Rectal ulcers	Advanced age, debilitation, constipation History of Crohn's disease	Anterior location Blood and mucus per rectum, sense of incomplete evacuation	

LGIB lower GI bleed, IBD inflammatory bowel disease, CKD chronic kidney disease, EHEC enterohemorrhagic *E. Coil*

### Watch Out

LGIB can be due to a large upper GI bleed (UGIB), always place nasogastric tube to aspirate for blood or coffee grounds (refer to chapter on UGI bleed) and confirm that bile is obtained so that you know you have assessed for duodenal bleeding.

### Watch Out

Diverticulosis is the most common cause of lower GI bleed.

**Watch Out**

Patients with watery progressing to bloody diarrhea and no fever should always be evaluated for EHEC.

**What Is the Most Likely Diagnosis?**

An elderly patient with a recent normal colonoscopy who presents with a large amount of bright red blood per rectum most likely has a lower GI bleed and is most likely due to colonic diverticulosis.

**Mnemonic for Most Common Causes of a LGIB Is H-DRAIN**

- Hemorrhoids
- Diverticular bleeds
- Radiation colitis
- Angiodysplasia
- Infectious/ischemic/IBD
- Neoplasms/polyps

**History and Physical****Why Is Age an Important Factor in a Patient with a LGIB?**

Acute LGIB in patients over age 50 is more likely to be diverticulosis, angiodysplasia, or malignancy, whereas in younger patients, the most common causes are infectious, hemorrhoids, anal fissures, and IBD.

**Why Are the Onset and Duration of Bleeding Important?**

Diverticular bleeding is arterial and as a result tends to present acutely with relatively large amounts of blood. Angiodysplasia and cancer are more chronic, and are more likely to present only with anemia or dark stools.

**What Do the Color and Amount of Blood Tell us About the Source of Bleeding?**

Color, amount of bleeding	Possible source(s)
<i>Dark maroon, mixed with stools</i>	Upper GI, small intestine, right colon
<i>Copious bright red blood (hematochezia)<sup>a</sup></i>	Right colon (e.g., diverticulum), rectum, anus, massive upper GI bleed with rapid transit
<i>Spots of blood on toilet paper, dripping after defecation</i>	Rectum, anus
<i>Scant, dark red blood</i>	Angiodysplasia
<i>Occult</i>	Polyp, colorectal cancer

<sup>a</sup>These patients may become hemodynamically unstable from blood loss

**Watch Out**

Right colonic diverticula are more likely to bleed while left colonic diverticula are more likely to get infected.

## What Is an Occult Bleed?

Occult bleeding means that the patient does not see any blood per rectum. The bleeding is only detected by fecal occult blood testing or by finding iron-deficiency anemia. Occult bleeding (particularly in older patients) raises suspicion for malignancy (especially colorectal cancer), and in younger patients, it may be due to inflammatory bowel disease or due to familial cancer syndromes (e.g., Familial Adenomatous Polyposis, Hereditary nonpolyposis colorectal cancer).

## What Associated Symptoms Are Important to look for and How Do They Help in the Differential Diagnosis?

Systemic symptoms such as fever and bloody diarrhea may indicate an infectious or inflammatory cause. Recurrent symptoms in younger patients are suspicious for IBD. Weight loss should raise suspicion for malignancy, especially in older patients who have changes in bowel habits and/or iron-deficiency anemia. Bleeding that follows straining at stool suggests an anorectal cause. In this latter setting, painless bleeding suggests internal hemorrhoids, whereas anal pain is suggestive of anal fissures (bleeding with fissures is usually minimal). Tenesmus, a sense of incomplete evacuation of stool, is most often seen with ulcerative colitis and infectious etiologies. Bleeding from diverticulosis and angiodysplasia tends to be painless. Abdominal pain (especially in elderly patients) should raise suspicion for ischemic colitis (particularly in the setting of low-flow states).

### Watch Out

Bloody diarrhea with recent travel to endemic areas raises suspicion for infectious causes.

## Why Is a Past History of LGIB on prior colonoscopy Important?

Patients with angiodysplasia tend to present with recurrent, painless bleeds. Patients with diverticulosis may also have chronic bleeding, although larger, acute bleeds are more typical. Colon cancer typically arises from a polyp and takes many years to transform to a malignant lesion. Thus, a history of a recent (<5 years) normal screening colonoscopy makes colon cancer very unlikely.

## Why Is a History of Pelvic Radiation on Prior Aortic Surgery Important?

Radiation can cause damage to the rectal mucosa, leading to radiation proctitis. Aortic surgery rarely results in erosion of the aortic graft into the duodenum, leading to an aortoduodenal fistula.

## Why Should One Inquire About Alcohol History and Look for Stigmata of Liver Cirrhosis?

Liver disease can lead to coagulopathy and portal hypertension. Although portal hypertension most commonly causes esophageal varices and upper GI bleeding, varices can also form in the rectal veins of the lower GI tract due to their systemic and mesenteric connections.

## What Clues Can Family History Provide?

Certain conditions, such as colorectal cancer and inflammatory bowel disease, can be hereditary.

## What Medications Can Exacerbate GI Bleeding?

Anticoagulants such as warfarin, aspirin, clopidogrel, and NSAIDs can exacerbate GI bleeding.

## **What Is the Implication of Abdominal Tenderness on Physical Examination?**

Abdominal tenderness is highly suggestive of colitis such as from IBD, ischemic colitis, or infectious diarrhea. Abdominal tenderness is unusual with bleeding from diverticulosis and angiodysplasia.

## **Can Upper and Lower GI Bleeds Be Distinguished Based on History and Physical Exam?**

Sometimes. Vomiting of blood or coffee grounds, in conjunction with maroon or black stools, is indicative of an upper GI bleed. Bright red blood per rectum is almost always a LGIB (the exception is the patient with massive upper GI bleed). Maroon stools, in the absence of vomiting, can be either an upper or lower GI source.

## **What Is the Significance of Finding Iron-Deficiency Anemia in Association with a LGIB?**

Iron-deficiency anemia in a man or a postmenopausal woman should raise suspicion for malignancy (especially colorectal cancer, particularly if the patient has never had screening). Although colorectal cancer usually causes occult bleeding, it may manifest as a larger, acute bleed when the cancer causes erosion through or ulceration of the bowel wall.

## **How Does Ischemic Colitis Classically Present?**

Ischemic colitis typically presents with left sided abdominal pain and bloody diarrhea in elderly patients with low-flow states, such as those with severe dehydration, heart failure, shock, and trauma.

## **What Are the Risk Factors for Diverticulosis?**

Older individuals (60 % of people over age 60 have diverticulosis) from Western countries or those who consume diets that are low in fiber, high in fat, and high in red meat are at risk. Obese individuals are also at increased risk. Inherited connective tissue disorders, such as Marfan's syndrome and Ehlers-Danlos syndrome can also increase the likelihood of diverticulum formation.

---

## **Etiology/Pathophysiology**

### **What Is a Diverticulum?**

A diverticulum is defined as a saclike protrusion through the colonic wall. The presence of diverticula is known as diverticulosis or diverticular disease. As a diverticulum herniates, the vasa recta become draped over the dome of the diverticulum, at which point they are only separated from the lumen by mucosa. Chronic damage and stress on the luminal side of the vasa recta lead to weakness of the arterial walls, eventually resulting in rupture.

### **What Causes a Diverticulum?**

High intraluminal pressure in the colon can cause the mucosa and submucosa to herniate through the muscular layer of the intestinal wall. Since not all layers are included, this is considered a false diverticulum.

### **What Is the Most Common Site of Diverticula? Why?**

90 % of diverticula occur in the sigmoid colon. As stool moves distally through the colon, water is reabsorbed and it becomes harder. Additionally, the diameter of the colonic lumen decreases. The combination of harder stool and decreased lumen diameter causes increased pressure and makes diverticulum formation more likely.

## How Common Is a Diverticular Bleed?

Although a diverticular bleed is the most common cause of an acute LGIB in patients over 50, it occurs in only a small percentage (3–5 %) of patients with diverticulosis.

## What Is the Natural History of a Diverticular Bleed?

75 % stop bleeding spontaneously. Each episode of a diverticular bleed increases the risk of a future bleed.

## Getting the terminology straight

Diverticulum	Saclone protrusion through the colonic wall
Diverticulosis	The state of having diverticula
Asymptomatic diverticulosis	No symptoms
Symptomatic diverticulosis	Diverticulitis or diverticular bleeds
Diverticular bleed	A diverticulum that bleeds
Diverticulitis	Microperforation or macroperforation of a diverticulum

### Watch Out

Significant GI bleeding from a diverticulum is from *diverticulosis*. *Diverticulitis* is not associated with bleeding.

## What Is Angiodysplasia? What Are the Risk Factors?

Angiodysplasia refers to focal submucosal areas of thin, weak, and dilated (ectatic) vessels in the GI tract, most commonly in the cecum and right colon in individuals over age 60. It is the most common vascular abnormality of the GI tract. Incidence increases with age, likely due to degeneration of the vascular walls. Bleeding is typically small in quantity or occult, often resulting in iron-deficiency anemia and intermittently heme-positive stools, but may present with larger bleeds. Unlike diverticular bleeds, which are arterial in origin, acute angiodysplasia bleeds generally produce less bleeding because their origin is venous. Angiodysplasia is associated with von Willebrand's disease, aortic stenosis, and chronic kidney disease.

## What Causes Ischemic Colitis?

The pathophysiology is decreased blood flow to the colon, causing nonocclusive (meaning not due to arterial thrombosis or embolism) ischemic colitis. The mucosa is affected first and depending on the severity of the ischemia, progression may occur through all layers of the colon. The most common areas to be affected are "watershed" areas which have relatively poor perfusion as they are in between two areas of the colonic blood supply (e.g., the right colon supplied by SMA, left colon by IMA, splenic flexure poorly supplied by both). In most cases, the ischemia is not transmural, meaning it does not affect the entire bowel wall, and most patients will recover after correction of their "low-flow" state.

## What Factors Can Precipitate Ischemic Colitis?

The factors that can precipitate ischemic colitis are dehydration, heart failure, shock, cardiovascular surgery, hypercoagulable states, extreme exercise, hemodialysis, and certain drugs (e.g., digitalis, vasopressors, cocaine).

## What Is the Natural History of Ischemic Colitis?

Most cases of ischemic colitis will resolve with supportive measures, while a minority of cases will require resection for transmural (i.e., full thickness of the colonic wall) infarction.

## What are the differences between ischemic colitis and acute mesenteric ischemia?

	<b>Ischemic colitis</b>	<b>Acute mesenteric ischemia</b>
<i>Pathophysiology</i>	Hypoperfusion due to low-flow state; ↓BP, ↓CO; can be caused by dehydration, heart failure, extreme exercise, vasoconstricting drugs	Arterial embolus or thrombosis
<i>Natural history</i>	80 % resolve spontaneously with supportive care (e.g., fluids, blood pressure management)	Usually leads to bowel necrosis requiring resection; high mortality
<i>Most commonly affected territories</i>	Segment of colon between arterial supplies, known as watershed area (e.g., splenic flexure is between SMA and IMA territories)	Small bowel (from ligament of Treitz) to mid transverse colon (SMA territory)
<i>Layers of bowel affected</i>	Usually mucosa only	Often transmural (i.e., all layers)
<i>Diagnosis</i>	Colonoscopy often shows mucosal changes	CT scan often shows small bowel wall thickening, occlusion of SMA and gas in the intestinal wall (known as pneumatosis)

BP blood pressure, CO cardiac output, SMA superior mesenteric artery, IMA inferior mesenteric artery

## Initial Management

### What Are the Initial Steps in the Management of a LGIB?

The first step is to place two large-bore IVs and send laboratory tests including a type and cross, CBC, chemistry, and INR/PTT. If the patient demonstrates evidence of significant blood loss, resuscitation should be instituted with crystalloid (normal saline or lactated Ringer's) followed by packed red blood cells as needed. A microcytic anemia raises suspicion for an underlying iron-deficiency anemia due to occult blood loss from colorectal cancer, but may also indicate a chronic bleed from angiodysplasia. Leukocytosis is often seen in infectious or inflammatory etiologies.

### What Is the Next Step?

Placement of nasogastric (NG) tube is recommended for all patients presenting with large-volume hematochezia. The NG tube is placed in order to rule out an upper GI bleed, because up to 10 % of cases of hematochezia are due to massive upper GI bleeds. If the NG tube aspirate is positive for blood or coffee grounds (partially digested blood), then the patient has an UGIB, and an esophagogastroduodenoscopy (EGD) is indicated. If the NG aspirate returns with bile (confirming the tip of the tube is in the duodenum) but without blood, this rules out an upper GI bleed. If the NG aspirate returns clear fluid (gastric juice) without blood, it rules out a bleed from the stomach, but does not rule out an upper GI bleed from the duodenum.

### How Does the Hemodynamic Stability of the Patient Affect the Subsequent Management and Diagnostic Work-Up?

A hemodynamically unstable patient needs admission to the ICU for careful monitoring. In addition, further work-up to find the source of bleed needs to be performed expeditiously. It should be noted that most LGIB stop spontaneously, and the need for urgent surgery as well as mortality associated with a LGIB is significantly less than for an UGIB.



### **What Is the First Diagnostic Test of Choice in an Unstable Patient? How Effective Is This Test in Visualizing the Source of LGIB in the Acute Setting?**

Colonoscopy is the first test of choice. Ideally the patient should first undergo a bowel prep to cleanse the bowel, in which case the colonoscopy is performed the subsequent day. However, if the patient is rapidly bleeding, colonoscopy is done urgently without the bowel prep. Because the colon is often filled with blood and stool, colonoscopy may fail to adequately visualize the bleeding site. However, it can generally determine whether the bleed is coming from somewhere within the colon or from proximal to the ileocecal valve (small bowel). This determination has important diagnostic and therapeutic implications. Colonoscopy cannot visualize the small bowel.

### **What If This Diagnostic Test Is Not Able to Visualize the Bleeding? What Are the Two Options for Localizing the Source of Bleed? What Are the Advantages/Disadvantages of Each Modality?**

If the patient is continuing to bleed, the next step is to perform either diagnostic arteriography or a tagged red blood cell scan (nuclear scintigraphy) using technetium-99 m. The decision to choose one over the other depends on the suspected rate of bleeding and the availability of these modalities. The advantage of the arteriography is that the study can be both diagnostic and therapeutic (the area of bleeding can be embolized). However, arteriography is invasive, and bleeding must be brisk (about 0.5–1 ml/min) to see it. It is also not as feasible to repeatedly perform arteriography if the patient stops bleeding and then rebleeds. Nuclear scanning detects bleeding at a much slower rate (only 0.1 ml/min), and since the radioactive agent remains labeled on the red blood cell for some time, repeat images can be obtained for up to 24 h. Nuclear scanning does not permit therapy and is not able to pinpoint the exact vessel/location of the bleed, but rather the general area.

### **What If These Modalities Fail to Identify the Exact Source of Bleeding? What Is the Next Step?**

This depends on whether the bleeding has stopped and the patient is stable or whether the bleeding is continuing and the patient is unstable. The next step also depends on whether the bleeding is thought to be coming from the colon or small bowel.

If the bleeding has stopped and the source is thought to be the small bowel (i.e., blood was seen on colonoscopy above the ileocecal valve), then small bowel studies are performed. These include a Meckel's nuclear scan (to look for bleeding from a Meckel's diverticulum), capsule endoscopy (barium study of the small bowel), and enteroscopy (fiber-optic scope of the proximal small bowel). If the bleeding has stopped and the source is not clear or is thought to be somewhere in the colon, repeat colonoscopy, nuclear scan, and/or arteriography can be considered if and when the patient rebleeds.

If the bleeding has not stopped and the patient is unstable, emergent laparotomy is recommended with total colectomy leaving the rectum, and end ileostomy, provided that the source of bleeding has at least been confirmed to be coming from somewhere in the colon. This can be as confirmed by nuclear scan, arteriography, or colonoscopy (fresh blood in colon and no blood coming from above ileocecal valve).

### **What If Arteriography Localizes the Source of Bleeding But Is Unable to Stop the Bleeding with Embolization?**

If bleeding is ongoing, surgery is recommended. Resection is determined by the localization (i.e., right colectomy for bleeding localized to the right colon). Removal of all the diverticula throughout the colon is not indicated.

---

## **Area Where You Can Get in Trouble**

### **Bleeding After Colonoscopic Biopsy or Polypectomy**

Bleeding after a colonoscopic biopsy can occur even several weeks later. It is important to obtain this history. Initial treatment consists of endoscopic injection of vasoconstrictive agents (e.g., epinephrine), cauterization, or clipping.

---

## Summary of Essentials

### History and Physical

- Color, quantity, and duration of bleeding are important
- Ask about anticoagulants and antiplatelet agents
- Right colon diverticulosis most common cause of LGIB
- Hematemesis/coffee ground emesis indicates UGIB

### Pathophysiology

- Diverticulosis
  - Increased intraluminal pressure (low-fiber diet)
  - Most common cause of LGIB
  - Right colon diverticula bleed (brisk and arterial)
  - Left colon diverticula get infected
- Angiodysplasia
  - Associated with aortic stenosis and kidney disease
  - Bleeding is slower (venous)
- Colon Cancer
  - Iron-deficiency anemia in males or postmenopausal females should raise suspicion for colon cancer
  - Massive LGIB rare
- Colitis
  - Inflammatory
  - Infectious
  - Ischemic

---

## Management

- Fluid resuscitation, NG tube to rule out UGIB, if large bleed admit to ICU
- Diagnostic studies
  - Colonoscopy
  - Nuclear-tagged RBC scan
  - Arteriography
- Most cases of LGIB will stop spontaneously
- Indications for surgery
  - Hemodynamically unstable despite resuscitation
  - Massive bleeding >6 units PRBC
  - Active bleeding with failure of embolization

---

## Suggested Reading

Alonso-Coello P, Guyatt G, Heels-Ansdell D, et al. Laxatives for the treatment of hemorrhoids. *Cochrane Database Syst Rev.* 2005; 4:CD004649.

Barnert J, Messmann H. Management of lower gastrointestinal tract bleeding. *Best Pract Res Clin Gastroenterol.* 2008;22:295–312.

Becquemin JP, Majewski M, Fermani N, et al. Colon ischemia following abdominal aortic aneurysm repair in the era of endovascular abdominal aortic repair. *J Vasc Surg.* 2008;47:258.

Gayer C, Chino A, Lucas C, Tokioka S, Yamasaki T, Edelman DA, et al. Acute lower gastrointestinal bleeding in 1,112 patients admitted to an urban emergency medical center. *Surgery.* 2009;146(4):600–6. discussion 606–7.

McGuire Jr HH. Bleeding colonic diverticula. A reappraisal of natural history and management. *Ann Surg.* 1994;220:653.

- McKinsey JF, Gewertz BL. Acute mesenteric ischemia. *Surg Clin North Am.* 1997;77:307.
- McPhee SJ, Papadakis MA. *Current medical diagnosis & treatment* 2011. New York: McGraw-Hill Medical; 2013.
- Peery AF, Barrett PR, Park D, et al. A high-fiber diet does not protect against asymptomatic diverticulosis. *Gastroenterology.* 2012; 142:266.
- Perry RJ, Martin MJ, Eckert MJ, et al. Colonic ischemia complicating open vs endovascular abdominal aortic aneurysm repair. *J Vasc Surg.* 2008;48:272.
- Ruiz-Tovar J, Morales V, Hervas A, et al. Late gastrointestinal complications after pelvic radiotherapy: radiation enteritis. *Clin Transl Oncol.* 2009;11(8):539–43.
- Touzios JG, et al. Diverticulosis and acute diverticulitis. *Gastroenterol Clin North Am.* 2009;38(3):513–25.
- Vernava AM, Longo WE, Virgo KS. A nationwide study of the incidence and etiology of lower gastrointestinal bleeding. *Surg Res Commun.* 1996;18:113–20.

Wendy Liu, Christian de Virgilio, Areg Grigorian,  
and Tracey D. Arnell

A 25-year-old male presents to the emergency department with a 1-day history of periumbilical abdominal pain which has now shifted to the right lower quadrant. He describes the pain as constant and a seven out of ten. He has vomited twice and reports that he has not eaten for 24 hours due to a lack of appetite. Physical examination is significant for a temperature of 99 °F, absent bowel sounds, and marked tenderness to palpation at 1/3 the distance from the anterior superior iliac spine to the umbilicus. When palpating in the left lower quadrant, he reports pain in the right lower quadrant (RLQ). Active flexion of his right hip and internal rotation of the right leg reproduces the pain. His skin in the RLQ is hypersensitive to touch. There is no rebound tenderness. Laboratory values are significant for leukocytosis  $13.5 \times 10^3/\mu\text{L}$  (normal  $4.1\text{--}10.9 \times 10^3/\mu\text{L}$ ), with 15 % bands. The urinalysis demonstrates 1+ WBCs without bacteria.

---

W. Liu, MD (✉)

Department of Surgery, Harbor – UCLA Medical Center, 1000 W. Carson Street, Box 461, Torrance, CA 90509, USA  
e-mail: [wylu@ucla.edu](mailto:wylu@ucla.edu)

C. de Virgilio, MD

Department of Surgery, Harbor-UCLA Medical Center, 1000 W. Carson Street, Torrance, CA 90509, USA  
e-mail: [cdevirgilio@labiomed.org](mailto:cdevirgilio@labiomed.org)

A. Grigorian, MD

Department of Surgery, University of California, Irvine, 333 City Blvd West, Suite 1600, Route. 81, Orange, CA 92868, USA  
e-mail: [agrigori@uci.edu](mailto:agrigori@uci.edu)

T.D. Arnell, MD

Department of Surgery, New York Presbyterian Columbia University, 177 Fort Washington, Suite 7-133, New York, NY 10032, USA  
e-mail: [ta2107@columbia.edu](mailto:ta2107@columbia.edu)

## Diagnosis

### What is the differential diagnosis of acute appendicitis in an adult? What clues on history and physical might direct you towards a specific diagnosis? How can other diagnoses be confused with appendicitis?

Diagnosis	History and physical/other	Mimicking features
<i>Inflammatory bowel disease (IBD)</i>	Abdominal pain, severe cramps, weight loss, bloody diarrhea, anemia, enterocutaneous fistula/anal fissures (Crohn's), toxic megacolon (ulcerative colitis)	Crohn's can present with RLQ pain due to inflammation limited to the ileocecal region (known as regional enteritis)
<i>Pancreatitis</i>	Epigastric pain radiating to the back, nausea, vomiting, anorexia, fever, tachycardia, cholelithiasis, gallstones, or alcohol abuse	Predominantly epigastric pain. With severe pancreatitis, ascites forms and may track down the right paracolic gutter (depressions found between the colon and abdominal wall) causing RLQ pain
<i>Cholecystitis</i>	Right upper quadrant (RUQ) pain radiating to back, nausea, vomiting, fever, palpation of RUQ during inspiration stops inspiration secondary to pain ( <i>Murphy's sign</i> )	Though pain is typically RUQ, a large inflamed gallbladder may cause RLQ pain
<i>Appendicitis</i>	Anorexia, vague periumbilical abdominal pain, vomiting, localized right lower quadrant pain ( <i>McBurney's point</i> ), Rovsing's sign, psoas sign	–
<i>Gastroenteritis</i>	Nausea, vomiting, watery diarrhea (viral), bloody diarrhea (certain bacteria), myalgia, fever	May cause diffuse abdominal tenderness and marked leukocytosis
<i>Nephrolithiasis</i>	Colicky flank pain that may radiate to inner thigh or genitals, nausea, vomiting, dysuria, hematuria	Ureteral pain may refer to RLQ
<i>Perforated duodenal ulcer (Valentino's syndrome)</i>	Sudden onset of epigastric pain, rigid abdomen, history of dyspepsia, NSAID use, recurrent ulcers, <i>H. pylori</i> infection	Initial pain is epigastric, then diffuse, but duodenal perforation may seal, enteric contents may track down right paracolic gutter causing subsequent RLQ pain
<i>Pyelonephritis</i>	Costovertebral angle tenderness, fever, pain on urination, vomiting	Renal and ureteral pain can refer to RLQ
<i>Sigmoid diverticulitis</i>	Pain in LLQ, fever, leukocytosis, nausea, diarrhea, constipation, common in elderly (acquired)	A large, floppy, redundant sigmoid colon may lie in the RLQ, thus presenting with RLQ instead of left lower quadrant (LLQ) pain
<i>Cecal diverticulitis</i>	Congenital solitary diverticulum	Identical to appendicitis
<i>Meckel's diverticulitis</i>	“Rule of 2's”: males 2× more common than females, occurs within 2 ft of the ileocecal valve, 2 types of tissue (pancreatic, gastric), found in 2 % of the population, can present at 2 years of age (with <i>painless rectal bleeding</i> )	Identical to appendicitis, in an adult, a Meckel's diverticulum can become infected ( <i>Meckel's diverticulitis</i> ) and present with RLQ pain

### What is the Differential Diagnosis of Appendicitis in Women and What Clues on History and Physical Might Direct you Towards a Specific Diagnosis?

Diagnosis	History and physical
<i>Pelvic inflammatory disease</i>	Neisseria gonorrhoeae or Chlamydia infection, purulent cervical discharge, <i>cervical motion tenderness</i> , adnexal tenderness, dysuria
<i>Ovarian torsion</i>	Acute onset of severe pelvic pain, adnexal mass, history of ovarian cysts
<i>Mittelschmerz</i>	Physiologic recurrent mid-cycle pain, mild and unilateral, duration ranges from few hours to few days, normal pelvic exam
<i>Ruptured ectopic</i>	Typically presents 6–8 weeks after last normal menstrual period, abdominal pain, amenorrhea, vaginal bleeding, breast tenderness, anemia (rarely hemorrhagic shock)

## What is the differential diagnosis of appendicitis in a child and what clues on history and physical might direct you towards a specific diagnosis?

Diagnosis	History and physical
<i>Mesenteric lymphadenitis</i>	Concomitant or recent URI <sup>a</sup> ; high fever; enlarged, inflamed, and tender lymph nodes in small bowel mesentery; generalized abdominal pain
<i>Yersinia enterocolitica (pseudoappendicitis)</i>	RLQ pain, fever, vomiting, bloody diarrhea, history of sick contacts (e.g., infected children at daycare)
<i>Pneumococcal pneumonia</i>	May be associated with nausea, vomiting, and diffuse abdominal pain
<i>Gastroenteritis</i>	Nausea, vomiting, watery diarrhea (viral), bloody diarrhea (certain bacteria), myalgia, fever
<i>Intussusception</i>	Nausea, vomiting, crampy abdominal pain, “red currant jelly” stool, “sausage-shaped mass in abdomen (12-month-old infant)

<sup>a</sup>Upper respiratory tract infection

## What Is the Most Likely Diagnosis?

Given the history of initial periumbilical pain that is now localized to the RLQ, associated with tenderness, leukocytosis with increased bands, the most likely diagnosis is acute appendicitis.

### Watch Out

Rule out an ectopic pregnancy with a beta-hCG pregnancy test for all women of childbearing age presenting with abdominal pain.

## History and Physical

### What Is Usually the First Symptom of Appendicitis and What Is the Classic Sequence of Symptoms?

In >95 % of cases of acute appendicitis, anorexia is the first symptom. The classic sequence of symptoms is anorexia, vague periumbilical abdominal pain, vomiting, and then a shift to localized right lower quadrant pain.

### What Is the Significance of Absent Bowel Sounds?

Absent bowel sounds indicate a paralytic ileus which in this setting would be secondary to inflamed/infected bowel.

### What Is a Hamburger Sign?

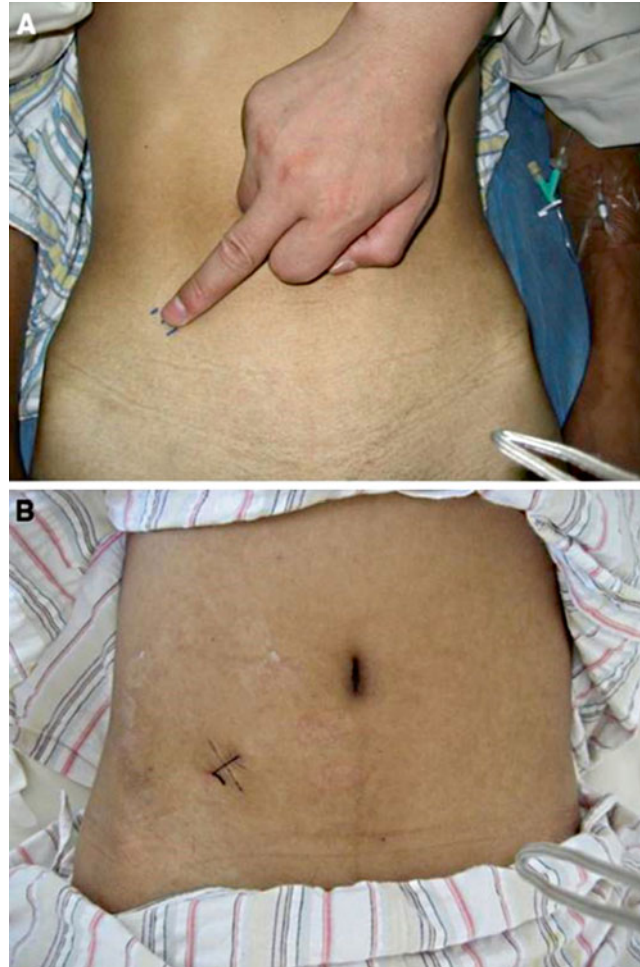
The majority of patients with acute appendicitis will have anorexia. If the patient is hungry, acute appendicitis is less likely. Inquire about the patient’s favorite food (e.g., hamburger, pizza), and ask if the patient would like to eat it. Patients with true anorexia will decline their favorite food (positive hamburger sign).

### What Are Rovsing’s, Psoas, and Obturator Signs and McBurney’s Point Tenderness?

Appendicitis creates an inflammatory response in the adjacent retroperitoneum and parietal peritoneum. These are signs (Table 20.1) of localized peritonitis in the right lower quadrant due to inflammation. *Rovsing’s sign* is right lower quadrant pain with palpation of the left lower quadrant. Compression in the LLQ stretches the abdominal wall triggering pain in the inflamed underlying RLQ parietal peritoneum. Appendicitis can also inflame the adjacent psoas or obturator muscles. *Psoas sign* is right lower quadrant pain on passive extension of the right hip or active flexion of the right hip. *Obturator sign* is RLQ

**Table 20.1** Signs of appendicitis

Sign	Description
<i>Rovsing's</i>	RLQ pain with palpation of LLQ
<i>Psoas</i>	RLQ pain on passive extension of the right hip or active flexion of the right hip
<i>Obturator</i>	RLQ pain on internal rotation of the hip, typical of a pelvic appendix
<i>McBurney's</i>	Tenderness to palpation at McBurney's point



**Fig. 20.1** McBurney's point. A. McBurney's point marked for mini incision. B. Incision appearance on postoperative day 4. The procedure began by making a small incision, 1.5–1.8 cm in length, according to the thickness of abdominal wall, at McBurney's point (With kind permission from Springer Science+Business Media: Surgical Endoscopy, Gasless single-incision laparoscopic appendectomy, 25, 2011, pg 1473, Chen D et al., Fig. 1)

pain on internal rotation of the hip which can occur with a pelvic appendix. *McBurney's point* (Fig. 20.1) is located at one-third of the distance along an imaginary line drawn from the anterior superior iliac spine to the umbilicus and marks the incision site for open appendectomies. *McBurney's sign* is maximal tenderness at McBurney's point.

## Pathophysiology

### What Explains the Transition from Periumbilical Pain to Right Lower Quadrant Pain in Appendicitis?

Autonomic nerves (sympathetic and parasympathetic) supply visceral peritoneum while the parietal peritoneum has somatic innervation derived from spinal nerves. The visceral peritoneum senses pain when stretched or distended and results in dull, poorly localized pain associated with nausea and diaphoresis. Often in the early hours of appendiceal inflammation, only the

visceral peritoneum is affected. The patient perceives a vague type of abdominal pain in the periumbilical region. In contrast, as the inflammation progresses, the parietal peritoneum becomes affected and results in a sharp, severe type of pain localized to the region of appendiceal inflammation at the right lower quadrant.

### **Is the Appendix Considered Foregut, Midgut, or Hindgut? And How Does That Influence Where the Visceral Pain in the Abdomen Is Perceived?**

The appendix, along with the small bowel (distal to the ligament of Treitz), cecum, ascending colon, and 2/3 of the transverse colon are derived from the midgut. Pain in the midgut is primarily perceived in the periumbilical region. In contrast, pain in the foregut (esophagus to distal duodenum) is usually perceived in the epigastrium, and pain in the hindgut (left colon and rectum) is perceived in the hypogastrium (suprapubic).

### **Why Is Hyperesthesia of the Skin a Sign of Acute Appendicitis?**

Parietal peritoneum is supplied by spinal nerves. With irritation of the parietal peritoneum, the area of skin supplied by the spinal nerves on the right at T10–T12 can become very sensitive to touch, a phenomenon known as cutaneous hyperesthesia.

### **What Is a Closed-Loop Obstruction?**

A closed-loop obstruction develops when a loop of bowel is obstructed at two points such that there is no outlet for the bowel contents and pressure. As pressure continues to build, the loop of bowel will continue to distend until venous pressure is exceeded followed by arterial inflow. With the blood supply to the loop compromised, ischemia and infarction ensues.

### **How Does a Closed-Loop Obstruction Pertain to Acute Appendicitis?**

In acute appendicitis, a commonly accepted etiology involves obstruction of the proximal appendiceal lumen by a fecalith (in adults) or lymphoid hyperplasia (in children). Since the appendix is a blind loop, this in essence creates a closed-loop obstruction. The appendiceal mucosa continues to secrete mucus. Resident bacteria in the appendix begin to multiply rapidly. Consequently, the appendix distends rapidly and intraluminal pressure exceeds venous but not arteriolar pressure. Vascular congestion ensues until arteriolar supply is compromised as well. Ischemia and gangrene occur first at areas with the poorest blood supply resulting in a weakened wall. Perforation eventually occurs at the antimesenteric border just beyond the point of obstruction where the tension is high. Increased luminal pressure alone is not directly responsible for the perforation.

### **What Are Some Other Examples of a Closed-Loop Obstruction?**

Obstructing colon cancer with functioning ileocecal valve, diverticulitis, incarcerated hernia, volvulus, acute cholecystitis, and Richter's hernia (only part of the circumference of the bowel wall is trapped within the hernia sac).

#### **Watch Out**

Children with acute appendicitis may have typical symptoms of a viral upper respiratory tract infection, followed by true onset of acute appendicitis.



## **What Are Other Causes of Appendiceal Obstruction?**

As mentioned above, fecaliths are the most common cause of appendiceal obstruction. In children, lymphoid hyperplasia obstructs the appendiceal lumen, most often as a result of a preceding viral infection. Other causes of appendiceal obstruction include inspissated barium (impacted bariolith) after radiological studies, tumors (adenocarcinoma of the appendix), ingested seeds, and parasites (e.g., *Ascaris lumbricoides*, *Enterobius vermicularis*).

## **What Is the Importance of a Retrocecal Appendix in Terms of Diagnosis?**

In patients with a retrocecal appendix, palpation of the inferior lumbar (Petit) triangle may elicit pain. The floor of the triangle is the internal abdominal oblique muscle, the inferior border is the iliac crest, and the margins are composed of two muscles, latissimus dorsi, and external abdominal oblique.

---

## **Workup**

### **What Are the Critical Laboratory Values Utilized in the Workup of Acute Appendicitis?**

The most important is leukocytosis with a left shift (increase in immature white cells, called band cells, also called bandemia). More recently, elevated C-reactive protein (CRP), a marker for inflammation, has been shown to be useful in the diagnosis of acute appendicitis. All women of childbearing age presenting with abdominal pain should receive a beta-hCG pregnancy test to rule out an ectopic pregnancy.

### **What Is the Significance of WBCs in the Urine Without Bacteria? How Might This Mislead the Clinician?**

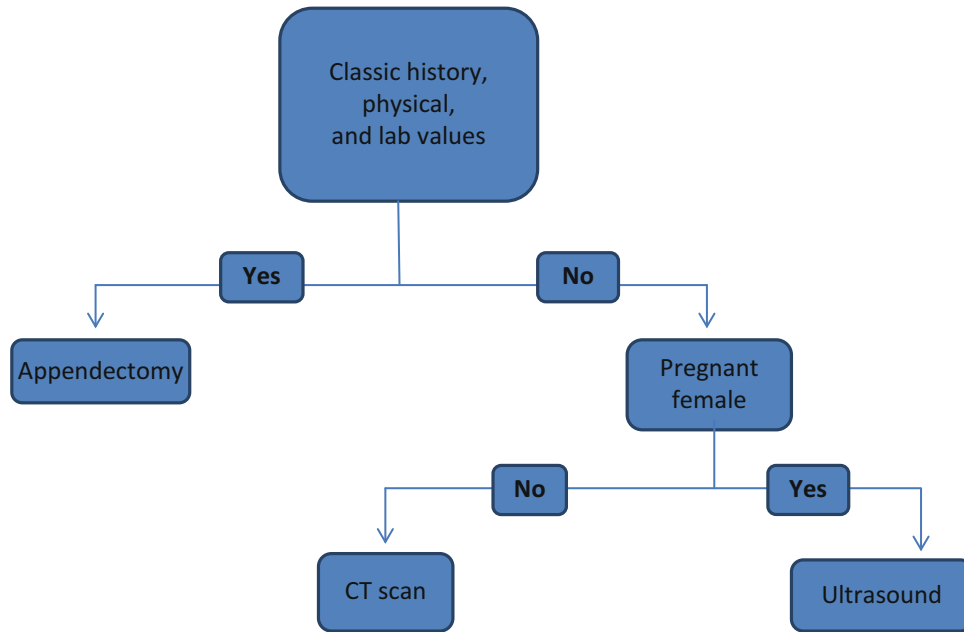
A few white blood cells can be seen in the urine (pyuria) with ureteral or bladder irritation by the inflamed appendix. This laboratory finding may mislead the clinician in believing the patient may have cystitis. However, bacteriuria (bacteria in urine) should not be present in catheterized urine specimen.

### **What Further Imaging Is Needed?**

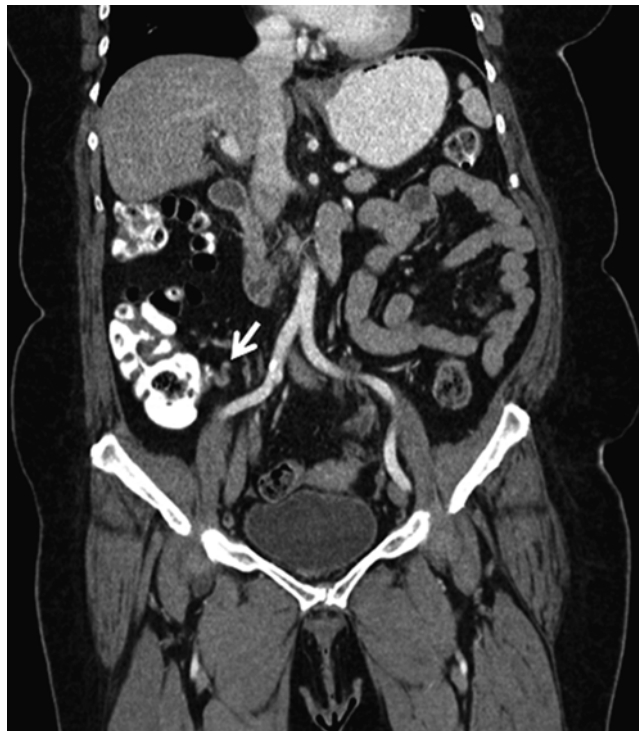Given the classic presentation in an adult male, no further imaging is needed (Fig. 20.2).

### **When Would Imaging Be Indicated? How Should the Use of Imaging Studies Differ Between Adults and Kids? Men and Women?**

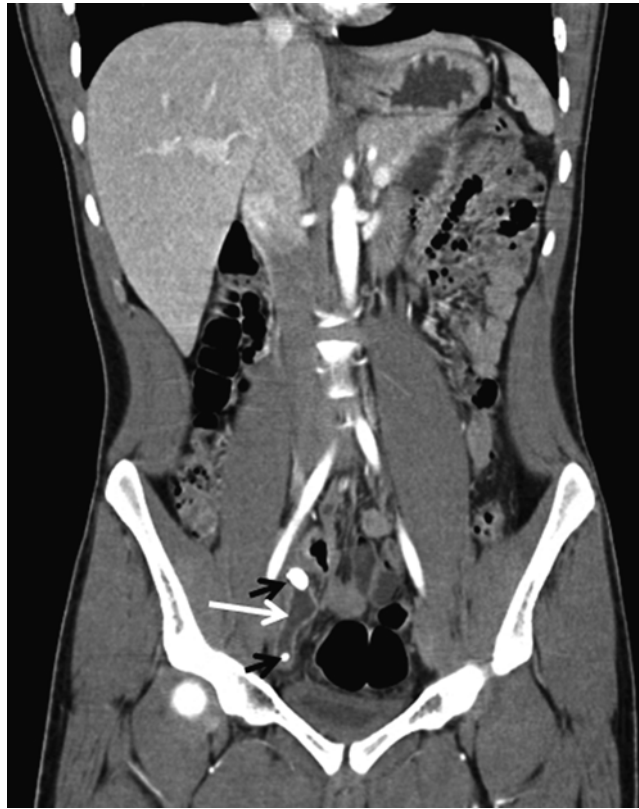In cases where the diagnosis is equivocal, ultrasonography and CT scan can be helpful. Ultrasound can identify a thick-walled, noncompressible tubular structure (dilated appendix) in the right lower quadrant. Peritoneal fluid and/or an abscess can sometimes be seen in advanced cases. Ultrasonography is particularly useful in women and children. In women, ultrasound is used to rule out gynecologic pathology such as ovarian torsion, tubo-ovarian abscess, or an ectopic pregnancy. Ultrasonography is used in children and pregnant women (MRI is another option in pregnancy), as the child and the fetus are more vulnerable to the effects of radiation. Also, because children have less periappendiceal fat, the appendix is not as readily visualized on CT scan. Thus CT scan is utilized in adult men and nonpregnant women when the diagnosis is unclear. CT findings consistent with acute appendicitis include periappendiceal fat stranding and an appendiceal diameter > 6 mm (Figs. 20.3 and 20.4).



**Fig. 20.2** Algorithm for acute appendicitis



**Fig. 20.3** Coronal CT showing the normal appendix (*white arrow*) as a thin tubular structure arising from the base of the cecum



**Fig. 20.4** Coronal CT showing a dilated, thick-walled, fluid-filled appendix containing appendicoliths, indicating acute appendicitis. *White arrows, dilated appendix; black arrows, appendicoliths*

### What Are the Radiographic Signs of Appendicitis?

Plain abdominal X-ray is generally not helpful in the diagnosis of acute appendicitis as there are no consistent and reliable findings. However, on occasion, a calcified fecalith will be seen in the RLQ, which is highly suggestive of appendicitis.

---

## Management

### What Is the Definitive Treatment for Appendicitis?

Surgical removal of the appendix (appendectomy) with either a laparoscopic or open approach.

### Is Laparoscopic or Open Appendectomy the Superior Approach?

Both laparoscopic and open appendectomy approaches are effective treatments for acute appendicitis. Controversy still exists over whether one is superior to the other. Studies have shown that laparoscopic appendectomy results in slightly decreased postoperative pain and faster return to normal activity. However, the duration of surgery is longer, and costs are higher with laparoscopy. The rate of wound complications is lower with laparoscopy, but interestingly, the rate of postoperative intra-abdominal abscess is higher. The decision over which approach to use is based on surgeon preference, patient characteristics, and patient preference.

## **What Is the Role of Pre- and Postoperative Antibiotics for Acute Non-Perforated Appendicitis? for Perforated Appendicitis?**

A single dose of preoperative antibiotics has been shown to reduce infectious complications and should be given to patients with both acute non-perforated and perforated appendicitis. In simple non-perforated appendicitis, antibiotics should not exceed 24 hours postoperatively. For perforated or gangrenous appendicitis, intravenous antibiotics should be given until the patient's fever and leukocytosis have resolved, which typically takes 3–5 days.

## **How Should You Proceed If You Are Performing a Laparoscopic Appendectomy and You Discover That the Appendix Appears to Be Normal? Do You Remove the Appendix Anyway? Are There Circumstances Where an Appendectomy Is Contraindicated?**

The rate of finding a normal appendix during laparoscopic appendectomy (negative appendectomy) is roughly 10 % and occurs more commonly in the elderly, infants, and young women. In general the appendix should be removed at that point even though it does not appear to be inflamed. That way, if the patient develops RLQ pain in the future, acute appendicitis is effectively ruled out. It is also important to search for other causes that can mimic appendicitis (e.g., inflammatory bowel disease, Meckel's diverticulitis, pancreatitis, cholecystitis). In the case of regional enteritis (Crohn's disease) involving the cecum, the appendix should not be removed because of the high risk of developing a cecal fistula.

---

## **Areas Where You Can Get in Trouble**

### **All Patients**

#### **Misdiagnosing Appendicitis as Cystitis**

Do not assume that pyuria rules out appendicitis and therefore misdiagnose a patient who has appendicitis as cystitis and treat with oral antibiotics. Bacteriuria (bacteria in urine) should not be present in catheterized urine specimen of a patient with appendicitis.

#### **Misdiagnosing Other Causes of Perforation as Appendicitis**

Any pathology that causes peritonitis (e.g., pelvic inflammatory disease, perforated ulcer) can cause the serosa of the appendix to get inflamed and lead to signs and symptoms suggestive of appendicitis. This is termed periappendicitis. If during surgery you see pus in the pelvis suggesting a perforated appendicitis, but then a non-perforated yet inflamed appendix is found, consider periappendicitis. Explore the abdomen carefully for another source for the peritonitis.

#### **Pseudoappendicitis**

Pseudoappendicitis refers to a disease which presents exactly like appendicitis but is due to another cause. The classic cause is a *Yersinia enterocolitica* infection which presents with RLQ pain, fever, vomiting, and bloody diarrhea. Patients may have sick contacts (e.g., teacher at daycare center). It is usually self-limited, but in immunosuppressed patients can result in fatal sepsis. Treatment consists of doxycycline.

### **Women**

#### **Missing Ovarian Torsion: A Surgical Emergency**

Right-sided ovarian torsion can be mistaken for acute appendicitis given similar symptoms such as right lower quadrant pain, fever, and leukocytosis. Transvaginal ultrasound and/or CT scanning can help with diagnosis. Ovarian torsion is a surgical emergency and delays can result in necrosis of the ovary. In fact, salvage of the ovary is only about 10 % in adults, due to delays in diagnosis.

### **Misdiagnosing Ruptured Appendicitis as Pelvic Inflammatory Disease (PID)**

Pelvic inflammatory disease can mimic ruptured appendicitis in that both can cause cervical motion tenderness and right adnexal tenderness. However, with PID, nausea and vomiting is less common. Additionally, the pain of PID is typically lower in the abdomen, in the bilateral lower quadrants from the onset, associated with a history of foul smelling vaginal discharge, and smear of vaginal discharge may show bacteria. It is important to inquire about risk factors for PID such as young age at first intercourse, unprotected intercourse, history of PID or other sexually transmitted diseases, and multiple sexual partners. Transvaginal ultrasound and/or CT scan are helpful.

### **Failure to Recognize a Ruptured Ectopic Pregnancy**

Implantation of the blastocyst in the ovary or fallopian tube can lead to rupture and, if on the right side, can mimic appendicitis. B-hCG level will be elevated and hematocrit may fall from intra-abdominal hemorrhage. The patient may be hypotensive and tachycardic from blood loss. Ruptured ectopic pregnancy is a surgical emergency.

### **Misdiagnosing Acute Appendicitis During Pregnancy**

Acute appendicitis is the most common surgical emergency in pregnancy. Traditionally, the diagnosis was considered particularly challenging because it was believed that as pregnancy advances, the normal anatomic relations become distorted, leading to atypical pain in the upper quadrants as a result of a shifted appendix. Recent studies have confirmed that the majority of pregnant women with appendicitis report pain in the RLQ in all three trimesters. Delaying diagnosis can result in increased risk of perforation. The risk of fetal loss with perforated appendicitis is markedly increased when compared to without perforation. Similarly, the risk of premature delivery is significantly increased. Conversely, performing an appendectomy for a pregnant patient without true appendicitis is associated with fetal loss and premature delivery as well. Establishing an accurate and early diagnosis with either ultrasound or MRI is crucial.

## **Children**

### **Under Age 5, Harder to Get History and Examine, and Are More Prone to Early Rupture**

Diagnosis of appendicitis is challenging in young children due to their inability to give an accurate history and frequent GI upset. Children <5 years of age more often present with perforated appendicitis (45 %), and their underdeveloped omentum is less capable of containing the rupture.

## **Elderly**

### **More Prone to Rupture**

Elderly patients tend to present later in their course of appendicitis, have an atypical presentation, and have a higher rate of rupture (>50 %). The higher rate of morbidity and mortality associated with perforated appendicitis means that the index of suspicion for appendicitis should be higher in the elderly.

### **Check for Anemia and Need to Think of Perforated Colon Cancer**

Incidence of colon cancer increases with age. Perforated colon cancer can mimic appendicitis in the elderly. The presence of microcytic anemia should prompt workup for colon cancer.

---

## **Areas of Controversy**

### **Is Appendicitis a True Surgical Emergency?**

Traditionally, acute appendicitis warrants emergent operation to prevent perforation. However, the risk of rupture in adults was shown to be low in the first 36 hours with a 5 % risk of rupture in each subsequent 12 hours period. Thus appendicitis should be treated urgently but is not necessarily a true surgical emergency.

## Can Acute Non-Perforated Appendicitis Be Managed Nonoperatively?

The concern is that treatment with antibiotics alone, may not prevent progression to gangrene and perforation. That being said, there are case series of acute non-perforated appendicitis being successfully treated with antibiotics alone. For the present, the gold standard of care for acute appendicitis is surgical appendectomy.

## Patients with Appendicitis and > 5-day History of RLQ Pain

If a patient has >5-day history of RLQ pain, the appendix by then has most likely ruptured. When it ruptures, one of two things happens. Either the infection spreads to cause diffuse peritonitis or the body (with the help of the omentum) walls off the perforation to create a localized abscess. In a patient who presents with a protracted history of RLQ pain (>5days), if they have localized pain and tenderness, the presumption is that they have formed an abscess. If this is confirmed with a CT scan, it is usually treated first with IV antibiotics. If a large abscess is seen, it is drained percutaneously. This approach results in lower morbidity and mortality compared to immediate appendectomy but requires longer hospital stay. The failure rate is 9–15 %, and if it fails, operative intervention is required.

## After Nonoperative Management of an Appendiceal Abscess, Is Interval Appendectomy Necessary?

Following successful nonoperative management of perforated appendicitis, interval appendectomy (performing appendectomy 6–8 weeks later) is controversial. The reasoning behind it is to prevent a recurrent attack of appendicitis. The majority of experts' opinion is that interval appendectomy is unnecessary. Oftentimes, at interval appendectomy, the residual appendix is scarred and involuted.

---

## Summary of Essentials

### History

- Anorexia (hamburger sign), nausea, vomiting
- Vague periumbilical pain that shifts to the RLQ

### Physical Exam

- McBurney's point tenderness
- Cutaneous hyperesthesia, Rovsing's, psoas, and obturator signs

### Laboratory

- Elevated WBC with left shift
- C-reactive protein
- Pregnancy test
- Urinalysis: sterile pyuria

### Diagnosis

- Oftentimes is a clinical diagnosis

## Imaging

- None needed with classic H&P and leukocytosis
- US: women and children
- Avoid CT in children (increased risk of malignancy) and pregnancy (risk to fetus)
- CT: if diagnosis is equivocal in men and nonpregnant women
- MRI: pregnant women

## Pathophysiology

- Closed-loop obstruction
- Fecalith in adults, lymphoid hyperplasia in children

## Management

- Appendectomy (open or laparoscopic)

## Special Situations

- Abnormal urinalysis does not rule out an appendicitis
- CT is the most sensitive test for appendicitis and may show fecalith, periappendiceal fat stranding, free fluid, or phlegmon
- Perforated appendicitis is a result of a closed-loop obstruction creating an ischemic mucosal wall and not a direct result of increased intraluminal pressure
- Most common cause of appendicitis is fecalith in adults, and lifetime incidence of acute appendicitis is 6–7 %
- Consider pseudoappendicitis in a patient with history suggestive of appendicitis + extensive diarrhea

---

## Suggested Reading

- Guidry SP, Poole GV. The anatomy of appendicitis. *Am Surg.* 1994; 60:68.
- Izbicki JR, Knoefel WT, Wilker DK, et al. Accurate diagnosis of acute appendicitis: a retrospective and prospective analysis of 686 patients. *Eur J Surg.* 1992;158:227.
- Liu JL, Wyatt JC, Deeks JJ, et al. Systematic reviews of clinical decision tools for acute abdominal pain. *Health Technol Assess.* 2006;10:1.
- Pittman-Waller VA, Myers JG, Stewart RM, et al. Appendicitis: why so complicated? Analysis of 5755 consecutive appendectomies. *Am Surg.* 2000;66:548.
- Temple CL, Huchcroft SA, Temple WJ. The natural history of appendicitis in adults. A prospective study. *Ann Surg.* 1995; 221:278.
- Varadhan KK, Humes DJ, Neal KR, Lobo DN. Antibiotic therapy versus appendectomy for acute appendicitis: a meta-analysis. *World J Surg.* 2010;34:199.

Areg Grigorian, Christian de Virgilio, and Tracey D. Arnell

A 57-year-old obese man is seen by his primary care physician for his yearly physical. He endorses a 20-lb weight loss in the past few months without changing his diet or exercise. He also reports pencil-thin stools and intermittent constipation. He feels that he cannot adequately evacuate his stool. There is no blood or mucus in his stool. He has smoked one pack per day for the past 20 years. He has a history of type 2 diabetes. He has never had a colonoscopy. Family history is negative for any cancer. On exam, he is afebrile with a heart rate of 78/min and blood pressure of 132/74 mmHg. His abdomen is soft and non-tender. No abdominal masses are palpated and he is non-distended. On rectal exam, he has no masses and no gross blood. Laboratory examination reveals a hematocrit of 37 % (normal 40–52 %).

## Diagnosis

### What is the Differential Diagnosis for a Change in Bowel Habits?

Condition	Change in bowel habits	Other characteristics
<i>Colorectal cancer</i>	Diarrhea, constipation, iron deficiency anemia (more so with right sided)	Anemia, fatigue, weight loss, decreased stool caliber
<i>Irritable bowel syndrome (IBS)</i>	Diarrhea alternating with constipation, +/- mucus, no blood	Symptom-based diagnosis, chronic abdominal pain relieved by BM, bloating, tenesmus, depression/anxiety common
<i>IBD (ulcerative colitis or Crohn's disease)</i>	Diarrhea +/- blood, mucus	Abdominal pain, severe cramps, weight loss, anemia (see section below)
<i>Celiac disease</i>	Pale, loose and greasy stool (steatorrhea), diarrhea	Weight loss, failure to thrive (in children), malabsorption, anemia, <i>dermatitis herpetiformis</i> (autoimmune maculopapular rash)
<i>Intestinal pseudo-obstruction</i>	Constipation	Bowel distention in the absence of anatomic lesions, abdominal distention, succussion splash, nausea, vomiting
<i>Thyroid disease</i>	Diarrhea (hyperthyroid) or constipation (hypothyroid)	Anxiety, tremor, palpitations, heat intolerance with hyperthyroidism; fatigue, cold intolerance with hypothyroidism
<i>Drugs (laxatives, antidiarrheal)</i>	Diarrhea or constipation	Medication-induced change in bowel habits, <i>melanosis coli</i> , weight loss, psychosocial comorbidities
<i>Infectious</i>	Diarrhea	Viral, bacterial or parasitic infection

BM bowel movement; IBD inflammatory bowel disease

A. Grigorian, MD (✉)

Department of Surgery, University of California, Irvine, 333 City Blvd West, Suite 1600, Route. 81, Orange, CA 92868, USA  
e-mail: [agrigori@uci.edu](mailto:agrigori@uci.edu)

C. de Virgilio, MD

Department of Surgery, Harbor-UCLA Medical Center, 1000 W. Carson Street, Torrance, CA 90509, USA  
e-mail: [cdevirgilio@labiomed.org](mailto:cdevirgilio@labiomed.org)

T.D. Arnell, MD

Department of Surgery, New York Presbyterian Columbia University, 177 Fort Washington, Suite 7-133, New York, NY 10032, USA  
e-mail: [ta2107@columbia.edu](mailto:ta2107@columbia.edu)



## What Is the Most Likely Diagnosis?

Given the patient's bowel symptoms, anemia, weight loss, and age, the most likely diagnosis is colon cancer until proven otherwise. His predominant symptoms are those of a slowly obstructing lesion as evidenced by a change in bowel habits with pencil-thin stools, which is most suggestive of a left-sided lesion.

## Screening

### What Screening Is Recommended for Colorectal Cancer?

The US Preventive Services Task Force (USPSTF) recommends screening in all adults of average risk, beginning at age 50 until age 75. The decision to screen individuals between 75 and 85 is made on an individual basis, whereas screening is not recommended for individuals over age 85. In patients with IBD, the screening recommendations vary.

### What Screening Is Recommended for Colorectal Cancer in Patients with a First-Degree Family Member with Colorectal Cancer?

These patients should begin screening at age 40 or 10 years prior to the onset of colorectal cancer in the first-degree relative, whichever comes first. They should continue screening every 5 years after.

### What Are the Differences Between the Various Screening Modalities?

The decision to use a particular screening tool needs to be made by the patient after discussing the benefits, risks, and financial considerations imposed on the patient. Table 21.1 goes over the key differences.

#### Watch Out

Diets rich in red meat can result in a false-positive fecal occult blood test (FOBT) test.

**Table 21.1** Screening for colorectal cancer

Screening	USPST F <sup>a</sup>	Interval	Features
<i>Colonoscopy</i>	Yes	Every 10 years	Visualizes the entire rectum and colon, can detect lesions less than 0.5 cm, able to remove polyps and attain biopsies, used as a follow-up test if other tests are equivocal, sedation required, 0.2 % perforation risk
<i>Flexible sigmoidoscopy</i>	Yes	Every 5 years +FOBT every 3 years	Limited to only the lower third of the colon, able to remove polyps and attain biopsies, sedation required; if + FOBT, must undergo colonoscopy
<i>Fecal occult blood test (FOBT)</i>	Yes	Annually	Of two types: traditional hemoccult chemical test (requires dietary modifications 3 days prior) and newer immunochemical test (greater sensitivity, lower specificity), can be done at home, positive test requires follow-up with colonoscopy
<i>Barium enema with sigmoidoscopy</i>	No	Every 5 years	Sigmoidoscopy is a mandatory adjunct to barium enema as the rectum is not well visualized, detects only 50 % of polyps larger than 1 cm, sedation not required, detection of mucosal inflammation is limited, useful if colonoscopy is incomplete owing to anatomic or pathologic barriers
<i>CT colonography</i>	No	Every 5 years	As likely as colonoscopy to detect lesions 10 mm or larger but may be less sensitive for smaller adenomas, requires bowel prep, does not require sedation, may identify incidental findings (i.e., extracolonic neoplasms or AAA), and does not allow for biopsy or polypectomy
<i>Capsule endoscopy</i>	No	Every 5 years	Low sensitivity/specificity, unable to attain biopsies, less invasive but requires more aggressive bowel prep, not available in the USA for screening

<sup>a</sup>US Preventive Services Task Force recommendations

## History and Physical

### What Is the Significance of the Patient's Unintended Weight Loss?

Unexplained weight loss is a cause for concern because it may suggest malignancy. In patients with colorectal carcinoma, it may signify disseminated disease. Although the pathogenesis of cancer-related cachexia is not fully understood, TNF-alpha seems to play a central role and has direct catabolic effects on skeletal muscle. Other causes of unexplained weight loss include depression, celiac disease, Addison's disease, chronic obstructive pulmonary disease, IBD, HIV, peptic ulcer disease, tuberculosis, and hyperthyroidism.

### What Are the Risk Factors for Colon Cancer?

The risk factors for colon cancer include older age (majority are over 50), African American race, IBD, family history, low-fiber/high-fat diet, sedentary lifestyle, obesity, smoking, alcohol, type 2 diabetes, and radiation therapy to the abdomen.

### Where Does Colon Cancer Rank in Terms of the Most Common Cancers in the Usa? In Terms of the Highest Overall Mortality?

	Incidence (in order of frequency)	Mortality (highest first)
<i>Men</i>	Prostate, lung, and colon	Lung, prostate, and colon
<i>Women</i>	Breast, lung, and colon	Lung, breast, and colon

### Are Right- or Left-Sided Colon Cancers More Common and How Do the Presentations Differ?

The majority of colon cancers are left sided and occur near the rectosigmoid junction. Left-sided colon cancers are more likely to cause a change in bowel habits and symptoms of obstruction. When stool reaches the sigmoid, it is often hard and devoid of excess fluid. The caliber of the lumen is also narrower on the left side, and with a circumferential tumor causing partial obstruction, patients report pencil-thin stools, often tinged with blood. Bowel habits can alternate between constipation and diarrhea. Patients report distention with lower abdominal colicky pain. Since the lesions are closer to the anal orifice, bright red blood per rectum (hematochezia) may be reported. A smaller number of colon cancers are right sided, and the most common finding is an insidious onset of iron deficiency anemia secondary to chronic GI blood loss. Rarely, if the tumor is rapidly growing, patients can experience severe pain, and a right lower quadrant mass may be appreciated on exam.

#### Watch Out

Melena is more common in right-sided colon cancers.

### Why Is the Rectal Examination Important in Suspected Colorectal Cancer?

The digital rectal exam (DRE) is often overlooked by the novice, yet it is of critical importance in the evaluation of a patient with possible colorectal cancer. A DRE by itself is not a good test for detecting colon cancer because its reach is limited. However, the value of the DRE lies in its ability to detect low rectal cancers because it allows the examiner to feel a mass,

which is suggestive of malignancy. In addition, distance from the anal verge, mobility, and anatomic relation to other pelvic structures can be assessed. A fixed mass is more likely to be locally advanced, and relation to the prostate, vagina, and sacrum is important for surgical planning.

## Pathophysiology

### What Is a Polyp and How Are They Generally Classified?

A polyp is a mass that protrudes into the lumen of the GI tract and can either be pedunculated (with a stalk) or sessile (flat). Nonneoplastic polyps can arise from abnormal mucosal maturation, inflammation, or colonic architecture. However, polyps arising from epithelial proliferation and dysplasia are true neoplasms and may have malignant potential. They are collectively known as adenomatous polyps or adenomas.

### Describe the Nonneoplastic Polyps

Type	Features
<i>Hyperplastic</i>	Small (<5 mm in diameter) and smooth; the <i>most common type</i> ; isolated polyps are typically benign it is now recognized that there are hyperplastic polyposis syndromes in which there may be a risk of malignancy
<i>Juvenile (hamartomatous)</i>	Rounded, smooth, and sometimes have a stalk (<2 cm); occur most commonly in children (<5 year old); usually present as a solitary rectal polyp that prolapses and the term “juvenile” refers to the way these polyps look under the microscope

### How Do Colon Cancers Develop?

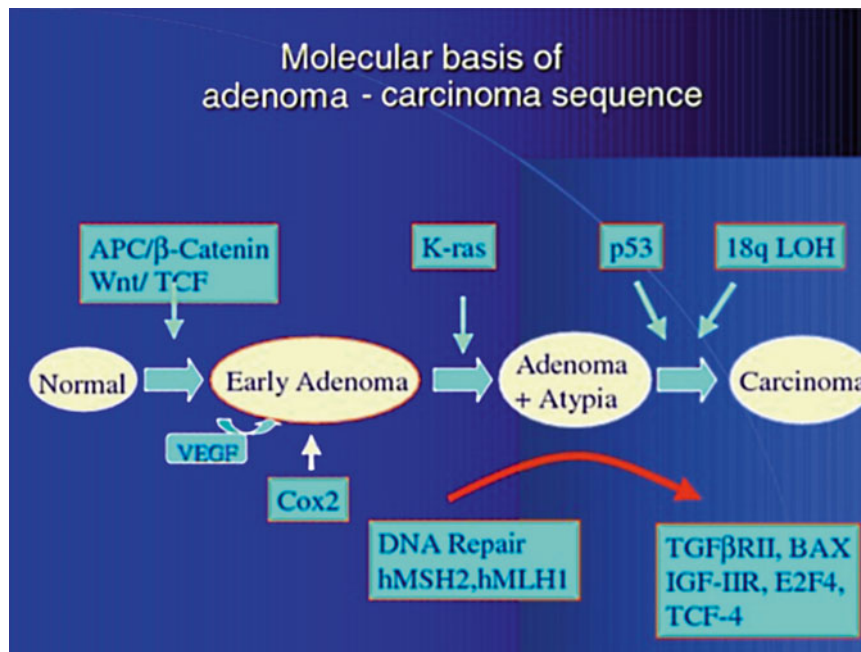
The majority of colon cancers arise from the adenoma-carcinoma sequence (Fig. 21.1). This is also known as the chromosome instability pathway since there is a stepwise accumulation of mutations leading to carcinoma. The sequence begins with a loss of the APC tumor suppressor gene resulting in decreased intercellular adhesion and increased proliferation. A subsequent KRAS mutation achieves unregulated intracellular signaling and transduction which allows for the formation of an adenoma. Adenomatous polyps are considered premalignant and it is estimated that 20 % will go on to become malignant. The malignant potential of an adenomatous polyp is related to the age of the patient, the size of the polyp, and the villous component. Finally, loss of the p53 tumor suppressor gene will increase tumorigenesis in an adenoma and result in carcinoma. In a smaller number of colon cancers, microsatellite instability plays a bigger role in which impaired DNA mismatch repair enzymes are unable to ensure the fidelity of a copied DNA strand, increasing the risk for developing cancer.

#### Watch Out

Juvenile polyposis syndrome can result in a large number of hamartomatous polyps in the stomach and colon occurring in children. Multiple hamartomatous polyps alongside with mucocutaneous hyperpigmentation spots on the lips and genitalia are concerning for Peutz-Jeghers syndrome.

### What Features of an Adenoma Are Associated with an Increased Malignant Risk?

There are four subtypes of adenomas (Table 21.2) that are based on their epithelial architecture. Their risk of malignancy is dependent on polyp size, architecture, and severity of dysplasia. Larger adenomas are more ominous with a 40 % chance of cancer in adenomas >4 cm. Disarrangements in architecture and severe dysplasia can also increase the risk of cancer.



**Fig. 21.1** Adenoma-carcinoma sequence (With kind permission from Springer Science+Business Media: Annals of Surgical Oncology, The Surgeon's Role in Cancer Prevention. The Model in Colorectal Carcinoma, 14(11), 2007, pg 3058, Chu DZJ, et al., Fig. 2)

**Table 21.2** Adenoma subtypes

Adenoma type	Features
<i>Tubular</i>	The most common type with the majority occurring in the rectosigmoid but can be found anywhere in the colon
<i>Villous</i>	Less common than tubular; tend to be larger and occur in older persons, typically in the rectum; more commonly sessile, and with cauliflower-like projections; high malignant potential
<i>Tubulovillous</i>	Composed of both tubular and villous features; can be pedunculated or sessile
<i>Sessile serrated</i>	Flat, broad-based polyps that can be mistaken for hyperplastic polyps; have high malignant potential; have a "sawtooth" appearance under the microscope

### Why Screen Every 10 Years When Using Colonoscopy?

The majority of adenocarcinomas arise from adenomatous polyps. Observational studies have suggested that the sequence from adenoma to carcinoma takes about 10 years. Visualizing the entire colon with a colonoscopy every 10 years is sufficient to catch the majority of these cancers. In patients with other risk factors, screening may need to occur more frequently.

### Why Is Colonoscopy Recommended and Not Flexible Sigmoidoscopy?

Flexible sigmoidoscopy is only able to visualize the rectum and the distal third of the colon, so polyps in the proximal colon will be missed. A colonoscopy can adequately visualize the entire colon.

### Why Is Barium Enema Alone Not Sufficient?

Retrospective studies have found that barium enemas detect less than half of all polyps and can miss up to 20 % of all cancers. Although studies are lacking, it is believed that barium enemas perform less well in the rectosigmoid junction owing to poor

visualization of the rectum with contrast. A flexible sigmoidoscopy is often employed as an adjunct to increase the sensitivity of the study. Its efficacy is also dependent on operator experience but may be a useful tool in places where colonoscopy is unavailable or difficult to perform.

### Where Are the Most Common Metastatic Sites for Colorectal Cancer?

Regional metastases are to the mesenteric lymph nodes (the N in the TNM system). The liver is the most common location of distant metastasis, owing to the venous drainage of the colon to the liver via the mesenteric veins draining to the portal system and the tendency for these cancers to spread hematogenously. Rectal cancers may have atypical locations for metastasis because they drain into the portal and systemic venous circulations. They may first metastasize to the lungs because the inferior rectal veins drain into the inferior vena cava via the internal iliac veins. Via the systemic veins, rectal cancers may also metastasize to the inguinal lymph nodes. Additionally, via sacral veins, rectal cancers may result in spine and brain metastasis. Other common locations for metastasis include the peritoneum, supraclavicular lymph node, and bones.

### What Hereditary Conditions Are Associated with Colon Cancer?

*Hereditary nonpolyposis colorectal cancer (HNPCC) or Lynch syndrome* is an autosomal dominant condition associated with multiple malignancies. The most common types are colorectal and endometrial, while the less common types are ovarian, stomach, breast, small bowel, pancreatic, kidney, and bile duct cancers. Lynch type 1 is caused by a heterozygous mutation in DNA mismatch repair genes and results in more colonic cancers, often on the right side and typically in the fourth decade of life. Lynch type 2 is caused by mutations in the MLH1 gene and results in more extracolonic cancers. Colon cancers associated with HNPCC still arise from adenomas, but the adenomas tend to be flat as opposed to polypoid. Also, the adenomas associated with HNPCC are more likely to become malignant and to do so more rapidly (within 2 or 3 years) than adenomas not associated with HNPCC.

*Familial adenomatous polyposis (FAP)* is an autosomal dominant condition in which patients develop hundreds to thousands of polyps in the colon, which if left untreated, can develop into cancer. The mutation is in the adenomatous polyposis coli (APC) gene. Polyps begin on average in the mid-teens but can appear as early as age 7. Prophylactic colectomy is often recommended to prevent the development of cancer. If left untreated, 100 % of patients develop cancer by the fourth or fifth decade of life.

#### Watch Out

Individuals with first-degree family members with FAP should begin screening with colonoscopy by age 10.

*Gardner's syndrome* is an autosomal dominant condition with variable penetrance, characterized by osteomas and colonic polyps. If left untreated, all patients develop colon cancer by the fourth or fifth decade of life.

*Turcot syndrome* is characterized by café au lait spots, malignant CNS tumors (often glioblastoma multiforme), and neoplastic colon polyps that progress to cancer. The exact cause is unknown, but some believe it is a variant of FAP.

### What Are the Modified Amsterdam Criteria for HNPCC?

They are diagnostic criteria to help clinicians identify families that are more likely to have Lynch syndrome. FAP needs to be ruled out to diagnose a patient with Lynch syndrome. The 3-2-1-1 rule can help you remember the requirements:

- 3 or more relatives with histologically verified cancers in the colon, endometrium, small intestine, or pelvis
- 2 or more successive generation affected
- 1 or more relatives diagnosed prior to age 50
- 1 should be a first-degree relative of the other two

## **What Is the Difference Between Synchronous and Metachronous Tumors?**

A synchronous tumor is a second primary cancer (nonmetastatic) that is present at the time of initial diagnosis. For this reason, it is important to examine the entire colon via colonoscopy, even if a colon cancer is discovered in the sigmoid colon. Metachronous tumors are primary cancers that develop elsewhere in the colon at least 6 months after the primary resection. This should be distinguished from recurrent cancer, in which the colon cancer returns at the margins of the surgical resection in the colon or mesentery.

---

## **Work-Up**

### **For the Patient Described Above, What Would Be the Next Steps in the Work-Up?**

Given that the patient is manifesting symptoms that are highly concerning for colon cancer, colonoscopy is recommended, with biopsy of any suspicious lesions.

### **Is There Any Role for Testing His Stool for Blood?**

In the case presented, there is sufficient suspicion for colon cancer and thus a strong indication for additional work-up, such that testing for blood in the stool is not important. An error would be to test the stool for blood and, if negative, assume there is no colon cancer. Additionally, any patient presenting with the complaint of rectal bleeding should not have a hemocult test performed as bleeding from all sources can be intermittent, and thus, the test may be a false negative. Evaluation should be based on their complaint.

### **Once a Diagnosis of Colon Cancer Is Established, What Laboratory Tests Are Recommended?**

Carcinoembryonic antigen (CEA) levels and liver enzyme tests are recommended. Elevation of liver enzymes (particularly alkaline phosphatase) is suggestive of possible liver metastasis.

### **Is CEA Useful for Screening? How Is It Used?**

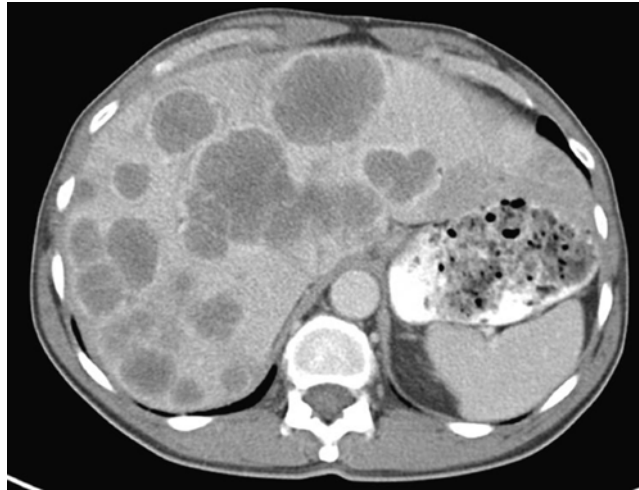
No. The low specificity and sensitivity of CEA make this an inaccurate screening tool for colorectal cancer. Very high CEA levels at diagnosis are suggestive of metastatic disease. Primarily, CEA levels are used as a marker for successful treatment and to detect recurrence. A drop in CEA levels following surgery is indicative of success of the intervention. However, not all patients with colorectal cancers have elevated CEA levels. After surgery, it is recommended to check the CEA every 3 months for the first 3 years to monitor for recurrence. Checking CEA levels as the sole method for disease recurrence is not recommended.

### **What Other Conditions Can Elevate CEA Levels?**

Gastritis, peptic ulcer disease, hepatic disease, pulmonary disease (i.e., COPD), diabetes, visceral cancers (e.g., gastric or pancreatic cancers), inflammatory bowel disease, chronic inflammatory conditions (e.g., rheumatoid arthritis), and smoking can elevate CEA levels.

### **What Additional Imaging, If Any, Is Recommended Once a Diagnosis of Colon Cancer Is Established?**

CT scans of the chest, abdomen, and pelvis are recommended to detect metastasis. Nearly 20 % of patients initially present with metastatic spread. CT of the abdomen and pelvis may identify distant metastasis to the liver. Its sensitivity and specificity for regional lymph nodes are poor. Additionally, the tumor may be visualized, and its relationship to surrounding structures, including possible invasion, can be evaluated. Chest imaging is done to look for pulmonary spread of disease. Routine use of PET scan does not add significant information and as such is not recommended (Fig. 21.2).



**Fig. 21.2** Axial CT of hypoenhancing liver masses consistent with metastases

### How Is the Work-Up of Colon and Rectal Cancers Different?

As compared to colon cancer, there is more at stake with rectal cancer in terms of preserving the sphincter muscles and thus fecal continence when planning a resection. The rectum is in a confined space, so there is also less room for the surgeon to work in terms of getting adequate lateral and distal resection margins. As such, with rectal cancer, it is imperative to determine if the cancer has spread outside the confines of the rectal wall and how close the tumor is to the sphincter muscles. Such information helps select patients that are appropriate candidates for sphincter-preserving surgery as well as those that may benefit from neoadjuvant therapy to shrink the tumor prior to surgery so as to make it more resectable later. For these reasons, transrectal ultrasound (TRUS) and MRI are obtained with rectal cancer. TRUS and MRI have been shown to have improved staging ability when compared to CT and physical exam in terms of local staging (tumor depth and involvement of adjacent organs in T stage). Locally advanced tumors as those with suspected mesenteric node involvement generally undergo chemotherapy and radiation prior to surgery (neoadjuvant). This has been shown to downstage and shrink tumors, increasing the chance for sphincter preservation, and decrease local recurrence rates.

#### Watch Out

*Adjuvant therapy* is a planned addition of therapeutic agents (i.e., chemotherapy, radiation, hormone therapy) following surgery in an attempt to treat micrometastatic or metastatic disease.

*Neoadjuvant therapy* is administered prior to surgery and often done to shrink or debulk tumors to make resection more amenable. *Salvage therapy* is an unplanned addition employed when standard therapy fails.

### How Do You Stage Colon Cancer?

The most commonly used staging system (Table 21.3) is the one described by the American Joint Committee on Cancer (AJCC). *T* (tumor) describes the size of the tumor and/or its depth of invasion. *N* (node) describes spread to regional lymph nodes. *M* (metastasis) indicates if the tumor has metastasized remotely.

## Management

### How Are Polyps That Are Found During Colonoscopy Managed?

Polyps can be removed with polypectomy and surveyed 1–5 years after for recurrence depending on the number and size of polyps. Any identified polyp must be removed in its entirety. If this cannot be done endoscopically, segmental surgical colonic resection is warranted.



**Table 21.3** AJCC staging of colon cancer

Stage	Types	Tumor	5-year survivability (%)
0	T in situ	Only involves the mucosa	> 95
I	T1N0, T2N0	Invades through the mucosa, invades through the submucosa	74
II	T3N0, T4N0	Invades through muscle layers, invades nearby tissues or organs	37–67
III	Any T, N1–N3	Lymph nodes involved	28–73
IV	Any T, any N, M1	Metastatic spread	6

Used with permission of the American Joint Committee on Cancer (AJCC), Chicago, Illinois. The original and primary source for this information is the AJCC Cancer Staging Manual, Seventh Edition (2010), published by Springer Science + Business Media

**Table 21.4** Location of colon cancer and procedure

Location of cancer	Operation
<i>Right-sided colon</i>	Right colectomy with ligation of the ileocolic artery
<i>Transverse colon</i>	Transverse colectomy or extended right colectomy with ligation of the ileocolic and middle colic artery
<i>Descending colon</i>	Left colectomy with ligation of IMA
<i>Sigmoid colon</i>	Left colectomy with ligation of IMA

IMA inferior mesenteric artery

## What Is a “Bowel Prep” and Why Is It Done?

A “bowel prep” essentially prepares the colon for surgery. The premise behind it is that it removes all stool from the colon, theoretically preventing stool spillage into the peritoneum when the colon is divided at surgery. For colonoscopy, it permits better visualization of polyps. Most bowel preps consist of orally ingested polyethylene glycol that the patient drinks on the day prior to the procedure. Some clinicians also use an oral nonabsorbable antibiotic prior to surgery to decrease colonic bacterial levels.

### Watch Out

Bowel prep should not be utilized in patients suspected of having an obstruction.

## What Are the Recommended Operations in Colon Cancer?

The location (Table 21.4) of the primary cancer is the main determinant for what procedure is most appropriate.

### Watch Out

Intraoperatively, the large bowel can be identified by the taenia coli (longitudinal white line) and taenia epiploica (fat appendages). Taenia tends to splay out when the colon becomes the rectum. In contrast, the small bowel does not have these features and is much smoother than the large bowel.

## What Operations Are Typically Offered to Patients with Rectal Cancer?

If the tumor is more than 3 cm from the dentate line, a low anterior resection (LAR) (remove part of the rectum through the abdomen and reconnect the proximal colon with the distal rectum) may be performed. If the tumor is within 3 cm of the dentate line, an abdominoperineal resection (APR) is more likely to be needed. An APR involves removing the entire distal rectum and anus including the sphincters, leaving a permanent colostomy.

## How Many Lymph Nodes Should Be Resected?

A minimum of 12 lymph nodes should be resected, allowing for more accurate staging and improved prognosis.



## **Why Is Neoadjuvant Therapy Used for Rectal Cancer and Not Colon Cancer?**

The goal of neoadjuvant therapy is to shrink the tumor so as to make it more amenable to a surgically curative resection and sphincter preservation. Because the rectum resides in a narrow space, resectability is more of an issue with rectal cancer than colon cancer. Thus neoadjuvant therapy may shrink the rectal tumor sufficiently enough to allow for a curative resection, potentially decreasing local recurrence, and may spare the patient from needing a permanent colostomy. Both radiotherapy and chemotherapy (chemoradiation) are recommended because chemotherapy makes the cancer cells more sensitive to radiation. Neoadjuvant therapy is rarely used in early stage colon cancer, as most colon cancers are surgically resectable. Postoperative chemotherapy is beneficial particularly in patients with locally advanced disease and/or positive lymph nodes. It may be considered in patients diagnosed with metastatic disease at the time of presentation.

## **Why Is Radiation Used for Rectal Cancer and Not Colon Cancer?**

Both types of cancers are radiosensitive, but radiation therapy is not feasible for colon cancer. To effectively irradiate the colon, the entire abdomen and/or pelvis would need to be irradiated. This would also irradiate the small bowel which is more vulnerable to acute radiation enteritis (manifested by persistent nausea, vomiting, abdominal cramping, fecal urgency, and watery diarrhea) as well as chronic radiation enteritis. The incidence of radiation enteritis and its chronicity increase as the dose of radiation and the percentage of normal bowel treated increase. The targeted field of radiation for rectal cancers is much smaller, making this complication less likely to occur.

## **What Are the Major Complications Specific to Colon Surgery?**

Injury to the ureters (with either right or left colectomy), duodenum (during right colectomy), or spleen (during left colectomy) and anastomotic leak are the major complications specific to colon surgery. Careful dissection and identification of structures during surgery is important for avoiding intraoperative injuries. Approximately 6 % of patients will develop an anastomotic leak which usually manifests in the first week after surgery with fever, abdominal pain and tenderness, ileus, and leukocytosis. Depending on the patient's clinical status, this may require urgent return to the operating room for exploration or additional imaging such as a CT scan. Patients with clinical signs of infection and a confirmed anastomotic leak should be taken to the operating room for exploration, washout, and ostomy diversion. Wound infections occur in as many as 25 % of patients and generally only require opening the incision to allow drainage of the infection.

---

## **Areas of Controversy**

### **What Is the Best Screening Method for Colorectal Cancer?**

A colonoscopy is considered the gold standard because it can visualize the entire colon, identify small polyps/adenomas, and perform polypectomies and biopsies.

### **Treatment of Stage IV Colon Cancer**

For patients with stage IV colon cancer, there has been debate as to whether the appropriate primary treatment is surgery with chemotherapy or chemotherapy alone. Recent studies have shown that resecting the primary tumor combined with chemotherapy drugs will lead to improved survival when compared to chemotherapy alone.

### **Is It Useful to Follow CEA Levels After Surgery?**

According to the recommendations made by the American Society of Clinical Oncology in 2005, it is recommended to check CEA levels every 3 months for the first 3 years following surgery.

## Summary of Essentials

### History and Physical

- Change in bowel habits, weight loss, and anemia in an adult are indicative of colon cancer until proven otherwise
- Right-sided colon cancer classically present with iron deficiency anemia, left-sided colon cancer present with obstructive symptoms (pencil-thin stools, constipation), rectal cancer with hematochezia
- Colon cancer is the 3rd most frequent cause of cancer-related deaths in men and women

### Screening

- Colonoscopy every 10 years between ages 50–75
- Screening should begin at age 40 or 10 years prior to onset of colorectal cancer in 1st-degree relative

### Pathophysiology

- Polyps arising from epithelial proliferation and dysplasia (adenomatous polyps) have true malignant potential
- Hyperplastic polyps are the most common type and almost always benign
- Adenoma-carcinoma sequence is primarily responsible; microsatellite instability is less so
- Lynch syndrome, FAP, Gardner's syndrome, and Turcot syndrome are inheritable conditions of colon cancer

### Diagnosis

- Diagnosis confirmation involves colonoscopy and tissue biopsy of suspicious lesions

### Work-Up

- No role for hemocult test with history highly suspicious for colon cancer
- CEA used as adjunct to other modalities to look for tumor recurrence; no screening role
- Colon cancer
  - CT scans of chest, abdomen, and pelvis
- Rectal cancer
  - MRI
  - TRUS

### Management

- Benign Polyps
  - Polypectomy and reassessment in 1-5 years
- Colon cancer
  - Right and/or left colectomy
  - Bowel prep prior to colectomy
  - Postoperative chemotherapy for locally advanced disease and/or positive lymph nodes
- Rectal Cancer
  - APR for tumor within 3 cm of dentate line; LAR for proximal rectal cancer (> 3 cm proximal to dentate line)

---

## Complications

- Right colectomy
  - Injury to the ureters
  - Injury to the duodenum
  - Anastomotic leak
- Left colectomy
  - Injury to the ureters
  - Injury to the spleen
  - Anastomotic leak

---

## Suggested Reading

- Amri R, Bordeianou LG, Sylla P, Berger DL. Impact of screening colonoscopy on outcomes in colon cancer surgery. *JAMA Surg.* 2013;148:747.
- Hamilton W, Round A, Sharp D, Peters TJ. Clinical features of colorectal cancer before diagnosis: a population-based case-control study. *Br J Cancer.* 2005;93:399.
- Siegel R, Ma J, Zou Z, Jemal A. Cancer statistics, 2014. *CA Cancer J Clin.* 2014;64:9.
- U.S. Preventive Services Task Force. Screening for colorectal cancer: U.S. Preventive Services Task Force recommendation statement. *Ann Intern Med.* 2008;149:627.

---

## Chronic Constipation Presenting With Severe Abdominal Pain

# 22

Vivek Sant and Tracey D. Arnell

An 80-year-old African American male presents with severe abdominal distention and no bowel movement or gas per rectum for 3 days, as well as recent onset of vomiting. He has Parkinson's disease and chronic constipation and lives in a nursing home. His medications include levodopa and benztropine, which he has been taking for several years. On physical examination, the patient's vital signs are T 37°C, heart rate 90/min, blood pressure 116/70 mmHg, and respiratory rate 22/min. He appears to be tachypneic but otherwise nontoxic, with mental status unaltered from his baseline. Lungs are clear to auscultation bilaterally. His abdomen is severely distended. He does not have any abdominal surgical scars. He is tympanitic but has no significant tenderness to palpation. There are no palpable hernias, and rectal exam demonstrates an absence of stool with no palpable masses or strictures. Laboratory tests include metabolic panel with BUN 26 mg/dL (normal 7–21 mg/dL), creatinine 1.4 mg/dL (0.5–1.4 mg/dL) and electrolytes within normal limits, WBC  $6.8 \times 10^3/\mu\text{L}$  (normal  $4.1\text{--}10.9 \times 10^3/\mu\text{L}$ ), lactate 0.9 mmol/L (0.5–2.2 mmol/L), and arterial blood gas (ABG): pH 7.48//PaCO<sub>2</sub> 30//PaO<sub>2</sub> 80//HCO<sub>3</sub> 24//SpO<sub>2</sub> 99 %. A plain upright abdominal radiograph shows a massively dilated loop of sigmoid with the apex pointing toward the right upper quadrant, consistent with the “coffee bean” or “bent-inner tube” sign; upright chest radiograph shows no free air under the diaphragm.

---

V. Sant, BA (✉)

Columbia University College of Physicians & Surgeons, 630 West 168th St., New York, NY 10032, USA  
e-mail: [vrs2117@columbia.edu](mailto:vrs2117@columbia.edu)

T.D. Arnell, MD

Department of Surgery, New York-Presbyterian, Columbia University Medical Center, 177 Fort Washington,  
Suite 7-133, New York, NY 10032, USA  
e-mail: [ta2107@columbia.edu](mailto:ta2107@columbia.edu)

## Diagnosis

### What is the Differential Diagnosis?

	Pathophysiology	Comments
<i>Colon cancer</i>	Mass causes mechanical LBO	History of weight loss, change in bowel habits, bloody stools
<i>Volvulus (sigmoid or cecal)</i>	Twisting of colon causes mechanical LBO	Sigmoid in elderly patients, debilitated or institutionalized patients with chronic constipation
<i>Diverticulitis (acute or chronic)</i>	Severe bowel wall edema may lead to LBO	Acute diverticulitis: pain and tenderness in LLQ
<i>Stricture</i>	Inflammation and scarring cause colonic narrowing	IBD, chronic diverticulitis, malignancy, abdominal/pelvic radiation; endoscopy can help identify cause
<i>Fecal impaction</i>	Inspissated stool in rectum or sigmoid causes mechanical LBO	Firm stool in rectal vault on exam
<i>Ogilvie's syndrome (pseudo-obstruction)</i>	Marked colonic distention without mechanical cause can lead to perforation	Debilitated, hospitalized patients, electrolyte imbalances, may decompress with neostigmine or colonoscopy
<i>Small bowel obstruction (SBO)</i>	Most common cause is adhesions in the USA, hernias worldwide	Nausea, extensive vomiting, abdominal surgical scar, hernia bulge
<i>Toxic megacolon</i>	Transmural inflammation of a markedly dilated colon, associated with ulcerative colitis, pseudomembranous colitis, other bacterial colitis	High fever, tachycardia, abdominal tenderness, acidosis, leukocytosis

IBD inflammatory bowel disease, LBO lower bowel obstruction

### What Is the Most Likely Diagnosis?

The massive, slowly progressive abdominal distention, combined with obstipation, and X-ray findings are consistent with a large bowel obstruction. The radiologic appearance is most consistent with a sigmoid volvulus.

## History and Physical

### What Is the Difference Between Obstipation and Constipation?

Constipation implies infrequent stools (<3 per week), usually associated with hard stools. Obstipation implies a complete absence of gas or stool per rectum, which is highly suggestive of a bowel obstruction.

### What Are the Classic Physical Exam Findings in Bowel Obstruction?

On physical exam, note the vitals (particularly the presence of fever or tachycardia > 100/min which in association with an intestinal obstruction suggest strangulation with bowel ischemia or perforation). Tachypnea is common with LBO as diaphragm excursion is impaired. On abdominal exam, check for irreducible hernias (leading cause of SBO worldwide). In uncomplicated bowel obstruction, tenderness is generally lacking. The abdomen may be distended and tympanitic. A rectal exam must be performed to rule out fecal impaction, rectal neoplasm, or stricture.

### What Clues on History and Physical Examination Help Distinguish Between a SBO and LBO?

SBOs tend to be associated with more pronounced vomiting. In an early SBO, bowel sounds are hyperactive, with “rushes and tinkles” (high-pitched sounds of hyperperistaltic small bowel). Large bowel obstruction is more likely to be associated with more pronounced distention, less or late onset vomiting, and decreased bowel sounds.

### **Why Is a History of Neurologic or Psychiatric Disorders Important?**

Drugs used to treat neurologic (such as Parkinson's) or psychiatric diseases can affect colonic motility and predispose to chronic constipation, elongation of the sigmoid, and volvulus, as well as colonic pseudo-obstruction.

### **What Is the Classic Presentation for Ogilvie's Syndrome?**

The patient presents with progressive massive abdominal distention over several days, nausea, and vomiting (similar to an LBO). However, unlike LBO, the classic setting is in someone who is already hospitalized and often in the postoperative setting.

### **What Are the 5 F's of Abdominal Distention?**

These are the five common causes of abdominal distention: fat (obesity), feces (fecal impaction), fetus (pregnancy), flatus (ileus or obstruction), and fluid (ascites). Flatus and fluid can be distinguished by whether the abdomen is tympanitic (gas) or dull (fluid) to percussion.

---

## **Etiology/Pathophysiology**

### **What Are the Most Common Causes of LBO?**

In the USA, malignancies (primarily colon cancer) are the most common cause of LBO (more than half of cases), followed by diverticulitis (either acute or chronic with a stricture) and then volvulus.

### **Where in the Colon Is a Cancer Most Likely to Cause an LBO?**

Left-sided colon (smaller diameter) cancers are more likely to cause LBO, whereas right-sided colon cancers are more likely to present with iron deficiency anemia.

### **What Is the Difference Between Malrotation and Volvulus?**

Malrotation is a congenital condition in which the bowel does not reside in its normal anatomic position. As a result, the bowel and its mesentery are not properly fixed/attached and are therefore prone to twisting and becoming obstructed. Provided the bowel and its mesentery do not twist, the malrotation remains asymptomatic. Volvulus is the term used to describe the twisting of the bowel. Volvulus can be a manifestation of malrotation. If the small bowel twists, the term used is midgut volvulus. Volvulus can also occur in the absence of malrotation (i.e., sigmoid volvulus).

### **How Does the Etiology Differ Between Sigmoid and Cecal Volvulus?**

Cecal volvulus is thought to be due to a congenital partial malrotation, in which the cecum and right colon are not fixed. Sigmoid volvulus is an acquired condition, thought to be caused by progressive stretching and redundancy of the sigmoid colon, which then twists on its narrow mesentery.

### **What Are the Risk Factors for Sigmoid Volvulus?**

Factors that lead to stretching and redundancy of the sigmoid include anticholinergic drugs (which impair motility), neurologic and psychiatric diseases (likely due to chronic constipation with stool retention), cystic fibrosis, Chagas' disease, and high fiber diet. Such a diet tends to create large, bulky stools that stretch out the sigmoid colon. Sigmoid volvulus is seen

more commonly in regions that are part of the so-called volvulus belt which includes Brazil, sub-Saharan Africa, and the Middle East, where diets are high in vegetables and fruits.

### **What Is Meant by the Term Complicated Volvulus?**

Complicated volvulus implies that there are bowel ischemia and its sequelae, such as gangrenous bowel and sepsis. This can be recognized on history and physical by the following: severe diffuse abdominal pain, fever, tachycardia, altered mental status, marked tenderness to palpation with peritoneal signs, and laboratory evidence of infection. The distinction between uncomplicated and complicated volvulus is important as it has therapeutic implications (see below).

---

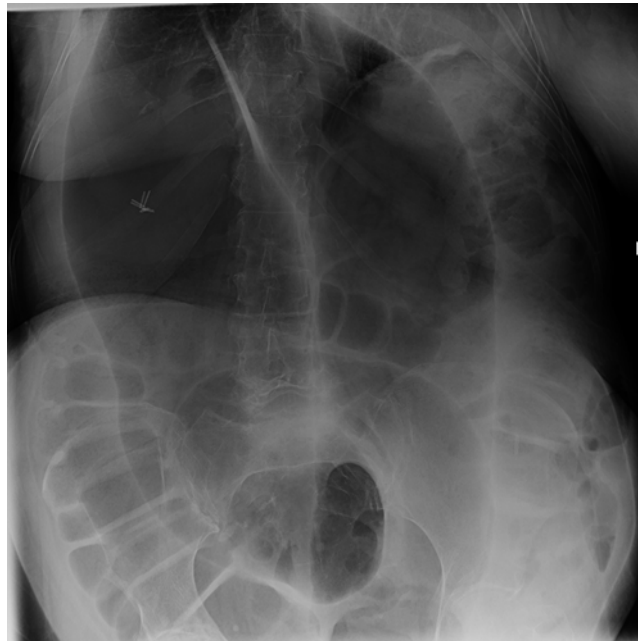## **Work-Up**

### **What Are the First Steps in the Work-Up of a Suspected Large Bowel Obstruction?**

The first steps are to obtain laboratory values and to include CBC, serum lactate, and serum chemistries to determine electrolyte abnormalities and the presence of dehydration. Leukocytosis (with a left shift) and lactic acidosis are concerning for the presence of bowel obstruction with ischemia, or complicated volvulus. In addition, the physical exam should evaluate for peritoneal signs, such as rebound or rigidity, indicative of an acute abdomen.

### **What Is the First Imaging Recommended for a Suspected Large Bowel Obstruction?**

Plain abdominal (supine and upright) and upright chest radiographs (to look for free air under the diaphragm) should be obtained. Plain abdominal X-rays can generally distinguish between an SBO (dilated loops of small bowel with multiple air fluid levels) and an LBO. Because cecal volvulus involves the proximal colon, these patients are more likely to have small bowel distention on X-ray. Figure 22.1 demonstrates the classic x-ray finding of a “coffee-bean” sign for sigmoid volvulus.



**Fig. 22.1** Abdominal x-ray showing the “coffee-bean” or “bent-inner tube” sign of sigmoid volvulus

### **What Additional Imaging Is Recommended?**

If the plain films are diagnostic of a volvulus, no further imaging is necessary. CT with oral and IV contrast is recommended if the diagnosis of large bowel obstruction is unclear. For volvulus it often demonstrates a “whirl” sign indicative of mesenteric twisting and dilated colon. CT has nearly 95 % sensitivity for detecting volvulus. CT may also be useful in assessing for other potential diagnoses, such as neoplasm, diverticular disease, and hernias. An alternative imaging modality is the contrast enema (provided there is no concern for perforation), which demonstrates a “bird’s beak” or “ace of spades” sign of narrowing at the point of obstruction. A contrast enema may also be therapeutic, in that it can sometimes untwist the volvulus.

---

## **Management**

### **What Are the Initial Steps in the Management of a Large Bowel Obstruction at Any Anatomic Location?**

Most patients with a large bowel obstruction require IV fluid resuscitation with placement of a Foley catheter to monitor urine output. A nasogastric tube may be placed for symptomatic relief in the vomiting patient.

### **What Is the Subsequent Treatment for a Sigmoid Volvulus?**

In uncomplicated sigmoid volvulus, the initial treatment of choice is to attempt an untwisting (detorsion) of the volvulus via endoscopy. Flexible sigmoidoscopy, rigid proctoscopy, and colonoscopy are all reasonable therapeutic options; the endoscope is advanced to the point of obstruction and then gradually advanced through the closed loop, decompressing it with an ensuing rush of gas and fecal contents. Care is then taken to inspect the mucosa for any signs of ischemia before removing the endoscope. Contrast enema is another therapeutic option in reducing the volvulus, but does not offer the benefit of allowing mucosal inspection. If detorsion fails, the patient must undergo urgent surgery.

### **Following Successful Detorsion of Uncomplicated Sigmoid Volvulus, What Is the Next Step in the Management?**

The recurrence rate after endoscopic detorsion of sigmoid volvulus is quite high. Thus in most cases, the patient will be scheduled for semi-elective sigmoid resection with or without primary anastomosis. The advantage of first performing endoscopic detorsion is that it addresses the acute problem, allowing for surgery to be performed less urgently, after fluid resuscitation and optimization of surgical risk factors. It also may prevent the need for a colostomy, as the ends of the colon can be anastomosed primarily. Some evidence suggests that elderly patients with significant comorbidities who are poor candidates for surgery may be managed nonoperatively.

### **How Is Complicated Sigmoid Volvulus Managed?**

Complicated sigmoid volvulus implies clinical suspicion for colonic ischemia and/or perforation, and as such, the colon needs to be resected. Thus endoscopic detorsion and contrast enemas should not be attempted. Intraoperatively, if the volvulized bowel is confirmed to be ischemic, it should not be detorsed but instead resected to prevent entry of bacteria and toxins into the systemic circulation. The colon is resected to viable margins. The proximal end of the colon is brought out as a colostomy.

### **What Is the Treatment for a Cecal Volvulus?**

Cecal volvulus is associated with a higher rate of bowel necrosis, failure of endoscopic detorsion, and recurrence. Thus attempted endoscopic detorsion is generally not recommended, and surgery is considered the first-line treatment for cecal volvulus (right colectomy with a primary anastomosis).



## What Factors Determine Outcomes of Volvulus?

The primary determinant of outcome is whether the volvulus is complicated or uncomplicated. Colonic ischemia and/or gangrene can precipitate septic shock with a high mortality rate.

---

## Area Where You Can Get in Trouble

### LBO in Pregnancy

LBO may not be readily recognized in pregnant patients, yet colonic volvulus is the second most common cause of intestinal obstruction in pregnancy (after SBO due to adhesions). Detorsion is indicated, but resection may be delayed until after delivery to improve surgical risk for the fetus and mother, especially given that most cases occur in the third trimester and thus may not result in a significant delay.

### Underestimating the Risks of Ogilvie's Syndrome

Although Ogilvie's syndrome is not a true mechanical obstruction, it can lead to progressive colonic dilatation and perforation. Thus once diagnosed, prompt management with neostigmine and/or colonic decompression should be instituted.

---

## Area of Controversy

### Percutaneous Endoscopic Colostomy Tubes

A less invasive and newly emerging treatment is the placement of two percutaneous endoscopic colostomy (PEC) tubes, similar in concept to the percutaneous endoscopic gastrostomy (PEG). Placing two tubes may provide adequate fixation to prevent recurrence until abdominal-colonic adhesions have time to form. However, this is not routinely performed in most centers.

---

## Summary of Essentials

### History and Physical

- LBO – gradual and severe abdominal distention, obstipation, and vomiting
- Uncomplicated volvulus – normal vitals, normal mental status, and non-tender abdomen
- Complicated volvulus – severe abdominal pain, fever, tachycardia, toxic appearance, peritoneal signs, and leukocytosis
- Look for abdominal scars and hernias and perform a rectal exam to assess other differential diagnoses

### Etiology/Risk Factors

- Most common causes of LBO
  - Cancer
  - Diverticulitis
  - Volvulus
- Sigmoid volvulus – acquired stretching of the sigmoid
  - Neuropsychiatric disease, institutionalization, chronic constipation, long-term anticholinergic use, high fiber diet, and pregnancy
- Cecal volvulus – congenital failure of fixation of the cecum

## Diagnosis

- Compared to LBO, SBO has faster onset and more likely to cause vomiting and high-pitched bowel sounds
- Patients with Ogilvie's syndrome are more likely to be already hospitalized and bedridden, often in the postoperative setting
- Abdominal X-ray
  - Sigmoid volvulus – “coffee”, “omega”, or “bent inner tube”, “kidney-bean” sign
  - Cecal volvulus – “comma” or “kidney bean” sign
- CT scan if equivocal X-ray findings
- Contrast enema may be diagnostic (“bird’s beak” sign) and therapeutic in reducing the volvulus
  - Water-soluble contrast (Gastrografin) rather than barium, to avoid peritonitis and scarring in case of perforation and barium leak
  - Bowel wall thickening, mesenteric edema, pneumatosis, and portal venous gas suggest ischemic bowel

## Management

- Therapy differs based on the location and severity of complication
  - Uncomplicated sigmoid volvulus – endoscopic detorsion followed by semi-elective resection
  - Complicated sigmoid volvulus – no detorsion attempted; emergent laparotomy with resection
  - Cecal volvulus – no detorsion attempted; take to OR for right colectomy
- Complications of surgery – wound infection, anastomotic leak, and recurrence. Without detorsion or resection – ischemia, perforation, and sepsis

---

## Suggested Reading

Arnell TD. Core subjects: colonic volvulus. *Am Soc Colon Rectal Surg*. 2002.

Dayton MT, Isenberg GA, Rakinic J, Thomas JS, Trudel JL. Colon, rectum, and anus. In: Lawrence PF, editor. *Essentials of general surgery*. 5th ed. Baltimore: Lipincott, Williams and Wilkins; 2013. p. 313–4.

Glasgow SC. Core subjects: colonic volvulus. *Am Soc Colon Rectal Surg*. 2012.

Schroepfel TJ, Fabian TC. The Colon. In: Gracias VH, Reilly PM, McKenney MG, Velhams GC, editors. *Acute care surgery: a guide for general surgeons*. 1st ed. New York: McGraw-Hill Inc; 2008. p. 82–5.

Paul N. Frank, Christian de Virgilio, and Tracey D. Arnell

A 55-year-old obese female presents with a 2-day history of left lower quadrant pain, nausea, anorexia, and low-grade fevers. The patient states that the pain is constant, moderately severe, and does not radiate anywhere. She does not recall anything that precipitated the pain. She has not eaten in 24 hours as she is not hungry. She has had no bowel movement for 48 hours. She denies vomiting and bloody or black stools and has no recent change in bowel habits, though she says she's been constipated most of her life. She has noted similar pain in the past, but never this severe, and has never sought medical attention before. She has never had a screening colonoscopy. Past history is significant for hypertension and diabetes. She has no prior surgery. On physical examination, her blood pressure is 130/70 mmHg, heart rate 110/min, temperature is 101.5 °F, and respiratory rate is 16/min. Abdominal exam reveals mild distention, no surgical scars, and no masses. Bowel sounds are absent. The left lower quadrant is moderately tender to palpation with guarding and no rebound tenderness. The remainder of the abdomen is nontender. Rectal exam is unremarkable. Pelvic exam reveals no cervical motion tenderness and no adnexal masses. Laboratory exam demonstrates a WBC of  $16 \times 10^3/\mu\text{L}$  (normal  $4.1 - 10.9 \times 10^3/\mu\text{L}$ ) with a left shift, Hgb of 13 g/dL (12–15 g/dL) and Hct of 39 % (35–46 %), normal electrolytes, and normal urinalysis.

## Diagnosis

### What is the differential diagnosis?

Condition	Comments
<i>Acute gastroenteritis</i>	Viral infection of the intestine; often presents with nausea and vomiting; diffuse abdominal pain; sometimes febrile
<i>Acute diverticulitis</i>	Inflammation of diverticula; most commonly in the sigmoid colon; LLQ pain; usually febrile
<i>Pelvic inflammatory disease</i>	Cervical motion/adnexal tenderness, foul-smelling vaginal discharge, sexually transmitted, most are premenopausal
<i>Acute appendicitis</i>	RLQ pain, fever, anorexia
<i>Sigmoid volvulus</i>	Twisting of the sigmoid colon around its mesentery; more common in elderly patients; presents as large bowel obstruction
<i>Ischemic colitis</i>	Hypoperfusion causes mucosal ischemia, most often to the splenic flexure of colon, usually self-limited, bloody diarrhea
<i>Acute mesenteric ischemia</i>	Sudden onset of severe diffuse abdominal pain out of proportion to examination, acute occlusion of SMA, ischemia to the entire small bowel, usually requires urgent surgery
<i>Inflammatory bowel disease</i>	History of abdominal cramps, bloody diarrhea, acute abdominal pain
<i>Colon cancer</i>	Change in bowel habits, weight loss, blood in stool

SMA superior mesenteric artery

P.N. Frank, MD (✉)

Department of Surgery, Harbor-UCLA Medical Center, 1000 W. Carson Street, Torrance, CA 90509, USA

e-mail: [PaulFrank521@gmail.com](mailto:PaulFrank521@gmail.com)

C. de Virgilio, MD

Department of Surgery, Harbor-UCLA Medical Center, 1000 W. Carson Street, Torrance, CA 90509, USA

e-mail: [cdevirgilio@labiomed.org](mailto:cdevirgilio@labiomed.org)

T.D. Arnell, MD

Surgery Department, New York Presbyterian Columbia University, 177 Fort Washington, Suite 7-133, New York, NY 10032, USA

e-mail: [ta2107@columbia.edu](mailto:ta2107@columbia.edu)

## What Is the Most Likely Diagnosis?

Given the patient's left lower quadrant (LLQ) pain and tenderness on exam, associated fever and leukocytosis, acute diverticulitis is the most likely diagnosis.

## History and Physical

### What Are the Risk Factors for Diverticulosis?

Obesity, diet low in fiber and high in fat and red meat, and advanced age are risk factors for the formation of diverticulosis.

## Etiology/Pathology/Pathophysiology

### Where in the Colon Do Diverticula Occur Most Frequently? Which Diverticula Are More Prone to Infection? Bleeding?

The vast majority of diverticula occur in the sigmoid colon. Diverticula in the left or sigmoid colon are more likely to become infected. Diverticula in the right colon are more likely to bleed.

### Do Diverticula Occur in the Rectum? Why/Why Not?

Rectal diverticula are extremely rare. It is hypothesized that they almost never occur because the taenia coli, the longitudinal bands of smooth muscle along the colon, coalesce into a circumferential band around the rectum, thereby eliminating points of weakness that precede a diverticulum.

### What Are True and False Diverticula? Are Sigmoid Diverticula True or False Diverticula?

There are three primary layers of the intestinal wall: the mucosa, submucosa, and muscularis. In a true diverticulum, all layers are part of an outpouching of the intestine. In a false diverticulum (such as sigmoid diverticula), only the mucosa and submucosa are part of the outpouching.

### What Are the Main Complications of Diverticulitis? How Would They Present?

Complication	Presentation
<i>Abscess</i>	Fever, localized pain, ileus, leukocytosis
<i>Perforation</i>	May seal spontaneously via the omentum (microperforation); can progress to purulent or feculent peritonitis (free perforation); diffuse abdominal tenderness, ileus, leukocytosis, fever
<i>Fistula</i>	Colovesical (refractory UTI, pneumaturia, fecaluria); colovaginal (feculent vaginal discharge)
<i>Stricture</i>	Partial large bowel obstruction; abdominal distention
<i>Large bowel obstruction</i>	Feculent vomiting, abdominal distention, obstipation

### What Are the Main Etiologies for a Colovesical Fistula?

Diverticulitis (most common), colon cancer, inflammatory bowel disease, bladder cancer, radiation injury, trauma, or foreign body.

**Watch Out**

When considering the etiology of fistulas and why fistulas do not close, think of “FRIEND” (F, foreign body; R, radiation; I, inflammation/infection; E, epithelialization; N, neoplasm; D, distal obstruction).

**How Does a Colovesical Fistula Present?**

Patients with colovesical fistula may present in a dramatic fashion with fecaluria (feces in the urine), pneumaturia (air in the urine), recurrent UTIs that are refractory to treatment, or by a UTI caused by multiple enteric organisms or anaerobes (most UTIs are single organism and aerobes).

**What Is Meant by Complicated Versus Uncomplicated Diverticulitis? What Is the Implication?**

Diverticulitis that occurs with abscess formation, colonic obstruction, diffuse peritonitis, or fistulization is considered complicated diverticulitis, whereas diverticulitis without these sequelae is known as uncomplicated diverticulitis.

**What Is the Hinchey Staging System?**

This is a grading schema to describe the severity of complicated diverticulitis.

**Why Might Sigmoid Diverticulitis Present with Right Lower Quadrant Pain?**

Some patients have an especially long, or redundant, sigmoid colon, which may be located in the right side of the abdomen. Hence, sigmoid diverticulitis in this region will cause RLQ pain.

---

**Diagnosis****How Is the Diagnosis of Diverticulitis Made?**

Diverticulitis is a clinical diagnosis.

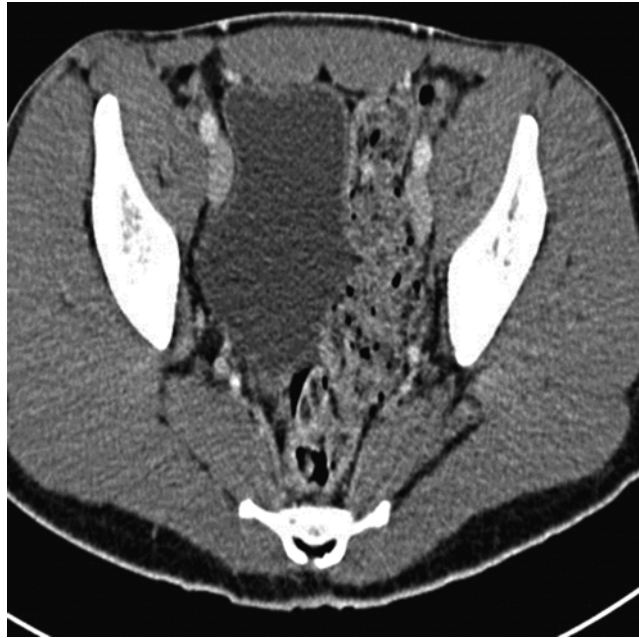---

**Work-Up****What Imaging Is Recommended?**

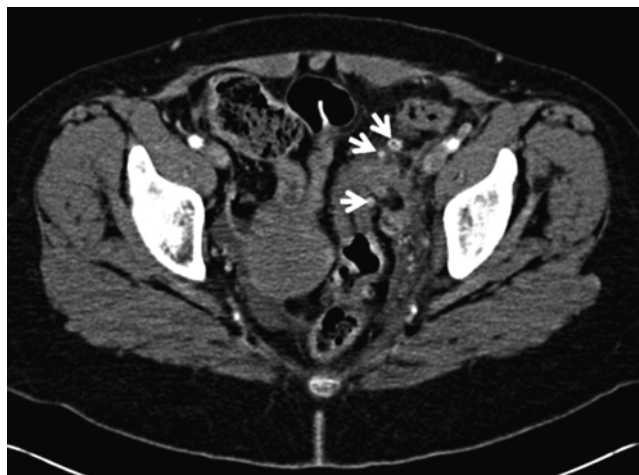CT scan (Figs. 23.1 and 23.2) is recommended.

**What Two Diagnostic Studies Are Contraindicated in the Acute Setting of Suspected Diverticulitis and Why?**

Barium enema and colonoscopy are contraindicated because, in an inflamed colon, there is increased risk of new perforation or exacerbation of existing perforation.



**Fig. 23.1** Axial CT of the pelvis showing a normal sigmoid colon with thin walls and filled with stool. There are no diverticula



**Fig. 23.2** Axial CT of the pelvis demonstrating sigmoid diverticula with significant wall thickening of the sigmoid colon, consistent with acute sigmoid diverticulitis. *White arrows: diverticula*

## Management

### What Is the First Step in the Management of Suspected Acute Diverticulitis?

Determine if the patient has complicated or uncomplicated diverticulitis and whether the patient demonstrates evidence of SIRS. To meet SIRS criteria, they must meet at least two of the following:

- $T > 100.4\text{ }^{\circ}\text{F}$  or  $T < 96.8\text{ }^{\circ}\text{F}$
- $\text{HR} > 90\text{ bpm}$
- Respiratory rate  $> 20\text{ breaths/min}$  or  $\text{PaCO}_2 < 32\text{ mmHg}$
- $\text{WBC} > 12,000/\text{mm}^2$  or  $\text{WBC} < 4,000/\text{mm}^2$  or  $> 10\%$  band forms

If the episode of diverticulitis is uncomplicated and without evidence of SIRS, the patient can be discharged home with oral antibiotics and clear liquids. Patients with acute diverticulitis who meet criteria for SIRS should be admitted to the hospital, placed NPO, and given IV antibiotics, fluids, and analgesia.

### **What Is the Subsequent Management for Uncomplicated Diverticulitis?**

The majority will resolve with the approach described above, without the need for surgery, and will not have another episode. The patient is discharged with dietary modification. If the patient fails to improve while hospitalized (persistent abdominal pain and tenderness, ongoing SIRS), the options are to either repeat the CT scan to look for an abscess that might require drainage or to take the patient to the operating room for a colon resection.

### **Management of Uncomplicated Diverticulitis**

<b>Clinical scenario</b>	<b>Management</b>
Uncomplicated diverticulitis (no SIRS)	No admission, oral antibiotics × 7–10 days, and clear liquids × 2–3 days
Uncomplicated diverticulitis with SIRS	Admit, IV antibiotics, NPO
Uncomplicated diverticulitis that fails to improve with IV antibiotics	Urgent colectomy with end colostomy

### **Following the Resolution of an Episode of Diverticulitis, What Intervention Is Essential 6–8 Weeks After Hospital Discharge?**

Since diverticulitis is a clinical diagnosis, other diagnoses can be confused with diverticulitis, specifically inflammatory bowel disease and colon cancer. As such, colonoscopy is recommended after the inflammation has subsided to rule out these diagnoses.

## **Complicated Diverticulitis**

### **What Is the Management of Complicated Diverticulitis?**

Depending on the specific complication, the recommendation is either urgent surgery, CT-guided drainage, or delayed surgery.

### **What Are the Indications for Urgent Surgery? What Operation Is Recommended in the Urgent Setting?**

Patients with evidence of diffuse peritonitis as a result of free colonic perforation should undergo urgent surgery. In this setting, the diseased colon is removed and an end colostomy is performed with the distal rectum closed and left in the abdomen. After the inflammation of acute diverticulitis resolves (in about 12 weeks), the end colostomy may be reversed and reattached to the rectum.

### **How Does One Determine the Proximal and Distal Extent of Colon Resection? What If There Are Diverticula Throughout the Colon?**

The proximal margin of resection should be proximal to the diseased colon, as evidenced by wall thickening and scarring, but it is not necessary to resect all diverticula-containing colon if it is not inflamed. The distal segment of resection should be to the start of the rectum, identified by the absence of distinct taenia coli.

## What Is the Recommended Treatment for Diverticulitis Complicated by a Localized Abscess?

Patients with a pericolic abscess with diameter less than 4 cm and without peritoneal signs can be treated with bowel rest and broad-spectrum antibiotics. If the abscess is larger than 4 cm, and they only have localized tenderness, CT-guided percutaneous drainage is indicated, as this will facilitate resolution of acute inflammation, which may allow for a one-stage surgical resection of the affected bowel (remember, there is an abscess, so this is complicated diverticulitis) at a later date.

## What Is the Recommended Treatment for Diverticulitis with a Colovesical Fistula?

The affected segment of the colon should be resected electively, and the bladder should be repaired. A Foley catheter will often be left in place postoperatively for a brief time. In poor surgical candidates, medical management with antibiotic therapy may be considered.

## Is the Presence of Free Air on CT an Absolute Indication for Urgent Surgery?

No. It has been shown that patients with acute diverticulitis with free intraperitoneal air, thereby meeting criteria for complicated diverticulitis, can be treated effectively with supportive care and possible percutaneous abscess drainage. These patients may undergo sigmoid colectomy at a later date.

## Management of Complicated Diverticulitis

Complication	Management
Free perforation with diffuse peritonitis	Emergent colectomy with end colostomy
Large bowel obstruction	Urgent colectomy with end colostomy
Large ( $\geq 4$ cm) localized abscess	CT-guided drainage followed by elective colon resection
Small ( $< 4$ cm) localized abscess	IV antibiotics followed by elective colon resection
Colovesical fistula	IV antibiotics followed by elective bladder repair and colon resection

## What Operation Is Performed in the Elective Setting for Sigmoid Diverticulitis? How Is This Operation Different Than Surgery in the Urgent or Emergent Setting?

In the elective setting, patients may undergo a one-step procedure wherein the diseased colon is resected and the proximal and distal segments are connected to one another. This is known as primary anastomosis. In the emergent or urgent setting, resection of the diseased colon without an anastomosis (resulting in a temporary end colostomy) is performed. At a later time, the proximal and distal ends of the remaining colon can be anastomosed.

## Areas of Controversy

### How Many Episodes of Uncomplicated Diverticulitis Are Acceptable Before Elective Surgery Is Recommended?

Most studies show that the rate of recurrence after diverticulitis is 10–30 %. There is currently no strict number of episodes of diverticulitis before surgery is recommended. Therefore, even patients with repeated episodes of uncomplicated diverticulitis may be managed medically as long as treatment remains effective.



---

## Benefit of Bowel Prep Before Elective Colon Surgery

It has long been believed that mechanical bowel prep (one or more laxatives) will reduce colonic bacterial burden and thus reduce the risk of infection. However, it has been shown that mechanical bowel prep alone does not reduce surgical site infections. Recent literature supports oral antibiotic bowel preparation along with systemic preoperative antibiotics.

---

## Areas Where You Can Get in Trouble

### Not Identifying the Ureter During Sigmoid Colon Resection

The ureters are retroperitoneal structures and are at risk of damage or complete transection during colonic resection if not identified and retracted.

---

## Summary of Essentials

### History and Physical

- Major risk factors are obesity, advanced age, and diet low in fiber, high in fat, and high in red meat
- Diverticulitis is a clinical diagnosis (LLQ pain and tenderness, fever, leukocytosis)

### Pathophysiology

- The sigmoid colon is the most common site
- Complicated diverticulitis: abscess, free perforation, fistula, stricture, and obstruction

### Diagnosis

- CT scan is the first-line imaging modality
- Avoid barium enema and colonoscopy in acute presentation because of increased risk of perforation
- Determine if complicated or uncomplicated
- Presence or absence of SIRS

### Management

- Uncomplicated diverticulitis without SIRS
  - Treated as outpatient
  - Oral antibiotics and clear liquids
- Uncomplicated diverticulitis with SIRS
  - Admit to hospital
  - NPO, IV fluids, IV antibiotics, and analgesia
  - Follow up with colonoscopy 4–6 weeks after acute episode to rule out malignancy and Inflammatory Bowel Disease
- Complicated diverticulitis usually requires surgery
  - Resect the affected colon and construct end colostomy if urgent
  - Sigmoid colectomy with primary anastomosis if not urgent

## Suggested Reading

- Costi R, Le Cauchy F, Bian A, et al. Challenging a classic myth: pneumoperitoneum associated with acute diverticulitis is not an indication for open or laparoscopic emergency surgery in hemodynamically stable patients. A 10-year experience with a nonoperative treatment. *Surg Endosc.* 2012;26(7):2061–71.
- Glebo BT. Elective surgical treatment of diverticulitis. *Clin Colon Rectal Surg.* 2004;17(3):183–6.
- Jacobs DO. Diverticulitis. *N Engl J Med.* 2007;357:2057–66.
- Kumar AS, Kelleher DC, Sigle GQ. Bowel preparation before elective surgery. *Clin Colon Rectal Surg.* 2013;26(03):146–52.
- Maykel JA, Opelka FG. Colonic diverticulosis and diverticular hemorrhage. *Clin Colon Rectal Surg.* 2004;17(3):195–204.

---

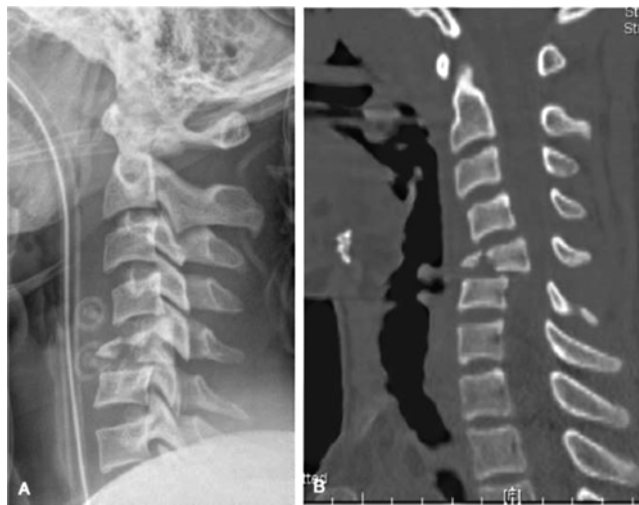**Part VIII**

**Neurosurgery**

Christian de Virgilio, Section Editor

Jose Manuel Sarmiento, Debraj Mukherjee,  
and Chirag G. Patil

A 25-year-old man was snowboarding down a slope and attempted to perform a trick off a ramp. He miscalculated the jump and landed directly on his head, without a helmet. He denied a loss of consciousness but immediately had difficulty moving his arms and legs. The ambulance crew placed him supine on a board with a hard cervical collar and blocks. In the emergency department, he is alert and oriented to person, place, and time, but he complains of severe neck pain. His heart rate is 80/min, blood pressure is 130/85 mmHg, respiratory rate is 13/min, and temperature is 97.8° F. He has 2/5 strength in his upper and lower extremities. He reports decreased sensation to pinprick and cold packs in all extremities but has preserved sensation to deep touch and pressure throughout the body. He has nonsustained clonus and brisk reflexes in his biceps, brachioradialis, triceps, patellar tendons, and Achilles tendons. His big toe points upwards with all other toes fanning out when the sole of his foot is stimulated with a blunt instrument. Rectal examination reveals preserved anal tone. His imaging is shown below (Fig. 24.1).



**Fig. 24.1** (a) Lateral radiograph and (b) computed tomographic scan (Reprinted from Youmans Neurological Surgery, Vollmer DG, Eichler ME, Jenkins III, AL, Assessment of the cervical spine after trauma, pp. 3166–3179. Copyright 2011, with permission from Elsevier)

J.M. Sarmiento, MD, MPH (✉)

Department of Neurosurgery, Cedars-Sinai Medical Center, Maxine Dunitz Neurosurgical Institute, 127 South San Vicente Boulevard, Suite A6600, Los Angeles, CA 90048, USA  
e-mail: [J.Manuel.Sarmiento@cshs.org](mailto:J.Manuel.Sarmiento@cshs.org)

D. Mukherjee, MD, MPH

Department of Neurosurgery, Cedars-Sinai Medical Center, Maxine Dunitz Neurosurgical Institute, 127 South San Vicente Boulevard, Suite A6600, Los Angeles, CA 90048, USA  
e-mail: [debraj.mukherjee@cshs.org](mailto:debraj.mukherjee@cshs.org)

C.G. Patil, MD, MS

Department of Neurosurgery, Cedars-Sinai Medical Center, Maxine Dunitz Neurosurgical Institute, 127 South San Vicente Boulevard, Suite A6600, Los Angeles, CA 90048, USA  
e-mail: [Chirag.Patil@cshs.org](mailto:Chirag.Patil@cshs.org)

## Diagnosis

### What is the Differential Diagnosis for Cervical Spine Injury? What Clues on History and Physical Examination Might Direct you Towards a Specific Diagnosis?

Diagnosis	History and physical
<i>Complete spinal cord injury</i>	Complete loss of motor and sensory function below level of lesion, including in the perineal and anal regions
<i>Brown-Sequard syndrome</i>	Ipsilateral motor weakness with associated upper motor neuron signs (spasticity, hyperreflexia, clonus, and positive Babinski's sign) and touch/proprioception loss below the level of the injury; also contralateral loss of pain and temperature sensation beginning one or two dermatome levels below the level of the injury
<i>Central cord syndrome</i>	Weakness and loss of sensory function in the upper extremity and proximal leg muscles; distal lower extremities are typically spared
<i>Anterior spinal artery syndrome</i>	Paraplegia and loss of pain and temperature sensation; the posterior columns are unaffected, leading to preserved deep touch/pressure, vibration, and proprioception

### What Is the Most Likely Diagnosis?

Anterior spinal artery syndrome due to burst fracture dislocation at C5. This is an incomplete spinal cord injury because the patient has some motor and sensory function in his extremities, as well as preserved anal tone. The patient's pertinent neurological examination findings (e.g., bilateral loss of motor, pain and temperature with preserved deep touch, and pressure throughout the body) are consistent with an anterior cord syndrome with associated myelopathic signs. Radiographic studies show evidence of a burst fracture at the C5 level. Additionally, he has signs of upper motor neuron dysfunction (Babinski's sign). The patient does not show evidence of spinal shock (no flaccid paralysis in extremities & reflexes are present) or neurogenic shock (no hypotension or bradycardia).

## History and Physical

### What Are the Most Common Cervical Spinal Levels Involved After Trauma?

The most common level of cervical vertebral fracture is C2 (approximately 1/3 of all C2 fractures are odontoid fractures) followed by C6 and C7. The most common level of subluxation injury is the C5–6 interspace, which is the area of greatest flexion and extension in the cervical spine.

### What Dermatome Level Supplies the Shoulders? What Must You Remember About the Dermatome Map When Testing Sensation on the Chest?

The shoulders are supplied by C4 (Table 24.1). When testing sensation on the chest, remember that there is a skip from C4 to T2, with C5 through T1 represented in the upper extremities.

#### Watch Out

A dermatome is a sensory region of the skin innervated by a nerve root.

**Table 24.1** Common dermatomal levels

Anatomical site	Dermatomal level
Shoulders	C4
Nipples	T4
Umbilicus	T10
Knees	L4
Perianal region	S4–S5

**Table 24.2** Deep tendon reflexes

Reflex	Involved nerve root(s)
Biceps	C5/C6
Brachioradialis	C6
Triceps	C7
Patellar tendon (knee jerk)	L4
Achilles tendon (ankle jerk)	S1

### Why Is It Important to Check Deep Tendon Reflexes?

Patients with injured nerve roots can have abnormal deep tendon reflexes (Table 24.2). Some patients with acute spinal cord injuries may initially have completely blunted reflexes during the acute stage of spinal shock but later develop hyperactive and brisk reflexes as the inhibitory forces from upper motor neurons are lifted.

### How Are Deep Tendon Reflexes Graded?

These are graded as 0 to 4+ with 2+ being normal. 0 is no response while 1+ is a sluggish one. A reflex that is more brisk than usual is 3+ and those with a clonus present are 4+.

### Clinically, What Is the Difference Between a Complete and Incomplete Spinal Cord Injury?

Patients with complete spinal cord injuries have no motor and sensory function below the level of injury. Patients with incomplete spinal cord injuries have some residual function below the level of injury.

### What Are the Devastating Clinical Examination Findings in Patients with Complete Spinal Cord Injury in the High Cervical Cord (at or Above C3)?

Inability to breathe due to diaphragmatic paralysis, as well as paralysis of all four limbs.

### What Is the Term for Sensory or Motor Dysfunction Caused by Pathology of a Nerve Root? What Are the Clinical Signs and Symptoms Associated with This Disorder?

Radiculopathy. The main symptom associated with radiculopathy is a burning, tingling pain that radiates down the limb. Clinical signs of radiculopathy include lower motor neuron signs such as loss of reflexes, weakness, and diminished sensation along dermatomal distributions.

### What Is the Term for Sensory or Motor Dysfunction Caused by Pathology of the Spinal Cord? What Are the Clinical Signs and Symptoms Associated with This Disorder?

Myelopathy. Patients experience intermittent neck pain that radiates into the shoulders or occiput. Clinical findings of myelopathy result from a spinal cord injury and include bilateral upper motor neuron signs (Table 24.3) such as diffuse hyper-reflexia, weakness and numbness in the extremities, and upward going toes (Babinski's sign).

#### Watch Out

Babinski's sign can be a normal finding in infants as old as age 2.

**Table 24.3** Upper motor neuron (UMN) and lower motor neuron (LMN) signs

Sign	UMN lesion	LMN lesion
Weakness	Yes	Yes
Fasciculations	No	Yes
Atrophy	No	Yes
Tone	Increased	Decreased
Reflexes	Increased	Decreased
Babinski's sign (plantar reflex)	Yes	No
Hoffmann's sign	Yes	No
Clonus	Yes	No

## Pathophysiology

### What Is Spinal Shock?

Spinal shock is a temporary, concussive-like syndrome associated with flaccid paralysis below the level of injury with loss of all reflexes, as well as urinary and rectal tone.

### In the Context of Trauma, Why Are Thoracic Spine Injuries Less Common Than Cervical Spine Injuries?

Thoracic vertebrae are more stable due to high facets and ribs that decrease motion. They also have more canal space because the thoracic spinal cord does not have anterior enlargements (as opposed to the cervical and lumbar spinal levels).

### What Is Sacral Sparing? What Is Its Significance in the Setting of Spinal Shock?

Sacral sparing refers to the sparing of function at the sacral nerve level, such as intact anal sphincter, or perianal sensation. When there is sacral sparing in a patient with spinal shock, the chance of functional neurological recovery is better compared to a situation where the sacral roots are affected.

### What Are the Common Mechanisms for Neck Injuries?

Flexion, extension, axial loading (vertical compression), and rotational injuries

### What Is Atlanto-Occipital Dislocation?

This occurs when the superior facets of the atlas vertebra lose its articulation with the occipital condyles at the base of the skull, resulting from ligamentous disruption between the occiput and the cervical spine.

#### Watch Out

Atlanto-occipital dislocation is the most unstable and dangerous injury of the cervical spine. Severe neurological morbidity and mortality are due to high cervical cord injury that can lead to quadriplegia and diaphragm paralysis. Patients with trisomy 21 are at a particularly higher risk for this injury and should always be screened prior to participating in any sports (e.g., Special Olympics).

## What is the Pathophysiology of the Three Most Common Incomplete Spinal Cord Injuries?

Syndrome	Comments
<i>Brown-Sequard syndrome</i>	Hemisection of the spinal cord, usually from penetrating trauma such as a gunshot or a stabbing, causing injury to the corticospinal tract (motor), posterior columns (proprioception, deep touch/pressure), and spinothalamic tracts (pain and temperature)
<i>Anterior cord syndrome</i>	Damage to the anterior two-thirds of the spinal cord classically due to severe flexion injury; this area receives its blood supply from the anterior spinal artery; the corticospinal and lateral spinothalamic tracts are affected bilaterally
<i>Central cord syndrome</i>	Damage to the central portion of the spinal cord classically associated with severe extension injury; patients who present with central cord syndrome are often elderly and have preexisting cervical stenosis

## Why Are the Distal Lower Extremities Typically Spared in Central Cord Syndrome?

This reflects the unique topographical organization of the spinal cord in which upper extremity motor function is represented at the medial aspects of the cord, while lower extremity motor function is represented at the lateral aspects of the cord. Thus motor function and sensation in the distal lower extremities are spared.

## Which Incomplete Cord Syndrome Carries the Best Prognosis for Recovery of Neurological Function, Bowel and Bladder Function, and Ambulatory Capacity?

Brown-Sequard syndrome

## Which Incomplete Cord Syndrome Carries the Worst Prognosis for Functional Recovery?

Anterior cord syndrome (about 10 % recover to ambulation).

---

## Work-Up

### How Do You Diagnose Spinal Cord Injuries and Cervical Vertebral Fractures?

Spinal cord injuries may be diagnosed with a thorough history and neurological examination. The diagnosis may be confirmed with the help of radiographic imaging modalities such as X-ray, CT scan, and MRI scan.

### What Are the NEXUS Criteria?

This is a validated decision rule to determine which adult patients need spine radiographs. Cervical spine radiographs are indicated for patients with trauma unless they have one of the disqualifying criteria, which can be remembered by the *NSAID* mnemonic.

- Neurologic deficit
- Spinal tenderness
- Altered mental status
- Intoxicated
- Distracting injury



## What Type of Radiographs Should Be Obtained?

Three X-ray views should be obtained to view the cervical spine: anteroposterior (AP), lateral, and open-mouth (odontoid).

## What Is the Indication for Ordering a CT Scan of the Cervical Spine?

Areas identified as possible pathology on the plain radiographs should be further investigated with CT imaging. A CT is useful for detecting vertebral fractures and identifying hematomas or disk fragments within the spinal canal. A CT scan is also required for the clearance of the cervical spine in comatose or obtunded patients and is useful in operative planning.

## What Is the Indication for Ordering an MRI Scan of the Cervical Spine?

An MRI scan is useful to detect injury to the spinal cord itself in patients with neurological deficits. MRI scans can show areas of contusion and edema within the spinal space and identify rupture of intervertebral disks and ligamentous injury. Furthermore, hematomas within the spinal canal will not be identified with radiographs and may occasionally be missed on CT, but are readily identified on MRI. Finally, MRI is typically the only imaging modality that detects abnormalities in patients with SCIWORA (see below).

## What Is SCIWORA?

*Spinal Cord Injury Without Radiographic Abnormalities*. Children and young adults are more susceptible to SCIWORA due to tearing or contusion of the spinal cord from overstretching and spinal column subluxation due to ligamentous laxity and flexibility of the developing spine. This occurs before any obvious soft tissue injury or fracture is observed in the vertebral column. SCIWORA occurs in 15–25 % of all pediatric cervical spine injuries. C2 is the most common level injured and the most common age is less than 3 years. Pediatric patients with SCIWORA may present with brief episodes of upper extremity weakness or paresthesias followed by delayed development of neurological deficits that appear hours to days later.

---

## Management

### What Are the General Treatment Principles for Patients with Cervical Spine Injury?

- Transport the patient with a rigid cervical collar on a spine board for immobilization.
- Early closed reduction with tongs or halo traction devices is recommended for awake patients with obvious subluxation on imaging causing spinal cord compression.
- Maintain blood pressure within normal limits with intravenous fluids and vasopressors (phenylephrine or dopamine) to reduce secondary injury.
- Insert a Foley catheter to monitor urinary output and prevent bladder distention in case of neurogenic urinary retention secondary to spinal cord injury. Administer stool softeners to prevent severe constipation.
- Order venous thromboembolism prophylaxis (i.e., low-molecular-weight heparin, heparin, or pneumatic compression stockings).
- Restore spinal stability by external orthoses (cervical collars, cervicothoracic devices, and halo orthosis) or surgical reduction and decompression.

### How Is Neurogenic Shock Treated?

Hypotension is treated with rapid infusion of crystalloid normal saline (0.9 % NaCl). If intravenous fluids are inadequate to maintain organ perfusion, dopamine or phenylephrine may be used. Bradycardia is treated with atropine or dopamine.

**Watch Out**

Neurogenic shock is a hemodynamic state wherein sympathetic outflow through the spinal cord has been disrupted, resulting in vasodilation, *bradycardia*, and dangerous hypotension. Spinal shock is the constellation of findings on neurological examination described previously. “Note that spinal shock and neurogenic shock are within the same continuum of spinal cord injury. Neurogenic shock is typically associated with more severe spinal cord injuries, and both neurogenic and spinal shock may be present simultaneously”.

**What Are the Goals of Management for Patients with Complete Spinal Cord Injuries or High Cervical Cord Injuries?**

Spinal stabilization to facilitate nursing and rehabilitation. Surgical decompression aims to maintain and regain function in the uppermost section of the injured cord where an incomplete injury may exist. Nonsurgical care focuses on functional rehabilitation, prevention of decubitus ulcers, bowel and bladder management, and avoidance of pneumonia and deep vein thrombosis.

**Why Is There a Lower Threshold for Surgical Intervention in Patients with Incomplete Spinal Cord Injury Versus Patients with Complete Spinal Cord Injury?**

Expedient open or closed reduction and cord decompression in patients with incomplete spinal cord injury have a higher likelihood of maintaining or regaining neurological function.

**What Are the General Indications for Emergent Surgery with Spinal Cord Injury?**

- Unstable vertebral fracture
- Non-reducible spinal cord compression with deficit
- Ligamentous injury with facet instability

**Watch Out**

Restoration of spinal stability is important to minimize the risk for secondary injury and to allow early mobilization of the patient to minimize the risks.

---

**Areas of Controversy****Steroid Therapy for Acute Spinal Cord Injury**

According to the 2013 guidelines for the management of acute cervical spine and spinal cord injuries, administration of methylprednisolone for the treatment of acute spinal cord injury is not recommended. Methylprednisolone is not FDA approved for this application, and there is no Class I or Class II evidence supporting the clinical benefit of steroids in the treatment of acute spinal cord injury.

## Areas Where You Can Get in Trouble

### Complications with the Exposure of the Anterior Cervical Spine

The most common complication of exposing the anterior cervical spine for decompressive surgery is recurrent laryngeal nerve injury. Injury to this nerve can paralyze the vocal cords and lead to a hoarse voice (unilateral nerve injury) and risk of or dyspnea (bilateral nerve injury). Patients may also have transient dysphasia and, rarely, perforation of the esophagus—a life-threatening condition due to the high risk of infection. Injuries of the carotid artery, jugular vein, and superior and inferior thyroid arteries are uncommon. Injury of the vertebral artery is a rare complication.

---

## Summary of Essentials

### History and Physical

- A thorough neurological examination is necessary for localization of spinal cord injuries
- Complete spinal cord injury: no motor and sensory function below the level of injury
- Incomplete spinal cord injury: some residual function below the level of injury
  - Brown-Sequard syndrome
  - Central cord syndrome
  - Anterior cord syndrome

### Pathophysiology

- Spinal shock: temporary, concussive-like syndrome associated with flaccid paralysis below the level of injury with loss of all reflexes, as well as urinary and rectal tone
- Neurogenic shock: a hemodynamic state wherein sympathetic outflow through the spinal cord has been disrupted, resulting in vasodilation, *bradycardia*, and dangerous hypotension

### Work-Up

- C-spine X-rays: anteroposterior (AP), lateral, and open-mouth (odontoid)
- CT is useful for detecting vertebral fractures and identifying hematomas or disk fragments within the spinal canal
- MRI is useful to detect injury to the spinal cord itself in patients with neurological deficits
  - Only imaging modality that detects abnormalities in patients with SCIWORA

### Management

- Rigid cervical collar on a spine board
- Early closed reduction with tongs or halo traction devices for awake patients with obvious subluxation on imaging causing spinal cord compression
- IV fluids
- Vasopressors (phenylephrine or dopamine) if neurogenic shock
- Foley catheter
- Stool softeners
- Venous thromboembolism prophylaxis

---

## Complications

- Exposure of the anterior cervical spine
  - Injury to the recurrent laryngeal nerve, leading to a hoarse voice and risk of aspiration

---

## Suggested Reading

- Hurlbert RJ, Hadley MN, Walters BC, Aarabi B, Dhall SS, Gelb DE, et al. Pharmacological therapy for acute spinal cord injury. *Neurosurgery*. 2013;72:93–105.
- Kokoska ER, Keller MS, Rallo MC, Weber TR. Characteristics of paediatric cervical spine injuries. *J Pediatr Surg*. 2011;36(1):100–5.
- Sonntag V, Hadley M. Management of nonodontoid upper cervical spine injuries. In: Cooper P, editor. *Management of posttraumatic spinal instability: neurosurgical topics*. Rolling Meadows: AANS Publications; 1990. p. 99–109.
- Sonntag V, Hadley M. Management of upper cervical spinal instability. In: Wilkins R, editor. *Neurosurgery update*. New York: McGraw-Hill; 1991. p. 222–3.
- Vollmer DG, Eichler ME, Jenkins III AL. Assessment of the cervical spine after trauma, chapter 312. In: *Youmans neurological surgery*. Philadelphia: Elsevier; 2011. p. 3166–79.

Ardavan Ariel Saadat, Brian Cristiano, and David S. Plurad

A 40-year-old male motorcyclist is brought to the emergency room by paramedics after rear-ending a car at highway speeds. He was wearing a helmet, but was thrown from his motorcycle. He was awake in the field, but then quickly became unconscious. His airway is patent and his respiration is shallow and irregular. His blood pressure is 150/90 mmHg, heart rate is 60/min, and respiratory rate is 20/min. In response to sternal rub, the patient moans and withdraws his right upper and lower extremity, he does not move the left upper or lower extremity, and he does not open his eyes (glasgow coma scale of 7). His right pupil is 6 mm and nonreactive, while his left is 3 mm and reactive to light. There is no obvious head injury or laceration. There is no discharge from the nose or ears; however, there is right hemotympanum. The oropharynx is clear. The remainder of the physical examination is normal.

## Diagnosis

### What Is the Differential Diagnosis for a Severe (GCS $\leq$ 8) Traumatic Brain Injury?

Diagnosis	Pathophysiology	Comments
<i>Epidural hematoma (EDH)</i>	Laceration of middle meningeal artery by temporal bone fracture (blood accumulates between the dura and skull)	Classic presentation: brief loss of consciousness, followed by a lucid interval, then a rapid decline in level of consciousness; better prognosis than subdural
<i>Subdural hematoma (SDH)</i>	Rupture of bridging veins resulting in the accumulation of blood between dura and arachnoid membrane	More likely to have associated brain parenchymal injury than epidural; acute and chronic forms
<i>Intraparenchymal hematoma</i>	Hemorrhage occurs in area of contused brain parenchyma	More likely to occur in association with hypertensive hemorrhage or arteriovenous malformation than with trauma; bleeding may be delayed
<i>Diffuse axonal injury (DAI)</i>	Rotational acceleration and deceleration results in stretching of axons between the gray and white matter	DAI is typically the underlying injury in shaken baby syndrome
<i>Subarachnoid hemorrhage (SAH)</i>	Trauma is most commonly caused by accumulation of blood in CSF-filled subarachnoid spaces, also caused by aneurysm rupture or arteriovenous malformation	Patient complains of “worst headache of my life”

A.A. Saadat, BS (✉)  
Baylor College of Medicine, 2425 Underwood Str Apt 356, Houston, TX 77030, USA  
e-mail: SAADAT@BCM.EDU

B. Cristiano, MD  
Department of Surgery, Harbor UCLA, 17031 Courtney Lane, Huntington Beach, CA 92649, USA  
e-mail: brian.cooper.cristiano@gmail.com

D.S. Plurad, MD  
Department of Surgery, Harbor-UCLA Medical Center, 1000 W. Carson Street, Box 42, Torrance, CA 90509, USA  
e-mail: dplurad@dhs.lacounty.gov

## What Is the Most Likely Diagnosis?

This patient has sustained a severe traumatic brain injury (TBI) as evidenced by a glasgow coma scale (GCS) of 7 (eyes-1, verbal-2, motor-4). He likely has a right-sided EDH which is supported by evidence of a right temporal bone fracture (hemo-tympanum). He also displays the classic sequence for EDH: consciousness, a brief lucid interval, and then progression to coma. The patient has objective signs of intracranial hypertension and uncal herniation, with a dilated nonresponsive right pupil and left-sided hemiplegia.

## History and Physical

### What Is the Definition of a TBI?

TBI results in a disruption of brain function. To meet the definition of TBI, the following criteria must be met: a period of loss of consciousness, loss of memory for events immediately before or after the accident, alteration in mental state at the time of the accident, and/or focal neurologic deficit.

### How Do You Calculate the Glasgow Coma Scale (GCS)?

The GCS (Table 25.1) is composed of three components: eye opening, verbal response, and motor response. By definition, a neurologically intact person has a GCS score of 15. A GCS score of 3–8 indicates severe TBI, 9–12 indicates moderate injury, and 13–15 indicates mild injury. There is a 28 % probability of mortality associated with scores of 7 or 8.

#### Watch Out

A patient with a GCS of 8 or less is considered to be in a coma and mandates establishment of an airway.

#### Watch Out

The GCS score should be frequently reassessed to determine if the patient's TBI is worsening.

### What Non-Head Trauma Factors Can Affect the GCS?

The GCS can be altered by alcohol and drug intoxication, sedatives, severe hypoxia, shock, and severe hypothermia.

### What Are Raccoon Eyes? What Is Battle's Sign?

Raccoon eyes are bilateral periorbital ecchymosis. Battle's sign is retroauricular ecchymosis. These signs should raise the suspicion of a basilar skull fracture.

**Table 25.1** Glasgow coma scale (GCS)

Eye opening	Best verbal response	Best motor response	Points
		Follows commands	6
	Oriented	Localizes pain	5
Spontaneous	Confused	Withdraws from pain	4
To voice	Inappropriate words	Decorticates posturing	3
To pain	Incomprehensible	Decerebrates posturing	2
None	None	None	1

## How Does the Physical Exam Help to Localize the Site of Intracranial Bleeding?

Paralysis generally occurs contralateral to the lesion, and abnormal pupillary findings will occur ipsilateral to the lesion. The above patient has a left hemiparesis and a blown pupil on the right, referring to a fixed and dilated pupil resulting from compression of the oculomotor nerve (CN 3) by the uncus of the temporal lobe. This localizes the lesion to the right.

## What if the Blown Pupil and the Posturing Are on the Same Side? How Do You Use These Findings to Lateralize the Suspected Lesion?

In about 1 out of 5 cases of uncal herniation, the paralysis occurs ipsilateral to the lesion (Kernohan syndrome). This occurs when the *contralateral* cerebral peduncle is displaced laterally against the *contralateral* tentorial incisure resulting in paralysis *ipsilateral* to the lesion, a false localizing sign. In this case the pupil is the more reliable lateralizing sign. Remember *dot marks the spot*.

## What Is the Implication of Abnormal Arm Flexion/Leg Extension with Pain Stimulation? Arm/Leg Extension?

Abnormal flexion in upper extremity and extension in lower extremity in response to painful stimuli is called *decorticate posturing*. Abnormal extension in upper and lower extremity in response to painful stimuli is called *decerebrate posturing*. These are primitive reflexes mediated by the brain stem when higher brain function is absent. While both are grave signs, decorticate posturing carries with it a better prognosis than decerebrate posturing.

## How Does the Presentation of Chronic SDH Differ from Acute SDH?

Acute SDH typically presents within 72 hours of head injury. Chronic SDH can have a delayed onset even months later. Chronic SDH typically affects the elderly, and presentation is often insidious: gait abnormalities, decreased levels of consciousness, aphasia, cognitive dysfunction, memory loss, and/or personality changes.

---

## Pathophysiology

### What Is a Concussion?

This is a term used for mild TBI. A concussion temporarily alters brain function by causing problems with memory, balance, coordination, and/or concentration. It may be associated with symptoms such as headaches, dizziness, confusion, personality changes, and irritability. Loss of consciousness is not required to establish the diagnosis of a concussion.

### What Is Uncal Herniation?

Uncal herniation occurs when a space-occupying lesion above the tentorium displaces the uncus of the temporal lobe medially and inferiorly over the tentorial incisure impacting on the ipsilateral oculomotor nerve (CN III) and ipsilateral cerebral peduncle, which contains the ipsilateral corticospinal tract. This results in an ipsilateral blown pupil and contralateral paralysis.

### What Is the Pathophysiology of an Epidural Hematoma?

Epidural hematoma is the accumulation of blood between the dura and skull. A temporal bone fracture from a head injury results in laceration of the middle meningeal artery (most common source) resulting in an EDH. EDHs have a biconvex

appearance on CT. Because the hematoma is from an arterial source, it may expand rapidly and may require urgent surgical evacuation.

### **What Is the Implication of a “Lucid” Interval with Head Injury?**

Initial loss of consciousness results from disruption of the brainstem arousal centers (RAS). The second loss of consciousness results from the expanding hematoma and mass effect. The interval between the first and second LOC is called the lucid interval, which may last minutes to hours. This is classically seen in EDH.

### **What Is the Pathophysiology of an Acute Subdural Hematoma?**

Acute subdural hematoma is the accumulation of blood between the dura and arachnoid membrane. It results from tearing of the bridging veins, which run from the cortex to the dural venous sinuses. SDHs have a crescent-shaped appearance on CT. The elderly, alcoholics, and patients on anticoagulation therapy are particularly susceptible. There is more often associated parenchymal injury and therefore worse prognosis.

#### **Watch Out**

The relatively atrophic brain parenchyma in the elderly increases tension on bridging veins making them more susceptible to injury after head trauma.

### **What Is the Formula for Cerebral Perfusion Pressure?**

Cerebral perfusion pressure (CPP) is the difference between mean arterial pressure and intracranial pressure (ICP).

### **What Other Factors Affect Cerebral Perfusion Pressure? What Is the Most Powerful Intracranial Vasodilator?**

Because the brain is encased by the rigid bony cranium, three components contribute to the ICP: brain tissue, CSF, and blood. In order to maintain constant ICP, an increase in one must result in a decrease in the volume of the other two components. This may lead to complications such as reduced cerebral blood flow (CBF) leading to brain ischemia. The most powerful vasodilator is blood CO<sub>2</sub> level. Lowering CO<sub>2</sub> via mild hyperventilation provides temporary therapeutic benefit for elevated ICP.

#### **Watch Out**

Hypotension is never caused by TBI: search for other sources.

### **What Is Cushing’s Triad? What Does It Mean? What Is the Pathophysiology?**

Cushing’s triad or Cushing’s reflex is the presence of hypertension, bradycardia, and an irregular respiratory rate. Cushing’s reflex is the physiologic response to increased intracranial pressure (ICP). In the presence of elevated ICP, systemic blood pressure increases in order to maintain cerebral perfusion pressure. The increased pressure results in negative feedback at the carotid sinus leading to bradycardia. The respiratory center is located in the medulla and will become impaired as a result of elevated ICP.



## What Is a Coup vs. Contrecoup Injury?

Coup refers to injury to brain tissue directly below the skull at the point of impact. However, the force of impact may thrust the brain tissue against the skull on the opposite site and cause injury. This is referred to as the contrecoup injury. Thus, contusion may occur on opposite sides of the brain.

## Initial Management

### What Initial Management Is Recommended for the Above Patient?

Initial management of this patient should follow the ABCDE model of primary assessment, resuscitation, secondary assessment, and definitive care per ATLS guidelines. A GCS of  $\leq 8$  (as in the present patient) is an indication for intubation so as to protect the airway and assure optimal oxygenation and ventilation. Moreover, intubation and paralysis can help facilitate ICP management. It is useful to document a neurologic exam prior to paralysis and intubation (part of the secondary survey), as this information can be useful and will be unobtainable once the patient is sedated/paralyzed. Next, he should receive a non-contrast head CT (HCT) with anticipation that expedient evacuation of a likely epidural hematoma will follow.

#### Watch Out

Since the patient is in coma, physical examination cannot be used to identify other injuries. Be sure to rule out other life-threatening injuries to the chest, abdomen, and pelvis given the mechanism of injury.

### What Are the Indications for Head CT with TBI?

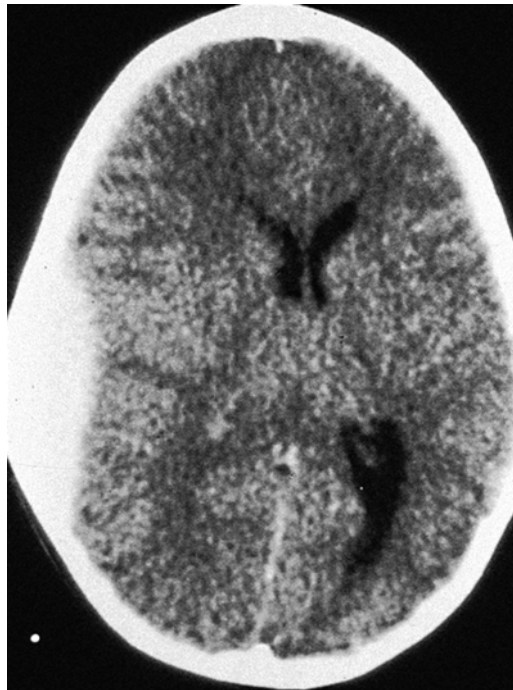
All patients with moderate (GCS 9–12) and severe (3–8) brain injury should get a non-contrast CT scan. Patients with mild brain injury who have certain risk factors (anticoagulation, alcohol abuse, elderly) should also undergo a CT scan.

#### Watch Out

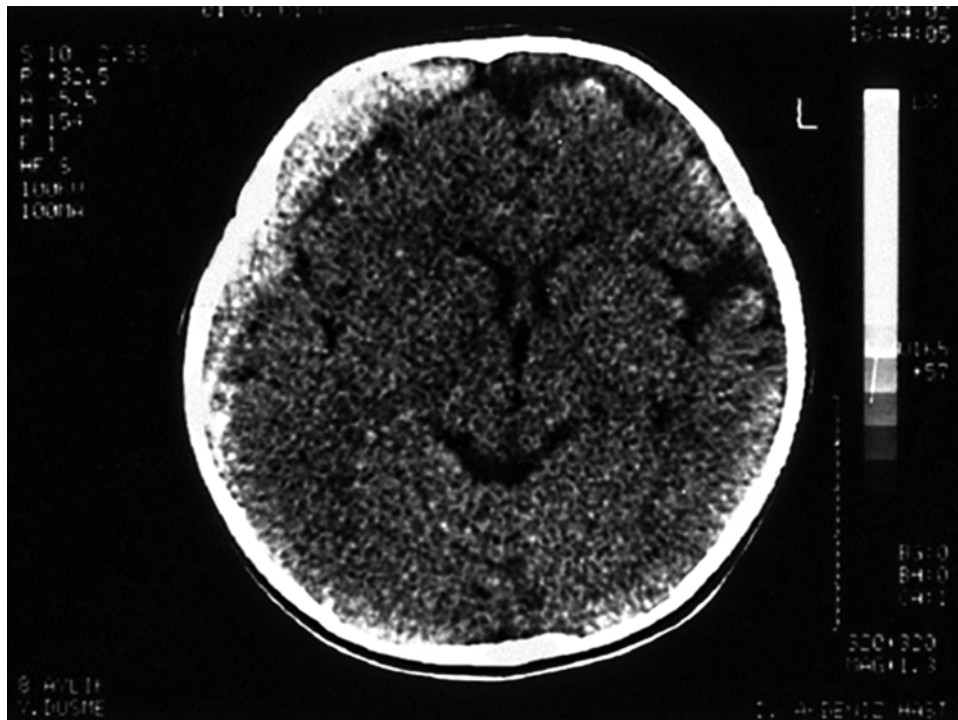
Both succinylcholine and ketamine can increase ICP and are relatively contraindicated in the setting of TBI. Rocuronium and etomidate would be better options.

### Describe the Findings on HCT Seen With EDH, SDH, and SAH Intraparenchymal Contusion

Findings	Diagnosis
Hyperdense lens-shaped (Fig. 25.1) density adjacent to skull, does not cross suture lines and is usually associated with a skull fracture	Acute epidural hematoma (EDH)
Hyperdense crescent-shaped (Fig. 25.2) density adjacent to brain parenchyma but not within sulci, crosses suture lines but not the falx	Acute subdural hematoma (aSDH)
Isodense or hypodense crescent-shaped density adjacent to brain parenchyma but not within sulci, crosses suture lines but not the falx, often presents with mass effect out of proportion to clinical findings	Chronic subdural hematoma (cSDH)
Hyperdense material adjacent to brain parenchyma tracing along gyri and sulci often in a coup, contrecoup pattern relative to injury	Traumatic subarachnoid hemorrhage (tSAH)
Hyperdense irregular lesions within brain parenchyma often in a coup, contrecoup pattern	Intraparenchymal contusion



**Fig. 25.1** Non-contrast head CT demonstrating an acute epidural hematoma (With kind permission from Springer Science+Business Media: Atlas of Clinical Neurology. Coma and Intensive Care Neurology, 2003, p. 102, Hanley DF et al., Fig. 4.32)



**Fig. 25.2** Non-contrast head CT demonstrating an acute subdural hematoma (With kind permission from Springer Science+Business Media: Childs Nerv Syst, Hemispheric cerebrovascular venous thrombosis due to closed head injury, 20, 2004, p. 240, Erdogan B., Fig. 1)

## What Are the Indications for ICP Monitoring?

ICP monitoring is indicated for the following patients:

- Severe TBI (GCS score 3–8) with abnormal head CT
- Severe TBI (GCS score 3–8) with normal head CT but with any two of the following: hypotension, posturing, or age  $\geq 40$
- When the neurological exam cannot be appropriately assessed due to sedation or anesthesia with suspicion of high ICP

Most patients with a significant TBI will meet one or more of the above criteria. Normal ICP is typically between 5 and 15 mmHg. Treatment is indicated for pressures greater than 20 mmHg in adult patients and lower levels for children and infants. The preferred method of ICP monitoring in the setting of trauma is with ventriculostomy tube that is able to be used for CSF drainage when ICPs become high.

### Watch Out

Patients with severe TBI are at risk of developing disseminated intravascular coagulation; be sure to follow coagulation labs and platelet count.

## What Is the Role of Hyperventilation?

Prior to ICP monitoring, mild hyperventilation is indicated in a patient with radiographic (CT findings) or clinical signs of intracranial hypertension. If indicated, hyperventilation is initiated with a goal of  $\text{PaCO}_2 = 30\text{--}35$  mmHg. This can temporarily reduce ICP through cerebral vasoconstriction. It is important to note that  $\text{PaCO}_2$  should not be reduced below 30 mmHg as it may dangerously decrease cerebral blood flow and even mild hyperventilation should be discontinued once other methods of ICP control are started.

## What Other Medical Treatment Options Are There for Intracranial Hypertension?

The head of the bed should be elevated to  $30\text{--}45^\circ$ . The cervical collar should be carefully loosened if restricting venous outflow. Hyperthermia should be treated if present. Mannitol is generally the first-line drug. Finally the patient can be paralyzed, and some advocate for therapeutic hypothermia. If ICP cannot be controlled with the above methods, a barbiturate coma or a decompressive craniectomy may be indicated.

## How Does Mannitol Work?

Mannitol is an osmotic diuretic. Mannitol increases the tonicity of the extracellular space, which causes a shift of water from the intracellular space (brain parenchyma) to the extracellular space. Additionally, by expanding the plasma volume, it reduces hematocrit and blood viscosity which increases cerebral blood flow ( $\text{O}_2$  delivery) and reduces ICP.

### Watch Out

Mannitol should be avoided in patients with hypotension or hypovolemia due to its volume-depleting effects.

## Is There a Role for Corticosteroids in the Treatment of TBI? What Is the Difference Between Vasogenic and Cytotoxic Edema?

There is no role for corticosteroids in the setting of TBI. Corticosteroids such as dexamethasone are routinely used in the treatment of cerebral edema caused by brain tumors and other inflammatory CNS processes. The mechanisms of edema in tumor and in trauma are fundamentally different. Tumors produce edema by causing inflammation (cytotoxic edema)

and will respond to corticosteroids. Trauma, in contrast, causes cerebral edema by triggering abnormal vasoregulation and by causing brain capillaries themselves to become abnormally leaky (vasogenic edema) and is not responsive to corticosteroids.

### **When Should a Craniotomy Be Performed for Acute EDH or SDH? What About Craniectomy?**

Craniotomy (removing skull flap to evacuate hematoma) is indicated for acute subdural and epidural hematomas that are associated with a midline shift  $>10$  mm, hematoma thickness  $>5$  mm, or ICP  $>20$  mmHg. The bone flap is returned after the hematoma is evacuated. With a craniectomy, the scalp is closed without replacing the bone flap. This allows the brain parenchyma to swell beyond the confines of the skull. The bone flap is usually stored for possible reimplantation at a later time. A decompressive craniectomy is performed if the patient's ICP cannot be managed medically. Usually as much bone as possible is removed over the temporal fossa, or a bilateral frontal (Kjellberg) craniectomy is performed. Smaller hematomas can reasonably be monitored with serial CT scans and are medically managed.

### **What Are the Guidelines for Repeat Imaging if a Nonoperative Management Is Planned?**

Many hematomas are managed nonoperatively. Urgent follow-up CT is indicated for new neurologic signs (e.g., pupillary dilation, hemiparesis), continued vomiting, worsening headache, loss of  $\geq 2$  points on GCS, or any signs of increased ICP. Some sources recommend a repeat head CT a few hours later to rule out a delayed hematoma (EPH, SDH, or contusions).

### **What Are the Criteria for Brain Death? What Conditions Must Be Ruled Out?**

Brain death refers to irreversible cessation of the entire brain function including the brain stem. To perform the exam, the patient must have a GCS of 3. The patient must be eutermic ( $>32.2$  °C), the PaO<sub>2</sub> must be greater than 90 mmHg, the SBP must be greater than 100 mmHg, and the patient cannot be sedated or paralyzed (a serum or urine drug screen may be needed). Declaration of brain death requires absence of brainstem reflexes (corneal, gag, oculoccephalic, and oculovestibular), no response to deep central pain, and the agreement of two physicians. If the above criteria are met, an apnea test is performed. The patient is disconnected from the ventilator and observed for respiratory effort. If there is no evidence of spontaneous respirations with a PaCO<sub>2</sub>  $>60$  mmHg, and the other criteria are met, the patient meets the criteria for brain death.

### **What Factors Affect Prognosis of Head Injury?**

Hypotension (SBP  $<90$ ), hypoxemia, hypercarbia, elevated ICP  $>20$  mmHg despite hyperventilation, and increasing age are associated with worse prognosis.

---

## **Areas You Can Get in Trouble**

### **Guidelines for Head CT in Children**

Children are at greater risk of malignancy from ionizing radiation from a CT scan as compared to adults. Thus the indications for a head CT scan in a child are stricter. Indications for head CT in children include a GCS of 14 or less, suspected basilar skull fracture, a palpable skull fracture, and altered mental status. On an individualized basis, other relative indications include loss of consciousness longer than 5 s; occipital, parietal, or temporal scalp hematoma; severe mechanism of injury; history of vomiting; severe headache; and child not acting normally per parent.

## Summary of Essentials

### History and Physical

- TBI may present with confusion, loss of consciousness, decreased level of consciousness, and amnesia
- GCS, cranial nerve exam, and sensory and motor exam
  - GCS of 8 or less = severe TBI
- Signs of basilar skull fracture
  - Raccoon's eyes (periorbital ecchymoses) and Battle's sign (postauricular ecchymoses)
- Intracranial hypertension
  - Hypertension, bradycardia, and respiratory irregularity (Cushing's triad)
  - Signs of uncal herniation: blown pupil and contralateral hemiparesis

### Pathophysiology

- Primary injury: occurs at the time of trauma from deformative and concussive forces and includes laceration, hemorrhage, and fracture
- Secondary injury: brain's response to injury and includes cellular ischemic injury, edema, inflammation, and disruption of blood flow
- Types of brain injury:
  - Epidural hematoma: laceration of the middle meningeal artery (most common source)
  - Subdural hematoma: rupture of the bridging veins
  - Diffuse axonal injury: stretching of axons between gray and white matter
  - Concussion: disruption of inflow and outflow tracts from reticular activating system
  - Contusion: hemorrhage within the brain parenchyma
  - Subarachnoid hemorrhage: accumulation of blood in subarachnoid space

### Initial Management

- Start with ABCs
- Intubate if severe TBI (GCS  $\leq$  8)
- Protect the patient's airway
  - Facilitate ICP management
  - STAT non-contrast head CT
- Coagulopathy should be sought and corrected
- ICP monitoring for select patients with moderate to severe TBI
- An ICP  $>$  20 should be treated aggressively
- Elevate the head of a bed
  - Intubate and paralyze
  - Mild hyperventilation (avoid prolonged hyperventilation)
  - Mannitol
  - Hypertonic saline
  - Control pyrexia/therapeutic hypothermia
  - Barbiturate coma
  - Subsequent Management
- Craniotomy with hematoma evacuation
  - Epidural hematomas  $>$  30 ml in volume or causing  $>$  10 mm of midline shift
  - Acute subdural hematomas  $>$  5 mm in thickness or causing  $>$  10 mm or shift
  - Decompressive craniectomy
  - Persistent severe intracranial hypertension despite medical management

- 
- Criteria for brain death
  - GCS of 3 while not hypoxic, normotensive, eutermic, not on sedatives, or paralytics
  - No cranial nerve reflexes
  - No respiratory effort observed during an apnea test
- 

### **Suggested Reading**

Bernat JL, Culver CM, Gert B. On the definition and criterion of death. *Ann Intern Med.* 1981;94(3):389–94.

Bullock MR, Chesnut R, Ghajar J, Gordon D, Hartl R, Newell DW et al. Guidelines for the surgical management of traumatic brain injury. *Neurosurgery.* 2006;58(Supplement):S2–1–S2–3. doi:[10.1227/01.NEU.0000210361.83548.D0](https://doi.org/10.1227/01.NEU.0000210361.83548.D0).

Sumas ME, Narayan RK. Head injury. In: Grossman GR, Loftus CM, editors. *Principles of neurosurgery.* 2nd ed. Philadelphia: Lippincott-Raven; 1999. p. 117–71.

---

**Part IX**

**Orthopedic**

Kevin W. Rolfe, Section Editor

Areg Grigorian and Kevin W. Rolfe

A 35-year-old male is involved in a motor vehicle collision (MCV) and is brought in by paramedics complaining of severe pain in his right leg and arm. In the ED, the patient is awake and alert. He has an obvious deformity of his right mid-humerus. There are no open wounds in the arm. He has a noticeable wrist-drop on the right and is unable to dorsiflex the wrist or extend the metacarpophalangeal joints. Radial pulse on the right is 2+. There is a 2 cm laceration over his mid-shin, with visible bone exposed. Distal motor and sensory function in his right leg are intact, and pedal pulses are 2+. There is no tenderness or deformity in his left thigh or left lower leg. X-ray imaging confirms a right mid-shaft humerus fracture (Fig. 26.1), a right femur fracture, and a right tibia and fibula fracture. X-rays of the left knee are negative.

---

### Diagnosis

#### What Is the Most Likely Diagnosis?

Given the vignette and radiographic findings, the diagnosis is straightforward. This is a polytrauma patient with multiple extremity fractures including a right closed humerus fracture with a nerve deficit, a closed right femur fracture, an open right tibia fracture, and possibly a left knee injury.

#### What Is the Likely Etiology of the Neurologic Deficit in His Right Arm?

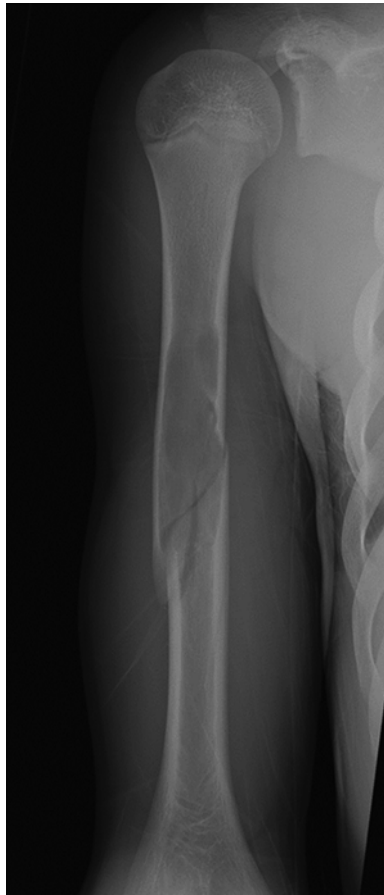
The most likely etiology of the patient's neurologic deficit is stretch or entrapment of the radial nerve due to the humeral shaft fracture. The radial nerve descends down the medial aspect of the humerus until a third of the way down, where it dives more posteriorly. At this level, the radial nerve runs in the spiral groove and remains in contact with the posterior surface of the humerus. Consequently, radial nerve injury is more common with middle and distal third humerus fractures where it can be stretched from bony disconnection or become entrapped between bone ends at the fracture site. The radial nerve gives off the branches that innervate the triceps in the axilla proximal to the lesion so triceps function remains intact. Patients will experience distal loss of function including wristdrop (weakness in extension), loss of metacarpophalangeal (MP) joint extension, and sensory loss over the dorsum of the hand.

---

A. Grigorian, MD  
Department of Surgery, University of California, Irvine, 333 City Blvd West, Suite 1600, Route. 81, Orange, CA 92868, USA  
e-mail: [agrigori@uci.edu](mailto:agrigori@uci.edu)

K.W. Rolfe, MD, MPH (✉)  
Orthopaedic Surgery, Harbor-UCLA Medical Center & Rancho Los Amigos Rehabilitation Center, 1000 W. Carson Street, 4th Floor,  
Torrance, CA 90509, USA  
e-mail: [kwrolfe@gmail.com](mailto:kwrolfe@gmail.com)





**Fig. 26.1** Right mid-shaft humerus fracture (With kind permission from Springer Science + Business Media: Skeletal Radiol, The “rising bubble” sign: a new aid in the diagnosis of unicameral bone cysts, 38, 2009, pg 598, Jordanov MI., Fig. 1)

#### Watch Out

Finger extension at the interphalangeal (IP) joints can still be accomplished by the intrinsic muscles controlled by the ulnar nerve (interossei and ulnar two lumbricals) and median nerve (radial two lumbricals).

---

## History and Physical

### What Should Be Assessed During Extremity Evaluation of a Trauma Patient?

After the primary survey is completed and all life-threatening injuries are addressed, the extremities should be evaluated to assess the four functional components (nerves, vessels, bones, and soft tissues). Injury to three of these four elements constitutes a “mangled extremity.”

### What Is an Open Fracture?

Open fractures are those with a conduit of communication between the fracture and the environment due to the disruption of the intervening soft tissue and skin. Because of the open communication, there exists a higher risk for infection. Bone healing is also slowed in open fractures and more often results in nonhealing known as a nonunion.

## How Does Fat Embolism Syndrome Present?

Fat embolism syndrome occurs in up to 15 % of polytrauma patients, particularly in association with long bone fractures like the femur. It typically presents between 24–72 hours following the trauma. The classic triad consists of respiratory symptoms, neurological changes, and a reddish-brown petechial rash. Respiratory findings such as hypoxemia, dyspnea, and tachypnea are the earliest manifestations. A chest x-ray may demonstrate Acute Respiratory Distress Syndrome (ARDS). Neurologic abnormalities develop afterwards, most often manifested by confusion, drowsiness or altered level of consciousness, and, in severe cases, seizure or paralysis. Lastly, the classic petechial rash develops, but in only 50–60 % of cases. The petechial rash results from extravasation of erythrocytes secondary to the occlusion of dermal capillaries by fat emboli. The rash, in the proper clinical context, is pathognomonic for fat embolism syndrome.

## What Is a Dangerous Sequela for a Tibia Fracture (or Forearm Fracture)?

Compartment syndrome. Don't forget the 6 Ps: pain out of proportion to injury with gentle passive stretch of the involved muscles, pressure (swollen and tense compartments), paresthesia, pulselessness, poikilothermia, and paralysis. This is a surgical emergency.

## What Concomitant Fracture Is Important to Consider in All Femur Fractures?

A concomitant femoral neck fracture. A missed femoral neck fracture may lead to avascular necrosis (AVN) if not treated. AVN is largely irreversible and leads to end-stage dysfunction of the hip joint.

---

## Pathophysiology

### What are Seddon's Three Basic Categories of Nerve Injury?

Type	Features
<i>Neuropraxia</i>	Minimal injury (myelin), but not axon or nerve sheath. Temporary nerve conduction block, loss of motor and sensory function, but not autonomic. Full recovery expected, hours to months.
<i>Axonotmesis</i>	Myelin plus axon disrupted, nerve sheath intact. Wallerian degeneration with motor sensory and autonomic paralysis. Recovery often incomplete, weeks to months, axon sprouts within nerve sheath.
<i>Neurotmesis</i>	Myelin, axon, and nerve sheath also damaged. Recovery variable and incomplete at best, usually requires surgery or results in permanent paralysis.

### How Fast Does an Injured Axon Regenerate?

Approximately 1 mm per day, though factors like age and nutritional status may affect the rate.

### Does Wallerian Degeneration Occur with Neurapraxia?

Not with neuropraxia. Yes for axonotmesis and neurotmesis.

### What Are the Three Layers of the Nerve Sheath?

Endoneurium, perineurium, and epineurium. Sunderland has further divided neurotmesis into three grades depending on whether the endoneurium alone is affected, the endoneurium and the perineurium are both affected, or all three layers including the epineurium (i.e., complete transection or avulsion) are affected.

## What are the Classic Nerve Injuries Associated with Fractures?

	Fracture	Classic nerve injured	Symptoms
<i>Upper extremity</i>	Humeral head/proximal humerus	Axillary	Impaired arm abduction
	Mid-shaft of the humerus	Radial	Impaired extension of elbow, wrist
	Supracondylar (humerus)	Anterior interosseous nerve (branch of median)	Impaired handgrip
	Distal radius	Median	Impaired thumb opposition
<i>Lower extremity</i>	Hip fracture dislocation	Sciatic (peroneal division)	Impaired knee flexion
	Fibular head	Fibular/peroneal	Foot drop, impaired eversion/dorsiflexion

## What Is the Presumed Pathophysiology of Fat Embolism Syndrome?

Embolization of fat and marrow from the fracture (or from surgical intramedullary rodding) into the bloodstream. There are both mechanical and metabolic theories as to how this embolization occurs after injury.

## Work Up

### What is the Extent of Imaging Recommended With All Long Bone Fractures?

The joint above and below any long bone fracture must always be evaluated radiographically.

### What Is a Floating Knee?

This is a term for the knee when an ipsilateral femur and tibia fracture are present. A floating knee tends to flail or float between bony disconnections above and below the injury.

## Management

### How Are Open Fractures Graded?

The Gustilo-Anderson grading system (Table 26.1) is used to grade open fractures. An increased grade correlates with a higher risk of *infection*, nonunion, and amputation.

### Is the Wound Size the Most Important Determinant of Severity for Open Fractures?

The energy imparted to the limb is the most important consideration. Any segmental or severely comminuted fracture should be at least a grade IIIA even if the wound is small. In some cases, a limb may have no open wounds, but may be at significant risk for amputation due to significant crush or high-energy injury.

**Table 26.1** Gustilo-Anderson grading system

Grade	Characteristics
<i>I</i>	Wound less than 1 cm with minimal contamination or soft tissue damage
<i>II</i>	Wound 1–10 cm without extensive soft tissue damage, flaps, or avulsions
<i>IIIA</i>	Wound greater than 10 cm or high energy, but with adequate soft tissue coverage
<i>IIIB</i>	IIIA with significant soft tissue injury requiring a flap or free tissue transfer
<i>IIIC</i>	IIIA with vascular injury that requires a vascular repair

**Table 26.2** *Clostridium tetani* infection

History of TT vaccination	Clean wounds	Dirty wounds
<3 doses	All should receive TT	All should receive both TT and TIG
≥3 doses	Should receive TT only if the last dose was more than 10 years ago	Should receive TT only if last dose was more than 5 years ago

### Which Patients With Open Fractures Should Be Given Antibiotic Coverage?

All open fractures are by definition contaminated and should receive antibiotics. Grade I and II open fractures are mainly at risk for gram-positive infections, so a first-generation cephalosporin is recommended. Grade III fractures are at higher risk of infection and should receive an aminoglycoside in addition to a cephalosporin. Antibiotics should be started as soon as possible after injury and continued for 24 hours if the wound can be closed. If closure is delayed, antibiotic coverage is recommended until 24 hours after final closure.

### What Antibiotics are Indicated for Open Fractures in Farm Accidents or Soil-Contaminated Wounds?

Penicillin or its equivalent is added to cover anaerobes, especially *Clostridium perfringens*. Gas gangrene has led to many amputations in the past.

### What Else Should Be Considered for Wounds Contaminated with Dirt and Soil?

Tetanus immune globulin (TIG) or tetanus toxoid (TT) administration depending on vaccine history and level of contamination (Table 26.2). Wounds at the highest risk for *Clostridium tetani* infection include those containing foreign bodies and/or necrotic tissue.

### What Are the Principles of Surgical Management of an Open Fracture? What Is the Optimal Timing?

Open fractures should be taken to the operating room as soon as possible for surgical irrigation and debridement, typically within 6 hours of injury (Grade IIIC injuries are a surgical emergency). All devitalized skin, tissue, and bone should be excised.

### How Are Skin Wounds Closed?

Grade I, II, and IIIA injuries typically receive primary closure, though some IIIA injuries may require multiple debridements before secondary closure due to significant contamination or inability to ascertain tissue viability at first look.

### Why Is It Important to Have Early Stabilization of Open Fractures?

Restoring length, alignment, and rotation helps protect the soft tissues around the injury and prevent further damage secondary to mobile fracture fragments. Restoration of length also helps reduce dead space which decreases rates of infection. Patients that receive earlier stabilization also have quicker recovery.

### What Is the Difference Between Open and Closed Reduction?

Reduction is the process of putting displaced bones back to their normal anatomic positions. This can either be done by direct manipulation of the bone through a surgical incision (open reduction) or indirectly by external manipulation of the limb manually or with a fracture table (closed reduction).

### **What Is the Difference Between Internal and External Fixation? What Are the Advantages/Disadvantages?**

Fixation, as the name implies, is the act of fixating or holding the bone in place with orthopedic instrumentation often referred to loosely as hardware (e.g., wires, plates, rods, screws, or pins). Internal fixation involves placement of the instrumentation entirely within the body and under the skin with no outside communication. These are typically left in place permanently. External fixation involves placement of pins or wires into the bone, but which extend outside the skin and body. These are often connected to metal rods and/or rings outside the body to maintain the bone alignment. External fixators are always removed at some point due to infection risk. The type of fixation to employ (internal or external) depends on the condition of the patient, associated injuries, and type/location of the fracture.

### **Can External/Internal Fixation Ever Be Done Without First Performing Reduction?**

Yes. When the fractured bone is in good alignment so that no manipulation is necessary, external or internal fixation may be used to stabilize a bone at risk of displacement without any fracture reduction being performed.

### **What Are the Main Management Concerns with a Femur Fracture?**

Patients with long bone fractures (e.g., femur, humerus), are at risk for fat embolism syndrome (discussed above). Femur fractures can also present with considerable blood loss since bone is highly vascular, and the thigh compartment can accommodate a large volume of blood. Patients should also be monitored for signs of hemorrhagic shock.

### **What Single Type of Orthopedic Fracture Is at the Greatest Risk for Hemorrhagic Shock?**

Pelvic fractures. Some are benign and cause minimal blood loss, while some are highly unstable and may require 10–15 units of blood transfusion or its equivalent due to the high pelvic volume into which blood may accumulate.

### **What Is the Optimal Timing of Femur Fracture Repair? What Is the Main Risk if Repair Is Delayed? What Are the Main Options in Repair?**

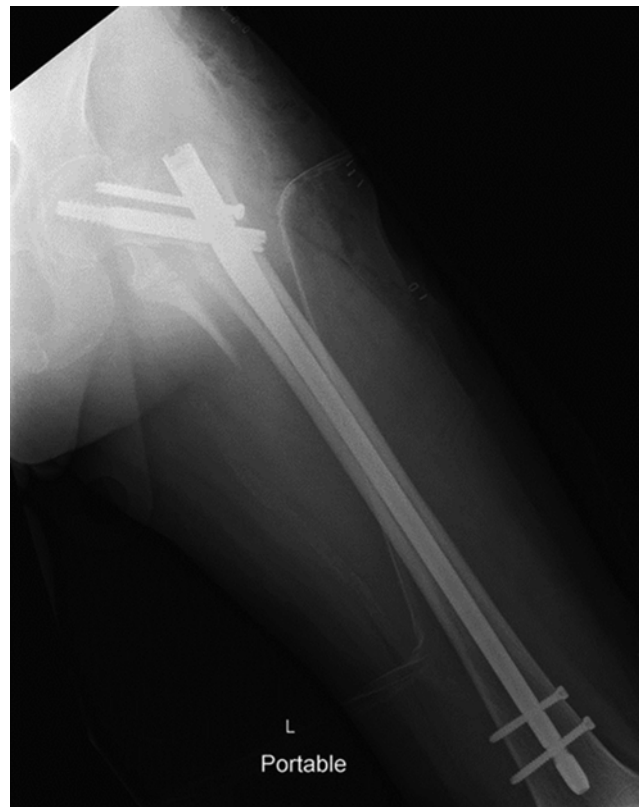The American College of Surgeons recommends definitive surgical management of femur fractures within 2–12 hours of injury in patients with polytrauma, provided that they are hemodynamically stable. Patients who undergo surgical repair within 24 hours have decreased rates of mortality and morbidity. Definitive management is most often accomplished with *intramedullary nailing* in the adult, though external fixation is sometimes used temporarily in unstable patients as this can be performed more quickly and easily and does not involve reaming the canal which can increase the risk of developing fat embolism syndrome (Fig. 26.2).

### **Do All Femur Fractures Require Fixation?**

No, children aged 3–5 years are often managed with spica casting and do not carry the same risk of morbidity and mortality associated with femur fractures in adults.

### **Is There an Important Consideration for a Femur Fracture in a Nonambulatory Child?**

Yes, child abuse. In some cases, these children are found to have fragile bones as in osteogenesis imperfecta.



**Fig. 26.2** Intramedullary nail for femoral fracture (With kind permission from Springer Science + Business Media: *Eur J Orthop Surg Traumatol*, Pseudoaneurysm of the profunda femoris artery following a long antegrade intramedullary nail for an unstable intertrochanteric hip fracture: A case report and review of the literature, 21, 2011, pg 295, Li X. et al., Fig. 3)

### **What Is the Management for Fat Embolism Syndrome?**

Management of fat embolism syndrome consists of supportive care including ventilatory support with high PEEP (positive end expiratory pressure) and early stabilization of the fractures. Corticosteroids have been reported to be beneficial in some patients, but there is not sufficient evidence to recommend corticosteroids in every patient.

### **What Is the Most Important Factor to Prevent Fat Embolism Syndrome Before It Occurs in a Polytrauma Patient?**

Early stabilization of long bone fractures within the first 24 hours.

---

## **Postoperative**

### **What Are the Important Risks Associated with Fracture Treatment?**

Infection, iatrogenic nerve or vessel injury, nonunion (failure to heal), malunion (healing in an improper position or alignment), or instrumentation failure.

---

## Areas of Controversy

### Limb Salvage or Amputation

When the lower limb has been severely damaged, it is often difficult to determine whether to attempt limb salvage or simply amputate the limb. Limb salvage is associated with prolonged hospitalization, multiple surgeries, and higher initial cost which may take a psychological toll on the patient. Patients, however, prefer limb preservation in most cases. Amputation is associated with faster initial return to function, but may have similar or higher long-term cost due to prosthetic limb needs. Of significant note, the old teaching that any plantar insensate foot should prompt amputation of a mangled limb is no longer a singular criterion in the decision to amputate or attempt salvage.

---

## Areas Where You Can Get in Trouble

### Missing Other Fracture

A joint above and below any fracture must always be assessed radiographically. This is one of the greatest sources of missed injury aside from incomplete clinical secondary surveys for additional injury. In some cases, a missed foot injury that was not treated properly at the outset will plague the patient more than the more dangerous femur fracture which has subsequently healed without sequelae.

#### Watch Out

In addition to compartment syndrome, beware of rhabdomyolysis and subsequent kidney failure in patients with crush injuries.

### Failure to Recognize a Compartment or Impending Compartment Syndrome

Multiple clinical assessments should be made to guard against this entity which is a surgical emergency. Direct compartment pressure measurements should be made if there is any doubt. The lower limb and forearm are most at risk, especially with crush injuries. The hand and foot are the second most common.

### Failure to Recognize a Significant Pelvic Fracture

High-energy pelvic fractures can lead to hemorrhagic shock and inadequate fluid resuscitation if not appreciated.

### Failure to Recognize a Neurologic Deficit

A radial nerve deficit as in this patient is important to determine as it may need separate treatment or dictate treatment options. Also, an unrecognized preoperative deficit may be attributed to an operative complication and/or lead to medicolegal issues.

---

## Summary of Essentials

### History & Physical

- Inquire as to the mechanism of injury
- Fat embolism syndrome (24–72 hours after injury): respiratory symptoms, neurological changes, and reddish-brown petechial rash
- Four functional components of extremity exam (nerves, vessels, bones, and soft tissues)

## Pathophysiology

- Fat Embolism Syndrome
  - Embolization of fat and marrow content from fractured long bones, especially femur, most affects brain and lungs
- Three nerve injuries: neuropraxia, axonotmesis, and neurotmesis
- Humeral shaft fractures associated with radial nerve injury and wrist drop
- Open fracture communicates with environment due to disruption of soft tissue and skin and requires special treatment due to infection risk

## Diagnosis

- Diagnosis usually straightforward with fractures after acute trauma
- Perform a thorough secondary survey to avoid missing additional fractures
- Radiographs must include the joint above and below all fractures seen on x-ray
- Any soft tissue wounds in conjunction with a fracture constitute an open fracture
- In patients with femoral fractures, always evaluate for femoral neck fracture

## Management

### Open Fracture

- All open fractures should receive antibiotic coverage: first-generation cephalosporin +/-aminoglycoside
- Open fractures should be managed within 6 hours
- Irrigation and surgical debridement
- External fixation for immediate and temporary control if unstable patient
- Definitive management with internal fixation

### Closed Fracture

- Managed within 2–12 hours with intramedullary nailing
- Reduces risk of fat embolism syndrome

### Postoperative

- Main surgical risks include infection, nonunion, malunion, nerve or vessel injury, and amputation in some cases

---

## Suggested Reading

- Advanced Trauma Life Support (ATLS) course manual, 8th ed. Chicago: American College of Surgeons; 2008.
- Ashford RU, Mehta JA, Cripps R. Delayed presentation is no barrier to satisfactory outcome in the management of open tibial fractures. *Injury*. 2004;35:411–6.
- Lieurance R, Benjamin JB, Rappaport WD. Blood loss and transfusion in patients with isolated femur fractures. *J Orthop Trauma*. 1992;6(2):175–9.
- Müller EJ, Siebenrock K, Ekkernkamp A, et al. Ipsilateral fractures of the pelvis and the femur–floating hip? A retrospective analysis of 42 cases. *Arch Orthop Trauma Surg*. 1999;119:179.
- Pollak AN. Timing of debridement of open fractures. *J Am Acad Orthop Surg*. 2006;14:S48–51.



John F. Fleming III, Aaron Beck, and Kevin W. Rolfe

A 26-year-old otherwise healthy male presents to the clinic with right knee pain after a skiing accident 3 days ago. The patient landed awkwardly after attempting a jump. He experienced immediate right knee pain necessitating ski patrol to bring him down the mountain. The patient reports hearing a “popping” noise when landing. Shortly after he noticed swelling around his knee, but he was still able to bear weight on his right leg. Today in clinic, the patient is able to ambulate with a single crutch on a slightly flexed knee without the knee buckling. On physical exam, a large effusion is present over his anterior knee. There is mild warmth and tenderness to palpation around the medial joint line. Muscle compartments in the leg are soft and pulses are 2+. Neurologic exam reveals normal motor and sensory function distal to the knee. The patient is able, but hesitant, to perform active or permit passive knee range of motion secondary to pain. There is increased knee laxity of 1 cm when an anterior force is applied to the tibia at 30° and 90°. There is no laxity with varus or valgus stress applied to the knee. Compression and axial rotation across the knee joint while extending it from a fully flexed position produces neither pain nor a palpable or audible snap.

---

J.F. Fleming III, MD (✉)

Orthopaedic Surgery, Harbor-UCLA Medical center, 1000 W. Carson Street, Torrance, CA 90509, USA  
e-mail: [jffleming@gmail.com](mailto:jffleming@gmail.com)

A. Beck, MD

Orthopaedic Surgery, Harbor-UCLA Medical center, 1000 W. Carson Street, Torrance, CA 90509, USA  
e-mail: [abeck510@gmail.com](mailto:abeck510@gmail.com)

K.W. Rolfe, MD, MPH

Orthopaedic Surgery, Harbor-UCLA Medical Center & Rancho Los Amigos Rehabilitation Center, 1000 W. Carson Street, 4th Floor, Torrance, CA 90509, USA  
e-mail: [kwrolfe@gmail.com](mailto:kwrolfe@gmail.com)

## Diagnosis

### What is the Differential Diagnosis for Acute Knee Pain and What Clues on History and Physical Examination Might Direct you Toward Specific Diagnoses?

Diagnosis	Comments
<i>Hemarthrosis, bone infarct</i>	History of hemophilia or sickle cell disease
<i>Septic arthritis</i>	Fever, unwillingness to bear weight or range a knee held constantly around 30° of flexion. <i>Neisseria gonorrhoeae</i> type common in sexually active young individuals
<i>Acute osteomyelitis</i>	Fever and constitutional symptoms especially in association with immunocompromised (HIV, sickle cell, diabetes, alcoholism, chronic corticosteroid use), intravenous drug abuse, or children
<i>Neoplastic</i>	Constitutional symptoms, typically more insidious onset (except acute fracture through tumoral bone); acute fracture across a benign preexisting bone lesion or cyst would not be distinguishable from ordinary fracture without imaging studies
<i>Inflammatory</i>	History of rheumatoid arthritis (flare up) or crystalline arthropathy; focal tenderness over the affected area (bursitis, tendinitis)
<i>Traumatic</i>	Onset of pain at time of acute sporting or vehicular injury; fractures associated with <i>unwillingness to bear weight</i> more than ligamentous or soft-tissue injuries, but may occur together; acute patellar or quadriceps tendon rupture prevents ability to actively, fully extend knee despite adequate passive motion
<i>Iatrogenic/ drugs</i>	History of recent knee injection (postinjection inflammation and/or infection)

#### Watch Out

Ligamentous injury classically presents with immediate swelling, while meniscal tears develops swelling the next day.

### What Is the Most Likely Diagnosis?

In a young healthy male with sudden knee pain immediately following a skiing accident, a traumatic etiology is most likely. Since the patient is able to bear weight, fracture is less likely, though not entirely ruled out. Anterior knee laxity on physical exam suggests anterior cruciate ligament (ACL) disruption. Varus and valgus stability go against associated medial collateral ligament (MCL) and lateral collateral ligament (LCL) disruption. As the patient's knee does not buckle despite a flexed knee gait during weight bearing in conjunction with no palpable tendon defects, quadriceps or patellar tendon rupture is less likely. Though commonly associated with ACL tears, meniscal tear is less likely in the presence of a negative McMurray sign (no pain, no palpable or audible snap with a compression and axial rotation maneuver of the knee while extending it from a fully flexed position).

## History and Physical Exam

### What are the Principle Components of the Knee Exam?

Component	Features
<i>Gait</i>	Look for obvious gait abnormalities
<i>Observation</i>	Fully expose and compare both knees, look for atrophy, past scars, swelling, bowing, and landmarks (e.g., patella, anterior tibial tuberosity)
<i>Palpation</i>	Temperature (e.g., warmth) and effusion (e.g., patella floats and “bounces” back when pushed down)
<i>Range of motion</i>	Active and then passive (e.g., clinician moves the joint), listen for crepitus
<i>Joint line tenderness</i>	Evaluate for medial or lateral meniscal injuries
<i>Neurovascular</i>	Check distal pulses and sensation of knee and lower legs
<i>Knee maneuvers</i>	Lachman's test, anterior drawer, McMurray's test, and pivotal shift tests (see Table 27.1)

**Table 27.1** Knee maneuvers

Structure	Clinical finding/test	Description
<i>Anterior cruciate ligament (ACL)</i>	Anterior drawer or Lachman's test	Knee flexed at 90°, forward traction on the lower leg causes the tibial plateau to move forward relative to the knee suggests torn ACL
<i>Posterior cruciate ligament (PCL)</i>	Posterior drawer test or "tibial sag" on 90° flexion	Knee flexed at 90°, posterior force on the lower leg causes the tibial plateau to move posteriorly relative to the knee suggests torn PCL
<i>Meniscal cartilage</i>	McMurray's test	Extending the knee from a fully flexed position (heels on buttocks) and simultaneously applying compression and axial rotation (torsion) across the joint; positive if pain or an audible or palpable snap (more specific) along the joint line signifying meniscal tear
<i>Lateral collateral ligament (LCL)</i>	Varus instability	Knee pressed laterally, foot pressed medially, significant laxity in this maneuver suggests LCL tear
<i>Medial collateral ligament (MCL)</i>	Valgus instability	Knee pressed medially, foot pressed laterally, significant laxity in this maneuver suggests MCL tear

## What Are the Classical Physical Exam Signs for Knee Injuries and How Are They Performed?

Table 27.1 describes all the clinical tests to evaluate knee pain. All are performed supine. Side-to-side comparison is most important to determine the presence of laxity or a soft end-point. For the pivot shift, the leg is lifted off the table while supported under the ankle. A valgus and internal compressive stress is applied while flexing the knee from full extension. As the knee flexes past 30°, a sudden clunk will occur as the iliotibial band reduces a subluxated knee if the ACL is disrupted. This test is considered pathognomonic for ACL disruption.

### Watch Out

Don't confuse McMurray's sign with Murphy's sign (stopping of inspiration with right upper quadrant palpation associated with acute cholecystitis).

## What is the Classic History for the Various Ligamentous Injuries in the Knee?

Ligament	Classic history
<i>Anterior cruciate ligament</i>	Posterior blow to the lateral knee
<i>Posterior cruciate ligament</i>	Anterior blow to the lateral knee
<i>Medial collateral ligament</i>	Lateral blow to the knee (varus stress)
<i>Lateral collateral ligament</i>	Medial blow to the knee (valgus stress)

## What Does a History of Locking or Catching Signify?

Locking or catching with range of motion of the knee is often referred to as mechanical symptoms and may signify a mechanical blockage to motion. This is most often associated with meniscal tears, especially mobile flaps. Other loose osteochondral bodies in the joint space can cause the same effect.

## Why Is It Important to Perform a Careful Vascular Exam?

Clinical entities like knee dislocation or proximal tibia fracture can pose a significant threat to the limb. Knee dislocations can damage the popliteal vessels creating a dysvascular limb which may lead to amputation if not recognized and treated. Pulses should always be assessed and ankle-brachial indices performed if there is any uncertainty.

### **Why Is It Important to Perform a Careful Neurologic Exam?**

Global instability after knee dislocation, significant ligamentous disruption, or fracture can damage the major nerves or branches traversing the region. Foot drop with damage to the peroneal nerve is among the most common. More aggressive or immediate stabilization of an unstable knee may be indicated to protect from or prevent further damage to these structures. Surgical exploration and nerve repair is sometimes needed.

### **What Is the Significance of Having Soft Muscular Compartments in the Lower Leg?**

This helps rule out compartment syndrome, which is a true surgical emergency with a limited window of time for intervention before irreversible tissue death.

### **What Is the Importance of Asking About Fever and Other Constitutional Symptoms Such as Fatigue, Weight Loss, Night Sweats, and Decreased Appetite?**

Constitutional symptoms are associated with tumors and infection and should be considered, even in the setting of trauma as these conditions can threaten the life and limb of the patient.

### **What Should Be Considered in Patients with Recurrent Fractures?**

Recurrent fractures may be attributed to alleged repeat minor trauma. However, one must consider a neoplastic lesion weakening the bone in appropriate patients. Osteosarcomas are malignancies that lay down bony osteoid material that can mimic healing fracture callus on radiographs. In children, parents often attribute musculoskeletal pains to the most recent daily fall of their child. The first clinical presentation may seem like a mere trauma but in reality be the first opportunity to recognize a malignancy or osteomyelitis.

### **What Is the Significance of Being Able to Bear Weight?**

Fractures and septic arthritis are less likely, though not precluded, when the patient can bear substantial weight on the limb.

### **Why Is It Important to Look for Lacerations or Wounds?**

Wounds or lacerations after a trauma may signify an *open fracture* which is also a surgical emergency.

---

## **Pathophysiology**

### **What Two Basic Mechanisms Lead to ACL Injury?**

Contact versus noncontact pivoting injuries. Contact injuries involve a direct blow to the knee, often a lateral or hyperextension blow to the knee (e.g., with a helmet as may be seen in football). However, noncontact ACL injuries are far more common and typically occur during awkward landings in pivoting sports including football, basketball, and soccer.

### **Is ACL Injury More Common in Men or Women?**

Among active sports participants, the incidence of ACL injury is 4–5 times more common in women for unclear reasons in part ascribed to differences in the pelvic anatomy and the influence of sex hormones. Since a greater percentage of men participate in at-risk sports relative to women, the overall occurrence remains greater in men.

## What Is the Terrible (aka “Unhappy”) Triad of the Knee?

MCL, ACL, and medial meniscus injuries

### Watch Out

Don't confuse the terrible triad of the knee with that of the elbow (elbow dislocation with coronoid and radial head fractures).

## What Is the Distribution of Blood Supply to the Meniscus and Why Is It Important?

The menisci receive blood peripherally from outside-in to cover only the outer 25–30 % of their diameter. Tears occurring in the outer “red” zone have the potential to heal and are often repaired. Inner tears in the “white zone” without a direct blood supply have little healing potential and are not repaired, but surgically debrided if needed.

## What Is the Significance of a “Popping” Noise on Traumatic Injury?

Although a “popping” noise on traumatic injury to the knee can occur with meniscal injuries, it is most commonly associated with ACL rupture. High tension on the ligament immediately before the tear may cause the audible noise. Some believe that the noise occurs due to sudden collision between the bone ends of the femur and tibia.

## What Injury Would You Expect from a Dashboard Knee Injury?

A dashboard knee injury occurs in a motor vehicle collision when a flexed knee hits the dashboard subjecting it to an anterior force. This mechanism is associated with posterior cruciate ligament (PCL) injury and a positive posterior drawer test.

## What Is the Normal Range of Motion of the Knee?

Range of motion of the knee is tested with the patient lying supine and the hip partially flexed. Normal range is 0–5° extension to 130–140° flexion.

## What Is the Significance of Being Unwilling (vs. Unable) to Range the Knee?

If the patient is unwilling to range the knee, then fracture or septic arthritis should be highly suspected. Without an acute trauma or x-rays showing fracture, septic arthritis should be considered and *arthrocentesis* (tapping the knee and sending the fluid for laboratory analysis) performed.

## What Is the Significance of Being Unable to Actively or Fully Extend the Knee While the Examiner Can Do So Passively?

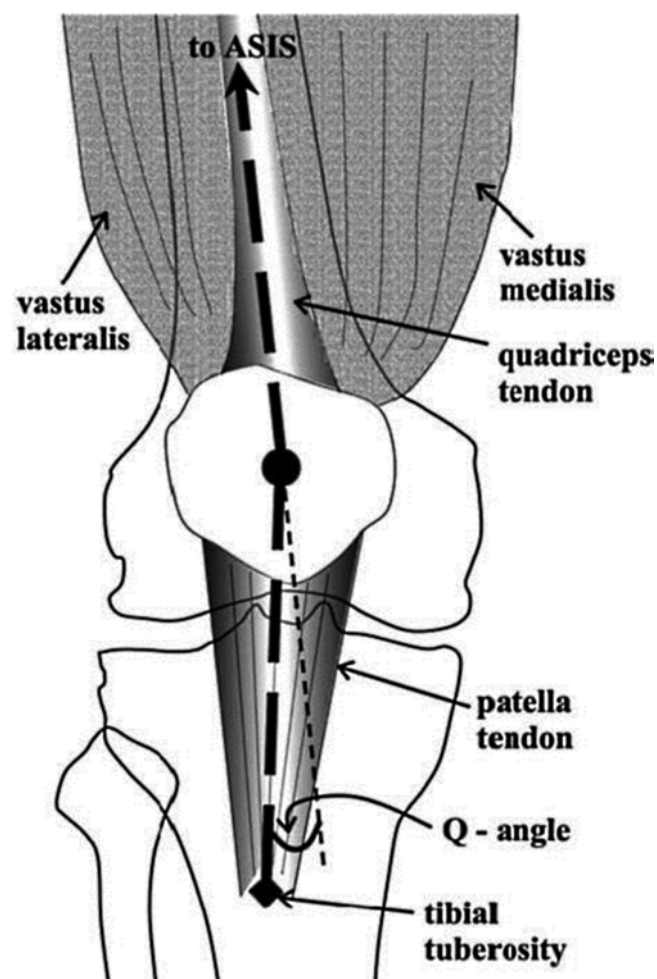
Inability to actively extend the knee to full extension suggests a mechanical block to motion versus disruption of the bones or tendons involved with knee extension. If passive extension is normal (but not active), then there is disruption of the quadriceps or patellar tendon or fracture of the patella or tibial tubercle. Note that these tendon ruptures are common in middle-aged, “weekend warrior” athletes.

## What About Pain at/or Near the Patella with an Intact Extensor Mechanism of the Knee?

Jumper's knee or patellar tendinitis is a common entity with pain along the patellar tendon near its attachment to the patella. A similar tendinitis may occur along the distal quadriceps tendon.

## Why Is It Important to Examine the Patella and Its Tracking?

The patella has often been called the "low back" of the knee, meaning its problems are often as difficult to treat as chronic low back pain. Patellar dislocations occur laterally and involve an increased Q-angle (Fig. 27.1). Flat feet and knock-knees (valgus) increase the Q-angle.



**Fig. 27.1** Measurement of the Q-angle is the angle formed by a line drawn from the ASIS to the patella and a second line from the patella to the tibial tuberosity (From Houghton KM. Review for the generalist: evaluation of anterior knee pain. *Pediatric Rheumatology* 2007;5:8. Open Access)

## Work-Up

### What Is the Next Step in the Work-Up of This Patient?

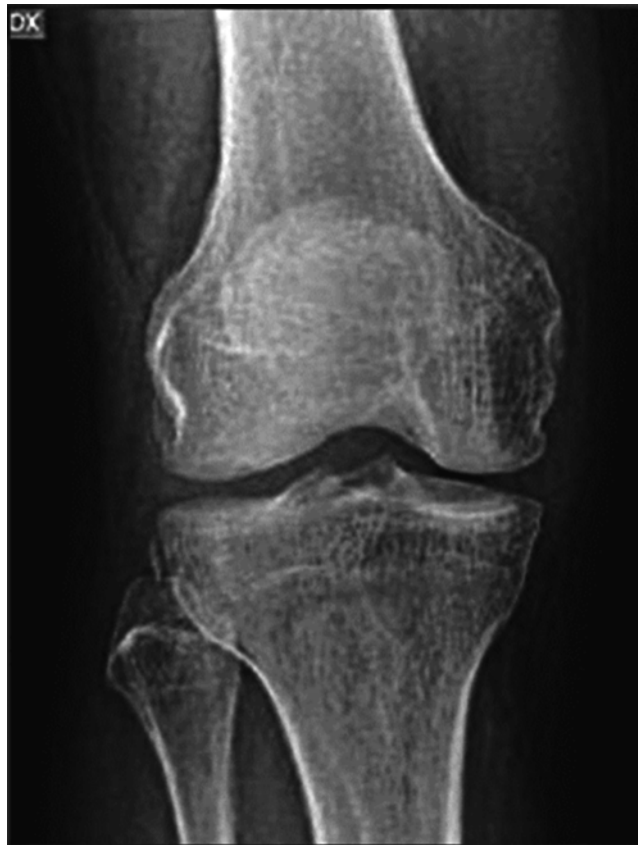Radiographs of the knee are taken to evaluate for fracture, alignment or deformity, infection, and tumor.

### What Radiographic Sign Is Pathognomonic for ACL Injury?

A Segond fracture or small fleck of bone avulsed from the lateral tibial plateau is almost universally associated with ACL disruption when it is seen (Fig. 27.2).

### What Is the Meaning of Patella Alta and Baja on an X-ray?

The patella may ride high (alta) due to unopposed pull from the quadriceps in the setting of a patellar tendon rupture. Conversely, it may ride low (baja) with quadriceps rupture.



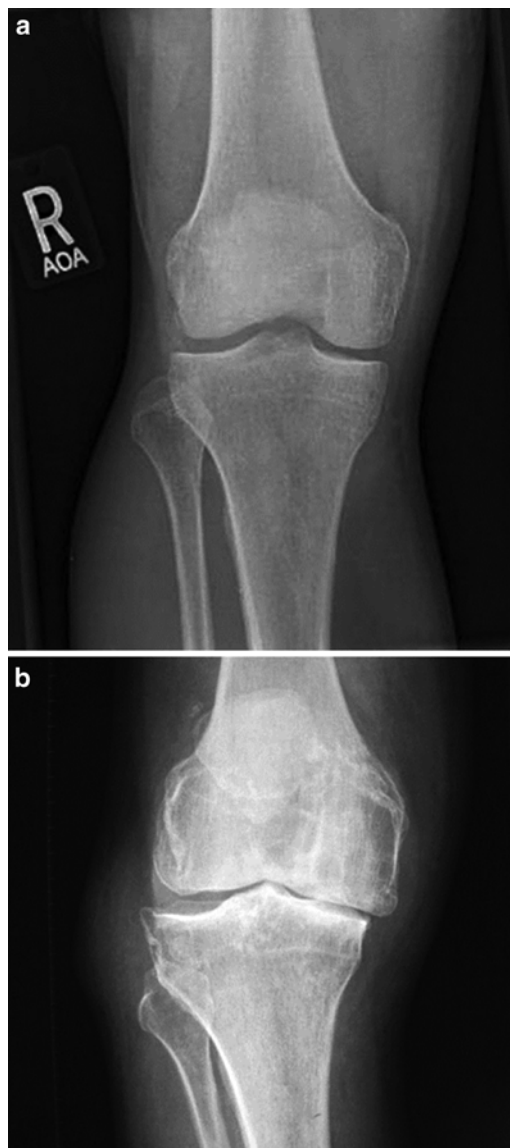
**Fig. 27.2** Segond fracture: lateral tibial plateau avulsion pathognomonic for ACL injury (With kind permission from Springer Science + Business Media: Orthopedic Sports Medicine, Anterior Cruciate Ligament Injuries, 2011, pg 346, Zaffagnini S et al., Fig. 26.2)

## What Are the Characteristic Radiographic Features of Osteoarthritis of the Knee and Why Is It Important to Consider After ACL Injury?

Radiographic changes consistent with degenerative arthritis in the knee include joint space narrowing, osteophytes (bone spurs), subchondral sclerosis, and subchondral cysts (Fig. 27.3). These changes are critical to recognize as ACL surgery is not appropriate in the setting of significant arthritis of the knee.

## What About Suspected Septic Arthritis or Crystalline Arthropathy?

A hot, swollen knee without a preceding trauma should prompt knee *arthrocentesis* (needle aspiration to obtain *synovial fluid* for culture and pathology including cell counts and crystal analysis). Unwillingness to bear weight or range the knee, especially with fever, suggests serious joint infection which is emergent. Gross purulence is infectious until proven otherwise though



**Fig. 27.3** (a) Normal radiograph of the knee (With kind permission from Springer Science+Business Media: European Orthopaedics and Traumatology. Primary meningococcal oligoarthritis of the knee—case report and review of the literature, 2, 2011, p 150, Abdul-Jabar HB et al., Fig. 1) (b) Arthritic knee (With kind permission from Springer Science+Business Media: Eur J Orthop Surg Traumatol. End-stage osteoarthritis of the knee presenting with foot drop. 17, 2007, p 400, Leonard & Murphy, Fig. 2)



**Watch Out**

Don't confuse arthrocentesis cell counts with those of cerebrospinal fluid (CSF) after lumbar puncture for meningitis, etc. Normal WBCs in CSF are up to 5 in adults and 20 in newborns, and 100–1,000 is highly likely to be a serious, infectious bacterial meningitis.

pseudogout can give this appearance as well. Pseudogout crystals are formed of calcium pyrophosphate and are positively birefringent. Gout crystals are formed of monosodium urate and negatively birefringent. White blood cell (WBC) counts in synovial fluid less than 200 are normal. Inflammatory conditions range from 200 to 50,000 and above 50,000 are infectious. There may be diagnostic ambiguity near the overlapping ranges between disease processes.

**What Imaging Would You Use to Confirm a Suspected ACL Injury?**

MRI is the best technique to evaluate the integrity of the ACL. Likewise, the menisci are best evaluated with MRI.

---

**Management****Is There a Role for Nonoperative Management of ACL Tears?**

Treatment for ACL injuries is made on an individualized basis. Partial tears to the ACL may occur from low-energy mechanisms, such as minor skiing accidents. These may be managed nonsurgically with activity modification, bracing, and physical therapy focused on strengthening the muscles which dynamically stabilize the knee, especially the hamstrings. Other indications for nonsurgical management of ACL injuries include older, less active individuals, those with advanced osteoarthritis, and those with an inability to tolerate surgery due to significant comorbidities. Note that acute symptomatic treatment includes the RICE formula: rest, ice, compress, and elevate.

**What Is the Management for the Patient in This Case?**

A young, healthy, athletic patient without preexisting arthritis involved in a high-energy injury that, most likely, wishes to return to a high level of athletic function is an excellent surgical candidate. Surgery entails arthroscopic *reconstruction* of the ACL, not repair. Reconstruction involves use of a tendon graft placed into bone tunnels across the knee in the femur and the tibia approximating the normal position of the ACL. Attempts at repair of the native ligament do not heal due to the intra-articular location and presence of synovial fluid which inhibits local healing.

**What Is the Management of a Meniscal Tear?**

Most clinicians try to exhaust conservative management before considering surgical repair. Most tears are small causing infrequent symptoms and can be managed successfully with the RICE approach. Surgery is considered for patients with persistent symptoms and/or disabling symptoms, and those involving large, complex tears in contact with the articular cartilage.

---

**Postoperative****What Are the Main Risks Associated with ACL Surgery?**

Risks include postoperative infection and septic arthritis which can damage precious cartilage which has virtually no capacity to regenerate and lead to early arthritis. In fact, apart from the primary goal of reestablishing knee stability to increase function, the long-term goal of ACL reconstruction is to slow the wear and tear breakdown of knee cartilage occurring with

abnormal knee motion with ACL dysfunction. This unproven hope is for many years longer of satisfactory native knee function to prevent or delay the need for knee replacement surgery upon reaching the stage of advanced symptomatic arthritis. Additional risks include knee stiffness, local saphenous neuroma from surgical incisions, and graft failure. Graft failure is much higher if a concomitant LCL disruption is missed and not treated. Poor or improper placement of the graft may also lead to ongoing instability or abnormal knee mechanics. A good postoperative rehabilitation program is also important to a good clinical outcome.

---

## Areas of Controversy

### What Are the Different Types of ACL Grafts Used?

Graft selection for ACL reconstruction includes *autograft* harvested from the patient (bone-patellar tendon-bone or hamstring tendon) versus cadaveric *allograft*. Advantages to autograft include decreased risk of disease transmission or immunologic reaction and faster incorporation of the graft. The cells of autograft are more viable as they are taken fresh from the patient at the time of surgery. Disadvantages to autograft include donor site morbidity such as anterior knee pain, weakness of knee flexion or pain with hamstring graft, and longer operating times. Allograft prevents donor site morbidity of autografts but carries a risk of disease transmission. Allografts are typically processed by freezing or irradiating to decrease immunogenicity and disease transmission, but the processing weakens the allograft and decreases cell viability and incorporation rates.

### What About ACL Injuries in Adolescents Who Have Not Completed Their Growth?

Since the ACL requires reconstruction and reconstruction involves drilling bone tunnels across the proximal tibia and distal femur, there is a risk of growth plate damage (physeal arrest) with ACL surgery in this age group. As a result, both physeal sparing and trans-physeal techniques have been attempted, though growth disturbance does not seem to differ between the techniques. Amount of remaining growth and risk of physeal arrest should be considered when deciding when to perform surgery on the ACL-deficient adolescent.

### Is Surgery Better Than Nonoperative Management for a Meniscal Injury?

A recent study randomized patients with meniscal injury to surgery or sham surgery (skin incision with no meniscal repair) and found no difference in outcome. The goal of surgery is to smoothen and abrade the torn meniscal edges and bordering synovium in an effort to promote healing.

---

## Areas Where You Can Get in Trouble

### Failure to Recognize a Knee Dislocation or Vascular Injury

The knee should be examined fully after significant trauma. Significant instability needs to be assessed and recognized on exam as it will change the acute management. Static radiographs may not reveal a globally unstable knee after dislocation due to spontaneous reduction or positioning of the knee during the x-ray. The vascular status of the limb must be considered with pulses and often the ankle-brachial index.

### Failure to Recognize a Septic (Infected) Knee Joint

If a septic knee is missed, the intra-articular cartilage can be completely destroyed by the bacteria. Cartilage has little to no capacity to heal, so the patient will be left with an end-stage arthritic knee joint with poor function.

## Summary of Essentials

### Diagnosis

- Acute trauma to knee with anterior knee laxity suggests ACL injury
- If patient can bear weight, fracture less likely

### History and Physical Exam

- Components of knee exam: gait, observation, palpation, range of motion, joint line tenderness, neurovascular, knee maneuvers
- Knee maneuvers: anterior drawer/Lachman's, posterior drawer, McMurray's test, varus/valgus instability
- Knee dislocations can damage vasculature creating dysvascular limb risking amputation
- Ligament injury presents with immediate swelling; meniscal injury has delayed swelling

### Etiology/Pathophysiology

- ACL Injury
  - Contact versus noncontact (more common) pivoting injuries
  - Audible pop during an acute sports-related injury involving an awkward landing or twisting mechanism
- Unhappy triad
  - MCL
  - ACL
  - Medial meniscus
- Q-angle in patellar dislocation

### Work-Up

- Start with radiographs to look for fracture, alignment or deformity, infection, and tumor
- MRI for confirmation

### Management

- Treatment made on individualized basis
- Exhaust all conservative options first
  - Rest
  - Ice
  - Compress
  - Elevate
- Consider nonoperative management for elderly and low-demand patients
- Surgery for reconstruction, not repair

### Postoperative

- Infection, knee stiffness, and graft failure
- Exhaust all conservative options before re-operating

## Suggested Reading

- Fu FH, Bennett CH, Lattermann C, Ma CB. Current trends in anterior cruciate ligament reconstruction. Part 1: biology and biomechanics of reconstruction. *Am J Sports Med.* 1999;27:821.
- Jackson JL, O'Malley PG, Kroenke K. Evaluation of acute knee pain in primary care. *Ann Intern Med.* 2003;139:575.
- Prodromos CC, Han Y, Rogowski J, et al. A meta-analysis of the incidence of anterior cruciate ligament tears as a function of gender, sport, and a knee injury-reduction regimen. *Arthroscopy.* 2007;23:1320.
- Spindler KP, Wright RW. Clinical practice. Anterior cruciate ligament tear. *N Engl J Med.* 2008;359:2135.

Aaron Beck, John F. Fleming III, and Kevin W. Rolfe

A 12-year-old African-American boy presents with right groin pain and a limp. He states that the pain is worse with walking and relieved by rest. The pain begins in his right groin and radiates to his right knee. The pain began about 1 month ago without antecedent trauma and has progressively worsened. He has no pain in any other joints or extremities. He denies any recent infections and reports no associated fevers, chills, or malaise. He participates in physical education at school, but is otherwise not involved in sports. He has no recent travel or camping trips and lives in an urban area. He takes no medications. There is no family history of joint problems. On physical examination, the patient is afebrile and appears to be moderately obese. The right lower extremity appears to be slightly externally rotated and he resists internal rotation. There is no leg length discrepancy. Neurologic and vascular exam are normal.

---

A. Beck, MD (✉)

Orthopaedic Surgery, Harbor UCLA Medical Center, 1000 W. Carson Street, Torrance, CA 90509, USA  
e-mail: [abeck510@gmail.com](mailto:abeck510@gmail.com)

J.F. Fleming III, MD

Orthopaedic Surgery, Harbor-UCLA Medical Center & Rancho Los Amigos Rehabilitation Center, 1000 W. Carson Street, 4th Floor, Torrance, CA 90509, USA  
e-mail: [jffleming@gmail.com](mailto:jffleming@gmail.com)

K.W. Rolfe, MD, MPH

Orthopaedic Surgery, Harbor-UCLA Medical Center & Rancho Los Amigos Rehabilitation Center, 1000 W. Carson Street, 4th Floor, Torrance, CA 90509, USA  
e-mail: [kwrolfe@gmail.com](mailto:kwrolfe@gmail.com)

## Diagnosis

### Differential Diagnosis for Groin Pain with a Limp or Refusal to Bear Weight

Etiology	History and Physical
Septic arthritis	Triad of fever, pain, and impaired range of motion; typically have underlying joint disease (e.g., rheumatoid arthritis)
Lyme disease	Ixodes tick bite ( <i>Borrelia burgdorferi</i> ); early signs include chills, fatigue, erythema chronicum migrans (bulls-eye rash); late signs include chronic synovitis, monoarthritis or oligoarthritis, aseptic meningitis
Psoas abscess	Fever, patient holds thigh in slight hip flexion and internal rotation, passive hip extension which stretches the psoas muscle is met with significant pain; can be associated with osteomyelitis of the spine or pelvic inflammatory disease
<b>Inflammatory</b>	
Juvenile idiopathic arthritis	Nonmigratory arthropathy affecting one or more joints for >3 months, morning stiffness, fevers
Transient synovitis	History of a recent upper respiratory tract or other viral infection in the presence of hip pain; most common cause of hip pain during childhood; pain is usually worse upon awakening and improves as the day progresses; often self-limiting
<b>Mechanical</b>	
Developmental dysplasia of the hip	Positive Barlow's and Ortolani's (provocation of hip dislocation or reduction, respectively), Galeazzi's sign (knees at unequal heights when hips/knees flexed), positive Trendelenburg sign; untreated will have delayed walking or abnormal gait
Legg-Calve-Perthes disease	Gradual progressive limp, slow onset of pain, decreased range of motion
Stress fracture	Insidious onset of pain with activity or repeated loading; typically, patient has no history of recent trauma; pain subsides at rest; local tenderness and swelling
Slipped capital femoral epiphysis	Obese, adolescent male aged 10–16 years old presenting with groin pain, painful limp, externally rotated hip, and not irritable (e.g., patient allows range of motion)
<b>Neoplastic</b>	
<i>Benign</i>	
Osteoid osteoma	Continuous, deep, aching bone pain in young patient; typically affects neck or back; unexplained, rigid, painful scoliosis
<b>Malignant</b>	
Osteosarcoma	Most common primary malignant bone tumor; more common in adolescent males; deep bony pain that progresses to palpable bony mass; typically affects distal femur
Ewing's sarcoma	Affects children 5–15 years old; bony pain, fever, fatigue, weight loss, pathologic fractures, palpable mass

### What Is the Most Likely Diagnosis?

The most likely diagnosis is slipped capital femoral epiphysis (SCFE). There are a number of factors from the patient's history and physical exam that support this diagnosis, including his age and ethnicity (discussed below).

## History and Physical

### What Important Demographic Factor Immediately Delimits the Differential Diagnosis for This Patient?

Age. Certain tumors or metastases which commonly effect the proximal femur in adults such as multiple myeloma or those that commonly spread to bone (recall the common "BLT and Kosher Pickle" mnemonic for breast, lung, thyroid, kidney, and prostate) are immediately off the list. Other tumors like acute lymphoblastic leukemia or neuroblastoma, which may present with joint pain initially, primarily occur in children younger than 5 years. Among the mechanical processes, transient synovitis peaks at 2–5 years (max around 12) and Legg-Calve-Perthes (or simply Perthes) at 4–8 years. Also, it would be highly unusual for developmental dysplasia of the hip (DDH) to have its first presentation at age 12 (screening for these begin at birth using Ortolani and Barlow maneuvers and ultrasound and orthopedic follow-up for any suspected abnormality). Coupled with the absence of fever and other constitutional symptoms, only a few diagnoses remain for groin pain with a painful limp in a 12-year-old.

## What Risk Factors Are Shared by Patients That Develop SCFE?

SCFE commonly presents at age 10–16 years old, males are more commonly affected than females (2:1), and the condition is more common among African-American and Polynesian ethnicities. *Obesity* is one of the strongest risk factors, presumably due to an increased load across the physis. 50 % of SCFE patients are at/or above the 90th percentile for weight; 70 % of patients are at or above the 80th percentile. Obesity creates increased mechanical loads across the proximal femoral physis, increasing the likelihood of slippage.

## What Is the Most Common Presentation of SCFE and Physical Exam Findings?

Children commonly present with an antalgic gait (painful limp) and occasionally an inability to weight bear because of pain. Pain associated with SCFE most commonly presents at the groin, but can also radiate and localize to the thigh or knee. On physical exam, SCFE patients present with decreased internal rotation, and the thigh is held most comfortably resting in external rotation. Internal rotation maneuvers recreate the pain. Though a painful limp can be a sign of tumor or infection, the absence of fever, malaise, and other constitutional symptoms goes against these.

## What Is the Significance of External Rotation of His Leg and Resisting Internal Rotation?

External rotation of the leg is the most common resting position of children with SCFE. This is the most comfortable position because of the mechanical direction of slippage. Often, obligatory external rotation can be observed in SCFE – when the hip is brought into flexion, the leg will involuntarily externally rotate.

## What If the Patient Holds the Thigh in Slight Hip Flexion and Internal Rotation?

This, especially in conjunction with fever or signs of infection, is classic for a psoas abscess with reflexive contracture of the psoas muscle due to spasm. Attempts at passive hip extension which stretch the psoas muscle are met with significant pain much like that seen in testing for compartment syndrome. Psoas abscess is often a sign of another underlying etiology like osteomyelitis of the spine, or pelvic inflammatory disease, especially in immunocompromised patients, so it is important to search for the primary source of the abscess.

### Watch Out

A hip held in flexion and internal rotation after a traumatic event, and without signs or symptoms of infection, is a hip dislocation until proven otherwise and is a surgical emergency. Hip dislocations carry a real risk of avascular necrosis.

## Why Is It Important to Examine the Hip in the Setting of Knee Pain?

Hip pathology may cause referred pain to the knee. Legg-Calve-Perthes disease and slipped capital femoral epiphysis can both initially present as knee pain, with no complaint of hip discomfort. Therefore, it is important to perform a complete physical exam to determine if knee pain is native to the knee or referred from the hip.

### Watch Out

In younger pediatric patients, a complaint of knee pain should lead to clinical and radiographic examination of the hip.

### **Why Is It Important to Consider Delayed Growth, Puberty, or Endocrinological Signs or Symptoms If SCFE Is Suspected?**

Several endocrine disorders are associated with SCFE including hypothyroidism, growth hormone abnormalities, renal osteodystrophy, hypopituitarism, and hyper- or hypoparathyroidism. These conditions can physiologically weaken the physis leading to slippage. Patients who are young (<10 years old) or thin (<50th percentile for weight) should be worked up for an underlying endocrinological disorder.

### **What Is the Significance of Pain that Radiates into the Groin?**

In this patient, the pain originates in the groin and radiates to the thigh toward the knee. Pain *originating* in the groin is highly suggestive of pathology in or around the hip joint. Pain that *radiates* to the groin is not typical of hip disease and suggests other pathology, particularly urologic, reproductive, or spinal etiologies.

#### **Watch Out**

Hernias, testicular disease, and ectopic pregnancies are important entities that cause pain which radiates to the groin.

### **Why Is It Important to Clarify the Meaning of Hip Pain on History?**

The average patient thinks hip pain is proximal and lateral thigh pain near the greater trochanter or buttock. The hip joint itself (femoral head articulation with the acetabulum) is well medial to this, and pain should be felt in the groin region, as expected from its anatomic position. If clarification reveals a lateral or buttock origin for the pain, then trochanteric bursitis, neurogenic claudication, sciatica, or sacroiliac joint pathology should be considered.

#### **Watch Out**

The shoulder is similar to the hip in that true glenohumeral arthritis is felt in the axilla (the armpit or “groin” of the shoulder). Unlike the hip joint where arthritis is common, musculoskeletal shoulder disease more commonly involves the rotator cuff or subacromial bursitis which is felt laterally over the shoulder akin to trochanteric bursitis of the hip.

### **What Would Be the Significance of a History of a Recent Upper Respiratory Tract or Other Viral Infection?**

A recent history of upper respiratory tract (URI) or viral infection in the presence of hip pain would suggest a postinfectious etiology, such as transient synovitis. Transient synovitis is the most common cause of hip pain during childhood, and though most common under 5, it can be seen into late adolescence. The pain is usually worse upon awakening and improves as the day progresses. As opposed to septic arthritis, transient synovitis presents with a mild or absent fever. The treatment for transient synovitis is usually observation as this condition is self-limiting. Note that this is a diagnosis of exclusion and a full work-up for septic arthritis, including aspiration if needed, must be done if there is any doubt.

### **Why Is It Important to Ask About Travel or Exposure to Wildlife?**

Recent travel or exposure to wildlife can raise the concern for special cases of septic arthritis. Travel outside the United States can be accompanied by an increased exposure to tuberculosis. Children are more likely than adults to present with extrapulmonary involvement. The most common site of musculoskeletal involvement is the spine, followed by large joints (hip, knee). Exposure to wildlife in the upper Midwest and New England can raise the concern for Lyme disease. Children with Lyme arthritis are usually able to bear weight, and the pain is typically less severe than with typical bacterial arthritis. The target lesion, erythema migrans, if seen or remembered, would lead to careful consideration and treatment for Lyme disease.



### **Why Is a Family History of Joint Disease Important?**

Family history of joint pain is an important clue for some disease processes. Developmental dysplasia of the hip (DDH) is thought to be largely multifactorial; however, family history is a strong risk factor. There is a 12 % risk of DDH when at least one parent is involved and a 36 % risk when both parents have a history of DDH. Additionally, juvenile idiopathic arthritis often has a genetic component.

### **Why Would a History of Corticosteroid Use Be Important?**

A history of steroid use can predispose the pediatric population to *avascular necrosis* of the femoral head, aka *osteonecrosis*. An adequate history is important because this diagnosis is clinically similar to Legg-Calve-Perthes disease (discussed in *pathophysiology*), which has an entirely different treatment algorithm.

### **What Are Other Important Risk Factors for Secondary Osteonecrosis of the Hip?**

In kids, sickle cell disease and marrow-replacing processes like Gaucher's disease are important risk factors. In adults, alcoholism, dysbarism (decompression sickness, "the bends," or caisson disease), trauma, and corticosteroid use are important etiologies to consider.

### **What Is the Significance of a Leg Length Discrepancy with This Clinical Presentation?**

Leg length discrepancy (LLD) points toward a mechanical pathology. Disruptions in the structural integrity of the long bones of the lower limb can lead to LLD. LLD is common in DDH and Legg-Calve-Perthes disease. Infections, tumor, or trauma can lead to disruption of the physis or bone, ultimately leading to a LLD, but not in the acute phase. SCFE may have a mild or apparent LLD due to the posture of the hip and thigh.

### **Why Is It Important to Examine the Back?**

A child with a longstanding LLD can develop a compensatory scoliosis.

### **What Is the Importance of Ability to Bear Weight or Range the Hip?**

Septic arthritis is a critical diagnosis and is highly likely in the setting of fever, refusal to bear weight, and refusal to allow even the slightest range of motion to the hip due to pain. An unstable SCFE may present similarly without the fevers or appearance of a sick patient. The unstable SCFE, therefore, presents more like an acute fracture, but without a specific antecedent trauma and is much less common than the stable type in which the patient can and will bear weight on the limb, though with a limp.

### **What Is an Antalgic Gait?**

Limping due to pain is referred to as an antalgic gait and is associated with a short stance phase on the affected limb. The patient wants to spend the least time needed on the painful limb to allow ambulation. Non-painful limping is common in early DDH and many neuromuscular disorders.

### **What Are the Component Steps in the Orthopedic Examination of a Painful Hip?**

Gait, observation/inspection, palpation, range of motion (active, passive), neurologic (motor, sensory), vascular (pulses), and any physical exam tests

## What Are Some Common Physical Exam Tests Utilized in the Examination of the Hip?

Test	Comments
<i>Thomas test for flexion contracture</i>	Patient lies supine and brings one knee to chest; if opposite leg is unable to remain completely extended, then this is indicative of a flexion contracture of the hip
<i>Trendelenburg test</i>	Patient in standing position and asked to lift one leg; the pelvis should remain level but if falls or dips inferiorly on the side of the raised leg, this is indicative of abductor muscle weakness on side of standing leg
<i>FABER</i>	<i>F</i> lexion, <i>A</i> Bduction, <i>E</i> xternal Rotation maneuver of the hip while patient is supine. If this position results in pain, it suggests sacroiliac joint pathology

## Pathophysiology

### What Is the Pathophysiology for the Orthopedic Mechanical Diagnoses?

Diagnosis	Pathophysiology and features
<i>Developmental dysplasia of the hip</i>	Abnormal hip development resulting in laxity, subluxation, or dislocation of the hip. Initial instability/laxity of the hip results in malpositioning of the femoral head in the developing acetabulum and incomplete formation of the hip socket. Dysplasia can lead to gradual dislocation, difficulty with ambulation, degenerative arthritis, and pain
<i>Legg-Calve-Perthes disease</i>	Unknown pathophysiology. Idiopathic osteonecrosis of femoral head. Typically presents age 4–8
<i>Stress fracture</i>	Repetitive overloading causing a fatigue fracture which overwhelms the body's remodeling and repair capacity, typically minimally or non-displaced
<i>Slipped capital femoral epiphysis</i>	Displacement of the metaphysis of the femoral neck from the epiphysis of the femoral head through the growth plate/physis, likely due to obesity and overloading of the physis, less commonly due to a weakened growth plate from an endocrinological disorder. The femoral neck displaces anteriorly and superiorly relative to the femoral epiphysis. Typically presents at age 10–16

## Work-Up

### What Laboratory Tests Would Be Useful and Why?

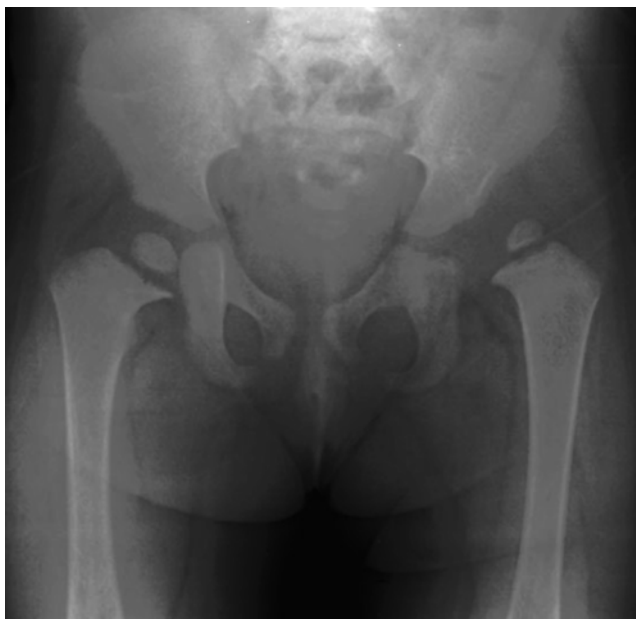Laboratory values are important to determine the etiology of musculoskeletal pathology. In this case, one must rule out infection via laboratory testing. Complete blood count, complete chemistry panel, erythrocyte sedimentation rate (ESR), and C-reactive protein (CRP) should be drawn to check for signs of infection. Septic arthritis in the pediatric population can be diagnosed using the Kocher criteria (Table 28.1). The predicted probability of septic arthritis is 3 % with one predictor, 40 % with two predictors, 93 % with three predictors, and 99 % with all four predictors. Additionally, blood cultures and joint aspirations should be drawn if there is a suspicion of infection.

### What Analysis Should Be Done If Joint Aspiration or Arthrocentesis Is Done for Suspected Infection?

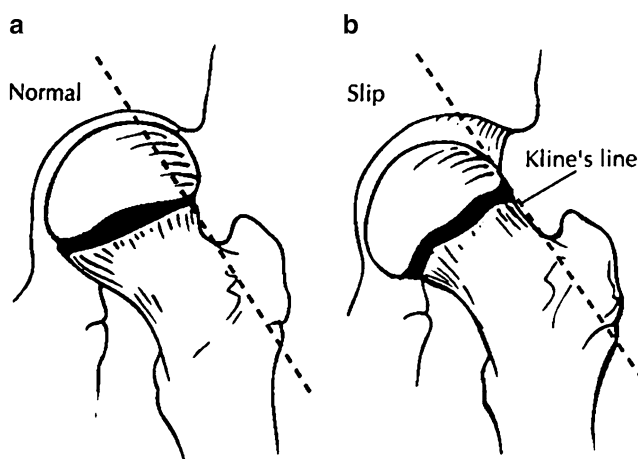
Cultures to include aerobic and anaerobic bacteria, fungi, and mycobacteria. Gram stain, fungal prep and acid-fast stains must be done in addition to culture. It is also important to perform cell counts and crystal analysis.

**Table 28.1** Kocher criteria to diagnose septic arthritis in pediatric population

Fever >38.5 C
Inability to bear weight
ESR > 20 mm/h
WBC > 12,000/ $\mu$ l



**Fig. 28.1** Developmental dysplasia of the hip radiograph showing normal right and subluxated left hip



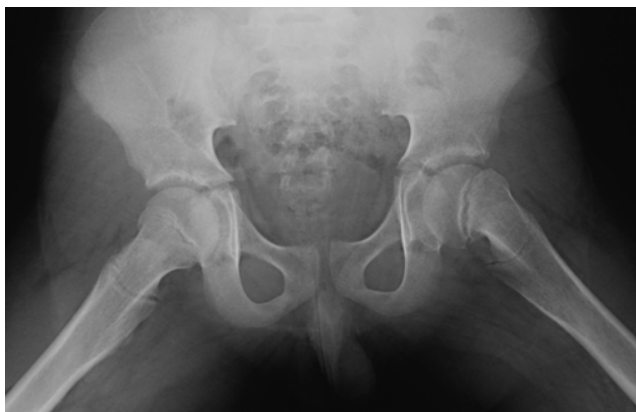**Fig. 28.2** SCFE schematic

### What Is the First Imaging That Would Be Recommended?

Plain film radiographs (x-rays) should be ordered first. AP and frog-leg lateral views of the pelvis should be ordered for any suspected hip pathology. If knee pathology is in question, additional plain radiographs of knee are ordered (AP, lateral, sunrise views). In pediatric populations, a complaint of hip or knee pain should both prompt hip radiographs.

### What Are the Classic X-ray Findings of Pediatric Orthopedic Mechanical Hip Disease?

Disease	X-ray finding
<i>Developmental dysplasia of the hip</i>	Subluxation or dislocation of the femoral head from the acetabulum. Difficult to assess on x-ray in infants (Fig. 28.1)
<i>Legg-Calve-Perthes disease</i>	Subchondral (under the cartilage) collapse of the bone of the femoral head
<i>Slipped capital femoral epiphysis</i>	Asymmetry of the femoral head on the neck. The ice cream appears to slide off the cone (Figs. 28.2 and 28.3)



**Fig. 28.3** SCFE radiograph (frog lateral) showing SCFE on left and normal right

### What Other Imaging Items Are Useful If the Diagnosis Is Unclear?

MRI is excellent at visualizing non-displaced stress fractures, early avascular necrosis or Legg Calve Perthes disease, as well as soft-tissue abnormalities of the ligaments, tendons, labrum, etc. MRI also adds to the work-up for local tumors and osteomyelitis about the hip. CT is excellent for fine evaluation of the bone tissue, but is used sparingly in children to avoid unnecessary radiation exposure. CT of the chest, abdomen, and/or pelvis is used in the work-up of malignant tumors to assess for metastases. Bone scans evaluate the metabolic activity of bone by recording uptake of venous injected radioactive material (i.e., technetium 99 m). They can be used to highlight an active area of infection or tumor, when the lesion is not otherwise evident (e.g., an osteoid osteoma, a small, but painful, benign bone tumor).

## Management

### What is the Management for the Following Items on the Differential?

<b>Infectious</b>	<b>Management</b>
Septic arthritis	Joint aspiration and blood cultures which dictate antibiotic selection; emergent incision and drainage
Lyme disease	Antibiotics (doxycycline, amoxicillin, or cefuroxime)
Psoas abscess	Antibiotics +/- incision and drainage
<b>Inflammatory</b>	
Juvenile idiopathic arthritis	DMARDs, NSAIDs, +/- steroid injections, frequent ophthalmologic exams; watch for C1–2 instability and myelopathy; as disease progresses, surgery of diseased joints is often necessary
Transient synovitis	Observation and NSAIDs; rule out septic arthritis
<b>Mechanical</b>	
Developmental dysplasia of the hip	0–6 months: Pavlik Harness 6–18 months: Surgical closed vs. open reduction with spica casting >18 months: surgical open reduction with pelvic osteotomies
Legg-Calve-Perthes disease	Most patients do not require treatment (symptomatic and supportive measures); treatment of advanced disease aims at <i>containment</i> (casting/bracing, femoral/pelvic osteotomies)
Stress fracture	Period of non- or protected weight bearing +/- casting/bracing
Slipped capital femoral epiphysis	In situ screw fixation across the capital physis
<b>Neoplastic</b>	
<i>Benign</i>	
Osteoid osteoma	Percutaneous radiofrequency ablation (RFA) if symptoms not controlled with NSAIDs
Other benign bone lesions	Observation vs. intralesional curettage and grafting
Pigmented villonodular synovitis	Arthroscopic removal of focal lesions; possible aggressive total synovectomy
<b>Malignant</b>	
Osteosarcoma	Neoadjuvant chemotherapy plus wide surgical resection
Ewing's sarcoma	Neoadjuvant chemotherapy plus wide surgical resection

DMARD=disease modifying antirheumatic drugs, NSAID=nonsteroidal anti-inflammatory drugs

---

## Complications

### What Are the Important Potential Complications of Surgery for SCFE?

There is a small window of bone for the screw to obtain purchase across the capital physis into the epiphysis from the neck. If the screw is a process too long, it may penetrate the hip joint and destroy the cartilage, known as chondrolysis. If the screw is too short, further slippage and dysfunction may occur, often necessitating additional larger-scale surgeries to correct the alignment of the hip. Avascular necrosis is also a dreaded complication.

---

## Areas of Controversy

### Do Both Hips Require In Situ Screw Fixation in Patients with SCFE?

At the time of presentation, most patients present with unilateral SCFE (80 %). Ultimately, bilateral involvement ensues in 10–60 % of cases. When a patient presents with unilateral SCFE requiring surgical fixation, some surgeons support prophylactic fixation of the contralateral, unaffected hip. It has been suggested that contralateral fixation should be considered in high-risk patients. Patients with a high risk for slippage of the contralateral hip include those younger than 10 years old, those with endocrinopathies, renal osteodystrophy, or a history of radiation therapy.

---

## Areas Where You Can Get in Trouble

### Never Miss Septic Arthritis

Most of the conditions in the differential for this case do not require absolute immediate intervention though symptomatic SCFEs are typically admitted and surgically pinned on an urgent basis. The only exception to this is septic arthritis due to typical bacterial pathogens like staphylococcus or streptococcus, which is a surgical emergency. Irreversible cartilage damage leading to end-stage destruction and dysfunction of the joint can occur in a matter of hours, so every minute counts. Thus, it is important to investigate and attempt to rule out this diagnosis early in the workup. The patient's history and laboratory values are primarily used to make the diagnosis of septic arthritis. Fever with refusal to move or bear weight on the joint is septic until proven otherwise. Laboratory values can be used along with the Kocher criteria to confirm the diagnosis. Once septic arthritis is suspected, the patient should be taken to the OR for emergent incision and drainage.

---

## Summary of Essentials

### History and Physical

- Obese, adolescent male aged 10–16 years old presenting with groin pain, painful limp, externally rotated hip, and not irritable (e.g., patient allows range of motion)
- Knee pain is referred from hip pathology in young children until proven otherwise

### Pathophysiology

- Excess loading across the physis causes slippage of the head on the neck of the femur; more correctly the epiphysis on the metaphysis
- Predisposing factors for weak physis in SCFE
  - Endocrine disorders
  - Osteodystrophy
  - Hypothyroid/hypopituitarism

---

## Work-Up

- SCFE confirmed by displacement of proximal femoral epiphysis on metaphysis seen on AP and/or frog lateral view of the hip
- Rule out emergent septic arthritis

## Management

- Admission to hospital for urgent in situ surgical pinning of the hip with a single screw
- Short period of protected weight bearing with crutches

## Complications

- Screw too short, inadequate fixation, additional slippage, avascular necrosis

---

## Suggested Reading

- Katz DA. Slipped capital femoral epiphysis: the importance of early diagnosis. *Pediatr Ann.* 2006;35(2):102–11.
- Kehl DK. Slipped capital femoral epiphysis. In: Lovell WW, Winter RB, Morrissy RT, Weinstein SL, editors. *Lovell & winter's pediatric orthopaedics*. 4th ed. Philadelphia: Lippincott, Williams & Wilkins; 1996.
- Kocher MS, Zurakowski D, Kasser JR. Differentiating between septic arthritis and transient synovitis of the hip in children: an evidence-based clinical prediction algorithm. *J Bone Joint Surg Am.* 1999;81(12):1662–70.
- Shultz WR, Weinstein JN, Weinstein SL, Smith BG. Prophylactic pinning of the contralateral hip in slipped capital femoral epiphysis: evaluation of long-term outcome for the contralateral hip with use of decision analysis. *J Bone Joint Surg Am.* 2002;84-A(8):1305–14.
- Uglow MG, Clarke NM. The management of slipped capital femoral epiphysis. *J Bone Joint Surg Br.* 2004;86(5):631–5.
- Weinstein SL, Mibarak SJ, Wegner DR. Developmental hip dysplasia and dislocation. *J Bone Joint Surg Am.* 2003;85:1824–32.

Arezou Tory Yaghoubian and Kevin W. Rolfe

A 45-year-old seamstress presents to the clinic with a 4-year history of paresthesias of the volar right thumb, index, and middle finger with associated pain. Patient notes symptoms are worse at night. She has no past medical history and no history of cancer. On examination, patient has decreased sensation on the volar thumb, index, and middle finger as well as the dorsal finger tips and a positive Tinel's sign and Phalen's test at the wrist. Strength in her abductor pollicis brevis is normal at 3/5 compared to the contralateral side and she has moderate thenar atrophy, but no hypothenar or intrinsic muscle atrophy. The hand is well perfused and there are no surgical or traumatic scars of the hand or wrist. Bilateral radial and ulnar pulses are normal.

## Diagnosis

### What is the Differential Diagnosis?

Etiology	Differential diagnosis
<i>Vascular</i>	Thoracic outlet syndrome, vasculitic neuropathy
<i>Infectious</i>	Medical neuropathy (e.g., leprosy, Lyme disease, HIV, hepatitis, post-herpetic neuralgia)
<i>Neoplastic</i>	Pancoast tumor invading brachial plexus, intracranial neoplasm, peripheral nerve tumor (e.g., schwannoma)
<i>Inflammatory or degenerative</i>	Cervical root pathology (radiculopathy), cervical cord pathology (myelopathy), carpal tunnel syndrome, pronator syndrome, cubital tunnel syndrome, ulnar tunnel (Guyon's canal) syndrome, radial neuropathy
<i>Traumatic</i>	Injury (median nerve, brachial plexus, spinal nerve or cord), post-traumatic syrinx, complex regional pain syndrome (CRPS)/reflex sympathetic dystrophy (RSD)
<i>Iatrogenic/drugs</i>	Local radiation-induced or systemic chemotherapy-induced plexopathy or neuropathy, injury from prior surgery
<i>Metabolic/endocrine</i>	Diabetic or other medical peripheral neuropathy including hypothyroidism, vitamin deficiency, heavy metal or other toxicity
<i>Autoimmune</i>	Multiple sclerosis (MS), Guillain-Barré Syndrome (GBS), sarcoidosis

A.T. Yaghoubian, MD (✉)  
 Plastic and Reconstructive Surgery, UCLA, 200 UCLA Medical Plaza, Los Angeles, CA 90095, USA  
 e-mail: [ayaghoub@ucla.edu](mailto:ayaghoub@ucla.edu)

K.W. Rolfe, MD, MPH  
 Orthopaedic Surgery, Harbor-UCLA Medical Center & Rancho Los Amigos Rehabilitation Center, 1000 W. Carson Street, 4th Floor, Torrance, CA 90509, USA  
 e-mail: [kwrolfe@gmail.com](mailto:kwrolfe@gmail.com)

## What Clues on History and Physical Examination Might Direct you Toward Specific Diagnoses?

Diagnosis	History/physical
<i>Thoracic outlet</i>	Positive Adson's or Wright's test, ulnar-sided symptoms most likely
<i>Medical neuropathy (infectious, metabolic, iatrogenic)</i>	Often diffuse and bilateral; history of cancer or its treatment, HIV, diabetes, nutritional deficiency, or toxic exposure
<i>Traumatic</i>	Acute injury with new onset of symptoms usually obvious; CRPS/RSD occurs later to a previously injured area that never fully recovered
<i>Autoimmune</i>	Typically more diffuse findings often including weakness (MS, GBS) or other systemic findings of the lung (sarcoid) or eye (MS)
<i>Cervical root</i>	Dermatomal distribution (vs. peripheral nerve), positive Spurling's test
<i>Cervical myelopathy</i>	Hyperreflexia, hand clumsiness, and gait unsteadiness on exam
<i>Carpal tunnel</i>	Positive Tinel's, Phalen's, or Durkan's test; median distribution of sensory symptoms
<i>Pronator syndrome</i>	Overlaps carpal tunnel, palmar cutaneous branch over thenar eminence also affected
<i>Other compressive neuropathies</i>	Radial or ulnar syndromes affect their respective peripheral nerve distributions or muscles; key is remembering the anatomy and innervation

### What Is the Most Likely Diagnosis?

Carpal tunnel syndrome. Nighttime dysesthesias in the median nerve distribution to only one hand without prior injury or congenital defect, particularly in association with isolated thenar muscle wasting is most likely carpal tunnel syndrome and is highly specific for this clinical entity. The differential diagnosis is very broad as carpal tunnel syndrome rarely presents exactly in the median nerve distribution, is often bilateral, and often occurs in association with other overlapping aches, pains, and medical conditions like diabetes. This makes the diagnosis more challenging.

## History and Physical

### What Is the Most Common Nerve Entrapment Syndrome in the Upper Extremity?

Carpal tunnel syndrome (CTS). The condition affects approximately 1 % of the general population and 5 % of the working population engaged in repetitive motion and grasping activities. Reports of prevalence of up to 25 % or more have been made for full-time computer operators.

### What Are Key Components in the Hand History Portion of the Exam?

Length of symptoms, sensory distribution of symptoms, history of dropping things, occupation or activity, nighttime symptoms (or worse at night, often needing to shake or wring the hands out vigorously), previous treatments (corticosteroid injection, wrist splints), and hand coordination. Of course, complete medical and surgical histories are also extremely important.

### What Is the Self-Administered Hand Diagram?

A blank hand diagram is given to the patient to delineate the bothersome areas front and back. Patients who diagram a median nerve distribution or close to it (the volar/palmar 3½ digits – thumb, index, middle, and half of the ring) are very likely to have carpal tunnel syndrome.

### What Are the Best Known Classic Signs of Carpal Tunnel Syndrome?

Tinel's sign and Phalen's test. Tinel's sign is elicited by gently percussing over the median nerve at the carpal tunnel. A positive sign is present if the patient describes an electrical shock sensation in the median nerve distribution. Phalen's test is performed by having the patient place the dorsal sides of each hand against each other in a position of maximal



wrist flexion for 30–60 s. The test is considered positive if the patient reports new or worsening paresthesias in the median nerve distribution of the affected hand(s). Both tests have variable sensitivity and specificity.

### **What Is Durkan’s Median Nerve Compression Test?**

Durkan’s involves squeezing the patient’s wrist with direct compression over the median nerve at the carpal tunnel using the examiner’s thumb. A positive test is obtained if the patient reports new or worsening numbness or tingling in some portion of the median nerve sensory distribution to the hand within 30–60 s.

### **Which of the Provocative Tests Are Thought to Be the Most Sensitive for CTS?**

Durkan’s median nerve compression test is thought to be the most sensitive for CTS.

### **Are There Any Other Overlapping Median Nerve Diagnoses to Consider?**

Proximal median nerve compression at the elbow often referred to as pronator syndrome, acute carpal tunnel syndrome, traumatic median nerve injury, or median nerve tumor (e.g., schwannoma).

### **What Physical Exam Finding Helps Distinguish Proximal Median Nerve Compression at the Elbow from Compression at the Carpal Tunnel?**

The palmar cutaneous branch of the median nerve branches prior to the carpal tunnel and travels above the transverse carpal ligament. It innervates the skin over the thenar eminence. Thus typical carpal tunnel syndrome will not show sensory dysesthesias in this area, whereas pronator syndrome will.

### **What Findings Help Distinguish Carpal Tunnel Syndrome from Cervical Spine Root Pathology?**

Much like the straight leg raise for sciatica of the lumbar spine, Spurling’s test may be used to elicit cervical root pathology (radiculopathy). The patient is asked to extend the neck, tilt and turn the head laterally to the affected side to determine if the hand dysesthesias occur or worsen with the maneuver.

#### **Watch Out**

C6 and C7 nerve roots overlap the median nerve distribution to the hand and are often confused with it. A key sensory distinction is that carpal tunnel syndrome does not affect the dorsal hand except for the finger tips. C6 and C7 nerve roots also affect the dorsum of the hand in the radial nerve distribution in addition to the median distribution.

### **What Is Thoracic Outlet Syndrome and What Confusion Arises from This Diagnosis on Physical Exam with Spinal Root Pathology?**

Thoracic outlet syndrome involves compression of the lower brachial plexus (ulnar symptoms predominate) or compression of the subclavian vessels between the anterior and middle scalene muscles, often associated with a *cervical rib* (check x-ray for this). Two classic tests are mentioned, Adson’s and Wright’s, both of which are frequently confused with the more useful Spurling’s test used for cervical radiculopathy. Adson’s test involves extension of the shoulder with the neck turned *toward* the affected side and may reproduce symptoms or cause reduction or loss of the pulse at the wrist. Wright’s test involves abduction and external rotation of the shoulder with the neck rotated *away* from the affected side and may similarly reproduce symptoms or cause reduction or loss of the pulse at the wrist.

**Watch Out**

Look for a Pancoast tumor of the lung on the x-ray if the presentation suggests thoracic outlet syndrome symptoms or brachial plexopathy.

**What About Myelopathy?**

Myelopathy is a dangerous and irreversible entity that often presents with hand pains or dyesthesias, but not neck pain. It should always be considered, especially when the hand pains do not follow an exact pattern of carpal tunnel syndrome. Hyperreflexia (and pathologic reflexes like Hoffmann's or suprapatellars) and heel-toe tandem gait should be checked. The patient may likewise complain of dropping things, but also incoordination of the hands for fine motor skills and decreased balance during ambulation. Many patients are referred to hand surgeons for alleged carpal tunnel syndrome which is really myelopathy. A neurologic exam is key, especially reflexes.

**What Is Acute Carpal Tunnel Syndrome?**

Acute CTS may be seen after a fracture or dislocation of the distal radius or wrist with acute compression of the median nerve.

**Watch Out**

Acute CTS is an emergency and requires immediate reduction of the fracture or dislocation and often surgical release of the carpal tunnel.

---

**Pathophysiology****What Nerve Is Compressed in CTS?**

The median nerve is compressed in CTS.

**What Does the Median Nerve Innervate in the Hand?**

Median nerve innervates the thenar muscles (abductor pollicis brevis, flexor pollicis brevis – superficial head and opponens pollicis) and the two radial lumbricals.

**What Is the Sensory Distribution of the Median Nerve in the Hand?**

Sensory distribution provides sensation to the radial volar 3.5 fingers and dorsal tips (thumb, index, middle, and half of the ring).

**Watch Out**

Finger numbering is not used by hand surgeons as it is unclear (i.e., is finger number 1 the thumb or the small finger, or is finger 1 the index and the thumb considered separately?). Always label the digits as thumb, index, middle, ring, and small fingers. If numbers are used on a test, the thumb is 1, index 2, middle 3, ring 4, and small 5 by convention, but bear in mind numbers are not ideal.

### **What Is the Origin of the Median Nerve from the Cervical Spine Roots?**

The origin of the median nerve from the cervical spine roots is C5-T1.

### **Where Is the Median Nerve Located in the Wrist?**

The median nerve is located in the carpal tunnel.

### **What Are the Boundaries of the Carpal Tunnel?**

Carpus dorsally (floor) and transverse carpal ligament volarly (roof). The scaphoid, trapezium, and sheath of flexor carpi radialis form its radial margin. The ulnar boundary consists of the triquetrum, hook of the hamate, and the pisiform.

### **How Many Structures Course Through the Carpal Tunnel and What Are the Contents of the Carpal Tunnel?**

10 (9 tendons and 1 nerve). Flexor digitorum superficialis (4), flexor digitorum profundus (4), flexor pollicis longus (1), and the median nerve (1). The median nerve is the most superficial structure in the carpal tunnel.

### **What Is the Pathophysiology of Carpal Tunnel Syndrome and Potential Causes?**

Idiopathic. The primary reason leading to the development of carpal tunnel syndrome is an increase in the interstitial pressure in the carpal tunnel that affects the median nerve. This increased pressure has numerous purported causes. In the vast majority of cases, however, no underlying etiology is identified despite a pathologic inflamed synovial tissue.

### **What Are the Major Risk Factors for Carpal Tunnel Syndrome?**

Women are affected 2–3 times more often than men with the most common age range of 40–60 years. Other risk factors include obesity, *pregnancy*, smoking, *activities involving repetitive movements or sustained wrist flexion or extension*, rheumatoid arthritis, *hypothyroidism*, and alcoholism. There is also a higher incidence among certain metabolic disorders like chronic kidney disease.

### **What Is the Significance of Thenar Wasting?**

Since the recurrent motor branch of the median nerve innervates the thenar muscle mass, long-standing or severe carpal tunnel disease can result in denervation of the thenar muscles. The profile of the thenar eminence of both hands as well as the strength of abductor pollicis brevis (palmar abduction) should always be checked.

### **What Are the Three Stages of Median Nerve Compression and Why Are They Important?**

Stage 1: Sensory symptoms (numbness, pain, tingling) at night. Stage 2: Symptoms occur also by day. Stage 3: Motor symptoms of weakness and/or muscle wasting, too. The importance is that later stages, especially stage 3, may not show positive findings like Tinel's, Phalen's or Durkan's test. The nerve is no longer hyperexcitable, but dying and hypoexcitable and does not respond to these maneuvers. These stages account for much of the variability in the sensitivity and specificity of these exam signs. As important, later stages of CTS, like myelopathy, are largely irreversible and surgical intervention should be entertained early to prevent progression.

## How Does the Presentation of a Median Nerve Lesion at the Elbow Differ from a Lesion at the Wrist?

Do not confuse carpal tunnel syndrome with the lesions described after acute laceration or injury to a nerve at the wrist or elbow, whether median or ulnar, which result in various claw deformities or dysfunctions. A median nerve laceration at the elbow results in the “hand of benediction” *when trying to form a fist*. Since the flexor digitorum profundus (FDP) tendons to the index and middle finger as well as the flexor pollicis longus (FPL) to the thumb do not function in a high median nerve lesion (elbow), only the ring and small fingers form the fist and the hand looks like that of papal benediction when trying to do so. The hand of benediction would not occur in a low median nerve lesion at the wrist below the innervation of those muscles.

## What About the Ulnar Claw?

Clawing of the hand refers to extension of the metacarpophalangeal (MP) and flexion of the interphalangeal (IP) joints of the hand. Three sets of intrinsic muscles normally afford counterbalancing MP flexion and IP extension (i.e., palmar interossei, dorsal interossei, and lumbricals). In an ulnar claw, all intrinsic muscles are denervated except the radial two lumbricals. Thus the index and middle finger are slightly less affected.

### Watch Out

Though a high ulnar lesion is worse than a lower one prognostically, a high lesion has a less severe hand claw as the FDP tendons of the ring and small fingers are also denervated, and so this lessens their resting tone contribution to the claw through IP joint flexion.

## What Is Froment’s Sign?

Froment’s sign is positive (abnormal) when the examiner can easily pull a flat piece of paper from the hand of the patient who uses thumb IP flexion via the FPL tendon of the median nerve (anterior interosseous branch) to grasp the paper. This occurs in an ulnar palsy when the strong thumb adductor which would normally hold the paper firmly between the thumb and the side of the index finger (i.e., key pinch, as in the manner in which a key is held in the hand) is denervated.

## What Systemic Condition Is Often Associated with CTS?

Hypothyroidism. No study clearly defines the relationship between hypothyroidism and CTS. One proposed mechanism involves the associated myxedema seen in patients with thyroid disease. The excess deposition of glycosaminoglycans and hyaluronic acid in subcutaneous tissue and the median nerve sheath may contribute to the development of CTS.

---

## Workup

### How Is Carpal Tunnel Diagnosed?

Exam and history. Semmes-Weinstein filament testing (as for diabetic or neuropathic feet) is the most sensitive sensory modality. Electromyography/nerve conduction studies (EMG/NCS) are useful in equivocal cases, typically due to an uncertain distribution of the symptoms. Classic findings on NCS are increased latencies and decreased conduction velocities across the wrist, although, EMG can be helpful. EMG is most useful to ruling out other pathologies. EMG may show slowing of median sensory or motor nerve conduction velocity at the wrist, prolonged distal motor or sensory latency, or denervation of the abductor pollicis brevis muscle.

## What About All Those Medical Neuropathies?

There are myriad of medical neuropathies which may need to be ruled out and which may overlap with CTS. Remember, CTS often presents in an inexact distribution or bilaterally and often in association with an aging person with overlapping clinical entities. The approach of the neurologist is to rule out treatable causes of neuropathy before embarking on symptomatic treatment using drugs like gabapentin. The workup will include EMG/NCS, multiple screening labs (vitamin deficiency, heavy metal or other toxicity, infection, thyroid disease, etc.), spinal tap, and/or nerve biopsy. Highly testable laboratory screening items include vitamin B12 (subacute combined degeneration of the cord), RPR for syphilis (tabes dorsalis), HIV, thiamine (alcoholism), TSH for thyroid disease, ANA (autoimmune disease), HbA1c (diabetes), and CRP (inflammatory process).

## What About Cervical Spine Disease?

A MRI and x-rays of the cervical spine would evaluate root or cord pathology.

### Watch Out

If patient cannot have a MRI due to an incompatible stent, pacemaker, etc., then the test of choice for spinal pathology is a CT *myelogram*. This involves a dural puncture and injection of contrast into the thecal sac to outline the spinal cord and nerve roots. It is not the same as a CT with intravenous contrast injected peripherally.

---

## Management

### What Is the Initial Treatment for Carpal Tunnel Syndrome?

Splinting of the wrist (not hand) in a neutral position. This position affords the lowest pressure in the carpal tunnel. NSAIDs and activity modifications are also first-line treatment modalities.

### What Is the Second Line of Treatment?

Carpal tunnel injection with local anesthetic and corticosteroid medication. Response to steroid injection is a good prognostic indicator for improvement with surgery if later needed. Similarly, failure to respond to injection (at least temporarily) suggests surgery is unlikely to improve symptoms.

### What Are Indications for Surgical Intervention for CTS?

Failure to respond adequately to conservative nonoperative management or thenar motor involvement is an indication for surgical intervention for CTS.

### Watch Out

Thenar atrophy or denervation of the abductor pollicis brevis muscle on EMG should prompt early surgical treatment as these are late-stage findings and largely irreversible. Surgery is primarily to prevent progression at this point.

---

## **What Is the Gold Standard Treatment for CTS?**

Carpal tunnel release which is surgical cutting of the transverse carpal ligament, the roof of the carpal tunnel. This is performed through a small open incision or endoscopically. Neurolysis or manipulation of the median nerve and its tissue coverings *does not* improve outcomes and are not typically performed.

## **How Is CTS Associated with Hypothyroidism Managed?**

This is initially treated conservatively with splinting of the wrist in a neutral position and NSAIDs while the hypothyroidism is treated. Typically, once the hypothyroidism is resolved, so will the CTS.

---

## **Complications**

### **What Are the Complications of Carpal Tunnel Release?**

Injuries to the median nerve, recurrent motor branch, or palmar cutaneous branch; chronic pain including neuroma, scar, or CRPS/RSD; injury to the superficial palmar vascular arch, infection, hematoma, and inadequate release; and recurrence are complications of carpal tunnel release.

---

## **Areas of Controversy**

### **Endoscopic Versus Open Carpal Tunnel Release**

Though long-term outcomes are equivalent, endoscopic release affords a quicker surgical recovery. However, the endoscopic technique has a higher rate of inadequate release of the transverse carpal ligament.

### **Need for EMG/NCS**

CTS is a clinical diagnosis and EMG/NCS is not required to treat it. It adds additional cost and is an uncomfortable test for most patients. When the diagnosis of CTS is less clear, it is a valuable test to consider, but practitioners vary as to their threshold to order the test.

---

## **Areas Where You Can Get in Trouble**

### **What Is the “Million Dollar Nerve”?**

The recurrent motor branch of the median nerve can be injured if the transverse carpal tunnel ligament is transected too radially. This nerve has a variable anatomic course and sometimes runs through the ligament without recurring thereby increasing risk of its transection. It has been called the million dollar nerve as iatrogenic injury to it has led to many million dollar lawsuits. The thumb will show greatly impaired function if the nerve is injured.

### **Injury to the Palmar Cutaneous Branch**

This nerve lies above the transverse carpal tunnel and helps distinguish proximal from distal median nerve compression as mentioned above. It can be easily cut during surgical release of the carpal tunnel and may lead to a very painful and difficult-to-treat neuroma despite improvement in carpal tunnel syndrome symptoms.

## Failure to Recognize Acute Carpal Tunnel Syndrome

This is an emergency. It typically presents after an acute fracture or dislocation around the wrist or distal radius and requires immediate orthopedic reduction and/or surgical release of the carpal tunnel.

## Failure to Recognize Spinal Pathology

Though root pathology is important and may overlap CTS, myelopathy is largely irreversible and may lead to paralysis if masquerading as CTS. Both CTS and myelopathy often present with hand numbness or tingling and complaints of dropping things. For myelopathy, check for hyperreflexia, gait imbalance, and ask about hand incoordination like deterioration in fine motor skills of the hand-like handwriting.

## Failure to Recognize a Treatable Neuropathy?

Remember to consider the medical workup for neuropathy, including thyroid disease and diabetes.

## Failure to Recognize Tumor

Pancoast lung tumors may invade the brachial plexus and masquerade as CTS. Also, rarely, a brain tumor may present initially with isolated hand symptoms.

---

## Summary of Essentials

### History

- Sensory dysesthesias in the median nerve distribution (3<sup>1</sup>/<sub>2</sub> radial digits volarly and dorsal tips), dropping things, symptoms worse at night time, job or activity involving repetitive movements of the hand/wrist

### Physical Exam

- Tinel's, Phalen's, and Durkan's tests
- Check for thenar atrophy

### Pathophysiology

- Majority of cases are idiopathic involving synovial inflammation and increased pressure within the carpal tunnel

### Diagnosis

- Diagnosis is clinically based on history and exam
- Equivocal cases should prompt EMG/NCS
- Rule out spinal disease with MRI and medical neuropathies with laboratory testing as indicated based on history and exam

## Management

- NSAIDs, wrist splinting, carpal tunnel injection
- Surgical release (open or endoscopic) for cases that fail conservative treatment or if muscle involvement (thenar wasting) is present

## Postoperative

- Painful scar or neuroma, injury to the recurrent motor branch, inadequate release (particularly endoscopic technique), and recurrence are important complications

## Additional Important Facts

- Beware of overlooking myelopathy or Pancoast's tumor
- Beware of overlooking a treatable peripheral neuropathy (e.g., syphilis, HIV, vitamin deficiency, heavy metal toxicity, cancer, rheumatologic condition, diabetes, thyroid disease)
- Beware of acute carpal tunnel syndrome, an emergency, after acute fracture or dislocation

---

## Suggested Reading

Bland JD. Carpal tunnel syndrome. *BMJ*. 2007;335:43.

MacDermid JC, Wessel J. Clinical diagnosis of carpal tunnel syndrome: a systematic review. *J Hand Ther*. 2004;17:309.



---

**Part X**

**Pediatric**

Steven L. Lee, Section Editor

Veronica F. Sullins and Steven L. Lee

A term male infant becomes cyanotic immediately after birth. His mother states she has had no access to prenatal care. Her pregnancy has otherwise been uncomplicated. On examination, the newborn is tachypneic and tachycardic, and his oxygen saturation is 75 %. He is grunting and has supracostal retractions. He has a barrel-shaped chest with decreased breath sounds on the left side. His abdomen is scaphoid and his heartbeat is displaced to the right. The amniotic fluid is clear.

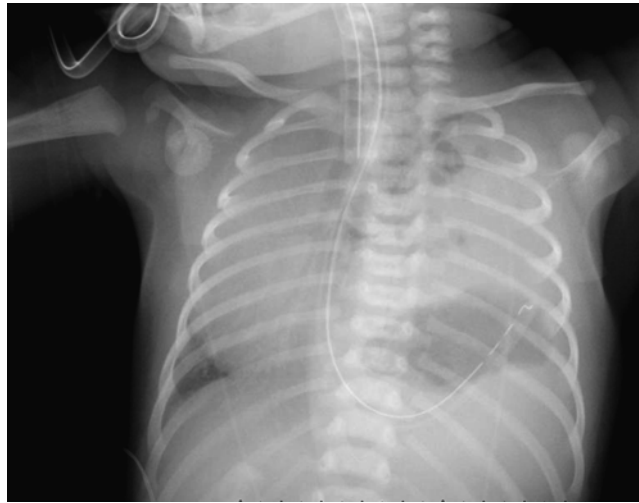## Diagnosis

### Differential diagnosis of surgical causes of neonatal respiratory distress

Diagnosis	Distinguishing features
Choanal atresia	Nasogastric tube (NGT) cannot be placed
Congenital diaphragmatic hernia (CDH)	Loops of intestine (left) or liver (right) above the diaphragm on CXR
Cystic lesions: Congenital cystic adenomatoid malformation (CCAM) Bronchopulmonary sequestration Congenital lobar emphysema (CLE)	Cystic lesion seen on CXR
Esophageal atresia +/- tracheoesophageal fistula (TEF)	Scaphoid abdomen, excessive salivation, +/- stomach bubble, +/- vomiting
Mediastinal lesions: Bronchogenic cysts Mediastinal masses	Diagnosed incidentally or patient develops infected cyst, secondary mass effects if large enough
Pneumothorax	Decreased breath sounds on affected side with collapsed lung on CXR

V.F. Sullins, MD  
Department of Surgery, Harbor-UCLA Medical Center, 1000 W. Carson Street, Box 25, Torrance, CA 90502, USA  
e-mail: [ronniesullins@gmail.com](mailto:ronniesullins@gmail.com)

S.L. Lee, MD (✉)  
Department of Surgery, Division of Pediatric Surgery, Harbor-UCLA Medical Center, 1000 W. Carson Street, Box 25, Torrance, CA 90509, USA  
e-mail: [sleemd@yahoo.com](mailto:sleemd@yahoo.com)



**Fig. 30.1** Chest radiograph of an infant with CDH

### **What Is the Most Likely Diagnosis?**

Congenital diaphragmatic hernia (CDH). The constellation of severe respiratory distress in a full-term neonate with absent breath sounds and a scaphoid abdomen should be highly suspicious for this condition, and a chest radiograph will confirm the diagnosis (Fig. 30.1). A scaphoid abdomen describes a sunken abdominal wall with a concave, rather than the normal convex shape. It implies a smaller volume of abdominal contents than normal and may also be seen in cases of proximal bowel obstruction and malnutrition. In CDH the abdomen is scaphoid because the intra-abdominal contents have herniated into the chest.

### **What Are the Most Common Causes of Neonatal Respiratory Distress?**

It is important to note that the most common causes of neonatal respiratory distress are not surgical. A benign condition, transient tachypnea of the newborn accounts for more than 40 % of cases of neonatal respiratory distress. It occurs when residual pulmonary fluid remains in the lung tissue after delivery. Chest radiograph typically shows diffuse parenchymal infiltrates and a “wet silhouette” around the heart. Symptoms may last from a few hours to multiple days. In premature babies, the most common cause of respiratory distress is hyaline membrane disease or respiratory distress syndrome. This is due to a decrease in surfactant production by type II alveolar cells. Homogenous opaque infiltrates with air bronchograms are typically seen on chest radiography. Another common medical cause in term or post-term infants is meconium aspiration syndrome, and meconium-stained amniotic fluid is seen. Although less common, persistent pulmonary hypertension, pneumonia, and non-pulmonary etiologies (i.e., cardiac, renal) are also in the differential diagnosis of newborn respiratory distress.

---

## **History and Physical**

### **What Is the Significance of the Supracostal Retractions and Grunting?**

Grunting and costal retractions (subcostal, intercostal, or supracostal) indicate severe respiratory distress and should alert the clinician to impending cardiorespiratory collapse. Patients of all ages who exhibit signs of severe respiratory compromise should be intubated and placed on mechanical ventilation.

## **What Information Does the Pulmonary Examination Provide?**

The absence of breath sounds in a newborn may be due to abnormal lung development in diagnoses such as pulmonary agenesis or bronchial atresia. Alternately, there may be a pneumothorax or a space-occupying lesion as in CCAM, CDH, teratoma, bronchopulmonary sequestration, and bronchogenic cyst.

## **Why Is the Heartbeat Displaced?**

A displaced heartbeat occurs when a space-occupying lesion has enough volume to shift the mediastinum towards the contralateral side. Frequently a barrel-shaped chest will accompany this finding.

## **Why Is the Absence of Prenatal Care Important?**

The majority of CDH is diagnosed prenatally by ultrasound examination or, in some cases, MRI. CDH can be successfully diagnosed as early as 15 weeks gestation; however, most are diagnosed by 24 weeks. Prenatal ultrasound findings of bowel loops seen in the thoracic cavity or shift of the heart and mediastinum towards the contralateral side are diagnostic of CDH. Therefore, the absence of prenatal care should alert the physician of the possibility of a malformation that is typically diagnosed in utero.

---

## **Pathophysiology**

### **What Is Thought to Be the Etiology of This Condition?**

Congenital diaphragmatic hernia results from failure of the septum transversum to completely divide the pleural and coelomic cavities during fetal development. Fusion of this diaphragmatic precursor is usually completed posteriorly by the 12th week of gestation. Herniation of intra-abdominal contents occurs during a critical period of lung development when the pulmonary arteries and bronchi are branching. Pulmonary hypoplasia results from decreased pulmonary mass and bronchiolar branching as well as dysfunctional surfactant production.

### **Are There Different Types?**

Approximately 85 % of CDH occurs on the left side, 10 % on the right side, and <5 % bilaterally. The most common variant is a posterolateral defect, known as a Bochdalek hernia. Anteromedial defects, or Morgagni hernias, are much more rare and occur in a para- or retrosternal location. Although most Morgagni hernias are asymptomatic, children are more likely to present with gastrointestinal symptoms or obstruction. Diaphragmatic eventration is an even more rare condition that involves thinning of an intact diaphragm due to incomplete muscularization. Finally, diaphragmatic agenesis is the most extreme form of CDH and is characterized by complete absence of the hemidiaphragm.

### **What Are the Changes that Occur During Childbirth that Allow the Neonate to Transition to Breathing Air?**

In utero, high pressure in the fetal pulmonary vasculature causes blood to flow away from pulmonary circulation and into systemic circulation. This is achieved through two fetal shunts. Most blood entering the right atrium is shunted through the foramen ovale into the left atrium, away from the right ventricle. Blood pumped into the pulmonary arteries from the right ventricle is shunted away from the pulmonary arterial tree into systemic circulation through the ductus arteriosus, which connects the main pulmonary artery to the aortic arch.

When a newborn takes his first breath of air, the pulmonary vascular bed transitions from a high resistance to a low resistance system causing an increase in pressure in the left atrium, relative to the right atrium. Blood flow then reverses across the foramen ovale and leads to its closure. The increase in oxygen concentration in the blood causes a local decrease in prostaglandins and subsequent closure of the ductus arteriosus.

**Table 30.1** Most common anomalies associated with CDH

<b>Associated anomalies</b>	<b>Incidence</b>
<i>Malrotation or nonrotation</i>	60–100 %
<i>Cardiovascular</i>	63 %
VSD/ASD	
Hypoplastic left heart	
<i>Genitourinary</i>	18–23 %
Undescended or ectopic testes	
Ectopic or horse shoe kidney	
<i>Limb</i>	10–16 %
Polydactyly	
Syndactyly	
<i>Central nervous system</i>	10–14 %
Neural tube defects	
Hydrocephalus	
<i>Chromosomal abnormality:</i>	10 %
Trisomy 13, 18, or 21	
Single-gene/chromosome defect	

VSD, ventricular septal defect; ASD, atrial septal defect

### How Is This Transition Affected by CDH?

Herniation of the abdominal contents into the thoracic cavity causes pulmonary hypoplasia on the ipsilateral side and to a lesser extent on the contralateral side. The mediastinum is shifted, thereby compressing the contralateral lung. Pulmonary hypoplasia combined with the muscular hyperplasia of the pulmonary arterial tree causes high resistance in the pulmonary arterial bed that does not reverse with the infant's first breath. The resultant hypoxemia, acidosis, and hypotension cause pulmonary vasoconstriction, worsening the patient's pulmonary hypertension. In summary, pulmonary hypertension results in decreased pulmonary blood flow and hypoxia and pulmonary hypoplasia results in decreased gas exchange and carbon dioxide retention.

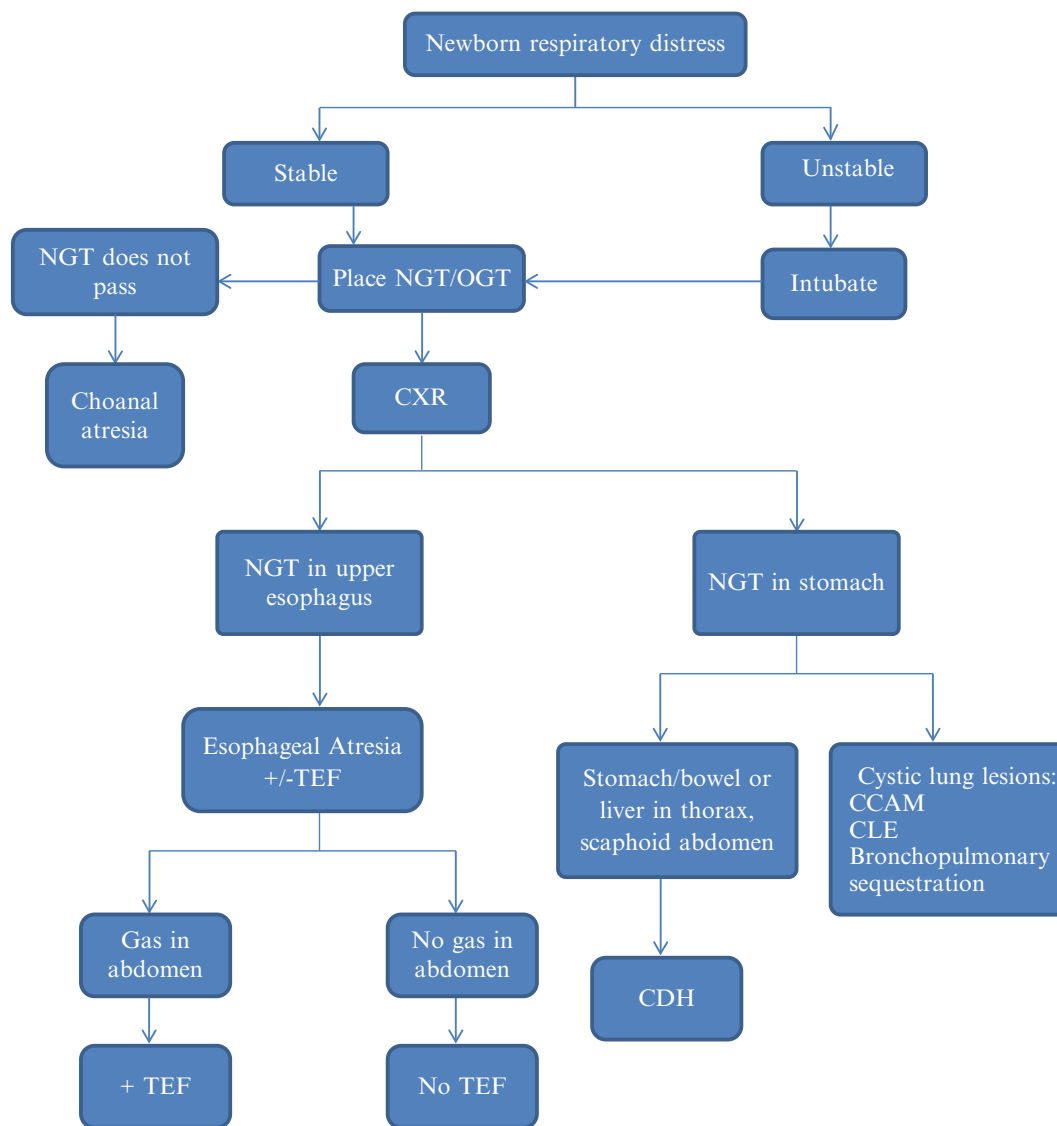
### Are There Associated Anomalies?

Approximately 50–60 % of affected infants have isolated CDH. CDH is considered complex when it exists in conjunction with other associated anomalies including structural malformations, chromosomal abnormalities, and single-gene mutations (Table 30.1).

## Workup

### What Is the Best Initial Diagnostic Test?

Surgical causes for newborn respiratory distress can be ruled out by placement of an orogastric tube (OGT) followed by chest radiograph. This may confirm some diagnoses and rule out others. In meconium aspiration syndrome or pneumonia, CXR may show patchy atelectasis or consolidation. An OGT curled in the upper esophagus may be due to esophageal atresia with or without a TEF. In CDH, if the lesion is on the left side, air- or fluid-filled bowel loops may be seen above the diaphragm. If the lesion is on the right side, the liver may be seen as a soft tissue mass in the thoracic cavity with absence of the normally seen intra-abdominal liver shadow. The heart and other mediastinal structures are shifted to the contralateral side, compressing the lung. If a feeding tube is placed prior to imaging, it may be seen within the thoracic cavity. Similarly, there will be abnormal lung fields in primary pulmonary lesions, such as CCAM, CLE, pulmonary atresia, bronchogenic cysts, and pulmonary agenesis. Choanal atresia can be diagnosed by inability to pass a nasogastric tube (NGT). A diagnostic algorithm for surgical causes of newborn respiratory distress is shown in Fig. 30.2.



**Fig. 30.2** Diagnostic algorithm for surgical causes of neonatal respiratory distress

#### Watch Out

In some cases, the initial CXR may be misleading so a high index of suspicion must be maintained in order to make the correct diagnosis.

## Prognosis

### What Is the Prognosis? What Are the Factors Affecting Prognosis?

Overall mortality has improved since the development of ECMO and surgical repair with current survival rates between 60 % and 80 %. Mortality is directly related to the degree of pulmonary hypoplasia and pulmonary hypertension as well as the presence of congenital anomalies, i.e., whether the CDH is isolated or complex.

## Management

### What Is the Most Important Step in Clinical Management?

Newborns with respiratory distress should be immediately intubated. An OGT should be placed to low continuous suction to decompress the stomach and proximal small bowel and may help available lung tissue expand further. To minimize injury to remaining lung tissue, low pressure ventilation settings should be used. Neonatal ICU admission and blood pressure support should be initiated as necessary.

### How Do You Manage Persistent Hypoxemia on Mechanical Ventilation?

First, it is important to maximize mechanical ventilation settings by increasing the fraction of inspired oxygen to 100 % while maintaining positive end expiratory pressure at physiologic levels (3–5 cm H<sub>2</sub>O) to ensure adequate opening of alveoli while minimizing barotrauma. High-frequency ventilation may be used if hypoxia and hypercarbia persist despite maximum conventional ventilation settings. Inhaled nitric oxide (NO) may also be used to improve pulmonary hypertension. For refractory or severe cases, extracorporeal membrane oxygenation (ECMO) may be used to stabilize and support unstable patients. Indications and contraindications for ECMO use vary according to each institution.

### What Is the Timing of Surgical Repair?

In the early era of surgical management of patients with CDH, surgery was performed immediately to repair the diaphragmatic defect. However, overall survival did not improve beyond 50 %. The goal in management of CDH is supporting lung function because survival is directly related to the degree of pulmonary hypoplasia and pulmonary hypertension. Repairing the diaphragm will not improve pulmonary function. Patients with mild symptoms requiring minimal support likely have little or no pulmonary hypertension and may undergo surgical repair after just 48–72 hours. However, in most patients, the timing of surgery is generally delayed. It is important to provide cardiopulmonary support and avoid lung injury while awaiting lung maturation and reversal of pulmonary hypertension. In most cases time will improve lung function.

#### Watch Out

Associated anomalies are common and therefore an appropriate family history, examination, and workup with echocardiogram, limb radiographs, and renal and cranial ultrasounds are required prior to definitive surgical repair of the diaphragmatic defect.

---

## Areas Where You Can Get in Trouble

### Initial Intubation

The infant should be intubated as quickly as possible. Every effort should be made to avoid blow-by oxygen or bag-mask ventilation prior to endotracheal intubation as these can worsen lung compression and mediastinal shift by filling the herniated stomach/intestines with additional air. In addition, any delay in securing an airway may worsen hypoxia and acidosis, thereby increasing the risk of persistent pulmonary hypertension.

### Ventilation Issues

Survival in CDH is directly related to the degree of pulmonary hypoplasia and resultant pulmonary hypertension. It has been shown that avoidance of hypoxia and barotrauma is critical in the management of patients with CDH. Since pulmonary

hypertension results in hypoxemia leading to worsening pulmonary hypertension, it may be tempting to manage the patient with hyperventilation and hypocarbia to increase post-ductal oxygen saturation (>90 %) and improve oxygenation and pulmonary hypertension. However, the higher ventilation settings required to achieve these goals increase barotrauma and worsen lung function, leading to poorer outcomes. Therefore, permissive hypercapnia (PCO<sub>2</sub> < 60 mmHg) may be necessary and a pre-ductal oxygen saturation of 80–95 % or PaO<sub>2</sub> around 60 mmHg is acceptable to avoid overventilation and barotrauma.

---

## Areas of Controversy

### Type of Repair: Open Versus Minimally Invasive Surgery (MIS)

Recently, with improvements in minimally invasive surgery (MIS) techniques and technology, CDH repairs have been successfully performed thoroscopically with encouraging reports of less pain, earlier recovery, and shorter length of hospitalization. However, there remain some concerns over hernia recurrence with the MIS technique. To date, most evidence is based on retrospective review and selection bias limits comparative data. Although no consensus currently exists, it has been suggested that the MIS approach be reserved for stable patients with isolated CDH (no additional anomalies), delayed presentation, and small diaphragmatic defects (not requiring patch repair).

### CDH and Malrotation

Intestinal malrotation or nonrotation is commonly encountered in patients with CDH and may be surgically treated. Malrotation is generally not a problem in the newborn period, and therefore, it is not a surgical emergency unless volvulus occurs. The timing of Ladd's procedure for malrotation depends on many factors including patient stability, type of repair (open versus MIS), age and size of patient, and ventilatory support. There is no current evidence regarding the timing of Ladd's procedure if malrotation is found with CDH. However, if the patient is stable and the CDH repair is open, a Ladd's procedure may be performed concurrently. If the patient is unstable or the CDH repair is done thoroscopically, repair of the patient's malrotation should be delayed. In the interim, patients who do not undergo a Ladd's procedure must be followed closely and caregivers must be educated in order to avoid the devastating complication of midgut volvulus.

### Use of ECMO

After the first successful use of ECMO in a patient with CDH in 1977, several retrospective studies have reported improved survival with ECMO. Interestingly, although many studies suggest a reduction in early mortality with ECMO, there has not been any long-term benefit demonstrated. In addition, the benefits of patients managed with ECMO may be due to selection bias. Thus, the use of ECMO is currently reserved for patients who fail conventional mechanical ventilation, and until larger, prospective, multi-institutional, randomized studies are performed, the indications for its use are institution dependent.

### Fetal Surgery

An evolving area of treatment involves in utero therapy, although the approach is still investigational and is limited to specialized centers. Fetal tracheal occlusion involves in utero placement of a balloon in the trachea, occluding it and inducing growth of the hypoplastic lung. This approach has been used successfully in fetuses diagnosed early with severe CDH. Although early studies reported improved survival, a recent NIH-sponsored prospective randomized trial was halted early when interim analysis demonstrated no survival advantage and increased rates of morbidity and premature birth compared to those managed with conventional care. Ongoing research is focused on determining which patients will benefit from prenatal therapy.



## Summary of Essentials

### History, Physical Examination, and Diagnosis

- The most common causes of newborn respiratory distress are not surgical
- Grunting and costal retractions and abnormal vital signs indicate severe respiratory compromise
- In stable patients, placement of an OGT/NGT followed by chest radiograph will confirm or rule out common surgical diagnoses
- In a newborn, severe respiratory distress with absent breath sounds and scaphoid abdomen suggests CDH
- CDH typically diagnosed in utero by prenatal ultrasound

### Etiology/Pathophysiology

- The majority occurs on the left side and the most common defect is posterolateral or Bochdalek hernia
- Herniation of abdominal contents results in pulmonary hypoplasia on ipsilateral and contralateral sides
- Pulmonary hypertension → decreased pulmonary blood flow and hypoxia; pulmonary hypoplasia → decreased gas exchange and carbon dioxide retention
- Common associated anomalies: chromosomal defects, rotational, cardiac (VSD/ASD), central nervous system, limb, and genitourinary defects
- Mortality directly related to degree of pulmonary hypoplasia and pulmonary hypertension and presence of congenital anomalies

### Management

- Immediate intubation with ventilator support if signs of respiratory distress
- Survival directly related to the degree of pulmonary hypoplasia and pulmonary hypertension
- The goal is to provide pulmonary support without further damaging the lungs
- Delay surgery to allow lungs to mature and pulmonary hypertension to improve or reverse
- Evaluate for other anomalies prior to surgery

### Watch Out

- Initial chest radiograph may be misleading. but a high index of suspicion should be maintained for correct diagnosis
- Avoid blow-by oxygen or excessive bag-mask ventilation → worsens lung compression and mediastinal shift

---

### Suggested Reading

- Dingemann C, Ure B, Dingemann J. Thorascopic procedures in pediatric surgery: what's the evidence? *Eur J Pediatr Surg.* 2014;24(1):14–9.
- Fauza DO, Wilson JM. Congenital diaphragmatic hernia and associated anomalies: incidence, identification, and impact on prognosis. *J Pediatr Surg.* 1994;29(8):1113–7.
- Haroon J, Chamberlain RS. An evidence-based review of the current treatment of congenital diaphragmatic hernia. *Clin Pediatr.* 2013;52(2):115–24.

Ziyad Jabaji, Veronica F. Sullins, and Steven L. Lee

A term newborn female presents with bilious vomiting 12 hours after an uneventful delivery. A prenatal ultrasound showed polyhydramnios, but the mother was lost to follow up. The infant passed meconium soon after birth. All vital signs are normal, and on physical examination the infant is well appearing. Her abdomen is soft and nontender with epigastric distension. She has a single palmar crease in both hands. An abdominal radiograph shows a “double-bubble.”

## Diagnosis

### What Is the Differential Diagnosis for Bilious Emesis in a Newborn?

The differential diagnosis of bilious emesis in a newborn is shown in below table. It is important to note that ileus secondary to sepsis or metabolic disorders may also manifest as bilious emesis (see chapter on infant with bilious emesis).

### Differential Diagnosis of Bilious Emesis in Neonatal Period (0–1 Month)

Diagnosis	Specific findings
<i>Duodenal atresia</i>	“Double bubble” on AXR, no distal bowel gas
<i>Hirschsprung’s disease</i>	Transition zone (caliber change) on contrast enema, absence of ganglion cells with hypertrophied nerve trunks on rectal biopsy
<i>Imperforate anus</i>	Bowel gas present, no anus on physical examination
<i>Incarcerated inguinal hernia</i>	Inguinal hernia with evidence of incarceration on physical exam
<i>Jejunioileal/colonic atresia</i>	Distal obstruction, microcolon on contrast enema
<i>Malrotation with midgut volvulus</i>	Corkscrew appearance of duodenum on contrast UGI, misplaced ligament of Treitz
<i>Meconium ileus/plug</i>	No passage of meconium, distended abdomen
<i>Necrotizing enterocolitis</i>	Prematurity, fixed dilated loop, or pneumatosis intestinalis on AXR

AXR, abdominal radiograph; UGI, upper gastrointestinal study

Z. Jabaji, MD (✉)

Department of Surgery, UCLA Medical Center, 10833 Le Conte Avenue, 72-229 CHS, Los Angeles, CA 90095, USA  
e-mail: [zjabaji@mednet.ucla.edu](mailto:zjabaji@mednet.ucla.edu)

V.F. Sullins, MD

Department of Surgery, Harbor-UCLA Medical Center, 1000 W. Carson Street, Box 25, Torrance, CA 90509, USA  
e-mail: [ronniesullins@gmail.com](mailto:ronniesullins@gmail.com)

S.L. Lee, MD

Department of Surgery, Division of Pediatric Surgery, Harbor-UCLA Medical Center, 1000 W. Carson Street, Box 25, Torrance, CA 90509, USA  
e-mail: [sleemd@yahoo.com](mailto:sleemd@yahoo.com)

---

## What Is the Most Likely Diagnosis?

In this instance, the relatively well-appearing baby and classic “double-bubble” (discussed in Work-Up) finding with absent distal gas on radiography is diagnostic of duodenal atresia. The epigastric distention on physical examination is caused by dilation of the stomach and proximal duodenum and should resolve after nasogastric tube placement. The incidence of this congenital malformation is 1 in 5,000 to 1 in 10,000 live births.

---

## History and Physical Examination

### What Is the Significance of Bilious Vomiting in a Newborn?

Vomit is bilious when it is yellow or green stained and implies reflux of enteric contents from distal to the ampulla of Vater. It indicates that the pylorus is patent and effectively rules out common stomach pathology such as pyloric stenosis. Bilious emesis in a newborn is usually caused by a surgical problem unless proven otherwise.

### What Is the Significance of Polyhydramnios?

Amniotic fluid volume is determined by a steady state between in utero swallowing and fetal urine production. Polyhydramnios is an excess amount of amniotic fluid for a given gestational age. While 50 % of pregnancies with polyhydramnios are idiopathic, known causes can be grouped into diseases that impair swallowing (congenital diaphragmatic hernia, duodenal atresia, esophageal atresia, gastroschisis, neck mass, neurologic devastation, tracheoesophageal fistula) or diseases that increase urine production (maternal diabetes, twin pregnancy).

### Does the Passage of Meconium Exclude the Diagnosis of an Intestinal Obstruction?

No. It is still possible to have a neonatal bowel obstruction with passage of meconium. Meconium is composed of ingested lanugo (fine body hair), amniotic fluid, bile, mucus, and shed epithelial cells. Though the former three will not pass with intestinal obstruction, mucus is secreted and epithelium is shed along the entire length of the intestine. Therefore, any meconium distal to the point of obstruction may still be passed.

---

## Pathophysiology

### What Is the Etiology of Duodenal Obstruction?

While the most common cause of congenital duodenal obstruction is duodenal atresia, rarely other congenital anomalies may be found. Causes of duodenal obstruction are classified as intrinsic (duodenal atresia versus intraluminal web) or extrinsic (adhesive Ladd’s bands, annular pancreas). Distal bowel gas may be seen in partial rather than complete duodenal obstruction. This is common with extrinsic causes and in cases of duodenal stenosis or web.

### What Is the Pathophysiology of This Condition?

Intrinsic duodenal obstructions arise from embryologic events around 6 weeks of gestation. Normal development causes rapid proliferation of the primitive gut epithelium and obliteration of the duodenal lumen, with recanalization over the next several weeks. Duodenal atresia results when there is a failure of the gut to recanalize and the lumen remains obliterated. This differs from the pathophysiology of jejunoileal atresias, which are thought to be a result of in utero vascular accidents leading to segmental intestinal ischemia and subsequent resorption.

**Watch Out**

While the point of obstruction in the majority of infants with duodenal atresia is distal to the ampulla of Vater, in 20 % the obstruction is proximal to the ampulla. This group of patients will present with nonbilious instead of bilious emesis.

**What Are the Associated Abnormalities?**

More than half of all babies with duodenal atresia or stenosis will have another congenital anomaly. Table 31.1 lists frequencies of the most common associated anomalies. In this patient, the single palmar crease is highly suggestive of Down syndrome, which can be confirmed with either ante- or postnatal chromosomal testing. Although nearly one third of patients with duodenal atresia have Down syndrome, it is not itself a risk factor for the development of duodenal atresia.

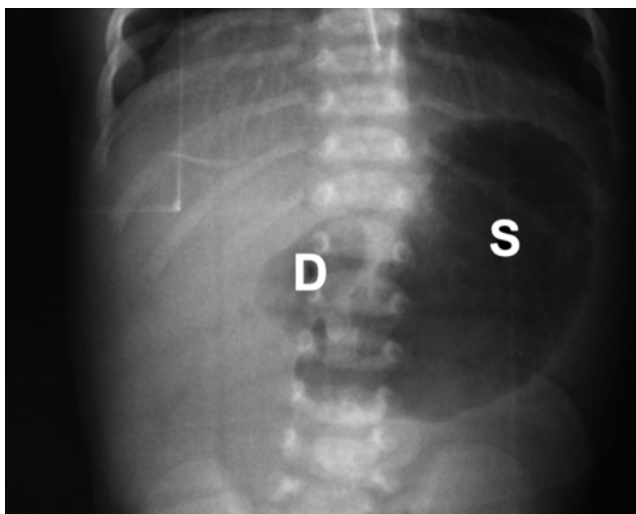
**Work-Up****What Is the First Imaging Study to Obtain?**

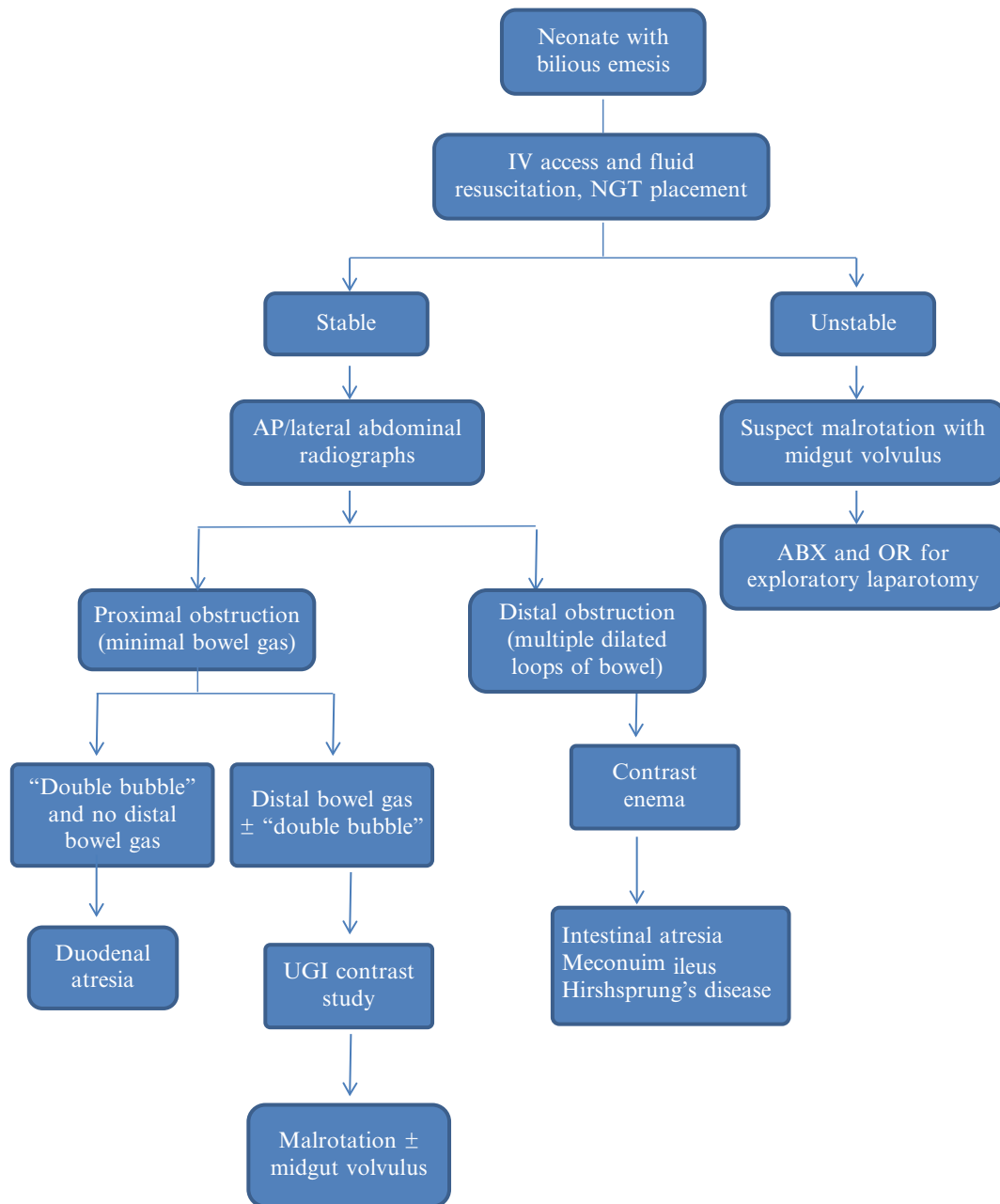
In stable patients, a 2-view plain abdominal radiograph after naso- or orogastric tube placement should be the first imaging study to obtain. It may help exclude gross perforation and give essential diagnostic information. The presence or absence and amount of bowel gas also will help differentiate between proximal and distal, and partial or complete obstruction. The patient's abdominal radiograph is shown in Fig. 31.1. Note the two large upper abdominal gas collections indicative of the dilated stomach and duodenal bulb. This is classically described as a "double-bubble."

**Table 31.1** Incidence of anomalies associated with duodenal atresia

Associated anomalies	Incidence (%)
Down syndrome (Trisomy 21)	28
Annular pancreas	23
Congenital heart disease	23
Malrotation	20
Esophageal atresia/TEF	9
Genitourinary	8
Anorectal	4
Other bowel atresia	4
Others (vertebral, musculoskeletal, biliary malformations, antral web)	11
<i>Any associated anomaly</i>	55

*TEF, tracheoesophageal fistula*

**Fig. 31.1** Anteroposterior abdominal radiograph showing the stomach (S) and duodenal bulb (D)



**Fig. 31.2** Diagnostic algorithm for neonatal bilious emesis. *IV*, intravenous; *NGT*, nasogastric tube; *AP*, anteroposterior; *ABX*, antibiotics; *OR*, operating room; *UGI*, upper gastrointestinal

### What Is the Next Step in Diagnosis?

The absence of distal bowel gas in the above radiograph secures the diagnosis of a complete duodenal obstruction, and no further testing is indicated. If any distal gas is seen, an upper gastrointestinal (UGI) contrast study is necessary to rule out malrotation with midgut volvulus, the most life-threatening condition. The UGI contrast study may also be helpful in diagnosing other etiologies of partial duodenal obstruction. A diagnostic algorithm is shown in Fig. 31.2.

## Management

### What Are the Initial Steps in the Management?

Since patients with duodenal atresia are rarely unstable, a thorough work-up and optimization should be performed prior to surgery. This includes securing intravenous access, initiating replacement of GI fluid and electrolyte losses, and placing a nasogastric tube for decompression of the stomach and proximal duodenum. If the patient is unstable these steps should be performed while preparing the operating room for laparotomy and the diagnosis of duodenal atresia should be questioned, as the most likely etiology is malrotation with midgut volvulus. In stable patients a peripherally inserted central catheter line should be considered for nutritional support, as feeds typically do not start until a few days after surgery.

### What Is the Timing of Surgery?

The timing of surgery depends on the clinical condition of the patient. In stable patients, surgery may be delayed until a thorough work-up has been completed, and the infant is hemodynamically optimized, typically within the first few days of life. To evaluate for associated anomalies, a careful history and physical examination, echocardiography, renal ultrasound, and spinal radiographs should be performed. Testing for chromosomal abnormalities may be initiated, but results are not necessary prior to surgery. If the child is extremely premature, surgery may be delayed for several weeks to allow for neonatal lung maturation and growth. If malrotation has not been adequately ruled out by the initial evaluation, surgery is considered urgent or emergent, especially if the patient is clinically unstable.

### What Are the Surgical Options?

If malrotation (with or without volvulus) is found, it should be corrected first. The treatment of choice for duodenal atresia is a duodenoduodenostomy to bypass the atretic segment. If this cannot be accomplished safely, a duodenojejunostomy may be performed.

---

## Areas Where You Can Get in Trouble

### Inadequate Preoperative Resuscitation

Since duodenal atresia is rarely a true surgical emergency, it is important that the child be adequately fluid resuscitated with correction of electrolyte imbalances preoperatively. If the patient is hypovolemic, induction of anesthesia or surgery itself may worsen existing hypotension or precipitate seizures due to electrolyte imbalances, end-organ damage from hypoperfusion, or cardiovascular collapse.

### Failure to Rule Out Cardiac Defects Prior to Surgery

Greater than 20 % of infants with duodenal obstructions also have cardiac defects. There is typically ample time to perform a thorough work-up before taking the patient to the operating room. Certain defects (typically cardiac), depending on the severity, will take precedence over repairing the duodenal atresia.

### Injury to an Annular Pancreas or the Ampulla

An annular pancreas is found in 1 in 5 children with duodenal obstruction. The cause of the obstruction in patients who have an annular pancreas is still intrinsic (duodenal atresia or web). It is important to recognize this early in the operation and avoid dividing or injuring the encircling ring of pancreatic tissue. Injury to the pancreatic ducts traversing the ring can lead to pancreatic enzyme leak and pancreatitis.

## Areas of Controversy

### Laparoscopic Versus Open Surgery

The role of laparoscopy in treating duodenal atresia is still being defined. Current reports of laparoscopic duodenoduodenostomy show good outcomes; however, operative times are longer than open procedures and the conversion rates to open operation can be high (>25 %). Although short-term outcomes are promising, long-term data are not yet available.

### Partial Duodenal Obstruction Versus Malrotation

In cases where the contrast UGI shows a “double-bubble” with distal gas, suggesting a partial duodenal obstruction, there may be a duodenal web with a small hole that allows some gas to pass distally. In stable patients, some advocate for performing surgery within 24–48 hours. In this case, the authors prefer to operate urgently, as the presence of the classic duodenal atresia radiographs does not rule out malrotation in the presence of distal gas.

---

## Summary of Essentials

### History, Physical Examination, and Diagnosis

- Bilious (green or yellow) vomiting in newborn (0–1 month) is a surgical problem until proven otherwise
- Passage of meconium does not rule out obstruction
- Stable patient: plain abdominal radiograph first → rule out gross perforation, proximal versus distal obstruction, presence or absence of distal gas
- “Double-bubble” + no distal gas = complete duodenal obstruction (usually duodenal atresia)
- If distal gas, suspect malrotation with midgut volvulus before duodenal web or partial duodenal obstruction

### Pathophysiology

- Etiology of duodenal obstruction: intrinsic versus extrinsic
- Duodenal atresia is due to failure of recanalization early in development
- >50 % have associated anomalies: Trisomy 21, annular pancreas, cardiac most common

### Management

- Correct fluid and electrolyte imbalances and place NGT first
- Rule out other anomalies prior to surgery
- Unstable patient → suspect malrotation with midgut volvulus, go to OR emergently
- Duodenoduodenostomy is procedure of choice

---

## Suggested Reading

- Godbole P, Stringer MD. Bilious vomiting in the newborn: how often is it pathologic? *J Pediatr Surg.* 2002;37(6):909–11.
- Kimura K, Mukohara N, Nishijima E, Muraji T, Tsugawa C, Matsumoto Y. Diamond-shaped anastomosis for duodenal atresia: an experience with 44 patients over 15 years. *J Pediatr Surg.* 1990;25(9):977–9.

Veronica F. Sullins and Steven L. Lee

A 7-month-old male infant presents with 2 episodes of green emesis, decreased stool and urine output, and lethargy. The mother states he was a full-term baby with no prior illnesses or surgery. He fed normally for months until the day prior to presentation. He had a normal, nonbloody bowel movement 24 hours ago. His heart rate is slightly elevated and he is normotensive and afebrile. He is lethargic but otherwise has a normal physical examination. His abdomen is soft, nontender, and nondistended.

## Diagnosis

### What is the Differential Diagnosis for Bilious Emesis in an Infant?

Diagnosis	Specific findings
<i>Adhesions</i>	Prior abdominal surgery, dilated loops of bowel with transition point to decompressed bowel on contrast study
<i>Enteric duplication cyst</i>	Fluid-filled structure not contiguous with stomach or small bowel on MRI/US
<i>Gastroenteritis</i>	History of fever, diarrhea, initial nonbilious emesis, diagnosis of exclusion
<i>Hirschsprung's disease</i>	Transition zone (caliber change) on contrast enema, absence of ganglion cells with hypertrophied nerve trunks on rectal biopsy
<i>Ileus secondary to other medical disease</i>	Metabolic derangements, electrolyte abnormalities, sepsis, multiple etiologies
<i>Incarcerated inguinal hernia</i>	Inguinal hernia with evidence of incarceration on physical exam
<i>Intussusception</i>	Target sign on US, possible preceding viral upper respiratory illness, "currant-jelly" stool
<i>Malrotation with midgut volvulus</i>	"Corkscrew" appearance of duodenum on contrast UGI, misplaced ligament of Treitz

MRI magnetic resonance imaging, US ultrasound, UGI upper gastrointestinal study

V.F. Sullins, MD (✉)

Department of Surgery, Harbor-UCLA Medical Center, 1000 West Carson Street, Box 25, Torrance, CA 90509, USA  
e-mail: [ronniesullins@gmail.com](mailto:ronniesullins@gmail.com)

S.L. Lee, MD

Department of Surgery, Division of Pediatric Surgery, Harbor-UCLA Medical Center, 1000 W. Carson Street, Box 25, Torrance, CA 90509, USA  
e-mail: [sleemd@yahoo.com](mailto:sleemd@yahoo.com)



## How does age Affect the Differential Diagnosis of Bilious Emesis?

<i>All ages<sup>a</sup></i>	Adhesions Hirschsprung's disease Incarcerated inguinal hernia Malrotation with midgut volvulus
<i>Neonate (0–1 month)</i>	Annular pancreas Duodenal atresia Imperforate anus Jejunioileal/colonic atresia Meconium ileus/plug Necrotizing enterocolitis
<i>Infant (1–24 months)</i>	Intussusception
<i>Child (2–12 years)</i>	Ileus secondary to appendicitis Intussusception

<sup>a</sup>In all ages, underlying sepsis or metabolic derangements may lead to ileus and bilious vomiting

## What is the Diagnosis?

Malrotation with midgut volvulus (Fig. 32.1) should always be suspected in an infant with bilious vomiting or any child with bilious vomiting and abdominal pain. While over half of children with malrotation present before 1 month of age with volvulus, or the twisting of the small bowel around its mesentery leading to intestinal ischemia, one third present between 1 month and 1 year of age.

### Watch Out

Malrotation with midgut volvulus may present with either bilious or nonbilious vomiting depending on where the obstruction occurs. All cases of suspected duodenal obstruction should be evaluated for malrotation with midgut volvulus.

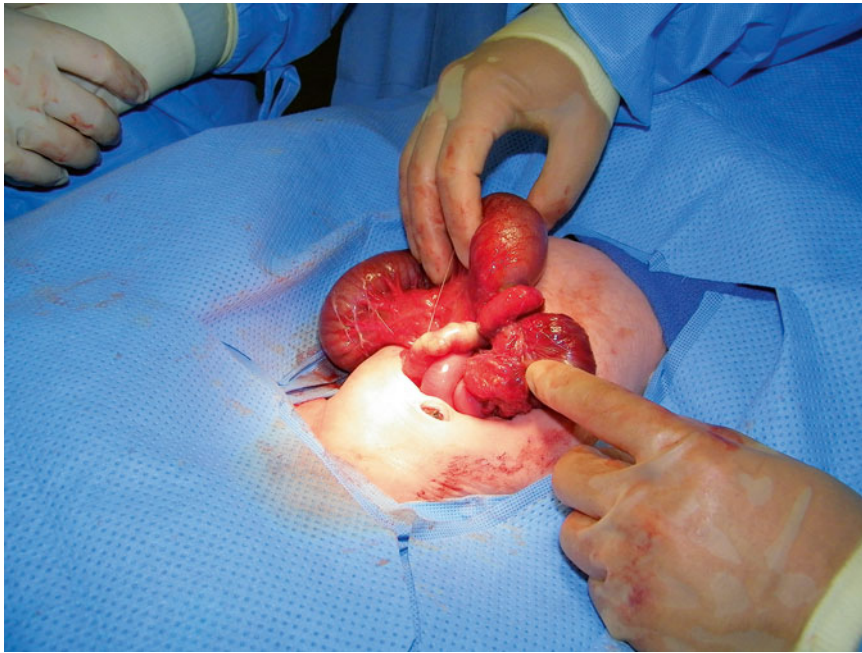
## History and Physical

### Why Is It Important to Distinguish Between Bilious and Nonbilious Vomiting in an Infant?

Bilious emesis is any green or yellow emesis. The presence of bile in an infant's vomit is essential diagnostic information because bilious emesis is most likely due to a surgically correctable lesion until proven otherwise. Obstructive processes proximal to the pylorus always cause nonbilious emesis, whereas bilious emesis implies a patent pylorus with obstruction distal to the ampulla of Vater. Distinguishing between proximal and distal causes of obstruction will determine what type of diagnostic study to perform.

### What Are the Associated Risk Factors?

Rotational defects are thought to be present in nearly all patients with congenital diaphragmatic hernia and abdominal wall defects such as gastroschisis and omphalocele. In children with these conditions, volvulus is rare due to both the abnormal anatomy and adhesions that develop after surgical repair. Patients with heterotaxy syndrome, or abnormal positioning of intra-thoracic or intra-abdominal organs, are likely to have malrotation and should therefore undergo a diagnostic workup. Intestinal atresias, in particular duodenal atresia, are also associated with and perhaps in part caused by malrotation and should therefore be assessed during surgical repair of the atresia. There are some syndromic associations that have been described including Trisomy 21 (Down syndrome).



**Fig. 32.1** Photograph of malrotation with midgut volvulus

---

## Workup

### What Is the First Imaging Study to Obtain?

Given that the patient is hemodynamically stable, the first study to obtain is a plain abdominal radiograph. While plain radiographs are rarely diagnostic, they may exclude gross perforation, which would reveal free air under the diaphragm. If there is evidence of perforation, no additional studies are needed and the patient should be taken to the operating room for urgent laparotomy. The presence and location of bowel gas on plain radiographs may also help determine whether the patient has a proximal (duodenum or proximal jejunum) or distal (ileum or colon) obstruction, which will then guide further workup based on the differential diagnosis (Fig. 32.2).

### What Is the Next Step in Diagnosis?

If no free perforation is seen, an upper gastrointestinal (UGI) contrast series (Fig. 32.3) should be obtained to visualize the duodenum and proximal small intestine.

---

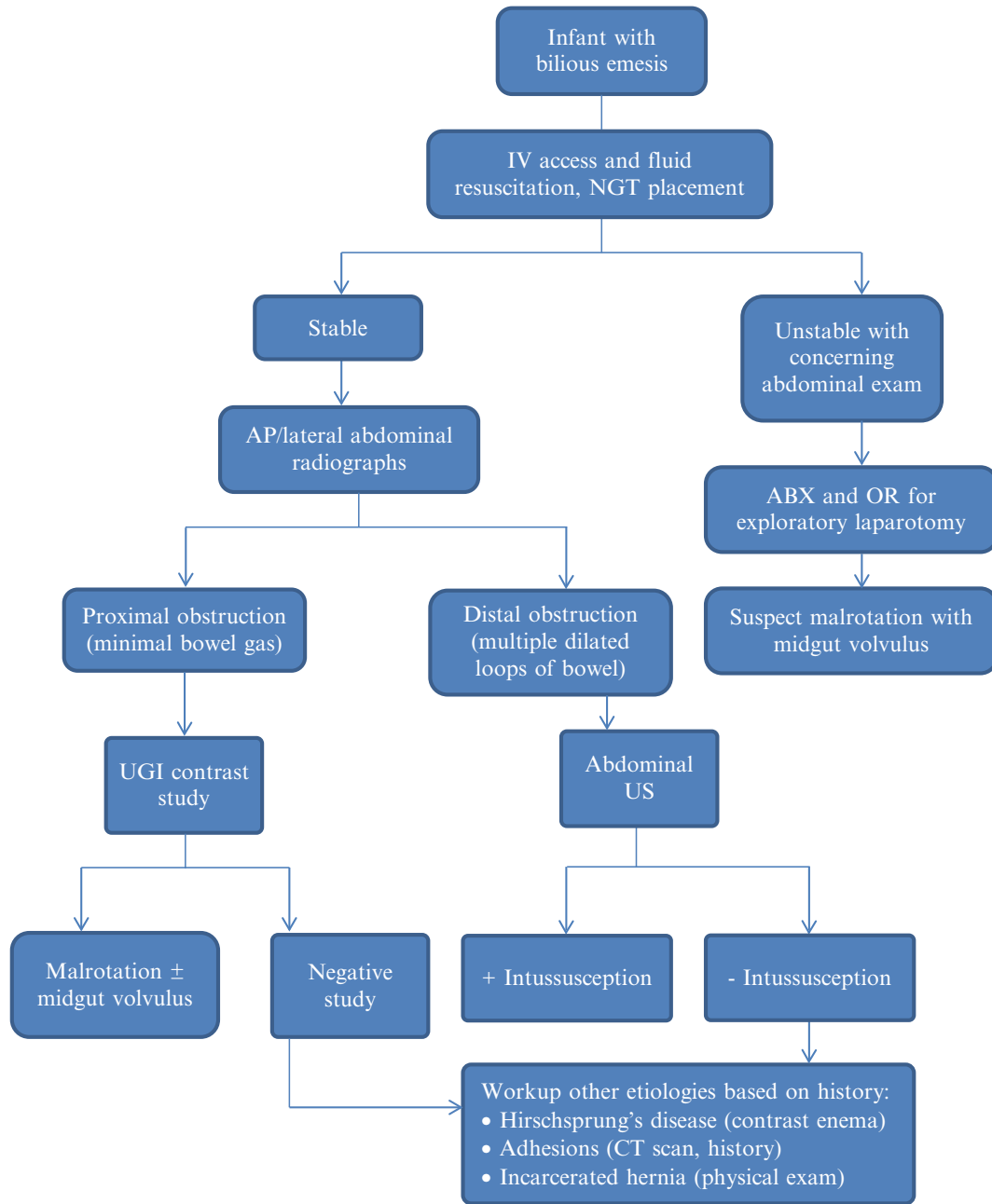
## Pathophysiology

### What Defines the Midgut?

The midgut is the portion of the gut that receives its blood supply from the superior mesenteric artery. In a fully developed fetus, it extends from the second part of the duodenum to two-thirds of the way across the transverse colon. The foregut structures are supplied by the celiac axis and the hindgut structures by the inferior mesenteric artery.

### What Is the Normal Developmental Sequence of Events of the Human Midgut?

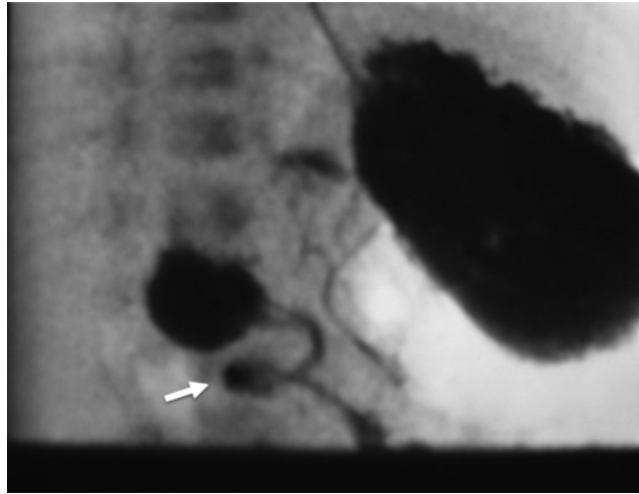
During the 6th week of gestation, the midgut elongates very rapidly and therefore must temporarily grow outside of the embryo. During this stage of umbilical herniation, the midgut rotates 90° counterclockwise around the axis of the superior



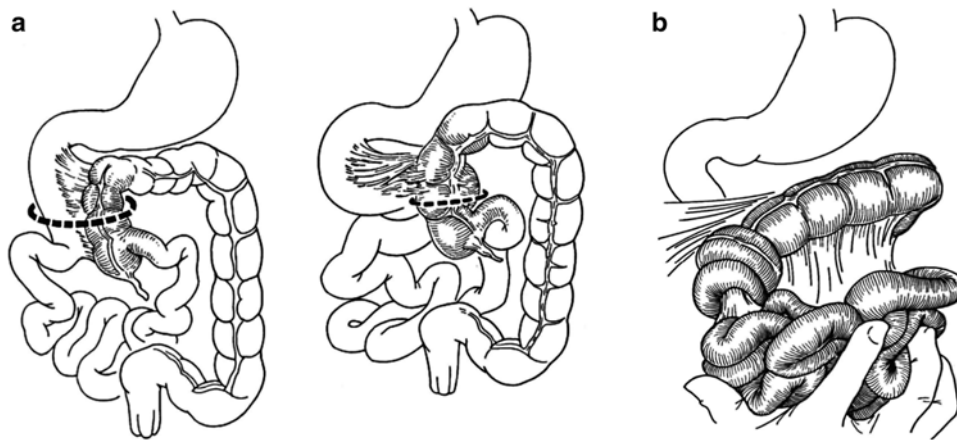
**Fig. 32.2** Diagnostic algorithm for bilious emesis in infancy. *IV* intravenous, *NGT* nasogastric tube, *AP* anteroposterior, *ABX* antibiotics, *OR* operating room, *UGI* upper gastrointestinal, *CT* computed tomography

mesenteric artery so that the proximal limb (small bowel) lies on the right side and the distal limb (colon) lies on the left side of the artery. Between the 10th and 12th week of gestation, the developing midgut returns into the abdominal cavity. The proximal limb passes behind the superior mesenteric artery and fixes to the left side of midline to form the duodenojejunal flexure or ligament of Treitz. The distal limb rotates counterclockwise a further 180° to place the cecum in

its final position in the right lower quadrant and the transverse colon anterior to the superior mesenteric artery. The duodenum and ascending colon then become fixed in their final retroperitoneal positions. Proper midgut rotation allows the base of the small bowel mesentery to extend from the ligament of Treitz diagonally down to the ileocecal junction, ensuring a broad base of attachment to the posterior abdominal wall.



**Fig. 32.3** UGI contrast study with small bowel follow through



**Fig. 32.4** Schematic of (a) malrotation (*dotted line encircles the narrow base at risk for volvulus*) and (b) midgut volvulus (From O'Neill, J. Principles of Pediatric Surgery, 7th edition. 2003, Mosby. Reprinted with permission from Elsevier)

### What Is the Etiology of This Condition?

Malrotation results from failure of the midgut to rotate and fix properly, typically during its return into the abdominal cavity. Although there are various degrees of malrotation, classically the ligament of Treitz is situated to the right of midline and the cecum fails to rotate the final 180° down to the right lower quadrant, placing it in the epigastrium. In attempts to fix the malpositioned colon into position, peritoneal attachments form between the right upper quadrant and the ascending colon, crossing the duodenum. Whether these bands cause duodenal obstruction is unclear. Most importantly, the base of the mesentery is narrow, thereby predisposing it to rotation about its axis or midgut volvulus (Fig. 32.4). This rotation gives the classic radiographic finding of a “corkscrew” appearance of the contrast in the lumen of the bowel (see arrow in Fig. 32.3). When acute midgut volvulus occurs, it results in duodenal obstruction and bilious vomiting. As it progresses, a strangulated, closed loop obstruction occurs and the intestine becomes ischemic.

### Does Malrotation Always Result in Midgut Volvulus? Is It Always Acute?

No. The diagnosis of malrotation is not itself a surgical emergency. However, it predisposes the infant to midgut volvulus. It is also not always acute, and acute presentations vary from intermittent to complete obstruction. If the acute volvulus is

incomplete or intermittent, the infant may appear well between episodes of vomiting. If the volvulus is chronic, the patient may present in childhood with chronic vomiting and recurrent abdominal pain or failure to thrive.

---

## Workup

### Are Plain Radiographs Necessary?

No. It is important to understand that if an infant has symptoms of acute gastrointestinal obstruction and is hemodynamically unstable, no additional evaluation is necessary. Rapid fluid resuscitation and immediate surgical intervention will provide the best chance at saving ischemic bowel.

#### Watch Out

In a patient with midgut volvulus, the most common bowel gas pattern seen on plain radiograph is normal. Suspicion should actually be heightened when a “normal” abdominal gas pattern is observed in an infant with bilious vomiting.

---

## Management

### What Is the Most Important Immediate Management Issue?

Acute midgut volvulus is a surgical emergency and any delay in operating may result in the loss of intestine. The patient should be rapidly fluid resuscitated and taken to the operating room for urgent laparotomy. An orogastric or nasogastric tube should be placed to decompress the stomach and broad-spectrum antibiotics should be given while preparing for the operating room. Delays in diagnosis may worsen intestinal ischemia, leading to loss of more intestinal tissue. In the most severe cases, the infant suffers a complete midgut infarction or loss of blood flow to intestine from the proximal jejunum to the mid-transverse colon. If this occurs, a massive small bowel resection is necessary and may result in an insufficient length of intestine to sustain the infant’s nutritional needs. This condition is called short bowel syndrome. Even with some intestinal adaptation after massive small bowel resection, short bowel syndrome patients may become dependent on lifelong total parenteral nutrition (TPN) or require small intestinal transplantation.

### What Operation Is Required?

The goals of the Ladd’s procedure are to relieve any intestinal obstruction and prevent the risk of recurrent volvulus. First, because volvulus typically occurs in a clockwise direction, the volvulus must be reduced by gently rotating the gut counterclockwise. Next, Ladd’s bands, or the peritoneal attachments from the right upper quadrant to the ascending colon, must be divided. The duodenum is then straightened and examined for intrinsic obstruction. The base of the mesentery must be widened by dividing peritoneal adhesions. Finally, the small bowel is positioned on the right side of the abdomen and the large bowel on the left, in complete nonrotation. These positions ensure the maximum distance between the duodenum and the ileocecal junction. Because the cecum and appendix are now in the left upper quadrant, most surgeons perform an appendectomy to avoid future misdiagnosis in the event that the patient develops appendicitis.

---

## Areas Where You Can Get in Trouble

### Delay in Diagnosis

While the emergent nature of malrotation with midgut volvulus may be obvious when an infant with bilious vomiting presents late and is extremely sick, most patients are not yet in extremis. Between attacks, infants with intermittent obstruction or incomplete volvulus may appear well. This may prompt additional tests and imaging studies (such as a contrast enema)

that will delay the diagnosis and worsen intestinal ischemia. Conversely, a patient who has incidentally been found to have malrotation and has no symptoms should have surgery at the earliest convenience.

### **Intraoperative Evaluation**

In some infants with malrotation, duodenal stenosis or atresia is present and is the cause of the duodenal obstruction. Therefore, to exclude these diagnoses, a large bore orogastric or nasogastric tube must be passed through the second part of the duodenum during surgery. Alternately, because a significant number of infants with atresias have associated malrotation, during surgery to repair a duodenal or jejunoileal atresia, the intestine must be evaluated for malrotation.

---

### **Areas of Controversy**

#### **Management of Minor Degrees of Malrotation**

While asymptomatic patients incidentally found to have classic malrotation (with the cecum in the mid-upper abdomen and the ligament of Treitz abnormally fixed) should have surgery at the earliest possible time, it is not clear how best to manage patients with minor degrees of malrotation or nonrotation. These patients have a wider mesenteric base and therefore a much lower likelihood of developing a midgut volvulus. In addition, a mobile or high position of the cecum may be present in normal, healthy individuals. In cases of chronic symptoms in older patients, surgery may not be beneficial, especially with evidence of nonclassical or minor degrees of malrotation.

#### **Infants with Complete Midgut Infarction**

Although the incidence of infants presenting with complete midgut infarction is low, the consequences are devastating. Mortality rates are approximately 65 % when more than 75 % of the bowel is necrotic and much higher in the presence of other congenital anomalies. In the tragic case of complete midgut infarction, some advocate for closing the abdomen without resection and providing palliative care. If a massive small bowel resection is performed and the patient subsequently develops short gut syndrome (inadequate intestinal length to absorb sufficient nutrients), a future small bowel transplant may be necessary. Short bowel syndrome patients who are TPN dependent may develop TPN-associated liver failure and require a liver transplantation as well.

---

### **Summary of Essentials**

#### **History, Physical Examination, and Diagnosis**

- Must determine bilious versus nonbilious emesis. Remember: green or yellow emesis = bilious emesis
- Bilious vomiting during infancy (1–24 months) is a surgical problem until proven otherwise
- Stable patient: plain abdominal radiographs first to exclude gross perforation
- If initial radiograph is negative: UGI contrast study to evaluate the duodenum and proximal small intestine
- Always suspect malrotation with midgut volvulus in infants with bilious vomiting or children with bilious vomiting and abdominal pain

#### **Etiology/Pathophysiology**

- Midgut is supplied by the superior mesenteric artery: second portion of duodenum → two-thirds of transverse colon
- Malrotation due to developmental failure of normal 270-degree counterclockwise midgut rotation

- Classic malrotation = narrow mesenteric base, ligament of Treitz located right of midline, cecum in the epigastrium, Ladd's bands from cecum to right upper quadrant, crossing duodenum
- Volvulus = midgut rotates around superior mesenteric artery axis → duodenal obstruction, vascular compromise of bowel
- Classic UGI radiograph: "corkscrew" appearance of contrast in bowel lumen

## Management

- Place nasogastric tube to decompress stomach; give antibiotics and IVF while preparing for laparotomy
- Hemodynamically unstable infant with acute gastrointestinal obstruction → rapid fluid resuscitation, immediate surgical intervention without additional studies
- Ladd's procedure: relieve obstruction by untwisting bowel; prevent future episodes by broadening mesenteric base

## Watch Out

- Malrotation with midgut volvulus may present with bilious or nonbilious vomiting depending on location of obstruction
- Most common bowel gas pattern on plain radiograph is normal
- During surgery, must exclude duodenal stenosis or atresia as cause of obstruction
- Delay in diagnosis may result in complete midgut infarction

---

## Suggested Reading

- Lamp B, Levin TL, Berdon WE, Cowles RA. Malrotation and midgut volvulus: a historical review and current controversies in diagnosis and management. *Pediatr Radiol.* 2009;39(4):359–66.
- Millar AJ, Rode H, Cywes S. Malrotation and volvulus in infancy and childhood. *Semin Pediatr Surg.* 2003;12(4):229–36.
- O'Neill J. Chapter 47: Rotational anomalies and volvulus. In: *Principles of pediatric surgery.* 7th ed. Mosby; 2003, pp 477–58.
- Strouse PJ. Disorders of intestinal rotation and fixation ("malrotation"). *Pediatr Radiol.* 2004;34(11):837–51.

Ziyad Jabaji, Veronica F. Sullins, and Steven L. Lee

A 6-week-old full-term male is brought into the emergency room for nonbilious emesis. The mother reports that he began regurgitating breast milk one week ago. Although intermittent at first, nonbilious emesis now occurs after every feeding and has become progressively more forceful with increased volume. His appetite remains vigorous, even immediately after vomiting. He is the mother's first child and his delivery was uneventful. His blood pressure is normal and he is afebrile but tachycardic. On physical examination, he is irritable and has a sunken fontanelle. A small, firm mass is palpated in the right upper quadrant.

## Diagnosis

### What Is the Differential Diagnosis?

The differential diagnosis of nonbilious emesis in infants is broad. A short list of pertinent diagnoses is provided in below table.

### Differential Diagnosis of Nonbilious Emesis in Infancy

Diseases managed medically	Diseases managed surgically
Acute gastroenteritis	Antral web
Gastroesophageal reflux disease	Enteric duplication cyst
Metabolic disorders (congenital adrenal hyperplasia, electrolyte imbalance, glycogen storage disease)	Gastroesophageal reflux disease
Pylorospasm	Pyloric atresia
	Pyloric stenosis

Z. Jabaji, MD (✉)  
 Department of Surgery, UCLA Medical Center, 10833 Le Conte Avenue, 72-229 CHS, Los Angeles, CA 90095, USA  
 e-mail: [zjabaji@mednet.ucla.edu](mailto:zjabaji@mednet.ucla.edu)

V.F. Sullins, MD  
 Department of Surgery, Harbor-UCLA Medical Center, 1000 West Carson Street, Box 25, Torrance, CA 90509, USA  
 e-mail: [ronniesullins@gmail.com](mailto:ronniesullins@gmail.com)

S.L. Lee, MD  
 Department of Surgery, Division of Pediatric Surgery, Harbor-UCLA Medical Center,  
 1000 W. Carson Street, Box 25, Torrance, CA 90509, USA  
 e-mail: [slleemd@yahoo.com](mailto:slleemd@yahoo.com)



---

## What Is the Most Likely Diagnosis?

Infantile hypertrophic pyloric stenosis (HPS). The incidence is approximately 1.5–4 in 1,000 live births. HPS affects predominantly males over females, with reported ratios of 2:1 to 5:1, and it is found more frequently in firstborn males. There is occasionally a positive family history and a reported association with use of oral erythromycin in infants.

---

## History and Physical

### Why Is It Important to Distinguish Between Biliious and Nonbiliious Vomiting in an Infant?

The presence or absence of bile in the emesis is useful diagnostic information. If the obstruction is proximal to the pylorus, the emesis will always be nonbiliious. Bile-stained emesis implies that the obstruction is distal to the ampulla of Vater. Children with biliious emesis are presumed to have a surgical problem unless proven otherwise.

### What Is the Classic History for HPS?

Projectile, nonbiliious vomiting in a healthy infant is classic for HPS. The infant may have been vomiting for 1 to 2 weeks, but the emesis will become progressively more forceful and voluminous. Infants will typically be brought to medical attention between 4 and 8 weeks, although the diagnosis can be made outside of this window.

### What Are the Classic Physical Examination Findings?

A dehydrated infant, as evidenced by a sunken fontanelle, with a palpable mass (described as an “olive”) in the right upper quadrant is classic for HPS. The “olive” represents a thickened and elongated pyloric muscle. However, if the infant is crying, the mass may not be palpable. Reverse peristaltic waves may also be seen in the upper abdomen. Physical examination of a crying infant can be quite challenging so it is important to ensure that the child is warm and comfortable. Bending the legs and offering a pacifier are both helpful. With the classic history and palpable “olive,” there is no need for additional studies. However, if a mass still cannot be appreciated, further work-up is warranted.

---

## Pathophysiology

### What Is the Etiology of This Condition?

For decades researchers have investigated the etiology of HPS, with inconclusive results. Some speculate that there is a failure of muscle relaxation in the pylorus, while others argue it is caused by deregulation of enteric hormones. Histologic evidence suggests that there is abnormal innervation with immature ganglia in the circular muscle layer of the pylorus. Genetic and maternal factors as well as environmental factors such as bottle feeding, use of oral macrolide antibiotics, and infection have all been implicated in the development of the disease. While theories and evidence are widely varied, the true etiology of HPS remains to be elucidated.

### What Is the Pathophysiology of This Condition?

Regardless of the etiology, there is universal consensus that HPS is characterized by hypertrophy and hyperplasia of the circular muscle layer of the pylorus. Muscle thickening causes the pyloric channel to become increasingly narrowed and elongated, eventually leading to gastric outlet obstruction. The smooth muscle of the stomach hypertrophies and dilates in response to vigorous peristalsis against an obstructed pylorus. As the stomach dilates and peristaltic contractions become stronger, the classic projectile vomiting of a large volume of gastric content occurs.

## Work-Up

### What Is the First Imaging Study to Obtain?

If there is no palpable “olive,” the gold-standard imaging modality is ultrasonography. Ultrasound measurements of pyloric channel length, muscle thickness, and diameter will diagnose HPS with a sensitivity and specificity close to 100 %. Most consider pyloric thickness greater than 3–4 mm and length greater than 15–16 mm diagnostic of HPS (Fig. 33.1). However, exact measurements vary based on the patient’s age and weight.

### What If the Diagnosis Is Still Uncertain?

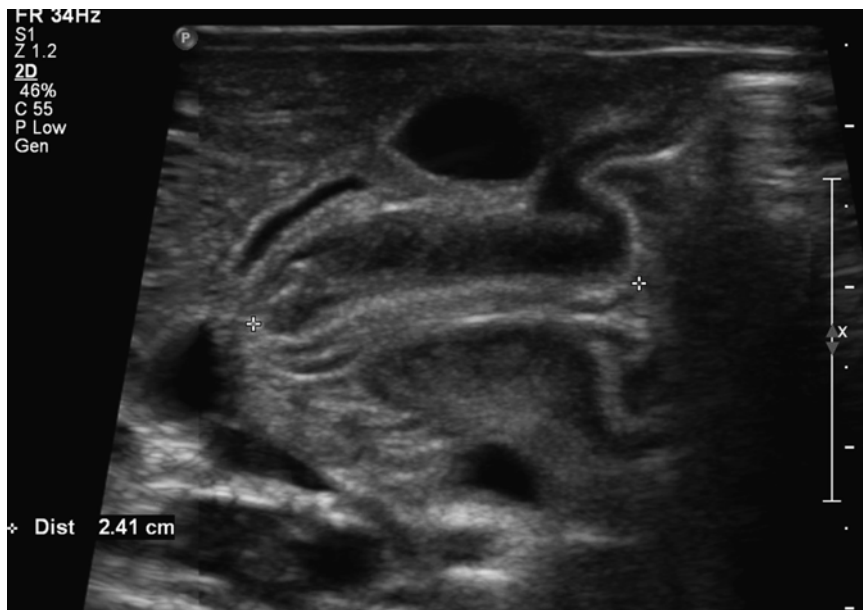
If ultrasound is equivocal, the diagnosis may be made with an upper gastrointestinal (UGI) contrast study. Typical findings include delayed gastric emptying, retrograde peristalsis in the stomach, and a string sign at the level of the pylorus. UGI studies may also be helpful in the setting of a negative ultrasound in order to assess for other pathology, particularly malrotation and gastroesophageal reflux.

#### Watch Out

In premature or small infants or in patients who present early in the disease process, ultrasound measurements may not meet criteria for HPS, as the thickness of the pylorus increases over time. This may lead to a false-negative study.

#### Watch Out

Contrast UGI studies have a risk of causing aspiration in infants, especially those with HPS (since they have gastric outlet obstruction) and should therefore be reserved for cases where the diagnosis is uncertain or malrotation with midgut volvulus cannot be ruled out.



**Fig. 33.1** Ultrasound image of pyloric stenosis (pyloric length is 24 mm)

## What Electrolyte Abnormalities Would You Expect?

Protracted, nonbilious vomiting results in a hypochloremic, hypokalemic metabolic alkalosis. Chloride ions are lost in gastric secretions and alkalosis is initially caused by loss of gastric HCl. Hypokalemia is a result of the combination of potassium ions being lost with vomiting and dehydration. Dehydration and subsequent hypovolemia increases aldosterone secretion, which in turn leads to activation of the Na<sup>+</sup>/K<sup>+</sup> pump in the renal tubules. In an attempt to increase water reabsorption, Na<sup>+</sup> is conserved at the expense of K<sup>+</sup>. As K<sup>+</sup> levels in the blood decrease, the kidney preferentially uses Na<sup>+</sup>/H<sup>+</sup> pump to maintain Na<sup>+</sup> and water reabsorption and prevent profound hypokalemia. This change leads to H<sup>+</sup> secretion and worsening metabolic alkalosis. Accordingly, urinalysis often reveals paradoxical aciduria.

---

## Management

### What Is the Most Important Immediate Management Issue?

The first step in management is to secure intravenous access and begin fluid resuscitation. Dehydration in patients with HPS is common due to prolonged, high-volume emesis. An initial isotonic fluid (normal saline) bolus of 20 ml/kg should be given to children with severe volume deficits, and subsequent resuscitation with 5 % dextrose 0.45 % NaCl should be initiated at 1.5 times the typical maintenance rate. A nasogastric tube is not routinely necessary. Once the child urinates, 20 mEq/L of KCl should be added to the intravenous fluid. Any electrolyte abnormalities should be corrected prior to taking the patient to the operating room.

#### Watch Out

Children have a higher body surface area-to-volume ratio than adults and are therefore more sensitive to volume loss. Any child with physical exam findings (decreased skin turgor, sunken fontanelle) or vital sign derangements should be considered to have moderate to severe hypovolemia.

### What Is the Treatment?

Surgery provides definitive treatment for pyloric stenosis. The procedure of choice is a Ramstedt pyloromyotomy. The abdomen is entered either laparoscopically or through a small transverse right upper quadrant incision. The pylorus is identified and an incision is made through the overlying serosa and the thickened pyloric muscularis. The pylorus muscle is then spread apart until the intact submucosa and mucosa are seen. Air or methylene blue is instilled through a nasogastric tube into the stomach to confirm there is no leak.

#### Watch Out

Remember that HPS is a medical emergency, not a surgical one. Restoration of fluids and electrolytes is paramount.

### What Is the Timing of Surgery?

Surgery is delayed until effective fluid resuscitation and electrolyte replacement have been performed. While not an emergency, surgery should be performed during the same admission. Most patients require 24 hours for adequate resuscitation. Patients with severe dehydration may require a longer period of rehydration prior to surgery. In general, patients are optimized for surgery when there is adequate urine output, the serum bicarbonate is less than 30 mmol/L, and the serum potassium is normal.

---

## When Can the Patient Resume Eating?

Following surgery, many children may begin oral feeding within a few hours. It is very common, however, for patients to vomit after surgery. This is most often due to either postoperative edema around the pylorus or, less commonly, an incomplete pyloromyotomy. Edema will resolve over a few days and the vomiting will subside. An incomplete pyloromyotomy will not likely resolve and the patient may require a repeat operation. Persistent vomiting beyond 3–4 days postoperatively is often indicative of this complication. Patients are typically discharged home 1 day after surgery.

---

## Areas Where You Can Get in Trouble

### Inadequate Resuscitation Prior to Surgery

Operating prior to adequate resuscitation is perilous for children with HPS. Anesthesia induction in hypovolemic children with electrolyte disturbances may precipitate catastrophic outcomes, including cardiovascular collapse and death. Children with severe electrolyte derangements or kidney disease may experience rapid fluid and electrolyte shifts, and potassium repletion in the setting of hypovolemia could lead to iatrogenic hyperkalemia or seizures.

### Postoperative Complications

In performing a pyloromyotomy, the surgeon must strike a balance between the risk of perforation and the risk of inadequate pyloromyotomy. Myotomies that are too superficial or too short do not adequately treat the primary disease process. Emesis beyond 3–4 days postoperatively should prompt an UGI evaluation. If there is persistent stenosis, reoperation may be required. Alternately, if the incision is made too deep (through the submucosa and mucosa), the myotomy becomes a full-thickness pyloric injury. This may result in leakage of gastric secretions and/or enteric contents. If the injury is recognized during surgery, it may be repaired immediately. Postoperatively, a leak may first present with fever or tachycardia, followed by feeding intolerance and leukocytosis. If not recognized early, the patient may subsequently develop peritonitis and sepsis. If a perforation is diagnosed postoperatively, the patient must be taken back to the operating room for exploration. Surgical management depends on the stability of the patient and the degree of contamination (contained versus uncontained leak).

---

## Areas of Controversy

### Laparoscopic Versus Open Repair

As with other general surgical diagnoses, there is some debate regarding the ideal approach. Both open and minimally invasive techniques are considered safe and successful. Initially laparoscopic pyloromyotomy was introduced out of concern for cosmetic outcome, given that scars grow with the patient, and a small childhood scar can become quite prominent in adulthood. However, advocates now point to decreased postoperative pain and infection rates as added benefits. Proponents of open surgery cite higher rates of undetected leaks and longer operating times with laparoscopy. Numerous studies have shown that the differences are relatively small and it is most important that the operating surgeon is comfortable with the planned approach.

### Nonsurgical Management

In North America, surgical management remains the standard of care; pyloromyotomy is regarded as the definitive treatment. Some European centers attempt diet modification and/or prolonged inpatient supportive care while awaiting resolution of the muscular hypertrophy. In some Asian countries, atropine has been used to medically manage HPS with variable success.

## Postoperative Feeding

While some surgeons begin postoperative feedings ad libitum, others begin a structured feeding schedule starting first with an oral electrolyte solution, followed by increasing amounts of breast milk or formula. There continues to be wide variation in structured feeding regimens. Recent data have shown that either postoperative feeding plan is safe and there is no difference in the length of hospital stay.

---

## Summary of Essentials

### History, Physical Examination, and Diagnosis

- Always determine if vomiting is bilious (green or yellow) or nonbilious
- Most common surgical cause of nonbilious vomiting in an infant: hypertrophic pyloric stenosis (HPS)
- Classic history: Projectile, nonbilious vomiting in healthy 4–8-week-old male
- Classic physical examination: palpable right upper quadrant “olive” mass, visible peristalsis over the epigastrium
- Ultrasound if diagnosis is unclear
- Diagnostic criteria
  - pyloric length > 15 mm
  - thickness > 3 mm
- Electrolyte abnormalities common: hypochloremic, hypokalemic metabolic alkalosis and paradoxical aciduria

### Pathophysiology

- Etiology not known
- Hyperplasia and hypertrophy of pylorus → gastric outlet obstruction

### Management

- Medical management first: fluid resuscitation, correct electrolyte imbalances
- Ramstedt pyloromyotomy is the gold standard: incise and split the muscular layers, leaving the mucosa and submucosa intact
- Delay surgery until infant is resuscitated and electrolyte levels are normal (may take 24–48 hours)
- Feeding starts hours after surgery; vomiting is common but should resolve

### Watch Out

- False negatives on ultrasound in premature/small infants or early in disease process
- Contrast UGI if equivocal ultrasound or concern for malrotation with midgut volvulus or GERD, risk of aspiration during study
- Abnormal vitals or positive physical exam findings = moderate to severe hypovolemia
- HPS is a medical emergency, not a surgical one
- Persistent vomiting post op: evaluate for incomplete pyloromyotomy
- Post op fever and tachycardia = perforation until proven otherwise

---

## Suggested Reading

- Iqbal CW, Rivard DC, Mortellary VE, Sharp SW, St Peter SD. Evaluation of ultrasonographic parameters in the diagnosis of pyloric stenosis relative to patient age and size. *J Pediatr Surg.* 2012;47(8):1542–7.
- Pandya S, Heiss K. Pyloric stenosis in pediatric surgery: an evidence-based review. *Surg Clin N Am.* 2012;92(3):527–39. vii–viii.
- St Peter SD, Holcomb GW, Calkins CM, Murphy JP, Andrews WS, Sharp RJ, Snyder CL, Ostlie DJ. Open versus laparoscopic pyloromyotomy for pyloric stenosis: a prospective, randomized trial. *Ann Surg.* 2006;244(3):363–70.

Justin P. Wagner and Steven L. Lee

An infant at 39 weeks gestation is born to a thin 19-year-old Caucasian G1P0 woman with no prior medical history. She quit smoking when she discovered she was pregnant. The pregnancy was planned, and it has been uncomplicated. Prenatal maternal laboratory studies were significant for an elevated serum alpha-fetoprotein level. Prenatal ultrasound examinations showed a fetus with free loops of intestine present in the amniotic cavity extruding through a small abdominal defect lateral to the base of the umbilical cord. The infant's APGAR scores are 8 and 9 at birth and 5 minutes later, respectively. Vital signs are within normal limits. The abdomen is scaphoid with loops of matted and inflamed small bowel protruding from a defect to the right of the umbilicus.

## Diagnosis

### What is the Differential Diagnosis for a Newborn With Abdominal Wall Defect and What Are The Common And Distinguishing Features?

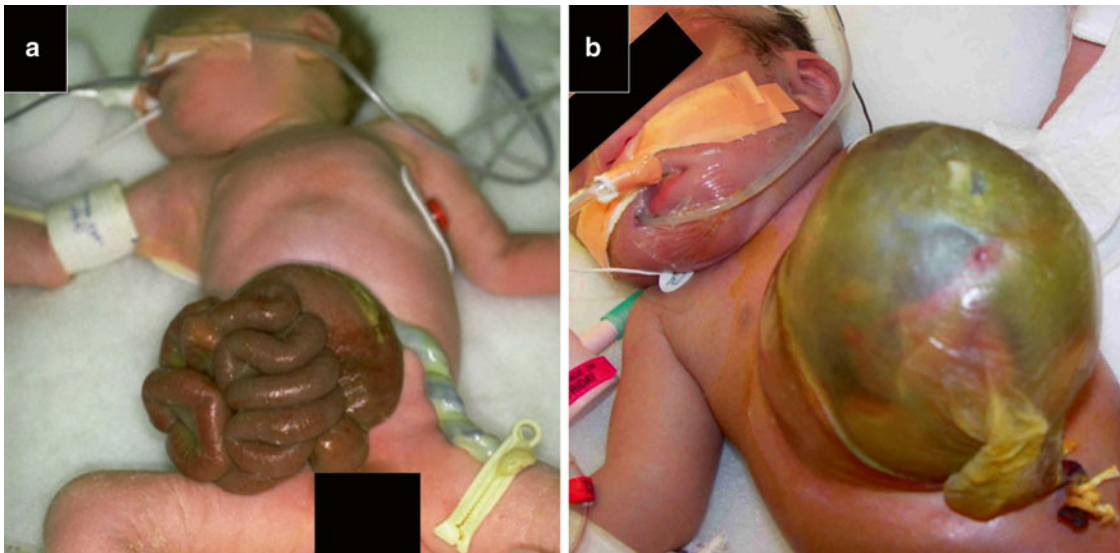
Diagnosis	Common features	Distinguishing features
<i>Gastroschisis</i>	Medial abdominal wall defect with evisceration of abdominal contents	No membrane over abdominal contents Evisceration usually to the right of umbilical stalk Higher risk to intestinal viability Diagnosis impossible before 12 weeks
<i>Omphalocele</i>	Midline abdominal wall defect with herniation of abdominal contents	Amnioperitoneal membrane covers abdominal contents Umbilical cord inserts into membrane Associated with other birth defects Diagnosis possible before 12 weeks if liver herniation present
<i>Bladder or cloacal exstrophy</i>	Extra-abdominal/pelvic sac containing herniated hemibladders, urethra, and possibly kidney and intestine	Defect usually inferior to umbilical stalk Two hemibladders separated by intestine Extensive defects associated with omphalocele and epispadias
<i>Prune belly syndrome</i>	Abdominal wall hypoplasia	Abdominal viscera contained within collagenous wall 95 % are in males Associated with hypoplastic prostate, bilateral undescended testes, infertility, and bladder outlet obstruction
<i>Urachal abnormality</i>	Communication of bladder and anterior abdominal wall, may be associated with cyst or sinus	Communication between bladder and a cystic mass pathognomonic for patent urachus Often associated with omphalocele and neural tube defects

J.P. Wagner, MD (✉)

Department of Surgery, David Geffen School of Medicine at UCLA, 757 Westwood Plz, Rm B711, Los Angeles, CA 90095, USA  
e-mail: [jwagner@mednet.ucla.edu](mailto:jwagner@mednet.ucla.edu)

S.L. Lee, MD

Department of Surgery, Division of Pediatric Surgery, Harbor-UCLA Medical Center, 1000 W. Carson Street, Box 25, Torrance, CA 90509, USA  
e-mail: [sleemd@yahoo.com](mailto:sleemd@yahoo.com)



**Fig. 34.1** Gastroschisis (a) and omphalocele (b)

### What Is the Most Likely Diagnosis in This Case?

The most likely diagnosis is gastroschisis in this case. The infant's mother has several risk factors associated with gastroschisis, including young age, Caucasian race, low body mass index (BMI), singleton pregnancy, and recent tobacco use. Prenatal ultrasound detects gastroschisis in about 70 % of cases. It is effective in distinguishing gastroschisis from omphalocele, and it is useful to evaluate visceral blood flow. In this case, the patient is born with eviscerated bowel and no sac, strongly suggesting a diagnosis of gastroschisis (Fig. 34.1a).

## History and Physical Examination

### Which of the Above Diagnoses Are the Most Common?

Gastroschisis occurs in 1 in 2–10,000 live births, while omphalocele occurs in 1 in 4–5,000 live births. The rest of the conditions are rare, occurring in fewer than 1 in 40,000 live births.

### What are the Specific Differences Between Gastroschisis and Omphalocele?

Factor	Gastroschisis (Fig. 34.1a)	Omphalocele (Fig. 34.1b)
<i>Location</i>	Paraumbilical (usually right-side)	Umbilical, epigastric, or hypogastric
<i>Defect size</i>	Often small (<5 cm)	Variable, often large
<i>Cord insertion</i>	Normal in umbilicus	Inserts in membrane
<i>Membrane</i>	Absent	Present (10–20 % rupture)
<i>Contents</i>	Bowel (gonads, liver, stomach)	Bowel, liver
<i>Bowel</i>	Matted, dilated, or thickened	Normal
<i>Malrotation</i>	Often present	Present
<i>Abdominal cavity</i>	Small	Small
<i>Maternal AFP level</i>	Elevated (greater than omphalocele)	Elevated
<i>GI function</i>	Ileus	Normal
<i>Associated GI anomalies</i>	Intestinal atresia (10–25 %)	Nonspecific, but higher overall risk
<i>Other associated anomalies</i>	Rare	Common (30–70 %) Beckwith-Wiedemann, Trisomies 13 and 18, Pentalogy of Cantrell Chromosomal in 50–70 % without liver herniation

AFP, alpha-fetoprotein

## What are the Risk Factors for Gastroschisis and for Omphalocele?

Maternal risk factor	Gastroschisis	Omphalocele
Age	<20 years	<20 or >40 years
Race	Caucasian	–
Pregnancy	Singleton	–
BMI	Low	High
Medical history	Frequent UTIs	SSRI use, potentially Heredity/associated heritable conditions in family history
Social	Cigarette smoking Recreational drug use Alcohol consumption	–

UTI, urinary tract infection; SSRI, selective serotonin reuptake inhibitor

## Pathophysiology

### What Is the Etiology of Gastroschisis?

While the etiology of gastroschisis is relatively unclear, it is thought to result from a vascular accident within the umbilical ring, leading to a local defect in the developing body wall and evisceration. Experts hypothesize that the defect from involution of the right umbilical vein, leaving a defect that is most often to the right of the umbilicus. The disease process is commonly limited to the local body wall defect and the herniated viscera.

### What Is the Etiology of Omphalocele?

Omphalocele is thought to develop from an arrest of lateral-body fold migration and body wall closure. This process takes place during the organogenesis phase. At embryonic week 5 of normal development, the midgut extrudes through the base of the umbilical cord and undergoes proliferation and rotation. The viscera return to the peritoneal cavity at fetal week 11 of gestation. Omphalocele is a result of persistent herniation of viscera contained within a sac that never returned to the abdomen during development. The failure of cell migration may be a manifestation of an underlying disease process that affects several other migrating cell types during development. Frequently, omphalocele is part of an association of birth defects with a common congenital cause. When the liver is extracorporeal (i.e., when a giant defect is present), a chromosomal abnormality is unlikely.

### Which Condition Is More Urgent? Why?

Both conditions are associated with intrauterine growth restriction and preterm delivery, and so frequent prenatal surveillance is indicated. Antenatal consultations with a maternal-fetal medicine specialist and a pediatric surgeon should be sought in either case.

Gastroschisis generally creates more urgent problems at delivery that require immediate pediatric surgical intervention. This derives from two problems: the fact that the bowel is not covered by a protective membrane and the associated intestinal abnormalities. The longstanding exposure of the bowel in utero to amniotic fluid often leads to markedly inflamed bowel. Soon after delivery, the pediatric surgeon is called to provide adequate protection of the exposed viscera and to evaluate the extent of intestinal anomalies. Concurrent malrotation with volvulus or intrauterine vascular compromise may result in intestinal atresia, obstruction, stenosis, necrosis, or perforation. Furthermore, the exposed bowel creates significant risk of insensible fluid and heat losses that can be substantial if the bowel remains unprotected.

With omphalocele, the membrane covering the bowel protects against these aforementioned urgent problems. Of greater concern long term, however, are the associated conditions such as Pentalogy of Cantrell, trisomy 13, and trisomy 18, all of which carry poor prognoses.



## Work-Up

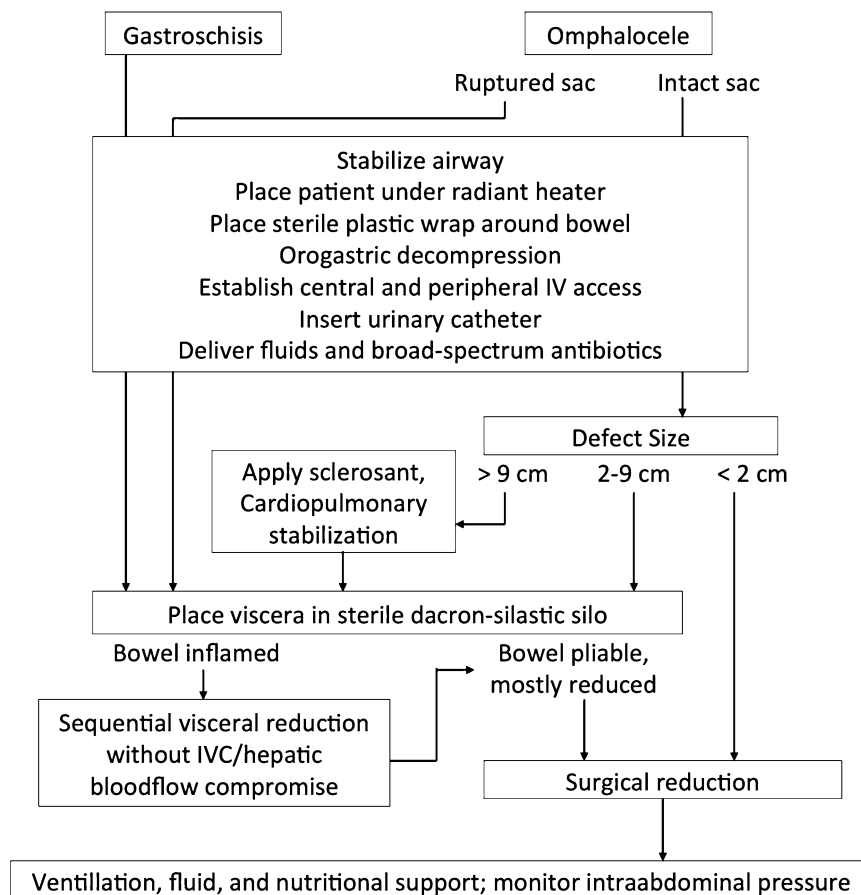
### What Is the Next Step in the Work-Up?

Postpartum stabilization is the top priority for infants born with gastroschisis and omphalocele, and diagnostic testing is reserved for the most critical issues. Metabolic disturbances are evaluated with blood laboratory testing, intravenous fluid intake and urine output are closely monitored, and X-rays are performed to evaluate general anatomy and the positions of implanted devices (i.e., endotracheal tubes, central venous catheters, and orogastric tubes). Stabilized infants with omphalocele undergo echocardiography to evaluate for associated congenital cardiac defects.

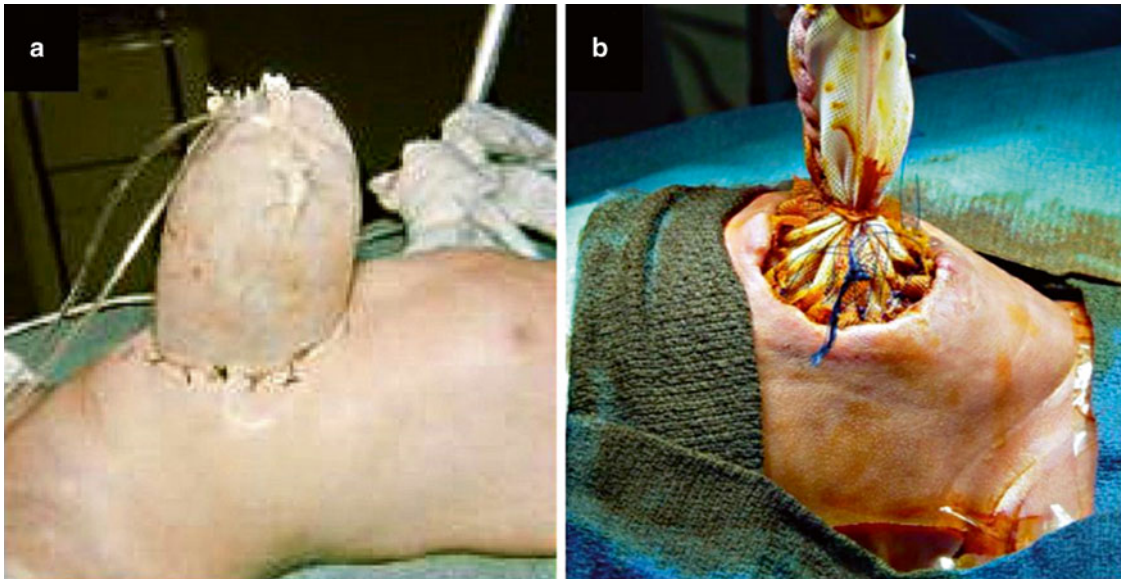
## Management

### What Is the Neonatal Management of Gastroschisis and Omphalocele?

At the time of delivery, the top priorities in the management of an infant with either gastroschisis or omphalocele (Fig. 34.2) include airway protection, thermal support, protection of herniated viscera, fluid maintenance, and establishment of intravenous access. Importantly, expeditious placement of a sterile plastic wrap protects exposed viscera from rapid heat and fluid loss. Small omphaloceles may be repaired surgically. Gastroschisis and large omphaloceles require placement of herniated contents in a Dacron-coated silastic silo. This maneuver permits gradual resolution of visceral inflammation and reduction into the peritoneal cavity. Infants with gastroschisis often develop prolonged ileus from intestinal inflammation, and so they require parenteral nutritional support during this phase. Omphaloceles rupture in up to 20 % of cases, either in utero or at the time of delivery. In the case of rupture, management is identical to that of gastroschisis. For giant omphaloceles, a caesarean



**Fig. 34.2** Neonatal management algorithm. IV, intravenous; IVC, inferior vena cava



**Fig. 34.3** Initial silo placement for gastroschisis (a) and complete reduction (b)

section may minimize the risk of traumatic rupture during delivery, though there is no evidence that caesarean delivery improves omphalocele outcome.

### What Is the Timing of the Closure of the Abdominal Wall Defect?

The defect is surgically repaired when the herniated contents have reduced significantly and there is sufficient abdominal wall laxity to accommodate a low-tension repair. Small omphaloceles (<2 cm) may undergo primary operative repair when the patient is stable. For large omphalocele defects and gastroschisis that have been temporized with a silo, the defect can be closed around reduced contents provided there is no tension (Fig. 34.3).

---

## Areas Where You Can Get in Trouble

### Not Recognizing Emergencies

As in all primary surveys, the infant's airway must be secured. Infants with compromised airways require emergent intubation. For a child with gastroschisis, the physical examination after delivery is critical. The bowel is closely inspected for signs of ischemia, segments of atresia, or volvulus, each of which may require urgent surgical intervention.

### Not Properly Protecting the Bowel

Upon securing the airway, thermal support is usually provided by a heating lamp. The viscera are wrapped with a sterile plastic covering. Saran Wrap is a reasonable temporizing option if there is a delay in acquiring a silo. Moist gauze dressings alone should be avoided because the infant can lose significant fluid and heat without a watertight plastic dressing.

### Not Addressing Nutritional Needs

The appearance of the bowel will dictate the nutritional support the child receives. Matted, inflamed intestines will likely be slow to function. In cases where gastrointestinal dysmotility is suspected, the infant should be supported with total parenteral nutrition until bowel function is restored.

## Not Recognizing Abdominal Compartment Syndrome After Repair

After the defect is surgically repaired, the infant must be monitored closely for signs of increased intra-abdominal pressure. Low urine output, insufficient ventilation, and positive fluid balance signify development of abdominal compartment syndrome. Prolonged mechanical ventilation may be necessary after reduction and abdominal closure.

---

## Areas of Controversy

### Timing of Elective Delivery

While late delivery is associated with increased risk of stillbirth, early delivery incurs the risks of prematurity. For this reason, this decision is made on a case-by-case basis, contingent on the least perceived risk to the fetus and to the mother.

### Method of Repair of Large Abdominal Wall Defect

When defects are large and reduction into the peritoneal cavity is limited, definitive surgical repair is more complex. For giant omphaloceles, a topical sclerosing agent may be applied to the defect edges to promote reduction. The defect can be covered with an inert sheet, leaving a large ventral hernia that can be sequentially folded inward, and ultimately covered with skin grafts. Additionally, tissue expanders may be implanted to generate enough abdominal domain to cover the volume of displaced viscera.

---

## Summary of Essentials

- Diagnosis:
  - Prenatal ultrasound is diagnostic in most cases
  - Gastroschisis is paraumbilical (typically to the right of the umbilicus) and has exposed bowel
  - Omphalocele has a sac (the umbilicus inserts into the sac) and is associated with more congenital defects
- Omphalocele-associated conditions:
  - Beckwith-Wiedemann Syndrome
  - Trisomy 13
  - Trisomy 18
  - Pentalogy of Cantrell
- Etiology:
  - Gastroschisis: in utero vascular insult, abdominal wall defect
  - Omphalocele: arrest of cell migration, incomplete return of midgut to the peritoneal cavity
- Neonatal management:
  - Ventilation:
    - Secure the airway
    - Difficulty ventilating suggests a problem with the lungs (congenital diaphragmatic hernia or pulmonary hypoplasia)
  - Normothermia and fluid management:
    - Radiant heater
    - Orogastric suction
    - Protect exposed viscera with plastic wrap
    - IV fluids and broad-spectrum antibiotics
  - Gastroschisis: surgical evaluation for atresia, ischemia, or volvulus; TPN when intestine appears inflamed
  - Protective silo and serial reduction
  - Surgical repair

- 
- Postoperative care:
    - Ventilator requirement after reduction may persist
    - Administer TPN if necessary
    - Monitor for abdominal compartment syndrome
- 

### **Suggested Reading**

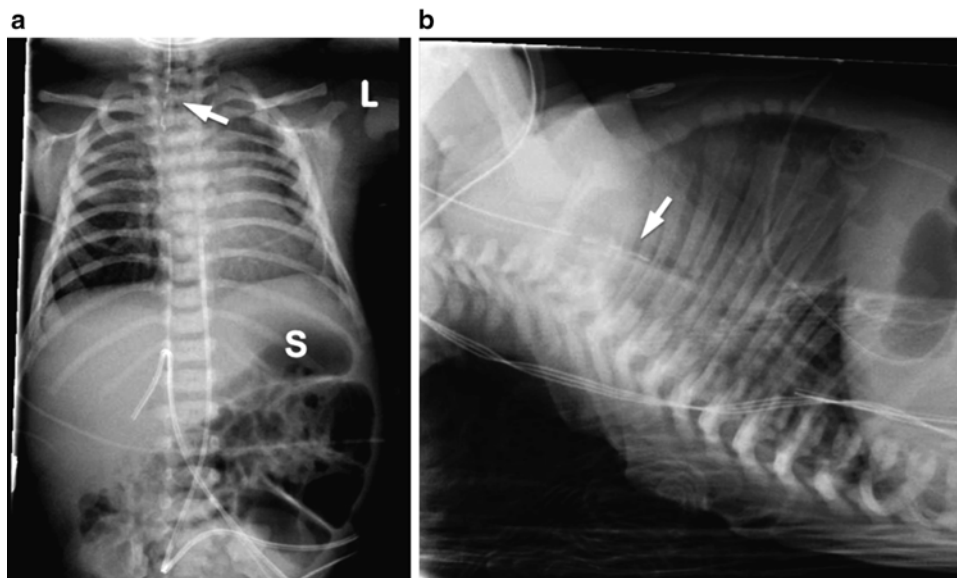
Henrich K, Huemmer HP, Reingruber B, Weber PG. Gastroschisis and omphalocele: treatments and long-term outcomes. *Pediatr Surg Int.* 2008;24(2):167–73.

Mac Bird T, Robbins JM, Druschel C, Cleves MA, Yang S, Hobbs CA. Demographic and environmental risk factors for gastroschisis and omphalocele in the National Birth Defects Prevention Study. *J Pediatr Surg.* 2009;44(8):1546–51.

Sadler TW. The embryologic origin of ventral body wall defects. *Semin Pediatr Surg.* 2010;19(3):209–14.

Veronica F. Sullins and Steven L. Lee

A term female newborn presents with excessive drooling. She is noted to have white frothy mucous building up in her mouth and nose, which recurs despite suctioning. She is also unable to tolerate any feedings. During her first feeding, she gagged and immediately spit up. There were no complications during birth. On examination, the newborn is normotensive and has a normal heart rate. Her oxygen saturation is 98 % but decreases to 80 % during feeding. She has bilateral rales and rhonchorous upper airway sounds. Her abdomen is distended and nontender. The patient receives anteroposterior and lateral chest radiographs (Fig. 35.1) after orogastric tube placement (arrows). The stomach (S) is shown in the anteroposterior radiograph.



**Fig. 35.1** (a, b) Anteroposterior and lateral chest radiographs

V.F. Sullins, MD (✉)

Department of Surgery, Harbor-UCLA Medical Center, 1000 West Carson Street, Box 25, Torrance, CA 90509, USA

e-mail: [ronniesullins@gmail.com](mailto:ronniesullins@gmail.com)

S.L. Lee, MD

Department of Surgery, Division of Pediatric Surgery, Harbor-UCLA Medical Center, 1000 W. Carson Street, Box 25, Torrance, CA 90509, USA

e-mail: [sleemd@yahoo.com](mailto:sleemd@yahoo.com)

## Diagnosis

### What Is the Differential Diagnosis of Excessive Drooling/Feeding Intolerance in a Newborn?

Diagnosis	Distinguishing features
<i>Choanal atresia</i>	Inability to pass NGT
<i>Cleft palate</i>	Defect seen on physical examination of the oral cavity
<i>Esophageal atresia with or without tracheoesophageal fistula</i>	OGT/NGT seen curled in upper esophageal pouch on AP and lateral radiographs
<i>Esophageal web or ring</i>	Usually asymptomatic until later in life, vomiting if symptomatic, circumferential partial obstruction on contrast esophagram
<i>Food sensitivity</i>	Normal anatomy, accompanying rash or diarrhea, specific food intolerance
<i>Gastroesophageal reflux</i>	Absence of anatomic abnormalities, frequent regurgitation or vomiting
<i>Laryngotracheoesophageal cleft</i>	Midline defect between posterior wall of larynx/trachea and anterior esophagus
<i>Mediastinal or tracheal compression</i>	Extrinsic compression of esophagus, lesion (tumor, vascular ring, foregut duplication, etc.) on chest XR, ultrasound, or CT scan
<i>Neurologic disorder</i>	Patent esophagus on contrast esophagram, uncoordinated peristalsis on swallow study

NGT nasogastric tube, OGT orogastric tube, AP anteroposterior, XR radiograph, CT computed tomography

### What Is the Most Likely Diagnosis?

Esophageal atresia (EA) with distal tracheoesophageal fistula (TEF) is the most likely diagnosis. Chest radiographs show the orogastric tube curled in the upper esophageal pouch confirming the diagnosis of EA. The presence of a gastric bubble suggests a connection from the trachea to the distal esophagus or a distal TEF. Absence of a gastric bubble is diagnostic of either EA without a TEF or EA with a proximal TEF. Focal infiltrates may indicate pneumonia secondary to aspiration of gastric contents or feedings.

## History and Physical

### What Is the Significance of Oxygen Desaturation that Only Occurs While Feeding?

Normal oxygen saturation at rest implies intact tracheobronchial anatomy. When a newborn has desaturations while feeding, it implies that there is a significant anatomic or functional problem with the proximal alimentary tract (nasopharynx, oropharynx, esophagus, or stomach).

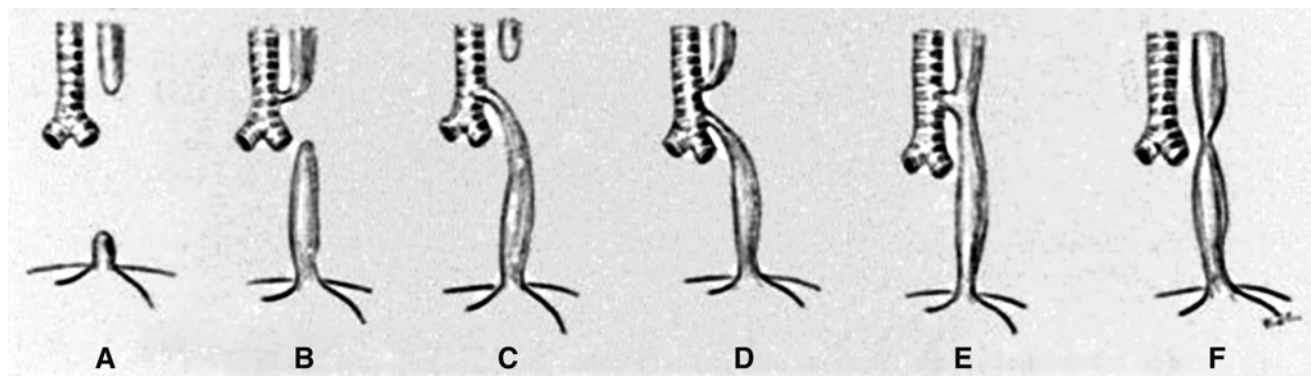
### What Are Other Possible Presentations of TEF?

In addition to excessive drooling or choking with feeds, newborns may also present with respiratory distress or pneumonia. The presentation of TEF is determined by the presence or absence of EA as well as the presence and severity of associated anomalies. Patients with small fistulas with a normal esophagus (H-type) may be asymptomatic and will not present until later in life with recurrent pneumonia or respiratory distress with feeding.

## Pathophysiology

### What Is Thought to Be the Etiology of This Condition?

Although the pathogenesis remains unknown, EA with or without TEF is thought to be caused by a defect in the development of the longitudinal tracheoesophageal fold that separates the most caudal part of the primitive foregut into the trachea and esophagus. It is believed that the fistula tract is derived from defective epithelial-mesenchymal interactions in a branch of the embryonic lung bud that fails to develop. An alternate theory is that the primitive foregut occludes, then there is a failure of recanalization.



**Fig. 35.2** Gross classification of esophageal atresia and tracheoesophageal fistula (From Coran, A. Pediatric Surgery. Copyright Elsevier (2012). Reprinted with permission)

**Table 35.1** Anomalies found in VACTERL

Category of anomaly	Specific anomalies
<u>V</u> ertebral	Hypoplastic or hemivertebrae
<u>A</u> norectal	Anal atresia or imperforate anus
<u>C</u> ardiovascular	ASD, VSD, tetralogy of Fallot, truncus arteriosus, transposition of the great arteries
<u>T</u> racheoesophageal	Tracheoesophageal fistula
<u>E</u> sophageal	Esophageal atresia
<u>R</u> enal	Renal agenesis, hypoplastic or dysplastic kidney, horseshoe kidney, renal ectopia, ureteral obstruction, vesicoureteral reflux
<u>L</u> imb	Displaced or hypoplastic thumb, polydactyly, syndactyly, radial aplasia

ASD Atrial septal defect, VSD Ventricular septal defect

### How Are the Different Types Classified?

EA and TEF are classified by their anatomic configuration, specifically the location of the TEF (Fig. 35.2). The most common is Type C, a proximal esophageal pouch with a distal TEF, accounting for approximately 85 % of cases. The next most common is pure EA without TEF (8 %).

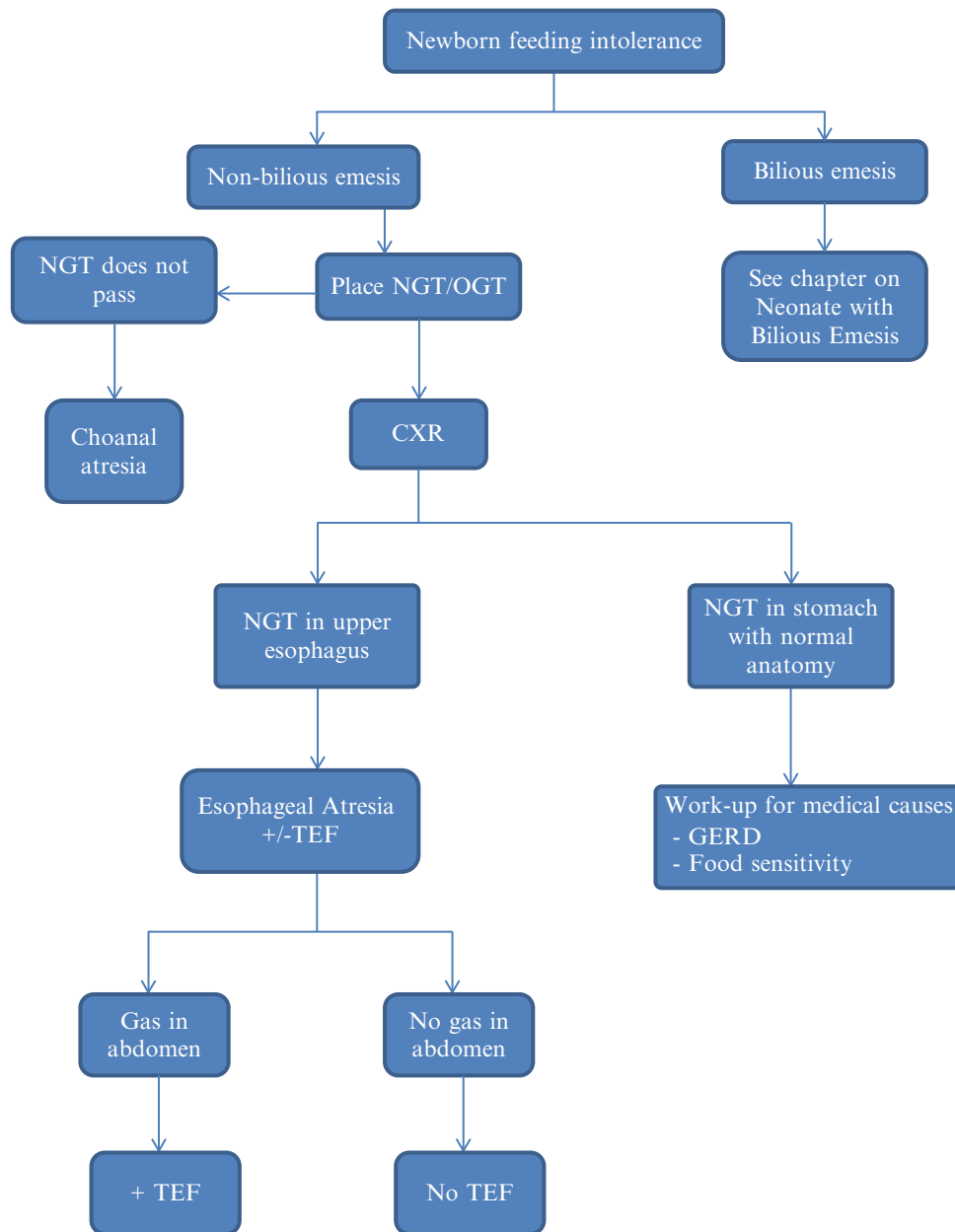
### What Are the Associated Anomalies?

Approximately 50 % of children with TEFs have associated anomalies including cardiac, urogenital, skeletal, vertebral, anorectal, gastrointestinal, and palatal or laryngeal anomalies. Associations and syndromes such as VACTERL (Table 35.1) and CHARGE (coloboma, heart defect, atresia choanae, retarded growth and development, genital abnormality, and ear abnormality) are frequently diagnosed. In addition, there are reports of associations with trisomies 18, 21, and 13 as well as single gene deletions. The most common associated anomalies are cardiovascular.

## Workup

### What Is the Best Initial Diagnostic Test?

If the newborn is stable, the best initial study is a chest radiograph (anteroposterior and lateral) after placement of a nasogastric or orogastric tube. Abnormal lung fields may demonstrate a pneumonia, primary lung lesion, or congenital diaphragmatic hernia. Esophageal atresia is diagnosed by visualization of the nasogastric tube coiled in the upper mediastinum, posterior to the larynx and trachea. A diagnostic algorithm for surgical causes of neonatal feeding intolerance is shown in Fig. 35.3.



**Fig. 35.3** Diagnostic algorithm for neonatal feeding intolerance

#### Watch Out

An anteroposterior chest radiograph alone may incorrectly diagnose EA if the naso- or orogastric tube is misplaced. A lateral chest radiograph is necessary to confirm that the tube is curled in the upper esophageal pouch and not the trachea or larynx.



## Are Other Studies Necessary for Diagnosis?

No. A history of newborn feeding intolerance and excessive drooling combined with the above chest radiographs are diagnostic. If the history is unclear or the radiographic findings are equivocal, a contrast esophagram may be performed by instilling barium through a catheter inserted into the esophagus and taking both lateral and anteroposterior radiographs. The improved quality of CT scans has made 3-dimensional imaging popular; however, it exposes the newborn to a much larger radiation dose and is not usually necessary to make the diagnosis.

### Watch Out

Contrast esophagrams have a risk of aspiration pneumonitis and should therefore be reserved for cases where the location of the fistula cannot be ascertained or the diagnosis is uncertain.

## Can the Diagnosis of TEF Be Made Prenatally?

While it is difficult to determine prenatally if a newborn has a TEF because air will not have entered into the alimentary tract through the fistula until after birth, EA may be manifested by polyhydramnios on prenatal ultrasound.

---

## Management

### What Is the First Step in Clinical Management?

If the patient is exhibiting signs of respiratory compromise, endotracheal intubation and mechanical ventilation are required. Preoperative management is aimed at minimizing the risk of aspiration. This may be achieved by continuous suction of the blind upper esophageal pouch and elevation of the infant's head. For patients who have developed pneumonia, broad-spectrum antibiotics should be given and a gastrostomy tube may be placed to prevent further reflux into the trachea. Patients without a pulmonary infection should be started on prophylactic antibiotics.

### Watch Out

Every effort should be made to avoid distending the gastrointestinal tract to avoid further aspiration and lung injury. This is especially important for patients who are receiving ventilator support.

### What Is the Timing of Surgical Repair?

The timing of surgery is based on the size and condition of the infant. Healthy infants with proximal EA and distal TEF may undergo surgical repair within the first few days of life. Patients with severe anomalies or respiratory failure secondary to pneumonia should have ligation of the TEF and placement of a gastrostomy tube for feeding, and definitive repair should be delayed until their clinical status improves. Surgery may be delayed several weeks especially in cases of severe respiratory distress syndrome or prematurity.

### Are Any Other Studies Needed Prior to Surgery?

Even stable infants who are fit for early repair must have a complete workup including thorough physical exam, cardiac and renal ultrasounds, and plain radiographs to evaluate for associated anomalies (Table 35.2). In addition, echocardiography provides essential anatomic information required for surgical repair.

**Watch Out**

The patient's anatomy must be accurately assessed prior to embarking on a surgical repair. Certain malformations may change the operative approach.

**What Is the Definitive Treatment?**

Definitive treatment consists of surgical division of the fistula tract with repair of the trachea and primary anastomosis of the esophagus. In most cases of isolated (H-type) TEF, a cervical approach is used. If the TEF is accompanied by EA, the upper and lower esophageal pouches must be mobilized through a right thoracotomy to create a tension-free anastomosis. Prior to performing the esophageal anastomosis, the fistula must be located and divided. In cases of pure esophageal atresia, patients are initially managed with gastrostomy tube placement and a staged approach to surgical repair.

**What Are the Complications After Surgical Repair?**

Approximately 15 % of patients have a leak at the esophageal anastomosis. Typically, leaks heal spontaneously, resulting in a stricture. If a leak occurs within the first few days postoperatively, surgical revision is usually required. Anastomotic strictures are very common and may be as high as 80 %. Typical management includes esophagoscopy and balloon dilation of the stricture. All patients have gastroesophageal reflux disease with an increased risk of Barrett's esophagus and esophageal cancer. Long-term, approximately 30 % will need a surgical anti-reflux procedure. Recurrence of the TEF has also been described and requires surgical repair.

**What Is the Prognosis?**

In infants without severe associated anomalies, survival rates are near 100 %. However, patients may have significant morbidity including anastomotic leak, tracheomalacia, gastroesophageal reflux disease, dysphagia, esophageal dysmotility, and pulmonary problems due to recurrent aspiration. In infants with significant comorbid conditions or who are not candidates for early repair, the survival rate is 80–95 %. Those with low birth weight and major cardiac anomalies have the lowest survival rates.

---

**Areas Where You Can Get in Trouble****Interrupted IVC**

Very rarely, the inferior vena cava (IVC) drains into the right atrium via the azygous system. During a typical EA/TEF repair, the azygous vein is divided to allow access to the TEF. Division of the azygous vein in a patient with an interrupted IVC will disrupt all venous return from the abdominal viscera and lower extremities and will lead to patient demise.

**Right-Sided Aortic Arch**

A right-sided aortic arch is present in just over 5 % of patients with esophageal atresia. Surgical repair typically is performed through a right thoracotomy incision and the presence of a right-sided aortic arch makes this approach technically very difficult. Failure to preoperatively diagnose a right-sided aortic arch may result in an inability to repair the esophagus, additional thoracotomy, or other unnecessary morbidity or mortality. Furthermore, a right-sided aortic arch is frequently associated with congenital heart disease or compression of the trachea or esophagus. If this anatomic malformation is diagnosed, repair of the esophageal atresia should be performed through a left thoracotomy.

## Intubation and TEF

In the presence of a TEF, intubation and mechanical ventilation should be avoided if possible. Positive pressure ventilation may result in significant gastric and abdominal distension due to air moving through the TEF and into the alimentary tract instead of into the lungs. Increasing abdominal distention and pressure decreases lung expansion and further compromises respiratory status. In addition to making single lung ventilation during surgical repair more tenuous, excessive amounts of air in the digestive tract may cause perforation and emergency operation.

---

## Areas of Controversy

### Operative Approach

The traditional approach for repair of EA with TEF is typically through a right thoracotomy incision. More recently, surgeons have demonstrated successful repair using a thoracoscopic approach, citing the improved visualization and avoidance of a thoracotomy as potential advantages. However, the procedure is more technically demanding, and in patients with already compromised pulmonary function, carbon dioxide insufflation may not be tolerated. Additional data are needed to prove the superiority of a minimally invasive approach especially with more difficult dissections and challenging anastomoses.

## Management of Pure Esophageal Atresia with a Long Gap Between Ends

Long gap EA remains a significant clinical and surgical challenge. A staged surgical approach is usually necessary. Multiple lengthening methods have been described. Some use distractive forces to bring the two ends of the esophagus together. Others describe division of the esophageal muscle layers to gain length. Lengthening techniques often result in strictures, leaks, or fistula formation and patients have long hospital stays and often have an aversion to eating. Another treatment strategy involves placement of an interposition graft using the stomach, colon, or jejunum. All conduits have specific long-term complications and durability is not optimal. Ongoing research is aimed at developing internal lengthening techniques.

---

## Summary of Essentials

### Diagnosis

- Differential diagnosis of feeding intolerance is broad: includes anatomic malformations of naso- and oropharynx, tracheobronchial tree, and esophagus, GERD, extrinsic esophageal compression, food sensitivity, and neurologic disorders

### History and Physical Examination

- Desaturations only while feeding imply anatomic or functional problem with proximal aerodigestive tract
- Best initial diagnostic test: anteroposterior and lateral chest radiography after nasogastric or orogastric tube placement

### Pathophysiology

- EA ± TEF caused by defect in the development of longitudinal tracheoesophageal fold separating foregut into trachea and esophagus
- EA and TEF classified according to the location of the TEF: EA with a distal TEF (Type C) most common
- >50 % have associated anomalies: cardiovascular most common, frequent VACTERL association
- Excellent prognosis in absence of significant anomalies, but patients have significant clinical sequelae resulting from surgical repair

---

## Management

- Patients with respiratory compromise → Intubation and mechanical ventilation
- Preoperative management goal: minimize risk of aspiration (nasal- or orogastric suction of upper esophageal pouch, head elevation, antibiotics)
- All need evaluation for associated anomalies: echocardiogram, renal ultrasound, radiographs
- Timing of surgery depends on patient's clinical condition, size, presence of associated anomalies
- Surgical repair: division of the fistula tract, repair of the trachea, and primary anastomosis of the esophagus
- Postoperative complications (anastomotic leak, stricture, gastroesophageal reflux disease) are very common

## Watch Out

- Avoid misdiagnosis → lateral chest radiograph to confirm esophageal placement of nasal- or orogastric tube
- Risk of aspiration pneumonitis with contrast esophagram
- Avoid distending gastrointestinal tract to avoid further aspiration and lung injury, especially in patients on ventilator support
- Vascular anatomy must be accurately assessed prior to surgery

---

## Suggested Reading

Alberti D, Boroni G, Corasaniti L, Torri F. Esophageal atresia: pre and post-operative management. *J Matern Fetal Neonatal Med.* 2011;24 Suppl 1:4–6.

Kunisaki SM, Foker JE. Surgical advances in the fetus and neonate: esophageal atresia. *Clin Perinatol.* 2012;39(2):349–61.

Pinheiro P, Silva A, Pereira R. Current knowledge on esophageal atresia. *World J Gastroenterol.* 2012;18(28):3662–72.

---

**Part XI**

**Skin**

Christian de Virgilio, Section Editor

Arezou Tory Yaghoubian and Junko Ozao-Choy

A 44-year-old fair-skinned Caucasian male who works as a lifeguard presents with a 1-cm pigmented skin lesion on the right forearm that has recently become variegated and larger in diameter. The patient denies itching, oozing, or bleeding associated with the lesion. He has a history of severe blistering childhood sunburns. The lesion is slightly elevated, asymmetric with ill-defined borders. There is no evidence of bleeding, ulceration, or excoriation. There are no satellite lesions or in-transit metastasis seen. Examination of the patient's right axilla and neck reveals no obvious lymphadenopathy. No other skin lesions are identified on physical examination.

---

A.T. Yaghoubian, MD  
Plastic and Reconstructive Surgery, UCLA, 200 UCLA Medical Plaza, Los Angeles, CA 90095, USA  
e-mail: [ayaghoub@ucla.edu](mailto:ayaghoub@ucla.edu)

J. Ozao-Choy, MD (✉)  
Division of Surgical Oncology, Harbor-UCLA Medical Center, 1000 W. Carson Street, Box 25, Torrance, CA 90509, USA  
e-mail: [jozao-choy@dhs.lacounty.gov](mailto:jozao-choy@dhs.lacounty.gov)

## Diagnosis

### What is the Differential Diagnosis and What Clues on History and Physical Examination Might Direct You Towards Specific Diagnoses?

Diagnosis	Malignant?	Comments
<i>Junctional nevi</i>	No	Dark, flat, smooth lesions. They are occasionally hairy and develop from the basal layer of epidermis. Nevi that are located on the palms and soles are usually junctional. They are benign lesions with a very low risk of malignant degeneration. <i>Most common mole of children,</i>
<i>Compound nevi</i>	No	Brown to black, well-circumscribed lesions that are < 1 cm in diameter. They may be elevated and are frequently hairy, arising from the epidermal-dermal interface and from within the dermis. Malignant transformation is rare.
<i>Intradermal nevi</i>	No	Light-colored, well-circumscribed lesions < 1 cm in diameter. Hairs are usually present and the cell distribution occurs in the dermis. Malignant transformation is rare. <i>Most common mole in adults.</i>
<i>Giant pigmented nevi</i>	No	Brown to black hairy lesions with an irregular nodular surface. They are frequently described as a bathing trunk type of lesion. <i>Malignant degeneration occurs in about 10 %. Excision is recommended.</i>
<i>Spitz nevi</i>	No	Smooth, round, pink-black lesions measuring 1–2 cm in diameter found mainly in children. They have increased cellularity and occur in nests within the upper dermis. Atypical nevi have a small risk of malignant degeneration.
<i>Pigmented actinic keratosis</i>	No	Premalignant lesions caused by sun exposure, sand paper texture, small, rough, erythematous, or brownish papules, often on the face, back, or neck, also called “cutaneous horn”.
<i>Keratoacanthoma</i>	No	Well-differentiated tumor originating from the pilosebaceous glands, develops rapidly and regresses spontaneously (outgrows blood supply and necroses) and presents as a cup-shaped tumor filled with keratin debris
<i>Seborrheic keratosis</i>	No	Common tumor in elderly presents as raised, discolored plaques, coin-like, waxy, “stuck-on” appearance.
<i>Dysplastic nevus</i>	No	Large, pigmented lesions, irregular border, frequently occur on the back, chest, buttocks, breast, and scalp and can be found in sun-exposed and sun-protected areas.
<i>Melanoma</i>	Yes	Proliferation of melanocytes, most common cause of death from skin cancer, presents as mole-like growth with “ABCD” (see below).
<i>Squamous cell carcinoma</i>	Yes	Proliferation of squamous cells characterized by formation of keratin pearls presents as ulcerated, nodular, mass with no telangiectasias, usually on the face (classically involving the lower lip).
<i>Basal cell carcinoma</i>	Yes	Most common cutaneous malignancy presents as elevated, pearl-like nodule with a central, ulcerated crater surrounded by telangiectasias (classically involving the upper lip).
<i>Metastatic tumors to skin</i>	Yes	In males, the most common sources are malignant melanoma (32 %), lung, colon, carcinoma of the oral cavity, larynx, and kidney. In females, the most common sources are breast (70 %), followed by melanoma, and ovary.

### What Is the Most Likely Diagnosis?

In a patient presenting with a recently changed skin lesion that has become variegated and larger in diameter with an asymmetric, irregular border, the most likely diagnosis is melanoma. Additionally, the patient’s fair-colored skin, occupation as a lifeguard, and history of blistering childhood sunburns further increase his risk of developing skin cancer.

## History and Physical

### What Risk Factors for Skin Cancer Are Common to SCC, BCC, and Melanoma?

A common pathway for increased risk for skin cancer (SCC, BCC and melanoma) is excessive exposure to ultraviolet (UV) light, particularly UVB. Immunosuppression is another recognized risk factor. For SCC and BCC, the risk is greatest with cumulative long-term UV exposure. With melanoma, both blistering sunburns and overall sun exposure are risk factors. Skin cancer is also more common in patients who have fair-colored skin and hair and blue eyes.

**Table 36.1** “ABCDEs” of Melanoma

<b>A</b> Asymmetry of lesion	Is the lesion round and symmetric or does it look asymmetric?
<b>B</b> Border irregularity	Do the borders of the lesion seem smooth and circumscribed or are they jagged and indistinct?
<b>C</b> Color variegation (different colors)	Does the lesion have one even pigmented color or does it have several shades of pigment in one lesion?
<b>D</b> Diameter >6 mm	Is the lesion bigger than about the size of a pencil eraser?
<b>E</b> Evolution (changing lesion)	Are there any big changes such as rapid growth, bleeding, or ulceration in the lesion?

### What Factors During Childhood/Teen Years Are Associated with an Increased Risk of Skin Cancer?

A blistering sunburn in childhood or adolescence more than doubles the chance of developing skin cancer, as does the use of a tanning salon.

### What Genetic Conditions Are Associated with an Increased Risk of Skin Cancer?

Xeroderma pigmentosum is a rare autosomal recessive condition that leads to photosensitivity due to deficient repair of DNA damaged by UV radiation. It leads to a very high rate of melanoma, BCC, and SCC at an early age.

### What Occupations Are Highly Associated with Skin Cancer?

Occupations that involve long-term sun exposure place patients at higher risk, such as a lifeguard, farmer, construction worker, gardener, and field worker.

### What Are Findings on Physical Examination that Differentiate a Benign Nevus from Melanoma?

The “ABCDEs” of melanoma (Table 36.1) can serve as a memory tool to help remember the common differentiating characteristics.

#### Watch Out

Hair growth on a skin lesion suggests that it is a benign nevus. Melanomas destroy hair follicles.

### What Is the Ugly Duckling Sign?

The ugly duckling sign is a concept that emerged after recognizing the limitations in the ABCDE mnemonic. Any skin lesion that looks different or out of place and thus an “ugly duckling,” in a nest of other similar appearing lesions is suspicious and recommended for biopsy.

### What Is It Important to Inquire About and Examine Areas of Chronic Skin Inflammation?

Chronic skin inflammation is a known risk factor for SCC. It can develop in chronic open burn wounds (Marjolin’s ulcer), chronic venous ulcers, and longstanding skin infections such as hidradenitis suppurativa and human papillomavirus.

#### Watch Out

Chronically non-healing wounds should be biopsied to rule out malignancy.



---

### **On What Areas of the Skin Are Melanomas Most Likely to Occur in Non-white Ethnicities?**

In African American, Asian, and Hawaiian populations, melanomas most often occur on areas of nonexposed skin with less pigment such as the palms, soles, mucous membranes, and nail regions.

### **What Is the Most Common Site of Melanoma in Men Versus Women?**

For men, the back is the most common site, while the legs are the most common site for women.

### **What Is the Most Common Site of Digital Melanoma?**

Great toe. Amputation and sentinel lymph node is the preferred treatment.

### **Does the Regular Use of SPF Protection Reduce the Risk of Skin Cancer?**

Yes, regular daily use of an SPF 15 or higher sunscreen reduces the risk of developing squamous cell carcinoma and melanoma by about half.

---

## **Etiology/Pathophysiology**

### **What Is a Nevi? Are Nevi a Risk for Malignant Transformation?**

An additional risk factor for melanoma includes dysplastic nevus syndrome (autosomal dominant disorder) characterized by multiple dysplastic nevi with increased risk for progression towards melanoma (10 % risk).

### **From Where Does Melanoma Arise?**

Melanoma originates from melanocytes, which are derived from neural crest cells. It can arise from a preexisting nevus or de novo as a new pigmented lesion (although a small percentage can be amelanotic).

### **What Is the Most Common Skin Cancer? Second Most Common? Which Skin Cancer Is Associated with the Greatest Number of Deaths?**

Basal cell carcinoma is the most common skin cancer (and most common overall cancer), followed by squamous cell cancer, whereas melanoma accounts for the most deaths.

### **What Is the Most Common Precancerous Skin Lesion?**

Actinic keratosis is the most common precancerous skin lesion. It is a rough scaly epidermal lesion that occurs in an area of the body subjected to chronic sun exposure. About 10–20 % undergo malignant transformation to SCC. Some actinic keratosis can be pigmented.

### **What Is Bowen's Disease?**

It is a squamous cell carcinoma in situ. It appears as a well-defined erythematous plaque covered by an adherent scaly yellow crust. There is no potential for metastasis.

**Table 36.2** Breslow thickness 5-year survival

Depth	5-year survival
<0.75 mm	95–100 %
0.75–1.5 mm	80–96 %
1.5–4.0 mm	60–75 %
>4.0 mm	50 %

### What Is the Metastatic Risk of BCC, SCC, and Melanoma?

Basal cell carcinoma can be locally destructive; however, metastases are rare. Squamous cell carcinomas do metastasize, but much less commonly than melanoma. The most common site for melanoma to metastasize is to other areas of the skin, followed by, lung, liver, brain, and bone.

#### Watch Out

The most common metastasis to the small bowel is melanoma.

### What are the 4 Subtypes of Melanoma?

Type	Prevalence	Features
<i>Superficial spreading</i>	50–60 %	Most common type of melanoma typically has a long horizontal growth phase before the vertical growth phase therefore better prognosis
<i>Lentigo maligna</i>	4–10 %	Lentiginous proliferation indicates the tumor remains at the junction, best prognosis, AKA “Hutchinson freckle”
<i>Acral lentiginous</i>	2–3 %	Typically found in the subungual, sole, or palm location, common in ethnic groups of color
<i>Nodular</i>	10–30 %	Worst prognosis due to rapid vertical growth, increased metastatic potential, 5 % amelanotic

#### Watch Out

Acral-lentiginous melanoma is not related to UV light exposure.

### What Is the Difference Between Clark Classification and Breslow Depth?

*Clark classification* of melanoma is a form of staging based on depth of tumor. This was measured by anatomic levels (i.e., involvement of epidermis vs. reticular dermis) and is currently not used in staging.

*Breslow depth* is based on the depth of invasion, which is the vertical height of the melanoma from the granular layer to the deepest area of penetration and is measured in millimeters. It is currently used for melanoma tumor staging. Most studies have shown that compared to the Clark method, Breslow depth of invasion is a more accurate prognostic indicator (Table 36.2). Breslow thickness correlates directly to the risk of local recurrence, metastasis, and survival rate.

## Workup

### What Is the Next Step in Differentiating the Skin Lesion?

All suspicious lesions should undergo a biopsy. If the lesion is small, it can be removed in its entirety (excisional biopsy) usually using an elliptical incision following Langer’s lines. If the lesion is large or involves cosmetically important areas, it is better to first biopsy only a part of the lesion (incisional biopsy). Most often a (4–5 mm) punch biopsy down through the dermis to get an

adequate depth of skin is performed. Shave biopsies are not recommended if melanoma is suspected as the true Breslow thickness can sometimes be obscured by this biopsy method. If the pathology comes back benign, no further treatment may be necessary. In the patient presented, an excisional biopsy can be performed as the lesion is small and located on the extremity. During the initial biopsy, no attempts are made to achieve a wide margin. Once the melanoma has been confirmed, the patient will require further treatment.

### Once the Diagnosis of Melanoma Is Established, What Additional Studies Should Be Obtained?

Further screening workup should include a chest x-ray, complete blood count, liver function tests, and serum lactate dehydrogenase (LDH) to rule out metastatic disease. LDH is a prognostic indicator in melanoma and has been found to be a sign of liver metastases. If clinically palpable lymph nodes are present in the setting of a melanoma, the patient should undergo a CT scan of the chest, abdomen, and pelvis and a PET scan to rule out metastatic disease. An MRI of the brain may also be indicated if the patient has symptoms of CNS metastasis (e.g., motor deficits, seizures, headaches).

### What Are Poor Prognostic Indicators with Melanoma?

Thicker lesions, ulceration, location on trunk, and male gender

## Management

### What Treatment Options Exist for SCC and BCC?

Treatment	Comments
<i>Electrodissection/curettage</i>	Can result in a 95 % cure rate; however, disadvantage is a lack of specimen for determining adequacy of resection
<i>Topical therapies</i>	Includes imiquimod, 5-FU
<i>Surgical excision</i>	Removes entire melanoma with border of normal appearing skin
<i>Radiation</i>	Recommended choice when excision not possible or used as adjuvant therapy when there are high risk lesions
<i>Cryotherapy</i>	Liquid nitrogen is used to freeze cancerous tissue and destroy it

### What Is the Primary Therapy for BCC/SCC Skin Cancers?

Excisional biopsy. Patients with lesions in cosmetically sensitive areas, aggressive tumor features, ill-defined lesions, or recurrent BCC/SCC are candidates for Mohs surgery (named after Dr. Frederic Mohs).

### What Type of Surgical Margins Do You Need for BCC vs. SCC?

BCC needs 3–5 mm, while SCC needs 5–10 mm.

#### Watch Out

If margins are positive, it is essential to re-excite the incision to clear margins.

### Which Type of Basal Cell Carcinoma Has the Worst Prognosis?

Morpheaform and is characterized by collagenase production.

**Table 36.3** Melanoma excision

<b>Tumor thickness</b>	<b>Excision margin</b>	<b>Lymph node treatment</b>
<i>Melanoma in situ</i>	0.5 cm	None
0–0.75 mm	1 cm	None
0.75–1 mm	1 cm	Sentinel lymph bx for high risk features*
1–2 mm	1–2 cm	Sentinel lymph bx
2–4 mm	2 cm	Sentinel lymph bx
>4 mm	2 cm **	sentinel lymph bx

\*high risk- lymphovascular invasion, Clark IV or V, positive deep margin on biopsy, ulceration, mitoses

\*\* no randomized controlled studies have specifically addressed this cohort

### How Is Melanoma Surgically Managed?

Once the diagnosis is established by punch or excisional biopsy, the area needs to be re-excised to obtain wider margins (Table 36.3), and in select cases, sentinel lymph node biopsy (SLNB) is obtained. The extent of margins and need for SLNB are determined by tumor thickness.

### What Is the Purpose of the Sentinel Lymph Node Biopsy (SLNB) and How Is It Performed?

SLNB is a way of staging clinically occult regional lymph node metastases. Patients with intermediate depth melanoma seem to have longer survival after elective lymph node dissection, suggesting that some patients without clinically evident lymph node involvement may also benefit from regional lymphadenectomy. Because of the morbidity associated with lymphadenectomy, elective lymph node dissection is not routinely performed. Instead, the draining lymph node basins are assessed by the sentinel lymph node biopsy technique.

### What Are the Indications for Lymph Node Dissection with Melanoma?

Lymph node dissection is reserved for patients with clinically palpable disease or those with a positive sentinel lymph node biopsy. To date, no published data from prospective trials are available on the clinical significance of micrometastatic melanoma in regional lymph nodes, but some evidence suggests that for patients with tumors of intermediate thickness and occult metastasis, survival is better among those patients who undergo immediate regional lymphadenectomy than it is among those who delay lymphadenectomy until the clinical appearance of nodal metastases.

### How Is Melanoma of the Fingernail Managed?

Amputation through the joint, just proximal to the lesion. Acral-lentiginous melanoma is found beneath the nail, on the palm of the hand, or on the sole of the foot. These lesions represent approximately 3 % of all cutaneous melanomas. The prognosis for subungual melanomas is worse than for other cutaneous melanomas, probably because of delay in diagnosis. When symptoms occur, 25–30 % of patients have metastases.

### What Is the Prognosis for Melanoma?

When disease is confined to the primary site, 5-year survival is 80–90 %. If lymph nodes are involved, this decreases to 30–50 %. Those with distant metastases have poor prognosis (10–15 % 5-year survival).

---

## **What Is the Follow Up Protocol for Melanoma?**

Thorough physical examination at 3–6-month intervals over the course of the first 3 years. Recurrent disease occurs locally, regionally, or systematically. Regional lymph node disease is the most common type of recurrence. The patient should also be sent for imaging depending on the stage of disease.

## **What Is Mohs Surgery? What Are the Main Indications for Its Use? Is It Appropriate for the Treatment of Melanoma?**

Mohs is a specialized technique of treating skin cancer. Its design is unique in that it integrates the role of the surgeon and pathologist to allow for identification of 100 % of surgical margins intraoperatively. Mohs involves tangential excisions of the lesion till margins are negative. Mohs has the advantage in that definitive excision and closure can be achieved on the same day. It also offers excellent cure rates and can achieve accurate margins, especially on the head, neck, hands, and other areas with a high risk of recurrence. In addition to the high cure rate, Mohs surgery is a tissue-sparing procedure. The need for wide, extensive excision is reduced because of the precise control of tumor margins. This is an important advantage in cosmetically and functionally sensitive areas. A disadvantage of Mohs is the difficulty associated with adequately preparing frozen sections for visualization of melanocytes, including the need for immunohistochemical stains. Because of this, Mohs is considered an unreliable method of resection for melanoma.

---

## **Areas Where You Can Get in Trouble**

### **Assuming that a Discolored Nail Bed Is a Benign Condition**

Blackened or darkened toenails may represent benign conditions and may be difficult to distinguish from a subungual melanoma on physical examination. Benign conditions include subungual hematoma (bleeding under the nail bed from trauma), benign streaks in the nail plate, benign subungual nevus, and onychomycosis. Dermoscopy can be helpful in distinguishing melanoma from a subungual hematoma. If the area is suspicious, a full thickness biopsy through the nail bed should be performed. The presence of atypia or melanoma in situ requires complete excision with clear margins.

### **Performing a Shave Biopsy for a Lesion When Melanoma Is Suspected**

Shave biopsy is typically inadequate as one cannot assess the depth of the lesion.

### **Relying Solely on the ABCDE Rule for Detecting Melanomas**

Not all melanomas follow the ABCDE rule. Nodular melanomas do not. These are usually a uniformly dark blue or black “berry-like” lesion that is mostly symmetric, elevated, and one colored. They grow vertically, not horizontally. In addition, there are a subset of melanomas which may not even be pigmented (amelanotic melanoma). Also some melanomas, with careful exam, can be detected at a diameter of less than 6 mm.

---

## **Areas of Controversy**

### **Is There Any Benefit for Surgical Resection for Stage IV (Distant Metastasis) Melanoma?**

A recent study in 2012 evaluating data from the MSLT-I trial demonstrated benefit of metastatectomy in patients with stage IV resectable disease. The study demonstrated that select patients with resectable stage IV disease had improved survival following surgical resection, regardless of the location or the number of metastases as compared to systemic medical therapy.

## Is Adjuvant Therapy Beneficial for Advanced Melanoma?

There has been no concrete evidence that adjuvant therapy prolongs survival in melanoma. Options include regional hyperthermic perfusion, chemotherapy using dacarbazine or immunotherapy with interferon. There is some evidence to suggest that there is an improved relapse-free survival and overall survival with high-dose interferon alpha-2b. For patients with in-transit and/or satellite lesions of the extremities, hyperthermic isolated limb perfusion with melphalan with or without TNF-alpha has resulted in high tumor response rates and palliative benefit.

## Are There Medical Therapies for Metastatic Melanoma Patients?

Ipilimumab, a CTLA-4 blocking antibody, and vemurafenib, a small molecule inhibitor which blocks B-raf, have both been shown to improve overall survival in metastatic melanoma in phase III randomized controlled trials. IL-2 was one of the first treatments approved by the FDA in 1998; however, no improvement of overall survival has been demonstrated in randomized trials.

Dacarbazine was approved in 1970 based on overall response rates; however, no effect on overall survival has been demonstrated in randomized trials.

## Melanoma Recurring Many Years After Initial Presentation

Patients may present in late adulthood with metastatic lesions and an undiagnosed primary tumor. These patients will often have a clue on H&P that indicates a resected melanoma tumor from early in life (i.e., missing toe). Melanomas sometimes have long time intervals between the initial tumor and recurrence.

---

## Summary of Essentials

### History and Physical

- New skin lesions require a thorough skin assessment and clinical evaluation of relevant nodal basins
- ABCDEs of melanoma can help differentiate from a benign nevus

### Differential Diagnosis

- Benign nevi
  - Spitz tumor, junctional nevi, compound nevi, intradermal nevi, giant/congenital pigmented nevi
- Other benign and precancerous
  - Actinic keratosis, dermatofibroma, keratoacanthoma, seborrheic keratosis, and dysplastic nevus
- Cancer
  - BCC, SCC, and melanoma

### Pathology/Pathophysiology

- Skin cancer incidence: BCC > SCC > melanoma
- Metastatic risk: melanoma > SCC > BCC (can be locally destructive, metastasis rare)
- Melanoma is a proliferation of melanocytes, derived from neural crest cells
  - Melanoma staged by Breslow based on depth of invasion

## Workup

- Biopsy all suspicious lesions
  - Excisional biopsy if small
  - Punch biopsy if large
- Melanoma
  - CXR, LFTs, LDH, CBC
  - PET and CT if clinically palpable nodes

## Management

- Melanoma
  - Re-excise with margins based on Breslow depth
  - Selective SLNB based on Breslow depth
  - Adjuvant therapy of questionable value
- BCC/SCC
  - 3–5 mm margins (BCC)
  - 5–10 mm margins (SCC)
  - Mohs
    - Tissue sparing
    - For cosmetically sensitive areas

## Watch Out

- Shave biopsies should not be performed for suspected melanoma
- Nodular and amelanotic melanomas do not follow the ABCDE rule

---

## Suggested Reading

- Balch CM, Gershenwald JE, Soong SJ, et al. Final version of 2009 AJCC melanoma staging and classification. *J Clin Oncol.* 2009;27:6199.
- Markovic SN, Erickson LA, Rao RD, et al. Melanoma Study Group of the Mayo Clinic Cancer Center, Malignant melanoma in the 21st Century, part 1: epidemiology, risk factors, screening, prevention, and diagnosis. *Mayo Clin Proc.* 2007;82(3):364–80.
- Rigel DS, Russak J, Friedman R. The evolution of melanoma diagnosis: 25 years beyond the ABCDs. *CA Cancer J Clin.* 2010;60:301.

# Right Leg Pain, Swelling, and Erythema for Two Days

37

Paul N. Frank and Christian de Virgilio

A 40-year-old male with diabetes mellitus and hepatitis C-related cirrhosis presents to the emergency department with a two-day history of right leg pain, redness, and swelling. He states that he thinks he may have been bitten in the leg by some kind of bug while sleeping. On physical examination, his temperature is 100.5 °F, heart rate is 110/min, blood pressure is 90/60 mmHg, and respiratory rate is 18/min. His right leg is markedly swollen as compared to the left. The skin overlying the calf region is erythematous, with one 3 cm bullae, and an area of violaceous skin. There is no palpable crepitus. Plain X-ray of the leg demonstrates gas bubbles within the soft tissue in the calf. The foot itself is pink and warm, with normal pulses. Laboratory values are significant for a BUN of 40 mg/dL (normal 7–20 mg/dL), serum glucose of 200 mg/dL (70–100 mg/dL), creatinine of 1.6 mg/dL (0.8–1.4 mg/dL), WBC of  $24 \times 10^3/\mu\text{L}$  ( $4.1\text{--}10.9 \times 10^3/\mu\text{L}$ ), hemoglobin of 9.5 g/dL (13.8–17.2 g/dL), and a serum sodium of 128 mEq/L (136–144 mEq/L).

## Diagnosis

### What is the Differential Diagnosis?

Condition	Comments
<i>Necrotizing soft tissue infection</i>	Acute infection of the deep fascia, often with crepitus, bullae, and necrosis of the subcutaneous tissue, mixed flora
<i>Cellulitis</i>	Infection of the deep dermis and subcutaneous fat presenting with redness and erythema without the tissue destruction characteristic of NSTI
<i>Cutaneous anthrax</i>	Painless or pruritic eschar surrounded by edema
<i>Hypersensitivity reaction</i>	No fever or leukocytosis, look for history of exposure to plants or animals
<i>Deep venous thrombosis</i>	Usually involves the leg, look for history of hypercoagulability, immobility, and/or inflammatory state (e.g., postsurgical, malignancy)
<i>Sweet's syndrome (acute febrile neutrophilic dermatosis)</i>	Acute eruption of tender erythematous plaques with vesicles, fever, and neutrophilia; classically caused by treatment with G-CSF; may involve almost any other organ system, particularly respiratory and GI tracts; also associated with pregnancy and malignancy
<i>Pyoderma gangrenosum</i>	Neutrophilic infiltration of the skin; exquisitely painful lesions; may involve almost any other organ system
<i>Erythema multiforme</i>	Erythematous or purpuric plaques and bullae with central clearing; involves the extremities, palms, and soles; associated with herpes simplex virus, mycoplasma, and malignancy
<i>Stasis dermatitis</i>	Dermal fibrosis and brawny edema secondary to venous incompetence; may become acutely inflamed with crusting and exudate; look for evidence or history of venous incompetence and DVT

G-CSF granulocyte colony-stimulating factor; NSTI Necrotizing soft tissue infection

P.N. Frank, MD (✉)

Department of Surgery, Harbor-UCLA Medical Center, 1000 W Carson Street, Torrance, CA 90509, USA

e-mail: [PaulFrank521@gmail.com](mailto:PaulFrank521@gmail.com)

C. de Virgilio, MD

General Surgery Residency Program, Department of Surgery, Harbor-UCLA Medical Center, 1000 W. Carson Street, Torrance, CA 90509, USA

e-mail: [cdevirgilio@labiomed.org](mailto:cdevirgilio@labiomed.org)



---

## What Is the Most Likely Diagnosis?

In a diabetic patient presenting with a painful, erythematous, swollen leg with bullae and violaceous skin along with radiographic evidence of gas bubbles within the soft tissues of the leg, the most likely diagnosis is necrotizing soft tissue infection (NSTI).

---

## History and Physical Examination

### What Is the Implication of Crepitus?

Crepitus implies the presence of gas within the tissues, most likely due to the presence of gas-forming organisms.

### What Are the Risk Factors for NSTI?

Factors that depress immunity and/or decrease tissue perfusion increase the risk for NSTI including diabetes mellitus, malnutrition, intravenous (IV) drug abuse, obesity, chronic alcohol abuse, chronic lymphocytic leukemia, chronic steroid use, renal failure, peripheral arterial disease, and cirrhosis.

#### Watch Out

NSTI is also seen following traumatic extremity injuries particularly in association with gross wound contamination and in postsurgical wounds.

### What Is the Implication of Bullae? Violaceous Skin?

The presence of bullae implies partial tissue death within the layers of the skin that allows for the collection of fluid between tissue layers. Violaceous skin implies a violet or purple discoloration secondary to ischemia.

### What Are the “Hard Signs” of Necrotizing Soft Tissue Infection (NSTI)? What Percent of Patients with NSTI Have Such Hard Signs?

Hypotension, crepitus, skin necrosis and bullae, and gas on X-ray are “hard signs” of NSTI. However, it has been shown that less than half of patients with NSTI will have hard.

### Why Is It Important to Distinguish Between Cellulitis and NSTI? How Do Laboratory Values Help?

Cellulitis and NSTI are surprisingly difficult to distinguish based on physical exam. Treatment of NSTI requires emergent surgical debridement of all infected tissue, whereas cellulitis simply requires antibiotics. As such, a high level of suspicion is required for a prompt diagnosis. Recent studies indicate that laboratory values are helpful (Table 37.1). The Laboratory Risk Indicator for Necrotizing Fasciitis (LRINEC) score has been developed in order to distinguish NSTI from other soft tissue infections.

---

## Pathophysiology

### What Is the Spectrum of NSTI?

NSTI can involve the skin and subcutaneous tissue (necrotizing cellulitis), the fascia (necrotizing fasciitis), and/or the muscle (necrotizing myositis).

---

### **What Are the Typical Organisms Seen in NSTI?**

NSTI may be monomicrobial or polymicrobial, and a classification scheme based on the infectious agent has been developed. Type I NSTI is a polymicrobial infection. Type II NSTI is an infection with group A *Streptococcus*. Type III NSTI is also known as clostridial myonecrosis and is caused by *Clostridium perfringens*.

### **What Is the Other Term Used for Necrotizing Myositis?**

Gas gangrene.

### **What Is the Implication of Culturing *Clostridium septicum* from the Wound?**

*Clostridium septicum* infection can lead to gas gangrene and is associated with occult malignancies, most often colon cancer.

### **What Is the Term for NSTI that Involves the Scrotum and/or Perineum?**

Fournier's gangrene.

---

## **Management**

### **What Are the Initial Steps in the Management of NSTI?**

The initial treatment of a patient with suspected NSTI consists of intravenous fluids, broad-spectrum IV antibiotics, and aggressive surgical debridement, which is the gold standard of diagnosis and treatment for NSTI.

### **How Do You Determine How Much Tissue to Debride?**

All soft tissues, including the skin, subcutaneous fat, fascia, and muscle, that show any evidence of infection must be extensively debrided to the point of seeing healthy bleeding tissue. It is not acceptable to leave behind a tissue that is of borderline viability, as the infection will often continue to extend postoperatively.

---

### **What If Extensive Muscle Necrosis Is Found?**

If extensive muscle necrosis is discovered during surgery, amputation may be necessary.

### **What Are the Intraoperative Findings that Confirm NSTI?**

Operative findings in NSTI include murky fluid (i.e., dishwater fluid), gray discoloration of the fascia, and lack of bleeding from the fascia. Additionally, the fascia may separate from the muscle too easily, without the normal resistance on digital exploration.

### **What Is the Role of a Second-Look Operation?**

Current recommendations are that a second-look operation should be scheduled 24 hours after the initial debridement to ensure that the infection has not reemerged. Patients may require multiple reoperations after the initial debridement.

---

## What Do You Do If Your Suspicion for NSTI Is High but You Are Not Certain of the Diagnosis?

If the diagnosis of NSTI is uncertain, yet the suspicion is high, surgical exploration is undertaken, as this is the gold standard of both diagnosis and treatment. The incision must be taken down to the fascia and muscle so both can be inspected.

## Is Imaging Beneficial in the Diagnosis of NSTI?

When the diagnosis is in question, plain X-rays are useful if they demonstrate gas in the soft tissue. CT scan may also be beneficial. A retrospective study of 20 patients with NSTI found asymmetric fascial thickening in 80 % of patients, gas tracking along fascial planes in 55 % of patients, and abscess formation in 35 % of patients.

## What Is the Anticipated Mortality Risk Associated with NSTI?

The overall expected mortality rate in NSTI is approximately 25 %, with various studies ranging from 19 % to 40 %.

---

## Areas of Controversy

### What Is the Role of Hyperbaric Oxygen?

The use of hyperbaric oxygen remains controversial, but is emerging as a potential adjuvant therapy to aggressive surgical debridement and ICU care in the treatment of NSTI. A recent study showed that hyperbaric oxygen reduced mortality in NSTI from 34 % to 11.9 % without causing delays in surgery or otherwise affecting treatment.

---

## Summary of Essentials

### History and Physical Examination

- Look for history of traumatic injury, even a small cut
- Acute onset of pain, swelling, and erythema
- Hard signs occur in less than half of patients
  - Hemodynamic instability
  - Crepitus
  - Bullae
  - Skin necrosis

### Diagnosis

- NSTI is a clinical diagnosis
- LRINEC score can help determine which patients are more likely to have NSTI instead of less life-threatening soft tissue infections
  - Low serum sodium and high WBC

### Management

- Immediate treatment includes IV fluids, broad-spectrum antibiotics, and emergent aggressive surgical debridement
- Multiple reoperations for further debridement are often necessary

## Suggested Reading

- Chan T, Yaghoobian A, Rosing D, et al. Low sensitivity of physical examination findings in necrotizing soft tissue infection is improved with laboratory values: a prospective study. *Am J Surg*. 2008;196(6):926–30.
- Escobar SJ, Slade JB, Hunt TK, Cianci P. Adjuvant hyperbaric oxygen therapy (HBO2) for treatment of necrotizing fasciitis reduces mortality and amputation rate. *Undersea Hyperb Med*. 2005;32(6):437–43.
- Wall DB, de Virgilio C, Black S, Klein SR. Objective criteria may assist in distinguishing necrotizing fasciitis from nonnecrotizing soft tissue infection. *Am J Surg*. 2000;179(1):17–20.
- Wong CH, Khin LW, Heng KS, Tan KC, Low CO. The LRINEC (Laboratory Risk Indicator for Necrotizing Fasciitis) score: a tool for distinguishing necrotizing fasciitis from other soft tissue infections\*. *Crit Care Med*. 2004;32(7):1535–41.
- Wysoki MG, Santora TA, Shah RM, Friedman AC. Necrotizing fasciitis: CT characteristics. *Radiology*. 1997;203(3):859–63.

---

**Part XII**

**Surgical Complications**

Christian de Virgilio, Section Editor

Areg Grigorian, Paul N. Frank, Christian de Virgilio,  
and Dennis Y. Kim

A 50-year-old male is scheduled to undergo an elective inguinal hernia repair. He has noted pain in the hernia, which is reducible, for the past year. His past history is significant for hypercholesterolemia and mild hypertension. He has had no prior surgery. He does not smoke and only drinks occasionally. Family history is positive for coronary artery disease. He takes aspirin and a statin. He takes no herbal remedies. On further questioning, he reports a history of excessive bleeding when he had a wisdom tooth extracted 20 years ago. Otherwise, he has no significant medical history. On physical examination, he has no stigmata of portal hypertension or cirrhosis. Intraoperatively, the patient is noted to have diffuse oozing from all tissues in the operative field. Despite attempts at complete hemostasis, the patient develops a postoperative hematoma which requires evacuation on postoperative day 2. Laboratory values include a normal chemistry panel, normal hemoglobin and hematocrit, a platelet count of 250,000 (normal 140,000–450,000), INR of 1.0, and a PTT of 45 (18–28).

---

A. Grigorian, MD

Department of Surgery, University of California, Irvine, 333 City Blvd West, Suite 1600, Route. 81, Orange, CA 92868, USA  
e-mail: [agrigori@uci.edu](mailto:agrigori@uci.edu)

P.N. Frank, MD

Department of Surgery, Harbor-UCLA Medical Center, 941 W. Carson Street, Torrance, CA 90509, USA  
e-mail: [PaulFrank521@gmail.com](mailto:PaulFrank521@gmail.com)

C. de Virgilio, MD

General Surgery Residency Program, Department of Surgery, Harbor-UCLA Medical Center, 1000 W. Carson Street, Torrance, CA 90509, USA  
e-mail: [cdevirgilio@labiomed.org](mailto:cdevirgilio@labiomed.org)

D.Y. Kim, MD (✉)

Department of Surgery, Harbor-UCLA Medical Center, 1000 W. Carson Street, Box 42, Torrance, CA 90509, USA  
e-mail: [dekim@dhs.lacounty.gov](mailto:dekim@dhs.lacounty.gov)

## Diagnosis

### What is the Differential Diagnosis of Bleeding in the Postoperative Setting?

Condition	Comments
<i>Surgical bleeding</i>	Bleeding from a major artery or vein that was missed during surgery must be ruled out first, especially in the immediate postoperative period
<i>Medications</i>	Inquire about aspirin, clopidogrel, heparin, warfarin, or any other antiplatelet or anticoagulant medication
<i>Inherited coagulation disorders</i>	Patients with von Willebrand disease may have a history of excessive bleeding after minor procedures or very heavy menses; hemophilia A and B usually present in childhood with spontaneous hemorrhage into joints (hemarthrosis)
<i>Liver disease</i>	Reduced production of clotting factors
<i>Renal failure</i>	Uremia impairs platelet function
<i>Disseminated intravascular coagulation (DIC)</i>	Seen with severe sepsis, malignancy, and childbirth complications; leads to bleeding and microthrombi; manifests with diffuse bleeding from wounds and surgical sites, hematemeses, digital cyanosis, renal insufficiency, and stroke
<i>The bloody vicious cycle (“lethal triad of death”)</i>	Refers to three factors that work in concert: more common after long operations, trauma, large volume of room temperature IV fluids, and in those who have suffered significant bleeding

### What Is the Most Likely Cause of the Bleeding in the Patient Described Above?

The bleeding is likely a medical bleed and not a surgical one. The finding of diffuse oozing at the time of operation together with a prolonged PTT would suggest an underlying bleeding diathesis.

### What is the Differential Diagnosis for Prolonged PTT and the Common Features?

Condition	PT	PTT	BT	Acquired/congenital	History and physical
<i>Acquired FVIII Inhibitors</i>	–	↑	–	Acquired	Occurs in postpartum, rheumatic disease, and malignancy; presents with purpura and soft tissue bleeding
<i>Antiphospholipid syndrome (SLE)*</i>	–	↑	–	Acquired	Young woman with malar rash, arthritis, photosensitivity, renal/cardiac symptoms, fevers, malaise, and recurrent pregnancy loss
<i>Hemophilia A</i>	–	↑	–	Congenital	Presents early in childhood with spontaneous bleeding in joints (hemarthroses) or life-threatening hemorrhage following minor trauma
<i>Hemophilia B</i>	–	↑	–	Congenital	Same as hemophilia A
<i>Heparin</i>	–	↑	–	Acquired	Postoperative prophylaxis for DVT and PE, decreases post-MI thrombus risk
<i>Von Willebrand disease</i>	–	–/↑	↑	Both	Young woman with bleeding after minor surgical procedure or history of excessive menses

Antiphospholipid syndrome is a *hypercoagulable* state  
 BT bleeding time, DVT deep vein thrombosis, PT prothrombin time, PTT partial thromboplastin time, SLE systemic lupus erythematosus

### What Is the Most Likely Diagnosis?

The above patient has an isolated prolonged PTT. Antiphospholipid syndrome associated with SLE is paradoxically a *hypercoagulable* state (see below) as opposed to causing bleeding. An acquired antibody to factor VIII (acquired hemophilia) is rare and is most commonly associated with postpartum patients, rheumatic disease, and cancer. Hemophilia A and B are clinically indistinguishable. With severe factor deficiencies, they present early in childhood with spontaneous bleeding in the joints (hemarthrosis) or life-threatening hemorrhage following trauma. Von Willebrand disease is not associated with a history of severe bleeding but rather with bleeding after minor surgical procedures or a history of excessive menses. Thus the most likely diagnosis is von Willebrand disease.

## History and Physical Examination

### Why Is It Important to Ask About a History of Bleeding After Minor Trauma/Procedures?

A history of bleeding suggests a predisposition to bleeding risk. Important questions to ask include a history of excessive bleeding in the mouth, epistaxis, bleeding into the muscle and joints, excessive menstrual bleeding, and excessive bleeding after minor procedures (dental extraction, skin biopsy).

### Why Is It Important to Ask About a Family History of Bleeding?

A family history of bleeding suggests there may be an inherited bleeding disorder.

### What Medical Conditions Are Risk Factors for Bleeding?

Liver and renal diseases, as well as nutritional deficiency, increase the risk of bleeding, the latter due to vitamin K deficiency. Malabsorption syndromes including short bowel syndrome and cystic fibrosis in particular lead to vitamin K deficiency. Cardiac disease, by virtue of the various antiplatelet agents often prescribed (aspirin, clopidogrel, warfarin), increases the risk of bleeding.

---

## Physiology/Pathophysiology

### What Is the Difference Between Primary and Secondary Hemostasis Disorders?

Disorders of primary hemostasis are usually due to abnormalities in platelets, whereas disorders of secondary hemostasis are usually due to factor abnormalities. Platelet abnormalities can be divided into quantitative or qualitative disorders. After primary hemostasis, the coagulation cascade (Fig. 38.1) generates thrombin, which converts fibrinogen in the platelet plug to fibrin. The fibrin is then cross-linked by factor VIII to form a stable platelet-fibrin thrombus. Impairment in this cascade can lead to disorders of secondary hemostasis and is most often due to factor abnormalities.

### What Is Coagulopathy?

This term is reserved for conditions that lead to an impairment of the body's ability to clot blood. Normal blood clotting involves as many as 20 different plasma proteins. When these proteins are missing or deficient, patients can present with bleeding symptoms that can range from mild to severe. This can occur spontaneously or following minor trauma. Metabolic acidosis and hypothermia exacerbate coagulopathy.

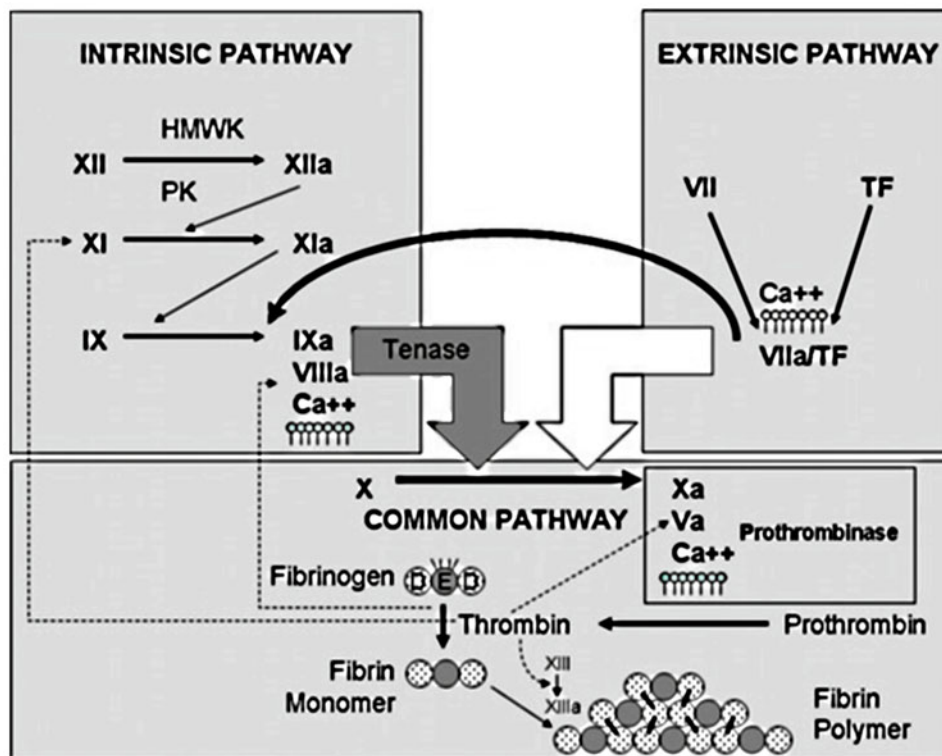
### What Is Meant by a Medical Versus a Surgical Postoperative Bleed?

A surgical bleed refers to bleeding that can be corrected with surgery, for example, bleeding from a focal area (an artery or vein) that was inadequately ligated or sutured during the initial surgery. A medical bleed refers to diffuse bleeding caused by underlying coagulopathy. Since medical bleeding is diffuse and caused by a bleeding disorder, reoperation is not beneficial.

### What Is the Pathophysiology of Von Willebrand Disease (VWD)? What Are the Subtypes?

Von Willebrand factor is a protein needed to form a platelet plug. When vascular tissue is damaged, the exposed subendothelial collagen is able to bind to von Willebrand factor (VWF). Platelets can then bind to VWF using the GPIb receptor to ultimately





**Fig. 38.1** Coagulation cascade. *HMWK* high molecular weight kinogen, *PK* prekallikrein, *TF* tissue factor (with kind permission from Springer Science+Business Media: Contemporary Cardiology: Antithrombotic Drug Therapy in Cardiovascular Disease, The Role of Coagulation in Arterial and Venous Thrombosis, 2010, pg 22, Kottke-Marchant K., Fig. 2)

**Table 38.1** Subtypes of VWD

Type	Inheritance	Quantitative or qualitative	Features
1	AD	Quantitative	The most common overall, often has mild symptoms
2	AD	Both	Contains 4 subtypes of which type 2A is most common, often has moderate symptoms
3	AR	Quantitative	Rare, causes the most severe symptoms

*AD* autosomal dominant, *AR* autosomal recessive

form the platelet plug and thus complete primary hemostasis. VWD is most commonly congenital but can be acquired. The congenital form has 3 subtypes (Table 38.1) causing both qualitative and quantitative defects. Since VWF is also a cofactor for factor VIII, severely decreased levels of VWF can lead to abnormally prolonged PTT, depending on the degree of activity reduction of factor VIII.

### How Does Renal Failure Cause Coagulopathy?

End-stage renal disease results in the presence of uremic toxins circulating in the blood, which cause platelet dysfunction. This can initially be managed with the administration of desmopressin and/or hemodialysis.

### How Does Liver Disease Cause Coagulopathy?

As liver disease worsens, so does the synthetic function of the liver manifested by a prolonged PT and increased INR. The majority of patients have thrombocytopenia and decreased production of coagulation factors. The thrombocytopenia is caused by a combination of increased sequestration in the spleen, deficiency of thrombopoietin, and immune-mediated destruction of platelets.

**Table 38.2** Thrombocytopenia presentation based on platelet count

Laboratory finding	Clinical presentation
Platelets > 100,000	Asymptomatic
Platelets 50,000 to 100,000	Occasional petechiae
Platelets 10,000 to 50,000	Purpura after minor trauma
Platelets < 10,000	Spontaneous bruising, bleeding gums

**Table 38.3** Thrombocytopenia

Etiology	Pathology	Labs	Management
<i>Impaired production</i>	Abnormal/reduced platelet precursor caused by drugs, infection, alcohol, mineral deficiency	Bone marrow biopsy shows ↓ megakaryocytes	Stop offending agent, replete deficiencies, treat underlying disorder
<i>Platelet pooling</i>	Splenic platelet sequestration		If symptomatic, splenectomy may be required
<i>HIT</i>	Heparin forms complex with platelet factor 4 → produces IgG antibodies which destroy platelets; remnants activate remaining platelets → thrombus	Sudden decrease in platelet count >50 %	Stop heparin, switch to direct thrombin inhibitor
<i>ITP</i>	Autoimmune production of IgG leading to platelet destruction	Platelets commonly < 50,000	<i>Children:</i> observe for spontaneous resolution, corticosteroids, and IVIG <i>Adults:</i> corticosteroids, IVIG, dapsone, danazol, and splenectomy
<i>TTP</i>	Platelets are consumed in the formation of microthrombi in small vessels, due to an enzyme deficiency (ADAMSTS13) that normally cleaves VWF multimers	↑ reticulocytes, blood smear shows evidence of hemolytic anemia (schistocytes)	Emergent plasmapheresis, corticosteroids, FFP, and splenectomy
<i>DIC</i>	Initial coagulopathy with widespread clot formation that quickly evolves to a state of pathologic consumption of platelets and coagulation factors	↑ INR, ↑ PTT, ↓ fibrinogen, ↑ fibrinogen split products, ↑ D-dimer, ↓ hemoglobin, ↓ hematocrit	Treat underlying disorder, platelets, FFP, and cryoprecipitate
<i>HELLP syndrome</i>	Pathogenesis unclear, sequela of eclampsia, and may be associated with aberrant placental development	↑ LFTs, ↓ hemoglobin, ↓ haptoglobin, schistocytes on blood smear	Methyldopa to reduce blood pressure, corticosteroids to speed lung maturity, induce labor if > 34 weeks

*DIC* disseminated intravascular coagulation, *FFP* fresh frozen plasma, *HIT* heparin-induced thrombocytopenia, *ITP* idiopathic thrombocytopenic purpura, *IVIG* intravenous immunoglobulin, *TTP* thrombotic thrombocytopenic purpura, *HELLP* hemolysis, elevated liver (enzymes), low platelets

**Watch Out**

Factor VIII is the only component of the clotting cascade not exclusively synthesized by the liver and remains at normal (or higher) levels during liver failure; all the other factor levels will decrease.

**What Are the Vitamin K-Dependent Clotting Factors?**

Factors II, VII, IX, and X, protein C, and protein S.

**How Is Thrombocytopenia Defined? How Do Various Platelet Count Thresholds Affect Bleeding?**

Thrombocytopenia is defined by a decreased number of platelets (<150,000) leading to increased risk of bleeding. The clinical severity of thrombocytopenia has an inverse relationship with the platelet count (Table 38.2).

**What Are the Causes for Thrombocytopenia?**

The differential for thrombocytopenia is vast (Table 38.3), but the most frequently encountered etiology is alcohol abuse.

**Table 38.4** Disseminated intravascular coagulation (DIC)

Etiology	Features
<i>Delivery</i>	Tissue thromboplastin in amniotic fluid activates the coagulation cascade
<i>Infection</i>	Sepsis can result in the induction of endothelial cells to make/release tissue factor; the most common mechanism involves TNF associated with gram-negative bacteria
<i>Cancer</i>	Auer rods in AML are potent activators of the coagulation cascade; mucin associated with adenocarcinoma can also activate the cascade

*TNF* tumor necrosis factor *AML* acute myeloid leukemia

**Watch Out**

Although HIT leads to thrombocytopenia, it is considered a hypercoagulable state.

**What Is the Mechanism of DIC?**

The initial coagulopathy occurs because of extensive activation of the clotting cascade, often by the release of endothelial tissue factor. Uncontrolled clotting and subsequent fibrinolysis lead to a deficiency in clotting factors resulting in abnormal bleeding. Despite subsequent fibrinolysis, the patient with DIC may form diffuse microthrombi in addition to having abnormal bleeding. DIC has a poor prognosis without early treatment as the microthrombi can cause widespread infarcts.

**Watch Out**

The common causes of DIC can be remembered with the mnemonic DIC: *d*elivery, *i*nfection, and *c*ancer (Table 38.4).

**Watch Out**

The primary treatment of DIC is to treat the underlying cause.

**What Is Physiological Fibrinolysis?**

Physiological fibrinolysis begins with the generation of fibrin and occurs when plasmin binds to it. It is associated with the breakdown of clots and is an essential component of the hemostatic system as it is required to limit the extent of clot formation, thus maintaining blood flow by keeping vasculature clear of thrombi.

**What Can the Abnormal Activation (pathological) of the Fibrinolytic Pathway Cause? How Is It Classified?**

This can result in bleeding and is associated with the presence of excess plasmin, which overwhelms the endogenous antiplasmin mechanisms leading to the consumption of coagulation factors and platelets, thus impairing the ability to form clots. Hyperfibrinolysis is further classified into primary and secondary. Primary hyperfibrinolysis results from an increase in circulating tissue plasminogen activator (tPA). Under normal conditions, tPA has low plasminogen activating capability that increases exponentially when bound to fibrin, thus limiting fibrinolysis until fibrin is generated by a preformed clot. During conditions where there is an excess amount of circulating tPA (i.e., decreased hepatic clearance, loss of antiplasmin mechanisms), there may be sufficient activity to increase plasmin generation without fibrin. Secondary fibrinolysis is a response to a systemic hypercoagulable state and increased amounts of fibrin. This most often occurs during a systemic inflammatory state, such as sepsis or DIC.

## What Coagulation Factors do INR and PTT Measure and What Drug Therapies can they Monitor?

	Measures	Coagulation factors	Monitors
INR	Extrinsic and common coagulation pathways	I (fibrinogen), II (prothrombin), V, VII, X	Warfarin
PTT	Intrinsic and common coagulation pathways	I, II, V, VIII, IX, X, XI, XII	Heparin

## Describe the Mechanism of the Commonly used Anticoagulant Medications

Medication	Mechanism of action	Reversible?
<i>Aspirin</i>	Irreversibly inhibits platelet cyclooxygenase enzymes, which results in decreased formation of PGE <sub>2</sub> and thromboxane A <sub>2</sub>	No
<i>Clopidogrel</i>	Blocks ADP receptors to suppress fibrinogen binding to platelets and thus inhibits platelet adhesion	No
<i>GP IIb/IIIa inhibitors (e.g., abciximab)</i>	Inhibit platelet aggregation by binding to platelet GP IIb/IIIa receptors	No
<i>Heparin</i>	Activates antithrombin III, activated antithrombin III inactivates thrombin and factor Xa	Protamine sulfate
<i>LMWH (e.g., enoxaparin)</i>	Binds to factor Xa to prevent clot formation	Protamine sulfate
<i>Direct thrombin inhibitor (e.g., argatroban)</i>	Inhibits thrombin to suppress factor activity and decrease platelet aggregation	No; hemodialysis may help
<i>Warfarin</i>	Inhibits vitamin K epoxide reductase, an enzyme required for the production of factors II, VII, IX, and X	Fresh frozen plasma (rapid acting), vitamin K (slow acting)

LMWH low molecular weight heparin

## Work-Up

### Prior to an Elective Operation, What Is the Most Important Preoperative Test to Identify a Patient at Risk for Bleeding During Surgery? Is Routine Laboratory Screening for Bleeding Disorders Necessary?

Clinical history remains the gold standard for preoperative assessment of hemostasis. Specifically, a history of excessive bleeding after minor procedures is important. In addition, in most cases, INR, PTT, and platelet count are ordered preoperatively. No additional routine screening for bleeding disorders is necessary.

## Management

### What Is the First Step in the Management of a Patient with Suspected Postoperative Bleeding?

Always start with the A (airway), B (breathing), and C (circulation) of resuscitation. Make sure the patient has adequate IV access and that baseline labs have been sent including a type and cross, CBC, INR, and PTT.

### At What Point Should Re-exploration Be Considered for a Patient Who Is Bleeding Postoperatively?

Re-exploration should only be done if there is a surgical bleed since a medical bleed is diffuse and unlikely to be corrected with surgery. Once a medical bleed is deemed unlikely and if the patient continues to actively bleed as evidenced by hemodynamic instability, the surgeon should then consider re-exploration.

### How Is Bleeding Secondary to Renal Failure Corrected?

Although desmopressin can initially be used, dialysis is considered the definitive management.

### How Is Bleeding Secondary to Liver Disease Corrected?

Fresh frozen plasma, cryoprecipitate, coagulation factors, and platelet transfusion.

### At What Threshold Should Platelets Be Administered?

The threshold for platelet transfusion remains controversial, but it is never recommended for platelet destructive processes (e.g., hemolytic uremic syndrome). For patients (bleeding or not) that will be undergoing an invasive procedure (e.g., surgery) and have platelet counts <50,000, a prophylactic platelet transfusion is acceptable. For all asymptomatic patients with platelet counts <10,000, a platelet transfusion is also given to prevent spontaneous intracranial bleeding.

### What Is the Best Way to Urgently Reverse Warfarin?

Fresh frozen plasma. Newer agents include prothrombin complex concentrates (PCCs), which are available as a “4-factor” or 3-factor” formulation.

---

## Complications

### What are the Different Types of Transfusion Reactions, their Causes, and Management?

Type	Timing	Pathology	Management
<i>Febrile nonhemolytic</i>	Minutes to hours after transfusion	The most common reaction, caused by cytokines from donor leukocytes	Self-limited, acetaminophen can help
<i>Acute hemolytic</i>	Within 24 hours of transfusion	ABO incompatibility leading to severe destruction of donor RBCs by preformed host antibodies	Stop transfusion, IV fluids to induce diuresis
<i>Delayed hemolytic</i>	1 to 14 days after transfusion	Rh antibodies leading to the destruction of donor RBCs, requires sensitization	Self-limited
<i>Anaphylactic</i>	Rapid and sudden onset	Shock results from anti-IgA antibodies, occurs in patients with selective IgA deficiency	Stop transfusion, epinephrine, intubation, fluid resuscitation
<i>Allergic/urticarial</i>	Minutes to hours after transfusion	Results from the plasma present in donor blood	Diphenhydramine

### What Is the Leading Cause of Transfusion-Related Fatalities?

Transfusion-related acute lung injury (TRALI) is a serious blood transfusion complication characterized by non-cardiogenic pulmonary edema. Although the incidence has decreased, it remains the leading cause of transfusion-related fatalities. The underlying mechanism has still not been elucidated but is thought to involve donor antibodies attacking the recipient’s white blood cells (WBCs). The antibody-WBC complex aggregates in the vasculature of the lungs leading to the release of inflammatory mediators which increase the permeability of the lung capillaries and thus lead to pulmonary edema. Fluid resuscitation and vasopressors are often required. Aggressive respiratory support is needed in the majority of cases.

## Areas You Can Get in Trouble

### Failing to Stop Antiplatelets/Anticoagulants in a Timely Fashion Prior to Surgery

Platelet aggregation recovers within 4 days of stopping aspirin, but clopidogrel must be stopped for 7–10 days to achieve a normal platelet aggregation response. After stopping warfarin, it usually takes 2 to 3 days for the INR to fall below 2.0 and 4 to 6 days for the INR to normalize. Once the INR is 1.5 or below, surgery can be performed with relative safety in most cases.

---

## Summary of Essentials

### History and Physical Examination

- Surgical bleeds result from inadequate hemostasis and may require reoperation
- Risk factors for coagulopathy: copious IV fluids or transfusions, hypothermia, metabolic acidosis, liver or kidney disease, DIC, family history of bleeding, and anticoagulant medications
- Beware of HIT in patients who have recently begun heparin therapy

### Work-Up

- The most important diagnostic modality for coagulopathy is a clinical history
- Warfarin is monitored with INR; heparin is monitored with PTT
- Always check for signs of liver and kidney dysfunction

### Management

- The treatments of uremic coagulopathy are desmopressin (acutely) and hemodialysis (more definitively)
- The treatment of hepatic coagulopathy is FFP
- Heparin can be reversed with protamine; warfarin can be reversed with FFP
- For most elective procedures, platelets > 50,000/microL are sufficient

### Complications

- TRALI is treated with IV fluids, vasopressors, and respiratory support

---

## Suggested Reading

Cosmi B, Alatri A, Cattaneo M, et al. Assessment of the risk of bleeding in patients undergoing surgery or invasive procedures: guidelines of the Italian Society for Haemostasis and Thrombosis (SISET). *Thromb Res.* 2009;124:e6.

Douketis JD. Perioperative management of patients who are receiving warfarin therapy: an evidence-based and practical approach. *Blood.* 2011;117:5044.

Segal JB, Dzik WH, Transfusion Medicine/Hemostasis Clinical Trials Network. Paucity of studies to support that abnormal coagulation test results predict bleeding in the setting of invasive procedures: an evidence-based review. *Transfusion.* 2005;45:1413.

Christy Anthony, Dennis Y. Kim, Christian de Virgilio,  
and Areg Grigorian

A previously healthy 65-year-old female underwent an emergent sigmoid colectomy and proximal colostomy for perforated diverticulitis. Intraoperatively, the patient was found to have extensive fecal contamination of the peritoneal cavity with minimal blood loss. She received 2 L of intravenous fluids during the operation. Twelve hours after surgery, the patient is found to have orthostatic hypotension with a blood pressure of 110/60 mmHg (supine), heart rate of 100/min, temperature of 99 °F, and respiratory rate of 14/min. Her mucous membranes appear to be dry and skin turgor is decreased. She does not have jugular venous distention, and the remainder of her cardiac and respiratory exams are unremarkable. The patient is noted to have only produced 30 cc of dark yellow urine in the last 3 hours. Postoperative laboratory values demonstrate an increasing BUN of 34 mg/dL (normal 7-21 mg/dL) and a doubling of her creatinine to 1.5 mg/dL (0.5-1.4 mg/dL). Hemoglobin and hematocrit are stable at 11 g/dL (12-15.2 g/dL) and 33 % (37-46 %).

## Diagnosis

### What is the differential diagnosis for acute kidney injury (AKI) in the postoperative setting?

Type	Causes	Pathophysiology
Prerenal	Hypovolemia (postsurgical bleeding, dehydration), decreased cardiac output (heart failure)	Inadequate perfusion of a normal functioning kidney
Intrinsic/ renal	Acute tubular necrosis (ATN) (e.g., renal artery occlusion; drugs: radiocontrast agents, aminoglycosides; rhabdomyolysis); interstitial nephritis (penicillin, cephalosporins, sulfa drugs, NSAIDs)	Prolonged ischemia of the kidney or toxins leading to parenchymal injury
Postrenal	Obstruction of urine benign prostate hypertrophy, prostate cancer, nephrolithiasis, bilateral ureteral ligation, urethral stricture	Increased nephron tubular pressure

C. Anthony, MD, BS (✉)

Department of Surgery, University of California Los Angeles, 1000 W. Carson Street, Box 25, Torrance, CA 90509, USA  
e-mail: [canthony@mednet.ucla.edu](mailto:canthony@mednet.ucla.edu)

D.Y. Kim, MD

Department of Surgery, Harbor-UCLA Medical Center, 1000 W. Carson Street, Box 42, Torrance, CA 90509, USA  
e-mail: [dekim@dhs.lacounty.gov](mailto:dekim@dhs.lacounty.gov)

C. de Virgilio, MD

General Surgery Residency Program, Department of Surgery, Harbor-UCLA Medical Center, 1000 W. Carson Street, Torrance, CA 90509, USA  
e-mail: [cdevirgilio@labiomed.org](mailto:cdevirgilio@labiomed.org)

A. Grigorian, MD

Department of Surgery, University of California, Irvine, 333 City Blvd West, Suite 1600, Route. 81, Orange, CA 92868, USA  
e-mail: [agrigori@uci.edu](mailto:agrigori@uci.edu)

### **What Is the Most Likely Cause for the Patient's Decreased Urine Output?**

The most likely cause for the patient's decreased urine output is prerenal AKI secondary to hypovolemia. Dehydration and third space losses are common following surgery, particularly in the setting of significant inflammation. The patient is oliguric with orthostatic hypotension, and there has been an acute increase in her serum BUN and creatinine (>20:1) which is consistent with prerenal AKI.

---

## **History and Physical Exam**

### **Why Is It Important to Review the Operative Record and the Anesthetic Record?**

In a patient with decreased urine output, it is useful to review the operative and anesthetic record to look for any events that may be contributing to the drop in urine output. For example, in patients who appear to be hypovolemic, checking the record for their estimated intraoperative blood loss, complications during the surgery that can relay possible sites of hemorrhage, administration of anticoagulants, requirement of pressors or blood products, and the amount of fluids received is essential in discovering the etiology.

### **What Is the Most Common Presentation of AKI?**

The most common presentation of AKI is prerenal azotemia. Most patients are asymptomatic and present with only a rise in BUN and creatinine (azotemia). The earliest sign of AKI is oliguria (please see below).

### **Are There Specific Physical Exam Findings for AKI?**

Physical exam signs that are specific for AKI are rare.

### **What Is the Difference Between Oliguria and Anuria?**

The normal urine output for an adult is considered 0.5–1.0 mL/kg/hour. For children, normal urine output is 1.0–2.0 mL/kg/hour. Oliguria describes decreased but not absent urine output and is defined as a urine output less than 0.5 mL/kg/hour for two consecutive hours. When the output becomes less than 50 mL–100 mL of urine over a 24-hour period, the patient is considered to be anuric. Producing absolutely no urine is unusual and may be a result of a technical error (discussed in section [Management](#)).

### **What Are the Most Common Nephrotoxic Medications?**

The most common nephrotoxic medications are intravenous contrast agents, aminoglycosides (e.g. gentamicin), amphotericin, cisplatin, cyclosporine, and NSAIDs.

---

## **Physiology/Pathophysiology**

### **Which Patients Are at Greatest Risk for Intravenous Contrast Induced AKI?**

Patients with preexisting renal damage (e.g., glomerulonephritis, diabetes) are at greatest risk. Contrast-induced acute kidney injury is widely defined as an absolute increase in serum creatinine of 0.5 mg/dL or a relative increase of 25 % from the baseline value, assessed 48–72 hours following intravascular administration of contrast media.



**Watch Out**

*N*-acetylcysteine, bicarbonate, and normal saline hydration may prevent contrast-induced renal failure. Prehydration with normal saline administered prior to the contrast has the most proven benefit in preventing contrast-induced nephrotoxicity.

**What Is the Major Force Favoring Filtration in the Kidney?**

High hydrostatic pressure in the glomerular capillary is responsible for ensuring filtration in the nephron tubules. In situations where hydrostatic pressure in Bowman space rises (postrenal AKI), filtering fluid becomes more difficult.

**Watch Out**

Increased BUN/Creatinine ratio may be seen in conditions other than hypovolemia: upper gastrointestinal bleed (high protein absorption), increased urea production (steroid therapy) and/or low muscle mass (decreases serum creatinine creation).

**Does Unilateral Ureteral Obstruction Lead to Renal Failure?**

In most cases, this will not lead to renal failure unless the patient has a solitary kidney.

**Is It Common to Have Oliguria Following Major Surgery? If So, Why?**

Yes. This is a result of the response of the adrenal cortex and posterior pituitary to stress from surgery leading to fluid loss and shifts. Aldosterone and anti-diuretic hormone (ADH) released in the first 24 hour after surgery are primarily responsible for both salt and water retention (discussed in section [Work-Up](#)). Oliguria lasting for more than 24 hours warrants investigation.

**Watch Out**

Postoperative bleeding can present as oliguria. Lab values such as hemoglobin and hematocrit may be misleading in detecting acute hemorrhage in the postoperative setting. It generally takes 8–12 hours for interstitial fluid to redistribute into the vascular space, and blood concentration will initially appear unchanged. In patients who receive fluid resuscitation, the hemoglobin will begin to drop over time as the fluid shifts into the plasma.

**Can Prerenal AKI Lead to Intrarenal AKI and Eventually Renal Failure?**

Prolonged periods of poor renal perfusion will directly damage the kidneys and lead to acute tubular necrosis (ATN), which will cause oliguria even after normal perfusion has been restored.

**How Does General Anesthesia Affect Cardiac and Renal Function?**

Most general anesthetics, commonly the inhaled volatile agents, result in myocardial depression and systemic vasodilation. This in turn can lead to a decrease in cardiac output and end-organ perfusion. In someone with no preexisting medical conditions or comorbidities, patients usually tolerate temporary fluctuations in their blood pressure without considerable change to their renal and cardiovascular function. However, patients with renal disease at baseline are more susceptible to insult resulting in worsening renal function.

## Work-Up

### What Is the Best Initial Test When Suspecting AKI?

The best initial tests are BUN and creatinine. A BUN/Cr ratio >20:1 with a clear history of hypoperfusion or hypotension is all one needs to diagnose prerenal AKI.

### What Other Tests Can Help Distinguish Between the Three Major Categories of AKI?

Urine sodium, fractional excretion of sodium ( $FE_{Na}$ ) (Table 39.1), and urine osmolality. During prerenal AKI, decreased blood pressure and/or intravascular volume will increase aldosterone which subsequently increases sodium reabsorption in the kidneys and results in a decreased  $FE_{Na}$ . Additionally, low intravascular volume results in an increase in ADH released from the posterior pituitary. This will lead to increased water reabsorption from the urine, increasing urine osmolality and concentrating the urine to a dark yellow hue. The relevant laboratory values for AKI are presented in Table 39.2.

#### Watch Out

$FE_{Na}$  is not reliable if the patient is receiving diuretics as they alter the renal excretion of electrolytes. In such a patient the Fe urea may be helpful.

### How Does Urinalysis Help?

The specific gravity and the presence of cells/casts are helpful in determining etiology (Table 39.3).

#### Watch Out

Urine dipstick is unable to differentiate between hemoglobin, myoglobin (rhabdomyolysis), and red blood cells.

**Table 39.1**  $FE_{Na}$  calculation

$$FE_{Na} = (U_{Na}/P_{Na}) / (U_{Cr}/P_{Cr})$$

$U_{Na}$  urine sodium,  $P_{Na}$  plasma sodium,  $U_{Cr}$  urine creatinine, and  $P_{Cr}$  plasma creatinine

**Table 39.2**  $FE_{Na}$ ,  $U_{OSM}$ ,  $U_{Cr}/P_{Cr}$ , and  $U_{Na}$

	$FE_{Na}$	$U_{OSM}$	$U_{Cr}/P_{Cr}$	$U_{Na}$
Prerenal	<1 %	>500	>40	<20
Intrinsic renal	>1 %	<350	<20	>40
Postrenal	>4 %	<50	<20	>40

**Table 39.3** Urinalysis

Finding	Suggests
High specific gravity	Volume depletion
Red cell casts	Glomerular disease
Hematuria	Renal emboli or stones
White blood cell casts	Infection or inflammation
Granular casts	Acute tubular necrosis

**Table 39.4** RIFLE criteria

Grade	Serum creatinine	GFR	Urine output
Risk	1.5-fold increase	Decrease by 25 %	< 0.5 ml/kg per hour for 6 h
Injury	2-fold increase	Decrease by 50 %	< 0.5 ml/kg per hour for 12 h
Failure	3-fold increase	Decrease by 75 %	< 0.3 ml/kg per hour for 24 h or anuria for 12 h
Loss	Complete loss of kidney function for more than 4 weeks		
ESRD	Complete loss of kidney function for more than 3 months		

*ESRD* end-stage renal disease

### What Are the RIFLE Criteria?

This allows clinicians to grade levels of kidney dysfunction based on serum creatinine, glomerular filtration rate (GFR), and urine output (Table 39.4).

### What Imaging Is Useful in the Work-Up of Oliguria?

Ultrasonography of the bladder, ureters, and kidneys is useful to assess for obstructive pathology. Bilateral or unilateral hydronephrosis with a BUN/Cr ratio > 20:1 is highly suggestive of postrenal AKI. Doppler ultrasonography is a cost-effective means of evaluating renal perfusion.

## Management

### When Encountering Low Urine Output, What Needs to Be Ruled Out First as an Easily Correctable Cause?

An obstructed urinary catheter needs to be ruled out first. One should first look for kinking in the tubing and flush the catheter to make sure it is not clogged.

### What Should Be Done Next?

Reviewing all medications and discontinuing nephrotoxic drugs should be done next. In addition, all renally excreted drugs will need to be dose adjusted.

### What Is a Fluid Challenge?

This involves giving an oliguric patient a bolus of normal saline (500 mL to 1 L) over a short amount of time (typically 30 min) in an effort to increase urine output. With a Foley catheter in place, urine output is recorded hourly. For patients with prerenal AKI due to hypovolemia with no other injuries to the kidney, urine output should increase.

## **What If the Patient Does Not Respond to Repeat Fluid Challenges? How Do You Assess Adequacy of Fluid Replacement?**

If repeat fluid challenges do not result in improvement in urine output, the possibilities are either that the patient remains hypovolemic and needs additional fluid or the oliguria is not due to hypovolemia. Inserting a central line so as to measure the central venous pressure (CVP) will help as one can more accurately determine volume status. A normal CVP is 8–12 mmHg. Values below indicate a persistent low intravascular volume and the need for additional fluid resuscitation. Once a normal CVP has been restored, if oliguria persists, postrenal and intrinsic renal etiologies must be considered.

## **What Should Be Done If the Patient Is Suspected of Having a Postrenal Obstruction?**

Insertion of a Foley catheter is often enough to relieve obstruction. If a Foley is already in place, replacing the catheter or irrigating it may be necessary.

## **What Are the Indications for Urgent/Emergent Dialysis?**

If the patient remains anuric and the renal failure persists, hemodialysis may be performed. Indications for emergent hemodialysis can be remembered with the AEIOU mnemonics: acidosis, electrolyte imbalance (hyperkalemia), intoxication (ethylene glycol), overload (fluid), and uremia.

## **What Is the Role of Diuretics in the Treatment of Oliguria?**

Diuretics may be beneficial in the setting of cardiogenic oliguria (such as in association with decompensated congestive heart failure). Diuretics are otherwise not beneficial.

## **What Is the Theoretical Role of Dopamine in the Treatment of Oliguria? What Is the Actual Role?**

Dopamine is an endogenous catecholamine which at low doses is known to increase the cardiac output while causing renal vascular dilation in an individual with normal renal function, thus improving perfusion to the organ and natriuresis while reducing the metabolic demands of the renal tubular system. However, dopamine can actually increase renovascular resistance in oliguric patients with AKI, further decreasing the blood flow to the kidney and worsening the insult. It has also been noted that dopamine can potentiate diuresis in patients who are already volume depleted, especially in patients who are receiving diuretics, as it augments the effects of diuretic agents. Dopamine is not currently recommended for the treatment of oliguria.

---

## **Areas You Can Get in Trouble**

### **MRI in Patient with Renal Failure**

Patients with renal failure that undergo gadolinium-enhanced MRI imaging are at risk for nephrogenic systemic fibrosis (NSF). Patients present with marked thickening and hardening of the skin in addition to fibrosis of internal structures, such as the muscle, fascia, lungs, and heart.

## Summary of Essentials

### History and Physical Exam

- AKI is often asymptomatic with only decreased urine output as the presenting sign
- Physical exam findings specific for AKI are rarely seen; earliest sign is oliguria
  - Oliguria:  $<0.5$  ml/kg/h for two consecutive hours
  - Anuria:  $< 50$  mL-100 ml/day

### Physiology/Pathophysiology

- Three types of AKI
  - Prerenal: BUN/Cr ratio  $>20:1$  often with history of hypotension/hypovolemia
  - Intrinsic renal/intrarenal: sequelae of prerenal AKI, ATN, and interstitial nephritis
  - Postrenal: obstruction secondary to BPH, tumor, stone, and stricture
- Contrast-induced AKI seen with preexisting renal disease
  - Increase in serum creatinine of 0.5 mg/dl within 48–72 hours
- Aldosterone and ADH primarily responsible for post-op oliguria

### Work-Up

- Best initial test is BUN and creatinine
- Urinalysis, urine sodium, fractional excretion of sodium ( $FE_{Na}$ ), and urine osmolality
- RIFLE criteria to grade kidney dysfunction (serum creatinine, GFR, and urine output)
- Ultrasonography of the bladder, ureters, and kidneys is useful to assess for obstructive pathology

### Management

- Flush Foley, stop nephrotoxic drugs, and fluid challenge
- Indications for urgent/emergent dialysis
  - AEIOU: acidosis, electrolyte imbalance (hyperkalemia), intoxication (ethylene glycol), overload, and uremia

---

### Suggested Reading

Galan A, Cowper SE, Bucala R. Nephrogenic systemic fibrosis (nephrogenic fibrosing dermopathy). *Curr Opin Rheumatol.* 2006;18:614.  
KDIGO clinical practice guideline for acute kidney injury. *Kidney Int Suppl.* 2012;2:8.  
Nash K, Hafeez A, Hou S. Hospital-acquired renal insufficiency. *Am J Kidney Dis.* 2002;39:930.

---

## Shortness of Breath Five Days After Surgery

40

Paul N. Frank, Kathleen Brown, and Christian de Virgilio

Five days after a laparoscopic left colectomy for colon cancer, a 55-year-old female represents to the emergency department with shortness of breath for the past 6 hours. She feels that she is breathing more rapidly and does not seem to be able to catch her breath. She denies any chest pain. Per report, the colon cancer was limited to the sigmoid colon, and the surgery was uneventful. She has no prior cardiac or pulmonary history. On physical exam the patient is found to have a temperature of 100.8 °F, respiratory rate of 26/min, heart rate of 110/min, and blood pressure of 130/85 mmHg. Lungs are clear to auscultation without wheezing or rales. The heart examination reveals a regular rate and rhythm without murmurs or rubs. Her abdomen is soft and nontender. The wound appears to be clean without drainage. Her left leg appears to be swollen up to the knee with pitting edema. The left calf is not tender to palpation. The right leg is not swollen. Distal pulses are normal. O<sub>2</sub> saturation on room air is 92 %. Arterial blood gas on room air reveals a pO<sub>2</sub> of 70 mmHg, a pCO<sub>2</sub> of 33 mmHg, a pH of 7.47, and an A-a gradient of 25. Laboratory values reveal a WBC of  $9.6 \times 10^3/\mu\text{L}$  (normal  $4.1 - 10.9 \times 10^3/\mu\text{L}$ ) and Hgb/Hct of 12 g/dL and 36 %. Chest X-ray is normal. ECG demonstrates sinus tachycardia but is otherwise unremarkable.

---

P.N. Frank, MD (✉)

Department of Surgery, Harbor-UCLA Medical Center, 1000 W. Carson Street, Torrance, CA 90509, USA  
e-mail: [PaulFrank521@gmail.com](mailto:PaulFrank521@gmail.com)

K. Brown, MD

Department of Radiological Sciences, David Geffen School of Medicine at UCLA, 757 Westwood Plaza, Suite 1621, Los Angeles, CA 90095, USA  
e-mail: [kbrown@mednet.ucla.edu](mailto:kbrown@mednet.ucla.edu)

C. de Virgilio, MD

General Surgery Residency Program, Department of Surgery, Harbor-UCLA Medical Center, 1000 W. Carson Street, Torrance, CA 90509, USA  
e-mail: [cdevirgilio@labiomed.org](mailto:cdevirgilio@labiomed.org)

## Diagnosis

### What Is The Differential Diagnosis for Postoperative Shortness of Breath?

Diagnosis	History and Physical	Comments
<i>Pneumonia</i>	Fever, dyspnea, dullness to percussion, prolonged intubation, aspiration, PPI use → ↑gastric pH leading to ↑gram-negative bacteria growth in stomach	Most common cause of nosocomial mortality, aspiration (right lower lobe if patient is upright, right upper lobe if patient is supine)
<i>Pulmonary embolism</i>	Recent travel (e.g., long airplane or car ride), immobilization, recent surgery, trauma or central line (within 3 months), cancer, history of DVT or PE, smoking, CVA, CHF, COPD, look for Virchow's triad (see below)	Usually from DVT in pelvic or leg veins
<i>Myocardial infarction</i>	H/o MI, diabetes, CHF	Surgery creates proinflammatory state, leads to plaque rupture and thrombosis of coronary artery
<i>Pneumothorax</i>	Diminished/absent breath sounds, associated with central line placement (US-guided line placement lowers risk)	Air leak in pleura allows equalization of negative pleural pressure with ambient pressure
<i>Cardiogenic pulmonary edema</i>	Rales, JVD, S3, bilateral leg swelling	PCWP > 18 mmHg
<i>Noncardiogenic pulmonary edema</i>	Sepsis, massive transfusion, trauma, pancreatitis; no rales, S3, or JVD	PaO <sub>2</sub> /FiO <sub>2</sub> < 200, hypoxemia with respiratory alkalosis; bilateral infiltrates on CXR, includes ARDS
<i>Anxiety</i>	Must rule out other causes first	Psychogenic
<i>Bleeding</i>	Hypotension, tachycardia, decreased urine output	Most often in the first hours after surgery

CVA cerebral vascular accident (i.e., stroke), CHF congestive heart failure, COPD chronic obstructive pulmonary disease, ARDS adult respiratory distress syndrome, DVT deep vein thrombosis, PCWP pulmonary capillary wedge pressure, MI myocardial infarction, JVD jugular venous distention

### What Is the Most Likely Diagnosis?

The differential diagnosis for acute shortness of breath with hypoxia is extensive. The primary etiologies in the postoperative period are shown above. Pneumonia and cardiogenic pulmonary edema are high on the list; however, the absence of physical exam evidence of fluid overload (JVD, rales, or crackles) points against cardiogenic pulmonary edema. Similarly a normal lung exam and normal CXR make pneumonia, atelectasis, and noncardiogenic pulmonary edema very unlikely. The combination of hypoxia, respiratory alkalosis, tachycardia, and a wide A-a gradient points to a pulmonary embolus (PE). This is further reinforced by a normal CXR and ECG. Finally, the unilateral leg swelling suggests that the source of PE is a leg deep vein thrombosis (DVT). This phenomenon is known as a venous thromboembolism (VTE).

## History and Physical Exam

### What Is Virchow's Triad? Which Part of the Triad Can Be Invoked in the Patient?

At least one of Virchow's triad is generally present for a venous thromboembolic event (VTE). The triad includes *stasis*, *endothelial injury*, and a *hypercoagulable state*. The patient described above has two of the triad: cancer, which is a cause of hypercoagulability, and stasis from being immobile during and after the operation. Surgery, just like other types of trauma, also induces a *hypercoagulable (prothrombotic) state*.

Stasis occurs during prolonged bed rest such as after an injury, a surgery, or a long plane flight or car ride. Walking causes the leg muscles to act as a pump to move blood back to the heart. In the immobile patient, venous blood will tend to collect in the legs, leading to *stasis*. Hypercoagulable states can be congenital or acquired. Injury to the vein can occur after a trauma (leg fracture) or an iatrogenicity (venous cannulation with a central line).

**Table 40.1** Wells score

Finding	Points
Signs and symptoms of DVT	3
PE most likely diagnosis	3
HR > 100	1.5
Prior DVT or PE	1.5
Immobilization within last 4 weeks	1.5
Malignancy within last 6 months	1
Hemoptysis	1

## What are The Risk Factors for VTE and Their Mechanism?

### *Stasis*

Immobilization

### *Endothelial injury*

Surgery

Trauma

Central line within last 3 months

History of DVT or PE

### *Hypercoagulability*

Smoking

Oral contraceptive pills

History of DVT or PE

Inherited disorders (e.g., factor V Leiden, protein C deficiency)

## What Is the Wells Score for PE?

The Wells score is calculated by adding the points associated with clinical findings in Table 40.1. A score of >4 points indicates a likely PE, whereas a score  $\leq$  4 points indicates a low likelihood of PE.

## What Are the Main Clinical Findings Associated with a DVT?

The main clinical findings are leg swelling, calf pain, warmth of leg, mild redness of calf, and calf tenderness.

### **Watch Out**

The left leg is 2× more commonly affected by DVT because the left iliac vein is often compressed by the right iliac artery. This phenomenon is known as May-Thurner syndrome.

## What Is Homans' Sign? Why Has It Fallen Out of Favor?

Homans' sign is a physical exam finding that was classically associated with DVT. The sign is considered positive when you can elicit calf pain with dorsiflexion of the foot. It is no longer used routinely because a positive sign does not likely indicate a DVT. It has a very low sensitivity of 30 %, which limits its clinical utility.



## The 5 Classic Causes of Postoperative Fever may be Remembered as the 5 Ws of Postoperative Fever

W	Etiology	Post-op day
Wind	Atelectasis	1–2
Water	Urinary tract infection	After 3
Wound	Wound infection	After 5
Walking	DVT/thrombophlebitis	7–10
Wonder drugs	Drug fever (e.g., antibiotics)	Anytime

### What Are the 5 Classic Causes of Postoperative Fever and When in the Postoperative Setting Would Each Be Expected to Occur?

#### Watch Out

Recent studies suggest that atelectasis does not cause a fever.

## Pathophysiology

### What Are the Most Commonly Inherited Causes of Hypercoagulability (Thrombophilia)?

Factor V Leiden and prothrombin mutation are the first and second most common inherited thrombophilias. Less common inherited thrombophilias include elevated protein C deficiency, protein S deficiency, antithrombin deficiency, and homocysteinemia.

#### Watch Out

Patients with a deficiency of protein C or S are at higher risk of developing warfarin-induced skin necrosis when warfarin is first initiated. Warfarin acts by inhibiting the function of vitamin K, which is a required coenzyme in the production of clotting factors II, VII, IX, and X, as well as proteins C and S. Proteins C and S inhibit the formation of blood clots. When warfarin is administered to a patient with low levels of proteins C and S at baseline, warfarin reduces these levels even more, thereby inducing a prothrombotic state, which can cause necrosis of the skin.

#### Watch Out

Factor V Leiden is the most common inherited cause of hypercoagulability associated with DVT.

### What Are the Most Common Acquired Causes of Hypercoagulability?

Advanced age, pregnancy, malignancy, oral contraceptives, hormone replacement therapy, smoking, obesity, nephrotic syndrome, and heparin-induced thrombocytopenia are common causes of hypercoagulability.

#### Watch Out

Heparin-induced thrombocytopenia may present as an acute drop in platelet levels (such that the new level is <50 % of baseline) in a patient who has begun heparin or low molecular weight heparin (LMWH) therapy within the last 4–10 days.

### **What if a Patient Has No Obvious Component of Virchow's Triad and Presents with Venous Thromboembolism (VTE)?**

Always try to identify on history if the patient manifests any of the three parts of Virchow's triad. If there are no obvious risk factors (such as recent surgery, known malignancy, recent trauma, plane flight, etc.), then a careful history and physical exam must be conducted to ascertain whether the patient has an undiagnosed malignancy or other hypercoagulable state.

### **What Is the Difference Between a Cardiac and Noncardiac Cause of Postoperative Pulmonary Edema?**

Pulmonary edema is defined as excess fluid in the alveoli. There are both cardiac (i.e., cardiogenic) and noncardiac (i.e., noncardiogenic) etiologies. Noncardiogenic pulmonary edema is caused by inflammation that leads to an increased pulmonary capillary permeability secondary to cytokine signaling. Specific etiologies of noncardiogenic edema include pneumonia, ARDS, pulmonary contusion, and fat embolism. Cardiogenic pulmonary edema arises from an increase in hydrostatic pressure within the capillaries of the lungs as a result of increased pulmonary venous pressure.

### **How Do You Distinguish Between Cardiogenic and Noncardiogenic Pulmonary Edema Based on History and Physical Exam? Why Is It Important to Distinguish Between Them?**

With cardiogenic pulmonary edema, there is usually an associated acute cardiac event, such as an MI, left ventricular failure, or dysrhythmia. Physical exam demonstrates evidence of an acute heart failure and a low flow state, such as S3 gallop, jugular venous distention, and crackles on auscultation, as well as cool, pale extremities (these findings are not present with noncardiogenic causes). Cardiogenic pulmonary edema is definitively demonstrated by measuring pulmonary capillary wedge pressure (PCWP) which is elevated (>18 mmHg), whereas PCWP is normal or low with noncardiogenic causes. Treatment of cardiogenic causes include reduction of preload, reduction of afterload, and, if needed, the addition of pressors (such as dobutamine). The mainstay of treatment of noncardiogenic pulmonary edema is ventilatory support.

#### **Watch Out**

Cardiogenic pulmonary edema on post-op day 3 may be the result of third spacing. The large volume of IV fluids administered to the patient perioperatively, which equilibrated in all body compartments, will return back to the vasculature often on post-op day 3. Elderly patients or those with poor heart function are particularly at risk, as the increased intravascular volume may overwhelm the heart and lead to elevated ventricular filling pressures, which can be transmitted into the pulmonary circulation.

### **What Are the Three Routes by Which a Patient Develops Postoperative Pneumonia?**

Postoperative pneumonia may be acquired via inhalation, aspiration, or hematogenous spread. After surgery, the cough reflex may be suppressed, and mucociliary transport may be inhibited by endotracheal intubation. Additionally, alveolar macrophage function may be inhibited by pulmonary edema. Accumulation of oral secretions in the airway is also a risk factor.

### **What Is an A-a Gradient? What Is the Differential of a Wide A-a Gradient?**

A-a gradient refers to the difference in partial pressure of oxygen between the alveoli ( $P_{A O_2}$ ) and arterial blood ( $P_{a O_2}$ ).

The normal A-a gradient,  $P_{A O_2} - P_{a O_2}$ , is given by

$$\text{normal A - a gradient} = \frac{\text{age in years}}{4} + 4$$

The differential diagnosis of a wide A-a gradient in the postoperative setting includes atelectasis, pneumonia, and pulmonary embolism.

## Work-Up

### What Is the First Step in the Work-Up of a Patient Suspected of Having a Pulmonary Embolism?

Determine the likelihood that the patient has a pulmonary embolism using the Wells score. If their score is  $\leq 4$ , the patient has a low likelihood of PE. If the score is  $>4$ , the patient has a high likelihood of PE. This will then determine the next step in the work-up.

### When There Is a High Suspicion of VTE, What Is the First Step in the Work-Up/Management?

Start heparin right away *before* the diagnosis is even established. Heparin is an anticoagulant—not a fibrinolytic. Hence, the purpose of heparin in VTE is not to dissolve the clot, but rather to prevent it from progressing/propagating. Following heparin administration, one should obtain a CT angiogram of the pulmonary arteries.

### When Suspicion of VTE Is Low, What Is the First Step in the Work-Up?

The first step is to obtain a D-dimer assay. D dimer is a product of the breakdown of fibrin by plasmin. There are many causes of elevated D-dimer levels, including VTE, recent surgery, malignancy, DIC, infection, pregnancy, and renal and cardiovascular disease. Hence, D dimer has very poor specificity, particularly in the postoperative setting. That being said, D dimer has a high negative predictive value. So even though most postoperative patients will have an elevated D dimer, D-dimer level  $<500$  ng/mL effectively can rule out PE in low-risk patients. If D dimer is elevated, the next step is to obtain a CT angiogram.

### In a Patient with PE, What are the Most Common Findings on ABG, ECG, and CXR?

Study	Most common finding
Arterial blood gas (ABG)	Acute respiratory alkalosis, hypoxemia, increased A-a gradient
Electrocardiogram (ECG)	Sinus tachycardia
Chest x-ray (CXR)	Normal

### What Are the Classic, Though Uncommon, Findings on CXR and ECG that are Associated with PE?

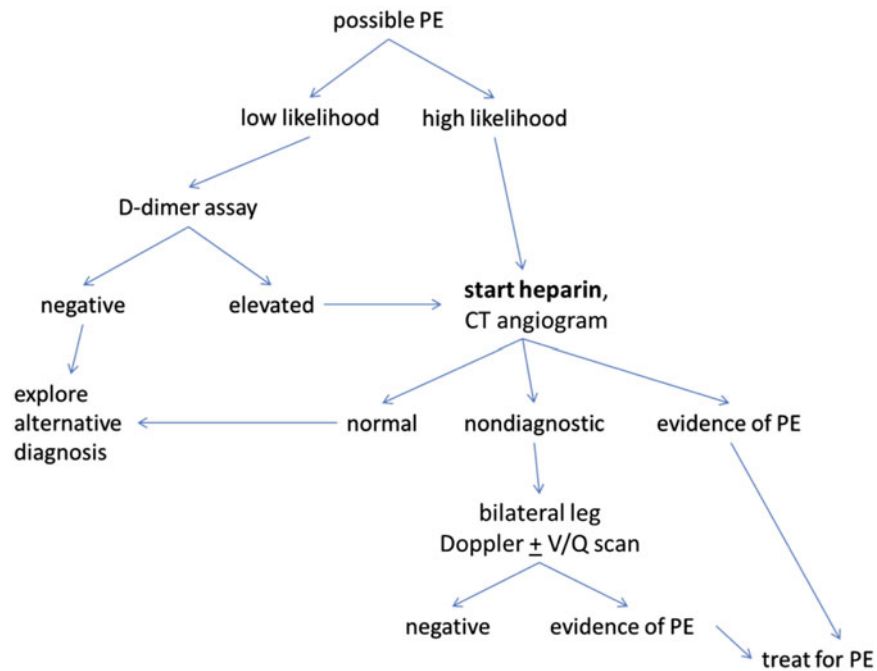
Westermark's sign (focal/regional pulmonary oligemia distal to embolus) on CXR represents a region of decreased pulmonary blood flow secondary to PE. It is highly specific but has a very low sensitivity. Hampton's hump (wedge-shaped density at periphery of lung) is another uncommon sign suggesting PE. The classic constellation of ECG findings is large S wave in lead I, large Q wave in lead III, and inverted T wave in lead III. This is seen in only 20 % of patients and is a sign of right ventricular strain.

### Since CXR Is Often Normal with a PE, How Does a CXR Help?

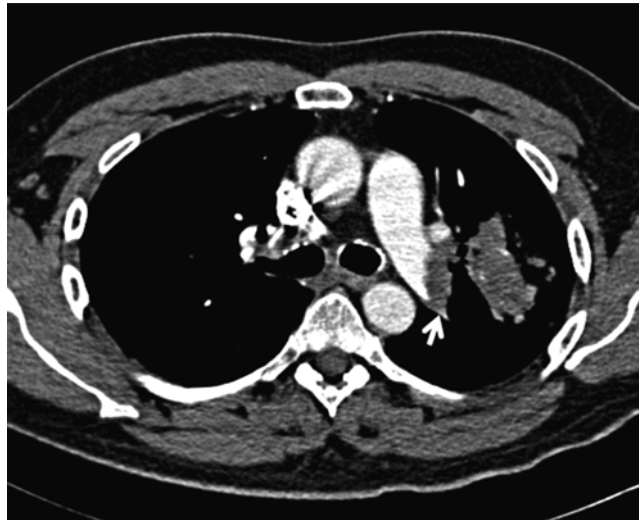CXR is actually quite useful in the diagnosis of PE, in that the absence of an abnormal CXR (no infiltrates, atelectasis, or fluid overload) in a hypoxic patient strengthens the suspicion for PE. Likewise, a normal ECG helps to rule out cardiac causes (MI, arrhythmia) of shortness of breath.

### What Are the Typical Findings on CT Angiography for PE? What Is the Sensitivity and Specificity?

CT angiography in PE (Fig. 40.2) will show a filling defect in the pulmonary arterial system. The sensitivity may range from 91 % to 100 %, and the specificity ranges from 83 % to 93 %.



**Fig. 40.1** What is the full diagnostic algorithm for a possible pulmonary embolism? *low likelihood* is based on Wells score  $\leq 4$ . *D-dimer* assay is considered normal if the *D-dimer* level is  $< 500$  ng/dL



**Fig. 40.2** Axial CT angiogram showing a filling defect in the left pulmonary artery consistent with pulmonary embolism

#### Watch Out

A large saddle embolus lodged in the common pulmonary artery can result in sudden death secondary to right heart failure.

## **How Does V/Q Scan Work? Why Has It Fallen Out of Favor for the Diagnosis of PE?**

Inhaled and intravenous radionuclides are administered, and their distribution throughout the lung fields is imaged. High suspicion for a PE occurs when there are multiple areas of perfusion deficit with normal lung ventilation. The results of a V/Q scan are given as high, intermediate, low, and very low probability of PE. The V/Q scan has fallen out of favor in the diagnosis of PE because a significant percentage of patients with low probability of PE on V/Q scan will end up actually having a PE. In order to better refine the utility of PE, a classification of very low probability of PE has been identified on V/Q scan that appears to have a high negative predictive value. Other drawbacks of V/Q scanning are that it takes time to perform and is not always readily available 24 hours a day.

## **If the Patient Is Critically Ill and Unable to Be Transported for Imaging, What Bedside Options Are There for the Indirect Diagnosis of PE?**

*Echocardiogram* may show indirect evidence of PE, such as right heart strain. Since most PE arise from DVT in the legs, a venous duplex (*Doppler ultrasound*) of the leg may demonstrate a venous thrombus.

## **How Is the Severity of PE Classified?**

PE is classified into low-risk, submassive, and massive PE. The classification is important as it affects management and prognosis. A low-risk PE has no evidence of right ventricular (RV) dysfunction and no evidence of myocardial necrosis. A submassive PE has been defined as evidence of RV dysfunction (on echocardiogram) or myocardial necrosis (based on elevated troponin or brain natriuretic peptide {BNP}) in the absence of systemic hypotension (systolic BP  $\geq$  90 mmHg). With a massive PE, there is the addition of sustained hypotension.

---

## **Management**

### **What Is the Initial Anticoagulant Management of PE?**

The initial management of PE is therapeutic anticoagulation with subcutaneous low molecular weight heparin or intravenous unfractionated heparin. In high probability patients, this should be instituted immediately while the diagnostic work-up is in progress, provided there are no contraindications to anticoagulation.

### **What If the Patient Has a History of or Suspected Heparin-Induced Thrombocytopenia (HIT)?**

A non-heparin-based anticoagulant should be given such as lepirudin, argatroban, or bivalirudin. These are direct thrombin inhibitors.

### **What If the Patient Has a Contraindication to Anticoagulation?**

If the patient has a contraindication to anticoagulation, such as ongoing bleeding, this is an indication for placement of an inferior vena cava filter (once the presence of PE has been confirmed).

### **What Are the Four Options for the Subsequent Treatment of PE?**

Once the diagnosis of PE is established, depending on the severity of the PE, patients may receive heparin alone, tPA (a thrombolytic agent), endovascular clot aspiration, or open pulmonary embolectomy. In most patients (low-risk PE), heparin alone is sufficient.

---

### When Should tPA Be Considered?

Intravenous tPA is *indicated* in patients with massive PE, *should be considered* in select patients with submassive PE, and is *not indicated* in low-risk PE. Contraindications to tPA include surgery within the last 2 weeks (such as in the patient presented), intracranial hemorrhage or malignancy, ischemic stroke within the last 3 months, suspected aortic dissection, active bleeding (other than menses), significant closed head trauma within 3 months, and severe hypertension (>185/110 mmHg). The greatest risk of tPA is fatal hemorrhage, including intracranial.

### When Should Open Pulmonary Embolectomy Be Considered?

Open pulmonary embolectomy may be considered in patients with massive PE who are not candidates for tPA therapy.

### What Is the Recommendation for Long-Term Anticoagulation After First-Time VTE?

Heparin or LMWH should be given for the first 5 days after VTE, and warfarin should be started on the first or second day such that the two anticoagulants overlap for 4–5 days. The goal INR should be 2–3. Patients should receive anticoagulation therapy for at least 3 months after VTE (when there is a reversible risk, such as in the recent surgery). For recurrent or unprovoked VTE, treatment is for at least 6 months.

---

## Areas Where You Can Get in Trouble

### Anticoagulation in Patients with Malignancy

Coumadin is the most frequently used long-term anticoagulant, but LMWH is better than warfarin in preventing recurrent VTE in patients with malignancy and therefore is the anticoagulant of choice.

### Anticoagulation During Pregnancy?

PE is a significant cause of maternal death in the United States, so aggressive therapy is warranted. Anticoagulation with LMWH or unfractionated heparin should be used to treat VTE in pregnancy. Warfarin is a teratogen and should not be given to pregnant women.

---

## Summary of Essentials

### History and Physical Exam

- Look for Virchow's triad (stasis, hypercoagulability, and endothelial injury)
- Sudden onset of dyspnea, pleuritic chest pain, and/or tachycardia
- Calculate Wells score

### Pathophysiology

- DVT is most likely to form in the leg, also at the site of intravenous catheter insertion, and less commonly in the arms

## Differential Diagnosis

- Patients with shortness of breath and pleuritic chest pain should also be evaluated for pulmonary edema (cardiogenic and noncardiogenic), myocardial infarction, and pneumonia

## Diagnosis

- If there is high suspicion of PE, start heparin immediately, even before the work-up is completed
- Patients with high suspicion of PE should also undergo CT angiography
- If CT angiogram is nondiagnostic, patients should undergo V/Q scanning
- D-dimer, BNP, and troponin labs should be sent
- Echocardiogram may be used to assess for evidence of right heart strain
- ECG will most commonly show sinus tachycardia in patients with PE

## Management

- IV heparin or subcutaneous LMWH
- Submassive PE—consider tPA
- Massive PE—tPA vs. pulmonary embolectomy
- IVC filter—only if contraindication to anticoagulation

## Special Conditions

- VTE with malignancy—LMWH: treatment of choice
- VTE in pregnancy—avoid Warfarin
- VTE with HIT—direct thrombin inhibitors

---

## Suggested Reading

Anand SS, Wells PS, Hunt D, et al. Does this patient have deep venous thrombosis? *JAMA*. 1998;279(14):1094–9.

Jaff M, McMurtry M, Archer S, et al. Management of massive and submassive pulmonary embolism, iliofemoral deep vein thrombosis, and chronic thromboembolic pulmonary hypertension: a scientific statement from the American Heart Association. *Circulation*. 2011;123:1788–830.

Johnson CM, Mureebe L, Silver D. Hypercoagulable states: a review. *Vasc Endovasc Surg*. 2005;39:123–33.

Nieuwdorp M, Stoes ES, Meijers JC, Buller H. Hypercoagulability in the metabolic syndrome. *Curr Opin Pharmacol*. 2005;5(2):155–9.

Niimi R, Hasegawa M, Sudo A, et al. Evaluation of soluble fibrin and D-dimer in the diagnosis of postoperative deep vein thrombosis. *Biomarkers*. 2010;15(2):149–57.

---

**Part XIII**

**Trauma**

Dennis Y. Kim, Section Editor



Areg Grigorian, Christian de Virgilio, and Dennis Y. Kim

A 35-year-old unrestrained male driver is brought in by paramedics following a motor vehicle collision (MVC). There was extensive passenger space intrusion and significant steering wheel deformity. On arrival to the emergency department, the patient is unconscious and unresponsive. His blood pressure is 80/40 mmHg and heart rate is 110/min. He has obvious facial fractures, with blood coming out of his mouth. His pupils are equal, round, and reactive to light. His breathing is shallow and labored. Breath sounds are clear bilaterally. He is not moving, does not open his eyes, and withdraws to pain. His abdomen is non-distended and non-tender to palpation. He has no obvious external signs of trauma on the abdomen. There are no obvious deformities in his extremities.

## Diagnosis

### Is this Patient in Shock? What Are the Different Types of Shock?

This patient appears to be in shock. There is no precise blood pressure cutoff that defines shock; rather, it is a state in which there is inadequate tissue perfusion and delivery of oxygen that is needed for aerobic metabolism, leading to hemodynamic instability and end-organ dysfunction. Hypotension in trauma patients is due to hypovolemic/hemorrhagic shock until proven otherwise. Other less common causes of shock (Table 41.1) in the trauma patient are cardiogenic shock (cardiac tamponade, tension pneumothorax, blunt cardiac injury) and neurogenic shock secondary to spinal cord injury.

**Table 41.1** Types of shock in the *trauma* setting

Type of shock	Clinical scenario	Mechanism
<i>Hypovolemic</i>	Any blunt or penetrating trauma with hemorrhage; burns	Decreased blood and plasma volume
<i>Cardiogenic</i>	Blunt cardiac injury, arrhythmias, cardiac tamponade, tension pneumothorax <sup>a</sup>	Failure of myocardial pump (blunt cardiac injury), decreased preload (cardiac tamponade, tension pneumothorax)
<i>Neurogenic</i>	High cervical spinal cord injury, warm well-perfused extremities, normo/bradycardic (different from other types of shock)	Autonomic dysfunction (loss of sympathetic tone) with peripheral vasodilation

<sup>a</sup>Some classify cardiac tamponade and tension pneumothorax as obstructive shock

A. Grigorian, MD (✉)  
Department of Surgery, University of California, Irvine, 333 City Blvd West, Suite 1600, Route. 81, Orange, CA 92868, USA  
e-mail: [agrigori@uci.edu](mailto:agrigori@uci.edu)

C. de Virgilio, MD  
General Surgery Residency Program, Department of Surgery, Harbor-UCLA Medical Center, 1000 W. Carson Street, Torrance, CA 90509, USA  
e-mail: [cdevirgilio@labiomed.org](mailto:cdevirgilio@labiomed.org)

D.Y. Kim, MD  
Department of Surgery, Harbor-UCLA Medical Center, 1000 W. Carson Street, Box 42, Torrance, CA 90509, USA  
e-mail: [dekim@dhs.lacounty.gov](mailto:dekim@dhs.lacounty.gov)

## History and Physical Exam

### What Are the Clinical Manifestations of Hypovolemic Shock?

Clinical manifestations of shock include tachycardia (*initial sign*), hypotension, pale and cool extremities, weak peripheral pulses, prolonged capillary refill (>2 s), low urine output, and altered mental status.

#### Watch Out

Young patients can be in hypovolemic shock but still maintain normal blood pressure, owing to a strong vascular tone which they can maintain until cardiovascular collapse is imminent.

### What Is the Significance of Blood at the Urethral Meatus?

Blood at the urethral meatus in the setting of blunt trauma is highly suggestive of a urethral injury secondary to a pelvic fracture. Other signs of urethral injury include perineal ecchymosis, scrotal hematoma, and a high-riding (non-palpable) prostate on digital rectal examination (DRE). Placing a urinary catheter (Foley) is contraindicated due to the risk of worsening a partial or complete urethral injury. Radiographic imaging (via a retrograde urethrogram {RUG}) should be performed first to confirm that the urethra is intact.

### What Is the Significance of Gross Hematuria?

Gross hematuria following blunt trauma strongly suggests an injury to the kidney or bladder. Renal injury is ruled out via a CT of the abdomen/pelvis with IV contrast. An injury to the bladder is best determined by either a CT cystogram or a retrograde cystogram.

## Pathophysiology

### How Much Blood Loss Is Necessary to Cause Hypotension (as in the Patient Above) in the Supine Position?

Hypotension in the supine position implies the patient has lost 30–40 % of his blood volume (Class III shock, see Table 41.2), which represents 1,500–2,000 ml of blood. Such knowledge helps the clinician in terms of calculating volume and type of fluid resuscitation (crystalloid or blood), searching for the source of blood loss, and determining the need for an operative intervention.

**Table 41.2** Shock class I–IV

	<b>Class I</b>	<b>Class II</b>	<b>Class III</b>	<b>Class IV</b>
<i>Blood loss (% blood volume)</i>	Up to 750 ml (<15 %)	750–1,500 ml (15–30 %)	1,500–2,000 ml (30–40 %)	>2,000 ml (>40 %)
<i>Heart rate</i>	Normal	Tachycardia (100–120)	Tachycardia (>120)	Tachycardia (>120)
<i>Blood pressure</i>	Normal	Normal to minimal change	Significantly decreased (SBP < 90 mmHg)	Significantly decreased (SBP < 90 mmHg)
<i>Pulse pressure</i>	Normal	Decreased	Decreased	Decreased (<25 mmHg)
<i>Respiratory rate</i>	Normal	Tachypnea	Tachypnea	Tachypnea

## What Are the 5 Main Sources of Major Blood Loss in Blunt Trauma?

The main sources are chest, abdomen, pelvis/retroperitoneum, long bones, and “street” or external.

## What Are the Most Likely Injuries in Each of These Locations that Would Lead to Major Blood Loss?

Given that hypotension in the supine position implies a blood loss of 1,500–2,000 ml, the clinician must consider what injuries might lead to such a large blood loss and the likely locations of such occult blood loss. In the chest, a massive hemothorax from a laceration of the lung or bleeding from torn intercostal arteries (both due to a rib fractures) is a leading cause. The liver is the most commonly injured organ following blunt abdominal trauma, but massive blood loss is most often due to splenic rupture. Massive retroperitoneal bleeding is most often due to pelvic fractures that tear small arterial branches off the internal iliac artery or pelvic veins. Renal trauma can also cause major retroperitoneal hemorrhage. Blunt injury to the abdominal aorta and IVC are exceedingly rare. A femur fracture can lead to a loss of one or two units of blood (each unit is about 500 ml). Thus bilateral femur fractures may lead to hypotension. Though often overlooked, because of its rich blood supply, large scalp lacerations can surprisingly lead to major external blood loss.

### Watch Out

Rapid deceleration injuries can lead to a descending aortic transection (distal to the ligamentum arteriosum), which is often fatal. If survived, the injury is usually contained within the mediastinum and is less likely to cause massive blood loss.

## What Cavity Should Not Be Considered to Be the Source of Hemorrhagic Shock and Why?

A closed-head injury should not be considered the source of hypovolemic shock (cannot lose that much blood into the cranium). In fact, a severe closed head may induce the Cushing reflex (hypertension and bradycardia) via a sympathetic response causing peripheral vasoconstriction in order to maintain adequate blood pressure and regulate perfusion to the brain. As a result of the vasoconstriction, the baroreceptors respond with increased parasympathetic stimulation of the heart, causing bradycardia. This response is seen in patients with increased intracranial pressure (ICP) and often heralds brain herniation.

---

## Initial Management

### What Are the ABCDE of Trauma Patient Management?

The American College of Surgeons has created recommendations for the evaluation of the trauma patient. The sequence of evaluation follows the likelihood for risk of death and disability. The initial evaluation makes up the *primary survey* for trauma patients. Although presented as a sequential algorithm, elements of the primary survey often occur simultaneously.

**Airway with C-spine precaution:** Severely injured patients can develop airway obstruction leading to inadequate ventilation and hypoxia within minutes. As a result, airway evaluation and management remains the first step in the assessment of the severely injured patient.

**Breathing:** Once the airway has been secured, it is important to assess the adequacy of oxygenation and ventilation. Inspect the chest wall looking for symmetrical chest movement and signs of injury, auscultate breath sounds bilaterally, and palpate for crepitus or chest deformity.

**Circulation:** Once the airway is secured and oxygenation is established, it is important to perform an initial evaluation of the patient’s circulatory status which starts with palpation of pulses. As a rough guide, if the radial pulse is palpable, then the

systolic pressure is at least 80 mmHg. If the carotid or femoral pulses are palpable, then systolic is about 60 mmHg. Establish peripheral vein access with two large bore (16 gauge or larger) IVs in the upper extremities and begin fluid resuscitation if necessary.

*Disability (neurologic evaluation):* The next step is to perform a focused neurological examination. The exam starts off by assessing the patient's level of consciousness using the Glasgow Coma Scale (GCS). The GCS is composed of three facets: eye, verbal, and motor responses.

*Exposure and environmental control:* During the primary survey, it is important that the patient is completely exposed to assess for injuries in discrete areas such as the scalp, axillae, and perineal areas. Warming blankets can be used to keep the patient warm.

### **What Is Included in the Secondary Survey of Trauma Patients?**

The primary survey should be done completely and quickly before moving on to diagnostic adjuncts and the secondary survey. If the patient is conscious and able to speak, a quick AMPLE history can be helpful (*Allergies, Medications, Past medical history, Last meal, Events preceding the trauma*). A careful and systematic head-to-toe physical exam should be done to ensure that nothing has been overlooked and to identify all major injuries.

### **What Is the First Step in the Management of the Patient Presented?**

The patient is unconscious so he cannot protect his airway. In addition, his breathing is labored and shallow. The first step is to establish an airway.

### **What Type of Airway and What Technique Are Recommended in the Trauma Setting?**

Orotracheal intubation is the most common method of securing an airway. In the trauma setting, this is performed using (a) rapid sequence intubation (RSI) and (b) with C-spine protection. RSI is designed to prevent aspiration in patients who have not been fasting. Rather than slowly titrating drugs to effect while utilizing bag-valve-mask ventilation ("bagging"), RSI involves administering immediate weight-based doses of sedatives (etomidate) and neuromuscular blocking agents in quick succession without "bagging." Since the trauma patient should be presumed to have a C-spine injury until proven otherwise, intubation must be performed with strict in-line cervical immobilization. This is a two-person technique.

### **What Are the Two Types of Surgical Airways? Which One Is More Appropriate in the Emergent Trauma Setting?**

The two surgical airways are cricothyrotomy (also called cricothyroidotomy) and tracheostomy. Cricothyrotomy is the surgical airway of choice in the emergency setting. This is because it is easier and faster to perform with fewer complications. Indications include severe facial trauma, angioedema, failed orotracheal intubation, and upper airway obstruction. An incision is made through the cricothyroid membrane, which is located between the thyroid {superior} and cricoid {inferior} cartilages. Cricothyrotomy is not generally a good long-term airway, as there is a tendency to develop subglottic stenosis. Tracheostomy (through the tracheal rings) is more time consuming to perform, requires significant expertise, and is therefore performed in a more elective setting. It is the surgical airway of choice for long-term management. Indications include malignancies causing upper airway obstruction and long-term need for mechanical ventilation (due to inability to wean).

### **Why Is Nasotracheal Intubation Not Recommended in the Trauma Setting?**

Trauma patients may have facial and basilar skull fractures. Attempts at nasotracheal intubation may lead to inadvertent intracranial passage of the nasotracheal tube.

## How Does One Confirm Proper Intubation?

Clinical indicators (e.g., misting of tube with ventilation, adequate breath sounds on auscultation) alone cannot be relied upon to confirm proper endotracheal placement. Confirmation of proper endotracheal tube placement is done by end-tidal CO<sub>2</sub> determination (capnography). A chest X-ray is subsequently performed to confirm that the endotracheal tube is not advanced too far in the tracheobronchial tree (i.e. past the carina).

### Watch Out

If peripheral access is unobtainable in young children (<6 years), a line can be placed in an intraosseous location (preferably tibial).

## Following Intubation and Confirmation of Proper Placement, What Is the Next Step in the Management of the Patient Presented?

After the “A” and the “B,” circulation (“C”) should be addressed. This begins with the establishment of two large bore (16 gauge) peripheral IVs. As the IVs are inserted, blood should be drawn for laboratory tests, most importantly for type and cross.

## Where Should the Peripheral IV Lines Be Placed?

Preferably one IV should be placed in each antecubital fossa. However, the placement should take into consideration potential sources of active hemorrhage. For example, if a patient has significant arm trauma, the IVs should be placed in a non-injured upper and/or lower extremity.

## Is a Central Line Indicated?

Peripheral IVs are preferred over central lines in the setting of trauma. Central lines (subclavian, internal jugular) require more time to place and are associated with more risks (iatrogenic pneumothorax), especially in the hypovolemic patient (central veins are collapsed). Peripheral IVs provide less resistance to flow, given the shorter length of the catheter. A central line is indicated if peripheral access is problematic and in the hemodynamically unstable patient (as in the present case), as such a line will permit hemodynamic monitoring (measurement of central venous pressure). The preferred central line in the trauma setting is the femoral vein for its ease of access.

### Watch Out

End-tidal CO<sub>2</sub> determination is not accurate for ensuring proper endotracheal tube placement if a patient is in cardiac arrest.

## What Is the Ideal Fluid Resuscitation Management for This Patient?

Initial fluid resuscitation consists of rapid infusion of warmed intravenous crystalloid (aqueous solution containing electrolytes). Normal saline (NS) and lactated Ringers (LR) are the preferred crystalloids in the trauma setting. Sodium is the main extracellular ion and as such is responsible for maintaining tonicity of the blood. NS contains only sodium and chloride (154 meq/l). LR is considered more physiologic (130 meq/l of Na, 109 meq/l of Cl, 28 meq of lactate, 4 meq/l of potassium, and 3 meq/l of calcium). The lactate is converted to bicarbonate by the liver and thus provides buffering. One to two liters of fluid should be rapidly administered in the initial resuscitation. Solutions with lower sodium concentration may cause hyponatremia, which may lead to cerebral edema and an increase in intracranial pressure.

## **Why Are Large Doses of K<sup>+</sup> Not Given in the Initial Resuscitation?**

Due to severe hemorrhage, trauma patients may be in shock, which leads to a decreased renal perfusion, a decreased glomerular filtration, and therefore, a decreased ability to excrete excess potassium. Trauma patients are at risk of developing hyperkalemia due to crush injuries. Since potassium is the main intracellular ion, such injuries may result in muscle cells releasing potassium. Of note, the amount of K<sup>+</sup> in LR is considered physiologic and is therefore considered acceptable.

## **What Is Colloid? What Is the Theoretical Benefit? Any Actual Benefit in Trauma Resuscitation?**

Colloids contain larger molecules that are insoluble, such as albumin, in addition to water and electrolytes. The theoretical benefit is that such large molecules do not freely diffuse across a semipermeable membrane, thus preserving intravascular osmotic pressure. In actuality, however, colloids have not been shown to be of benefit, are more expensive, and, in patients with traumatic brain injury, have been shown to be harmful.

## **What Is the Next Step If the Patient's Vital Signs Do Not Appropriately Respond to a Two-Liter Fluid Challenge?**

A patient who does not respond or only transiently responds to initial fluid resuscitation is termed a nonresponder or transient responder. The presumption must be that the patient is still actively bleeding. In such a case, a shift must be made to resuscitation with blood products (type O negative packed red blood cells {PRBCs} if type specific is not yet available). Once type-specific PRBCs are available, they are administered in a 1:1 or 2:1 ratio in conjunction with fresh frozen plasma (FFP).

## **After Appropriate Fluid Resuscitation Is Started, What Must Be Done Next?**

The source of bleeding must quickly be identified and stopped. Most often, such a patient will require immediate transport to the operating room (OR). Prior to taking the patient to the OR, however, an attempt should be made to determine if the bleeding is coming from the chest, abdomen, pelvis, or other source. If the patient is awake and alert and is exhibiting symptoms and signs of peritonitis, then an exploratory laparotomy is performed. If, on the other hand, the patient is unresponsive, or is not exhibiting signs of peritonitis, a focused assessment with sonography for trauma (FAST scan) is rapidly performed to look for fluid in the peritoneal cavity. If the FAST scan is positive, the patient is taken to the OR for an exploratory laparotomy. In addition, an X-ray of the chest is obtained to look for a massive hemothorax. In such a case, a tube thoracostomy (chest tube) is inserted. A pelvic radiograph is obtained to determine if there is a pelvic fracture that requires immediate stabilization. Further bleeding from a pelvic fracture is most often managed by embolization by interventional radiology (assuming the patient can be stabilized). CT scan is contraindicated in the unstable patient.

## **What Is the Role of Diagnostic Peritoneal Lavage (DPL) in the Trauma Patient?**

FAST scan has largely replaced DPL in most trauma centers. DPL is used in the setting of either an equivocal FAST scan or if FAST scan is not available. With DPL, a small abdominal incision is made under local anesthesia, and a catheter is inserted into the peritoneal cavity. The test actually begins with a peritoneal aspiration (termed diagnostic peritoneal aspiration {DPA}). If more than 20 cc of gross blood is aspirated, the study is considered positive, lavage is not necessary, and the patient is transported directly to the OR. If no blood is detected, the clinician may choose to perform a lavage of the peritoneal cavity with one liter of normal saline. DPL is positive if there are more than 100,000 RBCs/mm<sup>3</sup> identified by biochemical analysis of the lavage effluent. Some surgeons choose to only do the DPA, as it is unlikely that the peritoneum is the source of massive hemorrhage if the DPA is negative, and the fluid inserted into the peritoneal cavity may confound subsequent CT scans. DPA, like FAST scan, is not capable of detecting retroperitoneal bleeds.

## Subsequent Management

### What Is the Management of Intra-abdominal Bleeding Due to Splenic Injury?

The most common cause of intra-abdominal *bleeding* following blunt trauma is splenic injury (Fig. 41.1) (the most commonly injured organ is the liver). For *hemodynamically stable* patients with evidence of a splenic injury (based on FAST or CT scan) and no other indication for exploratory laparotomy, the preferred management is splenic embolization, if the appropriate personnel and resources are available. For hemodynamically unstable patients, the recommended management is surgical exploration and splenectomy or splenorrhaphy (repair of the spleen). In patients with splenic injuries that require a splenectomy, they must be vaccinated for *Streptococcus pneumoniae* and other encapsulated bacteria (*Haemophilus influenzae* type B and *Neisseria meningitidis*), ideally two weeks after surgery.

#### Watch Out

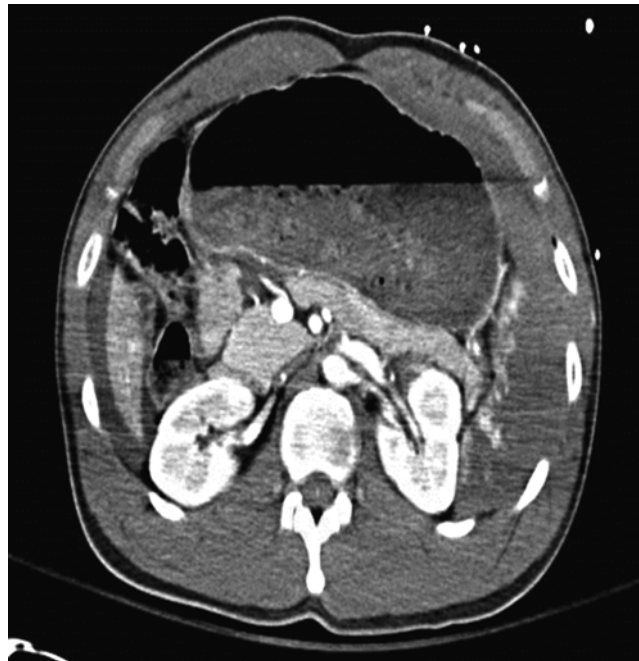Kehr's sign is acute referred pain in the left shoulder due to splenic injury.

### What Is the Management of Intra-abdominal Bleeding Due to Liver Injury?

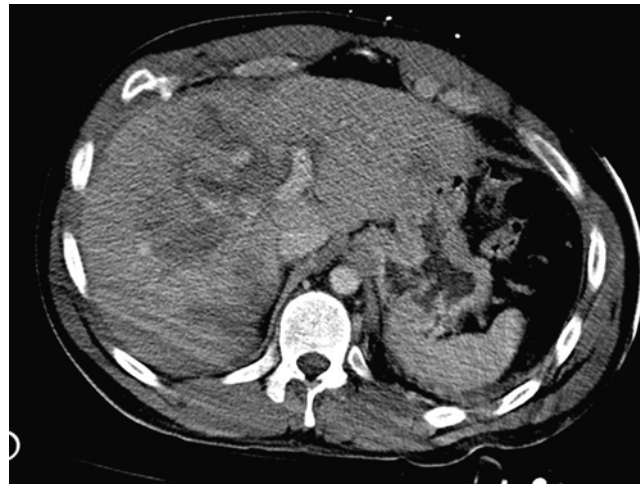The most commonly injured organ after blunt trauma is the liver (Fig. 41.2). Most patients with liver injury can be managed conservatively (without surgery). If the patient is stable, but demonstrates ongoing bleeding, embolization via interventional radiology is an accepted therapeutic adjunct. If the patient is unstable, surgical exploration is necessary. Bleeding from most liver injuries can be stopped intraoperatively using a combination of perihepatic packing (with laparotomy pads), cauterization, and/or suturing. If bleeding cannot be stopped, the laparotomy packs are sometimes left in situ for 24–48 hours.

#### Watch Out

During surgery for liver injury, the Pringle maneuver (clamping the portal triad) is utilized to temporarily control bleeding from hepatic artery or portal venous sources. Failure of the Pringle maneuver to stop bleeding implies that the bleeding is coming from the hepatic veins.



**Fig. 41.1** Axial CT showing a ruptured spleen with free fluid around the liver from blunt abdominal trauma



**Fig. 41.2** Axial CT showing severe blunt liver trauma as evidenced by regions of hypoenhancement suggesting laceration and/or vascular compromise

### **What Are the First Steps in the Management of Patients with a Pelvic Fracture? What Is the Subsequent Management?**

In addition to initial fluid resuscitation, if a patient with a pelvic fracture demonstrates evidence of ongoing bleeding, they should have their pelvic volume reduced by wrapping a pelvic binder or sheet around the greater trochanters of the femurs. If other sources of bleeding have been ruled out (i.e., a FAST exam is negative for free fluid in the abdomen, and chest X-ray is negative), the patient should undergo diagnostic and therapeutic angiography with embolization.

#### **Watch Out**

Military antishock trousers (MAST suits) or pneumatic antishock garments are different than using a pelvic sheet. MAST suits markedly increase systemic vascular resistance and have not been shown to be effective for pelvic fractures.

### **Areas You Can Get in Trouble**

#### **Failing to Recognize the Significance of Free Fluid in the Peritoneal Cavity When There Is No Solid Organ Injury**

Free fluid in the abdomen after blunt trauma is most often due to bleeding and is most often associated with an obvious injury to the spleen (most common) or liver. In the absence of major organ injury, free fluid may represent bleeding from a more occult source (such as a mesenteric artery), enteric contents (from a small bowel injury), or urine (from a bladder rupture).

#### **Treating Hypovolemic Shock Initially with Vasopressors**

The early use of vasopressors in the management of hemorrhagic shock is not recommended and may even be harmful in patients that have not been adequately resuscitated. Hypotension in the setting of trauma is usually due to hemorrhagic shock. Treatment is to give volume and identify and stop the source of hemorrhage. Patients with hypovolemic shock have a very high systemic vascular resistance due to vasoconstriction, which decreases perfusion to vital organs. Adding a vasopressor early on will only serve to aggravate the situation.



---

## Failing to Recognize the Threshold for Hypotension in Elderly Trauma Patients

The threshold for hypotension in trauma patients increases with age, as the elderly patients are more likely to be hypertensive at baseline. Hypotension is defined as systolic blood pressure less than 90–100 mmHg for patients 20–49 years of age, <120 mmHg for patients 50–69 years of age, and <140 mmHg for patients 70 years and older.

---

## Area of Controversy

### Management of a Pelvic Fracture in a Hemodynamically Unstable Patient

Most surgeons recommend angiographic embolization for ongoing bleeding from a pelvic fracture. However, if the patient is truly in severe shock, they may not be able to wait until an interventional radiologist is called in to perform such a procedure. As such, some trauma surgeons recommend taking the unstable pelvic fracture to the operating room for preperitoneal packing followed by angiographic embolization. Ligation of bilateral internal iliac arteries is another valid option in lieu of angiographic embolization.

---

## Summary of Essentials

### Diagnosis

- Types of shock in the trauma setting
  - Hypovolemic: blunt/penetrating trauma with hemorrhage, burns
  - Cardiogenic: blunt cardiac injury, arrhythmias, cardiac tamponade
  - Neurogenic: high cervical spinal cord injury, warm well-perfused extremities

### History and Physical Exam

- Clinical manifestations of shock
  - Tachycardia (initial sign), hypotension, pale and cool extremities, weak peripheral pulses, prolonged capillary refill (>2 s), low urine output, altered mental status
- Blood at urethral meatus may indicate urethral injury; Foley catheter contraindicated

### Pathophysiology

- Hypotension in supine position indicates 30–40 % loss of blood volume (class III)
- Five main sources of blood loss: chest, abdomen, pelvis/retroperitoneum, long bones, and “street” or external
- Closed-head injury is never a source of hypovolemic shock

### Initial Management

- Start with ABCs
- Orotracheal intubation is the most common method of securing an airway
  - RSI and C-spine protection
  - Nasotracheal intubation is not recommended
- Two surgical airways
  - Cricothyrotomy/cricothyroidotomy
    - Emergent airway of choice
    - Fast but not good long term

- Tracheostomy
  - Not for trauma as too time consuming
  - Airway of choice for long term
- Peripheral IVs are preferred over central lines in setting of trauma
  - LR or NS is the preferred crystalloids; no role for colloids
  - Blood products needed for nonresponders or transient responders
- Directly to OR if peritonitis is present
- FAST scan in unstable patient
  - DPL if equivocal FAST scan or if FAST scan is not available
- CT scan in stable patients

## Subsequent Management

- Splenic injury
  - Observation if stable and not bleeding
  - Splenic embolization for hemodynamically *stable* patients with blush on CT
- Surgical exploration and splenectomy or splenorrhaphy for hemodynamically *unstable* patients with splenic injury
  - Vaccinate for encapsulated bacteria ideally 2 weeks following splenectomy or prior to discharge from hospital
- Liver injury
  - Most are managed conservatively
  - Hemodynamically stable with ongoing bleeding require embolization
  - Hemodynamically unstable with ongoing bleeding require surgical exploration
- Pelvic fracture
  - Pelvic angiography and embolization if ongoing bleeding and appropriate personnel and resource immediately available

## Watch Out

- Free fluid in abdomen without solid organ injury may represent bleeding from a more occult source (such as a mesenteric artery), enteric contents (from a small bowel injury), or urine (from a bladder rupture)
  - The early use of vasopressors is not recommended and may even be harmful in patients that have not been adequately resuscitated

---

## Suggested Reading

- David Richardson J, Franklin GA, Lukan JK, et al. Evolution in the management of hepatic trauma: a 25-year perspective. *Ann Surg.* 2000;232:324.
- Schurink GW, Bode PJ, van Luijt PA, van Vugt AB. The value of physical examination in the diagnosis of patients with blunt abdominal trauma: a retrospective study. *Injury.* 1997;28:261.
- Wilson RH, Moorehead RJ. Management of splenic trauma. *Injury.* 1992;23:5.

Dennis Y. Kim and Areg Grigorian

A 24-year-old male is brought to the emergency room following a gunshot wound (GSW) to the left lower abdomen. On initial examination, his blood pressure is 80/65 mmHg, heart rate is 140/min, and respiratory rate is 26/min. He appears pale and is diaphoretic. He is unable to remain still secondary to pain. The patient's airway is patent and there are equal breath sounds bilaterally. He has a rigid abdomen with diffuse tenderness, guarding, and rebound. There is a single entry wound to the left lower quadrant. No other GSWs are noted on exam. Palpation of the patient's lower extremity pulses reveals a diminished left femoral pulse and a normal right femoral pulse. His left leg is cool to touch. The patient is urgently taken to the operating room.

---

### Diagnosis

#### What Is the Most Likely Diagnosis?

This patient suffered a penetrating injury to the abdomen. He is most likely in hemorrhagic shock secondary to bleeding in the peritoneal cavity. This is supported by his hemodynamic instability. Peritonitis on physical exam (e.g., rigid abdomen, diffuse tenderness, rebound) supports the presence of a concomitant bowel injury. In addition, a diminished left femoral pulse and a cold leg are suggestive of a left iliac arterial injury.

---

### History and Physical Exam

#### What Is the MIVT Prehospital Report?

*Mechanism, Injuries, Vitals, and Treatment*

#### What Are the Two Most Common Types of Penetrating Trauma?

Penetrating trauma refers to injuries caused by a foreign object that enters or penetrates tissues. Stab wounds and GSWs are the two most common forms of penetrating injuries. Stab wounds are low velocity and low kinetic energy injuries in which tissue

---

D.Y. Kim, MD (✉)

Department of Surgery, Harbor-UCLA Medical Center, 1000 W. Carson Street, Box 42, Torrance, CA 90509, USA  
e-mail: [dekim@dhs.lacounty.gov](mailto:dekim@dhs.lacounty.gov)

A. Grigorian, MD

Department of Surgery, University of California, Irvine, 333 City Blvd West, Suite 1600, Route. 81, Orange, CA 92868, USA  
e-mail: [agrigori@uci.edu](mailto:agrigori@uci.edu)

damage is isolated to the pathway of potential penetration, resulting in only localized injuries. Smaller hand guns deliver a lower velocity injury, while high-power shotguns can cause high-velocity injuries. The latter is more likely to result in tissue damage in areas remote from the bullet track.

#### Watch Out

Careful examination of the entire patient is critical to avoid missing penetrating injuries. The perineum and axilla should be examined for evidence of occult injury.

### What Three Physical Exam Findings Independently Mandate Immediate Operative Intervention in Patients with Penetrating Abdominal Trauma?

The three physical exam findings are hypotension, peritonitis, and evisceration. Prior to surgery, consideration should be given to perform an abdominal x-ray, if it can be performed without delay. Such plain films can provide useful information about the trajectory or path of bullets and potential injuries. The patient presented has two of these findings (hypotension and peritonitis), either of which merits emergent surgery.

### What Is a Tangential GSW? Do Patients with Findings of a Tangential GSW Require Any Further Workup?

Not all GSWs to the abdomen automatically mandate surgery. Tangential GSWs are injuries that have identifiable entry and exit wounds without clinical evidence of injury to deeper structures. Prior to simply dismissing such injuries as benign, however, it is important to recognize that tangential GSWs may be associated with significant blast effect or fragmentation. This may result in occult injury to underlying tissues, vessels, and organs. Patient with tangential GSWs should undergo further workup in the form of radiographic imaging and/or serial physical examinations.

## Anatomy

### What are the borders of the anterior abdomen, flank and back?

Location	Borders
<i>Anterior abdomen</i>	Xiphoid and costal margins superiorly, the anterior axillary lines laterally, and the inguinal ligaments and pubic symphysis inferiorly
<i>Flank</i>	Between anterior and posterior axillary lines from the level of the sixth intercostal space to the iliac crest
<i>Back</i>	Tips of the scapular superiorly, posterior axillary lines laterally, and the iliac crests inferiorly

### What Is the Significance of Injuries to the Thoracoabdominal Region?

Injuries to the thoracoabdominal regions can damage thoracic or abdominal structures including the diaphragm.

### What Three Distinct Regions Comprise the Internal Abdomen?

The three distinct regions are peritoneal cavity, pelvis, and retroperitoneum.

### Why Is It Difficult to Diagnose Injuries to Retroperitoneal Organs in Trauma Patients?

Injuries to retroperitoneal organs (Table 42.1) may not manifest with symptoms and signs of peritonitis due to their protected location. In addition, the Focused Abdominal Sonography for Trauma (FAST) exam is notorious for missing retroperitoneal bleeding.

**Table 42.1** Retroperitoneal organs

Duodenum (2nd–4th parts)
Pancreas
Kidneys
Ureters
Bladder
Ascending colon (posterior wall)
Descending colon (posterior wall)
Rectum (distal)

**Table 42.2** Retroperitoneal zones

	<b>Zone 1</b>	<b>Zone 2</b>	<b>Zone 3</b>
Location	Upper midline/central	Upper lateral	Lower midline/pelvic
Vascular structures	IVC, SMV, aorta, and its branches (celiac, SMA, proximal renal artery)	Renal artery and vein	Common/internal/external iliac arteries and veins
Mechanism			
Blunt	Explore	Selective	Do not explore
Penetrating	Explore	Explore	Explore

### What Is the Zone Classification for Retroperitoneal Hematomas?

Retroperitoneal hematomas are classified into zones, as it reminds the surgeon of what structures might be potentially injured and helps guide management. The ultimate decision as to whether to explore a retroperitoneal hematoma is based upon the hemodynamic status of the patient, the mechanism of injury, and the zone location (Table 42.2).

### What Are the Two Most Common Organs Injured Following a Penetrating Abdominal Injury?

The two most common organs injured are the small bowel followed by the liver.

### What Specific Injuries Must Be Ruled Out with GSW that Travels Across Pelvis?

A transpelvic GSW is at an increased risk of injuring the ureters, bladder, iliac vessels, rectum, and vagina. Patients with these injuries should undergo a proctoscopy to rule out injury to the rectum, in addition to a CT scan of the abdomen and pelvis. Females should undergo vaginal examination.

## Work-Up

### What Initial Workup Is Recommended for the Above Patient?

No workup is needed in this patient as he has clear indications for surgical intervention (both peritonitis and hemodynamic instability following penetrating trauma). He should be taken directly to the operating room.

### In the Absence of Hypotension, Peritonitis, or Evisceration, What Imaging Is Recommended for a Patient with Penetrating Abdominal Trauma?

CT of the abdomen and pelvis with intravenous contrast. If concern exists for multi-cavitary torso trauma, a CT chest should also be obtained.

## **Are Diagnostic Peritoneal Lavage (DPL) and FAST Helpful Studies in Patients with Penetrating Abdominal Trauma?**

The FAST exam is more useful for patients following blunt trauma. Its primary utility for penetrating abdominal trauma is to rule out cardiac tamponade (for thoracoabdominal injuries). Aside from this, the utility of FAST for penetrating abdominal trauma is limited. Similarly, DPL is more useful for blunt abdominal trauma, specifically if FAST is unavailable or equivocal.

### **Watch Out**

The FAST exam is not helpful in identifying injury to retroperitoneal structures.

## **Is There a Role for Local Wound Exploration for Penetrating Abdominal Injury?**

Particularly with anterior stab wounds (not flank), some recommend this approach, but only if performed by an experienced surgeon in a patient who does not have an indication for immediate surgery. The goal of local wound exploration is simply to determine if the injury has penetrated into the anterior fascia. If it has not, surgery can be avoided. Violation of the fascia is an indication for either an exploratory laparotomy or diagnostic laparoscopy to further look for peritoneal violation.

---

## **Initial Management**

### **What Are the First Steps in the Management of This Patient?**

Initial management of the trauma patient always begins with the primary survey to identify and treat immediately life-threatening conditions. The primary survey involves assessing the ABCDEs (airway with C-spine precautions, breathing, circulation, disability, and exposure). With penetrating injuries, attention should be directed to identifying the presence and location of all entry and exit wounds. It may be helpful to place radiopaque markers over these sites to help reconstruct the path or trajectory of bullets.

### **What Is a Massive Transfusion Protocol (MTP)? When Should It Be Initiated?**

An MTP is an institutionally derived protocol which is activated in patients with life-threatening hemorrhage or exsanguination. The primary purpose of an MTP is to provide blood component therapy (PRBCs, plasma, and platelets) early on in resuscitation, in a systematic, rapid, and efficient manner. By administering blood components early, the goal of MTP is to prevent the development of dilutional coagulopathy and hypovolemia. In the setting of massive hemorrhage, MTP has replaced the traditional resuscitation approach, which began with large volumes of crystalloid (lactated ringers or normal saline) followed by packed RBCs. Other blood products (e.g., platelets, plasma) were then supplemented later, based on laboratory values with the goal of treating any developing coagulopathies.

### **What Is Permissive Hypotension?**

In the past, in the setting of penetrating torso trauma and hypotension, efforts were focused on aggressive and early fluid resuscitation so as to restore a normal blood pressure. One of the emerging management principles for penetrating torso trauma patients is to avoid “popping the clot.” Several studies have challenged the practice of overly aggressive fluid replacement, arguing that it will lead to more bleeding by raising the blood pressure and creating a dilutional coagulopathy and that it does not address the source of bleeding. Some clinicians now elect to limit fluid resuscitation and permit mild hypotension (in the setting of penetrating trauma) at least until hemorrhage is controlled.

**Watch Out**

Permissive hypotension is only applicable to patients with penetrating torso trauma. This strategy should NOT be employed in patients with blunt trauma, especially in the presence of a head injury.

**Should Prophylactic Antibiotics and Analgesics Be Routinely Administered to All Patients with Penetrating Trauma?**

No. Routine antibiotics and analgesics can mask important signs and symptoms in trauma patients. The exception to this rule is if the patient has clear indications for surgical intervention on initial exam (e.g., peritonitis, hemodynamic instability). These patients should receive preoperative antibiotics to cover bowel flora.

**Should Tetanus Prophylaxis Be Routinely Administered to Patients with Penetrating Trauma?**

No. Only patients with <3 doses of tetanus toxoid or if immunization status is unknown along with a tetanus-prone wound (e.g., obvious soil contamination, > 6 h old) should receive tetanus prophylaxis.

**How Do You Manage a Patient Who Presents with Impalement?**

Patients who present with an impaled object (e.g., knife, arrow, rebar, etc.) should be assessed in the same manner as other patients with penetrating trauma. No attempt should be made to remove the impaling object until the anatomy of the injury has been identified on imaging studies. These objects are best removed in the operating room under controlled conditions.

---

**Subsequent Management****Why Are Trauma Patients Prepped and Draped from Chin to Knees in the Operating Room?**

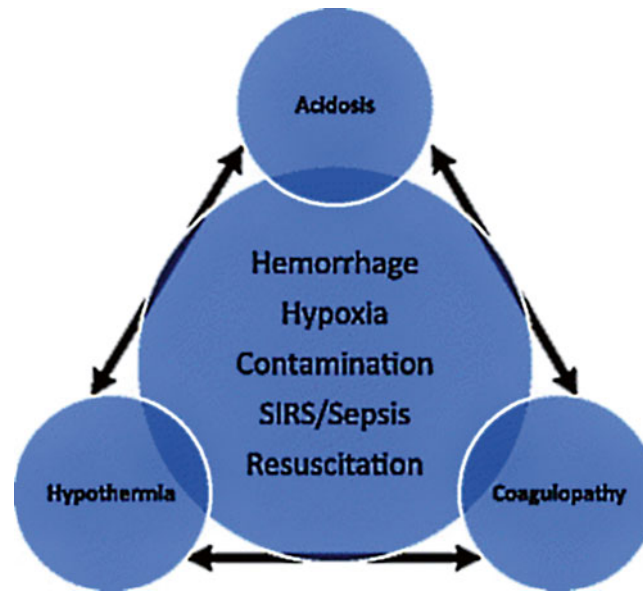
Trauma patients taken to the OR should be prepped widely to allow for management of all contingencies. Immediate access to the left chest is crucial should a trauma patient lose vital signs and require a resuscitative thoracotomy to maintain cardio-cerebral perfusion. Access to the groins allows for the harvesting of saphenous vein should a vascular conduit be required at the time of initial operation.

**What Is the Traditional Mainstay of Surgical Management for Patients with Penetrating Abdominal Trauma?**

Exploratory laparotomy is the traditional mainstay of surgical management for patients with penetrating abdominal trauma.

**Is There a Role for Laparoscopy Following Penetrating Abdominal Trauma?**

Yes, in select patients who do not have an indication for immediate laparotomy (hypotension, peritonitis, evisceration), laparoscopy can be utilized to determine if the penetrating injury has penetrated the peritoneum. If there is no peritoneal penetration, laparotomy is not necessary. If laparoscopy shows that the peritoneum is violated, a laparotomy is performed as laparoscopy is not sufficiently accurate to rule out all injuries (such as subtle bowel injuries). The value of laparoscopy is that it reduces the risk of a negative or nontherapeutic laparotomy, which is associated with up to 5 % mortality and 20 % morbidity rates.



**Fig. 42.1** Lethal triad of death in the trauma patient (with kind permission from Springer Science+Business Media: Front Line Surgery: A Practical Approach, Initial Management Priorities: Beyond ABCDE, 2011, p. 44, Beekley A., Fig. 3.3)

**Table 42.3** Criteria for non-op management of penetrating abdominal trauma

Hemodynamically stable patient
No peritonitis
Evaluable (normal mental status)
CT scan demonstrating no intra-abdominal injury

### What Is the “Lethal Triad of Death” in Trauma?

The lethal triad of death (Fig. 42.1) refers to the three key interrelated factors, which if left uncorrected could lead to death in the trauma patient.

### What Is Damage Control Surgery?

Patients with massive hemorrhage and multiple injuries are at high risk of death once hypothermia, coagulopathy, and acidosis develop intraoperatively. At that point, the surgeon must make the decision to stop surgery (even if every injury is not repaired), transport the patient to the ICU, and correct the lethal triad, with a plan to re-explore the patient after correction (in 24–48 hours). This approach is called damage control surgery. It involves limiting surgery to controlling life-threatening hemorrhage and temporarily controlling gastrointestinal contamination, followed by temporary closure of the abdomen and transfer to the intensive care unit for ongoing resuscitation. Once patients are adequately resuscitated, they are brought back to the operating room to undergo definitive repair of the injuries.

### When Is It Appropriate to Consider Nonoperative Management of Patients with Penetrating Abdominal Trauma?

Nonoperative management of penetrating abdominal wounds may be appropriate in a certain subset of patients. In order to be considered for nonoperative management, four essential criteria must be met (Table 42.3). Selective non-op management



is employed to reduce the incidence of nontherapeutic laparotomies and the complications associated with these operations. In general, most patients with penetrating abdominal trauma are managed with an exploratory laparotomy.

### **How Long Should Prophylactic Antibiotics Be Continued for Following a Trauma Laparotomy?**

Prophylactic antibiotics should be continued for 24 h. Even in the presence of a colon injury, a longer duration of antibiotics is not associated with a decreased incidence of infections and may predispose to the development of resistant organisms.

### **Do Patients with Small Bowel or Colon Injuries Require a Stoma?**

Rarely do patients with small bowel or colon injuries require a stoma. The majority of both small and large bowel injuries can be repaired primarily.

### **What Is the Best Management for a Patient with an External Iliac Artery Injury in the Presence of a Contaminated Abdomen due to a Colon Injury?**

As with all vascular injuries, the first steps involve obtaining arterial control proximally and distally to the injury. In the face of contamination with stool, autologous vein graft (such as reverse saphenous vein) is the bypass conduit of choice. Prosthetic grafts should be avoided in this situation. If damage control surgery is needed, a temporary shunt can be placed to bridge the arterial injury with planned repair within 24 h. Alternatively, the external iliac artery can be ligated and circulation restored to the lower extremity with a femoral artery to femoral artery bypass.

#### **Watch Out**

Patients with injuries to the colon and/or common iliac artery are at an increased risk for injury to the ureter.

---

## **Complications**

### **What Is Abdominal Compartment Syndrome? Who Is at Risk?**

Patients with multiple traumatic injuries, particularly intra-abdominal or retroperitoneal, who have received large volume of fluids and blood products are at risk of developing intra-abdominal hypertension (IAH) and abdominal compartment syndrome (ACS). ACS should be suspected in any severely injured patient who demonstrates decreased urine output, increasing peak pressures on the ventilator, and increasing vasopressor support, in the absence of another identifiable cause. Bladder pressure should be measured as it reflects intra-abdominal pressure. Treatment is to take the patient to the OR and perform a decompressive laparotomy by reopening the abdominal fascia and leaving the wound open.

---

## **Special Situations/Circumstances**

### **Thoracoabdominal Penetrating Wounds**

Penetrating injuries to this area can present a challenge as there may be concomitant injuries to the thoracic cavity, mediastinum, heart, diaphragm, retroperitoneum, and abdominal cavities. The decision regarding which cavity to enter first (chest or abdomen) is not always apparent.

## Summary of Essentials

### History and Physical Exam

- GSWs and stab wounds most common mechanisms
- Every effort should be made to identify all entry and exit wounds
- Hypotension, peritonitis, and evisceration mandate operation
- Tangential GSWs may cause blast injury

### Anatomy

- The peritoneal cavity, pelvis, and retroperitoneum comprise internal abdomen
- Injuries to retroperitoneal structures difficult to diagnose
- Retroperitoneal hematomas
  - Zone 1
  - Zone 2
  - Zone 3
- Liver and small bowel most commonly injured organs following penetrating abdominal trauma

### Workup

- Immediate operative exploration if either:
  - Hypotensive
  - Peritonitis
  - Evisceration
- FAST more helpful in blunt trauma
  - Still useful to rule out cardiac tamponade
- Local wound exploration only if:
  - Hemodynamically stable with anterior abdominal stab wound
- Liberal use of pan-CT scan (head to toe) if immediate operative exploration not indicated

### Initial Management

- Start with ABCs
- Initiate massive transfusion protocol in all unstable patients with suspected major blood loss, if available
- Consider permissive hypotension in patients with penetrating torso trauma

### Subsequent Management

- Damage control surgery
- Minimize operating time
  - Control hemorrhage
  - Temporary control of gastrointestinal injuries
  - Nonoperative management of penetrating abdominal trauma is the exception rather than the rule
- Most bowel injuries repaired primarily

---

## Complications

- IAH and ACS are commonly seen

---

## Suggested Reading

Nicholas JM, Rix EP, Easley KA, et al. Changing patterns in the management of penetrating abdominal trauma: the more things change, the more they stay the same. *J Trauma*. 2003;55:1095.

Velmahos GC, Demetriades D, Toutouzas KG, et al. Selective nonoperative management in 1,856 patients with abdominal gunshot wounds: should routine laparotomy still be the standard of care? *Ann Surg*. 2001;234:395.

Zafar SN, Rushing A, Haut ER, et al. Outcome of selective non-operative management of penetrating abdominal injuries from the North American National Trauma Database. *Br J Surg*. 2012;99 Suppl 1:155.

Zane W. Ashman, Areg Grigorian, Christian de Virgilio,  
and Dennis Y. Kim

A 30-year-old male is struck by a car while crossing the street. He is brought in by paramedics hemodynamically stable with a blood pressure of 130/70 mmHg, heart rate of 80/min, and a right knee deformity. His airway is intact and breath sounds are equal bilaterally. Abdominal and pelvic exams are unremarkable. There is swelling and an obvious deformity of his right knee. His right foot is pale and cool, with a 6 s capillary refill, whereas the left foot is pink and warm with <2 s capillary refill. Pulse examination reveals normal 2+ pulses in his left femoral, popliteal, dorsalis pedis, and posterior tibial arteries. On the right, there is a 2+ femoral pulse. The popliteal pulse cannot be examined due to pain. The right dorsalis pedis and posterior tibial artery pulses are non-palpable. Sensory and motor function is intact bilaterally. Because of severe knee pain, the right knee cannot be examined. There is no tenderness or deformity in the right thigh or in the tibia or ankle. The right lower extremity ankle-brachial index (ABI) is 0.65, whereas the left is 1.0.

---

### Diagnosis

#### What Is the Most Likely Diagnosis?

Given the mechanism of injury, deformity of the right knee, pale and cool right foot, and absence of distal pulses, this patient most likely has a right popliteal artery injury secondary to a posterior knee dislocation.

---

Z.W. Ashman, MD (✉)

Department of Surgery, Los Angeles County Harbor-UCLA Medical Center, 1000 W. Carson Street, Box 25, Torrance, CA 90509, USA  
e-mail: [zane.ashman@gmail.com](mailto:zane.ashman@gmail.com)

A. Grigorian, MD

Department of Surgery, University of California, Irvine, 333 City Blvd West, Suite 1600, Route. 81, Orange, CA 92868, USA  
e-mail: [agrigori@uci.edu](mailto:agrigori@uci.edu)

C. de Virgilio, MD

Department of Surgery, Harbor-UCLA Medical Center, 1000 W. Carson Street, Torrance, CA 90509, USA  
e-mail: [cdevirgilio@labiomed.org](mailto:cdevirgilio@labiomed.org)

D.Y. Kim, MD

Department of Surgery, Harbor-UCLA Medical Center, 1000 W. Carson Street, Box 42, Torrance, CA 90509, USA  
e-mail: [dekim@dhs.lacounty.gov](mailto:dekim@dhs.lacounty.gov)

## History and Physical Exam

### What Are “Hard” and “Soft” Signs of Vascular Injury?

Hard signs are specific, overt physical exam findings produced by clinically relevant vascular injury requiring immediate operative intervention. Imaging for vascular injuries in the presence of a hard sign is unnecessary as it may delay definitive treatment. Soft signs increase the index of suspicion for a vascular injury and their presence on exam should prompt further investigation (Table 43.1).

### What Are the 6 Ps of Limb Ischemia?

These physical exam findings include *pain*, *pallor*, *paresthesias*, *paralysis*, *pulselessness*, and *poikilothermia*. Of the 6 *Ps*, only pulselessness is considered a hard sign of vascular injury. These findings may be found in patients with both acute and chronic limb ischemia from a variety of causes.

### What Is the Implication of an Audible Bruit/Palpable Thrill Near an Artery in Association with Trauma?

It is highly suggestive of a traumatic arteriovenous fistula.

### What Are the Principles of the Physical Examination of an Injured Extremity?

Examination of injured extremity must assess vascular, neurologic, musculoskeletal, and soft tissue integrity of the entire limb, including the joints above and below the site of injury (Table 43.2). Comparison of potentially abnormal findings to the contralateral extremity is recommended.

**Table 43.1** Signs of vascular injury

Hard signs	Soft signs
Arterial/pulsatile bleeding	History of hemorrhage in the field
Persistent hemorrhage with shock	Small, stable, non-pulsatile hematoma
Expanding or pulsatile hematoma	Unexplained hypotension
Palpable thrill	Penetrating wounds in proximity to major vessels
Audible bruit	Associated nerve deficit
Absent pulse	Diminished or unequal pulses

**Table 43.2** Physical examination of the injured extremity

<b>Vascular</b>
Peripheral pulses above and below the site of injury
Perfusion of skin (warmth, color, and capillary refill)
Hard and soft signs of vascular injury
<b>Neurologic</b>
Sensation, strength, reflexes
<b>Musculoskeletal</b>
Fracture or gross deformity
Joint exam (passive and active range of motion, joint instability, effusion)
<b>Soft tissue</b>
Intact
Degree of contamination

## Pathophysiology

### What Is the Mechanism of Popliteal Artery Injury?

The popliteal artery is susceptible to traction and transection injuries due to its fixed course across the knee joint. The artery is tethered at both its superior border, as the superficial femoral artery exits the adductor hiatus, and its inferior border at the tendinous arch of the soleus. Along its course, the popliteal artery forms an anastomotic network around the knee by giving off paired geniculate branches. Posterior dislocation of the knee compresses the popliteal artery against the posterior aspect of the tibial plateau resulting in arterial injury. The most common presentation of popliteal artery injury is thrombosis with acute distal limb ischemia.

### What Are the Classic Orthopedic Fractures/ Dislocations That Are Associated with Arterial Injury ?

The Classic Orthopedic Fractures/Dislocations That Are Associated with Arterial Injuries are Detailed in Table 43.3.

### Why Is It Important to Promptly Reduce a Dislocation?

Dislocations that are left unreduced for a prolonged period of time are associated with poorer long-term outcomes including limited functional recovery. In the short term, these injuries are associated with significant pain and discomfort which are improved with reduction. Prompt reduction will allow for near-normal range of motion and use. Furthermore, dislocations associated with arterial injuries increase the risk of osteonecrosis of the involved bone.

#### Watch Out

Always reexamine a patient's vascular and neurological status after performing reduction.

### What Is a Minimal Vascular Injury?

Minimal vascular or arterial injuries refer to clinically silent injuries that are discovered on radiographic studies such as angiography or ultrasonography. These injuries usually have a benign or self-limited course. They involve small intimal flaps or irregularities.

**Table 43.3** Common skeletal and associated arterial injuries

Injury	Artery involved	Features
<i>Shoulder girdle dislocation</i>	Axillary artery	<i>Posterior</i> dislocations result from seizures and have an increased risk of axillary nerve injury. <i>Anterior</i> dislocations are more common and present with axillary artery injuries
<i>Clavicle fracture</i>	Subclavian artery	Patients may have associated pneumothorax and/or hemothorax
<i>Supracondylar fracture</i>	Brachial artery	Occurs more commonly in children; may result in Volkmann's contracture if left untreated
<i>Pelvic fracture</i>	Branches of internal iliac artery (superior gluteal and internal pudendal)	Arterial bleeding in the presence of severe <i>posterior</i> fractures is more likely to be due to an injury to the superior gluteal artery. Severe <i>anterior</i> fractures may result in injury to the internal pudendal artery; both can result in hemorrhagic shock (major source of blood loss)
<i>Hip dislocation</i>	Femoral artery	<i>Posterior</i> dislocations present with an internally rotated and adducted leg with an increased risk of sciatic nerve injury. <i>Anterior</i> dislocations present with externally rotated and abducted legs with an increased risk of femoral artery injury; risk of avascular necrosis if combined with femoral head fracture
<i>Knee dislocation</i>	Popliteal artery	Arterial injuries occur more frequently in patients with <i>posterior</i> dislocation and less with anterior
<i>Tibial plateau fracture</i>	Popliteal artery	Arterial injuries occur more frequently in patients with <i>medial</i> injuries and less with lateral

## Workup

### In the Presence of Hard Signs of Vascular Injury, What Additional Imaging Studies Are Needed?

No further imaging studies are needed in patients with hard signs of vascular injury. These patients should be taken directly to the operating room for hemorrhage control and identification of the underlying injury.

### In the Absence of Hard Signs of Vascular Injury, What Noninvasive Bedside Test Provides Objective Evidence of a Vascular Injury?

The ankle-brachial index (ABI) is the noninvasive bedside test that provides objective evidence of a vascular injury. The ABI compares the systolic blood pressure (SBP) of the lower extremities with the upper extremities via Doppler interrogation of the dorsalis pedis, posterior tibial, and brachial arteries. The test uses a standard blood pressure cuff placed just proximal to the artery in question. The index is the ratio of ankle SBP to brachial artery SBP. A normal ABI is between 1.0 and 1.2. An ABI of  $<0.90$  is highly sensitive and specific for arterial injury following both blunt and penetrating injuries.

### If This Noninvasive Imaging Is Abnormal, What Additional Vascular Imaging Study Is Recommended?

If the ABI is  $<0.9$ , additional vascular imaging is recommended. Options include formal contrast arteriography, computed tomography angiography (CTA), and duplex ultrasonography (Table 43.4). *CTA is currently the test of choice* due to its availability, rapidity, and noninvasive nature. Formal contrast arteriography requires calling in an interventional radiology team which further delays management and is invasive (requires direct femoral artery puncture).

### What Additional Radiologic Imaging Study Is Recommended for a Posterior Knee Dislocation?

After addressing immediately life-threatening injuries, plain film radiography of the dislocated knee is essential. It is important to recognize that one must not delay reduction of the joint. Postreduction films should be obtained to assess for the adequacy of reduction and to rule out a periarticular fracture. Following reduction, repeat clinical assessment of the neurovascular status of the extremity is mandatory.

### In Penetrating Trauma, Should an Angiogram Be Performed If the Bullet/Stab Wound Is Close to an Artery, Even If There Are No Signs of Injury?

No. So-called proximity injuries should raise the level of suspicion for vascular injury, but no further workup is warranted in the patient with a normal ABI in the absence of hard signs of vascular injury.

**Table 43.4** Modes of vascular imaging

Study	Advantages	Disadvantages
CTA	Rapid, readily available, noninvasive	Limited visibility of small/distal arteries; requires injection of intravenous contrast medium
Duplex ultrasonography	Accurate, noninvasive	Operator dependent, not readily available
Contrast arteriography	Highly sensitive, specific	Invasive, expensive, time intensive; requires injection of intra-arterial contrast medium

**Table 43.5** Mangled Extremity Severity Score components

Patient age
Severity of shock
Mechanism of injury
Skeletal/soft tissue Injury
Ischemia severity

## What Is the Mangled Extremity Severity Score and How Is It Used?

In certain situations, particularly those involving extensive soft tissue or musculoskeletal injury of an extremity, with or without associated neurovascular trauma, the limb is so severely injured that the likelihood of salvaging the limb is in doubt. The Mangled Extremity Severity Score (MESS) is one of the most commonly used scoring systems to quantify injury severity in patients with severe trauma of the extremities. It is designed to help surgeons decide whether to attempt limb salvage or proceed directly to amputation (Table 43.5).

Limb ischemia greater than 6 h, older patients, the presence of severe shock, high-energy wounds, and the presence of arterial and nerve injury are associated with a higher risk of limb loss. Even if a limb is salvageable, the potential for functional limb recovery needs to be considered. For example, if the tibial nerve is transected, there will be significant motor loss, and sensation to the plantar surface of the foot is lost. Even if the leg is salvaged, the motor deficit and lack of sensation will lead to an inability to effectively ambulate.

## Management

### What Are the First Steps in the Management of This Patient?

Initial management (Fig. 43.1) of the trauma patient begins with the primary survey to identify and treat immediately life-threatening conditions. The primary survey involves assessing the *ABCDEs* (*airway* with *C-spine* precautions, *breathing*, *circulation*, *disability*, and *exposure*). Among patients with extremity vascular trauma, aggressive efforts should be directed towards identifying and controlling bleeding. The secondary survey is performed only after completing the primary survey and consists of a detailed head-to-toe examination to identify all wounds and injuries not detected during the primary survey.

### Is There a Role for Tourniquets in Patients with Life-Threatening Hemorrhage of an Extremity?

Recent literature and guidelines support the use of tourniquets for exsanguinating extremity trauma. These may be placed in the prehospital/field setting and emergency or operating rooms. Improper placement of tourniquets may result in paradoxical bleeding if the pressure applied to the affected limb does not arrest arterial inflow while occluding venous outflow. Early application of tourniquets prior to the onset of shock is associated with improved outcomes. Minimizing tourniquet application time should be considered a priority in patients with major extremity vascular injuries.

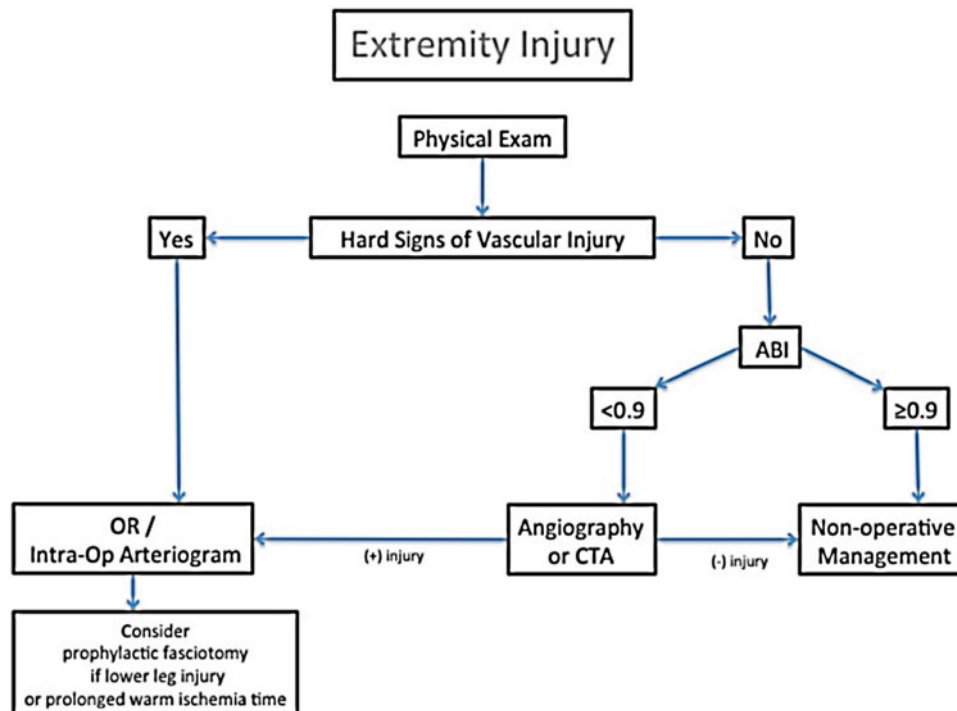
### What Is the Next Step in the Management of a Knee Dislocation?

Immediate reduction of the right knee dislocation is indicated in an ischemic limb. A thorough physical exam of the right lower extremity following reduction of the dislocated joint should focus on distal restoration of circulation and the presence or absence of neurologic impairment, ligamentous injury, and open fractures.

### What Is the Next Step Following Reduction?

Recheck the neurovascular status. If there is still no pulse, start intravenous heparin (provided that there are contraindications such as ongoing hemorrhage) and check the ABI. If ABI is  $<0.9$ , obtain a CTA. If CTA confirms arterial injury, take the patient to the operating room.





**Fig. 43.1** Algorithm for extremity injury management

### What Are the Principles of Operative Management of a Popliteal Artery Injury in This Setting?

The focus of operative management is restoration of circulation. Definitive management within 6 h of injury offers the best chance of limb salvage with minimal neurologic deficits in the ischemic limb.

Key steps to repair a popliteal artery injury:

1. Vascular control of artery proximal and distal to area of injury.
2. Administer heparin if not already given.
3. Resect damaged segment of artery (do not leave behind injured artery as it will be prone to thrombosis).
4. Pass Fogarty embolectomy balloon proximally and distally into artery to remove any clot.
5. Primary end-to-end anastomosis of normal artery if segment removed is <2 cm and if repair without tension.
6. If missing segment longer, place interposition graft.

### If a Conduit Is Needed to Replace the Injured Artery, Where Is It Taken from?

Autogenous vein grafts offer better long-term patency compared to prosthetic grafts and a lower risk of infectious complications following repair in contaminated wounds. The greater saphenous vein is harvested from the uninjured leg (and must be reversed due to valves). This approach is preferred to preserve collateral venous circulation of the injured leg in the context of a possible popliteal venous injury.

### What If the Popliteal Vein Is Also Injured?

Every attempt should be made to repair popliteal venous injuries. When compared to vein ligation, venous repair is associated with a decreased risk of postoperative venous hypertension and insufficiency, risk of amputation, and improved patency of the arterial repair due to greater outflow. Approaches for repair include primary repair via lateral venorrhaphy, end-to-end anastomosis, venous patch angioplasty, and interposition graft with autogenous vein or prosthetic graft. In the extreme case that the popliteal vein is irreparable, care should be taken to ensure ipsilateral saphenous venous outflow.

---

## What If There Is a Combined Orthopedic and Vascular Injury, Which Is Repaired First?

This depends on the severity of ischemia to the limb. Prolonged initial repair of an orthopedic injury may lead to irreversible muscle ischemia. Alternatively, secondary repair of the orthopedic injury, with required manipulation and stretching of the limb, risks disruption of the arterial repair. Insertion of an intravascular shunt prior to orthopedic stabilization allows for expeditious temporary restoration of blood flow. Following orthopedic fixation, definitive vascular repair may then be undertaken.

## Why Does Heparin Help?

Systemic heparin administration in the ischemic limb following trauma reduces rates of amputation by preventing microvascular thrombosis in the setting of a low-flow arterial circulation. Contraindications to heparinization include active hemorrhage, intracranial injury, and coagulopathy.

## What Are the Main Postoperative Complications Specific to This Procedure?

Thrombosis and compartment syndrome occur early in the postoperative period and threaten the viability of the affected limb. Early recognition of arterial occlusion with serial Doppler/physical exam is important because prompt thrombectomy can limit recurrent ischemia and reperfusion injury. Prophylactic fasciotomies of the lower extremity should be considered to decrease the risk for extremity compartment syndrome.

---

## Key Areas Where You Can Get in Trouble

### Assuming There Is No Arterial Injury Because the Patient Has Palpable Pulses

The pulse exam is very unreliable in adequately assessing vascular injury. It is not uncommon for the examiner to feel their own pulse. Additionally, retrograde flow from arterial collateral circulation may produce a palpable pulse despite substantial injury. Thus, always measure the ABI in conjunction with the pulse exam to confirm normal blood flow.

---

## Areas of Controversy

### The Role of Endovascular Repair

The use of endovascular techniques to repair extremity vascular trauma has increased over the last decade. Good candidates for endovascular repair are those that are hemodynamically stable with a wound location that is difficult to access surgically (proximal limb injuries with extension into the chest or abdomen, so-called junctional injuries). Patients at risk for compartment syndrome or those requiring embolectomy are not good candidates for endovascular repair.

---

## Summary of Essentials

### History and Physical Exam

- Always start with ABCs
- Suspect popliteal artery injury with posterior knee dislocation
- Look for hard signs of vascular injury
- Assess the neurologic and vascular function with any extremity injury

## Diagnosis

- No testing needed if hard sign present
  - Direct to OR
- ABI testing is sensitive and specific for extremity vascular injury
- CTA if soft signs of injury or abnormal ABI
- Vascular imaging not needed if normal pulse and normal ABI (>0.9)

## Management

- Immediately reduce dislocated joint
- Reassess neurovascular function after reduction
- Hard signs of vascular injury are indications for surgery
- Start heparin if pulseless extremity and no contraindications
- Repair injured artery with reverse saphenous vein from contralateral leg

## Prognosis

- Mangled Extremity Severity Score
  - Risk of limb loss depends on duration of limb ischemia, patient age, hemodynamic status, severity of neurovascular injury, and severity of soft tissue injury

## Special Situations

- Combined orthopedic and vascular injuries
  - Insert temporary shunt proximal and distal to injured artery, perform orthopedic repair, and then repair artery
  - If limb is not ischemic, perform orthopedic repair first and then arterial repair

---

## Suggested Reading

- Johnson CA. Endovascular management of peripheral vascular trauma. *Semin Intervent Radiol.* 2010;27(1):38–43.
- Vogel TR, O'Donnell PL, Jurkovich GJ. Trauma and thermal injuries. Injuries to the peripheral blood vessels. In: Ashley SW, editor. *ACS surgery* [online]. Philadelphia: Decker Intellectual Properties; 2012.

Erik Akopian, Christian de Virgilio, and Dennis Y. Kim

A 30-year-old male presents to the ED with a single gunshot wound (GSW) to the left neck. The patient is hemodynamically stable, with a blood pressure of 120/70 mmHg, heart rate of 100/min, respiratory rate of 16/min, and a Glasgow Coma Scale of 15. There is no stridor or odynophagia. He denies any weakness or numbness in his arms or legs. He is able to speak and states that his voice sounds normal to him. On physical examination, he is awake and alert. There is a single entry wound in the left mid-neck between the cricoid cartilage and the angle of the mandible with no bleeding. There is a moderate but non-expanding hematoma overlying the injury with no exit wound seen. There is no palpable crepitus or audible bruit. Neurological examination is normal.

---

### History and Physical Examination

#### What Are the Most Important Parts of the History and Physical Examination for a Patient with a Neck Injury?

Mechanism of injury (e.g., penetrating vs. blunt), location of injury, and clinical exam findings.

#### What Are Hard Signs of Vascular Injury?

“Hard signs” are physical exam findings that indicate the presence of a significant vascular injury. They include active arterial bleeding, pulsatile or expanding hematoma, or the presence of shock, and a palpable thrill or audible bruit. The presence of one or more of these findings is an indication for immediate surgical exploration.

---

E. Akopian, MD (✉)

Emergency Medicine, Los Angeles County – University of Southern California (LAC+USC), 1200 N. State Street, Room 1005,  
Los Angeles, CA 90033, USA  
e-mail: [akopiane@gmail.com](mailto:akopiane@gmail.com)

C. de Virgilio, MD

Department of Surgery, Harbor-UCLA Medical Center, 1000 W. Carson Street, Torrance, CA 90509, USA  
e-mail: [cdevirgilio@labiomed.org](mailto:cdevirgilio@labiomed.org)

D.Y. Kim, MD

Department of Surgery, Harbor-UCLA Medical Center, 1000 W. Carson Street, Box 42, Torrance, CA 90509, USA  
e-mail: [dekim@dhs.lacounty.gov](mailto:dekim@dhs.lacounty.gov)

## What is the Significance of the Following Signs/Symptoms?

Sign/symptom	Significance
<i>Stridor</i>	Stridor is a sign of upper airway obstruction caused by compression of the trachea from a large hematoma, soft tissue swelling, direct laryngeal injury, or bilateral recurrent laryngeal nerve injury. It warrants immediate attention to the airway, usually in the form of endotracheal intubation
<i>Odynophagia</i>	Pain with swallowing is suggestive of an injury to the oropharynx or esophagus
<i>Horner's syndrome</i>	The sympathetic fibers that innervate the pupil, eyelid, and skin surrounding the eye travel to these locations along the course of the common carotid and internal carotid arteries; thus Horner's syndrome (ptosis, miosis, and anhidrosis) may indicate injury to these vessels in the neck on the basis of anatomical proximity
<i>Thrill/bruit</i>	Damage to the subclavian or carotid artery and adjacent vein can create an arteriovenous fistula; turbulent blood flow causes the vein to vibrate, leading to a palpable rumble or a whooshing sound on auscultation
<i>Crepitus</i>	Crepitus is a sign of subcutaneous emphysema (air trapped under the skin) secondary to injury of the aerodigestive tract (trachea, bronchus, or esophagus) or lungs
<i>Hoarse voice</i>	Dysfunction of the vocal cord either because of direct trauma or damage to the vagus or recurrent laryngeal nerve causing ipsilateral vocal cord paralysis

## What Is the Diagnosis in This Patient?

The patient has a penetrating neck injury in Zone 2 of the neck (see discussion below), without hard signs of injury. Despite the lack of hard signs, injury to critical structures needs to be ruled out if the injury penetrates the platysma.

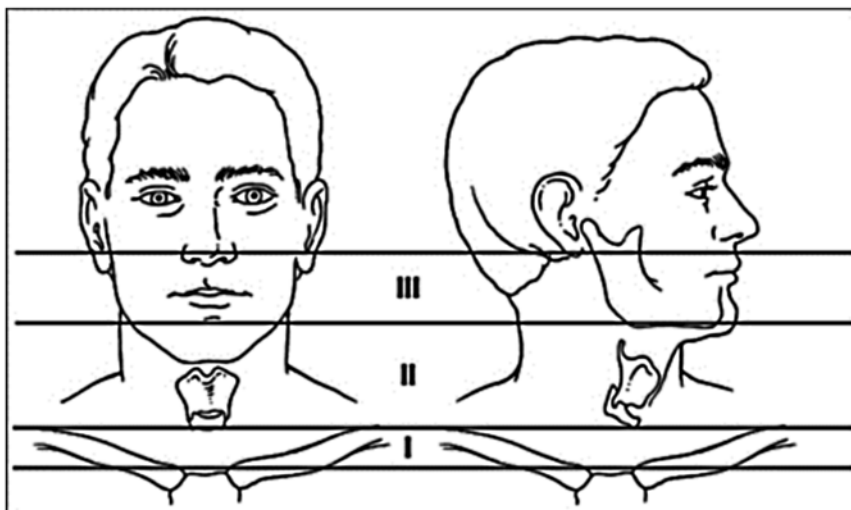
## Anatomy

### What Are the Zones of the Neck and What Are Their Borders?

In the setting of penetrating trauma, the neck is divided into three anatomic zones (Fig. 44.1) in order to summarize structures that are at risk for potential injury.

#### Watch Out

Remember that zones are numbered in the direction of carotid blood flow.



**Fig. 44.1** Zones of the neck (With kind permission from Springer Science+Business Media: Handbook of Cerebrovascular Disease and Neurointerventional Technique, Extracranial Cerebrovascular Occlusive Disease, 2009, p 670, Harrigan MR., Fig. 18.3)

## What Key Anatomic Structures are Contained Within the Three Zones of the Neck?

### Watch Out

The three structures located in the carotid sheath include common carotid artery, internal jugular vein, and vagus nerve.

Zone	Lower border	Upper border	Anatomic structures within zone
1	Clavicles and sternal notch	Cricoid cartilage	Great vessels, common carotid and vertebral arteries, lung apices, thymus, thoracic duct, distal trachea, esophagus, cervical spine, and brachial plexus
2	Cricoid cartilage	Angle of the mandible	Mid-carotid and vertebral arteries, jugular veins, esophagus, vagus nerve, recurrent laryngeal nerve, phrenic nerve, cervical spine, larynx, and trachea
3	Angle of mandible	Base of skull	Proximal internal and external carotid arteries, vertebral arteries, uppermost segments of jugular vein, oropharynx, and cervical spine

## Pathophysiology

### What Is the Significance of Whether or Not the Injury Has Penetrated the Platysma (Superficial Neck Muscle)?

Injuries that do not penetrate the platysma are by definition nonpenetrating neck injuries. As these injuries do not place the vital structures of the neck in harm's way, they do not require any further diagnostic workup or surgical exploration.

### What Types of Arterial Injuries Can Result from a Bullet Wound?

A bullet wound may cause a complete transection of the artery, pseudoaneurysm, intimal injury, dissection, or arteriovenous fistula. If a large artery is completely transected, the patient may quickly exsanguinate. Conversely, the ends of the severed artery may retract and vasoconstrict resulting in thrombus formation which may aid with temporary hemostasis.

### What Is a Pseudoaneurysm? How Does It Differ from a Hematoma?

A pseudoaneurysm develops when an artery sustains a focal full-thickness injury that is temporarily tamponaded by the surrounding soft tissue (it is not surrounded by the media or adventitia). This differs from a hematoma, in which there is no active or ongoing hemorrhage from an injured vessel. Blood continues to be pumped into the pseudoaneurysm cavity, creating a pulsatile quality that can be felt on exam as a pulsatile mass on palpation of the overlying skin.

### What Is an Arterial Intimal Injury? How Is It Managed? What About a Dissection?

The concussive or blast effect of a bullet may disrupt the intima of an artery. If the intimal injury is minor, it can be managed nonoperatively. A large intimal injury can occlude the lumen, leading to thrombosis. A large intimal injury can also create a false lumen. If blood enters the false lumen, a dissection occurs, which can also lead to occlusion of the artery. If the dissection extends high up into the intracranial carotid artery, it is generally managed nonoperatively with anticoagulation.

**Watch Out**

Know the differential diagnosis of a pulsating mass: AV fistula, aneurysm, and pseudoaneurysm.

**What Nerve Would Be Injured if This Patient Presented with Vocal Cord Paralysis?**

The recurrent laryngeal nerves, which supply the vocal cords, are both branches of the vagus nerve on their respective sides. They innervate all of the intrinsic muscles of the larynx except the cricothyroid (innervated by the external branch of the superior laryngeal nerve). Injury to the vagus nerve prior to the takeoff of the recurrent laryngeal nerve or damage to the recurrent laryngeal nerve itself leads to ipsilateral vocal cord paralysis. Normally the vocal cords are contracted to keep the airway open; paralysis of one vocal cord causes it to become fixed in a paramedian position and results in a hoarse voice. Bilateral paralysis of the vocal cords may result in complete upper airway obstruction.

**Watch Out**

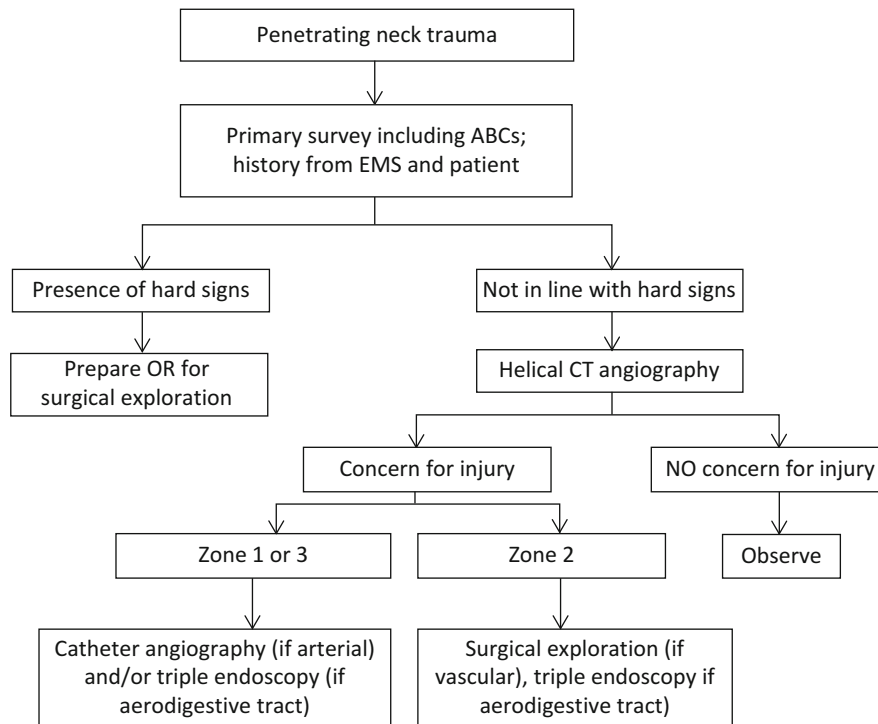
Damage to the phrenic nerve causes ipsilateral hemidiaphragm paralysis which may be seen on chest x-ray as an elevation of the diaphragm on the affected side.

**Workup****What Imaging Studies are Recommended for Patients with Penetrating Neck Trauma?**

Imaging study	Advantages	Disadvantages
<i>CT angiography</i>	Relatively fast, accurate, and readily available in most emergency departments	Nontherapeutic; requires injection of iodinated contrast medium
<i>Duplex ultrasonography</i>	Noninvasive; no need for contrast	Operator dependent; Zones 1 and 3 not well visualized; limited visualization in the presence of hematoma or subcutaneous air
<i>Femoral catheter angiography</i>	Diagnostic and therapeutic; first-line therapy for vascular injuries in Zones 1 and 3	Invasive; requires interventional radiologist or endovascular surgery support; risk of stroke, femoral artery injury, contrast-induced nephropathy
<i>Triple endoscopy (laryngoscopy, esophagoscopy, and bronchoscopy)</i>	Assesses for laryngeal, esophageal, and bronchial trauma	Does not visualize the carotid or vertebral arteries

**Management****What Are the First Steps in the Management of a Penetrating Neck Wound?**

The initial evaluation (Fig. 44.2) of all trauma patients begins with the primary survey. Airway, Breathing, and Circulation assume the highest priority in the initial assessment and management of the trauma patient as derangements in any one of the ABCs may result in significant morbidity and potentially death. The neck includes anatomic structures vital to the ABCs (the upper airway, the lungs, and the major blood vessels of the neck, respectively). A patient who speaks has a patent airway. In a penetrating neck injury, the airway can quickly become compromised by an expanding hematoma, bloody secretions, or deterioration in mental status, all of which may be indications for endotracheal intubation. A patient's respiratory rate and effort, oxygen saturation, and breath sounds are key factors in assessing breathing. Circulation can be assessed by blood pressure



**Fig. 44.2** Management algorithm for penetrating neck trauma

measurements and evaluation for ongoing significant bleeding. The ABCDE of the primary survey is completed by determination of the patient's Glasgow Coma Scale or *Disability* and complete *Exposure* to rule out other injuries.

### What Is the Next Step Following the Initial Management?

If hard signs are present (particularly expanding hematoma, hypotension, exsanguination), the patient needs to be taken directly to the operating room for exploration. For Zone 2 injuries (most common), a standard incision anterior to the sternocleidomastoid is made exploration. If there are no hard signs, the next step is to obtain helical CT angiography to rule out potential injuries to aerodigestive, vascular, and neurologic structures (see Fig. 44.2). If the CT is negative, no surgical intervention is needed. If the CT demonstrates concern for an injury but is not definitive, then triple endoscopy is recommended (if the concern is for injury to the aerodigestive tract) and/or catheter angiography via femoral artery (if the concern is for an arterial injury). Further management is determined by subsequent findings. If the CT shows a definitive injury, surgical intervention is recommended.

### What Do You Do in the ED if There Is Brisk Arterial Bleeding That Cannot Be Controlled with Direct Pressure?

In cases where direct pressure does not control bleeding from a wound, particularly those that involve a long tract, a Foley catheter can be placed into the wound and advanced, followed by inflation of the Foley balloon (and clamping the catheter lumen). This may permit temporary hemostasis by providing a tamponade effect on the bleeding vessel. The patient should then be urgently transported to the operating room.

### What if There Are No Hard Signs of Injury?

If there are no hard signs, the next step is to obtain helical CT angiography to rule out injuries to the carotid, jugular vein, esophagus, and cervical spine. If the CT is negative, no surgical intervention is needed. If the CT demonstrates concern for



an injury but is not definitive, then triple endoscopy is recommended (if the concern is for injury to the aerodigestive tract) and/or catheter angiography via femoral artery (if the concern is for an arterial injury). Further management is determined by subsequent findings. If the CT shows a definitive injury, surgical intervention is recommended (see Fig. 44.2).

### How Does the Zone of Injury Affect Management in Patients Without Hard Signs of Injury?

As previously mentioned, Zone 2 injuries are readily accessible via a standard neck incision. As such, when injuries are questionable, the threshold to explore is lower. Since Zone 1 injuries are harder to expose (need major chest incision) and Zone 3 injuries may be completely inaccessible (at skull base), exploration of these zones should be limited to situations where injuries have definitively been identified.

#### Watch Out

Patients with penetrating injuries above the clavicles should be evaluated for a pneumothorax.

### What Is the General Principle for the Operative Exposure of Vascular Injuries?

The most important principle is obtaining proximal and then distal control of the injured artery. This approach prevents one from directly entering into a large pulsating wound, only to encounter exsanguinating hemorrhage, and being unable to easily find the severed ends of an artery or vein. Once proximal and distal control is obtained, the injured site can be explored.

### What Are the Principles of Repair of a Carotid Injury?

After proximal and distal control are obtained, systemic heparin is administered (provided there are no contraindications or concern for bleeding elsewhere). Sections of artery that are bruised or that have intimal injury should be resected. If the ends of the artery can be approximated without tension (usually possible if <2 cm is resected), then a primary anastomosis is performed. Otherwise, a graft is interposed between the two ends. The ideal conduit is autogenous graft. The best option is usually the greater saphenous vein from the thigh. For that reason, whenever a major vascular injury is suspected, one or both thighs should always be prepped and draped in anticipation of a need to harvest of the greater saphenous vein in case a primary anastomosis cannot be completed successfully. The vein is anastomosed to the two ends of the severed artery. If the injury is to the external carotid artery, it can be safely ligated.

### How Do You Manage an Injury to the Internal Jugular Vein?

Ideally, the internal jugular vein is repaired using simple techniques such as a primary repair (termed lateral venorrhaphy) or end-to-end repair. If the jugular vein cannot be simply repaired or the patient is exsanguinating, then ligation of the vein both proximally and distally is an acceptable alternative. This is generally very well tolerated.

### How does the type of Arterial Injury Seen on Helical CT or Catheter Angiography Affect Management?

Injury type	Comments
<i>Pseudoaneurysm</i>	<i>Inherently unstable</i> and thus can rupture and cause massive blood loss in the trauma setting, needs surgical repair
<i>AV fistula</i>	Though not unstable, low resistance of vein means it will rarely close, will slowly enlarge over time, needs open surgical repair
<i>Intimal injury</i>	Usually stable, depending on size, may remodel and heal spontaneously

## Areas Where You Can Get in Trouble

### With GSW, Bullets May Cross Zones of the Neck

Determining missile trajectory solely on the basis wounds is not always reliable. Because so much of the management of penetrating neck trauma relies on which zone is violated, it is important to be aware of the possibility of multiple bullet fragments being created inside the neck or bullets ricocheting off bony structures. For this reason, in the stable patient, routine use of CTA is recommended.

### Not Addressing Airway First (Even with No Obvious Airway Compromise)

The thick fascial layers surrounding the neck limits the amount of outward displacement of tissue, causing internal compressible structures to become affected even when very little external sign of a hematoma is present.

### Missing a Blunt Carotid Injury

Blunt carotid injuries are easily missed as they are often clinically occult (hard signs such as expanding hematoma are uncommon). Therefore, a high level of suspicion is required to identify these injuries. The classic presentation would be a motor vehicle collision victim with a focal neurological deficit that is not explained by the head CT scan (i.e., no intracranial hematoma). Blunt carotid injury is caused by stretching of the vessel or direct trauma. Common mechanisms of blunt injury include hyperextension injuries of the neck, direct seatbelt trauma, near hanging, cervical spine fractures, and, less commonly, neck torsion from various activities (wrestling or chiropractic manipulation). In such instances, a CT angiogram of the neck should be obtained to rule out injury to the carotid and vertebral arteries. Treatment in most instances is anticoagulation only.

---

## Summary of Essentials

### History and Physical Examination

- Mechanism of injury, location of injury, and clinical exam findings are the most important parts of the history and physical examination in a patient with penetrating neck trauma
- Hard signs include arterial bleeding, shock, pulsatile or, expanding hematoma, and thrill/bruit
- Must assess for injuries to carotid and vertebral arteries, jugular vein, trachea, esophagus, and cervical spine
- Injuries from blunt trauma can easily be missed as there is usually little outward evidence (i.e., expanding hematoma) of an injury

### Anatomy

- Zone 1, clavicles/sternal notch to cricoid cartilage; Zone 2, cricoid cartilage to angle of mandible; Zone 3, angle of mandible to base of skull

### Pathophysiology

- High-velocity projectiles can cause damage to tissue that is not necessarily in the direct path of the bullet
- A bullet wound may cause a complete transection of the artery, pseudoaneurysm, intimal injury, or arteriovenous fistula
- Bilateral paralysis of the vocal cords often leads to complete upper airway obstruction
- Zone 2 injuries are surgically accessible via a standard neck incision
- Zone 1 and 3 injuries may be surgically inaccessible through a standard neck incision
  - If patient is stable, obtain imaging to prior to potential intervention with low threshold for endovascular or interventional radiological techniques for hemorrhage control

## Workup

- Patients with penetrating neck injury should be continuously reevaluated for airway compromise from an expanding hematoma with a low threshold for intubation
- CT angiography is highly specific for carotid/vertebral injury and readily available
- Duplex US is noninvasive and highly specific but poor at visualizing Zones 1 and 3

## Management

- Start with the ABCs
- Injuries that do not penetrate the platysma do not require surgical exploration
- If hard sign (expanding hematoma, active arterial bleed, shock), take directly to the OR for exploration
- If no hard signs, obtain helical CT angiogram
  - If no injury, no further treatment
  - If suspicion for aerodigestive tract injury, obtain triple endoscopy
  - If suspicion for vascular injury
    - Zone 2: surgical neck exploration
    - Zones 1 and 3: obtain catheter angiography
- First principle in operative management of vascular injury: obtain control of normal artery and vein proximal to the injury, followed by exposure and control distal to the injury
- The maximum amount of artery that can be removed and still allow for primary anastomosis is 2 cm (do not perform primary anastomosis under tension)
- If primary anastomosis is not possible, place interposition graft
  - Ideal conduit is autogenous graft (greater saphenous vein from the thigh)

## Watch Out

- Gunshot wounds may cross zones, so entrance wounds are not always reliable
  - Routine use of CTA is recommended
- Suspect blunt carotid injury with a focal neurological deficit that is not explained by the head CT scan
  - Treatment is usually nonoperative (anticoagulation)

---

## Suggested Reading

- Bell RB, Osborn T, Dierks EJ, et al. Management of penetrating neck injuries: a new paradigm for civilian trauma. *J Oral Maxillofac Surg.* 2007;65:691.
- Brywczyński JJ, Barrett TW, Lyon JA, Cotton BA. Management of penetrating neck injury in the emergency department: a structured literature review. *Emerg Med J.* 2008;25:711.
- Van Waes OJ, Cheriex KC, Navsaria PH, et al. Management of penetrating neck injuries. *Br J Surg.* 2012;99 Suppl 1:149.

Omid Yousefian, Christian de Virgilio, Areg Grigorian,  
and Dennis Y. Kim

A 20-year-old male is brought in by paramedics after suffering two stab wounds to his chest. In the emergency department (ED), the patient is awake but combative. He responds to questions by stating his name but is flailing his arms and shouting to everyone to leave him alone. His breath smells of alcohol. On physical examination, his blood pressure is 90/70 mmHg, heart rate is 110/min, and respiratory rate is 20/min. His airway is patent. Breath sounds are absent on the left and clear on the right. He has two stab wounds to the left chest, one just above and one just below the nipple. There is no bubbling of air from the wounds. There is palpable crepitus over the left chest. His neck veins appear to be distended. His trachea is midline. The heart sounds are difficult to hear, but the rate is regular without murmurs. The abdomen is soft and non-tender. The patient is logrolled and no other injuries are identified.

## Diagnosis

### What are Considered the “Lethal” Six Injuries of Thoracic Trauma?

Lethal six	Characteristics
<i>Airway obstruction</i>	Laryngeal trauma, foreign body aspiration, stridor, expanding neck hematoma, and gurgling
<i>Tension pneumothorax</i>	Hemodynamic instability, tracheal shift away from injury, one-way valve in injured lung
<i>Open pneumothorax</i>	Associated with open chest wall injury, air may enter pleural cavity through skin
<i>Massive hemothorax</i>	Lung parenchymal or intercostal artery injury, total whiteout of lung field
<i>Flail chest</i>	Two or more fracture sites in two or more consecutive ribs leading to paradoxical motion of chest wall, often have underlying lung contusion
<i>Cardiac tamponade</i>	Beck’s triad (hypotension, distended neck veins, muffled heart sounds)

O. Yousefian, BS (✉)  
Medicine Department, UCSD, 9800 Gilman Dr., La Jolla, CA 92093, USA  
e-mail: [oyousefi@ucsd.edu](mailto:oyousefi@ucsd.edu)

C. de Virgilio, MD  
Department of Surgery, Harbor-UCLA Medical Center, 1000 W. Carson Street, Torrance, CA 90509, USA  
e-mail: [cdevirgilio@labiomed.org](mailto:cdevirgilio@labiomed.org)

A. Grigorian, MD  
Department of Surgery, University of California, Irvine, 333 City Blvd West, Suite 1600, Route. 81, Orange, CA 92868, USA  
e-mail: [agrigori@uci.edu](mailto:agrigori@uci.edu)

D.Y. Kim, MD  
Department of Surgery, Harbor-UCLA Medical Center, 1000 W. Carson Street, Box 42, Torrance, CA 90509, USA  
e-mail: [dekim@dhs.lacounty.gov](mailto:dekim@dhs.lacounty.gov)

**Watch Out**

The most common cause of airway obstruction occurs in patients with diminished airway reflexes in which a relaxed tongue falls back against the rear of the pharynx.

**What are Considered the “Hidden” Six Injuries of Thoracic Trauma?**

<b>Hidden six</b>	<b>Characteristics</b>
<i>Blunt aortic injury</i>	High-energy rapid deceleration injury (e.g., fall from great height, high-speed MVC, aviation accident), widened mediastinum, deviation of the trachea to the right on CXR
<i>Esophageal injury</i>	Penetrating trauma, subcutaneous air
<i>Tracheobronchial injury</i>	Massive subcutaneous emphysema
<i>Diaphragmatic rupture</i>	Due to sudden rise in intra-abdominal pressure, stomach and colon are the most frequently herniated structures; penetrating thoracoabdominal injuries; delayed diagnosis frequent (may be asymptomatic)
<i>Blunt cardiac injury</i>	Spectrum from unexplained tachycardia, bundle branch block to cardiac rupture, associated with sternal fracture
<i>Pulmonary contusion</i>	Develops within first 24 hours, often not seen on initial CXR

**Watch Out**

The lethal six and hidden six make up the deadly dozen of thoracic trauma.

**Watch Out**

Do not assume that a combative trauma patient's behavior is due to intoxication; the combative nature may represent an underlying physiologic derangement such as hypoxia or cardiac tamponade.

**How Is the Diagnosis of Tension Pneumothorax Established?**

This is a clinical diagnosis without a need for X-ray confirmation (will delay treatment). Suspect tension pneumothorax in patients with hypotension, dyspnea, tachypnea, jugular venous distention, unilaterally absent breath sounds, and a deviated trachea to the unaffected side.

**How Is the Diagnosis of Traumatic Cardiac Tamponade Established?**

This is also considered a clinical diagnosis and requires prompt intervention. Patients that present with Beck's triad (hypotension, distended neck veins, and muffled heart sounds) should be suspected of having tamponade. The diagnosis can be supported with a FAST scan which demonstrates fluid in the pericardial sac. Patients may also exhibit pulsus paradoxus (decrease in systolic pressure  $\geq 10$  mmHg with inspiration).

**What Is the Most Likely Diagnosis in This Patient?**

Given that the patient has sustained a penetrating chest injury to the cardiac box in association with Beck's triad, there is a high suspicion for cardiac tamponade. The cardiac box is defined as the area of the anterior chest wall bounded by the sternal notch and clavicles superiorly, the nipples laterally, and the subcostal margin inferiorly. Up to a third of patients with a penetrating wound in this area may have an associated cardiac injury. In addition, he has absent breath sounds on the left, in association with hypotension; thus he may have a concurrent tension pneumothorax.

## History and Physical

### What Is the Differential Diagnosis for a Combative Trauma Patient?

The clinician should be aware that combative behavior (as in the present patient) can be a sign of hypoxia (so-called air hunger), hypovolemic or cardiogenic shock, and hypoglycemia. Alcohol and other substance use are common behaviors among this patient population.

### What Is the Differential Diagnosis of the Absent Breath Sounds on the Left?

Pneumothorax or massive hemothorax.

### What Is the Implication of a Penetrating Injury to the Chest That Is Above Versus Below the Nipple?

The diaphragm is a dome-shaped muscle that peaks at an imaginary line between the nipples. A penetrating injury above the nipple line likely only involves injury to the thoracic structures. However, injuries below the nipple line may result in damage to either thoracic structures, abdominal contents, or the diaphragm itself, thus prompting investigation of all these areas.

### Why Is It Important to Know the Type of Weapon Used in a Penetrating Injury?

Bullet injuries create unpredictable paths, and thus it is essential that the trajectory of the bullet is followed so as not to miss an injury. An entry and exit wound must be found. If there is no exit wound, the bullet must be located radiographically. Rarely, bullets may enter an artery and embolize.

### What Is the Concern Given That the Systolic and Diastolic Pressures in the Patient Presented Are So Close to Each Other?

A pulse pressure less than 30 mmHg is considered narrow. This implies a compromised stroke volume. In the trauma setting, the differential diagnosis for a narrow pulse pressure includes pericardial tamponade, hypovolemic shock, and cardiogenic shock.

### Why Is It Important to Roll the Patient Over?

In all patients with penetrating trauma, it is critical to check for wounds to the back that may otherwise be missed. The axilla and perineum are two other areas that should be examined in patients with penetrating mechanisms of injury. In general, cervical spine immobilization in patients with penetrating injuries is not required given the extremely low incidence of unstable cervical spine fractures.

### What Is the Significance of Air Bubbling from a Penetrating Chest Wound?

This is also referred to as a sucking chest wound, a type of open pneumothorax (Table 45.1). An open pneumothorax indicates there is an injury to the lung or bronchial tree that connects directly to the atmosphere. With a sucking chest wound, the chest wall defect is so large (at least  $2/3$  the diameter of the trachea) that inspired air takes the path of least resistance and enters into the chest cavity through the wound instead of through the trachea.

**Table 45.1** Types of pneumothorax

Type	Population	Mechanism
<i>Spontaneous</i>	Young, tall, thin, male, smokers	Spontaneous rupture of apical alveolar blebs
<i>Open</i>	All trauma patients	Free communication between the atmosphere and pleural space through an open chest wall wound
<i>Simple</i>	All trauma patients	Jagged rib fracture punctures lung; stab or gun shot wound
<i>Tension</i>	All trauma patients	Lung injury creates one-way valve
<i>Iatrogenic</i>	Patients with central line or thoracentesis	Direct needle injury to the lung

**Watch Out**

Always order a chest X-ray after putting in a central line to make sure you did not cause an iatrogenic pneumothorax.

**What Is Subcutaneous Emphysema?**

The word emphysema is derived from Greek *emphusēma* meaning trapped air. This condition occurs if air is trapped in the subcutaneous layer of the skin. The physical exam finding of subcutaneous emphysema on palpation is referred to as crepitus. In the trauma setting, subcutaneous emphysema is caused by a pneumothorax until proven otherwise.

**Pathophysiology****Why Is a Tension Pneumothorax Dangerous?**

Tension pneumothorax is considered the most dangerous type of pneumothorax because the injury creates a one-way valve effect. With each inspiration, air leaks out of the lung and into the pleural cavity. This leads to compression of the superior and inferior venae cavae, decreased preload, severe reduction in cardiac output, and hemodynamic instability.

**Watch Out**

A tension pneumothorax is rapidly exacerbated by positive pressure ventilation. Thus a tension pneumothorax should be decompressed with a chest tube as soon as it is suspected and prior to instituting positive pressure ventilation.

**What Is the Implication of Distended Jugular Veins?**

Distended jugular veins are suggestive of elevated jugular venous pressure (JVP), an indirect measure of central venous pressure. In the trauma patient, it should raise the suspicion of either cardiac tamponade or tension pneumothorax.

**What Causes Hypotension in Cardiac Tamponade?**

Although there are elevated pressures in all chambers of the heart, the primary reason why patients develop hypotension is because there is an exaggerated shift of the septum into the left ventricle and thus a compromised preload and cardiac output. As blood accumulates rapidly in the pericardial sac, the pericardial pressure exceeds the ventricular filling pres-

sure, resulting in reduced cardiac output. Eventually, the pericardial and left ventricular filling pressures equilibrate, resulting in a further decrease in cardiac output.

### **What Is the Most Important Factor in the Development of Cardiac Tamponade?**

The rapid accumulation of fluid is the most important factor. Traditionally, acute cardiac tamponade is associated with a sudden accumulation of 200 to 300 ml of intrapericardial fluid, whereas a chronic tamponade results from a slowly evolving accumulation of volumes between 1,000 and 2,000 ml.

### **Does a Normal Abdominal Examination Rule Out an Intra-abdominal Injury? Why or Why Not?**

No. A penetrating injury to the colon or small bowel may not immediately create peritonitis (it may take several hours to manifest). A reliable physical examination also requires a cooperative and reliable patient. Intoxication, a depressed mental status, and associated “distracting” injuries may all interfere with the accuracy of the abdominal examination. Since the patient described has an injury below the nipple, intra-abdominal injuries need to be ruled out.

### **Why Are Penetrating Chest Trauma Patients at Increased Risk of Air Embolism? How Would It Present?**

Air embolism can occur in both the venous and arterial systems. The main affected systems are the cardiovascular (e.g., chest pain, arrhythmia, and right-sided heart failure), respiratory (e.g., dyspnea, hypoxemia, and hypercarbia), and central nervous systems (e.g., confusion, altered mentation, and paradoxical cerebral embolism). Air emboli are potentially life-threatening. For example if the air were to enter the coronary arteries, blood flow to the heart may be interrupted. Concomitant injury to a bronchus and pulmonary vein may result in an air embolism. The underlying mechanism is believed to involve the traumatic creation of a fistula between an injured bronchus and pulmonary vein. Stab wounds or gunshot wounds near the hilum are the most common mechanism of such injuries as this is where these two structures lie in close proximity.

---

## **Initial Management**

### **What Is the First Step in the Management?**

The management of any trauma patient always starts with the primary survey (ABCDE) (airway with C-spine precautions, breathing, circulation, disability, exposure). The first question one should always ask is whether the patient needs to be intubated. This decision is usually not based on a specific criterion but rather based on the clinician’s best judgment.

### **Does the Patient Need to Be Intubated?**

No. He is able to talk and his airway is not obstructed.

#### **Watch Out**

Do not intubate and institute positive pressure ventilation in a patient with suspected tamponade. Positive pressure ventilation results in reduced cardiac filling, which can exacerbate the already compromised cardiac output seen in cardiac tamponade.



## What Is the Next Step?

The patient has absent breath sounds on the left. In a stable patient, the next step would be to obtain a chest X-ray to rule out a pneumothorax. However, the patient presented is hemodynamically unstable (BP < 100, HR > 100). There is concern for a possible tension pneumothorax, as such a needle decompression (needle thoracostomy) should be performed.

## What Is a Needle Thoracostomy? What Is the Indication for Placement? Where Is It Placed? Why Is That Location Chosen? What Needs to Follow After It Is Placed?

Needle thoracostomy allows for immediate thoracic decompression and is indicated in patients with clinical signs and symptoms (as in the present case) consistent with tension pneumothorax. A needle is placed in the 2nd or 3rd intercostal space, just above the rib, at the midclavicular line and is advanced until air is aspirated into the syringe. This is an ideal location as it minimizes risk to the heart or the collapsed lung. An immediate rush of air indicates successful decompression and helps convert a tension pneumothorax into a simple/closed pneumothorax.

### Watch Out

All patients that receive a needle thoracostomy for tension pneumothorax should undergo tube thoracostomy (chest tube) for definitive management. Though one might argue to go directly to a chest tube, in the setting of a tension pneumothorax, immediate decompression is needed, and a chest tube would require too much time.

## What Is a Tube Thoracostomy? What Is the Indication for Placement? Where Is It Placed?

Tube thoracostomy, or chest tube insertion, involves placing a hollow plastic tube between the 4th or 5th intercostal space at the midaxillary line into the chest to decompress a hemothorax and/or pneumothorax. If a massive hemothorax is encountered (>1.5 L immediately or >150–200 ml/h over 3 hours), immediate transport to the operating room for a thoracotomy is indicated.

### Watch Out

Tube thoracostomy is used to treat pneumothorax, while a thoracotomy is often performed by a surgeon in an emergency setting to perform lifesaving and invasive resuscitation maneuvers including internal cardiac massage and hemorrhage control.

## What Are the Goals and Guidelines for Resuscitative or Emergency Department Thoracotomy (EDT)?

EDT is performed in an attempt to resuscitate a trauma patient who has just gone into or is about to enter cardiac arrest. The primary goals of EDT include hemorrhage control, decompression of cardiac tamponade, cross-clamping of the descending thoracic aorta, facilitation of cardiac massage, prevention of air embolism, and repair of cardiac or pulmonary injuries. Table 45.2 discusses the indications and contraindications for EDT.

## What Is the Next Step?

Circulation is next. Palpate the central and peripheral pulses. If radial or femoral pulse is verified and is normal and no external bleeding is noticed, circulation can be considered stable temporarily. Two large-bore (14 or 16 gauge) IV catheters, one in each arm, are placed, and blood is drawn for testing (most importantly for type and cross for 4–6 units of packed red blood

**Table 45.2** Indications and contraindications for EDT

Indications	Contraindications
Penetrating trauma with <15 min of prehospital CPR	Penetrating trauma with CPR >15 min and no signs of life (e.g., respiratory effort, pupillary response, motor activity)
Blunt trauma with <5 min of prehospital CPR	Blunt trauma with CPR >5 min and no signs of life or asystole
Persistent severe postinjury hypotension (SBP ≤60 mmHg) or patient in extremis	

cells). Consider administration of a 1 liter bolus of fluid, either normal saline or Ringer's lactate. If there is any sign of external bleeding, manual pressure should be applied. If there are no central pulses, an immediate decision needs to be made as to whether to perform an EDT. In the case of severe or ongoing blood loss, the patient should be transfused with type O- blood.

**Watch Out**

IV catheters should be placed in an extremity above and opposite the site of truncal injury.

**Following the Primary Survey, What Is the Next Step in the Management?**

In this hemodynamically unstable patient, the source of instability needs to be quickly ascertained. A FAST scan should be performed to look for fluid around the pericardium. Fluid around the pericardium, coupled with the patient's hemodynamic instability, is highly suggestive of cardiac tamponade.

**Once Cardiac Tamponade Is Highly Suspected, What Is the Next Step?**

Intravenous fluids are useful in the initial management of cardiac tamponade as fluids increase preload. However, definitive management involves performing a median sternotomy, release of tamponade, and repair of the underlying cardiac injury. EDT would be indicated if the patient lost their vital signs. Pericardiocentesis is generally not recommended in trauma patients, particularly if surgical capabilities and resources will allow for rapid transport to the operating room. The patient presented is hemodynamically unstable, and there is strong evidence of cardiac tamponade. Thus the patient should be taken directly to the OR for a median sternotomy.

**Why Is Pericardiocentesis Not Recommended in the Trauma Setting?**

Performing pericardiocentesis in the trauma setting is controversial. It is thought to be unreliable as the needle is ineffective in removing what is essentially clotted blood within the pericardial sac. In certain clinical circumstances (i.e., long transport times, lack of available expertise or operating room availability), pericardiocentesis may be lifesaving and a helpful temporizing intervention prior to definitive repair. In general, pericardiocentesis is more effective in the non-trauma setting as the cause of tamponade is more likely to be nonclotted blood or serous fluid.

**What Is the Role of a Subxiphoid Window?**

Subxiphoid window is an open surgical diagnostic procedure that is performed in a stable patient in whom cardiac tamponade is suspected but not certain (e.g., FAST is unavailable or equivocal). The premise behind the technique is that if no blood is found upon opening the pericardium, a full median sternotomy can be avoided. Whereas if blood is found, a full median sternotomy is performed so as to adequately drain the pericardium and repair any associated cardiac injury. In the unstable patient, a subxiphoid window is contraindicated, as it will delay adequately decompressing and repairing the source of the tamponade.

## Are Vasopressors Recommended in the Management of Traumatic Cardiac Tamponade?

No. Most pressors will increase systemic vascular resistance (afterload) which will exacerbate myocardial dysfunction in the setting of traumatic pericardial tamponade.

## Subsequent Management

### What Should Be Immediately Ordered in All Patients That Present with Combative Behavior?

A rapid serum glucose measurement (e.g., finger-stick glucose), pulse oximetry, and a complete set of vital signs should be obtained in all such patients.

### How Much Pleural Fluid Can the Diaphragm “Hide” in an Upright Chest Radiograph?

Up to 500 cc of pleural fluid can be hidden by overshadow of the diaphragm.

### What Is the Classic Description for Cardiac Tamponade on Chest Radiograph?

It can appear as an enlarged water-bottle shaped cardiac silhouette on chest radiography. However, acute cases may appear normal.

### How Does a Chest Tube Drainage System Work, and How Do You Look for a Leak?

Chest tube drainage devices are composed of three chambers (Table 45.3). One can look for leaks by checking the water seal chamber on suction. Large leaks will be obvious and are evidenced by bubbles passing through the water seal fluid. If one suspects a small leak but no air bubbles are present, remove the suction, ask the patient to cough, and look for the air bubbles. If none are present, there is no leak.

#### Watch Out

All patients with a pneumothorax that require surgery under general anesthesia (e.g., laparotomy, fractured femur) should have a chest tube inserted, as the positive pressure ventilation may convert a simple pneumothorax into a tension pneumothorax.

### How Does Inspiring 100 % O<sub>2</sub> Help to More Rapidly Resolve a Pneumothorax?

Breathing 100 % oxygen instead of room air (which is 21 % oxygen) causes the alveolar partial pressure of nitrogen to fall which gradually washes out nitrogen from tissue and increases oxygen uptake into the vascular system. The subsequent increased pressure gradient between alveolar capillaries and the pneumothorax space results in an accelerated rate of absorption from the pleural space.

**Table 45.3** Chambers of chest tube draining system

Chamber	Purpose	Connects
<i>Collection</i>	Collects fluid, blood, and pus and measures the amount	Water seal chamber to chest tube
<i>Water seal</i>	One-way valve allows air to be removed from the pleural space but does not allow air to enter the pleural cavity	Suction-control chamber to the collection chamber
<i>Suction control</i>	Controls the amount of suction	Wall suction and the water seal chamber

### **How Is a Sucking Chest Wound Managed?**

Prehospital treatment of a sucking chest wound involves covering the chest wall defect with an occlusive dressing that is taped on three sides. This prevents air from entering the pleural space on inspiration while allowing air to escape during expiration, thereby resulting in re-expansion of the lung while minimizing the risk of developing a tension pneumothorax. In the ED, an occlusive dressing followed by tube thoracostomy is recommended.

### **How Is Flail Chest Managed?**

Analgesics should be given to control pain and prevent splinting, which may result in atelectasis, decreased FRC (functional reserve capacity), and hypoxia. Consideration should be given to placement of a thoracic epidural catheter. If oxygenation or ventilation is compromised, patients will require intubation with PEEP (positive end-expiratory pressure). Other routes of analgesia include paravertebral and intercostal blocks. The role of rib fixation remains to be defined.

### **What Can Increase the Risk of Developing an Air Embolism in a Patient Arriving with Penetrating Chest Trauma?**

Patients that are intubated with high positive pressure ventilation can develop air emboli if a concurrent bronchial and pulmonary vein injury is present. The high pressures favor movement of air from the bronchus into the pulmonary vein and eventually into the left atrium and the systemic arterial circulation.

---

## **Complications**

### **What Is the Most Dangerous Complication Following Pericardiocentesis?**

Laceration of a coronary vessel is the most dangerous complication of pericardiocentesis and can lead to worsening of cardiac tamponade.

### **What Nerve Is at Risk When Opening the Pericardium?**

Left phrenic nerve. It passes longitudinally over the posterior aspect of the pericardium of the left ventricle.

### **How Is a Recurrent or Persistent Hemothorax Managed If Chest Tube Drainage Fails?**

A thoracotomy is performed if the hemothorax is persistent or massive enough to cause a hemodynamic instability. If this fails to adequately drain the blood, and if the patient is stable, a video-assisted thoracoscopic surgery (VATS) procedure is recommended. Leaving a hemothorax undrained is not recommended, as the lung will not completely re-expand (trapped lung or fibrothorax), and creates a risk of empyema (infected hemothorax).

### **What Should You Consider When a Chest Tube Fails to Resolve a Pneumothorax?**

Make sure the chest tube is in the proper location and that there are no mechanical obstructions (e.g., kinking, clot in tube) or leaks in the system. If the chest tube is properly inserted and functioning, consider a major airway injury such as disruption of the bronchial tree. These patients require immediate intubation. Diagnosis is confirmed with bronchoscopy and repair entails a thoracotomy.

---

## Areas Where You Can Get in Trouble

### Long-Term Consequence of Missing a Diaphragm Injury

A diaphragmatic injury sustained on the right rarely has clinical significance. The liver usually prevents herniation of bowel into the chest. On the left side, the positive intra-abdominal pressure coupled with the absence of a significant barrier (e.g., liver) results in the migration of abdominal viscera into the thoracic cavity (diaphragmatic hernia). With time, the diaphragmatic defect enlarges and may present years later with an acquired diaphragmatic hernia with incarcerated bowel in the chest. The classic presentation is one of a chest pain and shortness of breath in a patient with a remote history of trauma. A chest X-ray will demonstrate bowel gas and air-fluid levels in the left chest. Surgical repair is needed and can be done through the abdomen or the chest, using a minimally invasive or open approach.

### Failure to Recognize Intra-abdominal Injury with a Penetrating Wound Just Below the Nipple

Penetrating wounds below the nipple can lead to thoracic, diaphragmatic, and/or abdominal injuries. All patients should undergo a chest x-ray. Intra-abdominal injury has a high risk for bowel injury and blood loss. For a stab wound injury below the nipple, CT scan is a useful study but should only be performed in the hemodynamically stable patient. Diagnostic laparoscopy can be used to rule out an injury to the diaphragm and other intraabdominal organs (e.g., stomach colon).

---

## Areas of Controversy

### How Accurate Is FAST in the Setting of Penetrating Trauma?

Most of the trauma literature has focused on the role of FAST in blunt trauma. The utility of FAST in penetrating trauma is limited with the exception of diagnosing cardiac tamponade and pneumothorax. Its greatest value is evidenced by the fact that it helps the clinician concentrate his/her efforts on cardiac, thoracic, or intraperitoneal injuries within minutes of the patient's presentation.

### Should Prophylactic Antibiotics Be Given for Chest Tube Placement?

The role of prophylactic antibiotics for patients receiving chest tubes has not been clearly defined, particularly in the setting of trauma. There is currently insufficient evidence to support the routine use of prophylactic antibiotics for these patients.

---

## Special Situations/Circumstances

### Following Chest Tube Placement for a Traumatic Pneumothorax/Hemothorax, When Is It Appropriate to Remove It? What Is the Main Risk During Removal?

To minimize the risk of infection, chest tubes should be removed as soon as it is safe to do so. Removing the chest tube is appropriate when there are no air leaks present and the lung is fully expanded, as evidenced on a chest radiograph. The main risk during the chest tube removal is air being inadvertently reintroduced into the pleural cavity, resulting in recurrent pneumothorax. Therefore, it is recommended to remove the chest tube either at the end of expiration or at peak inspiration.

## Patient with Uncontrollable Pain and Flail Chest Develops Deteriorating Blood Gases Following Blunt Trauma

This is concerning for pulmonary contusion with worsening shunt physiology and can be apparent during initial presentation, or it may be discovered following admission. Following a chest x-ray and ABG to rule out other causes of worsening gas exchange, early intubation should be considered for these patients.

### Summary of Essentials

#### History and Physical

- Cardiac tamponade and tension pneumothorax are clinical diagnoses
- Penetrating injury above nipple line likely only involves thoracic structures, while below nipple line involves thoracic structures, abdominal structures, or diaphragm
- Narrow pulse pressure (<30 mmHg) implies compromised stroke volume

#### Differential Diagnosis

- Deadly dozen of thoracic trauma
  - Lethal six: airway obstruction, tension pneumothorax, open pneumothorax, massive hemothorax, flail chest, and cardiac tamponade
  - Hidden six: blunt aortic injury, esophageal injury, tracheobronchial injury, diaphragmatic rupture, blunt cardiac injury, and pulmonary contusion

#### Pathology/Pathophysiology

- Tension pneumothorax can compress SVC/IVC and result in decreased CO
- Pericardial pressure exceeds ventricular filling pressure in cardiac tamponade resulting in hypotension
- The most important factor in cardiac tamponade is the rapid accumulation of fluid
- The underlying mechanism in air embolism is the traumatic creation of a fistula between an injured bronchus and pulmonary vein

#### Management

- Always start with primary survey: airway, breathing, circulation, disability, and exposure
  - Follow with FAST to look for fluid around the pericardium in patient suspected of having cardiac tamponade
- All combative patients in ER should get rapid serum glucose, pulse oximetry, and set of vitals
- Tension pneumothorax is initially treated with needle thoracostomy placed in the 2nd or 3rd intercostal space at the mid-clavicular line
  - Always follow this with chest tube
- EDT indications include:
  - Penetrating trauma with <15 min of prehospital CPR
  - Blunt trauma with <5 min of prehospital CPR
  - Persistent severe postinjury hypotension (SBP  $\leq$  60 mmHg) due to: cardiac tamponade, air embolism, or hemorrhage (intrathoracic, intra-abdominal, extremity, or cervical)
- Traumatic cardiac tamponade is most appropriately treated with median sternotomy
  - Subxiphoid window can be considered for equivocal cases
- Sucking chest wound is treated with occlusive dressing and chest tube
- Flail chest and respiratory compromise are treated with analgesics and intubation/mechanical ventilation

---

## Complications

- Laceration of a coronary vessel is the most dangerous complication of pericardiocentesis
- Persistent hemothorax is managed with repeat chest tube, VATS, or thoracotomy

## Watch Out

- Always order a chest X-ray after putting in a central line
  - Intubation and positive pressure ventilation in tension pneumothorax or cardiac tamponade can reduce cardiac filling

---

## Suggested Reading

ACS-COT Subcommittee on Outcomes Practice management guidelines for emergency department thoracotomy. *JACS*. 2001;193:303.

Anderson JR, Hunt I. Cardiac surgery. In: Russell RCG, Williams NS, Bulstrode CJK, editors. *Bailey and Love's short practice of surgery*. 24th ed. London: Arnold/Hodder Headline Group; 2004. p. 917.

Schoen FJ. The heart. In: Kumar V, Abbas AK, Fausto N, editors. *Robbins and Cotran pathologic basis of disease*. 7th ed. Philadelphia: Elsevier Saunders; 1999. p. 555–618.

Arezou Tory Yaghoubian, Areg Grigorian,  
Christian de Virgilio, and Dennis Y. Kim

A 25-year-old man (weight 70 kg) arrives to the emergency department an hour after sustaining burn injuries in a house fire. He is awake but appears confused and disoriented. He complains of a severe headache. On initial exam, his temperature is 101.6 °F, blood pressure is 90/74 mmHg, heart rate is 120/min, respiratory rate is 26/min, and oxygen saturation is 89 %. He has blistering, painful burns to the face with singed nasal hairs, and carbonaceous sputum. The burns on his chest and back are painless, circumferential, white, dry, and leathery. The bilateral upper extremities are also burned with painful, swollen, mottled areas with blisters that appear to have open weeping surfaces. The remainder of his skin that is not burned has a cherry-red appearance. He also has sunken eyes, a dry tongue, and slow capillary refill.

---

### Diagnosis

#### What Is the Diagnosis and Resulting or Associated Complications Affecting This Patient?

The patient has sustained severe burn injuries to the face, trunk, and extremities. He has second-degree burns to the face and bilateral upper extremities and third-degree burns to the chest and back. Singed nasal hairs and carbonaceous sputum coupled with his low oxygen saturation are concerning for inhalational injuries which are life-threatening and should be addressed immediately by securing the airway via intubation and administration of 100 % O<sub>2</sub>. The cherry-red appearance of his skin along with his confusion, disorientation, and history of being trapped in a house fire is concerning for carbon monoxide poisoning. Additionally, he is in hypovolemic shock secondary to the massive loss of fluid as a result of his burn injuries (burn shock).

---

A.T. Yaghoubian, MD (✉)

Plastic and Reconstructive Surgery, UCLA, 200 UCLA Medical Plaza, Los Angeles, CA 90095, USA  
e-mail: [ayaghoub@ucla.edu](mailto:ayaghoub@ucla.edu)

A. Grigorian, MD

Department of Surgery, University of California, Irvine, 333 City Blvd West, Suite 1600, Route. 81, Orange, CA 92868, USA  
e-mail: [agrigori@uci.edu](mailto:agrigori@uci.edu)

C. de Virgilio, MD

Department of Surgery, Harbor-UCLA Medical Center, 1000 W. Carson Street, Torrance, CA 90509, USA  
e-mail: [cdevirgilio@labiomed.org](mailto:cdevirgilio@labiomed.org)

D.Y. Kim, MD

Department of Surgery, Harbor-UCLA Medical Center, 1000 W. Carson Street, Box 42, Torrance, CA 90509, USA  
e-mail: [dekim@dhs.lacounty.gov](mailto:dekim@dhs.lacounty.gov)



## History and Physical

### What are the Different Levels of Burn Injury and How do They Present?

Degree	Involves	Presentation
1st ( <i>superficial</i> )	Epidermis only	Similar to sunburn; localized, painful, dry, blanching redness with <i>no blisters</i>
2nd ( <i>superficial partial thickness</i> )	All of the epidermis and some dermis	Painful, swollen, warm, mottled areas <i>with blisters</i>
2nd ( <i>deep partial thickness</i> )	All of the epidermis and some dermis	<i>Painless</i> , warm, white, mottled areas <i>with blisters</i> that appear to have open weeping surfaces
3rd ( <i>full thickness</i> )	All of the skin (epidermis and dermis)	<i>Painless</i> , white, dry, leathery, and do not blanch with pressure
4th	All of the skin and underlying bone, tendon, adipose, or muscle	Similar to third degree; disfiguring

#### Watch Out

The presence of pain is an easy way to differentiate superficial partial-thickness burns (with pain) from deep partial-thickness burns (without pain).

### What Are the Risk Factors for Burn Injuries?

Extremes of age, alcohol or substance abuse, smoking, violence, and low socioeconomic status.

### How Does One Determine the Severity of a Burn Injury?

Calculating the total body surface area (TBSA) affected by second- or third-degree burns will allow one to determine the severity of a patient's burn injuries. This can be approximated using the rule of nines (Fig. 46.1). The body is divided into regions whose surface areas are multiples of nine: head, 9 %; each arm, 9 %; anterior torso, 18 %; posterior torso, 18 %; each leg, 18 %.

#### Watch Out

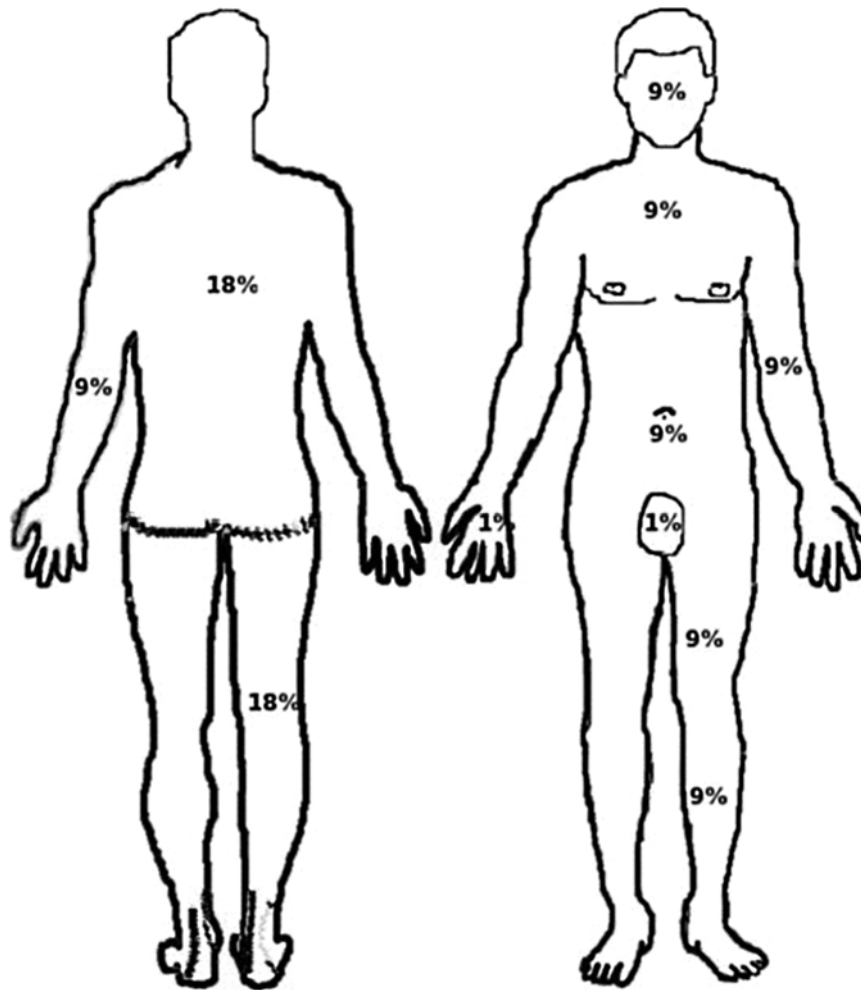
In areas of patchy involvement, the clinician can use his/her palm to estimate the surface area of the burn. The adult palm represents ~ 1% body surface area.

### What Are the Criteria for Transferring the Patient to a Burn Center?

- 2nd- or 3rd-degree burns > 10 % TBSA in patients <10 or > 50 years of age
- 2nd- and 3rd-degree burns >20 % TBSA in all patients
- 2nd- and 3rd-degree burns involving the hands, face, feet, genitalia, perineum, or skin overlying major joints
- Electrical and chemical burns
- Concomitant inhalational injury
- Significant preexisting medical conditions
- Suspected child abuse or neglect

### What Is the Significance of Carbonaceous Sputum?

Carbonaceous sputum indicates possible inhalational injury. A high degree of suspicion should be held for patients suffering burn injuries within enclosed areas with signs of significant facial burns, change in voice quality, singed nasal hairs,



**Fig. 46.1** Rule of 9s in adults

or carbonaceous sputum. There are three components of inhalational injury: upper airway edema, acute respiratory failure (secondary to a chemical pneumonitis from the products of combustion), and carbon monoxide poisoning.

### **What Is the Significance of Cherry-Red Skin in a Patient Rescued from a House Fire?**

This is a classic sign for carbon monoxide (CO) poisoning and typically occurs in patients that were exposed to smoke from house fires or the exhaust from a running car or gas heater. Patients initially present with headaches and other nonspecific constitutional symptoms such as nausea and dizziness. If severe or left untreated, CO poisoning may progress to seizures, coma, and multiorgan failure, and death.

### **What Is the Significance of a Second-Degree Burn That Progresses to a Third-Degree Burn While in the Hospital?**

This is concerning for a burn wound sepsis. Other things to look for include a discolored burn, eschar with green pigment, black necrotic skin, skin separation, and signs of sepsis. Fever is not always reliable since the body's primary temperature regulator, the skin, is often compromised in burn victims (discussed in *Pathophysiology*). The diagnosis of burn wound sepsis is based upon the bacterial concentration per gram of tissue in the burn wound or eschar. The finding of  $>10^5$  bacteria/g of tissue on quantitative analysis is highly suggestive of burn wound sepsis.

## What Is the Significance of a Circumferential Burn in the Extremity? How About If on the Chest?

Circumferential full-thickness burns in the extremity significantly increase the risk of developing compartment syndrome. Burn patients with circumferential extremity full-thickness burns with evidence of compromised distal perfusion should undergo escharotomy. Circumferential burns of the chest can compromise a patient's respiratory efforts due to the inflexible eschar and underlying tissue edema which can prevent chest wall motion and, thus, limit ventilation. These patients should also be considered for escharotomy.

## What Population of Patients Has the Highest Morbidity from Burn Injuries?

Children and the elderly

## What Other Risk Factors Are Associated With Increased Mortality in Burn Patients?

Greater than 40 % non-superficial TBSA, inhalational injury.

## Pathophysiology

### What are the Different Causes of Burns?

Cause	Comments
<i>Thermal</i>	Most common cause of burn injuries is scalding, typically from hot water
<i>Chemical</i>	Alkali burns are more damaging than acidic burns owing to their ability to penetrate tissues more deeply; acidic burns cause coagulation necrosis whereas alkali burns cause liquefactive necrosis
<i>Electrical</i>	Immediate life-threatening complication is cardiac arrhythmia; injuries are oftentimes out of proportion to the size of the external burn wound; patients may also develop muscle necrosis, posterior shoulder dislocations, myoglobinuria, and renal failure

#### Watch Out

Direct current (DC) electrocution (e.g., lightning) puts patients at risk for asystole, while alternating current (AC) electrocution (e.g., wall socket) puts patients at risk for ventricular fibrillation.

#### Watch Out

Cataracts are a long-term complication of electrical injury.

## Why Are Burn Patients at Increased Risk for Dehydration?

The skin acts as a protective barrier and plays an essential role in fluid and temperature regulation of the body. When the integrity of this protective layer is compromised, the skin becomes unable to regulate body temperature or prevent fluid from seeping out of the body. This can lead to hypovolemic shock if enough intravascular volume is lost.

## What Are the Physiologic Manifestations of a Burn in the First 24 hours?

Due to the release of catecholamines, the circulating glucose concentration is increased during the first 24 hours following thermal burn injury. Cardiac output is decreased to 40–60 % of the normal as a result of decreased plasma volume and increased systemic vascular resistance. Cardiac output then returns to normal but is not increased. The decrease in plasma volume, which occurs in part from a capillary leak, subsequently leads to a decrease in central venous pressure. In addition, there is a decrease in circulating erythrocyte volume, due in part to a direct destruction of erythrocytes by the injured tissue.

## Why Are Burn Patients at Higher Risk for Gastrointestinal Ulcers?

The diminished intravascular volume leads to decreased perfusion to the gastrointestinal tract, and the subsequent ischemic necrosis of gastric mucosa can put patients at increased risk for ulcer formation.

### Watch Out

An ulcer of the duodenum in patients with severe burns is known as a Curling's ulcer.

## What Organisms Are Classically Involved in Burn Wound Infections?

*Pseudomonas aeruginosa* is a gram-negative bacillus and is considered to be the most common cause of infections in burn patients, followed by *Staphylococcus aureus* and *Streptococcus pyogenes*. Fungal infections tend to occur in burn patients during the later stages of recovery because by this time the majority of bacteria have been eliminated by the use of topical antibiotics. The most common cause of fungal infection in burn patients is by *Candida albicans*. The most common cause of viral infection in burn patients is herpes simplex virus. Infections in burn patients can be problematic for multiple reasons. They may delay wound healing, encourage scarring, and can result in burn wound sepsis with resultant bacteremia.

## Work-Up

### What Is the First Step in the Evaluation of This Patient?

As with any other trauma patient, one should begin with the ABCs and perform a full history/physical examination. In this patient with signs of inhalational injury (singed nasal hairs, carbonaceous sputum, and decreased oxygen saturation), securing the airway via endotracheal intubation is essential.

### How Is Inhalational Injury Definitively Diagnosed?

Fiberoptic bronchoscopy. The clinical diagnosis of inhalational injury typically is made with clinical observation of facial burns, singed nasal hairs, and history of injury in an enclosed space. Other diagnostic features include carboxyhemoglobin > 10 %, oxygen saturation < 90 %, or a high probability V/Q scan. Chest x-rays are usually negative initially and have little value in diagnosing inhalational injury.

### What Is the Best Way to Evaluate for Carbon Monoxide (CO) Poisoning?

CO has nearly 200× more affinity for hemoglobin than oxygen. Thus the hemoglobin-oxygen dissociation curve shifts to the left, and more hemoglobin is bound by CO than it is by oxygen. Using a carbon monoxide pulse oximetry is the best way to evaluate for CO poisoning. However, this is not always available. Standard pulse oximetry is more readily available but is not always reliable since standard devices are unable to differentiate between oxygen and carbon monoxide bound to hemoglobin. Arterial blood gases will demonstrate a normal PaO<sub>2</sub> and decreased SaO<sub>2</sub>. CO poisoning is not a consumptive or destructive process, so hemoglobin would not be expected to change.

## How Do You Diagnose a Burn Wound Infection?

Punch biopsy demonstrating  $>10^5$  bacteria/g of burned tissue, in conjunction with burn wound histopathology and clinical systemic manifestations (i.e., fevers, tachycardia, etc.) qualifies as an invasive burn wound infection.

---

## Management

### How Would You Manage a Patient with Inhalational Injury?

Early intubation to prevent sudden loss of the airway due to the thermal injury and upper airway edema.

### How Do You Calculate the Appropriate Volume of Fluid Resuscitation for a Burn Victim in the First 24 hours?

The Parkland formula is commonly used to calculate the amount of volume resuscitation necessary for a patient with second- or third-degree burns involving more than 20 % TBSA. One-half of the total fluid volume should be administered in the first 8 hours *from the time of injury* and the second half in the subsequent 16 hours:

#### Parkland Formula

$$\text{Total fluid volume} = 4 \text{ cc / kg} \times \text{weight (kg)} \times \text{TBSA (\%)}$$

#### Watch Out

Urine output is a well-established parameter for guiding fluid management. The rate of fluid administration is titrated to a urine output of 0.5 mL/kg/h in adults and 2–4 mL/kg/h in kids.

### What Is the Management for CO Poisoning?

All these patients should be started on 100 % oxygen via non-rebreather face mask.

---

### What Type of Fluid Should Be Used Acutely in a Burn Patient?

Lactated Ringer's. Colloid solutions can increase pulmonary/respiratory complications within the first 24 hours of a burn injury. Use of normal saline will lead to hyperchloremic metabolic acidosis as high volumes will be required in burn victims.

### What Electrolyte Abnormality Must Be Closely Monitored in Burn Patients?

Burn victims should be monitored for abnormalities in serum sodium and potassium. Although hyponatremia can be related to the burn itself, it is often iatrogenic. While the Parkland formula can help calculate the fluid needs in burn victims, it cannot account for the subsequent compartmental fluid shifts that disrupt normal electrolyte levels. Hyponatremia can increase the risk of developing seizures in burn patients. Hyperkalemia can develop from the destruction of cells and tissues and can lead to cardiac conduction abnormalities.

### What Should Be Done for a Patient with a Circumferential Chest Burn and Deteriorating Respiratory Status?

Chest escharotomy. Escharotomy is performed by incising the constricting eschar, thereby improving chest wall compliance and respiration. Unlike a fasciotomy, escharotomy only involves incisions through the burned soft tissues and not the deeper

underlying structures. This procedure is painless as the nerve endings in the dermis are involved. Extremity escharotomies should also be considered in patients with full-thickness circumferential burns with evidence of compromised perfusion.

### What Are the Other Indications for Escharotomy?

Circumferential deep burns and neurovascular compromise of the extremity (e.g., weak pulse, decreased capillary refill, motor weakness, and decreased sensation).

### How Do You Manage Burn Wounds?

Following the institution of resuscitative measures, local treatment of burn wounds involves cleansing and debridement and application of antimicrobial agents and dressings. Serial tangential excision and debridement of the burn tissue is indicated. Skin grafting is performed after the wound bed is deemed clean. Skin grafts are contraindicated if there is evidence of infection.

### Should All Burn Patients Be Started on Prophylactic IV Antibiotics?

No. There have been no studies demonstrating the efficacy of prophylactic IV antibiotics in reducing burn wound infections. Instead, they are thought to select for resistant organisms.

### What Other Different Topical Burn Agents are Utilized in Burn Patients?

Agent	Comments
<i>Silver sulfadiazine (Silvadene)</i>	Commonly used topical burn agent; may result in granulocyte reduction (neutropenia and thrombocytopenia); poor deep tissue penetration and <i>ineffective</i> against <i>Pseudomonas</i>
<i>Sulfamylon or mafenide acetate</i>	Dispensed in a cream and a solution; it functions as a carbonic anhydrase inhibitor and may result in metabolic acidosis; deep tissue penetration and <i>effective</i> against <i>Pseudomonas</i> ; may be painful in application
<i>Silver nitrate</i>	Poor deep tissue penetration and <i>ineffective</i> against <i>Pseudomonas</i> ; brown staining of skin is common, and methemoglobinemia may rarely occur

### What Medication Should All Burn Patients Be Started on to Prevent Curling's Ulcers?

Proton pump inhibitors or H2 blockers.

### Can Patients with Severe Burn Injuries Be Fed Orally? Why or Why Not?

In general, the enteral route is the preferred method of delivery of nutrition. There is controversy regarding the benefits of early versus late initiation of nutrition. In patients in whom enteral tube feedings are not tolerated, parenteral nutrition should be considered.

### What Are the Principles of Management for Chemical Burns?

Protection of others from exposure and removal of patients from area of exposure. Following removal of all clothing, dry chemicals should be brushed off the patient. With few exceptions, copious irrigation is the most important principle in the management of chemical burns. The longer the acid/alkali material stays in contact with the patient's body, the worse the prognosis is.

---

## What Is the Key Management Principle for Patients with Electrical Burns?

Cardiac monitoring for 12–24 hours to look for arrhythmias, particularly when a high-voltage injury (>1,000 V) is suspected.

---

## Areas You Can Get in Trouble

### Child Abuse

Burn injuries account for a minority of child abuse cases and should be considered for all children presenting with burn marks characterized by sharply demarcated margins or deep localized contact injury (e.g., cigarette burn). Parents may have inconsistent histories or conflicting accounts of how their child received the burn injury.

### Chronic Nonhealing Wound

Patients with chronic nonhealing wounds are at increased risk for the development of squamous cell carcinoma of the skin (Marjolin's ulcer). All chronically non-healing wounds should be evaluated with a skin biopsy.

---

## Summary of Essentials

### History and Physical

- 1st degree (superficial), 2nd degree (superficial and deep partial thickness), 3rd degree (full thickness), and 4th degree
- Superficial partial thickness (with pain) and deep partial thickness (without pain)
- Severity of burns determined by TBSA approximated by rule of 9s:
  - Head, 9 %; each arm, 9 %; anterior torso, 18 %; posterior torso, 18 %; each leg, 18 %
- Carbonaceous sputum indicates possible inhalational injury

### Pathophysiology

- Thermal, chemical, and electrical
- Loss of skin barrier increases risk of fluid and temperature deregulation
  - Hypovolemic shock
  - Infection
- Increased age, TBSA, and inhalational injury are risk factors for mortality

### Workup

- Inhalational injury
  - Clinical diagnosis by presence of facial burns, singed nasal hairs, and history of injury in an enclosed space
  - Fiberoptic bronchoscopy for definitive diagnosis
- Burn wound infection
  - Punch biopsy demonstrating  $> 10^5$  bacteria/g

---

## Management

- Parkland formula
  - Total fluid volume =  $4 \text{ cc/kg} \times \text{weight (kg)} \times \text{TBSA (\%)};$  use lactated Ringer's
  - Titrate urine output to 0.5 mL/kg/h in adults and 2–4 mL/kg/h in kids
- Topic antibacterial agents, serial tangential excision, and debridement of the burn tissue

---

## Suggested Reading

Baxter CR. Management of burn wounds. *Dermatol Clin.* 1993;11:709.

Hagstrom M, Wirth GA, Evans GR, Ikeda CJ. A review of emergency department fluid resuscitation of burn patients transferred to a regional, verified burn center. *Ann Plast Surg.* 2003;51:173.

Monafo WW. Initial management of burns. *N Engl J Med.* 1996;335:1581.



---

# Severe Right Leg Pain After Tibia Fracture

Andrew Nguyen, Areg Grigorian, and Christian de Virgilio

A 30-year-old male is brought to the emergency department by paramedics after a motorcycle accident. He is complaining of severe pain in his right leg. His only injury is an obvious deformity of the right leg below the knee. Imaging reveals a fracture of the tibia and fibula. He is taken to the operating room for an open reduction and internal fixation (ORIF). Approximately eight hours after surgery, the patient complains of severe pain in his right leg. On physical examination, the right leg appears to be tensely swollen. He feels tenderness upon palpation, especially just lateral to his tibia. When his ankle is passively dorsiflexed, he grimaces in pain. His foot appears pink and well perfused. Pulses in the dorsalis pedis and posterior tibial are 2+. Doppler interrogation demonstrates biphasic signals in both arteries. Sensory exam of the right foot is intact except for numbness in the first web space.

---

## Diagnosis

### What is the Differential Diagnosis?

Diagnosis	Comments
<i>Compartment syndrome</i>	Severe pain in the calf with passive motion of the ankle, tense leg edema, recent trauma, pulse present
<i>Necrotizing soft tissue infection (NSTI)</i>	Acute infection of the skin, fascia, or muscle, often with crepitus, bullae, and necrosis of subcutaneous tissue, mixed flora
<i>Cellulitis</i>	Infection of the deep dermis and subcutaneous fat presenting with redness and erythema without the tissue destruction characteristic of NSTI
<i>Deep vein thrombosis</i>	Calf pain, leg edema, and cyanosis; evaluate for recent prolonged stasis, hypercoagulable state, and endothelial injury ( <i>Virchow's triad</i> )
<i>Acute limb ischemia</i>	Pain, pallor, pulselessness, paresthesias, paralysis, and poikilothermia; history of claudication or atrial fibrillation

---

A. Nguyen, MD (✉)

Department of Surgery, Harbor-UCLA Medical Center, 1000 West Carson Street, Box 461, Torrance, CA 90509, USA

e-mail: [annnguyen@ucla.edu](mailto:annnguyen@ucla.edu)

A. Grigorian, MD

Department of Surgery, University of California, Irvine, 333 City Blvd West, Suite 1600, Route. 81, Orange, CA 92868, USA

e-mail: [agrigori@uci.edu](mailto:agrigori@uci.edu)

C. de Virgilio, MD

Department of Surgery, Harbor-UCLA Medical Center, 1000 W. Carson Street, Torrance, CA 90509, USA

e-mail: [cdevirgilio@labiomed.org](mailto:cdevirgilio@labiomed.org)

## What Is the Most Likely Diagnosis?

In a patient presenting with a swollen, tense, and tender leg following ORIF, with pain on passive dorsiflexion and tenderness upon palpation in the compartments, the most likely diagnosis is a lower extremity compartment syndrome.

## History and Physical

### What Are the P's of Compartment Syndrome? How Do These P's Differ from Acute Limb Ischemia?

Compartments are relatively inflexible tissue envelopes throughout the body. Marked elevation in compartment pressure results in diminished capillary filling pressure. The resulting tissue ischemia produces symptoms of pain, paresthesia, pallor, paralysis, pulselessness, and poikilothermia (loss of temperature regulation ability). Acute limb ischemia produces similar symptoms, though loss of a pulse is an *early* result of a sentinel event such as embolus or vessel disruption. In compartment syndrome, pulselessness is a *late* sign.

### What Are Considered Early Signs of Compartment Syndrome?

As compartment pressures increase, the first symptom that manifests is pain, especially during passive range of motion. Progression of compartment syndrome results in nerve ischemia, producing a sensory deficit (paresthesia) before motor deficits. As capillary refill continues to diminish, pallor, paralysis, and poikilothermia may result.

### What Is Meant by Pain Out of Proportion to the Physical Exam Findings (Clinical Situation)?

The tense swelling of muscles in a compartment may eventually lead to ischemic necrosis. Such tissue ischemia creates marked pain. Yet, the physical exam and clinical situation may be deceptively benign. The foot itself often appears pink and well perfused and pulses are present (as in the present case). Thus the clinician may be lulled into believing that the pain is simply from the bone fracture. Compartment syndrome remains a clinical diagnosis. Great attention is required to carefully assess a patient with worsening or severe extremity pain after an injury.

## Anatomy

### How Many Compartments are there in the Upper Leg (thigh)? Lower leg? Upper Arm? Forearm?

Extremity	Number	Names
<i>Upper leg (thigh)</i>	3	Anterior, medial, posterior
<i>Lower leg</i>	4	Anterior, lateral, superficial posterior, deep posterior
<i>Upper arm</i>	2	Anterior, posterior
<i>Forearm</i>	3	Dorsal, volar, mobile wad

## Pathophysiology

### How Are the Etiologies of Compartment Syndrome Classified?

They can be classified as those that restrict (or decrease) compartment size or those that cause increased intra-compartment volume against the relatively fixed fascial envelopes (Table 47.1). Regardless of the cause, the end point is decreased capillary perfusion and tissue ischemia.

**Table 47.1** Etiologies of compartment syndrome**Decreased compartment size**

Plaster casts  
 Circumferential third-degree burn  
 External compression  
 Military anti-shock garments  
 Splints

**Increased compartment volume**

Vascular injury  
 Blast injury  
 Bone fracture  
 Crush injury  
 Electrical burns  
 Hematoma/bleeding  
 Ischemia/reperfusion  
 SIRS/sepsis  
*SIRS* systemic inflammatory response syndrome

**What Is the Pathophysiology of Compartment Syndrome?**

Extremity compartment syndrome begins with an extremity injury, such as a crush, burn, fracture, or reperfusion injury. Inflammatory mediators result in interstitial accumulation of serous fluid. Alternatively, an injury can cause bleeding into the compartment. Normal compartment pressures range from 5 to 10 mmHg. As pressures elevate past this, venules collapse and venous hypertension results. As the arterial-venous pressure gradient diminishes, this limits capillary perfusion and tissue ischemia results. If uncorrected, compartment syndrome can lead to tissue necrosis and permanent limb damage.

**Watch Out**

Tissue damage secondary to compartment syndrome can result in hyperkalemia, acidosis, and myoglobinuria, which can cause end-organ damage, most commonly, kidney failure.

**How Does Chronic Compartment Syndrome Differ from Acute Compartment Syndrome?**

Chronic or exertional compartment syndrome is less common; it results from tissue edema during exertional activity, causing swelling and pain within the compartment. Symptoms typically resolve with rest. Patients often have a long history of this condition, and diagnosis is based on clinical history and presentation. Chronic compartment syndrome is not a surgical emergency, but like acute compartment syndrome, it can be treated with fasciotomy if symptoms are severe.

**What Is the Significance of the First Web Space Numbness?**

For lower leg injuries, the anterior compartment is most susceptible to compartment syndrome. The deep peroneal nerve courses within this compartment and supplies motor fibers to the extensor digitorum brevis and extensor hallucis brevis, as well as afferent cutaneous sensation for the first web space. Nerve ischemia within the anterior compartment thus produces characteristic numbness between the first and second toes.

**What Is the Implication of Pulselessness in the Setting of Compartment Syndrome?**

The pathogenesis of compartment syndrome involves diminished arterial-venous pressure gradients and microvascular compromise. The increase in compartmental pressure required to develop compartment syndrome is not generally sufficient

to occlude arterial flow (thus pulselessness is not a feature of compartment syndrome). An absent pulse in the setting of compartment syndrome would imply extremely high compartment pressures and likely very advanced, irreversible tissue ischemia.

### What Is Volkmann's Ischemic Contracture?

Volkmann's ischemic contracture is a sequela of untreated compartment syndrome. It is classically seen in children following a supracondylar fracture that leads to marked swelling of the forearm muscles. An associated brachial artery injury from the fracture may also lead to ischemia. Untreated, the compartment syndrome leads to ischemic muscle that becomes fibrosed and contracted. The eventual result is a clawlike hand with flexion of the hand at the wrist as well as damaged and insensate nerves.

### What is the Pathophysiology of the Various Types of Compartment Syndrome?

Example	Underlying cause of compartment syndrome
<i>Circumferential third-degree burn</i>	Eschar forms after burn and reduces compartment size while capillary leak increases compartment edema
<i>Ischemia/reperfusion</i>	Local tissue inflammation causes capillary leak increasing compartment edema
<i>Large-volume resuscitation</i>	Underlying SIRS and capillary leak increase compartment edema
<i>Severe exertion</i>	Exertional activity causes tissue edema and increases compartment pressure in susceptible patients
<i>Severe hypotension</i>	Resulting SIRS and capillary leak increase compartment edema and also ischemia/reperfusion
<i>Prolonged surgery/immobilization</i>	Muscle crush injury from immobilization results in local inflammation, capillary leak, and compartment edema

### What Is Abdominal Compartment Syndrome? What Are the Risk Factors?

The abdominal cavity is a fixed compartment that is susceptible to elevated pressures causing mass effect to intra-abdominal organs. It typically occurs in trauma patients that receive massive fluid resuscitation.

### What Are the Clinical Manifestations of Abdominal Compartment Syndrome?

Elevated intra-abdominal pressures can impair respiration. The increased pressure adversely affects diaphragm expansion, increases intrathoracic pressure, decreases airway compliance, decreases total lung capacity and residual volume, and thus results in hypoxemia and hypercarbia. This may be manifested by an increase in peak airway pressures in mechanically ventilated patients. Abdominal compartment syndrome can compress the inferior vena cava and decrease venous return, manifesting as decreased cardiac output and decreased stroke volume. Compression of the kidney itself compromises renal perfusion and results in diminished urine output. Mortality is high with abdominal compartment syndrome and is greater if decompression is delayed. Unrecognized and untreated abdominal compartment syndrome results in multiple end-organ failure.

## Workup

### How Is the Diagnosis of Compartment Syndrome Established in an Extremity?

The diagnosis of extremity compartment syndrome is chiefly clinical and is based on the aforementioned findings of tense, tender, swollen compartments with pain on passive motion. With the classic history and physical examination, no further workup is necessary.

## What Is the Role of Measuring Compartment Pressures with Suspected Extremity Compartment Syndrome?

In the presence of a classic history and physical examination, measurement of compartment pressures is unnecessary and in fact would be contraindicated. Such measurements can be inaccurate and may lead to a false-negative result. Compartment pressures should only be measured in situations where suspicion of compartment syndrome is relatively low, so as to provide confirmatory documentation, or when the patient is obtunded, such that an accurate physical exam cannot be performed. A normal extremity compartment pressure is 5–10 mmHg; most authors advocate decompression in patients with a pressure of > 25–30 mmHg.

## How Is Abdominal Compartment Syndrome Diagnosed?

Abdominal compartment syndrome is not reliably defined on clinical exam, so there is greater reliance on pressure measurements. This is done by measuring bladder pressures. A bladder pressure >25–30 mmHg is highly suggestive of abdominal compartment syndrome.

---

## Management

### What Is the Treatment of Extremity Compartment Syndrome?

Treatment is immediate decompressive fasciotomy of all the compartments of the affected limb area.

### If Compartment Syndrome Is Suspected in the Anterior Compartment of the Lower Leg, How Many Compartments Should Be Released?

It is difficult to reliably rule out the absence of compartment syndrome in one compartment if another is affected. Furthermore, compartment syndrome may not be fully manifested in other compartments at the time of surgery. Most authors therefore advocate fasciotomy of all compartments of the affected part of the limb.

### What Compartment in the Lower Leg Is Most Often Missed During Fasciotomy?

The deep posterior compartment is the most difficult to open and is most often missed. Decompression of this compartment is vital for long-term foot function, as it contains both the posterior tibial and peroneal arteries and the tibial nerve.

### What Is the Treatment of Abdominal Compartment Syndrome?

Treatment is urgent decompressive laparotomy, with maintenance of an open abdomen and coverage with a vacuum-assisted suction device. Delayed closure of the abdomen is accomplished when tissue edema improves, and the fascial closure can be accomplished without intra-abdominal hypertension.

---

## Complications

### What Complications can Occur from Lower Leg Fasciotomy?

Complication	Comments
<i>Wound infection</i>	Most common complication; can occur in as many as 40 % of cases; likely that tissue necrosis plays a role
<i>Superficial peroneal nerve injury</i>	Passes superficially in lateral compartment and easily injured resulting in foot drop
<i>Incomplete fasciotomy</i>	Inadequate fascial incisions prohibit complete decompression of the compartment; generous skin and fascial openings are needed to fully decompress the leg
<i>Chronic swelling</i>	Can contribute to diminished limb function

## Summary of Essentials

### History and Physical

- Severe pain, tense swollen compartments
- Pain worsen with passive motion
- Pain out of proportion to clinical situation
- The 6 P's: pain, paresthesia, pallor, paralysis, poikilothermia, and pulselessness
  - Pulselessness in particular is a very late sign in compartment syndrome
  - The 6 P's are not consistently present

### Pathophysiology

- Decreased compartment size
  - Casts, circumferential burn, compression dressing, anti-shock garments, and splints
- Increased compartment volume
  - Trauma (bleeding, muscle swelling)
  - Ischemia/reperfusion

### Workup

- In the presence of a classic history and physical examination, no further workup is needed
- Measurement compartment pressures only if diagnosis is in doubt
  - Normal pressure is 5–10 mmHg
  - Intervention if > 25–30 mmHg

### Management

- Immediate decompressive fasciotomy of all the compartments of the affected area of the limb

### Prognosis

- Delay recognition/treatment may lead to limb loss, hyperkalemia, acidosis, and renal failure

---

## Suggested Reading

- Amendala A, Rorabeck CH. Chronic exertional compartment syndrome. In: Welsh RP, Shepard RJ, editors. *Current therapy in sports medicine*. Toronto: BC Decker; 1985. p. 250–2.
- Matsen 3rd FA. Compartmental syndrome. An unified concept. *Clin Orthop Relat Res*. 1975;113:8–14.
- Mubarak SJ, Hargens AR. Acute compartment syndromes. *Surg Clin North Am*. 1983;63(3):539–65.

---

**Part XIV**

**Upper Gastrointestinal**

Brian R. Smith, Section Editor

Areg Grigorian, Christian de Virgilio, Michael D. Sgroi,  
and Brian R. Smith

A 50-year-old male presents to the Emergency Department with a 3 hour history of bloody vomiting. He has no such prior history. The vomiting was not preceded by retching. He states that the blood was bright red. He currently feels slightly dizzy. He has no history of alcohol abuse. He has noted intermittent epigastric pain for the past 2 weeks that is relieved by taking oral antacid pills. On review of systems, he notes that he injured his knee a month ago and has been taking ibuprofen daily for pain relief. Physical exam reveals a blood pressure of 100/60 mmHg and a heart rate of 110 beats/min. There are no signs of jaundice. The abdomen is flat. No hepatosplenomegaly, caput medusae, or spider veins are appreciated. Laboratory values reveal a hematocrit of 40 %. Liver function tests are normal. INR and PTT are normal. BUN to creatinine ratio is 36.

---

A. Grigorian, MD (✉)

Department of Surgery, University of California, Irvine, 333 City Blvd West, Suite 1600, Route. 81, Orange, CA 92868, USA  
e-mail: [agrigori@uci.edu](mailto:agrigori@uci.edu)

C. de Virgilio, MD

Department of Surgery, Harbor-UCLA Medical Center, 1000 W. Carson Street, Torrance, CA 90509, USA  
e-mail: [cdevirgilio@labiomed.org](mailto:cdevirgilio@labiomed.org)

M.D. Sgroi, MD

Department of Surgery, University of California, Irvine, 333 City Blvd West, Suite 1600, Orange, CA 92868, USA  
e-mail: [sgroim@uci.edu](mailto:sgroim@uci.edu)

B.R. Smith, MD

Department of Surgery, UC Irvine Medical Center, VA Healthcare System Long Beach, 333 City Blvd West, Suite 1600, Orange, CA 92868, USA  
e-mail: [Smithbr@uci.edu](mailto:Smithbr@uci.edu)



## Diagnosis

### What is the Differential Diagnosis for an Upper GI Bleed and what Clues on History and Physical Examination Might Direct you Toward a Specific Diagnosis?

Diagnosis	Comments
<i>Gastritis</i>	Nausea, bloating, dyspepsia, NSAID abuse, <i>Helicobacter pylori</i> , alcohol abuse
<i>Gastric ulcer</i>	Epigastric pain after eating, weight loss, <i>Helicobacter pylori</i>
<i>Duodenal ulcer</i>	Epigastric pain with empty stomach relieved 2 h after eating, weight gain, <i>Helicobacter pylori</i>
<i>Erosive esophagitis</i>	Associated with infections (herpes simplex virus, <i>Cytomegalovirus</i> , <i>Candida</i> ), GERD, and drug ingestion (potassium chloride, NSAID) that gets lodged in esophagus
<i>Mallory-Weiss tear</i>	Forceful emesis and/or retching (after alcohol binge) followed by bloody emesis. Partial tear into mucosa/submucosa
<i>Esophageal varices</i>	Stigmata of liver disease including jaundice, spider angioma, gynecomastia, ascites, caput medusae, palmar erythema, asterixis, encephalopathy, alcohol abuse
<i>Gastric cancer</i>	Involuntary weight loss, dysphagia, bloating, early satiety
<i>Stress-related mucosal damage (ulcers and gastritis)</i>	Critically ill patients, severe trauma, severe burns (Curling ulcer), increased intracranial pressure (Cushing ulcer), shock, likely due to an inability to maintain integrity of the gastric mucosal barrier
<i>Angiodysplasia</i>	Degeneration of previously healthy small vessels, associated with chronic renal failure, valvular heart disease, CHF
<i>Isolated gastric varices</i>	Splenic vein thrombosis after acute pancreatitis
<i>Aortoenteric fistula</i>	Prior aortic surgery with graft eroding into distal duodenum
<i>Osler-Weber-Rendu disease</i>	Epistaxis, red nodules, and starry telangiectasias on the lips, nodular angiomas/telangiectasias in the small bowel

NSAID nonsteroidal antiinflammatory drug, GERD gastroesophageal reflux disease, CHF congestive heart failure

### What Are the Most Likely Diagnoses in This Patient?

With an upper gastrointestinal bleed, one should never assume what the source of bleeding is without performing an endoscopy. That being said, given the absence of stigmata of cirrhosis/portal hypertension, the absence of alcohol abuse, no history of retching, and a history of recent NSAID abuse, the most likely diagnoses are either acute gastritis or an ulcer. The question stem does not give any antecedent dyspepsia or prior symptoms to suggest a history of gastritis. NSAID use may mask the symptoms of dyspepsia.

## History and Physical

### What Information Can the Color and Texture of Stool or Emesis Provide?

The color and texture of stool or emesis (Table 48.1) can provide clues to the location of the GI bleed. Such information is vital, as it may influence the workup and management. Iron in the red blood cells, when exposed to gastric acid, becomes oxidized, resulting in a coffee-ground appearance. This oxidized blood can also be excreted in the stool, producing a tarry, blackened stool known as melena. Coffee-ground emesis and melena are both classic signs of upper GI bleeding. Bright-red blood or maroon-colored stools usually indicate bleeding in the lower GI tract. Rarely, bright-red blood

**Table 48.1** Color and texture of stool and emesis

Emesis or stool	Likely location of lesion
Bright-red bloody emesis	UGI
Coffee-ground emesis	UGI
Black, tarry, foul-smelling stool ( <i>melena</i> )	UGI (probable), LGI (possible)
Bright-red bloody stool ( <i>hematochezia</i> )	UGI (possible), LGI (probable)
Maroon-colored stool	UGI (probable), LGI (possible)

UGI upper gastrointestinal, LGI lower gastrointestinal

per rectum is the result of massive bleeding from the upper GI tract, as large volumes of blood act as a cathartic. The rapid transit prevents the blood from being subjected to the digestive enzymes.

### What Variables Adversely Affect Prognosis in a Patient with an Upper GI Bleed?

Increasing age (>60 years old), increased number of comorbid conditions (renal failure, liver failure, or heart failure), variceal bleeding (vs non-variceal), shock on presentation, increasing number of units of blood transfused, active bleeding during endoscopy, bleeding from a large (>2.0 cm) ulcer, recurrent bleeding, and need for emergency surgery.

## Pathophysiology

### What Are Esophageal Varices?

Esophageal varices are dilated tortuous veins located in the submucosa of the distal third of the esophagus that form as a result of portal hypertension. Given their size, high pressure, and superficial location, they are highly prone to erode and cause life-threatening bleeding. The primary venous drainage of the esophagus is via the esophageal veins that empty into the superior vena cava. However, distal veins within the submucosa empty into the left gastric vein (also known as the coronary vein), which normally drains into the portal vein. In the presence of cirrhosis, the portal vein has much more difficulty draining its blood into the scarred liver. Blood is forced to flow in a retrograde direction, under high pressure toward the tributaries of the portal vein.

### What Are the Differences Between Acute and Chronic Gastritis (Table 48.2)?

*Acute gastritis* is an *erosive*, superficial inflammation in the lining of the stomach secondary to the dysfunction of mucosal defenses. These defense mechanisms include the production of prostaglandins, bicarbonate, and somatostatin. All three reduce the inflammatory effects that gastric acid can have on the gastric mucosa. Increased hydrochloric acid secretion does not play a primary role, but low doses of alcohol have been shown to cause increased acid secretion (high doses do not) which may exacerbate erosions. NSAIDs, which are COX-1 and COX-2 inhibitors, reduce the production of prostaglandins and their protective mechanisms on the stomach lining. Consumption of corrosive materials (e.g., household cleaners, pesticides, gasoline, cosmetics) can also lead to acute gastritis.

*Chronic (atrophic) gastritis* is a *nonerosive* inflammation of the gastric mucosa. Type A or fundus-dominant chronic gastritis is associated with pernicious anemia in which the body produces autoantibodies to parietal cells leading to megaloblastic anemia and vitamin B12 deficiency. Type B or antral-dominant chronic gastritis is the most common form and is caused by a *Helicobacter pylori* infection leading to peptic ulcer disease and an increased risk of gastric cancer and mucosa associated lymphoid tissue (MALT) lymphoma.

### What Is a Dieulafoy's Lesion?

Dieulafoy's lesion is a rare cause of acute upper GI bleed. This is a vascular malformation in which a large tortuous artery that is aberrantly located in the submucosa, often in the lesser curvature of the stomach, is eroded by gastric acid. The classic finding on endoscopy is a small, pinpoint defect in the gastric mucosa which is not a primary ulcer but likely a result of the

**Table 48.2** Acute versus chronic gastritis

	Acute gastritis	Chronic gastritis
<i>Erosive</i>	Yes	No
<i>Etiology</i>	NSAID abuse, alcohol, steroids, uremia	Pernicious anemia, <i>H. pylori</i> infection
<i>Pathogenesis</i>	Decreased integrity of mucosal barrier	Inflammation related to autoantibodies or <i>H. pylori</i> infection

**Table 48.3** Bleeding vessels in peptic ulcer disease

Branch of the celiac	Type of ulcer	Location
<i>Splenic artery</i>	Gastric	Posterior wall of the stomach
<i>Left gastric artery</i>	Gastric	Lesser curvature of the stomach
<i>Gastrooduodenal artery</i>	Duodenal	Posterior wall of the first portion of duodenum

mechanical pressure from the pulsating large artery that progressively erodes through the mucosa. They are identified endoscopically and described as a visible vessel without an underlying ulcer present.

### What Are the Important Anatomic Correlations for Peptic Ulcer Disease?

The branches of the celiac trunk (Table 48.3) may be subject to erosion leading to severe hemorrhage if an ulcer penetrates through the gastrointestinal mucosa and into the vessel.

## Workup

### Why Might the Hemoglobin/Hematocrit Be Normal in Spite of a Major GI Bleed?

It is important to recognize that the hematocrit is a poor indicator of the severity of acute blood loss. Since the patient is losing whole blood, plasma and red cell volume decrease in the same proportion. As such, the hematocrit may not change at all initially, potentially misleading the clinician. A decrease in hematocrit may not reflect until 12–24 hours later, when the kidney begins to conserve sodium and water. Over time, the patient's hemoglobin will decrease further as fluid is administered with initial resuscitation. However, in a patient with significant bleeding, signs of hypovolemic shock will become apparent earlier. Initial signs of significant blood loss include tachycardia, low urine output, and a drop in blood pressure.

#### Watch Out

A patient's blood pressure may not drop until they have lost 30–40 % of their blood volume. By this time they are in significant shock and are at risk of developing end-organ damage secondary to hypoperfusion.

### What Happens to the BUN/Creatinine Ratio During an UGI Bleed?

The BUN/creatinine ratio increases. In the absence of renal insufficiency, a decreased hemoglobin/hematocrit combined with a BUN/creatinine ratio greater than 36 (normal less than 20) suggests an UGI bleed. This increase is a result of absorption of degraded blood products during intestinal transit and prerenal azotemia secondary to hypovolemia.

### What Part of the GI Tract Is Considered an Upper GI Bleed?

From the oropharynx to the distal duodenum (at the ligament of Treitz), which marks the transition from the retroperitoneal duodenum to the intraperitoneal jejunum; bleeding distal to the ligament of Treitz is considered a lower GI bleed.

### If a Patient Presents with Bloody Emesis and Bright-Red Blood Per Rectum, Is It an Upper or a Lower GI Bleed?

Bright-red blood per rectum is usually due to a lower GI bleed. However, massive UGI bleeding may cause such a rapid transit of the blood through the GI tract that it does not have time to be subjected to digestive enzymes, resulting in bright-red blood per rectum.

## What Is the Difference Between Obscure and Occult GI Bleeding?

Occult GI bleed is one that is not known to the patient. It is discovered by either fecal occult blood testing or by noting an iron deficiency anemia on blood testing. The majority of causes of both upper and lower GI bleeding can present as occult bleeding. Obscure GI bleeding is obvious bleeding that is known to the patient, but the source of the bleed, which tends to be recurrent, is hard to identify despite endoscopy. Obscure bleeding tends to arise from pathology in the small bowel and is difficult to visualize with either upper or lower endoscopy. Etiologies include small bowel vascular ectasia (most common), small bowel ulcers, lymphoma, leiomyoma, leiomyosarcoma, small bowel varices, Crohn's disease, and tuberculosis.

---

## Management

### What Are the First Steps in the Management of This Patient?

The first step in evaluation of an upper GI bleed involves fluid resuscitation (Fig. 48.1). All patients with hemodynamic instability manifested by hypotension, tachycardia, or active bleeding should receive two large-bore IV lines and a nasogastric tube (NGT) and have blood sent for a type & cross. Adequate resuscitation and stabilization are essential prior to upper endoscopy, which will determine the source of bleeding. The patient should be admitted to a monitored setting.

### What Is the Role of Placing an NG Tube?

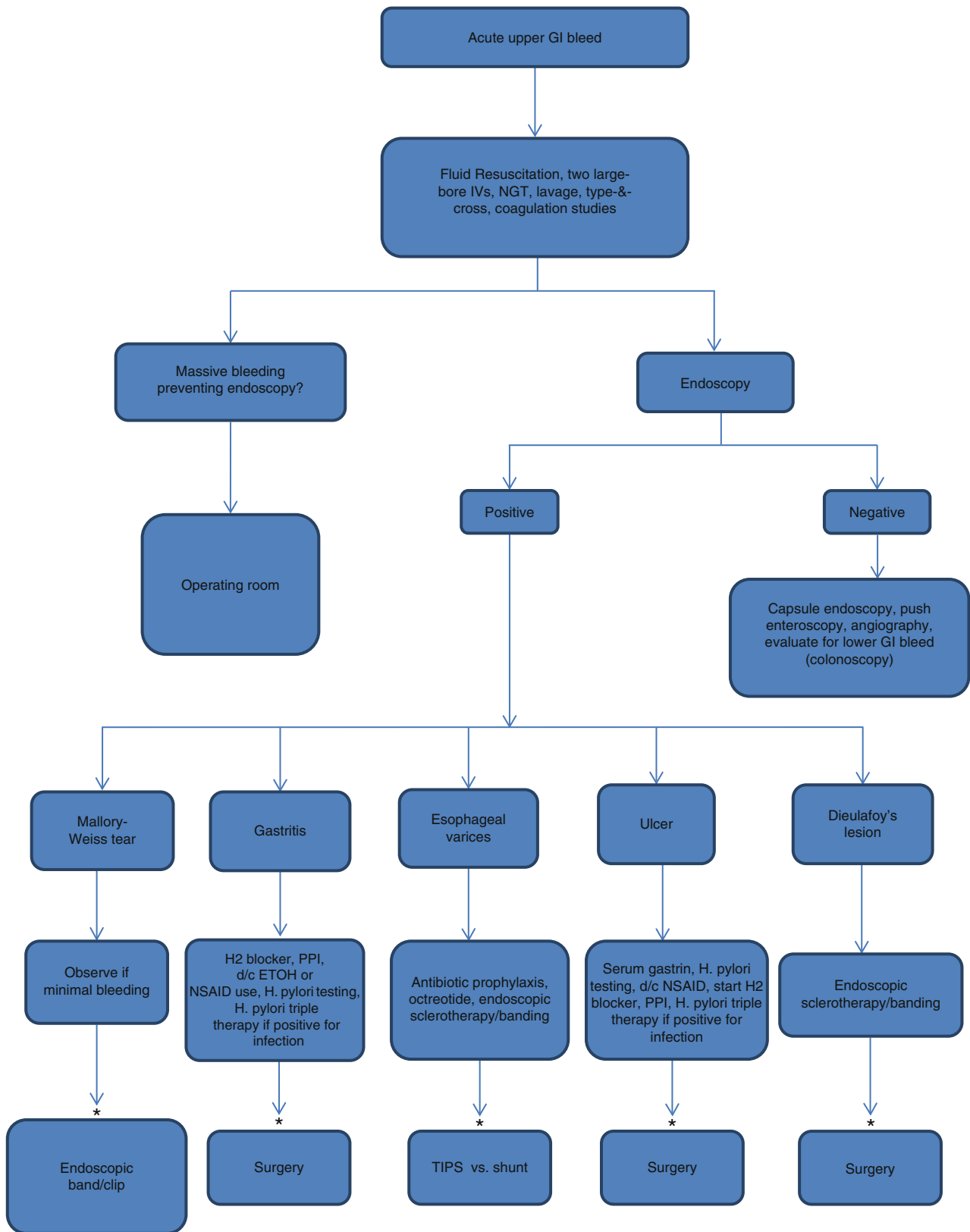
NG tube lavage is used to help differentiate between upper and lower GI bleeding. It is used commonly in patients presenting with melena. If NGT lavage returns blood or coffee grounds, the patient has an upper GI bleed. If clear, non-bilious fluid is returned, the source of bleeding is unlikely to be proximal to the pylorus of the stomach. If bilious fluid is returned with no blood, this makes it very unlikely that the upper GI tract is the source of bleeding, and thus it is likely to be distal to the ligament of Treitz. However, if the patient does not have an active bleed, then an NGT lavage can be unreliable. In addition, the NGT lavage facilitates proper visualization during endoscopy as it removes fresh blood and blood clots. Early upper GI endoscopy (first 24 h of hospitalization) has been shown to decrease hospital stay, need for surgery, and mortality. It is the most accurate tool for localizing the source of an upper GI bleed.

### What Fluid Is Used During NGT Lavage?

Room-temperature normal saline is the preferred irrigant. Traditionally, iced lavage was used because it was believed to help decrease bleeding by promoting vasoconstriction in nearby vessels. This has fallen out of favor because cold solutions stimulate the vagus nerve which may lead to increased acid secretion and gastric motility, both of which can exacerbate bleeding.

### What Is the Difference Between a "Type & Screen" and a "Type & Cross"? Which One Is More Appropriate in This Setting?

*Type & screen* is requested in circumstances that are not likely to require a blood transfusion, such as elective surgery. Typing determines ABO and Rh status. Screening involves identifying the presence of alloantibodies in the recipient's blood that may react with donor blood. A positive screen warrants an antibody panel because not all alloantibodies lead to clinically significant reactions. *Type & cross* is utilized when the likelihood of actually needing blood is high, as in the patient described above. In a crossmatch, the recipient blood is tested against donor packed cells to determine if there is a clinically significant response to any antigens on the donor's cells.



\* = if conservative management fails

**Fig. 48.1** Management algorithm of UGI bleed

### **What If the Patient Needs Blood Immediately?**

In emergent cases, if the patient is exsanguinating and time constraints preclude a type & cross, O-negative blood is administered. O is the universal donor because it does not contain A or B antigens, so the recipient will not mount an immune response to it.

### **How Should the Bed Be Positioned in a Patient Who Is Vomiting Blood?**

Provided that there are no contraindications (ongoing hypotension), it is recommended to elevate the head of the bed to an angle of 30° to prevent aspiration. Nevertheless, studies looking at the efficacy of the reverse Trendelenburg position in minimizing aspiration are lacking.

### **Following Resuscitation, What Is the Next Step in the Management?**

Any coagulopathy should be corrected with blood products, including fresh frozen plasma if the INR is elevated and platelets for severe thrombocytopenia. If the patient is taking any anticoagulants, they should be reversed with a major bleed. The majority of patients with UGI bleeding are typically started on an intravenous proton pump inhibitor (PPI). Pantoprazole, lansoprazole, and esomeprazole are the only intravenous formulations available in the United States.

### **In What Setting Should the Patient with an UGI Bleed Be Managed?**

UGI bleeding has a high mortality and should be managed in the ICU. Blood volume should be maintained using blood products and intravenous fluids. The patient will need continuous monitoring, which may include a central venous line for rapid transfusion access and central venous pressure monitoring as well as an arterial line to continuously monitor blood pressure and a Foley catheter to monitor urine output.

### **Following Stabilization, What Is the Next Step in the Management? What Is the Optimal Timing?**

Upper endoscopy is the next step. It is both diagnostic and often therapeutic. Ideally it should be performed within 12 h of admission.

### **What If Upper Endoscopy Fails to Show the Source of a GI Bleed, What Other Imaging Might Be Useful?**

When endoscopy fails to detect the source of bleeding, the patient has what is termed an obscure bleed. The next step depends on the severity of the bleeding. If bleeding is brisk, angiography is recommended as it allows for simultaneous therapeutic intervention (embolization of bleeding vessels). If bleeding is intermittent or minor, capsule video endoscopy and push enteroscopy are recommended. A technetium-99m-labeled red blood cell (tagged RBC) scan is more helpful for lower GI bleeding. It has a high sensitivity; however, it is not very specific and has trouble locating the exact location of small bowel bleeding. Tagged RBC scanning can detect slower bleeds (0.5 cc/min), while angiography will only detect more rapid bleeding (rate of 1 cc/min).

### **In the Absence of Varices, What Are the Endoscopic Therapeutic Options for UGI Bleed?**

Numerous endoscopic techniques are utilized to stop bleeding in the stomach and duodenum including: injection of epinephrine, bipolar electrocoagulation, heater probe coagulation, argon plasma coagulator, laser photocoagulation, application of hemostatic materials, and use of endoscopic clips.

## What are the Indications for Surgery in a Patient with an Upper GI Bleed?

Failure of endoscopic therapy (usually after 2 attempts)
Persistent hemodynamic instability despite aggressive resuscitations
Cardiovascular disease with predictive poor response to hypotension
Hemorrhagic shock
Excluding esophageal varices

## What Are the Surgical Options in a Patient with a Bleeding Ulcer That Fails Medical Management?

For *duodenal* ulcers the duodenum is opened longitudinally, and the bleeding ulcer is oversewn in three quadrants, so as to make sure that the bleeding gastroduodenal artery is properly ligated. If the patient is stable and if there is a long-standing history of ulcer treatment, a truncal vagotomy and pyloroplasty is performed to reduce recurrence. A third option in a stable patient is a highly selective vagotomy (HSV) (a tedious and technically demanding operation) which spares the innervation to the antrum and pylorus, thus minimizing the adverse effects on gastric emptying seen with a truncal vagotomy (delayed gastric emptying). Vagotomy works by reducing the stimulation of the parietal cells and the secretion of gastric acid. This procedure is recommended only if the patient has a type II or type III peptic ulcer. All patients should be treated for *H. pylori* postoperatively.

For *gastric* ulcers, the optimal treatment is to excise part of the stomach to include the ulcer, as there is a higher risk of underlying malignancy with gastric ulcers.

### Watch Out

Over the past few decades, there has been a declining need for surgery to treat peptic ulcer disease as a result of the widespread eradication of *H. pylori* and the use of proton pump inhibitors. The most common reason for surgical intervention in benign gastric ulcers is failure of the ulcer to completely heal after a 6-month trial of medical or endoscopic therapy.

## Special Management Circumstances

### If an Ulcer or Gastritis Is Found on Endoscopy, What Additional Studies/Therapies Are Recommended?

*H. pylori* infection is present in the majority of uncomplicated gastric or duodenal ulcers. Leaving this untreated can result in recurrent ulcers which may lead to perforation. In addition, there is an increased risk for the development of lymphoma in the stomach (MALToma, mucosa-associated lymphoid tissue lymphoma) as well as gastric adenocarcinoma. After confirmation of infection with *H. pylori* (see section below), the standard first-line therapy consists of “triple therapy” with a proton pump inhibitor such as omeprazole, along with clarithromycin and amoxicillin. Most patients are treated for 1 week.

### How Do You Test for *H. pylori* Eradication?

Because of the increasing presence of antibiotic-resistant *H. pylori*, it is recommended to confirm eradication of infection in all patients 4–6 weeks following treatment. The best test is the urea breath test (UBT). The urease produced by *H. pylori* can hydrolyze urea to produce CO<sub>2</sub> and ammonia, which can be traced using a labeled carbon isotope given by mouth to the patient. The patient should not be on a proton pump inhibitor because it can result in a false negative. The sensitivity and specificity of UBT are approximately 88–95 % and 95–100 %, respectively. Serologic testing demonstrates prior exposure to *H. pylori* by detecting IgG antibodies but is a poor choice to test for eradication. In patients with

biopsy-confirmed eradication, *H. pylori* titers decrease by approximately 50 % after 3 months. However, titers become undetectable in only 60 % of cured patients. Stool antigen testing using fecal assays is widely available, but its utility in checking for eradication is still not clear.

### **How Does the Management of UGI Bleed Differ for Esophageal Varices?**

Unlike other causes of UGI bleed, variceal bleeding is managed with short-term antibiotic prophylaxis (decreases infection risk and improves survival). Endoscopic band ligation is recommended as the first choice because it causes less injury to the esophagus (as opposed to cauterization or coagulation). Sclerosis is another option. Endoscopy is typically repeated in 48 hours to band any remaining vessels. Somatostatin (octreotide) and vasopressin are given to reduce portal blood flow. However, vasopressin causes systemic vasoconstriction and is therefore contraindicated in patients with coronary artery disease. If combination therapy and repeat endoscopic therapy fail to control bleeding, transjugular intrahepatic portosystemic shunting (TIPS) may be considered to lower portal pressure.

### **What Is the Best Way to Prevent Recurrent UGI Bleed from Esophageal Varices?**

For esophageal varices, long-term  $\beta$ -blocker (propranolol) use has been shown to decrease the likelihood of rebleeding. Beta-blockers are not useful in the acute setting.

### **How Does the Management of UGI Bleeding Differ for a Mallory-Weiss Tear?**

Mallory-Weiss tears are linear erosions in the gastroesophageal mucosa and submucosa that result from a sudden increase in intra-abdominal pressure. Precipitating factors include vomiting, retching, straining at stool, lifting, or coughing. The bleeding is almost always self-limited. Only in rare cases is sclerosing therapy or electrocautery needed. Surgery is even more rarely required and would consist of oversewing the bleed through a gastrotomy.

### **What Is the Best Way to Prevent/Treat Stress-Related Mucosal Damage (Stress Ulcers and Stress Gastritis)?**

The best way to prevent stress ulcers is by maintaining a gastric pH greater than 5 using intravenous proton pump inhibitors. Once diagnosed, most patients can be treated with an intravenous proton pump inhibitor. However if further intervention is necessary for resolution, angiographic embolization is the preferred therapeutic approach.

---

## **Areas Where You Can Get in Trouble**

### **Assuming That UGI Bleeding in an Alcoholic Is Due to Esophageal Varices**

Esophageal varices occur as a result of high pressures in the portal system, often secondary to alcohol-induced cirrhosis. Although alcohol is the prevailing cause of portal hypertension, hepatitis B and C are becoming more prominent. However, it is crucial to rule out other etiologies by performing an endoscopy. A Mallory-Weiss tear should be considered if the patient presents with a history of retching prior to bleeding. A careful history should be taken to determine if NSAIDs may have played a role.



---

## Failing to Recognize the Severity of Liver Disease

Cirrhosis can also predispose alcoholic patients to coagulopathies that can manifest with upper GI bleeding. All such patients should be screened with the proper studies (e.g., INR, PT), and any abnormalities should be corrected with blood products. It is also important to assess a cirrhotic patient's surgical risk based on Child's classification and the Model for End Stage Liver Disease (MELD) score, as this may influence surgical decision making.

---

## Areas of Controversy

### When Should Transfusion Be Given for an Acute UGI Bleed?

Blood transfusion is often necessary for an acute UGI bleed. There is no single laboratory or diagnostic criterion to base blood transfusion decisions. Recent studies suggest that a liberal policy of blood transfusion worsens outcome and that blood transfusion should be withheld unless the hemoglobin drops below 7 g/dl. Elderly patients and those with compromised cardiac function are at risk for volume overload when given a large number of blood transfusions.

### When Should Nonoperative Management Be Abandoned and Surgery Performed?

Similarly the decision of when to abandon nonoperative management is not well defined. Multiple factors related to the patients clinical status and hospital course need to be considered. Although no guidelines exist for the maximum number of transfusions allowed, most clinicians will transfuse up to 4 units of packed red blood cells (PRBCs) over the initial 24 hours or 10 units of PRBCs in total before considering taking the patient to the operating room.

---

## Summary of Essentials

### History and Physical Exam

- Do not forget to ask about alcohol and NSAID use
- Look for stigmata of alcoholic cirrhosis

### Pathology/Pathophysiology

- UGI bleeding is proximal to ligament of Treitz
- About 75 % of GI bleeding is from the upper GI tract
- Most common cause of melena is upper GI bleeding
- An occult bleed is defined by fecal occult blood positivity and/or iron deficiency anemia
- An obscure bleed is an obvious bleed without a source: think small bowel

### Differential Diagnosis

- Consider stress ulceration in a critically ill ICU patient
- Consider an aortoenteric fistula if the patient has a history of aortic surgery; workup with endoscopy and CT (gas/stranding around graft)
- Consider Mallory-Weiss tear if bleeding follows forceful vomiting

## Diagnosis

- When it is unclear whether the bleed is upper or lower GI, perform NG tube lavage
- UGI bleeding can increase BUN/creatinine ratio

## Management

- Start with ABCs (airway, breathing, circulation), two large-bore IVs, and type & cross
- With a massive bleed, consider intubation to protect the airway
- Liberal blood transfusion policy not helpful; restrict blood unless the hemoglobin drops below 7 g/dl
- Start PPI early
- Triple therapy for *H. pylori* eradication
- Admit to monitored setting
- Perform upper endoscopy within 12 hours
- Most bleeding successfully treated with endoscopic techniques
- Surgery only if endoscopy fails: duodenal ulcer (open duodenum, 3-point ligation of ulcer), gastric ulcer (excise and close for acute vs distal gastrectomy for chronic history of ulcer disease)
- Calculate MELD score

## Special Management Situations

- With isolated gastric varices along the greater curve, consider splenic vein thrombosis from prior pancreatitis; splenectomy is curative
- Gastric varices are more difficult to treat than esophageal varices and do not respond well to banding or sclerotherapy
- Mallory-Weiss tear: bleeding usually stops spontaneously

## Prevention

- Use proton pump inhibitors in patients on long-term NSAID therapy (e.g., rheumatoid arthritis) to prevent ulcers
- Propranolol helps prevent recurrent bleeding from esophageal varices; it is not helpful in an acute bleeding episode

---

## Suggested Reading

- Cooper GS, Chak A, Way LE, Hammar PJ, Harper DL, Rosenthal GE. Early endoscopy in upper gastrointestinal hemorrhage: Associations with recurrent bleeding, surgery, and length of hospital stay. *Gastrointest Endosc.* 1999;49:145–52.
- Gin-Ho L, Kwok-Hung L. A prospective, randomized trial of sclerotherapy versus ligation in the management of bleeding esophageal varices. *Hepatology.* 1995;22(2):466–71.
- Hari S, Teyssen S, Singer MV. Alcohol and gastric acid secretion in humans. *Gut.* 1993;34:843–7.
- Martinez V, Wu SV, Taché Y. Intracisternal antisense oligodeoxynucleotides to the thyrotropin-releasing hormone receptor blocked vagal-dependent stimulation of gastric emptying induced by acute cold in rats. *Endocrinology.* 1998;139:3730–5.
- Saltzman JR, Tabak YP, Hyett BH, Sun X, Travis AC, Johannes RS. A simple risk score accurately predicts in-hospital mortality, length of stay, and cost in acute upper GI bleeding. *Gastrointest Endosc.* 2011;74(6):1215–24.

Michael D. Sgroi and Brian R. Smith

A 56-year-old male with a history of gastroesophageal reflux disease (GERD), hypertension, and diabetes presents to the emergency room complaining of severe abdominal pain. The patient reports epigastric pain for months, but it has just acutely become intolerable over the last 8 h. He states that the chronic pain has been a “gnawing” pain that comes on after eating. He thought he was just having some indigestion and would take some antacids for relief. Late last night, the pain became excruciating and now he is having trouble moving. At initial exam, blood pressure is 130/70 mmHg, heart rate is 110 bpm, and temperature is 101.5 °F. He appears to be in severe distress secondary to pain. The patient refuses to straighten his legs because it hurts too much. He almost jumps off of the table when you press on his abdomen. He has diffuse guarding and rebound tenderness. Blood work is drawn displaying a WBC of 15 (normal  $4.1\text{--}10.9 \times 10^3/\mu\text{L}$ ), BUN of 35 (7–20 mg/dL), creatinine of 1.8 (0.5–1.4 mg/dL), serum amylase of 70 (30–110  $\mu\text{L}$ ), and lipase of 60 (7–60 u/L). An upright CXR demonstrates free air under the right diaphragm.

## Diagnosis

### What is the Differential Diagnosis and What Clues on History and Physical Examination Might Direct you Towards a Specific Diagnosis?

Diagnosis	History and physical
<i>Acute cholecystitis</i>	Persistent post-prandial right upper quadrant (RUQ) pain, positive Murphy’s sign; fever
<i>Acute pancreatitis</i>	Severe epigastric pain radiating straight through to back (2° cholelithiasis, alcohol abuse)
<i>Acute cholangitis</i>	Persistent RUQ pain, fever, jaundice ( <i>Charcot’s triad</i> )
<i>Perforated gastric or duodenal ulcer</i>	History of peptic ulcer disease (PUD), <i>H. pylori</i> or chronic NSAID use; abdominal guarding, rigidity, and rebound tenderness suggestive of peritonitis
<i>Diverticulitis</i>	Can present with signs of peritonitis; pain is usually located in the LLQ
<i>Small bowel obstruction</i>	Extensive nausea/vomiting may present with severe abdominal pain and marked abdominal distention

M.D. Sgroi, MD (✉)

Surgery Department, University of California, Irvine, 333 City Blvd West, Suite 1600, Orange, CA 92868, USA

e-mail: [sgroim@uci.edu](mailto:sgroim@uci.edu)

B.R. Smith, MD

Surgery Department, UC Irvine Medical Center, VA Healthcare System Long Beach, 333 City Blvd West, Suite 1600, Orange, CA 92868, USA

e-mail: [Smithbr@uci.edu](mailto:Smithbr@uci.edu)

---

## What Is the Most Likely Diagnosis?

The free air under the diaphragm indicates that the patient has a perforated viscus. This is supported by evidence of diffuse peritonitis on physical exam. The most common causes of free air under the diaphragm are perforated ulcers and perforated diverticulitis. Given the longstanding history of epigastric pain relieved by antacids, the most likely diagnosis is a perforated ulcer.

---

## History and Physical

### What Are the Most Common Symptoms in a Patient with PUD?

The most common symptom for patients with PUD is abdominal pain that is usually described as a burning in the epigastric region and non-radiating. However, the description and location of the pain can vary and be vague. Location of the ulcer can often be deciphered based on timing of symptoms. Patients with gastric ulcers often have pain during food consumption, while patients with duodenal ulcers have pain 2–3 h post-prandially. Other signs and symptoms include nausea, vomiting, abdominal distention, melena, and weight loss. A thorough history should be performed regarding a history of GERD, chronic NSAID use, and smoking. A family history of ulcers is also important, as genetics play a role. On physical exam, patients will often present with tenderness to palpation at the epigastrium.

### How Would a Patient with a Perforated Peptic Ulcer Present?

A perforated peptic ulcer has a very classic description of signs and symptoms. Patients will often present with an acute onset of sharp abdominal pain within the epigastric region that rapidly becomes diffuse. They may occasionally complain of shoulder pain secondary to diaphragm irritation (referred pain from the phrenic nerve). Approximately a third of patients will have a known history of PUD, and around 5–10 % will actually present with septic shock. On physical exam, the patient will likely be lying motionless and have peritonitis characterized by exquisite tenderness to palpation, abdominal guarding, and rigidity. The abdomen is usually not distended. Depending on the longevity of symptoms, the patient may have evidence of marked hypovolemia secondary to severe peritonitis. Laboratory findings are usually benign, other than a leukocytosis with left shift. Due to the location of the pain, pancreatitis should be in the differential diagnosis. Amylase and lipase should be ordered and will likely be within normal limits. If the patient presents in septic shock, they may have a metabolic acidosis with an elevated lactate. However, the acidosis can be masked by respiratory compensation or by the loss of acid via extensive vomiting.

---

## Pathophysiology

### How Common Are Peptic Ulcer Perforations and How Often Do They Result in Death?

Peptic ulcer disease (PUD) is one of the most common gastrointestinal disorders worldwide, accounting for an annual incidence rate of 0.1–0.19 % and prevalence of approximately 1.5 %. These rates have dramatically decreased since the introduction of appropriate medical therapy for *Helicobacter pylori* (antibiotics and proton-pump inhibitors). However, ulcers continue to be a common cause of perforated viscus as a result of the ongoing use of aspirin and nonsteroidal anti-inflammatory drug (NSAIDs) by the elderly. Gastroduodenal perforations occur in 2–10 % of patients with PUD and account for more than 70 % of deaths associated with PUD.

### What Is the Most Common Cause of Peptic Ulcers?

There are a variety of causative factors leading to the presentation of a gastric or duodenal ulcer, but the same common principle applies: destruction of the mucosal barrier by a variable combination of factors ranging from hypersecretion of acid to hyposecretion of mucosal defense mechanisms. In 1982, Barry Marshall and Robin Warren discovered the presence of *H. pylori* in peptic ulcers, which now account for more than 90 % of duodenal ulcers and up to 80 % in gastric ulcers. The inflammatory reaction caused by *H. pylori* invokes a hypersecretion of gastrin which in turn leads to an increase in acid

secretion. The acid hypersecretion will first lead to the development of antral gastritis, and if the *H. pylori* is not treated, an ulcer will likely form. The production of prostaglandins, bicarbonate, and somatostatin has been recognized to decrease in patients with *H. pylori* infections and normalizes once the bacteria are eradicated. Once the defense mechanisms have become ineffective, the entire stomach is a risk of pangastritis and ulcer development.

### How Do NSAIDs Lead to Peptic Ulcers?

Chronic NSAIDs are associated with approximately 15–20 % of patients found to have PUD. By inhibiting both COX-1 and COX-2 production, NSAIDs inhibit the secretion of prostaglandins and thromboxanes. Prostaglandins in particular are able to regulate inflammatory reactions within the gastric mucosa as well as reduce the production of acid by acting upon the parietal cells of the stomach. The chronic use of NSAIDs results in the unopposed secretion of acid and a reduction in mucosal defense. More than half of patients who present with peptic ulcer hemorrhage or perforation report the recent use of NSAIDs, including aspirin. To put into perspective, over 20 million people take NSAIDs on a regular basis. This chronic use is common in the elderly population, who are also on multiple other medications which may include steroids, aspirin, or anticoagulants. All of these factors will increase one's risk of an adverse event, with many remaining asymptomatic until they develop these life-threatening complications.

### What Are Some Other Factors that May Lead to the Presence of Peptic Ulcers?

Other factors that may lead to the formation of a peptic ulcer include smoking, alcohol, and high stress environments. Cigarette smoking has been found to double one's risk of developing PUD compared to nonsmokers. Smoking results in an imbalance between mucosa apoptosis and proliferation. Additionally, cigarette smoke has an inhibitory effect on prostaglandins and mucus proliferation, resulting in a decrease in defense mechanisms. Cushing and Curling stress ulcers in head trauma and burn patients, respectively, have also been described throughout the literature and, if left untreated, can progress to hemorrhage or perforation.

### What Are the Different Types of Peptic Ulcers and How Are They Categorized?

In 1957, the modified Johnson classification system was established to categorize gastric ulcers based on location (Table 49.1). Type I ulcers are located on the lesser curvature of the stomach near the incisura and are the most common of all peptic ulcers. Type II ulcers are found in two locations, the body of the stomach and the duodenum. Type III gastric ulcers are located in the prepyloric antrum. Type IV ulcers are within the cardia of the stomach near the gastroesophageal junction and tend to be highly painful. Type V ulcers are associated with NSAID use and can occur anywhere in the stomach. Type II and Type III ulcers have acid hypersecretion, while Types I, IV, and V all have disruptions in the mucosal protective defense mechanisms as the common etiology.

### How Does Vomiting Change a Patient's Acid/Base Balance?

Vomiting results in the loss of potassium and hydrochloric acid. The loss of the hydrogen ions leads to a metabolic alkalosis. If the vomiting continues, the patient will also start losing sodium. Hyponatremia is sensed by the macula densa of the

**Table 49.1** Types of gastric ulcers

Type	Location	Acid hypersecretion?
I	Lesser curvature	No
II	Lesser curvature and duodenum	Yes
III	Prepyloric	Yes
IV	Gastric cardia	No
V	Any location in stomach	No

kidneys and results in the activation of the renin/angiotensin/aldosterone system. This results in reabsorption of sodium and water within the renal tubules at the expense of hydrogen ions. This is also known as *contraction alkalosis*.

---

## Work-Up

### How Is the Diagnosis of Perforated PUD Established?

There are no established blood tests for PUD. The diagnosis of a perforated peptic ulcer is usually made with clinical examination and confirmed by radiologic findings. Patients usually present with an acute onset of sharp epigastric pain and display signs of an acute abdomen on physical exam. In the majority of patients, they will exhibit guarding with palpation and significant muscle rigidity, as well as evidence of a systemic inflammatory response syndrome (SIRS) (fever, tachycardia). These findings can be masked in obese patients due to extensive subcutaneous fat.

### What Laboratory Studies Should Be Sent?

Complete blood count and blood chemistries should be ordered. Blood test abnormalities may include leukocytosis with a left shift, elevated C reactive protein (CRP), decreased albumin, and elevated BUN and creatinine. Amylase and lipase should be obtained to exclude pancreatitis. Liver function tests should also be sent as patients with choledocolithiasis or cholecystitis often complain of epigastric pain rather than right upper quadrant pain.

### What Additional Diagnostic Studies Are Recommended for a Patient with a Suspected PUD?

The classic finding on an acute abdominal series or upright chest x-ray is pneumoperitoneum, a hyper-lucent area under one or both hemidiaphragms (although free air under the left diaphragm alone can be difficult to distinguish from the gastric air bubble). However, absence of pneumoperitoneum does not exclude the diagnosis of perforation. Within the elderly population, free intraperitoneal air on plain radiographs is absent in 40 % of patients who have perforation. For posterior gastric ulcers, care must also be taken to evaluate for retroperitoneal air. In this subset of patients, their abdominal exam may not be impressive due to little or no peritoneal soilage despite a significant and potentially life-threatening perforation. Due to the inflammatory reaction occurring in the abdominal cavity, thickened viscera may also be seen, depending on the length of time the patient has been perforated.

#### Watch Out

It is important to note that if a perforated peptic ulcer is suspected, barium UGI series (causes barium peritonitis) and upper endoscopy (insufflation of air may exacerbate perforation) are contraindicated.

### What Is the Role of CT Scan?

A CT scan of the abdomen with contrast (gastrografin) will be able to diagnose pneumoperitoneum and confirm the diagnosis of perforation. The contrast will also demonstrate if the perforation has sealed itself, which may allow for nonoperative management in select cases.

### What Is the Morbidity and Mortality of a Perforated Peptic Ulcer?

The morbidity and mortality following a perforated peptic ulcer is substantial with a mortality rate of over 25 %. Variables associated with worse prognosis are listed in Table 49.2. With each factor present, mortality increases.

**Table 49.2** Factors conferring worse prognosis in perforated peptic ulcer

Presence of major medical illness
Liver cirrhosis
Preoperative shock
Perforation longer than 24 h
Age > 65
Steroid use
Creatinine > 1.45 mg/dL

## Management

### What Is the Basic Principle of Surgical Treatment for Perforated Peptic Ulcer?

The surgical treatment of a perforated peptic ulcer was first described in 1885 by Johann Mikulicz-Radecki who stated “Every doctor faced with a perforated ulcer of the stomach or intestine must consider opening the abdomen, sewing up the hole...and carefully cleansing the abdominal cavity.” This concept holds true today as we continue to treat perforated ulcers in a similar fashion with some modifications. Sepsis has been found to occur in up to 18 % of patients with a peptic ulcer perforation; therefore, adequate volume resuscitation to provide organ perfusion (Grade A evidence) and careful monitoring within the Intensive Care Unit are necessary. If the patient has any changes in hemodynamics, invasive monitoring may be needed (central line, arterial line). A nasogastric tube should also be placed to decompress the stomach and attempt to decrease the amount of spillage into the abdominal cavity. The administration of effective broad spectrum intravenous antimicrobials within the first hour of recognition of septic shock (grade 1B) and severe sepsis without septic shock (grade 1C) should be the goal of therapy. Antibiotics should cover gram-positive, gram-negative, and anaerobic bacteria. If the patient is not already on a PPI, this should also be started as well as triple therapy if *H pylori* positive (clarithromycin, amoxicillin, and a PPI for 14 days).

### How Should a Perforated Peptic Ulcer Be Repaired?

The surgical approach for a perforated duodenal ulcer consists of through-and-through sutures at the site of the perforation which are then tied over a pedicled piece of omentum (known as an omental patch). The technique has not changed much since Graham introduced this method (also called a Graham patch). The omentum acts as a nidus for an inflammatory reaction as well as fibrin formation. If proper *H. pylori* treatment is given postoperatively to patients with a perforation, primary closure with omental patch is all that is necessary in the vast majority of cases. Prior to our understanding of the role of *H pylori* in ulcer diathesis, additional surgical procedures to reduce stomach acid secretion were often performed, but are now rarely necessary. Anti-secretion procedures lead to a longer operation and a significantly increased risk of complications. For perforated gastric ulcers, ulcer closure alone is not sufficient. Rather, primary ulcer excision (or a wedge resection) is needed, as this approach assures a tissue biopsy to rule out malignancy.

### Is There a Role for Conservative (Nonoperative) Management Even When a Perforated Ulcer Is Suspected?

Practice of the Taylor method, which includes nasogastric decompression, antibiotics, initiation of a PPI, and close observation, has been reported in the literature as a successful alternative to surgery in a specialized group of patients with a perforated ulcer that have already spontaneously sealed. Spontaneous sealing occurs in an estimated 40–80 % of perforations. Conservative therapy avoids an operation and its associated complications.

One may consider a conservative approach if the following criteria are met: (1) It has been less than 12 h since the onset of symptoms, (2) the patient is hemodynamically stable, (3) the patient is less than 70 years old, (4) the patient does not have a history of failed medical therapy for a peptic ulcer, (5) the patient has associated comorbidities that make the surgery too high risk, and (6) there is radiologic documentation that the perforation is sealed.

## Can Perforated Peptic Ulcers Be Treated Laparoscopically?

Laparoscopic repair is now considered a reasonable operative approach for perforated ulcers. One systematic review has shown that laparoscopic repair had similar mortality and reoperation rates compared to open surgery, as well as no statistical difference in primary outcomes. The conversion rate from laparoscopic to open surgery is between 12 % and 16 %. However, laparoscopic repair of peptic ulcer perforations should only be performed by an experienced laparoscopic surgeon. The advantage of laparoscopy is a smaller incision and less bleeding.

---

### Summary of Essentials

#### History and Physical

- Sudden onset severe epigastric pain that becomes diffuse
- History of peptic ulcer disease (PUD), *H. pylori*, smoking, chronic NSAID use
- Evidence of SIRS
- Patient lying motionless in bed
- Abdominal guarding, rigidity, and rebound tenderness

#### Pathophysiology

- Acid hypersecretion or mucosal defense hyposecretion
- Five types of gastric ulcers
  - Type I ulcers are on the lesser curve of the stomach
  - Type II ulcers are in the stomach and duodenum
  - Type III ulcers are prepyloric
  - Type IV ulcers are located proximal by the cardia
  - Type V ulcers are anywhere secondary to NSAID use

#### Workup

- Acute abdomen with diffuse peritonitis
- Leukocytosis with left shift
- Upright CXR: free air under diaphragm
- CT with oral gastrografin

#### Management

- Duodenal perforation
  - Primary closure with an omental patch
- Gastric perforation
  - Primary closure, biopsy, omental patch vs. wedge resection
  - Must rule out malignancy
- Triple therapy: clarithromycin, amoxicillin, and a PPI for 14 days (if *H. pylori* positive)
- Additional acid reduction surgery rarely needed



## Suggested Reading

- Bertleff MJ, Lange JF. Perforated peptic ulcer disease: a review of history and treatment. *Dig Surg*. 2010;27(3):161–9.
- Birks PM. Perforated peptic ulcer treated without operation. *Lancet*. 1947;iv:467–8.
- Bjorkman DJ. Current status of nonsteroidal anti-inflammatory drug (NSAID) use in the United States: risk factors and frequency of complications. *Am J Med*. 1999;107:3S.
- Bone RC, Balk RA, Cerra FB, Dellinger RP, Fein AM, Knaus WA, Schein RM, Sibbald WJ. ACCP/SCCM consensus conference committee. Definitions for sepsis and organ failure and guidelines for the use of innovative therapies in sepsis. The ACCP/SCCM consensus conference committee. American College of Chest Physicians/Society of Critical Care Medicine. 1992. *Chest*. 2009;136(5 Suppl):e28.
- Dellinger RP, Levy MM, Rhodes A, Annane D, et al. Surviving sepsis campaign guidelines committee including The Pediatric Subgroup. Surviving sepsis campaign: international guidelines for management of severe sepsis and septic shock, 2012. *Intensive Care Med*. 2013;39(2):165–228.
- Donovan AJ, Berne TV, Donovan JA. Perforated duodenal ulcer: an alternative therapeutic plan. *Arch Surg*. 1998;133:1166–71.
- Graham RR. The treatment of perforated duodenal ulcer. *Surg Gynecol Obstet*. 1937;64:235–8.
- Lagoo S, McMahon RL, Kakahara M, Pappas TN, Eubancks S. The sixth decision regarding perforated duodenal ulcer. *JLS*. 2002;6:359–68.
- McNamara RM. Acute abdominal pain. In: Sanders AB, editor. *Emergency care of the elder person*. St. Louis: Beverly Cram Publications; 1996. p. 219–43.
- Ramakrishnan K, Salinas RC. Peptic ulcer disease. *Am Fam Physician*. 2007;76:1005–12.
- Sanabria AE, Morales CH, Vellegas MI. Laparoscopic repair for perforated peptic ulcer disease. *Cochrane Database Syst Rev*. 2005;4, CD004778.
- Schein M. Perforated peptic ulcer. In: Schein M, Rogers PN, editors. *Schein's common sense emergency abdominal surgery*. Part III. Berlin: Springer; 2005. p. 143–50.
- Sivri B. Trends in peptic ulcer pharmacotherapy. *Fundam Clin Pharmacol*. 2004;18:23–31.
- Sung JJ, Kuipers EJ, El-Serag HB. Systematic review: the global incidence and prevalence of peptic ulcer disease. *Aliment Pharmacol Ther*. 2009;29(9):938–46.
- Zhang L, Ren JW, Wong CC, Wu WK, Ren SX, Shen J, Chan RL, Cho CH. Effects of cigarette smoke and its active components on ulcer formation and healing in the gastrointestinal mucosa. *Curr Med Chem*. 2012;19(1):63–9.

Michael D. Sgroi and Brian R. Smith

A 73-year-old Korean female presents complaining of abdominal pain, weight loss, and early satiety. She states that she has been experiencing a “gnawing” pain in the mid-epigastrium. The pain originated one year ago, but she thought it was acid indigestion. She took a proton-pump inhibitor (PPI) and some calcium carbonate, and the pain improved. The pain has progressively worsened and now she is experiencing dysphagia. Over the past 5 months, she has lost 25 lb, is easily fatigued, and unable to perform daily tasks around the house. The patient has a known medical history of coronary artery disease and a 50 pack-year history of smoking. She denies more than the occasional alcoholic beverage. She moved to the United States 10 years ago. Family history includes her father passing away of “some type of cancer.” Physical exam reveals tenderness to deep palpation in the mid-epigastrium as well as cachexia. Laboratory findings include anemia with a hemoglobin of 8.5 g/dL and hematocrit of 27 % as well as a low MCV. All other lab findings were within normal limits. A fecal occult blood test is also positive.

---

M.D. Sgroi, MD

Surgery Department, University of California, Irvine, 333 City Blvd West, Suite 1600, Orange, CA 92868, USA

e-mail: [sgroim@uci.edu](mailto:sgroim@uci.edu)

B.R. Smith, MD (✉)

Surgery Department, UC Irvine Medical Center, VA Healthcare System Long Beach, 333 City Blvd West, Suite 1600, Orange, CA 92868, USA

e-mail: [Smithbr@uci.edu](mailto:Smithbr@uci.edu)

## Diagnosis

### What is the Differential Diagnosis for a Patient with Vague Abdominal Pain, Weight Loss, Difficulty Eating, and Melena?

Diagnosis	Pertinent positives and negatives
<i>Peptic ulcer disease (PUD)</i>	Burning abdominal pain, nausea, vomiting, bloating. History of using a PPI or H2 blocker. Pain presents post-prandially and usually resolves on its own. Not likely to have significant weight loss. History of <i>H. pylori</i> and/or chronic NSAID use
<i>Gastroesophageal reflux disease (GERD)</i>	Post-prandial abdominal and chest pain (heartburn). Bitter taste in one's mouth. Regurgitation, bloating
<i>Pancreatitis</i>	Mid-epigastric pain. Significantly tender to palpation. Elevated pancreatic enzymes. Often a history of alcohol abuse or cholelithiasis
<i>Cholelithiasis</i>	Right upper quadrant or mid-epigastric pain, often post-prandial and intermittent (colicky). Elevated liver function tests (LFTs). Ultrasound positive for stones
<i>Hiatal hernia</i>	Sliding and paraesophageal hernias may cause upper abdominal pain and chest pain with or without GERD symptoms. May need immediate surgical intervention if signs of incarceration or strangulation (pain with nausea/vomiting)
<i>Gastric outlet obstruction</i>	Persistent nausea/vomiting and abdominal discomfort and bloating, possibly early satiety
<i>Small bowel obstruction</i>	Nausea/vomiting with vague abdominal pain. Patients will usually have a history of abdominal surgery, most common cause of an obstruction is adhesions
<i>Gastric cancer</i>	Vague abdominal pain, involuntary weight loss, early satiety, dysphagia, iron deficiency anemia, cachexia

### What Is the Most Likely Diagnosis?

In all elderly patients that have significant weight loss and a positive fecal occult blood test, the diagnosis is cancer until proven otherwise. Gastric cancer is rare in the United States, but is one of the most common cancers worldwide and is particularly common in Asians. In the United States, colon cancer would be higher on the list. However, due to the location of the pain, the weight loss, and the Korean decent, gastric cancer is most likely.

#### Watch Out

It is important to consider gastric cancer as part of your differential in any patient that presents with upper abdominal pain and significant weight loss as early diagnosis is critical to improved long-term survival. In the United States, approximately 50 % of gastric cancers have already spread past the confines of surgical resectability at the time of diagnosis, resulting in a high mortality rate.

## Epidemiology

### What Is the Prevalence of Gastric Cancer and What Causes It?

Gastric cancer is the 4th most common cancer worldwide but only 13th in the United States (US). This rate is even higher in the Far East, particularly Japan, Korea, and China where it has been the leading cause of death. Gastric adenocarcinoma accounts for approximately 90 % of all gastric cancers. There is a slight male predominance, with diagnosis usually occurring in the sixth to seventh decade of life.

Rates of gastric cancer have significantly decreased over the past century in the United States. This is likely due to the identification and eradication of *Helicobacter pylori* and the introduction of refrigeration. Since the introduction of triple therapy for *H. pylori* infections (amoxicillin, clarithromycin, and omeprazole), the prevalence of peptic ulcer disease as well as its progression to gastric cancer has declined in developed nations. In regard to refrigeration, it is thought that the improvement in food storage has led to a decrease in salt-preservation, pickling, or smoking of meat and a decrease in bacterial contamination.

**Table 50.1** Risk factors for the development of gastric cancer

Positive family history
Diet (high in nitrates, salt, fat)
Familial polyposis
Gastric adenomas
Hereditary nonpolyposis colorectal cancer
<i>Helicobacter pylori</i> infection, causing: Atrophic gastritis, intestinal metaplasia, dysplasia
Previous gastrectomy or gastrojejunostomy (>10 y ago)
Tobacco use
Ménétrier's disease
Type A blood
BRCA 1 and BRCA 2
HER2 gene overexpression
Peutz-Jegher's syndrome

**Watch Out**

Risk factors for the development of gastric cancer are multifactorial. It has been recognized that there is a synergism between *H. pylori* infections and other factors leading to a higher rate of gastric dysplasia and metaplasia.

**Screening****Is It Worth Screening Patients for Gastric Cancer?**

Due to the low rate in the United States, it has been found to not be cost effective to screen patients for gastric cancer. In Asian countries, where the rates of gastric cancer are much higher, screening with endoscopy has been found to be cost effective.

**Why Is the Mortality Rate So High for Gastric Cancer?**

Due to vague and often nonspecific presenting symptoms and a low rate of screening, particularly in the United States, most patients who are diagnosed with gastric cancer are already found to be stage III or stage IV and unresectable (see section Work-Up). At time of diagnosis, 50 % have disease that extends beyond locoregional confines. Of the 50 % that have local disease, only half of those patients appear to have a resectable cancer. These findings exemplify the importance of a thorough history and physical exam with further investigation of patients that are high risk or have alarm symptoms (early satiety, weight loss, dyspepsia in those over age 45).

**History and Physical****What Are the Most Common Symptoms for a Patient with Gastric Cancer?**

Weight loss and abdominal pain are the most common symptoms at the initial diagnosis. This may be accompanied by dysphagia, nausea, early satiety, and rarely a palpable mass. It is common for a patient to present to their primary care physician only complaining of dyspepsia, vague abdominal pain, and fatigue. Unfortunately, it often is not until the development of these more descriptive symptoms, known as “alarm symptoms,” that the physician further evaluates with diagnostic imaging or endoscopy. Patients with “alarm symptoms” are more likely to have gastric cancer, more likely to have advanced cancer at diagnosis, and more likely to have shorter survival.

Abdominal pain, when present, tends to be epigastric, vague, and persistent. Because of the stomach's ability to expand, tumors need to be large before the patient experiences pain or early satiety. In patients with linitis plastica, infiltration of large areas of gastric wall will lead to poor compliance and the presence of symptoms. Dysphagia is a common symptom for tumors that involve the cardia or proximal stomach. An acute gastrointestinal bleed is uncommon (5 %), but chronic occult melena is commonly seen.

### **Are There Specific Findings on Physical Exam?**

Physical exam findings are usually non-specific and often absent. If the patient does have physical findings, it is likely that they also have advanced disease. If the patient has an anterior gastric tumor, as it grows it may become palpable in the epigastric region. Palpable left supraclavicular nodes (Virchow's nodes) may be found in advanced stages, as well as periumbilical lymphadenopathy (Sister Mary Joseph nodes) and left axillary node (Irish's node). If the tumor is located in the antrum or more distal towards the pylorus, it may grow into the hepaticoduodenal ligament and lead to obstructive jaundice and elevated liver function tests.

---

## **Pathophysiology**

### **What Are the Two Histologic Types of Gastric Adenocarcinoma?**

#### **Intestinal-Type Gastric Adenocarcinoma**

This well-differentiated cell type arises from the gastric mucosa and is usually located in the distal stomach. This histologic type is more commonly seen in the sporadic patient that has high exposure to a poor diet, smoking, alcohol, and other environmental risk factors. This is also the type that has decreased with the eradication of *H. pylori* and other detrimental risk factors. Intestinal type accounts for 53 % of all gastric adenocarcinomas. Intestinal type has a stepwise pattern of progression leading to gastric adenocarcinoma. Patients will start with an *H. pylori*-induced inflammatory reaction (acute gastritis) which leads to chronic atrophic gastritis, intestinal metaplasia, dysplasia, and finally carcinoma.

#### **Diffuse-Type Gastric Adenocarcinoma**

This is a poorly differentiated tumor that is believed to originate from the lamina propria of the stomach and grows in an infiltrative, submucosal pattern. Unlike the intestinal type, the unorganized growing pattern leads to gastric thickening without a discrete mass. Diffuse-type gastric adenocarcinomas are most often found in the proximal stomach near the cardia. Because this type is related to congenital disorders, it is also most often found in younger patients compared to the intestinal type. These patients do not follow the typical histologic progression, instead jumping directly from chronic atrophic gastritis to adenocarcinoma.

### **What Is Linitis Plastica?**

Diffuse-type gastric cancer (Table 50.2) is highly metastatic and aggressive leading to its rapid progression. This rapid progression can lead to cancer seen in the esophagus or duodenum, as well as infiltration of the entire gastric wall, known as "linitis plastica" (plastic lining) named after the stiff, undistensible gastric wall that develops after it is infiltrated with tumor.

### **What Is the Vascular Supply to the Stomach?**

It is important to understand the blood supply to the stomach as this is how gastric cancer spreads. The vascular supply involves four major arteries: the left and right gastric arteries on the lesser curve and the left and right gastroepiploic arteries along the greater curve. All of the vessels that supply the stomach are derived from the celiac artery. The left gastric is a direct vessel off of the celiac artery. The right gastric most commonly is a branch of the common hepatic artery. The left and right

**Table 50.2** Types of gastric adenocarcinoma

<b>Intestinal</b>	<b>Diffuse</b>
Well differentiated	Poorly or undifferentiated
Distal stomach	Anywhere, but most often proximal stomach
Secondary to environmental factors	Secondary to congenital disorders
Decreasing in incidence	No change in incidence
Discrete mass	Generalized gastric hypertrophy
Progressive evolution to cancer over years	Aggressive and rapid progression

gastric arteries communicate on the lesser curvature of the stomach. The right gastroepiploic artery is a branch from the right gastric or common hepatic, and the left gastroepiploic artery is a branch of the splenic artery. These two communicate and supply blood to the greater curvature of the stomach.

### **Why Do Patients with Gastric Cancer Get Iron Deficiency Anemia?**

Anemia is due to slow intermittent bleeding of the tumor. As the patient loses blood through the GI tract in the form of melena, there is also iron and heme loss along with RBCs. Patients often do not show signs of anemia in the acute setting because the body has not yet compensated for the losses. It is in the chronic setting that one will see chronic anemic changes.

## **Workup**

### **What Is the Best Way to Diagnose a Patient with Suspected Gastric Cancer?**

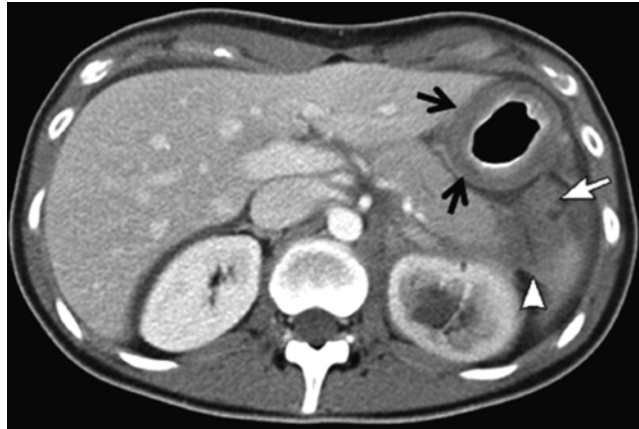
Upper endoscopy is the standard of care for diagnosing a patient with gastric cancer. This allows for direct visualization of the stomach mucosa, localization of the tumor for operative planning, and the ability to biopsy suspicious lesions. A single biopsy has a 70 % sensitivity, while multiple biopsies from an ulcerated lesion have a sensitivity greater than 98 %. Young patients that present with symptoms of dyspepsia and abdominal pain often undergo a barium swallow. This has a high false-negative rate and is even worse for early gastric cancer. Currently, tissue diagnosis and localization of the mass is best achieved with endoscopy. Even though it is a more invasive and costly study, it has a 70 % sensitivity with just a single biopsy and a 98 % sensitivity when multiple biopsies are taken.

### **Once the Diagnosis of Gastric Cancer Is Established, What Further Workup Is Recommended?**

Endoscopic ultrasound (EUS) is performed as it assists with TNM staging. EUS has been proven to provide more accurate assessment of tumor size, depth, and locoregional lymph node involvement compared to radiographic imaging. In addition, CT scan of the abdomen is performed to confirm that the patient is a surgical candidate. CT scanning will rule out liver metastasis as well as distant suspicious lymph nodes that were missed on EUS, either of which would preclude a curative resection (Fig. 50.1). More recently positron emission tomography scan (PET scan) has been proven to be highly accurate in detecting small metastases and lymph node involvement.

### **Why Is Staging of the Tumor Important?**

Following proper staging of a patient's tumor, the decision can be made as to the most appropriate intervention. If the patient has locoregional disease with no signs of distant metastases, and no contraindications to surgery, then surgical resection is the initial treatment. If the patient has distant metastases, or is not medically cleared for surgery, then chemotherapy or palliative care may be necessary. Certain patients that are medically fit and have advanced locoregional disease with high risk for metastases may also be candidates for neoadjuvant chemotherapy to maximize surgical resectability.



**Fig. 50.1** Axial CT of gastric adenocarcinoma showing a thickened stomach wall and a metastatic gastrosplenic mass. *Black arrows: thickened stomach. White arrows: gastrosplenic mass*

#### Watch Out

In patients with locally advanced gastric cancer, chemotherapy is effective when used prior to surgery.

## Management

### Does the Staging of Gastric Cancer Matter in Determining Treatment?

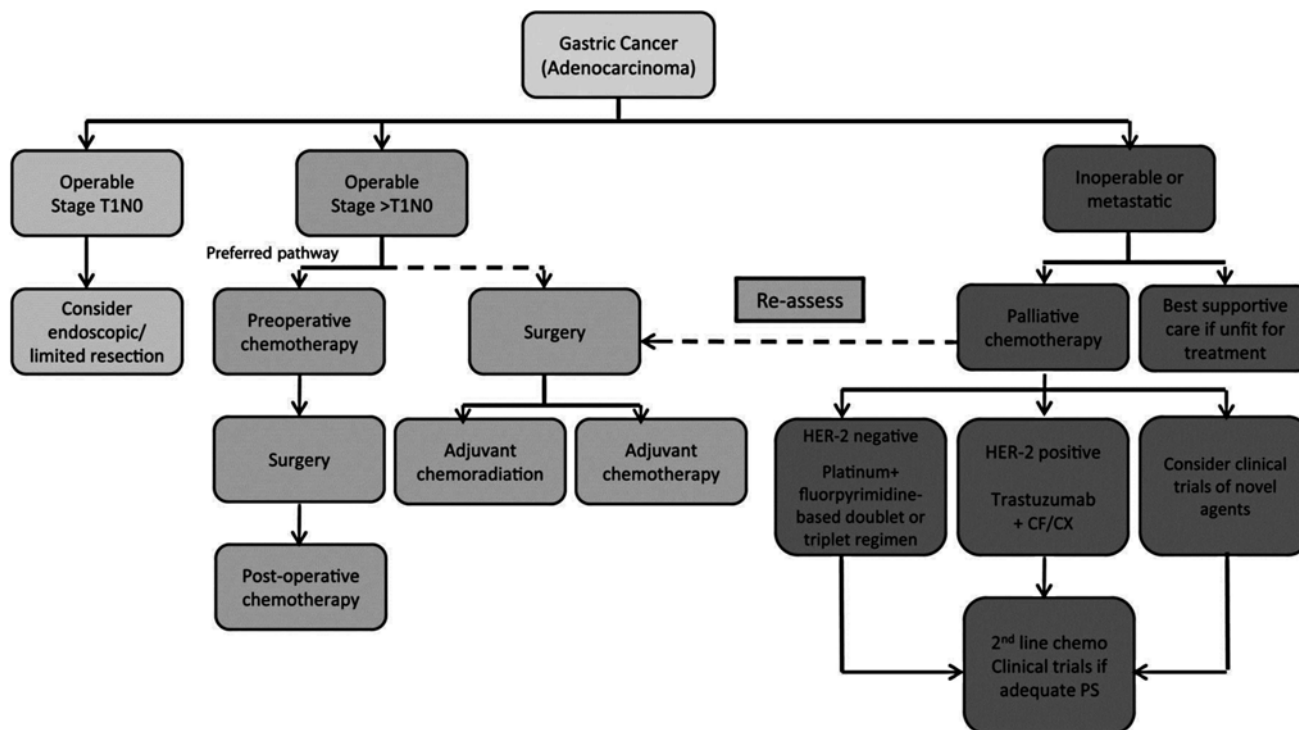
The management of gastric adenocarcinoma is dependent on the staging of the tumor. Surgery is the only curative therapy. However, a multi-therapeutic approach is recommended for locally advanced tumors. This includes neoadjuvant chemotherapy, adjuvant chemotherapy, or chemoradiation.

Surgery is the primary treatment for all early-stage gastric cancers, with R0 resection (no residual tumor) being the goal. R1 (microscopically positive residual tumor) and R2 (macroscopically positive residual tumor) are suboptimal and have high rates of recurrence. If the tumor does not invade the mucosa and lamina propria, one may consider an endoscopic mucosal resection. However, care should be taken to ensure adequate margins are attained. Five centimeter proximal surgical margins are necessary to assure that all submucosal tumor cells have been removed. Lymph nodes are unnecessary within this subgroup as the risk of metastases is minimal. A subtotal gastrectomy (removal of the distal 75 %) is the procedure of choice for distal gastric cancers. Most commonly, this results in removal of the antrum and body of the stomach, with the need for a gastrojejunostomy to recreate visceral continuity (either Bilroth II or Roux-en-Y reconstruction). For proximal tumors, a proximal gastrectomy or total gastrectomy is necessary for adequate resection margins. Again, a gastrojejunostomy or esophagojejunostomy will need to be constructed.

### Does It Matter How Many Lymph Nodes Are Removed?

At least 15 lymph nodes need to be resected for adequate staging of gastric adenocarcinoma. The perigastric lymph node channels that follow the greater and lesser curvature of the stomach should allow for adequate staging during subtotal or total gastric resection.

There are two types of lymph node dissections described in the literature for gastric cancer: D1 and D2 dissections. A D1 dissection involves a perigastric lymph node dissection, while a D2 dissection also involves hepatic, left gastric, celiac, and splenic artery dissection, as well lymph nodes in the splenic hilum. Currently, D2 dissections are recommended over D1 dissections. However, there continues to be controversy over this as two randomized trials have demonstrated a higher morbidity and mortality with D2 dissections.



**Fig. 50.2** Algorithm for gastric cancer

Laparoscopic gastric resection is safe and feasible for the advanced laparoscopic surgeon, allowing for quicker recovery, faster return of bowel function, reduced hospital stay, and less blood loss. Of particular importance with this approach is making sure that adequate margins are taken from the primary tumor and that an adequate lymph node dissection has been performed.

### Should Patients with Gastric Cancer Get Adjuvant Chemotherapy and Radiation?

As seen in Fig. 50.2, any gastric cancer that is greater than stage IB should be considered for a multi-therapeutic approach. Chemotherapy has been proven to be effective in both the pre- and postoperative patient. The MAGIC trial was the first study to show the effectiveness of perioperative chemotherapy prior to surgical resection, with improved outcomes and survival. This has been reproduced by another randomized trial that has confirmed these findings. Similarly, postoperative chemoradiation has been proven to improve overall survival. In one study, the combination of postoperative chemotherapy and radiation improved survival by 33 %.

### What Is the Role of HER2 Gene Amplification and Chemotherapy?

HER2 overexpression has been recognized as a molecular abnormality that increases the aggressive nature of breast cancer. More recently, there has been evidence that there is a role of HER2 overexpression in gastric cancer patients leading to poorer outcomes and a more aggressive disease. Similar to breast cancer, the HER2 gene has been recognized to respond to certain chemotherapy agents, such as trastuzumab; and therefore patients with gastric cancer should have genetic testing for the HER2 gene prior to the induction chemotherapy.



## What Are the Other Types of Gastric Cancer Other than Gastric Adenocarcinoma?

Gastric adenocarcinoma accounts for approximately 90 % of all gastric cancers. However, other causes of gastric cancer include gastrointestinal stromal tumors, gastric carcinoids, and gastric lymphomas.

### Gastrointestinal Stromal Tumors

Gastrointestinal stromal tumors are mesenchymal tumors of variable malignant potential that originate from the interstitial cells of Cajal (gastrointestinal pacemaker cells) within the GI tract. GISTs account for about 1 % of all gastric cancers, while 70 % of GISTs are located within the stomach. They are usually identified either on imaging or endoscopy. They are smooth submucosal masses with regular borders. There is near-universal expression of c-KIT and CD117 by GISTs. Biopsy is not necessary or recommended if there is a high endoscopic or radiographic suspicion for this tumor. Unlike adenocarcinomas, GISTs rarely spread through lymphatics, making a major gastrectomy frequently unnecessary. Two centimeter margins are recommended. In most cases, a wedge resection can be performed allowing for an anastomosis-free procedure. If the tumor is too large to permit complete resection, neoadjuvant therapy can be given with a tyrosine kinase inhibitor (Imatinib). This drug has proven effective in 70–80 % of GISTs.

### Gastric Carcinoids

These neuroendocrine tumors account for about 1 % of all gastric cancers. Neuroendocrine tumors can occur anywhere within the gastrointestinal tract, with only about 1–2 % occurring in the stomach, making this a very rare finding. For tumors less than 1–2 cm in size, it is reasonable to treat either endoscopically or with close observation. If the patient has a functional symptomatic tumor (i.e., gastrinoma resulting in Zollinger-Ellison Syndrome), a formal resection may be necessary.

### Gastric Lymphoma

The stomach is the most common site for a gastrointestinal lymphoma. The two most common types are lymphoma of the mucosa-associated lymphoid tissue (MALT) and diffuse large B cell lymphoma. The two of these account for about 90 % of all gastric lymphomas. MALT is most commonly associated with an *H. pylori* infection and can be completely treated with triple therapy against *H. pylori*. Historically, surgery was necessary for diffuse-type lymphoma. However, since the advent of chemotherapy agents, medical management is the current treatment. CHOP chemotherapy (cyclophosphamide, doxorubicin, vincristine, and prednisone) followed by radiation is the therapy of choice for high-grade lymphoma or that which does not respond to *H. pylori* therapy alone.

---

## Complications

### Why Do Patients Get Dumping Syndrome After a Gastric Resection?

One of the most common complications of a gastric resection is diarrhea secondary to dumping syndrome. Dumping syndrome is caused by the rapid distribution of food within the small intestine in the absence of the regulatory effect of the pyloric sphincter. The hyperosmolar state that ensues within the intestines leads to increased water secretion into the intestinal lumen, eventually leading to diarrhea and occasionally hypotension.

### What are the Common Complications that can Occur After a Gastric Resection?

Diarrhea
Early satiety
Dumping syndrome
Anastomotic leak
Afferent limb syndrome
Internal hernia
Small bowel obstruction
Marginal ulceration

## How Are Anastomotic Leaks Identified and Treated?

Patients with anastomotic leaks will present with abdominal pain and varying degrees of peritonitis, fevers, tachycardia, leukocytosis, and sepsis if not treated rapidly. If the patient is stable with no signs of peritonitis and there is concern for a leak, an upper GI with gastrografin should be ordered. Contrast extravasation will confirm a leak.

The first treatment in any patient that has an anastomotic leak is source control. This involves re-operation. If the leak is small, repair of the suture line and an abdominal washout and drainage are often all that is needed. Postoperatively, the patient will be kept NPO and placed on TPN. A nasogastric tube should be placed intraoperatively to reduce the gastric contents that may exacerbate the leak.

### Watch Out

A common question for students is how to manage a gastrointestinal anastomotic leak, and it is tempting to opt for resection and revision of the anastomosis. Do not choose this answer as your first option. You first control the leak and often are able to salvage the initial operation.

## Summary of Essentials

### History and Physical

- More common in men than women
- Alarm symptoms: vague abdominal pain, fatigue, early satiety, and weight loss
- Often diagnosed late due to absence of symptoms early on

### Pathophysiology

- The most common type: adenocarcinoma
- Two types of gastric adenocarcinoma: intestinal and diffuse
- More common in the Far East, secondary to increased prevalence of *H. pylori* and other environmental factors
- The most common cause: *H. pylori* infection
- Intestinal-type gastric cancer occurs in the distal stomach and usually associated with environmental factors
- Diffuse type is poorly differentiated, occurs most often in the proximal stomach, and is often related to congenital disorders
- Linitis plastica is the infiltration of the entire gastric wall with cancer and has a high mortality rate
- GIST tumors are smooth, submucosal tumors that express c-KIT and CD117

### Workup

- Endoscopy is the study of choice for diagnosis
- Further staging with CT of the chest, abdomen, and pelvis and/or PET scan

### Management

- Tumors stage IB or higher should receive preoperative chemotherapy
- Postoperative chemotherapy and radiation have been shown to improve overall survival
- If the tumor is distal in the stomach, a subtotal gastrectomy can be performed
- If the tumor is in the proximal stomach, a proximal gastrectomy or total gastrectomy is necessary

- Proximal resection margins should be 5 cm to maximize chances of R0 resection
- At least 15 resected lymph nodes are necessary to properly stage the tumor
- Low-grade MALT lymphoma is treated with *H. pylori* eradication; high-grade lymphoma requires chemotherapy

## Prognosis

- Five-year mortality remains high due to the majority of patients having advanced disease at diagnosis

## Suggested Reading

- Abdalla EK, Pisters PW. Staging and preoperative evaluation of upper gastrointestinal malignancies. *Semin Oncol.* 2004;31(4):513–29.
- Ajani JA, Barthel JS, Bekaii-Saab T, et al. NCCN Gastric Cancer Panel. *Gastric Cancer. J Natl Compr Canc Netw.* 2010;8(4):378–409.
- Bowrey DJ, Griffin SM, Wayman J, et al. Use of alarm symptoms to select dyspeptics for endoscopy causes patients with curable esophagogastric cancer to be overlooked. *Surg Endosc.* 2006;20:1725–8.
- Coggon D, Barker DJ, Cole RB, Nelson M. Stomach cancer and food storage. *J Natl Cancer Inst.* 1989;81(15):1178.
- Correa P. Human gastric carcinogenesis: a multistep and multifactorial process—First American Cancer Society Award Lecture on Cancer Epidemiology and Prevention. *Cancer Res.* 1992;52:6735–40.
- Cunningham D, Allum WH, Stenning SP, et al. Perioperative chemotherapy versus surgery alone for resectable gastroesophageal cancer. *N Engl J Med.* 2006;355:11–20.
- Dooley CP, Larson AW, Stace NH, et al. Double-contrast barium meal and upper gastrointestinal endoscopy. A comparative study. *Ann Intern Med.* 1984;101:538.
- Fuchs CS, Mayer RJ. Gastric carcinoma. *N Engl J Med.* 1995;333:32–41.
- Graham DY, Schwartz JT, Cain GD, Gyorkey F. Prospective evaluation of biopsy number in the diagnosis of esophageal and gastric adenocarcinoma. *J Intern Med.* 1994;236:679.
- Hohenberger P, Gretschel S. Gastric Cancer. *Lancet.* 2003;362:305–15.
- Janssen MJR, Fransen GAJ, Voutilainen M, et al. Alarm symptoms for gastric/oesophageal malignancy: a meta-analysis using individual patient data. *Gut.* 2005;54:A42.
- Kunz PL, Gubens M, Fisher GA, Ford JM, Lichtensztajn DY, Clarke CA. Long-term survivors of gastric cancer: a California population-based study. *J Clin Oncol.* 2012;30(28):3507.
- Kwee RM, Kwee TC. Imaging in local staging of gastric cancer: a systematic review. *J Clin Oncol.* 2007;25(15):2107–16.
- La Vecchia C, Negri E, D’Avanzo B, Franceschi S. Electric refrigerator use and gastric cancer risk. *Br J Cancer.* 1990;62(1):136.
- Longo WE, Zucker KA, Zdon MJ, Modlin IM. Detection of early gastric cancer in an aggressive endoscopy unit. *Am Surg.* 1989;55:100.
- Macdonald JS, Smalley SR, Benedetti J, et al. Chemoradiotherapy after surgery compared with surgery alone for adenocarcinoma of the stomach or gastroesophageal junction. *N Engl J Med.* 2001;345:725–30.
- Machida-Montani A, Sasazuki S, Inoue M, Natsukawa S, Shaura K, Koizumi Y, et al. Association of *Helicobacter pylori* infection and environmental factors in non-cardia gastric cancer in Japan. *Gastric Cancer.* 2004;7:46–53.
- Maconi G, Manes G, Porro GB. Role of symptoms in diagnosis and outcome of gastric cancer. *World J Gastroenterol.* 2008;14(8):1149–55.
- Morgenstern L. The Virchow-Troisier node: a historical note. *Am J Surg.* 1979;138:703.
- Pieslor PC, Hefter LG. Umbilical metastasis from prostatic carcinoma—Sister Joseph nodule. *Urology.* 1986;27:558.
- Reyes CD, Weber KJ, Gagner M, Divino CM. Laparoscopic vs open gastrectomy. A retrospective review. *Surg Endosc.* 2001;15:928–31.
- Scaife CL, Hunt KK, Patel SR, et al. Is there a role for surgery in patients with “unresectable” cKIT+ gastrointestinal stromal tumors treated with imatinib mesylate? *Am J Surg.* 2003;186:665–9.
- Siegel R, Naishadham D, Jemal A. Cancer statistics, 2013. *CA Cancer J Clin.* 2013;63(1):11–30.
- Stabile BE, Smith BR, Weeks DL. *Helicobacter pylori* infection and surgical disease—part II. *Curr Probl Surg.* 2005;42(12):796–862.
- Wanebo HJ, Kennedy BJ, Chmiel J, et al. Cancer of the stomach. A patient care study by the American College of Surgeons. *Ann Surg.* 1993;218:583–92.
- Yashiro M, Chung YS, Nishimura S, Inoue T, Sowa M. Establishment of two new scirrhous gastric cancer cell lines: analysis of factors associated with disseminated metastasis. *Br J Cancer.* 1995;72(5):1200.
- Ychou M, Boige V, Pignon J-P, et al. Perioperative chemotherapy compared with surgery alone for resectable gastroesophageal adenocarcinoma: an FNCLCC and FFCCD multicenter phase III trial. *J Clin Oncol.* 2011;29:1715–21.

Michael D. Sgroi and Brian R. Smith

A 55-year-old alcoholic male presents to the emergency department after experiencing severe chest pain. He is an obese male with a significant medical history that includes coronary artery disease, sleep apnea, hypercholesterolemia, as well as early liver cirrhosis secondary to alcohol abuse. The patient states that the chest pain started about 18 h ago after consuming far too much food at a buffet and binge drinking, which eventually lead to him feeling ill and forcefully vomiting. There was no blood in the vomitus. He states the pain is in his lower chest and radiates to the left side, back, and upper abdomen. The pain is aggravated by swallowing. At initial exam, his blood pressure is 105/90 mmHg, heart rate is 120/min, respiratory rate is 26/min, and temperature is 101.6 °F. He has crepitus with palpation around the sternum. His abdomen is soft and non-tender. A chest x-ray shows a left-sided pleural effusion. Laboratory examination is significant for a white blood count of  $17 \times 10^3/\mu\text{L}$  (normal  $4.1\text{--}10.9 \times 10^3/\mu\text{L}$ ) with 15 % bands). Serum troponin I is 0.1 mcg/mL (0–0.4 mcg/L).

## Diagnosis

### What Is the Most Likely Diagnosis?

Diagnosis	Comments
<i>Myocardial infarction</i>	Chest pain, more on the left side, left arm and jaw pain, diaphoresis, ST segment elevation, and elevated troponins
<i>Pericarditis</i>	Substernal, pleuritic chest pain, worse supine, better leaning forward, fever, tachycardia, friction rub, pulsus paradoxus
<i>Pneumothorax</i>	Chest pain, shortness of breath, tachycardia, decreased/absent breath sounds on the affected side
<i>Pneumonia</i>	Shortness of breath, fever, fatigue, productive cough, and decreased breath sounds on the affected side
<i>Aortic dissection</i>	Shearing or tearing chest pain radiating to upper back, shortness of breath, differences in blood pressure in arms, impending doom, severe HTN, history of Marfan's
<i>Peptic ulcer disease</i>	Post-prandial epigastric abdominal pain, nausea, vomiting, bloating
<i>Acute pancreatitis</i>	Epigastric pain radiating to the back, nausea, vomiting, anorexia, cholelithiasis, alcohol abuse, elevation of amylase/lipase
<i>Mallory-Weiss tear</i>	Forceful vomiting and retching, followed by UGI bleed, typically in alcoholic or bulimic patients; often resolves spontaneously
<i>Boerhaave's syndrome</i>	Forceful vomiting and retching, followed by chest pain and sepsis typically in alcoholic or bulimic patients; crepitus with palpation around the sternum

M.D. Sgroi, MD

Surgery Department, University of California, Irvine, 333 City Blvd West, Suite 1600, Orange, CA 92868, USA

e-mail: [sgroim@uci.edu](mailto:sgroim@uci.edu)

B.R. Smith, MD (✉)

Surgery Department, UC Irvine Medical Center, VA Healthcare System Long Beach, 333 City Blvd West, Suite 1600, Orange, CA 92868, USA

e-mail: [Smithbr@uci.edu](mailto:Smithbr@uci.edu)

**Watch Out**

Boerhaave's syndrome has high mortality if not recognized and treated in a timely fashion. The mortality rate is significantly greater in those that have a delay in diagnosis beyond 24 hours.

**What Is the Most Likely Diagnosis?**

In a patient presenting with chest pain after forceful vomiting (retching) accompanied by crepitus with palpation around the sternum, a left-sided pleural effusion, and evidence of systemic inflammatory response syndrome (fever, tachycardia, leukocytosis with a left shift), the most likely diagnosis is Boerhaave's syndrome, a type of spontaneous esophageal rupture.

**History and Physical****What Are the Risk Factors for Boerhaave's Syndrome?**

Patients at greatest risk are alcoholics. Binge drinking places patients at risk of forceful vomiting/retching. It can also occur in patients who overeat, which results in aggressive vomiting. It most commonly occurs in males 50–70 years old.

**Why Is Boerhaave's Syndrome So Often Unrecognized?**

There is a robust differential for a patient who presents with chest pain. Since its manifestations mimic so many other diseases, esophageal perforation often goes unsuspected or misdiagnosed.

**What Is Mackler's Triad?**

The principal symptoms include sudden lower thoracic pain, sometimes radiating to the back and aggravated by swallowing. *Mackler's triad* (vomiting, thoracic pain, and subcutaneous emphysema) is highly suggestive of the diagnosis of Boerhaave's syndrome. All three parts of the triad are found in less than one third of cases, which often leads to a delay in diagnosis. The clinical signs most often observed, in decreasing order of frequency, are vomiting (84 %), thoracic pain (79 %), dyspnea (53 %), epigastric pain (47 %), and dysphagia (21 %).

**What Is the Most Specific Sign of an Esophageal Rupture?**

Subcutaneous emphysema after forceful retching is pathognomonic for esophageal rupture. This is identified on physical exam by crepitus with palpation around the sternum. Unfortunately, this finding is not very sensitive, as it is seen in only 27 % of patients.

**How Does Boerhaave's Syndrome Differ from Mallory-Weiss?**

	<b>Boerhaave's syndrome</b>	<b>Mallory-Weiss</b>
<i>Population</i>	Alcoholics/bulimics after forceful vomiting	Alcoholic/bulimics after forceful vomiting
<i>Pathophysiology</i>	Full-thickness rupture of the esophagus secondary to increased intragastric pressure	Partial tear of mucosa at gastroesophageal junction, secondary to increased intragastric pressure
<i>Presentation</i>	Thoracic pain radiating to back, left-sided pleural effusion, signs of sepsis	Upper GI bleed
<i>Natural course</i>	Can progress to sepsis and death; most often will require immediate surgical repair and drainage	Most resolve spontaneously; surgery rarely indicated

## Pathophysiology

### What Are the Most Common Causes of Esophageal Perforation?

An esophageal perforation is a rare incident that often constitutes a surgical emergency. Despite improvements in detection and management, esophageal perforation remains a highly fatal disease with mortality rates reported as high as 40 %. The majority of perforations (approximately 60 %) are the result of an iatrogenic injury with upper endoscopy perforation being the most common cause. Other causes may include blunt or penetrating trauma, foreign body ingestion, or a perforating malignancy. The final 10–20 % of perforations account for “spontaneous” ruptures, also known as Boerhaave’s syndrome. Forceful vomiting causes a dramatic rise in intragastric pressure which is transmitted to the esophagus in the presence of a relaxed lower esophageal sphincter. If such a rise in pressure within the esophagus occurs in conjunction with a failure of relaxation of the cricopharyngeus muscle, then tremendous pressures are transmitted to the esophageal wall, leading to perforation.

### Why Do Patients with Boerhaave’s Syndrome Become So Septic?

The esophageal perforation leads to gross contamination of the mediastinum. The perforation often leads to rupture of the pleura as well, which is likely secondary to the gastric and bilious contents eroding through the lining. Once the pleura has been disrupted, gross contamination of the pleural cavity also occurs. It is the mediastinitis and pleuritis that eventually lead to sepsis and multiorgan failure and, if left untreated, will ultimately result in death.

## Work-Up

### What Is the First Step in Workup for a Patient Suspected of Having Boerhaave’s Syndrome?

When a patient presents with chest pain and sepsis, esophageal perforation should be suspected. The initial study should be a chest radiograph. The most common findings are a left-sided pleural effusion and atelectasis. The x-ray findings are usually left sided, as the most common location of a spontaneous esophageal perforation is on the left posterolateral aspect, about 2–3 cm proximal to the GE-junction. It should be noted, however, that a normal CXR will be seen in 12–33 % of patients. Normal radiograph findings may be due to a multitude of factors, the most common being the time interval between the perforation and the study. It is believed to take at least 1 hour post-perforation for pneumomediastinum to present on imaging.

### What Is the Role of Oral Contrast Studies in Diagnosing Boerhaave’s Syndrome? How About CT?

Oral contrast studies have a higher sensitivity for diagnosing esophageal perforations and therefore should be performed following a questionable CXR to confirm the diagnosis. Originally it was thought that an esophagogram with gastrografin should be performed as it was recognized to have a sensitivity of 90 %. However, current recommendations are to perform a CT with oral contrast because the sensitivity is even higher than that of an esophagogram. Additionally, it allows one to identify the extent of perforation into surrounding structures, while assisting with the decision on a surgical approach. Finally, if the patient is found not to have Boerhaave’s syndrome, a CT scan may enable one to make the appropriate differential diagnosis more rapidly (i.e., aortic dissection, pericarditis, pneumonia).

#### Watch Out

The use of water-soluble contrast is important when perforation is suspected, as barium escaping out of the esophagus may cause a severe inflammatory reaction in the mediastinum or pleura.

## Is There a Role for Endoscopy?

There is no role for endoscopy when perforation is suspected. The concern is that insufflation of air into the esophagus to help visualize the entire lumen may actually result in enlargement of the transmural opening and worsen the outcome for the patient.

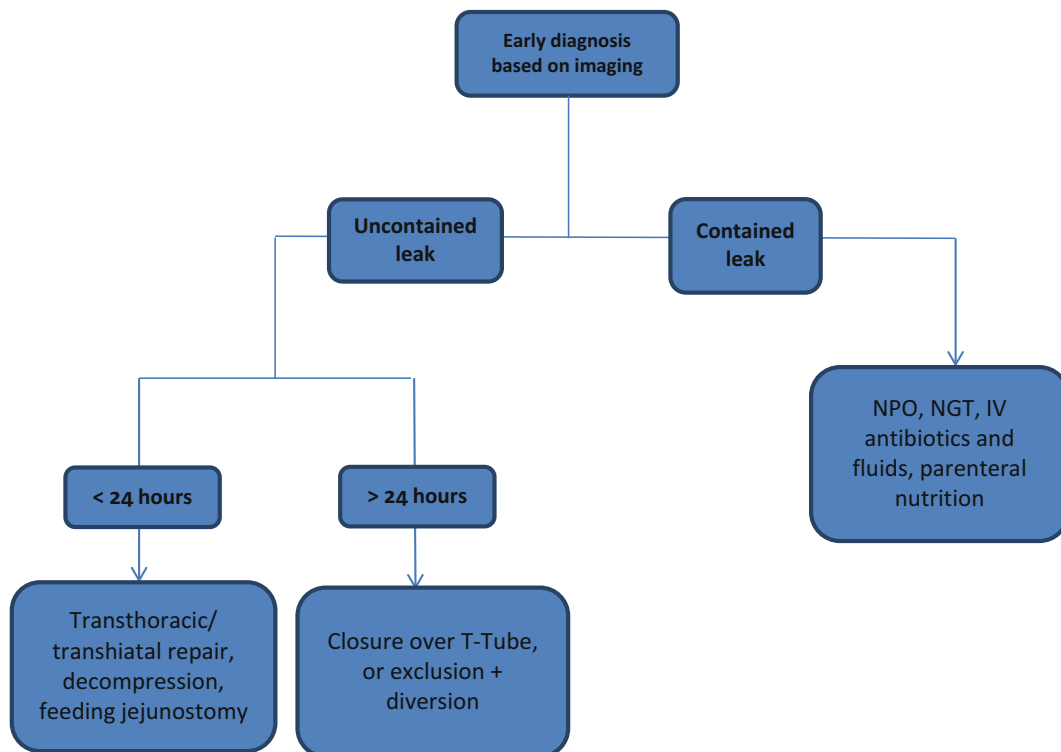
## Management

### What Are the Initial Steps in the Management of a Patient with Boerhaave's Syndrome?

As soon as the diagnosis of Boerhaave's syndrome is made, medical management should be initiated in an attempt to minimize sepsis and septic shock. The patient should be given aggressive intravenous fluid resuscitation, placed nothing per os (NPO), and immediately started on broad-spectrum antibiotics that cover oral bacteria, as well as an antifungal. An H<sub>2</sub>-blocker or proton-pump inhibitor should also be initiated to reduce gastric acid secretions. If the patient presents with evidence of severe sepsis, fluid resuscitation should be targeted to central venous pressure, and as such a central venous catheter should be inserted. In any patient with hemodynamic instability, an arterial line should also be placed. This will also give the physician the ability to start vasopressors if necessary.

### Does the Time Interval Between Perforation and Intervention Matter?

Most agree that the aim of treatment is to prevent further contamination, eliminate any infection via drainage of the pleura and mediastinum, and restore nutritional support. The key to optimum management is the early detection and treatment, ideally within 24 h. A systematic review of 726 patients showed that treatment delays greater than 24 h doubled the mortality rate. Once the diagnosis is made, a variety of treatment options are available, ranging from conservative management to options as aggressive as an esophagectomy (Fig. 51.1). Endoscopic interventions are now becoming more widely available and may be a new option for physicians to consider.



**Fig. 51.1** Algorithm for the treatment of a patient with Boerhaave's syndrome

## What Constitutes Conservative Management and Which Patients Are Candidates for It?

Historically, all patients with a spontaneous perforation received surgical management. However, nonoperative (conservative) management is now considered in a select group of patients and includes continuous nasogastric suction, intravenous broad-spectrum antibiotics, and parenteral nutrition. Conservative management is an accepted treatment in patients with minimal comorbidities, no signs of sepsis or septic shock, a perforation that has been present for less than 24 hours, and a leak that is small and contained or has sealed itself. Repeat imaging may occur at hospital day 7 to evaluate for spontaneous closure of the perforation. If there are no signs of extravasation, oral intake may be resumed. Oral antibiotics should be continued for 6–8 weeks. Currently, there is an approximate 20 % failure rate using medical management.

## What Are the Surgical Options for a Patient with Boerhaave's Syndrome?

If the esophageal perforation has not spontaneously sealed, surgery is typically recommended. The approach to surgical management is dependent on the time interval from perforation to diagnosis (<or>24 h), the location and size of the perforation, the degree of devitalized tissue, and the status of the patient (hemodynamically stable or unstable, medical comorbidities). The two main options are primary closure of the perforation and esophageal resection. Primary closure is preferred especially if the perforation is small and recent. All devitalized tissue surrounding the perforation must be debrided in order for surgical closure to be successful. This includes debridement of the mediastinum as well as the pleura, which is known as a *pleural decortication*. Following suture closure of the perforation, a reinforcement flap (of pleura and/or intercostal muscle) should be placed over the suture line to support the closure as well as decrease the chance of a leak. With a large hole, or with a prolonged delay, successful primary closure is unlikely, and esophagectomy will be needed. The esophagus is later reconstructed with interposed colon or jejunum. The most favorable outcome appears to be obtained in patients that are treated within 24 hours of injury and receive a primary closure of the perforation.

---

## Summary of Essentials

### History and Physical

- Alcoholics and bulimic patients after forceful emesis
- Most commonly occurs in males 50–70 with an alcohol or overeating history
- Iatrogenic injury by upper endoscopy is the most common cause of esophageal perforation
- Boerhaave's syndrome most commonly presents with thoracic pain radiating to lower back and aggravated by swallowing (Mackler's triad: chest pain, vomiting, and subcutaneous emphysema)

### Pathophysiology

- Boerhaave's syndrome is a transmural esophageal perforation secondary to increased intragastric pressure induced by vomiting; Mallory-Weiss is from a partial thickness tear

### Workup

- CXR should be the initial study; look for left-sided pleural effusion and atelectasis
- Pneumomediastinum after vomiting is pathognomonic
- Gastrografin esophagram or CT scan of the chest with water-soluble oral contrast should be performed to confirm the diagnosis



## Management

- The time interval between perforation and intervention is critical to the outcome
- Conservative management with continuous nasogastric suction, intravenous broad-spectrum antibiotics, and parenteral nutrition may be considered in healthy patients who have mild sepsis and a contained rupture within the mediastinum
- The goal is to perform surgery within 24 hours of the inciting event for best results
- Standard treatment is debridement of the necrotic tissue surrounding the perforation, primary suture closure, and coverage with a pedicle flap (pleura, fundoplication, omentum)
- Endoscopic stents are being used more often, but this is not considered standard of care as of yet

## Prognosis

- The mortality rate of Boerhaave's syndrome is approximately 50 %
- Death occurs secondary to contamination of the mediastinum and pleura, which eventually leads to sepsis, septic shock, and multiorgan failure

---

## Suggested Reading

- Altortjay A, Kiss J, Voros A, Bohak A. Nonoperative management of esophageal perforations. Is it justified? *Ann Surg.* 1997;225(4):415–21.
- Bladergoen MR, Lowe JE, Postlethwait RW. Diagnosis and recommended management of esophageal perforation and rupture. *Ann Thorac Surg.* 1986;42(3):235–9.
- Bresadola V, Terrosu G, Favero A, et al. Treatment of perforation in the healthy esophagus: analysis of 12 cases. *Langenbeck Arch Surg.* 2008;393:135–40.
- Brinster CJ, Singhal S, Lee L, Marshall MB, Kaiser LR, Kucharczuk JC. Evolving options in the management of esophageal perforation. *Ann Thorac Surg.* 2004;77(4):1475–83.
- Curci JJ, Horman MH. Boerhaave's syndrome: the importance of early diagnosis and treatment. *Ann Surg.* 1976;183:401–8.
- De Lutio di Castelguidone E, Merola S, Pinto A, Raissaki M, Gagliardi N, Romano L. Esophageal injuries: spectrum of multidetector row CT findings. *Eur J Radiol.* 2006;59(3):344–8.
- Griffiths EA, Yap N, Poulter J, Hendrickse MT, Khurshid M. Thirty-four cases of esophageal perforation: the experience of a district general hospital in the UK. *Dis Esophagus.* 2009;22(7):616–25.
- Hegenbarth R, Birkenfeld P, Beyer R. Roentgen findings in spontaneous esophageal perforation (Boerhaave's syndrome). *Aktuelle Radiol.* 1994;4(6):337–8.
- Horwitz B, Krevshy B, Buckman Jr RF, Fisher RS, Dabezies MA. Endoscopic evaluation of penetrating esophageal injuries. *Am J Gastroenterol.* 1993;88(8):1249–53.
- Nesbitt JC, Sawyers JL. Surgical management of esophageal perforation. *Am Surg.* 1987;53(4):183–91.
- Pate JW, Walker WA, Cole Jr FH, Owen EW, Johnson WH. Spontaneous rupture of the esophagus: a 30-year experience. *Ann Thorac Surg.* 1989;47(5):689.

---

**Part XV**

**Urology**

Jeremy M. Blumberg, Section Editor

Areg Grigorian and Jeremy M. Blumberg

A 13-year-old boy presents with acute onset of right lower quadrant and scrotal pain for the past 4 hours. He additionally reports nausea and one episode of vomiting. He denies any similar past pain and reports no history of trauma. On physical examination, the skin overlying the right side of the scrotum appears to be slightly erythematous and edematous. The right testicle appears to be lying significantly higher in the scrotum as compared to the left testicle. The entire right testicle is exquisitely tender to palpation, whereas the left one is nontender. He has an absent cremasteric reflex on the right.

**Diagnosis**

**What is the Differential Diagnosis?**

Diagnosis	Comments
<i>Testicular torsion</i>	Tender and swollen testicle that is displaced superiorly; mass may be felt in spermatic cord, <i>absent cremasteric reflex</i> , nausea, vomiting
<i>Torsion of testicular or epididymal appendage (appendix testis)</i>	Common cause of acute painful hemiscrotum in a child; the epididymal appendage (appendix testis) is located at the head of the epididymis; <i>blue-dot sign</i> is a classic finding; onset of pain is more gradual; <i>cremasteric reflex is maintained</i>
<i>Epididymitis and/or orchitis</i>	Scrotal pain relieved by supporting the scrotum, dysuria, induration, classically from mumps, more commonly bacterial
<i>Hydrocele</i>	Fluid in the tunica vaginalis, <i>will transilluminate</i> , increase in size with valsalva, often spontaneously resolve by 1 year of age
<i>Varicocele</i>	Tortuous dilation of pampiniform plexus, <i>does not transilluminate</i> , increase in size with valsalva, described as a “bag of worms”
<i>Appendicitis</i>	Anorexia, vague periumbilical abdominal pain, vomiting, localized right lower quadrant pain (McBurney’s point), Rovsing’s sign, psoas sign
<i>Fournier’s Gangrene</i>	Severe necrotizing infection in the perineal and scrotal region occurring most commonly in uncontrolled diabetic patients and immunocompromised
<i>Traumatic testicular rupture</i>	Patients have history of trauma to scrotum, scrotal pain, hematocele; results from a disruption to the connective tissue enveloping the testicle (tunica albuginea)
<i>Testis tumor</i>	Presents as firm, painless testicular mass that cannot be transilluminated; seminomas (germ cell tumors) are the most common type and are malignant

A. Grigorian, MD  
 Department of Surgery, University of California, Irvine, 333 City Blvd West, Suite 1600, Route. 81, Orange, CA 92868, USA  
 e-mail: [agrigori@uci.edu](mailto:agrigori@uci.edu)

J.M. Blumberg, MD (✉)  
 Urology, Renal Transplantation, Department of Surgery, Harbor-UCLA Medical Center, 1000 W. Carson Street, Torrance, CA 90509, USA  
 e-mail: [JBlumberg@mednet.ucla.edu](mailto:JBlumberg@mednet.ucla.edu)

---

### **What Is the Most Likely Diagnosis for this Patient?**

In a 13-year-old patient with a sudden onset of scrotal pain; with a swollen, superiorly displaced testicle; and with absent cremasteric reflex, the most likely diagnosis is testicular torsion.

---

### **History and Physical**

#### **Which Type of Testicular Trauma Is Most Common?**

Blunt testicular trauma is responsible for 85 % of cases. Of those, sports-related injuries are implicated in most of those traumas. Blunt trauma is usually associated with unilateral injuries, while penetrating trauma can involve both testes.

#### **What Is the Cremasteric Reflex?**

The cremasteric reflex is an elevation of the ipsilateral testicle by the cremasteric muscle in response to a stroking motion at the medial aspect of the upper thigh. When the medial thigh is stroked, sensory fibers from the femoral branch of the genitofemoral nerve (L1-L2) are stimulated. The sensory input travels to the spinal cord, where it synapses with the motor nerve from the genital branch of the genitofemoral nerve (L1-L2) to activate the cremasteric muscle and cause ipsilateral elevation of the testis.

#### **What Would Cause an Absent Cremasteric Reflex?**

The cremasteric reflex is absent with upper and lower motor neuron disorders, with spinal cord injury at L1-L2 (genitofemoral nerve), and usually in patients with testicular torsion. It is important to note that although the reflex is almost always absent in patients with testicular torsion, a present reflex does not exclude the possibility of testicular torsion.

#### **What Is Prehn's Sign? Is It Reliable?**

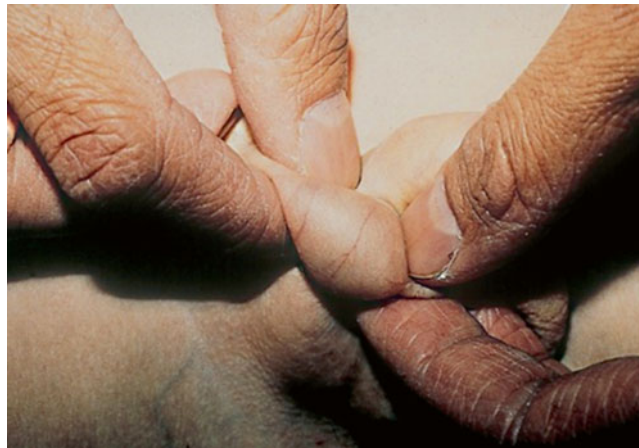Prehn's sign is positive when patients report pain relief with elevation of scrotal contents and negative when this does not relieve any pain. Classically, patients with epididymitis have a positive Prehn's sign, while testicular torsion patients have a negative sign. However, Prehn's sign is not a reliable distinguishing feature between testicular torsion and epididymitis, as a positive sign does not exclude the diagnosis of testicular torsion. Prehn's sign has been shown to be inferior to Doppler ultrasound to rule out testicular torsion.

#### **What Is the Blue-Dot Sign?**

This is a pathognomonic sign (Fig. 52.1) for torsion of testicular or epididymal appendage (appendix testes). Palpation of the testes reveals a small firm and tender nodule near the head of the epididymis that appears to have a blue discoloration.

#### **What Are the Four Cardinal Symptoms and Signs of Testicular Torsion?**

Nausea/vomiting, testicular pain duration of less than 24 hours, a superiorly displaced testicle, and an absent cremasteric reflex.



**Fig. 52.1** Blue-dot sign (With kind permission from Springer Science+Business Media: Atlas of Clinical Urology, Office Urology, 2003, p 3, Kaplan et al., Fig. 1.4b)

### What are the Important Differences Between Testicular Torsion and Appendix Testes Torsion?

Type	History and physical	Cremasteric reflex	Management
<i>Testicular torsion</i>	Sudden onset of tender and swollen testicle that is displaced superiorly; mass may be felt in spermatic cord, nausea, vomiting	Absent	Detorsion, followed by bilateral orchiopexy
<i>Appendix testes torsion</i>	Gradual onset of pain, most common cause of acute painful hemiscrotum in a child, the epididymal appendage (appendix testis) is located at the head of the epididymis, <i>blue-dot sign</i> is a classic finding	Present	Nonsteroidal anti-inflammatory drugs, ice packs, and scrotal support; uncontrolled pain can be managed with surgical excision of the appendix testes

### Pathology/Pathophysiology

#### What Congenital Defect Predisposes Children to Developing Testicular Torsion?

Congenital defects of the processus vaginalis can lead to failure of the testes to attach to the inner lining of the scrotum, increasing the risk of developing testicular torsion later in life. In particular, patients with *bell-clapper deformity* are at increased risk for testicular torsion. This occurs when there is a failure of normal posterior anchoring of the gubernaculum, testes, and epididymis, allowing the testes to freely rotate and swing within the tunica vaginalis of the scrotum similar to the gong (clapper) inside of a bell. This deformity is usually present in both testicles, placing both at risk for torsion.

#### What Are Other Risk Factors for Testicular Torsion?

Aside from the bell-clapper deformity, other risk factors include age (12–18 years old most common) and history of prior torsion.

## Work-Up

### If Suspicion for Testicular Torsion Is High, What Laboratory Tests Are Important to Obtain? What Is the Role of Additional Imaging?

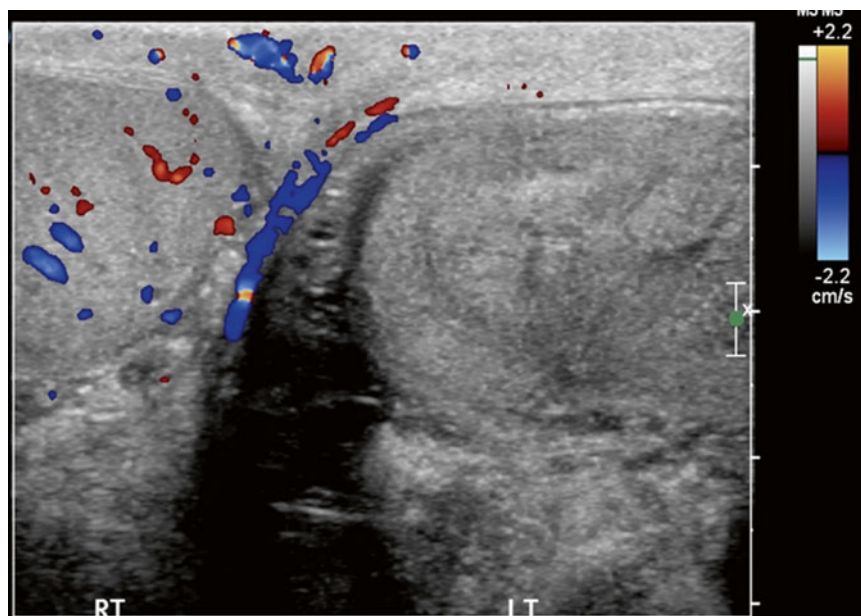
If clinical suspicion is high, imaging and/or laboratory work-up is not warranted and the clinician should proceed to prompt surgical intervention to restore blood flow to the testis.

### If Suspicion of Testicular Torsion Is Low, What Laboratory Tests Should Be Obtained? What Imaging Is Useful?

Urinalysis should always be ordered to rule out a urinary tract infection or epidymo-orchitis, as these may also present with scrotal pain. Imaging should only be obtained with equivocal clinical findings and when performance of imaging will not significantly delay treatment. Doppler (blood flow) ultrasound (imaging) of the scrotum is the image modality of choice. In the presence of torsion, Doppler interrogation should demonstrate an absence of arterial blood flow in the affected testicle. The sensitivity and specificity of Doppler ultrasound in the detection of testicular torsion range from 70 % to 100 % and 80 % to 100%, respectively. The ultrasound portion of the study can demonstrate other etiologies, such as a mass or evidence of trauma. Acute bleeding of testicular parenchyma appears hyperechoic, while older blood will appear hypoechoic (Fig. 52.2).

### In the Trauma Setting, What Are the Most Important Things to Look for During Doppler Ultrasound?

To determine if the tunica albuginea is violated (testicular rupture) as this would warrant surgical repair in the acute setting, one should also confirm adequate blood flow to the testes which ensures that the vascular pedicle is intact. Since torsion often occurs during performance of sporting activities, there may be confusion as to whether the scrotal pain is from trauma or torsion. Absence of arterial flow suggests torsion or severe trauma that has disrupted the blood supply.



**Fig. 52.2** Scrotal Doppler ultrasound showing absent flow in the left testis consistent with testicular torsion. Note: normal color flow in the right testicle (*left side of image*)

## Management

### **In the Setting of Suspected Testicular Torsion, What Is the Optimal Timing from Initial Evaluation to Definitive Management?**

The diagnosis of testicular torsion requires immediate surgical consultation with a urologist for intervention. Timing is of the utmost importance because the viability of a torsed testicle depends on how long the testicle remains torsed. One study demonstrated 100 % viability when detorsion was achieved within 4–6 hours, 20 % viability with detorsion after 12 hours, and 0–10 % viability if detorsion was performed after 24 hours.

### **What Is the Next Step in the Management for a Patient Suspected of Testicular Torsion and Is Confirmed on Ultrasound?**

If the duration of symptoms is <6 hours, some surgeons recommend manual detorsion in the emergency department. In most cases, if the physician is facing the patient, the testis should be twisted laterally, similar to “opening a book.” This must be followed by an elective orchiopexy (testicle fixed to scrotum to prevent retorsion). If there has been a significant delay from the onset of pain to diagnosis, the patient should be taken directly to the operating room for emergent surgical reduction of torsion.

### **What Should Also Be Done Following Surgical Reduction of Torsion?**

The affected side should be untwisted and orchiopexy should be performed to prevent recurrence. Since patients with torsion of one testicle are at risk for torsion of the contralateral one, bilateral orchiopexy is generally recommended at the time of surgery.

### **What if the Testicle Is Necrotic at the Time of Surgical Exploration?**

An orchiectomy is performed.

### **What Is the Recommended Management for Minor Trauma to the Testes?**

Minor trauma includes cases where there is no significant swelling, pain, or breaches in the integrity of the skin around the scrotum. These patients can be treated conservatively with scrotal support, ice packs, nonsteroidal anti-inflammatory drugs, and bed rest.

### **What Are the Operative Indications for Testicular Trauma?**

Operative indications include suspicion of violation of the tunica albuginea, rapidly expanding testicular hematoma, avulsion, scrotal degloving, and absence of blood flow as evidenced on doppler ultrasound. With the possible exception of superficial skin lesions, most clinicians elect to explore all penetrating testicular traumas in the operating room. Surgical exploration has proven to increase testicular salvage rates and preserve fertility. Earlier surgical interventions are associated with better outcomes. Delays in management increase the risk of testicular infarction.

---

## Prognosis

### **Does Loss of a Testicle from Torsion Affect Fertility?**

Only one testicle is needed for fertility. In the majority of patients who lose a testicle, fertility is not affected. On occasion, testicular necrosis and loss from torsion can lead to the formation of antisperm antibodies with a subsequent decrease in sperm count and decrease in motility.

## Areas Where You Can Get in Trouble

### Failing to Perform a Scrotal Exam in an Adolescent Male with Abdominal Pain and Vomiting

Testicular torsion can present with nausea, vomiting, and referred abdominal pain. It is imperative that a careful scrotal exam be performed in adolescent males with this presentation.

---

## Summary of Essentials

### Diagnosis

- Four cardinal signs/symptoms of testicular torsion
  - Nausea/vomiting
  - Testicular pain duration of less than 24 hours
  - Superiorly displaced testicle
  - Absent cremasteric reflex
- High clinical suspicion is all that is needed to prompt intervention

### History and Physical

- Prehn's sign classically negative for testicular torsion; however, this is not reliable
- Blue-dot sign is pathognomonic for appendix testes torsion
- Cremasteric reflex present in appendix testes torsion, absent with testicular torsion

### Pathophysiology

- Congenital defects of the processus vaginalis can lead to failure of the testes to attach to the inner lining of the scrotum
  - Bell-clapper deformity

### Work-Up

- If clinical suspicion is low for torsion, urinalysis should always be ordered to rule out a urinary tract infection or epidymo-orchitis
- Doppler ultrasound shows an absence of arterial blood flow in the affected testicle
- In trauma setting, look for violation of tunica albuginea

### Management

- Presentation <6 hours; attempt manual detorsion followed by elective orchiopexy
- Presentation >6 hours; patient should be taken directly to OR for surgical detorsion
- Orchiectomy performed for necrotic testicle

---

## Suggested Reading

- Cummings JM, Boullier JA, Sekhon D, Bose K. Adult testicular torsion. *J Urol.* 2002;167:2109.  
Kapasi Z, Halliday S. Best evidence topic report. Ultrasound in the diagnosis of testicular torsion. *Emerg Med J.* 2005;22:559.  
Rabinowitz R. The importance of the cremasteric reflex in acute scrotal swelling in children. *J Urol.* 1984;132:89.  
Wampler SM, Llanes M. Common scrotal and testicular problems. *Prim Care.* 2010;37:613.



Areg Grigorian and Jeremy M. Blumberg

A 22-year-old male presents with a left scrotal mass. He notes that he was playing soccer about 5 weeks ago and sustained mild trauma to the left hemiscrotum at that time. The trauma prompted him to palpate his testicle, at which time he noted the mass. The patient states that he had mild pain initially that resolved on its own and denies any hematoma. He denies any pain at this time. He states that the mass does not seem to be increasing in size and that it is approximately the size of a large almond. The mass, he notes, seems to be “in the middle” of his left testis. On review of symptoms he denies subjective fevers, chills, dysuria, gross hematuria, or urethral discharge. Physical examination reveals a firm 2 cm mass within the left testis. There is no pain to palpation. There are no epididymal masses bilaterally, and the right testis is normal to examination. Abdominal exam reveals no masses and no hepatomegaly. There are no supraclavicular nodes and no gynecostasia. Laboratory analysis reveals a normal urinalysis and complete blood count.

---

## Diagnosis

### Why Is the Location of a Scrotal Mass Important to Identify?

Identifying the precise locations of scrotal masses is an important part of the physical exam as it allows for an accurate differential diagnosis based on anatomic origin (i.e., spermatic cord, epididymis, or testes).

#### Watch Out

Despite a history of trauma, a young man (20–40 years old) with a testicular mass should be presumed to have testicular cancer until proven otherwise. Trauma to the scrotum or groin may prompt men to examine their testes leading to the discovery of an otherwise painless mass.

---

A. Grigorian, MD (✉)

Department of Surgery, University of California, Irvine, 333 City Blvd West, Suite 1600, Route. 81, Orange, CA 92868, USA  
e-mail: [agrigori@uci.edu](mailto:agrigori@uci.edu)

J.M. Blumberg, MD

Urology, Renal Transplantation, Department of Surgery, Harbor-UCLA Medical Center, 1000 W. Carson Street, Torrance, CA 90509, USA  
e-mail: [JBlumberg@mednet.ucla.edu](mailto:JBlumberg@mednet.ucla.edu)

## Describe the Cause(s) of Scrotal Masses Found Involving the Skin

Etiology	Features
<i>Epidermoid or pilar cysts</i>	Develop from epidermis or hair follicle and present as painless, slow growing, mobile, fluid-filled nodules; they occur most commonly in areas that have a lot of hair (e.g., scrotum, chest)
<i>Squamous cell carcinoma (SCC)</i>	Proliferation of squamous cells characterized by formation of keratin pearls; presents as ulcerated, nodular, mass with no telangiectasias; occurs in the 5th or 6th decade; associated with HPV and occupational exposure (soot, oil, and petroleum workers)

## What is the Differential Diagnosis of Scrotal Masses Involving the Spermatic Cord?

Etiology	Features
<i>Indirect inguinal hernia</i>	Mass increases in size with valsalva and emerges from internal ring, usually reducible (unless very large)
<i>Hydrocele</i>	Painless, unilateral scrotal mass, does not extend up spermatic cord, normal testis, transilluminates with flashlight
<i>Varicocele</i>	Feels like a “bag of worms,” more common on the left, associated with male infertility

## What is the Differential Diagnosis of Scrotal Masses Involving the Epididymis?

Etiology	Features
<i>Epididymitis</i>	Painful, tender epididymis, associated with UTI/STD and scrotal erythema/cellulitis, positive “Prehn’s sign” (relief of pain with elevation)
<i>Spermatocele</i>	Also called epididymal cyst, benign, typically painless, fluid-filled mass, cephalad and distinct from the testis, may transilluminate
<i>Torsion of testicular epididymal appendage (appendix testes)</i>	Most common cause of acute painful hemiscrotum in a child; the epididymal appendage (appendix testis) is located at the head of the epididymis; blue-dot sign is a classic finding; onset of pain is more gradual; cremasteric reflex is maintained

## What is the Differential Diagnosis of Scrotal Masses Found Involving the Testes?

Etiology	Features
<i>Orchitis</i>	Painful, tender testicle, most often viral (mumps) but also bacterial, associated with STD (in which case epididymis is also affected)
<i>Testicular torsion</i>	Sudden, severe onset of pain, testis may become swollen and high-riding, negative Prehn’s sign (pain not alleviated with elevation), most common in pubescent males, also seen in neonates, loss of cremasteric reflex, <i>surgical emergency</i>
<i>Testicular cancer</i>	Presents as firm, painless testicular mass that does not transilluminate; germ cell tumors are the most common type and are malignant

## What Is the Most Likely Diagnosis for this Patient?

In a 22-year-old male with a painless, firm, non-tender testicular mass, testicular cancer is the most likely diagnosis.

## History and Physical

### What Features on History and Physical Examination Favor the Diagnosis of Testicular Cancer?

Any painless mass within the testicle is cancer until proven otherwise. Most patients with testicular cancer present without symptoms, and most are young adults (average age between 20 and 35 years). On physical exam, the mass is within the testicle (as opposed to separate from it). Rarely, patients with testicular cancer may also have gynecomastia secondary to hormonally active tumors (secreting human chorionic gonadotropin).

### **What Is the Implication of Constitutional Symptoms in Association with a Painless Testicular Mass?**

The presence of constitutional symptoms in association with a painless testicular mass is highly suggestive of metastatic testicular cancer. Symptoms such as back or abdominal pain, weight loss, and nausea suggest retroperitoneal lymph node metastasis, whereas cough and shortness of breath suggest pulmonary metastasis.

### **What Risk Factors for Testicular Cancer Should Be Obtained on History?**

The vast majority of patients have no risk factors. The main risk factor is cryptorchidism (undescended testicle). Other risk factors include personal history of testicular cancer (contralateral testicle), family history of testicular cancer, Klinefelter's syndrome, and white race.

### **What Features on Physical Examination Favor a Nonmalignant Etiology?**

Masses that are extratesticular, bilateral, painful, mobile, fluid filled, and that transilluminate are less likely to be cancerous.

### **What Are the Main Diagnoses to Consider in the Presence of a Very Painful Scrotal Mass?**

Epididymitis and/or orchitis would be highest on the differential. During pubescence, testicular torsion and torsion of the appendix testis would be high on the list. An incarcerated hernia can be extremely painful, but is separate from the testicle and epididymis.

### **What Benign Processes Are Typically Painless?**

Spermatocele, varicocele, and hydrocele are usually painless. Careful examination will demonstrate that these masses are separate from the testicle itself.

### **What Physical Exam Maneuver Can Help Identify a Varicocele?**

Patients with varicoceles will often have the mass disappear upon lying down and reappear when the patient stands up. A varicocele feels like a spongy bag of worms.

#### **Watch Out**

Varicocele is associated with infertility.

---

## **Pathology/Pathophysiology**

### **Does Cryptorchidism Increase the Risk of Developing Testicular Cancer in the Undescended Testicle, the Contralateral Descended Testicle, or Both?**

It is more likely to occur in the undescended testicle. However, in nearly 25 % of these cases, testicular cancer develops in the contralateral descended testicle. This suggests that an undescended testicle may not play a direct role in the development of testicular cancer, but rather, there is some other phenomenon that leads to both testicular cancer and abnormal descent of the testicles during embryologic development.

## What Is the Most Common Subtype of Testicular Tumor? Is It Malignant?

Seminoma, a germ cell tumor, is the most common subtype and is considered malignant.

## What are the Major Pathologic Subtypes of Testicular Cancers?

<b>Seminomatous germ cell tumors (35 %)</b>	
Seminoma	Most common type in adults, highly responsive to radiotherapy, metastasize late, excellent prognosis, rare hCG production
<b>Nonseminomatous germ cell tumors (65 %)</b>	
Embryonal carcinoma	Malignant, necrosis common, aggressive with early hematogenous spread, AFP or hCG production
Yolk sac	Most common type in children, malignant, AFP production
Choriocarcinoma	Malignant, early hematogenous spread, hCG production
Teratoma	Benign and malignant types, derived from $\geq 2$ embryonic layers, AFP or hCG production
Mixed germ cell	Benign and malignant types, multiple nonseminomatous components
<b>Sex-cord stromal tumors</b>	
Leydig cell	Benign, associated with paraneoplastic syndromes (e.g., precocious puberty, hyperparathyroidism)
Sertoli cell	Benign, often clinically silent
<b>Other</b>	
Lymphoma	Malignant, commonly bilateral, occurs in older males, typically diffuse large B-cell type

**Table 53.1** Organisms causing epididymitis

<b>Organism</b>	<b>Age</b>
<i>Chlamydia trachomatis</i> (serotypes D-K)	Young adult (<35)
<i>Neisseria gonorrhoeae</i>	Young adult (<35)
<i>Escherichia coli</i>	Older adult (>35)
<i>Pseudomonas</i>	Older adult (>35)

## What Causes Gynecomastia in Patients with Testicular Cancers?

Choriocarcinoma, a germ cell tumor, is associated with ectopic human chorionic gonadotropin (hCG) production. Elevated levels of hCG can stimulate breast development, leading to gynecomastia. The alpha subunit of hCG is similar to TSH, so these patients can also present with symptoms suggestive of hyperthyroidism but without a goiter.

## What Are the Differences Between Epididymitis and a Spermatocele?

Epididymitis involves an infection of the epididymis (Table 53.1) and is an acute process that is often confused with torsion. Patients will often complain of dysuria and a tender epididymis. Spermatoceles develop as a result of a retention cyst, often at the head of the epididymis. They are often asymptomatic but can present clinically as painless, distinct masses from the testes that will transilluminate with light.

## Why Does a Varicocele Form? Why Is It More Often on the Left? Why Does It Affect Fertility?

The pathophysiology of a varicocele relates to impaired venous drainage. Veins in the pampiniform plexus slowly and progressively dilate and enlarge over time as a result of impaired drainage. It occurs more commonly on the left as venous drainage is less optimal (the left testicular vein enters the left renal vein at a right angle) than the right (which drains into the larger inferior vena cava at a more favorable angle). Stasis of venous blood appears to increase testicular temperature, increase seminal oxidative stress, and damage sperm DNA.

**Watch Out**

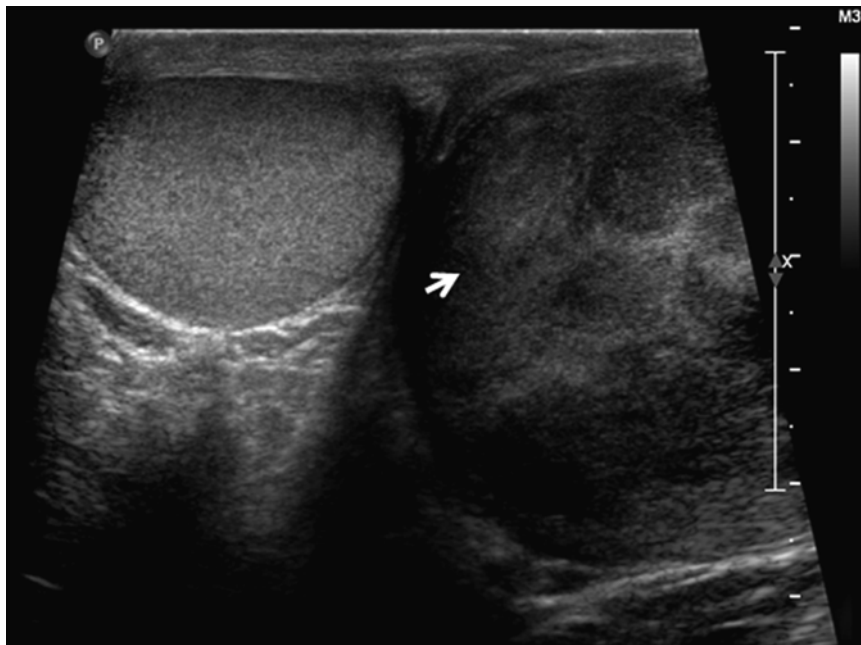
Sudden onset of a left-sided varicocele may be precipitated by thrombosis of the left renal vein (think of renal cell carcinoma).

**What Is the Pathophysiology of a Hydrocele?**

During fetal development, the peritoneum extends into the scrotum to become the processus vaginalis, a layer that encompasses the testes that are themselves enveloped by yet another layer, the tunica vaginalis. With normal development, the testes descend completely, and the surrounding tunica vaginalis separates from the processus vaginalis. When the embryological events do not occur, fluid can accumulate in either the tunica vaginalis or a persistent processus vaginalis, presenting as either fluid adjacent to the testes or fluid directly above the testis along the spermatic cord, respectively. Since they are fluid filled, hydroceles transilluminate light (unlike solid masses). Hydroceles that communicate with the peritoneum (via a patent processus vaginalis) change in size with Valsalva, whereas those that do not (noncommunicating) remain the same size. Hydroceles are very common in newborns and most resolve spontaneously within the first year of life as the tunica vaginalis separates from the processus vaginalis.

**Work-Up****What Are the Key Imaging Modalities for a Patient with Testicular Cancer?**

The demonstration on ultrasound of a solid mass (Fig. 53.1) within the testicle makes the likelihood of cancer very high, whereas a purely cystic, fluid-filled mass is unlikely to be malignant. Patients with a diagnosis of testicular cancer should be staged with a CT scan of the abdomen and pelvis (to look for retroperitoneal lymph node metastasis) and a chest x-ray (to look for pulmonary metastasis). If retroperitoneal lymph node metastases or a pulmonary nodule are discovered, a CT of the chest should be considered. Patients with neurologic symptoms should also have a CT or MRI of the brain.



**Fig. 53.1** Scrotal ultrasound showing an enlarged testicle with heterogeneous echotexture suggestive of infiltrative cancer. Compare with normal testis on the left of the image. *White arrow: abnormal testicle*

### **What Relevant Blood Tests should be obtained in a Patient with Testicular Cancer?**

Three blood tests— $\beta$ -hCG, AFP, and LDH—may be used to monitor patients who have been diagnosed with testicular cancer.  $\beta$ -hCG is elevated in some seminomatous cancers and in most nonseminomatous ones, whereas AFP is only elevated in nonseminomatous cancer. These markers are not sufficiently sensitive to be used as screening or diagnostic tools. They are more helpful for the purposes of staging, establishing prognosis, and following response to treatment. LDH levels are useful for prognostic purposes (high levels suggest a large tumor bulk), but not for diagnosis.

### **Is Percutaneous Biopsy for a Testicular Tumor Recommended?**

No. There is a high risk of seeding, or spreading the cancer, with a biopsy.

---

## **Management**

### **How Is Pathologic Confirmation of Testicular Cancer Determined?**

In patients with a testicular mass that is highly suspicious for malignancy (based on physical exam and ultrasound), radical inguinal orchiectomy is performed. The procedure is performed via an inguinal incision and consists of removal of the testicle and spermatic cord up to the point where it exits from the internal ring.

### **Why Is an Inguinal Incision Preferred Over a Scrotal One?**

Orchiectomy via a trans-scrotal incision is associated with a higher rate of local recurrence. The inguinal incision also allows a longer portion of the spermatic cord to be removed.

### **What Other Treatment Modalities Are Utilized After Initial Surgery for Testicular Cancer?**

Radiation, chemotherapy, and retroperitoneal lymph node dissection (RPLND) are additional treatment strategies utilized. The decision as to which of these modalities to use depends on the type and stage of the cancer. For instance, seminomas are highly radiosensitive, so the majority of patients receive radiation therapy. Seminomas and most nonseminomas respond well to chemotherapy. RPLND is primarily recommended for nonseminomas.

### **What Should Be Recommended for Patients About to Undergo Orchiectomy and/or chemotherapy?**

Patients who will undergo chemotherapy may have infertility issues as a result of their treatment. Although removing one testicle should not significantly affect fertility, young patients may feel more comfortable participating in cryopreservation of sperm to ensure that they can have children in the future.

### **Does Unilateral Orchiectomy Lead to Impotence?**

No. Unilateral orchiectomy does not affect erectile function. However, RPLND can injure nerves that affect erectile function.

## What are the key Differences Between a Seminoma and Nonseminoma?

	<b>Seminoma</b>	<b>Nonseminoma</b>
<i>Incidence</i>	Most common	Less common
<i>Elevated AFP levels</i>	No	Common
<i>Elevated BCG levels</i>	Rare	Common
<i>Radical inguinal orchiectomy</i>	Yes	Yes
<i>Radiation therapy</i>	Radiosensitive	Not radiosensitive
<i>Chemotherapy</i>	Yes	Yes
<i>Retroperitoneal lymph node dissection</i>	No	Yes (many patients)

---

## Summary of Essentials

### History and Physical

- Male patients aged 20–40 with a non-tender testicular mass should raise suspicion for testicular cancer

### Pathology/Pathophysiology

- Seminoma is the most common type of testicular tumor
- Cryptorchidism increases the risk of testicular cancer in both testicles, even the normally descended one

### Work-Up

- Ultrasound will show a solid mass within the testicle in testicular cancer
- CT of abdomen, pelvis should be used for staging
- Biopsy is contraindicated as it may seed cancerous cells

### Management

- Radical orchiectomy is a treatment for highly suspicious testicular cancer
- Additional therapy
  - Radiation (seminoma)
  - Chemotherapy (most testicular cancers)
  - RPLND (mostly non seminomas)

---

## Suggested Reading

Bosl GJ, Motzer RJ. Testicular germ-cell cancer. *N Engl J Med.* 1997;337:242.  
 Marth D, Scheidegger J, Studer UE. Ultrasonography of testicular tumors. *Urol Int.* 1990;45:237.  
 Powell TM, Tarter TH. Management of nonpalpable incidental testicular masses. *J Urol.* 2006;176:96.

Jeremy M. Blumberg and Kiran Gollapudi

A 68-year-old Caucasian man presents to the emergency department complaining of blood in his urine as well as small blood clots for 3 days. He denies dysuria, nocturia, urinary frequency or hesitancy, or a decreased urinary stream. He denies any fevers, chills, or weight loss. He has had similar episodes of visible blood in his urine in the last several months and has been treated twice with antibiotics for a possible urinary tract infection without improvement. He has a history of hypertension for which he takes a beta-blocker; otherwise he has had no surgeries and takes no other medications. He denies any family history of malignancy or renal disease. He denies any history of trauma and does not vigorously exercise. He has a 40-pack-year history of smoking and worked as a painter. On physical exam, he is afebrile with normal vital signs. His abdomen is soft, without any palpable masses. His genitourinary exam reveals a normal circumcised phallus without lesions and normal bilateral descended testicles. On digital rectal exam, his prostate is small without any nodularity, induration, or tenderness. On laboratory exam, his hematocrit is 42 % (normal 40–52 %), creatinine is 1.0 mg/dL (0.5–1.4 mg/dL), INR and PTT are normal, and PSA is 2 ng/dL (< 4 ng/dL). His urinalysis shows a large number of red cells, no white cells, no casts, and no bacteria.

---

J.M. Blumberg, MD

Urology, Renal Transplantation, Department of Surgery, Harbor-UCLA Medical Center, 1000 W. Carson Street, Torrance, CA 90509, USA  
e-mail: [JBlumberg@mednet.ucla.edu](mailto:JBlumberg@mednet.ucla.edu)

K. Gollapudi, MD (✉)

Department of Urology, David Geffen School of Medicine at UCLA, 10833 Le Conte Avenue, Los Angeles, CA 90095, USA  
e-mail: [Kiran.gollapudi@gmail.com](mailto:Kiran.gollapudi@gmail.com)



## Diagnosis

### What is the Differential Diagnosis for Gross Hematuria and What Aspects of the History and Physical can help Lead you Toward a Specific Diagnosis?

Condition	Comments
<i>Acute cystitis</i>	Bladder infection most commonly caused by enteric bacteria such as <i>E. coli</i> ; frequency, urgency, burning; pyuria, bacteriuria
<i>Bladder cancer</i>	Mainly urothelial carcinoma (formerly known as transitional cell carcinoma); painless hematuria; risk factors include tobacco and exposure to automobile exhaust or industrial solvents
<i>Benign prostatic hyperplasia (BPH)</i>	Obstruction of the urethra by an enlarged prostate; frequency, urgency, hesitancy, slow stream, nocturia
<i>Nephrolithiasis (kidney stones)</i>	May be made of calcium, uric acid, cysteine, or struvite; severe pain often in the flank
<i>Benign essential hematuria</i>	Diagnosis of exclusion
<i>Prostatitis</i>	Infection of the prostate gland, most commonly by urinary pathogens; fever, dysuria, perineal/back pain; avoid vigorous prostate exam
<i>Renal cancer</i>	Most common subtype is renal cell carcinoma (RCC); most are asymptomatic; small minority may present with flank pain, flank mass, and hematuria; smoking is a risk factor
<i>Pyelonephritis</i>	Mainly ascending infection of the kidney from a lower urinary tract infection (UTI); may cause systemic symptoms; costovertebral angle (CVA) tenderness on percussion
<i>Prostate cancer</i>	Most common non-skin malignancy in males; diagnosed via digital rectal exam (DRE), prostate-specific antigen (PSA), and/or biopsy; gross hematuria is rare
<i>Urethral stricture</i>	Similar symptoms to BPH; caused by scarring from infection, instrumentation, trauma, or cancer; usually benign
<i>Trauma</i>	Injury to genitourinary tract, e.g., Foley placement, penetrating injury to kidney
<i>Polycystic kidney disease (PKD)</i>	Flank pain, enlarged liver, kidney stones, hypertension; risk of subarachnoid hemorrhage; often positive family history
<i>Menstruation</i>	Blood can mix with the urine

### How do the Age of the Patient and the Chronicity of the Hematuria Alter the Likely Differential Diagnosis?

Age	Acute hematuria (<2 weeks)	Chronic hematuria (>2 weeks)
<i>Under 20</i>	UTI, Foley trauma, exercise	IgA nephropathy
<i>20–50</i>	UTI, Foley trauma, exercise, nephrolithiasis	Polycystic kidney disease; bladder, kidney, or prostate cancer
<i>Over 50</i>	UTI, Foley trauma, nephrolithiasis	Benign prostatic hyperplasia; polycystic kidney disease; bladder, kidney, or prostate cancer

### What Are the Most Likely Diagnoses for this Patient?

The patient described above has several factors that would raise concern for urologic malignancy. These factors include that he is an elderly male, the persistence of the hematuria, the fact that the hematuria is macroscopic (vs. microscopic), the absence of pain, the history of smoking, and possible exposure to carcinogenic chemicals as a painter. The absence of other urinary symptoms (hesitancy, nocturia) makes some of the more common causes of gross hematuria in elderly males (prostatitis, BPH) less likely as well. Trauma and vigorous exercise can also cause gross hematuria, but he denies this history. Furthermore, he does not have a significantly enlarged prostate on exam. There is no evidence on urinalysis of a urinary tract infection. The absence of casts or protein in the urine, combined with normal renal function, makes glomerular causes unlikely. In the absence of other significant history and laboratory anomalies, the likelihood of a urologic (kidney, ureter, bladder) malignancy is significantly increased and needs to be further investigated.

## History and Physical

### What Are the Differences Between Gross and Microscopic Hematuria?

Gross or macroscopic hematuria is suspected when urine is visibly pink, red, or brown, or when blood clots are voided. Microscopic hematuria is discovered due to the presence of red blood cells (RBCs) or heme on urinalysis or urine dipstick. Urologic malignancy is six to seven times more common in patients with gross hematuria. The presence of  $\geq 3$  RBCs/HPF on 2 of 3 properly collected urine specimens has traditionally warranted a complete hematuria workup. More recent guidelines suggest that a single urinalysis with  $\geq 3$  RBCs/HPF is sufficient to warrant a workup in patients with significant risk factors.

### Why is the Color and Consistency of the Urine Important?

Color/consistency	Implication
Bright red, thick consistency	<i>Moderate or severe active bleeding</i>
Pink	<i>Mild active bleeding</i>
Brown	<i>Old blood; glomerular bleeding</i>

### Other than Blood, What Can Make Urine Appear Red?

Certain foods (beets, rhubarb) and drugs (rifampin, sulfonamides, phenazopyridine, nitrofurantoin, phenytoin, levodopa, methyl-dopa, quinine, chloroquine, adriamycin, metronidazole) can have this effect. This is called pseudohematuria. Additionally, rhabdomyolysis—the destruction of muscle tissue, as in crush injuries—may release sufficient myoglobin into the bloodstream, and subsequently into the urine, to make the urine appear red or brown. Dark urine may also be seen in patients with elevated levels of conjugated bilirubin, as in biliary obstruction or certain metabolic diseases of the liver.

### What Is the Importance of Pain in Association with Hematuria?

Pain in association with hematuria strongly suggests infection or urinary obstruction. As such, urinary tract infection, pyelonephritis, and nephrolithiasis would be higher on the differential.

### What Is the Classic Presentation for Nephrolithiasis?

Ureteral stones present with acute colicky flank pain that may extend into the groin area if the stone is close to the bladder. The pain is described as colicky, with periods of severe pain during which the patient will not be able to stay still and will shift positions in an attempt to relieve their pain, followed by temporary resolution of the pain. This tendency to move around can help differentiate these patients from those with peritonitis as the latter prefer to remain rigid. Patients with nephrolithiasis may also complain of nausea, vomiting, and dysuria.

### What Are the Risk Factors for Nephrolithiasis?

Prior episodes of nephrolithiasis, family history, high protein diet, males > females, low fluid intake, dehydration, recurrent urinary tract infections, diabetes, gout, renal tubular acidosis, electrolyte abnormalities (e.g., hypercalcemia), and certain medications (e.g., acetazolamide, furosemide, allopurinol).

---

### **What Are the Most Common Symptoms/Presentation for Kidney Cancer? What Is the Classic Presentation?**

In most patients, renal cancer is discovered incidentally as a mass on imaging for other complaints. The classic presentation is the triad of flank pain, abdominal mass, and hematuria, but this is seen in only 10–15 % of patients.

### **What Are the Main Risk Factors for Renal Cancer?**

Smoking, male gender, older age, obesity, family history, and exposure to certain heavy metals and chemicals.

### **What Is the Most Common Presentation for Bladder Cancer? What Are the Risk Factors?**

Painless gross hematuria. A minority of patients will have urinary symptoms. Similar to renal cancer, risk factors include smoking, male gender, older age, family history, and exposure to heavy metals and chemicals. In addition, chronic bladder irritation and inflammation (from recurrent UTI, indwelling Foley, pelvic irradiation) increase the risk.

### **What Is the Most Common Presentation for Prostate Cancer? What Are the Risk Factors?**

Most prostate cancers are discovered incidentally because of PSA screening. On occasion, patients may present with urinary symptoms similar to BPH. With metastatic disease, the patient may present with bone pain, obstructive renal failure, or weight loss. The main risk factors are age >50, African-American race, high fat diet, and family history.

---

## **Anatomy**

### **What Comprises the Urinary Tract and Where Along the Tract Can Bleeding Arise?**

The kidneys, ureters, bladder, and urethra make up the urinary tract. The kidneys and ureters make up the upper urinary tract, while the bladder and urethra comprise the lower urinary tract. Bleeding can arise from anywhere along the tract, from the glomerulus to the distal urethra.

---

## **Pathology/Pathophysiology**

### **What Is the Difference Between Glomerular and Non-glomerular Hematuria? Why Is It Important to Distinguish Them?**

Glomerular hematuria implies that the blood is coming from the kidney itself. The most common causes include IgA nephropathy (Berger's disease), thin glomerular basement membrane disease, and hereditary nephritis (Alport's syndrome). Non-glomerular causes can originate from the upper (kidney, ureter) or lower (bladder, urethra) urinary tract. Glomerular causes are within the purview of nephrologists, whereas non-glomerular causes concern the urologist.

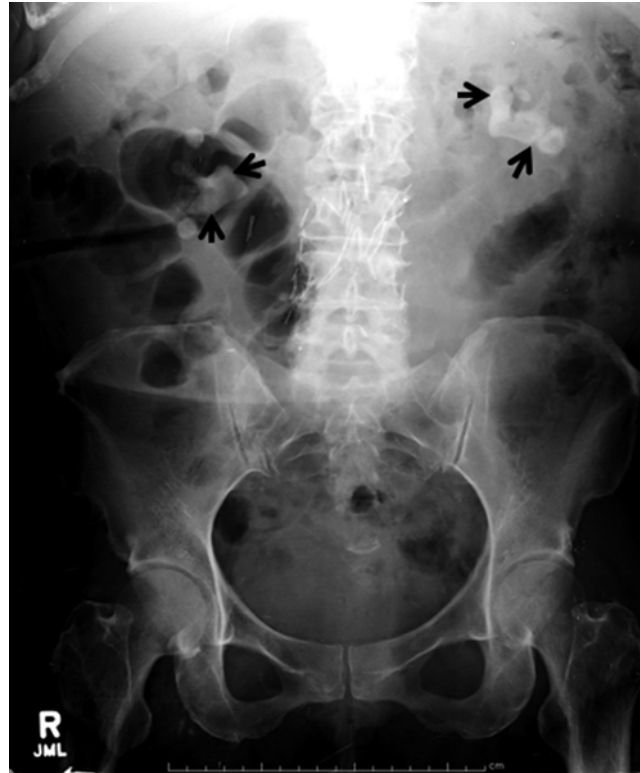## **Kidney Stones**

### **Where Do Renal Stones Develop and in What Circumstances Do They Lead to Symptoms?**

Stones can develop anywhere in the urinary tract but typically originate from the kidney or the renal pelvis. Many of these stones (<5 mm) will pass freely into the bladder and eventually exit the body during micturition. Stones do not cause symptoms unless they get lodged somewhere in the urinary tract and cause obstruction. The most common locations for a stone to get stuck are at points of narrowing in the GU tract: the ureteropelvic junction (UPJ), where the ureter crosses the iliac vessels, and the ureterovesical junction (UVJ).

**Table 54.1** Renal stones

Type	Etiology	Radiology	Features
<i>Calcium oxalate</i>	Hypercalciuria, Crohn's disease	Radiopaque	Most common type
<i>Struvite</i>	UTI secondary to urease + organism (e.g., <i>Proteus</i> , <i>Klebsiella</i> )	Radiopaque	Women affected more, can form staghorn calculi (outlining renal pelvis)
<i>Calcium phosphate</i>	Renal tubular acidosis, hyperparathyroidism	Radiopaque	Can form more readily in alkalinized urine
<i>Uric acid</i>	Low urinary pH, gout, chemotherapy, patients with ileostomies	Radiolucent	Can be treated by increase urinary pH (e.g., alkalinizing agents)

**Fig. 54.1** Abdominal X-ray showing branching radiopaque stones outlining the renal collecting system, consistent with staghorn calculi**Why Do High Protein Diets Increase the Risk of Developing Renal Stones?**

Breakdown of protein (e.g., fish, red meat, chicken) lowers the urinary pH and increases excretion of uric acid which can contribute to the formation of stones. Decreasing dietary protein, oxalate, and sodium intake decreases the risk of developing renal calculi.

**What Is the Most Common Type of Renal Stones and What Is the Leading Cause of This Type of Stone?**

The most common renal stone (Table 54.1) is calcium oxalate. The leading cause of calcium oxalate renal stones is hypercalciuria (Fig. 54.1).

**Renal Cancer****What Is the Most Common Type of Kidney Cancer?**

Renal cell carcinoma (RCC) is the most common primary tumor of the kidney. RCC arises from the renal tubule cells, and nearly 1/3 of patients have metastatic disease at the time of presentation. The most common histologic subtypes include clear cell (70%), papillary (15%), and chromophobe (5%).

### Where Is the Most Common Location for RCC Metastasis?

Lung, though RCC is known to metastasize to many different organs.

### What Genetic Syndromes Are Associated with RCC?

Most cases of RCC are sporadic, but several familial syndromes are associated with RCC.

These syndromes include von Hippel-Lindau (autosomal dominant, mutation of chromosome 3p), tuberous sclerosis (autosomal dominant, mutation of chromosome 9), and Birt-Hogg-Dube (autosomal dominant, mutation of chromosome 17).

### What Paraneoplastic Syndromes are Associated with RCC?

Paraneoplastic syndromes	Mediator
Polycythemia	Increased erythropoietin production
Hypercalcemia	PTH-like hormone production
Hypertension	Increased renin production
Cushing's syndrome	Ectopic cortisol production
Stauffer's syndrome	Reversible liver dysfunction; ↑ALP, ↑GGT, ↑ESR; hepatosplenomegaly; unknown mechanism

ALP alkaline phosphatase, GGT gamma-glutamyl transferase, ESR erythrocyte sedimentation rate

## Bladder Cancer

### What Is the Most Common Type of Bladder Cancer?

The most common type of bladder cancer is urothelial cell carcinoma (UCC), formerly referred to as transitional cell carcinoma. UCC can arise from the renal collecting system, ureters, bladder, or urethra. UCC are graded as either low grade or high grade. They are staged based on the depth of their invasion.

## Prostate Cancer

### What Is the Most Common Type of Prostate Cancer?

Prostatic adenocarcinoma.

## Workup

### What Is the First Step in the Workup of a Patient with Gross Hematuria?

The first step is to perform a urinalysis to confirm that there are, in fact, red blood cells in the urine. The urinary dipstick method (Table 54.2) detects hemoglobin in the urine. False-positive results can result from myoglobinuria (e.g., muscle breakdown secondary to intense exercise, rhabdomyolysis) or from solutions such as iodine that can cross-react with the dipstick indicator.

### What Is the Next Step in the Workup?

A positive dipstick analysis should be confirmed with a microscopic urinalysis. This analysis will provide the number of RBCs/HPF, the number of WBCs, and the presence of bacteria. In addition, the presence of crystals can be determined. Furthermore, the presence of dysmorphic RBCs and red blood cell casts suggests a glomerular source of bleeding.

#### Watch Out

Patients who give a history of gross hematuria should undergo a hematuria workup even if they do not have a positive urine dipstick or urinalysis.

**Table 54.2** Urine dipstick

Dipstick tests	Indications
<i>pH</i>	Depends on acid-base status
<i>Specific gravity</i>	Proportional to urine osmolality, appropriate changes to volume status indicate adequate renal concentrating ability
<i>Protein</i>	Proteinuria indicative of glomerular dysfunction
<i>Glucose</i>	Excessive glucose indicative of diabetes
<i>Blood</i>	Hematuria
<i>Ketones</i>	Present in DKA
<i>Nitrite</i>	Suggests presence of bacteria and UTI
<i>Leukocyte esterase</i>	Suggests presence of WBC and UTI

### What Additional Laboratory Tests Should be Ordered During the Hematuria Workup?

Lab tests	Why order?
<i>CBC</i>	WBC count if concerned about infection Hgb to determine if anemic from hematuria Plt count may reveal underlying thrombocytopenia
<i>Metabolic Panel</i>	BUN and creatinine to evaluate renal function
<i>PT/PTT/INR</i>	Rule out coagulopathy
<i>PSA</i>	Screen for prostate cancer in appropriate patients, can also be elevated in setting of UTI or recent instrumentation
<i>Urine culture</i>	Rule out infection
<i>Urine cytology</i>	Rule out urothelial malignancy

### How Does the Urinalysis Help Distinguish Between a Glomerular and a Non-glomerular Cause of Hematuria?

Urinary findings suggestive of a glomerular source for hematuria include brown-colored urine, red cell casts, dysmorphic red blood cells, and significant proteinuria. If the hematuria is thought to be of glomerular origin, the patient should be referred to a nephrologist. The workup of glomerular hematuria is beyond the scope of this chapter.

### What Workup Is Recommended for Non-glomerular Hematuria?

For non-glomerular hematuria, the workup depends on whether the hematuria is symptomatic or asymptomatic and whether the hematuria is microscopic or gross.

### What Workup Is Recommended for Symptomatic Non-glomerular Microscopic Hematuria?

This is most often associated with stones and infection. If the urinalysis demonstrates a UTI, appropriate antibiotic coverage is recommended. If there is no evidence of infection, kidney stones may be suspected.

### What Is the Best Diagnostic Test for Nephrolithiasis?

The test of choice is a non-contrast helical CT scan (CT-KUB) since it can detect the majority of stones and is more accurate than X-ray or sonogram. Ultrasonography is the procedure of choice in pregnant women and women of childbearing age, though stones are poorly visualized by ultrasound.

**Watch Out**

Non-contrast helical CT scans can be misleading in patients with HIV. Antiretroviral drugs (e.g., indinavir) can result in small radiolucent stones that can be missed. In such patients, a contrast-enhanced CT scan is more beneficial as it can show a filling defect at the location of these stones.

**What Further Workup Is Recommended in the Presence of Gross Hematuria?**

The strongest predictors for cancer are age over 50 and a history of gross (macroscopic) hematuria. As such, the majority of patients who present with gross hematuria should undergo a workup for malignancy. The workup consists of a CT urogram, urine cytology, and cystourethroscopy (for bladder and urethral pathology). CT urogram consists of non-contrast study (for urolithiasis), nephrogenic (for renal masses), and excretory phases (for urothelial lesions). Further workup is dictated based on the findings from these studies.

**Does Negative Urine Cytology Rule Out a Malignancy?**

No. A urine cytology detects abnormal-appearing urothelial cells that are concerning for a urothelial carcinoma of the bladder. The higher the tumor grade, the more likely urine cytology will be positive. The sensitivity of urine cytology for low grade tumors is less than 50 %. Also, in the presence of significant hematuria, cytopathologic analysis may not be able to pick up abnormal cells in the background of a significant number of RBCs.

---

**Management****What Is the Guiding Treatment Principle for Hematuria?**

Hematuria is managed by identifying and treating the underlying cause.

**Renal Stones****What Is the Best Management for Nephrolithiasis? How Does the Size of the Stone Change Management?**

Renal stones that are <5 mm are likely to pass on their own and should be managed with supportive therapy unless the patient is septic, has a solitary kidney, or has uncontrolled pain. Alpha-blockers such as tamsulosin can also be given to relax the ureteral wall. Stones between 5 and 9 mm should be managed using clinical judgment. Stones larger than 9 mm are unlikely to pass spontaneously and will therefore require more invasive treatment.

**What Are the Emergent Surgical Indications for Renal Stones?**

Obstructive stones that lead to urosepsis, intractable pain, progressive renal damage, or a solitary kidney (i.e., the patient only has one functional kidney) require ureteral stent placement or percutaneous nephrostomy tube placement.

**Renal Masses****What Are the Treatment Options for Renal Masses Concerning for RCC?**

Renal masses that are concerning for RCC are treated either with radical or partial nephrectomy depending on the size and location of the mass. In patients with small masses, or who are poor surgical candidates, surveillance as well as thermal or cryoablation are also options.

### **What Is a Radical Nephrectomy?**

A radical nephrectomy is the removal of the kidney, perinephric fat, Gerota's fascia, ureter, lymph nodes, and possibly, ipsilateral adrenal gland. However, in most cases, the ipsilateral adrenal gland can be preserved.

## **Bladder Cancer**

### **How Is Urothelial Carcinoma of the Bladder Treated?**

UCC is initially treated with transurethral resection for diagnosis and staging. Small superficial tumors can be treated with complete transurethral resection and potentially intravesical chemotherapy (mitomycin) or immunotherapy (bacillus Calmette-Guérin infused via urinary catheter). UCC has a high recurrence rate, and patients need to be closely monitored. The standard of care for nonmetastatic tumors that invade the detrusor muscle is radical cystectomy with urinary diversion.

### **What Is a Radical Cystectomy?**

Radical cystectomy involves the removal of the entire bladder and pelvic lymph nodes. In a male, the prostate and seminal vesicles are also removed. In a female, the cervix, uterus, fallopian tubes, and part of the vagina are also removed.

## **Prostate Cancer**

### **What Is a Radical Prostatectomy? Which Patients Are Appropriate Candidates for This Procedure?**

Removal of the prostate and seminal vesicles. Patients with disease contained to the prostate and a life expectancy of at least 10 years are good candidates.

### **What Are Nonsurgical Treatments for Prostate Cancer?**

External beam radiation, brachytherapy (placement of radioactive beads within the prostate), and androgen deprivation therapy. Patients who are poor surgical candidates or who have reduced life expectancy due to some other cause may receive nonsurgical therapy or active surveillance.

## **Special Circumstances**

### **What Are the Next Steps in Management if Significant Hematuria Persists Despite Foley Catheter Placement and Manual Irrigation?**

If the patient continues to have significant hematuria after manual irrigation, a 3-way Foley catheter can be placed and continuous bladder irrigation can be initiated. Continuous irrigation helps prevent the formation of new blood clots and also decreases exposure of potential bleeding sites in the lower urinary tract to urokinase. Urokinase is a serine protease that is present in urine that activates plasmin and the thrombolytic cascade. If hematuria does not improve or resolve with bladder irrigation, the patient may be taken to the operating room for cystoscopy. Cystoscopy allows for adequate clot evacuation, diagnosis of lower urinary tract pathology, and fulguration (i.e., electrical cauterization) of bleeding sites.

### **When Should a Patient Be Admitted to the Hospital for Gross Hematuria?**

The majority of patients with gross hematuria can be evaluated and treated in a non-emergent outpatient setting. A patient with significant and symptomatic gross hematuria should be admitted for inpatient management. The color and consistency of the urine, blood clots, and urinary retention may point to significant hematuria but are not absolute indications for admission. Active bleeding despite adequate bladder irrigation and symptomatic anemia are two indications for inpatient admission and workup.



## Areas You Can Get into Trouble

### Assuming Gross Hematuria Is Caused by a Benign Process

Many patients do not initially undergo a full hematuria workup because hematuria is assumed to be from a benign cause. For example, UTI is a common cause of hematuria. A UTI should be confirmed with a positive urine culture and not merely the presence of irritative voiding symptoms such as dysuria, urgency, and frequency. These symptoms can also be associated with bladder cancer. Risk factors for urologic malignancy should be identified during the history.

### Not Placing a Foley Catheter in the Setting of Significant Gross Hematuria

A Foley catheter should be placed if the patient has significant gross hematuria or blood clots. Failure to do so may result in urinary retention due to obstruction from the blood clots. All of the blood clots should be manually irrigated out of the bladder with a catheter tip syringe with either sterile saline or water. When hematuria is secondary to urethral or prostatic trauma, a Foley catheter can act to tamponade bleeding sites.

### Placing a Foley Catheter in the Setting of Trauma and Blood at the Urethral Meatus

A Foley catheter should not be placed in the setting of trauma (such as pelvic fracture) when blood is noted at the urethral meatus, as this represents a potential urethral injury. The Foley may convert a partial injury into a complete transection. A cystourethrogram should first be performed.

---

## Summary of Essentials

### History and Physical

- Pain with hematuria suggests UTI or urinary obstruction
- Painless gross hematuria raises suspicion for malignancy (especially in the elderly)
- Inquire about risk factors for malignancy

### Pathology/Pathophysiology

- Gross hematuria: urine that is visibly red, pink, or brown
- Microscopic hematuria: urine appears normal but RBCs are detected on urinalysis
- Pseudohematuria: red urine (without RBCs) due to certain foods, drugs, or metabolic disorders
- Renal carcinoma is usually asymptomatic and is usually discovered incidentally
  - Renal cell carcinoma (RCC) is most common
- Bladder cancer usually presents as painless gross hematuria
- Urothelial cell (transitional cell) is the most common
- Prostate cancer is usually discovered by PSA screening and prostate biopsy
  - Adenocarcinoma is the most common
- Kidney stone: calcium oxalate is the most common

### Workup

- Urine dipstick (for blood, protein), microscopic urinalysis
  - Dysmorphic RBCs or RBC casts suggest a glomerular cause:
    - Glomerular causes are treated medically by a nephrologist
    - Non-glomerular causes are often treated by a urologist

- Suspected kidney stone: Non-contrast CT; in women of childbearing age and children, ultrasonography should be used instead
- Most kidney stones are radiopaque (visible on X-ray)
- Gross hematuria (especially if >50 years old): malignancy workup
  - CT urogram
  - Urine cytology
  - Cystourethroscopy

## Management

- Kidney stones
  - <5 mm: will likely pass spontaneously
  - 5–9 mm: management individualized
  - >10 mm: extracorporeal shock wave lithotripsy, percutaneous nephrostomy, ureteroscopy, or rarely nephrolithotomy
- Renal cancer
  - Partial or radical nephrectomy
- Bladder cancer
  - Transurethral resection, infusion of mitomycin or BCG, or radical cystectomy
- Prostate cancer
  - External beam radiation, brachytherapy, androgen deprivation therapy, radical prostatectomy, or active surveillance

---

## Suggested Reading

Cohen RA, Brown RS. Clinical practice. Microscopic hematuria. *N Engl J Med.* 2003;348:2330.

Khadra MH, Pickard RS, Charlton M, et al. A prospective analysis of 1,930 patients with hematuria to evaluate current diagnostic practice. *J Urol.* 2000;163:524.

Nakamura K, Kasraeian A, Iczkowski KA, et al. Utility of serial urinary cytology in the initial evaluation of the patient with microscopic hematuria. *BMC Urol.* 2009;9:12.

---

**Part XVI**

**Vascular**

Christian de Virgilio, Section Editor

# Transient Loss of Vision in the Right Eye

Christian de Virgilio, Jessica Beth O’Connell,  
and Areg Grigorian

A 60-year-old male presents with an episode of vision loss in his right eye. The event occurred a week ago, began while he was sitting watching television, and resolved spontaneously after about 20 min. He described it as a curtain or shade that descended over his eye from top to bottom. He denied having any pain in the eye. He also denied any headaches, tiredness in his jaw while chewing, or any generalized fatigue. He denied any episodes of weakness or numbness on one side of his body or changes in his speech. He has a 30 pack/year history of smoking. He also has a history of hypertension and hypercholesterolemia. He denied a history of coronary artery disease or diabetes mellitus. He takes a beta-blocker and a statin. Physical examination reveals a systolic blood pressure of 140/70 mm Hg. He has normal carotid pulses and has a right carotid bruit. Neurologic examination is normal.

## Diagnosis

### Differential Diagnosis for Transient Monocular Vision Loss

Category	Conditions
Circulatory	<i>Embolus</i> from the carotid artery
	<i>Central retinal artery occlusion cherry red spot</i> on fundoscopy
	<i>Severe orthostatic hypotension</i> as seen in diabetics
	<i>Giant cell arteritis</i> ; jaw claudication, headaches, and increased ESR
	<i>Retinal vein occlusion</i> ; associated with chronic glaucoma, diabetes, and coagulopathy; patients report painless, monocular “cloudy vision,” and fundoscopy shows cotton wool spots, edema, and retinal hemorrhages
Ocular	<i>Retinal detachment</i> ; floaters
	<i>Open-angle glaucoma</i> ; gradual loss of vision from periphery to central
Neurologic	<i>Papilledema</i> ; associated with increased cerebral pressures (e.g., malignant hypertension, pseudotumor cerebri), headache, and bilateral disk swelling
	<i>Optic neuritis</i> ; associated with multiple sclerosis, inflammation of the optic nerve, painful visual loss
	<i>Retinal migraine or aura</i> ; result of vasospasm; painful vision loss

C. de Virgilio, MD  
General Surgery Residency Program, Department of Surgery, Harbor-UCLA Medical Center, 1000 W Carson Street,  
Torrance, CA 90505, USA  
e-mail: [cdevirgilio@labiomed.org](mailto:cdevirgilio@labiomed.org)

J.B. O’Connell, MD, FACS (✉)  
UCLA Department of Surgery, Greater Los Angeles VA Healthcare System, Gonda (Goldschmied) Vascular Center, 200 UCLA Medical  
Plaza, Suite 510-6, Los Angeles, CA 90095-6908, USA  
e-mail: [joconnell@mednet.ucla.edu](mailto:joconnell@mednet.ucla.edu)

A. Grigorian, MD  
Department of Surgery, University of California, Irvine, 333 City Blvd West, Suite 1600, Route. 81, Orange, CA 92868, USA  
e-mail: [areg.grig@gmail.com](mailto:areg.grig@gmail.com)

## **What Is the Most Likely Diagnosis for This Patient?**

Transient loss of vision, without other associated symptoms (such as headache, eye pain, floaters, and jaw tiredness when chewing), in a smoker with a carotid bruit is most likely due to embolus from the internal carotid artery (ICA).

---

## **History and Physical Examination**

### **What Is the Term for the Eye Symptom the Patient Describes?**

Amaurosis fugax is derived from Greek (amaurosis meaning darkness) and Latin (fugax meaning fleeting). The term describes transient vision loss and is described as a “curtain” or “shade” descending down the field of vision in one eye. It is often the result of atherosclerotic debris from a plaque in the internal carotid artery (ICA) that embolizes to the ophthalmic artery (the first branch off the ICA in the brain), leading to temporary ipsilateral retinal ischemia, typically lasting minutes.

### **In a Patient with This Eye Symptom, What Finding on Fundoscopic Ophthalmologic Examination Would Support a Carotid Artery Source of the Symptom?**

Hollenhorst plaques may be seen. They are cholesterol microemboli seen within the retinal arterioles that have a bright, yellow, and refractile appearance. They are considered highly suggestive of embolization from a plaque at the carotid bifurcation.

### **What If the Patient Instead Described Transient Motor and Sensory Loss of the Left Arm and Leg, What Term Would Be Used for Such a Symptom?**

A hemispheric TIA (transient ischemic attack). This is a focal neurologic deficit that lasts <24 hours, though the vast majority lasts 30 min or less.

### **How Does One Distinguish a TIA from a Stroke?**

The symptoms of a stroke persist >24 hours. Though in general, since most TIAs last less than an hour, symptoms lasting beyond that time are highly suggestive of a stroke.

### **Symptoms of Right Arm and Leg Weakness and Numbness Would Suggest Ischemia to What Part of the Brain?**

It would suggest ischemia to the contralateral brain, to the left motor cortex, which is in the territory of the middle cerebral artery. In addition, patients with ischemia to this territory may experience aphasia.

### **What Does a Carotid Bruit Signify?**

It is indicative of turbulent flow, most often due to a hemodynamically significant stenosis of the internal carotid artery due to atherosclerosis. The turbulent flow causes the artery distal to the stenosis to vibrate.

### **What Else Can Cause a Bruit in the Neck?**

Other causes include a murmur transmitted from the heart to the neck, such as from aortic stenosis (such a murmur will typically be louder when auscultated at the left sternal border as compared to the neck, and intensity will decrease with Valsalva), stenosis of the external carotid artery (considered a benign problem), and stenosis of the subclavian artery (can cause subclavian steal syndrome).

## Are Dizziness, Syncope, and Headaches Considered Symptoms of Carotid Stenosis?

Dizziness, syncope, and headaches are not considered symptoms of unilateral carotid stenosis. Rarely, bilateral carotid stenosis can lead to syncope secondary to cerebral hypoperfusion. Dizziness and syncope may be symptoms of vertebral artery disease.

## What Are the Risk Factors for Carotid Stenosis?

The risk factors for carotid stenosis are older age, male gender, hypertension, smoking, hypercholesterolemia, diabetes, and obesity.

## Anatomy

### How Do You Distinguish Between the Internal Carotid Artery (ICA) and External Carotid Artery (ECA) in the Neck?

The ICA has no branches in the neck.

### What Are the Branches of the External Carotid Artery?

The branches of the external carotid artery are the superior thyroid, ascending pharyngeal, lingual, facial, occipital, posterior auricular, maxillary, and superficial temporal (“some attendings like freaking out potential medical students”) arteries.

### What Is the First Branch of the Internal Carotid Artery?

The first branch is intracranial and is the ophthalmic artery.

### What Is the Classic Anterior Circulation Ischemic Stroke in Terms of Arterial Distribution and Symptoms?

An anterior circulation ischemic stroke (Table 55.1) is the most common type (70 % of cases) of stroke. The cortex is supplied by branches of the two internal carotid arteries and two vertebral arteries. The anterior cerebral artery (ACA) and the middle cerebral artery (MCA), both of which branch from the internal carotid, connect with the posterior cerebral artery (derived from the basilar artery) to form the circle of Willis. The MCA primarily supplies the lateral surface of the frontal, parietal, and superior temporal lobes. The deeper branches supply the basal ganglia and internal capsule. An occlusion of the MCA is the most common location for an anterior circulation stroke, resulting in contralateral spastic paralysis/weakness, gaze palsy, and aphasia.

**Table 55.1** Anterior circulation

Artery	Branches from	Supplies	Presentation with ischemia
Ophthalmic	Internal carotid artery	Retina	Amaurosis fugax; patients report sudden onset of painless loss of vision
Anterior cerebral artery	Internal carotid artery	Medial surfaces of the frontal and parietal lobes, corpus callosum, anterior portions of the basal ganglia, and internal capsule	Greater motor and sensory loss in the lower extremities than upper extremities, gait apraxia
Middle cerebral artery	Internal carotid artery	Lateral frontal, parietal, and superior temporal lobes, insula, claustrum, internal capsule	Greater motor and sensory loss of the upper extremities than the lower extremities, gaze palsy, aphasia, the <i>most common form</i> of anterior circulation ischemic stroke

## Why Is It Important to Distinguish Between Anterior and Posterior Circulation Symptoms?

Carotid plaques embolize to the anterior circulation, most often to the middle cerebral and less commonly into the anterior cerebral artery, thus causing anterior circulation symptoms. If the patient's symptoms are related to posterior circulation ischemia, then a carotid plaque should not be implicated as the source of the ischemia, and therefore, carotid endarterectomy would not be beneficial.

---

## Pathophysiology

### What Are the Two Main Causes of Stroke?

Strokes are broadly categorized into ischemic and hemorrhagic types. Ischemic stroke occurs when there is a blockage to the blood supply to the brain, whereas hemorrhagic stroke occurs when an artery ruptures and bleeds.

### Which Type Is More Common?

Eighty-five percent are ischemic.

### What Are the Main Causes of Hemorrhagic Stroke?

Causes of hemorrhagic stroke include *intracerebral* hemorrhage due to poorly controlled hypertension, trauma, congenital arteriovenous malformations, and *subarachnoid* hemorrhage due to a ruptured intracranial aneurysm.

### What Are the Main Causes of Ischemic Stroke?

The main causes are emboli (clot from somewhere else) and thrombosis (clot forming within the intracranial arteries).

### What Are the Main Sources of Cerebral Emboli?

Emboli arise from the rupture of plaque in the internal carotid artery (ICA) at the carotid bifurcation and from the heart (left atrial thrombus in association with atrial fibrillation, mural thrombus in association with acute myocardial infarction, endocarditis). Less commonly plaque from the aortic arch can embolize.

#### Watch Out

If a patient presents with a TIA or stroke in association with a deep vein thrombosis, consider paradoxical embolus, which travels from the vein to the right heart, across a patent foramen ovale to the left heart, and then to the carotid artery.

### What Is a Lacunar Stroke?

A lacunar stroke is an ischemic stroke that is caused by an occlusion of the deep penetrating arteries. The main risks are severe hypertension and diabetes. Lacunar infarcts are not generally thought to be due to large vessel (carotid) or cardiac embolization.

## How Is an Atherosclerotic Plaque Formed?

The initiating event leading to plaque formation is believed to be endothelial damage. Damaged vessel walls release thrombin, adenosine diphosphate (ADP), and cytokines stimulating platelet migration. This initiates a cascade of events ultimately leading to smooth muscle proliferation and fibroplasia resulting in a narrowed vessel.

## Why Does Atherosclerotic Plaque Localize at the Bifurcation of the Internal and External Carotid Artery?

Atherosclerotic plaque has a predilection for developing at arterial bifurcations. Bifurcations cause alterations in blood flow. Specifically, it alters the shear stress (forces) applied to the arterial intima. High shear stress (seen at the inner wall or flow divider of bifurcations) is healthy for the intima, whereas low shear stress (seen in outer walls) promotes plaque buildup. Additionally, blood flow in the outer wall of a bifurcation has areas of transient reversal of flow with stasis of blood. This transient reversal of blood flow coupled with the low shear stress within the region promotes conditions favorable for additional plaque buildup.

### Watch Out

Low shear stress promotes atherosclerotic plaque buildup.

## How Does a Carotid Stenosis Typically Cause Symptoms?

The symptoms from a carotid stenosis are the result of atherosclerotic emboli from the ICA at the carotid bifurcation embolizing distally into the brain. Symptoms are usually *not* due to a reduction in blood flow from a hemodynamic significant stenosis, as the other carotid and vertebral arteries provide adequate collateral blood flow via the circle of Willis.

## Is the Degree of ICA Stenosis Related to the Risk of Symptoms Developing?

As the atherosclerotic burden increases, the risk of developing symptoms increases. Larger plaques are more unstable and prone to rupture leading to a greater chance of distal embolization.

## What Determines Whether Brain Ischemia Symptoms Are Transient (TIA) or Permanent (Stroke)?

Whether embolic debris leads to a TIA or a stroke depends on the size of the embolus and on the body's fibrinolytic system. Fibrinolysis is responsible for dissolving a clot, which is primarily composed of fibrin. The endothelium releases tissue plasminogen activator (t-PA) which is involved in clot breakdown. t-PA converts plasminogen to its active form, plasmin, which is responsible for fibrin breakdown. TIAs are often caused by small clots that can be dissolved by the fibrinolytic system, often in less than 30 min, allowing the return of blood flow and neurologic function without cerebral infarction. Emboli from atrial fibrillation tend to be larger than those from a carotid plaque and are more likely to cause a stroke. If emboli are unable to dissolve and blood flow is severely diminished for a prolonged period of time, ischemic neurons become sufficiently anoxic and die, leading to permanent neurologic deficits.

## If a Patient has Had Multiple TIAs, with the Same Symptom Each Time, What Is the Most Likely Source of the TIA?

The carotid artery would be the most likely source. Blood flows in concentric laminar rings. Particles that enter the blood stream at the same point location consistently lodge distally at the same terminal branch point. Thus, emboli originating from



an internal carotid plaque will likely travel in the same direction each time, producing the same neurologic deficit consistently. In contrast, the emboli from atrial fibrillation can travel anywhere in the systemic circulation and result in a variety of conditions ranging from stroke to limb ischemia to bowel ischemia.

### **What Is the Difference Between a Stenosis and an Occlusion?**

A stenosis is a narrowing of the vascular lumen with antegrade flow maintained. An occlusion is a complete blockage of flow. At times, a very high-grade stenosis can be difficult to differentiate from an occlusion on ultrasound. In such circumstances, either CTA or MRA is helpful.

### **What Happens When the Internal Carotid Artery Occludes?**

The internal carotid artery typically occludes at its origin at the bifurcation in the neck. Since there are no branches in the neck, clot often propagates up into the brain. Depending on collateral blood flow, the clot may stop just before the ophthalmic artery or progress into the ACA or MCA. Thus, the occlusion may cause no symptoms, a TIA or a stroke. Collateral blood flow is supplied by the circle of Willis.

### **What Is a Symptomatic Carotid Artery Stenosis?**

A symptomatic carotid artery stenosis is one in which plaque from the carotid bifurcation is thought to be the source of emboli to the brain resulting in a TIA or a stroke within the anterior circulation. So classically, a carotid stenosis would be considered symptomatic if the patient had:

1. Left carotid: left eye amaurosis fugax or transient (TIA) or permanent (stroke) right arm and leg weakness/numbness and/or aphasia
  2. Right carotid: right eye amaurosis or transient (TIA) or permanent (stroke) left arm and leg weakness/numbness
- To be considered a symptomatic, the symptom should have occurred within the previous 6 months.

---

## **Workup**

### **How Useful Is the Presence of a Bruit for Detecting Carotid Artery Stenosis?**

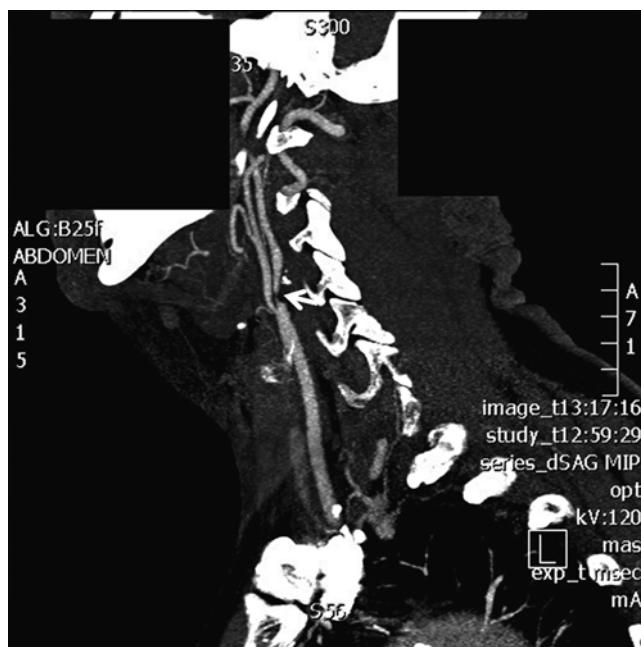The sensitivity and specificity of auscultation in detecting carotid artery stenosis are about 60–98 %, respectively. Because of the low sensitivity, physical examination is not sufficient in ruling out the carotid artery as the source of stroke.

### **What Is the Diagnostic Test of Choice for the Workup of Possible Carotid Stenosis?**

Carotid duplex scan is the first step in working up carotid stenosis. This noninvasive tool uses ultrasonography to visualize the plaque and Doppler to measure the rise in velocity of blood flow at the narrowed segment, which is proportional to the degree of stenosis.

### **Are Additional Diagnostic Studies Warranted?**

Carotid duplex is somewhat operator dependent and provides a range of % stenosis (0–49 %, 50–69 %, 70–99 %, occluded). Most surgeons obtain a second study to confirm the exact percent of the ICA stenosis, either via CT angiogram or MR angiogram (Fig. 55.1). Formal angiogram is rarely used due to cost, invasiveness, and its risk of causing a stroke (the catheter that is inserted into the carotid artery may break off plaque).



**Fig. 55.1** Lateral CT angiogram showing high-grade stenosis at the origin of the internal carotid artery (*white arrow*)

**Table 55.2** Management of carotid stenosis in a symptomatic patient

Degree of stenosis	Management
100 %	ASA, statin, and/or clopidogrel
70–99 %	CEA for men and women
50–69 %	CEA is of less benefit (more benefit in men and if symptoms are hemispheric; no benefit in women and if symptom is amaurosis fugax)
<49 %	ASA, statin, and/or clopidogrel

### Why Is It Important to Distinguish Between a High-Grade ICA Stenosis and a Complete Occlusion?

A high-grade stenosis may mandate operative intervention, whereas once there is a complete ICA occlusion, CEA is not indicated.

## Management

### What Are the Three Management Options for Symptomatic Carotid Stenosis?

The three management options for symptomatic carotid stenosis are medical management alone (aspirin {ASA}, clopidogrel, and statin), carotid endarterectomy (CEA), and carotid artery stenting (CAS).

### What Are the Determinants of Which Option to Choose?

Whether the patient is symptomatic or asymptomatic, the severity of the stenosis, the patient's surgical risk, and whether the stenosis is surgically accessible from a neck incision are the determinants of which option to choose.

### At What Percent of ICA Stenosis Should CEA Be Considered in Symptomatic Patients?

Benefit is greatest in symptomatic patients with high-grade (70–99 %) stenosis. Benefit is greater: (a) with hemispheric symptoms vs amaurosis fugax; (b) in men vs women; and (c) with increasing degree of stenosis. Refer to Table 55.2.

### Following a Stroke or TIA, What Is the Optimal Timing of CEA?

CEA should optimally be performed within 2 weeks. The greatest risk of another embolic event is within that time frame. As such, the benefit of CEA is greatest within this time period. The longer one waits, the greater the risk of another embolic stroke, thus obviating the benefit of CEA.

### Why Is CEA Not Recommended for a Symptomatic Patient with an Occluded (100 % Stenosis) ICA?

Once the ICA occludes, there is no further flow in the artery, and therefore no future risk of embolization and stroke. If one were to attempt CEA, one would find an occluded artery with no flow and clot extending all the way up into the brain.

### What If the Patient Has a Symptomatic ICA Stenosis that Resulted in a Stroke that Has Caused Complete Paralysis of the Arm and Leg as well as Aphasia, What Is the Role of CEA?

There is no role for CEA in a patient following a previous stroke resulting in severe neurologic deficits (complete hemiplegia). The goal of CEA is to protect the remaining viable motor and language regions, so as to prevent further damage. With complete hemiplegia and aphasia, there is essentially no further viable motor cortex to protect, and thus the risks of surgery outweigh the benefits.

### What Is the Anticipated Stroke Risk Reduction for CEA for a Symptomatic 70–99 % ICA Stenosis? For a 50–69 % Stenosis?

For a 70–99 % stenosis, CEA plus ASA (as compared with ASA alone) lowers the stroke rate at 2 years from 26 % to 9 % (or annually from 13 % to about 4 %). For a 50–69 % stenosis, it lowers the 5-year risk of stroke from 22 % to 16 % (or annually from about 4 % to 3 %).

### At What Percent of ICA Stenosis Should CEA Be Considered in Asymptomatic Patients?

Benefit is greatest in asymptomatic patients with 80–99 % stenosis. Benefit is greater: (a) in men vs women and (b) with increasing degree of stenosis. Although there is benefit from CEA if ICA stenosis is >60 %, most recommend CEA only if there is >80–99 % stenosis.

### Management of Carotid Stenosis In an Asymptomatic Patient

Degree of stenosis	Management
100 %	ASA, statin, and/or clopidogrel
60–99 %	CEA for men, medical management for women
<59 %	ASA, statin, and/or clopidogrel

CEA carotid endarterectomy, ASA aspirin

## What Is the Anticipated Stroke Risk Reduction for CEA for an Asymptomatic 60–99 % ICA Stenosis?

CEA reduces stroke at 5 years from 11 % to 5 % (or annually from about 2 % to 1 %).

## Why Is There Less Benefit from CEA in Women?

The data suggests that women are more likely to have unfavorable outcomes, such as surgical mortality, neurologic morbidity, and recurrent stenosis. This is likely a reflection of the fact that women have smaller caliber vessels putting them at risk for developing recurrent stenosis and perioperative carotid thrombosis.

## What Two Drugs Have Been Shown to Reduce the Risk of Perioperative Stroke After CEA?

The two drugs that have been shown to reduce the risk of perioperative stroke after CEA are perioperative ASA and statin.

## Why Is Blood Pressure Control Important Prior to CEA?

Poorly controlled BP has been shown to increase the risk of perioperative stroke. In addition, the manipulation of the carotid artery (and carotid sinus) during CEA is associated with baroreceptor dysfunction. Severe postoperative hypertension is associated with an increased risk of developing *cerebral hyperperfusion syndrome*. This occurs in 1 % of CEA patients about 2–7 days after surgery. Patients experience severe headaches, neurologic deficits, and/or seizures leading to intracerebral hemorrhage. This is believed to be due to an ischemia-reperfusion injury.

## What Cranial Nerves Are At Risk Of Injury During Cea? And What Neurologic Deficits Would Injuries To These Nerves Cause?

Cranial nerve	Presentation
VII ( <i>marginal mandibular branch</i> )	Droop in the corner of the mouth
IX ( <i>glossopharyngeal nerve</i> )	Difficulty in swallowing
X ( <i>vagus nerve</i> )	Hoarseness due to recurrent laryngeal nerve coming off distal to injury
XI ( <i>spinal accessory nerve</i> )	Diminished or absent function of the sternocleidomastoid or trapezius muscles
XII ( <i>hypoglossal nerve</i> )	Tongue deviation to the side of injury

## What Is an Acceptable Risk of Stroke/Death Following CEA?

The acceptable risk of stroke/death following CEA is <3 % for asymptomatic CEA and <6 % for symptomatic CEA.

## Areas of Controversy

### Carotid Stenting vs CEA for Symptomatic High-Grade (>70 %) ICA Stenosis

CEA has been the standard for invasive treatment of ICA stenosis. However, carotid artery stenting (CAS) has evolved as a less invasive alternative, initially developed for patients deemed to be at high surgical risk. The advantages of CAS include the ability to be performed under local anesthesia, no neck incision, minimal risk of nerve injuries, and lower risk of perioperative myocardial infarction. Recent consensus is that CAS has a higher risk of perioperative stroke as compared to CEA. As such, CAS is not

recommended for asymptomatic ICA stenosis, where the benefit of intervention is already less than symptomatic patients. CAS is more applicable for patients with symptomatic ICA stenosis who have a hostile neck (previous neck surgery, neck irradiation, lesion high in neck) that would make CEA more difficult or for those at high risk for general anesthesia.

### Should CEA Be Done for Any Asymptomatic ICA Stenosis?

The Asymptomatic Carotid Atherosclerosis Study (ACAS) and Asymptomatic Carotid Surgery Trial (ACST) have looked at outcomes in asymptomatic carotid stenosis patients undergoing CEA or medical management. Although CEA has reduced the incidence of stroke, the absolute benefit is small (absolute risk reduction from 11 % to 5 % at 5 years or approximately 1 % per year for ACAS), provided the combined perioperative stroke and death rate is <3 %. With the increasing data showing benefit of statins, for many patients, medical management is the recommended treatment in asymptomatic patients. In patients who have >80 % stenosis and a life expectancy >5 years and in a surgical center with a perioperative complication rate of <3 %, surgery is an appropriate alternative.

---

## Summary of Essentials

### Differential Diagnosis

- Amaurosis fugax differential diagnosis includes carotid embolus, central retinal artery occlusion, giant cell arteritis, retinal vein occlusion, retinal detachment, papilledema, and optic neuritis

### History

- TIA <24 hours, stroke >24 hours
- More common in men and smokers
- Classic carotid stenosis symptoms: 1) amaurosis fugax (ipsilateral) and 2) arm and leg weakness/numbness (contralateral) +/- aphasia (left carotid 99 % of time)
- Dizziness, syncope, and headaches *are not* typical carotid symptoms
- Stroke: the 4th leading cause of death in the United States

### Physical Exam

- Hollenhorst plaques (emboli to the retina on fundoscopic exam)
- Carotid bruit is specific but not sensitive

### Pathology/Pathophysiology

- Low shear stress promotes atherosclerotic plaque formation
- ICA causes neurologic symptoms secondary to embolization of atherosclerotic debris to the anterior circulation (middle cerebral, anterior cerebral arteries)
- Anterior circulation ischemic stroke is the most common type (70 %)
- Posterior circulation ischemic stroke not from carotid disease (most often from cardiac embolus)
- Carotid stenosis is a marker for coronary artery disease
- The most common cause of death in patients with carotid stenosis is myocardial infarction

### Workup

- Carotid duplex to determine % ICA stenosis
- Confirmatory imaging recommended (CTA or MRA)

---

## Management

- CEA
  - Greatest benefit for symptomatic 70–99 % ICA stenosis
  - Less benefit for symptomatic 50–69 % ICA stenosis
  - Less benefit for asymptomatic 60–99 % ICA stenosis
  - No benefit for <50 % ICA stenosis
- Carotid stenting
  - Higher risk of stroke than CEA (less risk of perioperative MI)
  - Best used for symptomatic ICA stenosis with high cardiac risk or hostile neck (radiated, prior surgery)
  - Not indicated for asymptomatic ICA stenosis

---

## Suggested Reading

- Barnett HJ, Taylor DW, Eliasziw M, et al. Benefit of carotid endarterectomy in patients with symptomatic moderate or severe stenosis. North American Symptomatic Carotid Endarterectomy Trial Collaborators. *N Engl J Med.* 1998;339(20):1415–25.
- Brott TG, Hobson 2nd RW, Howard G, et al. Stenting versus endarterectomy for treatment of carotid-artery stenosis. *N Engl J Med.* 2010;363:11–23.
- Executive Committee for the Asymptomatic Carotid Atherosclerosis Study. Endarterectomy for asymptomatic carotid artery stenosis. *JAMA.* 1995;273:1421–8.
- North American Symptomatic Carotid Artery Trial Collaborators. Beneficial effect of carotid endarterectomy in symptomatic patients with high-grade carotid stenosis. *N Engl J Med.* 1991;325:445–53.

Christian de Virgilio

A 65-year-old male presents with a 5-month history of progressively worsening right calf pain upon walking. He describes the pain as a tightening or cramping, and it comes on after walking two blocks. The pain forces him to stop walking and is relieved after he sits down for 10 min. He can then resume walking again. The pain comes on consistently at the same 2-block walking distance each time, unless he walks fast or uphill, in which case he can walk much less. He denies waking up at night with pain in his foot. Past medical history is significant for a 1 pack per day (ppd) smoking habit for 40 years and hypertension. Physical examination demonstrates a moderately obese male. He has normal 2+ femoral pulses bilaterally; nonpalpable (0) popliteal, dorsalis pedis, and posterior tibial pulses on the right side; and diminished (1+) popliteal, dorsalis pedis, and posterior tibial pulses on the left. He is moderately obese, yet both legs appear to be thin. The skin on his lower legs appears thinned out, flaky, and dry, with no hair. His toenails are thickened. There are no ulcers in his feet. Capillary refill is diminished in his right foot at 4 seconds (normal  $\leq 2$  s). Laboratory values reveal a total cholesterol of 280 mg/dl (normal  $< 200$  mg/dl), LDL of 160 mg/dl (65–180 mg/dl), and an HDL of 35/mg/dl ( $> 35$  mg/dL).

## Diagnosis

### What is in the Differential Diagnosis?

Disease	Pathophysiology	Symptoms
Claudication	Atherosclerotic plaque obstructing blood flow	Pain with walking Relieved with a few minutes of rest Reproducible at the same walking distance
Osteoarthritis of the hip or knee	Mechanical degeneration of joint structures	Not relieved with a few minutes of rest Not reproducible at the same walking distance
Spinal stenosis	Narrowing of the spaces of the vertebral column causing nerve root compression (neurogenic claudication)	Generalized weakness of both legs that worsen with walking Relieved by leaning forward
Sciatica	Irritation or compression of the sciatic nerve	Buttock pain, leg pain “shooting” down the posterior thigh
Chronic venous stasis	Incompetence of vein valves, pooling of blood in the legs	Worse after prolonged standing Leg swelling Relieved by elevating legs

C. de Virgilio, MD (✉)  
 General Surgery Residency Program, Department of Surgery, Harbor-UCLA Medical Center, 1000 W Carson Street,  
 Torrance, CA 90509, USA  
 e-mail: [cdevirgilio@labiomed.org](mailto:cdevirgilio@labiomed.org)

## What Is the Most Likely Diagnosis?

In a patient with a long-standing smoking history, hypertension, and a 5-month history of progressively worsening and reproducible right calf pain with exercise, the most likely diagnosis is claudication secondary to peripheral arterial disease (PAD). In addition, his physical exam (thin, flaky, dry, hairless legs) and diminished pulses are consistent with the diagnosis.

## History and Physical

### What Is Claudication, and What Is the Three-Part Definition that Should Be Obtained by History?

Claudication derives from the Latin word *claudicare* and means “to limp.” It is caused by a reduction in blood flow to the leg muscles, most commonly by an atherosclerotic plaque. It is not due to a blood clot or embolization. The reduced arterial blood supply cannot meet the metabolic demand of the muscles utilized during walking. The diagnosis can readily be suspected based on the three-part definition obtained by history: (1) pain in the leg with walking, (2) relieved within a few minutes of rest, and (3) reproducible at the same walking distance each time.

### Claudication Is a Symptom of What Underlying Disease?

Claudication is a symptom of peripheral arterial disease (PAD). PAD most often affects the lower extremities and less commonly the upper extremities and the intestinal and renal arteries. It is usually caused by atherosclerosis. It leads to a gradual slowly developing reduction in blood flow in the extremities (chronic limb ischemia).

### What Are the Main Risk Factors for PAD?

Main risk factors for PAD include smoking, diabetes, hypertension, hypercholesterolemia, advanced age, male gender, obesity, sedentary lifestyle, family history of vascular disease, heart attack, and stroke.

### What Is the Spectrum of Severity in PAD

The spectrum of severity is categorized by the Rutherford classification of chronic limb ischemia (Table 56.1)

### What Is Ischemic Rest Pain, and How Does It Present?

Ischemic rest pain is a sign of advanced PAD (Rutherford class 4). It typically presents in the foot, most commonly in the toes (as that is the distal most part of the limb, where the blood has the hardest time reaching). It occurs at night when the patient is lying supine, as the arterial blood flow is so poor that gravity is needed to get blood to the foot. The patient wakes up with the toes aching or feeling numb and is forced to get up and either walk around or dangle the painful leg over the edge of the bed. In advanced stages, the patient has to actually sleep in an inclined bed or in a chair to keep the painful foot in a dependent position.

**Table 56.1** The Rutherford classification system

Category	Patient presentation
0	Asymptomatic
1	Mild claudication
2	Moderate claudication
3	Severe claudication
4	Ischemic rest pain
5	Minor tissue loss
6	Major tissue loss



**Watch Out**

Always ask about rest pain, as the presence of rest pain identifies a patient as having limb-threatening ischemia.

**What Is Buerger's Sign?**

It is a physical examination sign of advanced chronic ischemia. The affected foot turns pale after it is elevated (usually for 1–2 min). Once the patient sits up and dangles the foot down, it becomes ruborous (like a cooked lobster). It is due to marked arteriolar dilation from chronic severe ischemia that causes a reactive hyperemia. Patients with ischemic rest pain typically will manifest Buerger's sign. Such patients will also have multiple levels of arterial obstruction and an accompanying low ankle brachial index (ABI) of <0.4. The absence of Buerger's sign makes ischemic rest pain very unlikely.

**Watch Out**

Do not confuse Buerger's sign with Buerger's disease (thromboangiitis obliterans), which presents with cyanotic and blue digits typically in young male smokers.

**What is the Differential Diagnosis of Ischemic Rest Pain?**

Disease	Pathophysiology	Symptoms/signs
Ischemic rest pain	Severe multilevel PAD; ABI <0.4	Awaken at night with pain in the forefoot Relieved by standing or dangling feet Dependent rubor
Diabetic neuropathy	Neural damage and conduction defects leading to sensory, motor, and autonomic nerve dysfunction	Bilateral burning in feet Not relieved by dependency Stocking-glove distribution No rubor
Night cramps	Idiopathic; precise mechanism is unknown, likely involves myopathic, neurologic, and metabolic causes	Calf cramping at night Numerous etiologies
Gout	Peripheral monoarthritis caused by deposition of sodium urate crystals in the joints	Pain and redness in the big toe (metatarsal-phalangeal joint) Hyperuricemia

ABI ankle brachial index

**How Many Pulses Should Be Examined?**

17 pulses (superficial temporal, carotid, brachial, radial, femoral, popliteal, posterior tibial, dorsalis pedis bilaterally, and aortic) should be examined.

**In Addition to a Pulse Deficit, What Other Findings on Leg Examination Would Support PAD?**

PAD causes a progressive loss of blood supply to the leg. The calf muscles atrophy; hair appendages die (hair loss), as do sweat glands (dry scaly skin); the skin thins out (shiny); and ulcers may develop. Capillary refill time becomes prolonged (normal is  $\leq 2$  s).

## Anatomy

### What Muscle Groups Are Affected by Claudication?

Claudication may affect all the major muscle groups associated with walking, including the buttock, anterior thigh, calf, and rarely the foot muscles. The calf muscles are supplied by the superficial femoral artery (SFA). The SFA, which travels through the Hunter/adductor canal, is the most common site for atherosclerosis in the lower extremities; therefore, calf claudication is the most common location of pain. The internal iliac arteries supply the buttocks. Thus, stenosis above the internal iliac arteries (aorta, common iliac arteries) would cause buttock claudication. The hamstrings are not primarily utilized with walking. Thus, pain in the back of the thigh is not characteristic of claudication.

### Where Is the Hunter/Adductor Canal Located?

This aponeurotic tunnel extends from the apex of the femoral triangle to the opening of adductor magnus (adductor hiatus). The SFA runs through this canal and becomes the above-knee popliteal artery just distal to it. The femoral triangle is bounded superiorly by the inguinal ligament, medially by the adductor longus, and laterally by the sartorius muscle.

#### Watch Out

The SFA is the most common location of atherosclerotic plaque, while the common femoral artery is the most common location of arterial emboli.

## Pathophysiology

### What Is Dependent Rubor?

Dependent rubor is a sign of advanced chronic ischemia. It occurs when dermal arterioles and capillaries no longer constrict in the presence of increased hydrostatic pressure. The arterioles in the foot become vasodilated in an effort to maximize blood and oxygen delivery. The vasodilation results in pooling of blood in the foot when it is in a dependent position. Patients with dependent rubor already have ischemic rest pain or are much more likely to progress to ischemic rest pain or nonhealing ulcers than patients with claudication alone.

### Why Is the Onset of Pain Consistently at the Same Walking Distance?

Claudication is usually caused by an atherosclerotic plaque, which is a fixed lesion that reduces the blood flow consistently by the same amount, provided the effort level is the same. As such, patients can often pinpoint the exact distance they can walk before the onset of pain. This helps distinguish the symptoms from other causes of leg pain.

If the patient reports a very wide range in walking ability (for instance, one day can only walk a few steps, another day can walk a mile), such symptoms would be inconsistent with claudication. Slight variability in the onset of pain, on the other hand, would support a diagnosis of claudication, provided the variability occurs when effort level changes, such as when walking faster or slower or up or down a hill, as oxygen demand will be different depending on the degree of effort.

### What Other Disease Processes Can Cause Claudication?

Buerger's disease, chronic embolization (though embolization is more likely to cause acute limb ischemia), vasculitis, and entrapment of the popliteal artery can also cause claudication.

## **What Condition Is Classically Associated with Claudication in the Upper Extremities?**

Subclavian steal syndrome is classically associated with claudication of the upper extremities. An atherosclerotic plaque contributes to the narrowing of the subclavian artery, causing retrograde flow in the vertebral artery during arm exercise. Patients report transient vertigo, dizziness, and less commonly, syncope, during arm exercise.

## **What Is Buerger's Disease?**

It is also known as thromboangiitis obliterans. Seen in young (<40), predominantly male, heavy smokers, it is an inflammatory and thrombotic process that causes occlusion of distal arteries (tibial) below the knee in the hands, as well as venous thrombosis. It is associated with a high rate of amputation and a lack of response to angioplasty or bypass. The only effective treatment is smoking cessation.

## **How Does the Location of the Muscle Affected Correlate with the Location of the Disease?**

The muscle groups affected by claudication are generally supplied by the arteries one level above. For example, buttock claudication is usually due to the obstruction of the aorta or common iliac arteries. Thigh claudication can be similarly due to aortoiliac disease. Calf claudication is typically due to superficial femoral artery disease. Foot claudication is extremely rare and is most often due to isolated tibial artery disease.

## **What Is Leriche Syndrome?**

It is a chronic, slowly developing occlusion of the infrarenal aorta most often seen in smokers, characterized by a triad: (1) buttock and thigh claudication, (2) absent femoral pulses, and (3) impotence (since the aorta is occluded, the blood flow to the internal iliacs is compromised, which in turn decreases blood supply to internal pudendal arteries causing erectile dysfunction). Because of the slow progressive nature, collaterals have time to enlarge and compensate, such that most patients only have claudication and not ischemic rest pain.

---

## **Work-Up**

### **What Is the Next Step in the Diagnostic Work-Up?**

The ankle brachial index (ABI) and arterial duplex scan are the next steps in the diagnostic work-up. The ABI measures the systolic pressure in the foot (ankle) and compares it to the arm (brachial artery). The normal ABI ranges from 1 to 1.2. It is measured with the patient in a supine position. A handheld Doppler and a blood pressure (BP) cuff are needed to measure ABI. The BP cuff is inflated while the Doppler is held on the dorsalis pedis artery. The cuff is inflated until the Doppler signal disappears. The cuff is slowly deflated until the signal returns. The systolic pressure at which the signal returns is recorded. The process is repeated with the posterior tibial and bilateral brachial arteries. The ABI is the ratio of the highest systolic pressure at the ankle/foot over the highest brachial systolic pressure. Normal is from 1 to 1.2. Diabetes can falsely elevate the ABI (see below). The arterial duplex scan uses a combination of ultrasound to detect plaques in the arteries and Doppler to detect areas of elevated velocity of blood flow, indicating that the plaque is causing a hemodynamically significant stenosis.

## How Is PAD Defined?

**PAD is Defined as an ABI < 0.9. The ABI Confirms the Diagnosis of PAD, Gives an Indication of Severity, and is a Useful Tool to Follow Progression**

Normal ABI	1.2–1.0
Mild disease	0.9–0.7
Moderate disease	0.7–0.4
Severe disease/rest pain	<0.4

## What Is the Typical ABI of a Patient with Claudication?

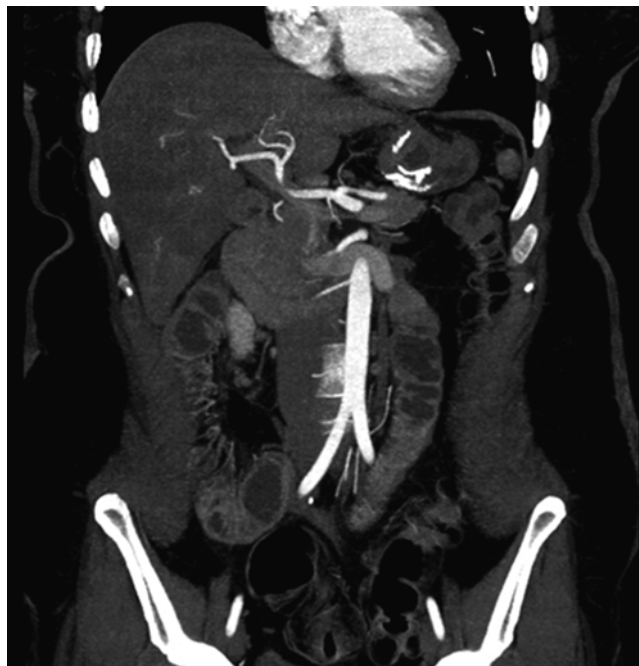Patients with claudication usually have an ABI in the 0.6–0.8 range.

## What Is the Typical ABI of a Patient with Ischemic Rest Pain?

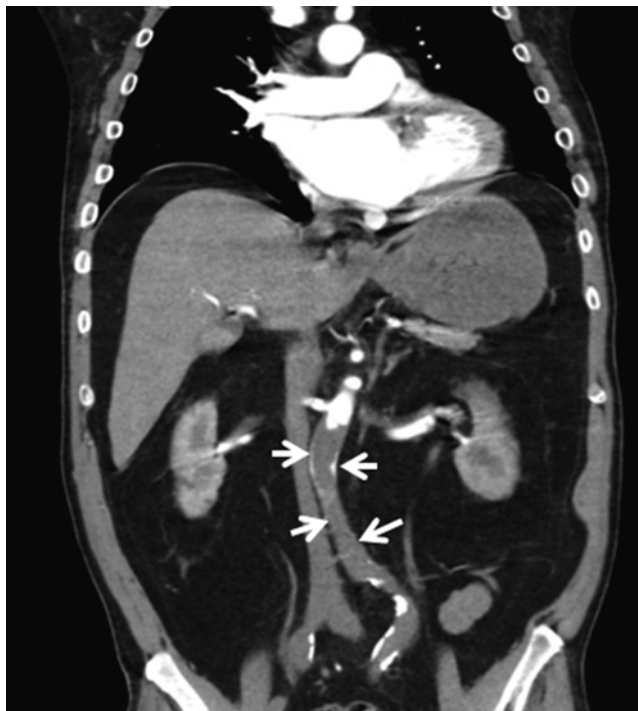Patients with ischemic rest pain usually have an ABI < 0.4.

## What Additional Studies Are Recommended?

Further diagnostic studies would include either CT angiogram or MR angiogram. However, these are only recommended for patients in whom an intervention is being planned (Figs. 56.1 and 56.2).



**Fig. 56.1** Coronal CT angiogram showing a normal aorta and common iliac arteries



**Fig. 56.2** Coronal CT angiogram showing occlusion of the abdominal aorta just below the renal arteries

### **Is There Any Value in Screening an At-Risk Population for Asymptomatic PAD?**

Patients with asymptomatic PAD have the same risk of adverse cardiovascular events (stroke and myocardial infarction) as patients with symptomatic PAD. As such it is of benefit to detect asymptomatic PAD to modify risk factors.

---

### **Prognosis**

#### **What Is the Risk of Limb Loss for Patients with Claudication?**

Provided the patient does not have ischemic rest pain or tissue loss, the 5-year risk of limb loss for all comers with claudication is surprisingly low at 5%. The 10-year risk of limb loss is 10%.

#### **What Is the Risk of Limb Loss for Patients with Ischemic Rest Pain in the Foot?**

Rest pain makes it highly likely (50%) that the patient will have limb loss at one year without intervention.

#### **What Symptoms/Signs Are Considered Limb-Threatening PAD and thus an Indication for More Aggressive Management?**

Ischemic rest pain, nonhealing ulcer, and gangrene are among the symptoms/signs.

## Management

### What Is the Initial Management of Claudication?

Since the risk of limb loss is so low, medical management is considered the initial approach. This should include smoking cessation and exercise. In addition, control of hypertension and diabetes and dietary modifications may help halt the progression of atherosclerosis, though these latter measures will not likely result in a direct observable improvement in walking distance.

### Are There Any Drugs Specifically Approved by the Food and Drug Administration (FDA) for Claudication?

Two drugs are FDA approved for claudication, but only one is considered effective. Cilostazol is a quinolinone derivative that has several actions but primarily inhibits platelet aggregation and is a vasodilator. It also inhibits thrombin formation and vascular smooth muscle proliferation, increases HDL, and lowers triglyceride levels. Studies have shown that about 40–50 % of patients note improvement in claudication after about a month of usage. It is considered the drug of choice but is contraindicated in patients with heart failure. Pentoxifylline is a methylxanthine derivative and is also FDA approved, though recent studies suggest that it is no better than placebo. It is a rheologic agent that lowers blood viscosity. It also increases red blood cell deformability to permit easier passage of red blood cells through the capillaries.

### What About a Statin? Does It Improve Claudication?

A statin should be given to most patients with PAD, even if the cholesterol levels are normal, as it has been shown to stabilize plaques via its anti-inflammatory effect and reduces the risk of stroke and myocardial infarction. In those with elevated cholesterol levels, the target is to lower the low-density lipoprotein to <100 mg/dl. If the patient has additional risk factors (such as prior myocardial infarction or diabetes), the target level is <70 mg/dl. Statins, though indicated, have not been shown to directly improve walking distance.

### What About Aspirin? Does It Improve Claudication?

Aspirin is recommended. Since there is a strong association between PAD and coronary and carotid atherosclerosis, aspirin is given to help prevent stroke and myocardial infarction. Aspirin inhibits platelet aggregation. It does so by suppressing the platelet's ability to produce thromboxane A<sub>2</sub> due to its irreversible inactivation of the cyclooxygenase (COX) enzyme. Aspirin, though indicated, has not been shown to directly improve walking distance.

### What About Clopidogrel?

Clopidogrel irreversibly inhibits platelet aggregation. It does not directly lead to an improvement in claudication, though it is utilized in PAD, as it has been shown to reduce the composite end point of stroke, myocardial infarction, or other vascular deaths in patients with PAD. However, there is debateable benefit to its use in combination with aspirin.

### What About Anticoagulants such as Heparin or Warfarin?

Claudication is due to an atherosclerotic plaque obstructing the blood flow *not* a blood clot or embolization. As such, there is no role for anticoagulants.

## **What Are the Invasive Therapeutic Options?**

Invasive therapeutic options are endovascular angioplasty/stenting (preferable in most patients) and open surgical techniques (endarterectomy or bypass).

## **If Medical Management Fails, Which Patients with Claudication Are Candidates for an Invasive Therapeutic Approach?**

Patients with disabling claudication (Rutherford class 2 or 3) are candidates for invasive treatment provided (1) they are good risk candidates for an intervention and (2) the symptoms are significantly affecting their lifestyle. For example, an elderly frail patient on home oxygen for pulmonary disease would not be a good risk candidate, and their walking distance is more likely limited by their pulmonary disease than by the PAD. A security guard or a mail carrier would much more likely be limited by the PAD. There is no role for invasive intervention in asymptomatic PAD.

## **Which Patients with PAD Should Go Directly to an Invasive Therapeutic Approach Rather than an Initial Attempt at Medical Management?**

Patients with Rutherford class 4, 5, or 6 should go directly to an invasive therapeutic approach as their risk of limb loss is significantly higher.

## **What Is the 5-Year Mortality for Patients with PAD?**

Mortality for patients with PAD is 30 % at 5 years and is primarily due to myocardial infarction, followed by stroke. Mortality is even higher for patients who continue to smoke.

---

## **Key Areas Where You Can Get in Trouble**

### **Failure to Inquire About Ischemic Rest Pain**

It is important to always inquire as to whether the patient endorses rest pain (Rutherford class 4). Rest pain is an indication for an invasive intervention as these patients are at significantly increased risk of limb loss. Ask the patient specifically if they ever wake up at night with pain in their foot and what they do to relieve it (such as dangle the foot over the edge of the bed or get out of bed). Rest pain can be confused with diabetic neuropathy. Neuropathic pain tends to be burning in nature, involves the whole foot (both feet usually), and is not relieved by dependency.

### **Confusing the Dependent Rubor of Rest Pain with Cellulitis (or Confusing Dependent Rubor with a Well-Perfused Foot)**

In patients with advanced PAD, ischemic rest pain is constant, requiring the patient to even sleep with their feet dangling or to sleep in a chair. This may lead to some dependent edema in the leg as well as to dependent rubor. The combination of redness and edema may confuse the diagnosis, and the clinician can mistake ischemia with cellulitis. The two can be distinguished by raising the foot. In ischemia, the red skin will be cool to touch, and upon elevation for 1–2 min, the rubor will disappear, and the foot will turn pale. With cellulitis, the red skin will feel warm, and the red color will persist with elevation.

### **Assuming that an ABI of 1.0 Is a Sign of Normal Circulation in a Diabetic Patient**

Diabetic patients may develop falsely elevated (>1.2) or falsely normal ABIs. Diabetic patients develop a unique form of arteriosclerosis known as Monckeberg's arteriosclerosis or medial calcinosis. It involves intense calcification of the medial

layer of the artery (typically the tibial vessels below the knee), which causes them to become rigid like a lead pipe. The result is that when one attempts to obtain an ABI, the blood pressure cuff is either unable to compress the artery or the pressure required to compress the artery is falsely elevated.

---

## Areas of Controversy

### Should a Patient with Claudication Who Is Still Smoking Undergo an Invasive Procedure?

As explained above, claudication (in the absence of ischemic rest pain) is not considered limb threatening. The primary treatment modality is lifestyle and risk factor modification. Studies have shown that if a patient continues to smoke, the disease will progress. Smoking is associated with worse outcomes for angioplasty, stenting, and bypass. Thus, many surgeons do not advocate pursuing an aggressive intervention until the patient has quit smoking. The counterargument is that the patient may need to see an immediate improvement in walking in order to embrace a healthier lifestyle.

### In a Patient with Advanced Chronic Limb Ischemia (Tissue Loss, Rutherford Class 5 or 6), Is It Better to Attempt Endovascular Approaches (Angioplasty/Stenting) or to Perform an Open Surgical Bypass (Using Reverse Saphenous Vein)?

Short-term outcomes (in terms of limb salvage) appear to be the same using endovascular and open surgical bypass approaches, though the endovascular approach is less invasive. However, some studies suggest that open surgical bypass provides better long-term (beyond 2 years) limb salvage rates.

---

## Summary of Essentials

### History

- Calf, thigh, or buttock pain with walking, relieved by rest, reproducible at same distance

### Physical Exam

- Absent pulses, muscle atrophy, hair loss, dry and atrophic skin, toe ulcers, and thickened toenails

### Pathology/Pathophysiology

- SFA is the most common site of disease in the lower extremities (the Hunter canal)

### Differential Diagnosis

- Neurogenic claudication (spinal stenosis), arthritis, sciatica, and chronic venous stasis

### Diagnosis

- By history and physical exam supplemented by ABI with Doppler
- Reserve CT or MR angiogram only if intervention is planned



## Management

- Conservative for claudication (Rutherford classes 1–3): smoking cessation, walking program, statin, and aspirin
- Best drug for PAD, cilostazol; less effective, pentoxifylline
- Interventional if with ischemic rest pain or tissue loss (Rutherford classes 4–6)
- Invasive treatment options include angioplasty/stenting (for stenosis and short occlusions), endarterectomy, and surgical bypass (long occlusions)

## Prognosis

- 5-year risk of limb loss only 5 % with claudication
- 5-year survival only 70 % (due mainly to MI)

## Special Situations

- Subclavian steal syndrome: arm claudication and dizziness
- Leriche syndrome: buttock claudication, absent femoral pulses, and impotence
- Buerger's disease: young male smokers with distal artery and vein occlusions

## Watch Out

- Falsely normal ABI in diabetics with medial calcinosis

---

## Suggested Reading

- Hirsch AT, Criqui MH, Treat-Jacobson D, et al. Peripheral arterial disease detection, awareness, and treatment in primary care. *JAMA*. 2001;286:1317.
- Layden J, Michaels J, Bermingham S, et al. Diagnosis and management of lower limb peripheral arterial disease: summary of NICE guidance. *BMJ*. 2012;345:e4947.
- McDermott MM, Greenland P, Liu K, et al. Leg symptoms in peripheral arterial disease: associated clinical characteristics and functional impairment. *JAMA*. 2001;286:1599.
- Rooke TW, Hirsch AT, Misra S, et al. Management of patients with peripheral artery disease (compilation of 2005 and 2011 ACCF/AHA Guideline Recommendations): a report of the American College of Cardiology Foundation/American Heart Association Task Force on Practice Guidelines. *J Am Coll Cardiol*. 2013;61:1555.

Edward D. Gifford and Michael de Virgilio

A 65-year-old obese male presents to the emergency department with sudden onset of severe left-sided abdominal pain that radiates to the left flank and back. The pain began 2 hours ago and started while he was watching television. He has never had the pain before. He denies any nausea or vomiting, changes in bowel habits, or bloody/black stools. Past history is significant for chronic obstructive pulmonary disease (COPD) and well-controlled hypertension. He does not drink alcohol but has smoked 1 pack per day for 35 years. On physical exam, blood pressure is 90/60 mmHg, heart rate is 120/min, respiratory rate is 24, and he is afebrile. He appears to be in moderate distress secondary to pain and has diaphoresis. Lungs are clear bilaterally to auscultation without rales or rhonchi. Cardiac exam reveals a regular rate and rhythm without murmurs, rubs, or gallops. His abdomen appears pale and is moderately tender to palpation diffusely but worse in the mid-abdomen and in the left lower quadrant. He has no rebound or guarding. A palpable tender pulsatile mass is felt in the midline just above the umbilicus. Rectal exam reveals no blood, stool, or masses. Femoral, popliteal and pedal pulses are 1+ bilaterally. Laboratory examination reveals a hemoglobin of 10.1 g/dL (normal 12.3–15.7 g/dL), hematocrit of 30.3 % (37–46 %), and WBC of  $11 \times 10^3/\mu\text{L}$  ( $4.1\text{--}10.9 \times 10^3/\mu\text{L}$ ). His AST and ALT are 30 u/L (5–35 u/L) and 45 u/L (7–56 u/L), respectively. The patient's lipase is 50 u/L (7–60 u/L) and amylase is 62 u/L (30–110 u/L).

## Diagnosis

### What is the Differential Diagnosis?

Diagnosis	History and physical examination
Ruptured AAA	Elderly; Caucasian; male; smoker with sudden onset of severe abdominal, left flank, left groin, and/or lower back pain; pulsatile abdominal mass; tachycardia; and hypotension
Perforated gastric or duodenal ulcer	Sudden onset of epigastric pain which then becomes diffuse, history of steroid or chronic NSAID use, abdominal guarding, rigidity, and rebound tenderness
Aortic dissection	Sharp, tearing chest pain radiating to the back; history of hypertension
Pancreatitis	Epigastric pain radiating to the back, nausea, vomiting, anorexia, fever and tachycardia associated with cholelithiasis, alcohol abuse
Diverticulitis	Pain begins in LLQ and may become diffuse; fever, nausea, diarrhea, constipation, common in elderly

AAA abdominal aortic aneurysm

E.D. Gifford, MD (✉)

Department of Surgery, Harbor UCLA Medical Center, 1000 West Carson Street, Box 461, Torrance, CA 90509, USA  
e-mail: [ted.gifford@gmail.com](mailto:ted.gifford@gmail.com)

M. de Virgilio

University of California Los Angeles, Los Angeles, CA USA

## What Is the Most Likely Diagnosis?

In a patient with significant risk factors (e.g., age, smoking, hypertension, COPD) presenting with a palpable pulsatile abdominal mass, acute onset of abdominal pain that is radiating to the left flank, and signs consistent with shock (e.g., hypotension, tachycardia, pallor and diaphoresis), along with anemia without other sources of obvious blood loss, the most likely diagnosis is a ruptured abdominal aortic aneurysm (AAA).

## History and Physical Examination

### What Is the Typical Presentation for an Unruptured AAA?

Most unruptured AAAs are asymptomatic and therefore go undetected. The first symptom of AAA in most patients is rupture, which is often fatal. For this reason, AAA is referred to as a silent killer. Those that are fortunately found are usually discovered incidentally in the course of a work-up for other medical problems, particularly given the increased use of imaging studies (CT, MRI, ultrasound). Rarely, as an AAA enlarges, patients can experience abdominal or lower back pain, the latter from compression of the spine. Thrombus commonly forms within the outer walls of an AAA. Though uncommon, the thrombus can embolize distally to the lower extremities.

### What Are the Risk Factors for AAA?

Risk factors for AAA include smoking, age over 60, Caucasian race, male, coronary artery disease, a history of extra-abdominal aneurysm such as femoral or popliteal aneurysms, atherosclerosis, family history of AAA, and hypertension. COPD is also a risk factor for AAA and is independent of smoking.

#### Watch Out

Smoking is by far the strongest risk factor for AAA (hypertension is the strongest risk factor for aortic dissection). Smoking one or more packs of cigarettes a day is associated with a 12 times increased risk for developing an AAA.

### Is Diabetes a Risk Factor for AAA?

No. While diabetes is an important risk factor for intimal atheroma formation, MI, stroke, and peripheral arterial disease, it is actually protective against AAA. While the protective mechanism of diabetes is not fully understood, one hypothesis is that glycation of matrix metalloproteinases (discussed in *Pathophysiology*) leads to their deactivation and thus decreases aortic remodeling.

### Is There a Role for Physical Examination in the Detection of AAA? What Are the Limitations?

Physical examination for the detection of AAA can be useful when carefully performed. The sensitivity/specificity of the physical examination for AAA increases as the AAA size increases and decreases as the patient's body mass index increases. Obesity is the biggest limiting factor in diagnosing an AAA on physical exam. In addition, the value of physical examination varies by practitioner and is limited in detecting smaller aneurysms.

### Is There a Role for AAA Screening? If So, Who Should Be Screened and How Often?

The American College of Cardiology, American Heart Association, and the US Preventive Services Task Force recommend screening with physical exam and one-time abdominal ultrasound for men between ages 65 and 75 who have had any smok-

ing history. First-degree relatives of a patient with AAA should be screened at age 60. If an AAA is found, it should be followed by US yearly if it is between 3 and 4 cm and biannually if between 4 and 4.5 cm.

### **In a Patient with an AAA, What Other Arteries Might Have Aneurysms? How Would You Screen for Them? What Is the Main Risk Associated with Those Aneurysms?**

Femoral and popliteal artery aneurysms are associated with AAA. This association is more common in males, and screening studies have identified an incidence of 14 % for either peripheral artery aneurysm. Femoral and popliteal aneurysms can sometimes be detected on physical exam. However, duplex ultrasonography is the recommended screening modality in patients found to have AAA. The main risk associated with these peripheral aneurysms is limb ischemia from thrombosis and/or distal embolization.

#### **Watch Out**

Thoracic aneurysms can present with dysphagia, hoarseness, dyspnea, and upper extremity edema.

---

## **Pathophysiology**

### **What Is the Normal Diameter of the Infrarenal Aorta? Does It Differ for Men Versus Women?**

The normal size of the infrarenal aorta is 2.0 cm in men and 1.8 cm in women.

### **What Is the Primary Defect in AAA?**

Although AAA is a multifactorial disease process, it ultimately leads to the degeneration of the medial layer through degradation of elastin and collagen.

### **At What Diameter Is the Infrarenal Aorta Considered to Be Aneurysmal?**

For an artery to be considered an aneurysm, there must be a focal area that is 1.5 times larger than the diameter of the non-aneurysmal artery above. In the case of the infrarenal aorta, this would mean that a diameter of about 3 cm or more is considered an aneurysm.

### **What Is the Average Annual Growth Rate of AAA?**

Studies examining the annual growth rate of small AAA estimate a rate of 2–4 mm/year. Patients found to have the so-called rapid expansion (>5 mm/6 months) should be referred for elective repair. In addition, routine monitoring is important in AAA as expansion tends to be in stepwise growth spurts rather than linear.

### **What Factors Influence Growth Rate?**

Ongoing smoking has been found to increase growth rate of AAA, whereas patients with diabetes have slower growth rates. The use of blood pressure medications has not been shown to consistently slow the growth rates of AAA.

## What Are Matrix Metalloproteinases (MMPs) and What Is Their Role in AAA Formation?

MMPs are important for collagen turnover, which is vital to inflammation and wound healing. Patients with AAA have abnormally high levels of MMP activity in the aortic wall, which weakens the arterial wall and contributes to the dilation of the aneurysm over time.

### Watch Out

Statin drugs have been shown to reduce the activity of MMPs.

## Is There a Genetic Component to AAA Formation?

Family history is a risk factor for AAA. First-degree relatives of patients with AAA have up to 12 times higher risk of developing the disease, and this is increased up to 18 times in siblings of patients with AAA. Interestingly, while male gender is an independent risk factor for AAA, familial groupings of AAA tend to occur more often in female relatives.

## If an AAA Ruptures, Where Does It Typically Do So?

AAA most commonly ruptures into the retroperitoneum (the aorta is a retroperitoneal structure) and most often to the left (the vena cava is on the right and may prevent rupture to that side). Free rupture into the peritoneum is rare and would likely lead to immediate death as there is no ability to tamponade the bleeding.

## What Is the Relationship Between AAA Rupture and Size?

As the aneurysm enlarges, the risk of rupture also increases. AAA with a 4–5-cm diameter has a 0.5–5 % annual chance of rupturing versus 30–50 % in an AAA > 8 cm diameter.

## Other than AAA Size, What Are Other Risk Factors for AAA Rupture?

Poorly controlled blood pressure, COPD (increase in systemic proteinase activity), and female gender (smaller aortas to begin with) have been associated with an increased risk of AAA rupture.

## What are the Primary Differences Between an Aortic Dissection and an AAA?

	<b>Aortic dissection</b>	<b>AAA</b>
Population	White male > age 60 or young patients with connective tissue disease (e.g., Marfan, Ehlers-Danlos)	White male > age 60
Strongest risk factor	Hypertension	Smoking
Presentation	Sharp, tearing chest pain radiating to the upper back	Typically asymptomatic; if ruptured, will present with severe abdominal pain, pulsatile abdominal mass, and shock
Pathophysiology	Intimal tear with dissection of blood through the medial layer forming a true and false lumen	Multifactorial processes leading to weakened medial layer
Location	Ascending aorta/aortic arch (Stanford A) or descending thoracic aorta (Stanford B) (distal to left subclavian); high stress regions	Usually arises below renal arteries but above the aortic bifurcation

## Work-Up

### What Is the First Step in the Evaluation of a Patient with a Suspected Ruptured AAA?

The first assessment in a patient with a suspected ruptured AAA should reflect the ABCs of management of unstable patients. If the patient is not in respiratory failure, intubation should be delayed until the patient is in the OR (the drugs used to intubate tend to make the patient more hypotensive). Two large-bore IVs should be established, one in each antecubital fossa.

### In a Patient with Suspected Ruptured AAA, What Is the Goal of Fluid Resuscitation?

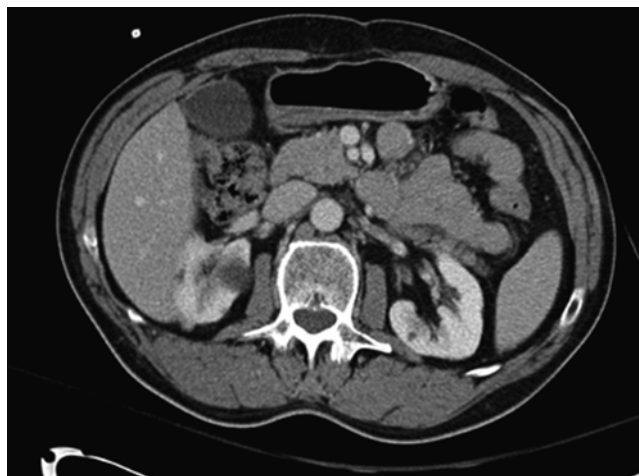Intuitively, one would want to aggressively hydrate the patient with large fluid boluses. However, in the setting of a suspected ruptured AAA, initial fluid resuscitation should be limited. Recent studies in trauma patients as well as in patients with ruptured AAA have advocated permissive hypotension rather than resuscitation to a normal systolic blood pressure. Patients should receive no more than 1 L crystalloid followed by the administration of blood products with a goal of maintaining systolic pressure greater than 70 mmHg. Massive fluid resuscitation prior to the OR tends to exacerbate hemorrhage by diluting out coagulation factors and by raising systolic blood pressure.

### What Imaging Is Recommended for Suspected Ruptured AAA in a Hemodynamically Stable Patient?

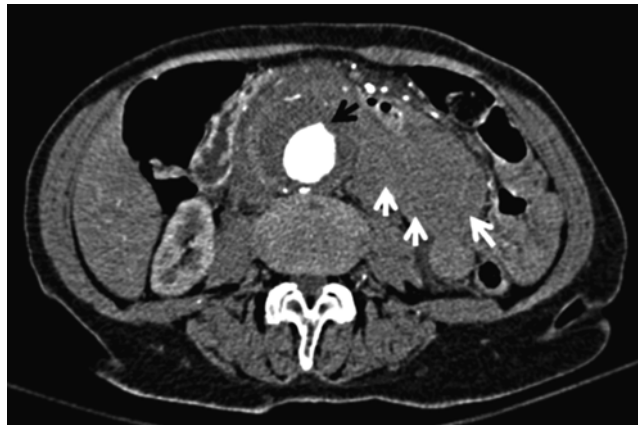The recommended imaging modality for suspected ruptured AAA is a CT angiogram. CT angiography offers the benefits of (1) confirming whether there is a ruptured AAA versus another diagnosis and (2), if it is a ruptured AAA, determining if it can be repaired via an endovascular approach (Figs. 57.1 and 57.2).

### How Does the Imaging of Choice Differ in a Hemodynamically Unstable Patient?

In the hemodynamically unstable patient, there is no role for CT scan. If the patient presents with severe abdominal pain and tenderness on exam, combined with a tender pulsatile mass and hemodynamic instability, the patient should be taken directly to the OR for an exploratory laparotomy. If there is no obvious pulsatile mass and time permits, a bedside abdominal ultrasonography is used to confirm the presence of a large AAA. Since the rupture is usually retroperitoneal, the ultrasound will not demonstrate the rupture nor will it show intraperitoneal fluid. As such, a presumptive diagnosis of a ruptured AAA is made by combining the clinical presentation, physical exam, and the finding of a large AAA on ultrasound.



**Fig. 57.1** Axial CT showing a normal aorta



**Fig. 57.2** Axial CT showing a ruptured abdominal aortic aneurysm with thrombus and large left-sided fluid collection consistent with rupture. *Black arrow: thrombus. White arrows: fluid collection*

## Management

### How Does AAA Size and Growth Rate Influence Management for an Asymptomatic AAA?

AAA measurement	Management
3–4.4 cm	Annual ultrasound
4.5–5.5 cm	Ultrasound every 3 months
>5.5 cm	Elective repair
Enlarging > 1 cm/year or symptomatic	Elective repair

## Non-ruptured Asymptomatic AAA

### Why Wait for the AAA to Reach this Size, Why Not Repair a Smaller AAA Since the Patient Is Theoretically Healthier and Is Younger?

The annual risk of rupture for an aneurysm <5.5 cm is very low, and morbidity and mortality of open surgical aneurysm repair is significant. Two large studies have demonstrated no survival benefit for early intervention for AAA <5.5 cm. Since the diameter of aortas is smaller in women, and women with AAA have a higher risk of rupture, the threshold for repair may be lower (around 5 cm), though no absolute criteria exist.

### What Surgical Options Are Available for Asymptomatic AAA?

The two available options are open repair and endovascular aneurysm repair (EVAR).

#### Watch Out

The main source of perioperative morbidity and mortality following both open repair and endovascular AAA repair is myocardial infarction.

### How Do the Two Surgical Approaches Compare in Terms of Perioperative Morbidity and Mortality? What About Long-Term Mortality?

Open repair is associated with higher risk of perioperative morbidity and mortality and longer time to full recovery, as compared with EVAR. However, long-term survival is equivalent for open repair and EVAR. This is likely related to the fact that EVAR reduces but does not eliminate the risk of AAA, and EVAR is associated with higher rates of re-intervention and re-intervention-associated complications. EVAR also has higher costs.

## Ruptured AAA

### What Are the Surgical Options for a Patient with a Ruptured AAA?

Patients with suspected rupture of an AAA can also undergo open repair or EVAR. If the patient is hemodynamically unstable, open repair is more expeditious. If the patient is relatively stable, either approach is appropriate (assuming that the patient is an EVAR candidate based on CT scan). Recent studies show that outcomes are the same for both approaches in terms of mortality.

### What Makes an AAA Unsuitable for EVAR?

The primary factor is whether there is space to deploy the stent between the takeoff of the renal arteries and the start of the infrarenal aneurysm (known as the aortic neck). If the neck is too short, standard EVAR techniques are not possible.

### What Is the Mortality Risk if an AAA Ruptures?

Overall mortality from AAA rupture is estimated at 80–90 %. Approximately half of all patients with ruptured AAA die before reaching a hospital, and of those who do arrive to the hospital alive, about 50 % will die.

### What Is the Main Achilles Heel of Endovascular Repair?

The main concern of EVAR is failure to fully exclude the aortic aneurysm. Persistent arterial flow into the aneurysm sac is known as an endoleak (Table 57.1). The concern of a persistent endoleak, particularly one at a high systolic pressure, is that the aneurysm will continue to grow and may eventually rupture despite treatment with EVAR. For this reason, following EVAR, patients require at least an annual lifetime follow-up to determine if an endoleak is present.

### Which Type of Endoleak Is the Most Common? Which Type Is the Most Dangerous? Why?

The most common type of endoleak is Type II, which is often self-limiting. Due to the low-pressure retrograde nature of persistent flow from the visceral branches, with time, these vessels usually occlude. The most worrisome endoleak following EVAR is Type I because the persistent flow from the aorta (anterograde) or iliac vessels (retrograde) in the aneurysm sac will maintain high pressures and continue to enlarge (and risk rupturing).

### How Should Patients Be Monitored After an Endovascular AAA Repair?

Following EVAR, the gold standard for monitoring is CT angiogram (CTA). Patients undergo CTA at one month and one year following EVAR and then yearly to evaluate for late endoleak. Duplex ultrasonography is an adjunctive tool for EVAR surveillance, although it has diminished specificity when compared to CTA.

### What Is the Most Common Cause of Mortality After Surgical Repair?

The most common cause of death in the immediate postoperative state is myocardial infarction.

**Table 57.1** Four types of endoleaks

Type	Features
<i>I</i>	Anterograde or retrograde flow from inadequate proximal or distal seal of the stent graft with the arterial wall
<i>II</i>	Retrograde flow from patent visceral branches within the aneurysm sac (i.e., patent lumbar, inferior mesenteric, internal iliac vessels)
<i>III</i>	Flow between junctional areas of overlapping stents within the aortic and iliac vessels
<i>IV</i>	Flow through the graft due to overly porous stent material



## Areas Where You Can Get in Trouble

### Assuming that an AAA Is Not Ruptured Because No Contrast Extravasation Is Seen on CT

If a patient with a ruptured AAA did not die in the field and has arrived to the ED with reasonable vital signs, it usually implies that the site of rupture has temporarily contained itself and that there is no ongoing exsanguination. Thus, CT scan imaging of a ruptured AAA will typically demonstrate fluid in the retroperitoneum (representing clotted blood) adjacent to the AAA but no actual contrast extravasation. In the setting of a patient presenting with acute abdominal pain, the finding of adjacent retroperitoneal fluid next to an AAA represents a ruptured AAA until proven otherwise.

### Ignoring Early-Onset Diarrhea After AAA Repair

A major concern of abdominal aneurysm repair, via both the open and endovascular approaches, is postoperative ischemic colitis, typically as a consequence of ligating/excluding the inferior mesenteric artery. Patients will develop abdominal pain, leukocytosis, and diarrhea (not always bloody) in the first few postoperative days. The goals of treatment are primarily supportive, including fluid hydration, keeping the patient NPO, and administering broad spectrum IV antibiotics to cover gram-negative aerobes and anaerobic organisms. Surgical intervention (sigmoid colon resection with colostomy) is reserved for patients who clinically deteriorate or those with full-thickness necrosis.

### Not Considering Aortoenteric Fistula as a Cause of GI Bleed After AAA Repair

An aortoenteric fistula is an erosion between the aorta and the duodenum, most commonly seen after AAA repair. It can present months or years after AAA repair with upper GI bleeding or melena. The fourth portion of the duodenum typically rests next to the aorta, near the proximal suture line, and erodes into it. Upper endoscopy is usually negative. Often the only clue is air or fluid around the aortic graft on CT scan. Since the aortic graft is infected, management requires excision of the aortic graft with extra-anatomic reconstruction (axillary to bi-femoral artery bypass) and long-term antibiotics.

---

## Area of Controversy

### Since EVAR Has a Lower Risk of Perioperative Mortality than Open Repair, Should We Lower Our Threshold for AAA Repair (i.e., < 5.5 cm) if the Patient Is an EVAR Candidate?

Although EVAR has a lower risk of perioperative complications and death, it is still associated with significant potential complications. In addition, patients with small AAA often have significant coexisting medical problems, so they are more likely to die in the long term from a cardiac event or from cancer than from a ruptured aneurysm. To date, there is no evidence that patients who are EVAR candidates would benefit from AAA repair at less than 5.5 cm.

---

## Summary of Essentials

### History and Physical Examination

- AAA is a silent killer; most are asymptomatic until rupture
- Ruptured AAA should be suspected in elderly male smokers who present with acute abdominal pain radiating to the back or flank, hypotension, tachycardia, and pallor and diaphoresis
- Many patients are obese, so a pulsatile abdominal mass may not be palpable

## Diagnosis

- In unstable patients, there is no time for a diagnostic work-up, so diagnosis is based on history and physical exam
- In stable patients, CT angiogram will elucidate the anatomy and determine whether the patient is a candidate for endovascular repair
- Abdominal ultrasound can diagnose the presence of an AAA and its size but is not accurate for determining rupture

## Screening

- Ultrasound screening
  - Men aged 65–75 with any smoking history or beginning at age 60 if they have a first-degree relative with AAA
  - Patients with femoral or popliteal artery aneurysm
  - An aortic diameter >3 cm is considered aneurysmal

## Management

- Ruptured AAA
  - Obtain IV access but limit fluids
  - Permissive hypotension (as low as 70 mm Hg)
  - Avoid intubation until in the OR
  - Stable vital signs.
    - Obtain CT to confirm diagnosis and determine if EVAR candidate
    - Urgent repair via open or EVAR
  - Unstable vital signs
    - Immediate transport for open repair
    - Consider US if diagnosis of AAA in question
- Non-ruptured AAA
  - <5.5 cm, observe
  - >5.5 cm
    - Open or EVAR

## Complications

- Myocardial infarction is most common cause of death
- Colonic ischemia if develops postoperative bloody diarrhea (early; days after surgery)
- Aortoenteric fistula if develops GI bleed (late; months to years later)

---

## Suggested Reading

Fink HA, Lederle FA, Roth CS, Bowles CA, Nelson DB, Haas MA. The accuracy of physical examination to detect abdominal aortic aneurysm. *Arch Intern Med.* 2000;160(6):833–6.

Golledge J, Karan M, Moran CS, et al. Reduced expansion rate of abdominal aortic aneurysms in patients with diabetes may be related to aberrant monocyte-matrix interactions. *Eur Heart J.* 2008;29(5):665–72.

Takayama T, Yamanouchi D. Aneurysmal disease: the abdominal aorta. *Surg Clin N Am.* 2013;93(4):877–91, viii.

Zachary D.C. Burke, Ziyad Jabaji, and Christian de Virgilio

A 65-year-old female presents to the emergency department with a 4 hour history of sudden onset of right leg pain, coolness, weakness, and numbness. She has no prior similar history. The pain began while she was sitting watching television. She has a history of hypertension and hypercholesterolemia and takes medication for both. She denies smoking. On review of systems, she has no prior history of pain in her right leg with walking. On physical examination, her lungs are clear to auscultation. Her heart rate is irregularly irregular without murmurs, rubs, or gallops. Her abdomen is soft and non-tender without a pulsatile mass. On the left side, the femoral, popliteal, dorsalis pedis, and posterior tibial pulses are 2+, with biphasic signals on Doppler. On the right side, the femoral, popliteal, dorsalis pedis, and posterior tibial pulses are absent, with a faint monophasic signal on Doppler. Her right calf is tender to palpation but is not edematous. She has normal appearing, supple skin in her legs with a normal hair pattern. The left foot is pink and warm with a 2 second capillary refill and normal motor and sensory function. Her right foot is pale and feels much colder than the left; capillary refill time is 6 seconds. The toes have decreased sensation to touch. Her strength is diminished in both plantar flexion and dorsiflexion of the ankle at 4+/5.

## Diagnosis

### What is the Differential Diagnosis?

Differential diagnosis	Key features/findings
Acute limb ischemia	Pain, pallor, pulselessness, paresthesias, paralysis, and poikilothermia; history of peripheral arterial disease (PAD), atrial fibrillation
Compartment syndrome	Severe pain in calf with passive motion of ankle, tense leg edema, recent trauma, pulse present
Phlegmasia cerulea dolens	Cyanotic leg and edema, massive deep vein thrombosis, associated with malignancy; evaluate for recent prolonged stasis, hypercoagulable state, endothelial injury ( <i>Virchow's triad</i> )
Cerebrovascular accident	May cause numbness and weakness but not pain or pulselessness; other neurological signs may be present
Disk herniation	History of back pain, DJD; paresthesias in dermatomal distribution (e.g., sciatica), possible weakness and sensory changes, but pulses present
Spinal cord tumor	Presents similarly to disk herniation; consider in patients with history of metastatic malignancy

*DJD* degenerative joint disease

Z.D.C. Burke, BA (✉)

David Geffen School of Medicine at UCLA, 10833 Le Conte Ave, Los Angeles, CA 90095, USA

e-mail: [zburke@mednet.ucla.edu](mailto:zburke@mednet.ucla.edu)

Z. Jabaji, MD

Department of Surgery, UCLA Medical Center, 10833 Le Conte Avenue, 72-229 CHS, Los Angeles, CA 90095, USA

e-mail: [zjabaji@mednet.ucla.edu](mailto:zjabaji@mednet.ucla.edu)

C. de Virgilio, MD

Department of Surgery, Harbor-UCLA Medical Center, 1000 W. Carson Street, Torrance, CA 90509, USA

e-mail: [cdevirgilio@labiomed.org](mailto:cdevirgilio@labiomed.org)

## What Is the Most Likely Diagnosis?

This patient's presentation is most consistent with acute limb ischemia (ALI). The presence of motor weakness often creates confusion and may inappropriately steer the clinician towards a neurologic differential diagnosis. However, the pale, cold foot, combined with the absence of pulses, as confirmed by decreased Doppler signal, rules out the majority of the diagnoses in the differential. The presence of an irregularly irregular heartbeat points towards a cardioembolic etiology of the ALI.

## History and Physical

### What Is the Difference in Timing Between Acute and Chronic Limb Ischemia?

Acute limb ischemia (ALI) is defined as any sudden decrease in perfusion to a limb that endangers its viability. Limb ischemia is considered acute when the symptoms have been present for less than 2 weeks, whereas chronic limb ischemia (CLI) is diagnosed if the condition has been present for greater than 2 weeks.

### What Are the 6 "Ps" of Acute Limb Ischemia?

Patients with ALI present with a constellation of signs and symptoms summarized by the "six Ps": *pain*, *pallor*, *pulselessness*, *paresthesias*, *paralysis*, and *poikilothermia/perishing cold*. Pulselessness is considered the defining feature of ALI, but pain is often the presenting symptom. Pain associated with ALI is frequently located in the foot and calf and often occurs at rest. This *stands in contrast* with intermittent claudication associated with CLI, which is described further below. Numbness is present in more than half of the patients with ALI. Paralysis is the most ominous sign of the "six Ps" and is a sign of severe ischemia that may be irreversible.

### Why Is the Cardiac History and Physical Important in Determining the Etiology of ALI?

Taking a thorough cardiac history and physical examination is essential when ALI is suspected. Embolic occlusion is a common etiology (Table 58.1) for ALI with 80 % of emboli coming from the heart. Atrial fibrillation, recent myocardial infarction, valvular disease, and congestive heart failure are all common conditions that predispose to cardioemboli. A focused cardiac history and physical examination should identify the presence of any of these diseases.

**Table 58.1** Common causes of acute limb ischemia

	<b>Etiology</b>	<b>Key features/findings</b>
<i>Thrombosis</i>	Thrombosis of stenosed artery	Vascular risk factors, history of claudication, signs of chronic ischemia in contralateral limb
	Thrombosis of previous graft	Vascular risk factors, known previous graft, surgical scars
	Hypercoagulable disorder	Known coagulopathy, history of prior de novo arterial thrombosis, no prior history of atherosclerotic PAD
	Arterial trauma	Recent trauma, recent vascular intervention
<i>Embolus</i>	Cardioembolic occlusion	Atrial fibrillation, valvular disease, CHF, recent MI, ventricular aneurysm, left atrial myxoma
	Embolism from popliteal/aortic aneurysm	Palpable pulsatile abdominal mass or popliteal mass in contralateral leg (often bilateral)
	Paradoxical embolism	DVT sends clot to the heart, crosses cardiac septal defect with embolization to the arterial tree
<i>Others</i>	Acute aortic dissection	Type A (involves aortic arch), type B (descending aorta), tearing back pain, Marfan's syndrome, HTN
	Systemic shock	Limb ischemia may be a late manifestation of shock, particularly with underlying chronic occlusive disease or high doses of vasopressors

*PAD* peripheral arterial disease, *CHF* congestive heart failure, *HTN* hypertension

**Watch Out**

Atrial fibrillation is the most common cause of acute arterial emboli.

**What Are the Key Findings that Point Towards an Embolic Etiology Rather than a Thrombotic Event?**

Since most emboli are of cardiac origin, prior known atrial fibrillation, an irregularly irregular rhythm (as in the patient above), or acute MI is highly suggestive of a cardioembolism. In addition, most thrombotic events occur in the setting of preexisting atherosclerosis in the leg arteries (which is usually a symmetric, bilateral process).

**Why Is It Important to Examine the Contralateral, Nonischemic Limb?**

Examining the contralateral leg allows the provider to compare each leg when assessing the subjective findings of pallor and poikilothermia. It also provides important information on the etiology of ischemia. Signs of long-standing ischemia such as absent pulses in the unaffected leg or ischemic ulcers, hairlessness, or atrophic skin changes in either leg suggest peripheral arterial disease (PAD), which raises suspicion for a thrombotic etiology of ALI. Since PAD is a diffuse disease process in the peripheral vasculature, a lack of any ischemic changes in the contralateral leg makes an embolic cause more likely.

**How Would You Best Assess this Patient's Atherosclerotic Disease History?**

The presence of underlying atherosclerotic disease should be assessed via a complete history that includes the presence of risk factors such as smoking and hypercholesterolemia, history of coronary artery or other vascular disease equivalents (including diabetes), and history of intermittent claudication and other signs of poor limb perfusion. Intermittent claudication is characterized by aching, cramping pain that is induced by exercise and relieved by rest (see separate claudication chapter). The pain most often affects the calf but may affect the thigh and buttock as well depending on the level of the chronic arterial stenosis.

**Why Is It Important to Ask About Past Interventions for PAD?**

It is important to determine if the patient has had previous interventions for PAD, as thrombosis of a previous graft is a frequent cause of ALI. Fractures, dislocations, or other causes of arterial trauma may also induce acute arterial thrombosis due to mechanical compression. Iatrogenic trauma such as that caused by recent arterial catheterization may also cause thrombosis and is more often missed than overt trauma.

---

**Pathophysiology****Where in the Arterial Tree do Cardiac Emboli Tend to Lodge?**

Generally, emboli lodge at arterial bifurcations (Table 58.2) due to the sudden reduction in arterial diameter. The bifurcation of the common femoral artery into the superficial femoral and profunda femoris arteries is the most common location for an embolus to lodge in the lower extremity. Patients with occlusion of the common femoral artery typically present with unilateral foot/calf pain and absent distal pulses in the affected leg. A femoral pulse may be present proximally and disappear distally. In contrast, bilateral pain and pulselessness suggest a saddle embolus at the aortic bifurcation or a nonvascular etiology. Popliteal occlusion often occurs where the artery divides into the anterior tibial and tibioperoneal trunk arteries and results in foot pain and absent pedal pulses with preserved femoral pulses. The popliteal pulse may be present as well.

**Table 58.2** Common locations of lower extremity embolic occlusion and their presentations

Location	Pulses	Symptoms
Aortic bifurcation	Absent bilaterally	Bilateral pain/weakness of thighs/calves, mottling of skin distal to umbilicus
Common femoral bifurcation	Absent throughout affected limb	Unilateral calf and foot pain
Popliteal bifurcation	Femoral pulse present, pedal pulses absent; popliteal pulse may be present as well	Unilateral foot pain; calf pain may be present as well

### Discuss How an Embolus Can Lead to Acute Limb Ischemia

Embolic causes of ALI account for approximately 30–40 % of cases. Of these, 80 % are associated with cardiac conditions including atrial fibrillation, recent MI (leading to mural thrombus), valvular disease, and left atrial myxoma. Each of these diseases can lead to formation of intracardiac thrombus which can embolize to a lower extremity artery. A focal dilation of an artery (aneurysm) leads to stasis and clot formation on the outer edges of the arterial wall. Such clot is prone to embolization, which may lead to ALI. More rarely, in situ thrombosis of an aneurysm can lead to ALI. Palpation for aneurysms in the aorta, femoral, and popliteal arteries should be included in the physical examination.

### Discuss How Thrombosis Can Lead to Acute Limb Ischemia

Thrombotic causes of ALI (approximately 50–60 % of cases) are usually associated with underlying atherosclerotic disease. There are two primary mechanisms believed to be responsible for atherosclerosis-related limb ischemia. Plaque buildup can lead to a progressive narrowing of the artery with subsequent low-flow states and stasis that compromise perfusion to tissue. The second mechanism involves intraplaque rupture with local hypercoagulability and hemorrhage, which can also prevent distal tissue from receiving enough oxygen-rich blood.

### How Long Can Muscle Tissue Withstand Ischemia Before Irreversible Damage Occurs?

Physiologic studies show that after an acute ischemic event, skeletal muscle tissue begins to show signs of irreversible cell damage after 3 hours and progresses to complete cell damage at 6 hours. Thus rapid diagnosis and treatment is essential in the suspected ALI.

## Work-Up

### What Are the Adjunct Tests to the Vascular Physical Examination?

Blood *flow* is detected by a handheld Doppler probe and converted to an audible acoustic signal. Doppler assessment is frequently more sensitive than the ability to palpate a pulse. The signal should be reported as triphasic, biphasic, monophasic, or absent. A healthy peripheral artery produces a triphasic signal (three sounds). This reflects initial forward systolic flow, followed by early diastolic retrograde flow attributable to high resistance, and finally forward diastolic flow. Biphasic signals are often normal but may represent an early disease state. Monophasic signals are clearly abnormal and signify a severe reduction in blood flow. Most patients with acute limb ischemia have absent Doppler signals, or at best, faintly monophasic signals. If a biphasic or triphasic arterial signal is present, the diagnosis of acute limb ischemia may still be correct but must be reconsidered.

Duplex scanning is another ultrasound modality used in the evaluation of ALI. Duplex scanning uses traditional sonography to visualize structures as well as Doppler to create a visual representation of flow direction and velocity. Duplex scanning is frequently used to determine the location of disease and to characterize lesions in preparation for surgery.

The ankle-brachial index or ABI is essential in the evaluation of chronic limb ischemia. With ALI, blood flow in the foot is severely reduced such that a blood pressure is typically not measurable; therefore, the ABI has limited utility.

**Table 58.3** TASC classification of ALI

Stage	Category	Prognosis	Sensory loss	Muscle weakness
<i>I</i>	Viable	Not immediately threatened	None	None
<i>IIa</i>	Marginally threatened	Salvageable with prompt treatment	Minimal (toes) or none	None
<i>IIb</i>	Immediately threatened	Salvageable with immediate revascularization	More than toes	Mild or moderate
<i>III</i>	Irreversible	Major tissue loss or permanent nerve damage inevitable	Profound, anesthetic	Paralysis or rigor

### How Is the Severity of Acute Ischemia Determined?

The severity of ALI is determined clinically, not radiographically. The presence of sensory and/or motor deficits are the most important prognostic factors. Doppler signal is also important as a measure of whether any arterial blood flow is present. The TASC II task force on the management of PAD created a severity scale used to differentiate extremities that are viable, threatened, and irreversibly damaged (Table 58.3).

### What Imaging Is Recommended?

The diagnosis of ALI is extremely time sensitive. Duplex scanning is a simple and convenient imaging modality to use for initial evaluation of ALI. A normal duplex scan is an inexpensive way to effectively rule out ALI. Though it is useful for examining the affected limb, it does not provide information about the proximal arterial tree (aorta and iliac arteries). CT angiogram (CT A) is the gold standard as it can be performed quickly and provides the option for cross-sectional reconstruction. It can provide information that duplex scanning cannot; for example, it provides the ability to identify proximal disease such as aortic aneurysms or dissection and still diagnose distal disease by rapidly scanning the arterial tree from the thoracic aorta to the feet bilaterally. In the past, formal contrast angiography (via transfemoral arterial puncture) was the gold standard for imaging occlusive disease. However, given the invasive nature, the use of contrast, and the potentially long delays (to call in an interventional radiologist), formal angiography is no longer the first-line test. When revascularization must be performed immediately, the patient may be taken directly to the OR with contrast angiography performed intraoperatively as needed (remembering that the urgency of work-up vs. immediate attempts at treatment is a clinical decision made by clinicians). Many elements of the work-up (particularly for embolic etiologies) can be undertaken postoperatively and should not delay revascularization.

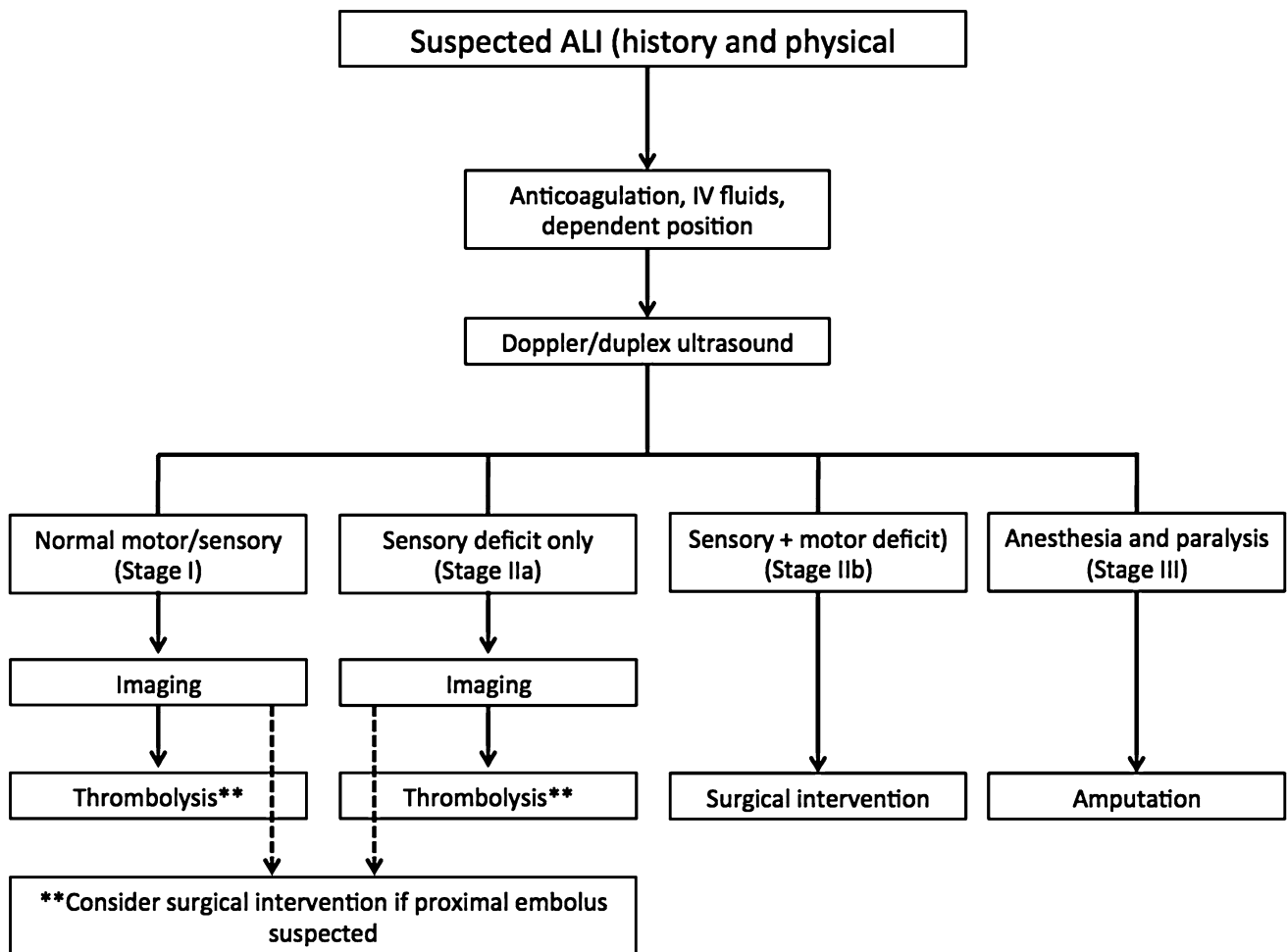
### What Imaging Should Be Done if an Embolus Is Suspected as the Cause for ALI? If a Paradoxical Embolus Is Suspected?

If an embolus is suspected, cardiac work-up with transthoracic echocardiography should be performed. If there are particular historical clues to suggest a venous thrombosis with paradoxical embolus (such as recent flights, pelvic surgery, asymmetrically swollen limbs, etc.), venous duplex scanning should be performed to evaluate for the presence of venous thrombus, and transthoracic echocardiogram and bubble study (intravenous injection of saline with bubbles in it and monitoring for echocardiographic evidence of the bubbles in the left side of the heart) should be performed to assess for cardiac septal defects that may allow paradoxical embolism of venous clots into the arterial circulation.

## Management

### What Are the Three Most Important Initial Management Steps?

Anticoagulation with heparin should be started (provided there is no contraindication such as bleeding) once the diagnosis of ALI is suspected. Do not wait for imaging in someone with a cold, pulseless foot. While heparin will not dissolve the clot, it is essential in preventing clot propagation into unaffected vascular beds while the patient's own fibrinolytic system dissolves



**Fig. 58.1** Management of acute limb ischemia

some of the clot. In addition to anticoagulation, the affected limb should be placed in a dependent position to improve flow. Finally, IV fluids should be started as volume expansion helps optimize perfusion through collateral vessels.

### What Are the Main Therapeutic Options for Acute Limb Ischemia?

The two mainstay treatment options for ALI are endovascular and open surgical revascularization. Endovascular treatment relies on catheter-based methods to achieve clot dissolution; these include catheter-directed tissue plasminogen activator (tPA thrombolysis), percutaneous aspiration thrombectomy, or percutaneous mechanical thrombectomy. Surgical options include surgical (Fogarty balloon) embolectomy, endarterectomy, and distal bypass. In some cases, heparin alone may be the best treatment option, particularly in patients with mild ischemia who are at high risk for complications from thrombolysis or surgery. For example, in a patient who presents with an acute MI and is not stable for transport to the operating room or the endovascular suite, heparin alone may suffice if the ischemia is mild.

### How Is One of the Above Therapeutic Approaches Chosen?

The therapeutic approach depends on the severity of ischemia. Endovascular therapy, though less invasive, may take 24–48 h to be completely effective. Thus, it is appropriate and preferred for most patients with less severe ischemia (those with a normal motor/sensory exam, i.e., stage I) or with only a sensory deficit (stage IIa) (Fig. 58.1). Surgical intervention is preferred for patients with severe ALI (those with a motor deficit, i.e., stage IIb) when immediate revascularization is indicated. For severe, stage III ALI (complete loss of motor/sensory function), primary amputation is often the best treatment option.



## **How Does the Etiology of the Ischemia Influence the Therapeutic Choice?**

The etiology of ALI is also used to dictate treatment choice. Surgical embolectomy is often preferred when cardioemboli are located in the proximal extremity or above the inguinal ligament. Additionally, patients with cardioembolic ALI should be treated with long-term anticoagulation, though the ideal duration is controversial. Catheter-directed thrombolysis is preferred when thrombus is suspected, as these lesions are often located in smaller, more distal vessels and associated with atherosclerotic lesions. Patients with small-vessel occlusions are not ideal candidates for surgery because they lack distal vessels that can be used as targets for anastomosis of a bypass graft. Patients with no antecedent history of PAD and no radiographic culprit lesion need to be worked up for a hypercoagulable disorder and treated appropriately.

## **What Is the Treatment for Irreversible Limb Ischemia? What Are the Renal and Electrolyte Sequelae of Reperfusing Ischemic or Dead Muscle?**

When ALI progresses to significant irreversible tissue damage (stage III), primary amputation should be performed. Revascularization of ischemic and dead muscle tissue can lead to a constellation of serious complications collectively known as reperfusion syndrome. These complications are caused by toxic products that are released from the damaged tissue into the general circulation. Rhabdomyolysis is the primary concern after reperfusion and can lead to acute renal failure in severe cases. Thus, it is important to monitor for elevated serum creatine phosphokinase (CPK) and myoglobinuria when revascularization is performed. Hyperkalemia may also occur as part of reperfusion syndrome as large amounts of potassium are released from the ischemic muscle. Acute respiratory distress syndrome (ARDS), disseminated intravascular coagulopathy (DIC), and shock are more rare complications of revascularization. Reperfusion syndrome is not limited to stage III ALI and should be considered whenever revascularization is performed.

---

## **Areas Where You Can Get into Trouble**

### **Mistaking the Diagnosis of ALI as a Neurological Condition**

Patients with ALI can easily be mistaken as having an acute neurologic event, especially if the ischemia has led to significant paresthesias and muscle weakness. Spinal cord/nerve root impingement by metastases, herniated disks, spondylolisthesis, or trauma may present similarly to ALI. A history of degenerative disk disease or malignancy that is known to metastasize to the spinal cord or dura may be present in such patients. A careful motor/sensory exam is essential in addition to the vascular exam. The presence of normal pulses combined with a normal ABI in the affected extremity effectively rules out ALI.

### **Failing to Monitor for Elevated CPK and Myoglobinuria**

After revascularization it is essential to monitor for reperfusion syndrome. Rhabdomyolysis is a potentially serious complication of limb revascularization, with up to 20 % of patients showing laboratory evidence of myoglobinuria. Of patients with CPK > 5,000 units/L, approximately half will develop acute kidney injury (AKI) caused by heme pigment, which precipitates in tubules leading to cast formation and direct toxic injury to proximal tubular cells. If rhabdomyolysis is suspected, prompt therapy with IV fluids and bicarbonate infusion should be started. IV fluids enhance renal perfusion and prevent ischemic injury while simultaneously increasing urine flow in order to limit intratubular cast formation and increase heme excretion. Bicarbonate causes alkalization of the urine, which prevents the precipitation of heme pigment. The prognosis for heme pigment-induced AKI is favorable with many patients returning to normal renal function.

### **Following Revascularization, the Patient Develops Peaked T Waves on the EKG**

Peaked T waves are an early sign of hyperkalemia and may portend more serious complications. Physiologically, excessive potassium leads to resting membrane depolarization and subsequent sodium channel inactivation in the cardiac conduction system. The resulting decreased membrane excitability causes EKG changes, conduction abnormalities, and arrhythmias. Patients that develop peaked T waves should be treated promptly with IV fluids (without potassium) and IV calcium gluconate,

which counteract the effects of potassium on resting membrane potential to prevent arrhythmia. Insulin is then administered to drive potassium into cells via activation of the Na-K ATPase pump. Glucose is given simultaneously to prevent hypoglycemia. Bicarbonate may also be used to drive potassium into cells via the hydrogen-potassium exchange buffering reaction. While these interventions stabilize cell membranes and drive potassium into cells, further treatments are needed to remove potassium from the body. These include loop diuretics, potassium binders such as sodium polystyrene (Kayexalate), or dialysis in severe cases. High-dose inhaled albuterol may also be administered.

---

## Areas of Controversy

### Is Catheter-Directed Thrombolysis (CDT) or Open Surgical Embolectomy Preferable for Suspected Cardiac Embolism to an Extremity?

While CDT is considered first-line treatment for most cases of stage I and IIa ALI, there is some controversy as to whether surgical embolectomy is preferable when the etiology is cardioembolic. Some feel that embolectomy is preferred in these situations because the clot may have resided in the heart for a long period of time before dislodging and moving to the limb and thus is more organized and resistant to tPA. However, this point has been controversial. One major trial found that in embolic ALI, both CDT and surgical embolectomy resulted in 100 % limb salvage rates at one year but 1-year survival in patients undergoing CDT was double that of patients undergoing embolectomy (100 % vs. 51 %).

---

## Summary of Essentials

### History and Physical

- ALI definition: decreased limb perfusion of <2 weeks duration
- History: heart disease, risk factors for vascular disease, prior vascular interventions, intermittent claudication, the 6 Ps (pain, paresthesias, pallor, paralysis, pulselessness, and poikilothermia)
  - Pain is often the presenting symptom
  - Pulselessness is the *sine qua non*
  - Paralysis portends the worst prognosis
- Try to determine if cause is thrombotic or embolic
- Exam of contralateral nonischemic limb may show signs of chronic peripheral arterial disease that indicates a thrombotic cause
- Examination of the heart may reveal conditions such as atrial fibrillation/flutter, valvular disease, or heart failure that indicate a likely embolic cause

### Pathophysiology

- Common causes: atrial fibrillation, acute MI. Other causes: trauma, thrombosis of an aneurysm, and hypercoagulable disorders
- Irreversible damage of skeletal muscle tissue begins at 3 h and maybe completed at 6 hours

### Diagnosis

- ALI is associated with motor/sensory deficits. Must consider a primary neurologic etiology in the differential
- Doppler ultrasound is fast and easy. CT angiography provides more information than formal angiography and is faster and noninvasive
- The severity of ALI is determined clinically, primarily by the motor/sensory exam
  - Viable, stage I (normal motor/sensory); marginally threatened, IIa (sensory deficit only); immediately threatened, IIb (motor and sensory deficit); irreversible ischemia, III (complete motor/sensory absence)

## Management

- Immediately begin IV heparin and IV fluids, and place limb in a dependent position
- Definitive treatment: catheter-directed thrombolysis or open surgical intervention
- Intervention is time sensitive
- Catheter-directed thrombolysis takes 24–48 h to complete
  - Use if stage I (no motor/sensory deficit) or IIa (sensory deficit only)
- Surgical revascularization is immediate
  - Preferred for stage IIb (sensory and motor deficit)
- Amputation for irreversible stage III (complete anesthesia and paralysis)

## Complications

- The most concerning complication of revascularization is reperfusion syndrome, which may include rhabdomyolysis and acute renal failure

## Areas Where You Can Get Into Trouble

- An acute neurologic event may be easily mistaken for ALI
- Monitoring for elevated serum CPK and myoglobinuria is essential in order to prevent acute renal failure secondary to rhabdomyolysis after revascularization

## Areas of Controversy

- Surgical embolectomy is often considered the preferred treatment for embolic ALI, but contemporary research is challenging this notion

---

## Suggested Reading

Campbell W, Ridler B, Szymanska T. Current management of acute leg ischaemia: results of an audit by the Vascular Surgical Society of Great Britain and Ireland. *Br J Surg.* 1998;85:1498–503.

Norgren L, Hiatt WR, Dormandy JA, Nehler MR, Harris KA, Fowkes FG, Rutherford RB, TASC II Working Group. Inter-society consensus for the management of peripheral arterial disease. *Int Angiol.* 2007;26(2):81–157. Review. PubMed PMID: 17489079.

---

**Acute Care Surgery****Christian de Virgilio and Areg Grigorian****Questions**

1. A 55-year-old man presents with a mass in the left groin that is intermittently painful. The mass protrudes upon straining and reduces when he is in the supine position. With the patient standing, there is an obvious mass in his left scrotum that protrudes from the internal ring and becomes more prominent when the patient coughs. Elective surgery is recommended. At surgery, the posterior wall of the hernia sac feels very thickened and is consistent with a possible sliding hernia. Which of the following is true regarding this type of hernia?
  - (A) Every attempt should be made to excise the entire sac
  - (B) It poses a higher risk of colon injury during repair
  - (C) It is more common on the right side
  - (D) It is most often associated with direct inguinal hernias
  - (E) The hernia sac should be divided at the internal ring
2. A 66-year-old woman presents to her family doctor complaining of a pain in her left groin that has appeared intermittently over the past several months. On physical exam, a soft mass is palpated in her left groin, below the inguinal ligament, and near her femoral pulse. On palpation, the mass is soft and slightly tender and disappears with gentle compression. Which of the following is true regarding these types of hernias?
  - (A) They are the most common hernia type in women
  - (B) The risk of strangulation is relatively low
  - (C) The hernia sac travels lateral to the femoral vein
  - (D) If discovered incidentally and the patient is asymptomatic, repair is not indicated
  - (E) It is associated with multigravida
3. A 30-year-old woman is recovering from an open cholecystectomy in the hospital. On the second postoperative day, she begins to complain of cramping abdominal pain without vomiting. She has no past medical or surgical history, and her postoperative course has been unremarkable. She is receiving oral hydrocodone for pain and is on a clear liquid diet. She has a temperature of 99.5 °F, blood pressure is 128/84 mmHg, and pulse is 82/min. Her physical exam is significant for absent bowel sounds, a mildly distended abdomen with mild diffuse tenderness without rebound or guarding. Which of the following would most benefit her abdominal findings?
  - (A) Encouraging ambulation
  - (B) Placement of a nasogastric tube
  - (C) Neostigmine
  - (D) Conversion of hydrocodone to a nonsteroidal anti-inflammatory drug
  - (E) Return to the operating room for exploration
4. A Richter's hernia:
  - (A) Most often contains colon or bladder in the posterior aspect of the sac
  - (B) Has a low risk of incarceration
  - (C) Most commonly presents as a small bowel obstruction
  - (D) Can mislead the clinician as strangulated bowel can easily be missed
  - (E) Should be manually reduced in the emergency department provided there is no evidence of bowel obstruction
5. A 55-year-old schizophrenic homeless man arrives to the ED with abdominal pain and vomiting. He reports that the abdominal pain started yesterday and has been worsening. He is afebrile, blood pressure is 122/86 mmHg, and heart rate is 116/min. In the ED he vomits green emesis without blood. His last bowel movement was 48 h

- ago. Physical examination reveals a large scar in his right upper quadrant. On abdominal examination, the abdomen is distended, with hyperactive bowel sounds, and is tympanic to percussion, with mild diffuse tenderness, and no rebound or guarding. WBC is  $9 \times 10^3/\mu\text{L}$  (normal  $4.1\text{--}10.9 \times 10^3/\mu\text{L}$ ). Abdominal series shows dilated loops of bowel with multiple air fluid levels. After fluid resuscitation, what is the most appropriate next step in management?
- (A) Nasogastric tube suction  
 (B) Laparoscopy  
 (C) Exploratory midline laparotomy  
 (D) Intravenous erythromycin  
 (E) CT scan of the abdomen
6. A worried mother presents to you with concerns that her 6-month-old boy has a large protrusion at his belly button that is worse when he cries but reduces when he is sleeping. On exam you palpate a 1 cm fascial defect at his umbilicus. Which of the following is true about this condition?
- (A) Elective repair is recommended  
 (B) The condition is associated with cardiac anomalies  
 (C) The size of the defect predicts that it will not likely close on its own  
 (D) The risk of incarceration is significant  
 (E) Repair should be delayed until the child is 4 years old
7. One week after open repair of a large right scrotal hernia, a 45-year-old male returns complaining of severe pain in his right testicle. On physical exam, the testicle appears to be slightly swollen and very tender to palpation. Doppler study demonstrates no flow within the right testicle with normal flow in the left. Which of the following is true about this condition?
- (A) It is most commonly due to thrombosis of the pampiniform plexus  
 (B) Urgent exploration of the right testicle is recommended  
 (C) It is most likely due to transection of the testicular artery  
 (D) It most likely represents testicular torsion  
 (E) The testicle will likely remain permanently enlarged
8. Following open inguinal hernia repair, a 50-year-old male complains of numbness and burning pain on the scrotum. This most likely represents injury to:
- (A) The genital branch of the genitofemoral nerve  
 (B) The femoral branch of the genitofemoral nerve  
 (C) The ilioinguinal nerve  
 (D) The lateral femoral cutaneous nerve  
 (E) The iliohypogastric nerve
9. A 65-year-old male presents to the ED with nausea, vomiting, and severe abdominal pain. Past history is significant for prior sigmoid colectomy for diverticulitis 10 years ago. On physical exam, his temperature is  $100.9^\circ\text{F}$ , blood pressure is 110/80 mmHg, and heart rate is 110/min. His abdomen has a well-healed midline scar and is distended. Bowel sounds are hyperactive with occasional rushes and tinkles. He has marked right upper quadrant tenderness to palpation with guarding. The rest of the abdominal exam is unremarkable. Abdominal series demonstrates one loop of markedly distended small bowel in the right upper quadrant with an air fluid level. No gas is seen in the colon or rectum. Laboratory values demonstrate a WBC count of  $18 \times 10^3/\mu\text{L}$  (normal  $4.1\text{--}10.9 \times 10^3/\mu\text{L}$ ) with 15 % bands and a serum lactate of 5 mmol/L (normal 0.5–1.6 mmol/L), BUN 30 mg/dL (7–21 mg/dL), and creatinine 1.2 mg/dL (0.5–1.4 mg/dL). Amylase, lipase, and liver chemistries are normal. NG tube and IV fluids are given. What is the next step in the management?
- (A) Exploratory laparotomy  
 (B) Admit for close observation  
 (C) Upper GI with small bowel follow through with barium  
 (D) Upper GI with small bowel follow through with Gastrografin  
 (E) Right upper quadrant ultrasound

**Answers****1. Answer B**

Sliding inguinal hernias have a much higher risk of colonic injury during repair than other hernias. This is because the posterior wall of the hernia sac is formed by a retroperitoneal organ (colon or bladder). A clue to the presence of a sliding hernia is the finding of a thickened posterior wall of the hernia sac at surgery, in association with a large indirect hernia (D) that has descended into the scrotum (direct hernias rarely descend into the scrotum). Attempting to completely excise the hernia sac (A) (which is otherwise normally done), or to divide the sac completely at the internal ring (E) (which is again normally recommended), would result in dividing the bowel or bladder. Sliding hernias are more common on the left side (C) (the sigmoid colon is less fixed and more likely to slide down than the right colon). A sliding hernia is an indirect inguinal hernia (D).

**2. Answer E**

Multigravida causes stretching of the abdominal musculature and increases the risk of femoral hernia. Femoral hernias occur in the femoral canal, inferior to the inguinal ligament traversing the empty space medial (C) to the femoral vein (recall the mnemonic "NAVEL" {from lateral to medial: femoral nerve, artery, vein, empty space, lymphatic}). The most common type of hernia in women, and in men, is an indirect inguinal hernia (A). Although femoral hernias appear infrequently (10 % of all hernias), they occur more commonly in females and have the highest risk of strangulation (B). Because of the high risk of strangulation, surgical repair of a femoral hernia is indicated (D) once diagnosed, regardless of whether the patient is having symptoms.

**3. Answer D**

Always consider a nonmechanical postoperative ileus in patients that have had a recent surgery. This occurs in up to 50 % of patients that have undergone abdominal surgery. Although the exact cause has not been elucidated, it most likely involves impaired peristalsis of intestinal contents. Inflammatory mediators (e.g., recent surgery) and opioid analgesics are thought to contribute to the development of postoperative ileus. Initial management should begin with changing pain medication to a non-opiate analgesic. Encouraging ambulation (A) should also be done for all postoperative patients, but is not as imperative as discontinuing opiates. If the patient's postoperative ileus continues with worsening symptoms (e.g., emesis), bowel decompression including a NGT (B) can be considered. Returning to the OR for exploration (E) is inappropriate for postoperative ileus. Neostigmine is used in patients with pseudo-obstruction (Ogilvie's syndrome).

**4. Answer D**

With a Richter's hernia, only one wall of the bowel protrudes into the hernia sac (A). That segment of bowel is prone to incarceration and strangulation but does so without associated symptoms, signs, or radiologic evidence of SBO (C). Therefore, it may easily mislead clinicians into thinking that the hernia is not incarcerated (B). Manual reduction of hernias (including Richter's) should not be attempted if strangulation is suspected as dead bowel will be reduced into the peritoneum. Strangulation should be suspected in the presence of fever, leukocytosis, acidosis, severe pain, or marked erythema overlying the skin of the hernia. It is often difficult to palpate a Richter's hernia, and it should be reduced in the operating room (E).

**5. Answer A**

This patient has evidence (on history, physical, and radiologic imaging) of a small bowel obstruction (SBO) that is most likely secondary to adhesions from prior surgery (scar in RUQ). SBO from adhesions can present many years after surgery. The initial management of SBO includes placing the patient NPO, aggressive intravenous fluid resuscitation (the patient is tachycardic and likely very dehydrated), and NG tube placement. Aside from the salutatory effect of NG decompression on the distended bowel, patients with SBO are at risk of aspiration. Once the patient has been adequately resuscitated, CT scan (E) with oral contrast is recommended as it is useful in confirming the diagnosis of SBO, determining if the SBO is partial or complete, and ruling out other diagnosis. Most patients with SBO due to adhesions improve with these maneuvers, and do not require surgery. Operative management (C) with laparotomy and lysis of adhesions should be considered in the following conditions: if the patient demonstrates evidence of clinical deterioration as manifest by increasing pain, tenderness, fever, leukocytosis, or acidosis. Operative management can be achieved either via open laparotomy or laparoscopy (B). Evidence of a complete SBO is a relative indication for surgery, but recent studies suggest that some of these patients resolve with nonoperative management as well. Intravenous erythromycin acts as a prokinetic agent and has some utility for gastroparesis, but not for a SBO (D).

**6. Answer E**

This patient has an umbilical hernia, which is a common finding in newborns. It is recommended that repair be delayed (A) until after the child is 4 years old, unless the defect is larger than 2 cm, the defect is growing, or there is evidence of strangulation. Umbilical hernias are not associated with the VACTERL (vertebral, anal, cardiac, tracheoesophageal fistula, renal, limb) complex of anomalies (B). Defects smaller than 2 cm will likely close spontaneously (C). It is very rare for umbilical hernias in children to incarcerate (D).

**7. Answer A**

This patient likely has ischemic orchitis secondary to damage to or thrombosis of the pampiniform plexus. This is most likely to occur in patients with large or densely adhered hernia sacs. The condition is usually self-limited (E), so urgent exploration (B) is not indicated. Ischemic orchitis is more commonly caused by injury to the pampiniform plexus than to the testicular artery (C). Testicular torsion (D) is less likely than a vascular injury in this case, although both would present with acute testicular pain and decreased or absent Doppler signal.

**8. Answer A**

The genital branch of the genitofemoral nerve provides sensation to the scrotum and the cremaster reflex. The femoral branch of the genitofemoral nerve (B) provides sensation to the proximal medial thigh. The ilioinguinal nerve (C) provides sensation to the lower abdomen and medial thigh. The lateral femoral cutaneous nerve (D) provides sensation to the lateral thigh as low as the knee. The iliohypogastric nerve (E) supplies the gluteal region.

**9. Answer A**

This patient has a SBO with evidence of ischemic or gangrenous bowel most likely secondary to adhesions from past surgery (e.g., sigmoidectomy). Necrotic bowel generally does not occur in association with a SBO unless there is a closed-loop obstruction. A closed-loop obstruction is a particularly dangerous form of bowel obstruction in which a segment of intestine is obstructed both proximally and distally. Gas and fluid accumulate within this segment of bowel, and cannot escape. This progresses rapidly to strangulation with risk of ischemia, gangrene, and subsequent perforation. Clues to ischemic bowel include the presence of acidosis, fever, leukocytosis, and severe localized pain (unusual for SBO). As such the patient will need exploratory laparotomy, and any bowel that is obviously nonviable needs to be resected. Most patients with SBO (without necrotic bowel) due to adhesions improve with conservative management, and do not require surgery. Observation is not appropriate for this patient (B). Upper GI studies (C–D) would not be indicated since this patient has strong evidence of necrotic bowel and requires urgent surgical intervention. RUQ ultrasound (E) is appropriate in the workup for cholelithiasis.

## Breast Cancer

### Areg Grigorian and Christian de Virgilio

#### Questions

1. A 30-year-old female presents with bloody discharge from her left breast that she has noticed intermittently for the past month. She denies any palpable breast mass, weight loss, fevers, or night sweats. She has no medical history or family history of breast cancer. The skin around the breast and areola are normal with no rashes or lesions. No breast mass is palpable, and there is no axillary lymphadenopathy. Ultrasound did not reveal any masses. What is the most likely diagnosis?
  - (A) Fibrocystic changes
  - (B) Intraductal papilloma
  - (C) Ductal carcinoma in situ (DCIS)
  - (D) Paget's disease of the breast
  - (E) Infiltrating ductal carcinoma
2. A 61-year-old female presents with swelling and redness of her entire left breast that has persisted for 4 weeks. On physical exam her temperature is 98.7 °F, pulse is 82/min, blood pressure is 136/78 mmHg, and respirations are 16/min. Her left breast appears larger than her right one. The entire breast is warm, and the skin is edematous. No breast masses are palpable. There is no nipple discharge or rashes. There are several palpable enlarged lymph nodes in her left axilla. Ultrasound and mammography show thickening of the skin but otherwise no masses. Which of the following is the best option for further management?
  - (A) Punch biopsy of skin
  - (B) Oral antibiotics
  - (C) Intravenous antibiotics
  - (D) Nonsteroidal anti-inflammatory drugs
  - (E) Incision and drainage
3. A 36-year-old woman is evaluated for a lump in her right breast that she noticed 5 months ago. She denies any nipple discharge, nipple retraction, or skin changes. She has no family history of breast cancer. On physical exam, the breasts appear normal. Palpation reveals a 1 cm dominant lump in the left upper quadrant that does not appear to be fixed to the surrounding structures. The patient has no other dominant masses in either breast. There is no axillary lymphadenopathy. Mammogram is negative. What is the next step in the management?
  - (A) Ultrasound-guided core needle biopsy
  - (B) Fine-needle aspiration
  - (C) MRI
  - (D) Follow-up clinical breast exam in 3 months
  - (E) Genetic testing
4. A 31-year-old breastfeeding female comes to the doctor for localized swelling, redness, and pain of the left breast. She also reports muscle aches and fatigue. On physical exam her temperature is 101.1 °F, pulse is 82/min, blood pressure is 126/68 mmHg, and respirations are 16/min. Physical exam reveals a localized area of erythema and warmth in the left breast with no palpable masses. There is no axillary lymphadenopathy. What is the most likely next course of action?
  - (A) Biopsy
  - (B) Antibiotic treatment and continue breast feeding
  - (C) Antibiotic treatment and encourage bottle-feeding only
  - (D) Diagnostic mammography
  - (E) Incision and drainage
5. A 17-year-old female presents with breast pain that she noticed for several months. She states that she feels multiple breast masses in both breasts. She denies any weight loss, fevers, or night sweats. She has no medical history or family history of breast cancer. Physical examination reveals that her heart has a regular rate and rhythm. The skin around the breast and areola are normal with no rashes or lesions. No solitary breast masses are palpable, but both breasts are lumpy and painful to palpation, most notably in the upper outer quadrants. There is no axillary lymphadenopathy. What is the most appropriate next step in management?
  - (A) Diagnostic mammography
  - (B) Excisional biopsy
  - (C) Ultrasound-guided core needle biopsy
  - (D) Reassurance and reexamine in 1 month
  - (E) Fine-needle aspiration (FNA)
6. A 71-year-old woman is evaluated for a lump in her right breast that she noticed 3 weeks ago. She denies any nipple discharge, nipple retraction, or skin changes. She has a sister who was diagnosed with breast cancer at the age of 57. She had menarche at the age of 9 and menopause at the age of 56. She had two children, one at the age of 39 and the other at the age of 41. On physical exam, the breasts are normal on inspection. Palpation reveals a 1.5 cm dominant lump that does not appear to be fixed to the surrounding structures in the left upper, outer quadrant. The patient has no other dominant masses in either breast. There is no axillary lymphadenopathy. What is the biggest risk factor in this patient predisposing her to breast cancer?
  - (A) Early menarche
  - (B) Family history of breast cancer



- (C) Older age  
(D) Age at first pregnancy  
(E) Late menopause
7. A 50-year-old woman comes to clinic to discuss treatment for a new diagnosis of breast cancer. Her annual screening mammogram revealed a 1.3 cm mass in the right breast. The patient does not have any other breast masses, skin changes, nipple discharge, or axillary adenopathy. Mammography revealed no other suspicious calcifications within the breast. Biopsy of the mass was performed and revealed infiltrating ductal carcinoma. Estrogen receptor, progesterone receptor, and Her2/neu receptor testing were negative. Which of the following is the best option for the management of this patient's breast cancer?
- (A) Lumpectomy and breast irradiation  
(B) Lumpectomy and hormone therapy  
(C) Lumpectomy and chemotherapy  
(D) Lumpectomy, sentinel node biopsy, and breast irradiation  
(E) Lumpectomy, sentinel node biopsy, breast irradiation, and chemotherapy
8. A 65-year-old woman returns to clinic for a 3-month follow-up. Three months ago she developed a pruritic, erythematous, ulcerated rash surrounding the areola of her right breast. She tried hydrocortisone 1 % on the lesion at the recommendation of her primary care physician, but the lesion persisted. She has no history of skin diseases in the family. She takes warfarin for atrial fibrillation. She started a new medication, hydrochlorothiazide, for hypertension about 3 months ago. Otherwise, she is healthy. What is the best next step in the management of this patient?
- (A) Punch biopsy of the skin lesion  
(B) Change hydrocortisone 1 % to triamcinolone to treat eczema  
(C) Treatment with antibiotics  
(D) Oral steroid course to treat psoriasis  
(E) Increase the dose of hydrocortisone
9. A 57-year-old woman comes to clinic to discuss surgical treatment for a new diagnosis of breast cancer. Her annual screening mammogram revealed a 1.7 cm mass in the right breast. Biopsy of the mass was performed and revealed infiltrating ductal carcinoma. Estrogen receptor and progesterone receptor testing were negative, while HER-2 receptor testing was positive. In addition to lumpectomy and breast irradiation, the treating doctor decides to add hormonal therapy with trastuzumab to the treating regimen. What study must be done prior to starting trastuzumab?
- (A) TSH and free T4  
(B) Liver function tests  
(C) Echocardiogram  
(D) Creatinine clearance  
(E) CXR
10. A 45-year-old female undergoes screening mammography which demonstrates an area of suspicious microscopic calcification in her right upper outer breast. Stereotactic-guided biopsy confirms ductal carcinoma in situ (DCIS). Which of the following is true about this condition?
- (A) It should be excised to a negative margin  
(B) It is considered a marker for malignancy in either breast  
(C) The cribriform type has a worse prognosis than the comedo type  
(D) It does not occur in men  
(E) Radiation therapy is an acceptable alternative to surgical excision

## Answers

### 1. Answer B

Although bloody nipple discharge should raise concern for cancer, intraductal papilloma is the most common cause of bloody nipple discharge. This is a benign breast tumor arising from the proliferation of mammary duct epithelium that classically occurs in females 20–40 years of age. Treatment includes excision, which is diagnostic as well as curative. Fibrocystic changes (A) are a common cause of breast pain in young females. Patients report painful breast tissue before menses with improvement during menstruation. Physical exam reveals fibrotic tissue and cystic, lumpy tissue. It may be associated with bilateral serous discharge. DCIS (C) and infiltrating ductal carcinoma (E) are more common in older women. DCIS most often presents as suspicious calcifications on mammography, and not with bloody nipple discharge. Although breast cancer can present with bloody nipple discharge, it is less common than intraductal papilloma, especially in a young woman. Paget's disease of the breast (D) causes an eczematous lesion on the breast that is associated with an underlying breast carcinoma. Given that this patient's skin exam is normal, this diagnosis is unlikely.

### 2. Answer A

The patient most likely has inflammatory breast carcinoma, an especially aggressive type of breast cancer. Inflammatory breast cancer can be easily confused with mastitis, as there is usually no palpable breast mass and ultrasound and mammography similarly are often negative. As such, it is imperative to perform a biopsy of the skin, which may show cancer cells invading the subdermal lymphatics. Additional workup should include a breast MRI (which is more likely to show the breast cancer in this setting than ultrasound and mammogram), as well as consideration for needle biopsy of the lymph nodes. Antibiotics (B–C) or NSAIDs (D) would be inappropriate. Incision and drainage (E) would be appropriate if there was an indication on physical examination or evidence of a breast abscess on ultrasound. Inflammatory breast carcinoma typically presents as swelling of the breast and with edematous skin due to obstruction of subdermal lymphatics by tumor (termed *peau d'orange*, meaning orange peel in French). At presentation, positive lymph node involvement is frequent, and approximately one-third of patients have distant metastases. Inflammatory breast carcinoma can present during pregnancy and should be suspected if suspected mastitis does not respond to appropriate antibiotic treatment.

### 3. Answer A

A diagnostic mammogram should be ordered in a woman over the age of 30 who presents with a new breast mass. Mammography helps to look for suspicious calcifications in other areas of the affected breast, characterize the mass, as

well as evaluate the contralateral breast. It is important to note that the mammogram may be normal despite the presence of a palpable breast cancer. For this reason, a tissue biopsy is recommended for palpable breast masses regardless of the mammogram results. Tissue sampling is best performed via ultrasound-guided core needle biopsy. Ultrasound also provides more information about the mass (cystic vs. solid). Fine-needle aspiration (B) is rarely used as it relies on cytology rather than histology. MRI (C) is not routinely needed. Follow-up examination in 3 months (D) without a biopsy would be inappropriate. Genetic testing (E) would be indicated if this patient had a strong family history of breast or ovarian cancer, but would not be done until tissue diagnosis of breast cancer is confirmed.

### 4. Answer B

The patient most likely has lactation mastitis. Lactation mastitis is a localized, painful inflammation of the breast accompanied by fever and malaise occurring in breastfeeding women. The diagnosis of mastitis is made clinically based on an erythematous, tender, swollen area of one breast associated with fever in a nursing mother. Other symptoms may include muscle pain (myalgias) and malaise. Transmission occurs via introduction of bacteria in small breaks in the skin caused by the trauma of breastfeeding. Most cases of lactation mastitis are a result of an infection by *Staphylococcus aureus*. Treatment consists of antibiotics to cover skin flora, symptomatic relief with analgesics including anti-inflammatory agents such as ibuprofen, and cold compresses to reduce local pain and swelling. Patients should be encouraged to continue breastfeeding (C) as this helps relieve any ductal obstruction that might be contributing to the infection. Biopsy (A) would be appropriate if the patient has suspected inflammatory breast carcinoma. Although very rare, inflammatory breast carcinoma can occur during pregnancy. If mastitis fails to resolve after antibiotics, then consideration should be given to performing a biopsy of the skin. Diagnostic mammography (D) would not be indicated at this time. Incision and drainage (E) is appropriate if there was evidence of a localized abscess with fluctuance. Ultrasound can help differentiate mastitis from a breast abscess.

### 5. Answer D

The history and physical exam is most consistent with a diagnosis of fibrocystic changes of the breast, which is considered a normal variant of the breast in adolescents and young adults. Patients will present with painful breast tissue before menses that improves during menstruation. On examination, fibrotic tissue may be palpated and is generally found in the upper outer quadrants of the breast. This patient should be counseled and instructed to look for these changes with a follow-up appointment in a month. Persistent cystic breast lesions can be evaluated and treated with fine-needle

aspiration (E), although this is not needed in children and adolescents. Cystic lesions that resolve with aspiration should be reevaluated with ultrasonography 3 months after aspiration (C). Excisional biopsy (B) may be warranted for cystic lesions that do not resolve with aspiration or for suspicious solid lesions. Diagnostic mammography (A) is not indicated for adolescents and should be reserved for females >30 years old who present with a breast mass.

#### 6. Answer C

The most important risk factors for breast cancer are female gender, increasing age, and a family history of premenopausal breast cancer. A new breast mass in a woman over the age of 50 should be considered cancer until proven otherwise, as it carries the highest relative risk of being cancer. A family history of breast cancer (B) can also significantly increase the risk of breast cancer, particularly if diagnosed in a premenopausal woman. The majority of inherited breast cancers are associated with BRCA1 or BRCA2 gene mutations. Other important risk factors associated with a slightly higher risk of developing breast cancer include early menarche (A), nulliparity or older age at first full-term pregnancy (D), and/or late menopause (E).

#### 7. Answer E

This patient is diagnosed with infiltrating ductal carcinoma. Treatment for stage I and II breast cancers includes the option of breast conserving therapy (BCT), which consists of excision of the primary tumor (lumpectomy), sentinel lymph node biopsy (SLNB), followed by radiation therapy to the remaining breast. Studies have shown that breast conserving therapy leads to survival rates that are equivalent to that of mastectomy (though a higher local recurrence rate), while providing a more aesthetically pleasing surgical result. Triple negative breast cancers (ER, PR and Her2/neu receptor) are thought to have a worse prognosis as it is insensitive to some of the best therapies (tamoxifen and aromatase inhibitors for hormone positive, and trastuzumab for Her2/neu positive). As such, chemotherapy is recommended postoperatively.

#### 8. Answer A

The presentation is concerning for Paget's disease of the breast. This presents as an eczematous, scaling, and ulcerating

lesion around the areola. Paget's disease of the breast is a type of DCIS that extends into the ducts to involve the skin of the nipple. Patients are initially misdiagnosed with a skin condition, including eczema and psoriasis, and receive a variety of ointments that do not resolve the lesion. Paget's disease of the breast is almost always associated with an underlying carcinoma and must be diagnosed via biopsy of the lesion. Trying different regimens of steroids and antibiotics is inappropriate given the high likelihood that she has cancer (B–E).

#### 9. Answer C

Trastuzumab is a monoclonal antibody that blocks the HER-2 receptors. The medication is used in the treatment of HER-2-positive breast cancers to help reduce recurrence and improves survival. Since there is a high risk of cardiomyopathy in patients receiving trastuzumab, it is recommended that all patients receive an echocardiogram prior to initiating therapy with trastuzumab. An alternative is to obtain a MUGA scan (multigated acquisition scan), which is a nuclear study that evaluates ventricular function. Trastuzumab-related cardiotoxicity is most often manifested by an asymptomatic decrease in ejection fraction. The optimal surveillance for trastuzumab-related cardiotoxicity is not well defined. The remaining answer choices are not needed prior to starting trastuzumab (A–B, D–E).

#### 10. Answer A

DCIS is characterized by malignant epithelial cells within the mammary ductal system, without invasion into the surrounding stroma. Comedo-type DCIS is typically high grade and associated with a worse prognosis (C). DCIS lesions have a high risk of subsequent invasive carcinoma at the site of the DCIS. As such if left unresected, it will often progress to invasive ductal cancer. Thus the mainstay of DCIS treatment is lumpectomy (excision of entire lesion with negative margins). Lobular carcinoma in situ is considered a marker for malignancy in either breast (B). Breast cancer in males is rare (1 % of all breast cancers) with most cases identified as invasive ductal carcinoma. DCIS can occur in men but is even more rare, as DCIS most often presents as abnormal calcifications on mammogram (D). Radiation therapy can be used in combination with surgical excision, but cannot replace it (E).

## Cardiothoracic

Areg Grigorian, Paul N. Frank, and Christian de Virgilio

### Questions

- A 65-year-old male presents with a painful nodule in his wrist that is determined to be a ganglion cyst. Despite attempts at aspiration, it recurs. He is unable to work as a computer programmer, is on disability, and is feeling depressed. He is scheduled for wrist surgery. He reports having been discharged 1 week ago for an episode of chest pain. Troponins were elevated at that time, but there was no elevation of his ST segment. Which of the following is the best recommendation?

  - Proceed with surgery with intraoperative transesophageal echocardiography
  - Proceed with surgery but perform under local anesthesia with sedation
  - Proceed with surgery only if echocardiogram shows normal ejection fraction
  - Proceed with surgery after aggressive beta blockade to get heart rate into low 60s
  - Postpone surgery for at least 4 weeks
- A 65-year-old male is about to undergo an elective inguinal hernia repair. Which of the following findings on history or physical would portend the highest operative risk?

  - Systolic, crescendo-decrescendo murmur at the sternal border of the right second intercostal space radiating into neck
  - A history of myocardial infarction 10 years ago
  - Insulin-dependent diabetes mellitus with an elevated HgbA1C
  - Renal insufficiency not yet on dialysis
  - Smoking
- A 65-year-old male undergoes a videoscopic right upper lobectomy for squamous cell lung cancer. On postoperative day one, he suddenly develops chest pain and diaphoresis. Blood pressure is 120/60 mmHg, and heart rate is 80/min. Serial highly sensitive troponin I assays demonstrate levels of 0.4, 0.3, and 0.01 ng/dl. ECG demonstrates nonspecific T wave changes with no ST segment elevation. Following the administration of oxygen, morphine, aspirin, and a beta-blocker, his symptoms resolve. What is the next step in the management?

  - Intravenous thrombolytic therapy
  - Percutaneous coronary intervention without stenting
  - Percutaneous coronary intervention with stenting
  - Coronary artery bypass graft (CABG)
  - Continue medical management and reevaluate as outpatient in 4–6 weeks
- A 17-year-old African American male presents for a pre-participation physical before track season. A harsh systolic murmur is heard at the second right intercostal space. He denies ever experiencing chest pain, dizziness, or difficulty breathing. Which of the following would be expected on further workup?

  - T wave inversion on ECG
  - Laterally displaced PMI on palpation
  - Weak femoral pulses compared to brachial pulses
  - Increased intensity of the murmur with Valsalva maneuver
  - Increased intensity of the murmur with squatting
- A 65-year-old woman arrives to the ED complaining of chest pain. Her past medical history includes hypertension, atherosclerosis, and coronary artery disease. She underwent a coronary artery bypass graft (CABG) 3 weeks ago for three-vessel disease. She reports that her chest pain worsens with inspiration and lessens when leaning forward. A friction rub is heard on auscultation. ECG shows global ST elevation. What is the most likely diagnosis?

  - Myocarditis
  - Myocardial infarction
  - Cardiac tamponade
  - Acute pericarditis
  - Pulmonary embolism
- An obese 52-year-old man with a 50-pack-year smoking history and hypertension controlled with chlorthalidone presents to a remote hospital without interventional capabilities with 30 min of crushing chest pain radiating to his left arm and jaw. Troponin and CK-MB levels are elevated, and ECG shows ST segment elevations in leads V1 through V4. He is treated with thrombolytic therapy, and his symptoms resolve. The next morning, the patient is found dead in his bed. Which of the following is the most likely cause of death?

  - Ventricular free wall rupture
  - Embolic stroke
  - Ventricular arrhythmia
  - Post-MI pericarditis
  - Overwhelming infection
- A 65-year-old female has breast cancer and a remote history of congestive heart failure. Her physician is planning to administer a chemotherapeutic agent that has potential for cardiac toxicity. Which of the following is the most accurate test to measure ejection fraction?

  - Multi Gated Acquisition Scan (MUGA) scan
  - Echocardiography
  - Electrocardiogram
  - Coronary angiography
  - Exercise stress test

8. A 76-year-old man is driven to the ED by his wife and is complaining of severe chest pain that started 30 min ago. He denies abdominal or extremity pain. Pulses in arms and legs are 2+. His kidney function is normal. CT scan shows an aortic dissection. Which of the following findings on CT scan would most strongly indicate the need for urgent surgery?
- (A) Dissection of entire descending thoracic aorta
  - (B) Involvement of common iliac arteries
  - (C) Involvement of renal arteries
  - (D) Extension into mesenteric vessels
  - (E) Involvement of origin of innominate artery
9. A 65-year-old female is diagnosed with aortic dissection beginning 2 cm distal to the left subclavian artery and extending distally. Her blood pressure is 180/70 mmHg, and her heart rate is 88/min. Peripheral pulses are all 2+, and her abdomen is soft and non-tender. What is the next best step in treatment?
- (A) Surgical repair
  - (B) Aggressive IV fluids
  - (C) Labetalol drip
  - (D) Endovascular repair
  - (E) Nicardipine drip
10. A 65-year-old man is rushed to the ED by ambulance after he suddenly lost strength and sensation in his left leg and arm. He was hospitalized 2 months ago with a NSTEMI. He is compliant with all of his medications and had been recovering well until the present episode. ECG shows normal sinus rhythm without evidence of ischemia. Chest X-ray is unremarkable. Carotid ultrasounds show <30 % stenosis bilaterally. What is the most likely etiology of the patient's present symptoms?
- (A) Ventricular thromboembolism
  - (B) Septic embolism to the brain
  - (C) Type A dissection involving the right carotid artery
  - (D) Thromboembolism from the left atrial appendage
  - (E) Paradoxical venous thromboembolism
11. A 66-year-old man is recovering in the ICU after receiving a CABG for coronary artery disease. On the fourth postoperative day, he complains of chest pain. He is sweating, anxious, short of breath, and nauseated. ECG shows evidence of right-sided MI. His blood pressure is 98/65 mmHg. What is the next best step in management?
- (A) Administer 1 L of normal saline
  - (B) Nitroglycerin
  - (C) Nitroprusside
  - (D) Nifedipine
  - (E) Lisinopril
12. A 63-year-old woman with diabetes is recovering in the ICU after receiving a CABG for coronary artery disease. On the sixth postoperative day, she starts complaining of chest pain. Her temperature is 101.4 °F, blood pressure is 108/72 mmHg, and pulse is 125/min. On physical exam, there is drainage from her sternal wound, and there is a crunching sound heard with a stethoscope over the precordium during systole. The sternum feels somewhat unstable to palpation. Her laboratory examination is significant for an elevated white blood count ( $16.7 \times 10^3/\mu\text{L}$ ). What is the most likely diagnosis?
- (A) Acute pericarditis
  - (B) Postoperative MI
  - (C) Empyema
  - (D) Acute mediastinitis
  - (E) Pneumonia
13. A 75-year-old male with severe aortic stenosis has a routine check-up at his primary care doctor. Which of the following symptoms portends the worst prognosis?
- (A) Exertional chest pain
  - (B) Swollen legs
  - (C) Fainting spells
  - (D) Mid-systolic murmur heard loudest at the upper right sternal border
  - (E) Small head nodding movements at each heartbeat
14. Which of the following is the most important risk factor for aortic dissection?
- (A) History of coronary artery bypass grafting (CABG)
  - (B) Giant cell arteritis
  - (C) Pregnancy
  - (D) Hypertension
  - (E) Bicuspid aortic valve
15. A patient is diagnosed with type A aortic dissection, and there is concern for cardiac tamponade. Which of the following findings would be the MOST consistent with cardiac tamponade?
- (A) Pulsus bisferiens
  - (B) Watson's water hammer pulse
  - (C) Peaked T waves
  - (D) Equalization of central pressures
  - (E) Pulsus alternans
16. A 67-year-old male is diagnosed with a type B aortic dissection. At the time of initial presentation on the previous day, his blood pressure was 178/110 mmHg. He was treated with intravenous beta-blocker, and his blood pressure was reduced to 112/60 mmHg and has remained in that range. However, one day later, he suddenly develops severe abdominal pain. His blood

pressure is measured to be 110/56 mmHg. Which of the following is the most likely explanation?

- (A) *C. difficile* infection
- (B) Occlusion of the superior mesenteric artery
- (C) Pancreatitis
- (D) Aortoenteric fistula
- (E) Diverticulitis

17. A 40-year-old male presents with acute chest pain and nausea. Serum troponin levels are elevated, and the ECG

demonstrates ST segment elevation. Which of the following would be the strongest contraindication to intravenous thrombolytic therapy?

- (A) Right knee arthroscopic surgery 1 month ago
- (B) Recently completed antibiotic course for *H. pylori* infection
- (C) Wide mediastinum on CXR
- (D) History of alcohol abuse
- (E) Endovascular aortic aneurysm repair 1 month ago

## Answers

### 1. Answer E

Proceeding with elective surgery 1 week after an acute MI is inappropriate (A–D). Patients with a recent MI are at significantly increased cardiac risk during noncardiac surgery, particularly within the first month after MI. Since the proposed operation is elective, options A–D would place the patient under unnecessary risk. Although performing the operation under local anesthesia with sedation (B) seems appealing, there is still considerable stress and cardiac risk with such an approach. The best recommendation for this patient is to postpone surgery for at least 4 weeks. At that point, consideration should still be given to cardiac stress testing prior to surgery or even further surgical delay, as the cardiac risk persists for at least 6 months after an MI.

### 2. Answer A

Major predictors of adverse postoperative cardiac events must be identified prior to elective noncardiac surgery. These include recent (within 1 month) MI, unstable or severe angina, decompensated CHF, and significant arrhythmias. Such cardiac conditions require postponing surgery and performing further cardiac workup. A systolic, crescendo-decrescendo murmur at the sternal border of the right second intercostal space radiating into the neck is highly suggestive of aortic stenosis and would require an echocardiogram to rule out severe aortic stenosis. Aortic stenosis impairs coronary perfusion, which can become further exacerbated during induction of anesthesia. From all the choices listed, it portends the highest operative risk. Lee's revised cardiac risk index identifies intermediate risk factors; these include known coronary artery disease (B) history of CHF, history of stroke or TIA, insulin-dependent diabetes (C), creatinine >2.0 mg/dl (possibly D), and high-risk surgery (i.e., aortic). Adding a point for each factor and assigning a score (from 0 to 6) are highly effective in stratifying cardiac risk. Interestingly, smoking (E) has not been shown to be an independent risk factor for adverse perioperative cardiac events in most studies.

### 3. Answer E

The patient has suffered a postoperative NSTEMI. Most NSTEMI (as opposed to a STEMI) in the postoperative setting are managed without percutaneous coronary intervention (PCI) with a combination of oxygen, morphine for pain relief, aspirin, and a beta-blocker. Optimally, an additional antiplatelet agent (such as clopidogrel) and intravenous heparin are also given, but this depends on how recent the operation was and the potential for postoperative bleeding. Consideration should be given to stress testing at 4–6 weeks after surgery, and depending on the results, PCI is then considered. Urgent PCI (B,C) is indicated in the setting of a STEMI, and in certain high-risk NSTEMIs (continued rise in

troponins, ongoing chest pain), but will require clopidogrel (again may not be desirable so soon after surgery) if a stent is placed. The patient described has a down trend of troponins and relief of symptoms, further supporting medical management. Emergent CABG (D) would be considered if PCI fails or is not technically feasible with severe three-vessel disease. Emergent operations for acute MI continue to have a high mortality despite many technological advances in myocardial protection. Thrombolytic therapy (A) is an alternative when PCI is not available but would be contraindicated within 2–3 weeks of major surgery.

### 4. Answer D

The patient likely has hypertrophic obstructive cardiomyopathy, an asymmetric thickening of the ventricular septum that creates a narrowing of the left ventricular outflow tract. Vigorous exercise places him at increased risk of sudden cardiac death. T wave inversion (A) would be found in ischemic heart disease, very unlikely in an otherwise healthy 17-year-old. Laterally displaced PMI (B) would be found in patients with congestive heart failure, also very unlikely in this patient. Weak femoral pulses compared to brachial pulses (C) is a finding in coarctation of the aorta, and would not create the characteristic murmur. Murmurs due to aortic regurgitation, mitral regurgitation, and ventricular septal defect (VSD) increase in intensity with squatting (E).

### 5. Answer D

Acute pericarditis is inflammation in the pericardial sac accompanied by pericardial effusion. It can occur following post-MI (termed Dressler's syndrome), chest radiation, or recent heart surgery. Patients present with pleuritic chest pain that lessens when leaning forward, friction rub heard on auscultation, global ST elevation, and PR depression. Patients with myocarditis (A) usually present with signs and symptoms of acute decompensating heart failure (e.g., tachycardia, gallop, mitral regurgitation, and edema). Chest pain accompanied with MI (C) would not be expected to lessen with leaning forward. Furthermore, *global* ST elevation would not be expected. Cardiac tamponade (C) can occur once the effusion reaches a critical mass in which cardiac output is compromised. Pulmonary embolism (E) can present with pleuritic chest pain, but it will not be influenced by positioning and is more likely to have ECG findings suggestive of right heart failure.

### 6. Answer C

It is important to know the timing of causes of death after MI. In the first 48 h after MI, death is likely due to ventricular arrhythmia. If arrhythmia occurs after 48 h, an implantable defibrillator should be placed. Ruptures of the myocardium, either as a ventricular septal rupture or free wall rupture (A), usually do not occur until 4–5 days after MI,

at which point the dead myocardium has been weakened by the body's inflammatory response. Post-MI pericarditis, also known as Dressler's syndrome, (D) usually occurs weeks or months after MI or cardiac surgery. An embolic stroke (B) would present with sudden onset of numbness on one side of the body, cranial nerve deficits, and/or aphasia. It is unlikely to cause death so quickly. There is no reason to believe the patient has sustained an overwhelming infection (E).

### 7. Answer A

The MUGA scan is the most accurate test in measuring ejection fraction. It is a noninvasive nuclear test that uses a radioactive isotope called technetium to evaluate the function of the ventricles. Though not as accurate, an echocardiogram (B) is used more commonly because it is cheaper and more readily available and can look for valve function as well as focal areas of wall motion abnormality. Electrocardiogram (C) and exercise stress test are unable to measure a patient's ejection fraction. Coronary angiography (D) is considered the gold standard in identifying coronary artery disease and can estimate ejection fraction, but is not as accurate.

### 8. Answer E

It is important to rapidly identify Stanford type A dissections, as they require urgent surgical intervention due to the fact that they can lead to cardiac tamponade, acute aortic valve insufficiency, acute MI, and stroke. A Stanford A dissection involves the ascending aorta and/or the aortic arch. Thus an aortic dissection involving the innominate artery is a Stanford type A. Stanford type B aortic dissection is more common. A Stanford type B dissection begins in the descending aorta, distal to the takeoff of the left subclavian artery (A–D). Stanford Type B dissections are much less likely to cause acute complications since the ascending aorta/aortic arch are not involved. A type B dissection may involve the mesenteric, renal, or iliac arteries, but not occlude them, as blood may continue to flow normally (either through the true or the false lumen). Most can be managed medically with blood pressure control (beta-blockers). Surgical intervention is needed if the involvement of these vessels leads to malperfusion (such as leg ischemia, bowel ischemia, or renal failure).

### 9. Answer C

Based on the description of the site of the dissection, this is a type B aortic dissection. These are usually managed medically (A) unless the patient has evidence of malperfusion. Since her peripheral pulses are all 2+ and her abdomen is soft and non-tender, there is no evidence of malperfusion. The goal is to maintain a relatively low blood pressure in order to minimize stress on the aorta. Aggressive IV fluids (B) will not reduce blood pressure and may actually raise it.

Nicardipine (E) will lower blood pressure, but intravenous beta-blocker is the treatment of choice because it also reduces the rate of pressure increase with each beat of the heart, which lowers the stress on the aortic wall. Endovascular therapy (D) is not routinely needed for most type B dissections.

### 10. Answer A

Patients with a recent history of myocardial infarction are at risk of thrombus formation on the scarred endocardium, which can then embolize to the brain and cause a stroke. Patients with a recent history of MI and evidence of thrombus on echocardiography should be treated with warfarin to maintain an INR of 2–3 and followed up within 3 months. Thromboembolism from the left atrial appendage (D) is a concern in patients with atrial fibrillation. Paradoxical venous thromboembolism (E) is a concern in patients with an atrial septal defect or patent foramen ovale, wherein a deep venous thrombus can travel through the defect into the left heart and ultimately to the brain. Septic embolism (B) is a concern in IV drug abusers and can lead to cerebral abscess. Type A dissection (C) would usually present with severe chest pain radiating to the back.

### 11. Answer A

This patient has a postoperative right-sided MI, resulting in compromised cardiac output secondary to decreased preload. One of the steps in management of right-sided MI is to administer fluids to help increase filling of the heart. Avoid nitrates (B, C) in these patients as it may further reduce preload. Acutely, patients with MI need oxygen, aspirin, analgesics, and beta-blockers. Dihydropyridine calcium channel blockers, such as nifedipine (D), are contraindicated in MI because of the associated peripheral vasodilation that may lead to reactive tachycardia and subsequently result in even more stress on the heart. ACE inhibitors (E) should be considered for long-term treatment after the acute episode has resolved.

### 12. Answer D

This patient's presentation is most concerning for acute mediastinitis. This is a life-threatening infection of the mediastinum with a very high mortality rate that is most commonly associated with cardiac surgery. The incidence rate is 1–2 % following CABG. The source of infection may be a sternal wound infection, combined with instability of the sternum that permits bacteria to enter the mediastinum. Hamman's sign is a crunching sound heard with a stethoscope over the precordium during systole and is suggestive of acute mediastinitis. Patients will frequently present with chest pain, increased drainage from sternal wound, fevers, and leukocytosis. Chest radiograph findings include pneumomediastinum and/or air-fluid levels within the mediastinum. A CT scan can also support the diagnosis by demonstrating dehiscence of the



sternum and stranding, fluid and air pockets within the anterior mediastinum. Management includes surgical debridement, drainage, antibiotics, and rewiring the sternum. Acute pericarditis (A) will present with pleuritic chest pain that lessens when leaning forward, friction rub heard on auscultation, and characteristic ECG findings (global ST elevation). Pneumonia (E) would present with shortness of breath, productive cough, and abnormal lung sounds. Postoperative MI (B) would not be expected to present with evidence of systemic inflammation. Empyema (C) is defined as pus in the pleural space, and would not explain the physical exam findings of sternal instability and Hamman's sign. CT scan would demonstrate a loculated fluid collection within the right or left pleural cavity.

### 13. Answer B

The classic signs of severe aortic stenosis are angina (A), syncope (C), and congestive heart failure (which may manifest as swollen legs). Of the three, congestive heart failure portends the worst prognosis, with median survival as low as 2 years. A loud mid-systolic murmur (D) indicates hemodynamically significant obstruction but is a better prognostic sign than an absent murmur, which indicates low blood flow across the valve. Small head nodding movements with each heartbeat (E) are known as de Musset's sign and is found in aortic regurgitation.

### 14. Answer D

All of the above are risk factors for aortic dissection (A–C, E). However, the most significant risk factor for aortic dissection is systemic hypertension.

### 15. Answer D

In cardiac tamponade, fluid (blood or effusion) in the pericardial space externally compresses the heart, which limits diastolic filling and reduces stroke volume. Since pericardial fluid is free flowing, the pressure is distributed equally along the pericardium. As this continues the rising pressure in the pericardium is transmitted to all four cardiac chambers resulting in equalization of central pressures. Pulsus bisferiens (A), also known as a biphasic pulse, refers to two strong systolic pulses with a mid-systolic dip, in other words, two pulses during systole. It can be seen in aortic regurgitation with or

without aortic stenosis and hypertrophic cardiomyopathy. Watson's water hammer pulse (B) is a pulse with a rapid upstroke and descent seen in patients with aortic regurgitation. Peaked T waves (C) is most often associated with hyperkalemia. It is unlikely to be seen in patients with cardiac tamponade since their ECG findings are characteristically low voltage. Pulsus alternans (E) is a physical exam finding wherein the amplitude of a peripheral pulse changes from beat to beat associated with changing systolic blood pressure. It is most commonly caused by left ventricular failure.

### 16. Answer B

Sudden onset of severe abdominal pain in association with an aortic dissection should always raise suspicion for malperfusion of the bowel which can lead to bowel gangrene and death. This most likely would occur if the dissection extends into, and suddenly occludes, the superior mesenteric artery, which supplies blood to the bowel from the ligament of Treitz to the mid-transverse colon. It is also important to recognize that bowel ischemia early on causes excruciating pain in the absence of peritonitis ("pain out of proportion to physical exam"). He has not been on broad-spectrum antibiotics, and has no reason to have *C. difficile* infection (A), which most often presents with vague abdominal pain and diarrhea. Pancreatitis (C) presents with epigastric pain radiating to the back, nausea, vomiting, anorexia, fever, and tachycardia and is most commonly associated with cholelithiasis and alcohol abuse. Aortoenteric fistula (D) is a possible long-term sequela in patients who have had an intra-aortic synthetic graft placed. Diverticulitis (E) is a common cause of left lower quadrant abdominal pain in elderly patients, and does not typically cause such sudden severe pain.

### 17. Answer C

Wide mediastinum on chest X-ray is concerning for aortic dissection. Patients with type A aortic dissection can present with coronary artery malperfusion and thus have a similar presentation as an acute MI. Suspected aortic dissection is considered an absolute contraindication to thrombolysis in patients with myocardial infarction. The remaining choices (A–B, D–E) are all relative contraindications for intravenous thrombolytics.

## Endocrine

**Areg Grigorian, Masha J. Livhitz, Christopher M. Reid, Michael W. Yeh, and Christian de Virgilio**

### Questions

- A 27-year-old woman has 3 months of intermittent spells of severe headache, heart palpitations, and sweating. A pregnancy test at her primary care doctor's office is positive. Further workup reveals that her plasma metanephrine level is 220 pg/ml (normal 12–60 pg/ml). What is the next step in establishing the diagnosis?

  - CT abdomen
  - Repeat plasma metanephrine level after the patient has delivered
  - MRI abdomen
  - $I^{131}$ -MIBG scan
  - Reassure patient that symptoms are related to pregnancy
- Preoperative medical optimization for a patient with a pheochromocytoma routinely includes:

  - Octreotide drip for 24 h before surgery
  - Control of hypertension with beta-blockade as first-line agent
  - Control of hypertension with alpha-blockade as first-line agent
  - Metyrosine
  - Diuretics for blood pressure management
- A 55-year-old otherwise healthy patient undergoes a non-contrast CT abdomen to evaluate for possible kidney stones and is incidentally noted to have a 8 cm mass in the left adrenal gland. The mass has irregular borders and high attenuation, suggesting a lipid-poor lesion, and appears to be adherent to the kidney. How should this patient be managed?

  - Observation with repeat CT scan in 3 months
  - Open adrenalectomy
  - Laparoscopic adrenalectomy
  - Radiation therapy
  - Percutaneous biopsy
- A 50-year-old female has been recently diagnosed with primary hyperparathyroidism. She comes in to her doctor complaining of increased bone pain in her legs. She is found to have elevated serum calcium, alkaline phosphate, and PTH. Her doctor decides to order plain films of her lower extremities. The radiographs show very thin bones with a stress fracture and bowing of both femur bones. She also has characteristic cysts with a moth-eaten appearance. What is the most likely diagnosis?

  - Osteoporosis
  - Osteopetrosis
  - Osteomalacia
  - Osteitis fibrosa cystica
  - Paget's disease of the bone
- A 60-year-old man is found to have a 3 cm right adrenal mass on CT scan which was obtained a month earlier following a MVC. He is asymptomatic, and does not report a history of hypertension or diabetes. What is the most appropriate next step in management?

  - Repeat CT scan in 6 months
  - Percutaneous needle biopsy
  - Biochemical workup for hormone excess
  - Laparoscopic adrenalectomy
  - No further follow-up is necessary
- An elderly nursing home patient has been bedridden for several months due to a series of debilitating strokes. Past medical history is significant for hypertension, controlled with a diuretic, and Paget's disease. Recently, the patient has been complaining of vague abdominal pain, constipation, and depressed mood. On physical examination, the patient is alert and oriented. Abdominal examination is unremarkable. Which of the following electrolyte abnormalities would most likely explain her symptoms?

  - Hyponatremia
  - Hypernatremia
  - Hyperphosphatemia
  - Hypocalcemia
  - Hypercalcemia
- Which of the following is most consistent with an aldosterone-secreting adrenal adenoma?

  - Hyperglycemia, hirsutism, and abdominal striae
  - Hypertension and hyperkalemia
  - Hypertension and hypokalemia
  - Elevated plasma metanephrine and hypertension
  - Increased vanillylmandelic acid excretion and hypertension
- A 35-year-old patient presents for a follow-up visit for an elevated serum calcium level of 12.8 mg/dL and an elevated PTH. He is a thin man without a significant past medical history. He reports that for the past 2 weeks he has been experiencing loose stools, polydipsia, and polyuria. On physical exam he was found to have large erythematous erosions with blisters over the lower abdomen. Which tumor would best explain the patient's symptoms and rash?

  - Insulinoma
  - Prolactinoma
  - VIPoma
  - Glucagonoma
  - Adrenal adenoma

9. A 32-year-old female patient arrives for follow-up for new-onset hypertension. She was started on hydrochlorothiazide 6 months ago. During her visit, she was found to have a blood pressure of 152/98 mmHg. She also complains of recent episodes where she experiences sudden palpitations, chest pain, diaphoresis, headache, and anxiety. Her laboratory exam demonstrates a calcium of 13.2 mg/dl (normal 8.5–10.2 mg/dl), PTH of 102 pg/ml (10–55 pg/ml), and an elevated plasma metanephrine. Which of the following would be an important additional component in the workup?
- (A) Fasting blood glucose  
(B) Prolactin level  
(C) MRI of the sella turcica  
(D) Serum calcitonin  
(E) Serum gastrin level
10. A 45-year-old man has had hazy vision for the past month, particularly when he is driving at night. He also endorses small rubberlike nodules on the skin of his trunk, back, arms, and legs that are not painful and do not itch. After seeing his ophthalmologist, he is diagnosed with bilateral cataracts and is scheduled to receive elective cataract surgery. During induction of anesthesia, following intubation, the patient's pressure increases from 110/70 to 200/90 mmHg. PaCO<sub>2</sub> is normal as is his pH. His temperature is 101.5 °F. An esmolol drip is immediately instituted, after which BP increases to 220/90 mmHg and an ECG shows T wave inversion. What is the most likely underlying etiology?
- (A) Intra-abdominal tumor  
(B) Malignant hyperthermia  
(C) Thyrotoxicosis  
(D) Inadequate anesthetic agent  
(E) Undiagnosed pituitary tumor
11. A 12-year-old boy presents to the doctor for a lump in his neck. He is healthy with no previous medical problems. On physical examination, he has a well-defined anterior neck mass, located in the midline and above the cricoid cartilage. The mother states that she has noted the lesion since he was about 2 years old. It does not bother him. On physical examination, the mass elevates with swallowing and is non-tender. He has no cervical adenopathy and no other complaints. The neck mass is described as a hypoechoic mass on ultrasonography. A subsequent thyroid scintigram is performed and confirms the thyroid gland is in its correct anatomic position. Which of the following would be recommended next for this mass?
- (A) FNA biopsy  
(B) Proceed to surgical excision  
(C) Reassurance and observation  
(D) TSH and free T4  
(E) CT scan
12. In addition to elevated plasma free metanephrine, a change in what other serum marker can help support the diagnosis of pheochromocytoma?
- (A) Plasma chromogranin A  
(B) Plasma superoxide dismutase  
(C) Malondialdehyde  
(D) CA 19–9  
(E) 5-Hydroxyindoleacetic acid (HIAA)
13. A 42-year-old man with a family history of endocrine tumors is diagnosed with MEN-2A after presenting with uncontrolled hypertension and subsequent genetic workup. He was found to have a right adrenal pheochromocytoma and asymptomatic hyperparathyroidism. What is the recommended surgical management for this patient?
- (A) Parathyroid surgery first, followed by adrenalectomy  
(B) Adrenalectomy first, followed by parathyroid surgery  
(C) Medical conditioning for 2 weeks prior to adrenalectomy, followed by parathyroid surgery  
(D) Medical conditioning for 2 weeks prior to simultaneous parathyroid surgery and adrenalectomy  
(E) Medical conditioning for 2 weeks followed by adrenalectomy only
14. A 39-year-old man is recovering from bilateral adrenalectomy for a pheochromocytoma. On his second postoperative day, he begins to complain of nausea, vomiting, weakness, blurry vision, and mild abdominal pain. His temperature is 102.9 °F, and blood pressure is 90/68 mmHg. His ECG shows sinus tachycardia. His laboratory examination from that morning showed:
- Sodium: 134 mEq/L (137–145 mEq/L)  
Potassium: 5.8 mEq/L (3.6–5.0 mEq/L)  
Calcium: 7.4 mg/dL (8.9–10.4 mg/dL)  
BUN: 12 mg/dL (7–21 mg/dL)  
Creatinine: 1.2 mg/dL (0.5–1.4 mg/dL)  
Glucose: 70 mg/dL (65–110 mg/dL)  
Albumin: 2.4 g/dL (3.5–4.8 g/dL)  
WBC 10.5 × 10<sup>3</sup>/μL (4.1–10.9 × 10<sup>3</sup>/μL)
- Which of the following can best explain this patient's current presentation?

- (A) Volume depletion  
(B) Sepsis  
(C) Hypocalcemia  
(D) Low cortisol  
(E) Loss of catecholamine production
15. A 56-year-old woman is recovering after undergoing total thyroidectomy for papillary carcinoma. Her temperature is 99.8 °F, blood pressure is 120/80 mmHg, and pulse is 90/min. During her postoperative examination by the intern, the patient complains of numbness and tingling around her mouth and in her hands and feet. What could have been done postoperatively to anticipate and potentially remedy these symptoms?
- (A) Check magnesium  
(B) Check parathyroid hormone  
(C) Check potassium  
(D) Check TSH and free T4  
(E) Carotid ultrasound
16. A 42-year-old man presents with new-onset hypertension and elevated hemoglobin (19 mg/dL) and hematocrit (58 %) levels on subsequent laboratory examination. A CT scan demonstrates bilateral adrenal masses suspicious for pheochromocytoma. His elevated hemoglobin and hematocrit are believed to be secondary to a paraneoplastic syndrome. What other tumor is classically associated with this same paraneoplastic syndrome?
- (A) Glioblastoma multiforme  
(B) Hemangioblastoma  
(C) Colorectal cancer  
(D) Wilms' tumor  
(E) Osteosarcoma
17. Which of the following is true regarding paragangliomas (extra-adrenal pheochromocytomas)?
- (A) The most common location is within the kidney  
(B) There is a decreased association with familial syndromes (e.g., MEN-2, Von Hippel–Lindau) compared to pheochromocytomas  
(C) They are less likely to be malignant compared to pheochromocytomas  
(D) Functional imaging (MIBG) is particularly useful to diagnose metastatic disease, particularly when CT/MRI are negative  
(E) They are different on a cellular level from intra-adrenal pheochromocytomas
18. A malignant pheochromocytoma is diagnosed by:
- (A) Pathologic identification of high mitotic rate, cellular atypia, and capsular invasion  
(B) Positive MIBG scan  
(C) Presence of metastasis at sites normally devoid of chromaffin tissue  
(D) Biomolecular markers  
(E) The presence of intractable hypertension
19. A 45-year-old female presents with a 2 cm painless mass in her right anterior neck that has been present for 3 months and slowly enlarging. On physical exam, the mass feels firm and moves up and down with swallowing. She denies weight loss, weight gain, heat intolerance, or anxiety. A serum TSH level is normal. The most important step in the workup is:
- (A) CT scan of the neck  
(B) MRI of the neck  
(C) Fine-needle aspiration (FNA)  
(D) Open biopsy  
(E) Nuclear scan
20. Three hours after total thyroidectomy for thyroid cancer, the patient complains of difficulty breathing. On physical examination, the patient has stridor and appears to be in moderate respiratory distress. Examination of the wound demonstrates tense swelling. The next step in the management is:
- (A) Immediately reopen wound at the bedside  
(B) Intubation  
(C) Emergent return to the operating room for wound exploration  
(D) Check oxygen saturation  
(E) Send arterial blood gas
21. During the course of a total thyroidectomy in a 40-year-old female, the surgeon divides the superior thyroid artery and vein in one large ligature. After dividing the vascular pedicle, the surgeon notices that it appears that a nerve was transected. The surgeon postoperatively should warn the patient that she will most likely have:
- (A) Permanent hoarseness  
(B) A droop in the corner of her mouth  
(C) Difficulty swallowing  
(D) Trouble hitting high notes when singing  
(E) A need for a permanent tracheostomy
22. A 45-year-old female presents to her physician complaining of abdominal pain. She has a history of recurrent kidney stones and was recently discharged from the hospital after undergoing ureteroscopic laser lithotripsy. Her laboratory examination is significant for calcium of 13.6 mg/dL (normal 8.5–10.2 mg/dL) and PTH of 112 pg/mL (10–55 pg/mL). She is scheduled for operative management of her underlying condition. At surgery, all four parathyroid glands are identified. Only one appears to be abnormally enlarged and is

- removed. Confirmation of curative resection is best achieved via:
- (A) Intraoperative ultrasound
  - (B) Intraoperative frozen section
  - (C) Intraoperative PTH levels
  - (D) Immediate postoperative serum calcium level
  - (E) Postoperative sestamibi scan
23. A 35-year-old female presents with bone pain, abdominal pain, and depressed mood. Her laboratory examination is significant for calcium of 11.3 mg/dL (normal 8.5–10.2 mg/dL) and PTH of 109 pg/ml (10–55 pg/mL). Localization of the enlarged gland or glands is best achieved by:
- (A) Preoperative MRI
  - (B) Preoperative ultrasound
  - (C) Preoperative sestamibi scan
  - (D) Preoperative FNA
  - (E) Intraoperative exploration of all four glands
24. A 38-year-old female arrives for her yearly physical. She has no complaints but was incidentally found to have laboratory markers suggestive of primary hyperparathyroidism. Subsequent workup reveals involvement of all four parathyroid glands. She remains asymptomatic. What is the best recommendation for management of this patient?
- (A) Observation
  - (B) Surgical removal of all four glands
  - (C) Surgical removal of 3.5 glands
  - (D) Biochemical monitoring of serum calcium and serum creatinine annually
  - (E) Cinacalcet

**Answers****1. Answer C**

This patient presents with the rare but classic presentation of pheochromocytoma during pregnancy. The preferred imaging modality in pregnancy is an MRI, due to the risks of exposing the fetus to radiation with other types of imaging (A, D). In men and non-pregnant women, CT with contrast can also be considered a first line imaging study. Pheochromocytoma is usually hyperintense on T2-weighted images due to its high water content. Failing to work up and treat a potential pheochromocytoma in pregnancy exposes the fetus and mother to a very high risk of mortality during the pregnancy and delivery (B, E).

**2. Answer C**

Patients with pheochromocytoma are volume depleted due to intense alpha-mediated vasoconstriction. Hypertension is controlled with alpha-blockade (e.g., phenoxybenzamine) for 10–14 days before surgery. This allows for volume expansion, and the patient is encouraged to liberally intake salt and fluids. The dose is titrated until hypertensive episodes are controlled, often resulting in mild orthostatic hypotension. Beta-blockers (B) can be used to decrease reflex tachycardia once appropriate alpha-blockade has been established. Initiating beta-blocker therapy prematurely can precipitate a hypertensive crisis due to unopposed alpha-adrenergic vasoconstriction. Octreotide (A) is a somatostatin analogue that may have minimal efficacy in the palliation of symptoms from malignant pheochromocytoma, but it has no role in preparing a patient for surgery. Metyrosine (D) inhibits catecholamine production and is a secondary agent for pheochromocytoma, though now rarely used. Diuresis (E) would be contraindicated as these patients are volume depleted.

**3. Answer B**

This patient was incidentally found to have an adrenal mass. Guidelines for surgical resection include tumors >6 cm, features on CT suspicious for malignancy (high attenuation, irregular borders, inhomogeneous), and those that are hormonally active. Most adrenal carcinomas are hormonally active. Thus the patient described has several indications for adrenalectomy. Open adrenalectomy is preferred when malignancy is suspected, as this allows for a wider resection with en bloc resection if adjacent structures are involved and eliminates the possibility of seeding the port sites that may occur with laparoscopic adrenalectomy (C). Laparoscopic adrenalectomy is preferred for benign lesions. Radiation therapy (D) is not the mainstay of treatment for adrenal cortical carcinoma. Percutaneous biopsy (E) is not recommended as there are no histologic features that diagnose adrenal cortical carcinoma and a biopsy may risk seeding the biopsy tract.

**4. Answer D**

Osteitis fibrosa cystica is a skeletal disorder that results from a surplus of parathyroid hormone. Patients experience increased bone pain, bone fractures, and skeletal deformities with bowing of the bones. Radiographs show thin bones, fractures, and cysts with a moth-eaten appearance. Osteoporosis (A) usually occurs in elderly patients and is characterized by decreased bone density with normal mineralization. It does not have any associated cyst-like features. Similarly, osteopetrosis (B) would not have any cysts seen on plain films. Paget's disease (E) results from overactive osteoclasts and osteoblasts leading to excessive bone turnover and is characterized by tibial bowing, kyphosis, increased cranial diameter, and deafness. Patients with Paget's disease and osteoporosis have normal serum calcium, while patients with osteomalacia (C) would be expected to have decreased serum calcium.

**5. Answer C**

The first step in the evaluation of an incidentally discovered adrenal mass is to perform a biochemical workup to determine if the tumor is functional or nonfunctional (E). In practice, it is common to order a single battery of tests: serum aldosterone, plasma renin activity, and a 24-h urine collection to simultaneously measure catecholamines, metanephrines, and cortisol. Given that this patient is normotensive, the suspicion for pheochromocytoma and hyperaldosteronism is low. In addition, adrenal masses <6 cm are unlikely to be malignant. If the mass is found to be a hormonally active adrenal adenoma, then laparoscopic adrenalectomy (D) would be recommended. If biochemical testing reveals a nonfunctioning mass, this small lesion may be observed with interval CT scanning (A). Percutaneous needle biopsy (B) cannot readily distinguish between benign and malignant primary adrenal tumors.

**6. Answer E**

Hypercalcemia can cause abdominal pain, constipation, mental status changes, and depressed mood (stones, bones, moans and groans). Prolonged immobilization is a known cause of hypercalcemia and is seen in adolescents and in other patients with increased bone turnover such as Paget's disease. Certain diuretics (thiazide) also cause hypercalcemia by increasing renal calcium resorption.

**7. Answer C**

Patients with hyperaldosteronism have hypertension and hypokalemia – not hyperkalemia (B). Aldosterone acts on the kidney to increase sodium reabsorption, and potassium is excreted to balance the positively charged sodium ions. Hyperglycemia, hirsutism, and abdominal striae (A) are more consistent with Cushing's syndrome. Elevated plasma metanephrine, hypertension, and increased vanillylmandelic

acid excretion (D, E) are all consistent with pheochromocytoma.

### 8. Answer D

Elevated serum calcium combined with elevated PTH is consistent with primary hyperparathyroidism. Rarely, it can be associated with MEN-1 which includes parathyroid, pituitary, and pancreatic pathology (3Ps). Pancreatic tumors include gastrinoma, insulinoma, VIPoma, and glucagonoma. Glucagonoma should be suspected in a patient with new-onset diabetes mellitus (even if thin), diarrhea, and the classic rash: annular, erythematous erosions with blisters over the lower abdomen (necrolytic migratory erythema). The patient's symptoms of polyuria and polydipsia are highly suggestive of diabetes mellitus. Insulinoma (A) is characterized by hypoglycemia, headache, visual changes, confusion, weakness, and diaphoresis. Prolactinomas (B) are excess prolactin-producing anterior pituitary tumors that may result in amenorrhea, galactorrhea, decreased libido, and gynecomastia. A VIPoma (C) (also called WDHA syndrome: watery diarrhea hypokalemia achlorhydria) presents with profuse diarrhea, but will not have any skin manifestations of the disease. An adrenal adenoma (E) is oftentimes benign, nonfunctional, and incidentally found on imaging (incidentalomas).

### 9. Answer D

Severe hypertension in a young patient should raise suspicion for surgically correctable causes such as aldosteronoma, Cushing's disease, coarctation of the aorta, fibromuscular dysplasia of the renal arteries, and pheochromocytoma. Her symptoms, combined with an elevated plasma metanephrine level, make pheochromocytoma the most likely cause. The addition of labs consistent with primary hyperparathyroidism (elevated calcium and PTH) suggests she has MEN-2A which is characterized by primary hyperparathyroidism, pheochromocytoma, and medullary thyroid cancer. Calcitonin is a reliable tumor marker for medullary thyroid cancer and should always be ordered to rule out this very aggressive cancer in this patient population. Fasting blood glucose (A) (insulinoma), prolactin levels (prolactinoma) (B), MRI of the sella turcica (C) (pituitary adenoma), and serum gastrin level (E) (gastrinoma) are all associated with MEN-1.

### 10. Answer A

A sudden rise in blood pressure after anesthetic induction raises concern for an undiagnosed pheochromocytoma, malignant hyperthermia, and thyrotoxicosis (thyroid storm). For each of these situations, cessation of anesthesia is recommended. There are several clues that point to pheochromocytoma as the cause. The administration of beta-blockers without alpha-blockade first leads to worsening hypertension due to unopposed alpha-mediated vasoconstriction as in the

case above. Pheochromocytoma is associated with neurofibromatosis-1 which may present with skin neurofibromas (rubberlike discolored skin lesions) and cataracts. Malignant hyperthermia (B) presents with muscle rigidity (most often the masseter), a rapid increase in core body temperature, a rise in end tidal CO<sub>2</sub>, arrhythmia, and a mixed metabolic and respiratory acidosis at anesthetic induction. Treatment is immediate cessation of surgery and dantrolene. Thyrotoxicosis (C) presents in a similar fashion to malignant hyperthermia (fever, hypertension, tachycardia); however, it is not associated with muscle rigidity or rising end tidal CO<sub>2</sub>. The associated hypertension and tachycardia respond to the administration of beta-blockade. It is due to a hypermetabolic state caused by excess thyroid hormone. Inadequate anesthetic agents (D) may lead to hypertension and tachycardia, but would not lead to high fevers. An undiagnosed pituitary tumor resulting in excess ACTH production can cause hypertension, but this will be accompanied with symptoms consistent with Cushing's disease (e.g., truncal obesity, abdominal striae, muscle wasting, hirsutism).

### 11. Answer B

This patient has a thyroglossal duct cyst, which is the most common midline congenital malformation of the neck. Though present at birth, these do not often appear until age 2 as baby fat recedes. During embryological development, the thyroid originates at the base of the tongue and travels down the thyroglossal duct to the anterior neck, where it normally involutes. However, if a persistent duct remains, it may undergo cystic dilation later in life and present as a well-defined anterior neck mass, located midline and above the cricoid cartilage. Unlike a brachial cleft cyst, this elevates with tongue protrusion or swallowing. Ectopic thyroid gland may be associated with thyroglossal duct cysts so it's necessary to confirm the thyroid gland is in its correct anatomic location prior to surgical intervention. The definitive management involves thyroglossal duct cyst excision or the Sistrunk procedure. Reassurance and observation (C) are inappropriate as thyroglossal duct cysts have a high rate of recurrent infections and a small risk of progressing to malignancy. FNA biopsy (A) is appropriate for a thyroid nodule, but not for suspected thyroglossal duct cyst. He does not have symptoms suggestive of hyper- or hypothyroidism so a thyroid panel would not be indicated (D). CT scan (E) is unnecessary for the diagnosis, and additionally should not be performed in such a young patient secondary to significant radiation exposure.

### 12. Answer A

Plasma free metanephrine is highly sensitive for pheochromocytoma but is more prone to false-positive results. Plasma chromogranin A is released from neuroendocrine cells and is elevated in the majority of patients with pheochromocytoma. It is nonspecific (i.e., it is elevated in other neuroendocrine

tumors) but can help confirm the diagnosis. Superoxide dismutase and malondialdehyde (B, C) are both markers for oxidative stress, and neither has been shown to be associated with pheochromocytoma. CA 19-9 (D) may be elevated in some patients with pancreatic cancer. Increased level of 5-hydroxyindoleacetic acid (HIAA) (E) would be expected in a patient with carcinoid syndrome.

### 13. Answer C

Patients with MEN-2A can develop pheochromocytoma, hyperparathyroidism, and medullary thyroid cancer. The definitive management for pheochromocytoma consists of medical conditioning with alpha-blockade and sometimes beta-blockade for at least 2 weeks, followed by an adrenalectomy (B). This should be performed first (A, D–E) because a pheochromocytoma can increase the risk of complications during the surgical management of other endocrine tumors. Although he is asymptomatic with respect to his hyperparathyroidism, parathyroid surgery is generally recommended for most patients with inherited forms, as it tends to be more aggressive and presents at a much younger age. Age less than 50 is an indication for parathyroid surgery for sporadic forms as well, as the patient is more likely to suffer one of the sequelae of hyperparathyroidism.

### 14. Answer D

If a patient that has undergone bilateral adrenalectomy presents postoperatively with severe hypotension and hypoglycemia, suspect Addisonian crisis (acute adrenal insufficiency) and check a cortisol level. This is considered to be a life-threatening condition caused by insufficient levels of cortisol, which is responsible for maintaining blood pressure and glucose homeostasis. Patients will present with nausea, vomiting, weakness, blurry vision, and mild abdominal pain. Laboratory exam would be expected to show hypoglycemia, hyperkalemia, and mild hyponatremia. Plasma ACTH levels will be low, and a Cortrosyn (synthetic ACTH) stimulation test will demonstrate a low cortisol response. This patient should receive immediate fluid resuscitation (normal saline) and intravenous corticosteroids. Acute adrenal insufficiency does not respond to vasopressors. Additionally, it can mimic sepsis. However, he does not meet SIRS criteria. Similarly, sepsis (B) is unlikely to present with this patient's lab abnormalities. Patients that have had major surgery should always be monitored for signs of internal hemorrhaging. Although his serum calcium is shown to be low (C), this should be corrected for hypoalbuminemia. His corrected serum calcium is 8.7 mg/dL, is within the normal range, and would not explain the hypotension (B). Although he may be volume depleted (A), this would not cause hypoglycemia or hyperkalemia. Loss of catecholamine production (E) may accompany Addisonian crisis and is also seen after removing a pheochromocytoma. It is associated with hypotension

and hypoglycemia; however, it will not cause hyperkalemia and hyponatremia.

### 15. Answer B

The patient most likely has hypocalcemia. Temporary hypoparathyroidism occurs in up to 30 % of patients after total thyroidectomy and generally lasts a few weeks. It is thought to be related to temporary ischemia to the adjacent parathyroid glands. Patients will complain of numbness and tingling in their hands and feet, as well as around the mouth. These patients should be managed with prompt oral calcium supplementation. Oral calcitriol may be added to increase calcium absorption from the gut. Some centers routinely check the postoperative PTH level for the purposes of anticipating hypocalcemia. Left untreated, hypocalcemic symptoms may progress to muscle twitching (including Chvostek's sign) and ultimately tetany, which is an emergency. IV calcium (gluconate or chloride) may be given in these circumstances, but its use can generally be avoided when patients are carefully monitored postoperatively. Symptoms of hypomagnesemia (A) are indistinguishable from hypocalcemia; however, low magnesium levels are not associated with thyroidectomy. Disturbances in potassium (C) and thyroid hormone (D) would not cause the symptoms described. Carotid ultrasound (E) would be indicated if the patient developed symptoms of a stroke or transient ischemic attack (one-sided arm and leg weakness/numbness).

### 16. Answer B

This patient most likely has an ectopic production of erythropoietin leading to high levels of hemoglobin and hematocrit. This paraneoplastic syndrome, termed polycythemia vera, is classically associated with pheochromocytoma, renal cell carcinoma, hepatocellular carcinoma, and hemangioblastoma (A, D–E).

### 17. Answer D

Paragangliomas arise from extra-adrenal chromaffin tissue, with the most common location being in the abdomen (organ of Zuckerkandl). They are essentially identical on a cellular level to intra-adrenal pheochromocytomas. However, they are more likely to have a hereditary basis (30–50% of cases) and to be malignant (15–35%). The diagnosis is made by biochemical analysis followed by imaging localization. It is particularly important to consider a whole body functional scan due to the higher propensity for multifocal and metastatic disease.

### 18. Answer C

There is currently no way to establish the diagnosis of malignancy in pheochromocytoma based on histopathologic evaluation (A). However, there are tumor characteristics that are associated with higher risk (e.g., larger size, extra-adrenal



location, certain genetic mutations, and a high tumor proliferative index). Malignancy is determined by the development of metastatic disease, defined by a recurrence in an area that normally does not have any chromaffin tissue (lymph nodes or a distant site such as the liver or lungs). MIBG scanning (B) can be useful to identify metastatic disease, but positivity of the primary tumor on MIBG does not determine whether it is malignant. Biomolecular markers (D) can differentiate a functional tumor from nonfunctional, but is unable to rule out malignancy. Similarly, intractable hypertension (E) is not a characteristic of malignancy.

### 19. Answer C

The most important step in the diagnostic workup of a thyroid nodule is to obtain a tissue sample. This is best obtained via fine-needle aspiration and is best done under ultrasound guidance. Thyroid nodules greater than 1 cm in size, nodules with ultrasound characteristics suggestive of malignancy (internal microcalcifications, e.g.), or those with a history of growth should undergo ultrasound guided FNA. CT (A) or MRI (B) would be appropriate for patients found to have clinical or sonographic evidence of locally advanced thyroid cancer that may extend into the aerodigestive tract or substernal region. Open biopsy (D), done by removing an entire thyroid lobe, should be done next if FNA results are suspicious for a follicular neoplasm. Nuclear scanning (E) has a very limited role in the preoperative setting. It is more beneficial in the postoperative setting to look for recurrent or metastatic malignancy.

### 20. Answer A

Don't forget the ABCs. This patient has a compromised airway and is in moderate respiratory distress. Normally, the first step to ensure an airway is via endotracheal intubation (B). However, a neck hematoma is in a closed space that leads to compression of the airway that may render safe intubation difficult or impossible. As such, the first step is to immediately open the neck wound at the bedside to decompress the hematoma. This will typically relieve the airway obstruction. The patient can then be transported emergently to the operating room for intubation, wound exploration, adequate hemostasis, and subsequent wound closure (C). Although thyroidectomy is considered a safe procedure, one well-known complication is airway obstruction following bleeding and hematoma formation which occurs within the first 24 h after thyroidectomy. Checking oxygen saturation (D) or waiting for labs (E) is never appropriate for a patient with a compromised airway.

### 21. Answer D

The superior laryngeal nerve lies adjacent to the superior thyroid artery and is thus at high risk of being injured during mobilization of the thyroid, particularly the superior pole.

The external branch of the superior laryngeal nerve permits singing in a high pitch. This nerve may be injured in up to 25 % of cases but is usually asymptomatic unless the patient is a singer or voice professional. Damage to the recurrent laryngeal nerve on one side results in a paralyzed vocal cord in a median or paramedian position. This manifests as hoarseness (A) and sometimes aspiration. The rate of permanent unilateral recurrent laryngeal nerve injury during thyroidectomy should be less than 2 % in expert hands. If both recurrent laryngeal nerves were injured during a total thyroidectomy, then both vocal cords could be paralyzed, and this may lead to a compromised airway which may necessitate a permanent tracheostomy (E). A droop in the corner of the mouth results from injury to the marginal mandibular branch of the facial nerve. Swallowing is controlled by multiple nerves (C) including the glossopharyngeal, vagus, and/or hypoglossal nerves.

### 22. Answer C

The surgical treatment of hyperparathyroidism depends on whether the pathology is a single adenoma (most common, remove single gland), more than one adenoma (remove abnormal ones), or four gland hyperplasia (remove 3.5 glands). Distinguishing these entities is not always obvious. Because of the short half-life of PTH (about 4 min), intraoperative rapid PTH testing aids in determining the completeness of parathyroid resection. The most commonly used protocol involves drawing PTH levels at the time of gland excision and again 10 min post-excision. A fall of >50 % in the PTH level is associated with a 98 % long-term cure rate. Given the small size of the parathyroid glands, it is generally not recommended to biopsy all of them for frozen section (B), as such a biopsy may render all the glands ischemic. Transient hypocalcemia is expected following parathyroidectomy so postoperative serum calcium level (D) is not indicative of cure. Oral calcium supplementation can help alleviate minor symptoms. Intraoperative ultrasound (A) is sometimes used when the abnormally enlarged gland cannot be found. Sestamibi (E) may be used if recurrent or persistent hyperparathyroidism develops, but is not routinely used for confirmation of successful surgery.

### 23. Answer C

Sestamibi scanning involves using a radioisotope, technetium-99 m, which is taken up by cells with high mitochondrial activity. It is more accurate for single adenomas than for four gland hyperplasia. Sestamibi scanning and to a lesser extent ultrasound (B) are the most frequently used imaging tests to localize the involved gland(s) in primary hyperparathyroidism. Localizing studies are generally not indicated in secondary or tertiary hyperparathyroidism, since multiple-gland hyperplasia is the expected underlying pathology. Preoperative FNA (D) is not helpful in the workup of primary

hyperparathyroidism. In about 85 % of patients, imaging will localize the abnormal parathyroid gland, and a great majority will have a single parathyroid adenoma. If localizing scans are negative, yet the diagnosis of primary hyperparathyroidism is clearly established, surgery is still performed at which time intraoperative exploration of all four glands (E) is performed.

#### 24. Answer C

With the increasing use of routine laboratory testing, most patients with primary hyperparathyroidism are currently discovered incidentally in asymptomatic patients. Although the patients may be asymptomatic, long-standing hyperparathyroidism can lead to kidney injury and osteoporosis. Evidence of such should be sought out via bone mineral density testing as well as calculation of creatinine clearance. For patients with asymptomatic hyperparathyroidism diagnosed through laboratory screening, a 2008 consensus statement recommended the following indications for surgery:

1. Serum calcium 1.0 mg/dL greater than the upper limit of normal
2. Creatinine clearance reduced to <60 mL/min
3. Bone mineral density with T-score less than -2.5 at any site
4. Age <50
5. Patients that do not desire or cannot undergo routine surveillance

The patient described meets the age criterion for surgical intervention. The surgical treatment of primary hyperparathyroidism due to four gland hyperplasia is to remove 3.5 glands. An acceptable alternative is to remove all four glands and to reimplant half of a gland within the muscles of the forearm. That way if the patient develops recurrent hyperparathyroidism, additional parathyroid tissue can be removed from the forearm under local anesthesia as opposed to reoperative neck surgery with the attendant risk of cranial nerve injury. Removal of all four glands (B) is not recommended as it will render the patient permanently hypocalcemic with a lifelong need for calcium supplementation. Observation (A) would not be appropriate for patients meeting criteria for surgery. Patients not selected for surgical therapy require biochemical monitoring of serum calcium and serum creatinine annually (D). Bone mineral density should be measured every 1–2 years. Cinacalcet (E), a calcimimetic, is mainly used to treat secondary hyperparathyroidism (seen in patients with renal failure). It may be considered to reduce the serum calcium in patients who are not candidates for surgery.

## Head and Neck

### Areg Grigorian and Christian de Virgilio

#### Questions

- A 65-year-old male is diagnosed with squamous cell laryngeal cancer. Examination of the neck reveals no adenopathy. At the time of biopsy, the cancer is determined to be small, and the vocal cord is still moving. It is determined that the laryngeal cancer is likely an early stage. Which of the following would be recommended next?

  - Chest X-ray
  - MRI
  - PET scan
  - Bronchoscopy
  - No additional imaging needed
- A 9-year-old male with a past medical history of Acute myeloid leukemia (AML) status post with bone marrow transplant presents with right ear pain and a headache. His vaccination history is not available. His mother reports that the pain started 3 days ago and is accompanied by pruritus and a sensation of fullness in the ear. His headache began suddenly and has gotten worse over the past 2 h. Otoloscopic examination reveals a green/gray discharge, an erythematous ear canal, and a normal-appearing tympanic membrane. What is the most likely organism responsible for this patient's presentation?

  - Streptococcus pneumoniae*
  - Haemophilus influenza*
  - Moraxella catarrhalis*
  - Mycoplasma*
  - Aspergillus niger*
- A 60-year-old homeless man arrives to the ED complaining of fevers, neck pain, extreme thirst, and difficulty breathing. He has several rotted teeth extracted recently. On physical examination, his temperature is 102.7 °F, heart rate is 120/min, respiratory rate is 24/min, and blood pressure is 120/70 mmHg. He has a strong smell of alcohol on his breath. He appears agitated, and his breathing is labored. His voice sounds brassy. He is leaning forward and spitting up his saliva. On physical exam his neck is markedly swollen on the left side just below his mandible. The overlying skin is red. No fluctuance is palpated. He is unable to open his mouth. What is the best next step in management?

  - Immediate incision and drainage at bedside
  - Laryngoscopy
  - Broad-spectrum antibiotics
  - Vigorous fluid hydration
  - Establish airway
- A 50-year-old male smoker presents with a 2 cm lymph node in his left mid neck that he states has been present for 8 weeks. He denies any symptoms. Flexible nasopharyngoscopy in the office is negative. CT of the neck and chest is negative. FNA of the node confirms metastatic squamous cell carcinoma. What is the next best step in the management?

  - Excision of lymph node
  - Modified radical neck dissection
  - Laryngoscopy
  - Radiation and chemotherapy
  - Laryngoscopy, esophagoscopy, bronchoscopy (or panendoscopy) with random biopsies
- A 6-year-old boy presents to the ED with fevers, hearing loss, and ear pain. He finished a 10-day course of amoxicillin 1 day ago to treat an episode of acute otitis media. His ear pain initially resolved after starting antibiotics but came back 2 days ago and is now localized behind the ear. His temperature is 101.3 °F, blood pressure is 110/82 mmHg, and pulse is 105/min. On physical examination, his ear is superiorly displaced. What is the best next step in management?

  - Observation with follow-up in 2 weeks
  - Oral corticosteroids
  - CT scan
  - Augmentin (amoxicillin with clavulanic acid)
  - Operating room
- A 30-year-old Asian woman arrives for her yearly physical. During examination of her mouth, you notice a bony, immobile mass in the midline of her hard palate. She has no complaints and reports that the mass has been there for the past year. What is the best next step in management?

  - Operative management
  - Medical management
  - Biopsy
  - Observation
  - Epstein-Barr virus-related serologic antibody test
- A 6-year-old girl arrives to the ED by paramedics after a follow-up visit to her doctor for acute otitis media. She was witnessed having two generalized tonic-clonic seizures over 15 min without recovering consciousness between seizures. Her mother reports that she has had recurrent fevers, headaches, and weakness of her right arm over the past 2 weeks. She has no seizure history. She went to Mexico over the weekend to visit her family. CT scan of the head shows a single rim-enhancing lesion with a thickened capsule and diminished hypodense

- central cavity. After stabilization, what is the most appropriate next step in management?
- (A) Pyrimethamine and sulfadiazine  
 (B) Albendazole with steroids  
 (C) Surgical drainage  
 (D) Phenytoin and valproate for at least 2 years  
 (E) Chemotherapy and radiation
8. A 45-year-old female presents with persistent hoarseness. Laryngoscopy reveals multiple cauliflower-like growths around her vocal cords bilaterally. Biopsy reveals an exophytic growth of keratinized squamous epithelium without malignancy. Which of the following is the most appropriate initial management?
- (A) Testing for HPV and laser fulguration  
 (B) Testing for HIV and laser fulguration  
 (C) Testing for EBV and radiation therapy  
 (D) Laryngectomy  
 (E) Antiviral medication
9. A 70-year-old woman presents with complaints of mouth pain while chewing and night sweats. She has had many past episodes of sialolithiasis in her parotid gland, but they often resolve spontaneously after a few days of sucking on lemon drops. Physical examination reveals a swollen right parotid gland which is later confirmed to be a pleomorphic adenoma. She undergoes a parotidectomy. Shortly after the procedure, she complains of numbness over her right earlobe. Which nerve was most likely injured?
- (A) Branch of the facial nerve  
 (B) Branch of the cervical plexus  
 (C) Branch of the trigeminal nerve  
 (D) Spinal accessory nerve  
 (E) Branch of the vagus nerve
10. A 28-year-old man presents for a routine annual physical exam. He has no significant past medical history. His temperature and vitals are stable, and his laboratory examination is benign. He smokes one pack per day. On physical examination, he has a freely moving 2 cm cervical lymph node. What is the best next step in management?
- (A) FNA  
 (B) CT scan of the head and neck with contrast  
 (C) CT scan of the head and neck without contrast  
 (D) Observation and follow-up in 3 weeks  
 (E) Panendoscopy
11. A 4-year-old boy is brought to the ED by his parents for difficulty breathing. His mother reports that he developed nasal congestion and malaise 2 days ago, but over the past 12 h, he has had continuous low-pitched coughs. His temperature is 101 °F. On physical exam, he has pharyngeal erythema, cervical lymphadenopathy, and inspiratory stridor. Neck radiograph shows subglottic narrowing of the airway. He appears to be in respiratory distress and subsequently requires rapid sequence intubation. What is the most likely diagnosis?
- (A) Respiratory distress syndrome  
 (B) Epiglottitis  
 (C) Laryngotracheobronchitis  
 (D) Bronchiolitis  
 (E) Laryngomalacia
12. Foreign body aspiration is a common occurrence in children. It can be potentially life threatening as it may obstruct the airway, preventing adequate oxygenation and ventilation. Where is the most likely location of obstruction in a patient younger than one?
- (A) Right mainstem bronchus  
 (B) Left mainstem bronchus  
 (C) Upper trachea  
 (D) Carina (cartilaginous ridge in the lower trachea)  
 (E) Larynx
13. A 45-year-old male presents with a mass in his face, just below his ear. He denies any symptoms. On physical exam, the mass appears to be within the parotid gland. The mass feels firm, non-tender, and somewhat mobile. The facial nerve is intact. There is no additional mass inside the mouth. The mass most likely represents a:
- (A) Pleomorphic adenomas (mixed tumor)  
 (B) Papillary cystadenoma (Warthin's tumor)  
 (C) Mucoepidermoid carcinoma  
 (D) Adenoid cystic carcinoma  
 (E) Oncocytoma
14. A 40-year-old female presents with soreness and chronic inflammation of her tongue and difficulty swallowing, stating that she feels like she is choking, particularly when eating solid foods. Laboratory examination is significant for a hemoglobin of 10.5 g/dL (normal 12–15.2 g/dL), hematocrit of 31 (37–46%), and MCV of 75 fL (80–100 fL). Which of the following is the best initial test to work up this condition?
- (A) Direct laryngoscopy  
 (B) Indirect laryngoscopy  
 (C) Bronchoscopy  
 (D) Esophagoscopy  
 (E) Esophagram
15. A 56-year-old male presents with chronic laryngitis that has persisted for 6 weeks. Prior to that, he acquired a cold, after which he first noticed a voice change. He also states that he is a teacher and thinks he may be wearing out his voice. He was evaluated by his primary

care doctor and was told it was likely due to a viral illness. Past medical history is otherwise negative. He quit smoking about 5 years ago. What is the next step in the management?

- (A) Five-day course of oral corticosteroids
  - (B) Oral antibiotics
  - (C) Offer reassurance and reassess in 4–6 weeks
  - (D) Indirect laryngoscopy in the office
  - (E) Direct laryngoscopy in the office
16. A 60-year-old male with poorly controlled diabetes presents to the ED with a 2-day history of fevers, nasal stuffiness, facial pain, and right retro-orbital headache.

On physical exam his temperature is 102.7 °F. The right side of his face is erythematous. There is a black eschar on his nose, as well as black discharge from his right nares. The skin on the right side of his face is numb to pin prick. Treatment consists of:

- (A) Broad-spectrum antibiotics and urgent wide surgical debridement
- (B) Liposomal amphotericin B and urgent wide surgical debridement
- (C) Broad-spectrum antibiotics alone
- (D) Liposomal amphotericin B alone
- (E) Hyperbaric oxygen

## Answers

### 1. Answer A

A chest X-ray is routinely performed to rule out a concurrent primary lung cancer or pulmonary metastases. This is important as a majority of laryngeal and lung cancers are attributed to smoking. In addition, the most common location for distant metastasis of head and neck squamous cell carcinoma is the lungs. Additional imaging such as MRI (B), PET (C), or bronchoscopy (D) is not considered necessary for early stage laryngeal cancer.

### 2. Answer E

This patient most likely has malignant otitis externa secondary to otomycosis. *Aspergillus niger* is the most common cause of otomycosis and can present very similarly to otitis externa. However, patients with otomycosis will complain of an intense fullness in the ear and pruritus, and physical exam will be significant for a gray exudate from the affected ear. Unlike otitis media, patients with otomycosis will have a normal-appearing tympanic membrane as this typically affects the external ear canal. The two high-risk populations for malignant otitis externa secondary to otomycosis include patients with acute myeloid leukemia and/or diabetic ketoacidosis. Depending on the extent of local spread, patients can present with a myriad of symptoms including blindness, headache, seizure, and coma. CT scan of the head will help evaluate the extent of damage and infiltration and help guide surgical management (e.g., debridement, washout). Answer choices A–C are all common causes of otitis media with *Streptococcus pneumoniae* being the most common organism. *Mycoplasma* (D) has been associated with bullous myringitis, which is characterized by vesicular inflammation of the tympanic membrane and is seen most commonly with untreated otitis media. Patients will present with very tender ear canals, and otoscopy shows large red vesicles on the tympanic membrane.

### 3. Answer E

Ludwig's angina is characterized by a progressive cellulitis in the floor of the mouth and often involves the submandibular space (which is divided by the mylohyoid muscle). It can present with fevers, neck pain, neck swelling, dental pain, dysphagia, and drooling. This can be life threatening as it can lead to airway obstruction. The majority of cases follow dental procedures which allow bacteria from a tooth infection to migrate into the submandibular space. Patients with labored breathing and marked swelling require an immediate airway. This may be achieved via endotracheal intubation or alternatively via a surgical airway (cricothyroidotomy or tracheostomy). The neck infection will then need immediate surgical drainage, (A) but this is best accomplished in the operating room. Broad-spectrum antibiotics (C) and IV fluids (D) are also necessary, but should not be prioritized over the airway.

Laryngoscopy (B) is not recommended as it will only delay establishment of the airway and any potential trauma/gagging may further compromise the airway.

### 4. Answer E

A solitary enlarged lymph node that persists beyond 3 weeks particularly in a middle-aged male smoker should be considered a metastatic lymph node until proven otherwise. Oftentimes, the patient will have symptoms (such as hoarseness, persistent sore throat, ulcerative lesions) that will guide the workup. But if no symptoms are present, a flexible nasopharyngoscopy is used initially to evaluate the nasal cavities, nasopharynx, oropharynx, hypopharynx, and glottis to look for a site of primary tumor. FNA is subsequently performed for to confirm that the solitary neck mass is a metastatic lymph node. Once FNA confirms this, CT scan of the neck may identify the primary. If the primary is still not evident, the next step is to try to identify the location of the primary tumor using a panendoscopy (also termed triple endoscopy) with random biopsies. This involves a complete endoscopic evaluation of the upper aerodigestive track, including laryngoscopy (C), esophagoscopy, and bronchoscopy under general anesthesia in the operating room. A neck dissection (B) would not be considered until after panendoscopy. Radiation and chemotherapy (D) may be used as adjuncts depending on the stage and grade of the primary tumor.

### 5. Answer C

Mastoiditis usually occurs days to weeks after an episode of acute otitis media. Patients present with fevers and complaints of a red, swollen, and tender area behind the ear (mastoid process). Physical exam may reveal a displaced ear on the affected side. The diagnosis can be confirmed with a CT scan of the mastoid process and is recommended for patients suspected of having mastoiditis. Patients with CT-confirmed acute surgical mastoiditis are candidates for mastoidectomy with insertion of a tympanostomy tube (E). Observation (A) is not an appropriate management for patients with mastoiditis. Oral corticosteroids (B) are not considered part of the management of acute mastoiditis. Augmentin (D) would be an appropriate choice for patients with acute otitis media suspected of having a resistant strain.

### 6. Answer D

This patient most likely has torus palatinus, a bony benign mass located on the hard palate of the mouth. The cause is unknown. It occurs more frequently in women and those of Asian descent. There is no associated malignant transformation. Biopsy (C) is not warranted and patients only need reassurance. Operative management (A) with surgical removal would be indicated only for symptomatic patients (e.g., interference with denture placements, pain, trouble swallowing). There is no medical management (B) available

for torus palatinus. Nasopharyngeal carcinoma, a rare tumor arising from the epithelium of the nasopharynx, occurs more frequently in patients of Asian descent and those infected with EBV (E). However, a bony outgrowth of the hard palate would not be expected in these patients.

### 7. Answer C

Although it occurs infrequently, brain abscesses are a complication of acute otitis media. It shows many of same manifestations as a brain tumor (space occupying) but with a much shorter timetable (week or two). Patients typically have a fever, acute onset of headache, focal neurologic findings (e.g., weakness in the right arm), seizure, and an obvious source, such as otitis media or mastoiditis. A MRI or CT of the head will find ring enhancing lesions. Treatment is open drainage (by a neurosurgeon). All these patients should also be started on empiric antibiotics. Although controversial, some clinicians also administer corticosteroids as it may have some benefit in decreasing the growth of the abscess and preventing cerebral edema. Ring-enhancing lesions and seizures can also be found in patients with CNS lymphoma, toxoplasmosis, or neurocysticercosis. CNS lymphoma primarily occurs in patients with AIDS. Pyrimethamine and sulfadiazine (A) would be the appropriate choice to treat patients with toxoplasmosis. Seizures secondary to neurocysticercosis (*Taenia solium*) can occur in patients with a recent travel history to Mexico, but this patient's temporal relation of her acute condition and a recent episode of otitis media make this less likely. Patients with neurocysticercosis should be started on antiparasitics, such as albendazole, and corticosteroids (B). Antiepileptics (D) can be used to manage her acute condition, but it is unlikely that she also has a concurrent seizure disorder obviating the need for long-term antiepileptic therapy. Chemotherapy and radiation (E) would be considered in patients with brain malignancies.

### 8. Answer A

Laryngeal papillomas or recurrent respiratory papillomatosis is a condition caused by human papilloma virus (HPV) types 6 and 11. Infection with the virus can lead to benign papillary tumors of the larynx (cauliflower-like growths) and presents primarily with hoarseness. It rarely gives rise to laryngeal carcinoma. Laser fulguration can be performed to destroy the papillary growths. Laryngectomy (D) would not be appropriate. HIV (B) can present with various AIDS-defining malignancies including Kaposi's sarcoma, non-Hodgkin's lymphoma, and cervical cancer. EBV (C) has been associated with nasopharyngeal carcinoma and Burkitt's lymphoma. Antiviral agents (e.g., cidofovir) are used as an adjunct to laser ablation to prevent recurrence, but they are not the primary treatment modality.

### 9. Answer B

Sialolithiasis (salivary ductal stones) can increase the risk of developing a tumor of the gland. Lemon drops will stimulate saliva production and help facilitate passage of the stone. Pleomorphic adenoma is benign and considered the most common neoplasm of the parotid gland. The greater auricular nerve is a branch of the cervical plexus (C2–C3) and provides cutaneous sensation to the lower portion of the ear, including the earlobe. The facial nerve (A), which traverses through the two lobes of the parotid gland, can also be injured and will present with facial droop. Injury to the trigeminal nerve (C) can cause widespread numbness in the face. However, this type of injury occurs rarely because of the deep location, immediate branching, and redundancy of these nerves. An injured spinal accessory nerve (D) will present with partial paralysis of the trapezius and sternocleidomastoid muscles. The auricular branch of the vagus nerve (E) provides cutaneous sensation to the ear canal, not the earlobe.

### 10. Answer D

The most appropriate recommendation for a young patient presenting with a newly discovered, isolated, and enlarged cervical node is observation with follow-up and reexamination in 3 weeks. If the node disappears, it most likely was inflammatory in nature. However, if this patient presented with any red-flag symptoms (e.g., dysphagia, odynophagia, dysphonia, hoarseness, and weight loss), additional workup would be required to rule out malignancy. CT scan (B, C) with contrast is the initial preferred imaging modality for a solitary neck mass that is concerning for malignancy (following a careful head and neck examination). FNA (A) is indicated for neck masses that are persistent, enlarging, or suspicious for malignancy. Panendoscopy (E) is performed in the operating room in the setting of a metastatic neck lymph node (when the primary is occult).

### 11. Answer C

Croup, also known as laryngotracheobronchitis, is caused by the parainfluenza virus and primarily affects young children. The cough associated with this condition is described as a low-pitched seal-like bark. The diagnosis can be confirmed by looking for the classic "steeple sign" on posteroanterior X-ray of the neck, which is indicative of subglottic narrowing. Patients are at risk for airway obstruction and will require intubation if they appear to be in respiratory distress. Management includes steroids and aerosolized racemic epinephrine. Respiratory distress syndrome of the newborn (A) is caused by surfactant deficiency. It occurs within 2 days of birth and presents with cyanosis, nasal flaring, crackles, and expiratory grunting. Epiglottitis (C) is a rapidly progressive

infection of the epiglottis, most commonly due to *Haemophilus influenzae type B*. Patients with epiglottitis may require intubation or even tracheostomy due to airway compromise from the swollen epiglottis. Bronchiolitis (D) is characterized by a viral infection of the bronchioles and occurs most commonly in patients <2 years old. Laryngomalacia (E) is a congenital abnormality of the laryngeal cartilage and can result in collapse of the supraglottic structures in newborns, leading to airway obstruction. Infants with laryngomalacia should be fed upright and remain in this position for at least 30 min after each feed.

### 12. Answer E

The larynx is the most common site for foreign body aspiration in children younger than 1, while the trachea (C, D) and right mainstem bronchus (A) are the most common sites in older children. The left mainstem bronchus (B) is a less frequent site for foreign body aspiration owing to its acute angle as it enters the lung versus an obtuse angle in the right. Patients with foreign body aspiration may have wheezing, but using a bronchodilator increases the risk of further pushing the foreign body down the airway. Order a chest X-ray if there is a suspicion for a foreign body obstruction. Bronchoscopy is recommended for definitive diagnosis. Extracting the foreign body requires a *rigid* bronchoscopy.

### 13. Answer A

Most salivary gland tumors are in the parotid gland, and the majority are benign (80 %). The most common type of parotid gland tumor is a pleomorphic adenoma. Although benign, it does have a known risk of malignant transformation that becomes as high as 10–25 % when present beyond 15 years. Warthin's tumor (B) is the second most common benign salivary tumor and is strongly related to smoking. Mucoepidermoid carcinoma (C) is the most common malignant salivary gland tumor. Facial nerve involvement is more suggestive of malignant transformation. The second most common malignancy is adenoid cystic carcinoma (D). Oncocytoma (E) is a rare (1–2%) salivary gland tumor and most often involves the parotid gland.

### 14. Answer E

The triad of dysphagia, esophageal webs (e.g., feeling of choking with solid foods), and iron-deficiency anemia is highly suggestive of Plummer-Vinson syndrome. The

pathophysiology still remains unclear but is most likely multifactorial. Barium esophagram is one of the most sensitive methods and diagnostic tests of choice to confirm the presence of esophageal webs, which appears as a thin projection off the postcricoid, anterior esophageal wall. If esophagram is equivocal, esophagoscopy (D) can be used next. Laryngoscopy (A–B) or bronchoscopy (C) is not typically required in the workup for Plummer-Vinson syndrome. However, if there is any concern for head and neck cancer (e.g., neck mass in patient with smoking history), a panendoscopy can be considered in the workup.

### 15. Answer D

In an older (>50) male patient with a history of smoking, presenting with persistent laryngitis and recent difficulty in projecting his voice, laryngeal cancer must be ruled out. The initial test is to evaluate the larynx and vocal cords with indirect laryngoscopy in the office (with administration of local anesthetic spray to the back of the throat). It is termed indirect, as it has a mirror that permits indirect visualization of the vocal cords. Structural abnormalities, such as masses, ulcers, or mucosal irregularities, may be noted, as well as motion of the vocal cords. Direct laryngoscopy (E) is done in the OR under general anesthesia. It involves insertion of a rigid metal tube directly into the larynx and allows for biopsies to be taken. Given the high likelihood of cancer, antibiotics (B) or reassurance (C) would be inappropriate.

### 16. Answer B

This patient's presentation is concerning for mucormycosis, most commonly caused by *Rhizopus* or *Mucor* fungi. Patients with poorly controlled diabetes and/or neutropenia are the most common groups affected with mucormycosis. They most often present with local invasion of the fungi into the facial sinuses and eventually the brain (e.g., sudden onset or worsening of headache), as in this patient. Black eschar on the nose and discharge from the nares is characteristic of mucormycosis. Management consists of immediate antifungal therapy with liposomal amphotericin B and surgical debridement. Antifungal therapy alone would be inappropriate, as well as antibiotics (A,C–D). Hyperbaric oxygen (E) is currently being investigated as an adjunctive therapy for select patients with mucormycosis. Mortality for mucormycosis ranges from 50 % to 75%.



## Hepatopancreaticobiliary

Areg Grigorian, Paul N. Frank, Danielle M. Hari, and Christian de Virgilio

### Questions

- A 55-year-old male arrives to the ED with 40 % total body surface area second and third degree burns over his arms and legs after hot tar spilled on him at a jobsite where he was working as a roofer. He is in critical condition and intubated in the ICU. On the fifth hospital day, he spikes a temperature of 102 °F, blood pressure is 110/80 mmHg, and pulse is 92/min. On physical exam he has tenderness on palpation of the RUQ and epigastrium, absent bowel sounds, and multiple healing burn wounds that appear to be clean. Laboratory exam demonstrates a WBC of  $16 \times 10^3/\mu\text{L}$  (normal  $4.1\text{--}10.9 \times 10^3/\mu\text{L}$ ) with 12 % bands, amylase of 180  $\mu\text{L}$  (normal 30–110  $\mu\text{L}$ ), lipase of 55  $\mu\text{L}$  (7–60  $\mu\text{L}$ ), alkaline phosphatase of 70  $\mu\text{L}$  (33–131  $\mu\text{L}$ ), and total bilirubin of 1.2 (0.1–1.2 mg/dl). An abdominal X-ray series reveals distended loops of small bowel and large bowel without air fluid levels and no free air under the diaphragm. An abdominal ultrasound demonstrates a distended gallbladder with pericholecystic fluid and no stones. What is the most likely underlying etiology?

(A) Acute pancreatitis  
(B) Cholecystitis  
(C) Cholangiohepatitis  
(D) Perforated duodenal ulcer  
(E) Acute cholangitis
- A 55-year-old woman is evaluated in the emergency department for a 2-day history of severe epigastric abdominal pain, nausea, and vomiting. In reviewing her past medical history, she states she was evaluated 6 months ago for mild, but similar intermittent abdominal pain and was lost to follow-up. She does not take any medications. She has 1-2 drinks of alcohol on social occasions. On physical examination, temperature is 99.2 °F, blood pressure is 132/82 mmHg, pulse is 101/min, and respirations are 20/min. There is epigastric tenderness and RUQ tenderness. Labs are drawn and shown below. What is the most likely diagnosis?

AST: 523  $\mu\text{L}$  (normal 5–35  $\mu\text{L}$ )  
ALT: 622  $\mu\text{L}$  (7–56  $\mu\text{L}$ )  
TBilli: 2.0 mg/dL (0.1–1.2 mg/dL)  
Alkaline phosphatase: 450  $\mu\text{L}$  (33–131  $\mu\text{L}$ )  
Amylase: 1300  $\mu\text{L}$  (30–110  $\mu\text{L}$ )  
Lipase: 1000  $\mu\text{L}$  (7–60  $\mu\text{L}$ )

(A) Acute pancreatitis secondary to alcohol  
(B) Acute pancreatitis secondary to gallstones  
(C) Acute pancreatitis secondary to hypertriglyceridemia  
(D) Acute pancreatitis secondary to hypercalcemia  
(E) Chronic pancreatitis
- A 60-year-old man presents with yellowing of his skin. He reports that he has unintentionally lost 10 lb over the last 5 months. He denies abdominal pain or fevers. He has also developed pruritus, dark urine, and clay-colored stools. He has smoked two packs per day for the past 40 years. On physical exam, his temperature is 98.6 °F, blood pressure is 110/86 mmHg, and pulse is 94/min. On physical examination, he appears jaundiced and has scleral icterus. He has fullness, suggestive of a mass in his RUQ that is not tender to palpation. What is the best term to describe this constellation of findings?

(A) Cullen's sign  
(B) Charcot's triad  
(C) Reynold's pentad  
(D) Courvoisier's sign  
(E) Murphy's sign
- A 46-year-old man is admitted to the hospital for severe epigastric pain of 12-h duration, nausea, two episodes of vomiting, and anorexia. His past medical history is significant for alcoholism and several admissions for alcohol withdrawal. On physical exam temperature is 99.6 °F, blood pressure is 137/84 mmHg, pulse is 99/min, and respirations are 16/min. There is moderate tenderness in the epigastrium to palpation, but the abdomen is soft and no masses are felt. There is no scleral icterus and no jaundice of the skin. Laboratory examination is shown below. What is the next step in management?

AST: 123  $\mu\text{L}$  (normal 5–35  $\mu\text{L}$ )  
ALT: 99  $\mu\text{L}$  (7–56  $\mu\text{L}$ )  
TBilli: 0.7 mg/dL (0.1–1.2 mg/dL)  
Lipase: 709  $\mu\text{L}$  (7–60  $\mu\text{L}$ )  
Alkaline phosphatase: 709  $\mu\text{L}$  (33–131  $\mu\text{L}$ )  
WBC:  $11 \times 10^3/\mu\text{L}$  (normal  $4.1\text{--}10.9 \times 10^3/\mu\text{L}$ )  
Hgb: 12.9 mg/dL (13.2–16.2 mg/dL)

(A) Start intravenous antibiotics  
(B) CT scan  
(C) ERCP with sphincterotomy  
(D) NPO, IV hydration, and analgesics  
(E) Chlordiazepoxide (Librium) for alcohol withdrawal
- A 45-year-old healthy woman arrives for follow-up after her primary care physician discovered gallstones incidentally while performing imaging studies for an unrelated event. She has no complaints and has a healthy diet but is worried about the stones. An abdominal ultrasound is repeated and demonstrates several stones in her gallbladder without any wall thickening. What is the recommended management for this patient?

- (A) Prophylactic cholecystectomy  
 (B) Ursodeoxycholic acid  
 (C) Endoscopic retrograde cholangiography (ERCP)  
 (D) Observation  
 (E) Extracorporeal shock wave lithotripsy
6. A 30-year-old man is admitted to the hospital for severe acute pancreatitis due to alcohol abuse. His hospital course is complicated by transient renal insufficiency. On hospital day 20, the patient complains of increasing epigastric abdominal pain, nausea, and vomiting. On physical examination, he has a fever of 102 °F and a heart rate of 110/min. Abdominal examination reveals marked epigastric tenderness. His lungs are clear bilaterally. WBC count is  $14.5 \times 10^3/\mu\text{L}$  (normal  $4.1\text{--}10.9 \times 10^3/\mu\text{L}$ ) with 10 % bands. Blood cultures are sent, and fluid bolus is given. What is the next step in management?
- (A) Start intravenous antibiotics  
 (B) CT scan of the abdomen with contrast  
 (C) ERCP with sphincterotomy  
 (D) Exploratory laparotomy for pancreatic debridement  
 (E) Laparoscopy
7. A 65-year-old man presents to the ED with RUQ pain. He is diagnosed with acute cholecystitis and undergoes a cholecystectomy the following day. He is discharged shortly after his procedure. Five days later, he arrives back to the ED with abdominal pain and low-grade fevers. On physical examination, his blood pressure is 120/70 mmHg, heart rate is 90/min, and temperature is 99.0 °F. He has diffuse mild abdominal tenderness to palpation. His laboratory examination is significant for white blood count of  $16.9 \times 10^3/\mu\text{L}$  (normal  $4.1\text{--}10.9 \times 10^3/\mu\text{L}$ ). What is the next best step?
- (A) Endoscopic ultrasound  
 (B) Exploratory laparotomy  
 (C) CT scan of abdomen  
 (D) ERCP with stenting  
 (E) HIDA scan
8. A 63-year-old man is admitted to the hospital for alcohol pancreatitis. At 48 h after admission, he manifested four of Ranson's criteria. On hospital day 6 he is reevaluated on rounds for increasing epigastric abdominal pain. He denies any vomiting. On physical exam temperature is 100.3 °F, blood pressure is 134/74 mmHg, pulse is 89/min, and respirations are 16/min. The belly is distended but soft, and there is still significant epigastric tenderness. CT scan is obtained and shows diffuse edema surrounding the pancreas with a pancreatic phlegmon, but no evidence of necrosis. What is most appropriate approach to his nutritional management?
- (A) Continue NPO and intravenous normal saline  
 (B) Clear liquid diet  
 (C) Enteral nutrition via feeding tube  
 (D) Parenteral nutrition via central line  
 (E) Parenteral nutrition via peripheral line
9. A 52-year-old insulin-dependent diabetic man is evaluated for vague epigastric pain, is diagnosed with GERD, and is treated with proton pump inhibitors with resolution of symptoms. In the course of the workup, however, an abdominal ultrasound was performed. No gallstones were seen, but an incidental 12 mm polyp was found within the gallbladder. What is the next best step in management?
- (A) Laparoscopic cholecystectomy  
 (B) Open cholecystectomy  
 (C) Percutaneous gallbladder drainage  
 (D) Endoscopic ultrasound  
 (E) Repeat ultrasound in 6 months
10. A 41-year-old man with alcoholism is admitted to the ICU with a diagnosis of acute pancreatitis. He has three Ranson's criteria on admission and two more at 48 h. He requires aggressive fluid resuscitation to maintain his blood pressure in the first 24 h, but over the next 3 days, his blood pressure stabilizes. On the third day of admission, he develops tachypnea, tachycardia, and hypoxia with oxygen saturation to 89 %. Central venous pressure is 8 mmHg. The patient is placed on nasal cannula, but the oxygen saturation remains the same. His temperature is 98.9 °F, pulse is 104/min, and blood pressure is 129/73 mmHg. A chest X-ray is obtained and shows bilateral infiltrates. Labs are drawn and shown below. What is the most likely diagnosis?
- AST: 75  $\mu\text{L}$  (normal 5–35  $\mu\text{L}$ )  
 ALT: 92  $\mu\text{L}$  (7–56  $\mu\text{L}$ )  
 WBC:  $11 \times 10^3/\mu\text{L}$  (normal  $4.1\text{--}10.9 \times 10^3/\mu\text{L}$ )  
 Arterial blood gas: pH 7.44, PaO<sub>2</sub> 66 mmHg, PaCO<sub>2</sub> 36 mmHg
- (A) Adult respiratory distress syndrome (ARDS)  
 (B) Pulmonary embolism  
 (C) Hospital-acquired pneumonia  
 (D) Fluid overload (pulmonary edema)  
 (E) Atelectasis
11. Which laboratory finding is consistent with obstructive jaundice?
- (A) Increased urine urobilinogen  
 (B) Increased urine conjugated bilirubin  
 (C) Increased stool stercobilin  
 (D) Indirect > direct hyperbilirubinemia  
 (E) Elevation of transaminases out of proportion to alkaline phosphatase

12. Which of the following is a risk factor for pancreatic cancer?
- Alcohol
  - Smoking
  - Prostate cancer in the family
  - Malabsorption
  - Pancreatic enzyme supplementation
13. A 60-year-old woman arrives to the emergency department with bloody emesis. She has a past medical history significant for hypertension and an episode of severe pancreatitis due to alcohol abuse 1 year ago and has since developed chronic pancreatitis. Her temperature is 98.6 °F, blood pressure 110/88 mmHg, and pulse of 88/min. Esophagogastroduodenoscopy shows bleeding coming from isolated gastric varices. Which of the following is most likely to successfully treat the bleeding?
- Liver transplantation
  - Endoscopic banding of the varices
  - Endoscopic sclerotherapy
  - TIPS (transjugular portosystemic shunt)
  - Splenectomy
14. A 56-year-old male undergoes a Whipple procedure for pancreatic adenocarcinoma. Two days later, there is about 30 cm<sup>3</sup> of white/opal opaque drainage emanating from the patient's drain. What is the most appropriate next step?
- Obtain abdominal CT scan
  - Obtain abdominal ultrasound
  - Send fluid for amylase level
  - Start octreotide
  - Initiate total parenteral nutrition (TPN)
15. Which of the following is an appropriate use of CA 19-9?
- Screening normal, healthy patients for pancreatic cancer
  - Screening at-risk patients for pancreatic cancer
  - Confirming diagnosis of pancreatic cancer in patients with periampullary mass on CT
  - Monitor for progression of disease following resection and/or adjuvant therapy
  - None of the above
16. A 45-year-old presents with a 1 day history of RUQ pain and tenderness, nausea, and vomiting. Physical examination is significant for marked RUQ tenderness and guarding. Laboratory values are significant for a WBC of  $12 \times 10^3/\mu\text{L}$  (normal  $4.1\text{--}10.9 \times 10^3/\mu\text{L}$ ) with 10 % bands, total bilirubin of 1.2 mg/dL (0.1–1.2 mg/dL), AST of 110  $\mu\text{L}$  (normal 5–35  $\mu\text{L}$ ), ALT of 120  $\mu\text{L}$  (7–56  $\mu\text{L}$ ), and alkaline phosphatase of 90  $\mu\text{L}$  (33–131  $\mu\text{L}$ ). RUQ ultrasound reveals several gallstones, a thickened gallbladder wall, and a normal common bile duct. Optimal management consists of:
- Schedule for elective outpatient laparoscopic cholecystectomy
  - Admit, IV antibiotics, laparoscopic cholecystectomy within 48 h of admission
  - Admit, IV antibiotics for 4–5 days followed by laparoscopic cholecystectomy
  - Admit, IV antibiotics until WBC normalizes, followed by outpatient laparoscopic cholecystectomy
  - Admit, IV antibiotics, ERCP, followed by laparoscopic cholecystectomy
17. A 40-year-old female presents with moderate epigastric abdominal pain. She has a history of intermittent RUQ pain after eating fatty foods. On physical examination she is afebrile with a heart rate of 100/min and blood pressure of 110/70 mmHg. She has moderate epigastric tenderness to palpation. Laboratory values are significant for a WBC of  $11 \times 10^3/\mu\text{L}$  (normal  $4.1\text{--}10.9 \times 10^3/\mu\text{L}$ ) with 3 % bands, total bilirubin of 1.2 mg/dL (0.1–1.2 mg/dL), AST of 250  $\mu\text{L}$  (5–35  $\mu\text{L}$ ), ALT of 300  $\mu\text{L}$  (7–56  $\mu\text{L}$ ), alkaline phosphatase of 150  $\mu\text{L}$  (33–131  $\mu\text{L}$ ), amylase of 1,300  $\mu\text{L}$  (30–110  $\mu\text{L}$ ), and lipase of 1,100  $\mu\text{L}$  (7–60  $\mu\text{L}$ ). RUQ ultrasound shows numerous small gallstones, normal gallbladder wall, and a normal common bile duct diameter of 0.4 mm. On the second hospital day, her pain has resolved; she is afebrile and has a normal heart rate, and her WBC count has normalized. The amylase has decreased to 350  $\mu\text{L}$ . Optimal management consists of:
- Proceed with laparoscopic cholecystectomy (LC) with intraoperative cholangiogram (IOC)
  - Wait 4–5 more days until amylase has completely normalized, and then proceed to LC with IOC
  - ERCP followed by LC during same hospitalization
  - Schedule for elective outpatient LC with IOC
  - ERCP only
18. A 50-year-old diabetic male presents with severe RUQ pain and fevers. On physical examination, his temperature is 103.5 °F, BP is 100/60 mmHg, and heart rate is 120/min. He has severe tenderness to palpation in the RUQ. WBC is  $20 \times 10^3/\mu\text{L}$  (normal  $4.1\text{--}10.9 \times 10^3/\mu\text{L}$ ) with 10 % bands, total bilirubin is 1.0 mg/dL (0.1–1.2 mg/dL), amylase is 90  $\mu\text{L}$  (30–110  $\mu\text{L}$ ), alkaline phosphatase is 90  $\mu\text{L}$  (33–131  $\mu\text{L}$ ), AST is 110  $\mu\text{L}$  (normal 5–35  $\mu\text{L}$ ), and ALT is 140  $\mu\text{L}$  (7–56  $\mu\text{L}$ ). RUQ ultrasound shows gallstones, a normal common

bile duct diameter, and a few gas bubbles within the wall of the gallbladder. IV fluids and antibiotics are administered. The next step in the management consists of:

- (A) Immediate cholecystectomy
  - (B) Admit to ICU for 24–48 h of IV antibiotics and careful monitoring
  - (C) Cholecystostomy
  - (D) CT scan of abdomen
  - (E) ERCP
19. A 58-year-old female underwent a CT scan of her abdomen and pelvis following a motor vehicle collision

1 month ago. She has no intra-abdominal injuries and was discharged from the ED. However, her gallbladder was incidentally noted to be heavily calcified. She is otherwise in good health and denies any abdominal pain. Her past history is significant for mild hypertension. Which of the following is the best recommendation?

- (A) Reassure patient that no follow-up is needed
- (B) Repeat CT scan in 1 year
- (C) Laparoscopic cholecystectomy
- (D) Check serum calcium and PTH levels
- (E) Obtain ERCP with brushings

## Answers

### 1. Answer B

Acalculous cholecystitis is a condition seen in patients that are critically ill such as those with multiorgan trauma, burns, or recent major surgery. The exact mechanism is unclear, but it is thought to be secondary to a combination of biliary stasis (from being NPO) and gallbladder ischemia as a result of hypovolemic and/or septic shock. The diagnosis can be difficult for several reasons. Patients are critically ill so a history may be unobtainable and physical exam may be unreliable. The imaging test of choice is ultrasound (US). Findings suggestive of acalculous cholecystitis include gallbladder wall thickening and pericholecystic fluid; however, such findings are not consistent. If US is not definitive, HIDA scan is the next test and is considered positive if the gallbladder is not visualized. However, false positives are seen in patients who have been NPO for a prolonged period (which many of these critically ill patients have). Gallstones are not implicated in this condition, and will not be seen on ultrasonography. Treatment of acalculous cholecystitis includes broad-spectrum antibiotics followed by urgent percutaneous cholecystostomy (if the patient is critically ill) or cholecystectomy (laparoscopic vs. open cholecystectomy) if the patient is stable enough to undergo general anesthesia. Acute pancreatitis (A) is in the differential; however, the patient's lipase is normal (more specific than amylase), and the amylase is only mildly elevated (acute pancreatitis requires an elevation 3x above normal). Mild hyperamylasemia can be seen with many intra-abdominal conditions including cholecystitis or bowel ischemia. Burn victims are at risk for stress-related mucosal damage (Curling ulcer) secondary to an inability to maintain the integrity of the gastrointestinal mucosal barrier. This may subsequently lead to perforated viscus (D) which will present with an acute abdomen and a plain film demonstrating free air under the diaphragm. Cholangiohepatitis (C) is associated with biliary parasites such as *Clonorchis sinensis* and is characterized by brown pigment stones that result from biliary sludge and dead bacterial cell bodies. Acute cholangitis (E) would present with evidence of cholestasis (jaundice and/or elevated liver enzymes) and biliary obstruction (dilated bile ducts on ultrasound).

### 2. Answer B

The most likely diagnosis is acute pancreatitis secondary to gallstones. More than half of all cases of pancreatitis are associated with either gallstones or alcohol. Patients with gallstone pancreatitis have extremely high serum amylase (sometimes in the thousands) and ALT (greater than 3x the upper limit of normal) as compared to other etiologies. A biliary etiology of pancreatitis is further supported by the elevated bilirubin and alkaline phosphatase which suggest at least a temporary obstruction of the common bile duct by a

gallstone. Most gallstones only transiently obstruct the common bile duct and pass on their own. Pancreatitis due to alcohol is seen in patients with long-standing heavy alcohol abuse (which is not suggested by the history in this patient), and not following a onetime binge. Chronic pancreatitis is rare with gallstones. It is most often seen in association with long-standing alcohol abuse. Patients present with chronic epigastric pain, steatorrhea, and/or diabetes. Amylase and lipase levels are often not elevated.

### 3. Answer D

The patient is presenting with painless jaundice, which should be considered as due to malignancy until proven otherwise. Courvoisier's sign is a term used to describe a palpable non-tender gallbladder that markedly distends as a result of a gradual common bile duct obstruction, most often by a pancreatic adenocarcinoma at the head of the pancreas (distal common bile duct and ampullary cancer are also in the differential). Gallstones typically cause sudden obstruction of the biliary tree and often harbor bacteria. They are almost always associated with pain and often trigger an inflammatory response. Charcot's triad (B) (RUQ pain, fever, and jaundice) and Reynold's pentad (C) (the triad plus hypotension and altered mental status) are associated with acute cholangitis most often secondary to a gallstone obstructing the distal common bile duct. Murphy's sign (E) (RUQ tenderness on palpation that stops inspiration) is associated with acute cholecystitis due to a gallstone obstructing the cystic duct. Cullen's sign (A) is a blue-red discoloration at the umbilicus, and the appearance is a result of digested blood products in the retroperitoneum, forming methemalbumin, that then travel towards the anterior abdominal wall. It is associated with retroperitoneal bleeding, as seen with hemorrhagic pancreatitis.

### 4. Answer D

The presentation is most consistent with pancreatitis secondary to alcohol. Lipase is more specific for pancreatitis than amylase. The vast majority of acute pancreatitis cases are due to peripancreatic inflammation, not infection. Antibiotics (A) are therefore not beneficial. CT scan (B) is not necessary to establish the diagnosis and should be reserved for situations where the diagnosis is in question or if the patient clinically deteriorates during the subsequent hospitalization. The most appropriate management is to make the patient NPO, aggressively hydrate, and administer analgesics. Routine use of an NG tube is unnecessary. ERCP (C) is utilized in gallstone pancreatitis, specifically if the patient demonstrates evidence of concomitant cholangitis or obstructive jaundice. Librium (E) may be utilized for alcohol withdrawal, but should not be prioritized ahead of aggressive hydration. The majority of patients resolve the episode of pancreatitis within 3–5 days using conservative management.

**5. Answer D**

Gallstones are commonly discovered incidentally in asymptomatic patients after imaging studies that are performed for unrelated reasons. Only 2–3% of asymptomatic patients develop biliary colic per year, and only a small fraction of those patients progress to complications from gallstones (such as acute cholecystitis, pancreatitis, acute cholangitis). For this reason, the vast majority of asymptomatic gallstones should not receive prophylactic cholecystectomy (A). Prophylactic cholecystectomy might be considered in patients who are planning extended travel to areas without healthcare access (Antarctica in the winter). Because patients with diabetes are at greater risk of developing complications from gallstones, some authors have recommended prophylactic cholecystectomy in diabetics. However, even in the diabetic population, it is reasonable to wait to see if symptoms develop. Ursodeoxycholic acid (B) can dissolve gallstones. However, it is completely successful in only about 1/3 of cases, only for cholesterol stones, is associated with side effects (diarrhea), and is costly. In addition, the stones may recur once the medication is stopped. ERCP (C) is an invasive procedure utilized for choledocholithiasis and acute cholangitis. Extracorporeal shock wave lithotripsy (E) is effective in breaking stones into small particles, but does not prevent stone recurrence.

**6. Answer A**

The patient is manifesting evidence of systemic inflammatory response syndrome (SIRS); the presentation is most concerning for a pancreatic abscess. When SIRS is diagnosed, the first steps include fluid administration, blood cultures, and prompt institution of intravenous antibiotics (within 1 h), preferably imipenem. This should be followed by a CT scan (B) with contrast looking for necrotic tissue (non-enhancing areas) and a possible pancreatic abscess. In the past, such a finding on CT would warrant immediate exploration for pancreatic debridement (D). However the current approach is termed a “step-up” approach, which consists of a series of increasingly more invasive interventions. This begins with a percutaneous attempt at drainage of any infected pancreatic collections. If that fails, the next step is laparoscopic drainage (E). Finally open surgical pancreatic debridement is recommended. ERCP (C) would be indicated for suspected acute cholangitis, usually in association with gallstones.

**7. Answer C**

Persistent abdominal pain, fevers, and nausea beyond a few days following laparoscopic cholecystectomy should raise suspicion of a bile duct injury or a bile leak from the cystic duct stump (due to the surgical clip inadvertently coming off). Imaging by CT scan should be obtained to look for a

fluid collection. Abdominal ultrasound is also an acceptable imaging modality, but CT provides more information about the amount of fluid and its location. Additionally, findings on CT will guide subsequent management. Endoscopic ultrasound (A) is primarily used in the setting of pancreatic or bile duct cancer to help determine resectability and look for adjacent enlarged lymph nodes. If the patient has evidence of infection, and a large fluid collection is found, a percutaneous drain should be placed. Bilious output suggests that bile has leaked (from the stump of the ligated cystic duct or worse from an injury to the common hepatic/bile duct). A HIDA scan (E) should be obtained next. If the common bile duct or common hepatic duct were inadvertently transected, the HIDA will show extravasation of tracer in the RUQ without tracer filling the small bowel. Such a finding would mandate exploratory laparotomy (B), and a loop of small bowel would need to be anastomosed to the proximal bile duct (hepaticojejunostomy). If on the other hand, the HIDA scan shows extravasation of tracer in the RUQ but tracer is seen in the small bowel, this confirms that the integrity of the main bile ducts. The most common cause for this latter finding is a cystic duct stump leak (as in the present case). Management is to perform ERCP with stenting (D) of the ampulla. This lowers the pressure in the biliary tree, creating a path of least resistance for the bile, thus permitting the cystic duct stump to seal.

**8. Answer C**

Patients with mild pancreatitis can often be managed being NPO along with intravenous hydration alone since recovery occurs rapidly, within 5–7 days, at which time oral intake can resume. However, patients with moderate-severe pancreatitis are unlikely to resume oral intake within 5–7 days, prompting the need for nutritional support. The most appropriate management is enteral nutrition. Enteral nutrition is provided through a nasojejunal tube, ideally placed past the ligament of Treitz as to not stimulate and irritate the pancreas. Enteral nutrition is preferred for those with a prolonged course of pancreatitis because it helps maintain the intestinal barrier and prevents bacterial translocation from the gut. In addition, enteral nutrition avoids the complications associated with parenteral nutrition including those secondary to venous access and blood stream infections. A 2010 meta-analysis of eight trials demonstrated that enteral nutrition significantly reduced mortality, multiorgan failure, infections, and the need for surgery as compared with those who received parenteral nutrition. Parenteral nutrition should only be initiated in patients who do not tolerate enteral feeding. In moderate-severe pancreatitis, oral feeding is not tolerated due to pain, nausea, or vomiting related to inflammation and edema causing gastric outlet obstruction, and should not be used.

**9. Answer A**

Gallbladder polyps are usually incidental findings, most are asymptomatic, and the vast majority are benign. Risk of malignancy is related to polyp size. Polyps <10 mm can be observed, whereas laparoscopic cholecystectomy is recommended for those  $\geq 10$  mm. Open cholecystectomy (B) is not necessary for a polyp. Percutaneous gallbladder drainage (C) is indicated for the management of acalculous cholecystitis. Endoscopic ultrasound (D) would not provide any additional information. A follow-up ultrasound (E) would be appropriate for small polyps.

**10. Answer A**

The patient has severe pancreatitis as evidenced by having five Ranson's criteria. Mortality is markedly increased with three or more such criteria. Mortality in the first week is due to multisystem organ failure (pulmonary, renal, cardiac). ARDS occurs in a variety of settings, including severe pancreatitis. The classic presentation is severe hypoxia, with an associated respiratory alkalosis and a CXR that shows bilateral infiltrates that is often symmetrical. Therapy includes starting mechanical ventilation with positive end-expiratory pressure (PEEP). The overall mortality is very high (>50%). Although a pulmonary embolism (B) may also present with hypoxia and a respiratory alkalosis, it is unlikely to present with bilateral infiltrates (the CXR is usually negative). Hospital-acquired pneumonia (C) would present with a productive cough, dyspnea, chills, pleuritic chest pain, decreased breath sounds, wheezing, and a CXR showing lobar consolidation. A patient with pulmonary edema (D) would have a CXR showing cephalization of vessels and Kerley B lines (i.e., prominent horizontal interstitial markings in lower lung fields), as well as an elevated CVP (>18 mmHg). Atelectasis (E) would appear as a white out of a lobe.

**11. Answer B**

Obstructive jaundice is an elevation of serum conjugated bilirubin due to inability to excrete it into the intestines via the biliary system. Thus there would be decreased available bilirubin in the intestine for intestinal bacteria to convert to urobilinogen and subsequently stercobilin. Although indirect and direct bilirubin are both elevated in obstructive jaundice, the direct component should be higher. Unconjugated bilirubin is bound to protein, and not filtered by the kidney. In patients with jaundice, conjugated bilirubin is elevated in the urine. The elevation in urine conjugated bilirubin gives it the brown ("tea-colored") discoloration. Elevation of transaminases out of proportion to alkaline phosphatase (E) would suggest hepatocellular injury.

**12. Answer B**

Smoking is a risk factor for pancreatic cancer. Pancreatic cancer is also more common in men, advanced age, in the

obese, and in African Americans. Chronic pancreatitis is the strongest risk factor pancreatic cancer, although alcohol consumption (A) per se is not. A family history of prostate cancer (C) is not a risk factor for pancreatic cancer. Although malabsorption (D) and pancreatic enzyme supplementation (E) is frequently associated with patients that have chronic pancreatitis, they are not themselves directly linked to an increased risk for pancreatic cancer.

**13. Answer E**

UGI bleeding from varices most often are the result of alcohol-related liver cirrhosis with subsequent portal hypertension. This leads primarily to esophageal varices and less commonly to concomitant gastric varices. Isolated gastric varices are uncommon. They often arise in association with splenic vein thrombosis (SVT), which forces all the venous drainage of the spleen to travel through the short gastric veins resulting in large gastric varices that are at risk for rupture and bleeding. The most common cause of SVT is pancreatitis (acute and chronic). The most common cause of chronic pancreatitis is alcohol abuse. Peripancreatic inflammation can lead to occlusion of the splenic vein, which is posterior to the pancreas. SVT does not lead to esophageal varices because the collaterals do not involve the esophageal vasculature. Diagnosis of SVT can be made by duplex ultrasound of the splenic vein. It can also be detected on a venous phase CT scan. Splenectomy effectively eliminates the enlarged short gastric veins and thus cures the gastric varices. Gastric varices are particularly dangerous as they tend to cause massive bleeding. In addition, they do not respond well to standard treatment for esophageal varices such as banding (B) or sclerotherapy (C). Both liver transplantation (A) and TIPS (D) would reduce portal hypertension and thus help remedy esophageal varices but would be ineffective for isolated gastric varices in the setting of SVT.

**14. Answer C**

The first step in working up a pancreatic leak is to test the drained fluid for amylase. In addition, serum amylase level should be checked as well. If fluid amylase level is high and output levels are high (>50 cm<sup>3</sup>/day), patient can be made NPO to decrease secretion of pancreatic fluid that accompanies oral intake. Imaging (A–B) can be done at a later time to evaluate adequacy of drainage. Octreotide (D) can be given to decrease pancreatic secretions, but it is not used routinely, and there is no evidence-based data that demonstrate cost-effective efficacy of octreotide use in this setting. TPN (E) is not routinely needed in this setting.

**15. Answer D**

At this time CA 19–9 is not recommended for screening pancreatic cancer, and is also not a diagnostic test. However,

many surgeons use CA 19–9 to monitor for recurrence following surgery.

### 16. Answer B

The patient presented has RUQ pain and tenderness, nausea, and an ultrasound demonstrating gallstones with a thickened gallbladder wall suggestive of acute cholecystitis. Mild elevations in ALT and AST can be expected with acute cholecystitis, as well as leukocytosis with a left shift. The patient should be admitted to the hospital, made NPO, given IV fluids, and IV antibiotics with gram negative, enterococcus, and anaerobic coverage. She should undergo laparoscopic cholecystectomy, ideally within 48 h (C–E). Multiple studies have shown that delaying surgery is of no benefit and, in fact, makes the operation technically more challenging due to more scarring. Elective outpatient laparoscopic cholecystectomy is appropriate for patients with biliary colic (A).

### 17. Answer A

This patient has acute pancreatitis, most likely secondary to gallstones (most common cause). She has had prior episodes of pain after eating fatty food, which is characteristic of symptomatic gallstones. In addition, the lipase and amylase are elevated (3× greater than the upper limit of normal). Cholecystectomy is considered the standard of care in patients with gallstone pancreatitis because there is a high risk of recurrent pancreatitis. Although most centers have traditionally waited until all laboratory values have normalized for patients with mild disease (may take 5–7 days) (B), recent randomized studies have demonstrated that cholecystectomy can be safely performed within 48 h of admission (in patients with mild pancreatitis) regardless of whether laboratory values have normalized (D). Thus this patient should proceed with LC with IOC since she demonstrates no evidence of severe pancreatitis. On the other hand, with severe pancreatitis, such as necrotizing pancreatitis, delaying gallbladder removal until complete resolution of the pancreatitis is recommended. The gallstones that cause pancreatitis are usually small, and as such, in the majority of cases, the stone remains impacted very briefly, only transiently

obstructing the ampulla of Vater, and soon after passes into the duodenum. As such persistent of a CBD stone is uncommon, and therefore ERCP is not usually needed (C, E).

### 18. Answer A

A diabetic patient presenting with symptoms suggestive of acute cholecystitis with high fevers, high WBC with left shift, and RUQ ultrasound demonstrating gas bubbles within the wall of the gallbladder should be suspected of having emphysematous cholecystitis, which is generally considered a surgical emergency. It is generally caused by gas-forming organisms, such as *Clostridia* and *E. coli*. Compared to acute cholecystitis, emphysematous cholecystitis is associated with a much higher mortality due to severe sepsis as the gallbladder becomes gangrenous. Broad-spectrum antibiotics (include high-dose penicillin or clindamycin to cover *Clostridia*) and fluid replacement are started immediately to stabilize the patient (B), but because of the risk of gangrene, these patients should undergo an immediate cholecystectomy. The diagnosis can be supported with CT scan of the abdomen (D) which will also demonstrate gas within the gallbladder wall. ERCP (E) is not indicated. Cholecystostomy (C) would not be an appropriate intervention for emphysematous cholecystitis as the necrotizing tissue infection would not be removed.

### 19. Answer C

A heavy calcified gallbladder is termed a porcelain gallbladder and is most commonly found incidentally on imaging for unrelated reasons. Patients are often asymptomatic. However, it is important to recognize that a porcelain gallbladder is associated with an increased risk of gallbladder adenocarcinoma. As such, the recommendation is that patients should undergo surgical management with laparoscopic cholecystectomy. Reassurance (A) or “watchful waiting” with annual CT scan (B) is not appropriate, even for asymptomatic patients, because of the risk for malignancy. There is no reason to suspect hyperparathyroidism, and so a serum calcium and PTH level would not be appropriate (D). ERCP with brushings is useful for suspected bile duct cancer, but not for suspected gallbladder cancer (E).



## Lower Gastrointestinal

Areg Grigorian and Christian de Virgilio

### Questions

- A 55-year-old male has been receiving serial ultrasound examinations to follow his abdominal aortic aneurysm (AAA). Over the past year, the aneurysm has rapidly enlarged to 5.8 cm, and he undergoes endovascular abdominal aortic aneurysm repair (EVAR). The operation itself is uneventful. However, on postoperative day 1, the patient develops a low-grade fever, left lower quadrant pain, and diarrhea that appears to be blood tinged. On physical examination, he has mild to moderate tenderness in the left lower quadrant without rebound or guarding. What is the next step in the workup?

  - CT scan of the abdomen and pelvis with oral and IV contrast
  - Exploratory laparotomy
  - Formal mesenteric arteriography
  - Flexible sigmoidoscopy
  - Abdominal ultrasound
- A 30-year-old man with colon cancer secondary to familial adenomatous polyposis (FAP) arrives for follow-up after receiving a total proctocolectomy with end ileostomy. He was found to have colon cancer after presenting at the age of 27 with unexplained rectal bleeding, diarrhea, and abdominal pain. Subsequent colonoscopy found multiple adenomatous polyps in his colon. He has a 5-year-old son, who is screened and is positive for the APC gene. What is the recommended screening for his son?

  - Colonoscopy starting at age 20
  - Flexible sigmoidoscopy starting at age 10
  - Colonoscopy starting at age 50
  - Annual fecal occult blood test
  - Annual barium enema
- A 66-year-old male presents with a large volume of maroon-colored stools combined with red blood. In the ED his blood pressure is 100/60 mmHg, and heart rate is 120/min. Physical examination is unremarkable. Two large bore IVs are inserted, and 2 liters of normal saline are given, after which the patient's vital signs normalize. Laboratory tests are sent, including a type and cross. What is the next step in the management?

  - Administer two units of O negative blood
  - Place NG tube for aspiration
  - Colonoscopy
  - Exploratory laparotomy
  - Place central line
- A 27-year-old man arrives to the emergency department complaining of bloody diarrhea and rectal urgency. He reports a normal appetite, and has not lost any significant weight. After initial workup yields no findings, he is referred to a gastroenterologist for a colonoscopy. He is found to have pseudopolyps in his colon, and subsequent biopsy results confirm ulcerative colitis. He is started on corticosteroids and sulfasalazine, which is able to control his symptoms. Which of the following is true regarding colon cancer and screening in patients with ulcerative colitis?

  - Screening for colon cancer is not necessary
  - Screening colonoscopy with random biopsies 8 years after disease onset
  - Screening colonoscopy with biopsy only if a suspicious polyp is seen
  - Screening colonoscopy annually once diagnosis is established
  - The risk of colon cancer is much less than with Crohn's disease
- A 50-year-old man comes to the doctor complaining of painful defecation. On occasion, blood is found on the toilet paper after wiping. He has been experiencing this problem for months but felt too embarrassed to seek medical attention. He has a history of constipation and has tried multiple stool softeners but to no avail. Rectal examination shows enlarged anal papillae with an edematous and hypertrophic skin tag in the posterior anal midline, most suggestive of a chronic fissure. He is referred to a surgeon and scheduled to undergo a lateral internal sphincterotomy. What is the most common complication of this procedure?

  - Bleeding
  - Anorectal sepsis
  - Fecal incontinence
  - Fistula formation
  - Nonhealing of fissure
- An 88-year-old woman with multi-infarct dementia undergoes a coronary artery bypass with the left internal mammary artery used as a conduit for three-vessel disease. Her operation is a success, and she is transferred to the ICU to recover. She is receiving opioids for pain relief. Over the next few days, she develops a markedly distended abdomen with no bowel sounds, pain, or rigidity. She has also not had a bowel movement for the past 48 h. Rectal examination does not demonstrate any retained stool. KUB demonstrates markedly distended colon with gas in the rectum, without air fluid levels. What part of the large bowel is the most likely to perforate?

  - Cecum
  - Transverse colon

- (C) Sigmoid colon  
(D) Rectum  
(E) There is very little risk of perforation
7. A 75-year-old man arrives to the ED with abdominal pain. He has never experienced this before but reports having left-sided abdominal pain over the last 2 days that is relieved temporarily after defecation. He has a temperature of 101.2 °F with a blood pressure of 142/88 mmHg and pulse of 88/min. His laboratory examination is significant for a WBC of  $14 \times 10^3/\mu\text{L}$  (normal  $4.1\text{--}10.9 \times 10^3/\mu\text{L}$ ) with 10 % bands. CT imaging reveals focal sigmoidal wall thickening with significant paracolic inflammation. He was treated as an in-patient for 3 days and discharged home without complications. Which of the following is the most appropriate follow-up option?
- (A) High-fiber diet alone  
(B) CT scan 2 weeks after resolution  
(C) Elective sigmoid colectomy  
(D) Barium enema  
(E) Colonoscopy
8. A 28-year-old woman presents to the ED because of abdominal pain that started 2 h ago. She has nausea and vomited twice in the last hour. She reports that the pain is predominantly in the right lower quadrant. On physical exam, her blood pressure is 120/60 mmHg, heart rate is 100/min, and she is afebrile. She is very tender in the RLQ on palpation at McBurney's point and has pain on passive extension of the right hip. Her WBC is  $14 \times 10^3/\mu\text{L}$  (normal  $4.1\text{--}10.9 \times 10^3/\mu\text{L}$ ), hemoglobin is 12 g/dL (12–15.2 g/dL), hematocrit is 36 % (37–46%), and platelet count is 250,000 (140–450,000). Her urinalysis shows 1+ white blood cells. Which of the following is the best next step in management?
- (A) Admit for observation  
(B) CT scan of the abdomen  
(C) Laparoscopic appendectomy  
(D) B-hCG  
(E) Broad-spectrum antibiotics
9. A 38-year-old presents with symptoms and signs of acute appendicitis and undergoes laparoscopic appendectomy. At surgery the terminal ileum and cecum appear to be red and inflamed. The appendix is removed uneventfully. Final pathology of the appendix demonstrates no evidence of acute appendicitis. Two weeks later, he presents back to the ED with feces draining from his right lower quadrant wound. Which of the following is the most likely explanation for why the drainage may not spontaneously stop?
- (A) A distal colonic obstruction  
(B) Chronic inflammation  
(C) An occult intra-abdominal abscess  
(D) A retained sponge in the abdomen  
(E) A missed malignancy
10. Which of the following is most likely to require *urgent* colectomy?
- (A) Cecal volvulus  
(B) Sigmoid volvulus  
(C) Acute diverticulitis  
(D) Cecal adenocarcinoma  
(E) Pseudomembranous colitis
11. A 55-year-old man starts a new security job that requires a physical exam by a doctor. He has no past medical history, and everyone in his family is healthy. He has a well-balanced diet and exercises every day. He is evaluated during a routine examination which includes a discussion of health maintenance issues. He is surprised to hear that it is recommended for a man of his age to get a colonoscopy. He asks if there are any other options available. Which of the following is an appropriate recommendation with respect to this health maintenance screening strategy?
- (A) Fecal occult blood test (FOBT) every 5 years  
(B) Annual rectal examination  
(C) Flexible sigmoidoscopy every 5 years + FOBT every 3 years  
(D) Annual CT colonography  
(E) Annual CEA levels
12. A 90-year-old man with Alzheimer's disease arrives from a nursing home with abdominal distention and pain for the past 12 h. He takes hydrochlorothiazide, donepezil, aspirin, and docusate. His physical exam reveals a temperature of 102 °F, blood pressure 90/70 mmHg, and pulse 112/min. His abdomen is rigid and diffusely tender with rebound and guarding. Laboratory examination is significant for WBC of  $15 \times 10^3/\mu\text{L}$  (normal  $4.1\text{--}10.9 \times 10^3/\mu\text{L}$ ), BUN of 25 mg/dL (7–21 mg/dL), and creatinine of 1.8 mg/dL (0.5–1.4 mg/dL). X-ray shows a markedly distended colon with a bent-inner tube sign. Following IV fluids and antibiotics, what is the best next step in management?
- (A) Decompression with colonoscopy  
(B) CT scan of the abdomen and pelvis  
(C) Exploratory laparotomy  
(D) Placement of a rectal tube  
(E) Admit to hospital for close observation
13. A 44-year-old man presents with right lower quadrant pain without rebound, nausea, and vomiting. CT scan shows bowel wall thickening near the ileocecal valve. He is scheduled for an appendectomy. Final pathology confirms acute appendicitis. In addition, an incidental 2.5 cm

- carcinoid tumor is found at the tip of the appendix. What is the most appropriate next step in management?
- (A) Observation
  - (B) Colonoscopy within the next 6 months
  - (C) UGI with small bowel follow through
  - (D) Chest X-ray
  - (E) Right hemicolectomy
14. A 64-year-old male returns for follow-up six months after successful sigmoid colectomy for colon cancer. Which of the following can lead to a falsely elevated serum CEA level?
- (A) Chronic wound infection
  - (B) Smoking
  - (C) Hyperglycemia
  - (D) Age
  - (E) Postoperative chemotherapy
15. A 4-year-old boy presents to the emergency department with right lower quadrant pain, nausea, and anorexia. On physical examination, his bowel sounds are absent, and he has marked tenderness in the right lower quadrant with guarding. The remainder of the abdominal exam is negative. Laboratory values reveal a leukocytosis with a left shift. What is the most likely initiating event for his acute condition?
- (A) Lymphoid hyperplasia
  - (B) Fecalith
  - (C) Parasitic infection
  - (D) Enlarged mesenteric lymph nodes
  - (E) Foreign body ingestion
16. A 50-year-old woman undergoes screening colonoscopy. During the procedure, she is found to have a dark discoloration of the entire colon with lymph follicles shining through as pale patches. What is the most likely underlying etiology?
- (A) Drinking lots of prune juice
  - (B) Colon cancer
  - (C) Laxative abuse
  - (D) Normal anatomic variation
  - (E) Inflammatory bowel disease
17. A 88-year-old man with Parkinson's disease and COPD is brought to the ED from a skilled nursing facility because his nurse noticed bright red blood in his adult diapers. His medications include hydrochlorothiazide, metformin, levodopa, salmeterol, and docusate. On admission, he is afebrile with normal blood pressure and pulse. Nasogastric tube (NGT) aspiration returns yellow bile. Colonoscopy shows bright red blood within the colon, multiple diverticula, but due to the large amount of stool and blood clots, no active bleeding sources are able to be seen. He continues to have blood per rectum over the next hour. Blood pressure is 120/70 mmHg and heart rate is 90/min. Which of the following is the most appropriate next step in management?
- (A) Exploratory laparotomy
  - (B) Transfuse two units of packed red blood cells
  - (C) 99mTc red blood cell (RBC) scintigraphy
  - (D) Esophagogastroduodenoscopy (EGD)
  - (E) Omeprazole and antibiotics
18. A 62-year-old female arrives to the ER with acute abdominal pain. She has a past medical history significant for diverticulitis. She is diagnosed with uncomplicated diverticulitis and managed with bowel rest and antibiotics. A year later, she has another episode of diverticulitis that was again successfully managed on an outpatient basis. Which of the following is this patient at higher risk for developing?
- (A) Crohn's disease
  - (B) Ulcerative colitis
  - (C) Colon cancer
  - (D) Anal cancer
  - (E) Stricture formation
19. Endocarditis secondary to which of the following organisms is associated with colon cancer?
- (A) *Streptococcus bovis*
  - (B) *Clostridia septicum*
  - (C) *Streptococcus bovis* and *Clostridia septicum*
  - (D) *Diphyllobothrium latum*
  - (E) *Cryptococcus neoformans*

## Answers

### 1. Answer D

Ischemic colitis is one of the complications that can occur after AAA repair. The etiology is thought to be due to the fact that the inferior mesenteric artery (IMA) is ligated (with open repair) or occluded (with endovascular repair). In the majority of patients, there is no consequence from ligating the IMA. Depending on collateral blood supply, the left colon may develop mucosal or full-thickness ischemia. Patients present with varying degrees of left lower quadrant pain, fever, diarrhea, or frankly bloody stool. Ischemic colitis is confirmed by flexible sigmoidoscopy that will demonstrate inflamed, friable mucosa, or full-thickness necrosis (bear in mind that a scope within the lumen cannot necessarily determine full-thickness necrosis). Treatment of ischemic colitis begins with placing the patient NPO and administering IV fluids and broad-spectrum antibiotics. If there is evidence of sepsis and/or peritonitis, the patient will require exploratory laparotomy (B), colonic resection, and a proximal colostomy. Since the cause of the ischemic colitis (ligation of the IMA) is known, and cannot be reversed, CT (A), formal mesenteric arteriography (C), and ultrasound (E) are not helpful.

### 2. Answer B

Familial adenomatous polyposis (FAP) is an autosomal dominant condition in which patients develop hundreds to thousands of polyps in the colon, which if left untreated, has a 100 % chance of developing into cancer by age 50. The mutation is in the adenomatous polyposis coli (APC) gene on chromosome 5. A child who has a parent with the mutation has a 50 % chance of inheriting the syndrome. Thus APC gene testing is recommended. If the child tests positive, screening with flexible sigmoidoscopy should begin at age 10 (as polyps can develop even in the teen years). Once a polyp is seen, surgery is recommended to remove the colon. Since the polyps begin on the left side of the colon, a full colonoscopy (A, C) is not required for screening. Annual fecal occult blood test (D) or barium enema (E) are not adequate screening tools in FAP.

### 3. Answer B

Prior to initiating a workup for GI bleeding, it is important to determine if the source is the upper or lower GI tract. If the patient is vomiting blood or has coffee ground emesis, then the source is clearly an UGI one. Since a massive UGI bleed can cause bleeding per rectum, it is imperative that an UGI source is ruled out first. This is achieved by placing an NG tube and aspirating for blood or coffee grounds. If it returns blood, an upper endoscopy should be performed first. If the aspirate returns bile, then an UGI bleed is ruled out. Since the patient responded to a fluid challenge, a blood transfusion (A) is not necessary. Colonoscopy (C) is not yet indicated

nor is surgery (D). A central line (E) should be considered if ongoing massive fluids/blood are needed.

### 4. Answer B

Patients with IBD are at increased risk of colon cancer. The risk is much greater for ulcerative colitis (UC) than with Crohn's and is related to the duration of illness and the extent of disease. For UC, the risk is low in the first 10 years of the disease (2–3%) but grows to 1–2% per year afterwards. UC patients should begin getting screened 8 years after disease onset and continue getting screened every 1–2 years after. *Random biopsies* are necessary in patients with UC undergoing screening with colonoscopy because in these patients, cancers do not follow the typical progression from polyp to cancer. A proctocolectomy removes the entire rectum and colon, which prevents patients with UC from developing cancer and no further surveillance is required.

### 5. Answer C

Anal fissure is the most common cause of minor painful rectal bleeding (hemorrhoids usually cause minor painless bleeding). To get an anal fissure, one needs two things: anal trauma (from hard stools) and a hypertonic/hypertrophied internal sphincter. The hard stool tears the anoderm, most often in the posterior midline (most vulnerable to damage due to a relatively diminished blood supply). Patients typically present with painful defecation and blood found on tissue after wiping. Chronic fissures become deeper and will have enlarged anal papillae with hypertrophic and edematous skin tags (sentinel pile). Medical management includes sitz baths (relaxes sphincter), fiber, and stool softeners. If this treatment fails, nitroglycerine ointment (limited by side effect of headaches) and botulinum toxin (injected into the internal sphincter) are the next steps in management. Patients that fail medical therapy can be considered for surgical treatment with lateral internal sphincterotomy, which is able to cure 95 % of cases. The risk of incontinence ranges from 5 % to 15 %. The other complications listed are uncommon (A–B, D–E).

### 6. Answer A

Ogilvie's syndrome is a pseudo-obstruction of the colon that is associated with bedridden, neurologically impaired or older patients, opiate use, recent surgery, trauma, or infection. The mechanism for this colon dysfunction is unknown. X-ray films will predominantly show a markedly colon without evidence of a bowel obstruction. Management consists of removing any drugs that may interfere with gut motility (e.g., opiates) and replacement of electrolytes (especially potassium). A colon larger than 10 cm is at risk for perforation and requires decompression with colonoscopy and neostigmine. Due to the law of Laplace (tension = pressure x radius), the cecum, being the part of the colon with the largest diameter, is the most common site for perforation (B–E).

### 7. Answer E

Diverticula occur as a result of herniation of mucosa through the colonic wall at sites where arteries enter the muscular layer. The incidence of diverticula increases with age, and it is believed to be present in 35 % of the population. When diverticula get infected (diverticulitis), often on the left side, patients can present with fever, leukocytosis, and LLQ pain that may be temporarily relieved following defecation. This patient has a moderate case of diverticulitis given the CT findings of significant inflammation in the sigmoid colon, fever, and leukocytosis. Treatment initially consists of bowel rest and IV antibiotics. Patients with acute diverticulitis should receive a follow-up colonoscopy to rule out malignancy (as the CT cannot readily distinguish diverticulitis from colon cancer). Colonoscopy should not be performed during the same hospitalization as the insufflation of air may lead to free perforation. Barium enema (with or without sigmoidoscopy) (D) is not a recommended screening tool for colon cancer. In addition to a colonoscopy, a fiber-rich diet (A) should be encouraged for all patients with diverticulitis to reduce the incidence of diverticula. Follow-up CT scan (B) is unlikely to provide any additional information other than confirming diverticula. Surgery (C) is recommended for cases with significant complications (e.g., complete obstruction, free perforation with diffuse peritonitis) and those that have failed medical management.

### 8. Answer D

The differential diagnosis of RLQ pain in women is more extensive than for men and should include ruptured ectopic pregnancy, ruptured cyst, ovarian torsion, and pelvic inflammatory disease. A B-hCG test should always be ordered in a woman of child-bearing age with abdominal pain to rule out pregnancy. If positive, a ruptured ectopic pregnancy should be high on the differential. Although the patient presented has McBurney's point tenderness and an elevated WBC, laparoscopic appendectomy (C) would not be recommended as of yet until the B-hCG is obtained. In addition, in women, ultrasonography is highly useful to rule out the aforementioned differential. CT scan (B) is not necessary to confirm the diagnosis of acute appendicitis. Rather it is used if the diagnosis is in question. Admission for observation (A) would not be appropriate. Do not assume that pyuria rules out appendicitis (an inflamed appendix can cause sterile pyuria).

### 9. Answer B

A rare complication after appendectomy is a cecal fistula. The findings on laparoscopy (inflamed terminal ileum and cecum) combined with a normal appendix indicate that the patient's actual diagnosis is likely Crohn's disease which can mimic appendicitis (in this setting, it is termed regional enteritis). If regional enteritis is found instead of appendicitis

at the time of laparoscopy, the appendix is removed even if it looks normal, provided the cecum is not involved in the inflammation. This prevents confusion in case the patient presents again with RLQ pain in the future. However, if the cecum is also inflamed in the setting of regional enteritis, the appendix should not be removed, as there is a risk that the stump of the appendix will blow out and form a fistula (as in the present case). Conditions that prevent fistulas from spontaneously closing can be remembered by the acronym "**HIS FRIEND**": high fistula output (>500 cm<sup>3</sup>/day), inflammatory bowel disease, short fistula (<2.5 cm), foreign body, radiation, infection, epithelialization, neoplasm, and distal obstruction. Although all the choices above can all contribute to non-closure of a fistula, chronic inflammation (from inflammatory bowel disease) is the most likely one.

### 10. Answer A

Cecal volvulus is due to a failure of fixation of the right colon (due to a congenital malrotation). Once diagnosed, treatment is to perform an urgent right colectomy, as it does not respond well to nonoperative management (it cannot effectively be detorsed with colonoscopy). Provided there is no evidence of ischemic bowel, sigmoid volvulus (B) is most often managed with initial endoscopic decompression, followed by a semi-elective sigmoid colectomy after performing a bowel prep. Most patients with diverticulitis (C) can be managed via a combination of antibiotics, bowel rest, and subsequent dietary modification (high fiber). Due to the large diameter of the cecum and the liquid nature of stool at that location, cecal adenocarcinoma (D) rarely presents with a large bowel obstruction (which would be the main indication for urgent surgery with colon cancer). Rather, it presents most commonly with iron deficiency anemia. Pseudomembranous colitis (E), due to *Clostridia difficile*, is successfully managed in most patients with oral metronidazole (and stopping the offending antibiotics). Other antibiotic choices include vancomycin and fidaxomicin. In rare cases, the colitis can progress to life-threatening sepsis (termed toxic colitis) that requires emergency total colectomy.

### 11. Answer C

A colonoscopy is considered the gold standard because it can visualize the entire colon, identify small polyps/adenomas, and take biopsies. However, not all patients are comfortable with this test and could benefit from learning about other options. Flexible sigmoidoscopy every 5 years with FOBT every 3 years is an alternative screening modality recommended by the American College of Radiology Joint Task Force. An annual FOBT (not every 5 years) is another appropriate alternative (A), but abnormal results should always be followed up with a colonoscopy. Annual rectal examination (B) is not considered adequate screening because of poor sensitivity (9 %). CT colonography done every 5 years

(not annually) (D) is as likely as colonoscopy to detect lesions 10 mm or larger but may be less sensitive for smaller adenomas. Serum CEA level (E) is used as a marker for colon cancer recurrence following surgery; however, CEA level lacks both sensitivity and specificity (it is elevated with other cancers and with benign conditions), such that it should never be used for colon cancer screening.

### 12. Answer C

Sigmoid volvulus occurs in debilitated and/or psychiatric patients. The twist in the colon leads to a closed loop obstruction which, if left untreated, leads to colonic ischemia, sepsis, and eventual colonic gangrene and perforation. Patients present with abdominal distention, pain, constipation, and vomiting. X-ray films may show an air filled closed loop of massively distended colon, referred to as a “bent-inner tube” or “coffee-bean” sign. Most patients can be managed by decompression with colonoscopy. However, this patient demonstrates evidence that the colon is already ischemic/gangrenous (fever, tachycardia, hypotension, peritonitis, leukocytosis). Thus colonic decompression (A) is contraindicated. Following fluid resuscitation and antibiotics, the patient requires urgent exploratory laparotomy with likely sigmoid colon resection and proximal colostomy. Similarly, with peritonitis and the classic plain X-ray finding, CT scan is unnecessary (B) and in fact may cause renal injury given his pre-renal azotemia. Placing a rectal tube (D) and admitting to the hospital (E) without surgery would not be appropriate.

### 13. Answer E

It is imperative that following appendectomy, the appendix is inspected and histologically examined by a pathologist as an appendiceal tumor is sometimes discovered incidentally. The most common appendiceal tumor is mucinous adenocarcinoma (it was previously thought to be carcinoid) with the majority of these tumors located at the tip of the appendix. If the tumor is  $\leq 1$  cm, an appendectomy is considered appropriate definitive management. For tumors larger than 1 cm and located at the base of the appendix or tumors  $\geq 2$  cm and located at the tip of the appendix, a right hemicolectomy is indicated. The other choices would not be appropriate (A–D).

### 14. Answer B

Carcinoembryonic antigen (CEA) is a glycoprotein, which is present in normal mucosal cells, but increased amounts are associated with adenocarcinoma, especially colorectal cancer. The major role of CEA in colon cancer patients is to allow clinicians to monitor for recurrence after intended curative treatment. Typically, patients achieve normal levels about 4–6 weeks after surgical intervention. Smoking up to 4 h prior to checking serum CEA can falsely elevate levels. CEA levels are also elevated with other cancers (e.g., medullary carcinoma of

the thyroid, pancreatic, gastric cancer) as well as benign conditions (IBD, pancreatitis, cirrhosis, and smoking), but not with the other choices provided (A, C, D, E). It is recommended to counsel all patients to quit smoking as it can affect postoperative monitoring and improves overall health.

### 15. Answer A

Acute appendicitis is triggered by an obstruction of the appendiceal lumen. In adults the obstruction is most commonly caused by a fecalith (B). However, in children the obstruction is most often due to lymphoid hyperplasia within the appendix that may be triggered by an antecedent viral infection. Thus patients may have a history of a recent viral infection prior to the acute appendicitis. Parasites (C), such as pinworm, and foreign body ingestion (E) can rarely obstruct the appendiceal lumen and cause appendicitis. Acute mesenteric adenitis (D) can mimic acute appendicitis. However, this is less common, and the vast majority present with mild diffuse abdominal pain as opposed to localized pain and tenderness at McBurney’s point.

### 16. Answer C

This patient most likely has melanosis coli, also known as pseudomelanosis coli, secondary to laxative abuse. This benign condition is often discovered incidentally during colonoscopy and is considered a disorder of pigmentation of the colonic wall. The dark discoloration is a result of lipofuscin in macrophages, and not melanin. Patients can be asymptomatic or sometimes present with watery or nocturnal diarrhea. The other options (A, B, D) are not consistent with the colonoscopic findings. Inflammatory bowel disease (IBD) (E) may show cobblestone mucosa, strictures, and/or pseudopolyps and a colon devoid of haustra.

### 17. Answer C

This patient is suffering from a lower GI bleed (LGIB). The risk of LGIB increases with age, a trend that is driven by the age-associated increase in the incidence of diverticular hemorrhage, which is the most common cause of LGIB. Colonoscopy is indicated, but in the acute bleed setting may not demonstrate the source of bleeding. Since the bleeding has not stopped and has not been localized, additional studies are indicated. Options include radiolabeled RBC scintigraphy or angiography. Scintigraphy has the advantage of being noninvasive, is more sensitive (it detects less brisk bleeding), and can be easily repeated. It is utilized when the patient is actively bleeding (provided they are stable) when colonoscopy cannot identify the source. Exploratory laparotomy (A) would be indicated if the patient is hemodynamically unstable from a massive LGIB as there is no time to identify the exact source. Transfusion (B) is not indicated given that the patient responded to IV fluids. EGD would be the first-line study for an upper GI bleed (D). Omeprazole

and antibiotics (E) would be indicated in a patient suspected of having ulcers secondary to *H. pylori*.

**18. Answer E**

One of the complications that may develop from recurrent bouts of diverticulitis includes stricture formation. In response to repeated inflammatory insults to the colon, a portion may become scarred and subsequently narrowed. These patients can present with a decreased caliber of stool, ileus, or bowel obstruction. Barium enema or colonoscopy is often used to diagnose patients. Diverticulitis does not increase the risk of developing IBD, colon cancer, or anal cancer (A–D).

**19. Answer C**

*Streptococcus bovis* and *Clostridia septicum* are both associated with colon cancer. The clinical context *S. bovis* comes up in most often is in that of patients suffering from endocarditis. *C. septicum* can spread hematogenously to muscle tissue and is also associated with the concomitant presence of hematologic malignancy. All patients found to be infected with these organisms should be scheduled for a colonoscopy to rule out colorectal malignancy. *Diphyllobothrium latum* (fish tapeworm) (D) and *Cryptococcus neoformans* (E) have not been linked to an increased risk of developing colon cancer.

## Neurosurgery

### Areg Grigorian and Christian de Virgilio

#### Questions

- A 32-year-old man presents with progressive frontal headaches. His symptoms started 2 months ago and often wake him up from his sleep. His vital signs are stable, and neurologic examination reveals no focal deficits. MRI brain imaging reveals a mass lesion, and subsequent biopsy is consistent with a type IV astrocytoma. Which of the following is true regarding this patient's illness?

  - It is considered the most common primary malignant brain tumor
  - Prognosis is good since the tumor is slow growing
  - The biopsy should demonstrate psammoma bodies
  - This tumor does not cross the corpus callosum
  - Interferon beta and glatiramer acetate are used in the management of this tumor
- Which of the following is true regarding diffuse axonal injury?

  - It is often associated with a lucid interval
  - Blurring of gray-white junctions is commonly found on imaging
  - It occurs following a tensile force
  - Persistent vegetative state is rare
  - Patients often have hyperdense fluid in the ventricles, sulci, and cisterns
- A 55-year-old female restrained driver arrives to the ED following a MVC. She sustained hyperextension of the cervical spine and hit her chest on the steering wheel. Neurologic examination shows spastic paraplegia and loss of pain sensation in both upper extremities. She is able to move both her legs and can differentiate vibratory sensation and light touch in both feet. What is the most likely etiology for her acute condition?

  - Central cord syndrome
  - Anterior spinal artery syndrome
  - Brown-Sequard syndrome
  - Cauda equina syndrome
  - Subacute combined degeneration of the spinal cord
- Which of the following findings would be expected in a patient presenting with a transtentorial (uncal) herniation?

  - Loss of gag reflex
  - Diplopia on attempted lateral gaze
  - Medial rectus palsy on attempted lateral gaze
  - Ptosis and a "down and out" eye
  - Paralysis of the sternocleidomastoid muscle
- Which of the following is the most common brain cancer?

  - Lung metastasis
  - Glioblastoma multiforme
  - Colon metastasis
  - Breast metastasis
  - Astrocytoma
- A 64-year-old homeless man is brought to the ED by paramedics after being found confused on the street. He has bruises on his head and arms with a few that appear to be new. He has alcohol on his breath. He is awake in the ED but unable to follow commands or answer questions. CT scan of the head without contrast demonstrates a crescent-shaped lesion. Which of the following is most associated with this patient's condition?

  - Family member with polycystic kidney disease
  - Congenital malformation
  - Torn bridging veins
  - Injured middle meningeal artery
  - Temporal bone fracture
- In a patient with an isolated head injury and concerns for increased intracranial pressure, which of the following would have the most potential to benefit the patient?

  - Hypertonic (3 %) saline solution
  - Ventilation with permissive hypercapnia
  - Trendelenburg position of bed
  - Intermittent D50 (dextrose) boluses
  - Nitroprusside drip
- A 20-year-old female arrives to the ED after slipping and hitting her head on ice and briefly losing consciousness. In the ED, she vomits twice. She denies amnesia. Her temperature is 98.9°F, blood pressure is 110/80 mmHg, and pulse is 80/min. Her GCS is 15. Her physical exam is normal with no papilledema. What is the most appropriate next step in management?

  - Admit for observation and order CT scan of the head only if she develops a neurologic deficit
  - Admit for observation and start corticosteroids
  - Order CT scan of the head without contrast now
  - Discharge home now
  - Discharge home with a tapered dose of corticosteroids
- A 48-year-old woman arrives for her 6-month follow-up after undergoing breast-conserving therapy to treat stage IIA breast cancer. Her only postoperative complication has been red patches of skin on her chest following radiation therapy. She does not complain of any pain or pruritus but does report having intense headaches in the mornings when she wakes up. Her temperature is 99.1°F,



blood pressure is 110/80 mmHg, and pulse is 90/min. Her physical examination is normal. She is worried that the red patches on her chest are suggestive of something more serious. Which of the following studies would be the most appropriate next step in management?

- (A) PET
  - (B) Cerebral angiogram
  - (C) Skin biopsy
  - (D) Carotid duplex
  - (E) CT scan of the head
10. A 29-year-old woman arrives to the ED following a jet ski accident. She has multiple bruises on her head, torso, and legs. She did not lose consciousness. Her temperature is 99.8°F, blood pressure is 108/78 mmHg, and pulse is 102/min. She only opens her eyes when you speak loudly to her. She is confused and screams in pain and withdraws when you palpate her left lower leg. Her imaging is pending. What is her calculated Glasgow Coma Scale?
- (A) 6
  - (B) 8
  - (C) 10
  - (D) 12
  - (E) 14
11. A 22-year-old patient arrives to the ED after falling off his bicycle and hitting his head. In the ED, he is clearly intoxicated and his speech is slurred. He denies any neck pain but is not cooperative during the exam. He is placed in a cervical spine collar. What is the optimal method for clearance of the cervical spine in this patient?
- (A) CT scan of the neck only
  - (B) MRI of the neck only
  - (C) MRI of the neck followed by a CT only if the MRI is negative
  - (D) CT scan of the neck followed by MRI only if the CT is negative
  - (E) The C-spine can be cleared using physical examination
12. A 50-year-old woman arrives to the ED after she was witnessed having two generalized tonic-clonic seizures over 15 min without recovering consciousness between episodes. Her seizures are resolved by the time she gets to the hospital. She had a toe removed for a skin tumor 10 years ago but does not remember any details. Review of systems reveals a loss of nearly 15 lb over the last 2 months. She has no other complaints. CT scan of the head reveals a solitary mass in the gray-white junction of the left temporal lobe with some surrounding edema. After further imaging and work-up is done, no other lesions are identified. Which of the following most likely represents the mass?
- (A) Type IV astrocytoma
  - (B) Metastasis
  - (C) Oligodendroglioma
  - (D) Meningioma
  - (E) Ependymoma
13. A 29-year-old male with no past medical history presents to the ED with the worst headache of his life. He was watching television when the headache started and is unlike any headache he has experienced before. It is located near the back of his head. He reports that his father had a kidney transplant at a young age. He is managed appropriately for his acute condition. His recovery is complicated by progressive lethargy, agitation, and eventual coma. Which of the following would most likely explain this complication?
- (A) Nephrogenic diabetes insipidus
  - (B) Central (neurogenic) diabetes insipidus
  - (C) Poor oral intake
  - (D) Cerebral salt-wasting syndrome
  - (E) Thyroid dysfunction
14. A 31-year-old male with HIV presents with headaches and night sweats. He is poorly compliant with his medications. His headaches are severe in the morning but subside throughout the day. He has no other complaints. His last CD-4 count was 95/mm<sup>3</sup>. His temperature is 98.9°F, blood pressure is 110/76 mmHg, and pulse is 88/min. His physical exam is normal. CT scan of the head shows a ring-enhancing lesion near his right primary motor cortex. What is the best next step in management?
- (A) Radiation
  - (B) Chemotherapy and radiation
  - (C) Pyrimethamine and sulfadiazine
  - (D) Stereotactic brain biopsy
  - (E) Restart highly active antiretroviral therapy (HAART)
15. A 61-year-old man with a past medical history of opioid dependence and diabetes presents with focal back pain and right leg weakness. He does not recall any recent trauma. He reports having “back surgery” nearly 20 years ago but does not remember why. He also reports helping his friend move furniture last week. His temperature is 101.4°F, blood pressure is 104/76 mmHg, and pulse is 102/min. Physical examination is significant for focal pain on palpation of his lower lumbar spine. Laboratory examination is significant for elevated ESR. Imaging is obtained. What is the best management approach for this condition?
- (A) Nonsteroidal anti-inflammatory drugs (NSAID)
  - (B) High-dose intravenous corticosteroids
  - (C) Long-term antibiotics alone

- (D) Physical therapy and education  
(E) Long-term antibiotics with surgical drainage
16. A 40-year-old female presents to the doctor with progressive weakness in both her arms for the past year. She is healthy and does not take any medications but reports being hospitalized 5 years ago for 2 days following a MVC in which she sustained severe and sudden whiplash injury. On physical examination, she has atrophy of the intrinsic muscles of both hands and an inability to differentiate between hot and cold in bilateral upper extremities. All other sensations are intact. What is the most likely underlying etiology?
- (A) Spinal spondylosis  
(B) Brachial plexus injury  
(C) Syringomyelia  
(D) Autoimmune condition  
(E) Herniated disk

## Answers

### 1. Answer A

Glioblastoma multiforme is a type IV astrocytoma and considered to be the most common primary malignant brain tumor in the United States. This tumor has a grave prognosis with life expectancy estimated to be <1 year from the time of diagnosis (B). On gross appearance, it can cross the corpus callosum (butterfly glioma) (D). On histologic appearance, it will stain with GFAP. Psammoma bodies are spindle cells concentrically arranged in a whorled pattern and are characteristic of a meningioma (C). Interferon beta and glatiramer acetate have been shown to decrease the frequency of future attacks in patients with multiple sclerosis (E).

### 2. Answer B

Patients with diffuse axonal injury following rapid deceleration trauma typically suffer instantaneous loss of consciousness followed by a persistent vegetative state (D). Prognosis is very poor. It occurs as a result of shearing forces (C). A CT scan of the head will show numerous minute punctate hemorrhages with blurring of gray-white junctions. A lucid interval (A) is often associated with an epidural hematoma. Hyperdense fluid in the ventricles, sulci, and cisterns (E) would be suggestive of a subarachnoid hemorrhage.

### 3. Answer A

This patient has central cord syndrome which classically occurs following hyperextension of the cervical spine but may also result from hyperflexion. The lateral corticospinal fasciculus is home to the motor tracts of the lower extremities and is often spared in central cord syndrome. The medial aspect hosts the motor tracts for the upper extremities and is disproportionately affected, often with profound hand weakness. Most patients regain functional recovery in a predictable fashion starting first with the lower extremities (if affected), then bladder/bowel function, and finally the upper extremities. Anterior spinal artery syndrome (B) results from a compressed anterior spinal artery. This presents with bilateral loss of motor, pain, and temperature below the lesion with partial sensory sparing (e.g., proprioception, vibration) since the posterior dorsal columns remain viable. Brown-Sequard syndrome presents with ipsilateral motor weakness with associated upper motor neuron signs (spasticity, hyperreflexia, clonus, and positive Babinski sign) and touch/proprioception loss below the level of the injury, also contralateral loss of pain and temperature sensation beginning one or two dermatome levels below the level of the injury. Cauda equina syndrome (D) may occur in a traumatic setting following compression of the lumbar nerve roots by a spinal fracture. Patients will present with perineal sensory deficit (saddle anesthesia), bowel/bladder incontinence, and pain/weakness in the lower extremities. Subacute combined degeneration of the spinal cord (E) is the term used to

describe the neurologic deficits (e.g., peripheral sensory deficits, loss of deep tendon reflexes) seen in patients with B12 deficiency.

### 4. Answer D

The uncus is a part of the medial temporal lobe and can herniate through the tentorium and compress the midbrain and brainstem during significant brain swelling. This will present with features that can be explained by local compression of nearby structures by the herniated uncus (e.g., mydriasis or “blown pupil,” ipsilateral ptosis, and “down and out” eye). Loss of gag reflex (A) would be expected in patients with an injured glossopharyngeal nerve (CN IX). This can occur in a patient with a posterior fossa tumor. Diplopia on attempted lateral gaze (B) is expected in patients with injury to the abducens nerve (CN VI), as in those patients with cavernous sinus malignancy. Medial rectus palsy on attempted lateral gaze (C) is commonly seen in patients with multiple sclerosis that have medial longitudinal fasciculus (MLF) syndrome. Paralysis of the sternocleidomastoid muscle would be expected in patients with a spinal accessory nerve injury.

### 5. Answer A

Malignant brain tumors are more commonly metastatic than primary (B, E). An estimated 24–45 % of all patients with cancer have metastatic lesions to the CNS. Nearly half of all brain metastasis are attributed to lung cancer. The second most common cancer to metastasize to the brain is breast (15 %) (D), followed by genitourinary (11 %), melanoma (9 %), and head and neck cancers (6 %). Prostate and colon cancers (C) do not commonly metastasize to the brain.

### 6. Answer C

This patient’s history and CT findings are most consistent with a subdural hematoma which is caused by torn bridging veins. Patients will experience progressive neurologic deficits which if left untreated can be fatal. CT scan of the head will demonstrate a crescent-shaped lesion that may extend across the entire hemisphere. This typically occurs in older or alcoholic patients with recent head trauma, often due to a fall. Elderly patients are at increased risk due to age-related cerebral atrophy which can exert tension on the bridging veins. A family member with polycystic kidney disease (A) is often seen in patients with subarachnoid hemorrhage due to the disease’s association with berry aneurysms in the Circle of Willis that are prone to rupture. Cerebral arteriovenous malformations (B) can spontaneously bleed and result in a sudden intense headache and/or loss of consciousness. A temporal bone fracture (E) and subsequent injury to the middle meningeal artery (D) can result in an epidural hematoma. This classically presents with a loss of consciousness in patients with head trauma, followed by a lucid interval,

and then a loss of consciousness again. The hematoma is lenticular (lens shaped) or convex in shape.

### 7. Answer A

Patients with increased intracranial pressure (ICP) will benefit with therapy aimed at decreasing ICP. Hypertonic saline solution will decrease cerebral edema by acting as an osmotic force, drawing fluid out of the tissues and into the blood and thus decrease ICP. Fluids that contain hypotonic saline (such as dextrose 5 % water) would have a deleterious effect (D). Mild hyperventilation to create hypocapnia is also beneficial as it induces mild vasoconstriction ( $\text{CO}_2$  is the most potent cerebral vasodilator). Excessive hyperventilation can be deleterious as it will decrease overall perfusion. Ventilation with permissive hypercapnia (B) is a technique used in ARDS that helps prevent barotrauma. However, hypercapnia (high  $\text{CO}_2$ ) would lead to cerebral vasodilation and worsen ICP. Patients with head injury should be placed in reverse Trendelenburg (head up) position. Trendelenburg position (C) will also increase ICP by using gravity to increase cerebral blood flow. Hyperglycemia (injured brain metabolizes glucose, leading to an increase in cerebral lactate with subsequent acidosis) and nitroprusside drip (vasodilation) (E) have also been associated with increased ICP.

### 8. Answer C

Numerous guidelines exist for when to perform a non-contrast CT in the setting of head trauma. The Canadian guidelines state that a head CT is indicated following minor head trauma and more than one episode of emesis, GCS <15 at 2 h after injury, evidence of basilar skull fracture (Battle's sign, raccoon eyes), focal neurologic deficit, age >65, dangerous mechanism of injury (e.g., ejected out of car), and suspected open or depressed skull fracture. Although she has a normal GCS, since she has vomited twice, a CT scan is indicated. Discharging the patient (D) would be inappropriate because she meets the criteria for getting a head CT. A patient with a minor, isolated head injury and a negative CT could be safely discharged (D) with instructions given to the patient and/or family/caregiver to look for signs of increased intracranial pressure (e.g., lethargy, vomiting, intense headaches, deficits in short-term memory, seizures, or focal neurologic deficits). Patients with these signs should return to the hospital immediately. Administration of corticosteroids (B, E) is not indicated in patients with head injury.

### 9. Answer E

Any postoperative breast cancer patient with a severe headache should be evaluated for metastasis to the brain with a CT scan of the head (A). Postoperative radiation therapy is offered in conjunction with breast-conserving therapy (e.g., lumpectomy) to appropriate patients. Complications of radiation therapy include pneumonitis, ulceration, sarcoma, con-

tralateral breast cancer, and red patches of skin or "radiation burns." Skin biopsy (C) is not needed to confirm this. These can be severe and very painful or, in this patient's case, can only be a cosmetic burden. Options A and B are not typically needed to evaluate for brain metastasis. Carotid disease does not typically present with headaches so duplex scan (D) would not be indicated.

### 10. Answer D

Once the ABCs have been addressed in a patient presenting with traumatic brain injury, one can assess a patient's level of consciousness by using the Glasgow Coma Scale (GCS) as part of the primary neurologic survey. GCS is composed of three components: eye opening, verbal response, and motor response. The sum total of the three components is the GCS score, which ranges from 3 to 15. This patient has an eye score of 3, verbal score of 4, and a motor score of 5. Thus, her GCS is 12 and classified as a moderate head injury.

### 11. Answer D

Missing cervical spine injuries can have catastrophic consequences for patients. The risk of neurologic sequelae is 10 times higher in patients with missed cervical injuries during initial screening versus those with injuries identified early on. CT imaging alone (A) may be sufficient to detect all clinically meaningful injuries in patients with normal mentation. However, obtunded or unexaminable patients may have higher rates of occult ligamentous injuries with this modality alone. Obtunded patients with a negative CT scan of the neck should be further evaluated with an MRI of the neck to optimally clear them of any cervical spine injury. CT scan of the neck should always be done first (B, C) in all patients being cleared from cervical spine injury, regardless of mentation. The C-spine can sometimes be cleared using physical examination (without imaging) (E). However, this is only true for patients that are awake, alert, cooperative, and without any distracting injuries.

### 12. Answer B

A solitary brain mass in the gray-white junction with surrounding edema is most consistent with a metastatic tumor. Although the most common source would be lung cancer, the history of a toe amputation highly suggests a subungual melanoma. This may occur even in patients with a remote history of melanoma. Type IV astrocytoma (glioblastoma multiforme) (A) is considered to be the most common primary malignant brain tumor in the United States. It can cross the corpus callosum, giving it a "butterfly" appearance. Oligodendroglioma (C) is a rare, slow-growing tumor often found in the frontal lobes. Meningioma (D) is the second most common primary tumor in adults. It arises from arachnoid cells and is characterized by psammoma bodies on histologic examination. Ependymoma (E) primarily affects

children and commonly occurs in the fourth ventricle leading to hydrocephalus. Patients have a poor prognosis.

### 13. Answer D

Patients with subarachnoid hemorrhage can have multiple complications after their initial presentation including rebleeding, hyperglycemia, acute hypoxia, and electrolyte abnormalities. Patients are at risk for symptomatic hyponatremia secondary to *cerebral salt-wasting syndrome*. This is thought to occur because of the inappropriate secretion of vasopressin resulting in water retention. In addition, these patients have increased levels of atrial natriuretic peptide and brain natriuretic peptide which contribute to salt wasting. Patients with hyponatremia may present with seizures, lethargy, agitation, confusion, and nausea, and if untreated, patients can eventually fall into a coma. Nephrogenic diabetes insipidus (A) is a renal dysfunction in which the collecting ducts are unresponsive to ADH, while central diabetes insipidus (B) is associated with decreased levels of ADH released from the posterior pituitary. Both of these conditions are associated with hypernatremia. Thyroid dysfunction (E) can rarely lead to loss of sodium. However, there is no evidence to believe the presented patient has any thyroid problems.

### 14. Answer C

HIV+ patients that present with CD-4 counts between 50 and 100 per mm<sup>3</sup>, and ring-enhancing lesions found on CT scan of the head should be suspected of having either toxoplasmosis or CNS lymphoma. These are clinically indistinguishable and occur in similar frequencies. Patients should always be started first on an empiric therapeutic trial of pyrimethamine and sulfadiazine to treat a presumed toxoplasmosis infection. If this does not resolve the patient's symptoms and/or findings (e.g., ring-enhancing lesions on CT), the next best step is to perform a stereotactic brain biopsy (D) to confirm CNS lymphoma. Additionally, HIV+ patients with CNS lymphoma almost always exhibit evidence of Epstein-Barr virus (EBV) in their cerebrospinal fluid (CSF). Although no consensus exists on treatment for HIV-related CNS lymphoma, few studies have looked at treatment with radiation therapy (A) or chemotherapy (B) and have reported only modest gains. Restarting HAART in a patient suspected of having toxoplasmosis or CNS lymphoma increases the risk of developing immune reconstitution inflammatory syndrome (IRIS) (E).

### 15. Answer E

This patient is most likely presenting with an epidural abscess. Patients with previous spinal surgeries (even if remote) or a history of IV drug abuse are at higher risk. The clinical triad of epidural abscesses includes focal back pain (or headache, if abscess is located intracranial), abnormal inflammatory parameters (fever, leukocytosis, elevated ESR), and neurologic deficits (e.g., right leg weakness). MRI is the imaging modality of choice to confirm the diagnosis. Patients should be started on long-term intravenous antibiotics and undergo surgical drainage of the abscess. NSAIDs, physical therapy, and education (A, D) would be appropriate recommendations for patients with lumbar strain. These patients would not be expected to have fevers or focal neurologic deficits. Current guidelines do not recommend corticosteroids (B) after acute spinal cord injury.

### 16. Answer C

This patient's arm weakness and inability to differentiate between hot and cold in the bilateral upper extremities are most likely due to syringomyelia, which is the presence of a cystic structure in the central cervical spinal cord. This most commonly occurs from congenital conditions (e.g., Arnold Chiari malformations) but may also occur months or years after a cervical spinal injury, such as whiplash (e.g., sudden distortion of the neck associated with extension). Trauma-induced syringomyelia typically involves the cervical spinal cord and results from impaired CSF drainage in the central canal of the spinal cord which may lead to a fluid-filled cavity that compresses the surrounding spinal cord. Patients will present with weakness and decreased pain and temperature sensation in bilateral upper extremities with no other sensory deficits. Spinal spondylosis occurs as a result of degenerative joint disease (e.g., osteoarthritis) and presents with radiculopathy secondary to affected nerve roots. Trauma-induced brachial plexus injuries (B) are more likely to occur immediately following the traumatic incident and will not present with an inability to differentiate between hot and cold in the upper extremities. An autoimmune condition (D), such as multiple sclerosis, will more than likely have two lesions and present in a relapsing-remitting course. A herniated disk (E) is likely but will present with radiculopathy in the affected nerve roots. Decreased sensation to hot and cold would not be expected.

## Orthopedic

### Areg Grigorian and Christian de Virgilio

#### Questions

- A 35-year-old female telemarketer presents with complaints of pain in her right wrist for the past 6 months. She also reports having numbness in her right hand that occurs with wrist flexion or extension. For the past month, she has been receiving corticosteroid injections after her doctor diagnosed her with carpal tunnel syndrome. However, her pain has dramatically increased over the past week and has started to affect her job performance. Her mother has rheumatoid arthritis. Her hand appears to be swollen and is tender to palpation. She is scheduled for a synovial fluid aspiration. Which of the following findings in the aspirate would indicate surgical intervention?

  - Glucose of 90 mg/dL
  - $1.8 \times 10^3/\mu\text{L}$  white blood cells/mcl
  - High abundance of rheumatoid factor
  - Negatively birefringent crystals
  - Thick yellow-green fluid
- An 11-year-old boy presents to his pediatrician because his mother is concerned that he has been limping for the past 3 days. He states that he is limping because of a dull, aching pain in the right groin and thigh that extends down to his right knee. He has no history of preceding trauma. The pain is increased by physical activity. On physical exam, there is a shift of the torso over the affected hip with standing. Which of the following explains this physical exam finding?

  - Weakness in hip abduction
  - Weakness in hip flexion
  - Weakness in hip extension
  - Weakness in knee extension
  - Weakness in knee flexion
- A 24-year-old woman presents to the ED with shoulder pain after a sports injury. She is found to have an anterior dislocation of the humeral head from the glenoid fossa. Which of the following is most likely to be injured in association with this type of dislocation?

  - Musculocutaneous nerve
  - Radial nerve
  - Axillary nerve
  - Brachial arterial
  - Medial clavicle
- A young man is doing some woodworking in his backyard when the saw blade falls off the harness and on to his hand, severing his right thumb. After raising the right arm and applying direct pressure to control bleeding, which of the following is the best recommendation to keep his digit viable for potential replantation?

  - Immediately place the digit directly in a small bag filled with cold water
  - Immediately place the digit directly on top of ice
  - Remove any dirt from the digit first, and then place directly on top of ice
  - Remove any dirt from the digit first with a clean damp cloth, and then place digit directly in cup of cold water
  - Remove any dirt from the digit first, wrap in a clean damp cloth, put in a plastic bag, and then place bag directly in cup of cold water
- A 20-year-old college football player sustained a knee injury following a tackle. In the ED, his knee is very swollen, and a proper examination is not possible due to pain. Plain X-rays of the knee are negative. He is discharged home with a knee brace and crutches. During follow-up 2 weeks later, the pain and swelling are significantly improved. Which of the following findings would be most consistent with a tear to the posterior cruciate ligament?

  - The lower leg sags on passive flexion of the knee at  $90^\circ$  while the patient is supine
  - The lower leg moves forward relative to the knee with forward traction
  - The foot moves laterally when the knee is pushed medially
  - The foot moves medially when the knee is pushed laterally
  - A clicking sensation is appreciated when the knee is flexed and the leg is rotated externally
- A 16-year-old boy arrives for his 1 month follow-up after straining his back and fracturing his tibia during a snowboarding accident. He has a long leg cast and uses crutches to get around. He reports that he lost the crutches given to him upon discharge but has been using an old pair that belonged to his older brother. His only complaint is a weak left hand that sometimes “falls” when he stretches out his arm. On physical exam, he has sensory deficits on the lateral dorsal side of his left hand. His leg is not bothering him and appears to be healing well. What is the most likely explanation for his upper extremity abnormalities?

  - Missed midshaft humerus fracture
  - Radial nerve injury
  - Long thoracic nerve injury
  - Ulnar nerve injury
  - Musculocutaneous nerve injury
- A 45-year-old alcoholic male presents with fevers and right-hand pain. He cannot recall what happened but

thinks he may have punched someone in the face in a bar fight two nights earlier. He has tried over-the-counter anti-inflammatory agents, but they have not helped decrease the pain. His temperature is 100.8°F, blood pressure is 132/88 mmHg, and pulse is 78/min. On physical exam, he has a skin break over his second phalanx-metacarpal region. He is holding his second finger in slight flexion. He has a sausage-shaped swelling of the finger, as well as flexor tendon sheath tenderness that extends the entire length of the tendon. His pain increases with passive motion of the finger. What is the most likely diagnosis?

- (A) Suppurative tenosynovitis due to *Eikenella corrodens*  
 (B) Gout  
 (C) Dupuytren's contracture  
 (D) Suppurative tenosynovitis due to *Pasteurella multocida*  
 (E) Felon
8. A 5-year-old boy is brought to the pediatrician because of left knee pain that is causing him to limp. His PMH is significant for severe asthma. He was recently hospitalized for a severe exacerbation requiring a prolonged steroid taper. On physical exam, his temperature is 98.7°F, blood pressure is 88/56 mm Hg, pulse is 76/min, and respirations are 16/min. He has a normal knee exam. Labs are drawn and show WBC of  $7.4 \times 10^3/\mu\text{L}$  (normal  $4.1\text{--}10.9 \times 10^3/\mu\text{L}$ ) and Hgb of 12.7 g/dL (12–15 g/dL). ESR and CRP are within normal limits. Which of the following is the most likely diagnosis?
- (A) Septic arthritis  
 (B) Osteomyelitis  
 (C) Slipped capital femoral epiphysis  
 (D) Torn ACL  
 (E) Osteonecrosis of the hip
9. A college athlete presents with shoulder pain. He reports that he was injured during basketball practice 2 days ago when his teammate ran into his shoulder. On physical examination, he has an edematous left shoulder. The clinician passively abducts the patient's shoulders to 90° and flexes to 30° while asking the patient to point his thumbs down. What muscle is the clinician trying to evaluate?
- (A) Supraspinatus  
 (B) Infraspinatus  
 (C) Teres minor  
 (D) Teres major  
 (E) Subscapularis
10. A 45-year-old Internet insurance salesman presents to his doctor with progressive pain in his left hand for 1 year. His pain is primarily limited to the left thumb and index finger. After finishing the physical examination, his doctor believes he has carpal tunnel syndrome (CTS). Which of the following did the doctor most likely find on physical examination to support this diagnosis?
- (A) Percussing the wrist elicits pain in all five fingers and the palmar surface  
 (B) Pain felt along the left thumb, index, middle finger when placing the elbow on a table and flexing the wrist for 60 s  
 (C) Pain felt along the left thumb, index, middle finger, and palmar surface when placing the elbow on a table and flexing the wrist for 60 s  
 (D) Radial deviation of the wrist upon wrist flexion  
 (E) Posterior and lateral forearm sensory deficit
11. A 2-week-old female born at 39 weeks gestation to a 36-year-old G2P1 female via normal spontaneous vaginal delivery comes to her pediatrician for her 2-week well-baby exam. The birth was unremarkable, and the baby went home with her mother after 2 days. She received prenatal care starting at 10 weeks gestation and had a normal, healthy pregnancy with no issues. On physical exam, as the hip is gently adducted and posterior pressure is applied, there is a palpable clunk. Which of the following is the next step in management?
- (A) Reexamine at 1-month exam  
 (B) CT scan of the hips  
 (C) X-ray of the hips  
 (D) Reassurance  
 (E) Ultrasound of the hips
12. A 45-year-old woman presents with pain in her right hand for 2 days. She reports falling down and attempting to break her fall with an outstretched hand. Physical examination is significant only for pain in the anatomic snuffbox of her right hand. She has no motor weakness or sensory deficits. What is the most appropriate next step in management?
- (A) Radiograph of hand and, if normal, recommend supportive care with follow-up  
 (B) Radiograph of hand and, if normal, recommend thumb spica cast with follow-up  
 (C) Thumb spica cast without radiograph  
 (D) Supportive care without radiograph  
 (E) CT scan of hand
13. An 88-year-old woman is brought in by ambulance after falling in her house. She complains of right hip pain. On physical exam, her temperature is 99.1°F, blood pressure is 110/75 mmHg, pulse is 110/min, and respirations are 20/min. The leg appears externally rotated and shortened. X-ray shows femoral neck fracture. Which of the following is a complication of femoral neck fracture?

- (A) Avascular necrosis  
(B) Lumbar radiculopathy  
(C) Long-term loss of hip abduction  
(D) Long-term loss of hip adduction  
(E) Osteosarcoma
14. A 28-year-old man presents to the ED with an inability to move his right arm. After his initial work-up and imaging is completed, he is found to have a posterior dislocation of the right shoulder. Which of the following are most commonly associated with this type of injury?
- (A) Fall on outstretched hand  
(B) Weight lifting  
(C) While walking dog, it suddenly tugs on leash  
(D) Electrocution  
(E) Surfing
15. An obese 11-year-old presents to his pediatrician because his mother is concerned that he has been limping for the past day. He states that he is limping because of dull pain in his right knee. He has no history of preceding trauma. The pain is increased by physical activity. On physical exam, there is tenderness to palpation at the anterior hip along with limitation in internal rotation of the hip. Knee exam is normal. Plain films show subluxation of the right femoral head. Which of the following is the most appropriate definitive treatment?
- (A) Supportive therapy with rest and ibuprofen  
(B) Aspiration of the synovial fluid along with appropriate antibiotic therapy  
(C) Weight loss program  
(D) Operative stabilization  
(E) Pavlik harness
16. An 18-year-old soccer player presents to her doctor 2 days after getting kicked in the knee during her championship game. She reports hearing a snap immediately after the injury, but her knee looked normal. The next day, she had a swollen kneecap with progressive pain. On physical exam, she has medial joint line tenderness and effusion. Her doctor notices an audible snap occurring when extending the knee from a fully flexed position while applying tibial torsion. What is the most likely diagnosis?
- (A) Collateral ligament tear  
(B) Anterior cruciate ligament tear  
(C) Stress fracture  
(D) Tendon displacement  
(E) Meniscus tear
17. A 32-year-old housekeeper comes to the physician for hip pain localized to the lateral aspect of the hip. The hip pain is interrupting her sleep. She denies any muscle weakness or numbness and tingling. The pain is not worse with physical activity. On physical exam, there is tenderness to palpation on the lateral aspect of her hip while in the lateral decubitus position. Which of the following is the most likely etiology of the hip pain?
- (A) Hip osteoarthritis  
(B) Meralgia paresthetica  
(C) Trochanteric bursitis  
(D) Osteonecrosis  
(E) Hip fracture
18. A 17-year-old male comes to the emergency department for the third time over the last month due to pain in his right thigh above his knee that is particularly bothersome at night. He was previously diagnosed with growing pains. Now he has developed swelling above his right knee and states his pain is worse. On physical exam, there is a soft tissue mass that is tender to palpation. The skin overlying the mass is erythematous. An X-ray is obtained and shows a “sunburst” pattern in the distal femur. What is the most likely diagnosis?
- (A) Ewing’s sarcoma  
(B) Osteosarcoma  
(C) Osteomyelitis  
(D) Osteochondroma  
(E) Osteoid osteoma
19. Football players are subjected to multiple sports injuries including valgus stressing of the knee, particularly when they get tackled in the lower extremities subjecting the knee joint to increased abduction. Determining injury to the soft tissue structures of the knee may prove to be difficult for non-orthopedic or sports medicine physicians. After a physical exam, what is the most appropriate study to order to help work-up a patient with pain following valgus stressing of the knee?
- (A) MRI  
(B) CT  
(C) Radiograph  
(D) Arthroscopy  
(E) Nerve conduction studies
20. An ambitious young surgeon decided to travel to Somaliland with an international medical team to provide services for patients that have not had any previous medical attention. His work involved traveling long distances by foot and standing up for many hours while performing minor and major surgeries for an intense 3-week period. After returning from the trip, he experiences fatigue and increasing pain upon palpation at the midpoint of his right leg that wakes him up at night. On physical exam, he has point tenderness in his proximal tibia with some surrounding edema of the skin. Plain X-ray of the tibia is negative. What is the most likely etiology for his pain?



- (A) Medial tibial stress syndrome (MTSS)
  - (B) Osgood-Schlatter
  - (C) Stress fracture
  - (D) Exertional compartment syndrome
  - (E) Osteomyelitis
21. A 25-year-old man arrives to the ED after a MVC. After primary survey and secondary survey are completed, he was found to have a right-sided pneumothorax, a fracture in the right clavicle, and a fracture of the left mid-shaft humerus. A bruit is heard over the right upper chest. What is the most appropriate next step after placing a chest tube and subsequent chest X-ray to confirm placement of the tube?
- (A) CT angiogram of the chest and arm
  - (B) Non-contrast CT of the shoulder and clavicle
  - (C) MRI study
  - (D) Nerve conduction test to assess for radial nerve injury
  - (E) Echocardiogram
22. A 28-year-old pregnant woman suffering from pre-eclampsia is being monitored in the hospital the night before her elective induction when she experiences a generalized seizure. After the successful delivery of a healthy baby boy the next morning, her doctor notices that she is unable to move her right arm. An upper extremity anteroposterior radiograph is taken but does not reveal any abnormalities. What is the most appropriate next step in management?
- (A) Repeat radiographic studies of the upper extremity
  - (B) MRI of the upper extremity
  - (C) CT scan of the upper extremity
  - (D) Operating room
  - (E) Reassurance and observation

## Answers

### 1. Answer E

This patient was recently diagnosed with carpal tunnel syndrome but presents with an acute episode of septic arthritis which can be managed with surgical washout. Any patient with an inflammatory condition that has a sudden and dramatic increase in pain should always be suspected of this and appropriately worked up with synovial fluid analysis. Surgical washout would be indicated in this patient if she had thick purulent (e.g., yellow-green) material. Furthermore, she was getting local injections of corticosteroid which is a relative indication for surgical washout given the potential immunocompromised state. Glucose  $<25$  mg/dL and WBC  $>2 \times 10^3/\mu\text{L}$  (often greater than  $50 \times 10^3/\mu\text{L}$ ),  $>2,000$  (often  $>50,000$ ) would be suggestive of septic arthritis (A, B). Rheumatoid factor (C) found in synovial fluid would be supportive of a diagnosis of rheumatoid arthritis, which is treated systemically. Finally, negative birefringent crystals (D) are the hallmark of gouty arthritis, which is not treated surgically.

### 2. Answer A

The patient is most likely exhibiting slipped capital femoral epiphysis (SCFE), which affects obese adolescent males. The physical exam finding being described is the Trendelenburg sign, which is a shift of the torso over the affected hip due to gluteus muscle weakness. In addition, physical exam may reveal that the patient's gait is altered with the patient taking a short step on the affected side to minimize weight bearing due to pain. The anterior hip may be tender to palpation. Despite a complaint of pain in the knee area, the knee examination is normal (D, E).

### 3. Answer C

Anterior dislocations of the humeral head increase the patient's risk for concurrent axillary nerve injury. All these patients should be evaluated for axillary nerve damage. This can cause paralysis of the deltoid and teres minor muscles as well as a loss of sensation over the upper lateral arm. Musculocutaneous nerve injuries (A) are not common in patients that have sports injuries. These patients will present with paralysis or weakness in the biceps and brachialis muscles. Radial nerve injuries (B) are associated with fractures of the humeral midshaft. Brachial arterial injury (D) is a concern for patients with a supracondylar fracture. Medial clavicle injury (E) is difficult to attain and is not expected to occur concurrently in patients that have an anterior dislocation of the humeral head.

### 4. Answer E

Severed body parts can sometimes be reattached if the proper steps to ensure tissue viability are taken. There are new and promising replantation techniques available. However, nerve regeneration continues to be a major limiting factor. Young

patients with sharp amputations and no crush injury are the best candidates for replantation. The best recommendation to keep an amputated digit viable is to remove any dirt from the digit first, wrap it in a clean damp cloth, put it in a plastic bag, and then place the bag directly in a cup of cold water. This will ensure viability for up to 18 h.

### 5. Answer A

The most consistent finding with a tear in the posterior cruciate ligament would be a lower leg that sags on passive flexion of the knee at  $90^\circ$  while the patient is supine. An ACL tear would present with the lower leg moving forward relative to the knee with forward traction (B). A tear in the MCL would present with a foot that moves laterally when the knee is pushed medially (C). A tear in the LCL would present with a foot moving medially when the knee is pushed laterally (D). A clicking sensation that is heard when the knee is flexed and the leg is rotated externally is known as McMurray's sign and is positive with a meniscal tear (E).

### 6. Answer B

Radial nerve injuries present with wrist drop and sensory loss to the posterior arm and lateral dorsal aspect of the hand. This most commonly occurs in patients that have had fractures to the humeral midshaft and those that use improperly fitted crutches. This patient is using crutches that belonged to his older brother and is likely responsible for his upper extremity abnormalities. If a fracture in the midshaft of the humerus (A) did not present clinically during the time of his snowboarding accident, it is unlikely to cause significant problems a month later. Long thoracic nerve injuries (C) can occur in women with breast cancer that receive axillary lymphadenectomy. This will present with scapular winging. Ulnar nerve injury (D) presents with sensory changes in the 4th and 5th digits. Musculocutaneous nerve injuries (E) will present with paralysis or weakness in the biceps and brachialis muscles.

### 7. Answer A

This patient has suppurative tenosynovitis with the characteristic four cardinal signs (Kanavel signs): flexor tendon sheath tenderness, fusiform swelling (sausage-shaped digits), pain with passive extension, and a semi-flexed posture of the involved digit. It is a closed space infection, and some may be associated with past penetrating injuries to the hand. The most likely organism is *Eikenella corrodens* which is often associated with human bites (e.g., punch in the mouth/face). *Pasteurella multocida* (D) can also cause suppurative tenosynovitis but is associated with cat scratches. Management of suppurative tenosynovitis involves mid-axial longitudinal incision and drainage. Gout (B) is a crystal-induced arthropathy that commonly first presents in the big toe (podagra). Dupuytren's contracture (C) is associated

with diabetes, smoking, and alcohol abuse. It presents with contractures in the fourth and fifth digits secondary to proliferation of the palmar fascia of the hand. Felon (E) is a term used to describe infection in the terminal joint space of the finger.

#### 8. Answer E

This patient is most likely exhibiting avascular necrosis of the proximal femoral head (hip) (Legg-Calvé-Perthes disease). Avascular necrosis of the hip typically presents as hip pain, anterior thigh pain, or referred knee pain as well as a limp (which may be painless) in children between the ages of 4 and 10 years with a male-to-female ratio of 4:1. Often, children are unable to localize hip pain and may state they have knee pain, confusing the picture. Avascular necrosis is usually idiopathic but may occur secondary to an underlying condition such as glucocorticoid use. Clinical features include insidious onset of hip pain and limp. Physical exam shows limitation in internal rotation of the hip. Initial radiographs are often normal. Later in the course, radiographs show fragmentation of the femoral head. Septic arthritis presents with acute onset of refusal to bear weight, pain, swelling, warmth, with fever, and leukocytosis (A). Osteomyelitis is spread hematogenously in children and affects the metaphysis of long bones. It presents with localized pain and fever along with leukocytosis and elevated ESR and CRP (B). Slipped capital femoral epiphysis (SCFE) affects obese adolescent males and presents with altered gait (C). Torn ACL affects adolescent girls more often and would present with a history of trauma, swelling at the knee joint, and increased anterior translation of the knee on physical exam (D).

#### 9. Answer A

This maneuver is called the drop arm test and is used to evaluate for a tear in the supraspinatus muscle, a rotator cuff injury. This is performed by passively abducting the patient's shoulders to 90° and flexing to 30° while asking the patient to point his thumbs down. The test is positive if the patient is unable to keep arms elevated after the examiner releases. The supraspinatus is part of the rotator cuff, along with the infraspinatus (B), teres minor (C), and the subscapularis muscles. Teres major (D) is not part of the rotator cuff.

#### 10. Answer B

Carpal tunnel syndrome is a clinical diagnosis and can be supported with a positive Tinel's and/or Phalen's sign. Tinel's sign is elicited by gently percussing over the median nerve at the carpal tunnel. A positive sign is present if the patient described an electrical shock sensation in the median nerve distribution (A). Phalen's test is performed by having the patient place their elbow on a table and flexing the wrist for 60 s. The test is considered positive if the patient reports

paresthesias in the median nerve distribution. The median nerve controls sensation to the thumb, index, middle, and half of the ring finger. Palmar sensation is not affected by carpal tunnel syndrome (C) because the superficial palmar cutaneous branch of the median nerve passes superficially to the carpal tunnel. Radial deviation of the wrist upon wrist flexion (D) would be expected with ulnar nerve injuries. Posterior and lateral forearm sensory deficit (E) would be expected with musculocutaneous nerve injuries.

#### 11. Answer E

This infant is exhibiting developmental dysplasia of the hip (DDH), which describes a spectrum of conditions that cause the abnormal development of the acetabulum and proximal femur in infants and children. In young infants, it is important to routinely evaluate for DDH using the Barlow and Ortolani maneuvers, which are physical examination techniques to detect hip instability that use adduction and posterior pressure to feel for dislocatability and abduction to feel for reducibility, respectively. If a sensation of a "clunk" is found on physical exam, further work-up is warranted including immediate referral to an orthopedic surgeon. Reassurance and reexamination would be inappropriate (A, D). Ultrasound is the primary imaging technique for assessing abnormalities of the hip until 4–6 months of age because plain X-rays have limited value in the first 6 months of life when the femoral head and acetabulum are not yet ossified (C). CT scan is not useful in the diagnosis of DDH (B). Treatment involves splinting, casting, and/or surgery.

#### 12. Answer B

This patient has a classic history for a scaphoid fracture. This injury usually occurs in patients that fall on an outstretched hand with the wrist extended and presents with tenderness in the anatomic snuffbox. Plain films are typically unrevealing of scaphoid fractures if taken soon after injury. If clinical suspicion is high, all patients should be immobilized with a thumb spica cast and reimaged 7–10 days later. Supportive care with or without radiographs is not appropriate for classic cases of scaphoid fractures (A, D). Radiographs are recommended for all patients (C) to look for more serious injuries that may be associated with scaphoid fractures. If patients are found to have signs suggestive of wide displacement or ligament disruption, then more advanced imaging studies should be done (E).

#### 13. Answer A

Femoral neck fractures are most commonly seen in elderly patients after a fall. Women sustain hip fractures more often due to their higher rates of osteoporosis. Femoral neck fractures have a relatively high rate of complications compared with extracapsular hip fractures because they are intracapsular. The risk for compromise in the blood supply to the

femoral neck as a result of the fracture increases the risk of complications, in particular avascular necrosis (AVN). Long-term loss of hip abduction/adduction is prevented with physical rehabilitation (C–D). Osteosarcoma (E) or lumbar radiculopathy (B) are not complications of a femoral neck fracture.

#### 14. Answer D

An anterior dislocation of the shoulder joint is the most common form of shoulder dislocation. Posterior dislocations are rare and occur most often in patients that have had generalized seizures or have been electrocuted. Patients with posterior shoulder dislocations will present with an adducted arm that is internally rotated, while anterior dislocations present with an externally rotated arm. Sport injuries (A) are more likely to cause anterior dislocations of the shoulder joint. Similarly, a sudden forceful subluxation of the shoulder that may occur from a dog tugging at the chain (C) can lead to an anterior shoulder dislocation. Weight lifters are at increased risk for thoracic outlet obstruction which presents with symptoms caused by obstruction of nerves and vessels passing from the thoracocervical region to the axilla (e.g., upper extremity paresthesia, weakness, and edema). Swimmers and surfers (E) are more likely to present with symptoms consistent with nerve impingement secondary to repetitive paddling.

#### 15. Answer D

The patient is most likely exhibiting slipped capital femoral epiphysis (SCFE), which affects obese adolescent males. In SCFE, the femoral head separates from the neck and slips posteriorly, resulting in a limp and impaired internal rotation. Patients often present with knee pain, so a high index of suspicion is necessary to diagnose SCFE. The physical exam finding includes altered gait such that the patient takes a short step on the affected side to minimize weight bearing due to pain and tenderness to palpation at the anterior hip. The diagnosis of SCFE is made with X-rays, which show the classic “ice cream slipping off the cone” suggesting posterior displacement of the femoral head. Obesity seems to be the strongest risk factor for SCFE, likely due to excessive mechanical stress on the physis (growth plate). Weight loss (C) can be beneficial to the overall health of the child and will decrease the risk of SCFE in the contralateral hip, but is not considered a definitive management for SCFE. Treatment involves operative stabilization using pinning of the hip joint. Supportive therapy with rest and ibuprofen would be the appropriate treatment for transient synovitis (A). Aspiration of the synovial fluid along with appropriate antibiotic therapy would be the treatment for septic arthritis (B). Pavlik harness (E) is used in the management of developmental dysplasia of the hip (DDH) to keep the hip in a flexed and abducted position.

#### 16. Answer E

This patient has a meniscal tear with a positive McMurray’s sign. This maneuver helps identify a meniscal tear and is positive if there is a palpable or audible snap occurring when extending the knee from a fully flexed position while applying tibial torsion. Meniscal tears can also present concurrently with other injuries. A medially directed blow to the lateral knee (valgus stress) results in the “unhappy triad”: medial meniscus tear, medial collateral ligament tear, and anterior cruciate ligament tear. Both ligamentous (A, B) and meniscal tears can produce popping sounds during the injury, but ligamentous tears have rapid swelling occurring immediately, while meniscal tears have delayed swelling occurring the next day. Stress fractures (C) do not typically occur in the patella following trauma. Instead, they occur more commonly in long bones (e.g., tibia) that are subjected to repeat stress. A patellar tendon displacement (D) will present with a patient unable to resume weight bearing, an indentation at the bottom of the kneecap, a proximally displaced patella, and hemarthrosis.

#### 17. Answer C

The most common cause of unilateral hip pain in the adult is inflammation of the trochanteric bursa. It is caused by friction of the gluteus medius tendon and the tensor fascia lata over the outer femur as a result of gait impairment, trauma, or infection. Untreated, the bursal wall thickens, fibroses, and gradually loses its ability to lubricate the outer hip. Hip osteoarthritis (A) most commonly presents in patients over 40 years of age. The principal symptom associated with osteoarthritis is hip pain, which is localized in the groin and exacerbated by activity and relieved by rest. Meralgia paresthetica is compression of the lateral femoral cutaneous nerve. The nerve is susceptible to compression. The principle symptom is numbness and tingling and/or burning pain localized in the upper outer thigh (B). Osteonecrosis presents with groin pain (D). Hip fracture would present with severe pain, inability to bear weight, and intolerance to movement of the hip (E).

#### 18. Answer B

Osteosarcomas are primary malignant tumors of bone. The primary presenting symptoms of osteosarcoma is localized pain that is typically present for an extended period of time and may be worse at night. On physical exam, there may be a soft tissue mass, which is frequently large and tender to palpation. Osteosarcomas have a predilection for the metaphysis of long bones and are most commonly found in the distal femur, proximal tibia, and proximal humerus. The first diagnostic test to work-up bone pain is an X-ray, which shows periosteal bone formation, lifting of the cortex, and the classic “sunburst pattern.” Growing pains present with recurrent, self-limited extremity pain. In contrast to bone pain, which is

unilateral, growing pains are bilateral. Ewing's sarcoma presents in a similar manner, but the radiographic appearance is described as "onion peel" appearance due to the periosteum being displaced by the underlying tumor causing the characteristic periosteal reaction that produces layers of reactive bone (A). Osteomyelitis presents with localized pain, fever, and leukocytosis of acute onset (C). Osteochondroma (exostosis) (D) is a benign, firm solitary bone tumor commonly occurring in teenage males. Osteoid osteoma (E) is a benign, painful growth of the diaphysis in long bones (e.g., femur, tibia). It also occurs in teenage males. The pain is characteristically worse at night but better with aspirin. On plain film, there is a central radiolucency surrounded by a sclerotic rim.

### 19. Answer A

A medially directed blow to the lateral knee (valgus stress) results in the "unhappy triad": medial meniscus tear, medial collateral ligament tear, and anterior cruciate ligament tear. The most appropriate test to order in soft tissue injuries of the knee is a MRI. This study is the most appropriate study to investigate soft tissue injuries of the knee. It is superior to CT (B) as it is better able to demonstrate ligamentous and meniscal lesions. However, its use should only be limited for patients in which the diagnosis is in question. MRI is no more accurate than the physical examination of an experienced clinician, and so referral to a sport medicine physician or orthopedic surgeon should be considered prior to ordering a MRI. Radiographic studies (C) are not typically helpful or performed for sports injuries, but they are useful in traumatic knee injuries. Arthroscopy can be used for diagnostic purposes if the MRI is equivocal or if it is abnormal and warrants subsequent surgical intervention. Although nerve injuries may accompany knee injuries, nerve conduction studies (E) are not typically ordered in work-up of soft tissue injuries of the knee.

### 20. Answer C

This surgeon most likely has a tibial stress fracture. This injury is common in patients that have a sudden change in physical activity and/or long periods of standing. His fatigue could be explained by jet lag and returning from an intense medical mission trip. Stress fractures present with pain upon palpation and some surrounding edema of the skin. After physical exam, the first step in evaluating a possible stress fracture is a plain film. It is unlikely to show up on plain films, and so clinical judgment should dictate whether to start appropriate therapy. MRI or bone scintigraphy can be considered next to further evaluate the injury. Most patients with stress fractures could be managed with supportive therapy: reduce activity to the level of pain-free functioning, over-the-counter analgesics, stretching exercises, and/or biomechanical stress-relieving measures. MTSS (A), also known as shin splints, is a common cause of exertional leg pain in athletes.

Patients with MTSS complain of vague, diffuse pain of the lower extremity, along the middle-distal tibia associated with exertion. Conversely, patients with exertional compartment syndrome (C) will present with exercise induced pain in the lower legs that quickly disappears with rest. This occurs in college athletes and long distance runners. The exact cause is not well understood, but several leading theories exist. During exercise, blood flow to the muscle increases, and in patients with constricted compartments (e.g., hypertrophic leg muscles in college athletes), this increased blood flow may result in increased pressures that can cause pain. Osgood-Schlatter disease (B) occurs in adolescence during a time when there is increased strain on the tibial tubercle (from repetitive quadriceps contraction via the patellar tendon). Exertional pain at the knees that resolves with rest is the most common complaint. Osteomyelitis (E) is a possibility and can be ruled out with a serum ESR. However, a stress fracture is far more likely.

### 21. Answer A

Most clavicle fractures can be managed conservatively with a shoulder string or brace for 6–8 weeks. However, all patients with fractures to the clavicle should receive a careful neurovascular examination since these patients are at risk for brachial plexus and axillary/subclavian arterial injury. CT angiogram is not routinely necessary, but is indicated in the presence of a thrill or bruit around the clavicle, diminished or absent radial/brachial pulse, fracture of the first rib, large hematoma in the supraclavicular region, or mediastinum widening on plain films. A CT scan (B) of the shoulder can help estimate the intra-articular extension of the clavicular fracture in the acromioclavicular joint; however, contrast should be given to look for arterial injury. MRI (C) can help diagnose coexistent injuries of rotator cuff or intra-articular disk of the acromioclavicular joint. Although radial nerve injuries can commonly accompany midshaft humeral fractures, they are more likely to present clinically with wrist drop and sensory loss to the posterior arm and lateral dorsal aspect of the hand. Nerve conduction studies (D) are typically not needed, particularly when there are no physical exam findings suggestive of nerve damage. Blunt cardiac injury can occur in patients following MVC. This should be considered if the patient presents with chest pain and/or hemodynamic instability. Given his age, the bruit heard in his chest is unlikely to be related to underlying cardiovascular disease. For these reasons, an echocardiogram is not indicated (E).

### 22. Answer A

Pregnant patients with preeclampsia or eclampsia that present with an inability to move the arm following a seizure are most likely suffering from a posterior shoulder dislocation. These are rare and occur most often in patients that have had

generalized seizures or have been electrocuted. Pregnant patients suffering from eclampsia are also at risk because of its association with seizures. Regular anteroposterior radiographs will often miss the diagnosis, and so patients suspected of having a posterior dislocation should receive axillary and lateral view radiographs. The axillary view is essential for diagnosis as it can help estimate the size of the

defect in the humeral head. If radiographs are equivocal, a CT scan (C) can be ordered next. MRI (B) is considered for older patients with shoulder dislocation as they are more likely to have concurrent rotator cuff injury. Reassurance is not appropriate for shoulder dislocation (E). Most patients are able to manage a shoulder dislocation with nonoperative therapy (D).

## Pediatric Surgery

Paul N. Frank, Areg Grigorian, and Christian de Virgilio

### Questions

- A 4-week-old boy presents with a 3-day history of forceful vomiting. The mother states that the vomitus only contains partially digested milk. She notes that the infant seems very hungry between feedings and drinks vigorously. Past history is significant for a skin infection for which the infant received oral erythromycin. On examination, the infant appears to be healthy appearing and in no acute distress. The physician feels there may be a small palpable mass in the right upper quadrant, but is not certain. Electrolytes are normal. What is the best way to establish the most likely diagnosis?

  - Plain abdominal x-rays
  - Laparoscopy
  - CT of the abdomen
  - Upper GI study with contrast
  - Ultrasound
- A 2-day-old male infant was diagnosed prenatally with Down syndrome. Delivery was uneventful, but pregnancy was complicated by polyhydramnios. The infant has had several episodes of bilious vomiting after breast feeding but is otherwise stable. Which of the following would be the most likely finding on further work-up?

  - Dilated loops of small bowel with air-fluid levels on abdominal x-ray
  - Inability to pass a nasogastric tube
  - Abdominal distention with erythema of the overlying skin
  - Two large air bubbles on abdominal x-ray
  - Narrowing of the distal rectum on GI contrast study
- A 12-day-old male born at 33 weeks becomes lethargic and hypothermic over the course of 24 h. He is not tolerating his formula feeds, has two episodes of bilious emesis, and has three episodes of bloody diarrhea. Physical exam reveals abdominal distention, visible loops of bowel, abdominal wall erythema, and absent bowel sounds. What is the most likely diagnosis?

  - Hirschsprung's disease
  - Duodenal atresia
  - Esophageal atresia with tracheoesophageal fistula
  - Necrotizing enterocolitis
  - Meconium ileus
- A newborn female infant is born to a 19-year-old G1P0 mother who smokes. On physical exam, the small bowel is eviscerated through an abdominal wall defect to the right of the umbilicus. The small bowel appears matted and dilated. The infant appears to otherwise be healthy. Which of the following would have been expected in prenatal screening?

  - Elevated b-hCG levels
  - Decreased estradiol levels
  - Elevated alpha-fetoprotein levels
  - Oligohydramnios
  - None of the above
- A 4-month-old baby girl is seen at her pediatrician's office for her well-child check. The parents raise a concern that she has been vomiting approximately 1/3 of her meals since 2 weeks of age. The emesis is the color of milk and is not bile-stained. There has been no change in the frequency or amount of emesis. She is exclusively breast-fed. On physical exam, mucous membranes are moist and the anterior fontanelle is open and flat. Her growth is at the 75th percentile for height and weight and has not changed significantly since birth. She is otherwise asymptomatic and without findings on physical examination. Which of the following is the most likely diagnosis?

  - Tracheoesophageal fistula
  - Duodenal atresia
  - Pyloric stenosis
  - Gastroesophageal reflux
  - Malrotation
- A 6-h-old male infant is noted to be dyspneic with an oxygen saturation of 86 %. Physical exam reveals subcostal retractions and moderate perioral cyanosis. Which finding on chest x-ray would be most suggestive of a nonsurgical diagnosis?

  - Loops of bowel in the left chest
  - Tip of orogastric tube located above carina
  - Diffuse pulmonary interstitial edema
  - Boot-shaped heart with upturned apex
  - Double-bubble sign just beneath the diaphragm
- A newborn full-term infant is noted to have several episodes of bilious emesis. He is otherwise stable. Which of the following is the LEAST likely diagnosis?

  - Pyloric stenosis
  - Duodenal atresia
  - Midgut volvulus
  - Hirschsprung's disease
  - Jejunal atresia
- A 5-week-old boy presents with a 6-day history of vomiting. The parents report that his vomiting is more forceful than his usual spit ups and contain significantly more volume. The mother describes the vomit as partially digested milk. Between episodes of vomiting, the baby feeds vigorously. The parents report that he has made only one wet

- diaper today. On physical exam, the baby appears lethargic. Mucous membranes are dry and the anterior fontanelle is open and sunken. Capillary refill is 2 s. The growth chart reveals a 0.5-lb weight loss since his clinic visit 7 days ago. What is the next step in management?
- (A) Surgical intervention  
(B) CT of the abdomen  
(C) Upper GI contrast study  
(D) Fluid resuscitation  
(E) Ultrasound
9. A 2-h-old male infant born at 39 weeks gestation is noted to be drooling. Prenatal ultrasound demonstrated polyhydramnios. Attempts at placement of an orogastric tube are unsuccessful as the tube only passes about 10 cm from the lips. What is the most important immediate concern for an infant with this condition?
- (A) Prevention of aspiration  
(B) Nutrition  
(C) Urgent surgical exploration  
(D) Establishing positive pressure ventilation  
(E) Confirmatory contrast esophagram
10. Which of the following is the next best step in the management of a 1-week-old infant born at full term with bilious emesis?
- (A) Abdominal ultrasound  
(B) Broad-spectrum antibiotics and blood cultures  
(C) Immediate operative repair  
(D) Contrast enema  
(E) IV fluids and nasogastric tube placement
11. A newborn male is found to have the majority of his small bowel eviscerated through an abdominal wall defect. The umbilicus appears to be intact. There is no membrane covering the bowel. The most important immediate risk to an infant with this condition is related to:
- (A) Sepsis  
(B) Respiratory compromise  
(C) Cardiac anomalies  
(D) Dehydration  
(E) Urinary obstruction
12. A 6-week-old boy presents with a 6-day history of non-bilious, forceful vomiting. Between episodes of vomiting, the baby feeds vigorously. On physical exam, the baby has dry mucous membranes with a sunken anterior fontanelle. Capillary refill is 2 s. He is otherwise asymptomatic without findings on physical exam. Ultrasound is obtained and is shown below. What electrolyte abnormality would you expect?
- (A) Hypochloric metabolic alkalosis  
(B) Hyperkalemic metabolic acidosis  
(C) Hyponatremic metabolism acidosis  
(D) Hyperkalemic metabolic alkalosis  
(E) Hyponatremic metabolic alkalosis
13. A 2-h-old male born at 39 weeks gestation is noted to have difficulty breathing. Which of the following would most strongly suggest a diagnosis of esophageal atresia with a tracheoesophageal fistula?
- (A) Worsening respiratory status with feeding  
(B) Olive-shaped mass palpable in the epigastric region  
(C) Improvement of respiratory status over the 24 h after birth  
(D) Chest x-ray showing dilated loops of small bowel in the left hemithorax  
(E) Scaphoid abdomen
14. A 2-h-old male born at 39 weeks gestation with difficulty breathing is diagnosed with esophageal atresia with a tracheoesophageal fistula and undergoes surgical repair, which was uncomplicated. Ten years later, the patient develops difficulty swallowing and often vomits undigested food shortly after eating. Which of the following is the most likely explanation for this?
- (A) Scleroderma  
(B) Gastroesophageal reflux  
(C) Esophageal cancer  
(D) Esophageal leak  
(E) Esophageal stricture
15. A 2-week-old male infant born at 26 weeks gestation is in the neonatal ICU when he becomes hypotensive and begins passing bloody stools. Which of the following is the most likely finding?
- (A) Palpable olive-shaped mass in the epigastric region  
(B) Double-bubble sign on abdominal x-ray  
(C) Loops of intestine in the left hemithorax on chest x-ray  
(D) Gas in the walls of the intestine  
(E) Donut sign on abdominal ultrasound
16. Which of the following ventilator settings or respiratory measurements would be LEAST acceptable for a newborn with congenital diaphragmatic hernia (CDH)?
- (A) 100% FiO<sub>2</sub>  
(B) PEEP of 20 cm H<sub>2</sub>O  
(C) Inhaled nitric oxide (NO)  
(D) PaCO<sub>2</sub> of 55 mmHg  
(E) PaO<sub>2</sub> of 65 mmHg
17. A male infant is born via normal spontaneous vaginal delivery at 39 weeks gestation to a 32-year-old G1P1. She had good prenatal care. The infant is heard grunting while trying to breathe, and he shows bilateral subcostal and intercostal retractions. The patient is observed



- closely for several hours following delivery, and his respiratory status improves over that time. Which of the following is the most likely explanation of this patient's course?
- (A) Spontaneous reduction of congenital diaphragmatic hernia
  - (B) Closure of the ductus arteriosus
  - (C) Resorption of excess pulmonary fluid
  - (D) Paramyxovirus infection
  - (E) Closure of the foramen ovale
18. A 34-year-old pregnant female at 36 weeks gestation undergoes ultrasound at her obstetrician's office. The ultrasound reveals polyhydramnios. Which of the following is the LEAST likely diagnosis?
- (A) Duodenal atresia
  - (B) Esophageal atresia
  - (C) Maternal diabetes
  - (D) Fetal posterior urethral valve
  - (E) Fetal anencephaly
19. A 2-week-old infant delivered at 35 weeks gestation is brought to the pediatrician by his mother who reports that he has had a harsh, barking cough and makes a high-pitched whistling sound when he inhales. He has been feeding poorly but has not had a fever. The mother also says that the patient has bouts of blue discoloration around his lips, more frequently when he is lying on his back than on his stomach. Chest x-ray is normal. What is the most likely diagnosis?
- (A) Foreign body aspiration
  - (B) Asthma
  - (C) Transient tachypnea of the newborn
  - (D) Tracheomalacia
  - (E) Congenital diaphragmatic hernia
20. A 1-week-old male presents with intolerance of breast-feedings as well as several episodes of bilious vomiting. On physical exam, the patient's blood pressure and temperature are normal. The infant appears to be in pain. However, the abdomen does not appear to be distended, and there is no tenderness to palpation. Plain abdominal x-ray shows an absence of gas within the bowel, but is otherwise unremarkable. A complete blood count and electrolytes are normal. What is the next step in the management?
- (A) Admit for observation
  - (B) Discharge patient and offer parents reassurance
  - (C) Exploratory laparotomy
  - (D) Upper GI study with oral contrast
  - (E) Abdominal ultrasound

## Answers

### 1. Answer A

Worsening respiratory status with feeding is suggestive of an anatomic or physiologic defect of the upper aerodigestive tract. The next step is to attempt to place an orogastric tube (OGT) and perform AP and lateral chest x-rays. Failure to pass an OGT with radiologic confirmation that the tube is in the upper esophagus is suggestive of esophageal atresia. An olive-shaped mass palpable in the epigastrium (B) suggests a diagnosis of pyloric stenosis. Dyspnea that resolves over the first 24 h of life (C), especially in a full-term neonate who is otherwise healthy, is likely transient tachypnea of the newborn, which is benign and self-limited. Loops of small bowel in the left hemithorax (D) suggest a congenital diaphragmatic hernia, as does a scaphoid abdomen (E) (it indicates that bowel contents are elsewhere such as in the chest).

### 2. Answer D

Given the history of polyhydramnios, bilious emesis, and Down syndrome, the most likely diagnosis is duodenal atresia. Because of the duodenal obstruction, there would be no gas in the small bowel. Air-fluid levels on abdominal x-ray (A) are characteristic of more distal intestinal obstruction. Inability to pass a nasogastric tube (B) is suggestive of choanal atresia. Abdominal distention with erythema of the overlying skin (C) is concerning for necrotizing enterocolitis. Narrowing of the distal rectum on GI contrast study (E) is found in Hirschsprung's disease.

### 3. Answer D

In a premature neonate with rather sudden systemic illness, feeding intolerance, and bloody stools, necrotizing enterocolitis would be the most likely diagnosis. Visible loops of distended bowel and abdominal wall erythema are additional classic findings. Initial treatment is to place the infant NPO, stomach decompression, and administration of IV antibiotics. Surgical management is indicated for suspected perforation, as evidenced by free intraperitoneal air or progressive clinical deterioration (rising WBC count, falling platelet count, worsening acidosis). Hirschsprung's disease (A) would present with failure to pass stool at birth and not a sudden decompensation. Duodenal atresia (B) presents with bilious vomiting, but due to the atresia, it presents at birth and with failure to pass meconium. Esophageal atresia with tracheoesophageal fistula (D) would present with respiratory distress during feeding. Meconium ileus (E) classically would present with failure to pass meconium at birth and raises concern for cystic fibrosis.

### 4. Answer C

Eviscerated bowel without a membrane covering it, with the abdominal wall defect to the right of the umbilicus, is termed gastroschisis. It is more common in young mothers and in

those who smoke during pregnancy. Maternal serum alpha-fetoprotein (AFP) tends to be elevated in cases of abdominal wall defects, including both gastroschisis and omphalocele (evisceration though the umbilicus and with a membrane covering bowel). Typically, maternal serum AFP is greater in gastroschisis than in omphalocele. Maternal serum AFP is checked as part of the triple screen or quad screen that is performed. Elevated maternal serum AFP is seen in other conditions such as multiple gestation, neural tube defects, abruptio placentae, or endodermal sinus tumor, making this a nonspecific marker for abdominal wall defects. Gastroschisis is associated with intestinal atresia. Since the fetus may be unable to swallow amniotic fluid, it is associated with polyhydramnios.

### 5. Answer D

Gastroesophageal reflux is a common complaint in infants less than 1 year of age. In the first year of age, the pylorus is not fully developed and therefore not fully functional, leading to occasional episodes of reflux (also called spitting up). Gastroesophageal reflux *disease* (GERD) is not diagnosed until the infant is failing to gain weight. Treatment of GERD includes thickening the feeds, keeping the infant upright after feeds, and feeding smaller amounts at shorter intervals. Tracheoesophageal fistula typically presents at birth with inability to control secretions. A rare "H" type (fistula without esophageal atresia) often presents in a delayed fashion but would present with recurrent respiratory infections from aspiration and not vomiting (A). Duodenal atresia would present as bilious vomiting in the newborn period and the classic "double-bubble" sign on abdominal x-ray (B). Pyloric stenosis presents with non-bilious, projectile vomiting in the first few weeks of life and typically not at 4 months of age (C). In addition, it would progressively worsen with time. Malrotation would present with abdominal distension and bilious vomiting (E).

### 6. Answer C

Diffuse pulmonary interstitial and/or alveolar edema suggests transient tachypnea of the newborn, which is self-limited and resolves within 1–2 days. Loops of bowel in the left chest (A) suggest a congenital diaphragmatic hernia. An orogastric tube that does not pass beyond the proximal esophagus (B) suggests an esophageal atresia. Boot-shaped heart with upturned apex (D) is found in infants with tetralogy of Fallot, a constellation of congenital cardiac anomalies, that specifically includes ventricular septal defect, pulmonary stenosis, large overriding aorta, and right ventricular hypertrophy. The double-bubble sign (E) is found in duodenal atresia.

### 7. Answer A

Bilious vomiting in the neonate should be considered a surgical emergency until proven otherwise. It implies obstruction

that is distal to the ampulla of Vater and likely from a congenital anomaly (B–E). Non-bilious emesis (of milk) is more likely to be physiologic (immaturity of the lower esophageal sphincter). An exception would be non-bilious vomiting that progressively worsens and is projectile in nature, which would raise suspicion for pyloric stenosis. Since the obstruction is at the pylorus, it does not allow for gastric contents to mix with bile. Pyloric stenosis also presents later, typically in the 3rd week of life.

#### 8. Answer D

The presentation is classic for pyloric stenosis. Although the management of pyloric stenosis is surgical, the first priority in these infants is rehydration. The infant is presenting with signs of moderate to severe dehydration including dry mucous membranes, a sunken fontanelle, delayed capillary refill, and decrease urinary output. The course warrants fluid resuscitation prior to any diagnostic work-up or consultations. After fluid resuscitation, the gold standard imaging modality is ultrasound to assess for pyloric stenosis (E). Only if ultrasound is negative or equivocal is an upper GI obtained (C). If imaging modalities demonstrate pyloric stenosis, surgical consultation is then obtained (A). CT of the abdomen is not warranted in the work-up of suspected pyloric stenosis (B).

#### 9. Answer A

Based on the classic history of polyhydramnios and excessive drooling in a newborn, the patient likely has esophageal atresia. The most important concern is prevention of aspiration. Nutrition (B) can be established after early surgical repair or via a gastrostomy tube if surgery is not undertaken (as in cases where the infant is premature or has pneumonia from aspiration). Urgent surgical exploration (C) is not indicated, as surgery may be delayed in some patients. Positive pressure ventilation (D) may distend the stomach and cause aspiration. Therefore, it should be avoided when possible. Contrast esophagram (E) is only performed if chest x-ray is nondiagnostic or if the location of the fistula cannot be identified. This study carries risk of aspiration pneumonitis from the contrast agent.

#### 10. Answer E

The first steps in treating a patient with bilious emesis are fluid resuscitation and gastrointestinal decompression (via NG tube). Once the IV fluid resuscitation has begun, the patient may undergo an upper GI study to evaluate for evidence of midgut volvulus, which may present with distended proximal bowel and a paucity of gas in the distal bowel. Broad-spectrum antibiotics (B) are not indicated as there is no evidence of infection. Operative repair (C) cannot occur until the patient has been stabilized and a diagnosis has been confirmed. Contrast enema (D) would be used to evaluate for

Hirschsprung's disease, which would present as failure to pass meconium and not necessarily bilious emesis.

#### 11. Answer D

This patient has gastroschisis. Since the intestines are outside of the abdominal cavity, insensible fluid losses will be much greater than in an infant without gastroschisis. Therefore, covering of the exposed intestine with moist gauze and IV fluid resuscitation are critical first steps in management. Such patients are also at risk of hypothermia. While exposed intra-abdominal contents increases risk of infection and sepsis (A), this is not as immediate of a concern as is dehydration. After operative repair, patients may be paralyzed to allow the abdominal wall to relax and stretch to accommodate the intestines. If the abdominal cavity is not sufficiently large to accommodate the bowel, the bowel is covered with a silo temporarily. Attempting to forcefully reduce all the small bowels and close it under tension will result in abdominal compartment syndrome, bowel ischemia, and respiratory compromise (B). Cardiac anomalies (C) are more of a concern in patients with omphalocele than gastroschisis, but regardless this is not an immediate concern. Urinary obstruction (E) is not a typical feature of gastroschisis, though it could rarely occur if the bladder were also herniated through the abdominal wall.

#### 12. Answer A

Laboratory evaluation in a patient with pyloric stenosis classically shows a hypochloric metabolic alkalosis. Chloride is typically lost in the gastric secretions (HCl) via vomiting. Alkalosis is caused by both a loss of protons (HCl) in the gastric fluid as well as secondary to a contraction alkalosis mediated by aldosterone secretion in the setting of hypovolemia. Hypokalemia is a late finding seen in infants who have been vomiting for prolonged period of time, also from contraction alkalosis. The infants also may have a paradoxical aciduria (acidic urine despite alkalosis). Initially, Na<sup>+</sup> in the renal tubule is reabsorbed in exchange for K<sup>+</sup> ions but as K<sup>+</sup> levels decrease, Na<sup>+</sup> is instead exchanged for H<sup>+</sup> ions. The presentation of adrenal crisis in an infant may mimic that of pyloric stenosis. However, infants with adrenal crisis typically have hyperkalemic acidosis (D) rather than the hypokalemic alkalosis that is typical of pyloric stenosis (B).

#### 13. Answer E

Ultrasound is the image modality of choice in diagnosing pyloric stenosis, as it does not require any radiation exposure. If ultrasound is negative or equivocal and pyloric stenosis is highly suspected, diagnosis may be attempted with a barium upper GI study with contrast. Upper GI was the test of choice prior to the advent of ultrasound. However, it must be done carefully as it risks causing aspiration given that the infant has a gastric outlet obstruction. Typical findings

include elongated pyloric canal (string sign) and delayed gastric emptying. In addition, upper GI studies are further helpful in the setting of a negative ultrasound in order to assess for other items on the differential diagnosis, particularly gastroesophageal reflux. Reassurance would be inappropriate if pyloric stenosis is highly suspected (A). Operative intervention with pylorotomy would be the definitive treatment should the child be diagnosed with pyloric stenosis, but confirmatory testing should be undertaken first (B). CT of the abdomen is not an imaging modality of choice for diagnosing pyloric stenosis (C).

#### 14. Answer E

Esophageal anastomotic stricture is a very common long-term complication of esophageal atresia with or without tracheoesophageal fistula repair. These cases may be treated with esophagoscopy with balloon dilation. There is no evidence given to suggest the patient has scleroderma (A), which is particularly unusual to present at age 10. The patient likely does have gastroesophageal reflux (B), as this is another typical side effect of surgical repair, but the symptoms described are more likely attributable to esophageal stricture. Esophageal leak (D) is more commonly a short-term complication, and many leaks will heal spontaneously. Finally, the patient is at increased risk for esophageal cancer (C), but this would be unlikely to develop so early in life.

#### 15. Answer D

This patient likely has necrotizing enterocolitis, which most commonly affects premature infants. It causes necrosis of segments of intestine. In the necrotic segments, gas may be found within the walls of the intestine, a finding known as pneumatosis intestinalis. A palpable olive-shaped mass in the epigastric region (A) suggests pyloric stenosis, which would present with non-bilious emesis, but not severe systemic illness. Double-bubble sign on abdominal x-ray (B) suggests duodenal atresia, which would also not present so acutely. Loops of intestine in the left hemithorax on chest x-ray (C) suggest congenital diaphragmatic hernia, which may present with respiratory difficulty. Donut sign on abdominal ultrasound (E) arises from intussusception of intestine, wherein one segment telescopes into another. This may occur at the ileocecal junction or at the site of a diverticulum and is a surgical emergency. However, it would not necessarily present as acute systemic illness.

#### 16. Answer B

Positive end expiratory pressure (PEEP) is designed to keep alveoli open throughout the respiratory cycle, even during expiration. This increases the surface area available for gas exchange. However, high levels of PEEP will increase the pressure within the alveoli to dangerously high levels and

may cause barotrauma, analogous to inflating a balloon until it nearly bursts. Therefore, PEEP should be maintained at or below 5 cm H<sub>2</sub>O. FiO<sub>2</sub> of 100 % (A) will maximize oxygenation. Inhaled NO (C) will cause pulmonary vasodilation, thereby reducing pulmonary hypertension. It has been shown that permissive hypercapnia, with PaCO<sub>2</sub> < 60 mmHg (D), and permissive hypoxia, with PaO<sub>2</sub> > 60 mmHg (E), allow for lower ventilation settings and less risk of barotrauma.

#### 17. Answer C

The patient described above is an otherwise healthy, full-term newborn whose mother had good prenatal care. Furthermore, his respiratory status improved in the hours after delivery. Therefore, the most likely diagnosis is transient tachypnea of the newborn, which resolves as excess pulmonary fluid is resorbed. Spontaneous reduction of congenital diaphragmatic hernia (A) is very unlikely. Closure of the ductus arteriosus (B) or foramen ovale (E) will have no effect on respiratory status in healthy patients. In patients with some cyanotic heart lesions, such as transposition of the great arteries (wherein the right ventricle ejects into the aorta and the left ventricle ejects into the pulmonary artery), closure of the ductus arteriosus or foramen ovale will have an adverse effect on blood oxygenation. Paramyxovirus (D) can lead to croup, which can lead to respiratory difficulty, but this diagnosis is unlikely given the patient's presentation.

#### 18. Answer D

Fetal posterior urethral valve prevents the fetus from passing urine via the urogenital tract, which reduces the amount of amniotic fluid present, and is referred to as oligohydramnios. Renal anomalies generally lead to oligohydramnios, whereas intestinal atresias are associated with excess amniotic fluid (polyhydramnios), as the fetus is unable to swallow amniotic fluid. The other items listed above are associated with excess of amniotic fluid.

#### 19. Answer D

Softness of the tracheal cartilage is known as tracheomalacia. Because the cartilaginous support is soft and flexible, the airway can collapse. The condition is usually worse when the patient is supine because gravity pulls the anterior trachea downward toward the posterior trachea, thereby occluding the upper airway. Foreign body aspiration (A) (such as a toy or food particles) would present similarly, but this is unlikely in a 2-week-old. Asthma (B) is also a consideration, but tracheomalacia should be ruled out first. Transient tachypnea of the newborn (C) usually resolves within 1–2 days after delivery. Congenital diaphragmatic hernia (E) generally presents at birth. Delayed presentations rarely do occur, but the chest x-ray would show loops of bowel, or part of the liver, in the thorax.

**20. Answer D**

Bilious vomiting in an infant should always raise suspicion for midgut volvulus (a complication of malrotation) which left untreated can lead to intestinal gangrene. Yet, early on, ischemic bowel provides few clinical clues to the impending catastrophe, as the physical exam may be benign, with no fever, no abdominal tenderness (as only the visceral peritoneum is initially affected), and normal laboratory values (there are no values that are diagnostic of bowel ischemia). Similarly, plain abdominal x-ray may be normal. By the time the infant has evidence of systemic inflammation, peritonitis, appears toxic, or has marked leukocytosis, there is a high likelihood that there is gangrenous bowel. The gangrene may

involve the entire small bowel. If such a patient survives, he/she may be subject to lifelong intravenous parenteral nutrition or may require small bowel transplantation. Thus further work-up is always required to rule out this potentially devastating problem (A–B). Given the paucity of findings, it would be premature to take this infant directly to the operating room (C). Ultrasound (D) is useful for pyloric stenosis (non-bilious vomiting) but not for midgut volvulus. Upper GI study with oral contrast is the best test as it will confirm failure of passage of the contrast, confirming a bowel obstruction, or show a malrotation. A normal study should demonstrate the normal C loop of the duodenum and show that the duodenal jejunal junction is to the left of the spine.

## Skin

Areg Grigorian, Paul N. Frank, and Christian de Virgilio

### Questions

- A 15-year-old girl develops short gut syndrome following resection of bowel secondary to leiomyosarcoma in the small intestinal wall. She is subsequently placed on long-term total parenteral nutrition (TPN) and is recovering well. A month later, she develops red and inflamed patches of dry and scaly skin around her mouth and eyes. Her hair also begins to thin, and she notices a bad taste when she gets her daily cherry-flavored chloraseptic spray to prevent dry throat. What is the most likely underlying etiology of her skin lesions and thinning hair?

  - Zinc deficiency
  - Copper deficiency
  - Pemphigus vulgaris
  - Chromium deficiency
  - Psoriasis
- A 30-year-old female of Scottish descent presents with a nodule on her face near the corner of her eye. The lesion measures 12 mm in diameter. The borders are irregular, and the center of the lesion is dark. Which of the following is the best recommendation?

  - Shave biopsy
  - Punch biopsy
  - Excisional biopsy with 1 mm margin
  - Excisional biopsy with 5 mm margin
  - Reexamination in 2 months
- A 64-year-old man who emigrated from Japan arrives to his doctor to discuss new skin lesions. His wife first noticed two discolored plaques on his back 2 weeks ago, but he now has multiple lesions all over his back, chest, and face. They are the size of a coin and appear to have a “stuck-on” appearance. He is afebrile, blood pressure is 136/86 mmHg, and he has a pulse of 90/min. The skin lesions do not itch, and they are not tender. He has no other complaints, and a review of systems is negative. He is more concerned about his cosmetic appearance. What is the best next step in management?

  - Reexamine in 2 weeks
  - Skin biopsy
  - Abdominal CT scan
  - Mohs procedure
  - Corticosteroids
- Which of the following would be best suited for Mohs surgery?

  - Superficial spreading melanoma in the arm
  - Nodular melanoma on the back
  - Basal cell carcinoma on the face
  - Subungual melanoma
  - Squamous cell carcinoma of the neck
- A 25-year-old female lifeguard presents to her doctor to discuss a new 10 mm skin lesion that she found on her right forearm that has been growing over the last month. The lesion has a heterogeneous dark blue color, is symmetric, and has been growing vertically. What is the most likely diagnosis?

  - Impetigo
  - Melanoma
  - Nevus
  - Molluscum contagiosum
  - Squamous cell carcinoma
- A 65-year-old obese male with diabetes and a history of IV drug abuse presents with a painful swollen left leg. Exam reveals dark purple discoloration and several large bullae over the calf. Vitals are temperature of 101.1 °F, heart rate of 120/min, and blood pressure of 92/68 mmHg. The CRP is 200 mg/L (normal < 10 mg/L), and the WBC is 28.3/mm<sup>3</sup> (normal 4–10/mm<sup>3</sup>). Creatinine is 2.0 mg/dL (normal 0.5–1.5 mg/dL), and Na is 127 mEq/L (normal 135–145 mEq/L). Distal pedal pulses are 1+. IV fluids and intravenous antibiotics are administered. Which of the following is the next best step?

  - X-ray of the leg
  - CT scan of the leg with IV contrast
  - Venous Duplex scan of the left leg
  - Measure compartment pressures
  - Emergent wide surgical debridement
- A 50-year-old field worker arrives to a free clinic to discuss a “sore” on his lower lip. He has had no trauma to the face. He reports that he first noticed the “sore” 6 months ago, and it has slowly gotten bigger. On physical exam, he has an ulcerated 1 cm nodule on his lower lip. There are no telangiectasias present. What is the most likely diagnosis?

  - Basal cell carcinoma
  - Squamous cell carcinoma
  - Lichen planus
  - Dermatitis herpetiformis
  - Melanoma
- Which of the following melanomas have the worst prognosis?

  - Superficial spreading
  - Nodular
  - Lentigo maligna
  - Acral lentiginous
  - Subungual

9. Which of the following melanomas do not follow the ABCDE mnemonic?
- (A) Superficial spreading
  - (B) Nodular
  - (C) Amelanotic
  - (D) Acral lentiginous
  - (E) Amelanotic and nodular
10. One day following extensive debridement of the right leg for a necrotizing soft tissue infection (NSTI), a 40-year-old male remains in the ICU, intubated, and requiring 70 % FIO<sub>2</sub>. White blood cell count has risen from a preoperative level of  $16 \times 10^3/\mu\text{L}$  (normal  $4.1\text{--}10.9 \times 10^3/\mu\text{L}$ ) to  $34 \times 10^3/\mu\text{L}$ . Serum lactate has also risen. Which of the following is the best next step in treatment?
- (A) Second-look operation
  - (B) Amputation of the right leg
  - (C) Broaden antibiotic coverage
  - (D) CT scan of the leg
  - (E) Start pressors
11. A 45-year-old female presents with a recent change in a preexisting mole on her anterior thigh. She states that the mole keeps bleeding, is darker, and has grown. The mole is 8 mm in diameter on physical exam. There are no palpable nodes in the groin. An excisional biopsy is performed with a 1 mm margin, and to a depth of the subcutaneous fat. Pathology reveals a melanoma that is 0.5 mm in thickness. The margins are negative. What is the next step in the management?
- (A) No further treatment
  - (B) Re-excision with 1 cm margins
  - (C) Interferon alpha
  - (D) Granulocyte-macrophage colony-stimulating factor (GM-CSF)
  - (E) Dacarbazine
12. Which of the following is the most common precancerous skin lesion?
- (A) Actinic keratosis
  - (B) Seborrheic dermatitis
  - (C) Seborrheic keratosis
  - (D) Compound nevi
  - (E) Keratoacanthoma
13. Where are melanomas in patients with dark skin most likely to occur?
- (A) Back
  - (B) Arms
  - (C) Legs
  - (D) Palms, soles, and mucous membrane
  - (E) Face

## Answers

### 1. Answer A

Zinc deficiency can occur in surgical patients on long-term total parenteral nutrition or in patients diagnosed with a malabsorption syndrome. This can present with alopecia, red and inflamed patches of dry and scaly skin around the mouth and eyes, abnormal taste, and impaired wound healing. Zinc supplementation will remedy this condition. Copper (B) and chromium (D) deficiency are rare but can also affect this patient population. The most common manifestations of copper deficiency include hematologic abnormalities (anemia, leukopenia) and myeloneuropathy. Chromium deficiency presents with impaired glucose tolerance and peripheral neuropathy. Pemphigus vulgaris (C) occurs as a result of autoimmune destruction of desmosomes between keratinocytes and is characterized by multiple skin and oral mucosa bullae. Psoriasis (E) is believed to have an autoimmune etiology and presents as salmon-colored plaques with a silvery scale that occur on extensor surfaces (e.g., patella).

### 2. Answer B

The lesion is concerning for melanoma and as such will require tissue confirmation to rule out cancer. Excisional biopsy (removing the entire lesion) (C), down to the subcutaneous fat, would be the preferred approach for a lesion on an extremity or torso. However, depending on the size of the lesion and its location (not desirable to make a cosmetically unappealing large incision if the lesion ends up being benign), an initial incisional biopsy (taking only a small sample) is preferred. Punch biopsy down through the dermis (to calculate Breslow thickness) is the preferred method in this setting. Shave biopsies (A) are not recommended if melanoma is suspected as the true Breslow thickness may not be measurable. During the initial biopsy, no attempts are made to achieve a wide margin. If the pathology comes back benign, no further treatment may be necessary. Excisional biopsy with a 5 mm initial margin (D) would not be indicated as the lesion may be benign. Reexamination (E) is not appropriate for a patient suspected of having melanoma.

### 3. Answer C

The skin lesions described are most likely to be seborrheic keratosis (SK). Isolated SKs occur commonly in the elderly. Sudden onset of multiple SKs (Leser-Trelat sign) suggests an underlying carcinoma of the gastrointestinal tract, most often gastric cancer. It is considered to be a result of a paraneoplastic syndrome associated with the cancer. The best next step in working up a suspected GI malignancy is an abdominal CT scan. Given the high likelihood of malignancy, it would be inappropriate to only reexamine the patient in 2 weeks (A). SKs have a characteristic appearance and typically do not need to be confirmed with a skin biopsy (B). Mohs (D) is a specialized tissue-sparing procedure for treating skin cancer.

It involves tangential excisions of the lesion until margins are negative. Mohs has the advantage in that definitive excision, and closure can be achieved on the same day. Corticosteroids (E) are not used in the management of SKs.

### 4. Answer C

Mohs is a specialized tissue-sparing technique of treating skin cancer in which the tumor is removed in a series of thin layers as opposed to one wide excision. The advantage is that it prevents excising excessive normal tissue and allows for immediate confirmation of negative surgical margins intraoperatively. It is best suited for basal cell and squamous cell CA in cosmetically sensitive areas such as the face. Mohs is not generally recommended for melanoma. This is because it is difficult to distinguish the normal skin from melanoma on frozen section (immunohistochemical stains are sometimes needed). Because of this, Mohs is considered by most surgeons to be an unreliable method of resection for melanoma (A, B, D). The treatment of choice for subungual melanoma is digital amputation.

### 5. Answer B

Nodular variant melanomas grow vertically, not horizontally. They are usually a uniformly dark blue or black “berry-like” lesion that is mostly symmetric, elevated, and one color. Impetigo (A) is a superficial bacterial infection oftentimes due to *Staphylococcus aureus*. It presents first as a flat macule and then a raised pustule that erodes and oozes a dry, honey-crusted serum. A nevus (C), or a mole, is described as a *small* (<6 mm) macule with sharp, symmetric borders, and an evenly distributed color. Molluscum contagiosum (D) is caused by the poxvirus and occurs most commonly in children and immunocompromised adults. It is characterized by small, firm, pink, and umbilicated papules. Squamous cell carcinoma (E) is a malignant proliferation of epithelial cells that presents as an ulcerated, nodular mass in sun-exposed areas.

### 6. Answer E

There is a very high likelihood that this patient has an NSTI. After IV fluids, blood cultures, and immediate antibiotics, the next best step is to perform an emergent wide surgical debridement. If the diagnosis of NSTI is uncertain, yet the suspicion is high, surgical exploration is still indicated, as this is the gold standard of both diagnosis and treatment. The incision must be taken down to the fascia and muscle, so both can be inspected. When the diagnosis is in question, plain X-rays (A) are useful as they may demonstrate gas in the soft tissue. CT scan (B) may also be beneficial for the same reason. Duplex scan of leg veins (C) is used to rule out deep venous thrombosis, which can present with leg swelling, but like compartment syndrome (E), it would not cause the laboratory abnormalities described.



**7. Answer B**

The most common type of lip cancer is squamous cell carcinoma (SCC). Lip cancer occurs much more commonly on the lower lip, as it gets more sun exposure than the upper lip. Occupations that involve long-term sun exposure (e.g., lifeguard, farmer, construction worker, gardener, and field worker) place patients at higher risk for developing skin cancer. SCC is described as an ulcerated, nodular mass without any telangiectasias. Basal cell carcinoma (A) presents as a pearly white nodule with a central ulcerated crater surrounded by dilated vessels (telangiectasias). Lichen planus (C) can be remembered as the “5 Ps”: pruritic, planar, polygonal, purple papules. It commonly involves the wrists and elbows and is associated with chronic hepatitis C infection. One of the manifestations of celiac disease includes dermatitis herpetiformis (D). It presents as pruritic vesicles and bullae that are grouped together (herpetiform). It only occurs in a minority of celiac patients and typically resolves with a gluten-free diet. Melanoma (E) presents as a mole-like growth and follows the ABCDE rule.

**8. Answer B**

Nodular variant melanomas are characterized by the absence of a radial growth phase. They are usually a uniformly dark blue or black “berry-like” lesion that is mostly symmetric, elevated, and one color. They are considered to be the most rapidly growing and aggressive variant of malignant melanoma. Typically, it arises on apparently normal skin (the head, trunk, and neck are the most common locations) vs. preexisting lesion. Ulceration is common, giving a poorer prognosis. Superficial spreading (A) is the most common type of melanoma. It typically has a long horizontal growth phase before the vertical growth phase which confers a better prognosis. Acral lentiginous melanomas (D) are typically found in the subungual (E), sole or palm location, and common in ethnic groups of color. Subungual tend to present late as they are often confused with a subungual hematoma.

**9. Answer E**

Amelanotic and nodular melanomas do not follow the ABCDE rule. As previously mentioned, nodular variant melanomas are characterized by the absence of a radial growth phase. They are usually a uniformly dark blue or black “berry-like” lesion that is mostly symmetric, elevated, and one color. They are considered to be the most rapidly growing and aggressive variant of malignant melanoma. Amelanotic melanomas are notoriously difficult to identify because this variant is deficient in pigment or is unable to produce any pigment at all. For this reason, they typically go unrecognized until the disease advances enough to locally invade the surrounding tissue. Superficial spreading (A) is the

most common type of melanoma. It typically has a long horizontal growth phase before the vertical growth phase which confers a better prognosis. Acral lentiginous melanomas (D) are typically found in the subungual, sole or palm location, and common in ethnic groups of color.

**10. Answer A**

A rising WBC and lactate after debridement are highly suggestive of progression of the NSTI. A second-look operation is often required, but in this case would be essential in order to ensure that no additional tissues have become involved since the initial debridement. Amputation (B) may be necessary, but only a second-look operation will indicate whether this is the case. CT scan (D) in the postoperative setting would be difficult to interpret due to postsurgical changes. With severe sepsis, pressors (E) may be necessary, but this would not be the definitive treatment. Furthermore, no hemodynamic parameters (blood pressure, central venous pressure) are provided that would indicate that pressors are needed. Patients with NSTI should always receive broad antibiotic coverage (C) at initial presentation as it is often due to a polymicrobial infection. However, the cornerstone of management is surgical debridement.

**11. Answer B**

Once the diagnosis of melanoma is established by punch or excisional biopsy, the area needs to be re-excised to obtain wider margins, and in select cases, sentinel lymph node biopsy (SLNB) is obtained. The extent of margins and need for SLNB are determined by tumor thickness. Patients with tumor thickness <1 mm (considered a thin melanoma) require an excision margin of only 1 cm. For melanomas that are thin, SLNB is generally not performed. Interferon alpha (C), GM-CSF (D), and dacarbazine (E) are all adjuvant therapy options for patients with melanoma. There has been no concrete evidence that adjuvant therapy prolongs survival in melanoma. However, there is some evidence to suggest that there is an improved relapse-free survival and overall survival with high-dose interferon alpha.

**12. Answer A**

Actinic keratosis presents as a rough, scaly patch of the skin that can vary in color (pink, red, brown). It is the most common precancerous skin lesion. It can progress to squamous cell carcinoma. Seborrheic dermatitis (cradle cap) (B) is a self-limited condition that commonly affects infants and presents as a yellow, greasy plaque on the scalp. Seborrheic keratosis (C) is a common tumor in the elderly and presents as raised, discolored plaques that appear coin-like, waxy, and with a “stuck-on” appearance. Both of these conditions are benign and not considered to be precancerous.

Compound nevi (D) are brown-black, well-circumscribed lesions that are <1 cm in diameter. They may be elevated and are frequently hairy, arising from the epidermal-dermal interface and from within the dermis. Malignant transformation is rare. Keratoacanthoma (E) is a low-grade subtype of squamous cell carcinoma that can grow rapidly and become large in size. Most will spontaneously get better within a year, but removal with surgery is still recommended.

**13. Answer D**

Melanocytes are found in equal numbers in most people (black or white). However, individuals with darker skin have melanocytes that produce more melanin, a protein which makes skin darker and helps protect from skin cancer by absorbing UV-B (B for bad) radiation. As such, in dark-skinned patients, melanomas are more likely to occur in areas that have less pigmentation such as the palms, soles, and mucous membranes.

## Surgical Complications

Areg Grigorian, Paul N. Frank, Christy Anthony, and Christian de Virgilio

### Questions

- A 55-year-old woman arrives to the emergency department with a 3-h history of severe epigastric pain that has been progressing in severity. She describes it as sharp, diffuse, and constant. Her past medical history is significant for chronic atrial fibrillation for which she takes warfarin. Her temperature is 100.6 °F, blood pressure is 102/66 mmHg, and pulse is 98/min and irregular. Physical examination reveals a diffusely tender and rigid abdomen, with guarding and rebound. An upright abdominal x-ray demonstrates free air under the right hemidiaphragm. Her laboratory exam findings include a hemoglobin 10.2 g/dl (normal 12–15 g/dl), platelets 110,000 (150,000–400,000), INR 2.5, and PTT 18 s (18–28 s). Which of the following is the best way to manage the INR in this patient?

  - Hold warfarin and allow INR to autocorrect
  - Oral vitamin K
  - Fresh frozen plasma
  - Intravenous vitamin K
  - Cryoprecipitate
- What is the most common CXR finding in a patient with pulmonary embolism (PE)?

  - Consolidation of one lobe
  - Fluffy bilateral infiltrates
  - Normal
  - Hampton's hump (a wedge-shaped, pleural-based consolidation)
  - Westermarck's sign (a focus of oligemia leading to collapse of pulmonary vessel)
- What is the most common ECG finding in a patient with PE?

  - Right ventricular strain
  - Right-axis deviation
  - S<sub>1</sub>Q<sub>3</sub>T<sub>3</sub>
  - Sinus tachycardia
  - Right bundle branch block
- What is the most common initial acid/base abnormality seen in patient with a PE?

  - Respiratory alkalosis
  - Respiratory acidosis
  - Metabolic alkalosis
  - Metabolic acidosis
  - Combined respiratory alkalosis and metabolic acidosis
- A 61-year-old obese female with a past medical history of diabetes undergoes laparoscopic cholecystectomy for acute cholecystitis. The operation is technically difficult and is converted to an open cholecystectomy. Twelve hours later, the patient complains of severe pain in the wound. She has a temperature of 102.8 °F, heart rate of 120/min, and a blood pressure of 110/70 mmHg. She appears ill. There is grayish foul-smelling drainage coming from the wound, which appears erythematous, swollen, indurated, and tender to touch. What is the next step in the management?

  - Reassure patient that wound infections do not occur so soon after surgery
  - Open a few of the wound staples to allow drainage
  - Broad-spectrum antibiotics
  - Return to OR for reclosure of the fascia
  - Broad-spectrum antibiotics and return to OR for aggressive wound debridement
- A 29-year-old female who is 8 months pregnant presents with symptoms and signs of acute cholecystitis and undergoes laparoscopic cholecystectomy uneventfully. However, she returns to the ED on postoperative day 4 with acute onset dyspnea and pleuritic chest pain. A pulmonary embolism is subsequently diagnosed. What is the most likely source of the thromboembolism?

  - The right common iliac vein
  - The left common iliac vein
  - The right popliteal vein
  - The right axillary vein
  - The left femoral vein
- A 50-year-old female undergoes right hepatic lobectomy for metastatic colon cancer. The operation took 6 h and was associated with significant bleeding. As a result, she was markedly hypotensive throughout the operation and received multiple units of blood products. She was admitted to the surgical ICU for further management. She received one dose of prophylactic antibiotics preoperatively, but is otherwise not receiving any medications. On postoperative day 1, her urine output is only 10 cc/h for 5 h. Her serum creatinine has risen from 1.2 to 2.0 mg/dl. Her blood pressure is 140/80 mmHg, and heart rate is 100/min. Lungs are clear to auscultation. Urine Na is 44 mEq/L, and FENa is 3.1 %. Which of the following is the most likely etiology?

  - Hypovolemia
  - Acute interstitial nephritis
  - Acute tubular necrosis
  - Cardiogenic shock
  - Obstructed urinary catheter
- A 64-year-old female was recently discharged following a morbid obesity surgery (gastric sleeve resection).

Her postoperative course was complicated by a DVT in her left leg, for which she received intravenous heparin and discharged with oral warfarin. She now presents with an area of discolored, purplish skin on her right thigh that began the prior day and is extremely painful. On physical exam, she is afebrile with a normal blood pressure and heart rate. There is a 6×6 cm area of purplish black skin over her right anterior thigh, and another smaller area on her right calf. On laboratory exam, her WBC count and serum glucose are normal. What is the most likely cause?

- (A) Vitamin K deficiency
  - (B) Protein C deficiency
  - (C) Heparin
  - (D) Thrombocytopenia
  - (E) Unrecognized hemophilia
9. A 40-year-old male is hospitalized after a hip replacement. On postoperative day 3, the astute medical student notices he has a new left-sided facial droop. Cardiac examination demonstrates a regular rate and rhythm without murmurs. Further exam reveals left arm and leg weakness and numbness. In addition, he has a swollen right calf that is 3 cm larger in diameter than the left calf when measured 10 cm below the tibial tubercle. Venous duplex ultrasound shows a noncompressible right femoral vein. What test is most likely to explain the etiology of the neurologic findings?
- (A) ECG
  - (B) CT of the chest
  - (C) Factor V Leiden testing
  - (D) Echocardiogram with bubble study
  - (E) Duplex ultrasound of the carotid artery
10. Which of the following findings on urinalysis would most strongly support the diagnosis of acute tubular necrosis?
- (A) Muddy brown casts
  - (B) Urine osmolality > 500
  - (C) Bland urine sediment
  - (D) Red cell casts
  - (E) White cell casts
11. A 65-year-old homeless man with poorly controlled diabetes presents to urgent care with severe pain and swelling in his left leg. Vital signs include a temperature of 102 °F, blood pressure of 132/78 mmHg, and heart rate of 102/min. On physical exam, he appears to be tachypneic. His left leg appears tense, and the skin is warm and red over his thigh and is tender to palpation. There is an area of the skin on the thigh that has a violaceous color with blistering. Laboratory testing demonstrates a WBC  $22 \times 10^3/\mu\text{L}$  (normal  $4.1\text{--}10.9 \times 10^3/\mu\text{L}$ ) with neutrophilic predominance and a serum Na of 128 mEq/L (137–145 mEq/L). What is the best next step in treatment?
- (A) Immediate IV heparin
  - (B) Venous duplex scan of left leg
  - (C) CT pulmonary angiogram
  - (D) Blood cultures, broad-spectrum antibiotics, and urgent surgical debridement
  - (E) Blood cultures and broad-spectrum antibiotics
12. A 78-year-old male is in the recovery room after an open inguinal hernia repair. His blood pressure is noted to be 70/55 mmHg, and pulse is 118 bpm. He is breathing normally. The patient has a history of hypertension for which he takes a diuretic. The operation itself was uneventful except that the nurses had difficulty inserting the urinary catheter. Given the hypotension, the patient is transferred to the ICU for close monitoring. The following hemodynamic parameters are obtained: cardiac output of 10.2 L/min (normal 5 L/min) and systemic vascular resistance of 450 dynes/sec/cm<sup>5</sup> (normal 700–1,600 dynes/sec/cm<sup>5</sup>). What is the next step in treatment?
- (A) Phenylephrine
  - (B) Dopamine
  - (C) Blood cultures and broad-spectrum antibiotics
  - (D) IV bolus of lactated Ringer's
  - (E) Norepinephrine
13. A 25-year-old woman is referred to an ENT surgeon with complaints of recurrent nosebleeds for the past month. She also reports that she has been easily bruising with minor trauma and her last menstrual period required double the change of tampons she typically uses. She does not report any blood in stool or urine. Her physical exam is significant for mild gingival bleeding and scattered bruises on her arms and legs. Her laboratory exam is significant for an isolated thrombocytopenia of 13,000 (normal 150,000–400,000). Bone marrow biopsy is normal other than an increase in megakaryocytes. What is the best initial management for this condition?
- (A) Platelet transfusion
  - (B) Corticosteroids
  - (C) Splenectomy
  - (D) Plasmapheresis
  - (E) Intravenous immunoglobulin (IVIg)
14. A 60-year-old female returns to the ED for right leg swelling 1 week after undergoing a right hemicolectomy for cecal adenocarcinoma. Duplex scan confirms a DVT and the patient is started on IV heparin. The patient's hospital course is further complicated by UTI and pneumonia. On hospital day 7, the morning CBC shows a platelet count of 55,000, down from a baseline of 140,000. What is the next immediate step?

- (A) Stop heparin  
(B) Stop heparin and start a direct thrombin inhibitor  
(C) Stop heparin and switch to low molecular weight heparin  
(D) Transfuse 2 units of platelets  
(E) Start corticosteroids
15. A 68-year-old female presents to the ED 1 week after total hip replacement. She became suddenly short of breath 2 h ago. Her vitals include a blood pressure of 100/60 mmHg, heart rate of 120/min, and respiratory rate of 30/min. On physical examination, lung sounds are clear. Chest x-ray is normal. Arterial blood gas shows a pH of 7.53, PaCO<sub>2</sub> 28, PaO<sub>2</sub> 70, and HCO<sub>3</sub> 25. Oxygen is given by nasal cannula. Which of the following is the next best step in the management?
- (A) Spiral CT angiogram of the chest  
(B) Intravenous heparin  
(C) Intravenous thrombolytic infusion  
(D) Venous duplex scan of both legs  
(E) Echocardiogram
16. A 45-year-old patient undergoes a hernia repair. He is a smoker. On postoperative day 2, his wound appears to be healing well, and he is discharged home. What type of operative wound is this considered to be?
- (A) Clean  
(B) Clean contaminated  
(C) Contaminated  
(D) Dirty infected  
(E) Elective
17. A 51-year-old male is brought to the ED by paramedics following a high-speed MVC. In the ED, his blood pressure is 120/70 mmHg, and heart rate is 100/min. Hemoglobin/hematocrit is 12 g/dL (13.2–16.2 g/dL) and 36 % (40–52 %), respectively. A CT scan shows a ruptured spleen, and he is taken urgently to the operating room. During surgery, the patient is hemodynamically stable and undergoes a splenectomy. No other injuries are found, and he does not require blood transfusion. Four hours postoperatively, the patient's blood pressure drops to 80/50 mmHg, heart rate is 120/min, and urine output, which was 50 cc/h for the first 2 h after surgery, is 10 cc/h for the past 2 h. The patient is awake and only complains of thirst. He appears pale. Breath sounds are clear. Despite two liters of IV fluids, the blood pressure remains 80/50 mmHg. Repeat hemoglobin/hematocrit is 10 g/dL and 30 %. What is the next step in the management?
- (A) CT scan  
(B) Diagnostic peritoneal lavage  
(C) 12-lead ECG  
(D) Chest x-ray  
(E) Return to operating room

## Answers

### 1. Answer C

The ideal method for reversing an elevated INR in a patient receiving warfarin depends on the urgency with which reversal is needed. The patient presented has peritonitis and free air under the diaphragm. As such, urgent surgery is required, and therefore urgent reversal of INR is necessitated. Of the choices provided, fresh frozen plasma (FFP) would provide the most immediate reversal. Holding warfarin (A) is not acceptable as it would take 3–4 days for reversal. Oral vitamin K (B) takes about 24 h, whereas IV vitamin K (D) takes about 8–12 h. Such strategies would be acceptable if surgery were not urgent and would have the benefit of avoiding transfusion of a blood product (FFP). Cryoprecipitate (E) has high levels of fibrinogen and von Willebrand factor but is not effective for warfarin reversal. Prothrombin complex concentrate is emerging as an alternative to FFP for rapid warfarin reversal. It more effectively reverses warfarin as compared to FFP (particularly in patients who are massively bleeding and have profoundly elevated INR), though it is associated with an increased risk of thrombotic events.

### 2. Answer C

Virchow's triad (hypercoagulability, immobility, endothelial injury) is a common risk factor for PE. Patients can present with dyspnea, pleuritic chest pain, cough, tachycardia, and/or hemodynamic instability. Most will have a normal appearing chest x-ray. If present, the most common abnormality is a platelike atelectasis with decreased lung volume. Hampton's hump (D) is seen in 20 % of patients with PE and is characterized by a wedge-shaped, pleural-based consolidation frequently seen laterally. Westermarck's sign (focal/regional pulmonary oligemia distal to embolus) (E) is even more rare and only seen in cases of saddle embolus. Consolidation of an entire lobe (A) is more consistent with lobar pneumonia. Fluffy bilateral infiltrates (B) seen on plain films are suggestive of pulmonary edema.

### 3. Answer D

The most common ECG finding in patients with PE is sinus tachycardia.  $S_1Q_3T_3$  (C) refers to a deep S wave in lead I, Q wave in III, and inverted T wave in III, and although it is considered a "classic" finding for PE, it is neither sensitive nor specific and found in only 20 % of patients. When pulmonary arterial pressures get high, ECG findings may demonstrate right ventricular strain (A). The remaining answer choices can all occur in patients with PE but appear infrequently (B, C, E).

### 4. Answer A

The most common acid/base abnormality seen initially in patients with PE is uncompensated respiratory alkalosis. Patients with PE can have hypoxia, and the physiologic

response to this is hyperventilation which results in a primary decrease in  $PCO_2$  (hypocapnia). Acute respiratory alkalosis causes light-headedness, confusion, peripheral paresthesias, cramps, and syncope. Eventually patients will have a compensated respiratory alkalosis as the body's excess  $HCO_3^-$  is buffered by extracellular hydrogen ion. Combined respiratory alkalosis and metabolic acidosis is seen initially in patients that have ingested a large amount of aspirin (E).

### 5. Answer E

The vast majority of fevers within the first 24 h of surgery are noninfectious in origin and are due to release of cytokines (not atelectasis as commonly stated {but before you challenge your chief residents, look it up for yourself!}). Postoperative wound infections typically do not occur until around the seventh postoperative day on average. There are rare exceptions. Group A beta-hemolytic *Streptococcus* and *Clostridium* are known to rarely cause devastating early (sometimes within hours) postoperative wound infections. For this reason, when a patient spikes a fever, always perform a directed physical exam, including looking at the wound. Clues to a wound infection include a warm, erythematous, painful wound with dishwater (grayish) foul-smelling discharge. Management consists of immediate broad-spectrum antibiotics (including high-dose penicillin to cover *Clostridium*) and a prompt return to the OR for aggressive wound debridement. Reassurance (A), bedside drainage (B), and antibiotics alone (C) would not be appropriate. Reclosure of the fascia (D) would be appropriate for fascial dehiscence. However, fascial dehiscence presents with a large volume of salmon-colored fluid draining from wound, not with fever and evidence of wound infection.

### 6. Answer B

DVTs occur more commonly in the left leg than the right due to the fact that the right common iliac artery often compresses the left common iliac vein (this condition is termed May-Thurner syndrome). The risk of DVT is further increased in pregnancy due to the gravid uterus causing further compression. The other sites listed are less common locations of DVT (A, C–E). Pregnant women cannot be treated with warfarin due to its teratogenicity.

### 7. Answer C

The patient is oliguric and has evidence of acute kidney injury (AKI). The high urine Na ( $>40$  mEq/L) and  $FENa >1$  % indicate an intrinsic (renal) etiology of AKI. The most common cause of renal AKI is acute tubular necrosis (ATN). Hypovolemia (A) causes prerenal azotemia. Prolonged periods of hypovolemia and hypotension lead to poor renal perfusion that directly damage the kidneys and lead to acute tubular necrosis (ATN). Acute interstitial nephritis (B) also causes intrarenal AKI. However, it is less common than ATN

and is an immune-mediated response to certain medications (e.g., penicillin, cephalosporins, sulfa drugs, NSAIDs). Classic findings include fever, rash, arthralgia, and urinary eosinophilia. Cardiogenic shock (D) can lead to prerenal AKI due to decreased renal perfusion. Prolonged urinary obstruction due to bilateral ureteral obstruction can lead to postrenal AKI. Urine findings are variable. An obstructed Foley (E) is a potential cause of oliguria, but is unlikely to cause AKI and certainly not so soon after surgery.

#### 8. Answer B

The history and exam are most consistent with warfarin-induced skin necrosis. Warfarin inhibits the carboxylation of the vitamin K-dependent clotting factors: II, VII, IX, X, protein C, and protein S. This can acutely lead to the relative deficiency of protein C, owing to its short half-life, and thus can result in an initial hypercoagulable state and subsequent thrombosis in the vasculature supplying the skin. Warfarin-induced skin necrosis is more common in patients who have a preexisting protein C deficiency. Vitamin K deficiency is seen with severe nutritional depletion and intestinal malabsorption and manifests with bruising and hemorrhage (A). Heparin can cause skin necrosis as well, but this is seen locally at the site of injection (patient however received IV heparin) and in a much smaller distribution (C). Thrombocytopenia results in petechiae, not skin necrosis (D). Patients with hemophilia may have a history of deep tissue bleeding into muscles and joints (hemarthrosis) and oftentimes have excessive bleeding after surgical procedures (E), but not skin necrosis.

#### 9. Answer D

The patient has symptoms and signs of a postoperative stroke. Most postoperative strokes are ischemic in nature (not hemorrhagic), and most ischemic strokes are embolic, arising from either the heart (in the setting of atrial fibrillation) or from a plaque at the carotid bifurcation in the neck. This patient, however, has a DVT. The combination of an acute DVT and a stroke suggests a paradoxical embolism, wherein a clot from the venous system enters the systemic (as opposed to pulmonary) circulation. The most likely explanation is an intracardiac shunt such as patent foramen ovale (PFO) or atrial septal defect (ASD). Such an anomaly would best be demonstrated with an echocardiogram with a bubble study. ECG (A) might be helpful if atrial fibrillation was suspected; however, the patient has a regular rate and rhythm. In the setting described above, a CT of the head would be the first study indicated. Head CT would confirm whether the patient did have a stroke, and whether the stroke was ischemic or hemorrhagic (but this was not an option), but CT would not be helpful for determining the source of an embolic stroke. CT of the chest (B) would be helpful if PE were suspected. Factor V Leiden testing is not routinely recommended following a first-time DVT. Duplex ultrasound

of the carotid arteries (E) may identify a plaque, but he is very young to have a carotid stenosis, and the concomitant DVT should raise a higher suspicion for paradoxical embolism.

#### 10. Answer A

In acute tubular necrosis, the renal tubular epithelial cells die and slough off into the urine. These appear as muddy brown casts. Urine osmolality >500 (B) and bland urine sediment (C) are both consistent with a prerenal AKI state. Red cell casts (D) are suggestive of injury to the glomerulus (e.g., glomerulonephritis). White cell casts (E) are suggestive of tubulointerstitial disease or acute pyelonephritis but may also be observed with many glomerular disorders.

#### 11. Answer D

The patient is homeless, which predisposes him to unsanitary conditions. Poorly controlled diabetes itself is an immunosuppressed state. Given this information about the patient, the presence of leukocytosis with neutrophilic predominance, and his physical exam findings (e.g., painful, erythematous, swollen leg with bullae and violaceous skin), this patient likely has necrotizing fasciitis. Management consists of blood cultures, broad-spectrum antibiotics, and urgent surgical debridement. Antibiotics and cultures alone would not be appropriate (E). Choices A–C are all appropriate considerations for patients presenting with a PE secondary to DVT.

#### 12. Answer D

The patient is in shock. Given the high cardiac output, and low systemic vascular resistance, septic and anaphylactic shock are the most likely. However, since the patient has not had any medications or unusual exposures and is breathing normally, it is most likely septic shock. Patients with difficult urinary catheterizations may have subsequent bacteremia which can result in septic shock. The first step in management of septic shock is aggressive IV fluid resuscitation with either normal saline (NS) or lactated Ringer's (LR). Norepinephrine (E) is considered as the first-line vasopressor for septic shock. Additionally, vasopressin can be used in combination with norepinephrine. Epinephrine is also used for septic shock, but after the above two. Dopamine (B) was initially believed to increase renal perfusion in patients with shock, but studies have failed to consistently demonstrate this. It is not typically recommended for patients with septic shock (except for the rare patient with associated bradycardia). Phenylephrine (A) is not recommended for septic shock except in highly selected patients. All patients with septic shock should also receive blood cultures before starting broad-spectrum antibiotics (C).

#### 13. Answer B

In a young patient presenting with recurrent epistaxis, isolated thrombocytopenia, and bleeding symptoms, an isolated

acquired thrombocytopenia should be considered. Immune thrombocytopenic purpura (ITP) is an autoimmune disease characterized by autoantibodies against platelets and thus is considered a consumptive process. In a patient with a platelet count <30,000 and bleeding symptoms, the recommended initial management is corticosteroids (B). If this does not control the symptoms, the next line of therapy includes IVIG (E), dapsone, or danazol. Splenectomy is considered a last resort after medical therapy fails (C). Platelet transfusion should never be administered to a patient with ITP because it is considered a consumptive process (A). Plasmapheresis is not one of the recommended treatments for ITP (D).

#### 14. Answer B

The findings here are consistent with heparin-induced thrombocytopenia (HIT), an immune reaction to heparin-platelet complexes. Despite the decrease in platelet count, this is a *hypercoagulable* state. Heparin should be discontinued immediately, and the patient should be started on a direct thrombin inhibitor (e.g., argatroban). Low molecular weight heparin (C) also has a risk of HIT. Platelet transfusion (D) is not indicated with a platelet count of 55,000. Corticosteroids (E) would not be appropriate for the management of HIT.

#### 15. Answer B

The patient presented has a high likelihood of PE, based on Wells criteria. The patient is in the postoperative setting, the CXR is normal, and the patient is tachycardic and slightly hypotensive, suggesting possible right heart strain from a massive PE. As such, the first step is to immediately start IV heparin, even before the diagnosis is confirmed with spiral CT (A). In patients with a low likelihood of PE, a D-dimer assay should be ordered first. Since D-dimer levels are often elevated after surgery, it has very poor specificity in the postoperative setting. That being said, D-dimer has a high negative predictive value. So even though most postoperative patients will have an elevated D-dimer, D-dimer level <500 ng/mL effectively can rule out PE in low-risk patients. IV thrombolytic infusion (C) would not be an appropriate management because the patient just had major surgery. Venous duplex scan of both legs (D) could subsequently be done to evaluate for DVT as the source for PE. Echocardiogram (E) with a bubble study would be appropriate if the patient presented with a combined stroke and acute DVT, suggestive of a paradoxical embolism.

#### 16. Answer A

There are four types of operative wounds. These are used to predict the likelihood of a postoperative wound infection and to guide the use of preoperative antibiotics. Clean wounds (class I) are those that do not involve entering an organ or cavity that is known to harbor bacteria (such as the alimentary, genitourinary, or reproductive tracts). Examples would be skin, eye, brain, or elective orthopedic surgery (and also hernia repair). Clean-contaminated (class II) wounds (B) are those in which an aseptically made wound enters the alimentary, respiratory, or genitourinary tracts (e.g., elective bowel resection, caesarean section). Contaminated (class III) wounds (C) occur secondary to trauma, breaks in sterile technique, or gross spillage from the gastrointestinal tract (e.g., GSW to the bowel). Dirty-infected (class IV) wounds (D) are those involving a preoperative infection (drainage of an abscess) or perforated viscera (e.g., abscess). Elective wound (E) is not a recognized type of wound. Patients that have optimized oxygen delivery to tissue are most likely to have normal wound healing. Factors known to increase the risk of wound infections include wound ischemia, diabetes, low albumin, steroids, poor arterial flow (e.g., peripheral arterial disease), smoking, and hypothermia.

#### 17. Answer E

The patient is in shock. The most likely etiology of the shock in this setting is hypovolemic shock, most likely from bleeding (in this case most likely the ligation of the splenic artery has come off). Massive postoperative bleeding after surgery is rare and can be difficult to recognize. It can present as oliguria, and differentiating bleeding from other causes of hypotension and oliguria can be difficult. Lab values such as hemoglobin and hematocrit are not useful in detecting acute hemorrhage in the postoperative setting. It generally takes 8–12 h for interstitial fluid to redistribute into the vascular space, and blood concentration will initially appear unchanged. This patient's hemoglobin/hematocrit has shown a significant drop, and in combination with his thirst, pale skin, mechanism of injury, and hemodynamic instability, he is most likely suffering from internal bleeding and will need to return to the OR. CT scan would be inappropriate for a patient with hemodynamic instability (A). An ECG (C) or a CXR (D) (the breath sounds are clear) are unlikely to be of value. Failure to recognize bleeding has fatal consequences. An alternative to immediate return to the OR would be to perform a bedside ultrasound (to look for fluid), if available.



## Trauma

**Areg Grigorian, Paul N. Frank, Christian de Virgilio, and Dennis Y. Kim**

### Questions

- A 25-year-old man arrives to the ED following a MVC with multiple abrasions on his abdomen. His blood pressure is 90/60 mmHg, and his pulse is 120/min. After a primary survey, a FAST exam is performed. Which of the following is a FAST exam poor at detecting?

  - Pericardial effusion
  - Single pneumothorax
  - Free peritoneal fluid in the hepatorenal space (Morrison's pouch)
  - Retroperitoneal fluid
  - Free peritoneal fluid in the perisplenic space
- A 23-year-old male is rushed to the ED by paramedics after sustaining a gunshot wound to the lateral neck at the level of the thyroid cartilage. The patient is hemodynamically stable and is able to speak. Physical exam shows no signs of hematoma, pulsatile bleeding, thrill, or bruit. Which of the following is the next step in management?

  - Surgical exploration
  - Wound closure
  - CT angiography
  - Intubation
  - Formal angiography
- A 41-year-old patient presents to the emergency department following a stab wound to the chest, just above the left nipple line. On initial exam, his blood pressure is 94/70 mmHg, and respiratory rate is 16/min. He has distended neck veins, and his heart sounds are muffled. A FAST exam demonstrates fluid in the pericardial sac. What is considered the first sign of this condition?

  - Electrical alternans
  - Impaired diastolic filling
  - "Water-bottle" shape on chest radiograph
  - Hypotension
  - Distended neck veins
- A pregnant woman in her second trimester arrives to the ED after a minor MVC. She has no injuries or complaints but is worried that her pregnancy is in danger. She has a nonstress test that shows two accelerations of fetal heart rate, each at least 15 beats per minute above baseline and lasting at least 15 s. She has no contractions, vaginal bleeding, or abdominal pain. A FAST exam is negative. What is the next best step in management?

  - Monitor the patient overnight
  - Biophysical profile
  - Discharge and follow-up in 2 weeks
  - CT of the abdomen
  - MRI of the abdomen
- A 40-year-old policeman is brought to the ED having suffered burns after helping to rescue a woman from a burning warehouse. His temperature is 99.8 °F, blood pressure is 100/70 mmHg, pulse is 95/min, and respiratory rate is 24/min. On physical examination, he has 40 % total body surface area deep partial and full-thickness burns to his face, arms, and back as well as a circumferential burn of his neck. He has singed nasal hairs, and there is carbonaceous sputum coming out of his mouth. His lungs are clear to auscultation bilaterally. ECG demonstrates premature ventricular contractions. What is the most appropriate next step in management?

  - Broad-spectrum antibiotics
  - Endotracheal intubation
  - IV fluid resuscitation
  - Cardiac enzymes and serial ECG
  - Bronchoscopy
- A 40-year-old man falls down approximately three stories in an attempt to commit suicide. EMS arrives on scene within 5 min, and he is rushed to the ED but loses vitals in the field and is dead on arrival (DOA). What is the most likely cause of death?

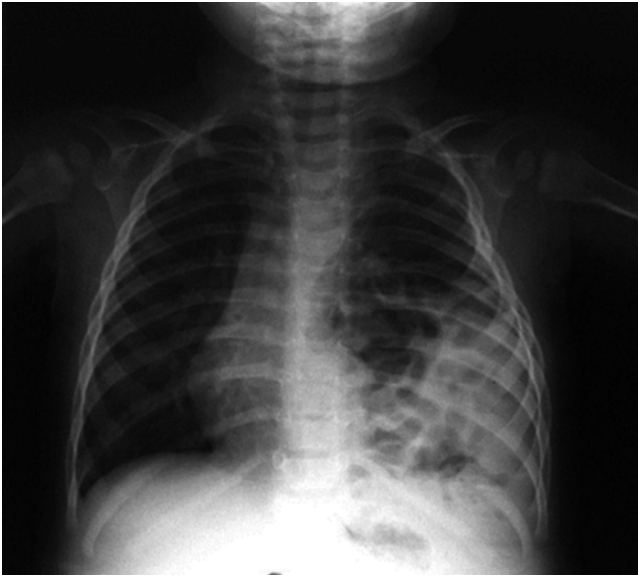
  - Thoracic aortic transection
  - Tension pneumothorax
  - Abdominal aortic transection
  - Ruptured spleen
  - Pulmonary artery transection secondary to a jagged rib edge
- A 25-year-old football player presents to the ED after sustaining a devastating tackle and hyperextension of his right knee. The knee appears to be posteriorly dislocated and the leg is swollen. Pedal pulses on the right appear to be diminished but present, whereas they are normal on the left. The remainder of his exam does not reveal any obvious signs of bleeding. What is the appropriate next step in management?

  - Fasciotomy of all four compartments of the lower leg
  - CT angiography
  - Immediate heparinization
  - Plain film of the knee, followed by reduction of the dislocation
  - MRI of the knee
- A 30-year-old male arrived via paramedics after getting struck in the abdomen by a golf cart while vacationing

with his family. He had no head trauma and only complained of mild abdominal pain. His vitals were normal and stable. A CT scan revealed no abnormal findings, and he was discharged on the same day. Three days later, he comes back to the ED complaining of fevers, nausea, poor appetite, and abdominal pain. A repeat CT scan shows a laceration at the neck of the pancreas with disruption of the pancreatic duct. What is the best next step in management?

- (A) Order serum amylase
- (B) Endoscopic retrograde cholangiography (ERCP)
- (C) CT-guided drainage
- (D) Magnetic resonance cholangiopancreatography (MRCP)
- (E) Exploratory laparotomy

9. A 40-year-old man is in a head-on MVC with a drunk driver on the freeway and is brought to the ED. He has a dark bruise from his seat belt across the left side of his neck. On physical examination, he is neurologically intact. However, his left eyelid is drooping, and his left pupil is constricted as compared to his right. CT scan with contrast demonstrates dissection of the left internal carotid that extends into the base of the skull. CT of the head and abdomen are negative. Which of the following would be the most appropriate management?
- (A) Left neck exploration
  - (B) Intravenous heparin administration
  - (C) Carotid stenting
  - (D) Thrombolytic therapy
  - (E) Observation
10. A 22-year-old male arrives to the ED by paramedics with a gunshot wound in the RUQ of his abdomen. He is anxious and complains of pain near his wound. His temperature is 99.1 °F, blood pressure is 114/78 mmHg, and pulse is 90/min. His abdomen is soft, and he has no rebound or guarding. A portable chest x-ray is normal, and nasogastric tube (NGT) demonstrates clear fluid with no blood. His rectal examination shows no blood. What is the most appropriate next step in management?
- (A) Serial physical examination
  - (B) Exploratory laparotomy
  - (C) CT scan of the abdomen
  - (D) Diagnostic peritoneal lavage
  - (E) FAST exam
11. A 62-year-old man with atrial fibrillation presents to the ED with a painful right lower leg. He has refused warfarin in the past. His physical exam is significant for an irregularly irregular heart rate and a painful right leg that is cool to touch with absent distal pulses. Pulses in the left foot are normal. He has significant motor weakness and sensory deficit in the right foot. Duplex scan reveals an occlusion of the right popliteal artery. He receives heparin and undergoes open surgical embolectomy. Following the procedure, his motor and sensory deficit dramatically improves. The next day, he experiences intense pain in the right calf. His right calf is swollen and tense, and the pain is worsened with passive dorsiflexion and plantar flexion of his right foot. He has palpable distal pulses. What is the most likely underlying etiology for his acute condition?
- (A) Interstitial edema
  - (B) Recurrent embolization
  - (C) Deep vein thrombosis (DVT)
  - (D) Atherosclerotic plaque
  - (E) Lymphedema
12. Burn patients are at risk for multiple infections. What is the most common organism to cause infection in burn patients?
- (A) *Staphylococcus aureus*
  - (B) *Streptococcus pyogenes*
  - (C) *Streptococcus agalactiae*
  - (D) *Pseudomonas aeruginosa*
  - (E) *Candida albicans*
13. A 10-year-old boy presents to the ED with severe abdominal pain after falling over his bicycle handles while attempting a trick and sustaining blunt injury to the abdomen. A CT scan shows oral contrast extravasation into the retroperitoneum that is coming from the posterior aspect of the duodenum. Which of the following is the best management recommendation?
- (A) Laparoscopy
  - (B) Exploratory laparotomy
  - (C) Observation
  - (D) Upper endoscopy to confirm injury
  - (E) CT-guided drainage
14. A 40-year-old alcoholic presents to the ED with a markedly swollen right forearm that is diffusely tender. He states that following an alcohol and heroin binge, he fell asleep on his arm for 12 h. He woke up to find his hand completely numb and unable to move it. On physical exam, he has normal brachial and radial pulses. His heart has a regular rate and rhythm. He is unable to extend his wrist when the hand is palm down. ECG reveals peaked T waves, and CPKs are 20,000 IU/L (normal 60–400 IU/L). What is the next step in management?
- (A) Propranolol
  - (B) Insulin + dextrose
  - (C) Calcium gluconate



**Fig. A.1** Chest x-ray (With kind permission from Springer Science+Business Media: *Pediatr Surg Int*, An unusual late presentation of a congenital diaphragmatic hernia, 21, 2005, p 1022, Yamamoto H. and Parikh DH., Fig. 2)

- (D) Kayexalate (sodium polystyrene)  
(E) Furosemide
15. A 5-year-old girl arrives to the ED with complaints of nausea, vomiting, and abdominal pain for the past day. She has no significant past medical history, but her mother reports that she was involved in a MVC about a month ago. She was restrained in a car seat and had blunt trauma to her abdomen. She had no complaints at the time. Her vital signs were normal, and she was subsequently discharged a few hours later. Her blood pressure is currently 112/82 mmHg, pulse is 90/min, and respiratory rate is 28/min. Her chest x-ray is shown above (Fig. A.1). What is the most likely diagnosis?
- (A) Gastroenteritis  
(B) Diaphragmatic hernia  
(C) Delayed splenic rupture  
(D) Hemothorax contusion  
(E) Pneumonia
16. A 32-year-old female is stabbed in the right lateral neck 1 cm above the clavicle. There is an expanding hematoma in her neck, and she is having great difficulty speaking. Breath sounds are absent on the right. Subcutaneous air is noted in her neck. What is the next step in management?
- (A) Intubation  
(B) Chest tube placement  
(C) Duplex ultrasound of the carotid  
(D) Operative repair  
(E) Esophagoscopy
17. A 25-year-old male arrives to the ED with a stab wound lateral to his umbilicus after being involved in a drunken fight at a local bar. You can smell alcohol on his breath, and he is uncooperative during the exam. His temperature is 99.2 °F, blood pressure is 90/60 mmHg, and pulse is 120/min. His abdomen is soft, non-tender with no rebound or guarding. What is the most appropriate next step in management?
- (A) Exploratory laparotomy  
(B) Local wound exploration  
(C) CT scan of the abdomen  
(D) Serial physical examination  
(E) FAST exam
18. In a patient presenting with acute limb ischemia in the right leg, what is the first structure to develop ischemic changes?
- (A) Fat  
(B) Nerve  
(C) Muscle  
(D) Skin  
(E) Bone
19. A 60-year-old man is recovering in the ICU after being rescued from a fire within a restaurant kitchen. He was trapped for a prolonged period of time. He received deep partial and full-thickness burns in over 30 % of his body. He has a past medical history of psoriasis controlled with topical steroids. On the seventh postoperative day, he becomes confused. His temperature is 96.1 °F, blood pressure is 98/72 mmHg, and pulse is 122/min. His burn wounds have focal areas with a brown color. His laboratory examination demonstrates a white blood count of  $14.7 \times 10^3/\mu\text{L}$  (normal  $4.1\text{--}10.9 \times 10^3/\mu\text{L}$ ) and a serum glucose of 250 mg/dL. What is the most likely etiology for this patient's acute condition?
- (A) Intercompartmental fluid shift  
(B) Adrenal insufficiency  
(C) Alcohol withdrawal  
(D) Carboxyhemoglobinemia  
(E) Inflammation
20. A 30-year-old unrestrained driver is brought in by paramedics after a high-speed MVC. In the ED, his heart rate is 110/min, blood pressure is 104/75 mmHg and decreases to 92/68 mmHg during inspiration. His tachycardia and hypotension persist despite aggressive fluid resuscitation. He appears pale, and his neck veins are distended. He has multiple bruises on his chest and abdomen. His chest x-ray is unremarkable. What is the most likely diagnosis?
- (A) Aortic transection  
(B) Cardiac tamponade

- (C) Severe lung contusion  
 (D) Tension pneumothorax  
 (E) Diaphragm injury
21. A 38-year-old obese construction worker arrives to the trauma bay after accidentally getting struck by a bulldozer at his job site. In the ED, his mental status is altered, with a GCS of 10. His blood pressure is 80/66 mmHg with a pulse of 112/min. He is given 2 liters of intravenous fluids, but his blood pressure and pulse remain the same. A FAST exam is inconclusive. A portable chest x-ray is negative, and a pelvic x-ray demonstrates bilateral pubic rami fractures. What is the best next step in management?
- (A) Diagnostic peritoneal lavage (DPL)  
 (B) Pelvic angiography with possible embolization  
 (C) Exploratory laparotomy  
 (D) Head CT scan  
 (E) Abdominal CT scan
22. A 25-year-old male is at a pool party and is heavily intoxicated. He dives into the shallow end of the pool and is subsequently found to be floating face down in the pool. He is rushed to the ED by paramedics in a cervical collar. In the ED he opens his eyes, nods his head appropriately to questions, and his pupils are equally round and reactive to light. However, he is not moving his arms or legs. There is no evidence of external bleeding. His blood pressure is 85/45 mmHg, and his heart rate is 70/min. Which of the following would most likely be seen in association with the injury described?
- (A) Low cardiac output  
 (B) Elevated SVR  
 (C) Priapism  
 (D) Parasympathetic blockade  
 (E) Thoracic spine injury
23. A construction worker is digging a trench when he cuts his arm on a rusty nail in the soil. He is 45 years old and has not been to the doctor since he was a teenager, but he is confident he received all of his vaccinations up to age 18. What is the next step in treatment?
- (A) Tetanus immunoglobulin only  
 (B) Tetanus vaccination only  
 (C) Tetanus immunoglobulin and vaccination  
 (D) Primary wound closure  
 (E) Clindamycin for 3 weeks
24. A 7-year-old boy presents to his pediatrician with a tense, painful, weak, and shortened forearm with a claw-like deformity of the hand. The mother states that 1 year earlier, the child fell backwards on his outstretched hand and suffered a supracondylar fracture that was treated with closed reduction and casting. The most likely explanation for the current physical exam findings is:
- (A) Nerve entrapment  
 (B) Suppurative tenosynovitis  
 (C) Ischemia/necrosis of forearm muscles  
 (D) Complex regional pain syndrome  
 (E) Improperly reduced fracture
25. A 65-year-old former firefighter arrives for follow-up for chronic wound in his right leg from a burn he suffered 25 years earlier. The wound has failed to heal despite repeat skin grafting. Recently, the wound has become more painful and larger, measuring 2×2 cm, and continuously drains. Multiple biopsies of the wound are taken. Which of the following is the most important contributing factor to this patient's presenting condition?
- (A) Radiation exposure  
 (B) Excess UV light exposure  
 (C) Work-related exposure to heavy metals  
 (D) Genetic predisposition  
 (E) Chronic inflammation
26. A 18-year-old man arrives to the ED combative and with severe shortness of breath, after suffering a stab wound to the chest. His blood pressure is 94/76 mmHg with a pulse of 120/min and respiratory rate of 28/min. Physical exam reveals a 2 cm stab wound on the left chest. Lung fields on the left have decreased breath sounds and are hyperresonant to percussion. His neck veins are distended. A needle is placed in the left second intercostal midclavicular line and aspirated until a gush of air is heard escaping the chest wall. A liter of normal saline is given, and blood pressure improves to 120/70 mmHg, and pulse decreases to 100/min. What is the best next step in management?
- (A) Transfuse O-negative blood  
 (B) Tube thoracostomy  
 (C) Chest x-ray  
 (D) CT scan of the chest  
 (E) Transport to the operating room for a thoracotomy
27. A 25-year-old male suffers a GSW to his right mid-thigh. On physical examination, there is no hematoma, no palpable thrill, and no bleeding from the wound. He has diminished but present pedal pulses on the right and normal pulses on the left. Neurological exam is normal. Ankle-brachial index on the right is 0.8 and 1.0 on the left. What is the next step in the management?
- (A) Surgical exploration of the leg  
 (B) CT angiography  
 (C) Formal angiography  
 (D) Observation  
 (E) Systemic heparinization

28. A 58-year-old intoxicated homeless man arrives to the ED after getting struck by an auto. His blood pressure on arrival was 98/55 mmHg with a pulse of 120/min. Following fluid resuscitation, his blood pressure increases to 120/70 mmHg, and pulse decreases to 80/min. His abdomen is distended and mildly tender, and he has no obvious source of blood loss. A CT scan of the abdomen and pelvis shows no intraperitoneal fluid, but demonstrates bilateral pelvic fractures and a large pelvic fluid collection adjacent to the fracture with a contrast blush within it. What is the best next step in management?
- (A) Military anti-shock trousers (MAST)
  - (B) External pelvic fixation
  - (C) Open reduction, internal fixation of pelvic fracture
  - (D) Exploratory laparotomy
  - (E) Emergency angiography with embolization
29. A 30-year-old male presents to the ED with a GSW to the right chest, just above his right nipple. In the ED, he complains of shortness of breath and severe right chest pain. His blood pressure is 110/70 mmHg, heart rate is 100/min, and respiratory rate is 20/min. On physical examination, his breath sounds are slightly diminished on the right. The trachea is midline. Neck veins are flat. The abdomen is non-tender. Upper extremity pulses are equal. A chest x-ray demonstrates a moderate right hemo- and pneumothorax. The bullet is seen in the upper chest. A chest tube is inserted into the right chest with an immediate output of 500 cc of dark blood, and after which the bleeding appears to slow down. What is the next step in the management?
- (A) Exploratory right thoracotomy
  - (B) Video-assisted thoracoscopic surgery (VATS)
  - (C) Admit to ICU for observation
  - (D) Repeat chest x-ray
  - (E) CT of the chest and abdomen
30. A 28-year-old man arrives to the ED following a high-speed MVC. He is in severe pain and breathing rapid shallow breaths. His blood pressure is 80/60 mmHg, heart rate is 120/min, and respiratory rate is 30/min. A segment of his right anterolateral chest wall exhibits paradoxical inward motion on inspiration. Despite supplemental oxygen, the respiratory rate remains the same. Breath sounds are equal bilaterally. The trachea is midline. What is the next best step in management?
- (A) Two liter bolus of normal saline
  - (B) Insert a right needle thoracostomy
  - (C) Endotracheal intubation
  - (D) Transfuse two units of O-negative blood
  - (E) Place tube thoracostomy (chest tube) on the right
31. Which of the following parameters would be most consistent with acute carbon monoxide poisoning?
- (A) Hemoglobin decreases
  - (B) PaO<sub>2</sub> decreases
  - (C) Oxygen content of blood decreases
  - (D) Oxidized hemoglobin increases
  - (E) Increased alveolar ventilation
32. Which of the following clinical scenarios is the best indication for four-compartment lower extremity fasciotomies?
- (A) After a crush injury with an open tibia and fibula fracture
  - (B) After successful revascularization of a leg that was ischemic for 6 h
  - (C) After repair of a femoral artery injury due to a GSW to the leg
  - (D) After repair of a combined popliteal artery and vein injury due to a gunshot injury
  - (E) After an electrical burn, with a tensely swollen and tender leg and numbness in the first web space

## Answers

### 1. Answer D

The FAST (focused abdominal sonogram for trauma) scan is a bedside ultrasound that is used to detect free fluid in the peritoneal cavity, around the pericardium, and in the thorax. The four areas of focus in a FAST exam are the hepatorenal space (C), perisplenic space (E), pouch of Douglas/rectovesical pouch, and pericardial space. FAST exam cannot distinguish blood from ascites and/or enteric content, is unable to detect retroperitoneal bleeds (from, for instance, a pelvic fracture), and is often times limited by obesity. FAST exam will be able to detect bowel perforation if there is free fluid and only if the bowel is within the peritoneum (so would miss injuries to parts of the duodenum, posterior walls of cecum, sigmoid). For detecting pericardial effusion (A), the sensitivity approaches nearly 100%. Although bilateral pneumothoraces may limit comparison of sides, a single pneumothorax (B) has a sensitivity of 95% and specificity approaching 100%.

### 2. Answer C

Penetrating neck trauma may result in injury to major blood vessels, the pharynx, esophagus, trachea, and/or cervical spine. Immediate surgical exploration (A) would be indicated if there were hard signs of vascular injury such as a pulsatile bleeding from the wound or rapidly expanding hematoma (the latter only after intubation {D} first to prevent airway compression). In the absence of hard signs of vascular injury, immediate surgical exploration is not necessary. Since physical examination is unreliable in terms of ruling out major injury, further imaging with CT angiogram (C) should be obtained. CT angiogram has largely replaced formal angiography (E) which was once considered the gold standard. Formal angiogram is invasive (requires a femoral artery catheterization), time consuming, costly, and is only useful to rule out arterial injuries. Wound closure (B) would only be appropriate for injuries that do not penetrate the platysma.

### 3. Answer B

In a patient presenting with hypotension, distended neck veins, and muffled heart sounds (Beck's triad) following a stab wound to the chest, the most likely diagnosis is cardiac tamponade. The first sign in cardiac tamponade is impaired diastolic filling, which compromises cardiac output, and ultimately results in hypotension and distended neck veins (D, E). Electrical alternans (B) is characterized by varying alterations in the amplitude of the QRS complex between beats. It can occur in various other conditions and is not always present in patients with cardiac tamponade. Radiographic images are often negative initially, but some may develop the characteristic "water-bottle" shape later in the course of the disease (C).

### 4. Answer C

Many worried pregnant patients arrive to the ED following minor trauma. Most patients do not have any significant clinical findings. Her nonstress test showed a normal strip. The criteria to discharge pregnant patients following minor trauma include contractions no more than every 10 min, no vaginal bleeding, no abdominal pain, and a normal fetal heart tracing. This patient meets the discharge criteria and does not need to be monitored overnight (A). Biophysical profile (B) is indicated in patients with an abnormal nonstress test. CT of the abdomen (D) would be inappropriate in a pregnant patient because of the high radiation risk to the fetus. Although there have been no ill effects reported from MRI use during pregnancy, there are no indications to warrant MRI use in this patient (E).

### 5. Answer B

Do not forget the ABCs of trauma. The airway should always be addressed first in the primary survey. Burn victims are at high risk for respiratory compromise since the supraglottic airway is susceptible to direct thermal injury and does not have the protection afforded to the infraglottic airway via the reflexive closure of vocal cords to intense heat. Circumferential burns of the neck further increase the risk of respiratory compromise by way of inelastic, circumferential eschars that may constrict the airway. Endotracheal intubation should be performed for all burn patients with acute respiratory distress, circumferential neck burns, full-thickness burns of the face or oropharynx, supraglottic edema, and progressive hoarseness, stridor, or wheezing. Broad-spectrum antibiotics (A) are not routinely recommended for the management of burn victims. Burn patients are also at risk for severe intravascular collapse and require significant volume replacement with IV fluid resuscitation (C). However, this should be addressed *after* securing the airway. Premature ventricular contractions are usually benign (D). If the patient did not have indications for immediate intubation (circumferential neck burn), bronchoscopy (E) would be indicated in the presence of singed nasal hairs and carbonaceous sputum to determine the presence of thermal damage to the airway.

### 6. Answer A

High-energy rapid deceleration chest trauma is most commonly caused by a fall from greater than two stories or from a motor vehicle accident (e.g., steering wheel striking the chest). This mechanism of injury is known to cause aortic injuries which may lead to aortic transection, and ultimately death. Autopsy studies of aviation accidents demonstrate that more than 30% of deaths are due to aortic transection. Overall, immediate mortality is greater than 70%. The majority of patients die instantly of exsanguination. Of those who survive, 49% will die within 24 h. Patients will present

with a widened mediastinum, deviation of the trachea to the right, and left-sided hemothorax on chest radiographs. They may also have fractures of bones (e.g., first rib, sternum, scapula) that are uncommonly broken as high energy is required to break them. The aortic tear is usually at the ligamentum arteriosum, located just distal to the subclavian take off, as the aortic arch is relatively fixed to that point. CT angiogram can confirm the diagnosis, and definitive management includes operative repair. Although a ruptured spleen (D) can lead to significant blood loss, instant death is highly unlikely. The remaining choices (B, C, E) can all cause instant death, but they occur in less frequency than thoracic aortic transection with this mechanism of injury. Abdominal aortic transection is extremely rare following blunt trauma as it is more mobile than the thoracic aorta.

### 7. Answer D

A dislocated limb has the potential of compromising arterial blood flow. As such prompt reduction is essential. However, prior to reduction, the first step is to obtain a plain film of the limb to confirm the dislocation and to rule out associated fractures. Following reduction, a postreduction film is needed to confirm proper alignment. Fasciotomy (A) would be indicated if there is concern for compartment syndrome (pain in calf muscles on passive motion, tense swelling, paresthesias); however, reduction of a dislocated knee would still take priority. CT angiography (B) would be performed after reduction if there is concern for arterial injury (ankle-brachial index <0.9). Heparinization (C) would be initiated after limb ischemia is diagnosed (e.g., cold, pulseless limb). MRI of the knee (E) is seldom indicated in the acute setting for knee injuries.

### 8. Answer E

The diagnosis of isolated pancreatic injury is often delayed as it is notoriously known to be missed initially on CT. If there is no associated splenic injury to cause bleeding or bowel injury to cause peritonitis, initial physical examination findings may be unremarkable. In addition, a serum amylase level (A) is neither specific nor sensitive for pancreatic injury. However, if there is pancreatic duct disruption, the release of enzymes will eventually lead to symptoms as in the patient presented above. Surgery is recommended for such major injuries. Minor pancreatic injuries without pancreatic duct disruption can be managed nonoperatively. In such cases, ERCP (B) is more sensitive and specific than MRCP (D) for ductal injury. CT-guided drainage (C) will not address the underlying pancreatic injury and would not be appropriate for this patient.

### 9. Answer B

The patient has sustained a blunt injury to the carotid artery as evidenced by a dissection in the left internal carotid artery.

Such an injury should be suspected whenever there is high-energy force to the head and/or neck. He is exhibiting evidence of Horner's syndrome (ptosis, meiosis, anhidrosis), as sympathetic nerve fibers can be interrupted with carotid injury. A dissection is a partial-thickness tear in an artery that begins in the intima and extends into the media. It can narrow or occlude the lumen. Most blunt carotid injuries are managed nonoperatively with anticoagulation (provided there is no contraindication). Thus observation (E) alone would be inappropriate for such a patient. Since the dissection extends to the base of the skull, it would be impossible to access and repair through a standard neck incision (A). Conservative management using heparin (B) is the most appropriate option and has been shown to reduce or prevent cerebral infarction in patients with blunt carotid injury. Carotid stenting (C) has a risk of causing a stroke and would not be appropriate for a dissection that extends to the base of the skull. Thrombolysis (D) is contraindicated in a patient with a carotid dissection and in patients with trauma causing acute vascular injury.

### 10. Answer C

Immediate exploratory laparotomy is recommended in the majority of patients with a GSW to the abdomen, particularly if the patient is hemodynamically unstable, has evidence of peritonitis, or has bowel evisceration. However, cooperative patients with gunshot wounds (GSW) to the abdomen that are hemodynamically stable, with no evidence of peritonitis, are candidates for nonoperative management (NOM). They should be evaluated further for injuries requiring surgical repair with an abdominal CT scan. This approach may avoid an unnecessary exploratory laparotomy (B) that carries significant morbidity. CT scan should still be done even for patients with wounds that appear to only be superficial. If the CT scan is normal, the patient can be managed with serial physical exams (A) and serial laboratory exams (e.g., white blood count). NGT can help identify gastric injuries, while rectal examination can help identify rectal or colon penetration by the bullet. Though occasionally utilized for penetrating trauma, DPL and FAST (D, E) are more appropriate for blunt trauma.

### 11. Answer A

It is important to note that acute limb ischemia (in this instance due to embolization of atrial thrombus secondary to atrial fibrillation), followed by reperfusion, is a well-recognized risk for the subsequent development of compartment syndrome. Ischemia-reperfusion results in an increase in vascular permeability to plasma proteins and progressive interstitial edema. This leads to an increase in interstitial pressure. When interstitial pressure exceeds capillary perfusion pressure, muscle ischemia and necrosis ensue. It is important to note that palpable pulses do not rule out compartment

syndrome. Treatment is an emergent 4-compartment fasciotomy. The lymph system (E) is not involved in the development of acute compartment syndrome. A recurrent embolus (B) would not be expected to present with a swollen leg and palpable distal pulses. DVT (C) can present with calf tenderness that is worsened with passive extension (Homan sign). However, the temporal relation to his presenting problem and the physical exam findings are more supportive for compartment syndrome. Atherosclerotic plaque (D) would be expected in a patient presenting with claudication secondary to peripheral arterial disease.

#### 12. Answer D

Infections in burn patients can be problematic for multiple reasons. It may delay wound healing, encourages scarring, and can result in bacteremia which may lead to sepsis. *Pseudomonas aeruginosa* is a gram-negative bacillus and is considered to be the most common cause of infections in burn patients. Methicillin-resistant *Staphylococcus aureus* (A) is also commonly seen in burn patients and difficult to treat due to a large number of virulence factors. *Streptococcus pyogenes* (B) is more of a concern in pediatric burn patients because they may have colonization of *Streptococcus pyogenes* in their oropharynx. *Streptococcus agalactiae* (C) is not an organism thought to infect burn patients. This organism can colonize the genitourinary tract and be transmitted to the neonate during birth which may result in bacteremia, pneumonia, or meningitis. Fungal infections tend to occur in burn patients during the later stages of recovery because by this time the majority of bacteria have been eliminated by the use of antibiotics. The most common cause of fungal infection in burn patients is by *Candida albicans* (E).

#### 13. Answer B

Duodenal injury following blunt abdominal trauma is rare. When it does occur, it is usually accompanied by other abdominal injuries. Isolated duodenal injuries are even more uncommon. In children, they have classically been reported following a direct blow to the epigastrium such as a bicycle handlebar injury. The retroperitoneal location of some portions of the duodenum may lead to a delay in diagnosis, as enteric contents spilling from the injury may not cause peritonitis. Contrast-enhanced CT scan of the abdomen can help confirm the diagnosis by detecting extravasation of oral contrast, the presence of retroperitoneal air, or a paraduodenal hematoma. Some duodenal injuries can be managed non-operatively. Specifically, a duodenal wall hematoma, without contrast extravasation does not require surgery. On the other hand, the presence of contrast extravasation confirms a full-thickness injury that mandates exploratory laparotomy. Depending on the extent of injury, primary repair can be performed. Because of the close relationship of the duodenum to the pancreas and the bile duct, resection of the duodenum

is often not possible. Upper endoscopy (D) would be contraindicated in the presence of bowel perforation. CT-guided drainage (E) will not address the underlying duodenal injury and would not be appropriate for this patient. Laparoscopy (A) would not likely be able to adequately assess and repair the duodenal injury.

#### 14. Answer C

This patient has evidence of compartment syndrome that has led to muscle necrosis (as evidenced by high CPKs and hyperkalemia). Though compartment syndrome is mostly thought of as caused by severe bleeding after trauma, there are many other causes. In this case, it occurred secondary to prolonged compression of the forearm muscles due to his alcohol and drug binge. This resulted in ischemia, followed by reperfusion, and then swelling and death of the muscles. An alcohol binge can also lead to Saturday night palsy, a colloquial term referring to radial neuropathy from falling asleep with one's arm hanging over a park bench (compressing the spiral groove which houses part of the radial nerve). Hyperkalemia is a known complication of muscle necrosis from compartment syndrome and can lead to peaked T waves, and if left untreated, fatal arrhythmias. Although all the options listed (A, B, D, E) are appropriate management options for hyperkalemia, calcium gluconate should be administered first to stabilize cardiac myocytes and prevent further damage, particularly because the electrolyte imbalance has already begun to affect the heart (e.g., peaked T waves).

#### 15. Answer B

The key to the diagnosis is the history of trauma combined with the chest x-ray. On initial inspection, the chest x-ray could be confused with a hemothorax (D) or pneumonia (E). However, the presence of multiple air pockets within the left lung field indicates that there are loops of bowel in the left chest, likely due to a traumatic left-sided diaphragmatic hernia. Traumatic diaphragmatic hernia (TDH) can occur following blunt abdominal trauma secondary to a sudden increase in intra-abdominal pressure. Diagnosis is frequently delayed since patients may be asymptomatic immediately following the traumatic episode. The stomach and colon are the most frequently herniated structures. Patients with TDH can present with both GI and respiratory symptoms. Gastroenteritis (A) is unlikely to present with an increased respiratory rate or an abnormal chest x-ray. Following blunt trauma, patients can very rarely present with a delayed splenic rupture, and this could cause a reactive left pleural effusion. However, once again, this would not cause loops of the bowel in the chest.

#### 16. Answer A

This patient has likely sustained damage to several structures of zone 1 of the neck. The first steps in management are



always ABC. Given that there is an expanding hematoma and she is having difficulty speaking, there is concern that her airway is compromised, so she should be intubated. Since the apices of the lungs are contained within zone 1 of the neck, and she has absent breath sounds, she likely has a pneumothorax and will also need a chest tube (B). Duplex ultrasound of the carotid (C) is not necessary since there is a hard sign of vascular injury. The patient requires operative repair (D), but the airway should be protected first. This patient may have sustained esophageal injury that will require repair as well, but esophagoscopy (E) should not be performed since she has a hard sign of vascular injury.

### 17. Answer A

This patient has a penetrating abdominal wound which is concerning for an intraperitoneal injury. Immediate exploratory laparotomy is recommended in patients with a penetrating injury to the abdomen if the patient is hemodynamically unstable, has evidence of peritonitis, has bowel evisceration, or is uncooperative (e.g., intoxicated). Further work-up (B–E) can be considered for patients that are hemodynamically stable, with no evidence of peritonitis.

### 18. Answer C

The muscle is the first structure to be affected by ischemic changes in acute limb ischemia, and since it is the primary mass of the tissue in the extremity, the extent and duration of muscle damage are the most critical aspects of limb reperfusion syndrome and subsequent compartment syndrome. The muscle can be tolerant of ischemia for up to 4 h. Irreversible nerve damage (B) occurs after 8 h of ischemia. Fat (A) changes remain reversible for up to 13 h, the skin (D) up to 24 h, while the bone (E) damage does not typically occur until after 4 days of ischemia.

### 19. Answer E

Patients with severe burns are at increased risk of burn wound sepsis. This patient has hypothermia, leukocytosis, and tachycardia. Thus he meets the diagnostic criteria for systemic inflammatory response syndrome (SIRS). Patients must have two of the following four in order to be diagnosed with SIRS: fever of more than 100.4 °F or less than 96.8 °F, heart rate of more than 90, respiratory rate of more than 20, or white blood count of >12,000/μL or <4,000/μL. SIRS due to an infection is called sepsis and can manifest with confusion or altered levels of consciousness (i.e., end-organ damage). Burn patients in particular are susceptible to bacterial infections. Changes in the color of the burn wound (to red, brown, or black) should raise suspicion for wound sepsis. Intercompartmental fluid shifts (A), or third spacing, occur when fluid that accumulated in the interstitium of tissues during the postoperative period shifts back into the intravascular space, typically on postoperative day three. This will

present with a patient that appears to be fluid overloaded. Tertiary corticoadrenal insufficiency (B) should always be on the differential for patients with long-term steroid use that develop hypotension. This occurs because of insufficient corticotropin-releasing hormone secretion by the hypothalamus. However, the risk is less in patients using topical steroids because of its decreased potency and limited systemic exposure. In addition, hypothermia would not be expected with adrenal insufficiency. Alcohol withdrawal (C) would be expected to begin within 24 h of the last drink (not 7 days later). It can present with a wide range of symptoms including tremulousness, insomnia, anxiety, diaphoresis, and autonomic hyperactivity. Burn patients are at risk of carbon monoxide poisoning (D), particularly when they are confined to a close space. However, carbon monoxide poisoning will present acutely (not 7 days later) with headaches, dizziness, and nausea.

### 20. Answer B

Patients with blunt chest trauma that present with persistent hypotension, tachycardia, and elevated JVP should be suspected of having an injury to the heart. Furthermore, this patient had a drop  $\geq 10$  mmHg in systolic blood pressure during inspiration (pulsus paradoxus) which supports a diagnosis of cardiac tamponade. Although cardiac tamponade classically causes a globular appearance of the heart on CXR, the cardiac silhouette may be normal. A lung contusion (C) would cause respiratory distress but not features of tamponade. An aortic transection (A) presents with a wide mediastinum and would not cause neck vein distention. Tension pneumothorax (D) may have distended neck veins, but the collapsed lung would be apparent on CXR combined with tracheal deviation. Diaphragmatic injury (D) can occur following blunt abdominal trauma and often present with GI and respiratory complaints though they may initially be asymptomatic.

### 21. Answer A

Hypotension after blunt trauma should be considered due to hemorrhage until proven otherwise. Head injury should not be considered the source of hypotension. The most likely sources of bleeding are the abdomen, pelvis, and chest. However, major chest bleeding has been ruled out by the negative CXR. In the stable patient, an abdominal CT (E) is the best test to rule out bleeding. However, the patient's hemodynamic instability precludes such a study. FAST scan is the test of choice in the unstable patient, but its utility is often limited in obese patients because of poor image quality. In equivocal cases, the next best choice is to perform a DPL to detect free fluid in the peritoneum, which would be an indication for exploratory laparotomy. Proceeding directly to exploratory laparotomy (C) would be appropriate if the patient manifested peritoneal signs. However, his altered mental status precludes a proper physical examination.

Pelvic bleeding is another potential source of bleeding, although pubic rami fractures rarely cause major bleeding (more likely with fractures of the posterior pelvis). If the DPL was negative, one would then pursue pelvic angiography (B) to rule out pelvic bleeding. Given the GCS of 10, a head CT (D) is indicated, but this would not take precedence over identifying the source of hemorrhagic shock first.

### 22. Answer C

The patient is displaying evidence of neurogenic shock with hypotension and an inappropriately normal heart rate (or bradycardia). Neurogenic shock is associated with a high cervical spinal cord injury (not thoracic spine injury {E}). Priapism (a sustained erection due to unopposed parasympathetic tone) is often a presenting sign of acute spinal cord injury. Neurogenic shock would be expected to present with a normal/high cardiac output (A), decreased SVR (B), and sympathetic blockade (D). Treatment is with intravenous fluids and if needed, pressor support (with an alpha agent for vasoconstriction).

### 23. Answer B

This patient has a dirty wound, but has likely had all three tetanus vaccinations. Based on the table below, the correct treatment is tetanus vaccination only. Antibiotics (E) are not indicated since the patient is not infected. Since this is a dirty wound, primary closure (D) may not be attempted in this case, and the wound may be packed instead (Table A.1).

### 24. Answer C

Children with supracondylar fractures are at risk for acute compartment syndrome. There are three mechanisms as to why this occurs: (1) the fracture is associated with an often unrecognized brachial artery injury that leads to ischemia in the compartments of the arm; (2) if the subsequent cast is placed too tightly, this may contribute to compartment syndrome; (3) initial bleeding and muscle damage/edema causes high pressures in the compartments of the arm leading to compartment syndrome. Compartment syndrome presents with the 6 Ps (pain, pallor, pulselessness, paresthesias, paralysis, and poikilothermia). Treatment is fasciotomy. Volkmann's contracture is the manifestation of unrecognized and untreated compartment syndrome. This occurs because

**Table A.1** Tetanus vaccination

History of TT vaccination	Clean wounds	Dirty wounds
<3 doses	All should receive TT	All should receive both TT and TIG
≥3 doses	Should receive TT only if the last dose was >10 years go	Should receive TT only if last dose was >5 years ago

TT tetanus toxoid, TIG tetanus immunoglobulin

prolonged ischemia can lead to muscle death and subsequent fibrotic changes within the tissue. Volkmann's contracture presents with a tense, painful, weak, and shortened forearm with a claw-like deformity of the hand. Nerve entrapment (A) is more likely to present acutely after the injury and will have deficits consistent with the distribution of a particular nerve. Suppurative tenosynovitis (B) is characterized by the four cardinal signs (Kanaval signs): flexor tendon sheath tenderness, fusiform swelling (sausage-shaped digits), pain with passive extension, and a semi-flexed posture of the involved digit. Complex regional pain syndrome (D) is a poorly understood phenomenon that occurs in patients that have had a crushing or soft tissue injury, typically to the distal extremities. They can present within days or months with intermittent pain, difficulty using the extremity, neglect-like symptoms, and rapid fatigability. An improperly reduced fracture would have been recognized earlier and corrected and would be unlikely to result in the deficits seen in this patient.

### 25. Answer E

Cutaneous squamous cell carcinoma arising from a chronic non-healing wound (such as a burn) is known as Marjolin's ulcer. Although all the answer choices (A–D) are considered independent risk factors for skin cancer, chronic inflammation is the most important contributing factor in Marjolin's ulcer and can be seen in burn wounds, scars, chronic ulcers, or sinus tracts. Carcinoma develops on average 20–30 years after the original burn. All chronic wounds that fail to heal after a long period should undergo a skin biopsy to rule out malignancy.

### 26. Answer B

This patient has a left-sided tension pneumothorax as confirmed by hypotension, distended neck veins, decreased breath sounds, and hyperresonant left chest. Immediate treatment is with needle thoracostomy, allowing for immediate thoracic decompression. This is preferred in the setting of a tension pneumothorax as it is faster than a chest tube, but provides only temporary relief. All these patients require a tube thoracostomy (chest tube) immediately following needle thoracostomy. Operative management (E) is not routinely indicated for patients with tension pneumothorax as needle decompression and subsequent tube thoracostomy are able to resolve most cases. If he had a significant hemothorax that continued to hemorrhage despite tube thoracostomy, surgical management could be considered as well as blood products (A). Tension pneumothorax is considered a clinical diagnosis, and confirmation with imaging (C, D) is not recommended as it delays definitive care in the unstable patient.

### 27. Answer B

Penetrating trauma to the extremities should be assessed for neurovascular injuries. Prompt surgical exploration (A)

would be indicated if the patient had hard signs of vascular injury (e.g., pulsatile bleeding, expanding hematoma). In the absence of such signs, an ABI should be checked. If the ABI is  $<0.9$ , suspicion for an arterial injury is high, and as such, imaging with CT angiography is the most appropriate management option. Formal angiography (C) can be considered if CT results are equivocal. Observation would be appropriate if he had a normal ABI. Systemic heparinization is sometimes used during the course of arterial repair if the injury led to thrombosis and an interposition vein graft is used.

### 28. Answer E

This patient's mechanism of injury and blood pressure drop are highly suggestive of hemorrhagic shock. Given that the patient responded well to IV fluids, it is appropriate to obtain CT imaging to look for the source of bleeding. If the source was intra-abdominal bleeding, the next step would be exploratory laparotomy (D). However, the CT indicates that the source is pelvic bleeding, likely from the pelvic fracture. Such bleeding is best managed via emergent pelvic angiography, which could be diagnostic and therapeutic (with embolization). MAST (A) suits were at one time popular as the compression was thought to tamponade bleeding. However, they have not been shown to be effective. External pelvic fixation (B) can reduce and stabilize fractures and thus lead to a slowing of bleeding, but is not considered as effective as angiographic embolization. Open reduction, internal fixation (C) is the definitive treatment for a pelvic fracture. But given the technical difficulty and long length of such an operation, it is not recommended acutely, and especially not in someone who is actively bleeding. Pelvic packing is emerging as an alternative to angiography for pelvic bleeding.

### 29. Answer D

This patient presents with a right hemo- and pneumothorax, and tube thoracostomy was able to evacuate 500 cc of dark blood. The most appropriate next step in management is to perform a repeat chest x-ray to ensure that the tube thoracostomy is in the right position and that the hemo- and pneumothorax have resolved. Exploratory right thoracotomy (A) would be indicated only if the initial output after chest tube placement was  $>1,500$  cc or if the patient continued to bleed briskly ( $>200$  cc/h for 3 h). VATS (D) is indicated if the chest tube has inadequately drained the hemothorax. But such a residual hemothorax would be drained via VATS only after failure of a second chest tube and only after waiting a few days (not acutely). CT of the chest is generally not needed if the CXR shows that the hemothorax is resolved, and CT of the abdomen (E) is unnecessary at this time as the bullet entered just above the nipple (and thus above the diaphragm) and is visualized in the chest, thus sparing the abdominal cavity.

### 30. Answer C

This is concerning for a flail chest, most commonly caused by blunt trauma. Although the diagnosis is made clinically with a paradoxical inward motion of the chest wall during inspiration, it is supported by imaging studies demonstrating two or more consecutive ribs broken at two or more sites. The primary morbidity related to flail chest is the frequent underlying pulmonary contusion that accompanies it and compromises adequate respiration. Furthermore, severe pain may also affect respiration. Always start with the ABCs of trauma. The best course of management for the above patient (given the marked tachypnea and flail chest) is to first ensure an airway with endotracheal intubation. This can be followed by two large bore IVs and fluids (A). Blood products (D) may be needed if he does not respond to fluids and continues to remain hemodynamically unstable. There is no indication for a needle thoracostomy (B) or chest tube given that the breath sounds are equal. Chest tube (E) may be indicated if the patient had a concurrent pneumothorax on subsequent CXR.

### 31. Answer C

Acute carbon monoxide (CO) poisoning affects the organs with the highest oxygen demand first. Patients will present in the early stages with neurologic complaints (e.g., headaches, dizziness, confusion) and cardiac symptoms (e.g., chest pain, arrhythmias). All these patients should be started on 100 % oxygen via nonrebreather facemask. CO has nearly 250× more affinity for hemoglobin than oxygen. Thus the hemoglobin-oxygen dissociation curve shifts to the left, and more hemoglobin is bound by CO than it is by oxygen. This decreases both the hemoglobin saturation (of oxygen) and the oxygen content in the blood. The arterial partial pressure of oxygen is not affected in CO poisoning (B), and so a compensatory increased alveolar ventilation would not be expected (E). CO poisoning is not a consumptive or destructive process, and so hemoglobin would not be expected to change (A). Oxidized hemoglobin, also known as methemoglobin, has a higher affinity for cyanide, and so patients with cyanide poisoning are oftentimes given nitrates to induce the oxidization of hemoglobin to help bind the cyanide for renal clearance.

### 32. Answer E

Electrical burns are deceptive as at the skin level there may be a relatively minor burn wound. Yet, the electrical current can penetrate deep into the soft tissues, leading to extensive injury to the soft tissues and muscle. Thus electrical burns are associated with the development of compartment syndrome. The best indication for fasciotomy is in the presence of compartment syndrome. Choice E is the only choice in which there is an absolute indication for fasciotomy as the patient has clear evidence of compartment syndrome. Numbness of the first web space is the classic finding of

anterior compartment syndrome, as the deep peroneal nerve travels within it, and it supplies sensation to the first web space. Options B, C, and D are relative indications for prophylactic fasciotomy, as they place the patient at increased

risk of subsequently developing compartment syndrome, although prophylactic fasciotomies are controversial. A crush injury (A) by itself is not considered an indication for prophylactic fasciotomy.

## Upper Gastrointestinal

Michael D. Sgroi, Brian R. Smith, Christian de Virgilio, Areg Grigorian, and Paul N. Frank

### Questions

- A 60-year-old male presents with gnawing epigastric pain that has been present for 8 weeks. The pain seems to get worse with eating. He denies nausea, vomiting, or early satiety. He has lost 10 lb and he attributes this to a poor appetite. He denies black or bloody stools. Physical examination is unremarkable. What is the next study to be ordered?

  - Barium swallow
  - CT scan
  - EGD
  - 6-week trial of proton pump inhibitor
  - Testing for *H. pylori*
- Which of the following is the strongest risk factor for gastric cancer?

  - Type A blood
  - H. pylori* infection
  - Smoking
  - Familial adenomatous polyposis
  - Family history
- A 70-year-old male with a history of smoking presents with vague upper abdominal and epigastric pain and coffee ground emesis. On EGD, a small ulcer is found in the stomach, with evidence of a large submucosal mass underneath the ulcer. Biopsy of the area is negative. CT scan confirms a 4-cm homogeneous, well-circumscribed, submucosal mass in the greater curvature of the stomach. What does this mass most likely represent?

  - Gastrointestinal stromal tumor
  - Gastric adenocarcinoma
  - Gastric lipoma
  - Metastatic carcinoma
  - Solitary fibrous tumor
- A 65-year-old female presents with coffee ground emesis  $\times 3$ . She has had vague upper abdominal pain for the past 2 months, relieved by taking antacids. In addition, she reports an involuntary weight loss of 10 lb. She denies NSAID or alcohol use. On physical examination, her blood pressure is 110/70 mmHg and HR is 80/min. Abdominal examination reveals mild epigastric tenderness with no rebound or guarding. Laboratory values are significant for a Hgb/Hct of 8.3 g/dL (normal 12–15 g/dL) and 24 % (36–44 %) with an MCV of 80 fL (80–100 fL), total bilirubin of 3.0 mg/dL (0.1–1.2 mg/dl), alkaline phosphatase of 250 IU/L (33–131 IU/L), a GGT of 270 IU/L (6–37 IU/L), an ALT of 300 IU/L (<35 IU/L), and an AST of 320 IU/L (<35 IU/L). The most likely diagnosis is:

  - Duodenal ulcer
  - Gastric ulcer
  - Pancreatic cancer
  - Ampullary cancer
  - Dieulafoy's lesion
- A young man from Armenia arrives to the ED complaining of a progressively bloody cough. He reports night sweats and fevers for the past month. He has been in the United States for 1 week visiting family. As you begin examining him, he coughs up a massive amount (200 ml) of bright red, foamy sputum and has difficulty speaking. Portable chest x-ray shows multifocal patchy and cavitary opacities in the right upper lobe with mediastinal lymphadenopathy. Given his increased risk for asphyxiation, the patient is intubated and placed in a right lateral decubitus position. What is the next best step in management?

  - Emergent thoracotomy in the OR
  - Bronchoscopy
  - Video-assisted thoracic surgery (VATS)
  - Emergency arteriography
  - INH, rifampin, ethambutol, and pyrazinamide
- A 50-year-old male presents to the ED stating that he passed a large amount of maroon stool earlier in the day. He is currently not passing any stool. He has not vomited. He denies abdominal pain or weight loss. He also has a history of nosebleeds. He takes no medications and does not drink alcohol. Physical examination is only significant for small red nodules on his lips. Abdominal examination is unremarkable. Upper endoscopy is negative. Which of the following is most likely to localize the site of the GI bleeding?

  - Capsule endoscopy
  - CT angiogram
  - Lower endoscopy
  - Formal angiography
  - Technetium-labeled red blood cell scan
- A 50-year-old female presents with massive UGI bleeding. In the ED, she is actively vomiting large amounts of bright red blood. She appears to be lethargic and pale. Blood pressure is 70/50 mmHg, heart rate is 120/min, and RR is 22/min. The next step in the management is:

  - Emergent upper endoscopy
  - Immediate orotracheal intubation
  - Place bed in reverse Trendelenburg position

- (D) Give 2 liter bolus of normal saline  
(E) Give two units of O-negative blood
8. A 48-year-old male presents with vomiting of bright red blood. He states that he has had a 1 month history of epigastric pain that is relieved by eating food. He denies weight loss. He does not take any medications or drink alcohol. He is hemodynamically stable in the emergency department. Following resuscitation, the patient undergoes upper endoscopy which reveals a posterior ulcer in the proximal duodenum which is actively bleeding. Despite numerous attempts at cauterization and injection with epinephrine, the gastroenterologist reports that she cannot stop the bleeding and the blood pressure drops to 70/50 mmHg. The next step in the management is:
- (A) Angiographic embolization  
(B) Transfer to ICU for ongoing transfusion of blood  
(C) Administer vasopressin  
(D) Exploratory laparotomy  
(E) Administer octreotide
9. A 45-year-old male with a history of alcohol abuse presents to the emergency department with an UGI bleed after a night of binge drinking. The patient reports that he repeatedly dry heaved, after which he began to note bright red blood in the vomitus. He is afebrile with normal vital signs. Upper endoscopy reveals a partial tear in the mucosa and submucosa of the stomach near the gastroesophageal junction. Which of the following is true about this condition?
- (A) It is usually related to portal hypertension  
(B) It is often associated with a left pleural effusion  
(C) It is associated with *H. pylori* infection  
(D) The bleeding is likely arising from the gastroduodenal artery  
(E) The bleeding most often stops spontaneously
10. A 65-year-old male presents with melena. He reports no abdominal pain and no vomiting. He denies a prior similar history. In the ED, he is tachycardic to 120/min with a blood pressure of 112/80 mmHg. Hemoglobin and hematocrit are 9.2 g/dL (normal 13–16 g/dL) and 28 % (40–52 %), respectively. Past history is significant for an aortobifemoral bypass 5 years earlier for severe claudication. Nasogastric (NG) tube aspiration returns clear fluid. The patient is admitted to the ICU for resuscitation, the melena ceases, and the hematocrit stabilizes. Upper endoscopy is negative, with no stigmata of bleeding. Following a bowel prep, colonoscopy is also negative. CT scan of the abdomen reveals gas around the proximal aortic graft. Which of the following is true about this condition?
- (A) Formal angiography is likely to demonstrate the source of bleeding  
(B) Gas around the aortic graft is not considered pathologic  
(C) The aortic graft will likely need to be removed.  
(D) Rebleeding is rare  
(E) This represents an occult bleed
11. What is the most common cause of an esophageal perforation?
- (A) Boerhaave syndrome (spontaneous perforation)  
(B) Iatrogenic  
(C) Foreign body  
(D) Esophageal cancer  
(E) Trauma
12. Which of the following is true of Boerhaave syndrome?
- (A) It most often presents with UGI bleeding  
(B) It is most often caused by an iatrogenic injury  
(C) It is a partial thickness tear of the esophagus  
(D) It is the most lethal GI perforation  
(E) Treatment consists of bowel rest and intravenous antibiotics
13. A 50-year-old Asian female complains of abdominal discomfort and weight loss. She has an EGD performed, and biopsy of a stomach lesion returns as mucosa-associated lymphoid tissue (MALT) lymphoma. Which of the following is the best treatment plan for this patient?
- (A) Chemotherapy  
(B) Radiation therapy  
(C) Combined chemotherapy and radiation  
(D) Clarithromycin, amoxicillin, and a proton pump inhibitor  
(E) Gastric resection
14. Which of the following is the first step in the treatment of a patient with Boerhaave syndrome?
- (A) Esophagectomy  
(B) Gastric decompression  
(C) Drainage of the mediastinum and pleura  
(D) Primary repair of the perforation with advancement flap coverage  
(E) Fluid resuscitation and IV antibiotics
15. A 65-year-old male presents with iron deficiency anemia. Fecal occult blood testing is positive. Upper endoscopy demonstrates an irregular ulcer in the body of the stomach. Biopsy confirms adenocarcinoma. Simultaneous endoscopic ultrasound (EUS) demonstrates that the mass has invaded into the submucosa. No enlarged nodes are

seen around the lesion. Which of the following would be the next best step in the management?

- (A) Proceed to gastric resection
- (B) CT scan of the abdomen
- (C) PET scan
- (D) Laparoscopy
- (E) Chemotherapy

16. Successful eradication of *H. pylori* is best documented by:

- (A) EGD with biopsy
- (B) Urea breath test
- (C) Blood antibody test
- (D) Stool antigen
- (E) Documentation is unnecessary provided symptoms have resolved

## Answers

### 1. Answer C

Epigastric pain and symptoms of dyspepsia are extremely common. It is reasonable in most young patients to start with a short trial of proton pump inhibitors (D). Alternatively, clinicians can employ the test-and-treat strategy in which they test for *H. pylori* first (E). Testing should only be done if the clinician plans to offer treatment for a positive test. However, in patients >55 years or in those with ALARM Symptoms, Anemia (iron deficiency), Loss of weight, **Anorexia**, **Recent** onset of progressive symptoms, *Melena*/hematemesis, Swallowing problems, upper endoscopy is required to rule out gastric cancer. CT scan (B) is usually performed after EGD to evaluate for distant metastasis. Operative resection should not be undertaken until the diagnosis is confirmed and the tumor is staged. Barium swallow (A) may identify gastric ulcers and infiltrating lesions, but it has a high false-negative rate and does not permit biopsy. Barium swallow may also be used to evaluate dyspepsia in younger patients.

### 2. Answer B

*H. pylori* is the strongest established risk factor for gastric cancer worldwide. *H. pylori* infections lead to gastritis, and without eradication of the infection, inflammatory changes may eventually lead to dysplasia and metaplasia. All the remaining choices (A, C–E) increase one's risk of developing gastric cancer but are not considered to be as strong as *H. pylori*.

### 3. Answer A

Gastrointestinal stromal tumors (GIST) are mesenchymal tumors that most often occur in the stomach and small intestine. As they grow, they can cause pressure necrosis, leading to erosion of the gastric mucosa and GI bleeding. Since the mass is submucosal, attempts at biopsy at the time of upper endoscopy are often negative. CT scan typically shows a well-circumscribed homogeneous mass. GIST are caused by a gain of function mutation (tumorigenesis) in the proto-oncogene *c-KIT*. Treatment is surgical resection, followed by imatinib mesylate, a selective tyrosine kinase inhibitor with action against mutant *c-KIT*. Gastric adenocarcinoma (B) starts in the mucosa; it would be unlikely to be biopsy negative. A lipoma (C) or a solitary fibrous tumor (E) would not likely erode into the mucosa. Melanoma (D) can metastasize to the stomach but does not typically present with a well-circumscribed mass.

### 4. Answer D

The patient is presenting with an unusual combination of an UGI bleed (coffee ground emesis) and obstructive jaundice (elevated bilirubin and rise in alkaline phosphatase with proportional rise in ALT and AST). Of the five options, ampullary cancer is the one that would most likely present as such. Pancreatic cancer (C), though it certainly can cause pain,

weight loss, as well as obstructive jaundice, is not associated with iron deficiency anemia or UGI bleed. Dieulafoy's lesion (E) typically presents with massive UGI bleeding, due to an abnormally located superficial arteriole that erodes. Diagnosis is difficult as it causes a pinpoint bleed that can only be seen when actively bleeding. Duodenal or gastric ulcers (A–B) would not cause obstructive jaundice.

### 5. Answer B

Massive hemoptysis with constitutional symptoms as described is likely from tuberculosis (TB). This is further supported by the patient's origin from a TB endemic area (e.g., Armenia, Mexico, Nigeria) and the CXR findings. The most common cause of massive hemoptysis in the world is TB. Immediate intubation is indicated to protect the airway. Once intubated and placed in the right lateral decubitus position (to prevent blood from entering the contralateral lung), the next best step in management involves localizing the source and controlling it with bronchoscopy. Emergent thoracotomy in the OR (A) can be considered if initial management options fail to control bleeding. VATS (C) offers a minimally invasive surgical technique to treat certain lung and chest wall diseases but is not currently used much in the emergency setting. Angiography (D) with embolization is a therapeutic option for massive hemoptysis. INH, rifampin, ethambutol, and pyrazinamide are used to treat TB but will not address the patient's acute condition.

### 6. Answer A

Melena can either be from an upper or a lower GI source. The presentation is classic for hereditary hemorrhagic telangiectasia (HHT) (also known as Osler-Weber-Rendu), an autosomal dominant disorder characterized by recurrent epistaxis, telangiectasia/red nodules of the face, lips, and/or GI tract, arteriovenous malformations (AVM), and a family history. GI bleeding most often occurs in the stomach and small bowel. If upper endoscopy is unable to confirm bleeding in the stomach, a capsule endoscopy (gelatin capsule containing a video recorder is swallowed, eventually retrieved in the stool, and permits visualization of the entire bowel) or push enteroscopy is used to assess for small bowel bleeding. Push enteroscopy uses a longer enteroscope or pediatric colonoscope to visualize the proximal jejunum. The subsequent step would be to perform lower endoscopy (C) (after a bowel preparation). However, colonic telangiectasias are very uncommon. Formal angiogram (D) would only be useful if the patient is actively bleeding at a rate of 1 ml/min (the patient is not currently bleeding), is an invasive procedure, and would not permit visualization of the extent of telangiectasias. Technetium-labeled red blood cell scan (E) may be useful if the patient is actively bleeding (at a rate of 0.5 ml/min) but is particularly ineffective in localizing the site of bleeding in the small bowel. A CT angiogram (B) would not



demonstrate telangiectasias of the small bowel (though it would be useful for identifying hepatic AVMs).

### 7. Answer B

The patient presented is suffering from a massive, ongoing UGI bleed. Management should always begin with the ABCs. Given the large amount of bleeding, combined with her hemodynamic instability, this patient's airway is at risk. As such, the correct answer is to emergently perform orotracheal intubation. Unlike an elective intubation, it should be performed using a rapid sequence intubation (RSI) technique. Reverse Trendelenburg (C) helps to prevent aspiration, but in the patient presented, it would be potentially dangerous given the marked hypotension. Following intubation and confirmation of appropriate placement, 2 liters of normal saline (D) would be administered. Given the massive bleeding, blood will also likely need to be administered. However, if the patient responds to the initial fluid bolus, O- blood may not be necessary (E). Following resuscitation, emergent endoscopy (A) to identify and treat the cause of the bleeding should be performed. Additionally, a Foley catheter should be placed to monitor urine output as an indication of the patient's volume status.

### 8. Answer D

The mainstay of therapy for UGI bleeding is endoscopic intervention. Techniques utilized include injection of epinephrine, sclerosing agents, clips, and cauterization. On rare occasion, if the bleeding cannot be controlled, then urgent surgical intervention is indicated. In the above case, the appropriate intervention is to surgically open the duodenum and oversee the ulcer in four quadrants to assure the artery has been ligated. Continuing blood transfusion alone is not appropriate (B). Although angiographic embolization (A) is occasionally utilized for GI bleeding in poor surgical risk patients, it would not be the first choice in someone who is hemodynamically unstable. Vasopressin (C) and octreotide (E) are used in the management of patients suffering from bleeding esophageal varices.

### 9. Answer E

The case represents a classic history and endoscopic findings of a Mallory-Weiss tear. The etiology is thought to be a sudden and rapid rise in the transmural pressure gradient at the gastroesophageal (GE) junction, associated with retching. It is most often seen following an alcoholic binge but can also be seen with any forceful vomiting or coughing. It is thought to more likely occur in patients with hiatal hernias. The tear is longitudinal, partial thickness, in the stomach, near the GE junction. The left gastroduodenal artery (D) is not involved. It usually resolves spontaneously. Though it is seen following an alcohol binge, it is not related to portal hypertension (A), or *H. pylori* (C), and does not cause a pleural effusion (B). Mallory-Weiss

is not to be confused with Boerhaave syndrome, which can also occur after forceful vomiting. In Boerhaave syndrome, the rapid rise in intrathoracic pressure can cause a full thickness perforation of the esophagus. The esophageal perforation results in esophageal contents spilling into the mediastinum and sometimes into the left chest, resulting in a left pleural effusion, subcutaneous emphysema, severe chest pain, and, if untreated, sepsis and death. Boerhaave syndrome requires broad-spectrum antibiotics and emergent surgery to seal the esophageal perforation and drain the mediastinal infection.

### 10. Answer C

GI bleeding, in association with a history of aortobifemoral bypass, is due to an aortoenteric fistula until proven otherwise. Patients typically have a "herald" bleed, followed later by exsanguinating hemorrhage (D). The NG aspirate returned clear fluid. This rules out bleeding from the stomach, but not from the duodenum. Thus the first diagnostic test of choice is still an upper endoscopy, but in aortoenteric fistulas, it is typically negative as the bleeding results from erosion of the aortic graft into the fourth portion of the duodenum which is usually not well visualized with a standard scope. The negative endoscopy essentially rules out the most common causes of UGI bleeding which include acute gastritis, as well as gastric and duodenal ulcers. A colonoscopy is generally not useful in the acute bleed setting, as the colon is filled with stool and clot. Thus, bowel prep is necessary. A negative lower endoscopy is less conclusive. Though it rules out colon cancer, other sources of lower GI bleed, such as diverticulosis and AVMs, may be hard to see if they are not actively bleeding. Nevertheless, with a negative upper and lower endoscopy, the bleeding is likely coming from the small bowel. This fulfills the definition of an *obscure bleed* (obvious bleeding, as evidenced by the melena, without an obvious source). An *occult* bleed is one that the patient is not aware of (detected only by fecal occult blood testing) (E). The diagnosis of an aortoenteric fistula is notoriously difficult to make. Angiography is poor at showing any abnormalities with an aortoenteric fistula (A). With an aortoenteric fistula, the aortic graft by definition is infected. Air, fluid, or stranding around the graft on CT scan beyond 6 weeks after surgery would be considered pathologic (B) and indicative of a graft infection. Treatment is to remove the graft. This can be done by either replacing it with a human cadaver homograft in situ or by performing an axillo-bifemoral bypass followed by removal of the aortic graft and aortic ligation.

### 11. Answer B

The most common cause of esophageal perforation is iatrogenic injury, usually from EGD, but also occasionally from endotracheal intubation or placement of a nasogastric tube. Boerhaave syndrome (A), foreign body (especially sharp or corrosive objects) (C), and esophageal cancer (D) may also

cause perforation, but they are less common than iatrogenic injury. Trauma (E), especially of the penetrating variety, may injure the esophagus, but this is less common than iatrogenic injury.

### 12. Answer D

Boerhaave syndrome is the term used for a perforation of the esophagus that occurs following forceful emesis (iatrogenic perforation is not called Boerhaave syndrome) (B). The full thickness tear (C) causes spillage of GI contents into the mediastinum and even the thorax. Since GI contents spill into the mediastinum instead of the peritoneum, the patient does not develop peritonitis. Rather, they often present with fever and chest pain. As such, the diagnosis is often delayed until the patient becomes severely septic. Among GI perforations, it has the highest overall mortality. Boerhaave syndrome most often occurs in males between the ages of 50 and 70, after excessive intake of food and alcohol. Unlike Mallory-Weiss tears, Boerhaave syndrome does not typically present with UGI bleeding (A). Treatment is surgical (repair hole in esophagus) (E). Outcomes are dependent on the timeliness of recognition and surgical management.

### 13. Answer D

MALT lymphoma is strongly associated with *H. pylori* infection and is unique in that it is curable with antibiotics (i.e., triple therapy). In addition to biopsy, testing for *H. pylori* should be performed. After triple therapy, cure should be confirmed. If it is determined that triple therapy has failed, other modalities such as chemotherapy (A), radiation therapy (B), a combination of both (C), and/or surgery (E) are utilized (E).

### 14. Answer E

All patients presenting with possible esophageal perforation should receive immediate IV fluids and antibiotics for the treatment of sepsis. Gastric decompression (B), mediastinal

and pleural drainage (C), and primary repair (D) of the esophagus should occur after initial stabilization, ideally within 24 h. Esophagectomy (A) is reserved for extreme cases with large perforation or wherein primary repair will cause stricture.

### 15. Answer B

EUS is performed as it assists with TNM staging. EUS has been proven to provide more accurate assessment of tumor size, depth, and locoregional lymph node involvement compared to radiographic imaging. The next step is to perform a CT scan of the abdomen to look for distant metastasis and confirm that the patient is a surgical candidate. CT scanning will rule out liver metastasis as well as distant suspicious lymph nodes that were missed on EUS, either of which would preclude a curative resection. Though not the standard of care, PET scan (C) is emerging as an accurate modality for detecting small metastases and lymph node involvement. The management of gastric adenocarcinoma is dependent on the staging of the tumor. Surgery with gastric resection (A) is the only curative therapy to date for gastric cancer. Laparoscopy (D) is sometimes utilized to look for peritoneal or omental metastasis which would preclude curative gastrectomy. Gastric cancer that is more advanced than stage IB should be considered for a multi-therapeutic approach with chemotherapy (E).

### 16. Answer B

Eradication may be confirmed by a urea breath test, fecal antigen test (D), or upper endoscopy performed 4 weeks or more after completion of therapy. Typically, noninvasive methods should be performed except in cases when a follow-up endoscopy is indicated (e.g., gastric cancer, preneoplastic lesions, MALT lymphoma). Blood antibody test (C) is unable to confirm eradication as IgG levels will remain elevated after the acute infection is resolved. Clinical resolution (E) of symptoms is inappropriate in confirming eradication of *H. pylori*, particularly in the setting of gastric cancer.

## Urology

### Areg Grigorian and Christian de Virgilio

#### Questions

- A 52-year-old male is brought to the hospital by his wife with complaints of intense pain that started around his right flank and now radiates to his right groin. He said that his urine appears pink. He appears to be in severe pain and is unable to remain still during examination. His abdominal exam is unremarkable. Urinalysis reveals 100 RBC/hpf. IV fluids and analgesics are administered. Which of the following is the most appropriate imaging?

  - Helical CT scan of the abdomen and pelvis without contrast
  - Helical CT scan of the abdomen and pelvis with contrast
  - Upright abdominal X-ray
  - Intravenous pyelogram (IVP)
  - Renal ultrasound
- A 30-year-old male is involved in a high-speed MVC. He was wearing his seatbelt. In the ED, he has a strong odor of alcohol. Blood pressure is 120/70 mmHg and heart rate is 80/min. His abdomen appears distended and mildly tender diffusely. The pelvis is stable. On rectal exam, the prostate feels normal. There is no blood at the urethral meatus. On insertion of a Foley catheter, there is gross hematuria. CT scan of the abdomen and pelvis with oral and IV contrast reveals a large amount of free fluid and contrast in the peritoneum. The liver and spleen appear to be normal as does the pelvis. What part of the genitourinary tract is most likely injured?

  - Ureter
  - Base of the bladder
  - Bladder dome
  - Renal hilum
  - Urethra
- A 14-year-old boy is diagnosed with a varicocele by his family physician. Which of the following is true about this condition?

  - It affects either side with similar frequency
  - It causes the testicle to ride high in the scrotum
  - It transilluminates on physical exam
  - It is related to impaired venous drainage
  - It is associated with an absent cremasteric reflex
- A 32-year-old newlywed man presents to the ED with intense pain in his penis. He reports having an accident falling in the bathroom. His temperature is 98.8 °F, blood pressure is 126/80 mmHg, and pulse is 110/min. His physical examination is significant for a blue discoloration at the base of a swollen and deviated penis. He has no ulcers or discharge. Retrograde urethrogram did not identify any urethral injuries. What is the best next step for this patient?

  - Abdominal and pelvic CT scan
  - Cystoscopy
  - Analgesics and bed rest
  - Surgical repair
  - Temporary suprapubic catheter
- A 78-year-old man arrives to the ED with colicky flank pain for the past 4 days that is now accompanied by nausea, vomiting, fever, and hematuria. Past medical history is significant for congestive heart failure and prior myocardial infarction. On physical examination, the patient has a blood pressure of 100/60 mmHg, temperature of 101 °F, and a heart rate of 110/min. Urinalysis reveals 150 RBC/hpf and 20 WBC/hpf. Laboratory tests demonstrate a WBC of  $15 \times 10^3/\mu\text{L}$  (normal  $4.1\text{--}10.9 \times 10^3/\mu\text{L}$ ) with 10 % bands. Imaging demonstrates a 10-millimeter stone lodged in the ureterovesicle junction with dilation of the right renal calyx. Broad-spectrum antibiotics are administered intravenously. What is the best next step in management?

  - Percutaneous nephrostomy tube
  - Open nephrostomy
  - Shock wave lithotripsy
  - Placement of a ureteral stent
  - Admit to ICU for close monitoring
- Which of the following is true regarding the circulation to the testes?

  - Each testis has a singular blood supply, which arises from the aorta
  - Testicular ischemia after inguinal hernia repair is most often due to accidental transection of the testicular artery
  - An ischemic testis does not lead to antisperm antibody formation
  - During surgery for an undescended testis, the testicular artery may need to be divided
  - Lymphatic drainage from the testis is to the inguinal lymph nodes
- A 45-year-old male presents with a new scrotal mass on the right side that he noticed a week earlier. It is non-tender. He reports no history of trauma. When the patient is standing, the scrotal mass is separate from the testicle and epididymis, feels like a “bag of worms,” and is soft, compressible, and non-tender. With the patient supine, the mass is unchanged. The left side is normal. What is the most appropriate next step in the management?

- (A) Scrotal support and NSAIDs  
(B) Surgical intervention  
(C) CT of the abdomen  
(D) Reassurance and observation  
(E) Ultrasound-guided biopsy of the mass
8. A 15-year-old boy arrives to the ED 4 h after experiencing a sudden onset of right testicular pain while playing soccer. He does not recall any specific trauma to his testicle during the game. He also reports nausea and vomiting. Physical examination reveals a tender and swollen right testicle that is displaced superiorly. The testicle appears to be lying transversely. He has an absent cremasteric reflex on the right. The left testicle is normal in location and is non-tender. What is the next step in management?
- (A) Ultrasound  
(B) Color Doppler ultrasound  
(C) Right orchiopexy  
(D) Bilateral orchiopexy  
(E) Scrotal support and nonsteroidal anti-inflammatory drugs
9. A 37-year-old obese woman arrives to the ED with left flank pain and hematuria. She has never experienced these symptoms before. Her past medical history includes Crohn's disease which has been controlled with mesalamine. She is afebrile with a blood pressure of 130/84 mmHg and a pulse of 104/min. Physical examination reveals a laparotomy scar in her right lower quadrant. She is given analgesics for pain control. What is the most likely etiology of her acute symptoms?
- (A) Gallstones  
(B) Hypercalciuria  
(C) Increased absorption of oxalate  
(D) Protease producing bacteria  
(E) Mesalamine
10. A 10-year-old boy presents to his doctor for follow-up 2 weeks after having an upper respiratory tract infection (URI). He complains of pain in his scrotum. It has been bothering him for the past 3 days but is more painful today. A scrotal ultrasound demonstrates an enlarged and rounded epididymis. His scrotal skin appears thickened. What other finding(s) would you suspect in this patient's history and physical?
- (A) Skin lesions and abdominal pain  
(B) Recent weight loss, night sweats, and fevers  
(C) Recent epididymitis  
(D) Sores in the mouth and swelling of the eyes  
(E) Painful urination
11. An infant is found to have an undescended left testicle shortly after birth. During his 6-month checkup, the left testicle remains undescended. What can be done to decrease this patient's risk of developing testicular cancer later in life to match that of a boy born without cryptorchidism?
- (A) Immediate orchiopexy  
(B) Orchiopexy within the next 6 months  
(C) Hormonal therapy  
(D) Observation until age two and then orchiopexy  
(E) Risk cannot be decreased to that of a boy without cryptorchidism
12. A 26-year-old man that recently emigrated from Sudan to the United States arrives to your office complaining of red urine. He does not experience any pain but says that for the last week his urine has appeared red. He also reports night sweats, fevers, and losing 10 pounds over the last 2 months without a change in his appetite. Cystoscopy is performed, and biopsies are taken of a tumor that appears nodular with a plaque-like and irregular surface. What is most likely to be seen on microscopic analysis?
- (A) Urothelial carcinoma (transitional cell carcinoma)  
(B) Squamous cell carcinoma  
(C) Adenocarcinoma  
(D) Mucinous (colloid) carcinoma  
(E) Small cell carcinoma
13. A 7-year-old boy presents to the doctor with a non-tender scrotal mass. His vitals are normal and stable and he has no other complaints. His mother reports that he has been behaving more aggressively at home and has gotten into two fights at school over the past month. Physical examination reveals a firm 2.5-cm mass within the right testicle. There are no epididymal masses bilaterally, although both testicles appear to be enlarged. He also has axillary hair. Laboratory analysis reveals a normal urinalysis. What is the most likely etiology of the testicular mass?
- (A) Leydig cell tumor  
(B) Sertoli cell tumor  
(C) Seminoma  
(D) Teratoma  
(E) Juvenile granulosa cell tumor
14. A male infant presents with a mass in his scrotum that has been present since birth. His mother states that the mass changes in size when the infant cries and does not seem to be painful. On exam, the mass appears to be adjacent to his testicle which is palpated posteriorly. The mass is soft and non-tender and transilluminates. There is no bulge or mass at the internal ring. What is the most appropriate next step in the management?
- (A) Surgical management  
(B) Medical management

- (C) Ultrasound  
(D) Needle aspiration  
(E) Reassurance
15. A 50-year-old man arrives to the ED with severe acute colicky flank pain and hematuria. The patient has a long-standing history of gout. Which of the following is true regarding the type of kidney stone the patient likely has?
- (A) Most are radiopaque  
(B) They are often seen in patients with hyperparathyroidism  
(C) Shock wave lithotripsy is not helpful  
(D) Sodium bicarbonate administration is beneficial  
(E) Suppressive antibiotics are helpful in prevention
16. A 20-year-old male presents with a right testicular mass. He noticed the mass after getting kneed in the groin during a basketball game 3 weeks earlier. He states that the mass is not tender. He denies any other symptoms. On physical examination, there is a firm 2-cm mass within the right testicle that is not tender. Ultrasound confirms a 2-cm homogeneous mass within the right testicle. CT scan of the abdomen and pelvis is negative. CXR is negative. Which of the following is the most appropriate next step in management?
- (A) Radical inguinal orchiectomy  
(B) Scrotal orchiectomy  
(C) Fine needle aspiration  
(D) Open testicular biopsy  
(E) Percutaneous biopsy

## Answers

### 1. Answer A

The presentation is consistent with nephrolithiasis. Initial management should focus on IV fluid hydration and analgesia. Recommended imaging includes a KUB (a supine X-ray of the abdomen) and a non-contrast CT of the abdomen and pelvis. The use of contrast (B) may interfere with visualization of the stone. An upright abdominal X-ray (C) is used to look for air-fluid levels in association with a small bowel obstruction or free air under the diaphragm. Such a film cuts off the pelvis and as such will miss many ureteral stones. IVP (D) has largely been replaced by CT. Renal ultrasound (E) may be used in pregnant patients but may miss stones; it is also used to look for hydronephrosis as an adjunct to KUB (if a CT scan is not obtained).

### 2. Answer C

Injuries to the genitourinary tract are commonly seen following blunt trauma. Bladder injuries typically occur when the bladder is full (such as following a drinking binge). Injuries to the bladder are divided into intraperitoneal and extraperitoneal. Intraperitoneal injuries will demonstrate a large amount of intraperitoneal free fluid (and contrast) on CT scan. Although the free fluid might initially be thought of as being blood, the absence of liver or spleen injury raises suspicion that the fluid is urine. Intraperitoneal injuries require laparotomy and repair. The bladder dome is the only region covered by the peritoneum and is considered the weakest portion; thus, it is prone to rupture. However, the most common overall location of bladder rupture is at the base of the bladder (B), which is located in the retroperitoneum. Retroperitoneal bladder injuries are most often associated with pelvic fractures and can be managed nonoperatively. The ureter (A) and renal hilum (D) are also located in the retroperitoneum. Urethral injury (E) is associated with blood at the urethral meatus and would not be expected to cause free fluid in the peritoneum.

### 3. Answer D

Varicocele is often an asymptomatic condition, but patients may complain of a vague discomfort and/or pain in the scrotum. The affected side will have a mass that feels similar to a “bag of worms” and will disappear upon lying down and reappear when the patient stands up. Varicoceles develop as a result of tortuous dilation of the pampiniform plexus of the veins surrounding the spermatic cord and testis. About 80 % occur on the left side (A). Since it is a venous drainage problem, varicoceles increase in size with Valsalva. Unlike a hydrocele that transilluminates (as it contains clear fluid), a varicocele does not (C). A testicle that is high in the scrotum (B) would raise concern for testicular torsion (if associated with sudden pain) or a partially undescended testicle. An absent cremasteric reflex (E) is seen with testicular torsion.

### 4. Answer D

The history of sudden penile pain following trauma combined with the physical examination is consistent with a penile fracture, which requires urgent surgical repair. It is due to a tear in the tunica albuginea with subsequent rupture of one or both of the corpus cavernosum. Failure to recognize and surgically manage the injury often results in permanent erectile dysfunction. Men are often embarrassed to describe the true nature of the injury so they fabricate stories that don't fit the clinical picture. Penile fractures most often occur during vigorous sexual activity. Most patients describe a “snapping” sound preceding the fracture. A hematoma rapidly develops within the corpus cavernosum and presents as a blue discoloration at the base of the penis, which is deviated at the fracture site. Prior to surgical exploration, a urethral injury should be ruled out with a retrograde urethrogram. CT scan (A) and cystoscopy (B) play no role in the evaluation of penile fractures. Analgesics and best rest (C) are not acceptable options for a patient suspected of having a penile fracture. Temporary suprapubic catheter (E) would not help address the underlying problem.

### 5. Answer A

Ureteral obstruction in association with sepsis requires emergent urinary decompression. This is most expeditiously achieved via a percutaneous nephrostomy tube. Shock wave lithotripsy (C) is unlikely to relieve the obstruction caused by a stone of this size. Open nephrostomy (B) is rarely indicated. Close monitoring in the ICU (E) as the sole management plan would be inappropriate for a patient with sepsis secondary to a blocked ureter. Hydration, analgesics, and bed rest would be appropriate for an uncomplicated and small renal stone without accompanying hydronephrosis. A ureteral stent (D) is an option; however, it is a more time-consuming procedure that will not be as expeditious in a septic patient compared to a percutaneous nephrostomy.

### 6. Answer D

The testes receive blood from three (A) sources: a testicular artery that arises directly from the aorta, from the cremaster artery which is a branch of the inferior epigastric artery, and from the deferential artery, or the artery to the ductus deferens which is a branch of the superior vesical artery. As such, the testicular artery can be divided in most patients without testicular ischemia developing. In fact, the testicular artery is sometimes intentionally divided in the setting of an undescended testicle, when the testicle is very high in the retroperitoneum and additional length is needed to bring it into the scrotum. The most common cause of testicular ischemia after inguinal hernia repair is injury to the pampiniform plexus which causes severe testicular congestion and subsequent ischemia (B). A blood-testis barrier exists, presumably to prevent sperm (which are formed during adolescence)

from coming in contact with the blood. In the setting of testicular necrosis, antisperm antibodies can form and adversely affect future fertility (C). Lymphatic drainage from the testicle is to periaortic nodes (E). This needs to be recognized in the metastatic work-up of testicular cancer.

### 7. Answer C

A scrotal mass that feels like a “bag of worms” is the classic description for a varicocele, which essentially represents dilated veins in the pampiniform plexus. Sudden onset of a right-sided varicocele should raise suspicion for a renal cell carcinoma that has occluded the inferior vena cava (IVC). The vast majority (80 %) of varicoceles are left sided due to the higher likelihood of impaired drainage of the left testicular vein (it enters the left renal vein at a right angle). Drainage of the right testicular vein is better as it enters at a less acute angle and directly into the inferior vena cava (IVC). Thus sudden onset of a right-sided varicocele raises suspicion that the IVC is obstructed. The best initial test is to perform a CT scan of the abdomen to look for a renal or other retroperitoneal mass. There is no known effective medical management for varicoceles, so that scrotal support and NSAIDs (A) would not be recommended. Varicoceles are associated with infertility (due to low sperm count and decreased motility). Surgical intervention (B) is considered for such an indication. Reassurance and observation (D) would not be appropriate as further work-up is indicated. Since a varicocele is a nest of dilated veins, attempts to biopsy would be contraindicated (E).

### 8. Answer D

The history and physical are classic for testicular torsion, including the age (adolescent), sudden onset of pain, testicular swelling, superior displacement of the testicle, and an absent cremasteric reflex. Constitutional symptoms (nausea and vomiting) are also common. Testicular torsion represents an emergency, as time is of essence. If a testicular torsion is reduced within 6 h of onset, there is a very high testicular salvage rate (>90 %), whereas with delays in management beyond 24 h, the testicular salvage rate plummets to <10 %. If the diagnosis is in doubt, color duplex scan (ultrasound with Doppler) (B) is recommended to look for the absence of blood flow in the affected testicle, but would be inappropriate in a patient with a clear-cut presentation as it would delay management. Ultrasound (A) is not helpful as it does not provide blood flow information. Treatment is surgical, via orchiopexy. Since the contralateral testicle is at risk, bilateral orchiopexy is recommended (C). Scrotal support and NSAIDs (E) would be inappropriate.

### 9. Answer C

Patients with Crohn’s disease that present with flank pain and hematuria should raise suspicion for nephrolithiasis secondary to hyperoxaluria. Her laparotomy scar suggests that she

had an ileocolic resection, which would predispose her to fat malabsorption as the terminal ileum is the principal site for fat absorption. In healthy patients, calcium binds to oxalate to prevent its absorption from the GI tract. In patients with increased amounts of fat in the GI lumen (e.g., Crohn’s status-post ileocolic resection), the calcium preferentially binds to fat leaving the unbound oxalate available for reabsorption and, thus, increases the risk of developing calcium oxalate renal stones. Hypercalciuria (B) would have been the most likely etiology had she not had Crohn’s. Protease producing bacteria (D) are associated with struvite stones and recurrent urinary tract infections. Gallstones (A) do not cause flank pain or hematuria, and mesalamine (E) is not a known risk factor for the development of renal stones.

### 10. Answer A

This patient’s history and ultrasound findings are suggestive of Henoch-Schönlein purpura (HSP). This classically develops after an URI or drug exposure (e.g., vancomycin) in young children. HSP is typically characterized by nonthrombocytopenic purpura, arthralgia, abdominal pain, intussusception, and, less frequently, scrotal pain. Rarely, scrotal pain may be the only manifestation of HSP. The sonographic findings of an enlarged, rounded epididymis are sufficiently characteristic to allow distinction from torsion in most cases. HSP patients may also develop thickened scrotal skin. Recent weight loss, night sweats, and fevers (B) can represent the constitutional symptoms seen in patients with testicular cancer. However, these patients present with a painless testicular mass. A young boy with no history of sexual activity would not be expected to have epididymitis (C) or a urethral tract infection with painful urination (E). Sores in the mouth and swelling of the eyes (D) are seen in patients with Behcet’s syndrome, a form of vasculitis. Patients with Behcet’s can also develop scrotal pain secondary to open sores. However, Behcet’s is very rare in the United States and more commonly seen in the Middle East and Asia.

### 11. Answer E

Infants born with cryptorchidism have an increased risk of developing testicular cancer later in life. An undescended testicle may be palpable high up in the inguinal canal, or nonpalpable, in which case it may be in the retroperitoneum or absent. Orchiopexy is a procedure to move an undescended testicle into the scrotum and anchor it to the scrotal wall. Orchiopexy has several theoretical benefits. It may improve fertility. An undescended testicle is thought to increase risk of infertility, as the warmer environment of the retroperitoneum or the inguinal canal leads to impairment of germ cell maturation. Undescended testicles are at higher risk of torsion. Orchiopexy prevents such a catastrophic event. Orchiopexy permits regular physical examination so as to detect any potential malignancies later in life. However, the act of lowering the testicle does not lower its future risk

of developing a malignancy (thus answers A–D are incorrect). The higher the testicle is found away from the scrotum, the higher the likelihood of developing testicular cancer later in life. Although the precise time to perform orchiopexy is not well established, most clinicians elect to do it shortly after the patient's first year of life so as to reduce the risk of infertility. Hormonal therapy (C) with intramuscular beta-hCG injection is sometimes used in an attempt to induce testicular descent; however, it is successful in only a minority of patients.

### 12. Answer B

The most common type of bladder cancer in the United States is urothelial carcinoma (transitional cell carcinoma) (A) and is well known to be associated with environmental carcinogens such as smoking and polycyclic aromatic hydrocarbons. However, in parts of the world that are endemic for schistosomiasis, such as Sudan, Egypt, and Tanzania, the most common variant is squamous cell carcinoma. The chronic granulomatous cystitis secondary to the parasite can result in squamous metaplasia and subsequent development of squamous cell carcinoma. Adenocarcinoma of the bladder (C) is rare in the developed world. Mucinoid carcinoma (D) is a subtype of adenocarcinoma and is characterized by abundant extracellular mucin. Small cell carcinoma (E) is often considered a subtype of urothelial carcinoma that is accompanied by small cell differentiation.

### 13. Answer A

Leydig cell tumors are benign sex cord-stromal tumors that are associated with high levels of androgen production that may result in precocious puberty in young boys. These children can behave more aggressively and develop early secondary sexual characteristic changes such as enlarged testicles, scrotum, and/or penis, and accelerated linear growth. Characteristic rod-shaped Reinke crystals may be seen on histology for Leydig cell tumors. Scrotal ultrasound would be the next diagnostic step as this can help visualize the mass in question and is also important to help evaluate the contralateral testicle. Ultrasound might also help distinguish between benign lesions, which are more often hyperechoic, and solid lesions that are more likely to be malignant and appear hypoechoic. Sertoli cell tumors (B) are benign and often clinically silent. Seminoma, a germ cell tumor, is the most common type and is considered malignant (C). Teratomas (D) can be benign or malignant, are derived from  $\geq 2$  embryonic layers, and are associated with AFP or hCG production. Granulosa cell tumor (E) is far more common in females and thus is associated most frequently with ovarian cancer.

### 14. Answer E

A hydrocele is a fluid collection within the processus and/or tunica vaginalis of the scrotum. Communicating hydroceles

develop as a result of failure of the processus vaginalis to close during embryologic development, allowing for peritoneal fluid to enter the scrotum. Noncommunicating hydroceles have no connection to the peritoneum, and fluid accumulation develops from the mesothelial lining of the tunica vaginalis. The majority of infants born with hydroceles will have spontaneous resolution by the time they are 1 year old; thus reassurance and observation are the most appropriate forms of management. Surgical repair (A) is not typically done unless the hydrocele is persistent past the first year of life. There are no available medical therapies (B) for managing hydroceles. There is no indication for ultrasound (C) with this classic presentation. Hydroceles are sometimes confused with hernias; however, ultrasound is neither sensitive nor specific for distinguishing the two. Ultrasound would be more suitable for ruling out malignancy in a young adult with a testicular mass. There is no role for needle aspiration (D).

### 15. Answer D

The most likely diagnosis in a patient with a past medical history significant for gout presenting with acute colicky pain and hematuria is nephrolithiasis secondary to uric acid renal stones. Unlike other types of renal stones, this type is radiolucent (A) and will not show up on X-ray. Patients with gout are at increased risk for developing uric acid stones. Sodium bicarbonate will alkalinize the urine to achieve a urinary pH of 6–6.5, as this would provide optimal conditions for dissolution of uric acid stones. Patients with hyperparathyroidism are more prone to developing calcium oxalate renal stones (B). Suppressing antibiotics (E) should be considered in the case of struvite stones secondary to recurrent urinary tract infections. Shock wave lithotripsy (C) may be added as an adjunct to urine alkalinization to further improve the stone-free rate.

### 16. Answer A

The demonstration on ultrasound of a solid mass (e.g., homogeneous) within the testicle makes the likelihood of cancer very high. Any painless mass within the testicle is cancer until proven otherwise. Most patients with testicular cancer present without symptoms and most are young adults (average age between 20 and 35 years). Trauma to the scrotum or groin may prompt men to examine their testes leading to the discovery of an otherwise painless mass. In patients with a testicular mass that is highly suspicious for malignancy (based on physical exam and ultrasound), radical inguinal orchiectomy is performed. Orchiectomy via a trans-scrotal incision (B) is associated with a higher rate of local recurrence. The inguinal incision also allows a longer portion of the spermatic cord to be removed. There is no role for biopsy (C–E) as there is a high risk of seeding or spreading the cancer with biopsy.



## Vascular

**Christian de Virgilio, Areg Grigorian, and Paul N. Frank**

### Questions

- A 67-year-old male smoker with a known abdominal aortic aneurysm (AAA) comes to the ED with the acute onset of flank pain. On physical exam, his blood pressure is 71/49 mmHg, pulse is 121/min, temperature is 98.9 °F, and respirations are 22/min. His abdominal exam reveals distention, a pulsatile abdominal mass, and diffuse tenderness without rebound. What is the most appropriate next step in management?

  - CT scan of the abdomen
  - Exploratory laparotomy
  - Transfusion of packed RBCs
  - Abdominal ultrasound
  - Diagnostic peritoneal lavage
- A 56-year-old man is seen in the ED for onset of severe pain and numbness in his left leg that began 30 min ago. He has a past medical history significant for hypertension, diabetes, and hyperlipidemia. Physical exam reveals a temperature of 98.3 °F, blood pressure of 134/74 mmHg, pulse of 89/min, and respiratory rate of 16/min. Heart is irregularly irregular with no murmurs appreciated. On extremity exam, there is absent pulses in the left femoral, popliteal, and pedal arteries. On the right, all pulses are 2+. The left foot is cool to touch as compared to the right. Sensation to pinprick is decreased on the left dorsum of the foot compared to the right. What is the most likely etiology of these findings?

  - Arterial thrombosis
  - Peripheral neuropathy
  - Arterial embolism
  - Cerebrovascular accident
  - Venous thrombosis
- A 68-year-old male with a 50-pack-year history of smoking presents with 2 h of left arm weakness. Physical exam shows 1+ strength in the left upper extremity and 3+ strength in the proximal left lower extremity. Which of the following is the next step?

  - Doppler ultrasound of the right carotid artery
  - Echocardiogram
  - Non-contrast CT brain
  - ECG
  - CT angiogram of the neck
- A 59-year-old male comes to see his primary care physician endorsing a 10-month history of increasing bilateral calf pain with exercise. He initially only felt discomfort after walking six blocks but now it occurs after only one block. The pain disappears with rest. His past medical history is significant for hypertension and hypercholesterolemia, for which he takes lisinopril and a statin. He has smoked two packs per day for the past 40 years. His physician orders a complete work-up and decides the patient most likely is suffering from claudication secondary to peripheral arterial disease (PAD). Which of the following findings would be the best way to support the diagnosis of PAD?

  - History of pain in legs with exertion
  - Diminished peripheral pulses on physical examination
  - A combination of history and physical examination
  - An ankle-brachial index <0.9
  - Arteriographic evidence of atherosclerotic plaques
- A 65-year-old male comes to the physician for a routine physical exam. He has a past medical history significant for hypertension and hyperlipidemia. He is on hydrochlorothiazide, aspirin, and a statin. He has a 10-pack-year smoking history but quit over 30 years ago. Which of the following screening tests is appropriate for this male?

  - CT scan of the abdomen
  - Duplex scan of the carotid arteries
  - Abdominal ultrasonography
  - Pulmonary spirometry
  - Ankle-brachial index (ABI)
- A 52-year-old male is seen at the ED for the acute onset of swelling in his right leg that began 6 h ago. He has a past medical history significant for hypertension and colon cancer being treated with chemotherapy in the outpatient setting. Physical exam reveals a temperature of 99.1 °F, blood pressure of 125/72 mmHg, pulse of 77/min, and respiratory rate of 16/min. On extremity exam, there are 2+ posterior tibialis and dorsalis pedis pulses bilaterally. The right leg is edematous, warm, and markedly more swollen than the left leg. What is the best initial study in the work-up?

  - Ankle-brachial index (ABI)
  - Venous duplex scan
  - CT angiogram of lower extremities
  - CT of the head
  - Measurement of compartment pressures
- Which of the following patients should undergo carotid endarterectomy (CEA)?

  - 70-year-old male with a history of transient painless right eye vision loss and 75 % stenosis of the right internal carotid artery (ICA)

- (B) 70-year-old male with a history of transient painless right eye loss and 100 % occlusion of the right ICA
- (C) 65-year-old female who sustained a stroke 1 week ago, is aphasic, has no motor function in her right arm or leg, and has 80 % left ICA stenosis
- (D) 68-year-old male who, 4 days ago, became acutely dizzy and passed out with 60 % right ICA
- (E) 72-year-old male with an irregularly irregular rhythm who presents with left-sided weakness for the last several hours and has a 40 % right ICA stenosis
8. A 70-year-old male presents with right calf pain after walking three blocks, forcing him to stop and rest. He denies pain at rest in his foot. He smokes one pack per day. His pulse is 74/min, respiratory rate is 16/min, and blood pressure is 136/86 mmHg. Physical examination reveals diminished pulses in his right foot. The ankle-brachial index on the right leg is 0.7. The next step in the management is:
- (A) Smoking cessation
- (B) CT angiogram
- (C) MR angiogram
- (D) Formal angiogram
- (E) Stenting of iliac artery
9. A 55-year-old male comes to the physician complaining of bilateral leg pain with walking that is relieved by rest. He has a history of hypertension, hyperlipidemia, chronic obstructive pulmonary disease, and a 30-pack-year smoking history. On physical exam, his blood pressure is 139/79 mmHg, temperature is 99.3 °F, pulse is 89/min, and respirations are 16/min. Present behind both knees are small pulsatile masses. What is most strongly associated with this finding?
- (A) Aortic dissection
- (B) Hypercoagulable state
- (C) Degenerative joint disease (DJD)
- (D) Abdominal aortic aneurysm (AAA)
- (E) Thoracic aortic aneurysm
10. A 62-year-old man presents to the physician with swelling in both legs that has been going on for several months. He has a past medical history significant for hypertension and hyperlipidemia. He states that the swelling becomes progressively worse throughout the day. He denies any pain associated with the swelling. Physical exam reveals a temperature of 99.1 °F, blood pressure of 125/72 mmHg, pulse of 77/min, and respiratory rate of 16/min. Heart is in regular rate and rhythm with no murmurs. JVP is 7 cm. The lungs are clear to auscultation. On extremity exam, there are strong posterior tibialis and dorsalis pedis pulses bilaterally. The legs are edematous up to the knee with a small patch of eczematous, erythematous-brown scaling skin rash located on the medial malleolus of the right ankle. Which of the following is the most likely cause of his edema?
- (A) Peripheral artery disease
- (B) Deep venous thrombosis
- (C) Renal protein loss
- (D) Reduced cardiac output
- (E) Valve incompetence
11. At a follow-up appointment 2 weeks after undergoing left carotid endarterectomy (CEA), it is observed that the patient's tongue deviates to the left when he is asked to stick his tongue out. Which of the following is the most likely explanation?
- (A) Perioperative stroke of the medulla
- (B) Hematoma compressing the musculature of the oropharynx
- (C) Injury to cranial nerve VII
- (D) Injury of cranial nerve X
- (E) Injury of cranial nerve XII
12. A 61-year-old man comes to the physician with an 8-month history of increasing bilateral calf pain during his morning walks. The pain disappears with rest. He reports that the last time he saw a doctor was 20 years ago. He has a 30 pack year smoking history, but recently quit. His pulse is 68/min, respirations are 18/min, and blood pressure is 126/76 mmHg. His total cholesterol is 320 mg/dL. His doctor recommends that the patient starts a statin and aspirin to reduce the risk of adverse cardiac events. In addition, he recommends that the patient begins an exercise walking program. What would the addition of this intervention provide for the patient?
- (A) It will improve his overall cardiac health but will not improve his walking distance
- (B) It would be expected to result in an increase in his ankle-brachial index
- (C) It is less effective than administering a vasodilator
- (D) It can result in a doubling of his walking distance
- (E) It is contraindicated
13. A 75-year-old male is recovering in the ICU from an open repair of a ruptured abdominal aortic aneurysm. On post-op day 1, he complains of abdominal pain and tenderness over the left lower quadrant, without rebound or guarding. On post-op day 2, he develops bloody diarrhea. Physical exam reveals a blood pressure of 129/79 mmHg, pulse of 100/min, temperature of 99.9 °F, and respirations of 16/min. What is the most likely etiology of his abdominal pain and bloody diarrhea?

- (A) Colonic ischemia  
 (B) *Clostridium difficile* colitis  
 (C) Diverticulitis  
 (D) Inflammatory bowel disease  
 (E) Colon cancer
14. A 44-year-old female is brought to the ED after a vehicle sideswiped her while she was on her motorcycle. She is complaining of right leg and knee pain. Initial survey reveals stable airway, breathing, and circulation. On exam, her heart has regular rate and rhythm; lungs are clear. No abdominal tenderness or rebound. There is 0/5 motor strength in dorsiflexion of the foot and decreased sensation to pinprick at the dorsum of the foot. The extremity is warm and well perfused, and dorsalis pedis, posterior tibialis, and popliteal pulses are 2+ bilaterally. What is the most likely etiology of her neurologic deficits?
- (A) Common peroneal nerve injury  
 (B) Compartment syndrome  
 (C) Arterial thrombosis  
 (D) Deep peroneal nerve injury  
 (E) Pain from the fracture
15. A 74-year-old male presents to the ED with loss of vision in his right eye. Which of the following findings is most suggestive of a nonsurgical diagnosis?
- (A) Bruit on auscultation of the right carotid artery  
 (B) Jaw pain with chewing  
 (C) Eighty percent stenosis of the right carotid artery on CT angiogram  
 (D) Left hand weakness  
 (E) Atrial mass on echocardiogram
16. In a patient with claudication, the 5-year risk of limb loss is about:
- (A) 2–5 %  
 (B) 8–10 %  
 (C) 20–25 %  
 (D) 40–50 %  
 (E) 70–80 %
17. A 69-year-old immigrant from Mexico comes into the hospital with a 2-day history of severe pain in his left calf. He took Vicodin that a neighbor gave him with only minimal relief. Over the last day, he has lost sensation and movement in his left foot, which prompted him to finally come to the hospital. He has had no medical care and has no past medical history. Physical exam reveals a temperature of 98.5 °F, blood pressure of 147/79 mmHg, heart rate of 85/min, and respiratory rate of 16/min. On extremity exam, there are absent popliteal, posterior tibialis, and dorsalis pedis pulses on the left. Sensation to pinprick is absent in the left, and he cannot plantar- or dorsiflex his foot. The skin of the foot appears to be mottled. Doppler of the foot vessels reveals no audible signals. What is the definitive treatment?
- (A) Catheter-assisted thrombolysis  
 (B) Open surgical intervention  
 (C) Amputation  
 (D) Aspirin  
 (E) Intravenous heparin
18. A 71-year-old man comes in to the physician, along with his wife, and reports a 4-month history of increasing left calf pain with exercise. He works as a grocery store manager and describes having the pain every morning after he walks from his car in the parking lot to the grocery store. The pain disappears once he is able to sit down. He has smoked one pack per day for the past 50 years. His pulse is 88/min, respirations are 18/min, and blood pressure is 156/96 mmHg. His total cholesterol is 300 mg/dL. His right ABI is 0.7. His wife is very worried and asks the physician what his prognosis is. In patients with this condition, the 5-year survival is:
- (A) The same as that of age- and gender-matched controls without claudication  
 (B) Reduced primarily due to the risk of limb gangrene  
 (C) Reduced primarily due to lung cancer  
 (D) Reduced primarily due to coronary artery disease  
 (E) Reduced primarily due to stroke
19. A 61-year-old patient with coronary artery disease, diabetes, and hypertension presents to the ED with difficulty speaking and right-sided hemiparesis. His wife reports that he had multiple episodes a few days ago where he had difficulty speaking but they only lasted a few minutes. A CT scan of the head without contrast did not identify any hemorrhage in the brain. His systolic blood pressure is found to be 230 mmHg. What is the most appropriate next step in management?
- (A) Labetalol  
 (B) Nimodipine  
 (C) Nitroglycerin  
 (D) Nitroprusside  
 (E) Hydralazine
20. A 62-year-old male presents to the physician with pain in his buttocks that comes on during his evening walks with his wife, forcing him to stop and rest. He also confides in you that he has been having difficulty maintaining an erection leading to marital problems. Physical exam is significant for absent femoral and distal pulses. What is the most likely diagnosis?

- (A) Leriche syndrome  
(B) Acute occlusion of the infrarenal aorta  
(C) Extensive atherosclerosis of the superficial femoral artery  
(D) Spinal stenosis  
(E) Bilateral hip osteoarthritis
21. A 65-year-old male presents with new onset claudication. An ABI confirms that he has peripheral arterial disease (PAD). Which of the following would provide the *least* amount of benefit to the patient?
- (A) Warfarin  
(B) Aspirin  
(C) Statin  
(D) Cilostazol  
(E) Clopidogrel
22. A 30-year-old male presents with a 4-month history of a painful right great toe. In addition, he states that when he walks about two blocks, his right foot hurts and he has to stop to rest. He has a 20 pack year smoking history. His pulse is 74/min, respirations are 18/min, and blood pressure is 126/80 mmHg. His total cholesterol is 160 mg/dl. His serum calcium is 9.4 mg/dL, and on physical examination, he has normal femoral and popliteal pulses bilaterally, but no palpable dorsalis pedis or posterior tibial pulses in either foot. The big toe is slightly bluish and tender to palpation. Which of the following is true about this condition?
- (A) It responds well to stenting  
(B) A bypass will be curative  
(C) Smoking cessation is the cornerstone of management  
(D) It is unlikely to be due to arterial occlusion  
(E) It most likely represents early atherosclerosis
23. A 65-year-old male carpenter states that his left arm gets tired when he uses it at work, forcing him to stop and rest. In addition, he notes that when using his left arm, he experiences dizziness and vertigo. He has a long-standing history of smoking. Physical examination reveals normal brachial and radial pulses on the right but markedly decreased brachial and radial pulses on the left. In addition, there is an audible bruit just above his left clavicle. Which of the following is true about this condition?
- (A) The dizziness and vertigo are due to blood being diverted from the anterior brain circulation  
(B) Stenting of the left subclavian artery may be helpful  
(C) Systolic blood pressure measurements in right and left arms are likely to be the same  
(D) It is most likely due to an inflammatory arteritis  
(E) It more commonly affects the right arm
24. A 63-year-old male comes to the physician's office for a nonhealing ulcer on his right great toe and intermittent calf pain. His calf pain is brought on by walking for 10 minutes and relieved by rest. He wakes up at night with pain in his great toe and has to get up to relieve it. He has a past medical history significant for hypertension, hyperlipidemia, and diabetes. He has a 30-pack-year smoking history. On physical exam, his temperature is 98.4 °F, pulse is 80/min, blood pressure is 139/82, and respirations are 16/min. His LDL is 70 mg/dL. Exam is significant for absent dorsalis pedis and popliteal pulses on the right. The ulcer appears dull gray without purulence. He has diminished sensation to light palpation in both feet. Ankle-brachial index is 0.3 on the right and 0.7 on the left. What is the most appropriate next step in management?
- (A) Diabetic shoe to offload pressure  
(B) Formal angiography of the lower extremities  
(C) Tight glucose control  
(D) Start oral antibiotics  
(E) Start heparin
25. A 68-year-old male comes to the physician's office for a nonhealing ulcer in his medial malleolus that has been present for several months. He has a past medical history significant for diabetes and hyperlipidemia. On physical exam, his temperature is 98.9 °F, pulse is 70/min, blood pressure is 133/79 mmHg, and respirations are 16/min. Physical exam is significant for pitting right leg edema up to the knee. The leg is warm, and the skin is shiny and has a reddish-brown appearance with several enlarged surface veins. The ulcer has granulation tissue without purulence. Dorsalis pedis pulses are 2+ bilaterally. Which of the following is most likely to assist in healing the ulcer?
- (A) A compressive dressing impregnated with zinc oxide  
(B) Diuretics  
(C) A custom-fitted diabetic shoe  
(D) Heparin  
(E) Oral antibiotics

## Answers

### 1. Answer B

This patient is presenting with a ruptured abdominal aortic aneurysm (AAA). Hemodynamically unstable patients presenting with classic symptoms and signs of aortic rupture such as hypotension, flank pain, and a pulsatile mass should be taken emergently to the operating room (OR) for immediate control of hemorrhage. Surgical intervention should not be delayed waiting for CT scan of the abdomen (A) or transfusion of packed red blood cells (C). In fact, permissive hypotension is preferable to aggressive fluid resuscitation prior to the OR, as excessive fluids prior to aortic control may lead to more bleeding. In patients with symptomatic non-ruptured or ruptured AAA who are hemodynamically stable, CT scan of the abdomen can be obtained to assess for feasibility of endovascular repair. For patients who are unstable and are not previously known to have AAA and who do not have a palpable pulsatile mass, ultrasound may be performed quickly prior to abdominal laparotomy, to confirm the presence of AAA, but cannot determine rupture (D). Diagnostic peritoneal lavage is not appropriate to rule out a ruptured AAA. The rupture occurs retroperitoneally, so that a DPL would likely be negative (E).

### 2. Answer C

This patient is presenting with acute limb ischemia (ALI) given the pain, pulselessness, and paresthesias (recall the “six Ps”). The etiology of ALI includes thrombus formation (most likely due to long-standing peripheral arterial disease in the legs), embolization (most often from the heart), and trauma. The patient is presenting with an irregularly irregular heart rate, suggesting atrial fibrillation, which is the most common source of arterial embolism. Arterial thrombosis (A) is another cause of ALI. Such patients often have a history of claudication and decreased pulses in the nonischemic leg. Peripheral neuropathy (B) is an important cause of numbness in diabetic patients and would cause decreased sensation in a stocking glove pattern starting on the dorsum of the foot, but would not account for the acute onset and absent pulses. Cerebral ischemia (D) would cause a hemiparesis on the contralateral side and would not cause decreased pulses. Venous thrombosis (E) or DVT would cause warmth, edema, and swelling in the affected leg.

### 3. Answer C

Patients who present with symptoms concerning for stroke should undergo a non-contrast CT scan of the brain to rule out intracranial hemorrhage. Once hemorrhage has been ruled out, consideration should be given for thrombolytic therapy for an ischemic stroke (intravenous if within 3 h of symptom onset, intra-arterial if within 6 h of onset). Doppler of the carotid artery (A), echocardiogram (B), ECG (D), or CT angiogram (E) may be performed to evaluate for the

cause of the stroke (carotid plaque vs. cardioembolic), but they are not part of the acute management of this patient.

### 4. Answer D

Peripheral arterial disease (PAD) is defined as an ankle-brachial index (ABI) < 0.9. The normal ABI ranges from 1 to 1.2. *Symptomatic* PAD can readily be diagnosed via history and physical examination (C), and in fact the classic history, combined with physical exam evidence of diminished pulses, is highly specific, but not sufficiently sensitive. Early PAD can be asymptomatic and is best detected by ABI. Arteriography (E) is invasive and is thus reserved for patients who are to undergo an interventional procedure (E). The pulse exam (B) is very subjective and cannot alone be relied upon to establish a diagnosis of PAD. History of pain in legs (A) with exertion is not specific to PAD.

### 5. Answer C

The United States Preventive Services Task Force (USPSTF) recommends a one-time screening for abdominal aortic aneurysm (AAA) by ultrasonography in men aged 65–75 that have any smoking history. There are no recommendations for women and men who have never smoked. CT of the abdomen (A) is not appropriate for AAA screening. Screening for carotid artery stenosis (B) is not recommended nor screening adults for chronic obstructive pulmonary disease using spirometry (D) or screening for peripheral artery disease with the ankle-brachial index (E).

### 6. Answer B

The most likely etiology is a deep vein thrombosis (DVT) given the swelling and history of colon cancer (hypercoagulability). The best diagnostic test is a venous duplex scan. An ABI (A) is appropriate for suspected peripheral arterial disease (PAD), however, that would not cause swelling. CTA (C) would be a useful follow-up study for PAD prior to a planned intervention. CT of the head (D) would be useful for a suspected stroke. Compartment pressure measurements (E) are sometimes used to rule out compartment syndrome when suspicion is low to moderate; however, it presents with pain with passive motion as well as the other “five Ps”: pain, pallor, paresthesias, paralysis, and poikilothermia. It classically presents after trauma or after ischemia reperfusion.

### 7. Answer A

The best indication for CEA is a symptomatic high (70–99 %)-grade ICA stenosis. Symptoms include ipsilateral arm/leg weakness or contralateral amaurosis fugax. Option A fits that description. Since strokes from ICA stenosis are characteristically embolic, once the artery completely occludes (B), there is no longer any embolic risk and thus no benefit from CEA. Patients who have had massive strokes and have no significant neurologic function to preserve (C)

should not undergo CEA (as the goal is to prevent further damage to the motor cortex). Dizziness and syncope (D) are not symptoms of ICA stenosis. The patient in answer E likely sustained a stroke secondary to his atrial fibrillation, as opposed to carotid artery embolism.

#### 8. Answer A

The patient has PAD, manifested by claudication, which is not immediately limb threatening. The diagnosis is confirmed by the ABI <0.9. Further testing is not necessary at this time to confirm the diagnosis. Additional imaging (B–D) should be reserved for patients in whom an intervention is being planned. Initial management of claudication includes smoking cessation, a walking program, and modification of risk factors (lipid-lowering agents, hypertension control). Stenting is a treatment option (after failed medical management), but one must first obtain imaging to properly plan a possible intervention.

#### 9. Answer D

The clinical scenario is consistent with a popliteal artery aneurysm. Popliteal artery aneurysms are the most common type of peripheral aneurysms. Risk factors for popliteal aneurysm include smoking, hypertension, male sex, and older age. Patients with a popliteal artery aneurysm have a high risk for aneurysm in the contralateral popliteal artery, femoral arteries, and abdominal aorta. Therefore, patients found to have a popliteal artery aneurysm should be screened with ultrasound for aneurysms at these locations. Hypercoagulable state (B) is associated with deep vein thrombosis. DJD (C) is associated with popliteal (Baker's) cysts. Popliteal aneurysms are not directly associated with thoracic aortic aneurysms (E) or aortic dissection (A).

#### 10. Answer E

Chronic venous insufficiency caused by valve incompetence is the most common cause of lower extremity edema. Edema secondary to valve incompetence is worse when the affected extremity is in the dependent position and improves with extremity elevation. Insufficient venous return causes blood to pool in dependent areas and results in increased capillary pressure causing fluid and red cells to leak out of the capillaries. The skin turns reddish brown due to hemosiderin deposition. Peripheral artery disease (A) causes atrophy of the affected muscles, decreased pulses, decreased hair growth, shiny skin, and claudication. Acute DVT (B) causes sudden onset of pain and swelling of the affected limb. Renal protein loss (C), most commonly caused by nephrotic syndrome, leads to decreased oncotic pressure. In the setting of decreased oncotic pressure, there is leakage of fluid into the interstitial space. Nephrotic syndromes would present with hypertension and widespread edema. Reduced cardiac output (D) would present with respiratory symptoms, crackles, and elevated JVP.

#### 11. Answer E

Cranial nerve deficits occur in about 8 % of patients after CEA. In 80–90 %, the deficit resolves within 6 months as the injury is due to nerve irritation from retraction and inflammation. In this case, the patient's tongue deviates to the left on protrusion, suggesting an injury to the left CN XII. Perioperative stroke of the medulla (A) would present with a larger constellation of symptoms. Hematoma (B) is a concern in the immediate postoperative period and would be more likely to compromise the airway than a specific cranial nerve. Injury to the marginal mandibular branch of CN VII (C) would cause a droop at the corner of the mouth. CN X (D) transection would lead to voice hoarseness.

#### 12. Answer D

The best medical management for sustained improvement in claudication is a walking program, which can double the walking distance (A). A supervised walking program, consisting of 40–50 min of walking 5 days per week is more effective than a non-supervised program. Contrary to common perception, a walking program does not appear to increase collateral blood flow nor does it reliably increase the ankle–brachial index (B). The exact mechanism by which it improves claudication is not known, but possible mechanisms include improvements in endothelial function, skeletal muscle metabolism, and blood viscosity and a reduction in systemic inflammation. In response to PAD, the distal arterial bed undergoes significant vasodilation. As such, administering pure vasodilators (C) are of no benefit.

#### 13. Answer A

This patient is presenting with bowel ischemia secondary to compromised blood flow during open surgical repair of the AAA. During aortic grafting, the inferior mesenteric artery is usually intentionally ligated, which rarely leads to inadequate colonic blood flow. The incidence of colonic ischemia is 7–27 % for open repair of ruptured AAA and 1–13 % for elective AAA repair. *C. difficile* colitis (B) presents with abdominal pain, fever, and watery diarrhea, typically following antibiotic use. Diverticulitis (C) presents with abdominal pain and fever but not bloody diarrhea. Inflammatory bowel disease (D) presents with bloody diarrhea, constipation, fecal incontinence, joint pain, and rash but is more chronic in nature. Colon cancer (E) presents as occult gastrointestinal bleeding, weight loss, and a change in bowel habits.

#### 14. Answer A

The most likely etiology of her neurologic deficits is transection of the common peroneal nerve at the fibular head. The most common presentation of peroneal nerve injury at the fibular neck is acute foot drop (difficulty dorsiflexing the foot against resistance or gravity) along with numbness of the dorsum of the foot. Compartment syndrome (B) presents

with the “five Ps”: pain (on passive motion), pallor, paresthesias, paralysis, and poikilothermia following trauma. However, this patient is warm and well perfused and is not complaining of any pain. Arterial thrombosis (C) can occur after trauma; however, the patient has normal distal pulses. Injury to the deep peroneal nerve (D) would cause numbness in the first web space. Pain at the fracture site (E) should not cause such a profound motor deficit nor would it cause a sensory deficit.

#### 15. Answer B

Jaw pain with chewing, or jaw claudication, is suggestive of giant cell arteritis, which is managed with steroids. The carotid bruit (A) is a common physical exam finding in patients with carotid stenosis. CT angiogram showing 80 % stenosis (C) confirms the diagnosis of carotid stenosis. Left hand weakness (D) may be found in patients who have had an middle cerebral artery stroke and may or may not be due to carotid emboli. An atrial mass on echocardiogram (E) may be an intracardiac tumor, such as atrial myxoma, that will need to be resected surgically.

#### 16. Answer A

Claudication alone, in the absence of ischemic rest pain or tissue loss, is a relatively benign condition that rarely leads to amputation. The risk of amputation is only about 2–5 %. Thus, medical management can safely be utilized as the first step in its management. Five-year mortality in claudicants, however, is significantly increased as compared to non-claudicants. This is predominantly due to an increased risk of myocardial infarction and to a lesser degree stroke.

#### 17. Answer C

The patient presents with irreversible acute limb ischemia. Muscle begins to become damaged after 3 h of ischemia, whereas irreversible ischemia sets in after 6 h. Exam findings that support irreversible ischemia include the 48-h duration of ischemia, profound sensory loss, paralysis of the muscles, mottling of the skin, and inaudible Doppler signals. When acute limb ischemia progresses to irreversible tissue damage, as in the case presented, primary amputation should be performed. Attempting to revascularize an irreversibly ischemic limb (besides not helping the limb) puts the patient at risk of developing reperfusion syndrome, which manifests with severe hyperkalemia, acidosis, and rhabdomyolysis that can lead to renal failure due to acute tubular necrosis.

#### 18. Answer D

Although claudication is associated with a very low 5-year risk of limb loss (2–5 %), it is associated with a significantly reduced 5-year survival (70 %) as compared to matched controls without claudication. This is primarily due to the associated coronary artery disease and risk of myocardial

infarction. Patients with claudication also have an increased risk of carotid stenosis and, as such, an increased risk of stroke, but stroke is not the primary cause of death in these patients.

#### 19. Answer A

This patient is suffering from an ischemic stroke. Permissive hypertension is considered beneficial following an ischemic stroke so as to maximize cerebral perfusion pressure (CPP). For ischemic strokes, do not use antihypertensive medications to lower blood pressure unless diastolic is greater than 120 mmHg or systolic is greater than 220 mmHg, to ensure proper cerebral perfusion. If it is due to a hemorrhage, keep systolic blood pressure less than 150 mmHg. In both cases, avoid nitroglycerin or nitroprusside (C, D), which can serve as potent vasodilators in the cerebral arteries and veins, increasing intracranial pressure (ICP). Recall that increasing ICP can further compromise CPP (CPP = mean arterial pressure – ICP). Labetalol can be used safely. In the case of hemorrhage, administer nimodipine (D) to avoid cerebral vasospasms related to irritants in blood. Hydralazine (E) is reserved for pregnant patients.

#### 20. Answer A

The triad of Leriche syndrome is (1) buttock and thigh claudication, (2) erectile dysfunction, and (3) absent femoral pulses. It is due to *chronic* (B) progressive atherosclerosis of the distal aorta and proximal common iliac arteries (not the superficial femoral artery) (C) that eventually occludes the aorta. Since the occlusion is gradual, collaterals have had a chance to enlarge and refill (reconstitute) the femoral arteries distally. Important collaterals come from the superior mesenteric artery, inferior mesenteric artery (superior hemorrhoidal), lumbar arteries, median sacral artery, and internal mammary (via epigastric arteries). Because the aorta and common iliac arteries are occluded, the blood supply to the buttocks (through the internal iliac arteries) is compromised, as is the blood supply to the penis (via the internal pudendal artery, a branch of the internal iliac artery). Thus the patients endorse buttock claudication, as well as erectile dysfunction. Because of the rich collateral supply around the distal aorta and the chronic nature of the occlusion, the ABI typically drops by only 30 % (to about 0.7). Thus toe gangrene is rare. Patients with diabetes typically develop atherosclerosis more distally in the leg, in the superficial femoral and tibial arteries (not in the aorta). Acute aortic occlusion is a devastating, severe acute ischemia of both lower legs, which manifests by rapid onset of motor and sensory loss. It is seen following a large embolus from atrial fibrillation lodging at the distal aorta. The sudden onset does not permit adequate collateral enlargement. Untreated, it results in limb loss, massive acidosis, and death. Spinal stenosis (D) compresses nerve roots, leading to generalized weakness of both legs that is worse

with walking. Unlike claudication, it is usually relieved by leaning forward (such as over a shopping cart).

### 21. Answer A

Warfarin is useful for the prevention of embolic events associated with atrial fibrillation and for the prevention of venous thrombotic events (such as deep venous thrombosis and pulmonary embolus). Since PAD is due to atherosclerosis and not due to embolus/thrombus, there is no evidence that warfarin benefits patients with PAD. Clopidogrel (E) inhibits platelet aggregation by blocking activation of the glycoprotein IIb/IIIa pathway. In patients with PAD, it has been shown to reduce the combined endpoint of stroke, myocardial infarction, and acute limb ischemia. Given its high costs, its routine use in PAD is not recommended. Cilostazol (D) is a quinolinone derivative that inhibits cellular phosphodiesterase. It inhibits platelet aggregation and is a direct arterial dilator. It inhibits vascular smooth muscle proliferation and improves the lipid profile. The exact mechanism by which it improves walking distance in patients with claudication is unclear. Aspirin (B) does not directly improve claudication but is effective in reducing the risks of stroke and acute coronary events, which are common in PAD patients. Statins (C) also does not directly improve walking distance but are beneficial in PAD patients via their lipid-lowering and anti-inflammatory (atherosclerotic plaque stabilizing) properties.

### 22. Answer C

Buerger's disease, also known as thromboangiitis obliterans, is a non-atherosclerotic vascular occlusive disease seen in young (<40), mostly male smokers. It predominantly involves the arteries in the leg below the knee (popliteal and tibial arteries). It also causes venous thrombosis. The cause is unknown. Stenting and surgical bypass (A–B) are ineffective as the occlusions involve the most distal arteries. The only effective treatment is smoking cessation. It is associated with high rates of amputation, especially if the patient continues smoking. The remaining answer choices (D–E) are not used in the management of Buerger's disease.

### 23. Answer B

Subclavian steal syndrome is due to an atherosclerotic stenosis or occlusion (D) of the subclavian artery, most commonly on the left side (E). This leads to claudication symptoms of the affected arm and can be detected on physical examination based on diminished pulses, a significant (>20 mmHg) difference in arm blood pressure (C), and often a bruit above the clavicle. In addition, as the patient exercises, the arteries in the affected arm dilate, lowering resistance, so as to receive more blood. Since the occluded subclavian artery

cannot increase blood flow, blood instead travels in a reverse fashion down the vertebral artery (the first branch off the subclavian) down to the arm, essentially stealing blood from the posterior circulation (A), leading to simultaneous symptoms of dizziness and vertigo.

### 24. Answer B

This patient has ischemic rest pain and a nonhealing ulcer, both of which are manifestations of critical peripheral artery disease (PAD) that are considered limb threatening. The patient will likely progress to an amputation unless blood flow is improved. As such, the next step is to obtain arterial imaging of the lower extremities. This can be done by either CT angiography, MR angiography, or formal transfemoral arteriography in anticipation of either balloon angioplasty, stenting, or an arterial bypass. Tight glucose control (C) will not help in achieving healing of an ischemic ulcer. Diabetic shoes are useful for ulcers that form over bony prominences in the setting of neuropathy. Although the patient has evidence of neuropathy, the location of the ulcer (distal toe), its appearance (lack of granulation tissue), absent pulse, and low ABI indicate that the ulcer is from arterial insufficiency. Oral antibiotics (D) are not indicated as there is no evidence of infection. Heparin (E) is helpful for acute limb ischemia but not for chronic PAD.

### 25. Answer A

The patient presents with a classic case of a venous stasis ulcer. These ulcers develop as a result of chronic venous insufficiency, due to vein valve incompetence. Such incompetence can be inherited or be the result of a prior DVT that scars and damages valves, rendering them incompetent. The ensuing venous hypertension results in increased capillary pressure causing fluid and red and white blood cells to leak out of the capillaries. When the red cells break and lyse, they release the iron-containing hemosiderin and lead to the classic reddish-brown discoloration seen in stasis dermatitis. The pooling of blood leads to capillary damage and activation of an inflammatory process. The exact cause of ulceration in venous stasis is unclear, but is likely a combination of leukocyte activation, endothelial damage, and intracellular edema. The cornerstone of treatment of venous stasis ulcers is compression therapy (A). The Unna boot is a compressive gauze that contains zinc oxide and calamine to promote wound healing. Diuretics (B) do not benefit venous insufficiency. Diabetic shoes (C) would be appropriate for a neuropathic ulcer, which would typically be located over a bony prominence. Heparin (D) would be indicated for a DVT but not for chronic venous stasis. Venous stasis ulcers can become infected and require antibiotics (E), however, their routine use is not recommended.



---

# Index

- A**
- Abdomen, acute  
diffuse peritonitis, 498  
physical exam, 496
- Abdominal aortic aneurysm (AAA)  
and aortic dissection, 574  
and EVAR (*see* Endovascular aneurysm repair (EVAR))  
average annual growth rate, 573  
blood pressure, 574  
COPD, 572  
CT scan, 578  
diabetes, 572  
diagnosis, 571–572  
diarrhea, 578  
endovascular approach, 575, 576  
female gender, 574  
femoral and popliteal artery aneurysms, 573  
fluid resuscitation, 575  
genetic component, 574  
GI bleeding/melena, 578  
hemodynamically unstable patient, 575  
infrarenal aorta, 573  
management, 576–577  
medial layer, 573  
MMPs, 574  
myocardial infarction, 577  
physical examination, 572  
ruptures, 574, 577  
screening, 572–573  
size, 574  
smoking, 572  
suspected ruptured, 575, 576  
unruptured, 572
- Abdominal compartment syndrome (ACS), 431, 432  
clinical manifestations, 476, 477  
risk factors, 476  
treatment, 477
- Abdominal pain  
AAA (*see* Abdominal aortic aneurysm (AAA))  
chronic constipation (*see* Constipation)  
left-sided abdominal pain, 571–579  
nausea and vomiting  
diagnosis, 15–16, 21  
history and physical exam, 16, 21  
management, 20–21  
pathophysiology, 21  
SBO (*see* Small bowel obstruction (SBO))  
pain, motor vehicle accident (*see* Motor vehicle accident and abdominal pain)  
penetrating trauma (*see* Penetrating abdominal trauma)  
RLQ (*see* RLQ abdominal pain)
- Abdominal ultrasound, 572, 575, 579
- Abdominal wall defect  
bowel protection, 353  
compartment syndrome, 354  
concurrent malrotation, 351  
gastroschisis, 350  
intubation, 353  
omphalocele, 350  
parenteral nutrition, 353  
postpartum stabilization, 352  
prenatal ultrasound, 349, 350  
sclerosing agent, 354  
visceral blood flow, 350
- ACS. *See* Abdominal compartment syndrome (ACS)
- Acute coronary syndrome, 49
- Acute kidney injury (AKI)  
acute tubular necrosis, 397  
causes, 396  
differences, oliguria and anuria, 396  
differential diagnosis, 395  
filtration, 397  
general anesthetics, 397  
initial test, 398  
laboratory values, 398  
management, 399–401  
MRI, renal failure, 400  
nephrotoxic medications, 396  
physical exam, 396  
prerenal azotemia, 396  
renal damage, 396–397  
review, operative and anesthetic records, 396  
RIFLE criteria, 399  
sigmoid and proximal colostomy, 395  
surgery, 397  
ultrasonography, 399  
unilateral ureteral obstruction, 397  
urinalysis, 398–399
- Acute limb ischemia (ALI)  
and ABI, 584  
and CLI, 582  
arterial tree, 583, 584  
atherosclerotic disease, 583  
atrial fibrillation, 583  
blood flow, 584  
cardiac history, 582  
CDT, 588  
common femoral bifurcation, 583  
CPK and myoglobinuria, 587  
CT A, 585  
definition, 582  
diagnosis, 581–582  
duplex scanning, 584, 585  
EKG, 587–588

- Acute limb ischemia (ALI) (*cont.*)  
 embolic causes, 584  
 embolus, 585  
 management, 585–587  
 muscle tissue, 584  
 neurological condition, 587  
 nonischemic limb, 583  
 open surgical embolectomy, 588  
 PAD, 583  
 physical examination, 582  
 popliteal bifurcation, 583  
 six Ps, 582  
 TASC classification, 585  
 thrombosis, 584  
 thrombotic event, 583
- Acute otitis media (AOM), 144, 145
- Adenocarcinoma, 196
- Adenoma  
 cortisol hypersecretion, 80  
 imaging, 81  
 pituitary, 83  
 prognosis, 84
- Adenoma-carcinoma, 228–229
- Adenomatous polyposis coli (APC), 230
- Adrenal mass  
 adrenal nodule, differential diagnosis, 77  
 adrenocortical carcinoma, 78, 79  
 aldosterone, 79  
 biochemical workup, 109  
 cortisol, 78  
 Cushing's syndrome, 78, 81, 83–85  
 functional tumor, 78  
 imaging characteristics, 83  
 laboratory testing, 81, 82  
 management, 81, 82, 83–84  
 nonfunctional, 83  
 pathophysiology, 80–81  
 percutaneous biopsy, 84–85  
 pheochromocytoma, 79  
 prognosis, 84  
 zones, adrenal gland, 79–80
- Adrenalectomy, 83–85
- Adrenocortical carcinoma  
 definition, 78  
 signs and symptoms, 79, 80
- Adrenocorticotrophic hormone (ACTH), 78, 84
- Air-fluid levels, 15, 16
- Airway obstruction, 44, 446, 449
- AKI. *See* Acute kidney injury (AKI)
- Alcoholic pancreatitis, 184
- Aldosterone  
 adenoma, 84  
 hypersecretion, 79  
 mineralocorticoid production, 80  
 serum, 82  
 sodium reabsorption, 81
- Alkaline phosphatase (ALP), 192
- Amaurosis fugax  
 description, 548  
 differential diagnosis, 556  
 vs. hemispheric symptoms, 554  
 symptomatic carotid artery stenosis, 552
- American College of Radiology's Breast Imaging Reporting and Data System (BI-RADS). *See* BI-RADS
- American Joint Committee on Cancer (AJCC) staging, 29
- Amylase, 175, 178, 182, 186
- Anaplastic thyroid cancer, 119
- Aneurysm  
 AAA (*see* Abdominal aortic aneurysm (AAA))  
 diameter, 573  
 EVAR (*see* Endovascular aneurysm repair (EVAR))  
 femoral and popliteal artery aneurysms, 573  
 infrarenal, 577  
 peripheral, 573  
 popliteal, 572
- Angina, 59, 61, 63  
 Prinzmetal, 54  
 unstable, 49
- Angiodysplasia, 205, 208, 211
- Ankle brachial index (ABI)  
 and arterial duplex scan, 563  
 Buerger's sign, 561  
 diabetic patients, 567–568  
 diagnosis of PAD, 564  
 diagnostic work-up, 563  
 patients with claudication, 564  
 patients with ischemic rest pain, 564
- Ankle-brachial index (ABI), 435, 438, 584
- Anterior cerebral artery (ACA), 549, 552
- Anterior cruciate ligament (ACL)  
 adolescents, 296  
 arthritic knee, 294  
 arthroscopic reconstruction, 295  
 autograft and allografts, 296  
 dysfunction, 295–296  
 MRI, 295  
 nonsurgical management, 295  
 osteoarthritis, 294  
 pivoting injuries, 290  
 radiographic sign, 293  
 rehabilitation program, 296  
 sex hormones, 290  
 tibial plateau avulsion, 293  
 traumatic injury, 291
- Anterior spinal artery syndrome, 256
- Aortic dissection  
 and aneurysms, 67  
 classification schemes (DeBakey and Stanford), 67–68  
 complications, 68–69  
 imaging, 69  
 initial event, 67  
 management, 69  
 Marfan's syndrome, 67  
 risk factors, 66  
 upper and lower extremities in patients, 67
- Aortic regurgitation, 71, 73
- Aortic stenosis (AS)  
 chest pain, 61  
 drugs to avoid, 62  
 dyspnea, 61  
 elective noncardiac surgery, 63  
 etiologies, 60  
 management, 64  
 indications for surgery, 62  
 mild, 62  
 statins, 62  
 with heart failure, 62  
 symptoms, 59
- Aortic transection, 417
- APC. *See* Adenomatous polyposis coli (APC)
- Appendectomy  
 after nonoperative management, 223  
 normal appendix, 221

- Appendicitis  
   acute, 219  
   adjacent retroperitoneum and parietal peritoneum, 215  
   children, 222  
   closed-loop obstruction pertain, 217  
   diagnosis, 214, 215  
   elderly, 222  
   hyperesthesia, 217  
   laboratory values, 218  
   misdiagnose, 221  
   non-perforated, 223  
   patient, RLQ pain, 223  
   periumbilical pain, 216  
   PID, 222  
   pre- and postoperative antibiotics, 221  
   pregnancy, 222  
   pseudoappendicitis, 221  
   radiographic signs, 220  
   surgical emergency, 222  
   symptom, 215  
   treatment, 220  
   women, 221, 222
- Aromatase inhibitors (AI), postmenopausal women, 32
- Aspirin, 566
- Asymptomatic AAA  
   non-ruptured, 576  
   size and growth rate management, 576
- Asymptomatic Carotid Atherosclerosis  
   Study (ACAS), 556
- Asymptomatic Carotid Surgery Trial (ACST), 556
- Atherosclerosis  
   anticoagulants, 566  
   blood flow to leg muscles, 560  
   carotid, 566  
   claudication, 562  
   SFA, 562  
   subclavian artery, 563
- Atherosclerotic disease, 583
- Atlanta criteria, 176
- Atrial fibrillation, 583
- Atypia of undetermined significance (AUS), 118
- Aural fullness, 145
- Autoinflation, 148
- Avascular necrosis (AVN), 279
- Axillary lymph node dissection (ALND)  
   perform, 31  
   survival, 32
- Azotemia, 395
- Azygous, 362
- B**
- Barium enema, 229
- Basal cell carcinoma (BCC)  
   morpheaform, 372  
   skin cancer, 370
- Beck's triad, 451, 452
- Beckwith-Weidemann, 350, 354
- Benign calcification, 43
- Benign prostatic hyperplasia (BPH), 534, 536
- BI-RADS, 40, 41, 43
- Bilioid emesis  
   infant  
     cecum, 341  
     differential diagnosis, 335, 336  
     duodenum/proximal jejunum, 337  
     intestinal atresias, 336  
     intraoperative evaluation, 341  
     malrotation, 336  
     midgut volvulus, 336  
     plain radiographs, 340  
     pylorus, 336  
     recurrent volvulus, 340  
     short bowel syndrome, 340  
     TPN, 340  
     Treitz, 339  
     UGI, 337, 339
- newborn  
     anteroposterior abdominal, 331  
     cardiac defects, 333  
     chromosomal abnormalities, 333  
     Down syndrome, 331  
     duodenal atresia, 330, 331  
     duodenal obstruction, 330  
     jejunoileal atresias, 330  
     malrotation, 334  
     meconium, 330  
     neonatal, 332  
     orogastric tube placement, 331  
     pancreas/ampulla, 333  
     polyhydramnios, 329  
     sepsis/metabolic disorders, 329
- Bilioid vomiting. *See* Bilioid emesis
- Bladder cancer  
   and urethra, 536  
   and urethral pathology, 540  
   differential diagnosis, 534  
   irrigation, 541  
   management, 543  
   presentation, 536  
   radical cystectomy, 541  
   symptoms, 542  
   types, 538  
   UCC, 538, 541
- Blood in urine  
   anatomy, 536  
   bladder (*see* Bladder cancer)  
   hematuria (*see* Hematuria)  
   nephrolithiasis, 535, 539, 540  
   pseudohematuria, 535
- Blunt carotid injury, 450
- Blunt trauma  
   blood loss, 417  
   cardiac injury, 415  
   gross hematuria, 416  
   liver injury, 421, 422  
   splenic injury, 421  
   urethral meatus, 416
- Bochdalek hernia, 323
- Boerhaave's syndrome  
   algorithm, treatment of patient, 514  
   and Mackler's triad, 512  
   chest radiograph, 513  
   CT scan, 513  
   diagnosis, 511–512  
   esophageal perforation, 513  
   vs. Mallory-Weiss, 512  
   management, 514  
   oral contrast studies, 513  
   pleural decortication, 515  
   risk factors, 512  
   spontaneous ruptures, 513  
   time interval, perforation and intervention matter, 514  
    unsuspected/misdiagnosed, 512

- Bowel habits, 225, 227
- BRCA
- BRCA1 and BRCA2 inherited mutations, 27
  - carriers, 30
  - mastectomy, 30
- Breast cancer
- AJCC staging, 29
  - BRCA, 27
  - chemotherapy, 33
  - fibrocystic changes, 27
  - metastatic, 28–29
  - physical examination, 26
  - risk factors, 26–27
  - stage 3, management, 30–31
  - stage 4, mastectomy, 35
  - stage I and II, surgical options, 30
  - triple-negative, 30
  - tumor markers, 30
  - types of nipple discharge, 27
- Breast dissection, axilla, 31
- Breast mass, right (new palpable mass)
- age of patient, 28
  - cancer (*see* Breast cancer)
  - complications, 33, 34, 36
  - diagnosis, 35
    - benign conditions, 25
    - malignant lesions, 26
    - patient, 26
  - elderly male, 34
  - etiology/pathophysiology, 35
  - imaging, 28
  - in women, 26
  - inflammatory breast carcinoma with cellulitis, 34
  - management
    - AI, postmenopausal women, 32
    - ALND, 31
    - axilla for breast dissection, 31
    - breast reconstruction, timing, 33
    - contradictions to BCT, 30
    - hormonal therapy, premise, 32
    - lymph node levels I–III dissection, 32
    - sentinel node, 31
    - simple mastectomy, 30
    - SLNB, 31
    - trastuzumab, 32
  - pathology/pathophysiology
    - of ‘Peau d’ Orange, 28
    - of nipple retraction, 28
  - pregnancy, 34
  - triple test, 28
- Breast reconstruction, timing, 33
- Breast-conserving therapy (BCT), 30
- contradictions, 30
  - partial mastectomy and SNLB, 30
- Bright-red blood per rectum, 484. *See also* Lower GI bleed (LGIB)
- Brown-sequard syndrome
- cervical spine injury, 256
  - spinal cord injuries, 256
- Buerger’s sign
- chronic ischemia, 561
  - ischemic rest pain, 561
  - thromboangiitis obliterans, 563
- BUN/creatinine ratio, 484
- Burn injury
- 2nd-/3rd-degree burns, 465
  - agents, 469
  - carbonaceous sputum, 464–465
  - cherry-red skin, 465
  - child abuse, 470
  - chronic nonhealing wounds, 470
  - circumferential chest burn, 468–469
  - circumferential full-thickness burns, 466
  - CO (*see* Carbon monoxide (CO))
  - dehydration, 466
  - description, 463
  - deteriorating respiratory status, 468–469
  - diagnosis, 463
  - different levels, 464
  - electrolyte abnormality, 468
  - escharotomy, 468, 469
  - fed orally, 469
  - first 24 hours, 467, 468
  - gastrointestinal ulcers, 467
  - inhalational injury of diagnosing, 467, 468
  - Lactated Ringer’s, 468
  - management, 468
    - burn wounds, 469
    - chemical burns, 469
    - electrical burns, 470
  - morbidity, 466
  - mortality, 466
  - pathophysiology, 466–467
  - patient evaluation, 467
  - prevent curling’s ulcers, 469
  - prophylactic IV antibiotics, 469
  - punch biopsy, 468
  - risk factors, 464
  - rule of 9s, 464, 465
  - total body surface area (TBSA), 464
  - viral infection, 467
- C**
- CA 19-9, 195
- Calcinosis, 567
- Calcium
- elevated PTH level, 93
  - hyperparathyroidism, 96
  - hypocalcemia, 96
  - metabolism, 88, 92
  - replacement, 96
  - serum, 93
  - total serum and ionized calcium level, 93
- Calf pain (right) with walking
- Buerger’s sign, 561
  - claudication (*see* Claudication)
  - diagnosis, 559–560
  - ischemic rest pain, 560
  - PAD (*see* Peripheral arterial disease (PAD))
- Cancer
- bladder (*see* Bladder cancer)
  - prostate (*see* Prostate cancer)
  - renal (*see* Renal cancer)
- Carbon monoxide (CO)
- classic sign, 465
  - hemoglobin-oxygen dissociation curve, 467
  - management, 468
  - pulse oximetry, 467
- Carcinoembryonic antigen (CEA) levels, 195, 231, 234
- Cardiac tamponade, 451–462
- Carotid
- ACAS, 556
  - ACST, 556
  - and cardiac embolization, 550

- bifurcation, 548, 550
- bruit, 548
- CAS, 553, 555, 556
- CEA, 553, 555, 556
- duplex scan, 552
- ECA (*see* External carotid artery (ECA))
- ICA (*see* Internal carotid artery (ICA))
- plaques, 550, 551
- stenosis
  - asymptomatic, 556
  - coronary artery disease, 556
  - diagnostic test, 552
  - dizziness, syncope and headaches, 549
  - management, 553, 554
  - risk factors, 549
  - symptomatic, 552, 553
  - symptoms, 551
- thrombosis, 555
- Carotid artery stenting (CAS), 553, 555–556
- Carotid duplex, 552, 556
- Carotid endarterectomy (CEA)
  - acceptable risk of stroke/death, 555
  - and CAS, 553
  - anterior and posterior circulation symptoms, 550
  - asymptomatic ICA stenosis, 556
  - blood pressure, 555
  - vs. carotid stenting, 555–556
  - complete ICA occlusion, 553
  - cranial nerves, 555
  - drugs, 555
  - ICA stenosis, 554–555
  - in women, 555
  - management, 553, 557
  - optimal timing, 554
  - perioperative stroke after, 555
  - stroke/TIA, 554
- Carotid injury repair, 448
- Carotid sheath, 445
- Carpal tunnel syndrome (CTS)
  - cervical spine, 311
  - Durkan's median nerve, 311
  - endoscopic technique, 316
  - flexor carpiradialis, 313
  - hypothyroidism, 314, 316
  - idiopathic, 313
  - median nerve, 312
  - NSAIDs, 315
  - palmar cutaneous, 311
  - Phalen's test, 310–311
  - proximal median nerve, 311
  - Tinel's sign, 310
- Catecholamines
  - pheochromocytoma, 104
  - plasma and urinary, 108
  - systemic effects, 102–103
- Catheter-directed thrombolysis (CDT), 588
- CDH. *See* Congenital diaphragmatic hernia (CDH)
- CEA levels. *See* Carcinoembryonic antigen (CEA) levels
- Cecal volvulus
  - diagnosis, 238
  - etiology/pathophysiology, 239
  - proximal colon, 240
  - treatment, 241
- Cellulitis, 377, 378
- Central cord syndrome, 256, 259, 262
- Cerebral perfusion pressure (CPP), 268
- Cerebral vascular accident (CVA), 404
- Cerebrospinal fluid (CSF), 295
- Cervical lymphadenectomy, 131
- Cervical spine (C-spine)
  - CT, 260
  - laryngeal nerve injury, 262
  - MRI scans, 260
  - subluxation injury, 256
  - thoracic vertebrae, 258
  - treatment, 260
- Charcot's triad, 168, 169
- Chemical burns
  - management principles, 469
  - pathophysiology, 466, 470
- Chemotherapy regimens, 33
- Chest and back pain
  - aortic dissections, 67–69
  - differential diagnosis, 65
  - first imaging modality, 69
  - increased pulse pressure, 67
  - laboratory tests, 69
  - Marfan's syndrome, 66
  - pathophysiology, 67–68
  - type A and type B aortic dissections, 70–71
  - widened mediastinum, 65, 66
- Chest pain after vomiting
  - Boerhaave's syndrome (*see* Boerhaave's syndrome)
  - description, 511
  - diagnosis, 511–512
  - endoscopy, 514
  - esophageal perforation, 513
  - esophageal rupture, 512
  - Mackler's triad, 512
  - management, 514–515
- Chest pain and syncope
  - AS (*see* Aortic stenosis (AS))
  - biomarkers, 61
  - cardiac murmurs, 59
  - controversies, 63
  - diagnosis, 58, 64
  - endocarditis, 60
  - imaging, 61
  - intensity of murmur, valvar disease, 59
  - intravenous drug abuse (IVDA), 60
  - laboratory tests, 61
  - physical exam, 64
  - Pulsus alternans, 59
  - Pulsus bisferiens, 59
  - significance of S4, 58
  - stroke volume, 61
  - systolic murmurs, 59
  - valvar problem, 61
- Chest pain, diaphoresis and nausea
  - acute coronary syndrome, 49
  - cardiac enzyme levels in blood, measurement, 50
  - controversies, 54–55
  - coronary vessel, 49
  - diagnosis, 48
  - ECG, 51
  - episodic chest pain, young person, 50
  - history and physical, 55
  - management, 55–56
    - CABG, 52–53, 54
    - NSTEMI, 52
    - PCI, 51
    - Prinzmetal Angina, 54

- Chest pain, diaphoresis and nausea (*cont.*)  
 STEMI, 51, 52  
 timing of intervention, 52  
 MI (*see* Myocardial infarction (MI))  
 pathophysiology, 55  
 UA, NSTEMI, and STEMI, difference between, 49
- CHL. *See* Conductive hearing losses (CHL)
- Choanal atresia, 358
- Cholangiocarcinoma, 193
- Cholangitis  
 asymptomatic elderly patient, 171  
 bloody diarrhea, 171  
 cholecystectomy, 172  
 diagnostic criteria, 168  
 gallstones, 169  
 imaging, 170  
 mortality rate, 169  
 obstructive jaundice, 168  
 patients percentage, 169  
 Reynold's pentad, 169
- Cholelithiasis, 175, 188
- Cholesteatoma, 144, 147
- Chronic limb ischemia (CLI), 582  
 endovascular and open surgical bypass approaches, 568  
 endovascular/open surgical bypass approaches, 568  
 Rutherford classification, 560
- Chronic obstructive pulmonary disease (COPD), 571
- Chronic otitis media (COM), 144, 149
- Chronic pain  
 acute fracture, 317  
 cervical spine, 315  
 CTS, 310  
 dysesthesias, 310  
 Froment's sign, 314  
 iatrogenic injury, 316  
 myelopathy, 312  
 neuropathies, 315, 317  
 palmar cutaneous, 316  
 pancoast lung tumors, 317  
 radial and ulnar pulses, 309  
 sensory distribution, 312  
 surgical histories, 310  
 thenar muscles, 313  
 Thoracic outlet syndrome, 311–312  
 ulnar claw, 314
- Chvostek's sign, 90
- Circumferential burns  
 and deteriorating respiratory status, 468  
 and neurovascular compromise, 469  
 chest, 463, 466  
 extremity, 466
- Cirrhosis  
 alcohol-induced, 489  
 and portal hypertension, 482  
 liver disease, 490  
 portal vein, 483
- Classic orthopedic fractures/dislocations, 437
- Claudication  
 ABI, 564  
 aspirin, 566  
 Buerger's disease, 562  
 calf, 563  
 chronic embolization, 562  
 clopidogrel, 566  
 definition, 560  
 dependent rubor, 562  
 diagnosis, 559–560  
 FDA, 566  
 foot, 563  
 heparin/warfarin, 566  
 invasive treatment, 567  
 Leriche syndrome, 563  
 limb loss, 565  
 management, 566  
 muscle groups, 562, 563  
 PAD symptom, 560  
 smoking, 568  
 statin, 566  
 subclavian steal syndrome, 563  
 vasculitis, 562  
 walking ability, 562
- Cleft palate, 358
- Clopidogrel, 566
- Cloquet's nodes, 12
- Closed loop obstruction, 17, 217, 224
- Clostridium septicum*  
 colon cancer, 379  
 gas gangrene, 379
- Clostridium tetani* infection, 281
- Coagulopathy  
 drug therapies, 391  
 end-stage renal disease, 388  
 hypothermia, 387  
 liver disease, 388  
 metabolic acidosis, 387
- Coffee-bean, 240
- Colon cancer  
 CEA levels after surgery, 234  
 complications, 236  
 development, 228  
 diagnosis, 235, 238  
 gangrene, 242  
 hereditary conditions, 230  
 history and physical, 235  
 incidence and mortality, 227  
 LBO, 239  
 location, 233  
 management, 235  
 pathophysiology, 235  
 PEC tubes, 242  
 rectal examination, 227–228  
 right/left-sided, 227  
 risk factors, 227  
 screening, 235  
 stage, 232, 233  
 stage IV treatment, 234  
 work-up, 232, 235
- Colonoscopy, 206, 210, 229, 231, 232, 234  
 and Barium enema, 247  
 inflammation, 249  
 screening, 245
- Colorectal cancer  
 metastatic sites, 230  
 rectal examination, 227–228  
 screening, 226, 234
- Colovesical fistula  
 etiologies, 246–247  
 fecaluria, 247  
 treatment, diverticulitis, 250
- COM. *See* Chronic otitis media (COM)
- Compartment syndrome, 581  
 abdominal, 476–477  
 and acute limb ischemia, 474  
 anterior compartment, 475

- chronic vs. acute, 475
  - classification, 474–476
  - complications, 477
  - diagnosis, 473–474, 476
  - implication of pulselessness, 475–476
  - intra-abdominal pressures, 476
  - lower arm, 474
  - lower leg, 474
  - management, 477
  - measurement, 477
  - pathophysiology, 475, 476
  - physical exam and clinical situation, 474
  - symptom, 474
  - upper arm, 474
  - upper leg, 474
  - Volkman's ischemic contracture, 476
  - Complicated volvulus
    - and uncomplicated, 241, 242
    - bowel ischemia and sequelae, 240
  - Computed tomography (CT)
    - acute epidural hematoma, 269, 270
    - subdural hematoma, 269, 270
  - Computed tomography angiography (CTA), 438, 439
  - Concussion, 267
  - Conductive hearing losses (CHL), 147–148
  - Congenital diaphragmatic hernia (CDH)
    - anomalies, 324
    - bowel obstruction, 322
    - hypoxia and barotrauma, 326
    - malnutrition, 322
    - malrotation, 327
    - pulmonary hypoplasia, 324
    - scaphoid abdomen, 322
  - Congestive heart failure (CHF), 59
  - Constipation, 19
    - and cecal volvulus, 239
    - and obstipation (*see* Obstipation)
    - complicated volvulus, 240
    - CT, 241
    - description, 237
    - diagnosis, 238
    - 5 F's of abdominal distention, 239
    - LBO (*see* Lower bowel obstruction (LBO))
    - malrotation, 239
    - management, 241–242
    - neurologic/psychiatric disorders, 239
    - Ogilvie's syndrome, 239
    - percutaneous endoscopic colostomy (PEC) tubes, 242
    - physical exam, 238
    - plain films, 241
    - SBO (*see* Small bowel obstruction (SBO))
    - sigmoid volvulus, 239–240
    - suspected large bowel obstruction, 240
  - Cooper's ligaments, 28
  - Corkscrew, 339, 342
  - Coronary artery bypass grafting (CABG)
    - best conduit, 53
    - coronary artery stenting, 53
    - improved outcomes in perioperative period, 53
    - in elective setting, indications, 52
    - long-term outcome, 52
    - off-pump, 53
    - predictors of mortality, 54
    - traditional, 52–53
  - Corticosteroids, 303, 315
  - Cortisol
    - functional tumors, 78
    - glucocorticoid production, 80
    - hypercortisolism, 78
    - hypersecretion, 78
    - secretion, normal and excessive, 81
  - Courvoisier's sign, 192
  - Cranioectomy, 271, 272
  - Creatine phosphokinase (CPK), 587, 589
  - Crepitus, 378, 443, 444
  - Crescendo-decrescendo murmur, 58
  - Cryptorchidism
    - pathology/pathophysiology, 527, 531
    - risk factor, 527
  - CT angiogram (CT A), 585
  - CTA. *See* Computed tomography angiography (CTA)
  - CTS. *See* Carpal tunnel syndrome (CTS)
  - Cullen's sign, 176
  - Cushing's syndrome, 78, 81, 83–85, 268, 273
  - CVA. *See* Cerebral vascular accident (CVA)
  - Cystectomy, 541, 543
  - Cystitis, 221
- D**
- Dashboard
    - knee injury, 291
    - PCL, 291
  - DCIS. *See* Ductal carcinoma in situ (DCIS)
  - DeBakey, 67
  - Decompressive fasciotomy, 477
  - Deep
    - circumferential burns, 469
    - localized contact injury, 470
    - partial-thickness burns, 464
  - Deep tendon
    - acute spinal cord injuries, 257
    - motor neurons, 257
  - Deep vein thrombosis (DVT), 404
  - Detorsion, 523, 524
  - Developmental dysplasia of the hip (DDH)
    - antalgic gait, 303
    - delimits, 300
    - joint disease, 303
    - LLD, 303
  - Diabetes, 377, 378
  - Diabetic neuropathy
    - differential diagnosis, 561
    - rest pain, 567
  - Diagnostic peritoneal lavage (DPL), 428
  - Dialysis, 400
  - Diaphragmatic hernia. *See* Congenital diaphragmatic hernia (CDH)
  - Dieulafoy's lesion, 483
  - Disseminated intravascular coagulation (DIC)
    - coagulopathy, 390
    - endothelial tissue factor, 390
    - fibrinolysis, 390
  - Diverticula
    - colon resection, 249
    - inflammation, 245
    - left/sigmoid colon, 246
    - rectum, 246
    - sigmoid, 246, 248
    - true and false, 246
  - Diverticulitis. *See* Diverticulosis
  - Diverticulosis
    - acute setting of suspected, 247
    - bleeding, 206
    - colovesical fistula, 246

- Diverticulosis (*cont.*)  
 complicated *vs.* uncomplicated, 247  
 complications, 246, 249–250  
 diagnosis, 204, 245, 247  
 elective surgery, 250  
 intervention, 249  
 pathophysiology, 211  
 rectum, 246  
 risk factors, 207, 246  
 sigmoid colon, 246, 247, 248  
 suspected acute diverticulitis, management, 248–249  
 true and false, 246  
 uncomplicated, management, 249
- Diverticulum  
 causes, 207  
 common site, 207  
 definition, 207  
 LGIB, 208
- Double-bubble  
 abdominal radiograph, 329  
 duodenal atresia, 330  
 UGI, 334
- Down syndrome, 331
- DPL. *See* Diagnostic peritoneal lavage (DPL)
- Ductal carcinoma, 34–35, 40
- Ductal carcinoma in situ (DCIS)  
*vs.* LCIS, 39–40  
 lymph node metastasis, 42
- Dumping syndrome, 508
- Duodenal atresia  
 congenital anomaly, 331  
 Down syndrome, 331  
 duodenoduodenostomy, 333  
 laparotomy, 333  
 polyhydramnios, 330
- Duodenal ulcer  
 and uncomplicated gastric, 488  
 bleeding ulcer, 488  
 diagnosis, 482
- Duodenoduodenostomy, 333
- Durkan's median nerve compression test, 311
- DVT. *See* Deep vein thrombosis (DVT)
- Dysphagia, 135, 139, 140
- E**
- ECG, 51
- Ehlers-Danlos syndrome, 66, 72, 207
- EKG, 587–588
- Electrical burns  
 cataracts, 466  
 management principles, 470  
 pathophysiology, 466, 470
- Electromyography/nerve conduction studies (EMG/NCS), 314
- Embolectomy, 586, 587, 588
- Emboli  
 and stroke, 554  
 and thrombosis, 550  
 atherosclerotic, 551  
 atrial fibrillation, 551, 552  
 CEA, 554  
 cerebral, 550
- Emesis, bloody. *See also* Bilious emesis  
 abandon nonoperative management, 490  
 acute *vs.* chronic gastritis, 483  
 alcoholics and bulimic, 515  
 and bright-red blood per rectum, 484  
 color and texture of stool, 482–483  
 diagnosis, 482  
 Dieulafoy's lesion, 483–484  
 esophageal varices, 483  
 management, 485–488  
 nonbilious, 343–348  
 PUD, 484  
 type & cross, 485  
 type & screen, 485  
 vomiting, 481
- Endarterectomy, 586
- Endocarditis, 60
- Endoleak, 577
- Endoscopic retrograde cholangiopancreatography (ERCP), 171, 178, 184, 187, 194
- Endoscopic ultrasound (EUS), 505
- Endoscopy  
 iatrogenic injury, 515  
 interventions, 514  
 management, 516  
 perforation, 513–514
- Endovascular  
 aneurysm repair (*see* Endovascular aneurysm repair (EVAR))  
 normal aorta, 575  
 ruptured AAA, 575, 576
- Endovascular aneurysm repair (EVAR)  
 AAA unsuitable, 577  
 achilles heel, 577  
 and open repair, 576, 577  
 CT angiogram (CTA), 577  
 endoleaks, 577  
 lower risk of perioperative mortality, 578
- Enteric duplication cyst, 335
- Epididymis  
 and spermatocele, 528  
 blue-dot sign, 520, 521  
 differential diagnosis, 526  
 organisms, 528  
 painful scrotal mass, 527  
 Prehn's sign, 520
- Epidural hematoma (EDH)  
 CT, 269, 270  
 temporal bone fracture, 265  
 intraparenchymal contusion, 269  
 meningeal artery, 267
- Epigastric abdominal pain  
 description, 493  
 diagnosis, 493–494  
 gnawing pain, 493  
 PUD (*see* Peptic ulcer disease (PUD))
- Epigastric pain  
 acute pancreatitis (*see* Pancreatitis)  
 amylase and lipase, 175  
 chronic pancreatitis, 186  
 complications, 186–188  
 hospitalization, 186  
 management, 184–185  
 nonsurgical conditions, acute abdomen, 176  
 pathophysiology, 177–180  
 prognosis, 180–181  
 retroperitoneum, 177  
 signs, symptoms and findings, 177  
 umbilicus and flank bruising, 176
- ERCP. *See* Endoscopic retrograde cholangiopancreatography (ERCP)
- Eschar  
 and tissue edema, 466  
 escharotomy, 468–469



- second-degree burn to third-degree burn, 465
- Esophageal anastomosis
  - interposition graft, 363
  - lengthening techniques, 363
- Esophageal perforation
  - Boerhaave's syndrome, 513, 515
  - pathophysiology, 513
  - unsuspected/misdiagnosed, 512
- Esophageal rupture, 512
- Esophageal varices
  - diagnosis, 482
  - pathophysiology, 483
  - UGI bleed
    - alcoholic, 489
    - management, 489
    - propranolol, 489
- Esophagectomy, 514, 515
- Esophagram, 358, 361, 363
- Eustachian tube, 146–147, 149
- Excessive drooling
  - abnormal lung, 359
  - anteroposterior, 357
  - aortic arch, 362
  - cardiovascular, 359
  - chest radiographs, 357, 361
  - EA, 358, 359
  - echocardiography, 361
  - esophageal anastomosis, 362
  - feeding intolerance, 358–360
  - fistula tract, 358
  - gastroesophageal reflux disease, 362
  - healthy infants, 361
  - IVC, 362
  - orogastric tube, 358
  - oxygen desaturation, 358
  - prophylactic antibiotics, 361
  - TEF, 358
  - thoracotomy incision, 363
  - VACTERL, 359
- External carotid artery (ECA), 549, 551
- External fixation, 282
- Extracorporeal membrane oxygenation (ECMO)
  - CDH, 327
  - mortality, 327
- Extremity fracture
  - axontmesis and neurotmesis, 279
  - bone fractures, 280
  - compartment syndrome, 284
  - concomitant fractures, 279
  - fat embolism syndrome, 279
  - femur fracture, 282
  - floating knee, 280
  - humerus fracture, 277, 278
  - limb salvage/amputation, 284
  - MCV, 277
  - nerve sheath, 279
  - neurologic deficit, 277, 284
  - skin wounds, 281
  - tibia fracture, 279
  - trauma patient, 278
  - X-ray imaging, 277
- F**
- Familial adenomatous polyposis (FAP), 230
- FAP. *See* Familial adenomatous polyposis (FAP)
- Fasciulata, 80
- Fat embolism syndrome, 279, 283
- Fecalith, 218, 220, 224
- Femoral hernias, 5, 6, 7
- Femur fractures
  - fat embolism syndrome, 282
  - intramedullary nail, 282, 283
  - mortality and morbidity, 282
  - osteogenesis, 282
- Fertility, 523
- Fetal surgery
  - hypoplastic lung, 327
  - tracheal occlusion, 327
- Fiber, diverticulosis, 246
- Fibroadenoma, 35
- Fine needle aspiration (FNA)
  - AUS/ FLUS, 118, 122
  - benign, 118
  - follicular neoplasm, 118
  - follicular thyroid carcinoma, 116
  - inadequate/nondiagnostic, 118
  - thyroid nodules, 117
- Fistula
  - epithelial-mesenchymal interactions, 358
  - esophagus, 362
  - TEF, 358
- Flail chest, 451, 459, 461
- Flatus, 14
- Flexible sigmoidoscopy, 229–230
- Flexor digitorum profundus (FDP), 314
- Flexor pollicis longus (FPL), 314
- Flushing, 102
- Focused abdominal sonography for trauma (FAST), 426, 428, 432
- Fogarty balloon, 586
- Follicular
  - cancer, thyroid lobectomy, 118
  - fine needle aspiration (FNA), 116
  - neoplasm, 118
- Follicular lesion of undetermined significance (FLUS), 118
- Fournier's gangrene, 379
- Functional tumor
  - biochemical analysis, 84
  - cortisol, aldosterone, or catecholamines, 77
  - hormone hypersecretion, 77
- G**
- Gail risk model, 39
- Gallstone pancreatitis
  - cholecystectomy, 187
  - distal common duct, 178
  - management plan, 184
  - urgent ERCP, 184
- Gardner's syndrome, 230
- Gas bubble, 377, 378
- Gas gangrene, 379
- Gastric adenocarcinoma
  - CT scanning, 505, 506
  - diffuse-type, 504, 505
  - epidemiology, 502
  - gastric carcinoids, 508
  - GISTs, 508
  - intestinal-type, 504, 505
  - lymph nodes, 506
  - management, 506
- Gastric cancer
  - adenocarcinoma (*see* Gastric adenocarcinoma)
  - adjuvant chemotherapy and radiation, 507

- Gastric cancer (*cont.*)  
 algorithm, 507  
 and MALT, 483  
 blood supply to stomach, 504, 505  
 development, 503  
 diagnosis, 502  
 diffuse-type, 504, 505  
 epidemiology, 502  
 EUS, 505, 506  
 GISTs, 508  
*H. pylori* infections, 502  
 HER2, 507  
 high mortality rates, 503  
 iron deficiency anemia, 505  
 lymph node dissections, 506–507  
 management, 506  
 PET scan, 505  
 physical exam, 504  
 screening patients, 503  
 symptoms, 503–504  
 upper abdominal pain and weight loss, 502  
 upper endoscopy, 505
- Gastric outlet obstruction, 248, 344, 345
- Gastric resection  
 complications, 508  
 dumping syndrome after, 508  
 laparoscopic, 507  
 lymph nodes, 506
- Gastric ulcer, 502  
 diagnosis, 482  
 endoscopy, 488  
 treatment, 488
- Gastroesophageal reflux disease (GERD), 502  
 history, 494  
 hypertension and diabetes, 493
- Gastrointestinal (GI) bleed  
 color and texture of stool/emesis, 482  
 endoscopy fails, 487  
 hemoglobin/hematocrit, 484  
 lower (*see* Lower GI bleed (LGIB))  
 mucosa and vessel, 484  
 obscure, 485  
 occult (*see* Occult GI (OGI) bleed)  
 upper (*see* Upper gastrointestinal (UGI) bleed)
- Gastrointestinal stromal tumors (GISTs), 508, 509
- Gastrointestinal ulcers, 467
- Gastroschisis  
 and omphalocele, 351–353  
 evisceration, 351  
 intestinal abnormalities, 351  
 silo placement, 353  
 umbilical vein, 351
- Glasgow coma scale (GCS)  
 mortality, 266  
 non-head trauma, 266
- Glenohumeral arthritis, 302
- Glomerular hematuria, 536, 539
- Glomerulosa, 80
- Grey-turner's sign, 176
- Groin mass. *See also* Hernias  
 complications, 10, 13  
 controversies, 11–12  
 differential diagnosis, 3–4, 12  
 history and physical, 4, 12  
 management, 9–10, 13  
 MINT masses, 3, 4, 12  
 pathology/pathophysiology, 5–8, 12  
 small bowel obstruction (SBO), 4
- Groin pain  
 acetabulum, 302  
 antalgic gait, 303  
 arthrocentesis, 304  
 delimits, 300  
 dysplasia, 305  
 hip flexion, 301  
 knee, 299  
 Legg-Calve-Perthes disease, 301, 306  
 Lyme disease, 302  
 musculoskeletal pathology, 304  
 osteonecrosis, 303  
 physical examination, 299  
 plain film radiographs, 305  
 SCFE, 300, 305  
 septic arthritis, 302, 303  
 URI, 302  
 weight, 300
- Gross hematuria, 534, 535, 538, 540, 541, 542
- Gunshot wound, left neck  
 advantages and disadvantages, 446  
 anatomy, 444–445, 449  
 areas, 449  
 diagnosis, 444  
 hard signs, vascular injury, 443  
 history and physical examination, 443, 449  
 management, 446–448, 450  
 pathophysiology, 445–446, 449  
 signs/symptoms, 444
- Gynecomastia, 525, 526, 528
- H**
- Hard signs, 436, 438, 441, 443
- Head and neck cancer  
 cervical lymph node, 137  
 controversies, 140  
 cranial nerve exam, 136  
 CT scan, 138  
 diagnosis, 134  
 etiology, 136–137  
 fine needle aspiration (FNA), 138  
 imaging modality, 138  
 inappropriate biopsy, 139  
 laboratory tests, 137, 139  
 life-threatening signs, 139  
 management, 139  
 missing cancer diagnosis, 139  
 open neck biopsy, 138  
 panendoscopy, 138  
 physical examination, 135  
 risk factors, 135  
 symptoms, 135  
 tissue sample, 138
- Head trauma  
 brain death, 272  
 coup vs. contrecoup injury, 269  
 CPP, 268  
 Cushing's reflex, 268  
 decorticate posturing, 267  
 EDH, 266  
 epidural hematoma, 267–268  
 hemotympanum, 266  
 hyperventilation, 271  
 ICP, 271  
 intracranial bleeding, 267

- intracranial hypertension, 271
- intraparenchymal contusion, 269
- lucid interval, 268
- malignancy, 272
- Raccoon eyes, 266
- SDH, 267
- TBI, 265
- uncal herniation, 267
- Hearing loss
  - adult, 144
  - child, 144
  - implication, 145
  - sudden deafness, 146
- Helicobacter pylori*
  - antibiotic-resistance, 488
  - gastric cancer, 502–503
  - gastric/duodenal ulcers, 488
  - intestinal-type gastric adenocarcinoma, 504
  - MALT, 508
  - postoperatively, 488
  - PUD, 483
  - urea breath test (UBT), 488
- Hemarthrosis, 288
- Hematochezia, 209
- Hematuria, 416
  - and manual irrigation, 541
  - chronicity, 534
  - differential diagnosis, 534
  - glomerular and non-glomerular, 536, 539
  - gross, 534, 535, 538, 540, 541, 542
  - laboratory tests, 539
  - macroscopic, 534, 535
  - management, 540
  - pain, 535
  - painless gross, 536
  - pseudohematuria, 535
  - treatment principle, 540
  - urine dipstick, 538, 539
- Hemophilia
  - antiphospholipid syndrome, 386
  - coagulation disorders, 386
- Hemoptysis, 128
- Hemorrhagic stroke, 550
- Heparin, 441, 566
- Hepatitis C-related cirrhosis, 377
- Hereditary nonpolyposis colorectal cancer (HNPCC), 230
- Hernias, 16–17, 21
  - diagnosis
    - direct and indirect inguinal, 8
    - imaging studies, 8
    - in adult, 8
    - in infant, 8
  - direct inguinal, 7, 9
  - femoral, 5, 6, 7
  - incarcerated hernia, 5, 10
  - indirect hernia sac, 11
  - indirect inguinal, 7, 9
  - inguinal, 5–7, 10–12
  - management, 9–11, 13
  - repair, nerve injury, 10
  - Richter's, 8, 11
  - sliding, 8, 11
  - strangulated, 5, 10
  - umbilical, 5, 6, 10
  - vas deferens and testicular vessels, 11
  - ventral or incisional, 5
- ventral/incisional, 12
- Herniation, 266, 267
- Hesselbach's triangle, 7
- Hinchey staging system, 247
- Hirschsprung's disease, 329
- HNPCC. *See* Hereditary nonpolyposis colorectal cancer (HNPCC)
- Hoarse voice
  - airway compromise, 131
  - bloody sputum, 128
  - chronic laryngitis, 131
  - consultation with otolaryngologist, 128
  - diagnosis, 127–128, 132
  - etiology/pathophysiology, 132
  - laryngeal cancer, 128, 129
  - nature of hoarseness, 128
  - pathophysiology
    - innervation of larynx, 129
    - laryngeal papillomas, 129
    - SCC, 129
  - patient history, 128
  - staging for laryngeal cancer, 130
  - treatments, 130–131
  - variables, prognosis for laryngeal cancer, 131
  - vocal cords, evaluation, 129, 130
- Hormonal therapy, 32
- Howship-Romberg sign, 16
- HPS. *See* Hypertrophic pyloric stenosis (HPS)
- Human chorionic gonadotropin (hCG)
  - blood tests, 530
  - gynecomastia, 528
- Humerus
  - polytrauma, 277
  - radial nerve injury, 277
  - X-ray imaging, 277
- Hyaline membrane disease, 322
- Hydrocele, 519
- Hyperaldosteronism, 81, 83
- Hyperbaric oxygen, 380
- Hypercalcemia
  - asymptomatic or mildly symptomatic, 89
  - differential diagnosis, 88
  - fatigue, constipation, and depressed mood, 88–89
  - gastrointestinal manifestations, 89
  - hypocalciuric, 92
  - neurological manifestations, 89
  - renal manifestations, 89
- Hypercalcemic crisis, 90, 97
- Hypercortisolism, 78
- Hyperparathyroidism (HPT)
  - 99-m technetium sestamibi scanning, 93–94
  - anterior neck mass, 90
  - asymptomatic, 96
  - diagnosis, 93, 98
  - family history, 90
  - history and physical, 98
  - management, 99
  - MEN disorders, 92
  - nonoperative management, 95
  - pathology, 91–92, 99
  - physical exam findings, 90
  - postmenopausal women, 89
  - primary
    - elevated PTH level, 93
    - laboratory tests, 92
    - management, algorithm, 97–98
    - parathyroidectomy, 93

- Hyperparathyroidism (HPT) (*cont.*)  
 pathology, 91–92  
 postoperative management, 95  
 risk factors, 89  
 radiologic findings, 93  
 secondary  
 parathyroidectomy, 95  
 pathophysiology, 92  
 surgical options, 95  
 tertiary, 92  
 types, 90–91
- Hyperperfusion syndrome, 555
- Hypertension (HTN)  
 blood pressure check, in arms and legs, 103  
 diagnosis, 110  
 differential diagnosis, 102  
 etiology/pathophysiology, 109  
 history and physical, 109  
 management, 110  
 orthostatic, 103
- Hypertensive crisis, 109
- Hyperthyroidism  
 severe or long-standing, 114  
 symptoms, 113
- Hypertrophic obstructive cardiomyopathy (HOCM), 58
- Hypertrophic pyloric stenosis (HPS)  
 dehydration, 346  
 genetic and maternal factors, 344  
 hypertrophies and dilates, 344  
 infantile, 344  
 pylorus, 344  
 resuscitation, 347  
 ultrasonography, 345
- Hypocalcemia  
 calcium replacement, 96  
 postoperative, 96, 121
- Hypoplasia  
 CDH, 324, 326  
 congenital anomalies, 325  
 thoracic cavity, 324
- Hypothyroidism  
 severe or long-standing, 114  
 symptoms, 114
- Hypovolemic shock, 415, 416, 419, 422, 423
- Hypoxia, 404
- I**
- IBD. *See* Inflammatory bowel disease (IBD)
- Imperforate anus, 329
- Incidentaloma, 79, 80
- Inferior vena cava (IVC), 362
- Infertility  
 chemotherapy, 530  
 varicocele, 527
- Inflammatory bowel disease (IBD), 171, 225, 231
- Inguinal hernias  
 asymptomatic, 11  
 direct, 5, 6, 9  
 in premature infant, 11  
 indirect, in adult, 5, 6, 9  
 repair in older infants/children, 10
- Inguinal ligament, 7
- Internal carotid artery (ICA)  
 and ECA, 549  
 ASA, 554  
 asymptomatic ICA stenosis, 556  
 atherosclerotic plaque, 551  
 CEA, 554, 555–556  
 cerebral emboli, 550  
 CT/MR angiogram, 552, 553  
 embolus, 548  
 eye symptom, 548  
 high-grade stenosis, 553
- Internal jugular vein injury, 448
- Intra-renal AKI, 397
- Intracranial pressure (ICP), 271
- Intravenous drug abuse (IVDA), 60
- Intubation, 361, 363, 364
- Intussusception, 335, 336
- Ischemia  
 acute limb ischemia, 474  
 nerve, 474, 475  
 pathophysiology, 478  
 tissue, 474, 475  
 Volkmann's ischemic contracture, 476
- Ischemic colitis  
 abdominal tenderness, 206  
 causes, 208  
 differences, mesenteric ischemia, 209  
 natural history, 209  
 presents, 207
- Ischemic rest pain  
 ABI, 563  
 advanced PAD, 560  
 and tissue loss, 565  
 Buerger's sign, 561  
 cellulitis, 567  
 differential diagnosis, 561  
 failure to inquire, 567  
 limb loss, 565  
 toes, 560
- Ischemic stroke, 550
- J**
- Jaundice  
 acute, 169  
 bilirubin level, 168  
 gallstones, 169  
 hepatic and posthepatic causes, 169–170  
 obstruction, 168  
 physical examination, 168
- K**
- Kehr's sign, 421
- Keratoacanthoma, 368, 375
- Kernohan syndrome, 267
- Kidney  
 AKI (*see* Acute kidney injury (AKI))  
 bean sign, 243
- Knee pain  
 ACL, 289  
 anterior knee laxity, 288  
 differential diagnosis, 288  
 dislocation/proximal tibia, 289  
 intra-articular cartilage, 296  
 lacerations/wounds, 290  
 ligamentous injuries, 289  
 maneuvers, 288, 289  
 meniscus injuries, 291, 296

- muscle compartments, 287
  - neurologic exam, 287, 290
  - patellar tendinitis, 292
  - radiographs, 293
  - range of motion, 291
  - tumors and infection, 290
  - varus and valgus, 288
  - vascular injury, 296
- L**
- Lactate dehydrogenase (LDH), 372
  - Lacunar stroke, 550
  - Ladd's bands, 340, 342
  - Laparotomy, 428, 429, 431
  - Large bowel obstruction (LBO), 19
  - Laryngeal cancer
    - early-stage, 130–131
    - hoarse voice, 128
    - prognosis, variables, 131
    - staging, 130
    - tests, 129
  - Laryngitis, chronic, 131
  - Laryngoscopy
    - direct and indirect, 129–130, 132
    - flexible fiberoptic, 129
    - mirror, 129
  - Larynx, 129
  - Lateral collateral ligament (LCL), 288, 289, 296
  - LBO. *See* Large bowel obstruction (LBO)
  - LCIS
    - DCIS *vs.*, 39–40
    - stereotactic biopsy, 42
  - Left anterior descending (LAD), 48, 49
  - Left lower quadrant (LLQ) pain
    - and fever, 245
    - and right, 247
    - colon surgery, 251
    - colovesical fistula (*see* Colovesical fistula)
    - CT scan, 247, 248
    - description, 245
    - diagnosis, 245–246
    - diverticulosis (*see* Diverticulosis)
    - hinchey staging system, 247
    - management, 248–249
    - ureters, 251
  - Leg length discrepancy (LLD)
    - DDH, 303
    - SCFE, 303
    - scoliosis, 303
  - Leg pain (right) after tibia fracture
    - compartment syndrome (*see* Compartment syndrome)
    - diagnosis, 473–474
    - Doppler interrogation, 473
    - open reduction and internal fixation (ORIF), 473
  - Legg-calve-perthes
    - avascular necrosis, 303
    - femoral epiphysis, 301
  - Leriche syndrome, 563, 569
  - Lethal triad of death, 386
  - LGIB. *See* Lower GI bleed (LGIB)
  - Limb ischemia, 436, 437, 439
  - Linitis plastica, 504, 509
  - Lipase, 175, 181, 182
  - Liver disease, 386, 388, 391
  - LLD. *See* Leg length discrepancy (LLD)
  - Lobular carcinoma, 34, 40
  - Loops of bowel, 19–20
  - Lower bowel obstruction (LBO)
    - colon cancers, 239
    - common causes, 239
    - diagnosis, 238, 243
    - history and physical examination, 238
    - in pregnancy, 242
    - Ogilvie's syndrome, 239
    - tachypnea, 238
  - Lower GI bleed (LGIB)
    - abdominal tenderness, 206
    - age, 205
    - alcohol history, 206
    - and upper GI bleed, 207
    - anticoagulants, 206
    - bleeding duration, 205
    - bright-red blood/maroon-colored stools, 482
    - causes, 205
    - colonoscopic biopsy/polypectomy, 210
    - color and bleeding amount, 205
    - diagnosis, 204, 207
    - diverticulosis, 207
    - emesis and bright-red blood per rectum, 484
    - etiology/pathophysiology
      - acute mesenteric ischemia, 209
      - angiodysplasia, 208
      - diverticulum, 207–208
      - ischemic colitis, 208–209
    - hereditary disease, 206
    - iron-deficiency anemia, 207
    - ischemic colitis, 207
    - management, 209–210
    - NG tube (NGT), 485
    - obscure and occult, 485
    - occult bleeding, 205
    - oropharynx, 484
    - pelvic radiation, 206
    - RBC scan, 487
    - symptoms, 206
  - Lumpectomy, 30, 35
  - Lymph node levels I–III dissection, 32
  - Lymphoid hyperplasia, 217, 218
  - Lymphoma, 134, 136, 140, 508, 510
  - Lynch syndrome, 230
- M**
- Mackler's triad, 512, 515
  - Macroscopic hematuria, 534, 535
  - Magnetic Resonance Cholangiopancreatography (MRCP), 194
  - Malformations, infection, neoplasm, and trauma (MINT), 3, 4, 12
  - Mallory-Weiss tear
    - vs.* Boerhaave's syndrome, 512
    - diagnosis, 511
    - management of UGI bleeding, 489
    - pathophysiology, 513, 515
  - Malrotation
    - CDH, 327
    - Ladd's procedure, 327
    - midgut volvulus, 339–340
  - Mammogram, 29, 34–36
    - abnormal screening, 40, 41
    - diagnosis, 38, 43
    - etiology/pathophysiology, 43
    - Gail risk model, 39

- Mammogram (*cont.*)
- history and physical, 43
  - in staging breast lesions, 40
  - in young women, 39
  - lymph node metastasis with DCIS, 42
  - management, 43
  - mortality, from breast cancer, 42
  - normal screening, 40, 41
  - pathophysiology
    - benign and malignant conditions, 39
    - DCIS vs. LCIS, 39–40
  - prophylactic bilateral mastectomy, 42
  - recommendations, 38
  - risks, 38–39
  - screening, 43
  - stereotactic biopsy, 40, 42
- Mangled extremity severity score (MESS), 439, 442
- Marfan's syndrome, 66, 67
- Massive transfusion protocol (MTP), 428, 432
- Mastectomy
- and SLNB, 31
  - simple, spared nipple and breast skin, 30
  - stage 4 breast cancer, 35
- Mastoiditis, 149, 150
- Matrix metalloproteinases (MMPs)
- and AAA formation, 574
  - glycation, 572
- McBurney, 216
- Mcmurray sign, 288, 289
- Meatus, urethral, 416, 423
- Meconium, 330
- Medial collateral ligament (MCL), 288
- Medial layer, 573, 574
- Median nerve
- cervical spine, 313
  - CTS, 312
  - sensory distribution, 312
  - wrist, 313
- Melanoma
- acral-lentiginous, 373
  - adjuvant therapy, 375
  - amputation, 370
  - basal cell carcinoma, 371
  - benign nevus, 369
  - dacarbazine, 375
  - dysplastic nevus syndrome, 370
  - LDH, 372
  - lymph node dissection, 373
  - Mohs surgery, 374
  - MSLT-I, 374
  - nonexposed skin, 370
  - recurrence, 374
  - sentinel lymph node, 370
  - SLNB, 373
- Melena
- color and texture of stool and emesis, 482–483
  - NG tube, 485
- MEN, 92, 109, 113
- Meniscal tear
- blood supply, 291
  - RICE approach, 295
  - traumatic injury, 291
- Mesenteric base
- midgut rotation, 338
  - peritoneal adhesions, 340
- Mesenteric ischemia, 209
- Metachronous tumors, 231
- Metanephrine, 102, 105, 110
- Microemboli, 548
- Middle cerebral artery (MCA), 549, 552
- Midgut volvulus
- mesenteric artery, 337
  - proximal limb, 338
  - short bowel syndrome, 341
  - TPN, 341
  - Treitz, 338
- Million dollar nerve, 316
- Minimally invasive surgery (MIS), 327
- Mohs, 374
- Monckeberg's arteriosclerosis, 567
- Motor vehicle accident and abdominal pain. *See also* Pedestrian struck
- blood loss
    - blunt trauma, 417
    - hypotension, 416
    - location, 417
    - sources, 417
  - diagnosis, 423
  - free fluid in abdomen, 422
  - gross hematuria, 416
  - hemorrhagic shock, 417
  - hypotension, 423
  - hypovolemic shock, 416
  - initial management, 423–424
    - ABCDE, 417–418
    - central lines, 419
    - Diagnostic Peritoneal Lavage (DPL), 420
    - establishment, airway, 418
    - fluid resuscitation, 419, 420
    - nasotracheal intubation, 418
    - peripheral IV Lines, 419
    - potassium amount, 420
    - proper intubation, 419
    - secondary survey, trauma patients, 418
    - surgical airways, 418
    - theoretical benefit?, 420
    - trauma setting, 418
  - pelvic fracture, 423
  - shock types, trauma setting, 415
  - subsequent management, 424
    - intra-abdominal bleeding, 421
    - liver injury, 421, 422
    - pelvic fracture, 422
    - splenic injury, 421
    - urethral injury, 416
    - vasopressors, 422
- Motor vehicle collision (MCV), 277
- MRCP. *See* Magnetic Resonance Cholangiopancreatography (MRCP)
- Mucosa-associated lymphoid tissue (MALT), 508, 510
- Muscle necrosis, 379
- Myelopathy, 256, 257
- hyperreflexia, 312
  - spinal pathology, 317
- Myocardial infarction (MI)
- acute, 49, 54
  - complications of, 54
  - diagnostic steps, 50
  - history and physical exam findings, 49
  - in women, 49
  - mechanisms of, 50
  - risk factors, 48

- second, cardiac enzyme, 50
- silent, 54
- with chest pain, 48
- Myoglobinuria, 587
- Myotomy, 347
- N**
- Nasogastric tube (NGT)
  - management, 485
  - room-temperature, 485
  - upper and lower GI bleeding, 485
- Neck mass, 134, 136–139. *See also* Thyroid mass
- Neck pain
  - anterior spinal artery syndrome, 256
  - atlanto-occipital dislocation, 258
  - Brown-Sequard syndrome, 259
  - central cord syndrome, 259
  - cervical spine injury, 256
  - CT scan, 255
  - dermatome, 256
  - lateral radiograph, 255
  - neurogenic shock, 260–261
  - NSAID, 259
  - sensory/motor dysfunction, 257
  - X-ray, 260
- Necrotizing enterocolitis, 329
- Necrotizing myositis, 379
- Necrotizing soft tissue infection (NSTI)
  - cellulitis, 378
  - clostridial myonecrosis, 379
  - fascia, 379
  - gas bubbles, 378
  - hard signs, 378
  - immunity and tissue perfusion, 378
  - incision, 380
  - monomicrobial/polymicrobial, 379
  - mortality risk, 380
  - plain X-rays, 380
  - scrotum and perineum, 379
  - spectrum, 378
- Neoplasm, 205
- Nephrectomy
  - management, 543
  - renal masses, 540–541
- Nephrogenic systemic fibrosis, 396
- Nephrolithiasis, 89, 93
  - colicky flank pain, 535
  - management, 540
  - nausea, vomiting and dysuria, 535
  - non-contrast helical CT scan (CT-KUB), 539
  - pain, 535
  - risk factors, 535
  - ultrasonography, 539
- Nerve. *See* Median nerve
- Nerve entrapment syndrome, 310
- Nerve injuries, 279, 280
- Nerve, artery, vein, empty space, lymphatic (NAVEL), 5
- Neurogenic shock, 415
- Nevi
  - benign, 375
  - dysplastic nevus syndrome, 370
  - melanoma, 370
- Nitrates, 503
- Nitroglycerin, 52, 54–55
- Nodule, thyroid
  - cancerous, 113
  - diagnostic algorithm, 122
  - FNA, 117
  - imaging studies, 117
  - nonoperative management, 120
  - nuclear imaging, 117
  - reporting system, 117
  - symptoms, 112
- Non-glomerular hematuria, 536, 539
- Non-ruptured asymptomatic AAA, 576
- Non-ST segment elevation myocardial infarction (NSTEMI), 52
- Nonbilious emesis, infant
  - begin fluid resuscitation, 346
  - bile-stain, 344
  - electrolyte replacement, 346
  - enteric hormones, 344
  - HPS, 344
  - hypokalemia, 346
  - intravenous access, 346
  - laparoscopy vs. open repair, 347
  - myotomy, 347
  - oral erythromycin, 344
  - pertinent diagnoses, 343
  - pyloromyotomy, 347
  - pylorus, 344
  - UGI study, 345
- Nonischemic limb, 583
- Nonneoplastic polyps, 228
- Nonsteroidal anti-inflammatory drug (NSAIDs)
  - acute vs. chronic gastritis, 483
  - and aspirin, 494
  - diagnosis, 482, 493
  - history, 494
  - peptic ulcers, 495
  - type V ulcers, 495
- NSTI. *See* Necrotizing soft tissue infection (NSTI)
- O**
- Obstipation, 16, 19, 21
  - and constipation, 238
  - and vomiting, 242
  - diagnosis, 238
- Obstructive jaundice, 168, 169, 194, 196
- Obturator, 215–216
- Occult GI (OGI) bleed
  - and obscure, 485
  - pathology/pathophysiology, 490
- Ogilvie's syndrome, 15, 238, 239, 242, 243
- Olive, 344, 345, 348
- OME. *See* Otitis media with effusion (OME)
- Omphalocele
  - congenital cardiac defects, 352
  - neonatal management, 352
  - organogenesis phase, 351
  - parenteral nutritional support, 352
  - peritoneal cavity, 352
  - viscera, 351
- Open fractures, 290
  - antibiotics, 281
  - bone healing, 278
  - Gustilo-Anderson grading, 280
  - limbs, 280
  - soft tissue and skin, 278
  - surgical management, 281
- Open reduction and internal fixation (ORIF), 473, 474

- Open surgical embolectomy, 588
- Orchiectomy, 523, 524
- Orchiopexy, 523, 524
- Orchitis and epididymitis, 527
- Orogastric tube (OGT), 324, 326
  - chest radiographs, 357, 358
  - EA, 360
- Osteonecrosis, 303
- Otalgia, 135, 139, 140
- Otitis externa, 144, 145, 149
- Otitis media with effusion (OME)
  - and external otitis, 145
  - cases, 146
  - causes, 146
  - diagnosis, 144
  - long-term complications, 149
  - management, 148–149
  - otalgia, 145
  - pathogens, 147
  - peak age, 144
  - pneumatic otoscopy, 147
  - risk factors, 145
  - symptom, 146
- Otorrhea, 145
- P**
- Painless
  - gross hematuria, 536, 542
- Painless jaundice
  - adjuvant therapy, 197
  - biliary obstruction, 197
  - Blumer's shelf, 193
  - CA 19-9 and CEA, 195
  - cancer and carcinoma risk factor, 193
  - Courvoisier's sign, 192
  - CT scan, 194
  - detection, 193
  - diagnosis, 192
  - ERCP, 194
  - hepatocellular damage, 194
  - laboratory findings, 194
  - management
    - biopsy, 196
    - complication, whipple/pancreatectomy, 197
    - neoadjuvant therapy, 196
    - pancreatic cancer unresectable, 195
    - postoperative pancreatic/biliary leak, 197
    - preoperative stenting, 196
    - surgery, 196
    - Whipple procedure, 196–197
  - MRCP, 194
  - painful vs. painless, 192
  - pathophysiology, 193
  - periumbilical mass, 193
  - posthepatic causes, 194
  - ultrasound, 194, 195
- Pale/acholic stools, 168
- Palmar cutaneous branch, 311, 316
- Palpitation
  - diagnosis, 102
  - history and physical, 109
  - in pheochromocytoma, 102
- Pancreatectomy, 196, 197
- Pancreatic adenocarcinoma, 196
- Pancreatic cancer
  - increased INR (PT), 197
  - management, 195
  - risk factors, 193
  - surgical management, 196
- Pancreatitis
  - acute
    - abdominal X-ray, 182
    - alcohol, 178
    - central gland necrosis, 180
    - concomitant acute cholangitis, 184
    - CT scan, 183–184
    - diagnose, 176
    - differences, chronic pancreatitis, 178
    - gallstones, 178
    - hemorrhagic pancreatitis, 180
    - hospitalization, 186
    - hyperamylasemia, 182
    - imaging, 182
    - interstitial edematous pancreatitis, 179
    - laboratory tests, 182
    - management algorithm, 185
    - mortality rate, 181
    - natural disease course, 181
    - necrotizing pancreatitis, 179–180
    - nonsurgical conditions, 176
    - organ failure, 179
    - phases, 178
    - prophylactic antibiotics, 187
    - pulmonary complications, 179
    - severity, 185
    - signs, symptoms and findings, 177
    - treatment, 184
  - adjuvant therapy, 197
  - chronic
    - complications, 186
    - surgical management, 186
  - complications, 197
  - controversies, 187
  - etiologies, 177
  - gallstone, 184
  - hypocalcemia, 181
  - medications, 177
  - missing hypercalcemia, 187
  - nutritional support, 188
  - pathophysiology, 177
  - postoperative drains, 197
  - pseudohyponatremia, 187
  - Ranson Criteria, 180–181
  - severity determination, 180
- Panendoscopy, 138, 140
- Papillary thyroid cancer, 113, 121, 123
- Papillomas, laryngeal, 129
- Paralysis, 549, 554, 582, 588, 589. *See also* Neck pain
- Parathyroid gland (PTH)
  - abnormal, 94
  - ectopic, 91
  - embryological development, 91
  - intraoperative PTH monitoring, 95, 96
  - parathyroid hyperplasia, 92
  - primary hyperparathyroidism, 93
  - renal transplantation, 92
- Parathyroidectomy
  - benefits, 96
  - primary hyperparathyroidism, 93
- Paresthesia
  - compartment syndrome, 474



- history and physical, 474, 478
- tissue ischemia, 474
- Parkland formula, 468, 471
- Partial thickness
  - deep, 463
  - superficial, 463
- Patella
  - ASIS, 292
  - dislocations, 292
  - tendinitis, 292
  - tendon rupture, 293
  - tibial tuberosity, 292
  - X-ray, 293
- Peaked T waves, 587–588
- Pedestrian struck
  - ABI, 435, 438
  - angiogram, 438
  - car accident, 435
  - classic orthopedic fractures/dislocations, 437
  - diagnosis, 435, 442
  - essentials, 440–441
  - hard signs, vascular injury, 438
  - history and physical exam, 436, 441
  - management, 442
    - algorithm, extremity injury management, 439, 440
    - autogenous vein grafts, 440
    - extremity, life-threatening hemorrhage, 439
    - heparin, 441
    - knee dislocation, 439
    - orthopedic and vascular injury, 441
    - popliteal artery injury, 440
    - popliteal vein repair, 440
    - postoperative complications, 441
    - reduction, 439
    - steps, 439
  - mangled extremity severity score, 439
  - minimal vascular injury, 437
  - penetrating trauma, 438
  - popliteal artery injury, 437
  - posterior knee dislocation, 438
  - skeletal and associated arterial injuries, 437
  - vascular imaging, 438
- Pelvic fractures, 282, 284
- Penetrating abdominal trauma
  - ACS, 431, 433
  - anatomy, 426–427, 432
  - CT, 427
  - diagnosis, 425
  - diagnostic peritoneal lavage (DPL) and FAST exam, 428
  - essentials, 432–433
  - indications, surgical intervention, 427
  - initial management, 432
    - impalement, 429
    - MTP, 428
    - permissive hypotension, 428–429
    - primary survey, 428
    - prophylactic antibiotics and analgesics, 429
    - tetanus prophylaxis, 429
  - local wound exploration, 428
  - MIVT prehospital report, 425
  - subsequent management, 432
    - criteria for non-op management, 430–431
    - damage control, 430
    - external iliac artery injury, 431
    - laparoscopy, 429
    - lethal triad of death, 430
    - operating room, 429
    - prophylactic antibiotics, 431
    - stoma requirement, small bowel or colon injuries, 431
    - traditional mainstay, 429
  - tangential GSW, 425, 426
  - thoracoabdominal penetrating wounds, 431
  - types, 425–426
  - x-ray, 426
- Pentalogy of Cantrell, 351, 354
- Peptic ulcer disease (PUD)
  - alcohol, 495
  - bleeding vessels, 484
  - causative factors, 494–495
  - classification, 495
  - emesis, 484
  - GI bleed (*see* Gastrointestinal (GI) bleed)
  - Helicobacter pylori*, 494–495
  - high stress environments, 495
  - NSAIDs, 495
  - perforated (*see* Perforated PUD)
  - smoking, 495
  - symptoms, 494
  - vomiting, 495–496
- Percutaneous balloon valvuloplasty, 63
- Percutaneous coronary intervention (PCI), 51
- Perforated PUD
  - blood count and chemistries, 496
  - CT scan, 496
  - diagnosis, 496
  - Graham patch, 497
  - laparoscopic repair, 498
  - management, 497
  - morbidity and mortality, 496–497
  - nonoperative management, 497
  - omental patch, 497
  - pathophysiology, 494
  - principle of surgical treatment, 497
  - suspicion, 496
- Perforated ulcer
  - and diverticulitis, 494
  - laparoscopic repair, 498
  - nonoperative management, 497
  - stomach/intestine, 497
- Perforation, 488
  - and exacerbation, 247
  - and hemorrhage, 495
  - colonic, 249
  - conservative therapy, 497
  - diagnosis, 496
  - diverticulitis complications, 246
  - duodenal, 494, 497, 498
  - gastroduodenal, 494
  - NSAIDs, 495
  - omental patch, 497
  - peptic ulcer (*see* Peptic ulcer disease (PUD))
- Periampullary cancer, 197
- Pericarditis, 51
- Peripheral arterial disease (PAD)
  - ABI, 564
  - and ALI, 581, 583
  - and carotid atherosclerosis, 566
  - and coronary, 566
  - asymptomatic, 565, 567
  - atherosclerotic, 582
  - clopidogrel, 566
  - CT/MR angiogram, 564–565

- Peripheral arterial disease (PAD) (*cont.*)  
 diagnosis, 560  
 etiology of ALI, 587  
 invasive therapeutic approach, 567  
 ischemic rest pain, 560, 567  
 limb-threatening, 565  
 management, 585  
 mortality for patients, 567  
 nonischemic limb, 583  
 pulse deficit, 561  
 risk factors, 560  
 spectrum of severity, 560  
 statin, 566  
 symptom, 560  
 thrombosis, 583
- Peritonitis, 247, 249  
 barium, 496  
 characterization, 494  
 diagnosis, 493–494
- Peritonsillar, 137, 140
- Permissive hypotension, 428–429
- Persistent herniation, 351
- Phalen's  
 CTS, 310  
 median nerve, 313  
 wrists, 309
- Pheochromocytoma, 79, 83  
 “rule of tens,” 103  
 adrenalectomy, complications, 108  
 and pregnancy, 109  
 asymptomatic, 103  
 biopsy, 109  
 catecholamine, 102–103  
 elevated hematocrit levels, 105  
 extra-adrenal, 104  
 genetic testing, 108  
 hereditary syndromes, 104  
 hyperglycemia, 105  
 hypertensive crisis, 105, 109  
 imaging studies, 106  
 laboratory tests, 105  
 malignant, 105, 108  
 predominant catecholamines, 104  
 prognosis, 108  
 surgical principles, 107  
 symptoms, 102–103  
 treatment, 106–107  
 urine or plasma testing, 105–106
- Phyllodes, 26
- Platysma, 444, 445, 450
- Pleural decortication, 515
- Pneumomediastinum, 513, 515
- Pneumothorax, 448  
 breath sounds absent, 453  
 FAST in blunt trauma, 460  
 iatrogenic, 454  
 open, 451, 453  
 tension, 451, 452, 454, 456, 458, 459, 461
- Polyhydramnios  
 amniotic fluid, 330  
 idiopathic, 330
- Polytrauma  
 extremity fractures, 277  
 fat embolism syndrome, 279, 283
- Popliteal artery, 437
- Post-renal, 397
- Posterior cruciate ligament (PCL), 291
- Posterior knee dislocation, 438
- Postoperative bleeding  
 anticoagulant medications, 391  
 antiphospholipid syndrome, 386  
 coagulation cascade, 387, 388  
 coronary artery disease, 385  
 diathesis, 386  
 fibrinolysis, 390  
 hemophilia, 386  
 hernia repair, 385  
 liver disease, 392  
 malabsorption syndromes, 387  
 platelets, 387, 392  
 PTT, 386  
 re-exploration, 391  
 renal failure, 392  
 reverse warfarin, 392  
 thrombocytopenia, 389  
 trauma, 387  
 vitamin K-dependent, 389
- Postoperative decreased urine output. *See* Acute kidney injury (AKI)
- Postprandial RUQ pain  
 biliary colic, 154  
 cholangitis, 164  
 cholecystectomy with acute cholecystitis, 163  
 cholelithiasis and acute cholecystitis, 154, 155  
 cholesterol gallstones, 154  
 diagnosis, 153, 164  
 differential diagnosis, 154  
 gangrenous cholecystitis, 163–164  
 history, 164  
 management, 161, 164–165  
 obese Hispanic female, 153  
 pathology, 164  
 pathophysiology  
 abdominal pain, 155  
 acute cholecystitis, 156  
 bile, 156  
 chronic cholecystitis, 156  
 gallstones, 156, 157  
 Murphy's sign, 155  
 patient's low-grade fever and tachycardia, 155  
 scapular pain, 155  
 somatic and visceral pain, 155  
 physical examination, 153  
 postoperative, 161–163, 165  
 urgent and emergent case, 154  
 work-up, 157–161
- Pre-renal AKI, 397
- Prehn's sign, 520
- Primary sclerosing cholangitis (PSC), 171
- Prinzmetal Angina, 54
- Projectile, 344, 348
- Prostate cancer  
 management, 543  
 nonsurgical treatments, 541  
 presentation, 536  
 prostatic adenocarcinoma, 538  
 radical prostatectomy, 541
- Prostate-specific antigen (PSA), 533, 536, 542
- Prostatectomy, 541, 543
- PSC. *See* Primary sclerosing cholangitis (PSC)
- Pseudoaneurysm, 445, 446, 448, 449
- Pseudohematuria, 535, 542

- Psoas, 215, 216  
Pulmonary autograft (Ross procedure), 63  
Pulmonary contusion, 452, 461  
Pulmonary embolus (PE)  
  determination, 408  
  differential diagnosis, 404  
  DVT, 404  
  indirect diagnosis, 410  
  initial anticoagulant management, 410  
  open, 411  
  severity, 410  
  treatment, 410  
  V/Q Scan, 410  
  VTE, 405  
  Wells score, 405  
Pulmonary hypoplasia, 323, 326  
Pulsatile mass, 571, 575  
Pulselessness, 582, 583, 585, 588  
  implication, 475–476  
  tissue ischemia, 474  
Pulsus alternans, 59  
Pulsus bisferiens, 59  
Pyloric stenosis  
  nonbilious vomiting, 348  
  Ramstedt pyloromyotomy, 345, 346  
  ultrasound, 345  
Pyloromyotomy  
  laparoscopy, 347  
  nonsurgical management, 347  
  Ramstedt, 346, 348
- Q**  
Q-angle, 292, 297
- R**  
Radiation, chemotherapy, and retroperitoneal lymph node dissection (RPLND), 530, 531  
Radical nephrectomy, 541  
Radiculopathy, 257  
Radioactive iodine (RAI) ablation, 119  
Ramstedt pyloromyotomy, 346, 348  
Ranson criteria  
  monitor improvement/deterioration, 181  
  scoring systems, 180–181  
Rectal cancer, 233, 234  
Recurrent fractures, 290  
Red blood cells (RBCs), 535  
Referred pain, 301  
Renal cancer  
  RCC, 537–538  
  risk factors, 536  
  symptoms/presentation, 536  
Renal cell carcinoma (RCC)  
  description, 537  
  genetic syndromes, 538  
  lung, 538  
  paraneoplastic syndromes, 538  
  renal masses, 540  
Renal masses  
  radical nephrectomy, 541  
  treatment options, 540  
Renal stones  
  high protein diets, 537  
  management, nephrolithiasis, 540  
  surgical indications, 540  
  symptoms, 536  
  type, 537  
Reperfusion  
  compartment syndrome, 475  
  pathophysiology, 476, 478  
Respiratory distress  
  Bochdalek hernia, 323  
  CDH, 322  
  chest radiograph, 322  
  chest x-ray (CXR), 324  
  choanal atresia, 324  
  congenital anomalies, 325  
  diaphragmatic defect, 326  
  ECMO, 325  
  fetal surgery, 327  
  hyaline membrane disease, 322  
  hypoxemia, 326  
  intubation, 326  
  mediastinum, 323  
  MIS, 327  
  pulmonary examination, 323  
  supracostal retractions, 321, 322  
Reticularis, 80  
Retina, 548, 556  
Retractions  
  grunting, 322  
  supracostal, 321  
Retroauricular ecchymosis, 266  
Richter's hernia, 8, 11  
Right lower quadrant (RLQ) pain. *See* RLQ abdominal pain  
Rinne tests, 147–148, 150  
RLQ abdominal pain  
  absent bowel sounds, 215  
  acute appendicitis, 215, 218  
  appendectomy, 223  
  bacteriuria, 218  
  diagnosis  
    adult, 214  
    child, 215  
    women, 214  
  hamburger sign, 215  
  imaging, 218–220  
  management, 220–221  
  McBurney's sign, 215–216  
  non-perforated appendicitis, 223  
  Obturator sign, 215–216  
  pathophysiology, 216–218  
  patient, RLQ pain, 223  
  Psoas sign, 215–216  
  radiographic signs, appendicitis, 218–220  
  Rovsing's sign, 215–216  
  surgical emergency, 222  
Rovsing's sign, 16, 215  
Rule of 9's, 464, 465, 470  
Ruptured AAA, 577  
Rutherford  
  classification of chronic limb ischemia, 560  
  claudication, 566  
  tissue loss, 568
- S**  
S4, 58  
Saddle embolus, 409  
Salivary gland, 135, 136

- SBO. *See* Small bowel obstruction (SBO)
- Saphoid abdomen, 322, 328
- SCC. *See* Squamous cell carcinoma (SCC)
- SCFE. *See* Slipped capital femoral epiphysis (SCFE)
- Scrotal mass
- description, 525
  - diagnosis, 525–526
  - epididymitis, 528
  - hydrocele, 529
  - inguinal incision, 530
  - nonseminoma, 531
  - orchiectomy/chemotherapy, 530
  - seminoma, 531
  - spermatocele, 528
  - testicular cancer (*see* Testicular cancer)
  - unilateral orchiectomy, 530
  - varicocele, 527, 528
- Scrotal pain
- blue-dot sign, 520, 521
  - blunt testicular trauma, 520
  - cremasteric reflex, 520
  - description, 519
  - diagnosis, 519–520
  - Prehn's sign, 520
  - testicular torsion (*see* Testicular torsion)
- Seborrheic keratosis, 368, 375
- Segment elevation myocardial infarction (STEMI)
- initial management, 51
  - long-term outcome, 52
  - reperfusion, 51
- Seminoma
- and nonseminomas, 530, 531
  - blood tests, 530
  - germ cell tumor, 528
  - pathology/pathophysiology, 528, 531
- Sentinel lymph. *See* Sentinel lymph node biopsy (SLNB)
- Sentinel lymph node biopsy (SLNB), 29, 31
- and mastectomy, 31
  - lymphadenectomy, 373
  - melanoma, 373
  - premise, behind, 31
- Sentinel node, 31
- Septic arthritis
- arthrocentesis, 291
  - crystalline arthropathy, 294–295
  - Kocher criteria, 307
  - limbs, 290
  - SCFEs, 307
- Shock
- hemorrhagic, 417
  - hypovolemic, 416
  - types, 415
- Shortness of breath, after surgery
- 5 classic causes, postoperative fever, 406
  - ABG, ECG and CXR, 408
  - anticoagulation during pregnancy, 411
  - CT angiography, 408, 409
  - diagnosis, 403, 411
  - DVT, 405
  - history and physical exam, 411
  - Homans' sign, 405
  - laparoscopy, left colectomy, 403
  - malignancy, 411
  - management, 411
    - anticoagulant, PE, 410
    - contraindication to anticoagulation, 410
    - heparin-induced thrombocytopenia (HIT), 410
    - intravenous tPA, 411
    - treatment, 410
  - pathophysiology, 411
    - A-a gradient, 407
    - acquired causes of hypercoagulability, 406
    - cardiogenic and noncardiogenic pulmonary edema, 407
    - inherited causes of hypercoagulability, 406
    - postoperative pneumonia, 407
    - VTE, 407
  - pulmonary embolism, 408, 409
  - risk factors, VTE, 405
  - V/Q Scan, 410
  - Virchow's triad, 404
  - Wells score, 405
- Sigmoid
- colectomy, 250
  - diverticula, 246, 247, 250
  - pelvis, CT scan, 248
  - ureter, 251
- Sigmoid volvulus
- and cecal, 239
  - bent-inner tube sign, 240
  - coffee-bean sign, 240
  - complicated, 241
  - diagnosis, 238
  - malrotation, 239
  - risk factors, 239–240
  - treatment, 241
  - uncomplicated, 241
- Silo, 352–354
- Skin cancer
- basal cell carcinoma, 370
  - immunosuppression, 368
  - SCC and BCC, 372
  - SPF, 370
  - sun exposure, 369
  - UV, 368
  - xeroderma pigmentosum, 369
- Skin lesion
- actinic keratosis, 370
  - benign conditions, 374
  - Bowen's disease, 370–371
  - Breslow depth, 371
  - chronic skin inflammation, 369
  - lymphadenopathy, 367
  - melanoma, 368
  - skin cancer, 368
  - ugly duckling sign, 369
- Sliding hernia, 8, 11
- Slipped capital femoral epiphysis (SCFE)
- antalgic gait, 301
  - avascular necrosis, 307
  - chondrolysis, 307
  - contralateral fixation, 307
  - endocrine disorders, 302
  - leg rotation, 301
  - obesity, 301
- Small bowel obstruction (SBO), 4
- adhesions, 242
  - and LBO, differentiation, 19
  - and postoperative ileus, 19–20
  - causes, 17
  - closed loop obstruction, 17
  - complete and partial, 19
  - diagnosis, 238, 243
  - history and physical examination, 238
  - Howship-Romberg sign, 16

- imaging, 18
  - laboratory tests, 18
  - management
    - initial steps, 20
    - nonviable bowel during laparotomy, 20
    - of early postoperative SBO, 20–21
    - operative vs. nonoperative, 20
  - mechanisms of fluid loss, 18
  - plain abdominal X-rays, 240
  - radiologic findings, 19
  - risk, 18
  - significance, 16
  - Soft muscular compartments, 290
  - Soft signs, 436, 442
  - Spermatocele, 527, 528
  - Spinal cord
    - cervical cord, 257
    - emergent surgery, 261
    - motor neurons, 257, 258
    - myelopathy, 257
    - rehabilitation, 261
    - steroid therapy, 261
    - thresholds, 261
    - vertebral fractures, 259
  - Spinal shock
    - flaccid paralysis, 258
    - sacral sparing, 258
  - Squamous cell carcinoma (SCC), 137, 138
    - basal cell carcinoma, 370
    - Bowen's disease, 370
    - of head and neck, tobacco, 129
    - of upper aerodigestive tract, consequences, 129
    - SPF, 370
  - Stab wound, chest
    - air bubbling, 453
    - areas, 460
    - cardiac box, 452
    - complications, 459, 462
    - differential diagnosis, 451, 453, 461
    - hidden six injuries, 452
    - history and physical exam, 461
    - initial management, 455–458
      - cardiac tamponade, 457
      - chest X-ray, 456
      - circulation, 456
      - indications and contraindications, EDT, 456, 457
      - intubated, 455
      - needle thoracostomy, 456
      - performing pericardiocentesis, 457
      - primary survey, 457
      - steps, 455
      - subxiphoid window, 457
      - traumatic cardiac tamponade, 458
      - tube thoracostomy, 456
    - lethal six injuries, 451–452
    - pathophysiology, 454–455, 461
    - penetrating injury, 453
    - risk of infections, 460
    - subcutaneous emphysema, 453
    - subsequent management, 458–459
    - suspect tension pneumothorax, 452
    - systolic and diastolic pressures, 453
    - traumatic cardiac tamponade, 452
    - weapon, 453
  - Stanford
    - acute MI, 71
    - ascending and descending aorta, 69, 70
    - diagnosis, 70–71
    - endovascular repair, 72
    - prognosis and definitive management, 71
    - surgical repair, 71
    - type A and type B, 68–69
  - Stereotactic biopsy
    - DCIS, 40
    - invasive ductal carcinoma, 42
    - LCIS, 42
  - Strangulated hernia, 5, 6, 10
  - Stress gastritis, 489
  - Stress ulcers, 489
  - Stridor, 444
  - Stroke, 404
    - hemorrhagic, 550
    - ischemic, 550
    - lacunar, 550
  - Subclavian steal syndrome, 562, 569
  - Subcutaneous emphysema, 512, 515
  - Subdural hematoma (SDH)
    - craniotomy, 272
    - head injury, 267
    - parenchymal injury, 268
  - Sudden deafness, 146
  - Superficial burn injury, 464
  - Superficial femoral artery (SFA)
    - atherosclerotic plaque, 562
    - hunter/adductor canal, 562
  - Suppressive thyroxine therapy, 119
  - Sweating, 102. *See also* Hypertension (HTN)
  - Symptomatic carotid artery stenosis
    - CEA, 554, 555
    - left and right carotid, 552
    - management, 553
  - Synchronous tumor, 231
  - Syncope. *See* Chest pain and syncope
  - Systemic inflammatory response syndrome (SIRS)
    - definition, 167, 251
    - management steps, 170–171, 248–249
- T**
- T-score, 90
  - Tamponade, cardiac, 451–462
  - TEF. *See* Tracheoesophageal fistula (TEF)
  - Testicular cancer
    - blood tests, 530
    - common subtype, 528
    - development, 527
    - diagnosis, 526
    - gynecomastia, 528
    - management, 530
    - metastatic, 527
    - pathologic subtypes, 528
    - percutaneous biopsy, 530
    - physical examination, 527
    - risk factors, 527
    - RPLND, 530
    - seminoma, 531
    - ultrasound, solid mass, 529
  - Testicular mass. *See also* Testicular cancer
    - diagnosis, 526
    - inguinal incision, 530
    - painless, 527
  - Testicular torsion
    - abdominal pain and vomiting, 524
    - and appendix testes torsion, 521

- Testicular torsion (*cont.*)  
 and epididymal appendage, 520  
 appendix testis, 527  
 bell-clapper deformity, 521  
 cardinal symptoms and signs, 520  
 congenital defects, 521  
 epididymis, 528  
 epididymitis/orchitis, 527  
 fertility, 523  
 imaging/laboratory work-up, 522  
 management, 523  
 operative indications, 523  
 orchiectomy, 523  
 risk factors, 521  
 scrotal Doppler ultrasound, 522  
 surgical reduction, 523  
 urinalysis, 522
- Tetanus immune globulin (TIG), 281
- Thenar atrophy, 309, 315, 317
- Thickness  
 circumferential full-thickness burns,  
 466, 469  
 deep partial, 464  
 full thickness, 464  
 superficial partial, 464
- Thoracic trauma  
 aorta, 456  
 decompression, 456  
 diaphragm injury, 460  
 epidural catheter, 459  
 hidden six injuries, 452  
 lethal six injuries, 451–452  
 penetrating injury, 453
- Thoracotomy, 456, 459, 462
- Thrombocytopenia  
 alcohol abuse, 389  
 platelet count, 389
- Thrombolysis  
 catheter-directed, 587  
 CDT, 588, 589  
 tPA, 586
- Thyroglobulin, 115
- Thyroid cancer  
 anaplastic, 119  
 central lymph node dissection, 119  
 central neck dissection (CND), 121  
 external beam radiation, 120  
 follow-up, 120  
 intraoperative frozen section, 119  
 iodinated IV contrast, 121  
 lateral neck dissection, 119  
 vs. lobectomy, 118  
 papillary, 113, 121  
 postoperative management, 119  
 Psammoma Bodies, 116  
 radioactive iodine, 119  
 risk factors, 113  
 types, 116
- Thyroid mass  
 actions of thyroid hormones, 115  
 diagnosis, 122  
 differential diagnosis, 112  
 embryologic origin, 115  
 family history, 121  
 function of thyroid gland, 114  
 history and physical, 122  
 laboratory tests, 116  
 management, 123  
 pathophysiology, 123  
 patient's diagnosis, 112  
 swallowing, 114  
 thyroid cartilage (*Adam's apple*), 114
- Thyroid-stimulating hormone (TSH) level, 117
- Thyroidectomy, 118–119, 120
- Tinel's, 309, 310, 313, 317
- Tinnitus, 144, 146
- Tissue necrosis  
 and permanent limb damage, 475  
 physical exam and clinical situation, 474
- Total parenteral nutrition (TPN), 340
- Tracheoesophageal fistula (TEF), 324  
 anomalies, 358  
 gastrostomy, 361  
 intubation, 363  
 polyhydramnios, 361  
 respiratory distress/pneumonia, 358
- Transesophageal echocardiography (TEE), 69
- Transfusion-related acute lung injury (TRALI)  
 fluid resuscitation, 392  
 pulmonary edema, 392  
 vasopressors, 392  
 WBCs, 392
- Transient ischemic attack (TIA)  
 and stroke, 548, 550–552, 554  
 fibrinolysis, 551  
 transient motor and sensory loss, 548
- Transient monocular vision loss  
 amaurosis fugax (*see Amaurosis fugax*)  
 anterior and posterior circulation symptoms, 550  
 anterior circulation ischemic stroke, 549  
 atherosclerotic plaque, 551  
 carotid (*see Carotid*)  
 description, 548  
 diagnosis, 547–548  
 emboli (*see Emboli*)  
 eye symptom, 548  
 hollenhorst plaques, 548  
 right arm and leg weakness, 548  
 stroke, 550  
 TIA (*see Transient ischemic attack (TIA)*)
- Trastuzumab, 32
- Trauma, penetration. *See Penetrating abdominal trauma*
- Traumatic brain injury (TBI)  
 corticosteroids, 271–272  
 CT, 269  
 neurologic deficit, 266
- Triple therapy, *H pylori* positive, 497, 498
- Trismus, 135, 140
- Trisomy 21, 331, 334
- Troponin, 50, 55
- Trousseau's Sign, 90
- Tubulovillous, 229
- Tumor, testicular. *See Testicular cancer*
- Tunica albuginea  
 Doppler ultrasound, 522  
 violation, 523, 524
- Turcot syndrome, 230
- Tympanostomy tube, 148
- U**
- Umbilical hernias, 5, 6, 10
- Uncomplicated volvulus, 240–243
- Unstable angina (UA)

- acute coronary syndrome, 49
  - NSTEMI and STEMI, difference between, 49
  - Upper gastrointestinal (UGI) bleed, 332
  - adversely affect prognosis, 483
  - blood transfusion, 490
  - BUN/creatinine ratio, 484
  - color and texture of stool and emesis, 482
  - Dieulafoy's lesion, 483–484
  - differential diagnosis, 482
  - emesis and bright-red blood per rectum, 484
  - endoscopic techniques, 487
  - esophageal varices, 489
  - fluid resuscitation, 485
  - GI tract, 484
  - indications for surgery, 488
  - liver disease, 490
  - Mallory-Weiss Tear, 489
  - management, 487
  - management algorithm, 485, 486
  - NGT, 485
  - obscure GI bleeding, 485
  - Upper respiratory tract (URI), 302
  - Urachal, 349
  - Ureteropelvic junction (UPJ), 536
  - Ureterovesical junction (UVJ), 536
  - Urine, postoperative decreased output. *See* Acute kidney injury (AKI)
  - Urothelial cell carcinoma (UCC), 538
- V**
- V/Q scan, 410
  - Vacterl, 359, 363
  - Vagotomy
    - and pyloroplasty, 488
    - HSV, 488
  - Valve replacement, 62–63
  - Vanillylmandelic acid, 105
  - Varicocele
    - diagnosis, 519
    - infertility, 527
    - pathophysiology, 528
    - sudden onset, left-sided, 529
  - Vascular accident, 351
  - Vascular imaging, 438, 442
  - Venous thromboembolic event (VTE)
    - high and low suspicion, 408
    - malignancy, 411, 412
    - pregnancy, 411, 412
    - recommendation, long-term anticoagulation, 411
    - risk factors, 405, 407
    - Virchow's triad, 404
  - Ventral or incisional hernias, 5
  - Vicious cycle, 386
  - Violaceous
    - ischemia, 378
    - radiography, 378
  - Virchow's triad, 404, 407
  - Viscus, 494
  - Vision loss, transient. *See* Transient
    - monocular vision loss
  - Vocal cord paralysis, 446
  - Volkmann's ischemic contracture, 476
  - Volvulus
    - and malrotation, 239
    - cecal (*see* Cecal volvulus)
    - colonic, 242
    - complicated, 240
    - diagnostic, 241
    - outcomes, 242
    - sigmoid (*see* Sigmoid volvulus)
  - Von Willebrand disease (VWD)
    - congenital form, 388
    - platelets, 387–388
  - VTE. *See* Venous thromboembolic event (VTE)
- W**
- Warfarin, 566
  - Weber, 147, 150
  - Weight loss and early satiety
    - complications, 508–509
    - description, 501
    - diagnosis, 502
    - epidemiology, 502–503
    - gastric adenocarcinoma (*see* Gastric adenocarcinoma)
    - gastric cancer (*see* Gastric cancer)
    - gastric resection (*see* Gastric resection)
    - HER2, 507
    - linitis plastica, 504, 505
    - lymph nodes, 506–507
    - management, 506–508
    - pathophysiology, 504–505
    - patient's tumor, 505
    - proton-pump inhibitor (PPI), 501
    - screening, 503–504
    - vascular supply to stomach, 504–505
  - Whipple procedure, 196–197
  - White blood cells (WBCs), 392