

Identifying the Inferior Oblique in Transconjunctival Blepharoplasty

56

Jemshed A. Khan

Prior to embarking upon transconjunctival blepharoplasty, the inferior oblique muscle should be clearly visualized. The inferior oblique is reliably located in the cleft between the nasal and central fat pads. Using cotton-tipped applicators, the nasal and central fat pads can be easily separated to allow the inferior oblique to come into view. Once identified, one can safely proceed with excision of the fat pads (Fig. 56.1).

The inferior oblique muscle originates from the periosteum adjacent to the proximal bony nasolacrimal duct and passes inferior to the nasal

fat pad and superior to the central fat pad. Arising from the inferior oblique is an expansion of connective tissue that sometimes restrains the contiguous fat of the central and lateral fat pads. This tissue, the arcuate expansion, may be divided if necessary (Fig. 56.2).

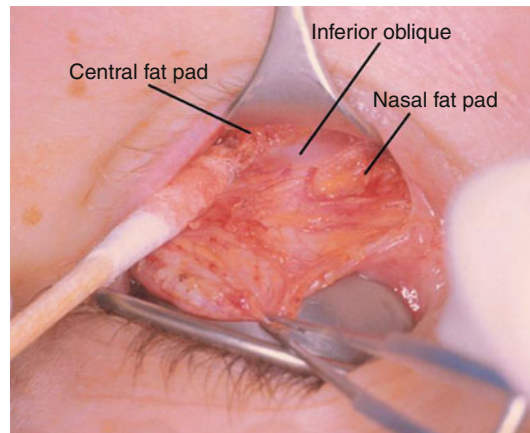


Fig. 56.1 Inferior oblique muscle is reliably located in the cleft or separation between the nasal and central fat pads

Reprinted from Chen WPD, Khan JA, McCord, Jr, CD. *Color Atlas of Cosmetic Oculofacial Surgery*. Philadelphia, PA: Butterworth Heinemann/Elsevier; 2004. With permission from Elsevier

J.A. Khan, MD
Department of Ophthalmology,
Kansas University School of Medicine,
Kansas University Medical Center,
Kansas City, MO, USA

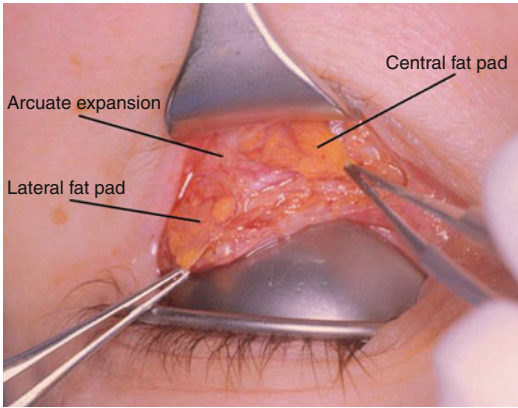


Fig. 56.2 The arcuate expansion sometimes constrains the central and temporal fat pads

Key Points

Recommended Instruments¹

- Khan-Jaeger laser eyelid plate.
- Castroviejo 0.5 mm toothed platform tying forceps.
- Desmarres retractor (dull finish).
- Bipolar cautery, hemostat (fine curved).
- Protective metal scleral contact lens.
- The inferior oblique can always be located between the nasal and central fat pads.
- If the fat is restrained between the central and lateral fat pads, look for and divide the anteriorly located fibrous band of tissue (arcuate expansion).
- The lateral fat pad is easier to remove once separated from the underlying lower eyelid retractor

¹Storz Instrument Company, St Louis, MO