

---

## Incisional Guidelines When Marking the Skin in Upper Eyelid Blepharoplasty

# 20

Sheri L. DeMartelaere, Todd R. Shepler,  
Sean M. Blaydon, Russell W. Neuhaus,  
and John W. Shore

For those patients without a discernible lid crease (Fig. 20.1), the following measurements can provide a good incisional guideline:

- 7–9 mm above the mid-eyelid margin for men and 8–10 mm for women
- 6 mm above the medial eyelid margin at the level of the punctum
- 6–8 mm above the lateral eyelid margin at the level of the lateral canthus
- Lateral eyelid crease incision then swings upward at the lateral canthus to end 15–18 mm from the lateral canthus at a 45° angle

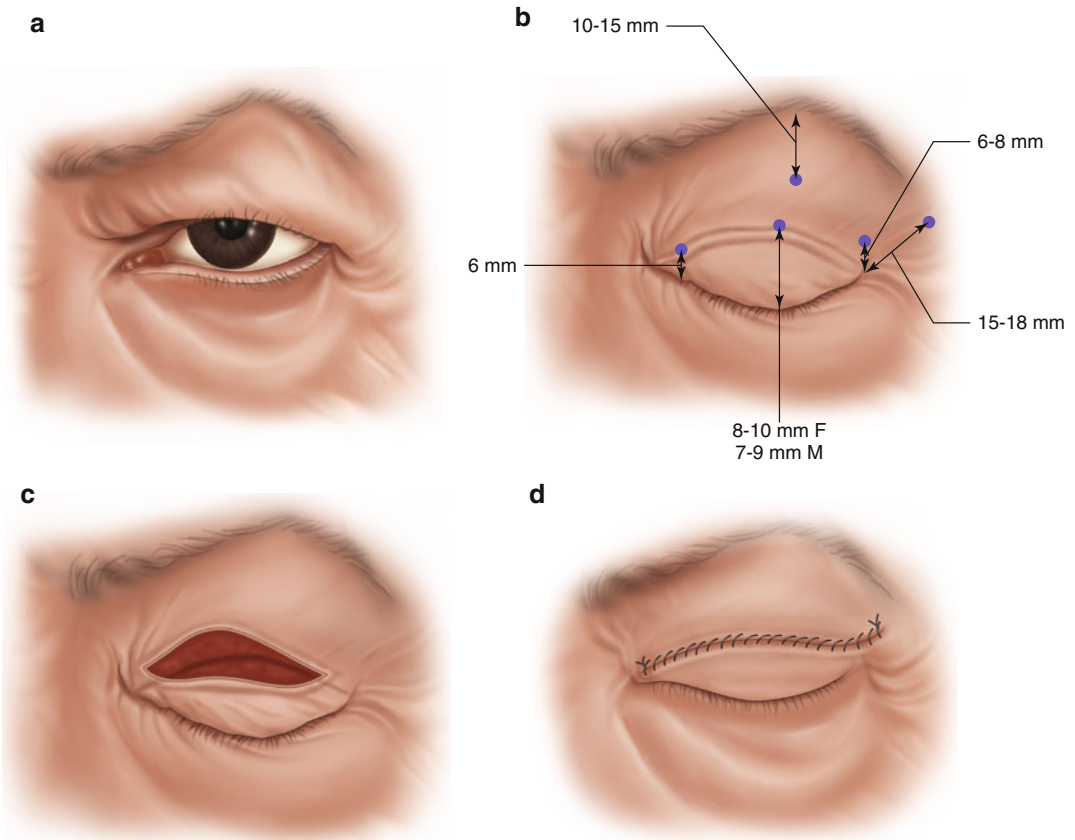
An axiom that is useful for those starting out: always leave behind at least 2 cm of skin between the lash margin and lower eyebrow hairs and you should never have difficulty with postoperative lagophthalmos. This means that the upper limit of skin excision should leave 10–15 mm of skin between the inferior brow and upper skin incision. This limit can be marked at the beginning of the case as a reminder.

---

S.L. DeMartelaere, MD, FACS (✉)  
Uniformed Services,  
University of the Health Sciences, San Antonio, TX, USA

Department of Surgery, Ocular and Orbital  
Trauma Service, Brooke Army Medical Center,  
San Antonio, TX, USA

T.R. Shepler, MD • S.M. Blaydon, MD  
R.W. Neuhaus, MD • J.W. Shore, MD  
Texas Oculoplastic Consultants, Austin, TX, USA



**Fig. 20.1** Artist's sketch depicting incision guidelines for upper eyelid blepharoplasty. **(a)** Preoperative sketch of upper eyelid dermatochalasis. **(b)** Castroviejo calipers are

used to measure the eyelid. **(c)** Planned incision. **(d)** Skin excision closed with running suture