

In-Office Brow and Forehead Lifting by a Quick Multi-incision Trichophytic Approach

103

John R. Burroughs

Rejuvenation of the brow and forehead is a critical cosmetic concern for many patients. An ideal approach would improve both forehead rhytids and brow ptosis, yet be easily performed and well tolerated in the office setting. Equally important is a long-lasting result that has low risk, instrument cost, and downtime. I have found, for many patients, the pre-hairline (trichophytic) with or without subcutaneous dissection forehead lift to be a great in-office procedure with high patient satisfaction. Suitable patients will tolerate the 2–3 incision placement sites and do not wish to have the hairline raised. Poor candidates are those with male pattern baldness, unstable hairlines, and inability to tolerate visible although when properly performed acceptable cosmetic incisions. Like most forehead lifting techniques, optimal results are achieved when performed with a simultaneous upper blepharoplasty. Natural-appearing brow elevation can be enhanced by the internal brow elevation technique (Burroughs et al. 2006).

When deciding to perform this type of a forehead lift, it is important to first determine if the patient only requires a bitemporal approach to elevate descent of lateral brow ptosis or if they will require a tri-incision approach with a third incision placed at the central forehead-hairline area. This third, central incision is necessary if

the patient has significant forehead rhytids and/or medial brow ptosis (Fig. 103.1). Another benefit to the temporal incisions is when properly placed and extended inferiorly, they can reduce the lateral eyelid rhytids (Fig. 103.2). I have rarely found the need to perform a complete incision across the entire forehead-hairline area, but this may be performed to address extensive forehead rhytids and severe brow ptosis (Niamtu 2008). Figure 103.3 shows a typical result that may be achieved with the tri-incision trichophytic approach.

Patients receive 10–20 mg oral diazepam with a combination acetaminophen-narcotic an hour before the procedure. The incision and dissection areas are first infiltrated in the subcutaneous plane with diluted lidocaine with epinephrine anesthetic (7 cc of preserved saline mixed with 3 cc of 2 % lidocaine with 1:100,000 epineph-

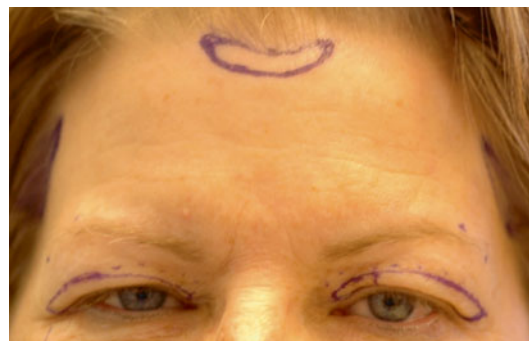

Fig. 103.1 Patient who was marked for a tri-incision trichophytic lift

J.R. Burroughs, MD, PC
Colorado Springs, CO, USA
e-mail: john@drjohnburroughs.com

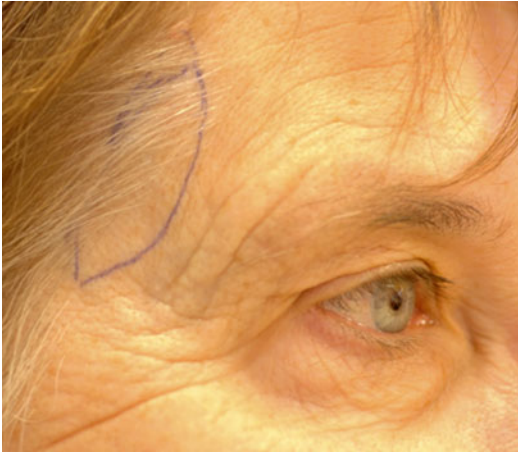

Fig. 103.2 Right temple marking for raising the lateral brow showing inferior extension to also address the lateral eyelid rhytids

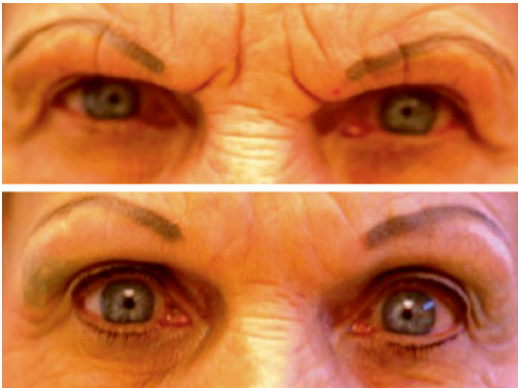


Fig. 103.3 Patient who underwent a tri-incision trichophytic lift, transblepharoplasty orbital ligament release, and Radiesse® filler to the glabella area showing the before and after result

rine). This is followed by 2 % lidocaine with 1:100,000 epinephrine and 0.5 % bupivacaine with 1:200,000 epinephrine. Supraorbital and supratrochlear blocks further anesthetize the forehead while minimizing the total amount of local injection required. The central incision area is more prone to bleeding, so I generally start with the lateral incisions first.

Extreme bevel-incision architecture is critical for optimal cosmesis. Upon closure, the incision should be just posterior to the hairline by a few millimeters. A #15 blade is used to

make the incisions with the angle beveled between 20 and 30° from the plane of the skin surface. When determining the placement of the lateral forehead incisions, I place a straight edge from the lateral ala through the desired high point of the eyebrows (generally at the outer one-third junction with the inner two-thirds). In females in particular, this lateral brow arching begins at the junction between the lateral limbus and lateral canthus. A surgical marking pen line is drawn through this area and defines the mid-portion of the lateral incisions. The lateral incision lengths vary from patient to patient but generally are 3–4 cm in length. Determining how much skin to remove is also quite variable depending upon the patient's anatomical findings, but usually, no more than 1.5–2.5 cm of central width is removed. A useful guideline is to measure preoperatively how much lift is desired for the lateral brows in millimeters and then doubling it for the maximal (central) width for the lateral incisions. Patients with taller foreheads and wider distances between the lateral brow and temple area hair may need the amount measured multiplied by 2.5 for more optimal lifting. It is important in males to not overlift thereby giving a prominent arch to the lateral brows, which will give an effeminate postoperative appearance.

Making these lateral incisions in the shape of a sharp half ellipse helps avoid skin bunching at the incision ends (“dog ears”). If too much skin is removed, the closure is difficult, or to achieve more lift, then subcutaneous dissection down toward the brow cilia may be performed to optimize the desired lift and wound closure. Keeping the dissection subcutaneous is the safest as it preserves the frontalis muscle and its motor nerves that run along the anterior aspect of the frontalis, and the sensory nerves mostly travel along the posterior aspect of the frontalis muscle. An alternative approach I find helpful is to just make the trichophytic incisions and then start subcutaneous dissection toward the brow cilia. Then using skin retractors or Adson forceps, pull the anterior forehead tissue and mark how much to remove to achieve the lift desired. Perpendicular

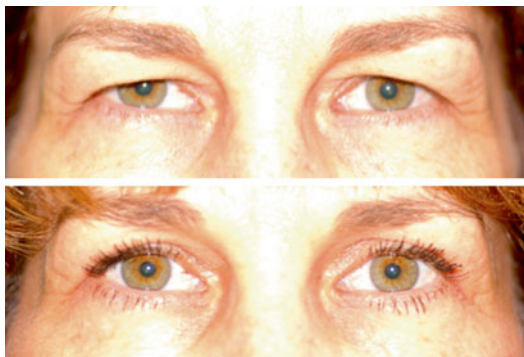

Fig. 103.4 Patient with greater lateral brow ptosis on the right side that underwent upper blepharoplasty and asymmetrical bitemporal trichophytic brow lift showing the before and after result

skin incisions can be performed through the subcutaneous dissected skin flap followed by suture placement to close the central incision and analyze the success of the lift. The suture can be easily removed and additional skin removed to achieve the desired result. Again, this can be variable depending if an upper blepharoplasty is also performed and if an internal brow elevation technique such as release of the orbital ligament has also been performed, which loosens the brow tissues and allows them to lift more easily (Burroughs et al. 2006). One benefit to this technique is the customizability as some patients may have significant brow position asymmetry preoperatively. Figure 103.4 shows a patient with more lateral hooding on the right side, so greater lift was performed on the right temporal incision than on the left. If more lift is still required, then instead of a half ellipse, a full ellipse of tissue can be removed from the scalp hair side as well, which when closed will lift the inferior temple and lateral brow tissue even further. I find fewer suture-abscess issues when utilizing monofilament suture, and most patients do well with buried 4-0 or 5-0 Monocryl. If more tension was present, then a longer lasting suture such as polydioxanone may be utilized, which is important to maintain cosmesis by avoiding scar widening. Superficial wound closure with running 6-0 Prolene should be achievable without considerable tension necessary.

The central incision, when needed, is usually 3–4 cm in length and follows the hairline (Fig. 103.1). It starts as a half ellipse with the elliptical portion extending onto the forehead skin. If there is a prominent widow's peak, then a bilobed half ellipse may be performed with the two ends joining at the inferior most portion of the central scalp hair. More considerable subcutaneous dissection can be performed to achieve more lift and closure without undue tension. If unintended overly aggressive skin removal was performed, then the wound can be taken down to the periosteum, and subperiosteal dissection can be done to facilitate wound edge closure. Dissection should be done posterior to the hairline only if needed as this will lessen the lift result.

When beginning this technique, it can be helpful to make the trichophytic incision and then perform subcutaneous dissection toward the brows. The central forehead tissue can then be lifted superiorly, and the amount of incision overlap will guide the skin removal. It is critical to make the incision beveled to foster scalp cilia growth through the incision thereby enhancing wound cosmesis. Closure is done in the same fashion as the lateral incisions.

I have not had the need for suction and only utilize a headlight when performing extensive subcutaneous dissection. Rarely, it is useful to pack one of the incisions with gauze and move onto another area if wound oozing is considerable until it slows or stops. Subcutaneous dissection carries very low risk yet provides the ability to achieve a superb and natural-appearing lift and forehead/eyelid rhytid reduction. Full-forehead trichophytic incision approach (Niamtu 2008) has been widely used, which enables full dissection of the forehead tissues and even superior access to the medial brow depressors, but I favor the trans-blepharoplasty approach and find that considerable subcutaneous dissection of the forehead can be achieved through the centrally placed incision.

When performed with a simultaneous upper blepharoplasty, it is critical to not remove too much skin, and I recommend performing the forehead lift first, so careful eyelid skin

measuring can be done and reduced if necessary to avoid lagophthalmos. Caution is also advised to avoid dissecting too deeply into the frontalis muscle to avoid injuring facial nerve branches or too superficially which can damage hair-bearing areas or cause skin necrosis of the mobilized flap. A head wrap is generally not necessary, but for patients that encountered more intra-op bleeding, it is prudent for 24 h to avoid hematoma formation. This forehead lift technique is extremely quick, especially for patients with lateral brow ptosis and a lateral low hairline. To avoid lowering the hairline any further, conversion from the half-ellipse incision to the full

ellipse may be performed to reduce hairline lowering. Alternatively, the hairline may be lowered in patients with a high hairline by only removing tissue below (caudal) the trichophytic incisions.

References

- Burroughs JR, Bearden WH, Anderson RL, McCann JD. Internal brow elevation at blepharoplasty. *Arch Facial Plast Surg*. 2006;8(1):36–41.
- Niamtu J. The subcutaneous brow- and forehead-lift: a face-lift for the forehead and brow. *Dermatol Surg*. 2008;34(10):1350–61.