

Sara L. Best
Stephen Y. Nakada
Editors

Minimally Invasive Urology

An Essential Clinical
Guide to Endourology,
Laparoscopy,
LESS and Robotics

 Springer

Minimally Invasive Urology

Sara L. Best • Stephen Y. Nakada
Editors

Minimally Invasive Urology

An Essential Clinical Guide
to Endourology, Laparoscopy,
LESS and Robotics

 Springer

Editors

Sara L. Best, MD
Department of Urology
University of Wisconsin School
of Medicine and Public Health
Madison, WI
USA

Stephen Y. Nakada, MD
Department of Urology
University of Wisconsin School
of Medicine and Public Health
Madison, WI
USA

ISBN 978-1-4939-1316-9 ISBN 978-1-4939-1317-6 (eBook)
DOI 10.1007/978-1-4939-1317-6
Springer New York Heidelberg Dordrecht London

Library of Congress Control Number: 2014949346

© Springer Science+Business Media New York 2015

This work is subject to copyright. All rights are reserved by the Publisher, whether the whole or part of the material is concerned, specifically the rights of translation, reprinting, reuse of illustrations, recitation, broadcasting, reproduction on microfilms or in any other physical way, and transmission or information storage and retrieval, electronic adaptation, computer software, or by similar or dissimilar methodology now known or hereafter developed. Exempted from this legal reservation are brief excerpts in connection with reviews or scholarly analysis or material supplied specifically for the purpose of being entered and executed on a computer system, for exclusive use by the purchaser of the work. Duplication of this publication or parts thereof is permitted only under the provisions of the Copyright Law of the Publisher's location, in its current version, and permission for use must always be obtained from Springer. Permissions for use may be obtained through RightsLink at the Copyright Clearance Center. Violations are liable to prosecution under the respective Copyright Law.

The use of general descriptive names, registered names, trademarks, service marks, etc. in this publication does not imply, even in the absence of a specific statement, that such names are exempt from the relevant protective laws and regulations and therefore free for general use.

While the advice and information in this book are believed to be true and accurate at the date of publication, neither the authors nor the editors nor the publisher can accept any legal responsibility for any errors or omissions that may be made. The publisher makes no warranty, express or implied, with respect to the material contained herein.

Printed on acid-free paper

Springer is part of Springer Science+Business Media (www.springer.com)

To the loving memory of Frank and Ayako Nakada

and

To Linda Best – for her unconditional love and support

Preface

In recent years, the field of urology has been transformed by notable developments in minimally invasive technology. Specifically, advances in small caliber flexible ureteroscopes and endoscopes, laparoscopic instrumentation, laparoendoscopic single-site surgery (LESS) and robotics have led to the rapid change from urology being an open surgical specialty to a predominantly minimally invasive surgical field.

This textbook provides an essential and comprehensive review of all aspects of minimally invasive urology, enlisting a wide array of leaders in the field known not only for their clinical prowess, but their commitment to education. As such, laparoscopic surgery, robotic surgery, endoscopic surgery, and LESS surgery are all reviewed within the context of renal cancer, renal reconstruction, bladder cancer, prostate cancer, female urology, stone disease, stricture disease, and benign prostatic hyperplasia. In each chapter, readers will find illustrated step-by-step advice from the experts on how to perform these procedures, as well as an equipment list. The book will wrap up with chapters on informed consent and cost, both also quite relevant to the practicing urologist. *Minimally Invasive Urology* will provide an invaluable reference to all urologists.

Madison, WI, USA
Madison, WI, USA

Sara L. Best, MD
Stephen Y. Nakada, MD

Contents

1 Laparoscopic and Robotic Access	1
Benjamin Woodson and Benjamin R. Lee	
2 Laparoscopic Renal Extirpative Surgery	11
Jessica Kreshover and Lee Richstone	
3 Laparoscopic and Robotic Reconstruction of the Upper Genitourinary Tract	21
Jeffrey C. Gahan and Jeffrey A. Cadeddu	
4 Laparoscopic and Robot-Assisted Adrenalectomy	33
Ravi Munver and Jennifer Yates	
5 Robot-Assisted Radical Prostatectomy	49
Bernardo Rocco, Rafael Ferreira Coelho, Gabriele Cozzi, Elisa De Lorenzis, and Vipul Patel	
6 Robot-Assisted Partial Nephrectomy	79
Jonathan Mobley and Brian M. Benway	
7 Robotically Assisted Radical Cystectomy	89
Granville L. Lloyd, E. Jason Abel, and Tracy M. Downs	
8 Robotic Pyeloplasty	105
Sri Sivalingam and Sara L. Best	
9 Robotic Abdominal Sacrocolpopexy	117
Sarah McAchran and Courtenay Moore	
10 Standard Laparoendoscopic Single-Site Surgery	131
Shashikant Mishra and Mihir Desai	
11 Robotic LESS Approaches	145
Dinesh Samarasekera and Jihad H. Kaouk	
12 Ureteroscopy for Treatment of Calculi	157
Necole M. Streepier and Stephen Y. Nakada	
13 Percutaneous Management of Large Renal Calculi (Percutaneous Nephrolithotomy)	169
Shubha De and Manoj Monga	

14	Endoscopic Incisions	177
	Philippe Violette and Hassan Razvi	
15	Non-laser Transurethral Resection of the Prostate	195
	Bilal Chughtai and Alexis E. Te	
16	Photoselective Vaporization of the Prostate	205
	David R. Paolone and Daniel H. Williams IV	
17	Holmium Laser Enucleation of the Prostate (HoLEP)	221
	John J. Knoedler and Amy E. Krambeck	
18	Informed Consent in Minimally Invasive Urology	231
	Matthew R. Thom and Howard N. Winfield	
19	Cost-Effectiveness in Minimally Invasive Urologic Surgery . . .	239
	Daniel Ramirez and Yair Lotan	
	Index	251

Contributors

E. Jason Abel Department of Urology, University of Wisconsin School of Medicine and Public Health, Madison, WI, USA

Brian M. Benway, MD Division of Urologic Surgery, Department of Surgery, Washington University School of Medicine, St. Louis, MO, USA
Midwest Stone Institute, St. Louis, MO, USA

Sara L. Best, MD Department of Urology, University of Wisconsin School of Medicine and Public Health, Madison, WI, USA

Jeffrey A. Cadeddu Department of Urology, University of Texas Southwestern Medical Center, Dallas, TX, USA

Bilal Chughtai, MD Department of Urology, Weill Medical College of Cornell University, New York, NY, USA

Rafael Ferreira Coelho, MD University of Central Florida School of Medicine, Orlando, FL, USA

Hospital Israelita Albert Einstein, Sao Paulo, SP, Brazil

Instituto do Câncer do Estado de São Paulo, Sao Paulo, SP, Brazil

Global Robotics Institute, Florida Hospital Celebration Health, Celebration, FL, USA

Gabriele Cozzi, MD Department of Urology, Clinica Urologica I. Università degli Studi di Milano, Milan, Italy

Department of Urology, Fondazione IRCCS Ca' Granda – Ospedale Maggiore Policlinico, Milan, Italy

Shubha De, MD Glickman Urologic and Kidney Institute, Cleveland Clinic, Cleveland, OH, USA

Elisa De Lorenzis, MD Department of Urology, Clinica Urologica I. Università degli Studi di Milano, Milan, Italy

Department of Urology, Fondazione IRCCS Ca' Granda – Ospedale Maggiore Policlinico, Milan, Italy

Mihir Desai, MD Department of Clinical Urology, Robotic Urologic Surgery, Keck Hospital of USC, USC Norris Comprehensive Cancer Center and Hospital, Los Angeles, USA

Tracy M. Downs Department of Urology, University of Wisconsin School of Medicine and Public Health, Madison, WI, USA

Jeffrey C. Gahan, MD Department of Urology, University of Texas Southwestern Medical Center, Dallas, TX, USA

Jihad H. Kaouk Department of Urology, Cleveland Clinic, Cleveland, OH, USA

John J. Knoedler, MD Department of Urology, Mayo Clinic, Rochester, MN, USA

Amy E. Krambeck, MD Department of Urology, Mayo Clinic, Rochester, MN, USA

Jessica Kreshover, MD, MS The Arthur Smith Institute for Urology, North Shore-Long Island Jewish Health System, New Hyde Park, NY, USA

Benjamin R. Lee, MD Department of Urology, Tulane University School of Medicine, New Orleans, LA, USA

Granville L. Lloyd, MD Department of Urology, University of Wisconsin School of Medicine and Public Health, Madison, WI, USA

Yair Lotan Department of Urology, University of Texas Southwestern Medical Center, Dallas, TX, USA

Sarah McAchran, MD Department of Urology, University of Wisconsin School of Medicine and Public Health, Madison, WI, USA

Shashikant Mishra, MD Department of Urology, Muljibhai Patel Urological Hospital, Nadiad, Gujarat, India

Jonathan Mobley, MD Division of Urologic Surgery, Department of Surgery, Washington University School of Medicine, St. Louis, MO, USA

Manoj Monga, MD Glickman Urologic and Kidney Institute, Cleveland Clinic, Cleveland, OH, USA

Courtenay Moore Department of Urology, Cleveland Clinic, Cleveland, OH, USA

Ravi Munver, MD, FACS Division of Urology, Department of surgery, Rutgers – New Jersey Medical School, Newark, NJ, USA

Department of Urology, Hackensack University Medical Center, Hackensack, NJ, USA

The John Theurer Cancer Center of Hackensack University Medical Center, Hackensack, NJ, USA

Stephen Y. Nakada, MD Department of Urology, University of Wisconsin School of Medicine and Public Health, Madison, WI, USA

David R. Paolone, MD Department of Urology, University of Wisconsin School of Medicine and Public Health, Madison, WI, USA

Vipul Patel, MD Department of Urology, Global Robotics Institute, Florida Hospital, Celebration Health, Celebration, FL, USA

University of Central Florida School of Medicine, Orlando, FL, USA

Daniel Ramirez Department of Urology, University of Texas Southwestern Medical Center, Dallas, TX, USA

Hassan Razvi, MD, FRCSC Division of Urology, Department of Surgery, Western University, London, Ontario, Canada

Urology, St-Joseph's Hospital, London, ON, Canada

Lee Richstone, MD The Arthur Smith Institute for Urology, North Shore-Long Island Jewish Health System, New Hyde Park, NY, USA

Bernardo Rocco, MD Department of Urology, Fondazione IRCCS Ca' Granda – Ospedale Maggiore Policlinico, Milan, Italy

Clinica Urologica I. Università degli Studi di Milano, Milan, Italy

Dinesh Samarasekera, MD Glickman Urologic and Kidney Institute, Department of Laparoscopic and Robotic Surgery, Cleveland Clinic, Cleveland, OH, USA

Sri Sivalingam Department of Urology, Cleveland Clinic, Cleveland, OH, USA

Necole M. Streeper Department of Urology, University of Wisconsin School of Medicine and Public Health, Madison, WI, USA

Alexis E. Te, MD Department of Urology, Weill Medical College of Cornell University, New York, NY, USA

Matthew R. Thom, MD West Alabama Urology Associates, DCH Regional Health System, Tuscaloosa, AL, USA

Philippe Violette, MD CM, FRCSC Department of Surgery, Western University, London, ON, Canada

Division of Urology, Western University, London, ON, Canada

Daniel H. Williams IV, MD Department of Urology, University of Wisconsin School of Medicine and Public Health, Madison, WI, USA

Howard N. Winfield West Alabama Urology Associates, DCH Regional Health System, Tuscaloosa, AL, USA

Benjamin Woodson, MD Department of Urology, Tulane University School of Medicine, New Orleans, LA, USA

Jennifer Yates Division of Urology, University of Massachusetts Medical School, Worcester, MA, USA

Department of Urology, UMASS Memorial Medical Center, Worcester, MA, USA

Benjamin Woodson and Benjamin R. Lee

Initial access into the peritoneal cavity is one of the most critical steps of any laparoscopic and robotic case. It is often overlooked in its importance within the overall success of the operation. If not performed correctly, laparoscopic access may be fraught with complications, adding to the potential morbidity and mortality of any case. In this chapter, we will review the various methods of laparoscopic and robotic access, as well as the potential complications. The technique is similar between the two minimally invasive modalities. Gaining access in laparoscopic and robotic surgery is the first step towards a successful surgery. With optimal placement of trocars and establishment of pneumoperitoneum, the subsequent execution of the procedure may be carried out in an ideal fashion, with the best possible chance of success.

There are two main types of laparoscopic and robotic access: open and closed. The closed approach is commonly referred to as the Veress technique, while the open approach is also known as the Hasson technique. Each has their associated advantages and disadvantages. Our preference is the Veress technique due to its ease and simplicity. There is also a technique known as direct trocar insertion, which is not commonly

used. The major complications of any access are the potential risk for injury to the bowel and the great vessels in the retroperitoneum and the less threatening complication of damage to blood vessels in the abdominal wall, which rarely can create a source of troublesome bleeding, requiring transfusions and return to the operating room. Furthermore, some of these injuries may not be recognized until the postoperative period, thereby increasing the associated morbidity. In the early learning curve, a significant proportion of the complications related to laparoscopic surgery occur during access and port placement [3], which decreases with experience [4].

Prior to any of the techniques for trocar placement, one should make sure to decompress the stomach with a nasogastric or orogastric tube, and a Foley catheter should also be placed to drain the bladder. These steps reduce the chance of injury to the GI tract and bladder due to distension.

The closed technique employs a Veress needle to gain peritoneal access. The Veress needle is actually named after the Hungarian physician, Janos Veres, who died in 1979 at the age of 76. He was a pulmonologist who invented the Veress needle in 1932. At that time, there was a high incidence of tuberculosis, and one of the accepted treatments at that time was creating an iatrogenic pneumothorax by puncturing the pleural cavity. This technique was fraught with complications, often with direct injury to the lung. Janos Veres invented a spring-loaded dual-needle system: one

B. Woodson, MD (✉) • B.R. Lee, MD
Department of Urology, Tulane University School of
Medicine, New Orleans, LA, USA
e-mail: brlee@tulane.edu

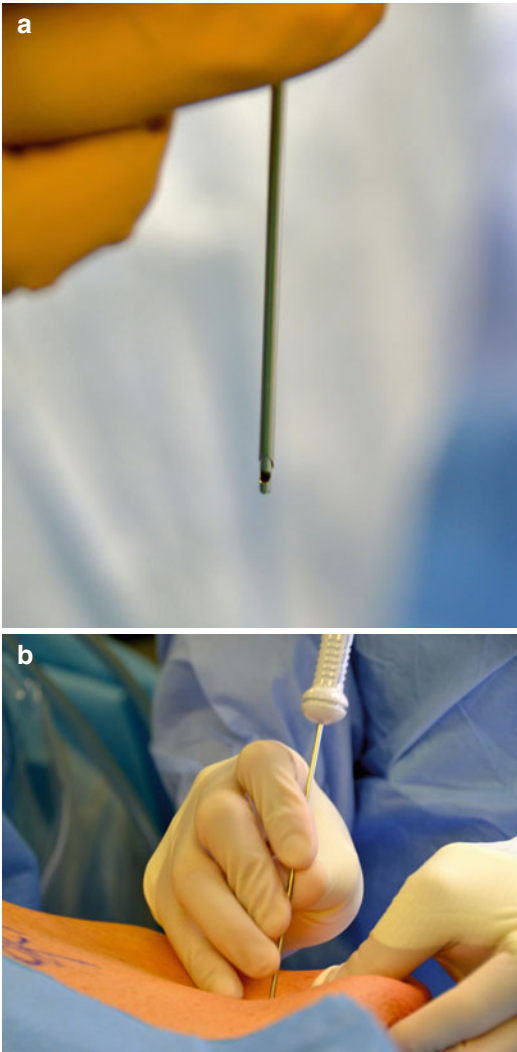


Fig. 1.1 (a) Veress tip—spring-loaded inner core retracts once the tip of the Veress needle traverses the muscle and enters the abdominal cavity. (b) Veress placement. Holding the Veress securely helps in accurate placement. Opening pressures of the pneumoperitoneum should be less than 10 mmHg

with a blunt tip that comprised the inner core and the other a sharp needle that made up the outer core (Fig. 1.1a). The blunt needle would retract when faced with the resistance of the skin and underlying costal muscles and would spring forward again once inside the pleural space, thereby protecting the viscera of the lung. In 1936, Veres published his experience of over 900 successful interventions. However, it was not until the 1970s,

with the gaining popularity of endoscopy, that Veres contributions were widely appreciated [1].

Today, the Veress needle has a bore of 2 mm and comes in lengths from 12 to 15 cm. It works on the exact same premise of an outer beveled needle with an inner spring-loaded stylet that springs forward again upon entry into space as described by Veres over 75 years ago. The Veress needle is the most common method used to gain peritoneal access. Out of 155,987 gynecological laparoscopic procedures, the Veress technique was used to gain access in 81 %. Alternatively, out of 17,216 general surgery procedures, the Veress needle was used for access in 48 %, whereas 46 % employed the Hasson technique (the remaining 6 % were accessed via the direct trocar insertion technique) [2].

The most common site of placement of the Veress needle is at the umbilicus. This is because this is the only location in the abdomen where there is no muscle or fat between the skin and peritoneum. Previous scars near this site, or a site on the abdomen, should dictate that the Veress needle be placed in another location—typically a minimum of 6 cm from the scar. Umbilical hernia is a contraindication to placement of the Veress needle in this location. Furthermore, the Veress needle may be introduced at any point throughout the abdomen and is usually based on surgeon preference and comfort level, as well as regard to the procedure being performed. It is always wise to study available imaging to check for anatomic abnormalities or variations, such as hepatomegaly or splenomegaly. Also, one should remember that if the patient is in the flank position, needle placement too far laterally can result in retroperitoneal insufflation. Selection for placement of the Veress needle should be away from subsequent first trocar location placement, since introduction of the trocar will push down on the abdominal wall, with consequent potential advancement of the tip of the Veress needle downward towards bowel.

The main advantage of using the Veress needle is quicker entry into the abdominal cavity, as well as a potentially reduced risk of a port-site hernia. The disadvantage of the Veress needle is an increased risk of major complications due to

its blind placement, such as bowel insufflation or bleeding, albeit a rare occurrence.

It is important that the stopcock on the Veress needle be open during its passage; this allows for the entry of air through the needle so that the bowel and omentum drop away from the elevated anterior abdominal wall. There are several ways to determine successful placement of the Veress needle in the peritoneal cavity (Fig. 1.1b):

1. Two “clicks”—two clicks are usually heard upon successful passage into the peritoneal cavity. The first click is heard when the needle traverses the fascia of the abdominal wall and the second as it is passed through the parietal peritoneum.
2. Aspiration—a saline-filled syringe is attached to the Veress needle and aspirated to make sure there is no return of blood or succus. If either of these contents is aspirated, the Veress needle can be removed with plans for careful inspection of intra-abdominal contents once the peritoneal cavity is safely accessed.
3. Hang drop—involved placing a drop of saline on the external surface of the Veress needle. If the saline drops quickly down the needle and disappears, then the needle is likely properly placed within the peritoneal cavity.
4. Low opening insufflations pressures—once the needle is in place and the CO₂ insufflation is begun, opening pressures below 10 mmHg generally confirm correct placement. Starting with a low flow of gas, confirming opening pressures <10 mmHg, and then increasing the gas flow rate are the most common and preferred approach by the authors.

Some surgeons may use a combination of the above techniques. The two “clicks” and low opening pressures obviously should be experienced upon every successful placement. There are some physicians who choose to omit the aspiration and hang drop test. A retrospective study did report that the double click, aspiration, and hang drop test were not confirmatory for proper placement of the Veress within the peritoneum. The same study reported that low opening insufflations pressure, less than 8 mmHg, was the most reliable method for confirming intraperitoneal placement [11]. The hang drop test may

prove to be additionally helpful in confirming proper placement in morbidly obese patients, when opening insufflations pressures may be borderline high or equivocal simply due to the higher resting pressures created by the compression of the abdominal cavity by a very large pannus.

Some surgeons perform the “waggle” test, in which the needle is moved from side to side. They believe that free movement of the needle tip indicates a properly placed needle. However, this maneuver should actually be condemned, as it can easily turn a small, 1.6 mm hole in a vessel or bowel into a considerably more problematic situation by lacerating the tissue within.

In morbidly obese patients, one can start with increasing insufflation pressures temporarily to 20 mmHg, in order to counter the weight of the abdominal pannus, and then after successful trocar placement, the pressure may be reduced to a working pressure of 15 mmHg. The increase in pneumoperitoneal pressure can be safely elevated to 20 mmHg in patients without significant cardiac or pulmonary comorbidities. This step increases the distance between anterior abdominal wall and peritoneal contents, as well as producing a more taught abdominal wall, which is important for controlling the amount of axial force necessary for trocar passage into the abdomen [4]. It has been shown that this maneuver can lengthen the distance between aortic bifurcation and the umbilicus from 0.6 cm at a pressure of 12 mmHg to 5.9 cm [13]. One should remember to return the insufflation pressure to 15 mmHg upon successful placement of trocars.

The open, or Hasson, technique is performed by making a small skin incision and bluntly dissecting down to fascia. Stay sutures are then passed through the fascia on opposite sides and tagged with a hemostat. The fascia is then incised, creating an opening just large enough to pass the trocar. If this incision is larger than is needed, difficulty in maintaining pneumoperitoneum throughout the case maybe encountered due to gas leaking out of the incision. Once the fascia is opened, blunt dissection may be used to dissect down to peritoneum. The peritoneum is then grasped with pickups or hemostats, brought

out of the wound, and opened sharply. A finger is inserted into the peritoneal cavity to assess for any adhesions. The blunt-tipped trocar can then be safely passed into the peritoneal cavity under direct visualization. The fascial stay sutures are then used to secure the trocar to the fascia, thereby preventing dislodgement later in the case. Many ports designed for use with the Hasson technique offer a balloon on the distal end of the trocar that is inflated within the peritoneal cavity and then retracted upward to compress against the abdominal wall, thus minimizing accidental displacement and also gas leaks. There may be a sponge on the proximal aspect of the trocar that may be compressed against the body wall to also help with securement of the port in addition to preventing gas leak. Disadvantages to the Hasson technique include increased time in placing this initial port, as well as an increased risk of gas leakage from the wound throughout the case, especially in obese patients. In cases of gas leaks from a port site, the leak can usually be minimized and pneumoperitoneum maintained by compressing Vaseline gauze around the leaking port site, by placing a sharp towel clamp around the skin edges or by simply suturing the fascial opening closed so there is a better seal around the port.

Direct trocar placement by physical elevation of the abdominal wall, without creation of a pneumoperitoneum or absence of Hasson "open" technique, is not advised or recommended due to increased risk of injury.

Complications of Laparoscopic Access

Fortunately, injury rates during laparoscopic access are relatively low, with most sources reporting risks ranging from .05 % to as high as .3 % [5]. However, most feel that the rates of complications are vastly underreported. A survey of 407 Canadian gynecologists indicated that at least 25 % of them had experienced access-related injuries [9]. It's been postulated that most studies come from surgeons and centers of high volume, whose complications rates would naturally be lower once they are past the learning

curve. Studies have indicated that 13–50 % of vascular injuries and approximately 40–50 % of bowel injuries are unrecognized until later in the postoperative period [4, 5].

One of the leading causes of death from laparoscopic access is major vascular injury and carries a mortality rate as high as 15 %. It is second only to anesthesia as the leading cause of mortality in laparoscopy [6]. It can occur during passage of the Veress needle or with placement of the trocar itself. Typically, injuries made with the Veress needle are self-limiting, and the Veress needle may simply be removed if no manipulation of the needle has occurred. In thin patients, the distance from the anterior abdominal wall to the retroperitoneum and its associated vascular structures may be as little as two centimeters [4]. The most commonly injured retroperitoneal vessel injured is the right common iliac artery, given that it lies just posterior to the umbilicus. However, any of the great vessels or their branches may lie in harm's way.

Injury to the inferior epigastric vessels is the most common minor vascular injury. If the injury is recognized and bleeding is brisk, a Foley catheter may be inserted through the fascial opening, the balloon inflated, and traction held on the Foley so that the bleeding is temporarily tamponaded until further control can be obtained. Alternatively, some advocate nothing more than maintaining traction on the Foley balloon for 24 h with subsequent removal the next day. The same authors maintain that sutures may be placed full thickness through the abdominal wall above and below the bleeding site to gain immediate hemostasis, with removal of these sutures after 24 h [10]. This maneuver can be performed using a port closure device, such as the Carter-Thomason, fascial closure device to pass suture above and below the site of bleeding in order gain hemostasis.

As stated previously, if a Veress needle is placed, with immediate suspicion for vascular injury, it may be removed and placed in a different location, with vigilant subsequent inspection of the original site upon successful entry into the abdomen. Alternatively, the Hasson technique can also be employed at that time, depending on

the surgeon's discretion. If a trocar is passed and blood is noted to be pooling or welling in the trocar upon removal of the obturator, the trocar should not be removed. Rather, a high suspicion of great vessel injury should exist, with potential consideration for conversion to exploratory laparotomy. One should also be aware that not all vascular injuries are immediately apparent; some retroperitoneal bleeds may not be diagnosed until the postoperative period.

Bowel injury is the third leading cause of death from laparoscopic procedures, behind anesthesia and vascular injury. Unfortunately, bowel injuries are often not recognized intraoperatively, and diagnosis may occur in a delayed fashion after the patient's condition has deteriorated significantly. A bowel injury carries a mortality rate of 2.5–5.0 % [4, 5]. It has been found that delayed recognition and patient age greater than 59 were both independent predictors of death in cases of bowel injury. One complication that can be easily missed is through-and-through passage of a trocar through a loop of bowel. In other words, the trocar has passed through the lumen of the bowel and comes out of the other side, with no real visual evidence of an injury, unless the surgeon passes all secondary trocars under direct vision and then goes back and visualizes the initial port as well (if a closed technique was used).

Recognizing these bowel injuries as early as possible is extremely important in mitigating the risk of patient mortality and in reducing morbidity. The most common presentation is "severe single trocar pain site, abdominal distension, diarrhea, and leukopenia followed by acute cardiopulmonary collapse secondary to sepsis within 96 h of surgery [16]." Bishoff et al. also reported that nausea and vomiting, ileus, and generalized abdominal pain were not common presentations. None of the patients had leukocytosis or peritoneal signs; only one had a fever greater than 38°C. The only reliable finding was a leukocytosis, with elevation on the manual differential, or bandemia. A high index of suspicion is paramount, and a CT scan with oral contrast can be obtained if concern exists in the postoperative period.

Bhoyrul et al. [7] studied 629 trocar injuries during a 3-year period from data mined from the Food and Drug Administration (FDA). Manufacturers are legally required to report incidents involving medical devices as dictated by the Safe Medical Devices Act, passed by Congress in 1990. In turn, hospitals are obligated to report device-related deaths to both the FDA and the manufacturer. Serious injuries may be reported to the manufacturer or FDA; the manufacturer is then required to disclose these injuries to the FDA within 30 days in the prior scenario. In their study, out of 629 trocar injuries, there were 32 deaths, with 26 (81 %) due to vascular injuries and the other 6 (19 %) being due to visceral (mostly bowel) injuries. Of these vascular injuries involving patient death, 23 % involved the aorta, and 15 % were a result of trauma to the inferior vena cava. The rest were attributable to injury to the iliacs or other vessels. In respect to the deaths due to bowel injuries, none were recognized intraoperatively. It should also be noted that in four of these cases, one involved a bleeding disorder undiagnosed prior to surgery, one had an abdominal aortic aneurysm that was unknown before surgery, one involved a trocar reinsertion into the abdomen without reinsufflating the abdomen, and one was a surgeon's first case. In looking at all injuries in the series—not just those involving mortality—it should be noted that a concomitant bowel injury occurred in 9 % of vascular injuries.

One must keep in mind patient anatomy during laparoscopic port placement. The distance between the retroperitoneal vessels and the anterior abdominal wall is only 3–4 cm and can be as little as 2 cm in thin patients. However, by inducing pneumoperitoneum or by raising the abdominal wall anteriorly manually with towel clips next to the area at planned trocar insertion, one may increase this distance to 8–14 cm [7]. One should also take extra care when placing trocars in those with abdominal wall laxity, such as those with atrophy of the muscle of the anterior abdominal wall and in females with a history of multiple pregnancies. This scenario will bring the anterior abdominal wall closer to the retroperitoneal vessels during port insertion if one is not careful.

When inserting ports in the umbilicus, it is generally recommended that port insertion should occur at a 90° angle to the skin to gain direct entry into the abdomen instead of scything the surface. Also, one should be aware that the bifurcation of the aorta is approximately at the level of the iliac crest. One of the most important tenets of laparoscopy is the need to control the axial force of entry during port placement; this may be the single most important step in preventing a catastrophic vascular injury. The axial force required for successful, safe trocar placement in each patient is different and is a learned motor and cognitive skill, with some reliance on muscle memory. It has been noted in studies that controlling the axial force is less difficult when the force needed is minimal in relation to the total upper body strength of the person passing the trocar [8]. Other factors that should be kept in mind as it relates to muscle memory and proprioception are the height of the table and the need to resist the urge to reach across the table to place a lateral port [5]. Trocars should be directed towards the organ of interest in order to avoid tearing of the fascia with subsequent placement of instruments and dissection.

Finally, laparoscopy and port placement do carry with it the small risks of a carbon dioxide gas embolism, which can potentially be fatal. The incidence has been reported to be .001 % in a review of 489,335 closed laparoscopy cases. This complication has not been reported with open laparoscopic techniques [4, 12]. The patient may experience arrhythmias, tachycardia, cyanosis, and ultimately cardiovascular collapse. The anesthesiologist will see a sharp rise in the end-tidal CO₂, and a mill-wheel murmur may be auscultated. If this occurs, the surgeon should immediately desufflate the abdominal cavity, and the patient should be placed in the left lateral decubitus position with the head down.

Types of Trocars

There are several types of trocars currently available. The authors' preference is to use a bladeless dilating trocar for subsequent decreased risk of hernia (Fig. 1.2a). Other alternatives are disposable,

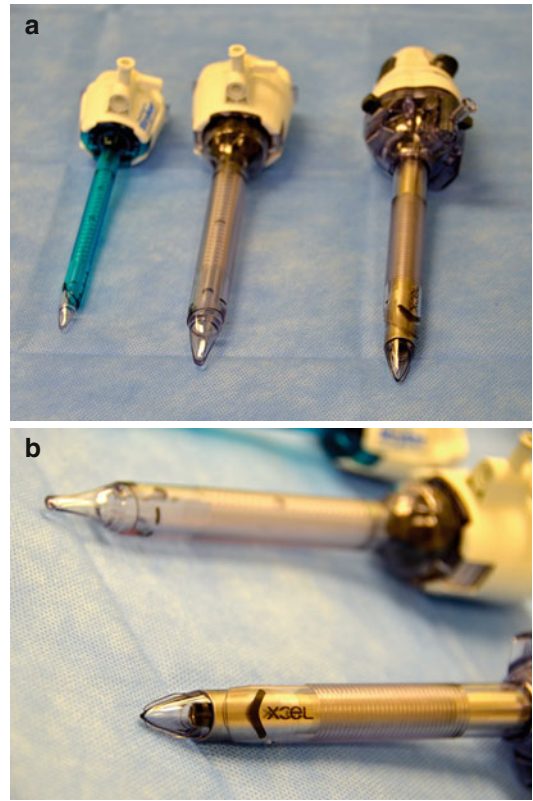


Fig. 1.2 (a) Bladeless, dilating trocars. (b) Note the ridges at lateral edge of trocar which separate and spread fascia rather than a blade which cuts tissue

shielded cutting trocars, visual entry trocars, bladeless dilating trocars, and radially expanding trocars. All of these are placed after initial insufflation of the abdomen with a Veress needle and always under direct visualization. With placement of any trocar, it is important to remember to extend the index finger of the dominant hand that is advancing the trocar to serve as a limit to how deep the trocar may be inserted. Our preference as well is to use an optical access, visualizing obturator, which allows the 10 or 5 mm laparoscope to be placed within the shaft of the trocar and allows direct visualization of the layers of muscle and subcutaneous fat as the tip of the trocar traverses the layers, in order to identify entry into the abdomen (Fig. 1.2b).

Optical access laparoscopic trocars have an obturator which is hollow, with a clear tip, allowing the laparoscope to be inserted into the obturator during passage into the peritoneal cavity. This displays each layer of the abdomen during

placement of the trocar. The visual obturators come in both bladed (Visiport, US Surgical, Norwalk, CT) and non-bladed varieties (Optiview, Ethicon, Cincinnati, OH). Optical access trocars have a great advantage of safely visualizing each layers of the abdominal wall during placement of the initial trocar and are highly recommended for all laparoscopic cases. Unfortunately, the robotic camera does not fit within the obturator of currently available optical access trocars.

These trocars can be combined with a bladeless, dilating trocars which are similar to the bladed tips in overall appearance, except the tip of the obturator is conically shaped plastic with a ridge on it. This trocar has a lower risk of cutting vessels in the abdominal wall during trocar insertion, as well as a lower risk of port-site hernia due to the lack of cutting the fascia, which ultimately translates into a smaller fascial defect. In contrast to the VersaStep, there is no inherent counter traction mechanism (i.e., dispersion of axial force into radial force) involved in placing the trocar. Thus, some feel that there is at least higher theoretical risk of a vascular injury to the retroperitoneal vessels associated with placement as compared to the VersaStep.

Disposable, shielded cutting trocars rely on the same principle as a Veress needle in its design and function. It has a bladed tip covered by a plastic sheath. The plastic sheath retracts when it meets resistance, thereby exposing the cutting tip as it passes through the abdominal wall, with subsequent retraction of the plastic sheath over the blade upon passage into the peritoneal cavity. Advocates of this trocar feel that there is less axial force needed to advance the trocar into the abdominal cavity, thereby lessening the likelihood of inadvertent passage of the trocar into the retroperitoneum, where the great vessels reside. However, others feel that there is more potential for harm during that very brief moment when the blade is still exposed immediately after passage into the peritoneal cavity, with subsequent increased risk of hernia.

Finally, radially expanding trocar, often referred to as the VersaStep trocar, is a bladeless trocar (Fig. 1.3). There is a theoretical lower risk of vascular injury within the abdominal wall, such

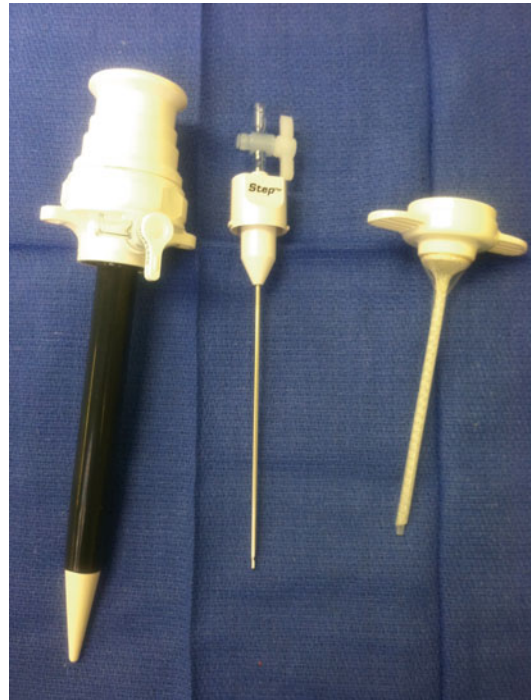

Fig. 1.3 VersaStep trocar. A sheath is placed over the Veress needle first during initial access. After withdrawing the Veress needle, the subsequent trocar is placed within the sheath, so that counterforce is applied during trocar placement

as the inferior epigastrics, as the tip displaces vessels out to the side rather than cutting through them. These create a smaller fascial defect, as it is just stretched rather than cut. As a consequence of stretching, in lieu of cutting, the fascia, these trocars typically have an extremely low leak rate of CO₂ compared to other trocars. More importantly, the counter traction provided by the webbed outer flange provides a counterforce to the axial force during placement. There is published data of almost 2,600 patients where no major vascular injuries occurred and where bare needle punctures into the small bowel, liver, and small mesenteric vessels were the only intra-abdominal injuries [5]. One complaint is that the smooth sides of the trocar lack the grip on the abdominal wall of other trocars and thus may make it more prone to accidental dislodgement during surgery. However, the authors have not found this to be a common occurrence in our practice. Also, it is generally held that these port sites do not require fascial closure. Series of bariatric patients in

which port-site hernia rates with the VersaStep were reviewed. They retrospectively studied 741 consecutive bariatric patients undergoing laparoscopy for gastric bypass surgery. Each patient had an initial supraumbilical Hasson port placed, with the rest of the ports employing the VersaStep system: two 12 mm ports and three 5 mm ports. Only the Hasson port was closed. There were no hernias at any of the VersaStep sites; there were nine incisional hernias at the Hasson site [14]. Nevertheless, there is at least one case report of a port-site hernia occurring with the VersaStep trocar [15].

Port-Site Hernias

Port-site hernias are a relatively rare yet serious complication of laparoscopic surgery. First reported in the literature in 1968 [17], it has an estimated prevalence of 0.5 % [18]. Most of these port-site hernias are associated with trocars that are at least 10 mm in diameter. In one series from the gynecologic literature, out of 840 port-site hernias, 86.3 % were associated with trocars that were ≥ 10 mm; 10.9 % occurred with ports between 8 and 10 mm; 2.7 % occurred with trocars ≤ 8 mm [19, 20].

It is generally held that port-site hernias are more apt to occur in the midline, rather than at the site of laterally placed ports [20]. Given that the umbilicus is the weakest point in the abdominal wall and is a commonly used access point for port placement, this finding is not surprising. Many surgeons, depending on the type of case, may extract the specimen through the umbilical port, thereby stretching and weakening the fascia. The counterargument is that multiple muscle and fascial layers of the lateral abdominal wall provide additional layers of protection against port-site hernias which midline access points cannot offer [20, 21]. Another proposed reason for the smaller risks posed by laterally placed ports is simply anatomic: the small bowel is in more direct and continuous contact with the abdominal midline than at points on the lateral abdominal wall [22].

Another risk factor for port-site hernias is obesity, due to the higher intra-abdominal pressures

and also due to a higher likelihood of improper closure of the wound as a result of the challenges posed by their body habitus [20].

The clinical presentation of a port-site hernia must be recognized quickly, and clinicians should carry a low index of suspicion for those patients with GI complaints or tenderness at the port site, especially when occurring within 14 days from surgery. GI complaints usually consist of abdominal pain, nausea and vomiting, and often abdominal distension—often the classic signs of small bowel obstruction. The diagnosis often can be made clinically but is usually clinched with a CT scan. Once realized, the patient should be taken to the operating room if signs and symptoms of an acute abdomen exist. The risk of nonoperative management delays surgical repair, with potential subsequent critical illness due to strangulation and necrosed bowel [20].

Ultimately, most of the literature supports closing those ports that are 10 mm in size or greater. Trocars less than 10 mm in size pose lower risk, though one should be aware that port-site hernias can still occur with these smaller ports. Moreover, port-site hernias can still occur in port sites that have been closed if the fascia tears. Thus, the physician's index of suspicion in the postoperative period should always remain high.

Fascial Closure

The Carter-Thomason fascial closure device is a simple yet effective way of closing port sites (Fig. 1.4a) and typically necessary only for ports which measure 10 mm or larger. Due to difficulty in closing fascia using traditional open methods with a needle driver, the Carter-Thomason device is a time-efficient and safe means of closing fascia under direct visualization. Also, it makes closing the peritoneal defect easier [23] in obese patients.

Application of the Carter-Thomason device starts with grasping a #1-Vicryl suture (with the needle cutoff) in the middle of the strand (Fig. 1.4b). A single hemostat holds both ends of

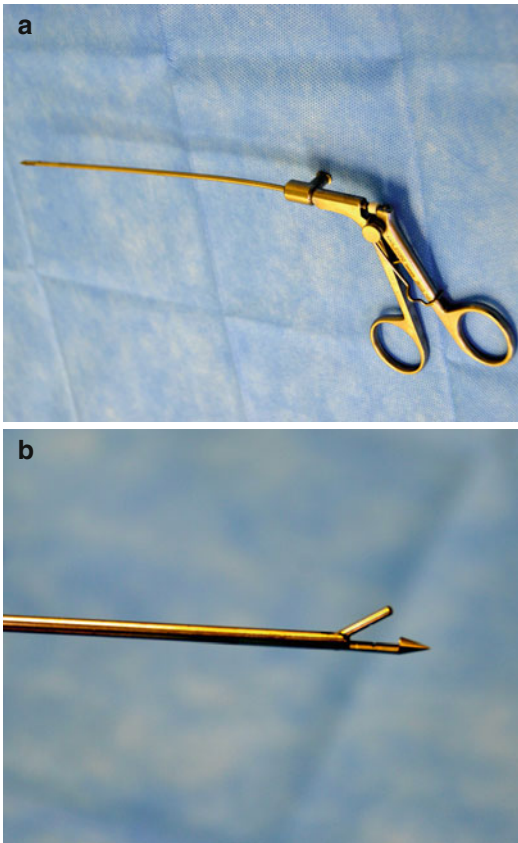


Fig. 1.4 (a) Carter-Thomason fascial closure device. (b) Tip of Carter-Thomason. A #1-Vicryl is placed through the abdominal wall, and instrument is withdrawn. After subsequent second pass on the opposite side of the incision with the instrument, the suture is grasped and withdrawn up out of the incision

the suture together to avoid inadvertent passage of the ends. Then, under direct laparoscopic vision through another port, the Carter-Thomason device is passed through the fascia on one side of the fascial defect into the abdominal cavity. The device is then withdrawn, leaving the free suture inside the abdominal cavity and then passed a second time through the opposite side of the trocar incision back into the abdominal cavity, where the free suture is grasped again and withdrawn through the skin. It is helpful to use a laparoscopic needle driver through a separate port to grasp the free suture and direct it towards the jaws of the Carter-Thomason device if there is any difficulty in retrieval.

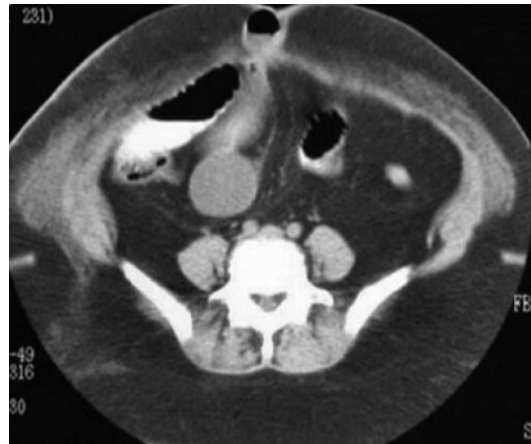

Fig. 1.5 CT scan of incisional hernia

Exiting the Abdomen

Port removal is often relegated to an afterthought as it pertains to the rest of the case. However, there still is the potential for complications during this final step of the operation. At the very least, it should be viewed as a final opportunity to assess the abdomen before completing the procedure. One should visually inspect the surgical area again to confirm adequate hemostasis. Also, one should inspect the bowel to ensure there is no evidence of injury or entrapment in trocar closure. The extraction side can be reinspected a final time to confirm adequate airtight fascial closure and decrease risk of incisional hernia (Fig. 1.5). Finally, all of the ports, with the exception of the final one, should be withdrawn under direct vision. The surgeon should make sure that there is no bleeding from any of the port sites in the anterior abdominal wall that could signify a serious vascular injury, such as a laceration to the epigastric vessels which potentially could have been tamponaded by the trocar up to that point in the case. Prior to removing the last port, all remaining carbon dioxide should be evacuated from the abdomen. Otherwise, a partial vacuum is present, and omentum and bowel may be drawn into the trocar upon its removal [22], thereby creating a port-site hernia or may lead to referred shoulder pain due to irritation to the diaphragm.

Summary

In summary, the surgeon should maintain a high index of suspicion for injury on every single case. It can be easy to be lulled into sense of complacency, or let one's vigilance decrease before the final closure is completed. One should always be mindful that a significant number bowel injuries go undiagnosed until the postoperative period, and a sizable number of vascular injuries, including those in the retroperitoneum, are not recognized intraoperatively. With a careful inspection at the end, with attention to detail, the risk of complication is minimized.

References

1. Szabo I, Laszlo A. Veres needle: in memoriam of the 100th birthday anniversary of Dr. Janos Veres, the inventor. *Am J Obstet Gynecol.* 2004;191(1):352–3.
2. Molloy D, Kaloo PD, Cooper M, et al. Laparoscopic entry: a literature review and analysis of techniques and complications of primary port entry. *Aust N Z J Obstet Gynaecol.* 2002;42:246–53.
3. Jansen FW, Kolkman W, Bakkum EA, et al. Complications of laparoscopy: an inquiry about closed versus open-entry technique. *Am J Obstet Gynecol.* 2004;190:634–8. *Pub Med:* 15041992.
4. Krishnakumar S, Tambe P. Entry complications in laparoscopic surgery. *J Gynecol Endosc Surg.* 2009;1(1):4–11.
5. Chandler JG, Corson SL, Way LW. Three spectra of laparoscopic entry access injuries. *J Am Coll Surg.* 2001;192:478–91.
6. Nordestgaard AG, Bodily KC, Osborne RW, et al. Major vascular injuries during laparoscopic procedures. *Am J Surg.* 1995;169:543–5.
7. Bhojru S, Vierra M, Nezhat C, et al. Trocar injuries in laparoscopic surgery. *J Am Coll Surg.* 2001;192:677–83.
8. Corson SL, Batzer FR, Gocial B, et al. Measurement of the force necessary for laparoscopic trocar entry. *J Reprod Med.* 1989;34:282–4.
9. Yuzpe AA. Pneumoperitoneum needle and trocar injuries in laparoscopy, a survey on possible contributing factors and prevention. *J Reprod Med.* 1990;35:485–90.
10. Phillips P, Amaral J. Abdominal access complications in laparoscopic surgery. *J Am Coll Surg.* 2001;192(4):525–36.
11. Teoh B, Sen R, Abbott J. An evaluation of four tests used to ascertain Veres needle placement at closed laparoscopy. *J Minim Invasive Gynecol.* 2005;12:153–8.
12. Neudecker J, Sauerland S, Neugebauer E, et al. The European Association for Surgery Clinical Practice Guideline on the pneumoperitoneum for laparoscopic surgery. *Surg Endosc.* 2002;16:1121–43.
13. Phillips G, Garry R, Kumar C, et al. How much gas is required for initial insufflation at laparoscopy? *Gynecol Endosc.* 1999;8:369–74.
14. Johnson WH, Fecher AM, McMahon RL, et al. Versastep trocar hernia rate in unclosed fascial defects in bariatric patients. *Surg Endosc.* 2006;20(10):1584–6.
15. Patel MS. Laparoscopic port site hernia at a 12 mm non-bladed Ethicon Endopath Excel VersaStep trocar site. *World J Colorectal Surg.* 2010;2(1), p 1.
16. Bishoff JT, Allaf ME, Kirkels W. Laparoscopic bowel injury: incidence and clinical presentation. *J Urol.* 1999;161:887–90.
17. Fear RE. Laparoscopy: a valuable aid in gynecologic diagnosis. *Obstet Gynecol.* 1968;31:297–309.
18. Swank HA, Mulder M, la Chapelle CF, et al. Systematic review of trocar-site hernia. *Br J Surg.* 2012;99:315–23.
19. Montz FJ, Folschneider CH, Munro MG. Incisional hernia following laparoscopy: a survey of the American Association of Gynecologic Laparoscopists. *Obstet Gynecol.* 1994;84:881–4.
20. Tonouchi H, Ohmori Y, Kobayashi M. Trocar site hernia. *Arch Surg.* 2004;139:1248–56.
21. Plaus WJ. Laparoscopic trocar site hernias. *J Laparoendosc Surg.* 1993;3:567–70.
22. Duron JJ, Hay JM, Msika S, et al. Prevalence and mechanisms of small intestinal obstruction following laparoscopic abdominal surgery: a retrospective multicenter study. *Arch Surg.* 2000;135:208–12.
23. Matthews BD, Heniford BT, Sing RF. Preperitoneal Richter hernia after a laparoscopic gastric bypass. *Surg Laparosc Endosc Percutan Tech.* 2001;11:47–9.

Laparoscopic Renal Extirpative Surgery

2

Jessica Kreshover and Lee Richstone

Equipment List

OR table (slider and kidney rest preferred)	12 mm working port (optional)
Small long gel rolls ×2	Laparoscopic specimen entrapment bag (12 or 15 mm)
Pillow	Multifire Endo GIA stapler® (for radical nephrectomy, available during partial nephrectomy) (Covidien, Mansfield, MA)
Small flat gel pad	Laparoscopic retractor, e.g., Endo Paddle 12 mm (available) (Covidien)
Towels	2–0 barbed, e.g., V-Loc® (Covidien, Mansfield, MA) or Vicryl suture ×2 (more available if needed, for partial nephrectomy)
3 in. silk tape	Laparoscopic Weck® Hem-o-lok® clip applicator with clips (Teleflex, Research Triangle Park, NC)

Thompson scope holder (optional)	Lapra-Ty® applier (Ethicon, Blue Ash, OH) (for partial nephrectomy)
Laparoscopic argon bovie	
Laparoscopic LigaSure® (Covidien, Mansfield, MA)	
Air seal generator	
Intraoperative ultrasound	
Veress needle 14G	
12 mm AirSeal® trocar and insufflation system (SurgiQuest, Milford, CT)	
10 mm camera port	
5 mm suction port	

Transperitoneal Approach

Patient Positioning

The patient is brought into the operating room and positioned supine on the table. After induction of anesthesia, the patient is placed in a modified lateral decubitus position at 30° with the ipsilateral side of the abdomen elevated. Gel rolls or pillows may be placed behind the back to aide in positioning. The contralateral arm is placed out on armrest at less than 90°. The ipsilateral arm is bent and placed across the chest. At this degree of rotation, the legs may remain in anatomic position

J. Kreshover, MD, MS (✉) • L. Richstone, MD
The Arthur Smith Institute for Urology,
North Shore-Long Island Jewish Health System,
New Hyde Park, NY, USA
e-mail: jkreshover@nshs.edu

and should not require bent knee positioning and/or elevation of the ipsilateral leg as there should not be a significant degree of hip adduction and thus no strain on the sciatic nerve. At this degree of rotation, there is also generally no need for an axillary roll. However, for obese patients, an axillary roll may be necessary to relieve any pressure on the brachial plexus. The patient is secured to the surgical table with tape or straps placed across the hips and across the chest (underneath

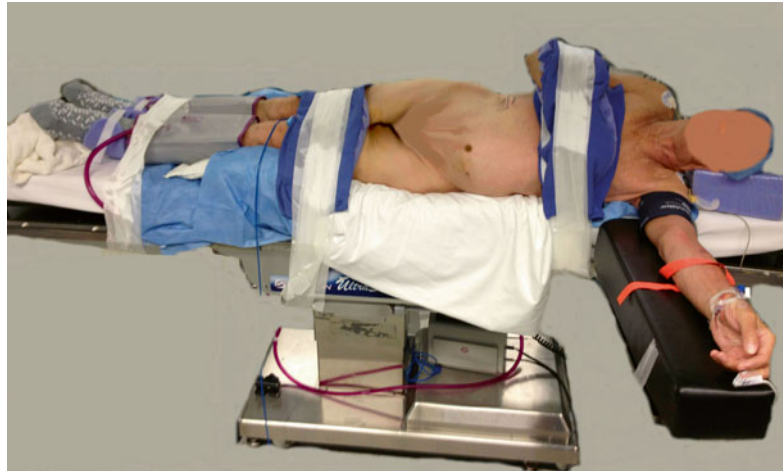
the ipsilateral arm). These authors prefer wide silk tape placed over gel pads and surgical towels. All pressure points should be padded to prevent soft tissue injury and rhabdomyolysis. (Refer to Table 2.1 for further description regarding positioning injuries.) The ipsilateral arm is loosely secured to prevent movement during the case. Bilateral legs are also loosely secured to the surgical table to prevent significant movement during the case. See Fig. 2.1.

Table 2.1 Complications [1]

Complication		Prevention	Management
Positioning injury	Brachial plexus injury	Axillary roll for lateral positioning; axillary roll for obese patients in modified lateral position; prevent abduction of contralateral arm >90°	Physical therapy
	Sciatic injury	Support ipsilateral leg with pillows to prevent adduction of hip particularly in flank position	Physical therapy
	Rhabdomyolysis	Keep all pressure points padded; minimize operative time	Aggressive hydration, consider urine alkalinization
Veress needle injury	To bowel	Appropriate selection of insertion site away from scars; use of OG/NG tube to decrease gastric distension; use of Hasson technique for complicated access	Do NOT insufflate; remove needle, examine, gross spillage requires evaluation and unlikely to be managed conservatively
	To liver/spleen	Appropriate selection of insertion site away from scars; use of Hasson technique for complicated access	Do NOT insufflate; remove needle, examine, hemostatic agents, or coagulation (argon beam); surgical consultation for large bleeds
	To gallbladder	Appropriate selection of insertion site away from scars; use of Hasson technique for complicated access	Do NOT insufflate; remove needle, examine, surgery consult, likely requires cholecystectomy
	To vasculature	Appropriate selection of insertion site away from scars; use of Hasson technique for complicated access	Do NOT insufflate; remove needle, examine, repair if necessary, open if necessary
vascular injury	Review and refer to CT/MRI imaging	Exposure, turn up pneumo; add trocars or open if necessary; repair vs ligate; for epigastric injuries (usually trocar related), full-thickness suture ligation should be used to control bleeding	
Bowel injury	Avoid cauterization near the bowel; take extra care during duodenal dissection	Intra-op repair, general surgery consults; exploration, general surgery consult (delayed)	
Liver/splenic injury	Avoid unnecessary traction on liver or spleen; care during Veress needle insertion	Hemostatic agents or coagulation (argon beam); surgical consultation for large bleeds	
Diaphragmatic injury	Avoid monopolar cautery use during lateral/apical dissection	Suture repair +/- chest tube placement	
Ureteral injury	Identification of the ureter early in dissection	Mobilization, debridement if necessary (cautery injury), tensionless suture repair, stent placement (intra-op); ureteral stent vs percutaneous nephrostomy with possible delayed repair (delayed)	

Table 2.1 (continued)

Complication	Prevention	Management
Urine leak	Closure of collecting system in separate layer	Placement of ureteral stent, percutaneous drainage of urinoma if necessary
Wound infection	Sterile prep	Antibiotics; opening wound and packing may be needed if abscess is suspected
Incarcerated hernia	Close all trocar sites 12 mm or larger or any port placed with cutting trocar	Exploration if clinical suspicion

Fig. 2.1 Modified lateral decubitus positioning

When positioned in this manner, there should be no need to flex the bed or to use kidney bar. Unlike open surgery, these maneuvers are unlikely to aide in exposure and have known potential associated morbidity. Once in position, the surgical bed should be lowered and then rotated toward the operating surgeon to ensure the patient remains secure and immobile.

Trocar Positioning

The surgeon stands on the contralateral side of the surgical bed. Access and pneumoperitoneum can be achieved via closed (Veress needle) or open (Hasson) techniques. The Veress needle may be inserted via the umbilicus or, in cases of prior midline abdominal surgery, subcostally. Two “clicking” sounds should be heard as the needle passes through fascia and peritoneum. Aspiration and saline drop test are used to help confirm intra-peritoneal location. Opening pressures should be ≤ 5 –10 mmHg. Refer to Table 2.1 for further

discussion regarding Veress needle injuries. Once insufflation pressure has reached 15 mmHg, trocar placement can take place.

Generally, the camera port (10 mm) is placed at the level of the umbilicus, a 5 mm port is placed in the subxiphoid position, and a 12 mm working port is placed in the lateral position of the ipsilateral side of the abdomen cephalad to the anterior superior iliac spine. Please refer to Fig. 2.2 for diagram of placement.

For right-sided procedures, there may be a need for an additional port for liver retraction. This port (5 mm) may be placed just superior and/or medial to the upper 5 mm trocar. A ratcheting grasper can then be placed from this medial port underneath the liver and then grasping the side wall to displace the liver cephalad and out of the surgical field. It is important that the grasper is placed cephalad enough through the abdominal wall to allow for adequate superior retraction of the liver and prevent clashing with the right-hand port. Liver retraction can also take place from an inferior approach by placing an additional 5 mm

Fig. 2.2 Laparoscopic port positioning. C = camera port, 12 = 12 mm port, 5 = 5 mm port

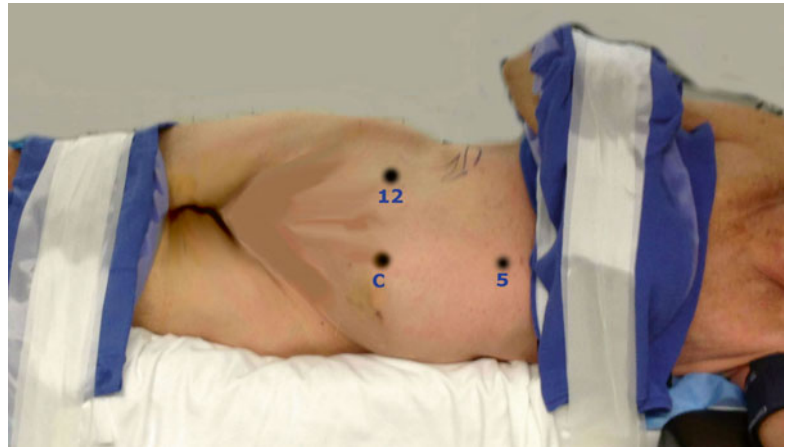
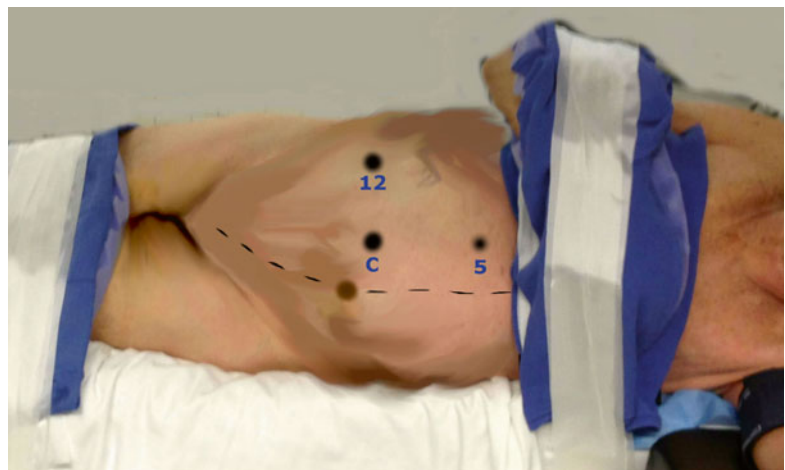


Fig. 2.3 Laparoscopic port shift for obese patients. C = camera port, 12 = 12 mm port, 5 = 5 mm port

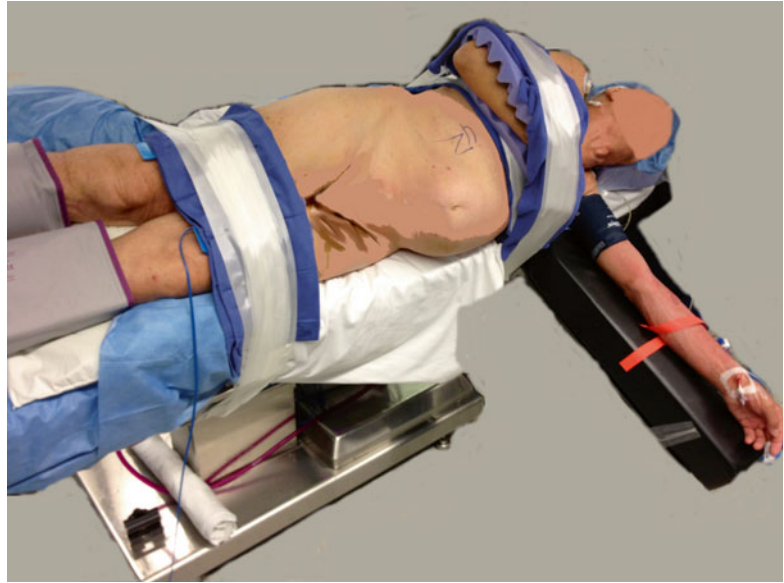

port lateral and cephalad to the lateral 12 mm port. A laparoscopic liver retractor can then be used to superiorly displace the liver without obstructing the left- and right-hand working ports.

There are additional considerations for trocar placement in specific patient populations. For obese patients, trocars should be shifted laterally secondary to habitus (Fig. 2.3). In patients with prior surgeries, initial trocar placement should take place away from prior surgical incisions. In patients with multiple prior surgeries and complicated abdomens, the surgeon must take great care with access to avoid complications. In select cases, after successful initial insufflation with a Veress needle, one can employ a second Veress needle in a proposed site for the initial trocar. If the surgeon hears a stream of air when that

location is probed with the second Veress needle, this suggests few if any adhesions in that area and raises confidence of this being a safe location for trocar placement (Richstone, unpublished data). For very complex abdomens, one should strongly consider the open Hasson technique for access or a retroperitoneal approach. For the open Hasson approach, a 10–12 mm incision is made through the skin, and blunt dissection is performed down to the fascia which is incised sharply. The peritoneum is grasped between two clamps and cut with Metzenbaum scissors. A Hasson trocar is then placed after a “360° sweep” with a finger to ensure proper entry into the peritoneal cavity and assess the abdomen for adhesions. Subsequent trocars can then be placed under direct visualization and with incisions hidden within prior

Fig. 2.4 Oblique final patient positioning



scars after it is ensured that there are no intra-abdominal adhesions that may prevent safe trocar placement.

Once trocars are placed, the surgical bed is lowered and rotated to the contralateral side to allow for medial displacement of intra-abdominal contents and to promote exposure of the retroperitoneum as in Fig. 2.4.

Simple/Radical Nephrectomy

The camera is placed via the umbilical 10 mm port. The 30° downward deflecting lens is the most common lens used. The camera may then be held and manipulated by a surgical assistant or by the Thompson laparoscopic camera holder. Next, the colon is reflected medially to expose the retroperitoneum. An incision is made along the white line of Toldt from the splenorenal (left) or hepatorenal (right) flexure inferiorly to below the level of the lower pole of the kidney. The colon is reflected medially. Care should be taken to avoid entrance into Gerota's fascia. With appropriate dissection, the anterior surface of Gerota's fascia remains intact as the posterior aspect of the mesocolon is dissected free. Holes within the mesentery may be made during this dissection and should be closed once identified to avoid

internal hernia. If the hole is small, laparoscopic metal clips may be used for closure. Larger holes may require suture reapproximation.

During right-sided procedures, care must be taken to identify and prevent injury to both the duodenum and gallbladder. Dissection should not take place on the duodenum itself. Kocher maneuver is typically needed to medially reflect the duodenum and expose the renal hilum and should be performed in a sharp, athermal manner. Attachments to Gerota's fascia should be taken down sharply and an adequate distance from the duodenum so that if bleeding is encountered, cautery can be safely used without risking injury to the duodenum.

Once the colonic reflection is complete, the anterior surface of the psoas muscle should be easily identified. If the muscle is not directly visualized, care should be taken to identify the gonadal vessel and/or ureter just inferior to the lower pole of the kidney. Dissection posterior to the gonadal vessels and ureter will allow for identification of the anterior surface of the psoas muscle. In obese patients, the field of vision is altered by lateralization of the ports, and thus the anatomy may appear aberrant. Dissection tends to be more medial than it appears, and hence clear identification of the vena cava (for right-sided procedures) and the aorta (for left-sided

procedures) should take place to ensure dissection within the appropriate planes.

With the psoas muscle identified, the overlying gonadal vein and ureter can be traced superiorly toward the renal hilum with a combination of sharp and blunt dissection. Generally, the ureter is retracted anteriorly, and the gonadal vessels may be retracted with it or left down in its anatomic position. The posterolateral aspect of the kidney can be dissected free bluntly. This allows for strong anterior retraction of the kidney to best expose the renal hilum. Careful dissection should take place around the renal hilum to identify the primary renal vein and renal artery, which generally lies posterior to the vein. Dissection takes place primarily in a blunt fashion with the suction/irrigator. Generally, there is thin connective tissue both inferior to and overlying the renal vein that needs to be transected to allow for complete identification. Preoperative imaging can be reviewed to check for aberrant renal vasculature so that these vessels can additionally be identified and controlled. Gonadal vessels, aberrant venous vasculature, and lumbar vessels may be clipped and transected as needed to aid in isolation of the hilum.

The renal artery should be controlled first. Laparoscopic endovascular stapler is used to transect the renal artery. Weck clips for arterial control are contraindicated by the FDA during laparoscopic donor nephrectomy secondary to potential for dislodgement with resultant profuse bleeding. As such, isolated Weck clips for control and transaction of the renal artery are not recommended (<http://www.fda.gov/Safety/MedWatch/SafetyInformation/SafetyAlertsforHumanMedicalProducts/ucm254363.htm>.) [2]. When the renal vein is obstructing appropriate visualization of the artery, a single Weck may be placed on the artery to allow for venous transection with endovascular stapler prior to arterial transection.

Once the hilar vessels are transected, dissection can continue superiorly. The adrenal gland may be spared during most radical nephrectomies including large upper pole tumors given the negative predictive value of modern cross-sectional imaging [3]. Indications for concomitant ipsilateral adrenalectomy are evidence of adrenal

metastasis on imaging, macroscopic evidence of disease at the time of surgery, or direct extension of tumor into the adrenal gland. In adrenal sparing surgery, dissection should take place in the plane between the adrenal gland and the upper pole of the kidney. Small adrenal branches may be encountered, and therefore meticulous hemostasis should be employed. This portion of the dissection is aided by use of the LigaSure.

Once complete, the only remaining attachments should be the lateral attachments of the kidney, which can be taken down with a combination of blunt and sharp dissection, and the ureter, which can be transected after placement of clips or with an additional reload of endovascular GIA stapler. The kidney is then placed within a laparoscopic specimen bag.

The site of extraction can be determined on an individual basis. Generally, the specimen is removed via the umbilical site. An incision is extended through the skin and then down through the fascia with care taken to avoid injury to intra-abdominal contents. The specimen bag can then be removed and the incision closed. The abdomen should be reinsufflated and the surgical bed inspected to ensure adequate hemostasis after a period of desufflation. The area should also be inspected for any evidence of injury to other intra-abdominal contents. Table 2.1 discusses management of these injuries as well as potential means of preventing other organ injury.

The fascia at the sites of 12 mm ports, cutting trocars, and (at surgeons discretion) 10 mm trocar sites should be closed to prevent hernia (see Table 2.1). A suture passer system may be employed with a 0 Vicryl or a doubled over 2-0 Vicryl suture that is placed under direct visualization through the fascia on either side of the trocar defect while the abdomen remains insufflated.

Partial Nephrectomy

Trocar placement, colonic reflection, and isolation of the renal hilum take place in a manner the same as that previously described for laparoscopic radical nephrectomy. The next steps of the procedure are dependent on tumor location.

For anterior tumors, some lateral mobilization of the kidney may be necessary to be able to outline the entirety of the tumor. For posterior tumors, the entire kidney must be mobilized to allow for flipping and/or twisting of the kidney to expose the area of interest. Complete mobilization involves freeing the upper pole of the kidney from the inferior border of the adrenal gland (as described in a radical nephrectomy procedure). Mobilization of the lower pole can easily take place after the ureter and gonadal vessels are identified and isolated, and the remainder of the attachments can be taken quickly without fear of injury to adjacent structures. Once adequate mobilization has been achieved, intraoperative ultrasound is used to identify the location of the renal mass and its characteristics (e.g., solid/cystic) and relationship to renal structures (e.g., vessels, collecting system). Preoperative imaging should be available for review to aide in this task.

Once the lesion is localized, the kidney should be positioned to allow for adequate exposure during resection. In rare occasions, the surgeon may place an additional 5 mm port for use as an assistant port to aide in retraction and/or exposure. Gerota's fascia is then incised away from the border of the tumor. The perinephric fat is dissected off the renal capsule around the area of the tumor with care taken to neither cut into the tumor nor remove the fat overlying the tumor. An outline of the line of incision can then be made into the renal capsule using shears (hot or cold) or monopolar hook. This incision should be made just lateral to the previously identified extent of the tumor to provide an adequate margin and prevent entering the tumor. A marked sponge may be placed in the abdomen at this time to prevent any blood loss that does occur from tracking into the contralateral side of the abdomen.

Next, a decision is made as to extent/type of vascular control needed for the procedure. There are many series reporting an off-clamp technique for excision of renal mass [4]. This method is associated with increased blood loss but has the ultimate goal of decreased (zero) ischemia and thus potential preservation of renal function. Surgeon preference should determine the method of vascular control to be used.

When a clamp technique is used, laparoscopic bulldog clamps can be placed on the main renal artery for complete occlusion or on segmental vessels for selective ischemia. Hilar clamp time should be limited to reduce the detrimental impact of warm ischemia on renal function [5]; however, the amount of kidney removed and underlying renal function are of greater consequence to postoperative renal function [6].

The renal capsule is then incised at the previously marked position. A combination of blunt and sharp athermal dissection is used to excise the renal mass. Vessels that are directly visualized during this dissection may be clipped prior to transection to aide in hemostasis. Extreme care should be taken to prevent violation of the tumor that could lead to tumor spillage. Gentle manipulation with the suction/irrigator or with a laparoscopic DeBakey forceps may be employed to handle the tumor. Often, the overlying perinephric fat may be used to aide in tumor retraction with decreased risk of injury to mass. Once the tumor is completely excised, the specimen should be placed directly into an entrapment sac. The resection bed should then be examined. Cold cup or excisional biopsies may be taken and sent for permanent or frozen section.

Hemostasis is then obtained using a variety of techniques. The tumor resection bed may be cauterized using argon beam coagulator. Hemostatic matrix (e.g., Floseal (Baxter, Deerfield, IL)) may be placed into the tumor bed. Additionally, some surgeons may employ a multilayered closure with initial placement of suture (3-0 Vicryl interrupted or running) along the floor of the defect to aide in both hemostasis and/or closure of the collecting system (refer to Table 2.1 for discussion of urine leaks). Renal parenchymal edges are then reapproximated. Absorbable suture (0, 2-0, or 3-0 Vicryl) with Lapra-Ty and/or barbed suture may be used to reapproximate the parenchymal edges. Suture must be placed at an adequate distance (approximately 1 cm) to the edge of the defect to prevent the suture from tearing through the renal parenchyma. Sutures should be pulled in the direction of placement to also prevent tissue tearing. This can be performed in an interrupted or running fashion. Sutures should be

placed until the renal edges appear well approximated and hemostasis is obtained. At this point, bulldog clamps can be removed from the renal hilum, and warm ischemia time can be calculated. Early clamp removal, prior to completion of the renorrhaphy, can be performed to limit ischemic time [7]. Mannitol administration can also be considered prior to hilar clamping with the theoretical potential for reduction of perioperative renal dysfunction. There is data to support the use of mannitol in animal models and within transplant literature, but clear benefit has not yet been seen within minimally invasive partial nephrectomy cohorts [8].

Once reperfusion has occurred, the kidney should be reexamined. Additional sutures may need to be placed to aide in hemostasis. The specimen is then extracted, and port sites can be closed as previously described in the nephrectomy section above. A closed suction drain should be left if there is known or suspected collecting system involvement. The drain is used as an aide to diagnose and manage urine leak after partial nephrectomy.

Retroperitoneal Approach

Choosing between transperitoneal and retroperitoneal approaches is a function of surgeon comfort as well as tumor location with posterior and/or apical tumors potentially being more easily accessed via the retroperitoneum. The retroperitoneal approach may also offer advantages in those patients with multiple intra-abdominal surgeries in which dissection down into the retroperitoneum may be difficult secondary to adhesions.

Patient Positioning

Unlike in the transperitoneal approach, the retroperitoneal approach requires full flank patient positioning. After induction of general anesthesia, the patient is positioned at 90° to the bed with the ipsilateral side up. Gel rolls or pillows may be placed behind the back to aide in positioning. It is

necessary to place an axillary roll to prevent brachial plexus injury with this position. The contralateral arm is placed out on armrest at less than 90°. The ipsilateral arm is draped over the chest in a neutral position and placed onto arm rest secured to the surgical table. At this degree of rotation, it is necessary to place contralateral leg in a bent position and then place pillows between the legs to elevate the ipsilateral leg and thus prevent a significant degree of hip adduction and/or strain on sciatic nerve. (Refer to Table 2.1 for further description regarding positioning injuries.) The patient is secured to the surgical table with tape or straps placed across the hips and across the chest (underneath the ipsilateral arm). These authors prefer wide silk tape placed over gel pads and surgical towels. All pressure points should be padded. The ipsilateral arm is loosely secured to prevent movement during the case. Bilateral legs are also loosely secured to the surgical table to prevent significant movement during the case.

Trocar Positioning

Once secured, the bed can be flexed and the kidney bar raised to increase the distance between the ribs and hips and hence maximize access to the retroperitoneum. An incision is then made approximately two fingerbreadths below the tip of the 12th rib along the posterior axillary line. Dissection is taken down through the lumbodorsal space until the retroperitoneum is entered. Blunt dissection or a trocar-mounted dissecting balloon is used to develop the retroperitoneal working space. A blunt 12 mm trocar can be placed within newly developed space and retroperitoneum. The trocar balloon is inflated, placed on tension at the level of the skin, and then insufflated to 15 mmHg (see Fig. 2.5). Working space is significantly diminished with this approach.

Partial Nephrectomy

It is necessary to obtain vascular control as the preliminary step. Dissection takes place in the plane between the anterior belly of the psoas

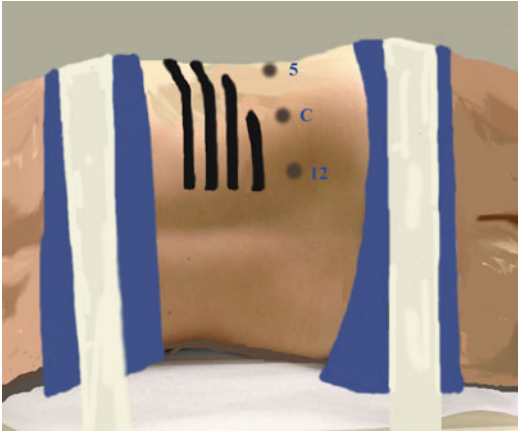


Fig. 2.5 Trocar positioning for retroperitoneal approach. C = camera port, 12 = 12 mm port, 5 = 5 mm port

muscle and the posterior aspect of the kidney. Lateral and anterior renal attachments should not be released until the hilum is identified as this will disrupt the natural retraction and hence make hilar identification more difficult.

The artery is encountered first. Partial nephrectomy proceeds as described previously.

References

1. Elsamra S, Pareek G. Complications of laparoscopic renal surgery. *Int J Urol.* 2010;17(3):206–14.
2. Food and Drug Administration [Internet]. Maryland: Medical device safety; 2011 [updated 20 Nov 2012; cited 12 July 2013]. Weck Hem-O-Lock Ligating clips safety alert. Available from: <http://www.fda.gov/Safety/MedWatch/SafetyInformation/SafetyAlertsforHumanMedicalProducts/ucm254363.htm>.
3. Yap SA, Alibhai SMH, Abouassaly R, Timilshina N, Margel D, Finelli A. Ipsilateral adrenalectomy at the time of radical nephrectomy impacts overall survival. *BJU Int.* 2011;111(3b):E54–8.
4. Rais-Bahrami S, George AK, Herati AS, Srinivasan AK, Richstone L, Kavoussi LR. Off-clamp versus complete hilar control laparoscopic partial nephrectomy: comparison by clinical stage. *BJU Int.* 2011;109(9):1376–81.
5. Desai MD, Gill IS, Ramani RP, Spaliviero M, Rybicki L, Kaouk JH. The impact of warm ischemia on renal function after laparoscopic partial nephrectomy. *BJU Int.* 2005;95(3):377–83.
6. Mir MC, Campbell RA, Sharma N, Remer EM, Li J, Demirjian S, et al. Parenchymal volume preservation and ischemia during partial nephrectomy: functional and volumetric analysis. *Urology.* 2013;82(2):263–9.
7. Nguyen MM, Gill IS. Halving ischemia time during laparoscopic partial nephrectomy. *J Urol.* 2008;179(2):627–32.
8. Power NE, Maschino AC, Savage C, Silberstein JL, Thorne D, Tarin T, et al. Intraoperative mannitol use does not improve long-term renal function outcomes after minimally invasive partial nephrectomy. *Urology.* 2012;79(4):821–5.

Laparoscopic and Robotic Reconstruction of the Upper Genitourinary Tract

3

Jeffrey C. Gahan and Jeffrey A. Cadeddu

Introduction

The first laparoscopic nephrectomy performed in 1991 revolutionized urology by demonstrating that extirpative surgery could be performed in a minimally invasive manner [1]. However, it wasn't until 3 years after Clayman performed the first laparoscopic nephrectomy that minimally invasive techniques for reconstruction were attempted. Schuessler performed the first laparoscopic pyeloplasty in 1993 [2, 3], which was followed shortly by Reddy and Evans and the first laparoscopic ureterovesical reimplant. Even in the aftermath of these reports, urologic reconstructive surgery was still largely performed as an open operation, with only select cases reserved for a minimally invasive approach. Reasons for this likely include a combination of lagging technology and the requirement of a new and challenging skill set (i.e., intracorporal suturing). However, as laparoscopic technology has advanced, along with the recent addition of robotic assistance, minimally invasive approaches in urologic reconstructive surgery have progressed. Currently, even uncommon and challenging reconstructive cases are being performed in a minimally inva-

sive manner. This chapter seeks to discuss some of the less common minimally invasive reconstructive surgeries being performed by providing a detailed description of each in conjunction with a brief review of the literature. Topics addressed in this chapter include distal ureteral reconstruction (ureteroneocystostomy, psoas hitch, Boari flap), ureteroneocystostomy, retrocaval ureter, and nephropexy. Table 3.1 gives a summary of the common instruments used for these cases.

Distal Ureter

Defects of the distal ureter may be the result of multiple etiologies. These include ischemia, trauma, periurethral fibrosis, malignancy, congenital disorders, and iatrogenic injuries. Currently, iatrogenic injuries account for 2–10 % of ureteral strictures and are commonly the result of gynecologic, endoscopic, or colorectal surgery. Distal ureteral stones and their treatment are also associated with an increased risk of stricture. Tas et al. reported that distal stones may cause ureteral stricture in up to 5.8 % of cases and found that larger stones (>1.0 cm) and impacted stones have higher stricture rates [4]. Roberts et al. similarly showed that stones impacted for prolonged periods (greater than 2 months) had a 24 % incidence of stricture formation [5]. Currently, with improved endoscopic equipment, the rate of long-term complications from stone treatment in

J.C. Gahan, MD (✉) • J.A. Cadeddu
Department of Urology,
University of Texas Southwestern Medical Center,
5323 Harry Hines Blvd J8106, Dallas, TX 75392, USA
e-mail: jeffrey.gahan@utsouthwestern.edu

Table 3.1 Common instruments used in laparoscopic or robotic reconstruction of the upper genitourinary tract

Laparoscopic	Robotic
5 mm monopolar scissors	8 mm monopolar curved scissors
5 mm atraumatic and/or Maryland graspers	8 mm Maryland Bipolar Forceps
5 mm right angle graspers	8 mm Cadier or Prograsp forceps(optional)
5 mm laparoscopic needle driver×2	8 mm needle driver×2
High-definition laparoscopic camera	High-definition 3D camera
10 mm 0° lens	12 mm 0° endoscope
10 mm 30° lens	12 mm 30° endoscope
5 mm trocar	8 mm robotic cannula×2
12 mm laparoscopic trocar	12 mm laparoscopic trocar (assistant port)
5 mm Ligasure (optional)	
<i>General equipment</i>	
Veress needle	
12 mm Visiport laparoscopic trocar	
Hem-o-lock clip applicator (small, medium, large)	
Angiographic 5 Fr 100 cm 0.038 in catheter	
Amplatz Superstiff J tip guide wire 0.035 in	
Flexible cystoscope	
Vessel loop	
6 Fr double J stent (length as appropriate)	
19 Fr full-flute 4-channel drain	
3-0 Vicryl 12 cm SH needle×3	
4-0 Vicryl 12 cm SH needle	
3-0 V-Loc V-20 12 cm absorbable suture (optional)	

the ureter is now <1 % [6]. Urothelial carcinoma in the distal ureter is a relatively uncommon cause of distal ureteral obstruction which may be treated with segmental ureterectomy and ureteral reimplant. Several reports in the urologic literature report this as a safe and effective method in select patients while preserving renal function [7, 8]. In the pediatric population, congenital defects of the distal ureter are the most common etiology requiring surgical correction, but this remains outside the topic of this chapter. In general, most distal ureteral defects may be managed by ureteroureterostomy given that the defect is short and uncomplicated. If the segment of damaged or involved ureter is sufficiently long, additional methods may be incorporated to bridge the gap including a psoas hitch and Boari flap. Table 3.2 outlines the approximate defect lengths that may be bridged with each reconstruction technique.

Table 3.2 Approximate involved or damaged distal ureter that may be bridged given each method of reconstruction

Ureteroureterostomy	<2 cm
Ureteroneocystostomy	2–5 cm
Psoas hitch	6–10 cm
Boari flap	12–15 cm

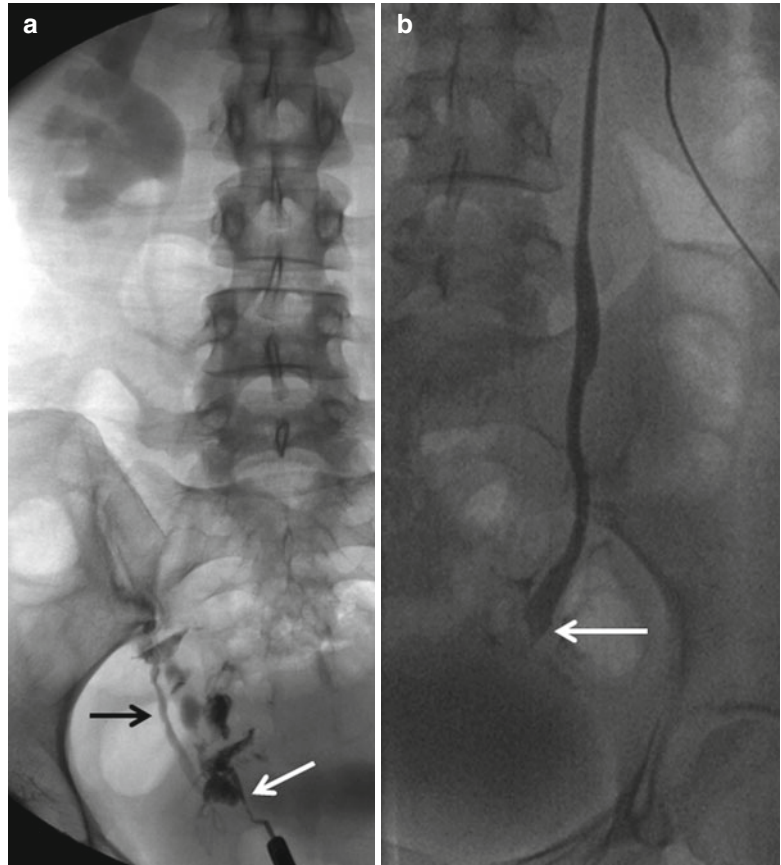
Work-Up of Distal Ureteral Strictures

When evaluating a ureteral stricture, proper imaging is essential to ensure correct treatment planning. A retrograde pyelogram (RPG) and now less commonly an intravenous pyelogram (IVP) accurately define the length and location of a distal stricture. However, antegrade and retrograde studies both may be needed to elucidate the true extent of ureteral involvement (Fig. 3.1). Cross-sectional imaging such as MRI or CT scan is also useful when evaluating ureteral strictures (Fig. 3.2) and may provide additional information to an IVP or RPG, especially when evaluating extrinsic causes of ureteral obstruction (non-urologic malignancy or fibrosis). In addition, despite their benign appearance, some strictures may be the result of malignancy and may not show the classical filling defect that is customarily seen. If there is any question as to the etiology of the stricture, a work-up for malignancy should be undertaken. This should include cytology, ureteroscopy with biopsy if possible, or brushing if biopsy is not feasible. Another critical analysis is the functional status of the ipsilateral renal unit. This can be evaluated using a diuretic renal scan. Impaired function on renal scan <25 % has been linked to poorer success rates after endoscopic reconstruction [9], while renal function less than 20 % may be cause for nephrectomy. Indications for ureteral reconstruction include compromised renal function, recurrent pyelonephritis, and pain due to obstruction.

Ureteroneocystostomy

Although the literature is mainly limited to case series for ureteroneocystostomy, these series have shown good overall success with laparoscopic and robotic approaches (Table 3.3). Without performing a psoas hitch or Boari flap, a 3–5 cm segment

Fig. 3.1 Iatrogenic distal ureteral injury during laparoscopic ablation of endometriosis. (a) The distal extent of ureteral injury (white arrow) and the apparent normal proximal ureter (black arrow) are seen on RPG along with moderate hydronephrosis. (b) An antegrade nephrostogram performed on the same patient shows a greater extent of proximal ureter (white arrow) involved than indicated by the RPG



of distal ureter may be bridged using solely this method. Obtaining this length is possible for two reasons. First, as the ureter enters the pelvis, it dives posteriorly. Mobilizing this ureteral segment and bringing it anteriorly generates ureteral length. Second, if the bladder has sufficient capacity and compliance, extensive mobilization may be sufficient to bridge gaps in this range.

Typically, this procedure is performed via a transperitoneal approach when performed laparoscopically or robotically. The patient is placed in the supine position on the OR table with their legs in spreader bars or in low lithotomy. This allows access to the patient's urethra and easy docking of the robot. Patient positioning and trocar placement are shown in Fig. 3.3. Access is typically gained using a Veress needle, the exact method which will be discussed in other chapters. If performed robotically, the trocar placement is similar to that of a prostatectomy, although the robotic trocar contralateral to the involved ureter is moved slightly caudal and

medial. Once pneumoperitoneum is established, the colon is reflected medially, and the ureter is identified as it crosses over the iliac vessels. The OR table can be rotated slightly, allowing gravity to help with colon retraction. Once circumferential access is gained to the ureter, a vessel loop is placed around it to allow for atraumatic manipulation. The ureter is then dissected distally to the strictured segment and divided (Fig. 3.4a). At this time, an evaluation of the ureteral length should be made by extending the ureter to the bladder.

In most instances, the bladder will need to be mobilized to accommodate a tension-free anastomosis. This is accomplished by releasing the bladder from the anterior abdominal wall and incising the contralateral medial umbilical ligament and possibly superior vesical artery if needed. Once accomplished, the bladder is then filled with 150–200 mL of saline, and the insertion point of the ureter determined. Our method of ureteroneocystostomy involves using a flexible cystoscope passed through the urethra to iden-

tify the new ureteral insertion point from inside the bladder. The back or rigid end of a wire is pushed through the detrusor muscle and secured with a laparoscopic grasper (Fig. 3.4b). An

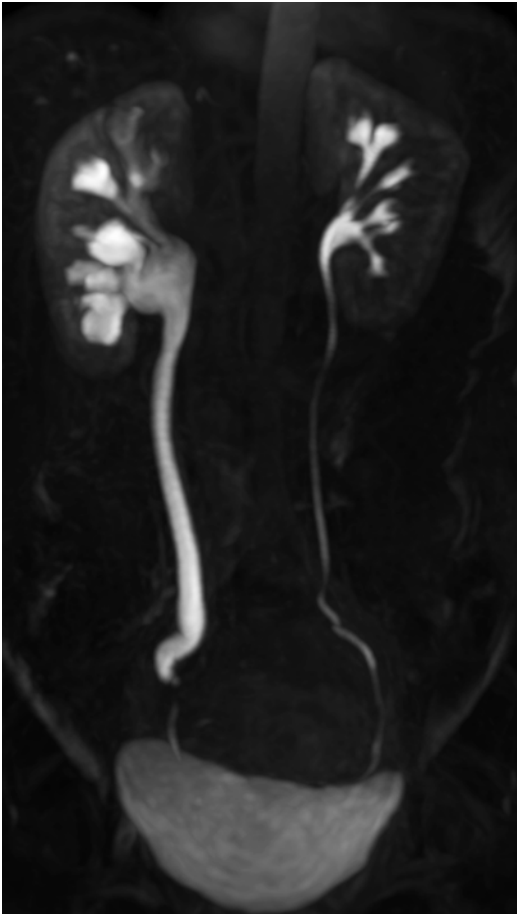


Fig. 3.2 Reconstructed MRI urogram demonstrating a distal right ureteral stricture with associated hydronephrosis due to an iatrogenic surgical injury

angiographic catheter is advanced over the wire (Amplatz Superstiff), and the wire is exchanged so the floppy end is advanced through the angiographic catheter and threaded up the ureter. This allows for easy subsequent stent placement. The cystostomy is slightly enlarged, and the ureter is spatulated on its posterior aspect. A spatulation of 1–2 cm may be required. Our preference is to perform a running anastomosis using two 3-0 vicryl sutures, one for the lateral wall and one for the medial wall. A drain should be left in place through the lateral assistant port.

Psoas Hitch

The psoas hitch is an effective method to bridge larger defects in the distal 1/3 of the ureter and can effectively accommodate defects 6–10 cm from the bladder. As a general rule, however, the psoas hitch is not sufficient on its own to bridge defects that extend beyond the pelvis. In addition to the standard work-up for ureteral strictures, when a psoas hitch is being contemplated, information about the bladder must be obtained. At minimum, a cystoscopy or cystogram documenting adequate bladder volume should be acquired. If there is concern for a neurogenic pathology, in some cases, urodynamics may be indicated to document adequate bladder compliance.

If performing the psoas hitch laparoscopically or robotically, the patient position and trocar placement are the same as for ureteroneocystostomy (Fig. 3.3). The steps for performing a psoas hitch are depicted in Fig. 3.5. The procedure is started with colon mobilization followed by iden-

Table 3.3 Robotic and laparoscopic series published for open, laparoscopic and robotic ureteral reimplant

	No.	Reimplant only	Psoas hitch	Boari flap	Follow-up (months)	Surgical success ^a (%)	Etiology	Approach
Wenske [10]	100	24	58	18	49	97	39 % TCC	Open
Kozim ^b [11]	24	4	4	2	24	100	40 % Calculus	Robot
Hemal ^b [12]	18	7	1	0	14	100	44 % Megaureter	Robot
Ogan [13]	6	5	1	0	13	100	66 % Iatrogenic	Lap
Soares [14]	11	7	1	2	18	100	40 % Calculus	Lap
Rasswiler [15]	10	0	6	4	–	100	30 % Iatrogenic	Lap

^aOperative success defined by imaging and symptom resolution

^bThese studies did not report the type of reconstruction for all cases

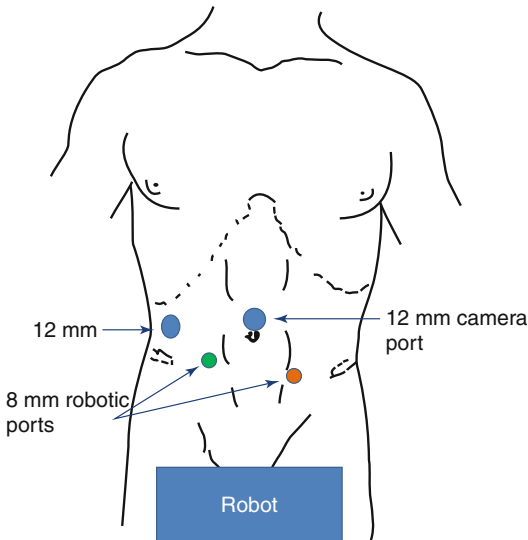


Fig. 3.3 Patient position and trocar placement for right robotic ureteroneocystostomy. Note the left robotic trocar (*orange*) is brought medial and caudal compared to the right (*green*). 12 mm trocars (*blue*) are used as the camera port and the right as a lateral assistant port. A similar port placement is used if performed laparoscopically

tification and dissection of the ureter. The bladder is mobilized and attachments are divided as needed, which may include the vas deferens or round ligament. In addition, the contralateral superior vesical artery may be divided for increased mobilization. Lastly, an anterior cystotomy made perpendicular to the plane of ureteral insertion and closed parallel can help advance the dome of the bladder to the ureter. This can be done either with a 3-0 vicryl or an absorbable 3-0 V-Loc suture. The bladder dome is then brought to the ipsilateral psoas muscle. This is secured to the psoas fascia using several nonabsorbable sutures (3-0 vicryl). Care must be taken to avoid entrapping the genitofemoral nerve which can be avoided by placing the stitches parallel to the psoas muscle fibers and only incorporating the psoas fascia. The ureteroneocystostomy is then performed as previously described with stent placement either at the time of ureteroneocystostomy or at the beginning of the case. Alternatively, some groups report performing the ureteroneocystostomy prior to the psoas hitch.

Although limited, reports indicate this to be a successful procedure with a greater than 85 % success in adults and children. Advantages to this

procedure include its relative simplicity and low complication rate.

Boari Flap

The Boari flap is an additional surgical technique that allows longer segments of damage to the distal ureteral to be bridged. Using this method, segmental defects up to 12–15 cm may be safely managed. As with the psoas hitch, the work-up must include a thorough evaluation of the bladder to ensure that it has sufficient capacity and compliance. Here, a small bladder capacity severely limits the length of the defect that may be bridged.

The patient positioning, trocar placement, and dissection of the ureter are the same as for a ureteroneocystostomy (Fig. 3.3). The bladder is completely dissected off the anterior abdominal wall, and the contralateral bladder attachments are divided as needed. The Boari flap is created by making an incision 2–3 cm from the bladder neck which is extended in an oblique fashion to the dome. The base of the flap should be at minimum 4 cm wide, with the apex being approximately 3 cm wide (Fig. 3.6a). The ratio of flap length to width should not exceed 3:1 to limit ischemia. Once the flap is created, the ureter is passed through a small opening in the distal flap, and a mucosa-to-mucosa anastomosis is performed using 4-0 monocryl suture (Fig. 3.6b). The distal end of the flap is secured to the psoas muscle. The remainder of the flap is tubularized over a double J stent (Fig. 3.6c). Because of the extensive sewing, a 3-0 V-Loc may be considered for this step. Creating a spiral flap may allow even longer segments of damaged ureter to be bridged (Fig. 3.7). It should be noted that the bladder capacity will be diminished, in some cases greatly, depending on the length of the Boari flap generated. A drain is left through the lateral assistant port.

Mid- and Proximal Ureteral Stricture

A short defect in the mid- or proximal ureter (Table 3.2) is appropriate for repair in the form of a laparoscopic or robotic ureteroureterostomy. When encountered in a trauma situation, this type

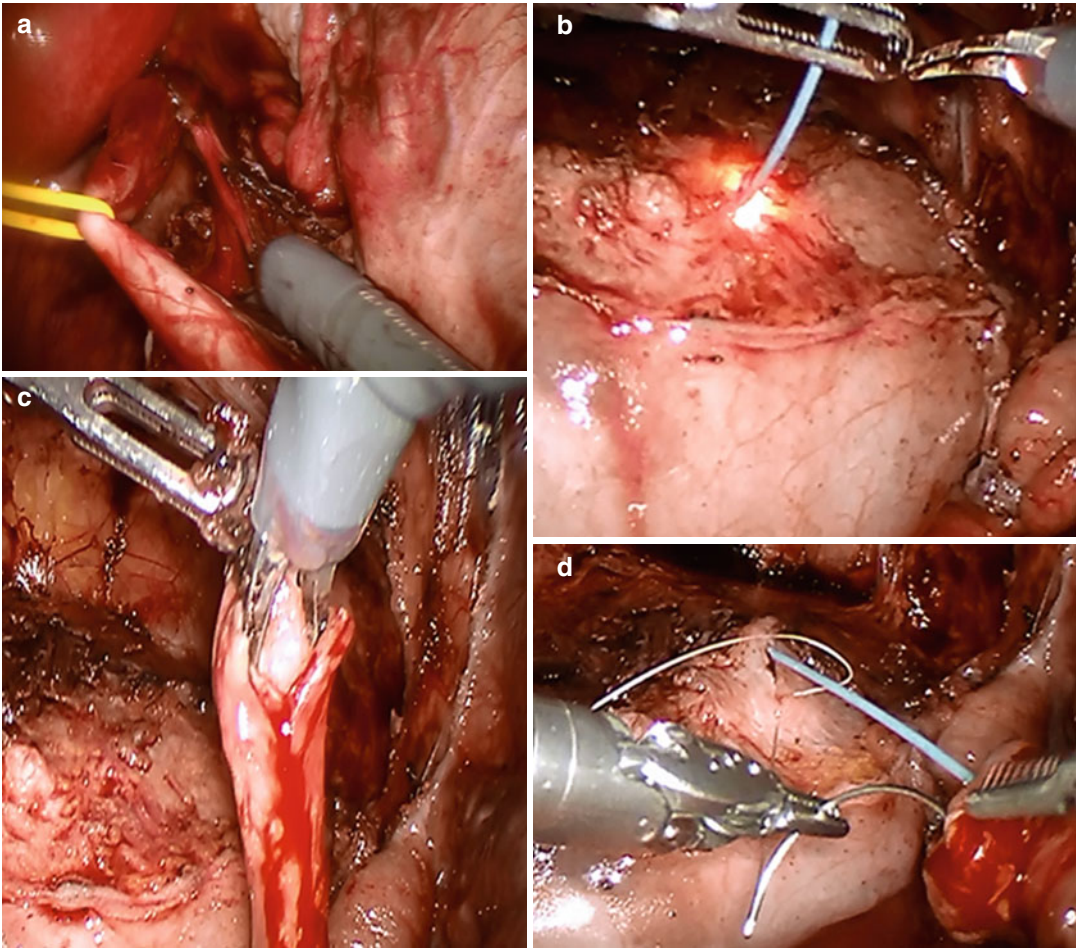


Fig. 3.4 Steps in a robotic ureteroneocystostomy. (a) The ureter is dissected to the level of the stricture and divided. A vessel loop aids in atraumatic manipulation. (b) A cystoscope is guided to the insertion point of the ureter and a wire is passed through the detrusor. (c) The ureter is spat-

ulated on its posterior aspect, and the scissors are used to calibrate the inner lumen to ensure no stricture. (d) The anastomosis is completed using a 3-0 vicryl suture over the wire. A double J stent is placed prior to completing the anastomosis

of repair will be most often performed through and open approach, although there are rare instances when a minimally invasive ureteroureterostomy may be indicated. Lower ureter strictures of similar length, however, may be managed best by ureteroneocystostomy. If a ureteroureterostomy is to be attempted, the defect must be short enough so that ureteral mobilization gives a tension-free anastomosis, as the rate of postoperative stricture formation is high if this criteria is not met. Trocar placement is dependent on the level of the stricture. For proximal and mid-ureteral strictures, (those most appropriate for a

ureteroureterostomy), we find it best to use a trocar configuration similar that of a nephrectomy with the patient in a 45° lateral position which allows the mobilized bowel to fall medially. Trocar adjustments may be made cranially or caudally depending on the stricture location (Fig. 3.8).

The procedure is begun by incising lateral to the colon along the line of Toldt and mobilizing this medially so that the retroperitoneum is exposed. The ureter can be identified as it crosses the iliac vessels or just caudal to the lower pole of the kidney posterior and lateral to the gonadal

Fig. 3.5 (a) The bladder is brought the psoas fascia after mobilization and an anterior neocystotomy is made if additional length is needed. (b) The bladder is tacked to the psoas fascia using a 3-0 vicryl suture and the neocystotomy is closed

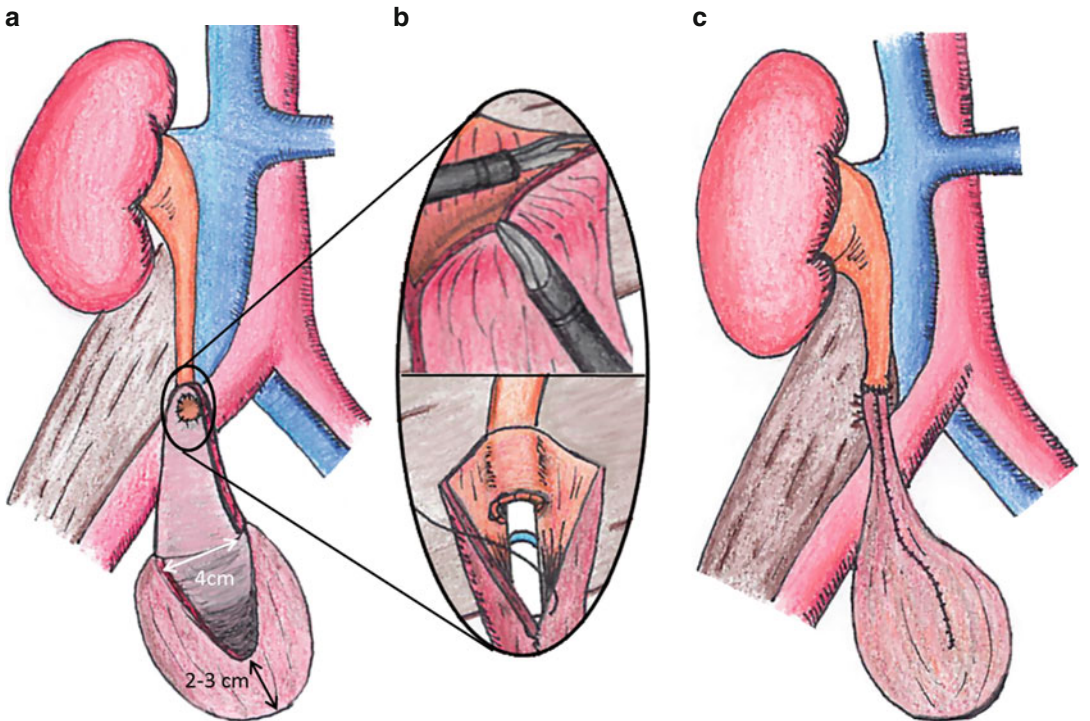
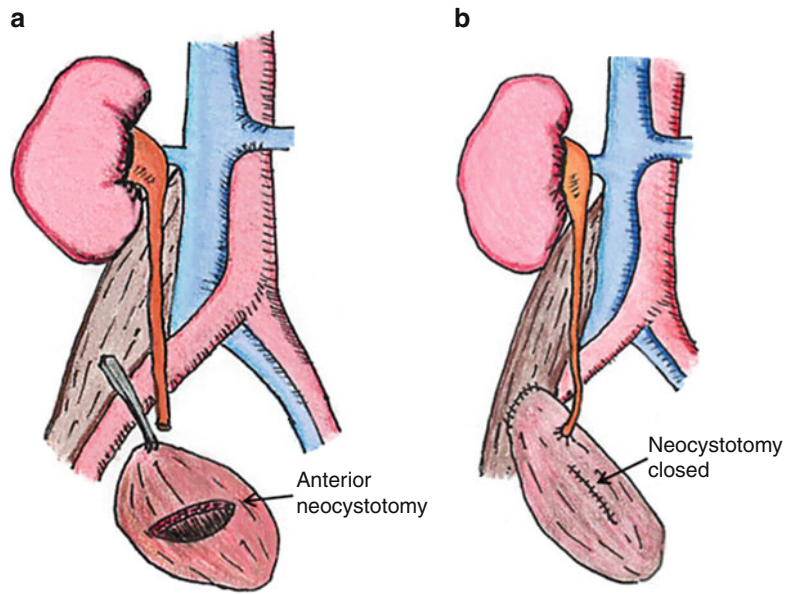


Fig. 3.6 (a) The Boari flap is created by incising approximately 2–3 cm from the bladder neck and the incision is carried to the bladder dome, with the base being at least 4 cm wide. (b) A mucosa-to-mucosa anastomosis is per-

formed by raising a mucosal flap and tunneling the ureter through this portion of the bladder flap. (c) The Boari flap is secured to the psoas muscle and the flap is tubularized over a double J stent

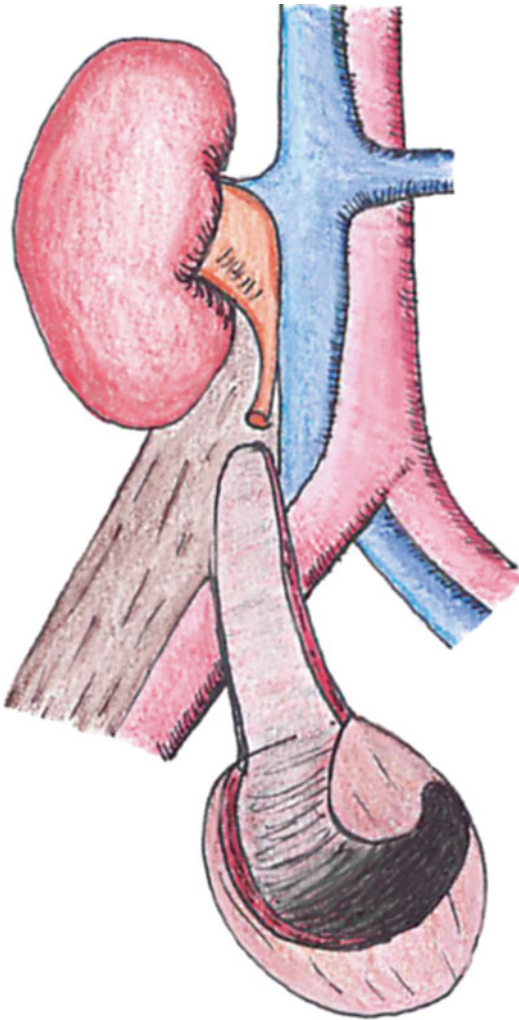


Fig. 3.7 A spiral flap can provide additional length when performing a Boari flap; however, this may result in significant loss of bladder volume

vein. Circumferential access should be gained, and a vessel loop passed around the ureter and secured with a hem-o-lock clip. Again, this allows for atraumatic manipulation of the ureter. Once the ureter is completely mobilized, the damaged segment should be excised to bleeding tissue. Both ends should be calibrated with a laparoscopic instrument (Fig. 3.4c) to ensure there is no remaining stricture. The ends are then spatulated 180° apart for approximately 1–1.5 cm. A small, absorbable suture should be used. We prefer a 4-0 vicryl in this setting. The suture is placed out to in so the knot remains on the outside. The back wall is then completed first and a ureteral

stent is placed over a wire into the bladder. If the bladder is filled with methylene blue, once the stent is in the bladder, blue efflux can be seen.

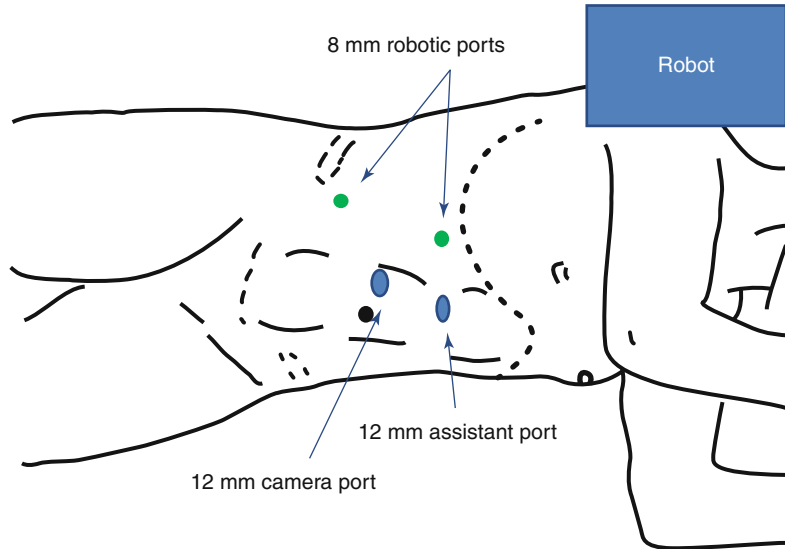
Retrocaval Ureter

Retrocaval ureter (RCU) is a rare congenital urologic anomaly where the ureter is forced to travel posterior to a persistent, posterior cardinal vein before emerging on the medial aspect and crossing anterior to the vein (Fig. 3.9). This is an uncommon abnormality with 1/1,000 births being affected. The persistent vein often causes a partial obstruction which leads to dilation of the proximal ureter. An S-shaped deformity on intravenous pyelogram or retrograde pyelogram with proximal ureteral dilation should alert the physician to the possibility of a retrocaval ureter (Fig. 3.9). A CT scan with IV contrast can provide a definitive diagnosis by demonstrating the persistent cardinal vein and obstructed ureter.

Surgical Intervention for RCU

Intervention for RCU is indicated if functional loss or persistent pain is experienced. Several case reports have demonstrated that a laparoscopic approach is feasible when attempting reconstruction of RCU [16, 17]. A ureteral stent can be placed at the beginning of the case in a retrograde fashion or may be placed intraoperatively, although this may be more cumbersome laparoscopically. Both transperitoneal and retroperitoneal approaches have been described [18–20]. For a transperitoneal approach, the ureter is first mobilized completely away from the vena cava and divided at the dilated, most distal segment. The ureter should be calibrated with the laparoscopic or robotic instrument (as previously shown) to ensure there is no area of stenosis. If such an area exists, this should be excised. In general, ample ureteral length should be available for repair. The ureteral ends are then spatulated 1.5–2 cm at opposite ends. The anastomosis is performed over the stent using two absorbable sutures (4-0 vicryl), with the posterior wall first, followed by the anterior wall. This anastomosis

Fig. 3.8 Patient position and trocar placement for a left robotic ureteroureterectomy. The use of the 4th robotic arm is general not necessary. A 12 mm assistant is placed cranial to the camera port near the midline. If performed laparoscopically, the 8 mm ports can be substituted for 5 and 10 mm trocar and the assistant port is optional



should be watertight and tension-free. A drain is then placed through either a lateral stab incision or through one of the laparoscopic trocars.

Although limited, the results of this repair have been favorable. In one of the largest series published, Chen et al. describes their series of 12 patients, all with significant improvement of hydronephrosis and all remaining symptom-free on follow-up. Of note, only 2 of 12 patients in this series required resection of the posterior segment of ureter. In general, case series describing RCU repair show the laparoscopic or robotic approach to be safe, with minimal postoperative pain, rather short convalescence and excellent short-term success [18–20].

Nephropexy

Symptomatic nephroptosis is a rare disease requiring surgical intervention in the form of nephropexy in select cases. Nephroptosis is characterized by the descent of the kidney by more than 5 cm (or 2 vertebral columns) when shifting from the supine to upright position. This condition affects females disproportionately and most commonly affects the right kidney (70 % of cases). Symptomatic nephroptosis, however, only occurs in approximately 10–20 % of the cases where nephroptosis is identified [21, 22]. The most common symptom is intermittent flank

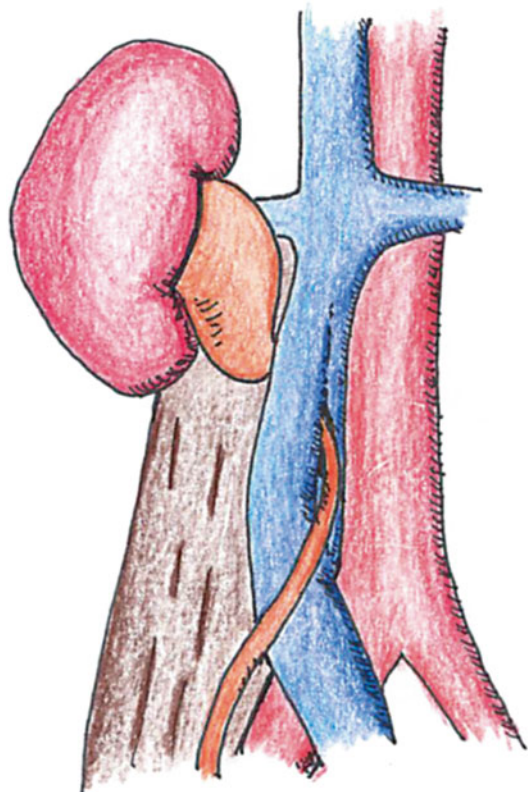
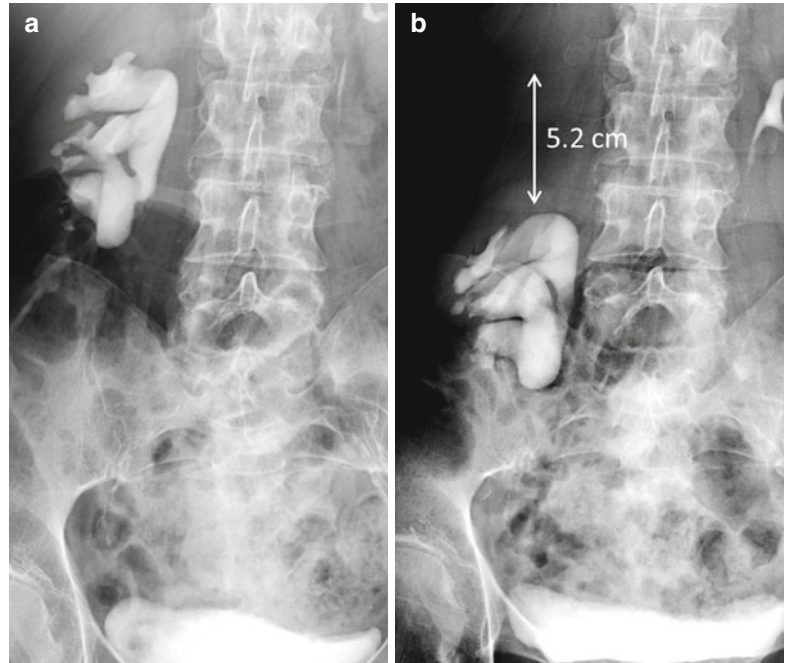


Fig. 3.9 Drawing depicting a retrocaval ureter. Note the dilation of the ureter proximal to the portion posterior to the vein

pain or pain in the lower abdominal quadrant that resolves when supine. Rarely, more severe symptoms are associated with nephroptosis

Fig. 3.10 (a) IVP when supine followed by (b) an upright IVP demonstrating a greater than 5 cm descent of the kidney



including recurrent UTI, pyelonephritis, renal stones, and hypertension. Nephroptosis is most commonly diagnosed on IVP in a supine then upright position (Fig. 3.10). The descent of the kidney more than 5 cm in the upright position suggests nephroptosis. There has been much debate as to who the proper operative candidate should be. Matsui et al. have argued that any patient with symptomatic nephroptosis is an operative candidate, while others have stated that function impairment must be demonstrated prior to performing a nephropexy [23]. Because of this requirement, several authors have advocated concomitant Doppler US to document impaired blood flow or diuretic renal scan to document impaired function of the nephrotic kidney prior to nephropexy [24].

Surgical Intervention for Symptomatic Nephroptosis

Laparoscopic or robotic nephropexy may be performed through a transperitoneal or retroperitoneal approach [23, 25, 26]. The patient is

positioned in a 45° lateral position as shown in Fig. 3.8. Once pneumoperitoneum has been established, a camera trocar is placed at the umbilicus. Two additional trocars are then placed, one 1/3 of the distance between the camera and xiphoid process just under the costal margin and the other approximately three fingerbreadths off the anterior iliac spine. The procedure is started with medial reflection of the colon. Gerota's fascia is then opened and the kidney is completely mobilized. The ureter is identified. Once freely mobile, the kidney is placed on upward traction to its ideal anatomic position. At this point, the exact method by which the kidney is best secured is subject to debate. We prefer a two- or three-point fixation method using an absorbable suture (2-0 vicryl). This involves placing a suture through the posterior abdominal wall (Fig. 3.11a) and then through the renal capsule (Fig. 3.11b) carefully avoiding deep bite into the renal parenchyma leading to bleeding. The suture is then tied. This can be repeated until the kidney is sufficiently held in position. Once secured, Gerota's fascia is re-approximated using hem-o-lock clips to provide additional support.

Fig. 3.11 Laparoscopic nephropexy. (A) The suture is first passed through the lumbar quadrate muscle or psoas muscle (*a*) then (B) passed through the renal capsule (*b*) and tied

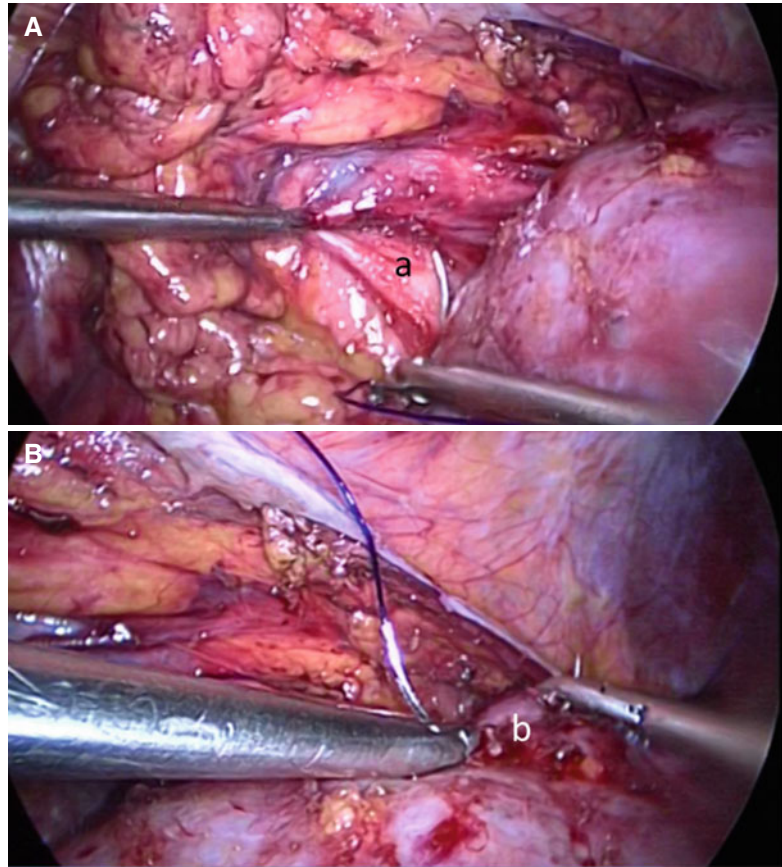


Table 3.4 Contemporary laparoscopic nephropexy series for symptomatic nephroptosis. Outcome defined as percentage of patients with symptomatic resolution

	No.	Follow-up (months)	Method	Outcome (%)
Fornara [27]	23	36	2-point fixation	91
Plass [22]	13	60	Polypropylene mesh	92
Chueh [25]	25	2–84	Running suture	84
Wyler [26]	12	41	3-point fixation	84
Gozen [28]	48	97	2-point fixation	95
Golab [29]	21	3	2-point fixation	100

A follow-up IVP is performed at 3 months to evaluate the success of the surgery based on radiographic criteria.

Table 3.4 shows the outcomes for contemporary laparoscopic nephropexy series. Several authors have reported using mesh [22, 30, 31]. In the series by Plass et al., absorbable mesh was reportedly used in the first six patients of the series, but due to early symptomatic recurrence,

this was changed to nonabsorbable polypropylene mesh [22]. However, due to the intense fibrotic reaction that may be induced by mesh, concerns with its use have arisen, specifically that of fibrous encapsulation of the ureter. Multiple authors report a simpler approach using a two or three interrupted sutures to secure the upper portion of the kidney to the abdominal wall and have reported good success with this method [26, 28, 29].

References

1. Clayman RV, et al. Laparoscopic nephrectomy. *N Engl J Med*. 1991;324(19):1370–1.
2. Schuessler WW, et al. Laparoscopic dismembered pyeloplasty. *J Urol*. 1993;150(6):1795–9.
3. Reddy PK, Evans RM. Laparoscopic ureteroneocystostomy. *J Urol*. 1994;152(6 Pt 1):2057–9.
4. Tas S, et al. Incidence of ureteral stricture after ureterorenoscopic pneumatic lithotripsy for distal ureteral calculi. *Arch Ital Urol Androl*. 2011;83(3):141–6.
5. Roberts WW, et al. Ureteral stricture formation after removal of impacted calculi. *J Urol*. 1998;159(3):723–6.
6. Harmon WJ, et al. Ureterscopy: current practice and long-term complications. *J Urol*. 1997;157(1):28–32.
7. Dalpiaz O, Ehrlich G, Quehenberger F, Pummer K, Zigeuner R. Distal ureterectomy is a safe surgical option in patients with urothelial carcinoma of the distal ureter. *Urol Oncol*. 2014;32:34.e1–8. PubMed PMID: 23506964.
8. Jeldres C, et al. Segmental ureterectomy can safely be performed in patients with transitional cell carcinoma of the ureter. *J Urol*. 2010;183(4):1324–9.
9. Wolf Jr JS, Elashry EM, Clayman RV. Long-term results of endoureterotomy for benign ureteral and ureteroenteric strictures. *J Urol*. 1997;158(3):759–64.
10. Wenske S, Olsson CA, Benson MC. Outcomes of distal ureteral reconstruction through reimplantation with psoas hitch, Boari flap, or ureteroneocystostomy for benign or malignant ureteral obstruction or injury. *Urology*. 2013;82(1):231–6.
11. Kozinn SI, et al. Robotic versus open distal ureteral reconstruction and reimplantation for benign stricture disease. *J Endourol*. 2012;26(2):147–51.
12. Hemal AK, et al. Experience with robot assisted laparoscopic surgery for upper and lower benign and malignant ureteral pathologies. *Urology*. 2010;76(6):1387–93.
13. Ogan K, et al. Laparoscopic ureteral reimplant for distal ureteral strictures. *JSLs*. 2008;12(1):13–7.
14. Soares RS, De Abreu Jr RA, Tavora JE. Laparoscopic ureteral reimplant for ureteral stricture. *Int Braz J Urol*. 2010;36(1):38–43.
15. Rassweiler JJ, et al. Ureteral reimplantation for management of ureteral strictures: a retrospective comparison of laparoscopic and open techniques. *Eur Urol*. 2007;51(2):512–22; discussion 522–3.
16. Gupta NP, et al. Retroperitoneoscopic ureterolysis and reconstruction of retrocaval ureter. *J Endourol*. 2001;15(3):291–3.
17. Ramalingam M, Selvarajan K. Laparoscopic transperitoneal repair of retrocaval ureter: report of two cases. *J Endourol*. 2003;17(2):85–7.
18. Ding GQ, et al. Pure transperitoneal laparoscopic correction of retrocaval ureter. *Chin Med J (Engl)*. 2012;125(13):2382–5.
19. Chen S, et al. Retroperitoneal laparoscopic reconstruction for retrocaval ureter: experience and literature review. *J Endourol*. 2012;26(9):1147–52.
20. Chen Z, et al. Treatment of retrocaval ureter by retroperitoneal laparoscopic ureteroureterostomy: experience on 12 patients. *J Laparoendosc Adv Surg Tech A*. 2011;21(9):803–7.
21. Hubner WA, Schramek P, Pfluger H. Laparoscopic nephropexy. *J Urol*. 1994;152(4):1184–7.
22. Plas E, et al. Long-term followup after laparoscopic nephropexy for symptomatic nephroptosis. *J Urol*. 2001;166(2):449–52.
23. Matsui Y, et al. Laparoscopic nephropexy: treatment outcome and quality of life. *Int J Urol*. 2004;11(1):1–6.
24. Barber NJ, Thompson PM. Nephroptosis and nephropexy—hung up on the past? *Eur Urol*. 2004;46(4):428–33.
25. Chueh SC, et al. Retroperitoneoscopic nephropexy for symptomatic nephroptosis. *Surg Endosc*. 2002;16(11):1603–7.
26. Wyler SF, et al. Retroperitoneoscopic nephropexy for symptomatic nephroptosis using a modified three-point fixation technique. *Urology*. 2005;66(3):644–8.
27. Fornara P, Doehn C, Jocham D. Laparoscopic nephropexy: 3-year experience. *J Urol*. 1997;158(5):1679–83.
28. Gozen AS, et al. Long-term outcome of laparoscopic retroperitoneal nephropexy. *J Endourol*. 2008;22(10):2263–7.
29. Golab A, et al. Retroperitoneoscopic nephropexy in the treatment of symptomatic nephroptosis with 2-point renal fixation. *Surg Laparosc Endosc Percutan Tech*. 2009;19(4):356–9.
30. El-Shazly MA. Laparoscopic nephropexy using polypropylene mesh. *Surg Laparosc Endosc Percutan Tech*. 2011;21(3):188–90.
31. Baldassarre E, et al. Robotic nephropexy in case of symptomatic nephroptosis. *Arch Ital Urol Androl*. 2011;83(3):160–2.

Ravi Munver and Jennifer Yates

Introduction

First described in 1992, laparoscopic adrenalectomy (LA) is performed for both benign and malignant conditions, including functional tumors, masses with radiographic findings suspicious for malignancy, solitary metastatic lesions, and nonfunctioning symptomatic lesions [1]. When compared to open adrenalectomy, LA offers shorter convalescence, improved cosmesis, and decreased postoperative pain [2–4]. In a recent review of the American College of Surgeons–National Surgery Quality Improvement Project database, LA was noted to have a significantly lower complication rate when compared with open adrenalectomy [5].

Patient selection is critical, and a complete preoperative evaluation in collaboration with an endocrinologist is important to identify metabolic aberrations caused by a functional adrenal mass. Preoperative optimization, including medical management of metabolic manifestations of the adrenal pathology, helps assure a successful outcome. Imaging studies may help prepare the surgeon, with attention paid to the size of the lesion, its vascular supply, and nearby structures that may pose a challenge (e.g., hepatomegaly). Patients selected for LA must be evaluated on an individual basis, and the surgeon’s experience and comfort level must be taken into consideration. While LA may be a feasible approach for many adrenal masses, a low threshold to convert to open surgery should be maintained. In this chapter, the surgical approaches to laparoscopic and robot-assisted adrenalectomy and partial adrenalectomy will be discussed.

R. Munver, MD, FACS (✉)
Division of Urology, Department of Surgery,
Rutgers University – New Jersey Medical School,
Newark, NJ, USA

Department of Urology, Hackensack University
Medical Center, 360 Essex Street, Suite 403,
Hackensack, NJ 07601, USA

The John Theurer Cancer Center of Hackensack
University Medical Center, Hackensack, NJ, USA
e-mail: munver@hackensackumc.org

J. Yates, MD
Division of Urology, University of Massachusetts
Medical School, Worcester, MA, USA

Department of Urology, UMASS Memorial
Medical Center, 55 Lake Ave North, Worcester,
MA 01605, USA

Indications and Contraindications

The indications for laparoscopic adrenalectomy may be classified into several categories (Table 4.1). These include functional tumors, nonfunctional symptomatic tumors, indeterminate cysts, solitary metastatic lesions, malignant lesions, and incidental adrenal lesions with features such as large size, rapid growth rate, and indeterminate radiographic characteristics.

Table 4.1 Indications/contraindications for laparoscopic adrenalectomy*Indications*

Aldosterone producing adenoma
 Cortisol producing adenoma
 Bilateral adrenal hyperplasia
 Pheochromocytoma
 Nonfunctioning adenoma >4–5 cm
 Symptomatic cyst
 Symptomatic myelolipoma
 Solitary adrenal metastasis

Contraindications

Large tumor >10 cm (relative)
 Morbid obesity (relative)
 Uncorrected coagulopathy (relative)
 Pyelonephritis (relative)
 Adrenocortical carcinoma (relative)
 Malignant pheochromocytoma (relative)
 Significant abdominal adhesions (relative)
 Severe cardiopulmonary disease (relative)
 Local invasion (absolute)
 Venous involvement (absolute)
 Pregnancy (absolute)

Functional adrenal adenomas that secrete hormones such as aldosterone and cortisol are among the most common indications for surgical excision of the adrenal gland. These benign lesions are optimal for laparoscopic excision due to their location and small size. While the exact size of an adrenal lesion prompting surgical exploration is controversial, most authorities agree that lesions greater than 4–5 cm should be removed because of the higher likelihood of malignancy. Smaller lesions are commonly benign and thus are frequently followed radiographically.

Laparoscopic excision of adrenal lesions larger than 10 cm or of adrenal carcinomas is controversial. While some experienced surgeons have approached these lesions laparoscopically, many authorities consider these to be contraindications to laparoscopic adrenalectomy. These cases can be exceedingly complex, with high complication rates and more frequent conversions to an open procedure. Large lesions or those with potential for local invasion are recommended to be managed using an open approach.

Relative contraindications to laparoscopic adrenalectomy include significant adhesions from prior surgery, morbid obesity, uncorrected coagulopathy, and cardiopulmonary disease that precludes hypercapnea that is associated with pneumoperitoneum.

Preoperative Evaluation

A complete history and physical examination is mandatory in the evaluation of a patient with an adrenal mass. While a complete discussion of the metabolic evaluation of adrenal lesions is beyond the scope of this chapter, a distinct effort to rule out the diagnosis of a pheochromocytoma is crucial, as dire consequences may result from a misdiagnosis. This can be accomplished by evaluating the patient's plasma-free metanephrines, along with confirmatory urinary catecholamine and metanephrine levels if necessary. A complete endocrinologic evaluation should also include measurement of serum electrolytes, serum hormone levels, and urine levels of steroid hormones and their metabolites. The exact tests ordered will depend on the observed clinical signs and symptoms as well as the patient's history and physical exam. In addition, stimulation studies such as the low- and high-dose dexamethasone suppression tests and measurement of plasma renin and aldosterone levels can be obtained if clinically warranted.

Radiographic imaging is essential in the evaluation of an adrenal mass. While a pathologic evaluation can yield a definitive diagnosis, invaluable information can be obtained from a properly performed radiographic study. Computed tomography (CT) scans with and without intravenous contrast, with thin 2–5 mm cuts, are vital in assessing adrenal lesions. Lipid-rich adenomas are commonly homogeneous lesions that measure less than ten Hounsfield units on noncontrast CT, while lipid-poor adenomas may be differentiated by measuring levels of enhancement or percent contrast washout. Lymphadenopathy and local invasion are features that are more consistent with a malignant lesion.

Magnetic resonance imaging (MRI) scans are also commonly obtained in the evaluation of adrenal masses. This study can provide additional information such as identifying adipose tissue within lesions and can improve the identification of invasion into surrounding structures. Metaiodobenzylguanidine (MIBG) scans have poor spatial resolution and play a limited role in the evaluation of adrenal lesions. However, this study can be helpful in localizing small pheochromocytomas. This is especially true for those patients with multiple endocrine neoplasia (MEN) syndromes who are high risk for extra-adrenal pheochromocytomas. Additionally, MIBG scans are useful in suspected cases of malignant or bilateral pheochromocytomas.

Once an adrenal lesion is determined to require removal, standard preoperative evaluation and preparation are required. Patients diagnosed with a pheochromocytoma require a more thorough preoperative assessment. This includes alpha-blockade for 2 weeks prior to surgery, along with the addition of beta-blockers to treat tachycardia or arrhythmias if present. Beta-blockers should only be given once complete alpha-blockade is achieved. Furthermore, these patients also require cardiac consultation for the evaluation of occult cardiomyopathy.

Relevant Anatomy

The arterial supply to the adrenal gland is highly variable. The adrenal glands typically draw their blood supply from arterial cascades arising from the inferior phrenic artery, aorta, and renal artery. Adrenal venous drainage also displays great variability. On the right side, a short adrenal vein typically provides drainage into the posterolateral aspect of the vena cava. On the left side, the adrenal vein usually drains into the left renal vein. Not uncommonly, accessory adrenal veins are present near the superior and medial diaphragmatic attachments and provide additional drainage into the inferior phrenic vein. Meticulous dissection and appreciation of retroperitoneal anatomy is required in order to avoid inadvertent vascular injury.

Patient Preparation, Operating Room Setup, and Patient Positioning

Informed consent with explanation of pertinent risks is obtained prior to the procedure. Patients are instructed to maintain a clear liquid diet for 12–24 h prior to surgery and administer a bowel preparation consisting of 300 ml of magnesium citrate on the prior day. Sequential compression devices are placed on the lower extremities, and a single dose of intravenous antibiotics is given 60 min prior to surgical incision. After induction of general anesthesia, an orogastric tube and Foley catheter are placed to decompress the stomach and bladder, respectively. Bilateral intravenous access may be beneficial as upper extremity exposure is limited once positioning is completed. Administration of nitrous oxide can lead to bowel distention and should be avoided.

For cases of pheochromocytomas, invasive arterial monitoring, large-bore intravenous access or central line placement is recommended. These patients must be aggressively hydrated prior to surgery, as hypotension is frequently encountered after the induction of anesthesia. Anesthetic agents such as propofol, ketamine, and halothane should be avoided.

The patient is placed in a modified lateral decubitus position (45–60°) with the flank situated over the kidney rest. The table may be flexed to increase the area between the iliac crest and costal margin. A bean bag or large gel rolls are used to support the patient in this position. Pillows are placed between the legs, and the dependent leg is flexed at the knee while the opposite leg is placed straight. The arms are placed parallel onto well-padded arm boards. The ankles, knees, dependent hip, shoulders, and brachial plexus are adequately padded. After verifying that all areas prone to pressure injury are well padded, the patient is secured to the operating table using 3" cloth tape across the shoulder and arm as well as across the hip. Figure 4.1 demonstrates proper patient positioning for left laparoscopic adrenalectomy. Positioning for right laparoscopic adrenalectomy is the mirror image of that for the left side. Furthermore, a needlescopic technique with 2–3 mm trocars can be employed.

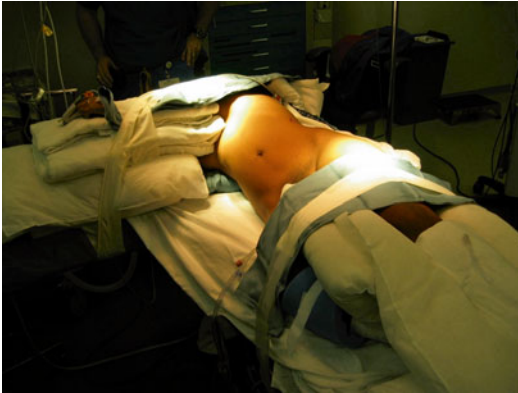

Fig. 4.1 Patient positioning for left laparoscopic adrenalectomy

Equipment

The instrumentation and setup for laparoscopic adrenalectomy is similar to that for laparoscopic renal surgery and consists of a video tower with a color monitor, video system, and CO₂ insufflator. Both 0° and 30° lenses are commonly used. A liver retractor is useful for right-sided procedures, and several types of retractors are commercially available. The liver retractor is held in place by an assistant or a self-retaining device that is attached to the operating table. The surgeon utilizes an atraumatic grasper, laparoscopic Kittner, or suction irrigator in the nondominant hand and a dissecting instrument in the surgeon's dominant hand. A variety of laparoscopic thermal energy devices are available. Ultrasonic shears may be useful for colon mobilization and adrenal vein dissection. A bipolar device has excellent hemostatic properties and may be used for performing the adrenal dissection. This device has been shown to significantly decrease blood loss and operative time during adrenal dissection compared to other devices. Furthermore, this device can be used to ligate and divide the adrenal vein, which obviates the need for hemostatic clips. Intraoperative ultrasound has also shown to be helpful in localizing small adrenal lesions, especially in obese individuals with extensive amounts of retroperitoneal adipose tissue. A laparoscopic specimen retrieval bag is required. The robotic approach with the daVinci™ Surgical System (Intuitive

Surgical – Sunnyvale, CA) utilizes a three- or four-arm robot which is controlled at the robotic console by the operating surgeon, while a bedside first assistant uses an accessory port for clip placement, suction, and additional maneuvers as needed. A variety of robotic instruments are available for robot-assisted adrenalectomy.

Equipment List for Laparoscopic Adrenalectomy

- Veress needle
- 5 or 10 mm laparoscope with 0 and 30° lenses
- 12 mm trocars
- 5 mm trocars
- Ultrasonic shears
- Bipolar vessel-sealing device
- Laparoscopic atraumatic grasping forceps
- Laparoscopic right angle
- Laparoscopic liver retractor and holder
- Laparoscopic Kittner
- Laparoscopic suction/irrigator
- Laparoscopic ultrasound probe
- Laparoscopic retrieval bag
- Laparoscopic stapling device (optional)
- Polymer or titanium hemostatic clips (5 or 10 mm)
- Oxidized cellulose polymer
- Other hemostatic agents (optional)
- Fascial closure device

Equipment List for Robot-Assisted Adrenalectomy

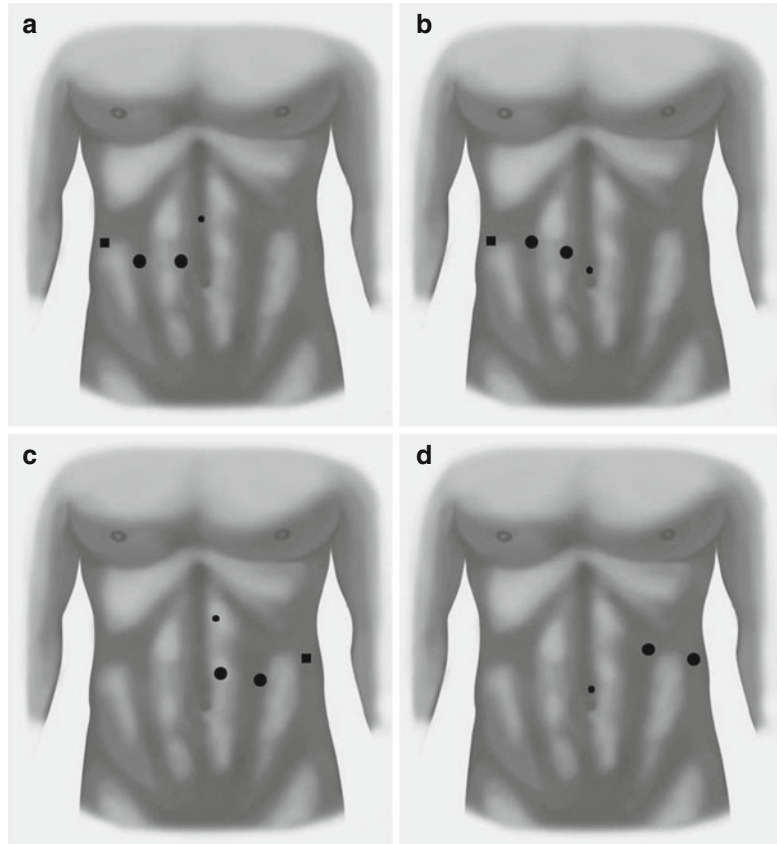
- Veress needle
- 12 mm robotic laparoscope with 0 and 30° lenses
- 5 or 10 mm laparoscope with 0 and 30° lenses (optional)
- 5 mm trocar
- 12 mm trocar
- 8 mm robotic trocars
- Robotic fenestrated bipolar forceps
- Robotic Maryland bipolar forceps
- Robotic curved monopolar scissors
- Laparoscopic liver retractor and holder
- Laparoscopic suction/irrigator
- Bipolar vessel-sealing device
- Laparoscopic ultrasound probe
- Laparoscopic retrieval bag
- Polymer or titanium hemostatic clips (5 or 10 mm)
- Oxidized cellulose polymer
- Other hemostatic agents (optional)
- Fascial closure device

Surgical Technique

Left Transperitoneal Laparoscopic Adrenalectomy

1. The patient is placed in the right lateral decubitus position. The patient should be positioned close to the abdominal edge of the bed to prevent laparoscopic instruments from colliding with the frame of the bed. The table may be flexed to increase the intra-abdominal working area if necessary, and the kidney rest can be partially elevated if desired. A bean bag or gel rolls are used to position the patient in the lateral decubitus position. An axillary roll is placed two fingerbreadths below the axilla. The lower arm is positioned on a well-padded arm board. The upper arm is supported either with a commercially available device or in another fashion such that it is parallel to the lower arm. The right scapula should be supported to prevent the arm from rotating posteriorly. The lower leg is gently bent, and the upper leg remains straight, with adequate pillows and padding. Once all of the areas prone to pressure are well padded, the patient is secured using 3-in. tape or an alternative method of choice. A Foley catheter and orogastric tube should be placed before starting the procedure.
2. A skin incision is made 2 cm superior to the umbilicus and to the left of the midline. The location of the incision can be modified in patients with a large abdominal pannus, in which case the initial trocar can be placed slightly more lateral and cephalad. Insufflation with a Veress needle to 15 mmHg or a Hassan technique is used to obtain pneumoperitoneum. A 5 or 12 mm trocar is placed at this site, and a laparoscope is used to inspect the abdominal contents. A 5 or 12 mm trocar is placed 2 cm below the xiphoid process to the left of the midline and is used for the a 30° laparoscope lens. A 12-mm trocar is placed 2 cm above the umbilicus in the midclavicular line (MCL). An accessory 5 mm trocar can be placed below the costal margin at the anterior axillary line (AAL) to assist in retraction of the kidney and other maneuvers. The periumbilical and MCL trocars are used for instrument passage, starting with atraumatic grasping forceps at the periumbilical trocar and ultrasonic shears or alternative energy device in the MCL trocar. Two options for trocar placement during left transperitoneal laparoscopic adrenalectomy are illustrated in Fig. 4.2.
3. The descending colon is mobilized along the white line of Toldt, avoiding entry into Gerota's fascia (Fig. 4.3). The spleen is mobilized extensively to allow visualization of the upper pole of the kidney and adrenal gland. Careful mobilization of the tail of the pancreas is required to avoid injury to this organ during this maneuver.
4. Dissection and exposure of the adrenal gland can begin either at the inferomedial aspect or the superomedial aspect. Initial dissection of the inferomedial aspect of the adrenal gland is performed in order to identify the renal hilum. In patients with a large amount of perinephric adipose tissue, an intraoperative ultrasound device may be useful to assist with localization of the adrenal gland.
5. The renal vein is identified and used as a landmark to identify the adrenal vein. A right-angle clamp is used to dissect the adrenal vein (Fig. 4.4). Once completely free from surrounding structures, the left adrenal vein can be divided between hemostatic polymer clips or with a bipolar vessel-sealing device. Figure 4.5 demonstrates use of a bipolar vessel-sealing device to ligate the vein. If a bipolar vessel-sealing device is used, the tissue should be sealed in several areas before transecting the vein in the middle of the sealed tissue.
6. After division of the adrenal vein, the adrenal gland can be retracted medially. The parenchyma of the kidney is identified as seen in Fig. 4.6. Lateral attachments of the adrenal gland are divided. Any remaining medial attachments are also divided. The ultrasonic shears or bipolar vessel-sealing device can be used as the adrenal attachments are often highly vascular. Small arterial branches from the inferior phrenic or renal arteries can be encountered and should be carefully divided

Fig. 4.2 Right transperitoneal laparoscopic adrenalectomy trocar placement is shown in images (a, b). Left transperitoneal laparoscopic adrenalectomy trocar placement is shown in images (c, d)



- Laparoscope trocar site (5 mm or 12 mm)
- Instrument trocar sites (10/12 mm)
- Accessory trocar site (5 mm)

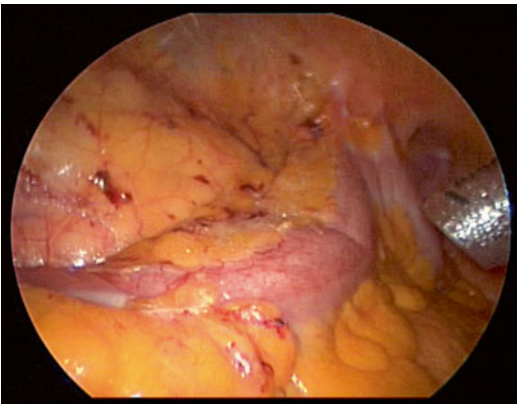


Fig. 4.3 The colon has been mobilized along the *white line* of Toldt to expose the kidney and left adrenal gland

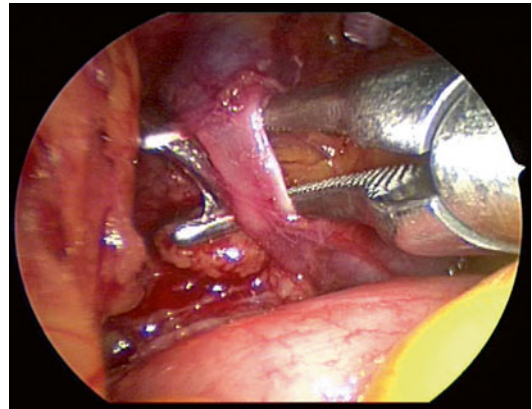


Fig. 4.4 A laparoscopic right-angle clamp is used to isolate the adrenal vein

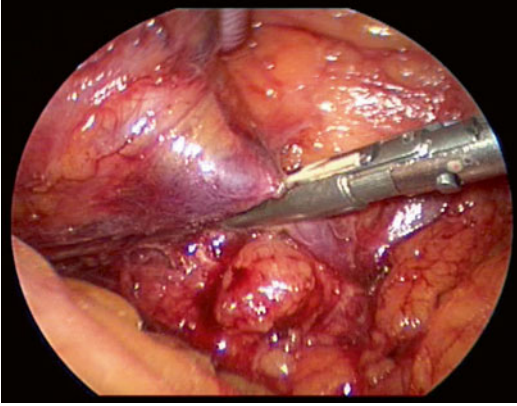


Fig. 4.5 The bipolar-sealing device is use to seal the adrenal vein in several places before dividing the vein

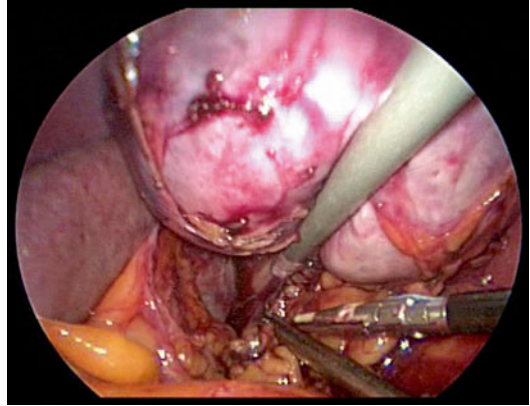


Fig. 4.7 The remaining medial attachments of the adrenal are divided. The adrenal mass can be seen at the top of the image

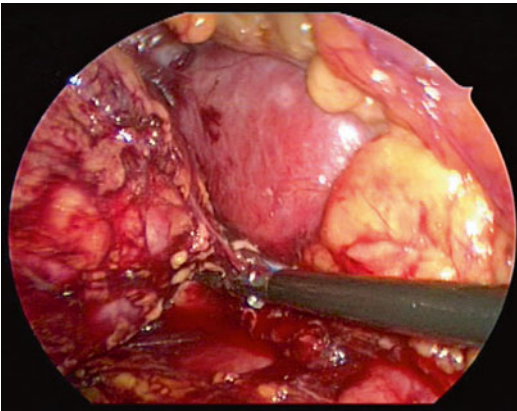


Fig. 4.6 After the left adrenal vein is divided, the adrenal can be retracted medially to expose the kidney parenchyma and attachments of the adrenal gland

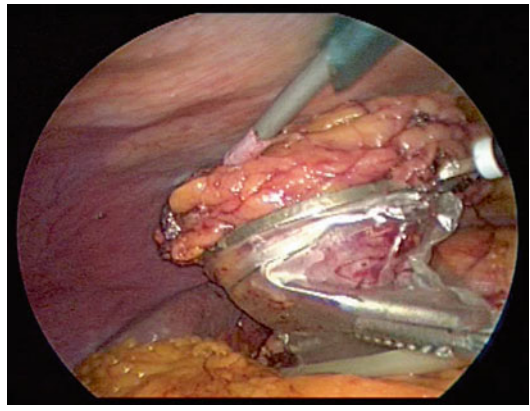


Fig. 4.8 The adrenal gland is placed in a laparoscopic retrieval bag

with clips or the bipolar vessel-sealing device. The adipose tissue between the renal vein and the inferolateral margin of the adrenal often contains segmental branches of the adrenal artery. Avoidance of these vessels is facilitated by carefully dissecting the tissue before dividing. Remaining closer to the margin of the adrenal gland can also assist in inadvertent vascular injury. Any additional superior attachments of the adrenal are divided. Figure 4.7 shows division of the remaining adrenal attachments using a bipolar vessel-sealing device.

7. The specimen is placed in a laparoscopic retrieval bag (Fig. 4.8).

8. The pneumoperitoneum is decreased to 5 mmHg, and the adrenal bed is inspected for bleeding. Hemostatic maneuvers, such as the use oxidized cellulose polymer, can be used based on surgeon preference. Oxidized cellulose polymer can be used in the setting of minor bleeding. If indicated, a hemostatic matrix such as Floseal™ can be used as well.
9. The specimen may be extracted from any of the trocar sites. Often, the trocar site incision will require enlargement in order to accommodate the specimen.
10. After specimen extraction, all trocar sites larger than 10 mm are closed under direct vision using a fascial closure device or open closure. Inspection of the trocar sites

after removal of the trocars should be performed to confirm the absence of bleeding. Skin incisions are closed using subcuticular sutures or skin staples.

Right Transperitoneal Laparoscopic Adrenalectomy

1. The patient is placed in the left lateral decubitus position. The patient should be positioned close to the abdominal edge of the bed to prevent laparoscopic instruments from colliding with the frame of the bed. The table may be flexed to increase the intra-abdominal working area if necessary, and the kidney rest can be partially elevated if desired. A bean bag or gel rolls are used to position the patient in the lateral decubitus position. An axillary roll is placed two fingerbreadths below the axilla. The lower arm is positioned on a well-padded arm board. The upper arm is supported either with a commercially available device or in another fashion such that it is parallel to the lower arm. The right scapula should be supported to prevent the arm from rotating posteriorly. The lower leg is gently bent, and the upper leg remains straight, with adequate pillows and padding. Once all of the areas prone to pressure are well padded, the patient is secured using 3-in. tape or an alternative method of choice. A Foley catheter and orogastric tube should be placed before starting the procedure.
2. An incision is made to the right of the midline, 2 cm above and 2 cm lateral to the umbilicus. The location of the incision can be modified in patients with a large abdominal pannus, in which case the initial trocar can be placed slightly more lateral and cephalad. A Veress needle is introduced into the abdominal cavity through the incision, or alternatively, a Hassan technique is used, and the abdomen is insufflated to 15 mmHg. A 12 mm trocar is placed at this site, and a laparoscope is used to inspect the abdominal contents. A 5 or 12 mm trocar is placed 2 cm below the xiphoid process to the right of the midline and is used for a 30° laparoscope lens. A 5 or 12 mm trocar is

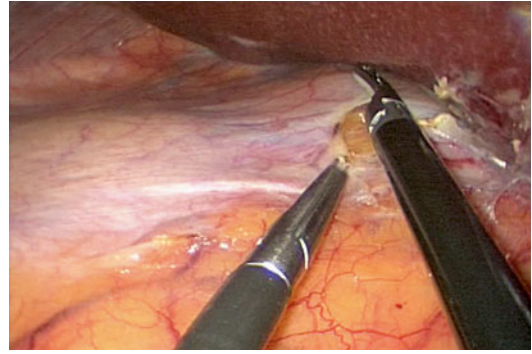


Fig. 4.9 Incision of the peritoneum overlying the right kidney and adrenal gland initiates mobilization of the liver

placed 2 cm above the umbilicus in the mid-clavicular line (MCL). An accessory 5 mm trocar is placed below the costal margin at the anterior axillary line (AAL). The instruments are advanced through the trocars, including ultrasonic shears or alternative energy device through the periumbilical trocar and atraumatic grasping forceps through the MCL trocar. The 5 mm accessory trocar is used for a liver retractor. This trocar configuration is shown in Fig. 4.2.

3. The liver is mobilized to expose the adrenal gland, starting with incision of the right triangular ligament. The posterior peritoneum is divided near the liver edge from the inferior vena cava to the abdominal side wall (Fig. 4.9). The liver must be mobilized extensively to provide adequate exposure to the inferior vena cava and the adrenal gland. A commercially available liver retractor is often useful to keep the liver out of the operative field, as shown in Fig. 4.10. A Kocher maneuver is performed to mobilize the duodenum and expose the inferior vena cava. The medial aspect of the inferior vena cava can then be traced cephalad to identify the adrenal vein. The renal hilum is often visible during this portion of the surgery, and care must be taken to avoid injury to the renal vein.
4. To localize the adrenal gland, the superior border of the kidney is identified, and Gerota's fascia is entered (Fig. 4.11). The ultrasonic shears can be used for this maneuver, with a bipolar vessel-sealing device that can be used for more

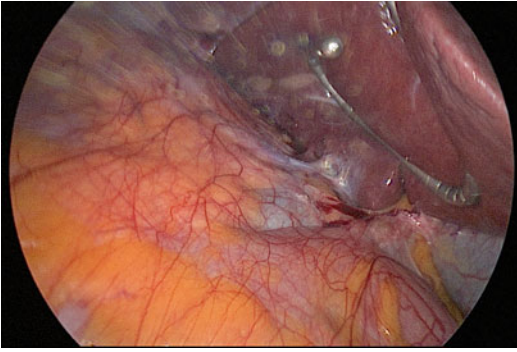


Fig. 4.10 A commercially available liver retractor is used to provide exposure to the right adrenal gland

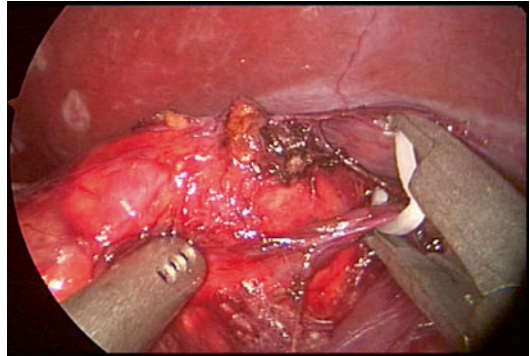


Fig. 4.12 Placement of a hemostatic polymer clip on the right adrenal vein. Note the short length and tangential course of the adrenal vein

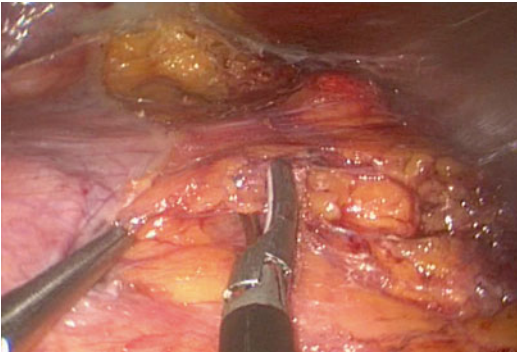


Fig. 4.11 Entry into Gerota's fascia using ultrasonic shears to locate the adrenal gland

vascular tissue. The adrenal gland is identified along the superomedial portion of the kidney. Care is taken to avoid injury to branches of the renal artery, which often can be found between the adrenal gland and the upper pole of the kidney. Minimal dissection of the adrenal gland is performed during this step, but rather localization of the adrenal gland is the intention.

5. Once the upper pole of the kidney and the edge of the adrenal gland are located as landmarks, dissection is initiated lateral to the inferior vena cava, along the superomedial aspect of the adrenal gland. Branches of the renal artery and vein can be encountered here, and cautious dissection is warranted to avoid injury to these structures. The adrenal gland can be retracted laterally to expose the medial tissue with the assistance of a laparoscopic Kittner or a suction-irrigator device.

6. The right adrenal vein is identified during the course of the dissection. A right-angle clamp is used to dissect the adrenal vein which is then either clipped with hemostatic polymer clips and divided or sealed and divided with a bipolar vessel-sealing device. Figure 4.12 demonstrates placement of a hemostatic polymer clip on the adrenal vein. The right adrenal vein is short in length, and care must be taken when manipulating and dividing the vein to avoid injury to the vein or inferior vena cava. If possible when using the vessel-sealing device, a short length of adrenal vein should be left on the inferior vena cava to allow for clip placement if bleeding is encountered. Many of the commercial vessel-sealing devices can seal tissue up to 7 mm in diameter, but each individual device's instruction manual should be reviewed in regard to limits of vessel-sealing capacity.
7. After division of the adrenal vein, the adrenal is dissected from the upper pole of the kidney and the surrounding structures. Ultrasonic shears or a bipolar vessel-sealing device is useful for the dissection of the adrenal tissue as this tissue often contains small perforating blood vessels. During dissection of the medial and lateral attachments of the adrenal, the renal artery and vein, including branches of the renal artery, can be seen and should be preserved. The bipolar vessel-sealing device is used in Fig. 4.13 to divide adrenal attachments to the liver and psoas muscle.

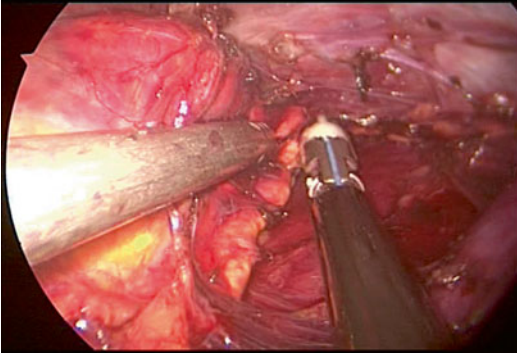


Fig. 4.13 After division of the adrenal vein, the adrenal gland is gently retracted away from the liver to allow division of the attachments to the liver and underlying psoas muscle. The bipolar vessel-sealing device is used to divide these attachments

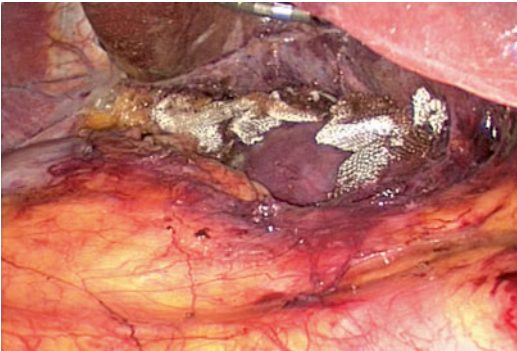

Fig. 4.14 After the adrenal gland has been placed in the laparoscopic specimen retrieval bag, the adrenal bed is inspected for any bleeding. Oxidized cellulose matrix is placed in the adrenal bed to aid with hemostasis

8. To avoid the rotation of the adrenal gland during dissection of the vein and medial tissues, the lateral attachments of the adrenal gland are divided last. Once the adrenal gland has been completely dissected from the surrounding structures, it is placed into a laparoscopic retrieval bag.
 9. The pneumoperitoneum is lowered to 5 mmHg, and the area is inspected for bleeding. Hemostatic maneuvers, including the use of oxidized polymer matrix, can be used as needed, as shown in Fig. 4.14.
 10. The specimen is removed through one of the 12 mm trocar sites, which can be enlarged as necessary. After specimen extraction, all
- trocar sites larger than 10 mm are closed under direct vision using a fascial closure device or open closure. Inspection of the trocar sites after removal of the trocars should be performed to confirm the absence of bleeding. Skin incisions are closed using subcuticular sutures or skin staples.

Right Retroperitoneal Laparoscopic Adrenalectomy

1. A skin incision is made 2 cm below the costal margin in the midaxillary line, and the underlying muscles are bluntly divided to gain access to the retroperitoneum. The peritoneum is retracted medially to provide room for the access device. A commercially available dissecting balloon is inserted into the incision, directed laterally and posterior to Gerota's fascia, and the balloon is inflated. A 30° lens can be placed through the balloon to assist in developing the retroperitoneal space. Once the retroperitoneal space is developed, a 10 or 12 mm trocar is placed, and the retroperitoneal space is insufflated to 15 mmHg. A 30° laparoscope lens is placed through the trocar. Additional trocars are placed under direct vision. A common configuration involves placement of two additional trocars (5 and 12 mm) 3–4 cm cephalad to the initial trocar in the anterior and posterior axillary lines. If desired, an additional 5 mm trocar may be placed for additional retraction or suction. For proper orientation, the psoas muscle should be identified posteriorly, and the kidney should be displaced anteriorly and medially. Proper trocar placement for right retroperitoneal laparoscopic adrenalectomy is depicted in Fig. 4.15.
2. The first step of the right-sided retroperitoneal approach is medial reflection of the peritoneum, which in turn reflects the liver and ascending colon. The renal hilum is located medial to the psoas muscle.
3. Right retroperitoneal laparoscopic adrenalectomy is initiated with identification of the inferior vena cava and the psoas muscle. The main adrenal vein is identified on the posterolateral aspect of the vena cava. The vein is isolated and divided.

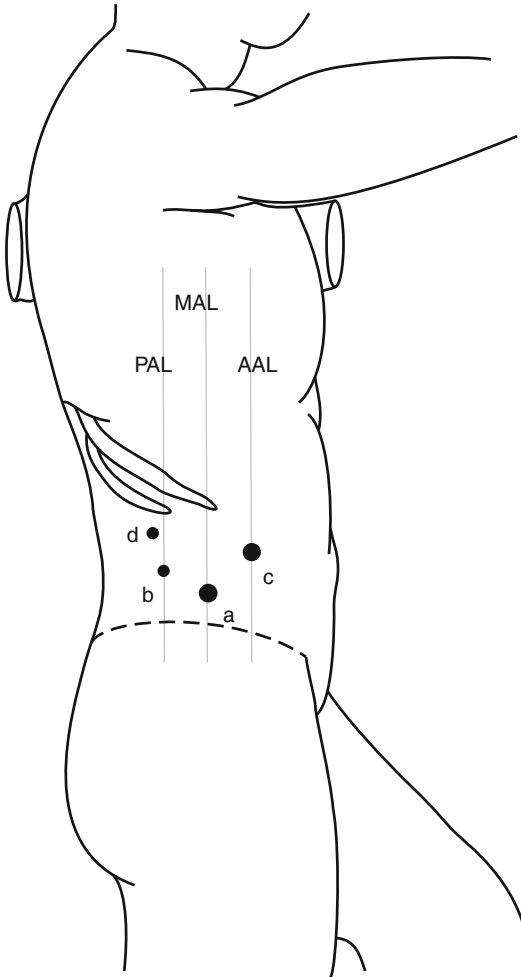


Fig. 4.15 Trocar configuration for retroperitoneal laparoscopic adrenalectomy: (a) 10 mm trocar (laparoscope); (b) 5 mm trocar (forceps or suction); (c) 12 mm trocar (thermal energy device); (d) 5 mm accessory trocar (retracting instrument or suction). MAL mid axillary line, AAL anterior axillary line, PAL posterior axillary line

- Using ultrasonic shears, dissecting forceps, or a bipolar vessel-sealing device, the medial and inferior surfaces of the adrenal gland are dissected off the renal vein and vena cava. Small vessels, including branches from the inferior phrenic artery, are identified, clipped, and cut. The inferior surface of the adrenal gland is dissected off of the upper pole of the kidney. Finally, the lateral surface of the kidney is dissected free, and the specimen is placed in a laparoscopic retrieval bag.

- The pneumoperitoneum is lowered to 5 mmHg, and the adrenal bed is inspected for bleeding. The 12 mm trocar site can be enlarged for specimen removal, and trocar sites 10 mm and larger are closed with a fascial closure device. The skin is closed with subcuticular sutures or skin staples.

Left Retroperitoneal Laparoscopic Adrenalectomy

- The configuration for left retroperitoneal laparoscopic adrenalectomy is the mirror image of that used for the right side.
- The first step of the left-sided retroperitoneal approach is medial reflection of the peritoneum, which in turn reflects the spleen and descending colon. The renal hilum is located medial to the psoas muscle.
- The renal hilum is identified, the renal artery is retracted caudally, and blunt dissection helps to identify the left adrenal vein. The vein is then carefully dissected, isolated, and divided.
- Next, the superior aspect of the adrenal gland is dissected from the diaphragm, and inferior phrenic vessels, if encountered, are divided. The lateral surface of the adrenal gland is dissected from the kidney. Cephalad retraction of the adrenal gland assists in dissection of the inferior surface from the kidney, and the lateral surface of the adrenal gland is dissected free. The specimen is freed from its surrounding tissues and placed in a laparoscopic retrieval bag.
- The pneumoperitoneum is lowered to 5 mmHg, and the adrenal bed is inspected for bleeding. The 12 mm trocar site can be enlarged to allow specimen removal, and trocar sites 10 mm and larger are closed with a fascial closure device. Skin incisions are closed with subcuticular sutures or skin staples.

Robot-Assisted Laparoscopic Adrenalectomy

- Robot-assisted laparoscopic adrenalectomy (RALA) requires several modifications to the

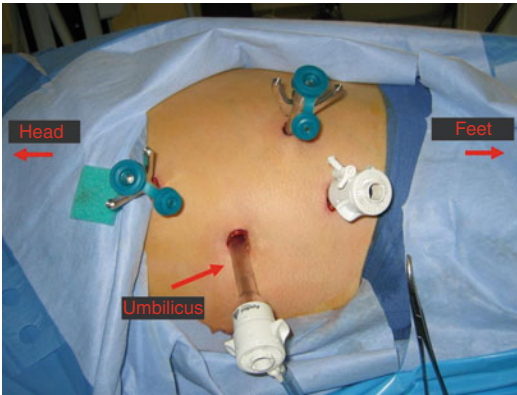


Fig. 4.16 Trocar placement for left robot-assisted laparoscopic adrenalectomy and partial adrenalectomy

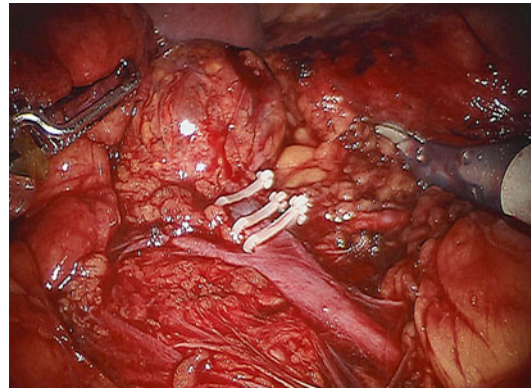


Fig. 4.17 The assistant has placed hemostatic polymer clips on the adrenal vein. The adrenal adenoma is seen beyond the third clip

standard transperitoneal laparoscopic adrenalectomy. A three-arm approach, with rotation of the bed (the foot of the bed tilted away from the side of the surgery), is utilized to facilitate docking of the robot. Trocar placement begins with placement of a 12 mm trocar lateral to the umbilicus, toward the side of the lesion. A 12 mm smooth, non-bladed trocar is placed in this location. If a Hassan technique is used to gain intra-abdominal access, a long, Hassan trocar can be utilized at this location. The exact location varies depending on the body habitus of the patient. This trocar can be placed more lateral in larger patients to optimize visualization. Once the robotic laparoscope trocar is placed, two 8 mm robotic trocars are placed under direct vision in a triangulated fashion, with a minimum distance of 8 cm between trocars to avoid robotic arm collision. A 12 mm assistant trocar is placed, usually caudad to the camera trocar, with 8 cm distance between the trocars. For right-sided procedures, a 5 mm trocar can be placed in the anterior axillary line for placement of a liver retractor. Trocar placement for left RALA is shown in Fig. 4.16.

2. Recommended instrumentation for RALA is listed in the Equipment section. The fenestrated bipolar forceps are an ideal tool for both robot-assisted laparoscopic kidney and adrenal surgery. The broad surface area of the instrument and rounded tip are ideal for gentle dissection and bipolar cautery when working

with vascular tissue. A fenestrated bipolar forceps is used for the left robotic arm and a monopolar scissors for the right arm. Alternatively, a Maryland bipolar forceps can be used for the left arm.

3. The steps for colon reflection and splenic mobilization (left side), liver and duodenal mobilization (right side), and identification of the adrenal vein are similar to those described above for laparoscopic transperitoneal adrenalectomy. When dissecting the adrenal vein, the assistant may utilize a 10 mm laparoscopic right-angle dissector through the 12 mm assistant trocar if needed. The assistant can also place hemostatic polymer clips on the adrenal vein as shown in Fig. 4.17. Alternatively, a bipolar vessel-sealing device can be advanced through the assistant trocar to divide the vein. If available, the robotic vessel-sealing device may be utilized.
4. Once the adrenal vein is divided, dissection of the adrenal gland from the surrounding tissue can be approached with several techniques. First, the fenestrated bipolar forceps are useful for hemostasis when working with vascular tissue and can be used in combination with the monopolar scissors. Second, the assistant can utilize a bipolar vessel-sealing device through the 12 mm assistant trocar as shown in Fig. 4.18. Third, the robotic vessel-sealing device may be utilized.

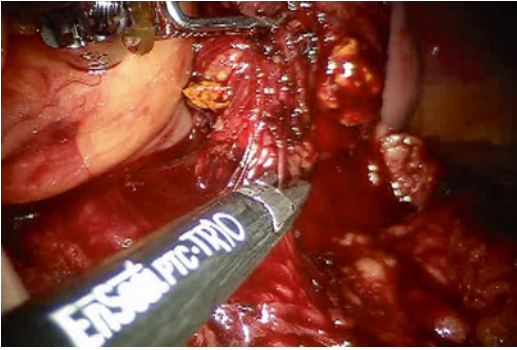


Fig. 4.18 A bipolar vessel-sealing device through the assistant trocar is used to divide the vascular tissue around the adrenal gland

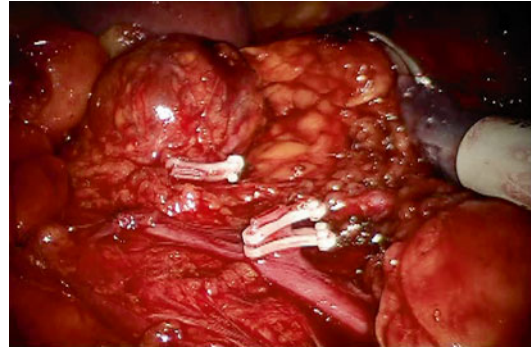


Fig. 4.19 The branch of the adrenal vein draining the adrenal mass is selectively divided, while the branch draining the normal adrenal is left intact

5. The remainder of the adrenalectomy proceeds as described in the previous sections, with the assistant trocar used to pass the bipolar-sealing device and other instruments as indicated.

Laparoscopic and Robot-Assisted Laparoscopic Partial Adrenalectomy

1. Laparoscopic and robot-assisted laparoscopic partial adrenalectomy (PA) is performed with the same configuration of trocars as used during laparoscopic or robot-assisted total adrenalectomy.
2. The decision to divide the adrenal vein is based on the proximity of the vein to the adrenal mass. The entire vein can be left intact if the surgeon feels that the adrenal mass can safely be dissected from the normal adrenal tissue without damage to the vein. In some cases, a branch of the adrenal vein that drains the adenoma can be selectively divided, leaving the remainder of the vein intact, as shown in Fig. 4.19.
3. Intraoperative ultrasonography can be useful to help identify the adrenal mass, especially when there is a significant amount of perirenal fat. Use of the ultrasound device to localize the adrenal mass is shown in Fig. 4.20.
4. Once the adrenal mass is identified, a bipolar vessel-sealing device can be used to excise the adenoma from the remainder of the adrenal

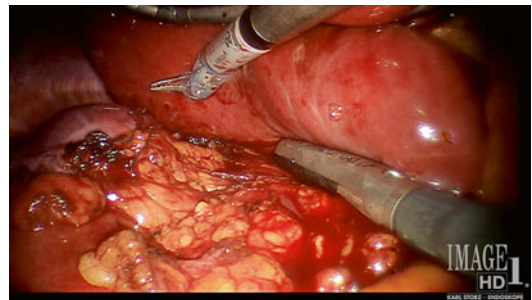


Fig. 4.20 Use of a laparoscopic ultrasound probe to identify the adrenal mass

- gland (Fig. 4.21). The bipolar vessel-sealing device provides hemostasis when dividing the vascular adrenal tissue. Alternatively, an endovascular stapling device, bipolar forceps, hemostatic polymer clips, or ultrasonic device can be used to divide the adenoma from the uninvolved adrenal tissue.
5. The remaining adrenal tissue is inspected for bleeding with the pneumoperitoneum decreased to 5 mmHg (Fig. 4.22). As discussed earlier, hemostatic agents such as oxidized cellulose polymer or other hemostatic matrices such as Floseal™ can be used.
6. The specimen is placed in a laparoscopic retrieval bag and removed through one of the 12 mm trocar sites. All trocar sites larger than 10 mm are closed with a fascial closure device, and the trocars are removed under direct vision. The skin is closed with subcuticular sutures or skin staples.

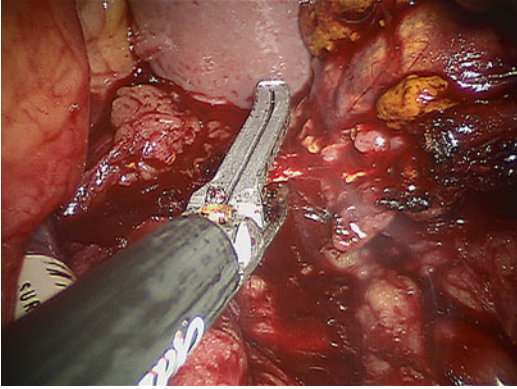


Fig. 4.21 The bipolar vessel-sealing device is used to excise the adenoma from the normal tissue

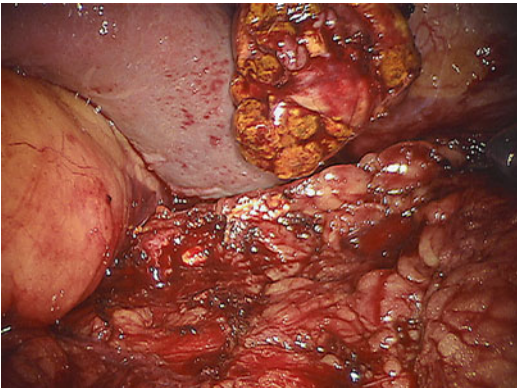


Fig. 4.22 The adrenal mass has been excised and is seen at the top of the image. The remaining adrenal tissue is inspected for bleeding

Complications of Laparoscopic Adrenalectomy

The complication rates of laparoscopic adrenalectomy in modern literature range from 0.2 to 11 % [5–11]. A comparison of laparoscopic and

open adrenalectomy was performed utilizing the National Surgery Quality Improvement Project. The authors found that the morbidity rate was significantly higher in the open group (18.8 %) when compared with the laparoscopic group (6.4 %) [5]. The incidence of complications varies among series, depending on the definition of a perioperative complication and the Clavien grade of complication reported. A number of factors are reported to affect the rate of complications and are not consistent between studies. Two studies found that obesity correlates with an increased complication rate [6, 11]. Prior ipsilateral open surgery, but not laparoscopic surgery, correlated with an increased rate of conversion to open adrenalectomy in one study [9]. Finally, one group found that the complication rate was significantly lower in patients undergoing laparoscopic adrenalectomy in a higher-volume medical center [6].

Bleeding is the most common complication during and after laparoscopic adrenalectomy, accounting for 40 % of complications. The next most common complication is injury to surrounding organs such as the liver, spleen, colon, pancreas, and diaphragm, accounting for less than 5 % of all complications. An appreciation for the adrenal anatomy and proximity to nearby structures can minimize the risk of complications. Excellent exposure to the adrenal gland with mobilization of nearby organs when necessary (spleen, pancreas, liver, duodenum) can improve outcomes and minimize morbidity. Listed in Table 4.2 are the more commonly reported complications of laparoscopic and robotic-assisted adrenalectomy and techniques to avoid and manage these complications.

Table 4.2 Complications of laparoscopic and robotic-assisted adrenalectomy and techniques to avoid and manage the complications

Complication	Techniques to avoid and manage complication
Bleeding from adrenal vein	<p>Early identification of the adrenal vein</p> <p>Appreciation for aberrant adrenal vein anatomy (branches, multiple veins)</p> <p>When utilizing bipolar vessel-sealing device, leave a small amount of vein tissue attached to the inferior vena cava for vascular control in the event that bleeding is encountered</p> <p>Pressure on the site of bleeding using a Ray-Tec® while exposure to the vein is obtained</p>
Bleeding from renal vein	<p>Awareness of proximity of renal vein to adrenal structures</p> <p>Pressure on the site of bleeding using a Ray-Tec® while exposure to the vein is obtained</p> <p>Careful exposure of renal vein and suture small defects with 5–0 prolene suture</p>
Bleeding from adrenal cortex	<p>Avoid aggressive manipulation of the adrenal gland and traumatic grasping devices</p> <p>If possible, avoid directly grasping adrenal tissue</p> <p>Pressure applied with a Ray-Tec® for several minutes can slow or stop bleeding</p> <p>Hemostatic agents may be necessary to stop bleeding</p>
Injury to inferior vena cava (IVC)	<p>Avoid with complete exposure of the margin of the IVC such that the insertion of adrenal vein into IVC can be visualized</p> <p>Avoid with gentle manipulation of the adrenal vein to avoid an avulsion injury</p> <p>Avoid by expecting anomalous veins (a second renal vein, lumbar veins) and preventing injuries – especially avulsion injuries – to these small vessels</p> <p>Repair small IVC injuries with 5–0 prolene suture</p> <p>If an IVC injury is noted, immediately notify the circulating nurse and anesthesiologist that blood loss and open conversion may be necessary</p> <p>Be prepared at the beginning of the procedure with laparoscopic and open vascular instruments</p> <p>Convert to open surgery early and expeditiously if the injury is beyond the scope of the surgeon's expertise to manage laparoscopically</p>
Diaphragmatic perforation	Avoidance of aggressive dissection lateral to the liver and spleen
Pancreatic injury	<p>Gentle but wide mobilization of the pancreas from the adrenal bed</p> <p>If injury is suspected, intraoperative general surgical consultation is needed</p> <p>If injury is suspected/repared, closed suction drainage of peritoneal space</p>
Duodenal injury	<p>Avoidance with Kocher maneuver to mobilize the duodenum from the adrenal bed</p> <p>Keep thermal energy instruments away from the duodenum</p>
Splenic injury	<p>Avoid with very gentle retraction on the spleen</p> <p>Cautious use of sharp instruments near the spleen</p> <p>If the spleen is noted to have attachments to omentum or mesentery, divide these attachments before mobilizing the spleen to avoid capsular tear</p> <p>Many splenic injuries can be managed with hemostatic agents – pneumoperitoneum should be decreased to 5 mmHg after application of these agents to ensure hemostasis</p> <p>General surgical consultation if bleeding persists or a large laceration is noted</p>
Injury to segmental renal arteries/partial renal infarct	<p>Avoid by careful dissection of the inferior margin of the adrenal gland – segmental renal arteries are often found in this area</p> <p>If bleeding is encountered from inadvertent injury to a segmental branch, hemostatic clips or bipolar vessel-sealing device (for vessels less than 7 mm) can be used</p>

Conclusions

Numerous reports and case-controlled studies have validated the benefits of the laparoscopic approach to adrenalectomy over the open approach. The majority of surgeons utilize the transperitoneal technique; however, many approaches have been reported in the literature, showing no distinct advantage of any specific technique. Laparoscopic adrenalectomy has consistently shown improved cosmesis, reduced hospital length of stay, decreased analgesic requirements, and a shorter convalescent period. Compared with open adrenalectomy, laparoscopic adrenalectomy is associated with fewer complications and improved perioperative parameters for patient care, without sacrificing the goals of the operation.

Laparoscopic adrenalectomy has evolved since it was initially described. Refinement in technique and increased experience have resulted in decreased operative times, blood loss, and postoperative pain. As such, laparoscopic adrenalectomy is recognized as the current standard for surgical removal of the adrenal gland. With experience, a detailed understanding of adrenal anatomy, and meticulous laparoscopic dissection, surgeons may further reduce complications associated with laparoscopic and robotic-assisted laparoscopic adrenalectomy.

References

1. Gagner M, Lacroix A, Bolte E. Laparoscopic adrenalectomy in Cushing's syndrome and pheochromocytoma. *N Engl J Med.* 1992;327:1033.
2. Prinze R. A comparison of laparoscopic and open adrenalectomies. *Arch Surg.* 1995;130:489–92.
3. Smith C, Weber C, Amerson J. Laparoscopic adrenalectomy: a new gold standard. *World J Surg.* 1999;23:389–96.
4. Gill I. The case for laparoscopic adrenalectomy. *J Urol.* 2001;166:429–36.
5. Eifenbein DM, Scarborough JE, Speicher PJ, et al. Comparison of laparoscopic versus open adrenalectomy: results from American College of Surgeons-National Surgery Quality Improvement Project. *J Surg Res.* 2013;184:216–20.
6. Bergamini C, Martellucci J, Tossi F, et al. Complications in laparoscopic adrenalectomy: the value of experience. *Surg Endosc.* 2011;25:3845–51.
7. Nguyen PH, Keller JE, Novitsky YW, et al. Laparoscopic approach to adrenalectomy: review of perioperative outcomes in a single center. *Am Surg.* 2011;77:592–6.
8. Grego F, Hoda MR, Rassweiler J, et al. Laparoscopic adrenalectomy in urologic centres: the experience of the German Laparoscopic Working Group. *BJU Int.* 2011;108:1646–51.
9. Mozeh H, Froysheter AB, Wang TS, et al. Is previous same quadrant surgery a contraindication to laparoscopic adrenalectomy? *Surgery.* 2012;152:1211–7.
10. Hattori S, Miyajima A, Maeda T, et al. Risk factors for perioperative complications of laparoscopic adrenalectomy including single-site surgery. *J Endourol.* 2012;26:1463–7.
11. Dancea HC, Obradovic V, Sartorius J, et al. Increased complication rate in obese patients undergoing laparoscopic adrenalectomy. *JSLs.* 2012;16:45–9.

Bernardo Rocco, Rafael Ferreira Coelho,
Gabriele Cozzi, Elisa De Lorenzis, and Vipul Patel

Introduction

Laparoscopic surgery represented a major breakthrough in the urologic field, due to the decreased intraoperative estimated blood loss, shorter hospital stay, and quicker return to function [1]. The main obstacle which prevented the widespread of the laparoscopic approach was the steep learning curve required for a surgeon to achieve proficiency [2].

The advent of robot-assisted laparoscopic surgery represented a great advantage both for experienced laparoscopic surgeons and for laparoscopically naïve ones.

Urologists experienced in laparoscopy found in the robot-assisted approach a better quality

of vision, with 3D resolution, precise movements, and no limitations on movements. On the other hand, open surgeons were provided with a minimally invasive technique with a simpler and faster learning curve [3].

In the field of oncologic urologic surgery, radical prostatectomy (RP) represents the leading application of the robotic approach [2].

At present, RP represents the standard for long-term cure of localized prostate cancer (PCa), with cancer-specific survival approaching 95 % at 15 years after radical surgery [4]. Since the first procedure performed by Binder in May 2000 [5], robot-assisted radical prostatectomy (RARP), carried out using the da

B. Rocco, MD
Department of Urology, Clinica Urologica I.
Fondazione IRCCS Ca' Granda – Ospedale Maggiore
Policlinico, Via Commenda, 15, 20122, Milan, Italy
e-mail: bernardo.rocco@gmail.com

R.F. Coelho, MD
Department of Urology, University of Central Florida
School of Medicine, Orlando, FL, USA

Department of Urology, Hospital Israelita Albert
Einstein, Sao Paulo, SP, Brazil

Department of Urology, Instituto do Câncer do
Estado de São Paulo, Sao Paulo, SP, Brazil

Department of Urology, Global Robotics Institute, Florida
Hospital Celebration Health, Celebration, FL, USA
e-mail: coelho@br@yahoo.com.br

G. Cozzi, MD • E. De Lorenzis, MD
Università degli Studi di Milano, Clinica Urologica I.
Fondazione IRCCS Ca' Granda - Ospedale Maggiore
Policlinico, Via Commenda, 15, 20122, Milan, Italy
e-mail: cozzi.gabriele@gmail.com;
elisa.delorenzis@gmail.com

V. Patel, MD (✉)
Department of Urology, Global Robotics Institute,
Florida Hospital, Celebration Health,
410 Celebration Place Suite 200,
Celebration, FL 34747, USA

University of Central Florida School of Medicine,
Orlando, FL, USA
e-mail: vipul.patel.md@fhosp.org,
vipul.patel@fhosp.org

Vinci Surgical System™ (Intuitive Surgical, Sunnyvale, CA, USA), has been rapidly accepted as a safe and efficacious treatment option for localized PCa [2]. RARP is currently the leading urologic use of the da Vinci system, and more than 80 % of the RPs performed in the USA in 2011 were done by robot-assisted surgery [3].

RARP can be performed either through a transperitoneal or subperitoneal approach, with more precision and choices for dissection, thanks to the system's 3D vision [3].

Indications for RARP are the same with those for radical retropubic prostatectomy (RRP) and laparoscopic radical prostatectomy (LRP). According to the American Urological Association (AUA) Guidelines 2007 (reviewed and validity confirmed 2011) [6], low-, intermediate-, and high-risk patients with localized PCa could undergo RARP. The European Association of Urology (EAU) Guidelines 2011 [7] identify four categories of patients who should undergo RARP: patients with low- and intermediate-risk localized PCa and a life expectancy >10 years, patients with stage T1a disease and a life expectancy of >15 years or a Gleason score (GS) of 7, selected patients with low-volume high-risk localized PCa, and highly selected patients with very-high-risk localized PCa (cT3b-T4 N0 or any T N1) in the context of multimodal treatment.

Surgical Technique

In 2007, Patel VR et al. described a technique for transperitoneal RARP [8], based on standard laparoscopic [9] and robotic [10] technique described previously. Some differences from these techniques were introduced: the dorsal vein stitch, the suspension stitch, early retrograde dissection of the neurovascular bundle, and continuous anastomosis described by Van Velthoven [11]. This technique, along with the modifications introduced since then, is here described step by step.

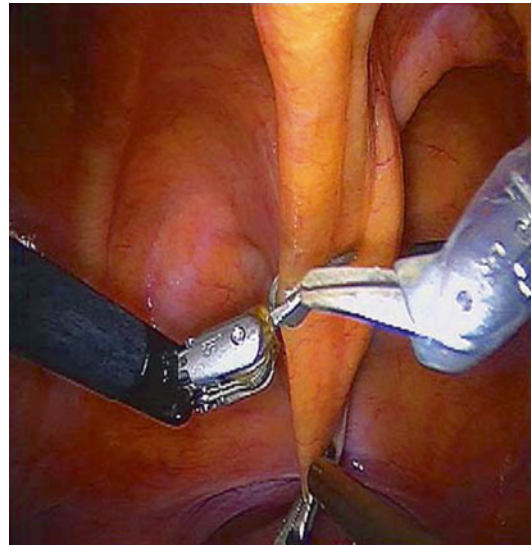


Fig. 5.1 Incising peritoneal fold to enter the retropubic space (Reprinted with permission from Patel VR [8])

Step 1: Incision of the Peritoneum and Entry into the Retropubic Space of Retzius

Instruments

- Right arm: Monopolar scissor (30 W)
- Left arm: Bipolar Maryland (30 W)
- Fourth arm: Prograsp
- Assistant: Microfrance grasper and suction
- Telescope: 0° binocular lens

Peritoneum is incised transversally through the median umbilical ligament (Fig. 5.1); the incision is extended on both sides in an inverted U fashion to the level of the vasa on either side. Counter-traction is provided by the assistant and the fourth arm. The peritoneum is dissected to the following boundaries: the pubic bone superiorly, the median umbilical ligaments laterally, and the vas deferens inferolaterally (Fig. 5.2). The pubic tubercle is found and followed laterally to the vasa. It is important to dissect the peritoneum all the way up to the base of the vasa to release the bladder and allow tension-free vesicourethral anastomosis.

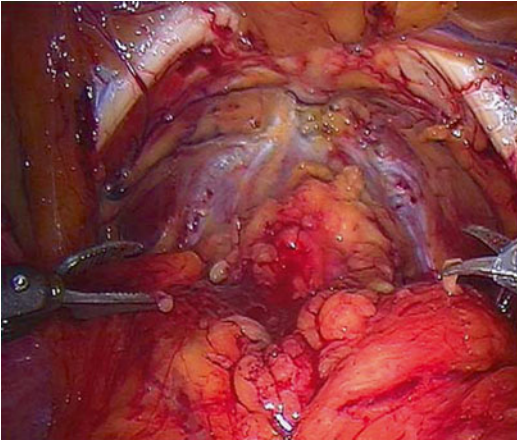


Fig. 5.2 Entry into the retropubic space of Retzius showing the boundary of dissection (Reprinted with permission from Patel VR [8])

Step 2: Incision of the Endopelvic Fascia (EPF) and Identification of the Dorsal Venous Complex (DVC)

Instruments

- Right arm: Monopolar scissor (30 W)
- Left arm: Bipolar Maryland (30 W)
- Fourth arm: Prograsp
- Assistant: Microfrance grasper and suction
- Telescope: 0° binocular lens

The important landmarks are the bladder neck, base of the prostate, levator muscles, and apex of the prostate (Fig. 5.3). Once adequate exposure has been obtained, the EPF is opened from the base of the prostate to immediately lateral to the reflection of the puboprostatic ligaments bilaterally using cold scissors. This is the area with the largest amount of space between the prostate and the levators and the point at which the prostate has most mobility. Proceeding from the base to the apex, the levator fibers are pushed off of the prostate until the DVC and urethra are visualized (Fig. 5.4). Extensive dissection of the apex at this time can lead to unnecessary and obtrusive bleeding, so it is important to dissect only that which is necessary to get in a good DVC stitch.

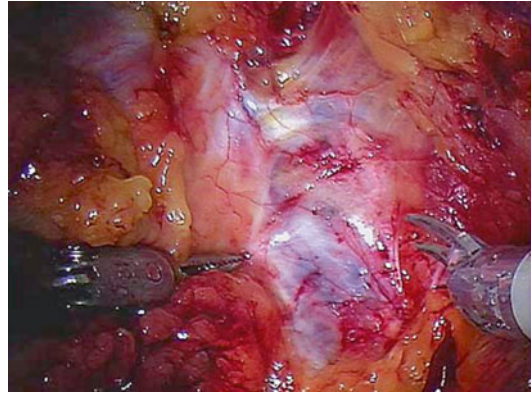


Fig. 5.3 The landmarks for incision of the EPF are the bladder neck, base of the prostate, levator muscles, and apex of the prostate (Reprinted with permission from Patel VR [8])

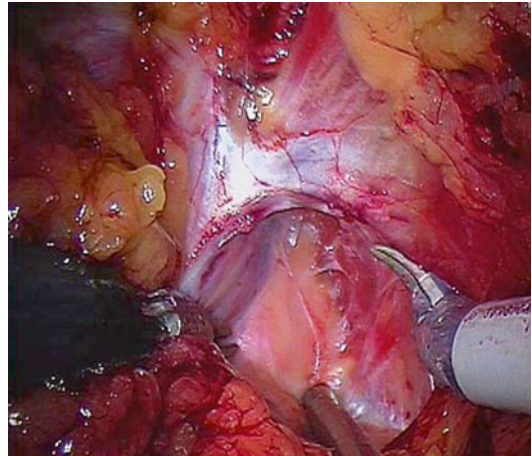


Fig. 5.4 Incision of the EPF and identification of the DVC (Reprinted with permission from Patel VR [8])

Step 3: Ligation of the DVC

Instruments

- Right arm: Robotic needle driver
- Left arm: Robotic needle driver
- Assistant: Laparoscopic scissor
- Telescope: 0° binocular lens

Robotic needle drivers are placed via the robotic ports. Patel et al. use a large needle with a non-braided absorbable suture such as

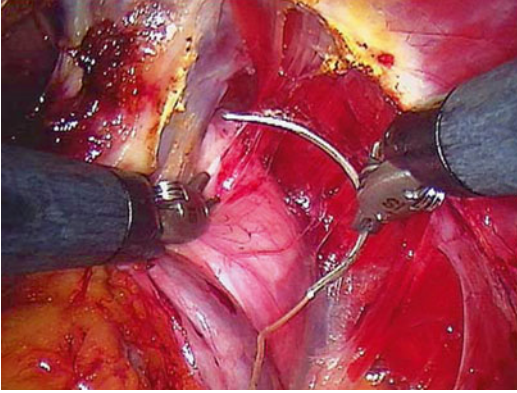


Fig. 5.5 A large CT1 needle is placed in the visible notch between the urethra and DVC (Reprinted with permission from Patel VR [8])

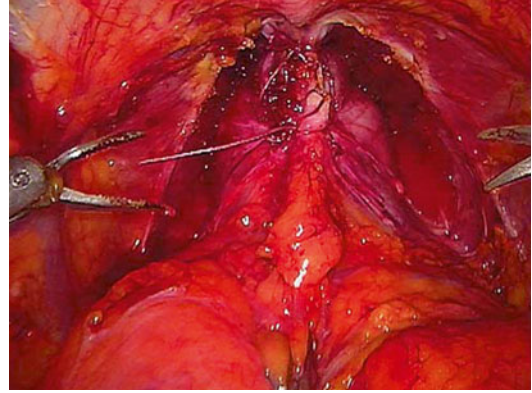


Fig. 5.7 Identification of the bladder neck by cessation of the fat extending from the bladder at the level of the prostatovesical junction (Reprinted with permission from Patel VR [8])

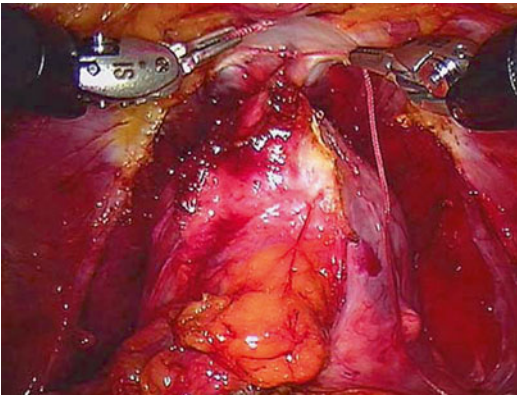


Fig. 5.6 Ligated DVC and performance of suspension stitch to suspend DVC to pubic bone (Reprinted with permission from Patel VR [8])

Polyglytone™ (e.g., Caprosyn™) on a large CT1 needle. The needle is held about 2/3 back at a slight downward angle and placed in the visible notch between the urethra and DVC (Fig. 5.5). The needle is pushed straight across at 90° and then the wrist is turned to curve around the apex of the prostate. The suture strength needs to be sufficient to allow the needle holders to pull up tight and perform a slip knot, which prevents the suture from loosening as it is tied. A second suture is placed to suspend the urethra to the pubic bone and secondarily ligate the DVC. The DVC is encircled and then stabilized against the pubic bone along with the urethra (Fig. 5.6). The aim of this technique is the stabilization of the urethra avoiding urethral retraction, facilitating the urethral dissection. Patel et al., in a prospec-

tive comparative study on 331 patients, found a significant advantage in terms of early recovery of continence at 3 months using a single anterior suspension stitch to the pubic bone (83 % vs. 92.9 %; $p=0.013$) [12].

Step 4: Anterior Bladder Neck Dissection

Instruments

- Right arm: Monopolar scissor (30 W)
- Left arm: Bipolar Maryland (30 W)
- Fourth arm: Prograsp
- Assistant: Microfrance grasper and suction
- Telescope: 30° binocular lens directed downwards

The laparoscope is changed to a 30° down-facing lens, which is optimal to see inferiorly. The bladder neck is identified by a cessation of the fat extending from the bladder at the level of the prostatovesical junction (Fig. 5.7). Another technique is to pull on the urethral catheter and visualize the balloon. However, this can be unreliable and misleading after transurethral resection of prostate (TURP) or with a median lobe or large prostate. The robotic arms also provide a moderate amount of visual and sensory feedback to facilitate localization of the boundaries. The bladder is dissected off the prostate in the midline using a sweeping motion of the monopolar scissor while visualizing the bladder fibers. The key is to

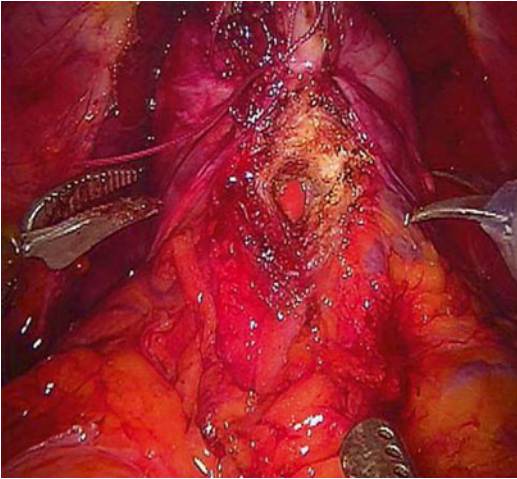


Fig. 5.8 Division of anterior bladder neck (Reprinted with permission from Patel VR [8])

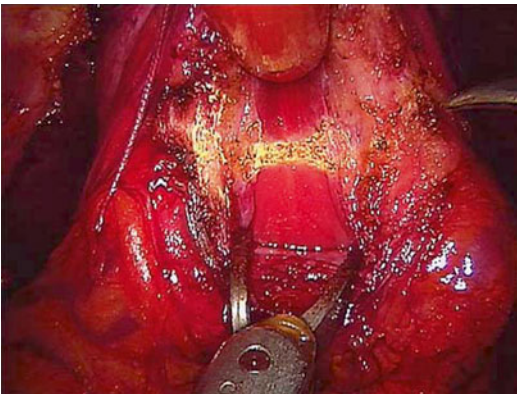


Fig. 5.9 Incising the middle portion of posterior bladder neck (Reprinted with permission from Patel VR [8])

stay in the midline to avoid lateral venous sinuses till the anterior bladder neck is opened and then dissect on either side of the bladder neck. Once the anterior urethra is divided, the Foley catheter is retracted out of the bladder using the fourth arm, and upward traction is applied to expose the posterior bladder neck (Fig. 5.8).

Step 5: Posterior Bladder Neck

Instruments

- Right arm: Monopolar scissor (30 W)
- Left arm: Bipolar Maryland (30 W)
- Fourth arm: Prograsp

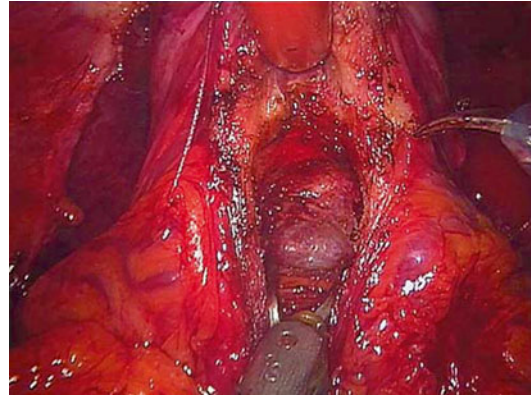


Fig. 5.10 Completed posterior dissection exposing the seminal vesicles (Reprinted with permission from Patel VR [8])

- Assistant: Microfrance grasper and suction
- Telescope: 30° binocular lens directed downwards

During the posterior bladder neck dissection, the difficulty is in appreciating the posterior tissue plane between the bladder and prostate and the direction and depth of dissection necessary to locate the seminal vesicles. After incision of the anterior bladder neck, any remaining peripheral bladder attachments should be divided to flatten out the area of the posterior bladder neck and allow precise visualization and dissection of the posterior plane. The full thickness of the posterior bladder neck should be incised at the precise junction between the prostate and the bladder (Fig. 5.9). The lip of the posterior bladder neck is then grasped with the fourth arm and used for gentle traction to visualize the natural plane between the prostate and bladder. The dissection is directed posteriorly and slightly cranially (towards the bladder) to expose the seminal vesicles. It is important to avoid dissecting caudally (towards the prostate) as there is a possibility of entering the prostate and missing the seminal vesicles completely (Fig. 5.10).

Step 6: Seminal Vesicle Dissection

Instruments

- Right arm: Monopolar scissor (30 W)
- Left arm: Bipolar Maryland (30 W)

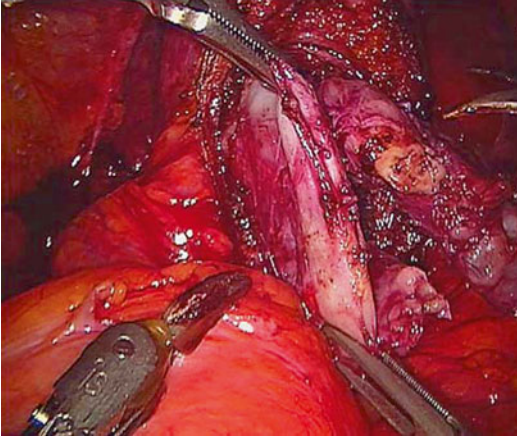


Fig. 5.11 Vas retracted by the fourth arm and the assistant (Reprinted with permission from Patel VR [8])

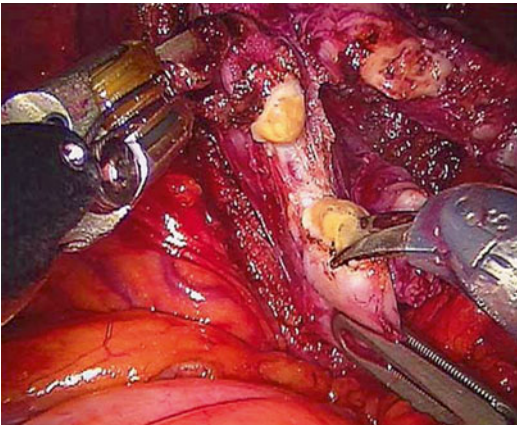


Fig. 5.12 The vas is followed posteriorly to expose the tips of the seminal vesicles (Reprinted with permission from Patel VR [8])

- Fourth arm: Prograsp
- Assistant: Microfrance grasper and suction
- Telescope: 30° binocular lens directed downwards

Once the bladder has been dissected off the prostate, the vasa and seminal vesicles can be identified. The thin fascial layer over the seminal vesicles and vasa should be opened to free the structures for retraction. The fourth arm is used to retract the vasa superiorly. Both vasa are then incised, and the inferior portion of the vas is retracted by the assistant (Fig. 5.11). The vas is then followed posteriorly to expose the tips

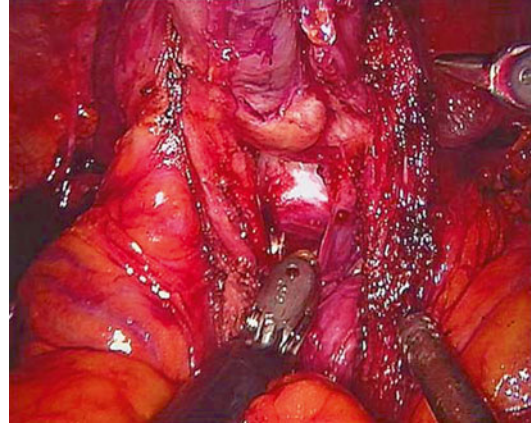


Fig. 5.13 Incision of Denonvilliers' fascia is made at the base of the seminal vesicles to expose the clear pearly white plane between the prostatic capsule and the rectum (Reprinted with permission from Patel VR [8])

of the seminal vesicles. Small perforating vessels are cauterized with the bipolar grasper and divided or clipped with a 5 mm clip or Hem-o-lok (Fig. 5.12).

Step 7: Denonvilliers' Fascia and Posterior Dissection

Instruments

Right arm: Monopolar scissor (30 W)

Left arm: Bipolar Maryland (30 W)

Fourth arm: Prograsp

Assistant: Microfrance grasper and suction

Telescope: 30° binocular lens directed downwards

The seminal vesicles must be dissected all the way to the base to allow for appropriate elevation of the prostate and identification of the posterior Denonvilliers' fascia (Fig. 5.13). The incision of Denonvilliers' fascia is made at the base of the seminal vesicles. The correct plane can be identified by the presence of a clear pearly white plane between the posterior prostatic capsule and the rectum. When entered correctly, the plane is avascular and spreads easily with the Maryland dissector with minimal bleeding. The posterior space is dissected widely to fully release the prostate and facilitate rotation during the nerve sparing (Fig. 5.14).

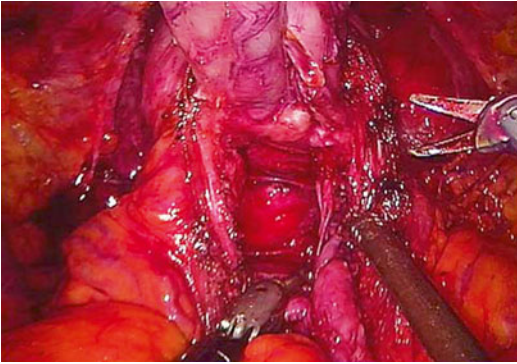


Fig. 5.14 Completed posterior dissection to fully release the prostate (Reprinted with permission from Patel VR [8])

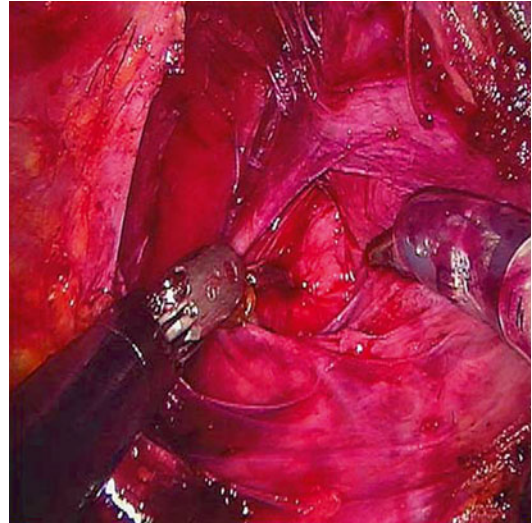


Fig. 5.16 Development of plane between the prostate capsule and the NVB (Reprinted with permission from Patel VR [8])

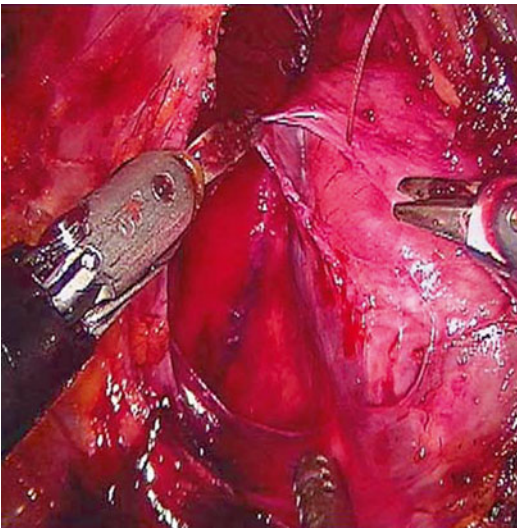


Fig. 5.15 Incision of the periprostatic fascia at the level of the apex and midportion of the prostate (Reprinted with permission from Patel VR [8])

Step 8: Nerve Sparing

Instruments

- Right arm: Monopolar scissor (30 W)
- Left arm: Bipolar Maryland (30 W)
- Fourth arm: Prograsp
- Assistant: Microfrance grasper and suction
- Telescope: 30° binocular lens directed downwards

The approach to the nerve sparing is retrograde, mirroring the open approach. The periprostatic

fascia is incised at the level of the apex and mid-portion of the prostate (Fig. 5.15). Gentle spreading of the tissue on the lateral aspect of the prostate will allow the prostatic capsule and the neurovascular bundle (NVB) to be identified. No thermal energy is used during dissection of the NVB or ligation of the pedicle. At the apex of the prostate, a plane between the NVB and prostate capsule can be identified and separated (Fig. 5.16). The NVB is then released in a retrograde manner towards the prostatic pedicle. The NVB is stabilized with the Maryland dissector and the prostate is gently stroked away using the scissors. The plane between the NVB sheath and the prostate capsule is relatively avascular, consisting of only small tributary vessels; therefore, no energy or clipping is required close to the path of the NVB. As the dissection proceeds in a retrograde fashion, the NVB can clearly be seen being released off of the prostate. The prostate pedicle can then be thinned out with sharp dissection and the path of the NVB clearly delineated at this level. The clear definition of the anatomy allows the placement of two clips on the pedicle away from the NVB and sharp incision to release the prostate completely (Fig. 5.17). It is important to release the NVB to the apex of

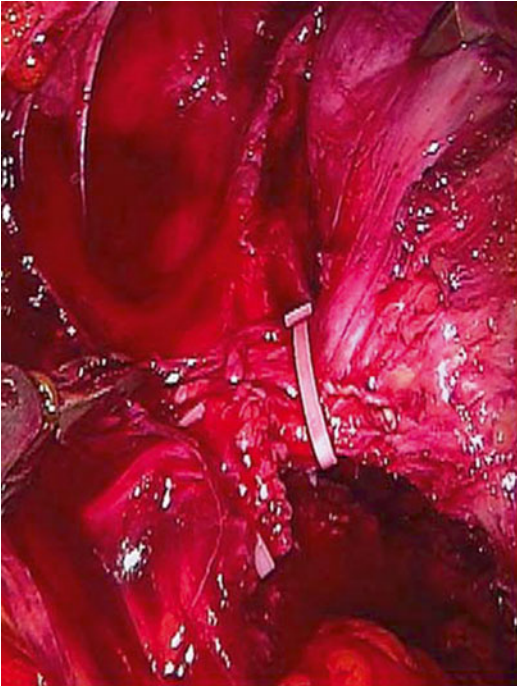


Fig. 5.17 The prostate pedicle ligated away from the NVB under direct vision (Reprinted with permission from Patel VR [8])

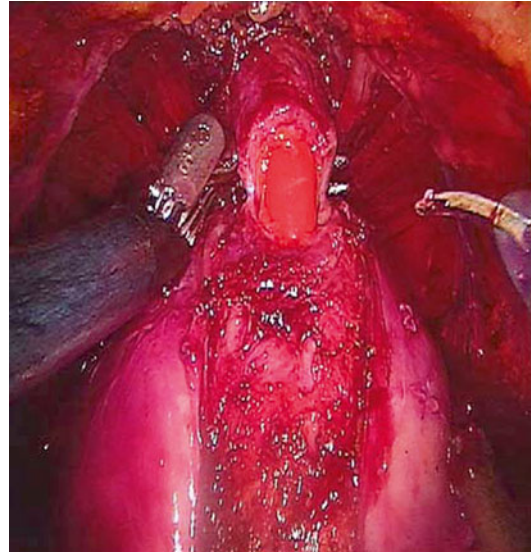


Fig. 5.19 Urethra is incised at the apex of the prostate under direct vision (Reprinted with permission from Patel VR [8])

the prostate in order to prevent injury during the apical dissection.

Step 9: Apical Dissection

Instruments

- Right arm: Monopolar scissor (30 W)
- Left arm: Bipolar Maryland (30 W)
- Fourth arm: Prograsp
- Assistant: Microfrance grasper and suction
- Telescope: 30° binocular lens directed downwards

The landmarks are the ligated DVC, urethra, apex of the prostate, and NVB. Ligation of the DVC prevents bleeding which may interfere with the apical dissection and division of the urethra under direct vision (Fig. 5.18). Cold scissors are used to divide the DVC and a long urethral stump is developed, as a longer urethral stump facilitates the anastomosis and may improve continence. Complete dissection of the apex and urethra is facilitated by the robotic magnification. The urethra is then incised at the apex of the prostate under direct vision to completely liberate the prostate (Fig. 5.19).

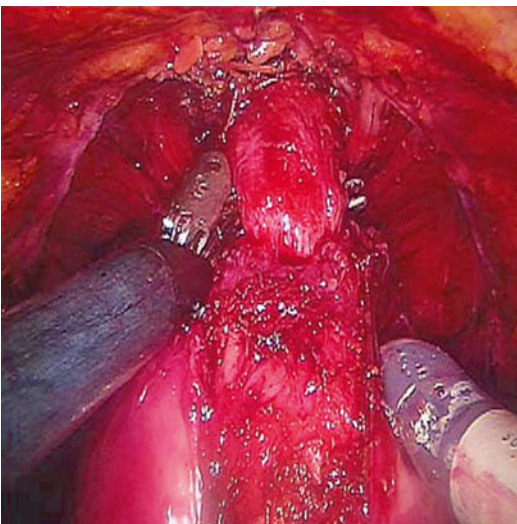


Fig. 5.18 Complete apical dissection to achieve long urethral stump (Reprinted with permission from Patel VR [8])

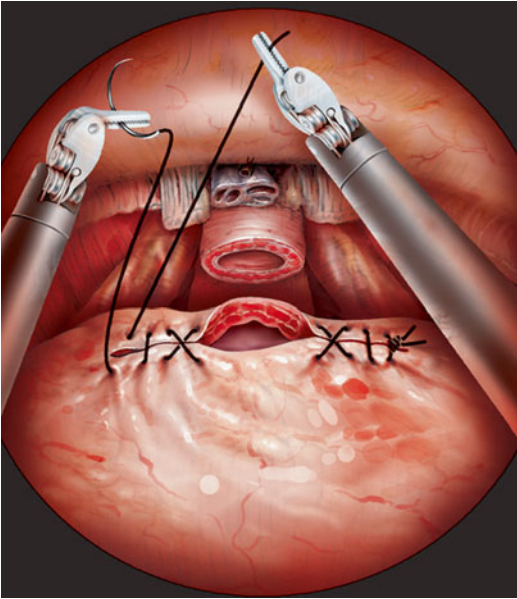


Fig. 5.20 Modified transverse plication for bladder neck reconstruction (Reprinted with permission from Lin VC [13])

Step 10: Bladder Neck Reconstruction

Instruments

- Right arm: Robotic needle driver
- Left arm: Robotic needle driver
- Fourth arm: Prograsp
- Assistant: Microfrance grasper and suction

Bladder neck preservation is usually attempted during RARP, but, in case of large prostate volume or large median lobe or in patients with previous TURP, a bladder neck reconstruction can be necessary. Before starting the bladder neck reconstruction, it is essential to check the position of the ureteric orifices and their distance from the edge of the bladder neck. Bilateral plication over the lateral aspect of the bladder is then performed using sutures of 3-0 poliglecaprone, 13 cm long, in a RB-1 needle (Ethicon Inc. Somerville, NJ, USA). The suture begins laterally and runs medially until the bladder neck size matches that of the membranous urethra. The same suture then runs laterally, back to the beginning of the suture, and is tied (Fig. 5.20). Occasionally additional stitches need to be placed, if indicated, until the

bladder neck size matches that of membranous urethra [13].

Step 11: Reconstruction of the Posterior Musculofascial Plate

Instruments

- Right arm: Robotic needle driver
- Left arm: Robotic needle driver
- Fourth arm: Prograsp
- Assistant: Microfrance grasper and suction
- Telescope: 30° binocular lens directed downwards

In 2006, Rocco F et al. proposed a technique for restoration of the posterior aspect of the rhabdosphincter (RS) which demonstrated to shorten time to continence in patients undergoing RRP [14]. In 2007, Rocco B et al. described the application of the posterior reconstruction technique to transperitoneal laparoscopic radical prostatectomy (LRP) [15], while, in 2008, Coughlin et al. applied the posterior reconstruction of the rhabdosphincter to RARP with some minor technical modifications [16]. The technique has been further modified in 2011 [17].

The reconstruction is performed using two 3-0 poliglecaprone sutures (on RB-1 needles) tied together, with each individual length being 12 cm. Ten knots are placed when tying the sutures to provide a bolster. The free edge of the remaining Denonvilliers' fascia is identified after the prostatectomy and approximated to the posterior aspect of the RS and the posterior median raphe using one arm of the continuous suture. As a rule, four passes are taken from the right to the left and the suture is tied (Fig. 5.21a, b). The second layer of the reconstruction is then performed with the other arm of the suture approximating the posterior lip of the bladder neck (full thickness) and the vesicoprostatic muscle, as described by Walz et al. [18], to the posterior urethral edge and to the already reconstructed median raphe (Fig. 5.22a, b). This suture is then tied to the end of the first suture arm.

One of the key steps for an appropriate reconstruction is the preservation of the Denonvilliers'

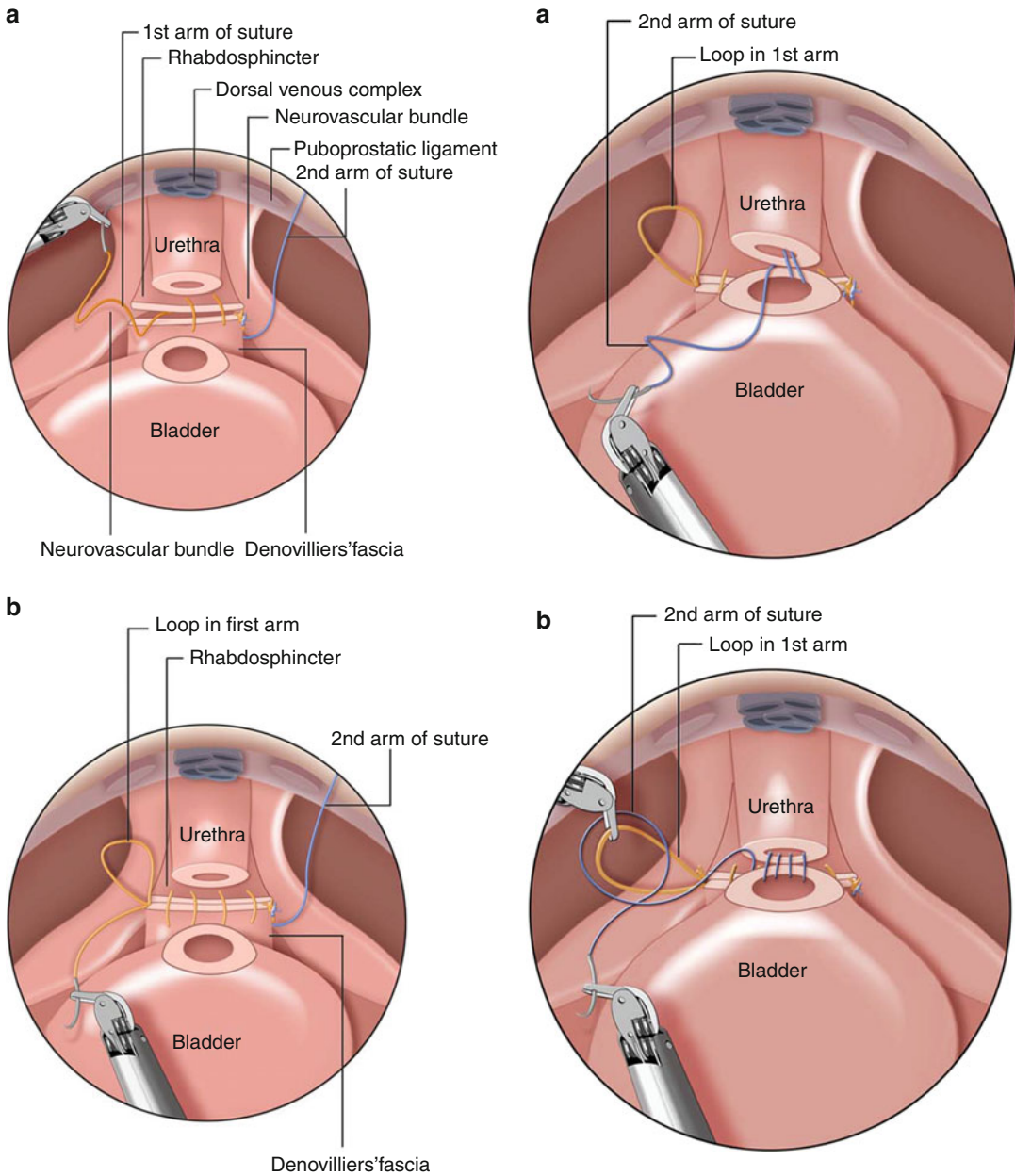


Fig. 5.21 (a) First layer of posterior reconstruction. (b) The free edge of the remaining Denonvilliers' fascia is approximated to the posterior aspect of the rhabdosphincter reconstruction (Reprinted with permission from Coelho RF [17])

fascia when dissecting the posterior plane between the prostate and the rectal wall. If this dissection is performed at the perirectal fat tissue, the Denonvilliers' fascia is not adequately spared, precluding posterior reconstruction.

Fig. 5.22 (a) Second layer of posterior reconstruction. (b) The posterior lip of the bladder neck and vesicoprostatic muscle is sutured to the posterior urethral edge reconstruction (Reprinted with permission from Coelho RF [17])

A recent systematic review showed that the reconstruction of the posterior musculofascial plate improves early return of continence within the first 30–45 days after RP (Fig. 5.23); furthermore, trend towards lower leakage rates has been found in patients who received the posterior reconstruction (Fig. 5.24) [19].




Fig. 5.23 Continence at 30–45 days from catheter removal: cumulative analysis. 95 % confidence interval of RR, 1.15–2.14; $p=0.004$). *M-H* Mantel–Haenszel, *CI* confidence interval (Reprinted with permission from Rocco B [19])
 prostatic musculofascial plate at 30–45 days after surgery (relative risk [RR], 1.57;

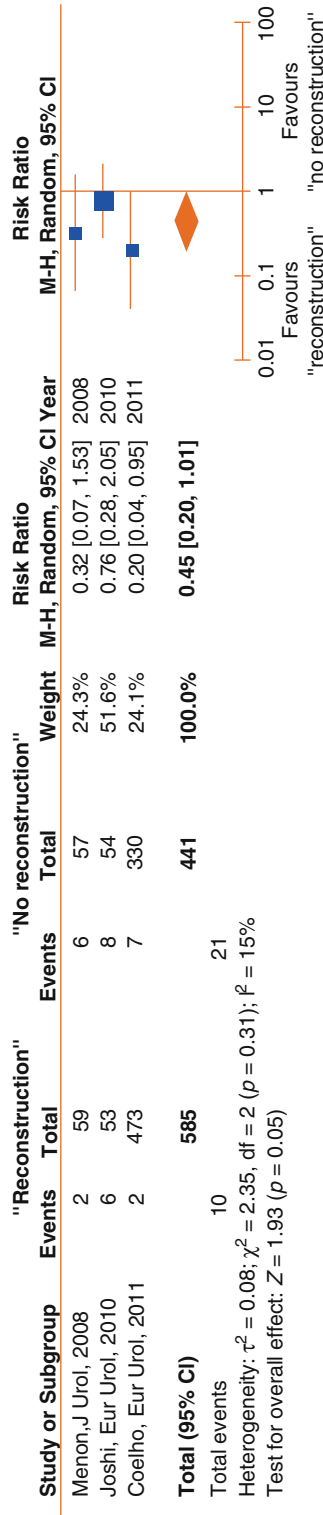


Fig. 5.24 Leakage on cystogram: cumulative analysis. A trend towards lower leakage rates is shown in the reconstruction of the prosthetic musculofascial plate group (relative risk [RR], 0.45; 95 % confidence interval of RR, 0.2–1.01; $p=0.05$). *M-H* Mantel–Haenszel, *CI* confidence interval (Reprinted with permission from Rocco B [19])

Step 12: Urethrovesical Anastomosis

Instruments

- Right arm: Robotic needle driver
- Left arm: Robotic needle driver
- Assistant: Suction and scissor
- Telescope: 30° binocular lens directed downwards

The urethra and bladder are reapproximated using a continuous suture as per the technique described by Van Velthoven [11]. Two 20 cm 3-0 Monocryl sutures on RB-1 needles of different colors are tied together with ten knots to provide a bolster. The posterior urethral anastomosis is performed first with one arm of the suture. Three passes are made through the bladder and two passes through the urethra and the suture is pulled straight up in order to bring the bladder down. The posterior anastomosis is continued in a clockwise direction from the 5 to 9 o'clock position obtaining adequate bites of tissue (Fig. 5.25). This is followed by completion of the anterior anastomosis with the second arm of the suture in a counterclockwise fashion (Fig. 5.26). The key to performing quick watertight anastomosis is to have an adequate urethral length, normal-sized bladder neck, clear operative field, and perineal pressure. A Foley catheter is placed and saline is irrigated to confirm watertight anastomosis. A Jackson–Pratt drain is placed around the anastomosis, and all the trocars are removed under direct vision.

Robot-Assisted Lymph Node Dissection

The lymph node drainage of the prostate appears to be in the following order: external iliac and obturator (38 %), internal iliac (25 %), common iliac (16 %), para-aortic/para-caval (12 %), pre-sacral (8 %), and inguinal (1 %) [20].

Indications for lymph dissection during RARP are the same with those during RRP: patients with intermediate-risk PCa (cT2a and/or PSA of 10–20 ng/ml and/or biopsy Gleason score of 7), patients with high-risk PCa (>cT2b and/or PSA of >20 ng/ml and/or biopsy Gleason

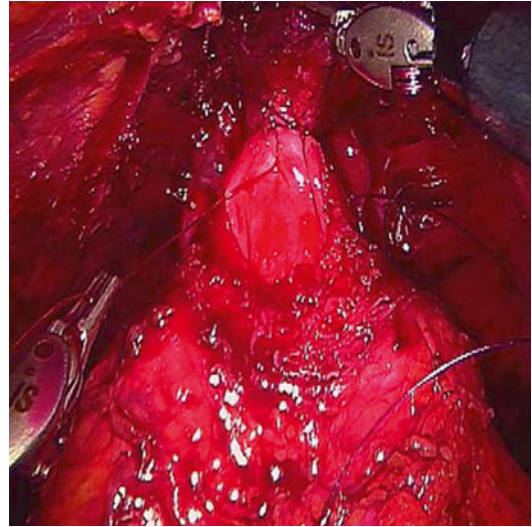


Fig. 5.25 Posterior urethral anastomosis starting at 5 o'clock position (Reprinted with permission from Patel VR [8])

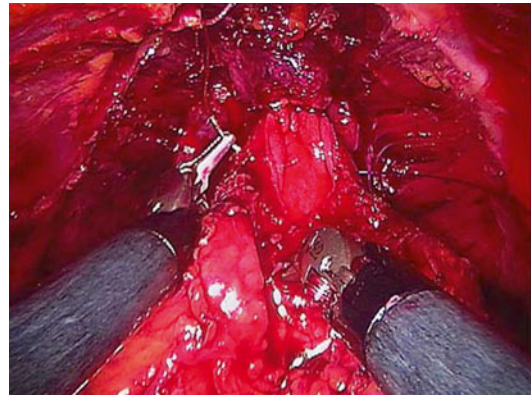


Fig. 5.26 Completion of posterior anastomosis in a clockwise direction (Reprinted with permission from Patel VR [8])

score of ≥ 8), or patients with ≥ 7 % likelihood of having node metastases according to available nomograms [21].

An appropriate pelvic lymph node dissection (PLND) includes removal of all node-bearing tissue from an area bounded by the external iliac artery anteriorly, the pelvic sidewall laterally, the bladder wall medially, the floor of the pelvis posteriorly, Cooper ligament distally, and the common iliac artery/ureter crossing proximally. When these anatomic boundaries are respected, PLND usually retrieves ≥ 10 lymph nodes [21].

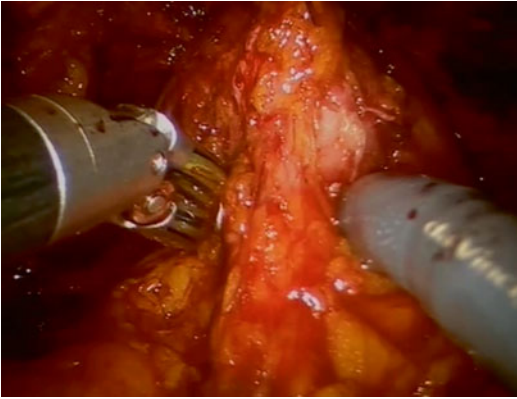


Fig. 5.27 The line of dissection of the anterior bladder neck can be identified by means of a symmetric pressure of the right and left arm

Freicke et al. [22], Ham et al. [23], and Menon et al. [24] reported the feasibility of an extended lymph node dissection in course of RARP, including external iliac, internal iliac, and obturator lymph nodes. They obtained mean numbers of nodes ranging from 12 to 19 and positive node rates ranging from 11 to 24 %, according to the different patient characteristics [25].

Chung et al. [26] compared transperitoneal and extraperitoneal limited dissection, showing a similar lymph node yield with a slightly higher risk of postoperative lymphoceles for the extraperitoneal approach.

Tips and Tricks and Challenging Cases

Dissection of the Bladder Neck

Dissection of the bladder neck represents one of the most challenging steps of RARP, particularly in the presence of difficult anatomic conditions, which can be natural, such as the presence of a median lobe, or due to previous surgery, as in case of previous surgery for benign prostatic hyperplasia (BPH).

The line of dissection of the anterior bladder neck can be identified by pulling the catheter, operating a traction with the fourth arm, or by means of a symmetric pressure of the right and left arm (Fig. 5.27). The use of a low monopolar energy helps in maintaining the features of the tissue and so in distinguishing the muscular

tissue of the detrusor from the glandular tissue of the prostate.

The approach to the posterior bladder neck is based on two opposite tractions: that on the catheter superiorly and that on the bladder neck cranially. The incision begins on the lateral aspects of the detrusor (Fig. 5.28). After releasing the lateral muscular fibers, and so transferring the traction on the midline, the bladder neck is dissected. A constant traction is made by means of the left arm; the scissors, with separate blades, develop the surgical plane, until the seminal vesicles are visible (Fig. 5.29).

In presence of a median lobe, traction on the catheter can help identifying an eventual asymmetry of the lobes. The dissection of the anterior bladder neck begins again on the midline, until the catheter is identified and suspended. The lateral aspects of the detrusor are separated, while a traction is exerted with the left arm. When the median lobe becomes evident, the point of traction is changed to improve exposition (Fig. 5.30). Special attention should be given to the thickness of the posterior aspect of the bladder neck. In 2012, Coelho et al. reviewed postoperative outcomes of 1,693 patients who underwent RARP performed by a single surgeon. Three hundred and twenty three (19 %) presented a median lobe (ML). The authors did not find significant differences between patients with or without ML in terms of estimated blood loss, length of hospital stay, pathologic stage, complication rates, anastomotic leakage rates, overall PSM rates, and PSM rate at the bladder neck. The median overall operative time was slightly greater in patients with ML (80 vs. 75 min, $P < 0.001$); however, there was no difference in the operative time when stratifying this result by prostate weight. Continence rates were also similar between patients with and without ML at 1 week (27.8 % vs. 27 %, $P = 0.870$), 4 weeks (42.3 % vs. 48 %, $P = 0.136$), 12 weeks (82.5 % vs. 86.8 %, $P = 0.107$), and 24 weeks (91.5 % vs. 94.1 %, $P = 0.183$) after catheter removal [27].

The bladder neck defect after TURP can create many difficulties in the dissection (Fig. 5.31). The catheter is pulled cranially and superiorly,

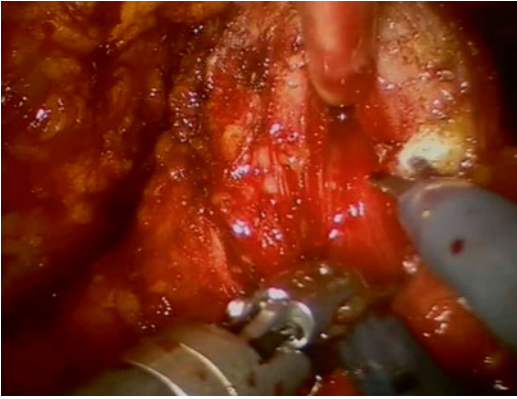


Fig. 5.28 The dissection of the posterior bladder neck begins on the lateral aspects of the detrusor

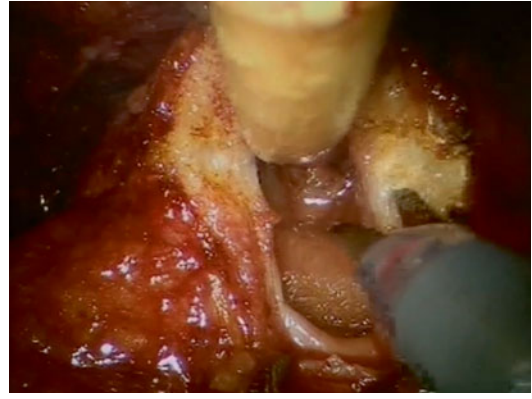


Fig. 5.31 Bladder neck defect after transurethral resection of the prostate

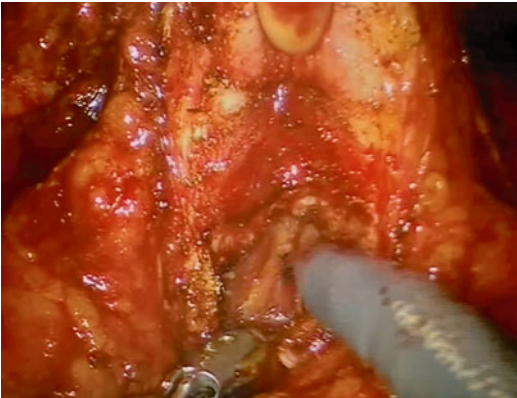


Fig. 5.29 The dissection of the posterior bladder neck ends when the seminal vesicles are visible

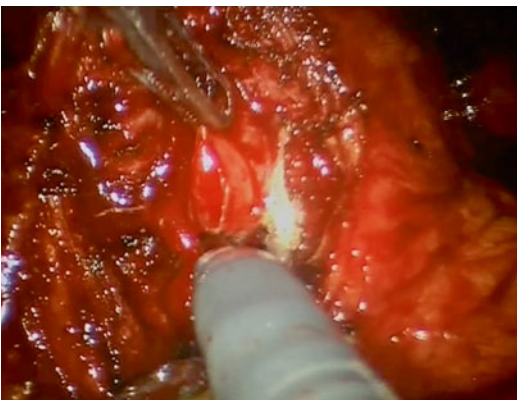


Fig. 5.30 Traction on the median lobe improves exposition

exposing the large defect of the bladder neck. Here it is even more important to separate the lateral aspect before dissection on the midline. The presence of scar tissue can make it more difficult to distinguish the muscular from the glandular tissue.

The Role of the Prostatic Vasculature as a Landmark for Nerve Sparing During Robot-Assisted Radical Prostatectomy

In 2011, Patel VR et al. performed a retrospective video analysis of 133 consecutive patients who underwent RARP with nerve sparing performed using a retrograde, antegrade, or combined approach [28].

After opening sharply the levator fascia over the prostate, they observed the presence of a distinctive prostatic artery (PA) which could be found between the midprostate and base. The artery entered the prostate on the anterolateral aspect, and it was easily recognized by its large size and tortuosity (Fig. 5.32a). Delicately developing a plane of dissection between the PA and the prostate resulted in a natural detachment of the neurovascular bundle (NVB) from the prostate. For a complete NS, the correct plane of dissection was recognized by the presence of pearly areolar tissue and was gently developed posteriorly following the prostatic contour until the previously created posterior plane was reached. After detaching the prostate, it was evident that

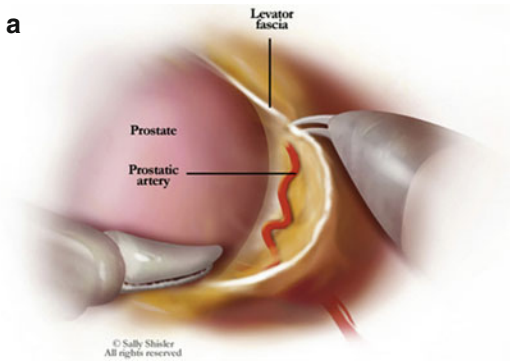
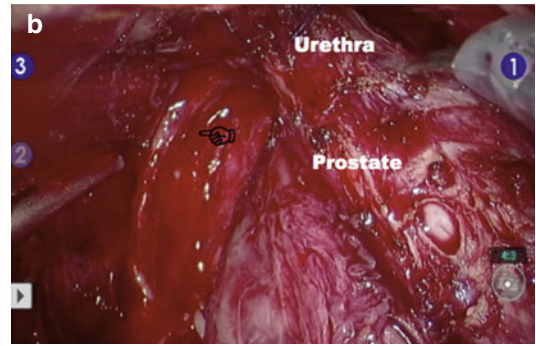


Fig. 5.32 (a) The prostatic artery (PA) can be recognized after opening the levator fascia on the base of the prostate. It has a large diameter and a tortuous configuration, which makes it easy to be recognized intraoperatively. It continues alongside the prostate occupying the medial aspect of



the neurovascular bundle (NVB). (b) Complete left nerve sparing; the prostate has been detached from the NVB. Note how the pointed PA follows the course of the NVB and enters the perineum behind the urethra (Reprinted with permission from Patel VR [28])

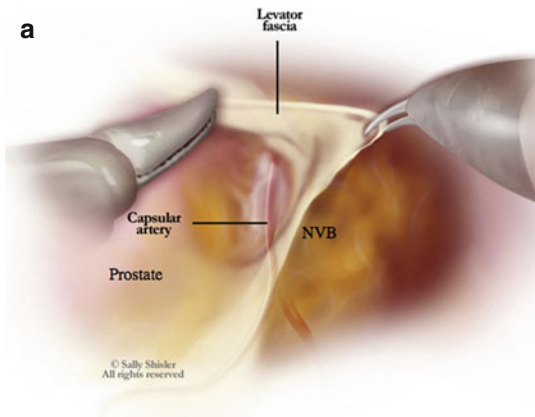
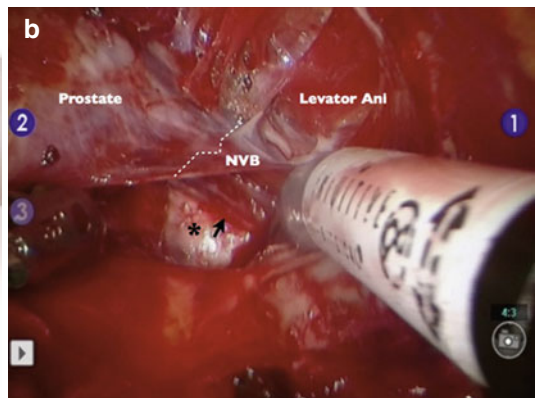


Fig. 5.33 (a) Capsular arteries (CAs) can be recognized after opening the levator fascia. They are found more distally than the prostatic artery (PA), at the level of the mid-prostate. CAs are thin, harder to identify, and do not have a tortuous configuration like the PA. They usually end in small twigs at the apex and do not perforate into the perineum. (b) A plane of dissection has been developed between the landmark CA and the prostate. Notice that as



the dissection gets deeper, additional CAs are found along the medial aspect of the neurovascular bundle (NVB; arrow). The right plane of dissection for a complete nerve sparing is to stay on the medial aspect of the CAs, through the pearly areolar tissue between the prostate and the NVB (asterisk) (Reprinted with permission from Patel VR [28])

the PA was located at the most medial aspect of the NVB and followed its course down into the perineum (Fig. 5.32b).

In absence of a distinctive PA, the presence of multiple capsular arteries (CAs) was another common finding. These arteries are found on the lateral aspect of the prostate forming a mesh throughout the thickness of the NVB. The most superficial of these CAs can be recognized after opening the levator fascia over the prostate. It is

located over the medial border of the NVB fat, close to the point where the fat ends over the prostate (Fig. 5.33a). In this case, the plane of dissection can be reached by delicately sweeping the plane between the CA and the prostate with the robotic scissors. This plane is less pronounced and harder to find than in the presence of a distinctive PA. A key to its identification is to follow the direction of the prostatic contour. As the dissection gets deeper between the CA and

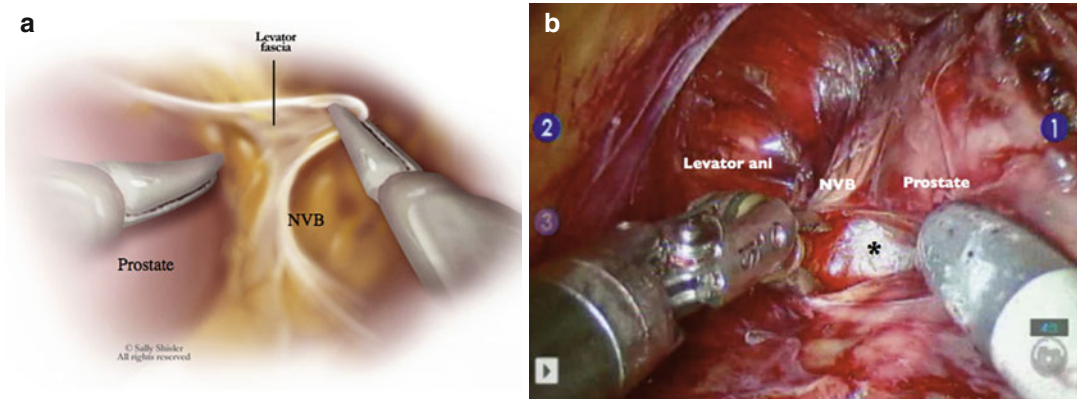


Fig. 5.34 (a) The point where the neurovascular bundle (NVB) fat ends on the lateral aspect of the prostate is usually evident and can be used as landmark for nerve sparing when no elements of the prostatic artery can be identified. (b) Development of a plane between the NVB

fat and the prostate leads to a natural detachment of the prostate from the NVB at the areolar plane existing between them (*asterisk*) (Reprinted with permission from Patel VR [28])

the prostate, multiple CAs can be found at different depths at the medial border of the NVB (Fig. 5.33b). The right plane of dissection is maintained by following the pearly areolar tissue between these arteries and the prostate. At the end of the dissection, the plane created will meet the previously developed posterior plane.

The authors measured the area of residual nerve tissue on the posterolateral aspect at the level of the midprostate as a way to assess the amount of nerve preservation. The area of residual nerve tissue was significantly less when the NS was performed medial to the landmark artery (LA) (median inter quartile range (IQR) of 0 [0–3] mm² vs. 14 [9–25] mm²; $p < 0.001$). The overall positive surgical margin (PSM) rate for the 133 patients was 9.02 % (12 of 133), with 8.3 % (9 of 108) in pT2 and 12 % (3 of 25) in pT3. Side-specific PSM rate in those patients with an NS performed medial to the LA was 3.2 %.

In 27 % of the operated sides, the authors were not able to find any LAs after opening the levator fascia over the prostate. Because the CAs are embedded in fatty tissue, an increased amount of fat in the NVB can prevent the identification of these small vessels. Although the amount of fat contained in the NVB is variable and depends on individual body habitus, a constant finding was the configuration of this fat on the prostate. The NVB fat forms an apron embedding the prostate

on the posterior and lateral aspects, and a delimitation of the NVB fat lying over the prostate can usually be identified (Fig. 5.34a). The authors found that the plane of dissection between the NVB and the prostate could be found by gently sweeping the fat at the point where it ends over the lateral border of the prostate. The plane is extended along the prostatic contour until the areolar plane is reached and dissection reaches the previously created posterior plane (Fig. 5.34b).

Salvage RARP

Radiation therapy is one of the treatment options for prostate cancer. According to the EAU Guidelines [7], three-dimensional conformal radiotherapy (3D-CRT) is the gold standard, while intensity-modulated radiotherapy (IMRT), an optimized form of 3D-CRT, is becoming more widely used as is image-guided radiotherapy.

According to the American Society for Therapeutic Radiology and Oncology (ASTRO) criteria, recurrence after RT for localized PCa can be defined by a PSA value of 2 ng/ml above the nadir after RT [29]. With a 40–60 % biochemical recurrence (BCR) rate after RT for clinically localized prostate cancer, approximately 30,000 men will present with BCR annually in the United States [30].

Among the different salvage procedures, only salvage RP(sRP) has cancer control results for a ≥ 10 -year follow-up in a substantial portion of

patients (30–40 %). However, sRP is technically demanding, and experienced surgeons are needed to optimize outcomes: in fact, RT-induced cystitis, fibrosis, and tissue plane obliteration can lead to significant complications, such as rectal injuries, anastomotic stricture, and urinary incontinence [31]. The da Vinci Surgical System helps the surgeon in performing salvage surgery by its 3D vision and 10× magnification, which help careful dissection [32].

According to Chen et al. [33], ideal candidates for salvage surgery should be young and healthy and have a life expectancy of >10 years. They also suggested to study these patients with cystoscopy, which can identify subtrigonal tumor extension, and urodynamic study. In fact, men with a poorly compliant bladder or subclinical detrusor hyperreflexia are poor candidates for sRP alone: in these cases, augmentation cystoplasty can be considered.

Distant metastases are less frequent in patients who initially presented with a low-risk disease (PSA <10 ng/ml, PSA velocity <2.0 ng/ml per year, biopsy Gleason score of ≤6, T1c or T2a tumor stage) [34], a time to PSA failure >3 years [35], a PSA doubling time >8–12 months [36, 37], and a PSA level at the time of salvage therapy <10 ng/ml [38]. Thus, patients with these features are expected to achieve a better outcome from sRP.

In 2008, Jamal et al. [39] reported a case of salvage RARP (sRARP). Since then, some authors highlighted some expedients in order to reduce the morbidity of sRARP. In the multi-institutional experience described by Chauhan et al., before performing the anastomosis, the integrity of the rectal wall was assessed in a similar three-step fashion: first, an inspection of the rectal wall was performed under 10× magnification and 3D vision of the da Vinci Surgical System; then the pelvic cavity was filled with normal saline while insufflating the rectal tube (the absence of bubbles signified no major injuries); and finally, a flexible sigmoidoscope was inserted into the rectum and the robotic camera light was turned off: any transillumination suggested a thinning of the rectal wall [40]. In this 15-patient series, the median operative time, the median estimated blood loss, and the median length of hospital stay

were 140.5 min, 75 ml, and 1 day, respectively. There were no rectal injuries. Two (13.3 %) patients had a positive surgical margin. A total of three (20 %) patients had postoperative complications. One patient had a deep vein thrombosis (Clavien grade II), one had wound infection (Clavien grade II), and one patient had an anastomotic leak (Clavien grade Id). An anastomotic stricture (Clavien grade IIIa) later developed in this same patient, which was managed by direct visual internal urethrotomy. Of the patients, 71.4 % were continent. At a median follow-up of 4.6 months (IQR 3–9.75 months), four (28.6 %) patients presented with biochemical recurrence after sRARP.

Clinical Practice

Comparison Between RRP, LRP, and RARP

In 2010, Coelho et al. compared available evidences for RRP, LRP, and RARP provided by high-volume centers, identifying published series of 250 patients or more [41]. This review was conducted to compare perioperative, functional, and oncological outcomes of the three approaches in the absence of randomized trials.

The weighted means for operative time were 165 min (range 131–204 min) for RRP, 162.6 min (130–236 min) for the RARP series, and 205 min (100–266 min) for the LRP series. The mean estimated blood loss (EBL) for RRP, LRP, and RARP was 951, 291.5, and 164.2 ml, respectively. The mean intraoperative and postoperative RRP transfusion rates for RRP, LRP, and RARP were 20.1, 3.5, and 1.4 %, respectively. In terms of hospital stay, RP series account for a weighted mean of 3.48 days; the mean hospital stay for LRP and RARP was 4.87 and 1.43 days, respectively.

The weighted mean postoperative complication rates for RRP, LRP, and RARP were 10.3 % (range of means 4.8–26.9 %), 10.98 % (range of means 8.9–27.7 %), and 10.3 % (range of means 4.3–15.7 %), respectively. The mean open conversion rate for RARP was 0.34 % (range of

means 0–1.6 %) and for LRP was 1.76 % (range of means 0–2.4 %). The pathologic stage in the RARP series was of 78.2 % pT2 tumors and 20.5 % pT3 tumors. LRPs were performed on 64 % pT2 and 32.6 % pT3 tumors, and RRP on 64.3 % pT2 and 31.5 % pT3 tumors. RARP revealed a mean overall PSM rate of 13.6 %, whereas LRP and RRP yielded a PSM of 21.3 and 24 %, respectively. The mean PSM rate for pT2 and pT3 tumors in the RARP series was 9.6 and 37.1 %, respectively; in the open series, it was 16.8 and 42 %, respectively; and in the LRP series, it was 12.4 and 39.2 %, respectively.

In this study, the definition of continence adopted to collect the data from the studies was the use of no absorbent pads or the use of one pad only for security. The weighted mean continence rates at 12 months of follow-up for RRP, LRP, and RARP were 79, 84.8, and 92 %, respectively.

The weighted mean potency rates for patients who underwent RRP with unilateral or bilateral nerve sparing, at 12 months of follow-up, were 43.1 and 60.6 %, respectively. The LRP weighted mean potency rates for patients who received unilateral and bilateral nerve-sparing procedures, at 12 months of follow-up, were 31.1 and 54 %, respectively; finally, RARP patients who received unilateral and bilateral nerve-sparing procedures had potency rates, at 12 months of follow-up, of 59.9 and 93.5 %, respectively.

In conclusion, the Authors found that LRP and RARP were associated with decreased operative blood loss and decreased risk of transfusion when compared with RRP. Lower weighted mean PSM rates and higher continence and potency rates were observed after RARP compared with RRP and LRP.

A 2013 paper [42] compared early oncologic outcomes of 961 ORP and 493 RARP performed by experienced surgeons in a high-volume center. Despite a short follow-up (1 year), Silberstein et al. found that RARP, when performed by highly experienced surgeons, was not associated with lower rates of BCR-free survival or higher rates of PSMs. Furthermore, their findings demonstrated no worse outcomes for higher-risk patients receiving RARP when emphasis is placed on strict adherence to oncological surgical principles.

Best Practice Recommendations for RARP: The Pasadena Consensus Panel

In 2012, a consensus conference of 17 world leaders in prostate cancer and radical prostatectomy was organized in Pasadena, California, and at the City of Hope Cancer Center, Duarte, California, under the auspices of the European Association of Urology Robotic Urology Section to systematically review the currently available data on RARP, to critically assess current surgical techniques, and to generate best practice recommendations to guide clinicians and related medical personnel [21].

The Pasadena Consensus Panel (PCP) [21] confirmed the indications for RARP, identical to those accepted for RRP and for LRP. Furthermore, the PCP identified some patients subgroups who should be treated by an “experienced” surgeon, such as obese patients [body mass index (BMI) >30], patients with prostate volume >70 cm³, patients with previous TURP or other surgery for BPH, patients with large median lobe, high-risk patients requiring extended pelvic lymph node dissection, and patients with previous pelvic surgery. Only very experienced surgeons should perform salvage RARP after radiation therapy, cryotherapy, or high-intensity focused ultrasound (HIFU) [43].

Considering deeper insights into the distribution and course of the cavernous nerves which in recent years have allowed clinicians to increase their knowledge about prostate anatomy and specifically about the network of nerves surrounding the prostate, seminal vesicles, and urethral sphincter [18], the PCP also reviewed indications for nerve-sparing surgery.

A maximum preservation of cavernous nerves (CNs) (*full* nerve sparing) can be obtained by following the plane between the prostatic capsule and the multilayer tissue of the prostatic fascia. This kind of nerve sparing is recommended for sexually active and functional men without comorbidities and limited-risk disease. *Partial* nerve sparing, obtained following the planes within the multilayer tissue of the prostatic fascia, is recommended for preoperative potent men

without comorbidities and intermediate- or high-risk localized disease, while patients with erectile dysfunction and/or comorbidities, or not interested in sexual activity, should undergo *minimal* nerve sparing, that is, the preservation of CNs running at the posterolateral surface of the prostate. When the disease is clearly extraprostatic, patients should undergo a non-nerve-sparing surgery [21].

Regarding PLND, the PCP agreed that a bilateral extended PLND is indicated for intermediate- and high-risk patients. A PLND should be considered optional in low-risk patients (D'Amico criteria [44] or N+ risk <3 % according to available nomograms).

Concerning the patient preparation, the PCP gave the following indications: ≥ 4 –6 weeks should pass from biopsy to surgery; it is standard procedure to advise patients to stop taking all anticoagulants a week before surgery, although some emerging evidence suggests that allowing continued low-dose nonsteroidal anti-inflammatory drugs or aspirin is not associated with the occurrence of bleeding events and could be beneficial in preventing serious adverse cardiac thrombotic events; early mobilization and mechanical venous thromboembolism (VTE) prophylaxis are advised in patients without risk factors, while patients with increased risk of VTE should be treated with low molecular weight heparin (LMWH) until the patient is no longer at increased risk of VTE (generally 5–7 days) or prolonged for a longer period (28 days after surgery), especially for very-high-risk patients (e.g., previous VTE); antibiotic prophylaxis (a single perioperative course) using second- or third-generation cephalosporin is recommended.

The PCP discussed the application of RARP to patients with high-risk PCa. The available studies suggest that RARP is a feasible option for men with high-risk PCa and can achieve equivalent oncologic and functional outcomes compared with RRP. Several studies have challenged the use of RARP in high-risk patients, suggesting that complication and positive margin rates are too high; however, the PCP agreed that the findings could reflect early experience with robotic technology and surgeons who are still on their learning curve.

Current Clinical Practice

In 2013, Ficarra et al. published a survey of 145 robotic surgeons, whose aim was to evaluate surgeons' adherence to current clinical practice for RARP and offer a baseline assessment to measure the impact of the Pasadena recommendations, since the survey was conducted before the publication of the PCP recommendations [45].

86.2 % of surgeons reported using the four-arm da Vinci® Surgical System. The primary access for pneumoperitoneum was performed using the Hasson technique by 68 % of surgeons and using a Veress needle by the remaining 32 %. 87.9 % of surgeons preferred a transperitoneal approach. 75.9 % choose an antegrade approach, 11.2 % a retrograde, and 12.9 % a combined one. 76.7 % preferred to minimize bladder neck dissection. The dorsal vascular complex was controlled using sutures by 90.5 %. The seminal vesicle dissection was performed using only clips (athermal) by 50.9 %, monopolar cautery by 19 %, and bipolar cautery by 20.7 %. The remaining 9.4 % declared use of both mono- and bipolar devices. For the posterior dissection, a plane between Denonvilliers' fascia and the prostate capsule (Denonvilliers' preservation) was the standard approach for 12.9 %. Conversely, a plane between Denonvilliers' fascia and the rectum (Denonvilliers' resection) was always preferred by 13.8 %. The remaining 73.3 % surgeons declared choosing between these approaches according to the clinical stage. Anterolateral prostatic fascia dissection to preserve the cavernous nerves was performed without energy (athermal) by 90.5 %. An antegrade release of the NVBs was the standard technique for 37 %, while retrograde or combined approaches were used by 10 and 53 %, respectively. In patients with low-risk disease and suitable for nerve sparing, 28.4 % planned an interfascial dissection as the standard approach; 32.8 % an intrafascial dissection, and 38.8 % choose the most appropriate plan according to intraoperative features.

The posterior reconstruction of the musculofascial plate was usually performed by 51.7 %, while 19.8 % declared to sometimes perform this reconstructive step. 61.2 % did not

perform any anterior reconstruction technique; 19.8 % made an anterior suspension according to Patel's technique, 6.9 % according to Tewari's technique, and 12 % according to other nonstandardized techniques.

The urethrovaginal anastomosis was usually made with running sutures by 96.6 %.

During PLND, the standard template included the obturator area only for 12.9 % of surgeons; the obturator and external iliac areas for 20.6 %; the obturator, external iliac, and internal iliac areas for 38.7 %; all the previous plus the common iliac area for 25 %; and also the aorta bifurcation area for the remaining 2.6 %.

A drain was always placed by 73.3 %. The use of a suprapubic catheter with the aim to reduce the discomfort from the presence of a transurethral catheter was a standard practice for only 5.1 %. Before catheter removal, a cystogram was always taken in all cases by 38.8 % of surgeons, never by 28.4 %, and only in difficult cases by the remaining 32.8 %.

Outcomes or RARP

Perioperative Outcomes and Complications

Perioperative complications are a major surgical outcome for radical RARP. In 2012, Novara et al. published a systematic review and meta-analysis whose aim was to evaluate complication rates following RARP, risk factors for complications after RARP, and surgical techniques to improve complication rates after RARP. A cumulative analysis of all studies comparing RARP with RRP or LRP in terms of perioperative complications was also performed [46].

Between the factors which could affect perioperative outcomes of RARP, higher BMI resulted to be related to longer operative time; higher prostate volume was associated with longer operative time, higher blood loss, longer catheterization time, and slightly longer in-hospital stay; prior BPH surgery was associated with longer operative time; and the presence of median lobe

Table 5.1 Mean complication rates after RARP

Complication	Rate (%)
Blood transfusion	2.0
Lymphocele/lymphorrhea	3.1
Urine leak	1.8
Reoperation	1.6

was associated with longer operative time and higher blood loss.

Perioperative outcomes were not affected by the adoption of the transperitoneal approach compared with the extraperitoneal approach, by preservation of the bladder neck, or by the adoption of interfascial dissection of the neurovascular bundle.

The mean complication rate of RARP is 9 % (range, 3–26 %). Main complications are summarized in Table 5.1. Prostate volume and number of cases performed are independent predictors of the occurrence of complications of any grade, whereas the number of cases performed is an independent predictor of high-grade complications. Preoperative PSA and presence of cardiac comorbidity are independent predictors of medical complications of any grade, whereas age, biopsy GS, presence of hyperlipidemia, and gastroesophageal reflux disease are associated with surgical complications of any grade [47].

Comparison of RARP with RRP and LRP approach showed that blood loss and transfusion rate are lower in RARP than in RRP, whereas only transfusion rate is lower in RARP than in LRP. All the other parameters are similar, regardless of the surgical approach [46].

Oncologic Outcomes

Long-term data regarding biochemical recurrence of PCa after RARP are sparse because few centers have been performing this procedure for more than 5 years.

More data are available on other outcomes that can be considered surrogates for oncologic control (e.g., positive surgical margins [PSMs] rates).

PSMs defined as tumor at the inked margin of the prostatectomy specimen are a risk factor for

disease progression after surgery [21]. The impact of PSMs on cancer-related outcome has been studied extensively, even if a clear association between PSMs and cancer-specific mortality was shown in only a single large population-based study, indicating that patients with PSM had a 1.7-fold higher risk of death compared with those without [48].

A recent systematic review by Novara et al. [25] evaluated oncologic outcomes after RARP in terms of lymph node yield, PSMs, use of adjuvant therapy, and biochemical recurrence (BCR)-free survival. This systematic review revealed that extended lymph node dissection yielding a reasonably high number of lymph nodes is feasible during RARP.

The mean PSM rate reported was 9 % in pT2 diseases, 37 % in pT3, and 50 % in pT4. The authors found that the most relevant predictors of PSMs are tumor features (e.g., PSA, pT stage, Gleason score, and prostate volume), surgeon-related characteristics (e.g., caseload, type of RARP training, and prior surgical experience), or procedure-related issues (e.g., type of nerve-sparing approach, technique for dorsal venous complex control). Much evidence suggests that PSMs in pT2 disease are, for the most part, iatrogenic and hence potentially avoidable [49].

Very few data are available on the use of adjuvant therapies, this could mean that a limited number of patients received such treatments following RARP [25]; on the other hand, the use of adjuvant therapies might depend on patient selection and indications that are affected by local practice.

The most detailed available RARP series reports BCR-free survival estimates of 95.1, 90.6, 86.6, and 81.0 % at follow-up durations of 1, 3, 5, and 7 years, respectively (median follow-up, 5 years) [21].

All the cumulative analyses performed by Novara et al. [25] comparing RARP with RRP and LRP demonstrated similar PSMs rates and BCR-free survival estimates, regardless of the surgical approach.

Continenence Outcomes

While incontinence and impotence are the two chief drawbacks of RP [50], incontinence seems

to be the problem that troubles patients most, even if its incidence is inferior to that of impotence. According to the EAU Guidelines 2011 [7], incontinence persists 1 year after RP in 7.7 % of cases, while the AUA Guidelines 2007 (reviewed and validity confirmed 2011) [6] report post-RP incontinence rates ranging from 3 to 74 %.

The International Continence Society defined incontinence as “the complaint of any involuntary leakage of urine” [51, 52]. Stress incontinence is the most frequently observed type of incontinence after radical prostatectomy, even if a considerable number of patients present a mixed urge and stress syndrome.

Sphincter dysfunction is mainly a result of injury to the sphincter mechanism during prostatic surgery; considering this mechanism, incontinence is usually associated with abdominal pressure increase. In the most severe cases, it can be gravitational [53].

In 2012, Ficarra et al. [54] performed a systematic review evaluating prevalence and risk factors for urinary incontinence after RARP and comparing RARP versus RRP or LRP in terms of the urinary continence recovery rate.

In this study, 12 months’ urinary incontinence rates (using no pad as the continence definition) ranged from 4 to 31 %, with a mean value of 16 %. Methodological aspects (like continence definitions, tools used for data collection, different follow-up intervals) can influence the prevalence of urinary incontinence after RARP.

The authors found that the most relevant pre-operative predictors of urinary incontinence after RARP were patient age, BMI, comorbidity index, lower urinary tract symptoms, and prostate volume. Puboprostatic-sparing techniques, bladder neck preservation, selective dorsal venous complex division, nerve-sparing technique, and posterior musculofascial and anterior reconstruction were identified as surgical aspects potentially able to reduce the risk of urinary continence after RARP. However, only a few comparative studies analyzed the impact of some of these surgical aspects on urinary continence recovery. In their cumulative analyses, Ficarra et al. demonstrated a statistically significant advantage in favor of RARP in comparison with RRP and LRP in terms of 12 months’ urinary continence recovery (Fig. 5.35).

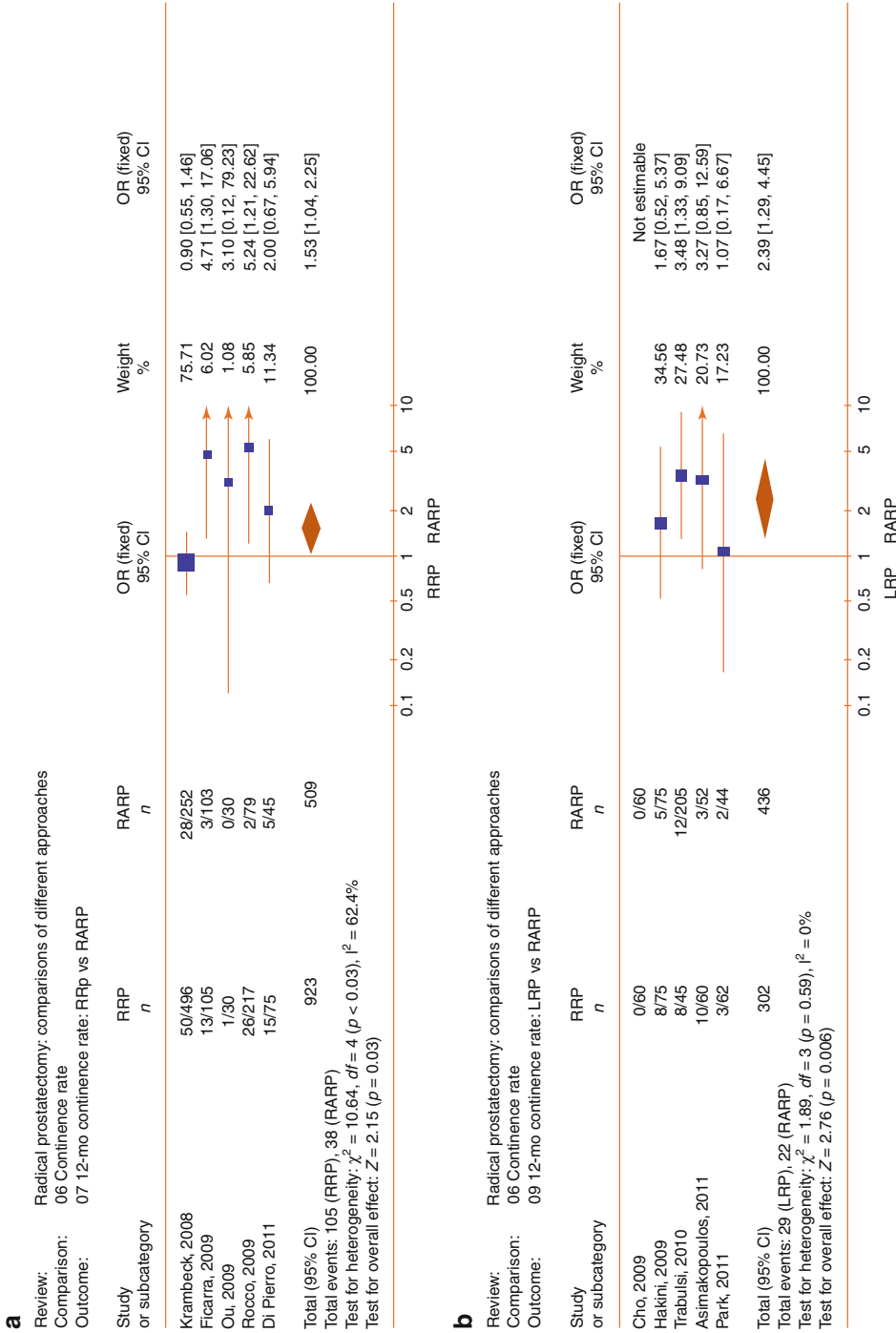


Fig. 5.35 (a) Cumulative analysis of studies comparing robot-assisted radical prostatectomy versus retropubic radical prostatectomy in terms of 12 months urinary continence recovery. (b) Cumulative analysis of the studies comparing robot-assisted radical prostatectomy versus laparoscopic radical prostatectomy in terms of 12 months' urinary continence recovery. *CI* confidence interval, *LRP* laparoscopic radical prostatectomy, *OR* odds ratio, *RARP* robot-assisted radical prostatectomy (Reprinted with permission from Ficarra [54])

Potency Outcomes

The neurovascular bundles (NVBs) were first described in 1982 by Walsh and Donker. These authors demonstrated that erectile dysfunction following RP occurred secondary to injury to the cavernosal nerves (CNs), a group of parasympathetic nerves originating from the pelvic plexus and running together with arteries and veins (capsular vessels of the prostate) on a prominent NVB on the posterolateral aspect of the prostate and eventually ending in the corpus cavernosum of the penis [55].

Further studies about the distribution of nerves within the NVB demonstrated that these nerves are organized into three functional compartments, in which the CNs are located on the anteromedial aspect of the NVB closest to the prostate. Other nerves within the NVB located laterally and inferiorly to the CN innervate the levator muscle and rectum, respectively [56, 57].

A recent systematic review of the literature by Ficarra et al. [58] reported that nerve-sparing RARP was associated with an incidence of 12- and 24-months erectile dysfunction ranging from 10 to 46 % and from 6 to 37 %, respectively. These widely different rates of erectile dysfunction are attributable especially to the different definitions of erectile dysfunction.

This systematic review showed that for patients who underwent RARP, relevant predictors of outcome are age at surgery, baseline erectile function, presence of comorbidities, extension of the nerve-sparing procedure, and use of athermal or thermal dissection.

Concerning the comparison between RARP and RRP, this study demonstrated, for the first time, a significant advantage in favor of RARP in comparison with RRP in terms of 12 months' potency rates (Fig. 5.36).

The Concept of "Trifecta"

Widespread prostate-specific antigen (PSA) screening and the consequent diagnosis of prostate cancer in younger and healthier men with organ-confined disease have underlined

the importance of urinary and sexual function recovery after surgery [4]. Since Salomon et al. in 2003 first reported functional and oncological outcome combined in their series of open, laparoscopic, and perineal prostatectomy [59], the term "trifecta" was adopted to describe concomitant oncological, continence, and potency outcomes in 2004, at the Challenges in Laparoscopy Conference, in Rome, and at the Evolving Strategies in Prostate Cancer Meeting in New York in September 2005 [60].

Since the introduction of the concept, some authors reported trifecta rates after RARP in preoperatively continent and potent men (Table 5.2). They also reported many factors which influence trifecta rates: Shikanov et al. [61] noticed that trifecta rates vary significantly depending on the tools used for continence and potency evaluation; Patel et al. [4] found that younger men had a shorter time achieving the trifecta when compared with older men at 6 weeks, 3 months, and 6 months after surgery; Xylinas et al. [62] reported age ≥ 60 years, initial PSA ≥ 10 ng/ml, and bilateral nerve-sparing surgery as factors associated with 2-year trifecta at multivariate analysis; Novara et al. [63] identified age at surgery and preoperative erectile function as the only independent predictors of trifecta rates.

In conclusion, RARP provides excellent control of prostate cancer, with the possibility to obtain the trifecta in selected patients.

Beyond the Trifecta: The "Pentafecta"

In 2011, Patel VR et al. reported a new concept for reporting outcomes of RARP: the "pentafecta" [64]. In addition to the traditional trifecta outcomes, two perioperative variables were included in the pentafecta: no postoperative complications and negative surgical margins. The idea of this new method for reporting outcomes of RARP came from the consideration that perioperative complications can affect the satisfaction with the procedure even in patients who would later achieve the trifecta. The authors reported pentafecta outcomes of 332 potent men who underwent RARP with bilateral nerve sparing and who had 1

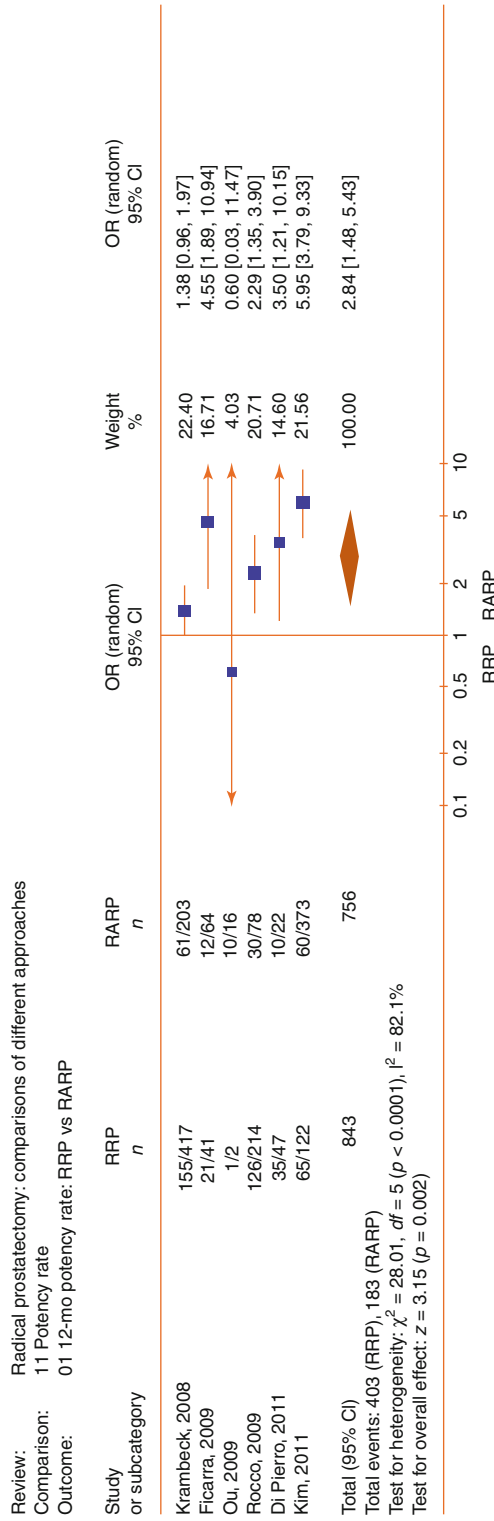


Fig. 5.36 Cumulative analyses of 12 months’ potency rates following robot-assisted radical prostatectomy or retropubic radical prostatectomy. *CI* confidence interval, *OR* odds ratio, *RARP* robot-assisted radical prostatectomy, *RRP* retropubic radical prostatectomy (Reprinted with permission from Ficarra [58])

Table 5.2 Trifecta rates for RARP series

Author	Year of publication	Number of patients	Follow-up (months)	Definition of BCR, continence, and potency	BCR-free survival	Continence	Potency	Trifecta
Shikanov et al. [61]	2009	380	24	PSA > 0.2 ng/ml; 0 pads; ESI	3 months: 99 % 6 months: 97 % 12 months: 96 % 24 months: 91 %	3 months: 57–33 % ^a 6 months: 80–60 % ^a 12 months: 92–73 % ^a 24 months: 98–80 % ^a	3 months: 57–44 % ^a 6 months: 63–50 % ^a 12 months: 82–62 % ^a 24 months: 93–69 % ^a	3 months: 34–16 % ^a 6 months: 52–31 % ^a 12 months: 71–44 % ^a 24 months: 76–44 % ^a
Patel et al. [4]	2010	404	18	Two consecutive PSAs > 0.2 ng/ml; 0 pads; ESI > 50 % of times with or without the use of oral PT51	6 weeks: 98.7 % 3 months: 97.5 % 6 months: 96.7 % 12 months: 95 % 18 months: 91.4 %	6 weeks: 67.7 % 3 months: 85.4 % 6 months: 95.7 % 12 months: 97.4 % 18 months: 97.9 %	6 weeks: 53.5 % 3 months: 68.8 % 6 months: 81.7 % 12 months: 91.5 % 18 months: 96.6 %	6 weeks: 42.8 % 3 months: 65.3 % 6 months: 80.3 % 12 months: 86 % 18 months: 91 %
Novara et al. [63]	2011	242	12	Adjuvant therapies or PSA > 0.2 ng/ml; no urine leakage; IIEF-6 ≥ 18 with or without the use of oral PT51	95.5 %	89 %	60 %	57 %
Ou et al. [65]	2013	94	12	Two consecutive PSAs > 0.2 ng/ml; no pads use; ESI with or without the use of oral PT51	94.7 %	97.9 %	87.2 %	81.9 %
Xylinas et al. [62]	2011	500	24	PSA ≥ 0.2 ng/ml 0 pads; ESI with or without the use of oral PT51	12 months: 89 % 24 months: 88 %	12 months: 78 % 24 months: 88 %	12 months: 54 % 24 months: 63 %	12 months: 44 % 24 months: 53 %
Yip et al. [66]	2012	235	12	PSA > 0.2 ng/ml 0 pads; ESI with or without the use of oral PT51	–	72.5 %	–	31/83 (37.3 %)

^aPatients stratified by subjective-objective evaluation

BCR biochemical recurrence, ESI erection sufficient for intercourse, PT51 phosphodiesterase type 5 inhibitors

year of follow-up. Continence, potency, biochemical recurrence-free survival, and trifecta rates at 12 months were 96.4, 89.8, 96.4, and 83.1 %, respectively. With regard to the perioperative outcomes, 93.4 % had no postoperative complication during the surgical procedure or within 90 days after surgery, and 90.7 % had negative surgical margins. The overall trifecta rates were 43.1, 64.1, 79.2, and 83.1 % at 6 weeks and 3, 6, and 12 months, respectively. The pentafta rates at 3 and 6 months were 51.8 and 66.9 %, respectively. The pentafta rate at 12 months was 70.8 %. When stratifying outcomes by patient age, the pentafta rates were 75.9, 68.9, and 62.1 % for patients ≤ 55 years, 56–65 years, and >65 years, respectively. The most common reasons for not achieving the trifecta were erectile dysfunction (57.1 % of patients not achieving trifecta), followed by BCR (19.6 %) and urinary incontinence (19.6 %). The most common reasons for not reaching the pentafta were erectile dysfunction (35.0 %) and PSM (31.9 %). On multivariable analysis, patient age was the only factor independently associated with the pentafta.

References

- Hemal AK, Menon M. Robotics in urology. *Curr Opin Urol.* 2004;14(2):89–93.
- Babbar P, Hemal AK. Robot-assisted urologic surgery in 2010 – advancements and future outlook. *Urol Ann.* 2011;3(1):1–7.
- Piechaud P. State of the art: urologic surgery. *J Visc Surg.* 2011;148(5 Suppl):e27–9.
- Patel VR, Coelho RF, Chauhan S, Orvieto MA, Palmer KJ, Rocco B, et al. Continence, potency and oncological outcomes after robotic-assisted radical prostatectomy: early trifecta results of a high-volume surgeon. *BJU Int.* 2010;106(5):696–702.
- Binder J, Kramer W. Robotically-assisted laparoscopic radical prostatectomy. *BJU Int.* 2001;87(4):408–10.
- American Urological Association guidelines 2007 (reviewed and validity confirmed 2011). Web Site. <http://www.auanet.org/content/clinical-practice-guidelines/clinical-guidelines/main-reports/proscan07/content.pdf>.
- Heidenreich A, Bellmunt J, Bolla M, Joniau S, Mason M, Matveev V, et al. EAU guidelines on prostate cancer. Part 1: screening, diagnosis, and treatment of clinically localised disease. *Eur Urol.* 2011;59:61–71.
- Patel VR, Shah KK, Thaly RK, Lavery H. Robotic-assisted laparoscopic radical prostatectomy: the Ohio State University technique. *J Robot Surg.* 2007;1:51–9.
- Guillonneau B, Vallancien G. Laparoscopic radical prostatectomy: the Montsouris technique. *J Urol.* 2000;163:1643.
- Pasticier G, Rietbergen JBW, Guillonneau B, Fromont G, Menon M, Vallancien G. Robotically assisted laparoscopic radical prostatectomy: feasibility study in men. *Eur Urol.* 2001;40:70–4.
- Van Velthoven RF, Ahlering TE, Peltier A, Skarecky DW, Clayman RV. Technique for laparoscopic running urethrovesical anastomosis: the single knot method. *Urology.* 2003;61(4):699–702.
- Patel VR, Coelho RF, Palmer KJ, Rocco B. Periurethral suspension stitch during robot-assisted laparoscopic radical prostatectomy: description of the technique and continence outcomes. *Eur Urol.* 2009;56(3):472–8.
- Lin VC, Coughlin G, Savamedi S, Palmer KJ, Coelho RF, Patel VR. Modified transverse plication for bladder neck reconstruction during robotic-assisted laparoscopic prostatectomy. *BJU Int.* 2009;104(6):878–81.
- Rocco F, Carmignani L, Acquati P, Gadda F, Dell’Orto P, Rocco B, et al. Restoration of posterior aspect of rhabdosphincter shortens continence time after radical retropubic prostatectomy. *J Urol.* 2006;175(6):2201–6.
- Rocco B, Gregori A, Stener S, Santoro L, Bozzola A, Galli S, et al. Posterior reconstruction of the rhabdosphincter allows a rapid recovery of continence after transperitoneal videolaparoscopic radical prostatectomy. *Eur Urol.* 2007;51(4):996–1003.
- Coughlin G, Dangle PP, Patil NN, Palmer KJ, Woolard J, Jensen C, et al. Surgery illustrated – focus on details. Modified posterior reconstruction of the rhabdosphincter: application to robotic-assisted laparoscopic prostatectomy. *BJU Int.* 2008;102(10):1482–5.
- Coelho RF, Chauhan S, Orvieto MA, Sivaraman A, Palmer KJ, Coughlin G, et al. Influence of modified posterior reconstruction of the rhabdosphincter on early recovery of continence and anastomotic leakage rates after robot-assisted radical prostatectomy. *Eur Urol.* 2011;59(1):72–80.
- Walz J, Burnett AL, Costello AJ, Eastham JA, Graefen M, Guillonneau B, et al. A critical analysis of the current knowledge of surgical anatomy related to optimization of cancer control and preservation of continence and erection in candidates for radical prostatectomy. *Eur Urol.* 2010;57:179–92.
- Rocco B, Cozzi G, Spinelli MG, Coelho RF, Patel VR, Tewari A, et al. Posterior musculofascial reconstruction after radical prostatectomy: a systematic review of the literature. *Eur Urol.* 2012;62(5):779–90.
- Mattei A, Fuechsel FG, Bhatta Dhar N, Warncke SH, Thalmann GN, Krause T, et al. The template of the primary lymphatic landing sites of the prostate should be revisited: results of a multimodality mapping study. *Eur Urol.* 2008;53(1):118–25.

21. Montorsi F, Wilson TG, Rosen RC, Ahlering TE, Artibani W, Carroll PR, et al. Best practices in robot-assisted radical prostatectomy: recommendations of the Pasadena consensus panel. *Eur Urol*. 2012;62(3):368–81.
22. Feicke A, Baumgartner M, Talimi S, Schmid DM, Seifert HH, Müntener M, et al. Robotic-assisted laparoscopic extended pelvic lymph node dissection for prostate cancer: surgical technique and experience with the first 99 cases. *Eur Urol*. 2009;55(4):876–83.
23. Ham WS, Park SY, Rha KH, Kim WT, Choi YD. Robotic radical prostatectomy for patients with locally advanced prostate cancer is feasible: results of a single-institution study. *J Laparoendosc Adv Surg Tech A*. 2009;19(3):329–32.
24. Menon M, Shrivastava A, Bhandari M, Satyanarayana R, Siva S, Agarwal PK. Vattikuti Institute prostatectomy: technical modifications in 2009. *Eur Urol*. 2009;56(1):89–96.
25. Novara G, Ficarra V, Mocellin S, Ahlering TE, Carroll PR, Graefen M, et al. Systematic review and meta-analysis of studies reporting oncologic outcome after robot-assisted radical prostatectomy. *Eur Urol*. 2012;62(3):382–404.
26. Chung JS, Kim WT, Ham WS, Yu HS, Chae Y, Chung SH, et al. Comparison of oncological results, functional outcomes, and complications for transperitoneal versus extraperitoneal robot-assisted radical prostatectomy: a single surgeon's experience. *J Endourol*. 2011;25(5):787–92.
27. Coelho RF, Chauhan S, Guglielmetti GB, Orvieto MA, Sivaraman A, Palmer KJ, et al. Does the presence of median lobe affect outcomes of robot-assisted laparoscopic radical prostatectomy? *J Endourol*. 2012;26(3):264–70.
28. Patel VR, Schatloff O, Chauhan S, Sivaraman A, Valero R, Coelho RF, et al. The role of the prostatic vasculature as a landmark for nerve sparing during robot-assisted radical prostatectomy. *Eur Urol*. 2012;61(3):571–6.
29. Roach 3rd M, Hanks G, Thames Jr H, Schellhammer P, Shipley WU, Sokol GH, et al. Defining biochemical failure following radiotherapy with or without hormonal therapy in men with clinically localized prostate cancer: recommendations of the RTOG-ASTRO Phoenix Consensus Conference. *Int J Radiat Oncol Biol Phys*. 2006;65(4):965–74.
30. Eandi JA, Link BA, Nelson RA, Josephson DY, Lau C, Kawachi MH, et al. Robotic assisted laparoscopic salvage prostatectomy for radiation resistant prostate cancer. *J Urol*. 2010;183(1):133–7.
31. Kimura M, Mouraviev V, Tsivian M, Mayes JM, Satoh T, Polascik TJ. Current salvage methods for recurrent prostate cancer after failure of primary radiotherapy. *BJU Int*. 2010;105(2):191–201.
32. Kaouk JH, Hafron J, Goel R, Haber GP, Jones JS. Robotic salvage retropubic prostatectomy after radiation/brachytherapy: initial results. *BJU Int*. 2008;102(1):93–6.
33. Chen BT, Wood Jr DP. Salvage prostatectomy in patients who have failed radiation therapy or cryotherapy as primary treatment for prostate cancer. *Urology*. 2003;62 Suppl 1:69–78.
34. Nguyen PL, D'Amico AV, Lee AK, Suh WW. Patient selection, cancer control, and complications after salvage local therapy for post-radiation prostate-specific antigen failure: a systematic review of the literature. *Cancer*. 2007;110(7):1417–28.
35. Freedland SJ, Humphreys EB, Mangold LA, Eisenberger M, Dorey FJ, Walsh PC, et al. Risk of prostate cancer-specific mortality following biochemical recurrence after radical prostatectomy. *JAMA*. 2005;294(4):433–9.
36. Zagars GK, Pollack A. Kinetics of serum prostate-specific antigen after external beam radiation for clinically localized prostate cancer. *Radiother Oncol*. 1997;44(3):213–21.
37. Zelefsky MJ, Ben-Porat L, Scher HI, Chan HM, Fearn PA, Fuks ZY, et al. Outcome predictors for the increasing PSA state after definitive external-beam radiotherapy for prostate cancer. *J Clin Oncol*. 2005;23(4):826–31.
38. Rogers E, Ohori M, Kassabian VS, Wheeler TM, Scardino PT. Salvage radical prostatectomy: outcome measured by serum prostate specific antigen levels. *J Urol*. 1995;153(1):104–10.
39. Jamal K, Challacombe B, Elhage O, Popert R, Kirby R, Dasgupta P. Successful salvage robotic-assisted radical prostatectomy after external beam radiotherapy failure. *Urology*. 2008;72(6):1356–8.
40. Chauhan S, Patel MB, Coelho R, Liss M, Rocco B, Sivaraman AK, et al. Preliminary analysis of the feasibility and safety of salvage robot-assisted radical prostatectomy after radiation failure: multi-institutional perioperative and short-term functional outcomes. *J Endourol*. 2011;25(6):1013–9.
41. Coelho RF, Rocco B, Patel MB, Orvieto MA, Chauhan S, Ficarra V, et al. Retropubic, laparoscopic, and robot-assisted radical prostatectomy: a critical review of outcomes reported by high-volume centers. *J Endourol*. 2010;24(12):2003–15.
42. Silberstein JL, Su D, Glickman L, Kent M, Keren-Paz G, Vickers AJ, et al. A case-mix-adjusted comparison of early oncological outcomes of open and robotic prostatectomy performed by experienced high volume surgeons. *BJU Int*. 2013;111:206–12.
43. Rocco B, Cozzi G, Spinelli MG, Grasso A, Varisco D, Coelho RF, et al. Current status of salvage robot-assisted laparoscopic prostatectomy for radiorecurrent prostate cancer. *Curr Urol Rep*. 2012;13(3):195–201.
44. D'Amico AV, Whittington R, Malkowicz SB, Schultz D, Blank K, Broderick GA, et al. Biochemical outcome after radical prostatectomy, external beam radiation therapy, or interstitial radiation therapy for clinically localized prostate cancer. *JAMA*. 1998;280:969–74.
45. Ficarra V, Wiklund PN, Rochat CH, Dasgupta P, Challacombe BJ, Sooriakumaran P, et al. The European Association of Urology Robotic

- Urology Section (ERUS) survey of robot-assisted radical prostatectomy (RARP). *BJU Int.* 2013;111(4):596–603.
46. Novara G, Ficarra V, Rosen RC, Artibani W, Costello A, Eastham JA, et al. Systematic review and meta-analysis of perioperative outcomes and complications after robot-assisted radical prostatectomy. *Eur Urol.* 2012;62(3):431–52.
 47. Agarwal PK, Sammon J, Bhandari A, Dabaja A, Diaz M, Dusik-Fenton S, et al. Safety profile of robot-assisted radical prostatectomy: a standardized report of complications in 3317 patients. *Eur Urol.* 2011;59:684–98.
 48. Wright JL, Dalkin BL, True LD, Ellis WJ, Stanford JL, Lange PH, et al. Positive surgical margins at radical prostatectomy predict prostate cancer specific mortality. *J Urol.* 2010;183(6):2213–8.
 49. Yossepowitch O, Bjartell A, Eastham JA, Graefen M, Guillonneau BD, Karakiewicz PI, et al. Positive surgical margins in radical prostatectomy: outlining the problem and its long-term consequences. *Eur Urol.* 2009;55(1):87–99.
 50. Penson DF, McLerran D, Feng Z, Li L, Albertsen PC, Gilliland FD, et al. 5-year urinary and sexual outcomes after radical prostatectomy: results from the prostate cancer outcomes study. *J Urol.* 2005;173(5):1701–5.
 51. Abrams P, Cardozo L, Fall M, Griffiths D, Rosier P, Ulmsten U, et al. The standardisation of terminology in lower urinary tract function: report from the standardisation sub-committee of the International Continence Society. *Urology.* 2003;61(1):37–49.
 52. Cartwright R, Cardozo L. Usage of international continence society standardized terminology: a bibliometric and questionnaire study. *Neurourol Urodyn.* 2010;29(8):1373–9.
 53. Ficazzola MA, Nitti VW. The etiology of post-radical prostatectomy incontinence and correlation of symptoms with urodynamic findings. *J Urol.* 1998;160(4):1317–20.
 54. Ficarra V, Novara G, Rosen RC, Artibani W, Carroll PR, Costello A, et al. Systematic review and meta-analysis of studies reporting urinary continence recovery after robot-assisted radical prostatectomy. *Eur Urol.* 2012;62(3):405–17.
 55. Walsh PC, Donker PJ. Impotence following radical prostatectomy: insight into etiology and prevention. *J Urol.* 1982;128(3):492–7.
 56. Costello AJ, Brooks M, Cole OJ. Anatomical studies of the neurovascular bundle and cavernosal nerves. *BJU Int.* 2004;94(7):1071–6.
 57. Schatloff O, Chauhan S, Sivaraman A, Kameh D, Palmer KJ, Patel VR. Anatomic grading of nerve sparing during robot-assisted radical prostatectomy. *Eur Urol.* 2012;61(4):796–802.
 58. Ficarra V, Novara G, Ahlering TE, Costello A, Eastham JA, Graefen M, et al. Systematic review and meta-analysis of studies reporting potency rates after robot-assisted radical prostatectomy. *Eur Urol.* 2012;62(3):418–30.
 59. Salomon L, Saint F, Anastasiadis AG, Sebe P, Chopin D, Abbou CC. Combined reporting of cancer control and functional results of radical prostatectomy. *Eur Urol.* 2003;44(6):656–60.
 60. Pierorazio PM, Spencer BA, McCann TR, McKiernan JM, Benson MC. Preoperative risk stratification predicts likelihood of concurrent PSA-free survival, continence, and potency (the trifecta analysis) after radical retropubic prostatectomy. *Urology.* 2007;70(4):717–22.
 61. Shikanov SA, Zorn KC, Zagaja GP, Shalhav AL. Trifecta outcomes after robotic-assisted laparoscopic prostatectomy. *Urology.* 2009;74(3):619–23.
 62. Xylinas E, Durand X, Ploussard G, Campeggi A, Allory Y, Vordos D, et al. Evaluation of combined oncologic and functional outcomes after robotic-assisted laparoscopic extraperitoneal radical prostatectomy: trifecta rate of achieving continence, potency and cancer control. *Urol Oncol.* 2011;31(1):99–103.
 63. Novara G, Ficarra V, D’Elia C, Secco S, Cavalleri S, Artibani W. Trifecta outcomes after robot-assisted laparoscopic radical prostatectomy. *BJU Int.* 2011;107(1):100–4.
 64. Patel VR, Sivaraman A, Coelho RF, Chauhan S, Palmer KJ, Orvieto MA, et al. Pentafecta: a new concept for reporting outcomes of robot-assisted laparoscopic radical prostatectomy. *Eur Urol.* 2011;59(5):702–7.
 65. Ou YC, Yang CK, Wang J, Hung SW, Cheng CL, Tewari AK, Patel VR. The trifecta outcome in 300 consecutive cases of robotic-assisted laparoscopic radical prostatectomy according to D’Amico risk criteria. *Eur J Surg Oncol.* 2013;39(1):107–13.
 66. Yip KH, Yee CH, Ng CF, Lam NY, Ho KL, Ma WK, Li CM, Hou SM, Tam PC, Yiu MK, Fan CW. Robot-assisted radical prostatectomy in Hong Kong: a review of 235 cases. *J Endourol.* 2012;26(3):258–63.

Jonathan Mobley and Brian M. Benway

Introduction

The introduction of nephron-sparing surgery ushered in a new era in the management of localized renal cell carcinoma. However, with the widespread adoption of minimally invasive approaches to renal surgery, there was noted an increase in the utilization of laparoscopic radical nephrectomy at the expense of partial nephrectomy [1]. This troubling trend likely stemmed from the relatively high barrier of entry for laparoscopic partial nephrectomy, which carries with it a steep learning curve of several hundred cases [2, 3], putting the procedure out of reach for all but the highest volume renal surgeons.

First introduced in 2004 by Gettman and colleagues [4], robot-assisted partial nephrectomy (RAPN) initially failed to distinguish itself as an intervention of choice to nephron-sparing surgery, struggling to provide domains of superiority over the established approaches of the time

[4, 5]. However, with refinements in platform technology and technique, RAPN has quickly disseminated throughout the international urologic community, becoming the standard approach for nephron-sparing surgery at many centers.

The introduction of the da Vinci S platform (Intuitive Surgical, Sunnyvale, CA, USA) was an important factor in creating the opportunity for RAPN to take flight, owing to the smaller form factor of the robotic arms, which avoid many of the external collisions which plagued procedures performed on the older robotic platforms, and allowing for a four-arm approach that reduces the reliance upon the assistant [6]. In addition, the addition of the TilePro software allowed for real-time integration of imaging data into the surgical viewfinder, thus facilitating identification of tumor margins and configuration [6, 7].

Furthermore, refinements in technique have continued to propel RAPN to the forefront of nephron-sparing surgery. These innovations include the introduction of the sliding-clip renorrhaphy, which reduces surgical time while providing a strength of repair that is more secure than traditional tied-suture closures [8–11]. Early unclamping techniques [12, 13] and minimal-ischemia techniques have also been introduced to reduce the degree of ischemic insult to the kidney [14, 15].

Indeed, with a learning curve of less than 30 procedures [10, 16, 17], RAPN offers a lower barrier of entry for minimally invasive nephron-sparing surgery than the traditional laparoscopic approach.

J. Mobley, MD
Division of Urologic Surgery, Department of Surgery,
Washington University School of Medicine,
St. Louis, MO, USA

B.M. Benway, MD (✉)
Division of Urologic Surgery, Department of Surgery,
Washington University School of Medicine,
4960 Children's Place, St. Louis, MO 63110, USA

Midwest Stone Institute, St. Louis, MO, USA
e-mail: benwayb@wudosis.wustl.edu

This, in turn, has arguably led to a reversal in the troubling utilization trend of minimally invasive radical nephrectomy over nephron-sparing techniques [18], with greater dissemination of partial nephrectomy than ever before.

Equipment (Transperitoneal and Retroperitoneal Approaches)

1. 30° angled scope
2. Veress needle
3. Two standard 12-mm trocars (transperitoneal) and one standard 12-mm and one 12-mm trocar with a balloon anchor (retroperitoneal). Dilating balloon (retroperitoneal)
4. 2–3 standard robot trocars
5. One standard 5-mm trocar (for right-sided transperitoneal procedures)
6. Long-tip laparoscopic suction device
7. Robotic or laparoscopic bulldog clamps with laparoscopic applier OR laparoscopic Satinsky clamp
8. Laparoscopic scissors
9. Laparoscopic needle drivers
10. Laparoscopic or robotic ultrasound probe
11. Lapra-Ty applier with ample supply of clips
12. Weck Hem-o-lok applier with clips
13. 2–0 suture for deep layer, barbed or polyglactin
14. 0 polyglactin suture for renorrhaphy
15. Surgicel or Nu-Knit (optional)
16. Floseal or Surgiflo (optional)
17. Laparoscopic retrieval bag
18. Closed-system drain (optional)
19. Suture or staples for closure
20. Open nephrectomy pan on standby

Robot-Assisted Partial Nephrectomy, Transperitoneal Approach

Introduction

The transperitoneal approach to robot-assisted partial nephrectomy is less technically demanding than a retroperitoneal approach and is

recommended as a starting point for surgeons new to RAPN. The approach and landmarks should be familiar to those surgeons accustomed to pure laparoscopic renal surgery. The use of a 4-arm approach aids in retraction and can reduce the reliance upon the assistant; however, the additional arm does increase the potential for external collisions of the robotic arms. This approach is not well suited for posterior tumors, especially upper pole posterior masses.

Step by Step

1. Begin by preparing the renorrhaphy sutures on the back table. A 0 polyglactin suture is cut to a length of 12 cm. A knot is tied at the end, followed by a Lapra-Ty (Ethicon, Cincinnati, OH, USA) and a Weck Hem-o-lok clip (Teleflex, Research Triangle Park, NC). Prepare at least six sutures prior to beginning, with additional sutures for larger masses.
2. Place the patient in a standard flank position, with the top of the iliac crest over the break in the table. Flex the table to open up and flatten the flank.
3. The pneumoperitoneum is obtained by placing a Veress needle along the paramedian line.
4. The transperitoneal robot-assisted partial nephrectomy can be performed with a three-arm or four-arm approach. Figure 6.1 illustrates the port placement for both the three-arm and four-arm approach. A 12-mm camera port is placed lateral to the umbilicus. The remaining trocars are placed under direct vision. During right-sided cases, an additional 5-mm subxiphoid port can be placed to assist with liver retraction.
5. The robot is not docked at a 90° angle from the bed. Instead, the robot is docked along an imaginary line from the camera port to the expected region of the hilum. The 30° down lens is used to perform the procedure. A ProGrasp forceps and monopolar scissors are used during the three-arm approach, and an additional ProGrasp forceps can be used for the four-arm approach.

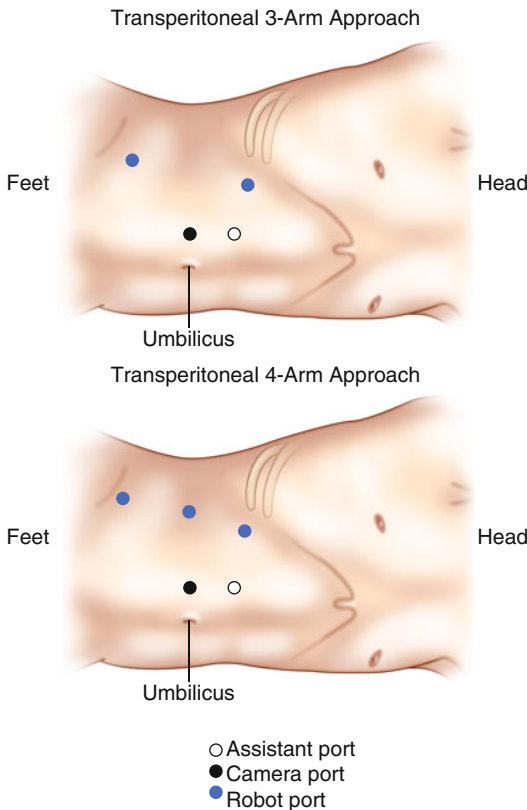


Fig. 6.1 The illustration demonstrates the trocar placement for a right retroperitoneal robot-assisted partial nephrectomy. Notice that the camera and three robot ports are all inline. This allows the surgeon to connect the incisions if conversion to an open procedure is required

6. The white line of Toldt is incised lateral to the colon, and the colon is reflected medially. The proper plane of dissection can be identified by the difference in color in the mesenteric fat and Gerota's fascia. The perinephric fat has a paler yellow color, while the mesenteric fat tends to be a brighter yellow. Incising between the two separate fat planes will allow for medial reflection of the colon and peritoneum [19]. The splenocolic and leinorenal ligaments are incised, and the spleen and pancreas are allowed to fall medially during left-sided procedures. During right-sided surgeries, the duodenum may require an additional Kocher maneuver to expose the renal hilum. The Kocher maneuver is performed by sharply incising

the posterior peritoneum lateral to the duodenum. The duodenum can then be swept medially.

7. The ureter and gonadal vessels are identified inferiorly. The gonadal vessels can be mobilized medially and dissection lateral to the gonadal can be performed until the psoas muscle is identified laterally.
8. Retract the ureter laterally with the long arm of the ProGrasp forceps, placing the renal hilum on stretch.
9. Dissection is continued medially until the renal vein is identified. On the left side, identification of the renal vein can be performed by following the left gonadal vein from a caudal to cranial direction. On the right side, the inferior vena cava is often visualized early and can be traced superiorly until the right renal vein is identified. A window is made in the tissue cranial and caudal to the renal vein for future clamping.
10. The renal artery is identified by retracting the renal vein cranially. The gonadal vein may require ligation with 5-mm clips in order to allow cranial retraction of the left renal vein. A window is made in the tissue cranial and caudal to the renal artery.
11. The adrenal gland will require separation from the kidney in cases of upper pole masses.
12. 12.5 g of mannitol is given intravenously to the patient.
13. The renal mass is identified with an intraoperative ultrasound. Gerota's fascia is opened and the perinephric fat overlying the mass is widely excised to provide adequate exposure to the renal capsule. The fat overlying the mass can be removed with a laparoscopic spoon and sent for analysis. The renal capsule is scored with cautery to delineate the margins of excision.
14. The hilum is then controlled by applying bulldog clamps or a Satinsky clamp. It is recommended to clamp the artery doubly. Clamping of the renal vein is optional, but advisable for deeply endophytic or hilar masses. If a Satinsky clamp is used, the assistant must remain vigilant and help to prevent external collisions with the robotic arms.

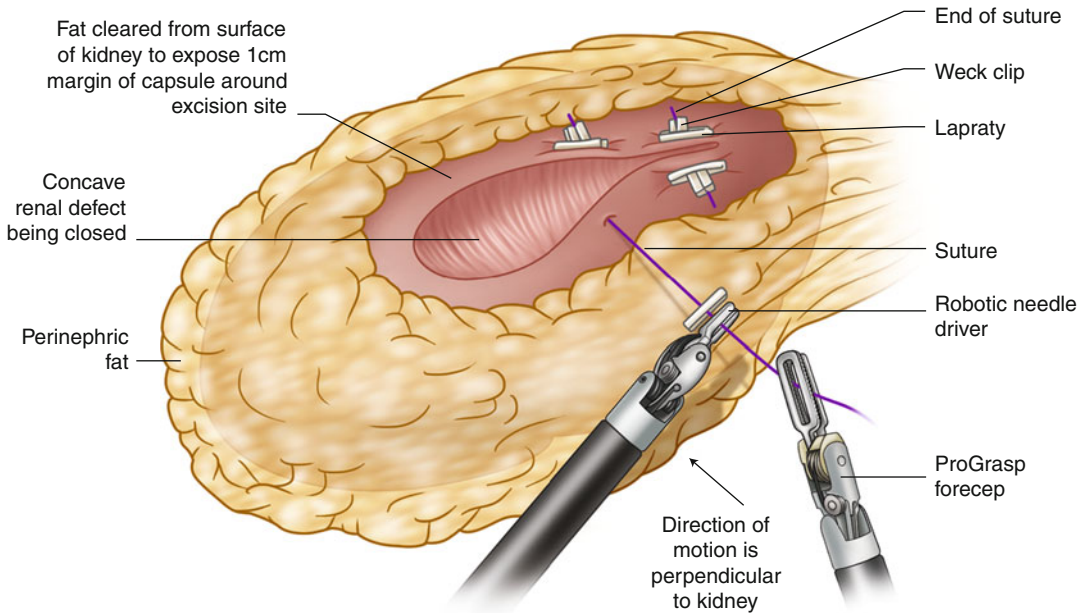


Fig. 6.2 The illustration demonstrates the trocar positioning for both the transperitoneal 3-arm and 4-arm approach to a right robot-assisted partial nephrectomy

15. The tumor is excised with the monopolar scissors. During excision, the assistant uses a long-tip laparoscopic suction device to aid in retraction and evacuation of blood. After complete excision of the tumor, the specimen is placed superior to the kidney and left until the renorrhaphy is complete.
16. A 9-in. 2-0 barbed or polyglactin stitch with a Lapra-Ty at the end is used to close the collecting system and assist with hemostasis of the deep renal bed. The suture is first passed through the far side of the excision bed, approximately 1 cm from the parenchymal margin, and the deep margin is then closed with a running suture. The suture is then brought through the near side to close the collecting system, and a Lapra-Ty clip is placed after the final needle pass (not required for barbed suture).
17. The renal defect is closed using a sliding-clip renorrhaphy technique using the previously made renorrhaphy sutures [10]. The suture is placed through the far side of the excision bed and then brought through the near side, entering and exiting approximately 1 cm from the parenchymal margin. A Weck Hem-o-lok clip is placed on the suture and then slid to reapproximate the defect, with force applied perpendicular to the capsule. Proper tension has been reached when the capsule dimples slightly. Renorrhaphy sutures are spaced 1 cm apart until the defect is closed. After all sutures are placed, a Lapra-Ty clip is placed to lock the repair in place and prevent backsliding of the Hem-o-lok clips. Figure 6.2 illustrates the sliding-clip renorrhaphy technique.
18. The bulldog clamps are removed from the renal artery and vein, keeping the renorrhaphy in view if possible. Should brisk bleeding be encountered, the artery can be reclamped. The insufflation pressure should be decreased to 5 cm Hg, and the tumor bed is inspected for hemostasis. Additional sutures can be placed or hemostatic agents applied as needed.
19. The specimen is placed into a laparoscopic retrieval bag through the assistant port.
20. The robot is undocked. The retrieval bag is removed and all incisions closed.
21. The specimen can be inspected on the back table to ensure adequate tumor margins.

Robot-Assisted Partial Nephrectomy, Retroperitoneal Approach

Introduction

A retroperitoneal approach to robot-assisted partial nephrectomy is ideal for posterior tumors, especially tumors confined to the posterior upper pole. In addition, the retroperitoneal approach may be suitable for patients with extensive prior abdominal surgery. It is not particularly well suited for anterior masses, due to the limited ability to manipulate the kidney.

The retroperitoneal approach to renal surgery can be challenging, as there are few visual cues to aid the surgeon in maintaining orientation. Perhaps the most important landmark is the psoas muscle, which should be identified as soon as possible. Another important cue is the orientation indicator on the console viewfinder itself.

Step by Step

1. Begin by preparing the renorrhaphy sutures on the back table. A 0 polyglactin suture is cut to a length of 12 cm. A knot is tied at the end, followed by a Lapra-Ty clip and a Weck Hem-o-lok clip. Prepare at least six sutures prior to beginning the procedure, with additional sutures for larger masses.
2. Place the patient in a standard flank position, with the top of the iliac crest over the break in the table. Place an axillary roll under the patient and secure the upper arm in a position that is rotated toward the head as much as possible to prevent interference with the robot arms. Flex the table to open up and flatten the flank. Secure, pad, and prepare the patient in the same fashion as for a transperitoneal approach.
3. Identify the 12th rib and make a 12-mm incision just caudad to the tip of the 12th rib. Insert a finger into the incision and push through the subcutaneous tissues and perforate the fascia. The finger should now be able to curl under the tip of the 12th rib. Use the finger angled cephalad to gently develop the

space between the posterior aspect of the kidney and the psoas muscle to allow for placement of the dilating balloon.

4. Place the dilating balloon into the space that has been created and inflate to 40 pumps of the bulb to further develop the retroperitoneal space. Deflate the balloon, and place a 12-mm camera trocar. A trocar with a small anchoring balloon is recommended to maintain pneumoperitoneum.
5. Place an 8-mm robot trocar further posterior along the 12th rib, in the midaxillary line. Use the tip of the suction irrigator or a laparoscopic Kittner to gently reflect the peritoneum anteriorly, thus developing the retroperitoneal space. Continue until enough space has been developed to place the remaining two trocars. Care must be taken not to perforate the peritoneum, as this will severely compromise visualization and working space.
6. Place the remaining two robotic trocars and the 12-mm assistant port as outlined in Fig. 6.3.
7. The robot is docked from the anterior side of the patient bed. For a left-sided procedure, the bed is angled 20° counterclockwise, and the robot is brought over the left arm and shoulder toward the flank. The medial right arm should be equipped with a ProGrasp forceps, the lateral right arm with the scissors, and the left arm with a ProGrasp forceps. A 30° upward-angled lens is used.
8. Developing the retroperitoneal space at this juncture can be quite challenging, and absent any landmarks, it is important to remain mindful of the orientation indicator in the console viewfinder. Develop the space toward the anticipated location of the psoas muscle. Once this structure has been identified, it will serve as an important landmark to maintain orientation. The psoas should be kept at the bottom of the screen and as horizontal as possible to ensure proper orientation.
9. Between the kidney and the psoas, carefully develop the space to identify the hilum. Identification of the hilum is perhaps easier in the retroperitoneal approach, as the artery

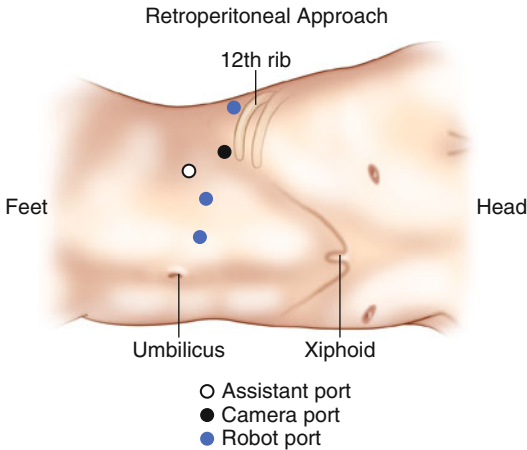


Fig. 6.3 The partial nephrectomy defect is closed using the sliding-clip renorrhaphy technique. An interrupted suture ending with a Weck clip and Lapra-Ty is sewn from the renal parenchyma into the defect and then exits the opposite parenchymal side. The assistant places another Weck clip on the remaining suture, and the two renal edges are approximated by sliding the clip toward the kidney until the two edges meet. The suture is then secured by placing a Lapra-Ty distal to the final Weck clip

is encountered first, and the pulsatile motion of the artery is generally readily recognizable. However, the kidney is often more caudad than would seem intuitive, a common point of disorientation for those just beginning with the retroperitoneal approach. It is important at this juncture to review the imaging to ensure that all arterial structures are identified.

10. Identify and reflect the perinephric fat in the anticipated region of the mass. Again, the kidney may seem a bit more caudad than would be expected. The fat should be cleared down to the capsule, and at least a 1-cm margin of capsule surrounding the mass should be cleared. This will aid renorrhaphy during reconstruction.
11. Perform intraoperative ultrasonography to identify the extent of the mass. Score the capsule with cautery to mark the capsular boundaries of the excision. If clamping is to be performed, instruct the anesthesia provider to administer 12.5 g of mannitol intravenously.
12. While the mannitol is beginning to circulate, take a moment to ensure that all necessary sutures and clips are available.
13. If clamping is to be performed, place bulldog clamps on the hilar vessels, beginning with the artery. It is recommended to doubly clamp the artery. Clamping of the renal vein is optional but is recommended for highly endophytic or central tumors. As an alternative, a laparoscopic Satinsky clamp can be placed through a 5-mm trocar; however, with this approach, the assistant must take great care to ensure that the robotic arms do not collide with the Satinsky clamp. As such, a Satinsky clamp is not recommended for a 4-arm approach. For polar tumors, arteries may be selectively clamped to minimize ischemic insult to the unaffected areas of the kidney.
14. Using the robotic scissors, excise the mass, ensuring that the mass is not entered. Should the mass be entered, immediately retrace and recapture. Note any large vessels that are divided, as well as any areas of entry into the collecting system. Once the excision is complete, place the mass aside for later retrieval.
15. At this juncture, a deep margin may be sent. The cortex can be cauterized, but cautery should be used sparingly on the medullary structures and near the collecting system.
16. Switch the right arm scissors for a needle driver. Leave the ProGrasp in the left arm position.
17. Closure of the deep layer with special attention to the collecting system and large patent vessels should be performed. We recommend using a 2-0 barbed suture, as it minimizes the need to place excessive tension on very delicate tissue. A second suture may be used for large defects.
18. Perform a sliding-clip renorrhaphy to close the defect. A bolster is neither required nor recommended. Place sutures at intervals of approximately 1 cm. Once the final throw of each suture has been placed, the assistant places a Weck Hem-o-lok clip on the suture, which is then slid into place by holding the

suture perpendicular to the capsule with the ProGrasp forceps and straddling the clip with the needle driver. Slide until the capsule of the kidney is slightly dimpled.

19. Once all sutures have been placed, retighten each suture individually before the assistant places a Lapra-Ty clip to lock the Hem-o-lok clip in place.
20. Remove the bulldog clamps, beginning with the vein if applicable. Then cautiously remove the arterial clamps, ideally keeping the renorrhaphy in view. If brisk pulsatile bleeding is encountered, quickly reclamp the artery. However, a small to moderate amount of oozing from the repair is expected immediately after unclamping the artery, especially with early unclamping techniques. This bleeding should slow as the reperfused kidney swells and passively increases the tension of the renorrhaphy sutures. Place additional renorrhaphy sutures and retighten existing sutures as necessary.
21. If possible, cover the repair with fat. Hemostatic agents may be applied, but are

not necessary. A drain may be placed if there are concerns over the integrity of caliceal repair.

22. Place the specimen and any overlying fat in a laparoscopic retrieval sac. Undock the robot and extract the specimen through the assistant port site while leaving the remaining trocars in place. The extraction incision should be large enough to allow for extraction without squeezing the specimen, as this may lead to rupture.
23. The fascia of the extraction site and camera port site should be closed. However, fascial closure of the remaining trocar sites is not necessary. Irrigate the incisions before closing the skin.

Postoperative Considerations

Table 6.1 lists potential complications of RAPN with the appropriate managements, while Table 6.2 provides perioperative outcomes for multiple RAPN series.

Table 6.1 Potential postoperative complications of robot-assisted partial nephrectomy

Grade	Complication	Treatment
1	Ileus	Supportive care
	Hemorrhage/hematoma	
	Acute renal failure	
	Wound infection	
2	Hemorrhage/hematoma/anemia	Blood transfusion
	Infections: UTI/pyelonephritis/wound	Antibiotics
	Urinoma	Antibiotics
	DVT/PE	Anticoagulation
3	Hemorrhage/pseudoaneurysm	Immediate post-op: re-exploration
		Delayed: angioembolization
	Urine leak/urinoma	Ureteral stent with possible percutaneous drain
	Pneumothorax	Thoracostomy tube
4	DVT/PE	IVC filter
	Acute renal failure	Dialysis
	Cardiac arrhythmia/MI	Cardiac consultation and ICU
	Stroke	Neurology consult and ICU
	Respiratory distress	Pulmonary consult, ICU, and possible mechanical ventilation

UTI, urinary tract infection; *DVT*, deep venous thrombosis; *PE*, pulmonary embolism; *IVC*, inferior vena cava; *MI*, myocardial infarction; *ICU*, intensive care unit

Table 6.2 Perioperative outcomes in robot-assisted partial nephrectomy series

Reference	Cases (<i>n</i>)	Mean tumor size (cm)	Mean OR time (min)	Mean WIT (min)	Mean EBL (ml)	Mean LOS (days)	Positive margins (<i>n</i>)	Complications, Clavien grade (grade: <i>n</i>)	Mean F/U (months)
Gettman et al. [4]	13	3.5	215	22	170	4.3	1	I: 1, ileus	2-11
Caruso et al. [5]	10	2.0	279	26.4	240	2.6	None	I: 1, retention	NR
Kaul et al. [20]	10	2.0	155	21	92	1.5	1	I: 1, urine leak II: 1, transfusion III: 1, re-exploration with nephrectomy	15
Rogers et al. [21]	8	3.6	192	31	230	2.6	None	None	3
Aron et al. [22]	12	2.4	242	23	329	4.7	None	I: 1, ileus II: 1, a.fib 1, PE 1, transfusion 1, CHF	7.4
Deane et al. [23]	11	2.3	229	32.1	115	2.0	None	III: 1, re-exploration	16
Rogers et al. [24]	11	3.8	202	28.9	220	3.0	None	III: 2, urine leak requiring stent	NR
Wang et al. [25]	40	2.5	140	19	136	2.5	1	II: 1, DVT 1, transfusion III: 1, urine leak requiring stent Unknown grade: 4	NR
Ho et al. [26]	20	3.5	82.8	21.7	189	4.8	None	None	>12
Michli et al. [27]	20	2.7	142	28	263	2.8	None	II: 1, PE III: 1, abscess requiring percutaneous drainage	NR
Benway et al. [10]	50	2.5	145.3	17.8	140	2.5	1	II: 2, transfusion 1, readmission for hypertension crisis Unknown grade: 2	NR
Gong et al. [28]	29	3.0	197	25	220	2.5	None	"No major"	15
Benway et al. [29]	129	2.9	189	19.7	155	2.4	5	II: 1, transfusion III: 3, urine leak requiring a stent or nephrostomy tube 1, re-exploration and nephrectomy for hematoma Unknown grade: 6	>12

OR, operating room; WIT, warm ischemia time; EBL, estimated blood loss; LOS, length of stay

Patients should be closely monitored for hemorrhagic complications, heralded by a decrease in urine output and hypotension. Significant drops in hematocrit which do not respond to transfusion or unstable hypotension warrant re-exploration with revision of the renorrhaphy or completion nephrectomy.

Patients may develop temporary renal insufficiency, which generally responds to maintaining hydration and tincture of time. Should renal function not return to baseline, consider nephrology consultation.

Urine leaks may occur due to incomplete closure of a collecting system entry, or from ischemic necrosis of the repair. This may require placement of a ureteral stent and percutaneous drainage of the urinoma.

Focally positive margins do not generally warrant re-exploration or re-excision, as residual disease is unlikely [30]. It is recommended, however, that special attention be given to the resection site on follow-up imaging.

Arteriovenous malformation or pseudoaneurysm may occur and is heralded by the onset of bright red gross hematuria approximately 2–3 weeks after the procedure. In addition to close monitoring of hematocrit and transfusion when indicated, embolization of the affected arterial segment is recommended.

References

1. Abouassaly R, Alibhai SMH, Tomlinson G, et al. Unintended consequences of laparoscopic surgery on partial nephrectomy for kidney cancer. *J Urol*. 2010;183:467–72. Available at: <http://www.ncbi.nlm.nih.gov/pubmed/20006875>. Accessed 24 Mar 2014.
2. Link RE, Bhayani SB, Allaf ME, et al. Exploring the learning curve, pathological outcomes and perioperative morbidity of laparoscopic partial nephrectomy performed for renal mass. *J Urol*. 2005;173:1690–4. Available at: <http://www.ncbi.nlm.nih.gov/pubmed/15821559>. Accessed 24 Mar 2014.
3. Gill IS, Kavoussi LR, Lane BR, et al. Comparison of 1,800 laparoscopic and open partial nephrectomies for single renal tumors. *J Urol*. 2007;178:41–6. Available at: <http://www.ncbi.nlm.nih.gov/pubmed/17574056>. Accessed 24 Mar 2014.
4. Gettman MT, Blute ML, Chow GK, et al. Robotic-assisted laparoscopic partial nephrectomy: technique and initial clinical experience with Da Vinci robotic system. *Urology*. 2004;64:914–8. Available at: <http://www.ncbi.nlm.nih.gov/pubmed/15533477>. Accessed 14 Aug 2013.
5. Caruso RP, Phillips CK, Kau E, et al. Robot assisted laparoscopic partial nephrectomy: initial experience. *J Urol*. 2006;176:36–9. Available at: <http://www.ncbi.nlm.nih.gov/pubmed/16753361>. Accessed 3 Sept 2013.
6. Rogers CG, Laungani R, Bhandari A, et al. Maximizing console surgeon independence during robot-assisted renal surgery by using the Fourth Arm and TilePro. *J Endourol*. 2009;23:115–21. Available at: <http://www.ncbi.nlm.nih.gov/pubmed/19178173>. Accessed 24 Mar 2014.
7. Bhayani SB, Snow DC. Novel dynamic information integration during da Vinci robotic partial nephrectomy and radical nephrectomy. *J Robot Surg*. 2008;2:67–9. Available at: <http://link.springer.com/10.1007/s11701-008-0083-9>. Accessed 24 Mar 2014.
8. Cabello JM, Benway BM, Bhayani SB. Robotic-assisted partial nephrectomy: surgical technique using a 3-arm approach and sliding-clip renorrhaphy. *Int Braz J Urol*. 2009;35:199–204.
9. Bhayani SB, Figenshau RS. The Washington University Renorrhaphy for robotic partial nephrectomy: a detailed description of the technique displayed at the 2008 World Robotic Urologic Symposium. *J Robot Surg*. 2008;2:139–40. Available at: <http://link.springer.com/10.1007/s11701-008-0096-4>. Accessed 24 Mar 2014.
10. Benway BM, Wang AJ, Cabello JM, et al. Robotic partial nephrectomy with sliding-clip renorrhaphy: technique and outcomes. *Eur Urol*. 2009;55:592–9. Available at: <http://www.ncbi.nlm.nih.gov/pubmed/19144457>. Accessed 2 July 2013.
11. Benway B, Cabello J, Figenshau RS, et al. Sliding-clip renorrhaphy provides superior closing tension during robot-assisted partial nephrectomy. *J Endourol*. 2010;24:605–8.
12. San Francisco I, Sweeney M, Wagner A. Robot-assisted partial nephrectomy: early unclamping technique. *J Endourol*. 2011;25:2–5.
13. Nguyen MM, Gill IS. Halving ischemia time during laparoscopic partial nephrectomy. *J Urol*. 2008;179:627–32; discussion 632. Available at: <http://www.ncbi.nlm.nih.gov/pubmed/18082215>. Accessed 24 Mar 2014.
14. Kaczmarek BF, Tanagho YS, Hillyer SP, et al. Off-clamp robot-assisted partial nephrectomy preserves renal function: a multi-institutional propensity score analysis. *Eur Urol*. 2013;64:988–93. Available at: <http://www.ncbi.nlm.nih.gov/pubmed/23122834>. Accessed 24 Mar 2014.
15. Tanagho YS, Bhayani SB, Sandhu GS, et al. Renal functional and perioperative outcomes of off-clamp versus clamped robot-assisted partial nephrectomy: matched cohort study. *Urology*. 2012;80:838–43.

- Available at: <http://www.ncbi.nlm.nih.gov/pubmed/22921704>. Accessed 26 May 2013.
16. Mottrie A, De Naeyer G, Schatteman P, et al. Impact of the learning curve on perioperative outcomes in patients who underwent robotic partial nephrectomy for parenchymal renal tumours. *Eur Urol.* 2010;58:127–32. Available at: <http://www.ncbi.nlm.nih.gov/pubmed/20399002>. Accessed 24 Mar 2014.
 17. Haseebuddin M, Benway BM, Cabello JM, et al. Robot-assisted partial nephrectomy: evaluation of learning curve for an experienced renal surgeon. *J Endourol.* 2010;24:57–61.
 18. Patel HD, Mullins JK, Pierorazio PM, et al. Trends in renal surgery: robotic technology is associated with increased use of partial nephrectomy. *J Urol.* 2013;189:1229–35. Available at: <http://www.ncbi.nlm.nih.gov/pubmed/23085300>. Accessed 24 Mar 2014.
 19. Bhayani SB. da Vinci robotic partial nephrectomy for renal cell carcinoma: an atlas of the four-arm technique. *J Robot Surg.* 2008;1:279–85. Available at: <http://link.springer.com/10.1007/s11701-007-0055-5>. Accessed 21 July 2013.
 20. Kaul S, Laungani R, Sarle R, et al. da Vinci-assisted robotic partial nephrectomy: technique and results at a mean of 15 months of follow-up. *Eur Urol.* 2007;51:186–91; discussion 191–2. Available at: <http://www.ncbi.nlm.nih.gov/pubmed/16822607>. Accessed 3 Sept 2013.
 21. Rogers CG, Singh A, Blatt AM, et al. Robotic partial nephrectomy for complex renal tumors: surgical technique. *Eur Urol.* 2008;53:514–21. Available at: <http://www.pubmedcentral.nih.gov/articlerender.fcgi?artid=2644902&tool=pmcentrez&rendertype=abstract>. Accessed 3 Sept 2013.
 22. Deane LA, Lee HJ, Box GN, et al. Robotic versus standard laparoscopic partial/wedge nephrectomy: a comparison of intraoperative and perioperative results from a single institution. *J Endourol.* 2008;22:947–52. Available at: <http://www.ncbi.nlm.nih.gov/pubmed/18397157>. Accessed 3 Sept 2013.
 23. Aron M, Koenig P, Kaouk JH, et al. Robotic and laparoscopic partial nephrectomy: a matched-pair comparison from a high-volume centre. *BJU Int.* 2008;102:86–92. Available at: <http://www.ncbi.nlm.nih.gov/pubmed/18336600>. Accessed 3 Sept 2013.
 24. Rogers CG, Metwalli A, Blatt AM, et al. Robotic partial nephrectomy for renal hilar tumors: a multi-institutional analysis. *J Urol.* 2008;180:2353–6; discussion 2356. Available at: <http://www.pubmedcentral.nih.gov/articlerender.fcgi?artid=2648867&tool=pmcentrez&rendertype=abstract>. Accessed 3 Sept 2013.
 25. Wang AJ, Bhayani SB. Robotic partial nephrectomy versus laparoscopic partial nephrectomy for renal cell carcinoma: single-surgeon analysis of >100 consecutive procedures. *Urology.* 2009;73:306–10. Available at: <http://www.ncbi.nlm.nih.gov/pubmed/19038419>. Accessed 3 Sept 2013.
 26. Ho H, Schwentner C, Neururer R, et al. Robotic-assisted laparoscopic partial nephrectomy: surgical technique and clinical outcomes at 1 year. *BJU Int.* 2009;103:663–8. Available at: <http://www.ncbi.nlm.nih.gov/pubmed/18990172>. Accessed 12 Aug 2013.
 27. Michli EE, Parra RO. Robotic-assisted laparoscopic partial nephrectomy: initial clinical experience. *Urology.* 2009;73:302–5. Available at: <http://www.ncbi.nlm.nih.gov/pubmed/19038432>. Accessed 3 Sept 2013.
 28. Gong Y, Du C, Josephson DY, et al. Four-arm robotic partial nephrectomy for complex renal cell carcinoma. *World J Urol.* 2010;28:111–5. Available at: <http://www.ncbi.nlm.nih.gov/pubmed/19499225>. Accessed 3 Sept 2013.
 29. Benway BM, Bhayani SB, Rogers CG, et al. Robot assisted partial nephrectomy versus laparoscopic partial nephrectomy for renal tumors: a multi-institutional analysis of perioperative outcomes. *J Urol.* 2009;182:866–72. Available at: <http://www.ncbi.nlm.nih.gov/pubmed/19616229>. Accessed 3 Sept 2013.
 30. Sundaram V, Figenshau RS, Roytman TM, et al. Positive margin during partial nephrectomy: does cancer remain in the renal remnant? *Urology.* 2011;77:1400–3. Available at: <http://www.ncbi.nlm.nih.gov/pubmed/21411126>. Accessed 24 Mar 2014.

Granville L. Lloyd, E. Jason Abel, and Tracy M. Downs

Introduction

The role of robot-assisted radical cystectomy (RARC) in the treatment of bladder cancer is evolving. Advocates suggest that this minimally invasive operation offers less blood loss, less pain, and the promise of shorter hospitalizations with fewer complications and equivalent oncologic outcomes. Most of these putative advantages have yet to be proven and are balanced against the increased upfront cost of the robotic platform and longer operative times. Nevertheless, the evidence available to date suggests a robust future for this relatively novel technology.

Modern radical cystectomy with lymph node dissection, as described by Marshall and Whitmore in 1949, has been associated with high complication rates. In that pioneering report of six patients, two expired of surgical complication before leaving the hospital and at least another two had significant morbidity [1]. Since that time, the application of improved operative and in-hospital strategies and care pathways has resulted in decreased mortality and morbidity, but modern series of open radical cystectomy (ORC)

continue to be plagued by significant complication rates. When the standardized Clavien-Dindo [2] complication reporting scale is strictly applied, open cystectomy complication rates at centers of excellence reach into the 60–70 % range [3]. Other high-volume centers have reported lower rates, albeit in the absence of a standardized reporting system [4].

History of Minimally Invasive Cystectomy

Beginning with pure laparoscopic cystectomy in 1995 [5, 6] and transitioning to the robotic approach in 2002 [7], several modestly sized series have been published. Despite a paucity of large, multicenter prospective comparative trials, selected series have shown a benefit to robotic approaches with few data reporting RARC outcomes to be inferior to open cystectomy in clinical or oncologic efficacy. Assessments of cost benefit have also been very difficult to extrapolate beyond any single institution, but in light of the cost of treatment of surgical complications, there exists potential to be cost-effective despite higher upfront costs if RARC results in decreased complications. It bears mentioning that one analysis suggested that the cost of a single complication of cystectomy adds \$27,936 to the bill [8], while the incremental cost of the robotic system was found to be \$1,640 in a contemporaneous report [9].

G.L. Lloyd, MD (✉) • E.J. Abel • T.M. Downs
Department of Urology, University of Wisconsin
School of Medicine and Public Health,
Third Floor, 1685 Highland Avenue,
Madison, WI 53705, USA
e-mail: lloyd@urology.wisc.edu

Guidelines have been established that can be used to assess quality of cystectomy and associated lymph node dissection, regardless of approach. Herr et al. and the Bladder Cancer Collaborative Group evaluated the collective experience of 16 experienced surgeons from four major institutions over a 3-year period (2000–2003) to propose standards for radical cystectomy and pelvic lymph node dissection [10]. A total of 1,091 cystectomy cases were evaluated. Patients were of varying ages, health states, and clinical stages of bladder cancer. Of the 16 surgeons, seven operated on <50 cases, five on 50–100, and four completed >100. Surgeons used a standard or extended bilateral node dissection in 80 % of patients and 20 % had a limited lymph node dissection (9 %) or no node dissection (11 %).

A limited lymph node dissection was used in 35 % of patients aged >75 years and in half receiving previous extensive pelvic treatment (pelvic surgery, chemotherapy, and radiation therapy). The overall positive margin rate was 6.5 %, and margins were positive in 12 % of patients with locally advanced disease. The mean number of lymph nodes examined for all patients was 12.5 (Ref 5 – see ref 11 from original Herr paper) but varied widely among individual patients having anatomically similar lymph node dissections.

For experienced surgeons, defined as performing at least ten radical cystectomy surgeries per year, the collaborative group proposed surgical quality benchmarks. The benchmarks stated the surgeon should achieve negative surgical margins in >90 % of cases and remove a mean of 10–14 nodes, recognizing that such standards will not be met in some of the most difficult cases.

Whether the operation is performed through a minimally invasive approach (robotic or laparoscopic) or open surgical approach, the principles of radical cystectomy remain the same. Surgeons are accountable for surgical margins, extent of node dissection, and both serve as quality metrics, which have been proven to correlate with bladder cancer survival outcomes.

It is worth noting that most series of RARC well exceed these guidelines for margin status and nodal collection (positive margins under 10 % and greater than ten lymph nodes collected).

Undoubtedly, case and patient mix will impact any surgeon or institution's outcomes.

Surgical Indications and the Learning Curve

Urothelial carcinoma that invades the detrusor muscle and superficial disease resistant to intravesical treatment are the primary indications for radical cystectomy. The possibility of decreased surgical morbidity may allow for higher utilization of “early” cystectomy in cases of high-grade superficially invasive disease, an indication that is commonly underutilized. In some unusual histologic variants such as nested variant or micropapillary disease, immediate cystectomy may be recommended for superficial disease [11].

Learning Curve

Similar to all surgical procedures, robotic cystectomy has a learning curve. One assessment suggested that complication rates decrease after 20 cases while blood loss, margin status, and lymph node yield were constant across higher vs. lower tertiles of case volume in the hands of surgeons already experienced in ORC [12]. Roswell Park Cancer Center [13] and the International Robotic Cystectomy Consortium database [14] both show a clear decrease in surgical time that is associated with a surgeon completing 20 cases; interestingly, this was achieved at Roswell Park Cancer Center despite increasing time being devoted to the LND and resulting higher nodal yields. Some of the earliest cases in both those reports lasted over 10 h in total operative time, but improvements appear rapid.

Presumably, the surgeons involved in the generation of these curves had significant exposure to both open cystectomy and robotic prostatectomy, and these learning curves may not be representative of what a less experienced practitioner could experience. Also, a significant element in the operative speed may be a surgical team improvement as familiarity with the steps of the case is developed beyond that which comes from increased surgeon efficiency. It seems reasonable

that in a surgeon’s early experience, especially those with less experience with RALP, case selection be confined to patients with lower body mass index (BMI) and those without significant comorbidities.

Comparative outcomes are still hard to assess at this relatively early point on the track record of robotic cystectomy, but it is worth noting that in virtually all published series, robotic cystectomy takes longer to perform than open, but is associated with notably lower blood loss (Fig. 7.1).

Patient Selection

The selection of robotic vs. open approach is clearly one best assessed in the context of each individual surgeon and team experience.

Obesity

Laparoscopic surgery is generally suitable for the obese, although the ventilatory challenges of the Trendelenburg position can be prohibitive in certain patients. An initial assessment of ventilator

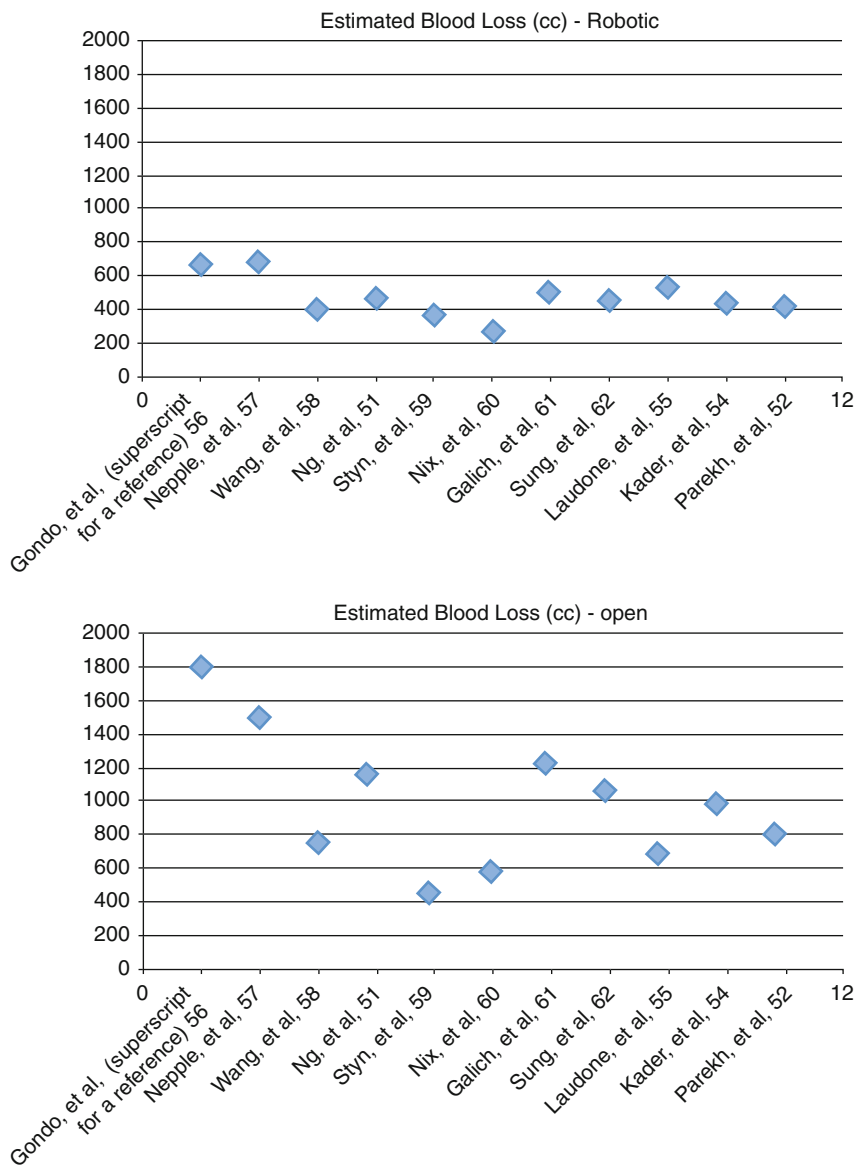


Fig. 7.1 Estimated blood loss, by study, from the robotic and open arms of 11 published comparative studies. All studies show statistical significance between ORC and RARC in estimated blood loss [49, 50, 52–60]

pressures in the Trendelenburg position is critical, especially in patients at risk of extended surgical times. Extra-long trocars are available for the obese, and Butt et al. showed that outcomes were not different between BMI under 25 and those above 30, although they found the positive margin rate to be higher for obese patients compared to nonobese when confronted with higher T-stage disease [15]. Results from the largest currently available database suggest a small but statistically significant additional risk of complication in those with a BMI over 30 [16]. Surgeon and institutional experience should guide patient selection.

Prior Surgery

Prior surgery was initially viewed as a relative contraindication to laparoscopic abdominal entry and surgery [17]. As experience has grown, those relative contraindications have been overcome. Groups have reported success with robotically assisted approaches in virtually all challenging situations, including cystectomy in the presence of prior ostomy [18].

Neoadjuvant Chemotherapy

Neoadjuvant chemotherapy is a level 1 recommendation in many cases of MIBC [19]. Recent results from the 939 patient International Robotic Cystectomy Consortium database suggest that there exists an increased risk of complications in those patients that undergo neoadjuvant chemotherapy with a relative risk of any complication and high-grade complication in the range of 1.5–1.8 in the first 90 days [16].

Elderly

Muscle invasive cancer is primarily a disease of the elderly. Despite large reports showing that radical cystectomy is feasible and safe and remains the most effective modality for the treatment of MIBC in patients over the age of 80, use of this modality is lower than in younger counterparts [20]. While surgical selection is undoubtedly more challenging in the truly elderly, patients lacking severe comorbidities should be considered for this operation. Paradoxically,

some newer reports suggest that RC may be particularly well suited to the elderly [21]. This may be directly related to the nearly universal finding of lower blood loss and presumably decreased fluid shifts with the robotic approach when compared to open.

Prior Radiotherapy

Robot-assisted salvage prostatectomy after failed local radiotherapy has been shown to be not only feasible but in at least some hands able to produce results that are superior to open prostatectomy in similar conditions [22]. Salvage open cystectomy after failed curative radiotherapy for bladder cancer appears feasible but has been associated with a significant complication rate; one series found a 16 % 3-month mortality rate and a tripling of anastomotic leaks at 9 % compared to 3 % in non-radiated patients [23]. In another series LND was performed in only 48 % by surgeon preference and presumably represents the increased difficulty of perivascular dissection in the postradiation setting [24]. A report addressing ORC after 60 Gy or more of pelvic radiation showed 32 % likelihood of Clavien-Dindo grade 3–5 complications at 90 days and an overall complication rate of 77 % [25]. These are higher than most contemporary non-radiated series, but appear reasonable in this setting.

Given the apparent feasibility of robotic-assisted prostate surgery after radiation, the extension of the operation to include the bladder in this same situation seems reasonable, especially given the decreased need for urethral anastomotic reconstruction in the setting of conduit urinary diversion. Published reports are scant; nonetheless, in experienced hands this may prove to be an appropriate therapy [26]. The largest database of RARC to date, the International Robotic Cystectomy Consortium, records 15 cases of postradiation RARC representing just 2 % of the total recorded patients [16]. Specific outcomes are not reported for these patients, however, preventing conclusions. In our experience, the operation is feasible but technically challenging; centers possessing experience with salvage robotic-assisted prostatectomy will likely be comfortable with this operation.

Palliative Cystectomy

Palliative cystectomy is a poorly studied area of this disease. Appropriate indications for this operation are poorly defined, but include persistent hemorrhage and avoidance of pelvic morbidity. The balance of surgical risk to benefit for this major operation is difficult to calculate, but palliative cystectomy is generally best applied to younger patients with significant ongoing morbidity from localized tumor, in the setting of adequate functional and nutritional status. One smaller series addressing cystectomy in patients over 75 years of age included seven cystectomies for palliative indications such as intractable hematuria and pain. These patients experienced a much higher morbidity and a 29 % in-hospital mortality when compared to the curative intent cohort, but no attempt was made to compare them to nonoperated counterparts [27]. Other reports in the open surgical literature show acceptable results for palliative cystectomy managed with cutaneous diversion and avoidance of bowel resection [28]; whether these challenging cases are appropriate for a robotic approach remains unstudied.

Lymph Node Dissection

The ability to perform a pelvic lymph node dissection (PLND) is a critical component of high-quality surgery for bladder cancer, serving as a diagnostic and therapeutic procedure [29]. Multiple large series have demonstrated that performing PLND contributes to improved survival in patients with bladder cancer [30]. The optimal extent of PLND and best outcome measures of PLND quality continue to be debated which is evident in the literature on robotic cystectomy. A standard PLND is defined as removal of lymph tissue up to the common iliac bifurcation to include the internal iliac, obturator, and external iliac lymph nodes [31]. Extended PLND is generally thought to include the standard template as well as lymph nodes up to the aortic bifurcation, laterally to the genitofemoral nerve, distally to the node of Cloquet, as well as the presacral

lymph nodes [32]. Evidence of survival benefit for extended vs. standard PLND is debated, given the many variables to consider in the series used for evidence of benefit. Several authors have proposed that lymph node yield may indeed be a surrogate of surgical quality since it correlates with survival outcomes [33]. However, consensus opinions on the superiority of survival outcomes in extended PLND cite the low level of evidence, but note the improved diagnostic ability and trend towards improved disease-free survival in extended PLND [34].

With the advent of robotic surgery for bladder cancer, the debate over technical aspects of PLND has continued. Effect on survival outcomes is most evident in large series that include higher-stage tumors with several years of follow-up. However, data describing outcomes of RARC with PLND are not mature, and early series were selected for lower-risk tumors, which may not demonstrate the benefit of PLND as well as more comprehensive series. For these reasons, some authors question whether these outcomes can be judged with the available data [35], and reserve judgment about efficacy until the results of randomized trials are mature. Nevertheless, the ability to recapitulate the technique of open cystectomy and PLND has been investigated. In a study by Davis et al., the authors performed robotic extended PLND for bladder cancer in 11 patients with open extended PLND performed directly afterward in the same patients [36]. In 80 % of patients, no additional lymph nodes were detected with the open technique, demonstrating that a high-quality dissection is possible using a robotic technique. The median operative time for the PLND was 117 min, demonstrating the investment in time necessary for robotic extended PLND. Although the benefit of extended PLND will continue to be debated, it appears that robot PLND can provide a similar lymph node dissection to open techniques.

Robot-assisted radical cystectomy – equipment list (note that requirements for intracorporeal diversion are not included here).

1. Da Vinci Surgical System (Intuitive Surgical, Sunnyvale, CA). “S” or “Si” recommended.

2. Veress Needle or access device of choice, 2×10/12 mm disposable ports, 3×8 mm robotic ports, 5 mm assist port.
3. Da Vinci instruments – Monopolar Da Vinci scissors, bipolar fenestrated grasper, 2× Da Vinci Large Needle Driver. Consider da Vinci vessel sealer if available. Fourth arm – “Prograsp” graspers.
4. Hem-o-lok clip applicators (2) with large clips.
5. Laparoscopic vascular staplers, articulating, “45” and “60” as desired.
6. Suture:
 - (a) Male: 2–0 Vicryl on rb-1 and SH as needed and as surgeon preference for dorsal venous complex.
 - (b) Female: same as male, likely will need 9” 2-0 Vicryl on SH for repair of the anterior vaginal wall.
 - (c) Others: we recommend having a 4-in., 4-0 Prolene on Rb-1 with Lapra-Ty® pre-affixed in the event of vascular/venous injury during lymphadenectomy.
7. 5 mm suction irrigator (long).
8. Appropriate open surgical equipment for performance of diversion.
9. Port closure device for 12 mm ports, if desired.

Technique

Positioning

Patients are positioned supine with a mild break in the table. In order to secure the patient to the table in Trendelenburg position, the use of chest straps or direct skin-to-gel adhesion is utilized. Skin-to-gel positioning is effective but, for longer cases, can be associated with skin traction burns on the patient’s back if steep Trendelenburg is used. If intracorporeal diversion is contemplated, shallower Trendelenburg will facilitate bowel manipulation without gravitational effects pulling the bowel cephalad and out of the robotic operative field.

The legs are separated on orthopedic spreader bars or placed in low lithotomy in well-padded stirrups; the thighs should be close and parallel to the abdomen to minimize distortion of the pelvic floor. Orogastric/nasogastric tubes and bladder drainage catheter are placed.

Ports

Port placement is similar to that utilized in robotically assisted prostatectomy, but modified a few centimeters upwards to give better access to the upper pelvic vessels for extended lymph node dissection. Different approaches exist for assistance; some surgeons prefer to use two bedside assistants in lieu of the so-called “4th arm” of the robotic system. An additional upper paramedian assist port may be helpful to facilitate stapled control of the bladder vasculature if stapling is planned.

Our approach to male cystectomy occurs in a stepwise fashion as follows:

1. Ureteral identification and dissection

Beginning on the right, the ureters are identified at the level of the common iliac artery (Fig. 7.2). This may be used as the superior boundary for lymph node dissection template at a later point if desired. Using great care to preserve vascular tissue around the ureter as much as possible, the ureter is dissected free for a small distance above the vessels and followed into the deep pelvis to the ureterovesical junction (Fig. 7.3). Small feeder vessels originating from the iliac system are usually encountered and controlled with cautery; caution is important to avoid any cautery effect on or near the ureter and the associated extramural longitudinal blood supply. An identical procedure is completed on the contralateral side; maximization of length and blood supply on the left side is especially important given the need for tunneling at a later date.
2. Completion of posterior plane

Once the ureters are freed to their hiatus with the bladder, the peritoneal incisions are connected and the retrovesical space developed behind the bladder. Ureters may be tagged, clipped, and cut at this point; we prefer to leave them intact to assist with orientation. Dissection proceeds carefully behind the bladder and seminal vesicles to the level of the prostate; Denonvillier’s fascia is transected, and at the level of the prostate, the prerectal yellow fat is identified and the rectum carefully dissected free from the prostate as far as possible. Vasa deferentia are clipped and cut,

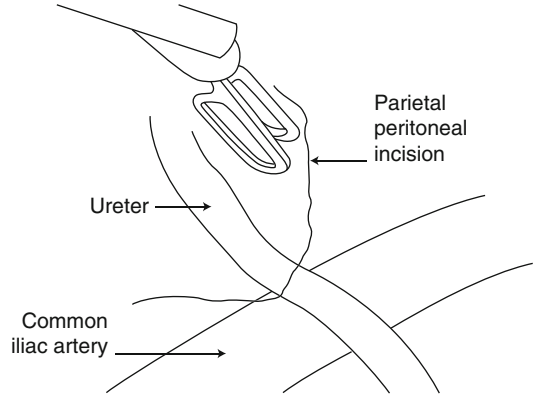
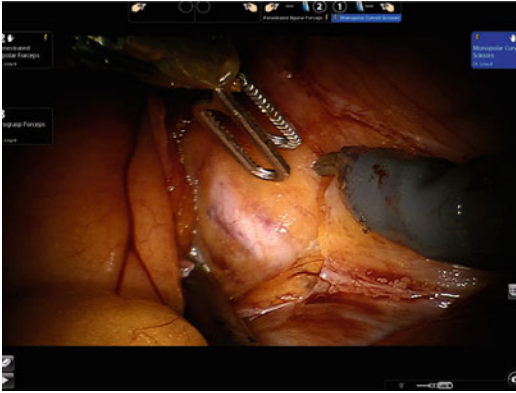

Fig. 7.2 The parietal peritoneum is incised and the ureter on the right is identified as it crosses the common iliac artery

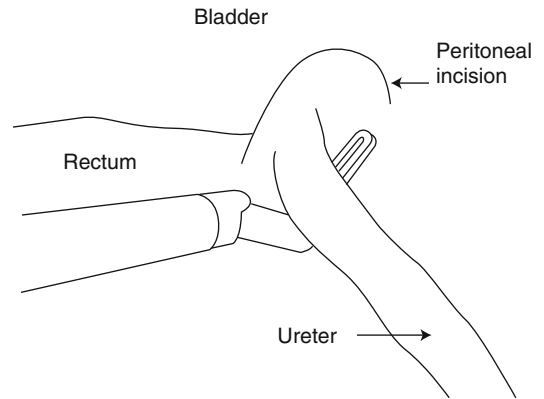
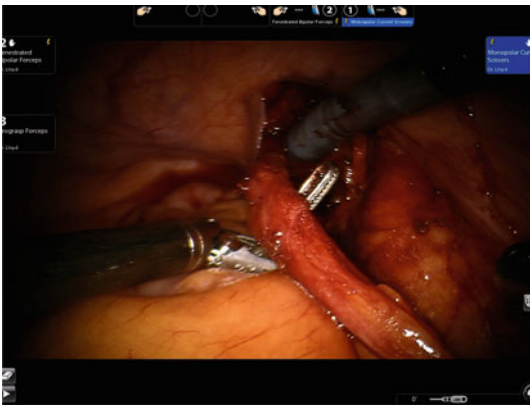


Fig. 7.3 The ureter is circumferentially freed with maximal preservation of periureteral tissue and dissected to the hiatus of the bladder

and the small arterial branches to the seminal vesicles are carefully controlled with clips or cautery as appropriate. The lateral bounds of this dissection are the vascular pedicles of the bladder and prostate, beginning with the superior vesical artery. Great care is taken to widely establish separation between the rectum and bladder to minimize chances of rectal injury.

3. Lateral space creation

Delineation of the lateral aspects of the bladder and vascular pedicles is performed at this point. The goal of this step is the identification of the vascular pedicles. Peritoneal incision is performed along the lateral aspect of the medial collateral ligament, with care taken to leave the anterior suspension of the bladder

intact. Early release of the anterior bladder support will significantly increase difficulty in posterior dissection from the loss of bladder support and should be avoided. The lateral incisions are connected to the posterior incision to form a “u” and the space lateral to the bladder freed distally to the endopelvic fascia and nerve sparing/prostatic fascial release performed if nerve sparing is desired. Even with anterior anatomical support intact, the “fourth arm” can be well utilized to additionally retract the bladder so as to provide stretch on the pedicles and facilitate dissection. The endopelvic fascia is released in the fashion of radical prostatectomy. Next, the medial umbilical ligaments are transected close to their junction with the internal iliac artery.

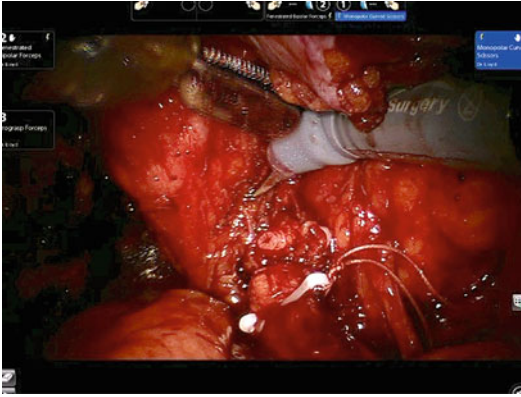
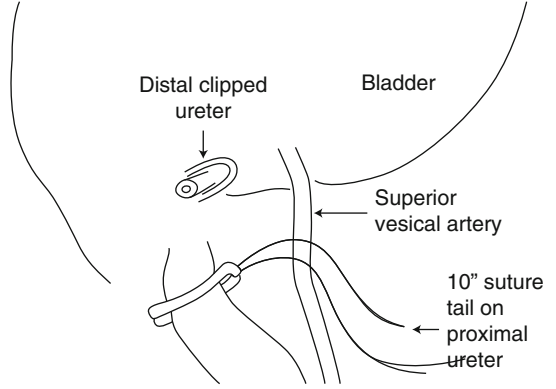


Fig. 7.4 Once the posterior and lateral spaces have been adequately developed, the ureter is doubly clipped and transected. For extracorporeal diversion, the clip on the



proximal ureter is tagged with a 10'' 3-0 Vicryl for identification and manipulation

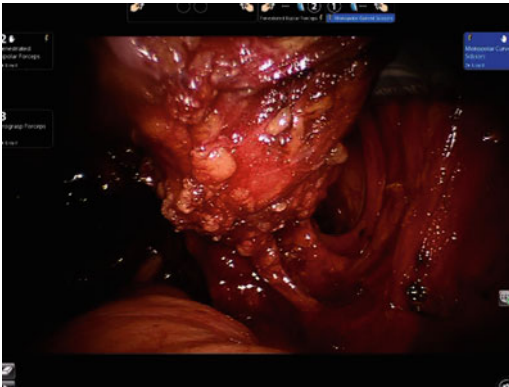


Fig. 7.5 With the ureter tucked into the upper abdomen, the rectum is dissected posteriorly away from the bladder and the vascular pedicle is identified

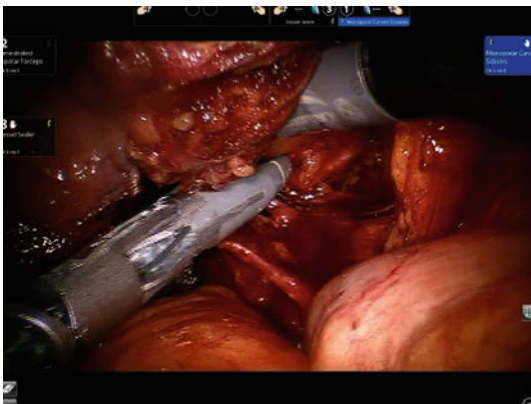
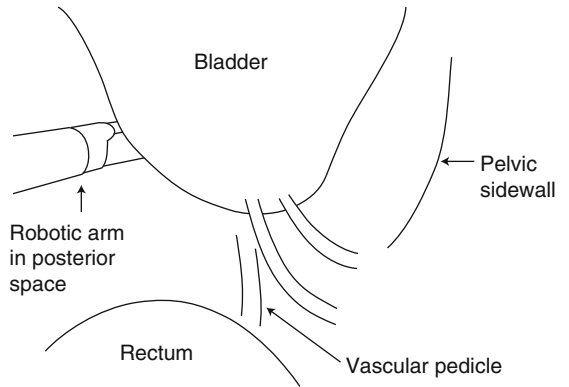
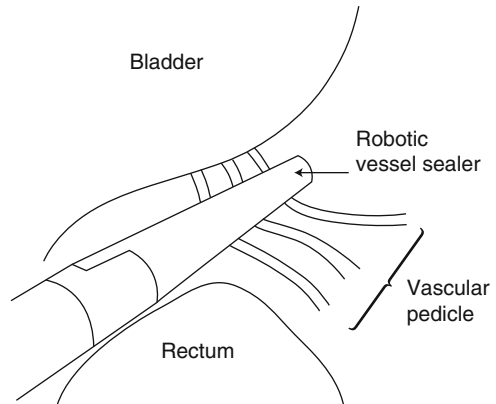


Fig. 7.6 Once the upper portion of the vascular pedicle is isolated, it can be clipped or cauterized at surgeon preference. This is shown here with the robotic vessel sealer



The ureters are doubly clipped, divided, and tucked into the upper abdomen well away from the operative field (Figs. 7.4 and 7.5). We recommend Hem-o-lok clips (Teleflex Medical, Research Triangle Park, NC, USA) with a color-coded 10" suture tied to the heel of the clip that is applied proximally to facilitate manipulation of the ureter through a smaller incision at diversion.

4. Takedown of vascular pedicles

Many different technologies are available for safe control of the superior vesical artery and vascular pedicles of the bladder. Clips, laparoscopic stapling devices, and direct ablation with other hemostatic technology can be employed at surgeon discretion (Fig. 7.6). Those using an externally applied laparoscopic stapler may consider using a 12 mm upper paramedian port to assist application of this device along the axis of the pedicles as the angles encountered from the lateral ports may be awkward for stapler use. As in prostatectomy, adequate distal division of attachments facilitates mobility and completion of the apical dissection. We have had favorable experience with the robotic vessel sealer (Intuitive Medical, Sunnyvale, CA, USA) and are assessing its utility for division of the superior vesical artery, which we have historically secured with clips. A group at Vanderbilt compared the similar LigaSure Impact device (Covidien, Dublin, Ireland) to stapler use and found no difference in blood loss and a simplification of vascular control during cystectomy [37].

5. Control of dorsal venous complex

The balance of anterior bladder suspension is now released and the anterior space of Retzius dissected. In men, the dorsal venous complex is controlled after placement of 1–2 securing sutures in the fashion of a radical prostatectomy. A vascular stapler may be utilized alternatively.

6. Dissection of urethra

The urethra is dissected free. If neobladder is planned, care is taken to preserve adequate urethral length. The bladder side of the specimen is controlled with a Hem-o-lok clip to prevent spillage of contents during transection. If ileal conduit is planned, the urethra is

dissected as far distal as possible. If the patient has had previous pelvic radiation, the stump is carefully oversewn to prevent persistent urethral leakage of peritoneal fluid through a fixed and fibrotic urethra. If there is likelihood of subsequent urethrectomy such as known CIS or prostatic invasion, margins are sent and a clip left to allow identification of complete urethral extirpation should that become necessary later. The specimen is freed and placed in a large bag; we prefer the 12 mm Inzii device (Applied Medical, Rancho Santa Margarita, CA, USA) as it allows use of smaller 12 mm ports with full bag size.

7. Lymph node dissection

Lymph node dissection is completed with an upper boundary to the level of the ureters crossing the iliac artery. This is carried laterally along the upper edge of the iliac artery adjacent to the genitofemoral nerve, with great care taken to remove all tissue surrounding the great vessels and into the obturator fossa. Finally, all tissue is removed from the distribution of the internal iliac artery in the deep pelvis. The specimen is placed in a separate smaller bag; we do not label tissue laterality as this has no additive benefit in prognosis or therapy. Clips are utilized selectively to decrease risk of lymph leak. In high-risk cases, or those felt likely to benefit from extended dissection, LND can be carried as high as the level of the inferior mesenteric artery on the aorta.

Creation of Extracorporeal Urinary Diversion

For ileal conduit, diversion may be performed either intracorporeally or extracorporeally. For surgeons newer to RAC, extracorporeal diversion is familiar and expedient. Once the lymphadenectomy has been completed, the ureters are recovered from where they have been tucked in the upper quadrants and good mobility verified. Ideally, freedom that extends a short distance above the common iliac artery will be available, especially on the left side.

The ileum and ileocecal junction should be identified; a premeasured suture can be utilized to march out 15–20 cm of terminal ileum and a long tagging suture of 3-0 silk placed in the serosa at the distal extent of the anticipated conduit. This is left full length to allow easy extraction through a small incision. Any attachments of the cecum that may hamper terminal ileal freedom are taken down.

Next, the ureter must be passed behind the sigmoid at roughly the level of the sacral promontory. With the colon gently retracted anteriorly, a passageway can usually be developed by gentle manipulation behind the incised retroperitoneum. Care should be taken to avoid vascular injury when crossing the midline, especially in the setting of aneurysmal dilatation or ectasia. Once an instrument has been easily passed from right to left and an appropriately sized space created behind the colon, the left ureteral tagging suture is grasped and the ureter pulled through to the right where it can be again assessed for adequate length and freedom. Alternatively, left ureteral passage can be accomplished open, although this often requires a larger abdominal incision.

Once both ureters lie in the right paracolic gutter and the terminal extent of planned conduit is tagged, all three tagging sutures are placed in a needle driver through an assist port and secured in place. The robot is undocked and table taken out of Trendelenburg; a small incision is made in the subumbilical midline and all tagging sutures passed out of it. The small bowel is pulled up and bowel resection performed to provide an adequate conduit of roughly 15 cm without unnecessary redundancy. It has been our preference to mature the ostomy at the premarked site prior to performing the ureteroenteric implantation. Once this is done, spatulated ureteral implants of roughly 1.5 cm are made with urinary diversion stents inserted via the matured ostomy and up each ureter. Interrupted 4-0 Monocryl used for implantation with great care taken to avoid any trauma to the distal ureter. A 4-0 chromic suture is used to secure the stent to the mucosa of the ostomy. At this point a closed suction drain is gently placed in the pelvis through a lateral port site, the fascia and incision are closed, and the patient taken to recovery.

Creation of Intracorporeal Urinary Diversion

Non-continent Urinary Diversion (Ileal Conduit)

Intracorporeal urinary diversion can be divided broadly into six major steps: port placement, patient repositioning, bowel segment identification, bowel resection/bowel reanastomosis, ureteroenteric anastomosis, and ileal conduit stoma completion. Below is a summary of each step individually.

Port Placement and Patient Repositioning

Most centers use port placement for robot-assisted cystectomy that is similar to their robot-assisted prostatectomy port placement. When performing an intracorporeal urinary diversion, the bedside surgical assistant should have two assistant ports (at least 12 mm) to allow passage of the stapler from either the left or right side of the patient. Passage of the stapler from the left side has technical advantages and provides a better angle for the urinary diversion portion of the robotic-assisted cystectomy. If a right-side bedside assistant is preferred for the extirpative portion of the procedure, a 12-mm port can be exchanged for the 8-mm fourth arm port to allow stapler passage from the left during the urinary diversion [38].

After the RARC and lymph node dissection portions of the operation have been completed, the robot is undocked allowing for the patient position to be changed from steep Trendelenburg to a neutral operating room bed position. The robot is then re-docked for the urinary diversion. It is optional to re-dock the fourth robotic arm or use this lateral 8 mm port for the bedside assistant. Alternatively, if the cystectomy portion can be completed with less head-down positioning, it may prove unnecessary to reposition the bed.

Bowel Segment Selection for Urinary Diversion

The first step is to identify the ileocecal junction and spare 15–20 cm of terminal ileum. A 20-cm silk suture or a premarked Penrose drain is used to aid in the measurement of the appropriate bowel length to be utilized for the ileal conduit.

Once the segment of ileum is identified, the proximal and distal ends of the bowel are tagged with a 3-0 Vicryl stitch.

Bowel Resection and Reanastomosis

The next step is to harvest the ileal segment and restore intestinal continuity. An atraumatic Cadiere forceps (Intuitive Surgical Inc, Sunnyvale, CA, USA) are used in the right and left robotic arms for bowel manipulation. Distal transection of ileum is performed with an endovascular 60-mm laparoscopic stapler (endoGIA, Covidien, Norwalk, CT, USA). The stapler is introduced by the bedside assistant through the left lateral 12-mm assistant port while the robotic surgeon aligns the bowel and mesentery to be divided.

The stapler is placed in a perpendicular orientation across the bowel and mesentery, with the tips of the stapler aimed at the root of the mesentery. The Endo GIA stapler is fired to divide the bowel and mesentery. The identical technique is used at the other end of the bowel segment. The initial tissue load (3.5-mm thickness) transects the small bowel and a portion of the adjacent mesentery. If necessary, the mesenteric window can be further developed using electrocautery or an additional vascular stapler load (2.5-mm thickness). The transected bowel segment (close to the cecum) can be marked with a purple-dyed 3-0 Vicryl suture. After proximal division of the ileal segment, another purple-dyed 3-0 Vicryl suture is placed to mark the proximal transected ileum. The Endo GIA stapler is reintroduced into the 12-mm left lateral port and the arms for bowel manipulation. To restore intestinal continuity, the violet sutures on the proximal and distal cut ends of the bowel are used for traction. The anastomosis is created by excising a small amount of stapled bowel at each end with robotic scissors. Bowel continuity is reestablished with a standard side-to-side ileoileal anastomosis using a 60-mm laparoscopic tissue stapler load to anastomose the adjacent antimesenteric ileal walls. To complete the bowel anastomosis, the remaining bowel opening is stapled closed by deploying the same Endo GIA stapler transversely to finish the side-to-side anastomosis. The mesenteric defect is not closed. The ileoileal bowel anastomosis is performed cephalad to the excluded ileal conduit

segment, keeping the isolated ileal conduit segment caudal to the mesentery. If there is difficulty in obtaining the appropriate orientation, the stapler should be introduced through a different port.

Ureterointestinal Anastomosis and Ileal Conduit Stoma

An approach that mimics the technique used in an extracorporeal urinary diversion is typically selected by the surgeon. Two of the more commonly employed techniques are the Wallace or Bricker techniques for ureterointestinal anastomosis. The assistant grasps the stay suture on the selected segment of the ileum. A small opening is made in the distal staple line (ostomy end) which allows passage of the laparoscopic suction/irrigator into the ileal conduit for this segment to be irrigated prior to the ureterointestinal anastomosis. The distal end of the conduit following the ureterointestinal anastomosis will be fashioned into a stoma at a premarked area for the stoma on the abdominal wall.

Both ureters are spatulated 2 cm and the posterior walls of the ureters are sutured side to side (Wallace technique) using 15 cm running 4-0 Biosyn or Monocryl. Two single-J 40-cm ureteral stents with the guide wire inserted are introduced through the distal end of the ileal conduit. The stents are then pushed up into the ureters on each side, the guide wires removed, and the ureterointestinal anastomosis is completed using two 15-cm 4-0 Biosyn or Monocryl sutures.

For the Bricker technique, each ureter is spatulated approximately 2 cm, and an incision is made at the selected site on the ileal conduit for the anastomosis. A continuous 4-0 Monocryl or 4-0 Vicryl suture on an RB-1 needle is used for the anastomosis. After suturing the posterior wall, with three interrupted stitches, a 7 F, single-J, ileoureteral stent is inserted through the distal end of the conduit and advanced up the ureter into the renal pelvis. The anterior wall is closed using a continuous suture. The identical procedure is then performed on the contralateral side.

Before undocking the robot, the ostomy side of the conduit is tagged with a 3-0 polyglactin suture and brought out through the closest port site to the ostomy site. This allows the surgeon to readily locate the conduit at the time of ostomy creation.

Continent Urinary Diversion (Orthotopic Ileal Neobladder)

When constructing an orthotopic ileal neobladder, a segment of bowel that can easily descend into the deep pelvis is selected. It is important to mark the midpoint and ends of this segment with sutures. To ensure this segment reaches the urethra, a tonsil clamp (female patients) or a Lowsley retractor (male patients) can be advanced through the urethra, so the suture on the selected segment of the ileum can be grasped to ensure adequate descent of the midpoint of the bowel to the urethra in a tension-free manner [39].

Multiple techniques of intracorporeal orthotopic neobladder construction have been described previously [38–46]. In this section, we highlight several of the key technical points for the more commonly performed intracorporeal orthotopic neobladders.

U-Shaped Stapled Reservoir

For the U-shaped staple reservoir, the antimesenteric border of the bowel segment is lightly cauterized using the monopolar scissors to distinctly mark the antimesenteric border. Next, the suture identifying the midportion of the bowel segment is grasped, thereby pulling the segment into the deep pelvis, which allows the bowel to be oriented into a U shape. To help approximate the antimesenteric sides, three sutures, spaced 3 cm apart, are placed along the antimesenteric border. At the proximal and distal edges of the bowel segment, laparoscopic scissors are used to excise a small portion of the staple line.

Through the 12-mm right-sided assistant port, the endoscopic stapler is advanced so that each jaw of the stapler is placed into the previously opened ends of the proximal and distal bowel segment. The stapler is deployed on the antimesenteric portion of each bowel section, which effectively detubularizes the bowel and forms the reservoir. The remaining bowel opening is closed after the ureterointestinal anastomosis is completed by either firing an additional staple load or using a 2–0 Vicryl suture on an SH needle.

To complete the neobladder, the last step is to anastomosis the neobladder to the urethra. Pruthi et al. [39] originally describe using a 3-0 Vicryl

suture on a round-bodied (RB) needle and placing two interrupted sutures at the 5 o'clock and 7 o'clock positions posteriorly. Following placement of the posterior stitches, a new Foley catheter (20 or 22 French) is introduced into the neobladder and the remainder of the anastomosis completed in a running fashion on each side.

Studer Neobladder

After finishing the radical cystectomy and the pelvic lymph node dissection, the first step is to make an anastomosis between the ileum and the urethra. Wiklund and colleagues use the 0° lens during this initial step [43]. Appropriate mobilization of the ileum allows for a tension-free urethral anastomosis and also facilitates the suturing required to construct the neobladder.

An alternative way to pull the ileal segment downward to the urethra uses two Liga-Loop (Braun-Dexon, Spangenberg, Germany) strings positioned through the mesenteric border around the intestine and adjacent to the site of the anastomosis [44].

A 20 French opening is made in the antimesenteric site on the ileum using robotic scissors. A running anastomosis is completed using the Van Velthoven technique with two 18 cm long 4-0 Biosyn® suture. A 50-cm segment of the ileum will be used to construct the orthotopic neobladder. The ileum is stapled 40 cm proximal and 10 cm distal to the urethral-ileal anastomosis. After restoring the bowel continuity, the distal 40 cm of the isolated ileal segment is detubularized along its antimesenteric border, leaving a 10 cm intact proximal isoperistaltic afferent limb. Next, the posterior part of the Studer reservoir is closed using a running suture (25 cm, 3-0 Biosyn®). After completing the posterior part, the distal third to half of the anterior portion of the reservoir is closed using the same suture material. The remaining portion of the neobladder is left open to facilitate the ureterointestinal anastomosis and closed as the last part of the procedure using a running 3-0 Biosyn® suture. The urethral catheter balloon is then inflated and the neobladder filled to check for any leakage.

When placing the ureteral stents, the single-J 40-cm ureteral stents are introduced through two

separate 4-mm incisions in the lower abdominal wall and then pulled through the afferent limb and advanced up the ureters into the renal pelvis. Each stent is anchored to the afferent limb using a 15 cm 4-0 Biosyn® suture. Optionally, the stents can be internalized and secured to the urethral catheter with nonabsorbable sutures and the stents are removed 3 weeks postoperatively at the same time of Foley catheter removal.

Others have reported slightly different modifications and techniques to creating the Studer neobladder intracorporeally. Desai and colleagues report using intravenous indigo-cyanine green to identify the major mesenteric blood vessels to be preserved in selecting the ileal segment for construction of the neobladder [42]. This group uses a marked Penrose drain or an open ureteral access stent as a ruler. Sixty centimeter of ileum is selected; the proximal 15 cm is reserved as the afferent limb of the neobladder. From the remaining 44 cm, an undyed suture is placed at 22 cm to denote the apex of the posterior plate for the Studer neobladder. The undyed marking suture (at 22 cm) can be grasped by the fourth robotic arm and retracted into the pelvis, which aids in the symmetrical alignment of the two 22 cm ileal segments.

The urethroileal anastomosis is completed prior to anterior closure of the pouch by Desai and colleagues [42]. Another option to the Van Velthoven technique is to use a double armed 3-0 or 4-0 suture on an RB-1 needle to complete the urethra-neobladder anastomosis. Anterior closure is aided by the placement of a midpoint horizontal mattress suture that divides the anterior closure into two equal halves with alignment of the neobladder edges.

Blute Jr. and colleagues evaluated the pressure-flow characteristics of various neobladder configurations used in intracorporeal urinary diversions [47]. Four neobladder configurations were constructed, each using 20 cm of human cadaveric small intestine. The hand-sewn Studer pouch was compared with a circular loop, W-pouch, and U-pouch with stapled anastomoses. The cystometric capacities of the stapled U-pouch, W-pouch, Circle pouch, and Studer pouch were 167.3, 177.5, 114, and 145.2 ml, respectively. The first increase in intravesical

pressure was at 90.3, 103, 50, and 85 ml, respectively. The greatest compliance of 3.81 ml/cmH₂O was demonstrated in the U-pouch, with the W-pouch revealing a compliance of 3.44 ml/cmH₂O. The least compliant neobladder was the circle pouch (2.24 ml/cmH₂O) followed by the standard Studer pouch (2.94 ml/cmH₂O). While a limitation of this study is that only 20 cm of cadaveric small intestine was used in this study, the authors concluded that alternative neobladder configurations demonstrate equivalent pressure-flow studies in this experimental model.

Complications and Cost Analysis

Thorough doctor-patient discussion of complications relevant to RARC should include all the complications seen in ORC, and the possibility of access-related injury to bowel or vasculature and need for conversion to open surgery should be noted. Comparison of complication rates between ORC and RARC is difficult and requires use of a validated reporting system such as the Clavien-Dindo. Further, it is becoming apparent that many complications, including a fair amount of those termed major (Clavien grades 3–5), occur more than 30 days after surgery, thus favoring 90-day complication rates as most useful. Kauffman et al. showed that while 16 % of their RARC had major complications by this definition, fully half of those occurred between 31 and 90 days of surgery [48]. Nonrandomized comparisons from this same institution showed significant differences in 30-day overall complication rates as well as 90-day major complication rates favoring RARC [49]. However, a more recent prospectively randomized trial from Memorial Sloan-Kettering failed to show a difference in complication rates between these two modalities at that institution according to a late-breaking release at the 2013 American Urological Association meeting. Another recent trial has reported early pathologic data showing equivalent nodal collection and margin rates; long-term outcomes are still to be determined [50].

In the modern era, no discussion is complete without a cost analysis, and this is especially true regarding the new and expensive technology

associated with the daVinci platform. Multiple factors contribute to the overall expense of an operation: direct surgical costs in the operating room that include time and technology, hospital costs that are largely related to length of stay, and costs incurred by complications in the hospital as well as after discharge. It bears noting the previously cited data suggesting that a large number of complications occur after 30 days and are only captured on 90-day postoperative follow-up.

Within the domain of direct costs, RAC is more costly: amortization of the robotic system itself, disposable goods and OR time generally all exceed the in-room costs of ORC. At one institution that produces open cystectomy outcomes that are closely comparable to RAC (equivalent complication rates and hospital stay; ORC showing higher transfusion rates), costs were close with RAC consuming \$1,640 more in direct hospital costs [9].

Ignoring improvements in hard-to-define concepts such as societal costs associated with less work missed and similar issues, cost-effectiveness can still occur if a new technology decreases other more expensive medical events. Cystectomy, by nature rife with complications, is an excellent venue for such assessment. The cost of complications associated with cystectomy is impressive: a 2007 analysis of these costs by Konety and Allareddy from the National Inpatient database showed costs from each complication incurred another 29 % in costs above baseline, and two complications added 65 % to the bill [51]. A 2012 analysis that was limited to hospital-acquired complications by Kim et al. found that a single complication doubled the in-hospital costs of the operation (from \$26,306 to \$54,242) although their definition of complication was issues that occurred at a rate of only 11 % and thus more likely to represent higher-grade problems [8]. Any significant decrease in events of this cost magnitude clearly opens the door for expensive equipment to easily pay for itself.

Assessments directly comparing ORC to RARC cost are limited. Cost modeling is difficult to do and can be influenced by geography, baseline robotic volume, robot-associated costs, surgeon and team experience, accuracy of complication capture, presence of cystectomy pathway, and countless other factors that influence true total

cost. A recent large comparison of 100 ORC to 100 RARC showed an estimated ORC blood loss of 986 ml compared to RARC losses of 423 ml, with transfusion rates of 47 and 15 %, respectively [52]. In this series, complications were substantially more common in the ORC cohort, including more than twice as common in the severe Clavien grades III–V major complications (10 % vs. 22 %). Conversely, an interim report from Memorial Sloan-Kettering in New York, released at the 2013 AUA meeting, found no difference in hospitalization or 90-day complication rates in their hands [53]. In the face of changing costs, the improved efficiency of experience and economies of scale that apply to this operation, no clear answer will exist until multi-institutional and regional assessments are completed.

Conclusion

The application of robot assistance to radical cystectomy offers an interesting and enticing alternative to open surgery. In virtually all published reports to date, this approach results in lower blood loss but longer surgical times when compared to its open counterpart. The expense of robotic technology must be continually justified by improvements in efficacy, morbidity and cost. Whether robot-assisted laparoscopy becomes the standard approach for radical cystectomy remains to be seen. But regardless of the answer to this always-dynamic query, lessons learned from the investigation will continue to benefit patients undergoing cystectomy by any technique in the future.

References

1. Marshall VJ, Whitmore WF. A technique for the extension of radical surgery in the treatment of vesical cancer. *Cancer*. 1949;2:424.
2. Dindo D, Demartines N, Clavien PA. Classification of surgical complications: a new proposal with evaluation in a cohort of 6336 patients and results of a survey. *Ann Surg*. 2004;240:205.
3. Shabsigh A, Korets R, Vora KC, et al. Defining early morbidity of radical cystectomy for patients with bladder cancer using a standardized reporting methodology. *Eur Urol*. 2009;55:164.

4. Lowrance WT, Rumohr JA, Chang SS, et al. Contemporary open radical cystectomy: analysis of perioperative outcomes. *J Urol*. 2008;179:1313.
5. de Badajoz Sánchez E, Gallego Perales JL, Reche Rosado A, et al. Laparoscopic cystectomy and ileal conduit: case report. *J Endourol*. 1995;9:59.
6. Puppo P, Perachino M, Ricciotti G, et al. Laparoscopically assisted transvaginal radical cystectomy. *Eur Urol*. 1995;27:80.
7. Gettman MT, Blute ML, Peschel R, et al. Current status of robotics in urologic laparoscopy. *Eur Urol*. 2003;43:106.
8. Kim SP, Shah ND, Karnes RJ, et al. The implications of hospital acquired adverse events on mortality, length of stay and costs for patients undergoing radical cystectomy for bladder cancer. *J Urol*. 2012;187:2011.
9. Smith A, Kurpad R, Lal A, et al. Cost analysis of robotic versus open radical cystectomy for bladder cancer. *J Urol*. 2010;183:505.
10. Herr H, Lee C, Chang S, et al. Standardization of radical cystectomy and pelvic lymph node dissection for bladder cancer: a collaborative group report. *J Urol*. 2004;171:1823.
11. Kamat AM, Dinney CP, Gee JR, et al. Micropapillary bladder cancer: a review of the University of Texas M. D. Anderson Cancer Center experience with 100 consecutive patients. *Cancer*. 2007;110:62.
12. Richards KA, Kader K, Pettus JA, et al. Does initial learning curve compromise outcomes for robot-assisted radical cystectomy? A critical evaluation of the first 60 cases while establishing a robotics program. *J Endourol*. 2011;25:1553.
13. Guru KA, Perlmutter AE, Butt ZM, et al. The learning curve for robot-assisted radical cystectomy. *JSLs*. 2009;13:509.
14. Hayn MH, Hussain A, Mansour AM, et al. The learning curve of robot-assisted radical cystectomy: results from the International Robotic Cystectomy Consortium. *Eur Urol*. 2010;58:197.
15. Butt ZM, Perlmutter AE, Piacente PM, et al. Impact of body mass index on robot-assisted radical cystectomy. *JSLs*. 2008;12:241.
16. Johar RS, Hayn MH, Stegemann AP, et al. Complications after robot-assisted radical cystectomy: results from the International Robotic Cystectomy Consortium. *Eur Urol*. 2013;64:52.
17. Gadacz TR, Talamini MA. Traditional versus laparoscopic cholecystectomy. *Am J Surg*. 1991;161:336.
18. Lloyd G, Rashid H, Wu G. Complex pelvic surgery in the setting of prior ostomy. Kyoto: World Congress of Endourology; 2011.
19. Meeks JJ, Bellmunt J, Bochner BH, et al. A systematic review of neoadjuvant and adjuvant chemotherapy for muscle-invasive bladder cancer. *Eur Urol*. 2012;62:523.
20. Hollenbeck BK, Miller DC, Taub D, et al. Aggressive treatment for bladder cancer is associated with improved overall survival among patients 80 years old or older. *Urology*. 2004;64:292.
21. Knox ML, El-Galley R, Busby JE. Robotic versus open radical cystectomy: identification of patients who benefit from the robotic approach. *J Endourol*. 2013;27:40.
22. Kaffenberger SD, Keegan KA, Bansal NK, et al. Salvage robotic assisted laparoscopic radical prostatectomy: a single institution, 5-year experience. *J Urol*. 2013;189:507.
23. Chahal R, Sundaram SK, Iddenden R, et al. A study of the morbidity, mortality and long-term survival following radical cystectomy and radical radiotherapy in the treatment of invasive bladder cancer in Yorkshire. *Eur Urol*. 2003;43:246.
24. Eswara JR, Efstathiou JA, Heney NM, et al. Complications and long-term results of salvage cystectomy after failed bladder sparing therapy for muscle invasive bladder cancer. *J Urol*. 2012;187:463.
25. Eisenberg MS, Dorin RP, Bartsch G, et al. Early complications of cystectomy after high dose pelvic radiation. *J Urol*. 2010;184:2264.
26. Lee DJ, Rothberg MB, McKiernan JM, et al. Robot-assisted radical cystoprostatectomy in complex surgical patients: single institution report. *Can J Urol*. 2009;16:4664.
27. Zebic N, Weinknecht S, Kroepfl D. Radical cystectomy in patients aged > or = 75 years: an updated review of patients treated with curative and palliative intent. *BJU Int*. 2005;95:1211.
28. Nogueira L, dos Reis RB, Machado RD, et al. Cutaneous ureterostomy with definitive ureteral stent as urinary diversion option in unfit patients after radical cystectomy. *Acta Cir Bras*. 2013;28 Suppl 1:43.
29. Karl A, Carroll PR, Gschwend JE, et al. The impact of lymphadenectomy and lymph node metastasis on the outcomes of radical cystectomy for bladder cancer. *Eur Urol*. 2009;55:826.
30. Buscarini M, Josephson DY, Stein JP. Lymphadenectomy in bladder cancer: a review. *Urol Int*. 2007;79:191.
31. Mills RD, Fleischmann A, Studer UE. Radical cystectomy with an extended pelvic lymphadenectomy: rationale and results. *Surg Oncol Clin N Am*. 2007;16:233.
32. Stein JP. The role of lymphadenectomy in patients undergoing radical cystectomy for bladder cancer. *Curr Oncol Rep*. 2007;9:213.
33. Youssef RF, Raj GV. Lymphadenectomy in management of invasive bladder cancer. *Int J Surg Oncol*. 2011; 2011: Article ID 758189.
34. Tilki D, Brausi M, Colombo R, et al. Lymphadenectomy for bladder cancer at the time of radical cystectomy. *Eur Urol*. 2013;64:266.
35. Keren Paz GE, Laudone VP, Bochner BH. Does minimally invasive surgery for radical cystectomy provide similar long-term cancer control as open radical surgery? *Curr Opin Urol*. 2013;23:449.
36. Davis JW, Gaston K, Anderson R, et al. Robot assisted extended pelvic lymphadenectomy at radical cystectomy: lymph node yield compared with second look open dissection. *J Urol*. 2011;185:79.

37. Thompson IM, Kappa SF, Morgan TM, et al. Blood loss associated with radical cystectomy: a prospective, randomized study comparing Impact LigaSure vs. stapling device. *Urol Oncol.* 2013;32:45.e11–5.
38. Johnson D, Castle E, Pruthi RS, et al. Robotic intracorporeal urinary diversion: ileal conduit. *J Endourol.* 2012;26:1566.
39. Pruthi R, Nix J, McRackan D, et al. Robotic-assisted laparoscopic intracorporeal urinary diversion. *Eur Urol.* 2010;57:1013.
40. Collins J, Tyritzis S, Nyberg T, et al. Robot-assisted radical cystectomy: description of an evolved approach to radical cystectomy. *Eur Urol.* 2013;64:654.
41. Collins J, Wiklund P, Desai M, et al. Total intracorporeal robotic cystectomy: are we there yet? *Curr Opin Urol.* 2013;23:135.
42. Goh A, Gill I, Lee D, et al. Robotic intracorporeal orthotopic ileal neobladder: replicating open surgical principles. *Eur Urol.* 2012;62:891.
43. Hosseini A, Adding C, Nilsson A, et al. Robotic cystectomy: surgical technique. *BJU Int.* 2011;108:962.
44. Jonsson M, Adding L, Hosseini A, et al. Robot-assisted radical cystectomy with intracorporeal urinary diversion in patients with transitional cell carcinoma of the bladder. *Eur Urol.* 2011;60:1066.
45. Josephson D, Chen J, Chan K, et al. Robotic-assisted laparoscopic radical cystoprostatectomy and extracorporeal continent urinary diversion: highlight of surgical techniques and outcomes. *Int J Med Robot.* 2010;6:315.
46. Murphy D, Anderson P. Robotic radical cystectomy with intracorporeal neobladder: ready for prime time? *Eur Urol.* 2013;64(5):742–3.
47. Blute M, George A, Herati A, et al. Intracorporeal neobladder reconstruction: pressure-flow urodynamic studies in cadaveric orthotopic neobladders. *BJU Int.* 2012;109:434.
48. Kauffman EC, Ng CK, Lee MM, et al. Critical analysis of complications after robotic-assisted radical cystectomy with identification of preoperative and operative risk factors. *BJU Int.* 2010;105:520.
49. Ng CK, Kauffman EC, Lee MM, et al. A comparison of postoperative complications in open versus robotic cystectomy. *Eur Urol.* 2010;57:274.
50. Parekh DJ, Messer J, Fitzgerald J, et al. Perioperative outcomes and oncologic efficacy from a pilot prospective randomized clinical trial of open versus robotic assisted radical cystectomy. *J Urol.* 2013;189:474.
51. Konety BR, Allareddy V. Influence of post-cystectomy complications on cost and subsequent outcome. *J Urol.* 2007;177:280.
52. Kader AK, Richards KA, Krane LS, et al. Robot-assisted laparoscopic vs open radical cystectomy: comparison of complications and perioperative oncological outcomes in 200 patients. *BJU Int.* 2013;112:E290.
53. Laudone V, Silberstein J, Keren-Paz G, et al. Interim analysis of a prospective, randomized trial comparing robotic and open radical cystectomy. Presented at the American Urological Association Annual Meeting. San Diego, 2013.
54. Gondo T, Yoshioka K, Nakagami Y, et al. Robotic versus open radical cystectomy: prospective comparison of perioperative and pathologic outcomes in Japan. *Jpn J Clin Oncol.* 2012;42:625.
55. Nepple KG, Strobe SA, Grubb RL, et al. Early oncologic outcomes of robotic vs. open radical cystectomy for urothelial cancer. *Urol Oncol.* 2013;31:894.
56. Wang GJ, Barocas DA, Raman JD, et al. Robotic vs open radical cystectomy: prospective comparison of perioperative outcomes and pathological measures of early oncological efficacy. *BJU Int.* 2008;101:89.
57. Styn NR, Montgomery JS, Wood DP, et al. Matched comparison of robotic-assisted and open radical cystectomy. *Urology.* 2012;79:1303.
58. Nix J, Smith A, Kurpad R, et al. Prospective randomized controlled trial of robotic versus open radical cystectomy for bladder cancer: perioperative and pathologic results. *Eur Urol.* 2010;57:196.
59. Galich A, Sterrett S, Nazemi T, et al. Comparative analysis of early perioperative outcomes following radical cystectomy by either the robotic or open method. *JSLs.* 2006;10:145.
60. Sung HH, Ahn JS, Seo SI, et al. A comparison of early complications between open and robot-assisted radical cystectomy. *J Endourol.* 2012;26:670.

Sri Sivalingam and Sara L. Best

Abbreviations

UPJO	Ureteropelvic junction obstruction
LP	Laparoscopic pyeloplasty
RAP	Robot-assisted pyeloplasty
LESS	Laparoendoscopic single-site surgery

Introduction

Although open Anderson-Hynes dismembered pyeloplasty was historically the criterion standard for the definitive treatment of ureteropelvic junction obstruction (UPJO), minimally invasive approaches such as laparoscopic pyeloplasty (LP) and robot-assisted laparoscopic pyeloplasty (RAP) are arguably the current gold standard [1]. The first purely laparoscopic pyeloplasty was reported in 1993 [2, 3]. However, the technical nuances and steep learning curve associated with laparoscopic pyeloplasty made the rapid adoption of laparoscopy for this procedure

difficult, primarily due to the technical complexity of intracorporeal suturing. The introduction of the da Vinci robotic system (Intuitive Surgical, Sunnyvale, CA) facilitated the adoption of minimally invasive pyeloplasty and gained rapid popularity by significantly simplifying and shorting intracorporeal suturing time [4]. The robotic and laparoscopic approaches for pyeloplasty continue to evolve, and as experience with the technique grows, RAP may ultimately become the reference gold standard approach.

Minimally invasive pyeloplasty has similar functional outcomes compared to the open approach but with the advantages of improved postoperative convalescence, cosmesis, and lower short-term morbidity [5, 6]. Several studies have shown that laparoscopic dismembered pyeloplasty has equivalent efficacy compared to open pyeloplasty [7, 8]. Similarly, RAP has demonstrated therapeutic equivalence to LP [9, 10], with a faster learning curve and easier adoption than standard laparoscopy due to its distinct advantage with intracorporeal suturing. The increased degrees of freedom, wristed instrumentation, and 3D vision unique to the robotic platform facilitate reconstruction, decrease the learning curve for the procedure, and reduce surgeon fatigue, thus popularizing RAP over standard laparoscopy in a trend similar to that of the robotic prostatectomy [11, 12]. Overall, there has been a dramatic shift from open to minimally invasive pyeloplasty since 2005 [13]. Specifically,

S. Sivalingam
Department of Urology, Cleveland Clinic,
Cleveland, OH, USA

S.L. Best, MD (✉)
Department of Urology,
University of Wisconsin School of Medicine
and Public Health, 1685 Highland Ave,
Madison, WI 53705, USA
e-mail: best@urology.wisc.edu

one study showed a 23-fold increase from 2.4 to 55.3 % in minimally invasive pyeloplasty from 1998 to 2009 [14]. This trend favoring minimally invasive pyeloplasty was primarily driven by the increased use of RAP, which accounted for 45 % of all cases in comparison to 10 % for pure laparoscopy in 2009 [14].

This chapter will detail the application of RAP, with specific details on operative technique. Contemporary outcomes and complications of this procedure will also be presented.

Robotic Versus Laparoscopic Pyeloplasty

The first detailed report of laparoscopic pyeloplasty was in 1993 [3], and although it was shown to be a feasible procedure, the technique demanded advanced laparoscopic skills for the intracorporeal suturing in the reconstruction. Despite these challenges, in many centers, laparoscopic pyeloplasty took the lead over open pyeloplasty, highlighting the demand for more minimally invasive approaches [1]. With the introduction of the da Vinci robotic surgical system, intracorporeal suturing became much easier and tempered the learning curve. Consequently, several trials have emerged comparing the two approaches (Table 8.1). In the systematic review and meta-analysis by Braga et al. in 2009 [9], the authors analyzed eight available studies at that time and compared the outcomes of the two approaches. They noted that although there was a 10-min advantage with the RAP, this did not translate into statistical significance. Five of the eight studies had a shorter hospital stay (by 0.5 days) for the robotic approach, which was statistically (if not clinically) significant. Both RAP and LP had similar complication rates and success rates. A more recent meta-analysis comparing RAP to LP reviewed 12 studies with 347 and 299 cases of RAP and LP, respectively [22]. This meta-analysis noted advantages of a shorter suturing time and hospital stay with the robotic approach. Interestingly, while there was no significant difference in total operative times, a subgroup analysis of suturing time found an 18-min

advantage with RAP, based on a meta-analysis of four studies. It is conceivable that the time gained with suturing is balanced by docking and undocking of the robot [20] and the potentially faster dissection to expose the retroperitoneum and ureter with pure laparoscopy. Hospital stay was significantly shorter by 0.75 days in the RAP group, and again, there were no differences in success or complication rates.

Based on these meta-analyses, the literature to date suggests that both LP and RAP provide excellent outcomes with low complication rate. However, the shorter learning curve associated with RAP has led to its dominance in many minimally invasive practices including pyeloplasties. In one study assessing trends in pyeloplasty, open pyeloplasty and RAP were each performed in 45 % of cases, while 10 % of cases were done laparoscopically [14].

Retroperitoneal Versus Transperitoneal Approach

The ureteropelvic junction (UPJ) can be accessed via a transperitoneal or retroperitoneal route. Although most laparoscopic or robot-assisted urological surgeries are performed transperitoneally, there may be unique advantages with the retroperitoneal approach as it provides direct access to the renal pelvis, avoids urine leak into the peritoneal cavity, and potentially hastens recovery. Outcomes of both retroperitoneal and transperitoneal approaches appear similar. The original description of retroperitoneal RAP was in the pediatric population in 2004 [23]. Subsequently, the first report in adults was by Kaouk and colleagues in 2008 [24]. In this series, all cases were performed by a single surgeon with prior experience in retroperitoneal LP. Retroperitoneal access was achieved through a 1.2-cm incision at the tip of the 12th rib, and subsequently, the lumbodorsal fascia incised and retroperitoneal space developed by balloon dissection. The authors indicate that although the transperitoneal approach affords the advantage of familiarity of the operative field, and a larger working space, there are significant benefits for the retroperitoneal approach such as

Table 8.1 Comparative series of robotic versus laparoscopic pyeloplasty

		N	Mean age	BMI (L/R)	Laterality (L/R)	Crossing vessel	EBL	OR Time	Drain (days)	Hospital LOS (days)	Complications (%)	Success rates (%)
Kumar and Nayak [15]	LP	11	25				46	150 (11–200)	1.36	2.9	None	100
	RAP	19	21				54	129 (70–180)	1.58	2.8	None	100
Olweny et al. [16] ^a	LP	10	35.8	26.7	5/5		42	188		2.6	20	
	RAP	10	40.3	21.8	3/7		56	226		2.6	10	
Garcia-Galisteo et al. [17]	LP	33		n/a				152.1 ± 23.3		4.5 ± 1.5	51.5 %	93.9
	RAP	17	33.9	n/a				121.6 ± 13.3		2.4 ± 0.5	23.5 %	94.1
Hemal et al. [18]	LP	30	28.1		20/10	2		145 ± 44		5.5 ± 3.8	10 %	97
	RAP	30	24.9		19/11	3		99 ± 29		2.5 ± 0.8	3.3 %	93
Kim et al. [19]	LP	58	Peds	n/a	n/a			196 ± 38		0.9 ± 0.23	3.4 %	97
	RAP	84	Peds					188 ± 45.8		1.5 ± 0.55	0	99
Link et al. [20]	LP	10	38.0	24.3	6/4		NSD	80.7 ± 21.9*			None	
	RAP	10	46.5	23.0	5/5		NSD	100.2 ± 9.1*			10 % (1 delayed urine leak)	
Weise and Winfield [21]	LP	14	24.5		11/3	7/14		271		2	0	
	RAP	31	26		17/14	23/31		299		2	0	

Abbreviations: *BMI*, body mass index; *EBL*, estimated blood loss; *Peds*, pediatric cases only; *NSD*, no significant difference

^aLESS LP versus LESS RAP

*significantly different, p=0.018

lower risk of bowel injury and direct approach to the UPJ. In retroperitoneal LP series, the technical challenge of intracorporeal suturing was exacerbated by the smaller working space in the retroperitoneum, and finding a potential crossing vessel was also more challenging. However, according to Kaouk and coauthors, the wristed instrumentation of the da Vinci system helped overcome the limitation of working in a confined space. The outcomes and complications were also similar to that of standard transperitoneal RAP. Cestari et al. recently published their series of retroperitoneal versus transperitoneal RAP in 36 and 19 patients, respectively [25]. These authors also found similar outcomes in the two groups but noted similar challenges for the retroperitoneal approach, namely, gaining access, limited working space, and the loss of familiar anatomic landmarks. The confined space can also make identification of crossing vessels more difficult. The authors also noted that antegrade stent placement is more challenging during retroperitoneal RAP [25]. This, however, can be overcome with retrograde placement via flexible cystoscopy without any interruption in the procedure.

The choice to pursue the retroperitoneal approach is based on the surgeon's preference and experience with the technique. There is a paucity of literature comparing the two approaches, and therefore, conclusive statements regarding the superiority of one approach versus the other cannot be made at this time. The remainder of this chapter will focus on the transperitoneal approach.

LESS Pyeloplasty

With the emergence of a LP and RAP, laparoscopic single-site surgery (LESS) has been of interest in an effort to further minimize surgical invasiveness and improve morbidity. The LESS approach also offers patients improved cosmesis by decreasing the number of ports from 3 to 5 (standard LP) to a single periumbilical incision that is often concealed [26]. Although this approach further raises the level of complexity in performing the procedure, in experienced hands,

complication rates are similar to those with other minimally invasive approaches [26]. Early reports with LESS have demonstrated equivalent outcomes compared to conventional LP with no differences in hospital stay, analgesic requirements, and minor and major complications [27]. LESS can be performed using either laparoscopic or robotic approaches, but some surgeons have found the ergonomic challenges of LESS to be better addressed using the robotic platform. In particular, the wristed instrumentation, surgeon-controlled camera, and ability to electronically reassign the hand controls ("masters") after crossing the instruments have been cited as particular advantages of robotic LESS. Harrow et al. reported on their series of LESS pyeloplasty comparing outcomes of LESS LP versus RAP [28].

Robot-Assisted Laparoscopic Pyeloplasty: Equipment List

1. Da Vinci Surgical System (Intuitive Surgical, Sunnyvale, CA)
2. Veress needle, 2–10-/12-mm disposable ports, 8-mm robotic ports, GelPort (for LESS)
3. Right arm – Monopolar da Vinci Hot Shears, da Vinci Potts scissors, da Vinci Large Needle Driver
4. Left arm – Prograsp forceps, da Vinci Fine Tissue Forceps, da Vinci Large Needle Driver
5. Fourth arm – not typically employed for pyeloplasty
6. Assistant – 5-mm suction irrigator
7. Liver retraction port – atraumatic locking grasper (right-sided procedures only)

Technical Description

Patient Preparation

After a thorough preoperative evaluation of the patient's suitability for the procedure, any anticoagulant medications are stopped a week prior to the procedure. A modified bowel preparation consisting of 10 oz of magnesium citrate is

administered on the day before surgery. Urinalysis is performed before surgery and any urinary tract infection treated accordingly, and preoperative antibiotics are given prior to commencing the procedure. In our practice, a routine ureteral stent is not placed preoperatively to avoid ureteral edema and potential masking of an intraureteral stenosis. However, the stent can be placed prior to the robotic positioning and a retrograde pyelogram can be performed at this time.

Patient Positioning

After induction of anesthesia, a Foley catheter is placed and, after draining the initial bladder contents, is clamped so that the bladder will fill during the procedure, facilitating antegrade stent placement. The patient is placed in a modified lateral decubitus position with the affected flank facing upward. All pressure points are carefully padded, the lower leg is flexed, and the upper leg is kept straight. Pillows are secured in between the legs and secured with tape. The patient is well secured to the operating table to allow for ample airplane

rotation. The operating table is then gently flexed to elevate the kidney and open the space between the ipsilateral hip and ribs (Fig. 8.1a, b).

Port Placement (Standard RAP)

The table is rotated maximally to position the patient in a near-supine orientation. A small skin incision is made below the inner crease of the umbilicus to allow for Veress needle placement. After confirmation of safe intraperitoneal Veress entry with aspiration and drop test, pneumoperitoneum is established to 15 mmHg. A 10-mm incision is then made within the umbilicus, and a visual optical dilating trocar is used to insert the first 10-mm port using a 0° lens. In larger or more obese patients, it may be helpful to lateralize the trocar sites, including the camera port, few centimeters lateral and superior to the umbilicus. The two 8-mm robotic ports are placed under direct vision in the upper and lower quadrants. Care must be taken to ensure the remote centers of the ports lie within the fascia to avoid unnecessary enlargement of the fascial defects.

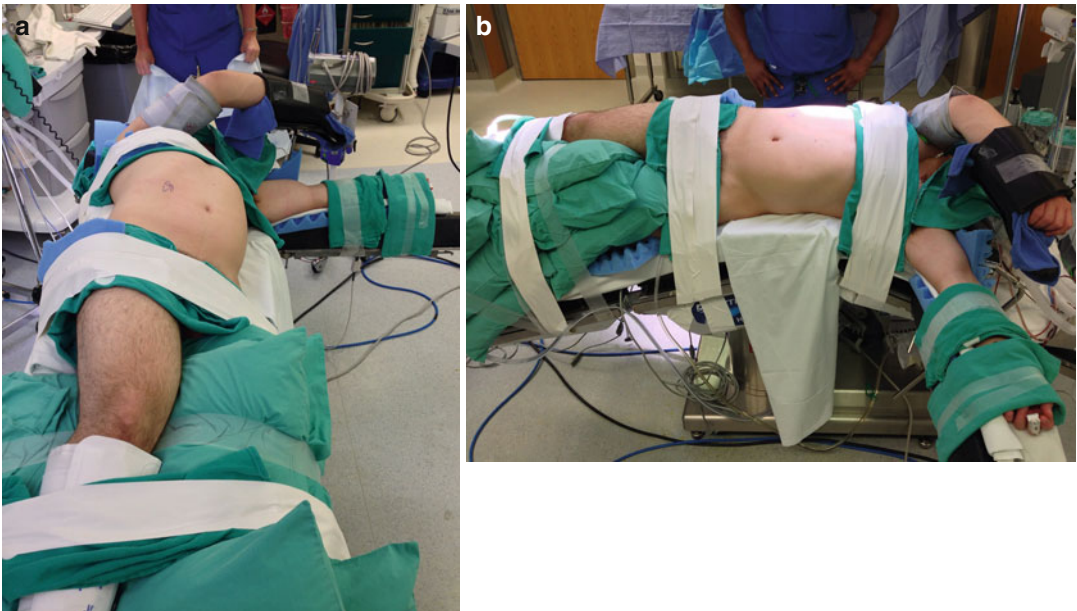


Fig. 8.1 (a, b) Patient positioning in modified lateral decubitus with careful padding of pressure points. Patient is secured with cloth tape to enable airplaning the table for port placement and subsequent docking of the robot

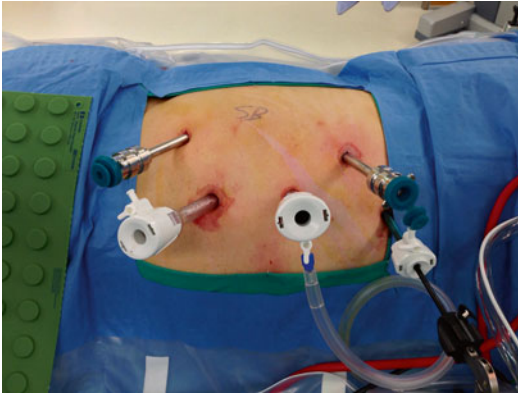


Fig. 8.2 Optimal port placement for right robot-assisted pyeloplasty, with a single 10-mm assist port and a 5-mm liver retraction port

For right-sided procedures, a 5-mm subxiphoid trocar can be placed, and an atraumatic locking grasper can be used to elevate the liver by clipping the grasper to the sidewall, though this is not necessary unless the liver edge drapes over the UPJ. A 12-mm assistant port is then placed in the midline between the umbilicus and the xiphoid (Fig. 8.2). The table is rotated so that the patient lies on his/her side and the robot is docked.

Port Placement (LESS RAP)

The patient is positioned and the table maximally rotated as above. A 2.5-cm intraumbilical incision is then made. The fascia is then elevated with 0 Vicryl stitches and is incised sharply and the peritoneum is lifted and incised. The fascial incision is extended to the length of the skin incision, and a GelPOINT LESS port device (Applied Medical, Rancho Santa Margarita, CA, USA) is placed through the incision, ensuring that loops of bowel are not caught within the ring [16]. A 5- and 8-mm robotic trocar are placed, along with an 8.5-mm robotic camera trocar and a 10-mm assistant trocar through the GelPOINT® port, and the abdomen is insufflated to 15 mmHg (Fig. 8.3). The table is rotated back to the initial position and the robot is docked. The camera is loaded in the “30° up” orientation to diminish clashing of instruments. A left 5-mm robotic hook cautery (or scissors) and a right 5-mm tissue grasper are

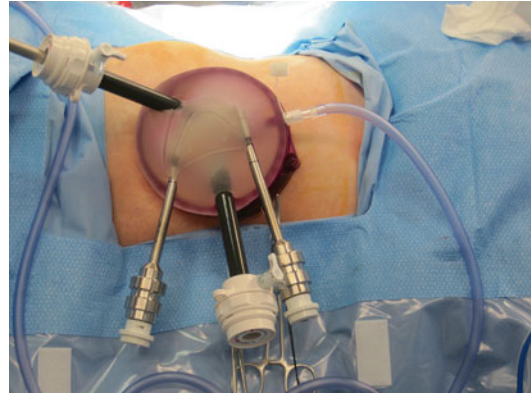


Fig. 8.3 Port placement for a robotic LESS pyeloplasty using a GelPOINT® device that was placed through a 2.5-cm umbilical incision

deployed in the respective robotic ports, criss-crossing at the level of the fascia. The robotic console is programmed so that the surgeon’s left hand controls the instrument on the left side of the screen and vice versa, resulting in intuitive manipulation of the instruments. This ability to reassign the masters at the console for LESS procedures is yet another unique advantage of the robotic platform.

Exposure of the Renal Pelvis and Ureter

The colon is reflected medially along the white line of Toldt. The peritoneum overlying the inferior aspect of the kidney is then carefully dissected and mobilized off Gerota’s fascia, which is then incised to locate the ureter which is carefully dissected free of the surrounding tissues. The ureter is traced cranially toward the renal pelvis, and meticulous efforts are made to avoid excessive handling/manipulation of the ureter and to leave tissue surrounding it to maintain perfusion. As dissection of the ureter approaches the renal pelvis, care should be taken to identify and preserve any crossing vessels. Since the goal is to preserve any crossing arteries, as these are “end vessels” that provide the sole perfusion for a portion of the kidney, the ureter and renal pelvis should be gently dissected free from these arteries.

Periodically during the dissection, the surgeon must assess the “slack” on the ureter to obtain an eventual tension-free anastomosis. This is usually not problematic, but occasionally, additional mobilization of the renal pelvis and more distal ureter must be performed. Once the ureter and renal pelvis are adequately mobilized, the ureter is sharply transected at the UPJ using Potts scissors. The ureter is then laterally speculated to about 1.5–2 cm after excision of any scarred tissue, and the corresponding area of the renal pelvis is spatulated medially. The renal pelvis and ureter are brought anterior to any crossing vessels.

Stone Removal (if Indicated)

If stones are present within the renal collecting system, a flexible nephroscope can be introduced through the assistant trocar and advanced into the renal pelvis. The renal pelvis incision can be compressed around the scope to minimize the leakage of irrigant into the abdominal cavity, and the suction irrigator can be used to remove any excess irrigant fluid within the peritoneal cavity. Stones can be removed with an appropriate basket and extracted through the port. If stones are particularly numerous or large, in some cases, it may be helpful to place them in a laparoscopic retrieval sac for removal at the end of the case.

Antegrade Stent Placement

A 14-gauge angiocatheter is passed percutaneously through the anterior abdominal wall in the subcostal region and a stiff wire passed through it, which is advanced down the spatulated ureter with robotic assistance. The angiocatheter is removed leaving the wire in place, and a double-J stent is then passed over the wire down through the ureter and then the wire removed, leaving a curl in the proximal end. Confirmation that the distal end of the stent lies within the bladder can be made if the Foley was clamped at the beginning of the case by looking for urine dripping out the proximal end.

Anastomosis

A 3-0 Vicryl suture is used to perform the initial anastomotic stitch between the ureter (at the bottom of the spatulation) and the lateral tip of the renal pelvis. The anastomosis is made anterior to any crossing vessels, if present. The posterior aspect of the anastomosis is then sewn in a running fashion with this 3-0 Vicryl suture. Before closing the anterior aspect, the curl of the stent is placed within the renal pelvis. The anterior aspect of the anastomosis is closed with a separate running stitch. The closure is then examined to ensure a tension-free, water-tight anastomosis. The anastomosis is then covered with a small amount of fibrin tissue sealant. Pneumoperitoneum is briefly dropped to 5 mmHg and hemostasis is confirmed and subsequently reestablished to 15 mmHg.

Drain Placement and Closure

A 19-French round drain is placed in the perinephric region through the lower quadrant robotic trocar site and sutured to the skin. The remaining 10-/12-mm trocars are removed under direct vision closed under direct laparoscopic vision using a Carter-Thomason device. The 8-mm robotic trocar sites typically do not need to be closed unless the fascia is felt to have become over-dilated.

The complication rate for robotic pyeloplasty has been comparable with the standard open approach. A recent meta-analysis of 12 studies revealed an overall complication rate of 8.9 % with RAP. Although there are variations in technique and experience, the reported overall complication rates are within 15 %, and this decreases further if Clavien grade 1 complications are excluded [29]. The reported treatment-specific complications include postoperative hemorrhage, infection, urine leak (requiring percutaneous drainage and/or prolonged stenting), stent migration (requiring ureteroscopy for stent extraction), and sewn-in stent.

The complication rate associated with LESS RP and conventional LESS pyeloplasty is comparable,

between 10 and 20 % [16, 26]. Specific complications reported in the LESS approach include urine leak requiring nephrostomy tube placement or conversion to multiport pyeloplasty. In comparative studies, it is noteworthy that the complication rate in initial series of conventional LESS pyeloplasty was higher than that of robotic LESS pyeloplasty, suggesting perhaps a faster learning curve for robotic LESS [16].

Table 8.2 highlights select contemporary series with associated complication rates.

Follow-Up

Typically, the patient may be started on a clear liquid diet the day of surgery and advanced appropriately based on the patient's recovery. Ambulation is encouraged by postoperative day 1, and if drain output is minimal, the Foley catheter may be removed for a voiding trial 36–48 h after surgery. The drain output must be monitored during this period to ensure that any potential urine leak is not exacerbated by reflux during voids. If the drain fluid is noted to increase, it may be sent for a creatinine measurement to confirm a urine leak, and if present, the Foley catheter should be reinserted and the drain maintained. If no such increase is noted, or fluid creatinine is negative, the drain may be removed and the patient may be discharged. Stent removal is arranged in 4–6 weeks, and follow-up diuretic renogram may be obtained in 4–8 weeks after stent removal to establish a postoperative baseline.

Outcomes

As discussed previously and shown in Table 8.1, the success rates for RAP are reported as >94 %, and as such, it is difficult to ascertain the specific causes for treatment failures. While most studies indicate that RAP and LP have similar outcomes, the Laparoscopic and Robotic Pyeloplasty Collaborative Group was assembled to further elucidate any subtle determinants of outcomes [36]. In this multi-institutional collaboration, 759 cases from 15 centers were evaluated, comparing 274 LP and 465 RAP with a mean follow-up of 11 months. Although overall there were no significant differences in outcomes between the LP and RAP groups, in bivariate analysis, RAP was associated with a decreased need for secondary procedures than LP (3.2 % versus 9.5 %, $p=0.001$). In this series, Lucas et al. showed that the 2-year freedom from secondary procedures was 87 % for LP versus 95 % for RAP, 81 % versus 93 % for patients with versus without previous endopyelotomy, and 88 % versus 95 % for patients with versus without intraoperative crossing vessels, respectively. However, on multivariate analysis, the use of RAP versus LP was no longer found to be related to freedom from secondary procedures.

In the 1–6 % of failures with RAP, secondary treatment may be necessary, which may include endopyelotomy, repeat pyeloplasty, extensive reconstruction with ureteral substitution, long-term stent or NT placement, or, rarely, nephrectomy.

Table 8.2 Table of complications from select studies

Study	N	Complication							Comment
		Conversion	Clavien 1	Clavien 2	Clavien 3a	Clavien 3b	Clavien 3c	Clavien 3d	
Kumar and Nayak [15]	19	0	0	0	0	0	0	0	Comparison of RAP versus LP; no complications in either group
Moreno-Sierra et al. [30]	10	1 (10%)	0	0	0	0	0	0	Initial experience with RAP, 1 complication of lower pole ischemia
Sivaraman et al. [31]	168	11 (6.6%)	0	11 (6.6%)	0	6 (5.4%)	0	0	Comparison of 1° versus 2° RAP; 5% versus 14% complication rates in 1° versus 2° repair, respectively
Olweny et al. [16] ^b	10	1 (10%)	0	0	1	0	0	0	Comparison of LESS RAP versus LESS LP; no significant differences in complications observed
Niver et al. [32] ^b	117	18 (15.3%)	0	2	0	0	14	0	Comparison of 1° versus 2° RAP; 15% complications in each group
Etafy et al. [33]	61	7 (11.4%)	0	3	2 ^a	1	2 ^a	0	Review of 61 consecutive patients at a single institution
Sethi et al. [34] ^b	41	3 (7.3%)	0	0	1	1	2	0	Comparison of stented versus unstented RAP; no clinically significant differences
Bird et al. [10]	98	5 (5.1%)	0	0	0	0	0	0	Comparison of RAP versus LP; complications for both groups infrequent
Erdeijan et al. [35]	88	5 (5.7%)	0	0	1	1	4	0	A comparison of experienced surgeons and trainees; no significant differences
Cestari et al. [25] ^b	55	1	0	1	0	0	0	0	Comparison of transperitoneal versus retroperitoneal RAP

^aRepeat patient^bKey paper

References

1. Winfield HN. Management of adult ureteropelvic junction obstruction—is it time for a new gold standard? *J Urol.* 2006;176(3):866–7.
2. Kavoussi LR, Peters CA. Laparoscopic pyeloplasty. *J Urol.* 1993;150(6):1891–4.
3. Schuessler WW, Grune MT, Tecuanhuey LV, Preminger GM. Laparoscopic dismembered pyeloplasty. *J Urol.* 1993;150(6):1795–9.
4. Gettman MT, Blute ML, Chow GK, Neururer R, Bartsch G, Peschel R. Robotic-assisted laparoscopic partial nephrectomy: technique and initial clinical experience with DaVinci robotic system. *Urology.* 2004;64(5):914–8.
5. Klingler HC, Remzi M, Janetschek G, Kratzik C, Marberger MJ. Comparison of open versus laparoscopic pyeloplasty techniques in treatment of uretero-pelvic junction obstruction. *Eur Urol.* 2003;44(3):340–5.
6. Bauer JJ, Bishoff JT, Moore RG, Chen RN, Iverson AJ, Kavoussi LR. Laparoscopic versus open pyeloplasty: assessment of objective and subjective outcome. *J Urol.* 1999;162(3 Pt 1):692–5.
7. Brooks JD, Kavoussi LR, Preminger GM, Schuessler WW, Moore RG. Comparison of open and endourologic approaches to the obstructed ureteropelvic junction. *Urology.* 1995;46(6):791–5.
8. Baldwin DD, Dunbar JA, Wells N, McDougall EM. Single-center comparison of laparoscopic pyeloplasty, Acucise endopyelotomy, and open pyeloplasty. *J Endourol.* 2003;17(3):155–60.
9. Braga LH, Pace K, DeMaria J, Lorenzo AJ. Systematic review and meta-analysis of robotic-assisted versus conventional laparoscopic pyeloplasty for patients with ureteropelvic junction obstruction: effect on operative time, length of hospital stay, post-operative complications, and success rate. *Eur Urol.* 2009;56(5):848–57.
10. Bird VG, Leveillee RJ, Eldefrawy A, Bracho J, Aziz MS. Comparison of robot-assisted versus conventional laparoscopic transperitoneal pyeloplasty for patients with ureteropelvic junction obstruction: a single-center study. *Urology.* 2011;77(3):730–4.
11. Kawachi MH. Counterpoint: robot-assisted laparoscopic prostatectomy: perhaps the surgical gold standard for prostate cancer care. *J Natl Compr Canc Netw.* 2007;5(7):689–92.
12. Willis DL, Gonzalgo ML, Brotzman M, Feng Z, Trock B, Su LM. Comparison of outcomes between pure laparoscopic vs robot-assisted laparoscopic radical prostatectomy: a study of comparative effectiveness based upon validated quality of life outcomes. *BJU Int.* 2012;109(6):898–905.
13. Monn MF, Bahler CD, Schneider EB, Sundaram CP. Emerging trends in robotic pyeloplasty for the management of ureteropelvic junction obstruction in adults. *J Urol.* 2013;189(4):1352–7.
14. Sukumar S, Sun M, Karakiewicz PI, et al. National trends and disparities in the use of minimally invasive adult pyeloplasty. *J Urol.* 2012;188(3):913–8.
15. Kumar R, Nayak B. Robotic versus conventional laparoscopic pyeloplasty: a single surgeon concurrent cohort review. *Indian J Urol.* 2013;29(1):19–21.
16. Olweny EO, Park SK, Tan YK, Gurbuz C, Cadeddu JA, Best SL. Perioperative comparison of robotic assisted laparoendoscopic single-site (LESS) pyeloplasty versus conventional LESS pyeloplasty. *Eur Urol.* 2012;61(2):410–4.
17. Garcia-Galisteo E, Emmanuel-Tejero E, Navarro Vilchez P, Garcia-Galisteo J, Baena-Gonzalez V. Comparison of the operation time and complications between conventional and robotic-assisted laparoscopic pyeloplasty. *Actas Urol Esp.* 2011;35(9):523–8.
18. Hemal AK, Mukherjee S, Singh K. Laparoscopic pyeloplasty versus robotic pyeloplasty for ureteropelvic junction obstruction: a series of 60 cases performed by a single surgeon. *Can J Urol.* 2010;17(1):5012–6.
19. Kim W, Abdelshehid C, Lee HJ, Ahlering T. Robotic-assisted laparoscopic prostatectomy in umbilical hernia patients: University of California, Irvine, technique for port placement and repair. *Urology.* 2012;79(6):1412 e1411–1413.
20. Link RE, Bhayani SB, Kavoussi LR. A prospective comparison of robotic and laparoscopic pyeloplasty. *Ann Surg.* 2006;243(4):486–91.
21. Weise ES, Winfield HN. Robotic computer-assisted pyeloplasty versus conventional laparoscopic pyeloplasty. *J Endourol.* 2006;20(10):813–9.
22. Wang F, Xu Y, Zhong H. Robot-assisted versus laparoscopic pyeloplasty for patients with ureteropelvic junction obstruction: an updated systematic review and meta-analysis. *Scand J Urol.* 2013;47:251–64.
23. Olsen LH, Jorgensen TM. Computer assisted pyeloplasty in children: the retroperitoneal approach. *J Urol.* 2004;171(6 Pt 2):2629–31.
24. Kaouk JH, Hafron J, Parekattil S, et al. Is retroperitoneal approach feasible for robotic dismembered pyeloplasty: initial experience and long-term results. *J Endourol.* 2008;22(9):2153–9.
25. Cestari A, Buffi NM, Lista G, et al. Retroperitoneal and transperitoneal robot-assisted pyeloplasty in adults: techniques and results. *Eur Urol.* 2010;58(5):711–8.
26. Best SL, Donnally C, Mir SA, Tracy CR, Raman JD, Cadeddu JA. Complications during the initial experience with laparoendoscopic single-site pyeloplasty. *BJU Int.* 2011;108(8):1326–9.
27. Tracy CR, Raman JD, Bagrodia A, Cadeddu JA. Perioperative outcomes in patients undergoing conventional laparoscopic versus laparoendoscopic single-site pyeloplasty. *Urology.* 2009;74(5):1029–34.
28. Harrow BR, Bagrodia A, Olweny EO, Faddegon S, Cadeddu JA, Gahan JC. Renal function outcomes after laparoendoscopic single site pyeloplasty. *J Urol.* 2013;190:565–9.

29. Clavien PA, Sanabria JR, Strasberg SM. Proposed classification of complications of surgery with examples of utility in cholecystectomy. *Surgery*. 1992;111(5):518–26.
30. Moreno-Sierra J, Castillon-Vela I, Ortiz-Oshiro E, et al. Robotic Anderson-Hynes dismembered pyeloplasty: initial experience. *Int J Med Robot*. 2013;9:127–33.
31. Sivaraman A, Leveillee RJ, Patel MB, et al. Robot-assisted laparoscopic dismembered pyeloplasty for ureteropelvic junction obstruction: a multi-institutional experience. *Urology*. 2012;79(2):351–5.
32. Niver BE, Agalliu I, Bareket R, Mufarrij P, Shah O, Stifelman MD. Analysis of robotic-assisted laparoscopic pyeloplasty for primary versus secondary repair in 119 consecutive cases. *Urology*. 2012;79(3):689–94.
33. Etafy M, Pick D, Said S, et al. Robotic pyeloplasty: the University of California-Irvine experience. *J Urol*. 2011;185(6):2196–200.
34. Sethi AS, Regan SM, Sundaram CP. Robot-assisted laparoscopic pyeloplasty with and without a ureteral stent. *J Endourol*. 2011;25(2):239–43.
35. Erdeljan P, Caumartin Y, Warren J, et al. Robot-assisted pyeloplasty: follow-up of first Canadian experience with comparison of outcomes between experienced and trainee surgeons. *J Endourol*. 2010;24(9):1447–50.
36. Lucas SM, Sundaram CP, Wolf Jr JS, et al. Factors that impact the outcome of minimally invasive pyeloplasty: results of the Multi-institutional Laparoscopic and Robotic Pyeloplasty Collaborative Group. *J Urol*. 2012;187(2):522–7.

Sarah McAchran and Courtenay Moore

Introduction

Urologic and urogynecologic surgeons specializing in female pelvic medicine and reconstructive surgery have been early adapters of new and minimally invasive techniques to treat both urinary incontinence and pelvic organ prolapse (POP) with the goal of improving both anatomic and subjective outcomes while minimizing morbidity. In the last 5 years, robotic approaches to POP have gained a strong foothold as surgeons have adapted this technology to the abdominal sacrocolpopexy (ASC) procedure, the universally considered “gold-standard” procedure to treat POP [1]. The utilization of robotic technology has led to decreased intraoperative morbidity as well as faster convalescence.

Abdominal surgery for pelvic organ prolapse (POP) has a long history, originating with the Mayo procedure which described securing the uterus to the anterior abdominal wall. Eventually, attempts to create a more natural vaginal axis and to prevent enterocele formation led to the suturing

of the vaginal apex directly to the anterior longitudinal ligament of the sacrum. The subsequent addition of a piece of material, either autologous or synthetic, to bridge the gap between the vaginal apex and the sacrum led to the contemporary version of the abdominal sacrocolpopexy.

The first minimally invasive alternative to the open ASC was the laparoscopic sacrocolpopexy (LSC) [2]. This enabled the performance of a highly successful abdominal procedure while avoiding a large abdominal incision, abdominal packing and retracting, and extensive bowel manipulation. This translates into shorter recovery time, reduction in postoperative pain, and a lower rate of postoperative ileus. LSC and ASC procedures have demonstrated similar success rates [3–5]. However, the rigidity of laparoscopic instrumentation limits surgical dexterity with suturing as well as sacral and apical vaginal dissection. Robotic technology alleviates these limitations by improving visualization of the surgical field with three-dimensional imaging. Additionally, the seven degrees of freedom in articulation as well as the stability of the instrument (tremor control) enable the surgeon to perform complex procedures with precision and accuracy.

Given the recent adoption of this technology, true evaluation of long-term outcomes are decades away; however, one center has published data comparing outcomes for 51 patients who underwent either an open ASC or a robotic

S. McAchran, MD (✉)
Department of Urology, University of Wisconsin
School of Medicine and Public Health,
1685 Highland Ave, Madison, WI 53705, USA
e-mail: mcachran@urology.wisc.edu

C. Moore
Department of Urology, Cleveland Clinic,
Cleveland, OH, USA

abdominal sacrocolpopexy (RASC) procedure between 2006 and 2007 with a mean follow-up of 44 months [6]. Anatomic improvement based on Pelvic Organ Prolapse Quantification (POP-Q) examination and subjective improvement based on questionnaire data were similar between the two groups suggesting that the addition of robotic technology does not hinder outcomes.

It is estimated that the lifetime risk of surgical intervention for POP is 11 % for women who reach 80 years of age [7]. As the population ages, the prevalence of this problem will continue to increase and the need to find a minimally invasive, durable repair that can be widely adopted by a reconstructive specialist continues to grow.

Indications/Contraindications

Commonly accepted indications for sacrocolpopexy include multicompartiment pelvic organ prolapse, symptomatic prolapse in younger women, recurrent prolapse after failed vaginal prolapse repair, severe vaginal vault prolapse, and vaginal vault prolapse in women with significant vaginal shortening as a result of prior surgeries. It is an appropriate procedure for women who wish to remain sexually active.

Relative contraindications for RASC are similar to those for most laparoscopic procedures and depend on the surgeon's experience and the complexity of the case. These include a history of multiple prior abdominal or pelvic procedures, severe chronic obstructive pulmonary disease, and morbid obesity. RASC traditionally requires a steep Trendelenburg position that may put patients with morbid obesity, pulmonary disease, and gastroesophageal reflux disease at higher risk for increased airway pressures, poor ventilation, and aspiration pneumonia. Prolonged surgical procedures in the steep Trendelenburg position can increase intraocular pressure, with case reports of retinal detachment and blindness [8]. Both open and laparoscopic approaches can be achieved with less steep Trendelenburg and thus should be considered for patients with the aforementioned comorbidities, or for those with retinal disease.

Sacrocolpopexy with Concomitant Hysterectomy

Strictly speaking, ASC describes the repair of post-hysterectomy vaginal vault prolapse. However, many with POP still have their uterus, necessitating concomitant hysterectomy. There are conflicting data regarding mesh erosion with concurrent total hysterectomy and open ASC [9–11]. The rate of erosion of the vaginal portion of the suspending mesh into the vagina varies between studies from 2 to 10 %. Patients suffering from this complication generally present with granulation tissue and a seropurulent or serosanguinous discharge per vagina. This can be accompanied by pain or tenderness and dyspareunia. Any combination of mesh and/or suture material may be extruded. The pathophysiology of this process is not known and the term “erosion” is used simply to describe the unplanned presence of mesh in the vagina. Erosion may be the result of inflammatory reaction to the foreign body, or infection of the foreign body. Alternatively, it may be due to the host's own immune response to the graft. Management of these erosions can be quite complicated with associated morbidity [12, 13].

Because mesh erosion tends to occur along suture lines, concomitant hysterectomy performed at the time of ASC is a logical risk factor given the proximity of the vaginal cuff closure to the suspending mesh. The risk is amplified by the potential for cuff dehiscence, which one study placed as an incidence of 4.1 % for robotic procedures [14]. Perhaps the most convincing study evaluating risk factors for mesh erosion is the subset analysis of the CARE trial performed by the members of the Pelvic Floor Disorders Network [10]. The CARE trial was a randomized surgical trial of 322 stress-continent women with stages II–IV POP conducted to investigate the benefit of an adjuvant Burch colposuspension at the time of ASC. This prospectively designed study followed 322 patients out to 2 years with 93 % of the patients completing the 2-year assessment. Eighty-three patients had a concomitant hysterectomy. There was a 6 % mesh/suture erosion rate within 2 years of surgery. In this study,

concurrent hysterectomy was a modifiable risk factor for mesh/suture erosion.

For this reason, if hysterectomy is to be performed at the time of robotic-assisted repair of prolapse, then a cervical-sparing procedure is preferred. The cervical-sparing procedure obviates the need for vaginal cuff closure and leads to shorter operative time and less blood loss [15]. The remainder of this chapter will focus on repair of post-hysterectomy vaginal vault prolapse with the RASC.

Robotic Abdominal Sacrocolpopexy Equipment List

Non-disposable

Da Vinci Surgical System (Intuitive Surgical, Sunnyvale, CA)

Veress needle

12 mm robotic port

Three 8 mm robotic ports (2 optional)

10/12 mm laparoscopic port

0° and 30° down robotic camera

Robotic monopolar curved scissors

Robotic grasping forceps

Robotic double fenestrated grasper

Two robotic needle drivers

Laparoscopic scissors

Laparoscopic grasping forceps

Handheld vaginal retractor

Cystoscope with 30° and 70° lenses

Disposable

Laparoscopic suction

Polypropylene mesh

Technical Description

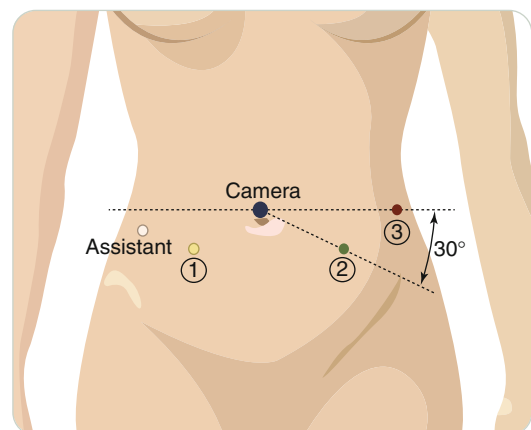
Patient Preparation and Positioning

As previously noted, steep Trendelenburg positioning is required for adequate pelvic visualization and dissection. Antiskid devices such as a gel pad or bean bag should be employed. Sequential compression devices are placed on the patient's legs. The patient's arms are padded and tucked taking care to protect all the bony prominences. The legs are placed in low-profile Allen

stirrups in a low lithotomy position with the thighs roughly parallel to the floor when the table is level. The knees should not be flexed more than 60° to prevent femoral nerve compression. The buttocks are placed so that they extend approximately 1 in. beyond the end of the table. To further insure against patient movement once the Trendelenburg position is employed, cross straps can be placed across the patient's chest. Prior to beginning the procedure, the table should then be placed into steep Trendelenburg position and observation for and remediation of any patient movement can occur. The patient is prepped from the nipples to the proximal thigh, including the vagina. Either an orogastric or nasogastric tube is placed. Once the patient is draped, a 16-French Foley catheter is inserted.

Placement of Instruments

The robotic ports are placed in a W configuration with the camera port placed at the level of the umbilicus (Fig. 9.1). When the distance between the umbilicus and the pubic symphysis is less than 15 cm, the camera port should be placed above the umbilicus to allow for adequate visualization of the sacral promontory. Pneumoperitoneum is obtained after gaining access to the peritoneal cavity using a Veress needle at the umbilicus. After confirmation of safe intraperitoneal entry



4-Arm Port Placements

Fig. 9.1 Port placement (From Intuitive Surgical)

with aspiration and drop tests, pneumoperitoneum is established to 15 mmHg. A 10 mm incision is then made within the umbilicus and a visual optical dilating trocar is used to insert the first 10 mm port using a zero-degree lens. Using a 0° or 30° up robotic camera, four additional ports are placed under direct vision. A total of three 8 mm robotic ports are placed as well as an additional 10/12 mm accessory laparoscopic port in the right lateral abdominal wall to allow passage of instruments, mesh, and sutures. The right and left robotic ports are placed 10 cm to the right or left of the umbilicus and approximately 30° inferior to the camera port. The third robotic port is placed as far lateral as possible to the patient's left side, approximately 3 cm from the iliac crest and at least 10 cm from the left instrument port, at the level of the camera port. The final laparoscopic port is placed on the patient's far right side, approximately 8 cm from the right instrument port, just below the level of the camera port (Fig. 9.2).

The OR table is lowered and the patient is placed in steep Trendelenburg position to allow bowel contents to retract naturally cephalad and the robot is docked. RASC can be accomplished with traditional docking between the legs at the foot of the bed. However, with the robotic cart side-docked 45° lateral to the patient's left leg, vaginal access during the procedure is improved (Fig. 9.3) [16, 17]. The bedside surgeon stands on the patient's right as does the scrub assistant.

Gaining Exposure

If not already in use, the zero-degree robotic camera is placed. The abdomen and pelvis are inspected and adhesions are addressed robotically. The sigmoid colon is identified. A fenestrated bipolar forceps can be used in the third robotic arm to retract the sigmoid colon laterally. If one is using the 2-arm robot, then a suture can be used to retract the sigmoid colon. There are several methods for doing this. A Keith needle can be used to pass a retracting suture into the abdomen through the skin. Using the robotic arms, the retracting suture is then passed through an epiploic append-

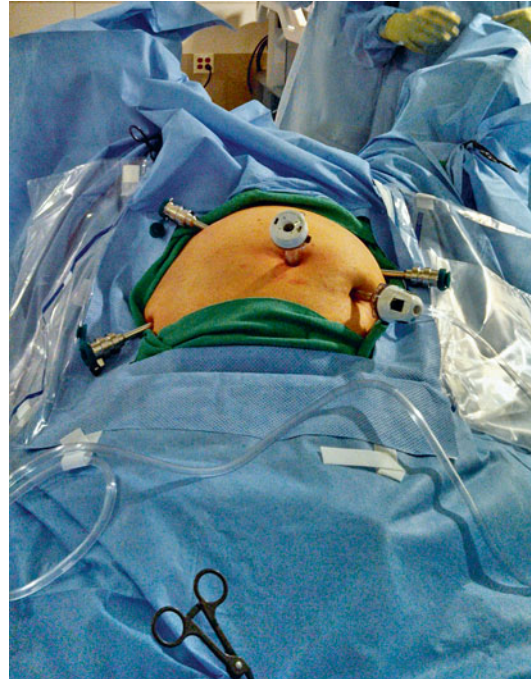

Fig. 9.2 Port in place after insufflation. In this view from the head looking toward the legs, the 10/12 camera port and accessory port are easily distinguished from the three robotic arm ports. The third robotic port, the most cephalad of the three, is placed as far lateral as possible to the patient's left side, approximately 3 cm from the iliac crest and at least 10 cm from the left instrument port, at the level of the camera port

age or the tenia of the sigmoid colon and then back through the skin near the entry site. This is gently secured at the skin level with a clamp.

The following structures should be identified: the sacral promontory which is just below the bifurcation of the iliac arteries, the right ureter which is approximately 3 cm lateral to the sacral promontory, vagina, bladder, and rectum (Fig. 9.4) [18]. To identify the vagina, a vaginal obturator is placed and manipulated by the bedside assistant. A round tipped endo-anal or EEA sizer may be placed transvaginally (Fig. 9.5). Alternatively, a customized handheld vaginal retractor can be used. CooperSurgical manufactures a two disposable Sacro tips that attach to their RUMI® handle, one of which is used for sacrocolpopexy and the other which can be used for sacrocervicopexy.

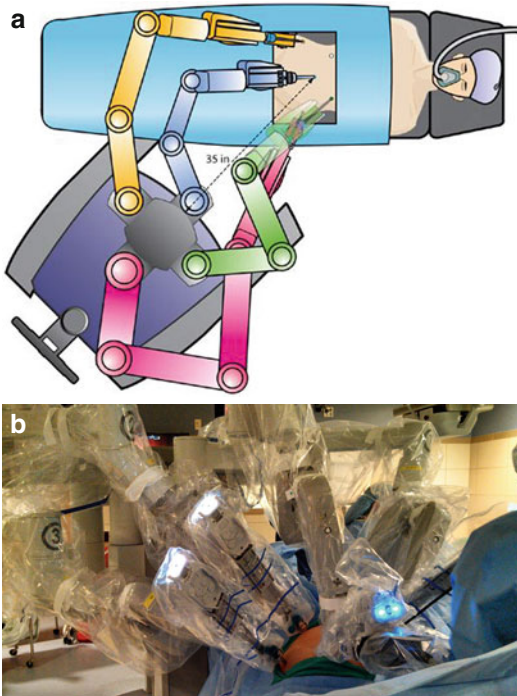


Fig. 9.3 Side docking: Side docking allows for easier access to the vagina and easier manipulation of the vaginal obturator by the bedside assistant. In the cartoon, *red* is arm #3, *green* is arm #2, the camera is *blue*, and *yellow* is arm #1. Note that arm #3 is almost parallel to the floor. (a) cartoon, (b) intra-operative photo

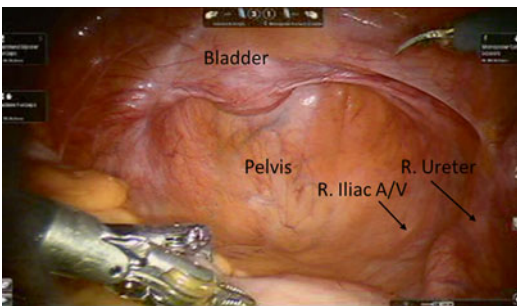


Fig. 9.4 Pelvic anatomy. Prior to any dissection, one can identify the bladder, iliac artery and vein, and right ureter

With the vaginal obturator in place, the plane between the anterior wall of the vagina and the bladder is developed (Fig. 9.6). The peritoneum over the vaginal apex is incised with cautery applied via the monopolar curved scissors in the

right hand and the Maryland bipolar forceps in the left hand. This should be a relatively bloodless plane, and after the initial use of cautery to incise the peritoneum, the remaining dissection is performed sharply without cautery to prevent devascularization of the vaginal wall (Fig. 9.7). The bladder can be filled to help demarcate the appropriate plane, or a cystoscopic light can be introduced into the bladder. This plane should be dissected for a minimum of 3 cm distal to the vaginal apex to allow space for placement of the mesh. The lack of direct tactile feedback can make this dissection challenging, particularly in patients who have undergone prior reconstructive procedures. In a recently published series of 85 cases performed by an experienced robotic surgeon, the rate of inadvertent cystotomy was 4.7 % [15].

The rectovaginal space is similarly developed. The peritoneum over the posterior vaginal wall is elevated, and the vagina is separated from the rectum posteriorly. An EEA sizer placed per rectum can help to identify the rectovaginal septum.

After adequate vaginal mobilization, attention is then turned to the sacral promontory and to exposure of the anterior longitudinal ligament of the sacrum (Fig. 9.8). The 30° down scope allows for better visualization of the sacrum. The peritoneum overlying the sacral promontory is grasped and incised with the monopolar endoshears. Blunt dissection can then be used to clearly identify the anterior longitudinal ligament in preparation for suture placement. Extreme care is taken to avoid injury to the presacral veins, as this can cause life-threatening bleeding. The magnification and 3-D visualization afforded by the robotic technique provide enhanced visualization of the presacral vasculature. The peritoneal incision can then be extended in a caudal direction toward the posterior cul-de-sac and vaginal cuff to allow for retroperitonealization of the mesh at completion of the procedure. Alternatively, a peritoneal tunnel can be created using blunt dissection from the promontory to the cul-de-sac [15]. This eliminates the need for a peritoneal closure at the end of the case, which can be time-consuming.

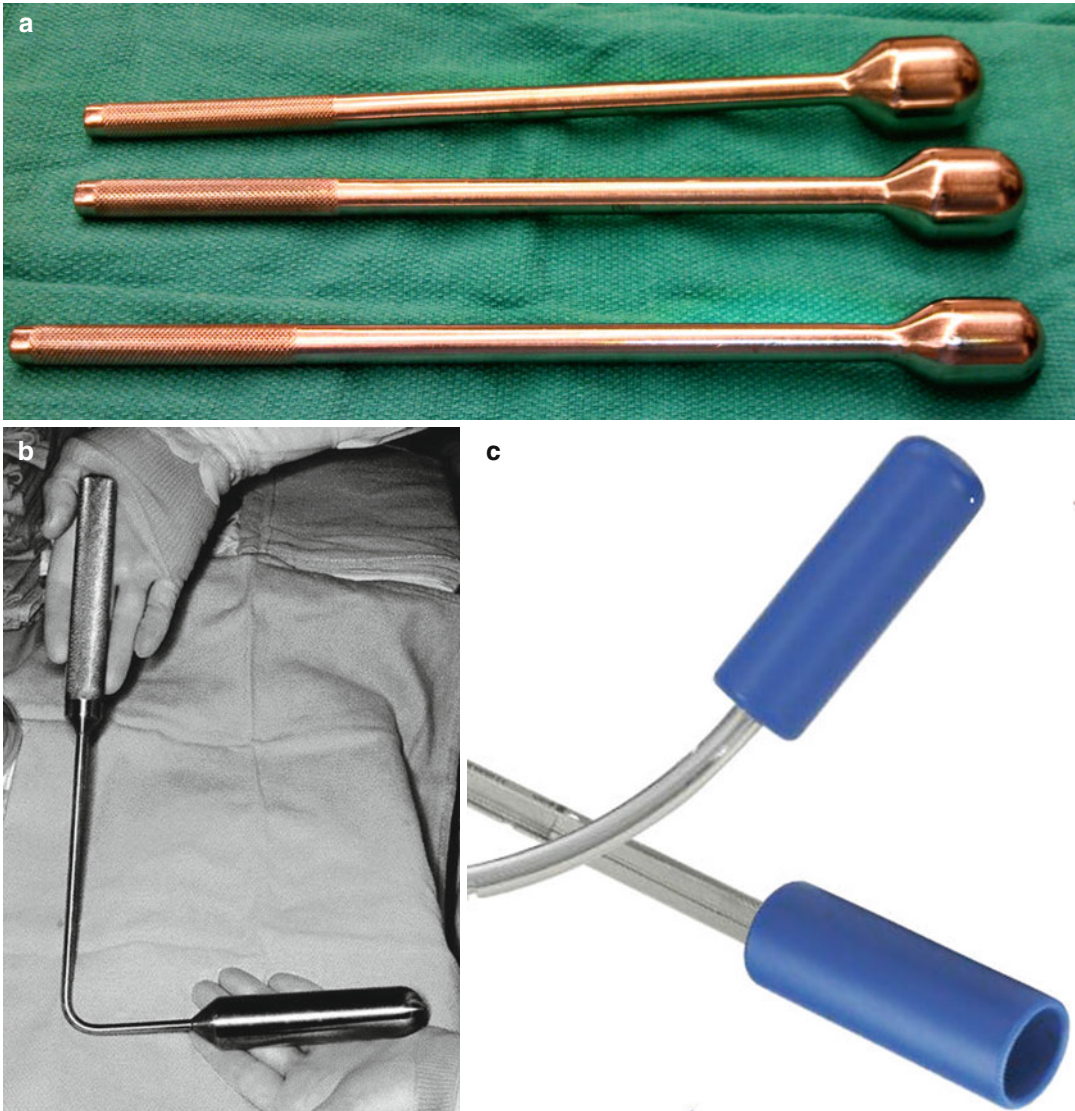

Fig. 9.5 Various options to use as the vaginal obturator: (a) EEA sizers, (b) customized vaginal retractor used at the Mayo Clinic, (c) CooperSurgical disposable

Sacrocolpopexy Tips and Sacrocervicopexy Tips for RUMI® System Handle. (a) EEA sizer, (b) from Mitchell et al. [19], and (c) RUMI Sacrocolpopexy Tip

Mesh Placement

Next, two or three nonabsorbable sutures, cut to approximately 7 cm, are placed into the exposed portion of the sacral promontory (Fig. 9.9). These sutures with needles attached are left in the abdomen for mesh fixation. 2.0 Gore-Tex, 0.0 or 2.0 Ethibond, and 2.0 Prolene have all been described [15, 19–22].

The polypropylene mesh, either in two separate strips (3–5 cm × 12–15 cm) or prefashioned in a Y configuration, is passed into the field through the assistant port and sutured to the posterior and anterior vaginal wall. Currently, AMS, Bard, and Ethicon have a precut macroporous Y-shaped mesh designed specifically for ASC (Fig. 9.10). Alternatively, the anterior and posterior arms of the self-cut mesh can be sewn

Fig. 9.6 Using the third robotic arm to retract the bladder anteriorly, the peritoneum over the vaginal cuff is exposed. Note the grasper in the left hand and the endoshears in the right hand

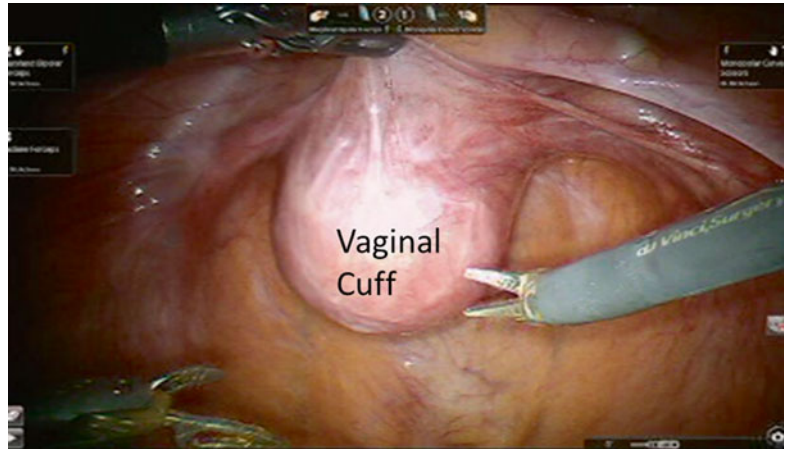


Fig. 9.7 The peritoneum overlying the anterior vagina has been dissected allowing a plane to develop between the vagina and the bladder. This will be the site for the anterior mesh attachment

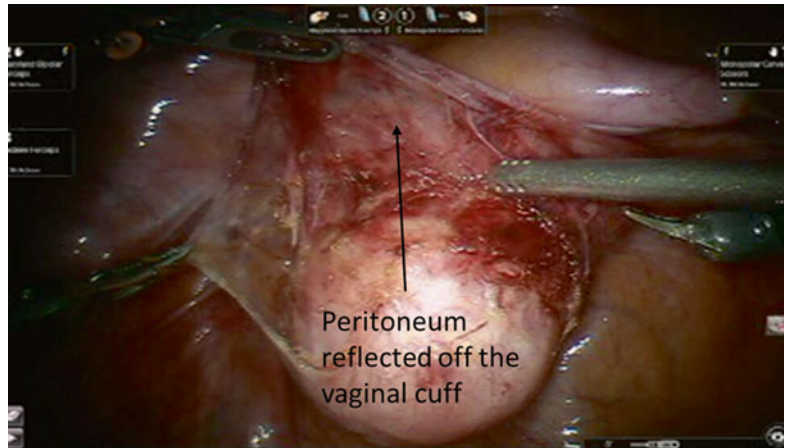


Fig. 9.8 Sacral dissection with the posterior peritoneum incised and the anterior longitudinal ligament exposed

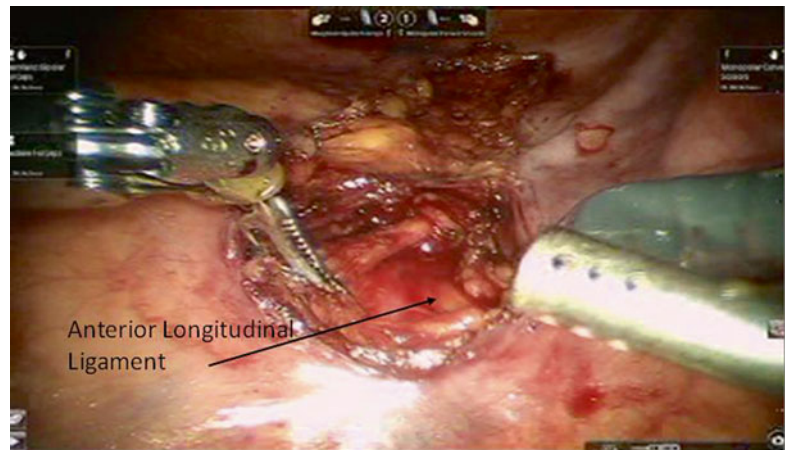


Fig. 9.9 The anchoring suture for the sacral portion of the mesh is placed through the anterior longitudinal ligament

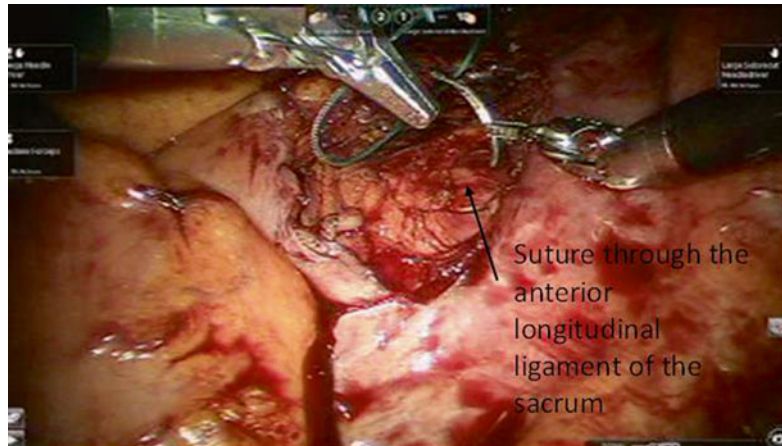


Fig. 9.10 Macroporous Y-shaped prefabricated mesh. Pictured is the Artisyn™Y-Shaped Mesh by Ethicon

together with permanent suture before introduction into the abdomen.

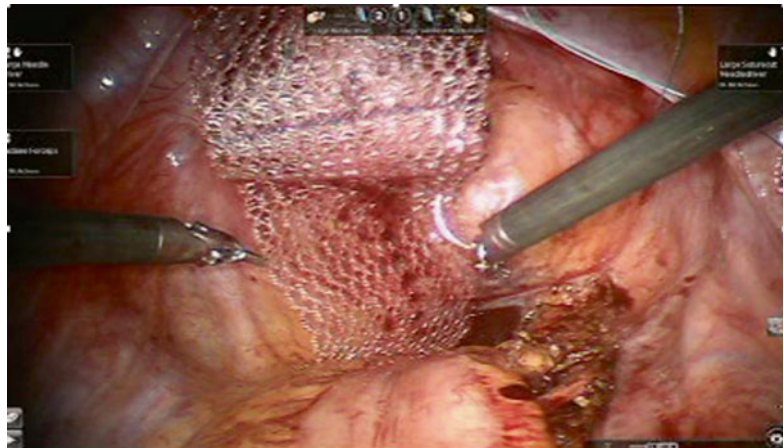
With the vaginal obturator in place and the endoshears swapped for a needle driver, the mesh is affixed to the anterior vaginal wall with a series of 4-8 interrupted sutures cut to 6.0 in. in length (Fig. 9.11). Placing the distal and lateral corner sutures first facilitates placement of the remaining sutures. Traditionally, nonabsorbable sutures, often 2.0 Gore-Tex, have been used to affix the mesh to the vagina. Because Gore-Tex is a monofilament suture, it is thought to be less likely to extrude vaginally. Recently, the procedure has been described using 2-0 polyglactin suture for this portion of the procedure [22, 23]. In two small series, both of which had 2-year follow-up, the rate of vaginal mesh erosion was less than 3%. It is proposed that polyglactin suture which is completely absorbed in 56–70 days will retain its strength in the first few weeks while tissue ingrowth incorporates the mesh into the vaginal wall and then absorbed, eliminating the risk of suture extrusion in the long term. The effect this may have on prolapse recurrence rates in the long term remains unknown.

The posterior arm of the mesh is then affixed to the posterior vaginal wall (Fig. 9.12). The third robotic arm can be used to grasp the apical end of the mesh, allowing the posterior arm to drape over the posterior vaginal wall. Excess mesh

Fig. 9.11 With an obturator in the vagina, the mesh is attached to the anterior vaginal wall

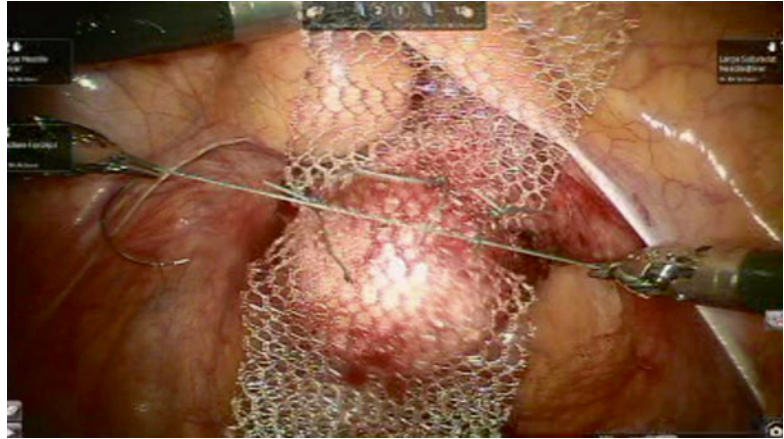

Fig. 9.12 Using the third robotic arm to retract the sacral portion of the mesh, the posterior arm of the mesh is affixed to the vagina. Note that the vaginal obturator is used to deflect the vagina anteriorly



from the anterior and posterior limbs is trimmed with either robotic scissors or the scissor portion of the *SutureCut*TM needle driver.

Finally, the apical portion of the mesh is held in place against the sacral promontory while the console or bedside surgeon examines the vagina to assess the degree of prolapse reduction. The mesh tension should be adjusted appropriately to reduce the prolapse without putting excess tension on the vaginal walls. The previously placed sutures in the anterior longitudinal ligament of the sacrum are then passed through the mesh at the chosen location (Fig. 9.13). Excess apical mesh is trimmed and the mesh is retroperitonealized by reapproximating the peritoneum over the

mesh with 2-0 Vicryl suture (Figs. 9.14 and 9.15). Additional sutures can be used to approximate the peritoneum overlying the bladder to cover the mesh near the vaginal cuff. The LAPRA-TY® (Ethicon) device can be helpful in securing the suture for this portion of the procedure.

At this point, it is prudent to perform cystoscopy after the intravenous administration of indigo carmine. This allows the surgeon to assess for ureteral patency and bladder integrity prior to completing the procedure. Once completed, the ports are removed. Fascial closures are performed on the 10/12 mm ports. The 8 mm robotic ports do not require fascial closure. The skin is closed with subcuticular sutures and port sites are covered with skin glue.

Fig. 9.13 The mesh is secured to the sacrum with at least two fixating sutures

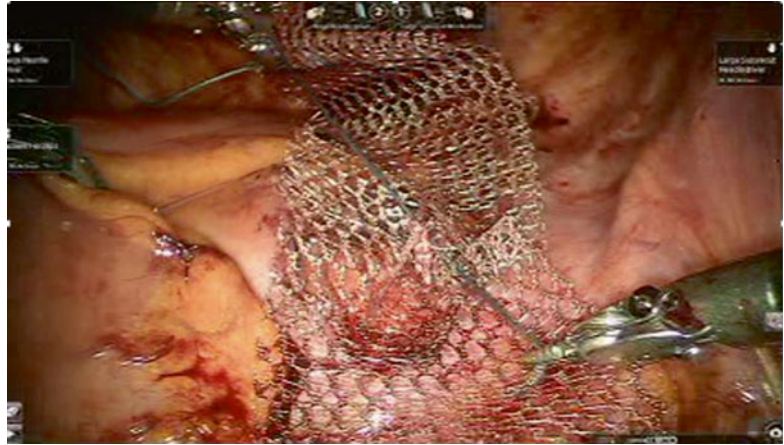


Fig. 9.14 The posterior peritoneum is reapproximated over the mesh using a 2-0 Vicryl suture

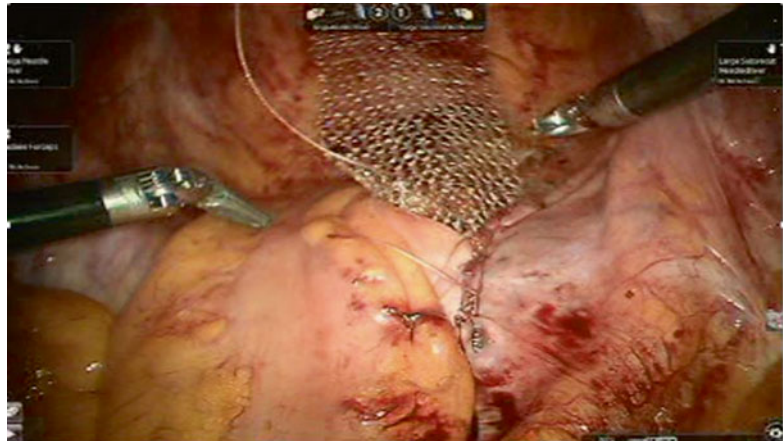
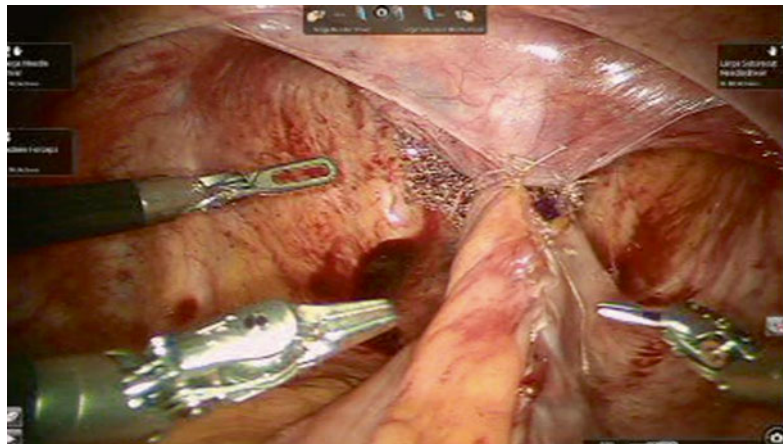


Fig. 9.15 The mesh is almost completely retroperitonealized



Outcomes

Several studies, some prospective, have demonstrated reduced hospital stay, reduced blood loss when compared to open sacrocolpopexy, and comparable patient outcomes when compared to open and laparoscopic techniques. The majority of prolapse recurrences were either anterior or posterior wall recurrences and were treatable with vaginal repairs. A randomized controlled trial comparing RASC with either the open or laparoscopic technique has not been published.

Table 9.1 summarizes the outcomes from the available published series. Geller et al. have the longest follow-up at 44.2 months; however, the study population is only 23 patients [6]. In that series, they reported no recurrence of apical prolapse but 21 % of patients with recurrent anterior or posterior wall prolapse. They do not comment on whether or not the recurrent prolapse was symptomatic or how it was addressed. The mesh erosion rate was 8 %.

The largest series from Siddiqui et al. followed patients for 12 months [28]. It should be noted that this group includes the 23 patients from Geller's study. In this larger cohort, the

recurrent prolapse rate was 8 % and the mesh erosion rate was 2.4 %.

Both the Geller and Siddiqui papers compare their RASC patients with open patients who were subjects of the Colpopexy and Urinary Reduction Efforts, or CARE trial. This was a prospective randomized multicenter trial of women with stress continence who underwent open abdominal sacrocolpopexy between 2002 and 2005 for symptomatic POP and also received either concomitant Burch urethropexy or no urethropexy. A recent long-term follow-up of the CARE cohort of patients was published by Nygaard et al. [29]. These patients were followed at 2, 5, and 7 years with a robust 126 of the original 233 patients completing 7-year follow-up. For this study, anatomic failure was defined as failure requiring retreatment or POP-Q evaluation demonstrating descent of the vaginal apex below the upper third of the vagina, or anterior or posterior vaginal wall prolapse beyond the hymen. Symptomatic failure was defined as failure requiring retreatment or self-reported bulge. Using these composite outcomes criteria, by the 5-year follow-up study, nearly one-third of women met the composite failure definition. However, 95 % had no retreat-

Table 9.1 Summary of trials reporting RASC outcomes

Authors	<i>N</i>	Follow-up (mos)	Anatomic results	Reoperation for POP	Mesh erosion
Moreno Sierra et al. [24]	31	24.5	0 % recurrent apical prolapse	None	NR
Tan-Kim et al. [25]	43	6	0 % recurrent apical prolapse	NR	5 %
Akl et al. [21]	80	4.8	1.25 % recurrent apical prolapse	2 rectocele/cystocele repairs, 1 revision of mesh sacrocolpopexy	6 %
Kramer et al. [23]	21	25.2	5 % recurrent apical prolapse, 57 % recurrent vaginal wall prolapse	12 secondary cystocele or rectocele repairs	0 %
Geller et al. [6] ^a	23	44.2	0 % apical recurrent apical prolapse, 21.1 % recurrent vaginal wall prolapse	NR	8 %
Elliott et al. [26]	21	12–36 (mean 24)	5 % recurrent apical prolapse, 5 % recurrent vaginal wall prolapse	1 open sacrocolpopexy, 1 rectocele repair	9.5 %
Belsante et al. [22]	35	28	0 % apical recurrent apical prolapse, 8.5 % recurrent vaginal wall prolapse	3 rectocele/cystocele repairs	2.8 %
Matthews et al. [15]	85	6	0 % apical recurrent apical prolapse, 5.8 % recurrent vaginal wall prolapse	1 rectocele repair	2.3 %
Ploumidis et al. [27]	95	34	0 % apical recurrent apical prolapse, 4.2 % recurrent vaginal wall prolapse	NR	1.0 %
Siddiqui et al. [28] ^a	125	12	8 % recurrent prolapse	3 rectocele repairs	2.4 %

^aDenotes overlapping patient populations

ment for POP. This suggests that, with time, even with the gold-standard open ASC, there is progressive loss of anatomic support. Despite this progressive loss of anatomic support, ASC generally provides relief of POP symptoms.

Additionally, in this study, by year 2, 3 of the 322 women enrolled in CARE had suture erosion and 17 had mesh erosion. There were 6 additional cases of mesh erosion and 1 suture erosion in the extended CARE population by year 7. Erosions occurred with all mesh types placed. This data provided the basis for an estimated probability of mesh erosion at 10.5 %.

It is safe to say that this is likely the most objective, least biased data available on long-term outcomes after ASC, and it demonstrates a significant anatomic failure rate in the long term as well as a 10.5 % risk of mesh complications that continue to accrue over time. While outcomes of robotic procedures should be expected to be comparable to the open procedures, they are unlikely to be better, and this data on both prolapse recurrence and mesh erosion rate should be factored into patient counseling when discussing this procedure.

Complications

The major complications of recurrence and mesh erosion have been reviewed; however, several other intraoperative and postoperative complications can occur.

Intraoperative Complications

The dissection of the sacral promontory can be fraught with difficulty if care is not taken to identify the presacral veins. If these are injured, they can be a source of significant bleeding. If bleeding does occur, this can be controlled with electrocautery or placement of Hem-o-lok-applied clips by the bedside assistant. If bleeding persists, then open conversion may be required.

Inadvertent injury to the vagina, bladder, and rectum can all occur during the vaginal dissection.

Mitchell et al. recommend meticulous closure of the bladder in two layers to ensure a watertight closure [19]. If successful closure is achieved, then the procedure does not need to be aborted. They do recommend maintaining Foley catheter drainage for 1–2 weeks postoperatively. Belsante et al. report on 5 vaginotomies which were oversewn with 2-0 polyglactin sutures [22]. The mesh was then placed away from the vaginotomy repair to minimize the risk of secondary mesh erosion. One of these patients was noted to have an apical mesh erosion at 6-month follow-up, and this was treated with excision and vaginal closure. Matthews comments on her 4 cystotomies and 2 proctotomies [15]. Both rectal injuries occurred in the distal rectum near the perineal body in women who had undergone prior repair. The rectal injury was repaired in two layers and patients were kept on a low-residue diet for 2 weeks postsurgery. No further complications were noted.

Postoperative Complications

Mesh erosion has been discussed. Other complications include urinary tract or wound infection. Port site hernias may occur and often require open reduction and repair. Lastly, as with any abdominal surgery, small bowel obstruction may occur.

Future

ASC with synthetic mesh remains the gold-standard POP repair; however, the need for general anesthesia, longer operative time, and increased invasiveness compared with vaginal approaches limit its use. The addition of robotic technology is appealing to both the patient and surgeon as a minimally invasive alternative with acceptable morbidity and complication rates. Several prospective series have demonstrated the safety and feasibility of RASC with outcomes comparable to the open approach. Randomized prospective studies with long-term follow-up are needed to determine the efficacy, morbidity, and patient satisfaction of RASC.

References

- Nygaard IE, McCreery R, Brubaker L, et al. Abdominal sacrocolpopexy: a comprehensive review. *Obstet Gynecol.* 2004;104(4):805–23.
- Nezhat CH, Nezhat F, Nezhat C. Laparoscopic sacral colpopexy for vaginal vault prolapse. *Obstet Gynecol.* 1994;84(5):885–8.
- Paraiso MF, Walters MD, Rackley RR, Melek S, Hugney C. Laparoscopic and abdominal sacral colpopexies: a comparative cohort study. *Am J Obstet Gynecol.* 2005;192(5):1752–8.
- Klauschie JL, Suozzi BA, O'Brien MM, McBride AW. A comparison of laparoscopic and abdominal sacral colpopexy: objective outcome and perioperative differences. *Int Urogynecol J Pelvic Floor Dysfunct.* 2009;20(3):273–9.
- Hsiao KC, Latchamsetty K, Govier FE, Kozlowski P, Kobashi KC. Comparison of laparoscopic and abdominal sacrocolpopexy for the treatment of vaginal vault prolapse. *J Endourol.* 2007;21(8):926–30.
- Geller EJ, Parnell BA, Dunivan GC. Robotic vs abdominal sacrocolpopexy: 44-month pelvic floor outcomes. *Urology.* 2012;79(3):532–6.
- Olsen AL, Smith VJ, Bergstrom JO, Colling JC, Clark AL. Epidemiology of surgically managed pelvic organ prolapse and urinary incontinence. *Obstet Gynecol.* 1997;89(4):501–6.
- Awad H, Santilli S, Ohr M, et al. The effects of steep trendelenburg positioning on intraocular pressure during robotic radical prostatectomy. *Anesth Analg.* 2009;109(2):473–8.
- Brizzolara S, Pillai-Allen A. Risk of mesh erosion with sacral colpopexy and concurrent hysterectomy. *Obstet Gynecol.* 2003;102(2):306–10.
- Cundiff GW, Varner E, Visco AG, et al. Risk factors for mesh/suture erosion following sacral colpopexy. *Am J Obstet Gynecol.* 2008;199(6):688 e681–685.
- Wu JM, Wells EC, Hundley AF, Connolly A, Williams KS, Visco AG. Mesh erosion in abdominal sacral colpopexy with and without concomitant hysterectomy. *Am J Obstet Gynecol.* 2006;194(5):1418–22.
- Quiroz LH, Gutman RE, Fagan MJ, Cundiff GW. Partial colpocleisis for the treatment of sacrocolpopexy mesh erosions. *Int Urogynecol J Pelvic Floor Dysfunct.* 2008;19(2):261–6.
- South MM, Foster RT, Webster GD, Weidner AC, Amundsen CL. Surgical excision of eroded mesh after prior abdominal sacrocolpopexy. *Am J Obstet Gynecol.* 2007;197(6):615 e611–615.
- Kho RM, Akl MN, Cornella JL, Magtibay PM, Wechter ME, Magrina JF. Incidence and characteristics of patients with vaginal cuff dehiscence after robotic procedures. *Obstet Gynecol.* 2009;114(2 Pt 1):231–5.
- Matthews CA, Carroll A, Hill A, Ramakrishnan V, Gill EJ. Prospective evaluation of surgical outcomes of robot-assisted sacrocolpopexy and sacrocervicopexy for the management of apical pelvic support defects. *South Med J.* 2012;105(5):274–8.
- Woods DL, Hou JY, Riemers L, Gupta D, Kuo DY. Side-docking in robotic-assisted gynaecologic cancer surgery. *Int J Med Robot.* 2011;7(1):51–4.
- Einarsson JI, Hibner M, Advincula AP. Side docking: an alternative docking method for gynecologic robotic surgery. *Rev Obstet Gynecol.* 2011;4(3–4):123–5.
- McCullough M, Valceus J, Downes K, Hoyte L. The ureter as a landmark for robotic sacrocolpopexy. *Female Pelvic Med Reconstr Surg.* 2012;18(3):162–4.
- Mitchell CR, Gettman M, Chow GK, Elliott D. Robot-assisted sacrocolpopexy: description and video. *J Endourol.* 2012;26(12):1596–9.
- Rosenblum N. Robotic approaches to prolapse surgery. *Curr Opin Urol.* 2012;22(4):292–6.
- Akl MN, Long JB, Giles DL, et al. Robotic-assisted sacrocolpopexy: technique and learning curve. *Surg Endosc.* 2009;23(10):2390–4.
- Belsante M, Murray S, Dillon B, Zimmern P. Mid term outcome of robotic mesh sacrocolpopexy. *Can J Urol.* 2013;20(1):6656–61.
- Kramer BA, Whelan CM, Powell TM, Schwartz BF. Robot-assisted laparoscopic sacrocolpopexy as management for pelvic organ prolapse. *J Endourol.* 2009;23(4):655–8.
- Moreno Sierra J, Ortiz Oshiro E, Fernandez Perez C, et al. Long-term outcomes after robotic sacrocolpopexy in pelvic organ prolapse: prospective analysis. *Urol Int.* 2011;86(4):414–8.
- Tan-Kim J, Menefee SA, Luber KM, Nager CW, Lukacz ES. Robotic-assisted and laparoscopic sacrocolpopexy: comparing operative times, costs and outcomes. *Female Pelvic Med Reconstr Surg.* 2011;17(1):44–9.
- Elliott DS, Krambeck AE, Chow GK. Long-term results of robotic assisted laparoscopic sacrocolpopexy for the treatment of high grade vaginal vault prolapse. *J Urol.* 2006;176(2):655–9.
- Ploumidis A, Spinoit AF, Naeyer GD, et al. Robot-assisted sacrocolpopexy for pelvic organ prolapse: surgical technique and outcomes at a single high-volume institution. *Eur Urol.* 2014;65:138–45.
- Siddiqui NY, Geller EJ, Visco AG. Symptomatic and anatomic 1-year outcomes after robotic and abdominal sacrocolpopexy. *Am J Obstet Gynecol.* 2012;206(5):435 e431–435.
- Nygaard I, Brubaker L, Zyczynski HM, et al. Long-term outcomes following abdominal sacrocolpopexy for pelvic organ prolapse. *JAMA.* 2013;309(19):2016–24.

Shashikant Mishra and Mihir Desai

Laparoendoscopic single-site surgery (LESS) represents an evolution in laparoscopic surgery to potentially further reduce morbidity and improve cosmesis [1, 2]. The term LESS has been recently coined to incorporate a group of related techniques that perform laparoscopic surgery through a single access site in the abdomen typically concealed in the umbilical scar [3]. LESS came in vogue due to a perceived impression that reducing the number of ports would naturally result in reduced morbidity and improve cosmesis of conventional multi-port laparoscopy. Since its initial report by Raman and colleagues, LESS surgery has increasingly been used to perform various urological procedures including those on the kidney, ureter, bladder, and prostate. At the time of this writing, a total of 1,023 manuscripts written have been reported on LESS of which 328 have been from urology. The aim of the current chapter is to describe specialized instrumentation and technical nuances with respect to LESS renal surgery.

S. Mishra, MD (✉)
Department of Urology, Muljibhai Patel Urological Hospital, Dr. Virendra Desai Road, Nadiad, Gujarat 387001, India
e-mail: mishra@mpuh.org

M. Desai, MD
Department of Clinical Urology, Robotic Urologic Surgery, Keck Hospital of USC, USC Norris Comprehensive Cancer Center and Hospital, Los Angeles, USA

Access Instrumentation

LESS can be performed by inserting conventional laparoscopic ports through a single umbilical incision or with the use of one of the commercially available multichannel trocars. The advantage of the single-site approach of using typically three low-profile laparoscopic trocars minimizes the need of specialized instrumentation as relates to access (Fig. 10.1). In contrast, the single-port approach utilizes a variety of purpose-specific ports that have multiple channels for use of the optic and instruments [4]. Some of the clinically used industry-driven access devices for LESS are TriPort™ and QuadPort™ (Olympus Medical, Tokyo, Japan), Uni-X Single Port™ (Pnavel Systems, Cleveland, OH, USA), and GelPort™ (Applied Medical, USA). These trocars are all typically inserted through a single umbilical incision although extra umbilical sites have also been utilized (Table 10.1).

The TriPort™ and QuadPort™ (Olympus Medical, Tokyo, Japan) (Fig. 10.2) are the most commonly used and known FDA-approved, first-generation access system. The TriPort and TriPort Plus have a smaller ring compared to the larger QuadPort. Each device consists of a retractor component and a valve component, where the instruments are inserted. The design advantages of this port are tight seal, completely flexible, and no internal profile and the ability to



Fig. 10.1 Shows images of the TriPort (1×10 mm and 2×5 mm channels) and QuadPort (2×12 mm, 1×5 mm, 1×15 mm channels). The TriPort can be passed through a 1–3 cm incision and the QuadPort through a 1–6 cm

incision. The TriPort has a new version TriPort Plus that has an additional 5 mm channel with the same ring diameter that has been developed specifically for LESS cholecystectomy

Table 10.1 Commercially available specialized LESS trocars

Port	Manufacturer	Lumens	Incision size
Multiple trocars through single incision	Various	Various	2.5 cm
R-Port™/TriPort™	Advanced Surgical Concepts, Wicklow, Ireland	5 mm×2, 12 mm	2–3 cm
QuadPort™	Advanced Surgical Concepts, Wicklow, Ireland	5 mm, 15 mm, 10 mm×2	2.5–6.5 cm
Uni-X™	Pnavel Systems, NJ, USA	5 mm×3	2 cm
SILS™ Port	Covidien Mansfield, MA, USA	5 mm×3 or 12 mm, 5 mm×2	2 cm
GelPort™	Applied Medical, Rancho Santa Margarita, CA, USA	Various	Various

use curved, straight, and articulating instruments. Additionally, specimens can be easily retrieved through the TriPort and QuadPort by detaching the valve without the need to remove the ring.

The GelPort™ (Applied Medical, USA) was already in use in hand-assisted laparoscopic surgery and is now modified for use in LESS (Fig. 10.3). It has a GelSeal cap that provides a pseudo abdomen for a larger platform for triangulation, incorporates insufflation and smoke evacuation capabilities, provides a flexible fulcrum for improved instrument articulation, and maintains pneumoperitoneum. There is an

Alexis wound protector/retractor that accommodates 1.5–7 cm incisions. GelPort™ also facilitates extracorporeal anastomosis and specimen retrieval while protecting the incision site. The low-profile sleeves accommodate 5–12 mm instrumentation and offers greater freedom of movement due to low-profile design. The advantage of the GelPort is that the exact location of the ports can be selected by the surgeon as is the length of the fascial incision. Thus, for procedures that require extraction, one can make a larger incision and position the working ports to achieve triangulation in the small space.

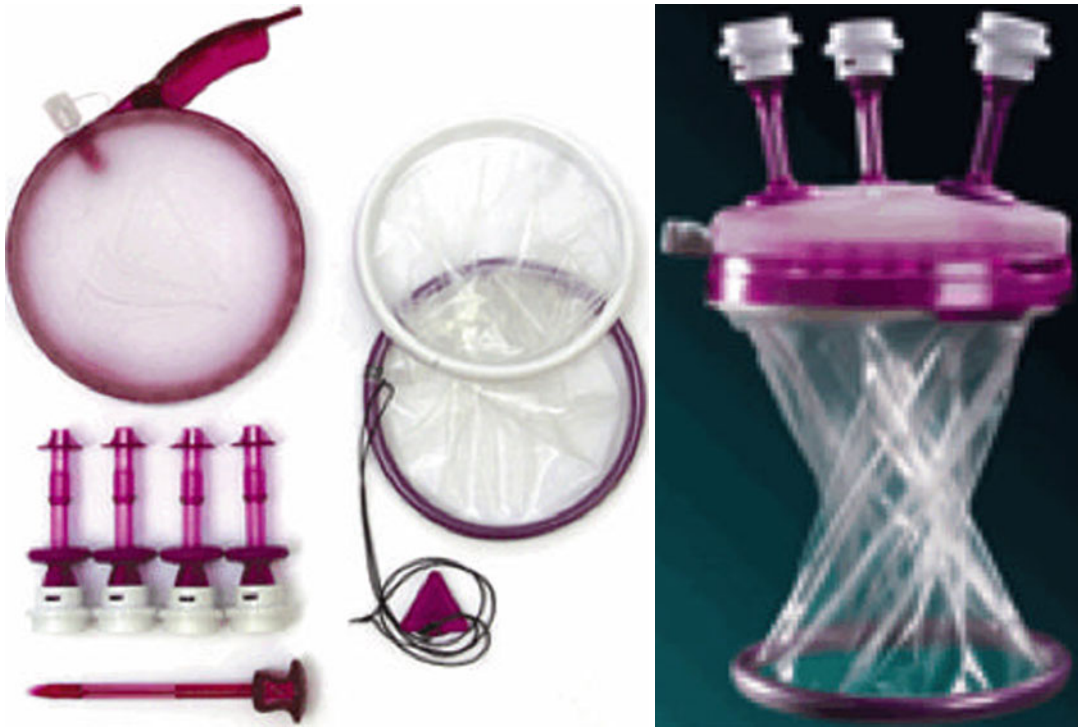

Fig. 10.2 Shows images of the GelPOINT (Applied Medical). This device can be inserted through a 2–7 cm incision and uses rigid trocars inserted through the gel.

The advantage of this port is that the ports can be spaced as needed and additional ports inserted through the gel as required

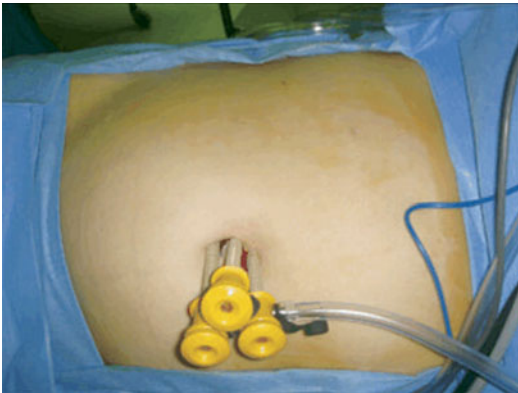

Fig. 10.3 Picture showing multiple standard low-profile ports inserted through a single skin incision

Other access devices (SILS Port™ (Covidien), X-Cone™ (Karl Storz), Air Seal™ (SurgiQuest), SLASS™ (Ethicon), and Octoport™ (Daikin Surgical, Korea)) that have been infrequently used and a detailed description of which are beyond the scope of this chapter.

Optics with LESS

Optics has also been optimized to accommodate the needs of LESS. Conventional laparoscopes result in external clashing because of their large camera head and light cable exiting at 90° (Fig. 10.4). Newer scopes combine light and camera systems to keep the camera head and light cord out of the operative field. In addition, extra-long scopes allow the camera operator to work outside of the operative space, providing the surgeon with more room to operate (Fig. 10.5). Most recently, endoscopes with a deflectable tip have been developed to provide the adequate angle of view while keeping the assistants' hand outside the already cramped working space during LESS surgery (Fig. 10.6). Various endoscope systems used with LESS are outlined in Table 10.2. In addition to technologic developments, many technical tips may help minimize clashing between the camera assistant and surgeon (Fig. 10.7).




Fig. 10.4 Shows clashing of a typical right-angle light cable during LESS surgery

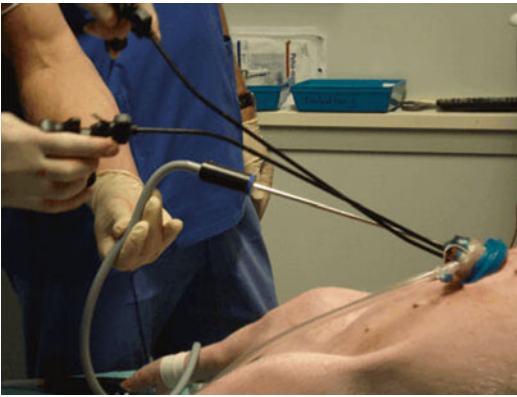


Fig. 10.5 Coaxial optical systems that incorporate both the imaging and light cables in the same axis of the telescope help minimize clashing with working instruments. Longer telescopes especially with a malleable handle may also help further remove the camera assistant's hand away from the surgeon's hands thus further minimizing clashing




Fig. 10.6 Deflectable tip optical systems also help restore the viewing angle and externally minimize clashing by enabling moving the assistant's hand completely out of the way. Figure on the left shows that a straight rigid telescope

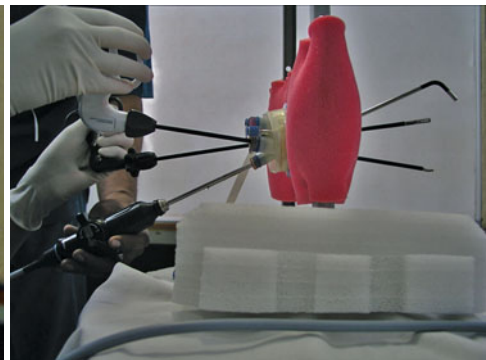
LESS Instruments

Clashing of hands and instruments is inherent to LESS and much of the instrument development is aimed at minimizing clashing and restoring triangulation. LESS procedures can be performed using a combination of conventional straight, bent rigid, and actively articulating instruments.

Straight instruments: The parallel and close distance of the right-hand and left-hand instrument shafts of standard laparoscopic instruments through a single access site results in crowding of the laparoscope and instruments. The surgeon can hold instruments in a different axis (Fig. 10.8) and use variable length instruments which help to keep away the working hand from the retracting hand (Fig. 10.9) to partially offset this limitation.

Rigid bent instruments: The availability of instruments with a single or multiple bends is available. The advantage is that these are generally reusable, resulting in a minimum increase in disposable cost. The bends are strategically located to improve triangulation and/or increase space external to the port to reduce clashing (Fig. 10.10). Limitations of these instruments are that the bends are fixed and not always optimal. Additionally, these instruments require specialized trocars to be inserted.

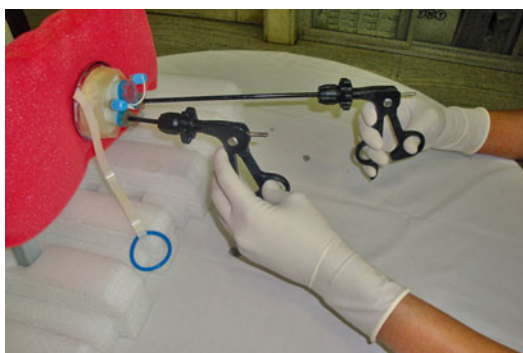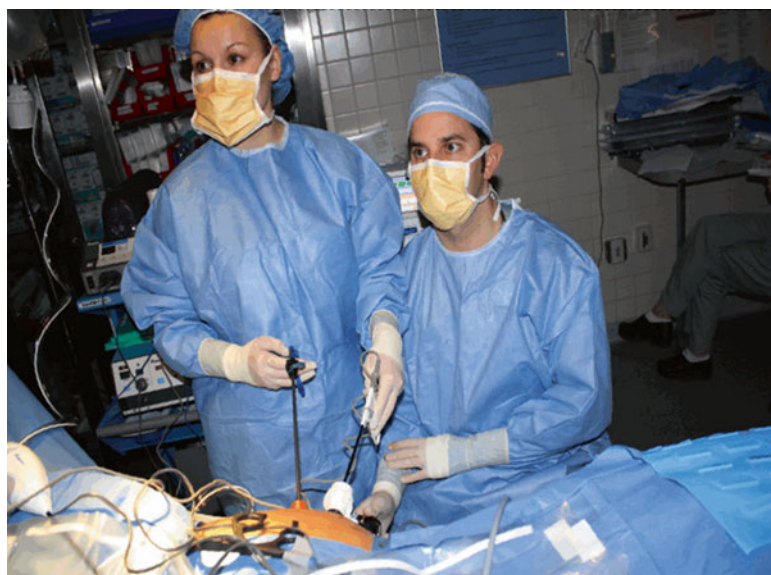Actively articulating instruments: Several actively articulating instruments that have a wristed internal motion are available for LESS surgery (Fig. 10.11). The articulation is typically controlled by intuitively manipulating the handle



has a suboptimal viewing angle compared to the left where the deflecting tip restores optimal viewing angle. Also notice the optimization of hands externally with the deflecting tip telescope

Table 10.2 Commercially available optics used with LESS

Brand	Instrument description	Size (mm)	Manufacturer
EndoEye™	Rigid 30° and flexible tip 0° endoscopes	5	Olympus America Inc. Center Valley, PA, USA
RealHand™	Flexible graspers, needle holders, dissectors, cautery, and scissors	5	Novare Surgical Cupertino, CA, USA
Autonomy Laparo-Angle™	Flexible graspers, needle holders, dissectors, cautery, and scissors	5	Cambridge Endoscopic Devices Inc., Framingham, MA, USA
Rotulator™	Flexible graspers, dissectors, cautery, and scissors	5	Covidien Mansfield, MA, USA

Fig. 10.7 Having the assistant seated and surgeon standing also helps minimize crowding and clashing**Fig. 10.8** Using variable length instruments in the right and left hand helps minimize external clashing

around a pivot point. The advantages of actively articulating instruments are that the angle of articulation can be changed and these instruments can be inserted through standard straight

rigid trocars. Limitations include relative lack of robustness, cost, and a learning curve to control articulation.

Experts have varied in their choice of instruments and often surgeons use a combination of straight, bent, and articulating instruments during LESS procedures.

New Technologies in LESS

Magnetic anchoring and guidance system (MAGS) is a novel technique that may alleviate many of the current challenges of LESS. The system centers around intracorporeal instruments that are delivered through the single access site and anchored through the abdominal wall with extracorporeal magnetic devices. The theoretical

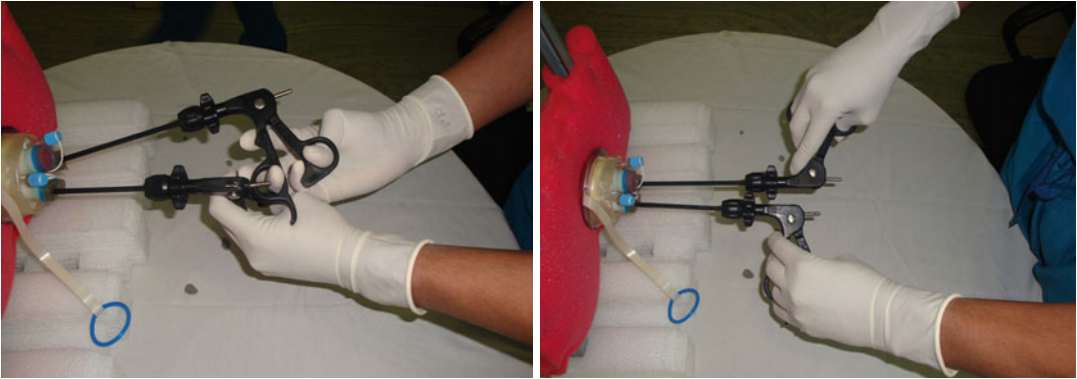


Fig. 10.9 Holding instruments in different axes helps reduce clashing



Fig. 10.10 Shows pre-bent instruments

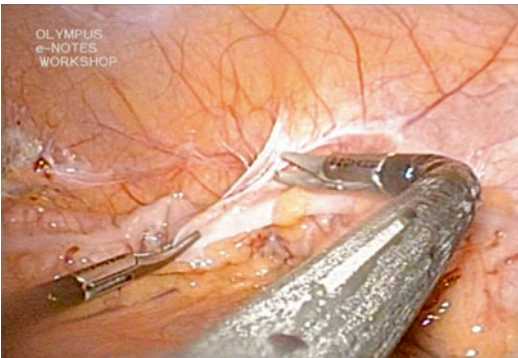


Fig. 10.11 Actively articulating scissors helps restore triangulation

benefits of this system are externally controlled, continuously adjustable positioning without need for external incisions or dedicated ports, reduction of internal and external collisions, restoration of triangulation, and improvements in

visualization. Recently, the initial clinical experience with the MAGS camera for LESS nephrectomy and appendectomy was described [5]. During these procedures, the entire dissection was carried out with rigid, straight instruments with only MAGS camera visualization. The authors found the use of MAGS camera resulted in fewer instrument collisions, improved surgical working space, and provided an image comparable to conventional laparoscopy. Although currently limited by a fixed 0° lens, fixed focus, external wires, magnets requiring a thin abdominal wall, and limited light delivery, innovations on the horizon aim to address each of these issues [5, 6].

Another area of development is the use of in vivo robotic instruments with the potential to provide a stable platform while providing precise tip maneuverability [7]. Similar to MAGS, these robots are delivered through the single incision and come in two types: either independently mobile or fixed to a base that extends through the port. Several examples have been described such as pan and tilt cameras, 3D-imaging systems, mobile adjustable-focus robotic cameras (MARC), and mobile biopsy graspers [6, 7]. These instruments seek to minimize internal and external clashing while providing improved dexterity and intuitive tissue manipulation which could be used alone or in conjunction with standard LESS instrumentation as well as with each other. Although their applications are currently limited, further developments aim to increase

battery life, increase the complexity of allowable maneuvers, and transition to wireless technology for control [7].

Common LESS Clinical Procedures

In general, standard LESS surgery has been performed for extirpative and reconstructive renal surgery. The majority of pelvic LESS has been performed using robotic assistance and will be described elsewhere in the text.

Patient selection: In general, patients of average build and height should be preferred so that the kidney is within reach of the umbilicus. For obese patients, the incision can be moved outside the umbilicus. For extraction of larger specimens, a larger incision should be used from the outset to improve mobility and having some triangulation. Finally, threshold for adding ports should be minimal.

LESS Nephrectomy

Technical tips: The actual steps for an LESS simple or radical nephrectomy are no different than conventional multiport laparoscopy. Certain technical nuances may facilitate LESS nephrectomy. LESS nephrectomy may be performed through the umbilicus or using an extra umbilical access. In obese patients, the umbilicus may fall far away from the kidney because of a mobile pannus and so making a single access lateral to and cephalad to the umbilicus may be preferred. This may enable reach of instruments but is cosmetically inferior. Alternatively, some surgeons prefer a Pfannenstiel approach that is cosmetically excellent and may also have less pain compared to the transumbilical approach. During LESS nephrectomy, upper pole dissection is the most difficult part and may require the use of articulating or bent instruments. Another technical step that is helpful for augmenting retraction is the use of suspending sutures. These sutures can be internally sutured to the abdominal wall or externally controlled via Keith needles. The threshold to use a hybrid technique with the

addition of 2, 3, or 5 mm ports should be low and may be necessary in obese patients, larger tumors, and inflammatory benign conditions with extensive perirenal scarring. Initial reports mainly focused on the treatment of benign conditions, but more recent studies have expanded to include LESS for the management of renal tumors.

Clinical LESS nephrectomy: In their series of 100 LESS cases, Desai et al. reported the outcomes of 14 patients undergoing LESS simple nephrectomies. The mean operative time (ORT) was 145 ± 69 min, estimated blood loss (EBL) was 109 ± 81 ml, hospital length of stay (LOS) was 2 ± 1 days, and time to complete recovery was 32 ± 6 days. There were no conversions and surgical outcomes found to be comparable to conventional laparoscopy [8]. Raman et al. performed a retrospective case-control study comparing LESS nephrectomy in 11 patients with conventional laparoscopic nephrectomy in 22 patients. The mean tumor size was 5.5 cm. The study found no difference in ORT, EBL, analgesic use, LOS, and complication rate. Patient benefit was found to be limited to a cosmetic advantage [9]. Raybourn et al. also found no difference when comparing 10 LESS nephrectomies to 10 laparoscopic simple nephrectomies [10]. Tugcu et al. subsequently performed a prospective randomized trial comparing LESS nephrectomy in 14 patients to standard laparoscopic nephrectomy in 13 patients for the treatment of benign disease. No difference was observed in ORT, EBL, transfusion rates, and LOS. However, the visual analog pain score (VAS) and use of postoperative analgesics were significantly lower in the LESS nephrectomy group in the days immediately following surgery (postoperative days 1–3). In addition, the time to return to normal activities was significantly shorter in the LESS nephrectomy group (10.7 vs. 13.5 days, $p=0.001$). There were no intraoperative or postoperative complications in either group. LESS nephrectomy was found to be more expensive than conventional laparoscopy (\$1,600–2,000 vs. \$450–600) [11]. Stolzenburg et al. described their experience with LESS radical nephrectomy (RN) in 42 patients. The mean tumor size was 5.45 cm, ORT was 135 min (75–200), and EBL was 158 ml

(50–1,100). All surgical margins were negative. An extra 3 mm needlescopic instrument was used in 19 patients. The authors found needlescopic instruments helpful for retraction of the liver in right-sided cases. Three cases were converted to conventional laparoscopy due to the need for retraction and hemostasis in 2 patients and extensive adhesions in 1 patient. Intraoperatively, a bowel injury was identified in 1 patient and repaired without the need for colostomy [12]. Greco et al. reported their experience with LESS RN in 33 patients for renal tumor. The mean tumor size was 4.1 ± 1.4 cm, ORT was 143.7 ± 24.3 min, EBL was 122.3 ± 34.1 ml, VAS on discharge was 1.9 ± 0.8 , and LOS was 3.8 ± 0.8 days. All tumors were organ confined and all surgical margins negative. The conversion rate to conventional laparoscopy was 3 %. The overall complication rate was 12.1 %. Major complications requiring surgical repair were an incisional hernia and a bowel injury [13]. Seo et al. compared LESS RN in 10 patients with conventional laparoscopic RN in 12 patients who underwent surgery during the same time period. No cases were converted to conventional laparoscopic or open surgery. There was no difference in ORT, time to oral intake, pain control, LOS, and complication rate. There was a trend toward decreased blood loss in the LESS RN group (185.7 ± 121.9 vs. 324.0 ± 187.0 , $p=0.065$), but was not statistically significant [14].

Retroperitoneal LESS Nephrectomy

LESS nephrectomy has also been described through a retroperitoneal approach. While the retroperitoneal approach does not offer the benefit of “scarless” surgery, it does have some distinct advantages. The retroperitoneal approach allows more direct access to the kidney and renal hilum, has a reduced need for the retraction of internal organs, and poses less risk of peritoneal contamination by spillage of urinary contents [15]. In addition, the retroperitoneal approach maintains peritoneal integrity, which can be important in end-stage renal disease patients who wish to perform peritoneal dialysis [16, 17].

The retroperitoneal approach offers a different set of surgical challenges. It is more difficult to check anatomical landmarks than transperitoneal RLESS, and there is more clashing of laparoscopic instruments due to the relatively smaller working space [15]. Bent instruments are often not suitable for the retroperitoneal space, and flexible instruments have been found to be insufficient for providing the robust retraction and dissection necessary in a retroperitoneal LESS nephrectomy [18].

White et al. reported their initial experience with retroperitoneal LESS. The series included cryoablation, partial nephrectomy, metastasectomy, and cyst decortication. They reported that the retroperitoneal approach is superior to the transperitoneal approach in posterior lesions and patients who have undergone previous intra-abdominal surgery. In addition, the authors commented that LESS is better than the standard laparoscopic retroperitoneal surgery because of improved cosmesis and likely decreased risk of inadvertent peritonotomy and epigastric vessel or bowel injury [19].

Chen et al. performed retroperitoneal LESS nephrectomy in 16 patients for the management of benign nonfunctioning kidneys. The mean ORT was 85 min (75–140), EBL was 56 ml (20–110), mean time to resuming oral diet 1.5 days, and LOS was 4 (3–5) days. One case was converted to open surgery for failure to progress in a patient with genitourinary tuberculosis resulting in severe adhesions surrounding the kidney. No major intraoperative or postoperative complications were observed. The authors found removal of retroperitoneal fat and adjacent tissue outside Gerota’s fascia helpful in overcoming the limitations of the working space. In addition, they recommended using one bent instrument and one straight instrument to achieve triangulation. This helps avoid clashing because of the different instrument lengths [20]. Similar findings were documented by Chueh et al. in their retrospective review of retroperitoneal LESS nephrectomies for a variety of indications [16].

The use of retroperitoneal LESS RN using a homemade port for the management of renal masses in six patients was reported by Chung

et al. The Mean ORT was 235 min (190–335), EBL was 42 ml (10–100 ml), time to oral intake was 45.4 h (12–72), and LOS was 5.8 days (5–8). All procedures were performed using standard laparoscopic instruments and no conversions or complications were noted [17]. Pak et al. also described their experience with retroperitoneal LESS nephrectomy using a homemade port in their clinical series. Four patients underwent RN with a mean ORT of 227.5 ± 50 min, EBL of 170 ± 156.8 ml, and LOS of 3.7 ± 0.5 days. Ten patients underwent simple nephrectomy with a mean ORT of 168.7 ± 29.2 min, EBL of 113 ± 149.8 ml, and LOS of 4.6 ± 1.5 days. One patient required a transfusion, but there were no major perioperative complications [18].

LESS Partial Nephrectomy (PN)

Partial nephrectomy (PN) has become the standard for the surgical management of localized renal masses. PN achieves oncologic outcomes comparable to RN, while maximizing preservation of renal function [21]. LESS PN, while technically demanding, is feasible in carefully selected patients.

Aron et al. reported their experience with LESS PN in five patients. PN was performed using renal hilar clamping and sutured renal reconstruction. The median tumor size was 3 cm (1–5.9), ORT was 270 min (240–345), EBL was 150 ml (100–600), VAS 48 h after surgery was 2 (0–6), and the median LOS was 3 days (3–22). The median WIT was 20 min (11–29). An additional 5 mm port was required in one case to aid in retraction of the liver. There were no intraoperative complications and all surgical margins were negative. The postoperative course of one patient was complicated by a pulmonary embolism and bleeding from a pseudoaneurysm. Based on their experience, the authors recommended avoiding LESS PN in (1) patients with enlarged livers because of difficult retraction, (2) obese/tall patients because of difficulty reaching the hilum and adequately mobilizing the upper pole of the kidney, and (3) patients with solitary kidneys or renal insufficiency if hilar clamping is necessary [22].

In an attempt to minimize the risk of ischemic renal injury, Kaouk et al. performed LESS PN in five patients without hilar clamping. Hemostasis was obtained using argon beam coagulation, Surgicel, and various BioGlues. The mean tumor size was 2.1 ± 1.1 cm, ORT was 160 ± 25 min, EBL was 420 ± 475 ml, VAS at discharge was 1.7 ± 1.2 , and LOS was 3.2 ± 1.6 days. One case was converted to standard laparoscopy to control bleeding in a difficult location. The patient required transfusion with 2 units and underwent 16 min of WIT. One patient with a negative intraoperative frozen margin had a final positive pathology. Based on their experience, the authors concluded that LESS PN is best suited for small, exophytic, anterior, lower pole tumors [23].

More recently, Cindolo et al. reported their experience with LESS PN in six patients performed without hilar clamping. Hemostasis was obtained using electrocautery and a bolster. The mean renal size was 2.1 cm (1–3.5), ORT was 148 min (30–550), EBL was 201 ml (30–550), time to oral intake was 2.6 days, and LOS was 6 days (3–10). One case was converted to standard laparoscopy because of excessive bleeding in a patient with a posterior tumor. No transfusions were necessary. One patient suffered a cerebrovascular accident postoperatively with subsequent transitory left hemiparesis [24].

LESS Nephroureterectomy

Technical nuances: The technical tips for the nephrectomy portion of radical nephrectomy all apply for nephroureterectomy. The distal cuff may be performed by a secondary transvesical access using a TriPort or similar trocar. Again, one must recognize that urothelial cancer is potentially aggressive and also requires a thorough lymphadenectomy that may be difficult to perform using LESS approach.

Clinical experience: There are only a handful of studies evaluating LESS nephroureterectomy. Most comprise a small subset description in published operative series for LESS. In their series of 100 patients who underwent LESS procedures,

Desai et al. reported two patients who underwent LESS nephroureterectomy. The ORT was 90 and 200 min, EBL 75 and 300 ml, and LOS were 5 and 1 days. There were no complications, or conversions, but an additional 5 mm port was added in one case. The distal ureter was managed by cystoscopic resection and laparoscopic Endo GIA stapling of the distal ureter [8].

Alternative techniques for management of the distal ureter have been published. Ponsky et al. described their technique for performing LESS nephroureterectomy completely through a Pfannenstiel incision in 1 patient. The kidney and ureter were mobilized through a Pfannenstiel single port and an open bladder cuff was taken through the same incision to remove the distal ureter. The ORT was 409 min, EBL was 200 ml, and LOS was 4 days. The surgical margin was negative. The main challenge of operating through a Pfannenstiel incision was the extended distance from the incision to the kidney, which was overcome with the use of bariatric instruments [25].

Lee et al. published their experience with pure LESS nephroureterectomy for the surgical management of upper tract urothelial carcinoma using a homemade port in ten patients. The distal ureter was managed by circumferentially dissecting around the ureteral orifice and resecting the ureter through an extravesical approach. The resulting bladder defect was closed in two layers. The mean ORT was 225.63 ± 65.87 min but significantly decreased with increasing experience. The mean EBL was 187.50 ± 83.45 ml and the LOS was 4.75 ± 3.37 days. There was one positive surgical margin in a pT3N2 disease. An open incision was required to complete the renal hilar lymphadenectomy in one case and an open Gibson incision was required due to severe adhesions around the distal ureter in a second case. There were no major complications [26].

Khanna et al. described their experience performing RLESS nephroureterectomy in three patients. Each case in the series was performed differently. In the first case, the distal ureter was managed through an open Gibson incision. In the second case, the GelPort was placed through a Gibson incision, and the same incision was used to manage the distal ureter. In the third case, the

nephrectomy was performed through the umbilicus using the GelPort. The robot was then reoriented toward the pelvis to perform the distal ureterectomy. The mean ORT was 300 min, EBL was 183 ml, and LOS was 3.3 days. There were no major complications. One case was converted to standard laparoscopy due to difficulty visualizing and accessing the upper pole of the kidney when the single port was placed through a Gibson. All surgical margins were negative. There was no evidence of disease recurrence at 17.8 months [27].

LESS Donor Nephrectomy (DN)

Laparoscopic living donor nephrectomy (LDN) has been the standard of care since its introduction in 1995 [28]. This has led to decreased morbidity, improved cosmesis, and shorter recovery time. Studies have shown laparoscopic donor nephrectomy produces allografts of similar immediate and long-term function to open surgery [29, 30]. Efforts are constantly being made to further decrease the morbidity to the donor. LESS DN can be the potential next step, given development of multichannel ports and articulating instruments. LESS can minimize the morbidity associated with extra trocar sites, such as hernias, pain, and bleeding due to epigastric vessel injury [31].

Technical nuances: Apart from the technical tips mentioned earlier, there are several that may enable smooth performance of donor nephrectomy. Access may be transumbilical or Pfannenstiel. It is important to have an adequate size extraction incision so that extraction is atraumatic and expeditious. It also is advantageous to entrap the graft in a specimen retrieval bag for minimizing ischemia time. Single-port trocars that allow an adequate size extraction incision upfront and admit a 15 mm bag such as GelPOINT (Applied Medical) and QuadPort (Olympus Medical) are preferred.

Clinical experience: The first LESS DN was performed by Gill et al. in 2008 through an

intra-umbilical incision in four patients. The LESS DN technique otherwise duplicated the steps of a conventional laparoscopic donor nephrectomy. At the time the procedure was performed, it was called embryonic natural orifice transumbilical endoscopic surgery (E-NOTES) [32]. Since that time, multiple studies have demonstrated the feasibility and efficacy of LESS DN.

Ramasamy et al. retrospectively compared conventional LDN in 663 patients versus LESS DN in 101 patients. LESS DN was found to have a longer mean ORT (156.8 vs. 148 min, $p=0.02$), lower EBL (91.3 vs. 121.9 ml, $p=0.003$), higher oral but lower intravenous hospital analgesic requirements ($p<0.001$ and 0.002 , respectively), and shorter LOS (2.4 vs. 2.9 days, $p<0.001$). The LESS DN group had a higher WIT (3.9 vs. 4 min, $p=0.03$), but the graft function was similar to that of conventional LDN. There was no difference in the overall 30-day complication rate (7.1 % vs. 7.9 %, $p>0.05$). There was 1 major complication (Clavien grade 3–5) in the LESS DN group and 8 major complications in LDN group. One LDN patient required conversion to open for a vascular complication [31].

Canes et al. performed a matched-pair comparison between 17 LESS DN and LDN patients. There was no difference in ORT, EBL, LOS, or VAS. After discharge, LESS DN was associated with significantly fewer days on oral pain medication (6 vs. 20 days, $p=0.01$), days off work (18 vs. 46 days, $p=0.0009$), and days to 100 % physical recovery (29 vs. 83 days, $p=0.03$). WIT was higher in LESS (6.1 vs. 3 min, $p<0.0001$); however, graft function was immediate and comparable between groups. One allograft in the LESS group thrombosed postoperatively [33].

Kurien et al. reported the results of their randomized clinical trial comparing LESS DN ($n=25$) versus LDN ($n=25$). There was no difference in ORT and EBL. The postoperative patient pain scores were significantly lower in the LESS DN after 48 h (1.24 ± 0.72 vs. 2.08 ± 0.91 , $p=0.0004$). The LESS DN had shorter LOS (3.92 ± 0.76 vs. 4.56 ± 0.82 days, $p=0.003$). The WIT in the LESS DN group (5.11 ± 1.01 vs. 7.15 ± 1.84 min, $p<0.0001$) was longer, but the total ischemia times in both groups were similar.

There was no difference in intraoperative (16 % vs. 8 %, $p=0.2$) and postoperative complications (16 % vs. 20 %, $p=0.99$). One patient in the LDN groups suffered sudden cardiac death, resulting in graft loss. There was no graft loss in the LESS DN group. The estimated glomerular filtration rates of recipients at 1 year were comparable for both groups. The donor's quality of life, body image, and cosmetic scores were comparable for both groups [34].

Afaneh et al. published a retrospective matched-pair comparison between LESS DN and LDN in 50 patients. The mean ORT was greater in LESS (166 ± 28.7 vs. 129 ± 29.8 min, $p<0.0001$), with a trend toward decreasing operative time with increasing case number. There was no difference in EBL, VAS, and LOS. Patients reported a shorter time to complete recovery was faster in LESS DN patients (24.4 ± 5.3 vs. 27.0 ± 4.9 days, $p=0.01$). There was no difference in WIT or the number of complications. One LESS DN patient was converted to hand-assisted laparoscopy because of GelPort device leakage and failure to maintain pneumoperitoneum. A second patient was converted to conventional laparoscopy to optimize hilar dissection. There was one major complication in the LESS DN group, a grade 3 laceration to the posterior midpole cortex during extraction. The allograft maintained normal function and the patient's creatinine was 1.08 at 15 months. One patient in the LPN group had one adrenal vein injury and another patient had a splenic laceration [30].

It is critical to ensure the safety of the donor and harvesting of the donor allograft in perfect condition. The largest concern is increased WIT, likely due to the extra time needed to create an adequate fascial incision for allograft extraction [31, 33, 34]. However, most available evidence suggests that the range of WIT reported in the literature has a negligible effect on both short- and long-term allograft function [30, 33].

LESS DN has much potential to minimize morbidity to the donor. LESS provides improved cosmesis and less morbidity from trocar-associated pain. A common complaint in LPN patients is lingering discomfort in the lower quadrant trocar incision. This is the main working port

during LDN and is eliminated with LESS technique [33].

LESS DN has a steep learning curve. However, with proper training, careful patient selection, and thorough planning, LESS DN has the potential to become the future gold-standard procedure [35].

Pediatric LESS Surgery

Modifications to adult laparoscopic techniques for pediatric patients have resulted in the successful application of laparoscopic surgery in children [36]. LESS has been used for multiple procedures in children such as nephrectomy, orchietomy, and varicocelectomy [37]. Their well-defined tissue planes, minimal intra-abdominal fat, and relatively thin abdominal walls make pediatric patients ideal for the application of laparoscopic techniques. However, their smaller internal working space and large equipment relative to pediatric patients make LESS challenging.

Koh et al. presented the largest series of LESS nephrectomy to date for poorly functioning hydronephrotic kidneys in patients ranging in age from infants to adolescents. The mean operative time was 139 min (85–205), EBL was 18 ml (5–150), and LOS was 1.5 days (1.0–2.1). A 3 mm needlescopic accessory port was used early in the experience in five cases. No intraoperative complications were noted. Postoperatively, two boys developed unilateral ipsilateral hydroceles. The mean operative times and LOS is comparable to that of conventional laparoscopy in children. Pediatric LESS procedures have been demonstrated to be feasible in multiple studies and warrant further study [38–40].

LESS Pyeloplasty

Pyeloplasty remains an excellent indication for LESS. It typically occurs in young healthy patients interested in cosmesis. Additionally, there is no need for extraction of large specimens and so the incision can be conveniently hidden in

the umbilicus. For reconstructive procedures, adding a 2–5 mm trocar and performing a hybrid procedure may assist in safe completion of the procedure.

Tracy et al. retrospectively compared 14 LESS pyeloplasty with 28 conventional pyeloplasties. They reported comparable outcomes and used an additional 3–5 mm port to facilitate suturing and place a drain. Similarly, Stein et al. also reported equivalent efficacy and perioperative morbidity comparing 16 LESS versus conventional pyeloplasties. A 2 mm additional port was used to facilitate suturing.

Conclusion

LESS surgery is appropriate for patients interested in better cosmesis. Ablative and reconstructive renal procedures are appropriate, and threshold for converting to standard laparoscopy should be low. Better instrumentation, especially dedicated robotic platforms, may enable the wider use of LESS surgery.

References

1. Raman JD, Bensalah K, Bagrodia A, et al. Laboratory and clinical development of single keyhole umbilical nephrectomy. *Urology*. 2007;70(6):1039–42.
2. Desai MM, Rao PP, Aron M, et al. Scarless single port transumbilical nephrectomy and pyeloplasty: first clinical report. *BJU Int*. 2008;101(1):83–8.
3. Gill I, Advincula A, Aron M, et al. Consensus statement of the consortium for laparoendoscopic single-site surgery. *Surg Endosc*. 2010;24:762.
4. Guillotreau J, Crouzet S, Haber GP. Access techniques, platforms and instruments for LESS. *Arch Esp Urol*. 2012;65(3):285–93.
5. Cadeddu JA, Fernandez R, Desai M, et al. Novel magnetically guided intra-abdominal camera to facilitate laparoendoscopic single-site surgery: initial human experience. *Surg Endosc*. 2009;23:1894–9.
6. Raman JD, Scott DJ, Cadeddu JA. Role of magnetic anchors during laparoendoscopic single site surgery and NOTES. *J Endourol*. 2009;23(5):781–6.
7. Canes D, Lehman AC, Farritor SM, et al. The future of NOTES instrumentation: flexible robotics and *in vivo* minirobots. *J Endourol*. 2009;23(5):787–92.
8. Desai MM, Berger AK, Brandina R, et al. Laparoendoscopic single-site surgery: initial hundred patients. *Urology*. 2009;74:805.

9. Raman JD, Bagrodia A, Cadeddu JA. Single-incision, umbilical laparoscopic versus conventional laparoscopic nephrectomy: a comparison of perioperative outcomes and short-term measures of convalescence. *Eur Urol.* 2009;55:1198.
10. Raybourn Iii JH, Rane A, Sundaram CP. Laparoendoscopic single-site surgery for nephrectomy as a feasible alternative to traditional laparoscopy. *Urology.* 2010;75:100.
11. Tugcu V, Ilbey Y, Mutlu B, et al. Laparoendoscopic single-site surgery versus standard laparoscopic simple nephrectomy: a prospective randomized study. *J Endourol.* 2010;24:1315.
12. Stolzenburg J-U, Kallidonis P, Ragavan N, et al. Clinical outcomes of laparo-endoscopic single-site surgery radical nephrectomy. *World J Urol.* 2012;30:589–96.
13. Greco F, Veneziano D, Wagner S, et al. Laparoendoscopic single-site radical nephrectomy for renal cancer: technique and surgical outcomes. *Eur Urol.* 2012;62:168–74.
14. Seo I, Lee J, Rim J. Laparoendoscopic single-site radical nephrectomy: a comparison with conventional laparoscopy. *J Endourol.* 2011;25:465.
15. Hemal A. Laparoscopic retroperitoneal extirpative and reconstructive renal surgery. *J Endourol.* 2011; 25:209.
16. Chueh S-CJ, Sankari BR, Chung S-D, et al. Feasibility and safety of retroperitoneoscopic laparoendoscopic single-site nephrectomy: technique and early outcomes. *BJU Int.* 2011;108:1879.
17. Chung S-D, Huang C-Y, Tsai Y-C, et al. Retroperitoneoscopic laparo-endoscopic single-site radical nephrectomy (RLESS-RN): initial experience with a homemade port. *World J Surg Oncol.* 2011;9:138.
18. Pak C-H, Baik S, Kim CS. Initial experience with retroperitoneal laparoendoscopic single-site surgery for upper urinary tract surgery. *Korean J Urol.* 2011; 52:842.
19. White WM, Goel RK, Kaouk JH. Single-port laparoscopic retroperitoneal surgery: initial operative experience and comparative outcomes. *Urology.* 2009; 73:1279.
20. Chen Z, Chen X, Luo Y, et al. Retroperitoneal laparoscopic single-site (LESS) simple nephrectomy: initial experience. *J Endourol.* 2012;26:647–51.
21. Patil MB, Lee DJ, Gill IS. Eliminating global renal ischemia during partial nephrectomy: an anatomical approach. *Curr Opin Urol.* 2012;22:83–7. doi:10.1097/ MOU.0b013e32834ef70c, 9000.
22. Aron M, Canes D, Desai MM, et al. Transumbilical single-port laparoscopic partial nephrectomy. *BJU Int.* 2009;103:516.
23. Kaouk JH, Goel RK. Single-port laparoscopic and robotic partial nephrectomy. *Eur Urol.* 2009;55:1163.
24. Cindolo L, Berardinelli F, Gidaro S, et al. Laparoendoscopic single-site partial nephrectomy without ischemia. *J Endourol.* 2010;24:1997.
25. Ponsky LE, Steinway ML, Lengu IJ, et al. A Pfannenstiel single-site nephrectomy and nephroureterectomy: a practical application of laparoendoscopic single-site surgery. *Urology.* 2009;74:482.
26. Lee J, Kim S, Moon H, et al. Initial experience of laparoendoscopic single-site nephroureterectomy with bladder cuff excision for upper urinary tract urothelial carcinoma performed by a single surgeon. *J Endourol.* 2011;25:1763.
27. Ratner L, Ciseck L, Moore R, et al. Laparoscopic live donor nephrectomy. *Transplantation.* 1995;60:1047.
28. Nicholson ML, Kaushik M, Lewis GRR, et al. Randomized clinical trial of laparoscopic versus open donor nephrectomy. *Br J Surg.* 2010;97:21.
29. Afaneh C, Aull MJ, Gimenez E, et al. Comparison of laparoendoscopic single-site donor nephrectomy and conventional laparoscopic donor nephrectomy: donor and recipient outcomes. *Urology.* 2011;78:1332.
30. Ramasamy R, Afaneh C, Katz M, et al. Comparison of complications of laparoscopic versus laparoendoscopic single site donor nephrectomy using the modified Clavien grading system. *J Urol.* 2011;186:1386.
31. Gill IS, Canes D, Aron M, et al. Single port transumbilical (E-NOTES) donor nephrectomy. *J Urol.* 2008;180:637.
32. Canes D, Berger A, Aron M, et al. Laparo-endoscopic single site (LESS) versus standard laparoscopic left donor nephrectomy: matched-pair comparison. *Eur Urol.* 2010;57:95.
33. Kurien A, Rajapurkar S, Sinha L, et al. Standard laparoscopic donor nephrectomy versus laparoendoscopic single-site donor nephrectomy: a randomized comparative study. *J Endourol.* 2011;25:365.
34. Desai M. Single-port surgery for donor nephrectomy: a new era in laparoscopic surgery? *Nat Clin Pract Urol.* 2009;6:1.
35. Lee DJ, Kim PH, Koh CJ. Current trends in pediatric minimally invasive urologic surgery. *Korean J Urol.* 2010;51:80.
36. Kocherov S, Lev G, Shenfeld OZ, et al. Laparoscopic single site surgery: initial experience and description of techniques in the pediatric population. *J Urol.* 2011;186:1653.
37. Koh CJ, De Filippo RE, Chang AY, et al. Laparoendoscopic single-site nephrectomy in pediatric patients: initial clinical series of infants to adolescents. *Urology.* 2010;76:1457.
38. Cabezalí Barbancho D, Gómez Fraile A, López Vázquez F, et al. Single-port nephrectomy in infants: initial experience. *J Pediatr Urol.* 2011;7:396.
39. Tracy CR, Raman JD, Bagrodia A, Cadeddu JA. Perioperative outcomes in patients undergoing conventional laparoscopic versus laparoendoscopic single-site pyeloplasty. *Urology.* 2009;74:1029–34.
40. Stein RJ, Berger AK, Brandina R, Patel NS, Canes D, Irwin BH, Aron M, Autorino R, Shah G, Desai M. Laparo-endoscopic single-site pyeloplasty: a comparison with standard laparoscopic pyeloplasty. *BJU Int.* 2011;107(5):811–5.

Dinesh Samarasekera and Jihad H. Kaouk

Introduction

It has been established that robotic-assisted laparoscopic surgery has several advantages when compared to standard laparoscopic surgery. Optics, ergonomics, dexterity, and precision are all enhanced with use of the robotic platform for a number of urologic procedures. For these reasons, it was postulated that the application of robotics to laparoendoscopic single-site surgery (LESS) could overcome some of the constraints seen with the conventional laparoscopic approach. Issues such as instrument clashing, inability to achieve effective triangulation for dissection, and difficulties with intracorporeal suturing have limited the widespread adoption of conventional LESS in urology.

Kaouk et al. [1] reported the first experience with R-LESS in 2008 (radical prostatectomy and nephrectomy, pyeloplasty). They noted that intracorporeal suturing and dissection were easier, as compared with standard LESS. Since then there have been numerous reports and refinements in

technique from the same group, for a number of different urologic procedures [2–4]. Furthermore, there have been a number of series that have compared R-LESS to either standard laparoscopy, conventional LESS, or standard robotic surgery [2, 5, 6]. While these studies have been small and retrospective in nature, they have shown that R-LESS is not inferior with regard to perioperative outcomes and may offer better cosmesis. Additionally, the surgeons found the EndoWrist technology and three-dimensional high-definition camera beneficial. However, despite the advantages of the robotic platform, R-LESS is not free of challenges which are similar to conventional LESS. Instrument clashing remains an issue, due to the bulky external profile of the current robotic system. Other issues include lack of space for the assistant at the bedside, inability to incorporate the 4th robotic arm for retraction, and difficulties with triangulation. Although solutions for some of these issues are currently under development [7, 8], R-LESS is still very much in its infancy.

Standard robotic surgery and R-LESS share numerous similarities. The setup of the operating room is identical, as well as all the instruments, drapes, sutures, etc. Docking of the robot is also identical, although the arms may be angled differently to minimize instrument clashing. With regard to the procedures, almost all of the steps of standard robotic surgery are carried out in R-LESS. That being said, there are improvisations that are made

D. Samarasekera, MD (✉)
Glickman Urologic and Kidney Institute, Department
of Laparoscopic and Robotic Surgery
Cleveland Clinic, 9500 Euclid Avenue/Q10-1,
Cleveland, OH 44195, USA
e-mail: samarad@ccf.org

J.H. Kaouk
Department of Urology, Cleveland Clinic,
Cleveland, OH, USA

because of the limited space with R-LESS. For example, because there is no space for the 4th arm, which is often used to retract tissue, various other techniques have been employed (i.e., stay and marionette sutures). Also other strategies are employed to minimize instrument clashing, such as moving the two arms and camera together in unison. For this reason, this chapter will focus on the equipment and aspects of each procedure that are specific to R-LESS and differ from standard robotic surgery.

Access/Trocar Placement

An important distinction must be made with regard to access in R-LESS, and that is *single port vs. single site*. Single-port access utilizes a single skin and fascial incision, through which a multichannel access platform is placed (Fig. 11.1). The endoscope and instruments are all placed through the access platform. Single-site access also utilizes a single skin incision; however, multiple fascial incisions are made, through which the access platform and low profile ports are placed (Fig. 11.2). The point of access can be umbilical or extra-umbilical. The umbilical access point has been most commonly utilized [9], as the scar can more easily be hidden and cosmesis maximized.

Single-Port Access

A number of different access devices for single port EXIST access, including a TriPort [1] and a GelPort [2]. Single-port access for upper- and lower-tract R-LESS procedures is similar. A 2–5-cm trans-umbilical incision is made, either directly through the umbilicus or using a semicircular incision concealed within the umbilicus. Dissection then proceeds, using a combination of blunt dissection and electrocautery, to the anterior rectus fascia. A 3–4-cm vertical incision is then made in the linea alba, access to the peritoneal cavity is gained, and the chosen multichannel access device is placed. Stay sutures can be placed in the fascia to aid with port placement

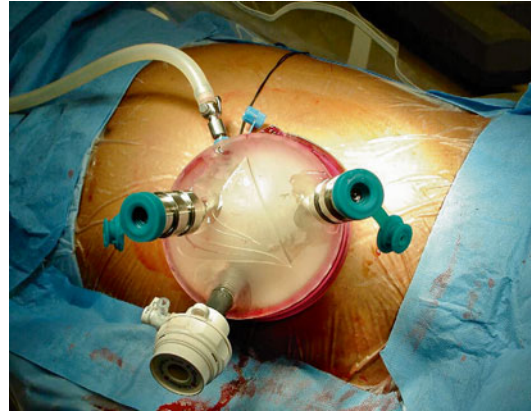


Fig. 11.1 Single-port access (GelPOINT)

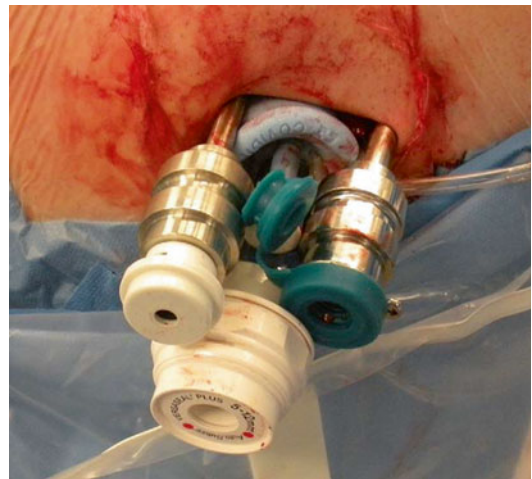


Fig. 11.2 Single-site access (SILS Port)

and wound closure, if desired. If the GelPort is to be used, the wound protector is placed first. Next the GelSeal cap is placed, after the port sites have been marked on its surface.

Depending on the procedure/pathology, access can be transperitoneal or extraperitoneal, as both approaches have been described. Additionally a transvesical approach has been utilized, specifically for robotic enucleation of the prostate [10].

Single-Site Access

In a similar fashion to single-port access, an incision is created intraumbilically (3–4.5 cm), and

the umbilicus is released from the rectus fascia. A 2-cm incision is then made through the linea alba. The robotic ports are then placed through the same umbilical incision, but through separate fascial stab incisions. Typically they are tunneled under the skin to the appropriate location. For example, during an R-LESS radical prostatectomy, the first 8-mm robotic port is placed at the most caudal part of the incision and tunneled as far laterally as possible. The subsequent robotic port is then placed on the opposite side of the incision, in a similar fashion. Finally, a multichannel port is inserted through the fascial incision into the peritoneal cavity (or extraperitoneal space).

Multichannel Port Selection

A number of different multichannel ports have been used for R-LESS (Table 11.1); however, there have been no direct head-to-head comparisons. In Kaouk et al.'s initial R-LESS series, the R-port (Advanced Surgical Concepts, Dublin, Ireland) was used. This port consists of one 12-mm channel, two 5-mm channels, and an insufflation cannula. The port is placed using the Hasson technique through a 2-cm umbilical

incision. The authors made no specific comments with regard to the performance of the port, and there were no reported issues with pneumoperitoneum leakage or instrument crowding. White et al. [13] reported their experience with 50 patients, which included 24 renal procedures and 26 pelvic procedures. They used three different commercially available ports, including the SILS Port, the R-port, and the GelPort/GelPOINT. The authors mentioned of the three multichannel ports used, they preferred the SILS Port because of its durability, the free exchange of cannulas of varying size, and the ease of passage of staplers, clip applicators, sutures, and entrapment bags through the port. However, they noted that gas leakage was experienced with three multichannel ports, which was usually caused by a fascial incision that was too large. To combat this they placed a fascial suture or petroleum impregnated gauze along the tract of the port. Stein et al. [2] used the GelPort laparoscopic access system to perform 4 R-LESS upper tract procedures (pyeloplasty $n=2$, partial nephrectomy $n=1$, radical nephrectomy $n=1$). They concluded that the GelPort was beneficial for R-LESS, because it allowed for greater spacing and flexibility of port placement and easier access to the surgical field for the bedside assistant. Although fascial incision

Table 11.1 Currently available multichannel ports

Instrument	Study	Features	Advantages	Disadvantages
SILS Port (Covidien)	White et al. [4]	Flexible Expands after insertion to prevent air leak	Accommodates 3 variable-sized ports and instruments	Difficult insertion with large abdominal wall
GelPort/GelPOINT (Applied Medical)	White et al. [3]	GelSeal cap creates pseudoabdomen	Larger working platform for spacing of trocars	Requires larger fascial incision
	Olweny et al. [6] Stein et al. [2] Fareed et al. [10]	Insufflation port on side	Easier specimen extraction	Gas leakage during longer procedures
	Lee et al. [11] Arkoncel et al. [5]	Surgical glove placed over a wound retractor	Low cost Widely available Flexible port placement	Fragile; tears with inserting/reinserting robotic instruments Ballooning of port with high insufflation pressures

Table adapted from White et al. [4] and Autorino et al. [12]

they used was larger to place the port (2–2.5 cm), they found that this facilitated specimen extraction, especially during the radical nephrectomy. Finally, there have been a number of centers that have had experience using a homemade port, both for conventional LESS and R-LESS. Lee et al. [11] reported the largest series of R-LESS procedures using a homemade port, which consisted of an Alexis wound retractor (Applied Medical, Rancho Santa Margarita, CA) and a standard size 7 surgical glove stretched over top. They utilized a 5–6-cm fascial incision to place the wound retractor. Four trocars were placed through the fingers of the glove, including two 8-mm robotic trocars and two 12-mm optical trocars. They performed 68 upper tract procedures, including 51 partial nephrectomies, 12 nephroureterectomies, 2 adrenalectomies, 2 radical nephrectomies, and 1 simple nephrectomy. The authors felt that the homemade port offered greater flexibility of port placement than any of the commercially available multichannel devices, as well as being extremely cost-effective. Limitations included the susceptibility of the glove to tearing with insertion of the robotic instruments, the larger fascial incision required to place the wound retractor, and ballooning of the glove under higher pneumoperitoneum pressures (>20 mmHg). However, the authors concluded that their homemade port was a safe, effective, low-cost alternative to commercially available multichannel ports.

Docking the Robot

There are only a few subtle differences between docking the robot for standard robotic surgery and R-LESS. The DaVinci Si model has been preferred over the S because of the enhanced visualization, ability to customize the console settings ergonomically, and smaller external profile, which helps to minimize clashing of the robotic arms [13, 14]. Otherwise, the robot is brought into the surgical field in a standard fashion, which is from behind the patient and over the shoulder for upper tract procedures and in between the patient's legs for lower-tract procedures. Additionally, because of the limited

working space, the majority of R-LESS procedures employ a two-arm approach.

There have been a number of strategies employed in order to minimize clashing of the robotic arms, which is a limitation that is encountered with the current robotic platforms. Joseph et al. [7, 15] developed a “chopstick” technique, whereby the robotic instruments are crossed at the abdominal wall to reduce instrument clashing and improve triangulation. This concept had already been used in conventional LESS; however, the crossing of instruments and resultant “reverse handedness” made the cases very challenging. However, with the DaVinci system, the inputs to the left and right hand effectors can be switched electronically, which eliminates the reverse handedness and restores intuitive control of the instruments as they appear on the screen.

Instrumentation

The vast majority of the R-LESS procedures to date have been performed with standard instruments (Table 11.2), as task-specific tools are currently under development and testing. Two of the larger clinical series both report the use of standard 8- and 5-mm instruments for a wide range of R-LESS procedures [11, 13]. White et al. [4] described using an 8-mm instrument in the right hand and a 5-mm pediatric instrument in the left hand for their R-LESS prostatectomy series of 20 patients. The authors felt this configuration maximized the benefit of each instrument. The 5-mm instruments do not articulate but instead deflect, which greatly increased their range of motion. Conversely the authors found that the EndoWrist action of the standard 8-mm instruments greatly facilitated complex tasks, such as suturing. Furthermore, they reported that the 8-mm robotic Hem-o-lok clip applicator was beneficial during nerve sparing, as clip placement was in the surgeon's hands and clashing with the bed-side assistant's instruments was minimized.

Intuitive Surgical Inc. has also addressed the problem of instrument collision and developed a set of R-LESS-specific instruments. The set consists of a multichannel access platform with

Table 11.2 Instrumentation currently available for Robotic LESS procedures

Instrument	Features	Advantages	Disadvantages
8-mm EndoWrist monopolar shears	7° of freedom	Instrument articulation allows access to difficult operative angles	Larger profile; increased instrument clashing because of lack of deflection
8-mm EndoWrist monopolar hook	90° of articulation		
8-mm EndoWrist Prograsp grasper	Intuitive motion and fingertip control motion		
8-mm/5-mm needle drivers	scaling and tremor reduction		
8-mm Hem-o-lok applier		Clips can be applied by operating surgeon	Time-consuming; extra large clip size is not available
5-mm Schertel grasper	Robust snake-wrist architecture Intuitive motion and fingertip control Motion scaling and tremor reduction	Lower profile; triangulation is increased secondary to instrument deflection; functional in a tight working space	Lack of distal instrument tip articulation decreases overall range of motion; decreased grip strength
5-mm Harmonic scalpel	Nonwristed instrument based on Ethicon Endo-Surgery Harmonic technology Simultaneously cuts and coagulates Motion scaling and tremor reduction	Can be applied by the operating surgeon; time efficient	Does not articulate; increased amount of instrument clashing

Table adapted from White et al. [4] and Autorino et al. [12]

channels for four ports and an insufflation valve. The ports themselves consist of two with curved cannulas for the robotic instruments and two with straight cannulas for the endoscope and assistant instruments. The robotic instruments are also curved and are designed to cross at the abdominal wall, effectively separating the arms in space extracorporeally. Furthermore, the design of the system also minimizes internal instrument collision with the camera, as they are not arranged in parallel. We described the first urologic applications in the laboratory at our center [8, 16]. Both the porcine model and human cadavers were used to perform a number of upper tract procedures (i.e., pyeloplasty, partial nephrectomy, etc.). Setup and docking times were comparable with the standard robotic system, and there were no significant complications. All procedures were completed successfully without need for completion. Major limitations included collision with the assistant instruments, which at times limited

suction and retraction, and the lack of articulation of the robotic instruments, which made suturing difficult when required. The majority of clinical experience with the single site instruments has been with cholecystectomy [17, 18]; however, Cestari et al. [19] reported their experience in a highly selected group of nine patients with a UPJO. Exclusion criteria included BMI >30 kg/m², a large renal pelvis, previous abdominal/renal surgery, and concomitant stone disease. All procedures were performed successfully without the need for conversion or additional ports. Mean OR time was 166 min.

A number of different lens configurations have been used with the 12-mm robotic camera during R-LESS procedures. For their R-LESS prostatectomy series, White et al. [4] attempted to use the 0° lens for all procedures, but found that the 30° upward lens was beneficial in instances where instrument clashing occurred by positioning the scope out of the path of the instruments. For

upper tract procedures, all lens configurations have been used, with no clear advantage favoring one particular choice. It seems that when choosing a lens, one must tailor it to the particular situation and consider port placement, the degree of instrument clashing, and the pathology at hand.

Upper Tract Urologic Surgery

Radical Nephrectomy

Positioning and docking of the robot for an R-LESS radical nephrectomy is identical to that of a conventional robotic radical nephrectomy. Typically the robot is used in a three-armed approach, as there really is no room for the 4th arm. The port is typically placed at the umbilicus, and a multitude of different types have been used for R-LESS radical nephrectomy (homemade, GelPort, SILS Port, etc.). As previously mentioned, Stein et al. [2] found the GelPort device beneficial for R-LESS radical nephrectomy due to ease of specimen extraction. Once the robot is docked, dissection proceeds in an identical fashion to a standard robotic radical nephrectomy, which begins with mobilization of the colon along the white line of Toldt. Standard 8-mm robotic instruments can be used, including the monopolar scissors, monopolar hook, or harmonic scalpel. The ureter and renal hilum are identified in a standard fashion and controlled. The hilum can be controlled with a standard endoscopic stapler passed through the assistant port. The ureter can be clipped with assistant placed Hem-o-lok clips or by the operating surgeon using the robotic clip applier. The specimen can then be placed in an entrapment bag and removed through the umbilical incision.

White et al. [3] performed a retrospective comparative analysis of ten patients who underwent R-LESS radical nephrectomy. They were matched to a similar cohort of ten patients who underwent conventional laparoscopic radical nephrectomy. Patients were similar at baseline, with no significant difference in ASA score, BMI, or tumor size. The SILS Port and the GelPort were both used, and the robot was docked in a 3-arm approach. There was no difference

between R-LESS and conventional laparoscopy nephrectomy with regard to median operative time, estimated blood loss, visual analogue scale, or complication rate. The R-LESS group had a lower median narcotic requirement during hospital admission (25.3 morphine equivalents vs. 37.5 morphine equivalents; $p=0.049$) and a shorter length of stay (2.5 d vs. 3.0 d; $p=0.03$).

Partial Nephrectomy

Positioning, port placement, and initial dissection for R-LESS partial nephrectomy are identical to that of a radical nephrectomy. Once the tumor is exposed, decisions about hilar clamping are typically made based on tumor characteristics and are at the surgeon's discretion. Laparoscopic ultrasound can be introduced through the assistant port and is an important tool for determining the margins of resection. Tumor resection and renorrhaphy are similar to that of a standard robotic partial nephrectomy, and a number of techniques have been reported. Partial nephrectomy has become the gold standard for treatment of the small renal mass, and as the result there has been more published series with R-LESS PN. Lee et al. [11] described 68 consecutive R-LESS procedures using a homemade port, 51 of which were R-LESS PN. Mean tumor size was 3.0 cm, and mean EBL was 322 mL. The authors noted that the transfusion rate was 14 %, largely due to bleeding during tumor resection and a single renal vein injury. Also two patients required conversion to a mini-incisional open procedure, one due to persistent hilar bleeding post resection and the other for inability to access the tumor. Arkoncel et al. [5] compared a "hybrid" R-LESS PN technique in 35 patients with 35 patients who underwent standard robotic PN. The "hybrid" technique consisted of a homemade port (surgical glove stretched over a wound retractor) at the umbilicus which housed the 2 8-mm robotic ports and a 12-mm camera port and a separate 12-mm assistant port. Patients were similar at baseline, with equivalent tumor complexity. The OR time (187.5 vs 171.7 min, $p=.110$), warm ischemia time (29.5 vs 28.8 min, $p=.209$), blood loss (257 vs 242.5 mL, $p=.967$), complication rate (17.1 vs 11.4 %, $p=.495$), and transfusion rate (8.6 vs

2.9 %, $p = .303$) were comparable in both groups. Furthermore, pain scores, length of hospitalization, and morphine equivalents used were also comparable. There was no significant difference in complication rates, or need for conversion. Of note, the authors found that there was noticeable restriction of the robotic arms with the R-LESS approach, which required timely adjustment and angulation by the bedside assistant, for successful completion of the case.

Dismembered Pyeloplasty

We described a right dismembered pyeloplasty in our initial report on R-LESS in 2008 [1]. The patient is placed in 45° lateral decubitus position, and the table is flexed. The robot brought into the field over the patient's shoulder and docked to the single port. In our initial description we used an R-port (Advanced Surgical Concepts, Dublin, Ireland); however, other ports have been described in other series, including the GelPOINT [2, 6, 15]. Typically the 30° upward lens is used. The ureter is also typically pre-stented as it is difficult to do it in an antegrade fashion given the lack of available ports. The dissection proceeds in a standard fashion, and the stented ureter is identified and dissected towards the renal pelvis. The hook electrocautery or monopolar scissors is typically used to perform this dissection. The stenotic UPJ is then excised with monopolar scissors, and the ureter is spatulated. A watertight anastomosis is then performed over the stent, using the robotic needle driver, in an interrupted or running fashion. A drain is left and brought out through the umbilical incision.

It has been postulated that patients undergoing minimally invasive pyeloplasty might be ideal candidates for LESS as they are usually young with benign pathology, and the procedure is non-extirpative, thereby not requiring a larger incision for specimen extraction. To overcome the challenges associated with standard LESS, the robotic platform has been applied (R-LESS). Despite the fact that the current generation robotic system was not designed for single-site surgery, surgeons noticed that dissection and suturing was easier [1]. The unifying conclusion from series is that use of the robotic system helps to reduce the

technical difficulty of LESS pyeloplasty and shortens the learning curve associated with the procedure. Olweny et al. [6] compared ten patients who underwent conventional LESS (C-LESS) pyeloplasty with ten patients who underwent R-LESS. Perioperative outcomes were analyzed including OR time, EBL, complications, morphine usage, and length of stay in hospital (LOS). Cosmetic and long-term functional outcomes were not included in the analysis. There was no significant difference between R-LESS and C-LESS except for OR time, which was significantly longer for R-LESS (226 vs. 188 min, $p = 0.007$). Additionally there were two conversions to standard laparoscopy in the C-LESS group as compared to none in the R-LESS group. Despite there being no clear advantage for R-LESS with regard to outcomes, the authors found the superior optics and EndoWrist technology of the robotic system beneficial. Cestari et al. [19] tested the feasibility and short-term perioperative outcomes of the da Vinci single-site surgery platform in nine patients with a UPJO. The system uses a novel single-port access device with curved cannulas and robotic instruments. Additionally the instruments are crossed at the abdominal wall, to minimize clashing and improve triangulation. All cases were completely successful without complication or conversion. However, the authors noted the main limitation of the system was the lack of articulation of the instruments, which is the principal advantage gained with the application of the robotic system to LESS.

Pelvic Urologic Surgery

Radical Prostatectomy

Robotic-assisted laparoscopic prostatectomy has gained widespread adoption in the United States and is one of the most frequently performed robotic procedures. In 2007 we reported our initial series of four patients who underwent conventional LESS radical prostatectomy [20] and found that the procedure was very technically difficult. The application of robotics to LESS radical prostatectomy has reduced the learning

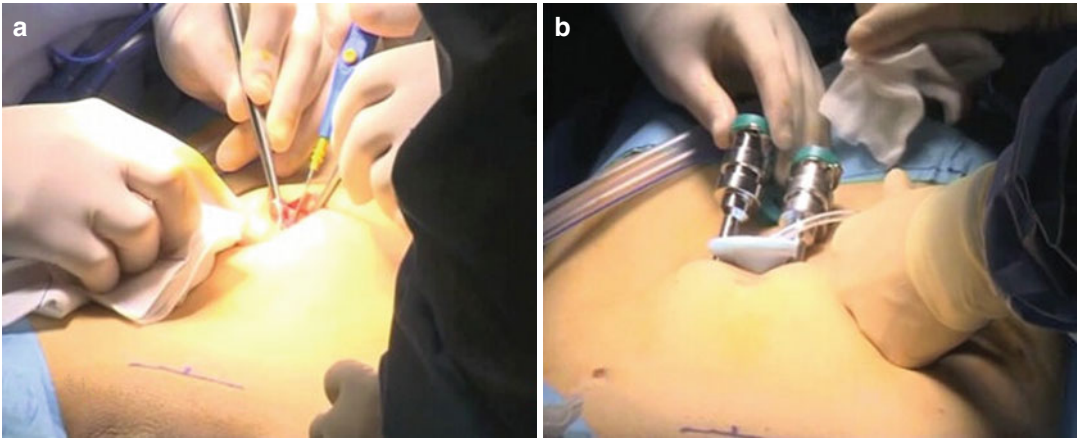


Fig. 11.3 (a) 3 cm umbilical incision is made (b) single port access device and robotic trocars are placed through separate fascial incisions

curve associated with this procedure, especially with regard to intracorporeal suturing. Patient positioning and docking of the robot are identical to that of a standard robotic prostatectomy.

The technique we describe herein is for a single-site access, where the multichannel and robotic ports are placed through the same skin incision, but separate fascial incisions. An incision is created intraumbilically (3–4.5 cm), and the umbilicus is released from the rectus fascia (Fig. 11.3). A 2-cm incision is created through the linea alba. The initial robotic port (8 mm) is placed at the most caudal portion of the incision on the right side and directed as far laterally as possible. This is repeated on the opposite side. A multichannel port is then inserted through the fascial incision into the abdomen. The patient is positioned in steep Trendelenburg, and the robot is then docked using a three-armed approach. The robotic 12-mm scope is introduced through the multichannel port and the robotic instruments through the two 8-mm ports.

Bladder mobilization is performed using the 8-mm EndoWrist (Intuitive Surgical) monopolar shears in the right hand and a 5-mm EndoWrist Schertel grasper in the left. Instruments are not intentionally crossed throughout the procedure. Using a 30° lens looking upward or a 0° lens, the peritoneum is widely incised high on the under-surface of the anterior abdominal wall, and dissection of the bladder is performed. Using the

8-mm EndoWrist monopolar shears in the right hand and a 5-mm EndoWrist Schertel grasper or 8-mm EndoWrist ProGrasp forceps in the left, fatty tissue is swept free from the pubic symphysis exposing the endopelvic fascia, which is then incised. The prostate is mobilized off the levator fibers.

An 8- and 5-mm EndoWrist robotic needle driver are used to ligate the dorsal venous complex with a 2.0 polyglactin suture (Vicryl). A back-bleeding stitch is placed across the anterior surface of the prostate. A suture can be placed through the abdominal wall and passed through the distal bladder neck or prostatic base and then exited out of the abdominal wall to serve as a retractor in a “marionette” fashion (Fig. 11.4). The anterior bladder neck is transected. The urethral catheter is suspended from the abdominal wall with a 2-0 suture in the previously described marionette fashion. The posterior bladder neck is then gradually dissected away from the prostate. The anterior layer of Denonvilliers fascia is incised, and the vas deferens and seminal vesicles are mobilized with the 5-mm harmonic scalpel in a non-nerve-sparing approach and athermally with Hem-o-lok clips (Teleflex Medical, Research Triangle Park, NC, USA) in a nerve-sparing approach. The vas deferens and seminal vesicles are retracted anteriorly with either the left or right robotic instrument or with marionette sutures if needed. In a non-nerve-sparing procedure, a

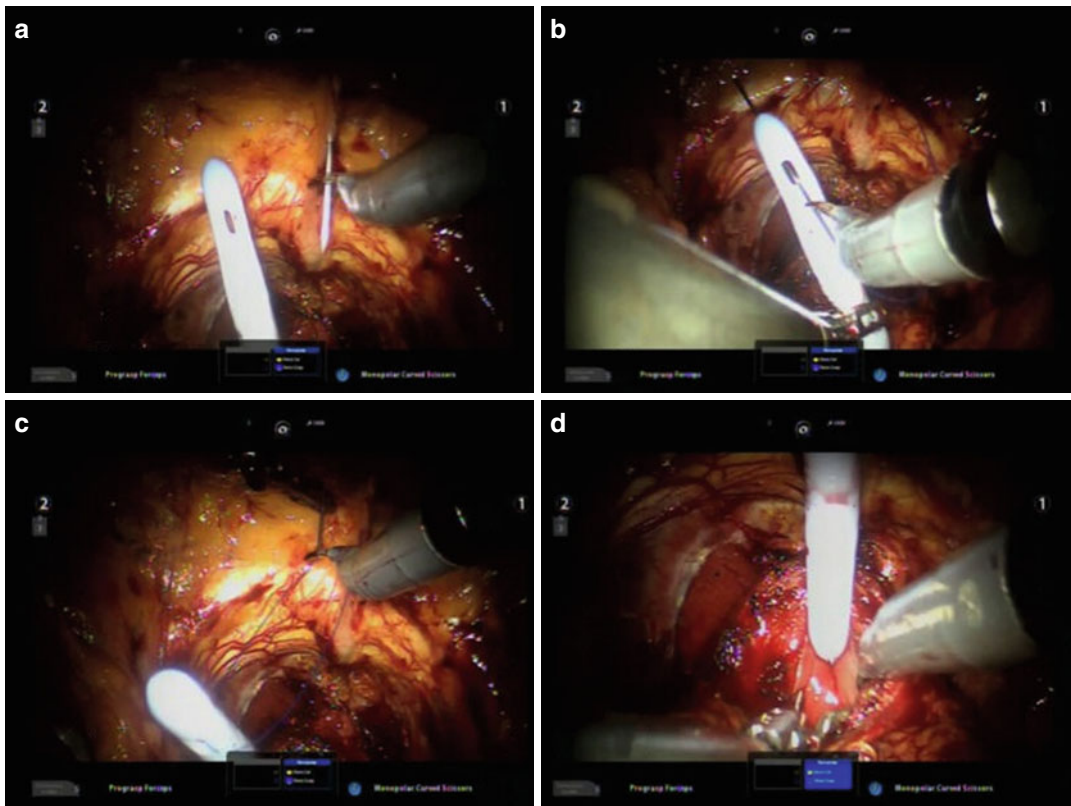


Fig. 11.4 “Marionette” suture technique. (a) Suture is placed through the abdominal wall. (b) Suture is brought through the eye of the Foley catheter. (c) Suture is then

brought back out through the abdominal wall. (d) Suture is tensioned to provide effective retraction during posterior bladder neck dissection

5-mm harmonic scalpel is used in the right hand to cauterize the lateral pedicles bilaterally. Additionally, the harmonic scalpel is used to detach the lateral border of the prostate and the neurovascular bundle from the perirectal fat. An interfascial nerve-sparing approach is accomplished with a combination of sharp dissection and robotically applied Hem-o-lok clips. Assistant retraction with the suction device and/or marionette sutures allows for placement of Hem-o-lok clips. The 8-mm monopolar shears are used to incise the ligated dorsal vein complex, exposing the underlying urethra. The urethra is transected without cautery. The tip of the urethral catheter is withdrawn, and the posterior urethral wall is transected sharply. Complete dissection of the prostate apex is accomplished in a retrograde fashion; the prostate is released and placed in a

10-mm entrapment bag. A standard lymph node dissection is performed in the identical manner to our robot-assisted laparoscopic prostatectomy (RALP) technique. External iliac nodal tissues, as well as nodes from the obturator fossa, are included in the dissection. The specimen is removed with a laparoscopic grasper. Robotic needle drivers in the left and right hand are used to complete the vesicourethral anastomosis. Two sutures of 2-0 poliglecaprone 25 (Monocryl) on an RB-1 needle are placed in a semicircular “running” fashion starting from the 6 o’clock position towards the 12 o’clock and then tied together. A 20-F Foley catheter is inserted under vision into the bladder before completion of the anastomosis. The anastomosis is tested by instilling 100 mL of saline into the bladder to ensure water tightness. A Jackson-Pratt drain is placed in the

pelvis and exited through a separate fascial stab but via the same skin incision.

A number of groups have reported their experience with R-LESS radical prostatectomy [21, 22], the largest including 20 patients by White et al. [4] from our center. We used a single-site approach, with an SILS Port and two 8-mm standard robotic trocars (or one 8-mm and one 5-mm trocar) placed through separate fascial incisions. Standard 8-mm EndoWrist (Intuitive Surgical) monopolar shears and a 5-mm EndoWrist Schertel grasper were used during dissection. The majority of patients were D'Amico low risk (45 %). Mean age was 60.4 years, and mean BMI was 25.4 kg/m². Because the fourth arm was not used, retraction was accomplished by assistant suction or marionette sutures. Mean OR time was 187.6 min, and EBL was 128.8 mL. There was one conversion to standard robotic prostatectomy because of a large median lobe and need for more effective retraction. Also, 2 cases required an additional 8-mm port placed outside of the umbilical incision due to issues with triangulation and leakage of gas from the SILS Port. There were four positive margins, but no patients experienced biochemical recurrence at 1-year follow-up. We also found a trend towards improved urinary continence, with five patients completely pad-free over the follow-up period. Three patients underwent an interfascial nerve-sparing technique, and one had SHIM score of >21 at 3 months postoperatively. Five patients had a leak at the urethrovesical anastomosis on cystogram done 1 week post surgery and required an additional week of catheterization. We concluded that R-LESS is feasible and less challenging than conventional LESS. Instrument clashing was virtually eliminated by staggering the robotic trocars, and marionette sutures allowed for effective retraction despite inability to use the 4th arm. Assistant-driven retraction with the suction was also important and facilitated by placing a 15–30° downward bend, in the distal 1/3 of the instrument.

Single-Port Transvesical Enucleation of the Prostate (STEP)

The open simple prostatectomy remains the gold standard in surgical therapy for prostates larger

than 80 g. However, there is still the potential for significant morbidity associated with this procedure, including significant hemorrhage. A number of centers have recently reported their experience with single-port transvesical enucleation of the prostate (STEP) as a minimally invasive alternative. For this procedure ports are placed through the bladder, and the prostate adenoma is enucleated.

The procedure is performed under general anesthesia with the patient in low lithotomy position. Initially, cystoscopy and transurethral incision of the prostatic urethra can be performed at the apex using a Collins knife. The skin incision is then marked at the highest portion of the bladder with the aid of a percutaneously placed spinal needle and confirmed cystoscopically. A 3-cm skin incision is made three fingerbreadths above the symphysis pubis. The bladder wall is cleared of prevesical fat and entered sharply between two stay sutures. At this point the cystoscope is substituted with a Foley catheter and the balloon was inflated with 5 mL sterile water and then clamped. The wound protector ring of the GelPort TM (Applied Medical, Santa Margarita, California, USA) is inserted through the incision. The Foley catheter is excluded from the port sleeve and pushed against anterior bladder neck at the 12 o'clock position. The GelPort sleeve is then tightened by securing the outer ring. A 12-mm trocar is inserted at the 6 o'clock position in the GelPort and is used for the robotic camera and for carbon dioxide (CO₂) insufflation. A 30° upward facing lens is utilized. Two 5-mm ports are placed on the right and a single 8-mm port on the left, equidistant from the closed midline pre-made hole in the GelPort. Closure of the pre-made hole was necessary to prevent CO₂ leakage. Pneumovesicum was created with CO₂ set to 20 mmHg. The robot is then introduced into the surgical field between the patient's legs and docked. Using the Harmonic scalpel in the right hand and a 5-mm Schertel grasper in the left, a semicircular incision is made through the bladder mucosa immediately overlying the adenoma from the 3 o'clock to the 9 o'clock position. The prostatic adenoma is readily identified and an avascular plane is created, utilizing the 5-mm

monopolar cautery, between the adenoma and the prostatic capsule. Enucleation is carried distally to the apex. Once the apex is enucleated, the adenoma is free, as the mucosal attachments were previously incised cystoscopically. Hemostasis is confirmed, and a 22–24-French three-way Foley catheter is inserted. The prostatic adenoma is extracted through the GelPort ring after removing the outer gel pad. A watertight cystotomy closure can be performed in two layers using 2-0 absorbable suture. The fasciotomy is closed using running 0 absorbable suture, and 4-0 absorbable subcuticular suture was used for skin closure.

Fareed et al. [10] reported our experience with STEP, using the da Vinci surgical robot. Nine patients underwent R-STEP with a GelPort (Applied Medical, Santa Margarita, CA) as the access platform. Robotic instruments consisted of a 5-mm Schertel grasper and harmonic scalpel. Mean gland size was 146.4 mL (83–304 mL) based on transrectal ultrasound. Mean OR time was 3.8 h (2.75–4.75), and EBL was 584.4 mL (150–1,200). One patient required conversion to an open prostatectomy and was excluded from the analysis. Two patients required cystoscopy, fulguration, and clot evacuation postoperatively for clot retention. Additionally one patient developed a DVT which required anticoagulation, and one patient suffered a perioperative myocardial infarction, requiring admission to the ICU. At 1-month follow-up, mean IPSS was 4.83 (2–15), Qmax was 20.1 mL/s (6–36), and PVR was 75.75 mL (0–360). We concluded that while R-LESS is technically feasible and effective in treating bladder outlet obstruction, there was a high rate of complications.

Future Directions

While the application of robotics to LESS has been beneficial, there are still several drawbacks, such as instrument clashing and reduced space for the bedside assistant. This is largely due to the fact that the current da Vinci system has not been specifically designed for the single-site application. Additionally the R-LESS-specific robotic platform lacks the EndoWrist technology, which has obvious limitations. It is clear that an R-LESS-specific design would incorporate a low

external profile and articulating instruments and allow sufficient space for the bedside assistant. There are currently a number of LESS-specific robotic prototypes under development, including one that is completely deployed into the peritoneal cavity [23–25]. However, R-LESS remains in its infancy, and much development is needed for a flawless, task-specific system that effectively mimics standard robotic surgery.

Conclusion

The application of robotics to LESS (R-LESS) has addressed many of the limitations seen with the conventional LESS technique. The EndoWrist technology allows for superior dissection, triangulation, and intracorporeal suturing. However, R-LESS is still in its infancy, as the current iteration of the da Vinci robotic platform has not been designed for LESS. As a result of the bulky extracorporeal profile, instrument clashing and limited space at the bedside remain important issues. Solutions such as the da Vinci Single-Site™ platform have been designed to address these challenges; however, their full clinical potential has not yet been reached as further testing is required. The ideal robotic platform for R-LESS would be low profile and task specific and would allow for deployment through a single incision. Additionally the instruments would be articulating, and there would be effective triangulation and retraction. Further advancements in the field of robotic surgery are necessary before LESS becomes widely adapted.

References

1. Kaouk JH, Goel RK, Haber GP, Crouzet S, Stein RJ. Robotic single-port transumbilical surgery in humans: initial report. *BJU Int.* 2008;103:366–9.
2. Stein RJ, White WM, Goel RK, Irwin BH, Haber GP, Kaouk JH. Robotic laparoendoscopic single-site surgery using GelPort as the access platform. *Eur Urol.* 2010;57:132–7.
3. White MA, Autorino R, Spana G, et al. Robotic laparoendoscopic single-site radical nephrectomy: surgical technique and comparative outcomes. *Eur Urol.* 2011;59:815–22.

4. White MA, Haber G-P, Autorino R, et al. Robotic laparoendoscopic single-site radical prostatectomy: technique and early outcomes. *Eur Urol.* 2010;58:544–50.
5. Arkoncel FR, Lee JW, Rha KH, Han WK, Jeoung HB, Oh CK. Two-port robot-assisted vs standard robot-assisted laparoscopic partial nephrectomy: a matched-pair comparison. *Urology.* 2011;78:581–5.
6. Olweny EO, Park SK, Tan YK, Gurbuz C, Cadeddu JA, Best SL. Perioperative comparison of robotic assisted laparoendoscopic single-site (LESS) pyeloplasty versus conventional LESS pyeloplasty. *Eur Urol.* 2012;61:410–4.
7. Joseph RA, Goh AC, Cuevas SP, et al. Chopstick surgery: a novel technique improves surgeon performance and eliminates arm collision in robotic single-incision laparoscopic surgery. *Surg Endosc.* 2010;24:1331–5.
8. Haber GP, White MA, Autorino R, et al. Novel robotic da Vinci instruments for laparoendoscopic single-site surgery. *Urology.* 2010;76:1279–82.
9. Kaouk JH, Autorino R, Kim FJ, et al. Laparoendoscopic single-site surgery in urology: worldwide multi-institutional analysis of 1076 cases. *Eur Urol.* 2011; 60:998–1005.
10. Fareed K, Zaytoun OM, Autorino R, et al. Robotic single port suprapubic transvesical enucleation of the prostate (R-STEP): initial experience. *BJU Int.* 2012; 110(5):732–7.
11. Lee JW, Arkoncel FRP, Rha KH, et al. Urologic robot-assisted laparoendoscopic single-site surgery using a homemade single-port device: a single-center experience of 68 cases. *J Endourol.* 2011;25:1481–5.
12. Autorino R, Kaouk JH, Stolzenburg J, et al. Current status and future directions of robotic single-site surgery: a systematic review. *Eur Urol.* 2013;63:266–80.
13. White MA, Autorino R, Spana G, Hillyer S, Stein RJ, Kaouk JH. Robotic laparoendoscopic single site urological surgery: analysis of 50 consecutive cases. *J Urol.* 2012;187:1696–701.
14. Seideman CA, Yung KT, Faddegon S, et al. Robot-assisted laparoendoscopic single-site pyeloplasty: technique using the da Vinci Si robotic platform. *J Endourol.* 2012;26:971–4.
15. Joseph RA, Salas NA, Johnson C, et al. Chopstick surgery: a novel technique enables use of the da Vinci robot to perform single-incision laparoscopic surgery [video]. *Surg Endosc.* 2010;24:3224.
16. Kaouk JH, Autorino R, Laydner H, et al. Robotic single-site kidney surgery: evaluation of second-generation instruments in a cadaver model. *Urology.* 2012;79:975–9.
17. Morel P, Hagen ME, Bucher P, et al. Robotic single-port cholecystectomy using a new platform: initial clinical experience. *J Gastrointest Surg.* 2011;15: 2182–6.
18. Konstantinidis KM, Hirides P, Hirides S, et al. Cholecystectomy using a novel Single-Site(1) robotic platform: early experience from 45 consecutive cases. *Surg Endosc.* 2012;26:2687–94.
19. Cestari A, Buffi NM, Lista G, et al. Feasibility and preliminary clinical outcomes of robotic laparoendoscopic single-site (R-LESS) pyeloplasty using a new single-port platform. *Eur Urol.* 2012;62:175–9.
20. Kaouk JH, Goel RK, Haber GP, et al. Single port laparoscopic radical prostatectomy. *Urology.* 2008;72:1190–3.
21. Barret E, Sanchez-Salas R, Cathelineau X, et al. Re: initial complete laparoendoscopic single-site surgery robotic assisted radical prostatectomy (LESS-RARP). *Int Braz J Urol.* 2009;35:92–3.
22. Leewansangtong S, Vorrakitatorn P, Amornvesukit T, et al. Laparo-endoscopic single site (LESS) robotic radical prostatectomy in an Asian man with prostate cancer: an initial case report. *J Med Assoc Thai.* 2010;93:383–7.
23. Wortman TD, Strabala KW, Lehman AC, et al. Laparoendoscopic single-site surgery using a multifunctional miniature in vivo robot. *Int J Med Robot.* 2011;7:17–21.
24. Sekiguchi Y, Kobayashi Y, Watanabe H, et al. In vivo experiments of a surgical robot with vision field control for single port endoscopic surgery. *Conf Proc IEEE Eng Med Biol Soc.* 2011;2011:7045–8.
25. Kobayashi Y, Tomono Y, Sekiguchi Y, et al. A surgical robot with vision field control for single port endoscopic surgery. *Int J Med Robot.* 2010;6:454–64.

Necole M. Streeper and Stephen Y. Nakada

Introduction

The first ureteroscopic stone removal was reported in 1980 by Perez-Castro-Ellendt and Martinez-Pineiro. Since that time, the advancement in the technology for endoscopic instrumentation has allowed the treatment modalities for ureteral stones to evolve, largely replacing open surgery and blind basketing. Medical expulsive therapy (MET) to facilitate spontaneous stone passage is generally accepted as the first line of treatment for ureteral calculi <10 mm in a patient with controlled pain and no indications for early surgical intervention [1–3]. There are three locations where the ureter narrows and are common locations for stone obstruction, including: ureteropelvic junction (UPJ), upon crossing the iliac vessels, and ureterovesical junction (UVJ). When ureteral calculi fail to progress after a sufficient trial of time, generally 4–5 weeks, then surgical intervention is recommended.

Other indications for surgical intervention include persistent obstruction causing renal dysfunction, solitary kidney, recurrent urinary tract infections, large stone burden, and presence of unremitting renal colic. Consideration of the fol-

lowing is essential when making decisions about treatment of both renal and ureteral calculi: probability of stone-free rate, need for additional procedures, and morbidity related to the treatment modality. This chapter will focus on the indications, technical considerations, and complications of ureteroscopy for both renal and ureteral calculi.

Indications for URS Management of Renal Calculi

The treatment modalities that are considered for renal calculi include ureteroscopy (URS) with intracorporeal lithotripsy, extracorporeal shock wave lithotripsy (ESWL), and percutaneous nephrolithotomy (PCNL). Traditionally, renal calculi have been treated with either ESWL or PCNL; however, advancement in ureteroscopic technology now permits URS as an acceptable alternative [4–6]. Ureteroscopy is associated with high treatment success, >90 %, for renal stones less than 2 cm, regardless of location within the kidney [7]. PCNL is the preferred management of stones >2 cm, with the exclusion of patients with irreversible coagulopathy and severe morbid obesity who can be treated with URS with less associated morbidity. In addition, URS is considered an effective treatment for ESWL-failure stones and for renal stones with associated ureteral stone burden [8].

N.M. Streeper • S.Y. Nakada, MD (✉)
Department of Urology, University of Wisconsin
School of Medicine and Public Health,
1685 Highland Ave, Madison, WI 53705, USA
e-mail: nakada@urology.wisc.edu

Lower pole renal stones present increased technical difficulty when performing URS due to its anatomic location. It is often difficult to navigate the ureteroscope into the lower pole due to the angle and amount of flexion required of the ureteroscope. The degree of flexion is limited once the laser fiber is inserted into the scope; therefore, in certain instances, it is more advantageous to displace the stone with a basket to an upper pole calyx, prior to lithotripsy [9]. With regard to ESWL for calculi in the lower pole, patients may fail to clear the fragments from the kidney given the position and angle of the lower pole to the renal pelvis. Pearle et al. performed a prospective, randomized multicenter trial and did not find a statistically significant difference in stone-free rates between ESWL and URS for lower pole renal calculi less than 1 cm [10]. Another study evaluated URS compared to PCNL for stones between 1.5 and 2 cm located in the lower renal pole and found stone-free rates to be comparable, 89.2 and 92.8 %, respectively [11].

Indications for URS Management of Ureteral Calculi

The accepted treatment methods for ureteral calculi include medical expulsive therapy (MET), extracorporeal shock wave lithotripsy (ESWL), ureteroscopy (URS), and percutaneous nephrolithotomy (PCNL) with antegrade ureteroscopy if necessary. Decision concerning treatment modality takes into consideration stone size, stone location, stone composition, presence or absence of infection, patient comorbidities, and patient preference.

Guidelines state that MET should be offered to patients with ureteral stone <10 mm as first-line therapy, although certain circumstances may indicate need for earlier surgical management including uncontrolled pain, infection/sepsis, or acute kidney injury [1, 3, 12]. The preferred agent for MET is alpha-blockers [12, 13]. The success of MET and the average amount of time required to pass a stone is dependent on stone size, for example, 95 % of stones less than 4 mm

pass spontaneously by 31 days for stones less than 2 mm and 40 days for stones between 2 and 4 mm compared to 47 % of stones between 5 and 10 mm [1, 14]. Therefore, stone size plays a significant role when deciding between initial MET and another treatment modality. Given that the spontaneous passage of stone with MET may take 4–6 weeks and may be accompanied with renal colic, the patient needs to be appropriately counseled and may prefer to have earlier surgical intervention.

According to the AUA Guidelines for the management of ureteral calculi, both ESWL and URS are acceptable first-line treatments [1]. Aboumarzouk et al. performed a meta-analysis of 7 randomized controlled trials to compare ESWL and URS [15]. The stone-free rate was significantly better for URS than for ESWL (92 % vs. 77 %, RR 0.84, 95 % CI 0.73–0.96). The rate of secondary procedure was higher for ESWL in comparison to URS (21 % vs. 3 %, RR 6.18, CI 3.68–10.38). However, URS was associated with higher complications, which were minor, and longer hospital stay [15]. In addition, URS has also been found to be more cost-effective when compared to ESWL for treatment of stones that have failed a trial of MET [16].

Stone Composition and URS

The Hounsfield unit (HU) density may be calculated on CT imaging to suggest potential stone composition [17]. ESWL-resistant stones include cystine, brushite, and calcium oxalate monohydrate. URS should be considered over ESWL in patients with these stone compositions due to poor stone-free rate outcomes and risk of additional procedures; therefore, it is important to identify these stones with higher likelihood of fragmentation resistance preoperatively to adequately inform the patient when making treatment decisions. Studies suggest that stone attenuation, measured in HU, is the best predictor of ESWL success [18, 19]. Ouzaid et al. found that stones with measured HU density <970 had a 96 % stone-free rate compared to those with >970

HU had a 38 % stone-free rate and concluded that those patients with increased likelihood of poor outcome with ESWL should undergo alternative therapy [19]. The pulsed (coumarin) dye laser is ineffective against cystine and calcium oxalate monohydrate and should not be utilized in these instances. The Ho: YAG laser is effective against all stone compositions and is the preferred laser lithotripter.

Special Considerations

During surgical planning, the following patient characteristics should be given special considerations: children, pregnancy, coagulopathies or bleeding disorders, and patient body habitus (Table 12.1).

Several studies have shown that ureteroscopy is safe and efficacious in the pediatric population, with comparable stone-free rates and complications when compared to the adult population [1, 20–22]. Treatment decision should consider the child's size and genitourinary tract anatomy. If the available ureteroscope will not accommodate the small diameter of the pediatric urethra or ureter, then a less invasive approach with ESWL would be favored.

Ureteroscopy is safe during pregnancy if patients fail conservative management of an obstructing ureteral stone [23, 24]. The holmium: YAG laser is the intracorporeal lithotripter of choice and has proven to be safe to be utilized on pregnant patients. Ultrasound may be used rather than fluoroscopy during treatment if trained personnel are available. Other approaches to reduce radiation exposure to the fetus include low-dose fluoroscopy and the use of an x-ray shield over the pelvis shielding the fetus. When making treatment decisions, it is important to consider that pregnancy is associated with hypercalciuria and accelerated encrustation of stents/nephrostomy tubes; therefore, exchanges may need to be every 4–8 weeks. The most favorable timing for surgical intervention is during the second trimester. The first trimester carries increased risk to the fetus, and

Table 12.1 Special considerations during treatment decision-making

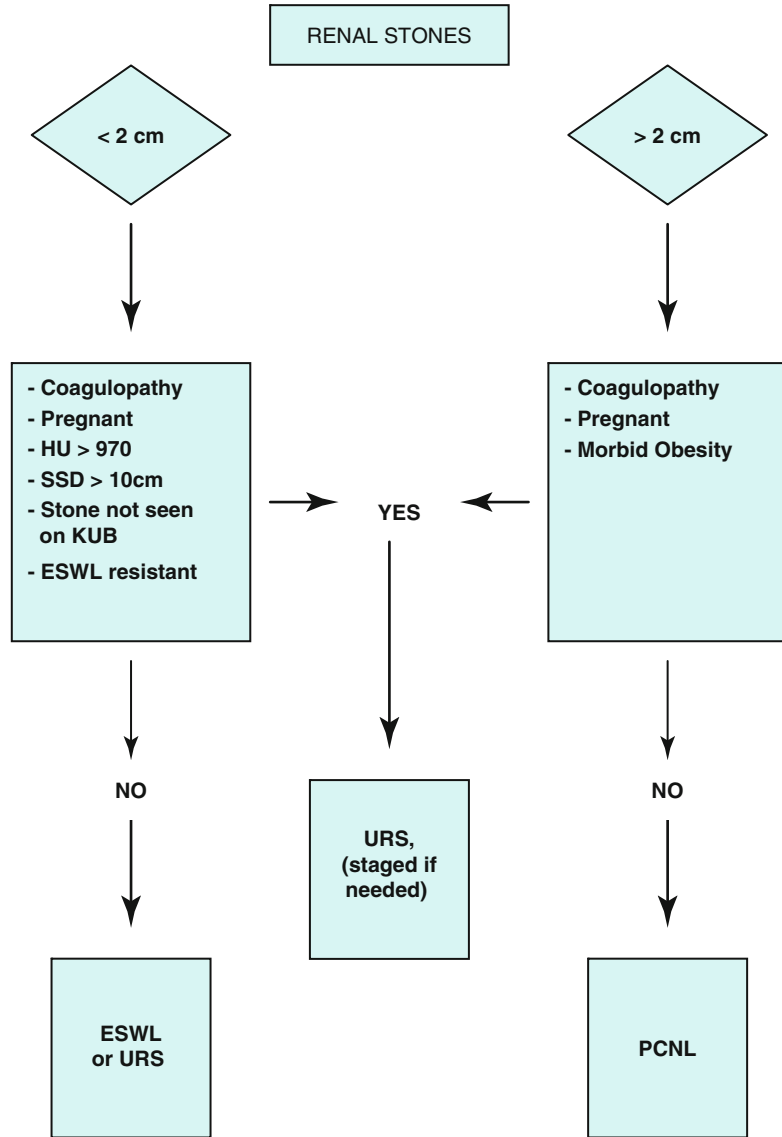
Patient factors	Anatomical	
	features	Stone features
Obesity	Solitary kidney	Size
Coagulopathy	Horseshoe kidney	Stone composition
Comorbidities	Ectopic kidney	Hounsfield unit (HU) density
Pregnancy	Lower pole stone	ESWL resistant
Renal insufficiency	Skin-to-stone distance	Coexisting ureteral stones

the third trimester can be more technically challenging due to the patient's habitus. ESWL is contraindicated during pregnancy.

Patients with coagulopathy or on anticoagulation medication are poor candidates for both ESWL and PCNL due to increased bleeding risk. Watterson et al. showed that ureteroscopy with holmium: YAG laser lithotripsy is safe for this patient population without correcting coagulopathies or cessation of anticoagulation medications preoperatively [25]. Electrohydraulic lithotripsy (EHL) has a higher rate of mucosal damage and is not recommended for use in this population. Similar stone-free rates, intraoperative and postoperative complications have been reported when compared to patients with normal coagulation [25]. In patients that are anticoagulated, we have noticed an increased likelihood of perirenal bleeding postoperatively, likely secondary to guidewire perforation. In these patients, using a wireless access may be a favorable approach.

Body habitus is an important factor when deciding treatment modality, given that both ESWL and PCNL have limitations in patients who are obese [26]. It is known that patients with large skin-to-stone distances (SSD) have poorer outcomes with ESWL [27, 28]. Pareek et al. found that ESWL in patients with a SSD greater than 10 cm is likely to fail [27]. For PCNL, limitations include length of access sheath and instrumentation as well as anesthetic risk in the prone position. URS can be safely performed in obese patients since stone-to-skin distance is not an indicator of success and studies have proven it to be efficacious [29, 30].

Fig. 12.1 Algorithm for the treatment of renal stones



URS may be indicated due to patient comorbidities that preclude treatment by ESWL or PCNL, even for very large renal stones >2 cm, in patients with coexisting ureteral stones, coagulopathy, morbid obesity, pregnancy, or renal anomalies [31, 32]. Treatment may be done in planned staged procedures to minimize the risk of prolonged anesthesia time. An algorithm for the treatment of renal stones as shown in Fig. 12.1 can be used to guide decision-making in patients with these clinical features.

Preoperative Considerations

Prior to surgical intervention for calculi, the patient should undergo preoperative anatomic imaging with CT non-contrast scan, ultrasound, KUB, or IVP. This will provide important details concerning the stone including the location and size that will aid in treatment modality decision-making. Our standard remains to obtain CT imaging, because in addition to the above information, the Hounsfield unit density and skin-to-stone distance may be calculated in

order to predict success with alternative treatment options [17, 27, 28]. A detailed history and physical examination should be completed, and the patient should be medically optimized prior to surgery. Preoperative laboratory evaluation should include a urine culture, or urine dipstick in uncomplicated cases, 1 week prior to the surgery date and treated with culture-specific antibiotics, if necessary. Based on the AUA Best Practice Policy Statement, the antimicrobial prophylaxis of choice to be given prior to ureteroscopy is a fluoroquinolone or TMP-SMX with a duration of less than or equal to 24 h [33]. Alternative choices include: aminoglycoside (aztreonam) ± ampicillin, first- or second- generation cephalosporin, or amoxicillin/clavulanate [33].

Technique

Table 12.2 lists an example of the instrument list required for ureteroscopic stone management, of course surgeon preference may differ. The patient is placed in the dorsal lithotomy position. A 20–22 F rigid cystoscope is inserted through the urethra into the bladder. The ureteral orifice is cannulated with a guidewire, typically requiring guidance with an open-ended catheter and advanced to the level of the renal pelvis. Rarely, it may be necessary to perform a retrograde pyelogram using a 5 F open-ended ureteral catheter to delineate the anatomy of the collecting system prior to placement of the guidewire.

For a distal or mid-ureteral stone, the semirigid ureteroscope is used to enter the ureter alongside the guidewire up to the level of the stone. The semirigid ureteroscope has a larger working channel and is preferred over flexible ureteroscopes for distal stones because of their tendency to buckle within the bladder. Depending on the size of the stone, it may be extracted with a basket or fragmented with holmium laser lithotripsy. Generally, stones that are less than 4 mm may be successfully removed with a basket or preferably graspers given the ease of stone release if necessary. When removing stone fragments, care must be taken to make sure the stone is withdrawn without resistance because ureteral avulsion is a

Table 12.2 An example of a list of instruments required to perform ureteroscopy for the treatment of calculi

Rigid cystoscope (20–22 F) with 30° lens
Open-ended ureteral catheter (5 F)
Guidewire (Boston Scientific Sensor, following should be available: straight and angled Boston Scientific Glidewire and Boston Scientific Amplatz Super Stiff)
Flexible ureteroscope (Olympus P5 180–270)
Semirigid ureteroscope (ACMI Micro-6)
Camera and light source
Irrigation setup and endoscopic irrigator (Pathfinder, Boston Scientific Single Action Pumping System)
Adaptor (Applied Medical Sureseal, US Urology UroSeal)
Holmium laser fiber (200 or 270 μm) with setup
Radiopaque contrast (omnipaque)
Basket (2.2 F N-circle, Cook 2.4 F N-compass)
Double J ureteral stent (6 F, 22–28 cm)
Optional – Cook ureteral access sheath (12/14 F or 14/16 F, 35–45 cm)
Optional – Cook Ascend AQ dilation balloon
Optional – Cook dual lumen catheter or 8/10 F ureteral dilator

risk if this is not done properly [34]. In addition, no blind basketing should be done for this reason.

For proximal ureteral or renal calculi, a flexible ureteroscope is used. The flexible ureteroscope may either be inserted over a guidewire or a ureteral access sheath may be utilized based on surgeon's preference. Ureteral sheaths are available in the following sizes: 10/12 F to 14/16 F and lengths 20–55 cm. The sheath is advantageous when removing individual stone fragments as it facilitates repetitive access into the upper tract while decreasing operative time, improving stone-free rate, and causing minimal associated morbidity [35, 36]. Without a sheath, the repetitive insertion and withdrawal of the ureteroscope increases the likelihood of ureteral injury. In addition, sheaths decrease the need for additional ureteral dilation. If the ureteral sheath does not insert easily, the inner obturator may be passed initially and then attempt placement of the entire device subsequently. Using a ureteral sheath has also been shown to decrease intrapelvic pressure during ureteroscopy [37]. Delvecchio et al. found a similar ureteral stricture rate, 1.4 %, in patients who had a ureteral access sheath utilized during

Table 12.3 Guidelines for ureteroscopy without a safety wire

Renal procedures primarily	Avoid in patients with UPJ obstruction or duplicated systems
Stone treatment primarily	Avoid in patients with intrinsic ureteral disease or impacted stones
Straightforward ureteral access	No stone distraction
Replace guidewire through ureteroscope prior to removal	

their ureteroscopy [38]. However, there is a theoretical risk of ischemic effects with the use of a ureteral sheath, and, therefore, it is best not to use large sheaths for long periods of time.

Pulverization of the stone into small enough fragments for spontaneous passage obviates the need for repetitive reentry into the upper tract to remove stone fragments, and a ureteral sheath is not necessary when using this technique [39]. We prefer this approach considering that less instrumentation will decrease the likelihood of ureteral injury. Schatloff et al. performed a randomized study comparing the two methods, stone fragment retrieval and pulverization of the stone with spontaneous fragment passage, and found that not actively retrieving fragments leads to higher rates of unplanned medical visits [40]. However, there need to be further studies done to elucidate whether these two techniques lead to different stone-free rates, postoperative complications, and need for secondary treatment.

If the use of a safety wire is preferred, then prior to insertion of the ureteroscope, a dual lumen catheter, or an 8/10 F dilator, may be inserted over the guidewire and a safety wire may be placed at that time. Patel et al., and other studies, have shown that the ureteroscope is sufficient access into the collecting system, and there is no need for a safety wire [39, 41, 42]. This approach allows easier access for the ureteroscope, often obviating the need for a sheath. As long as this approach is used selectively (see Table 12.3), it is efficient, safe, and effective [41]. The disadvantages to using a safety wire include: cost, obtrusiveness, and additional wire trauma.

At the conclusion of the case, a ureteral stent is typically placed. Several decisions will

need to be made concerning the stent, including size, length, duration of stent, and utilization of the string or dangler. Leaving the string on the stent aids in removing the stent postoperatively without the need for further invasive procedures. However, leaving the string, while more convenient, places the patient at a higher risk for accidental premature removal of the stent. A string should only be left if the stent is needed for 7 days or less. Longer periods of time make the likelihood of accidental stent removal more likely. One technique is to leave the string shorter in the male so that it is in the anterior urethra, facilitating cystoscopic removal without having to enter the bladder while also eliminating premature stent removal. The stent is typically left in place between 2 and 4 days following routine ureteroscopy and for longer duration, 4–6 weeks, following ureteral injury or dilation of ureteral stricture.

Placement of the stent may be accomplished with the use of the rigid cystoscope under direct visualization or fluoroscopically. For placement under direct visualization, a rigid cystoscope is back-loaded onto the guidewire and advanced into the bladder to visualize the ureteral orifice. The stent is advanced through the cystoscope with the pusher until the distal black marker is in the ureteral orifice and the proximal end of the stent is in proper position within the renal pelvis. At this point, the guidewire is withdrawn enough to see the proximal end of the stent coil into good position under fluoroscopic visualization. Attention is then turned to the distal end of the stent. The cystoscope is withdrawn to the bladder neck, and the stent is advanced until the distal end is at the bladder neck. The guidewire is completely removed, and the distal end of the stent will subsequently be curled within the bladder.

The second approach to placement of the ureteral stent is under fluoroscopic visualization alone; see Fig. 12.2 which outlines the steps as described below. The ureteral stent is advanced over the guidewire using the pusher. The C-arm should be positioned over the bladder, and the pusher should be advanced until the radiopaque marker is at the mid-pubic symphysis. Maintaining the pusher in the same

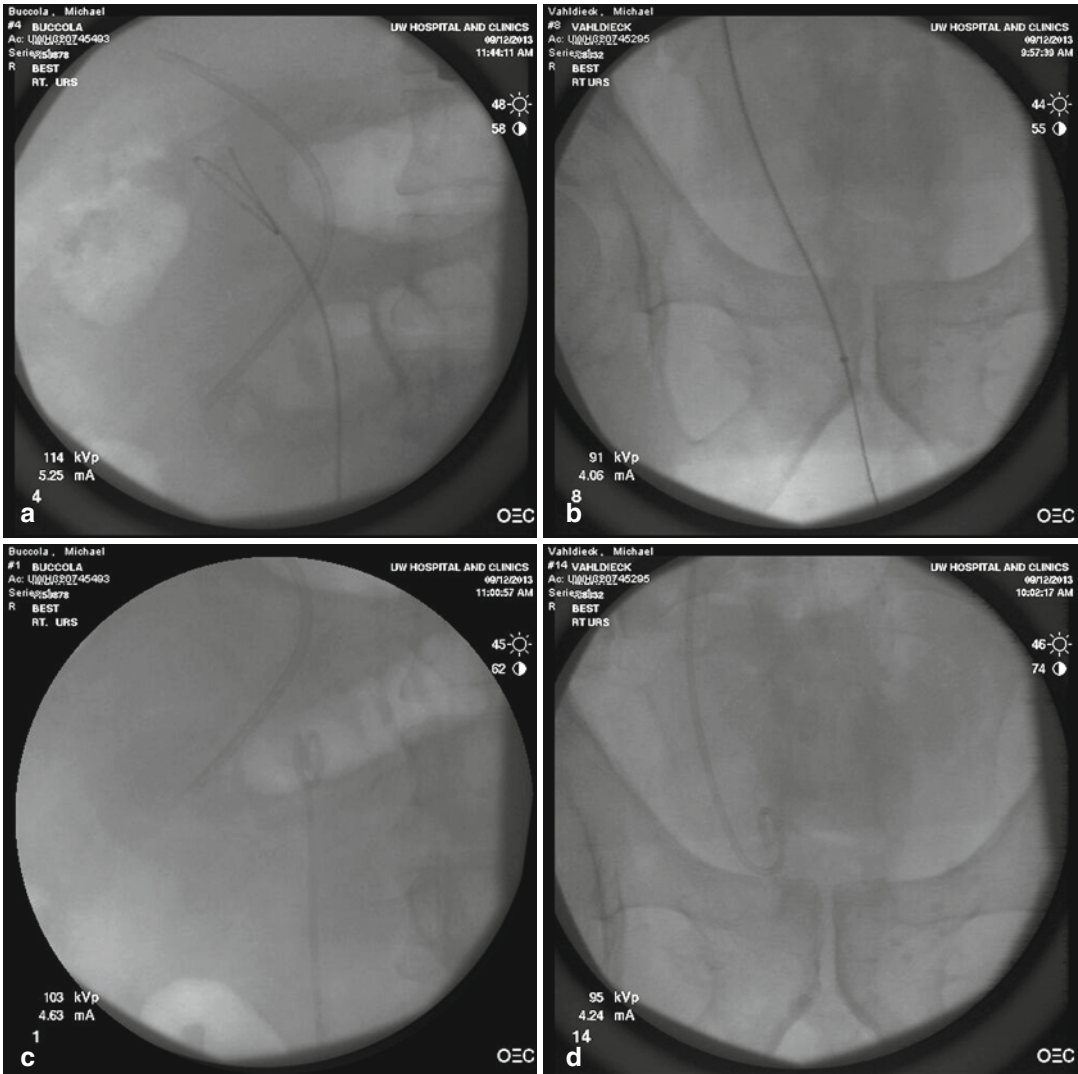


Fig. 12.2 Fluoroscopic placement of a ureteral stent. (a) A guidewire is advanced to the level of the renal pelvis and coiled. (b) The ureteral stent is advanced over the guidewire using the pusher. The C-arm should be positioned over the pubic symphysis and the pusher should be advanced until the radiopaque marker is at the mid-pubic symphysis. (c) Maintaining the pusher in the same posi-

tion, the C-arm should be positioned over the kidney and the guidewire withdrawn enough to see the proximal end coil within the renal pelvis. (d) The C-arm should again be positioned over the pubic symphysis to ensure that the pusher is still in proper location. Once verified, the guidewire is completely removed, deploying the distal end of the stent to coil within the bladder

position, the C-arm is moved to the kidney to ensure that the proximal end of the stent is in good position. The guidewire is withdrawn enough to see the proximal end coil within the renal pelvis. The C-arm is then relocated over the bladder, and fluoroscopy is used to ensure that the marker on the pusher is still in the proper location. Once verified, the guidewire is

completely removed, deploying the distal end of the stent to coil within the bladder.

There is an increasing trend to forgo placement of a ureteral stent after uncomplicated ureteroscopy for treatment of calculi, with data suggesting no difference in complication rates [43–45]. Traditionally, stents were placed due to theoretical risk of ureteral edema from instrumentation

causing edema, passage of stone fragments or blood clots, and ureteral stricture, all with risk of obstruction leading to renal colic. Technology has advanced over the years leading to smaller instruments that were less traumatic, leading to more recent studies that have suggested that ureteral stents may not be necessary in all patients [43–45]. There are some complications or high-risk patients that require stenting, including ureteral injury, stricture, large residual stone burden, solitary kidney, renal insufficiency, and patients with coagulopathies.

Current Ureteroscopes

Table 12.4 reviews the specifications of the flexible ureteroscopes that are currently available. Flexible ureteroscopes vary in the degree of active deflection, maximal and tip diameter, presence of secondary deflection, and the type of lens. There have been advances over the years in the primary active deflection capabilities of flexible

ureteroscopes to 270°, as well as scopes that have a second lever allowing for secondary active deflection up to 310° (Gyrus-ACMI DUR-8 Elite, Stryker Flexvision U500), allowing for increased access into the lower pole and acutely angled access into the lower pole and acutely angled access into the lower pole and acutely angled access into the lower pole and acutely angled access into the lower pole and acutely angled access into the lower pole [46]. Scopes that have variable upward and downward deflection, such as 180°/270° as seen in Olympus URF-P5 and URF-V, allow for greater options in maneuverability when attempting access into more challenging calyces.

The majority of flexible ureteroscopes have a 3.6 F working channel. Instruments should be passed through the working channel with the ureteroscope in a neutral position. The insertion of devices into the working channels inhibits the degree of deflection as well as decreases irrigation flow [47]. Given the size of the working channel, instruments should be less than 3 F in order to maximize irrigation flow. An irrigation system is necessary to maintain proper visualization of the lumen of the ureter and the renal collecting system during ureteroscopy. Either a hand irrigation system, such as Pathfinder bulb

Table 12.4 Specifications of current flexible ureteroscopes

Scope	Tip diameter (F)	Maximal shaft diameter (F)	Working channel diameter (F)	Active deflection in degrees (up/down)	Presence of active secondary deflection	View (°)	Type of lens
Olympus							
URF-P5	5.3 F	8.4 F	3.6 F	Up 180°/down 275°	No	90	Analogue
URF-V	8.3 F	9.9 F	3.6 F	Up 180°/down 275°	No	90	Digital
URF-P6/P6R	4.9 F	7.95 F	3.6 F	Up 275°/down 275°	No	90	Analogue
Gyrus-ACMI							
AUR-7	7.2 F	11 F	3.6 F	Up 120°/down 160°	No	80	Analogue
DUR-8 Elite	6.75 F	8.7 F	3.6 F	Up 170°/down 180°	Yes – down 130°	80	Analogue
DUR-8	6.75 F	8.7 F	3.6 F	Up 170°/down 180°	No	80	Analogue
DUR-8 ULTRA	8.6 F	9.36 F	3.6 F	Up 270°/down 270°	No	80	Analogue
DUR-D	8.7 F	9.3 F	3.6 F	Up 250°/down 250°	No	80	Digital
Storz							
Flex-X2	7.5 F	8.4 F	3.6 F	Up 270°/down 270°	No	110	Analogue
Flex-XC	8.5 F	8.5 F	3.6 F	Up 270°/down 270°	No	90	Digital
WOLF							
Cobra	6 F	9.9 F	3.3 F × 2	Up 270°/down 270°	No	85	Analogue
Viper	6 F	8.8 F	3.6 F	Up 270°/down 270°	No	85	Analogue
Stryker							
FlexVision U500	6.9 F	–	3.6 F	Up 275°/down 275°	Yes	90	Analogue

or single action pump system syringe, or a pressurized irrigation system can be utilized. Hand irrigation systems allow for greater control over the amount of irrigant used as well as prevention of retrograde stone migration [48]. Pressurized irrigation up to 300 mmHg can be used during ureteroscopy; however, it is advisable to utilize a ureteral access sheath in order to maintain lower intrapelvic pressure [37].

Semirigid ureteroscopes are primarily used for distal ureteral stones and have some advantages including larger working channels and resistance to buckling in the bladder. Olympus GyruS-ACMI, Wolf, Storz, and Stryker all produce a variety of semirigid ureteroscopes that vary in angle of eyepiece, optics, scope diameter, length, and number and size of the working channels.

Current Lithotripters

Fragmentation of calculi may be accomplished using the following devices: ultrasonic lithotripsy, electrohydraulic lithotripsy (EHL), laser lithotripsy, or pneumatic lithotripsy [49, 50]. The holmium: YAG laser is the most widely utilized laser for intracorporeal lithotripsy and is effective against all stone compositions [51]. It fragments stones through a photothermal mechanism. The typical initial power/frequency setting and laser fiber size are 0.8 J at 8 Hz with a 200 micro laser fiber. The holmium laser has largely replaced the electrohydraulic and ultrasonic lithotripsy since it has the ability to be utilized with both semirigid and flexible ureteroscopes, precision with minimal depth of precision 0.4 mm, and capability of other urologic treatments including ablation of tumors, fulguration, and endoureterotomy. The Stone Breaker is a single-pulse mode nonelectric pneumatic lithotripter that uses carbon dioxide cartridges. It is inflexible and may be used only with the semirigid ureteroscope.

Wolf et al. described different techniques for stone fragmentation utilizing the holmium laser [52]. One commonly used technique is dusting the stone into small enough fragments that may spontaneously pass. This can be accomplished by either using the dancing or chipping technique as

described by Wolf et al., in which the laser fiber is either brushed back and forth across the stone to ablate in layers or the laser fiber is directed toward the periphery of the stone until small fragments of the stone are chipped off [52]. An alternative method, the popcorn technique, does not require the laser fiber to be in direct contact with the stone. Instead the laser fiber is positioned near a collection of stones within a dependent portion of the calyx. The laser is fired continuously, creating rapid stone motion within the calyx and ablation of the stone results from collision of the stone fragments with the laser fiber [52].

Complications

Acute complications from ureteroscopy include: bleeding, infection, ureteral stent discomfort, ureteral injury, and need for secondary treatment. Late complications include: renal damage and ureteral stricture [53, 54]. Complications are typically minor and may be avoided by patient selection, careful systematic technique, sterilization of urine in patients with active infection, and the use of appropriate prophylactic antibiotics. In patients that have ureteral stent discomfort, alpha-blockers have been shown to be useful [55, 56]. Inaccurate sizing of the ureteral stent can lead to increased stent discomfort; therefore, it is important to make sure the stent does not cross midline due to excessive length [57].

Key Points

- For ureteral stones <10 mm, MET should be offered to patients as first-line therapy, although certain circumstances may indicate the need for earlier surgical management including uncontrolled pain, infection/sepsis, or acute kidney injury.
- Treatment decision for renal calculi should take into consideration HU density, skin-to-stone distance, presence of coagulopathy, and stone size.
- For ureteral calculi, both ESWL and URS with laser lithotripsy are considered first-line

treatment. However, in the following instances, URS is preferred over ESWL: coagulopathy, pregnancy, SSD > 10 cm, ESWL-resistant stone, or HU density > 970.

- Patients should be adequately informed about the treatment modalities, including the risks and benefits associated with each modality, taking into consideration the stone size, location, possible composition, and patient comorbidities.
- Complications of ureteroscopy that should be discussed with the patient include bleeding, infection, stent discomfort, ureteral stricture, and the need for secondary procedure.

References

- Preminger GM, Tiselius HG, Assimos DG, Alken P, Buck AC, Gallucci M, et al. Guideline for the management of ureteral calculi. *Eur Urol.* 2007;52(6):1610–31.
- Parsons JK, Hergan LA, Sakamoto K, Lakin C. Efficacy of alpha-blockers for the treatment of ureteral stones. *J Urol.* 2007;177(3):983–7.
- Bader MJ, Eisner B, Porpiglia F, Preminger GM, Tiselius HG. Contemporary management of ureteral stones. *Eur Urol.* 2012;61(4):764–72.
- Smith RD, Patel A. Impact of flexible ureterorenoscopy in current management of nephrolithiasis. *Curr Opin Urol.* 2007;17(2):114–9.
- Krambeck AE, Murat FJ, Gettman MT, Chow GK, Patterson DE, Segura JW. The evolution of ureteroscopy: a modern single-institution series. *Mayo Clin Proc.* 2006;81(4):468–73.
- Wignall GR, Canales BK, Denstedt JD, Monga M. Minimally invasive approaches to upper urinary tract urolithiasis. *Urol Clin North Am.* 2008;35(3):441–5.
- Perlmutter AE, Talug C, Tarry WF, Zaslaw S, Mohseni H, Kandzari SJ. Impact of stone location on success rates of endoscopic lithotripsy for nephrolithiasis. *Urology.* 2008;71(2):214–7.
- Cocuzza M, Colombo JR, Cocuzza AL, Mascarenhas F, Vicentini F, Mazzucchi E, et al. Outcomes of flexible ureteroscopic lithotripsy with holmium laser for upper urinary tract calculi. *Int Braz J Urol.* 2008;34(2):143–9.
- Auge BK, Dahm P, Wu NZ, Preminger GM. Ureteroscopic management of lower-pole renal calculi: technique of calculus displacement. *J Endourol.* 2001;15(8):835–8.
- Pearle MS, Lingeman JE, Leveillee R, Kuo R, Preminger GM, Nadler RB, et al. Prospective, randomized trial comparing shock wave lithotripsy and ureteroscopy for lower pole caliceal calculi 1 cm or less. *J Urol.* 2005;173(6):2005–9.
- Bozkurt OF, Resorlu B, Yildiz Y, Can CE, Unsal A. Retrograde intrarenal surgery versus percutaneous nephrolithotomy in the management of lower-pole renal stones with a diameter of 15–20 mm. *J Endourol.* 2011;25(7):1131–5.
- Segura JW, Preminger GM, Assimos DG, Dretler SP, Khan RI, Lingeman JE, et al. Ureteral Stones Clinical Guidelines Panel summary report on the management of ureteral calculi. The American Urological Association. *J Urol.* 1997;158(5):1915–21.
- Hollingsworth JM, Rogers MA, Kaufman SR, Bradford TJ, Saint S, Wei JT, et al. Medical therapy to facilitate urinary stone passage: a meta-analysis. *Lancet.* 2006;368(9542):1171–9.
- Miller OF, Kane CJ. Time to stone passage for observed ureteral calculi: a guide for patient education. *J Urol.* 1999;162(3):688–90.
- Aboumarzouk OM, Kata SG, Keeley FX, Nabi G. Extracorporeal shock wave lithotripsy (ESWL) versus ureteroscopic management for ureteric calculi. *Cochrane Database Syst Rev.* 2011;(12):CD006029.
- Lotan Y, Gettman MT, Roehrborn CG, Cadeddu JA, Pearle MS. Management of ureteral calculi: a cost comparison and decision making analysis. *J Urol.* 2002;167(4):1621–9.
- Nakada SY, Hoff DG, Attai S, Heisey D, Blankenbaker D, Pozniak M. Determination of stone composition by noncontrast spiral computed tomography in the clinical setting. *Urology.* 2000;55(6):816–9.
- Kacker R, Zhou L, Macejko A, Thaxton CS, Stern J, Liu JJ, et al. Radiographic parameters on noncontrast computerized tomography predictive of shock wave lithotripsy success. *J Urol.* 2008;179:1866–71.
- Ouzaid I, Al-Qahtani S, Dominique S, Hupertan V, Fernandez P, Hermieu JF, et al. A970 Hounsfield units (HU) threshold of kidney stone density on non-contrast computed tomography (NCCT) improves patients' selection for extracorporeal shock-wave lithotripsy (ESWL): evidence from a prospective study. *BJU Int.* 2012;110(11):E438–42.
- Tiryaki T, Azili MN, Ozmert S. Ureteroscopy for treatment of ureteral stones in children: factors influencing the outcome. *Urology.* 2013;81(5):1047–51.
- Desai M. Endoscopic management of stones in children. *Curr Opin Urol.* 2005;15(2):107–12.
- Raza A, Smith G, Moussa S, Tolley D. Ureteroscopy in the management of pediatric urinary tract calculi. *J Endourol.* 2005;19(2):151–8.
- Semins MJ, Trock BJ, Matlaga BR. The safety of ureteroscopy during pregnancy: a systematic review and meta-analysis. *J Urol.* 2009;181(1):139–43.
- Lifshitz DA, Lingeman JE. Ureteroscopy as a first-line intervention for ureteral calculi in pregnancy. *J Endourol.* 2002;16(1):19–22.
- Watterson JD, Girvan AR, Cook AJ, Beiko DT, Nott L, Auge BK, et al. Safety and efficacy of holmium: YAG laser lithotripsy in patients with bleeding diatheses. *J Urol.* 2002;168(2):442–5.

26. Calvert RC, Burgess NA. Urolithiasis and obesity: metabolic and technical considerations. *Curr Opin Urol.* 2005;15(2):113–7.
27. Pareek G, Hedican SP, Lee FT, Nakada SY. Shock wave lithotripsy success determined by skin-to-stone distance on computed tomography. *Urology.* 2005;66(5):941–4.
28. Patel T, Kozakowski K, Hruby G, Gupta M. Skin to stone distance is an independent predictor of stone-free status following shockwave lithotripsy. *J Endourol.* 2009;23(9):1383–5.
29. Aboumarzouk OM, Somani B, Monga M. Safety and efficacy of ureteroscopic lithotripsy for stone disease in obese patients: a systematic review of the literature. *BJU Int.* 2012;110(8):E374–80.
30. Chew BH, Zavaglia B, Paterson RF, Teichman JM, Lange D, Zappavigna C, et al. *J Endourol.* 2013;27(6):710–4.
31. Riley JM, Stearman L, Troxel S. Retrograde ureteroscopy for renal stones larger than 2.5 cm. *J Endourol.* 2009;23(9):1395–8.
32. Breda A, Ogunyemi O, Leppert JT, Lam JS, Schulam PG. Flexible ureteroscopy and laser lithotripsy for single intrarenal stones 2 cm or greater—is this the new frontier? *J Urol.* 2008;179(3):981–4.
33. Wolf Jr JS, Bennett CJ, Dmochowski RR, Hollenbeck BK, Pearle MS, Schaeffer AJ. Best practice policy statement on urologic surgery antimicrobial prophylaxis. *J Urol.* 2008;179(4):1379–90.
34. de la Rosette JJ, Skrekas T, Segura JW. Handling and prevention of complications in stone basketing. *Eur Urol.* 2006;50(5):991–8.
35. Kourambas J, Byrne RR, Preminger GM. Does a ureteral access sheath facilitate ureteroscopy? *J Urol.* 2001;165(3):789–93.
36. L'esperance JO, Ekeruo WO, Scales Jr CD, Marguet CG, Springhart WP, Maloney ME, et al. Effect of ureteral access sheath on stone-free rates in patients undergoing ureteroscopic management of renal calculi. *Urology.* 2005;66(2):252–5.
37. Rehman J, Monga M, Landman J. Characterization of intrapelvic pressure during ureteropyeloscopy with ureteral access sheaths. *Urology.* 2003;61(4):713–8.
38. Delvecchio FC, Auge BK, Brizuela RM, et al. Assessment of stricture formation with the ureteral access sheath. *Urology.* 2003;61(3):518–22.
39. Johnson GB, Portela D, Grasso M. Advanced ureteroscopy: wireless and sheathless. *J Endourol.* 2006;20(8):552–5.
40. Schatloff O, Lindner U, Ramon J, Winkler HZ. Randomized trial of stone fragment active retrieval versus spontaneous passage during holmium laser lithotripsy for ureteral stones. *J Urol.* 2010;183(3):1031–5.
41. Patel SR, McLaren I, Nakada SY. The ureteroscope as a safety wire for ureteronephroscopy. *J Endourol.* 2012;26(4):351–4.
42. Dickstein RJ, Kreshover JE, Babayan RK, Wang DS. Is a safety wire necessary during routine flexible ureteroscopy? *J Endourol.* 2010;24(10):1589–92.
43. Hollenbeck BK, Schuster TG, Seifman BD, Faerber GJ, Wolf Jr JS. Routine placement of ureteral stents is unnecessary after ureteroscopy for urinary calculi. *Urology.* 2001;57(4):639–43.
44. Chen YT, Chen Y, Wong WY, Yang SS, Hsieh CH, Wang CC. Is ureteral stenting necessary after uncomplicated lithotripsy? A prospective, randomized controlled trial. *J Urol.* 2002;167(5):1977–80.
45. Pengfei S, Yutao L, Jie Y, et al. The results of ureteral stenting after ureteroscopic lithotripsy for ureteral calculi: a systematic review and meta-analysis. *J Urol.* 2011;186(5):1904–9.
46. Holden T, Pedro RN, Hendlin K, Durfee W, Monga M. Evidence-based instrumentation for flexible ureteroscopy: a review. *J Endourol.* 2008;22(7):1423–6.
47. Pasqui F, Dubosq F, Tchala K, Tligui M, Gattegno B, Thibault P, et al. Impact on active scope deflection and irrigation flow of all endoscopic working tools during flexible ureteroscopy. *Eur Urol.* 2004;45(1):58–64.
48. Hendlin K, Weiland D, Monga M. Impact of irrigation systems on stone migration. *J Endourol.* 2008;22(3):453–8.
49. Denstedt JD, Clayman RV. Electrohydraulic lithotripsy of renal and ureteral calculi. *J Urol.* 1990;143:13–7.
50. Denstedt JD, Eberwein PM, Singh RR. The Swiss lithoclast: a new device for intracorporeal lithotripsy. *J Urol.* 1992;148:1088–90.
51. Bagley D, Erhard M. Use of the holmium laser in the upper urinary tract. *Tech Urol.* 1995;1(1):25–30.
52. Hecht SL, Wolf Jr JS. Techniques for holmium laser lithotripsy of intrarenal calculi. *Urology.* 2013;81:442–5.
53. Schuster TG, Hollenbeck BK, Gaerber GJ, Wolf Jr JS. Complications of ureteroscopy: analysis of predictor factors. *J Urol.* 2001;166(2):538–40.
54. Johnson DB, Pearle MS. Complications of ureteroscopy. *Urol Clin North Am.* 2004;31(1):157–71.
55. Lamb AD, Vowler SL, Johnston R, Dunn N, Wisemann OJ. Meta-analysis showing the beneficial effect of a-blockers on ureteric stent discomfort. *BJU Int.* 2011;108(11):1894–902.
56. Yakoubi R, Lemdani M, Monga M, Villers A, Koenig P. Is there a role for a-blockers in ureteral stent related symptoms? A systematic review and meta-analysis. *J Urol.* 2011;186(3):928–34.
57. Rane A, Saleemi A, Cahill D, Sriprasad S, Shrotri N, Tiptaft R. Have stent-related symptoms anything to do with placement technique? *J Endourol.* 2001;15(7):741–5.

Percutaneous Management of Large Renal Calculi (Percutaneous Nephrolithotomy)

13

Shubha De and Manoj Monga

Percutaneous nephrolithotomy (PCNL) is standard of care for large (>2 cm) renal calculi. PCNL requires specialized instrumentation and unique surgical skill sets covering such broad topics as intraoperative imaging, percutaneous access, endoscopic manipulation, and intracorporeal lithotripsy. Though the majority of cases are for urolithiasis, percutaneous access to the collecting system allows for the diagnosis and treatment of a variety of pathologies. While other minimally invasive approaches to nephrolithiasis may be limited in application by stone size, location, and density, PCNL know relatively few boundaries.

While stones >2 cm are traditionally managed by PCNL, smaller stones may be selected for PCNL based on location, skin to stone distance, and/or stone density. The Lower Pole 1 study was a prospective randomized trial comparing shockwave lithotripsy (SWL) to PCNL in lower pole stones. Stones over 1 cm in the lower pole had poor stone-free rates (21 %) with SWL which decreased inversely to stone size. In contrast, PCNL was found to have 95 % stone-free rates independent of stone burden [1]. The European Association of Urology recommends PCNL for stones greater than 1.5 cm in the

lower pole and >2 cm in all other locations [2]. Skin to stone distance >110 mm and mean Hounsfield units >900 also decrease the stone-free rate of SWL by half [3] and can be a powerful method of identifying patients who may be better suited for PCNL. Anatomic considerations such as ureteric strictures, impacted stones, urinary diversions, and reimplanted ureters may benefit from percutaneous access for smaller stones.

Exclusions from PCNL

PCNL is contraindicated in those who cannot undergo general anesthetic, are at increased risk of bleeding (anticoagulated), or cannot tolerate significant bleeding and/or transfusion. Those with poor respiratory function may not tolerate the prone position or be able to tolerate the small risk of pneumothorax/hydrothorax associated with securing percutaneous access to the kidney. PCNL should only be performed after treatment of urinary tract infections, and all patients' urine should be cultured prior to surgery. Anatomic variations should be considered, and the position of the retrorenal colon or spleen or liver, pelvic kidneys, horseshoe kidneys, and crossed fused ectopia should alert the urologist to consider ultrasound- or CT-guided nephrostomy tube placement, so as to minimize the risk of inadvertent organ or vascular injury.

S. De, MD (✉) • M. Monga, MD
Glickman Urologic and Kidney Institute, Cleveland
Clinic Foundation, 9500 Euclid Ave, Bldg Q10,
Cleveland, OH, USA
e-mail: shubhade@gmail.com; mongam@ccf.org

Positioning

Traditionally after the patient is placed under general anesthetic and intubated, cystoscopy and ureteric catheter insertion are performed either in the supine, dorsal lithotomy, or prone split leg position. Most commonly, percutaneous access and lithotripsy are performed in the prone position; however, supine, modified lateral, lateral decubitus, and prone-flexed position have also been used. A meta-analysis comparing supine versus prone position identified four studies, with equivalent outcomes for stone-free rates and bleeding. Procedure time was reduced with supine positioning; however, larger stones were treated in the prone position [4]. Benefits of supine surgery are reported to include improved patient and surgeon comfort, lower intrarenal pressures, better renal drainage, and easily accessible urethral meatus [5]. Advantages of prone access include improved access to multiple calyces, better scope manipulation, improved collecting system distention, and shorter tract lengths [6].

Percutaneous Access

The most common strategies to gaining renal access under fluoroscopic guidance include the triangulation, bull's-eye, retrograde percutaneous, and endoscopic-assisted approaches. Retrograde pyelograms, using contrast and/or air, are performed before all procedures which do not use flexible ureteroscopy to select the appropriate calyx under direct vision.

The triangulation technique uses two fluoroscopic planes to align the access needle with the appropriate calyx while avoiding the overlying ribs. Using the initial pyelogram, the anteroposterior (AP) orientation of the intensifier dictates the medial limit of the needle. Two more locations are selected at right angles (lateral and inferior to the initial position), and the intersection of all three points estimates the required trajectory of the needle. The bull's-eye approach uses the AP position of the C-arm to establish needle tip position overlying the appropriate calyx. The C-arm is then rotated approximately 30° toward the surgeon, and by fix-

ing the needle point at the previously identified location, the hub is aligned with the intensifier to give a bull's-eye appearance on fluoroscopy. With the trajectory established, the needle is advanced, and depth is confirmed by rotating the C-arm back to its AP position. The retrograde approach utilizes a steerable catheter positioned under fluoroscopic or ureteroscopic guidance. A puncture wire is then advanced (retrograde) through the calyx, renal parenchyma, retroperitoneum, and out to the skin for through-and-through access.

Tract Size

Standard rigid nephroscopes are 26 Fr and utilize a 30 Fr working sheath for adequate manipulation and drainage. Recently, a significant amount of interest has been placed in mini-percs and micro-percs. Reducing the working tract to 24 Fr or smaller, mini-percs have been widely used in the pediatric and adult population, particularly in geographical locations where access to flexible ureteroscopy and/or SWL may be limited. Porcine studies evaluating renal scarring after 30 Fr and 11 Fr sheath insertion showed no significant differences in surgical morbidity or histopathology [7].

Even smaller diameter instruments are now being clinically evaluated, utilizing a 4.85 Fr (16 gauge) "all seeing needle" scopes. Stones are fragmented to dust using up to a 272 μm laser fiber, and recent randomized trial comparing micro-percs to ureteroscopy for stones <1.5 cm showed similar stone clearance rates [8].

Endoscopic-Guided Percutaneous Nephrolithotomy

Equipment List

- C-arm and monitor
- Cystoscopy video tower
- Fluoroscopy-compatible OR table
- Steris split leg extensions
- Wall suction
- Adjustable height irrigation stands with pressure bags

Cystoscopy

- 20 Fr rigid cystoscope (women)
- 15 Fr. flexible cystonephroscope (men)
- Endoscopy camera
- Sensor wire (0.038 in, 150 cm, Boston Scientific)
- Flexi-Tip 10 Fr dual-lumen catheter (0.038 in, 150 cm, Cook Medical)
- Amplatz Super Stiff guidewire (0.038 in, 180 cm, Boston Scientific)

Flexible Ureteroscopy

- Flexible ureteroscope
- Adjustable biopsy valve (Gyrus ACMI)
- Single action pump (Boston Scientific)
- Ureteric access sheath (Flexor, Cook Medical)
 - 35 cm length (females)
 - 45 cm length (males)
 - 9.5/12 or 12/14 Fr. (14/16 Fr. if pre-stented)
- Nitinol basket (Halo, Sacred Heart Medical)

Percutaneous Access with Through-and-Through Safety Wire

- Chiba needle (18 Fr, 15 cm Cook Medical)
- Chiba needle holder
- Bentson wire, 10 cm flex tip (0.038 in, Boston Scientific)
- 5 Fr open-ended ureteric catheter
- X-Force balloon dilator (30 Fr, Bard Medical)

Stone Fragmentation

- Rigid nephroscope (Richard Wolf, 25 cm length)
- Flexible cystonephroscope
- Cyberwand (Gyrus ACMI)
- 100W holmium:YAG laser with 365um laser fibers (for flexible cystonephroscope)

Stone Capture Devices

- Perc NCircle (12 Fr, 38 cm, Cook Medical)
- 2-prong reusable graspers
- Cook N-Circle (4.5 Fr) (for flexible cystonephroscope)
- Sacred Heart Halo (1.5 Fr) (for antegrade ureteroscopy)

Tubeless Drainage

- Double-J ureteric catheter (7 Fr)
- 2-O Prolene suture
- 18 Fr Foley catheter (coude tip for men)

Procedure**Step 1: Positioning and Setup** (Fig. 13.1)

General anesthetic with endotracheal intubation is performed by anesthesia on the patient's gurney, and then the patient is placed prone onto a reversed OR table. This allows the table to accommodate a mobile C-arm unit and split leg extensions. The patient is placed with their genitalia freely accessible at the edge of the bed. Arms are placed in the superman position on arm boards maintaining an axillary angle of $<90^\circ$ with appropriate axillary padding to avoid brachial plexus injury. The head is maintained with neutral positioning of the C-spine, using a foam face pad. Increased ocular pressures are to be avoided, and the endotracheal tube needs to be well seated and secured during any repositioning. Legs are loosely fixed to the split leg extensions using 2' broad silk tape and pillowcases to avoid skin abrasions. The legs are then abducted to 30° .

Two chest rolls are placed longitudinally along the anterior axillary line. The diameter of these rolls should allow for a neutral C-spine positioning, and the breasts are to be placed medially. Placing rolls too medially under the abdomen may cause the colon to be forced posteriorly, potentially increasing the risk of bowel injury during renal access. All pressure points are padded and pneumatic stockings are maintained for anti-embolic prophylaxis.

Once the patient is positioned, the table is placed in a mild Trendelenburg to keep the patient's back parallel to the floor, ensuring AP imaging is not distorted. The genitals, perineum, and flank are prepped widely, and percutaneous nephrolithotomy drapes are placed over the flank, with leg drapes covering the split leg extensions. The flank catch pouch is fixed to suction, and a receptacle is placed on the floor under the genitals to catch irrigation.

On the contralateral side of the patient, the fluoroscopy screen is at shoulder level, with the C-arm aligned with the respective flank. The endoscopic tower is aligned with the patient's thigh and initially directed toward the operator seated to perform the initial cystoscopy. The monitor is adjusted to an ergonomic position to avoid neck strain, in either the sitting or standing

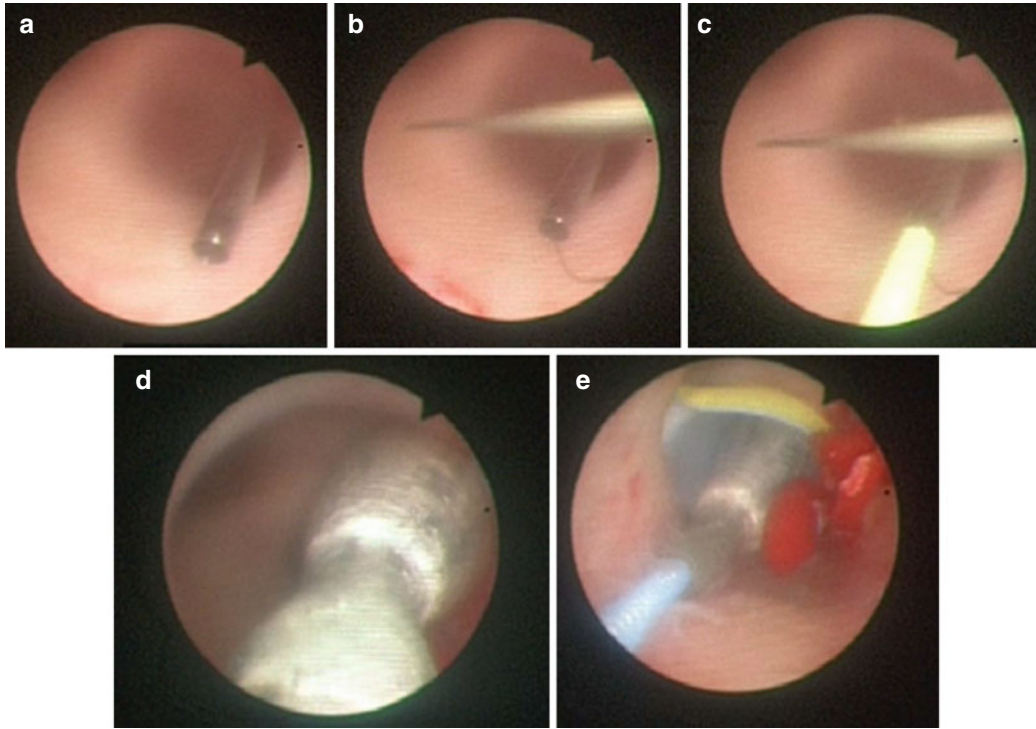


Fig. 13.1 Endoscopic view of percutaneous access: (a) needle piercing selected papilla, (b) deploying endoscopic basket, (c) guidewire placed through needle and grasped

by basket, (d) visualization of balloon dilator placement and inflation, and (e) sheath placement

position. The camera and light cord are secured to the drape, and typically only one tower provides visualization for the initial cystoscopy, flexible ureteroscopy, and PCNL. The irrigation stand is placed at the patient's ipsilateral shoulder, and tubing is fixed to the drape and brought down to the cystoscope. Extra suction tubing is maintained on field for use during nephroscopy and/or ultrasonic lithotripsy.

Step 2: Prone Cystoscopy and Ureteroscopy

A cystoscopy is initially required to survey the bladder, trigonal anatomy, and to place guidewires. Rigid cystoscopy (20 Fr cystoscope, 30° lens) can be used in women, while men require a flexible cystoscopy in the prone position. It is important to clear air from the tubing as this will rise to the trigone in the prone position and obscure the ureteral orifices.

If the patient is pre-stented, a stent grasper is used to deliver the distal curl to the meatus, at which point it may be used to place the initial guidewire. If the initial survey shows significant mucosal edema or inflammation or stent incrustation, a guidewire may be placed alongside the stent prior to removal.

The ureteric orifice will be located superior-lateral when the patient is prone. By starting at the bladder neck 12 o'clock position then sweeping laterally, the ureteric ridge can be followed to 2 and 8 o'clock positions where the ureteral orifice will generally be encountered. With previous bladder neck or prostate surgery, prolapse, and classification benign prostatic hypertrophy (BPH), the ureteric orifices may not be in the expected positions. Careful observation for urine jets or intravenous indigo carmine or methylene blue may help identify the ureteral orifice.

Once the ureteric orifice is identified, a Sensor guidewire is advanced to the level of the kidney

using fluoroscopic confirmation. A 10 Fr dual-lumen catheter is then used to introduce an Amplatz Super Stiff guidewire while providing mild dilation of the ureter. During advancement, one may appreciate a “tight” ureter, which can help in selecting the appropriate ureteric access sheath diameter. “Grittiness” while advancing the dual lumen may indicate ureteric stones distal to the tip of the catheter and may warrant fluoroscopic or ureteroscopic inspection and confirmation.

Once both wires are placed, the Sensor wire is maintained as a safety wire and fixed to the drape (using a hemostat). The Super Stiff becomes the working wire, and it is important to fluoroscopically ensure that the metal wire core extends past the point to which the ureteric access sheath needs to travel.

The size of the sheath selected should be tailored to the patient. Optimal length would place the tip of the sheath in the proximal ureter, without too much excess sheath protruding from the urethral meatus. With proper placement, the maximal amount of ureteral mucosa is protected, and renal drainage of irrigation and stone fragments is achieved. Typically a 45 cm sheath is used in men and 35 cm in women. If previously stented, most ureters accommodate a 14/16 Fr sheath. Most ureters accommodate 12/14 Fr, though a small number of patients require even smaller sheaths (9.5/11.5 Fr). It is important to be cognizant of the external diameter of your flexible ureteroscope prior to access sheath selection, as not all scopes will fit the smallest diameter access sheaths.

With the working Super Stiff wire in position, the ureteric access sheath is advanced to the proximal ureter. The inner dilator and sheath are assembled, so both are seated properly, and the outer surface is wetted to activate the hydrophilic coating to decrease resistance. Back-loading the sheath over the working wire (with the penis outstretched in men), a change in resistance may be met at the membranous urethra and the ureteric orifice. Fluoroscopy should be used during advancement if resistance is encountered and as the sheath approaches the renal pelvis. If the

smallest available sheath will not advance, consider secondary manipulations such as sequential dilation with coaxial dilators, balloon dilation, JJ stent insertion and passive dilation, advancing the ureteroscope over a wire, or an alternative access strategy (fluoroscopy or ultrasound guided).

Once the sheath is placed, the dilator and Super Stiff wire are removed. Flexible ureteroscopy is then performed using intermittent pressure irrigation via a single action pump. This allows visualization of the relationship of the stone burden to the calyceal anatomy. Stones can be basketed and repositioned prior to gaining percutaneous access, so as to minimize the number of renal access sites and optimize the selection of the access site least likely to be associated with risk of complication or interference from the overlying ribs. On occasions, small stone collections (often appearing as large single stones on imaging) can be removed ureteroscopically, potentially sparing a puncture.

An appropriate calyx is selected, using the endoscopic visualization of air bubbles to confirm a posterior position (Fig. 13.2). The C-arm is rotated until the tip of the ureteroscope is seen “end-on,” confirming that the bull’s-eye tract will be in line with the tip of the calyx. If the calyx is obscured by an overlying rib, the C-arm can be rotated superiorly or inferiorly to throw the projection of the calculus above or below the rib, respectively, or a different calyx can be selected.

Renal Puncture and Access

Once the appropriate calyx has been selected, the tip of the scope is held steady against the center of the papilla, by an assistant. The fluoroscopic image is then rotated so the patient’s spine is at the top of the screen. This allows for more intuitive needle movements in relation to the fluoroscopic image. The tip of a Chiba needle is then positioned (using a needle holder) in line with the tip of the scope (under fluoroscopy, on expiration). The shaft of the needle is then manipulated so its trajectory is in line with the C-arm and scope tip forming a bull’s-eye. Once this angle is

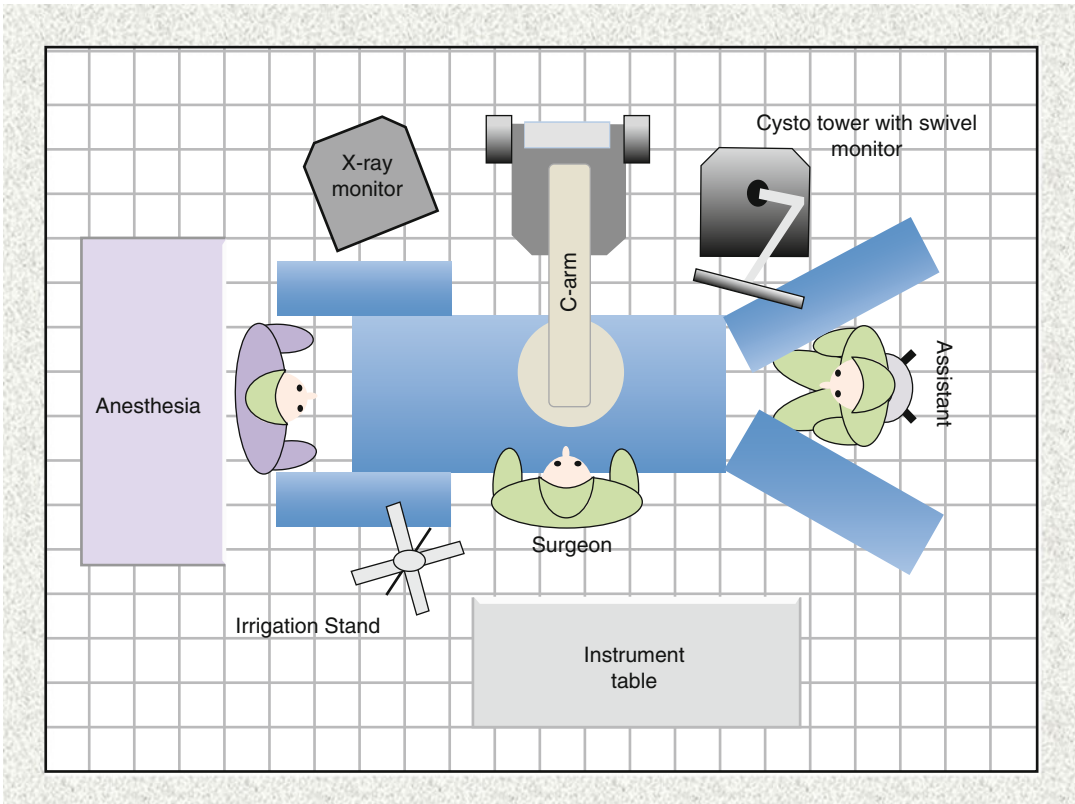


Fig. 13.2 Bird's-eye view of the surgical suite equipment and personnel setup

established, it is maintained and anesthesia is directed to hold respirations. The needle is advanced through the skin, and the C-arm is rotated back to an AP position to monitor the depth of advancement of the needle as it approaches the tip of the ureteroscope. Once the needle appears to meet the scope on fluoroscopy, anesthesia can resume ventilation, and the assistant inspects the calyx and identifies the tip of the needle endoscopically.

The inner stylet of the needle is removed and irrigation effluxes from the needle hub. While maintaining the needle tip under direct vision, a Bentson wire is advanced through the Chiba needle, and a Halo basket (Sacred Heart Medical) is advanced through the working channel of the ureteroscope and used to grasp the wire. The wire is then pulled down the ureter and sheath to the urethral meatus for through-and-through access.

Once at the urethral meatus, it is held by the assistant under tension, and a 2 mm skin incision is made at the needle site to accommodate antegrade

advancement of a 5 Fr open-ended ureteric catheter. This catheter is used to replace the Bentson wire with the Amplatz Super Stiff guidewire. The tip of the Amplatz Super Stiff that extends out of the urethral meatus is secured with a hemostat.

Tract Dilation

With the Super Stiff in place, a 10 mm skin incision is made, and the 15 cm balloon dilator is advanced over the wire (with the preloaded 30 Fr working sheath). The ureteroscope is returned to the selected calyx, and the tip of the dilator is observed entering the collecting system. Direct visualization of the dilation ensures that the balloon is not placed too deep (injuring the collecting system) or too shallow (requiring a second dilation). Using the Bard X-Force, dilation to 30ATM is performed, and spot fluoroscopy confirms no residual wasting. If the balloon is not uniformly dilated at maximal pressures, reinflation and holding for 30 s is given to

maximize stretching, and then if not dilated, the balloon is deflated and Amplatz sequential dilators are used.

Once the balloon is adequately inflated, the sheath is advanced in a gentle forward twisting motion, while holding the balloon to avoid inadvertent advancement. The sheath is identified ureteroscopically, and the bevel rotated to the optimal position. The ureteroscope is then removed, leaving the access sheath in place to drain the kidney during nephroscopy. The rigid nephroscope, with its outer suction sheath, is then inserted after removal of the dilating balloon. A combination of irrigation (initially under gravity drainage) and suction is used to clear any clots that may have been created with tract dilation.

Lithopaxy and Tubeless Technique

Rigid nephroscopy is then performed, aided by the knowledge gained by ureteroscopy of where the majority of the stone burden will be encountered. Stones <1 cm can be grasped and removed through the sheath. Reusable 2-prong graspers are typically used for smaller stone fragments. The Perc NCircle disposable grasper can be used in tighter spaces or calyces, as the basket can be opened behind the stone.

If fragmentation is required, a variety of instruments may be helpful based on accessibility. The Cyberwand gives the most efficient stone fragmentation and provides continuous suction which evacuates stone dust and small fragments. If calculi cannot be accessed with the rigid nephroscope, the holmium laser can be utilized to fragment the stones with the assistance of a flexible nephroscope.

If a calyx is unreachable by flexible nephroscopy, a guidewire or basket can be advanced into the calyx like a filiform to help guide the tip to the target. The scope can be turned upside down (leaving the camera in the original orientation), as many scopes have a tighter radius for upward deflection. Flexible antegrade or retrograde ureteroscopy can also be performed as the access sheath maintains easy ureteral access. If stones are located in these difficult areas, laser lithotripsy can be performed, or the stone can be moved ureteroscopically to a

location more accessible with for nephroscopic extraction.

Once the upper tract is deemed clear on visual inspection, fluoroscopy is used on high magnification. The working sheath is gently manipulated under fluoroscopy to help identify any residual fragments. With the upper tract cleared, antegrade flexible ureteroscopy is performed as the ureteral access sheath is removed under vision to identify any fragments in the ureter that require basket extraction and to assess the ureter for mucosal injuries or perforations.

We perform a “tubeless approach” with a double-J ureteric stent for 5–7 days, unless a significant impaction was encountered with a ureteral calculus. A nephroureteral stent is left to maintain access only in situations where intraoperative bleeding precluded a complete inspection of the collecting system, and fluoroscopic evaluation suggests residual fragments that could be removed with a second-look procedure.

The working Super Stiff wire is removed by placing a 5 Fr catheter over it to avoid abrasions as it slides over the mucosa. The stent is then advanced retrograde over the Sensor safety wire, and placement is fluoroscopically confirmed. The nephrostomy sheath is removed, and 1–2 vertical mattress sutures are placed in the skin to approximate the edges. These stitches are removed at the time of stent removal. A dressing made of 4×4 gauze and paper tape is used, and an 18 Fr Foley catheter (coude tip in men) is placed in all patients. The urethral catheter is maintained for 24–48 h, depending on the time of discharge of the patient.

Outcomes and Complications

Common complications from PCNL include pain, hematuria, and infection. A global study using the clinical research office of endourology (CROES) database identified complications in 20.5 % of 5,724 patients though 80 % were considered minor. Bleeding and fevers were found in approximately 2.5 % cases, while hydrothorax, pneumothorax, hematuria, UTIs, and bowel injuries were all <0.5 %. Risk factors for increasing the severity of complications included american society of anesthesia (ASA) scores, use of anticoagulation,

positive urine culture, and presence of cardiovascular disease [9]. Data from the National Inpatient Database found that transfusion rates are between 4 and 7.6 % and vary depending on the volume of the center at which they are performed [10].

A retrospective analysis of our endoscopic-guided approach was compared to fluoroscopic-guided access (performed by radiology) and was found to significantly reduce fluoroscopy time to 3.2 min and lower the number of accesses required (1.03 vs 1.22) during PCNL. Though no differences in complications were noted, 8 % of fluoroscopically attained cases were aborted due to bleeding compared to 0 % with endoscopic-guided access. The endoscopic-guided approach decreased the need for secondary procedures (2 % vs 12 %, $p < 0.05$) [11].

Conclusion

Many alternatives exist with regard to patient positioning and method of gaining renal access. The prone split leg position facilitates endoscopic-guided access, which places the control in the hands of the urologist, irrespective of level of training in fluoroscopic techniques. The accuracy of access into the tip of the most appropriate calyx improves outcomes and decreases the need for secondary procedures.

References

- Albala DM, Assimos DG, Clayman RV, Denstedt JD, Grasso M, Gutierrez-Aceves J, et al. Lower pole I: a prospective randomized trial of extracorporeal shock wave lithotripsy and percutaneous nephrostolithotomy for lower pole nephrolithiasis-initial results. *J Urol*. 2001;166(6):2072–80.
- Turk C, Knoll T, Petrik A, Sarica K, Skolarikos A, Straub M, et al. Guidelines on urolithiasis-Update March 2013. *Eur Urol*. 2013;40: p 362–71.
- Wiesenthal JD, Ghiculete D, D'A Honey RJ, Pace KT. Evaluating the importance of mean stone density and skin-to-stone distance in predicting successful shock wave lithotripsy of renal and ureteric calculi. *Urol Res*. 2010;38(4):307–13.
- Wu P, Wang L, Wang K. Supine versus prone position in percutaneous nephrolithotomy for kidney calculi: a meta-analysis. *Int Urol Nephrol*. 2011;43(1): 67–77.
- Ibarluzea G, Scoffone CM, Cracco CM, Poggio M, Porpiglia F, Terrone C, et al. Supine Valdivia and modified lithotomy position for simultaneous antero-grade and retrograde endourological access. *BJU Int*. 2007;100(1):233–6.
- Friedlander JL, Duty BD, Smith AD, Okeke Z. Percutaneous nephrostolithotomy: an assessment of costs for prone and Galdakao-modified supine Valdivia positioning. *Urology*. 2012;80(4):771–5.
- Traxer O, Smith 3rd TG, Pearle MS, Corwin TS, Saboorian H, Caddeu JA. Renal parenchymal injury after standard and mini percutaneous nephrostolithotomy. *J Urol*. 2001;165(5):1693–5.
- Sabnis RB, Ganesamoni R, Doshi A, Ganpule AP, Jagtap J, Desai MR. Micropercutaneous nephrolithotomy (microperc) vs retrograde intrarenal surgery for the management of small renal calculi: a randomized controlled trial. *BJU Int*. 2013;112(3):355–61.
- Labate G, Modi P, Timoney A, Cormio L, Zhang X, Louie M, et al. The percutaneous nephrolithotomy global study: classification of complications. *J Endourol*. 2011;25(8):1275–80.
- Kadlec A, Ellimoottil C, Guo R, Trinh Q-D, Sun M, Turk T. Contemporary volume-outcome relationships for percutaneous nephrolithotomy: results from the Nationwide Inpatient Sample. *J Endourol*. 2013;27:1107–13.
- Isac W, Rizkala E, Liu X, Noble M, Monga M. Endoscopic-guided versus fluoroscopic-guided renal access for percutaneous nephrolithotomy: a comparative analysis. *Urology*. 2013;81(2):251–6.

Philippe Violette and Hassan Razvi

Introduction

The endourological management of urinary tract obstruction is continually evolving and adapting to new clinical scenarios and technological advances. With the trend toward adoption of minimally invasive procedures to treat a variety of urological conditions, endoscopic incisional techniques to manage ureteropelvic junction (UPJ) obstruction and ureteral and urethral strictures have been widely embraced by urologists and patients alike. While there is a paucity of level I evidence confirming the exact role of endoscopic incisional procedures compared to laparoscopic and open reconstructive surgical alternatives, endourological interventions have become an established part of our armamentarium.

Despite lesser success rates compared to open and laparoscopic reconstructive approaches, the perception especially among patients of shorter

hospital stays and a speedier convalescence make these procedures attractive for the management of upper and lower urinary tract obstructive conditions.

In this chapter, we will review the indications, techniques, equipment, and outcomes related to the endourological management of ureteropelvic junction obstruction (UPJO) and ureteral and urethral strictures employing incisional methods.

Ureteropelvic Junction Obstruction

Congenital or primary ureteropelvic junction obstruction (UPJO) has a reported incidence of 1/1,000–1/2,000 newborns [1]. While the most common time of presentation is childhood, patients may present at all ages. Presenting features vary with patient age and may include a flank mass, flank pain often exacerbated by fluid diuresis, urinary tract infections, urinary stone formation, and incidental discovery related to abdominal imaging for other conditions. The indications for intervention include the presence of symptoms, loss of renal function, and the development of upper tract stones or urinary tract infections.

Open pyeloplasty was long considered the treatment of choice for those patients with indications for surgical correction. In an effort to reduce the morbidity of this procedure, a number of minimally invasive alternatives have evolved. These include balloon dilation, electroincision

P. Violette, MD CM, FRCSC (✉) • H. Razvi, MD, FRCSC
Division of Urology, Department of Surgery,
Western University, London, Ontario Canada

Urology, St-Joseph's Hospital,
268 Grosvenor Street,
London, ON N6A 4V2, Canada
e-mail: philippedenis.violette@gmail.com;
hrazvi@uwo.ca

Table 14.1 Selected contemporary results of endopyelotomy with >36 months' follow-up

Author	Patient number	Primary (%)	Secondary (%)	Follow-up Mean (range)
DiMarco et al. [39]	182	65		3 years
		55		5 years
		41		10 years
Minervini et al. [38]	49 antegrade	70		24 months (3–62)
	19 retrograde	56		46 months (6–106)
Doo et al. [28]	77	67.5		37 months (3–98)
Vaarala et al. [105]	18 antegrade	92		152 months
	29 retrograde	86		77 months
Knudsen et al. [45]	61	65	74	55 months (16–138)
	19			
Ponsky and Stroom [106]	35	73	80	75 months (39–133)
	5			
Butani and Eshghi [6]	135	96	85	60 months (3–72)
	20			
El-Nahas et al. [107]	50		86	6 years (1.2–13.8)
Park et al. [4]	20		57–70 ^a	47 months (6–138)

^aOutcome varied by type of primary intervention for UPJ obstruction

using a cutting balloon (Acucise), antegrade percutaneous and retrograde endopyelotomy, endopyeloplasty, and laparoscopic and robotic surgery. Laparoscopic and robotic surgical skills and instruments have greatly advanced in the last decade. As such laparoscopic and robotic pyeloplasty have become reasonable first-line options for most adult and pediatric patients with primary UPJ obstruction. In fact, results from many large series report success rates equivalent to open surgery with relatively low morbidity. In this era, it could be questioned whether there is any role for incisional techniques in the management of UPJ obstruction. Endopyelotomy retains a useful role, however, in select patients. In particular, the management of secondary or failed open or laparoscopic/robotic attempts may be suitably appropriate for endopyelotomy [2–5]. Success rates for secondary endopyelotomy range from 70 to 87 % with long-term follow-up [2, 4, 6]. This is comparable or superior to primary endopyelotomy, 67–85 % success [7] (Table 14.1). It has also been suggested, for patients with less severe grades of hydronephrosis, that endopyelotomy might be considered as the first option for primary UPJ obstruction [8].

Balloon dilation had its early proponents; however, long-term follow-up was not associated with durable results [9, 10]. Similarly, the use of an electrocautery balloon incision device (Acucise) which allowed for fluoroscopic-guided incision as well as dilation was associated with modest short-term success; however, more robust follow-up revealed inferior results with the potential for major hemorrhagic complications due to inadvertent incision of a crossing vessel [11, 12].

In contrast percutaneous endopyelotomy and retrograde endopyelotomy have success rates of 67–90 % and 60–87.5 %, respectively, and for a time became widely considered the procedures of first consideration for primary UPJO in adults [13]. The outcomes of contemporary series are listed in Table 14.1.

Endopyelotomy has also been applied in the pediatric population with success [14]. The use of this technique, however, has been limited to adolescent or preadolescent patients. There is also some evidence to suggest that secondary endopyelotomy may not be as effective in the pediatric population especially with younger patients with small caliber ureters [15, 16]. Additionally, wide

acceptance of endopyelotomy among the pediatric urologists has been tempered by the use of fluoroscopy and the need for multiple general anesthetics, first to conduct the procedure and then for stent removal.

With experience, the unfavorable prognostic features for endopyelotomy failure have become more well defined and include a long stenotic UPJ segment (>2 cm in length), massive hydronephrosis, and poor renal function [7, 8, 17]. A high-insertion anatomical arrangement has been thought to be a suboptimal arrangement for any incisional-based techniques; however, this effect has not been substantiated in the literature [18–20]. The effect of a crossing vessel on the success of endopyelotomy has been the subject of considerable debate. In a series by Van Cangh et al., an aberrant crossing vessel was identified in 39 % of UPJ obstructions and was associated with a decrease in success rates from 86 to 42 % [21]. A study performed by Sampaio et al. of 280 renal vascular endocasts has demonstrated that the inferior segmental artery crosses anteriorly to the UPJ in 45 % of cases [22]. These authors argue that these so-called aberrant vessels may often represent normal anatomy, which does not cause obstruction but can increase the dilation of a redundant intrinsically obstructed pelvis. Furthermore, Zeltser et al. have shown that 19 % of nonobstructed UPJs have crossing vessels [23].

In the following section, the surgical steps involved in endopyelotomy via antegrade and retrograde approaches will be reviewed.

Technique: Percutaneous Antegrade Endopyelotomy

The preoperative preparation is similar to that conducted for patients undergoing percutaneous nephrolithotomy. Preoperative prophylactic antibiotics for all patients undergoing percutaneous renal access and upper tract endoscopy are recommended [24]. Ideally, a CT urogram or non-contrast CT and retrograde pyelogram will have been performed in order to assess the UPJ

anatomy and to aid in percutaneous tract planning. Note should be made of the length of the narrowed segment, presence and location of concomitant stone(s), degree of hydronephrosis, and ipsilateral adjacent structures such as proximity to the colon or spleen.

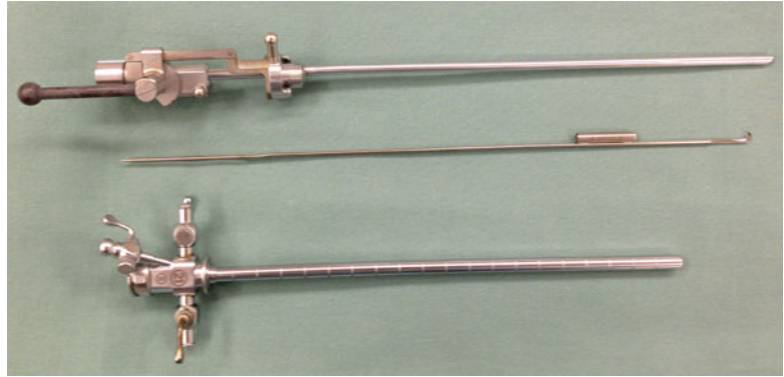
After general anesthesia, the patient is placed in prone position, and care is taken to protect all joints and pressure points with adequate padding and support. Prone flexible cystoscopy is then performed with retrograde advancement of a Teflon-coated guidewire into the kidney followed by a 5 F ureteric catheter. Contrast is then instilled via the catheter to opacify the collecting system allowing further characterization of the UPJ narrowing and to assist in obtaining percutaneous renal access.

Should bypassing the UPJ be unsuccessful with a Teflon-coated guidewire, a hydrophilic guidewire with or without the aid of an angled 5 F angiographic catheter (Kumpe catheter) can provide additional control in directing the guidewire should there be significant tortuosity.

Once the upper collecting system is opacified, fluoroscopy is used to select a posterior mid-pole or upper pole calyx for puncture. In general, an upper or middle pole posterior calyx is preferable to facilitate as straight a path as possible to the UPJ, minimizing torque on the renal parenchyma.

An 18 gauge access needle is used to enter the collecting system through a renal papilla. A hydrophilic guidewire is then advanced, and an effort is made to pass the guidewire through the UPJ and down the ureter into the bladder. The Kumpe catheter can be very useful in accomplishing this step. Often though, it is not possible to advance the wire past the UPJ initially due to the intrinsic narrowing or a voluminous renal pelvis. The hydrophilic wire can then be exchanged for an extra-stiff guidewire, and this wire can be curled with ample wire within the renal pelvis prior to dilation of the tract. Upon completion of the tract dilation step, nephroscopy can then be employed to facilitate guidewire advancement under direct vision. Should that also be unsuccessful, a long exchange wire (270 cm length)

Fig. 14.1 Endopyelotome with cold knife



can be advanced in a retrograde fashion through the lumen of the open-ended ureteral catheter and the tip grasped using the rigid nephroscope and a duckbill forceps. The wire can then be brought out through the flank creating through and through access.

Tract dilation maybe employed using either serial dilators or balloon catheter as for standard percutaneous nephrolithotomy. Dilation permitting placement of a 30 Fr working sheath will allow passage of a rigid nephroscope should concomitant stone fragmentation and removal be required. If calculi are present, they should be completely removed first, prior to endopyelotomy to avoid extrusion of stone fragments into the periureteral space. Should no stone fragmentation or extraction be required and in an effort to reduce unnecessary trauma to the renal parenchyma, tract dilation to 24 Fr may be adequate if one intends to utilize the cold knife endopyelotome as this instrument's outer sheath diameter is 21 Fr in size.

Once guidewire access across the stricture is secured, the obstructed area is dilated using a ureteral balloon-dilating catheter under fluoroscopic guidance. A 6-mm-diameter, 10-cm-length balloon is usually adequate for this step. The balloon dilation allows the area of narrowing to be clearly demarcated and makes the next step of endoscopic incision easier to accomplish by providing some working space for the endoscope and endopyelotomy blade.


An endopyelotome has been classically used to incise the UPJ (Fig. 14.1) employing a “cold

knife” technique originally described by Smith et al. [25, 26]. The incision is made to encompass the entire width of the narrowed segment and extending at least 1 cm proximally and distally. Depth is judged to be adequate when perinephric fat is seen. Balloon dilation is then repeated to confirm that all fibrotic bands have been transected. Various blades can be used; however, it is our preference to use the hooked blade (Fig. 14.2). Other techniques of incision have also been described using electro-surgical incision and laser energy sources. No reports to date favor one cutting modality over the other despite theoretical arguments to the contrary [27–29].

Regardless of the tool used, the incision should be made in a true lateral orientation to minimize the risk of lacerating a crossing vessel. Prior to incision, the UPJ area is visualized for obvious pulsations suggesting the location of nearby arteries.

Once the incision is complete, the UPJ is stented in an antegrade fashion. The basis for stent insertion is related to the initial work of Davis who described the technique of intubated ureterotomy [30, 31]. The optimal stent size and minimal period of stent placement have been debated since Davis' original work. It should be noted that there is currently no consensus about which stent is best with some authors advocating the use of smaller 6–8 Fr internal ureteral stent [32, 33]. Others believe that larger stents are of greater benefit [34]. Our practice has been to insert a 14/7 Fr endopyelotomy stent in an antegrade fashion.

Fig. 14.2 Hooked blade for endopyelotome



In addition to an internal stent, nephrostomy tube drainage is also suggested. Our routine is to use a 16 Fr Council-tip catheter. A Foley catheter should also remain in situ and removed once the nephrostomy tube has been removed and the tract site is no longer leaking. Premature Foley catheter removal may lead to ongoing urine reflux, possible urine extravasation, or persistent flank drainage. Generally the nephrostomy tube is removed within 48–72 h if the urine is not bloody and the patient is afebrile.

The optimal period of internal stent drainage remains a point of ongoing debate. When Davis described the intubated ureterotomy technique in 1943, stenting for 6 weeks was recommended and this has remained a common practice [30]. A number of more contemporary series have noted little difference in short-term results with 2 or 4 weeks of stenting [35–37].

Once the stent is removed, the patient should be followed with some form of anatomical imaging such as a CT urogram or IVP as well as a diuretic renogram. Our routine is to perform the IVP or CT urogram at 6 weeks post-stent removal and then a Lasix renogram 6 weeks later. Repeat imaging is then performed yearly or sooner if the patient develops flank pain. The optimal duration of follow-up is open to debate. It is known that the majority of endopyelotomy failures occur within the first 2 years; however, recurrences can occur as up to 10 years after surgery [38, 39]. In contrast, Albani et al. showed by unadjusted Kaplan-Meier method that all recurrences in their series occurred within the first 3 years [40]. It has been our practice to perform follow-up imaging for 5 years.

Desai and colleagues have reported short-term results using a modified technique they call endo-

pyeloplasty [41]. This approach incorporates percutaneous antegrade endopyelotomy incision with intracorporeal suturing using a Heineke-Mikulicz re-approximation [41, 42]. The exact role of this technical modification remains to be determined at this time.

Technique: Retrograde Endopyelotomy

While the contraindications for considering this approach include all of the criteria mentioned above for the antegrade technique, the additional caution for the retrograde approach is the presence of renal calculi requiring treatment. The risk of performing a retrograde endopyelotomy in the presence of proximal stones is that of extravasation of stone fragments through the endoureterotomy incision. The main advantage of retrograde endopyelotomy is direct visualization of the UPJ without the need for percutaneous access. The retrograde approach has been associated with less blood loss, shorter hospital stay, and quicker recovery as compared to antegrade endopyelotomy [43]. The main disadvantage of this approach is that the endoscope used is smaller resulting in a narrower field of vision, less irrigation flow, and a smaller working space compared to the antegrade technique.

Retrograde endopyelotomy is performed with the patient under general anesthesia placed in lithotomy position. Cystoscopy is performed and a retrograde pyelogram conducted to assess the UPJ anatomy, with particular attention directed to the length and degree of narrowing. An extra-stiff guidewire is then inserted and coiled in the renal pelvis. A dual-lumen catheter or an 8/10 F

coaxial dilator is then used to place a second safety wire across the UPJ, prior to making an incision. When faced with a very tight UPJ or with ureteral tortuosity, the troubleshooting steps described above may need to be employed. The safe performance of retrograde endopyelotomy requires the placement of two guidewires if one will be employing a flexible ureteroscope. If at least one wire cannot be placed across the UPJ, then the procedure should be aborted and a different approach selected.

Once a guidewire has been placed, balloon dilation catheter is performed such that the balloon straddles the area of narrowing. We use a 6 Fr 10 cm balloon and inflate until the “waisting” is no longer evident. This step provides some working space for the next step.

Retrograde endopyelotomy is most commonly performed using a flexible ureteroscope. In men the length of the urethra mandates use of a flexible ureteroscope to access the UPJ properly. In order to pass the flexible ureteroscope, the second wire is used to advance the instrument in a coaxial fashion to the UPJ using fluoroscopic guidance. While a semirigid ureteroscope may reach the UPJ in most women, the potential for inadvertent ureteral trauma is higher. Should one's intention be to use a semirigid ureteroscope, then only one guidewire would be necessary.

Once the UPJ is visualized, attention is paid for pulsations which may indicate a crossing vessel. Once the scope can pass into the renal pelvis, the incision is performed in a true lateral direction extending 1 cm proximal and distal to the site of the narrowing. While electrosurgery using a Bugbee electrode has been described, the holmium:YAG laser seems particularly suited to this application [38, 44]. The 200 μm laser fiber is small enough to permit the degree of scope deflection required while also allowing cutting precision. Typical laser settings for holmium:YAG laser incisions are 0.5–1.5 J/pulse with a rate of 5–15 Hz. After laser incision, the balloon dilation catheter is reinserted over the guidewire and inflated to confirm complete incision of the narrowed segment.

Once endopyelotomy has been performed, an endopyelotomy stent is placed in a retrograde fashion. We select an endopyelotomy stent one size longer than the patient's height would dictate as others have suggested to prevent downward migration of the proximal end into the freshly incised UPJ [45]. A Foley catheter is placed for 48 h. The ureteral stent is left in situ for 6 weeks. Follow-up anatomical and functional imaging is conducted as described above for the percutaneous antegrade approach.

Ureteral Strictures

Ureteral strictures remain a common malady and may develop from many causes including penetrating trauma, iatrogenic injury, stone impaction, malignancy, radiation, and infections such as tuberculosis and schistosomiasis. Iatrogenic strictures are now the most common cause as a result of ureteroscopic, gynecological, vascular, and general surgical procedures [46–50].

A variety of reconstructive procedures maybe considered for the management of ureteral strictures. The technique chosen will depend on a number of important factors including the etiology of the stricture, the site, the degree of ureteral and periureteral tissue involvement, renal function, and the patient's overall health status. Historically, open surgery employing various techniques such as ureteroureterotomy, ureteroneocystostomy +/- psoas hitch, Boari flap, or transureteroureterostomy was the initial treatment of choice. More rarely ileal ureteral interposition, Davis intubated ureterotomy, or renal autotransplantation is required. While many of these procedures are associated with a significant period of patient recovery, for many clinical scenarios, they still retain an important role.

With the development of minimally invasive approaches to ureteral stricture management, patient morbidity has been reduced; however, success rates remain inferior to the open approaches. Over the years, a number of endoscopic management options for ureteric strictures have evolved including ureteral stent placement,

balloon dilation, and endoureterotomy utilizing different incisional techniques.

Ureteral stent placement is an effective short-term intervention to protect the kidney from the effects of obstruction while definitive therapy is being considered. In select circumstances, regularly scheduled stent changes may also be a solution for managing patients who due to significant medical comorbidities or short life expectancy may not be candidates for reconstructive efforts.

Balloon dilation alone is rarely a definitive management strategy for ureteral stricture disease with reported success rates between 40 and 75 % [51, 52]. On occasion however, a short-segment stricture with minimal or no periureteral fibrosis and good vascular supply may be successfully managed by dilation alone [53–55]. More often, balloon dilation is carried out in conjunction with endoureterotomy. Endoureterotomy can be performed using antegrade or retrograde approaches. In general, strictures involving the distal and middle ureters are approached in a retrograde manner using a semirigid ureteroscope, and for those strictures of the upper ureter, an antegrade percutaneous approach or retrograde technique with a flexible ureteroscope is employed.

Success rates are comparable for each approach (66–83 %) [56–60]. A clear understanding of the cause of the stricture may give insights into the feasibility and potential success of a minimally invasive approach vs. a more major reconstructive effort. Preoperative imaging should include some type of contrast study including either a CT urogram, intravenous pyelogram, retrograde pyelogram, or antegrade nephrostogram to allow characterization of the stricture location, length, and lumen caliber. A completely obliterated ureteral lumen will be destined to fail an incisional approach, and an open or laparoscopic reconstructive approach should be conducted. Renal function of both the affected and contralateral units should be documented and nuclear renography should be performed. If renal function is significantly compromised, nephrectomy may be the more prudent approach. If there is question whether the

stricture is truly obstructive, diuretic renography should also be performed.

Favorable prognostic factors for endoureterotomy success include short-segment distal strictures (<2 cm), non-radiated field, and relatively good ipsilateral renal function. Ipsilateral renal function of less than 25 % function has been shown to be associated with lower success rates [34, 46, 47, 61].

Technique: Endoureterotomy

Preoperative evaluation is similar to that described for endopyelotomy. General anesthesia is typically used for these procedures; however, spinal anesthesia can also be considered especially for those patients with middle or distal strictures where a retrograde approach is planned. For retrograde endoureterotomy, the patient is positioned in lithotomy, and for the antegrade approach, the patient is placed prone as for percutaneous renal stone surgery.

Regardless of the approach, the first step should be to conduct a good-quality retrograde pyelogram or antegrade study to visualize the narrowed ureteral segment. Whether the approach is antegrade or retrograde, a guidewire should then be placed across the stricture segment. Often, this can be a challenging step, and one might need to resort to a use of a hydrophilic wire and a Kumpe catheter to negotiate through the area of involvement. Should it be impossible to pass the wire due to a completely obliterated lumen, endoureterotomy is not recommended. The risk of straying outside the lumen is a significant risk potentially leading to vascular or bowel injury. While the “cut to the light method”, in which a new lumen is created using both fluoroscopic and visual guidance from above and below the stricture, has been described for this scenario, results have not been durable [62–64]. If a semirigid ureteroscope is to be used, a single guidewire is adequate. If a flexible ureteroscope will be required, a second guidewire is advanced to the level of the stricture for coaxial advancement of the endoscope.

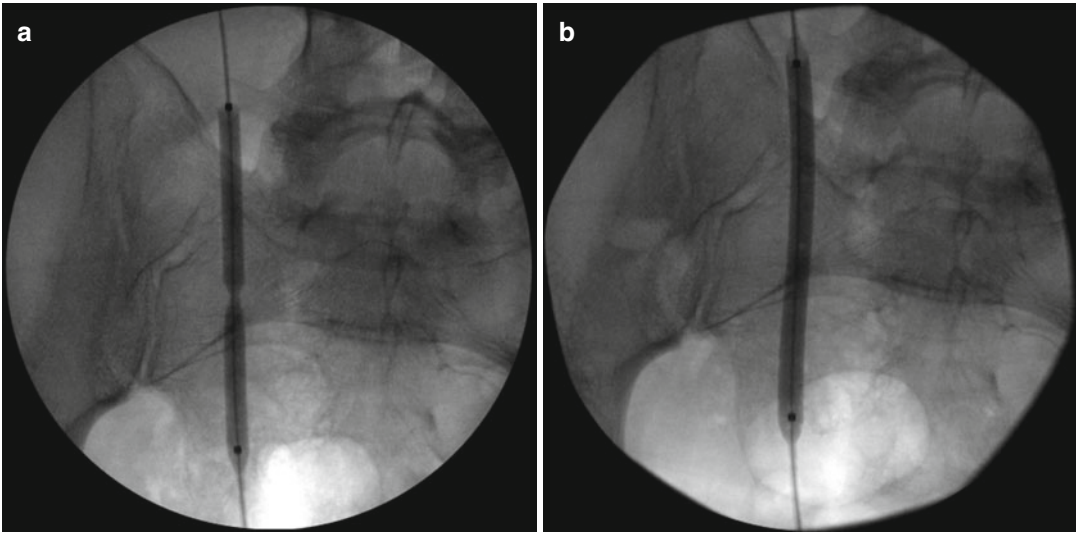


Fig. 14.3 (a) “Waisting” seen during balloon dilation of ureteral stricture. (b) Resolution of “waisting” with adequate dilation of ureteral stricture

Once the guidewire has been placed, balloon dilation using a 6 or 7 Fr 10 cm ureteral balloon dilation catheter is performed, removing if possible any “waisting” or luminal narrowing (Fig. 14.3).

Ureteroscopy is then performed to visualize the stricture. One should look for nearby vascular pulsations, especially for those ureteral strictures near the iliac vessels. Endoureterotomy incision has been performed with cold knife, electrosurgery, and laser energy sources [56, 58, 62, 65, 66]. As with endopyelotomy, no clear advantage appears to exist for one modality over another. The holmium:YAG laser has been widely adopted in most contemporary series as the preferred tool. The ability to precisely incise tissue using both flexible and semirigid instruments without compromising irrigant flow is just some of the advantages with the laser.

The location of the incision is an important decision in order to avoid inadvertent injury to periureteral vascular structures. For those strictures involving the upper ureter, the incision should be oriented laterally or posterolaterally similar to the plane of an endopyelotomy incision [67]. The goal in this instance is to avoid the medial blood supply to the ureter or a crossing vessel. For those strictures involving the mid-ureter where the iliac vessels may be nearby and

the ureteral blood supply enters from a lateral direction, the incision is made in an anterior direction [60]. Prior to incising the mid-ureter, it is important to inspect the lumen for pulsations indicative of the iliac vessels. An inadvertent laceration of an iliac vessel can result in a massive hemorrhage and may be life threatening. For those distal ureteral strictures beneath the iliac vessels, an anteromedial incision is recommended [64, 67]. One should also be cognizant of bowel structures which may also be in close proximity. A careful review of the preoperative CT scan can help plan the safest site of incision.

The incision should be made full thickness such that periureteric fat is identified. After incision, balloon dilation is repeated to ensure there is not persistent narrowing.

Following endoureterotomy a stent should be placed. For distal or proximal strictures, an endopyelotomy stent may be used. As with endopyelotomy, the optimal size and duration of stenting remains unclear. We generally leave the stent for 6 weeks.

After stent removal, either a CT urogram or IVP is performed 6 weeks later. Diuretic renography should also be performed 3–6 months later to rule out persistent obstruction and document any change in renal function. Depending on the cause

Table 14.2 Selected contemporary results of endoureterotomy

Author	Patient number	Orthotopic (%)	Transplant (%)	Ureteroenteric (%)	Follow-up Mean (range)
Razdan et al. [66]	50	74			75 months (6–108)
Lane et al. [59]	19	68			36 months (5–84)
Hibi et al. [108]	18	80			60 months (46–74)
Gnessin et al. [58]	35	79			27 months (10–72)
Kristo et al. [109]	3		100		24 months (6–33)
Gdor et al. [72]	6		67		58 months (13–89)
He et al. [73]	8		62 ^a		16 months (4–45)
Mano et al. [68]	12 ^b		83		44 months (2–68)
Laven et al. [83]	16			57	20 months (9–41)
Watterson et al. [61]	23			71	23 months (3–68)
Poulakis et al. [85]	40			60.5	38 months (12–85)
Milhoua et al. [110]	15			33	23 months (6–86)

^aWith one procedure

^bAll patients had previously been treated with balloon dilation

of the stricture, recurrence may be a potential concern requiring periodic radiologic and functional surveillance for some years afterward. Success rates reported by contemporary series are listed in Table 14.2.

Special Situations

Transplant Ureterovesical Anastomotic Strictures

Ureterovesical anastomotic strictures occur in 1–5 % [68–70] of renal transplant patients and are often ischemic in nature. Open revision reimplantation can be technically challenging. Endoureterotomy has been successfully performed in renal transplant recipients with ureterovesical anastomotic strictures [71, 72]. The prognosis for these strictures is similar to other etiologies in that a short anastomotic stricture (<1 cm) is most likely to be treated effectively. In contrast, recurrent or long ischemic strictures are least likely to respond. Gdor et al. reported a small series in which 4 patients with strictures shorter than 1 cm were successfully treated with a single incision at 58 months follow-up (range 13–89) whereas 2 patients with strictures longer than 1 cm failed [72]. He et al. report a similar finding of 1 recurrence of 6 patients with strictures

<1 cm compared with recurrence at 4 and 6 months in 2 patients with strictures >1 cm [73]. The technique is similar to previously described and can be approached in either a retrograde or antegrade fashion. Most often an antegrade approach is required utilizing a flexible endoscope (Fig. 14.4). Stricture incision using the holmium laser should be directed anteromedially, and an internal double pigtail or internal/external stent should be kept postoperatively [72]. Six weeks of stenting seems prudent although as for all incisional techniques this recommendation is not based on any compelling data.

Ureteroenteric Anastomotic Strictures

Ureteroenteric anastomotic strictures occur in approximately 3–10 % of patients after cystectomy and urinary diversion [74–78]. The ureteroenteric stricture rates appear to be similar between continent and incontinent diversions; however, the type of anastomosis greatly influences long-term patency. A refluxing anastomosis tends to have lower stricture rates than non-refluxing [76, 79]. Additionally, the left ureter is more commonly affected due to the higher risk of ischemia as a result of the greater amount of ureteral mobilization required [80, 81]. Robotic vs. open procedures seem to have similar rates of stricture formation [78].

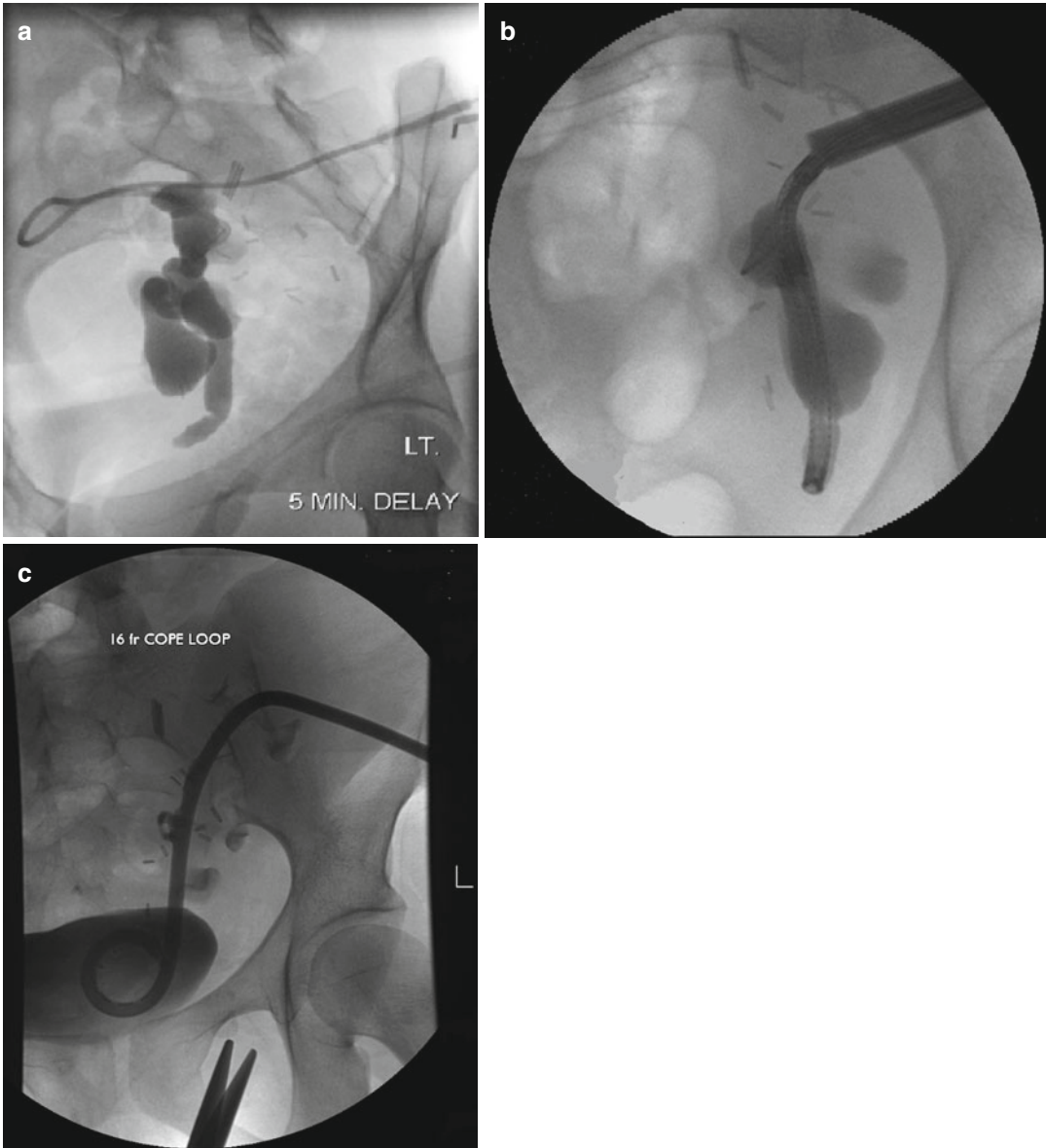


Fig. 14.4 (a) Nephrostogram demonstrating ureteral stricture in a transplant ureter. (b) Flexible endoscope

used to visualize and incise the stricture. (c) Cope loop stent placed across the stricture after incision

Imaging studies are important in the evaluation. Most commonly, patients who develop a ureteroenteric stricture will have a nephrostomy tube placed to relieve the obstruction. The percutaneous access serves as excellent way to visualize the degree of stricture by allowing performance of an antegrade nephrostogram. A CT urogram is also very helpful in identifying adjacent structures

especially the bowel. A loopogram may also help in clarifying the anatomy (Fig. 14.5). In patients who underwent cystectomy and urinary diversion for urothelial malignancy, the potential for recurrent malignancy as the cause of the obstruction should be entertained and excluded through thorough review of the cystectomy pathology, preoperative imaging, and urine cytology results [82].

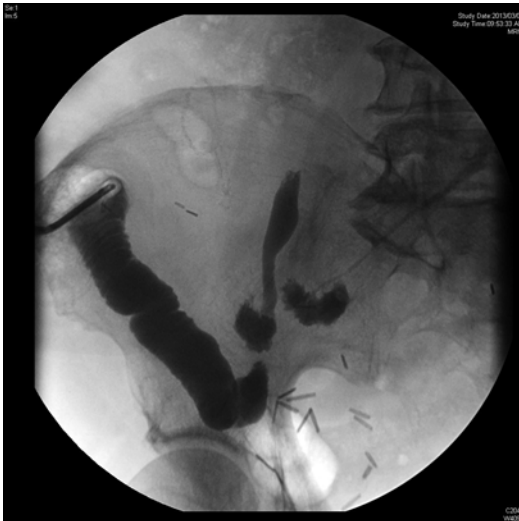

Fig. 14.5 Loopogram imaging of ureteroenteric stricture

While both retrograde and antegrade approaches have been described, the antegrade technique is most commonly used. We have found that for many patients a flexible cystoscope passed antegrade can reach the anastomotic site and allow a better field of view and irrigant flow than the flexible ureteroscopes. As for other types of strictures, guidewire advancement across the narrowed segment is essential. Failure to achieve this critical step should lead to abandonment of an endoscopic incision with consideration given to open repair. We employ a similar technique as described above with initial balloon dilation followed by holmium:YAG laser incision and then repeat dilation.

Overall, the success rates for endoureterotomy for ureteroenteric strictures are reported between 50 and 80 % [56, 61, 83–86] (Table 14.2). This data is based on several small case series in which primarily antegrade endoureterotomy was performed. Watterson et al. reported a 71 % symptomatic and radiologic success in a series of 23 patients with a mean follow-up of 22 months [61]. They noted, however, that success rates decreased with time with recurrence of 15 % at 1 year and 44 % at 3 years. These results concur with Pakoulis et al. who additionally report uniform failure at 4 months among 6 patients who underwent repeated endoureterotomy [85]. Laven et al.

reported a lower success rate of 57 % at 20 months but noted that 5 of their 6 recurrences involved left-sided strictures [83]. In a follow-up of their series, the success rate dropped to 50 % at 35 months [84]. To date Schondorf et al. have presented the largest series which compares 96 endourological procedures to 35 open surgical procedures and report a 26 % success rate for endourological procedures at 29 months. Unfortunately, balloon dilation alone and Acucise are included among the patients in the endourological procedures arm, procedures known to be associated with lower success rates compared to visually guided incisional techniques [86].

Urethral Strictures

The incidence and etiology of urethral strictures vary across the globe. In the UK, the national incidence of urethral stricture has been estimated at 10/100,000 men in their youth, increasing to 100/100,000 by age >65 years [87]. In the US VA hospital system, the incidence of urethral stricture was 193/100,000 in 2003 and as high as 627/100,000 among men over 65 on Medicare [88]. The most common causes of urethral strictures include blunt perineal trauma, pelvic fractures, instrumentation induced, infection, and inflammatory processes [89].

Many open surgical and endoscopic approaches to urethral strictures have been described. Urethral dilation has been widely practiced for millennia. Although simple to perform, rarely does dilation alone provide a long-term cure unless the stricture is very short in length and in the absence of any significant degree of spongiofibrosis [90]. Visual internal urethrotomy is a relatively simple procedure technically and is associated with minimal postoperative morbidity. As a consequence, urethrotomy has become the most commonly performed procedure replacing open urethroplasty for a generation of urologists. More recent experiences, however, have led to a revival in the use of open urethroplasty, to some degree fueled by the high rates of stricture recurrences seen with internal urethrotomy. Quite clearly, visual internal urethrotomy has been a procedure that has been

overutilized in the past and may have contributed to worsening of the initial stricture as a result of the repeated surgical trauma in many patients. A more thoughtful approach to the use of this modality of treatment is clearly warranted.

As for all of the incision techniques described in this chapter, patient selection is paramount to the success of visual internal urethrotomy. Most successful results are found for those patients with short (<1.5–2 cm) strictures involving the bulbous urethra in the absence of deep or dense spongiofibrosis [91, 92]. Under these conditions, up to 70 % of patients will be stricture-free at 3 months, and 50–60 % of these will remain stricture-free at 4 years [93]. Under less selected conditions, typical success rates vary from 20 to 35 % [91]. The decision on which initial treatment is selected should be based on characteristics of the stricture and treatment goals in conjunction with patient preferences. Should visual internal urethrotomy be selected as the initial modality of treatment, it seems prudent to at least recommend a reassessment of all of the options if there is stricture recurrence [91, 94].

The key characteristics that define a urethral stricture include location, length, depth, and presence of spongiofibrosis. On physical exam, spongiofibrosis and the depth of stricture can be palpated. Location and length can be determined by either cystourethroscopy, retrograde urethrogram, or endoluminal or transcutaneous ultrasound. Some authors suggest that ultrasound may be the preferred modality for evaluating length of stricture [95]. Cystoscopy with a flexible or pediatric cystoscope can also be a valuable tool to evaluate stricture characteristics. If a patient has a suprapubic tube for retention, then an antegrade cystoscopy can also be performed to visually inspect the stricture.

Technique: Internal Urethrotomy

Internal urethrotomy is most commonly performed with the patient in lithotomy position, under spinal or general anesthesia. Urethroscopy is usually performed with a rigid instrument to confirm the location of the stricture and degree of luminal narrowing. Depending on the severity of



Fig. 14.6 “Half-moon” blade used for cold knife visual internal urethrotomy

the stricture, either an adult or pediatric cystoscope is used. It is our preference in most cases to pass a Teflon-coated Bentson guidewire across the stricture and into the bladder at the time of initial urethroscopy. This facilitates coaxial dilation which then makes advancement of the visual urethrotome easier. The guidewire also facilitates passage of a Council catheter at the completion of the urethrotomy without difficulty.

Visual internal urethrotomy can be performed using either a cold knife urethrotome, electrosurgical incision, or holmium:YAG laser. All techniques appear comparable in terms of short-term success and complications [96]. Our preference is to perform cold knife incision using the “half-moon” blade (Fig. 14.6). Regardless of the

Table 14.3 Selected contemporary results of visual internal urethrotomy

Author	Procedure	Patient number	Patency (%)	Follow-up
				Mean (range)
Albers et al. [99]	Cold knife with CIC (66 %)	357	73 %	4.6 years (0.75–16)
	Cold knife (unknown adjuvant)	580	55 %	3.2 years (0.25–3.5)
Steenkamp et al. [91]	Cold knife	104	60 % <2 cm	12 months (1–49)
	Filiform	106	20 % >4 cm	
Heyns et al. [93]	Cold knife or filiform + stricture-free at 3 months	168	50 %	24 (2–63)
Hafez et al. [98]	Cold knife (pediatric)	31	35.5 %	6.6 years (2–20)
Hosseini et al. [102]	Cold knife + CIC	34	66 %	12 months
	Cold knife + steroid gel CIC	30	70 %	12 months
Lauritzen et al. [100]	Urethrotomy	162	69 %	23 months (0.2–70)
	Urethrotomy + CIC	55	81 %	29 months (1–66)
Gucuk et al. [101]	Cold knife + steroid gel CIC	15	80 %	16 months (6–18)
	Cold knife + CIC	15	53 %	16 months (6–18)
	Cold knife + Foley (3 days)	15	40 %	16 months (6–18)
Mazdak et al. [103]	Cold knife (<i>n</i> =22)	22	50 %	13 months (1–25)
	Cold knife + submucosal steroid	23	78 %	
Tavakkoli Tabassi et al. [111]	Cold knife + placebo	36	58 %	8 months (6–24)
	Cold knife + steroid injection	34	65 %	8 months (6–24)
Jordan et al. [104]	Dilation or VIU + Foley	29	17 %	12 months
	Dilation or VIU + Memokath	63	79 % ^a	12 months

^a69 % had Memokath stent in situ at 12 months

cutting modality used, a single 12 o'clock incision is most commonly performed through the avascular scar and into healthy bleeding tissue. Care should be taken, however, to avoid very deep incisions into the corpora to prevent excessive bleeding. The stricture should be incised slightly beyond its length and full depth to allow healing by secondary intention.

A urethral catheter should be kept in place postoperatively. Controversy exists regarding the optimal size or duration of catheterization. Some authors suggest that longer catheter times are associated with better long-term results, while others report no differences with 6 weeks vs. 7 days of catheterization [97, 98]. Others suggest that prolonged catheterization longer than 3 days increases stricture recurrence [99]. Alternatively some benefit has been shown with intermittent self-catheterization postoperatively [100]. Other authors suggest further improvement with steroid lubrication of the catheter or steroid injection at the time of urethrotomy [101–103]. Results from a sampling of contemporary series are listed in Table 14.3.

There is no standardized follow-up regimen post visual internal urethrotomy. Given the high expected failure rate, as high as 80 % depending on patient selection [91, 104], it seems prudent to reassess patients periodically. The use of IPSS, uroflowmetry, and post-void residual determination performed serially may allow earlier detection of stricture recurrences before urinary retention occurs.

Conclusions

Endoscopic management of UPJ obstruction, ureteral stricture, and urethral stricture disease provides a minimally invasive alternative to more technically complex procedures and can have satisfactory success rates in appropriately selected patients. Improvements in equipment and technique have allowed endoscopic techniques to become a first-line option in select patients for the treatment of upper and lower tract obstruction. Complications have not been well described quantitatively in the literature; however, these techniques are generally considered to have low morbidity and are well tolerated by patients.

Endopyelotomy and Endoureterotomy Equipment List

Percutaneous access: Needle trocar 18GA × 15 cm disposable, Glidewire 0.035 in. × 150 cm angled tip, angiographic beacon tip (Kumpe) catheter 5 Fr × 0.038 in. × 40 cm (65 cm optional), Amplatz extra-stiff 0.035 in. × 150 cm straight-tip Teflon-coated guidewire, balloon dilator set with 30 Fr access sheath, or coaxial dilators 12–30 Fr.

Retrograde access: Flexible cystoscope, Bentson 0.035 in. × 145 cm Teflon-coated straight guidewires, Pollack ureteral 5 Fr 70 cm open-ended flexi-tip ureteral catheter, 12 cc Luer-Lok syringe, contrast Conray 200 (or Isovue 200).

Working instruments: For antegrade procedure at UPJ, rigid nephroscope, duckbill forceps, Ascend ureteral catheter 6 mm × 10 cm dilation balloon 65 cm length, 21 Fr endopyelotome, hook blade.

For antegrade ureteral or proximal retrograde procedure: flexible ureteroscope, holmium:YAG laser and fibers (150–270 nm).

For retrograde procedure in distal ureter: Semirigid ureteroscope 6.9 Fr with 150–400 nm holmium:YAG laser fibers.

Others: 8/10 Fr coaxial dilator and working sheath, Council-tip 2-way 16 Fr Foley catheter

Visual Internal Urethrotomy Equipment List

Working instruments: Rigid cystoscope 21 F (if tight stricture, consider 7.5 F pediatric cystoscope), urethrotome with half-moon blade, Bentson guidewire, Cook/Amplatz urethral dilators 12–30 F.

Other: Council-tip 2-way 16–18 Fr Foley catheter.

References

- Solari V, Piotrowska AP, Puri P. Altered expression of interstitial cells of Cajal in congenital ureteropelvic junction obstruction. *J Urol.* 2003;170(6 Pt 1):2420–2.
- Jabbour ME, Goldfischer ER, Klima WJ, Stravodimos KG, Smith AD. Endopyelotomy after failed pyeloplasty: the long-term results. *J Urol.* 1998;160(3 Pt 1):690–2.
- Acher PL, Nair R, Abbaraju JS, Dickinson IK, Vohra A, Sriprasad S. Ureteroscopic holmium laser endopyelotomy for ureteropelvic junction stenosis after pyeloplasty. *J Endourol.* 2009;23(6): 899–902.
- Park J, Kim WS, Hong B, Park T, Park HK. Long-term outcome of secondary endopyelotomy after failed primary intervention for ureteropelvic junction obstruction. *Int J Urol.* 2008;15(6):490–4.
- Patel T, Kellner CP, Katsumi H, Gupta M. Efficacy of endopyelotomy in patients with secondary ureteropelvic junction obstruction. *J Endourol.* 2011; 25(4):587–91.
- Butani RP, Eshghi M. Cold-knife retrograde endopyelotomy: a long-term follow-up. *J Endourol.* 2008; 22(4):657–60.
- Canes D, Berger A, Gettman MT, Desai MM. Minimally invasive approaches to ureteropelvic junction obstruction. *Urol Clin North Am.* 2008;35(3):425–39.
- Ost MC, Kaye JD, Guttman MJ, Lee BR, Smith AD. Laparoscopic pyeloplasty versus antegrade endopyelotomy: comparison in 100 patients and a new algorithm for the minimally invasive treatment of ureteropelvic junction obstruction. *Urology.* 2005;66(5 Suppl):47–51.
- McClinton S, Steyn JH, Hussey JK. Retrograde balloon dilatation for pelviureteric junction obstruction. *Br J Urol.* 1993;71(2):152–5.
- Webber RJ, Pandian SS, McClinton S, Hussey J. Retrograde balloon dilatation for pelviureteric junction obstruction: long-term follow-up. *J Endourol.* 1997;11(4):239–42.
- Weikert S, Christoph F, Müller M, Schostak M, Miller K, Schrader M. Acucise endopyelotomy: a technique with limited efficacy for primary ureteropelvic junction obstruction in adults. *Int J Urol.* 2005;12(10):864–8.
- Sofras F, Livadas K, Alivizatos G, Deliveliotis C, Albanis S, Melekos M, et al. Retrograde acucise endopyelotomy: is it worth its cost? *J Endourol.* 2004;18(5):466–8.
- Jacobs BL, Kaufman SR, Morgenstern H, Hollenbeck BK, Wolf Jr JS, Hollingsworth JM. Trends in the treatment of adults with ureteropelvic junction obstruction. *J Endourol.* 2013;27(3):355–60.
- Tállai B, Salah MA, Flaskó T, Tóth C, Varga A. Endopyelotomy in childhood: our experience with 37 patients. *J Endourol.* 2004;18(10):952–8.
- Braga LH, Lorenzo AJ, Skeldon S, Dave S, Bagli DJ, Khoury AE, et al. Failed pyeloplasty in children: comparative analysis of retrograde endopyelotomy versus redo pyeloplasty. *J Urol.* 2007;178(6):2571–5.
- Veenboer PW, Chrzan R, Dik P, Klijn AJ, de Jong TP. Secondary endoscopic pyelotomy in children with failed pyeloplasty. *Urology.* 2011;77(6):1450–4.

17. Nadu A, Mottrie A, Geavlete P. Ureteropelvic junction obstruction: which surgical approach? *Eur Urol Suppl.* 2009;8(9):778–81.
18. Yanke BV, Lallas CD, Pagnani C, McGinnis DE, Bagley DH. The minimally invasive treatment of ureteropelvic junction obstruction: a review of our experience during the last decade. *J Urol.* 2008;180(4):1397–402.
19. Chow GK, Geisinger MA, Stroom SB. Endopyelotomy outcome as a function of high versus dependent ureteral insertion. *Urology.* 1999;54(6):999–1002.
20. Shalhav AL, Giusti G, Elbahnasy AM, Hoenig DM, Maxwell KL, McDougall EM, et al. Endopyelotomy for high-insertion ureteropelvic junction obstruction. *J Endourol.* 1998;12(2):127–30.
21. Van Cangh PJ, Wilmart JF, Opsomer RJ, Abi-Aad A, Wese FX, Lorge F. Long-term results and late recurrence after endoureteropyelotomy: a critical analysis of prognostic factors. *J Urol.* 1994;151(4):934–7.
22. Sampaio FJ. Vascular anatomy at the ureteropelvic junction. *Urol Clin North Am.* 1998;25(2):251–8.
23. Zeltser IS, Liu JB, Bagley DH. The incidence of crossing vessels in patients with normal ureteropelvic junction examined with endoluminal ultrasound. *J Urol.* 2004;172(6 Pt 1):2304–7.
24. Wolf JS, Bennett CJ, Dmochowski RR, Hollenbeck BK, Pearle MS, Schaeffer AJ. Best practice policy statement on urologic surgery antimicrobial prophylaxis. Copyright © 2007 American Urological Association Education and Research, Inc.® Updated Sept 2008. Revised Feb 2012.
25. Karlin GS, Badlani GH, Smith AD. Endopyelotomy versus open pyeloplasty: comparison in 88 patients. *J Urol.* 1988;140(3):476–8.
26. Lee WJ, Badlani GH, Karlin GS, Smith AD. Treatment of ureteropelvic strictures with percutaneous pyelotomy: experience in 62 patients. *AJR Am J Roentgenol.* 1988;151(3):515–8.
27. Stilling NM, Jung H, Nørby B, Osther SS, Osther PJ. Retrograde ureteroscopic holmium laser endopyelotomy in a selected population of patients with ureteropelvic junction obstruction. *Scand J Urol Nephrol.* 2009;43(1):68–72.
28. Doo CK, Hong B, Park T, Park HK. Long-term outcome of endopyelotomy for the treatment of ureteropelvic junction obstruction: how long should patients be followed up? *J Endourol.* 2007;21(2):158–61.
29. Bernardo NO, Smith AD. Percutaneous endopyelotomy. *Urology.* 2000;56(2):322–7.
30. Davis DM. Intubated ureterotomy: a new operation for ureteral and ureteropelvic stricture. *Surg Gynecol Obstet.* 1943;76:513–23.
31. Davis DM, Strong GH, Drake WM. Intubated ureterotomy; experimental work and clinical results. *J Urol.* 1948;59(5):851–62.
32. Moon YT, Kerbl K, Pearle MS, Gardner SM, McDougall EM, Humphrey P. Evaluation of optimal stent size after endourologic incision of ureteral strictures. *J Endourol.* 1995;9(1):15–22.
33. Berkman DS, Landman J, Gupta M. Treatment outcomes after endopyelotomy performed with or without simultaneous nephrolithotomy: 10-year experience. *J Endourol.* 2009;23(9):1409–13.
34. Wolf Jr JS, Elashry OM, Clayman RV. Long-term results of endoureterotomy for benign ureteral and ureteroenteric strictures. *J Urol.* 1997;158(3 Pt 1):759–64.
35. Mandhani A, Kapoor R, Zaman W, Kumar A, Bhandari M, Gambhir S. Is a 2-week duration sufficient for stenting in endopyelotomy? *J Urol.* 2003;169(3):886–9.
36. Kumar R, Kapoor R, Mandhani A, Kumar A, Ahlawat R. Optimum duration of splinting after endopyelotomy. *J Endourol.* 1999;13(2):89–92.
37. Pearle MS. Use of ureteral stents after endopyelotomy. *J Endourol.* 1996;10(2):169–76.
38. Minervini A, Davenport K, Keeley Jr FX, Timoney AG. Antegrade versus retrograde endopyelotomy for pelvi-ureteric junction (PUJ) obstruction. *Eur Urol.* 2006;49(3):536–42.
39. Dimarco DS, Gettman MT, McGee SM, Chow GK, Leroy AJ, Slezak J. Long-term success of antegrade endopyelotomy compared with pyeloplasty at a single institution. *J Endourol.* 2006;20(10):707–12.
40. Albani JM, Yost AJ, Stroom SB. Ureteropelvic junction obstruction: determining durability of endourological intervention. *J Urol.* 2004;171(2 Pt 1):579–82.
41. Desai MM, Gill IS, Carvalhal EF, Kaouk JH, Banks K, Raju R. Percutaneous endopyeloplasty: a novel technique. *J Endourol.* 2002;16(7):431–43.
42. Desai MM, Desai MR, Gill IS. Endopyeloplasty versus endopyelotomy versus laparoscopic pyeloplasty for primary ureteropelvic junction obstruction. *Urology.* 2004;64(1):16–21.
43. Shalhav AL, Giusti G, Elbahnasy AM, Hoenig DM, McDougall EM, Smith DS. Adult endopyelotomy: impact of etiology and antegrade versus retrograde approach on outcome. *J Urol.* 1998;160(3 Pt 1):685–9.
44. Nakada SY, Johnson M. Ureteropelvic junction obstruction. Retrograde endopyelotomy. *Urol Clin North Am.* 2000;27(4):677–84.
45. Knudsen BE, Cook AJ, Watterson JD, Beiko DT, Nott L, Razvi H, et al. Percutaneous antegrade endopyelotomy: long-term results from one institution. *Urology.* 2004;63(2):230–4.
46. Adiyat KT, Meuleners R, Monga M. Selective post-operative imaging after ureteroscopy. *Urology.* 2009;73(3):490–3.
47. Elashry OM, Elgamasy AK, Sabaa MA, Abo-Elenien M, Omar MA, Eltatawy HH, et al. Ureteroscopic management of lower ureteric calculi: a 15-year single-centre experience. *BJU Int.* 2008;102(8):1010–7.
48. Manger JP, Mendoza PJ, Babayan RK, Wang DS. Use of renal ultrasound to detect hydronephrosis after ureteroscopy. *J Endourol.* 2009;23(9):1399–402.
49. Schatloff O, Lindner U, Ramon J, Winkler HZ. Randomized trial of stone fragment active

- retrieval versus spontaneous passage during holmium laser lithotripsy for ureteral stones. *J Urol.* 2010;183(3):1031–5.
50. Pearle MS, Lingeman JE, Leveillee R, Kuo R, Preminger GM, Nadler RB, et al. Prospective randomized trial comparing shock wave lithotripsy and ureteroscopy for lower pole caliceal calculi 1 cm or less. *J Urol.* 2008;179(5 Suppl):S69–73.
 51. Banner MP, Pollack HM, Ring EJ, Wein AJ. Catheter dilatation of benign ureteral strictures. *Radiology.* 1983;147(2):427–33.
 52. Shapiro MJ, Banner MP, Amendola MA, Gordon RL, Pollack HM, Wein AJ. Balloon catheter dilation of ureteroenteric strictures: long-term results. *Radiology.* 1988;168(2):385–7.
 53. Richter F, Irwin RJ, Watson RA, Lang EK. Endourologic management of benign ureteral strictures with and without compromised vascular supply. *Urology.* 2000;55(5):652–7.
 54. Goldfischer ER, Gerber GS. Endoscopic management of ureteral strictures. *J Urol.* 1997;157(3):770–5.
 55. Ravery V, de la Taille A, Hoffmann P, Moulinier F, Hermieu JF, Delmas V, et al. Balloon catheter dilatation in the treatment of ureteral and ureteroenteric stricture. *J Endourol.* 1998;12(4):335–40.
 56. Singal RK, Denstedt JD, Razvi HA, Chun SS. Holmium:YAG laser endoureterotomy for treatment of ureteral stricture. *Urology.* 1997;50(6):875–80.
 57. Corcoran AT, Smaldone MC, Ricchiuti DD, Averch TD. Management of benign ureteral strictures in the endoscopic era. *J Endourol.* 2009;23(11):1909–12.
 58. Gnessin E, Yossepowitch O, Holland R, Livne PM, Lifshitz DA. Holmium laser endoureterotomy for benign ureteral stricture: a single center experience. *J Urol.* 2009;182(6):2775–9.
 59. Lane BR, Desai MM, Hegarty NJ, Stroom SB. Long-term efficacy of holmium laser endoureterotomy for benign ureteral strictures. *Urology.* 2006;67(5):894–7.
 60. Patel RC, Newman RC. Ureteroscopic management of ureteral and ureteroenteral strictures. *Urol Clin North Am.* 2004;31(1):107–13.
 61. Watterson JD, Sofer M, Wollin TA, Nott L, Denstedt JD. Holmium: YAG laser endoureterotomy for ureterointestinal strictures. *J Urol.* 2002;167(4):1692–5.
 62. Conlin MJ, Gomella LG, Bagley DH. Endoscopic ureteroureterostomy for obliterated ureteral segments. *J Urol.* 1996;156(4):1394–9.
 63. Goda K, Kawabata G, Yasufuku T, Hara I, Fujisawa M, Kamidono S, Okada H. Cut-to-the-light technique and potassium titanyl phosphate laser ureterotomy for complete ureteral obstruction. *Int J Urol.* 2004;11(6):427–8.
 64. Knowles DR, Staiman VR, Gupta M. Long-term results of the treatment of complete distal ureteral stenosis using a cutting balloon catheter device. *J Urol.* 2001;166(6):2087–90.
 65. Yamada Y, Honda N, Hibi H, Taki T, Mitsui K, Fukatsu H. Holmium:YAG laser endoureterotomy in the treatment of ureteroenteric stricture following Indiana urinary diversion. *Int J Urol.* 2001;8(6):326–9.
 66. Razdan S, Silberstein IK, Bagley DH. Ureteroscopic endoureterotomy. *BJU Int.* 2005;95 Suppl 2:94–101.
 67. Preminger GM, Clayman RV, Nakada SY, Babayan RK, Albala DM, Fuchs GJ, et al. A multicenter clinical trial investigating the use of a fluoroscopically controlled cutting balloon catheter for the management of ureteral and ureteropelvic junction obstruction. *J Urol.* 1997;157(5):1625–9.
 68. Mano R, Golan S, Holland R, Livne PM, Lifshitz DA. Retrograde endoureterotomy for persistent ureterovesical anastomotic strictures in renal transplant kidneys after failed antegrade balloon dilation. *Urology.* 2012;80(2):255–9.
 69. Giessing M. Transplant ureter stricture following renal transplantation: surgical options. *Transplant Proc.* 2011;43(1):383–6.
 70. Streeter EH, Little DM, Cranston DW, Morris PJ. The urological complications of renal transplantation: a series of 1535 patients. *BJU Int.* 2002;90(7):627–34.
 71. Schumacher M, Studer UE, Danuser H. Antegrade endopyelotomy for treatment of ureteropelvic junction obstruction in transplanted kidneys. *J Endourol.* 2006;20(5):305–8.
 72. Gdor Y, Gabr AH, Faerber GJ, Wolf Jr JS. Holmium:yttrium-aluminum-garnet laser endoureterotomy for the treatment of transplant kidney ureteral strictures. *Transplantation.* 2008;85(9):1318–21.
 73. He Z, Li X, Chen L, Zeng G, Yuan J, Chen W, et al. Endoscopic incision for obstruction of vesico-ureteric anastomosis in transplanted kidneys. *BJU Int.* 2008;102(1):102–6.
 74. Studer UE, Burkhard FC, Schumacher M, Kessler TM, Thoeny H, Fleischmann A, Thalmann GN. Twenty years experience with an ileal orthotopic low pressure bladder substitute—lessons to be learned. *J Urol.* 2006;176(1):161–6.
 75. Katkooi D, Samavedi S, Adiyat KT, Soloway MS, Manoharan M. Is the incidence of uretero-intestinal anastomotic stricture increased in patients undergoing radical cystectomy with previous pelvic radiation? *BJU Int.* 2010;105(6):795–8.
 76. Hautmann RE, de Petriconi RC, Volkmer BG. 25 years of experience with 1,000 neobladders: long-term complications. *J Urol.* 2011;185(6):2207–12.
 77. Shimko MS, Tollefson MK, Umbreit EC, Farmer SA, Blute ML, Frank I. Long-term complications of conduit urinary diversion. *J Urol.* 2011;185(2):562–7.
 78. Anderson CB, Morgan TM, Kappa S, Moore D, Clark PE, Davis R, et al. Ureteroenteric anastomotic strictures after radical cystectomy—does operative approach matter? *J Urol.* 2013;189(2):541–7.

79. Pantuck AJ, Han KR, Perrotti M, Weiss RE, Cummings KB. Ureteroenteric anastomosis in continent urinary diversion: long-term results and complications of direct versus nonrefluxing techniques. *J Urol.* 2000;163(2):450–5.
80. Skinner DG, Crawford ED, Kaufman JJ. Complications of radical cystectomy for carcinoma of the bladder. *J Urol.* 1980;123(5):640–3.
81. Månsson W, Ahlgren G, White T. Glomerular filtration rate up to 10 years after urinary diversion of different types. A comparative study of ileal and colonic conduit, refluxing and antirefluxing ureteral anastomosis and continent caecal reservoir. *Scand J Urol Nephrol.* 1989;23(3):195–200.
82. Raj GV, Tal R, Vickers A, Bochner BH, Serio A, Donat SM, et al. Significance of intraoperative ureteral evaluation at radical cystectomy for urothelial cancer. *Cancer.* 2006;107(9):2167–72.
83. Laven BA, O'Connor RC, Steinberg GD, Gerber GS. Long-term results of antegrade endoureterotomy using the holmium laser in patients with ureterointestinal strictures. *Urology.* 2001;58(6):924–9.
84. Laven BA, O'Connor RC, Gerber GS, Steinberg GD. Long-term results of endoureterotomy and open surgical revision for the management of ureteroenteric strictures after urinary diversion. *J Urol.* 2003;170(4 Pt 1):1226–30.
85. Poulakis V, Witzsch U, De Vries R, Becht E. Cold-knife endoureterotomy for nonmalignant ureterointestinal anastomotic strictures. *Urology.* 2003;61(3):512–7.
86. Schöndorf D, Meierhans-Ruf S, Kiss B, Giannarini G, Thalmann GN, Studer UE, et al. Ureteroileal strictures after urinary diversion with an ileal segment—is there a place for endourological treatment at all? *J Urol.* 2013;190(2):585–90.
87. Mundy AR, Andrich DE. Urethral strictures. *BJU Int.* 2011;107(1):6–26.
88. Santucci RA, Joyce GF, Wise M. Male urethral stricture disease. *J Urol.* 2007;177(5):1667–74.
89. Tonkin JB, Jordan GH. Management of distal anterior urethral strictures. *Nat Rev Urol.* 2009;6(10):533–8.
90. Naudé AM, Heyns CF. What is the place of internal urethrotomy in the treatment of urethral stricture disease? *Nat Clin Pract Urol.* 2005;2(11):538–45.
91. Steenkamp JW, Heyns CF, de Kock ML. Internal urethrotomy versus dilation as treatment for male urethral strictures: a prospective, randomized comparison. *J Urol.* 1997;157(1):98–101.
92. Zehri AA, Ather MH, Afshan Q. Predictors of recurrence of urethral stricture disease following optical urethrotomy. *Int J Surg.* 2009;7(4):361–4.
93. Heyns CF, Steenkamp JW, De Kock ML, Whitaker P. Treatment of male urethral strictures: is repeated dilation or internal urethrotomy useful? *J Urol.* 1998;160(2):356–8.
94. Chapple C. Anterior urethral surgery: current concepts and future directions. *Eur Urol.* 2010;58(1):42–5.
95. Morey AF, McAninch JW. Ultrasound evaluation of the male urethra for assessment of urethral stricture. *J Clin Ultrasound.* 1996;24(8):473–9.
96. Dutkiewicz SA, Wroblewski M. Comparison of treatment results between holmium laser endourethrotomy and optical internal urethrotomy for urethral stricture. *Int Urol Nephrol.* 2012;44(3):717–24.
97. Hansen IR, Jensen RA. Recurrence after optical internal urethrotomy. A comparative study of long-term and short-term catheter treatment. *Urol Int.* 1984;39(5):270–1.
98. Hafez AT, El-Assmy A, Dawaba MS, Sarhan O, Bazeed M. Long-term outcome of visual internal urethrotomy for the management of pediatric urethral strictures. *J Urol.* 2005;173(2):595–7.
99. Albers P, Ulbright TM, Albers J, Miller GA, Orazi A, Crabtree WN, et al. Tumor proliferative activity is predictive of pathological stage in clinical stage A nonseminomatous testicular germ cell tumors. *J Urol.* 1996;155(2):579–86.
100. Lauritzen M, Greis G, Sandberg A, Wedren H, Ojdeby G, Henningsohn L. Intermittent self-dilatation after internal urethrotomy for primary urethral strictures: a case-control study. *Scand J Urol Nephrol.* 2009;43(3):220–5.
101. Gucuk A, Tuygun C, Burgu B, Oztürk U, Dede O, Imamoğlu A. The short-term efficacy of dilatation therapy combined with steroid after internal urethrotomy in the management of urethral stenoses. *J Endourol.* 2010;24(6):1017–21.
102. Hosseini J, Kaviani A, Golshan AR. Clean intermittent catheterization with triamcinolone ointment following internal urethrotomy. *Urol J.* 2008;5(4):265–8.
103. Mazdak H, Izadpanahi MH, Ghalamkari A, Kabiri M, Khorrami MH, Nouri-Mahdavi K, et al. Internal urethrotomy and intraurethral submucosal injection of triamcinolone in short bulbar urethral strictures. *Int Urol Nephrol.* 2010;42(3):565–8.
104. Jordan GH, Wessells H, Secrest C, Squadrito Jr JF, McAninch JW, Levine L, et al. Effect of a temporary thermo-expandable stent on urethral patency after dilation or internal urethrotomy for recurrent bulbar urethral stricture: results from a 1-year randomized trial. *J Urol.* 2013;190(1):130–6.
105. Vaarala MH, Marttila T, Paananen I, Hellström P. Retrospective analysis of long-term outcomes of 64 patients treated by endopyelotomy in two low-volume hospitals: good and durable results. *J Endourol.* 2008;22(8):1659–64.
106. Ponsky LE, Stroom SB. Retrograde endopyelotomy: a comparative study of hot-wire balloon and ureteroscopic laser. *J Endourol.* 2006;20(10):823–6.
107. El-Nahas AR, Shoma AM, Eraky I, El-Kenawy MR, El-Kappany HA. Percutaneous endopyelotomy for secondary ureteropelvic junction obstruction:

- prognostic factors affecting late recurrence. *Scand J Urol Nephrol.* 2006;40(5):385–90.
108. Hibi H, Ohori T, Taki T, Yamada Y, Honda N. Long-term results of endoureterotomy using a holmium laser. *Int J Urol.* 2007;14(9):872–4.
109. Kristo B, Phelan MW, Gritsch HA, Schulam PG. Treatment of renal transplant ureterovesical anastomotic strictures using antegrade balloon dilation with or without holmium:YAG laser endoureterotomy. *Urology.* 2003;62(5):831–4.
110. Milhoua PM, Miller NL, Cookson MS, Chang SS, Smith JA, Herrell SD. Primary endoscopic management versus open revision of ureteroenteric anastomotic strictures after urinary diversion—single institution contemporary series. *J Endourol.* 2009;23(3):551–5.
111. Tavakkoli Tabassi K, Yarmohamadi A, Mohammadi S. Triamcinolone injection following internal urethrotomy for treatment of urethral stricture. *Urol J.* 2011;8:132–6.

Bilal Chughtai and Alexis E. Te

Equipment List

Continuous-flow resectoscope (22–27 French)
0° lens, 30° lens
Sterile lubricant
Otis urethrotome
Male sounds (8–30 F)
Bipolar resection system
 PK system (Gyrus/ACMI)
 Bipolar resection system (Storz)
Saline irrigant
 Sterile, pyrogen-free, the reservoir 30 cm
 above the level of the symphysis
Ellick evacuator

Bipolar TURP

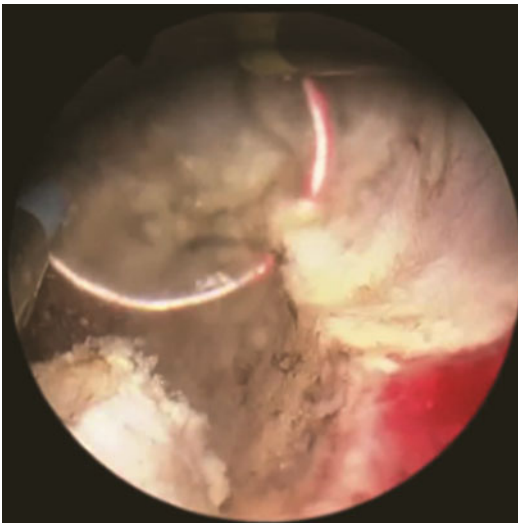
Bipolar transurethral resection of the prostate (biTURP) is an endoscopic technique that is similar to monopolar TURP, available as the PK system by Gyrus/ACMI, an Olympus Corporation (Tokyo, Japan) subsidiary, the TURis system by Olympus Corporation (Tokyo, Japan), and a bipolar resection system by Karl Storz (Tuttlingen, Germany). biTURP requires the use of a 22–27 Fr continuous-flow resectoscope and specialized electrodes which contain the active electrode. The electrodes for the PK and the Storz systems also contain the return electrode (Fig. 15.1), whereas the TURis system relies on a return electrode located on the inner sheath of the resectoscope.

All biTURP systems rely on the ability to generate a plasma corona vaporization field in normal saline media (Fig. 15.2). The short distance between the active and return electrodes and the ionic media allows high current to be generated with little changes in voltage. These systems rely on specialized generators that measure impedance and allow a constant current between electrodes with separate settings for “cutting” (200–280 W for TURis, 160–200 W for PK) and “coagulation” (120 W for TURis and 80 W for PK).

Electrosurgically based transurethral resection of the prostate (TURP) represents the gold standard in endoscopic treatment of symptomatic BPH. With the introduction of improved medical therapy and minimally invasive options, the

B. Chughtai, MD (✉)
Department of Urology, Weill Medical College
of Cornell University, 1300 York Ave, 261,
New York, NY 10065, USA
e-mail: bic9008@med.cornell.edu

A.E. Te, MD
Department of Urology, Weill Medical College of
Cornell University, 1300 York Ave, 261, New York,
NY 10065, USA
e-mail: aet2005@med.cornell.edu

Fig. 15.1 Gyrus bipolar loop**Fig. 15.2** Activated corona

number of TURPs performed in the United States has declined [1], but the procedure still remains the most effective treatment option after failure of conservative management or medical therapy.

Multiple electrosurgical transurethral options are available for treating BPH. In this chapter, we will focus on discussing the bipolar TURP.

Indication of the Procedure

The assessment of any man who presents with Lower urinary tract symptoms (LUTS) secondary to BPH begins with the medical history. The

medical history should include any causes that may lead to bladder dysfunction including cerebral vascular accidents, neurologic disorders, previous surgical procedures or trauma, and history of prostate disease. A complete review of patients' medications is necessary [2].

It is important to assess severity and bother of LUTS using validated measures and questionnaires. The most commonly used validated measure is the International Prostate Symptom Score (IPSS). The IPSS has been validated in many subpopulations and is available in several languages. Scores categorize symptoms as either mild (score 0–7), moderate (score 8–19), or severe (score 20–35) LUTS [2].

Following the detailed medical history, the physician should proceed with a general and focused physical examination. Physical examination should always include an abdominal examination assessing for a palpable bladder, which may be a sign of urinary retention. Attention for hernias, surgical scars, and genital abnormalities should be paid. Physical examination should always include a DRE. All men should get a urinalysis to rule out the presence of blood or urinary tract infection. In addition, patients should be worked up as per American Urological Association guidelines [2].

Surgical intervention is an appropriate treatment for patients with moderate-to-severe LUTS and for patients who have developed AUR or other BPH-related complications. Surgery is recommended for patients who have renal insufficiency

secondary to BPH; those who have recurrent UTIs, bladder stones, or gross hematuria due to BPH; and those who have LUTS refractory to other therapies. The presence of a bladder diverticulum is not an absolute indication for surgery unless associated with recurrent UTI or progressive bladder dysfunction.

Patient Preparation

The patient is brought into the operating room and positioned in dorsal lithotomy position in preparation for biTURP. Anesthesia is made in consultation with the anesthesiologist and based on patient's preference and medical history. In the absence of any spinal or neuromuscular problems with the patient, the selection of general or spinal/epidural anesthesia is a risk-benefit discussion involving the patient, surgeon, and anesthesiologist.

Preoperative antibiotic use has become the standard of care prior to TURP. Patients without a history of positive urinary culture or symptoms preoperatively can be given a single parenteral dose of a first-generation cephalosporin. Several studies have evaluated the use of antibiotics preoperatively, and the majority supports the use of a single parenteral dose [3, 4]. Those with symptoms and a positive culture should be treated with culture-specific antibiotics prior to undergoing TURP. Penicillin-allergic patients can receive either gentamicin alone or a fluoroquinolone. All patients should be given a single parenteral dose of antibiotics prior to TURP. Many authors recommend continuing at least oral antibiotic therapy until after the Foley catheter is removed [5].

Patient Positioning

Lithotomy Position

All bony areas should be adequately padded; care should be taken to avoid pressure on the lateral aspect of the knee. In addition, care should be taken to avoid hyperflexion of the hip and knee joint. Guidelines for deep venous thrombosis

should be followed as per American Urological Association guidelines.

Surgical Technique

Insertion of Resectoscope

The outer sheath of the resectoscope is lubricated with sterile lubricant. The obturator is placed through the sheath to ensure there are no sharp edges when performing the initial urethroscopy. The instrument should pass atraumatically as possible and the instrument should pass without force.

If there is difficulty with passing the instrument, either male sounds or an Otis urethrotome should be used to either blindly perform a urethrotomy or dilate the urethra to one size larger than the resectoscope. Once the anterior urethra is adequately dilated or a urethrotomy performed, the resectoscope is passed under direct vision. The anterior urethra, bulbar urethra, verumontanum, external urethral sphincter, and prostatic urethra should be evaluated. Following this, a pan cystoscopy is performed to evaluate the position of the ureteral orifices and intertrigonal ridge. The bladder should also be inspected for any foreign bodies, stone, or mucosal lesions.

Operative Technique

The most important principle in performing a TURP is to formulate a plan and then proceed in an orderly, stepwise fashion. The initial procedure described by Nesbit and then reviewed and revised by Holtgrew is the method most commonly applied [17, 18]. The resectoscope is positioned in the midprostatic fossa, and the loop is extended out to ensure adequate clearance of the bladder neck.

Resection begins at approximately 1 o'clock and is continued in a clockwise fashion to 5 o'clock (Fig. 15.3). The depth of resection should be approximately far down enough to expose the fibers of the prostatic capsule around the bladder neck. Once this area is adequately resected,

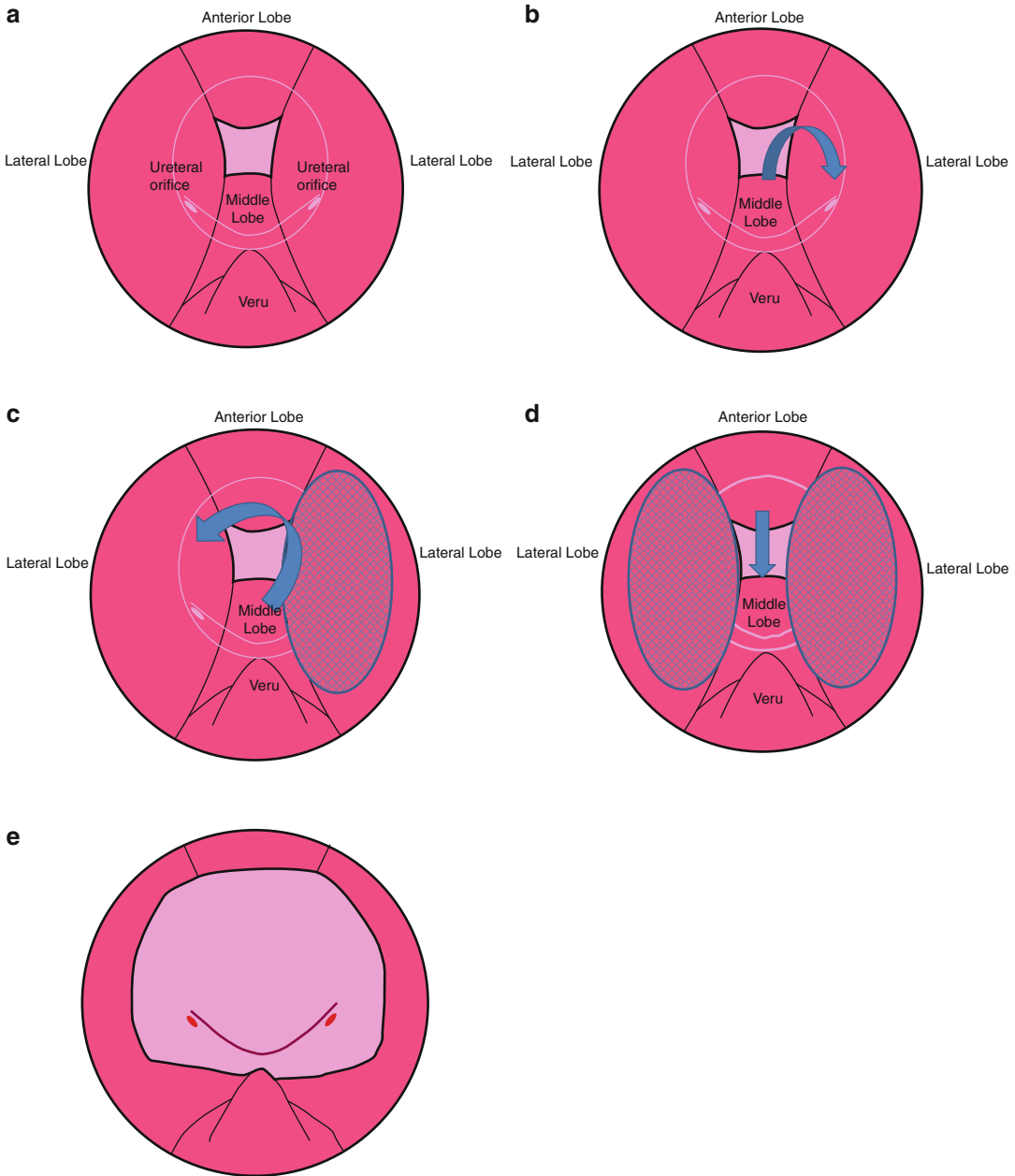


Fig. 15.3 Bipolar transurethral resection technique. (a) Once the resectoscope is brought into the bladder and a full urethroscopy is performed, the relevant landmarks are identified. These include the verumontanum, which represents the distal extent of the resection and the ureteral orifices. (b) Resection begins at the 2 o'clock position to the depth of the prostatic capsule. The resection is taken to the intersection of the lateral lobe to the middle lobe. (c) Attention is then drawn to the 11 o'clock

position. The resection is taken to the intersection of the lateral lobe to the middle lobe. (d) Once both lateral lobes are resected to the level of the prostatic capsule, attention is drawn to the middle lobe. The resection is taken to the level of the bladder neck fibers; the distal extent of the resection is to the verumontanum. (e) As the resection is completed, the inflow should be turned off so that the bladder pressure is lowered and all areas of bleeding are coagulated

attention is turned to the 11 o'clock position, and a similar resection is carried out counterclockwise to the 6 o'clock position. Hemostasis should be achieved at each area prior to advancing to the next point area of resection.

After the bladder neck has been resected, the prostate adenoma tissue is debulked in quadrants. The verumontanum is visualized, and the resectoscope is placed just proximal to this important landmark. We prefer to take long, deep swipes often angling the scope contralaterally to get adequate depth of the resection. The fibrous capsule can be visualized after resection to assess completeness. Pulsatile arterial bleeding often is encountered near the capsule and at the bladder neck, as the prostate blood supply arises peripherally. Arteries should be cauterized immediately as the blood loss obscures the view and prevents precise resection. The length of resection should be premeasured, with the resection swipes falling just short of the verumontanum.

Apical tissue that is just proximal to the external sphincter may remain and may extend distal to the veru [19]. Resection in this area carries an increased risk of incontinence and discretion is utilized. The verumontanum must not be cut or coagulated, as this can result in painful ejaculation secondary to ejaculatory duct obstruction. Care must be taken not to injure the sphincter during resection because this may cause postoperative urinary incontinence. The tissue is carefully resected with short sweeps. At the completion of resection, the bladder should easily be visible with the resectoscope at the level of the verumontanum.

Once resection is completed, an Ellick evacuator is used to remove all adenoma chips from the bladder. All chips must be removed as any chip left in the bladder may later occlude the urinary catheter causing obstruction, bladder spasms, and increased postoperative hemorrhage. After several evacuations with the Ellick, the resectoscope is then replaced and the bladder visually inspected. Any remaining chips can be snared with the loop and removed, with care taken to inspect all bladder diverticula if present. Final hemostasis is achieved with careful coagulation

of any bleeding points. The resectoscope is then removed with a final visual inspection of the bladder, prostatic fossa, and urethra. The bladder should be left full, and overly aggressive irrigation is not needed as this can disrupt clots that formed and increase bleeding.

A 24 Fr 3-way Foley catheter is left with 30–60 cc in the balloon at a slow rate of continuous bladder irrigation. More fluid can be placed in the balloon if a larger resection has been performed, but more volume often leads to increased number and severity of bladder spasms. If persistent bleeding results which does not readily clear with slow irrigation, gentle traction is placed on the catheter until the irrigant is clear. Traction can be placed with as gentle a maneuver as placing the hub of the Foley in one of a variety of catheter-securing devices on the leg or with the more traditional use of cloth tape on the calf. The minimum amount of traction to clear the irrigant of gross bleeding is the best used. Traction may also cause involuntary contractions which may contribute to bleeding. Short-acting antimuscarinic agents may be considered to decrease bladder spasms.

If vigorous bleeding continues despite irrigation and gentle traction, arterial bleeding may be the cause. Prior to leaving the operating room, the resectoscope should be reintroduced, and the prostatic fossa and bladder neck should be inspected for arterial bleeding.

Postoperative Care

Immediately post-TURP, the patient is brought to the recovery room. The patients are monitored the spinal/epidural anesthesia has begun to wear off. Electrolyte abnormalities are uncommon.

Traction is usually released by 12–24 h post-operation, and continuous bladder irrigation is slowly weaned off over the next 12–24 h. If the effluent is clear after irrigation is off for 3–5 h, the catheter can be discontinued. Patients are usually given a trial of voiding on postoperative day number one, and if they void, they are discharged.

Results

The introduction of a bipolar plasmakinetic system with saline irrigation fluid was intended to reduce conductive trauma and associated bladder neck stenosis and urethral strictures, lessen risk of capsular lesion, improve endoscopic orientation, and eliminate TUR syndrome [5]. It has been shown, in multiple studies, to improve perioperative hemostasis, in addition to reducing the risk of TUR syndrome [5–7] while maintaining improvements in IPSS, QoL, Qmax, and PVR [8], including over the course of several years [9, 10]. Bipolar TUVP theoretically allows for longer surgeries on larger prostates while preserving the benefits of endoscopic surgery including shorter indwelling catheter times, less bleeding, and decreased risk for TUR syndrome [11].

Geavlete et al. completed a prospective, three-armed study with 510 randomized patients to compare monopolar TURP vs. bipolar TURP vs. bipolar TUVP. Patients undergoing bipolar TUVP produced statistically significantly better improvements in IPSS and Qmax than both monopolar and bipolar TURP at 18 months (by 3.3 and 2.9 and 3.5 ml and 3.1 ml, respectively, $p < 0.05$), although the QoL, PVR, and PSA of each group were found to be statistically similar ($p > 0.05$) [12]. Seckiner et al. performed a prospective, randomized study of 21 patients undergoing TURP vs. 23 with bipolar TUVP with 1 year follow-up; they observed comparable improvements in IPSS, QoL, and Qmax, but did not report whether those improvements were statistically significant [13]. Nuhoğlu et al. conducted a similar prospective, randomized study with 90 patients undergoing monopolar TURP vs. bipolar TUVP, demonstrating similar results in IPSS, Qmax, and PVR also with equivalence at 1 year ($p > 0.05$). However, patients who had undergone bipolar TUVP were significantly less frequently affected by hyponatremia ($p < 0.005$) and had significantly shorter catheter retention times (73.2 ± 13.4 vs. 54.3 ± 11.8 , $p < 0.005$) [11]. In separate prospective, randomized trials, comparing monopolar TURP vs. bipolar TUVP, Hon et al. and

Patankar et al. also reported similar improvement in IPSS, QoL, Qmax and PVR, and IPSS and Qmax, respectively, although with shorter or uncertain durations of follow-up [14, 15].

In the longest study reported comparing monopolar TURP vs. bipolar TUVP, Xie et al. found that in those patients treated with bipolar TUVP, there was a 15.55-point decrease in IPSS, a 2.66-point decrease in QoL, a 1.09 ng/ml decrease in serum PSA, a 16.55 ml/s increase in Qmax, and an 82.79 ml decrease in PVR after 5 years, statistically equivalent to those of the patients treated with monopolar TURP [10] (see Table 15.1).

Only one study has reported inferior performance compared to TURP. Kaya et al. demonstrated worse IPSS and Qmax improvement at 3 years with bipolar TUVP, although their study was limited by a small sample size ($n = 25$ and 15) [9].

One of the largest studies with the longest duration of follow-up was reported by Erturhan et al. where 120 patients were randomized to either plasmakinetic biTURP or monopolar TURP for treatment of symptomatic BPH. Catheterization time was shorter in the biTURP group (3 vs. 4.5 days, $p < 0.001$) as was time to discharge (3 vs. 5 days, $p < 0.001$) and operative time (36 vs. 57 min, $p < 0.001$). Improvement in Qmax was also better in the biTURP group (12.3 ml/s improvement vs. 11.3 ml/s, $p < 0.001$). IPSS score improved similarly in both groups (20 points monopolar TURP group vs. 19 points biTURP group) after 12 months, as did both QoL scores (2 in both groups) and PVR (–110 cc for monopolar TURP vs. –99 cc for biTURP). Clot retention was significantly higher for patients undergoing monopolar TURP (17 vs. 2 patients, $p = 0.0001$) as well as bleeding requiring transfusion (7 vs. 1 patient, $p = 0.0001$) and severe dysuria (7 pts vs. 2 patients, $p = 0.025$). Not all complications however were confined to the monopolar TURP group. Interestingly, TUR syndrome was not significantly different between the two groups (2 vs. 0 patients, $p = 0.15$). More urethral injuries (3 vs. 0 patients, $p = 0.01$) and meatal strictures (3 vs. 2 patients, $p = 0.025$) occurred in the biTURP group. Overall, this study suggests that while symptom improvements are similar using

Table 15.1 Outcomes and complications

Authors	Trial size	Follow-up (months)	Operative time	Catheterization time	TUR syndrome	Postop change in hemoglobin	Hospital stay	Change in Qmax (ml/s)	Change in PVR
Xie et al. (2012) [10]	110 mTURP, 110 bTURP	60	60.01 min mTURP, 55.03 min bTURP ($p=0.033$)	3.61 days mTURP, 2.70 days bTURP ($p<0.001$)	2 patients mTURP, 0 patient bTURP ($p=0.477$)	1.58 g/dl mTURP, 1.22 g/dl bTURP ($p=0.014$)	5.19 days mTURP, 4.18 days bTURP ($p<0.001$)	15.29 ml/s mTURP, 16.55 ml/s bTURP ($p=0.176$)	81.91 ml mTURP, 82.79 bTURP ($p=0.176$)
Chen et al. (2010) [20]	50 mTURP, 50 bTURP	24	60 min mTURP, 59 min bTURP ($p=0.82$)	N/A	0 patient mTURP, 0 patient bTURP	1.6 g/dl mTURP, 1.1 g/dl bTURP ($p=0.008$)	N/A	16.9 ml/s mTURP, 18.4 ml/s bTURP ($p=0.72$)	N/A
Michielsen et al. (2007) [16]	120 mTURP, 118 bTURP	18	44 min mTURP, 56 min bTURP ($p<0.001$)	4.5 days mTURP, 4.0 days bTURP ($p=0.201$)	1 pt mTURP, 0 pt bTURP ($p=1.00$)	1.3 mg/dl mTURP, 1.4 mg/dl bTURP	5.1 days mTURP, 4.9 days bTURP ($p=0.591$)	N/A	N/A
Yoon et al. (2006) [4]	53 mTURP, 49 bTURP	12	72.6 min mTURP, 74.2 min bTURP ($p=0.451$)	3.12 days mTURP, 2.28 days bTURP ($p=0.012$)	N/A	0.62 g/dl mTURP, 0.67 g/dl bTURP ($p=0.278$)	4.27 days mTURP, 3.52 days bTURP ($p=0.034$)	10.2 ml/s mTURP, 10.1 bTURP ($p=NS$)	N/A
Starkman et al. (2005) [21]	18 mTURP, 25 bTURP	18	N/A	3.2 days mTURP, 1.8 days bTURP ($p=0.12$)	N/A	N/A	2.1 days mTURP, 1.2 days bTURP ($p=0.11$)	N/A	N/A
Autorino et al. (2009) [22]	35 mTURP, 35 bTURP	48	53 min mTURP, 49 min bTURP ($p=0.07$)	N/A	N/A	1.0 g/dl mTURP, 0.8 bTURP g/dl ($p=0.09$)	N/A	15 ml/s mTURP, 12.7 bTURP ($p=0.44$)	30 ml mTURP, 38 ml bTURP ($p=0.3$)
Kong et al. (2009) [23]	51 mTURP, 51 bTURP	12	NS (no values given)	57.7 h mTURP, 37.2 h bTURP ($p=0.03$)	N/A	1.8 g/dl mTURP, 0.6 g/dl bTURP ($p=0.01$)	2.6 days mTURP, 1.5 days bTURP ($p=0.02$)	11.91 ml/s mTURP, 12.63 ml/s bTURP ($p=NS$)	81.63 ml mTURP, 82.79 ml bTURP
Ho et al. (2007) [24]	52 mTURP, 48 bTURP	12	58 min mTURP, 59 min bTURP ($p=NS$)	N/A	2 pts mTURP, 0 pts bTURP ($p<0.05$)	1.8 mg/dl mTURP, 1.2 mg/dl bTURP ($p=NS$)	N/A	At 12 months, NS difference (no exact values given)	N/A

both technologies, several of the complications are seen at a reduced rate with biTURP [3]. This study, like many of the early studies is limited by relatively low number of patients and short duration of follow-up.

Another large randomized control trial reported by Michielsen et al. examined the use of bipolar TURIs, i.e., bipolar resection performed in saline vs. monopolar TURP [16]. They found that, in contrast to the above study, there was no difference in the rates of complications, specifically clot retention (6 vs. 4, $p=0.75$), blood transfusion (1 vs.4, $p=0.21$), TUR syndrome (1 vs. 0, $p=1.0$), hospital stay (4.9 vs.5.1 days, $p=0.591$), catheterization time (4.0 vs.4.5 days, $p=0.2$), or urinary retention (5 vs.3, $p=0.72$) in monopolar TURP vs. biTURP, respectively. The only difference seen between the groups was operative time, which was significantly shorter in the monopolar TURP group (44 min vs. 56 min, $p=0.001$) at the cost of a larger decrease in serum sodium levels for monopolar TURP patients (-2.23 vs. -1.47 , no p value given). The number needed to treat (NNT) to avoid an episode of TUR syndrome from monopolar TURP calculated in this study was 50 patients. There was no data regarding symptom score, Qmax, or PVR improvement in this study. This study did not have any long-term follow-up data as the presented data was only collected during these patients' initial hospital stay (no mean follow-up reported). The authors concluded that bipolar TURP is safe and efficacious compared to monopolar TURP although the difference in postoperative complication rates was not clinically significant [16].

Yoon et al. reported on a study of 102 men undergoing monopolar TURP ($n=53$) vs. biTURP ($n=49$) [4]. Improvements in IPSS (11.7 biTURP vs. 12.1 monopolar TURP, $p>0.05$) and Qmax (10.1 biTURP vs. 10.2 monopolar TURP, $p>0.05$) were no different between the two groups as were the rate of postoperative complications. The durations of both catheterization and hospitalization were significantly lower in the biTURP group (2.28 days vs. 3.12 days, $p=0.012$; 3.52 days vs. 4.27 days, $p=0.034$, respectively) (see Table 15.1).

Complications

Geavlete et al. found that bipolar TUVF produced fewer complications than TURP (1.2 % vs. 9.4 % capsular perforation, $p=0.004$; 23.5 h vs. 72.8 h catheterization period, $p=0.0001$; and 0.5 g/dl vs. 1.6 g/dl hemoglobin drop, $p=0.0001$, respectively) [12], while others observed statistically similar rates of complication between bipolar TUVF and TURP, e.g., Xie et al. reported similar rates of urinary retention ($p=0.477$), UTI ($p=1$), TUR syndrome ($p=0.477$), and blood transfusion ($p=0.477$) between monopolar TURP and bipolar TURP [10].

Conclusions

While more long-term studies on the efficacy of biTURP are necessary, it appears that biTURP provides a reasonable and efficacious alternative for transurethral resection of the prostate when compared to traditional modalities.

References

- Merrill RM, Hunter BD. The diminishing role of transurethral resection of the prostate. *Ann Surg Oncol.* 2010;17(5):1422–8.
- McVary KT, Roehrborn CG, Avins AL, et al. Update on AUA guideline on the management of benign prostatic hyperplasia. *J Urol.* 2011; 185(5):1793–803.
- Erturhan S, Erbagci A, Seckiner I, Yagci F, Ustun A. Plasmakinetic resection of the prostate versus standard transurethral resection of the prostate: a prospective randomized trial with 1-year follow-up. *Prostate Cancer Prostatic Dis.* 2007;10(1):97–100.
- Yoon CJ, Kim JY, Moon KH, Jung HC, Park TC. Transurethral resection of the prostate with a bipolar tissue management system compared to conventional monopolar resectoscope: one-year outcome. *Yonsei Med J.* 2006;47(5):715–20.
- Rassweiler J, Schulze M, Stock C, Teber D, Rosette JD. Bipolar transurethral resection of the prostate technical modifications and early clinical experience. *Minim Invasive Ther Allied Technol.* 2007;16(1):11–21.
- Mamoulakis C, Trompeter M, de la Rosette J. Bipolar transurethral resection of the prostate: the 'golden standard' reclaims its leading position. *Curr Opin Urol.* 2009;19(1):26–32.
- Gillera JP, Thaly RK, Chernoff AM. Rapid communication: bipolar PlasmaKinetic transurethral resection of the prostate: reliable training

- vehicle for today's urology residents. *J Endourol.* 2006;20(9):683–7.
8. Ho HS, Cheng CW. Bipolar transurethral resection of prostate: a new reference standard? *Curr Opin Urol.* 2008;18(1):50–5.
 9. Kaya C, Ilktac A, Gokmen E, Ozturk M, Karaman IM. The long-term results of transurethral vaporization of the prostate using plasmakinetic energy. *BJU Int.* 2007;99(4):845–8.
 10. Xie C-Y, Zhu G-B, Wang X-H, Liu X-B. Five-year follow-up results of a randomized controlled trial comparing bipolar plasmakinetic and monopolar transurethral resection of the prostate. *Yonsei Med J.* 2012;53(4):734–41.
 11. Nuhuğlu B, Balci MBC, Aydin M, et al. The role of bipolar transurethral vaporization in the management of benign prostatic hyperplasia. *Urol Int.* 2011;87(4):400–4.
 12. Geavlete B, Georgescu D, Multescu R, Stanescu F, Jecu M, Geavlete P. Bipolar plasma vaporization vs monopolar and bipolar TURP—A prospective, randomized, long-term comparison. *Urology.* 2011;78(4):930–5.
 13. Seckiner I, Yesilli C, Akduman B, Altan K, Mungan NA. A prospective randomized study for comparing bipolar plasmakinetic resection of the prostate with standard TURP. *Urol Int.* 2006;76(2):139–43.
 14. Hon NHY, Brathwaite D, Hussain Z, et al. A prospective, randomized trial comparing conventional transurethral prostate resection with PlasmaKinetic® vaporization of the prostate: physiological changes, early complications and long-term followup. *J Urol.* 2006;176(1):205–9.
 15. Patankar S, Jamkar A, Dobhada S, Gorde V. PlasmaKinetic Superpulse transurethral resection versus conventional transurethral resection of prostate. *J Endourol.* 2006;20(3):215–9.
 16. Michielsen DP, Debacker T, De Boe V, et al. Bipolar transurethral resection in saline—an alternative surgical treatment for bladder outlet obstruction? *J Urol.* 2007;178(5):2035–9; discussion 2039.
 17. Nesbit RM. *Transurethral prostatectomy.* Thomas Springfield; 1943.
 18. Holtgrewe HL. *Transurethral prostatectomy.* *Urol Clin North Am.* 1995;22(2):357–68.
 19. Hawtrey CE, Williams RD. Historical evolution of transurethral resection at the University of Iowa: Alcock and Flocks. *J Urol.* 2008;180(1):55–61.
 20. Chen Q, Zhang, L, Fan Q, et al. Bipolar transurethral resection in saline vs traditional monopolar resection of the prostate: results of a randomized trial with a 2-year follow-up. *BJU Int.* 2010;106:1339–43.
 21. Starkman J, Santucci R. Comparison of bipolar transurethral resection of the prostate with standard transurethral prostatectomy: shorter stay, earlier catheter removal and fewer complications. *BJU Int.* 2005;95:69–71.
 22. Autorino R, Damiano R, Lorenzo G, et al. Four-year outcome of a prospective randomised trial comparing bipolar plasmakinetic and monopolar transurethral resection of the prostate. *Eur Urol.* 2009;55:922–31.
 23. Kong C, Ibrahim M, Zainuddin Z. A prospective, randomized clinical trial comparing bipolar plasma kinetic resection of the prostate versus conventional monopolar transurethral resection of the prostate in the treatment of benign prostatic hyperplasia. *Ann Saudi Med.* 2009;29(8):429–32.
 24. Ho H, Yip S, Lim K, et al. A prospective randomized study comparing monopolar and bipolar transurethral resection of the prostate using transurethral resection in saline (TURIS) system. *Eur Urol.* 2007;52:517–24.

David R. Paolone and Daniel H. Williams IV

History

Laser vaporization of the prostate as a means of addressing bladder outlet obstruction from benign prostatic hyperplasia (BPH) was first described by Malek and colleagues at the Mayo Clinic [1]. This technique utilizes a laser with a wavelength of 532 nm, putting it in the visible green light spectrum. Energy at this wavelength is preferentially absorbed by oxyhemoglobin, but not by the irrigation fluid. Hence, the term photoselective vaporization of the prostate (PVP) is used to describe the endoscopic removal of obstructing prostate tissue using the GreenLight laser (American Medical Systems, Minnetonka, Minnesota, USA). The selective absorption of the energy by the oxyhemoglobin leads to superheating of the vascular prostate tissue and subsequent vaporization of the tissue. Heat-induced coagulation of superficial vasculature occurs at the same time, leading to excellent hemostasis as the tissue is removed. The depth of penetration of the 532 nm laser is only 0.8 mm, and extensive coagulative necrosis of the tissue is minimized. This leads to very efficient removal of obstructing tissue in a near bloodless operating field while

reducing the potential for extended postoperative tissue sloughing.

The GreenLight laser wavelength of 532 nm is created by doubling the frequency of a 1,064 nm Nd:YAG laser and hence halving its wavelength. This is achieved with the use of a potassium-titanyl-phosphate (KTP) crystal. The prototype was able to achieve 60 W of power, and the first commercially available system, the GreenLight PV system, utilized 80 W. While this device allowed for excellent vaporization, and early studies showed comparable results to standard treatments for BPH such as transurethral resection of the prostate and open prostatectomy [2–7], the relatively low power and thin beam made the treatment of larger or less-vascular prostates challenging.

The next iteration of the device was the GreenLight laser HPS generator (2006). This was able to achieve 120 W of power by utilizing a lithium triborate (LBO) crystal instead of KTP. The same ADD Stat fiber that was used with the initial generator was also used with the HPS. This silica laser fiber has a 1.75 mm outer diameter and a 600 μm conducting core diameter. It is side-firing with a 70° forward deflection. The higher power HPS was able to achieve an 88 % more collimated beam, a smaller spot size, and an 8 % beam divergence versus 15 % for the PV. This resulted in much greater power density in W/cm^2 . The HPS also added a dual power mode with two foot pedals so that the surgeon

D.R. Paolone, MD (✉) • D.H. Williams IV, MD
Department of Urology, University of Wisconsin
School of Medicine and Public Health,
One South Park Street, Madison, WI 53715, USA
e-mail: david.paolone@uwmf.wisc.edu

could rapidly alternate between vaporizing and coagulating tissue. A more compact air-cooled system replaced the previous need for water cooling of the laser generator.

The most recent advancement in photoselective vaporization of the prostate is the development of the GreenLight laser XPS system (2010). Like the HPS, it also quasi-continuously emits the 532 nm laser beam using a LBO crystal. Its 50 % increase in power necessitated the improvement of the laser fiber to deliver the energy. The new MoXy fiber to be used with the XPS has a larger outer diameter of 2.10 mm, an increased conducting core diameter of 750 μm , and a metal cap. It is also continuously cooled with normal saline inflow. It has the same 8° divergence as the ADD Stat laser fiber, but the larger conducting core diameter creates a 50 % larger spot size. The combination of 50 % smaller spot size but 50 % more power maintains the same power density in W/cm^2 as the HPS and ADD Stat. Hence, a greater volume of prostate tissue can be efficiently vaporized with the new GreenLight laser XPS and MoXy laser fiber.

Indications

Patients with symptomatic lower urinary tract symptoms (LUTS) have a variety of options from which to choose for management of their symptoms. These options include behavioral strategies such as caffeine and fluid restriction, alpha-blocker medication, 5-alpha-reductase medication, antimuscarinic medication, and surgical intervention. Surgical options include open prostatectomy, transurethral resection of the prostate (TURP), transurethral incision of the prostate (TUIP), laparoscopic or robotic prostatectomy, transurethral holmium laser ablation of the prostate (HoLAP), transurethral holmium laser enucleation of the prostate (HoLEP), and photoselective vaporization of the prostate (PVP).

Surgical intervention is indicated for patients with complications from their BPH and those who do not achieve satisfactory symptom relief from medical management. Complications requiring surgical intervention include renal insufficiency

due to BPH, recurrent urinary tract infections, bladder calculi, and gross hematuria due to BPH urinary retention [8]. Bladder diverticula do not represent an absolute indication for surgery unless associated with recurrent urinary tract infections or progressive bladder dysfunction [8].

Preoperative Preparation and Evaluation

Assessment of the patient's LUTS can be easily achieved with a validated questionnaire such as the American Urological Association Symptom Index (AUA-SI) or International Prostate Symptom Score (IPSS). Preoperative assessment can confirm the severity of LUTS and the impact on quality of life, and it provides a baseline to which postoperative scores can be compared as a measure of improvement. Patients with predominantly storage symptoms (frequency, urgency, nocturia) should be informed of the possible persistence of these symptoms postoperatively and the need for antimuscarinic medications for relief.

Preoperative history is important to gauge the patient's risk of other complicating urological conditions such as urethral stricture, bladder cancer, urinary tract infection, urinary incontinence, urinary retention, and bladder calculi. A history of hematuria should be appropriately evaluated when present.

Physical examination should include palpation of the lower abdomen to assess for bladder distension, penile examination to detect severe phimosis or meatal stenosis, and digital rectal examination. A brief neurological assessment can detect overt derangement that might suggest a neurological condition affecting the patient's LUTS such as diabetes mellitus, spinal stenosis, or multiple sclerosis. Uroflowmetry and a check of the patient's post-void residual (PVR) by ultrasound can help to confirm the diagnosis of bladder outlet obstruction, and they provide a means of assessing improvement if measured again postoperatively. Formal urodynamic testing is reserved for those patients with more complicated clinical scenarios.

A standard laboratory, cardiology, pulmonary, and imaging preoperative evaluation appropriate

for any surgical patient should be performed prior to performing a PVP. Urinalysis and urine culture, if indicated, would also be appropriate as patients should be free of bacteriuria, if possible, prior to surgery. Additional unique considerations for those patients undergoing a PVP include an assessment of prostate size and shape, necessity of discontinuing anticoagulant medication, and prostate cancer screening.

Measurement of prostate size has implications for the feasibility of performing a PVP as well as for expected length of surgery. Digital rectal examination can provide a general idea of the size of the prostate, but it is notoriously unreliable and may significantly underestimate the size of a median lobe and an intravesical portion of the prostate. Transrectal ultrasound and CT scanning provide more reliable estimations of prostate size and should be employed prior to surgery in those cases where precise knowledge of the size of the prostate will alter surgical approach and planning. Although not routinely recommended for assessing a typical patient with LUTS, cystoscopy may provide additional preoperative information regarding the shape of the prostate, location of the ureteral orifices, and size of the intravesical portion of the prostate. Cystoscopy will also detect a urethral stricture or bladder stones as possible contributing factors to the patient's LUTS and is indicated in the evaluation of patients with hematuria prior to pursuing a PVP.

Patients who are candidates for surgical intervention for BPH are also likely to be within the age range where prostate cancer screening is considered appropriate. A thorough discussion of the risks and benefits of prostate cancer screening should be undertaken with every man with a greater than 10-year life expectancy prior to pursuing a PVP. A prostate biopsy should be pursued in those men with palpable prostate nodules or with serum prostate-specific antigen (PSA) elevation. PSA also can be a surrogate indicator of prostate size, in that a PSA >1.5 usually correlates to a prostate volume of about 30 g.

Although it is generally advisable to discontinue oral antiplatelet and anticoagulation medications prior to surgery when deemed safe for the patient's overall medical condition, one of the

advantages of PVP is the ability to perform this procedure even in those patients who must continue taking these medications. Several studies have demonstrated the safety and effectiveness of PVP in patients undergoing the procedure while taking oral anticoagulation medication [9, 10].

Informed consent for PVP includes a thorough and detailed discussion about the surgical risks of transurethral prostate surgeries. Surgical complications are discussed below in detail, but those that should be discussed include a 20 % risk of prolonged hematuria (lasting more than 2 weeks), a 20 % risk of irritative voiding symptoms, an approximately 5 % risk of urinary retention requiring placement of a Foley catheter, a urinary incontinence rate of about 1 %, a postoperative urinary tract infection risk of 3 %, and a rare chance of damage to the bladder neck or ureteral orifices [1, 5, 11–16].

Operative Technique

Successful completion of a PVP is dependent upon an attentive operating room staff and a properly maintained collection of equipment dedicated to photoselective vaporization of the prostate. First and foremost is the GreenLight laser XPS 180 W output device. A supply of MoXy laser fibers must also be kept on hand, with at least two fibers available for each PVP to be done in case of fiber breakage. The preferred cystoscope is a 23 Fr continuous-flow scope with a 30° telescope. A beak visual obturator is needed to allow initial passage of the scope. The working channel of the scope must be large enough to accept the MoXy fiber. An approximately 20 cm section of tubing is attached to the outflow valve of the scope to allow gentle drainage away from the surgeon. Two room temperature 3 L normal saline bags are hung through a Y-tube adaptor to provide inflow irrigation. The operating room staff must remain attentive to the fluid levels throughout the case, and replace empty bags as needed. A separate 1 L normal saline bag provides cooling to the MoXy fiber. A self-sealing nipple at the working port prevents leakage around the laser fiber. A high definition video system with a laser filter placed between the telescope lens and

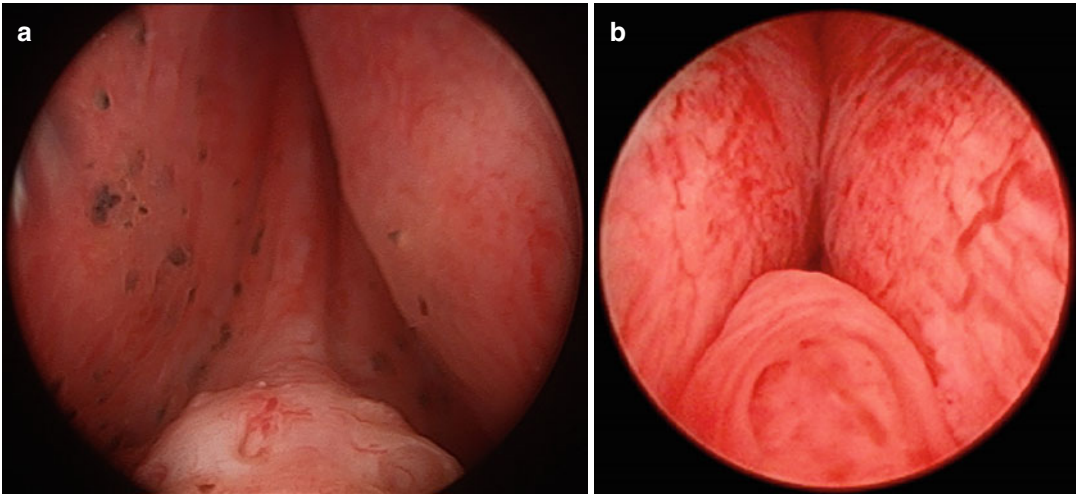


Fig. 16.1 Cystoscopy prior to initiating the PVP demonstrates significant BPH with complete visual obstruction by the median lobe (a) and lateral lobes (b). The bladder neck is not visualized from the verumontanum

camera allows optimal visualization during the procedure. Various styles of laser goggles are available, and the surgeon should choose one that allows excellent clarity and is comfortable to wear for potentially several hours. Urethral sounds should be available, and a 24 Fr or a 26 Fr resectoscope is also important to have as backup. At the completion of the procedure, an 18 Fr 2-way catheter is typically placed, but larger-sized 3-way catheters and continuous bladder irrigation should also be available should there be significant hematuria.

After induction of anesthesia, either general or spinal, the patient is placed in the dorsal lithotomy position. The genitals and perineum are prepped and draped in the standard fashion for cystoscopy. A 23 Fr continuous-flow cystoscope is introduced into the urethra and bladder. Dilation of the urethral meatus with sounds may be needed to facilitate passage of the cystoscope. A careful inspection of the entire bladder urothelium is undertaken, and the laser fiber for the procedure is only opened once a lack of any unexpected findings such as bladder tumors or calculi has been confirmed. Careful attention is paid to the location and position of the ureteral orifices, especially in relation to their proximity to the bladder neck and median lobe. The prostatic urethra is also carefully visualized to generate a

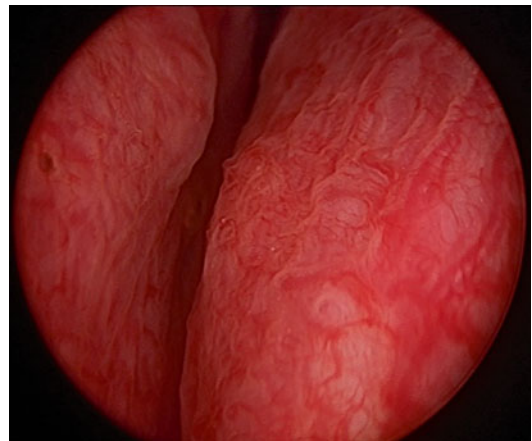


Fig. 16.2 Nodules of BPH within the mid-prostatic urethra are visually obstructing the bladder neck

strategy for completing the PVP (Figs. 16.1 and 16.2). Particular note is made of the length of the prostatic urethra to prevent vaporization proximal to the bladder neck or distal to the verumontanum.

After introduction of the laser fiber, the PVP is begun. General strategies for achieving the most efficient vaporization are pursued. These include maintaining only a 1–2 mm distance between the laser fiber and the tissue being treated, rotating the fiber no more than 30° from the neutral position to prevent diffusion of the laser beam, keeping the rotation of the fiber at a slow pace

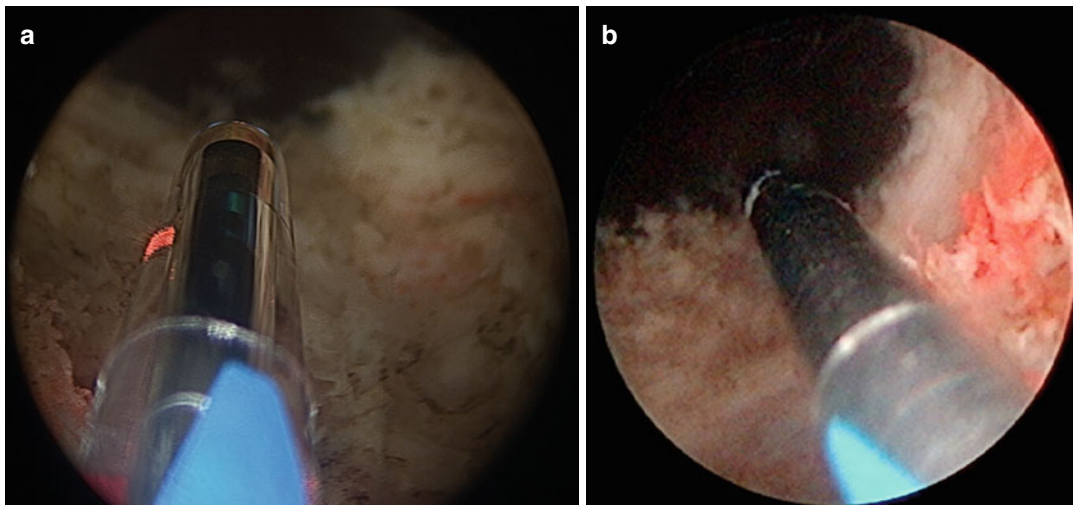


Fig. 16.3 The 120 W HPS 2090 fiber (a) and the 180 W XPS MoXy fiber (b) are shown at the optimal extension from the end of the cystoscope and the proper distance

from the tissue being treated. The blue arrows demonstrate that the beams are aimed toward the tissue and away from the lens

(0.5–1 sweeps/s), and withdrawing the cystoscope at a speed of only a few millimeters per second. The speed of the fiber rotation and the angle of the rotation have been shown to have effects on vaporization efficiency in ex vivo analysis [12, 13]. The fiber is marked with a blue arrow and a red stop sign (Fig. 16.3) to help prevent firing the laser toward the cystoscope lens, and careful attention must be given to observing these markings. In addition, the cystoscope is rotated within the prostatic urethra so that the beak of the scope is always 180° from the tissue being treated. The appearance of bubbles as the tissue is being treated is a reliable indicator of effective vaporization. The initial power settings are 80 W for vaporization and 30 W for coagulation. The vaporization power is increased to 120 W once enough tissue has been cleared in the prostate fossa that the working channel can be easily traversed without the laser fiber being forced into contact with the prostate tissue. The vaporization power is increased to 180 W as necessary for the largest or most fibrous glands.

The authors' technique for completing the PVP begins first by performing vaporization at the 5 o'clock and 7 o'clock positions from the bladder neck to the level of the verumontanum in order to help distinguish the lateral lobes from the median

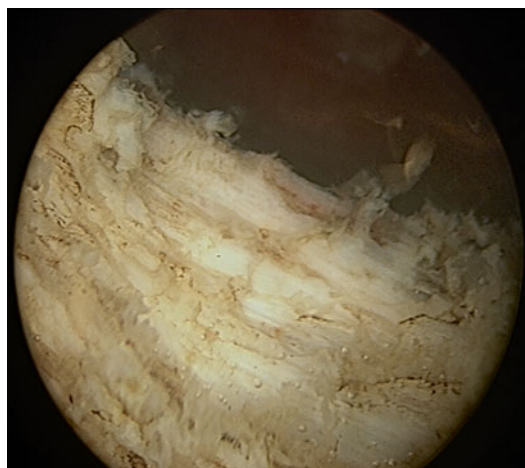


Fig. 16.4 The proper depth of surgical resection is reached once the circular fibers of the prostate capsule are seen

lobe and to define the surgical level of the capsular fibers. The right and left lateral lobes are vaporized next by performing sweeps from the bladder neck to the verumontanum in a stepwise progression from the posterior aspect of the lobe to the anterior aspect of the lobe on each side. The treatment continues in this fashion until the circular fibers of the prostate capsule are recognized (Fig. 16.4). The median lobe of the prostate is then vaporized from a lateral to medial direction beginning at the blad-

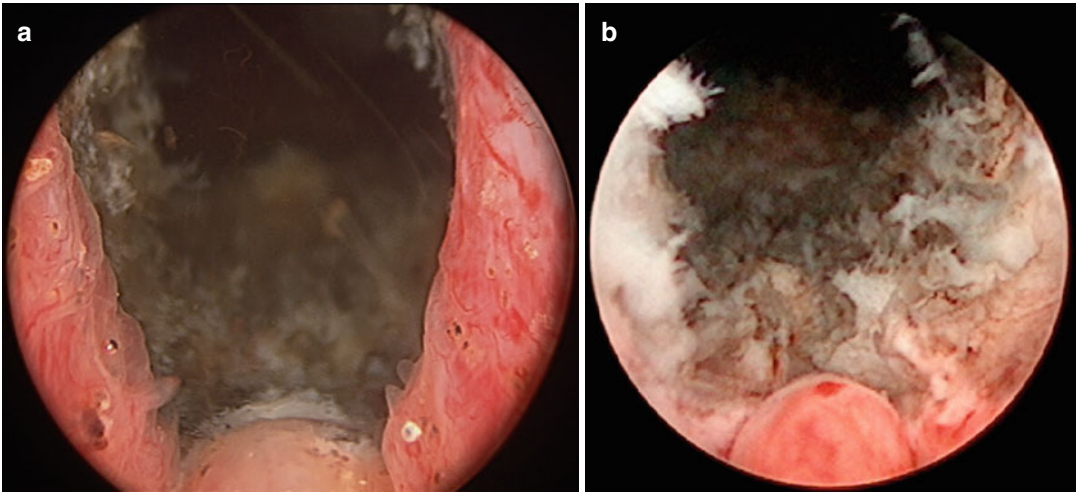


Fig. 16.5 The verumontanum is preserved during PVP (a), and vaporization is not performed on tissue distal to it in order to minimize risk of thermal injury to the external sphincter. At completion of the PVP, an open channel is

seen from the verumontanum to the bladder neck. It is not unusual to see a shaggy surface (b) within the fossa after a successful PVP

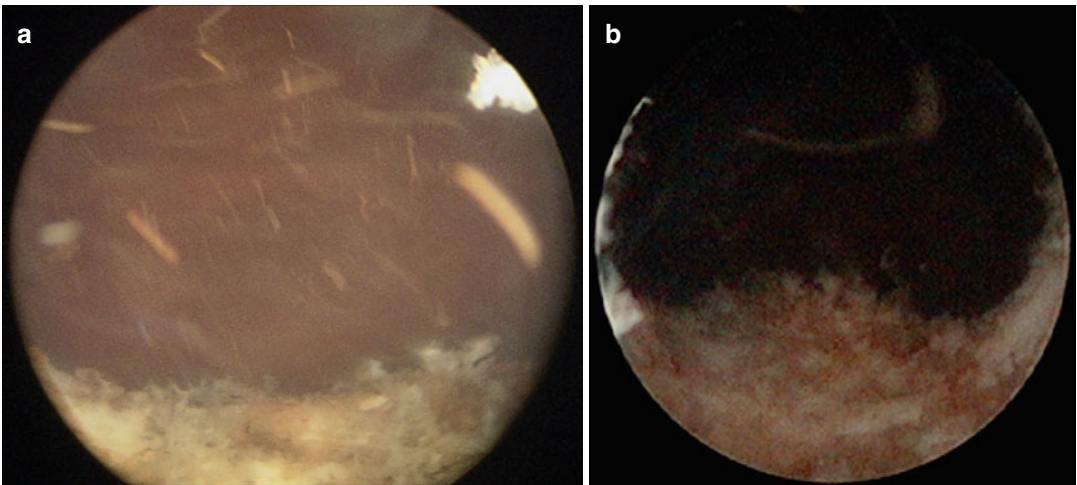


Fig. 16.6 When viewed from the mid-prostatic urethra, any visual evidence of obstruction by prostate tissue is absent (a), and the bladder neck is wide open at the completion of the PVP (b)

der neck and proceeding distally to the verumontanum. The median lobe is approached from both lateral directions in this manner until the posterior bladder neck is completely flattened to the level of the trigone. Care is taken to recognize the ureteral orifices, which can be marked at the start of the procedure by applying a short burst of vaporization or coagulation energy to the nearby bladder mucosa. Any residual apical tissue is vaporized to complete the procedure and allow a fully unob-

structed view from the verumontanum through the prostatic urethra (Figs. 16.5 and 16.6). This technique is very similar to that described by Malek [17] and the Basel technique [14]. Those patients with a large median lobe may require partial or complete vaporization of the median lobe prior to the lateral lobes in order to optimize visualization and irrigation.

A modified technique that utilizes deep incisions into the prostate lobes has been described

[10]. A midline incision that is carried down to the trigone is performed first. A second incision is then made lateral to the median lobe on one side, and the tissue in between these incisions is completely vaporized. The same maneuver is then performed on the contralateral side. Incisions high on the lateral lobes are then made, and the tissue of the lateral lobes is vaporized down to the floor of the prostate.

A spiral technique is another method to perform the PVP [18]. In this technique, a clear channel is achieved in a stepwise fashion, as if spiraling down through the prostate. A complete area of the prostate along its length is vaporized in a 360° manner beginning at the bladder neck, proceeding next to the proximal later lobes, and finishing with the floor of the prostate and the apex.

The anterior start technique initially begins with vaporization between the 11 o'clock and 1 o'clock positions from the bladder neck proximally to the level of the verumontanum distally [18]. Vaporization of the lateral lobes is performed next. The median lobe is flattened, and creation of a midline incision through the median lobe then allows completion of its vaporization in a medial to lateral direction bilaterally.

Whichever technique a surgeon utilizes, it should be consistent and reproducible, yet also be applicable to prostates of various sizes and shapes. The procedure is assessed for completion when the inflow irrigation is stopped and the prostate fossa is viewed with the cystoscope placed at the verumontanum (which should still be preserved). A wide-open channel into the bladder should be seen with no remaining visually obstructing tissue present. A TURP-like defect is considered critical to reduce the risk of the patient needing a secondary procedure (Figs. 16.5 and 16.6). The ureteral orifices are inspected to ensure they remain intact. Stopping the inflow irrigation also allows for assessment of bleeding from the prostate fossa.

There are various techniques for managing troublesome bleeding encountered during the PVP. Raising the height of the irrigation fluid will often improve visualization. Once the view becomes less bloody, the fluid may be lowered to

its initial height. Specific sites of bleeding within the fossa may be vaporized using the coagulation setting of the laser. Care should be taken to avoid aiming the beam directly into a bleeding vessel. The vaporization setting can also be used to achieve hemostasis by moving the laser fiber an increased distance away from the tissue being treated and thus defocusing the beam. Coagulation rather than vaporization occurs as the working distance from the fiber to the tissue is increased. If visualization is adequate to allow for continued safe vaporization, bleeding will often slow or stop as the prostatic channel size is increased, and the flow of the continuous irrigation becomes more vigorous. It is often helpful to focus on vaporizing the lateral lobe contralateral to an annoying bleeding site for a period of time and then periodically reassessing the status of the bleeding as the flow improves. If the degree of bleeding becomes significant enough that visualization is impaired to the point that vaporization cannot be safely continued, it may be necessary to remove the cystoscope and place a resectoscope to achieve hemostasis. Once the bleeding site has been fulgurated with the resectoscope, the cystoscope can be replaced and the PVP completed, or the procedure may be completed as a TURP. The need for placing the resectoscope to control bleeding should be a rare event and in the authors' experience occurs in less than 1 % of cases.

Once the PVP is deemed complete, and the hemostasis at the end of the procedure deemed appropriate, the cystoscope is removed and an 18 Fr Foley catheter is placed. If no bloody drainage is noted from the Foley after the bladder is completely drained, then it is connected to a gravity drainage bag and the patient reversed from anesthesia. If continuous bloody drainage is noted from the Foley, then several minutes of hand irrigation with a bulb or piston syringe is undertaken to see if this is able to clear the urine. If this maneuver is unsuccessful, then the 18 Fr Foley is removed and replaced by a larger-sized 3-way catheter. If the urine appears to be clearing on moderate continuous bladder irrigation, then the patient is reversed from anesthesia. In the rare event that the urine does not clear with continuous

bladder irrigation and an arterial bleeder is suspected, then a resectoscope should be placed and the bleeding site fulgurated if found.

The authors wish to highlight a few “tricks of the trade” points to keep in mind when performing PVP, especially early in the learning phase:

- Be sure to complete the online training modules on the AMS website (http://www.ams-greenlight.com/phys_resource_training.html).
- Take advantage of the GreenLight PVP simulator that was recently developed by AMS, as this should be useful for urologists learning this technique.
- At the start of the case, create a good working channel within the prostatic urethra in order to optimize flow of irrigation. The laser power may initially need to be kept low (80 W) when making this channel. The vaporization power can be increased (120 W or higher) once the channel is open enough to allow for good flow of irrigant.
- Control bleeding early and don't fall behind on this, as the combination of blood and saline irrigant make for difficult endoscopic visualization.
- Over time, one's efficiency of movement and sweeping of the laser fiber improves, and surgeons will find that they will spend more time with their foot on the firing pedal than not.
- Fully vaporize an area of tissue before moving on to another area, as previously treated tissue becomes more difficult to vaporize, thus decreasing laser efficiency.
- Choose straightforward cases to start with when early in the learning curve. These cases include patients with smaller glands, who are not on anticoagulation, who are not in retention, and who do not have significant median lobes.
- Emphasize practice-based learning and improvement strategies by videotaping your procedures and evaluating and critiquing yourself and others. Much can be learned by even a few minutes of doing so!

Postoperative Management

The need for postoperative catheterization following PVP done under general anesthesia is at the discretion of the surgeon. Those done under

spinal anesthesia may benefit from overnight placement of a catheter given the increased risk of urinary retention following spinal anesthesia. It is the standard practice of the authors to leave a catheter overnight in patients undergoing PVP, and the patient is instructed to remove the catheter himself on the first postoperative morning if the urine does not demonstrate any significant hematuria. Those patients taking oral anticoagulant medication may benefit from a longer trial of catheterization in order to reduce the risk of clot retention. Those patients with preoperative urinary retention may also benefit from longer catheterization times and a formal trial of voiding in the office rather than self-removal of the catheter at home. Several clinical trials have demonstrated reduced mean catheterization times for patients undergoing PVP relative to TURP [4, 6, 19].

Those patients noted to have significant hematuria at the completion of the PVP often require additional interventions to help the urine to clear. Instilling more water into the catheter balloon and placing it on traction will often help to stop bleeding from the prostate fossa. Manual irrigation of the catheter is also often successful in slowing bleeding and preventing clot formation. However, for those patients in whom significant hematuria persists despite these maneuvers, a period of time utilizing continuous bladder irrigation may be necessary. The continuous bladder irrigation may be weaned over several hours so that the patient may still go home the day of surgery, although in some cases overnight hospitalization may be necessary.

Patients are encouraged to increase their fluid intake as soon as they are transferred from the recovery room to the outpatient unit. This increased fluid consumption should be maintained for several days after surgery, and oral intake and diet can return to preoperative levels if the urine remains clear at home with the catheter out. Narcotic pain medications should be avoided if possible, but patients are given a prescription to fill if necessary. Patients are advised to limit postoperative activities for 1–2 weeks after surgery. Lifting should be restricted to less than 10 lb, and strenuous exercise should be avoided. Sexual activity is also discouraged for 1–2 weeks.

Patients can generally discontinue any medications they were taking for management of LUTS after they have undergone a PVP. Those patients who experience persistent gross hematuria may benefit from the initiation or resumption of a 5-ARI. Similarly, postoperative storage symptoms including urinary frequency, urgency, and urge incontinence may warrant continuation of an antimuscarinic medication in those taking these preoperatively or initiation of such medications for patients in whom these symptoms develop de novo after surgery. Resumption of oral anticoagulant medications can be advised at the surgeon's discretion and as deemed appropriate by the patient's cardiologist or internist.

Patients are typically seen in 2–3 weeks following surgery for a postoperative visit or in 2–3 days if a formal trial of voiding is needed. Problems such as dysuria, storage symptoms, hematuria, tissue sloughing, or other concerns are addressed at the postoperative visit. A PVR is routinely checked to rule out impending urinary retention. The patients then return in 3 months for uroflowmetry, assessment of PVR, and assessment of LUTS with the AUA-SI. Any lingering concerns are sought, and those patients with poor symptom relief or very poor flow rates on uroflowmetry undergo cystoscopy to evaluate for incomplete tissue removal, urethral stricture, or bladder neck contracture. A serum PSA can be checked in appropriately selected patients to establish a new baseline for future screening.

Efficacy

Assessment of the efficacy of PVP with regard to improvement in LUTS and urodynamic parameters is limited by a paucity of randomized clinical trials comparing PVP to other established surgical treatment options. In addition, the studies which have been published do not typically utilize the latest iteration of the device, the 180 W XPS system. Nonetheless, the data thus far demonstrate comparable improvement to that achieved with TURP and OP, with potential benefit in regard to surgical complications.

In 2006, Bouchier-Hayes and associates published a randomized trial comparing TURP to PVP done with the 80 W system [4]. A similar reduction of approximately 50 % in IPSS was seen for both the PVP and the TURP groups. The Qmax improved by 167 % for the PVP patients and 149 % for the TURP patients, a significant increase for both. Post-void residual volumes also showed significant decreases, and similar trends were seen in relation to bother and quality of life scores. The length of catheterization was less in the PVP group (mean of 12.2 h) than in the TURP group (44.5 h). A significant difference in length of stay was also noted, with the mean of the PVP group being 1.08 days and the mean of the TURP group being 3.4 days.

An early study comparing TURP to 80 W PVP in patients with large (>70 mL) prostates noted a significant difference in IPSS, Qmax, and PVR values at 6 months in favor of TURP [6]. The procedure was significantly shorter for the TURP group (mean of 51 min versus 87 min), but the length of hospital stay (4.8 days versus 2 days) and length of catheterization (3.9 days and 1.7 days) were shorter in the PVP group.

A study comparing 120 W PVP with TURP in patients with a mean prostate volume of approximately 60 mL shows more promising results [2]. As seen in the other studies, the mean catheterization time of 1.4 days in the PVP group was significantly shorter than the 2.7 days in the TURP group. Mean hospital stay also favored PVP (2.3 days versus 4.1 days). Functional outcome with regard to increase in Qmax, decrease in IPSS, and decrease in PVR was notable for dramatic improvement in all three compared with preoperative values. The degree of improvement in both the PVP group and the TURP group was comparable at all time points of follow-up out to 36 months.

A second randomized clinical trial comparing 120 W PVP with TURP was published in 2011 and provided a 2-year follow-up [5]. Similar IPSS reduction was seen for both PVP and TURP at 2 years (–15.7 and –14.9, respectively). There was no significant difference in the increase in Qmax between PVP and TURP (+14.5 and +13.1 mL/s, respectively). Length of hospital

stay and time to catheter removal were significantly shorter with PVP.

Similar symptomatic improvement and changes in urodynamic parameters have also been noted in PVP as compared to OP. Alivizatos and colleagues assessed men with prostate glands >80 mL in size who were randomized to either 80 W PVP or transvesical open enucleation at 1 year [3]. All functional parameters improved significantly compared to baseline values in both groups. The IPSS did not differ between the two groups at 3, 6, and 12 months postoperatively. There were no significant differences between the two groups in the Qmax and PVR after surgery. The prostate volume was significantly reduced to a greater degree in the OP group. Another trial evaluating PVP and OP in men with glands >80 mL provided an 18-month follow-up [7]. There was no difference in IPSS between the two groups at 3, 6, 12, and 18 months postoperatively. At 18 months there were no significant differences between the two groups in Qmax and PVR. As seen in the previous study, the prostate volume was lower in the OP group.

A recent study to look at the efficacy of the GreenLight laser XPS system showed excellent early functional improvement in key parameters up to 6 months following treatment [20]. Mean IPSS scores improved from 19.6 preoperatively to 9.4. Maximum urinary flow rate increased from 8.4 to 21.0 mL/s. There was also a drop in PVR from a mean of 190 mL to a mean of 35 mL. The study was notable for approximately a quarter of the patients having a prostate volume >80 mL. Statistically significant drops in both PSA values and prostate volume at 3 months postoperatively confirm the effectiveness of the XPS system in removing a large amount of prostate tissue.

Photoselective vaporization of the prostate has also been studied in men suffering from urinary retention prior to surgery. Ruszat and colleagues published a subgroup analysis of their results using PVP in men with refractory urinary retention [21]. At 24 months postoperatively, they found a peak urinary flow rate of 19.4 mL/s in men with retention versus 23.3 mL/s in men without retention who has also undergone the

procedure. IPSS for the two groups was found to be 4.4 versus 6.5, respectively. Postoperative urinary retention and complication rates were comparable for the two groups. Being in urinary retention also did not have any negative impact on the outcome of 180 W GreenLight laser PVP in the study by Bachmann and associates [20].

There are few studies examining the long-term durability of PVP. Hai reported on the 5-year outcomes on 246 of the first 321 patients who underwent PVP at his institution [22]. The average improvement in AUASS was 79 %, while the average improvement in maximal flow rate was 172 %. The overall retreatment rate was 8.9 %; 19 of the 246 were treated with a repeat PVP due to re-obstruction from prostate adenoma, and 3 underwent transurethral incision of the bladder neck. A study of 500 consecutive patients with mean follow-up of 30 months found a retreatment rate of 6.8 % because of insufficient first vaporization or regrowth of prostate tissue [23].

Complications

Complications related to PVP can be categorized as intraoperative, early postoperative, and late. All are relatively infrequent and comparable to those seen in other surgical interventions for BPH.

Intraoperative

Intraoperative bleeding may occur with PVP, but the need for blood transfusion is significantly less likely than what is seen with TURP [2, 24]. In a randomized, prospective trial using the 120 W laser, Al-Ansari et al. reported that 20 % of TURPs needed blood transfusions, but none of the PVPs did [2]. In the same study, 16.7 % of TURPs had capsular perforated capsule versus none with PVP, and 5 % of TURPs had TUR syndrome versus none of PVPs. Even in those patients on anticoagulation, the occurrence of significant intraoperative bleeding is less than TURP [9, 10]. Conversion to TURP because of

intraoperative bleeding is a potential adverse event that patients should be warned of prior to PVP. Conversion rates are generally low (<5 %) but increase as gland size increases [24].

Other intraoperative complications of endoscopic surgery for BPH to be considered include capsule perforation and TUR syndrome. However, because the irrigating fluid used during PVP is isotonic to saline, the theoretical risk of TUR syndrome should be very low. The GreenLight laser is selective for oxyhemoglobin, and thus minimally vascular tissue such as the fibrotic prostate capsule should be much less susceptible to the effects of the treatment. This reduces the likelihood of capsule perforation compared to the electrocautery of TURP. One recent study comparing TURP and PVP found a 16.7 % capsule perforation rate and 5 % risk of TUR syndrome in the patients undergoing TURP with no patient in the PVP group experiencing these complications [2]. Another comparison found a 0.4 % versus 6.3 % capsular perforated capsule rate between the PVP and TURP groups, respectively [23].

Early Postoperative Complications

Early postoperative complications following PVP include urinary retention, hematuria, dysuria, urinary tract infection, ejaculatory dysfunction, recatheterization, and readmission.

Studies using the 80 W laser report rates of urinary retention ranging from 1 to 15.4 %, transient hematuria in 4–18 %, transient dysuria in 7–30 %, culture-documented UTIs in 6 %, and ejaculatory dysfunction (either decreased volume of ejaculate or retrograde ejaculation) ranging from 36 to 55 % [19, 25–31]. In a large single-center study of 500 patients using the 80 W laser, Ruszat and colleagues reported early postoperative complication rates including hematuria (9.8 %), transfusion (0.4 %), immediate repeat surgery (0.6 %), urosepsis (0.4 %), dysuria (14.8 %), urge incontinence (2.4 %), and UTI (6.8 %) [23, 24].

Studies using the 120 W laser report rates of urinary retention at 8 %, UTI in 6 %, a recatheter-

ization rate of 1–5 %, transient hematuria in 12 % 120 W 12 %, and the need for antimuscarinics to control storage symptoms as being the same as in TURP [5]. In one study using the 120 W laser, the postoperative readmission rate was 6 % (3 of 50 patients) including 2 for hematuria and 1 for a febrile UTI [5]. In another study using the 120 W laser, 60 patients (versus 60 TURPs) were followed for a mean of 36 months, and at follow-up, no patient had had clot retention (versus 10 % of TURPs); however, 93 % reported urgency or dysuria (versus 32 % of TURPs) [2].

In a 2010 meta-analysis of published studies on PVP, Ahyai and colleagues found postoperative urinary retention in 9.9 %, clot retention in 0 %, secondary resection rates of 2.1 %, secondary bleeding in 0.7 %, urosepsis in 0 %, and UTI with fever 12 % [32]. Except for clot retention, these numbers were all higher than TURP, bipolar TURP, TUVP, and HoLEP but did not reach statistical significance.

Late Postoperative Complications

Urethral stricture represents one potential late complication from PVP. One study with long-term follow-up found an overall stricture rate of 4.4 %, the vast majority of which were in the bulbar urethra (>90 %) [23]. The stricture was noted in the first year in 86 % of patients with a stricture. This group found that their urethral stricture rate fell significantly after switching from a 26 Fr cystoscope to a 22.5 Fr instrument. In one trial comparing PVP to TURP, urethral stricture was noted in 5.1 % of the PVP patients and 8.1 % of the TURP patients at 6 months follow-up [6]. These patients did undergo internal urethrotomy as treatment for the stricture. In a study by Alivizatos and associates comparing PVP to OP, only 2 of 65 patients in the PVP group and 1 of 60 patients in the OP group required treatment for urethral stricture [3]. Capitan et al. found that 2 of 50 patients developed urethral meatal stenosis, 6 % developed a urethral stricture, 2 % had urinary incontinence, and there were no bladder neck contractures [5].

Bladder neck contracture is another potential late complication of PVP. However, much like for urethral stricture, the incidence is generally low. No patient experienced a bladder neck contracture in one comparative study of PVP versus TURP with a 2-year follow-up, while 4 % of the TURP patients experienced this complication [5]. In a randomized clinical trial comparing PVP to OP with an 18-month follow-up, 0 % versus 3.3 % of patients were noted to have bladder neck contractures in the PVP and OP groups, respectively [7].

Patients undergoing PVP should be informed about the possibility of urinary incontinence and erectile dysfunction as part of informed consent of the procedure. The actual incidence of these conditions appears to be quite low in the published literature. In both comparison to OP and TURP, PVP has demonstrated no significant difference in effect on erectile function [3, 4]. Like with TURP, retrograde ejaculation does occur commonly.

Ruszat et al. reported in their single-center study of 500 PVP procedures using the 80 W laser with a 2.5-year mean follow-up of late postoperative complication of bladder neck contracture in 3.6 %, urethral stricture in 4.4 %, retreatment rates of 6.8 %, and incontinence in 1.2 % [23]. Using the 120 W laser, Al-Ansari et al. reported in their 60 patients with a mean follow-up of 36 months rates of late complications of needing a redo procedure in 11 % and bladder neck contractures in 7.4 % [2]. In a meta-analysis by Ahyai et al., rates of late postoperative complications included bladder neck contracture in 5 %, urethral stricture in 6.3 %, repeat procedure in 5.6 %, and dysuria in 8.5 % [32].

Special Considerations

Safety of PVP in Men Who Require Continuous Anticoagulation

One of the highly touted advantages of PVP over TURP is that its laser technology allows for a virtually bloodless tissue ablation technique. PVP therefore may be performed safely for patients

with medical comorbidities, including a high-risk patient on anticoagulation and antiplatelet therapies [33].

In a two-center study of 66 medically comorbid patients with an ASA score of three or more, Reich et al. reported a 14-point IPSS score reduction and a 222 % improvement in Qmax at 1 year, with an 11 % recatheterization rate and one patient requiring a redo procedure [27].

In a study of 116 men who underwent PVP while continuing warfarin, aspirin, or clopidogrel therapies, no bleeding complications were observed and no patients required blood transfusions. Of note, these patients did have higher rate of postoperative bladder irrigation (17 % versus 5.4 % of controls) resulting in longer postoperative catheterization time [9]. These findings have been confirmed in other studies [10, 34].

Safety and Efficacy of PVP in Men with Large Prostates

A number of studies have demonstrated the safety and efficacy of PVP on large prostates. Significant improvements in Qmax and IPSS scores have been reported [28, 35]. However, operating times, the probability of a staged procedure, and the number of laser fibers used to complete the procedure were higher in men with large prostates when compared with smaller prostate glands. Good functional outcomes were maintained, but the incidence of postoperative recatheterization was 5, and 23.1 % of patients needed a reoperation within 1 year [28, 35]. These apparent drawbacks of treating large prostates with the early 80 W systems have been minimized with the advent of more powerful (180 W) laser systems.

Another study found a higher safety profile of PVP as compared with TURP [6]. When compared to open prostatectomy for glands >80 mL, PVP patients had longer operating times but shorter catheterization and hospitalization times [3]. Complications and improvements in voiding parameters were similar in both groups. The open prostatectomy group had a higher transfusion rate.

Learning Curve

The learning curve for any surgery plays an important role in its overall acceptance. PVP has been shown to have a shorter learning curve than HoLEP, and this is likely the reason for the greater popularity of PVP [36]. Additionally, some consider PVP to be easier to learn and perform than TURP with reports of urologists feeling comfortable performing TURPs after about 50 procedures [37, 38] and others reporting competence in PVP after performing 10–20 (or fewer) procedures depending on gland size [37]. As with learning any new technique or procedure, the authors advise a mentorship training period to adequately and safely perform PVP.

Cost

An issue worth mentioning is the cost-effectiveness of PVP, as the generator and laser fibers are expensive. A number of studies have examined and summarized the issue of cost of PVP versus TURP [39]. A Swiss study showed similar financial costs for PVP and TURP. OR and postoperative care costs were higher for TURP, while the costs of disposable materials were higher for PVP [40]. Similarly, an Australian study showed that when performed as a same-day surgery procedure and despite the higher cost of equipment and disposables, PVP was less expensive than TURP. Cost savings with PVP generally were due to shorter hospital stays, shorter catheterization times, and lower complication rates [4].

A 2006 study examined the clinical outcomes and cost characteristics of PVP, TUMT, TUNA, interstitial laser coagulation, and TURP using a decision analytic Markov model. In this model, PVP resulted in the largest beneficial changes in IPSS, Qmax, and QoL scores, and the expected cost per patient at all time points was lowest for PVP. The cost savings of PVP was due to lower rates of adverse events and retreatments [41].

It is important to keep in mind that the cost-effectiveness of any treatment depends on the different reimbursement systems in different

countries. Therefore, it is difficult to draw general conclusions that are applicable to every country or health-care delivery system.

Conclusions

PVP is one of a number of laser technologies available for the treatment of lower urinary tract symptoms due to benign prostatic obstruction. This treatment carries with it a quick learning curve, a low risk of bleeding, the ability to perform the surgery if men are unable to stop blood thinning agents, a short postoperative catheterization, and a short hospital stay. However, the equipment is expensive, and there are increased retreatment and dysuria rates as compared to TURP. Urologists need to be aware of the advantages and disadvantages of not only PVP but of the array of new technologies available for the surgical treatment of LUTS due to BPO. Ultimately, each urologist needs to know and review their own outcomes with benign prostate surgeries and offer their patients the treatments that in their own hands have the best outcomes and fewest complications, particularly in the era of cost-conscious and evidence-based medicine.

References

1. Malek RS. Contemporary management of the benign obstructive prostate: an overview. *Mayo Clin Proc.* 1998;73(6):589.
2. Al-Ansari A, Younes N, Sampige VP, Al-Rumaihi K, Ghafouri A, Gul T, et al. GreenLight HPS 120-W laser vaporization versus transurethral resection of the prostate for treatment of benign prostatic hyperplasia: a randomized clinical trial with midterm follow-up. *Eur Urol.* 2010;58(3):349–55.
3. Alivizatos G, Skolarikos A, Chalikopoulos D, Papachristou C, Sopilidis O, Dellis A, et al. Transurethral photoselective vaporization versus transvesical open enucleation for prostatic adenomas >80 ml: 12-mo results of a randomized prospective study. *Eur Urol.* 2008;54(2):427–37.
4. Bouchier-Hayes DM, Anderson P, Van Appledorn S, Bugeja P, Costello AJ. KTP laser versus transurethral resection: early results of a randomized trial. *J Endourol.* 2006;20(8):580–5.
5. Capitan C, Blazquez C, Martin MD, Hernandez V, de la Pena E, Llorente C. GreenLight HPS 120-W laser vaporization versus transurethral resection of the

- prostate for the treatment of lower urinary tract symptoms due to benign prostatic hyperplasia: a randomized clinical trial with 2-year follow-up. *Eur Urol*. 2011;60(4):734–9.
6. Horasanli K, Silay MS, Altay B, Tanriverdi O, Sarica K, Miroglu C. Photoselective potassium titanyl phosphate (KTP) laser vaporization versus transurethral resection of the prostate for prostates larger than 70 mL: a short-term prospective randomized trial. *Urology*. 2008;71(2):247–51.
 7. Skolarikos A, Papachristou C, Athanasiadis G, Chalikopoulos D, Deliveliotis C, Alivizatos G. Eighteen-month results of a randomized prospective study comparing transurethral photoselective vaporization with transvesical open enucleation for prostatic adenomas greater than 80 cc. *J Endourol*. 2008;22(10):2333–40.
 8. McVary KT, Roehrborn CG, Avins AL, Barry MJ, Bruskewitz RC, Donnell RF, et al. Update on AUA guideline on the management of benign prostatic hyperplasia. *J Urol*. 2011;185(5):1793–803.
 9. Ruzsat R, Wyler S, Forster T, Reich O, Stief CG, Gasser TC, et al. Safety and effectiveness of photoselective vaporization of the prostate (PVP) in patients on ongoing oral anticoagulation. *Eur Urol*. 2007;51(4):1031–8; discussion 8–41.
 10. Sandhu JS, Ng CK, Gonzalez RR, Kaplan SA, Te AE. Photoselective laser vaporization prostatectomy in men receiving anticoagulants. *J Endourol*. 2005;19(10):1196–8.
 11. Gu X, Strom K, Spaliviero M, Wong C. Intermediate outcomes of GreenLight HPS laser photoselective vaporization prostatectomy for symptomatic benign prostatic hyperplasia. *J Endourol*. 2011;25(6):1037–41.
 12. Kauffman EC, Kang HW, Choi BB. The effect of laser-fiber sweeping speed on the efficiency of photoselective vaporization of the prostate in an ex vivo bovine model. *J Endourol*. 2009;23(9):1429–35.
 13. Osterberg EC, Kauffman EC, Kang HW, Koullick E, Choi BB. Optimal laser fiber rotational movement during photoselective vaporization of the prostate in a bovine ex-vivo animal model. *J Endourol*. 2011;25(7):1209–15.
 14. Shim M, Kwon T, Kim SC, Ha SH, Ahn TY. Changes in serum prostate-specific antigen levels after potassium-titanyl-phosphate (KTP) laser vaporization of the prostate. *Korean J Urol*. 2010;51(2):111–4.
 15. Spaliviero M, Araki M, Culkin DJ, Wong C. Incidence, management, and prevention of perioperative complications of GreenLight HPS laser photoselective vaporization prostatectomy: experience in the first 70 patients. *J Endourol*. 2009;23(3):495–502.
 16. Spaliviero M, Strom KH, Gu X, Araki M, Culkin DJ, Wong C. Does Greenlight HPSTM laser photoselective vaporization prostatectomy affect sexual function? *J Endourol*. 2010;24(12):2051–7.
 17. Malek RS, Kuntzman RS, Barrett DM. High power potassium-titanyl-phosphate laser vaporization prostatectomy. *J Urol*. 2000;163(6):1730–3.
 18. Gomez Sancha F, Bachmann A, Choi BB, Tabatabaei S, Muir GH. Photoselective vaporization of the prostate (GreenLight PV): lessons learnt after 3500 procedures. *Prostate Cancer Prostatic Dis*. 2007;10(4):316–22.
 19. Bachmann A, Schurch L, Ruzsat R, Wyler SF, Seifert HH, Muller A, et al. Photoselective vaporization (PVP) versus transurethral resection of the prostate (TURP): a prospective bi-centre study of perioperative morbidity and early functional outcome. *Eur Urol*. 2005;48(6):965–71; discussion 72.
 20. Bachmann A, Muir GH, Collins EJ, Choi BB, Tabatabaei S, Reich OM, et al. 180-W XPS GreenLight laser therapy for benign prostate hyperplasia: early safety, efficacy, and perioperative outcome after 201 procedures. *Eur Urol*. 2012;61(3):600–7.
 21. Ruzsat R, Wyler S, Seifert HH, Reich O, Forster T, Sulser T, et al. Photoselective vaporization of the prostate: subgroup analysis of men with refractory urinary retention. *Eur Urol*. 2006;50(5):1040–9; discussion 9.
 22. Hai MA. Photoselective vaporization of prostate: five-year outcomes of entire clinic patient population. *Urology*. 2009;73(4):807–10.
 23. Ruzsat R, Seitz M, Wyler SF, Abe C, Rieken M, Reich O, et al. GreenLight laser vaporization of the prostate: single-center experience and long-term results after 500 procedures. *Eur Urol*. 2008;54(4):893–901.
 24. Ruzsat R, Wyler SF, Seitz M, Lehmann K, Abe C, Bonkat G, et al. Comparison of potassium-titanyl-phosphate laser vaporization of the prostate and transurethral resection of the prostate: update of a prospective non-randomized two-centre study. *BJU Int*. 2008;102(10):1432–8; discussion 8–9.
 25. Bachmann A, Ruzsat R, Wyler S, Reich O, Seifert HH, Muller A, et al. Photoselective vaporization of the prostate: the basel experience after 108 procedures. *Eur Urol*. 2005;47(6):798–804.
 26. Malek RS, Kuntzman RS, Barrett DM. Photoselective potassium-titanyl-phosphate laser vaporization of the benign obstructive prostate: observations on long-term outcomes. *J Urol*. 2005;174(4 Pt 1):1344–8.
 27. Reich O, Bachmann A, Siebels M, Hofstetter A, Stief CG, Sulser T. High power (80 W) potassium-titanyl-phosphate laser vaporization of the prostate in 66 high risk patients. *J Urol*. 2005;173(1):158–60.
 28. Sandhu JS, Ng C, Vanderbrink BA, Egan C, Kaplan SA, Te AE. High-power potassium-titanyl-phosphate photoselective laser vaporization of prostate for treatment of benign prostatic hyperplasia in men with large prostates. *Urology*. 2004;64(6):1155–9.
 29. Sulser T, Reich O, Wyler S, Ruzsat R, Casella R, Hofstetter A, et al. Photoselective KTP laser vaporization of the prostate: first experiences with 65 procedures. *J Endourol*. 2004;18(10):976–81.
 30. Te AE, Malloy TR, Stein BS, Ulchaker JC, Nseyo UO, Hai MA, et al. Photoselective vaporization of the prostate for the treatment of benign prostatic hyperplasia: 12-month results from the first United States multicenter prospective trial. *J Urol*. 2004;172(4 Pt 1):1404–8.

31. Volkan T, Ihsan TA, Yilmaz O, Emin O, Selcuk S, Koray K, et al. Short term outcomes of high power (80 W) potassium-titanyl-phosphate laser vaporization of the prostate. *Eur Urol.* 2005;48(4):608–13.
32. Ahyai SA, Gilling P, Kaplan SA, Kuntz RM, Madersbacher S, Montorsi F, et al. Meta-analysis of functional outcomes and complications following transurethral procedures for lower urinary tract symptoms resulting from benign prostatic enlargement. *Eur Urol.* 2010;58(3):384–97.
33. Van Cleynebreugel B, Srirangam SJ, Van Poppel H. High-performance system GreenLight laser: indications and outcomes. *Curr Opin Urol.* 2009;19(1):33–7.
34. Yuan J, Wang H, Wu G, Liu H, Zhang Y, Yang L. High-power (80 W) potassium titanyl phosphate laser prostatectomy in 128 high-risk patients. *Postgrad Med J.* 2008;84(987):46–9.
35. Pfitzenmaier J, Gilfrich C, Pritsch M, Herrmann D, Buse S, Haferkamp A, et al. Vaporization of prostates of >or =80 mL using a potassium-titanyl-phosphate laser: midterm-results and comparison with prostates of <80 mL. *BJU Int.* 2008;102(3):322–7.
36. de la Rosette J, Alivizatos G. Lasers for the treatment of bladder outlet obstruction: are they challenging conventional treatment modalities? *Eur Urol.* 2006;50(3):418–20.
37. Bouchier-Hayes DM. Photoselective vaporization of the prostate — towards a new standard. *Prostate Cancer Prostatic Dis.* 2007;10:S10–4.
38. Rajbabu K, Chandrasekara SK, Barber NJ, Walsh K, Muir GH. Photoselective vaporization of the prostate with the potassium-titanyl-phosphate laser in men with prostates of >100 mL. *BJU Int.* 2007;100(3):593–8; discussion 8.
39. Alivizatos G, Skolarikos A. Photoselective vaporization of the prostate. Review of cost implementation to BPH treatment. *Prostate Cancer Prostatic Dis.* 2007;10:S15–20.
40. Ruszat R, Wyler S, Seifert H. Photoselective vaporization (PVP) vs. transurethral electroresection of the prostate (TURP): a comparative cost analysis. *EAU Congress Paris Abstract No 996. Eur Urol Suppl.* 2006;5:271.
41. Stovsky MD, Griffiths RI, Duff SB. A clinical outcomes and cost analysis comparing photoselective vaporization of the prostate to alternative minimally invasive therapies and transurethral prostate resection for the treatment of benign prostatic hyperplasia. *J Urol.* 2006;176(4 Pt 1):1500–6.

John J. Knoedler and Amy E. Krambeck

Introduction

Transurethral resection of the prostate (TURP) is still considered the gold standard treatment for benign prostatic hyperplasia (BPH). However, its current use is limited to small- and medium-sized prostates due to an overall morbidity rate of 15–20 % [1] and blood transfusion rate ranging from 5 to 11 % [2]. Treatment of large-sized prostate glands has been deferred to the suprapubic prostatectomy approach, which is associated with significant immediate postoperative patient morbidity, even using a robotic approach. Patients currently undergoing treatment for BPH are progressively older with more comorbidities; thus, there is an increased need for more minimally invasive procedures in the current treatment era. In an attempt to limit the morbidity associated with standard TURP and/or suprapubic prostatectomy, several laser therapies have been introduced for the treatment of BPH, including neodymium:yttrium aluminum garnet (Nd:YAG), the holmium:YAG, and the potassium-titanyl-phosphate (KTP) lasers [3]. These lasers have been used to coagulate, vaporize, and cut prostatic tissue overgrowth using a variety of techniques. The holmium laser has been further developed to

allow for actual prostatic lobe enucleation with subsequent tissue removal.

Holmium laser enucleation of the prostate (HoLEP) has emerged as an effective transurethral treatment option for patients suffering from symptomatic BPH of any size [4]. By using the holmium laser to incise the prostate gland, the laser scope to manually enucleate, and the morcellator to remove a large bulk of tissue from the bladder, the suprapubic prostatectomy technique is recreated during the HoLEP procedure without any abdominal or bladder incision. A multitude of publications have supported the safety and efficacy of HoLEP for small- and large-gland BPH [4–20], even in the presence of bleeding diatheses and anticoagulation [17]. HoLEP has been found to be as effective as TURP [7–11, 19] and open suprapubic prostatectomy [5, 7, 16] for the treatment of obstructive BPH, with the benefit of less morbidity. Long-term studies of patients undergoing HoLEP demonstrate sustained relief from BPH symptoms from 4 to 10 years postoperative, with very low retreatment rates, ranging from 0 to 4 % [12, 16, 18, 21, 22].

The efficacy of HoLEP lies in its excellent tissue debulking capabilities. Large case series have shown that HoLEP produces a prostate volume and prostate-specific antigen reduction of 60–90 % [6, 13–15, 18]. Another benefit of HoLEP is the potential to be performed as an outpatient procedure with catheter removal within 24 h of surgery. When compared to contemporary

J.J. Knoedler, MD (✉) • A.E. Krambeck, MD
Department of Urology, Mayo Clinic,
200 First Street SW, Rochester, MN 55905, USA
e-mail: Knoedler.John@mayo.edu

ablative procedures, HoLEP has the advantage of actual tissue removal for pathologic specimen examination, greater prostate volume reduction, and durable long-term results, while maintaining low morbidity [23].

Since HoLEP is a laser-based procedure, it is performed using normal saline irrigant, thus eliminating the risk of dilutional hyponatremia, also known as TUR syndrome. Furthermore, since the laser not only incises but also coagulates, it can perform pinpoint control of bleeding vessels as they enter the capsule of the prostate. The precise control of bleeding vessels at the time of transection has nearly eliminated the need for blood transfusion after HoLEP in patients without bleeding diathesis. Evidence demonstrates the feasibility of radical prostatectomy after HoLEP; the concomitant treatment of bladder, ureteral, and renal stones at time of HoLEP; and the limited impact of HoLEP on erectile function [24]. Investigators have reported that once the initial investment for the laser is factored out, HoLEP is more cost-effective compared with TURP and open prostatectomy due to a shorter length of hospitalization and decreased need for ancillary interventions (i.e., blood transfusion and continuous bladder irrigation) [19]. One criticism of the HoLEP procedure is the steep learning curve, which has limited its incorporation into many general urologists' practices. Thus, the focus of the chapter will be to describe the current technique of HoLEP including available equipment, a step-by-step guide to the procedure, and anticipated postoperative recovery and complications.

Current Equipment Used for HoLEP

Equipment List

1. 100 W holmium laser unit
2. 550 μ end-fire laser fiber
3. 30° cystoscope lens
4. Video tower and a freely swinging camera head
5. Normal saline irrigation
6. Continuous flow resectoscope (26–28 F) with modified inner sheath with a stabilizer

7. 6 F stabilizing catheter
8. Van Buren sounds
9. Ellik evacuator
10. Offset rigid nephroscope
11. 5 mm tissue morcellator
12. Alligator grasper
13. 20 F catheter with mandarin guide

The holmium laser is a pulsed solid-state laser with a wavelength of 2.140 nm. Unlike other available laser systems, the holmium laser is a contact laser with a depth of penetration in prostatic tissue of only 0.4 mm. The laser is highly absorbed by water (absorption peak of water: 1.940 nm), which makes up 60–70 % of the prostate [24]. This water absorption produces an energy density that heats the prostatic tissue to greater than 100° Celsius [3]. With such high heats created, the tissue is vaporized without deep coagulation for a “what you see is what you get” effect, eliminating delayed tissue sloughing. The holmium laser produces very little char effect, which allows the laser to precisely cut and dissect tissue it is in direct contact with without obscuring surgical planes. When the laser is not in direct contact with the tissue, it can dissipate heat causing coagulation of vessels to a depth of 2–3 mm [3]. The holmium laser is a multipurpose laser and can be used not only for tissue cutting (as in the treatment of urinary strictures) and coagulation (treatment of urothelial tumors) but also for fracturing of stones [5, 25, 26]. To perform HoLEP in an efficient manner, a high-powered laser is necessary and, in general, the 100 W VersaPulse holmium laser (Lumenis, Santa Clara, CA) is used (Fig. 17.1).

The holmium laser energy can be transmitted along flexible quartz fibers of varying diameters, ranging from 200 to 100 μ m. The ability to use multiple-sized fibers allows the holmium laser to be used with not only a cystoscope but also rigid and flexible ureteroscopes. In general, a larger laser fiber is necessary to perform HoLEP, and the 550 μ m end-fire fiber is generally preferred (Fig. 17.2). Several different companies offer both disposable and reusable quartz laser fibers. The ability to sterilize and reuse the laser fibers up to 20–30 uses gives HoLEP a theoretical eco-

nomical advantage over other prostate laser treatments [24]. When performing HoLEP, the laser fiber is routinely stripped of its protective cladding, over several inches, and then placed through a 6 Fr stabilizing catheter (Cook, Spencer, IN). The catheter is secured in place with a Luer-Lok injection port (Baxter, Deerfield, IL).

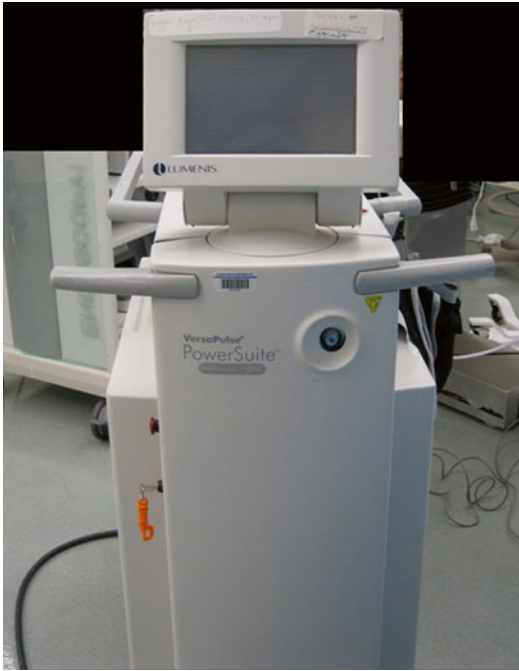

Fig. 17.1 The 100 W VersaPulse holmium laser used to perform HoLEP

Two different companies provide laser scopes that can be used to perform HoLEP. Olympus (Hamburg, Germany) has a 27 Fr continuous flow resectoscope with a modified inner sheath that incorporates a laser fiber channel and bridge (Fig. 17.3) (we utilize the Olympus scope), and Storz (Tuttlingen, Germany) manufactures two different-sized continuous flow laser scopes to perform HoLEP: a 26 Fr instrument with a dedicated inner sheath and stabilizing guide and a 28 Fr instrument with a dedicated inner sheath and stabilizing ring. Regardless of laser scope used to perform HoLEP, a 30° lens is necessary to adequately visualize the prostate and laser fiber. Due to the extreme hand movements necessary to perform HoLEP, an endoscopic camera with a swivel base is necessary, as direct use of the eyepiece is neither feasible nor safe. High-definition video systems such as those provided by Stryker (Kalamazoo, MI) and Olympus (Hamburg, Germany) make visualization of the plane between capsule and adenoma much easier, but are not necessary to perform the procedure. Since HoLEP is a laser-based therapy, normal saline irrigation is used in all cases.

Once enucleation of the prostate has been completed, the tissue must be removed using a tissue morcellator. To introduce the tissue morcellator, the inner working elements of the laser scope are removed leaving only the outer sheath and replaced with a modified offset long 26 Fr nephroscope with

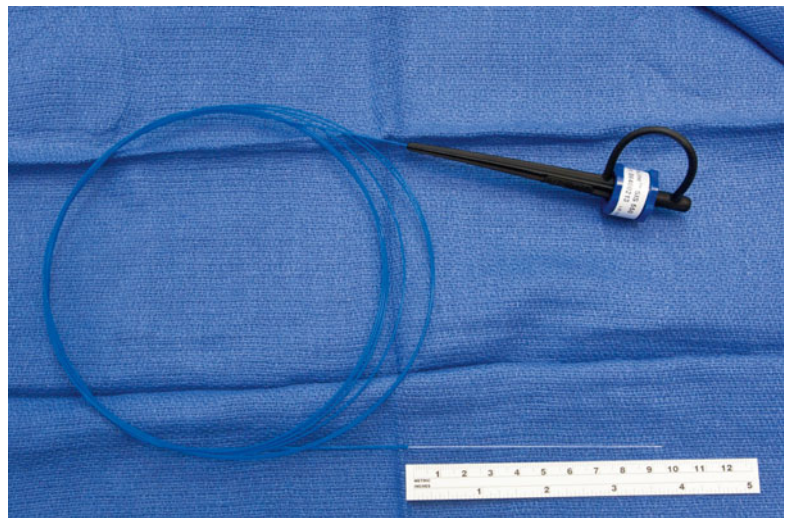


Fig. 17.2 The 550 μm quartz laser fiber used to perform HoLEP

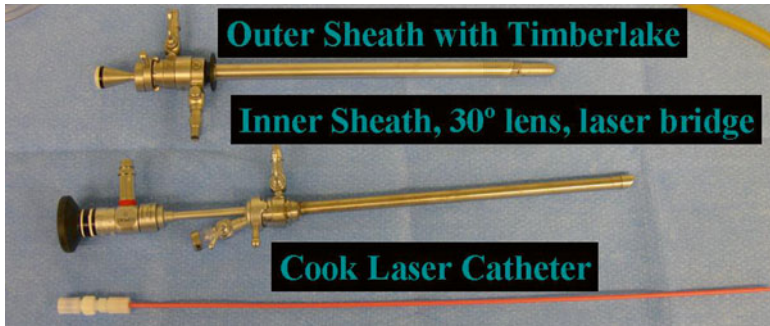

Fig. 17.3 The disassembled laser scope and protective laser catheter. The device shown is the Storz 28 Fr set consisting of a 28 Fr outer sheath, inner sheath with stabiliz-

ing ring, and 30° telescope lens. The laser catheter fits through the working element of the scope and is held in place by the stabilizing ring

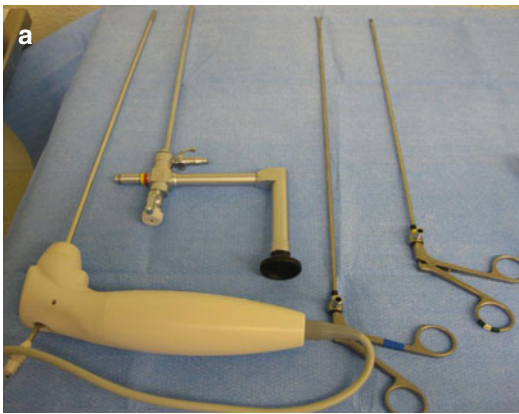
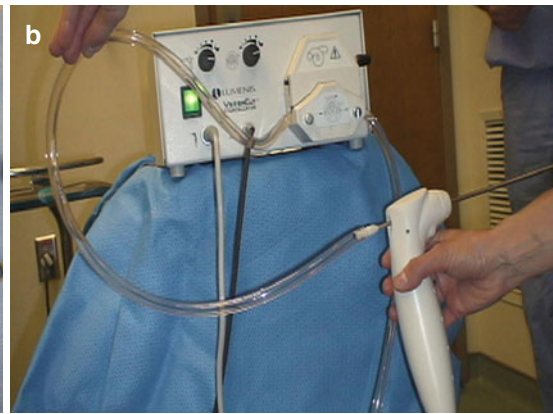


Fig. 17.4 (a) The long nephroscope shown here has a 5 mm working channel which permits passage of the morcellator as well as grasping forceps. The grasping forceps can be used to remove small fragments rather than mor-



cellating. **(b)** The Lumenis VersaCut morcellator has a pump suction device which allows for simultaneous removal of the prostate tissue at time of morcellation

a 5 mm working channel (Olympus or Storz). The tissue morcellator is then introduced through the 5 mm working channel (Fig. 17.4a). The VersaCut morcellator (Lumenis) consists of a hand piece with reciprocating blades and controller box with suction pump and is operated solely by a foot pedal (Fig. 17.4b). Partial depression of the foot pedal produces suction only, and complete depression allows for movement of the morcellator blades with suction. Due to the intense suction produced by the morcellator, it is important to have two water inflows through the nephroscope to keep the bladder distended, preventing inadvertent damage by the morcellator. The Richard Wolf company (Vernon Hills, IL) has also developed a morcellator, the Piranha. This morcellator has separate controls

for suction and morcellation and is run by a trigger handpiece. Comparison of the two morcellators has demonstrated excellent tissue removal; however, in ex vivo testing, the Lumenis morcellator was more efficient at tissue removal [27]. After all the tissue is removed, a standard urethral catheter is placed for at least 6 h or until hematuria has decreased to an acceptable amount.

HoLEP: Step By Step

Preoperative Evaluation

Prior to undergoing HoLEP, patients should have an appropriate preoperative evaluation. Though

work-up may be tailored to the individual patient, this should typically include a patient history, AUA symptom score (or appropriate validated metric), and urinary flow with post-void residual. Laboratory evaluation including complete blood count (CBC), electrolytes with creatinine, and serum PSA should be obtained. In general, patients should undergo a preoperative cystoscopy and prostate ultrasound for operative planning. The cystoscopy is particularly important to rule out other causes of urinary obstruction such as urethral stricture disease and also assess for other pathology such as bladder calculi or tumor. The prostate ultrasound is beneficial for operating room planning time since size of the prostate dictates case duration. If the patient suffers from severe urgency frequency or has other neurologic comorbidities, a full urodynamic study can be beneficial in differentiating between significant detrusor instability and bladder outlet obstruction.

As with any surgical procedure, a detailed informed consent is mandatory. Though the risk of clinically significant bleeding is relatively low, even in the setting of anticoagulation or bleeding diathesis [17], the possibility of transfusion should be discussed. Patients should be informed of the risks, both short term and long term of both stress and urge urinary incontinence, and the possibility of ongoing urinary retention particularly in those patients who presented with preoperative urinary retention [21]. Patients should also be counseled on the small but real risk of urethral and bladder injury which can occur at time of dilation or morcellation. The series by Krambeck et al. notes frequent inconsequential bladder mucosal injury, but only one full-thickness injury requiring repair out of 1,065.

Operative Preparation

Patients are positioned in the dorsal lithotomy position and induced with general endotracheal anesthesia. The urethra is calibrated to 28 or 30 F depending on the cystoscope set used, taking care to dilate only the anterior urethra and not disrupt the prostatic urethra. The continuous flow resectoscope sheath is placed with the Timberlake

obturator, and then the operating laser scope with 6 F laser stabilizing catheter is placed. A 550 μ laser fiber is stripped of its most distal cladding over 2–3 in. and placed through the laser stabilizing catheter. Normal saline irrigation is used, thus preventing TUR syndrome, and the outflow tract of the continuous flow resectoscope is attached to tubing that drains to gravity over the trap.

Assessment of Anatomy and Creation of Posterior Plane

Once the resectoscope is placed, the anatomy of the patient is assessed. Ideally, the surgeon should be aware of any important variations, such as a large median lobe preoperatively. Attempt is made to visualize the ureteral orifices; however, these may be obscured by prostatic intrusion into the bladder, particularly with a large median lobe. The surgeon must then decide whether bilobar or trilobar hypertrophy exists and whether a median lobe must be enucleated separately.

If a significant median lobe is present, the surgeon begins by incising at the 5 or 7 o'clock positions at the bladder neck and carrying the incision towards the apex, stopping before the verumontanum (Fig. 17.5). The laser is set at 2

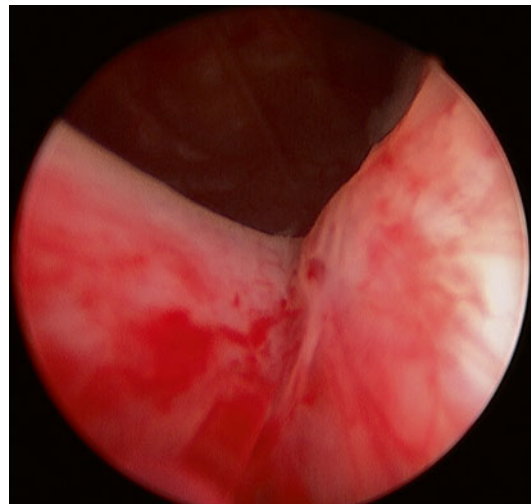


Fig. 17.5 View of the initial posterior incision, starting at the 6 or 5 and 7 o'clock position depending on the presence of a median lobe

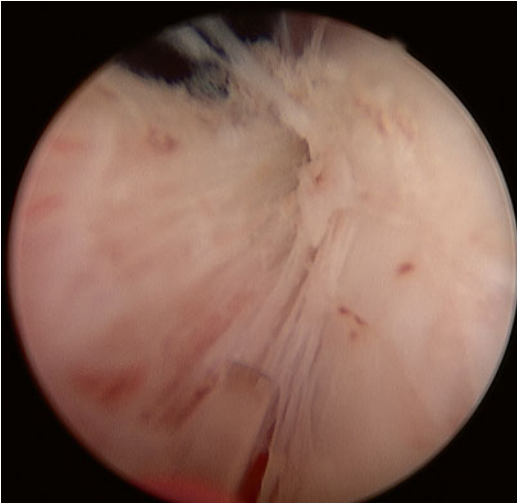


Fig. 17.6 Circular fibers at the bladder neck, identifying the capsule

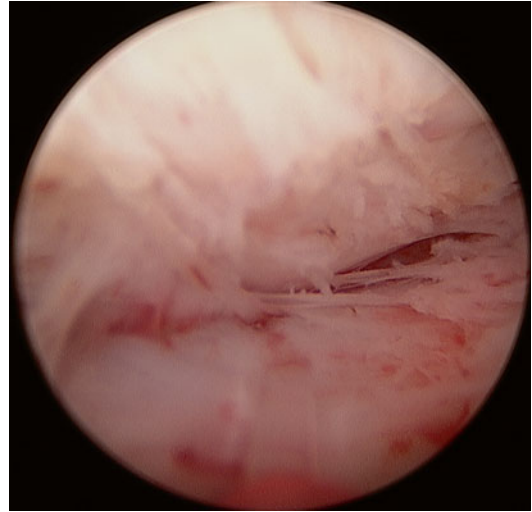


Fig. 17.7 The cobweb appearance with separation of the adenoma from the prostatic capsule

Joules (J) and 40 or 50 Hertz (Hz). The initial groove created by the incision is deepened until the capsule is reached, which can be identified most readily by circular fibers near the bladder neck (Fig. 17.6). This depth near the bladder neck should be familiar to surgeons with experience with TURP or photoselective vaporization of the prostate and serves as a landmark to establish depth. By gently moving the nose of the scope in the horizontal plane, the groove can be widened to help identify the capsule. A second identical incision is then made at either the 5 or 7 o'clock position of the bladder neck, on the opposite side of the median lobe. Once both bladder neck incisions are developed, the surgeon then begins to undermine the median lobe. The laser is moved transversely to connect the plane between the two lateral grooves along the apex of the median lobe. The resection is then gradually carried proximally, using the beak of the scope to lift the adenoma upward into the lumen of the prostatic urethra, establishing tissue traction and working space for the laser to cut underneath. The proper plane should demonstrate a cobweb appearance with separation of the adenoma from the prostatic capsule (Fig. 17.7). The plane of this resection gradually slopes upward as the resection is carried towards the bladder neck. Once arrived proximally, the adenoma of the median lobe is

separated and pushed into the bladder. When separating the adenoma from the bladder neck, the surgeon must take care to dissect closely to the bladder neck fibers. If the plane is too superficial, the dissection will track up the back of the adenoma leaving a large piece of tissue at the bladder neck, and if the dissection is too deep, the trigone can be undermined. Furthermore, care should be taken to avoid inadvertent injury to the ureteral orifices or back wall of the bladder as the adenoma is separated from the bladder neck. This can be accomplished by insuring the adenoma is not pushed back against the bladder wall, but is rather balanced in an upright position in the bladder.

If the median lobe is small or moderately sized, it does not need to be enucleated separately. A single posterior groove can be made at either the 5, 6, or 7 o'clock position depending on the anatomy of the prostate. The median lobe or posterior tissue is then enucleated with the lateral lobe tissue.

Enucleation of Lateral Lobes

After enucleation of the median lobe, or the single posterior incision if a formal median lobe enucleation is not performed, attention is then

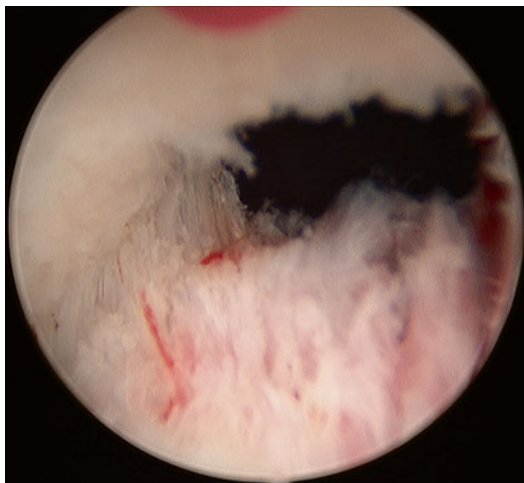


Fig. 17.8 The anterior plane of dissection carried from the 10 to 2 o'clock position through the bladder mucosa so that the scope enters the lumen of the bladder, note the laser fiber and capsule superiorly and the adenoma inferiorly

turned to the lateral lobe tissue. The lateral lobes are enucleated individually, beginning at the apex just proximal and lateral to the verumontanum, to avoid injury to the sphincter. A superficial incision of the mucosa is created by making a short horizontal cut, just enough to allow entrance of the beak of the scope. The laser energy can then be decreased to 2 J and 20 Hz to limit potential collateral damage to the sphincter. The scope is then gently rotated around the apex of the adenoma using mainly blunt dissection and limited lasering until the scope is positioned in the 12 o'clock position, with capsule residing above the scope and adenoma below. The laser energy is then increased to the initial starting settings of 2 J and 40 or 50 Hz. The anterior plane of dissection is then carried towards the bladder neck, utilizing the scope to push down the adenoma separating it from the capsule above. The laser is used to separate attachments and control any bleeding vessels. The anterior plane of dissection is carried from the 10 to 2 o'clock position through the bladder mucosa so that the scope enters the lumen of the bladder (Fig. 17.8).

The two lobes are then divided by repositioning the scope in the prostatic urethra and dividing the anterior commissure at the 12 o'clock

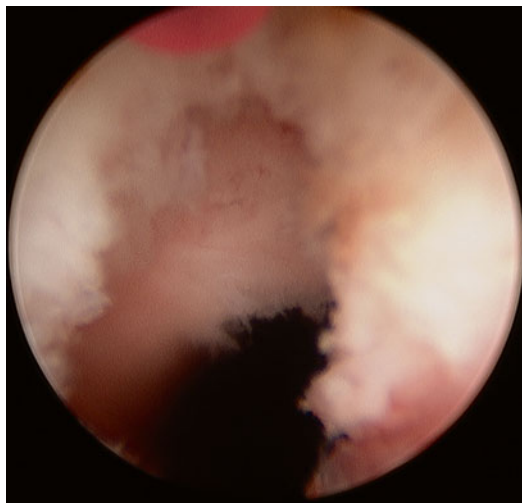


Fig. 17.9 The two lobes are divided by repositioning the scope in the prostatic urethra and dividing the anterior commissure at the 12 o'clock position

position (Fig. 17.9). The incision is carried from the bladder neck to the apex into the space previously created by the anterior dissection, checking to ensure that this does not carry into the sphincter.

Once the lobes are divided, the mucosal strip of tissue attaching the adenoma to the area of the sphincter must be divided. The encircle technique is performed by positioning the scope inverted at the 12 o'clock position near the bladder neck. The scope is then rotated around the outer edge of the adenoma while hugging the capsule until it is oriented appropriately in the 6 o'clock position. The mucosal strip is now positioned to one side of the scope and the sphincter on the other. The scope is then pulled distally to allow the strip to fall in front of the scope where it can be transected safely without concern for sphincter injury.

After the division of the mucosal strip, the remainder of the lobe is enucleated by joining the lateral and posterior planes working distally towards the bladder neck. Once the adenoma is nearly completely detached, the adenoma is pushed into the bladder using the beak of the scope. The final attachments at the bladder neck are severed, and the adenoma is freed into the bladder (Fig. 17.10). Attention is then turned

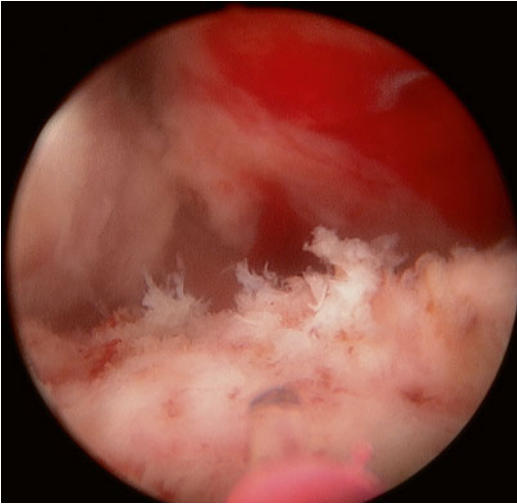


Fig. 17.10 View of the enucleated lateral lobes pushed into the bladder

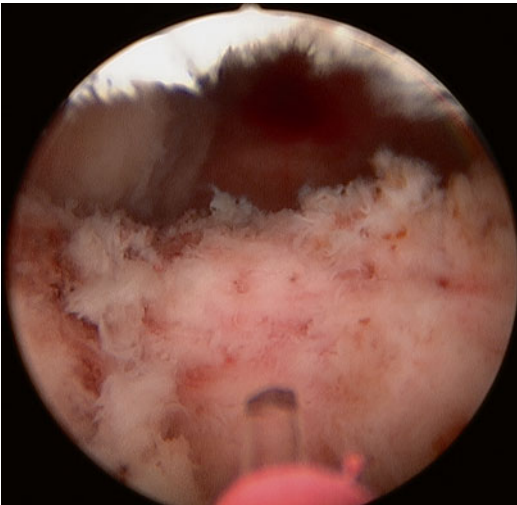


Fig. 17.11 View of the widely opened prostatic fossa

to the contralateral lobe, which is dissected in a similar fashion. At the conclusion, a widely patent prostatic fossa can be visualized (Fig. 17.11).

Once the enucleation is completed, hemostasis must be achieved. Though the holmium laser does an excellent job at sealing small vessels during enucleation, it is typically necessary to control small bleeders. This is accomplished by pulling the tip of the laser fibers a few millimeters away from the tissue, to provide a more coagulative effect. Taking time to achieve

adequate hemostasis will improve visualization during morcellation.

Following enucleation, the resected tissue is removed using a tissue morcellator. As mentioned earlier, the inner working elements of the laser scope are removed and replaced with a modified offset long 26 Fr nephroscope with a 5 mm working channel. The tissue morcellator is then introduced through the 5 mm working channel. The morcellator uses a combination of suction and cutting blades to remove the tissue; therefore, care must be taken to have high fluid flow through the scope, as the suction can rapidly deflate the bladder and rapidly bring the bladder wall into the proximity of the morcellator, causing serious injury. Once the bulk of the tissue is removed, any small residual fragments can be grasped with an alligator forceps or flushed from the bladder using an Ellik.

Finally, a 20 F catheter is placed over a mandarin catheter guide. Continuous bladder irrigation may be necessary depending on the degree of hematuria noted. To improve bladder neck hemostasis, some tension may need to be applied to the catheter for a brief period of time. The catheter is typically maintained overnight and removed the following day. Patients must be able to void after catheter removal, and post-void residual volume checked to ensure there is no urinary retention.

Anticipate Post-op Results

Since the HoLEP procedure is a complete debulking of the prostate, it is of little surprise that durable long-term outcomes are possible. Naspro and colleagues recently reviewed the literature for HoLEP and reported durable results at a mean follow-up of 43.5 months. They found a mean post-procedure Q_{max} of 21.9 ml/s and mean reoperative rate of 4.3 % (range 0–14.1 %) [24]. The authors also noted a significant mean decrease in serum PSA levels from baseline (mean 63–1.63 ng/dl, postoperatively) and transrectal ultrasound prostate volume (mean: from 68 to 27.2 ml, postoperatively). At longest follow-up, the overall re-intervention rate was low at 0–5.4 %.

The group from Methodist Hospital in Indianapolis, Indiana, evaluated their experience with over 1,000 HoLEP procedures performed [21]. The mean preoperative transrectal ultrasound prostate volume was 99.3 g (range 9–391), American Urological Association (AUA) symptom score 20.3 (1–35), and Qmax 8.4 cc/s (1.1–39.3). Overall complication rates were low, occurring in only 2.3 % of the cohort. Mean follow-up was 287 days, ranging from 6 days to 10 years. At most recent follow-up, the mean AUA symptom score was 5.3, and Qmax was 22.7 cc/s. Only 3 (0.3 %) of patients were in urinary retention and the authors site that all three patients had findings consistent with an atonic bladder, not obstruction. Only one patient underwent a second HoLEP procedure for bleeding prostatic regrowth, not obstruction. Urethral stricture and bladder neck contractures occurred in less than 2 % of the cohort. Similarly, Elmansy et al. report rates of stricture and bladder neck contracture at 10-year follow-up of 0.8 and 1.6 %, respectively [22].

Despite durable long-term results, immediately postoperatively patients undergoing HoLEP can experience mild to moderate storage symptoms in the form of urgency and even urge incontinence. By 1 month postoperatively, the symptoms are present in approximately 30 % of patients and by 3 months only 10 % [24]. The symptoms respond well to anticholinergic therapies and pelvic floor exercises, and in general are self-limiting. The series of over 1,000 HoLEP procedures reports a less than 5 % overall incontinence rate at long term [21]. Elmansy et al., in a review of 949 patients over 10 years, found that presence of diabetes mellitus, larger volume prostate gland, and a greater reduction in postoperative PSA were all predictive of postoperative stress urinary incontinence [28]. Other potential complications that can occur at the time of surgery or in the immediate postoperative period are hematuria, clot retention, bladder or urethral injury, and any complication that can occur from general anesthesia (Table 17.1).

HoLEP appears to have limited impact on sexual function, similar to TURP and open suprapubic prostatectomy [24]. No difference in IIEF erectile function domain scores has been

Table 17.1 Complications of HoLEP among a series with 10-year follow-up [21]

Complication	Occurrence (%)
Bladder perforation	0.1
Clinically significant hematuria	0.7
Urethral stricture	2.3
Bladder neck contracture	1.5
Significant short-term stress incontinence	12.5
Significant short-term urge incontinence	11.5
Significant long-term stress incontinence	1.8
Significant long-term urge incontinence	1.5
Re-resection due to adenoma regrowth	0.1
Persistent urinary retention ^a	0.03

^aThree total patients, including two with documented atonic bladder and 1 who developed neurogenic bladder following HoLEP due to spinal cord injury

observed pre to 2 years postoperatively. However, patients should be counseled on the development of retrograde ejaculation, which has been noted in over 75 % of patients followed over 6 years and can affect patient sexual satisfaction [12].

Summary

This chapter has outlined the utility of holmium laser enucleation of the prostate as supported by the literature, provided a guide to performing HoLEP including the standard required equipment, and reviewed the anticipated postoperative results of the procedure. HoLEP is a safe, effective, minimally invasive surgical treatment of BPH. It has demonstrated durable results, with such a significant degree of de-obstruction that subsequent surgical revision is rare. With a relatively low morbidity compared to standard TURP and the ability to resect large volumes of tissue, HoLEP continues to evolve into a new gold standard for the treatment of BPH.

References

1. Mebust WK, Holtgrewe HL, Cockett AT, Peters PC. Transurethral prostatectomy: immediate and postoperative complications. a cooperative study of

- 13 participating institutions evaluating 3,885 patients. 1989. *J Urol.* 2002;167(2 Pt 2):999–1003.
2. AUA Practice Guidelines Committee. AUA guideline on management of benign prostatic hyperplasia (2003). Chapter 1: diagnosis and treatment recommendations. *J Urol.* 2003;170(2 Pt 1):530–47.
3. Kuntz RM. Current role of lasers in the treatment of benign prostatic hyperplasia (BPH). *Eur Urol.* 2006;49(6):961–9.
4. Toohar R, Sutherland P, Costello A, Gilling P, Rees G, Maddern G. A systematic review of holmium laser prostatectomy for benign prostatic hyperplasia. *J Urol.* 2004;171(5):1773–81.
5. Kuntz RM, Lehrich K. Transurethral holmium laser enucleation versus transvesical open enucleation for prostate adenoma greater than 100 gm.: a randomized prospective trial of 120 patients. *J Urol.* 2002;168(4 Pt 1):1465–9.
6. Matlaga BR, Miller NL, Lingeman JE. Holmium laser treatment of benign prostatic hyperplasia: an update. *Curr Opin Urol.* 2007;17(1):27–31.
7. Kuntz RM, Ahyai S, Lehrich K, Fayad A. Transurethral holmium laser enucleation of the prostate versus transurethral electrocautery resection of the prostate: a randomized prospective trial in 200 patients. *J Urol.* 2004;172(3):1012–6.
8. Ahyai SA, Lehrich K, Kuntz RM. Holmium laser enucleation versus transurethral resection of the prostate: 3-year follow-up results of a randomized clinical trial. *Eur Urol.* 2007;52(5):1456–63.
9. Montorsi F, Naspro R, Salonia A, Suardi N, Briganti A, Zanoni M, et al. Holmium laser enucleation versus transurethral resection of the prostate: results from a 2-center, prospective, randomized trial in patients with obstructive benign prostatic hyperplasia. *J Urol.* 2004;172(5 Pt 1):1926–9.
10. Gilling PJ, Mackey M, Cresswell M, Kennett K, Kabalin JN, Fraundorfer MR. Holmium laser versus transurethral resection of the prostate: a randomized prospective trial with 1-year followup. *J Urol.* 1999;162(5):1640–4.
11. Wilson LC, Gilling PJ, Williams A, Kennett KM, Frampton CM, Westenberg AM, et al. A randomised trial comparing holmium laser enucleation versus transurethral resection in the treatment of prostates larger than 40 grams: results at 2 years. *Eur Urol.* 2006;50(3):569–73.
12. Gilling PJ, Aho TF, Frampton CM, King CJ, Fraundorfer MR. Holmium laser enucleation of the prostate: results at 6 years. *Eur Urol.* 2008;53(4):744–9.
13. Kuo RL, Kim SC, Lingeman JE, Paterson RF, Watkins SL, Simmons GR, et al. Holmium laser enucleation of prostate (HoLEP): the Methodist Hospital experience with greater than 75 gram enucleations. *J Urol.* 2003;170(1):149–52.
14. Elzayat EA, Habib EI, Elhilali MM. Holmium laser enucleation of the prostate: a size-independent new “gold standard”. *Urology.* 2005;66(5 Suppl):108–13.
15. Elzayat EA, Elhilali MM. Holmium laser enucleation of the prostate (HoLEP): the endourologic alternative to open prostatectomy. *Eur Urol.* 2006;49(1):87–91.
16. Kuntz RM, Lehrich K, Ahyai SA. Holmium laser enucleation of the prostate versus open prostatectomy for prostates greater than 100 grams: 5-year follow-up results of a randomised clinical trial. *Eur Urol.* 2008;53(1):160–6.
17. Elzayat E, Habib E, Elhilali M. Holmium laser enucleation of the prostate in patients on anticoagulant therapy or with bleeding disorders. *J Urol.* 2006;175(4):1428–32.
18. Elzayat EA, Elhilali MM. Holmium laser enucleation of the prostate (HoLEP): long-term results, reoperation rate, and possible impact of the learning curve. *Eur Urol.* 2007;52(5):1465–71.
19. Fraundorfer MR, Gilling PJ, Kennett KM, Dunton NG. Holmium laser resection of the prostate is more cost effective than transurethral resection of the prostate: results of a randomized prospective study. *Urology.* 2001;57(3):454–8.
20. Kuo RL, Paterson RF, Kim SC, Siqueira Jr TM, Elhilali MM, Lingeman JE. Holmium Laser Enucleation of the Prostate (HoLEP): A Technical Update. *World J Surg Oncol.* 2003;1(1):6.
21. Krambeck AE, Handa SE, Lingeman JE. Experience with more than 1,000 holmium laser prostate enucleations for benign prostatic hyperplasia. *J Urol.* 2013;189(1 Suppl):027.
22. Elmansy HM, Kotb A, Elhilali MM. Holmium laser enucleation of the prostate: long-term durability of clinical outcomes and complication rates during 10 years of followup. *J Urol.* 2011;186(5):1972–6.
23. Aho TF, Gilling PJ. Current techniques for laser prostatectomy—PVP and HoLEP. *Arch Esp Urol.* 2008;61(9):1005–13.
24. Naspro R, Bachmann A, Gilling P, Kuntz R, Madersbacher S, Montorsi F, et al. A review of the recent evidence (2006–2008) for 532-nm photoselective laser vaporisation and holmium laser enucleation of the prostate. *Eur Urol.* 2009;55(6):1345–57.
25. Wheelahan J, Scott NA, Cartmill R, Marshall V, Morton RP, Nacey J, et al. Minimally invasive laser techniques for prostatectomy: a systematic review. The ASERNIP-S review group. Australian Safety and Efficacy Register of New Interventional Procedures—Surgical. *BJU Int.* 2000;86(7):805–15.
26. Wilson LC, Gilling PJ. From coagulation to enucleation: the use of lasers in surgery for benign prostatic hyperplasia. *Nat Clin Pract Urol.* 2005;2(9):443–8.
27. Cornu JN, Terrasa JB, Lukacs B. Ex-vivo comparison of available morcellation devices during Holmium laser enucleation of the prostate through objective parameters. *J Endourol.* 2012; Epub ahead of print.
28. Elmansy HM, Kotb A, Elhilali MM. Is there a way to predict stress urinary incontinence after holmium laser enucleation of the prostate? *J Urol.* 2011;186(5):1977–81.

Matthew R. Thom and Howard N. Winfield

Introduction

The role and ethical obligation of providing each patient relevant information regarding medical procedures is not a new concept. However, the legal ramifications of the informed consent process have evolved dramatically over the past century. Similarly, the ever-changing and rapid advancement of urologic surgery requires that the physician-surgeon must be ever aware of the planned procedures, the alternatives, and a detailed understanding of potential risks. In this way, the patient should receive a comprehensive and informed discussion with the patient. Having the knowledge is only part of the consent process; the surgeon must be able to process all information and then deliver this information in a concise but detailed enough manner in a language that the patient can understand, synthesize, be able to ask appropriate questions, and then decide on appropriate course of action, either acceptance or refusal. The ability of obtaining an informed consent is not necessarily an innate skill for all physicians but is something that must be taught and learned over time with appropriate experiences further helping communication with the patient and his or her family. This chapter will

focus on the basics of the informed consent process and provide a framework that the urologist may use for the discussion of minimally invasive urologic surgery with their patients.

Historical and Legal Background of Informed Consent

The modern doctrine of informed consent emerged during the early eighteenth century with the gradual triumph of certain rights of the individual. During worldly events such as the American and French revolutions, the idea of each human possessing certain inalienable rights to freedom of self-determination became integral to the politics, the philosophy, and the culture of modern Western civilization. Since that time, several landmark legal decisions in the United States have molded the informed consent process into what it represents today. One such well-known case, *Schloendorff vs. Society of New York Hospital* [1], involved a patient bringing suit against her surgeon for failing to obtain consent for performing a hysterectomy. Although no action was taken against the surgeon, Justice Benjamin Cardozo's decision included several precedent-setting statements that established the legal requirement for consent. One such statement, "every human being of adult years and sound mind has a right to determine what shall be done with his own body," connected consent with the principle of self-determination. In 1972, the

M.R. Thom, MD (✉) • H.N. Winfield, MD
West Alabama Urology Associates,
DCH Regional Health System,
701 University Blvd. E, Suite 908, Tuscaloosa,
AL 35401, USA
e-mail: matthew.thom@dchsystem.com

Table 18.1 Four fundamental elements for valid decision making during the process of informed consent

1. The patient or surrogate must possess the capacity to make a decision, consenting to or refusing treatment
2. There must be disclosure by the physician of the information that the patient or surrogate needs in order to be adequately informed
3. The patient or surrogate must demonstrate comprehension of the information
4. The patient or surrogate must consent to or refuse treatment in a voluntary fashion

Faden and Beauchamp [3]

US Court of Appeals in reviewing a case later referred to as the Canterbury Decision [2] enunciated four “first principles” to guide physicians in a process of shared decision making and informed consent. These principles found in Table 18.1 [3] include the obligation to disclose information needed by a reasonable person to make an informed decision under reasonable circumstance and that the obligation of informed consent may be set aside only under exceptional circumstances: emergencies for life-saving treatment and rare situations in which disclosure presents the threat of harm to the patient’s well-being. These and related cases generated changes in surgical culture by defining the standard of care to which surgeons must adhere. Now, inadequate informed consent is usually considered a tort of negligence rather than battery. The courts further enhanced patient self-determination by explicitly requiring and clarifying the nature and content of a patient’s informed consent for surgery.

Basics of Informed Consent

Beyond the law, informed consent is the cornerstone of ethical surgical practice because it safeguards respect for patients. It recognizes that patients are independent persons endowed with self-worth and the basic human right of independence. Informed consent highlights the regard for patients’ rights to make decisions for themselves according to their own concept of what constitutes the good life and with freedom to act on their decisions. Based on the standard conception of medical ethics, informed consent is fundamental

to ethical practice because it is the mechanism by which patients autonomously authorize medical interventions as courses of treatments. Informed consent of a competent patient gives control to the individual to accept or reject healthcare interventions and manage their medical destiny on the basis of their own personal values and goals while also functioning as a constraint on physician’s power and paternalistic instincts. Before discussing the specifics of the minimally invasive urologic surgery, an overview of the basic components and fundamentals of informed consent is warranted. Informed consent represents the process whenever the patient is educated about the treatment options, alternatives to the options, the potential risk and complications of the treatments, the intended benefits of treatment, and reasonable expectations. Because of its legal origins and the requirement for the patient’s signature on a printed consent form, some surgeons view consent solely as a legal prerequisite that often is delegated to a junior colleague. But the patient’s signature on the surgical consent form is not the patient’s consent. Informed consent represents the process of communication and dialogue between the physician and patient; thus, a signed alone consent form does not guarantee consent but is merely the culmination and formalization of the preceding discussion and agreement between physician and patient or patient surrogate. The urologist must be aware of the ever-changing and advancing field to insure that all specific alternatives were discussed and that the discussion of potential risks must include not only immediate threat but represent the future long-term sequelae of the procedure given the nature of many urologic surgeries. Medical ethicists and legal authorities have identified key elements that when presented together established true conditions for a valid consent [4]. These include a voluntary decision making, patient competence, full disclosure, understanding and acknowledgement of facts and information, and ultimately authorization or decline of the proposed course of treatment. These key elements have been reiterated by several national organizations including the American Medical Association [5], American College of Surgeons [6], Joint Commission on

Table 18.2 Essential elements of informed consent

The nature of the proposed therapeutic (or diagnostic) intervention
The purpose and intended benefits
The possible risks and consequences
The probability of success
The feasible alternatives
The patient's prognosis without the proposed intervention

American Urological Association [Internet] [10]

Accreditation of Healthcare Organizations [7], Department of Health and Human Resources Center for Medicare and Medicaid services [8], and the Federation of State Medical Boards [9]. Table 18.2 lists the essential elements of informed consent that require discussion and disclosure with the patient as stated by the American College of Surgeons and American Urological Association (AUA) [10]. Also, the AUA, in conjunction with the American Medical Association, includes in its ethical standards a statement on informed consent found in Box 18.1 [11].

Box 18.1

Ethical standards statement on informed consent

I will consider informed consent integral to providing appropriate medical or surgical care. I recognize that my patient must be provided with all of the information necessary to consent and to make his own choice of treatment, regardless of my own advice or judgment. The information provided must include known risks and benefits, costs, reasonable expectations and possible complications, available alternative treatments and their cost, as well as the identification of other medical personnel who will be participating directly in the care delivery. Wherever feasible, I will respect my patient's rights and be limited by the scope of my patient's consent

American Medical Association [Internet] [11]

Decision-making capacity refers to the ability of a patient to make a particular healthcare decision within the confines of a certain clinical context. Capacity should not be confused with competence, with the former representing the physician's ability to assess each individual

patient's capacity to understand their health situation and the later pertaining to a legal determination made by the courts of law. There are three standards for determining healthcare decision-making capacity: outcome-based, category-based, and function-based, with the first two considered unethical given the inherent biases they include during the informed consent process [12]. Function-based standard entrusts the physician to assess the patient's or surrogate's ability to understand all necessary information, reason with a relatively consistent set of values, and communicate preferences to the physician. When assessing capacity, one must account for the underlying mental health of the patient as psychiatric consultation may prove helpful in making this determination.

The consent process is not solely physician driven and relies on both a competent surgeon and a competent, informed patient or patient's surrogate in the situation of a minor, incompetent or incapacitated patient. In obtaining informed consent, most advocate a process of shared decision making. With this view, physicians must engage patients and their family to participate in the deliberations about the procedure, and information flow should be two-way. Therefore, the physician and patient share in the final decision-making process. In addition, physicians have a duty, based on their own values and status as mere agents, to respectfully challenge their patients when they perceive the patient's choices are contrary to their own interest. A most important part of informed decision process is disclosure. Disclosure is a duty of the physician to insure the patient or surrogate is presented with appropriate information to make a healthcare decision. There are exceptional circumstances in which it may be permissible for physicians to set aside the duty of disclosure. In emergencies, disclosure may be impossible or so time-consuming as to jeopardize the health of the patient. Patients or surrogates may also waive their rights to information that would otherwise be disclosed. In exceedingly rare instances, physicians may invoke therapeutic privilege out of concern that disclosure may actually harm, rather than benefit, the patient. Finally, after all information has been presented,

Table 18.3 Major complications of laparoscopic urologic surgery

Procedures	Abdominal (%)	Pelvic (%)
Overall complications	13.2	22.6
Intraoperative/postoperative	5.7/7.5	3.6/19
Deaths	0.2	0
Vascular injury	2.8	0.5
Bowel injury	1.1	1.2
Adjacent organ injury	1.1	0.8
Conversion rate	1.7	1.7

Parsons et al. [14], Vallancien et al. [15]

the physician must ensure that patients or surrogates have understood or comprehended the disclosed information. A practical way in doing this is to ask the patient or surrogate to repeat in their own words what they believe they are consenting to or refusing voluntarily. Persuasion in making these recommendations is legitimate; however, it is unethical to use either manipulation or coercion in an effort to secure consent.

There are several unresolved issues when obtaining an informed consent. Given the complexity of minimally invasive urologic procedures, the degree of disclosure is often confusing and a matter of debate and uncertainty. A true and complete informed consent whereas the patient has a complete and total understanding would require a good amount of prior knowledge and for most patients is not obtainable. Therefore, surgeons need to disclose what they believe is sufficient based on facts and information about the magnitude of possible harm by addressing specific adverse events with obligation to disclose risks that are likely to occur. This disclosure should be based on what a reasonable patient would wish to know. With advancement of minimally invasive urology, disclosure to patient should include the importance of making the patient aware of the learning curve for proposed procedure and surgeon experience.

Informed Consent for Urologic Minimally Invasive Surgery

Introduction

Other chapters of this text will discuss the nature and incidence of procedure-specific complications and their management. Although

minimally invasive procedures are ultimately similar to open procedures at their core, laparoscopy, robotics, and all minimally invasive urology present an entirely different and additional set of potential risks, which must be adequately discussed with the patient during the informed consent process. An examination of the general complications reveals aspects of laparoscopy that the surgeon should be aware of and have litigious risk. The overall incidence of complications in laparoscopic urologic intervention (see Table 18.3) has been historically low around 4 %, with mortality being distinctively unusual, less than 0.08 % [13]. Yet, with increasing complexity and with advancement of techniques and procedures, rates or complications have appeared to rise with some literature reporting complication rates as high as 12 % [14]. These are most commonly vascular in origin followed by bowel injury, with pelvic surgery having a higher incidence of immediate complications compared with transabdominal procedures.

Conversion to Open

The inability to complete an operation in a minimally invasive fashion should not be viewed as a failure or complication. The preoperative consultation with the patient and consent should consider this possibility. Multiple factors should alert the surgeon as to the increased possibility of open conversion including prior abdominal surgery, patient habitus, or specific abnormalities as seen on preoperative exam. The patients' medical comorbidity may not allow the patient to tolerate laparoscopic or robotic intervention. Although sometimes difficult to predict which patients may require conversion, the rates do seem to decrease

with surgeon experience. Incidence of open conversion is generally low, less than 2 % in larger series for the experienced laparoscopic surgeon [15]. Clearly, this is largely surgeon dependent. The necessity for emergent conversion due to bleeding or other injury should be avoided with an elective conversion bearing much better outcomes. Thus, a frank discussion with the patient regarding surgeon experience and possibility of conversion must be disclosed preoperatively. The urologists' skill to perform open surgery continues to be very important in the event of conversion. Unfortunately with the increasing utilization and advancement of minimally invasive surgery as well as low conversion rate, training in open pelvic and abdominal/retroperitoneal surgery is becoming less and less common for residents. Furthermore, urologists in practice, overtime, may not be able to maintain satisfactory skills in open surgery.

Laparoscopic Access

Creation of pneumoperitoneum with access to the intra-abdominal or extraperitoneal spaces is the first step in performing minimally invasive urologic surgery. Although at times seemingly trivial, this critical and essential aspect of the operation may be associated with significant patient morbidity and can be the primary complication of malpractice claims. Access may be gained with either the closed, Veress needle or open, Hasson, techniques, any of which have been associated with complications. Incidence of access injuries is low with injury to vasculature and abdominal viscera occurring more commonly particularly with the close needle technique and blind trocar insertion. Device and equipment malfunction is rarely involved with such injuries. It is important for the surgeon to understand and be facile with both the closed- and open-entry techniques with the placement of trocars under direct vision, when applicable. The surgeon must be capable of managing these injuries appropriately and quickly. Preoperative evaluation and discussion during the informed consent process regarding ability to perform laparoscopic access is important.

Positioning

As with open urologic procedures, patient positioning on the operating table may result in temporary and rarely permanent morbidity unless proper precautions are considered. Advancement in minimally invasive procedures undertaking more complex anatomy and procedures have exposed patients to different positioning-related injuries, often due to longer surgical time and need for unnatural positioning, including modified flank or steep Trendelenburg. Proper positioning and padding is necessary to avoid neuromuscular injury. This process starts with an appropriate preoperative discussion with the patient of the possibility and overview of this possible risk. No problem is more vexing to physician and patient than postoperative nerve injury; a technically successful procedure is marred by a significant musculoskeletal complication. The incidence is largely unknown, but a large meta-analysis demonstrated a rate of 2.7 % in over 1,500 laparoscopic procedures [16].

Deep Vein Thrombosis (DVT)

The risk of venous thromboembolism in laparoscopic and robotic-assisted operations appears to be low, with rates between 0.2 and 1.2 %. There is no evidence that acute venous thromboembolism occurs more frequently with minimally invasive surgery compared with open procedures [17]. Specifically, the rate of symptomatic DVT between minimally invasive radical prostatectomy and open prostatectomy is similar at 0.5 % [18]. The American Urological Association (AUA) has released a "Best Practice Statement" for the prevention of DVT in patients undergoing urologic surgery [19]. Although no randomized trials have been performed to date addressing the issue of prophylaxis in patients having laparoscopic or robotic surgery, the AUA panel recommends the use of pneumatic compression stockings placed prior to such procedures for all patients. Additionally, the AUA acknowledges that certain high-risk groups may require the use of low-dose unfractionated heparin or low-molecular-weight heparin before, during, and/or

after the procedure. A nonrandomized study looked at rates of DVT between groups of patients undergoing upper tract laparoscopic procedures receiving standard of care with sequential compression devices versus subcutaneous heparin on the day of procedure. The rate of DVT was 1.2 % for both groups but the rate of hemorrhagic complications (most major) was higher in the heparin group at 9.3 %, compared with 3.5 % in sequential compression device group [20].

Issues with Robotics

Although the application of robotic assistance in urology has been present for over 10 years, the technology and techniques should still be considered new and thus the informed consent process with patients should be thorough. The standard disclosure of the risk and benefits that surgeons should provide to their patients is constantly changing as the short- and long-term results of robotic surgery evolve. This is especially true for any urologic technique that is novel and only recently been performed. It is this surgeon's duty to inform the patient and their family the details of the proposed operation as well as the surgeon's experience with this type of surgery. A discussion and disclosure of the number of procedures a particular surgeon has performed and the familiarity of that particular procedure is mandated. One important aspect for all robotic surgery is to discuss the remote nature of the surgery (i.e., the console surgeon is physically removed away from the operating table and the patient). In addition, it is important to explain to the patient the possibility of robot equipment failure and the possible need to convert to standard laparoscopy or an open procedure. Overall, robotics is very successful with a malfunction rate (uncorrectable errors) of less than 0.5 % [21].

Discussion of Innovations

Urologic surgeons are fortunate to practice in a field with continuous improvements in equipment and techniques as well as innovative new

procedures. Much of current minimally invasive operative urology would have been unimaginable over 25 years ago. However, one must view these advancements carefully and respect the ethical and legal obligations to the patients we care for. There has been very rapid growth of laparoscopic and robotic surgery, often based on small, nonrandomized, and retrospective clinical trials. Urologists must remain cautious and critical in the adoption of new operations, especially if safety and benefits have not been clearly delineated. The urologist must be willing to have a comprehensive discussion with one's patient anytime they intend to use new equipment, technology, or approach. This should include a careful review of the proven "gold standards" as well as alternatives. Whether it is feasible to prove the efficacy, effectiveness, equanimity, and economy of new procedures remain to be determined, but without such evidence, exposure to medical malpractice will exist. This aspect is also important regarding surgeon credentialing for robotic and laparoscopic surgery at hospitals, as all new procedures clearly have a learning curve. Most facilities have specific credentialing guidelines for surgeons including inanimate, animal, or cadaveric hands-on training, mandatory participation as assistant surgeon for sufficient number of cases, as well as monitored cases by an expert surgeon in that particular technique and/or operation. Surgeons must demonstrate proficiency before being allowed to schedule primary cases. The future of credentialing is likely to dramatically change as the brief weekend courses are unlikely to be considered sufficient from both regulatory and ethical points of view. These mandates are important to protect the physician, hospital, and most importantly patients.

Improving the Surgical Consent Process

Several pitfalls have been identified with the surgical consent process. Two such drawbacks are the perceived or real lack of time for dialogue with patients and poor timing of the consent

discussion [22]. All surgeons should conceptualize the consent process as not a discrete event but as an ongoing bidirectional process of communication, education, question answering, and listening that proceeds through the continuum of care. The surgeon must remember that each individual patient will bring to the discussion their own personal values, information, knowledge, and understanding biases based on what they have heard from family and friends relative to their disease process as well as potential treatment options. Recital of a premeditated discussion will work with the majority of patients but may need to be modified in certain situations based on patient characteristics. Also, the surgeon cannot rely on the belief that the patient has a clear understanding simply by the verbal acknowledgement of the consent discussion. Providing supplementary materials such as descriptive handouts and videos will assist the patient and allow sufficient time to digest the medical information and be capable of asking further pertinent questions. A follow-up discussion prior to procedure will help to crystallize what is surgically planned and certainly limit subsequent confusion or litigious behavior on the part of the patient. This is particularly important in discussing advanced laparoscopic, robotic, and other minimally invasive procedures. A review of patients undergoing laparoscopic urologic surgery demonstrated a positive impact on postoperative satisfaction scores by employing videos during the preoperative consent process [23]. Ensuring adequate communication with patients has been shown to have an important secondary benefit with reduction of surgical malpractice claims [24]. Patients are often encouraged to have a “living will” or at least identify the next of kin who can assist with health-related decisions should the patient become incapacitated. Although unlikely with the vast majority of urologic procedures, there certainly is that risk with minimally invasive intervention. Therefore, all patients facing elective surgery in our practice are asked and encouraged to execute a legal health-care directive document identifying person(s) to make health-related decisions for them. Finally, surgeons must always remember to maintain an attitude of hope with their patients and families.

A strong patient-surgeon relationship, nurtured by good communication, mutual understanding, and trust, remains a powerful therapeutic instrument.

Conclusion

With the ever-advancing and changing field of urology, informed consent for minimally invasive urologic procedures is important and continually evolving. Urologist must continue to stay informed so as to provide comprehensive, clear, and legally acceptable informed consent documentation for their patients.

References

1. Court Hearing: *Schloendorff v Society of New York Hospital* 211 NY 125, 105 NE 92. 1914.
2. Court Hearing: *Canterbury v Spence*, 464 F2d 772 (DC Cir 1972), 409 US 1064. 1972.
3. Faden RR, Beauchamp TL. A history and theory of informed consent. New York: Oxford University Press; 1986.
4. Meisel A, Roth LH, Lidz CW. Toward a model of the legal doctrine of informed consent. *Am J Psychiatry*. 1977;134(3):285–9.
5. American Medical Association [Internet]. Informed consent. <http://www.ama-assn.org/ama/pub/category/4608.html>. Accessed Sept 2013.
6. American College of Surgeons [Internet]. Statement on principles. http://www.facs.org/fellows_info/statements/stonprin.html.
7. Joint Commission on Accreditation of Healthcare Organizations [Internet]. Hospital Accreditation Standards. Joint Commission Resources. http://www.jointcommission.org/standards_information/standards.aspx.
8. Department of Health and Human Resources Center for Medicare and Medicaid Services [Internet]. Revisions to the hospital interpretive guidelines for informed consent. <http://www.cms.hhs.gov/SurveyCertificationGenInfo/downloads/SCLetter07-17.pdf>.
9. Federation of State Medical Boards, [Internet]. Report of the special committee on outpatient surgery. http://www.fsmb.org/pdf/2002_grpol_Outpatient_Surgery.pdf.
10. American Urological Association [Internet]. Valid decision making: the law and ethics of informed consent or refusal. www.auanet.org.
11. American Medical Association [Internet]. Joint statement with American Urological Association on informed consent. <http://www.ama-assn.org/ama/pub>.

12. Drane JF. Competency to give informed consent: a model for making clinical assessments. *JAMA*. 1984;252(7):925-7.
13. Fahlenkamp D, Rassweiler J, Fornara R, Frede T, Loening SA. Complications of laparoscopic procedures in urology: experience with 2407 procedures at 4 German centers. *J Urol*. 1999;162:765-70.
14. Parsons JK, Varkarakis I, Rha KH, Jarrett TW, Pinto PA, Kavoussi LR. Complications of abdominal urologic laparoscopy: longitudinal five-year analysis. *Urology*. 2004;63(1):27-32.
15. Vallancien G, Cathelineau X, Baumert H, Doublet JD, Guillonnet B. Complications of transperitoneal laparoscopic surgery in urology: review of 1,311 procedures at a single center. *J Urol*. 2002;168(1):23-6.
16. Wolf JS, Marcovich R, Gill IS, Sung GT, Kavoussi LR, Clayman RV, Polascik TJ. Survey of neuromuscular injuries to the patient and surgeon during urologic laparoscopic surgery. *Urology*. 2000;55(6):831-6.
17. Abdel-Meguid T, Gomella L. Prevention and management of complications. St. Louis: Quality Medical Publishing; 1996.
18. Secin FP, Jiborn T, Bjartell AS, Fournier G, Salomon L, Abbou CC, et al. Multi-institutional study of symptomatic deep venous thrombosis and pulmonary embolism in prostate cancer patients undergoing laparoscopic or robot-assisted laparoscopic radical prostatectomy. *Eur Urol*. 2008;53(1):134-45.
19. Forest JB, Clemens JQ, Leveillee R, Lippert M, Pisters L, Touijer K, et al. Best practice policy statement for the prevention of deep vein thrombosis in patients undergoing urologic surgery. 2008.
20. Montgomery JS, Wolf JS. Venous thrombosis prophylaxis for urological laparoscopy: fractionated heparin versus sequential compression devices. *J Urol*. 2005;173(5):1623-6.
21. Lavery HJ, Thaly R, Albala D, Ahlering T, Shalhav A, Lee D, et al. Robotic equipment malfunction during robotic prostatectomy: a multi-institutional study. *J Endourol*. 2008;22(9):2165-8.
22. Edwards WS, Yahne C, Thomas G. Orr memorial lecture: surgical informed consent: what it is and is not. *Am J Surg*. 1987;154:574-8.
23. Sahai A, Kucheria R, Challacombe B, Dasgupta P. Video consent: a pilot study of informed consent in laparoscopic urology and its impact on patient satisfaction. *JLS*. 2006;10(1):21-5.
24. Levinson W, Roter DL, Mullooly JP, Dull VT, Frankel RM. Physician-patient communication: the relationship with malpractice claims among primary care physicians and surgeons. *JAMA*. 1997;277:553-9.

Daniel Ramirez and Yair Lotan

Introduction

With the rising costs of healthcare in the United States, financial and economic factors are having a greater effect on how medical care is delivered and how medical technology is developed [1, 2]. It has been estimated that, in the coming years, healthcare expenditure in the United States will make up 18.4 % of the gross domestic product [1]. Insurers, hospitals, and government agencies are closely monitoring these healthcare expenditures. These institutions ultimately have an enormous impact on the services available to physicians and patients. In order for urologists to reliably provide the best care and value to our patients, it is imperative that we understand the economic effects our treatment decisions have on our patients and the healthcare system as a whole.

In any discipline, enhancement of accountability and execution is contingent on each party having common objectives which take into consideration the motives and interests of each participant in the system. In healthcare, different participants often have different priorities and goals that have made how we measure success

difficult. Therefore, it is important that we have a shared goal and clearly defined path toward improvement with defined measures and values. Value in healthcare has previously been defined as patient outcomes achieved per dollar amount spent [3, 4]. Reporting and evaluating outcomes while comparing costs are crucial parts of improving outcomes on a wider scale and will help physicians make educated decisions to reduce cost while maintaining the best value for their patients. In this chapter, we will explore economic aspects of healthcare while focusing on minimally invasive urology.

Understanding Economics Related to Healthcare

In order to understand healthcare economics, one must learn the language and become acquainted with the important parts of the system. These economic-related parameters include payer perspectives, costs versus charges, and discounting. We will define these terms and discuss the importance of these issues in this section of the chapter.

Payer Perspectives

When discussing healthcare costs, there are three payer perspectives that are involved: society, hospital systems, and patients themselves. Understanding

D. Ramirez • Y. Lotan, MD (✉)
Department of Urology,
University of Texas Southwestern Medical Center,
5323 Harry Hines Boulevard, Dallas,
TX 75390-9110, USA
e-mail: yair.lotan@utsouthwestern.edu

the prospective of each of these players will help us understand the true costs of healthcare and how they affect the entirety of the system.

The societal prospective includes direct and indirect costs. Direct costs are defined as the costs directly paid into the healthcare system by Medicaid and Medicare, private insurers, and direct costs taken into account in the overall national healthcare budget. Indirect costs are more difficult to gauge and may include loss of gross national revenue due to loss of productivity during illness, recovery, or that incurred by caregivers.

The payer perspective of hospital systems typically is more straightforward to measure as most of the resources are accounted for, itemized and budgeted. Costs incurred by the hospital system include the resources needed to deliver care (diagnostic testing, procedures, postoperative care, follow-up, etc.). These costs include direct costs that can be individualized to each patient treated. Such costs include tests, procedures, room and board, nursing care, etc. Other costs taken on by hospitals are those that cannot be individualized to each patient and those include administrative overhead and capital equipment (i.e., surgical supplies such as monitors, hospital beds, etc.). When measuring cost-effectiveness of surgical procedures, the cost of capital equipment plays a major role. For example, the use of robotics in prostatic surgery has not changed the payment a hospital receives, though the use of the robot increases the cost to the hospital since the hospital has the added cost of purchase and maintenance of the robot as well as the nonreusable equipment utilized in each case [5, 6]. The budget for the hospital system is usually divided among the different departments. When obtaining new technologies or maintaining existing equipment, the cost must be viewed in relation to the entire hospital budget since added costs in one area may result in cost savings in others. For example, laparoscopic nephrectomy has added costs for operative equipment but results in significantly lower overall hospital costs as a result of shorter length of stay and lower use of postoperative medications [7, 8].

The patient's payer perspective can be subjective and depends on employment status, social and familial support, and individual insurance plans. These idiosyncrasies make measuring patient costs problematic. Ultimately, access to care is influenced primarily by the ability to pay for it. A patient with healthcare coverage through employers or those with financial independence are typically more likely to seek preventative and proactive healthcare, whereas those patients without insurance may delay their care until they must be urgently seen. These factors may have lesser effects in societies that provide free or heavily subsidized medical care to its citizens. It is still unclear what impact the Affordable Care Act will have on urologic care in America.

Costs Versus Charges

There exists a pervasive misunderstanding between what a provider charges, what they are actually reimbursed, and the true cost of a service. This confusion makes reviewing the literature difficult as the terms *charge* and *cost* are used interchangeably. The charge for a specific service takes into consideration the direct and indirect costs to the provider and profit margins. These values may vary greatly from region to region and between hospital systems as there are significant differences in the manner in which these figures are derived. While charge data is typically easier to obtain from hospital accounting offices, they include profit margins and thus do not accurately reflect resource allocation. Other confounding factors in regard to charge figures include differences in cost-to-charge ratios and reimbursement rates. Hospitals usually do not get paid what they charge as price negotiations with insurers, and patients typically drive reimbursements down. Thus, cost figures serve as a more uniform way to determine the value of a service and compare different management options.

Unfortunately, there can exist variability between cost figures as well. In terms of capital equipment and technology, utilization has a direct

effect on cost. This is true for robotic platforms, hospital beds, laparoscopic equipment, etc. As the capital equipment is utilized for more patients, the unit cost per patient decreases. On the other hand, costs of medications and single-use items can be ascertained with more accuracy, though their costs are highly variable from vendor to vendor and typically depend on the volume of purchase.

Discounting is used to compare current costs to future costs [9] and is typically used when near-term value is prized more so than later outcomes [10, 11]. A yearly discounting rate of 3 % to future costs is typically used in most cost analyses and is based on annual inflation rates in the United States [11]. Discounting is necessary in cost comparison analyses involving treatments which have high initial cost but potential cost-effective benefits that take time to emerge [12, 13]. Furthermore, it is important to account for inflation and adjust costs over time especially in retrospective analyses since costs may appear to increase when comparing new procedures versus old procedures when in fact there is no difference after adjusting for inflation.

The Economics of Nephrolithiasis

Treatment of stone disease in the United States is associated with a high cost due to the disease prevalence and high rates of recurrence. Lifetime prevalence of nephrolithiasis in the United States has risen to 8 % over the last decade [14], and annual total indirect and direct costs of treatment were estimated to be \$5 billion [15, 16]. These costs will likely continue to rise as prevalence of stone disease increases especially considering the fact that diabetes and obesity which are both risk factors for stone disease are also increasing in prevalence. In 2000, nearly two million outpatient visits were documented for the primary diagnosis of urolithiasis, and between 1992 and 2000, outpatient visits for management of stone disease increased to 40–43 % [15].

As previously discussed, there exist indirect costs related to stone disease. The incidence of

urolithiasis peaks during the most productive adult years, between the ages of 20 and 60. Indirect costs include social service fees and loss of productivity of patients and caregivers alike. A review of over 300,000 insured US workers found that renal stone disease accounted for \$3,500 more in medical costs annually compared to matched workers without urolithiasis [16]. This study also found that 30 % of employees with stone disease missed 19 h of work per year on average and the cost of outpatient medications accounted for 18 % of spending.

Potential ways to lower the overall cost of treating stone disease include reducing the prevalence of urolithiasis and lowering treatment-related costs. Improved guidelines for acute management, optimizing surgical timing, and the use of medical expulsive treatment may facilitate future cost reductions. Reduction of stone recurrences through medical management of stone disease is another potential area of improvement. Refining dietary recommendations, developing new medications, improving compliance, and reducing obstacles to evaluation and treatment may also improve rates of recurrence and prevalence.

Reducing the Cost of Treating Stone Disease

Theoretically, the cost of surgical management of stone disease can be reduced by decreasing physician reimbursement, cost of the procedure, and cost of hospitalization. Reducing physician reimbursement has not reduced the cost of surgical procedures, and future reductions in physician reimbursement will likely result in decreased access to services for patients. Physician reimbursements have decreased to 25–32 % from 1995 to 2004 [17]. Over that time, reimbursement rates have decreased by \$236, \$55, and \$174 for shockwave lithotripsy (SWL), ureteroscopy (URS), and percutaneous nephrolithotomy (PCNL), respectively. In addition, these decreases in reimbursement did not take into consideration inflation; thus, the changes are actually higher

than what is reported. If compensation for physicians continues to decline, it may result in some urologists abandoning certain treatments and tests. This in turn will have a negative consequence on the cost of services as availability will be reduced, making resources scarcer. A study by O'leary et al. published in 2002 demonstrated that 16 % of urologist discontinued several surgeries secondary to decreased reimbursement rates [18]. It has been previously shown that every 1 % reduction in Medicare fees for "overpriced" surgeries results in a 0.09 % decrease in volume of procedures [19]. This decrease in availability will likely affect patients in rural communities where access to care is limited. Consequences of limited access to care include an increase in indirect costs such as travel and loss of work as well as potential increase in complications related to delay in care.

Surgical Management of Stone Disease

Traditionally, SWL has been the most common treatment choice for management of small stones [20]. Improvement in the clinical outcomes and cost-effectiveness of SWL hinges on selecting patients who are more likely to be treated successfully. Recently, slowing the rate of shocks during SWL has been shown to improve treatment efficiency and decrease costs by 50 % [21]. Endoscopy for the management of nephrolithiasis has recently become more popular among recently trained urologists [20, 22]. While there are few randomized trials comparing URS to SWL, available data shows an advantage of URS when compared to SWL in management of distal ureteral stones, with lack of evidence to conclusively compare results for stones in other areas [23]. Regardless of the heterogeneity and limited scope of study, ureteroscopy has been shown to be more cost-effective than SWL [24, 25]. Further studies regarding cost comparison of these approaches will need to review short-term costs (i.e., operative supplies, hospital stay, OR time), long-term costs (i.e., need for future intervention, future stone events), and indirect costs (i.e., loss of productivity, travel, out-of-pocket expenses).

A study by Chu et al. retrospectively reviewed the use of pre-placed stents prior to URS and demonstrated that the use of a pre-placed stent reduced the indirect and direct costs in patients with stones >1 cm, though this study only reviewed reimbursement data [26]. More research focusing on cost analysis is required to establish the cost-effectiveness on URS for larger stones, staged procedures, timing of stenting, and comparison to alternative treatment strategies such as PCNL.

PCNL is the standard of care for renal stones >2 cm in size [27] and has been shown to have superior stone-free rates and decrease costs in these patients [28]. PCNL may incur higher short-term costs secondary to inpatient hospitalization and disposable equipment costs, but its superiority in removing large burdens of stone leads to a long-term cost benefit [24, 28]. Bagrodia et al. demonstrated that the only factor associated with increased cost with PCNL was stone size as larger stones were more likely to increase cost by increasing need for second-look procedures [29]. In a follow-up study on the same cohort of patients, Raman et al. determined that second-look flexible nephroscopy was cost-effective when done in patients who still had >4 mm of stone burden [30]. The cost-benefit analysis was greatly impacted by the supposition that these patients would likely go on to have further stone episodes requiring surgical treatment and, therefore, incurring more costs. In regard to patients with sizeable bilateral stone burden, it is not well defined if staged versus synchronous management is cost-effective. Another study addressed this issue and found that bilateral synchronous PCNL reduced cumulative OR time, length of hospitalization, and overall cost [31]. In the same study, the authors reported that physician reimbursement was significantly decreased compared to staged methods offering a disincentive for urologists to follow this approach. This is a critical point as certain reimbursement arrangements can affect how physicians practice and may provide disincentives for physicians to pursue cost-effective treatment modalities overall.

Tubeless PCNL has become an attractive alternative in select patients to reduce morbidity

and improve convalescence. Studies have shown its efficacy in decreasing length of stay, decreasing postoperative narcotic requirement, operative time, and leakage of urine [32]. While this technique may be cost-effective in certain cases, there is no available data to support such a claim. More studies are needed to evaluate tubeless PCNL and compare it to more traditional methods as these patients often require ureteral stenting and staged procedures.

The majority of the expense of treatment of urolithiasis is associated with high costs of equipment as the majority of care is provided on an outpatient basis. Ten to 20 % of new stones lead to symptomatic presentations, and 50 % of these symptomatic patients ultimately require surgery [33]. According to the UDA, 54 % of stones are treated via SWL, 41 % via URS, and 5 % by PCNL [15]. The cost of a modern ureteroscope can range from \$12,000 to 15,000 with estimated durability being 11–14 cases [34]. This does not take into account maintenance costs, which can range from \$3,500 to \$5,900 per scope. It has been shown that after repairing a ureteroscope one time, additional maintenance needs increase, so much so that it may be more cost-effective to replace device initially than to repair it multiple times [35]. Techniques can be employed to reduce the incidence of damage to ureteroscopes, including displacing lower pole stones to more accessible areas of the collecting system to minimize undue torquing to the device, avoiding engagement of the laser beam while the tip of the fiber is within the working port, using smaller caliber fibers and baskets, and using ureteral access sheaths to protect the scope. SWL machines typically cost more than \$500,000 and efficacy of newer models has been shown to be inferior to the original HM3 units [28]. When performed on an outpatient basis, URS is more cost-effective than SWL and both have low morbidity [28].

When patients present with an acute stone episode, the large majority is managed as outpatients, with 25–30 % admitted to the hospital. Many of these patients who are admitted are still managed expectantly. Clark et al. found that amid 6,406 patients admitted to a hospital in the United

States, only 24 % had their stone definitive treated during their admission [36]. Among the 2,895 patients who were managed conservatively, the mean length of hospitalization was 2.7 days and the average patient was charged \$2,153. While many of these patients were admitted for pain control, identifying patients requiring surgical treatment at presentation could potentially save the additional expense of conservative management and possible loss of productivity from postponing surgery. Preventing needless hospital admissions could potentially decrease overall costs as well. Furthermore, the use of medical expulsive therapy has been shown to reduce time to stone passage and associated costs [37].

In conclusion, the cost of nephrolithiasis is likely to rise due to increased prevalence from a growing population and increase in risk factors such as obesity and diabetes. Controlling costs will require optimization of treatment by selection of the most effective treatments and improved prevention strategies.

Economics of Laparoscopic Surgery

Evaluating costs of new technologies requires understanding of the main costs of the new technology such as purchase and maintenance as well as any cost benefit. Surgical therapies are usually driven by costs of equipment (capital, maintenance, and disposables), operative time, and length of stay [7, 8, 38–40]. Other factors that play a significant role in cost analysis of laparoscopic procedures are changes in reimbursement rates, provider incentives, and indirect social costs. Measuring the cost-effectiveness of a specific technique or procedure becomes difficult as different hospitals have different units of measurement and, in some cases, pay different capital costs for the same equipment. This can potentially pose limitation to applicability of data from single institutions as this may not be generalizable to other institutions.

Laparoscopic surgery requires specialized equipment not used in open surgery that potentially adds significant costs to the procedure. These costs include initial capital costs (expenses

incurred when purchasing the equipment) and cost incurred for each individual case. The capital cost can be amortized over multiple years and divided over the number of cases the equipment is used to determine an expense-per-case value. Instruments that are used by multiple services or that have multiple purposes typically add minimal cost per case. Operative equipment costs can also vary greatly from surgeon to surgeon depending on the instruments they prefer. For instance, the choice between hemostatic instruments can significantly influence the expense for a single procedure. Some devices that are commonly used include 5 mm endoscopic clip applicators (\$149.99, Ethicon, Flower Mound, TX), endoscopic staplers (Endo-GIA 60 mm reticulating load \$202, U.S. Surgical, Norwalk, CT), and Hem-o-lok clips (\$57.95 each, Weck Closure Systems, Research Triangle Park, NC). Floseal Matrix and Tisseel fibrin glue (Baxter, Deerfield, IL) cost around \$589 and \$655 per unit, respectively. The use of ablative technologies can also add increased expense to laparoscopic cases, as a single radiofrequency ablation probe used with the Starburst RITA platform (AngioDynamics, Mountain View, CA) or Cool-tip system (Covidien, Mansfield, MA) can add over \$1,000 per case [41]. While these prices have changes overtime, they appear to only be increasing. From 2000 to 2004, the price of annual contracts between high-volume hospitals and laparoscopic equipment suppliers increased more than 4 % even though the number of cases performed annually across the country grew. The increase in cost of laparoscopic equipment has been greater for hospitals with a lower volume of cases.

Operative times and fees associated with anesthesia also account for a large portion of total cost for a procedure. Each additional hour in the operative room can range from \$600 to \$1,400 at the different hospitals at our institution [8, 42]. With laparoscopic surgery, operative times are also impacted by surgeon experience and are characteristically longer at the beginning of a learning curve and vary between procedures. In 2002, Patel et al. demonstrated that for hand-assisted laparoscopic nephrectomy, it took a learning curve of 40 cases to decrease operative times on

average from 275 to 175 min [43]. Laparoscopic radical prostatectomy has proven to be a harder procedure to master, as Guillonnet et al. showed that operative times decreased only on average 66 min over the first 100 cases of a surgeon's experience [44].

Operative times may effect whether a urologist decides which procedures he or she will perform open versus laparoscopic as operative times effect reimbursement rates. Overall, Medicare reimbursement rates for laparoscopic urologic procedures have remained relatively stable compared to their open equivalents; however, the rates of reimbursement are only marginally higher for the laparoscopic techniques. The literature consistently reveals shorter operative times for open versus laparoscopic cases. Operative times are shorter for open versus laparoscopic radical prostatectomy (160 versus 200 min) and pyeloplasty (168 versus 180 min) [6, 44–48]. Operative times for laparoscopic versus open nephrectomy have proven to be similar only among experienced laparoscopists who have overcome their initial learning curves [8, 49–51]. With longer operative times and longer learning curves for laparoscopic procedures, there is a disincentive for urologists to perform certain laparoscopic surgeries as reimbursement rates on a per-hour basis may be higher for open procedures. Current reimbursement models may not offer equivalent payment for different procedures based on their difficulty or required time.

The key advantages of laparoscopic procedures are decreased time to recovery, decreased blood loss, and decreased length of hospitalization. These factors influence direct, measurable costs and indirect costs. A shorter length of stay results in room and board cost savings, decreased nursing costs, and decreased use of intravenous fluids and medications. Recovery continues after the patient is discharged home and several studies have demonstrated decreased time to convalescence and return to work after laparoscopic surgery. Bhayani et al. showed that the complete time to recovery for laparoscopic versus open radical retropubic prostatectomy was 30 versus 47 days, respectively [52]. Rassweiler et al. also showed a faster time to convalescence for laparoscopic

prostatectomy, on average returning to normal activities 25 days sooner as compared to patients who underwent open surgery [48]. Dunn et al. retrospectively compared patients who underwent laparoscopic and open nephrectomies and found that patients who underwent the laparoscopic technique returned to normal activities 32 days quicker [53]. According to the income report from the 2012 Census of Population and Housing from the United States Census Bureau, the average American worker earned about \$117 per day in 2011 [54]. This amounts to a \$1,755 loss in productivity for a 15-day period of missed work per patient. The cost savings seen with decreased time in convalescence for laparoscopic surgery may eliminate the incremental cost associated with the procedure.

For laparoscopy, many procedures that were once performed primarily by experts have become routinely performed in most training programs. As such, the cost component of performing laparoscopy is at best a side note. One would not consider performing an open nephrectomy in lieu of a laparoscopic nephrectomy if the case was feasible and the surgeon was trained. Factors that can be modified to reduce cost are the use of more reusable instruments, reduced reliance on expensive hemostatic adjuncts, and performing a procedure laparoscopically rather than incorporating robotic assistance as will be discussed below.

Economics of Robotic Surgery

While robotic surgery has become increasingly more popular as an alternative for urologic procedures [55], there still exist sizeable barriers to widespread use including absence of long-term outcomes and increased costs. Regardless of these issues, robotic surgery has become more prevalent due to decreased length of hospitalization, reduced learning curves for difficult procedures, comparable clinical outcomes to the alternative, and increasing patient demand [56]. Nonetheless, the economic impact of the robotic platform is substantial, and its use should be evaluated thoroughly by institutions planning on

adopting it to ensure the technology can be adopted in a cost-effective way [57]. Several experts contend that robotic surgery may not be an economic practice option when compared to open or laparoscopic approaches [58].

The da Vinci robotic system (Intuitive Surgical, Sunnyvale, CA) was introduced in 2000 and has since been adopted as an alternative for many urologic procedures. By 2009, 1395 da Vinci platforms have been introduced in the United States and Europe [59]. The main challenge to widespread adoption is increased operative costs with some reports demonstrating that it increases costs by \$1,000–2,500 per procedure in the United States [60]. Due to this decreased cost efficiency, there still exists an immense amount of doubt among skeptics regarding the ability to widely adopt the technology. Worldwide financial troubles have shifted many societies to institute austerity measures that have placed healthcare groups under more pressure in justifying increased costs. The potential for the robot to establish itself as a cornerstone in urologic surgery will rely on future studies being able to demonstrate cost benefits related to indirect cost savings, easier training, and improved short- and long-term patient outcomes. As the technology improves, new platforms are introduced and current patents expire, capital and disposable costs may decrease with time, but this remains to be seen.

As previously discussed, the principal monetary considerations in comparing costs between various procedures comprise operative costs, complications, outcomes, and length of hospitalization. The primary drawbacks of robotic technology are its high capital, maintenance, and disposable costs. The current cost of a robotic platform is estimated to be \$2 million dollars. The annual contract cost for maintenance is estimated to be \$150,000. This does not include the cost of instruments (estimated to be \$2,000 each with a maximum of 10 uses each). This means that the robot would add over \$1,000 per case if the hospital acquiring the technology is performing on average 300 robotic cases a year. This cost decreases with increased utilization of the platform; thus, if a hospital owns a robotic system,

it is their prerogative to use it as much as possible to decrease per-case costs, but this does not take into account the cost of disposable equipment which adds cost to each case.

Operative time and length of stay are other factors that influences costs associated with surgery. The use of the robot has shown to decrease operative times and length of hospitalization relative to laparoscopic procedures [61], but currently, the savings in these two areas do not compensate for the increased capital and maintenance costs [6]. Ficarra et al. published a systematic review comparing open, laparoscopic, and robotic prostatectomy [62]. In regard to open versus robotic prostatectomy, they found that the robotic approach was associated with decreased estimated blood loss (EBL), shorter hospitalization, improved sexual and continence outcomes, and an improved learning curve [63]. When including laparoscopic prostatectomy, they found that robotic and laparoscopic procedures had similar sexual and continence outcomes and EBL [62]. Open surgery was associated with shorter operative times in this review [62]. This study was limited by the fact that cost analysis and long-term outcomes were not reviewed.

Many studies have compared costs between robotic, laparoscopic, and open urologic procedures. Lotan et al. reviewed the literature to assess costs associated with robotic, laparoscopic, and open prostatectomy and used data from a large county hospital to assess potential costs [6]. Their finds suggested that the average cost of open prostatectomy would be \$6,473, while a robotic approach averaged \$10,269. Bolenz et al. compared costs between robotic, laparoscopic, and open prostatectomy and found that, even while initial capital costs for the robot were excluded, the cost of robotic surgery was \$1,000 more per case [56]. These costs were directly associated with the increased cost of disposable equipment. A recent systematic review of cost of radical prostatectomy found that minimally invasive RP (MIRP) which includes laparoscopic and robotic-assisted approaches was more expensive than radical retropubic prostatectomy (RRP) in most studies, mainly due to increased surgical instrumentation costs [64].

The range of costs was \$4,075–\$6,296 for RRP and \$5,058–\$11,806 for MIRP with RALP having the highest direct costs. There has been one study that met internationally standardized criteria for health economic evaluations and compared 77 consecutive RALPs which were retrospectively matched with 154 RRP by D'Amico risk [65]. The study included direct costs as well as readmissions and adjuvant treatments during the first post-prostatectomy year and included the costs for acquisition and maintenance of the robot. RALP was more effective with regard to cancer removal, continence, and erectile function but also more costly than RRP, with mean RALP costs about twice that of RRP at 1 year postoperatively.

One area that has a significant impact on cost of prostate cancer care is the need for adjuvant therapies. The need for adjuvant radiation therapy after prostatectomy can increase healthcare expenditures by twofold to threefold [66]. A study of SEER-Medicare data from 2004 to 2006 including 4,247 men who underwent radical prostatectomy found that factors associated with increased receipt of adjuvant therapies were positive surgical margins, high-risk group, lymph node-positive disease, but surgical approach was not associated with the use of adjuvant therapies. The median expenditures attributable to post-prostatectomy hormonal therapy, radiation therapy, and radiation with hormonal therapy were \$1,361, \$12,040, and \$23,487 [66].

A review of the literature found no difference in prostatectomy techniques with respect to need for salvage therapy, biochemical recurrence rates, and cancer-specific survival, but there was some evidence of lower positive margin rates even though this data was not based on randomized trials [67]. Future studies will need to determine if the robotic approach will demonstrate long-term benefits that will justify its increased costs.

Other types of robotic surgeries are increasing in popularity in urology, including partial nephrectomy, cystectomy, pyeloplasty, and pediatric procedures. Smith et al. recently performed a cost comparison analysis of open versus robotic cystectomy, and the robotic approach was on average \$1,634 more expensive [68].

Some contend that this cost may be offset by short hospitalization in these patients [69]. Link et al. review cost data between laparoscopic and robotic pyeloplasty and demonstrated that a robotic approach increased the cost of surgery by a factor of 2.7 [70].

Several studies have evaluated the costs associated with different partial nephrectomy techniques. A meta-analysis evaluating open partial nephrectomy (OPN), laparoscopic partial nephrectomy (LPN), and robot-assisted partial nephrectomy (RALPN) identified 7 RALPN, 18 LPN, and 8 OPN studies comprising a total of 477, 2,220, and 2,745 procedures, respectively [71]. Weighted mean OR time was 188, 200, 193 min; weighted mean LOS was 2.6, 3.2, and 5.9 days for RALPN, LPN, and OPN, respectively. The analysis found that LPN was the most cost-effective approach at a mean direct cost of \$10,311, with a cost advantage of \$1,116 and \$1,652 over OPN (\$11,427) and RALPN (\$11,962), respectively. A single-center retrospective study compared the 6-month costs associated with nephron-sparing procedures for cT1a renal tumors [72]. The study included 52 OPN, 48 RALPN, 44 laparoscopic radiofrequency ablation (LRFA), and 29 computed tomography-guided radio frequency ablation (CTRFA). Median total costs associated were \$17,018, \$20,314, \$13,965, and \$6,475, for OPN, RLPN, LRFA, and CTRFA, respectively. Not surprisingly, multivariable linear regression showed that surgical approach ($P=0.007$), length of stay ($P<0.001$), and OR time ($P<0.001$) were significant predictors of total cost. Another recent single institution cost analysis including 325 patients who underwent partial nephrectomy found that RALPN costs were higher than LPN (\$632, $P=0.005$), but not significantly higher than OPN (\$313, $P=0.14$) [73]. Again, the cost of instrumentation and supplies were the main contributors to cost of robotic procedures. This was compensated by lower LOS compared to open but not laparoscopic procedures. Furthermore, if robot purchase and maintenance cost were included in the analysis, each RALPN would be approximately \$1,300 and \$1,000 more expensive than LPN and OPN, respectively.

One can discern from the above analyses that robotic technology significantly increases the cost of surgery. Most of these fees are incurred from purchasing and equipment and maintenance costs. Currently, the demonstrated benefits of reduced EBL, hospital stay, and length of surgery are incapable of offsetting these expenses. There is future potential in proving that the robot is worth the cost, but longer-term data is required. The reduced learning curve associated with robotic surgery may decrease long-term costs. Also, as previously mentioned, newer platforms and expiring patents may drive down current market prices for the technology, though this is largely speculative. In short, the only way to prove that robotic surgery is worth the price is to demonstrate positive long-term outcomes and to diminish the overall cost.

Conclusion

As more aspects of urologic care are treated with minimally invasive approaches, the financial implications of minimally invasive urology will have a greater impact on overall cost. Technologic advances are intrinsic to medical care and usually offer positive improvements in patient care. Up to now, such advances have been uniformly embraced with little consideration of the added cost. As national healthcare costs rise out of proportion of our ability to pay for them, there will be a greater emphasis on not only advancing medicine but also considering the cost-effectiveness of medical care.

References

1. Heffler S, Smith S, Keehan S, Clemens MK, Zezza M, Truffer C. Health spending projections through 2013. *Health Aff (Millwood)*. 2004; Suppl Web Exclusives:W4-79-93.
2. Hellander I, Bhargavan R. Report from the United States: the U.S. health crisis deepens amid rising inequality—a review of data, fall 2011. *Int J Health Ser*. 2012;42(2):161-75.
3. Porter ME. Value-based health care delivery. *Ann Surg*. 2008;248(4):503-9.
4. Porter ME. What is value in health care? *N Engl J Med*. 2010;363(26):2477-81.

5. Anderson JK, Murdock A, Cadeddu JA, Lotan Y. Cost comparison of laparoscopic versus radical retropubic prostatectomy. *Urology*. 2005;66(3):557–60.
6. Lotan Y, Cadeddu JA, Gettman MT. The new economics of radical prostatectomy: cost comparison of open, laparoscopic and robot assisted techniques. *J Urol*. 2004;172(4 Pt 1):1431–5.
7. Lotan Y, Gettman MT, Roehrborn CG, Pearle MS, Cadeddu JA. Cost comparison for laparoscopic nephrectomy and open nephrectomy: analysis of individual parameters. *Urology*. 2002;59(6):821–5.
8. Lotan Y, Duchene DA, Cadeddu JA, Koeneman KS. Cost comparison of hand assisted laparoscopic nephrectomy and open nephrectomy: analysis of individual parameters. *J Urol*. 2003;170(3):752–5.
9. Cairns J. Discounting and health benefits: another perspective. *Health Econ*. 1992;1(1):76–9.
10. Fleming C, Wasson JH, Albertsen PC, Barry MJ, Wennberg JE. A decision analysis of alternative treatment strategies for clinically localized prostate cancer. Prostate Patient Outcomes Research Team. *JAMA*. 1993;269(20):2650–8.
11. Russell LB, Gold MR, Siegel JE, Daniels N, Weinstein MC. The role of cost-effectiveness analysis in health and medicine. Panel on Cost-Effectiveness in Health and Medicine. *JAMA*. 1996;276(14):1172–7.
12. Lotan Y, Svatek RS, Sagalowsky AI. Should we screen for bladder cancer in a high-risk population? A cost per life-year saved analysis. *Cancer*. 2006;107(5):982–90.
13. Svatek RS, Lee JJ, Roehrborn CG, Lippman SM, Lotan Y. Cost-effectiveness of prostate cancer chemoprevention: a quality of life-years analysis. *Cancer*. 2008;112(5):1058–65.
14. Scales Jr CD, Smith AC, Hanley JM, Saigal CS. Prevalence of kidney stones in the United States. *Eur Urol*. 2012;62(1):160–5.
15. Pearle MS, Calhoun EA, Curhan GC. Urologic diseases in America project: urolithiasis. *J Urol*. 2005;173(3):848–57.
16. Saigal CS, Joyce G, Timilsina AR. Direct and indirect costs of nephrolithiasis in an employed population: opportunity for disease management? *Kidney Int*. 2005;68(4):1808–14.
17. Lotan Y, Cadeddu JA, Roehrborn CG, Stage KH. The value of your time: evaluation of effects of changes in medicare reimbursement rates on the practice of urology. *J Urol*. 2004;172(5 Pt 1):1958–62.
18. O'Leary MP, Baum NH, Blizzard R, et al. 2001 American Urological Association Gallup Survey: changes in physician practice patterns, satisfaction with urology, and treatment of prostate cancer and erectile dysfunction. *J Urol*. 2002;168(2):649–52.
19. Escarce JJ. Effects of lower surgical fees on the use of physician services under Medicare. *JAMA*. 1993;269(19):2513–8.
20. Matlaga BR. Contemporary surgical management of upper urinary tract calculi. *J Urol*. 2009;181(5):2152–6.
21. Koo V, Beattie I, Young M. Improved cost-effectiveness and efficiency with a slower shockwave delivery rate. *BJU Int*. 2010;105(5):692–6.
22. Scales Jr CD, Krupski TL, Curtis LH, et al. Practice variation in the surgical management of urinary lithiasis. *J Urol*. 2011;186(1):146–50.
23. Matlaga BR, Jansen JP, Meckley LM, Byrne TW, Lingeman JE. Treatment of ureteral and renal stones: a systematic review and meta-analysis of randomized, controlled trials. *J Urol*. 2012;188(1):130–7.
24. Matlaga BR, Jansen JP, Meckley LM, Byrne TW, Lingeman JE. Economic outcomes of treatment for ureteral and renal stones: a systematic literature review. *J Urol*. 2012;188(2):449–54.
25. Lotan Y, Gettman MT, Roehrborn CG, Cadeddu JA, Pearle MS. Management of ureteral calculi: a cost comparison and decision making analysis. *J Urol*. 2002;167(4):1621–9.
26. Chu L, Farris CA, Corcoran AT, Averch TD. Preoperative stent placement decreases cost of ureteroscopy. *Urology*. 2011;78(2):309–13.
27. Preminger GM, Assimos DG, Lingeman JE, Nakada SY, Pearle MS, Wolf Jr JS. Chapter 1: AUA guideline on management of staghorn calculi: diagnosis and treatment recommendations. *J Urol*. 2005;173(6):1991–2000.
28. Lotan Y, Pearle MS. Economics of stone management. *Urol Clin North Am*. 2007;34(3):443–53.
29. Bagrodia A, Gupta A, Raman JD, Bensalah K, Pearle MS, Lotan Y. Predictors of cost and clinical outcomes of percutaneous nephrostolithotomy. *J Urol*. 2009;182(2):586–90.
30. Raman JD, Bagrodia A, Bensalah K, Pearle MS, Lotan Y. Residual fragments after percutaneous nephrolithotomy: cost comparison of immediate second look flexible nephroscopy versus expectant management. *J Urol*. 2010;183(1):188–93.
31. Bagrodia A, Raman JD, Bensalah K, Pearle MS, Lotan Y. Synchronous bilateral percutaneous nephrostolithotomy: analysis of clinical outcomes, cost and surgeon reimbursement. *J Urol*. 2009;181(1):149–53.
32. Yuan H, Zheng S, Liu L, Han P, Wang J, Wei Q. The efficacy and safety of tubeless percutaneous nephrolithotomy: a systematic review and meta-analysis. *Urol Res*. 2011;39(5):401–10.
33. Lotan Y, Cadeddu JA, Roehrborn CG, Pak CY, Pearle MS. Cost-effectiveness of medical management strategies for nephrolithiasis. *J Urol*. 2004;172(6 Pt 1):2275–81.
34. Landman J, Lee DI, Lee C, Monga M. Evaluation of overall costs of currently available small flexible ureteroscopes. *Urology*. 2003;62(2):218–22.
35. Carey RI, Gomez CS, Maurici G, Lynne CM, Leveillee RJ, Bird VG. Frequency of ureteroscope damage seen at a tertiary care center. *J Urol*. 2006;176(2):607–10; discussion 610.
36. Clark JY, Thompson IM, Optenberg SA. Economic impact of urolithiasis in the United States. *J Urol*. 1995;154(6):2020–4.
37. Bensalah K, Pearle M, Lotan Y. Cost-effectiveness of medical expulsive therapy using alpha-blockers for

- the treatment of distal ureteral stones. *Eur Urol.* 2008;53(2):411–8.
38. Gettman M, Lotan Y, Roerhborn CG, Cadeddu JA, Pearle MS. Cost-effective treatment for ureteropelvic junction obstruction: a decision tree analysis. *J Urol.* 2003;169(1):228–32.
 39. Lotan Y, Gettman MT, Roerhborn CG, Pearle MS, Cadeddu JA. Laparoscopic nephrectomy is cost effective compared with open nephrectomy in a large county hospital. *JLSLS.* 2003;7(2):111–5.
 40. Ogan K, Lotan Y, Koeneman K, Pearle MS, Cadeddu JA, Rassweiler J. Laparoscopic versus open retroperitoneal lymph node dissection: a cost analysis. *J Urol.* 2002;168(5):1945–9; discussion 1949.
 41. Bensalah K, Zeltser I, Tuncel A, Cadeddu J, Lotan Y. Evaluation of costs and morbidity associated with laparoscopic radiofrequency ablation and laparoscopic partial nephrectomy for treating small renal tumours. *BJU Int.* 2008;101(4):467–71.
 42. Lorenzo AJ, Samuelson ML, Docimo SG, Baker LA, Lotan Y. Cost analysis of laparoscopic versus open orchiopexy in the management of unilateral nonpalpable testicles. *J Urol.* 2004;172(2):712–6.
 43. Patel VR, Leveillee RJ. Hand-assisted laparoscopic nephrectomy for stage T1 and large stage T2 renal tumors. *J Endourol.* 2003;17(6):379–83.
 44. Guillonau B, Rozet F, Cathelineau X, et al. Perioperative complications of laparoscopic radical prostatectomy: the Montsouris 3-year experience. *J Urol.* 2002;167(1):51–6.
 45. Benoit RM, Cohen JK. The relationship between quality and costs: factors that affect the hospital costs of radical prostatectomy. *Prostate Cancer Prostatic Dis.* 2001;4(4):213–6.
 46. El-Feel A, Davis JW, Deger S, et al. Laparoscopic radical prostatectomy—an analysis of factors affecting operating time. *Urology.* 2003;62(2):314–8.
 47. Lepor H, Kaci L. Contemporary evaluation of operative parameters and complications related to open radical retropubic prostatectomy. *Urology.* 2003;62(4):702–6.
 48. Rassweiler J, Seemann O, Schulze M, Teber D, Hatzinger M, Frede T. Laparoscopic versus open radical prostatectomy: a comparative study at a single institution. *J Urol.* 2003;169(5):1689–93.
 49. Gill IS, Meraney AM, Schweizer DK, et al. Laparoscopic radical nephrectomy in 100 patients: a single center experience from the United States. *Cancer.* 2001;92(7):1843–55.
 50. Janetschek G, Jeschke K, Peschel R, Strohmeier D, Henning K, Bartsch G. Laparoscopic surgery for stage T1 renal cell carcinoma: radical nephrectomy and wedge resection. *Eur Urol.* 2000;38(2):131–8.
 51. Jeschke K, Wakonig J, Winzely M, Henning K. Laparoscopic partial cystectomy for leiomyoma of the bladder wall. *J Urol.* 2002;168(5):2115–6.
 52. Bhayani SB, Pavlovich CP, Hsu TS, Sullivan W, Su L. Prospective comparison of short-term convalescence: laparoscopic radical prostatectomy versus open radical retropubic prostatectomy. *Urology.* 2003;61(3):612–6.
 53. Dunn MD, McDougall EM, Clayman RV. Laparoscopic radical nephrectomy. *J Endourol.* 2000;14(10):849–55; discussion 855–847.
 54. DeNavas-Walt C, Proctor BD, Smith JC. Income, poverty, and health insurance coverage in the United States: 2011 U.S. Census Bureau, Current population reports. Sept 2012.
 55. Ahmed K, Khan MS, Vats A, et al. Current status of robotic assisted pelvic surgery and future developments. *Int J Surg.* 2009;7(5):431–40.
 56. Bolenz C, Gupta A, Hotze T, et al. Cost comparison of robotic, laparoscopic, and open radical prostatectomy for prostate cancer. *Eur Urol.* 2010;57(3):453–8.
 57. Becker C. Nowhere to run, or hide. Current economic downturn may exacerbate hospitals' weakness with buildings, technology costs, reimbursements. *Mod Healthc.* 2008;38(16):6–7, 16, 11.
 58. Graefen M. Editorial comment on: cost comparison of robotic, laparoscopic and open radical prostatectomy for prostate cancer. *Eur Urol.* 2010;57(3):458.
 59. Intuitive surgical, annual report 2009. 2009. https://materials.proxyvote.com/Approved/46120E/20100222/AR_53320/HTML2/intuitive_surgical-ar2009_0002.htm. Accessed 28 July 2013.
 60. Rocco B, Djavan B. Robotic prostatectomy: facts or fiction? *Lancet.* 2007;369(9563):723–4.
 61. Lotan Y. Economics of robotics in urology. *Curr Opin Urol.* 2010;20(1):92–7.
 62. Ficarra V, Novara G, Artibani W, et al. Retropubic, laparoscopic, and robot-assisted radical prostatectomy: a systematic review and cumulative analysis of comparative studies. *Eur Urol.* 2009;55(5):1037–63.
 63. Ficarra V, Cavalleri S, Novara G, Aragona M, Artibani W. Evidence from robot-assisted laparoscopic radical prostatectomy: a systematic review. *Eur Urol.* 2007;51(1):45–55; discussion 56.
 64. Bolenz C, Freedland SJ, Hollenbeck BK, et al. Costs of radical prostatectomy for prostate cancer: a systematic review. *Eur Urol.* 2014;65:316–24.
 65. Hohwu L, Borre M, Ehlers L, Venborg Pedersen K. A short-term cost-effectiveness study comparing robot-assisted laparoscopic and open retropubic radical prostatectomy. *J Med Econ.* 2011;14(4):403–9.
 66. Williams SB, Gu X, Lipsitz SR, Nguyen PL, Choueiri TK, Hu JC. Utilization and expense of adjuvant cancer therapies following radical prostatectomy. *Cancer.* 2011;117(21):4846–54.
 67. Huang KH, Carter SC, Hu JC. Does robotic prostatectomy meet its promise in the management of prostate cancer? *Curr Urol Rep.* 2013;14(3):184–91.
 68. Smith A, Kurpad R, Lal A, Nielsen M, Wallen EM, Pruthi RS. Cost analysis of robotic versus open radical cystectomy for bladder cancer. *J Urol.* 2010;183(2):505–9.
 69. Ng CK, Kauffman EC, Lee MM, et al. A comparison of postoperative complications in open versus robotic cystectomy. *Eur Urol.* 2010;57(2):274–81.

70. Link RE, Bhayani SB, Kavoussi LR. A prospective comparison of robotic and laparoscopic pyeloplasty. *Ann Surg.* 2006;243(4):486–91.
71. Mir SA, Cadeddu JA, Sleeper JP, Lotan Y. Cost comparison of robotic, laparoscopic, and open partial nephrectomy. *J Endourol.* 2011;25(3):447–53.
72. Castle SM, Gorbatiy V, Avallone MA, Eldefrawy A, Caulton DE, Leveillee RJ. Cost comparison of nephron-sparing treatments for cT1a renal masses. *Urol Oncol.* 2013;31:1327–32.
73. Laydner H, Isac W, Autorino R, et al. Single institutional cost analysis of 325 robotic, laparoscopic, and open partial nephrectomies. *Urology.* 2013;81(3):533–8.

Index

A

- Abdominal sacrocolpopexy (ASC)
 - clinical outcomes, 128–129
 - complications
 - intraoperative, 130
 - postoperative, 130
 - with concomitant hysterectomy
 - CARE trial, 120
 - mesh erosion, 120
 - risk factor, 120
 - indications/contraindications, 120
 - operating technique
 - additional port placement, 122
 - bladder retraction, 123, 125
 - equipment list, 121
 - mesh placement (*see* Mesh placement, ASC)
 - patient preparation and positioning, 121
 - pelvic anatomy, 122, 123
 - pneumoperitoneum, 121–122
 - sacrum visualization, 123, 125
 - side docking, 122, 123
 - sigmoid colon identification, 122
 - vaginal obturator placement, 122, 124
 - vaginal wall devascularization, 123, 125
 - W configuration, 121
- Adrenalectomy
 - laparoscopic (*see* Laparoscopic adrenalectomy)
 - Robotic (RALA)
 - adrenal vein draining, 47
 - bipolar vessel-sealing device, 46, 47
 - hemostatic polymer clips, 46
 - instrumentation for, 46
 - intraoperative ultrasonography, 47
 - trocar placement, 45, 46
- Air Seal™, 135

B

- Bipolar transurethral resection of the prostate (biTURP)
 - bipolar plasmakinetic system, 202
 - BPH, 197–199
 - complications, 203, 204
 - equipment list, 197
 - Gyrus bipolar loop, 197, 198

- indication, 198–199
- monopolar TURP *vs.* bipolar TURP *vs.* bipolar TUVP, 202
- outcomes, 202, 203
- patient positioning, 199
- patient preparation, 199
- plasma corona vaporization field, 197, 198
- postoperative care, 201
- resectoscope insertion, 199
- techniques, 199–201
- Boari flap, 25, 27, 28
- Bull's-eye approach, 172

C

- Carter-Thomason fascial closure device, 8, 9
- Clinical research office of endourology (CROES), 177
- Cost-effectiveness
 - healthcare economics
 - costs *vs.* charges, 242–243
 - payer perspectives, 241–242
 - laparoscopic surgery
 - advantages of, 246–247
 - equipment costs, 246
 - Medicare reimbursement rates, 246
 - operative times and fees, 246
 - nephrolithiasis
 - equipment cost, 245
 - incidence of, 243
 - inpatient cost, 245
 - medical expulsive therapy, 245
 - PCNL, 244–245
 - physician reimbursement, 243–244
 - prevalence of, 243
 - SWL, 244
 - photoselective vaporization of prostate (PVP), 219
 - robotic surgery
 - adjuvant radiation therapy, 248
 - disadvantages, 247–248
 - operative time and length of stay, 248
 - retropubic prostatectomy (RRP), 248
 - vs.* laparoscopic, 248
 - vs.* open prostatectomy, 248

D

- Deep vein thrombosis (DVT), 237–238
- Distal ureteral reconstruction
 - Boari flap, 25, 27, 28
 - nephropexy, 29–31
 - psoas hitch, 24–25, 27
 - retrocaval ureter (RCU), 28–29
 - ureteral strictures (*see* Ureteral strictures)
- Donor nephrectomy (DN)
 - clinical experience, 142–143
 - clinical trial, 143
 - complication, 143
 - E-NOTES, 143
 - GelPOINT™ and QuadPort™, 142
 - multichannel ports and articulating instruments, 142
 - short and long-term allograft function, 143
 - learning curve, 144

E

- Electrohydraulic lithotripsy (EHL), 167
- Embryonic natural orifice transumbilical endoscopic surgery (E-NOTES), 143

Endopyelotomy

- aberrant crossing vessel, 181
- adolescent/preadolescent patients, 180
- equipments, 192
- outcomes, 180
- patients selection, 180
- percutaneous antegrade approaches
 - cold knife technique, 182
 - 16 Fr Council-tip catheter, 183
 - 5 F ureteric catheter, 181
 - Heineke-Mikulicz re-approximation, 183
 - hooked blade, 182, 183
 - incidence, 180
 - patient position, 181
 - rigid nephroscope and duckbill forceps, 182
 - serial dilators/balloon catheter, 182
 - Teflon-coated guidewire, 181
- primary and secondary endopyelotomy, 180
- prognostic features, 181
- retrograde approaches, 183–184

Endoscopic incisions

- UPJO
 - endopyelotomy (*see* Endopyelotomy)
 - high-insertion anatomical arrangement, 181
 - incidence, 179
 - indications, 179
 - laparoscopic and robotic pyeloplasty, 180
- ureteral strictures
 - balloon dilation, 185
 - causes, 184
 - endoureterotomy, 185–187, 192
 - incidence rates, 185
 - management, 184
 - minimally invasive approaches, 184
 - ureteral stent placement, 185

- ureteroenteric anastomotic strictures, 187–189
- ureterovesical anastomotic strictures, 187, 188

urethral strictures

- characteristics, 190
- incidence and etiology, 189
- internal urethrotomy, 190–192
- treatment modality, 190

Endoureterotomy

- cold knife, 186
- contemporary results, 187
- cut to the light method, 185
- diuretic renography, 186–187
- electrosurgery, 186
- equipments, 192
- good-quality retrograde pyelogram/antegrade study, 185
- holmium:YAG laser, 186
- laser energy sources, 186
- location of, 186
- waisting/luminal narrowing, 186

Extracorporeal shock wave lithotripsy (SWL), 159–162**F**

- Food and Drug Administration (FDA), 5, 16, 133

G

- GelPort™, 133–135

H

- Hang drop test, 3
- Hasson technique, 70
- Holmium laser enucleation of prostate (HoLEP)
 - adenoma separation, 228
 - anatomy assessment, 227
 - circular fibers identification, 228
 - cobweb appearance, 228
 - efficacy, 223–224
 - equipment list
 - history of, 223
 - initial posterior incision, 227
 - lateral lobes enucleation
 - anterior commissure division, 229
 - anterior plane of dissection, 229
 - catheter placement, 230
 - hemostasis, 230
 - mucosal strip division, 229
 - mucosa superficial incision, 229
 - patent prostatic fossa visualization, 229–230
 - resected tissue removal, 230
 - patient positioning, 227
 - post-op results, 230–231
 - preoperative evaluation
 - cystoscopy, 227
 - informed consent, 227

laboratory evaluation, 227
 patient history, 226–227
 Hounsfield unit (HU) density, 160–161

I

Informed consent process
 adequate communication, 239
 basics of
 degree of disclosure, 236
 essential elements, 234–235
 ethical standards statement, 235–236
 patient's signature, 234
 decision making principles, 234
 disadvantages, 238–239
 follow-up discussion, 239
 historical and legal background, 233–234
 innovative procedures, 238
 laparoscopic urologic surgery
 complications of, 236
 deep vein thrombosis (DVT), 237–238
 laparoscopic access, 237
 open conversion, 236–237
 patient positioning, 237
 robotics issues, 238
 Schloendorff vs. Society of New York Hospital, 233
 International Prostate Symptom Score (IPSS), 157, 191, 198, 202, 208, 215, 216

K

Kaplan-Meier method, 183

L

Laparoendoscopic single-site surgery (LESS), 110
 advantage, 133
 coaxial optical systems, 135, 136
 crowding and clashing minimizing, 135, 137
 deflectable tip optical system, 135, 136
 donor nephrectomy
 clinical experience, 142–143
 clinical trial, 143
 complication, 143
 E-NOTES, 143
 GelPOINT™ and QuadPort™, 142
 multichannel ports and articulating instruments, 142
 short and long-term allograft function, 143
 learning curve, 144
 endoscope systems, 135, 137
 instruments
 actively articulating instrument, 136–138
 holding instruments, 136, 138
 length instruments, 136, 137
 rigid bent instruments, 136, 138
 MAGS, 137–139
 nephrectomy, 139–140
 nephroureterectomy, 141–142
 partial nephrectomy (PN), 141

patient selection, 139
 pediatric surgery, 144
 pyeloplasty, 144
 retroperitoneal approach, 140–141
 R-LESS (*see* Robotic-laparoendoscopic single-site surgery (R-LESS))
 right-angle light cable, 135, 136
 Laparoscopic adrenalectomy (LA)
 anatomy, 37
 complications of, 48–49
 equipment, 38
 indications and contraindications, 35–36
 informed consent, 37
 intraoperative ultrasonography, 47
 left retroperitoneal, 45
 left transperitoneal
 bipolar-sealing device, vein ligation, 39, 41
 colon mobilization, 39, 40
 hemostatic maneuvers, 41
 kidney parenchyma identification, 39, 41
 laparoscopic retrieval bag, 41
 patient positioning, 39
 remaining medial attachments division, 41
 renal hilum identification, 39
 skin incision, 39
 trocar placement, 39, 40
 wound closure, 41–42
 operating room setup, 37
 patient positioning, 37, 38
 patient preparation, 37
 patient selection, 35
 preoperative evaluation
 computed tomography (CT) scans, 36
 history and physical examination, 36
 imaging studies, 35
 magnetic resonance imaging (MRI), 37
 medical management, 35
 right retroperitoneal, 44–45
 right transperitoneal
 bipolar vessel-sealing device, 43, 44
 Gerota's fascia, 42, 43
 hemostatic polymer clip placement, 43
 liver mobilization, 42
 liver retractor, 42, 43
 patient positioning, 42
 peritoneum incision, 42
 retrieval bag, 44
 Laparoscopic and robotic access
 complications
 bowel injury, 5
 causes of death, 4
 FDA, 5
 port placement, 5–6
 rate, 4
 vascular injury, 4–5
 CT scan, incisional hernia, 9
 fascial closure, 8–9
 Hasson technique, 1, 3–4
 port-site hernias, 8

- Laparoscopic and robotic access (*cont.*)
 trocars, 6–8
 Veress technique
 Veress needle, 1–3
 Veress placement, 2, 3
- Laparoscopic renal extirpative surgery
 retroperitoneal approach
 partial nephrectomy, 18–19
 patient positioning, 12–13, 18
 trocar positioning, 18, 19
 simple/radical nephrectomy, 12–13, 15–16
 transperitoneal approach
 Hasson approach, 14–15
 laparoscopic port positioning, 13, 14
 liver retraction, 13–14
 medial displacement, 15
 obese patients, 14
 partial nephrectomy, 17–18
 patient positioning, 11–13
 Veress needle injury, 12, 13
- Laser lithotripsy, 167
- LESS. *See* Laparoendoscopic single-site surgery (LESS)
- Lower urinary tract symptoms (LUTS), 198–199. *See also*
 Photoselective vaporization of prostate (PVP)
- M**
- Magnetic anchoring and guidance system (MAGS),
 137–139
- Medical expulsive therapy (MET), 160
- Mesh placement, ASC
 anchoring suture, 124, 126
 anterior vaginal wall, 126, 127
 2.0 Gore-Tex nonabsorbable sutures, 126
 macroporous Y-shaped prefabricated mesh, 124, 126
 posterior vaginal wall, 126, 127
 retroperitonealization, 127, 128
 sacral promontory, 127, 128
 wound closure, 127
- N**
- Nephrectomy
 partial
 closed suction drain, 18
 hemostasis, 17–18
 kidney mobilization, 17
 off-clamp technique, 17
 retroperitoneal approach, 18–19
 tumor location, 16, 17
 upper tract urologic surgery, 152–153
 simple/radical, 15–16
- Nephropexy, 29–31
- Nephroscopy, 174
- Nephroureterectomy
 clinical experience, 141–142
 technical tips, 141
- Non-laser transurethral resection. *See* Bipolar
 transurethral resection of the prostate
 (biTURP)
- O**
- Octoport™, 135
- P**
- PCNL. *See* Percutaneous nephrolithotomy (PCNL)
- Pelvic organ prolapse (POP). *See* Abdominal
 sacrocolpopexy (ASC)
- Percutaneous nephrolithotomy (PCNL), 244–245
 anatomic variations, 171
 bull's-eye approach, 172
 endoscopic-guided renal access
 cystoscopy, 174–176
 equipment list, 172–173
 patient positioning and setup, 173–174
 ureteroscopy, 174–176
 lithopaxy and tubeless techniques, 177
 Lower Pole 1 study, 171
 nephrolithiasis, 170
 outcomes and complications, 177–178
 patient position, 172
 renal puncture and access, 175–176
 retrograde approach, 172
 tract dilation, 176–177
 tract size, 172
 triangulation technique, 172
- Photoselective vaporization of prostate (PVP)
 complications
 early postoperative, 217
 intraoperative, 216
 late postoperative, 217–218
 cost effectiveness, 219
 efficacy, 215–216
 history
 greenlight laser HPS generator, 207–208
 greenlight laser wavelength, 207
 greenlight laser XPS system, 208
 indications, 208
 learning curve, 219
 operative technique
 bladder irrigation, 213–214
 BPH nodules, 210
 cystoscopy, 210
 23 Fr continuous-flow cystoscope introduction,
 210
 hemostasis maintenance, 213
 laser goggles, 210
 midline incision, 213
 MoXy laser fiber, 209
 power settings, 211
 prostate capsule identification, 211
 prostate fossa bleeding, 213
 spiral technique, 213
 tricks, 214
 verumontanum preservation, 212
 postoperative management
 follow-up visits, 215
 hematuria, 214
 increased fluid intake, 214
 urinary retention, 214

preoperative preparation and evaluation, 208–209
 special considerations
 continuous anticoagulation, 218
 large prostates, 218
 Pneumatic lithotripsy, 167
 Psoas hitch, 24–25, 27
 Pyeloplasty, 144

Q

QuadPort™, 133–135

R

Radical prostatectomy

8-and 5-mm EndoWrist robotic needle driver, 154
 Jackson-Pratt drain, 155–156
 Marionette suture technique, 154, 155
 8-mm EndoWrist monopolar shears, 154, 156
 5-mm EndoWrist Schertel grasper, 154, 156
 8-mm monopolar shears, 155
 RALP technique, 155
 single port access device and robotic trocars, 154
 umbilical incision, 154

Retrocaval ureter (RCU), 28–29

Robot-assisted laparoscopic adrenalectomy (RALA)

adrenal vein draining, 47
 bipolar vessel-sealing device, 46, 47
 hemostatic polymer clips, 46
 instrumentation for, 46
 intraoperative ultrasonography, 47
 trocar placement, 45, 46

Robot-assisted laparoscopic prostatectomy (RALP) technique, 155

Robot-assisted partial nephrectomy (RAPN)

da Vinci S platform, 81
 postoperative considerations, 87–89
 retroperitoneal approaches
 anatomical landmarks, 85
 clamp removal, 87
 hilum identification, 85–86
 mass excision, 86
 12-mm camera trocar placement, 85
 patient positioning, 85
 perinephric fat identification, 86
 ProGrasp™ forceps, 85
 Satinsky clamp placement, 86
 sliding-clip renorrhaphy technique, 85, 86
 12th rib identification, 85
 ultrasonography, 86

transperitoneal approaches

anatomical landmarks, 82
 bulldog clamps removal, 84
 clamping, 83
 equipment, 82
 Gerota's fascia, 83
 Kocher maneuver exposure, 83
 patient positioning, 82

pneumoperitoneum identification, 82
 port placement, 82
 ProGrasp™ forceps and monopolar scissors, 82
 renal vein identification, 83
 renorrhaphy sutures, 82
 sliding-clip renorrhaphy technique, 84
 trocar placement, 82, 83
 tumor excision, 84
 ureter and gonadal vessels identification, 83
 ureter retraction, 83
 white line of Toldt incision, 83

Robot-assisted pyeloplasty (RAP)

advantages of, 107
 clinical outcomes, 114
 equipment list, 110
 follow-up, 114
 LESS, 110
 operating technique
 anastomosis, 113
 antegrade stent placement, 113
 complication, 114, 115
 drain placement and closure, 113–114
 GelPOINT™ LESS port device placement, 112
 intraumbilical incision, 112
 patient positioning, 111
 patient preparation, 110–111
 pneumoperitoneum establishment, 111
 renal pelvis and ureter exposure, 112–113
 right-sided procedures, 112
 stone removal, 113
 Veress needle placement, 111
 retroperitoneal vs. transperitoneal approach, 108, 110
 vs. laparoscopic, 108, 109
 vs. open pyeloplasty, 107

Robot-assisted radical prostatectomy (RARP)

anterior bladder neck dissection, 54–55
 apical dissection, 58
 bladder neck dissection
 median lobe traction, 64, 65
 posterior dissection, 64, 65
 seminal vesicles identification, 64, 65
 symmetric pressure, right and left arm, 64
 transurethral resection, 64, 65
 bladder neck reconstruction, 59
 continence outcomes, 72, 73
 da Vinci Surgical System™, 51–52, 70
 Denonvilliers' fascia and posterior dissection, 56, 57
 dorsal venous complex (DVC)
 identification, 53
 ligation of, 53–54
 endopelvic fascia (EPF) incision, 53
 Hasson technique, 70
 indications for, 52
 lymph node dissection, 63–64
 nerve sparing
 instruments, 57, 58
 prostatic vasculature, 65–67
 salvage, 67–68

Robot-assisted radical prostatectomy (RARP) (*cont.*)

- oncologic outcomes, 71–72
- Patel's technique, 70–71
- pentafecta concept, 74, 77
- perioperative outcomes and complications, 71
- peritoneum incision, 52, 53
- posterior bladder neck dissection, 55
- posterior musculofascial plate reconstruction
 - continence, 30–45
 - days, 60, 61
 - Denonvilliers' fascia identification, 59
 - equipment, 59
 - leakage, 60, 62
 - 3-0 poliglecaprone sutures, 59
 - posterior lip suturing, 59, 60
- potency outcomes, 74
- practice recommendations, 69–70
- retropubic space entry, 52, 53
- seminal vesicle dissection, 55–56
- Trifecta concept, 74
- urethrovaginal anastomosis, 63
- vs. RRP, 68–69

Robotic-laparoscopic single-site surgery (R-LESS)

- partial nephrectomy, 152–153
- pyeloplasty, 144
- radical prostatectomy
 - 8-and 5-mm EndoWrist robotic needle driver, 154
 - Jackson-Pratt drain, 155–156
 - Marionette suture technique, 154, 155
 - 8-mm EndoWrist monopolar shears, 154, 156
 - 5-mm EndoWrist Schertel grasper, 154, 156
 - 8-mm monopolar shears, 155
 - RALP technique, 155
 - single port access device and robotic trocars, 154
 - umbilical incision, 154
- single access device port
 - Air Seal™, 135
 - GelPOINT™, 135
 - GelPort™, 133, 134, 135
 - Octoport™, 135
 - SILS Port™, 134, 135
 - SLASS™, 135
 - TriPort™ and QuadPort™, 133–135
 - Uni-X Single Port™, 133, 134
 - X-Cone™, 135
- STEP, 156–157
- upper tract urologic surgery
 - dismembered pyeloplasty, 153
 - partial nephrectomy, 152–153
 - radical nephrectomy, 152

S

- SILS Port™, 134, 135
- Single-port transvesical enucleation of the prostate (STEP), 156–157
- SLASS™, 135

T

- TriPort™, 133–135

U

- Ultrasonic lithotripsy, 174
- Uni-X Single Port™, 133, 134
- Ureteral strictures
 - common instruments, 21, 22
 - endoscopic incisions
 - balloon dilation, 185
 - causes, 184
 - endoureterotomy, 185–187, 192
 - incidence rates, 185
 - management, 184
 - minimally invasive approaches, 184
 - ureteral stent placement, 185
 - ureteroenteric anastomotic strictures, 187–189
 - ureterovesical anastomotic strictures, 187, 188
 - etiology, 21
 - imaging, 22
 - incidence of, 21
 - ipsilateral renal unit, 22
 - during laparoscopic ablation, 22, 23
 - mid-and proximal, 25–26, 28
 - MRI urogram, 22, 24
 - ureteroneocystostomy
 - angiographic catheter advancement, 24
 - laparoscopic grasper, 24
 - patient positioning, 23
 - patient positioning and trocar placement, 23, 25
 - robotic and laparoscopic series, 22, 24
 - tension-free anastomosis, 23
 - ureteral length evaluation, 23
- Ureteroneocystostomy
 - angiographic catheter advancement, 24
 - laparoscopic grasper, 24
 - patient positioning, 23
 - robotic and laparoscopic series, 22, 24
 - tension-free anastomosis, 23
 - trocar placement, 23, 25
 - ureteral length evaluation, 23
- Ureteropelvic junction obstruction (UPJO). *See also* Robot-assisted pyeloplasty (RAP)
 - endopyelotomy (*see* Endopyelotomy)
 - high-insertion anatomical arrangement, 181
 - incidence, 179
 - indications, 179
 - laparoscopic and robotic pyeloplasty, 180
- Ureteroscopy (URS)
 - algorithm, 162
 - body habitus, 161
 - children, 161
 - coagulopathy/anticoagulation medication, 161
 - complications, 167
 - flexible ureteroscopes, 166–167

Hounsfield unit (HU) density, 160–191
indications, 159–160
instruments, 163
lithotripters, 167
locations, 159
pregnancy, 161
preoperative considerations, 162–163
safety wire, 164
semirigid ureteroscope, 167
stent placement, 164
stone fragment retrieval and pulverization, 164
ureteral stent placement, 164–166

V

VersaStep™ trocar, 7–8

W

Waggle test, 3

X

X-Cone™, 135