

# Radial Longitudinal Deficiency: Thumb Hypoplasia

8

Michael A. Tonkin

## Introduction

Thumb hypoplasia (underdevelopment) accompanies many congenital conditions, including thumb duplication, transverse deficiencies and symbrachydactyly, brachydactyly, cleft hand complex and ulnar longitudinal deficiency, congenital constriction ring syndrome and other miscellaneous conditions such as the thumbs of Apert and Rubinstein–Taybi syndromes. Each condition represents its own specific challenges, but the principles remain the same. An optimal thumb demands appropriate size and shape, stability and mobility. No matter what the cause, surgery is directed towards the addition or removal of tissue, correction of deformity, stabilisation of unstable joints and/or the creation of joint mobility. At times there is a conflict between stability and mobility. Although generalisations are not necessarily applicable to all individual cases, the achievement of optimal mobility at the carpometacarpal (CMC) joint is perhaps the major determinant of effective thumb mobility, with less importance placed on the metacarpophalangeal (MCP) and interphalangeal (IP) joints. In principle, mobility may be sacrificed for stability at these levels.

Classical thumb hypoplasia, as part of a radial longitudinal deficiency, is a specific entity. It may accompany varying degrees of forearm radial hypoplasia or absence, or may occur alone. In the former instance this has been classified in the Swanson/International Federation of Societies for Surgery of the Hand (IFSSH) system within Group I: “Failure of Formation”, but in the latter instance has been variably placed within this group and within Group V: “Undergrowth” [1, 2]. In the more recently proposed OMT system, it is classified as a “Failure of Axis Formation/Differentiation—affecting the

radial-ulnar axis of the entire upper limb” or the “radial-ulnar axis of the hand plate” when the thumb alone is affected [3, 4]. This latter circumstance is uncommon, as a close clinical and radiological examination will nearly always reveal some proximal hypoplasia, even if subtle.

Thumb hypoplasia is often bilateral, although mild grades may be overlooked. Associations, syndromic and non-syndromic, are not uncommon (Table 8.1) [5]. Assessment of cardiac, gastrointestinal, renal, vertebral and other musculoskeletal anomalies, and investigation of possible blood disorders, such as those associated with thrombocytopenic absent radius (TAR) and Fanconi’s anaemia are routine and have generally been performed by the referring paediatrician. Genetic counselling may be warranted.

## Classification

Müller, in 1937, introduced the concept of a teratogenic sequence resulting in increasing severity of thumb hypoplasia [6]. He didn’t specify the precise anomalies associated with a particular grade of severity, although many subsequent reviews have attributed four grades of hypoplasia to his name. In 1967, Blauth refined Müller’s concept, defining five grades of thumb hypoplasia (Fig. 8.1) [7, 8]. A number of modifications to this classification have been suggested. That of Manske is most commonly quoted in the literature, but does involve significant changes to the definitions of Blauth [9, 10]. Blauth viewed the hypoplastic thumb according to grades of severity, with increasing bone and joint hypoplasia accompanied by increasing soft tissue hypoplasia. He distinguished Grade 2 from Grade 3 according to the presence or absence of a CMC joint, retaining the thumb in the former case but advising reconstruction of an alternative CMC joint in the latter. Manske moved this distinction into a sub-classification of Grade 3, in which Grade 3A has a CMC joint and Grade 3B does not. Buck-Gramcko added a 3C in which only the distal one-third of the metacarpal remained (Fig. 8.2) [11]. The Manske classification distinguishes

M.A. Tonkin, M.B.B.S., M.D., F.R.A.C.S., F.R.C.S. (Ed Orth) (✉)  
Department of Hand Surgery and Peripheral Nerve Surgery,  
Royal North Shore Hospital, The Children’s Hospital at Westmead,  
University of Sydney, Sydney, NSW 2065, Australia  
e-mail: [mtonkin@med.usyd.edu.au](mailto:mtonkin@med.usyd.edu.au)

between Grades 2 and 3A by the absence or presence of extrinsic musculotendinous anomalies. Such a sub-classification suggests that extrinsic anomalies develop with more severe grades of hypoplasia but are not present in less severe grades (Grades 1 and 2), and that these occur after the insult to intrinsic musculotendinous units. In my experience,

if surgical reconstructions of thumb intrinsics, MCP joint instability and first web hypoplasia are indicated, there are always some extrinsic anomalies. These may or may not deserve reconstruction. It is of interest that neither the classification of Blauth nor Manske considered the stability or mobility of the CMC joint in those grades in which the proximal metacarpal is present (Blauth Grade 2, Manske Grades 2 and 3A). Manske specifically equated the presence of the proximal metacarpal with a stable CMC joint and proximal metacarpal absence with an unstable joint. Buck-Gramcko defined the 3A thumb as having an unstable CMC joint and described significant extrinsic anomalies within Grade 2.

I favour Müller's concept of increasing hypoplasia of all thumb elements, of soft tissues, bones and joints, occurring concurrently, and Blauth's distinction between Grades 2 and 3 according to the presence or absence of the proximal metacarpal. In its original form, the Blauth classification also provides logical guidelines for treatment by grade. In the main, Grade 2 thumbs are reconstructed; Grade 3 thumbs are removed and the index finger is pollicised. Manske and Buck-Gramcko moved these alternative treatment recommendations to within Grade 3, distinguishing between 3A and 3B.

Some who are classification "splitters" may choose to subclassify Grade 2 according to which components of the thumb would be improved by surgical reconstruction and the techniques whereby this is achieved. Smith advised a Grade 2A or 2B on the basis of uniaxial or global MCP joint instability [12, 13]. This could be extended to specify differences in other aspects of Grade 2 hypoplasias. The classification "lumpers" may prefer to designate the classification of Grade 2 to all such thumbs, regardless of the reconstructive techniques utilised. However, as Buck-Gramcko states "the assessment of results is difficult, especially because the outcome depends on the preoperative condition in the severity of the deformity" [11]. It is clear that the surgical reconstruction of a thumb with uniaxial MCP joint instability, intrinsic hypoplasia and a mildly hypoplastic first web, when accompanied by minor extrinsic anomalies not requiring reconstruction, is

**Table 8.1** Associations of thumb hypoplasia, aplasia and triphalangism<sup>a</sup>

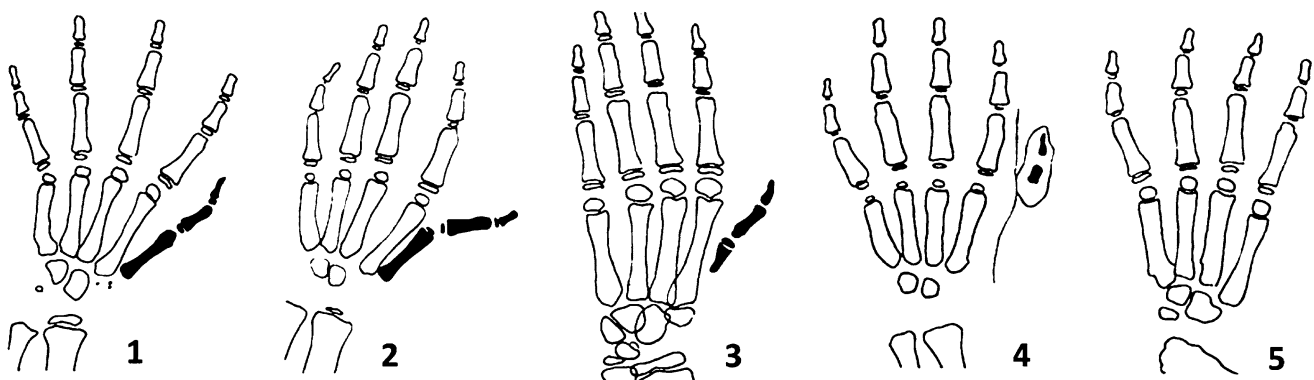
Frequent in:

Aase S.  
Baller-Gerold S.  
Congenital microgastria-limb reduction complex  
Deletion 13q S.  
Fanconi pancytopenia S.  
Holt-Oram S.  
Levy-Hollister S.  
Nager S.  
Oculo-auriculo-vertebral spectrum  
Radial aplasia-thrombocytopenia S.  
Roberts-SC phocomelia  
Rothmund-Thomson S.  
Townes-Brocks S.  
VATERR Association  
Yunis-Varon S.

Occasional in:

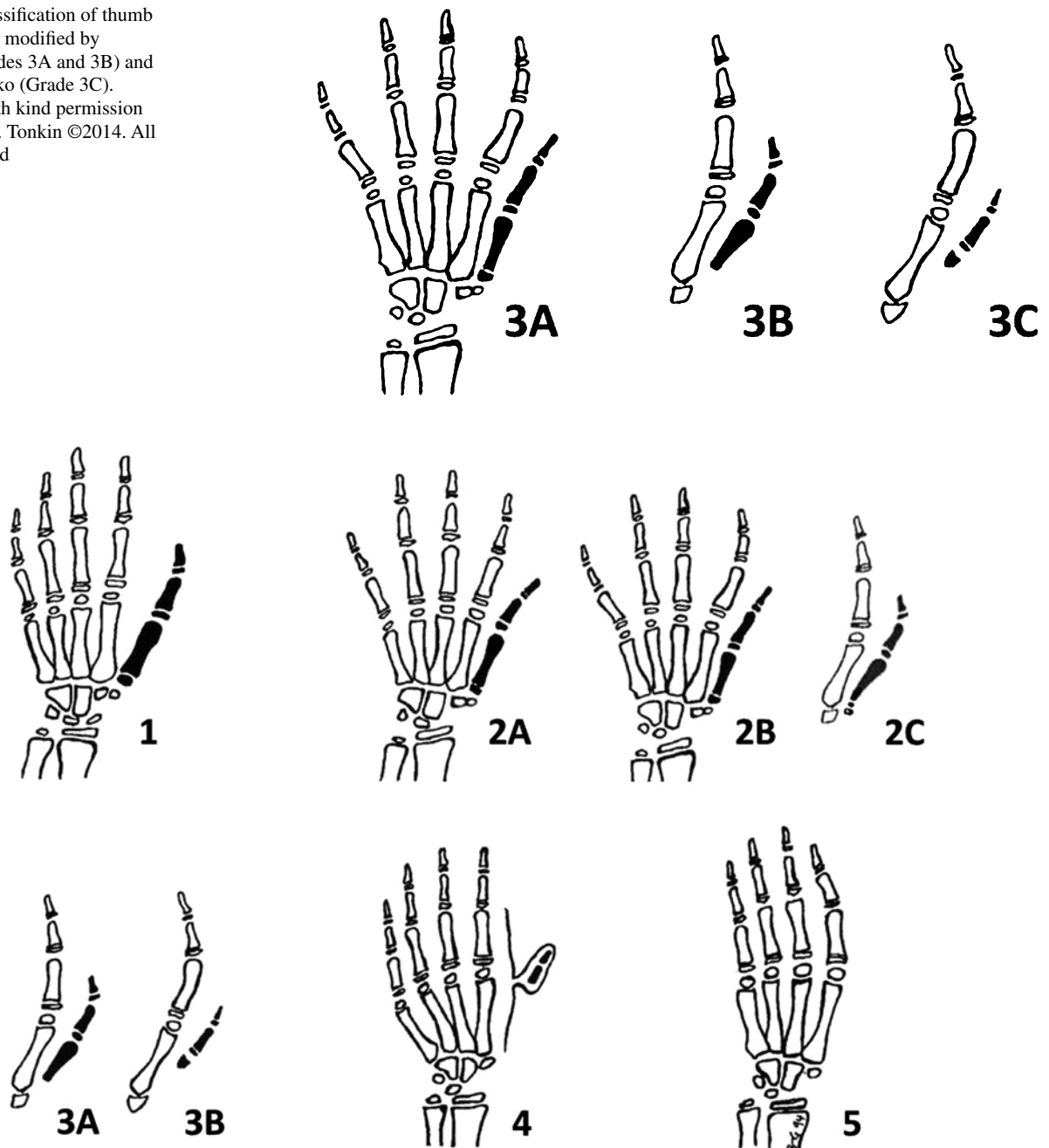
De Lange S.  
Foetal aminopterin/methotrexate S.  
Foetal valproate S.  
Fibrodysplasia ossificans progressiva S.  
Fraser S.  
Fryns S.  
Hypomelanosis of Ito  
Lenz microphthalmia S.  
Miller S.  
Monozygotic (MZ) twinning and structural defects—general  
MURCS Association  
Popliteal pterygium S.  
Trisomy 18S.

<sup>a</sup>Adapted from [5]



**Fig. 8.1** Blauth grades of thumb hypoplasia 1–5. Published with kind permission of Michael A. Tonkin ©2014. All rights reserved

**Fig. 8.2** Classification of thumb hypoplasia as modified by Manske (Grades 3A and 3B) and Buck-Gramcko (Grade 3C). Published with kind permission of Michael A. Tonkin ©2014. All rights reserved



**Fig. 8.3** Proposed modified Blauth classification. Published with kind permission of Michael A. Tonkin ©2014. All rights reserved

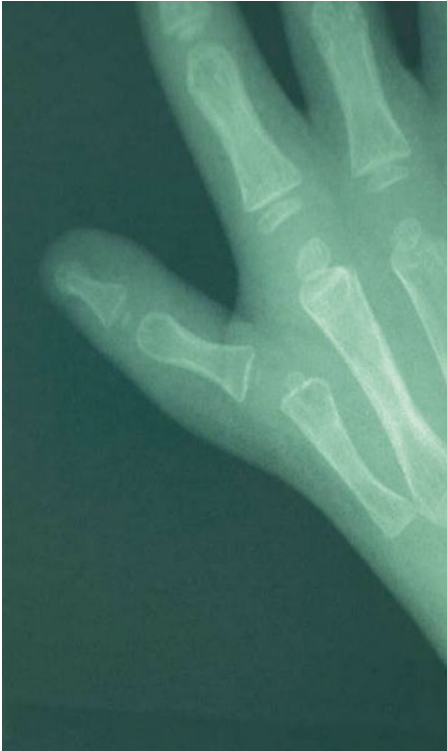quite different from the reconstruction of a thumb with global MCP joint instability, severe hypoplasia of the first web and intrinsic absence, in association with a pollex abductus anomaly and/or hypoplasia or aplasia of the extrinsic flexors and extensors and/or abnormal alignment and insertion of these.

The following classification is offered as one maintaining the integrity of Blauth's skeletal classification and the teratological sequence of increasing severity of hypoplasia proposed by Müller, Blauth and others (Fig. 8.3). The subdivisions within grades do not create separate categories for

each anatomical anomaly and its treatment, but allow the results of surgical reconstructions to be compared for "similar" thumbs:

*Grade 1:* The thumb is small, there is some hypoplasia of the thenar musculature and there may be mild extrinsic anomalies. However, the joints are stable and mobile. No surgery is indicated.

*Grade 2:* Thumb hypoplasia is more severe and would benefit from reconstruction. The CMC joint is present. Intrinsic and extrinsic anomalies are more significant and



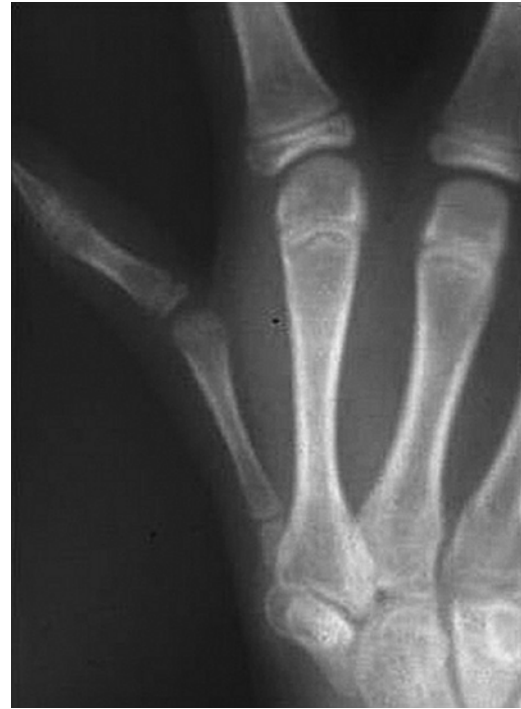**Fig. 8.4** Blauth Grade 2 (A, B) thumb hypoplasia with proximal metacarpal flare. Published with kind permission of Michael A. Tonkin ©2014. All rights reserved

there is MCP joint instability and first web underdevelopment. An increasing severity of hypoplasia is recognised according to the clinical and radiological examinations:

**2A:** Mild. Hypoplasia of intrinsic muscles; uniaxial MCP joint instability; and adduction of the first metacarpal with first web deficiency. Management includes release of the first web, MCP joint ulnar collateral ligament (UCL) reconstruction and an opposition transfer as appropriate. Mild extrinsic anomalies do not demand attention.

**2B:** Moderate. The intrinsic hypoplasia and first web insufficiency are more severe. MCP joint instability is multiplanar, requiring reconstruction of soft tissues other than the UCL alone. Chondrodesis or formal fusion may be necessary in a minority. Extrinsic anomalies demand reconstruction for optimal thumb function and prevention of recurrence of deformity. CMC joint stability and mobility are adequate as indicated by radiological evidence of a proximal flare at the first metacarpal base (Fig. 8.4).

**2C:** Severe. Increasing hypoplasia of all structures, with severe global MCP joint instability (“elephant’s trunk sign”), gross extrinsic hypoplasia, and an inadequate CMC joint—clinically unstable or immobile. These thumbs may also be identified by the radiological appearance of loss of the proximal metacarpal base flare, which tapers proximally (the “pencil sign”)



**Fig. 8.5** Blauth Grade 2C thumb hypoplasia with an inadequate CMC joint. Published with kind permission of Michael A. Tonkin ©2014. All rights reserved

(Fig. 8.5). The thumb requires a more significant first web release and skin transposition, an opposition transfer and extrinsic reconstruction. A chondrodesis or fusion of the MCP joint, and reconstruction of the CMC joint through stabilisation or mobilisation creates a satisfactory albeit compromised thumb ray. Rarely, pollicisation may be considered to provide a superior result for the most severe of these Grade 2C hypoplasias.

**Grade 3:** Increasing hypoplasia of all structures. The CMC joint is absent (Fig. 8.6).

**3A:** Absence of the proximal metacarpal.

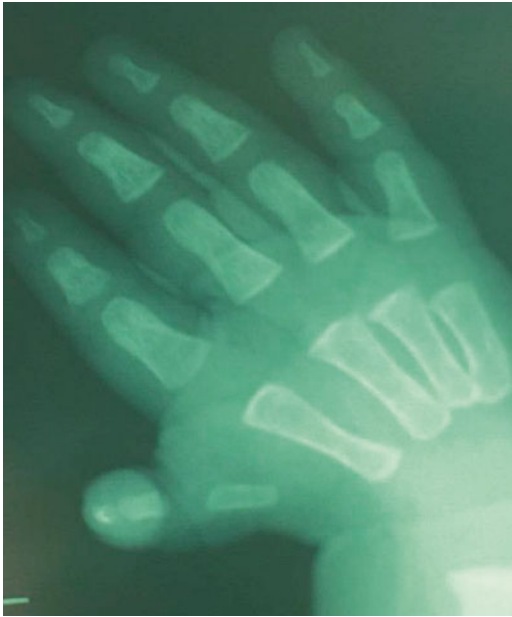**3B:** Distal metacarpal remnant is the only remaining metacarpal component.

**Grade 4:** Metacarpal absence. The floating thumb with phalanges is connected by a skin bridge to the index finger ray.

**Grade 5:** Thumb absence.

Pollicisation remains the optimal surgical reconstruction for Grades 3, 4 and 5. However, such a decision for children with Grade 3 and 4 thumbs may be complicated by concerns about the creation of a four-digit hand. More recently, alternative methods of construction of a CMC joint, through transfer of vascularised and non-vascularised joints and/or bone, have shown some encouraging results and may be indicated when the need to retain five digits is paramount [14–17]. The precise reconstructive procedure may be tailored to the degree of hypoplasia and the amount of bone available within the thumb to be retained. The surgical techniques are easier to perform





**Fig. 8.6** Grade 3A—absent proximal metacarpal. Published with kind permission of Michael A. Tonkin ©2014. All rights reserved

and the results of such surgery are likely to be better for Grade 3A thumbs than for those of Grade 3B or 4. In Grade 5 hypoplasia, a vascularised toe transfer is perhaps the only feasible method of creating five digits.

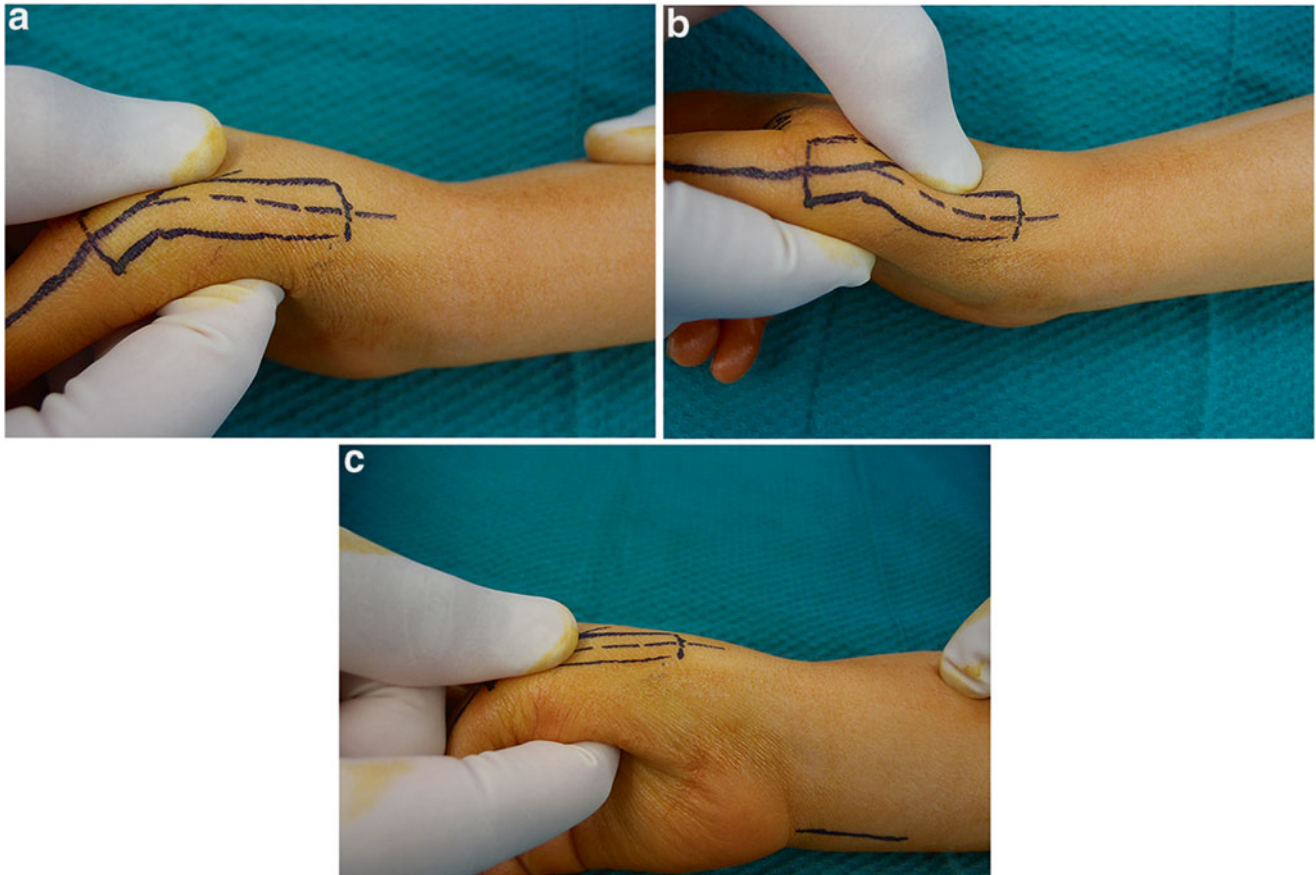
## Surgery

When the child is under anaesthesia, a further preoperative examination assists decision making. CMC joint stability and mobility, or the lack thereof, MCP joint instability and the passive range of IP joint motion can be confirmed at this time (Fig. 8.7a–c). Final decisions await the detail of anomalous anatomy revealed at surgical exploration.

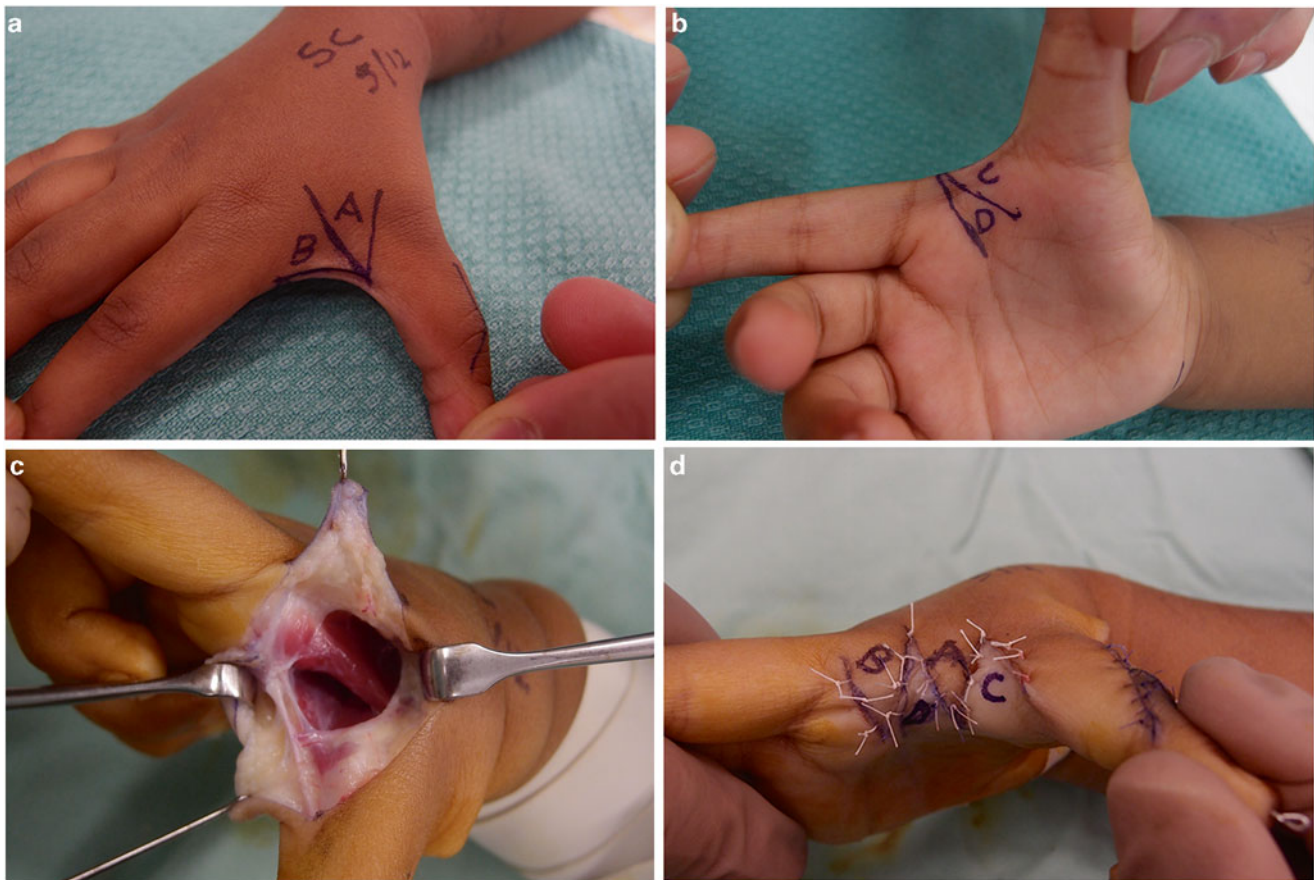
## Surgical Techniques

### First Web Insufficiency

A four- or five-flap web-plasty are the most common techniques of first web deepening (Fig. 8.8a–d). Rotation and



**Fig. 8.7** (a–c) Assessment of CMC joint stability/motion at surgery. Published with kind permission of Michael A. Tonkin ©2014. All rights reserved



**Fig. 8.8** (a–d) Four flap first web-plasty. Published with kind permission of Michael A. Tonkin ©2014. All rights reserved

advancement of tissue from the dorsum of the hand may be indicated for more severe first web deficiency. It is very uncommon to require tissue from distant sources, such as a pedicled posterior interosseous artery flap or radial forearm flap, or even a free tissue transfer. They may be considered if reconstruction in Grades 3, 4 and 5 is undertaken.

The adductor pollicis and first dorsal interosseous muscles, both supplied by the ulnar nerve, are intact but play a role in the adduction of the first metacarpal and first web insufficiency. The thumb is weak and too aggressive a release of these muscles may position the thumb better but weaken it further. The fascia over each muscle should be divided (see Fig. 8.8c). Some gentle recession of the first dorsal interosseous from the thumb metacarpal or of the transverse component of the adductor pollicis may be indicated, but tenotomies should be avoided.

### Metacarpophalangeal Joint Instability

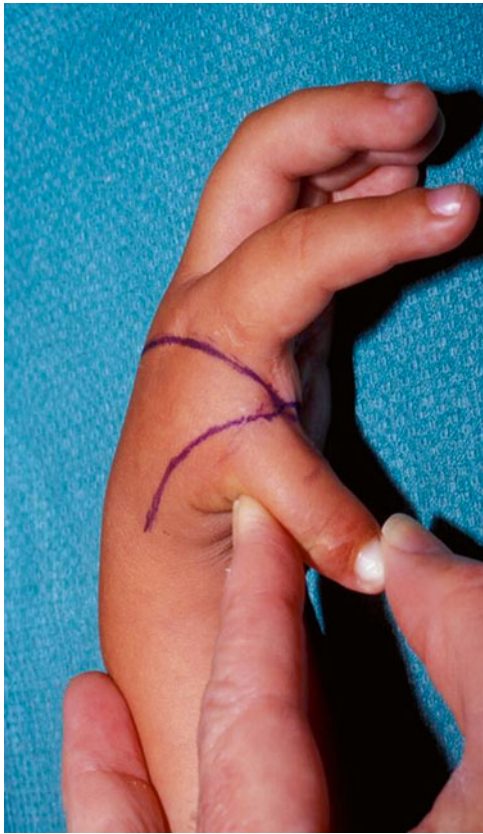In determining the optimal stabilisation procedure, consideration must be given as to whether the instability is predominantly a loss of UCL integrity (Grade 2A) or whether the instability is global (Grade 2B), requiring a more sophisticated reconstruction or even a chondrodesis or fusion of the joint (Fig. 8.9).

There are two common methods of reconstruction of the UCL. One is to use available local tissue, imbricating capsule and ligamentous structures, such as they are, on the ulnar side of the joint. The other is to introduce tissue which is extrinsic to the joint to cater for the deficiencies of the local structures. The terminal part of a flexor digitorum superficialis (FDS) tendon used for an opposition transfer is a popular source.

Whichever reconstruction of the UCL is performed, it will fail if there is an abnormal abduction force crossing the MCP joint on its radial side, most commonly in association with a pollex abductus anomaly in which there is a flexor to extensor connection [18]. Attention must be directed to this if the joint forces are to be balanced and the UCL reconstruction protected.

My preference is to assess the calibre of the MCP joint ulnar soft tissues at the time of surgery. If they are satisfactory, I proceed to a double-breasting of these structures and protect the joint with a fine Kirschner-wire (K-wire). A strip of palmar plate can supplement this reconstruction. A 2- to 3-mm width may be mobilised, maintaining its insertion at the proximal phalanx base, transferring its proximal origin dorsally to the metacarpal head-neck junction. A similar technique may be applied for radial collateral ligament instability. If local tissue is adequate for collateral ligament

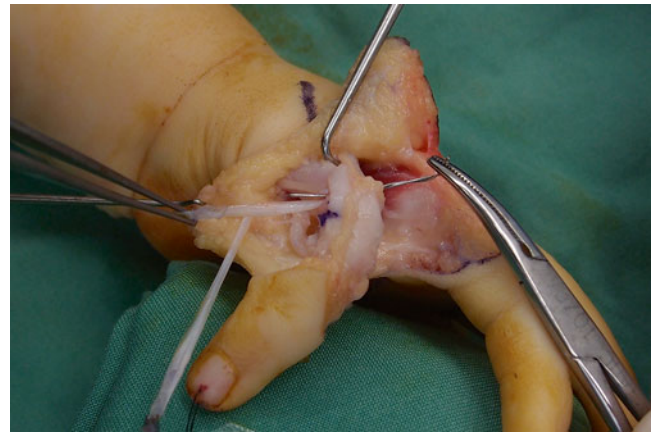




**Fig. 8.9** Assessment of metacarpophalangeal (MCP) joint instability at surgery. Published with kind permission of Michael A. Tonkin ©2014. All rights reserved

reconstruction, the abductor digiti minimi (ADM) is used as an opposition transfer as described below. If the soft tissues are inadequate, then I will proceed to an FDS opposition transfer. One slip of the terminal part of the FDS is passed through a drill hole at the head-neck junction of the metacarpal, from radial to ulnar side, and is sutured to the base of the proximal phalanx and to soft tissues attached to this. Lister and subsequently Smith have advocated placing drill holes through the proximal phalanx, but I have tended to avoid this in the child because of the proximity of the growth plate and the small size of the bone.

One alternative for moderate global instability (Grade 2B) is to use two slips of FDS to reconstruct ulnar and radial collateral ligaments (Fig. 8.10). For MCP joint hyperextension instability, the whole of the palmar plate may be advanced proximally and fixed at the head-neck junction of the metacarpal, creating a check rein (Fig. 8.11a, b). I prefer this complex combination of soft tissue reconstructions to chondrodesis or fusion, unless the underdevelopment of articular surfaces is profound indeed. There is severe global instability. The “elephant’s trunk sign” is indicative (Fig. 8.12a, b). The condyles of the head of the metacarpal are severely underdeveloped on the palmar aspects, with the shape of the metacarpal head, viewed end-on, triangular in



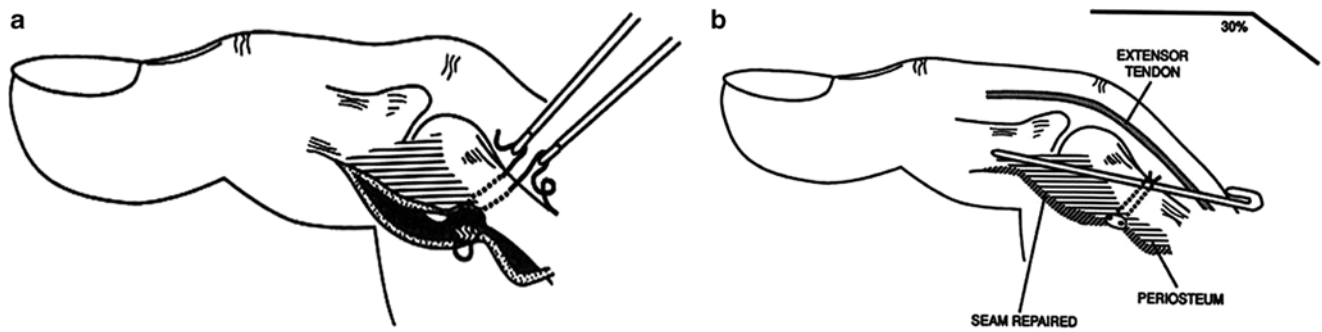
**Fig. 8.10** Use of an FDS slip to create an MCP joint ulnar collateral ligament. Published with kind permission of Michael A. Tonkin ©2014. All rights reserved

appearance, curving palmarwards in the manner of an elephant’s trunk. The base of the proximal phalanx is of small diameter and is planar with no concavity. A formal arthrodesis can be performed but this does shorten the thumb and is only possible if there is epiphyseal ossification. A chondrodesis, fixing the cartilaginous surfaces with one or two fine wires, will stabilise the joint, at least temporarily. This is necessary for the degree of underdevelopment present in Grade 2C thumbs.

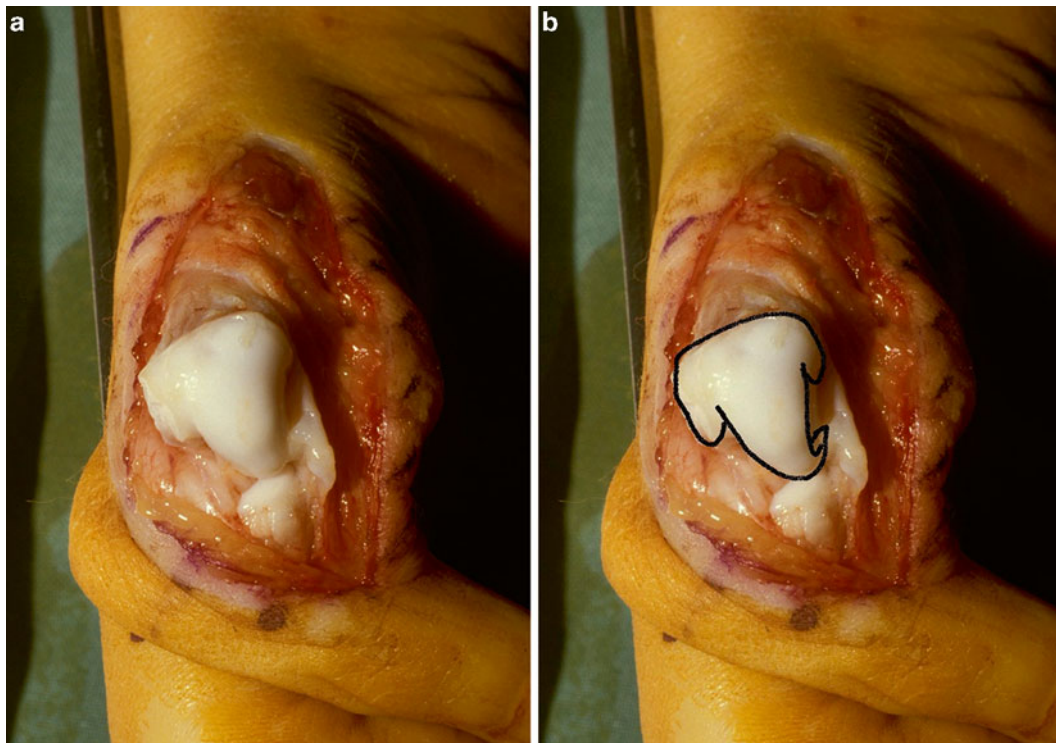
Correction of MCP joint instability is vital to the protection of the underdeveloped CMC joint. Radial deviation at the MCP joint results in adduction of the metacarpal and basal subluxation at the CMC joint, a zig-zag deformity. If an MCP joint fusion or chondrodesis is necessary, this lengthens the lever arm, which places increased stress across the CMC joint. An unstable CMC joint may be further compromised. In this instance, one must consider the necessity of a soft tissue stabilisation at the CMC joint level, a relatively difficult reconstruction using free tendon graft in a figure-of-eight fashion. A soft tissue release for an immobile CMC joint is possible but care must be taken for fear of instability. Rarely, in circumstances of severe MCP joint instability and significant proximal hypoplasia, in spite of the presence of a CMC joint, alternative methods of CMC joint reconstruction such as pollicisation may be considered.

### Opposition Transfers

The main alternatives are an ADM (Huber) transfer and an FDS transfer. There are proponents of both but there is no clear indication of the superiority of one over the other. The use of the ADM diminishes the power of abduction of the little finger but provides some thenar bulk. It is a better pronator of the thumb ray. The FDS transfer removes a flexor from the usually more mobile ulnar digits (ring finger), perhaps decreasing grip strength, and fails to provide any bulk to the thenar eminence. The FDS is superior in providing



**Fig. 8.11** (a, b) Advancement of the palmar plate proximally to prevent hyperextension instability of the MCP joint. Published with kind permission of Michael A. Tonkin ©2014. All rights reserved



**Fig. 8.12** (a, b) The “elephant’s trunk” sign of global MCP joint instability. Published with kind permission of Michael A. Tonkin ©2014. All rights reserved

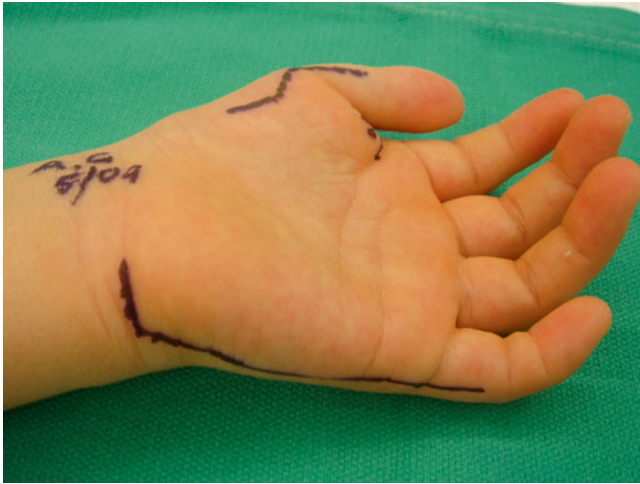
palmar abduction but pronates less effectively. When additional tissue is needed to stabilise the MCP joint, the FDS can provide this as described above.

### Abductor Digiti Minimi Transfer

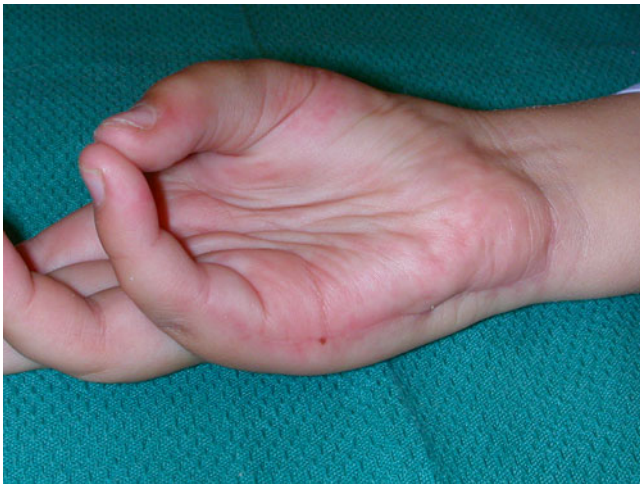The incisions are shown in Fig. 8.13. The ulnar incision at the junction of glabrous and dorsal skin provides a very pleasing cosmetic result (Fig. 8.14). Proximally, the incision should curve around the wrist crease at the level of the pisiform so that the origin of the ADM may be mobilised, if necessary, for length. Distally, the insertion of the abductor should be incised from the base of the proximal phalanx but

the tendon contribution to the extensor mechanism dorsally should also be harvested to provide adequate length (Fig. 8.15). This tissue is not of adequate quality to be extended to the ulnar side of the joint for ligament construction. I do not transfer the origin of the ADM to the flexor retinaculum as suggested by some for fear of interference with the neurovascular pedicle. Its origin may be mobilised fairly aggressively, maintaining some attachment to both the flexor carpi ulnaris (FCU) and the pisiform proximally. Tunnelling of the muscle is a little more difficult with the ulnar incision than with a para-hypothenar incision. It is necessary to make certain that no retinacular fibres of the aponeurosis impede





**Fig. 8.13** Medial incision for abductor digiti minimi (ADM) transfer. Published with kind permission of Michael A. Tonkin ©2014. All rights reserved

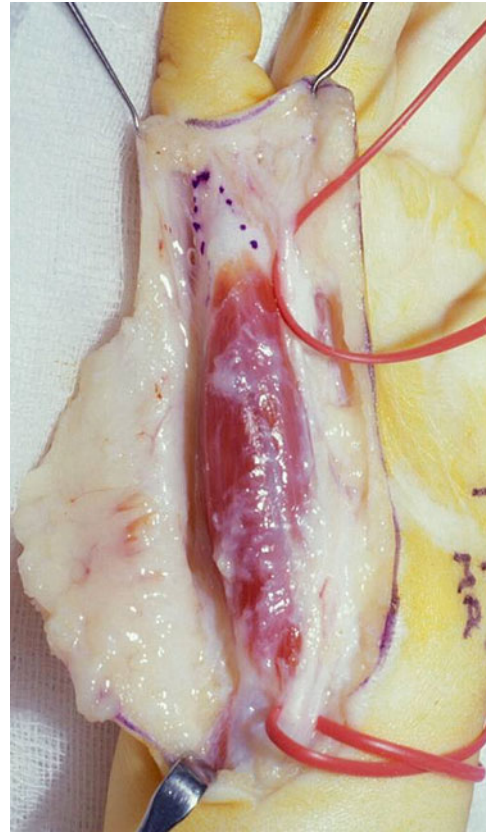


**Fig. 8.14** Scar from medial incision following ADM transfer; note opposition and thenar bulk. Published with kind permission of Michael A. Tonkin ©2014. All rights reserved

its passage and that the neurovascular bundle is not kinked during its transfer. Insertion at the thumb is into the abductor pollicis brevis (APB) remnant if it is present. Otherwise it is better to attach the transfer to the head-neck junction of the metacarpal rather than to the proximal phalanx, as the latter insertion tends to create a radial deviating force which may challenge the UCL reconstruction.

#### Flexor Digitorum Superficialis Transfer

Incisions are shown in Fig. 8.16. The FDS transfer is sutured to the periosteum at the head-neck junction with one slip passed through the metacarpal to be used for UCL reconstruction (see Fig. 8.10). The FDS transfer demands reconstruction of a pulley to allow an optimal direction of pull so that pronation of the thumb ray is possible. This is achieved

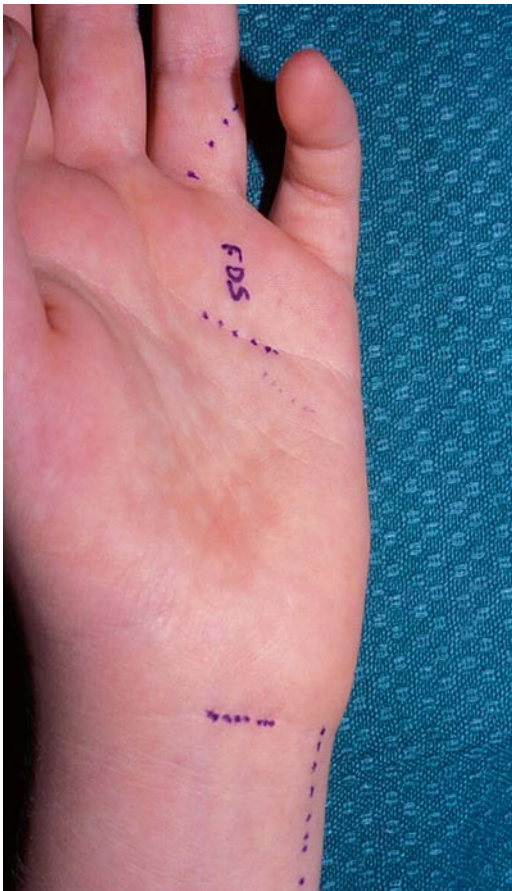

**Fig. 8.15** Dissection for ADM transfer with distal extension to gain tendon length. Published with kind permission of Michael A. Tonkin ©2014. All rights reserved

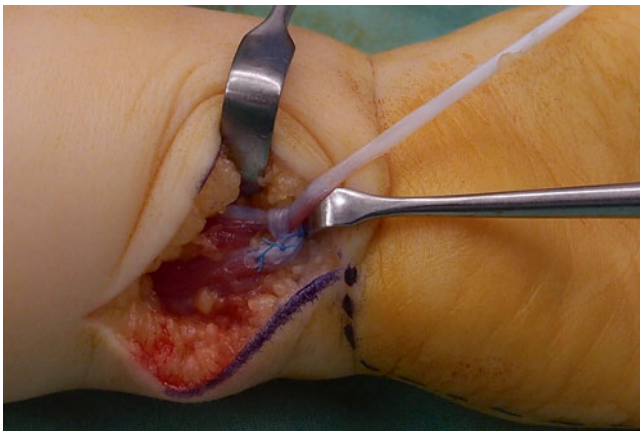
with a distally based slip of FCU (Fig. 8.17). It is possible to also prolong a radial slip to assist in reconstruction of the radial collateral ligament for global instability, sometimes in association with a proximal advancement of the palmar plate, as described previously. This aggressive soft tissue reconstruction at the MCP joint reduces the necessity to consider a primary MCP joint chondrodesis or a fusion, or at least allows delay of such a procedure until a later stage if failure of the soft tissue reconstruction demands a more permanent solution.

#### Extrinsic Tendon Reconstruction

Failure to correct a pollex abductus anomaly (flexor to extensor connection) will lead to a recurrence of MCP joint UCL instability, metacarpal adduction and possible CMC joint instability. Flexor pollicis longus (FPL) anomalies are common. Traction on the FPL at the level of the MCP joint will alert the surgeon to eccentric distal insertions and abnormal origins. In the former, deviation of the IP joint or lack of full flexion is evident. In the latter, there is minimal excursion of the musculotendinous unit with proximal traction. Any connection between the flexor and extensor mechanism must be divided (Fig. 8.18). In these instances the pulley system is

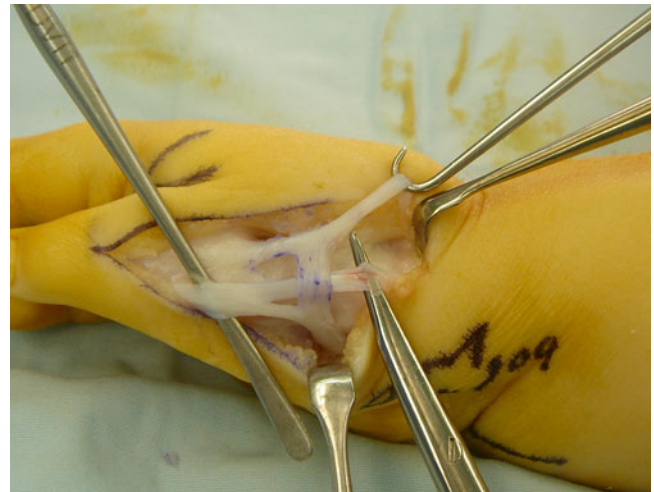

**Fig. 8.16** Incisions for FDS transfer. Published with kind permission of Michael A. Tonkin ©2014. All rights reserved

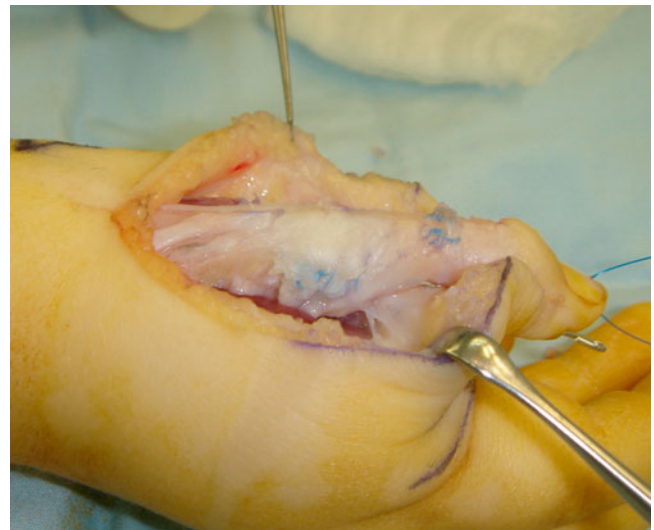


**Fig. 8.17** FDS opposition transfer through an FCU pulley. Published with kind permission of Michael A. Tonkin ©2014. All rights reserved

often incompetent. This may be reconstructed at proximal phalangeal level with a strip of extensor retinaculum or a strip of local tendon (Fig. 8.19). Sometimes, particularly following release of a pollex abductor anomaly, the FPL tendon will continue to bowstring across the radial aspect of the MCP



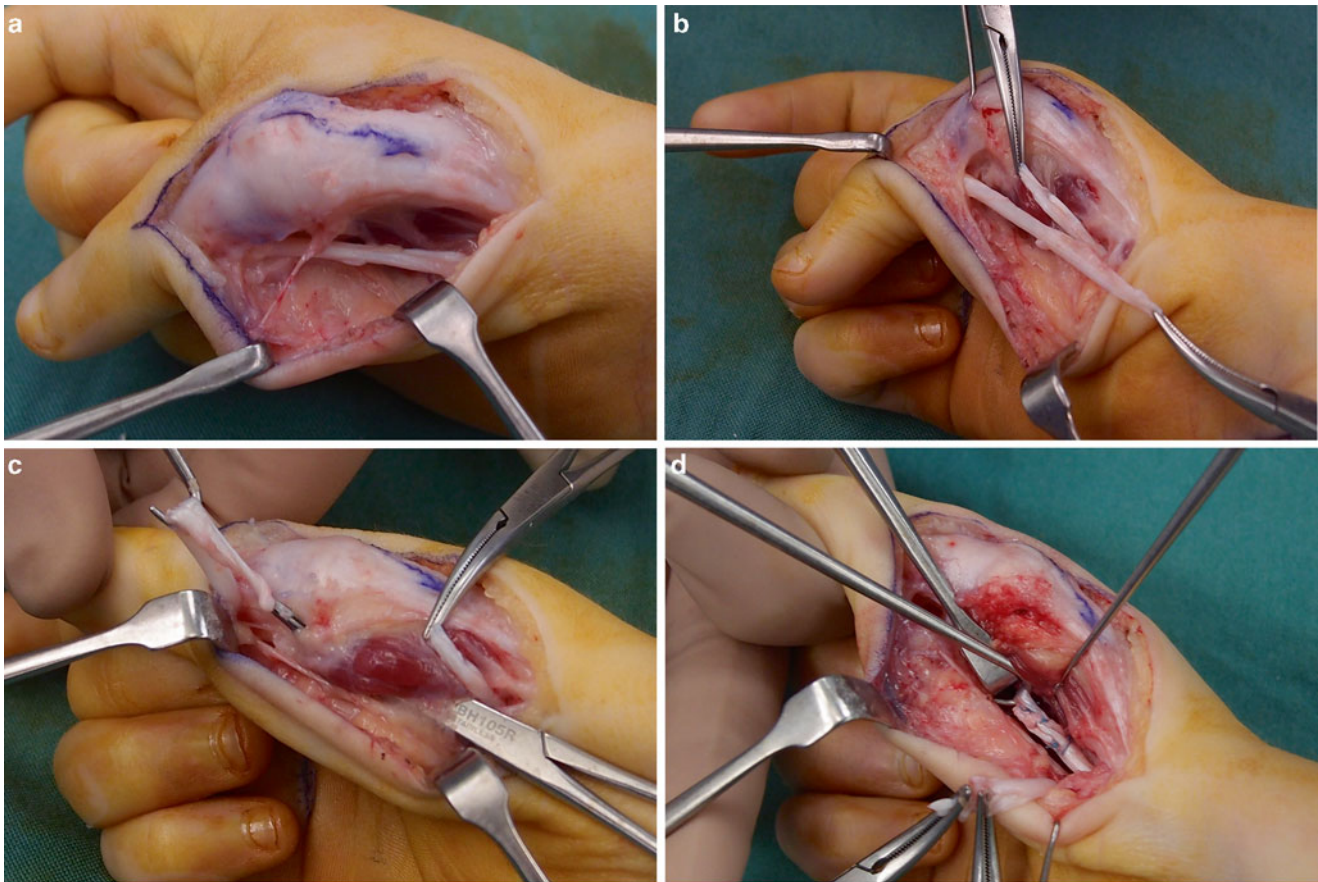
**Fig. 8.18** Pollex abductor connection between extrinsic extensors and flexor. Published with kind permission of Michael A. Tonkin ©2014. All rights reserved



**Fig. 8.19** Realignment of flexor pollicis longus and pulley reconstruction. Published with kind permission of Michael A. Tonkin ©2014. All rights reserved

joint, placing at risk the efficacy of both the UCL reconstruction and the opposition transfer, as the deviating force will tend to recreate the radial deviation deformity at the MCP joint. I believe that, just as in reconstruction for thumb duplications, axial malalignment of extrinsic tendons is one of the main causes of surgical failure. It is possible that axial realignment of FPL following the first web release and MCP joint stabilisation may well compromise gliding of the tendon and, if it is present passively, active IP joint flexion. This loss is less important than the presence of a deforming force post-operatively. The radial-most aspect of the tendinous insertion of flexor pollicis brevis (FPB), or perhaps the adductor pollicis, may be elevated from its insertion, allowing transposition





**Fig. 8.20** (a–d) Z-division and realignment of FPL in the correct longitudinal axis. Published with kind permission of Michael A. Tonkin ©2014. All rights reserved

of FPL ulnarwards. The intrinsic, resutured distally, create a pulley and prevent subluxation of FPL radially. Rarely, I have divided the FPL in a Z fashion, either proximal to the wrist or distal to the carpal tunnel, to allow realignment and stabilisation in the longitudinal axis of the thumb. The tendon ends are sutured side to side (Fig. 8.20a–d).

If there is minimal passive IP joint motion, I do not proceed to sophisticated extrinsic flexor reconstruction. A superficialis transfer to a well-formed FPL tendon without an adequate proximal muscle belly is a possibility when there is a satisfactory passive range of motion. A staged flexor tendon reconstruction with preliminary insertion of a silastic rod, pulley reconstruction and subsequent superficialis transfer is rarely necessary but may be considered in certain circumstances. Eccentric extensor and flexor insertions should be centralised. An extensor indicis proprius (EIP) transfer may replace extensor pollicis longus (EPL) or extensor pollicis brevis (EPB) function, when occasionally indicated.

### Pollicisation

I believe that pollicisation provides optimal thumb function and a very satisfactory appearance when the CMC joint is

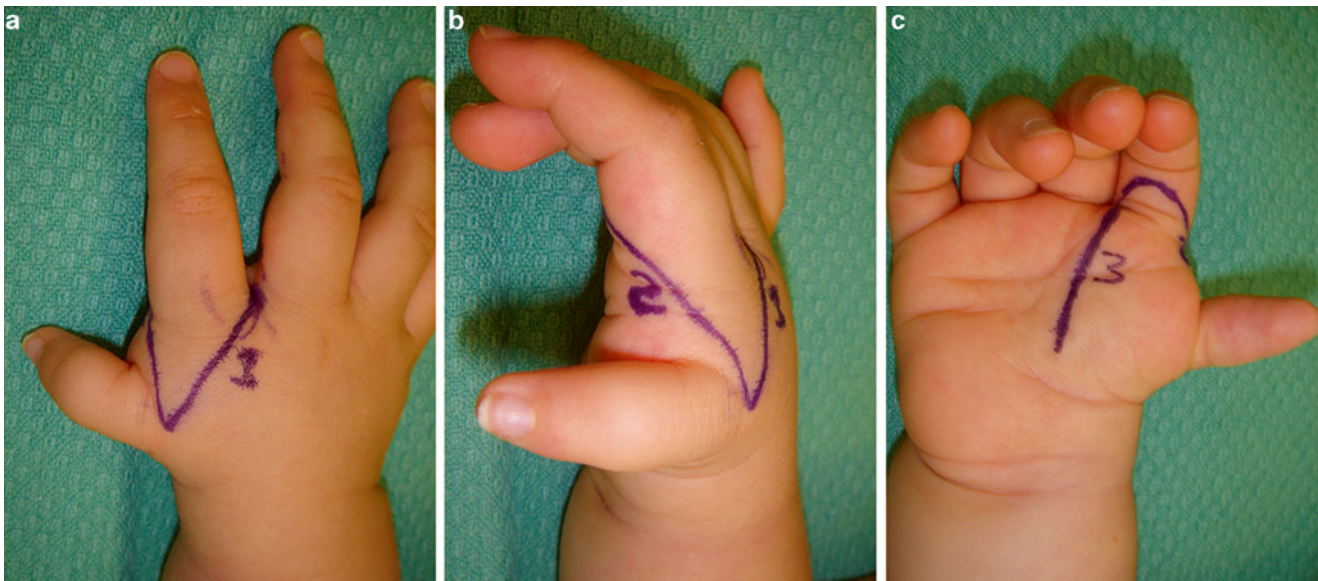
absent in Grades 3, 4 and 5 hypoplasia. Such a procedure may also be considered, uncommonly, in cases of Grade 2C hypoplasia in which, in spite of the presence of a proximal metacarpal, the global hypoplasia is so severe that reconstruction would provide an inferior thumb to that achieved by pollicisation (positive “elephant’s trunk” and “pencil” signs). The necessity to retain five digits for social, racial or religious reasons must not be underestimated. In these instances, the alternative reconstructions outlined below are considered.

The technique of Buck-Gramcko is that followed by most surgeons [19]. A number of modifications have been offered, with alterations in placement of incisions and specific techniques of CMC joint and tendon reconstruction. However, the younger surgeon will find a reliable friend if he/she adheres to Buck-Gramcko’s method.

### Incisions

The surgery is performed under tourniquet. Some prefer not to utilise a Martin or Esmarch bandage to exsanguinate the limb, so that venous and arterial vasculature patterns are more obvious. My preference is to use a bandage to exsanguinate

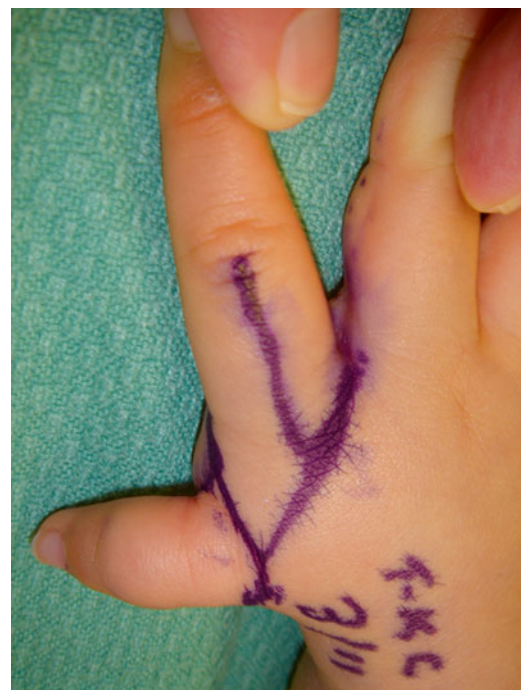



**Fig. 8.21** (a–c) Z concept of pollicisation skin incision with the three limbs marked. Published with kind permission of Michael A. Tonkin ©2014. All rights reserved

the limb. Over a relatively short period of time, the vessels fill with blood allowing identification and I believe this to be preferable to the excessive bleeding which may occur as the tourniquet time progresses. The surgeon may move from palmar to dorsal dissection sites whilst this phenomenon evolves.

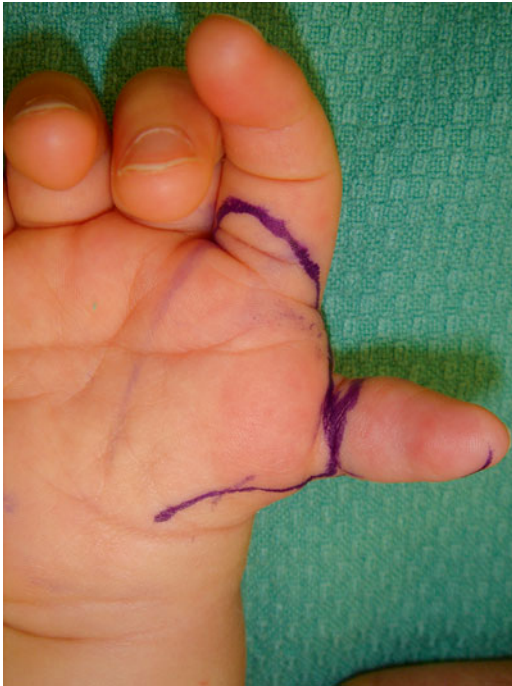The concept of the incisions forming a modified z-plasty may be helpful (Fig. 8.21a–c). The first limb begins dorsally and distally at the index-middle web, and extends proximally and obliquely to the radial border of the hand proximal to the index finger MCP joint. The second limb extends from the proximal point of the first limb onto the palmar aspect of the proximal phalanx to meet the origin of the first limb in the index-middle web space. The third limb extends proximally from the palmar limb, in the line of the index-middle intermetacarpal space. These flaps are transposed when the index finger is rotated and recessed proximally. A number of subtleties of modification cater for specific demands. The palmar incision in the digit should be extended to just proximal to the proximal interphalangeal (PIP) joint when the index finger is well developed and mobile (see Fig. 8.21c). A longer thumb is preferable if there is significant index finger stiffness as greater length compensates for lack of mobility. In this instance the palmar incision is moved proximally towards the basal finger crease. A longitudinal incision extended distally from the dorsal limb incision to the PIP joint allows access to the extensor mechanism and its lateral bands for construction of thumb intrinsic mechanisms and the extrinsics, EPB and abductor pollicis longus (APL) (Fig. 8.22). The third palmar limb may be moved radially to incorporate excision of a Grade 3 or Grade 4 thumb (Fig. 8.23). Alternatively, the excision of such may be incorporated into the second, more radial limb (Figs. 8.22 and 8.24).



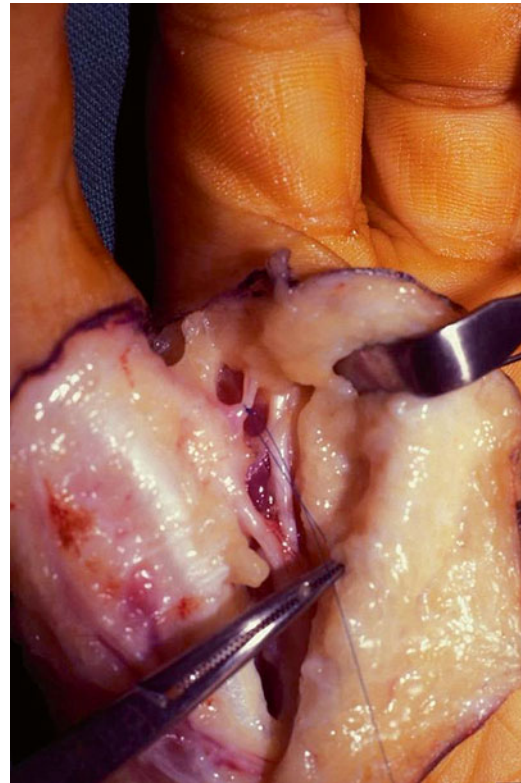**Fig. 8.22** Dorsal incision for intrinsic reconstruction. Published with kind permission of Michael A. Tonkin ©2014. All rights reserved

### Palmar Dissection

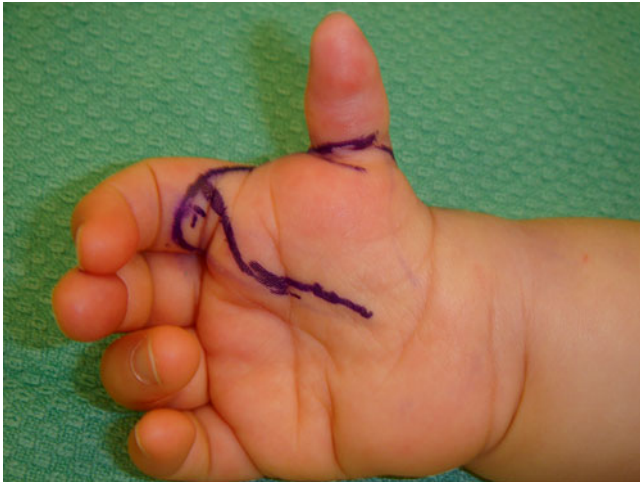I prefer to begin with the palmar dissection. The neurovascular bundle of the index-middle web is identified. A radial neurovascular bundle is usually present. However, the radial digital artery to the index finger may be very small, perhaps even absent, in Grade 5 hypoplasia which is accompanied by index finger hypoplasia. The neurovascular bundles on either side of the digit are mobilised using microsurgical



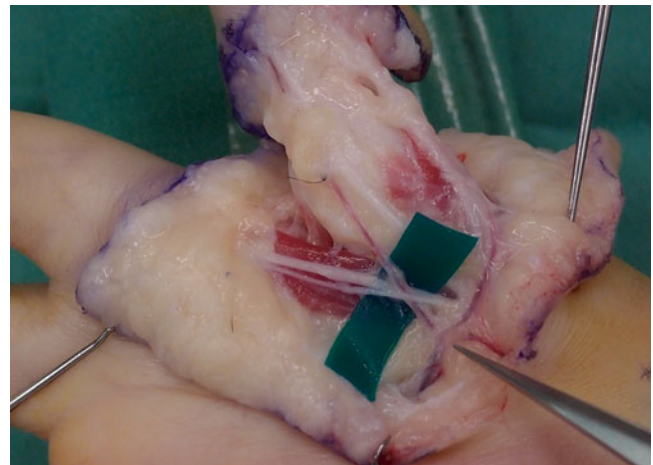
**Fig. 8.23** Incorporation of Grade 3 thumb to be excised into third limb of pollicisation incisions. Published with kind permission of Michael A. Tonkin ©2014. All rights reserved



**Fig. 8.25** The radial digital artery to the middle finger is tied off. Published with kind permission of Michael A. Tonkin ©2014. All rights reserved



**Fig. 8.24** Incorporation of Grade 3 thumb to be excised into second limb of pollicisation incisions. Published with kind permission of Michael A. Tonkin ©2014. All rights reserved



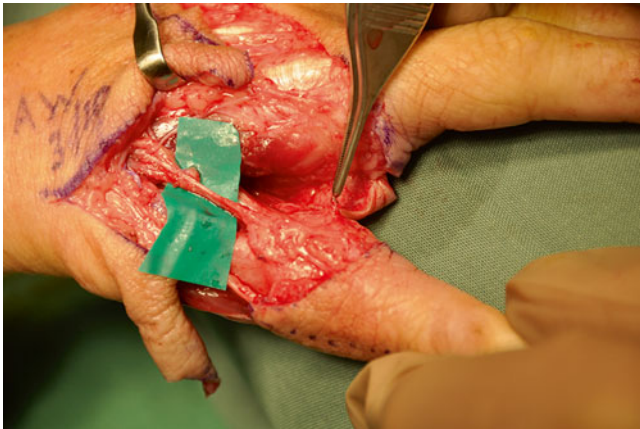
**Fig. 8.26** Dissection of a neural ring to prevent common digital artery compromise. Published with kind permission of Michael A. Tonkin ©2014. All rights reserved

instruments and magnification. Inspection of the second common digital artery will determine the level of bifurcation into digital arteries to the adjacent sides of the index and middle fingers. The radial digital artery to the middle finger is tied off (Fig. 8.25). The neurovascular pedicle is dissected proximally. A neural ring is relatively common but can usually be attended to by intraneural dissection of the common digital nerve (Fig. 8.26). An awareness of the possibility of arterial compromise with proximal recession

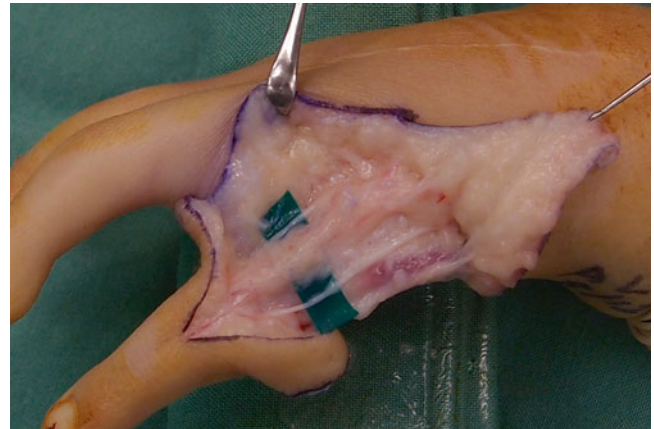
of the digit, either due to a neural ring or fascial structures, should prevent this complication.

Rarely, anomalies of the common digital artery demand an alteration in strategy. The vessel may arise from the deep palmar arch. In this instance the artery is short and may not allow proximal recession of the digit without compromising its arterial supply. It may be necessary to divide the deep

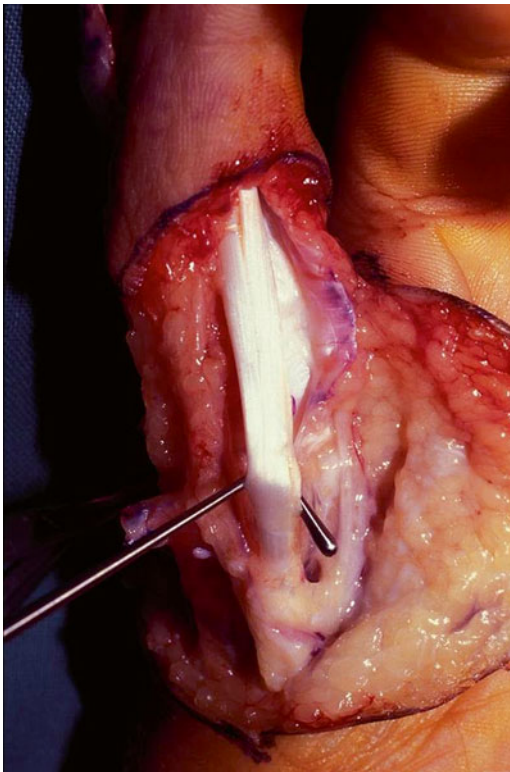




**Fig. 8.27** Dorsal metacarpal artery connecting with palmar digital system. Published with kind permission of Michael A. Tonkin ©2014. All rights reserved



**Fig. 8.29** Dorsal veins and nerves. Published with kind permission of Michael A. Tonkin ©2014. All rights reserved



**Fig. 8.28** Release of A1 and A2 pulleys. Published with kind permission of Michael A. Tonkin ©2014. All rights reserved

arch, following preliminary clamping and assessment of any compromise in vascularity to the hand, to gain length. In one instance, I have found absence of a palmar common digital artery but with a large dorsal metacarpal artery connecting to the palmar system at the head-neck junction (Fig. 8.27). Pollicisation was performed with the digit nourished by this vascular pedicle.

A1 and A2 pulleys are divided (Fig. 8.28). The A3, A4 and A5 pulleys become the thumb A1, oblique and A2

pulleys, respectively. Some routinely shorten the flexor digitorum profundus (FDP), but I have not found this necessary unless pollicisation is performed at greater than 5 years of age. A z-shortening can be performed proximal to the wrist to avoid increasing the possibility of adhesions within the dissected area of the palm.

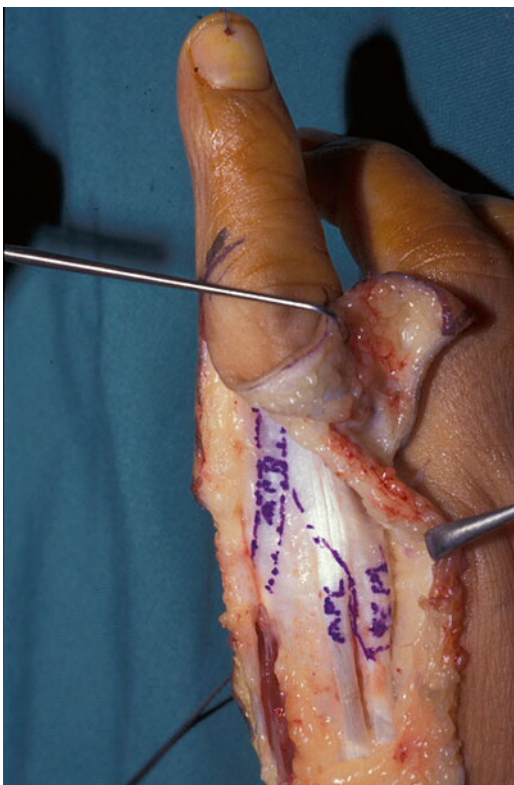The dissection of the intrinsic muscles, the first dorsal and first palmar interossei, begins on the palmar side, mobilising the musculotendinous units to the MCP joint level, but protecting the neural supply of each.

### Dorsal Dissection

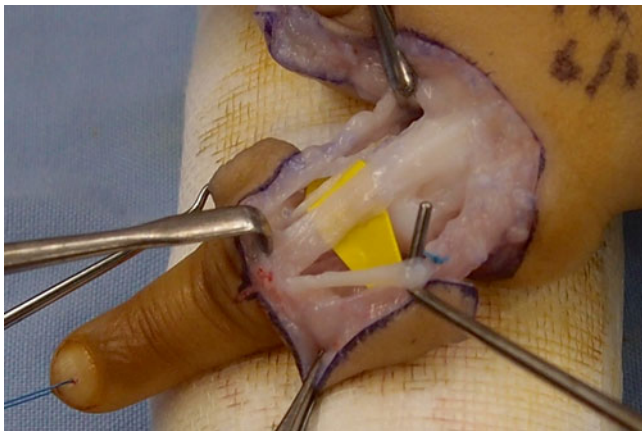
Thin dorsal flaps are elevated until the dorsal venous architecture is identified so that one or two veins, along with superficial dorsal nerves, can be mobilised separately from the flaps and the underlying digit (Fig. 8.29). This prevents kinking of vessels, compromising venous return, when the digit is recessed proximally.

The extensor mechanism is inspected to assess the presence or absence of EIP and the quality of extensor digitorum communis (EDC) (Fig. 8.30). Excursion is often poor when radial deficiency accompanies thumb hypoplasia. Subsequent dissection of the extrinsic extensors and the intrinsic contributions to the extensor mechanism are performed before division of the extensors and with the skeleton intact. This allows distal mobilisation of the extensor mechanism to the level of the PIP joint, separating the lateral band contributions to this level, but maintaining continuity with the first dorsal interosseous and the first palmar interosseous muscles on radial and ulnar sides, respectively (Fig. 8.31). Release of the intrinsic attachments to either side of the base of the proximal phalanx must respect the integrity of the capsule and ligaments of what will become the new CMC joint (Fig. 8.32a, b). Although some recommend ablation of the blood supply to the physis of the metacarpal, others prefer not to interfere with any contribution which may maintain





**Fig. 8.30** Intrinsic and extrinsic tendons outlined prior to reconstruction. Published with kind permission of Michael A. Tonkin ©2014. All rights reserved



**Fig. 8.31** Dissection of radial and ulnar lateral bands without division. Published with kind permission of Michael A. Tonkin ©2014. All rights reserved

the integrity of the physis of the proximal phalanx. Premature physeal closure and a short first metacarpal in the reconstructed thumb is a consequence of growth plate compromise of the index finger proximal phalanx.

At this point, the EIP and EDC may be divided at the level of the MCP joint. Any remaining attachments of the intrinsic musculature are then dissected in a sub-muscular extra-periosteal manner from the metacarpal diaphysis.

Retractors are then placed around the head-neck junction of the metacarpal, protecting all other structures, particularly the palmar neurovascular bundles, whilst an osteotomy is performed at the head-neck junction of the metacarpal. In the young child, a Beaver blade or small osteotome is most satisfactory for the purpose. Some bone nibblers can be used to flower the metaphyseal perimeter of the head of the metacarpal by simply breaking bone fragments, which remain attached to the periosteum. This leaves bone with osteogenic potential to assist in bone union of the new trapezium to the metacarpal base (see below). The physis is removed using a fine curette and Beaver blade so that the new trapezium will not grow longitudinally. If ossification has occurred in the head of the metacarpal, it is easy to establish that the growth plate has been adequately removed. Care needs to be taken when ossification has not occurred, so that the articular surface of the metacarpal head is not breached.

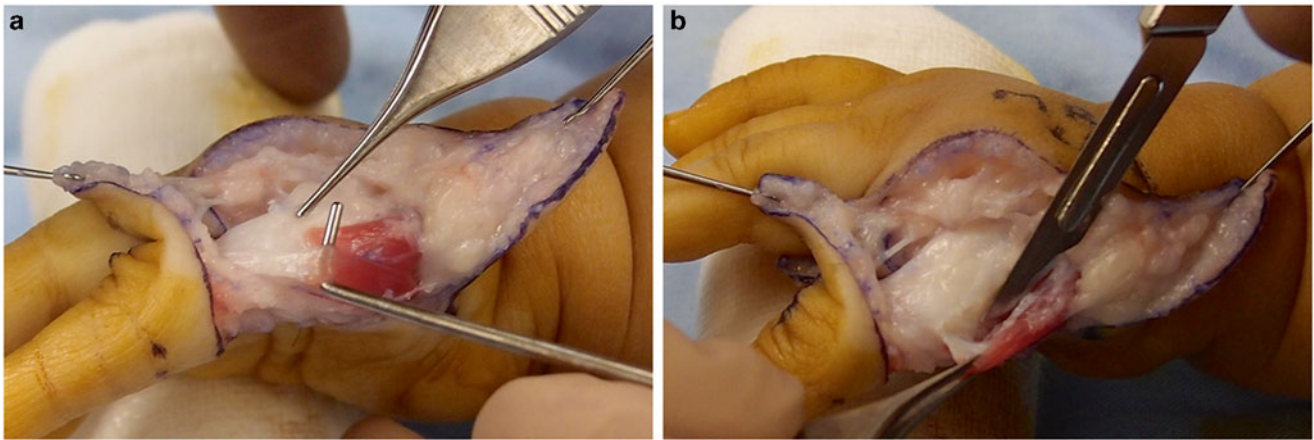
### CMC Joint Reconstruction

An integral part of the success of a pollicisation is the creation of a new CMC joint and there are a number of principles in reconstruction which are important:

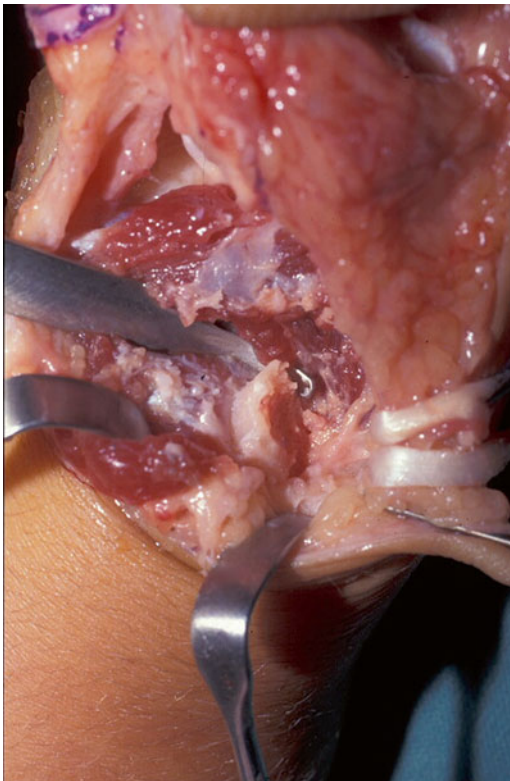
- Optimal positioning of the new thumb ray in palmar abduction, radial abduction and appropriate rotation.
- Placement of the thumb ray in an anterior plane to that of the finger CMC joints.
- Hyperextension of the index finger MCP joint to prevent a hyperextension deformity of the new CMC joint.

It is difficult to satisfy all of the above parameters and obtain bony apposition between the index finger metacarpal head and base. Buck-Gramcko suggested retention of the metacarpal base to be necessary only in cases with relatively short phalanges. In these cases, the metacarpal head was fixed to the base using one or two K-wires. If the phalanges were of normal length, his initial description did not retain the metacarpal base and the metacarpal head was sutured to the joint capsule and carpal bones. Subsequently, most, including Buck-Gramcko, have preferred to retain the base. The plane of osteotomy incision of the metacarpal is varied, with both a transverse osteotomy at the metacarpal base and an oblique osteotomy in either coronal or sagittal planes being described. Some prefer K-wire fixation to promote head to base union as described by Buck-Gramcko [19–22]. Some eschew this [23]. Manske wrote of the importance of a fibrous union rather than a bony union between the retained base and head [24, 25], creating a pseudarthrosis at this articulation. He proposed that using sutures rather than K-wires for fixation permitted increased mobility of the new thumb.

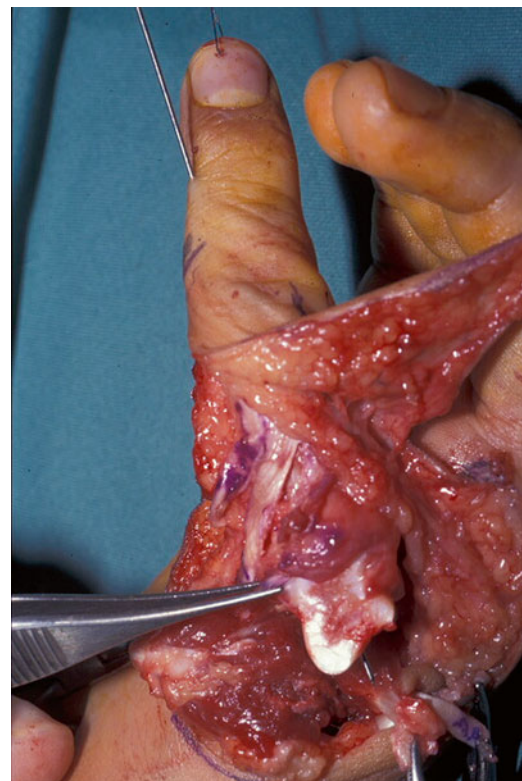
A concern is one of possible instability of the new trapezium. However, the effect on functional outcomes according to the presence or absence of bone union between the metacarpal head (new trapezium) and the metacarpal base has not



**Fig. 8.32** (a, b) Dissection of first dorsal interosseus from capsule of MCP joint. Published with kind permission of Michael A. Tonkin ©2014. All rights reserved



**Fig. 8.33** Oblique osteotomy at base of index finger metacarpal. Published with kind permission of Michael A. Tonkin ©2014. All rights reserved



**Fig. 8.34** K-wire placement through index finger with metacarpal head flexed. Published with kind permission of Michael A. Tonkin ©2014. All rights reserved

been determined. My preference is to aim for bone union whilst satisfying the above criteria of positioning.

An oblique osteotomy leaving the bone longer dorsoradially allows a satisfactory compromise in positioning the thumb optimally and maintaining some bone to bone contact (Fig. 8.33). A fine K-wire is placed antegrade through the flexed metacarpal head and phalanges of the index finger and then driven retrograde into the carpus with the thumb in the

desired position, removing the wire at 5 weeks (Fig. 8.34). Before fixing the thumb to the carpus in this manner, two gauge 2-0 Ticron sutures are placed through the base of the metacarpal and into the metacarpal head, to be tightened following wire fixation of the thumb to the carpus. This method compromises the position of pronation, as 90° only is possible if one is to maintain an anterior lie of the new trapezium in relationship to the metacarpal base and some bone to



bone apposition. Thirty degrees of radial abduction and 40° of palmar abduction is ideal. The less mobile digit may be fixed at lesser angles of radial and palmar abduction. Passive joint motion and the quality of the extrinsic and intrinsic motors play a role in this decision.

### Tendon Reconstruction

The EIP, if present, is shortened and re-sutured to the central extensor mechanism to the PIP joint of the index finger. Most refer to this as a construction of EPL function. However, the insertion of the central slip into the middle phalangeal base of the index finger mimics EPB anatomy of the thumb, rather than EPL anatomy. The new tendon does simulate the adductor-retropulsion action of EPL. The tension of repair should be firm but less than full. Too tight a repair will result in retropulsion of the pollicised digit, particularly if a balance is not achieved following the reconstruction of APB. EDC helps stabilise the position of the new thumb metacarpal, more so if its route and positioning are modified to better mimic the function of APL. It is attached to the periosteum at the dorso-radial aspect of the index proximal phalanx, avoiding the growth plate. If EIP is absent, EDC is used for EPB construction.

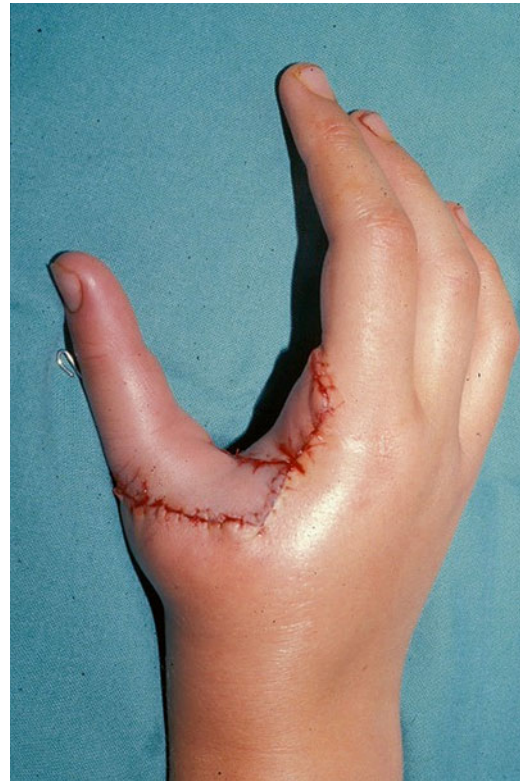Although Buck-Gramcko advises dividing the lateral bands, shortening and resuturing them to create an APB and an adductor from the first dorsal interosseous and the first palmar interosseous, respectively, I tend to concertina these tendons without dividing them and suture them together under as firm a tension as is possible. It is necessary to mobilise both lateral bands to beyond the PIP joint of the index finger, particularly that from the first dorsal interosseous so that its ability to abduct and rotate is optimal. This also decreases a tendency of the lateral bands to hyperextend the new MCP joint of the thumb. A gauge 5-0 Ticron suture is used to secure the tendon reconstructions.

When thumb hypoplasia is accompanied by radial hypoplasia, there is often a camptodactyly of the index finger. My preference is to deal with any significant flexion deformity of the new thumb MCP joint at a second procedure, for fear of interfering with the viability of the pollicised digit.

The tourniquet is released to check the vascularity of the thumb. Flaps are then refashioned so that they may be sutured into position with a pleasing contour. The skin tension within the flaps will assist the musculotendinous reconstruction in maintaining the position of the thumb once the wire is removed (Fig. 8.35).

### Reconstruction of Grades 3, 4 and 5 Thumb Hypoplasia

When pollicisation is unacceptable to parents and/or patient, reconstruction of Grades 3, 4 and 5 thumbs is possible [14–17]. A vascularised second toe metatarsophalangeal (MTP) joint may be transferred to the carpus or to the base of



**Fig. 8.35** Position of reconstructed thumb. Published with kind permission of Michael A. Tonkin ©2014. All rights reserved

the shaft of the second metacarpal. The metatarsal head becomes the new trapezium and the proximal phalanx becomes the thumb metacarpal. Non-vascularised transfers are also utilised. An extrinsic extensor can be reconstructed using EIP from the index finger. A superficialis tendon can be transferred as a flexor and an opposition transfer is created in the manner described for Grade 2 hypoplasia.

An alternative is to transfer the distal two-thirds of the fourth metatarsal bone (non-vascularised), reversing this and using the metatarsal head as the new joint. The shaft is fixed distally to the remnant of the metacarpal or proximal phalanx of the Grade 3 or 4 thumb [26].

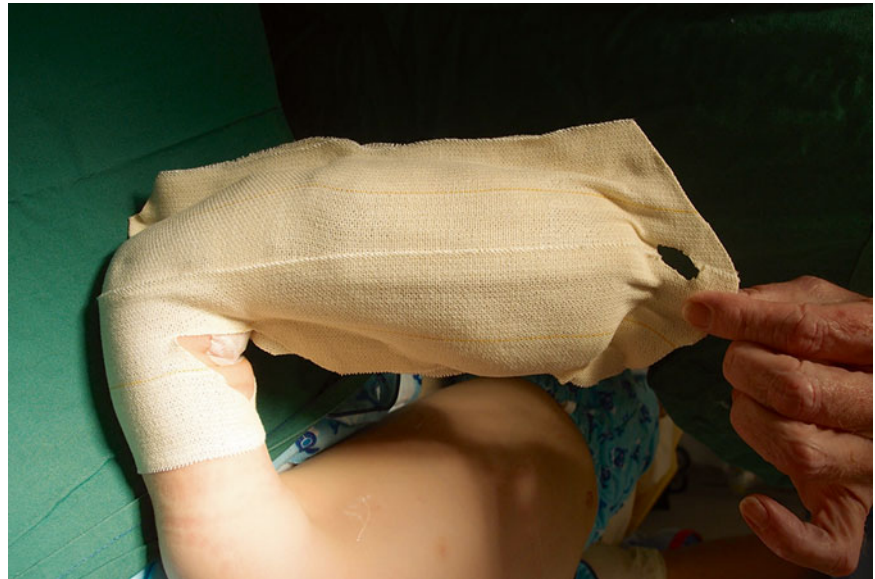Flaps are necessary to recreate the first web in all such cases.

Multiple surgeries are often necessary to create a stable thumb with some mobility. The patient has five digits. The width of the hand is maintained, which assists grip. However, the problems are many: scarring is significant; the “new” thumb remains small and may require lengthening; joints are often unstable, requiring fusion subsequently; and mobility is poor.

Full toe transfers have been utilised by some for Grade 5 hypoplasia. However, the lack of normal proximal tissues and the lack of cortical representation, render the function of such transfers less than satisfactory. Skin transfer through pedicle or free flaps are necessary for first web construction.



**Fig. 8.36** Post-operative dressing. Published with kind permission of Michael A. Tonkin ©2014. All rights reserved

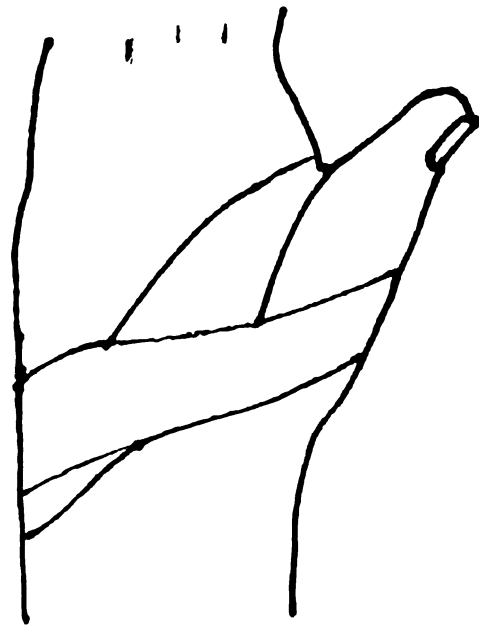


It is not my practice to apply these reconstructive procedures to young children. If pollicisation is refused, some of the above techniques may be indicated at a later age if the child is using the thumb. Carefully selected surgery may stabilise a joint or even provide a joint through an MTP transfer. An opposition tendon transfer may improve function. Such reconstructions should be limited to those who have not excluded the rudimentary thumb but use it for some activities. The results remain inferior to those obtained from a well-performed pollicisation. However, five digits are retained.

### Post-operative Management

Following reconstructive surgery of Grade 2 thumbs and pollicisation procedures, I retain the forearm and hand in an inclusive plaster for 5 weeks. Occasionally the child escapes from the plaster, but the technique taught by Foucher is effective. Two U-slabs of plaster cover the hand and forearm to elbow. Three-inch Elastoplast tape is used as a stirrup around the elbow to prevent the plaster cast from slipping (Fig. 8.36).

Wires are removed in the clinic at 5 weeks. A soft dressing is used for 1 or 2 weeks with twice-daily bathing and massage of scars. A low-profile elastic splint, as practised by Manske and others, helps maintain opposition without interfering greatly with mobilisation (Fig. 8.37) [25]. A deviating force should not be applied beyond the MCP joint. Radial deviation may simulate opposition but is a false friend. Buddy strapping of the two radial fingers discourages side-to-side use of these for pinch and encourages use of the new thumb. The therapists may assist in retraining by introducing the child to games which utilise desired thumb activities. In the main, the child is his/her best therapist. FPL function usually returns from 3 months or thereabouts.



**Fig. 8.37** Soft tissue splint. Published with kind permission of Michael A. Tonkin ©2014. All rights reserved

## Results and Complications

Functional results following pollicisation are entirely dependent upon the preoperative status. Those with a significant radial longitudinal deficiency are severely disadvantaged. The wrist may be unstable, in spite of the best attempts to stabilise the carpus on the end of the ulna. Extrinsic musculotendinous units to the index finger, in particular, have poor excursion; joints tend to be stiff with camptodactyly of the

index finger a common finding. The index finger is hypoplastic. As a consequence, the thumb function and appearance are compromised. Nevertheless, it is my experience and that of others that in nearly all instances the child will use the pollicised digit for certain activities. Side-to-side pinch utilising the more mobile ulnar digits may be preferred for smaller diameter objects. Strength and motion are significantly diminished in comparison to age-related normal values. These results contrast with those following pollicisation of a near-normal index finger in a limb with minimal, if any, discernible radial longitudinal deficiency.

Kozin [27] found a grip strength of 67 % of the opposite side and Clark [21] reported 43 % of the opposite side. My review of 42 pollicisations found results very similar to those of Manske [24]. Grip strength was reduced to 40 % of age-related normal values when the preoperative status of the limb and index finger was normal or near-normal, in comparison to Manske's 31 %. These values decreased alarmingly with significant radial longitudinal deficiency when the index finger was of poor quality, with values of 6 % and 15 % for my patients and those of Manske, respectively. Strength of pinch was similar in the two studies and with the same significant decrease in those with poor quality limbs and index fingers. In the latter instance, lateral pinch measured 9 % (Manske 14 %) of age-related normal values. This improved to 30 % (Manske 38 %) in those children not disadvantaged by the accompanying deficiencies. These trends are also apparent for measurements of total active motion of the digit, with an average of 26° of motion at the MCP joint when combining all patients undergoing pollicisation (Manske 42°) and 26° at the IP joint (Manske 25°). Radial abduction averaged 44°. Sixty percent of patients could oppose to the pulp of the little finger, 17 % to the ring finger and 23 % to the middle finger only, again with motion being significantly improved in those without concomitant deformities. The Jebsen timed test for functional tasks found an increased time as a percentage of published normal values, 200 % for those patients with concomitant deficiency and 130 % in those with good preoperative status. These figures were a little poorer than those of Manske.

The results in both studies were not significantly altered by the age of the patient at the time of the operation. In my group, 14 patients repeated the study 3 years apart. The strength measurements and time to completion of Jebsen tasks improved with age, but they remained the same relative to age-related normal values.

These results are consistent with those published by others [19–25, 27–34].

Percival introduced a scale to measure function incorporating strength, motion, ability to perform certain tasks, sensibility and appearance [28]. In his 30 pollicisations, 73 % were graded good or excellent, 17 % fair and 10 % poor.

Vekris and others found similar results in 21 pollicisations, with 75 % excellent, 19 % good and 6 % poor [33].

Goldfarb, in conjunction with Manske and others, evaluated the objective features and aesthetic outcomes of 31 pollicised digits, comparing these with normal thumbs [35]. They found the average length of the pollicised digit relative to the long finger proximal phalanx to be 90 % compared to an age-matched normal average of 71 %. The girth of the pollicised digit relative to the long finger was 92 % compared to an age-matched normal average of 132 %. The nail width of the pollicised digit relative to the nail width of the long finger was 96 % compared with an age-matched normal thumb average of 104 %. The visual analogue scale for subjective aesthetic analysis of these pollicised digits averaged 7.3 for the caregiver, 6 for the therapist and 6.4 for the surgeon. They concluded that pollicised digits are longer, but have reduced girth and nail width compared with age-matched normal thumbs.

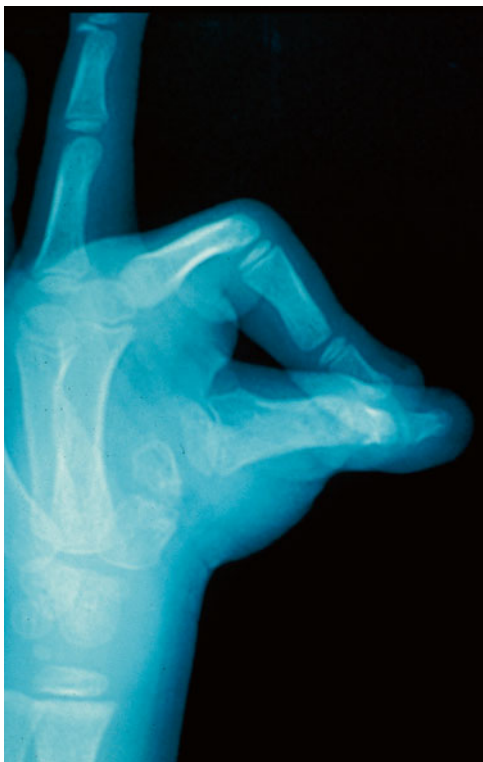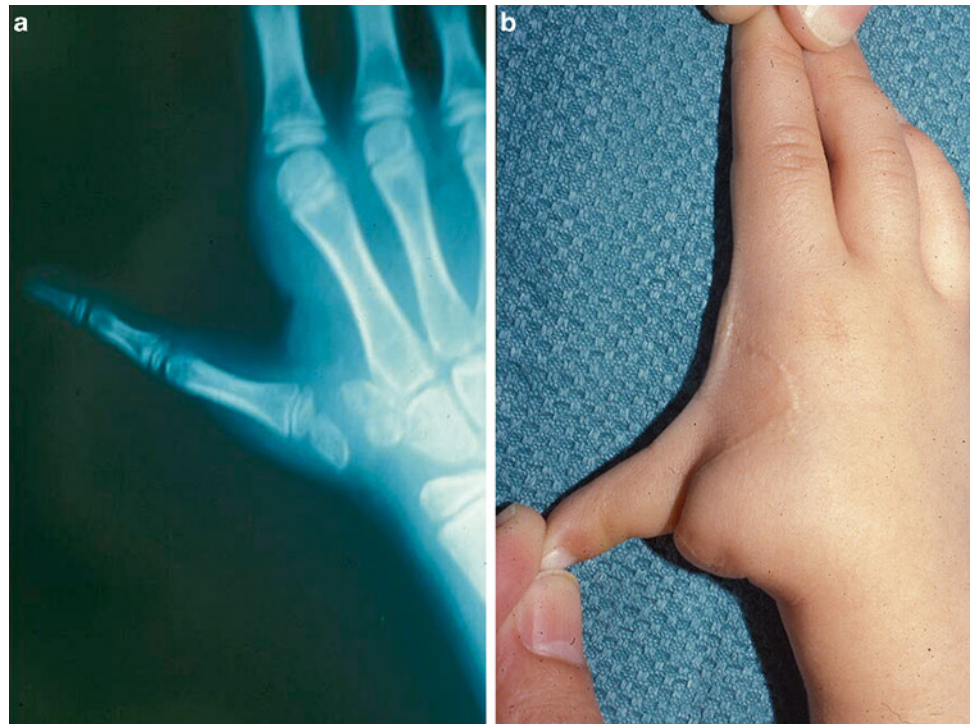
Intra-operative complications are associated with vascular compromise, arterial and/or venous; denervation of the dorsal and/or palmar interossei during mobilisation; and poor position of the digit—often in association with inadequate motors or inappropriate tension in musculotendinous reconstructions and skin suture. Failure to flex the MC head may create a radial abduction (hyperextension) deformity of the metacarpal. Partial flap necrosis is uncommon, but is reported. Secondary surgery is not uncommon with some reports of a high incidence of opposition transfers to better position and move the digit. Instability of both the new trapezium or the new CMC joint may follow a failure to adequately stabilise the MC head to the MC base or capsule, or from loss of structural integrity of the index finger MCP joint collateral ligaments during harvest (Figs. 8.38a, b and 8.39). Flexion contractures of the MCP joint may be secondary to excessive CMC joint radial abduction or to the preoperative status of the index finger.

In 96 pollicisations, I have stabilised a mobile trapezium in two cases, revised two webs which were too deep and v-shaped, performed one tendon transfer to increase radial abduction, one metacarpal osteotomy to better position the thumb, and three MCP joint fusions for flexion contractures.

Functional results of reconstruction of Grade 2 hypoplastic thumbs may be assessed utilising the same parameters as those used to assess the results of pollicisation. However, the disparate anomalies within this grade of thumb hypoplasia render comparisons difficult. As discussed under the sub-heading of Classification, different definitions of characteristics according to grade and, consequently, the alternative reconstructions which have been performed, do not allow comparison of like with like. Sub-classification along the lines that have been suggested in this chapter would assist in addressing this difficulty. Some have reported results according to Manske's classification but the comparison still



**Fig. 8.38** (a, b) Instability of the new trapezium. Published with kind permission of Michael A. Tonkin ©2014. All rights reserved



**Fig. 8.39** Instability of the “new” CMC joint. Published with kind permission of Michael A. Tonkin ©2014. All rights reserved

remains less than perfect as some include correction of extrinsic anomalies within Grade 2 thumbs. Graham and Louis reported the results of reconstruction of 14 Manske Grade 3A thumbs with improved thumb IP joint motion of an

average of 20°, but with two patients with mild MCP joint UCL instability [36]. Abdel-Ghani and Amro reported excellent stability of the thumb MCP joint in 71 % of patients. Opposition of the thumb to the little finger was excellent in eight of nine patients [37].

I have reviewed 22 patients with 21 opposition transfers, 15 first web plasties, 2 metacarpal osteotomies for realignment and 7 with attention to extrinsic anomalies. MCP joint stabilisation was performed by double breasting of the tissues present on the ulnar side of the joint in 15, reconstruction with an FDS slip in 3, and chondrodesis in 1. Assessment of active motion in comparison to the opposite unaffected thumb (when appropriate) found 34 % of IP joint motion, 60 % of MCP joint motion, 51 % of palmar abduction and 58 % of radial abduction. Kapandji’s opposition assessment revealed a mean score of 6.6. Lateral pinch was 51 % of the opposite unaffected thumb, tripod pinch 59 % and power grip 82 % of the unaffected side. There was no significant difference in metacarpal lengths according to a thumb-index finger metacarpal length ratio between affected and opposite unaffected thumbs. The metacarpal width as a ratio of thumb to index was 78 % in affected thumbs and 84 % in opposite unaffected thumbs. Mild hypoplasia (Grade 1) of the opposite thumb does compromise the validity of these results. When compared with age-related normal values the difference may be greater. Mild instability at the IP joint was found in one. Moderate instability was present at the MCP joint level in seven. In three further patients, global instability was apparent at the time of assessment. These results suggest, as do the findings of others, that although MCP joint motion may be

decreased, good mobility can be obtained at the CMC joint and retained at the IP joint if present preoperatively, and that stability and strength are improved. A Visual Analogue Scale assessment by parent and patient provided a mean score of 6.6 for function and a mean score for appearance of 7.

Complications of reconstructions of Grade 2 thumbs relate to continuing or recurrent MCP joint instability and poor function of the opposition transfer—denervation of ADM or adhesion formation impairing FDS gliding. Both problems tend to result in a recurrence of first metacarpal adduction and radial deviation at the MCP joint. Malalignment of extrinsic tendons plays a significant role in this deformation.

In my series, there was one patient with mild instability at the IP joint and ten with instability at the MCP joint. Four of the latter were considered to be severe enough to revise to arthrodesis, three with global MCP joint instability. One further patient underwent first web revision surgery.

It is generally considered that reconstruction of Grade 3 and 4 thumbs provides poorer results than those obtained by pollicisation. The first web space often remains deficient. Mobility is poor and strength is compromised in comparison to a pollicised index finger. However, some report encouraging results with microsurgical reconstruction, which is more likely to provide growth than those reconstructions relying on non-vascularised bone grafts. Foucher et al. reviewed five patients with vascularised transfer of the second MTP joint to reconstruct a CMC joint [15]. Mobility was poor; hypoplasia of the thumb was seen in all five patients, ranging from 59 to 85 % of the opposite thumb; flexion contractures were present in two patients; grip strength measurements averaged 33 % and pinch strength 13 % of measurements in the opposite hand. Shibata et al. found marginally better function and grip than in pollicised digits, but poorer pinch strength and total active motion [16]. Tu et al. also found poor motion with a mean total active range of 60°. In many cases, the patients do not use the thumb consistently for pinch [38]. However, five digits are retained.

In all, results of surgical treatment of the hypoplastic thumb are dependent on the state of the digit to be reconstructed or to be pollicised and the presence or absence of accompanying limb deformities. Valid assessments and comparisons of results await the development of a more sophisticated scoring scale along the lines of that proposed by Percival, one that incorporates the preoperative status of the digit to be reconstructed or pollicised. Attention to technical details brings beneficial outcomes for patients and is rewarding for surgeons.

## References

- Swanson AB. A classification for congenital malformations of the hand. *N J Bull Acad Med.* 1964;10:166–9.
- Swanson AB. A classification for congenital limb malformations. *J Hand Surg Am.* 1976;1(1):8–22.
- Oberg KC, Feenstra JM, Manske PR, Tonkin MA. Developmental biology and classification of congenital anomalies of the hand and upper extremity. *J Hand Surg Am.* 2010;35(12):2066–76.
- Tonkin MA, Tolerton SK, Quick TJ, Harvey I, Lawson RD, Smith NC, et al. Classification of congenital anomalies of the hand and upper limb: development and assessment of a new system. *J Hand Surg Am.* 2013;38(9):1845–53. doi:10.1016/j.jhsa.2013.03.019.
- Jones KL. Smith's recognizable patterns of human malformation. 6th ed. Philadelphia, PA: Elsevier Saunders; 2006. p. 908.
- Müller W. Die angeborenen Fehlbildungen der menschlichen Hand. Leipzig: Thieme; 1937.
- Blauth W. Der hypoplastische Daumen. *Arch Orthop Unfallchir.* 1967;62:225–46.
- Blauth W, Schneider-Sickert F. Congenital deformities of the hand. An atlas of their surgical treatment. Translated by UH Weil. Berlin: Springer; 1981. p. 120–1.
- Manske PR, McCarroll Jr HR. Reconstruction of the congenitally deficient thumb. *Hand Clin.* 1992;8(1):177–96.
- Manske PR, McCarroll Jr HR, James M. Type III-A hypoplastic thumb. *J Hand Surg Am.* 1995;20(2):246–53.
- Buck-Gramcko D. Congenital malformations of the hand and forearm. State of the Art Part III. European medical bibliography. *Hand Surg.* 1993;3(4):15–21.
- Smith P. Lister's the hand. Diagnosis and indications. 4th ed. London: Churchill Livingstone; 2002. p. 505–512.
- Smith P, Sivakumar B, Hall R, Fleming A, Blauth II thumb hypoplasia: a management algorithm for the unstable metacarpophalangeal joint. *J Hand Surg Eur Vol.* 2012;37(8):745–50.
- Yamauchi Y, Fujimaki A, Yanagihara Y, Yoshizaki K. Reconstruction of floating thumb. Especially on the use of metatarsophalangeal joint grafting. *Seikeigeka (Orthop Surg).* 1979;30:1645–8.
- Foucher G, Medina J, Navarro R. Microsurgical reconstruction of the hypoplastic thumb, type IIIB. *J Reconstr Microsurg.* 2001;17(1):9–15.
- Shibata M, Yoshizu T, Seki T, Goto M, Saito H, Tajima T. Reconstruction of a congenital hypoplastic thumb with use of a free vascularized metatarsophalangeal joint. *J Bone Joint Surg Am.* 1998;80(10):1469–76.
- Matsuzaki H, Toishi S, Yoshizu T. A Blauth IIIB hypoplastic thumb reconstructed with a vascularized metatarsophalangeal joint transfer: a case report with 28 years of follow up. *Hand Surg.* 2009;14(1):63–8.
- Tupper JW. Pollex abductus due to congenital malposition of the flexor pollicis longus. *J Bone Joint Surg Am.* 1969;51(7):1285–90.
- Buck-Gramcko D. Pollicization of the index finger. Method and results in aplasia and hypoplasia of the thumb. *J Bone Joint Surg Am.* 1971;53(8):1605–17.
- Kozin SH. Pollicization: the concept, technical details, and outcome. *Clin Orthop Surg.* 2012;4(1):18–35.
- Clark DI, Chell J, Davis TR. Pollicisation of the index finger. A 27-year follow-up study. *J Bone Joint Surg Br.* 1998;80(4):631–5.
- Egloff DV, Verdant C. Pollicization of the index finger for reconstruction of the congenitally hypoplastic or absent thumb. *J Hand Surg Am.* 1983;8(6):839–48.
- Taghinia AH, Upton J. Index finger pollicization. *J Hand Surg Am.* 2011;36(2):333–9.
- Manske PR, Rotman MB, Dailey LA. Long-term functional results after pollicization for the congenitally deficient thumb. *J Hand Surg Am.* 1992;17(6):1064–72.
- Manske PR. Index pollicization for thumb deficiency. *Tech Hand Up Extrem Surg.* 2010;14(1):22–32.
- Chow CS, Ho PC, Tse WL, Hung LK. Reconstruction of hypoplastic thumb using hemi-longitudinal metatarsal transfer. *J Hand Surg Eur Vol.* 2012;37(8):738–44.
- Kozin SH, Weiss AA, Webber JB, Betz RR, Clancy M, Steel HH. Index finger pollicization for congenital aplasia or hypoplasia of the thumb. *J Hand Surg Am.* 1992;17(5):880–4.



28. Percival NJ, Sykes PJ, Chandraprakasam T. A method of assessment of pollicisation. *J Hand Surg Br.* 1991;16(2):141–3.
29. Staines KG, Majzoub R, Thornby J, Netscher DT. Functional outcome for children with thumb aplasia undergoing pollicization. *Plast Reconstr Surg.* 2005;116(5):1314–23.
30. Netscher DT, Aliu O, Sandvall BK, Staines KG, Hamilton KL, Salazar-Reyes H, Thornby J. Functional outcomes of children with index pollicizations for thumb deficiency. *J Hand Surg Am.* 2013;38(2):250–7.
31. Ceulemans L, Degreef I, Debeer P, De Smet L. Outcome of index finger pollicisation for the congenital absent or severely hypoplastic thumb. *Acta Orthop Belg.* 2009;75(2):175–80.
32. Foucher G, Medina J, Lorea P, Pivato G, Szabó Z. Pollicization in congenital differences. *Handchir Mikrochir Plast Chir.* 2004;36(2–3):146–51.
33. Vekris MD, Beris AE, Lykissas MG, Soucacos PN. Index finger pollicization in the treatment of congenitally deficient thumb. *Ann Plast Surg.* 2011;66(2):137–42.
34. Sykes PJ, Chandraprakasam T, Percival NJ. Pollicisation of the index finger in congenital anomalies. A retrospective analysis. *J Hand Surg Br.* 1991;16(2):144–7.
35. Goldfarb CA, Deardorff V, Chia B, Meander A, Manske PR. Objective features and aesthetic outcome of pollicized digits compared with normal thumbs. *J Hand Surg Am.* 2007;32(7):1031–6.
36. Graham TJ, Louis DS. A comprehensive approach to surgical management of the type IIIA hypoplastic thumb. *J Hand Surg Am.* 1998;23(1):3–13.
37. Abdel-Ghani H, Amro S. Characteristics of patients with hypoplastic thumb: a prospective study of 51 patients with the results of surgical treatment. *J Pediatr Orthop B.* 2004;13(2):127–38.
38. Tu YK, Yeh WL, Sananpanich K, Ueng SW, Chou YC, Ma CH, Lee ZL. Microsurgical second toe-metatarsal bone transfer for reconstructing congenital radial deficiency with hypoplastic thumb. *J Reconstr Microsurg.* 2004;20(3):215–25.