

Dominique Dempah, Moaz Abulfaraj,
and Maurice E. Arregui

Outline

- Introduction to EUS
- Development of EUS
- EUS equipment
 - Scopes
 - Linear
 - Radial
 - Forward viewing minicatheter
 - Intraductal ultrasound
 - Ultrasound console
- General technique of use
- Clinical uses of EUS in the foregut
 - EUS in esophageal diseases
 - EUS in gastric diseases
 - EUS in biliary diseases
 - EUS in pancreatic diseases
 - EUS in diagnosis of upper abdominal masses
- The future of EUS in the upper abdomen

Development of EUS

Endoscopic ultrasound was developed in the early 1980s and introduced into practice in the late 1980s. It was used to remedy the radiologic shortcomings in visualizing the pancreas, which is located deep in the abdomen and obscured by air in the bowel lumen. It shortly became apparent that EUS would

also provide outstanding imaging of the different layers of the esophageal, gastric, and intestinal wall as well as visualization of the lymph nodes close to the digestive tract. These findings led to the prominent role of EUS on the preoperative staging of gastrointestinal tumors. The development of linear probes in the early 1990s ushered the era of interventional EUS while greater miniaturization led to the development of intraductal ultrasound for direct access into the bile ducts and the pancreatic duct [1, 2].

Equipment

Echoendoscopes

The technique of EUS combines endoscopy which enables direct visualization of the mucosal surface of any enteric surface that can be reached by an endoscopic instrument and echography through a small ultrasound transducer fitted on the tip of an endoscope (echoendoscope) and thus brought into the close vicinity of the area or the organ to be studied. The close proximity of the ultrasound probe allows use of high ultrasonic frequencies (generally 5–20 MHz but can be as high as 30 MHz). As a result, excellent definition in the order 1/10 of 1 mm can be achieved, and lesions as small as 1–2 mm can be visualized in the GI wall, pancreas, bile ducts, etc. [1].

Currently, there are two distinct types of echoendoscopes used for clinical practice: radial and linear (Figs. 11.1 and 11.2). Both of these have a 4-cm distal rigid tip that houses the optics, ultrasound transducer, and electronic components. This is an important feature to note as it can make intubation of the esophagus and duodenum technically challenging. Care must be taken to avoid bowel perforation when negotiating these scopes into the duodenum as the distal segment of the echoendoscope is inflexible [2]. The radial and linear echoendoscopes provide both video endoscopy and sonographic imaging. The radial echoendoscope creates a sonographic image that is 360° and is perpendicular to the shaft

D. Dempah, MD
Department of Surgery, St. Vincent's Hospital,
8235 Spyglass Dr. Apt 2A, Indianapolis, IN 46260, USA
e-mail: ddempah@gmail.com

M. Abulfaraj, MD, FRCS
Department of General Surgery, St. Vincent Hospital Indianapolis,
635 Danforth St., Carmel, IN 46032, USA
e-mail: dr_moaz82@yahoo.com

M.E. Arregui, MD, FACS (✉)
Department of General Surgery, St. Vincent's Hospital,
8402 Harcourt Rd. Suite 815, Indianapolis, IN 46260, USA
e-mail: arregui@ameritech.net




Fig. 11.1 Shown here is a linear tip echoendoscope. This type of tip creates a sagittal view

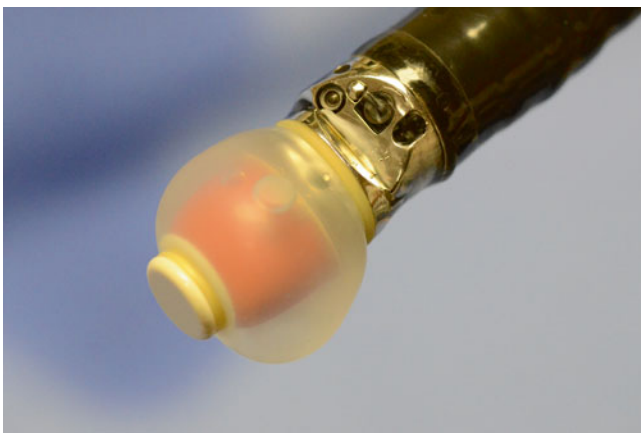

Fig. 11.2 Shown here is a radial tip echoendoscope with the balloon inflated. This type of tip creates axial views

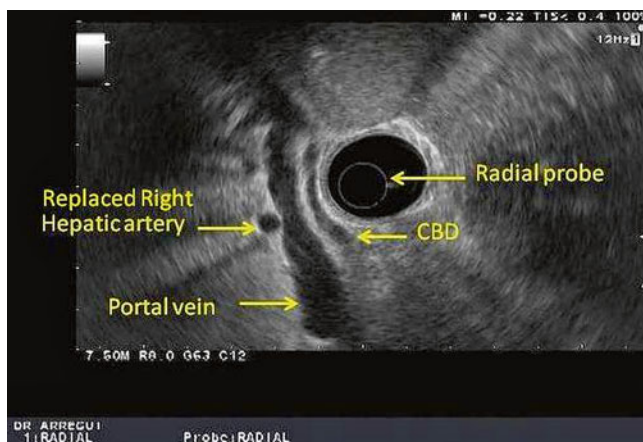


Fig. 11.3 This is a radial view of the porta hepatis obtained with a radial echoendoscope. *CBD* common bile duct

of the scope resulting in a cross-sectional image (Fig. 11.3). There are two types of radial echoendoscopes that are commercially available, mechanical and electronic. They differ in the way the sonographic image is produced. The mechani-

cal radial scope creates an ultrasound image with rotating piezoelectric crystals in the transducer that detect a sound wave and convert it to an electronic signal. The electronic radial scope has improved spatial and contrast resolution as its transducer consists of multiple fixed nonrotating elements, where each transmits and receives ultrasound waves that are converted to an image by an electrical signal. Furthermore, the electronic radial array echoendoscope has the added features of pulse wave and color Doppler to identify vascular and ductal structures [2]. Overall, the image quality is better with the electronic echoendoscope, but the mechanical echoendoscope is cheaper and can image with higher frequencies. The radial echoendoscopes are only used for diagnostic purposes as the images are more easily interpreted due to the 360° feature.

The linear echoendoscope creates a sonographic image that is parallel to the shaft of the scope resulting in a sagittal sector image as opposed to the circumferential cross-sectional image of the radial echoendoscope [3]. This allows the operator to trace the path of a needle as it is inserted out of the operating channel in real time and thus enables therapeutic capabilities and interventions such as EUS-guided FNA (fine needle aspiration biopsy), EUS-guided injection therapies, and EUS-guided drainage procedures [2]. The standard linear echoendoscope is actually curvilinear and oblique viewing, similar to the side-viewing duodenoscope used for ERCP. It also has a lever on the handle called the elevator that raises the instruments passed through the accessory channel and thus allows fine movements. This configuration carries some inherent drawbacks. First, linear and radial echoendoscopes only allow side-viewing endoscopy as opposed to the more intuitive forward viewing of a gastroscope, for example. There is also a “push back phenomenon,” where the force of the needle advancement might cause the scope to push back. Finally, the size of the accessory device is limited by the angulation of the accessory channel at the endoscope tip and the elevator [4]. Forward-viewing curvilinear echoendoscopes have been recently developed to overcome these challenges with the theoretical advantages of superior endoscopic visualization, easier deployment and manipulation of devices and needles, as well as better transmission of force to the needle. These forward-viewing scopes also have an increased tip deflection, but they also have a narrower ultrasound scanning range and lack an elevator. Early data on forward-viewing echoendoscopes suggest EUS visualization is comparable to the oblique-viewing linear echoendoscope in the upper gastrointestinal tract. Furthermore, endoscopists have reported increased ease of device deployment and better force transmission [4]. Currently, these forward-viewing echoendoscopes are mainly used for research purposes.

In addition to the conventional linear and radial echoendoscopes, catheter mini-ultrasound probes and intraductal




Fig. 11.4 A minicatheter can be seen through the working port of a duodenoscope




Fig. 11.5 An intraductal ultrasound is passed on a guidewire catheter through the working port of a duodenoscope

ultrasound (IDUS) probes have been developed. The catheter miniprobes can be used for lesions in or near the gastrointestinal mucosa or when an obstruction precludes the safe use of an echoendoscope. Their outer diameter ranges from 1.7 to 3.1 mm, which allows their passage through the working channel of an upper endoscope or duodenoscope (Fig. 11.4). These probes have a limited life span due to breakdown of the driveshaft that spins the ultrasound transducer tip, especially when used through a duodenoscope because the elevator causes repeated trauma to the probe.

Transpapillary IDUS catheters (Fig. 11.5) are high-frequency wire-guided catheters that are typically used during endoscopic retrograde cholangiopancreatography (ERCP). These probes produce high-quality cross-sectional images of the pancreatic and biliary ducts with resolution ranging from 0.07 to 0.18 mm. Not only are these probes high frequency, but the fluid in the ducts where they are inserted serves as an excellent acoustic window which improves resolution [2]. The use of IDUS to evaluate the biliary tree was first published in 1992, but despite reports indicating its value in decreasing the rate of recurrent biliary stones after endoscopic sphincterotomy, its utilization in clinical practice

remains low [5]. Other indications include cholangiocarcinoma, evaluation of pancreatic cystic tumors, pancreatic islet cell tumors, and biliary and pancreatic duct strictures.

Console Function

It is essential to be familiar with the various functions of the EUS console as well as to understand when to apply the different US functions when acquiring images in order to make more accurate clinical diagnosis. We will discuss some of the important functions. The depth/range function changes the display depth of the image. It is helpful to start with the greater depth range for initial scanning and identify any gross abnormality and magnify the near-field view for more detailed study. Similarly, using the frequency function, one should start with a lower frequency to scan through a wide range of structures. Indeed lower frequency allows greater penetration but lower resolution. Once a lesion is identified, frequency can be increased to obtain a better resolution, which refers to the ability to discriminate between two points along the beam path. The focus function allows convergence of the US beam to a particular depth to achieve an image with a higher lateral resolution. The gain function adjusts the overall sensitivity of the gray-scale image. If it is turned too high, the image will be too white, and if it is turned too low, the image will be too dark. The Doppler function not only allows identification of blood flow in vessels but also provides information regarding the direction of the flow and its velocity. The power Doppler function has a higher sensitivity in detecting blood flow because background noise is reduced. However, it does not give any information on flow direction and velocity. Annotations features are also available to measure and mark any structures or lesions [6]. (Refer to section “Control panel” in Chap. 3 for more information.)

General Technique of Use

Most echoendoscopes are oblique viewing and the process of pharyngeal intubation is nearly blind similar to a duodenoscopy. The echoendoscope is inserted into the pharynx with the tip deflected downward. Once in the pharynx, the tip is gently advanced in the esophagus. Forceful intubation must be avoided to prevent perforation. In difficult cases, excluding a Zenker’s diverticulum or other unusual anatomic abnormalities, a diagnostic gastroscopy may be advisable. For both radial and linear EUS, recognition of key landmarks is vital for proper orientation. Filling the GI lumen with water is helpful when the GI wall is being examined. Radial images are axial circumferential images that are more easily interpreted partly because axial imaging is more familiar to most. Linear images are sagittal sector images that are more

limited and more difficult to interpret. To facilitate performance of the exam and interpretation of the image, linear EUS requires the use of key movements, which include advancement and withdrawal, clockwise and counterclockwise torquing, and angulation. Torquing is achieved either by using the right hand to torque the shaft of the echoendoscope or by changing the direction of the handle by turning the left wrist or body. Angulation of the tip is mainly performed by using the up-down control. It is also important to ensure proper coupling by continuous suction and by keeping the tip of the echoendoscope pressed against the mucosa. For example, with a linear scope in the mediastinum, the abdominal aorta should be identified first as a large hypoechoic tubular structure with the echoendoscope shaft held at neutral position. Doppler can confirm vascularity. As the scope is advanced distally in the esophagus into the proximal stomach, the celiac artery (Fig. 11.6) and superior mesenteric artery should be seen next arising from the aorta. At the level of the celiac artery, clockwise rotation allows examination of the left adrenal gland (Fig. 11.7) superior to the kidney, while

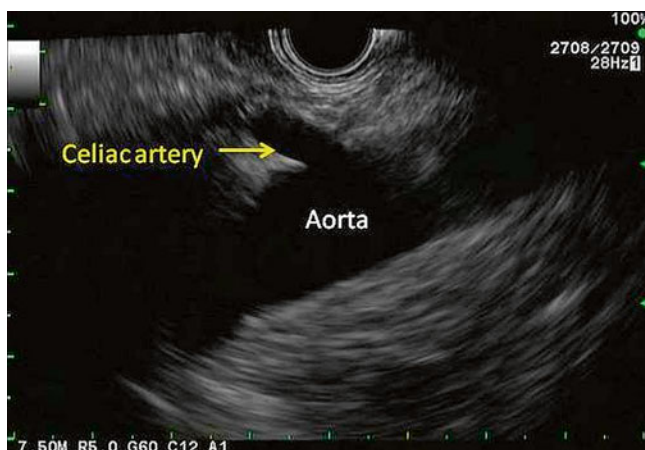

Fig. 11.6 The celiac artery can be seen coming off the aorta. This view is obtained through a linear echoendoscope

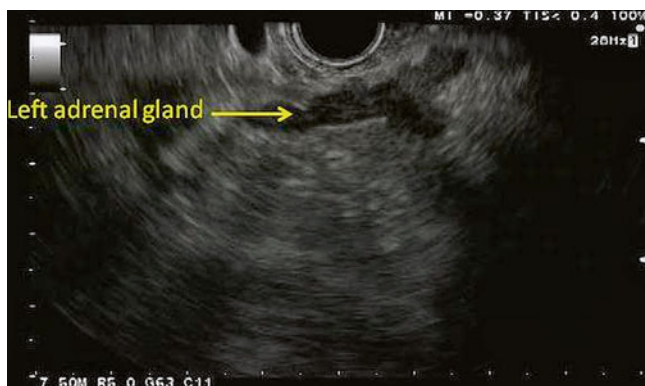


Fig. 11.7 Depicted here is the typical sonographic appearance of a left adrenal gland. It is a V- or Y-shaped organ with a hypoechoic cortex and a hyperechoic inner medulla

counterclockwise rotation will allow visualization of the left lobe of the liver [3].

Clinical Uses of Endoscopic Ultrasound in the Foregut

Esophageal Disease

The esophagus is the easiest part of the gastrointestinal tract to evaluate with EUS and thus plays an important role in the staging of esophageal cancer particularly with the increasing use of neoadjuvant therapy. EUS allows accurate assessment of depth of invasion and the nodal status. However, its role in identifying metastatic disease is limited. The esophagus has five ultrasonographic layers, namely, mucosa, muscularis mucosa, submucosa, muscularis propria, and adventitia (Fig. 11.8). Puli et al. conducted a meta-analysis and reported a sensitivity of 81–90 % and specificity of 99 % for T staging. The accuracy of T staging with T4 tends to be higher in comparison to T1 [7]. In advanced tumors where the lumen is too narrow to allow examination with the echoendoscope, a mini-ultrasound probe can be used through the endoscope to assess the depth of the invasion. EUS can identify local lymph nodes including paraesophageal, paratracheal, subcarinal, and aortopulmonary groups. In addition, it allows biopsy of any suspicious nodes. EUS has a sensitivity and specificity of 84.7 and 84.6 %, respectively, which improves to 96.7 and 95.5 % with the use of FNA [7]. EUS allows visualization and biopsy of metastatic lymph node, particularly celiac adenopathy with sensitivity of 67 % and

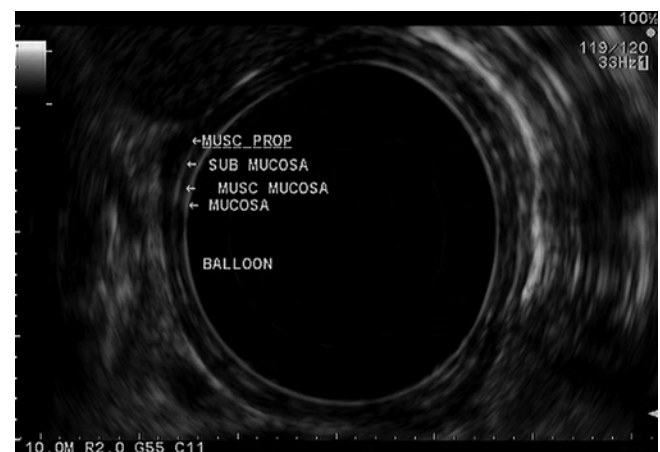


Fig. 11.8 A radial view of the esophageal layers is obtained with a radial echoendoscope. Beginning from the lumen (balloon) and extending outward, the mucosa, muscularis mucosa (musc mucosa), submucosa, and muscularis propria (musc prop) layers can be seen. The mucosal layers (mucosa and submucosa) are hyperechoic, while the muscular layers (muscularis mucosa and muscularis propria) are hypoechoic

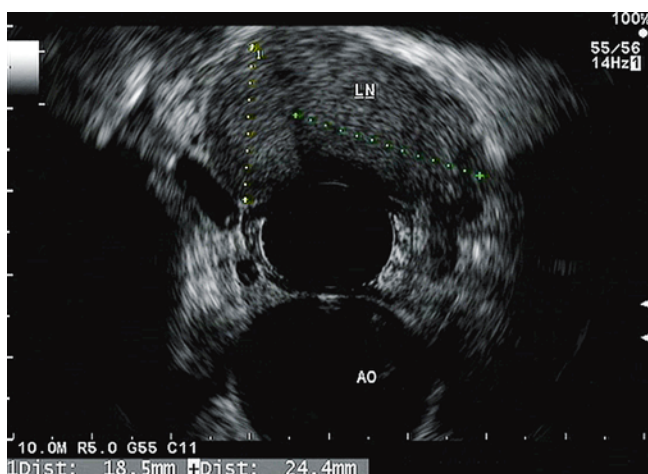


Fig. 11.9 An enlarged lymph node (LN) is seen in the mediastinum. The aorta (AO) can also be seen at 6 o'clock

specificity of 98 %. EUS can also be helpful to visualize much of the liver, with exception to the subdiaphragmatic part of the right lobe.

Gastric Disease

Similar to the esophagus, EUS plays an important role in the management of gastric cancer. It can help in determining if the patient requires neoadjuvant treatment and also if the patient is a candidate for endoscopic resection. The overall accuracy of EUS for T staging is 75 %, and the accuracy tends to be higher for more advanced disease. It has an accuracy of 77 % for T1, 65 % for T2, 85 % for T3, and 79 % for T4 [8]. However, EUS is 86 % sensitive and 91 % specific in differentiating early “T1/T2” from advanced “T3 and T4” lesions [9]. Higher-frequency (12–20 MHz) ultrasound probes have lower depth of penetration and lower accuracy to stage advanced lesions. Nevertheless, higher frequencies have a higher accuracy for differentiating smaller lesions, which can be particularly helpful for tumors that appear to be amenable for endoscopic resection. Endoscopic ultrasound has a sensitivity of 74 % and specificity of 80 % in lymph node staging and allows biopsy of any clinically suspicious lymph nodes. Suspicious lymph nodes are usually hypoechoic, round, and larger than 10 mm in size (Fig. 11.9). EUS can also identify ascites and can evaluate many parts of the liver.

Biliary Disease

Transabdominal US is the gold standard for evaluation of gallbladder stones. However, it can miss small stones. In patients with suspected gallbladder stones and a nondiagnostic

transabdominal US, EUS can be used to evaluate for occult cholelithiasis given its higher-frequency resolution and its closer proximity to the biliary system as compared with transabdominal US. Similarly in patients with acute idiopathic pancreatitis, EUS can be used to rule out occult cholelithiasis or microlithiasis. EUS has also emerged as a minimally invasive procedure for the evaluation of choledocholithiasis, especially among patients with intermediate probability of common duct stones. In this setting, transabdominal US is not very sensitive, and ERCP is associated with a small but not insignificant risk of serious complications. Because of these potential complications such as pancreatitis, cholangitis, perforation, and hemorrhage, ERCP should ideally be reserved for patients with proven common bile duct stones. EUS allows detection of common bile duct stones with sensitivities similar to MRCP and even ERCP in some studies. The exam is usually started with the echoendoscope in the long position in the duodenal bulb. The scope is advanced to the superior angle of the duodenal bulb and the tip is deflected downward. The transducer is then moved slowly along the course of the gallbladder using torque and tip deflection as needed to image the body, fundus, and neck of the gallbladder. The normal gallbladder appears as a large fluid-filled (anechoic) structure with a thin-layered wall. The common bile duct, common hepatic duct, and portal vein are also seen in their long axis with the scope in this position. Doppler can be used to distinguish blood vessels such as the portal vein and gastroduodenal artery from the bile ducts. The scope can then be placed in the short position at the level of the papilla similar to the endoscope position when performing ERCP. This allows identification of the bile duct in the periampullary area. The bile duct can also be followed proximally to the gallbladder and also the level of the bifurcation [10].

EUS can also be used in the management of biliary obstruction. ERCP remains the gold standard for drainage of biliary obstruction caused by benign or malignant diseases. However, conventional ERCP may be difficult in cases of impacted stone at the ampulla, ampullary stenosis, or ampullary carcinoma. In such cases, other options, which are considered to be more invasive and morbid, would include PTC or CBDE. In addition, ERCP may be impossible in patients who have altered anatomy due to previous gastric surgery or duodenal bulb obstruction. More recently, EUS has been used to drain the biliary tree as a safe valid alternative to other options with adequate clinical and technical success. EUS-guided cholangiogram was first reported by Wiersma in 1996 [11] and EUS-guided drainage was first reported by Giovannini in 2001 [12]. A therapeutic linear echoendoscope with a large working channel is used to access and stent the biliary tree using a technique similar to EUS-guided cystgastrostomy. The CBD is visualized through the duodenal bulb or the left hepatic duct is visualized through the stomach by

ultrasound. Doppler is used to avoid puncturing a vessel. A 19-gauge needle then is used to puncture the duct and bile aspirated. Afterward, contrast is injected under fluoroscopy and a cholangiogram is performed to delineate the biliary tree and area of obstruction. This is followed by advancing a guidewire into the hepatic duct. The needle then is removed, and dilator is inserted to dilate the tract. A double-pigtail or metallic stent is inserted across the area of obstruction [13]. Early complications include bleeding, right hepatic duct obstruction, cholangitis, and pneumoperitoneum. Late complications include stent migration and cholangitis.

Pancreatic Disease

EUS plays a tremendous diagnostic and therapeutic role in the management of benign and malignant pancreatic disease. For pancreatic cancer, EUS has a high sensitivity, comparable to dual-phase CT for tumors greater than 15 mm, but it is more sensitive than CT for tumors less than 15 mm. Therefore, although a pancreas protocol CT with intravenous contrast should be the initial imaging technique for diagnosis and staging of pancreatic cancer, EUS is a valuable complementary study especially when the CT findings are equivocal. EUS-guided FNA also allows tissue diagnosis, which is *sine qua non* for neoadjuvant therapies. In regard to pancreatitis, multiple EUS criteria have also been established for the diagnosis of chronic pancreatitis.

Evaluation of the pancreas includes a transduodenal view and transgastric view. The transduodenal view allows visualization of the head of the pancreas. The echoendoscope is inserted in the second portion of the duodenum, which contacts the duodenal mucosa and is slowly withdrawn into the duodenal bulb with counterclockwise torque. The pancreatic head and pancreatic duct can be traced, and at the apex of the duodenal bulb, the portal vein and the common bile duct can be seen parallel to each other. The scope is then withdrawn in the stomach until the pancreas can be visualized again. At this point, counterclockwise torque and advancement of the scope allow visualization of the body and neck of the pancreas, while clockwise torque and withdrawal allow visualization of the tail of the pancreas [3]. EUS offers various therapeutic options in pancreatic disease.

A pancreatic pseudocyst is a collection of fluid around the pancreas with a wall that lacks epithelium and develops secondary to pancreatitis and pancreatic ductal disruption (Fig. 11.10). Most pseudocysts are asymptomatic and usually resolve spontaneously. Indications for intervention include biliary obstruction, gastric outlet obstruction, bleeding, infection, and increasing in size. Surgical drainage was the treatment of choice for symptomatic pancreatic pseudocyst. However, in recent years endoscopic drainage has emerged as a less invasive alternative to surgery and is gaining more acceptance as an effective approach in the therapy

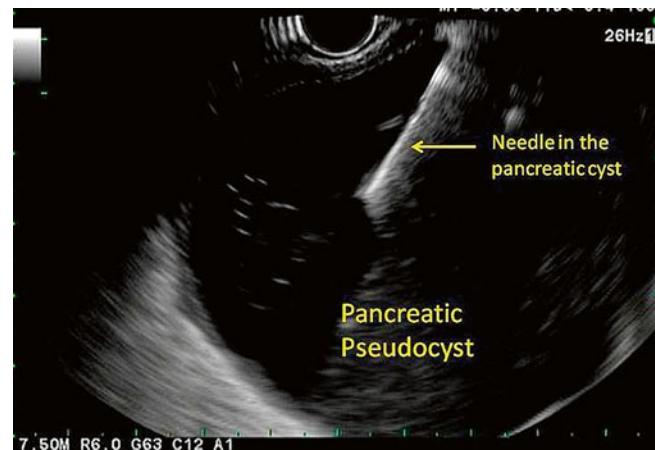
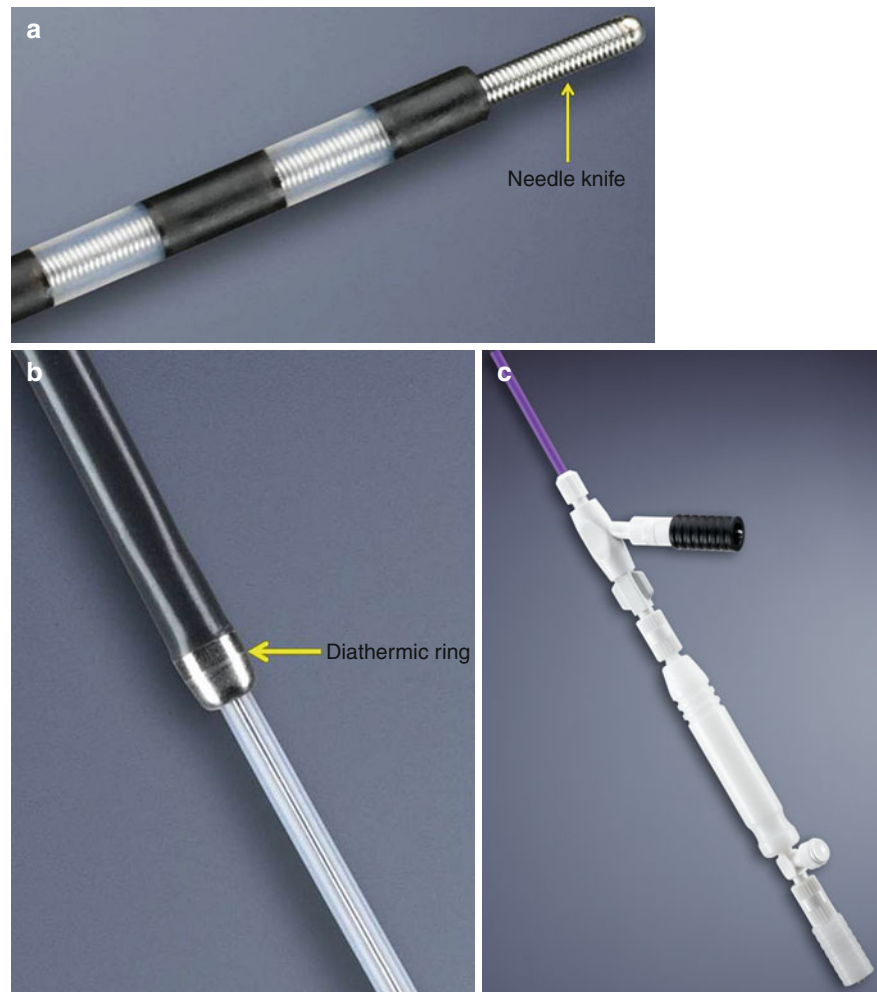


Fig. 11.10 A needle is inserted in a pancreatic pseudocyst during an endoscopic cystgastrostomy. One can clearly see the hyperechoic needle

of symptomatic pancreatic pseudocysts. More recently, EUS guidance has been advocated to increase technical success rate and to decrease the risk of bleeding and perforation, particularly in patients who fail to demonstrate bulging on endoscopy and in those with portal hypertension [14]. EUS-guided drainage might not be feasible in cases where there is an interposing vessel between the cyst and stomach or duodenal wall. Absence of direct contact between the cyst and the stomach, which usually occurs in small cysts (<6 cm), is a contraindication. Coagulopathy is a relative contraindication due to the risk of bleeding that might be difficult to control with endoscopic measures. Several studies confirm advantages of endoscopic ultrasound including a shorter hospital stay, lower total costs, and its less invasive approach. It is also a more appropriate approach for high-risk patients and in those who cannot tolerate a general anesthetic. Varadarajulu et al. compared surgical to EUS-guided cystgastrostomy and reported similar treatment success rate in both groups with a shorter hospital stay using the mean hospital stay (2.65 vs. 6.5 days, $P < 0.05$) as well as a lower cost in the EUS group [15]. Several complications have been reported including bleeding, perforation, stent migration, aspiration, and infection. Infection occurs as a result of premature occlusion of the stent and contamination of the cyst. To perform an endoscopic cystgastrostomy, a therapeutic linear echoendoscope with a large working “3.8-mm” channel is used to access and stent the pseudocyst in one step. The pseudocyst is visualized through the stomach or duodenal bulb to confirm that there is no fatty tissue in between, and color Doppler is applied to avoid puncturing a vessel or pseudoaneurysm. The cystotome (a needle knife and an outer catheter with diathermic ring) is used to puncture the pseudocyst (Figs. 11.10 and 11.11a, b). Fluid can be withdrawn and sent for analysis, cytology, lipase, CEA, gram stain, and culture, when infection is suspected. Afterward, contrast is injected under fluoroscopy to delineate the boundaries of the

Fig. 11.11 (a) The cystotome: the needle knife at the tip uses electrocautery energy to puncture the wall of a pseudocyst during an endoscopic cystgastrostomy. (b) The cystotome: the diathermic ring allows dilation of the tract created by the needle knife by cauterizing through the pseudocyst wall during an endoscopic cystgastrostomy. (c) The cystotome: the handle has a black connector for energy and a distal port for contrast injection



cyst (Fig. 11.11c). The outer catheter is introduced and the diathermic ring is used to dilate the tract by applying electrocautery. A guidewire is advanced and coiled inside the pseudocyst and a double-pigtail stent is inserted unless pancreatic necrosis or if a thick fluid containing significant amount of debris is encountered. In this case, multiple larger-caliber stents are placed followed by a nasocystic catheter for continuous irrigation and lavage of the cyst. If necrosis is persistent despite irrigation, the tract can be dilated with balloon dilator to over 12 mm at a later date and a direct endoscopic necrosectomy can be performed using forceps and snare to debride the cyst cavity [16]. Some studies advocate routine nasocystic catheter for irrigation in all patients with pseudocysts regardless presence or absence of abscess or necrotic debris to increase the clinical success rate and decrease the rate of recurrence [17]. Perforation and bleeding are the two most feared complications of the EUS-guided cystgastrostomy. Perforations tend to occur more commonly with pseudocysts, which arise from the uncinate process and are drained transgastrically [18]. This usually happens after the pseudocyst is decompressed and the distance between the stomach and the pseudocyst increases which might cause dislodgment of the stent and leakage of gastric contents.

Patients with such complications can be treated conservatively with gastric decompression, intravenous antibiotics, and close observation in the absence of sepsis and peritonitis. Bleeding can originate from the gastric or duodenal wall, which is usually controlled with endoscopic measures, or it can originate from a branch of the splenic artery, which requires angioembolization. Aspiration is a major complication in patients with giant pseudocyst. These patients should have the procedure done under general anesthetic with endotracheal intubation to protect the airway. Other complications include stent migration and infection.

Pain of pancreatic origin is a significant problem in patients with chronic pancreatitis and inoperable pancreatic cancer. This pain is usually difficult to control and has a major significant negative impact on patients' quality of life. These patients usually require a significant amount of analgesia including opioids, which are associated with significant side effects such as addiction, tolerance, and constipation. Non-pharmacological options include ERCP and stenting of the pancreatic duct, celiac nerve block, or neurolysis. Celiac nerve block can be done percutaneously, surgically, or more recently EUS guided. EUS celiac nerve block has been found to be more effective than a percutaneous approach [19].

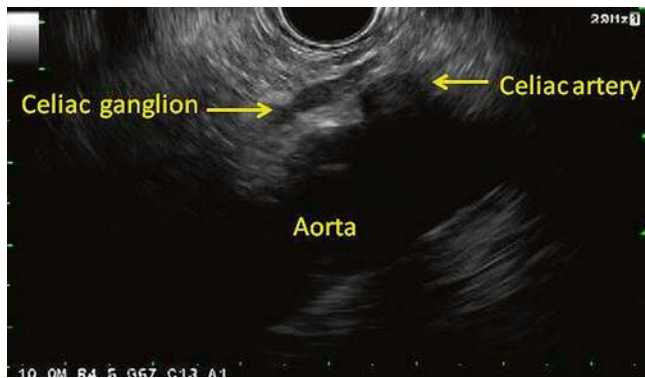


Fig. 11.12 The celiac ganglion can be seen as hypoechoic almond- or oval-shaped structure usually to the left of the celiac artery takeoff and proximal to the superior mesenteric artery

Multiple studies reported the effectiveness of EUS celiac block with a success rate up to 94 % [20]. The effectiveness increases when the ganglion is visualized and with the use of alcohol rather than steroids [20]. However, the ganglia are not visible up to 19 % of the time. In such cases, injection on both sides of the celiac trunk was found to be more effective than injecting just one side in one prospective trial [21]. Complications from the procedure are diarrhea and transient hypotension. Some patients have exacerbation of pain after the procedure, which starts in the recovery room and can last up to 2 days. Interestingly, these patients tend to have better long-term response to the treatment once the pain subsides. To perform a celiac ganglion block, a linear echoendoscope is advanced to about 40 cm, and the aorta is visualized and traced to the celiac trunk. The celiac ganglia are usually located along the celiac artery or between the celiac artery and the origin of the superior mesenteric artery. The average number of ganglia is 3 with size ranging from few millimeters to few centimeters (Fig. 11.12). A 22–25-gauge needle is inserted through the working channel and color Doppler is applied. Color Doppler is helpful to avoid puncturing a vessel and to prevent injecting bupivacaine intravascularly, which can cause a potentially lethal cardiac arrest. The toxic effects of an intravascular injection of bupivacaine can be treated by infusion of lipid emulsion [22]. The needle is applied to the center of each ganglion and injected with 10–30 ml of 50 % bupivacaine. Twenty ml of absolute alcohol in cases of pancreatic cancer or 40 mg of triamcinolone in cases of chronic pancreatitis is injected in addition to the bupivacaine. Most endoscopists avoid using alcohol in chronic pancreatitis [23] despite a higher efficacy in controlling pain because of alcohol's permanent effect, which can lead to chronic diarrhea that can be difficult to control by antidiarrheal medications. Some patients develop agitation during direct ganglia injection, which usually lasts for a few seconds. If there is no visible ganglion, then injection to the right, left, and base of the celiac trunk can be performed.

EUS in Diagnosis of Upper Abdominal Masses

Aside from FNA biopsy of pancreatic, biliary, and hepatic masses as described earlier, EUS can be used in the diagnosis of retroperitoneal masses, especially left adrenal masses that are accessible through EUS. Many studies have demonstrated the safety and utility of EUS-guided biopsy of left adrenal masses. Dewitt et al. from the Indiana University School of Medicine described their experience with EUS-guided biopsy of the left adrenal gland. They found that EUS-guided FNA of the left adrenal gland had a high sensitivity for cancer and that nondiagnostic biopsies were more common with diffusely enlarged glands compared with glands with a focal mass [24]. Bodtger et al. from the Copenhagen University Hospital showed that EUS-FNA of an enlarged left adrenal gland altered the TNM staging in 70 % and treatment in 48 % in patients with established or suspected lung cancer with adrenal metastasis [25].

The Future of EUS in the Upper Abdomen

EUS has already established itself as a powerful diagnostic and therapeutic tool in the management of diseases in the upper abdomen. Further advances in imaging such as sonoelastography, contrast enhancement, tridimensional EUS, and real-time optical diagnosis can potentially increase the diagnostic accuracy of EUS. Sono-elastography allows real-time visualization of tissue strain and hardness displayed in a transparent layout over the gray-scale images in a similar fashion to color Doppler. It can potentially help to select which lymph node to biopsy and help to differentiate between masses from chronic pancreatitis and pancreatic cancer in the setting of a nondiagnostic FNA. Microbubble contrast agents can be used as vascular signal enhancers to detect low-velocity and low-volume flow. This can also help to differentiate between focal pancreatitis and pancreatic cancer. Contrast harmonic imaging with microbubble-specific software allows visualization of vascular and parenchymal phases similar to computer tomography but with the advantage of being real time. Microbubble contrast agents can also be used to target specific endothelial cell surface receptors *in vivo* when coupled to monoclonal antibodies. This could lead to *in vivo* quantification of the targeted receptors and monitoring of treatment response. Furthermore, there is some evidence that enhanced cellular uptake of drugs and gene occurs in the presence of ultrasound, a process called sonoporation. Therefore, the combination of sonoporation and targeted contrast agents when coupled with chemotherapeutic agents could lead to targeted treatment. Tridimensional EUS can improve depiction of the spatial relationship between tumors and major surrounding vessels and thus improve staging especially in the case of pancreatic cancer where the assessment of mesenteric vessels involvement is

critical. Confocal laser endomicroscopy probes have been miniaturized to allow EUS-guided placement near the lesion of interest. Images obtained through these probes are high quality and essentially yield real-time histopathology [26].

EUS holds an important therapeutic role in the management of benign pancreaticobiliary disorders. Its role as a therapeutic vector in malignant disorders appears to be expanding and is the subject of much research. EUS-guided injection of antitumor agents in pancreatic cancer, EUS-guided brachytherapy, and EUS-guided alcohol ablation of left adrenal metastasis from small cell lung carcinoma [27] are being reported. Furthermore, the transfer of ablative technologies to the EUS field could make EUS-guided radiofrequency or microwave ablation along with EUS-guided electroporation new therapeutic options.

Conclusion

The applications of EUS have been expanding since its introduction. Standard equipment and technique have made EUS reproducible, reliable, and amenable to teaching. It is now an essential diagnostic and therapeutic tool in the management of benign and malignant upper gastrointestinal diseases. A thorough understanding of the current and future uses of EUS will enhance one's ability to properly manage diseases of the foregut.

References

- De Angelis C, Martini M, Recipi A, et al. Instruments and accessories for diagnostic endoscopic ultrasound (radial scanning and miniprbes). *Minerva Med.* 2007;98:253–60.
- Leblanc JK. An overview of endoscopic ultrasound equipment. *Minerva Gastroenterol Dietol.* 2008;54:177–87.
- Seewald S, Ang TL, Soehendra N. Basic technique of handling the linear echoendoscope and how it differs from the radial echoendoscope. *Gastrointest Endosc.* 2009;69:S78–80.
- Iwashita T, Nakai Y, Lee JG, et al. Newly-developed, forward-viewing echoendoscope: a comparative pilot study to the standard echoendoscope in the imaging of abdominal organs and feasibility of endoscopic ultrasound-guided interventions. *J Gastroenterol Hepatol.* 2012;27:362–7.
- Ang TL, Fock KM. Intraductal ultrasound in biliary disorders. *J Gastroenterol Hepatol.* 2008;23:1520–7.
- Lee YT. Basic functions of linear EUS processor and when to use them. *Gastrointest Endosc.* 2009;69:S64–7.
- Puli SR, Reddy JB, Bechtold ML, Antillon D, Ibdah JA, Antillon MR. Staging accuracy of esophageal cancer by endoscopic ultrasound: a meta-analysis and systematic review. *World J Gastroenterol.* 2008;14:1479–90.
- Cardoso R, Coburn N, Seevaratnam R, Sutradhar R, Lourenco LG, Mahar A, Law C, Yong E, Timmouth J. A systematic review and meta-analysis of the utility of EUS for preoperative staging for gastric cancer. *Gastric Cancer.* 2012;15 Suppl 1:S19–26. Epub 2012 Jan 12.
- Mocellin S, Marchet A, Nitti D. EUS for the staging of gastric cancer: a meta-analysis. *Gastrointest Endosc.* 2011;73:1122–34.
- O'Neill DER, Saunders MD. Endoscopic ultrasonography in diseases of the gallbladder. *Gastroenterol Clin North Am.* 2010;39:289–305.
- Wiersema MJ, Sandusky D, Carr R, et al. Endosonography-guided cholangiopancreatography. *Gastrointest Endosc.* 1996;43:102–6.
- Giovannini M, Moutardier V, Pesenti C, Bories E, Lelong B, Delpero JR. Endoscopic ultrasound-guided bilioduodenal anastomosis: a new technique for biliary drainage. *Endoscopy.* 2001;33(10):898–900.
- Siddiqui AA, Sreenarasimhaih J, Lara LF, et al. Endoscopic ultrasound-guided transduodenal placement of a fully covered metal stent for palliative biliary drainage in patients with malignant biliary obstruction. *Surg Endosc.* 2011;25:549–55.
- Park DH, Lee SS, Moon SH, Choi SY. Prospective randomized trial. Endoscopic ultrasound-guided versus conventional transmural drainage for pancreatic pseudocysts. *Endoscopy.* 2009;41(10):842–8. Epub 2009 Oct 1.
- Varadarajulu S, Lopes TL, Wilcox CM, et al. EUS versus surgical cyst-gastrostomy for management of pancreatic pseudocysts. *Gastrointest Endosc.* 2008;68:649–55.
- Gardner TB, Coelho-Prabhun N, Gordon SR, et al. Direct endoscopic necrosectomy for the treatment of walled-off pancreatic necrosis: results from a multicenter U.S. series. *Gastrointest Endosc.* 2011;73:718–26.
- Puri R, Mishra SR, Thandassery RB, Sud R, Eloubeidi MA. Outcome and complications of endoscopic ultrasound guided pancreatic pseudocyst drainage using combined endoprosthesis and naso-cystic drain. *J Gastroenterol Hepatol.* 2012;27(4):722–7. doi:10.1111/j.1440-1746.2012.07089.x.
- Varadarajulu S, Christein JD, Wilcox CM. Frequency of complications during EUS-guided drainage of pancreatic fluid collections in 148 consecutive patients. *J Gastroenterol Hepatol.* 2011;26(10):1504–8. doi:10.1111/j.1440-1746.2011.06771.x.
- Santosh D, Lakhtakia S, Gupta R, et al. Clinical trial: a randomized trial comparing fluoroscopy guided percutaneous technique vs endoscopic ultrasound guided technique of coeliac plexus block for treatment of pain in chronic pancreatitis. *Aliment Pharmacol Ther.* 2009;29:979–84. This is a well-designed randomized trial evaluating the efficacy of EUS-directed versus percutaneous celiac plexus block. This paper is a good example of the type of prospective research that is needed to evaluate EUS-directed therapies.
- Levy MJ, Topazian MD, Wiersema MJ, et al. Initial evaluation of the efficacy and safety of endoscopic ultrasound-guided direct ganglia neurolysis and block. *Am J Gastroenterol.* 2008;103:98–103.
- Lemelin V, Lam E, Sahai A. A prospective trial of central versus bilateral celiac plexus bloc/neurolysis in 160 patients: bilateral injection is safe and is more effective. *Gastrointest Endosc.* 2005;61(5):AB77.
- Foxall G, McCahon R, Lamb J, et al. Levobupivacaine-induced seizures and cardiovascular collapse treated with intralipid. *Anaesthesia.* 2007;62(5):516–8.
- Puli SR, Reddy JB, Bechtold ML, Antillon MR, Brugge WR. EUS-guided celiac plexus neurolysis for pain due to chronic pancreatitis or pancreatic cancer pain: a meta-analysis and systematic review. *Dig Dis Sci.* 2009;54(11):2330–7. Epub 2009 Jan 10.
- Dewitt J, Alsatie M, Leblanc J, et al. Endoscopic ultrasound-guided fine needle aspiration of left adrenal gland masses. *Endoscopy.* 2007;39:65–71.
- Bodtger U, Vilman P, Clementsen P, et al. Clinical impact of endoscopic ultrasound-fine needle aspiration of left adrenal masses in established or suspected lung cancer. *J Thorac Oncol.* 2009;4(12):1485–9.
- Saftoiu A. State-of-the-art imaging techniques in endoscopic ultrasound. *World J Gastroenterol.* 2011;17(6):691–6.
- Artifon ELA, Lucon A, Sakai P, et al. EUS-guided alcohol ablation of left adrenal metastasis from non-small-cell lung carcinoma. *Gastrointest Endosc.* 2007;66(6):1201–5.