

Lee J. Skandalakis
John E. Skandalakis
Editors

**Surgical Anatomy
and Technique**
A Pocket Manual
Fourth Edition

 Springer

Surgical Anatomy and Technique

Fourth Edition

Lee J. Skandalakis
John E. Skandalakis
Editors

Surgical Anatomy and Technique

A Pocket Manual

Fourth Edition

With contributions by Panagiotis N. Skandalakis

 Springer

Editors

Lee J. Skandalakis, MD, FACS
Centers for Surgical Anatomy
and Technique
Emory University School
of Medicine
Piedmont Hospital
Atlanta, GA, USA

John E. Skandalakis, MD, FACS
Centers for Surgical Anatomy
and Technique
Emory University School
of Medicine
Piedmont Hospital
Atlanta, GA, USA

ISBN 978-1-4614-8562-9

ISBN 978-1-4614-8563-6 (eBook)

DOI 10.1007/978-1-4614-8563-6

Springer New York Heidelberg Dordrecht London

Library of Congress Control Number: 2013949138

© Springer Science+Business Media New York 1995, 2000, 2009, 2014

This work is subject to copyright. All rights are reserved by the Publisher, whether the whole or part of the material is concerned, specifically the rights of translation, reprinting, reuse of illustrations, recitation, broadcasting, reproduction on microfilms or in any other physical way, and transmission or information storage and retrieval, electronic adaptation, computer software, or by similar or dissimilar methodology now known or hereafter developed. Exempted from this legal reservation are brief excerpts in connection with reviews or scholarly analysis or material supplied specifically for the purpose of being entered and executed on a computer system, for exclusive use by the purchaser of the work. Duplication of this publication or parts thereof is permitted only under the provisions of the Copyright Law of the Publisher's location, in its current version, and permission for use must always be obtained from Springer. Permissions for use may be obtained through RightsLink at the Copyright Clearance Center. Violations are liable to prosecution under the respective Copyright Law.

The use of general descriptive names, registered names, trademarks, service marks, etc. in this publication does not imply, even in the absence of a specific statement, that such names are exempt from the relevant protective laws and regulations and therefore free for general use.

While the advice and information in this book are believed to be true and accurate at the date of publication, neither the authors nor the editors nor the publisher can accept any legal responsibility for any errors or omissions that may be made. The publisher makes no warranty, express or implied, with respect to the material contained herein.

Printed on acid-free paper

Springer is part of Springer Science+Business Media (www.springer.com)

*Dedicated to my father John Skandalakis who has
reached out from the grave to provide valuable
assistance for this edition.*

Preface to the Fourth Edition

*“They will soar on wings like eagles;
they will run and not grow weary,
they will walk and not be faint.”*

ISAIAH 40:31

In this fourth edition of *Surgical Anatomy and Technique: a Pocket Manual*, several chapters were revised and a new chapter has been added. In the chapter on the abdominal wall and hernias, operating room strategies have been updated and techniques of historical interest only have been removed. A major addition to the chapter is a section on the anatomy and principles of component separation. The chapter on the pancreas was brought up-to-date by Drs. Harrison S. Pollinger and Marty T. Sellers with the addition of laparoscopic pancreatectomy. Any techniques that involve the use of the Harmonic Scalpel or the LigaSure have been updated to reflect those instruments. Much credit goes to Dr. Monica A. Hum, who did a major revision of the longest chapter in this book, Colon and Anorectum. This revamp involved extensive rewriting; I am most appreciative of her thoughtful emendation.

In the liver chapter, Dr. Marty T. Sellers clarified for all of us the segmental anatomy of this organ. Dr. Eyal Ben-Arie made some very useful additions to the treatment of the vascular system through vascular access procedures. Dr. John G. Seiler III completely revised the carpal tunnel chapter. We have also added an additional chapter, Miscellaneous Procedures, which includes subclavian vein catheter insertion, chest tube insertion, and sural nerve and muscle

viii Preface to the Fourth Edition

biopsies. I am delighted that we were also able to include a new chapter on Bariatric Surgery written by doctors Kevin McGill and Charles Procter. This material is timely considering the ranks of the morbidly obese are increasing daily.

We have tried again to present what are considered to be basic surgical techniques. As more surgeons train in laparoscopic surgery, what were once considered advanced laparoscopic techniques have now become basic laparoscopic techniques. It is for this reason that I felt compelled to ask Dr. Pollinger to add the section on a laparoscopic pancreatectomy. Though many might consider it to be an advanced technique, the actual mechanics of removing the distal pancreas laparoscopically do not differ from performing this procedure in an open fashion. What is different is the placement of ports and the positioning of the patient in concert with “advanced” laparoscopic instruments and devices. Once again, if a suture is mentioned, it is only a suggestion. As we all know, there are many alternatives to various suture materials.

Though the senior and principal author (JES) passed away in 2009 he continues to influence this and future editions of this text. He is sorely missed.

Atlanta, GA, USA

Lee J. Skandalakis, MD, FACS

Acknowledgments

I am truly privileged to have been allowed to revise *Surgical Anatomy and Technique: a Pocket Manual*. The associates at Springer Science+Business Media have made everything easy. I appreciate the faith and confidence that Richard Hruska, Senior Editor of Clinical Medicine, placed in me by green-lighting this project. Andy Kwan, Editorial Assistant, provided crucial assistance at the beginning of the revision.

Originally, I had my doubts about allowing illustrations to be executed in-house at Springer. I just did not see how it would be possible to create a finished product without sitting down with the illustrators and explaining what we needed, then having them give me something a few days later, etc. Connie Walsh, Developmental Editor, worked with Carol Froman, Senior Editor, Department of Surgery, Emory University School of Medicine, so that the production of this book (including the illustrations) proceeded seamlessly. Truthfully, if it were not for Carol there would not be a revised edition. Phyllis Bazinet and Cynthia Painter provided editorial support at Emory for previous editions.

I would like to thank Dr. Christian P. Larsen, who was the Chairman of the Department of Surgery at Emory, for throwing his support behind this project and allowing it to go forward. Emory University School of Medicine is in good hands with Chris as the newly appointed Dean. I wish him the best.

Finally, I would like to thank Dr. Panagiotis G. Skandalakis for his great ideas for this book and the wonderful illustrations that kick-started this entire endeavor.

Contents

Preface to the Fourth Edition	vii
Acknowledgments.....	ix
1 Skin, Scalp, and Nail.....	1
2 Neck	17
3 Breast	91
4 Abdominal Wall and Hernias	113
5 Diaphragm.....	217
6 Esophagus	253
7 Stomach.....	295
8 Duodenum.....	345
9 Pancreas	361
10 Small Intestine	405
11 Appendix.....	419
12 Colon and Anorectum	431
13 Liver.....	515
14 Extrahepatic Biliary Tract.....	565

xii Contents

15	Spleen.....	605
16	Adrenal Glands	635
17	Vascular System	665
18	Uterus, Tubes, and Ovaries	689
19	Carpal Tunnel.....	703
20	Microsurgical Procedures	715
21	Miscellaneous Procedures.....	723
22	Bariatric Surgery	727
	Index	743

Contributors

Eyal Ben-Arie, MD

Piedmont Heart Institute
Piedmont Hospital
Atlanta, GA, USA

J. Dewayne Colquitt, MD, FACS

Department of Surgery
Piedmont Hospital
Atlanta, GA, USA

Seth D. Force, MD

Department of Surgery
Emory University
School of Medicine
Atlanta, GA, USA

Monica A. Hum, MD, FACS, FASCRS

Atlanta Colorectal Surgery
Atlanta, GA, USA

Kevin McGill, MD, FACS

Buckhead Bariatrics
Piedmont Hospital
Atlanta, GA, USA

xiv Contributors

Daniel L. Miller

Department of Surgery
Emory University School of Medicine
Atlanta, GA, USA

Petros Mirilas, MD, MSurg, PhD

Centers for Surgical Anatomy & Technique
Emory University School of Medicine
Atlanta, GA, USA

Deepak G. Nair, MD

Sarasota Vascular Specialists
Sarasota, FL, USA

Harrison Scott Pollinger, DO, FACS

Piedmont Transplant Institute
Piedmont Hospital
Atlanta, GA, USA

Charles D. Procter, Jr., MD, FACS

Buckhead Bariatrics
Atlanta, GA, USA

John Gray Seiler, III, MD

Georgia Hand, Shoulder & Elbow
Atlanta, GA, USA

Lee J. Skandalakis, MD, FACS

Centers for Surgical Anatomy and Technique
Emory University School of Medicine
Piedmont Hospital
Atlanta, GA, USA

John E. Skandalakis, MD, FACS

Centers for Surgical Anatomy and Technique
Emory University School of Medicine
Piedmont Hospital
Atlanta, GA, USA

Marty T. Sellers, MD, MPH

Piedmont Transplant Institute
Piedmont Hospital
Atlanta, GA, USA

C. Daniel Smith, MD

Department of Surgery
Mayo Clinic
Jacksonville, FL, USA

Robert B. Smith, III, MD, FACS

Emory University School of Medicine
Atlanta, GA, USA

Ramon A. Suarez

Emory University School of Medicine
OB/GYN Education, Obstetrics and Gynecology
Piedmont Hospital
Atlanta, GA, USA

Skin, Scalp, and Nail

ANATOMY

■ SKIN AND SUBCUTANEOUS TISSUE (FIG. 1.1)

The skin is composed of two layers: the epidermis (superficial) and the dermis (under the epidermis). The thickness of the skin varies from 0.5 to 3.0 mm.

The epidermis is avascular and is composed of stratified squamous epithelium. It has a thickness of 0.04–0.4 mm. The palms of the hands and the soles of the feet are thicker than the skin of other areas of the human body, such as the eyelids.

The dermis has a thickness of 0.5–2.5 mm and contains smooth muscles and sebaceous and sweat glands. Hair roots are located in the dermis or subcutaneous tissue.

Vascular System

There are two arterial plexuses: one close to the subcutaneous fat (subdermal) and the second in the subpapillary area. Venous return is accomplished by a subpapillary plexus to a deep plexus and then to the superficial veins. A lymphatic plexus is situated in the dermis, which drains into the subcutaneous tissue.

Nervous System

For innervation of the skin, there is a rich sensory and sympathetic supply.

Remember:

- ✓ The epidermis is avascular.
- ✓ The dermis is tough, strong, and very vascular.

2 1. Skin, Scalp, and Nail

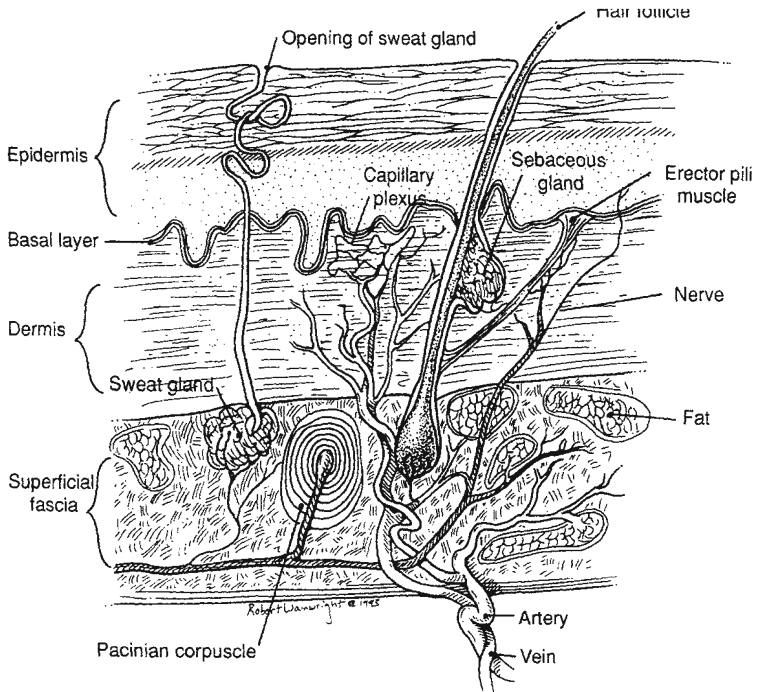


Figure 1.1. Structures of the skin.

- ✓ The superficial fascia is the subcutaneous tissue that blends with the reticular layer of the dermis.
- ✓ The principal blood vessels of the skin lie in subdermal areas.
- ✓ The basement membrane is the lowest layer of the epidermis.
- ✓ The papillary dermis is the upper (superficial) layer of the dermis, just below the basement membrane.
- ✓ The reticular dermis is the lower (deep) layer of the dermis, just above the fat.

■ SCALP

The following mnemonic device will serve as an aid in remembering the structure of the scalp (see also Fig. 1.2).

<i>Layers</i>	<i>Description</i>	<i>Observations</i>
S Skin	Hair, sebaceous glands	
C Connective close subcutaneous tissue	Superficial layer avascular deep layer vascular (internal and external carotid lymphatic network). Nerves are present (cervical, trigeminal)	Bleeding due to gap and nonvascular contraction
A Aponeurosis epicranial, galea	Aponeurosis of the occipitofrontalis muscle	Sensation present
L Loose connective tissue	Emissary veins	Dangerous zone = extracranial and intracranial infections
P Pericranium—periosteum		No sensation. Heavy fixation at the suture lines, so infection is limited

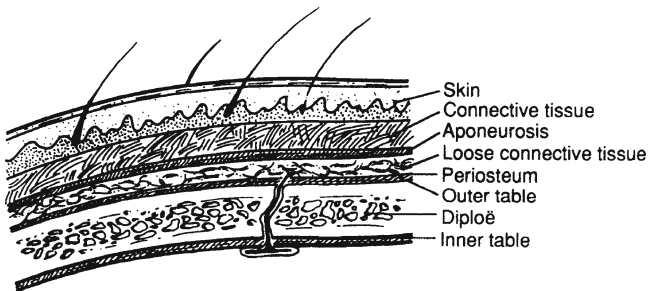


Figure 1.2. Structures of the scalp.

Vascular System

Arterial Supply

The arteries of the scalp are branches of the internal and external carotid arteries. The internal carotid in this area becomes the supratrochlear and supraorbital arteries (Fig. 1.3), both of which are terminal branches of the ophthalmic artery. The external carotid becomes a large occipital artery and two small arteries: the superficial temporal and the posterior auricular (see Fig. 1.3). Abundant anastomosis takes place among all these arteries. All are superficial to the epicranial aponeurosis.

Venous Drainage

Veins follow the arteries.

4 1. Skin, Scalp, and Nail

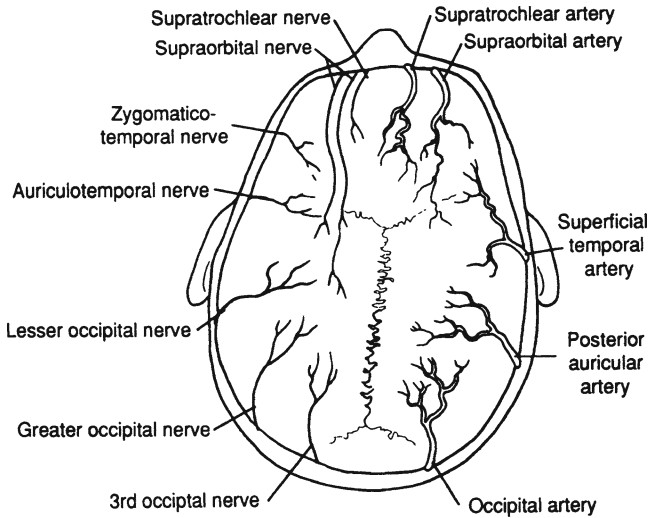


Figure 1.3. Arterial blood supply shown on *right*. Nerve distribution shown on *left*. Veins are not shown, but follow the arteries.

Lymphatic Drainage

The lymphatic network of the scalp is located at the deep layer of the dense connective subcutaneous tissue just above the aponeurosis (between the connective tissue and aponeurosis). The complex network has frequent anastomoses. The three principal zones are the frontal, parietal, and occipital.

Note:

- ✓ The blood supply of the scalp is rich. Arteries are anastomosed very freely.
- ✓ The arteries and veins travel together in a longitudinal fashion.
- ✓ A transverse incision or laceration will produce a gap. Dangerous bleeding will take place from both vascular ends due to nonretraction of the arteries by the close, dense, connective layer.
- ✓ Always repair the aponeurotic galea to avoid hematoma under it.
- ✓ With elective cases (excision of sebaceous cysts, etc.), whenever possible, make a longitudinal incision.
- ✓ Drain infections promptly. Use antibiotics to prevent intracranial infections via the emissary veins.
- ✓ Shave 1–2 cm around the site of the incision or laceration.
- ✓ After cleansing the partially avulsed scalp, replace it and débride the wound; then suture with nonabsorbable sutures.

- ✓ Use pressure dressing as required. Sutures may be removed in 3–5 days.
- ✓ Be sure about the diagnosis. A very common sebaceous cyst could be an epidermoid cyst of the skull involving the outer or inner table, or both, with extension to the cerebral cortex. In such a case, call for a neurosurgeon. The best diagnostic procedure is an AP and lateral film of the skull to rule out bony involvement.
- ✓ Because the skin, connective tissue, and aponeurosis are so firmly interconnected, for practical purposes, they form one layer: the surgical zone of the scalp.

Nerves (Figs. 1.3 and 1.4)

The following nerves innervate the scalp (their origins are in parentheses):

- Lesser occipital (second and third ventral nerves)
- Greater occipital (second and third dorsal nerves)
- Auriculotemporal (mandibular nerve)
- Zygomaticotemporal and zygomaticofacial (zygomatic [maxillary] nerve)

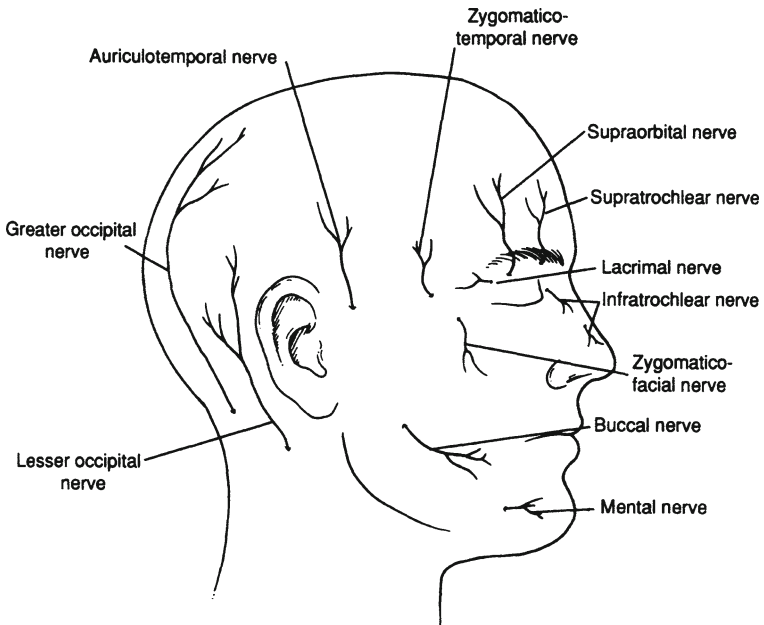
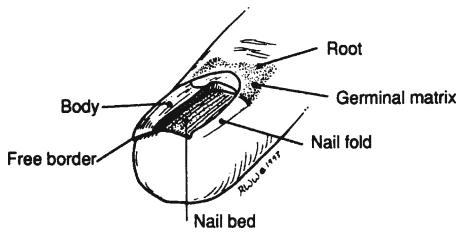
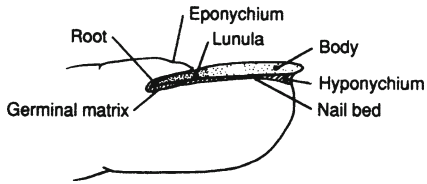


Figure 1.4. Nerves of the scalp and face.

6 1. Skin, Scalp, and Nail



- Supraorbital (ophthalmic nerve)
- Supratrochlear (ophthalmic nerve)

■ NAIL

The anatomy of the nail may be appreciated from Figs. 1.5 and 1.6.

TECHNIQUE

■ BENIGN SKIN LESIONS (FIGS. 1.7, 1.8, AND 1.9)

Benign skin lesions fall into several groups. Cystic lesions include epidermal inclusion cysts, sebaceous cysts, pilonidal cysts, and ganglia. Another group includes warts, keratoses, keloids, hemangiomas, arteriovenous malformations, glomus tumors, and capillary malformations.

A third group includes decubitus ulcers, hidradenitis suppurativa, and burns. Junctional, compound, and intradermal nevi and malignant lentigos compose another group.

- Step 1.** For a cyst, make an elliptical incision. For a noncystic lesion, be sure to include approximately 2.0 mm of tissue beyond the lesion when making the elliptical incision.

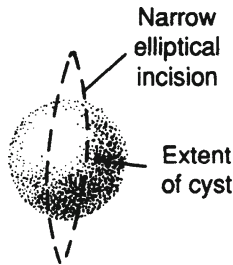


Figure 1.7. Incision for cyst removal.

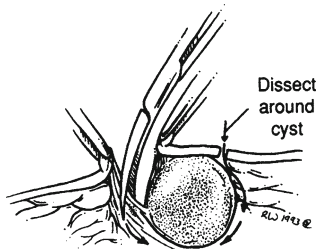


Figure 1.8. Dissection to subcutaneous tissue.

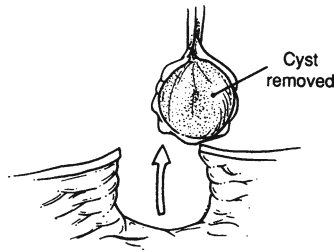


Figure 1.9. Excision of cyst.

- Step 2.** Place the incision along Langer's lines (Kraissl's) and perpendicular to the underlying muscles, but seldom parallel to the underlying muscle fibers.
- Step 3.** Dissect down to the subcutaneous tissue but not to the fascia. Avoid breaking the cyst, if possible.
- Step 4.** Handle the specimen with care by not crushing the skin or the lesion.
- Step 5.** Close in two layers. Undermine the skin as required. Remember that the dermis is the strongest layer. For the dermis, use absorbable synthetic interrupted suture 3-0 (undyed Vicryl); for the epidermis, use 5-0 Vicryl subcuticular continuous and reinforce with Steri-strips or skin glue. It is acceptable to use 6-0 interrupted nylon sutures very close to the edges of the skin and close to each other.
- Step 6.** Remove interrupted sutures in 8-10 days and again reinforce with Steri-strips, especially if the wound is located close to a joint. For most cases, a nylon epidermal continuous suture may be left in for 2 weeks without any problems.

■ MALIGNANT SKIN LESIONS (FIGS. 1.10 AND 1.11)

Malignant skin lesions include melanoma, basal cell carcinoma, squamous cell carcinoma, sweat gland carcinoma, fibrosarcoma, hemangiopericytoma, Kaposi's sarcoma, and dermatofibrosarcoma protuberans.

When removing the lesion, 1.0 cm of healthy skin around it must also be removed, as well as the subcutaneous layer.

Remember:

- ✓ Send specimen to the lab for frozen section of the lesion and margins.
- ✓ Prior to surgery explain to the patient about scarring, recurrence, margins, etc.
- ✓ If the case involves a large facial lesion, obtain the advice of a plastic surgeon.

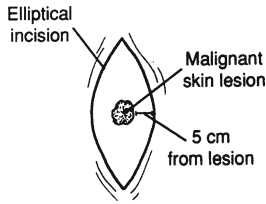


Figure 1.10. Incision for removal of malignant skin lesion.




Figure 1.11. Resection of malignant skin lesion.

Melanoma

Staging of Malignant Melanoma (After Clark)

- Level I.** Malignant cells are found above the basement membrane.
- Level II.** Malignant cells infiltrate into the papillary dermis.
- Level III.** Malignant cells fill the papillary layer and extend to the junction of the papillary and reticular layers but do not enter the reticular layer.
- Level IV.** Malignant cells extend into the reticular layer of the dermis.
- Level V.** Malignant cells extend into the subcutaneous tissue.

Tumor Thickness (After Breslow)

- Level I.** Tumor thickness less than 0.76 mm
- Level II.** Tumor thickness 0.76–1.5 mm
- Level III.** Tumor thickness 1.51–2.25 mm
- Level IV.** Tumor thickness 2.26–3 mm
- Level V.** Tumor thickness greater than 3 mm

Controversy

Surgical oncologists differ in their approach to treatment. Some advocate regional lymphadenectomy when there is clinical adenopathy and no distal metastasis. Others believe in prophylactic lymph node excision.

10 1. Skin, Scalp, and Nail

Remember:

- ✓ Perform a sentinel lymph node biopsy and, if positive, follow up with a complete lymph node dissection. Amputate a digit if melanoma is present. Be sure to consider the size, depth, and topography of the defect.
- ✓ For all pigmented nevi, ask for a second opinion from another pathologist.

Lesion Thickness and Regional Lymph Node Staging

Most surgeons today do not excise more than 1.5 cm around the lesion on the face or 3 cm elsewhere. For Breslow's levels 1 and 5, very few lymphadenectomies are performed. The philosophy is that with a level 1 lesion, the chance of metastasis is remote; hence, a lymph node dissection is not warranted. The level 5 lesion is so advanced that a lymph node dissection does no good. For intermediate levels 2–4, lymphadenectomy can be therapeutic. In some studies the breakpoint for indicated sentinel lymph node biopsy is 1.2 mm thickness for the melanoma. In our practice, a sentinel lymph node biopsy is done first and, if positive, is followed by a complete lymphadenectomy. If there are palpable lymph nodes, then a radical lymphadenectomy is performed.

■ SENTINEL LYMPH NODE BIOPSY

- Step 1.** Radiologist has localized sentinel lymph node preoperatively by injecting radioisotope and blue dye around the lesion (on breast: around nipple).
- Step 2.** In operating room, incision is made over the area with the highest radioactivity count.
- Step 3.** Dissect down to lymph node.
- Step 4.** Using Geiger counter as well as looking for the blue lymph node, identify and remove the sentinel lymph node.
- Step 5.** If frozen section of sentinel lymph node is found to be positive, proceed to full lymph node dissection.

■ SKIN GRAFTS

Free skin grafts include split-thickness grafts, postage-stamp grafts (a type of split-thickness graft), full-thickness grafts, and pinch grafts (not described here due to space limitations). Another classification, pedicle grafts, also is not described because a general surgeon who lacks the proper training to perform pedicle grafts should refer such cases to a plastic surgeon.

Split-Thickness Graft (Epidermis Plus Partial Dermis)

DEFINITION: Large pieces of skin including part of the dermis

INDICATIONS: Noninfected area

CONTRAINDICATIONS: Infection, exposed bone without periosteum, exposed cartilage without perichondrium, and exposed tendon without sheath

DONOR AREA: Abdomen, thigh, arm

COMPLICATIONS: Infection, failure to take, contractures

- Step 1.** Prepare both areas. Skin of donor area must be kept taut by applying hand or board pressure.
- Step 2.** Remove estimated skin. We use a Zimmer dermatome set at a thickness of 0.03 cm for harvesting of skin. In most cases, we mesh the skin using a 1.5:1 mesh ratio.
- Step 3.** Place the graft over the receiving area.
- Step 4.** Suture the graft to the skin. If the graft was not meshed, perforate it for drainage.
- Step 5.** Dress using Xeroform gauze covered by moist 4×4s or cotton balls. Then cover with roll gauze of appropriate size circumferentially.
- Step 6.** Change dressing in 3 days.

Alternative procedure: Place a wound VAC white gauze over the graft. Change in 5–7 days.

Postage-Stamp Graft

In this procedure, multiple grafts are placed 3–5 mm from each other.

Full-Thickness Graft

DEFINITION: The skin in toto, but not the subcutaneous tissue

INDICATIONS: Facial defects, fresh wounds, covering of defects after removal of large benign or malignant tumors

CONTRAINDICATIONS: Infections

DONOR AREA: Same as in split thickness grafts; also postauricular, supraclavicular, or nasolabial

TECHNIQUE: Same as in split thickness skin grafts

■ SCALP SURGERY

Excision of Benign Lesion

- Step 1.** Cut hair with scissors. With razor, shave hair 1 cm around the lesion.
- Step 2.** Make longitudinal or elliptical incision, removing small ovoid piece of skin.

12 1. Skin, Scalp, and Nail

Step 3. Elevate flaps.

Step 4. Obtain hemostasis.

Step 5. Remove cyst.

Step 6. Close skin.

Excision of Malignant Lesion (Melanoma, Squamous Cell Epithelioma)

The procedure is similar to that for a benign lesion. For melanoma, make a wide excision depending upon the thickness of the lesion as reported by the pathologist. Scalp melanomas metastasize, and sentinel lymph node biopsy should be performed, regardless of depth: if radical neck surgery is done for frontal lesions, include the superficial lobe of the parotid; for temporal and occipital lesions, include the postauricular and occipital nodes. When a posterior scalp melanoma is present, a posterior neck dissection should be performed.

See details on malignant skin lesions earlier in this chapter.

For squamous cell epitheliomas, wide excision is the procedure of choice. If the bone is involved, plastic and neurosurgical procedures should follow.

Biopsy of Temporal Artery

Temporal artery biopsy is used to diagnose patients with symptoms such as fever, weight loss, or malaise and more specifically headaches, loss of visual acuity, diplopia, and temporal artery tenderness.

Step 1. Shave hair at the point of maximal pulsation at the preauricular area or above the zygomatic process.

Step 2. Make longitudinal incision (Fig. 1.12).

Step 3. Carefully incise the aponeurosis (Fig. 1.13).

Step 4. After proximal and distal ligation with 2-0 silk, remove arterial segment at least 2 cm long (Fig. 1.14).

Step 5. Close in layers.

Remember:

- ✓ The temporal artery is closely associated with the auriculotemporal nerve, which is behind it, and with the superficial temporal vein, which is also behind it, medially or laterally.
- ✓ In front of the ear, the temporal artery is subcutaneous and is crossed by the temporal and zygomatic branches of the facial nerve.
- ✓ Perform biopsy above the zygomatic process.

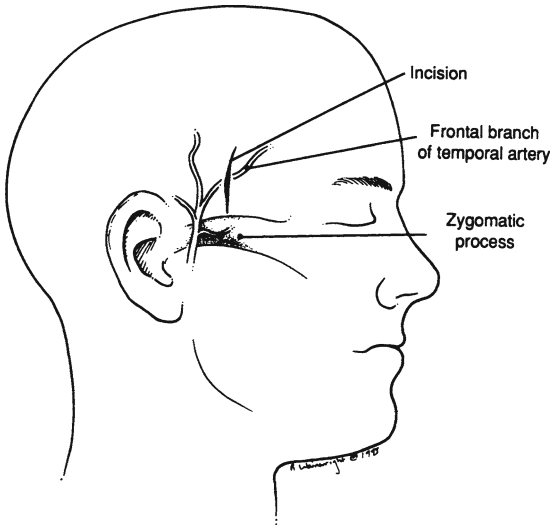


Figure 1.12. Anatomical landmarks for temporal artery biopsy.

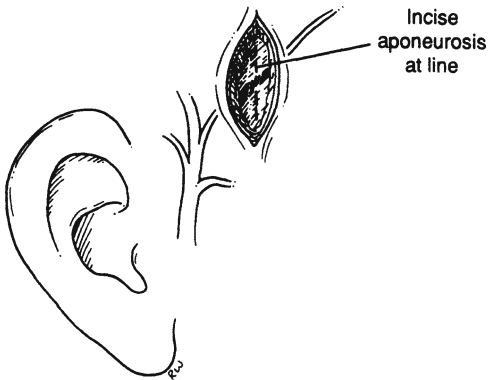


Figure 1.13. Incision for temporal artery biopsy.

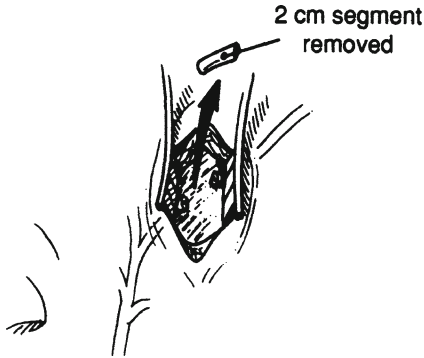


Figure 1.14. Removal of arterial segment.

■ INGROWN TOENAIL

DEFINITION: Inflammatory process with or without abscess formation secondary to embedment of the lateral or medial edge of the nail into the nail fold.

Conservative Treatment

Good hygiene requires that the nail be cut in transverse, straight fashion without any trimming of the edges (the square nail-cutting technique). Carefully elevate the embedded edge and insert a piece of cotton between the infected nail fold and the nail. Repeat the procedure until the ingrown nail edge grows above and distal to the nail fold.

Total Excision (Avulsion) of Nail

- Step 1.** Prepare distal half of foot.
- Step 2.** Use double rubber band around the proximal phalanx for avascular field. Inject lidocaine, 1–2 % without epinephrine, at the lateral and medial aspect of the second phalanx.
- Step 3.** Insert a straight hemostat under the nail at the area of the inflammatory process until the edge of the instrument reaches the lunula.
- Step 4.** Roll instrument and nail toward the opposite side for the avulsion of the nail.
- Step 5.** Occasionally a small fragment of nail remains in situ and should be removed.

Step 6. Excise all granulation tissue.

Step 7. Cover area with antibiotic ointment and apply sterile dressing.

Partial Excision of Nail and Matrix (Figs. 1.15, 1.16, and 1.17)

Proceed as in total excision; except in step 4, remove only the involved side of the nail. Remove all granulation tissue, necrotic skin, matrix, and periosteum.

Remember:

- ✓ The removal of the matrix in the designated area should be complete. Use curette as required. If in doubt, make a small vertical incision at the area for better exposure of the lateral nail and matrix to aid complete removal of these entities.

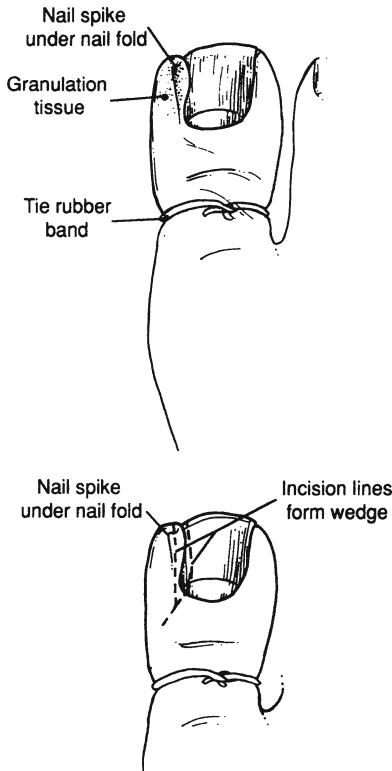


Figure 1.15. Preparation of nail, showing incision lines.

16 1. Skin, Scalp, and Nail

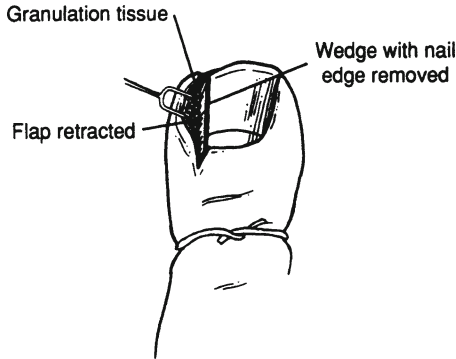


Figure 1.16. Avulsion.

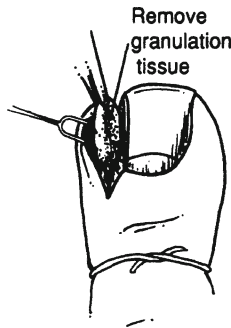


Figure 1.17. Removal of granulation tissue.

Radical Excision of Nail and Matrix

Follow the total excision procedure described above, and then continue with steps 4a–4d:

Step 4a. Make vertical incisions medially and laterally.

Step 4b. Elevate flaps for exposure of the matrix.

Step 4c. Remove matrix in toto with knife and, as required, with curette.

Step 4d. Loosely approximate the skin.

Note: This procedure is done only if there is no evidence of inflammatory process.

ANATOMY

■ ANTERIOR CERVICAL TRIANGLE (FIG. 2.1)

The boundaries are:

- Lateral: sternocleidomastoid muscle
- Superior: inferior border of the mandible
- Medial: anterior midline of the neck

This large triangle may be subdivided into four more triangles: submandibular, submental, carotid, and muscular.

Submandibular Triangle

The submandibular triangle is demarcated above by the inferior border of the mandible and below by the anterior and posterior bellies of the digastric muscle.

The largest structure in the triangle is the submandibular salivary gland. A number of vessels, nerves, and muscles also are found in the triangle.

For the surgeon, the contents of the triangle are best described in four layers, or surgical planes, starting from the skin. It must be noted that severe inflammation of the submandibular gland can destroy all traces of normal anatomy. When this occurs, identifying the essential nerves becomes a great challenge.

Roof of the Submandibular Triangle

The roof—the first surgical plane—is composed of skin, superficial fascia enclosing platysma muscle and fat, and the mandibular and cervical branches of the facial nerve (VII) (Fig. 2.2).

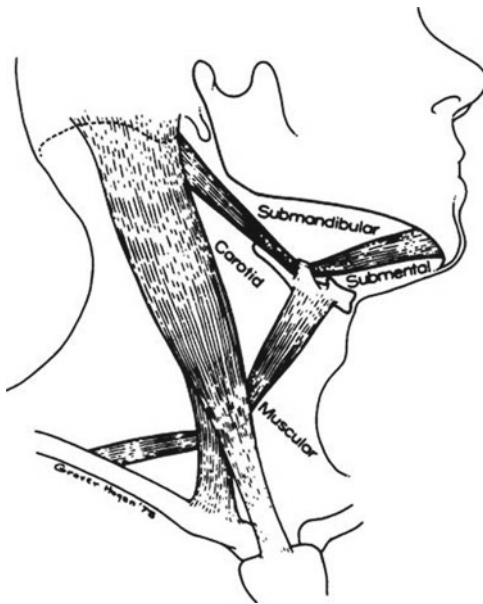


Figure 2.1. The subdivision of the anterior triangle of the neck (By permission of JE Skandalakis, SW Gray, and JR Rowe. *Am Surg* 45(9):590–596, 1979).

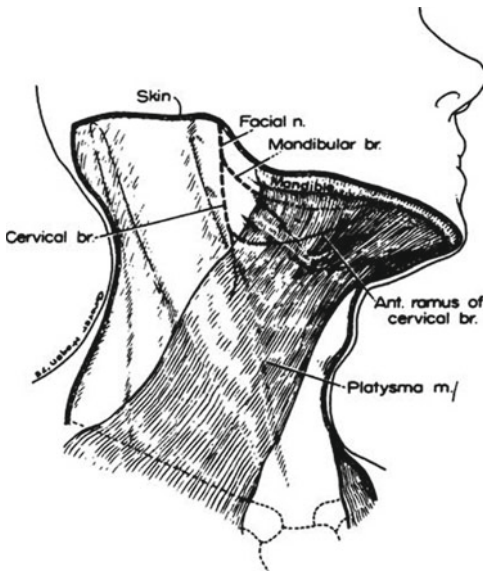


Figure 2.2. The roof of the submandibular triangle (the first surgical plane). The platysma lies over the mandibular and cervical branches of the facial nerve (By permission of JE Skandalakis, SW Gray, and JR Rowe. *Am Surg* 45(9):590–596, 1979).

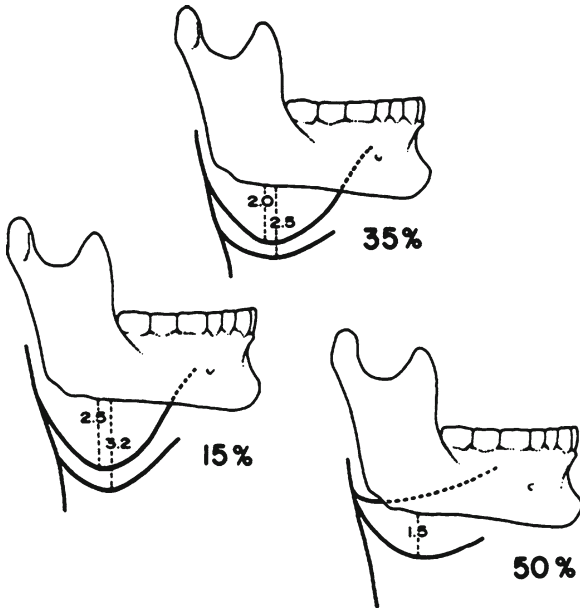


Figure 2.3. The neural “hammocks” formed by the mandibular branch (*upper*) and the anterior ramus of the cervical branch (*lower*) of the facial nerve. The distance below the mandible is given in centimeters, and *percentages* indicate the frequency found in 80 dissections of these nerves (By permission of JE Skandalakis, SW Gray, and JR Rowe. *Am Surg* 45(9):590–596, 1979).

It is important to remember that: (1) the skin should be incised 4–5 cm below the mandibular angle, (2) the platysma and fat compose the superficial fascia, and (3) the cervical branch of the facial nerve (VII) lies just below the angle, superficial to the facial artery (Fig. 2.3).

The mandibular (or marginal mandibular) nerve passes approximately 3 cm below the angle of the mandible to supply the muscles of the corner of the mouth and lower lip.

The cervical branch of the facial nerve divides to form descending and anterior branches. The descending branch innervates the platysma and communicates with the anterior cutaneous nerve of the neck. The anterior branch—the ramus colli mandibularis—crosses the mandible superficial to the facial artery and vein and joins the mandibular branch to contribute to the innervation of the muscles of the lower lip.

Injury to the mandibular branch results in severe drooling at the corner of the mouth. Injury to the anterior cervical branch produces minimal drooling that will disappear in 4–6 months.

The distance between these two nerves and the lower border of the mandible is shown in Fig. 2.3.

Contents of the Submandibular Triangle

The structures of the second surgical plane, from superficial to deep, are the anterior and posterior facial vein, part of the facial (external maxillary) artery, the submental branch of the facial artery, the superficial layer of the submaxillary fascia (deep cervical fascia), the lymph nodes, the deep layer of the submaxillary fascia (deep cervical fascia), and the hypoglossal nerve (XII) (Fig. 2.4).

It is necessary to remember that the facial artery pierces the stylomandibular ligament. Therefore, it must be ligated before it is cut to prevent bleeding after retraction. Also, it is important to remember that the lymph nodes lie within the envelope of the submandibular fascia in close relationship with the gland. Differentiation between gland and lymph node may be difficult.

The anterior and posterior facial veins cross the triangle in front of the submandibular gland and unite close to the angle of the mandible to form the common facial vein, which empties into the internal jugular vein near the greater cornu of the hyoid bone. It is wise to identify, isolate, clamp, and ligate both of these veins.

The facial artery—a branch of the external carotid artery—enters the submandibular triangle under the posterior belly of the digastric muscle and under the stylohyoid muscle. At its entrance into the triangle it is under the subman-

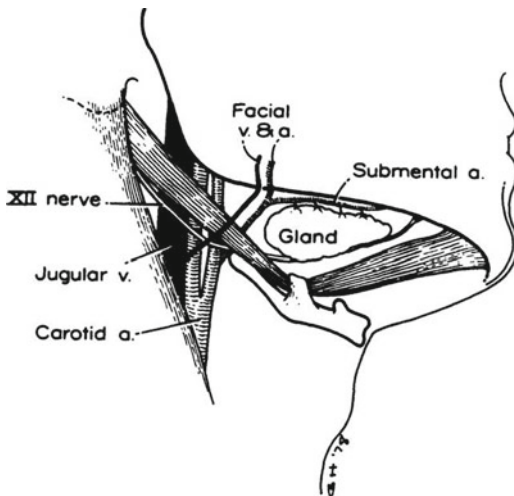


Figure 2.4. The contents of the submandibular triangle (the second surgical plane). Exposure of the superficial portion of the submandibular gland (By permission of JE Skandalakis, SW Gray, and JR Rowe. *Am Surg* 45(9): 590–596, 1979).

dibular gland. After crossing the gland posteriorly, the artery passes over the mandible, lying always under the platysma. It can be ligated easily.

Floor of the Submandibular Triangle

The structures of the third surgical plane, from superficial to deep, include the mylohyoid muscle with its nerve, the hyoglossus muscle, the middle constrictor muscle covering the lower part of the superior constrictor, and part of the styloglossus muscle (Fig. 2.5).

The mylohyoid muscles are considered to form a true diaphragm of the floor of the mouth. They arise from the mylohyoid line of the inner surface of the mandible and insert on the body of the hyoid bone into the median raphe. The nerve to the mylohyoid, which arises from the inferior alveolar branch of the mandibular division of the trigeminal nerve (V), lies on the inferior surface of the muscle. The superior surface is in relationship with the lingual and hypoglossal nerves.

Basement of the Submandibular Triangle

The structures of the fourth surgical plane, or basement of the triangle, include the deep portion of the submandibular gland, the submandibular (Wharton's) duct, lingual nerve, sublingual artery, sublingual vein, sublingual gland, hypoglossal nerve (XII), and the submandibular ganglion (Fig. 2.6).

The submandibular duct lies below the lingual nerve (except where the nerve passes under it) and above the hypoglossal nerve.

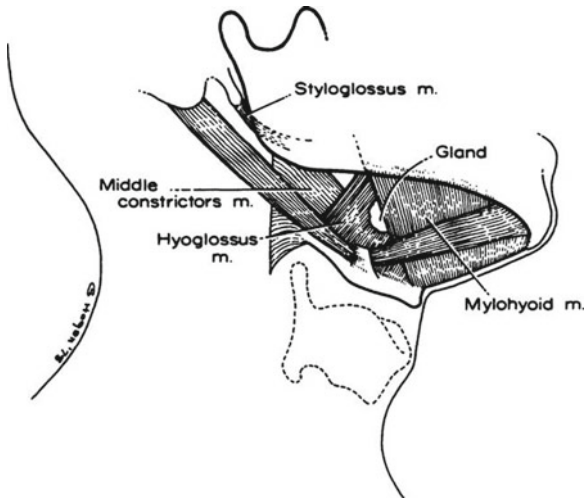


Figure 2.5. The floor of the submandibular triangle (the third surgical plane). Exposure of mylohyoid and hyoglossus muscles (By permission of JE Skandalakis, SW Gray, and JR Rowe. *Am Surg* 45(9):590–596, 1979).

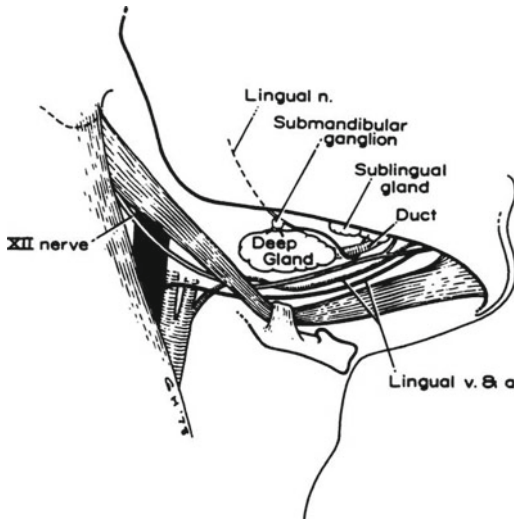


Figure 2.6. The basement of the submandibular triangle (the fourth surgical plane). Exposure of the deep portion of the submandibular gland, the lingual nerve, and the hypoglossal (XII) nerve (By permission of JE Skandalakis, SW Gray, and JR Rowe. *Am Surg* 45(9):590–596, 1979).

Lymphatic Drainage of the Submandibular Triangle

The submandibular lymph nodes receive afferent channels from the submental nodes, oral cavity, and anterior parts of the face. Efferent channels drain primarily into the jugulodigastric, jugulocarotid, and jugulo-omohyoid nodes of the chain accompanying the internal jugular vein (deep cervical chain). A few channels pass by way of the subparotid nodes to the spinal accessory chain.

Submental Triangle (See Fig. 2.1)

The boundaries of this triangle are:

- Lateral: anterior belly of digastric muscle
- Inferior: hyoid bone
- Medial: midline
- Floor: mylohyoid muscle
- Roof: skin and superficial fascia

The lymph nodes of the submental triangle receive lymph from the skin of the chin, the lower lip, the floor of the mouth, and the tip of the tongue. They send lymph to the submandibular and jugular chains of nodes.

Carotid Triangle (See Fig. 2.1)

The boundaries are:

- Posterior: sternocleidomastoid muscle
- Anterior: anterior belly of omohyoid muscle
- Superior: posterior belly of digastric muscle
- Floor: hyoglossus muscle, inferior constrictor of pharynx, thyrohyoid muscle, longus capitis muscle, and middle constrictor of pharynx
- Roof: investing layer of deep cervical fascia

Contents of the carotid triangle: bifurcation of carotid artery; internal carotid artery (no branches in the neck); external carotid artery branches, e.g., superficial temporal artery, internal maxillary artery, occipital artery, ascending pharyngeal artery, sternocleidomastoid artery, lingual artery (occasionally), and external maxillary artery (occasionally); jugular vein tributaries, e.g., superior thyroid vein, occipital vein, common facial vein, and pharyngeal vein; and vagus nerve, spinal accessory nerve, hypoglossal nerve, ansa hypoglossi, and sympathetic nerves (partially).

Lymph is received by the jugulodigastric, jugulocarotid, and jugulomohyoid nodes and by the nodes along the internal jugular vein from submandibular and submental nodes, deep parotid nodes, and posterior deep cervical nodes. Lymph passes to the supraclavicular nodes.

Muscular Triangle (Fig. 2.1)

The boundaries are:

- Superior lateral: anterior belly of omohyoid muscle
- Inferior lateral: sternocleidomastoid muscle
- Medial: midline of the neck
- Floor: prevertebral fascia and prevertebral muscles; sternohyoid and sternothyroid muscles
- Roof: investing layer of deep fascia; strap, sternohyoid, and cricothyroid muscles

Contents of the muscular triangle include: thyroid and parathyroid glands, trachea, esophagus, and sympathetic nerve trunk.

Remember that occasionally the strap muscles must be cut to facilitate thyroid surgery. They should be cut across the upper third of their length to avoid sacrificing their nerve supply.

■ POSTERIOR CERVICAL TRIANGLE (FIG. 2.7)

The posterior cervical triangle is sometimes considered to be two triangles—occipital and subclavian—divided by the posterior belly of the omohyoid muscle or, perhaps, by the spinal accessory nerve (see Fig. 2.7); we will treat it as one.

The boundaries of the posterior triangle are:

- Anterior: sternocleidomastoid muscle
- Posterior: anterior border of trapezius muscle
- Inferior: clavicle
- Floor: prevertebral fascia and muscles, splenius capitis muscle, levator scapulae muscle, and three scalene muscles
- Roof: superficial investing layer of the deep cervical fascia

Contents of the posterior cervical triangle include: subclavian artery, subclavian vein, cervical nerves, brachial plexus, phrenic nerve, accessory phrenic nerve, spinal accessory nerve, and lymph nodes.

The superficial occipital lymph nodes receive lymph from the occipital region of the scalp and the back of the neck. The efferent vessels pass to the

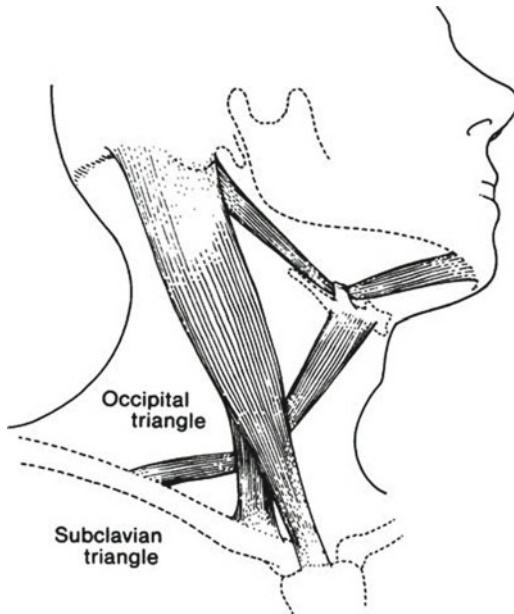


Figure 2.7. The posterior triangle of the neck. The triangle may be divided into two smaller triangles by the omohyoid muscle (By permission of JE Skandalakis, SW Gray, and JR Rowe. *Anatomical Complications in General Surgery*. New York: McGraw-Hill, 1983).

deep occipital lymph node (usually only one), which drains into the deep cervical nodes along the spinal accessory nerve.

■ FASCIAE OF THE NECK

Our classification of the rather complicated fascial planes of the neck follows the work of several investigators. It consists of the superficial fascia and three layers that compose the deep fascia.

Superficial Fascia

The superficial fascia lies beneath the skin and is composed of loose connective tissue, fat, the platysma muscle, and small unnamed nerves and blood vessels (Fig. 2.8). The surgeon should remember that the cutaneous nerves of the neck and the anterior and external jugular veins are between the platysma and the deep cervical fascia. If these veins are to be cut, they must first be ligated. Because of their attachment to the platysma above and the fascia below, they do not retract; bleeding from them may be serious. For all practical purposes, there is no space between this layer and the deep fascia.

Deep Fascia

Investing, Anterior, or Superficial Layer (Figs. 2.9 and 2.10)

This layer envelops two muscles (the trapezius and the sternocleidomastoid) and two glands (the parotid and the submaxillary) and forms two spaces (the supraclavicular and the suprasternal). It forms the roof of the anterior and posterior cervical triangles and the midline raphe of the strap muscles.

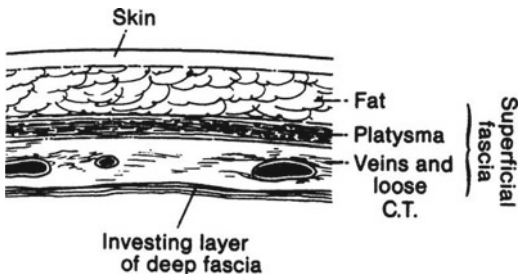


Figure 2.8. The superficial fascia of the neck lies between the skin and the investing layer of the deep cervical fascia (By permission of JE Skandalakis, SW Gray, and JR Rowe. *Anatomical Complications in General Surgery*. New York: McGraw-Hill, 1983).

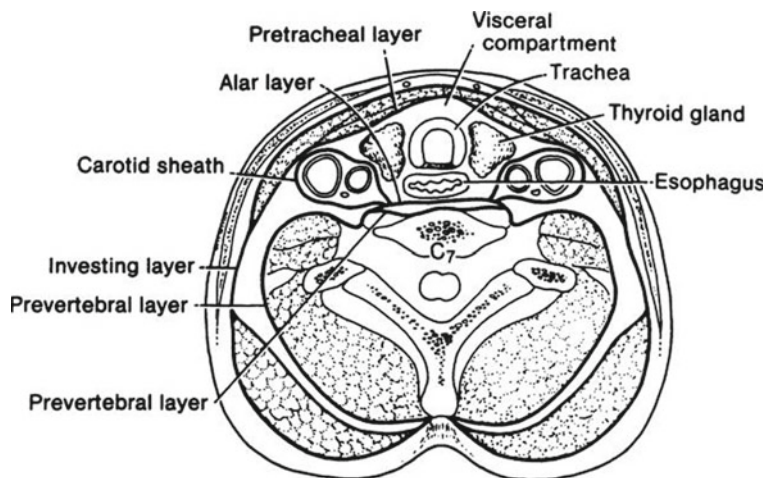


Figure 2.9. Diagrammatic cross section through the neck below the hyoid bone showing the layers of the deep cervical fascia and the structures that they envelop (By permission of JE Skandalakis, SW Gray, and LJ Skandalakis. In: CG Jamieson (ed), *Surgery of the Esophagus*, Edinburgh: Churchill Livingstone, 19–35, 1988).

Pretracheal or Middle Layer

The middle layer of the deep fascia splits into an anterior portion that envelops the strap muscles and a posterior layer that envelops the thyroid gland, forming the false capsule of the gland.

Prevertebral, Posterior, or Deep Layer

This layer lies in front of the prevertebral muscles. It covers the cervical spine muscles, including the scalene muscles and vertebral column anteriorly. The fascia divides to form a space in front of the vertebral bodies, the anterior layer being the alar fascia and the posterior layer retaining the designation of prevertebral fascia.

Carotid Sheath

Beneath the sternocleidomastoid muscle, all the layers of the deep fascia contribute to a fascial tube, the carotid sheath. Within this tube lie the common carotid artery, internal jugular vein, vagus nerve, and deep cervical lymph nodes.

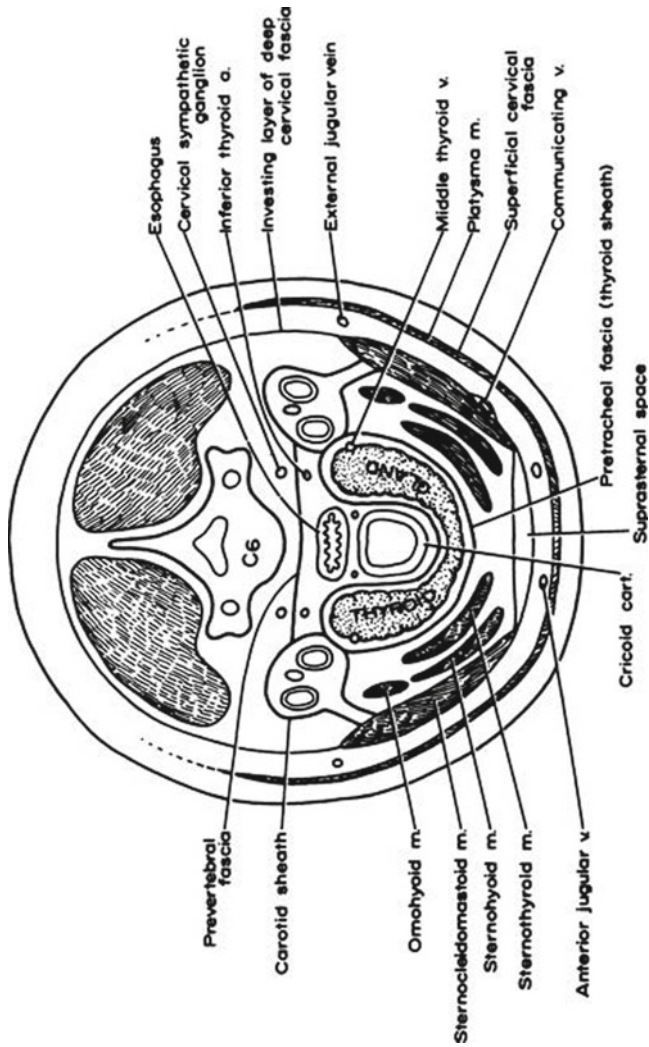


Figure 2.10. Diagrammatic cross section of the neck through the thyroid gland at the level of the sixth cervical vertebra showing the fascial planes, muscles, and vessels that may be encountered in an incision for thyroidectomy (By permission of JT Akin and JE Skandatakis. *Am Surg* 42(9):648-652, 1976).

Buccopharyngeal Fascia

This layer covers the lateral and posterior surfaces of the pharynx and binds the pharynx to the alar layer of the prevertebral fascia.

Axillary Fascia

This fascia takes its origin from the prevertebral fascia. It is discussed in Chap. 3.

■ SPACES OF THE NECK

There are many spaces in the neck defined by the fasciae, but for the general surgeon the visceral compartment is the most important; be very familiar with its boundaries and contents.

The boundaries of the visceral compartment of the neck are:

- Anterior: pretracheal fascia
- Posterior: prevertebral fascia
- Lateral: carotid sheath
- Superior: hyoid bone and thyroid cartilage
- Posteroinferior: posterior mediastinum
- Anteroinferior: bifurcation of the trachea at the level of the fifth thoracic vertebra

Contents of the spaces of the neck include: part of esophagus, larynx, trachea, thyroid gland, and parathyroid glands.

■ LYMPHATICS OF THE NECK/RIGHT AND LEFT THORACIC DUCTS

The overall anatomy of the lymphatics of the head and neck may be appreciated from Table 2.1 and Fig. 2.11.

The thoracic duct originates from the cisterna chyli and terminates in the left subclavian vein (Fig. 2.12). It is approximately 38–45 cm long. The duct begins at about the level of the second lumbar vertebra from the cisterna chyli or, if the cisterna is absent (about 50 % of cases), from the junction of the right and left lumbar lymphatic trunks and the intestinal lymph trunk. It ascends to the right of the midline on the anterior surface of the bodies of the thoracic vertebrae. It crosses the midline between the seventh and fifth thoracic vertebrae to lie on the left side, to the left of the esophageal wall. It passes behind the great vessels at the level of the seventh cervical vertebra and descends slightly to enter the left subclavian vein (see Fig. 2.12). The duct may have multiple entrances to the vein, and one or more of the contributing lymphatic trunks may enter the subclavian or the jugular vein independently. It may be ligated with impunity.

Table 2.1 Lymph nodes and the lymphatic drainage of the head and neck

<i>Lymphatics</i>		
<i>Location</i>	<i>From</i> <i>To</i>	
Superior horizontal chain: Submental nodes	Submental triangle Skin of chin, lip, floor of mouth, tip of tongue	Submandibular nodes or jugular chain
Submandibular nodes	Submandibular triangle Submental nodes, oral cavity, face, except forehead and part of lower lip	Intermediate jugular nodes, deep posterior cervical nodes
Preauricular (parotid) nodes	In front of tragus Lateral surface of pinna, side of scalp	Deep cervical nodes
Postauricular (mastoid) nodes	Mastoid process Temporal scalp, medial surface of pinna, external auditory meatus	Deep cervical nodes
Occipital node	Between mastoid process and external occipital protuberance Back of scalp	Deep cervical nodes
Vertical chain: Posterior cervical (posterior triangle) nodes	Subparotid nodes, jugular chain, occipital, and mastoid area	Supraclavicular and deep cervical nodes
Superficial Deep	Along external jugular vein Along spinal accessory nerve	
Intermediate (jugular) nodes	All other nodes of the neck	Lymphatic trunks to left and right thoracic ducts
Jugulocarotid (subparotid) nodes	Angle of mandible, near parotid nodes	

(continued)

Table 2.1 (continued)

		<i>Lymphatics</i>	
	<i>Location</i>	<i>From</i>	<i>To</i>
Jugulodigastric (subdigastric) nodes	Junction of common facial and internal jugular veins	Palatine tonsils	
Jugulo-carotid (bifurcation) nodes	Bifurcation of common carotid artery close to carotid body	Tongue, except tip	
Jugulo-omohyoid (omohyoid) nodes	Crossing of omohyoid and internal jugular vein	Tip of tongue	
Anterior (visceral) nodes			
Parapharyngeal nodes	Lateral and posterior wall of pharynx	Deep face and esophagus	Intermediate nodes
Paralaryngeal nodes	Lateral wall of larynx	Larynx and thyroid gland	Deep cervical nodes
Paratracheal nodes	Lateral wall of trachea	Thyroid gland, trachea, esophagus	Deep cervical and mediastinal nodes
Prealaryngeal (Delphian) nodes	Cricothyroid ligament	Thyroid gland, pharynx	Deep cervical nodes
Pretracheal nodes	Anterior wall of trachea below isthmus of thyroid gland	Thyroid gland, trachea, esophagus	Deep cervical and mediastinal nodes
Inferior horizontal chain:			
Supraclavicular and scalene nodes	Subclavian triangle	Axilla, thorax, vertical chain	Jugular or subclavian trunks to right lymphatic duct and thoracic duct

By permission of JE Skandalakis, SW Gray, and JR Rowe. *Anatomical Complications in General Surgery*. New York: McGraw-Hill, 1983.

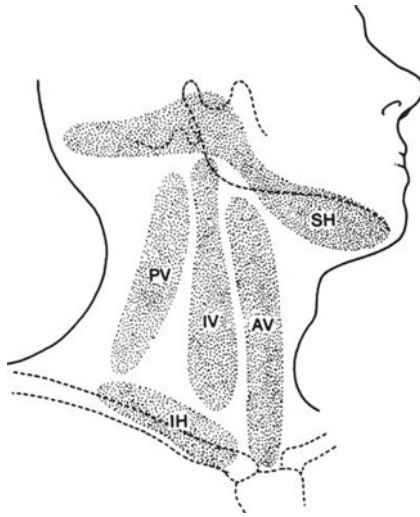


Figure 2.11. The lymph nodes of the neck. *SH* superior horizontal chain, *IH* inferior horizontal chain, *PV* posterior vertical chain, *IV* intermediate vertical chain, *AV* anterior vertical chain (By permission of JE Skandalakis, SW Gray, and JR Rowe. *Anatomical Complications in General Surgery*. New York: McGraw-Hill, 1983).

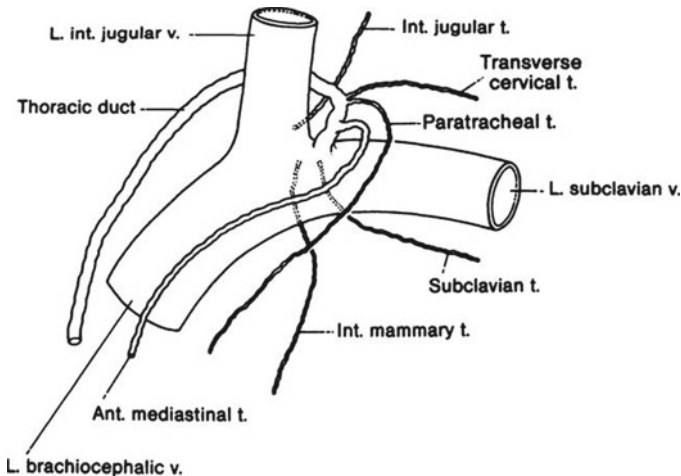


Figure 2.12. The thoracic duct and main left lymphatic trunks. Trunks are variable and may enter the veins with the thoracic duct or separately (By permission of JE Skandalakis, SW Gray, and JR Rowe. *Anatomical Complications in General Surgery*. New York: McGraw-Hill, 1983).

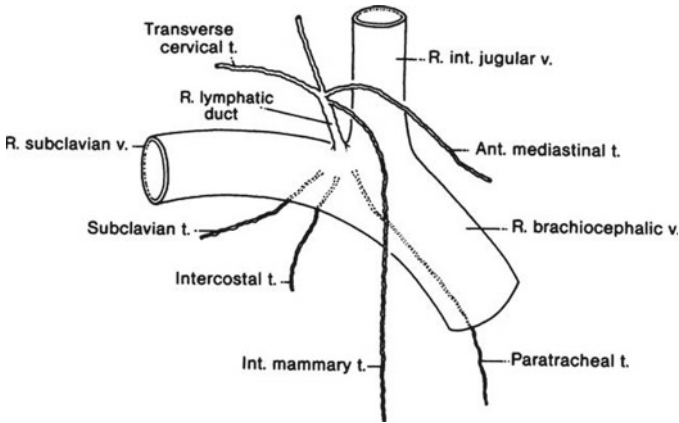


Figure 2.13. The right lymphatic duct is formed by the junction of several lymphatic trunks. If they enter the veins separately, there may be no right lymphatic duct (By permission of JE Skandalakis, SW Gray, and JR Rowe. *Anatomical Complications in General Surgery*. New York: McGraw-Hill, 1983).

The thoracic duct collects lymph from the entire body below the diaphragm, as well as from the left side of the thorax. Lymph nodes may be present at the caudal end, but there are none along its upward course. Injury to the duct in supraclavicular lymph node dissections results in copious lymphorrhea. Ligation is the answer.

The right lymphatic duct is a variable structure about 1 cm long formed by the right jugular, transverse cervical, internal mammary, and mediastinal lymphatic trunks (Fig. 2.13). If these trunks enter the veins separately, there is no right lymphatic duct. When present, the right lymphatic duct enters the superior surface of the right subclavian vein at its junction with the right internal jugular vein and drains most of the right side of the thorax.

■ ANATOMY OF THE THYROID GLAND

The thyroid gland consists typically of two lobes, a connecting isthmus, and an ascending pyramidal lobe. One lobe, usually the right, may be smaller than the other (7 % of cases) or completely absent (1.7 %). The isthmus is absent in about 10 % of thyroid glands, and the pyramidal lobe is absent in about 50 % (Fig. 2.14). A minute epithelial tube or fibrous cord—the thyroglossal duct—almost always extends between the thyroid gland and the foramen cecum of the tongue.

The thyroid gland normally extends from the level of the fifth cervical vertebra to that of the first thoracic vertebra. It may lie higher (lingual thyroid), but rarely lower.

Capsule of the Thyroid Gland

The thyroid gland has a connective tissue capsule which is continuous with the septa and which makes up the stroma of the organ. This is the *true* capsule of the thyroid.

External to the true capsule is a well-developed (to a lesser or greater degree) layer of fascia derived from the pretracheal fascia. This is the *false* capsule, *perithyroid sheath*, or *surgical capsule*. The false capsule, or fascia, is not removed with the gland at thyroidectomy.

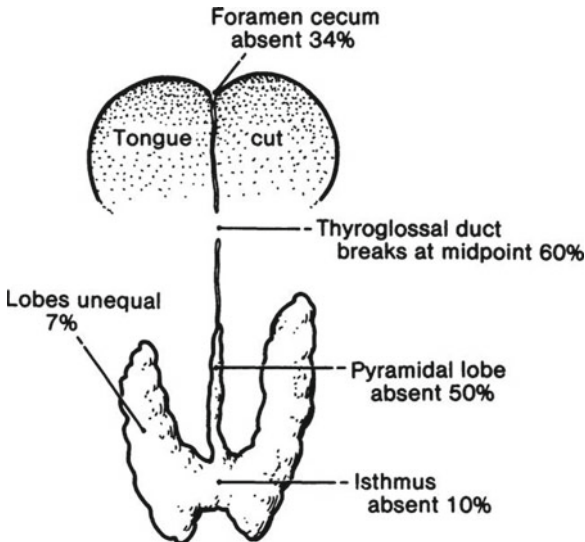


Figure 2.14. Normal vestiges of thyroid gland development. None are of clinical significance, but their presence may be of concern to the surgeon (By permission of JE Skandalakis, SW Gray, and JR Rowe. *Anatomical Complications in General Surgery*. New York: McGraw-Hill, 1983).

The superior parathyroid glands normally lie between the true capsule of the thyroid and the fascial false capsule. The inferior parathyroids may be between the true and the false capsules, within the thyroid parenchyma, or lying on the outer surface of the fascia.

Arterial Supply of the Thyroid and Parathyroid Glands

Two paired arteries, the superior and inferior thyroid arteries, and an inconstant midline vessel—the thyroid ima artery—supply the thyroid (Fig. 2.15).

The superior thyroid artery arises from the external carotid artery just above, at, or just below the bifurcation of the common carotid artery. It passes downward and anteriorly to reach the superior pole of the thyroid gland. Along part of its course, the artery parallels the external branch of the superior laryngeal nerve. At the superior pole the artery divides into anterior and posterior

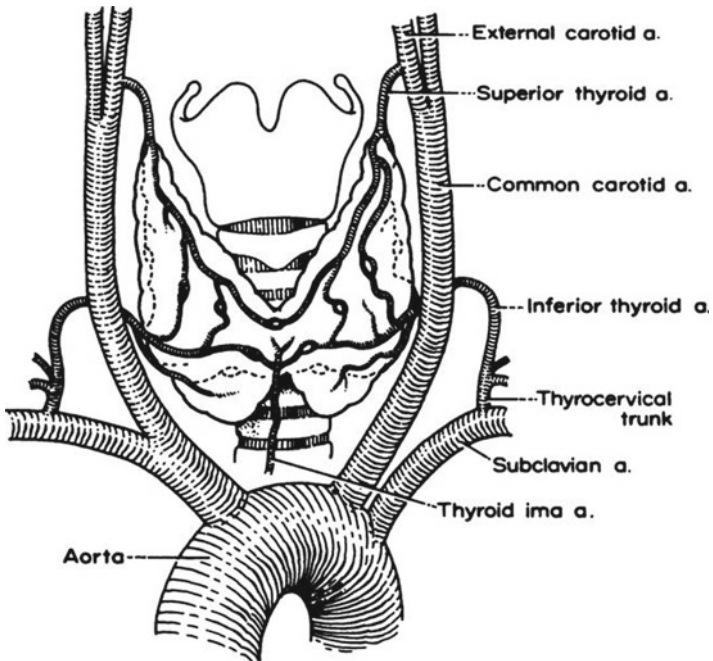


Figure 2.15. The arterial supply to the thyroid gland. The thyroid ima artery is only occasionally present (By permission of S Tzinis, C Droulias, N Harlaftis, et al. *Am Surg* 42(9):639–644, 1976).

branches. From the posterior branch, a small parathyroid artery passes to the superior parathyroid gland.

The inferior thyroid artery usually arises from the thyrocervical trunk, or from the subclavian artery. It ascends behind the carotid artery and the internal jugular vein, passing medially and posteriorly on the anterior surface of the longus colli muscle. After piercing the prevertebral fascia, the artery divides into two or more branches as it crosses the ascending recurrent laryngeal nerve. The nerve may pass anterior or posterior to the artery, or between its branches (Fig. 2.16). The lowest branch sends a twig to the inferior parathyroid gland. On the right, the inferior thyroid artery is absent in about 2 % of individuals. On the left, it is absent in about 5 %. The artery is occasionally double.

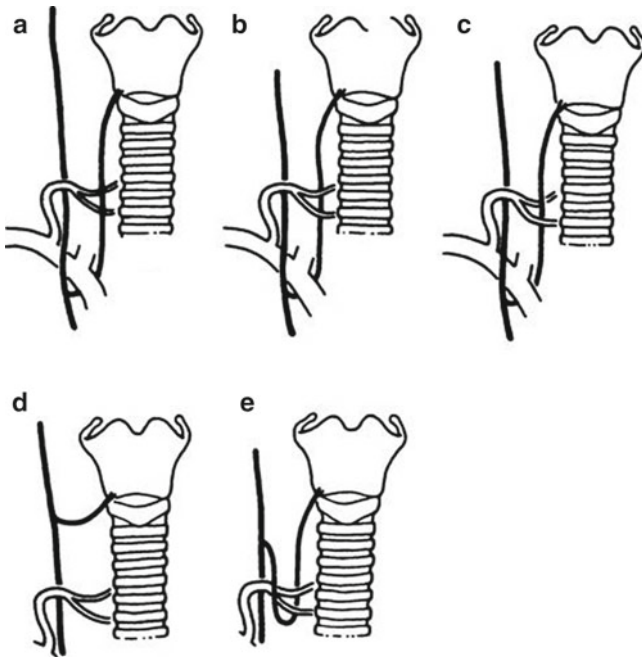


Figure 2.16. Relations at the crossing of the recurrent laryngeal nerve and the inferior thyroid artery. (a–c) Common variations. Their frequencies are given in Table 2.2. (d) A nonrecurrent nerve is not related to the inferior thyroid artery. (e) The nerve loops beneath the artery (By permission S Tzinias, C Droulias, N Harlaftis, et al. *Am Surg* 42(9):639–644, 1976).

The arteria thyroidea ima is unpaired and inconstant. It arises from the brachiocephalic artery, the right common carotid artery, or the aortic arch. Its position anterior to the trachea makes it important for tracheostomy.

Venous Drainage

The veins of the thyroid gland form a plexus of vessels lying in the substance and on the surface of the gland. The plexus is drained by three pairs of veins (Fig. 2.17):

- The superior thyroid vein accompanies the superior thyroid artery.
- The middle thyroid vein arises on the lateral surface of the gland at about two-thirds of its anteroposterior extent. No artery accompanies it. This vein may be absent; occasionally it is double.
- The inferior thyroid vein is the largest and most variable of the thyroid veins.

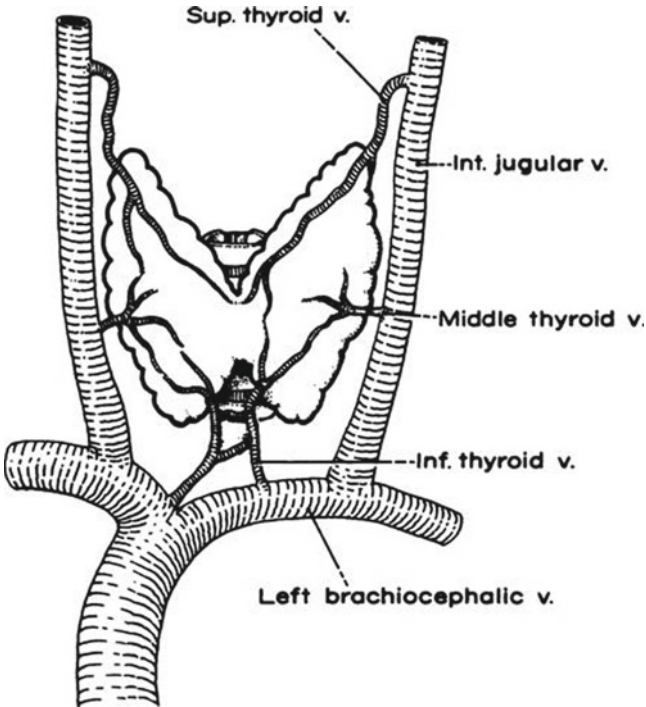


Figure 2.17. The venous drainage of the thyroid gland. The inferior thyroid veins are quite variable (By permission S Tzinias, C Droulias, N Harlaftis, et al. *Am Surg* 42(9):639–644, 1976).

Recurrent Laryngeal Nerves (Figs. 2.16 and 2.18)

The right recurrent laryngeal nerve branches from the vagus as it crosses anterior to the right subclavian artery, loops around the artery from posterior to anterior, crosses behind the right common carotid, and ascends in or near the tracheoesophageal groove. It passes posterior to the right lobe of the thyroid gland to enter the larynx behind the cricothyroid articulation and the inferior cornu of the thyroid cartilage.

The left recurrent laryngeal nerve arises where the vagus nerve crosses the aortic arch, just distal to the origin of the left subclavian artery from the aortic arch. It loops under the ligamentum arteriosum and the aorta, and ascends in the same manner as the right nerve. Both nerves cross the inferior thyroid arteries near the lower border of the middle third of the gland.

In about 1 % of patients, the right recurrent nerve arises normally from the vagus, but passes medially almost directly from its origin to the larynx without looping under the subclavian artery. In these cases, the right subclavian artery arises from the descending aorta and passes to the right behind the esophagus. This anomaly is asymptomatic, and the thyroid surgeon will rarely be aware of it prior to operation. Even less common is a nonrecurrent left nerve in the presence of a right aortic arch and a retroesophageal left subclavian artery.

In the lower third of its course, the recurrent laryngeal nerve ascends behind the pretracheal fascia at a slight angle to the tracheoesophageal groove. In the middle third of its course, the nerve may lie in the groove or within the substance of the thyroid gland.

The vulnerability of the recurrent laryngeal nerve may be appreciated from Table 2.2.

Exposure of the Laryngeal Nerves

The recurrent laryngeal nerve forms the medial border of a triangle bounded superiorly by the inferior thyroid artery and laterally by the carotid artery. The nerve can be identified where it enters the larynx just posterior to the inferior cornu of the thyroid cartilage. If the nerve is not found, a nonrecurrent nerve should be suspected, especially on the right.

In the lower portion of its course, the nerve can be palpated as a tight strand over the tracheal surface. There is more connective tissue between the nerve and the trachea on the right than on the left. Visual identification, with avoidance of traction, compression, or stripping the connective tissue, is all that is necessary.

The superior laryngeal nerve arises from the vagus nerve just inferior to its lower sensory ganglion just outside the jugular foramen of the skull. The nerve passes inferiorly, medial to the carotid artery. At the level of the superior cornu of the hyoid bone it divides into a large, sensory, internal laryngeal branch and

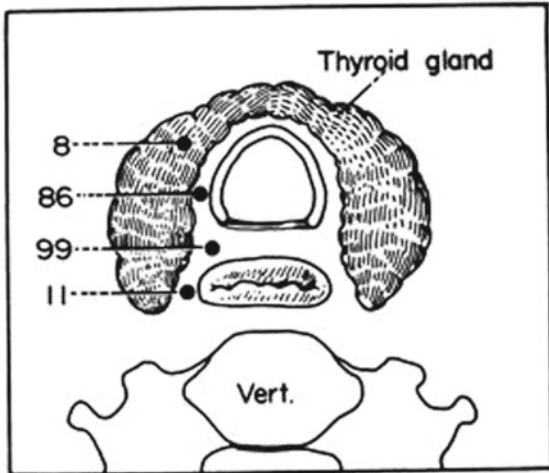
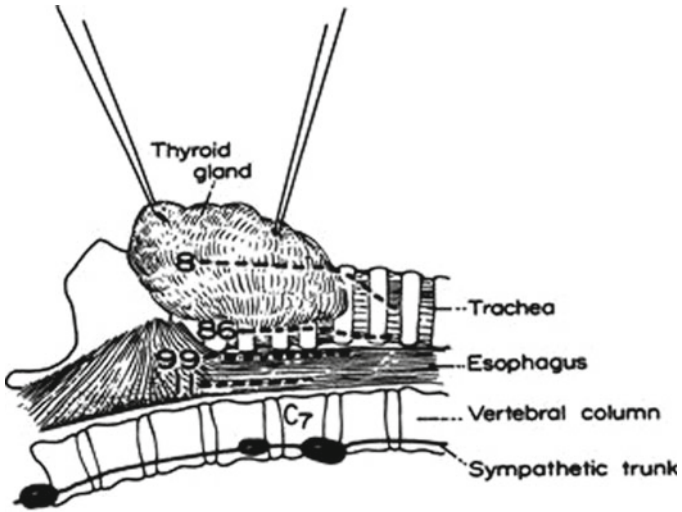


Figure 2.18. The course of the recurrent laryngeal nerve at the level of the thyroid gland in 102 cadavers. In about one-half of the cases, the nerve lay in the groove between the trachea and the esophagus. (Top) Lateral view. (Bottom) Cross-sectional view (By permission of JE Skandalakis, C Droulias, N Harlaftis, et al. *Am Surg* 42(9):629–634, 1976).

a smaller, motor, external laryngeal branch, serving the cricothyroid muscle and the cricopharyngeus. The point of division is usually within the bifurcation of the common carotid artery (Fig. 2.19).

Table 2.2 Recurrent laryngeal nerve vulnerability

<i>Cause of vulnerability</i>	<i>Percent encountered</i>
Lateral and anterior location	1.5–3.0
Tunneling through thyroid tissue	2.5–15.0
Fascial fixation	2.0–3.0
Arterial fixation	5.0–12.5
Close proximity to inferior thyroid vein	1.5–2.0+

Data from Chang-Chien Y. Surgical anatomy and vulnerability of the recurrent laryngeal nerve. *Int Surg* 1980; 65:23

The internal laryngeal branch is rarely identified by the surgeon (Fig. 2.20).

The external laryngeal branch, together with the superior thyroid vein and artery, passes under the sternothyroid muscles, posterior and medial to the vessels. The nerve then passes beneath the lower border of the thyrohyoid muscle to continue inferiorly to innervate the cricothyroid muscle.

Remember:

✓ The results of injury to the recurrent laryngeal nerve and the external branch of the superior laryngeal nerve are as follows:

- *Unilateral recurrent nerve injury.* The affected vocal cord is paramedian owing to adduction by the cricothyroid muscle. Voice is preserved (not unchanged).
- *Unilateral recurrent and superior laryngeal nerve injury.* The affected cord is in an intermediate position, resulting in hoarseness and inability to cough. The affected cord will move toward the midline with time. Voice improves, but improvement is followed by narrowing of the airway. Tracheostomy becomes necessary.

Postoperative hoarseness is not always the result of operative injury to laryngeal nerves. From 1 to 2 % of patients have a paralyzed vocal cord prior to thyroid operations. Researchers at the Mayo Clinic examined 202 cases of vocal cord paralysis, of which 153 (76 %) followed thyroidectomy, 36 (18 %) were of various known etiologies, and 13 (6 %) were of idiopathic origin. We strongly advise the general surgeon to perform a mirror laryngoscopy prior to thyroidectomy.

We believe that the patient should be told that in spite of all precautions, there is a possibility of some vocal disability following thyroidectomy.

A sympathetic ganglion can be confused with a lymph node and removed when the surgeon operates for metastatic papillary carcinoma of the thyroid. In one of our patients, the inferior cervical and first thoracic ganglia were fused

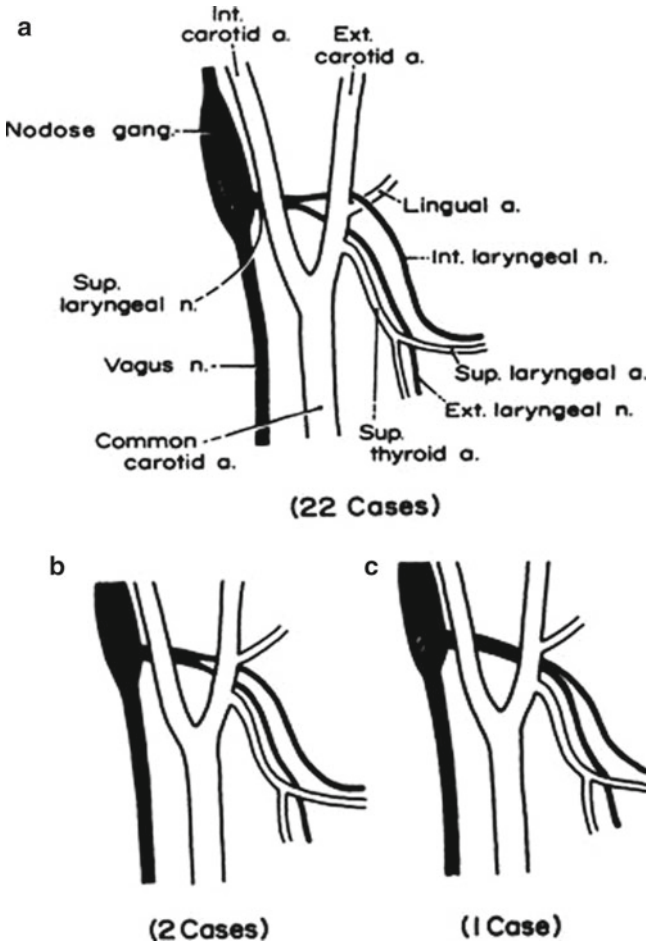


Figure 2.19. Branching of the superior laryngeal nerve and the carotid arteries. (a) The internal branch crosses the external carotid artery above the origin of the lingual artery. (b) The internal branch crosses below the origin of the lingual artery. (c) The nerve divides medial to the external carotid artery (By permission of C Droulias, S Tzinas, N Harlaftis, et al. *Am Surg* 42(9):635–638, 1976).

to form a nodelike structure that was removed. The surgeon must identify any apparent lymph node related to the vertebral artery and fixed in front of the transverse process of the seventh cervical vertebra.

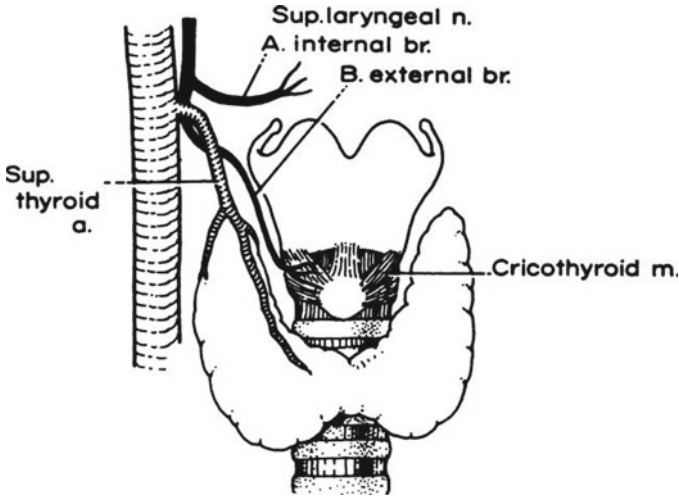


Figure 2.20. Relations of the internal and external branches of the superior laryngeal nerve to the superior thyroid artery and the upper pole of the thyroid gland (By permission of C Droulias, S Tzinias, N Harlaftis, et al. *Am Surg* 42(9):635–638, 1976).

Injury to the cervical sympathetic nerve results in Horner's syndrome: (1) constriction of the pupil, (2) partial ptosis of the upper eyelid, (3) apparent enophthalmos, (4) dilatation of the retinal vessels, and (5) flushing and drying of the facial skin on the affected side.

Persistent Remnants of the Thyroglossal Duct

The foramen cecum of the tongue and the pyramidal lobe of the thyroid gland are normal remnants of the thyroglossal duct. Between these structures is a very small epithelial tube, usually broken in several places. Occasionally these epithelial fragments hypertrophy, secrete fluid, and form cysts. Drainage or aspiration of these cysts is futile and often results in formation of a fistula, usually infected.

All fragments of the duct, the foramen cecum, and the midportion of the hyoid bone should be removed (Sistrunk procedure). Recurrence of the cyst is the result of failure to remove the entire duct or the central portion of the hyoid bone.

■ ANATOMY OF THE PARATHYROID GLANDS

The parathyroid glands are usually found on the posterior surface of the thyroid gland, each with its own capsule of connective tissue. They are occasionally included in the thyroid capsule, or one of them may even follow a blood vessel deep into a sulcus of the thyroid.

Extreme locations are very rare, although glands have been found as high as the bifurcation of the carotid artery and as low as the mediastinum. In practice, the surgeon should start at the point at which the inferior thyroid artery enters the thyroid gland. The superior parathyroid glands will *probably* lie about 1 in. above it, and the inferior parathyroid glands will *probably* lie 1/2 in. below it. If the inferior gland is not found, it is more likely to be lower than higher.

It is not uncommon to have more or fewer than four parathyroid glands.

Blood Supply

The inferior thyroid artery is responsible in most cases for the blood supply of both the upper and lower parathyroid glands (see material on arterial supply of thyroid and parathyroid glands).

■ ANATOMY OF THE TRACHEA

The trachea, together with the esophagus and thyroid gland, lies in the visceral compartment of the neck. The anterior wall of the compartment is composed of sternothyroid and sternohyoid muscles. It is covered anteriorly by the investing layer of the deep cervical fascia and posteriorly by the prevertebral fascia (Fig. 2.9). The trachea begins at the level of the sixth cervical vertebra. Its bifurcation is at the level of the sixth thoracic vertebra in the erect position, or the fourth to fifth thoracic vertebrae when supine.

Vascular System

The chief sources of arterial blood to the trachea are the inferior thyroid arteries. At the bifurcation, these descending branches anastomose with ascending branches of the bronchial arteries.

Small tracheal veins join the laryngeal vein or empty directly into the left inferior thyroid vein.

The pretracheal and paratracheal lymph nodes receive the lymphatic vessels from the trachea.

Nervous System

The trachealis muscle and the tracheal mucosa receive fibers from the vagus nerve, recurrent laryngeal nerves, and sympathetic trunks. Small autonomic ganglia are numerous in the tracheal wall.

Anatomic Landmarks

The usual site of a tracheostomy is between the second and fourth or third and fifth tracheal rings. Several structures are encountered. The platysma lies in the superficial fascia and is absent in the midline. The anterior jugular veins may lie close to the midline; more importantly, they may be united by a jugular venous arch at the level of the seventh to eighth tracheal rings in the suprasternal space of Burns.

The investing layer of deep cervical fascia is encountered when the superficial fascia is reflected. Deep to the investing fascia are the sternohyoid and sternothyroid muscles. These muscles lie between the investing layer and the pretracheal fascia on either side of the midline.

Within the visceral compartment under the pretracheal fascia, the isthmus of the thyroid gland will be found, except that in 10 % it is absent. A thyroid ima artery is possible, as well as a suspensory ligament of the thyroid and a levator thyroid muscle in, or close to, the midline.

■ PAROTID GLAND (FIG. 2.21)

Relations of the Parotid Gland

The parotid gland lies beneath the skin in front of and below the ear. It is contained within the investing layer of the deep fascia of the neck, called locally the parotid fascia, and the gland can be felt only under pathological conditions.

The boundaries are:

- Anterior: masseter muscle, ramus of mandible, and medial pterygoid muscle
- Posterior: mastoid process, sternocleidomastoid muscle, and posterior belly of the digastric muscle and facial nerve
- Superior: external auditory meatus, and temporomandibular joint
- Inferior: sternocleidomastoid muscle and posterior belly of digastric muscle
- Lateral: investing layer of deep cervical fascia, skin, and platysma muscle
- Medial: investing layer of deep cervical fascia, styloid process, internal jugular vein, internal carotid artery, and pharyngeal wall

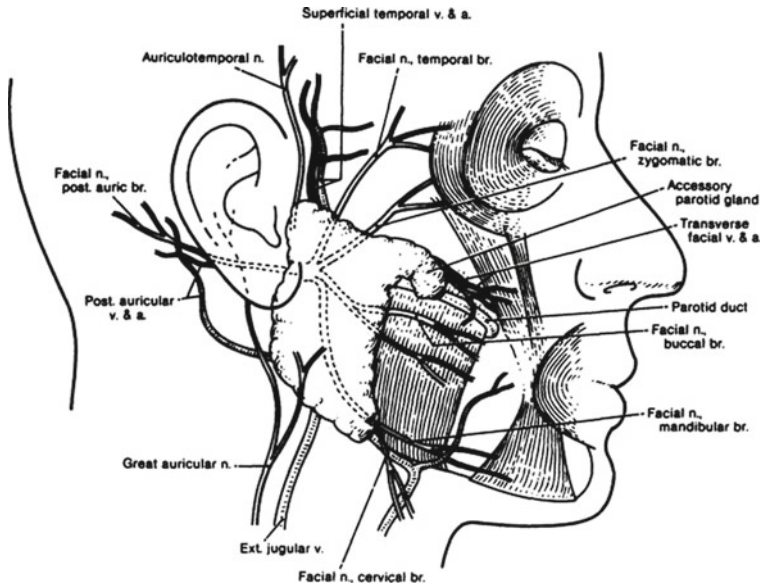


Figure 2.21. Relations of the parotid gland to the facial nerve and its branches (By permission of JE Skandalakis, SW Gray, and JR Rowe. *Anatomical Complications in General Surgery*. New York: McGraw-Hill, 1983).

From the anterolateral edge of the gland, the parotid duct (Stensen's) passes lateral to the masseter muscle and turns medial at the anterior margin of the muscle. The duct pierces the buccinator muscle and enters the oral cavity at the level of the upper second molar tooth.

Structures Traversing the Parotid Gland

Facial Nerve

There is a superficial lobe and a deep lobe of the gland; the branches of the facial nerve run between them. In contrast, some anatomists visualize the gland as essentially unilobular, with the branches of the facial nerve enmeshed within the gland tissue with no cleavage plane between nerve and gland. The view that one may accept does not change the actual surgical procedure.

The main trunk of the facial nerve enters the posterior surface of the parotid gland about 1 cm from its emergence from the skull through the stylomastoid foramen, about midway between the angle of the mandible and the cartilaginous ear canal (Fig. 2.21). At birth the child has no mastoid process; the stylomastoid foramen is subcutaneous.

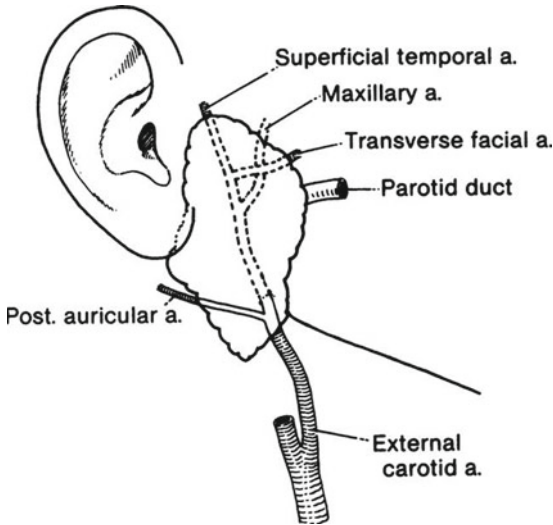


Figure 2.22. Relations of the parotid gland to branches of the external carotid artery (By permission of JE Skandalakis, SW Gray, and JR Rowe. *Anatomical Complications in General Surgery*. New York: McGraw-Hill, 1983).

About 1 cm from its entrance into the gland, the facial nerve typically divides to form five branches: temporal, zygomatic, buccal, mandibular, and cervical. In most individuals, an initial bifurcation called the pes anserinus forms an upper temporofacial and a lower cervicofacial division, but six major patterns of branching, based on a series of simple to complex arrangements, have been distinguished.

Arteries

The external carotid artery enters the inferior surface of the gland and divides at the level of the neck of the mandible into the maxillary and superficial temporal arteries. The latter gives rise to the transverse facial artery. Each of these branches emerges separately from the superior or anterior surface of the parotid gland (Fig. 2.22).

Veins

The superficial temporal vein enters the superior surface of the parotid gland. It receives the maxillary vein to become the retromandibular vein. Still within the gland, the retromandibular vein divides. The posterior branch joins the posterior auricular vein to form the external jugular vein. The anterior branch

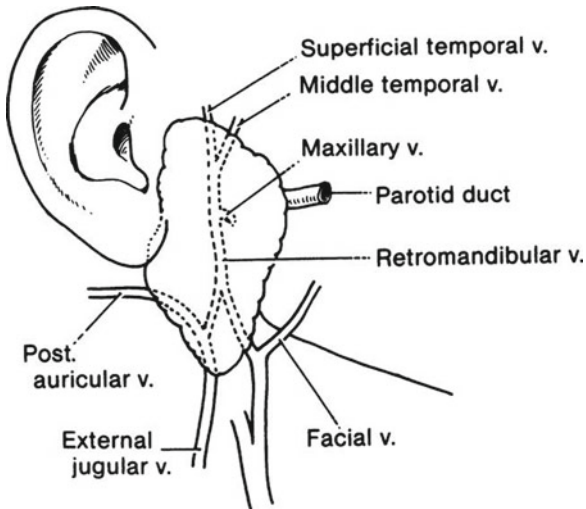


Figure 2.23. Relations of the parotid gland to tributaries of the external and internal jugular veins (By permission of JE Skandalakis, SW Gray, and JR Rowe. *Anatomical Complications in General Surgery*. New York: McGraw-Hill, 1983).

emerges from the gland to join with the facial vein, thereby forming the common facial vein, a tributary to the internal jugular (Fig. 2.23). Remember, the facial nerve is superficial, the artery is deep, and the retromandibular vein lies between them.

Lymphatics

The preauricular lymph nodes in the superficial fascia drain the temporal area of the scalp, upper face, lateral portions of the eyelids, and the anterior pinna. Parotid nodes within the gland drain the gland itself, as well as the nasopharynx, nose, palate, middle ear, and external auditory meatus. These nodes, in turn, send lymph to the subparotid nodes and eventually to the nodes of the internal jugular vein and spinal accessory chains (Table 2.1).

Great Auricular Nerve

The great auricular nerve reaches the posterior border of the sternocleidomastoid muscle and, on the surface of the parotid gland, follows the course of the external jugular vein. It is sacrificed at parotidectomy. Injury to this nerve results in numbness in the preauricular region, lower auricle, and the lobe of the ear, but it disappears after 4–6 months.

Auriculotemporal Nerve

The auriculotemporal nerve, a branch of the mandibular division of the trigeminal cranial nerve, traverses the upper part of the parotid gland and emerges with the superficial temporal blood vessels from the superior surface of the gland. Within the gland, the auriculotemporal nerve communicates with the facial nerve.

Usually, the order of the structures from the tragus anteriorly is the following: auriculotemporal nerve, superficial temporal artery and vein, and temporal branch of the facial nerve. The auriculotemporal nerve carries sensory fibers from the trigeminal nerve and motor (secretory) fibers from the glossopharyngeal nerve.

Injury to the auriculotemporal nerve produces Frey's syndrome, in which the skin anterior to the ear sweats during eating ("gustatory sweating").

Parotid Bed

Complete removal of the parotid gland reveals the following structures (the acronym VANS may be helpful in remembering them):

- One Vein: internal jugular
- Two Arteries: external and internal carotid
- Four Nerves: glossopharyngeal (IX), vagus (X), spinal accessory (XI), and hypoglossal (XII) (Fig. 2.24)
- Four anatomic entities starting with S: styloid process, and styloglossus, stylopharyngeus, and stylohyoid muscles

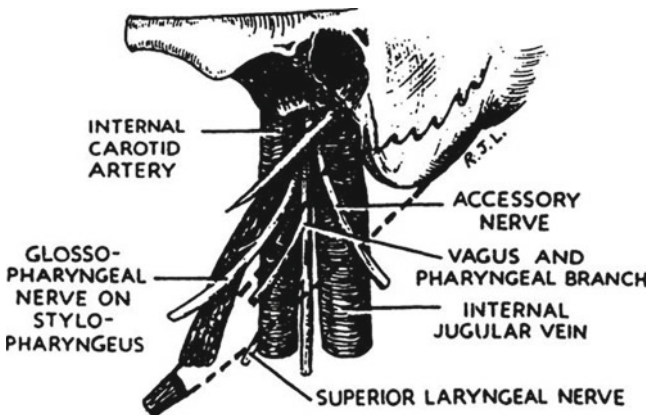


Figure 2.24. Lateral view of the structures in the left carotid sheath at the base of the skull. The posterior belly of the digastric is shown in dotted outline. The hypoglossal nerve (not shown) hooks around the vagus and appears between the artery and the vein below the lower border of the digastric (By permission of RJ Last. *Anatomy: Regional and Applied*. Baltimore: Williams & Wilkins, 1972).

■ IDENTIFICATION OF THE FACIAL NERVE

The main trunk of the facial nerve is within a triangle bounded by the mastoid process, the external auditory meatus, and the angle of the mandible. The lower tip of the mastoid process is palpated and a fingertip is placed on the lateral surface pointing forward. The trunk of the facial nerve will be found deep and anterior to the center of the fingertip.

Remember:

- ✓ The stem of the nerve lies between the parotid gland and its fascia, deep in front of the mastoid, and medially at the midpoint between the mandibular angle and the cartilaginous ear canal. The stylomastoid foramen and the facial nerve are subcutaneous.

The facial nerve and its branches are in danger during parotidectomy. The facial trunk is large enough for anastomosis of the cut ends, should this be necessary.

■ BRANCHIAL CLEFT SINUSES AND CYSTS

Anatomy of Branchial Remnants

Fistulas

Fistulas are patent duct-like structures that have both external and internal orifices. Cervicoaural fistulas extend from the skin at the angle of the jaw, and may open into the external auditory canal. These fistulas lie anterior to the facial nerve. They are remnants of the ventral portion of the first branchial cleft (Fig. 2.25).

Lateral cervical fistulas almost always arise from the ventral portion of the second branchial cleft and pouch. They originate on the lower third of the neck on the anterior border of the sternocleidomastoid muscle. The path is upward through the platysma muscle and deep fascia. Above the hyoid bone the track turns medially to pass beneath the stylohyoid and the posterior belly of the digastric muscle, in front of the hypoglossal nerve, and between the external and internal carotid arteries. It enters the pharynx on the anterior surface of the upper half of the posterior pillar of the fauces (Fig. 2.26a). It may open into the supratonsillar fossa or even into the tonsil itself.

Sinuses

External sinuses are blindly ending spaces that extend inward from openings in the skin. *Internal sinuses* are blindly ending spaces that extend outward from openings in the pharynx.

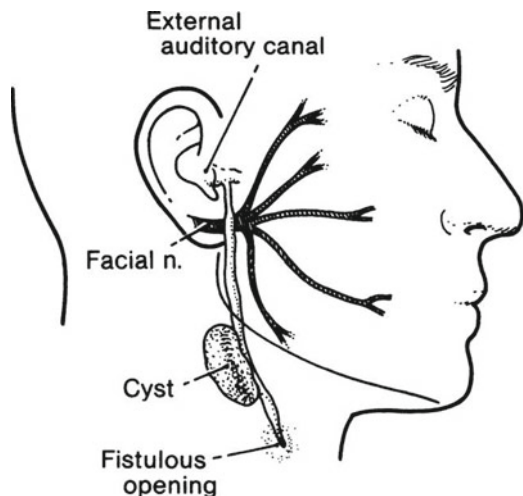


Figure 2.25. Congenital cervicoaural fistula or cyst. This is a persistent remnant of the ventral portion of the first branchial cleft. The tract may or may not open into the external auditory canal (modified by permission of AH Bill and JL Vadheim. *Ann Surg* 142:904, 1955).

External sinuses usually arise at the anterior border of the sternocleidomastoid muscle and end in a cystic dilatation (Fig. 2.26b). Internal sinuses are usually asymptomatic and hence undetected.

Cysts

Cysts are spherical or elongated spaces lying in the track of a branchial pouch or cleft and have no communication with the pharynx or skin.

Superficial cysts lie at the edge of the sternocleidomastoid muscle. Deeper cysts lie on the jugular vein or in the bifurcation of the carotid artery (Fig. 2.26c). These are of branchial cleft origin and are lined with stratified squamous epithelium. Cysts on the pharyngeal wall deep to the carotid arteries are usually of branchial cleft origin. They are lined with ciliated epithelium unless inflammatory or pressure changes have occurred (Fig. 2.27).

The external and internal carotid arteries just above the bifurcation of the common carotid artery are especially prone to injury while performing excision of the branchial remnants, because a second-cleft cyst or the path of a second-cleft fistula will lie in the crotch of the bifurcation.

Remember:

- ✓ A first-cleft sinus or cyst passes over or under the facial nerve below and anterior to the ear. The cyst may displace the nerve either upward or

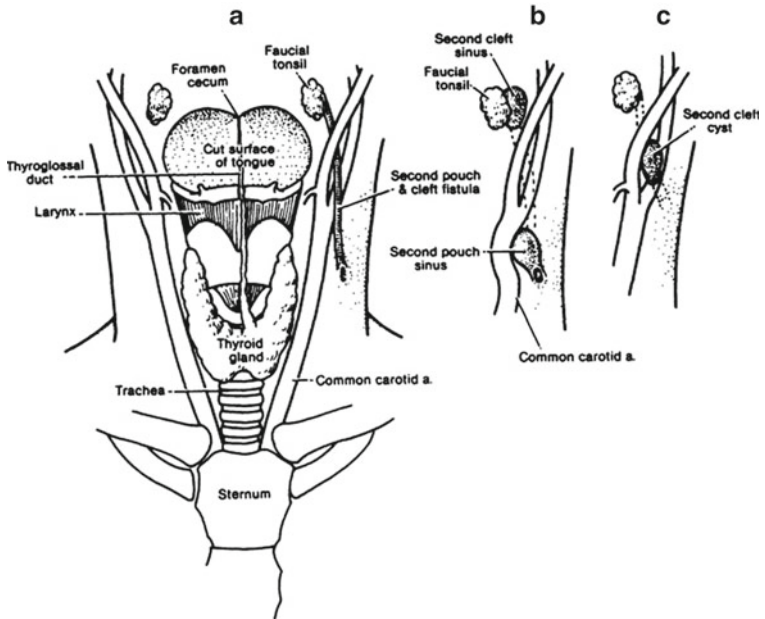


Figure 2.26. Track of a second-pouch and second-cleft fistula passing from the tonsillar fossa of the palatine (faucial) tonsils to the neck. (a) Complete fistula. (b) External (cervical) and internal (pharyngeal) sinuses. (c) Cyst of branchial cleft origin lying in the carotid notch (By permission of JE Skandalakis, SW Gray, and JR Rowe. *Anatomical Complications in General Surgery*. New York: McGraw-Hill, 1983).

downward. While removing the cyst, the surgeon must be careful to protect the nerve.

- ✓ Several nerves will be found above the pathway of a second-cleft or second-pouch branchial fistula:
 - Mandibular and cervical branches of the facial nerve
 - Spinal accessory nerve, which may be injured when trying to free a cyst or fistulous tract from the sternocleidomastoid muscle
 - Descendens hypoglossi—superior root of the ansa cervicalis—which may be cut with impunity
 - Hypoglossal nerve (the fistula crosses the nerve above the bifurcation of the common carotid artery)
 - Superior laryngeal nerves
 - Vagus nerve, which lies parallel to the carotid artery. (The fistula crosses the nerve near the level of the carotid bifurcation.)

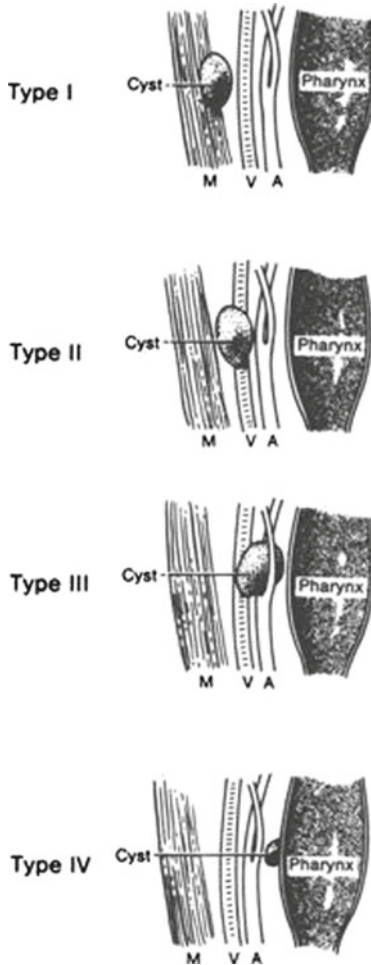


Figure 2.27. Incomplete closure of the second branchial cleft or pouch may leave cysts. Type I, superficial, at the border of the sternocleidomastoid muscle. Type II, between the muscle and the jugular vein. Type III, in the bifurcation of the carotid artery. Type IV, in the pharyngeal wall. Types I, II, and III are of second-cleft origin; Type IV is from the second pouch. M=sternocleidomastoid muscle; V=jugular vein; A=carotid artery (By permission of JE Skandalakis, SW Gray, and JR Rowe. *Anatomical Complications in General Surgery*. New York: McGraw-Hill, 1983).

TECHNIQUE

■ MASSES OF THE NECK

Diagnosis of nonthyroid neck masses follows a well-marked pathway. With a little rounding of the figures, an easily remembered rule is apparent:

Rule of 80

- 80 % of nonthyroid neck masses are neoplastic.
- 80 % of neoplastic neck masses are in males.
- 80 % of neoplastic neck masses are malignant.
- 80 % of malignant neck masses are metastatic.
- 80 % of metastatic neck masses are from primary sites above the clavicle.

In addition, the probable diagnosis may be based on the average duration of the patient's symptoms:

Rule of 7

- Mass from inflammation has existed for 7 days.
- Mass from a neoplasm has existed for 7 months.
- Mass from a congenital defect has existed for 7 years. However, acquired immune deficiency syndrome (AIDS) perhaps changes these rules a little.

■ PAROTIDECTOMY

Position the head and prepare the skin as in thyroid surgery, but uncover the lateral angle of the eye and the labial commissure. Sterilize the external auditory canal. Use intravenous antibiotic of choice.

Step 1. Incision: Inverted T or modified Y (Figs. 2.28 and 2.29)

Inverted T: Make a vertical preauricular incision about 3 mm in front of the ear with downward curved extension at the posterior angle of the mandible. Make a transverse curved incision 3 cm below the mandible with posterior extension close to the mastoid.

Modified Y: Make vertical pre- and postauricular incisions that unite approximately at the angle of the mandible, forming a Y which again meets a transverse incision 3 cm below the mandible.

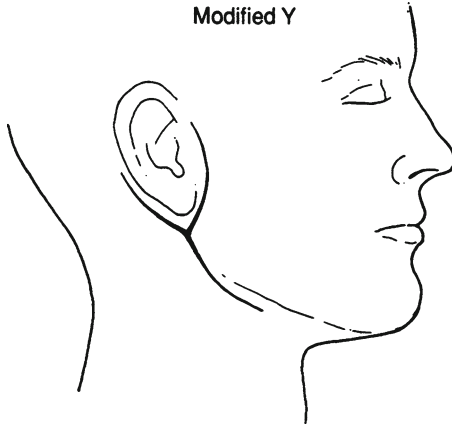


Figure 2.28. Modified Y incision.

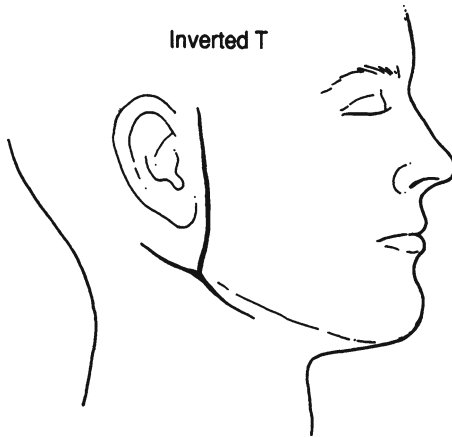


Figure 2.29. Inverted T-incision.

Make a deep incision into the superficial cervical fascia (anteriorly, fat and platysma; posteriorly, fat only).

Step 2. Formation of flaps (Fig. 2.30).

Carefully elevate skin and fat using knife, scissors, and blunt dissection upward, medially, laterally, downward, and posteriorly.

For the upper flap, provide traction upward and medially on the dissected skin, and laterally toward the external auditory canal. Form the lower flap by dissection of the skin downward and posteriorly toward the mastoid process.

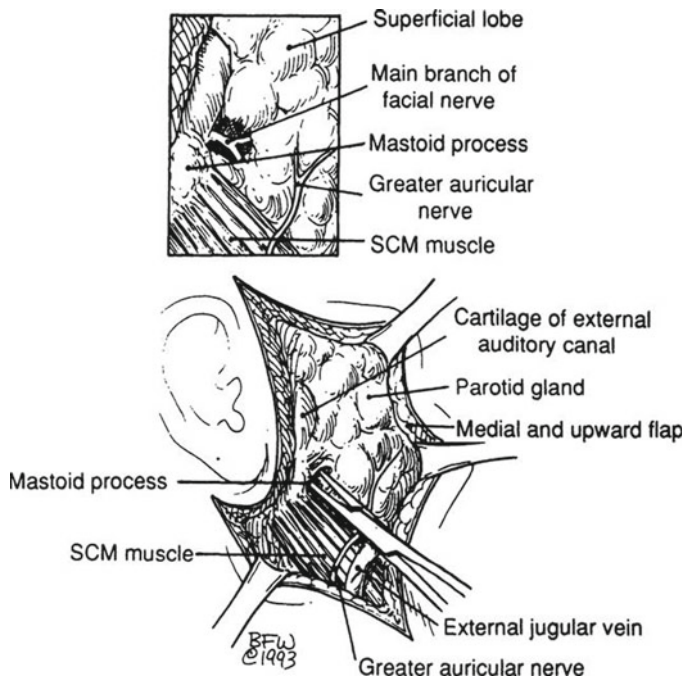


Figure 2.30. Parotid gland exposure. *Inset:* Facial nerve and greater auricular nerve.

Remember:

- ✓ Sacrifice the great auricular nerve and the posterior facial vein. Both are very close to and topographically situated in the vicinity of the lower flap and the lower parotid border.

Step 3. Facial nerve identification (Fig. 2.31)

- a. Place the distal phalanx of the left index finger on the mastoid, pointing to the eye of the patient.
- b. Carefully incise the parotid fascia and further mobilize the superficial part of the parotid.
- c. Insert a hemostat between the mastoid and the gland and bluntly spread the gland medially.
- d. The stem of the nerve will always be found at a depth of less than 0.5 cm. If there is any doubt whether the nerve has been identified, use electrical stimulation.

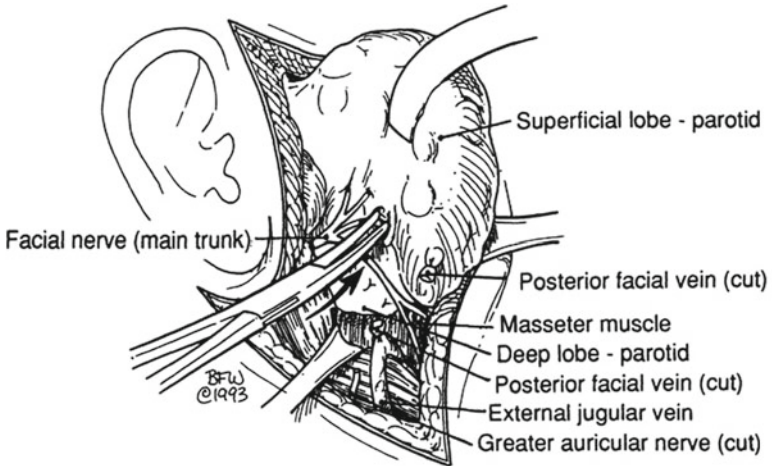


Figure 2.31. Facial nerve identification.

- e. Exert upward traction on the superficial lobe and, with a curved hemostat, begin dissection over the nerve.
- f. Identify all five branches.

Step 4. Resection of the superficial lobe (Fig. 2.32).

With gentle traction of the gland and further anterior nerve dissection toward the periphery of the gland, totally mobilize and resect the superficial lobe. As the dissection is carried toward the ends of the branches of the facial nerve, Stensen's duct will be encountered and should be ligated and divided.

Step 5. Resection of the deep lobe (Fig. 2.33)

The following anatomical entities should be kept in mind:

- Pterygoid venous plexus
- External carotid artery
- Maxillary nerve
- Superficial temporal nerve
- Posterior facial vein

All the above should be ligated. Pterygoid venous plexus bleeding may be stopped by compression. Do not go deep: remember VANS (see "Parotid Bed" earlier in this chapter). Remove the deep lobe carefully, working under the facial nerve by the piecemeal dissection technique. Obtain good hemostasis.

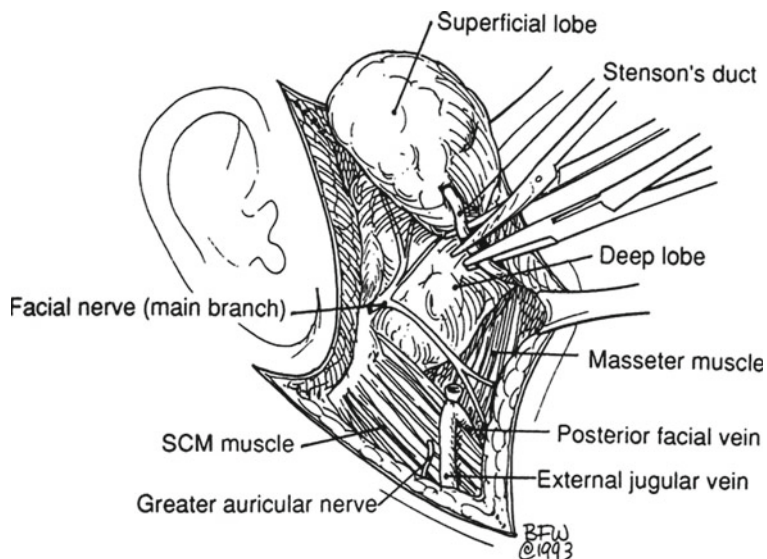


Figure 2.32. Resection of the superficial lobe.

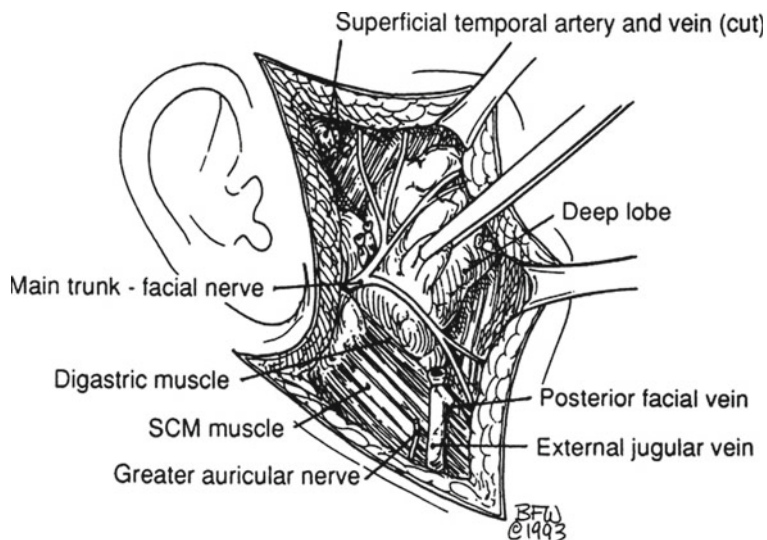


Figure 2.33. Resection of the deep lobe.

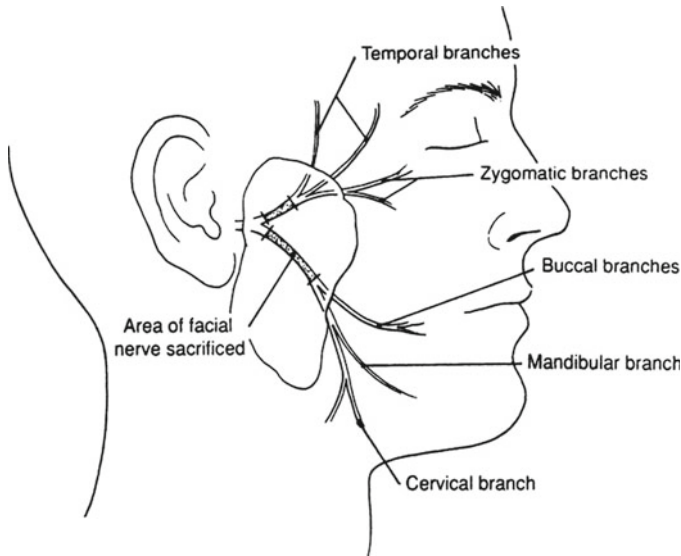


Figure 2.34. Typical positions of the branches of the facial nerve.

Radical Parotidectomy (Fig. 2.34)

Excise the parotid in toto, as well as the facial nerve and the regional lymph nodes; also, if necessary, perform ipsilateral radical neck dissection.

Autologous graft microanastomosis should be considered for reconstruction of the facial nerve. The greater and lesser occipital nerves can serve as donors.

Remember:

- ✓ Try to save zygomatic marginal branches if possible. If not, use microanastomosis end to end.

Insert a Jackson–Pratt drain through a lower stab wound. To close the wound, use interrupted 3-0 Vicryl for platysma and fat, and interrupted 6-0 nylon for skin.

■ RESECTION OF SUBMAXILLARY GLAND (FIGS. 2.1, 2.2, 2.3, 2.4, 2.5, AND 2.6)

POSITION AND PREPARATION: As in parotidectomy. The upper half of the face should be covered, but the labial commissure should be uncovered.

INCISION: Make a transverse incision 3 cm below the lower border of the mandible. Incise the superficial fascia from the anterior border of the sternocleidomastoid muscle (SCM) to 2–3 cm from the midline (Fig. 2.35).

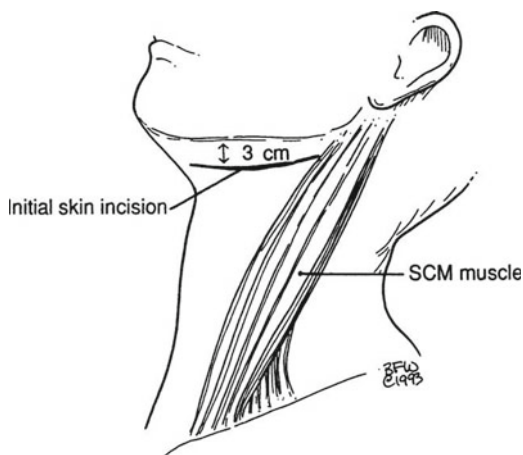


Figure 2.35. Incision of the superficial fascia.

Remember:

- ✓ The two branches of the facial nerve (mandibular and cervical) are under the platysma and the deep fascia of the submaxillary gland. Identify and protect them. Apply retractors carefully.

Surgical Field in View:

- Superior: inferior border of mandible
- Inferior: digastric and stylohyoid muscles
- Medial: mylohyoid muscle
- Lateral: sternocleidomastoid muscle
- Center: deep cervical fascia covering the gland

The common facial vein, its anterior tributary, or its posterior tributary is now in view close to the sternocleidomastoid muscle. Continue to observe the marginal branch of the facial nerve, which is superficial to the facial vessels (occasionally at a lower level).

Remember:

- ✓ There are lymph nodes outside the capsule close to the vessels. With benign disease, removal of these is not necessary.

Step 1. Ligate the facial vessels (Fig. 2.36).

Step 2. With curved hemostat, separate inferiorly the gland from the digastric muscle (Fig. 2.37).

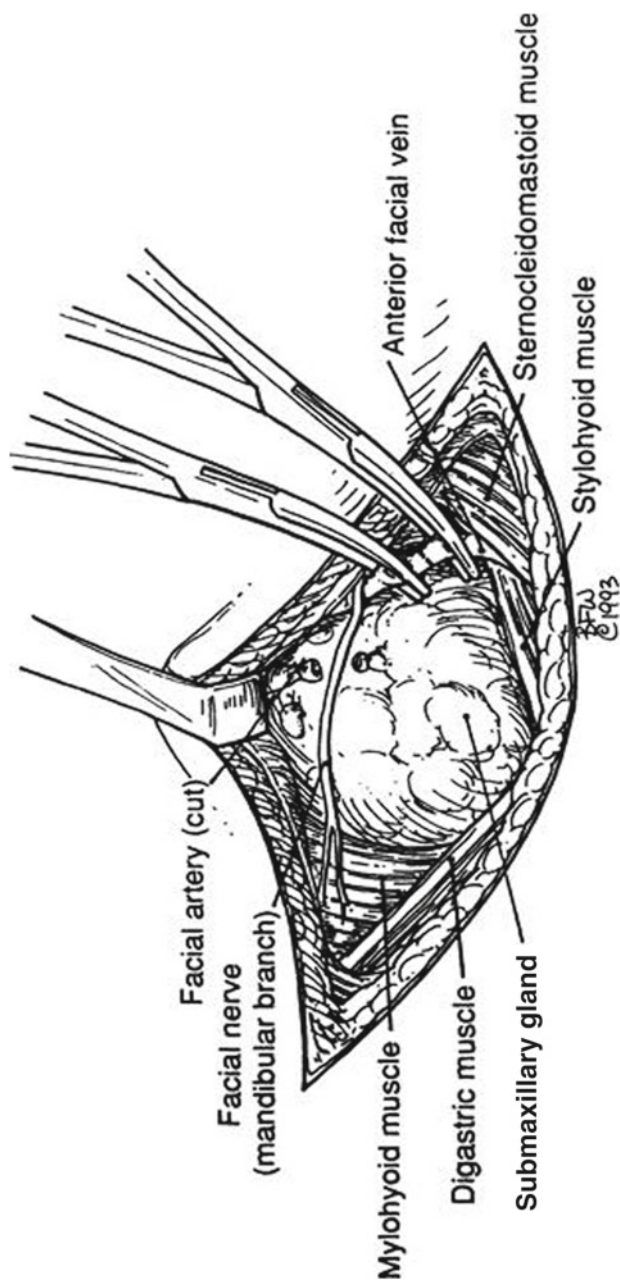


Figure 2.36. Exposure of common facial artery, vein, and nerve.

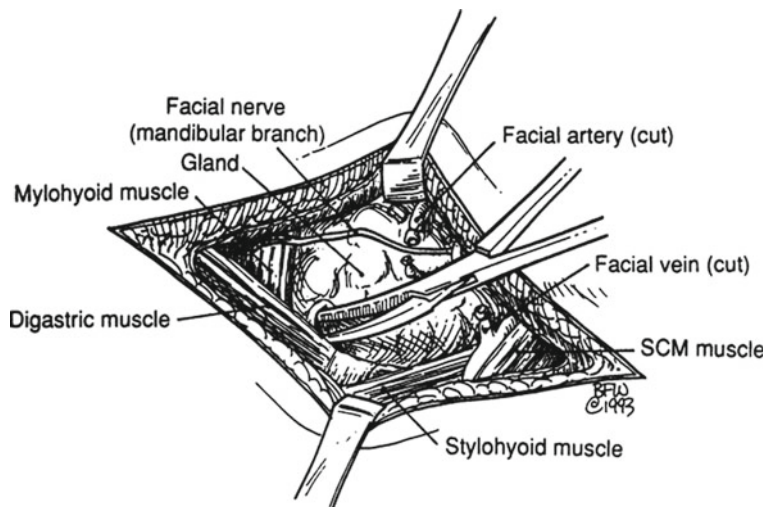


Figure 2.37. Exposure of the gland.

Remember:

- ✓ The hypoglossal nerve is located very close to the digastric tendon and is accompanied by the lingual vein and, deeper, by the external maxillary artery. Both vessels should be ligated carefully. Elevate the mylohyoid muscle to expose the deep part of the submaxillary gland. Separate the gland slowly. Just under the gland and cephalad to it, the following anatomical entities are in view: lingual nerve, chorda tympani, submaxillary ganglion, and Wharton's duct.

Step 3. Ligate and cut Wharton's duct. Protect the lingual nerve (Fig. 2.38). Continue blunt dissection.

Step 4. Insert Jackson–Pratt drain and close in layers.

Caution: Avoid injury to the mandibular, hypoglossal, and lingual nerves.

■ THYROIDECTOMY

Step 1. Position

- a. Put the patient in semi-Fowler position.
- b. Patient's neck should be hyperextended.
- c. Place small pillow at the area of the upper thoracic spine, beneath the shoulders.
- d. Place a doughnut support under the head.

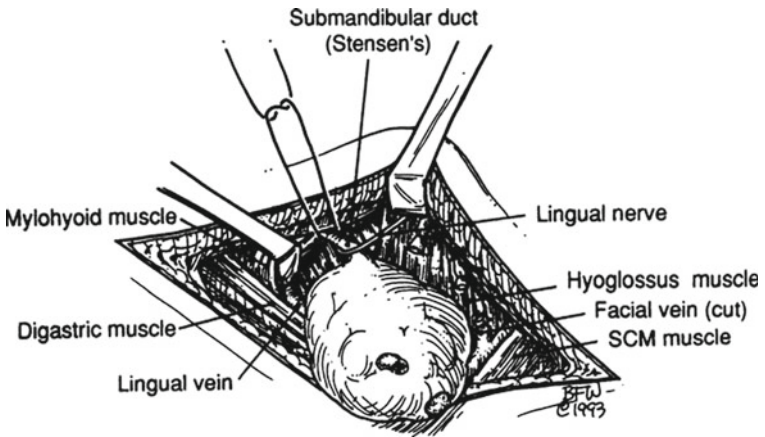


Figure 2.38. Blunt dissection.

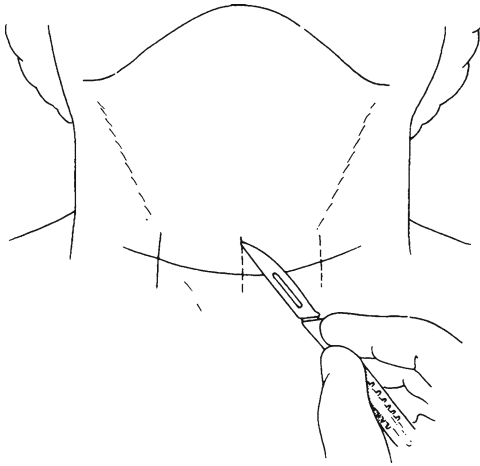


Figure 2.39. Location for incision.

Step 2. Preparation of skin

- a. Use Betadine or any other solution of the surgeon's choice.
- b. Be sure the chin and long axis of the body are aligned at the midline.
- c. With 2-0 silk, mark the location of the incision, two fingerbreadths above the sternal notch.
- d. Use a knife to mark very superficially the middle and edges of the previously marked location of the incision.

Step 3. Incise the low collar symmetrical mark of the skin, carrying out the incision through the superficial fascia (subcutaneous fat and platysma). Establish good hemostasis by electrocoagulation or ligation using silk (Figs. 2.39 and 2.40).

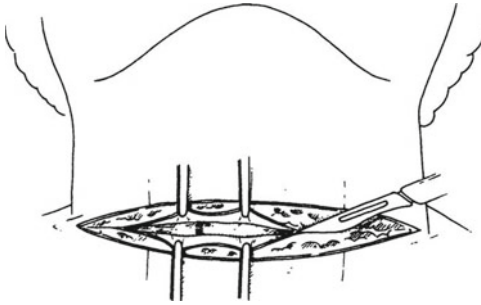


Figure 2.40. Incision through superficial fascia.

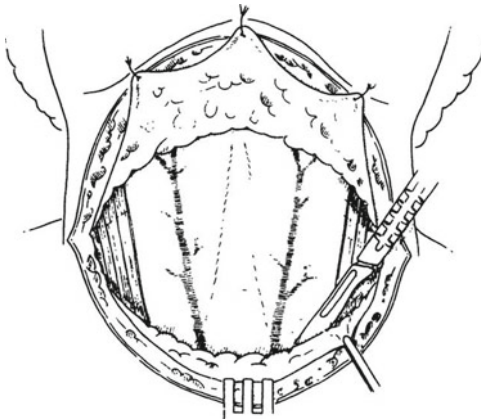


Figure. 2.41. Elevation of flaps.

Step 4. Formation of flaps (Fig. 2.41)

By blunt dissection, elevate the upper flap to the notch of the thyroid cartilage and the lower flap to the jugular (sternal) notch. Use Mahorner's, Murphy's, or other self-retaining retractors.

Step 5. Opening of the deep fascia (Figs. 2.42 and 2.43)

The opening is accomplished by a longitudinal midline incision along the raphe of the strap muscles, which is actually the deep fascia.

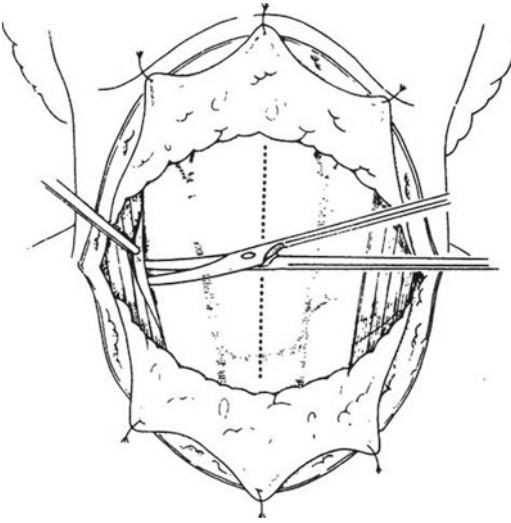


Figure 2.42. Raphe of strap muscles.

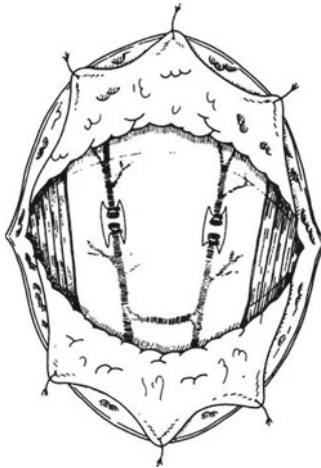


Figure 2.43. Incising strap muscles.

Step 6. Elevation of the strap muscles (Figs. 2.44, 2.45, and 2.46)

The sternohyoid muscles are easily elevated, but the thyrohyoid and sternothyroid muscles are attached to the false thyroid capsule and should be separated carefully to avoid injuring the gland and causing

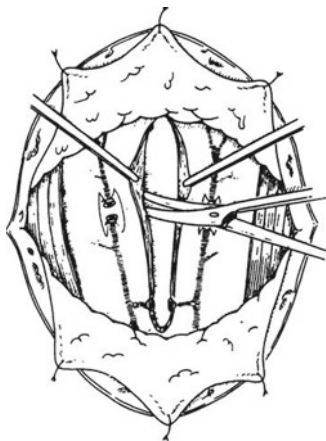


Figure 2.44. Sternohyoid muscles.

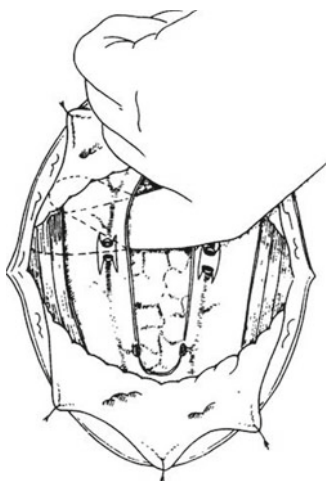


Figure 2.45. Breaking of attachments.

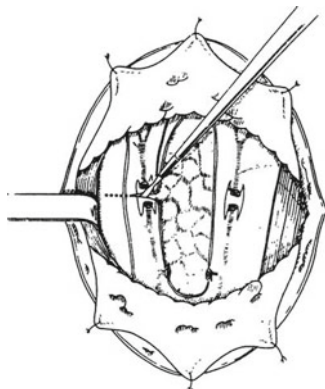


Figure 2.46. Separation and division.

bleeding. In extremely rare cases, when the thyroid gland is huge, section of the strap muscles becomes necessary. Divide them at the proximal (upper) one-third to avoid paralysis due to injury of the ansa hypoglossi (C₁, C₂, C₃, and XII).

The sternohyoid muscles are the most superficial, and the sternothyroid and thyrohyoid are underneath. For practical purposes, the thyrohyoid is an upward continuation of the sternothyroid.

Step 7. Exposure and mobilization of the gland

With all strap muscles elevated and retracted, the index finger of the surgeon is gently inserted between the thyroid and the muscles (Fig. 2.45). A lateral elevation is also taking place, occasionally using all the fingers except the thumb. It not only breaks the remaining muscular or pathological attachments, but enables the surgeon to appreciate the gross pathology of the gland in toto. Occasionally the strap muscles should be divided (Figs. 2.46 and 2.47).

The anatomy of the normal and the abnormal must be studied carefully regarding size, extension, consistency, and fixation of the gland. Is a pyramidal lobe present? How thick is the isthmus? Are a Delphian node and other lymph nodes present? If so, excision of the Delphian node and perhaps one or two of the other palpable lymph nodes is in order. Frozen section should follow.

Step 8. Total lobectomy (Figs. 2.48, 2.49, and 2.50)

- a. Retract the lobe medially and anteriorly by special clamps or deep sutures outside the lesion.
- b. Ligate the middle thyroid vein.

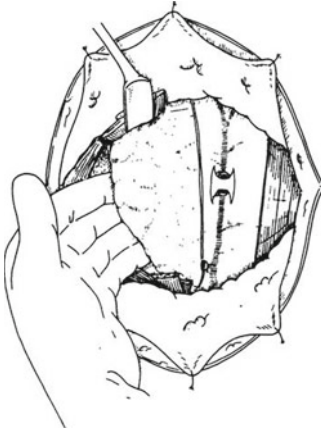


Figure 2.47. Lateral elevation.

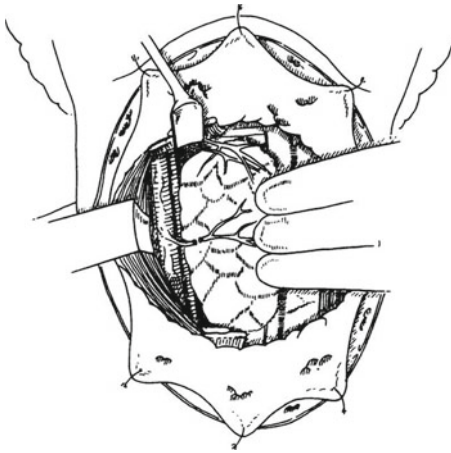


Figure 2.48. Exposure.

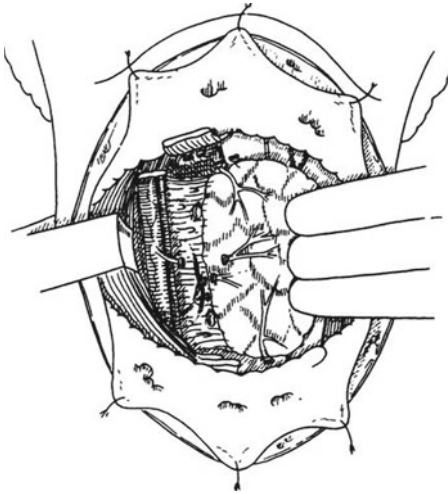


Figure 2.49. Retraction.

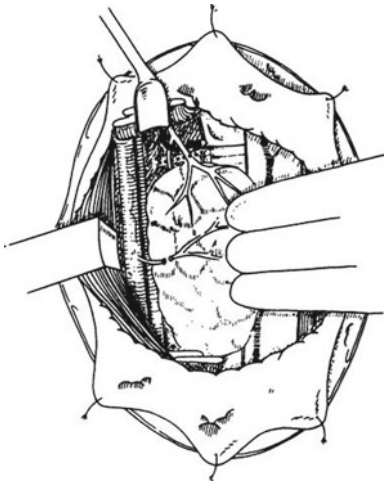


Figure 2.50. Ligation.

- c. Identify the recurrent laryngeal nerve by blunt dissection into the tracheoesophageal groove.
- d. Identify and protect the parathyroids.
- e. Ligate the inferior thyroid artery. Superior and inferior pole vessels may also be divided with the Ligasure or Harmonic scalpel.
- f. Ligate the lower pole vessels.
- g. Carefully ligate the upper pole. Perform en masse ligation, thereby ligating the superior thyroid artery, or, if possible, prepare the artery above the pole and ligate.
- h. Dissect the lobe from the trachea by dividing the gland between straight mosquitoes. With 3-0 silk, suture ligate the tissue that is clamped over the trachea. Alternatively the Harmonic Scalpel can be used with the same effect.
- i. If the pyramidal lobe is present, ligate its most distal part and remove it together with the lobe. Send the specimen to the lab for frozen section.
- j. Ligate the isthmus, if present.
- k. Obtain meticulous hemostasis.

Step 9. Subtotal thyroidectomy.

Apply multiple hemostats at the thyroid parenchyma and partially transect the gland. Use 4-0 silk suture ligation for suture ligation of the thyroid parenchyma and surface veins. If possible, approximate the segment to the trachea. Both upper pole remnants or the tracheoesophageal remnant should weigh approximately 5–6 g.

■ PARATHYROIDECTOMY

Step 1. The following steps are a strategy for finding abnormal parathyroid locations.

- a. Perform preoperative CT angiogram (CTA) to identify parathyroid adenoma.
- b. Explore the superior surface of the thyroid gland. Ligate the middle thyroid veins, retract the lobe medially and anteriorly, and expose the recurrent laryngeal nerve.
- c. Dissect the superior anterior mediastinum as far as possible, with special attention to the thymus or its remnant behind the manubrium.
- d. Explore the region above the upper pole of the thyroid gland as far as the hyoid bone.
- e. Explore the retroesophageal, retropharyngeal, and retrosternal spaces.
- f. Perform subtotal thyroidectomy.

- g. Confirm removal of parathyroid adenoma via intraoperative parathyroid monitoring.
- h. Further explore the mediastinum at a second operation. This should be done only after the pathology report on thymus and thyroid tissue has been received and no parathyroid tissue is reported.

Remember:

- ✓ The best anatomical landmark is the inferior thyroid artery.
- ✓ The most useful instrument for palpation is the distal phalanx of the index finger.

Step 2. In the patient with a localized gland identified by CTA, the incision is made directly over the gland between the sternocleidomastoid muscle and the strap muscles. In a patient with hyperplasia, remove 3½ glands. The remaining ½ gland can be left in situ or implanted into the sternocleidomastoid muscle. In any case, cryopreserve a parathyroid for reimplantation in case the patient becomes hypoparathyroid. When a patient is explored for a suspected adenoma, the healthy glands will be smaller than normal. If a parathyroid adenoma has been identified by CTA, it is not necessary to identify all the glands. After removal of the enlarged gland, there should be at least a 50 % reduction in the PTH level. If the PTH level does not show a significant decrease, then the presence of a second and possibly a third adenoma should be investigated. Always send adenomas for frozen section. If the gland is determined to be malignant, the surrounding tissue should be removed.

Step 3. Reconstruction

Insert a Penrose or a Jackson–Pratt drain. Close the midline and the superficial fascia, approximating the marked points and avoiding dog-ears. Closure of the skin is up to the surgeon: use subcuticular sutures with Steri-strips, interrupted 6-0 nylon, or clips. Remember to check the vocal cords as soon as the endotracheal tube has been removed.

■ THYROID REOPERATION

Step 1. Carefully read the patient's previous operating report.

Step 2. Inspect vocal cords.

Step 3. Incise through the previous scar, but add 1–2 cm on each side laterally.

Step 4. Make flaps as in thyroidectomy.

Step 5. Identify the sternocleidomastoid muscle; incise, dissect, and elevate its medial border.

Step 6. Carefully elevate the strap muscles.

Step 7. There are two ways to reexplore the thyroid: from the periphery (this anatomically intact area has less scar tissue) to the center, and from the midline/isthmus area to the periphery.

a. From the periphery to the center

Most likely, the virgin area after thyroid surgery is the area corresponding to the medial border of the sternocleidomastoid. The best anatomical landmark is the proximal part of the inferior thyroid artery, since the distal was probably ligated. Any white, thin, cordlike structure should be protected, since this is probably the recurrent laryngeal nerve. If in doubt, stop the dissection in this area and try to find the nerve at the cricothyroid area above, or at the supraclavicular area below. The most virgin area is just above the clavicle, and the least virgin (if total lobectomy was performed previously) is the cricothyroid area. The parathyroids will be found above and below the inferior thyroid artery. The remnants of the thyroid glands will be found in the tracheoesophageal groove or in the area of the upper thyroid pole.

b. From the midline/isthmus area to the periphery

The anatomical area to be explored with this procedure is the tracheoesophageal groove, in the hope that the recurrent laryngeal nerve is somewhere in the vicinity. Small curved mosquito or Mixter clamps may be used for elevation of the thyroid remnants, location of the nerve, and location of the parathyroids.

If reexploration is performed for malignant disease, then a modified radical neck dissection is in order. In the modified procedure the sternocleidomastoid muscle and the internal jugular vein are preserved. The recurrent nerve also should be saved; it should be sacrificed only if it is fixed to the tumor.

■ PARATHYROID REOPERATION

Step 1. Read about normal and abnormal locations of parathyroids.

Step 2. Carefully read the patient's previous operating report and pay special attention to:

a. Number of parathyroids removed.

b. Sites (right or left).

- c. Together with the radiologist, study all possible results of techniques for localization (ultrasonography, CTA, MRI, sestamibi scan, selective venous catheterization with parathyroid hormone immunoassay evaluation, digital subtraction angiography).

Step 3. Reexplore the neck as in thyroidectomy.

Step 4. Locate and mark the inferior thyroid artery.

Step 5. Protect the recurrent laryngeal nerve.

Step 6. Palpate the “certain” location and all possible locations of parathyroid glands, such as tracheoesophageal groove, retropharyngeal, retroesophageal, retrocarotid, anterior mediastinum (thymus), posterior mediastinum, middle mediastinum (pericardium) within the carotid sheath, suprathyroid, infrathyroid, intrathyroid, and posterior triangle.

Step 7. Remove the tumor. A patient diagnosed with hyperplasia probably has one gland or only 1/2 of the fourth gland (if the patient has only four glands) with hyperplastic or adenomatous changes. Perform a total parathyroidectomy and transplant multiple pieces (1 mm in diameter) of the adenoma or the hyperplastic gland into the biceps muscle, being sure to mark the location. If there is an adenoma that was not found previously, remove it. If the frozen section is determined to be malignant, the surrounding tissue should be removed.

■ THYROGLOSSAL DUCT CYSTECTOMY (FIG. 2.51)

Position and prepare as for thyroidectomy.

Step 1. Make a transverse incision over the cyst. Incise the superficial fascia (fat and platysma) and mark the skin at the midline to facilitate good closure. Formation of flaps: the upward elevation reaches the hyoid bone and extends cephalad 1–2 cm. Elevate the lower flap almost to the isthmus of the thyroid gland. One self-retaining retractor is enough to keep the field open. Open the deep fascia in a longitudinal fashion.

Step 2. Dissect the cyst and isolate it with a small hemostat and plastic scissors (Fig. 2.52). The involved anatomical entities depend upon the location of the cyst (Fig. 2.53): suprahyoid (rare), hyoid (common), and infrahyoid or suprasternal (rare). (Knowledge of the embryology plays a great role here.)

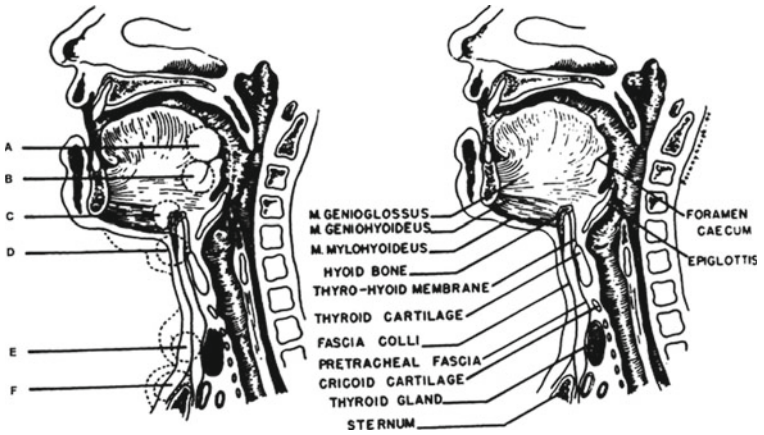


Figure 2.51. Various locations of thyroglossal duct cysts. (A) In front of the foramen caecum. (B) At the foramen caecum. (C) Above the hyoid bone. (D) Below the hyoid bone. (E) In the region of the thyroid gland. (F) At the suprasternal notch. About 50 % of the cysts are located at (D), below the hyoid bone (by permission of GE Ward, JW Hendrick, and RG Chambers. *Surg Obstet Gynecol* 89:728, 1949).

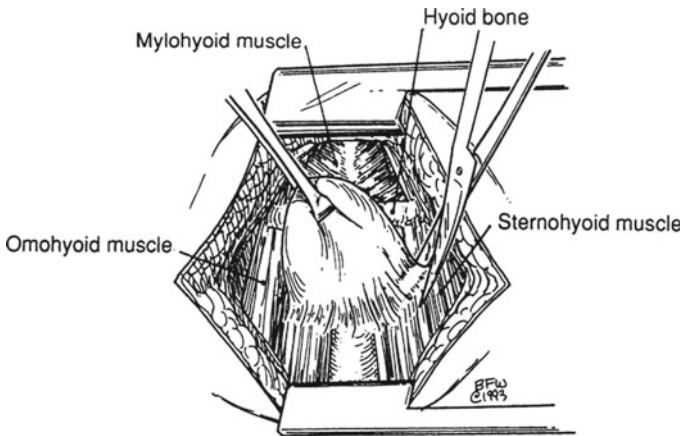


Figure 2.52. Dissection of cyst.

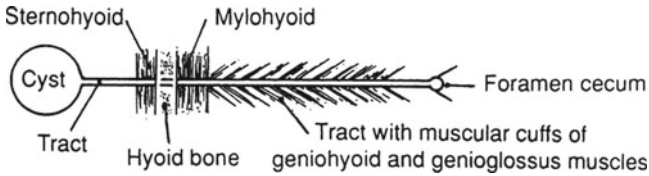


Figure 2.53. Diagrammatic presentation of tract.

Remember:

- ✓ The embryologic path of descent of the thyroid gland (from the foramen cecum to the manubrium sterni).
- ✓ The thyroglossal duct (a midline cordlike formation) travels, in most cases, through the hyoid bone.
- ✓ The anatomical entities involved in most of the cases are:
 - Foramen cecum
 - Thyroid membrane
 - Mylohyoid muscle
 - Geniohyoid muscle
 - Genioglossus muscle
 - Sternohyoid muscle
 - Anterior belly of digastric muscle
- ✓ The mylohyoid is fixed to the hyoid bone above; the sternohyoid is fixed to the hyoid bone below.
- ✓ Occasionally, the anterior belly of the digastric muscle may partially cover the hyoid bone laterally.
- ✓ The geniohyoid is between the thyroid membrane and the mylohyoid.

Step 3. Take special care of the hyoid bone and tract. Clean the central part of the hyoid bone, but be sure to leave some cuffs of sternohyoid and mylohyoid attached to the bone, as well as some cuffs of the underlying geniohyoid and genioglossus attached to the cephalad tract (Fig. 2.54). Insert a curved hemostat under the central part of the hyoid bone. With heavy scissors or small bone cutter, cut the bone on both sides. Continue upward dissection bilaterally to the midline where the tract is located. The thyrohyoid membrane is now exposed (Fig. 2.55).

Step 4. The foramen cecum also requires special attention. The anesthesiologist's index finger is inserted into the patient's mouth, elevating the foramen cecum. With continuous cephalad dissection, the surgeon reaches the foramen cecum by palpating the finger of the

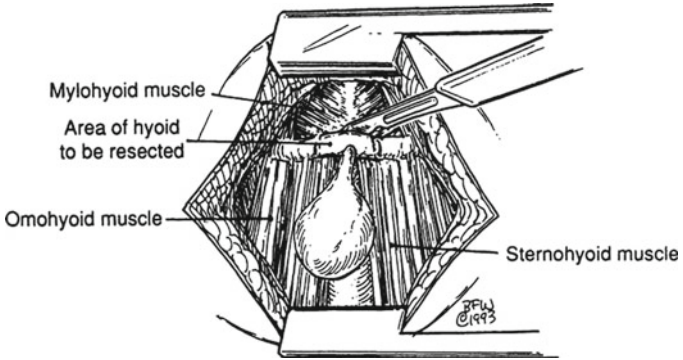


Figure 2.54. Preparation of surgical field.

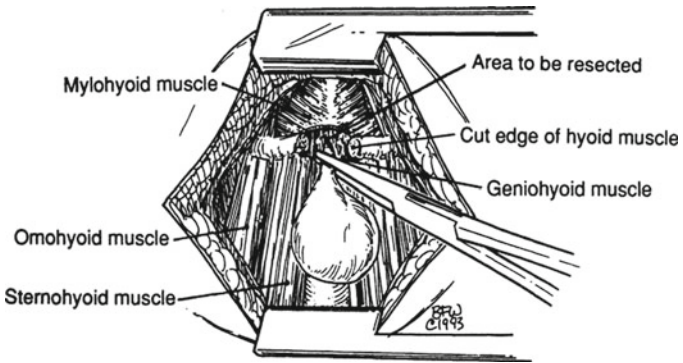


Figure 2.55. Resection.

anesthesiologist just under the thyrohyoid membrane. Excise the foramen cecum in continuity and close the defect with figure-of-eight 4-0 chromic catgut or any other absorbable suture. Drainage is up to the surgeon. Establish good hemostasis. Irrigate with normal saline (Fig. 2.56).

Step 5. Reconstruction. Perform midline approximation of the mylohyoid and sternohyoid with interrupted sutures as for thyroid operation.

Note:

- ✓ In the case of a sinus without cyst, follow the same steps.

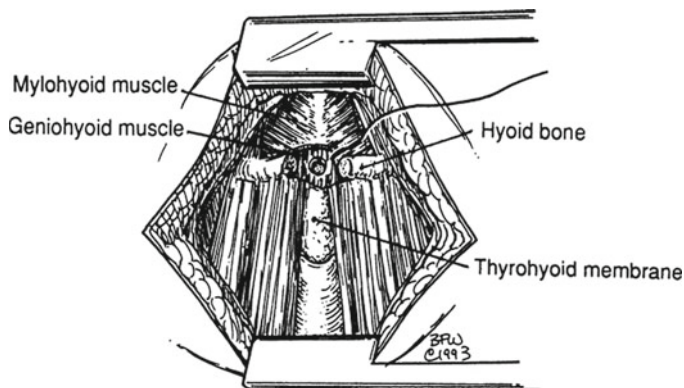


Figure 2.56. Closure of defect.

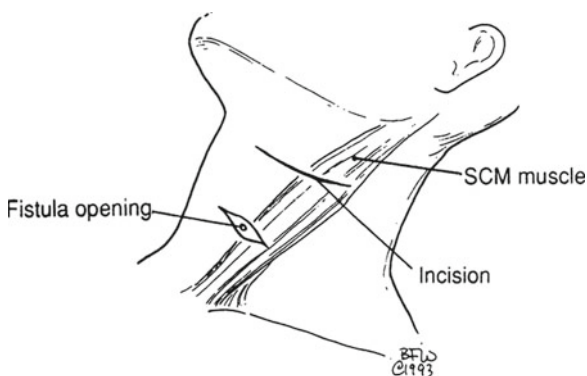


Figure 2.57. Location of incision.

■ EXCISION OF BRANCHIAL CLEFT CYST OR FISTULA

- Step 1.** Above a cyst, make a small transverse incision; around a sinus, make an elliptical incision. Multiple incisions will be necessary if the cyst or sinus is low (Fig. 2.57).
- Step 2.** Separate and elevate the sternocleidomastoid muscle, always using the medial border (Fig. 2.58).
- Step 3.** Visualize the carotid sheath and hypoglossal nerve (Fig. 2.59).

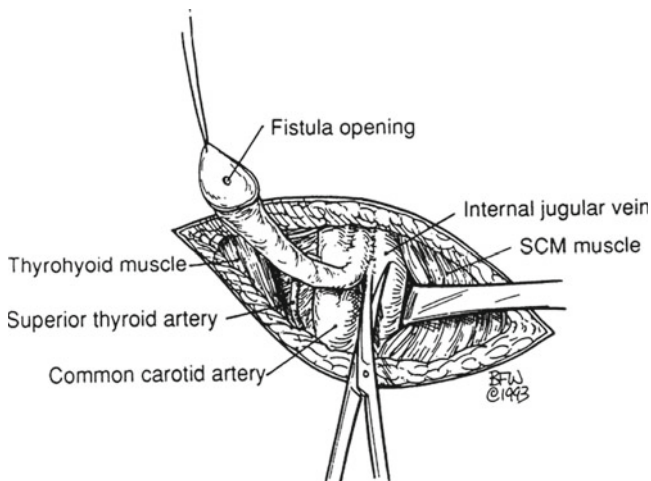


Figure 2.58. Exposure of fistulous tract.

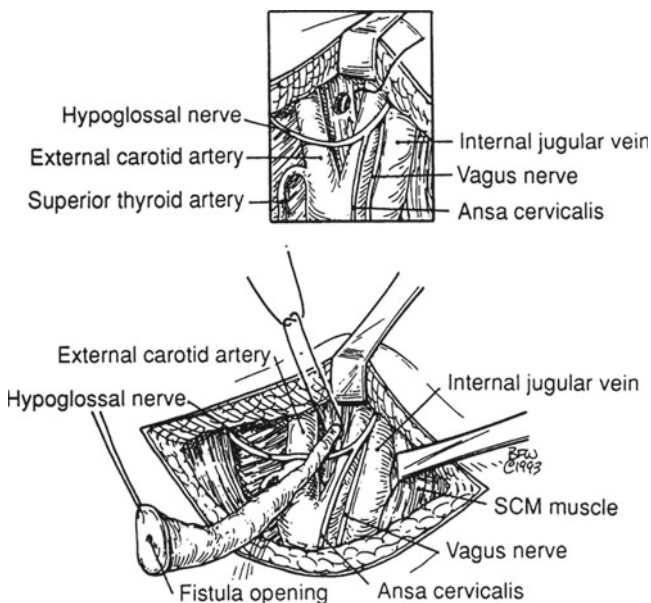


Figure 2.59. Excision of fistula inset: structures of surgical field.

Step 4. Continue dissection of the cyst or sinus cephalad toward the pharyngeal wall.

Step 5. Excise the minute pharyngeal wall if pathology exists.

■ RADICAL NECK DISSECTION

Overview

A radical neck dissection must be planned as a curative procedure. It involves complete excision of the primary lesion, together with all nonessential structures and their lymph nodes, collecting lymph trunks, fascia, and fat. The bed of a radical neck dissection is bounded superiorly by the inferior border of the mandible, inferiorly by the clavicle, posteriorly by the anterior border of the trapezius muscle, and anteriorly by the midline.

Lymphatic tissue must be removed as completely as possible. Nonlymphatic tissue falls into three categories: (1) structures that can be sacrificed with impunity, (2) structures whose sacrifice is controversial, especially for cosmetic reasons, and (3) structures that must be preserved unless directly invaded by cancer. Structures in these categories are listed in Table 2.3.

Anatomical Elements

Superficial Cervical Fascia

The anterior cutaneous nerves and the supraclavicular nerves must be sacrificed. The platysma muscle should be preserved.

Deep Cervical Fascia

The deep cervical fascia must be removed as completely as possible, since lymph nodes and lymphatic vessels are largely distributed in the connective tissue between the layers of the fascia. The carotid sheath and the internal jugular vein also should be sacrificed.

Anterior Triangle

- Submental triangle: Remove the entire contents.
- Submandibular triangle: Remove the submaxillary gland and lymph nodes.
- Carotid triangle: Remove the internal jugular vein. High ligation of the vein is facilitated by removal of the lower pole of the parotid gland. The great auricular nerve and all superficial branches of the cervical nerves should be cut. All lymph nodes along the internal jugular vein must be removed. The final result is shown in Fig. 2.60.

Table 2.3 Synopsis of radical neck procedures

<i>Structures</i>	<i>May be sacrificed</i>	<i>Controversial</i>	<i>Must be preserved^a</i>
Organs	Submaxillary gland, lower pole of parotid gland	None	Thyroid gland, parathyroid glands
Muscles	Omohyoid, sternocleidomastoid	Platysma, digastric, stylohyoid	All other muscles
Vessels	External jugular vein, facial artery and vein, superior thyroid artery, lingual artery	Internal jugular vein	External carotid artery, internal carotid artery, subclavian artery and vein, thoracic duct
Nerves	Anterior cutaneous C ₂ -C ₃ , supraclavicular C ₃ -C ₄ , ansa hypoglossi, great auricular nerve	Spinal accessory nerve	Mandibular branch of facial nerve, superior laryngeal nerve, recurrent laryngeal nerve, facial nerve, lingual nerve, hypoglossal nerve, phrenic nerve, vagus nerve, cervical sympathetic nerve, carotid sinus nerves, brachial plexus, nerves to rhomboid and serratus muscles

^aUnless invaded by cancer (by permission of JE Skandalakis, SW Gray, and JR Rowe. *Anatomical Complications in General Surgery*. New York: McGraw-Hill, 1983)

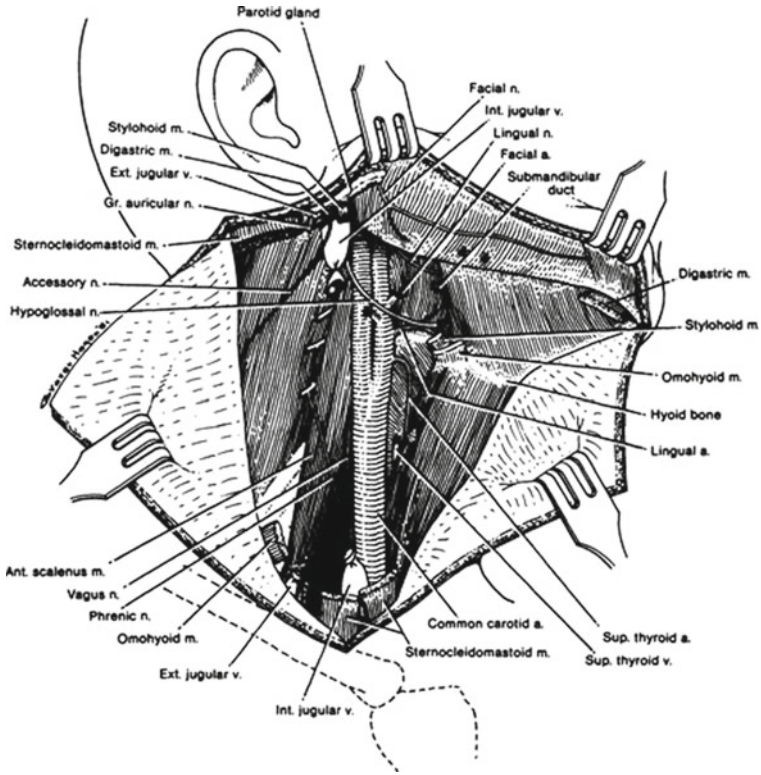


Figure 2.60. The completed radical dissection of the neck. Remaining structures may be removed if they are involved in malignant growth (modified from OH Behrs. The surgical anatomy and technique of parotidectomy. *Surg Clin NA* 57:477–493, 1977 with permission from Elsevier Limited).

Posterior Triangle

Remove all tissue above the spinal accessory nerve without injury to the nerve. With blunt dissection, free the nerve from the underlying tissue. Ligate the external jugular vein close to the subclavian vein, and transect the sternocleidomastoid and omohyoid muscles.

The area beneath the spinal accessory nerve is the “danger zone” of Behrs. It contains a number of structures that must be saved if possible: the nerves to rhomboid and serratus muscles, the brachial plexus, the subclavian artery and vein with the anterior scalene muscle between, and the phrenic nerve. The object of dissection in this area is to remove completely the transverse

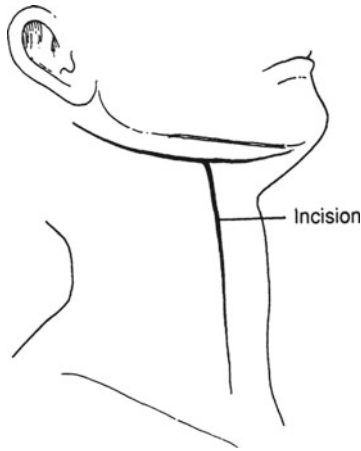


Figure 2.61. T-incision.

cervical (inferior horizontal) and spinal accessory chains of lymph nodes (see Fig. 2.11).

Deep to the sternocleidomastoid muscle and posterolateral to the internal jugular vein, the thoracic duct on the left and the right lymphatic duct on the right lie in a mass of areolar connective tissue. They should be preserved if possible; if they have been injured, ligate.

Between the jugular vein and the carotid artery lies the ansa cervicalis, which innervates the strap muscles of the neck. This nerve is on or in the carotid sheath medial to the internal jugular vein. It may be cut with impunity.

Procedure

Position and prepare as in parotidectomy.

Step 1. Incision (Figs. 2.61, 2.62, and 2.63)

Make a T-incision with the horizontal part extending from the midline to the submastoid area approximately 3 cm below the inferior border of the mandible and the vertical part extending from the midpoint of the horizontal down to 1 cm above the clavicle. Alternative incisions are the H type, the I type, or one shaped like an H lying on its side (lazy H).

The upper flap of the horizontal part. Incise the superficial fascia (fat and platysma) by deepening the skin incision and elevate the upper flap. The anterior facial vessels are located at the upper part of the flap snaking in front of the mandible. The mandibular

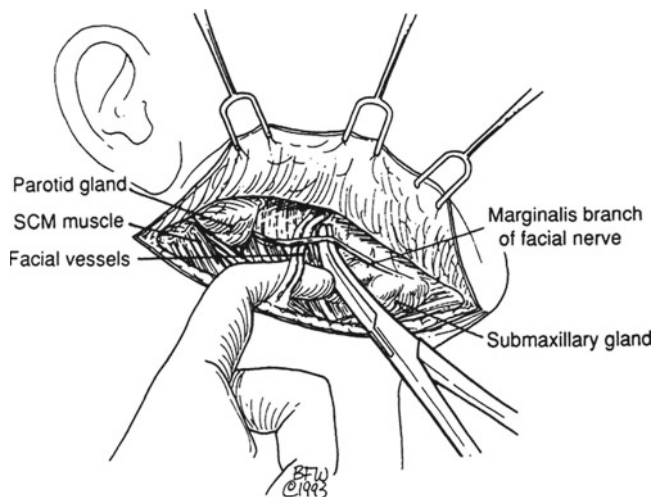


Figure 2.62. Development of upper flap.

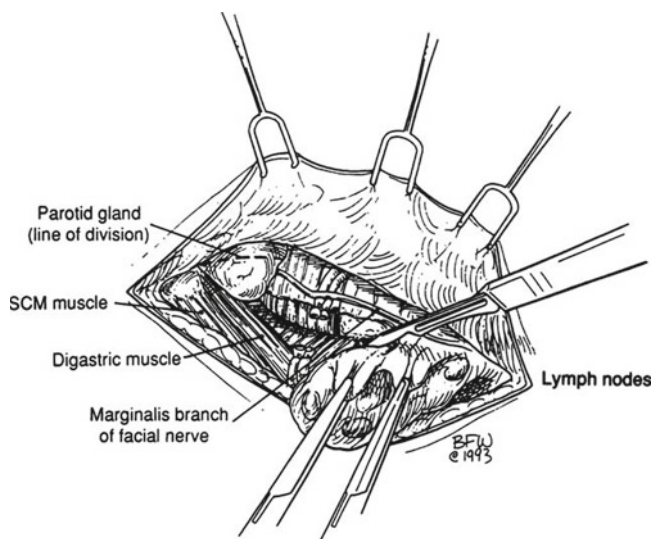


Figure 2.63. Dissection of submental and submandibular triangles.

and cervical branches of the facial nerves are located superficially to these vessels. Protect both nerves, especially the marginal branch, by careful dissection and isolation. If necessary, the cervical branch may be cut. Elevate the anterior facial vessels, then clamp, divide, and ligate them.

Detach the deep cervical fascia from the mandible and push it downward bluntly, including the submental area and the submaxillary gland, fat, and lymph nodes. Occasionally, the lower pole of the parotid is removed below the disappearing point of the marginal branch. Then, in this procedure, the contents of the submental and submandibular triangles are dissected as well as the lower pole of the parotid.

Vertical incision and formation of flaps. To form flaps, deepen the existing skin incision. Prepare the anterior neck triangle and elevate the anterior flap to the midline and the posterior flap to the anterior border of the trapezius muscle. The sternocleidomastoid muscle is essentially in the middle of the surgical field.

Step 2. Exploration of the posterior triangle (Fig. 2.64)

The following anatomical entities should be identified:

- Spinal accessory nerve
- External jugular vein
- Cervical nerves (not shown)
- Brachial plexus (between anterior and middle scalene) (not shown)
- Phrenic nerve (resting on the anterior scalene) (not shown)

All but the spinal accessory nerve are under the “carpet” (the splitting of the deep fascia) of the floor of the posterior triangle.

Carefully ligate the external jugular vein close to the subclavian vein while protecting the other four entities listed above. The upper part of the posterior triangle is cleaned by blunt dissection, pushing fibrofatty tissue and lymph nodes cephalad.

Step 3. After elevating and protecting the anatomical entities of the carotid sheath, carefully transect the clavicular and sternal insertions of the sternocleidomastoid muscle.

The next step is a low division of the omohyoid behind the sternocleidomastoid muscle. Continue cleaning the floor of the posterior triangle (Figs. 2.65 and 2.66).

Step 4. Open the anterior wall of the carotid sheath, ligate the internal jugular vein close to the clavicle, and remove the sheath together with the vein and all fibrofatty tissue in the vicinity. Protect the phrenic nerve, and ligate the transverse scapular and transverse cervical arteries and the

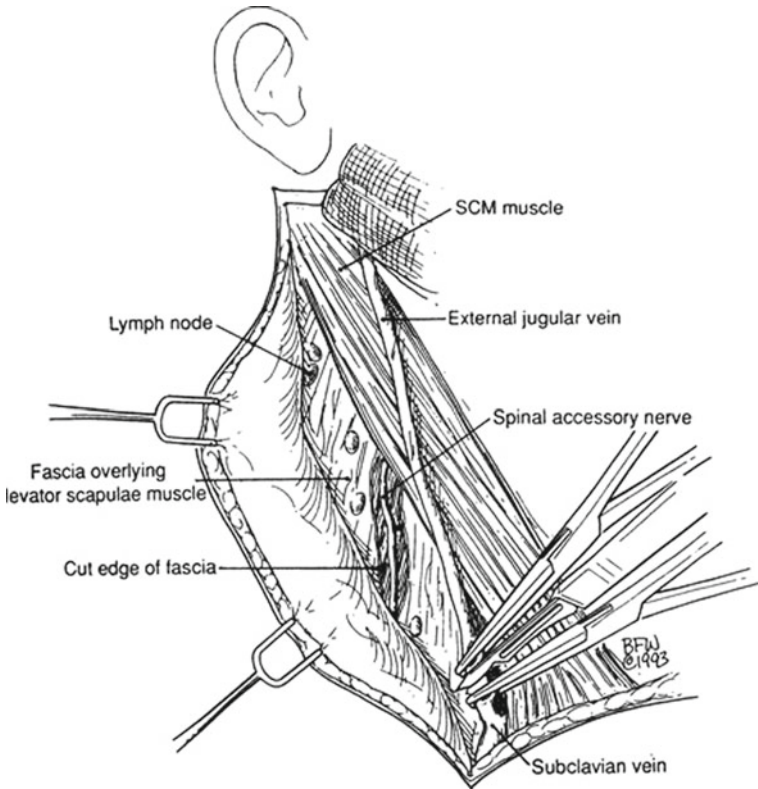


Figure 2.64. Contents of posterior triangle.

right or left thoracic ducts as required. Proceeding upward, remember the posterior belly of the digastric muscle is an excellent anatomical landmark. Just underneath are internal and external carotid arteries; the internal jugular vein, which should be ligated; cranial nerves (X, XI, XII); and the sympathetic chain (Fig. 2.67).

- Step 5.** Working now at the anterior triangle, avoid cutting the external branch of the superior laryngeal nerve. Ligate the branches of the external carotid artery. Protect and save the hypoglossal nerve. Continue to work on both the submental and the submandibular triangles. Ligate the submaxillary duct, but protect and save its fellow traveler, the lingual nerve. Spare the submaxillary ganglion. Establish good hemostasis (Fig. 2.68).
- Step 6.** Remove the specimen en bloc (Fig. 2.69). Figure 2.60 shows the surgical field after removal of the specimen.

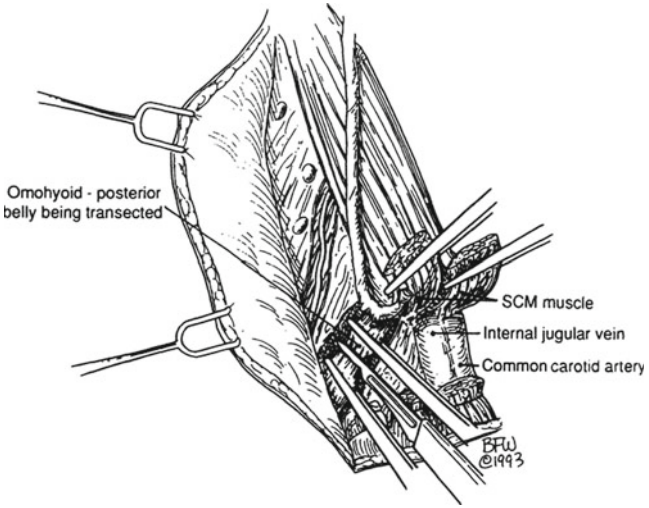


Figure 2.65. Transection of omohyoid muscle.

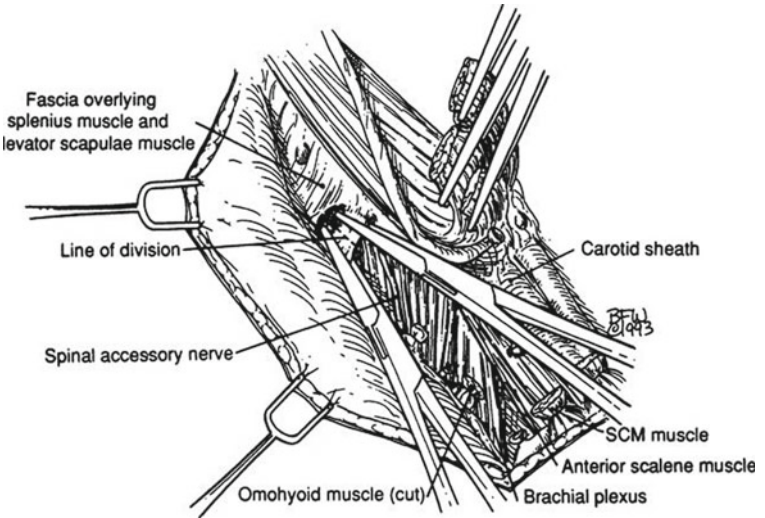


Figure 2.66. Exploration of overlying fascia.

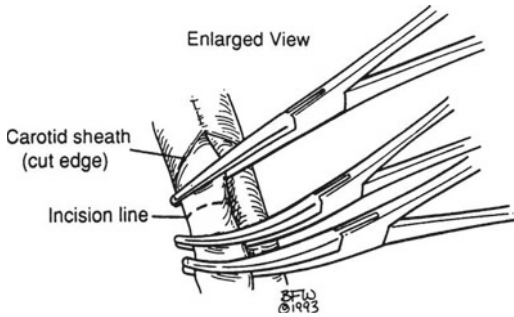


Figure 2.67. Removal of carotid sheath.

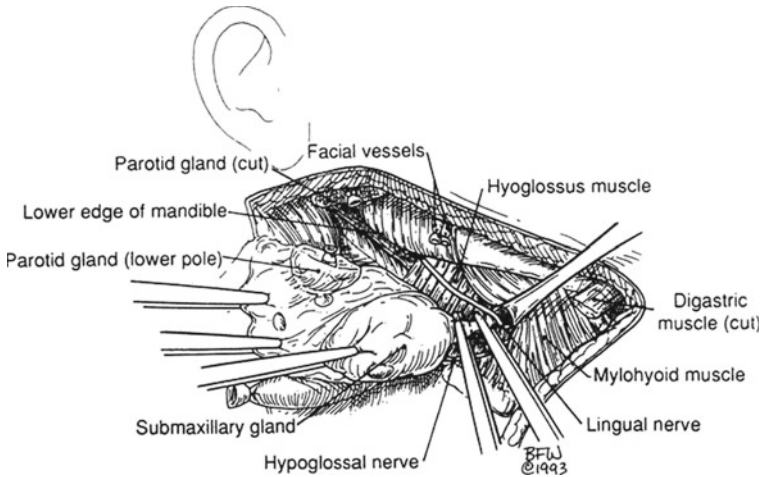


Figure 2.68. Dissection of anterior triangle.

Note:

- ✓ Under certain circumstances, such as thyroid cancer, a modified radical neck dissection or central neck dissection may be more appropriate than the radical dissection.

In the beautiful book, *An Atlas of the Surgical Techniques of Oliver H. Beahrs* (Beahrs OH, Kiernan PD, Hubert JP Jr. Philadelphia: Saunders, 1985), Dr. Beahrs gives an excellent description of the technique of radical neck dissection, one of the most complicated surgeries of the human body. We strongly advise the reader to consult his book, as well as an article in *Surgical Clinics of North America* 1977;57(4):663–700, Philadelphia: Saunders.

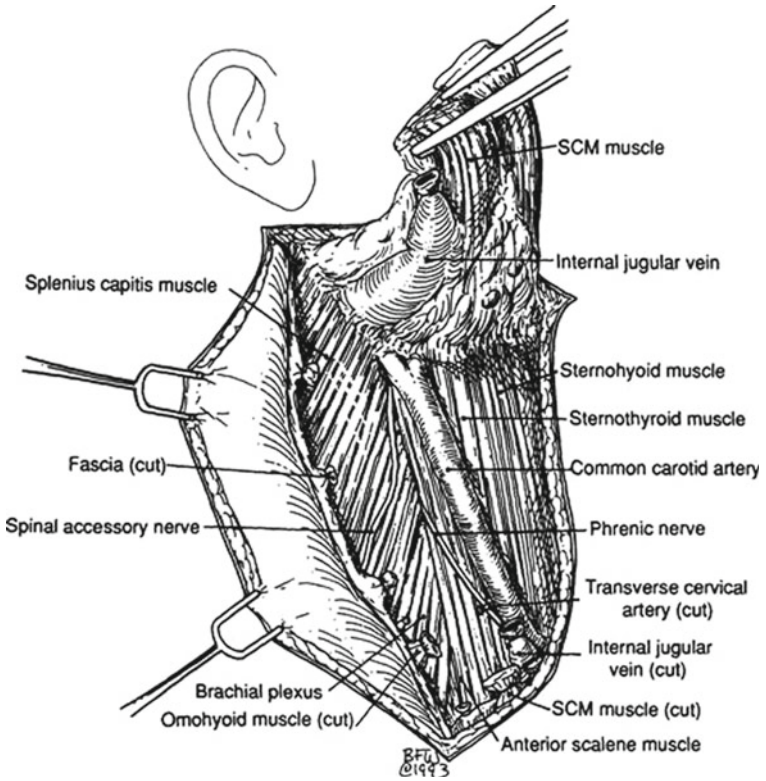


Figure 2.69. Specimen removal.

■ TRACHEOSTOMY

Step 1. Position: semi-Fowler; hyperextension of the neck; small pillow at the area of the upper thoracic spine beneath the shoulders; doughnut support under the head.

Step 2. Preparation of skin: use Betadine or any other solution of surgeon's choice.

Be sure that chin and long axis of the body are aligned at the midline. Mark the location of the incision with 2-0 silk, two fingerbreadths above the sternal notch.

With a knife, mark very superficially the middle and edges of the previously marked location of the incision.

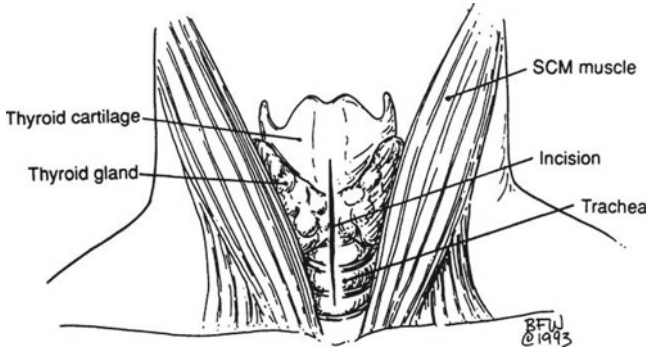


Figure 2.70. Incision for tracheostomy.

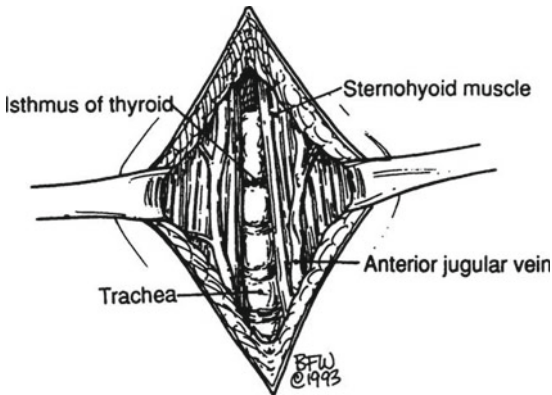


Figure 2.71. Thyroid isthmus.

Use of an endotracheal tube is a wise step.

Step 3. In children, make a vertical incision to avoid injury of the arteries and veins located under the anterior border of the sternocleidomastoid muscle.

In adults, use vertical or transverse incision and proceed as in thyroid surgery (Fig. 2.70).

Step 4. Locate the thyroid isthmus. The inferior thyroid vein and thyroid ima artery should be ligated (Fig. 2.71).

Step 5. Clean the anterior wall of the trachea below the isthmus.

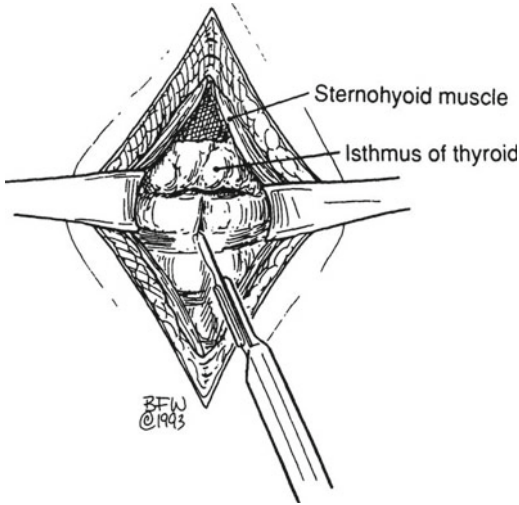


Figure 2.72. Incising trachea.

Remember:

- ✓ Dissection too deep toward the superior mediastinum will injure the jugular venous arch, and dissection too lateral will injure the vessels of the carotid sheath. The thyroid isthmus should be retracted or cut between clamps for more tracheal room.

Step 6. Immobilize and elevate the anterior tracheal wall using a hook at the lower border of the cricoid cartilage.

Step 7. Make a vertical incision through the second or third tracheal ring or form a window at the anterior tracheal wall by removing the anterior central segment of the two rings (Fig. 2.72).

Remember:

- ✓ Be careful when you incise the trachea. The posterior wall of the trachea is not protected, so injury to the esophagus is an obvious risk.
- ✓ Protect the cricoid cartilage and first tracheal ring to avoid postoperative tracheal stenosis.

Step 8. Spread the tracheal opening with a tracheal spreader. Insert a Hardy–Shiley tracheostomy tube as the endotracheal tube is slowly backed out (Fig. 2.73).

Step 9. With umbilical tape, secure the tube around the patient’s neck. Pack iodoform in the subcutaneous tissue around the tracheostomy tube.

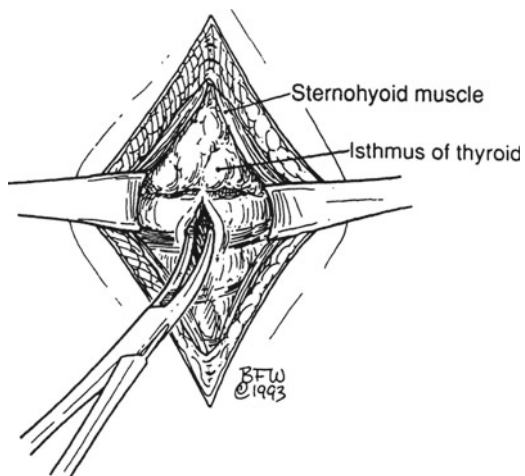


Figure 2.73. Tracheal opening.

ANATOMY

■ GENERAL DESCRIPTION OF THE BREAST

The adult female breast is located within the superficial fascia of the anterior chest wall. The base of the breast extends from the second rib superiorly to the sixth or seventh rib inferiorly and from the sternal border medially to the midaxillary line laterally. Two-thirds of the base of the breast lies anterior to the pectoralis major muscle; the remainder lies anterior to the serratus anterior muscle. A small part may lie over the aponeurosis of the external oblique muscle.

In about 95 % of women, there is a prolongation of the upper lateral quadrant toward the axilla. This tail (of Spence) of breast tissue enters a hiatus (of Langer) in the deep fascia of the medial axillary wall. This is the only breast tissue found normally beneath the deep fascia.

■ DEEP FASCIA

The deep pectoral fascia envelops the pectoralis major muscle, and the clavipectoral fascia envelops the pectoralis minor and part of the subclavius muscles. The axillary fascia lying across the base of the axillary pyramidal space is an extension of the pectoralis major fascia and continues as the fascia of the latissimus dorsi. It forms the dome of the axilla (Fig. 3.1a). Where the axillary vessels and nerves to the arm pass through the fascia, they take with them a tubular fascial sleeve, the axillary sheath.

The clavipectoral fascia (Fig. 3.1a) can be thought of as consisting of five parts:

- The attachment to the clavicle and the envelope of the subclavius muscle
- That part between the subclavius and pectoralis minor muscles, referred to by some as “the costocoracoid membrane”

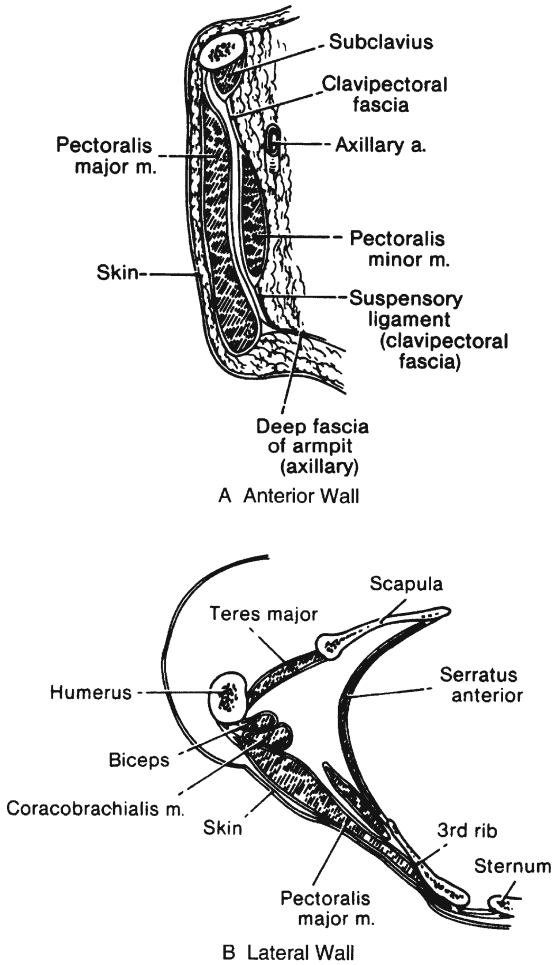


Figure 3.1. Diagram of the walls of the axilla (modified by permission of JV Basmajian and CE Slonecker. *Grant's Method of Anatomy*, 11th ed. Baltimore: Williams & Wilkins, 1989).

- The thickened lateral band between the first rib and the coracoid process, the costocoracoid ligament
- The pectoralis minor envelope
- The suspensory ligament of the axilla attaching to the axillary fascia

■ AXILLA

The axilla is shaped like a pyramid with an apex, a base, and four walls. The apex is a triangular space bordered by the clavicle, the upper border of the scapula, and the first rib. The base consists of the axillary fascia beneath the skin of the axillary fossa. The anterior wall is composed of three muscles—the pectoralis major, the pectoralis minor, and the subclavius—and the clavipectoral fascia, which envelops the muscles and fills the spaces between them. The posterior wall is formed by the scapula and three muscles: the subscapularis, the latissimus dorsi, and the teres major. The medial wall consists of the lateral chest wall, with the second to sixth ribs, and the serratus anterior muscle. The lateral wall is the narrowest of the walls, being formed by the bicipital groove of the humerus (Fig. 3.1b).

The axilla contains lymph nodes (about which more will be said); the axillary sheath, which covers blood vessels and nerves; and the tendons of the long and short heads of the biceps brachii muscle and the coracobrachialis muscle (Fig. 3.2).

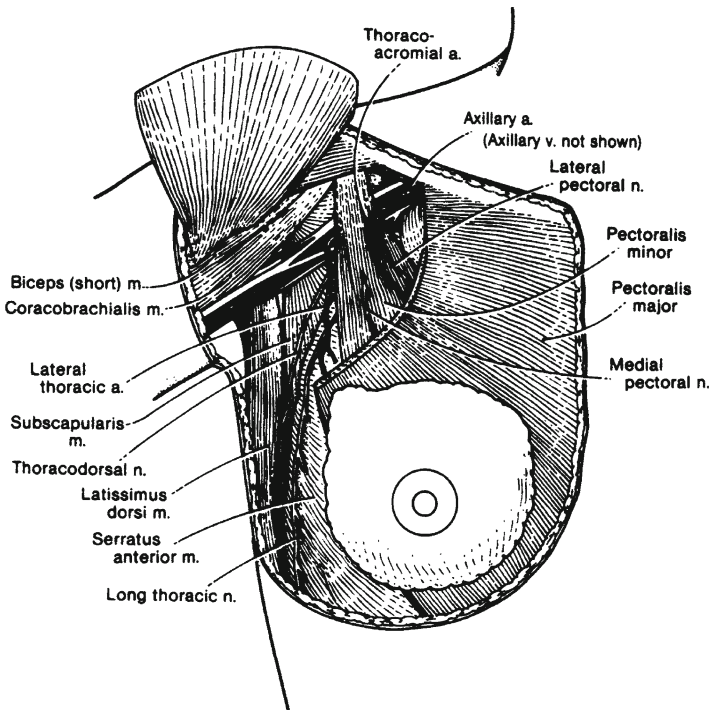


Figure 3.2. Topography of the axilla. Anterior view (By permission of JE Skandalakis, SW Gray, and JR Rowe. *Anatomical Complications in General Surgery*. New York: McGraw-Hill, 1983).

■ MUSCLES AND NERVES

The muscles and nerves with which the surgeon must be familiar are listed in Table 3.1.

■ MORPHOLOGY OF THE BREAST

Each breast is composed of between 15 and 20 lobes, some larger than others, within the superficial fascia, which is loosely connected with the deep fascia. Between the superficial and deep fasciae is the retromammary (submammary) space, which is rich in lymphatics (Fig. 3.3).

Each lobe has a duct terminating at the nipple. These lobes, together with their ducts, are anatomical but not surgical units. A breast biopsy is not a lobectomy; in the latter, parts of one or more lobes are removed.

In the fat-free area under the areola, the dilated portions of the lactiferous ducts (the lactiferous sinuses) are the only sites of actual milk storage. Intraductal papillomas may develop here.

The suspensory ligaments of Cooper form a network of strong connective tissue fibers passing between the lobes of parenchyma and connecting the dermis of the skin with the deep layer of the superficial fascia. Occasionally the superficial fascia is fixed to the skin in such a way that ideal subcutaneous total mastectomy is impossible.

With malignant invasion, portions of the ligaments of Cooper may contract, producing a characteristic fixation and retraction or dimpling of the skin. This must not be confused with the retraction called *peau d'orange* secondary to lymphatic obstruction.

■ VASCULAR SYSTEM OF THE BREAST

Arterial Supply

The breast is supplied with blood from three sources, with considerable variation (Figs. 3.2 and 3.4).

Internal Thoracic Artery

The internal thoracic (or internal mammary) artery is a branch of the subclavian artery that parallels the lateral border of the sternum behind the internal intercostal muscles.

Table 3.1 Muscles and nerves involved in mastectomy

<i>Muscle</i>	<i>Origin</i>	<i>Insertion</i>	<i>Nerve supply</i>	<i>Comments</i>
Pectoralis major	Medial half of clavicle, lateral half of sternum, second to sixth costal cartilages, aponeurosis of external oblique muscle	Greater tubercle of humerus	Lateral anterior thoracic nerve	Clavicular portion of pectoralis forms upper extent of radical mastectomy; lateral border forms medial boundary of modified radical mastectomy; both nerves should be preserved in modified radical procedure
Pectoralis minor	Second to fifth ribs	Coracoid process of scapula	Medial anterior thoracic nerve	
Deltoid	Lateral half of clavicle, lateral border of acromion process, spine of scapula	Deltoid tuberosity of humerus	Axillary nerve	
Serratus anterior (three parts)	1. First and second ribs 2. Second to fourth ribs 3. Fourth to eighth ribs	Costal surface of scapula at superior angle Vertebral border of scapula Costal surface of scapula at inferior angle	Long thoracic nerve	Injury produces "winged scapula"

(continued)

Table 3.1 (continued)

<i>Muscle</i>	<i>Origin</i>	<i>Insertion</i>	<i>Nerve supply</i>	<i>Comments</i>
Latissimus dorsi	Back, to crest of ilium	Crest of lesser tubercle and inter-tubercular groove of humerus	Thoracodorsal nerve	Anterior border forms lateral extent of radical mastectomy; injury results in weakness of rotation and abduction of arm
Subclavius	Junction of first rib and its cartilage	Groove of lower surface of clavicle	Subclavian nerve	
Subscapularis	Costal surface of scapula	Lesser tubercle of humerus	Subscapular nerve	Subscapular nerve should be spared
External oblique aponeurosis	External oblique muscle	Rectus sheath and linea alba, crest of ilium		Remember the interdigitation with serratus anterior and pectoralis muscles
Rectus abdominis	Ventral surface of fifth to seventh costal cartilages and xiphoid process	Crest and superior ramus of pubis	Branches of 7th to 12th thoracic nerves	Rectus sheath is lower limit of radical mastectomy

By permission of JE Skandalakis, SW Gray, and JR Rowe. *Anatomical Complications in General Surgery*. New York: McGraw-Hill, 1983

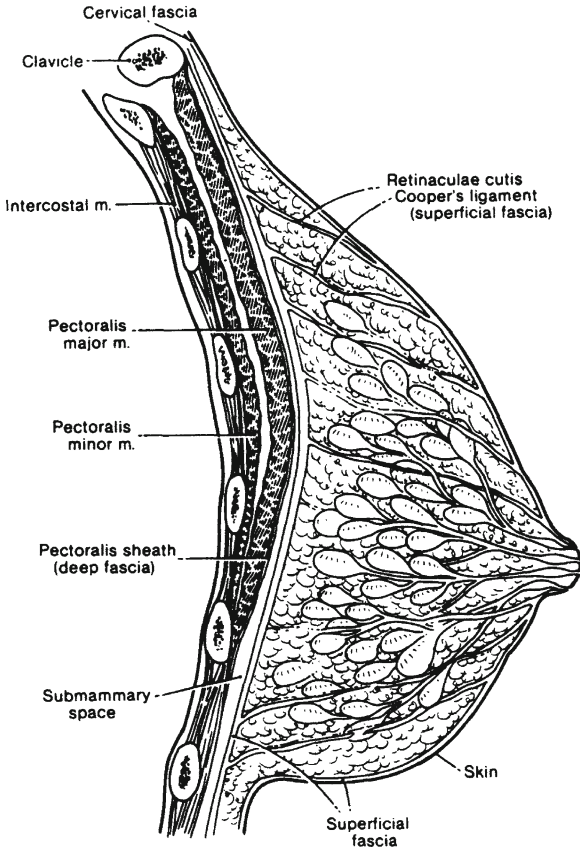


Figure 3.3. Diagrammatic sagittal section through the nonlactating female breast and anterior thoracic wall (By permission of JE Skandalakis, SW Gray, and JR Rowe. *Anatomical Complications in General Surgery*. New York: McGraw-Hill, 1983).

Branches of the Axillary Artery

Four branches of the axillary artery may supply the breast. They are, in order of appearance, (1) the supreme thoracic branch, (2) the pectoral branches of the thoracoacromial artery, (3) the lateral thoracic arteries, and (4) unnamed mammary branches.

Intercostal Arteries

The lateral half of the breast may also receive branches of the third, fourth, and fifth intercostal arteries.

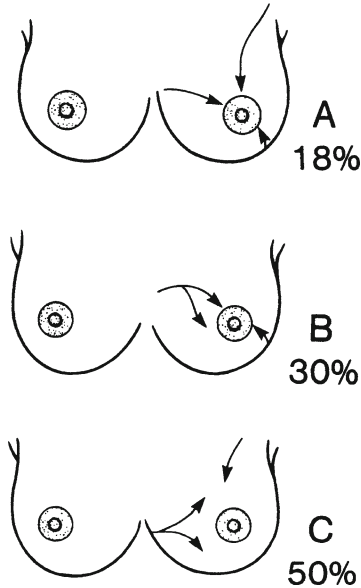


Figure 3.4. (a) The breast may be supplied with blood from the internal thoracic, axillary, and intercostal arteries in 18 % of individuals. (b) In 30 %, the contribution from the axillary artery is negligible. (c) In 50 %, the intercostal arteries contribute little or no blood to the breast. In the remaining 2 %, other variations may be found (By permission of JE Skandalakis, SW Gray, and JR Rowe. *Anatomical Complications in General Surgery*. New York: McGraw-Hill, 1983).

Venous Drainage

The axillary, internal thoracic, and the third to fifth intercostal veins drain the mammary gland. These veins follow the arteries.

Lymphatic Drainage (as Reported by Haagensen) (Fig. 3.5)

Lymph nodes occur in inconstant groups of varying numbers. Many nodes are very small. The following is a useful grouping, including the average number of nodes in each group.

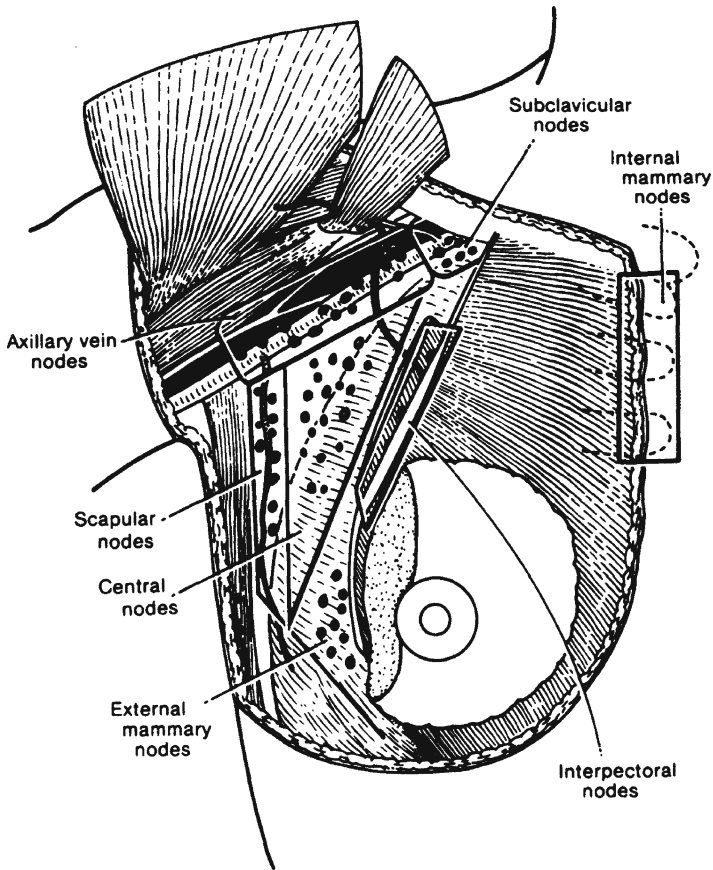


Figure 3.5. Lymph nodes of the breast and axilla. Classification of Haagensen and coworkers (modified by permission of CD Haagensen. *Lymphatics of the Breast*. In: Haagensen CD, Feind CR, Herter FP, Slanetz CA Jr, Weinberg JA. *The Lymphatics in Cancer*. Philadelphia: Saunders, 1972, pp. 342–347).

Axillary Drainage (35.3 Nodes)

Group 1. External mammary nodes (1.7 nodes). These lie along the lateral edge of the pectoralis minor, deep to the pectoralis major muscle, along the medial side of the axilla following the course of the lateral thoracic artery on the chest wall from the second to the sixth rib.

- Group 2.** Scapular nodes (5.8 nodes). These lie on the subscapular vessels and their thoracodorsal branches.
- Group 3.** Central nodes (12.1 nodes). This is the largest group of lymph nodes and the nodes most easily palpated in the axilla. They are embedded in fat in the center of the axilla.
- Group 4.** Interpectoral nodes (Rotter's nodes) (1.4 nodes). These lie between the pectoralis major and minor muscles. Often there is a single node. They are the smallest group of the axillary nodes and will not be found unless the pectoralis major is removed.
- Group 5.** Axillary vein nodes (10.7 nodes). This is the second largest group of lymph nodes in the axilla. They lie on the caudal and ventral surfaces of the lateral part of the axillary vein.
- Group 6.** Subclavicular nodes (3.5 nodes). These lie on the caudal and ventral surfaces of the medial part of the axillary vein. Haagensen and coworkers consider them to be inaccessible unless the pectoralis minor muscle is sacrificed.

Internal Thoracic (Mammary) Drainage (8.5 Nodes)

The nodes, about four or five on each side, are small and are usually in the fat and connective tissue of the intercostal spaces. The internal thoracic trunks empty into the thoracic duct or the right lymphatic duct. This route to the venous system is shorter than the axillary route.

The presence of regional lymph nodes is an important prognostic indicator and suggests systemic disease. Performing a sentinel lymph node biopsy can spare the patient an unnecessary axillary dissection. If a sentinel node is positive, the resultant axillary dissection is not—in most surgeons' view—a curative procedure, but one that controls local disease. In most patients, positive axillary nodes mandate chemotherapy.

■ SURGICAL ANATOMY OF MASTECTOMY

Anatomy of the Triangular Bed of Modified Radical Mastectomy

The medial side of the surgical field is the upward and medially retracted axillary margin of the pectoralis major muscle. The lateral side is the medial border of the latissimus dorsi muscle and the superior side is the axillary vein. The floor of the triangular bed is formed by the serratus anterior and the subscapularis muscles. This results in a smaller triangle than would be used for a radical mastectomy, but one that is adequate for good dissection (Fig. 3.6).

After the breast and the underlying fascia are removed, a good dissection consists of (1) removing remnants of the pectoralis major fascia at its axillary

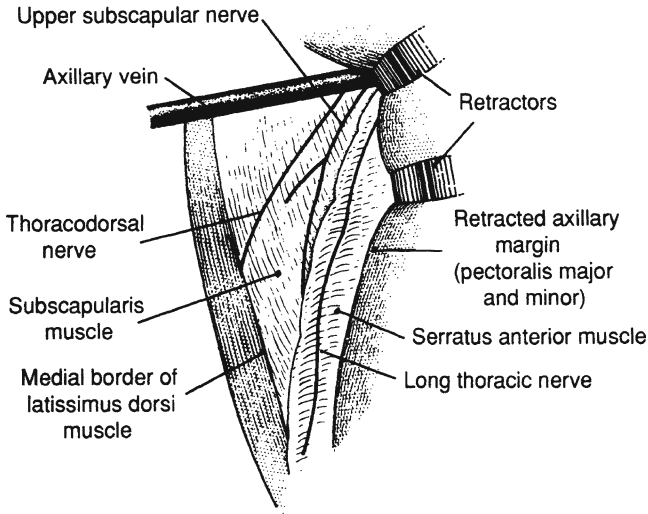


Figure 3.6. The triangular bed of a modified radical mastectomy. The pectoralis muscles are retracted, rather than removed. Modified from LJ Skandalakis, MD Vohman, and JE Skandalakis, et al. The axillary lymph nodes in radical and modified radical mastectomy. *Am Surg* 45(9):552–555, 1979 with permission from American Surgeon.

border, (2) entering the axilla by incising and stripping the axillary fascia, (3) further stripping the fascia of the pectoralis minor (lower clavipectoral fascia), (4) exposing the axillary vein, (5) downward dissection of axillary fat and lymph nodes after ligating tributaries of the axillary vein from the thoracic wall, and (6) continuing the dissection downward, partially removing the fasciae of the serratus anterior, the subscapularis, and the medial border of the latissimus dorsi muscles.

Remember:

- ✓ The *thoracodorsal nerve* lies on the subscapularis muscle and innervates the latissimus dorsi muscle (Fig. 3.6). If it is cut, internal rotation and abduction will be weakened, although there is no deformity. The nerve and its associated vessels can be found near the medial border of the latissimus dorsi about 5 cm above a plane passing through the third sternochondral junction. Once located, the neurovascular bundle should be marked with an umbilical tape. If there is obvious involvement of lymph nodes around the nerve, it must be sacrificed.

102 3. Breast

- ✓ The *long thoracic nerve* innervates the serratus anterior muscle and lies on it (Fig. 3.6). Section of the nerve results in the “winged scapula” deformity. Unless actually invaded by cancer, this nerve should be spared. The landmark for locating the nerve is the point at which the axillary vein passes over the 2nd rib. Careful dissection of this area will reveal the nerve descending on the second rib posterior to the axillary vein.
- ✓ The *medial anterior thoracic nerve* is superficial to the axillary vein and lateral to the pectoralis minor muscle. The *lateral anterior thoracic nerve*, which is the nerve supply of the clavicular as well as of the sternal portions of the pectoralis major muscle, also is superficial to the axillary vein and lies at the medial edge of the pectoralis minor.
- ✓ If branches of one or both anterior thoracic nerves are injured, the result will be atrophy of the pectoralis major and minor muscles. If the few lymph nodes of the interpectoral group are involved and are fixed to the nerves, these nerves should be sacrificed.

TECHNIQUE

■ BREAST BIOPSY

Excisional Breast Biopsy

Step 1. Make a circumareolar or curved incision directly over the lesion along Langer's lines (Fig. 3.7.)

Step 2. Raise skin flaps to approach the lesion (Fig. 3.8).

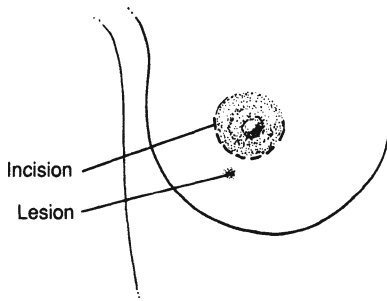


Figure 3.7. Incision following Langer's lines.

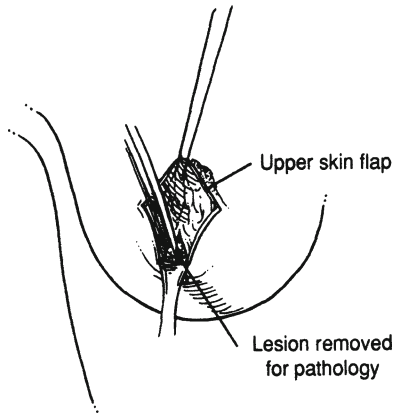


Figure 3.8. Creation of flaps.

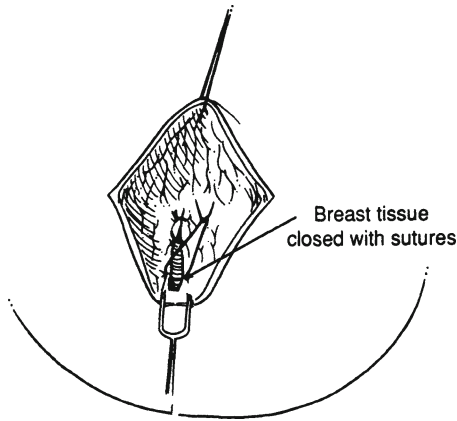


Figure 3.9. Suturing the defect.

Step 3. Excise the lesion with a margin of normal breast tissue.

Step 4. Establish good hemostasis with electrocautery. Approximate the mammary tissue with 2-0 Vicryl. Some surgeons prefer not to approximate the breast defect, reasoning that if hemostasis is good, in time the formed seroma will form fibrous tissue and no skin depression will result. We prefer to place a few superficial sutures, approximating the edges of the defect and leaving the cavity in situ. Use subcutaneous interrupted sutures with 4-0 Vicryl and close the skin with running 4-0 Vicryl subcuticular sutures (Fig. 3.9).

Step 5. Apply an ice bag to the breast for 24 h.

Note: If localization procedure is required, it is performed in the radiology department and then the patient is brought to the operating room.

■ MODIFIED RADICAL MASTECTOMY

Step 1. Mark the contour of the breast to determine its edges, especially when the patient is obese. This minimizes unnecessary dissection (Fig. 3.10).

Step 2. If the lesion has been found by aspiration biopsy to be malignant, use the incision of your choice and allow 4-5 cm around the lesion. Use the same procedure when a scar or incision is present from a previous biopsy.

Step 3. Use electrocautery for the formation of the upper and lower flaps (medial or lateral as per incision). The superior flap should be taken

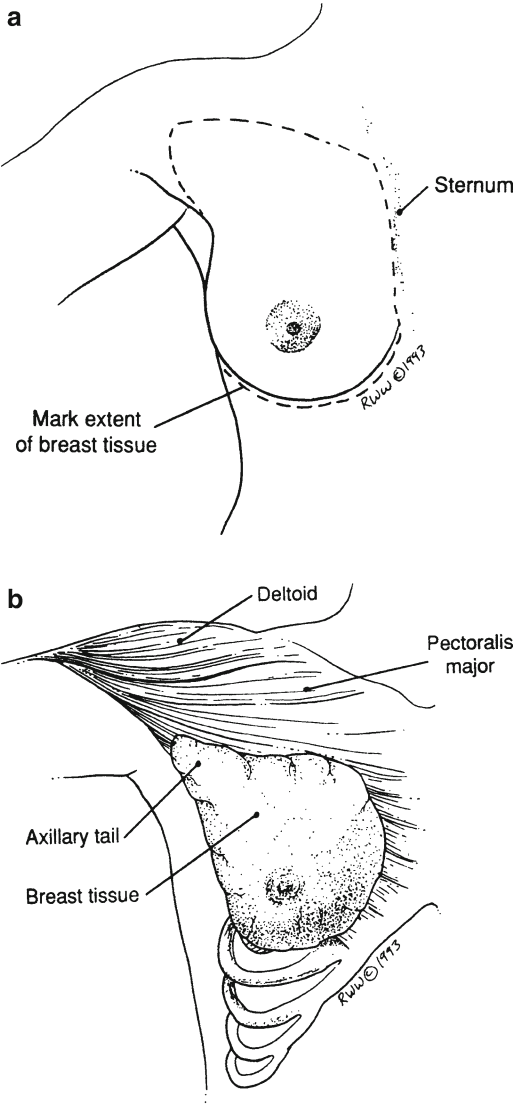


Figure 3.10. (a) Breast contour. (b) Underlying structures.

to the clavicle or well above the superior margin of the breast which is sometimes easily seen. The inferior flap should be taken down to the inframammary fold (Fig. 3.11).

- Step 4.** Begin the dissection of the breast medially. Elevate it sharply off the pectoralis fascia. There are many arterial perforators entering the breast in this area that will require ligation with 2–0 Vicryl. The harmonic scalpel or LigaSure device can be used in lieu of ligations.
- Step 5.** As the breast is elevated and the axilla is approached, the clavipectoral fascia is encountered. When this is opened, there is access to the axilla (Fig. 3.12). Protect the pectoralis major and minor. Occasionally, however, the pectoralis minor should be cut for a more complete axillary dissection (Fig. 3.13).
- Step 6.** Locate the axillary vein and its tributaries. With 3–0 or 4–0 Vicryl, ligate in continuity all the tributaries toward the breast. Protect the brachial plexus and axillary artery (Fig. 3.14).
- Step 7.** Using a scalpel or Metzenbaum scissors, gently evacuate the axillary contents of fat and lymph nodes, pushing them toward the breast in continuity (Fig. 3.15).
- Step 8.** Five nerves should be identified and protected if possible (Figs. 3.2 and 3.16):
- Long thoracic, where the axillary vein passes over the second rib
 - Thoracodorsal, at the medial border of the latissimus dorsi
 - Medial anterior thoracic (pectoral), superficial to the axillary vein and lateral to the pectoralis minor muscle
 - Lateral anterior thoracic (pectoral), at the medial edge of the pectoralis minor and superficial to the axillary vein
 - Subscapular, at the vicinity of the subscapular artery and vein
- Step 9.** Place two Jackson–Pratt drains: the first to drain the inferior skin flap and the axilla and the second to drain the superior skin flap. Close the subcutaneous tissue with interrupted 3–0 Vicryl and close the skin with the stapler (Fig. 3.17).

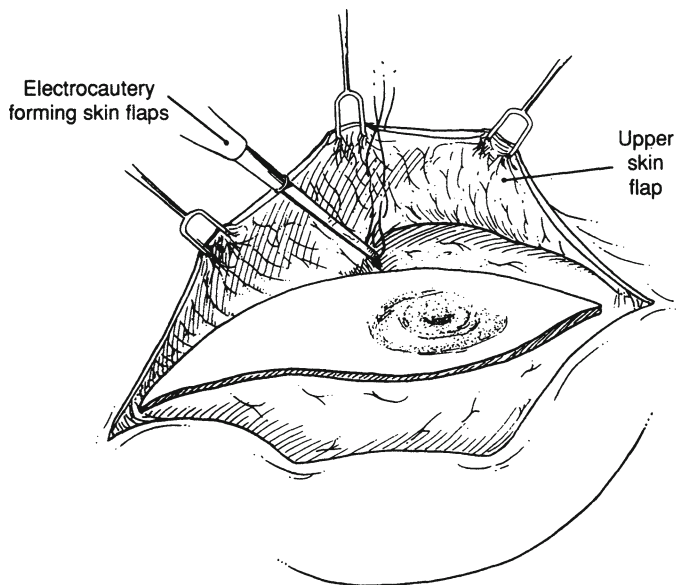


Figure 3.11. Flap formation.

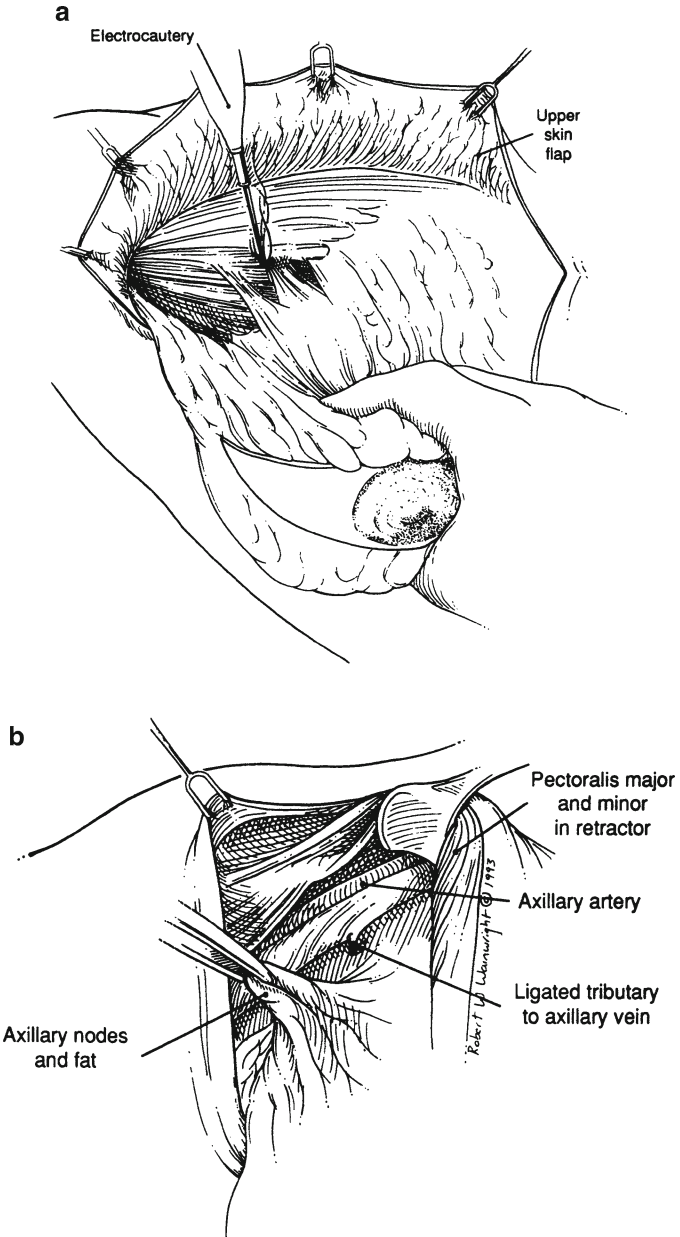


Figure 3.12. (a) Axilla is exposed. (b) Structures of the axillary region.

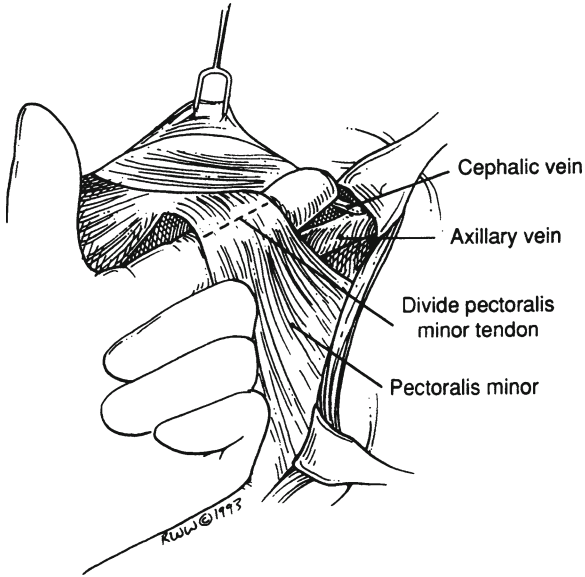


Figure 3.13. Pectoralis minor.

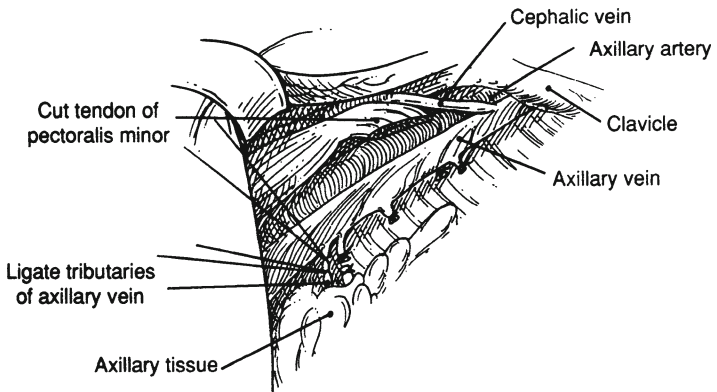


Figure 3.14. Axillary vein and artery.

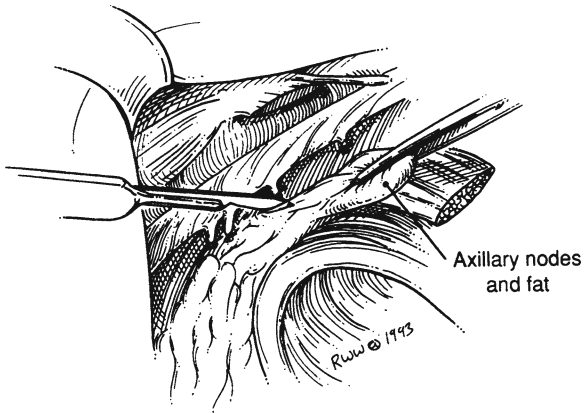
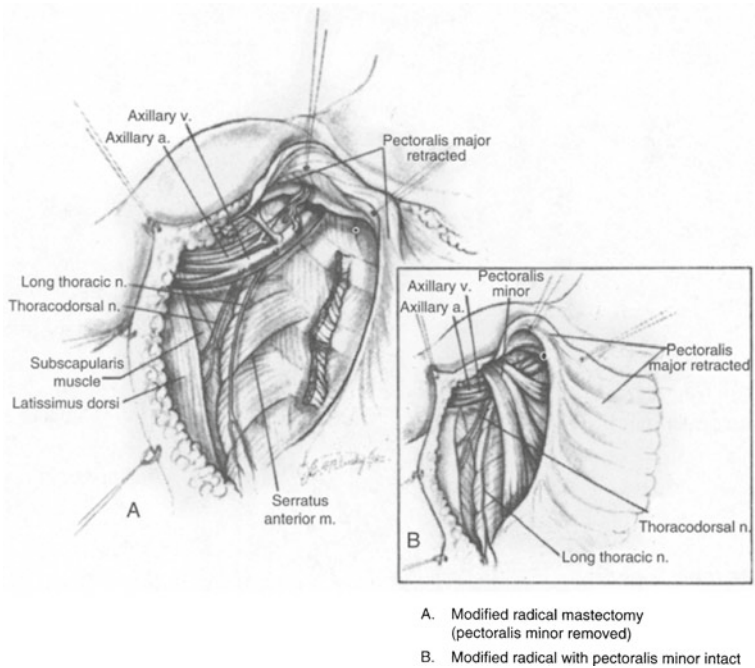


Figure 3.15. Evacuation of axillary contents.



- A. Modified radical mastectomy (pectoralis minor removed)
- B. Modified radical with pectoralis minor intact

Figure 3.16. Bed of modified radical mastectomy. *Inset:* Pectoralis major and minor are retracted (By permission of SW Gray, JE Skandalakis, and DA McClusky. *Atlas of Surgical Anatomy for General Surgeons*, Baltimore: Williams & Wilkins, 1985).

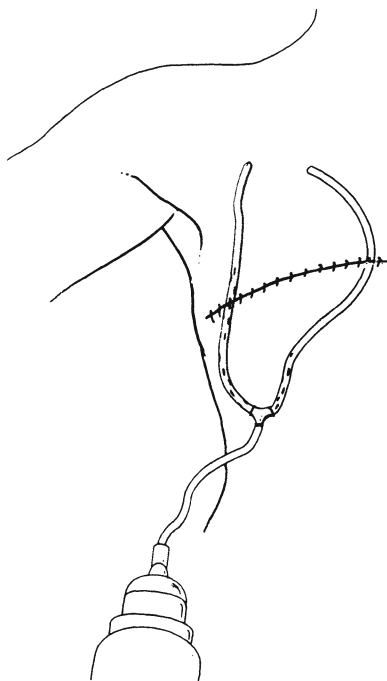


Figure 3.17. Placement of drains.

■ LUMPECTOMY WITH SENTINEL LYMPH NODE BIOPSY AND AXILLARY DISSECTION

A lumpectomy is the removal of a lesion with an adequate margin of mammary tissue determined by frozen section to be free of tumor. The surgeon must present the pathologist with a well-oriented specimen, marked with sutures, and ensure that the pathologist use the newest techniques for establishing and diagnosing tumor-free margins. The surgeon emphasizes to the pathologist the importance of obtaining hormone receptor assays. The specimen should be submitted as soon as it is removed.

- Step 1.** Make a cosmetic incision. Remove the tumor and healthy mammary tissue and send it to the lab for frozen section (see technique for excisional breast biopsy, described previously in this chapter).
- Step 2.** Proceed with sentinel lymph node biopsy, previously described in Chap. 1.

112 3. Breast

Step 3. We prefer to make a transverse incision at the lower axilla. Try to avoid making skin flaps, but if absolutely necessary, make only an upper flap. Retract both pectoral muscles. Locate the axillary vein at the medial area of the pectoralis minor and begin ligating its tributaries. Remember that the anterior border of the latissimus dorsi is located at the lateral wall of the axilla. Carefully proceed toward the medial axillary wall. Be sure to protect the thoracodorsal nerve, which is close to the anterior margin of the latissimus dorsi muscle, and the long thoracic nerve, which is under the fascia of the serratus anterior muscle. Complete the dissection and separate the specimen from the axillary vein. Remove the specimen and mark its upper portion with a silk suture. Drain the axillary cavity with two Jackson–Pratt drains. For more information, read about axillary dissection in “Modified Radical Mastectomy,” which immediately precedes this description.

Step 4. Close the wound in two layers.

Abdominal Wall and Hernias

ANATOMY

■ GENERAL DESCRIPTION OF THE ANTERIOR ABDOMINAL WALL

The anterior abdominal wall can be thought of as having two parts: anterolateral and midline. The *anterolateral portion* is composed of the external oblique, internal oblique, and transversus abdominis muscles (often referred to as “the three flat muscles of the anterior abdominal wall”). These muscles are arranged such that their fibers are roughly parallel as they approach their insertion on the rectus sheath.

The *midline (middle) portion* is composed of the rectus abdominis and pyramidal muscles. The rectus muscle is enclosed in a stout sheath formed by the bilaminar aponeuroses of the three flat muscles, which divide and pass anteriorly and posteriorly around it. The sheath attaches medially to the linea alba (Fig. 4.1), which is formed by decussation. In 10–20 % of the subjects, the pyramidal muscle is absent on one or both sides, but when present its insertion into the linea alba is a landmark for an accurate midline incision.

The following array shows some comparisons between the structures of the upper three-quarters of the midline portion of the abdominal wall and the lower one-quarter:

Upper midline

Linea alba well developed
Right and left recti well separated
Anterior and posterior layers of rectus sheath present
Aponeurosis of external oblique weak or absent

Lower midline

Linea alba poorly developed
Right and left recti close together
Only anterior layer of rectus sheath present
Aponeurosis of external oblique strong and well developed

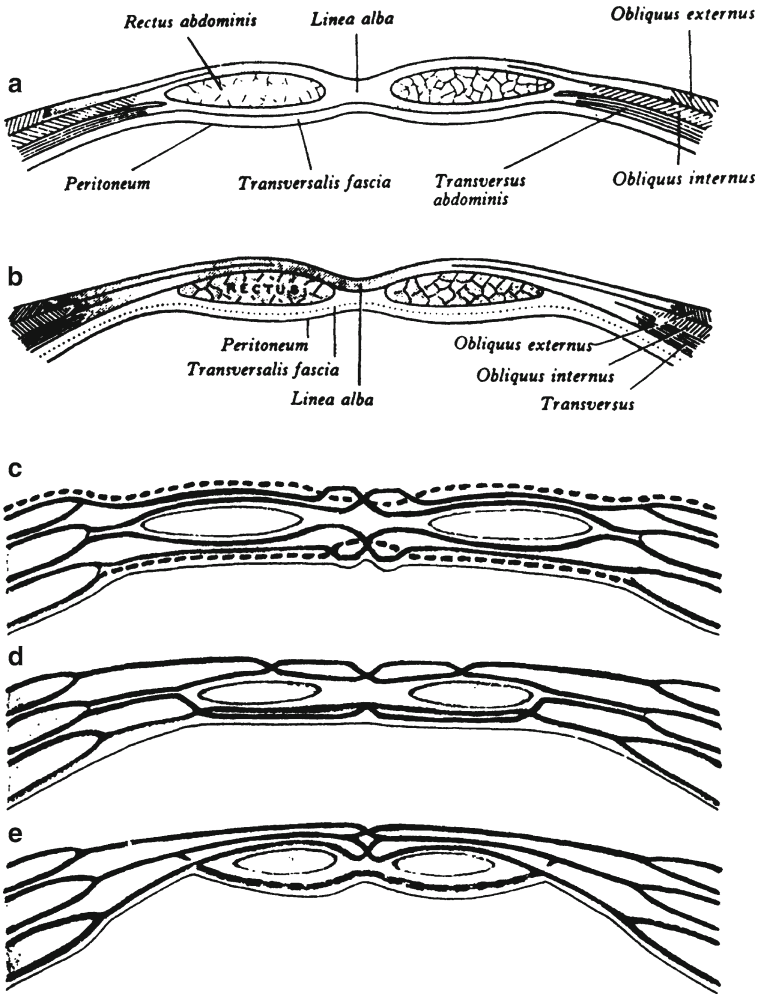


Figure 4.1. (a) Transverse sections through the anterior abdominal wall, traditional view: immediately above the umbilicus. (b) Below the arcuate line. (c–e) Schematic transverse sections through the ventral abdominal wall showing bilaminar aponeuroses, external oblique, internal oblique, transversus abdominis, and sites of linear decussation that compacted from linea alba (By permission of PL Williams, R Warwick, and M Dyson, et al. (eds.), *Gray's Anatomy*, 37th ed. Edinburgh: Churchill Livingstone, 1989).

In the lower one-quarter of the abdominal wall, the aponeuroses of the internal oblique and transversus abdominis muscles pass anterior to the rectus muscle, which is bounded posteriorly by the transversalis fascia only (Fig. 4.1). The dividing line is the linea semicircularis of Douglas, which marks the level at which the rectus sheath loses its posterior wall. The line is well marked if the change is abrupt, but less definite if the change is gradual.

■ UMBILICAL REGION

The variations of the anatomy of the umbilical region may be appreciated from the drawing presenting the relations of the umbilical ring to the linea alba, round ligament, urachus (median umbilical ligament), and umbilical fascia (Fig. 4.2).

Figures 4.3 and 4.4 present variations of the umbilical fascia in relation to several anatomical entities. Note that in Fig. 4.4a, the fascia covers the umbilical ring in toto.

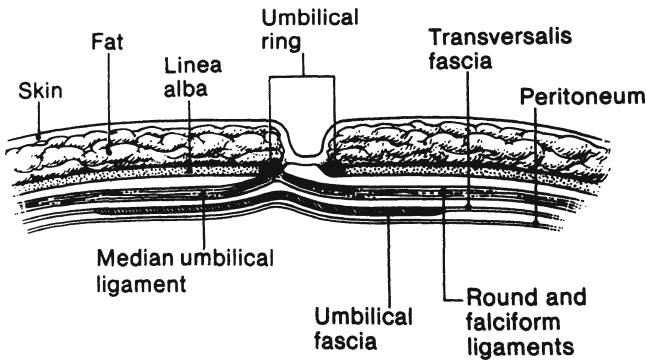


Figure 4.2. Diagrammatic sagittal section through a normal umbilicus showing the relation of the umbilical ring to the linea alba, the round ligament, the urachus, and the umbilical and transversalis fasciae. Note the absence of subcutaneous fat over the umbilical ring (By permission of JE Skandalakis, SW Gray, AR Mansberger, et al. *Hernia: Surgical Anatomy and Technique*. New York: McGraw-Hill, 1989).

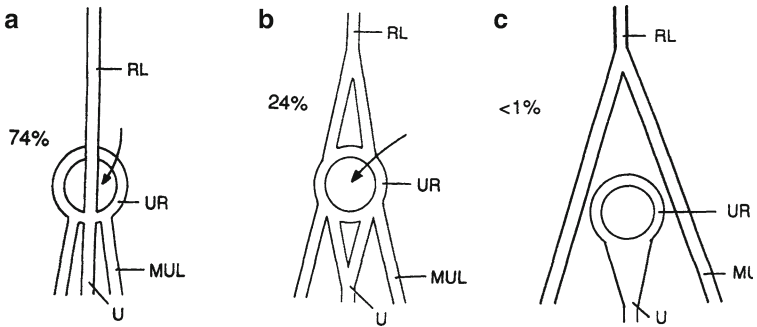
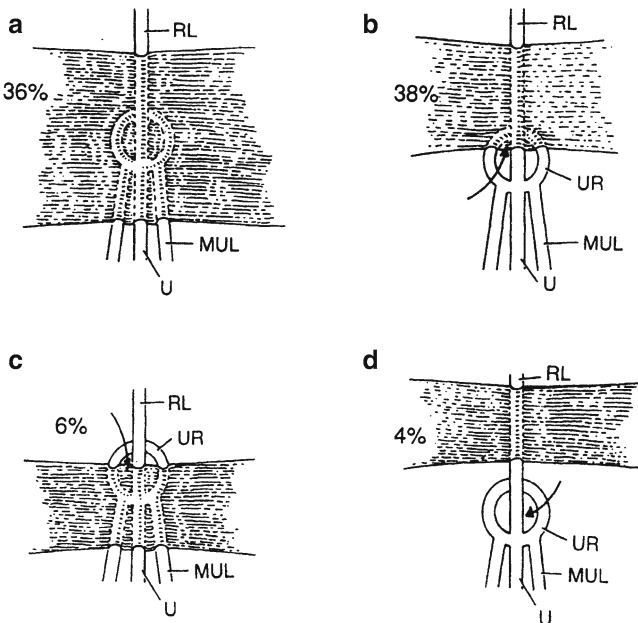


Figure 4.3. Variations in the disposition of the umbilical ligaments as seen from the posterior (peritoneal) surface of the body wall. Arrows indicate (a) usual relations (74 %) of the umbilical ring (UR), the round ligament (RL), the urachus (U), and the medial umbilical ligaments (MUL). The round ligament crosses the umbilical ring to insert on its inferior margin. (b) Less common configuration (24 %). The round ligament splits and is attached to the superior margin of the umbilical ring. (c) Rare configuration (less than 1 %). The round ligament branches before reaching the umbilical ring. Each branch continues with the medial umbilical ligament without attaching to the umbilical ring (modified by permission of R Orda and H Nathan. *Int Surg* 58(7):454–464, 1973).



■ LAYERS OF THE LOWER ANTERIOR BODY WALL

In the inguinal region, the layers of the abdominal wall are:

- Skin.
- Subcutaneous fasciae (Camper and Scarpa) containing fat (superficial fascia).
- Innominate fascia (Gallaudet). It is not always recognized as a distinct entity. Its absence is of no surgical importance. It is responsible for the formation of the external spermatic fascia.
- External oblique aponeurosis, including the inguinal, lacunar, and reflected inguinal ligaments.
- Spermatic cord.
- Transversus abdominis muscle and aponeurosis, internal oblique muscle, falx inguinalis (Henle), and the conjoint tendon (when present).
- Anterior lamina of transversalis fascia.
- Posterior lamina of transversalis fascia.
- Preperitoneal connective tissue with fat.
- Peritoneum.

■ FOSSAE OF THE LOWER ANTERIOR ABDOMINAL WALL (FIG. 4.5)

The inner (posterior) surface of the anterior body wall above the inguinal ligament and below the umbilicus is divided into three shallow fossae on either side of a low ridge formed in the midline by the median umbilical ligament, the obliterated urachus. Each of these fossae is a potential site for a hernia. From lateral to medial, these fossae are:



Figure 4.4. Variations in the presence and form of the insertion of the umbilical fascia as seen from the posterior (peritoneal) surface of the body wall. (a) The thickened transversalis fascia forms the umbilical fascia covering the umbilical ring (36 %). Arrows indicate (b) the umbilical fascia covers only the superior portion of the umbilical ring (38 %); (c) the umbilical fascia covers only the inferior portion of the umbilical ring (6 %); (d) though present, the umbilical fascia does not underlie the umbilical ring (4 %). (No figure: fascia is entirely absent in 16 %). (modified by permission of R Orda and H Nathan. *Int Surg* 58(7): 454–464, 1973).

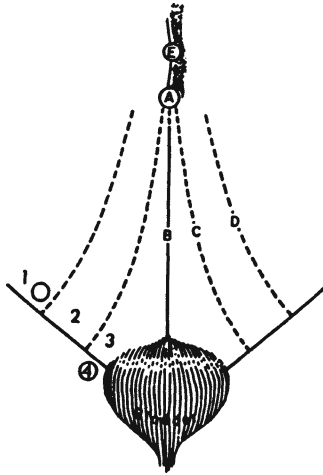


Figure 4.5. Diagram of the fossae of the anterior abdominal wall and their relation to the sites of groin hernias: (A) umbilicus, (B) median umbilical ligament (obliterated urachus), (C) medial umbilical ligament (obliterated umbilical arteries), (D) lateral umbilical ligament containing inferior (deep) epigastric arteries, and (E) falciform ligament. Sites of possible hernias: (1) lateral fossa (indirect inguinal hernia), (2) medial fossa (direct inguinal hernia), (3) supravesical fossa (supravesical hernia), and (4) femoral ring (femoral hernia) (By permission of JS Rowe, JE Skandalakis, and SW Gray. *Am Surg* 39(5):269–270; 1973).

- The *lateral fossa*, bounded medially by the inferior epigastric arteries. It contains the internal inguinal ring, the site of indirect inguinal hernia.
- The *medial fossa*, between the inferior epigastric artery and the medial umbilical ligament (remnant of the umbilical artery). It is the site of direct inguinal hernia.
- The *supravesical fossa*, between the medial and the median umbilical ligaments. It is the site of external supravesical hernia.

■ ANATOMICAL ENTITIES OF THE GROIN

Superficial Fascia (Fig. 4.6)

This fascia (described here only for the male) is divided into a superficial part (Camper) and a deep part (Scarpa). The superficial part extends upward on the abdominal wall and downward over the penis, scrotum, perineum, thigh, and buttocks. The deep part extends from the abdominal wall to the penis (Buck's fascia), the scrotum (dartos), and the perineum (Colles' fascia).

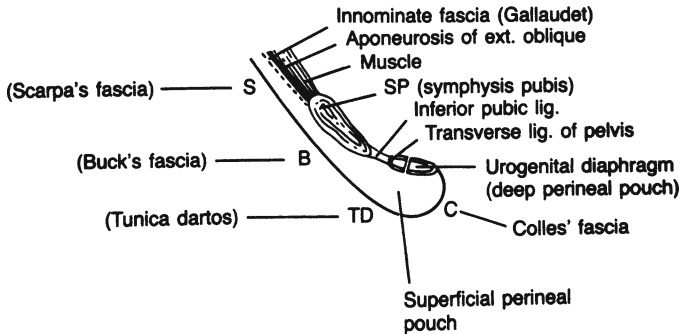


Figure 4.6. Diagram of the relations of the superficial fasciae of the inguinal area showing the formation of the superficial perineal pouch (By permission of JE Skandalakis, SW Gray, AR Mansberger, et al. *Hernia: Surgical Anatomy and Technique*. New York: McGraw-Hill, 1989).

Usually two spaces are formed: the superficial perineal cleft and the superficial perineal pouch. The cleft is situated between Colles' fascia and the muscle fascia that covers the muscles of the superficial perineal pouch. The pouch is defined by the perineal membrane, the external perineal fascia (Gallaudet), and the ischiopubic rami.

Aponeurosis of the External Oblique Muscle (Fig. 4.6)

Below the arcuate line (Douglas), the aponeurosis of the external oblique muscle joins with the aponeuroses of the internal oblique and transversus abdominis muscles to form the anterior layer of the rectus sheath. This aponeurosis forms or contributes to three anatomical entities in the inguinal canal:

- Inguinal ligament (Poupart)
- Lacunar ligament (Gimbernat)
- Reflected inguinal ligament (Colles)

(Included sometimes is the pectineal ligament (Cooper), which is also formed from tendinous fibers of the internal oblique, transversus, and pectineus muscles.)

Inguinal Ligament (Poupart) (Fig. 4.7)

This is the thickened lower part of the external oblique aponeurosis from the anterior superior iliac spine laterally to the superior ramus of the pubic tubercle. The middle one-third has a free edge. The lateral two-thirds is attached strongly to the underlying iliopsoas fascia.

120 4. Abdominal Wall and Hernias

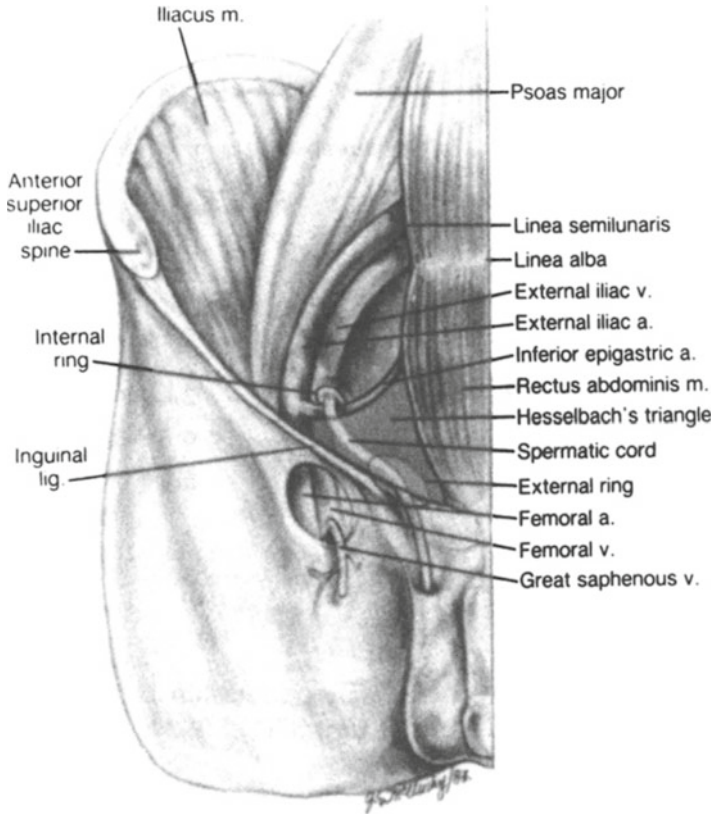


Figure 4.7. Hesselbach triangle, site of direct inguinal hernia. Medial border of triangle is related to the lateral border of the rectus abdominis, site of supravesical hernia (By permission of SW Gray, JE Skandalakis, and DA McClusky. *Atlas of Surgical Anatomy for General Surgeons*. Baltimore: Williams & Wilkins, 1985).

Lacunar Ligament (Gimbernat) (Fig. 4.8)

This is the most inferior portion of the inguinal ligament and is formed from external oblique tendon fibers arising at the anterior superior iliac spine. Its fibers recurve through an angle of less than 45° before attaching to the pectineal ligament. Occasionally it forms the medial border of the femoral canal.

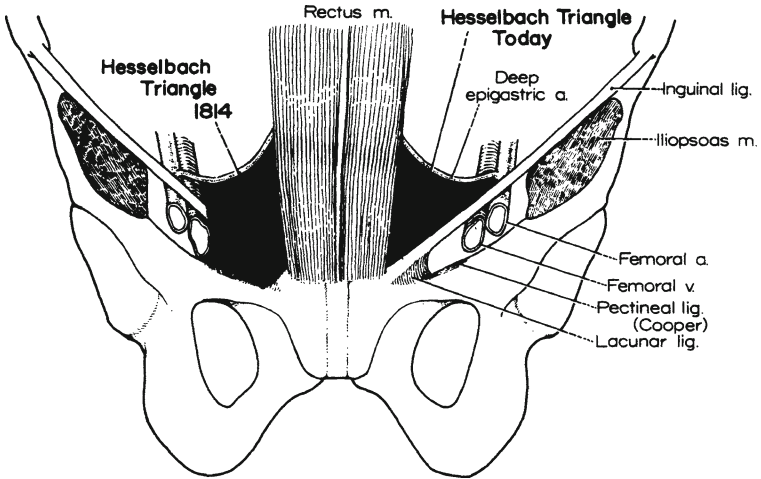


Figure 4.8. *Left*: triangle described by Hesselbach (1814). *Right*: the slightly smaller triangle accepted today (By permission of JE Skandalakis, SW Gray, and JR Rowe. *Anatomical Complications in General Surgery*. New York: McGraw-Hill, 1983).

Pectineal Ligament (Cooper) (Fig. 4.8)

This is a thick, strong tendinous band formed principally by tendinous fibers of the lacunar ligament and aponeurotic fibers of the internal oblique, transversus abdominis, and pectineus muscles and, with variation, the inguinal falx. It is fixed to the periosteum of the superior pubic ramus and, laterally, the periosteum of the ilium. The tendinous fibers are lined internally by transversalis fascia.

Conjoined Area (Fig. 4.9)

By definition, this is the fusion of fibers of the internal oblique aponeurosis with similar fibers from the aponeurosis of the transversus abdominis muscle, just as they insert on the pubic tubercle, the pectineal ligament, and the superior ramus of the pubis.

The above configuration is rarely encountered; published data suggest that it will be found in 5 % of individuals or fewer. We have proposed the term *conjoined area*. This has obvious practical application to the region containing the falx inguinalis (Henle ligament), the transversus abdominis aponeurosis, the inferomedial fibers of the internal oblique muscle or aponeurosis, the reflected inguinal ligament, and the lateral border of the rectus sheath.

122 4. Abdominal Wall and Hernias

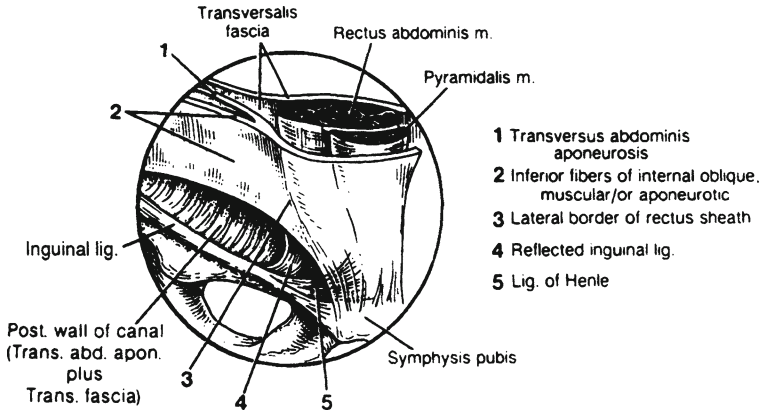


Figure 4.9. The “conjoined area” (By permission of JE Skandalakis, GL Colborn, SW Gray, et al. *Contemp Surg* 38(1):20–34, 1991).

Arch of the Transversus Abdominis

The inferior portion of the transversus abdominis, the transversus arch, becomes increasingly less muscular and more aponeurotic as it approaches the rectus sheath. Close to the internal ring, it is covered by the much more muscular arch of the internal oblique muscle. Remember that in the inguinal canal region, the internal oblique is muscular. The transversus abdominis is aponeurotic.

Falx Inguinalis (Henle Ligament) (Fig. 4.9)

Henle ligament is the lateral, vertical expansion of the rectus sheath that inserts on the pecten of the pubis. It is present in 30–50 % of individuals and is fused with the transversus abdominis aponeurosis and transversalis fascia.

Interfoveolar Ligament (Hesselbach)

This is not a true ligament. It is a thickening of the transversalis fascia at the medial side of the internal ring. It lies anterior to the inferior epigastric vessels.

Reflected Inguinal Ligament (Colles') (Fig. 4.9)

This is formed by aponeurotic fibers from the inferior crus of the external ring that extend to the linea alba.

Iliopubic Tract (Fig. 4.10)

This is an aponeurotic band extending from the iliopectineal arch to the superior ramus of the pubis. It forms part of the deep musculoaponeurotic layer together with the transversus abdominis muscle and aponeurosis and the transversalis fascia.

The tract passes medially, contributing to the inferior border of the internal ring. It crosses the femoral vessels to form the anterior margin of the femoral sheath, together with the transversalis fascia. The tract curves around the medial surface of the femoral sheath to attach to the pectineal ligament. It can be confused with the inguinal ligament.

Transversalis Fascia (Fig. 4.11)

Although the name transversalis fascia may be restricted to the internal fascia lining the transversus abdominis muscle, it is often applied to the entire connective tissue sheath lining the abdominal cavity. In the latter sense, it is a fascial layer covering the muscles, aponeuroses, ligaments, and bones. In the inguinal area the transversalis fascia is bilaminar, enveloping the inferior epigastric vessels.

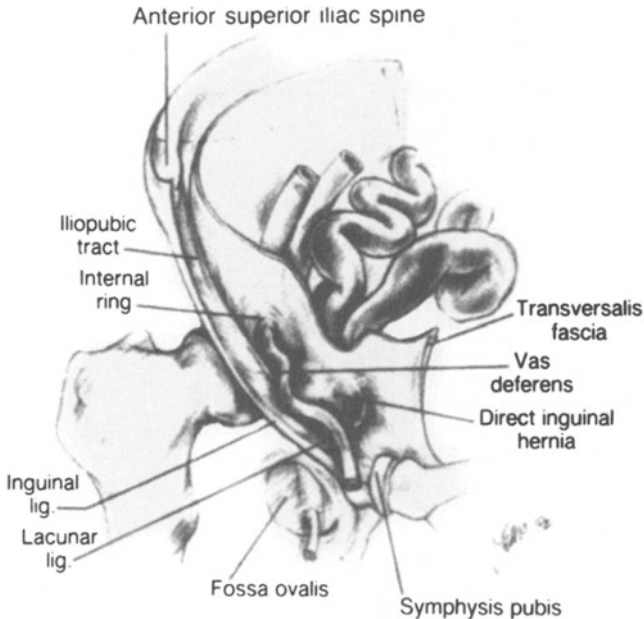


Figure 4.10. Site of direct inguinal hernia. Note the internal ring and the iliopubic tract (By permission of SW Gray, JE Skandalakis, and DA McClusky. *Atlas of Surgical Anatomy for General Surgeons*. Baltimore: Williams & Wilkins, 1985).

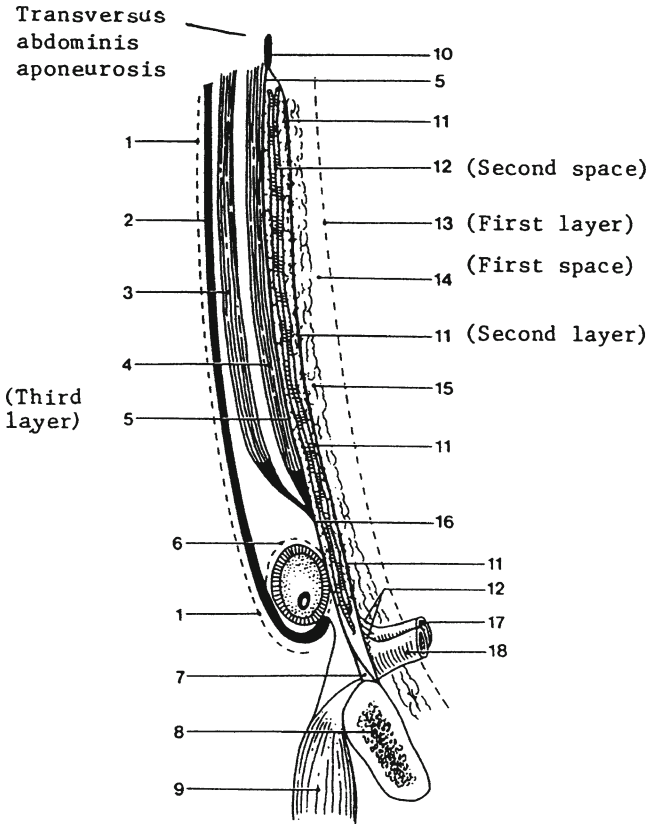


Figure 4.11. Highly diagrammatic representation of the layers and spaces of the inguinal area and the space of Bogros: (1) innominate fascia; (2) external oblique aponeurosis; (3) internal oblique muscle; (4) transversus abdominis muscle and its aponeurosis; (5) transversalis fascia anterior; (6) external spermatic fascia; (7) Cooper ligament; (8) pubic bone; (9) pectineus muscle; (10) transversalis fascia; (11) transversalis fascia posterior lamina; (12) vessels; (13) peritoneum; (14) home (space) of the prosthesis, space of Bogros; (15) preperitoneal fat; (16) transversus abdominis aponeurosis and anterior lamina of transversalis fascia; (17) femoral artery; and (18) femoral vein (drawn by RC Read. From Skandalakis JE, Colborn GL, Androulakis JA, Skandalakis LJ, and Pemberton LB. Embryologic and anatomic basis of inguinal herniorrhaphy. *Surg Clin North Am* 73(4):799–836, 1993, with permission).

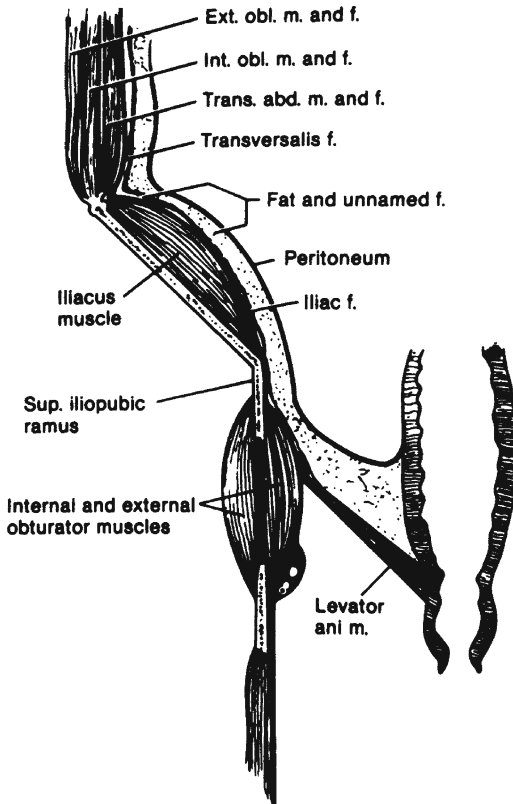


Figure 4.12. Diagram of the normal relations of the transversalis fascia in the lateral and lower parts of the abdominal wall (By permission of EW Lampe. Transversalis fascia. In: Nyhus LM, and Condon RL. *Hernia*, 3rd ed. Philadelphia: Lippincott, 1989).

Related to the transversalis fascia is the space of Bogros, which is, for all practical purposes, a lateral extension of the retropubic space of Retzius. It is located just beneath the posterior lamina of the transversalis fascia out in front of the peritoneum (Fig. 4.11). The space of Bogros is used for the location of prostheses during the repair of inguinal hernias.

Figure 4.12 shows normal relations of the transversalis fascia in the lateral and lower parts of the abdominal wall.

Iliopectineal Arch

This is a medial thickening of the iliopsoas fascia deep to the inguinal ligament. The surgeon does not directly use this arch, but it is important as the junction of a number of structures of the groin. These structures are:

- The insertion of fibers of the external oblique aponeurosis.
- The insertion of fibers of the inguinal ligament.
- The origin of part of the internal oblique muscle.
- The origin of part of the transversus abdominis muscle.
- Part of the lateral attachment of the iliopubic tract. It contributes also to the lateral wall of the femoral sheath.

Hesselbach Triangle (Fig. 4.8)

As described by Hesselbach in 1814, the base of the triangle was formed by the pubic pecten and the pectineal ligament. The boundaries of this triangle as usually described today are:

- Superolateral: the inferior (deep) epigastric vessels
- Medial: the rectus sheath (lateral border)
- Inferior (or, the base): the inguinal ligament

This is smaller than that described by Hesselbach in 1814. Most direct inguinal hernias occur in this area.

Inguinal Canal

The inguinal canal in the adult is an oblique rift in the lower part of the anterior abdominal wall. It measures approximately 4 cm in length. It is located 2–4 cm above the inguinal ligament, between the opening of the external (superficial) and internal (deep) inguinal rings.

The external, or superficial, inguinal ring is a triangular opening in the aponeurosis of the external oblique muscle. The superior and inferior crura form the margins of the ring: the superior crura are composed of the aponeurosis of the external oblique itself, and the inferior crura are formed by the inguinal ligament.

The internal, or deep, inguinal ring is a normal defect in the transversalis fascia shaped like an inverted V or U. Its arms— anterior and posterior—are a special thickening of the transversalis fascia, forming a sling. Its inferior border is formed by another thickening of the transversalis fascia—the iliopubic tract—which is not always very aponeurotic. The ring's position in the transversalis fascia corresponds to the middle of the inguinal ligament.

The contents of the inguinal canal for males and females are as follows.

Male

The spermatic cord contains a matrix of connective tissue continuous with the preperitoneal connective tissue. The cord consists of:

- Ductus deferens
- Three arteries: the internal spermatic (testicular), deferential, and external spermatic (cremasteric)
- One venous plexus (pampiniform)
- Genital branch of the genitofemoral nerve
- Ilioinguinal nerve
- Sympathetic fibers from the hypogastric plexus
- Three layers of fascia: the external spermatic fascia, a continuation of the innominate fascia; the middle, cremasteric layer, continuous with the internal oblique muscle fibers and muscle fascia; and the internal spermatic fascia, an extension of the transversalis fascia

Female

- Round ligament of the uterus
- Genital branch of the genitofemoral nerve
- Cremasteric vessels
- Ilioinguinal nerve
- Coverings as described for the male, although usually less distinct

The *anterior wall* of the inguinal canal is formed by the aponeurosis of the external oblique muscle (Fig. 4.13) and by participation of the internal oblique muscle more laterally. The *superior wall* (“roof”) of the canal is formed by the arching lower borders of the internal oblique and transversus abdominis muscles and their aponeuroses. The *inferior wall* is formed by the inguinal and lacunar ligaments. From both anatomical and surgical standpoints, the *posterior wall* is the most important wall of the inguinal canal. The posterior wall (“floor”) is formed primarily by fusion of the aponeurosis of the transversus abdominis muscle and the transversalis fascia in three-fourths of subjects, yielding a strong wall, and by only the transversalis fascia in the remainder—yielding a weak wall (Figs. 4.14 and 4.15). Medially the posterior wall is reinforced by the internal oblique aponeurosis.

Fruchaud viewed hernias not by their clinical presentation, but rather by their origin within the groin, in an area he termed the myopectineal orifice (Fig. 4.16). This area is bounded superiorly by the arch of the internal oblique muscle and transversus abdominis muscle, laterally by the iliopsoas muscle, medially by the lateral border of the rectus muscle and its anterior lamina, and inferiorly by the pubic pecten. The inguinal ligament spans and divides this framework.

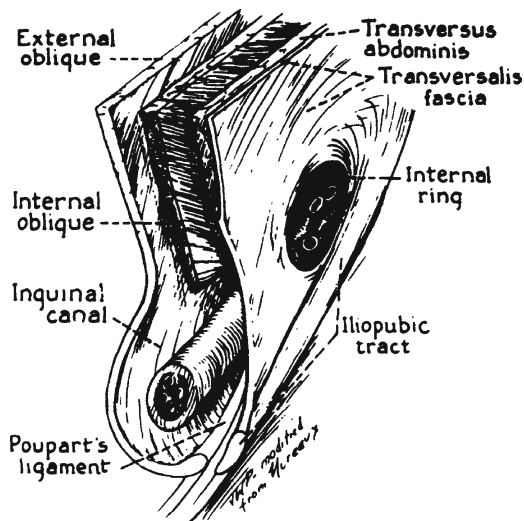


Figure 4.13. Parasagittal section through right mid-inguinal region, illustrating separation of the musculoaponeurotic lamina into anterior and posterior inguinal walls (By permission of LM Nyhus. The preperitoneal approach and iliopubic tract repair of inguinal hernia. In: Nyhus LM, and Condon RL. *Hernia*, 3rd ed. Philadelphia: Lippincott, 1989).

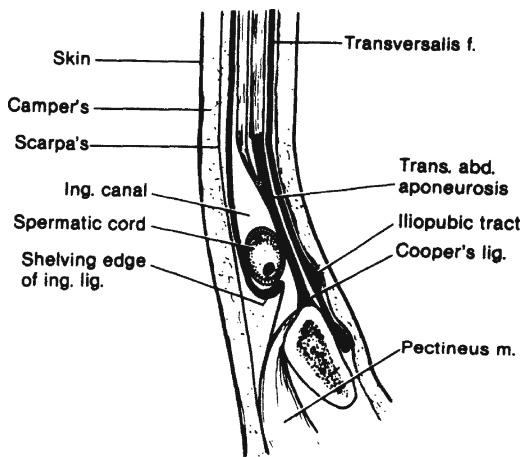


Figure 4.14. Diagrammatic cross section of a "strong" posterior inguinal canal wall. Notice the thickness and extent of the aponeurosis of the transversus abdominis muscle (By permission of EW Lampe. *Transversalis fascia*. In: Nyhus LM, and Condon RL. *Hernia*, 3rd ed. Philadelphia: Lippincott, 1989).

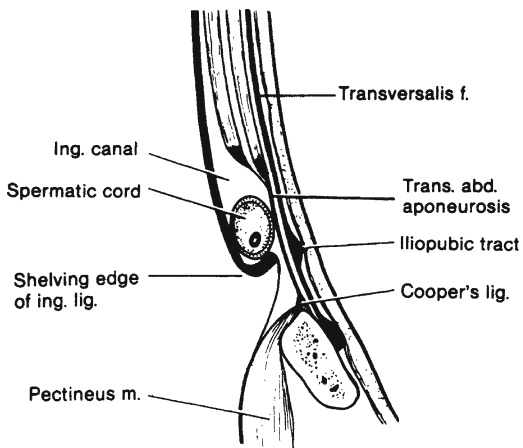


Figure 4.15. Diagrammatic cross section of a "weak" posterior inguinal canal wall. Compare with Fig. 4.14 (By permission of EW Lampe. *Transversalis fascia*. In: Nyhus LM, and Condon RL. *Hernia*, 3rd ed. Philadelphia: Lippincott, 1989).

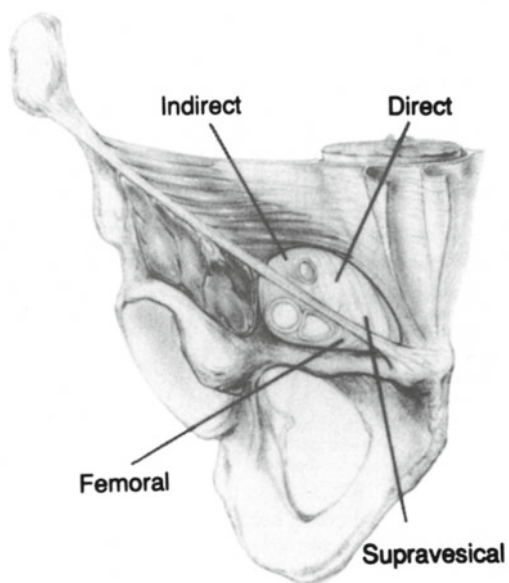


Figure 4.16. Anterior view of Fruchaud's myopectineal orifice (modified by permission of GE Wantz. *Atlas of Hernia Surgery*. New York: Raven Press, 1991, p. 4).

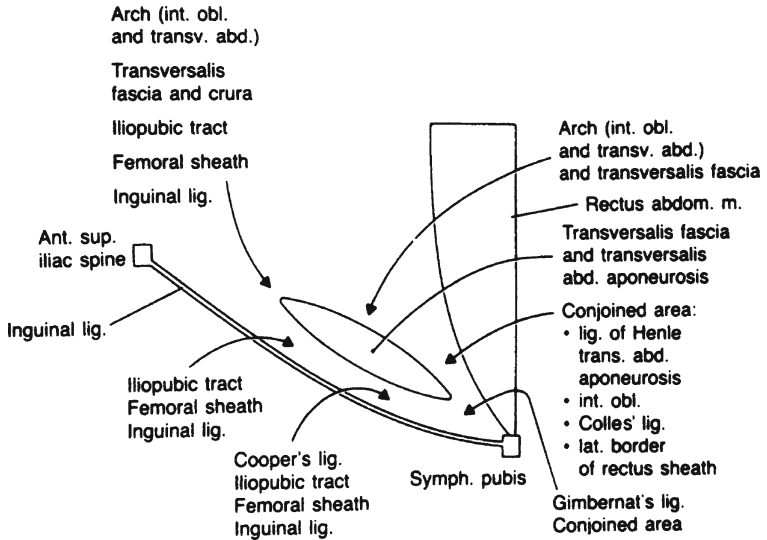


Figure 4.17. Highly diagrammatic presentation of the surgical ellipse (By permission of JE Skandalakis, SW Gray, AR Mansberger, et al. *Hernia: Surgical Anatomy and Technique*. New York: McGraw-Hill, 1989).

Surgical Ellipse (Fig. 4.17)

With the patient in the supine position, the surgeon is dealing with the following anatomical areas and entities of the inguinal region, which are incorporated into an elliptical area: floor of the inguinal canal, superior medial edge (above), inferior lateral edge (below), medial apex, and lateral apex.

The *floor* (posterior wall) of the ellipse is formed by the transversus abdominis aponeurosis and the transversalis fascia. If the posterior wall is intact, its integrity prevents herniation (Figs. 4.14 and 4.15): none of the four types of inguinal hernia (indirect, direct, external supravesical, femoral) will develop.

The *superior medial (upper) edge* of the ellipse is formed by the conjoined area and the arch (internal oblique muscle and transversus abdominis muscle with their aponeuroses).

The *inferior lateral (lower) edge* is formed by the inguinal ligament, iliopubic tract, femoral sheath, and Cooper ligament. The iliopubic tract, femoral sheath, Cooper ligament, and occasionally the inguinal ligament are used for repair.

The *medial apex*—close to the symphysis pubis—is formed by Gimbernat ligament below and the conjoined area above.

The *lateral apex*—at the internal ring—is formed by the arch (internal oblique and transversus abdominis muscles and aponeuroses), transversalis fascia and crura, iliopubic tract, femoral sheath, and inguinal ligament.

Remember:

- ✓ The transversalis fascia and transversus abdominis aponeurosis together are “good stuff” for repair of inguinfemoral herniation.

Femoral Canal and Its Sheath

The femoral canal—within the groin area, below the inguinal ligament—is 1.25–2 cm long and occupies the most medial compartment of the femoral sheath. The femoral sheath is formed anteriorly and medially by the transversalis fascia and some transversus aponeurotic fibers, posteriorly by the pectineus and psoas fasciae, and laterally by the iliacus fascia. The sheath forms three compartments, the most medial of which is the femoral canal, through which a femoral hernia may pass. The boundaries are:

- Lateral: a connective tissue septum and the femoral vein
- Posterior: the pectineal ligament (Cooper)
- Anterior: the iliopubic tract or the inguinal ligament or both
- Medial: the aponeurotic insertion of the transversus abdominis muscle and transversalis fascia or, rarely, the lacunar ligament

■ BLOOD SUPPLY OF THE ANTERIOR ABDOMINAL WALL**Arterial Supply**

Where there have been no previous incisions, the blood supply to the abdominal wall creates no problem. Where scars are present, the surgeon should be familiar with the blood supply to avoid necrosis from ischemia to specific areas. If possible, the surgeon should proceed through an existing scar.

The lower anterolateral abdominal wall is supplied by three branches of the femoral artery. They are, from lateral to medial, the superficial circumflex iliac artery (Fig. 4.18), the superficial epigastric artery, and the superficial external pudendal artery. Branches of these arteries travel toward the umbilicus in the subcutaneous connective tissues. The superficial epigastric artery anastomoses with the contralateral artery, and all three arteries have anastomoses with the deep arteries.

The deep arteries lie between the transversus abdominis and the internal oblique muscles. They are the posterior intercostal arteries 10 and 11, the anterior branch of the subcostal artery, the anterior branches of the four lumbar arteries, and the deep circumflex iliac artery.

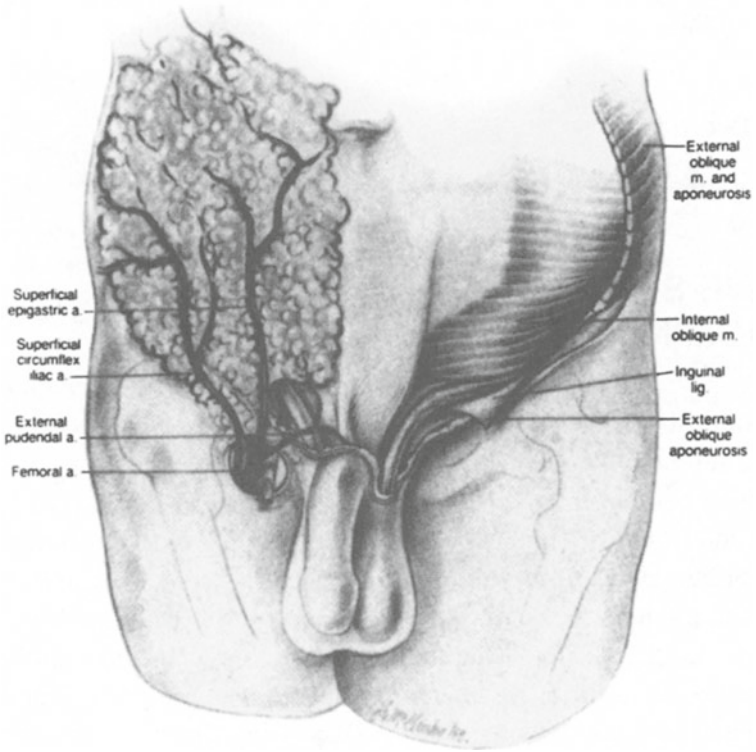


Figure 4.18. The skin of the lower abdominal wall has been removed to show the superficial branches of the femoral artery (By permission of SW Gray, JE Skandalakis, and DA McClusky. *Atlas of Surgical Anatomy for General Surgeons*. Baltimore: Williams & Wilkins, 1985).

The rectus sheath is supplied by the superior epigastric artery, which arises from the internal thoracic artery, and the inferior epigastric artery, which arises from the external iliac artery just above the inguinal ligament.

The superior epigastric artery enters the upper end of the rectus sheath, deep to the rectus muscle. Musculocutaneous branches pierce the anterior rectus sheath to supply the overlying skin. The perforating arteries are closer to the lateral border of the rectus than to the linea alba. Creating an incision too far laterally will result in bleeding from the several perforating arteries; cutting the musculocutaneous nerves will cause muscle paralysis.

The inferior epigastric artery arises in the preperitoneal connective tissue. It enters the sheath at or below the level of the semicircular line of Douglas, passing between the rectus muscle and the posterior layer of the sheath.

Venous Drainage

The veins follow the arteries.

■ NERVE SUPPLY OF THE ANTERIOR ABDOMINAL WALL

Both the anterolateral portion of the abdominal wall and the rectus abdominis muscle are supplied by anterior rami of the 7th to the 12th thoracic nerves and the first lumbar nerve (Fig. 4.19). A branch—the lateral cutaneous ramus—arises from each anterior ramus and pierces the outer two flat muscles, innervating the external oblique and forming the lateral cutaneous nerve. The anterior rami of the last six thoracic nerves enter the posterior layer of the rectus sheath, innervating the rectus muscle and sending perforating branches through the anterior layer of the sheath to form the anterior cutaneous nerves. The first lumbar nerve forms an anterior cutaneous nerve without passing through the sheath. These relationships are shown diagrammatically in Fig. 4.19. Rectus muscle paralysis, with weakening of the abdominal wall, will result from section of more than one of these nerves.

The nerves of the lower abdominal wall area are illustrated in Fig. 4.20.

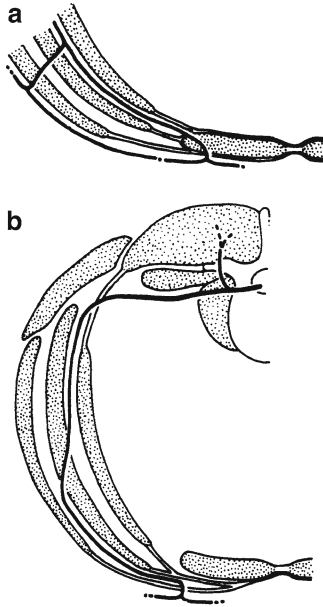


Figure 4.19. The course of the anterior ramus of segmental nerves in the anterior body wall. (a) 7th to 12th thoracic nerves. (b) First lumbar nerve (By permission of JE Skandalakis, SW Gray, and JR Rowe. *Anatomical Complications in General Surgery*. New York: McGraw-Hill, 1983).

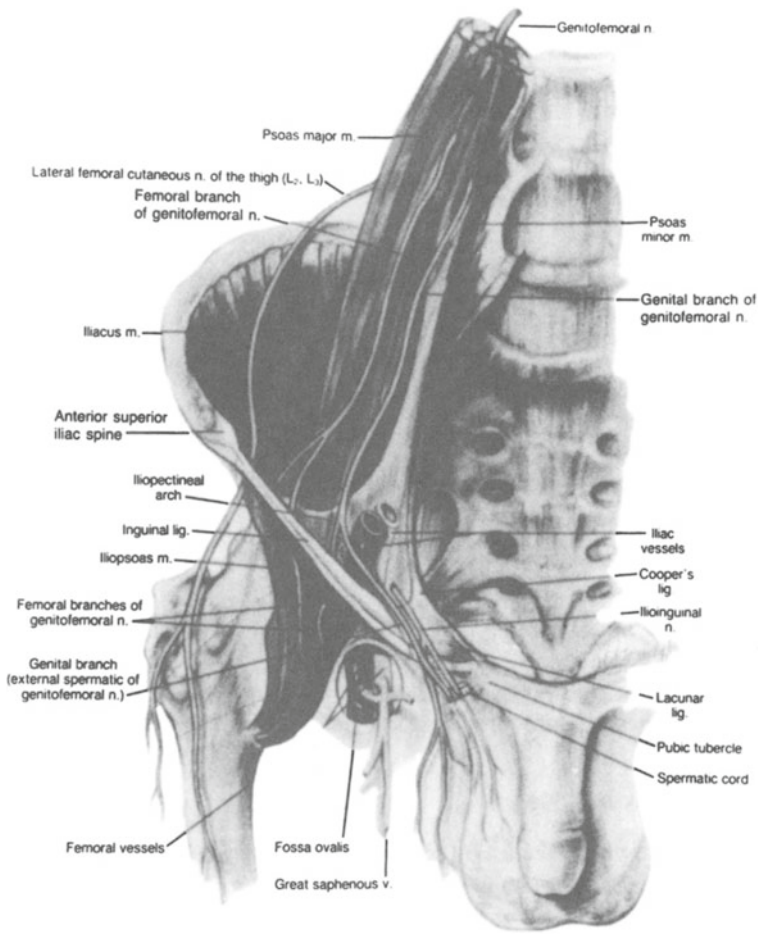


Figure 4.20. Nerves of the inguinal region with which the surgeon should be familiar with (By permission of SW Gray, JE Skandalakis, and DA McClusky. *Atlas of Surgical Anatomy for General Surgeons*, Baltimore: Williams & Wilkins, 1985).

■ PANORAMA OF LAPAROSCOPIC CADAVERIC ANATOMY OF THE INGUINAL AREA (FIGS. 4.21, 4.22, 4.23, 4.24, 4.25, 4.26, 4.27, 4.28, 4.29, 4.30, 4.31, 4.32, 4.33, 4.34, 4.35, AND 4.36)

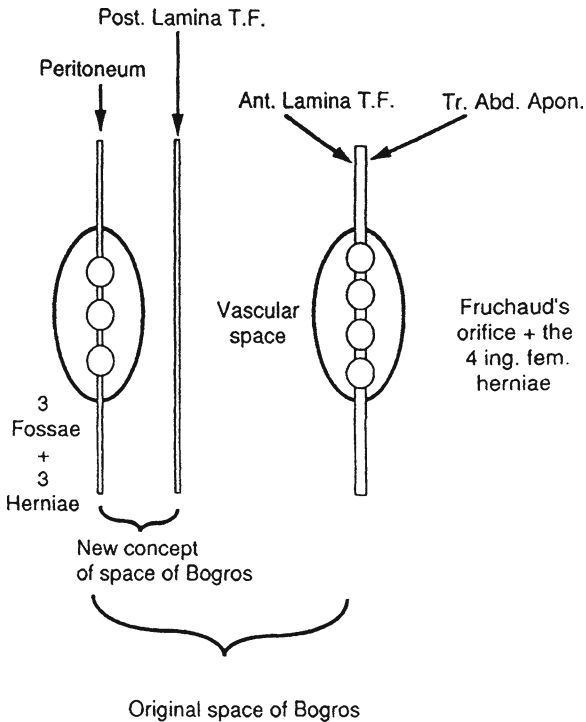


Figure 4.21. Highly diagrammatic presentation of laparoscopic anatomy of the inguinal area demonstrating layers, fossae, and spaces (From Colborn GL, Skandalakis JE. Laparoscopic cadaveric anatomy of the inguinal area. *Prob Gen Surg* 12(1):13–20, 1995, with permission).

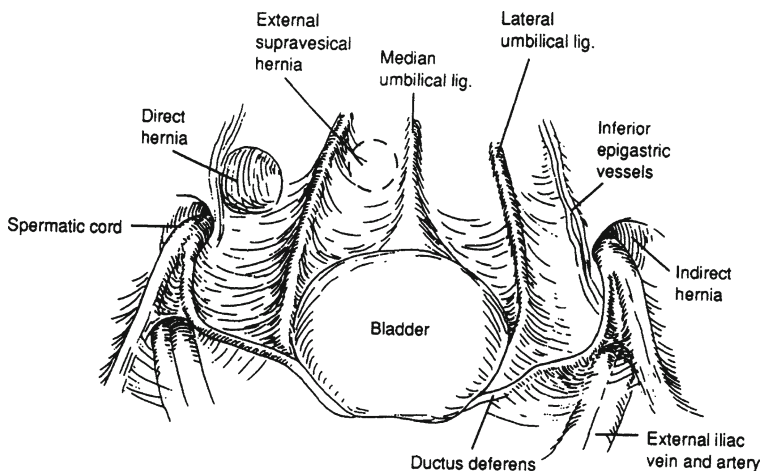


Figure 4.22. Laparoscopic topographic anatomy of the inguinal region. In men, the spermatic vessels join the vas deferens to form the spermatic cord. The presence of a fascial defect lateral or medial to the inferior epigastric vessels defines an indirect or a direct hernia, respectively (modified by permission from JH Peters, and AE Ortega. Laparoscopic inguinal hernia repair. In: Hunter JG, and Sackier JM, eds. *Minimally Invasive Surgery*. New York: McGraw-Hill, 1993, p. 300).

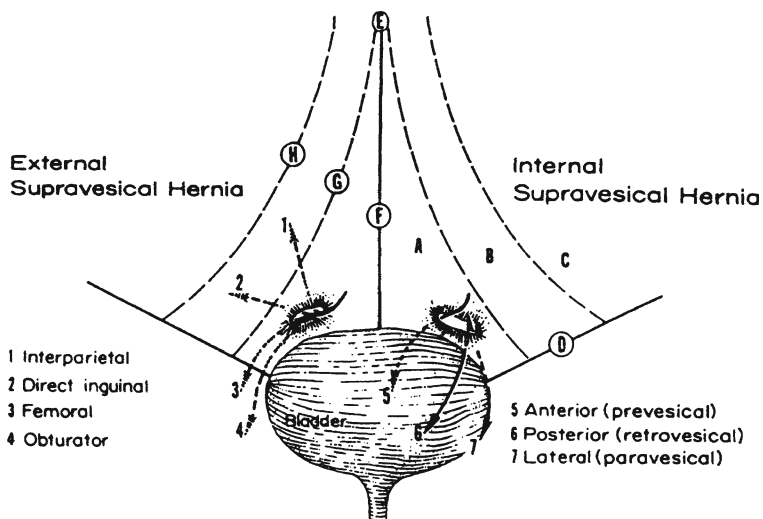
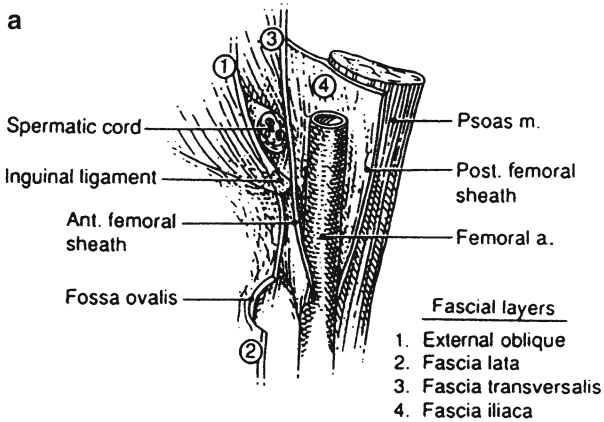


Figure 4.23. The bladder and anterior abdominal wall viewed posteriorly. Possible pathways of external supravescical hernias are shown on the *left* and those of internal supravescical hernias are shown on the *right*. (A) Supravescical fossa with mouth of supravescical hernia. (B) Medial fossa. (C) Lateral fossa. (D) Inguinal ligament. (E) Umbilicus. (F) Middle umbilical ligament (obliterated urachus). (G) Lateral umbilical ligament (obliterated umbilical artery). (H) Inferior (deep) epigastric artery (By permission of PN Skandalakis, LJ Skandalakis, SW Gray, and JE Skandalakis. *Supravescical hernia*. In: Nyhus LM, and Condon RE, eds. *Hernia*, 4th ed. Philadelphia: Lippincott, 1995, p. 401).

a



b

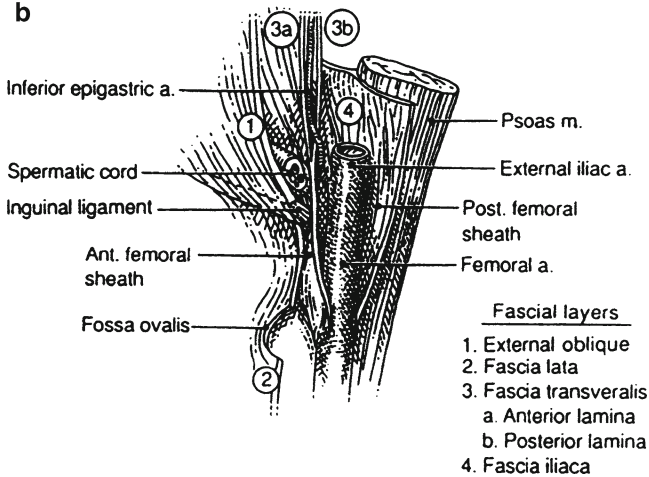


Figure 4.24. (a) Highly diagrammatic drawing of the transversalis fascia and femoral sheath (old concept). (b) Highly diagrammatic drawing of the transversalis fascia and femoral sheath (new concept), emphasizing the bilaminar nature of the transversalis fascia in the inguinal area (By permission of JE Skandalakis, GL Colborn, JA Androulakis, et al. Embryologic and anatomic basis of inguinal herniorrhaphy. *Surg Clin North Am* 73:817, 1993).

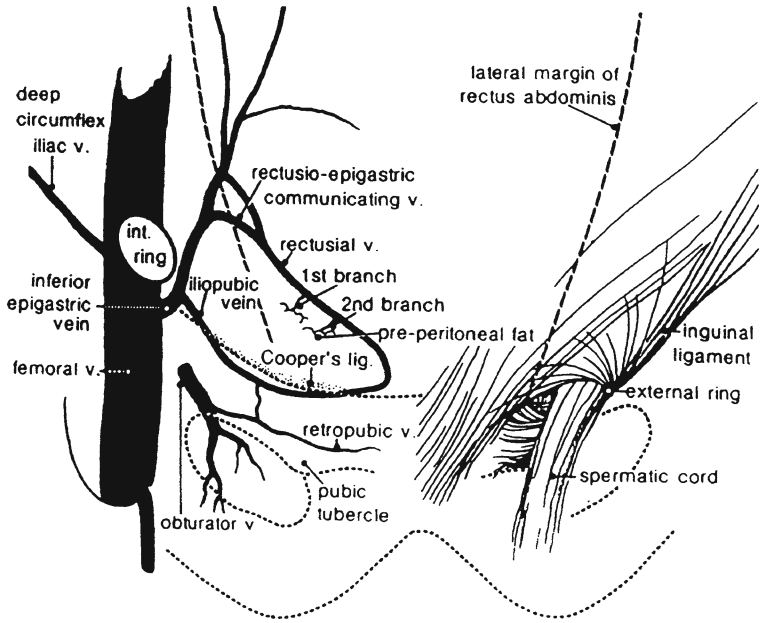


Figure 4.25. The deep inguinal vasculature within the space of Bogros (By permission of R Bendavid. The space of Bogros and the deep inguinal venous circulation. *Surg Gynecol Obstet* 174:355–358, 1992).

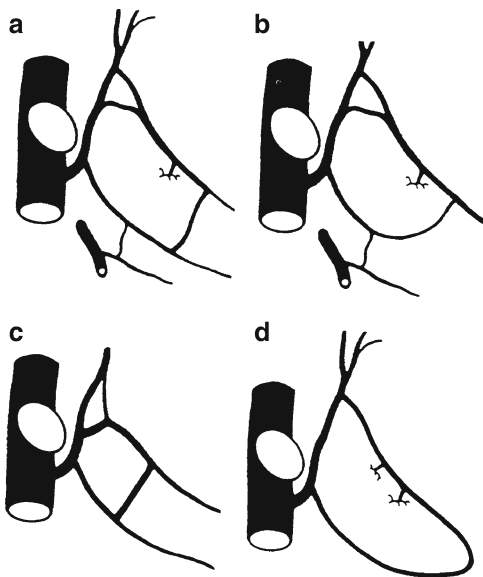


Figure 4.26. (a–d) Variations in the vasculature of the deep inguinal venous system (By permission of R Bendavid. The space of Bogros and the deep inguinal venous circulation. *Surg Gynecol Obstet* 174: 355–358, 1992).

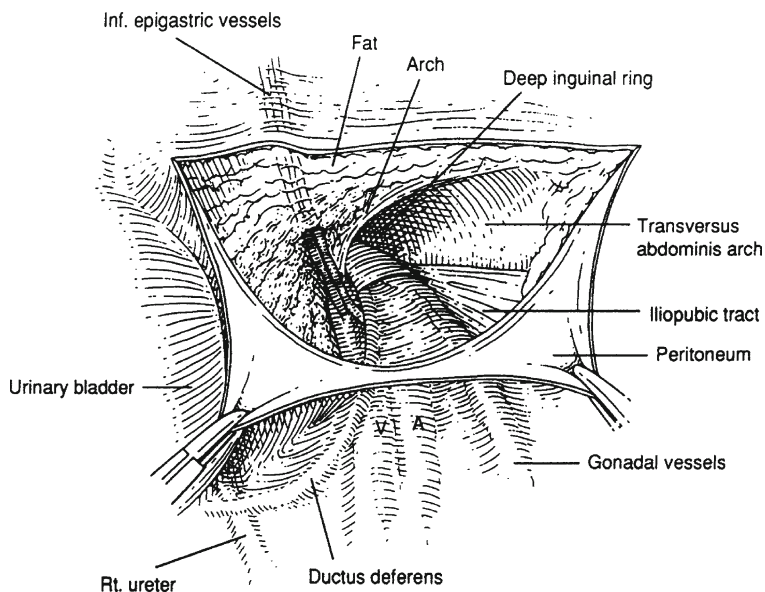


Figure 4.27. After incising and retracting the peritoneum, the inferior epigastric vessels (the most superficial anatomical entities) will be seen. The arch and the iliopubic tract may or may not be seen (From Colborn GL, and Skandalakis JE. Laparoscopic cadaveric anatomy of the inguinal area. *Prob Gen Surg* 12(1): 13–20, 1995, with permission).

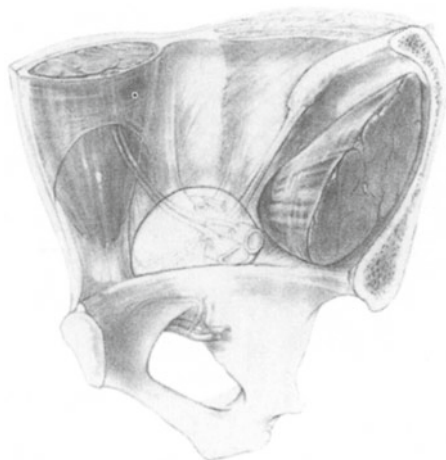


Figure 4.28. Posterior view of myopectineal orifice of Fruchaud. The boundaries are as follows: superior, the arch; lateral, iliopsoas muscle; medial, lateral edge of rectus abdominis muscle; and inferior, pubic pecten (By permission of GE Wantz and Lippincott-Raven. *Atlas of Hernia Surgery*. New York: Raven Press, 1991).

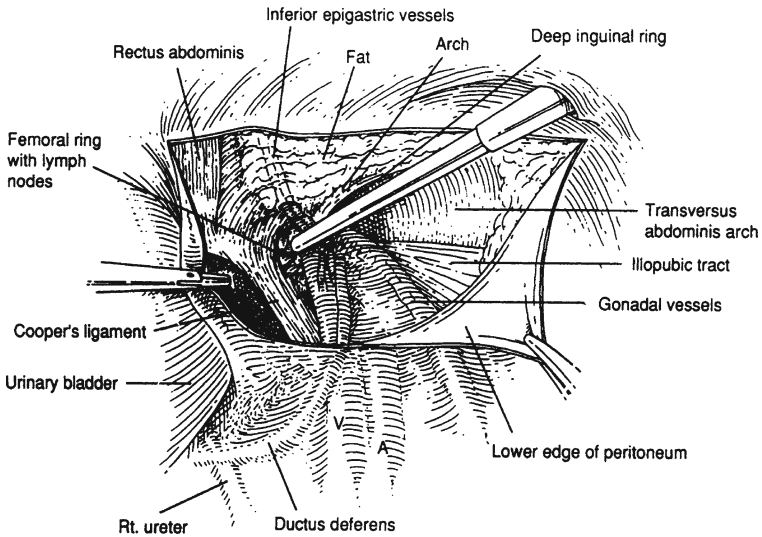


Figure 4.29. With more cleaning the arch, iliopubic tract, and ligament of Cooper can be seen (From Colborn GL, and Skandalakis JE. Laparoscopic cadaveric anatomy of the inguinal area. *Prob Gen Surg* 12(1):13-20, 1995, with permission).

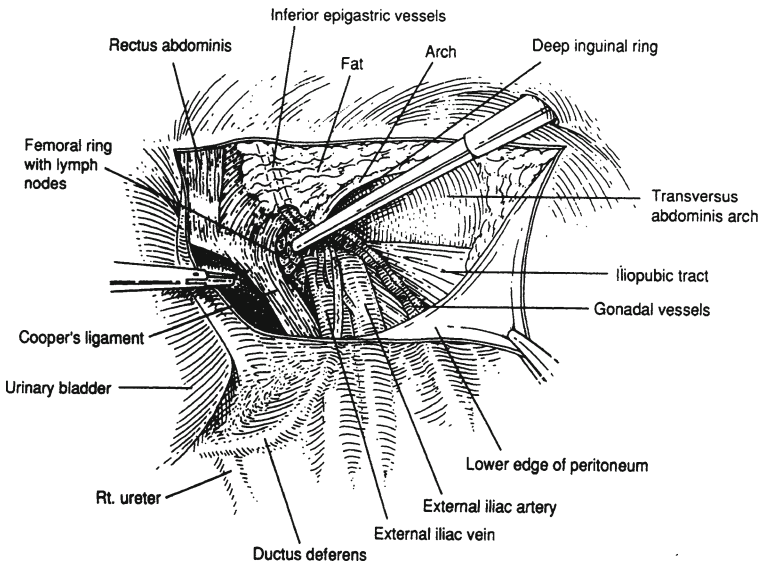


Figure 4.30. With further cleaning, more entities will be seen: the spermatic cord and the iliac vessels (From colborn GL, and Skandalakis JE. Laparoscopic cadaveric anatomy of the inguinal area. *Prob Gen Surg* 12(1):13-20, 1995, with permission).

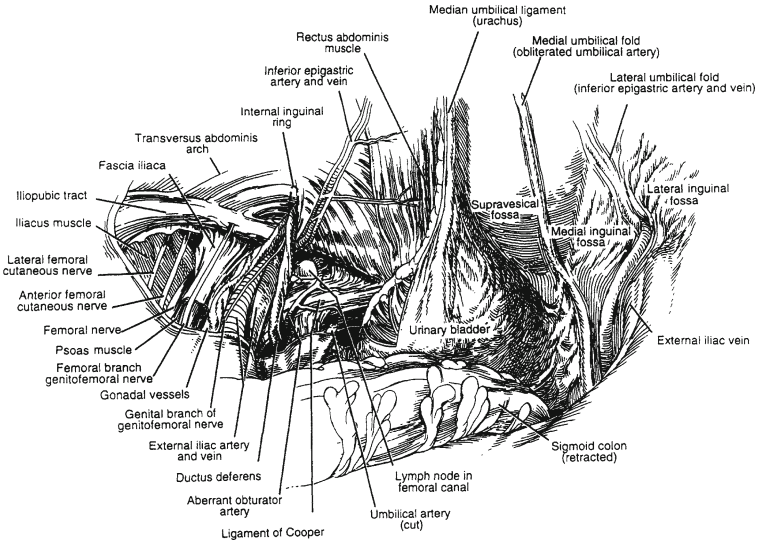


Figure 4.31. Panoramic laparoscopic view of the anatomical entities of the inguinal area (From Colborn GL, and Skandalakis JE. Laparoscopic cadaveric anatomy of the inguinal area. *Prob Gen Surg* 12(1):13–20, 1995, with permission).

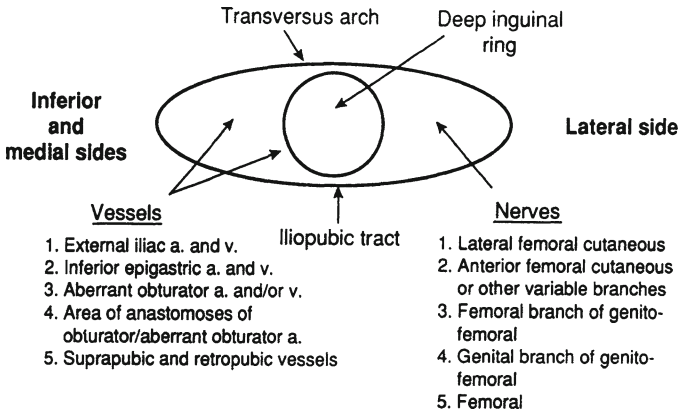


Figure 4.32. Highly diagrammatic presentation of the vessels and nerves related to the iliopubic tract (From Colborn GL, and Skandalakis JE. Laparoscopic cadaveric anatomy of the inguinal area. *Prob Gen Surg* 12(1):13–20, 1995, with permission).

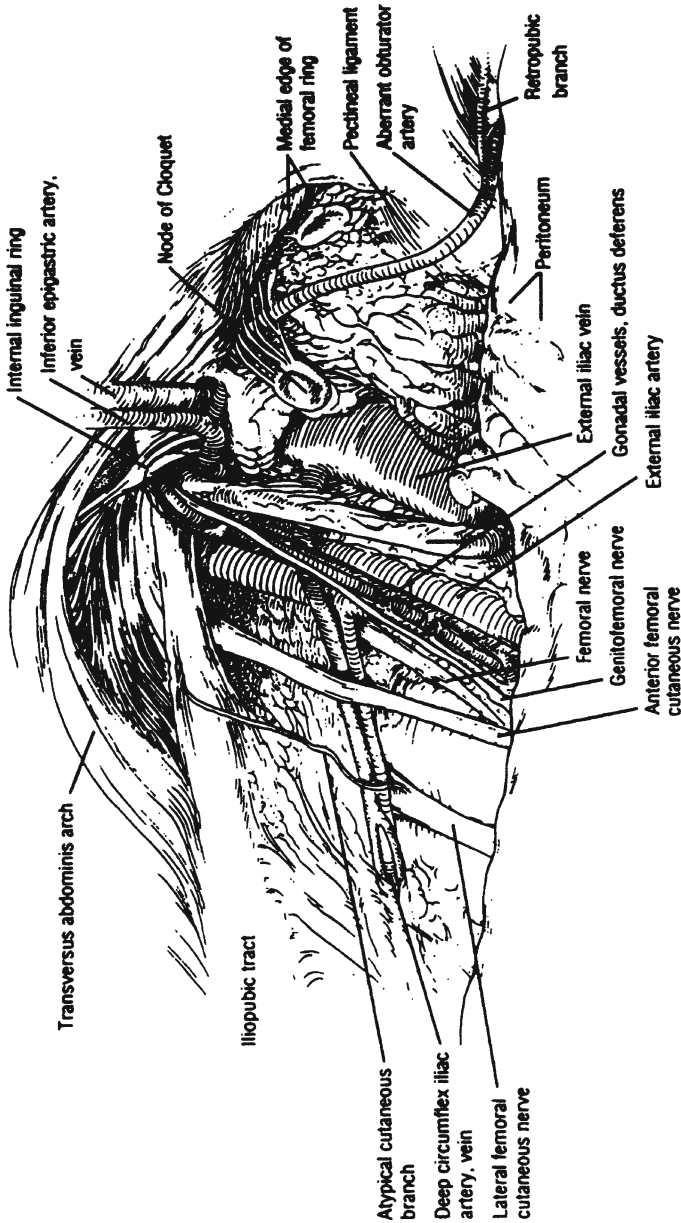


Figure 4.33. Another panoramic laparoscopic view of the anatomy of the inguinal area (By permission of WG Brick, GL Colborn, TR Gadacz, et al. Crucial anatomic lessons for laparoscopic herniorrhaphy. *Am Surg* 61:175, 1995).

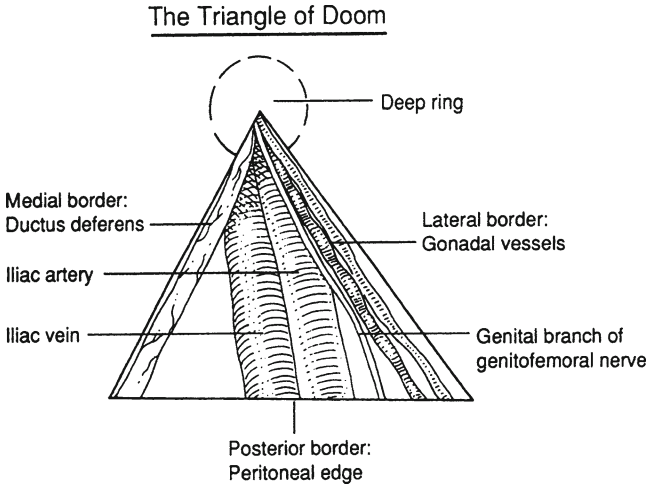


Figure 4.34. The triangle of doom (From Colborn GL, and Skandalakis JE. Laparoscopic cadaveric anatomy of the inguinal area. *Prob Gen Surg* 12(1):13–20, 1995, with permission).

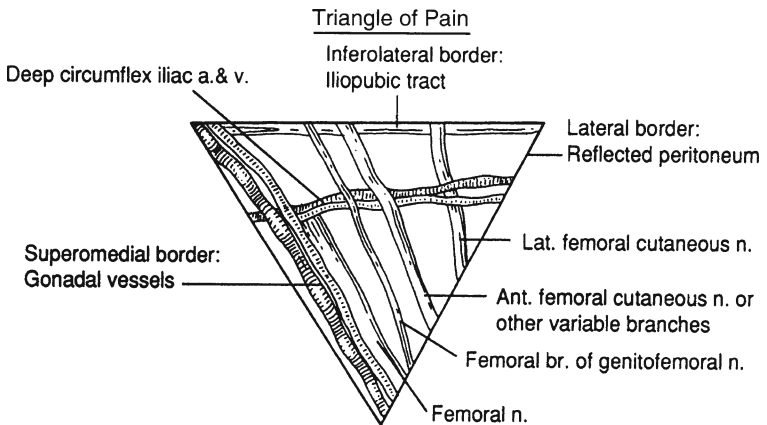


Figure 4.35. The triangle of pain (From Colborn GL, and Skandalakis JE. Laparoscopic cadaveric anatomy of the inguinal area. *Prob Gen Surg* 12(1):13–20, 1995, with permission).

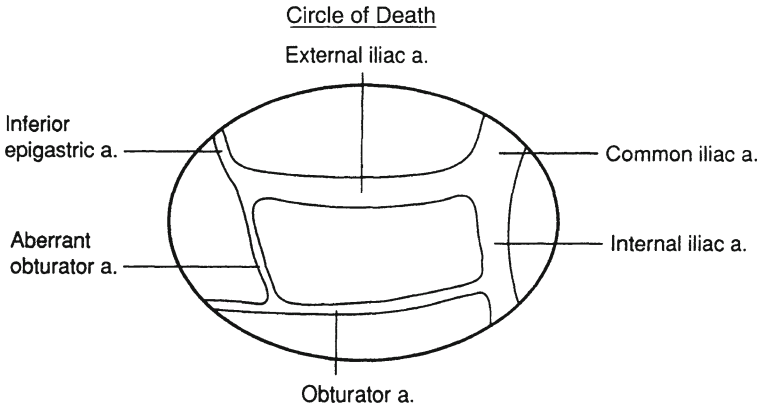


Figure 4.36. The circle of death (From Colborn GL, and Skandalakis JE. Laparoscopic cadaveric anatomy of the inguinal area. *Prob Gen Surg* 12(1):13–20, 1995, with permission).

■ GENERAL DESCRIPTION OF THE POSTERIOR (LUMBAR) BODY WALL

The lumbar area of the posterior body wall is bounded:

- Superiorly: by the 12th rib
- Inferiorly: by the crest of the ilium
- Posteriorly: by the erector spinae (sacrospinalis) muscles
- Anteriorly: by the posterior border of the external oblique muscle

In this area, the body wall is composed of the following layers of muscle and fascia:

- Thick, tough skin.
- Superficial fascia: two layers of fibrous tissue with fat between them.
- A superficial muscle layer composed of the latissimus dorsi muscle posterolaterally and the external oblique muscle anterolaterally.
- Thoracolumbar fascia containing three layers: posterior, middle, and anterior. The posterior and middle layers envelop the sacrospinalis muscle, and the middle anterior layer envelops the quadratus lumborum. Another characteristic of the middle layer of the thoracolumbar fascia is its lateral continuation to the transversus abdominis aponeurosis by fusion

148 4. Abdominal Wall and Hernias

of all three layers. Therefore, the transversus abdominis aponeurosis should be accepted on faith as part of the thoracolumbar fascia.

- A middle muscular layer of the sacrospinalis, internal oblique, and serratus posterior inferior muscles.
- The deep muscular layer, composed of the quadratus lumborum and psoas muscles.
- Transversalis fascia.
- Preperitoneal fat.
- Peritoneum.

Within this area, two triangles may be described: the inferior lumbar triangle (Petit) and the superior lumbar triangle (Grynfeltt).

The base of the inferior lumbar triangle is the iliac crest. The anterior (abdominal) boundary is the posterior border of the external oblique muscle. The posterior (lumbar) boundary is the anterior border of the latissimus dorsi muscle. The floor of the triangle is formed by the internal oblique muscle with contributions from the transversus abdominis muscle and the posterior lamina of the thoracolumbar fascia. The triangle is covered by superficial fascia and skin.

The base of the superior lumbar triangle is the 12th rib and the serratus posterior inferior muscle. The anterior (abdominal) boundary is the posterior border of the internal oblique muscle; the posterior (lumbar) boundary is the anterior border of the sacrospinalis muscle. The floor of the triangle is formed by the aponeurosis of the transversus abdominis muscle arising by fusion of the layers of the thoracolumbar fascia. The roof of the triangle is formed by the external oblique and latissimus dorsi muscles.

The two triangles can be compared as follows:

<i>Inferior triangle</i>	<i>Superior triangle</i>
Upright triangle (apex up)	Inverted triangle (apex down)
Smaller	Larger
Less constant	More constant
Less common site of lumbar hernia	More common site of lumbar hernia
No nerves	12th thoracic nerve
No nerves	First lumbar nerve
Vascular	Avascular
Covered by superficial fascia and skin	Covered by latissimus dorsi muscle
Floor: thoracolumbar fascia, internal oblique muscle, and (partially) transversus abdominis muscle	Floor: union of the layers of the thoracolumbar fascia to form the aponeurosis of the transversus abdominis

In *hernias through the inferior lumbar triangle* (Fig. 4.37), the boundaries are as follows: if the hernia is small, the ring is formed by the thoracolumbar fascia and fibers of the internal oblique muscle; if it is larger, the ring may include the boundaries of the whole inferior triangle. Enlargement of the ring is by section of the fascia.

In *hernias through the superior lumbar triangle* (Fig. 4.37), the boundaries are as follows: if the hernia is small, the hernial ring is formed by the aponeurosis of the transversus abdominis only; if it is large, it may occupy the entire superior triangle. It may be necessary to enlarge the ring by a medial or lateral incision, or both, midway between the 12th rib and the crest of the ilium.

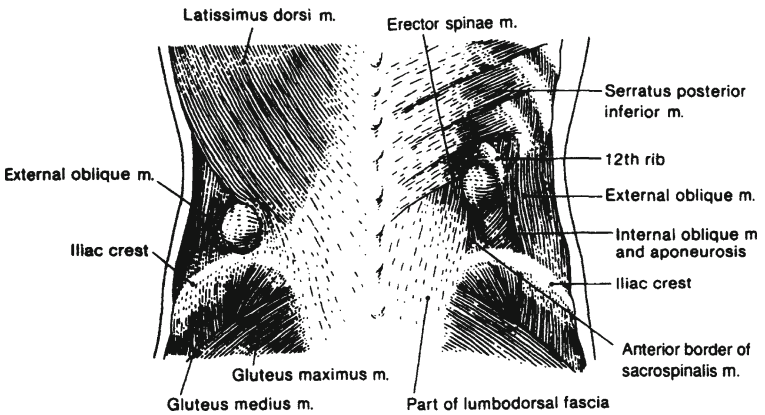


Figure 4.37. *Left*: an inferior hernia through Petit triangle. The base of the triangle is formed by the iliac crest. *Right*: a superior hernia through Grynfeltt triangle. The base of the inverted triangle is formed by the 12th rib (By permission of JE Skandalakis, SW Gray, AR Mansberger, et al. *Hernia: Surgical Anatomy and Technique*. New York: McGraw-Hill, 1989).

TECHNIQUE

■ INCISIONS OF THE ANTERIOR ABDOMINAL WALL

Principles

There are three requirements for a proper abdominal incision:

- Accessibility
- Extensibility
- Viability

A surgeon must plan the incision, taking personal preferences into account. The following rules should be observed where they apply:

- ✓ The incision should be long enough for a good exposure and for room to work, but short enough to avoid unnecessary complications.
- ✓ Where possible, skin incisions should follow Langer's lines.
- ✓ Excise existing scars and proceed, rather than making incisions parallel to the scars.
- ✓ Split muscles in the direction of their fibers, rather than transecting them. The rectus muscle is an exception, because it has a segmental nerve supply and therefore no risk of denervation.
- ✓ Do not superimpose the openings formed through different layers of the abdominal wall.
- ✓ Wherever possible, avoid cutting nerves.
- ✓ Retract muscles and abdominal organs toward, not away from, their neurovascular supply.
- ✓ Insert drainage tubes in separate small incisions. Insertion in the main incision may weaken the wound.
- ✓ Pay close attention to cosmetic considerations, but not at the expense of the requirements of accessibility, extensibility, and viability, as noted previously.
- ✓ Be sure closure follows anatomical topography.
- ✓ Viability dictates using care in patients with multiple abdominal incisions. New incisions must be placed such that skin necrosis is avoided.

Surgical Anatomy of Specific Incisions

Abdominal incisions are legion. Some have descriptive names; others are eponymous. For practical purposes, we will describe only the major types of incisions without discussing their many variations (Fig. 4.38).

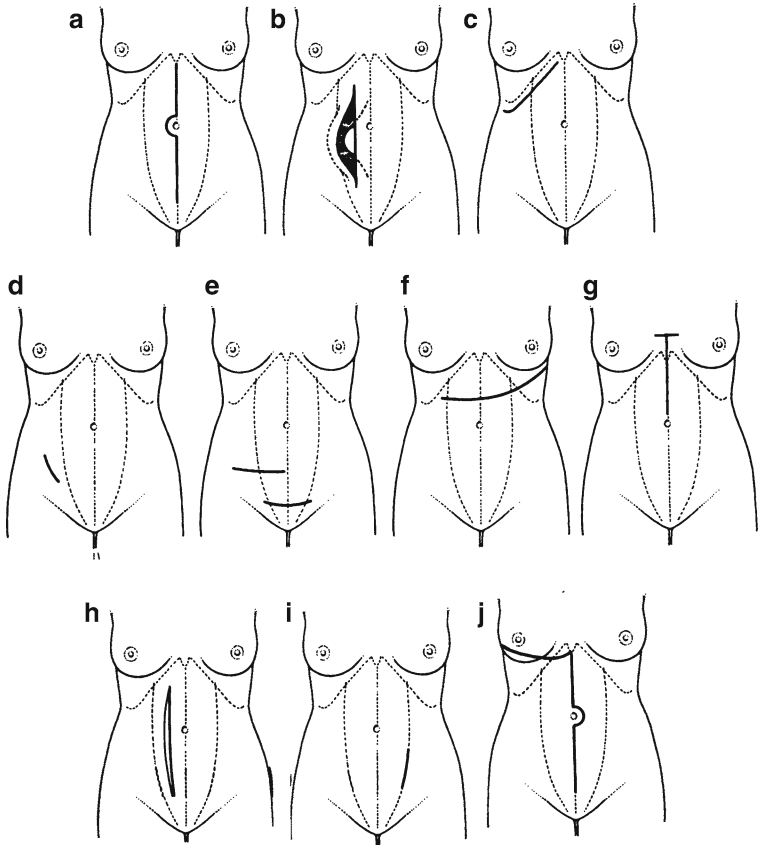


Figure 4.38. Varieties of abdominal incisions. (a) Midline (linea alba) incision. (b) Paramedian (rectus) incision with muscle retraction. (c) Subcostal incision. (d) McBurney incision. (e) Transverse abdominal incision. (f) and (g) Two types of thoracoabdominal incisions. (h) Paramedian (rectus) incision with muscle splitting. (i) Pararectus incision. (j) "Hockey stick" (thoracoabdominal) incision (By permission of JE Skandalakis, SW Gray, and JR Rowe. *Anatomical Complications in General Surgery*. New York: McGraw-Hill, 1983).

Vertical Incisions

Upper Midline Incision

Incisions of the linea alba and the transversalis fascia may reveal abundant and well-vascularized fat in the upper midline (Fig. 4.39a). We suggest that the incisions of the peritoneum be made slightly to the left of the midline to avoid the ligamentum teres in the edge of the falciform ligament. If it is encountered,

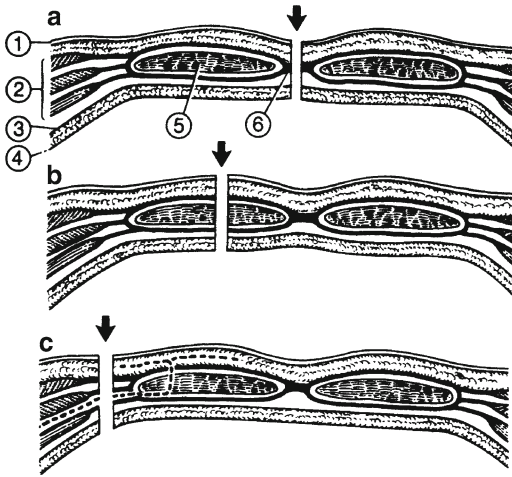


Figure 4.39. Vertical incisions. (a) Incision through the linea alba. (b) Incision through the rectus muscle (paramedian) splitting the muscle. (c) Incision lateral to the rectus sheath (pararectus). Segmental nerves to the rectus muscle (*broken line*) will be cut. (1) Skin, (2) three flat muscles and their aponeuroses, (3) transversalis fascia, (4) peritoneum, (5) rectus abdominis muscle, (6) linea alba (By permission of JE Skandalakis, SW Gray, and JR Rowe. *Anatomical Complications in General Surgery*. New York: McGraw-Hill, 1983).

it may be ligated and divided. Close the linea alba from above downward. Alternatively, closing from caudal to cranial may be easier and cause less evisceration as you approach the costal margin.

A *thoracic extension* of a midline abdominal incision may be made through the eighth intercostal space as far as the scapula. In this procedure, the midline incision is exploratory, and the need for the thoracic extension depends on the pathology revealed by the exploration.

Sternal splitting may be used to continue the midline incision superiorly.

A *lateral extension* to one or even both sides may be L- or T-shaped.

A *downward continuation* of an upper midline incision is always an available option.

Lower Midline Incision

There are some anatomical differences in the midline above and below the umbilicus. The linea alba is narrow and more difficult to identify below. Remember that the bladder must always be decompressed.

An *upward extension* of a lower midline incision is always available to the surgeon. The incision should go around the umbilicus to the left to avoid the ligamentum teres and an unclear umbilicus.

Lateral extensions are the same as those of upper midline extensions.

Occasionally the anatomy of the umbilicus permits a *transumbilical extension*. The surgeon must be sure the umbilical folds are clean.

Rectus (Paramedian) Incision

This incision is preferred by the surgeon who wishes to close the abdominal wall in layers (Fig. 4.39b). It does not destroy muscle tissue or nerves. Retract the rectus muscle laterally to prevent tension on vessels and nerves (Fig. 4.40).

Feasible extensions may be made as described for midline incisions.

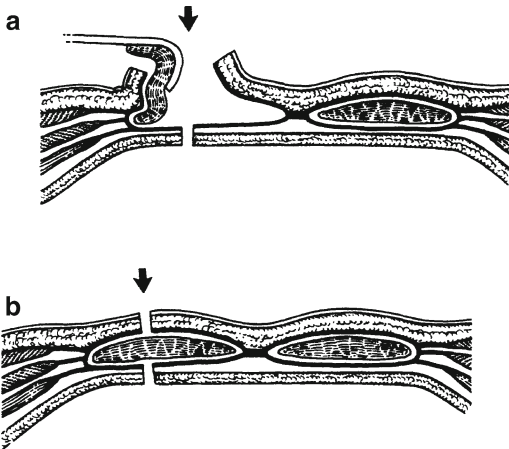


Figure 4.40. Incision through the rectus sheath without muscle splitting. (a) Lateral retraction of the rectus muscle following incision of the anterior layer of the sheath. (b) Release of traction allows intact muscle to bridge the incision through the sheath (compare with Fig. 4.39b) (By permission of JE Skandalakis, SW Gray, and JR Rowe. *Anatomical Complications in General Surgery*. New York: McGraw-Hill, 1983).

Pararectus Incision

The incision is made along the lateral border of the rectus sheath. This is an *undesirable incision* because it cuts across the nerve supply to the rectus muscle (Fig. 4.39c). The blood supply from the inferior epigastric artery also may be compromised.

Extensions will further injure nerves and blood vessels.

Transverse Incisions

In this type of incision, both rectus sheath and muscle are cut. All the transverse incisions may be extended in the midline.

Upper Abdomen

The rectus muscle and the flat muscles may be cut in the line of the skin incision.

Lower Abdomen (Pfannenstiell Incision)

This incision is made horizontally just above the pubis. The anterior rectus sheaths and the linea alba are transected and reflected upward 8–10 cm. The rectus muscles are retracted laterally, and the transversalis fascia and the peritoneum may be cut in the midline. The iliohypogastric nerve must be identified and protected (Fig. 4.41).

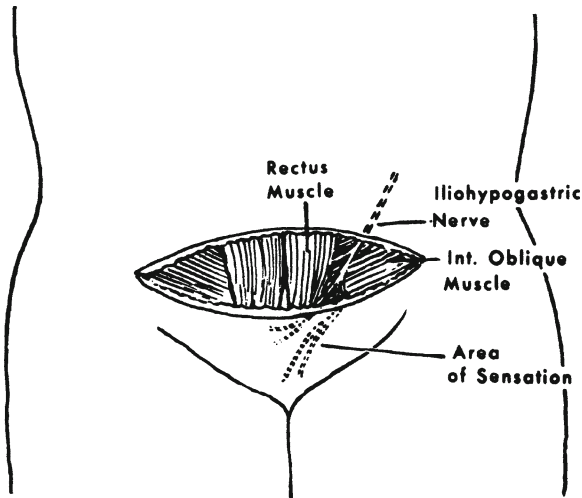


Figure 4.41. Pfannenstiell transverse abdominal incision showing the iliohypogastric nerve between the internal oblique muscle and the external oblique aponeurosis just lateral to the border of the rectus muscle (By permission of CR Grosz. *Am J Surg* 142:628, 1981).

The lower abdominal incision may be extended laterally by dividing the tendinous attachment of the rectus muscle to the pubis. Lateral extension also may be attained by leaving the rectus muscle attached, but retracting it medially and splitting the muscles of the anterolateral wall. This usually requires ligation of the inferior epigastric vessels. Extension too far laterally may jeopardize the iliohypogastric and ilioinguinal nerves (Fig. 4.42).

Oblique Incisions

An oblique incision can be extended laterally to the contralateral side of the body or to the same side by following the costal arch and avoiding the nerves. It may be extended upward or downward on the linea alba. It may be extended obliquely upward through the costal arch if it is necessary to convert it to a thoracoabdominal incision.

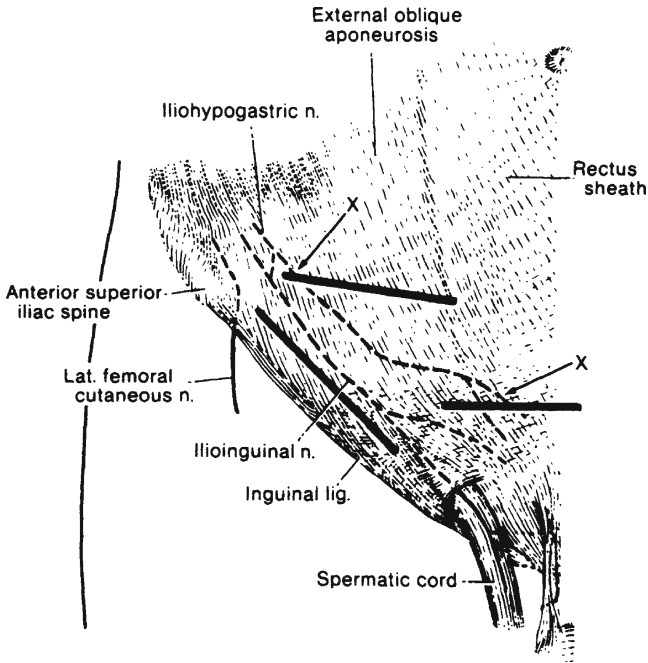


Figure 4.42. The courses of the iliohypogastric and ilioinguinal nerves. Transverse incisions carried too far laterally may cut the iliohypogastric nerve. Inguinal incisions may injure the ilioinguinal nerve directly or it may be inadvertently included in a suture during closure of the incision (By permission of JE Skandalakis, SW Gray, and JR Rowe. *Anatomical Complications in General Surgery*. New York: McGraw-Hill, 1983).

Subcostal Incision

The rectus sheath is incised transversely. The rectus muscle is cut and the external oblique muscle is split and retracted. The incision should extend laterally no further than necessary in order to avoid cutting intercostal nerves. The operator usually sees the small eighth and the larger ninth nerves. The latter should be retracted and preserved.

The external oblique, internal oblique, and transversus abdominis muscles usually can be split. Occasionally, the external oblique fibers must be cut laterally and downward.

A subcostal incision two fingerbreadths below and parallel to the right costal margin is the incision most frequently used.

McBurney Incision

The skin is incised for about 8 cm starting 4 cm medial to the right anterior superior iliac spine and extending downward on a line from the spine to the umbilicus. The aponeurosis of the external oblique and the internal oblique and transversus abdominis muscles are split in the direction of their fibers. The iliohypogastric nerve, deep to the internal oblique muscle, must be identified and preserved.

A McBurney incision may be extended upward and laterally for several centimeters without cutting muscles. Medial extension requires transecting the rectus sheath and muscle. In some instances, it is easier to close the incision and make a new one.

Thoracoabdominal Incisions

Various incisions have been reported for exposure of lesions in the upper abdomen and lower thorax. Thoracic incisions have been made through intercostal spaces 5–9 or by resection of ribs 7–9. The abdominal portion of the incision has been either a midline or a transverse continuation of the thoracic incisions. It may or may not extend into the rectus abdominis.

Use this incision only if it is absolutely necessary.

Dehiscence of the Incision

Obesity, prolonged ileus or bowel obstruction, and wound infection are important factors of dehiscence. Dehiscence is caused by poor quality of the tissue or suturing with bites that are too small, placed too far apart, or tied too tightly. Because wounds in patients with hypoproteinemia heal slowly, hyperalimentation is recommended for those whose protein intake is at all questionable.

In contaminated cases, secondary closure of the skin 4–5 days later is a mature surgical decision. The sutures at the initial closure may be placed, but not tied until later. Good hemostasis, débridement, irrigation, good approximation of skin, absence of tension, and avoidance of dead spaces all contribute to good healing without wound dehiscence, postoperative incisional hernia, or a disfiguring scar.

■ INCISIONAL HERNIAS

Location

Incisional hernias may be located in any part of the abdominal wall, since they are the result of incisions made for some type of surgery. The usual sites are as follows:

- Upper midline
- Umbilical
- Lower midline
- Lateral upper quadrant
- Lateral lower quadrant
- Suprapubic, transverse
- Lumbar

Overall Etiology and Pathogenesis

- Surgery: dehiscence, infection, and poor anatomical knowledge or technique
- Obesity
- Pregnancy
- Straining or severe cough
- Abdominal distention
- Collagen synthesis disorder
- Diabetes
- Malnutrition
- Ascites
- Concomitant steroid therapy

Preoperative Evaluation and Care

- Consider CT scan, gastrointestinal and small bowel series, and barium enema
- Bowel prep, if indicated
- Cleansing of the abdominal wall with Hibiclens or pHisoHex 12 and 1 h prior to surgery
- Shaving the abdominal wall in the operating room
- Intravenous antibiotics in the operating room prior to making the incision and for the first 24 h postoperatively

Operating Room Strategy

I always try to repair these hernias with a nonabsorbable hernia patch. My preference is the Ventrío ST Hernia Patch. If the defect is large, I use an appropriately sized Ventrío ST. If the defect is too small to accept this mesh, then I will close it with an interrupted 0 Nurolon suture. Smaller defects do well with a small Ventralex ST Hernia Patch. With large incisional hernias an appropriately sized Ventrío ST mesh is used, so that there is a 5 cm overlap between the edge of the mesh and the fascial edge. I always try to approximate the fascia to the midline over the mesh. Approximation often will require the use of some type of component separation.

Patients with infected mesh will need a biologic product when they undergo reconstruction by fascial component separation. My preference is for a non-cross-linked porcine product. Placement of the biomes mesh follows the same objectives as noninfected repair: the mesh is placed as an underlay, with a 5 cm overlap between the edge of the fascia and the edge of the mesh. With infected mesh, however, the biomes mesh is secured with multiple transfascial sutures. Generous skin flaps are raised and the external oblique muscle is incised from the anterior superior iliac spine directly up to the costal margin. This is done on each side and should give 5–10 cm of advancement for both sides.

The closure for the defect depends on its size. We recommend the following:

Very Small Defects

- Step 1.** Remove scar by elliptical incision (Fig. 4.43).
- Step 2.** Dissect skin flaps and subcutaneous tissue on both sides of defect down to the aponeurotic area, approximately 3–4 cm around the defect (Fig. 4.44).
- Step 3.** If possible, avoid opening the sac. If this is not possible, remove sac and carefully palpate the defect or defects. Remove all scars and attenuated tissues.
- Step 4.** Close the defect vertically or transversely with interrupted No. 0 Nurolon, with bites 2–2.5 cm from the ring.
- Step 5.** Close in layers.

Larger Defects

For larger defects Ventralex ST or Ventrío ST patch repair is highly recommended: it consists of implanting a prosthesis deep to the muscles of the abdominal wall (Figs. 4.45, 4.46, and 4.47). The Ventrío ST patch has the advantage of “pockets,” which can be tacked easily to the overlying fascia by the use of either interrupted sutures or a laparoscopic tacking device. The Ventralex

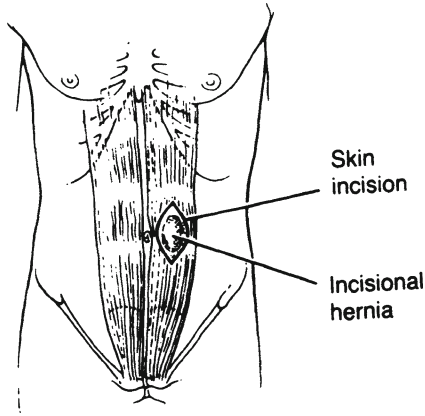


Figure 4.43. Herniation at the site of a left rectus incision (By permission of JE Skandalakis, SW Gray, AR Mansberger, et al. *Hernia: Surgical Anatomy and Technique*. New York: McGraw-Hill, 1989).

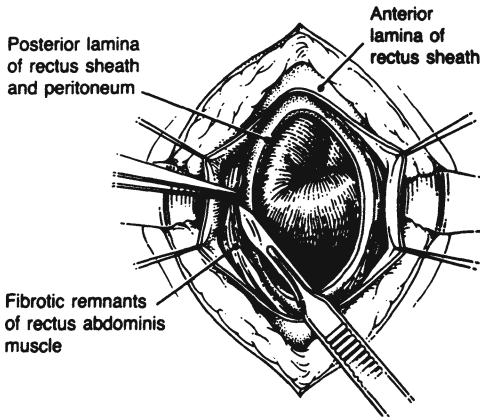


Figure 4.44. Dissection around the ring (By permission of JE Skandalakis, SW Gray, AR Mansberger, et al. *Hernia: Surgical Anatomy and Technique*. New York: McGraw-Hill, 1989).

has a strap that can be pulled up through the defect, thus pulling the patch tight against the anterior abdominal wall. The straps are then sutured to the overlying fascia or fascial ring. It is important to use a mesh size that allows for a 5 cm overlap between the fascial edge and the edge of the mesh.

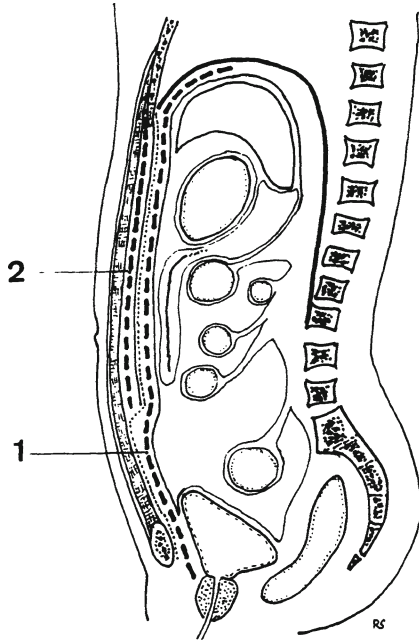


Figure 4.45. Schematic representation of a paramedial sagittal cross section of the trunk, showing the two retroparietal cleavable spaces used for prosthetic repair of large hernias. *Broken line 1*, the retrofascial preperitoneal space used at the lower part of the wall. *Broken line 2*, the retrorectal space used at the supraumbilical part of the wall (modified by permission of Odimba BFK, Stoppa R, Laude M, Henry X, and Verhaeghe P. *J Chir (Paris)* 117(11):621–627; 1980).




Figure 4.46. Schematic representation of a horizontal cross section of the wall at its upper level, with a mesh prosthesis (*broken line*) in the retrorectal cleavable space (courtesy Dr. Rene F. Stoppa).

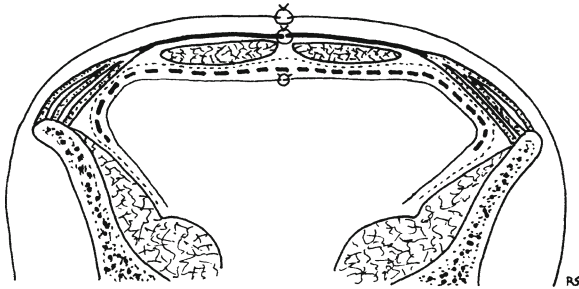


Figure 4.47. Schematic representation of a horizontal cross section of the wall at its lower level, with a mesh prosthesis (*broken line*) in the retrofascial preperitoneal cleavable space (courtesy Dr. Rene F. Stoppa).

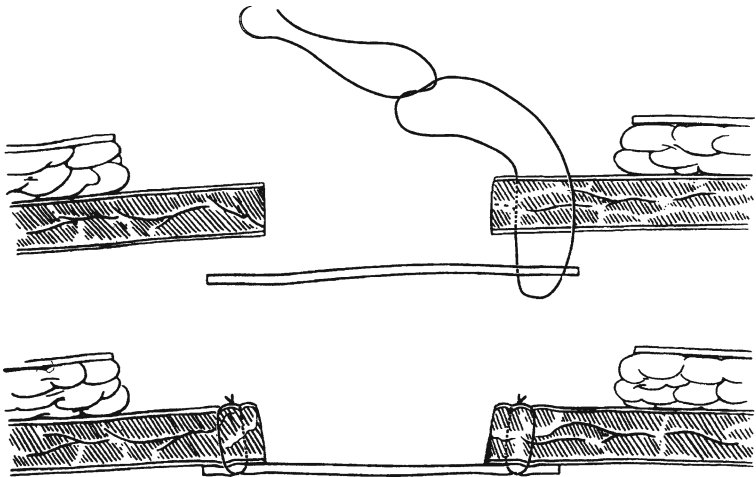


Figure 4.48. *Above*: fixing the deep layer to the posterior surface of the transversalis fascia. *Below*: fixing a second layer to the anterior surface of the fascia (By permission of JE Skandalakis, SW Gray, AR Mansberger, et al. *Hernia: Surgical Anatomy and Technique*. New York: McGraw-Hill, 1989).

An alternative procedure follows:

- Step 1.** Suture Kugel, Gore-Tex, or Marlex prosthesis to the posterior surface of the transversalis fascia.
- Step 2.** Use Gore-Tex suture or 2-0 Prolene. Pass suture through prosthesis and all fascial layers (Fig. 4.48).

162 4. Abdominal Wall and Hernias

Step 3. Jackson–Pratt drains should be used. Insert drains through separate stab wounds. Secure the catheter to the skin.

Note:

- ✓ When infected mesh is removed, it should be replaced with a biomes product (e.g., pigskin, human cadaveric skin) instead of nonabsorbable mesh. Expect to reoperate on these patients in a few years to repair their recurrent hernia.
- ✓ When placing Marlex or Gore-Tex, interrupted transfascial sutures are mandatory. Allow for at least a 5 cm overlap of mesh and fascia.
- ✓ When placing a Ventrion patch use the laparoscopic tacking device, which should be inserted in the anterior pocket of the patch (Fig. 4.49). This placement will fix the patch circumferentially to the overlying fascia.
- ✓ Don't hesitate to view the repair with the laparoscope and to place more tacks as needed.
- ✓ While there are surgeons who believe that abdominal pressure alone keeps a large prosthesis in place, the author prefers fixation.
- ✓ The description of the anatomical fixation of a large prosthesis is *only approximately* as follows:
 - *Upper midline:* costal arch, lateral flat muscles, or rectus sheath.
 - *Umbilical:* lower costal arch; anterior superior iliac spine (if possible); lateral flat muscles; or rectus sheath.
 - *Lower midline:* linea semicircularis, pectineal ligament, space of Retzius, rectus sheath, lateral flat muscles, pubic tubercles, and symphysis pubis.
 - *Lateral upper:* costal arch, anterior superior iliac spine (if possible), rectus sheath, myoaponeurotic flat muscles, or lateral flat muscles.

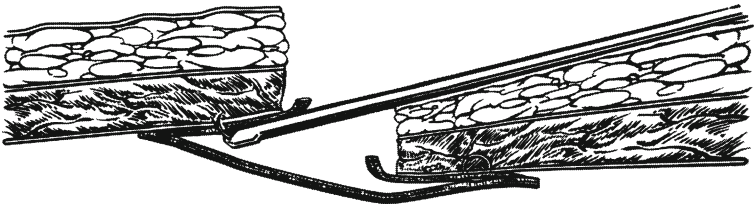


Figure 4.49. Tacking the Kugel patch.

- *Spigelian*: anatomical closure of defect. Remember that the sac is under the aponeurosis of the external oblique.
 - *Lateral lower*: iliac crest, right and left ligaments of Cooper, rectus sheath, or lateral flat muscles.
 - *Lumbar*: external oblique, latissimus dorsi, or iliac crest.
- ✓ On occasion, I have placed bone screws with attached sutures to fix the mesh to the pelvis.

■ COMPONENT SEPARATION (FIG. 4.50)

Component separation is required when the patient has a large incisional or ventral hernia or when infected mesh is being removed, resulting in a large defect. The goal is to place mesh deep to the muscles, secure it with transfascial sutures, and approximate the patient's fascia to the midline, over the mesh. This requires release of the abdominal wall components, the external oblique muscle and rectus sheath bilaterally.

- Step 1.** Excise the previous incision.
- Step 2.** Debride scar tissue, peritoneum, and fatty fascia.
- Step 3.** Perform lysis of adhesions. Make sure that the peritoneum of the anterior abdominal wall is devoid of bowel or omental adhesions.
- Step 4.** Elevate skin flaps on each side with a Bovie. It usually is necessary to go as far lateral as the anterior superior iliac spine, because this is where the external oblique muscle must be separated in order to advance the muscle flaps.
- Step 5.** Using the Bovie, separate the external oblique muscle starting at the anterior superior iliac spine and ending at the costal margin. This should give 5–10 cm of advancement on each side. Again with the Bovie open the rectus sheath longitudinally.
- Step 6.** Choose an appropriately sized piece of mesh. The patient's fascia should be pulled to its midline position so that after the mesh is placed in the abdomen, the edge of the mesh will have a 5 cm overlay.
- Step 7.** Secure the mesh circumferentially with transfascial sutures. Make sure that the fascia is pulled toward the midline when estimating where the sutures will be placed. In a successful mesh placement, the patient's fascia will approximate at the midline without causing any buckling of the mesh.
- Step 8.** Place a 10 mm Jackson–Pratt drain under each skin flap.
- Step 9.** Close the wound in layers, using a 3 0 Vicryl for subcutaneous tissue and a 4 0 Vicryl for subcuticular tissue.

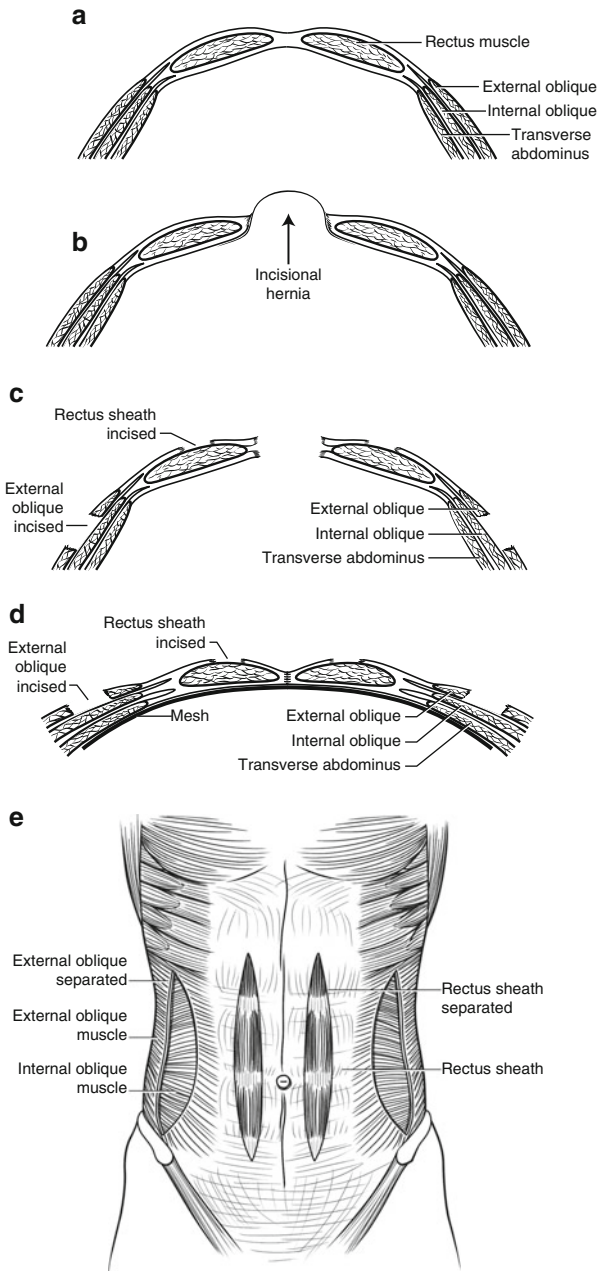


Figure 4.50. (a) “Components” (external oblique muscle and rectus sheath) released. (b–e) Completed operation showing abdominal muscles approximated at the midline with mesh in place.

Note:

- ✓ Depending on the circumstances it may be necessary to secure the mesh to the anterior superior iliac spine and the costal margin. This can be done with a 0 or #1 Prolene on a stout mayo needle, usually a #6.

■ EPIGASTRIC HERNIA (HERNIA THROUGH THE LINEA ALBA)

An epigastric hernia (or hernia through the linea alba) is a protrusion of preperitoneal fat or a peritoneal sac with or without an incarcerated viscus. It occurs in the midline between the xiphoid process and the umbilicus.

In Fig. 4.51, a peritoneal sac containing omentum has formed through a defect in the rectus sheath. The sac is covered only with skin and fat.

- Step 1.** Make a vertical or transverse incision over the mass.
- Step 2.** Dissect the fat down to the linea alba superiorly and inferiorly and to the anterior lamina of the rectus sheath laterally (Fig. 4.52).
- Step 3.** Close the small defect in the linea alba transversely with interrupted 0 Nurolon suture (Fig. 4.53).
- Step 4.** Close subcutaneous tissue and skin.

Note:

- ✓ Alternatively, this repair can be performed using Ventrilo or Ventralex patches, as previously described.

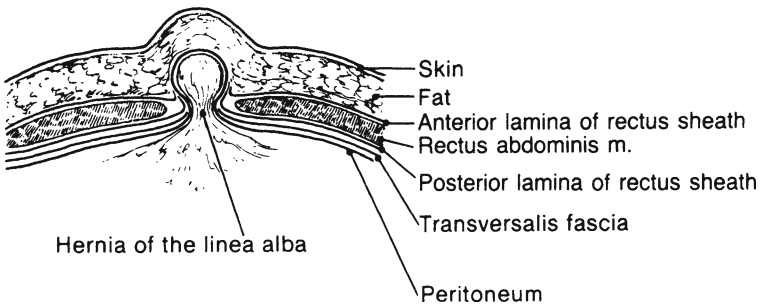


Figure 4.51. Hernia of the linea alba (By permission of JE Skandalakis, SW Gray, AR Mansberger, et al. *Hernia: Surgical Anatomy and Technique*. New York: McGraw-Hill, 1989).

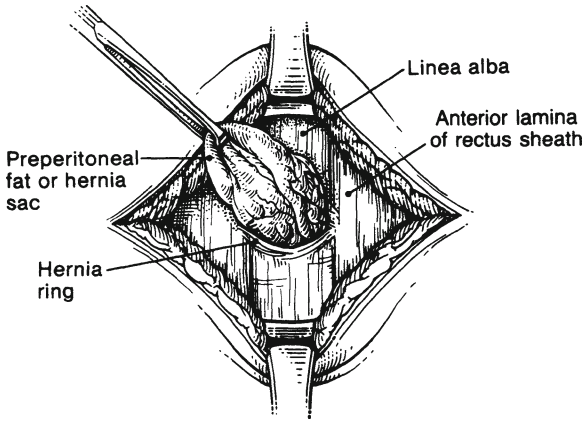


Figure 4.52. Fat is dissected (By permission of JE Skandalakis, SW Gray, AR Mansberger, et al. *Hernia: Surgical Anatomy and Technique*. New York: McGraw-Hill, 1989).

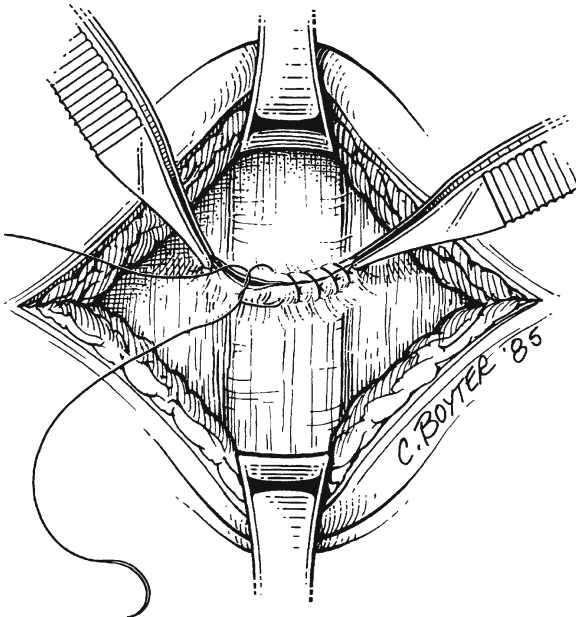


Figure 4.53. Closure of the small defect (By permission of JE Skandalakis, SW Gray, AR Mansberger, et al. *Hernia: Surgical Anatomy and Technique*. New York: McGraw-Hill, 1989).

■ UMBILICAL HERNIA

Small Umbilical Hernia (Fig. 4.54a–g)

Step 1. Make an infraumbilical incision from the 3 o'clock position to the 9 o'clock position.

Step 2. Dissect the sac circumferentially to free it from the surrounding subcutaneous tissue (Fig. 4.54a, b).

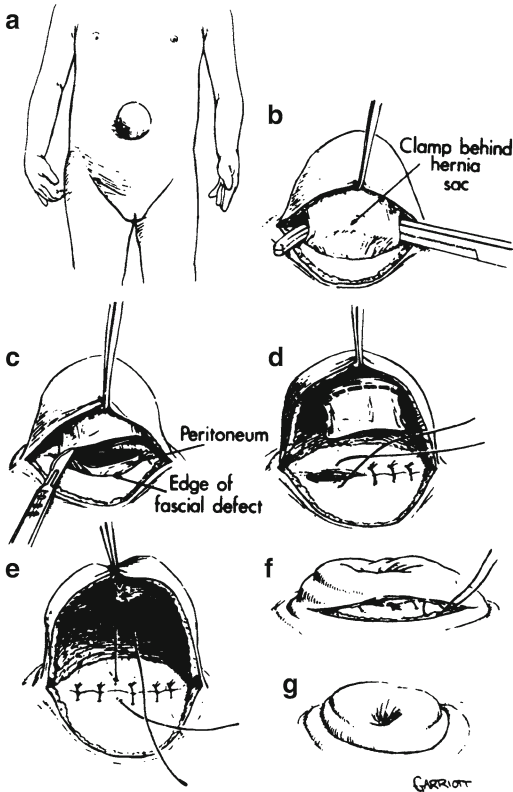


Figure 4.54. Umbilical herniorrhaphy. (a) After umbilicus is grasped and elevated, incision is made in an infraumbilical skin crease. (b) Blunt dissection. Hernial sac encircled with clamp. (c) Sac opened and divided. Interrupted sutures placed and tied. (d) Absorbable sutures placed and tied to help obliterate dead space. (e and f) Skin is closed with subcuticular absorbable sutures. (g) Redundant skin is left alone (By permission of RP Hormel. Umbilical hernia. In: Nyhus LM, and Condon RL. *Hernia*, 3rd ed. Philadelphia: Lippincott, 1989).

168 4. Abdominal Wall and Hernias

Step 3. Divide the sac and excise the excess sac down to the ring (Fig. 4.54c).

Step 4. Use an interrupted 0 Surgilon to close the ring (Fig. 4.54d, e).

Step 5. Close the skin (Fig. 4.54f, g).

Note:

- ✓ We use this technique when the defect is too small to accept a Ventralex patch.

Large Umbilical Hernia, Using Mesh

Umbilical hernias in adults may be the result of large, untreated infantile hernias that failed to close spontaneously. Umbilical hernias in the adult do not close spontaneously.

Step 1. Make an infraumbilical incision from the 3 o'clock position to the 9 o'clock position.

Step 2. Using a Kelly clamp, dissect on each side of the umbilical sac, which usually is adherent to the overlying skin. Pass the Kelly clamp behind the hernia sac.

Step 3. Dissect the hernia sac away from the overlying skin. Continue the dissection of the sac circumferentially down to and below the umbilical ring. Sometimes this is difficult or impossible; in that case, transect the sac.

Step 4. An appropriately sized Ventralex patch can be inserted into and below the umbilical ring. The straps of the Ventralex patch are sutured to the overlying fascia with an interrupted 2-0 PDS suture (Fig. 4.55a-c). Usually, it is possible to close the fascia over the mesh.

Step 5. The overlying umbilical flap is sutured down to the umbilical ring, thus reestablishing a normal-appearing umbilicus. The subcutaneous tissue is closed with an interrupted 3-0 Vicryl. The skin is then closed with a running 4-0 Vicryl subcuticular.

Note:

- ✓ In almost all cases, larger umbilical hernias in adults are repaired using a Kugel patch. In fact, any defect that can accept a small Kugel Ventralex patch is repaired that way. The patch is placed subfascially and the "tails" of the patch are sutured to the fascia.

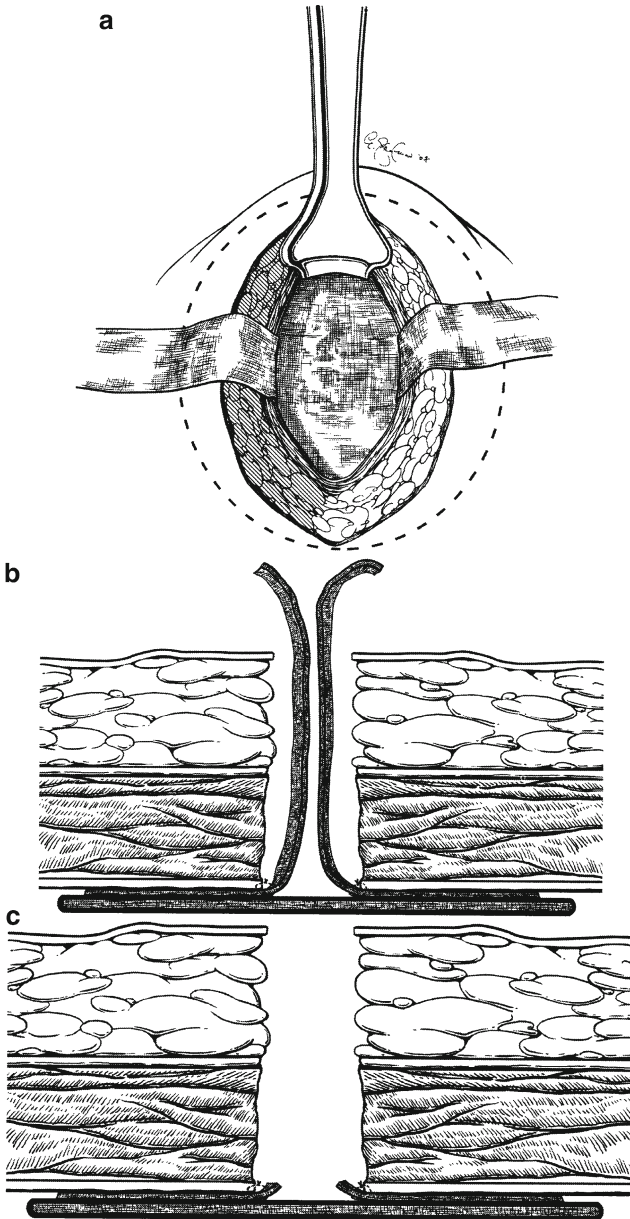


Figure 4.55. (a) Insertion of patch. (b) Straps. (c) Suturing.

■ SPIGELIAN (LATERAL VENTRAL) HERNIA

A spigelian hernia is a spontaneous protrusion of preperitoneal fat, a peritoneal sac, or, less commonly, a sac containing a viscus, through the spigelian zone (fascia) at any point along its length. The zone is bounded medially by the lateral margin of the anterior lamina of the rectus sheath and laterally by the muscular fibers of the internal oblique muscle. The surgeon should be familiar with three entities in this area:

- The semilunar line (of Spiegelhel) marks the lateral border of the rectus sheath. It extends from the pubic tubercle to the tip of the costal cartilage of the ninth rib.
- The semicircular line (arcuate line, fold, or line of Douglas) marks the caudal end of the posterior lamina of the aponeurotic rectus sheath, below the umbilicus and above the pubis. Unfortunately, the semilunar and semicircular lines are not easily seen in the operating room.
- The spigelian fascia (zone, aponeurosis) is composed of the aponeuroses of the external oblique, internal oblique, and transversus abdominis muscles. The region between these muscles and the lateral border of the rectus muscle defines the spigelian fascia. For all practical purposes, the spigelian fascia is formed by the approximation and fusion of the internal oblique and transversus abdominis aponeuroses. If the fusion of these aponeuroses is loose, a “zone” rather than a fascia is formed. The external oblique aponeurosis remains intact over the hernia. Anterior abdominal wall hernias can occur above or below the semicircular line (Fig. 4.56).

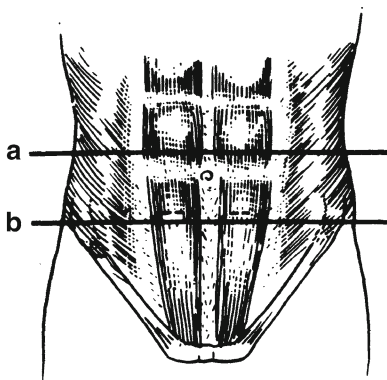


Figure 4.56. Anterior abdominal wall hernias. (a) Hernia above the semicircular line. (b) Hernia below the semicircular line (By permission of JE Skandalakis, SW Gray, AR Mansberger, et al. *Hernia: Surgical Anatomy and Technique*. New York: McGraw-Hill, 1989).

As illustrated in Fig. 4.57a, herniation usually begins with preperitoneal fat passing through defects in the transversus abdominis (A_1) and internal oblique (A_2) aponeuroses. In Fig. 4.57b, note that the transversus abdominis and the internal oblique are broken. However, the aponeurosis of the external oblique muscle remains intact and, with the skin, forms the covering of the hernia.

Repair of Spigelian Hernia

- Step 1.** Make a transverse or vertical incision through the aponeurosis of the external oblique muscle over the palpable mass. If the mass is not palpable at examination, make a midline or vertical rectus incision. If the hernia is incarcerated, the ring should be incised medially toward the rectus abdominis muscle.
- Step 2.** Retract the aponeurosis of the external oblique muscle, revealing the internal oblique muscle and the hernial sac.
- Step 3.** Open the sac; inspect its contents, ligate, and push the sac into the abdomen.
- Step 4.** Free the ring of spigelian fascia from preperitoneal fat and peritoneal adhesions (Fig. 4.58).
- Step 5.** Close the defect in the transversus abdominis and the internal oblique muscle with 0 Surgilon interrupted sutures.
- Step 6.** Close the defect in the aponeurosis of the external oblique muscle with 2-0 Vicryl.
- Step 7.** Close the skin with interrupted sutures or clips.

Note:

- ✓ Alternatively, repair of this hernia can be done using a Ventrion patch as described in the section on incisional/ventral hernias.

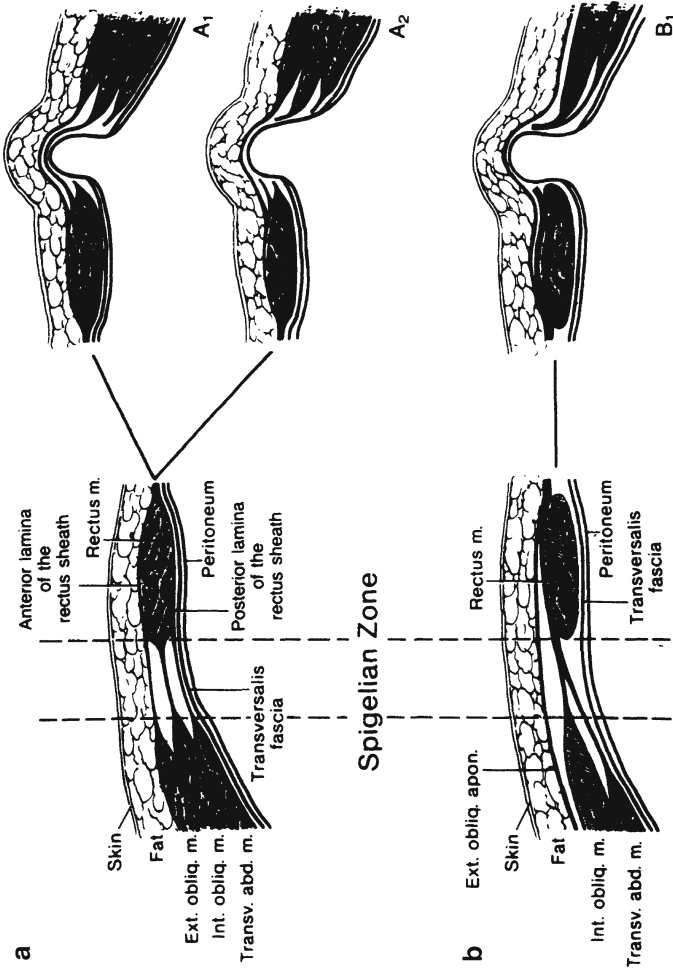


Figure 4.57. (A₁) Transversus abdominis broken; (A₂) Transversus abdominis and internal oblique broken; (B₁) Transversus abdominis and internal oblique broken (By permission of JE Skandalakis, SW Gray, AR Mansberger, et al. *Hernia: Surgical Anatomy and Technique*. New York: McGraw-Hill, 1989).

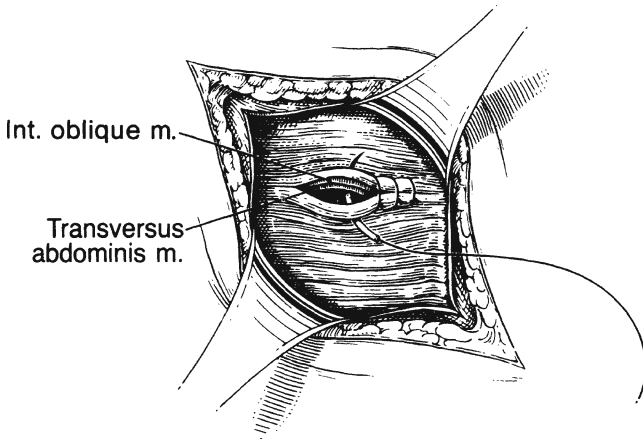


Figure 4.58. Closure of defect (By permission of JE Skandalakis, SW Gray, AR Mansberger, et al. *Hernia: Surgical Anatomy and Technique*. New York: McGraw-Hill, 1989).

GROIN HERNIAS

Three types of hernia—indirect inguinal, direct inguinal, and external supravescical—may emerge through the abdominal wall by way of the external inguinal ring above the inguinal ligament. A fourth type, femoral hernia, emerges beneath the inguinal ligament by way of the femoral canal. These four hernias make up 90 % of all hernias.

NON-MESH GROIN HERNIA REPAIRS

■ INDIRECT INGUINAL HERNIA

An indirect inguinal hernia leaves the abdomen through the internal inguinal ring and passes down the inguinal canal a variable distance along with the spermatic cord or round ligament.

Several repairs are employed for indirect hernias when not using mesh. For younger patients with a small indirect hernia, a Marcy repair can work well. For larger indirect hernias in which the floor is involved, a McVay or Bassini repair can be used.

Cooper Ligament Repair of Indirect Inguinal Hernia

Step 1. Incise the skin approximately 2–3 cm above and parallel to the inguinal ligament (a transverse, gently curved incision following the lines of Langer is another option). With bilateral herniorrhaphy, both male and female patients will appreciate a symmetrical incision. Incise the subcutaneous fascia (Camper) and the fascia of Scarpa by sharp dissection. Open the aponeurosis of the external oblique muscle in the direction of its fibers. The external ring can be found with ease.

Remember:

- ✓ Ligate the large veins (superficial epigastric, superficial circumflex, and external pudendal). Small vessels can be treated by electrocoagulation.
- ✓ Protect the ilioinguinal nerve.
- ✓ If the hernia is recurrent, it will be necessary to excise the preexisting scar, both for cosmetic reasons and for good healing.

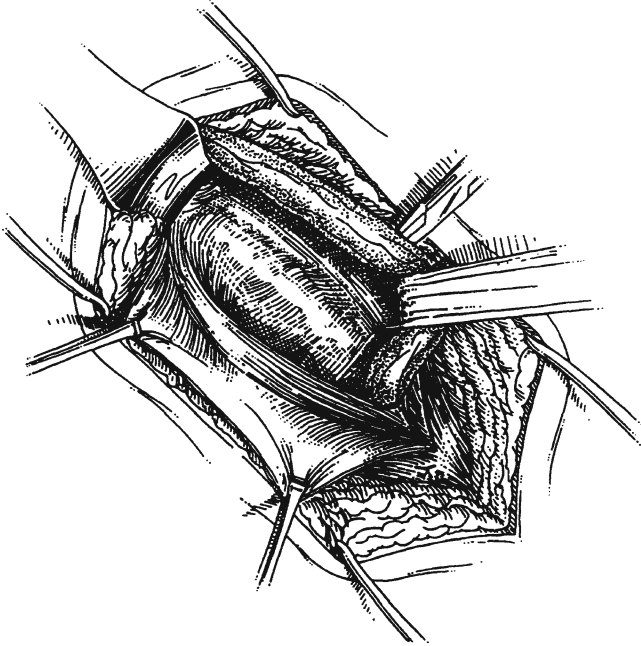


Figure 4.59. Floor of inguinal canal (By permission of JE Skandalakis, SW Gray, AR Mansberger, et al. *Hernia: Surgical Anatomy and Technique*. New York: McGraw-Hill, 1989).

- Step 2.** Elevate the spermatic cord carefully and retract with a Penrose drain. Observe the floor of the inguinal canal (Fig. 4.59).
- Step 3.** Identify the sac located anteromedial to the spermatic cord. Dissect it at the internal ring and lateral to the deep epigastric vessels.
- Step 4.** Ligate and amputate the sac. Occasionally, if there is too much relaxation at the internal ring, the ligated sac should be fixed under the transversus abdominis muscle, which is the upper boundary of the internal ring. Leave the distal part of the sac in situ and open (Wantz procedure) to avoid anatomical complications.
- Step 5.** We agree with Nyhus that a single technique is not appropriate for all patients. The following steps illustrate our technique:
- a. With 0 Surgilon, suture the conjoined area to the ligament of Gimbernat (Fig. 4.60).
 - b. Suture the conjoined area to the ligament of Cooper. This may require three sutures (Fig. 4.61).

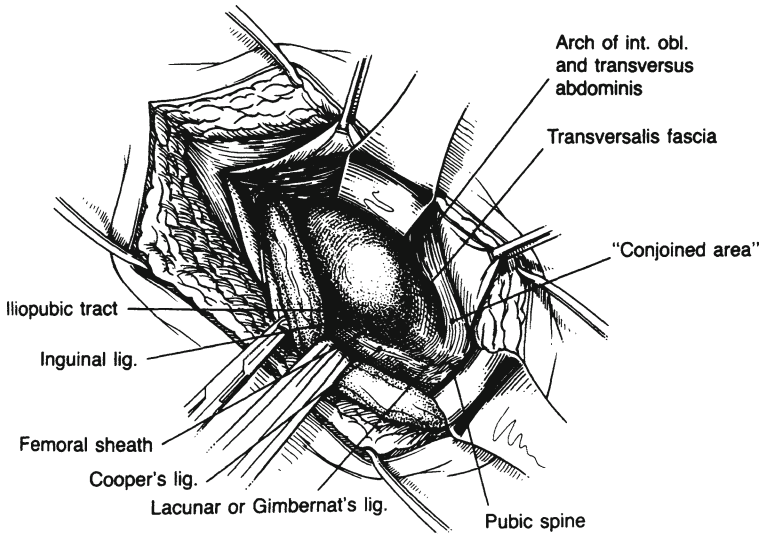


Figure 4.60. Bulging of direct hernia (cord pulled laterally) (By permission of JE Skandalakis, SW Gray, AR Mansberger, et al. *Hernia: Surgical Anatomy and Technique*. New York: McGraw-Hill, 1989).

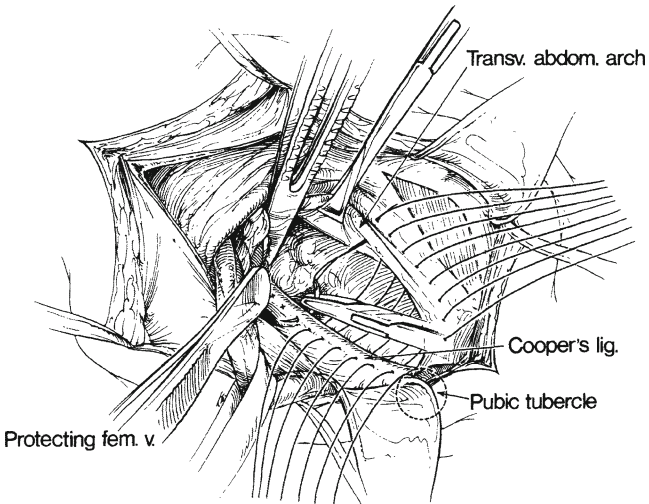


Figure 4.61. Placement of sutures (From Rutledge, RH. The Cooper Ligament Repair. In: Fitzgibbons, RJ Jr., and Greenburg, AG, eds. *Nyhus and Condort's Hernia*, 5th ed. Philadelphia: Lippincott Williams & Wilkins, 2002, p. 143, with permission).

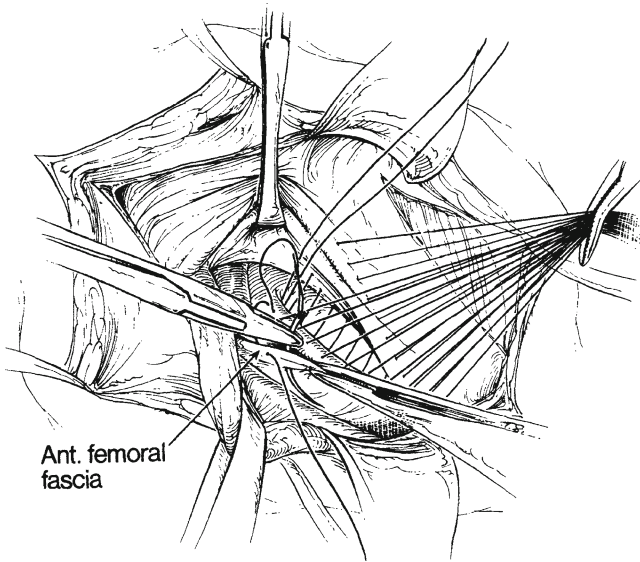


Figure 4.62. Placement of transition suture (From Rutledge, RH. The Cooper Ligament Repair. In: Fitzgibbons, RJ Jr., and Greenburg, AG, eds. *Nyhus and Condon's Hernia*, 5th ed. Philadelphia: Lippincott Williams & Wilkins, 2002, p. 144, with permission).

- c. The Cooper ligament dives deep, so a transition suture is required (Fig. 4.62). This will transition the repair from the Cooper ligament to the Poupart ligament. Without this transition suture a femoral defect will be left, thus allowing for the possibility of a recurrence through the femoral canal. The transversus abdominis arch is sutured to the Poupart ligament, the iliopubic tract, and the Cooper ligament (Fig. 4.63).
- d. The remainder of the sutures incorporates the arch and transversalis fascia, the iliopubic tract, and the inguinal ligament. The distal phalanx of the fifth finger should be inserted with ease into the deep ring, thereby ensuring that the closure is not too snug.

Step 6. Tie all sutures. Close the aponeurosis of the external oblique muscle with a running 2-0 PDS. The spermatic cord may be placed under the aponeurosis of the external oblique muscle.

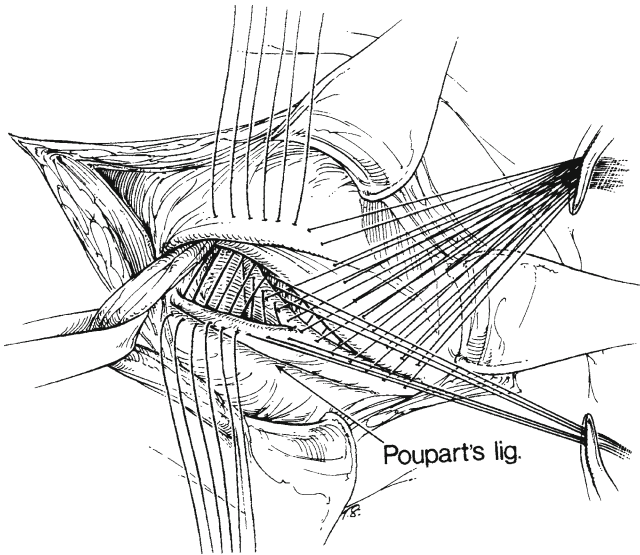


Figure 4.63. Closure of femoral canal (From Rutledge, RH. The Cooper Ligament Repair. In: Fitzgibbons, RJ Jr., and Greenburg, AG, eds. *Nyhus and Condon's Hernia*, 5th ed. Philadelphia: Lippincott Williams & Wilkins, 2002, p. 144, with permission).

Step 7. Perform a relaxing incision. This was placed at the reflection of the external oblique aponeurosis medially. The lamellae are scored with the Bovie such that they separate, exposing the underlying rectus muscle.

Step 8. Close Scarpa fascia with interrupted 3-0 Vicryl. Close the skin.

■ SLIDING INDIRECT INGUINAL HERNIA

A sliding indirect inguinal hernia contains the herniated viscus which makes up all or some of the posterior wall of the sac. The bladder, colon, ovaries, and uterine tube may be involved.

Repair of Sliding Indirect Inguinal Hernia

Communicating and noncommunicating sliding hernias are shown in Fig. 4.64. The internal ring is wider than usual due to the thick spermatic cord. Coincidental direct hernia or weakness of the posterior wall is a strong possibility.

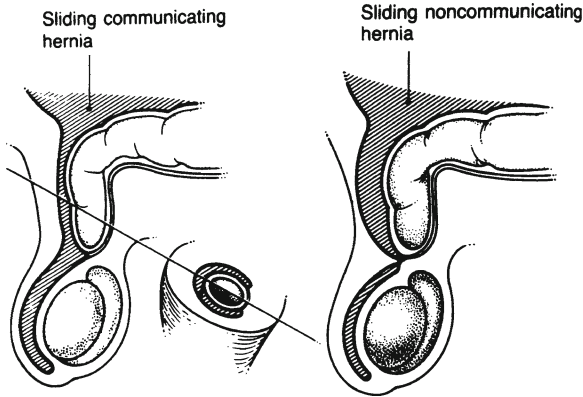


Figure 4.64. Two types of sliding indirect inguinal hernia (By permission of JE Skandalakis, SW Gray, AR Mansberger, et al. *Hernia: Surgical Anatomy and Technique*. New York: McGraw-Hill, 1989).

The hernial sac is located anterior and medial to the cord, as in an indirect hernia. The descending viscus forms the posterior wall of the empty processus (Fig. 4.65).

- Step 1.** Mobilize the sac and open it high and anteriorly. Do not dissect the viscus from the posterior wall of the sac.
- Step 2.** If there is excess anterior wall of the sac, trim it carefully (Fig. 4.66).
- Step 3.** Close the remnants of the sac. Finish the repair as in indirect inguinal hernia.

■ DIRECT INGUINAL HERNIA

A direct inguinal hernia passes through the floor of the inguinal canal in the Hesselbach triangle, which is covered by the transversalis fascia and the aponeurosis of the transversus abdominis muscle, if present.

Repair of Direct Inguinal Hernia

- Step 1.** After incising as in indirect hernia, notice the bulging of the direct hernia with the cord pulled laterally (Fig. 4.60).
- Step 2.** Open the floor of the canal with a Bovie and excise attenuated tissue.
- Step 3.** The suturing technique for direct inguinal hernia is the same as for indirect hernia, performing a Cooper ligament or a McVay repair.

180 4. Abdominal Wall and Hernias

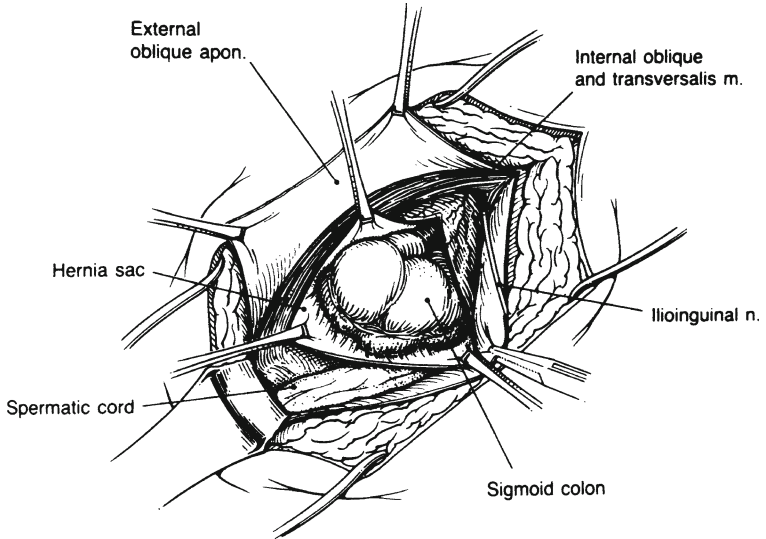


Figure 4.65. Location of hernia sac (By permission of JE Skandalakis, SW Gray, AR Mansberger, et al. *Hernia: Surgical Anatomy and Technique*. New York: McGraw-Hill, 1989).

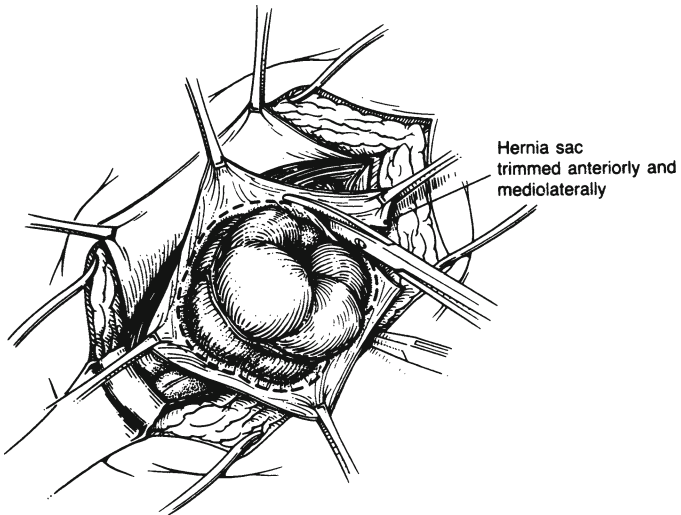


Figure 4.66. Excess tissue is trimmed (By permission of JE Skandalakis, SW Gray, AR Mansberger, et al. *Hernia: Surgical Anatomy and Technique*. New York: McGraw-Hill, 1989).

Follow the precautions outlined for indirect inguinal hernia. Close Scarpa fascia with interrupted 3-0 chromic.

Step 4. Close the skin.

■ SHOULDICE TECHNIQUE

Follow steps 1–4 for Cooper Ligament Repair of Indirect Inguinal Hernia, which is described previously in this chapter.

Step 5. Incise the posterior wall of the inguinal canal from the internal ring, avoiding the deep epigastric vessels, and travel downward medially, ending at the pubic tubercle (Fig. 4.67).

Step 6. Elevate the narrower medial flap as much as possible, but do not elevate the lower lateral flap.

Step 7. Start the first suture line at the pubic bone. Use stainless steel wire and approximate the deep part (white line) of the elevated medial flap to the free edge of the lateral flap. Tie the wire at the internal ring, but do not cut (Fig. 4.68).

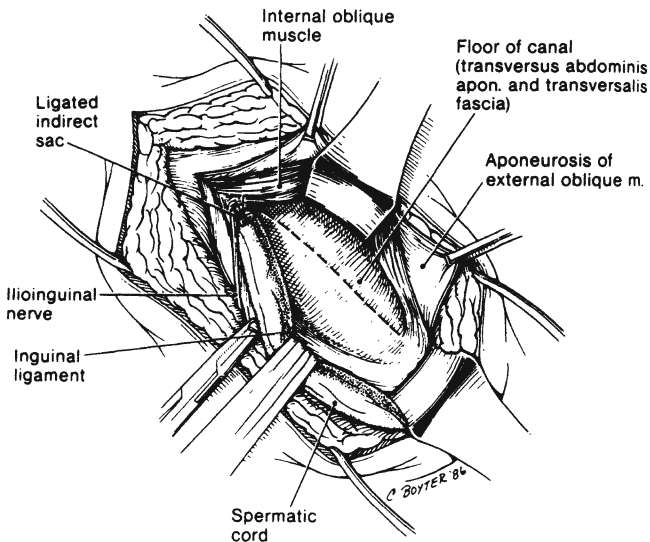


Figure 4.67. Incision of posterior wall (floor) (By permission of JE Skandalakis, SW Gray, AR Mansberger, et al. *Hernia: Surgical Anatomy and Technique*. New York: McGraw-Hill, 1989).

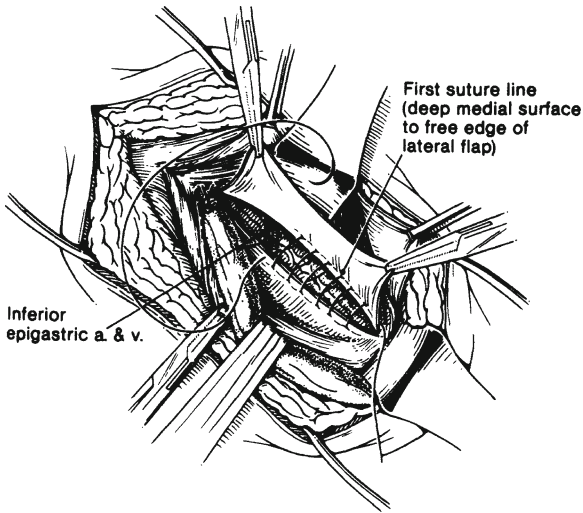


Figure 4.68. Approximation of deep part (By permission of JE Skandalakis, SW Gray, AR Mansberger, et al. *Hernia: Surgical Anatomy and Technique*. New York: McGraw-Hill, 1989).

- Step 8.** Using the same uncut wire suture, approximate the free edge of the medial flap in a continuous way to the shelving edge of the inguinal ligament, traveling downward from the internal ring to the pubic bone. Tie and cut the wire at the pubic bone (Fig. 4.69).
- Step 9.** Using steel wire, start the third suture line at the internal ring, approximating the internal oblique, transversus arch, and the conjoined area to the inguinal ligament. Tie the suture at the area of the pubic tubercle, but do not cut.
- Step 10.** Using the same suture, reapproximate the same anatomical entities as in step 11 from the pubic tubercle to the internal ring (Fig. 4.70).
- Step 11.** Close the external oblique aponeurosis above the spermatic cord. Occasionally, if there is too much tension, the aponeurosis is closed under the spermatic cord.
- Step 12.** Close the superficial fascia and skin as described previously.

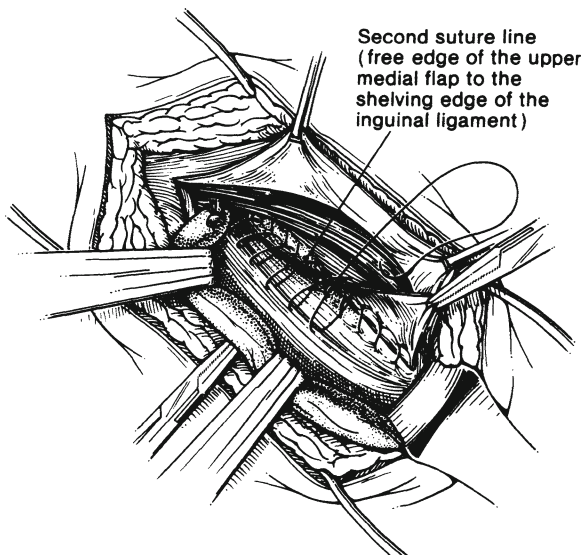


Figure 4.69. Approximation (continued) (By permission of JE Skandalakis, SW Gray, AR Mansberger, et al. *Hernia: Surgical Anatomy and Technique*. New York: McGraw-Hill, 1989).

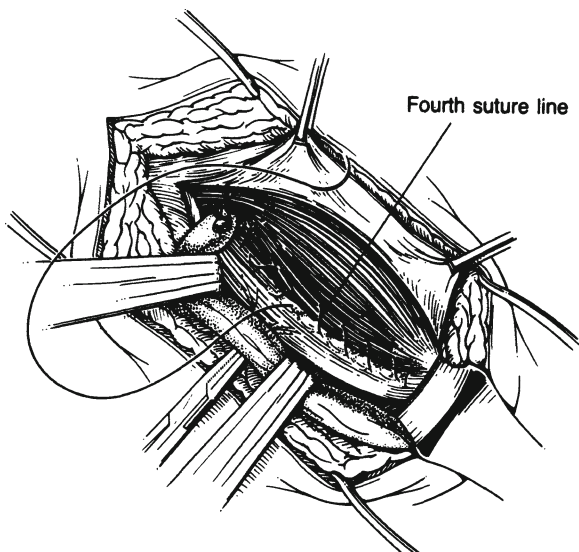


Figure 4.70. Approximation from pubic tubercle to the internal ring (By permission of JE Skandalakis, SW Gray, AR Mansberger, et al. *Hernia: Surgical Anatomy and Technique*. New York: McGraw-Hill, 1989).

■ RELAXING INCISION (FIG. 4.71)

A great deal of tension can result from a newly created inguinal floor in a Cooper ligament repair. This tension can be relaxed using the relaxing incision.

The surgeon should be familiar with the formation of the anterior lamina of the rectus sheath. Below the semicircular line (Douglas or arcuate), there is no posterior aponeurotic layer of the rectus sheath. The anterior layer is formed by the bilaminar aponeuroses of the internal oblique and transversus abdominis muscles and reinforced by the aponeurosis of the external oblique muscle. The aponeurosis of the external oblique muscle may “touch down,” or attach, at the lateral or medial half of the anterior lamina. It almost never does so at the linea semilunaris (lateral border of the rectus abdominis) or at the linea alba.

The relaxing incision is made just lateral to the line of attachment (“touch-down”) of the external oblique aponeurosis to the anterior lamina of the sheath. This is at the point where the fused internal oblique and transversus abdominis aponeuroses form the rectus sheath. The incision starts at the pubic crest and extends upward 5–8 cm. The length of the incision depends on the local anatomy and pathology.

A good anatomical relaxing incision will protect the external oblique aponeurosis and will not permit the rectus muscle to form a myocele. Avoid the iliohypogastric nerve. Also avoid a linea alba incision or an incision at the linea semilunaris by carefully elevating the medial flap of the aponeurosis of the external oblique muscle (Fig. 4.71).

When the direct or large indirect hernia repair is complete, the relaxing incision allows the transversus abdominis to slide inferiorly and laterally. As the incision opens, the rectus muscle is exposed, but the overlying intact superficial lamina (external oblique aponeurosis) of the rectus sheath prevents the development of a hernia.




Figure 4.71. Diagrammatic drawing of the relaxing incision. X, point of relaxing incision at the anterior lamina of the rectus sheath. (black triangle), “touchdown” of the external oblique aponeurosis, always between the linea alba and semilunar line (By permission of JE Skandalakis, SW Gray, AR Mansberger, et al. *Hernia: Surgical Anatomy and Technique*. New York: McGraw-Hill, 1989).

■ EXTERNAL SUPRAVESICAL HERNIA

An external supra-vesical hernia leaves the peritoneal cavity through the supra-vesical fossa, which lies medial to the site of the direct inguinal fossae. Its subsequent course is that of a direct inguinal hernia (see above).

The repair procedure is the same as for direct inguinal hernia. The surgeon should be careful to protect the iliohypogastric nerve, which is located medial to the superior edge of the surgical ellipse.

■ FEMORAL HERNIA

A femoral hernia is a protrusion of preperitoneal fat or intraperitoneal viscus through a weak transversalis fascia into the femoral ring and the femoral canal. Figure 4.72 shows typical and atypical pathways taken by the femoral hernial sac, and Fig. 4.73 illustrates possible locations of aberrant obturator arteries.

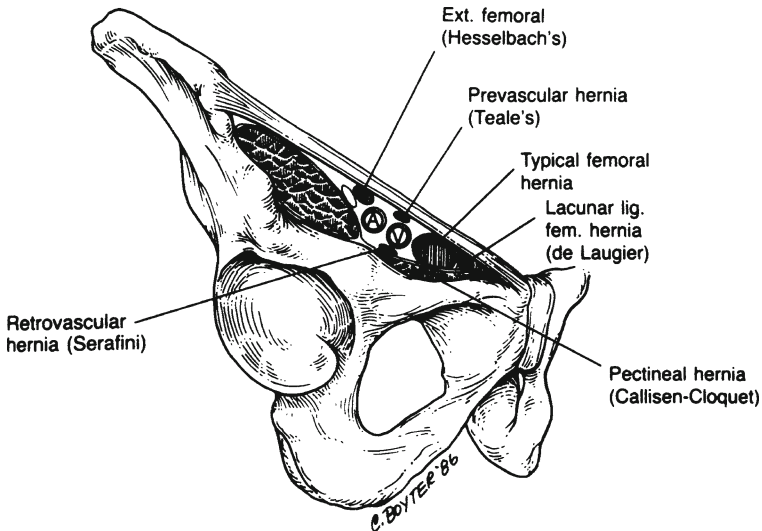


Figure 4.72. Femoral hernia. Typical and atypical pathways taken by the femoral hernial sac. Note the possible relations to the femoral artery (A) and femoral vein (V) (By permission of JE Skandalakis, SW Gray, AR Mansberger, et al. *Hernia: Surgical Anatomy and Technique*. New York: McGraw-Hill, 1989).

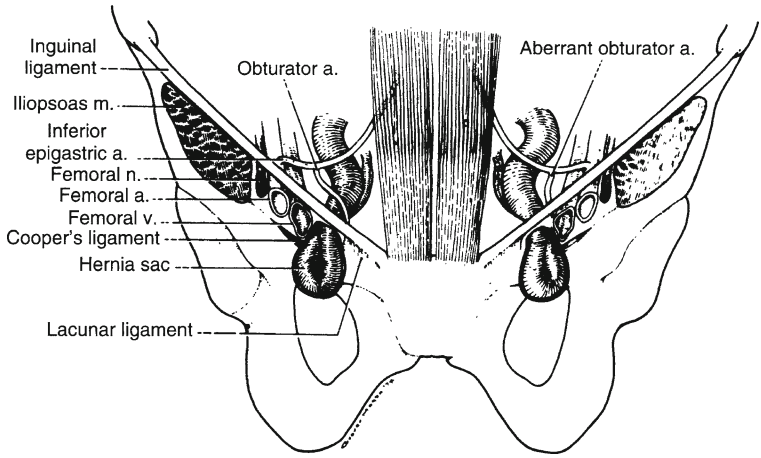


Figure 4.73. Femoral hernia. The *left half* of the drawing shows an aberrant obturator artery (40 %) passing medial to the hernial sac, making it dangerous to incise the lacunar ligament. The *right half* of the drawing shows an aberrant obturator artery passing lateral to the hernial sac, making it safe to incise the lacunar ligament (By permission of JE Skandalakis, SW Gray, and JT Akin. *Surg Clin North Am* 54(6):1227–1246; 1974).

A femoral hernia can be approached in one of the several ways: (1) repair through infrainguinal incision, (2) Cooper ligament repair, and (3) preperitoneal approach using the Nyhus method with mesh or the Kugel repair. If a femoral hernia is to be repaired via a Cooper ligament repair, it is important that the floor of the canal be opened and the preperitoneal space be evaluated. Anything that is incarcerated in the femoral canal must be reduced. It is important that the transition suture between the inguinal ligament and Cooper ligament and the conjoined area be placed securely. It is that suture that prevents the femoral hernia from recurring.

The authors' preference for repair of a femoral hernia is to place mesh in the preperitoneal position; please refer to the Kugel repair. By placing a Kugel patch in the preperitoneal space, there is coverage not only of the femoral canal but also the Hesselbach triangle and the internal ring. In short, the myopectineal orifice of Fruchaud is covered in its entirety. Quite often the femoral hernia is incarcerated and strangulated and therefore extremely difficult—if not impossible—to reduce without incising the inguinal (Poupart) ligament or the lacunar (Gimbernat) ligament.

Femoral Hernia Repair Above the Inguinal Ligament

- Step 1.** Make an incision above the inguinal ligament as in direct hernia. Incise the internal oblique muscle, the transversus abdominis muscle, and the transversalis fascia without entering the peritoneum. Blunt dissection in the preperitoneal space will direct the surgeon to the neck of the hernial sac, which should not be opened at this time.
- Step 2.** Isolate the sac under the inguinal ligament at the fossa ovalis; with the index and middle finger of the other hand, gently push the unopened sac upward through the femoral canal into the inguinal canal (Figs. 4.74 and 4.75). If the hernia is not strangulated, this pressure is very useful. If the hernia is incarcerated or strangulated, the contents of the sac should be examined and not permitted to return to the abdominal cavity.
- Step 3.** Open the floor of the canal and proceed with a Cooper ligament repair.

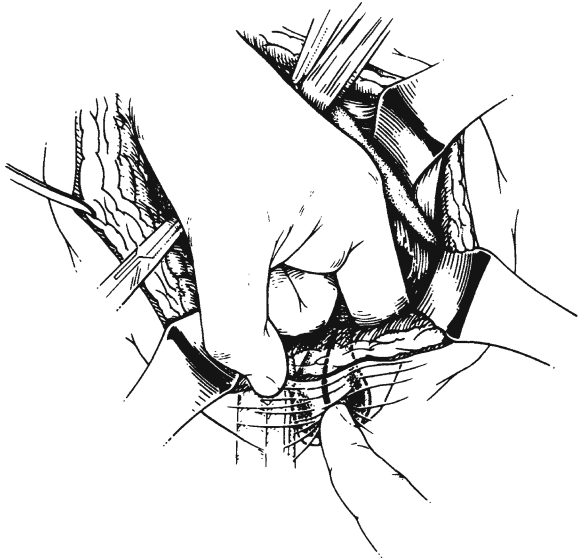


Figure 4.74. Sac is manipulated through femoral canal into inguinal canal (By permission of JE Skandalakis, SW Gray, AR Mansberger, et al. *Hernia: Surgical Anatomy and Technique*. New York: McGraw-Hill, 1989).




Figure 4.75. Femoral hernia is now an inguinal hernia (By permission of JE Skandalakis, SW Gray, AR Mansberger, et al. *Hernia: Surgical Anatomy and Technique*. New York: McGraw-Hill, 1989).

Note:

- ✓ An alternative method of reduction requires sectioning of the lacunar ligament. Before the ligament is incised, the surgeon must be certain that an aberrant obturator artery is not present. Gently manipulate the sac into the posterior wall without losing the contents. An assistant should hold the mass firmly with the thumb and index finger. Open the sac and inspect the contents. If the viscus is vital, trim and ligate the sac. Proceed with the repair as in direct inguinal hernia. If the viscus is not vital, follow resection and anastomosis with the usual repair.

Femoral Hernia Repair Below the Inguinal Ligament

- Step 1.** Make a vertical or transverse incision just above the femoral swelling (Fig. 4.76).
- Step 2.** Isolate the swelling by careful sharp dissection and digital maneuver until the sac is exposed.
- Step 3.** Carefully open the sac. Fluid (which is always present) is sent to the lab for culture and sensitivity testing (Fig. 4.77).

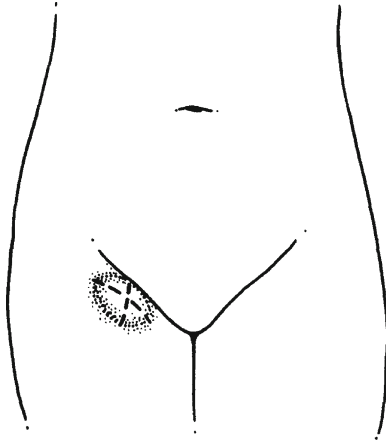


Figure 4.76. Incision site (above femoral swelling) (By permission of JE Skandalakis, SW Gray, AR Mansberger, et al. *Hernia: Surgical Anatomy and Technique*. New York: McGraw-Hill, 1989).

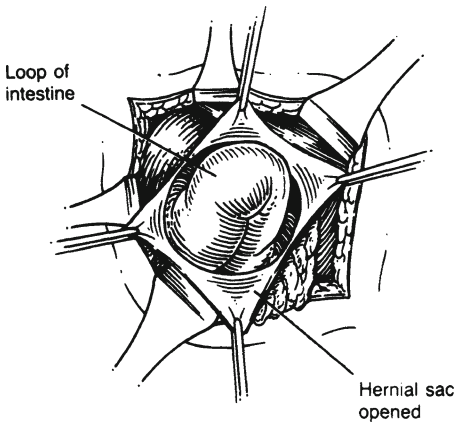


Figure 4.77. Sac opened and contents inspected (By permission of JE Skandalakis, SW Gray, AR Mansberger, et al. *Hernia: Surgical Anatomy and Technique*. New York: McGraw-Hill, 1989).

190 4. Abdominal Wall and Hernias

- Step 4.** Inspect the contents of the sac. If viable, push the contents gently into the abdominal cavity. If constriction of the neck does not permit the return of the viscus into the peritoneal cavity, the hernial ring should be cut. It is our opinion that the best anatomical entity to sacrifice in this situation is the inguinal ligament, not the lacunar ligament.
- Step 5.** Ligate the sac with 2-0 Vicryl and excise it. Gently push the sac into the peritoneal cavity so that the canal is as clean as possible.
- Step 6.** Using 0 Nurolon, suture the inguinal ligament to the pectineal fascia or to Cooper ligament; we prefer Cooper ligament (Figs. 4.78 and 4.79).
- Step 7.** Close the subcutaneous fat and the skin. If the contents of the sac (bowel) are not viable, the assistant should keep the loop in situ, holding it firmly. Make a lower midline incision immediately; resection and anastomosis of the bowel must be done from above. Use of drains or closure of the wound depends on whether there was any contamination of the fossa ovalis or the peritoneal cavity.

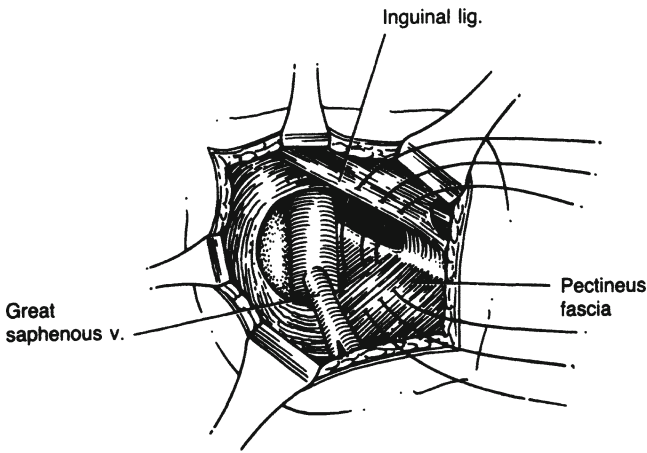


Figure 4.78. Suturing inguinal ligament (By permission of JE Skandalakis, SW Gray, AR Mansberger, et al. *Hernia: Surgical Anatomy and Technique*. New York: McGraw-Hill, 1989).

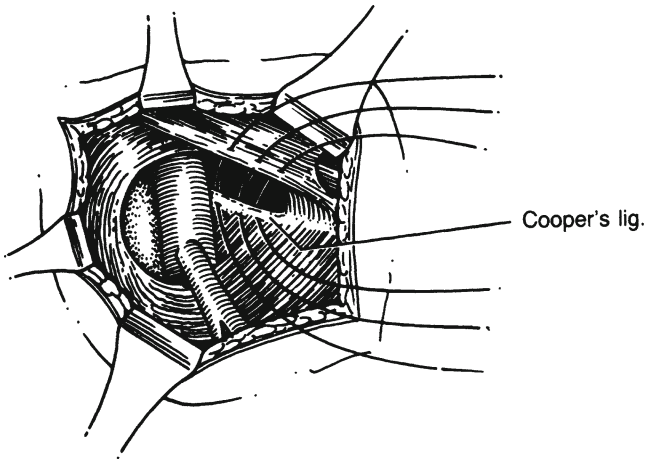


Figure 4.79. (Continued) (By permission of JE Skandalakis, SW Gray, AR Mansberger, et al. *Hernia: Surgical Anatomy and Technique*. New York: McGraw-Hill, 1989).

MESH GROIN HERNIA REPAIRS: POSTERIOR APPROACH

■ NYHUS PROCEDURE (PREPERITONEAL APPROACH)

Figure 4.80 shows important anatomical structures of the posterior inguinal wall as seen from the preperitoneal approach. Figure 4.81 is the same view, demonstrating sites of groin hernias. Figure 4.82 shows the operative approach to the preperitoneal space. It is rarely necessary to ligate and sever the inferior epigastric artery and vein.

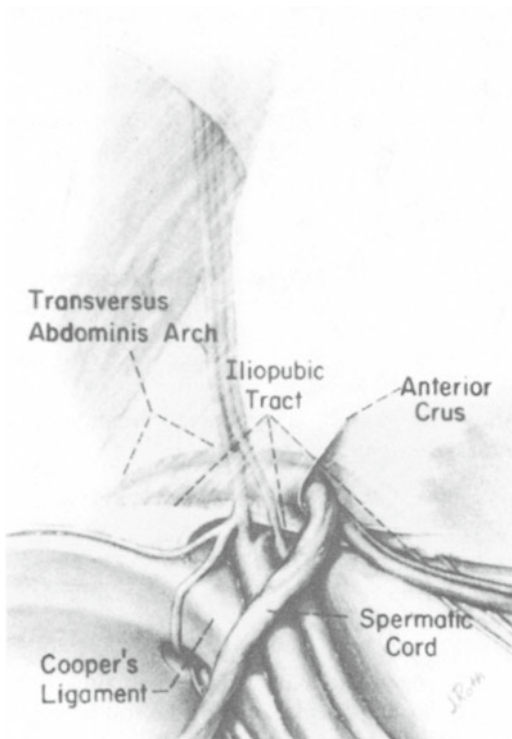


Figure 4.80. Posterior inguinal wall (preperitoneal approach) (By permission of LM Nyhus. The preperitoneal approach and iliopubic tract repair of inguinal hernia. In: LM Nyhus, and RL Condon. *Hernia*, 3rd ed. Philadelphia: Lippincott, 1989).

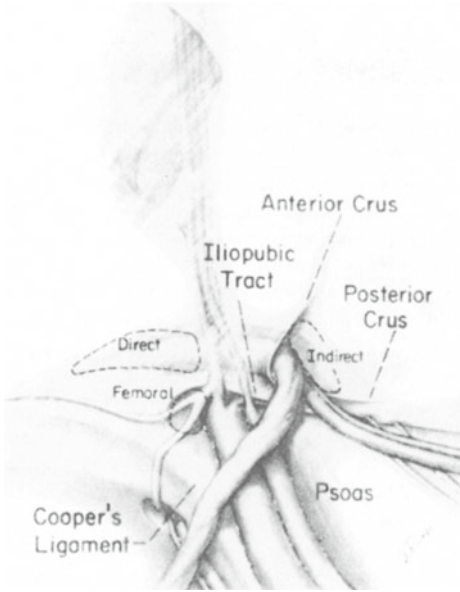


Figure 4.81. Sites of common groin hernias (preperitoneal approach) (By permission of LM Nyhus. The preperitoneal approach and iliopubic tract repair of inguinal hernia. In: LM Nyhus, and RL Condon. *Hernia*, 3rd ed. Philadelphia: Lippincott, 1989).

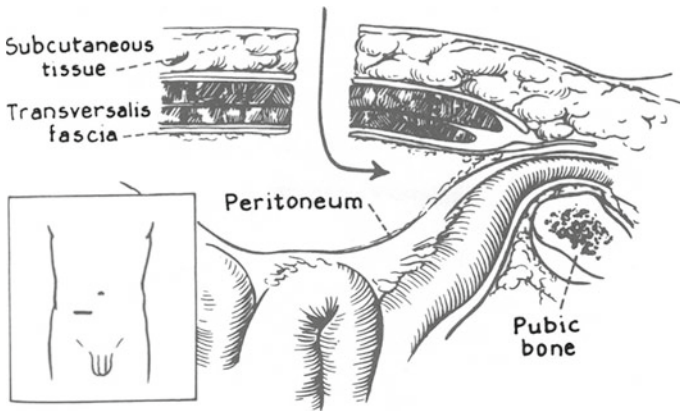


Figure 4.82. Operative approach to preperitoneal space. *Inset*: incision site (By permission of LM Nyhus. The preperitoneal approach and iliopubic tract repair of inguinal hernia. In: LM Nyhus, and RL Condon. *Hernia*, 3rd ed. Philadelphia: Lippincott, 1989).

Nyhus Procedure for Direct, Indirect, and Femoral Inguinal Hernias

- Step 1.** Two fingerbreadths above the symphysis pubis, make a transverse skin incision 4–8 cm long.
- Step 2.** After the skin and subcutaneous tissues have been incised and the rectus sheath exposed, estimate the level of the internal ring by inserting the left index finger into the external ring. This simple maneuver allows visualization of the location of the internal ring in the surgeon's mind's eye. The incision in the anterior rectus fascia should be placed so that it will pass just cephalad to the internal ring.
- Step 3.** Make a transverse fascial incision beginning over the midrectus of the affected side (Fig. 4.83).
- Step 4.** Enlarge the incision by separating and cutting the fascia and muscle fibers of the external oblique, internal oblique, and transversus abdominis muscles. The transversalis fascia is seen in the depth of the wound. When the transversalis fascia is cut, the preperitoneal space of Bogros is entered and the proper plane of dissection is achieved.
- Step 5.** Upon entering the space of Bogros, initiate blunt dissection using the finger and sponge on stick. Mobilize the spermatic cord with a Penrose drain. Dissect out the cord and reduce the sac or ligate and transect the sac. Leave the distal end open. If there is a direct sac, it will reduce with gentle traction using a sponge on stick.

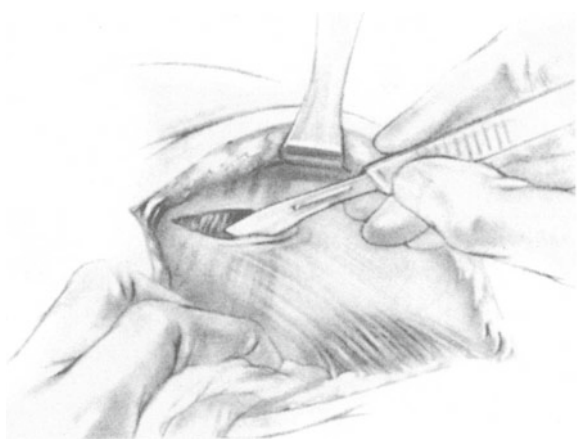


Figure 4.83. Transverse fascial incision begins over midrectus muscle of the affected side (By permission of LM Nyhus. The preperitoneal approach and ilio-pubic tract repair of inguinal hernia. In: LM Nyhus, and RL Condon. *Hernia*, 3rd ed. Philadelphia: Lippincott, 1989).

Step 6. Tailor a piece of Marlex mesh and place it such that the Hesselbach triangle, femoral canal, internal ring, and surgical incision will be covered by it. Suture the mesh inferiorly to the pubic bone and Cooper ligament. Make a 2–3 cm incision laterally in the mesh to allow the spermatic cord to pass through it. Close the opening such that there is just enough room for the cord to pass through. Bring the superior edge of the mesh underneath the superior edge of the wound. Close the wound with interrupted 0 Surgilon, incorporating the mesh into the closure.

Note:

- ✓ This repair is ideal for femoral hernias because the mesh covers not only the Hesselbach triangle and internal ring but also the femoral canal.

■ RECURRENT HERNIAS: INGUINAL AND FEMORAL

A recurrent hernia is one that appears at the site of the initial operation with pathology identical to that for which repair was previously undertaken.

There are several operations to choose from when deciding how to approach a recurrent inguinal or femoral hernia. Selection depends primarily on how the previous hernia was repaired. Was it an anterior or posterior approach? Was mesh used?

Our approach is fairly simple: we try to operate in virgin territory. If the patient had a preperitoneal approach that employed mesh, we will approach the hernia anteriorly, perhaps using a Lichtenstein repair. If the patient had an anterior approach—with or without mesh—we prefer a preperitoneal approach, most likely a Kugel repair. Advantages of staying in virgin territory include lowering the risk of injuring the nerves in the inguinal region and decreasing the likelihood that the spermatic cord will need to be dissected out a second or possibly third time, thus risking an atrophic testicle. If the patient has had a previous anterior repair as well as a posterior or preperitoneal repair, our preference would be to perform another preperitoneal repair using a larger piece of mesh to completely cover the Hesselbach triangle, femoral canal, and internal ring. Our mesh of choice would be the Kugel patch.

■ KUGEL HERNIA REPAIR (PREPERITONEAL PATCH)

Step 1. The preperitoneal space is entered through a muscle-splitting incision made at a point approximately halfway between the anterior superior iliac spine and the pubic tubercle (or a little higher) (Fig. 4.84).

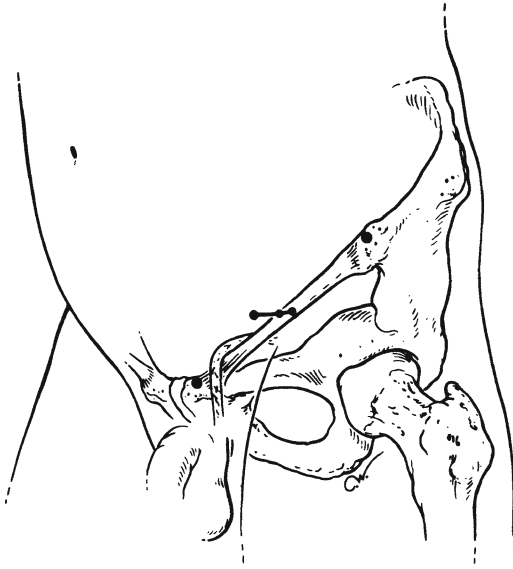


Figure 4.84. External view showing anatomical landmarks used to locate point of incision (used with permission of Surgical Sense, Inc.).

- Step 2.** Open the transversalis fascia vertically about 3 cm, and enter the preperitoneal space at a point just cephalad to the internal ring (Fig. 4.85).
- Step 3.** Use blunt dissection with finger or sponge on stick to free the peritoneum from the overlying transversalis fascia. Carefully separate the cord structures from the adjacent peritoneum and hernial sac (“posteriorization of the cord”).
- Step 4.** Dissect a preperitoneal pocket extending over to the symphysis medially, down over the iliac vessels posteriorly, about 3 cm lateral and superior to the transversalis incision, and roughly paralleling the inguinal ligament (Fig. 4.86).
- Step 5.** Insert the Kugel patch by passing the right index finger through the slit in the anterior layer of the patch, aiming toward the pubic bone (Fig. 4.87) (sliding the patch in over a narrow malleable retractor simplifies placement).
- Step 6.** The patch should lie about three-fifths above the level of the inguinal ligament and two-fifths below it. When the mesh is properly placed in the space of Bogros, the peritoneum is deep to it; the cord

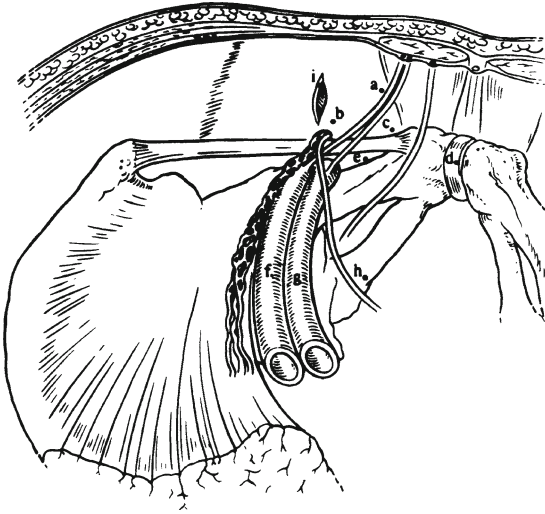


Figure 4.85. Preperitoneal view of the left groin and pelvis showing the transversalis incision (*i*) just superior to the internal ring. (*a*) Inferior epigastric vessels; (*b*) Internal ring; (*c*) Direct space; (*d*) Symphysis pubis; (*e*) Femoral canal; (*f*) Iliac artery; (*g*) Iliac vein; (*h*) Vas (used with permission of Surgical Sense, Inc.).

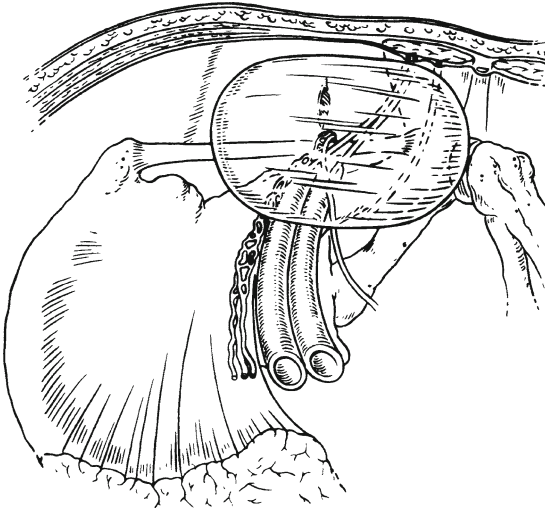


Figure 4.86. Preperitoneal view showing the area of dissection (used with permission of Surgical Sense, Inc.).

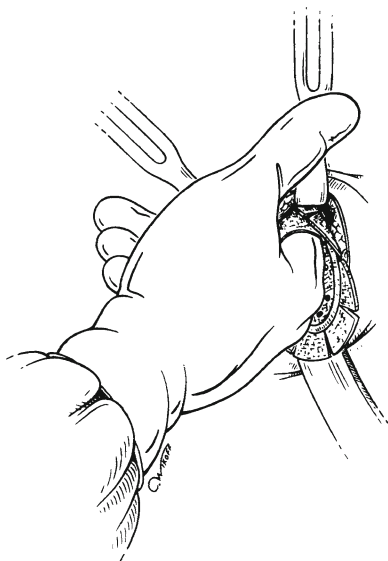


Figure 4.87. Insertion of the patch through the open wound (used with permission of Surgical Sense, Inc.).

structures are anterior and lateral to it. The mesh covers the Hesselbach triangle, internal ring, femoral canal, and the muscle-splitting incision that was made through the internal oblique and transversus abdominis muscles (Fig. 4.88).

Step 7. The transversalis fascia is closed with a single interrupted absorbable suture “catching” the anterior layer of the patch near its superomedial edge. The patch should be anchored only in *a single* location. Close the remainder of the wound with absorbable suture. For very large direct hernias we sometimes secure the patch to the pubic tubercle.

■ STOPPA PROCEDURE

This procedure uses the giant prosthetic reinforcement of the visceral sac (GPRVS). The defect of the abdominal wall is not repaired, but is reinforced with a large prosthesis placed in the preperitoneal area (Bogros’ space) that, for all practical purposes, replaces or reinforces the endopelvic fascia.

The technique is essentially the same for unilateral and bilateral repair. No sutures are used, but the intra-abdominal pressure keeps the prosthesis in situ (Fig. 4.89).

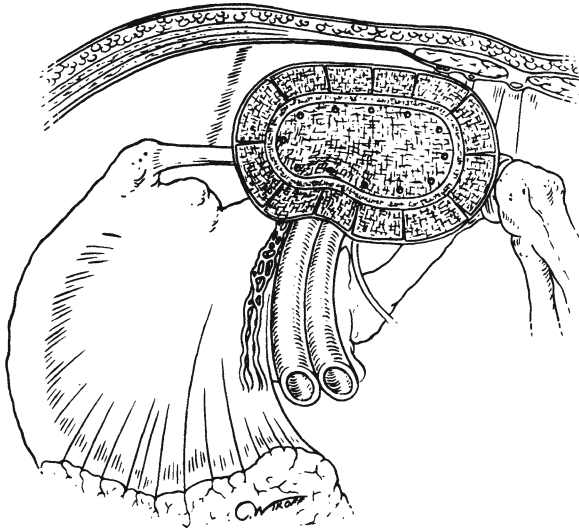


Figure 4.88. Preperitoneal view of the patch in position: parallel to the inguinal ligament, medial edge over to the symphysis, lateral and superior edge beyond the incision, and the posterior edge laying back onto the iliac vessels (used with permission of Surgical Sense, Inc.).

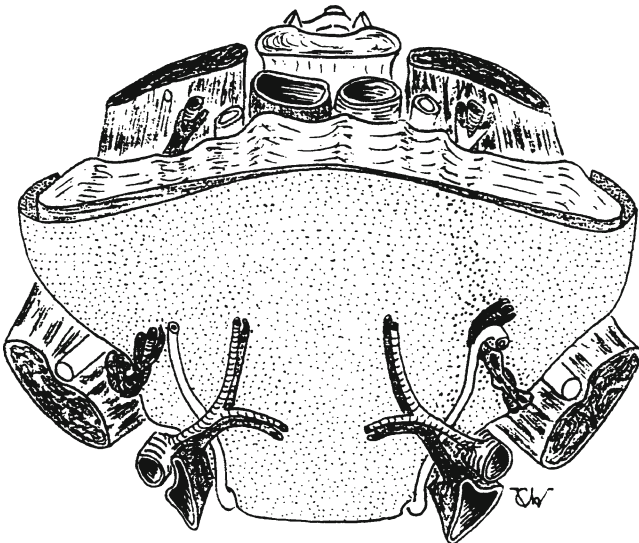


Figure 4.89. Stoppa procedure (courtesy Dr. Rene F. Stoppa).

■ LAPAROSCOPIC INGUINAL HERNIA REPAIR

The laparoscopic approach to repairing groin hernias allows “minimally invasive” access to the preperitoneal space for subsequent mesh herniorrhaphy. The rationale for this approach relies on two basic concepts. First, viewing the posterior inguinal wall through the preperitoneal space reveals the origin of all groin hernias and their close proximity within the myopectineal orifice (Fig. 4.90). A piece of mesh placed over the myopectineal orifice will repair all types of groin hernia simultaneously and without additional incisions or dissection (Fig. 4.91). Second, when closing a defect with mesh, there are obvious mechanical advantages to placing the mesh behind the defect and against the pressures that are creating herniation, rather than on top of the defect where it can easily be pushed away (Fig. 4.92). Laparoscopic access to the preperitoneal space allows placement of a large piece of mesh over the myopectineal orifice, for a truly “tension-free” repair, without the need for the larger incision used during the traditional preperitoneal repair of Nyhus. This “minimally invasive” technique allows patients to return to full activities immediately with a more comfortable recovery, when compared with other techniques of groin hernia repair. It is especially suited to recurrent or bilateral hernias. It should be avoided in patients who have had previous preperitoneal or lower midline incisions, or when there is a significant scrotal component to the hernia.

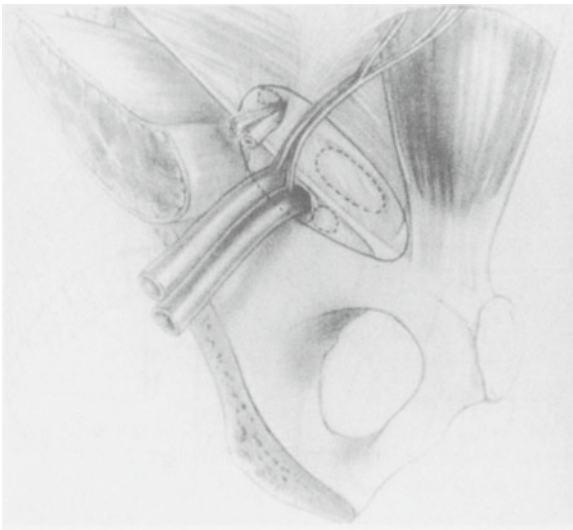


Figure 4.90. Posterior view of Fruchaud's myopectineal orifice (*left*) (permission courtesy of Origin Medsystems Inc.).

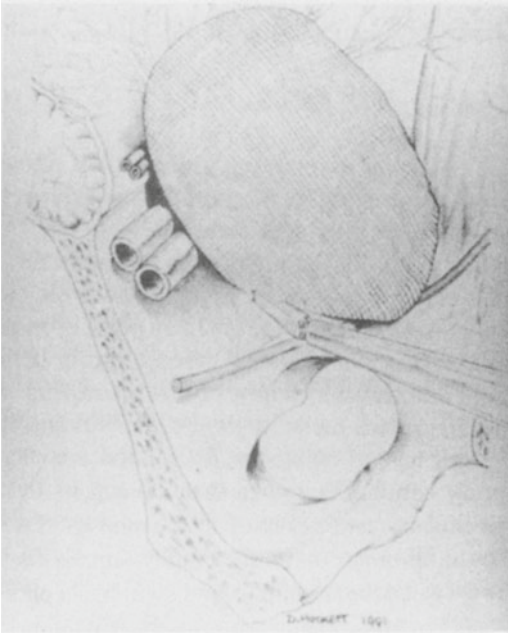


Figure 4.91. Mesh coverage of myopectineal orifice (*left*) (permission courtesy of Origin Medsystems Inc.).

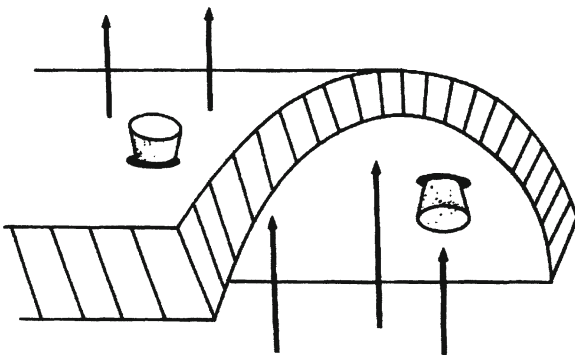


Figure 4.92. Mechanical benefits of placing mesh behind defect (preperitoneal) to resist intra-abdominal forces promoting herniation.

202 4. Abdominal Wall and Hernias

POSITION: Supine with both arms tucked

ANESTHESIA: General

OTHER: Biodrape

- Step 1.** Through a 10 mm infraumbilical incision, expose the anterior surface of the anterior rectus sheath slightly to the left or right of the linea alba. Incise the anterior rectus sheath longitudinally and retract the rectus muscle fibers laterally, thereby exposing the anterior surface of the posterior rectus sheath.
- Step 2.** Using the anterior surface of the posterior rectus sheath as a guide, insert a preperitoneal dissection balloon, Spacemaker by Covidien, into the preperitoneal space (Fig. 4.93), and advance it to position the end of the balloon just behind the symphysis pubis. Inflate the balloon to dissect the preperitoneal space (Fig. 4.94).
- Step 3.** Remove the balloon portion of the device leaving the trocar in place. Insufflate the preperitoneal space to a pressure of 10 mmHg. Place two 5 mm cannulas in the midline, one immediately suprapubic and the second midway between the umbilicus and symphysis pubis (Fig. 4.95).

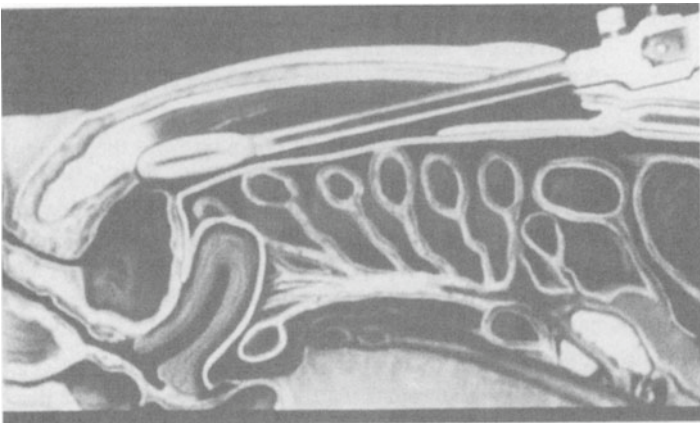


Figure 4.93. Preperitoneal dissecting balloon inserted into the preperitoneal space and positioned just dorsal to symphysis pubis (permission courtesy of Origin Medsystems Inc.).

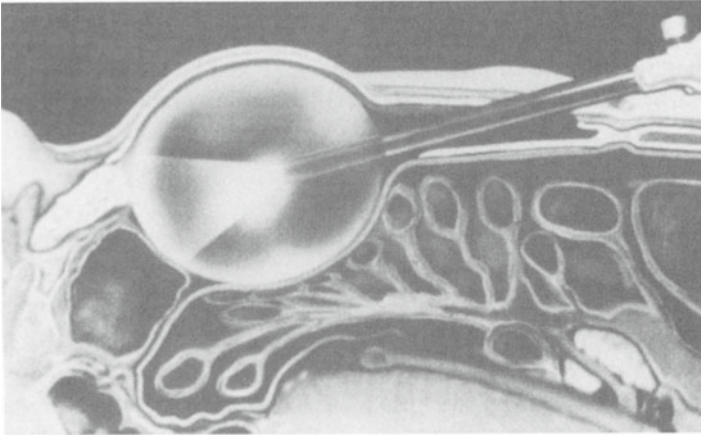


Figure 4.94. Preperitoneal dissecting balloon inflated to dissect the preperitoneal space (permission courtesy of Origin Medsystems, Inc.).

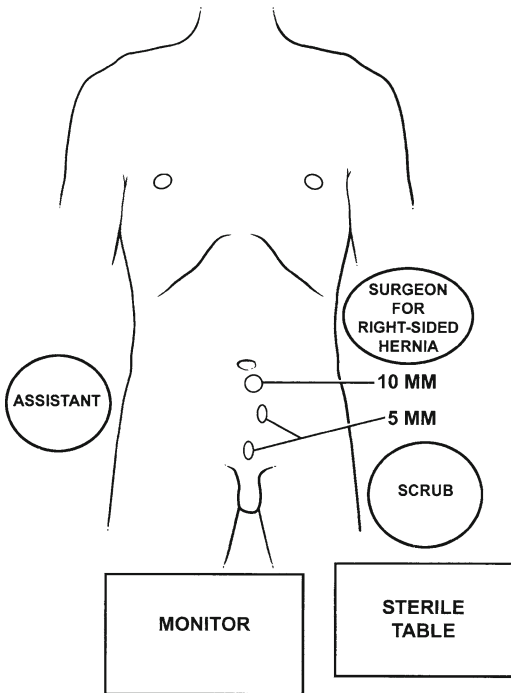


Figure 4.95. Operating room setup and cannula sites for extraperitoneal laparoscopic inguinal hernioplasty.

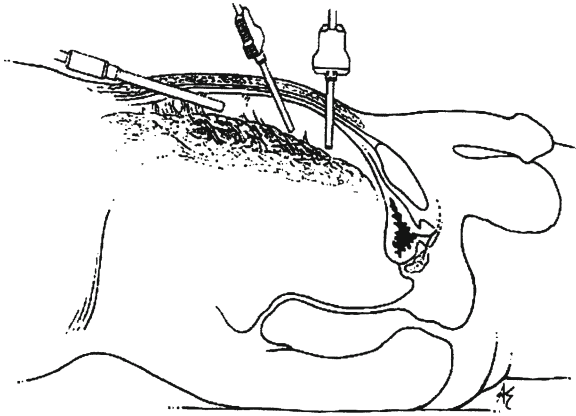


Figure 4.96. Operating within the preperitoneal space laparoscopically.

- Step 4.** Using a camera through the infraumbilical cannula and laparoscopic dissecting instruments through the two 5 mm cannulas, begin dissection of the preperitoneal space (Fig. 4.96).
- Step 5.** Dissect and expose Cooper ligament from the symphysis pubis to just medial to the iliac vessels. This will expose Hesselbach triangle posteriorly, and during this dissection any direct or femoral hernia can be identified and reduced. Be careful not to injure an aberrant obturator artery, which frequently crosses Cooper ligament near the femoral canal and adjacent to Gimbernat ligament (see Fig. 4.36).
- Step 6.** While holding the epigastric vessels anteriorly and against the ventral abdominal wall with one hand, further dissect the preperitoneal space laterally and dorsally by pushing the peritoneum away from the abdominal wall. The peritoneum is loosely adherent to the ventrolateral abdominal wall up to the level of the arcuate line. Leave dissection of the cord structures for last.
- Step 7.** Dissect the internal ring and look for the hernial sac of an indirect hernia. Reduce an indirect hernia by pulling the sac out of the internal ring. If this is difficult, the neck of the sac can be isolated and divided at the internal ring. Peel the peritoneum off the cord structures to complete the dissection of the myopectineal orifice.
- Step 8.** The gonadal vessels and vas deferens should be protected throughout the dissection.

- Step 9.** A piece of nonabsorbable mesh measuring 10×15 cm is rolled and placed within the peritoneal space through the 10 mm camera cannula. The mesh is unrolled and positioned over the myopectineal orifice. Alternatively an anatomically shaped precut Parietex mesh can be used.
- Step 10.** Affix the mesh using a laparoscopic tacking device. Place tacks along Cooper ligament from the symphysis pubis to just medial to the iliac vessels and along the ventral and lateral abdominal wall. Avoid the epigastric vessels. Do not place any tacks dorsal (or lateral and inferior to the cord structures) to the iliopubic tract laterally, where the femoral branch of the genitofemoral nerve, lateral femoral cutaneous nerve of the thigh, and genital branch of the genitofemoral nerve lie (see Figs. 4.31 and 4.35).
- Step 11.** Desufflate the preperitoneal space while holding the dorsolateral corner of the mesh against the abdominal wall. The peritoneum will hold this corner of the mesh in place.
- Step 12.** Remove the cannulas and close the fascia of the anterior rectus sheath with absorbable 0 suture. Close the skin on all cannula sites with a subcuticular 4-0 absorbable subcuticular suture.

Note:

- ✓ If the patient has a large sac that extends into the scrotum and is difficult to remove, do not waste time trying to retrieve it. Transect it at the internal ring and close the resulting defect in the peritoneum using an Endoloop.

MESH GROIN HERNIA REPAIRS: ANTERIOR APPROACH

■ LICHTENSTEIN TENSION-FREE HERNIORRHAPHY

Dissect out the spermatic cord as per indirect hernia repair. For the Lichtenstein repair, use either precut mesh or tailor your own; we prefer the precut product. Suture the mesh to the pubic tubercle. Next, position the mesh on the floor of the canal and bring the cord through the “tails” of the mesh; suture the mesh to Poupart ligament, the conjoined area, and the arch (Fig. 4.97).

For the repair of recurrent or femoral hernia, clean the defect, and dissect and invaginate the sac. Roll a strip of 10×2 cm polypropylene into a cylindrical plug, and insert it into the defect until it fits snugly. Suture the plug to the edges of the defect with interrupted 2-0 polypropylene suture. If necessary to secure the plug, use more sutures (Fig. 4.98).

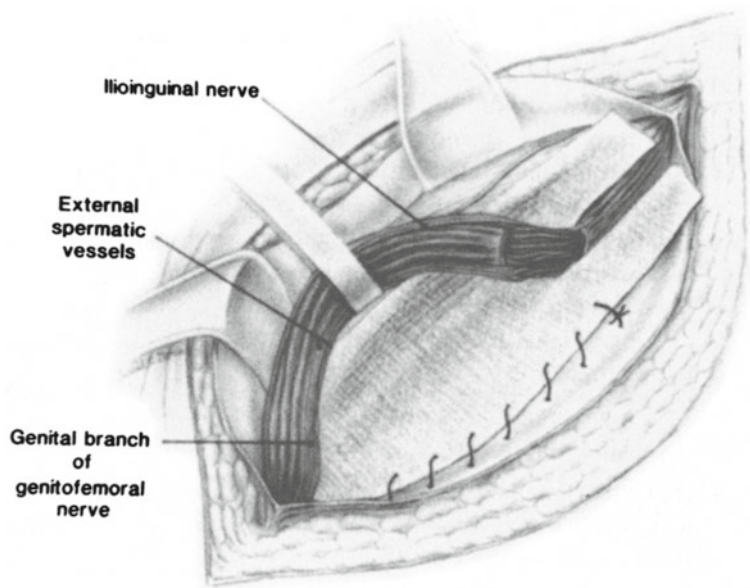


Figure 4.97. Lichtenstein repair (By permission of PK Amid, AG Shulman, IL Lichtenstein. *Am J Surg* 165:369–371; 1993).

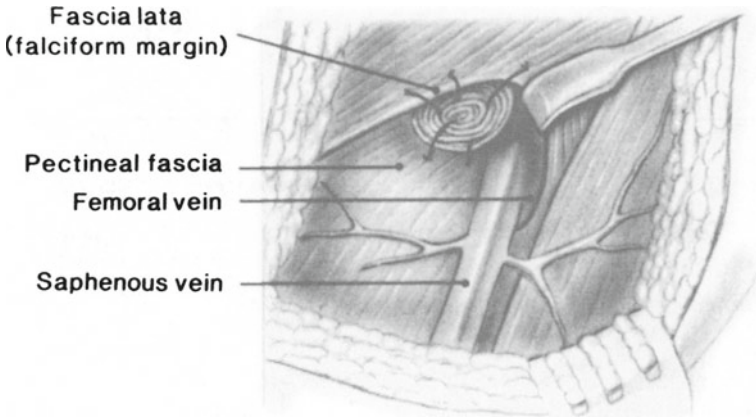


Figure 4.98. Suture placement (courtesy Dr. Irving L. Lichtenstein).

■ BARD PLUG AND PATCH REPAIR

- Step 1.** Approach inguinal canal as in anterior approach through oblique inguinal skin incision. Through subcutaneous tissue, open external oblique aponeurosis.
- Step 2.** Mobilize spermatic cord and dissect out sac. If direct hernia, score base of sac with Bovie (Fig. 4.99).
- Step 3.** Insert an appropriately sized plug into internal ring (or direct defect if this is a direct hernia). Mesh should go into preperitoneal space (Fig. 4.100).
- Step 4.** With three or four sutures, secure mesh to internal oblique or conjoined area (Figs. 4.101 and 4.102).
- Step 5.** Place onlay patch with tails around cord and secure to pubic tubercle, Poupart ligament, conjoined area, and internal oblique (Fig. 4.103).
- Step 6.** Close external oblique, subcutaneous tissue, and skin.

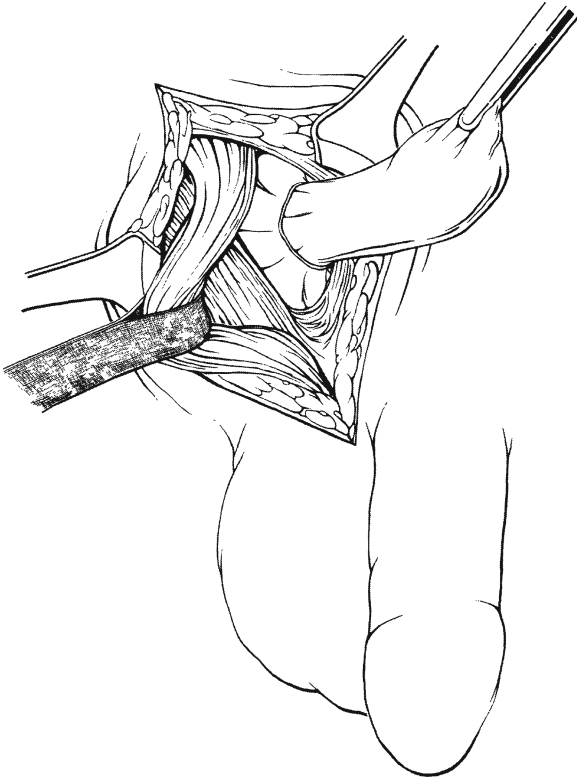

Figure 4.99. Sac dissected.

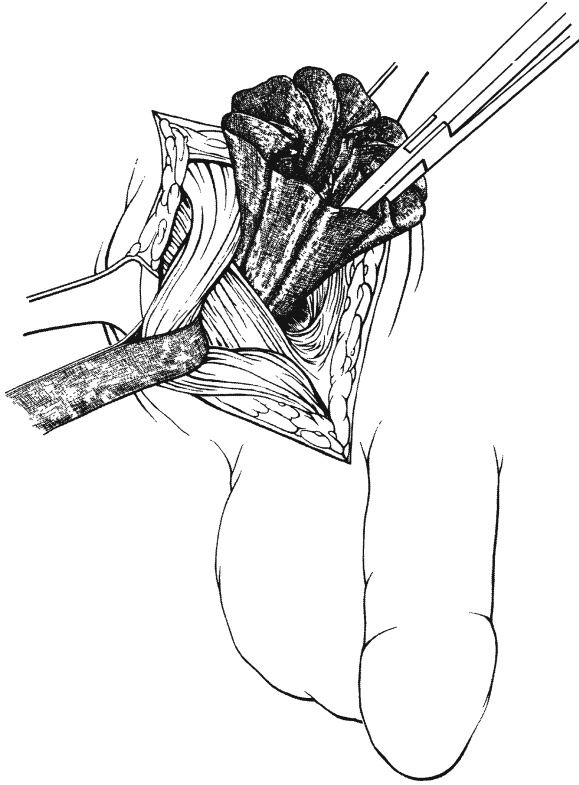


Figure 4.100. Mesh insertion.

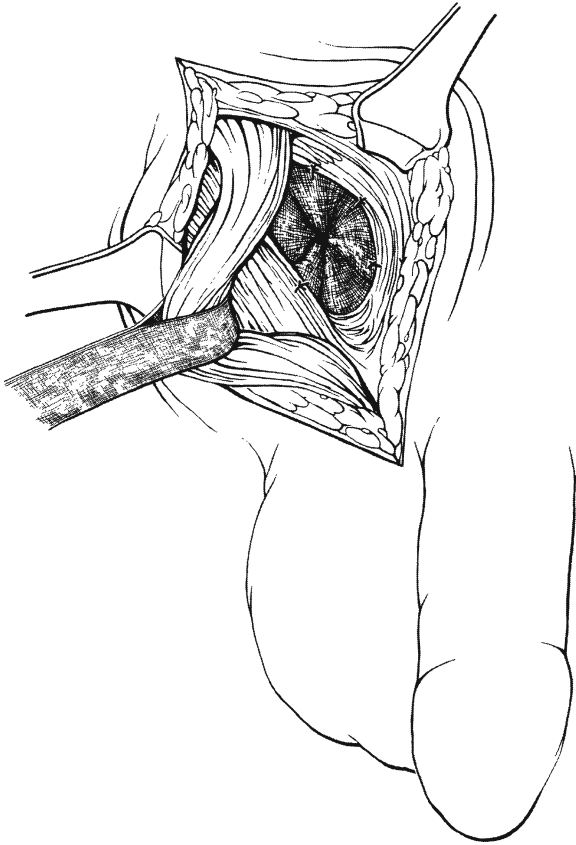

Figure 4.101. Securing mesh to internal oblique.

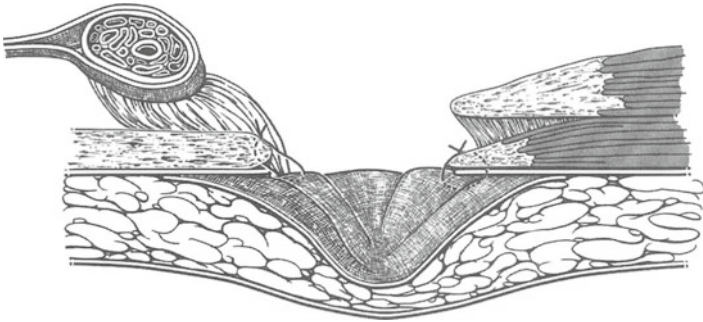


Figure 4.102. Suturing mesh at conjoined area.

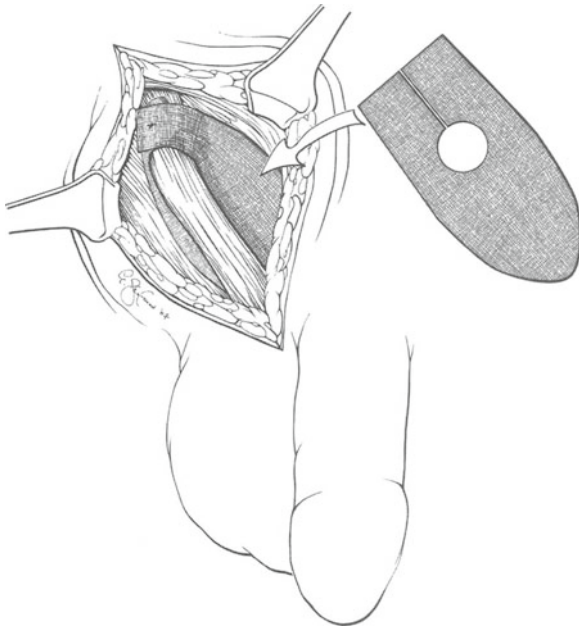


Figure 4.103. Onlay patch.

OTHER REPAIRS

■ HYDROCELE

A hydrocele is a collection of abnormal fluid within the sac of the tunica vaginalis; it may be associated with a hernia. There are several varieties of hydrocele. We describe repair of adult noncommunicating hydrocele. A communicating hydrocele—one that changes in size, as determined by patient observation—requires a high ligation of the sac in addition to partial excision of the hydrocele. Repair of pediatric hydrocele should be done by a pediatric surgeon.

Repair of Adult Noncommunicating Hydrocele

- Step 1.** For exploration, make a transverse incision. Because the terminal vascular branches in the scrotum lie transversely, this minimizes bleeding.
- Step 2.** Carefully divide the three uppermost layers of the testis. Deliver the testis with its covering outside the scrotum.
- Step 3.** Withdraw the fluid from the sac (Fig. 4.104) and observe the spermatic cord.

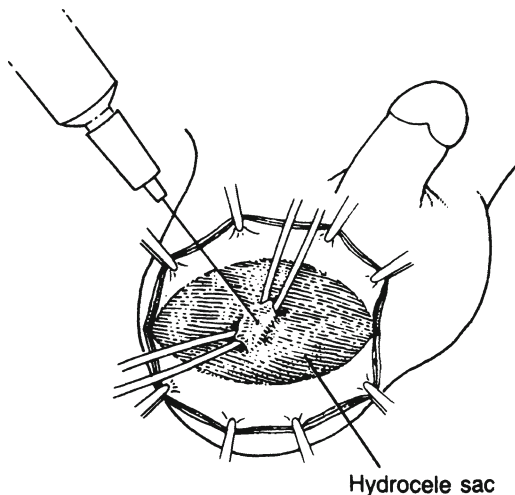


Figure 4.104. Draining the hydrocele sac (By permission of JE Skandalakis, SW Gray, AR Mansberger, et al. *Hernia: Surgical Anatomy and Technique*. New York: McGraw-Hill, 1989).

- Step 4.** Observe the covering of the spermatic cord.
- Step 5.** Open the tunica vaginalis and perform a subtotal or total removal of the sac.
- Step 6.** Approximate the dartos muscle and close the skin. Use only a few catgut sutures for the approximation, thereby avoiding skin inversion due to dartos retraction.

■ LUMBAR HERNIA REPAIR (DOWD-PONKA)

- Step 1.** Make an incision—oblique or vertical—over the hernia site. Remember that in the upper hernia, the sac lies beneath skin, superficial fascia, and latissimus dorsi muscle (Fig. 4.105).

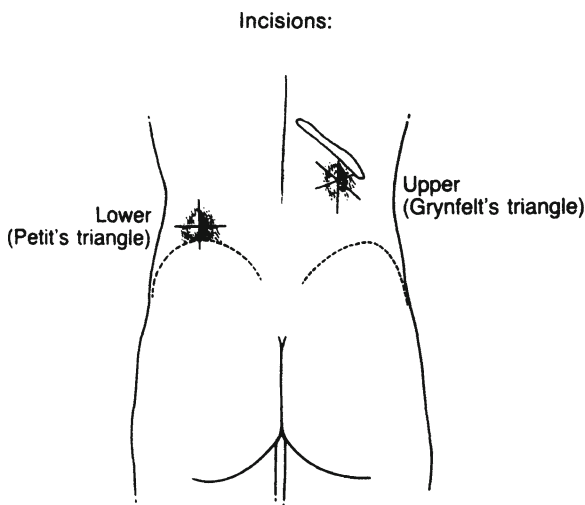


Figure 4.105. Lumbar hernia sites (By permission of JE Skandalakis, SW Gray, AR Mansberger, et al. *Hernia: Surgical Anatomy and Technique*. New York: McGraw-Hill, 1989).

214 4. Abdominal Wall and Hernias

Step 2. Dissect out the sac and reduce.

Step 3. Place a Marlex or Prolene patch over the defect, and suture to the external oblique and latissimus dorsi muscles and lumbar periosteum using 3-0 interrupted Surgilon (Fig. 4.106). Alternatively, place an appropriately sized Kugel patch subfascially and suture in an interrupted fashion.

Step 4. Approximate the external oblique and latissimus dorsi muscles over the patch as far as possible without tension. Cut a flap of gluteal fascia, as shown by the dotted line in Fig. 4.107.

Step 5. Use the flap of gluteal fascia turned up to cover the defect remaining and secure it to the present muscles with 0 Surgilon interrupted sutures (Fig. 4.108).

Step 6. Close the subcutaneous fat and skin. Jackson–Pratt drains may be necessary.

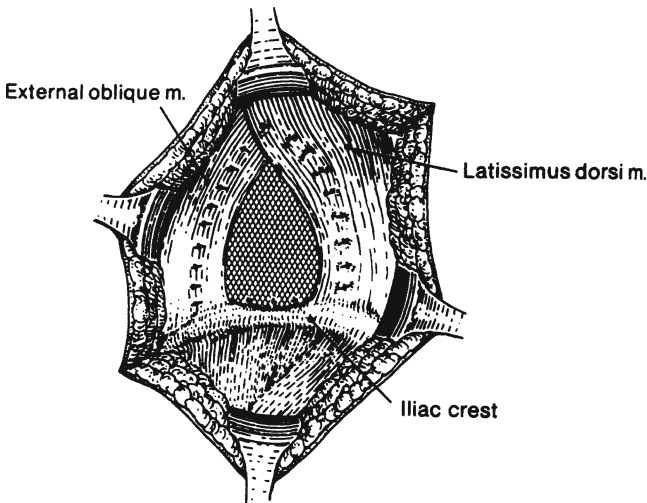


Figure 4.106. Suturing the patch (By permission of JE Skandalakis, SW Gray, AR Mansberger, et al. *Hernia: Surgical Anatomy and Technique*. New York: McGraw-Hill, 1989).

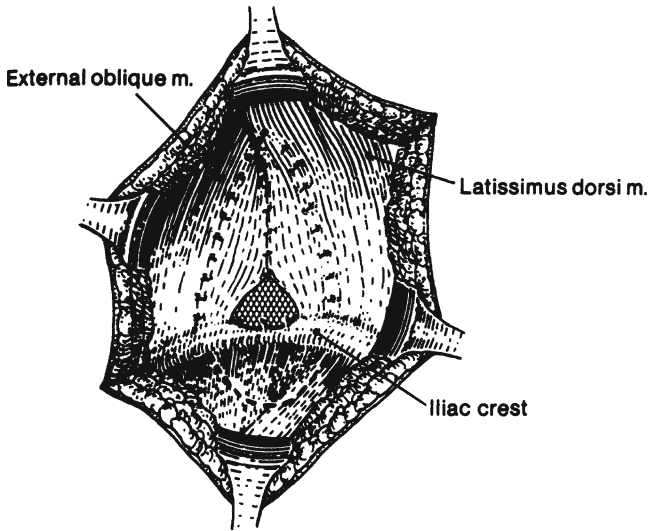


Figure 4.107. Approximating the muscles (By permission of JE Skandalakis, SW Gray, AR Mansberger, et al. *Hernia: Surgical Anatomy and Technique*. New York: McGraw-Hill, 1989).

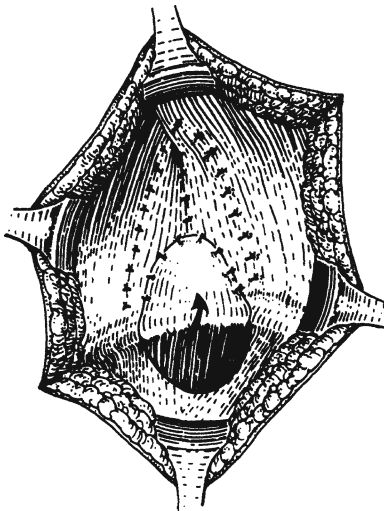


Figure 4.108. Securing the gluteal fascia flap (By permission of JE Skandalakis, SW Gray, AR Mansberger, et al. *Hernia: Surgical Anatomy and Technique*. New York: McGraw-Hill, 1989).

5

Diaphragm

■ ANATOMY

The diaphragm is a musculomembranous entity separating the thorax from the abdomen. The muscular part originates anteriorly from the xiphoid process, laterally from the inner surface of the six lower cartilages, and posteriorly from the medial and lateral lumbosacral arches, the median arcuate ligament, and the bodies of the three upper lumbar vertebrae. The muscular part inserts on the central tendon.

■ CRURA

The crura arise from the anterior surface of the first to fourth lumbar vertebrae on the right, the first two or three lumbar vertebrae on the left, and from the intervertebral disks and the anterior longitudinal ligament. The crural fibers pass superiorly and anteriorly, forming the muscular arms that surround the openings for the aorta and the esophagus. They then insert on the central tendon. At their origins from the vertebrae, the crura are tendinous, becoming increasingly muscular as they ascend into the diaphragm proper (Fig. 5.1). Studies have found that in 90 % of cadavers, posteriorly and medially, from their vertebral origins to the level of the tenth thoracic vertebra, the crura are tendinous. Sutures to approximate the crura should always be placed through the tendinous portions.

The pattern of the crural arms at the esophageal hiatus is variable. In one-half or more, both right and left arms arise from the right crus (Fig. 5.2a). In another one-third or more, the left arm arises from the right crus and the right arm

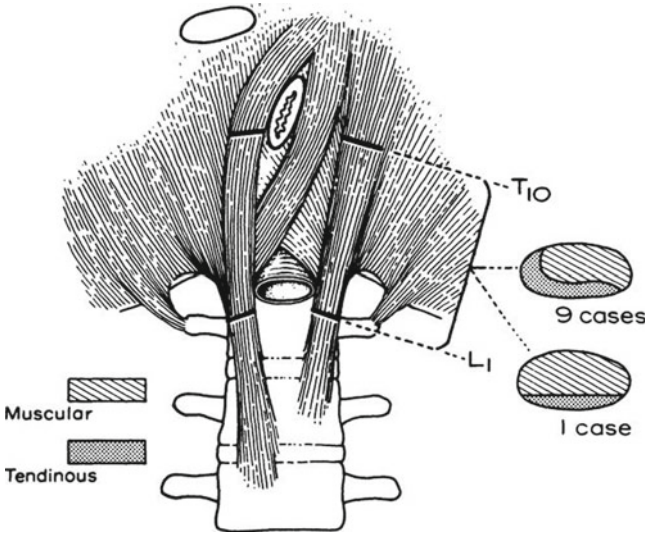


Figure 5.1. The crura consist of both tendinous and muscular tissue; only the tendinous portion holds sutures. In nine out of ten persons, the medial edge of the crura is tendinous. From SW Gray, JS Rowe, and JE Skandalakis. Surgical anatomy of the gastroesophageal junction. *Am Surg* 45(9):575–587, 1979. Reprinted with permission from American Surgeon.

arises from both crura (Fig. 5.2b). The remaining individuals present a variety of uncommon patterns. Hiatal hernia is not associated with any specific hiatal pattern.

■ OPENINGS OF THE DIAPHRAGM

Hiatus of the Inferior Vena Cava

The hiatus of the inferior vena cava lies in the right dome of the central tendon about 2.5 cm to the right of the midline and at the level of the eighth thoracic vertebra. The margins of the hiatus are fixed to the vena cava, which is accompanied by branches of the right phrenic nerve (Fig. 5.3).

Esophageal Hiatus

The elliptical esophageal hiatus is in the muscular portion of the diaphragm 2.5 cm or less to the left of the midline at the level of the tenth thoracic vertebra

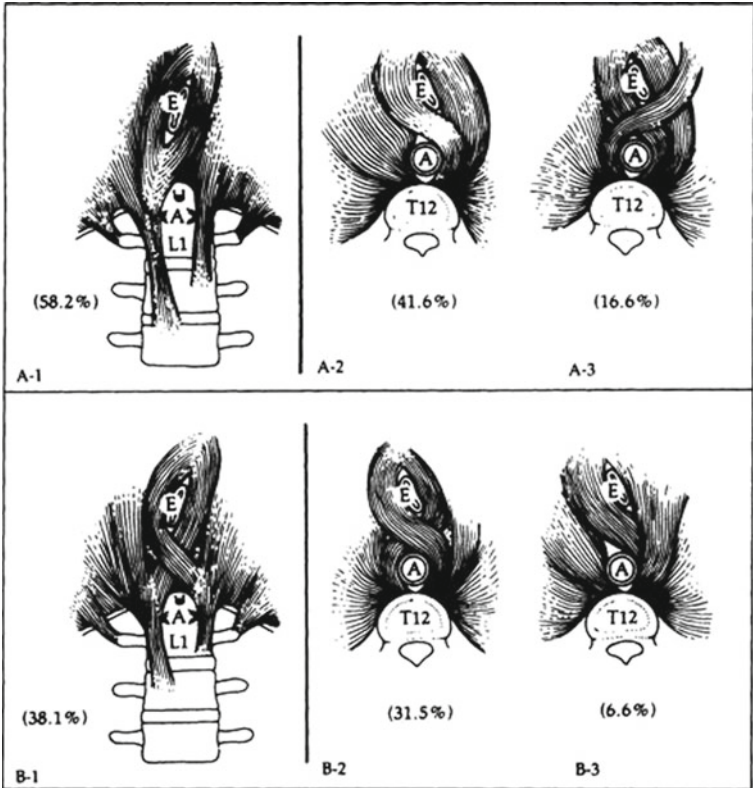


Figure 5.2. The most common patterns of the diaphragmatic crura. (a-1) and (b-1) seen from below. (a-2, a-3) and (b-2, b-3) seen from above. E esophagus, A aorta (By permission of JE Skandalakis, SW Gray, JS Rowe, et al. In: LM Nyhus, and RJ Baker. *Mastery of Surgery*, 2nd ed. Boston: Little, Brown, 1992, pp. 377–396).

(Figs. 5.4 and 5.5). The anterior and lateral margins of the hiatus are formed by the muscular arms of the diaphragmatic crura. The posterior margin is formed by the median arcuate ligament (Fig. 5.6). The anterior and posterior vagal trunks and the esophageal arteries and veins from the left gastric vessels pass through the hiatus with the esophagus.

Regardless of its components, the normal hiatus should admit one or two of the surgeon's fingers if there is no folding of the peritoneum into the mediastinum.

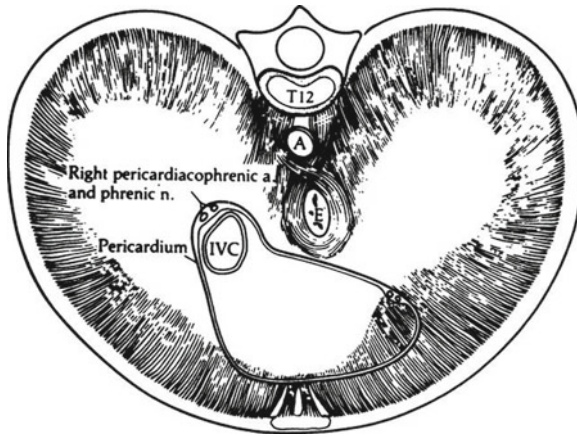


Figure 5.3. The diaphragm viewed from above. The area in contact with the pericardium is indicated. The pericardial fibrous tissue is continuous with that of the diaphragm (By permission of JE Skandalakis, SW Gray, JS Rowe, et al. In: LM Nyhus, and RJ Baker. *Mastery of Surgery*, 2nd ed. Boston: Little, Brown, 1992, pp. 377–396).

The following means of narrowing the hiatus have been preferred:

- Vertical posterior approximation of the crura (Fig. 5.7a). This is a commonly used method.
- Vertical anterior approximation of the crura (Fig. 5.7b). Some surgeons recommend this type of repair. It has the following advantages: (1) it is easier than posterior approximation; (2) the crura are more tendinous anteriorly; and (3) the procedure accentuates the gastroesophageal angle.
- Horizontal narrowing of the hiatus (Fig. 5.7c). In some patients, a transverse defect is apparent; hence a horizontal approximation is appropriate.

Aortic Opening

The oblique course of the aorta takes it behind the diaphragm rather than through it (Fig. 5.5). The thoracic duct and (usually) the azygos vein accompany the aorta through the “opening.” At the level of the 12th thoracic vertebra, the anterior border of the opening is bridged by the median arcuate ligament. Laterally the diaphragmatic crura form the margins of the opening.

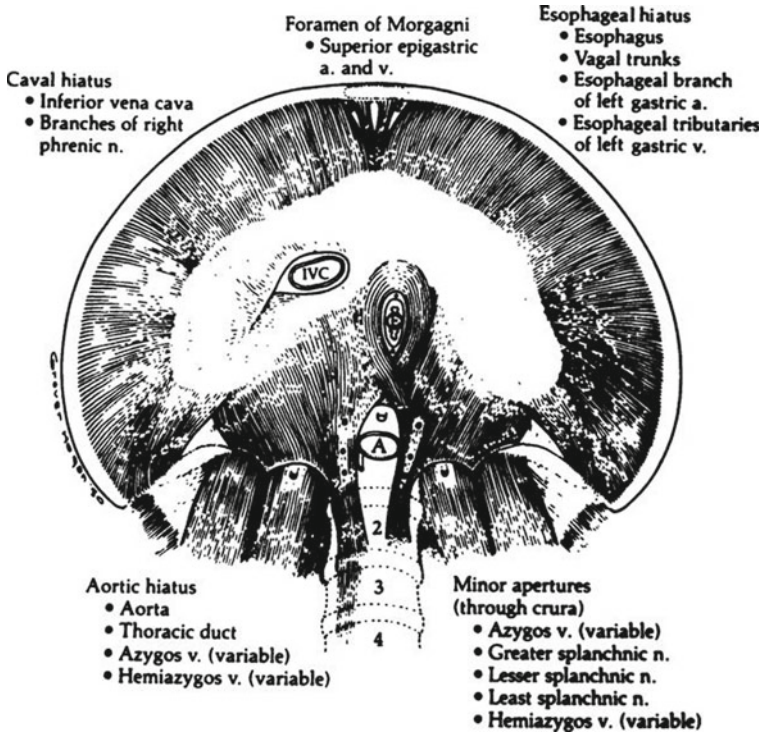


Figure 5.4. The apertures of the diaphragm seen from below and the structures traversing them (By permission of JE Skandalakis, SW Gray, JS Rowe, et al. In: LM Nyhus, and RJ Baker. *Mastery of Surgery*, 2nd ed. Boston: Little, Brown, 1992, pp. 377–396).

Other Openings in the Diaphragm

Anteriorly, the superior epigastric vessels pass through the parasternal spaces (foramina of Morgagni). In the dome of the diaphragm, the phrenic nerves pierce the upper surface to become distributed over the lower surface between the muscle and peritoneum.

The azygos vein may pass behind the diaphragm with the aorta (to the right of the right crus), or it may pierce the right crus. Also passing through the crura are the greater, lesser, and least thoracic splanchnic nerves (Fig. 5.4).

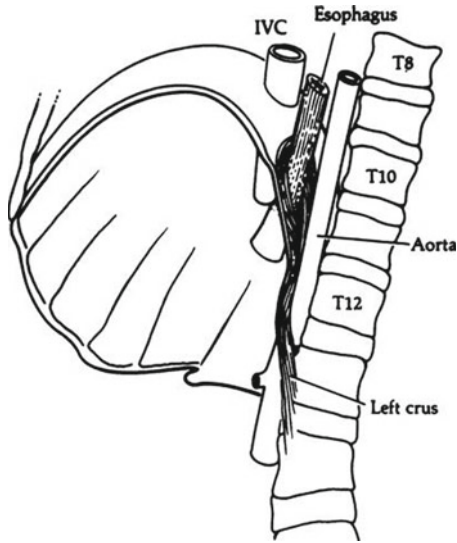


Figure 5.5. The diaphragmatic openings for the inferior vena cava (IVC), the esophagus, and the aorta as seen from the left (By permission of JE Skandalakis, SW Gray, JS Rowe, et al. In: LM Nyhus, and RJ Baker. *Mastery of Surgery*, 2nd ed. Boston: Little, Brown, 1992, pp 377–396).

Median Arcuate Ligament

The esophageal hiatus is separated from the aortic hiatus by fusion of the arms of the left and right crura. If the tendinous portions of the crura are fused, the median arcuate ligament is present as a fibrous arch passing over the aorta, connecting the right and left crura. If the fusion is muscular only, the ligament is ill defined or absent.

The median arcuate ligament passes in front of the aorta at the level of the first lumbar vertebra, just above the origin of the celiac trunk (Fig. 5.6). In 16 %, a low median arcuate ligament covers the celiac artery and may compress it.

In about 50 % of cadavers with hiatal hernia studied, the ligament was sufficiently well developed to use in surgical repair of the esophageal hiatus. In the remainder, there was enough preaortic fascia lateral to the celiac trunk to perform a posterior fixation of the gastroesophageal junction (GEJ). At operation surgeons must avoid the celiac ganglion, which is just below the arcuate ligament.

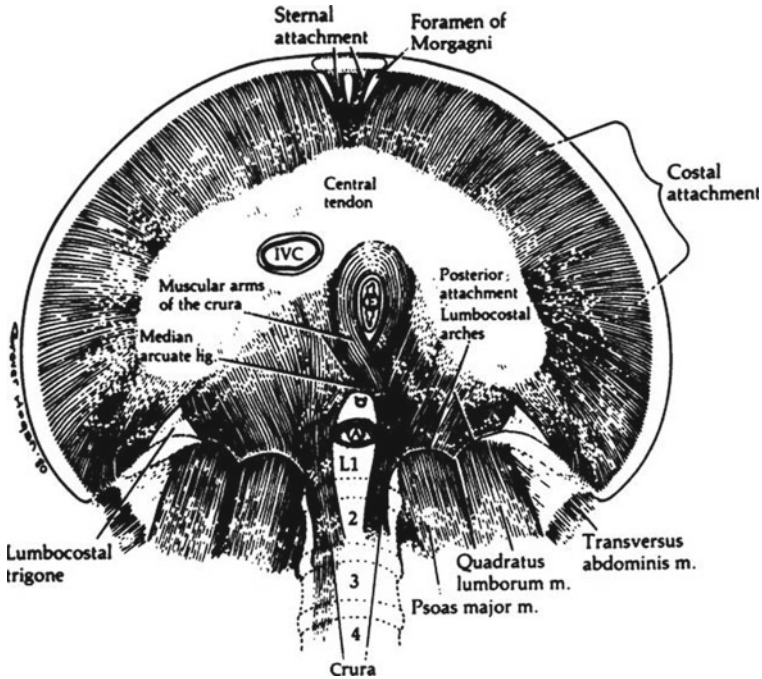


Figure 5.6. The attachments of the muscles of the diaphragm seen from below (By permission of JE Skandalakis, SW Gray, JS Rowe, et al. In: LM Nyhus, and RJ Baker. *Mastery of Surgery*, 2nd ed. Boston: Little, Brown, 1992, pp. 377–396).

■ DIAPHRAGMATIC-MEDIASTINAL RELATIONS

The fibrous tissue of the central tendon is continuous with the fibrous pericardium over much of the anterosuperior surface of the diaphragm (Fig. 5.3).

In addition to the pericardium, the mediastinum on the right contains the inferior vena cava; right phrenic nerve and pericardiophrenic vessels; right pulmonary ligament; esophagus with the right vagal trunk; thoracic duct; azygos vein and azygos arch; vertebral bodies; greater and lesser right thoracic splanchnic nerves; right sympathetic trunk; and right posterior intercostal arteries (Fig. 5.8).

In the left mediastinum are the pericardium; left phrenic nerve and pericardiophrenic vessels; esophagus; left vagal trunk; descending aorta; vertebral

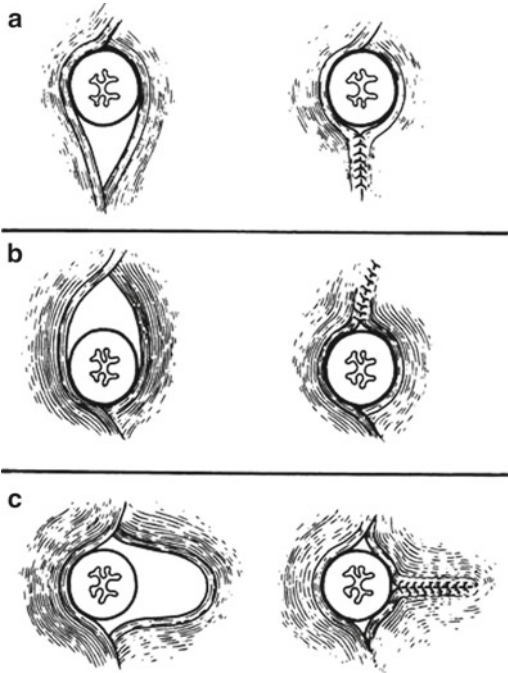


Figure 5.7. Three methods of narrowing the esophageal hiatus. (a) Vertical with posterior approximation of the crura. (b) Vertical with anterior approximation of the crura. (c) Horizontal with shortening of one crus (By permission of JE Skandalakis, SW Gray, and JR Rowe Jr. *Anatomical Complications in General Surgery*. New York: McGraw Hill, 1983).

bodies; hemiazygos vein, accessory hemiazygos vein, highest intercostal vein; greater and lesser left thoracic splanchnic nerves; and left sympathetic trunk.

The triangle (of Truesdale) formed by the pericardium, aorta, and diaphragm contains the left pulmonary ligament and the distal esophagus. In sliding hiatus hernia, the stomach is in this triangle (Fig. 5.9).

The remainder of the superior surface of the diaphragm is covered with parietal pleura. The approximation of the right and left pleurae between the esophagus and the aorta forms the so-called mesoesophagus. The right pleura is in contact with the lower third of the esophagus almost as far down as the esophageal hiatus (Fig. 5.10). This proximity creates the risk of accidental entrance into the pleural cavity during abdominal operations on the esophageal hiatus. Even so, because surgeons work on the right side of the operating table, they are more likely to produce a pneumothorax or hemopneumothorax on the left.

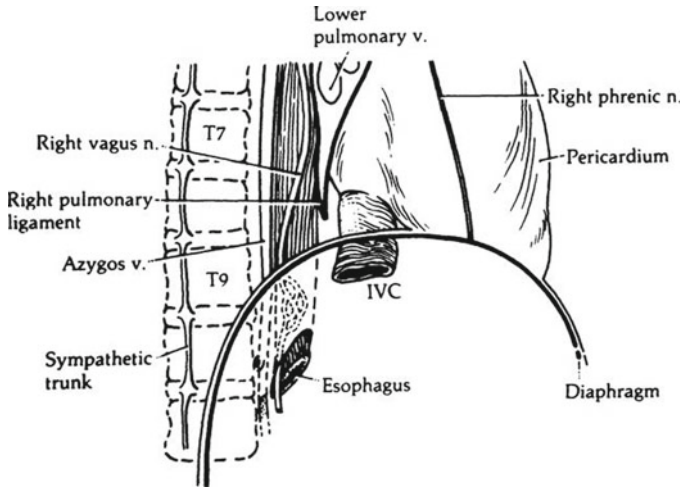


Figure 5.8. Structures in the inferior portion of the right mediastinum (By permission of JE Skandalakis, SW Gray, JS Rowe, et al. In: LM Nyhus, and RJ Baker. *Mastery of Surgery*, 2nd ed. Boston: Little, Brown, 1992, pp. 377–396).

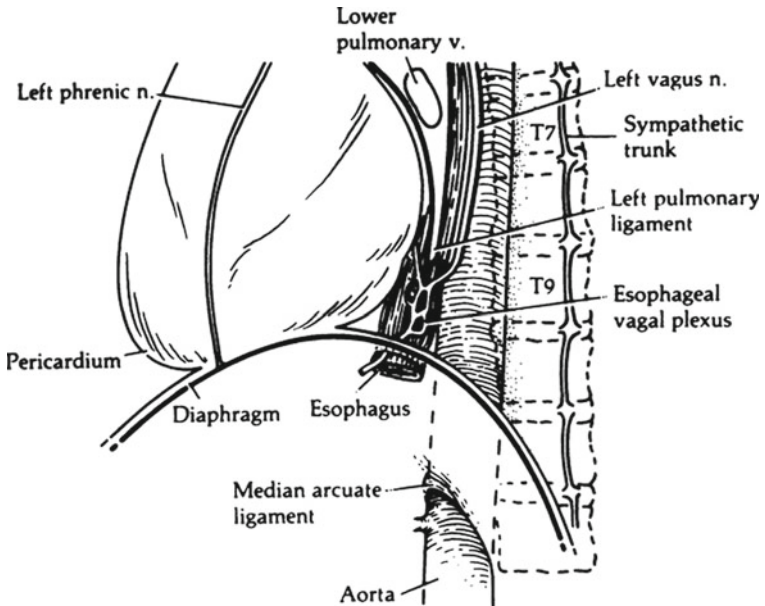


Figure 5.9. Structures in the inferior portion of the left mediastinum (By permission of JE Skandalakis, SW Gray, JS Rowe, et al. In: LM Nyhus, and RJ Baker. *Mastery of Surgery*, 2nd ed. Boston: Little, Brown, 1992, pp. 377–396).

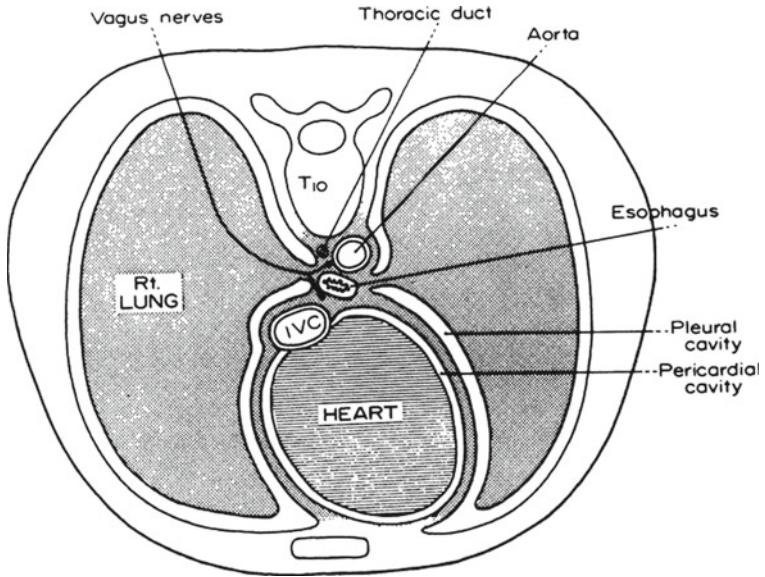


Figure 5.10. Cross section through the thorax at the level of T₁₀ showing the relation of the pleura to the distal esophagus. From SW Gray, JS Rowe, and JE Skandalakis. *Surgical anatomy of the gastroesophageal junction. Am Surg* 45(9):575–587, 1979. Reprinted with permission from American Surgeon.

■ VASCULAR SYSTEM OF THE DIAPHRAGM

Arterial Supply

The arterial supply to the superior surface of the diaphragm consists of two branches from the internal thoracic arteries—the pericardiophrenic and musculophrenic arteries—and two branches from the thoracic aorta—the superior phrenic arteries. All these branches are small.

The major blood supply to the diaphragm is to the inferior surface. It comes from the inferior phrenic arteries, which arise from the aorta or the celiac axis just below the median arcuate ligament of the diaphragm. In a small percentage of individuals, the right inferior phrenic artery arises from the right renal artery. The inferior phrenic arteries also supply branches to the suprarenal glands (Fig. 5.11).

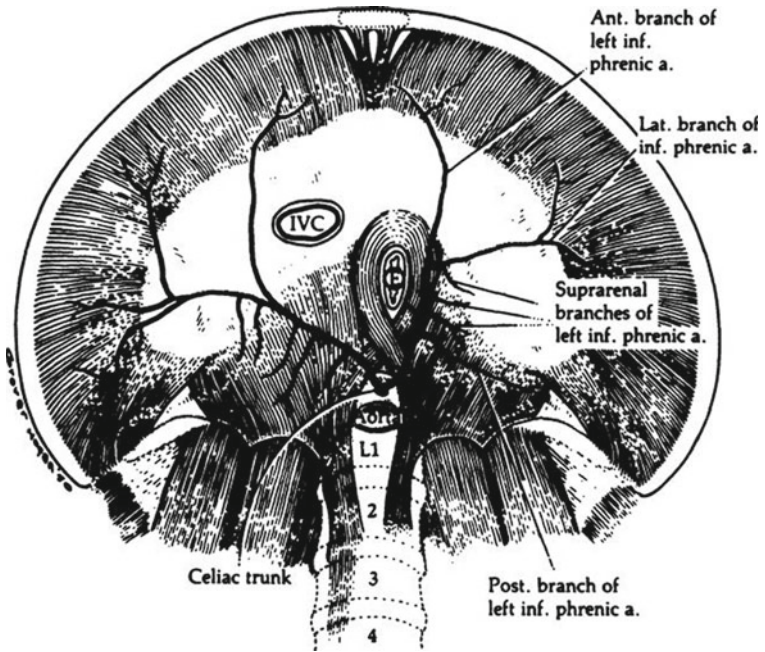


Figure 5.11. Arterial supply of the diaphragm from below. The inferior phrenic arteries may arise from the celiac trunk or directly from the aorta (By permission of JE Skandalakis, SW Gray, JS Rowe, et al. In: LM Nyhus, RJ Baker. *Mastery of Surgery*, 2nd ed. Boston: Little, Brown, 1992, pp 377–396).

Venous Drainage

On the superior and inferior surfaces, the veins run with the arteries (Fig. 5.12).

Lymphatic Drainage

All the diaphragmatic lymph nodes lie on the superior surface of the diaphragm. These nodes can be divided into anterior, middle, and posterior groups (Fig. 5.13). They receive drainage from the upper surface of the liver, the gastroesophageal junction, and the abdominal surface of the diaphragm.

Efferent lymph vessels from these nodes drain upward to parasternal and mediastinal nodes anteriorly and to posterior mediastinal and brachiocephalic nodes posteriorly.

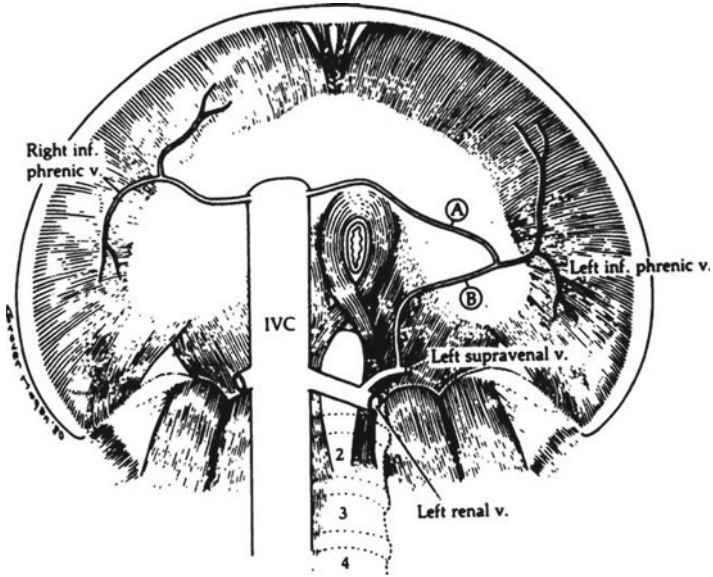


Figure 5.12. Venous drainage of the diaphragm from below. The left inferior phrenic vein may enter the inferior vena cava (A), the left suprarenal vein (B), or both (By permission of JE Skandalakis, SW Gray, JS Rowe, et al. In: LM Nyhus, RJ Baker. *Mastery of Surgery*, 2nd ed. Boston: Little, Brown, 1992, pp. 377–396.

■ NERVE SUPPLY OF THE DIAPHRAGM

The right phrenic nerve enters the diaphragm through the central tendon just lateral to the opening for the inferior vena cava. Occasionally it passes through that opening with the vena cava. The left phrenic nerve pierces the superior surface of the muscular portion of the diaphragm just lateral to the left border of the heart (Fig. 5.14).

The peripheral portions of the pleura and peritoneum have an independent sensory innervation that arises from the 7th to the 12th intercostal nerves.

■ STRUCTURES AT OR NEAR THE ESOPHAGEAL HIATUS (FIG. 5.15)

Several structures lie close to the esophageal hiatus of the diaphragm and hence may be injured in surgical procedures on the hiatus. They are:

- Left inferior phrenic artery and left gastric artery
- Left inferior phrenic vein

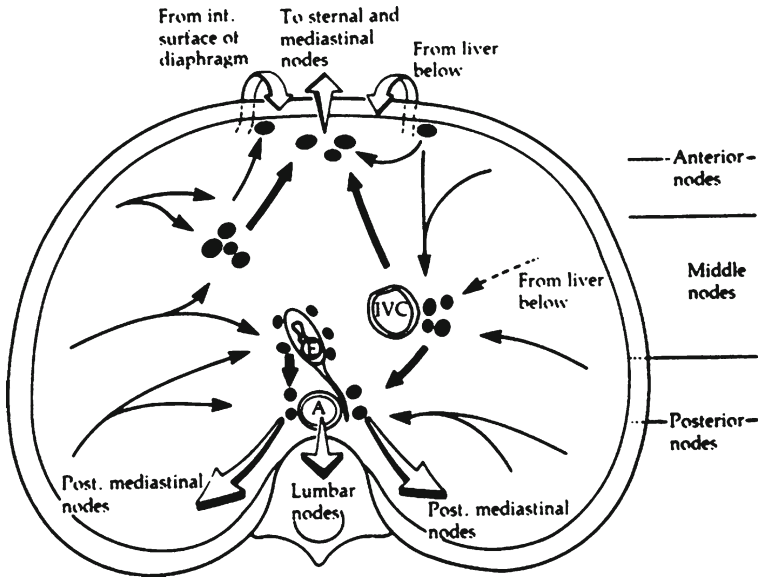


Figure 5.13. Lymphatic drainage of the diaphragm seen from above. The diaphragm receives lymph from the liver below and sends it to ascending sternal, anterior, and posterior mediastinal nodes (By permission of JE Skandalakis, SW Gray, JS Rowe, et al. In: LM Nyhus, and RJ Baker. *Mastery of Surgery*, 2nd ed. Boston: Little, Brown, 1992, pp. 377–396).

- Left gastric (coronary) vein
- Aberrant left hepatic artery, if present
- Other vessels (celiac trunk, aorta, inferior vena cava)
- Vagal trunks (Fig. 5.16)
- Celiac ganglia
- Thoracic duct
- Subphrenic spaces
- Lower esophagus

Extensive mobilization or skeletonization of the lower esophagus may result in perforation during a surgical procedure, or afterward, from subsequent local ischemia.

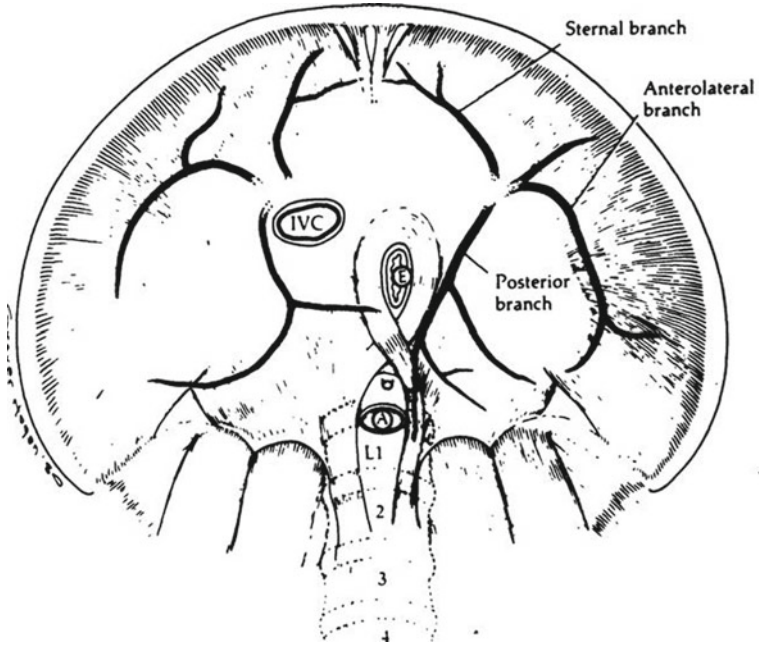


Figure 5.14. The major branches of the phrenic nerves from below. Each phrenic nerve divides just before entering the diaphragm from above (By permission of JE Skandalakis, SW Gray, JS Rowe, et al. In: LM Nyhus, RJ Baker. *Mastery of Surgery*, 2nd ed. Boston: Little, Brown, 1992, pp. 377–396).

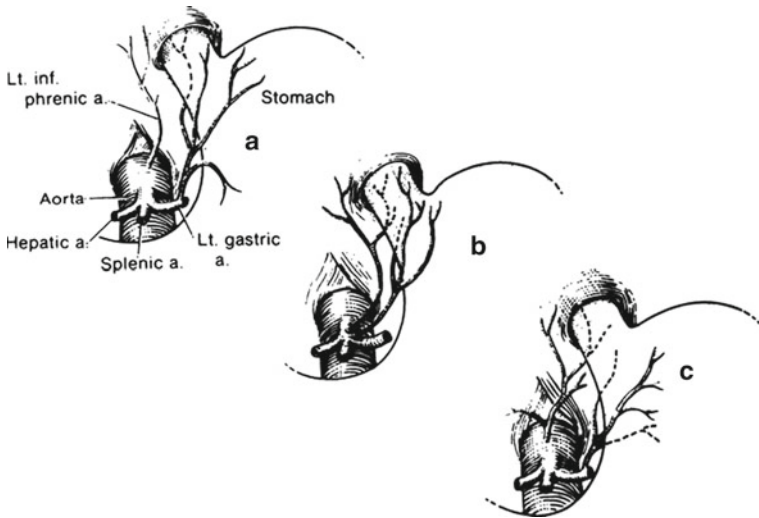


Figure 5.15. Variations in the blood supply to the distal esophagus and the esophageal hiatus. **(a)** The inferior phrenic artery supplies the margin of the hiatus. An esophageal branch of the left gastric artery supplies the esophagus and anastomoses with the thoracic esophageal arteries. This is the most frequent pattern. **(b)** The esophagus is supplied by esophageal branches of the left gastric and the inferior phrenic arteries without cranial anastomoses. **(c)** The esophagus is supplied entirely by a branch of the inferior phrenic artery, which anastomoses with the thoracic esophageal arteries. This pattern is rare (By permission of JE Skandalakis, SW Gray, and JR Rowe Jr. *Anatomical Complications in General Surgery*. New York: McGraw-Hill, 1983).

232 5. Diaphragm

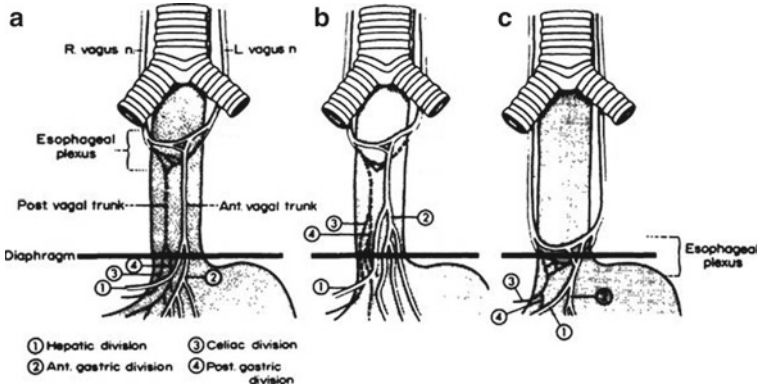


Figure 5.16. Where four or more vagal structures emerge through the hiatus, they may be (a) divisions that have separated just above the diaphragm, (b) divisions and their branches that arise above the diaphragm, or (c) elements of the esophageal plexus that extend below the diaphragm. The vagal trunks are entirely within the abdomen (By permission of JE Skandalakis, JS Rowe, SW Gray, et al. *Surgery* 75(2):233–237, 1974).

TECHNIQUE

■ DIAPHRAGMATIC HERNIA

Normal anatomy of the esophageal hiatus is shown in sagittal section in Fig. 5.17a. *Hiatus hernia* is a protrusion of a portion of the stomach into the thoracic mediastinum through the esophageal hiatus of the diaphragm. It includes a hernial sac (Table 5.1).

Several types of hiatus hernia are recognized today: sliding hiatus, paraesophageal hiatus, combined sliding and paraesophageal, congenital short esophagus, and traumatic diaphragmatic.

In sliding hiatus hernia, the esophagus moves freely through the hiatus, with the gastroesophageal junction in the thorax or in the normal position at different times. Sliding hernias make up 90 % of all hiatus hernias (Fig. 5.17b). A sac is present. An uncommon type of sliding hernia is one that becomes secondarily fixed in the thorax by adhesions. The esophagus in such patients appears to be too short to reach the diaphragm because of contraction of the longitudinal muscle coat.

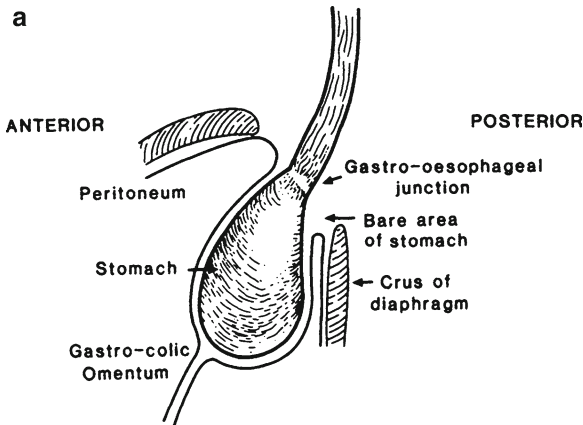


Figure 5.17. Esophageal hiatus in sagittal section with (a) normal anatomy and (b–e) the various abnormalities described in the text: (b) sliding hiatus hernia, (c) paraesophageal hiatus hernia, (d) combined sliding and paraesophageal hiatus hernia, (e) congenital short esophagus (From SW Gray, LJ Skandalakis, and JE Skandalakis. Classification of hernias through the esophageal hiatus. In: Jamieson, GG (ed.) *Surgery of the Esophagus*. Edinburgh: Churchill Livingstone, 1988, pp. 143–148. Reprinted with permission).

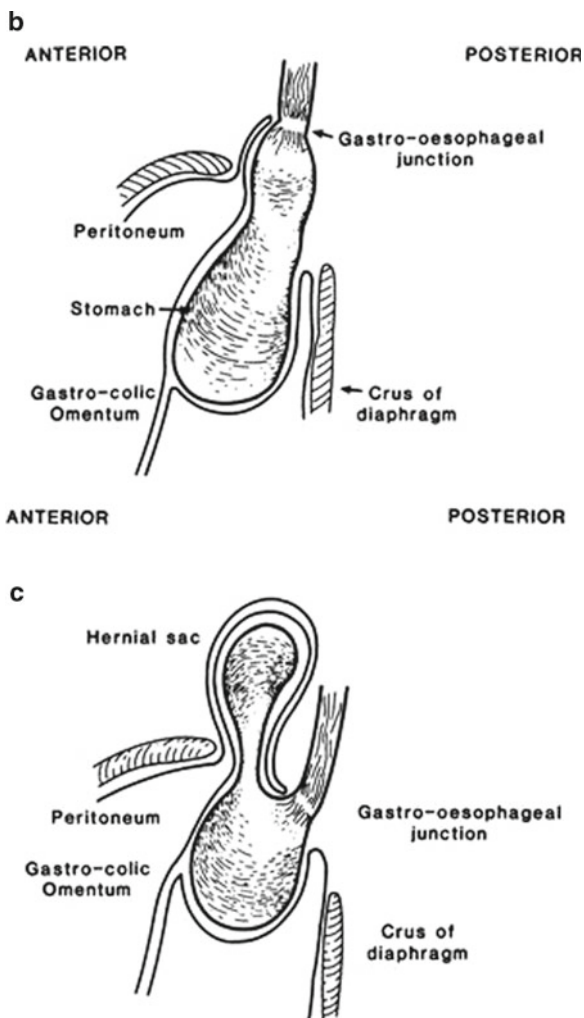


Figure 5.17 (continued)

In paraesophageal hiatus hernia, the gastroesophageal junction remains in its normal location. The gastric fundus cardia and greater curvature bulge through the hiatus beside the esophagus; a sac is present. Volvulus of the herniated stomach is a major complication (Fig. 5.17c).

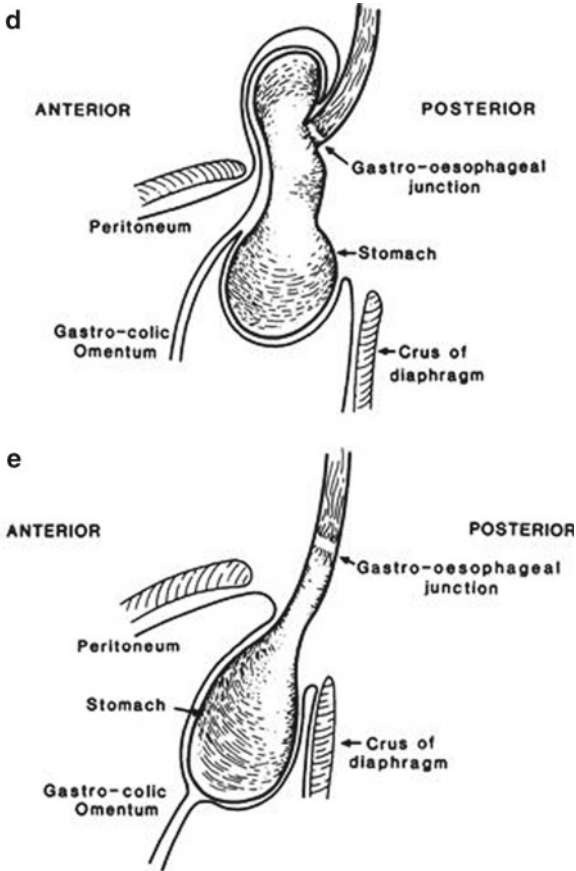


Figure 5.17 (continued)

A combined sliding and paraesophageal hernia occurs when the gastroesophageal junction is displaced upward, as in a sliding hernia, and the fundus and greater curvature are herniated, as in a paraesophageal hernia (Fig. 5.17d).

Much debate centers around the classification of the congenital short esophagus. Three conditions must be considered. (1) In the *grossly normal esophagus*, the

Table 5.1 Hernia through the esophageal hiatus

<i>Hernia</i>	<i>Anatomy</i>	<i>Sac and contents</i>	<i>Remarks</i>
Sliding hiatus hernia	Congenital potential hernia. G-E junction and cardia are displaced upward to enter the mediastinum above the diaphragm. The phrenoesophageal membrane is attenuated. The herniated stomach may move freely or become fixed in the thorax	Sac lies anterior and to the left of herniated stomach. Contents: cardia, stomach	A large hiatus (admitting three fingers) may be a predisposing factor. Actual herniation usually occurs in middle life but has been seen in newborn
Fixed hiatus hernia			
"Pure" paraesophageal hernia	Congenital potential hernia. The G-E junction and cardia are in normal position. The fundus has herniated through the hiatus into the thorax beside the esophagus	Sac lies anterior to esophagus and posterior to pericardium. Contents: cardia and fundus of stomach	An enlarged hiatus may be a predisposing factor. Actual herniation occurs in adult life
Combined sliding and paraesophageal hernia	Congenital potential hernia. The G-E junction, cardia, and much of the greater curvature of stomach have herniated into the thorax	Sac lies anterior to esophagus and posterior to pericardium in right posteroinferior mediastinum. Sac may contain fundus and body of stomach, omentum, transverse colon, and spleen	A hiatus already enlarged by a hiatus hernia. Progresses to complete thoracic stomach with volvulus
Congenital short esophagus	Congenital hernia. The G-E junction and cardia are displaced upwards and fixed in the thorax	No sac present	This lesion is rare. It appears to result from failure of the embryonic esophagus to elongate enough to bring the G-E junction into the abdomen

From SW Gray, LJ Skandalakis, and JE Skandalakis. Classification of hernias through the esophageal hiatus. In: Jamieson, GG (ed.) *Surgery of the Esophagus*. Edinburgh: Churchill Livingstone, 1988, pp. 143-148. Reprinted with permission

lower portion of the esophagus is lined by gastric mucosa (Barrett esophagus). This may be described also as heterotopic gastric mucosa. (2) In the *irreducible partially supradiaphragmatic true stomach*, the stomach has herniated into the thorax through an enlarged diaphragmatic esophageal hiatus and become fixed. This is true fixed hiatus hernia. (3) *Partially supradiaphragmatic true stomach* exists from birth and is not reducible. This is true “congenital short esophagus” (Fig. 5.17e) and is very rare.

Remember: When performing surgery for esophageal hernia, to:

- ✓ Avoid injury to the vagus nerves.
- ✓ Avoid injury to the mediastinal pleura.
- ✓ Avoid injury to the left hepatic vein.
- ✓ Avoid perforation of the esophagus.
- ✓ Watch for an aberrant blood supply to the left triangular ligament.
- ✓ Watch for accessory bile ducts.
- ✓ Consider inserting a bougie.
- ✓ Consider gastropexy or gastrostomy.
- ✓ Consider an antireflux procedure.

Repair of Sliding Hiatus Hernia

- Step 1.** A transverse, oblique, or vertical midline incision may be used. Incise the triangular ligament and retract the left lobe of the liver. Incise the peritoneal coverings of the esophagus; then pass a Penrose drain beneath the esophagus for traction.
- Step 2.** Dissect the greater curvature of the stomach, beginning at the cardia and continuing toward the gastrosplenic ligament and the vasa brevia. One or two vasa brevia may be divided, but damage to the spleen must be avoided (Fig. 5.18).
- Step 3.** Dissect the diaphragm and the tissue beneath the esophagus. A widened hiatus can be repaired with 0 nonabsorbable sutures, carefully avoiding the underlying aorta, celiac axis, and pleura. Do not constrict the esophagus (Fig. 5.19).
- Step 4.** Nissen Fundoplication. The anesthesiologist passes a No. 50 French dilator into the esophagus to prevent constriction by an excessively tight fundic wrap.

Remember:

- ✓ Avoid the gas-bloat syndrome by protecting the vagus nerve and maintaining an adequate lumen in the distal esophagus.
- ✓ If the vagus nerve is transected, perform a pyloroplasty.

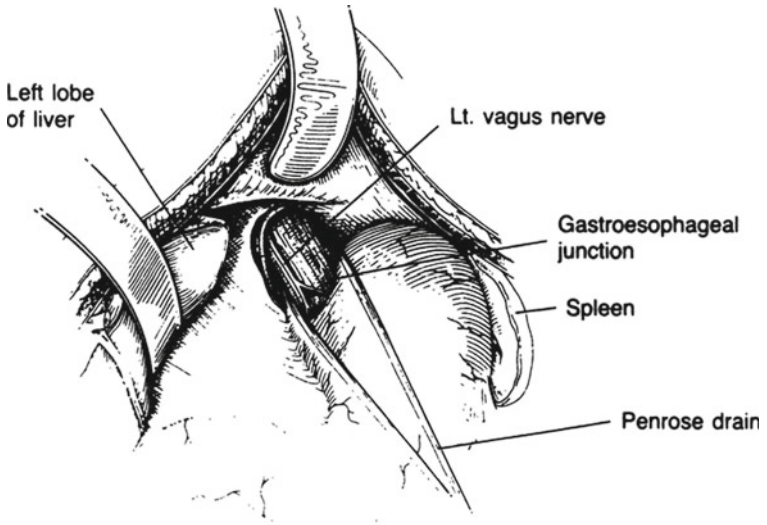


Figure 5.18. Placement of Penrose drain (By permission of JE Skandalakis, SW Gray, AR Mansberger, et al. *Hernia: Surgical Anatomy and Technique*. New York: McGraw-Hill, 1989).

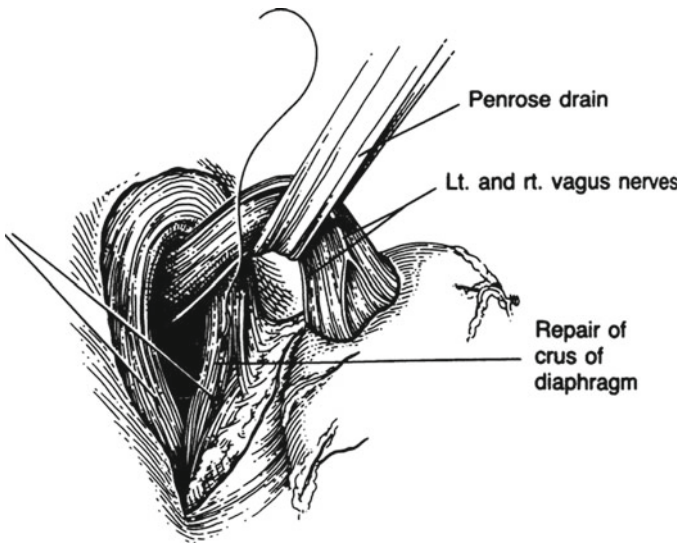


Figure 5.19. Repair of hiatus (By permission of JE Skandalakis, SW Gray, AR Mansberger, et al. *Hernia: Surgical Anatomy and Technique*. New York: McGraw-Hill, 1989).

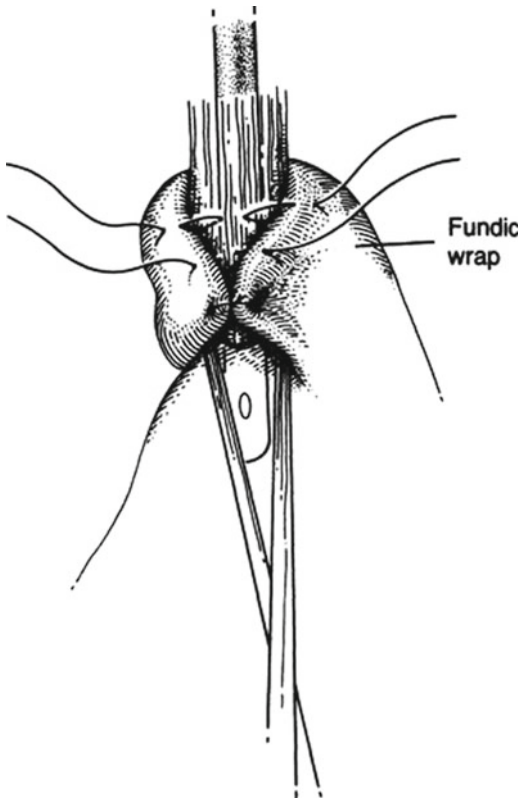


Figure 5.20. Fundic wrap (By permission of JE Skandalakis, SW Gray, AR Mansberger, et al. *Hernia: Surgical Anatomy and Technique*. New York: McGraw Hill, 1989).

- ✓ If the pylorus is stenotic, pyloroplasty is again recommended.
- ✓ If chronic peptic ulcer disease (duodenal ulcer) is present, vagotomy and pyloroplasty should be performed.
- ✓ It is nearly impossible to make a Nissen fundoplication too loose and very easy to make it too tight, so err on the side of the former.

Step 5. Wrap the fundus of the stomach 360° around the lower esophagus, and insert 2-0 silk sutures from the stomach to the esophagus to the stomach (Fig. 5.20).

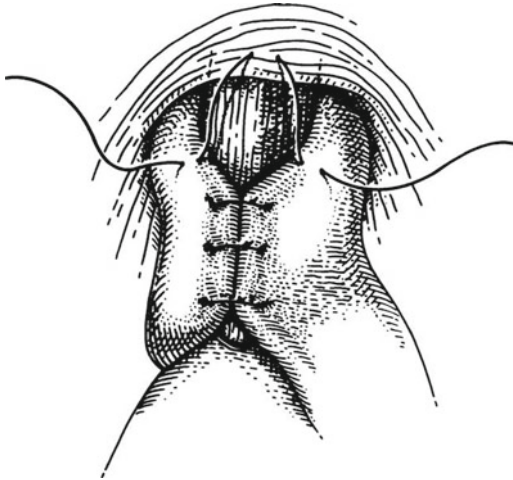


Figure 5.21. Suturing the wrap (By permission of JE Skandalakis, SW Gray, AR Mansberger, et al. *Hernia: Surgical Anatomy and Technique*. New York: McGraw Hill, 1989).

Step 6. Place at least four sutures to complete the wrap and place collar sutures between the wrap and the esophagus (at the upper portion) and between the wrap and the stomach (at the lower portion) (Fig. 5.21).

Step 7. Perform a Stamm gastrostomy and close the abdominal wall.

Note:

- ✓ When the wrap is completed, and prior to placing the lower collar suture, the surgeon should be able to place one finger between the wrap and the anterior esophageal area (see Fig. 5.27).

Repair of Paraesophageal Hernia

Procedure:

- Step 1.** Open the abdomen as for sliding hiatus hernia. Incise the left triangular ligament of the liver.
- Step 2.** Reduce the stomach and esophagus into the abdomen (Fig. 5.22).
- Step 3.** Open the hernia sac and expose the esophagus. Protect the anterior vagal trunk, and excise the sac (Fig. 5.23).
- Step 4.** Perform anterior approximation of the crura with interrupted 0 non-absorbable sutures (Fig. 5.24). Alternatively, perform posterior

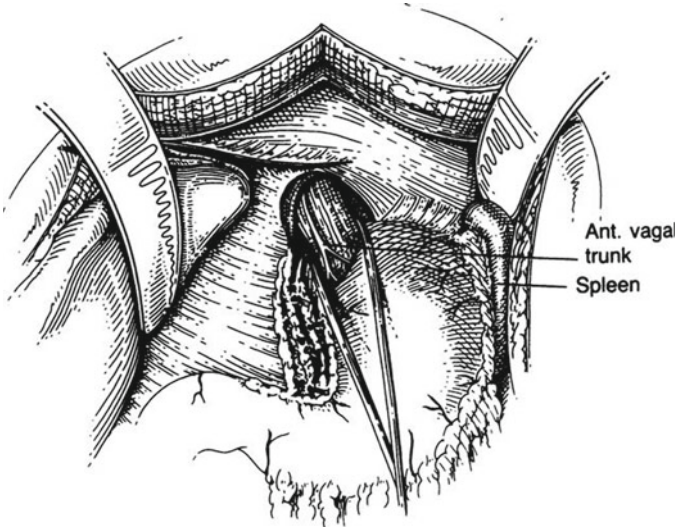


Figure 5.22. Paraesophageal hernia (By permission of JE Skandalakis, SW Gray, AR Mansberger, et al. *Hernia: Surgical Anatomy and Technique*. New York: McGraw Hill, 1989).

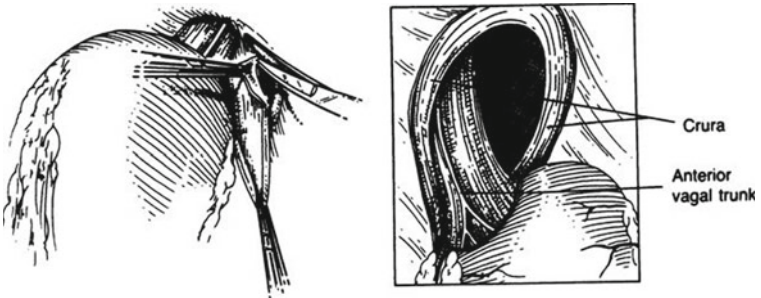


Figure 5.23. Excision of the sac (By permission of JE Skandalakis, SW Gray, AR Mansberger, et al. *Hernia: Surgical Anatomy and Technique*. New York: McGraw Hill, 1989).

approximation of the crura. Occasionally the lesser curvature of the stomach is sutured to the left crus posteriorly with interrupted 2-0 silk sutures. The diaphragm should admit one finger between it and the esophagus (Figs. 5.25, 5.26, and 5.27).

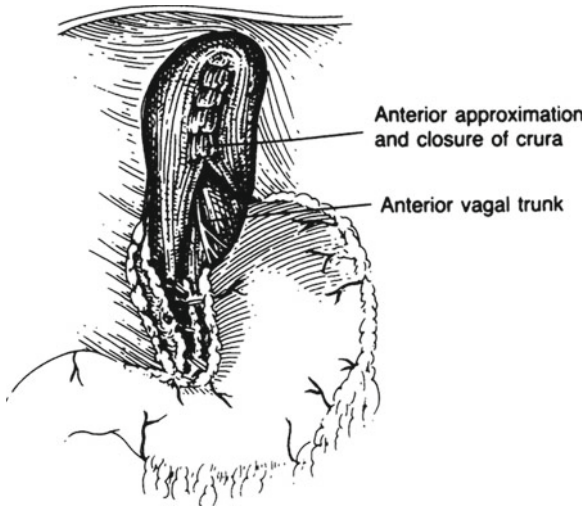


Figure 5.24. Anterior approximation (By permission of JE Skandalakis, SW Gray, AR Mansberger, et al. *Hernia: Surgical Anatomy and Technique*. New York: McGraw-Hill, 1989).

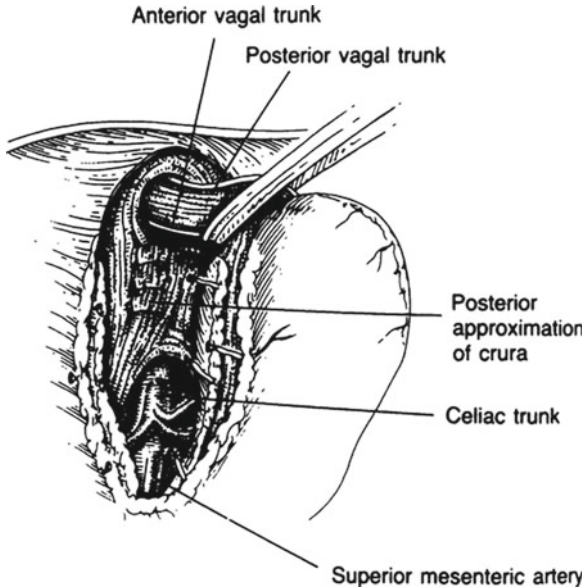


Figure 5.25. Posterior approximation (By permission of JE Skandalakis, SW Gray, AR Mansberger, et al. *Hernia: Surgical Anatomy and Technique*. New York: McGraw-Hill, 1989).

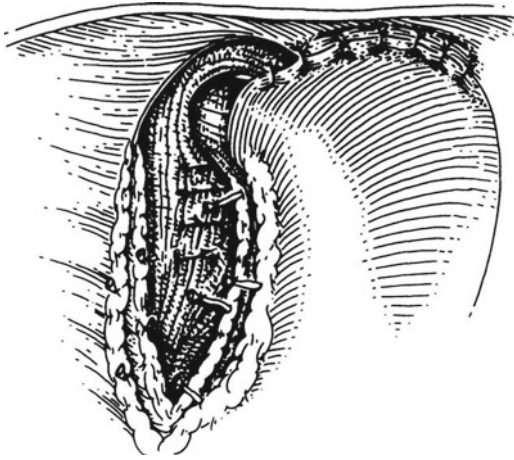


Figure 5.26. Suturing of fundus (By permission of JE Skandalakis, SW Gray, AR Mansberger, et al. *Hernia: Surgical Anatomy and Technique*. New York: McGraw-Hill, 1989).

- Step 5.** The fundus of the stomach may be sutured to the undersurface of the diaphragm with 3-0 silk to add stability to the anatomical repair (Fig. 5.26).
- Step 6.** A fundic wrap (see Nissen Fundoplication, step 4 of “Repair of Sliding Hiatus Hernia,” earlier in this chapter) may be added to the repair in those unusual instances where a mixed paraesophageal hernia with reflux is present (Fig. 5.27).

Repair of Traumatic Diaphragmatic Hernia

- Step 1.** Explore the abdomen through an upper midline incision.
- Step 2.** Identify the defect and determine its extent. Inspect the intestines and other organs in the abdominal cavity for injury.
- Step 3.** Approximate the edges of the diaphragm with interrupted 0 nonabsorbable sutures.
- Step 4.** Insert a chest tube.

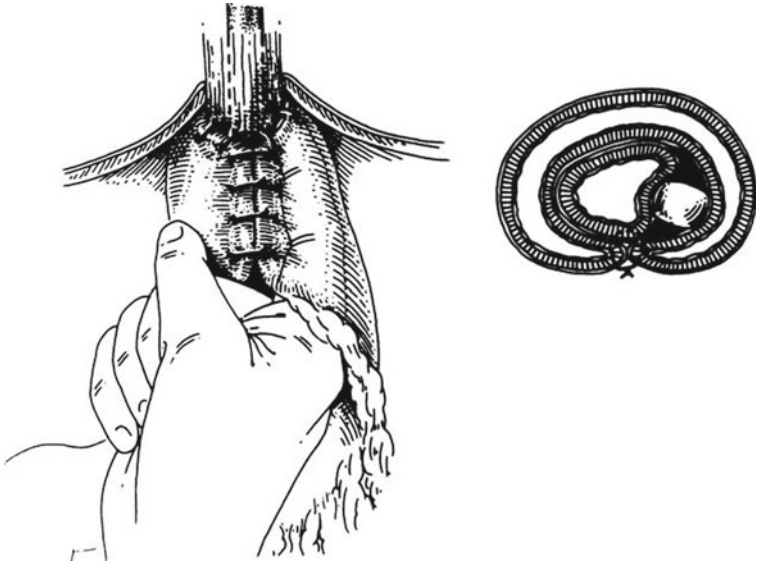


Figure 5.27. Fundic wrap. Inset: cross section of repair (By permission of JE Skandalakis, SW Gray, AR Mansberger, et al. *Hernia: Surgical Anatomy and Technique*. New York: McGraw-Hill, 1989).

Laparoscopic Nissen Fundoplication

Various types of fundoplication have been used in the treatment of hiatal hernia and/or gastroesophageal reflux disease (GERD). Of these, the Nissen fundoplication (360° wrap) (Fig. 5.28) has been the most widely performed and studied. It has been proven durable and effective in the control of GERD and in maintaining an intra-abdominal location of the gastroesophageal junction (GEJ) after hiatal hernia repair.

Since 1992, the laparoscopic technique of Nissen fundoplication has replaced the traditional open operation. It provides patients with a significantly enhanced postoperative recovery and excellent long-term outcomes. Rather than a hospital stay of 5–7 days and a 6-week postoperative convalescence—which is necessary with open fundoplication—patients who have had laparoscopic Nissen fundoplication remain hospitalized only 24 h and return to their usual activities within 1–2 weeks.

PREOPERATIVE: Mild laxative evening before surgery (e.g., one bottle of magnesium citrate orally)

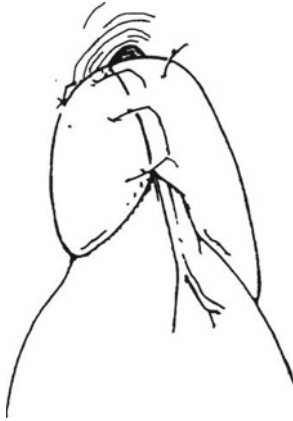

Figure 5.28. The Nissen fundoplication with 360° fundic wrap. The completed wrap should be no greater than 2 cm in length.

Note:

- ✓ Esophagoscopy and barium swallow should confirm diagnosis.
- ✓ 24-h esophageal pH monitoring or esophageal motility studies may be necessary.

POSITION: Supine with legs in stirrups to allow surgeon to operate from between the patient's legs (Fig. 5.29)

ANESTHESIA: General

OTHER: Foley catheter, orogastric tube, and pneumatic compression hose

- Step 1.** Prep and drape the patient so that either laparoscopy or open surgery can be performed.
- Step 2.** Establish carbon dioxide pneumoperitoneum to 15 mmHg with a Veress needle inserted through a stab incision just below the umbilicus.
- Step 3.** Insert five cannulas as detailed in Fig. 5.29.
- Step 4.** Position liver retractor inserted through cannula No. 2 so that the left lobe of the liver is retracted ventrally, thereby exposing the anterior surface of the proximal stomach near the GEJ.
- Step 5.** First assistant—using instrument inserted through cannula No. 5—grasps the anterior stomach just distal to the GEJ retracting caudally.
- Step 6.** Operating through cannulas Nos. 3 and 4, use the Harmonic Scalpel to open the hepatogastric omentum over the caudate lobe of the liver and just above the hepatic branch of the vagus nerve

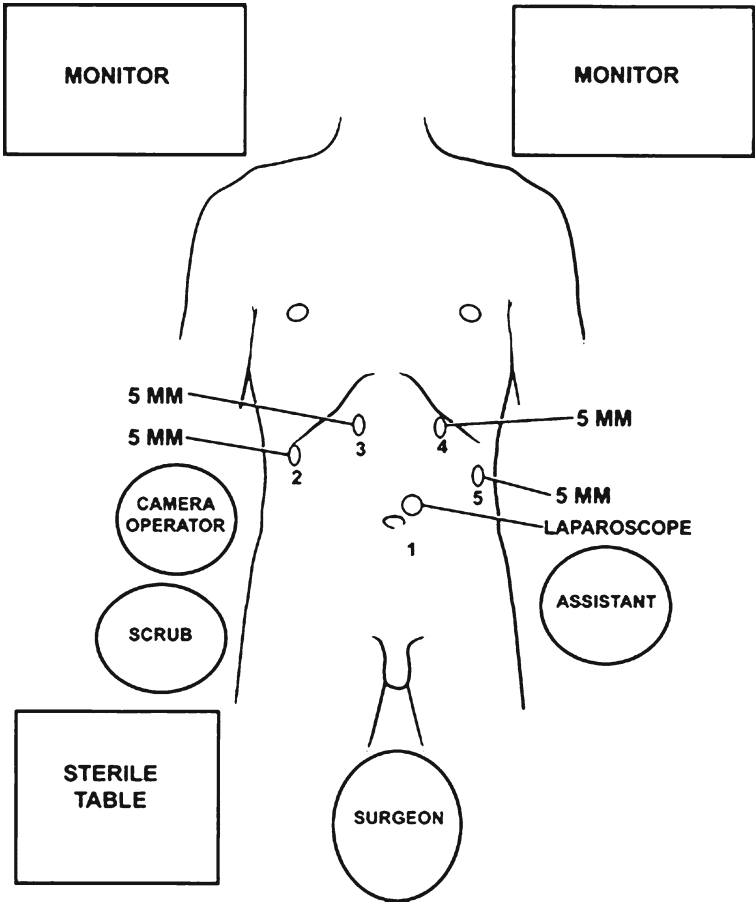


Figure 5.29. Operating room setup and trocar placement for laparoscopic Nissen fundoplication.

(Fig. 5.30). This exposes the right crus of the diaphragm (**Note:** Either an accessory or replaced left hepatic artery may course within the hepatogastric omentum and should be sought and protected).

Step 7. Be aware that the anterior vagus nerve can be injured during the following dissection; however, it is usually tight against the anterior wall of the esophagus and easily avoided. Continuing with the Harmonic Scalpel, carry this incision to the patient's left through the phrenoesophageal ligament anteriorly and over to the anterior surface of the left crus.

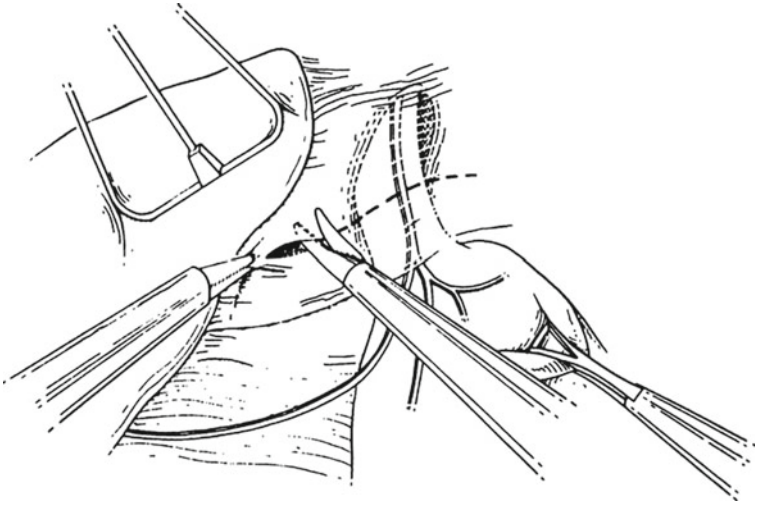


Figure 5.30. Dissection begins by opening the hepatogastric omentum over the caudate lobe of the liver and cephalad to the hepatic branch of the vagus nerve. The incision is carried across the phrenoesophageal ligament (*broken line*).

Step 8. Dissect the right crus from its base through the crural arch. Similarly dissect the left crus from base through arch.

Step 9. Dissect gently between the crura at their bases and thereby open the retrosophageal window. Look for and protect the posterior vagus nerve (Fig. 5.31). Pass a one-inch Penrose drain around the distal esophagus (Fig. 5.32), and use this Penrose as a handle for further dissection. Dissect the distal esophagus out of the chest until at least 2–3 cm of distal esophagus can be pulled below the diaphragm without tension.

Note:

- ✓ By dissecting the right and left crura of the diaphragm and thoroughly dissecting the esophageal hiatus, the distal esophagus is safely isolated.
- ✓ Compared to the anterior vagus nerve, the posterior vagus is often more distant from the esophagus and can be injured more easily during this dissection.
- ✓ Once it is identified, the posterior vagus should be left within the Penrose to protect it from injury during esophageal mobilization.

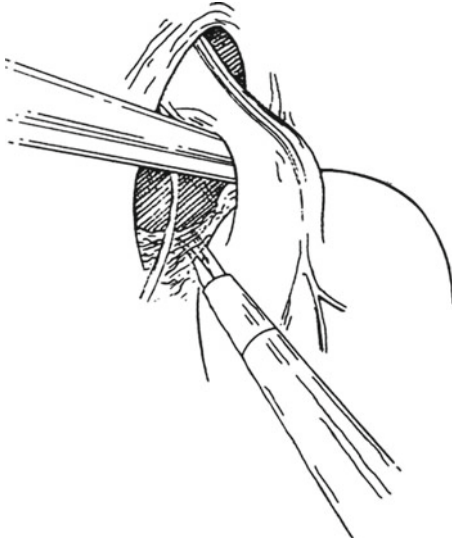


Figure 5.31. By dissecting at the base of the crura, the retroesophageal window can be widely opened and the posterior vagus nerve identified and protected.

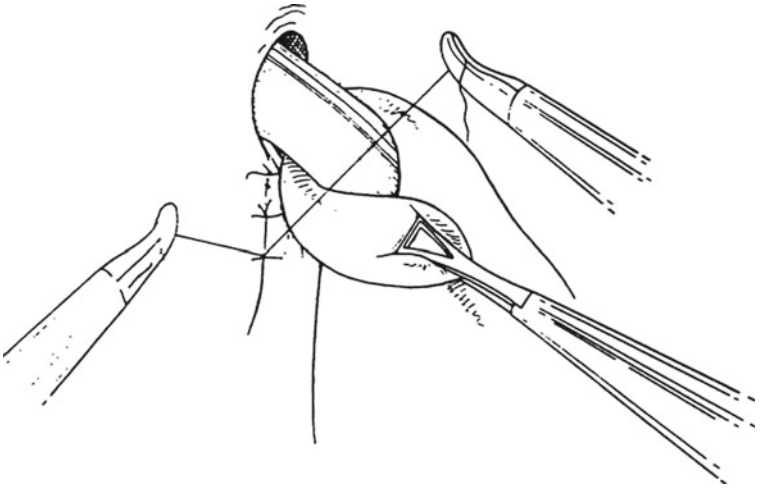


Figure 5.32. A Penrose drain is used to encircle and retract the esophagus.

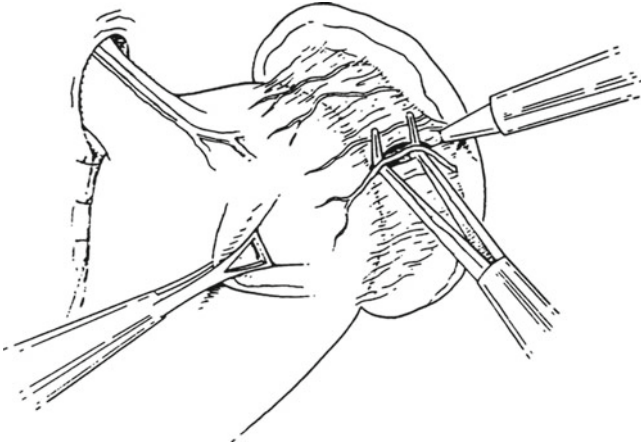


Figure 5.33. The short gastrics are taken down beginning one-third of the way down the greater curvature of the stomach working cephalad.

Step 10. Mobilize the gastric fundus. Enter the lesser sac one-third of the way down the greater curve of the stomach from the angle of His and isolate and divide short gastric vessels working back toward the GEJ (Fig. 5.33). This is best done with the Harmonic Scalpel. Divide any filmy attachments between the posterior wall of the proximal stomach and anterior surface of the pancreas.

Note:

- ✓ Great care must be taken to avoid injury to the short gastrics or the spleen. Bleeding during mobilization of the gastric fundus may require laparotomy for control.
- ✓ One or two “posterior” short gastric vessels or the left inferior phrenic artery are often encountered near the base of the left crus and should be expected. The Harmonic Scalpel should be used for the short gastric vessels.

Step 11. Bring the mobilized gastric fundus through the retroesophageal window and around the distal esophagus anteriorly to ensure adequate mobilization (Fig. 5.34).

Note:

- ✓ When the hold on the gastric fundus is released, it should remain behind the esophagus and through the retroesophageal window. If the fundus exits the retroesophageal window and

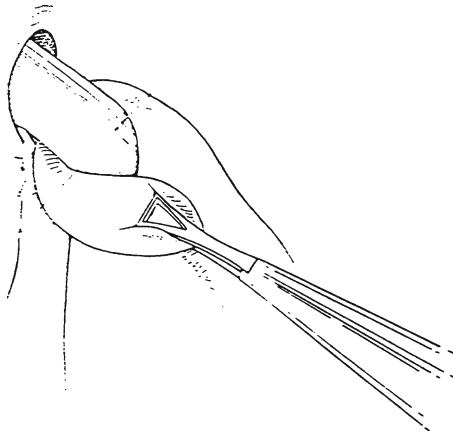


Figure 5.34. The mobilization of the gastric fundus is tested by bringing it through the retroesophageal window anteriorly over the distal esophagus.

returns to its premobilized position, further mobilization is necessary (look for retrogastric connections or divide more short gastric vessels).

- Step 12.** Before completing fundoplication, reconstruct the esophageal hiatus by approximating the right and left crura behind the esophagus using interrupted 0 nonabsorbable suture. Use as many stitches as necessary to efface the crura with the distal esophagus (Fig. 5.35).
- Step 13.** Complete the fundoplication around a 50–60 French esophageal dilator inserted by the anesthesiologist. Two to three 2-0 nonabsorbable sutures are placed with bites taking full-thickness gastric fundus and partial thickness anterior esophageal wall. When completed, the wrap should be no greater than 2 cm in length (see Fig. 5.28).

Note:

- ✓ Avoid the anterior vagus nerve.
- ✓ Sutures from the wrap to the diaphragm are optional.

- Step 14.** Remove cannulas and allow carbon dioxide insufflation to entirely escape the abdominal cavity.
- Step 15.** Close the fascia of the 10 mm incisions with an absorbable 0 suture and the skin with a subcuticular 4-0 absorbable suture.
- Step 16.** Patients are maintained on a soft diet for 4 weeks postoperatively.

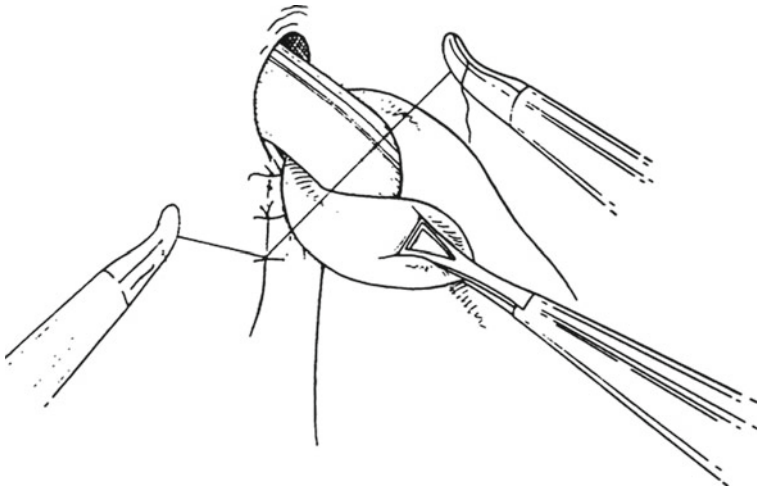


Figure 5.35. The crura are approximated using interrupted sutures tied intra- or extracorporeally.

6

Esophagus

ANATOMY

■ GENERAL DESCRIPTION OF THE ESOPHAGUS

Length of the Esophagus

The esophagus is about 25 cm in length. The most useful reference point is the upper incisors, which are about 15 cm above the pharyngoesophageal junction; if the external nares are included, 2–3 cm must be added. In defining the esophagus, it is adequate to divide it into cervical, thoracic, and abdominal segments.

Constrictions of the Esophagus

Major Constrictions

There are three major constrictions:

- The cricopharyngeal or pharyngoesophageal constriction (diameters 1.7×2.3 cm).
- The bronchoaortic constriction. Anatomically there are two separate constrictions: the aortic at the level of T4 with diameters of 1.9×2.3 cm and the bronchial at the level of T5 with diameters of 1.7×2.3 cm.
- The diaphragmatic constriction at the level of T9 or T10 with a diameter of 2.3 cm.

These constrictions define two regions of dilatation: superior (between the cricopharyngeal and bronchoaortic constrictions) and inferior (between the bronchoaortic and diaphragmatic constrictions).

254 6. Esophagus

Minor Constrictions (Seen Occasionally)

- A retrosternal constriction may lie between the pharyngoesophageal and the aortic constrictions.
- A cardiac constriction may lie behind the pericardium and is produced if right atrial enlargement is present, as in mitral stenosis.
- A supradiaphragmatic constriction may be produced by a tortuous, arteriosclerotic aorta.

Curves of the Esophagus

The esophagus has three gentle curves: in the neck, behind the left primary bronchus; below the bifurcation of the trachea; and behind the pericardium. In terms of vertebral levels, the esophagus is to the left of the midline at T1, to the right at T6, and to the left again at T10.

Remember the three Cs: three constrictions and three curves. Most esophageal pathology (e.g., lodgment of foreign bodies, burns from caustic chemicals, and cancer) is located at or close to these constrictions. The bronchoaortic constriction is the most frequently involved.

■ TOPOGRAPHY AND RELATIONS OF THE ESOPHAGUS

The tubercle of the cricoid cartilage is the single constant landmark of the upper esophageal opening.

Pharyngoesophageal Junction

The muscular pharyngeal wall is formed by three overlapping muscles: the superior, middle, and inferior pharyngeal constrictors. The inferior constrictor muscle (Fig. 6.1) blends inferiorly with the sphincter-like transverse cricopharyngeal muscle, which blends with the circular, muscular esophageal wall. Between the two parts of the cricopharyngeal muscle is the weak area (triangle) of Killian. There is another weak area between the lower transverse and the muscular coat of the esophagus (Fig. 6.1). These weak areas may become the site of acquired pulsion diverticula (Zenker's, above; Laimer's, below). They also are the sites of possible perforation by an esophagoscope.

Two anatomical entities at this point contribute to narrowing of the esophageal lumen: internally the hypopharyngeal fold and externally the cricopharyngeal muscle. At this location perforation by instruments, lodgment of foreign bodies, spasm, and neoplasms tend to occur.

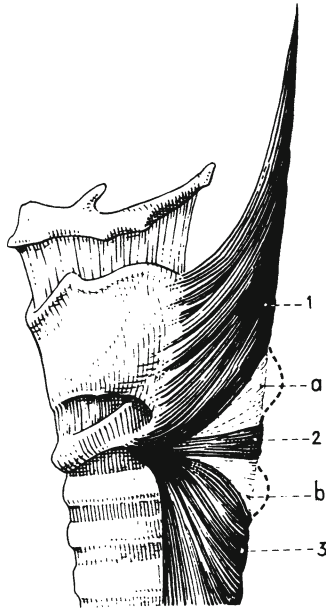


Figure 6.1. The lateral aspect of the pharyngoesophageal junction showing (a) the upper weak area; (b) the lower weak area; (1) the oblique fibers of the inferior constrictor muscle; (2) the cricopharyngeal muscle; (3) the muscularis of the esophagus (From J Terracol and RH Sweet. *Diseases of the Esophagus*. Philadelphia: Saunders, 1958).

The cricopharyngeal muscle and the lower border of the cricoid cartilage demarcate the end of the pharynx and the start of the esophagus. The so-called inferior constrictor of the pharynx, the cricopharyngeal muscle, originates from the thyroid and cricoid cartilages. It is composed of two parts, the upper oblique and the lower transverse; the lower transverse is probably the cricopharyngeal sphincter.

Logically, a diverticulum above the transverse portion of the cricopharyngeal muscle should be recognized as pharyngeal, and one originating below as esophageal. However, in the literature this distinction is not always made (Fig. 6.2). For example, a diverticulum originating above the junction, which should be called Zenker's, may instead be referred to as pharyngoesophageal or esophageal, causing confusion.

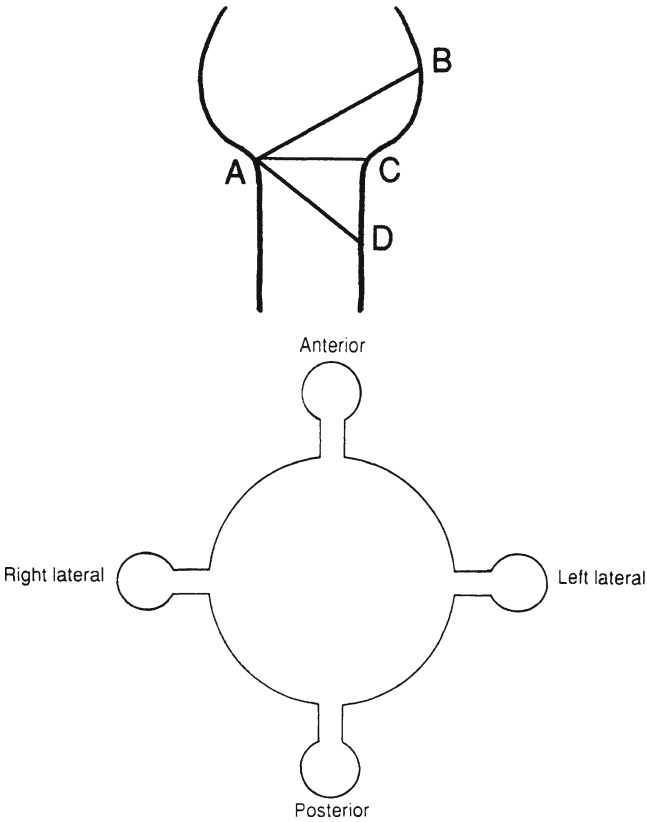


Figure 6.2. *Top*: highly diagrammatic presentation of the musculature of the pharyngoesophageal junction. AB=oblique muscle; AC=transverse muscle; AD=muscular coat. Sites of potential diverticula are as follows: ABC=Killian's triangle (1908)=pharyngeal diverticulum; ABD=Zenker's diverticulum (1878)=pharyngoesophageal diverticulum; ACD=esophageal weakness=esophageal diverticulum. A congenital diverticulum has a wide neck and includes all layers. An acquired diverticulum has a narrow neck and no muscular coat. *Bottom*: highly diagrammatic presentation of diverticula. *Note*: The anterior diverticulum is a rare congenital condition.

Cervical Esophagus

The cervical esophagus is approximately 5–6 cm long and extends from C6 to T1, or from the cricoid cartilage and cricopharyngeal muscle to the thoracic inlet at the level of the sternoclavicular joints. The carotid tubercle (of Chassaignac),

which is the palpable anterior tuberosity of the transverse process of C6, is a good anatomical landmark. It projects somewhat to the left of the trachea, and incisions are commonly made on this side to approach the esophagus.

Anteriorly, the cervical esophagus is covered by the larynx and trachea.

Anterolaterally, there are four anatomical entities related to the esophageal wall on each side (see Fig. 2.15). From the periphery inward they are: the carotid sheath, the inferior thyroid artery, the lobe of the thyroid gland, and the recurrent laryngeal nerve. Also related to the distal cervical esophagus on the left side is the thoracic duct.

Posteriorly, the cervical esophagus is related to: the alar fascia, the prevertebral fascia, the longissimus cervicis muscle, and the vertebrae.

Between the alar fascia and the prevertebral fascia is the retrovisceral space, the so-called danger space that extends down the mediastinum and ends approximately at the level of T4.

Pretracheal Space

The space in front of the trachea is not related directly to the esophagus. It is related clinically, however, since perforations of the anterior esophageal wall may open into the pretracheal space and therefore the mediastinum, producing a serious or even fatal mediastinitis.

Thoracic Esophagus

The thoracic portion of the esophagus extends from the level of T1 to T10 or T11.

Successful esophageal surgery requires knowledge of the anatomy of the mediastinum; we remind the reader that the thoracic esophagus is located in the superior and posterior mediastinum. The key structure of the superior mediastinum is the aortic arch. The posterior mediastinum displays venous structures on the right and arterial structures on the left.

The anterior relations of the thoracic esophagus from above downward consist of the following structures: trachea and aortic arch, right pulmonary artery, left main bronchus, esophageal plexus below the tracheal bifurcation, pericardium and left atrium, anterior vagal trunk, esophageal plexus, and esophageal hiatus.

The posterior relations of the thoracic esophagus are: vertebral column, longus colli muscle, right posterior intercostal arteries, left thoracic duct obliquely from T7 to T4, right pleural sac, azygos vein, hemiazygos vein, accessory hemiazygos vein, anterior wall of the aorta, esophageal plexus of the vagus nerve below the tracheal bifurcation, and sometimes the posterior vagal trunk.

The lateral relations on the right are mediastinal pleura, azygos vein, right main bronchus, root of right lung, right vagus nerve, and esophageal plexus (Fig. 6.3).

258 6. Esophagus

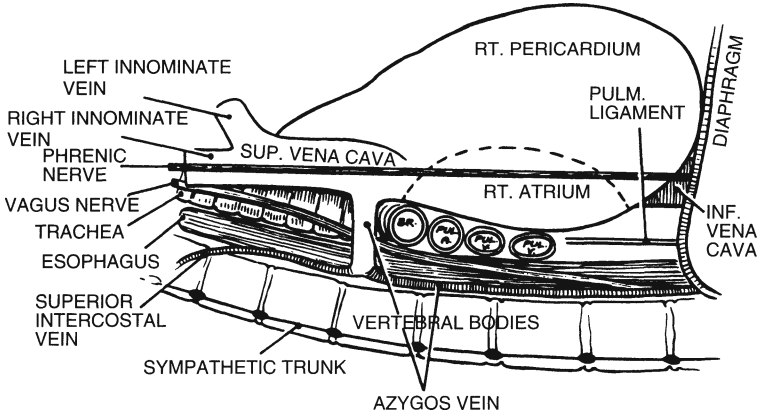


Figure 6.3. Highly diagrammatic view of the right mediastinum showing the disposition of its contents. BR bronchus, PUL pulmonary (By permission of JE Skandalakis, SW Gray, and LJ Skandalakis. In: GG Jamieson. *Surgery of the Esophagus*. Edinburgh: Churchill Livingstone, 1988, pp. 19–35).

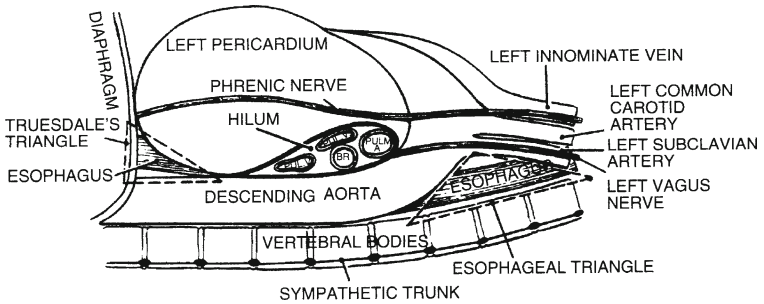


Figure 6.4. Highly diagrammatic view of the left mediastinum showing the disposition of its contents. BR bronchus, PUL pulmonary (By permission of JE Skandalakis, SW Gray, and LJ Skandalakis. In: GG Jamieson. *Surgery of the Esophagus*. Edinburgh: Churchill Livingstone, 1988, pp. 19–35).

The lateral relations on the left are aortic arch, left subclavian artery, left recurrent laryngeal nerve, left vagus nerve, thoracic duct from T4 to C7, pleura, and descending thoracic aorta (Fig. 6.4).

The following structures are between the esophagus and the left mediastinal pleura: left common carotid artery, left subclavian artery, aortic arch, and descending aorta. The entire length of the thoracic esophagus is directly related to the right mediastinal pleura except where the arch of the azygos vein crosses above the right main bronchus.

Surgical Considerations

- ✓ From a surgical standpoint, lesions of the upper half of the thoracic esophagus should be explored through a right thoracotomy to avoid technical problems with the aortic arch. Lesions of the lower half of the thoracic esophagus can be explored through a left or a right thoracotomy.
- ✓ With the right-sided approach, the azygos vein should be ligated and divided where it crosses the right wall of the esophagus to empty into the posterior wall of the superior vena cava. The azygos vein may be ligated with impunity. However, ligation of the superior vena cava between the atrium and the azygos vein cannot be tolerated if the azygos vein has been ligated.
- ✓ The esophageal triangle in the left side of the mediastinum is formed by the descending arch of the aorta, the subclavian artery, and the vertebral column. The floor of the triangle is formed by the left mediastinal pleura beneath which the esophagus is located (Fig. 6.4).
- ✓ The lower end of the thoracic esophagus, which is covered by pleura, may be found in the triangle of Truesdale. The triangle of Truesdale is formed by the diaphragm below, the pericardium above and anteriorly, and the descending aorta posteriorly (Fig. 6.4). The posterior approximation of the right and left pleurae between the esophagus and the aorta forms the so-called meso-esophagus. The right pleura is in contact with the lower one-third of the esophagus, almost to the diaphragmatic hiatus. This proximity of the right pleura to the hiatus introduces the risk of pneumothorax during abdominal operations on the hiatus. The anterior approximation of the two pleurae is at the sternal angle (see Fig. 5.10).

Anatomic Weak Points

Two anatomically weak areas of the esophageal wall—one above and one below the cricoid muscle—have been mentioned. They can become the sites of pulsion diverticula. Another weak area, the left lateral posterior wall of the esophagus near the diaphragm, is occasionally the site of spontaneous idiopathic rupture of the healthy esophagus.

Abdominal Esophagus and Gastroesophageal Junction (Fig. 6.5)

External Junction

The gastroesophageal junction lies in the abdomen just below the diaphragm.

The abdominal esophagus is said to be from 0.5 to 2.5 cm in length and occasionally as long as 7 cm. The surgeon has access to an appreciable length of esophagus below the diaphragm.

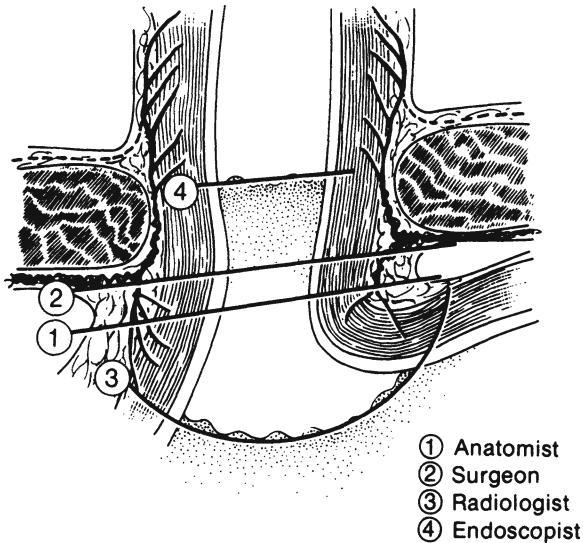


Figure 6.5. Views of the “gastroesophageal junction” by four specialties. Each is correct (By permission of JE Skandalakis, SW Gray, and JR Rowe. *Anatomical Complications in General Surgery*. New York: McGraw-Hill, 1983).

The abdominal esophagus lies at the level of the 11th or 12th thoracic vertebra and is partially covered by peritoneum in front and on its left lateral wall. Relations with surrounding structures are as follows:

ANTERIOR: The posterior surface of the left lobe of the liver, the left vagal trunk, and the esophageal plexus

POSTERIOR: One or both crura of the diaphragm, the left inferior phrenic artery, and the aorta

TO THE RIGHT: The caudate lobe of the liver

TO THE LEFT: The fundus of the stomach

Internal Junction

The histological junction between esophagus and stomach is marked by an irregular boundary between stratified squamous epithelium and simple columnar epithelium. Above the boundary, islands of columnar gastric epithelium may be present at all levels of the esophagus. The lower esophagus may occasionally be lined by gastric mucosa. A biopsy specimen to identify histologic

changes in the mucosa should be taken more than 2 cm above the epithelial junction to avoid most of these patches.

Part of the problem of defining the gastroesophageal junction is the fact that this mucosal boundary does not coincide with the external junction described above. In the living patient, the situation is even less simple. The submucosal connective tissue is so loose that the mucosa moves freely over the underlying muscularis. Even at rest, the junctional level may change. Figure 6.5 shows the internal gastroesophageal junction from the point of view of four specialties.

“Cardiac Sphincter”

There is a sphincter at the cardiac orifice of the stomach that normally permits swallowing but not reflux. A slight thickening of the circular musculature of the distal esophagus has been described.

Several other structures have been held responsible for closing the cardia: the angle (of His) at which the esophagus enters the stomach, the pinchcock action of the diaphragm, a plug of loose esophageal mucosa (mucosal rosette), the phrenoesophageal membrane, and the sling of oblique fibers of the gastric musculature.

Esophageal Hiatus and the Crura (See Chap. 5)

Surgical Considerations

Placing 0 silk sutures deep in the crura, including the attached pleura, is absolutely necessary for narrowing the hiatus. The surgeon must be certain the sutures are in the tendinous portions of the crura and not in the muscular part only.

Phrenoesophageal Ligament

Where the esophagus passes from the thorax into the abdomen through the diaphragmatic hiatus, a strong, flexible, airtight seal is necessary. The seal must be strong enough to resist abdominal pressure, which tends to push the stomach into the thorax, and flexible enough to give with the pressure changes incidental to breathing and the movement incidental to swallowing. A seal known as the phrenoesophageal ligament or membrane consists, in principle, of the following elements: pleura, subpleural (endothoracic) fascia, phrenoesophageal fascia (of Laimer), transversalis (endoabdominal subdiaphragmatic) fascia, and peritoneum (Fig. 6.6).

The first and last of these elements provide the requirement for airtightness; the middle three provide flexibility and strength. The ligament exists in infants, is attenuated in adults, and does not exist in adult patients with hiatal hernia.

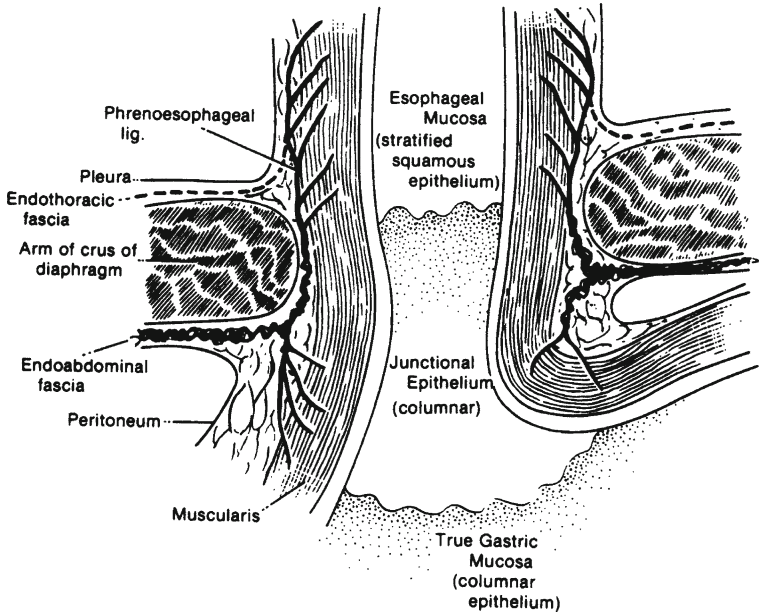


Figure 6.6. Diagram of a coronal section through the gastroesophageal junction and the esophageal hiatus of the diaphragm (By permission of JE Skandalakis, SW Gray, and JR Rowe. *Anatomical Complications in General Surgery*. New York: McGraw-Hill, 1983).

The development of the phrenoesophageal ligament can be summarized as follows:

- In newborn infants, the phrenoesophageal ligament is present.
- In adults, the ligament is attenuated and subperitoneal fat accumulates at the hiatus.
- In adults with hiatal hernias, the ligament for all practical purposes does not exist.

SURGICAL CONSIDERATIONS: Dividing the phrenoesophageal ligament will mobilize the cardia, but the surgeon undertaking a Hill procedure must be prepared to find the ligament ill defined or absent.

Peritoneal Reflections

HEPATO-GASTRIC (GASTROHEPATIC) LIGAMENT: The abdominal esophagus is contained between the two layers of the hepatogastric ligament. The ligament contains the following structures: left gastric artery and vein;

hepatic division of left vagus trunk; lymph nodes; occasionally, both vagal trunks; occasionally, branches of the right gastric artery and vein; and the left hepatic artery when it arises from the left gastric artery (in 23 % of cases).

GASTROSPLENIC (GASTROLIENAL) LIGAMENT: The hepatogastric ligament encloses the abdominal esophagus on the right; its leaves rejoin on the left of the esophagus to form the gastrosplenic ligament. The lesser sac lies behind these ligaments (for more information, see Chap. 15).

■ GASTROPHRENIC LIGAMENT (SEE CHAP. 7, STOMACH)

The Structure of the Esophageal Wall (Fig. 6.7)

Mucosa

The esophagus is lined with a thick layer of non-keratinizing, stratified squamous epithelium continuous with the lining of the oropharynx.

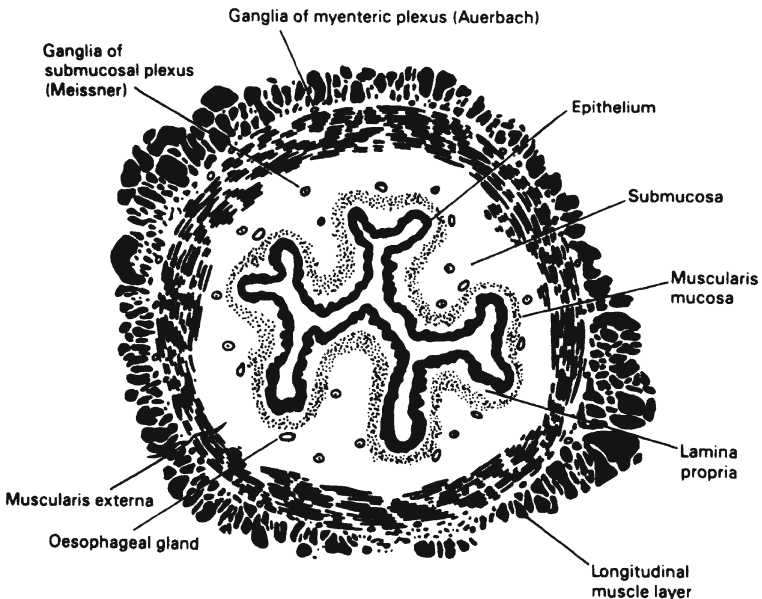


Figure 6.7. Cross section of the esophagus showing the layers of the wall. The longitudinal and circular layers of the muscularis externa contain striated muscle fibers decreasing distally (By permission of JE Skandalakis, SW Gray, and LJ Skandalakis. In: GG Jamieson, *Surgery of the Esophagus*. Edinburgh: Churchill Livingstone, 1988, pp. 19–35).

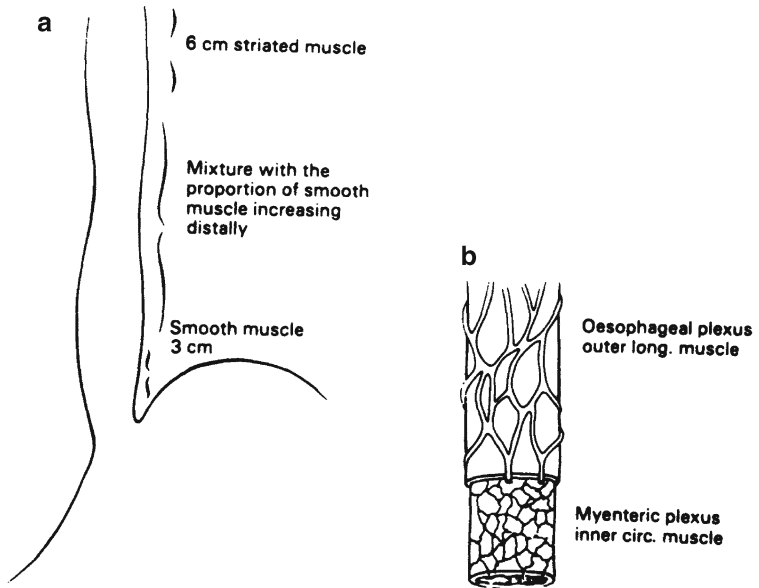


Figure 6.8. (a) relative distribution of smooth and striated muscle in the esophagus. (b) the extrinsic and intrinsic nerves of the esophagus (By permission of JE Skandalakis, SW Gray, and LJ Skandalakis. In: GG Jamieson, *Surgery of the Esophagus*. Edinburgh: Churchill Livingstone, 1988, pp. 19–35).

Submucosa

A layer of loose connective tissue lies external to the mucosa. *The thick submucosa is the strongest part of the esophageal wall.* It is this layer with the lamina propria that the surgeon must count on for a sound esophageal anastomosis.

Muscularis Externa

The chief muscles of the esophagus are an internal circular layer and an external longitudinal layer. Both layers in the upper quarter of the esophagus are large striated (voluntary) muscle fibers. In the second quarter, striated and smooth (involuntary) fibers are mingled; the lower half contains only smooth fibers (Fig. 6.8).

Adventitia

The connective tissue of the mediastinum around the esophagus is not a true layer of that organ, and it does not provide the surgeon with a firm anchorage

for sutures. It is the lack of a serosa that contributes to the complication of anastomotic disruption following esophageal resection and anastomosis.

Nerve Supply to the Esophagus

Intrinsic Nerve Supply

Within the esophageal wall there are two plexuses of nerves: Meissner's plexus in the submucosa and Auerbach's plexus in the connective tissue between the circular and longitudinal muscularis externa.

Extrinsic Nerve Supply

The esophagus receives nerves from three sources: cerebrospinal, sympathetic, and parasympathetic (vagal).

Blood Supply of the Esophagus

The blood supply, segmental or not, is adequate for intramural anastomoses. Poor technique, not poor blood supply, is responsible for leakage (Tables 6.1 and 6.2).

Lymphatics of the Esophagus

The esophageal lymphatics form plexuses in the mucosa (lamina propria), submucosa, muscularis, and adventitia.

Lymph nodes are generously distributed along the esophagus, and groups of nodes have been named by their relations to adjacent organs (Fig. 6.9). "Skip areas" of up to 8 cm between lymph nodes involved in cancer may be encountered.

A few generalities about "unpredictable" drainage may be stated. Nodes of the cervical esophagus drain to internal jugular, supraclavicular, and upper paratracheal nodes. Nodes of the posterior thoracic region drain to posterior mediastinal, intercostal, and paraesophageal nodes. Nodes of the anterior thoracic region drain to tracheal, hilar, subcarinal, paracardial, and celiac nodes. Cancer involves paratracheal nodes on the right more often than those on the left. Posterior hilar nodes are more often involved than are other nodes at the carina.

Among patients with carcinoma of the cervical and upper thoracic esophagus, celiac nodes are involved in 10 %. In cases of carcinoma of the middle one-third, the celiac nodes are involved in 44 %. In view of the anatomical distribution of lymphatics, less than subtotal esophagectomy is not a sound procedure. For better results, esophageal resection from 6 to 10 cm above and below the tumor is mandatory.

Table 6.1 Arterial supply of the esophagus

<i>Esophageal segment</i>	<i>Primary</i>	<i>Secondary or occasional</i>
Cervical	Br. of inferior thyroid aa. Anterior: trachea and esophagus Posterior: esophagus and longitudinal trachea and transverse anastomoses	Br. of pharyngeal aa. Br. of subclavian a. Br. of bronchial a. Superior thyroid a.
Upper thoracic	Br. of subclavian a. or lower branches of inferior thyroid a.	Ant. esophagotracheal a. from aortic arch
Mid-thoracic	L. bronchial a. ascending br. to esophagus and trachea; descending br. to esophagus R. bronchial a. branches as L. but smaller Ascending and descending branches may arise directly from aortic arch	R. internal thoracic R. costocervical trunk R. subclavian a.
Lower thoracic	Superior and inferior esophageal aa. from aorta	Branches from R. intercostal aa.
Abdominal	Branches of L. gastric a. L. inferior phrenic a.	Variable: R. inferior phrenic a. Branches from splenic a. Branches from superior suprarenal a. Accessory L. hepatic a. Celiac trunk

By permission of JE Skandalakis, SW Gray, and LJ Skandalakis. *Surgical Anatomy of the Esophagus*. In: GG Jamieson. *Surgery of the Esophagus*. Edinburgh: Churchill Livingstone, 1988, pp. 19–35

Table 6.2 Venous drainage of the esophagus

<i>Esophageal segment</i>	<i>Venous drainage</i>	<i>Termination</i>
Cervical and superior thoracic (upper 1/3)	Inferior thyroid vein Bronchial vein	Innominate vein Superior vena cava Highest intercostal vein
Thoracic (middle 1/3)	Azygos and hemiazygos veins	Superior vena cava
Inferior thoracic and abdominal (lower 1/3)	Left gastric vein Left inferior phrenic vein	Portal vein

Source: Skandalakis JE, Gray SW, Skandalakis LJ. *Surgical anatomy of the oesophagus*. In: Jamieson GG, ed. *Surgery of the Oesophagus*. Edinburgh: Churchill Livingstone, 1988; with permission

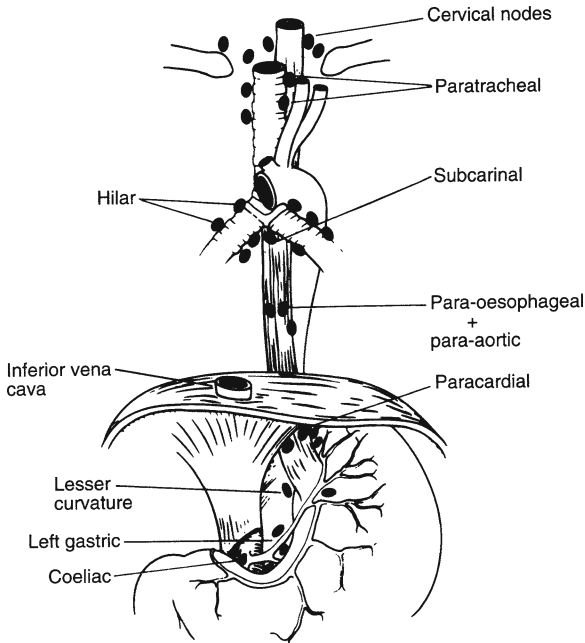


Figure 6.9. Diagram of the groups of lymph nodes draining the esophagus. There is no standard terminology (By permission of JE Skandalakis, SW Gray, and LJ Skandalakis. *Surgical Anatomy of the Esophagus*. In: GG Jamieson, *Surgery of the Esophagus*. Edinburgh: Churchill Livingstone, 1988, pp. 19–35).

Lymphatic Drainage of the Gastroesophageal Junction

It has been stated that cancer at the cardia spreads by lymphatics and usually appears first below the diaphragm among the gastrohepatic, gastrophrenic, gastrosplenic, and gastrocolic lymph nodes. Early metastasis to the liver may follow invasion of the gastric veins. Extension to the peripancreatic nodes is unusual. Isolated involvement of the diaphragm can occur. One study found that splenic hilar nodes were involved in 11 % of spleens of patients with cancer of the gastroesophageal junction.

Metastatic spread above the diaphragm is less common, though not rare. Tumors of the esophagus just above the diaphragm may metastasize to the gastrohepatic nodes and liver.

Thus, the lymphatic channels at the cardia follow the arteries: the left gastric with its esophageal branches and the splenic with its left gastroepiploic and vasa brevia. Unorthodox dissemination, however, must not be overlooked.

TECHNIQUE

■ PHARYNGOESOPHAGEAL DIVERTICULUM

- Step 1.** Incise as in thyroidectomy, but with extension to the right or the left according to the location and presentation of the diverticulum, and less extension to the opposite side. Divide the subcutaneous fascia (fat and platysma) and use special retractors for traction (Fig. 6.10).
- Step 2.** Retract the sternocleidomastoid (SCM) muscle laterally and isolate the carotid sheath. The ansa hypoglossi, which is located in front of or within the sheath, should be saved if possible and sacrificed only if absolutely necessary. We like to divide the omohyoid muscle and ligate the middle thyroid vein. As in thyroidectomy, the thyroid lobe is retracted medially, and the recurrent nerve is found and protected. Ligate and divide the inferior thyroid vein if necessary (Fig. 6.11).
- Step 3.** The upper part of the diverticulum may be seen medial to the SCM and lateral to the thyroid lobe and to the recurrent nerve but between the inferior pharyngeal constrictor above and the esophagus below (Fig. 6.12).
- Step 4.** By blunt dissection, separate the diverticulum from all surrounding structures. Elevate it, carefully clean its neck, clamp it with two clamps, and remove it (Figs. 6.12 and 6.13).
- Step 5.** Close the diverticulum base with 4-0 synthetic absorbable interrupted suture material. Close the cricopharyngeal muscle with mattress interrupted 3-0 synthetic nonabsorbable sutures (Fig. 6.14).
- Step 6.** Close the wound as in thyroidectomy. Drainage is up to the surgeon.

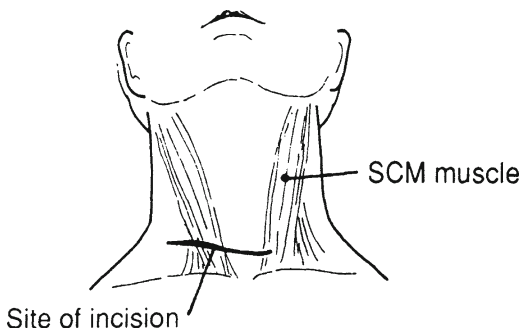


Figure 6.10. Division of subcutaneous fascia.

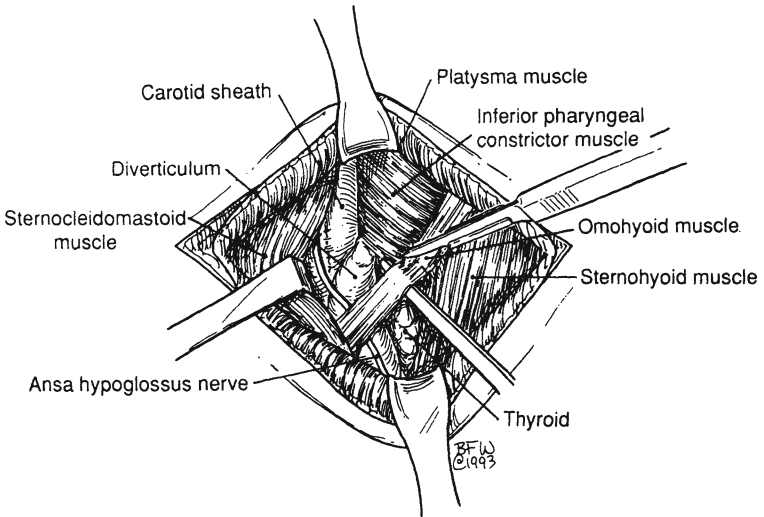


Figure 6.11. Division of omohyoid muscle.

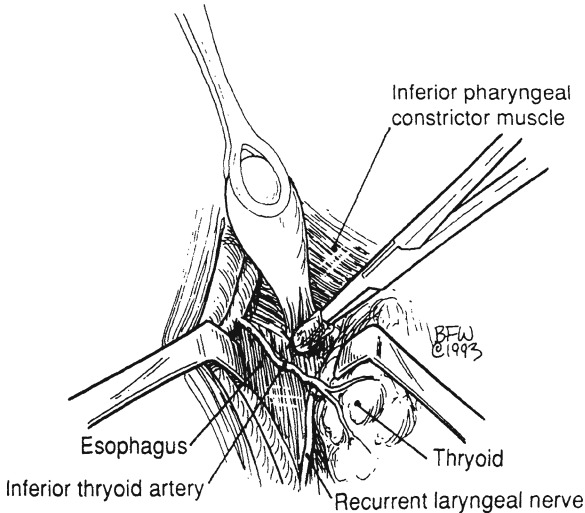


Figure 6.12. Elevation of diverticulum.

Another method of amputation of the diverticulum is the use of TA-30 or TA-55 staples longitudinally or transversely. Be sure to proceed as follows:

Step 1. Establish good myotomy (Fig. 6.15).

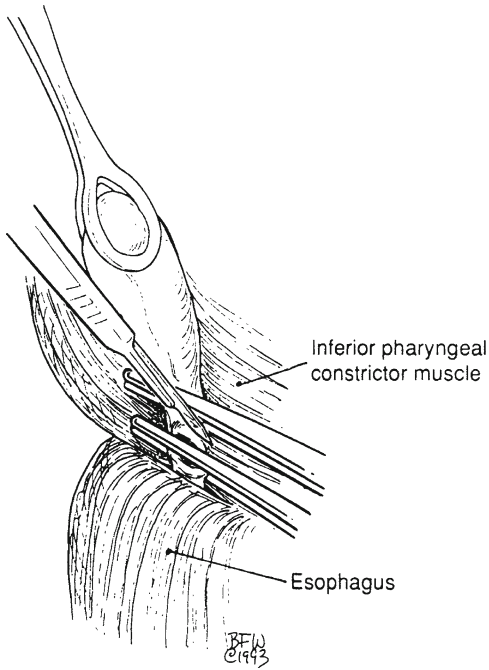


Figure 6.13. Clamping of diverticulum.

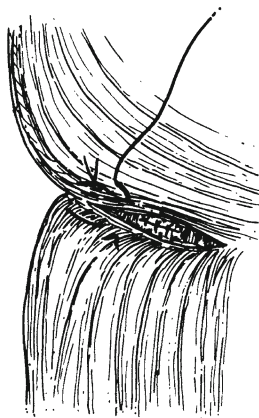


Figure 6.14. Closure of diverticulum base and cricopharyngeal muscle.

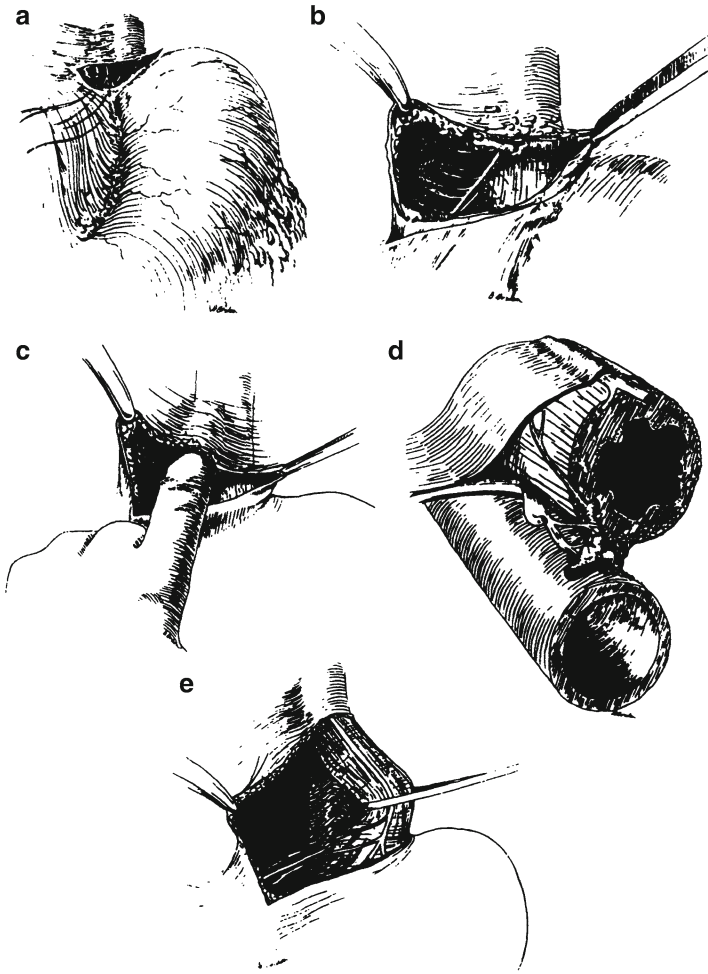


Figure 6.15. Exposure of periesophageal space. (a) Incision. (b) Division of adventitial and adipose tissue. (c) Finger is used to identify abdominal esophagus. (d) The "stout" or dorsal meso-esophagus is disrupted by digital pressure and final perforation. If the meso-esophagus is "very stout," divide between clamps with direct vision, avoiding the posterior right esophageal wall. (e) The esophagus is retracted. At least 5 cm of the distal esophagus should be mobilized (By permission of PE Donahue and LM Nyhus. *Surg Gynecol Obstet* 152:218–220, 1981).

Step 2. Isolate the neck of the diverticulum, if present.

Step 3. Insert 40F Maloney dilator into the esophagus, if it has not been inserted previously.

■ ACHALASIA OR CARDIOSPASM

Modified Heller's Procedure

Step 1. Make a transverse incision of the phrenoesophageal ligament. The abdominal esophagus is further prepared by blunt and sharp dissection, exposing the periesophageal space. Isolate both vagi. Slowly use the index finger to penetrate the avascular ligaments of the gastroesophageal junction (Fig. 16.15).

Step 2. Pass a Penrose drain around the esophagus for traction. Now the posterior mediastinum, as well as the stenotic segment of the abdominal esophagus with dilated proximal segments, is in view (Fig. 6.16).

Step 3. Make a longitudinal incision through the longitudinal and circular muscle layers until mucosal surface is exposed (dotted line in Fig. 6.17 indicates incision).

Step 4. Use the Penrose drain or the index finger for downward traction of the gastroesophageal junction. Continue the incision cephalad

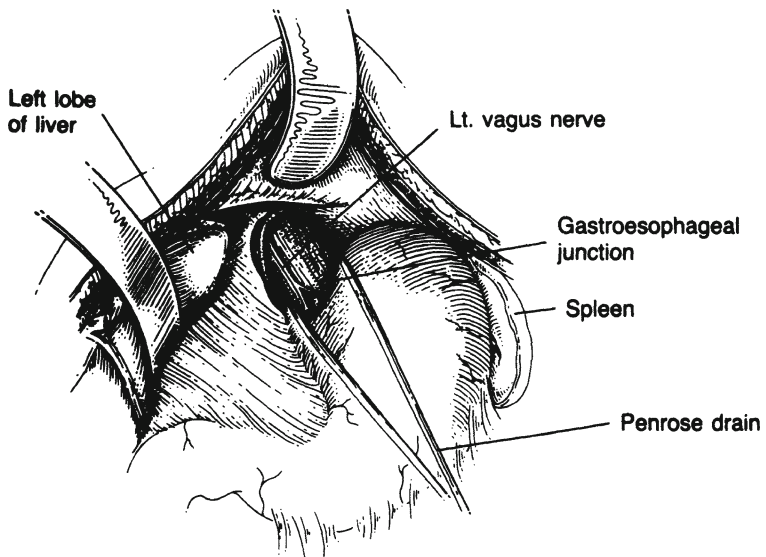


Figure 6.16. Dissection of the greater curvature of the stomach.

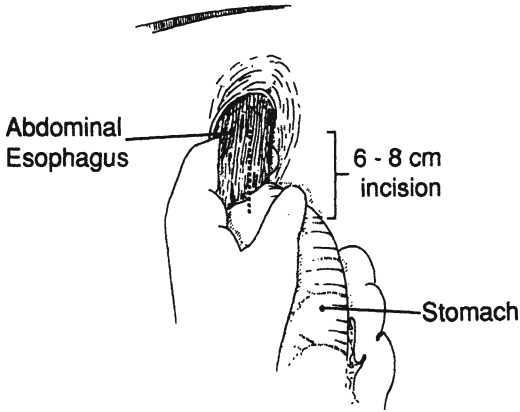


Figure 6.17. Exposure of mucosal surface.

for about 2 cm above the point where the esophagus begins to dilate. Continue the myotomy caudally as far as the gastroesophageal junction. Do not continue the incision more than 1 cm into the gastric musculature (Figs. 6.18 and 6.19).

- Step 5.** Dissect out at least a 50 % circumference of the mucosa from the mucosal coat.
- Step 6.** For a partial fundoplasty (valvuloplasty), suture the gastric fundus at the posterior esophageal wall, as well as to the left and right margin of the myotomy (Figs. 6.19 and 6.20). Alternatively, a Nissen fundoplication may be done.
- Step 7.** Close the abdominal walls.

■ TRANSHIATAL ESOPHAGECTOMY

Abdominal Portion

- Step 1.** The patient is placed in supine position. The head is turned to the right.
- Step 2.** Make an upper midline abdominal incision from the left of the xiphoid process to the umbilicus (Fig. 6.21).
- Step 3.** Apply Mayo Third Arm and Balfour retractors for better exposure of the hiatus and the abdominal cavity. A reverse Trendelenburg position of the patient is advised (Fig. 6.22).
- Step 4.** Explore the abdomen to rule out metastatic disease and assess resectability.

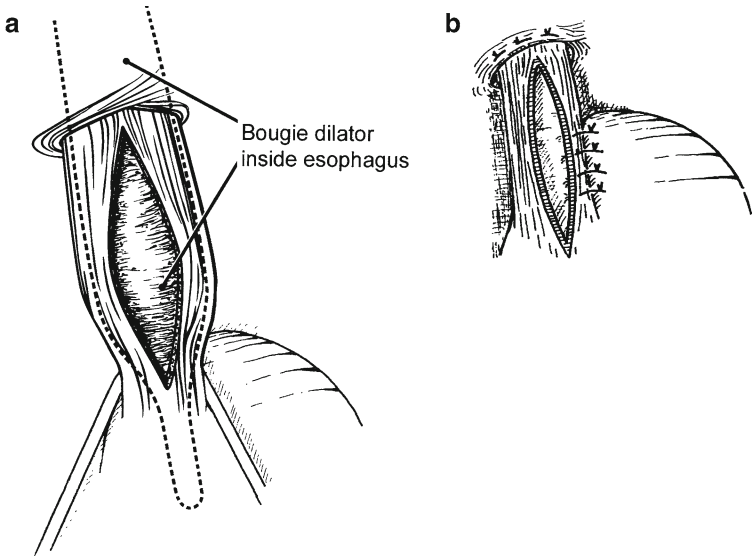


Figure 6.18. (a) Insertion of bougie. (b) Continuation of myotomy.

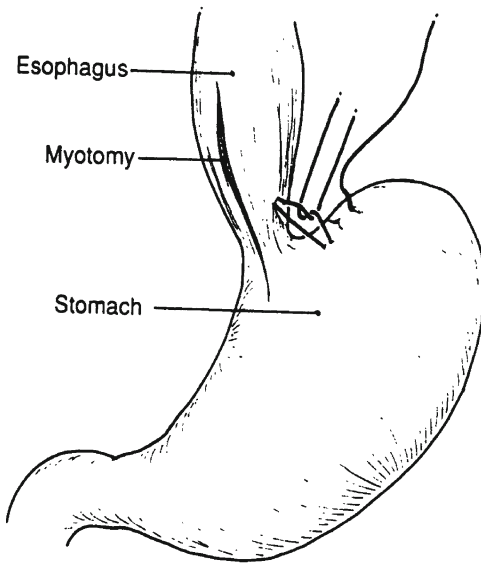


Figure 6.19. Suturing of gastric fundus.

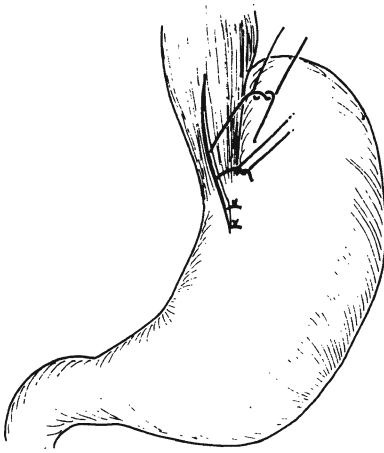


Figure 6.20. Continuation of suturing.

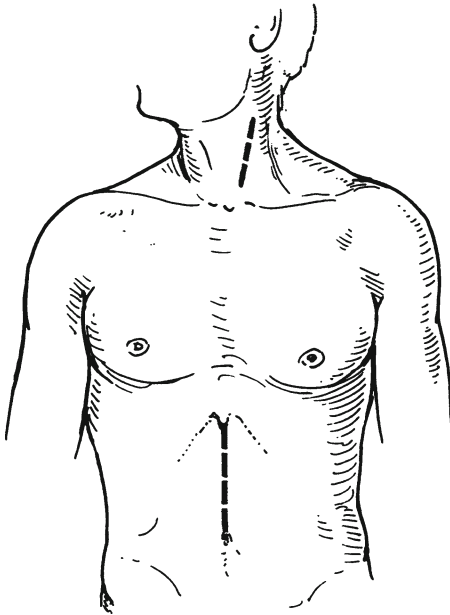


Figure 6.21. Midline upper abdominal and oblique left cervical incisions (From RI Whyte and MB Orringer. Surgery for neoplasms of the esophagus. In: KI Bland, CP Karakousis, and EM Copeland. *Atlas of Surgical Oncology*. Philadelphia: Saunders, 1995, with permission).

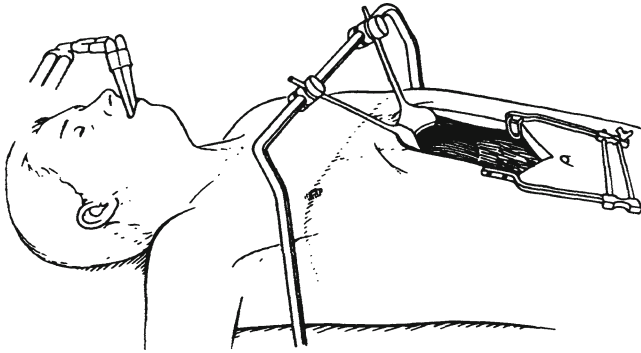


Figure 6.22. Retractors in situ (From VF Trastek. Esophagectomy: Transhiatal. In: JH Donohue, JA van Heerden, and JRT Monson. *Atlas of Surgical Oncology*. Cambridge, MA: Blackwell Science, 1995, with permission).

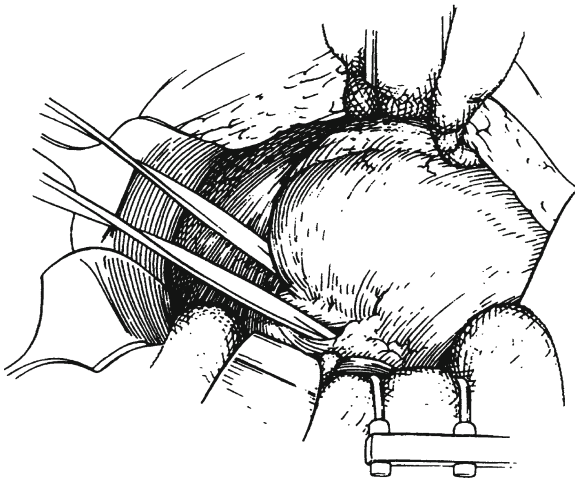


Figure 6.23. Penrose drain around the esophagus (From VF Trastek. Esophagectomy: Transhiatal. In: JH Donohue, JA van Heerden, and JRT Monson. *Atlas of Surgical Oncology*. Cambridge, MA: Blackwell Science, 1995, with permission).

- Step 5.** Divide the left triangular and left coronary ligaments with cautery; retract the left lobe of the liver upward and to the right.
- Step 6.** Divide the phrenoesophageal ligament. Identify the gastroesophageal junction. Encircle the abdominal esophagus by blunt palpation and sharp dissection, and place a Penrose drain around it (Fig. 6.23).

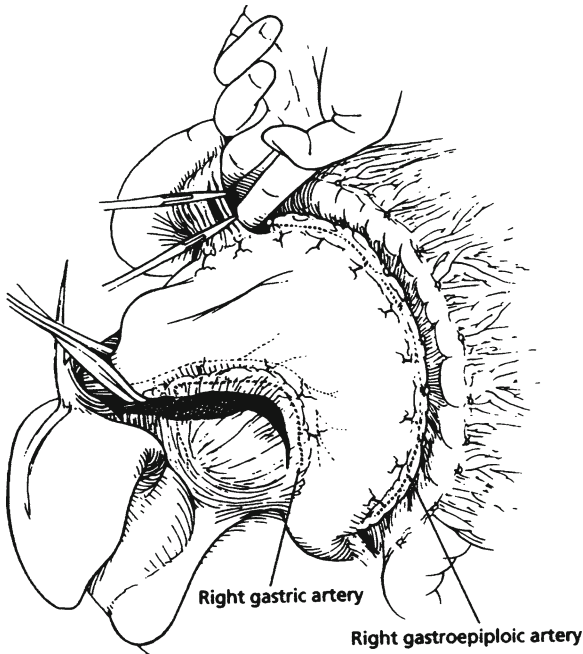


Figure 6.24. Division of the short gastric and left gastroepiploic vessels (From VF Trastek. Esophagectomy: Transhiatal. In: JH Donohue, JA van Heerden, and JRT Monson. *Atlas of Surgical Oncology*. Cambridge, MA: Blackwell Science, 1995, with permission).

- Step 7.** Detach the greater omentum from the stomach to the pyloric area; it is essential to preserve the right gastroepiploic and gastroduodenal vessels.
- Step 8.** Divide and ligate the short gastric and left gastroepiploic vessels. Avoid injury to the spleen (Fig. 6.24).
- Step 9.** Via the lesser sac divide and ligate the left gastric vessels separately and sweep the nodal tissue toward the lesser curvature.
- Step 10.** Perform Kocherization of the duodenum and a drainage procedure (pyloromyotomy, pyloroplasty, or pyloric injection of 200 units of Botox). Preserve the right gastric and right gastroepiploic vessels. The stomach is now totally mobilized from the hiatus to the pylorus, and its vitality is secured by the right gastroepiploic and right gastric vessels.

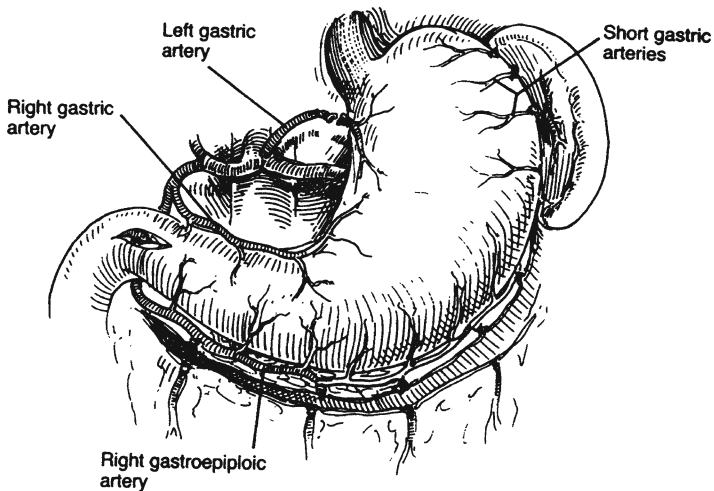


Figure 6.25. Mobilization of the stomach for esophageal replacement. The greater curvature has been mobilized, preserving the right gastroepiploic and right gastric arteries. The short gastric and left gastric arteries are divided, and a pyloromyotomy is performed (From RI Whyte and MB Orringer. *Surgery for Neoplasms of the Esophagus*. In: KI Bland, CP Karakousis, and EM Copeland. *Atlas of Surgical Oncology*. Philadelphia: Saunders, 1995, with permission).

- Step 11.** Mobilize the abdominal esophagus distally by retracting on the Penrose drain (Figs. 6.25 and 6.26).
- Step 12.** Enlarge the hiatus by partial division of the right crus. Continue mobilizing the esophagus up to the level of the carina. Avoid injury to the azygos vein and membranous trachea. If necessary, control minor bleeding with packing. Perforating vessels from the aorta can be divided under direct visualization.

Cervical Portion

- Step 1.** Make an oblique left cervical incision along the medial border of the SCM muscle from the level of the sternal notch to just below the mandible.
- Step 2.** Retract the SCM laterally, divide the omohyoid and sternothyroid muscles, and retract laterally the carotid sheath. Divide and ligate the inferior thyroid artery.

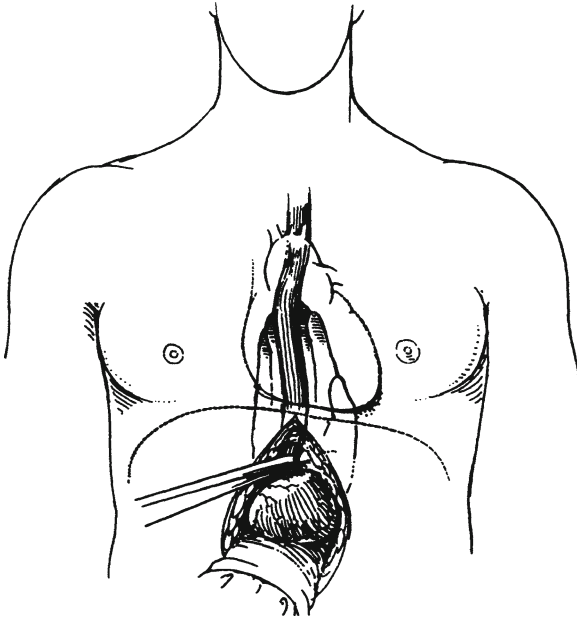


Figure 6.26. Mobilization of the lower portion of the esophagus during transhiatal esophagectomy. A Penrose drain, encircling the esophagogastric junction, is used to provide countertraction while the posterior midline dissection is performed with the volar aspects of the fingers against the esophagus (From RI Whyte and MB Orringer. *Surgery for Neoplasms of the Esophagus*. In: KI Bland, CP Karakousis, and EM Copeland. *Atlas of Surgical Oncology*. Philadelphia: Saunders, 1995, with permission).

- Step 3.** Carefully mobilize the esophagus. Identify the left recurrent laryngeal nerve, and retract the trachea and thyroid gland medially. Enter the retrosophageal space medial to the carotid and jugular vessels. By blunt dissection, develop the posterior plane. Insert a Penrose drain around the esophagus. Avoid injury of the great auricular accessory recurrent laryngeal nerve (Fig. 6.27).
- Step 4.** Slowly and carefully perform total anterior and posterior esophageal mobilization via cervical and hiatal approach using the right and left index fingers; they will meet each other close to or just above the carina (Fig. 6.28).
- Step 5.** With an endoscopic gastrointestinal anastomosis (GIA) stapler, divide the cervical esophagus approximately 5 cm distal to the cricopharyngeal muscle (Fig. 6.29).

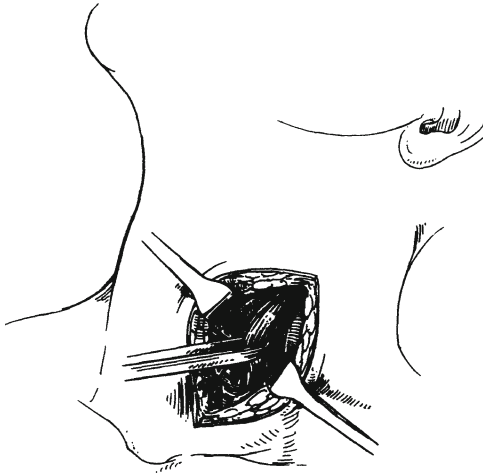


Figure 6.27. An oblique cervical incision used for transhiatal esophagectomy. The platysma and omohyoid muscles are divided; the sternocleidomastoid muscle is retracted posteriorly, and a Penrose drain is placed around the cervical esophagus (From RI Whyte and MB Orringer. *Surgery for Neoplasms of the Esophagus*. In: KI Bland, CP Karakousis, and EM Copeland. *Atlas of Surgical Oncology*. Philadelphia: Saunders, 1995, with permission).

- Step 6.** Suture a Penrose drain at the distal end of the divided cervical esophagus. If not using a stapler, apply stay sutures at the proximal end to keep the esophageal mucosa in situ.
- Step 7.** Pull the Penrose drain down via the posterior mediastinum, and deliver the esophagus into the abdominal wound via the diaphragmatic hiatus.

Preparation of the Gastric Conduit (Neoesophagus) and Anastomosis

- Step 1.** Using a linear GIA 75 stapler, divide the stomach distal to the gastroesophageal junction to remove a portion of the greater curvature and the adjacent lymph nodes (Fig. 6.30). Oversewing the staple line with 3-0 interrupted silk Lembert sutures is optional. The resection specimen will contain approximately 90 % of the esophagus and proximal one-third of the stomach. Obtain frozen section analysis of esophageal and stomach margins prior to anastomosis.

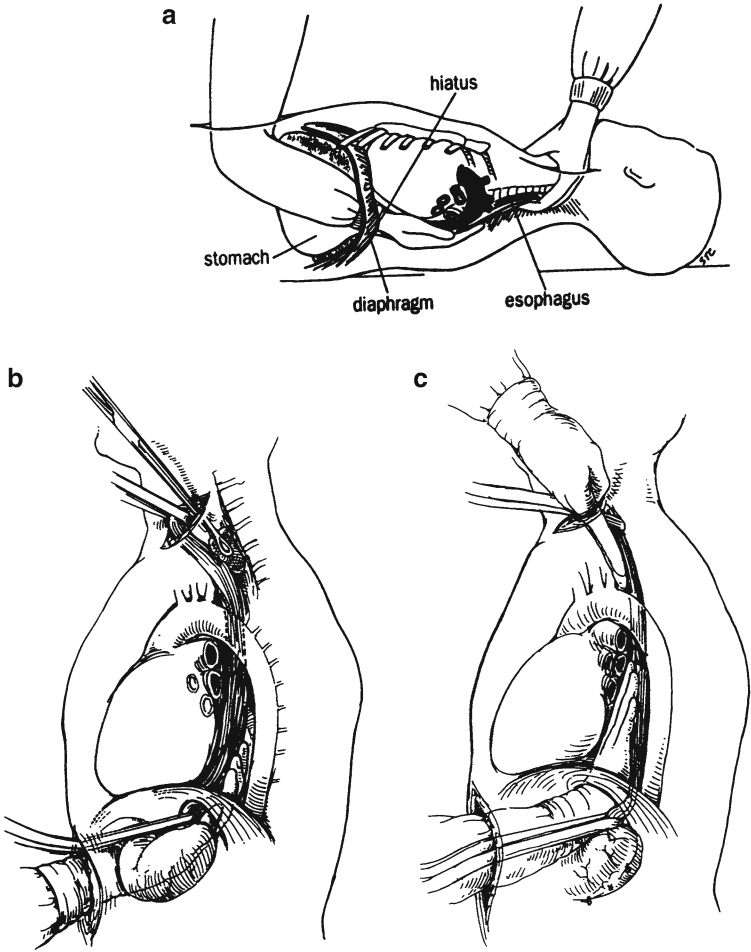


Figure 6.28. (a) Working from both incisions, the entire esophagus is mobilized. (b) A sponge on a stick, inserted through the cervical incision into the posterior mediastinum, facilitates mobilization of the esophagus away from the prevertebral fascia. (c) Mobilization of the anterior aspect of the esophagus during transhiatal esophagectomy. The palmar aspects of the fingers are placed against the esophagus, and pressure is exerted posteriorly to minimize cardiac displacement and resultant hypotension [(a) From RN Edie, RW Solit, JD Mannion, JJ Shannon. Esophageal Surgery. In: FE Rosato, DJ Barbot (eds). *Atlas of General Surgical Technique*. New York: Gower, 1992, with permission. (b) and (c) From RI Whyte and MB Orringer. *Surgery for Neoplasms of the Esophagus*. In: KI Bland, CP Karakousis, and EM Copeland. *Atlas of Surgical Oncology*. Philadelphia: Saunders, 1995, with permission].

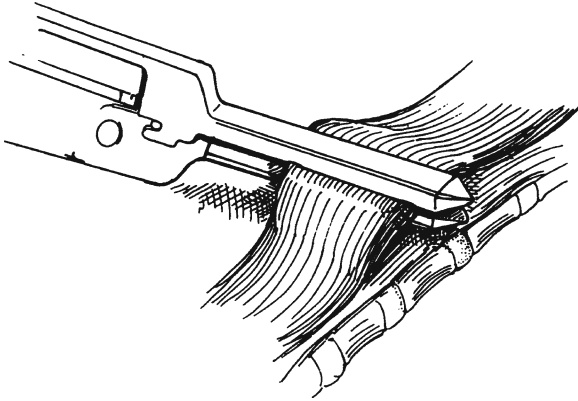


Figure 6.29. Division of the cervical esophagus with a gastrointestinal anastomosis (GIA) stapler (From RI Whyte and MB Orringer. *Surgery for Neoplasms of the Esophagus*. In: KI Bland, CP Karakousis, and EM Copeland. *Atlas of Surgical Oncology*. Philadelphia: Saunders, 1995, with permission).

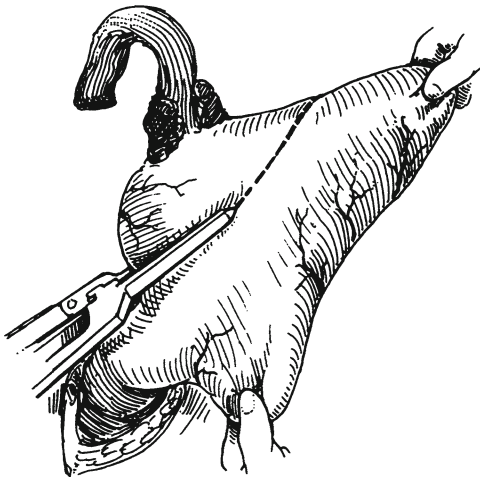


Figure 6.30. After resection of the esophagus, the stomach is divided with sequential applications of the GIA stapler at least 4–6 cm away from palpable tumor (From RI Whyte and MB Orringer. *Surgery for Neoplasms of the Esophagus*. In: KI Bland, CP Karakousis, and EM Copeland. *Atlas of Surgical Oncology*. Philadelphia: Saunders, 1995, with permission).

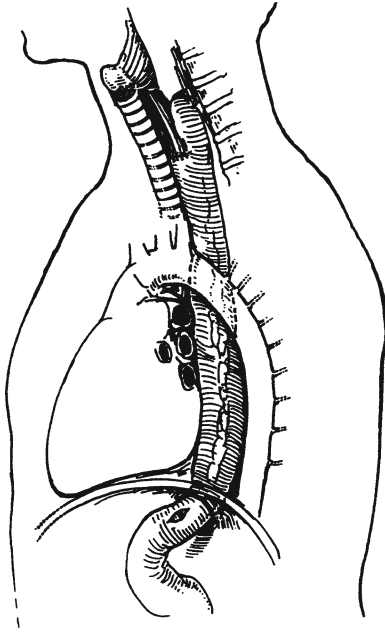


Figure 6.31. The final position of the intrathoracic stomach after transhiatal esophagectomy. The gastric fundus is suspended from the prevertebral fascia several centimeters above the cervical anastomosis, and the pyloromyotomy is located 2–3 cm below the diaphragmatic hiatus (From RI Whyte and MB Orringer. *Surgery for Neoplasms of the Esophagus*. In: KI Bland, CP Karakousis, and EM Copeland. *Atlas of Surgical Oncology*. Philadelphia: Saunders, 1995, with permission).

- Step 2.** Position the gastric conduit (neoesophagus) gently from below into the posterior mediastinum and push it up to the cervical incision, making sure that no rotation of the stomach (stapled portion of stomach to the patient's right) has occurred (Fig. 6.31).
- Step 3.** In an end-to-side technique with single-layer interrupted 4-0 PDS, double layered 3-0 silk, or a combined endoscopic GIA stapler and sutures, anastomose the stomach to the oblique opening of the cervical esophagus (Fig. 6.32). It is paramount for the anastomosis to have good blood supply, no tension, and no evidence that residual cancer or Barrett's esophagus is present at the anastomosis.

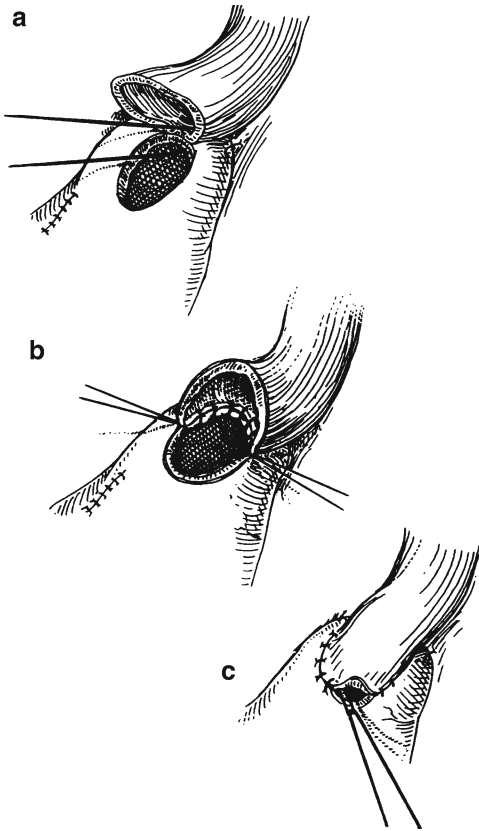


Figure 6.32. (a) and (b). Construction of an end-to-side cervical esophagogastric anastomosis. The posterior portion is completed with knots tied on the inside. (c) The last anterior sutures are placed with a 46-French bougie (not shown) in place and tied with the knots on the outside (From RI Whyte and MB Orringer. *Surgery for Neoplasms of the Esophagus*. In: KI Bland, CP Karakousis, and EM Copeland. *Atlas of Surgical Oncology*. Philadelphia: Saunders, 1995, with permission).

- Step 4.** Place a flat, closed-system suction drain in the retroesophageal space, and bring it out through a separate stab incision laterally. Carefully inspect the abdominal cavity and posterior mediastinum for bleeding.
- Step 5.** Close incisions. If the pleural cavity is violated, place chest tubes bilaterally.

Postoperative Care

Notwithstanding which surgical approach is chosen, the nasogastric tube is kept on low suction. It is usually removed on the fifth postoperative day. Chest tubes are removed in the absence of an air leak when pleural drainage is less than 200 cc/day.

A water-soluble radiographic contrast swallow study is performed on the fifth postoperative day. If no leakage or obstruction is noted over the subsequent 3 days, the patient's diet is advanced to a postgastrectomy diet.

■ IVOR LEWIS APPROACH

Approximately 17,500 new cases of carcinoma of the esophagus occur each year in the United States. Surgical resection continues to play an important role in the treatment of this disease and can be performed in a variety of ways. In 1946, Ivor Lewis described an operative approach for neoplasms of the distal esophagus including an abdominal procedure to surgically stage the tumor and mobilize the stomach, followed by a right thoracotomy to resect the involved esophagus and stomach and reestablish gastrointestinal continuity with an esophagogastric anastomosis in the chest. Currently, the Ivor Lewis approach is widely applied for any carcinoma occurring in the middle and lower esophagus or gastroesophageal junction.

All patients with upper- and mid-esophageal tumors should undergo either rigid or fiberoptic bronchoscopy prior to resection to rule out tumor invasion into the membranous trachea. Tracheal invasion is an absolute contraindication to resection.

Abdominal Portion

- Step 1.** Intubate the patient with a double-lumen endotracheal tube and place patient in a supine position for the abdominal portion of the procedure. An upper midline incision is made extending from the xiphoid process to just above the umbilicus (Fig. 6.33a).
- Step 2.** Explore the abdomen thoroughly to rule out metastases of the liver, peritoneum, and omentum; these would preclude resection. Abdominal retractors such as the Buchwalter or Omni-Tract can be used to facilitate exposure of the stomach.
- Step 3.** Divide the left triangular and left coronary ligaments of the liver with electrocautery. The left lobe of the liver can then be retracted to the right with the abdominal retractor. Divide the phrenoesophageal ligament and encircle the esophagus, at the hiatus, with a large Penrose drain. The right crus of the diaphragm can be divided to ensure that four fingers can easily fit through the hiatus, thus avoiding any compression on the gastric conduit.

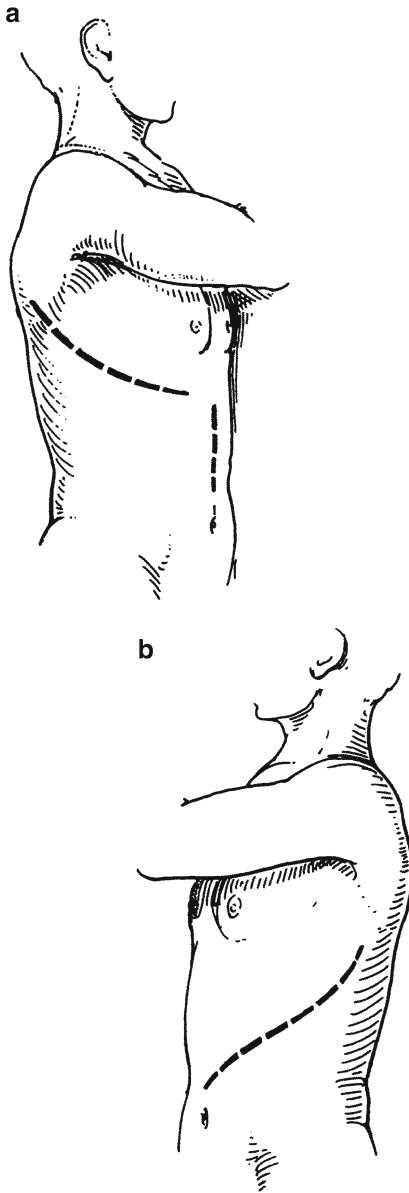


Figure 6.33. (a) Abdominal and right posterolateral thoracotomy. (b) Thora-coabdominal incision (From RI Whyte and MB Orringer. *Surgery for Neoplasms of the Esophagus*. In: KI Bland, CP Karakousis, and EM Copeland. *Atlas of Surgical Oncology*. Philadelphia: Saunders, 1995, with permission).

- Step 4.** Detach the greater omentum from the stomach, taking care not to injure the right gastroepiploic artery.
- Step 5.** Divide the short gastric vessels. This can be done by first ligating the vessels or by using a coagulating/cutting device such as the LigaSure (Valleylab, Boulder, CO) or the Harmonic Scalpel (Ethicon Endo-Surgery, Inc., Cincinnati, OH).
- Step 6.** The stomach is then retracted cephalad and the left gastric artery and vein are dissected close to the aorta and inferior vena cava. All nodal tissue should be swept toward the stomach to ensure that it is included in the resected specimen. The artery and vein are individually ligated with silk sutures and divided.
- Step 7.** Perform a Kocher maneuver to mobilize the duodenum. Since the stomach is denervated by the esophagectomy, a pyloromyotomy or Heineke–Mikulicz pyloroplasty is usually performed at this point.
- Step 8.** Insert a feeding jejunostomy tube.

Thoracic Portion

- Step 9.** The patient is placed in a left lateral decubitus position, re-prepped, and redraped, and the right lung is deflated to facilitate the esophageal dissection. Make a right posterolateral thoracotomy through the fourth or fifth interspace. The serratus anterior muscle is usually not divided but reflected anteriorly. Explore the chest to rule out pulmonary or pleural metastases which would preclude resection (Fig. 6.34).

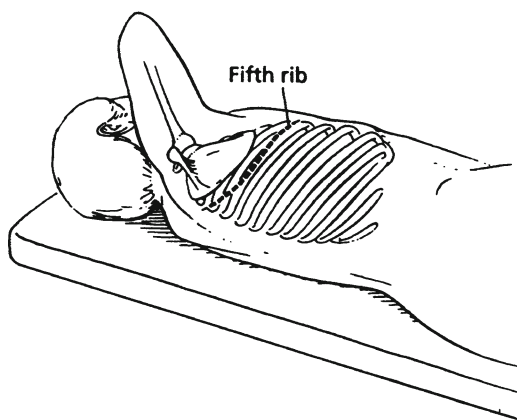


Figure 6.34. Right thoracotomy (From Trastek VF. Esophagectomy: transhiatal. In: Donohue JH, van Heerden JA, and Monson JRT. *Atlas of Surgical Oncology*. Cambridge, MA: Blackwell Science, 1995, with permission).

288 6. Esophagus

- Step 10.** Going from distal to proximal, open the mediastinal pleura anterior and posterior to the esophagus. Avoid injury to the thoracic duct, which lies between the aorta, vertebrae, and azygos vein. When thoracic duct injury is suspected, the duct should be ligated at the hiatus.
- Step 11.** Encircle the esophagus with a Penrose drain below the level of the carina. All periesophageal tissue and lymph nodes should be included in the resection. Ligate and divide the azygos vein. Dissect the esophagus away from the airway, taking care not to injure the membranous portion of the carina or left main stem bronchus (Fig. 6.35).
- Step 12.** Mobilize the stomach into the chest taking care to keep the lesser curvature positioned laterally. For distal tumors, transect the esophagus above the level of the azygos vein; for more proximal tumors, transect higher up. Oncologic principles dictate a margin that is a minimum of 9 cm from the tumor.

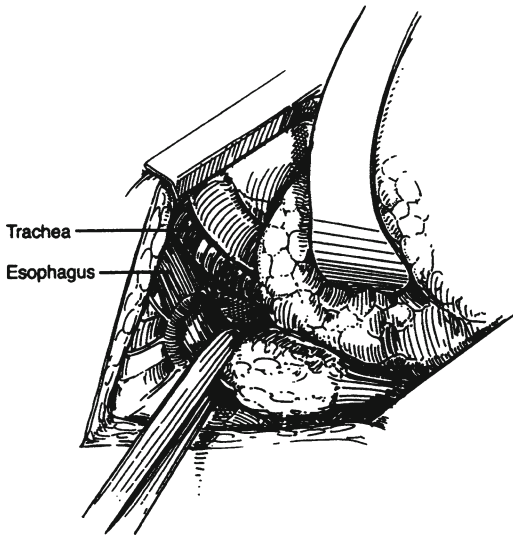


Figure 6.35. Mobilization of mid-esophageal tumor through a right thoracotomy. A Penrose drain is placed around the esophagus, which is dissected away from the posterior membranous trachea. Division of the azygos vein facilitates the dissection (From RI Whyte and MB Orringer. Surgery for Neoplasms of the Esophagus. In: KI Bland, CP Karakousis, and EM Copeland. *Atlas of Surgical Oncology*. Philadelphia: Saunders, 1995, with permission).

- Step 13.** Use a linear stapler (GIA) to divide the stomach beginning at the angle of His and extending toward the lesser curvature. Ligate and divide the left gastroepiploic artery after its second or third branch; the gastric transection is continued through this area on the lesser curve of the stomach. The gastric staple line may be oversewn with a running 3-0 absorbable suture.
- Step 14.** Place a Satinsky clamp several centimeters above the point of esophageal transection and divide the esophagus with a scalpel. The specimen is then sent for proximal and distal frozen section margins. With an electrocautery, make a linear gastrotomy the same width as that of the esophagus. Perform the esophagogastric anastomosis in single- or double-layer fashion. Single-layer anastomoses are constructed using interrupted 3-0 silk suture. For a two-layer anastomosis, sew the posterior portion of the outer layer first, followed by the inner layer, and finally the anterior portion of the outer layer. Double-layer anastomoses can be constructed with an inner layer of 3-0 absorbable suture in a running fashion or with 3-0 nonabsorbable suture in an interrupted fashion. The outer layer is performed with interrupted 3-0 nonabsorbable suture. The outer layer should include only the muscle layer of the esophagus while the inner layer should include the mucosa in addition to the muscle layers (Fig. 6.36).

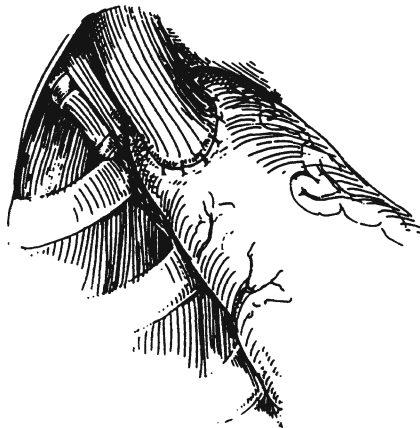


Figure 6.36. An intrathoracic esophagogastric anastomosis is placed at the apex of the right chest after the gastric fundus is suspended from the prevertebral fascia (From RI Whyte and MB Orringer. *Surgery for Neoplasms of the Esophagus*. In: KI Bland, CP Karakousis, and EM Copeland. *Atlas of Surgical Oncology*. Philadelphia: Saunders, 1995, with permission).

290 6. Esophagus

Step 15. Prior to completing the anastomosis a nasogastric tube should be advanced through the anastomosis into the stomach. Place two pleural tubes: one near the anastomosis and one near the diaphragm. Close the chest.

■ OTHER APPROACHES (SUMMARIZED)

Ivor Lewis–McKeown (Three-Stage) Esophagectomy

This procedure utilizes the incisions of the Ivor Lewis esophagectomy with an added left cervical incision for the anastomosis. The procedure is used for proximal tumors where an intrathoracic anastomosis would not allow for an acceptable margin. This approach also allows for a cervical lymph node dissection. The abdominal and thoracic portions are performed in the same manner as in the Ivor Lewis esophagectomy except that the right chest portion is performed first followed by the abdominal portion, and ending with the cervical portion. The cervical portion follows the same technique described in the transhiatal esophagectomy.

Left Thoracoabdominal Esophagectomy

This approach was the original approach to esophagectomy and is still employed for distal tumors. This procedure does not allow for a very proximal anastomosis because of the presence of the aortic arch, and therefore it is not useful for more proximal tumors.

The patient is placed in a right lateral decubitus position, and a left posterolateral thoracotomy is performed through the seventh interspace (Fig. 6.33b). The incision may be extended across the costal margin and the rectus muscle is divided. The diaphragm is opened in a radial fashion leaving a 2-cm rim of diaphragm on the chest wall. This avoids injury to the phrenic nerve branches while leaving enough diaphragm on the chest wall to facilitate closure. The rest of the esophagectomy is performed in a manner similar to the Ivor Lewis esophagectomy. The benefits of this approach are that it avoids the need for a separate abdominal incision and for repositioning of the patient, as required in an Ivor Lewis esophagectomy.

■ COLON INTERPOSITION

The colon may be used as an esophageal substitute in situations where the stomach is not usable. The left, right, or, less commonly, transverse colon may be used. The blood supply to the left and right colonic conduits is based on the

ascending branch of the left colic artery and the middle colic arteries, respectively. If the ileocolon is to be used, the right colic artery, in addition to the middle colic artery, must be spared.

- Step 1.** Mobilize the colon by dividing the lateral peritoneal reflection of the right or left colon extending to the hepatic or splenic flexure.
- Step 2.** Detach the greater omentum from the transverse colon, taking care not to injure the middle colic vessels.
- Step 3.** Assess the colon's arterial vascular supply by holding up the transverse colon and transilluminating the mesocolon. Place atraumatic vascular clamps across all arteries that are to be divided. For example, if the left colon will be used, clamps should be placed on the middle colic artery and across the vascular arcades at the proximal and distal points of colonic transection. This acts as a good test of the remaining blood vessel (ascending branch of left colic artery, for a left colon conduit) (Fig. 6.37). The clamps should be left on for 10–15 min and the colon serially inspected for color, pulse, and peristalsis. If the colon does not look viable, a different conduit should be used.
- Step 4.** Divide the colon with a GIA stapler. When using the left colon, divide it proximal to the middle colic vessels and distal to the ascending branch of the left colic artery. The middle colic artery should be divided close to the superior mesenteric artery to avoid injuring the marginal artery and its arcades. When using the right colon, divide it distal to the middle colic artery and proximal to either the terminal ileum or the cecum. If the ileum is to be used, both the right and middle colic arteries must be retained. If the distal ileum is not used, divide the right colic artery as it branches off the superior mesenteric artery and retain the middle colic artery.
- Step 5.** Perform an end-to-end colocolonic anastomosis (Fig. 6.38) to re-establish colonic continuity. Bring the colonic conduit through the chest and anastomose it to the remaining esophagus. The colonic conduit can be placed in a substernal position or, preferably, in the posterior mediastinum.

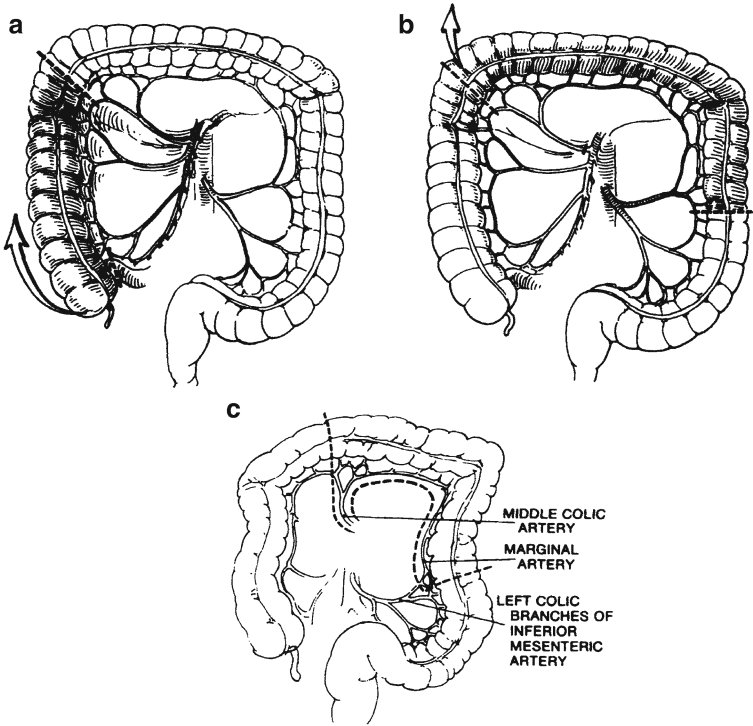


Figure 6.37. Segments of colon can be used as esophageal substitutes. (a) The right colon, with its vascular supply, which is based on the right branch of the middle colic artery, is rotated as an isoperistaltic segment. (b) The left colon, with its vascular supply, which is based on the ascending branch of the left colic artery, is brought up in an isoperistaltic fashion. (c) The vascular anatomy of the transverse and descending colon. Division of the transverse colon at the right of the middle colic vessels [(a) and (b) From RI Whyte and MB Orringer. *Surgery for Neoplasms of the Esophagus*. In: KI Bland, CP Karakousis, and EM Copeland. *Atlas of Surgical Oncology*. Philadelphia: Saunders, 1995, with permission. (c) From JA Waldhausen and WS Pierce. *Johnson's Surgery of the Chest*, 5th ed. Chicago: Year Book Medical, 1985, with permission].

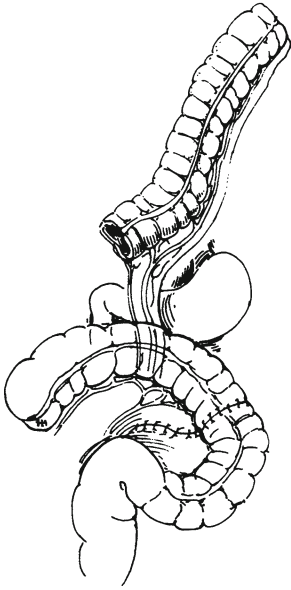


Figure 6.38. Colocolonic end-to-end anastomosis. Note the vascular pedicle of the colonic segment (From JA Waldhausen and WS Pierce. *Johnson's Surgery of the Chest*, 5th ed. Chicago: Year Book Medical, 1985, with permission).

Stomach

ANATOMY

■ TWO GASTRIC UNITS

From the viewpoint of a surgeon, the stomach is part of two almost-separate organ systems, each with its special pathology and surgical approach. The first can be called the “proximal gastric surgical unit.” It contains the proximal stomach, distal esophagus, and esophageal hiatus of the diaphragm (Fig. 7.1). The second is the “distal gastric surgical unit,” which includes the gastric antrum and pylorus, together with the first part of the duodenum (Fig. 7.2).

Proximal Gastric Surgical Unit

The length of the abdominal esophagus ranges from 0.5 to 2.5 cm. Its relations with surrounding structures are:

ANTERIOR: Posterior surface of left lobe of liver

POSTERIOR: Right crus of diaphragm, and aorta

RIGHT: Caudate (spigelian) lobe of liver

LEFT: Fundus of stomach

The cardiac orifice is the gastroesophageal junction. The fundus, for all practical purposes, is the upper part of the body which, in the supine position, augments upward. The body is the part of the stomach between the antrum and the fundus.

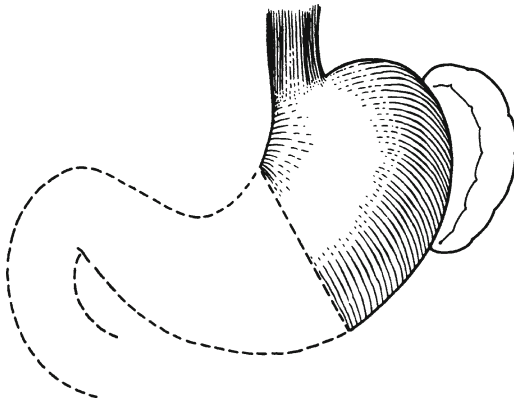


Figure 7.1. The proximal gastric surgical unit. The two ends of the stomach acquire different lesions, and operations require different methods (By permission of JE Skandalakis, SW Gray, and JR Rowe. *Anatomical Complications in General Surgery*. New York: McGraw-Hill, 1983).

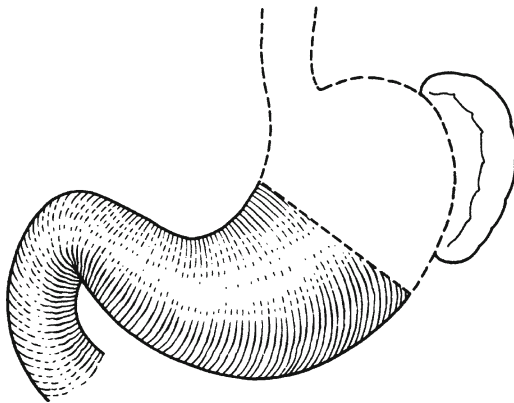


Figure 7.2. The distal gastric surgical unit. Most gastric surgery takes place in this area (By permission of JE Skandalakis, SW Gray, and JR Rowe. *Anatomical Complications in General Surgery*. New York: McGraw-Hill, 1983).

Distal Gastric Surgical Unit

The gastric antrum, pylorus, and first portion of the duodenum form a unit from an embryologic, physiologic and, certainly, a surgical viewpoint.

Gastric Antrum

In the opened stomach, the antrum is easily distinguished from the body of the stomach by its mucosa, which is flatter and without rugae. It is histologically distinct, being without chief or parietal (acid-producing) cells. The margin of the antrum is irregular, but definite. Externally the antrum is difficult to demarcate. The boundary on the lesser curvature usually lies at the incisura angularis; it is usually found in textbook drawings, but in the operating room it is inconstant and often absent.

Surgeons not planning a gastrotomy to locate the antral margin can use the “crow’s foot” of the anterior descending vagal trunk as a landmark. The antrum can be expected to begin 3–4 cm cranial to the crow’s foot, about 8–10 cm proximal to the pylorus. On the greater curvature, there is no good landmark. In most cases the boundary extends from a point on the lesser curvature 2/5 of the way from the pylorus to the esophagus to a point on the greater curvature 1/8 of the distance from the pylorus to the esophagus.

Pylorus

The pylorus is a region of the stomach variously called the pyloric canal, pyloric ring, and pyloric valve. Proximally, it merges into the gastric antrum without a definite external boundary; distally, it ends abruptly at the thin-walled duodenum.

At the pyloroduodenal junction, the continuity of the circular musculature is interrupted by an annular septum that arises from the connective tissue of the submucosa. Proximal to this ring, the circular muscle layer is thickened to form the pyloric sphincter. Distal to the ring, the circular muscle coat at the duodenum is thinner.

First Part of the Duodenum

The distal gastric surgical unit includes only the first 2.5 cm of the duodenum (for more information, see Chap. 8.)

Relations of the Distal Gastric Surgical Unit

Posteriorly the unit is related to the:

- Floor of lesser sac
- Transverse mesocolon
- Head and neck of pancreas
- Aorta and celiac trunk and its branches
- Celiac ganglion and plexus
- Hepatic triad
- Gastroduodenal artery

298 7. Stomach

Anteriorly the unit is related to the:

- Anterior abdominal wall
- Medial segment of left lobe and anterior segment of right lobe of liver
- Transverse mesocolon
- Neck of gallbladder (if stomach is empty)

■ GASTRIC WALL

The gastric wall consists of the serosa, the muscular layer, submucosal layer, and mucosal layer.

The distal esophagus is lined by stratified squamous epithelium; the abdominal esophagus is lined with mucous cells. Simple columnar cells compose the mucosal layer of the cardia. The mucosal layer of the fundus and body consists of two types of cells: parietal (oxyntic) acid-secreting cells and chief pepsin-secreting cells.

■ LIGAMENTS

Hepatogastric Ligament (Lesser Omentum)

The hepatogastric ligament is the proximal part of the lesser omentum. It extends from the porta hepatis to the lesser curvature of the stomach and upward as the ventral mesentery of the abdominal esophagus. The ligament contains:

REGULARLY: Left gastric artery and vein; hepatic division of the anterior vagal trunk; anterior and posterior gastric divisions of the vagal trunks (nerves of Latarjet); lymph nodes and vessels.

OCCASIONALLY: An aberrant left hepatic artery (23 % of individuals) in proximal part of hepatogastric ligament; distally and to the right, branches of the right gastric artery and vein. In this region also are the common hepatic artery and portal vein; here they rise ventrally to gain their positions in the hepatoduodenal segment of the lesser omentum.

Hepatoduodenal Ligament

The hepatoduodenal ligament is the distal part of the lesser omentum, extending from the liver to the first 2.5 cm of the duodenum. The free edge envelops the hepatic triad (the proper hepatic artery, portal vein, and extrahepatic biliary ducts) as well as the hepatic plexus and lymph nodes.

Gastrocolic Ligament

The gastrocolic ligament is a portion of the greater omentum passing from the greater curvature of the stomach and the first part of the duodenum to the transverse colon.

Gastrosplenic Ligament

See Chap. 15.

Gastrophrenic Ligament

The gastrophrenic ligament is continuous with the hepatogastric ligament to the left of or, perhaps, opposite the esophagus. It has an avascular area through which the surgeon's finger can safely pass and through which a Penrose drain can be inserted around the cardia to pull down the esophagus. This is a useful maneuver in vagotomy. The upper part of the ligament is avascular, and the lower part contains short gastric arteries and veins, and lymph nodes.

■ VASCULAR SYSTEM OF THE STOMACH (FIG. 7.3)

Arterial Supply

Following is a summation of all the arteries that supply the stomach. Each of the principal arteries of supply originates from the celiac trunk.

- Left gastric
 - Ascending branch (gives rise to esophageal)
 - Descending branch (gives rise to gastric)
- Hepatic
 - Right gastric
 - Gastroduodenal
 - Anterior superior pancreaticoduodenal
 - Retroduodenal
 - Posterior superior pancreaticoduodenal
 - Supraduodenal
 - Right gastroepiploic (major branches)
- Splenic
 - Posterior gastric
 - Short gastrics
 - Left gastroepiploic (major branches)

The stomach can survive after ligation of all but one of its primary arteries, and extragastric ligation will not control bleeding from a gastric ulcer.

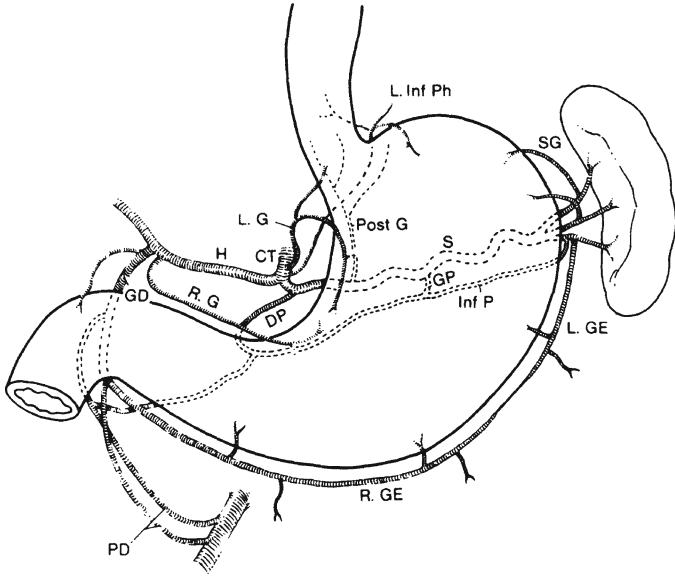


Figure 7.3. The arterial supply to the stomach: *L. Inf Ph* left inferior phrenic artery, *SG* short gastric artery, *L. GE* left gastroepiploic artery, *R. GE* right gastroepiploic artery, *S* splenic artery, *GP* great pancreatic artery, *Inf P* inferior pancreatic artery, *PD* pancreaticoduodenal artery, *DP* dorsal pancreatic artery, *GD* gastroduodenal artery, *R. G* right gastric artery, *H* hepatic artery, *CT* celiac trunk, *L. G* left gastric artery, *Post G* posterior gastric artery (By permission of JE Skandalakis, SW Gray, and JR Rowe. *Anatomical Complications in General Surgery*. New York: McGraw-Hill, 1983).

Venous Drainage

The veins, for all practical purposes, follow the arteries.

Lymphatic Drainage

The lymphatic drainage of the stomach consists of four zones as follows (Fig. 7.4):

- Zone I (inferior gastric): drains into the subpyloric and omental nodes
- Zone II (splenic): drains into the pancreaticosplenic nodes
- Zone III (superior gastric): drains into the superior gastric nodes
- Zone IV (hepatic): drains into the suprapyloric nodes

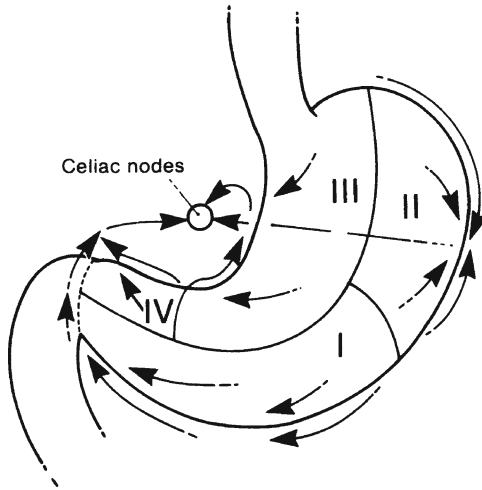


Figure 7.4. Diagram of the lymphatic drainage of the stomach. Most of the drainage finds its way to the celiac nodes: the “vortex of the metastatic whorl” (By permission of JE Skandalakis, SW Gray, and JR Rowe. *Anatomical Complications in General Surgery*. New York: McGraw-Hill, 1983).

■ PARASYMPATHETIC NERVES (VAGUS NERVES)

The left and right vagus nerves descend parallel with the esophagus and contribute to a rich external esophageal nerve plexus between the level of the tracheal bifurcation and the level of the diaphragm. From this plexus, two vagal trunks—anterior and posterior—form and pass through the esophageal hiatus of the diaphragm. Each trunk subsequently separates into two divisions (Fig. 7.5).

From the anterior vagal trunk, the hepatic division passes to the right in the lesser omentum, branching before it enters the liver. One branch turns downward to reach the pylorus and, sometimes, the first part of the duodenum. The second division, the anterior gastric, descends along the lesser curvature of the stomach, giving branches to the anterior gastric wall.

From the posterior trunk arise the celiac division, which passes through the celiac plexus, and the posterior gastric division, which supplies branches to the posterior gastric wall.

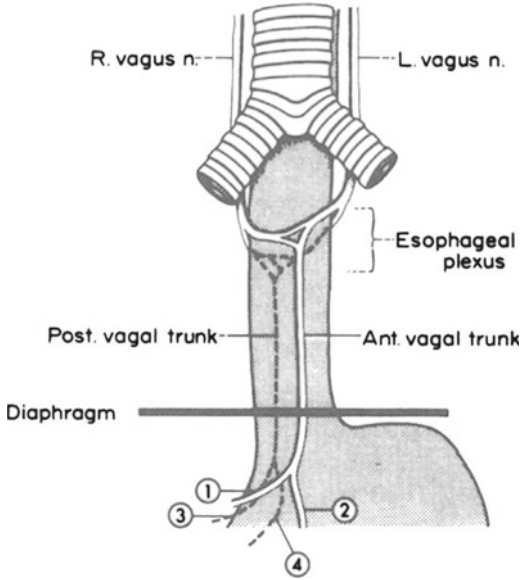


Figure 7.5. The terminology of vagal structures of the thorax and abdomen. In this example, two vagal trunks pass through the hiatus to enter the abdomen. 1=hepatic division; 2=anterior gastric division; 3=celiac division; 4=posterior gastric division (By permission of JE Skandalakis, JS Rowe, and SW Gray. *Surgery* 75(2):233–237, 1974).

Identification of Vagal Structures at the Hiatus

The basic configuration and variations of the vagus nerves at the esophageal hiatus are well known, but the thoracic pattern is not visible to the abdominal surgeon, who must proceed on the basis of the structures that can be seen. A study of components of the esophageal hiatus in 100 cadavers found the following:

- Two vagal structures only (88 %) (Fig. 7.5). The usual structures at the esophageal hiatus are the anterior and posterior vagal trunks, which have not yet split to form the four typical divisions discussed above. Both trunks are usually to the right of the midline of the esophagus. The posterior trunk lies closer to the aorta than to the esophagus (Fig. 7.6).
- Four vagal structures (7 %) (Fig. 5.16a). The four divisions of the vagal trunks (hepatic, celiac, anterior gastric, and posterior gastric) appear when division has occurred above the diaphragm.

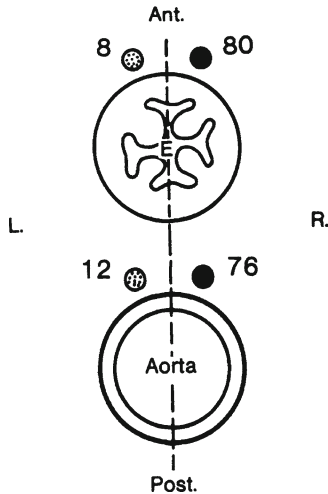


Figure 7.6. The relation of the anterior and posterior vagal trunks to the aorta and the esophagus, showing the number of specimens with vagal trunks lying to the right or left of the midline. In most but not all of the 88 specimens, the trunks are to the right of the midline. Note that the anterior trunks are closer to the esophagus than are the posterior trunks (By permission of JE Skandalakis, JS Rowe, and SW Gray. *Surgery* 75(2):233–237, 1974).

- More than four structures (5%). When there are more than four structures at the hiatus, these may be divisions and branches of divisions (Fig. 5.16b) (the anterior and posterior trunks lie entirely within the thorax), or elements of the esophageal vagal plexus (Fig. 5.16c) (the anterior and posterior trunks lie entirely within the abdomen).

Distribution of the Vagus Nerves to the Stomach

Anterior Gastric Division

The separation of the anterior gastric and hepatic divisions occasionally occurred above the diaphragm, but the divisions usually lay on the abdominal esophagus or the cardia.

In almost all cases, a major branch of the anterior gastric division formed the principal anterior nerve of the lesser curvature (anterior nerve of Latarjet). It usually lay from 0.5 to 1.0 cm from the lesser curvature.

From 2 to 12 branches pass from the principal nerve to the stomach wall. The average in the subjects in the above-mentioned study was six.

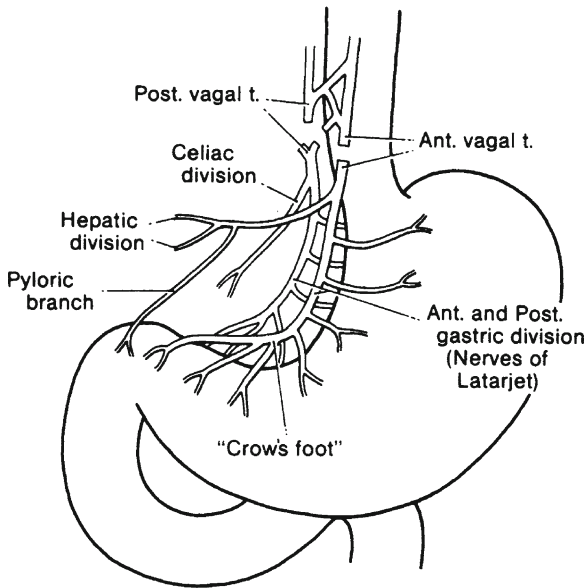


Figure 7.7. Truncal vagotomy results in vagal denervation of all abdominal organs. A concomitant drainage procedure is required for gastric stasis (By permission of JE Skandalakis, SW Gray, and JR Rowe. *Anatomical Complications in General Surgery*. New York: McGraw-Hill, 1983).

Constant landmarks on the stomach are difficult to obtain. The position of the incisura angularis often has to be estimated. Although we have often seen the nerve of Latarjet branch in the "crow's foot" formation, this pattern is far from constant, being equivocal in some cases and absent in many (Fig. 7.7).

Hepatic Division

The hepatic division of the anterior vagal trunk usually separates from the anterior gastric division at the level of the abdominal esophagus (Fig. 7.8). It lies between the leaflets of the avascular portion of the hepatogastric ligament. It is frequently found in multiple branches that are usually closely parallel.

Posterior Gastric Division

In most subjects, the posterior gastric division forms the principal posterior nerve of the lesser curvature (posterior nerve of Latarjet). As a rule, the posterior nerve appears to terminate slightly higher on the lesser curvature and possesses fewer gastric branches than does the anterior nerve. In no case has a posterior nerve been observed to reach the duodenum.

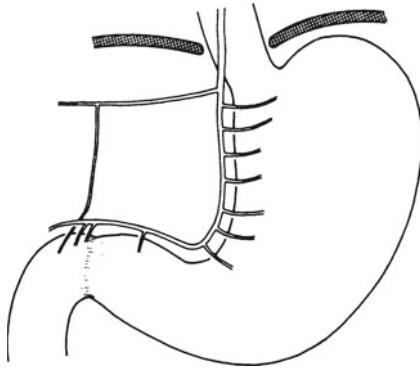


Figure 7.8. “Typical” distribution of anterior gastric and hepatic divisions of the vagus (modified by permission of JE Skandalakis, SW Gray, RE Soria, et al. *Am Surg* 46(3):130–139, 1980).

Celiac Division

The celiac division is the largest of the four vagal divisions. It lies in the gastropancreatic peritoneal fold. In all cases, it is single and leads directly to the celiac plexus. The celiac division may follow the left gastric artery or the right crus of the diaphragm or take an intermediate position in the triangle bounded by the artery, the crus, and the right margin of the stomach.

■ SYMPATHETIC NERVES

The sympathetic chains, the thoracic splanchnic nerves containing afferent and efferent fibers, and the celiac ganglia form the basic elements for the sympathetic innervation of the stomach and duodenum.

TECHNIQUE

■ GASTROSTOMY

Stamm Gastrostomy

The surgeon chooses the type of incision, and a good preoperative evaluation helps greatly in the decision. The authors favor a small upper-midline incision, which may be extended, if necessary.

- Step 1.** With Babcock clamps, elevate the anterior wall of the stomach approximately 6–10 cm from the gastroduodenal junction. Place and tie two purse-string sutures of 3-0 silk or Vi cryl 120° from each other (Fig. 7.9).
- Step 2.** Make a very small stab incision (usually 0.5 cm in length) in the center of the designated area of the purse-string sutures and insert an 18–22 Foley balloon catheter (Fig. 7.9).
- Step 3.** Insert the catheter and inflate the balloon. Tie the inner purse string very tightly, then tie the outer purse string; do not cut it or remove the needles (Fig. 7.10).
- Step 4.** Pull the catheter until it reaches the gastric mucosa at the gastric stab wound. Use gentle movements to ensure that the balloon is well attached to the gastric mucosa. Stitch the purse-string sutures to the anterior abdominal wall. To make certain that dead space does not exist, use a third 3-0 silk suture to fix the gastric wall to the anterior

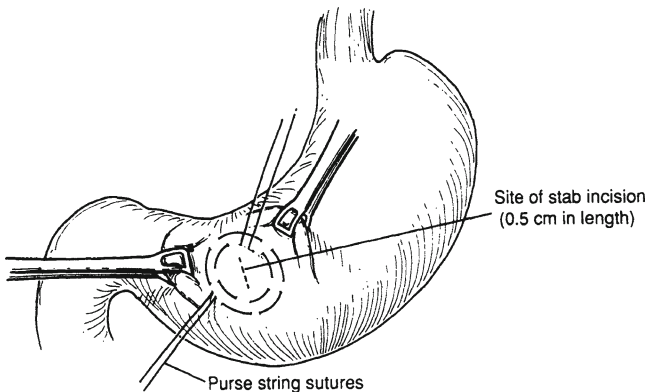


Figure 7.9. Purse-string sutures at anterior wall of stomach.

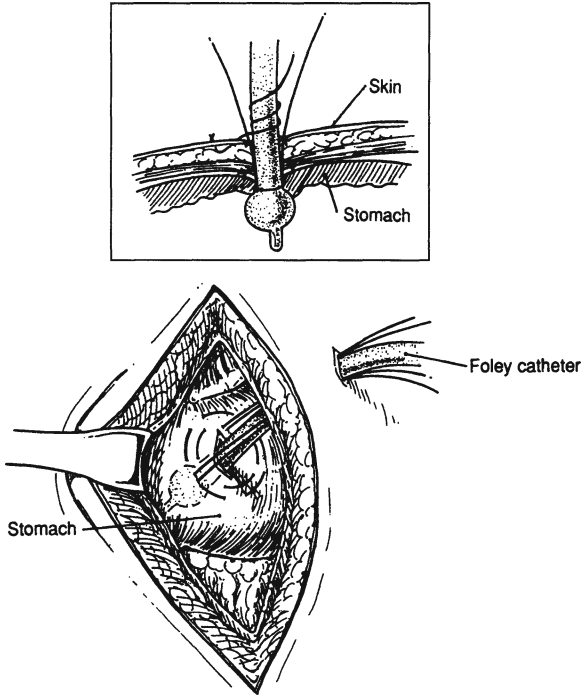


Figure 7.10. Placement of catheter (*Inset: detail of catheter and balloon*).

abdominal wall. Close the skin and use a 2-0 silk suture to secure the gastrostomy tube to the skin of the abdominal wall.

Note:

- ✓ There are other types of gastrostomies, including Witzel and Janeway. They are seldom used today.

■ GASTROJEJUNOSTOMY

Retrocolic

- Step 1.** Make an upper-midline incision or incision of the surgeon's choice.
- Step 2.** The location of the stoma should be close to the pylorus at the most dependent area of the greater curvature. Place a Babcock clamp in an oblique fashion at the lesser curvature and at the greater curvature (Fig. 7.11).

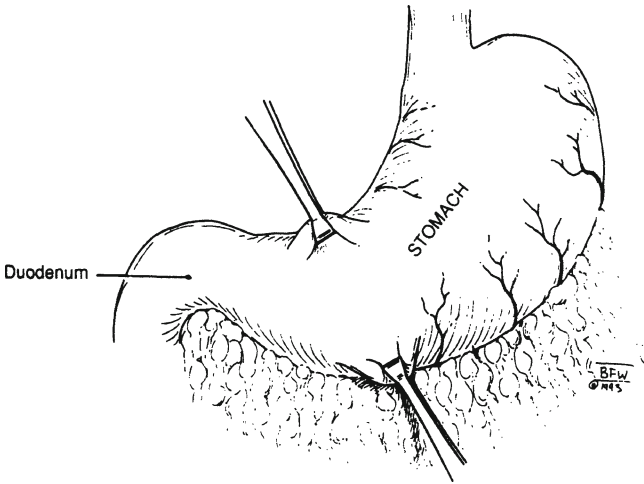


Figure 7.11. Clamps placed at lesser curvature.

Step 3. Lift the transverse colon to evaluate its mesocolon. Protect the middle colic artery by noting its location. Identify an avascular area and incise it; in most cases, it will be to the left of the middle colic artery. The posterior wall of the stomach projects through the opening in such a way that the lesser curvature is located at the lowest corner of the mesenteric opening. Using interrupted 4-0 silk, suture the mesentery to the gastric wall at this point (Fig. 7.12).

Step 4. Again using interrupted 4-0 silk sutures, attach to the gastric wall (proximal to the lesser curvature) a jejunal loop that is approximately 15 cm distal to the ligament of Treitz. Anastomose the loop to the posterior gastric wall in two layers using a running 3-0 chromic suture for the mucosal layer and a 3-0 silk interrupted suture for the seromuscular layer (Figs. 7.13, 7.14, and 7.15).

Note:

✓ Alternatively, a stapled anastomosis is acceptable.

Step 5. Close the abdominal wall.

Antecolic (Fig. 7.16)

Follow steps as in the retrocolic gastrojejunostomy. The jejunal loop is anterior to the colon; therefore, attach it to the posterior wall of the stomach at the most dependent part of the greater curvature through an opening of the gastrocolic ligament.

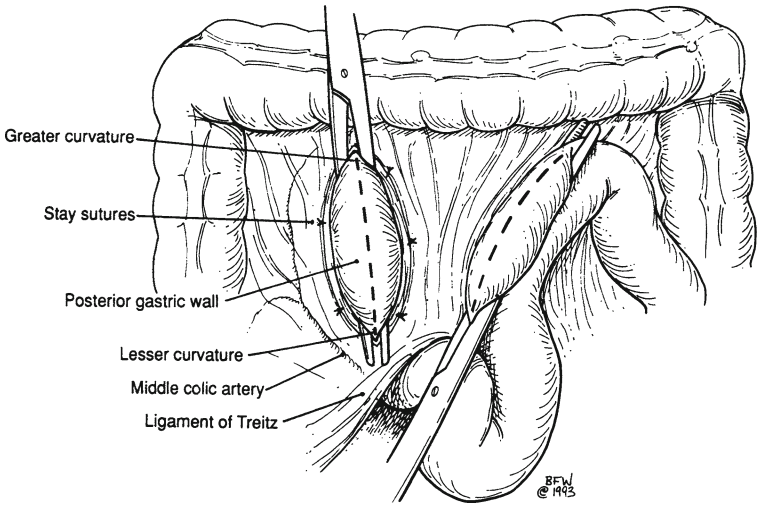


Figure 7.12. Locating the avascular area prior to incision.

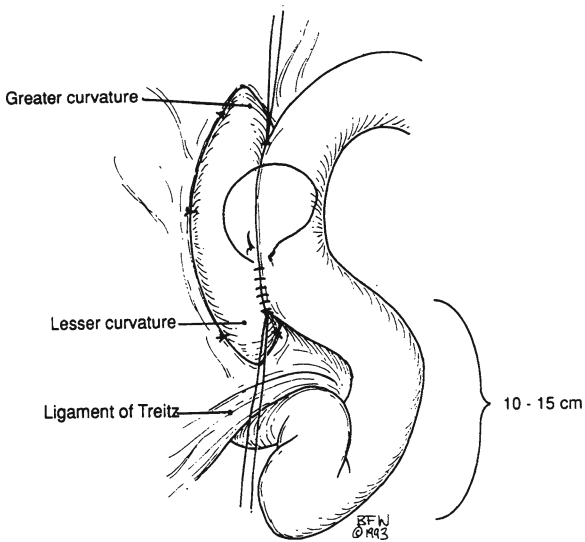


Figure 7.13. Mesentery is sutured to gastric wall. Note location of ligament of Treitz.

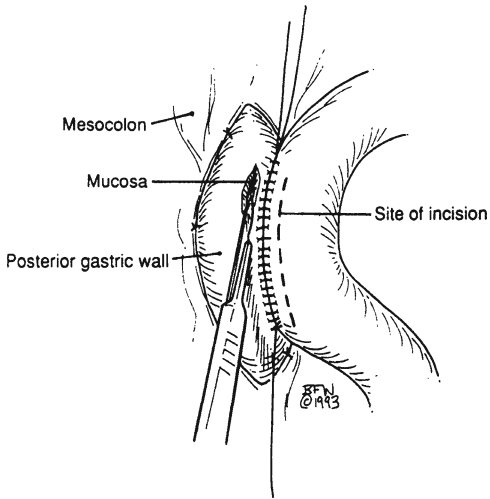


Figure 7.14. Enterotomy and gastrotomy.

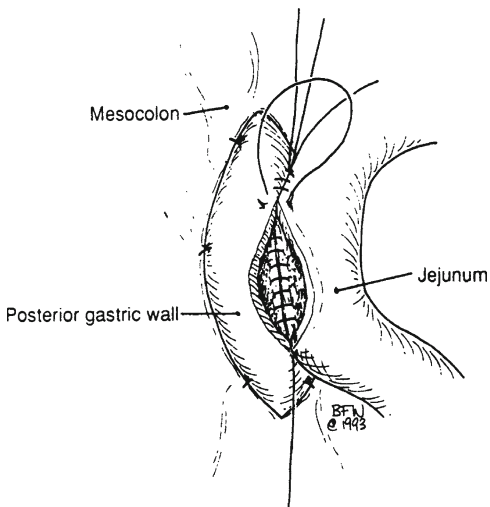


Figure 7.15. Anastomosing the jejunal loop to the posterior gastric wall.

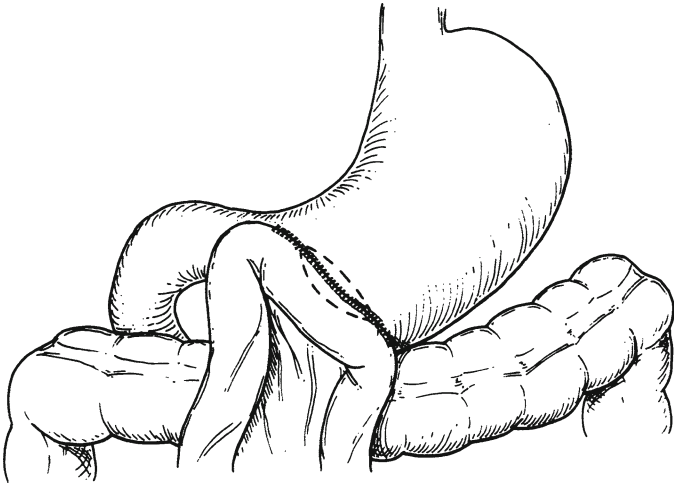


Figure 7.16. Antecolic gastrojejunostomy.

■ PERFORATED ULCERS

Perforated Peptic Ulcers

Graham Patch (Figs. 7.17 and 7.18)

- Step 1.** Perform detailed and complete cleansing by irrigating the peritoneal cavities. Pay special attention to the suprahepatic and subhepatic areas: the right and left pericolic gutters should be cleaned and the pelvis should be irrigated vigorously.
- Step 2.** Using no more than two or three sutures, plug the perforated ulcer with omentum. Then, using a 3-0 silk or synthetic absorbable, take a full-thickness bite of duodenum on each side of the perforation. Tie the sutures above the omental piece.
- Step 3.** Irrigate, and then close in layers using repeated irrigation. Drainage is up to the surgeon. Intravenous antibiotics, which were started prior to surgery, should be continued for at least 48 h.

Note:

- ✓ Occasionally the perforated ulcer is associated with partial obstruction, bleeding, or both. Sometimes, especially 6 h after the onset of perforation, local edema exists and interferes with approximating or closing the perforation with sutures. In this

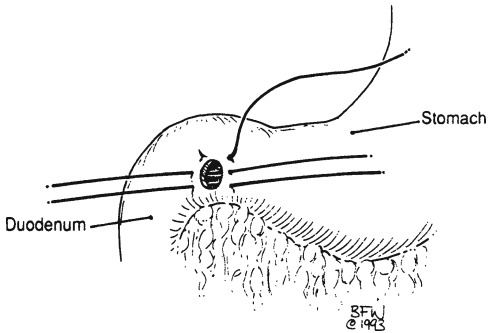


Figure 7.17. Attaching omental plug.

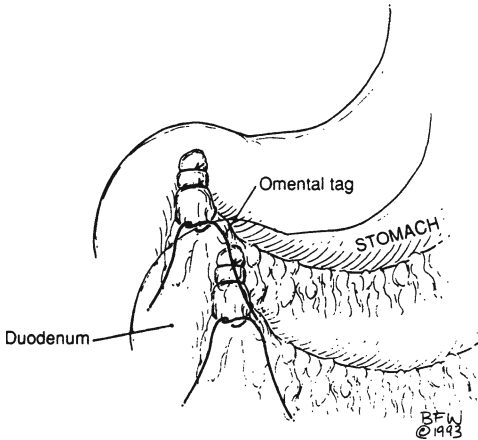


Figure 7.18. Closure in layers.

case an antrectomy and Billroth II anastomosis may be necessary. The ulcer should be included in the specimen. If the duodenum is too inflamed or scarred to close, a Malecot catheter is placed in it and closed around it.

- ✓ If bleeding is present, it is probably arising from a posterior wall ulcer penetrating the gastroduodenal artery. Therefore, the patient has two problems: an anterior perforated ulcer and a posterior bleeding ulcer. Suture the artery superficially. Remember that the duct of Santorini is under the artery and in

10 % of cases it is the only duct of the exocrine pancreas. If the suture incorporates the duct, pancreatitis can result. Occasionally in early perforation a truncal or superselective vagotomy with pyloroplasty could be indicated, or perhaps a truncal vagotomy with Billroth II procedure.

- ✓ Be sure to administer intravenous antibiotics prior to incision and for 24–48 h postoperatively.

Perforated Gastric Ulcers

Since most gastric neoplasms are malignant, the surgeon should always remember that a perforated gastric ulcer could be of benign or malignant origin.

Step 1. Clamp the perforated ulcer with a Babcock clamp. After the peritoneal cavity has been thoroughly cleansed, remove the ulcer and send it to the lab for frozen section. During this time, irrigation of the peritoneal cavity continues, and the surgeon devises the patient's treatment strategy.

Step 2. If the ulcer is benign, close the gastric wall in two layers: the first with through-and-through absorbable suture and the second with Lembert seromuscular suture of 3-0 or 4-0 silk. A stapling device can also be used to close the gastric wall. If the ulcer is malignant, the surgeon should consider performing a subtotal gastrectomy, especially if the perforation took place within 6 h of surgery.

Note:

- ✓ It is the authors' policy to excise the ulcer in toto and send it to the lab for frozen section.

An ulcer of the *high anterior gastric wall* may be excised by making a circumferential incision around it. The procedure is aided by deep seromuscular sutures proximal and distal to the ulcer. If the ulcer is benign, close in two layers; if malignant, perform total gastrectomy (surgical philosophy is to never use a Billroth I with gastric malignancy).

When working with an ulcer of the *high posterior gastric wall*, which is very high and close to the gastroesophageal junction, establish good proximal mobilization of the stomach and abdominal esophagus. Turn the stomach in such a way that the greater curvature lies posterior and the lesser curvature lies anterior. From this point, the procedure is the same as for an anterior gastric wall ulcer excision. Again, additional procedures depend upon the benignity or malignancy of the ulcer.

■ PYLORIC STENOSIS (FIG. 7.19)

Although this procedure is usually performed by a pediatric surgeon, we will present the technique because it is done occasionally by general surgeons.

- Step 1.** Make a right upper quadrant muscle-splitting incision.
- Step 2.** Deliver the pylorus and the pyloric tumor from the peritoneal cavity.
- Step 3.** Hold the tumor firmly with the thumb and index finger in such a way that the proximal duodenum is pushed up to the distal pylorus, protecting the duodenal mucosa.
- Step 4.** Carefully incise the serosa and pyloric muscle. Using the Benson spreader with extreme care, further separate the muscle. With the pyloric mucosa exposed, check for mucosal perforation and, if present, close with 4-0 silk.
- Step 5.** Close the abdominal wall.

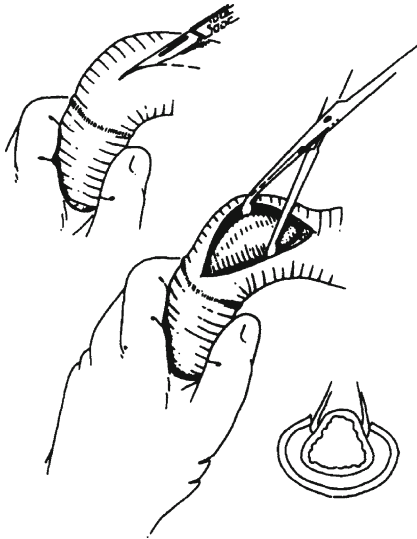


Figure 7.19. Pyloric stenosis. *Top:* Muscle-splitting incision. *Middle:* Pylorus and pyloric tumor are delivered. *Bottom:* Exposed mucosa.

■ PYLOROPLASTY

Heineke–Mikulicz Pyloroplasty

- Step 1.** Perform a Kocher maneuver. Place two sutures, one superior and one inferior to the middle of the proposed longitudinal pyloroduodenal incision (Fig. 7.20).
- Step 2.** Close the transverse duodenotomy in a longitudinal fashion. Apply traction on the two previously placed sutures and close in two layers using 3-0 chromic and 3-0 silk.

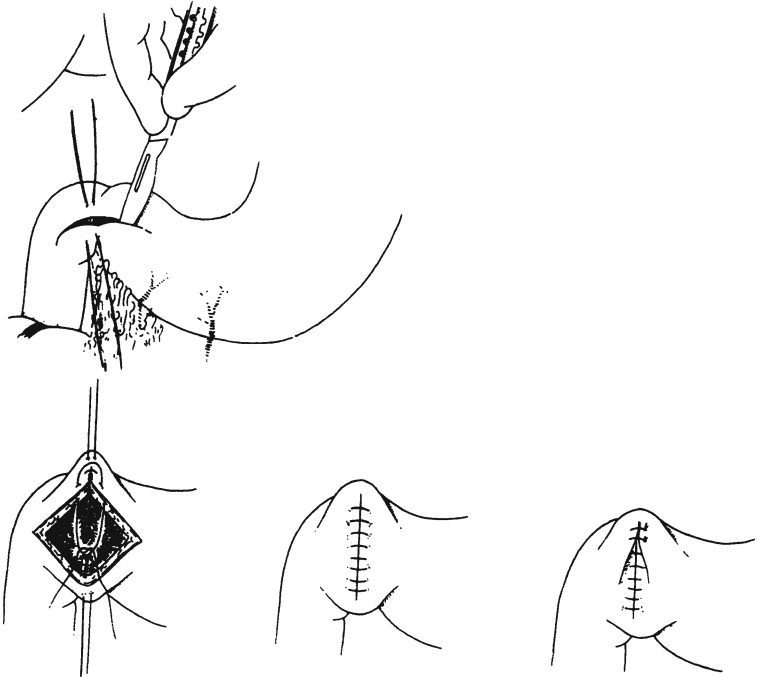


Figure 7.20. Heineke–Mikulicz pyloroplasty (see text for details).

Finney Pyloroplasty (Fig. 7.21)

- Step 1.** Mobilize the first and second portions of the duodenum by performing a Kocher maneuver.
- Step 2.** With interrupted Lembert suture of 3-0 silk, appose the pyloric area of the stomach and the first portion of the duodenum.
- Step 3.** Make a U-shaped, inverted incision to include the distal pyloric antrum and the proximal second portion of the duodenum. Locate the ulcer and excise it.
- Step 4.** Close the gastroduodenal opening in layers. Truncal vagotomy may be done if surgery is performed immediately after the perforation of the ulcer.

■ **GASTRECTOMIES**

Determination of Some Anatomical Boundaries

Following are some arbitrary guidelines on which to base gastric resections (Fig. 7.22). All may be helpful; none are completely satisfactory. *All are described from the lesser curvature to the greater curvature.*

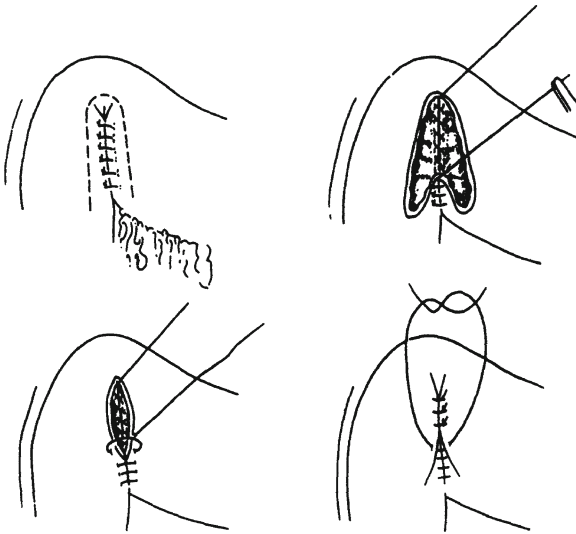


Figure 7.21. Finney pyloroplasty (see text for details).

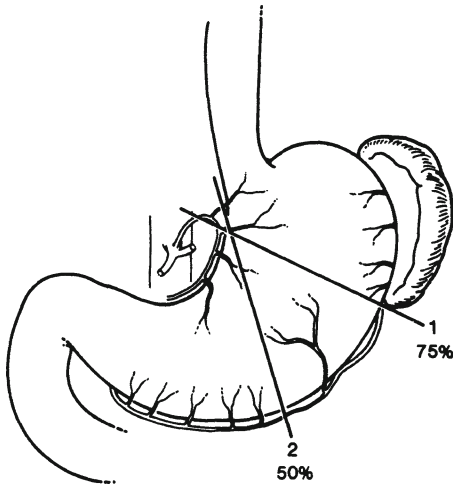


Figure 7.22. Some arbitrary landmarks for partial gastric resection: (line 1) 75 % resection; (line 2) 50 % resection (By permission of JE Skandalakis, SW Gray, and JR Rowe. *Anatomical Complications in General Surgery*. New York: McGraw-Hill, 1983).

Guideline for 75 % Gastric Resection

- A line extending from the first branch of the left gastric artery to a point approximately 2.5 cm below the spleen or to a point in the avascular area between the short gastric artery and the left gastroepiploic artery (Fig. 7.22).

Guidelines for 50 % Gastric Resection

- A line extending from the third vein below the gastroesophageal junction on the lesser curvature (which is near the descending branch of the left gastric artery) to the midpoint of the left gastroepiploic artery where it comes closest to the gastric wall on the greater curvature.
- See Guidelines for Antrectomy (below) and Fig. 7.22.

Guidelines for Antrectomy

- The classic external landmarks for the antrum have been the incisura angularis proximally and the pyloric sphincter distally. The proximal landmark is vague and inconsistent. An alternative solution follows:

A line extending from the origin of the ascending esophageal branch of the left gastric artery (2–3 cm from the esophagus) to the anastomosis between the right and left gastroepiploic arteries. This anastomosis is, unfortunately, neither obvious nor constant.

The line is usually drawn at the midpoint of the greater curvature. This will remove the antrum together with a small cuff of distal fundus. This is about equal to a 50 % resection and has the advantage of leaving none of the antral gastrin-producing cell area (Fig. 7.22).

Location of the Antral Boundary

Deciding how much stomach to resect would be easy if one knew the location of the boundary between the acid-producing gastric glands and the gastrin-producing pyloric glands.

Gastrotomy with Direct Observation

Some surgeons feel that there is an internally visible demarcation between the relatively smooth surface of the antral mucosa and the rugose surface of the body mucosa. Others have found this apparent difference to be misleading. Present evidence is that the antral junction may be an irregular line of demarcation or, more often, a zone of transition about 2 mm wide at the lesser curvature and about 3 mm wide at the greater curvature.

Estimation Based on Averages

On the lesser curvature the boundary between the antrum and the body is $2/5$ of the distance from the pylorus to the cardia; on the greater curvature the boundary is $1/8$ of the distance from the pylorus to the cardia.

Some other factors must be considered (Fig. 7.23). The position of the junction may shift with the pathologic state of the stomach. Also, the area of gastrin-producing antral mucosa appears to expand in the presence of a gastric ulcer, while remaining unchanged in the presence of a duodenal ulcer.

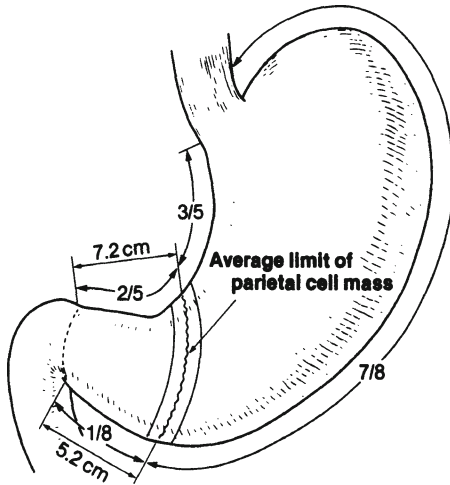


Figure 7.23. The antrum–body junction in the “average stomach” is found at $2/5$ of the distance from the pylorus to the cardia along the lesser curvature and $1/8$ of the same distance along the greater curvature (By permission of JE Skandalakis, SW Gray, and JR Rowe. *Anatomical Complications in General Surgery*. New York: McGraw-Hill, 1983).

Estimation Based on Landmarks

There are no landmarks on the greater curvature, but on the lesser curvature three landmarks may be used to help determine the junction of the antrum and body: the pylorus, the “crow’s foot” of the gastric divisions of the vagus nerve, and the incisura angularis.

- The boundary of the antrum starts on the lesser curvature 6–10 cm proximal to the pyloric valve.
- The boundary of the antrum starts on the lesser curvature 3–4 cm proximal to the “crow’s foot” (Fig. 7.7).
- The boundary of the antrum starts at the incisura angularis (which may or may not be present).

As one can see, the preceding guidelines are arbitrary and unsatisfactory.

Mobilization of the Stomach

Mobilization of the stomach may be obtained by (1) incising the gastrosplenic ligament and leaving the spleen in place, (2) mobilizing the spleen and preserving the short gastric arteries, or (3) removing the spleen.

320 7. Stomach

Further mobilization of the stomach may be achieved by incision of the phrenoesophageal ligament to permit the distal esophagus to be brought into the abdomen. Inconstant avascular adhesions between the posterior surface of the stomach and the pancreas may require division.

Mobilization of the Duodenum

The first step is the method of Kocher. The peritoneum lateral to the duodenum is sectioned from the epiploic foramen downward, and the duodenum and head of the pancreas are raised from the underlying vena cava. A laparotomy pad may be placed behind the duodenum and pancreas. Further mobilization may be obtained by separating the first part of the duodenum from the pancreas.

In performing an esophagoduodenectomy after total gastrectomy, as much as 3.5 cm can be gained by sectioning the cystic duct and artery (with removal of the gallbladder), partially releasing the common bile duct, and allowing the duodenum to be rotated.

Complications of Ligation of the Left Gastric Arteries

Ischemia of the Gastric Remnant

Following a radical subtotal gastrectomy, the blood supply to the remaining gastric pouch comes from:

- Ascending branches of the left gastric artery
- Anterior short gastric arteries
- Left inferior phrenic artery
- Descending branches from thoracic esophageal branches
- Posterior gastric artery

Ischemia Resulting in Gastric Necrosis with Subsequent Anastomotic Leakage and Peritonitis

T-Closure of Stomach or Duodenum

T-closures of the stomach or duodenum are not recommended because the blood supply to the resulting corners may be inadequate. A long gastrotomy incision for the management of massive upper gastrointestinal bleeding should not extend past the pylorus, so that if a subsequent gastric resection seems desirable, a T-closure of the duodenal stump may be avoided. Similarly, if the surgeon believes a pyloroplasty may be required, a long exploratory incision might force her or him to make a T-closure of the pylorus. Figure 7.24 shows the recommended exploratory incisions for evaluating gastroduodenal hemorrhage.

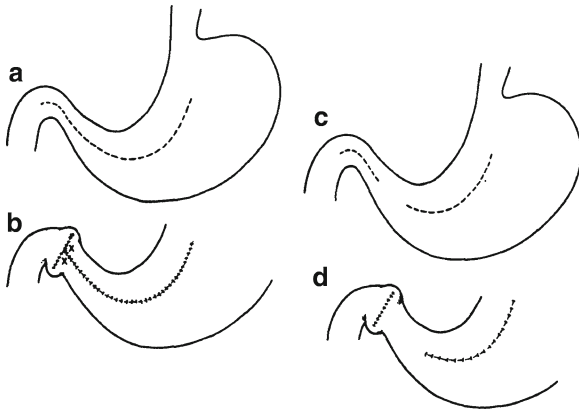


Figure 7.24. Gastrostomy incisions: (a) Long incision extending into pylorus. (b) Closure of long incision resulting in corners (x) that may become ischemic. (c) Two separate incisions. (d) Closure avoids the corners of the preceding incision (By permission of JE Skandalakis, SW Gray, and JR Rowe. *Anatomical Complications in General Surgery*. New York: McGraw-Hill, 1983).

It has been demonstrated that the entire stomach can be perfused through the right gastroepiploic artery alone.

Ischemia of the Duodenal Cuff

The duodenal branches of the pancreaticoduodenal arcades should be treated as end arteries and preserved if possible. This may be especially important in those patients having few, widely spaced (2–3 cm) duodenal branches (Fig. 7.25).

To be within the zone of safety, the minimum length required for anastomosis is 1–2 cm.

Control of Hemorrhage from the Gastroduodenal Artery

The rich submucosal vasculature of the stomach and duodenum becomes a disadvantage in the control of massive hemorrhage from ulcerative erosion of the gastroduodenal artery.

Careful suture ligation of the bleeding site from the inside is the only procedure recommended.

The retroduodenal portion of the gastroduodenal artery is about 2.5 cm from the pylorus and separated by about 0.8 cm (range 0.4–1.2 cm) of pancreatic tissue.

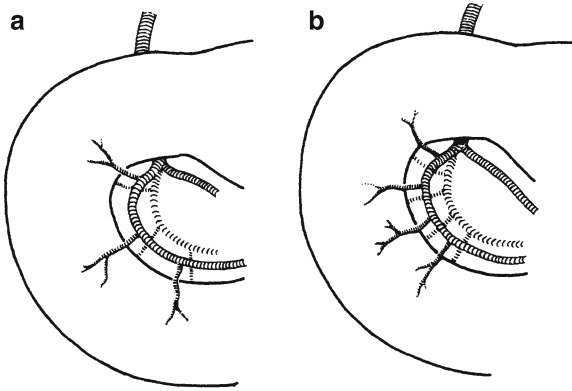


Figure 7.25. Variations of arteries to the duodenum. (a) Widely spaced arterial branches. (b) Closely spaced arterial branches. These branches should be treated as end arteries and as many as possible should be preserved (By permission of JE Skandalakis, SW Gray, and JR Rowe. *Anatomical Complications in General Surgery*. New York: McGraw-Hill, 1983).

Middle Colic Artery

A gastrectomy requires the surgeon to enter the lesser peritoneal cavity. Typically, entrance is obtained through the anterior leaf of the greater omentum (Fig. 7.26a). With reasonable care, the surgeon usually avoids perforating the transverse mesocolon, in which lies the middle colic artery.

In the presence of pathology, such as gastric ulcer or pancreatitis, the posterior leaf of the greater omentum and the posterior wall of the stomach may have become fixed to the transverse mesocolon and pancreas, thus eliminating the cavity of the lesser sac and giving the surgeon no warning that the mesocolon has been penetrated (Fig. 7.26b).

Even in the absence of abnormal fixation, should surgeons attempt to enter the lesser sac too far inferiorly, they will pass through the fused anterior leaf and transverse mesocolon (Fig. 7.26c). Under either circumstance, the middle colic vessels may be inadvertently ligated and divided along with the gastroepiploic branches.

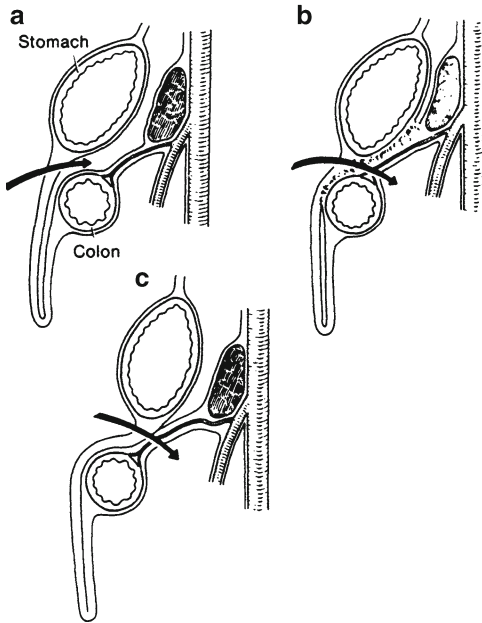


Figure 7.26. Entrance to the lesser sac. (a) Normal anatomy. The *arrow* indicates entrance through the greater omentum. The middle colic artery in the transverse mesocolon is in no danger. (b) Pathological fixation of the omentum and posterior wall of the stomach with the transverse mesocolon. (c) Normal anatomy, but entrance so far inferior may injure the middle colic artery (By permission of JE Skandalakis, SW Gray, and JR Rowe. *Anatomical Complications in General Surgery*. New York: McGraw-Hill, 1983).

Posterior Gastric Artery

A posterior gastric artery as much as 2 mm in diameter may arise from the proximal or middle third of the splenic artery. It supplies the posterior wall of the upper body, the fundus, and the cardia. Unrecognized, it may be a source of troublesome hemorrhage.

Because there are numerous types of gastrectomies and modifications (antecolic, retrocolic, large stoma [Polya's], small stoma [Hofmeister], Roux-en-Y, etc.), presentation of all of them is not possible within the scope of this book (Figs. 7.27 and 7.28). We have included subtotal distal gastrectomy (Billroth I and II), the difficult duodenal stump, total gastrectomy for cancer, vagotomy, and highly selective (or proximal gastric) vagotomy.

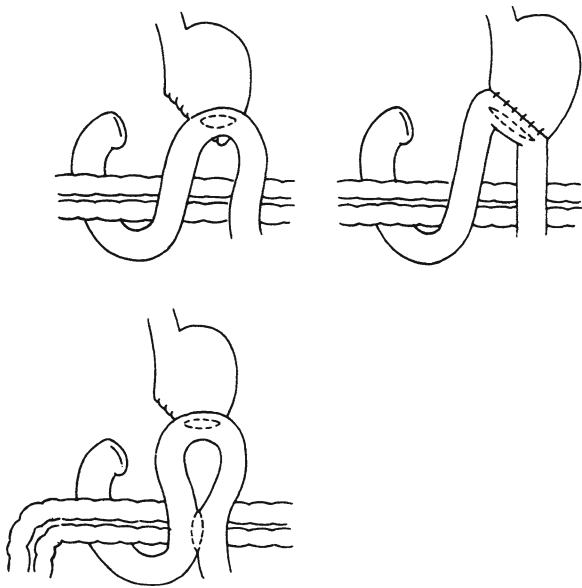


Figure 7.27. Partial gastrectomies: gastric resections and variations.

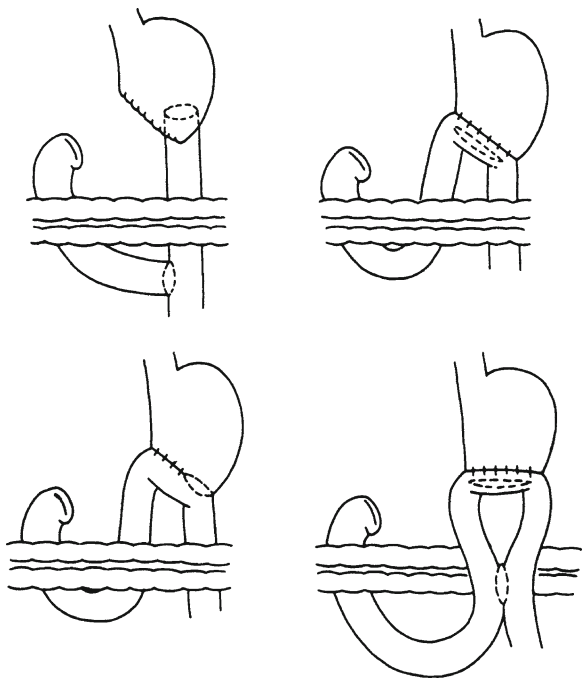


Figure 7.28. (Continued).

Subtotal Distal Gastrectomy

Billroth I (Figs. 7.29, 7.30, and 7.31)

Step 1. Mobilize the distal stomach by careful ligation of the arteries and veins of the lesser and greater curvature, distal to the point of the gastric transection. The surgeon now decides whether to perform a 75 or 50 % gastrectomy or antrectomy and ligates the vessels accordingly.

- a. Ligation of the gastrocolic ligament: Start in the vicinity of the origin of the left gastroepiploic vessels by carefully dividing the ligament between clamps. Ligate with 2-0 silk, proceeding from left to right to reach the gastroduodenal junction. The Harmonic Scalpel, also, can be used here.
- b. Remember that the middle colic artery is within the leaflets of the transverse mesocolon. Carefully separate the transverse mesocolon from the posterior gastric wall to avoid injuring this vessel, which occasionally is not anastomosed with the marginal artery and, therefore, may cause problems for the transverse colon.

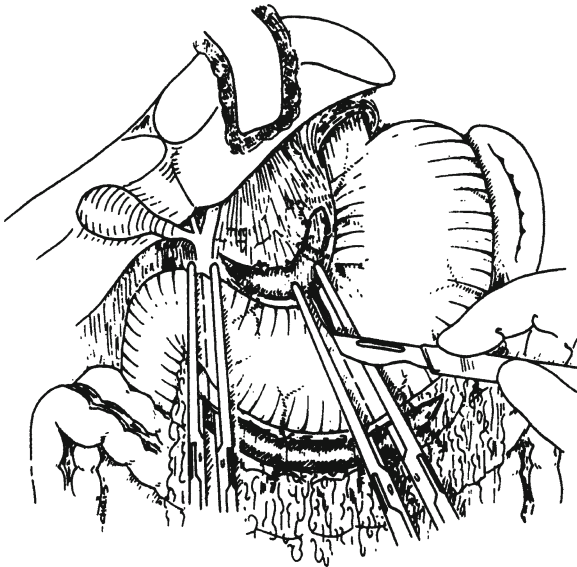


Figure 7.29. Transection of distal stomach.

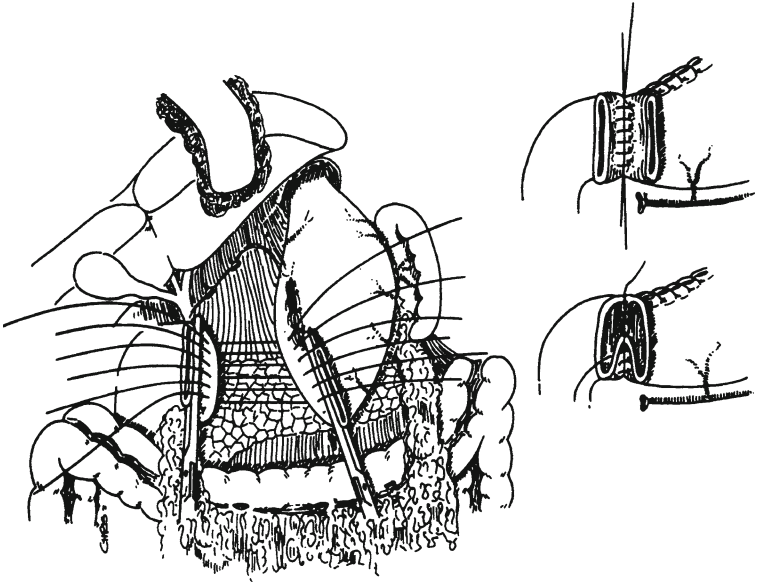


Figure 7.30. Stomach is divided. Closure in two layers.

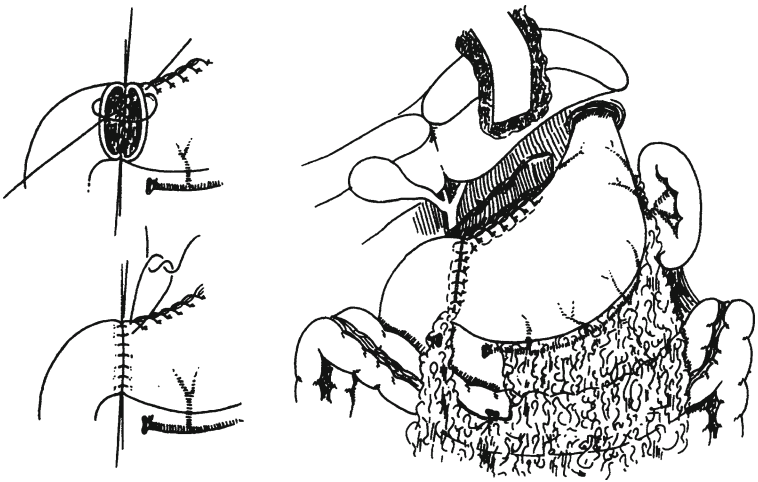


Figure 7.31. Gastric and duodenal walls approximated. Gastric wall is anastomosed to duodenum.

- c. Use small, curved mosquito clamps to skeletonize the gastroduodenal area by ligating the vessel with 3-0 or 4-0 silk.
- Step 2.** Ligate the vessels of the lesser curvature and the right gastric artery (to avoid duodenal ischemia, ligate only the number of vessels necessary to perform the anastomosis). Continue dissecting and ligating toward the left gastric artery, which should be doubly ligated.
- Step 3.** Place two seromuscular sutures just below the duodenal transection line and a Kocher clamp just distal to the pylorus, but not in the duodenum. Divide the duodenum just distal to the Kocher clamp; this will ensure that no gastric mucosa is left at this level. We prefer not to use any clamps at the duodenum.
- Step 4.** At the designated line of gastric division, place clamps: noncrushing proximally and crushing (Kocher) distally, directed toward the lesser curvature. Divide the stomach and remove the specimen. Place a suture, as an indicator, at a point of the noncrushing clamp designating the two areas of the gastric remnant, one toward the lesser curvature (which will be closed), and one toward the greater curvature (which will be anastomosed to the duodenum). The first area should be closed with two layers, using 3-0 chromic continuous oversewn, and after removal of the clamp, with 3-0 interrupted silk. Alternatively, a TA-90 stapler may be used for closing the lesser curvature. We like to cover the staple line with 3-0 silk Lembert sutures.
- Step 5.** Because of some peculiar mobility of the gastric mucosa, we apply Babcock clamps, bringing the mucosal and submucosal layers together so the gastric mucosa will not retract. Obtain hemostasis. Using interrupted 3-0 silk, approximate the gastric and duodenal wall posteriorly. Remove clamps and anastomose the gastric opening (including the gastric wall in toto) to the duodenum. Use a running 3-0 chromic for the mucosae and interrupted 3-0 silk seromuscular for the outside.

Remember the Angle of Sorrow:

- ✓ This is where three suture lines come together at the lesser curvature area when the stomach and duodenum are anastomosed. It should be reinforced with 3-0 silk, taking seromuscular bites of both sides of the lesser curvature and the duodenum (Fig. 7.32).

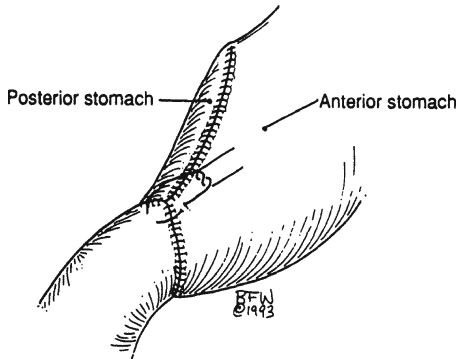


Figure 7.32. Angle of sorrow. Reinforcing the juncture.

Billroth II

Step 1. Mobilize the stomach for 75 or 50 % gastrectomy or antrectomy as described previously for Billroth I. Also, mobilize the first portion of the duodenum to allow enough room for a two-layer closure or for use of the TA-55 stapler across the duodenum. The staple line can be supported with interrupted 3-0 silk Lembert sutures. Also, we like to cover the suture line with any piece of fat that may be present in the vicinity.

Step 2. There are many modifications of the Billroth II gastrectomy. The surgeon may decide to use the opening of the gastric remnant in toto or to use part of it as we described in Billroth I. In Figs. 7.33, 7.34, 7.35, 7.36, 7.37, 7.38, 7.39, 7.40, 7.41, 7.42, and 7.43 we present the retrocolic method, but the antecolic method (not illustrated) is acceptable on rare occasions.

Difficult Duodenal Stump

Step 1. Close the duodenal stump as perfectly as possible. We prefer to make a small abdominal stab wound overlying the duodenal stump and insert an 18–22 Malecot catheter. Make a small cut distal to the suture line of the stump in the duodenal wall and insert the tip of the catheter, directed downward to the second portion of the duodenum. Use 3-0 silk sutures on each side of the duodenostomy tube and cover the area with an omental piece. Bring the tube out through the anterior abdominal wall stab wound. Secure the tube to the skin with a 2-0 silk suture.

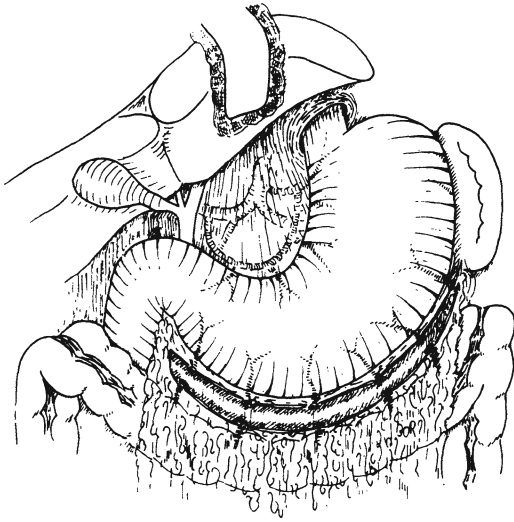


Figure 7.33. Mobilization of the stomach and first part of the duodenum.

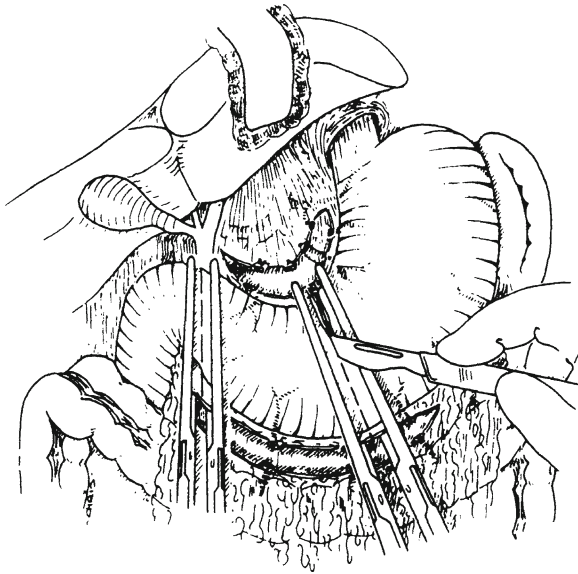


Figure 7.34. Transect and remove the distal stomach and a small part of the first portion of the duodenum.

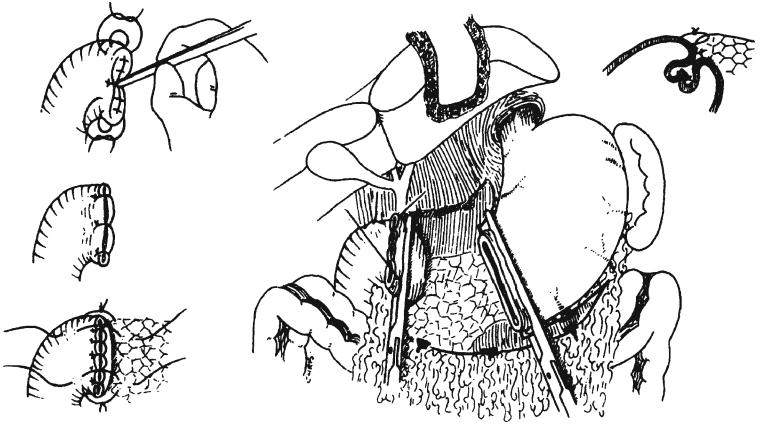


Figure 7.35. The specimen is removed and the duodenal opening is closed in two layers.

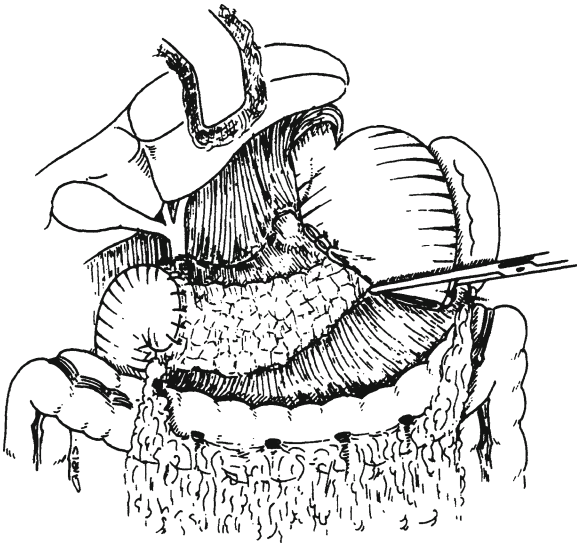


Figure 7.36. Partial closure of the gastric opening at the lesser curvature side.

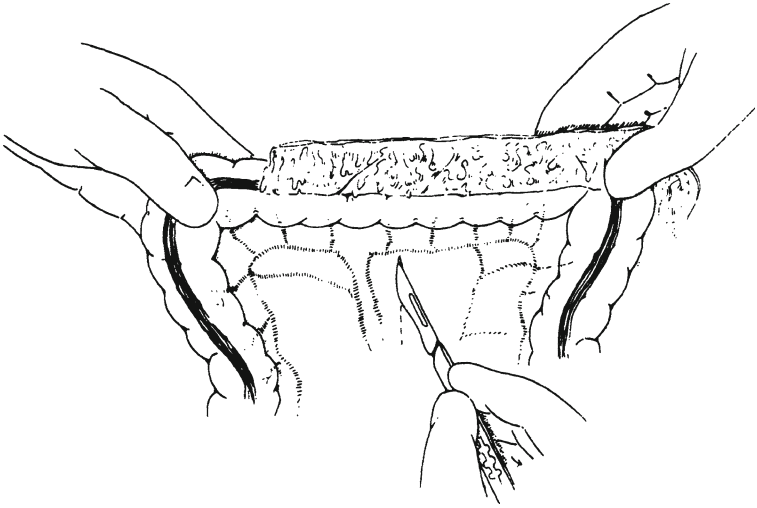


Figure 7.37. Elevate the transverse colon. If preparing a retrocolic anastomosis, insert a proximal jejunal loop through an avascular area of the mesocolon.

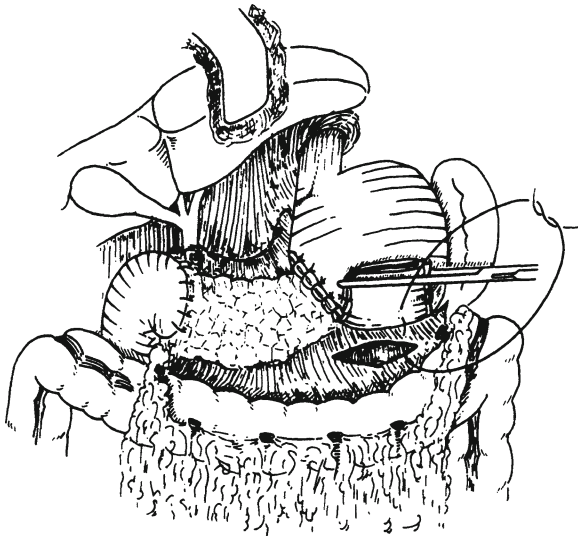


Figure 7.38. Suturing of the mesocolon to the posterior gastric wall close to the opening.

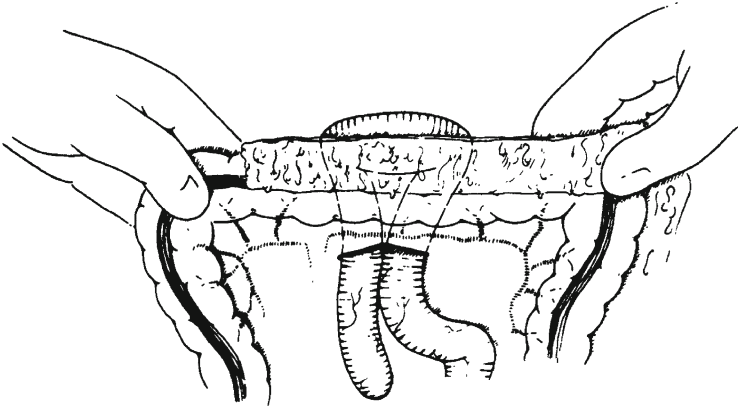


Figure 7.39. The proximal loop is inserted through the opening of the mesocolon.

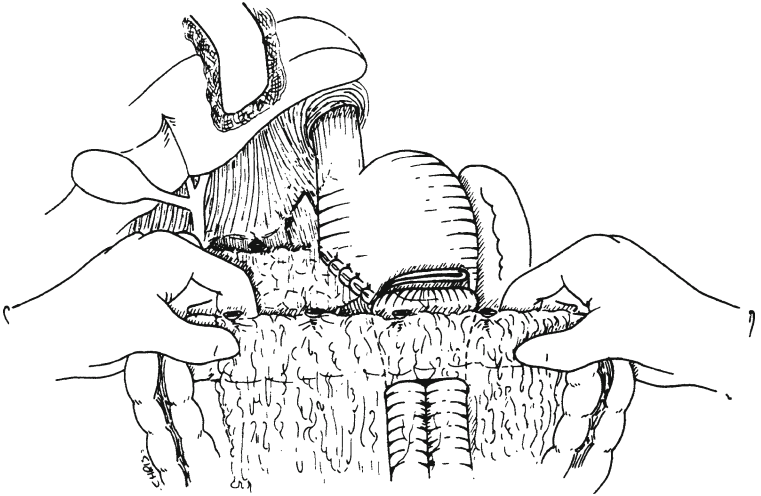


Figure 7.40. The four-layer anastomosis (see also Figs. 7.41 and 7.42).

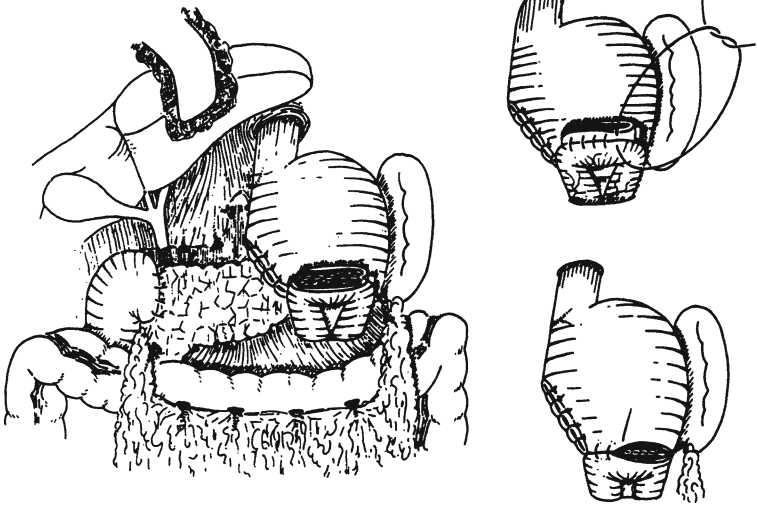


Figure 7.41. The four-layer anastomosis (continued in Fig. 7.42).

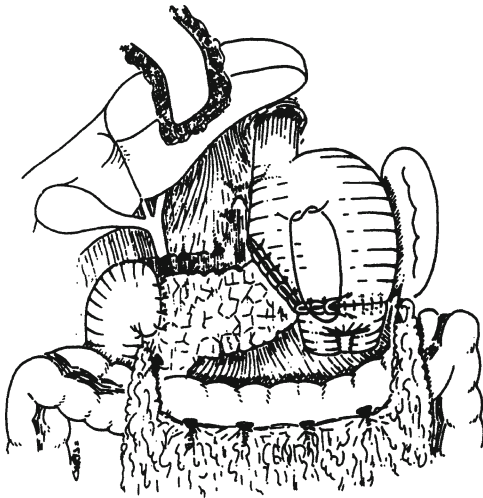


Figure 7.42. Completion of the four-layer anastomosis.

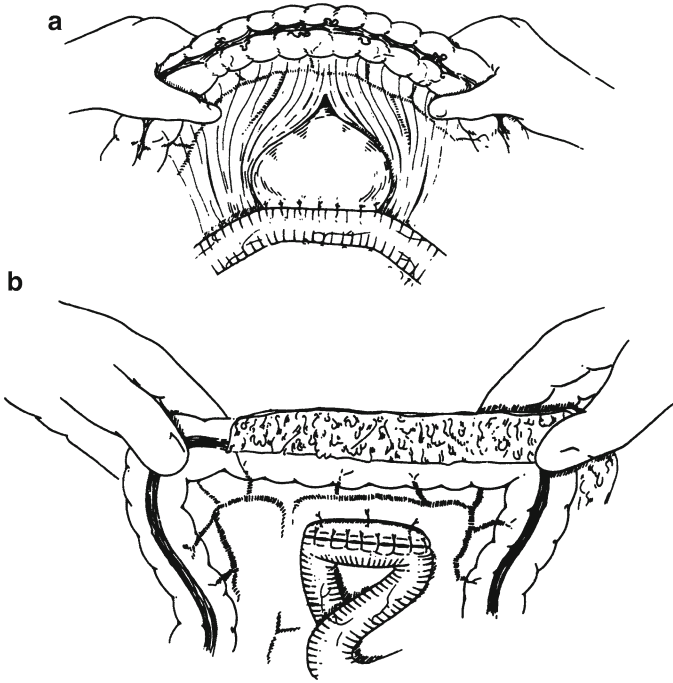


Figure 7.43. (a) and (b) An alternative method of anastomosis, bringing the stomach down the mesocolic opening and securing the gastric wall with interrupted sutures to the transverse mesocolon.

Total Gastrectomy for Cancer

The specimen should include the following (Fig. 7.44):

- Gastroesophageal junction
- Lesser omentum (hepatogastric and partial hepatoduodenal ligaments)
- Distal pancreas, as required
- Greater omentum, including gastrocolic ligament, but protecting the transverse mesocolon, which contains the middle colic artery
- Spleen
- Left lobe of the liver, if required by the presence of local extension
- Other neighboring anatomical entities involved by metastasis or by direct extension
- All the lymphovascular tissue around the stomach

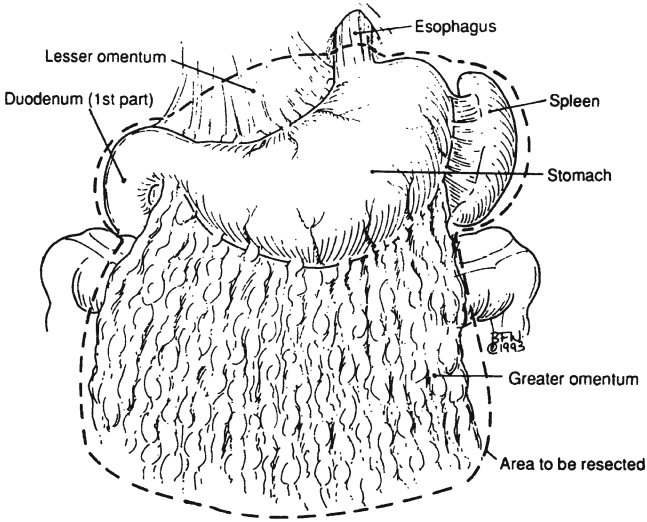


Figure 7.44. Resection site for total gastrectomy.

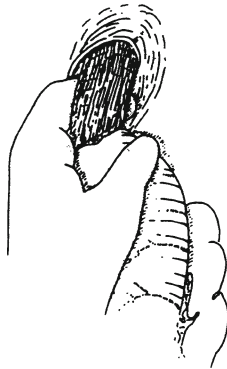


Figure 7.45. Blunt penetration.

- Step 1.** Approach the gastroesophageal area and, with the index finger, penetrate the local avascular ligaments (Fig. 7.45). Insert a Penrose drain for traction of the abdominal esophagus.
- Step 2.** Elevate the greater omentum and carefully separate it from the transverse colon (Figs. 7.46 and 7.47). Treat the duodenum and the lower pole of the spleen with care. If the surgeon decides to perform a splenectomy, the splenic veins and ligaments should be ligated and

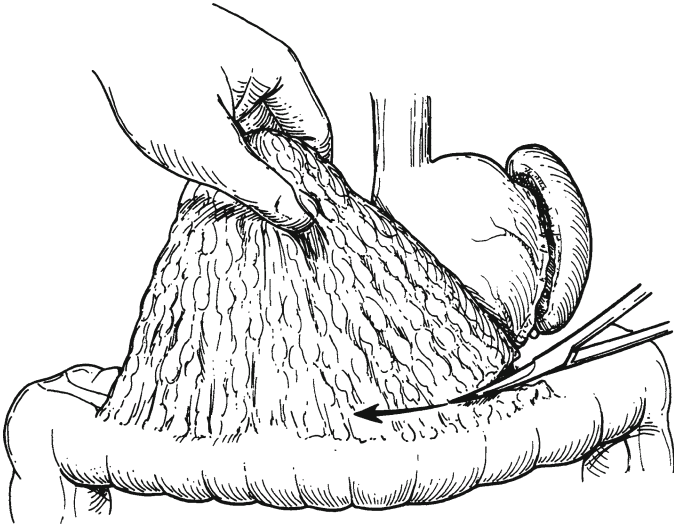


Figure 7.46. Greater omentum elevated.

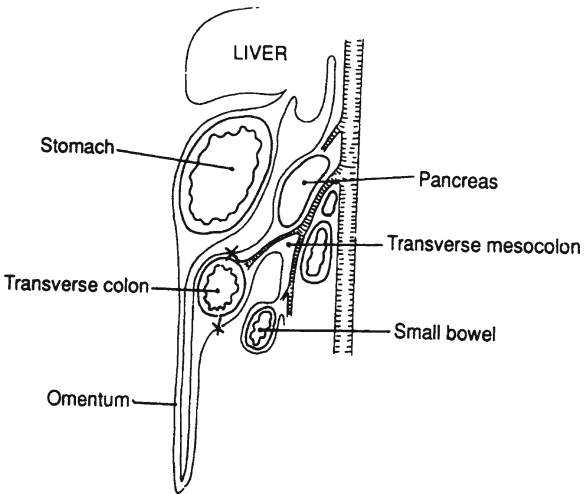


Figure 7.47. Relationship of omentum to transverse colon. X=points of separation.

cut. Continue the upward dissection of the greater omentum, with ligation of the upper short gastric vessels.

- Step 3.** Remove the lesser omentum. Ligate doubly the right and left gastric arteries. We prefer sharp and blunt dissection, pushing all the tissues from the porta hepatis toward the greater curvature (Fig. 7.48).
- Step 4.** With complete gastric mobilization from the gastroesophageal junction to the proximal portion of the second part of the duodenum, divide the duodenum and the abdominal esophagus (Fig. 7.49). Place 3-0 silk stay sutures on each side of the esophagus (Fig. 7.50). Remove the specimen.
- Step 5.** Perform duodenal closure as described previously. Gastrointestinal continuity is accomplished by a Roux-en-Y esophagojejunal anastomosis as follows. Divide the jejunum between the GIA stapler. Sacrifice one (preferably) or two arterial arcades. Pass the distal end of the divided bowel through a small hole of the transverse colon. Anastomose end to side with the esophagus using 4-0 interrupted silk (Fig. 7.51). Be careful that the esophageal mucosa retracts upward, and be sure to include all the esophageal layers in your bites. Before the anterior layer is closed, pass the nasogastric tube into the jejunal loop. We protect the anastomosis with two or three interrupted silk sutures, anchoring the jejunal wall just below the suture line to the esophageal hiatus.

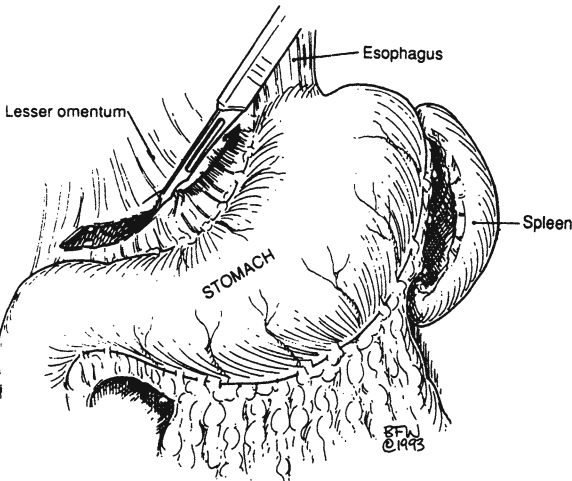


Figure 7.48. Removal of lesser omentum.

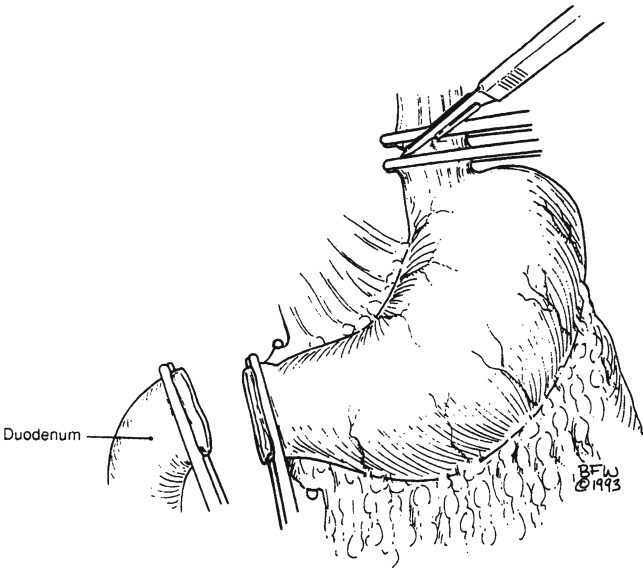


Figure 7.49. Stomach divided from abdominal esophagus and the duodenum.

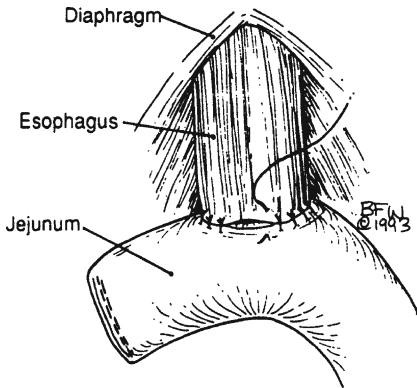


Figure 7.50. Placement of stay sutures.

Step 6. Anastomose the opening of the proximal jejunum to the jejunal loop in two layers. Fix the opening of the transverse mesocolon to the jejunum with a few 4-0 silk interrupted sutures (Fig. 7.52).

Step 7. Close the abdomen.

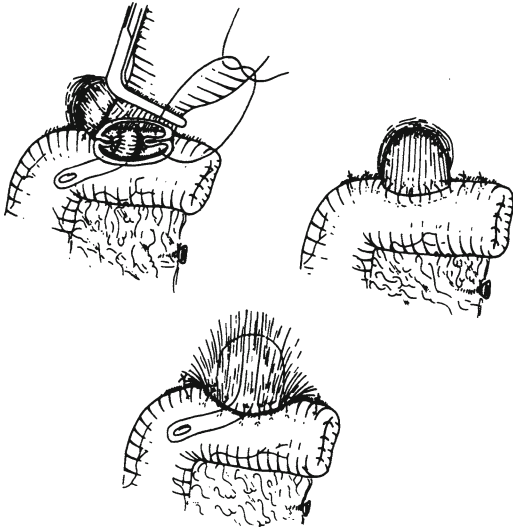


Figure 7.51. Duodenal closure (see text).

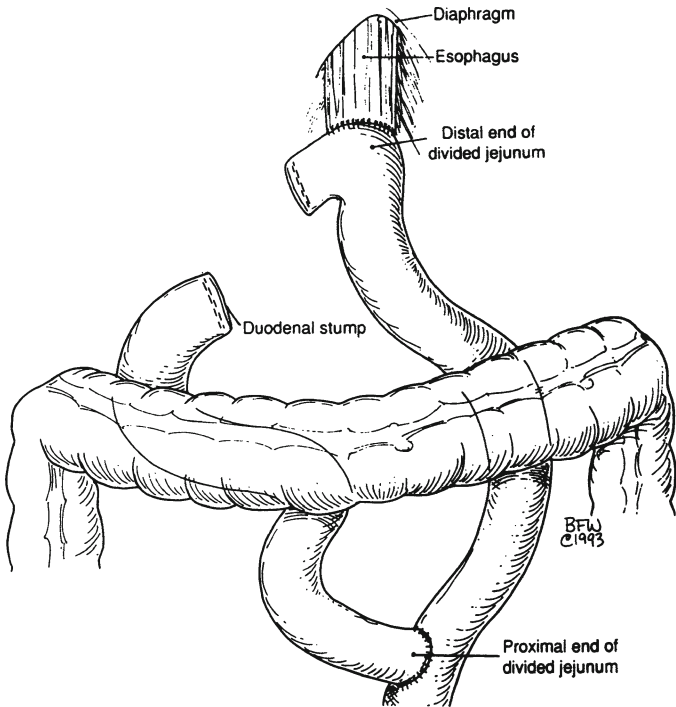


Figure 7.52. Completed end-to-side esophagojejunal and jejunojejunal anastomoses.

■ VAGOTOMIES

There are four types of vagotomy: truncal, selective, parietal cell, and extended proximal.

Truncal Vagotomy

A truncal vagotomy is performed by sectioning the anterior and posterior trunks within the abdomen (Fig. 7.7). This procedure destroys the vagal innervation to the stomach and all other abdominal viscera. Identification is subordinate in this procedure; complete transection is the goal. Complete skeletonization of the abdominal esophagus is mandatory, and pyloric drainage is usually necessary.

Selective Vagotomy

In selective vagotomy, only the anterior and posterior descending nerves of the gastric divisions (nerves of Latarjet) are divided (Fig. 7.53). The hepatic branch of the anterior division, including the pyloric branch, and the celiac branch of the posterior division are preserved. Thus, the stomach is denervated, while the vagal fibers to the pylorus, the biliary tract, and the intestines remain intact.

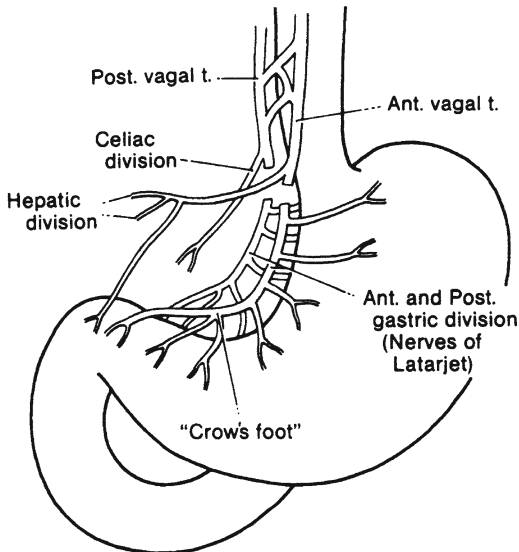


Figure 7.53. Selective vagotomy preserves the celiac and hepatic divisions but will not denervate the pylorus, biliary tract, and remaining intestinal tract (By permission of JE Skandalakis, SW Gray, and JR Rowe. *Anatomical Complications in General Surgery*. New York: McGraw-Hill, 1983).

Parietal Cell Vagotomy

A parietal cell vagotomy may also be called “highly selective vagotomy,” “superselective vagotomy,” “proximal gastric vagotomy,” or “acidosecretive vagotomy.” The goal is denervation of the proximal two-thirds of the stomach only, preserving the antral and pyloric innervation as well as the hepatic and celiac divisions (Fig. 7.54). Denervation is accomplished by sectioning of the proximal gastric branches of the descending anterior and posterior nerves of Latarjet while preserving the distal branches to the antrum and pylorus.

The distal extent of a highly selective vagotomy is to the left of the “crow’s foot,” about 7 cm from the pylorus. This may or may not coincide with the location of the boundary between the antrum and the body of the stomach. Various authors state that the distal limit of dissection should be between 5 and 10 cm from the pylorus.

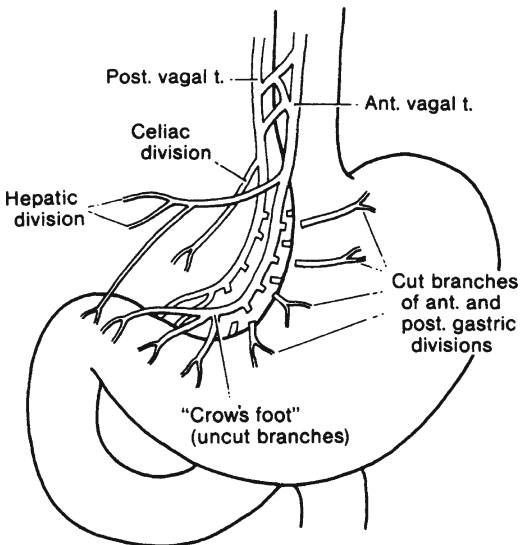


Figure 7.54. Parietal cell (superselective) vagotomy preserves antropyloric as well as celiac and hepatic innervation. There is some risk of perforation as a result of ischemia of the lesser curvature (By permission of JE Skandalakis, SW Gray, and JR Rowe. *Anatomical Complications in General Surgery*. New York: McGraw-Hill, 1983).

Extended Proximal Vagotomy

Extended proximal vagotomy for complete gastric denervation as shown in Fig. 7.55 consists of vagal denervation of the gastric fundus and greater curvature.

Remember:

- ✓ Vagotomy may be said to be complete if no areas of parietal cell activity can be found with a pH probe; if activity is found, the vagotomy is incomplete. Clinically, vagotomy may be considered complete if there is no recurrence of an ulcer.

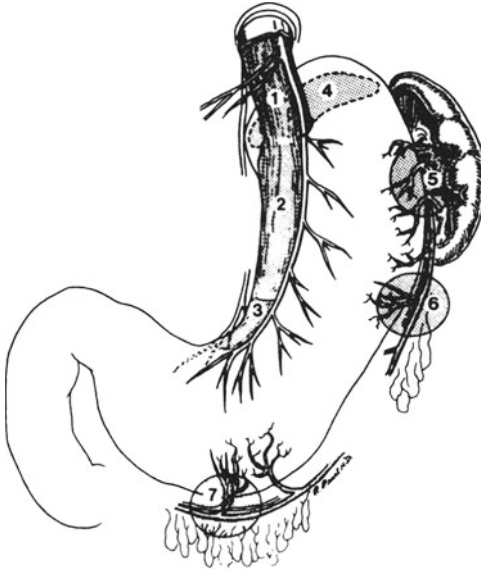

Figure 7.55. The seven areas of vagotomy. Preganglionic efferent vagus nerves reach the parietal cell mass in seven areas. Area 1 is the periesophageal region; area 2 is the lesser curve of the stomach; area 3 is the crow's foot area; area 4 is represented by the *broken line*, as the gastropancreatic fold is not visible anteriorly; area 5 is the region of short gastric vessels; area 6 is the left gastroepiploic pedicle; and area 7 is the right gastroepiploic pedicle. Areas 3, 4, 6, and 7 are divided routinely during extended highly selective vagotomy. Area 5 is preserved because the nerves at this site cannot be divided without sacrificing essential blood supply to the proximal part of the stomach (By permission of PE Donahue, HM Richter, KJM Liu, et al. *Surg Gynecol Obstet* 176(1):40, 1993).

- ✓ Gastric branches arising from vagal trunks proximal to the separation of the major division may be present and, if so, must be sectioned. The first and highest of such posterior branches is the “criminal nerve of Grassi.”

Truncal Vagotomy

- Step 1.** Mobilize the abdominal esophagus by peritoneal incision of the gastroesophageal junction. Palpate the abdominal esophagus. Locate the anterior vagus nerve and mobilize it with a nerve hook. Remove a segment of the nerve, clip the proximal and distal ends, and send the specimen to the lab for frozen section (Fig. 7.56).
- Step 2.** Palpate the posterior area. The nerve may be located close to the aorta between the right and left diaphragmatic crura and slightly right of the midline. Again, remove a segment of the nerve, clip the proximal and distal ends, and send to the lab for frozen section (Fig. 7.57).
- Step 3.** Because the vagus nerve exhibits many vagaries, it is important to skeletonize the esophagus.

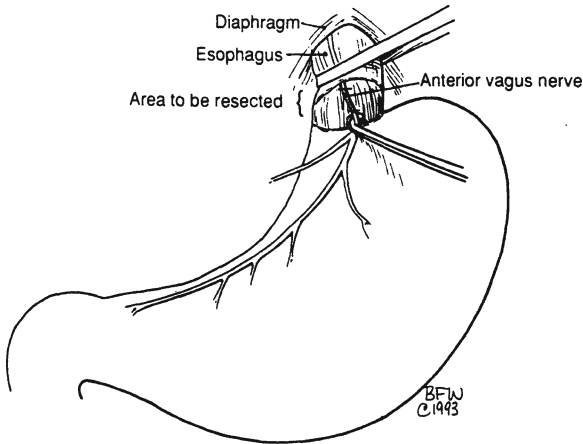


Figure 7.56. Sectioning of anterior vagus nerve.

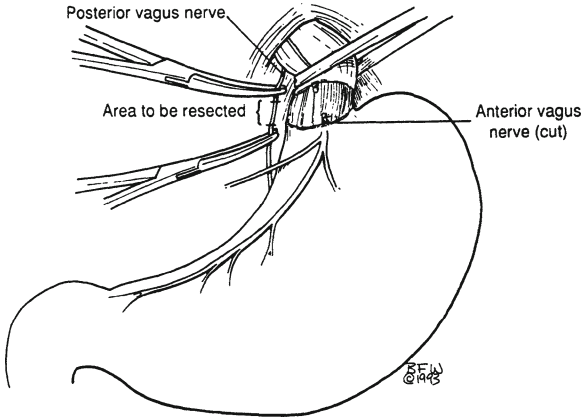


Figure 7.57. Sectioning of posterior vagus nerve.

Parietal Cell Vagotomy

Step 1. Mobilize the abdominal esophagus at the periesophageal space. Localize the right and left vagus nerves, which should be protected. Localize the nerves of Latarjet. Protect the hepatic division and celiac divisions.

Step 2. Mobilize the distal half of the greater curvature. Starting approximately 6 cm from the pylorus, begin an upward dissection of the neurovascular elements between the inner curve and the nerve of Latarjet, by dividing and ligating them with 4-0 silk. Continue dissection toward the cardiac angle.

Remember:

- ✓ Protect the trunks
- ✓ Protect the nerves of Latarjet
- ✓ Protect the pyloric branch
- ✓ Protect the crow's foot

Step 3. Re-peritonealize the lesser curve by approximating the anterior and posterior walls with interrupted 3-0 silk.

Duodenum

ANATOMY

■ GENERAL DESCRIPTION OF THE DUODENUM

The first, or superior, portion of the duodenum (5 cm long) passes upward from the pylorus to the neck of the gallbladder. The proximal end is movable and enclosed by the same peritoneal layers that invest the stomach. The distal half of the first portion becomes retroperitoneal. Posteriorly, this portion is in intimate contact with the common bile duct, portal vein, and gastroduodenal artery. The duodenum is separated from the inferior vena cava by a small amount of connective tissue.

The second, or descending, portion (7.5 cm long) lies posterior to the transverse mesocolon and anterior to the right kidney and inferior vena cava. The left border is attached to the head of the pancreas. The common bile and pancreatic ducts open into the left side of this portion of the duodenum.

The third and fourth portions of the duodenum lie inferior to the transverse mesocolon. Their cranial surfaces are in contact with the uncinate process of the pancreas (Fig. 8.1). The parietal peritoneum covering the fourth portion of the duodenum contains folds beneath which are blind recesses or paraduodenal fossae.

The third, or horizontal, portion of the duodenum (10 cm long) passes to the left and slightly upward, crossing anterior to the inferior vena cava and posterior to the superior mesenteric artery and vein. The fourth, or ascending, portion (2.5 cm long) passes upward and slightly to the left, crossing the spine anterior to the aorta. It may cover the origin of the inferior mesenteric artery from the aorta. The duodenum ends at the duodenojejunal flexure, which usually lies immediately to the left of the aorta.

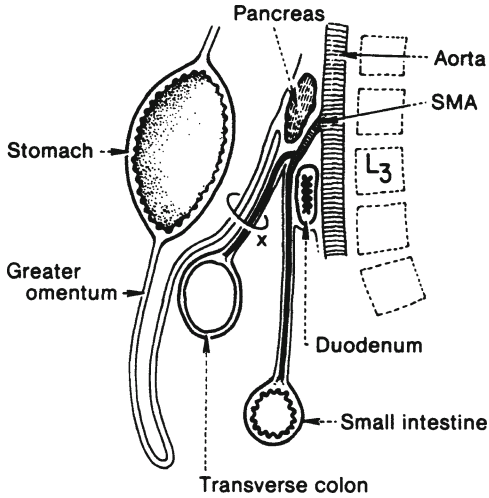


Figure 8.1. Diagrammatic sagittal section showing the position of the duodenum in relation to the aorta and the superior mesenteric artery. The transverse mesocolon is marked by an X. SMA superior mesenteric artery (modified by permission of SW Gray, JT Akin, JH Milsap, et al. *Contemp Surg* 10:33–56, 1977).

At the gastroduodenal junction, the continuity of the circular musculature is interrupted by a ring-shaped septum of connective tissue derived from the submucosa. Proximal to this ring, the circular muscle layer thickens to form the pyloric sphincter of the stomach; distal to the ring there is an abrupt decrease in the thickness of the circular muscle to form the relatively thin-walled duodenum. This decrease results in a pyloric “os pylorus” surrounded by a duodenal fornix. This arrangement must be kept in mind when performing pyloromyotomy.

The gastroduodenal junction is marked internally by the submucosal glands of Brunner; this may not correspond to the muscular junction. The submucosal glands may extend a few centimeters into the pylorus, and occasionally, antral gastric mucosa may prolapse through the pylorus to produce a radiological finding, but not a true clinical syndrome.

The duodenojejunal junction is marked externally by the attachment of the suspensory ligament of Treitz. This ligament or muscle is a fibromuscular band that arises from the right crus of the diaphragm, inserting on the upper surface of the duodenojejunal flexure. It passes posterior to the pancreas and the splenic vein and anterior to the left renal vein.

Usually the suspensory ligament inserts on the duodenal flexure and the third and fourth portions of the duodenum (Fig. 8.2b). Alternatively, it may insert on the flexure only (Fig. 8.2a), or on the third and fourth portions only (Fig. 8.2c), or there may be multiple attachments (Fig. 8.2d).

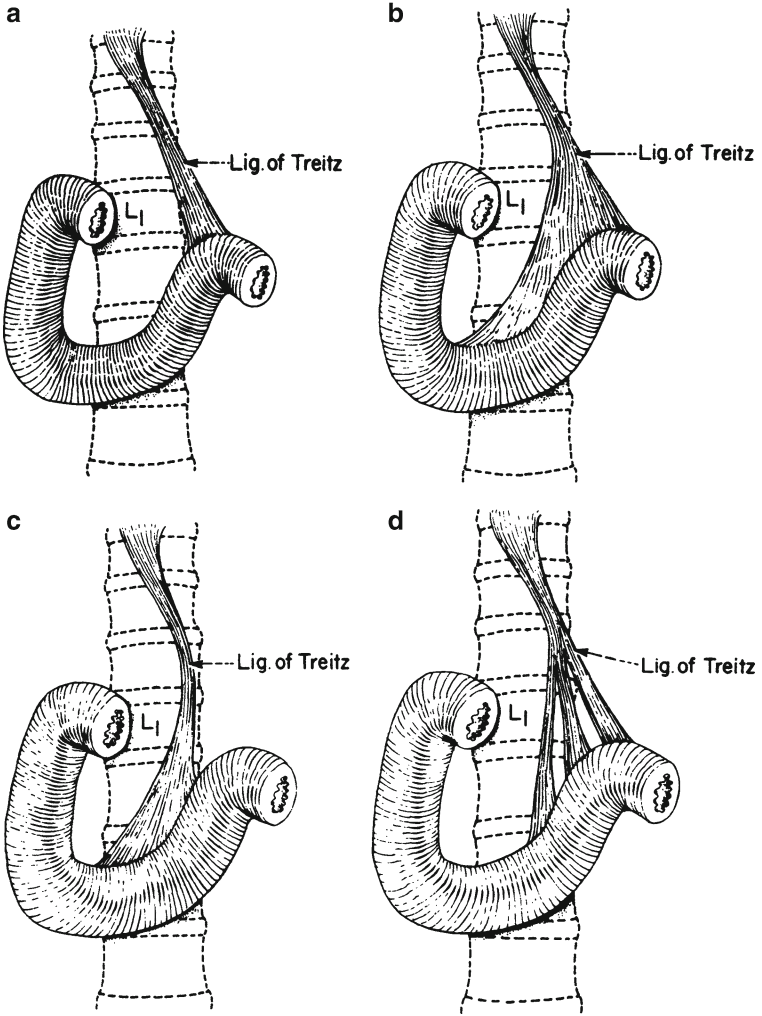


Figure 8.2. Four configurations of the suspensory ligament of Treitz: (a) attachment to the duodenojejunal flexure. (b) Attachments to the flexure and the third and fourth portions of the duodenum. (c) Attachments to the third and fourth portions only. (d) Multiple separated attachments of the suspensory ligament (By permission of JE Skandalakis, JT Akin, JH Milsap, et al. *Contemp Surg* 10:33-56, 1977).

■ VASCULAR SYSTEM OF THE DUODENUM

Arteries

The blood supply of the duodenum is confusing due to the diverse possibilities of origin, distribution, and individual variations (Figs. 8.3, 8.4, and 8.5). This is especially true of the blood supply of the first portion of the duodenum.

The first part of the duodenum is supplied by the supraduodenal artery and the posterior superior pancreaticoduodenal branch of the gastroduodenal artery (retroduodenal artery as described by Edwards, Michels, and Wilkie), which is a branch of the common hepatic artery.

The remaining three parts of the duodenum are supplied by an anterior and a posterior arcade. Pancreatic and duodenal branches spring from the arcades. Those supplying the duodenum are called arteriae rectae; they may be embedded in the substance of the pancreas.

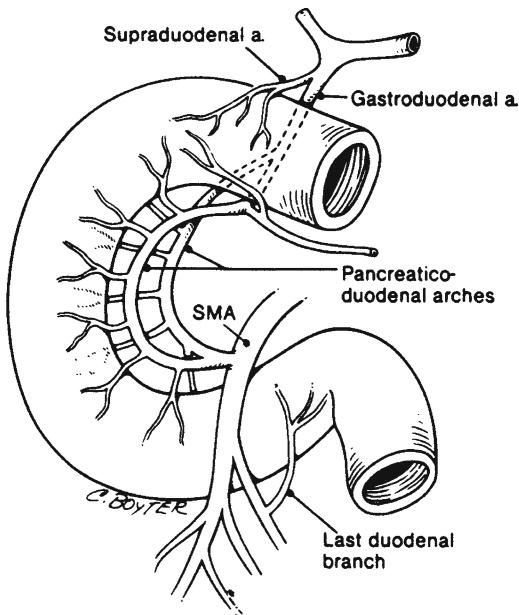


Figure 8.3. Major arterial supply to the duodenum. SMA superior mesenteric artery. From SW Gray, GL Colborn, LB Pemberton, LJ Skandalakis, and JE Skandalakis. *Am Surg* 15(4):257–261; 15(5):291–298; 15(7):469–473; 15(8):492–494, 1989. Reprinted with permission from American Surgeon.

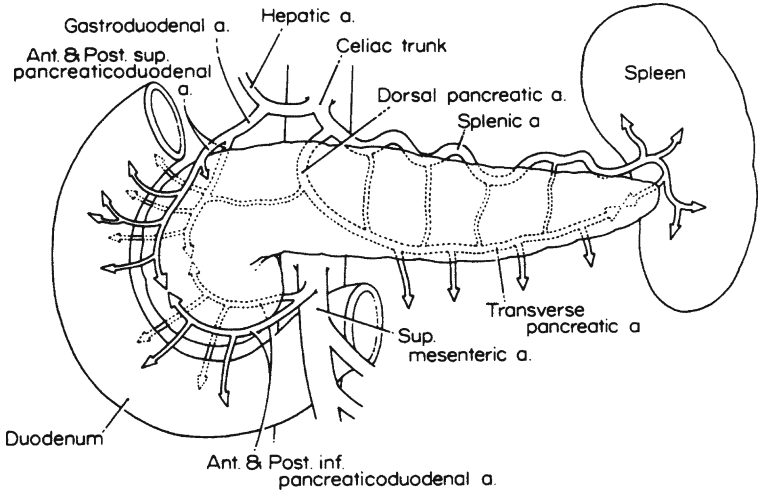


Figure 8.4. Anterior view of arterial supply of the duodenum and pancreas (By permission of JE Skandalakis, SW Gray, JS Rowe, et al. *Contemp Surg* 15(5):17-40 and 15(6):21-50, 1979).

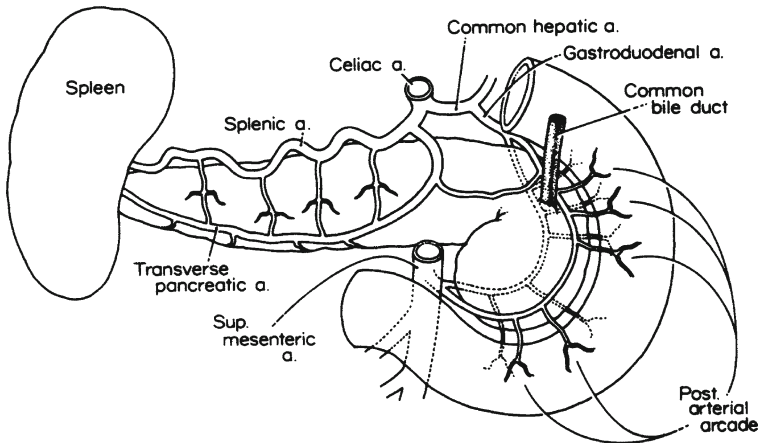


Figure 8.5. Posterior view of arterial supply of the duodenum and pancreas (By permission of JE Skandalakis, SW Gray, JS Rowe, et al. *Contemp Surg* 15(5):17-40 and 15(6):21-50, 1979).

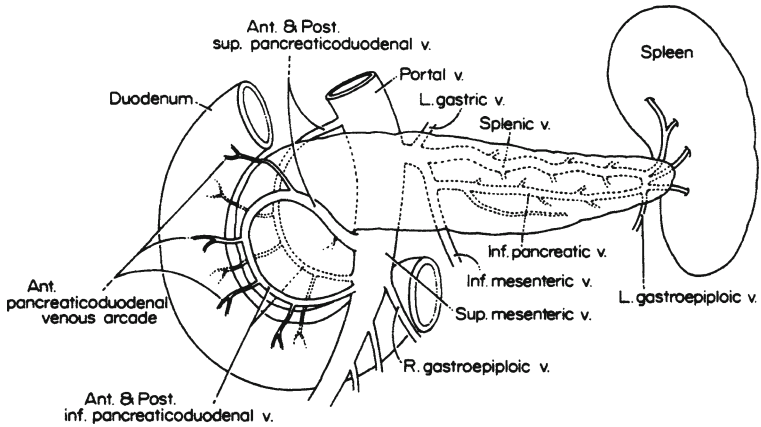


Figure 8.6. The venous drainage of the duodenum and pancreas: anterior view (By permission of JE Skandalakis, SW Gray, JS Rowe, et al. *Contemp Surg* 15(5):17–40 and 15(6):21–50, 1979).

Four arteries contribute to the pancreaticoduodenal vascular arcades:

- The anterior superior pancreaticoduodenal arteries (commonly two in number) arise from the gastroduodenal artery on the ventral surface of the pancreas.
- The posterior superior pancreaticoduodenal (retroduodenal) artery usually crosses in front of the common bile duct, then spirals to the right and posterior to the duct, descending deep to the head of the pancreas. Several of the retroduodenal artery branches anastomose inferiorly with rami from the posterior branch of the inferior pancreaticoduodenal artery.
- Third and fourth, the anterior inferior pancreaticoduodenal artery and the posterior inferior pancreaticoduodenal artery arise from the superior mesenteric artery or its first jejunal branch, either separately or from a common stem.

The surgeon should be sure to ligate only one of the two arcades—superior or inferior.

Veins

The veins of the lower first part of the duodenum and the pylorus usually open into the right gastroepiploic veins (Figs. 8.6 and 8.7).

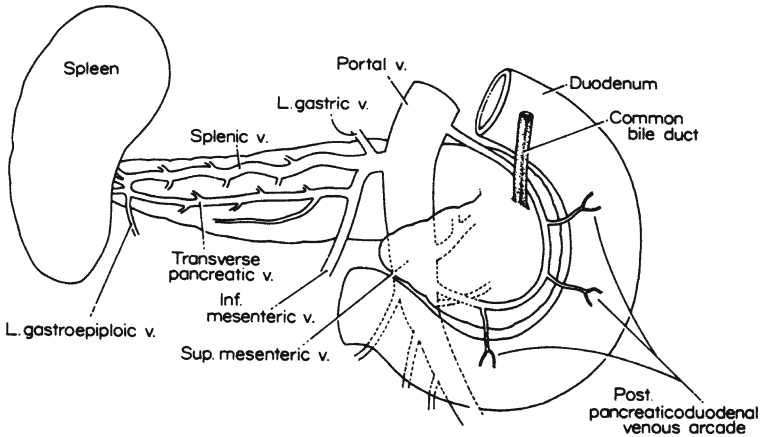


Figure 8.7. The venous drainage of the duodenum and pancreas, and formation of the hepatic portal vein: posterior view (By permission of JE Skandalakis, SW Gray, JS Rowe, et al. *Contemp Surg* 15(5):17–40 and 15(6):21–50, 1979).

The venous arcades draining the duodenum follow the arterial arcades and tend to lie superficial to them.

Lymphatic Drainage

The duodenum is richly supplied with lymphatics (Fig. 8.8). Collecting trunks pass over the anterior and posterior duodenal wall toward the lesser curvature to enter the anterior and posterior pancreaticoduodenal lymph nodes.

The lymphatics of the duodenum have received very little attention, even though some studies of the lymphatics of the pancreas have been conducted.

■ NERVE SUPPLY OF THE DUODENUM

Within the duodenal wall are the two well-known neural plexuses of the gastrointestinal tract. Meissner's plexus is in the submucosa, and Auerbach's plexus is between the circular and longitudinal layers of the muscularis externa. In 6 of 100 specimens studied, nerves from the hepatic division of the anterior vagal trunk gave rise to one or more branches that innervated the first part of the duodenum. In most specimens, some branches could be traced upward toward the gastric incisura. The vagaries of the vagus nerve are well known.

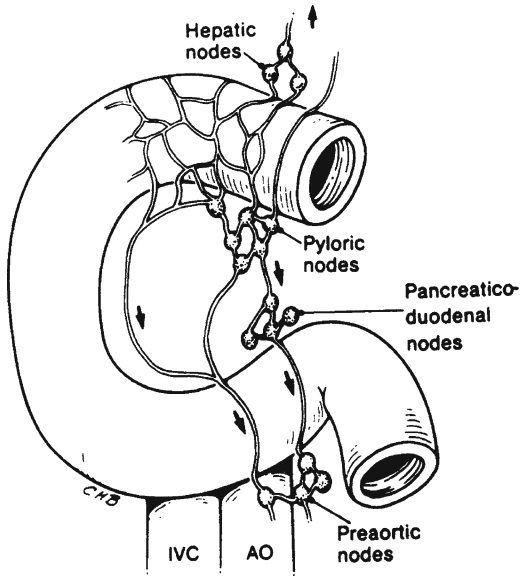


Figure 8.8. Diagrammatic presentation of duodenal lymphatics. *Ao* aorta, *IVC* inferior vena cava. From SW Gray, GL Colborn, LB Pemberton, LJ Skandalakis, and JE Skandalakis. *Am Surg* 15(4):257–261; 15(5):291–298; 15(7):469–473; 15(8):492–494, 1989. Reprinted with permission from American Surgeon.

TECHNIQUE

Surgery of the duodenum includes duodenotomy, duodenostomy, duodenal resection, and partial anastomosis with stomach or jejunum. Most of these surgical techniques are described in other chapters in connection with other organs such as the stomach (see Chap. 7) and the pancreas (see Chap. 9). The authors present here only the duodenal exposure and the superior mesenteric artery syndrome (vascular compression of the duodenum).

■ SURGICAL APPLICATIONS

Good results from surgical procedures in the first part of the duodenum can be anticipated if surgeons have good anatomical knowledge and if they practice good technique and conservative skeletonization. The blood supply to this area is questionable. The duodenum is one of the most difficult areas to approach when operating, because the duodenum and pancreas are fixed; the duodenum and pancreas share a common blood supply (superior and inferior pancreaticoduodenal arcades), and the area of the opening of the common bile duct and pancreatic ducts is very complex. A pancreaticoduodenectomy should be performed when malignant disease is found; but with benign disease, a more conservative approach, such as segmental resection, is the preferred treatment.

The proximal third of the duodenum is difficult to deal with because of its relationship to the head of the pancreas and the uncinate process. It is important to be aware of the superior mesenteric vessels, the transverse mesocolon with its marginal artery and the middle colic artery, and the inferior mesenteric artery, which the third portion of the duodenum covers in most cases. The surgeon should proceed slowly when dealing with the uncinate process, which is closely related to the superior mesenteric vessels. The inferior pancreaticoduodenal arcades yield many small vessels; small twigs from the superior mesenteric artery are present.

The fourth portion of the duodenum is related to two important anatomical entities: the ligament of Treitz and the inferior mesenteric vein, located to the left of the paraduodenal fossae. This portion is a useful place to begin exploring the distal duodenum (third and fourth portions), and the surgeon should remember that mobilization of the right colon and transection of the ligament of Treitz are necessary for good exposure of the distal duodenum. The divisions of the intestinal branches of the superior mesenteric artery provide the blood supply, which is similar to that of the rest of the small bowel. The arteries have no collateral circulation, and the wall has the least efficient blood supply in the antimesenteric border. (The duodenum does not have a mesentery; the middle of the anterior wall, which is covered by peritoneum, should be considered “antimesenteric.”)

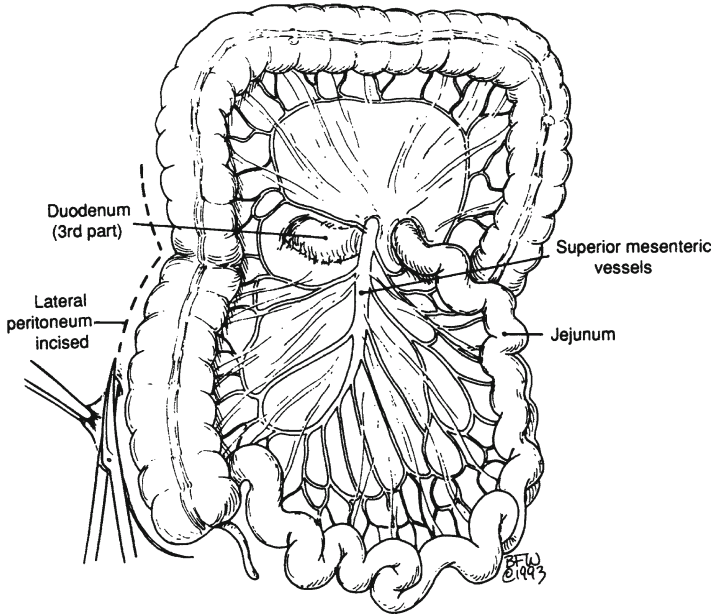


Figure 8.9. Mobilization of the right colon by incision of the lateral peritoneum and exposure of the third part of the duodenum by incision of the transverse mesocolon. Note that the superior mesenteric vein is not identified.

■ EXPOSURE AND MOBILIZATION OF THE DUODENUM (FIGS. 8.9, 8.10, AND 8.11)

It may be necessary to expose the duodenum to search for traumatic injury, to perform pancreatic procedures, to explore the distal common bile duct, to section the suspensory ligament for relief of duodenal compression, or to reduce a redundant proximal loop of a gastrojejunostomy above the transverse mesocolon. Exposure can be accomplished by the following maneuvers:

- Mobilization of the second and proximal third portions of the duodenum is obtained by incising the parietal peritoneum along the descending duodenum (second portion) and retracting it medially; this is the Kocher maneuver. The posterior wall of the duodenum can be examined, and the retroduodenal and pancreatic portions of the common bile duct can be explored.

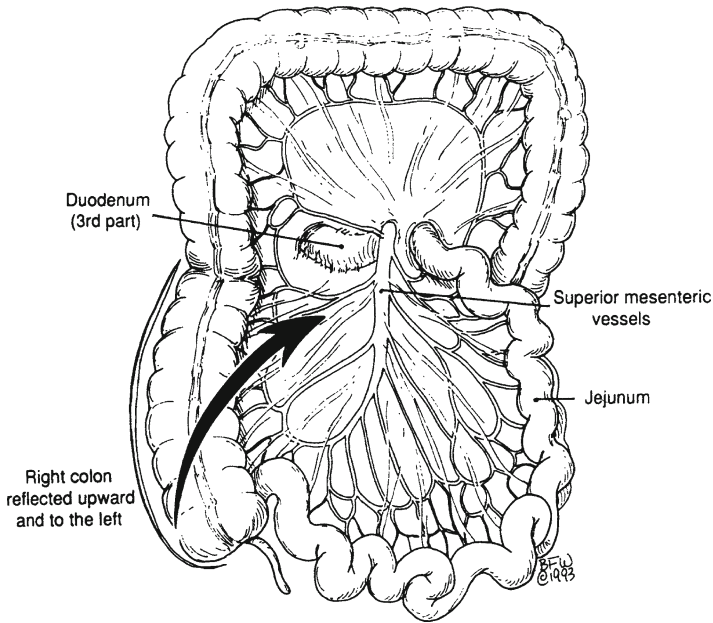


Figure 8.10. Arrow indicating medial retraction of the right colon. Note that the superior mesenteric vein is not identified.

- An incision through the transverse mesocolon or the gastrocolic omentum or reflection of the right half of the colon exposes the third portion of the duodenum, proximal to the superior mesenteric vessels; this is the Cattell maneuver (Fig. 8.10).
- Incision through the gastrocolic omentum and further reflection of the right colon provide exposure of the duodenum distal to the superior mesenteric vessels. By dividing the parietal fold just inferior to the paraduodenal fossa, the distal duodenum can be visualized. The duodenum can be further mobilized by transection of the suspensory muscle.

Surgical Notes to Remember:

- ✓ It is impossible to perform duodenectomy alone because the head of the pancreas is fixed to the duodenal loop; the only practical procedure is pancreaticoduodenectomy.
- ✓ It is important not to ligate both the superior and the inferior pancreaticoduodenal arteries. The result may be necrosis of the head of the pancreas and of a large part of the duodenum.

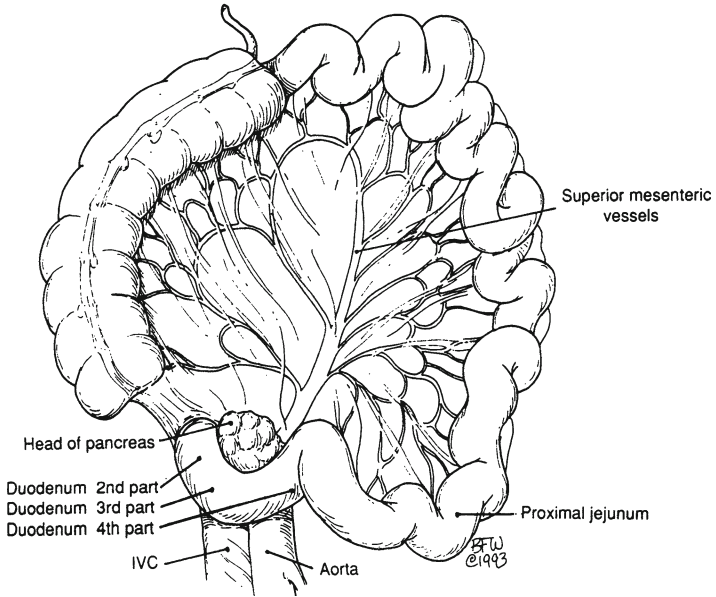


Figure 8.11. Cattell maneuver. IVC inferior vena cava.

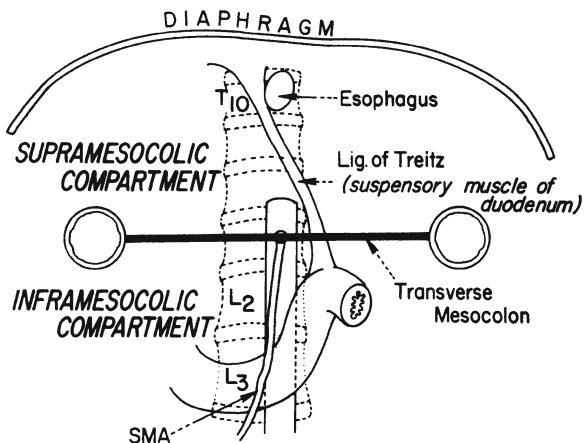
- ✓ The accessory pancreatic duct (of Santorini) passes under the gastrointestinal artery. To avoid injury to or ligation of the duct, ligate the artery away from the anterior medial duodenal wall where the papilla is located. “Water under the bridge” applies to the gastroduodenal artery and the accessory pancreatic duct as well as to the relation of the uterine artery and ureter. In 10 % of cases, the duct of Santorini is the only duct draining the pancreas; therefore, it would be catastrophic if the duct were ligated accidentally along with the gastroduodenal artery.
- ✓ No more than 2 cm of the first part of the duodenum should be skeletonized. If more is skeletonized, a duodenostomy may be necessary to avoid “blowout” of the stump secondary to poor blood supply.
- ✓ The suspensory ligament may be transected and ligated with impunity.
- ✓ When dealing with a large, penetrating posterior duodenal or pyloric ulcer, the surgeon should remember that the proximal duodenum shortens because

of the inflammatory process (duodenal shortening); the anatomical topography of the distal common bile duct as well as the opening of the duct of Santorini (the minor duodenal papilla) and the ampulla of Vater (the major duodenal papilla) is distorted; and leaving the ulcer in situ is a wise decision. Useful procedures include careful palpation or visualization of the location of the ampulla of Vater or common bile duct exploration with a catheter insertion into the common bile duct and the duodenum.

- ✓ The common bile duct, in most cases, is located to the right of the gastroduodenal artery at the posterior wall of the first portion of the duodenum. In many cases, the artery crosses the supraduodenal portion of the common bile duct anteriorly or posteriorly, a phenomenon also observed with the posterior superior pancreaticoduodenal artery, which crosses the common bile duct ventrally and dorsally.

■ REPAIR OF VASCULAR COMPRESSION OF THE DUODENUM (FIGS. 8.2, 8.11, 8.12, 8.13, 8.14, 8.15, AND 8.16)

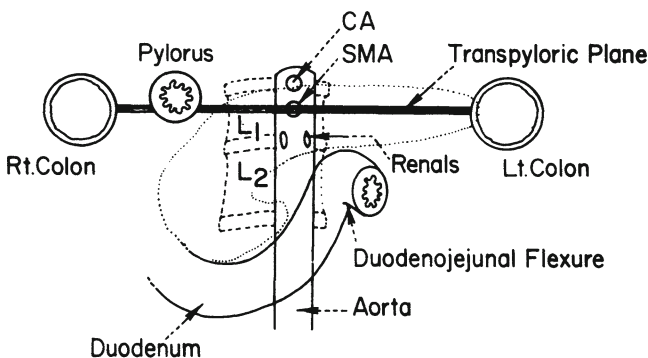
- Step 1.** Isolate, ligate, and divide the ligament of Treitz. This allows the duodenum to drop far enough for the surgeon to insert two fingers between the duodenum and the origin of the superior mesenteric artery.
- Step 2.** If the duodenum does not fall sufficiently, a duodenojejunostomy or gastrojejunostomy is the next step.



Supra and Inframesocolic Compartments

Notice the origin of lig. of Treitz and the normal location of duodenum.

Figure 8.12. Normally, the duodenum crosses the spine at the level of the third lumbar vertebra. It is suspended in this position by the ligament of Treitz. SMA superior mesenteric artery (By permission of JE Skandalakis, JT Akin, JH Milsap, et al. *Contemp Surg* 10:33-56, 1977).



Transpyloric Plane

With a little imagination the pancreas and transverse mesocolon are at the same line.

Figure 8.13. The superior mesenteric artery arises at the level of the first lumbar vertebra, between the celiac axis and the renal arteries. CA celiac artery, SMA superior mesenteric artery (By permission of JE Skandalakis, JT Akin, JH Milsap, et al. *Contemp Surg* 10:33-56, 1977).

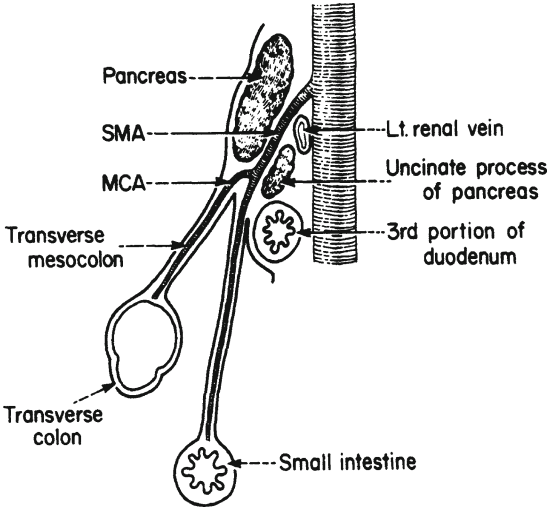


Figure 8.14. Diagrammatic sagittal section showing the duodenum between the superior mesenteric vessel and the aorta. *MCA* middle colic artery, *SMA* superior mesenteric artery (By permission of JE Skandalakis, JT Akin, JH Milsap, et al. *Contemp Surg* 10:33–56, 1977).

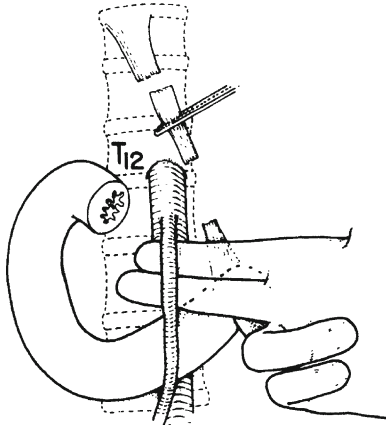


Figure 8.15. Section of the ligament of Treitz will usually allow the duodenum to drop far enough to admit two fingers between the superior mesenteric artery and the aorta (By permission of JT Akin, JH Milsap, SW Gray, et al. *Contemp Surg* 10:33–56, 1977).

360 8. Duodenum

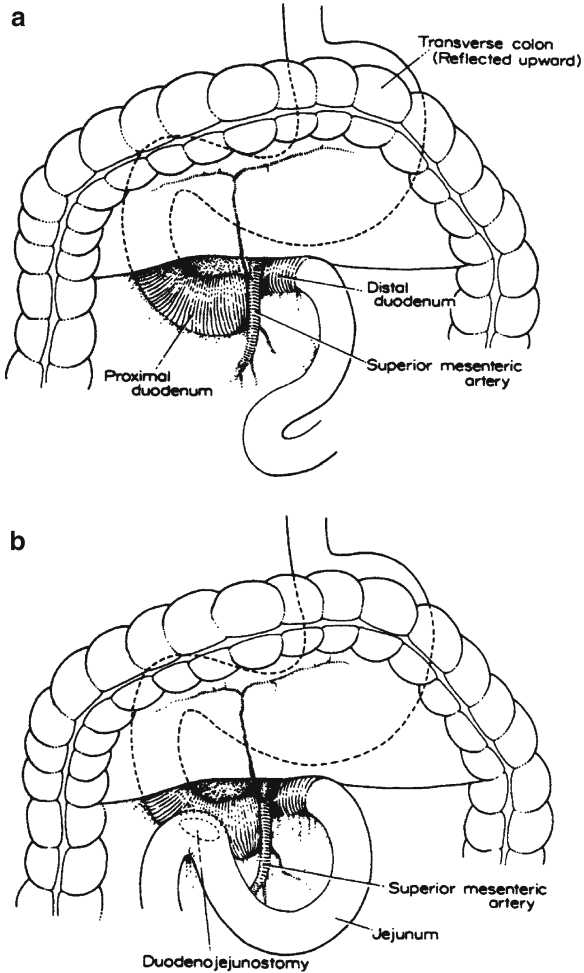


Figure 8.16. (a) Note the dilated proximal duodenum. (b) Duodenojejunostomy bypassing the obstruction (By permission of SW Gray, LJ Skandalakis, JS Rowe, et al. In: LM Nyhus and RJ Baker. *Mastery of Surgery*, 2nd ed. Boston: Little, Brown, 1992, pp. 764–772).

Pancreas

ANATOMY

■ GENERAL DESCRIPTION OF THE PANCREAS

The pancreas lies transversely in the retroperitoneal sac, between the duodenum on the right and the spleen on the left. It is related to the omental bursa above, the transverse mesocolon anteriorly, and the greater sac below. For all practical purposes, the pancreas is a fixed organ.

Anteriorly, the pancreas is related to other organs from right to left as follows (Fig. 9.1):

ABOVE: Duodenum, pylorus, liver, stomach, spleen

BELOW: Duodenum, jejunum, transverse colon, spleen

INTERMEDIATE: Transverse colon, mesocolon, transverse mesocolon, spleen

On the anterior surface of the head of the pancreas and across the duodenum, the transverse mesocolon is very short, so that the colon itself is attached to the underlying organ.

The second and third parts of the duodenum are overlapped by the head of the pancreas; therefore, there is a pancreatic “bare area” of the duodenum (Fig. 9.2) that is not covered by peritoneum. A second bare area exists on the anterior surface of the second portion of the duodenum, where the transverse colon is attached. With pancreatic cancer or pancreatitis, the pancreas and the mesocolon, together with its middle colic artery, become firmly fixed.

Posteriorly the pancreatic bed in the retroperitoneal space consists of an area between the hilum of the right kidney, the hilum of the spleen, the celiac artery,

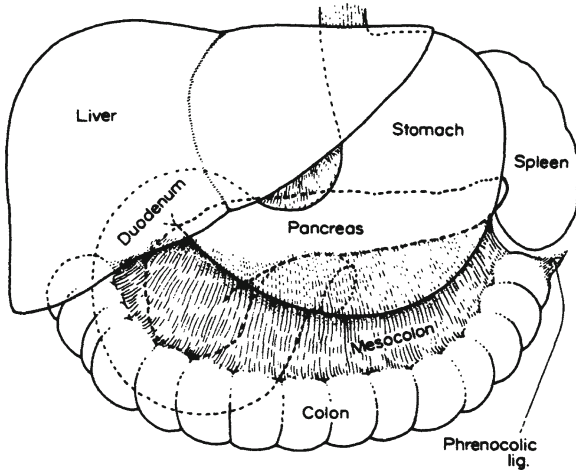


Figure 9.1. Anterior relationships of the pancreas (By permission of JE Skandalakis, SW Gray, JS Rowe, et al. *Contemp Surg.* 1979;15(5):17–40).

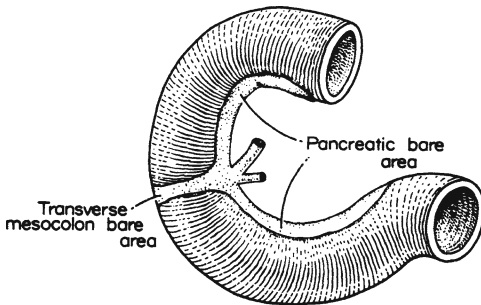


Figure 9.2. Bare areas of the duodenum. The entire concave surface is in intimate contact with the pancreas; the attachment of the transverse mesocolon crosses the anterior surface of the second portion (By permission of JE Skandalakis, SW Gray, JS Rowe, et al. *Contemp Surg.* 1979;15(5):17–40).

and the inferior mesenteric artery. From right to left, the area contains the hilum of the right kidney, the inferior vena cava, the portal vein, the superior mesenteric vein, the aorta, the left kidney, and the hilum of the spleen (Fig. 9.3).

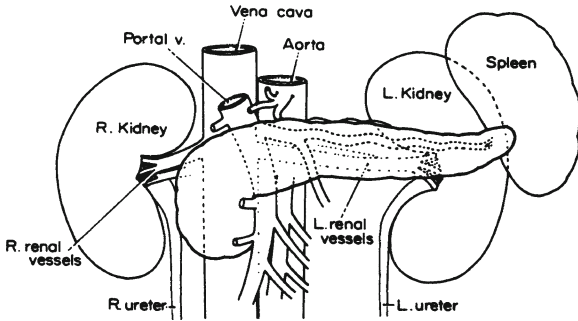


Figure 9.3. Posterior relationships of the pancreas. Anterior view (By permission of JE Skandalakis, SW Gray, JS Rowe, et al. *Contemp Surg.* 1979;15(5)17–40)

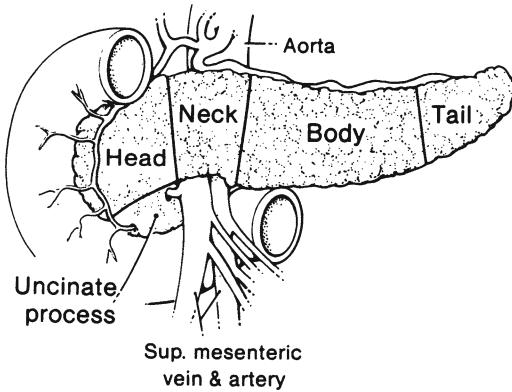


Figure 9.4. The five parts of the pancreas. The line between the body and the tail is arbitrary (By permission of JE Skandalakis, SW Gray, and JR Rowe. *Anatomical Complications in General Surgery.* New York: McGraw-Hill; 1983).

■ PARTS OF THE PANCREAS

The pancreas may be arbitrarily divided into five parts: head, uncinate process, neck, body, and tail (Fig. 9.4).

Head

The head of the pancreas is that portion lying to the right of the superior mesenteric artery and vein. The head adheres to the duodenal loop.

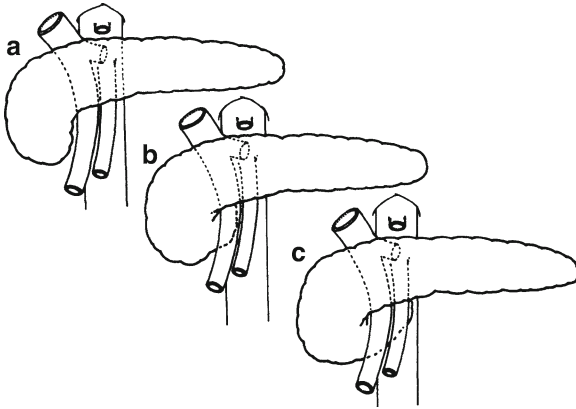


Figure 9.5. Variations in the extent of the uncinate process of the pancreas. (a) Does not reach superior mesenteric vessels. (b) Reaches across superior mesenteric vein almost to superior mesenteric artery. (c) Reaches beyond superior mesenteric artery (By permission of JE Skandalakis, SW Gray, JS Rowe, et al. *Contemp Surg.* 1979;15(5):17–40).

The anterior pancreaticoduodenal arcade can be seen upon the ventral surface of the head of the pancreas, coursing roughly parallel with the duodenal curvature. The posterior pancreaticoduodenal vascular arcade is a major entity on the posterior surface of the head. This surface is close to the hilum and medial border of the right kidney, right renal vessels and the inferior vena cava, the right crus of the diaphragm, and the right gonadal vein. The head may be related to the third part of the common bile duct in a variety of ways.

Uncinate Process

The uncinate (“hooklike”) process is an extension of the head of the pancreas and is highly variable in size and shape. It passes downward and slightly to the left from the principal part of the head. It further continues behind the superior mesenteric vessels and in front of the aorta and inferior vena cava. In sagittal section, the uncinate process lies between the aorta and the superior mesenteric artery, with the left renal vein above and the duodenum below (see Fig. 8.14).

The uncinate process may be absent or may completely encircle the superior mesenteric vessels (Fig. 9.5). If the process is well developed, the neck of the pancreas must be sectioned from the front to avoid injury to the vessels. Short vessels from the superior mesenteric artery and vein supply the uncinate process and must be carefully ligated.

Neck

The neck, from 1.5 to 2 cm in length, can be defined as the site of passage of the superior mesenteric vessels and the beginning of the portal vein dorsal to the pancreas.

The gastroduodenal artery passes to the right of the neck and provides origin for the anterior superior pancreaticoduodenal artery. Posterior to the neck, the portal vein is formed by the confluence of the superior mesenteric and splenic veins. Near the inferior margin of the pancreatic neck, one can often see the terminations of the inferior pancreaticoduodenal vein and right gastroepiploic vein where they drain into the superior mesenteric or splenic veins or into the portal vein proper.

The inferior mesenteric vein drains, with essentially equal frequency, into the splenic vein, the superior mesenteric vein, or the site of formation of the portal vein. Careful elevation of the neck and ligation of anterior tributaries, if present, are necessary. Bleeding can make it difficult to evaluate the structures lying beneath the neck.

The portal vein receives the posterior superior pancreaticoduodenal, right gastric, left gastric, and pyloric veins. It is fairly common for an anomalous vein to enter the anterior surface.

Body

The anterior surface of the body of the pancreas is covered by the double layer of peritoneum of the omental bursa that separates the stomach from the pancreas. The body is related to the transverse mesocolon, which divides into two leaves: the superior leaf covers the anterior surface and the inferior leaf passes inferior to the pancreas. The middle colic artery emerges from beneath the pancreas to travel between the leaves of the transverse mesocolon (see Fig. 8.14).

Posteriorly, the body of the pancreas is related to the aorta, the origin of the superior mesenteric artery, the left crus of the diaphragm, the left kidney and its vessels, the left adrenal gland, and the splenic vein (Fig. 9.3). Small vessels from the pancreas enter the splenic vein and, during pancreatectomy, must be ligated in order to preserve the vein and the spleen.

Tail

The tail is relatively mobile. Its tip reaches the hilum of the spleen in 50 % of cases. Together with the splenic artery and the origin of the splenic vein, the tail is contained between two layers of the splenorenal ligament.

The outer layer of this ligament is the posterior layer of the gastrosplenic ligament. Careless division of this ligament may injure the short gastric vessels. The ligament itself is almost avascular, but digital manipulation should stop at

the pedicle. Commonly a caudate branch arises from the left gastroepiploic or an inferior splenic polar branch and passes to the tip of the tail of the pancreas. Anticipate this branch in the pancreaticosplenic ligament.

■ PANCREATIC DUCTS

The main pancreatic duct (of Wirsung) and the accessory duct lie anterior to the major pancreatic vessels. Pathological ducts are readily palpated and opened from the anterior surface.

Because of the developmental origin of the two pancreatic ducts, several variations are encountered; most can be considered normal. The usual configuration is seen in Fig. 9.6a:

- Both ducts open into the duodenum (Fig. 9.6a).
- The duct of Wirsung carries the entire secretion; the duct of Santorini ends blindly (Fig. 9.6b).
- The duct of Santorini carries the entire secretion; the duct of Wirsung is small or absent (Fig. 9.6c).

The greatest diameter of the main pancreatic duct is in the head of the pancreas, just before the duct enters the duodenal wall.

Less than 3 ml of contrast medium will fill the main pancreatic duct in the living patient, and 7–10 ml will fill the branches and the smaller ducts.

Duodenal Papilla

The duodenal papilla (of Vater) lies at the end of the intramural portion of the common bile duct. It is on the posteromedial wall of the second part of the duodenum, to the right of the second or third lumbar vertebra in most cases. On endoscopy, the papilla was found to the right of the spine at the level of the second lumbar vertebra in most patients. The distance of the papilla from the pylorus is highly variable, ranging from 1.5 to 12 cm. Inflammation of the proximal duodenum may shorten the distance; the pylorus is not a useful landmark.

The present concept of musculature is that there is a complex of four sphincters composed of circular or spiral smooth muscle fibers surrounding the intramural portion of the common bile and pancreatic ducts. The complex may be broken into four separate sphincters, as shown in Fig. 9.7.

The sphincteric complex varies from 6 to 30 mm in length, depending on the obliquity of the ducts. In some individuals, the complex may extend into the pancreatic portion of the common bile duct. This is important to know, because complete anatomical transection of all elements of the complex may not be necessary for satisfactory function. Incision by 5-mm steps while testing with a suitable dilator will help limit the incision to the shortest length necessary to obtain the desired results. On the mucosal surface of the duodenum, the

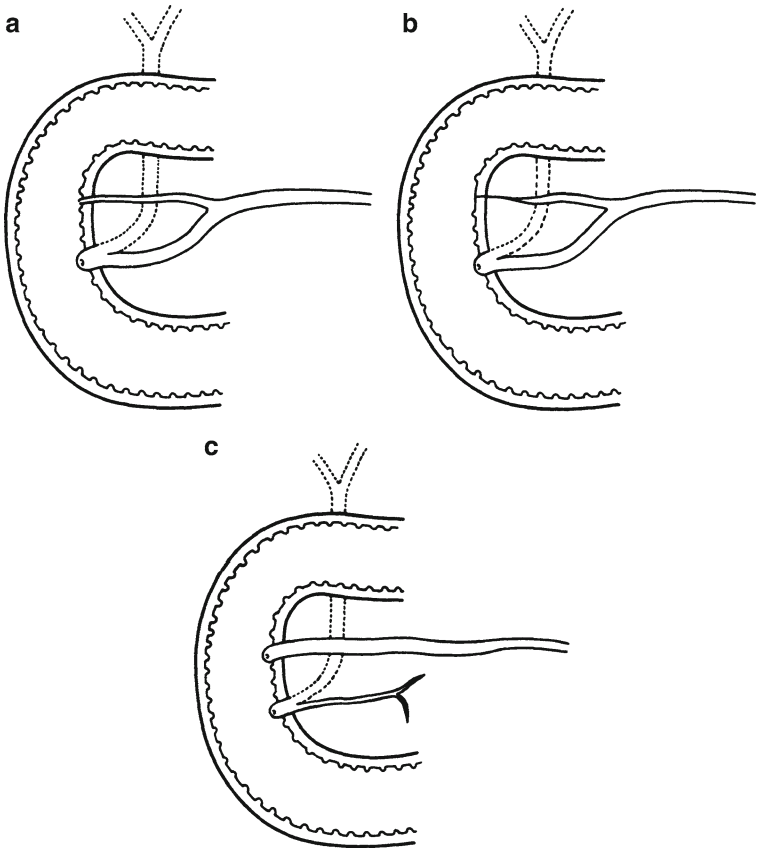


Figure 9.6. Variations of the pancreatic ducts. (a) Both ducts open into the duodenum. (b) The accessory duct ends blindly in the duodenal wall. (c) The main duct is smaller than the accessory duct and they are not connected (modified by permission of JE Skandalakis, SW Gray, JS Rowe, et al. *Contemp Surg.* 1979;15(5):17–40).

duodenal papilla of Vater is found where a longitudinal mucosal fold meets a transverse fold to form a T (Fig. 9.8).

These are some practical considerations:

- Too much lateral or distal traction on the opened duodenum may erase the folds and distort the T.
- The papilla is often covered by a transverse fold. One must gently elevate the folds in the assumed location.

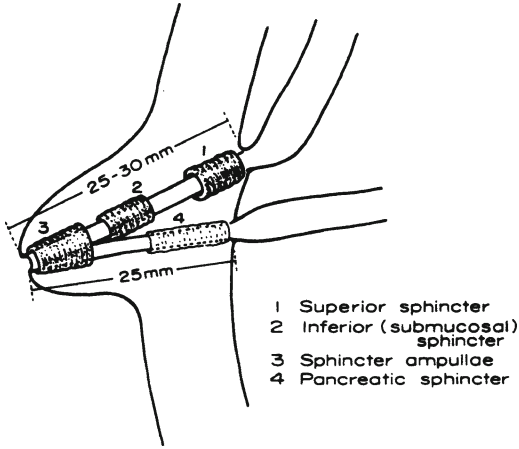


Figure 9.7. Diagram of the four entities composing the sphincter of Boyden (measurements from White TT. *Surgical anatomy of the pancreas*. In: Carey LC (ed). *The Pancreas*. St Louis: CV Mosby Co; 1973) (By permission of JE Skandalakis, SW Gray, JS Rowe, et al. *Contemp Surg*. 1979;15(5):17-40).

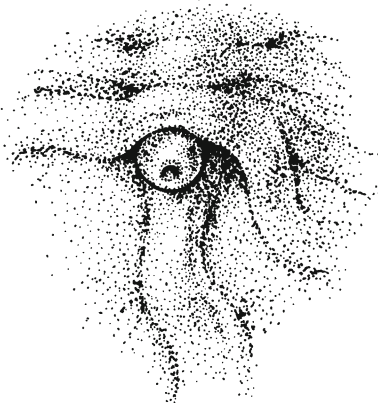


Figure 9.8. The T arrangement of mucosal folds of the duodenum indicates the site of the major duodenal papilla. Mucosal fold may cover orifice of papilla in some cases. Major papilla is rarely this obvious (By permission of JE Skandalakis, SW Gray, JS Rowe, et al. *Contemp Surg*. 1979;15(5):17-40).

- If the T is not apparent and the papilla cannot be palpated, the common bile duct must be probed from above.
- A duodenal diverticulum lying close to the papilla may present difficulties for the surgeon or the endoscopist. The papilla has been found in a

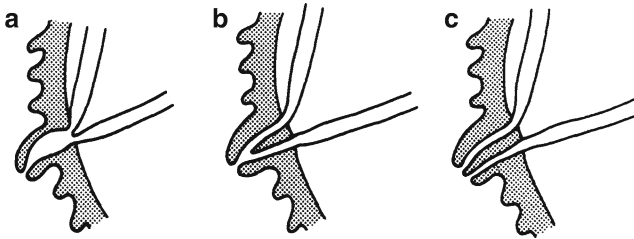


Figure 9.9. Diagram of the relations of the pancreatic and common bile ducts. (a) Minimal embryonic absorption of the ducts into the duodenal wall; an ampulla is present. (b) Partial embryonic resorption of the ducts; no true ampulla is present. (c) Maximum embryonic resorption of the ducts; two separate orifices open on the papilla (By permission of JE Skandalakis, SW Gray, JS Rowe, et al. *Contemp Surg.* 1979;15(5):17–40).

diverticulum; it separated from the duodenal wall and was immediately reimplanted.

The ampulla is the common pancreaticobiliary channel below the junction of the ducts within the papilla (Fig. 9.9a). If the septum between the ducts extends to the orifice of the papilla, there is no ampulla.

The most useful classification is as follows:

- Type 1.** The pancreatic duct opens into the common bile duct at a variable distance from the orifice of the major duodenal papilla. The common channel may or may not be dilated (85 %) (Fig. 9.9a, b).
- Type 2.** The pancreatic and common bile ducts open separately on the major duodenal papilla (5 %) (Fig. 9.9c).
- Type 3.** The pancreatic and common bile ducts open into the duodenum at separate points (9 %).

■ VASCULAR SYSTEM OF THE PANCREAS

The vascular system of the pancreas is complex and nontypical. Nevertheless, a “general plan” is shown in the previous chapter in Figs. 8.4 and 8.5; remember that variations are common. The pancreas is supplied with blood from both the celiac trunk and the superior mesenteric artery.

In general, it appears that the blood supply is greatest to the head of the pancreas, less to the body and tail, and least to the neck. The head of the pancreas and the concave surface of the duodenum are supplied by two pancreaticoduodenal arterial arcades (anterior and posterior). Ligation of both vessels will result in duodenal ischemia and necrosis. All major arteries lie posterior to the ducts.

370 9. Pancreas

Pancreatic Arcades

The gastroduodenal artery divides to form the anterior superior and posterior superior pancreaticoduodenal arteries.

The anterior inferior pancreaticoduodenal artery arises from the superior mesenteric artery at or above the inferior margin of the pancreatic neck. It may form a common trunk with the posterior inferior artery. Ligation of the jejunal branch itself will endanger the blood supply to the fourth part of the duodenum.

Dorsal Pancreatic Arcade

The dorsal pancreatic arcade lies posterior to the neck of the pancreas and, often, posterior to the splenic vein.

Transverse Pancreatic Artery

The transverse (inferior) pancreatic artery is the left branch of the dorsal pancreatic artery, and it supplies the body and tail of the pancreas.

Branches of the Splenic Artery

The splenic artery is located on the posterior surface of the body and tail of the pancreas (see Fig. 8.5). From 2 to 10 branches of the splenic artery anastomose with the transverse pancreatic artery. The largest of these, the great pancreatic artery (of von Haller), is the main blood supply to the tail of the pancreas. Ligation of the splenic artery does not require splenectomy, but ligation of the splenic vein does.

Caudal Pancreatic Artery

The caudal pancreatic artery arises from the left gastroepiploic artery or from a splenic branch at the hilum of the spleen.

Venous Drainage

In general, the veins of the pancreas parallel the arteries and lie superficial to them. Both lie posterior to the ducts in the body and tail of the pancreas. The drainage is to the portal vein, splenic vein, and superior and inferior mesenteric veins (see Figs. 8.6 and 8.7).

The hepatic portal vein is formed behind the neck of the pancreas by the union of the superior mesenteric and splenic veins (see Fig. 8.7).

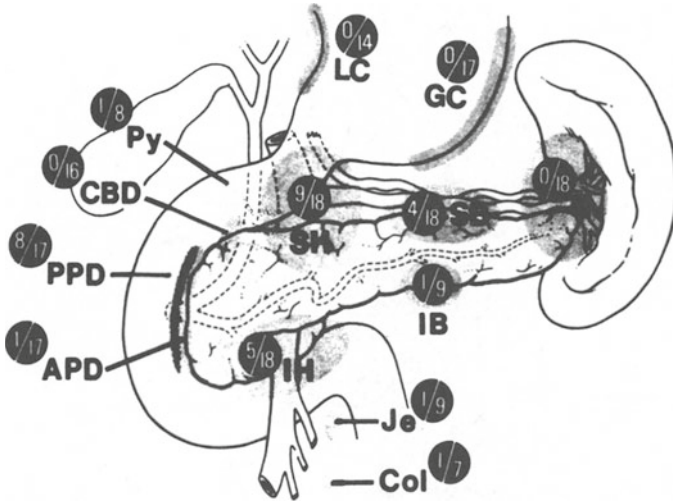


Figure 9.10. Chief groups of lymph nodes receiving lymphatic vessels from the pancreas. *SH* superior head, *IH* inferior head, *PPD* posterior pancreaticoduodenal, *APD* anterior pancreaticoduodenal, *SB* superior body, *IB* inferior body, *S* splenic, *GC* greater curvature, *LC* lesser curvature, *Py* pylorus, *CBD* common bile duct, *Je* jejunum, *Col* colon. In the Whipple resection (indicated by the stippled vertical line), the *SB*, *IB*, and *S* groups usually are not removed. From AL Cubilla, PJ Fitzgerald. Cancer of the exocrine pancreas: The pathologic aspects. *CA Cancer J Clin.* 1985;35(1):2–18. Reprinted with permission from Wiley.

The portal vein lies behind the pancreas and in front of the inferior vena cava, with the common bile duct on the right and the common hepatic artery on the left.

Lymphatic Drainage

Figure 9.10 shows the chief groups of lymph nodes receiving lymphatic vessels from the pancreas. Lymphatic drainage may prove to be as complex and nontypical as the arterial supply.

■ NERVE SUPPLY OF THE PANCREAS

Innervation of the pancreas occurs by the sympathetic division of the autonomic nervous system through the splanchnic nerves and by the parasympathetic division through the vagus nerve. In general, these nerves follow blood vessels to their destinations.

The celiac ganglion is the central station of both sympathetic and parasympathetic innervation. Extirpation—surgical or chemical—of the celiac ganglion should interrupt afferent fibers of both sympathetic and parasympathetic systems.

■ ECTOPIC AND ACCESSORY PANCREAS

Pancreatic tissue in the stomach, duodenal wall, ileal wall, Meckel’s diverticulum, or at the umbilicus is not unusual. Less common sites are the colon, appendix, gallbladder, omentum or mesentery, and in anomalous bronchoesophageal fistula. Most such pancreatic tissue is functional. Islet tissue is often present in gastric and duodenal heterotopia, but it is usually absent in accessory pancreatic tissue elsewhere in the body. Figure 9.11 shows the possible sites of heterotopic pancreatic tissue.

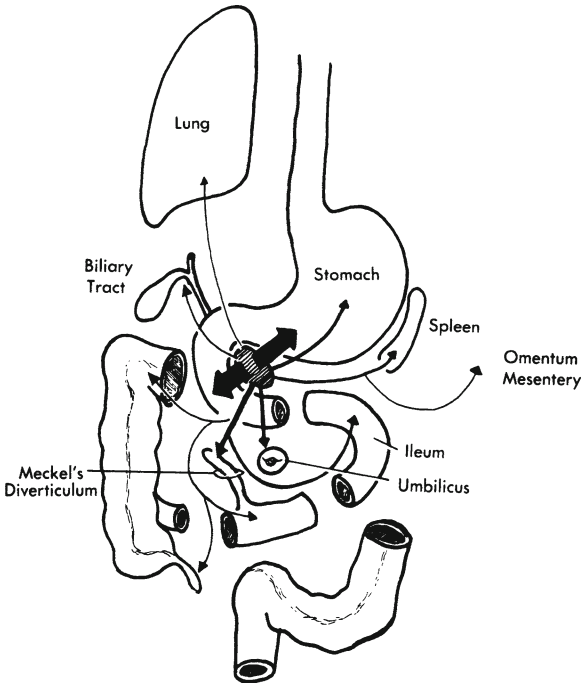


Figure 9.11. Sites of pancreatic heterotopia. The relative frequency is indicated by the width of the arrows. The stomach and duodenum are by far the most common sites (By permission of JE Skandalakis, SW Gray, RR Ricketts, et al. The pancreas. In JE Skandalakis and SW Gray. Embryology for Surgeons. 2nd ed. Baltimore: Williams & Wilkins, 1994).

TECHNIQUE

■ EVALUATION OF RESECTABILITY OF THE PANCREAS

The authors strongly advise angiograms prior to surgery. Also, we suggest the following steps in the operating room:

1. Good general exploration of the abdomen with special attention to the pancreas.
2. Attention to specific areas of lymph node drainage that are accessible without further incision. These are the pyloric and pancreaticoduodenal nodes and the nodes at the root of the mesentery (Fig. 9.10).
3. Further investigation of lymph nodes, which requires some incision of the hepatogastric omenta. This will also require a Kocher maneuver. Inspect the pancreaticoduodenal, celiac, and left gastric nodes, together with nodes of the superior and inferior pancreatic borders.
4. Assuming that the diagnosis of cancer has been determined and that the exploration outlined above has indicated a resectable lesion, these final steps should be undertaken before the start of the actual resection:
 - a. Further exploration of the area of the muscle of Treitz to ensure mobility of the fourth part of the duodenum and the first portion of the jejunum.
 - b. Evaluation of the posterior surface of the head of the pancreas and the distal common bile duct to ensure that there is no fixation to underlying structures, including the inferior vena cava.
 - c. Gentle examination of the uncinate process and elevation of the neck of the pancreas with one or two fingers to ensure that they are not fixed to the superior mesenteric vessels or to the portal vein.
 - d. Final review of the local anatomy to identify any previously undetected vascular anomalies. Any available angiograms should be studied.

■ EXPLORATION OF THE PANCREAS

There are several possible routes to exploration of the pancreas, which may be used individually or in combination, each with particular advantages and disadvantages:

- Through the gastrocolic ligament. This is the route used by most surgeons.
- Through the hepatogastric omentum. This is useful in patients with exceptionally ptotic stomachs.

- Detaching the greater omentum from the transverse colon. This is time consuming, but it gives better visualization of the entire lesser sac.
- Through the mesocolon. This gives only limited exposure of the pancreas and risks injury to the middle colic blood vessels.
- Kocher maneuver. This provides good exposure of the posterior surface of the head of the pancreas.
- Mobilizing the splenic flexure, the spleen, and tail of the pancreas. This is appropriate when partial pancreatectomy and splenectomy or splenic preservation are seriously contemplated.

■ PUESTOW PROCEDURE

PRIOR TO SURGERY: Endoscopic retrograde cholangiopancreatography; bowel preparation.

POSITION: Supine.

ANESTHESIA: General.

OTHER: Insert nasogastric tube and Foley catheter.

- Step 1.** To enter the lesser sac, divide the gastrocolic ligament using clamps and ligate the vessels (Fig. 9.12).
- Step 2.** Kocherize the duodenum. Perform detailed palpation of the pancreas. Visualize and palpate the dilated pancreatic duct that snakes obviously at the anterior surface of the pancreas.

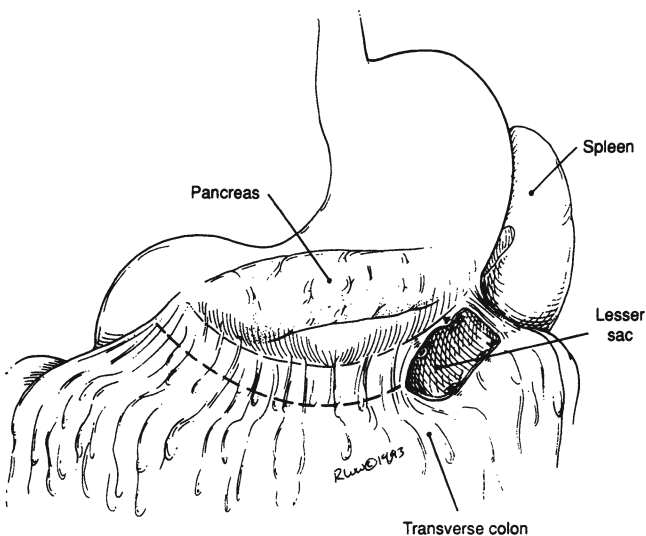


Figure 9.12. Exposure of lesser sac.

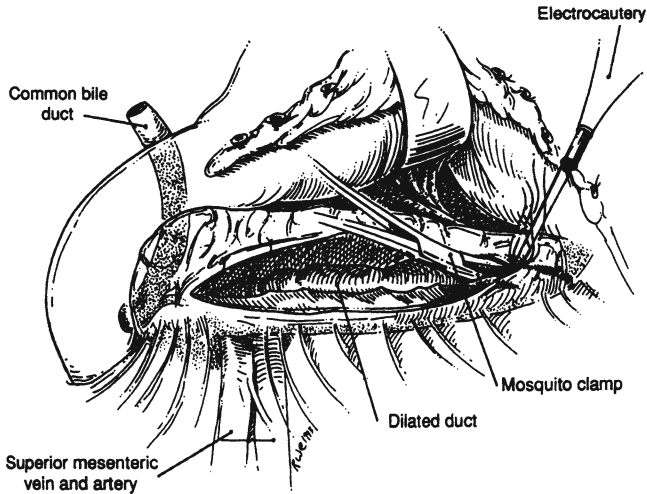


Figure 9.13. Incision with electrocautery.

- Step 3.** Using an 18-gauge needle, aspirate the pancreatic duct with a syringe. Incise the pancreatic duct enough to insert a small, right-angle, curved mosquito clamp into the lumen of the duct. Incise along its length with electrocautery. The pancreatic incision should be 6–8 cm or more if there is ductal dilatation at the head of the pancreas with formation of pancreatic lakes (Fig. 9.13).
- Step 4.** Locate the ligament of Treitz and transect a loop of jejunum approximately 30 cm from it. Ligate the mesenteric vessels. Divide the jejunum with a gastrointestinal anastomosis (GIA) stapler (Fig. 9.14).
- Step 5.** Elevate the transverse colon and incise an avascular area of the transverse mesocolon to permit the previously closed distal jejunal limb (Roux-en-Y) to pass into the lesser sac (Fig. 9.15).
- Step 6.** Perform a side-to-side pancreaticojejunostomy by placing interrupted 3–0 silk sutures between the seromuscular layer of jejunum and the pancreatic capsule (Figs. 9.15, 9.16, and 9.17). A running suture is acceptable.
- Step 7.** Suture the jejunal loop to the edges of the opening of the transverse mesocolon with a few 4–0 silk sutures (Fig. 9.17).
- Step 8.** Create the jejunojejunostomy by anastomosing the proximal jejunal segment to the Roux-en-Y in an end-to-side fashion, approximately

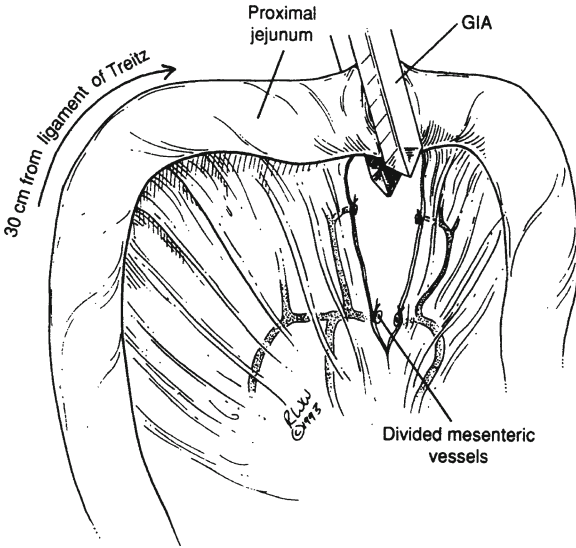


Figure 9.14. Division of jejunum.

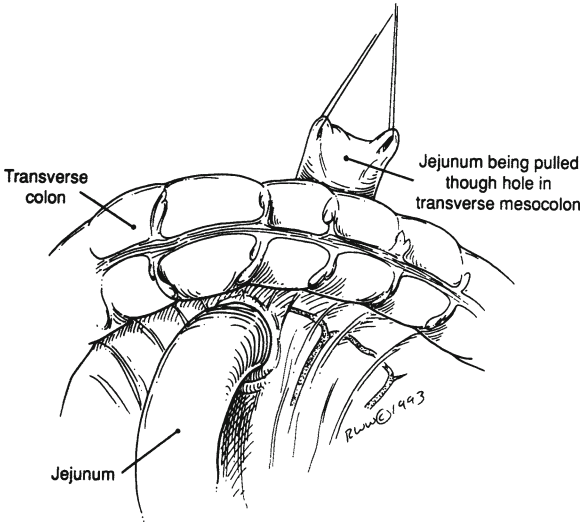


Figure 9.15. Incision of transverse mesocolon.

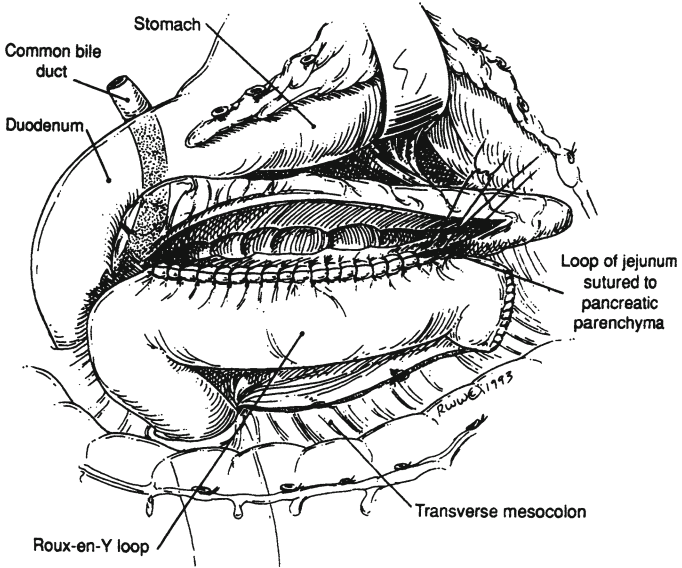


Figure 9.16. Side-to-side pancreaticojejunostomy.

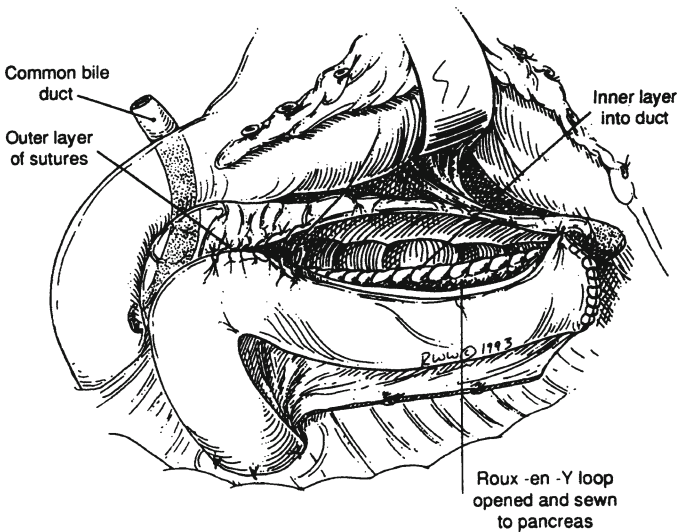


Figure 9.17. Jejunal loop is sutured.

45 cm distal to the pancreaticojejunostomy. The anastomosis is done in standard two-layer fashion (Fig. 9.18).

Step 9. Figure 9.19 shows the completed anastomoses. Perform cholecystectomy, insert Jackson–Pratt drain, and close in layers.

Note:

- ✓ The pancreaticojejunostomy is not a mucosa-to-mucosa anastomosis.

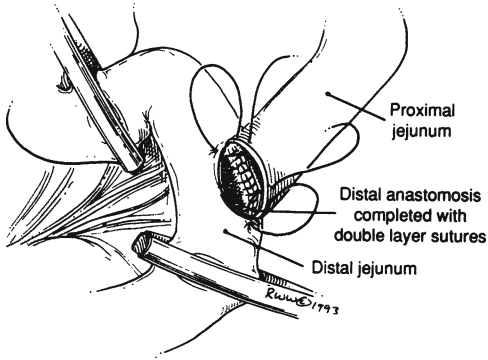


Figure 9.18. Jejunojunction.

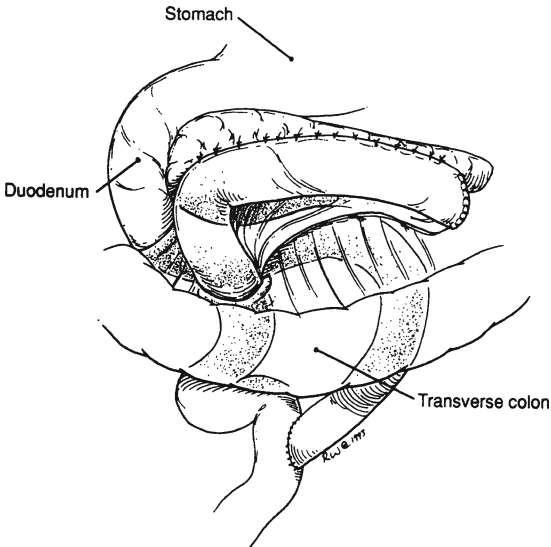


Figure 9.19. Completion of Puestow procedure.

■ PANCREATECTOMIES

Embryologically, anatomically, and surgically, the head of the pancreas, the common bile duct, and the duodenum form an inseparable unit. Their relations and blood supply make it impossible for the surgeon to remove completely the head of the pancreas without removing the duodenum and the distal part of the common bile duct. The only alternative procedure, the so-called 95 % pancreatectomy, leaves a rim of pancreas along the medial border of the duodenum to preserve the duodenal blood supply.

Ninety-Five Percent Distal Pancreatectomy for Chronic Pancreatitis

In spite of the procedure's name, far more than 5 percent of the pancreas usually remains after performing 95 % distal pancreatectomy (orientation: Fig. 9.20). The percentage depends on the size of the head and the presence or lack of the uncinate process.

- Step 1.** Explore and intubate the common bile duct and perform cholecystectomy.
- Step 2.** Mobilize the head, uncinate process, body, and tail of the pancreas. The uncinate process should be treated carefully if present. Care must also be taken with the following vessels: splenic artery, splenic vein, superior mesenteric vein, and tributaries. Using 4–0 silk, carefully ligate small veins without traction. Mobilize the neck by dis-

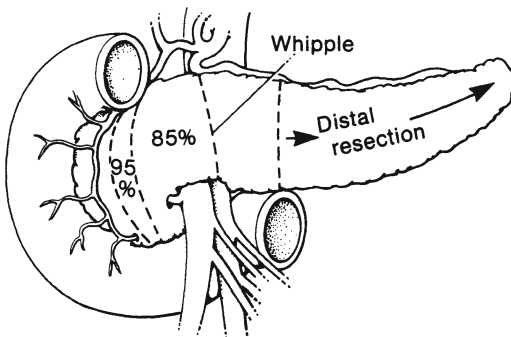


Figure 9.20. Partial pancreatectomy: 95 % pancreatectomy; 85 % pancreatectomy; Whipple procedure; distal pancreatectomy. Distal pancreatectomy includes resection from any point between 4 and 5 to the tip of the tail (By permission of JE Skandalakis, SW Gray, and JR Rowe. *Anatomical Complications in General Surgery*. New York: McGraw-Hill; 1983).

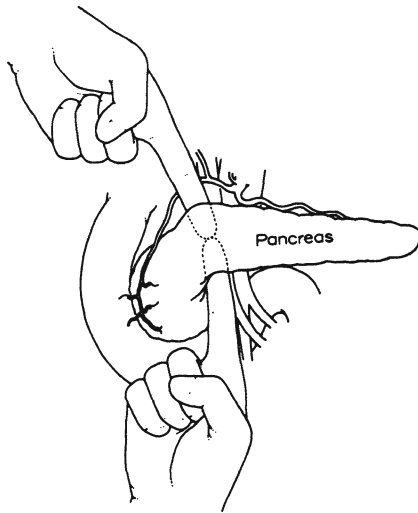


Figure 9.21. Exploration of the pancreas. The surgeon's index fingers are passed behind the neck of the pancreas. The neck should separate easily from the underlying vessels (By permission of JE Skandalakis, SW Gray, JS Rowe, et al. *Contemp Surg.* 1979;15(6):21–50).

secting bluntly with the index fingers between the posterior surface of the pancreas and the underlying superior mesenteric vessels (Fig. 9.21).

- Step 3.** Using electrocautery, divide the head of the pancreas from the remaining gland very close to the duodenal loop (Fig. 9.22). For the duodenum and thin pancreatic rim to survive, it is very important to protect the superior and inferior pancreaticoduodenal arteries. One of these vessels can provide sufficient blood, so if the other is accidentally injured and ligated, no harm results; but *do not ligate both*. Palpate and preserve the third and fourth portions of the common bile duct.
- Step 4.** Identify the divided pancreatic duct and close it with a mattress suture of 4–0 nonabsorbable material. Doubly ligate the splenic artery, the splenic vein, and their tributaries, and perform splenectomy (Figs. 9.23, 9.24, 9.25, and 9.26). Remove specimen consisting of distal pancreas and spleen.
- Step 5.** Insert Jackson–Pratt drain, and close the abdominal wall in layers.

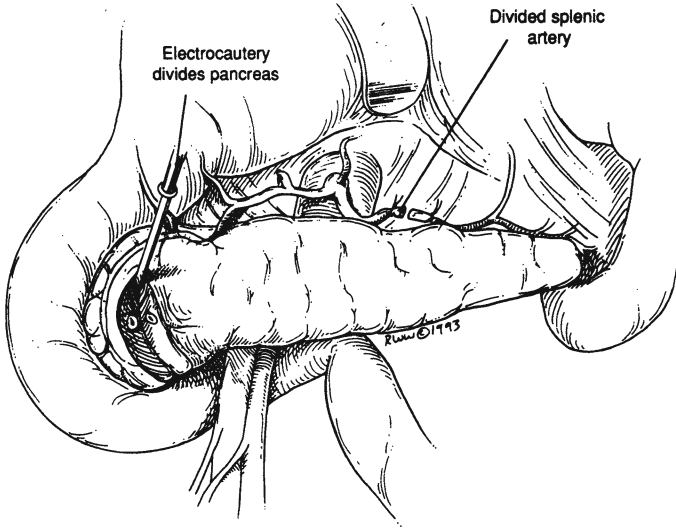


Figure 9.22. Division of head of pancreas.

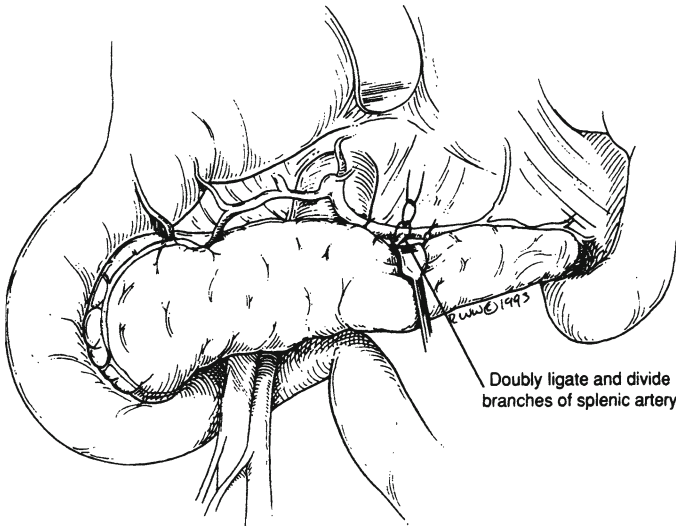


Figure 9.23. Preparation for splenectomy.

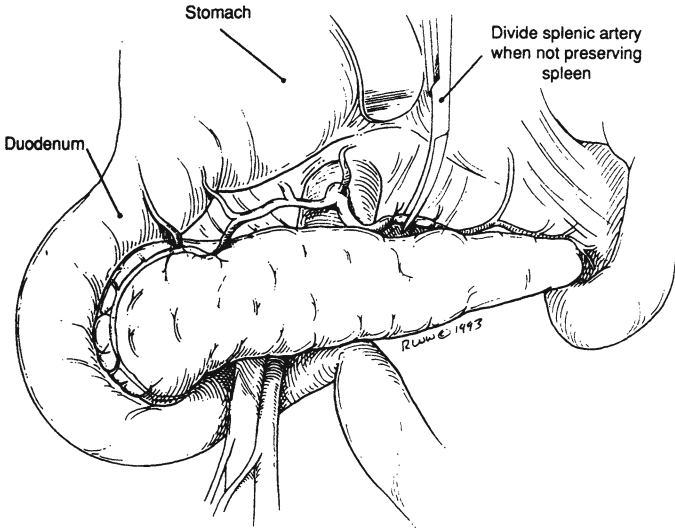


Figure 9.24. Division of splenic artery.

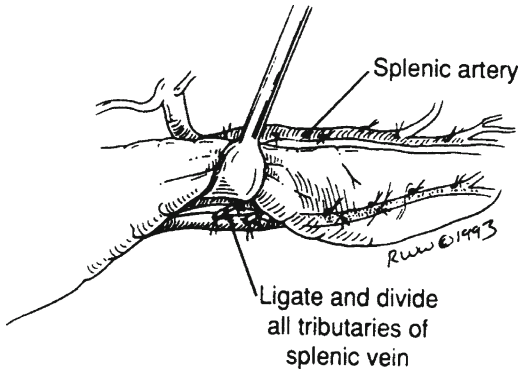


Figure 9.25. Preparing splenic vein tributaries.

Distal Pancreatectomy (with or Without Splenectomy)

For orientation see Fig. 9.12. Keep in mind all the technical steps of the previously discussed pancreatic procedures when performing the following:

- Step 1.** Transect the pancreas approximately where it crosses the portal vein (Fig. 9.27).
- Step 2.** Create a Roux-en-Y loop by anastomosing the pancreatic head or part of the remaining body by invagination to a divided jejunal loop

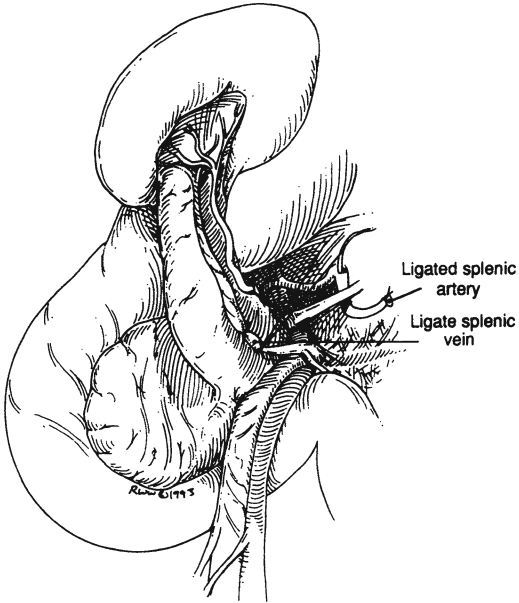


Figure 9.26. The ligated vessels.

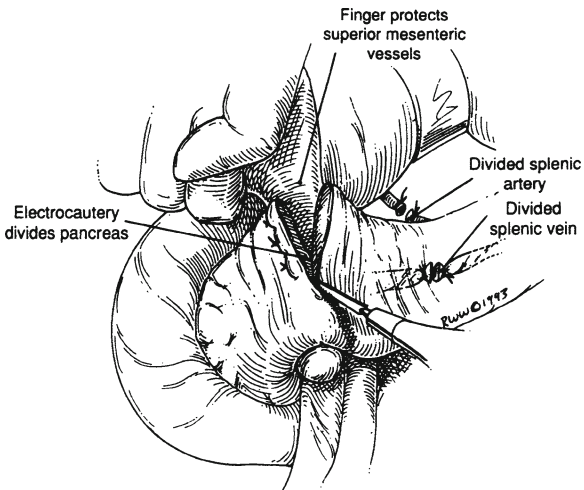


Figure 9.27. Transection of pancreas.

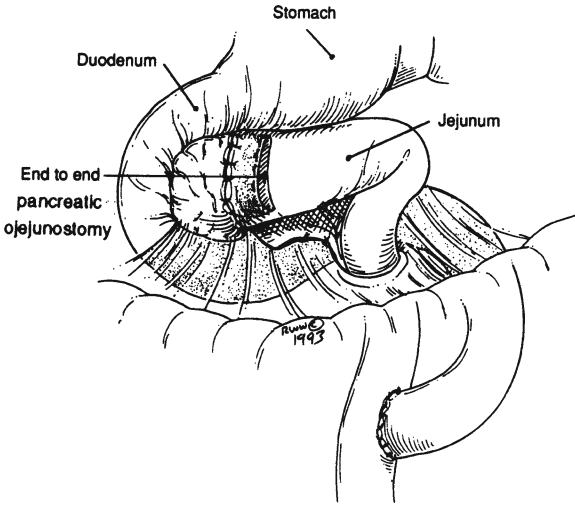


Figure 9.28. End-to-end pancreaticojejunostomy.

approximately 45 cm from the ligament of Treitz (as described in step 11 of the procedure for pancreaticoduodenectomy, below) using an end-to-end pancreaticojejunostomy. Fashion an end-to-side jejunojunction (Fig. 9.28), producing continuity of the gastrointestinal tract plus a defunctionalized limb of approximately 60 cm.

Note:

- ✓ An alternative method is to oversew the pancreas and drain the area.

Total Pancreatectomy (with or without Splenectomy)

- Step 1.** The pancreas is not divided; therefore, there is no pancreaticojejunostomy. Remove both the spleen and the pancreaticoduodenal duo in continuity.
- Step 2.** With 3-0 silk, carefully ligate all arterial or venous branches connecting the spleen, pancreas, and duodenum. These vascular collections are totally unpredictable and the surgeon should be careful to avoid traction. Occasionally a splenopancreatic ligament is present and should be ligated close to the pancreas.

Pancreaticoduodenectomy

Whipple Procedure

There are many modifications of the Whipple procedure. To present all of them step by step is beyond the scope of this book. We present our technique below.

The specimen of a typical Whipple operation includes:

- Distal stomach
- Duodenum
- Part of the proximal jejunum
- Head, neck, and uncinete process of the pancreas
- Distal biliary tree (distal common hepatic duct, gallbladder, common bile duct).

Note:

- ✓ The biliary duct resection depends on the extension of the tumor and the insertion of the cystic duct.

PREPARATION PRIOR TO SURGERY: (1) Celiac and superior mesenteric artery arteriography may be useful. Have the films in the operating room. (2) Antibiotics: both prior to and during surgery. (3) Bowel preparation.

INDICATIONS: (1) Pancreatic malignancy. (2) Duodenal malignancy. (3) Distal common bile duct malignancy.

POSITION: Supine.

ANESTHESIA: General.

Step 1. Make a bilateral subcostal or long midline incision.

Step 2. General exploration, the last evaluation being the pancreaticoduodenal area including hepatogastroduodenal ligament and celiac axis.

Step 3. Duodenal mobilization by good Kocherization and elevation of the duodenopancreatic duo from the retroperitoneal space and the great vessels. The gastocolic ligament may be divided now or later, and the lesser sac should be explored.

Step 4. Identify elements of the hepatic triad:

- Common bile duct
- Portal vein: medial to the common bile duct. (Dissection of the portal vein is facilitated by dividing the gastroduodenal artery.)
- Hepatic artery: medial to the portal vein
- Identify, also, the superior mesenteric vein by blunt and sharp dissection, since no venous branches are inserted into the anterior surface of the superior mesenteric vein. The dissection of the superior mesenteric vein can be started at the inferior border of the pancreas.

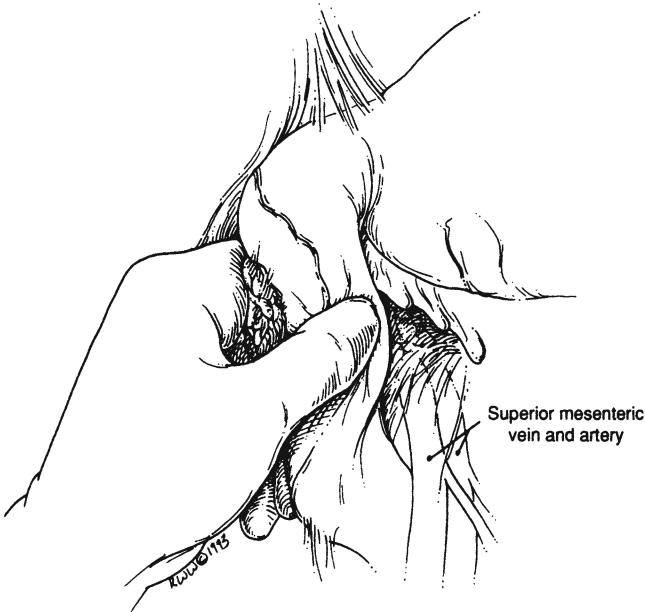


Figure 9.29. Protecting the head of the pancreas.

- If both the portal vein and the superior mesenteric vein are fixed, this means tumor involvement, unresectability, and, perhaps, the possibility of a bypass procedure.
- Continue with the following two procedures:
 - a. Duodenal Kocherization and insertion of the index finger under the head of the pancreas, the distal phalanx reaching the great vessels (Fig. 9.29).
 - b. Dissection of the portal vein at the superior and inferior borders of the pancreas. The surgeon should be able to approximate both index fingers as indicated in Fig. 9.21.
- Good separation by both procedures of the duodenum and pancreas means resectability. If a transduodenal-pancreatic biopsy is being considered, this may be a good time to do it.

Step 5. As in distal gastrectomy, divide lesser and greater omentum. Apply TA-90 stapler just proximal to antrum and divide stomach.

Step 6. Arterial steps: If the anatomy is typical and orthodox and no replacing right hepatic artery is present, localize, isolate, ligate, and divide the gastroduodenal artery close to its origin from the hepatic artery. Do the same to the right gastroepiploic artery (see Fig. 7.3).

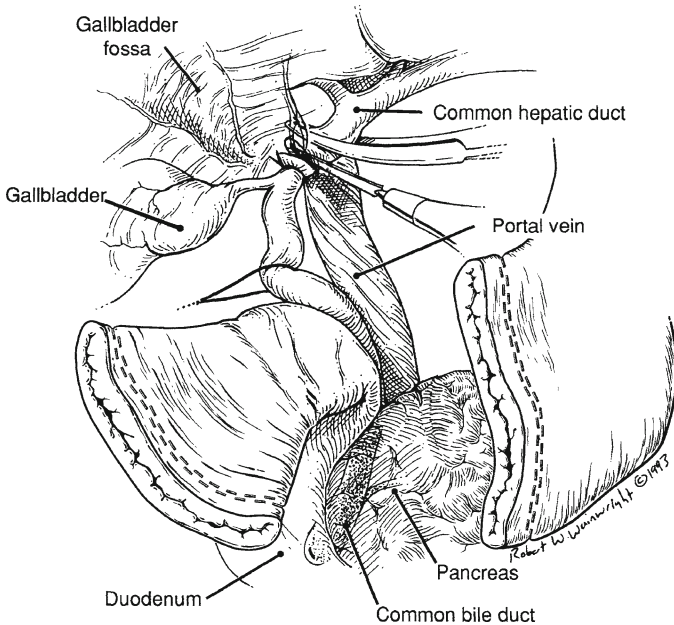


Figure 9.30. Preparing the common hepatic duct.

- Step 7. Biliary steps:** Mobilize the gallbladder. Localize, isolate, divide, and clamp the common hepatic duct with a small noncrushing clamp proximally and a small mosquito clamp distally, just above the exodus of the cystic duct or in that vicinity. Divide the common hepatic duct and ligate with 3-0 silk close to the cystic duct (Fig. 9.30).
- Step 8. Pancreaticoduodenectomy steps:** After total exposure of the superior mesenteric vein, and with the left index finger under the neck of the pancreas, divide the pancreatic parenchyma using electrocautery (Fig. 9.31). Ligate the small veins and arteries. Shave the remaining distal pancreas and send the specimen to the lab for frozen section.
- Step 9.** Localize the ligament of Treitz in the paraduodenal fossae. Using the GIA stapler, divide the jejunum approximately 10–12.5 cm distal to the ligament of Treitz. Be careful not to injure the inferior mesenteric vein, which is located to the left of the paraduodenal fossae. Clamp, divide, and ligate the mesentery at the mesenteric border of the proximal jejunal limb. With careful digital elevation of the proximal jejunum and fourth and third portions of the duodenum, push the jejunal loop gently under the vessels and to the right (Fig. 9.32).
- Step 10.** If the uncinate process is still attached and if the uncinate process ligament is present, it should be divided between clamps, and the

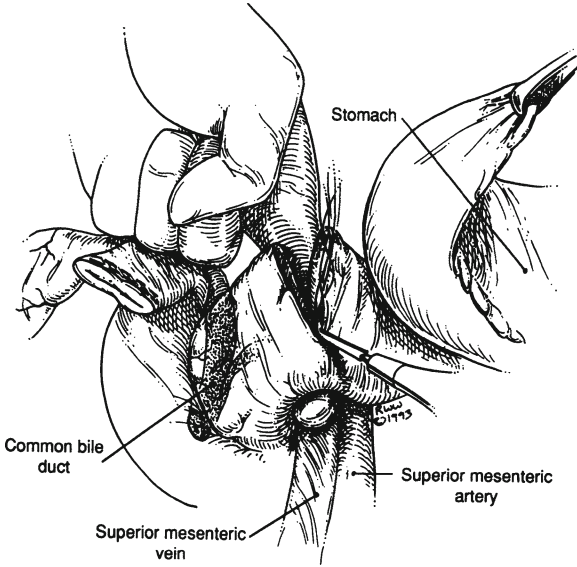


Figure 9.31. Division of parenchyma.

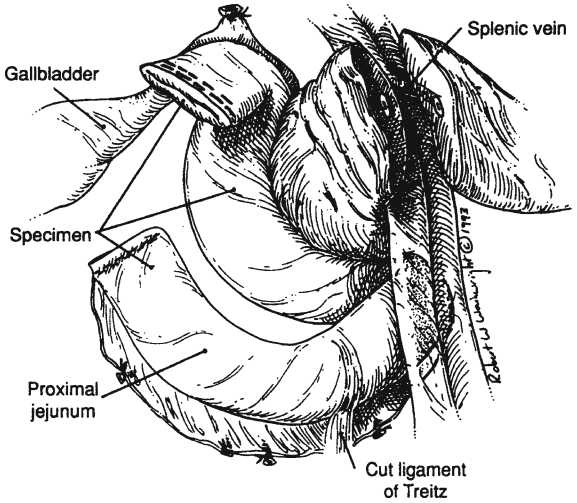


Figure 9.32. Specimen is harvested.

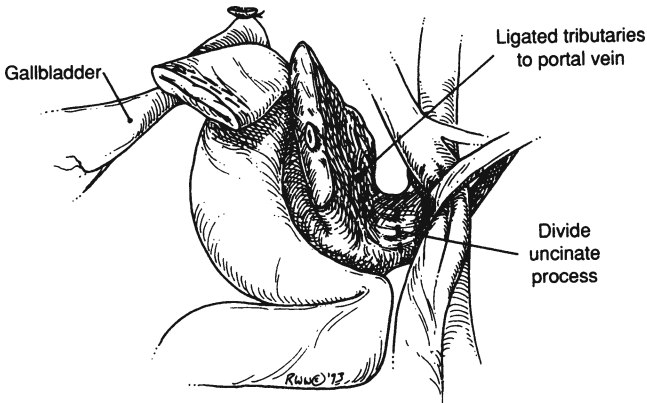


Figure 9.33. Division of uncinat process.

distal part should be ligated (Fig. 9.33). Carefully dissect the uncinat process from the portal vein and the superior mesenteric vein. Send the specimen to the lab for more frozen sections.

Step 11. The anastomoses to be formed: pancreaticojejunostomy, hepatojejunostomy (choledochojejunostomy), gastrojejunostomy (Figs. 9.34, 9.35, and 9.36).

- a. End-to-end pancreaticojejunal anastomosis is accomplished by invagination of the pancreas into the intestinal lumen using two-layer closure of interrupted silk.
- b. Perform a single-layer, end-to-side choledochojejunostomy using 4-0 interrupted synthetic absorbable material. Tack the jejunum to the abdominal surface of the liver with a few 4-0 silk sutures.
- c. Form an end-to-side gastrojejunostomy in the usual manner, in two layers, using 3-0 chromic and 3-0 silk.

Step 12. Insert a Jackson-Pratt drain to drain Morison's pouch and the area of the pancreaticojejunostomy. Close the abdomen in layers.

For more details, we advise the reader to use the following text books:

- Cameron JL. Atlas of Surgery. Philadelphia: Decker; 1990.
- Chassin JL. Operative Strategy in General Surgery. 2nd ed. New York: Springer; 1994.
- Skandalakis JE, Gray SW, and Rowe JS Jr. Anatomical Complications in General Surgery. New York: McGraw-Hill; 1983.

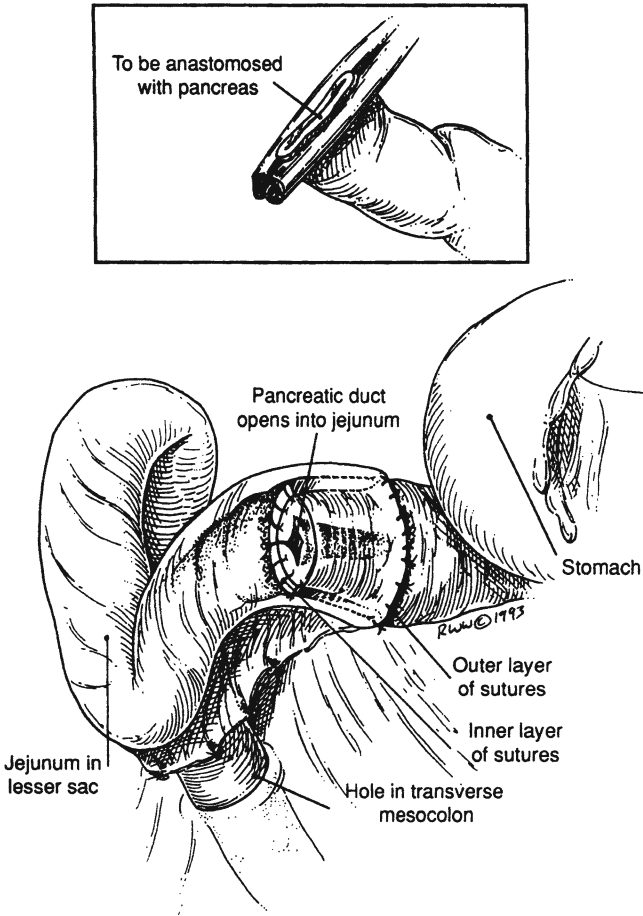


Figure 9.34. Placement of sutures.

Laparoscopic Distal Pancreatectomy

In comparison to the laparoscopic resection of other solid organs (spleen, kidney, adrenal, liver), laparoscopic pancreatic resection (LPR) has been relatively slow to progress. However, with advances in surgical technology (ultrasonic scalpel, electrothermal bipolar vessel-sealing (EBVS) devices and endovascular staplers), LPR has evolved to achieve excellent patient outcomes as well as shorter length of stay, earlier patient convalescence, and less

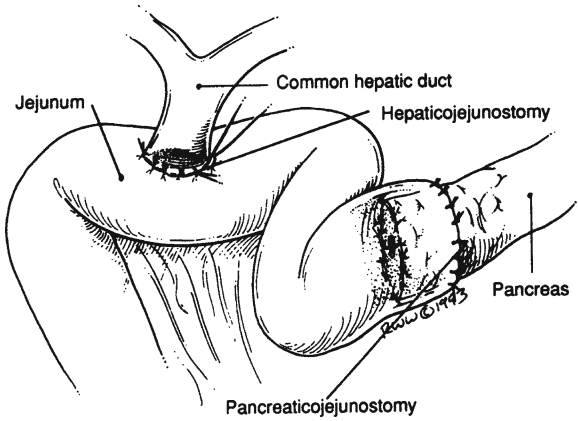


Figure 9.35. Tacking the jejunum.

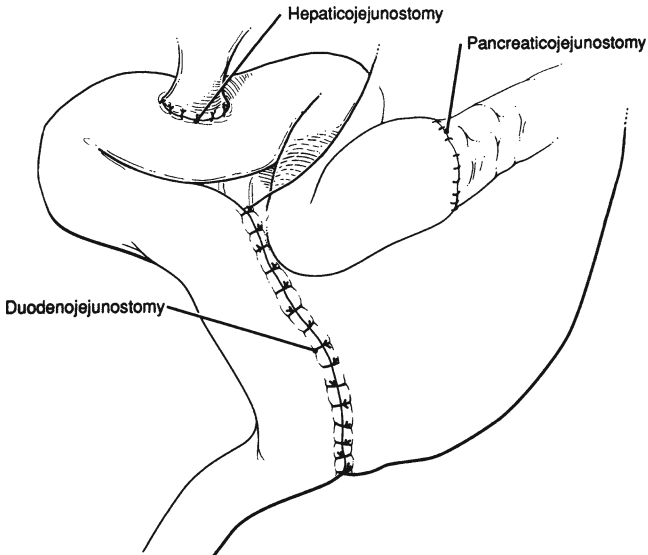


Figure 9.36. Duodenojejunostomy.

postoperative pain (equivalent to other minimally invasive solid organ surgery). We present here the indications for LPR, patient positioning, operative set up, trocar site and hand port positioning, as well as the operative technique and steps of the operation.

In experienced hands, 80 % of the body and tail of the pancreas can be safely resected laparoscopically. All benign and premalignant lesions of the body and tail are amenable to LPR. Large malignant lesions of the pancreas, especially those of the pancreatic head, are still better served utilizing an open approach, unless surgery is performed at a center experienced with minimally invasive pancreaticoduodenectomy. Consistent with other advanced laparoscopic techniques, contraindications to LPR include morbid obesity, prior laparotomy with known adhesive disease, and the diagnosis of severe portal hypertension.

Patient positioning for LPR depends on the location of the target lesion. For lesions localized to the distal body and tail of the pancreas, the patient should be positioned in the semi-lateral decubitus position with the left side up. This can be achieved easily with the use of a bean-bag device. For lesions of the body, closer to the head of the pancreas, exposure is often better approached with the patient in the supine position. Instrumentation necessary for LPR can be found in Table. 9.1.

The position of the trocar sites depends on whether a hand-assisted approach is to be used. For most lesions, unless small and of the distal tail, we have found the use of a hand port to be very helpful. Use of the hand cuts down operative time and can aid tremendously in the exposure and mobilization of the pancreas. This is especially useful when attempting splenic preservation, as the hand can be critical for the dissection of the pancreas off of the splenic vessels.

Step 1. Insufflate the abdomen using a Veress needle through the umbilicus.

Step 2. Trocar placement: We utilize (2) 12 mm trocars, (1) 5 or 10 mm trocar, and a hand port in the upper midline location or the right subcostal position depending of the size and location of the lesion. One 12 mm trocar is placed at the infraumbilical position to serve as the main camera port. The other 12 mm trocar serves as the stapler trocar site; it is placed in the right lower abdomen, lateral to the rectus muscle. The other 5 mm trocar serves as the assistant/suction

Table 9.1

Laparoscopic pancreatic resection instrumentation

0° and 30° laparoscopes
 Hand port device
 12 mm and 5 mm trocars
 10 mm clip applier
 Endovascular GIA stapler (articulating)
 EBVS device
 Laparoscopic US probe
 Laparoscopic fibrin glue applicator

port; it is best placed in the left lower abdomen. All trocars should be placed at a minimum of 8–10 cm apart to minimize “sword fighting” during the dissection. The hand port serves as the site for specimen extraction. As deemed necessary, extra 5 or 10 mm trocars can be added during the progression of the operation to facilitate exposure. Perform diagnostic laparoscopy.

- Step 3.** If there is no evidence of regional or distant metastatic disease, the operation is commenced by first gaining exposure to the lesser sac. This is facilitated by using the EBVS device to divide the gastrocolic omentum from the pancreatic head to the splenic flexure. The White Line of Toldt should also be taken down to mobilize the splenic flexure. To further mobilize the stomach and to facilitate exposure of the distal pancreas and spleen, the short gastric vessels should be taken down for the entire length of the greater curve. The stomach can be retracted in a cephalad fashion through the assistant port to fully expose the entire pancreas.
- Step 4.** Mobilization of the pancreas, the next step of the operation, can be the most challenging. If the most delicate of dissection techniques are not followed, untoward bleeding from small peripancreatic and areolar tissue veins can lead to open conversion. Mobilization commences with division of the tissue of the inferior border of the pancreas, utilizing either the ultrasonic dissector or the EBVS device to open the plane of tissue of the peritoneal reflection of the transverse mesocolon. Continue until the splenic vein is visualized. The splenic vein is traced proximally and distally until the inferior mesenteric vein and portal vein/SMV confluence have been clearly identified.
- Step 5.** Dissection is continued along the superior border of the pancreas in a similar fashion until the splenic artery is identified. To aid in retraction, a Penrose drain can be used to encircle the pancreas body while dissecting it off of the splenic vessels. Laparoscopic ultrasound can be performed at this time to precisely localize the target lesion and to determine how much pancreas should be mobilized for safe transection of the gland and formation of an adequate margin.
- Step 6.** At this point in the operation, the decision must be made if the pancreas can be resected with splenic preservation or if tandem splenectomy will be required. Splenic preservation is possible in about 60–80 % of cases. Cases where splenic preservation will not be possible include intense inflammatory changes associated with prior episodes of pancreatitis, presence of severe portal hypertension, as well as involvement of the tumor with the splenic vein. All of these clinical scenarios should be determined with preoperative cross-sectional imaging; affected patients should be given prophylactic triple vaccination.

Step 7. For cases where LPR will require splenectomy, it is best to mobilize the spleen and pancreatic tail in a lateral-to-medial fashion prior to gland transection. If splenic preservation is feasible, it can often be helpful to transect the gland first and then mobilize the remainder of the gland in a medial-to-lateral fashion. When pancreas transection is to be performed first (prior to medial-to-lateral mobilization), the peritoneum overlying the splenic artery is opened and the vessel is circumferentially mobilized and isolated. Using a 2.0 mm Endovascular GIA (gray load) stapling device, the artery is transected proximal to the transection line of the pancreas. A relatively avascular plane can then be found between the splenic vein and the pancreas. To facilitate separate transection of the gland with the stapler, the pancreas can be mobilized off the anterosuperior border of the splenic vein with the ultrasonic scalpel. However, if this plane is not accessible due to bleeding from small peripancreatic veins, the pancreas and splenic vein can be stapled en masse with a 3.5 mm (blue load) loaded ENDO GIA stapler. The proximal pancreatic staple line will often ooze after transection. Staple line bleeding can be controlled with clips or low-voltage cautery. Using the ultrasonic dissector, dissection of the distal specimen is continued medial to lateral below the plane of the vein to include mobilizing the lateral and posterior attachments of the spleen. The entire specimen (pancreas and spleen) is then placed in an endo-catch bag and removed through the hand port incision.

Step 8. The pancreas staple line is again inspected. If an open pancreatic duct is suspected, it should be reinforced by suture ligation with permanent suture. At this time, fibrin glue is used to coat the staple line and peripancreatic tissue. After hemostasis is achieved, a closed suction drain can be brought through one of the trocar sites and placed adjacent to the staple line.

Note:

- ✓ When performing LPR with splenic preservation, the only significant difference is the meticulous dissection involved in mobilizing the body and tail of the pancreas off of the splenic vessels. Again, opening the peritoneum of the inferior border of the pancreas is often the best approach. Once the splenic vein is identified, the pancreas is retracted with the help of the Penrose drain, and the small venous tributary branches from the pancreas to the splenic vein can be divided with the combination of 5 mm clips and the ultrasonic dissector. Once complete mobilization of the specimen is achieved, the gland is transected as previously described, preserving the splenic vessels and spleen.

LPR is becoming the preferred approach for the management of most benign and premalignant lesions of the body and tail of the pancreas. Outcomes from several large institutional series have shown that this approach is feasible and effective, with decreases in morbidity and length of stay. Perioperative complication rates, specifically pancreatic leak and fistula rates, are similar to those of open pancreatic resection.

For more details, we advise the reader to view the following journal articles:

- Park AE. Therapeutic laparoscopy of the pancreas. *Ann Surg.* 2002;236:149.
- Lillemoe KD. Distal pancreatectomy: indications and outcomes in 235 patients. *Ann Surg.* 1999;229:693.
- Fernandez-Cruz L. Outcome of laparoscopic pancreatic surgery: endocrine and non-endocrine tumors. *World J Surg.* 2002;26:1057.

■ TRANSDUODENAL PANCREATIC BIOPSY

Step 1. Make a subcostal incision.

Step 2. Mobilize the duodenum by Kocherization. Palpate the proximal pancreas for localization of mass (Fig. 9.29).

Step 3. Place 4–0 silk seromuscular traction sutures anteriorly on the middle part of the descending duodenum. With the traction sutures elevating the anterior duodenal wall, make a small vertical incision by electrocautery.

Step 4. Holding the head of the pancreas with the left hand, insert a Trucut biopsy needle through the posterior duodenal wall into the pancreatic tumor, avoiding the hepatopancreatic ampulla (Fig. 9.37). Send at least two specimens to the lab for frozen section.

Step 5. Close the duodenum in two layers using 4–0 silk in a transverse fashion.

Step 6. Insert a Jackson–Pratt drain and close the wound.

Note:

- ✓ Fine-needle aspiration of the head of the pancreas through the duodenum is also acceptable.

■ DRAINAGE OF PANCREATIC PSEUDOCYST

Internal Drainage

There are several procedures: Roux-en-Y, cystogastrostomy, cystoduodenostomy, and cystojejunostomy with Braun jejunojunctionostomy.

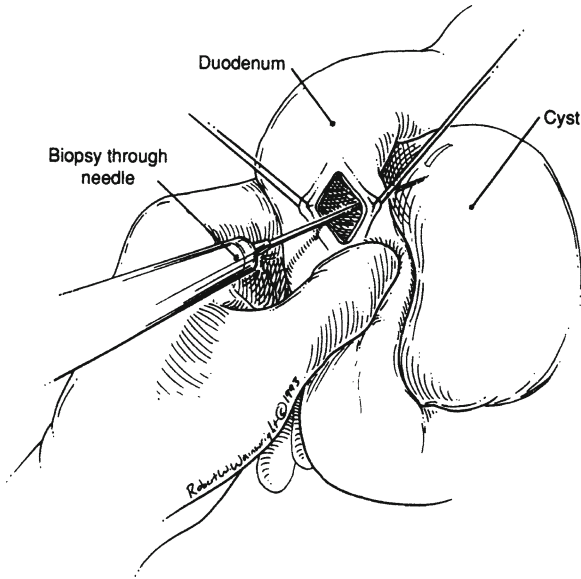


Figure 9.37. Extraction of biopsy specimens.

PRIOR TO SURGERY: (1) Endoscopic retrograde cholangiopancreatography. (2) Sonography. (3) Antibiotics. (4) CT scan. (5) Bowel preparation

Note:

✓ Not all of the preceding are necessary for every patient

POSITION: Supine on operating room X-ray table

ANESTHESIA: General

INCISION: Up to the surgeon

Determine possible location of the cyst and select procedure, keeping in mind the most dependent point for drainage.

Roux-en-Y

Step 1. After elevating the transverse colon, the pancreatic cyst in the lesser sac will present well. For all practical purposes, it is located behind the transverse mesocolon. Identify it by palpation and minimal aspiration. Be sure the cyst is solitary; if in doubt, do an operating room cystogram.

Step 2. Prepare a 40- to 60-cm loop of proximal jejunum and perform a Roux-en-Y cystojejunostomy in two layers, as described previously (Figs. 9.38 and 9.39).

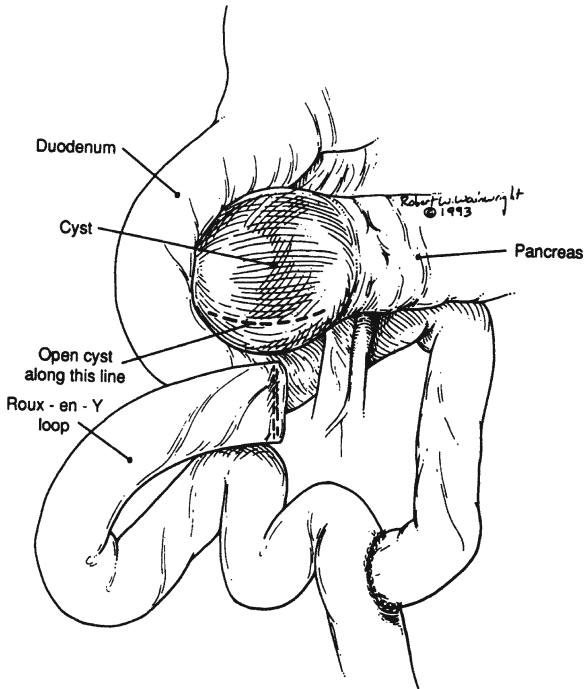


Figure 9.38. Site for opening the cyst.

Cystogastrostomy

- Step 1.** Make an anterior gastric wall incision corresponding to the location of the cyst (Fig. 9.40).
- Step 2.** Aspirate the cyst (Fig. 9.41).
- Step 3.** With the needle in situ, perform a posterior gastric wall incision including the cyst wall (Fig. 9.42).
- Step 4.** Suture the cyst wall to the posterior gastric wall with interrupted 2–0 absorbable synthetic sutures (Fig. 9.43).
- Step 5.** Suture the anterior gastrotomy (Fig. 9.44).
- Step 6.** Close the wound.

Note:

- ✓ Perform cystogastrostomy only when cyst is fixed with the posterior gastric wall.

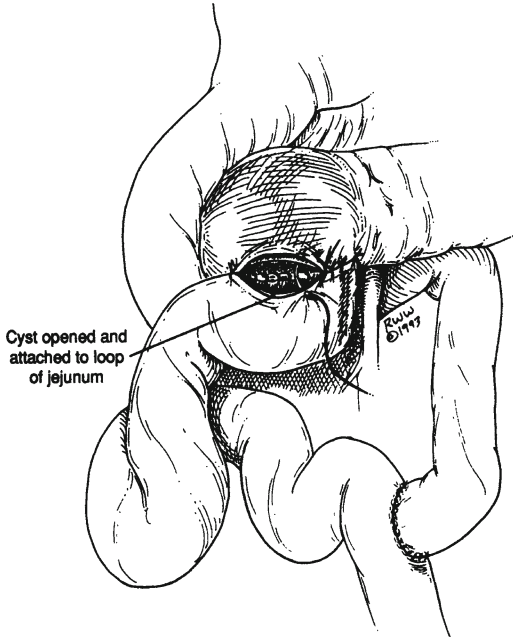


Figure 9.39. Roux-en-Y.

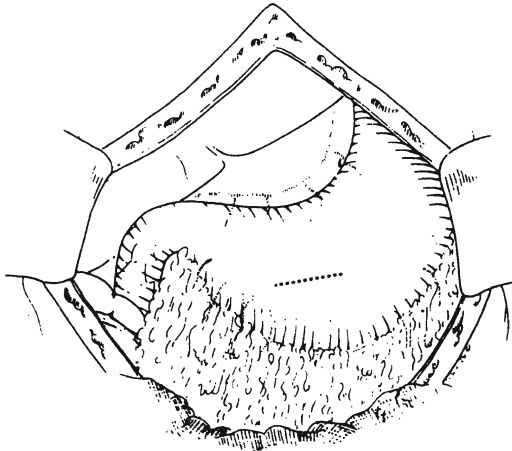


Figure 9.40. Site of cystogastrostomy incision.

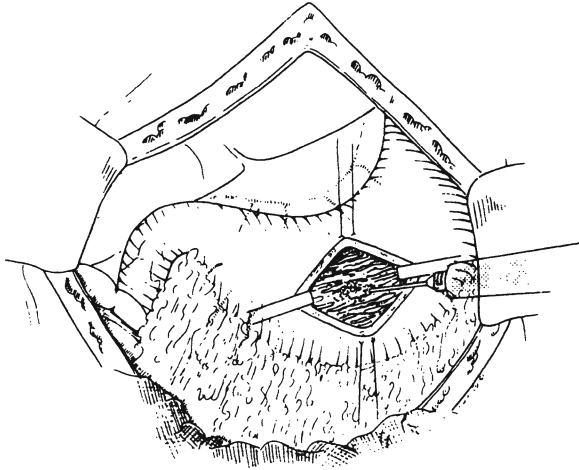


Figure 9.41. Cyst aspiration.

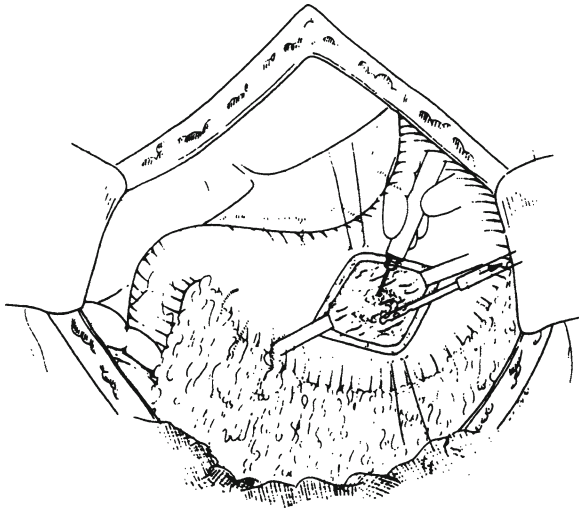


Figure 9.42. Incision site.

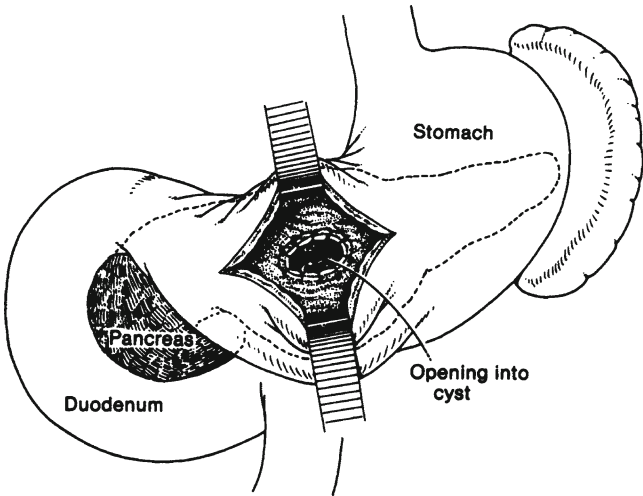


Figure 9.43. Cystogastrostomy. The anterior wall of the stomach is opened and the pancreatic cyst incised through the posterior wall. The stomach wall and the cyst are sutured to provide drainage (By permission of JE Skandalakis, SW Gray, and JR Rowe. *Anatomical Complications in General Surgery*. New York: McGraw-Hill; 1983).

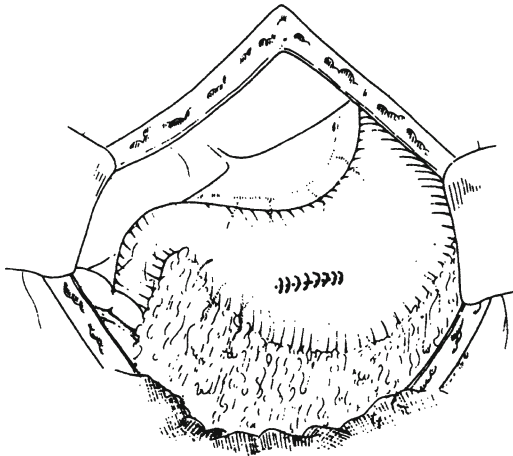


Figure 9.44. Suture site.

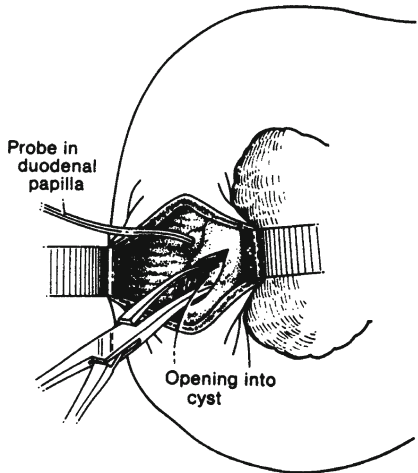


Figure 9.45. Cystoduodenostomy. A probe is placed in the duodenal papilla to identify and protect the pancreatic duct. The pancreatic cyst is incised through the duodenal wall and the opening is sutured (By permission of JE Skandalakis, SW Gray, and JR Rowe. *Anatomical Complications in General Surgery*. New York: McGraw-Hill; 1983).

Cystoduodenostomy

- Step 1.** Locate the cyst. Perform a longitudinal duodenotomy.
- Step 2.** The papilla should be visualized. Pass a small probe or catheter through it to reach the ampulla (Fig. 9.45).
- Step 3.** Incise the duodenum and cyst. Anastomose with 3–0 absorbable synthetic material (posterior row).
- Step 4.** Close duodenal wall transversely.
- Step 5.** Close abdominal wall. Decision whether to insert Jackson–Pratt drain is up to the surgeon.

Note:

- ✓ Be careful with the duct of Santorini. In 10 % of cases, it is the only pancreatic drainage.

Cystojejunostomy

Anastomose the cyst with a jejunal loop and perform a Braun entero-enteroanastomosis (Fig. 9.46) or a Roux-en-Y procedure (Fig. 9.47).

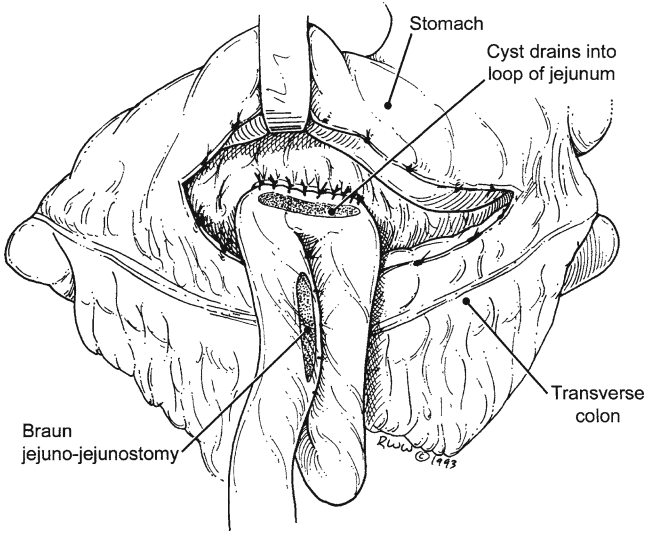


Figure 9.46. Site of Braun procedure.

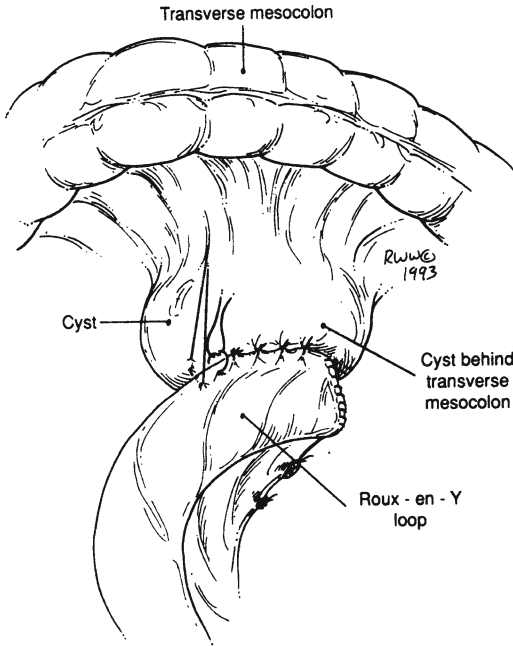


Figure 9.47. Roux-en-Y.

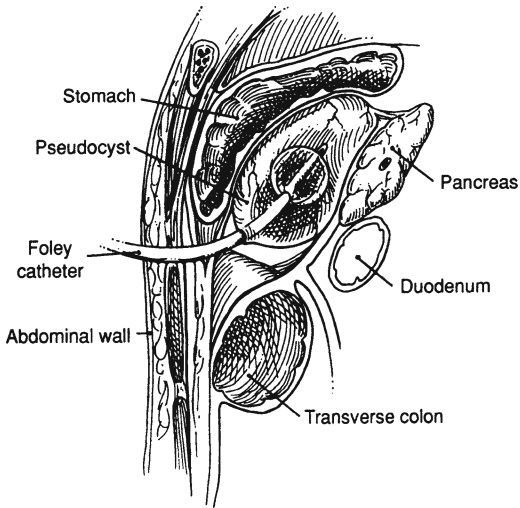


Figure 9.48. Insertion of Foley catheter.

External Drainage

External drainage is not recommended except when there is an abscess formation and the patient cannot tolerate a long procedure.

Step 1. Incise gastrocolic ligament.

Step 2. Aspirate cyst for culture and sensitivity.

Step 3. Isolate anterior wall of cyst and incise it. Pack or drain, depending on degree of infection. Occasionally, if the cyst is small, a Foley catheter may be indicated (Fig. 9.48).

10

Small Intestine

ANATOMY

■ GENERAL DESCRIPTION OF THE SMALL INTESTINE

Information about the duodenum has already been presented in detail in Chap. 8. In this chapter, general descriptions of the intestine include the duodenum, but the primary focus here is on the jejunum and ileum.

Length of the Intestine

The length of the alimentary tract in humans has proven surprisingly difficult to measure. An average of 6–6.5 m for the small intestine has been widely quoted in textbooks. This figure bears an unknown relation to the length of the intestine in the living patient, since at death the intestines elongate; tonus is lost much faster in longitudinal muscle than in circular muscle. There is some evidence that intestinal length is greater in obese individuals.

The surgeon is more concerned with the length of intestine remaining after a resection than with the amount resected. Before the intestine is removed accurate measurements should be made with the least manipulation possible.

Dimensions of the Mesentery

The length of the mesentery measured between the attachment to the intestine and the root of the mesentery usually does not exceed 20–25 cm.

Layers of the Wall of the Intestine

The intestinal wall is composed of a serosa of visceral peritoneum, longitudinal and circular muscle, a submucosa of connective tissue, and a mucosa of connective tissue, smooth muscle, and epithelium (Fig. 10.1). The integrity of an anastomosis is greater if the submucosa is included.

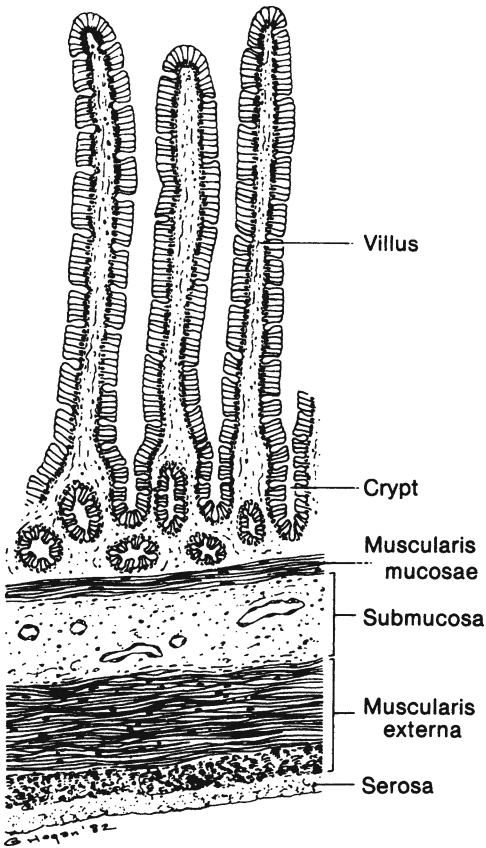


Figure 10.1. Section through the wall of the small intestine. The submucosa should be included in stitches forming an anastomosis (By permission of JE Skandalakis, SW Gray, and JR Rowe *Anatomical Complications in General Surgery*. New York: McGraw-Hill, 1983).

Anatomy of the Ileocecal Valve

The ileocecal valve in most patients resembles the cervix protruding into the vagina or the pyloric opening into the duodenum (Fig. 10.2).

The closing mechanism of the papilla is formed by two rings of thickened circular muscle, one at the base of the papilla and one at the free end.

■ VASCULAR SYSTEM OF THE SMALL INTESTINE

Arterial Supply

The intestinal vessels may be appreciated from Fig. 10.3. The superior mesenteric artery arises from the aorta below the origin of the celiac trunk.

From the arches of the arcades, numerous arteries (the vasa recta) (Figs. 10.3 and 10.4) arise and pass (without cross-communication) to enter the intestinal wall. They may bifurcate to supply each side or they may pass singly to alternate sides of the intestine. Before piercing the muscularis externa, the vasa recta branch beneath the serosa, but do not anastomose. There is no collateral circulation between the vasa recta or their branches at the surface of the intestines. This configuration provides the best supply of oxygenated blood to the mesenteric side of the intestine and the poorest supply to the antimesenteric border.

Venous Drainage

The veins travel with the arteries in the mesentery to reach the superior mesenteric vein.

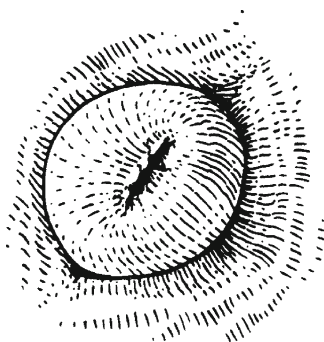


Figure 10.2. The papillary appearance of the ileocecal valve in the living patient (By permission of JE Skandalakis, SW Gray, and JR Rowe. *Anatomical Complications in General Surgery*. New York: McGraw-Hill, 1983).

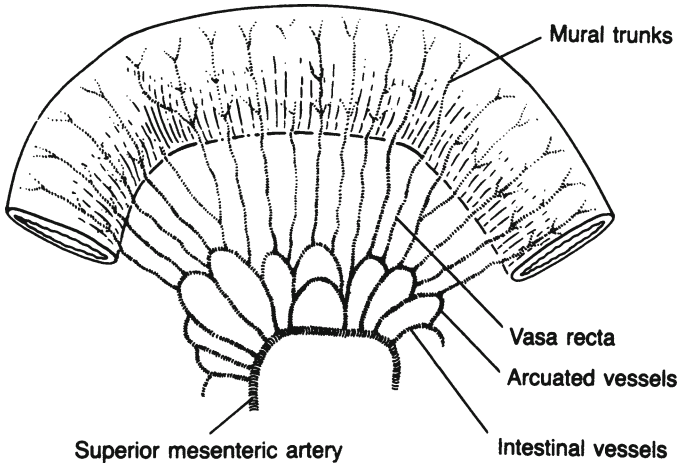


Figure 10.3. Arterial supply to the small bowel (By permission of JE Skandalakis, SW Gray, AR Mansberger, et al. *Hernia: Surgical Anatomy and Technique*. New York: McGraw-Hill, 1989).

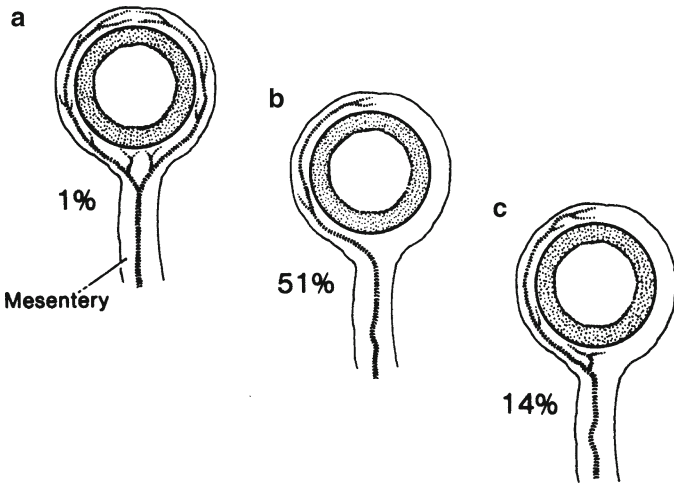


Figure 10.4. (a) The vasa recta may divide into two short vessels to the mesenteric side of the intestine and two long vessels supplying the rest of the intestinal wall. (b) More frequently, a single, long vessel supplies one side of the intestine, alternating with a vessel supplying the other side. (c) A single long and a single short vessel serving one side only. The remaining 34 % are various combinations of paired, single, long, and short vessels (By permission of JE Skandalakis, SW Gray, and JR Rowe. *Anatomical Complications in General Surgery*. New York: McGraw-Hill, 1983).

Lymphatic Drainage

The lymphatic flow is to nodes lying between the leaves of the mesentery. More than 200 small mesenteric nodes lie near the vasa recta and along the intestinal arteries. Drainage from these is finally to the large superior mesenteric lymph nodes at the root of the mesentery. Efferent vessels from these and the celiac nodes form the intestinal lymphatic trunk, which passes beneath the left renal artery and ends in the left lumbar lymphatic trunk (70 %) or the cisterna chyli (25 %).

■ ABNORMAL DEVELOPMENT OF THE SMALL INTESTINE

Meckel's Diverticulum

When present, Meckel's diverticulum arises from the antimesenteric surface of the ileum approximately 40 cm from the ileocecal valve in infants and approximately 50 cm from the valve in adults; it may be less than 15 cm or as much as 167 cm from the valve (Fig. 10.5). Not less than 2 m of ileum should be inspected to ascertain that a diverticulum has not been overlooked. The diverticulum may be as short as 1 cm or as long as 26 cm. In 75 % of individuals, the diverticulum will be from 1 to 5 cm; the rest will be longer.

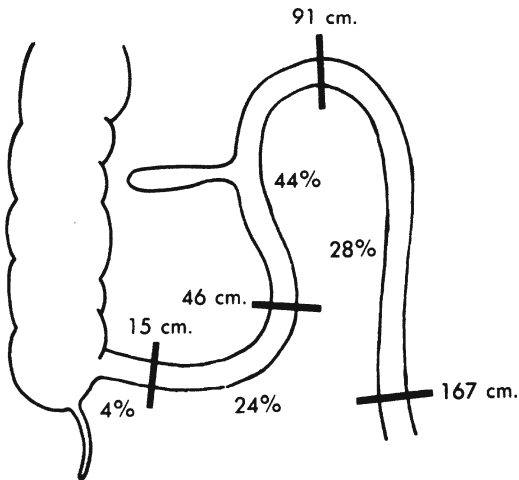


Figure 10.5. Location on the ileum and frequency of occurrence of Meckel's diverticulum (By permission of JE Skandalakis, SW Gray, RR Ricketts, et al. The small intestines. In: Skandalakis JE and Gray SW. *Embryology for Surgeons*, 2nd ed. Baltimore: Williams & Wilkins, 1994).

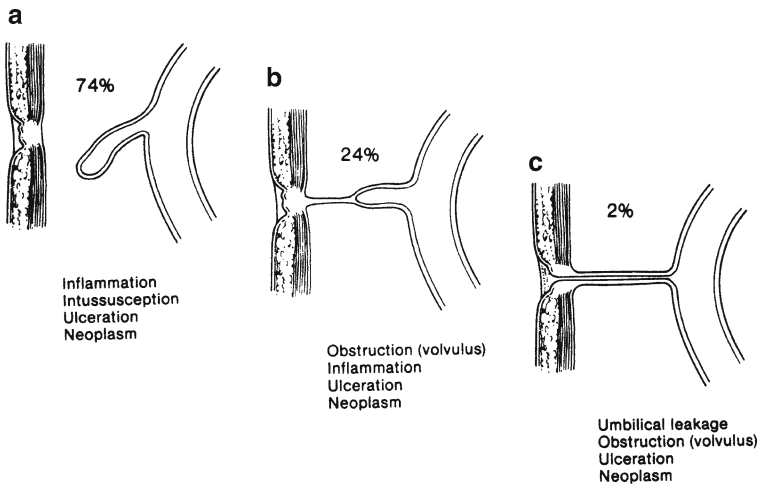


Figure 10.6. Three major types of Meckel's diverticulum. (a) Diverticulum with free end not attached to the body wall. (b) Diverticulum connected to the anterior body wall by a fibrous cord. (c) Fistula opening through the umbilicus (By permission of JE Skandalakis, SW Gray, and JR Rowe. *Anatomical Complications in General Surgery*. New York: McGraw-Hill, 1983).

The diverticulum may be free and mobile or its tip may be attached to the anterior body wall at the umbilicus. In a few cases, the structure is patent to the outside (omphaloideum fistula), a solid cord, or a cystic remnant (Fig. 10.6).

The mucosa of the diverticulum is largely ileal; gastric, pancreatic, or duodenal mucosa may also be present.

■ SURGICAL ANATOMY OF INTUSSUSCEPTION

An intussusception is created when a proximal segment of intestine (the intussusceptum) invaginates into the portion of intestine immediately distal to it (the intussuscipiens) (Fig. 10.7).

Meckel's diverticulum is the most common identifiable cause of intussusception in children. Other known causes are intestinal polyps, duplications, atresias, and tumors of the intestine, but 85 % of our cases of intussusceptions in children could not be assigned to any cause.

In adults, our "2/3 rule" may be applied (all numbers are approximate): 2/3 of adult intussusceptions are from known causes. Of these, 2/3 are due to neoplasms. Of the neoplasms, 2/3 will be malignant. Reduction of the intussusception may be spontaneous or it may be achieved by barium enema or operation.

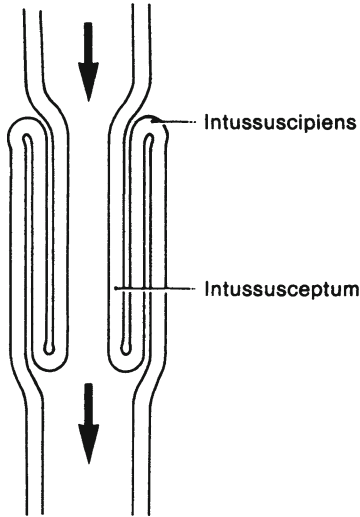


Figure 10.7. Diagram of the anatomy of an intestinal intussusception. Such a formation can enlarge distally until the leading edge reaches the anus (By permission of JE Skandalakis, SW Gray, and JR Rowe. *Anatomical Complications in General Surgery*, New York: McGraw-Hill, 1983).

For children, we recommend reduction with resection if necessary; for adults, we recommend resection without reduction.

■ ANATOMIC GUIDELINES FOR SURGERY

There is no good way to identify an isolated loop of small intestine without following it in one direction to the duodenojejunal junction or in the other direction to the ileocecal junction.

Exposure and Mobilization

Few organs are more easily exposed and mobilized than are loops of small intestine. Adhesions from previous surgery are the chief obstacles to good mobilization.

The only procedures we perform in this part of the gastrointestinal tract are resection and anastomosis of the small bowel. In benign disease, we make every effort to save the ileocecal valve, but when malignancy is present, resection is essential. When dealing with resection of the small bowel, the surgeon should always be conservative. The decision in the operating room should be based on pathology, such as tumor (benign or malignant), mesenteric thrombosis of arterial or venous type, and inflammatory processes, such as regional enteritis, tumors of the mesentery causing a desmoplastic reaction, and Meckel's diverticulum.

TECHNIQUE

■ RESECTION OF SMALL BOWEL FOR TUMOR

- Step 1.** In the case of a small bowel tumor, proximal and distal margins of 10 cm are appropriate. Score the mesentery of the small bowel with the Bovie.
- Step 2.** Using a hemostat, ligate the vessels of the mesentery of the small bowel with 2-0 or 3-0 silk (Figs. 10.8 and 10.9).
- Step 3.** Using a 75-mm gastrointestinal anastomosis (GIA) stapler, transect the small bowel proximally and distally. When applying the GIA stapler, make sure that the stapled end is on the antimesenteric border of the small bowel (Fig. 10.9).
- Step 4.** Apply bowel bulldogs to the small bowel so that enteric contents do not spill.
- Step 5.** Align the two segments of small bowel such that the antimesenteric borders abut each other (Fig. 10.10). Using straight Mayo scissors transect the stapled corner of the small bowel at the antimesenteric border.

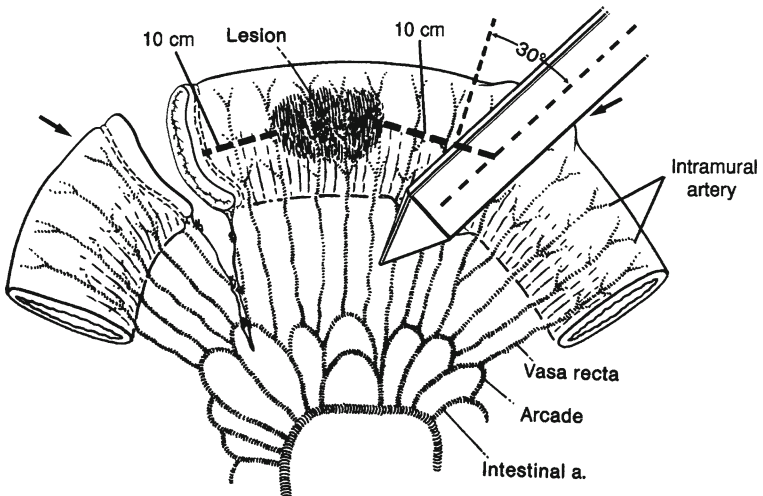


Figure 10.8. Recommended position of noncrushing clamps for segmental resection of intestine. The 30° angle from a vertical transection preserves as much of the antimesenteric blood supply as possible (arrows) and slightly increases the functional diameter of the anastomosis (modified by permission of JE Skandalakis, SW Gray, and JR Rowe. *Anatomical Complications in General Surgery*. New York: McGraw-Hill, 1983).

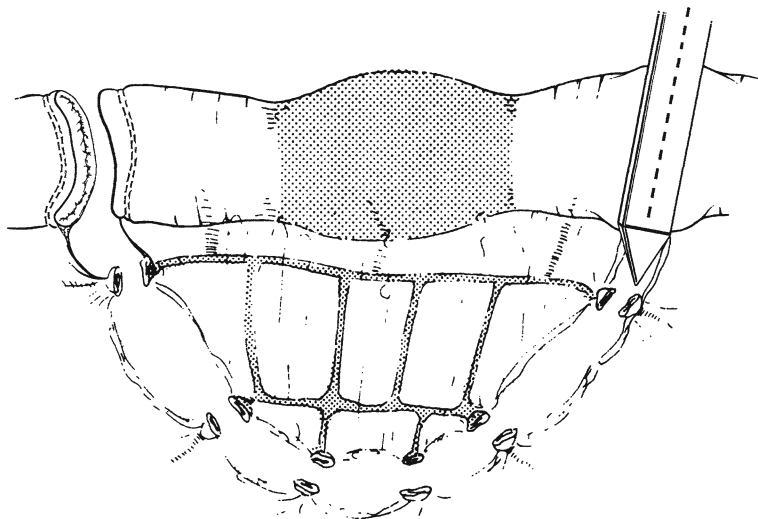


Figure 10.9. Ligation of vessels.

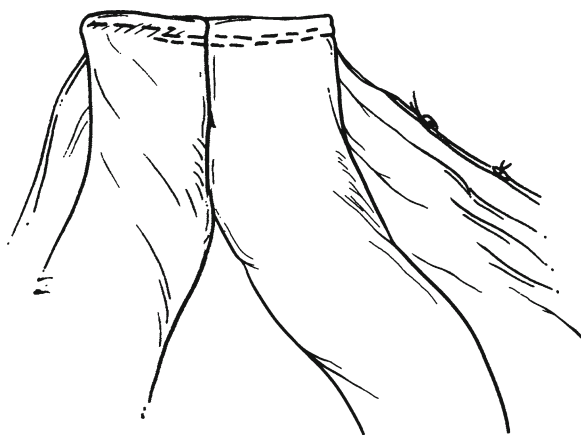


Figure 10.10. Transection and stapling.

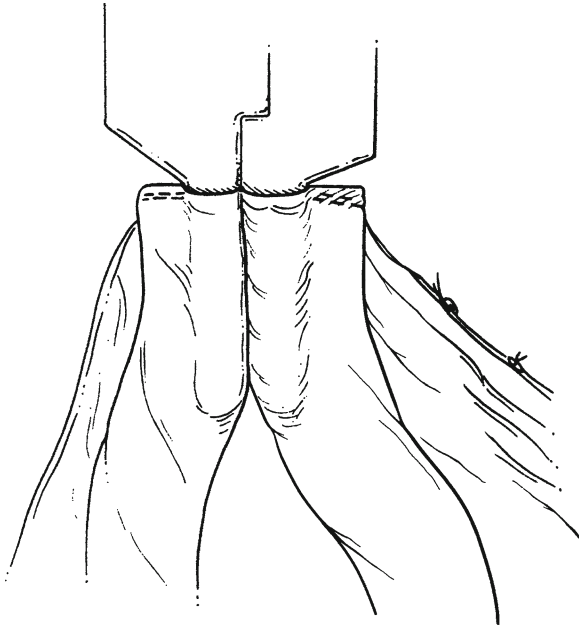


Figure 10.11. Orientation of GIA stapler.

- Step 6.** Insert each arm of the GIA stapler into the small bowel through the previously created opening and approximate the stapler such that the antimesenteric portions of the small bowel are in proximity to each other. Fire the stapler. Remove the stapler and briefly inspect the mucosal surface of the anastomosis for bleeding (Fig. 10.11).
- Step 7.** Using a 60 mm thoracoabdominal (TA) stapler, close the resultant enterotomy.
- Step 8.** Close the mesentery of the small bowel with an interrupted 3–0 silk suture.
- Step 9.** Place a supporting 3–0 silk suture in the crotch of the anastomosis.

■ MECKEL'S DIVERTICULUM (ORIENTATION FIG. 10.5)

We prefer a wedge resection of the diverticulum with extension to the mesenteric wall or a segmental resection of the ileum and end-to-end anastomosis in one or two layers (Fig. 10.12) or a stapled functional end-to-end anastomosis (see preceding procedure for resection of small bowel for tumor).

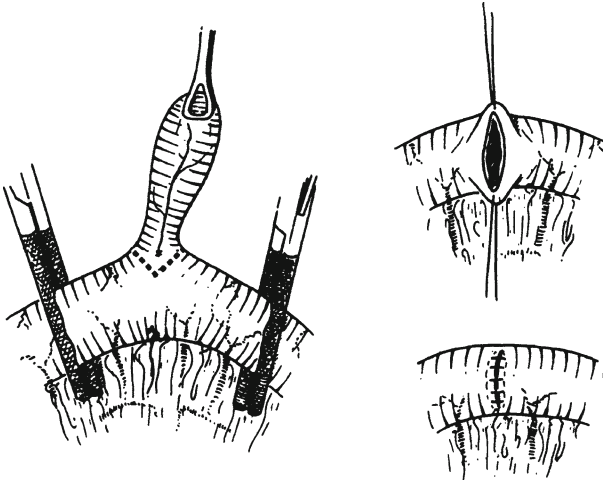


Figure 10.12. Resection of Meckel's diverticulum.

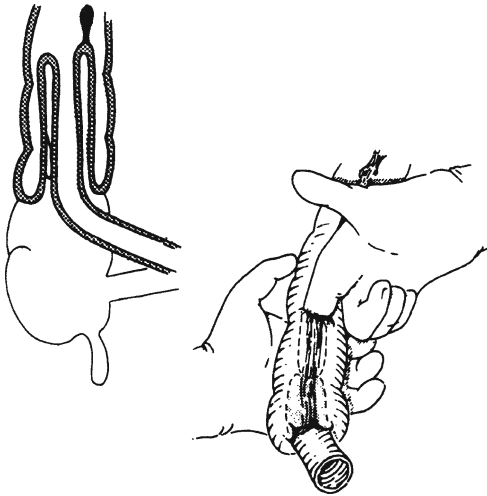


Figure 10.13. Reduction of intussusception.

■ INTUSSUSCEPTION (ORIENTATION FIG. 10.7)

The terminal ileum may be intussuscepted into the cecum (Fig. 10.13). In children, first try to reduce the intussusception with a barium enema administered by an experienced radiologist. If intussusception is not reduced, perform

surgery and reduction (Fig. 10.13). If changes such as ischemia or gangrene develop in the bowel wall, resection and anastomosis will be necessary.

The authors do not reduce intussusceptions in adults, but instead resect them, because most are caused by malignant tumors (see “2/3 rule” above).

■ WITZEL JEJUNOSTOMY

- Step 1.** Select a loop of the proximal jejunum approximately 15 cm from the ligament of Treitz (Fig. 10.14).
- Step 2.** Make a stab wound in the abdominal wall and insert a catheter.
- Step 3.** Make a small incision on the enteric wall. Insert a catheter. Place purse-string sutures of 3-0 Vicryl and tighten them around the catheter (Figs. 10.15 and 10.16).
- Step 4.** Create a seromuscular tunnel 5 cm long using 4-0 silk interrupted sutures (Fig. 10.17). Secure in a Stamm position to the anterior abdominal wall.
- Step 5.** Fix the catheter to the skin.

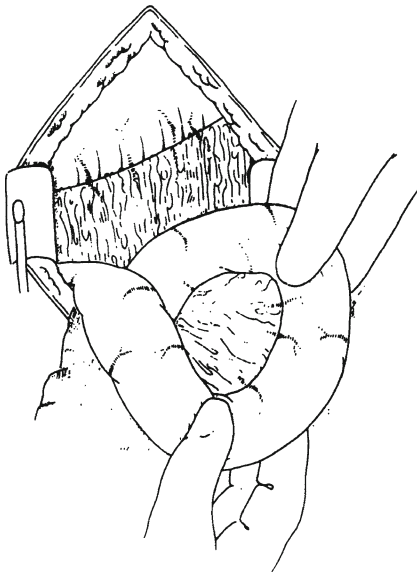


Figure 10.14. Selection of loop.

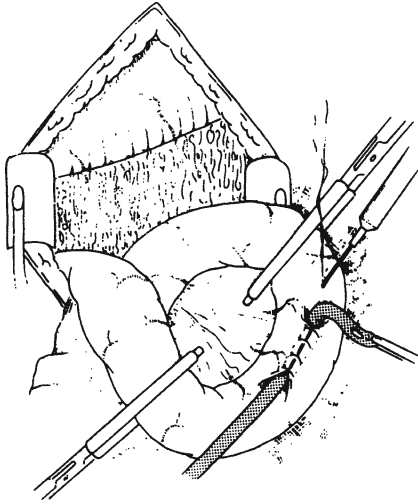


Figure 10.15. Wall is incised.

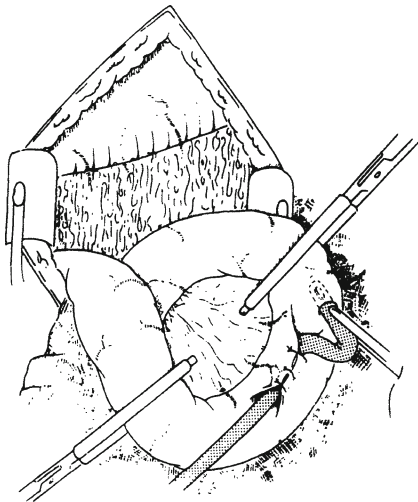


Figure 10.16. Introduction of catheter.

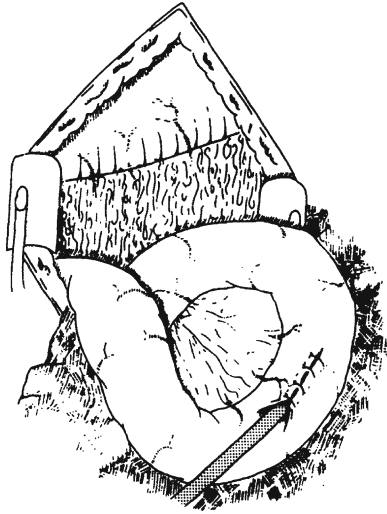


Figure 10.17. The seromuscular tunnel.

■ FEEDING JEJUNOSTOMY

Perform this procedure in the same way as Stamm gastrostomy, except use a small T-tube in a loop of jejunum 15 cm distal to the ligament of Treitz. To prevent torsion secure the jejunum to the anterior abdominal wall 5 cm proximal and distal to the Stamm.

ANATOMY

■ RELATIONS AND POSITIONS OF THE APPENDIX

The appendix arises from the posteromedial side of the cecum about 1.7 cm from the end of the ileum. The cecum is related posteriorly to the iliopsoas muscle and the lumbar plexus of nerves. Anteriorly it is related to the abdominal wall, the greater omentum, or coils of ileum. The base of the appendix is located at the union of the teniae. For all practical purposes, the anterior tenia ends at the appendiceal origin.

Five typical locations of the appendix, in order of frequency, are:

Retrocecal-retrocolic, free or fixed

Pelvic or descending

Subcecal, passing downward and to the right

Ileocecal, passing upward and to the left, anterior to the ileum

Ileocecal, posterior to the ileum

Studies have found that the first two positions are the most common, but with significant variations.

■ MESENTERY

The mesentery of the appendix is embryologically derived from the posterior side of the mesentery of the terminal ileum. The mesentery attaches to the cecum as well as to the proximal appendix. It contains the appendicular artery.

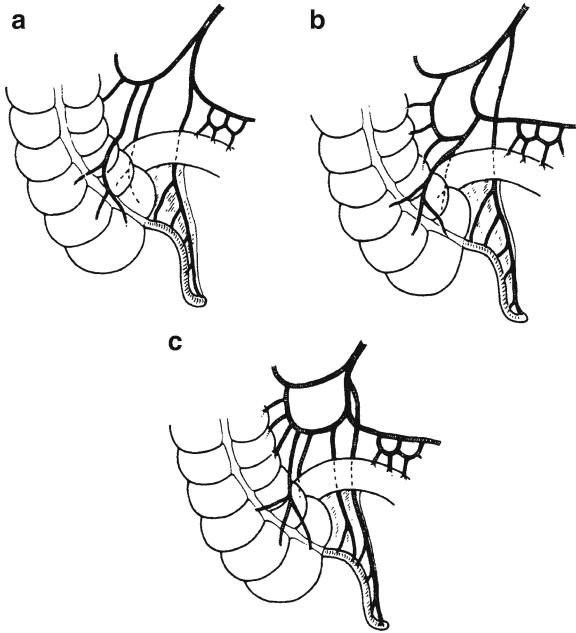


Figure 11.1. Blood supply to the appendix. (a, b) Usual type with a single appendicular artery. (c) Paired appendicular arteries (By permission of JE Skandalakis, SW Gray, and JR Rowe. *Anatomical Complications in General Surgery*. New York: McGraw-Hill, 1983).

■ VASCULAR SYSTEM OF THE APPENDIX

Arterial Supply

The appendicular artery arises from the ileocolic artery, an ileal branch, or from a cecal artery. Although the appendicular artery is usually singular (Fig. 11.1), duplication is often seen. In addition to the typical appendicular artery, the base of the appendix may be supplied by a small branch of the anterior or posterior cecal artery.

Venous Supply

The appendicular artery and the appendicular vein are enveloped by the mesentery of the appendix. The vein joins the cecal veins to become the ileocolic vein, which is a tributary of the right colic vein.

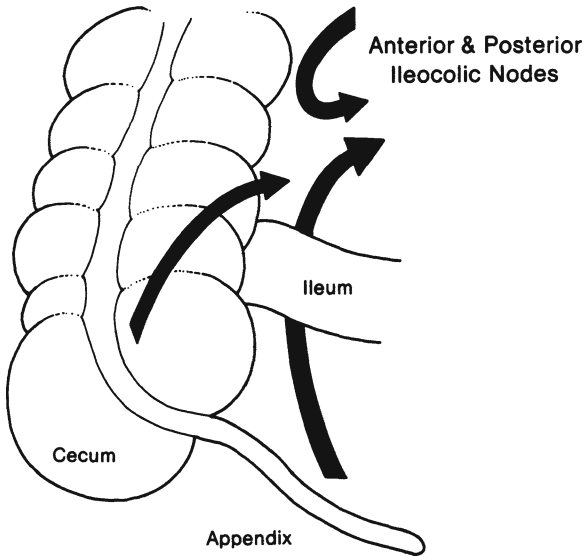


Figure 11.2. Lymphatic drainage of the appendix (By permission of JE Skandalakis, SW Gray, and JR Rowe. *Anatomical Complications in General Surgery*. New York: McGraw-Hill, 1983).

Lymphatic Drainage

Lymphatic drainage from the ileocecal region is through a chain of nodes on the appendicular, ileocolic, and superior mesenteric arteries through which the lymph passes to reach the celiac lymph nodes and the cisterna chyli (Fig. 11.2). Some studies describe a secondary drainage (which passes anterior to the pancreas) to subpyloric nodes.

TECHNIQUE

■ APPENDECTOMY

The incision for appendectomy is usually made over McBurney's point. It is made at right angles to a line between the anterior superior iliac spine and the umbilicus at $2/3$ the distance from the umbilicus; $1/3$ of the incision should be above the line, and $2/3$ should be below.

The cecum should be identified first. It can be distinguished from the transverse colon by the absence of attachments of the omentum. If the cecum cannot be located, malrotation of the intestines or undescended cecum should be considered.

When the cecum has been identified, one of the teniae coli can be traced downward to the base of the appendix. In spite of the great mobility of the tip, the base of the appendix always arises from the cecum at the convergence of the teniae. In exposing a deeply buried retrocecal appendix, it may be necessary to incise the posterior peritoneum lateral to the cecum. Congenital absence of the appendix is too rare to be considered seriously, but its apparent absence may be the result of intussusception. In such a case, there should be an obvious dimple at the normal site of the appendix. Of course, the surgeon should inspect the abdomen for signs of previous operation.

- Step 1.** Choice of incision is up to the surgeon. We prefer McBurney (Fig. 11.3).
- Step 2.** Incise the aponeurosis of the external oblique along the lines of its fibers (Fig. 11.4).
- Step 3.** Use a curved Kelly clamp to make an opening on both the internal oblique and the transversus abdominis muscles. Enlarge the opening with the Kelly clamp and insert two Richardson's retractors.
- Step 4.** If the transversalis fascia is divided together with the flat muscles, occasionally there will be a thick stroma of preperitoneal fat which can be pushed laterally, or sometimes medially, revealing the peritoneum.
- Step 5.** Elevate the peritoneum and, if applicable, the transversalis fascia. Make a small opening in the peritoneum with a knife or scissors, then enlarge it with both index fingers and insert the retractors of your choice (Fig. 11.5).
- Step 6.** Take cultures of the free peritoneal fluid and, using moist gauze, pull the cecum out of the wound. In most cases, the appendix is delivered with the cecum or may be seen.
- Step 7.** Grasp and study the mesentery of the appendix and reinsert the cecum into the peritoneal cavity. Divide the mesoappendix between clamps (Fig. 11.6).

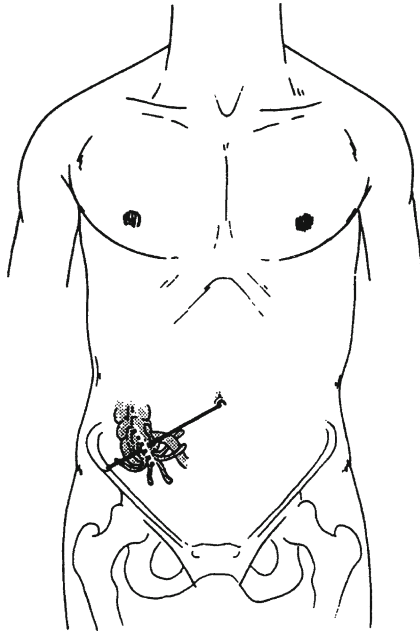


Figure 11.3. Locating McBurney's point.

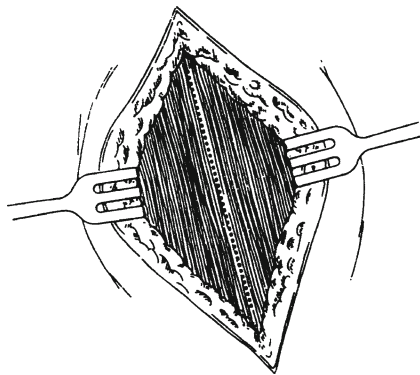


Figure 11.4. Incision follows direction of fibers.

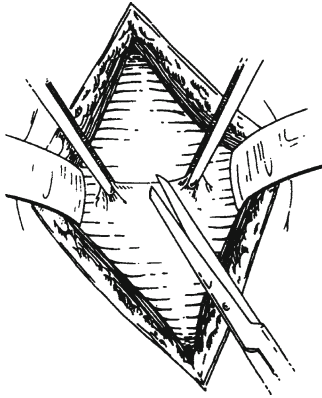


Figure 11.5. Preparing the peritoneum.

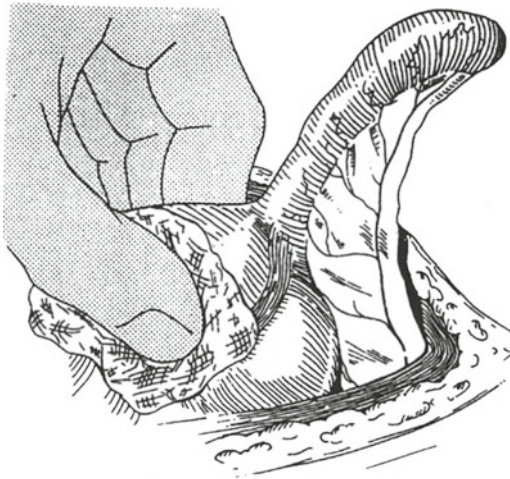


Figure 11.6. Examining the appendix and its mesentery.

Step 8. Ligate the mesoappendix with 2-0 silk (Fig. 11.7).

Step 9. With hemostasis completed, lift the appendix straight up and attach two clamps to its base. Remove the clamp close to the cecum. Ligate the appendiceal base doubly with 0 chromic catgut. Stump inversion is done only when the base of the appendix is necrotic. When inverting, use a 3-0 silk purse string (Figs. 11.8 and 11.9).

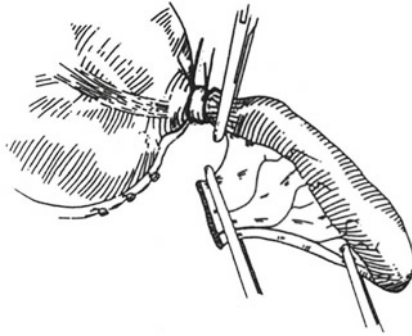


Figure 11.7. Ligation site.

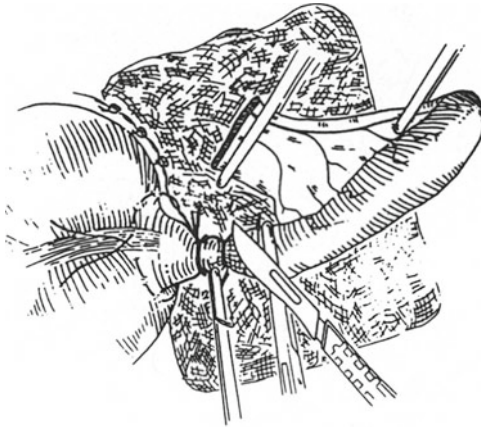


Figure 11.8. Ligation.

- Step 10.** Divide the appendix between the clamp and the catgut ligatures using a knife with phenol and alcohol or electrocautery (Fig. 11.10). (Alternatively, the appendix can be divided with a GIA stapler.)
- Step 11.** Irrigate. Close in layers using catgut or absorbable synthetic suture. If peritonitis is present, close the muscle, but not the skin. The authors use iodoform gauze to pack the wound (Figs. 11.11, 11.12, and 11.13).

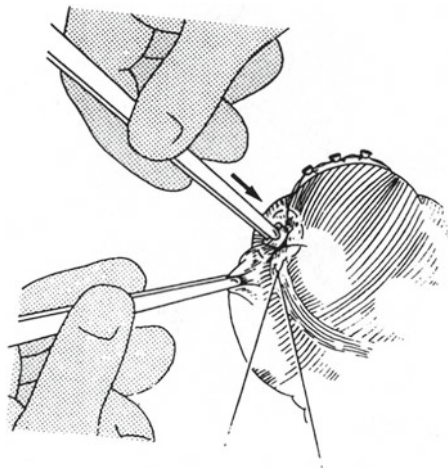


Figure 11.9. Inversion.

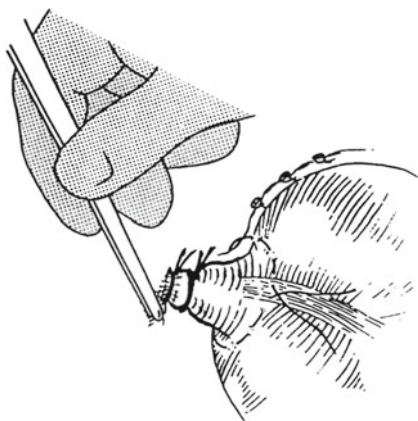


Figure 11.10. Division.

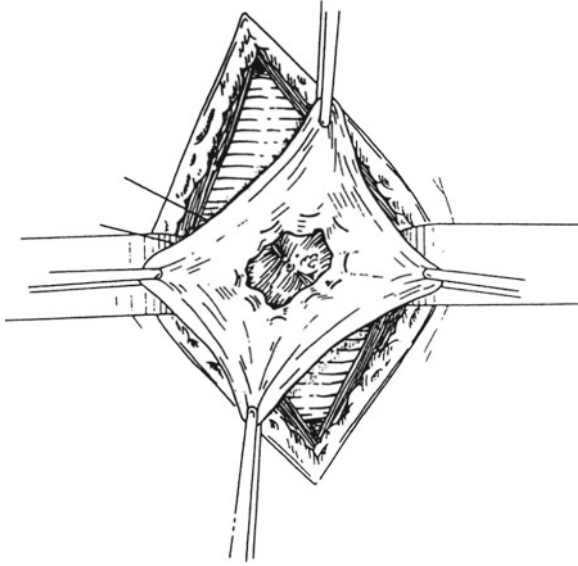


Figure 11.11. Packing the wound.

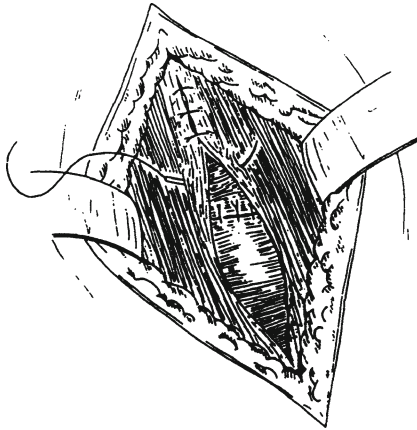


Figure 11.12. Closing in layers.

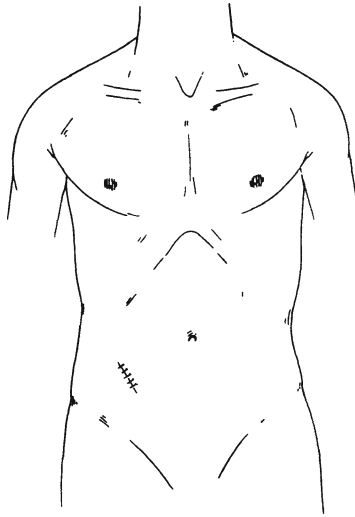


Figure 11.13. Skin is closed.

■ LAPAROSCOPIC APPENDECTOMY

- Step 1.** Make a 5 mm umbilical incision (Fig. 11.14) and insufflate the abdominal cavity with a Veress needle.
- Step 2.** Place a 5-mm trocar through the umbilicus. Insert the 5 mm laparoscope.
- Step 3.** Under direct vision place a 12-mm port in a suprapubic position: this size is needed for the endoscopic GIA.
- Step 4.** Place another 5-mm port left of midline, halfway between the umbilicus and the suprapubic port.
- Step 5.** Using a laparoscopic Babcock or DeBakey, grasp the appendix and apply traction such that the mesoappendix is visualized. Use the Harmonic scalpel or a LigaSure to take down the mesoappendix (Fig. 11.15).
- Step 6.** Through the suprapubic port, insert the GIA loaded with GI staples. Fire the endoscopic GIA, transecting the appendix. Usually one firing is sufficient; however, it may need to be repeated (Fig. 11.16).

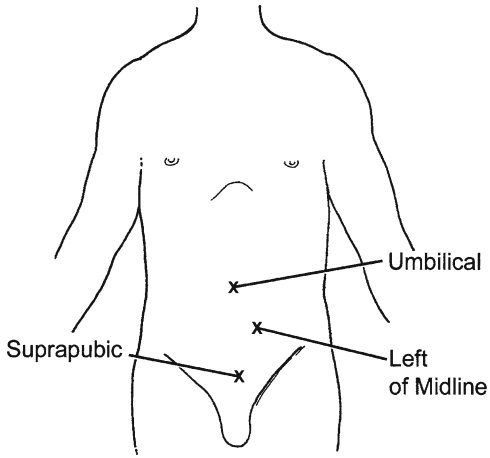


Figure 11.14. Location of incision and port placement.

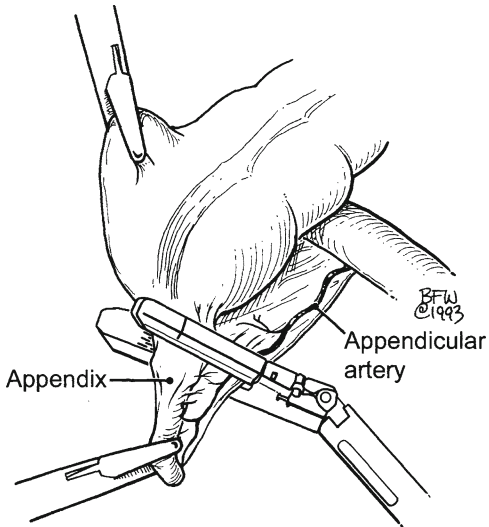


Figure 11.15. Division of the appendix with the Endo GIA stapler.

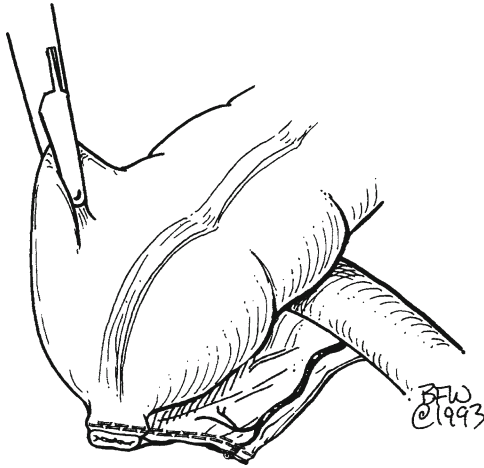


Figure 11.16. Removal of the appendix.

Step 7. Place the appendix into an endoscopic pouch and remove it through the suprapubic incision (Fig. 11.16).

Step 8. Close the suprapubic fascial defect with a 0 Vicryl suture. Close the skin.

Note:

- ✓ The patient should have an orogastric tube placed to decompress the stomach, as well as a Foley catheter for bladder decompression. There are instances when the stomach can reach to the level of the umbilicus; decompression will avoid perforation with the Veress needle.
- ✓ The Foley catheter will decompress the bladder and keep it from being injured during placement of the 12 mm suprapubic trocar. However, the trocar should be carefully observed while it is being placed in the suprapubic position. The author has experienced iatrogenic trocar injury to the bladder even though the bladder was decompressed and the insertion was viewed. So, be careful.

Colon and Anorectum

ANATOMY

■ GENERAL DESCRIPTION OF COLON AND ANOECTUM

The large intestine, or colon, about 144 cm long, extends from the terminal ileum to the anus. The classic divisions are the cecum, colon proper, rectum, and anal canal. A surgical unit, the right colon, is composed of the cecum, ascending colon, and hepatic flexure. The surgical unit of the left colon consists of the distal transverse colon, splenic flexure, and descending and sigmoid colons.

Cecum

The cecum—the first 5 cm of the large bowel just below the ileocecal valve—lies in the right iliac fossa, and in about 60 % of living, erect individuals, it lies partly in the true pelvis. In approximately 20 %, almost the entire posterior surface of the cecum is attached to the posterior abdominal wall, and, at the other extreme, in approximately 24 %, the cecum is wholly unattached. Among the latter are cases of pathologically mobile cecum, in which the lower part of the ascending limb, in addition to the cecum, is unattached.

A fold of peritoneum from the mesentery of the terminal ileum may cross the ileum to attach to the lower colon and the cecum. This fold, the mesentery, and the ileum may form a superior ileocecal fossa. Below is an inferior ileocecal fold and an inferior ileocecal fossa (Fig. 12.1). These folds are inconstant, and the associated fossae can be shallow or absent. Occasionally a retrocecal fossa is present. In some subjects a fixed terminal ileum may be present and, rarely, a common ileocecal mesentery.

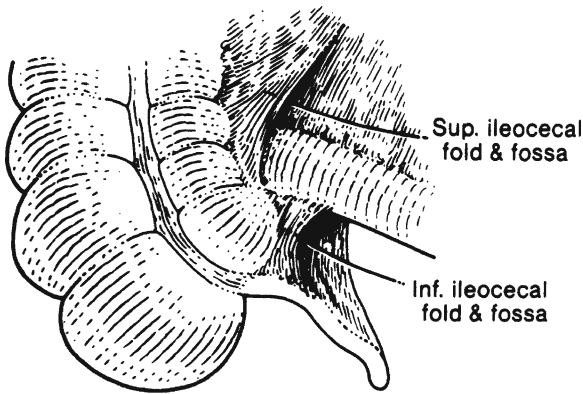


Figure 12.1. Superior and inferior ileocecal folds forming fossae (By permission of JE Skandalakis, SW Gray, and JR Rowe. *Anatomical Complications in General Surgery*. New York: McGraw-Hill, 1983).

Colon Proper

The ascending limb of the colon proper is normally fused to the posterior body wall and covered anteriorly by the peritoneum. There are variations of incomplete fusion ranging from a deep lateral paracolic groove to the persistence of an entire ascending mesocolon (Fig. 12.2). A mesocolon long enough to permit volvulus occurs in approximately 11 %. In cadavers, the ascending colon may be mobile in approximately 37 % of cases. A mobile cecum, together with a mobile right colon, may be present.

Where the mesocolon is present, the cecum and the proximal ascending colon are unusually mobile. It is this condition that is termed mobile cecum and which can result in volvulus of the cecum and the right colon (Fig. 12.3) as well as cecal bascule.

Two conditions must be present for right colon volvulus to occur: (1) an abnormally mobile segment of colon and (2) a fixed point around which the mobile segment can twist.

The transverse colon begins where the colon turns sharply to the left (the hepatic flexure) just beneath the inferior surface of the right lobe of the liver. It ends at a sharp upward and then downward bend (the splenic flexure) related to the posterolateral surface of the spleen. The tail of the pancreas is above. The anterior surface of the left kidney lies medially.

The transverse colon has a mesentery which has fused secondarily with the posterior wall of the omental bursa (see Fig. 8.1). At the splenic flexure, the colon is supported by the phrenocolic ligament, a part of the left side of the transverse mesocolon.

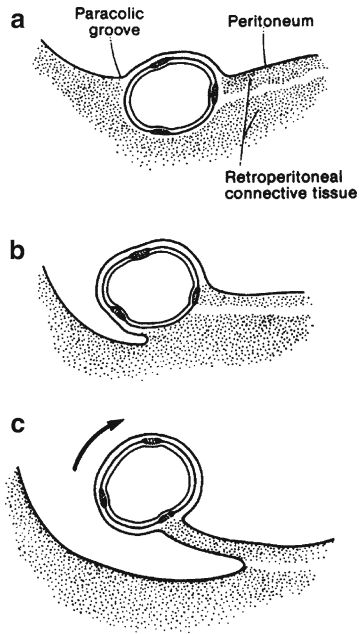


Figure 12.2. Degrees of attachment of the right colon to the abdominal wall. (a) Normal retroperitoneal location of the colon. (b) Paracolic gutter. (c) Mobile colon with mesentery (By permission of JE Skandalakis, SW Gray, and JR Rowe. *Anatomical Complications in General Surgery*. New York: McGraw-Hill, 1983).

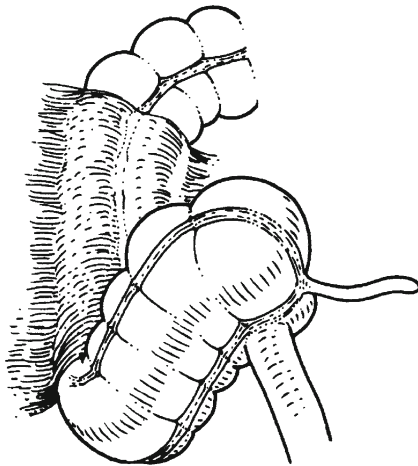


Figure 12.3. Mobile cecum, distal ileum, and proximal right colon. This configuration is subject to volvulus (By permission of JE Skandalakis, SW Gray, and JR Rowe. *Anatomical Complications in General Surgery*. New York: McGraw-Hill, 1983).

434 12. Colon and Anorectum

The descending colon is covered anteriorly and on its medial and lateral sides by peritoneum. It normally has no mesentery. When a mesentery exists, it is rarely long enough to permit a volvulus to occur.

At the level of the iliac crest, the descending colon becomes the sigmoid colon and acquires a mesentery. The sigmoid colon is described as having two portions: iliac (fixed) and pelvic (mobile). The average length of the attachment and the average breadth of the mesentery are shown in Fig. 12.4a. The left ureter passes through the base of the sigmoid mesocolon through the intersigmoid mesenteric recess (Fig. 12.4b).

Rectum and Anal Canal

There are many definitions of the junction between the sigmoid colon and the rectum that are inconsistent with each other. Most surgeons consider the rectosigmoid junction to be at the level of the sacral promontory. Anatomists consider the rectosigmoid junction to be located at the level of S3. Others consider the rectosigmoid junction to be the narrowest portion of the large intestine where the teniae fuse together to form a single anterior tenia. The haustra and mesocolon terminate and the diverticula are no longer able to form.

The surgeon considers the anal canal to be the region lying distal to the insertion of the levator ani muscle. The surgical anal canal has a length of 4 cm: 2 cm above the pectinate line and 2 cm below (Fig. 12.5). The functional anal canal extends for 4 cm from the anorectal ring to the intersphincteric groove.

■ LAYERS OF WALL OF LARGE INTESTINE

Colon

The layers of the wall of the large intestine are essentially similar to those of the wall of the small intestine. The chief differences are (1) the absence of mucosal villi, (2) longitudinal muscularis externa in three discrete bands (teniae) rather than in a continuous cylinder, (3) the presence of epiploic appendices (appendages); and (4) the presence of haustra or sacculations.

The epiploic appendages are of interest to the surgeon because they may be the sites of diverticula (Fig. 12.6a). Fat may conceal the presence of the diverticulum on inspection, but fecaliths in the diverticula are frequently palpable. The appendages are also subject to infarction and torsion; both produce symptoms of an acute abdomen. Epiploic appendages should be ligated without traction. This prevents unintentional pulling of a loop of a long colic artery into the appendiceal neck and its accidental inclusion in the ligation (Fig. 12.6b).

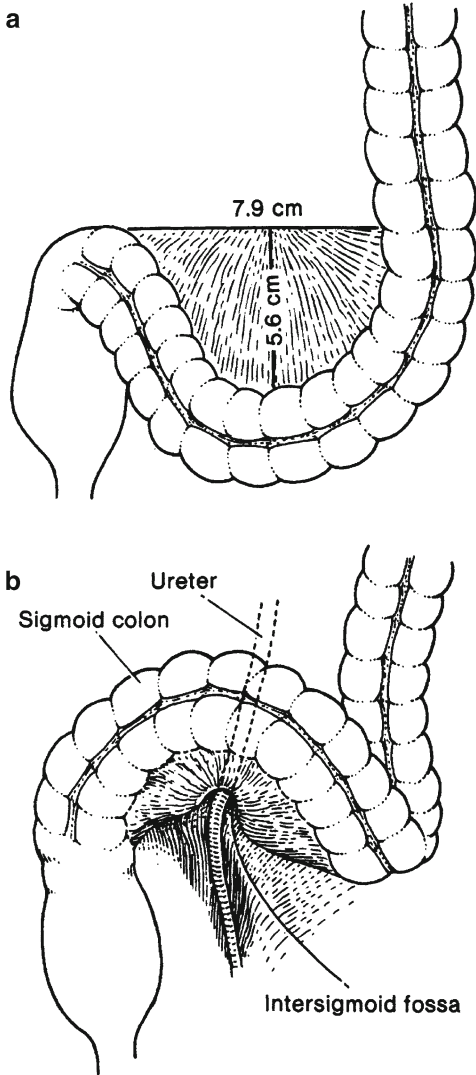


Figure 12.4. (a) Average measurements of the sigmoid mesocolon. (b) The relation of the base of the sigmoid mesocolon to the left ureter (By permission of JE Skandalakis, SW Gray, and JR Rowe. *Anatomical Complications in General Surgery*. New York: McGraw-Hill, 1983).

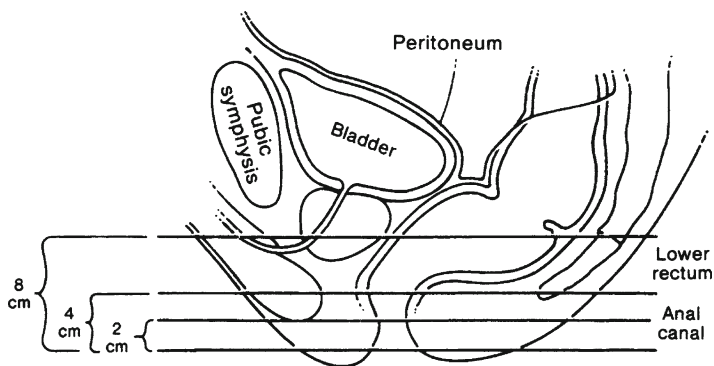


Figure 12.5. The line of peritoneal reflection on the rectum; lateral view in the male. More of the rectum is covered anteriorly than posteriorly. The measurements of the anal canal and lower rectum from the anal verge are approximate (By permission of JE Skandalakis, SW Gray, and JR Rowe. *Anatomical Complications in General Surgery*. New York: McGraw-Hill, 1983).

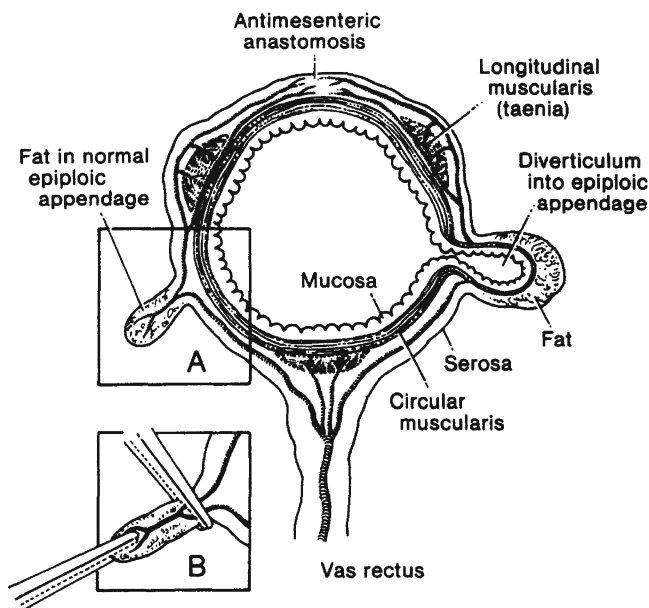


Figure 12.6. Diagram of the transverse colon showing long and short branches of the vasa recta. On the left is a normal epiploic appendage; on the right, a diverticulum extending into an epiploic appendage. *Inset*: Effect of too much traction on an epiploic appendage resulting in injury to a long branch of a vas rectus followed by antimesenteric ischemia (By permission of JE Skandalakis, SW Gray, and JR Rowe. *Anatomical Complications in General Surgery*. New York: McGraw-Hill, 1983).

Rectum

Grossly, the rectum has no teniae, epiploic appendages, or haustra. The rectum is 12–15 cm in length. It passes through the levator ani to become the anal canal. After surgical mobilization, the rectum can be stretched to 15–20 cm in length. The valves/folds straighten out and contribute to the extra length.

The upper rectum contains one to four crescentic plicae, the rectal folds, or valves of Houston. Typically there are three folds: left superior, right middle, and left inferior. The folds are encountered by the sigmoidoscope at 4–7, 8–10, and 10–12 cm from the anal verge. The middle rectal fold corresponds to the level of the anterior peritoneal reflection

Anal Canal

The Musculature of the Wall of the Anal Canal

The anorectal ring (palpable as the puborectalis) is located at the junction of the internal anal sphincter and the levator ani complex. The anal canal is approximately 4 cm long.

Two layers of smooth muscle surround the anal canal. The innermost layer is formed by a greatly thickened circular coat which is continuous with the circular muscularis externa of the colon. This is the internal sphincter of the anal canal (Fig. 12.7). The second smooth muscle layer is composed of longitudinal fibers continuous with the fibers of the teniae coli. It descends between the internal and external anal sphincters. The lowest portions traverse the external anal sphincters.

The longitudinal muscle fibers prevent separation of the sphincteric elements from each other and also permit a telescopic movement between internal and external sphincters. We witness this in the operating room when the external sphincter rolls back and the internal sphincter rolls forward.

Composed of striated muscle, the external sphincter has three separate fiber bundles or loops: subcutaneous, superficial, and deep. It is useful to consider the three parts separately (Figs. 12.8 and 12.9), but the three loops together form an efficient anal closure. Any single one of the loops is capable of maintaining continence to solid stools but not to fluid or gas. The subcutaneous portion surrounds the outlet of the anus, attaching to the perianal skin anteriorly. Some fibers completely encircle the anus.

The superficial portion surrounds the anus and continues within the ano-coccygeal ligament, which attaches posteriorly to the coccyx. This creates the small triangular space of Minor behind the anus. Anteriorly, some fibers insert into the transverse perineal muscles at the perineal body, creating a potential space toward which anterior midline fistulas may point. The deep portion surrounds the canal, with no obvious anterior or posterior attachments. In Shafik's view, the deep portion and the puborectalis muscle are a single unit.

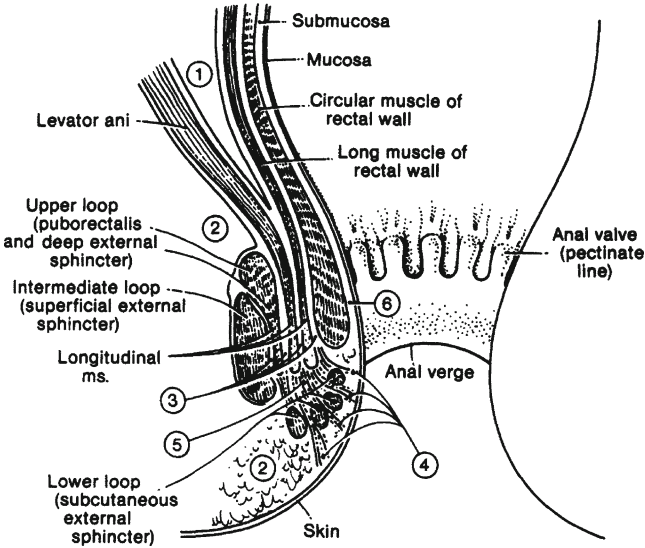


Figure 12.7. The spaces of the anus and rectum: (1) pelvirectal space; (2) ischio-rectal space; (3) intersphincteric spaces; (4) subcutaneous space; (5) central space; (6) submucous space (By permission of JE Skandalakis, SW Gray, and JR Rowe. *Anatomical Complications in General Surgery*. New York: McGraw-Hill, 1983).

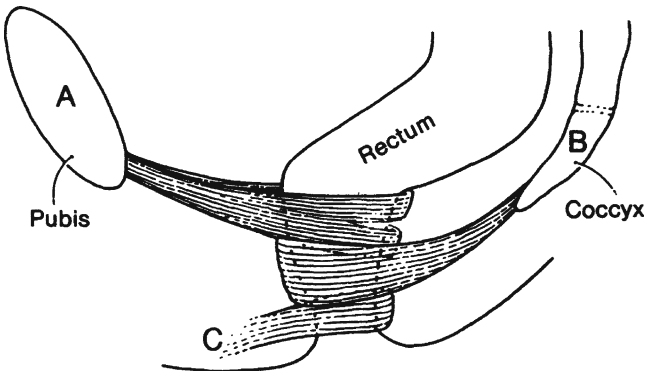


Figure 12.8. The three loops of the external anal sphincter. Each loop is a separate sphincter with distinct attachments, muscle bundles, and innervations. Continence depends on the preservation of at least one of the three. Some subcutaneous muscle fibers encircle the anus; some attach to the perianal skin anteriorly at C (By permission of JE Skandalakis, SW Gray, and JR Rowe. *Anatomical Complications in General Surgery*. New York: McGraw-Hill, 1983).

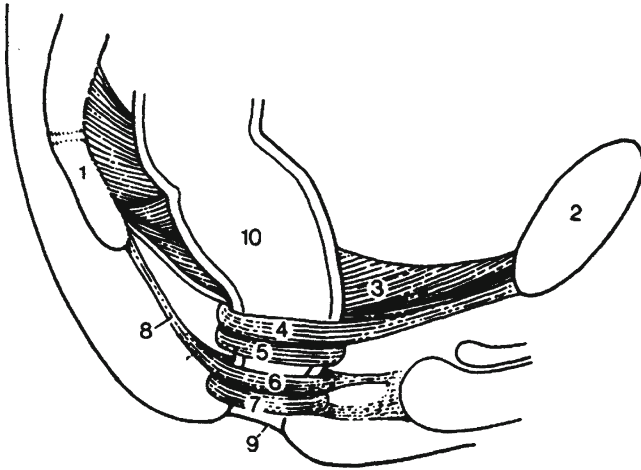


Figure 12.9. Diagram of the extrinsic muscles of the surgical anal canal. (1) Coccyx; (2) pubis; (3) levator ani muscle; (4) puborectalis muscle; (5) deep external sphincter; (6) superficial external sphincter; (7) subcutaneous external sphincter; (8) anococcygeal ligament; (9) anal verge; (10) rectum (By permission of JE Skandalakis, SW Gray, and JR Rowe. *Anatomical Complications in General Surgery*. New York: McGraw-Hill, 1983)

Lining of the Surgical Anal Canal

There are three histologic regions of the anal canal, which extend from the anal verge to approximately 1 cm above the dentate line. The *cutaneous zone*, up to the anal verge (anocutaneous line), is covered by pigmented skin that has hair follicles and sebaceous glands. Above the anal verge is the *transitional zone*, which consists of modified skin that has sebaceous glands without hair. It extends to the pectinate line defined by the free edges of the anal valves. Above the line begins the *true mucosa of the anal canal* (Fig. 12.10).

The pectinate line is formed by the margins of the anal valves—small mucosal pockets between the five and ten vertical folds of the mucosa known as the anal columns of Morgagni. An anal pit or sinus is located above each valve, draining the anal glands. These columns extend upward from the pectinate line to the upper end of the surgical anal canal, at the level of the puborectalis sling. They are formed by underlying parallel bundles of the muscularis mucosae. The actual junction of stratified squamous and columnar epithelia is usually just above the pectinate line; hence, the mucocutaneous line is not precisely equivalent to the pectinate line.

The pectinate line is the most important landmark in the anal canal. It marks the transition between the visceral area above and the somatic area below. The arterial supply, the venous and lymphatic drainage, the nerve supply, and the character of the lining all change at or very near the pectinate line (Table 12.1).

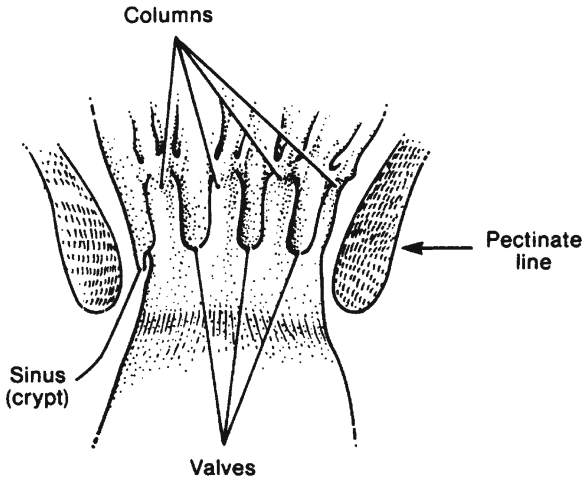


Figure 12.10. The interior of the anal canal showing the rectal columns, anal valves, and anal sinuses (crypts). They form the pectinate line (By permission of JE Skandalakis, SW Gray, and JR Rowe. *Anatomical Complications in General Surgery*. New York: McGraw-Hill, 1983).

■ PERITONEAL REFLECTIONS

The entire upper one-third of the rectum is covered by peritoneum (Fig. 12.5). The peritoneum leaves the rectum and passes anteriorly and superiorly over the posterior vaginal fornix and the uterus in females or over the superior ends of the seminal vesicles and the bladder in males. This creates a depression, the rectouterine or rectovesical pouch.

■ FASCIAL RELATIONS AND TISSUE SPACES

Shafik recognized six potential spaces around the rectum. They are important because they may become sites of infection. Knowledge of the spaces will avert injury during surgery. The fascial layers that bound these spaces help limit the spread of both infection and neoplastic disease, although all the spaces are potentially confluent with one another (Figs. 12.7 and 12.11).

The perianal space surrounds the anal canal along the anal verge and is surrounded laterally by fat. The perianal space connects to the superficial postanal space, which is the space located below the anococcygeal ligament. The perianal space also communicates with the intersphincteric space, which is located between the anal sphincters. The intersphincteric space contains most

Table 12.1 The pectinate line and changes in the surgical anal canal

	<i>Below the pectinate line</i>	<i>Above the pectinate line</i>
Embryonic origin	Ectoderm	Endoderm
Anatomy		
Lining	Stratified squamous	Simple columnar
Arterial supply	Inferior rectal artery	Superior rectal artery
Venous drainage	Systemic, by way of inferior rectal vein	Portal, by way of superior rectal vein
Lymphatic drainage	To inguinal nodes	To pelvic and lumbar nodes
Nerve supply	Inferior rectal nerves (somatic)	Autonomic fibers (visceral)
Physiology	Excellent sensation	Sensation quickly diminishes
Pathology		
Cancer	Squamous cell carcinoma	Adenocarcinoma
Varices	External hemorrhoids	Internal hemorrhoids

By permission of JE Skandalakis, SW Gray, and JR Rowe. *Anatomical Complications in General Surgery*. New York: McGraw-Hill, 1983

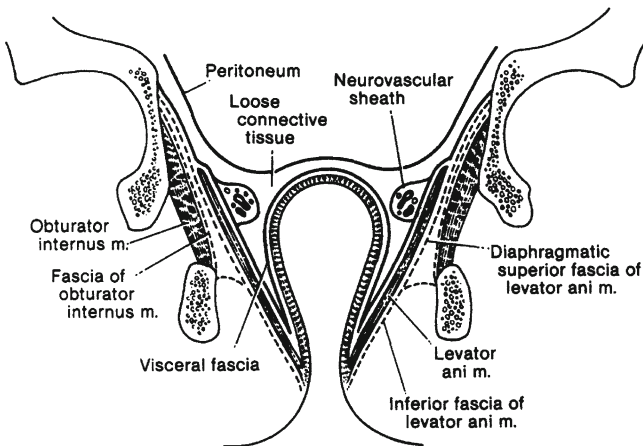


Figure 12.11. Diagram of some of the fasciae of the pelvis seen in coronal section (By permission of JE Skandalakis, SW Gray, and JR Rowe. *Anatomical Complications in General Surgery*. New York: McGraw-Hill, 1983).

of the anal glands. The ischiorectal space is lateral to the perianal space and contains the pudendal nerves and vessels. The apex of the ischiorectal space is formed by the levator and obturator muscles. The ischiorectal space is bound anteriorly by the transverse perineal muscles and bound posteriorly by the gluteal skin. Posteriorly, the ischiorectal space communicates with the deep postanal space, deep to the anococcygeal ligament. An infection communicating in this space is the horseshoe abscess.

■ PELVIC DIAPHRAGM AND CONTINENCE

The floor of the pelvis is the pelvic diaphragm (Fig. 12.12), which is composed of two paired muscles: the levator ani and the coccygeus. The levator ani can be considered to be made up of three muscles: the iliococcygeus, the pubococcygeus, and the puborectalis.

The puborectalis, the superficial and deep parts of the external sphincter, and the proximal part of the internal sphincter form the so-called anorectal ring. This ring can be palpated; since cutting through it will produce incontinence, it must be identified and protected during surgical procedures. The puborectalis is

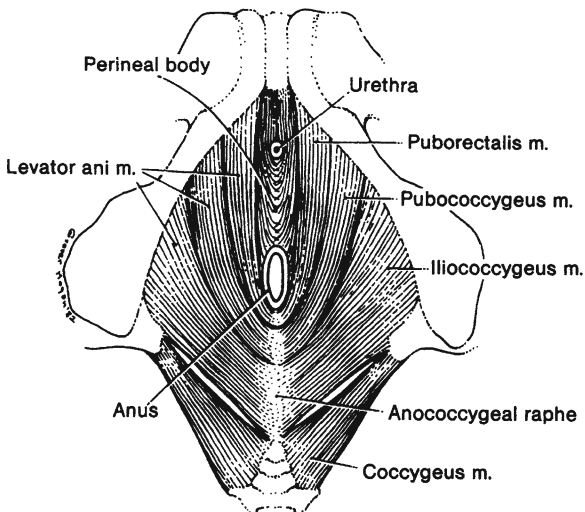


Figure 12.12. Diagram of the pelvic diaphragm from below. Note that the levator ani is composed of three muscles: puborectalis, pubococcygeus, and iliococcygeus. Some authors would exclude the puborectalis from the levator ani (By permission of JE Skandalakis, SW Gray, and JR Rowe. *Anatomical Complications in General Surgery*. New York: McGraw-Hill, 1983).

essential to maintaining rectal continence and is considered by some authors to be part of the external sphincter and not a part of the levator ani. The puborectalis is attached to the lower back surface of the symphysis pubis and the superior layer of the deep perineal pouch (urogenital diaphragm). Fibers from each side of the muscle pass posteriorly and then join posterior to the rectum, forming a well-defined sling (Fig. 12.12). The puborectalis passes adjacent to the vagina where it attaches laterally and is known as the pubovaginalis, supporting the rectum and vagina. It also supports the bladder and the urethra, pulling these anteriorly with contractions. When the puborectalis is lax, the levator sags, the anorectal angle becomes obtuse, and the pelvic floor muscles can relax. Over time, the pelvic floor weakens, a change that can lead to pelvic organ prolapse and incontinence.

■ VASCULAR SYSTEM OF THE COLON AND RECTUM

Arteries of the Colon

Superior Mesenteric Artery

The cecum and the ascending colon receive blood from two arterial branches of the superior mesenteric artery: the ileocolic and right colic arteries (Fig. 12.13). These arteries form arcades from which vasa recta pass to the medial colonic wall.

As the vasa recta reach the surface of the colon, they divide into short and long branches, the former serving the medial or mesenteric side of the colon and the latter serving the lateral and antimesenteric side. The long branches send twigs into the epiploic appendages (see Fig. 12.6).

Middle Colic Artery

The transverse colon is similarly supplied by the middle colic artery from the superior mesenteric artery. A study found that in about one-third of cases the splenic flexure was supplied by the middle colic artery; in the remainder, the flexure and the left portion of the transverse colon were supplied by the left colic artery, a branch of the inferior mesenteric artery.

Inferior Mesenteric Artery

The inferior mesenteric artery arises from the aorta opposite the lower portion of the third lumbar vertebra. The length of the artery prior to its first branch varies from 1.5 to 9.0 cm.

The branches of the inferior mesenteric artery are the left colic artery, with its ascending and descending branches for the descending colon, one to nine sigmoid arteries for the sigmoid colon, and the superior rectal (hemorrhoidal) artery for the rectum (Figs. 12.13 and 12.14c). An accessory middle colic artery is present in roughly 40 % of subjects.

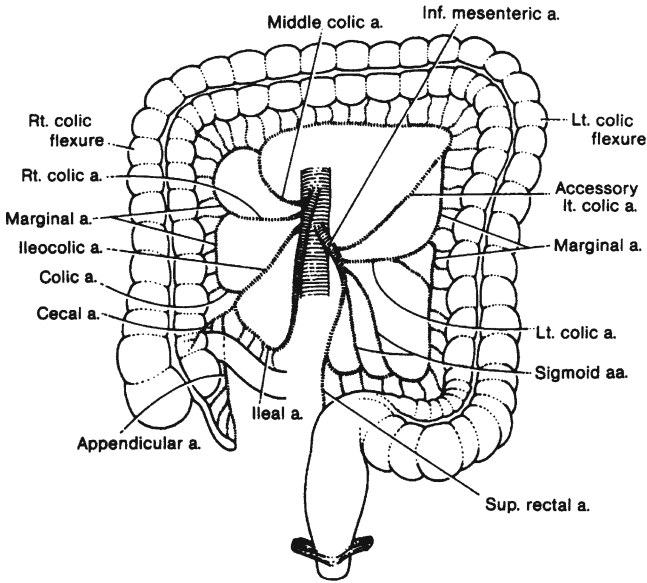


Figure 12.13. Schema of the blood supply to the large intestine. There are many variations of this basic pattern (By permission of JE Skandalakis, SW Gray, and JR Rowe. *Anatomical Complications in General Surgery*. New York: McGraw-Hill, 1983).

Division of the inferior mesenteric artery close to its root has been shown to increase the reach of the colon to the pelvis after proctectomy, leading to less tension on the colorectal or coloanal anastomosis.

Marginal Artery (of Drummond)

The marginal artery is composed of a series of anastomosing arcades between branches of the ileocolic, right colic, middle colic, left colic, and sigmoidal arteries. These form a single, looping vessel. The marginal artery courses roughly parallel with the mesenteric border of the large intestine, from 1 to 8 cm from the intestinal wall (Fig. 12.14a–c). It may or may not terminate at the superior rectal artery (Fig. 12.14c). Occasionally, however, the continuity of this artery is disrupted in one or more points.

Arteries of the Rectum and Anal Canal

The arteries of the rectum and anal canal are the unpaired superior rectal artery, the paired middle and inferior rectal arteries, and median sacral rectal arteries (Fig. 12.15). The superior rectal (hemorrhoidal) artery arises from the inferior

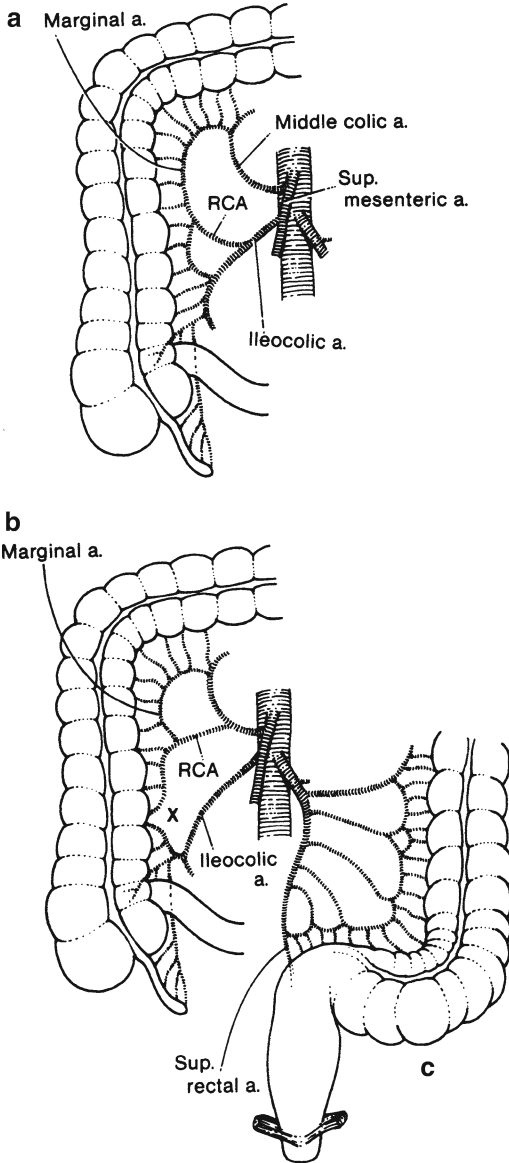


Figure 12.14. Variations of the arteries to the right colon. RCA right colic artery (a) Usual pattern. (b) The marginal artery is incomplete at "X." (c) Arteries to the left colon. There may be fewer sigmoid arteries than shown here (By permission of JE Skandalakis, SW Gray, and JR Rowe. *Anatomical Complications in General Surgery*. New York: McGraw-Hill, 1983).

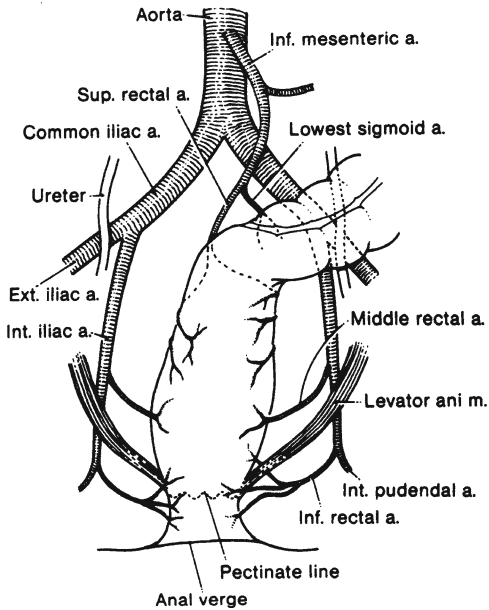


Figure 12.15. Diagram of the arterial supply to the rectum and anus. The median sacral artery supplying a few small branches to the posterior wall of the rectum is not shown in this figure (By permission of JE Skandalakis, SW Gray, and JR Rowe. *Anatomical Complications in General Surgery*. New York: McGraw-Hill, 1983).

mesenteric artery and descends to the posterior wall of the upper rectum. Supplying the posterior wall, it divides and sends right and left branches to the lateral walls of the middle portion of the rectum down to the pectinate (dentate) line.

One study has found that the main trunk of the middle rectal artery was inferior to the rectal stalk and could be endangered when the rectum is separated from the seminal vesicle, prostate, or vagina. In our experience, the middle rectal artery is usually absent in the female. It is probably replaced by the uterine artery. In the male, the chief beneficiaries of the artery are the rectal musculature and the prostate gland.

The inferior rectal (hemorrhoidal) arteries arise from the internal pudendal arteries and proceed ventrally and medially to supply the anal canal distal to the pectinate line.

The median sacral artery arises just above the bifurcation of the aorta and descends beneath the peritoneum on the anterior surface of the lower lumbar

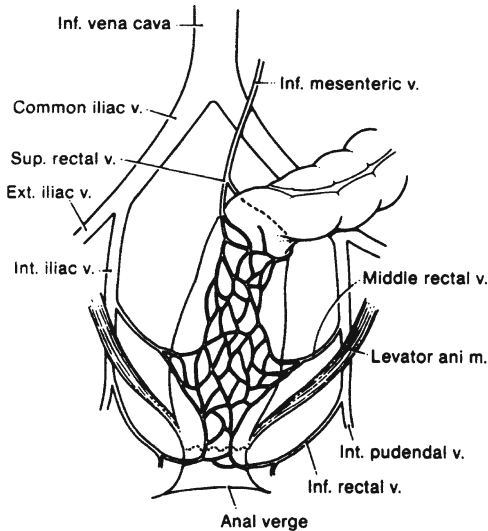


Figure 12.16. Diagram of the venous drainage of the rectum and anus. The superior rectal vein drains to the portal system, and the middle and inferior rectal veins drain to the systemic veins. The venous plexus between the veins forms a portacaval shunt (By permission of JE Skandalakis, SW Gray, and JR Rowe. *Anatomical Complications in General Surgery*. New York: McGraw-Hill, 1983).

vertebrae, the sacrum, and the coccyx. It sends several very small branches to the posterior wall of the rectum.

Venous Drainage of the Colon, Rectum, and Anus

The veins of the colon follow the arteries. On the right, the veins join to form the superior mesenteric vein. The superior rectal vein drains the descending and sigmoid colon; it passes upward to form the inferior mesenteric veins.

The rectum is drained by the superior rectal veins, which enter the inferior mesenteric veins. This drainage is to the portal system. The middle and inferior rectal veins enter the internal iliac vein and thus drain into the systemic circulation (Fig. 12.16).

Remember:

- ✓ Anastomoses occur between the superior rectal vein (portal) and the middle and inferior rectal veins (systemic), constituting a potential portosystemic shunt.

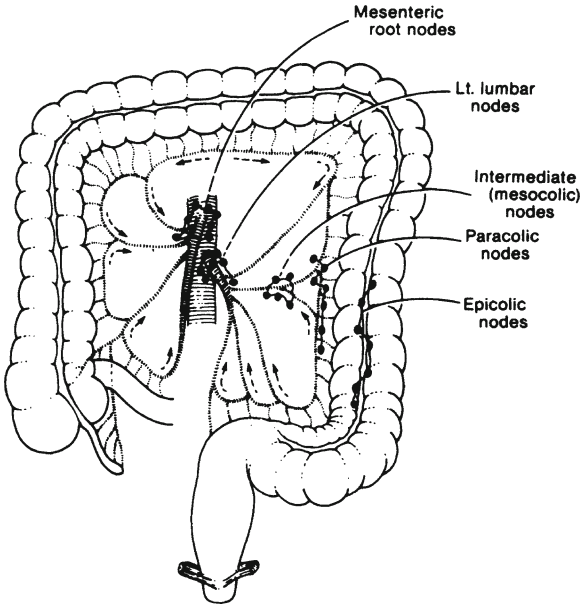


Figure 12.17. The lymphatics of the colon follow the arteries and drain to the principal nodes at the root of the mesentery. The path is by way of the epicolic, paracolic, and mesocolic lymph nodes (By permission of JE Skandalakis, SW Gray, and JR Rowe. *Anatomical Complications in General Surgery*. New York: McGraw-Hill, 1983).

Lymphatic Drainage of the Colon

The lymph nodes of the large intestine have been divided into four groups: epicolic, under the serosa of the wall of the intestine; paracolic, on the marginal artery; intermediate, along the large arteries (superior and inferior mesenteric arteries); and principal, at the root of the superior and inferior mesenteric arteries (Fig. 12.17). This last group includes mesenteric root nodes (which also receive lymph from the small intestine), aortic nodes, and left lumbar nodes.

Wide resection of the colon should include the entire segment supplied by a major artery. This also will remove most, but not all, of the lymphatic drainage of the segment (Fig. 12.18).

Lymphatic Drainage of the Rectum and Anal Canal

The lymph channels of the rectum and anal canal form two extramural plexuses, one above and one below the pectinate line. The upper plexus drains through the posterior rectal nodes to a chain of nodes along the superior rectal

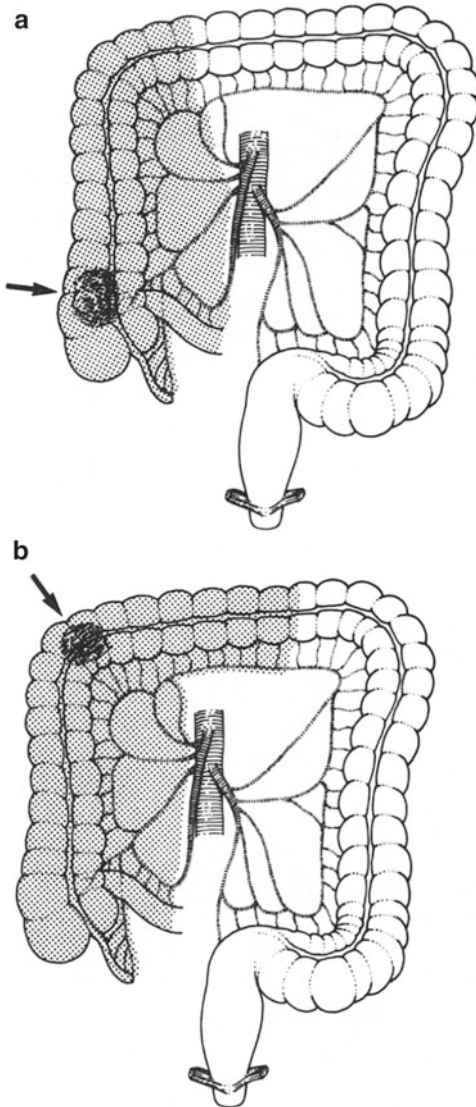


Figure 12.18. Resection of the colon should include the entire area served by a major artery as well as the lesion itself. Most of the lymphatic drainage will be included. Areas of resection (*shaded*) for lesions in various segments of the colon are shown in (a–f). An *arrow* indicates the site of the lesion (By permission of JE Skandalakis, SW Gray, and JR Rowe. *Anatomical Complications in General Surgery*. New York: McGraw-Hill, 1983).

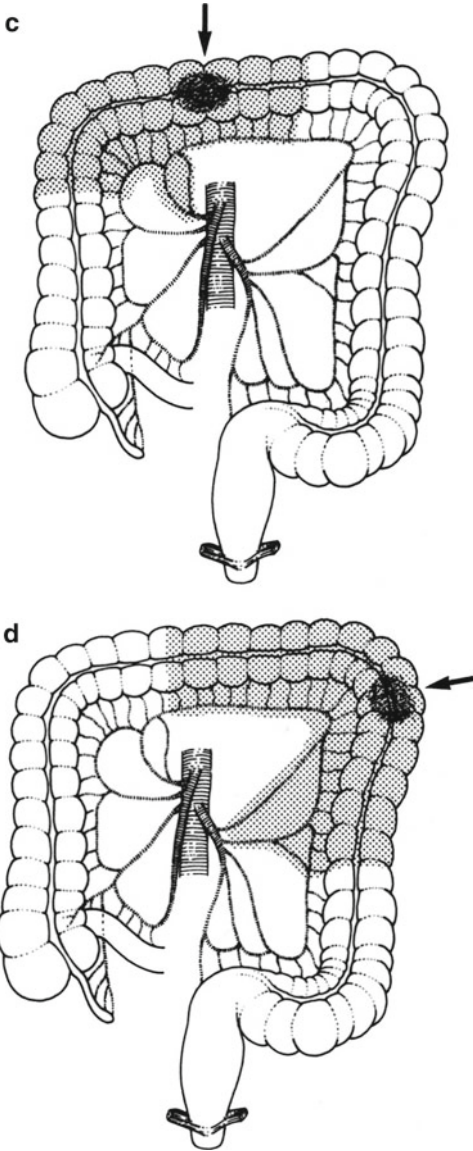


Figure 12.18. (continued)

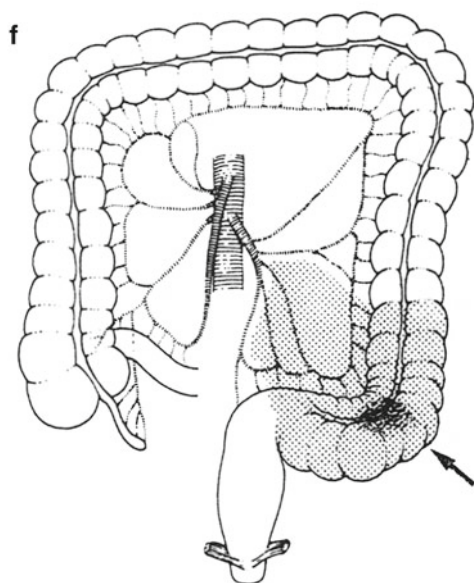
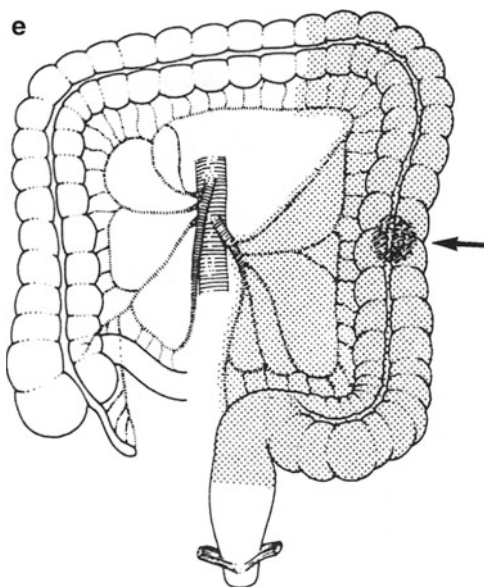


Figure 12.18. (continued)

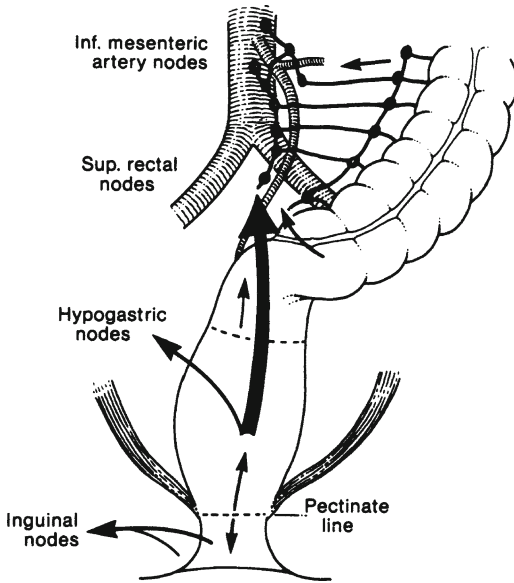


Figure 12.19. Lymphatic drainage of the sigmoid colon, rectum, and anus. Above the pectinate line, drainage is to the inferior mesenteric nodes. Below the line, drainage is to the inguinal nodes (By permission of JE Skandalakis, SW Gray, and JR Rowe. *Anatomical Complications in General Surgery*. New York: McGraw-Hill, 1983).

artery to the pelvic nodes (Fig. 12.19). Some drainage follows the middle and inferior rectal arteries to the hypogastric nodes. Below the pectinate line, the plexus drains to the inguinal nodes.

The “watershed” of the extramural lymphatic vessels is at the pectinate line. The watershed for the intramural lymphatics is higher, at the level of the middle rectal valve (Fig. 12.20). These two landmarks may be kept in mind by the mnemonic “two, four, eight,” meaning:

- 2 cm = anal verge to pectinate line
- 4 cm = surgical anal canal (above and below the pectinate line)
- 8 cm = anal verge to middle rectal valve

Downward spread of lesions of the rectum is rare; perhaps only 2 % may spread downward. A margin of 2–3 cm distal to the tumor should be allowed in anterior resection.

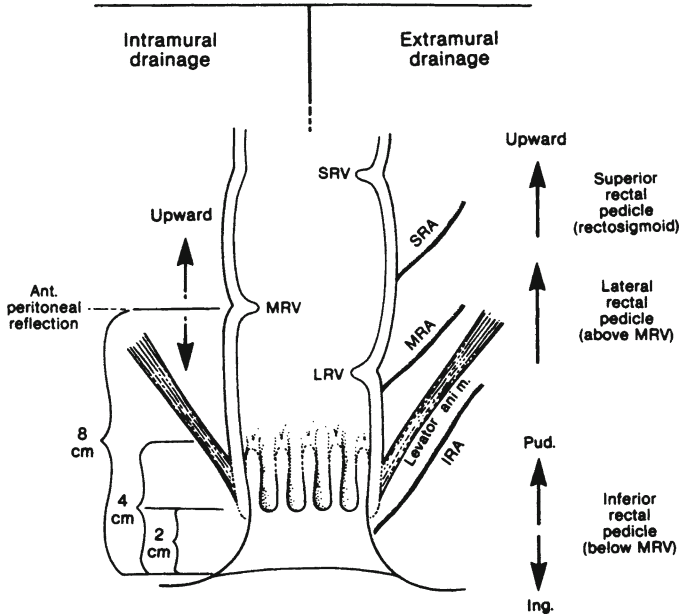


Figure 12.20. Diagram of lymph drainage of the anus and rectum. The watershed for extramural drainage is at the pectinate line (Figure 12.19). The watershed for intramural drainage is at the level of the middle rectal valve, about 8 cm above the anal verge. *IRA* inferior rectal artery, *MRA* middle rectal artery, *SRA* superior rectal artery, *LRV* lower rectal valve, *MRV* middle rectal valve, *SRV* superior rectal valve (By permission of JE Skandalakis, SW Gray, and JR Rowe. *Anatomical Complications in General Surgery*. New York: McGraw-Hill, 1983).

■ NERVE SUPPLY OF THE RECTUM AND ANUS

Motor innervation of the internal rectal sphincter is supplied by sympathetic fibers that cause contraction and by parasympathetic fibers that inhibit contraction. The parasympathetic fibers are carried by pelvic splanchnic nerves which also convey the afferent nerve fibers that mediate the sensation of rectal distention. The external rectal sphincter is innervated by the inferior rectal branch of the internal pudendal nerve and by the perineal branch of the fourth sacral nerve.

The pelvic splanchnic nerves (parasympathetic and sensory) and the hypogastric nerve (sympathetic) supply the lower rectal wall. These two sources together form the rectal plexus. The levator ani muscles are supplied by the nerve to the levator ani, usually a branch from S4, with variant contributions from S3 and S5.

454 12. Colon and Anorectum

The inferior rectal branches of the internal pudendal nerve follow the inferior rectal arteries and supply the sensory innervation of the perianal skin.

Remember:

- ✓ The pudendal nerve innervates the external sphincter and possibly the puborectalis muscle. The sympathetic nerves have no influence on the muscular wall of the rectum. Evacuation is accomplished by the pelvic splanchnic nerves; continence is maintained by the pudendal and the pelvic splanchnic nerves.

TECHNIQUE

■ DECALOGUE OF GOOD COLON SURGERY

1. Bowel preparation of choice.
2. Administer intravenous antibiotics within 1 h of making your incision during the surgery and for 24 h afterward.
3. Use orogastric/nasogastric tube and Foley catheter when appropriate.
4. Understand anatomy of blood supply and lymphatics. When performing cancer surgery, ligate vessels at their origins.
5. Good technique for performing anastomosis includes:
 - a. Observing whether the cut edges of the intestinal segments to be anastomosed have good texture and color and are bleeding slightly. Avoid formation of hematmata at the anastomotic area.
 - b. Clearing all fatty tissue from the anastomotic area by removing, without traction, the mesenteric border and the epiploic appendages.
6. Avoid tension on the anastomosis.
7. Use headlight.
8. Be familiar with all surgical procedures and their modifications.
9. Identify the ureters to avoid injury.
10. Reapproximate the mesentery to avoid internal hernias.

■ CECOPEXY

Occasionally, the cecum and ascending colon are very mobile (Fig. 12.21). To avoid volvulus of the right colon and, therefore, intestinal obstruction, a cecopexy extending up to the ascending colon is performed. Suture the cecal and ascending tenia to the lateral peritoneum with interrupted 3-0 synthetic absorbable material or silk, and perform an appendectomy (Fig. 12.22).

■ COLOSTOMY

Loop Colostomy

A loop colostomy (Fig. 12.23) is feasible only in the transverse or sigmoid colon because a mesentery is required. If the transverse mesocolon is short, mobilization of the hepatic and splenic flexures will provide a more mobile loop.

Sigmoid loop colostomy is, for practical purposes, left colon colostomy. The stoma should be located at the junction of the descending and the sigmoid

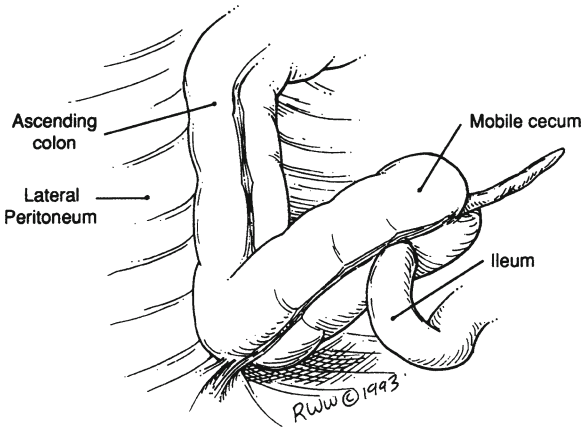


Figure 12.21. Mobile cecum.

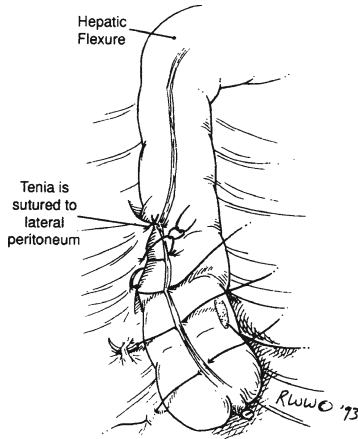


Figure 12.22. Teniae have been sutured.

colon so that the peritoneal fixation of the descending colon will protect the proximal stoma from prolapse.

Loop Transverse Colostomy

- Step 1.** Make a 4- to 6-cm transverse incision at the right, or occasionally left, lateral border of the rectus abdominis muscle (Fig. 12.24).
- Step 2.** Divide the anterior rectus sheath, rectus abdominis muscle, and posterior sheath.

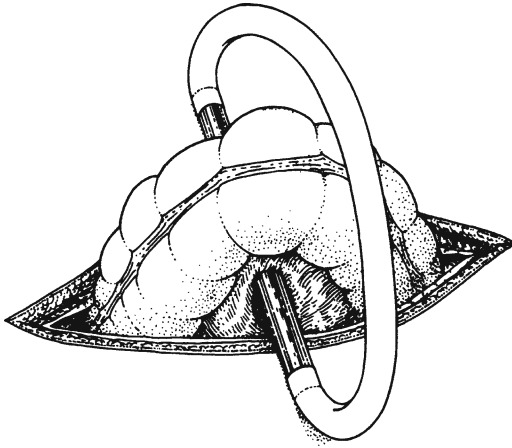


Figure 12.23. Loop colostomy. The loop of colon has been brought through the incision, held in place by a glass tube with rubber tubing connecting its ends (By permission of JE Skandalakis, SW Gray, and JR Rowe. *Anatomical Complications in General Surgery*. New York: McGraw-Hill, 1983).

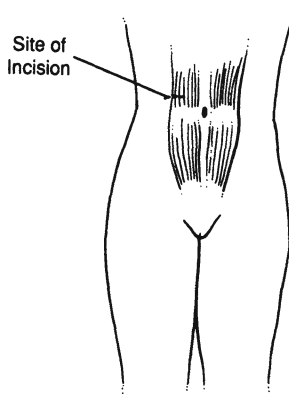


Figure 12.24. Transverse incision.

- Step 3.** Deliver the transverse colon into the wound outside the peritoneal cavity and form a small hole at the omentum and the mesenteric border of the colon to permit the entrance of a plastic rod (Fig. 12.25).
- Step 4.** Open the colon as shown and mature to the skin with 4-0 Vicryl sutures (Fig. 12.26). However, maturation of the colostomy in the operating room depends on the philosophy of the surgeon (Fig. 12.27).

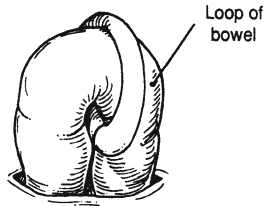


Figure 12.25. Colon loop.

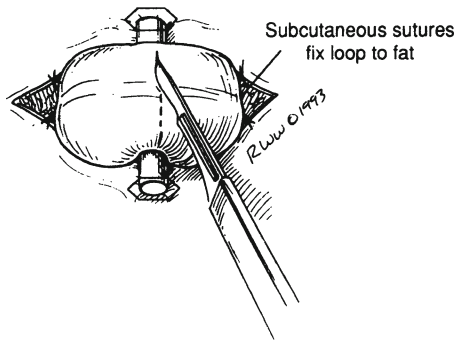


Figure 12.26. Fixation sutures.

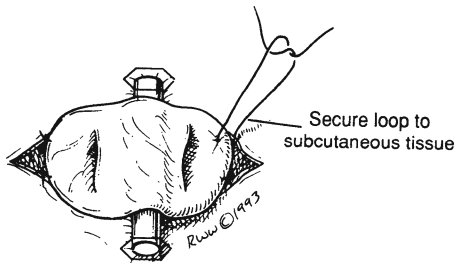


Figure 12.27. The loop transverse colostomy.

End Colostomy

The stoma is located along the lower descending colon or along the upper sigmoid colon. Preoperative marking for stoma sites is of utmost importance as it will decrease the number of complications due to poor placement (dermatitis,

poor pouching, hernias). Good mobilization of the colon is essential, especially when the stoma is at the lower descending colon or at the iliac part of the sigmoid colon. The mesenteric root should be incised very carefully to avoid bleeding, which would jeopardize the vitality of the bowel. The procedures of end colostomy are the same as in left colectomy, except that the proximal end is secured to a skin opening and the distal loop is reinserted into the peritoneal cavity.

- Step 1.** In the vicinity of the left lower quadrant, excise a round piece of skin approximately 2 cm in diameter. Use electrocoagulation for the division and separation of fat. Expose the fascia and make a longitudinal incision (Fig. 12.28a–d).
- Step 2.** Separate the rectus muscle fibers longitudinally and expose the peritoneum as in appendectomy (Fig. 12.28e). Direct two fingers from the original incision to the new, round one (Fig. 12.29). Open the peritoneum and insert a Babcock clamp through the skin opening into the peritoneal cavity and grasp the proximal end of the colon. Gently manipulate the end through the skin. The authors prefer a length of 4–5 cm of proximal colon to hang outside the skin.
- Step 3.** If the surgeon prefers operating room maturation, then the closed end of the proximal colon should be excised. The full thickness of the colonic wall is sutured with 4-0 Vicryl absorbable sutures to the seromuscular wall and then to the edges of the skin. The tip of the stoma should be located about 1 cm above the skin level to allow for ease of pouching.

Prasad End Loop Colostomy

- Step 1.** Prior to surgery, place a mark for the stoma close to the obstruction (Fig. 12.30). Note where the patient wears his/her waistband. Avoid folds of fat. Have the patient sit upright to ensure appropriate marking.
- Step 2.** Using a GIA stapler, perform a typical segmental colectomy appropriate to the disease.
- Step 3.** Bring the proximal end of the colon through the abdominal wall. Then deliver the antimesenteric corner of the distal colonic staple line through the skin incision (Fig. 12.31).
- Step 4.** Mature the proximal colon by removing the staple line and suturing the edges to the seromuscular wall and then to the edges of the skin using 4-0 Vicryl absorbable sutures. The tip of the stoma should be located about 1 cm above the skin level to allow for ease of pouching. The distal colon is then matured by removing the stapled corner and fixing it to the proximal colon and to the skin (Figs. 12.32 and 12.33).

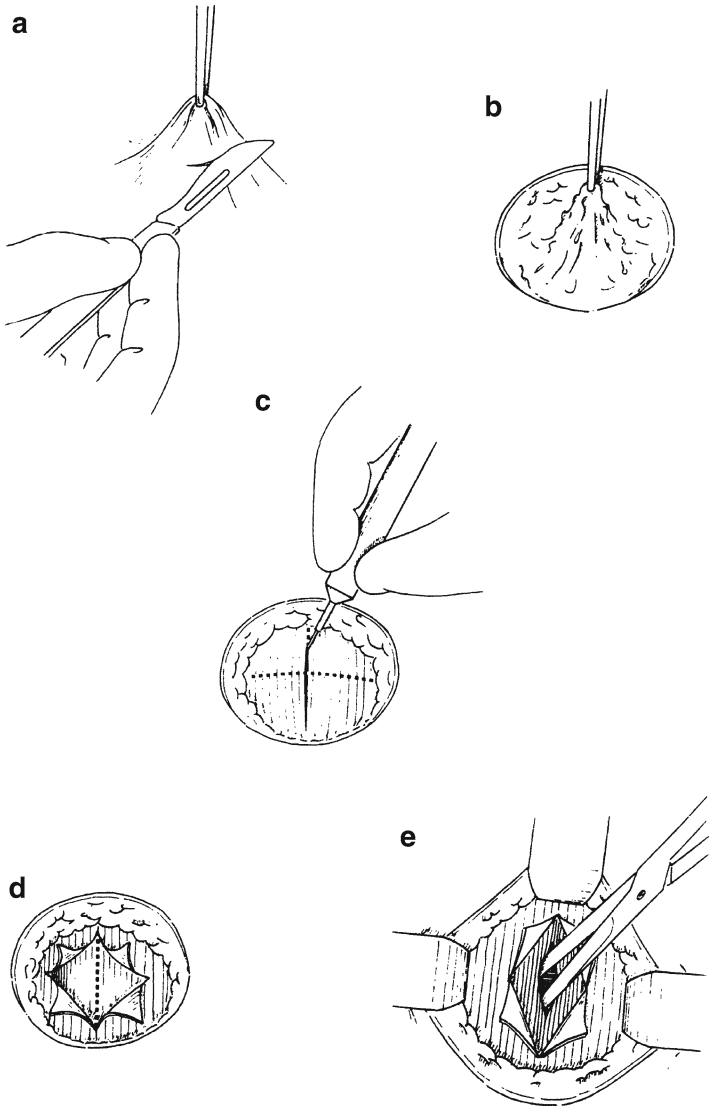


Figure 12.28. (a) Excision, (b) separation of fat, (c) division of muscles, (d) exposure, and (e) opening.

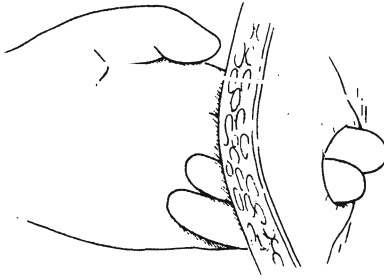


Figure 12.29. Insertion of fingers.

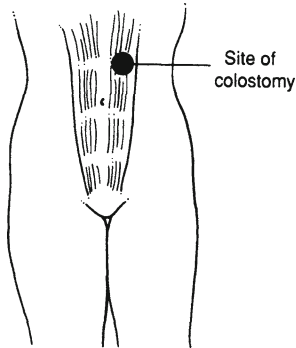


Figure 12.30. Stoma site.

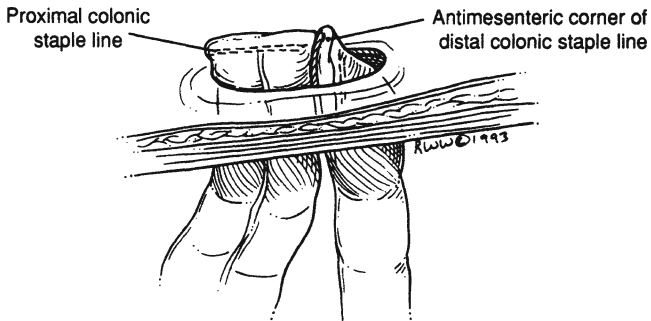


Figure 12.31. Delivering the divided colon.

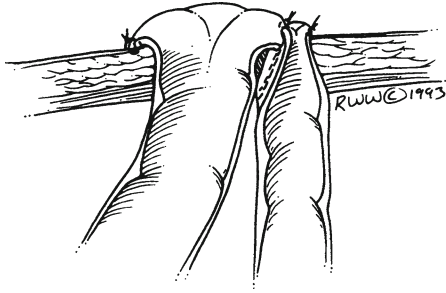


Figure 12.32. Relation of stoma to skin level.

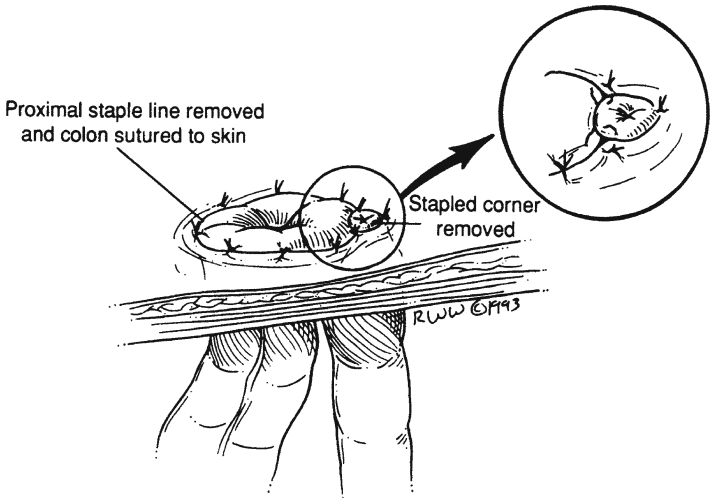


Figure 12.33. The matured stoma. *Inset*: Fixation of distal colon.

■ COLON RESECTION

Figure 12.18 shows the extent of colectomy recommended for cancer at various sites in the colon. A standard right colectomy is essentially a midline resection, including a few centimeters of the terminal ileum, the cecum, right colon, and proximal half of the transverse colon. These are the segments served by the ileocolic, right colic, and right branches of the middle colic arteries (Fig. 12.18b).

In left colectomy, the lowest sigmoid artery may be too short for adequate sigmoid resection.

PREOPERATIVE PREPARATION:

- Colonoscopy and biopsy
- Mark lesion submucosally with India ink
- Consider ureteral stent placement, especially if the patient has had prior surgeries, inflammation, or radiation
- Orogastric/nasogastric tube, Foley catheter, warming elements in the operating room
- Bowel preparation, including mechanical prep of choice, and intravenous antibiotics prior to incision

POSITION: Supine or lithotomy

ANESTHESIA: General

INCISION: Surgeon preference

Right Colectomy (Fig. 12.18a)

- Step 1.** As soon as the abdomen is open, decide whether to use the routine or no-touch technique. With the no-touch technique that we prefer, we proceed as follows:
 - a. Lumina of terminal ileum and transverse colon can be occluded with umbilical tape or atraumatic clamps proximal and distal to the tumor (Fig. 12.34).
 - b. Vessels are ligated at their origin (at the superior mesenteric artery or superior mesenteric vein) for complete isolation of the lymphovascular tree (Figs. 12.34 and 12.35).
- Step 2.** Explore the peritoneal cavity, saving until last the vicinity of pathology, i.e., the cecum, ascending colon, or right transverse colon.
- Step 3.** Make a very superficial incision at the mesentery indicating the line of resection, which should be lateral to the umbilical tape ligatures (Figs. 12.34 and 12.35).
- Step 4.** Carefully mobilize the right colon (cecum, ascending, right transverse) by incising the peritoneal reflection of the paracolic area. Elevate the colon with the index finger, protecting the duodenum, right ureter (over the right common iliac artery), and superior mesenteric vessels (Fig. 12.35).
- Step 5.** Carry out partial omentectomy, removing the right 3/4 of the greater omentum, including the corresponding part of the gastrocolic ligament, if necessary (Fig. 12.36).
- Step 6.** Ligate the two lymphovascular pedicles (ileocolic and middle colic), keeping in mind that occasionally the right colic artery springs

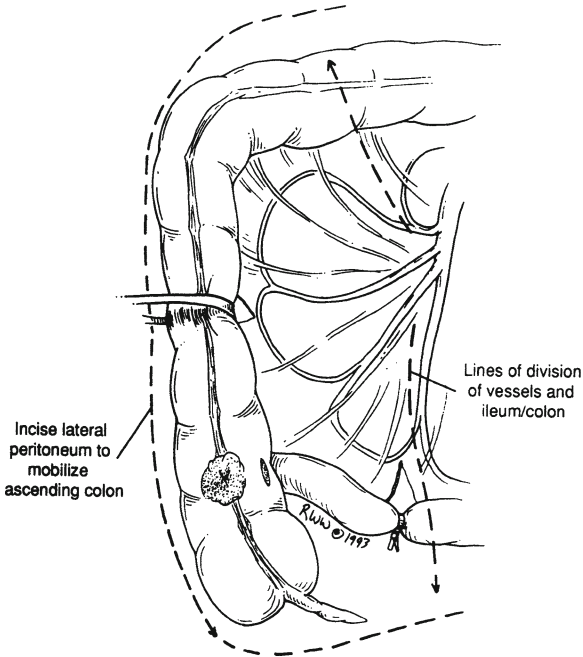


Figure 12.34. Lines of vascular division. Incision site.

directly from the superior mesenteric artery. These ligations should be done carefully to avoid injury to the superior mesenteric vessels as well as to branches of the middle colic supplying the left transverse colon.

Remember:

- ✓ There are several variations to the anatomy here. Ligate the vessels twice using Mixer clamps or a reliable vessel-sealing source.

Step 7. Be sure that both colon and ileum have a good blood supply. We prefer a side-to-side ileotransverse anastomosis using the stapling device. This is done as follows:

- a. Division of the ileum by GIA stapler (Fig. 12.37).
- b. Division of the colon by GIA stapler (Fig. 12.37).
- c. Align colon and ileum side by side with their antimesenteric edges adjacent to each other (Fig. 12.38).
- d. Partial excision of the antimesenteric corner of the stapled ileal and colonic edges.

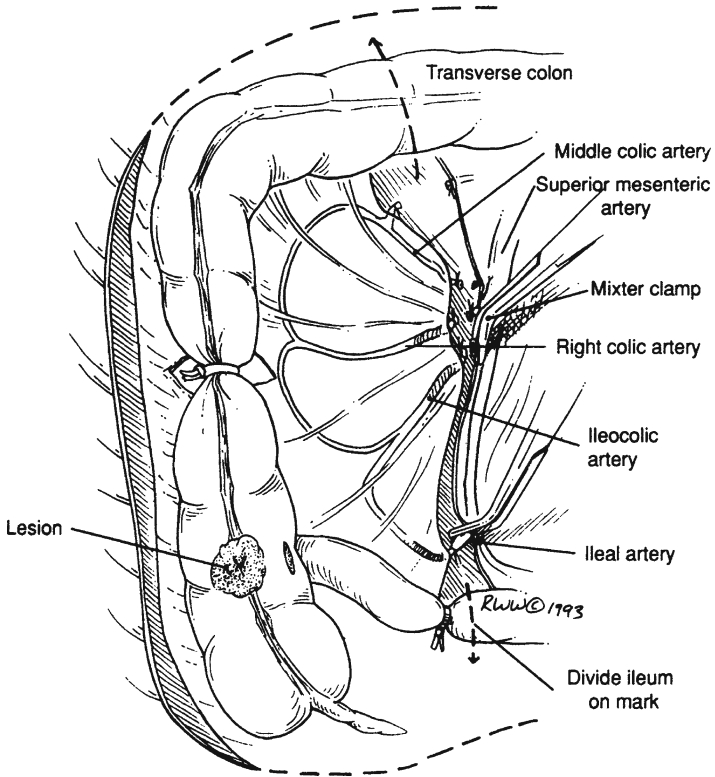


Figure 12.35. Line of resection.

- e. At the defect, insert the two parts of the GIA stapler, one into the ileal lumen and the other into the colonic lumen. Be sure that the ends of the two parts are at the same point. Fire the instrument. Remove the GIA stapler, inspect the lumina for bleeding, and use the TA stapler to close the triangular areas (Fig. 12.39). The authors like to reinforce the staple line with a few interrupted 3-0 silk Lembert sutures.

Step 8. Close the mesenteric defect with interrupted 3-0 silk/Vicryl.

Note:

- ✓ Alternatively, a two-layer end-to-end anastomosis can be done using a running 3-0 chromic for the mucosal layer and interrupted 3-0 silk Lembert sutures for the seromuscular layer (Fig. 12.40).

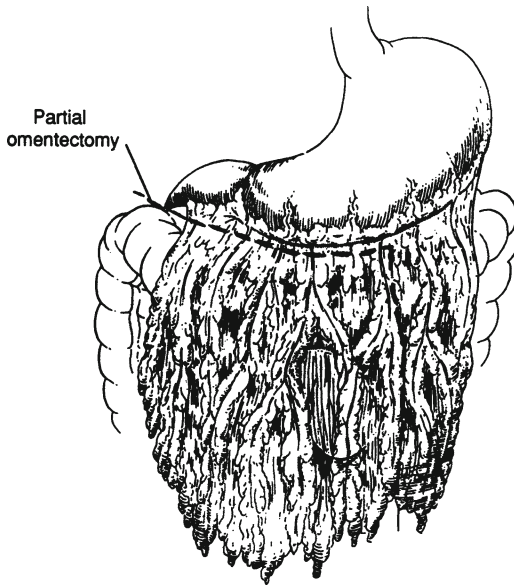


Figure 12.36. Partial omentectomy.

Left Colectomy

Medial to Lateral Approach

Step 1. As soon as the abdomen is open, determine the portion of colon to be removed by identifying the site of the lesion. Evaluate for margins of resection. Identify the vessels to be ligated at their origin:

- a. Origin at the root of the inferior mesenteric vessels in cases of malignancy, for complete isolation of the lymphovascular tree (Fig. 12.18e)
- b. Origin at the root of the left colic vessels (Fig. 12.18d) or sigmoidal branches, for benign disease (Fig. 12.18f)

Step 2. Explore the peritoneal cavity, saving until last the vicinity of pathology, i.e., the distal transverse colon, the left colon, and the sigmoid colon.

Step 3. Retract the left colon at the ligament of Treitz. Make a very superficial incision at the mesentery indicating the line of resection to isolate the inferior mesenteric vein (found at the level of the

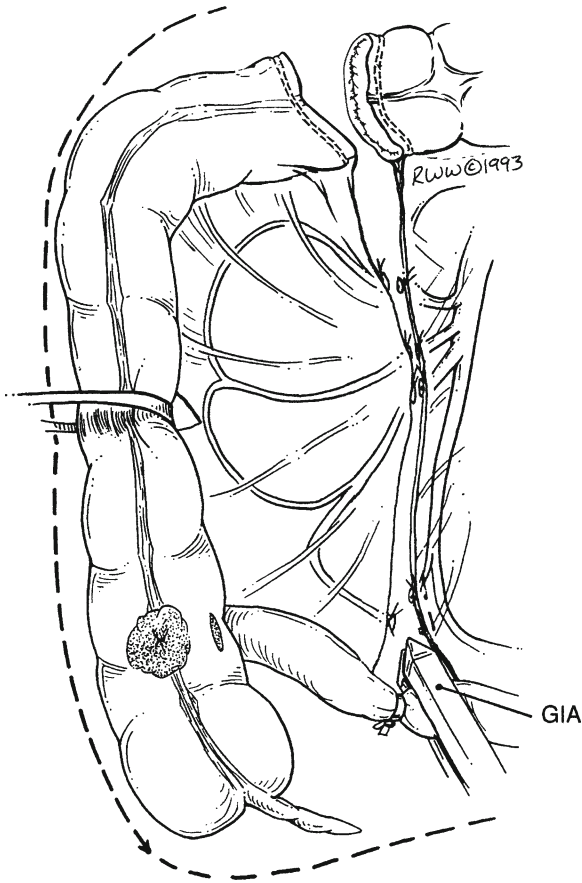


Figure 12.37. Colon and ileum divided.

ligament of Treitz) and artery (found anterior to the aorta above the bifurcation of the common iliac artery). Ligate the pedicles.

Step 4. Carefully mobilize the left colon (distal transverse colon, descending colon, proximal sigmoid colon) by incising the peritoneal reflection of the paracolic area. Elevate the colon with the index finger, protecting the duodenum, tail of pancreas, and left ureter.

Step 5. Carry out partial omentectomy, if necessary.

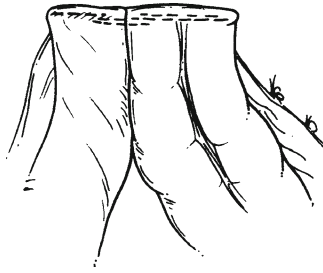


Figure 12.38. Alignment of colon and ileum.

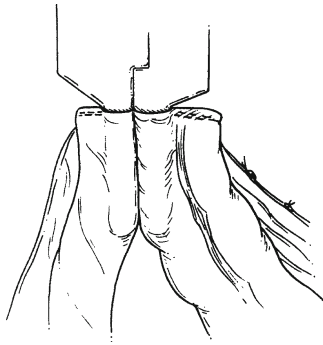


Figure 12.39. Insertion of stapler.

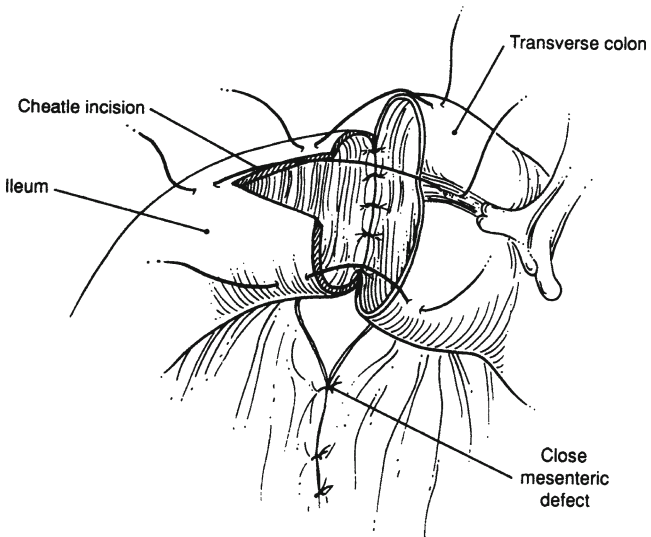


Figure 12.40. Anastomoses.

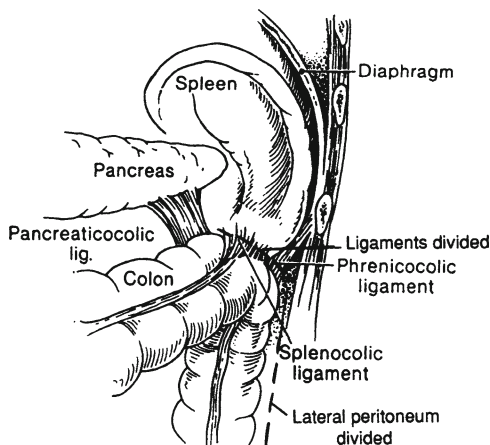


Figure 12.41. Relation of the pancreaticocolic, phrenicocolic, and splenocolic ligaments to the transverse mesocolon (By permission of JE Skandalakis, GL Colborn, LB Pemberton, et al. *Prob Gen Surg* 7(1):1–17, 1990).

Many steps for this procedure are similar to the right colectomy. There are three dangerous points, from above downward (from the left upper quadrant to the pelvis):

- The splenocolic, phrenicocolic, and pancreaticocolic ligaments should be divided carefully to avoid rupture of the splenic capsule or injury to the pancreas (Fig. 12.41).
- Avoid injury to the third portion of the duodenum, which almost always covers the origin of the inferior mesenteric artery and its downward continuation, the superior rectal artery. The third part of the duodenum is especially vulnerable if it is located low.
- Identify the left ureter, which may be found crossing the left common iliac vessels. Knowing its location minimizes the possibility it will be injured (Fig. 12.42).

Remember:

- ✓ The reverse Trendelenburg position can be helpful to mobilize the splenic flexure.

Step 6. Be sure that both ends of colon have a good blood supply. We prefer a side-to-side colocolic anastomosis using the stapling device. This is done as follows:

- a. Division of the proximal colon by GIA stapler.
- b. Division of the distal margin of colon by GIA stapler.

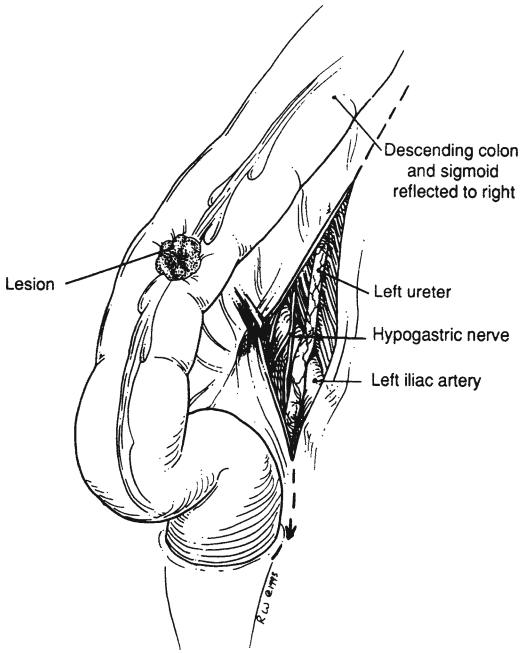


Figure 12.42. Location of left ureter.

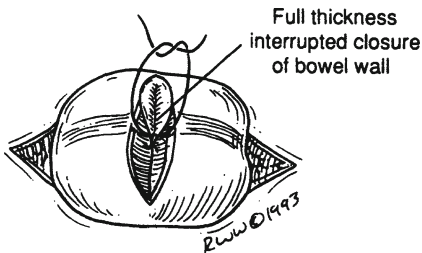


Figure 12.43. Alignment for closure.

- c. Align the two ends of colon side by side with their antimesenteric edges adjacent to each other (Fig. 12.43).
- d. Partial excision of the antimesenteric corners of the two stapled colonic edges.
- e. At the defect, insert the two parts of the GIA stapler, one into the proximal colon lumen and the other into the distal colonic lumen. Be sure that the ends of the two parts are at the same point.

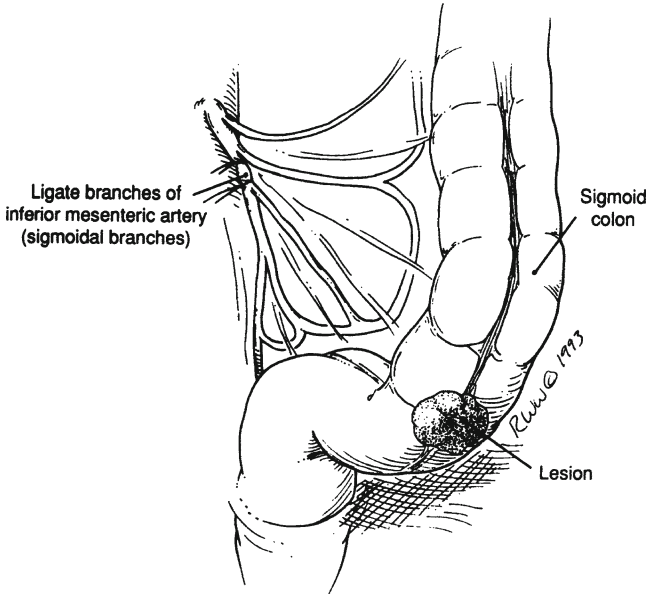


Figure 12.44. Ligation of vessels.

Fire the instrument. Remove the GIA stapler, inspect the lumina for bleeding, and use the TA stapler to close the triangular areas. The authors like to reinforce the staple line with a few interrupted 3-0 silk Lembert sutures.

Step 7. If possible, close the mesenteric defect with interrupted 3-0 silk/Vicryl.

Low Anterior Resection, Triple-Staple Procedure (Fig. 12.18f)

Study the previous information on left colectomy. Mobilize the splenic flexure to avoid tension on your colorectal anastomosis. Dissect under the superior rectal artery to the left colic artery and inferior mesenteric artery. Ligate the vessels (Fig. 12.44).

Step 1. Mobilize the rectosigmoid colon: incise the lateral peritoneal reflection upward to the splenic flexure; incise gently downward to the sacral promontory and the presacral area. Sharp dissection with electrocautery should be used. Blunt dissection by the surgeon's hand is not advisable (Fig. 12.45).

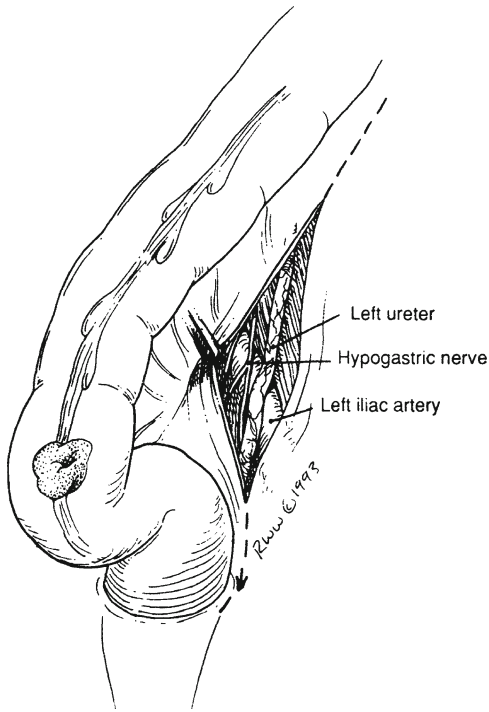


Figure 12.45. Exposure of presacral fascia.

Remember:

- ✓ The presacral fascia is part of the endopelvic fascia, without lymphatics, and it is not necessary to remove it. Invasion of the fascia by cancer means it is not curable (Fig. 12.45).
- ✓ Between the fascia and the presacral periosteum, a network of veins drains into the sacral foramina. To avoid bleeding and injury to the fascia, dissect very close to the posterior colonic wall; bleeding is extremely difficult to stop, even with ligation of both hypogastric arteries. Inserting tacks at the bleeding points is helpful (Fig. 12.46). Floseal spray can be useful. A small section of rectus muscle can be excised and cauterized to the bleeding point to seal the site.
- ✓ To avoid dysfunction of the urinary bladder, as well as impotence in the male, dissect the left ureter carefully because it travels together with the left hypogastric nerve. Both are located at the posterolateral pelvic wall and hypogastric artery, and the nerve is medial to the ureter (Fig. 12.45).

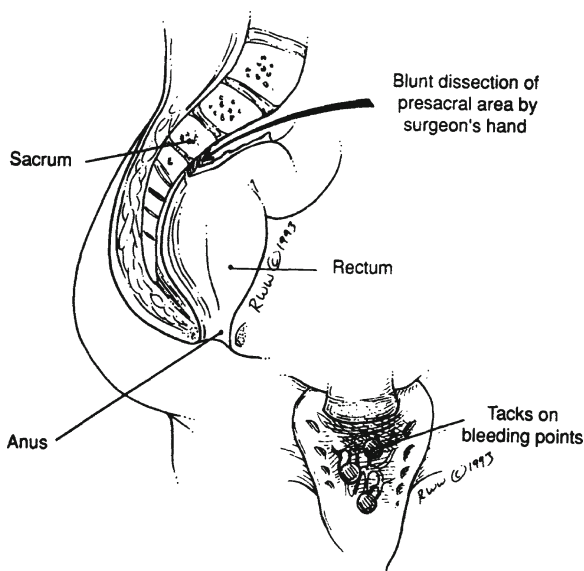


Figure 12.46. Dissection at posterior colonic wall. Inset: Locations for tacks.

- Step 2.** In males, dissect at the prostatic area by dividing Denonvilliers fascia. In females, divide the cul-de-sac and further separate the urinary bladder and vaginal wall from the rectum.
- Step 3.** After satisfactory mobilization of the rectosigmoid, ligate the lymphovascular elements as described in the left colon resection and proceed downward for further vascular ligation and further careful rectal detachment, as described above (steps may vary depending on sex, local topographical anatomy, and obesity of the patient).
- Step 4.** Place a TA stapler approximately 3–4 cm below the tumor and fire, thus placing a double row of staples across the rectosigmoid. Place an angled bowel clamp proximal to the staple line and divide the colon between the staple line and the bowel clamp (Fig. 12.47). Alternatively, a curved Contour stapler can be used.
- Step 5.** Place a bowel clamp where the proximal line of excision is to be, divide the colon, and remove the specimen.
- Step 6.** *The triple-staple technique.* This is accomplished by inserting the anvil of the EEA into the proximal colon and then stapling the colon closed with the anvil inside (Fig. 12.48). The anvil-connecting end, which is cone shaped and sharp, can then be pushed through the line of staples.

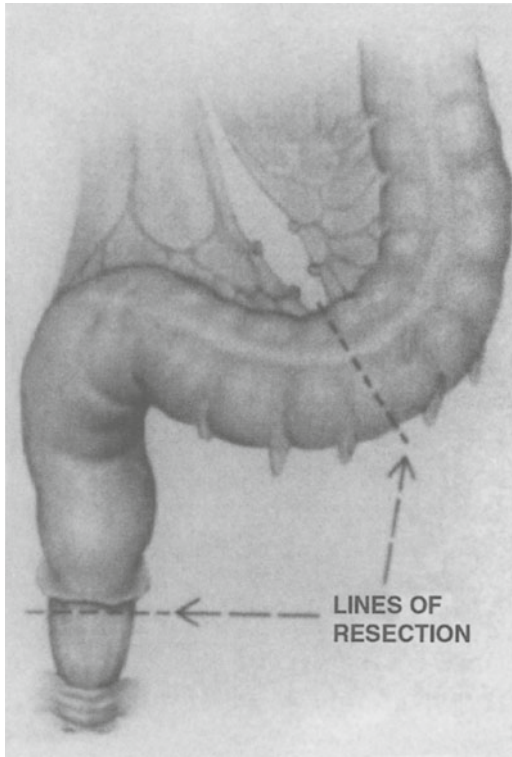


Figure 12.47. Resection sites (Copyright 1980, 1994, United States Surgical Corporation. All rights reserved. Reprinted with the permission of the United States Surgical Corporation).

- Step 7.** Next insert the EEA into the rectum, and when up against the staple line, begin to turn the knob on the device so that the connector end (also sharp and cone shaped) will slide through the TA staple line (Fig. 12.49).
- Step 8.** Next the connectors from the anvil and the EEA snap together (Fig. 12.50). The knob at the end of the EEA is then slowly turned, thus approximating the proximal colon and distal rectum (Fig. 12.51).
- Step 9.** When they are correctly approximated as indicated on the dial of the EEA, the device can be fired. The knob on the EEA is then opened one turn, and the EEA is then rotated gently and removed from the rectum.

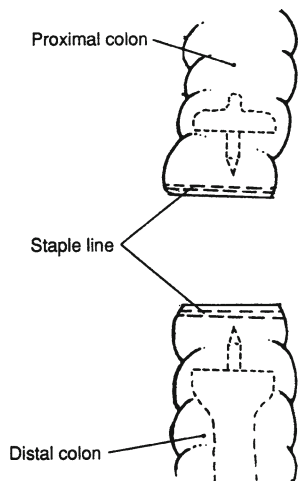


Figure 12.48. The triple-staple technique: staple line.

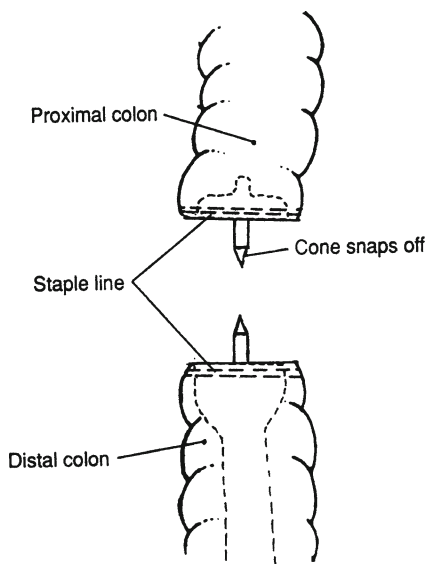


Figure 12.49. Advancing through the staple line.

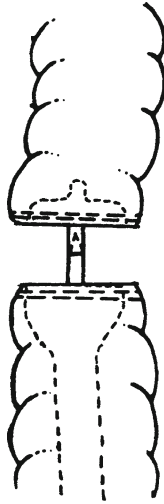


Figure 12.50. Connectors snap together.




Figure 12.51. Approximation of proximal colon and distal rectum.

Note:

- ✓ There should be two complete doughnuts of tissue present in the EEA indicating a satisfactory anastomosis (if the surgeon has any doubt about the anastomosis, a temporary colostomy or diverting loop ileostomy can be done. One month following the surgery a low-pressure Gastrografin enema can be done, and if no leakage occurs, the ostomy can be closed).

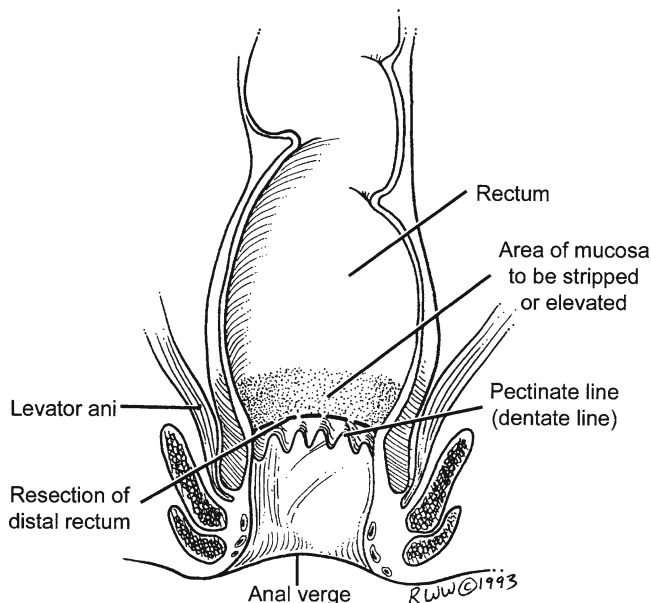


Figure 12.52. Proctocolectomy.

Step 10. Air test the colorectal anastomosis. Occlude the bowel proximal to the colorectal anastomosis. Fill the pelvis with saline irrigation and submerge the anastomosis. Inspect the anastomosis with a rigid proctosigmoidoscope or simply insufflate air via the anus until the area around the anastomosis is tense. Evacuate the saline irrigation. Placement of closed suction (e.g., Jackson–Pratt) drainage per the surgeon. Close in layers.

Total Colectomy and Ileoanal Anastomosis/Restorative Proctocolectomy with Ileoanal J-Pouch

POSITION: Lithotomy

Step 1. Perform a typical proctocolectomy from the ileocecal junction (terminal ileum) to the levator ani level (Figs. 12.52. and 12.53).

Step 2. With the specimen out of the peritoneal cavity, prepare a J-pouch construction using the terminal ileum, which may be mobilized carefully. Make the loop approximately 15–20 cm long. Approximate the parts of the loop four or five times using 4-0 silk-interrupted sutures. Be sure to have the distal part of the terminal ileum facing upward (Fig. 12.54).

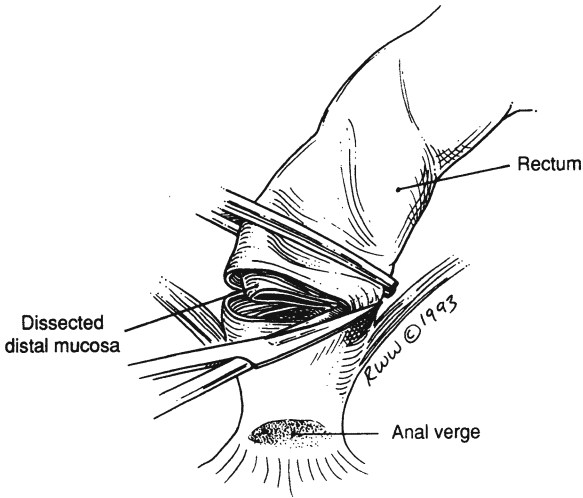


Figure 12.53. Resection site.

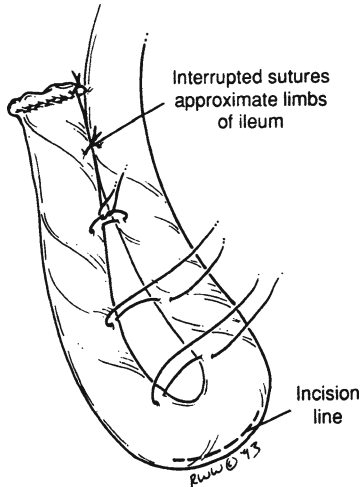


Figure 12.54. J-pouch construction.

- Step 3.** Use the GIA stapler to anastomose both limbs, forming a common ileoileal pouch (Fig. 12.55).
- Step 4.** Anastomose the apex of the pouch to the vicinity of the dentate line with deep bites of 3-0 Vicryl absorbable suture in an interrupted fashion (Fig. 12.56).

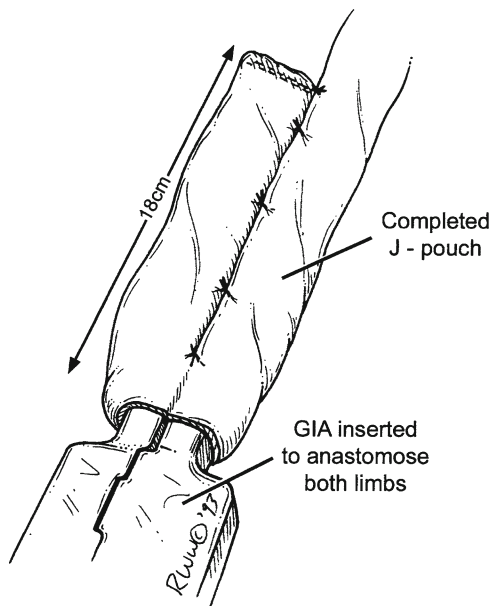


Figure 12.55. Creating the common ileoileal pouch.

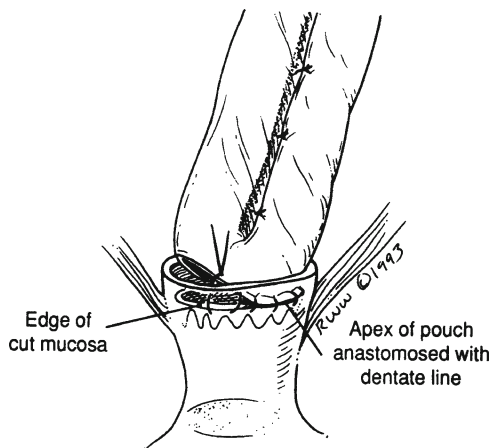


Figure 12.56. Anastomosis with interrupted sutures.

An alternative procedure is done by performing the J-pouch and anal anastomosis using the double- or triple-staple technique, allowing the anastomosis to be performed almost at the dentate line. The EEA anvil can be placed into the J-pouch with stapling via the anus. Be sure the vagina is not incorporated into the stapler prior to firing the stapler in female patients.

Step 5. Air test the ileoanal anastomosis by occluding the small bowel above the J-pouch. Despite a negative air leak test, the authors advise a diverting ileostomy to protect the anastomosis.

Step 6. Two months postoperatively, a Gastrografin study should be done to check the anastomotic pouch to the last 2 cm of the rectum. If the condition is satisfactory, the ileostomy can be closed.

Abdominoperineal Resection

An abdominoperineal resection includes removal of the rectum via an abdominal and perineal resection; these two procedures can be performed with two surgical teams synchronously or sequentially by a single team. When performed sequentially, it can be performed starting in the supine lithotomy position and then in the prone jackknife position.

Reassess the tumor via digital rectal exam or rigid proctosigmoidoscopy if performing this surgery for cancer resection. Remember to place ureteral stents to facilitate intraoperative identification of the ureters as needed.

The *abdominal phase* of an abdominoperineal resection includes presacral dissection to mobilize the rectum, which will be removed during the perineal phase. The abdominal portion is simply a proctectomy without creation of an anastomosis and formation of a permanent end colostomy.

An abdominal exploration is first performed to evaluate for metastatic disease. The small bowel is packed into the upper abdomen.

The sigmoid colon is mobilized to the right side and down to the rectovesical or rectouterine fossa by medial and lateral incision of the peritoneal ligaments of the sigmoid colon. To allow for a tension-free colostomy creation, upward mobilization of the distal descending colon along the white line of Toldt is necessary. Mobilization of the splenic flexure is usually not necessary. The left ureter and left gonadal vessels are visualized; the inferior mesenteric artery and its downward continuation as the superior rectal artery are identified. The surgeon is ready to enter the presacral area.

Most of the bleeding is from the presacral veins which lie beneath the endopelvic fascia. As noted earlier, to avoid bleeding and injury to the fascia, dissect very close to the posterior colonic wall; bleeding is extremely difficult to stop, even with ligation of both hypogastric arteries. Inserting tacks at the bleeding points is helpful (Fig. 12.46). Floseal spray can be useful. A small section of rectus muscle can be excised and cauterized to the bleeding point to seal the site.

Use electrocautery for the perirectal tissues and the fascia of Waldeyer, which bridges the sacrum and coccyx to the lower rectum. The St. Mark's retractor is useful to complete the procedure.

The tip of the prostate, with Denonvilliers' fascia, or the tip of the uterine cervix as well as the tip of the coccyx may now be palpated; the hypogastric nerve and hypogastric (pelvic) plexus must be preserved lest there be problems with ejaculation or a neurogenic bladder.

The ureter (and the lateral ligaments of the rectum) must be traced deep into the pelvis by careful dissection without elevation. Division of the colon and formation of the colostomy may now be performed. The rectum must be mobilized completely to the levator ani muscles to make removal via the perineal dissection easier. Care must be taken to ensure the mesorectal capsule is intact for malignant cases. The rectum can be tucked down into the pelvis. A closed suction drain can be attached to the top of the rectal stump to facilitate palpation of the top of the rectum. The abdomen can be closed and the colostomy matured.

The *perineal phase* of the abdominoperineal resection encounters the following structures: the pudendal vessels, which should be ligated; the levator sling, which should be excised widely; and the membranous urethra of the male in which a Foley catheter has been placed prior to surgery. Use sharp dissection to separate the prostate from the lower rectum. Important landmarks to use are the coccyx, ischial tuberosities, and perineal body. The rectum is removed, detaching it from the drain. The pelvic peritoneum should be closed to avoid herniation and obstruction of the small bowel. The perineum should be closed in layers.

The perineal phase is a separation of the surgical anal canal (the last 4 cm of the anorectum) from the pelvic diaphragm by dissection and sacrifice of the sphincteric apparatus and by removing the specimen and all perineal tissues related to the spaces around the anus (ischioanal, fossae, retroanal, etc.)

- Step 1.** Prep the perineum, vagina, and anus. Close the anal orifice by using a subcutaneous continuous purse-string suture of 0 silk at the skin of the anal verge. Make an elliptical perianal incision approximately 3 cm from the closed anus (Fig. 12.57).
- Step 2.** Use silk to suture ligate the inferior and middle rectal vessels and all vessels at the lateral aspect of the wound. Dissection and ligation can also be performed with a tissue sealing device (Ligasure, Enseal, Harmonic Scalpel, etc.). End the procedure with sharp dissection, and remove the specimen by division of the pelvic diaphragm with cautery or knife (Figs. 12.58 and 12.59).
- Step 3.** Remove the rectum. The drain is positioned in the pelvis. If an omental flap was brought down, it is also placed in the pelvis. Hemostasis is checked.

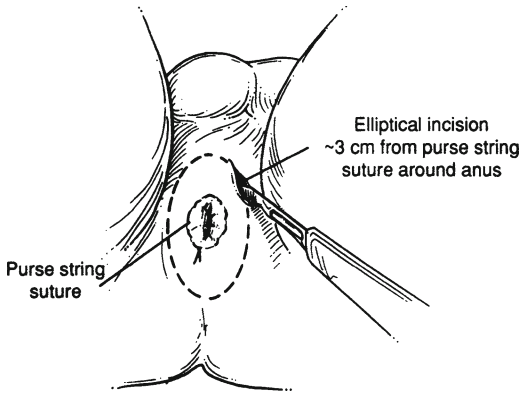


Figure 12.57. Perianal incision.

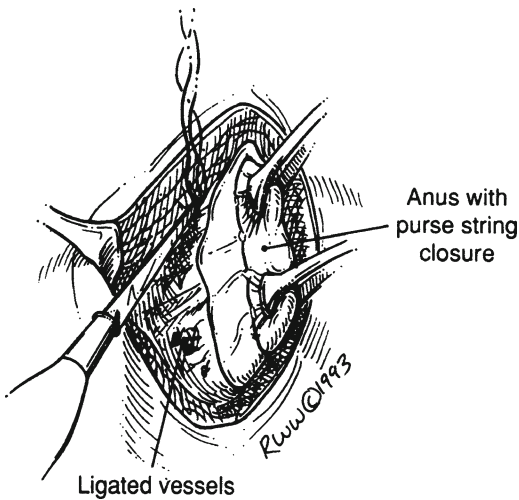


Figure 12.58. Sharp dissection.

- Step 4.** Approximate the right and left pelvic diaphragms with synthetic absorbable suture. The tissues are closed in layers with absorbable sutures.
- Step 5.** Close the perineal wound in layers with 2-0 and 3-0 Vicryl sutures. The skin may be closed with absorbable sutures.

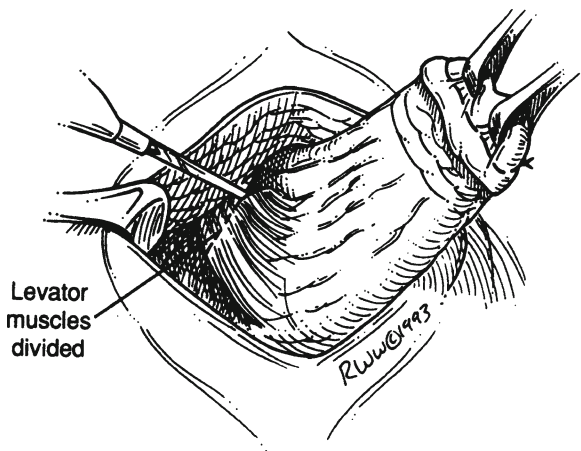


Figure 12.59. Removal of rectum.

■ GENERAL PRINCIPLES OF LAPAROSCOPIC HAND-ASSISTED COLECTOMY

- ✓ Lithotomy position
 - Provides the advantage of additional standing room.
 - Provides access to the GI tract for assessing anastomosis in left-sided cases and for intraoperative colonoscopy or rigid proctosigmoidoscopy in some cases where the polyp or lesions is difficult to identify.
 - Is ideal for dissection of the flexures.
- ✓ GelPort/Handport insertion
 - Choose sensible port sites. A low transverse incision for a right colectomy in an obese male is an exercise in futility, while the same in a thin woman can be embarrassingly simple.
 - Use a small incision for maximal efficiency and proceed with simple open dissection.
 - Place all trocars well away from the GelPort to avoid sword fighting.
 - Instruments should be placed through trocars under direct vision or palpation to avoid inadvertent bowel injury.

484 12. Colon and Anorectum

- Seat the port properly to avoid loss of pneumoperitoneum.
 - Always remember that the GelPort can be used like a regular trocar by simply placing a trocar through the gel.
- ✓ Access
- Placing the GelPort first allows insufflation under direct vision by placing a port through the gel.
 - All other ports are placed under direct vision to avoid blind insertion and trauma.
 - In particularly elastic abdominal walls, protection can be provided by inserting the hand prior to gently inserting the port.
 - Angled laparoscopes allow identification of epigastric vessels, which helps avoid injury during port insertion. Using a 30- or 45-degree scope facilitates dissection of the flexures and any dissection in the pelvis.
 - Nonbladed trocars minimize trauma at the port site.
 - Small skin incisions allow better seating of trocars and avoid inadvertent pullout of trocars.
 - Disposable trocars leak less than nondisposable trocars. The use of disposable trocars will help to maintain good pneumoperitoneum, which is essential.
- ✓ Dissection
- The assistant uses both hands: one for the camera and one to assist in tissue dissection.
 - The principle of tissue triangulation allows you to maintain a broad plane of dissection with minimal trauma and maximal traction. Use extra trocars as needed to allow for best traction and countertraction.
 - The principle of traction and countertraction always applies. Traction during dissection facilitates dissection and visualization.
 - Use a tissue sealing device for grasping, division of planes, and ligation of vessels. Current tissue sealing devices can divide vessels 5–7 mm in diameter. Larger vessels can also be divided with an endovascular stapler.
 - Make proper use of gravity. Frequent steep position changes are mandatory; this greatly improves visualization.
 - Assess and reassess your plane, dissect in a broad plane, and identify important structures within the plane of dissection before moving to another site.

■ LAPAROSCOPIC COLECTOMIES

Laparoscopic Left Colectomy, Sigmoid Colectomy, and Low Anterior Resection

- Step 1.** The patient is given general anesthesia and placed in the lithotomy position. Use a Foley catheter to decompress the bladder and an orogastric or nasogastric tube to decompress the stomach (Fig. 12.60).
- Step 2.** The surgeon begins on the patient's right. Starting this way gives the surgeon an idea concerning the anatomy of the left and sigmoid colon and redundancy of the sigmoid. This positioning also results in better placement of the trocars or the GelPort. If planning to use hand assistance, create a small incision (periumbilical or Pfannenstiel) and place the GelPort wound protector. This allows initial open dissection of the sigmoid colon and entry by the White line of Toldt. Depending on the patient's body habitus, a great deal of dissection can be done through this open incision, including transection of the mesocolon, lysis of adhesions, and separation of any inflammatory adhesions. Place the GelPort cover, obtain pneumoperitoneum, and

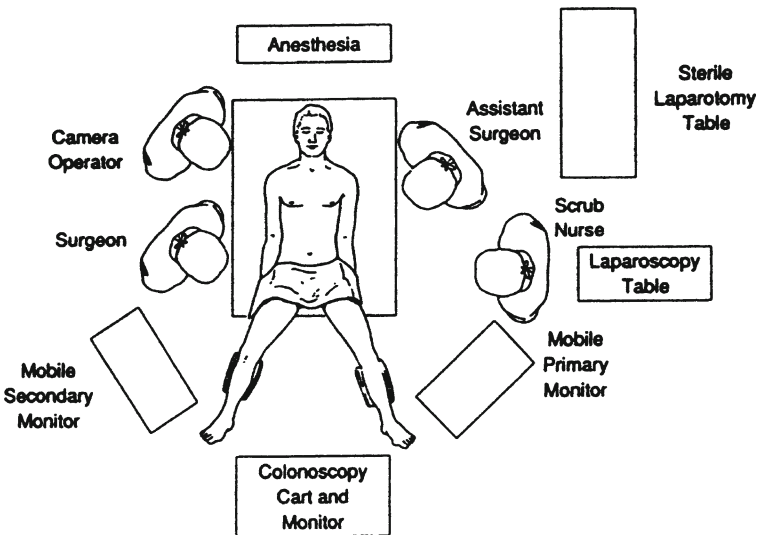


Figure 12.60. Operating room arrangement for sigmoid resection. From ME Franklin, Jr. Laparoscopic surgery of colon and rectum (ME Arregui, RJ Fitzgibbons Jr., N. Katkhouda, JB McKernan, and A Reich (eds.). *Principles of Laparoscopic Surgery: Basic and Advanced Techniques*. New York: Springer-Verlag, 1995, with permission).

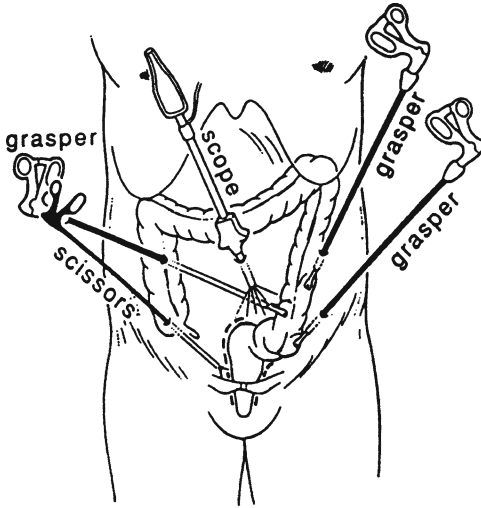


Figure 12.61. Trocar placement for low anterior and abdominal peritoneal resection. ME Franklin, Jr. *Laparoscopic surgery of colon and rectum* (From ME Arregui, RJ Fitzgibbons Jr., N. Katkhouda, JB McKernan, and A Reich (eds.). *Principles of Laparoscopic Surgery: Basic and Advanced Techniques*. New York: Springer-Verlag, 1995, with permission).

place the trocars. Usually trocars are placed in the abdomen as indicated in Fig. 12.61.

Step 3. The patient is in Trendelenburg and the table is rotated so that the patient's right side is down. Place graspers through the trocars to provide traction on the sigmoid colon to bring it medially and superiorly. Begin dissection lateral to the sigmoid colon along the white line of Toldt. Often the tissue sealing device is placed through the right lower quadrant port, and a grasper is placed in the right upper quadrant port to facilitate the dissection with countertraction. Grasp the rectosigmoid and retract toward the right to expose the left mesorectum. Incise the mesorectum. Continue in the left gutter along the white line of Toldt, carrying it all the way up as high as possible to the splenic flexure. This is facilitated by the surgeon placing traction on the sigmoid and left colon and dividing the avascular plane under the peritoneum in the paracolic gutter. The assistant is in charge of both the camera and of maintaining traction of the colon cephalad for dissection along a broad plane. This allows for easy identification of the left ureter and gonadal vessels.

The dissection can be taken up to the splenic flexure, and, if necessary, the splenic flexure can be mobilized (Figs. 12.62 and 12.63).

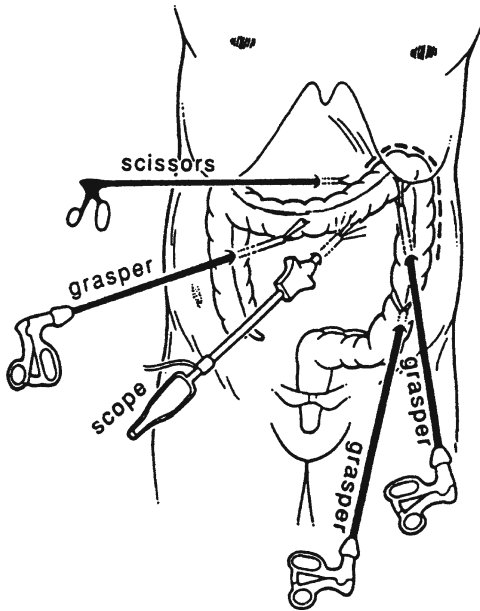


Figure 12.62. Trocar placement for splenic flexure and left colon. ME Franklin, Jr. Laparoscopic surgery of colon and rectum (From ME Arregui, RJ Fitzgibbons Jr., N. Katkhouda, JB McKernan, and A Reich (eds.). *Principles of Laparoscopic Surgery: Basic and Advanced Techniques*. New York: Springer-Verlag, 1995, with permission).

We usually mobilize the splenic flexure to avoid tension on our colorectal or colocolic anastomosis.

- Step 4.** Mobilize the splenic flexure. This is accomplished best with the surgeon between the patient's legs. The LLQ (or LUQ) port is used for dissection from the proximal descending colon around the splenic flexure to the distal transverse colon. The patient is still rotated right side down with leveling of the Trendelenburg from full reverse to flat. The assistant grasps the omentum and retracts it cephalad. The surgeon places gentle traction on the left colon and near the splenic flexure. The avascular plane between the omentum and the colon is divided over the distal transverse colon. The attachments of the colon to the spleen (splenocolic ligament) are divided carefully, avoiding the tail of the pancreas and the duodenum.
- Step 5.** Distally, the dissection is taken down to the peritoneal reflection (for sigmoid colectomy) or to the rectum, as identified by the coalescence of the teniae. For positioning, the surgeon now stands on

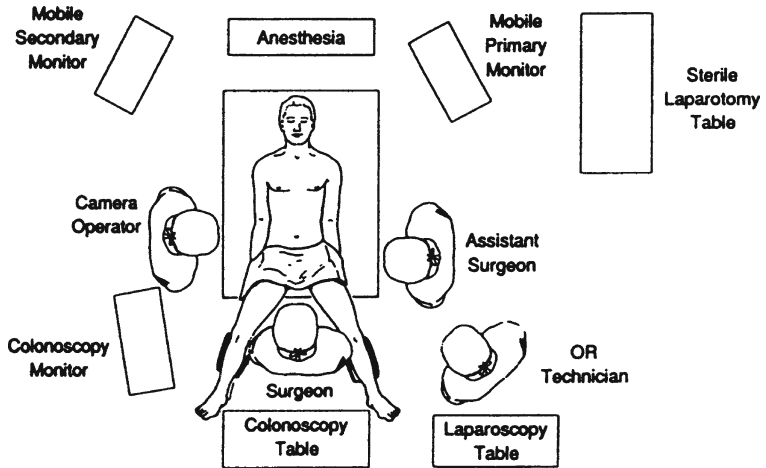


Figure 12.63. Operating room arrangement for splenic flexure mobilization. ME Franklin, Jr. Laparoscopic surgery of colon and rectum (From ME Arregui, RJ Fitzgibbons Jr., N. Katkhouda, JB McKernan, and A Reich (eds.). *Principles of Laparoscopic Surgery. Basic and Advanced Techniques*. New York: Springer-Verlag, 1995, with permission).

the patient's left. With the patient in the lithotomy position in steep Trendelenburg, the right side of the mesorectum is divided with the tissue sealing device. Dissection is facilitated by having the surgeon grasp the rectosigmoid and place traction on it toward the left, thus exposing the right mesorectum. Placement of the angled scope in the RLQ or RUQ, with the tissue sealing device in the umbilical port, should facilitate this dissection. Early dissection of the right mesorectum aids later vascular dissection and is more naturally performed from the left of the patient.

When performing a low anterior resection, the rectal dissection as previously described should progress beyond at least 2 cm further distal than the distal edge of the tumor to allow for adequate resection margins. Attention should be given to locating the left ureter; this can be facilitated by placing ureteral stents preoperatively.

- Step 6.** The surgeon and the assistant now move back to the same (right) side of the patient. Depending on the surgery, the stapler or tissue sealing device can be introduced through the RLQ port to divide the sigmoidal branches, the left colic vessels, or the inferior mesenteric vessels. Retract the colon laterally. If possible, use the tissue sealing device to score the mesentery of the left/sigmoid colon. Develop a window in the mesocolon and then another window either more

proximally or distally. Divide the mesentery, taking care to avoid the left ureter. Repeat division of the mesentery until the segment of colon is mobilized.

Step 7. Distally, divide the colon or rectum by inserting the endoscopic GIA through the right lower quadrant trocar. Once the portion of colon to be removed is freed, it can be extracted via a small abdominal incision or via the GelPort incision site. If only laparoscopic trocars were used, make an incision about 4 cm long in the abdomen to extract the colon. Use of a wound protector can help to compress the anterior abdominal wall fat and has been proven to decrease skin infections. Remove the colon through this site; transect the specimen and remove it from the field.

Step 8.

- 8a. For left colectomy, the colocolic anastomosis will be made with a GIA stapler extracorporeally (see “Left Colectomy” described earlier in this chapter). For sigmoid colectomy or low anterior resection, the colorectal anastomosis will be made using an EEA stapler; usually a 29-mm EEA is appropriate, but the sizers should always be used to determine the appropriate diameter. Place the anvil of the EEA into the proximal colon, which is then purse-stringed around the anvil-connecting end.
- 8b. For sigmoid colectomy and low anterior resection, extracorporeal colorectal anastomoses: the EEA stapler can be placed via the anus and connected to the anvil under direct vision. The anastomosis can be created once the surgeon is satisfied with the orientation of the mesentery and after ensuring all other nearby structures are protected. The colorectal anastomosis should then be air tested with the pelvis filled with saline. Fill the pelvis with saline and insert a rigid sigmoidoscope into the rectum for a short distance so as to insufflate the colorectal segment and look for air bubbles, which would indicate an incomplete anastomosis. If a leaking site is discovered, suture ligate (Lembert sutures) and retest the anastomosis. Otherwise, a diverting ostomy should be created. If no air leak is noted, the irrigant is removed. Hemostasis is ensured. The omentum (if still present) is laid back into anatomical position. The fascia can be then be closed.
- 8c. For sigmoid colectomy and low anterior resection, intracorporeal colorectal anastomoses: with the anvil in place as described, place the proximal colon back into the abdomen; close fascia using a 0 PDS. Reinsufflate pneumoperitoneum and obtain visualization. Grasp the end of the anvil using an instrument made specifically for that purpose. Next, insert the EEA into the rectum and advance it until it is seen gently pushing up against the rectal stump. Slowly turn the knob at the end of the EEA stapler until the point that attaches to the EEA starts to “tent up” the rectal stump. Then push this sharp, cone-shaped end of the EEA

through the rectal stump just anterior to the rectal stump staple line. Manipulate the anvil until it snaps onto the EEA. Slowly turn the knob at the end of the EEA, thus approximating the proximal colon and rectum. Recheck the mesentery to ensure proper orientation. Check the vagina to ensure it is not incorporated into the stapler prior to firing. When the stapler and anvil head are correctly approximated as indicated on the EEA, fire the device. Remove the EEA from the rectum. One complete doughnut of tissue from the proximal colorectal segment and one from the distal segment should be present in the EEA stapler to indicate a satisfactory anastomosis.

- Step 9.** The colorectal anastomosis can then be air tested with the pelvis filled with saline as described above in step 8b. If no air leak is noted, the pneumoperitoneum is relieved. Remove all trocars under direct vision and close the fascia at each of the sites with a 0 Vicryl suture. The extraction site can be closed with 1 PDS. Close the skin with a 4-0 Vicryl subcuticular suture.

Laparoscopic- and Hand-Assisted Right Colectomy

- Step 1.** After general anesthesia, place the patient in “laparoscopic” lithotomy position and place a nasogastric or orogastric tube and Foley catheter.
- Step 2.** Make a periumbilical incision for GelPort placement (Fig. 12.64). This allows initial open dissection of the transverse colon and entry to the lesser sac. Depending on the patient’s body habitus a great deal of dissection can be done through this open incision, including transection of the mesocolon, lysis of adhesions, and separation of any inflammatory adhesions. Place trocar ports for access.
- Step 3.** The surgeon stands on the patient’s left along with the assistant.
- Step 4.** With the patient in Trendelenburg position and left side down, the surgeon grasps the cecum and right colon retracting it toward the patient’s left. The white line of Toldt is divided caudally and cephalad. Perform this dissection up to and around the hepatic flexure. If using hand assistance, the surgeon’s index finger can be strategically placed underneath the lateral attachments of the colon and the hepatocolic ligament for easier dissection and traction. The assistant retracts the omentum cephalad during the hepatic flexure mobilization. The dissection proceeds from lateral to medial. During this phase all small bowel is manipulated to the left upper quadrant. Carefully identify the ureter and gonadal vessels. This portion of the dissection is complete when the duodenum is visualized, and there is no tension of the transverse colon reaching to the GelPort opening. Continue the dissection toward the patient’s lesser sac, dissecting the avascular plane between the omentum and transverse colon.

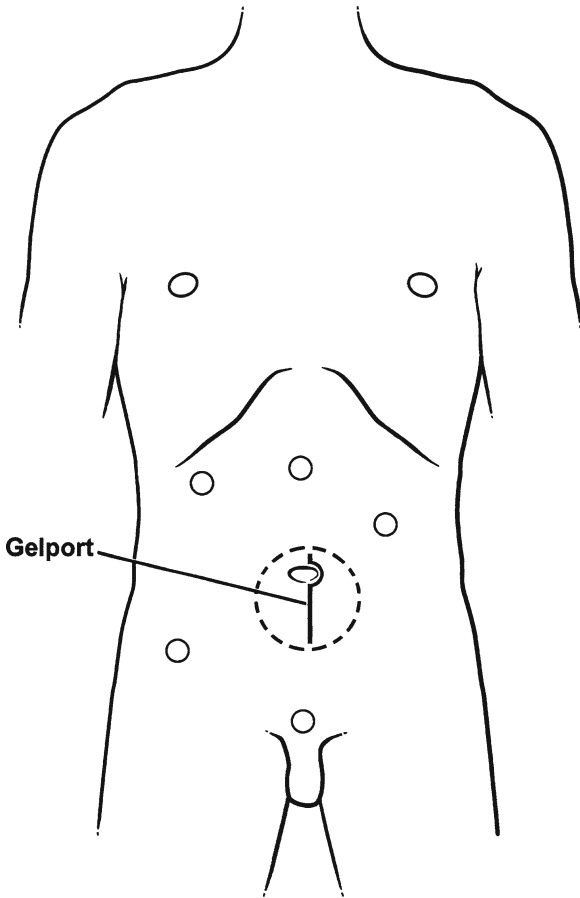


Figure 12.64. Periumbilical incision.

- Step 5.** Ligate the vessels with the vessel sealing device or the endoscopic GIA, with vascular staples. With good mobilization the mesocolon can be divided through the periumbilical incision.
- Step 6.** Bring out the transverse colon and ileum through the periumbilical incision. During this phase, the GelPort acts as a wound retractor and wound protector. Perform a stapled anastomosis using a 75-mm GIA and 60-mm TA. The mesentery is reapproximated, whereas in the left colectomy it is not.
- Step 7.** Close the midline wound with 1 PDS. Close the skin with 4-0 Vicryl.

Total Abdominal Laparoscopic Colectomy

Total abdominal laparoscopic colectomy is accomplished by combining the previously described techniques for right colectomy and left/sigmoid colectomy. Keep in mind that the surgeon will be changing position from the left side to the right side of the table.

It is recommended that the surgeon starts along the sigmoid colon and mobilizes proximally, ending at the terminal ileum. This allows for the most redundant mobile portions of the colon to be mobilized first, leaving the terminal ileum and rectum to help maintain orientation.

Table 12.2.

Table 12.2 Synopsis of laparoscopic colectomies

Right colectomy lateral to medial	<ul style="list-style-type: none"> • Mobilize cecum and right white line of Toldt • Identify and protect right ureter and duodenum • Divide hepatocolic and gastrocolic ligaments • Divide ileocolic, right colic, and right branch of middle colic vessels • Divide bowel and create ileocolic anastomosis 			
Right colectomy medial to lateral	<ul style="list-style-type: none"> • Isolate and divide ileocolic, right colic, and right branch of middle colic vessels • Separate right colon and mesentery from retroperitoneum • Divide hepatocolic and gastrocolic ligaments • Divide bowel and create ileocolic anastomosis 			
	Port location	Patient position	Surgeon position	Monitor location
Number of ports: 4 or 5	Umbilical (camera) 12 LLQ 5 LUQ or subxiphoid 5 RLQ or suprapubic 5			
Hepatic flexure mobilization		Right side elevated Reverse Trendelenburg	Between legs or patient's left	Right shoulder
Ascending colon dissection		Right side elevated Trendelenburg	Patient's left	Right hip

(continued)

Table 12.2 (continued)

Left colectomy lateral to medial	<ul style="list-style-type: none"> • Mobilize sigmoid colon and white line of Toldt • Identify and protect left ureter, tail of pancreas, and duodenum • Divide lienocolic and gastrocolic ligaments • Divide inferior mesenteric vessels and left branch of middle colic vessels • Divide bowel and create colocolic anastomosis 			
Left colectomy medial to lateral	<ul style="list-style-type: none"> • Isolate and divide inferior mesenteric vessels and left branch of middle colic vessels • Separate left colon and mesentery from retroperitoneum • Divide lienocolic and gastrocolic ligaments • Divide bowel and create colocolic anastomosis 			
Low anterior resection	<ul style="list-style-type: none"> • Mobilize sigmoid colon and white line of Toldt • Identify and protect left ureter, tail of pancreas, and duodenum • Divide lienocolic and gastrocolic ligaments • Divide inferior mesenteric vessels and left branch of middle colic vessels • Dissect beneath superior rectal vessels behind rectum • Divide bowel and create colorectal anastomosis 			
	Port location	Patient position	Surgeon position	Monitor location
Number of ports: 4 or 5	Umbilical (camera) 12 RLQ 5 RUQ or subxiphoid 5 LLQ or suprapubic 5/12			
Splenic flexure mobilization		Left side elevated Reverse Trendelenburg	Between legs or patient's right	Left shoulder
Descending colon dissection		Left side elevated Neutral	Patient's right	Left hip
Rectal dissection		Pelvis elevated Trendelenburg	Patient's right	Left hip or between legs

■ PROCEDURES OF THE SURGICAL ANAL CANAL AND PERIANAL REGIONS

No anorectal procedure should be undertaken without digital and proctoscopic examination. The following section details the anatomy as encountered by the examiner's finger or as seen in the anoscope or sigmoidoscope. Digital examination should always precede anoscopy or sigmoidoscopy. It relaxes the sphincters and reveals any obstruction that might be injured by the anoscope or sigmoidoscope.

The anal verge separates the pigmented perianal skin from the pink transition zone. The verge is the reference line for the position of all other structures encountered (Fig. 12.65).

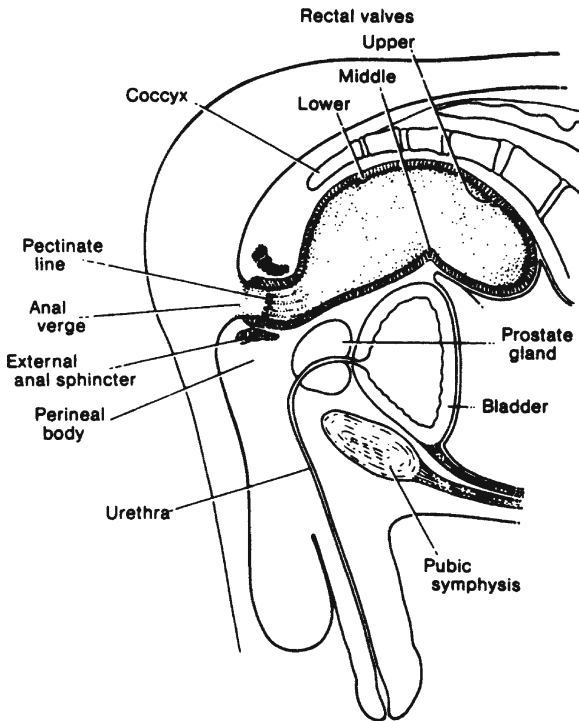


Figure 12.65. Diagram of anorectal landmarks for sigmoidoscopic examination: patient in knee/chest or knee/elbow position (By permission of JE Skandalakis, SW Gray, and JR Rowe. *Anatomical Complications in General Surgery*. New York: McGraw-Hill, 1983).

When the gloved and lubricated index finger is inserted so that the distal interphalangeal joint is at the anal verge, the subcutaneous portion of the external (voluntary) sphincter is felt as a tight ring around the distal half of the distal phalanx (Fig. 12.66a). The fingertip should detect the pectinate line of anal valves that lies about 2 cm above the anal verge. The anal columns (Morgagni) above the valves also may be felt. External hemorrhoids, polyps, and hypertrophied anal papillae in this region are readily detected. Good palpation of the prostate in males is paramount.

Further insertion of the finger to the level of the middle interphalangeal joint brings the first joint to the anorectal ring formed by the deep component of the external sphincter, the puborectalis loop, and the upper margin of the internal sphincter. The ring is felt posteriorly and laterally, but not anteriorly (Fig. 12.66b).

Still further penetration of the finger to the level of the metacarpophalangeal joint allows the distal phalanx to enter the rectum. The left lower rectal fold may often be touched. At this point the pelvirectal space lies lateral and the rectovesical or rectovaginal space lies anterior. Further anterior to the rectum one can palpate the prostate gland in men (Fig. 12.66c) and the upper vagina and cervix in women.

The anoscope should be inserted, aimed at the patient's umbilicus. At 5 cm from the anal verge, the tip will be at the anorectal ring (Fig. 12.67a). With the obturator removed, the left lower rectal fold might be visible. With a sigmoidoscope, at about 8 cm from the verge, the middle rectal fold may be seen. This is the level of the peritoneal reflection. The superior rectal fold is reached at 10–12 cm, and beyond this, passage of the instrument is easy (Fig. 12.67b).

For the surgeon, the most dangerous area is between the middle and superior rectal folds, just above the peritoneal reflection. This is the area in which perforation by the sigmoidoscope may occur.

Ischiorectal Abscess: Incision and Drainage

POSITION: Prone jackknife.

ANESTHESIA: Local; in most cases, as an office procedure, particularly if a fluctuant area is palpable around the anus.

PROCEDURE: Make an incision (elliptical shape, extending radially and long enough to drain the cavity) as close to the anus as possible, depending, of course, on the localized maximum swelling and tenderness (Fig. 12.68). Perform intracavitary digital examination to break possible septa (Fig. 12.69). Light packing with gauze should be removed in 24 h (Fig. 12.70).

Remember:

- ✓ Later, if fistulas requiring excision develop, they will be close to the anal verge.

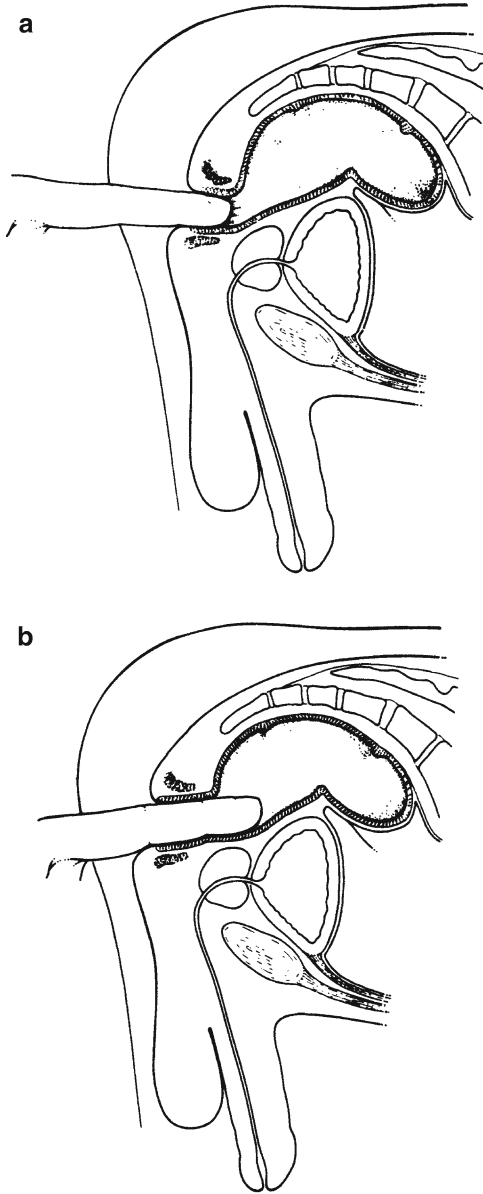


Figure 12.66. Digital examination (a). Distal interphalangeal joint at the anal verge. Hemorrhoids can be detected at this stage (b). Middle interphalangeal joint at the anal verge (c). Metacarpophalangeal joint at the anal verge. The tip of the finger is at or just above the inferior rectal valve (By permission of JE Skandalakis, SW Gray, and JR Rowe. *Anatomical Complications in General Surgery*. New York: McGraw-Hill, 1983).

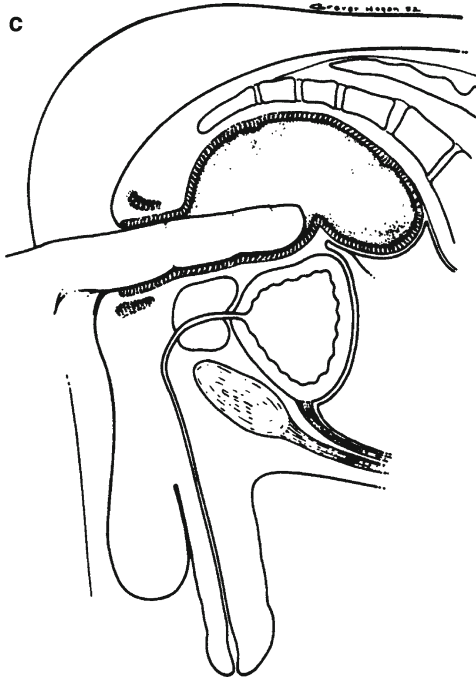


Figure 12.66. (continued)

Anal Fistulectomy (Figs. 12.71, 12.72, 12.73, 12.74, and 12.75)

Identify the primary internal opening of the tract. Identify the relation of the tract to the anal sphincters and, in particular, to the puborectalis muscle. To maintain continence, minimize the amount of sphincter muscle to be divided.

Fistulectomy is the complete removal of the fistula tract. Fistulotomy is the laying open of the tract with the tract curetted.

PREOPERATIVE PREPARATION: 1–2 enemas.

POSITION: Prone jackknife.

ANESTHESIA: General or spinal.

EXAMINATION: Digital, dilatation, retractor of choice, and very careful external and internal probing. Methylene blue staining or peroxide may be of great help to localize the internal fistula opening. Avoid creating a false tract with probing while identifying the course of the primary tract. If the tract is palpable along the surface, it is likely superficial. Supralelevator induration may be a sign of deeper involvement or cephalad extension of the abscess. Identify any secondary tracts or extensions.

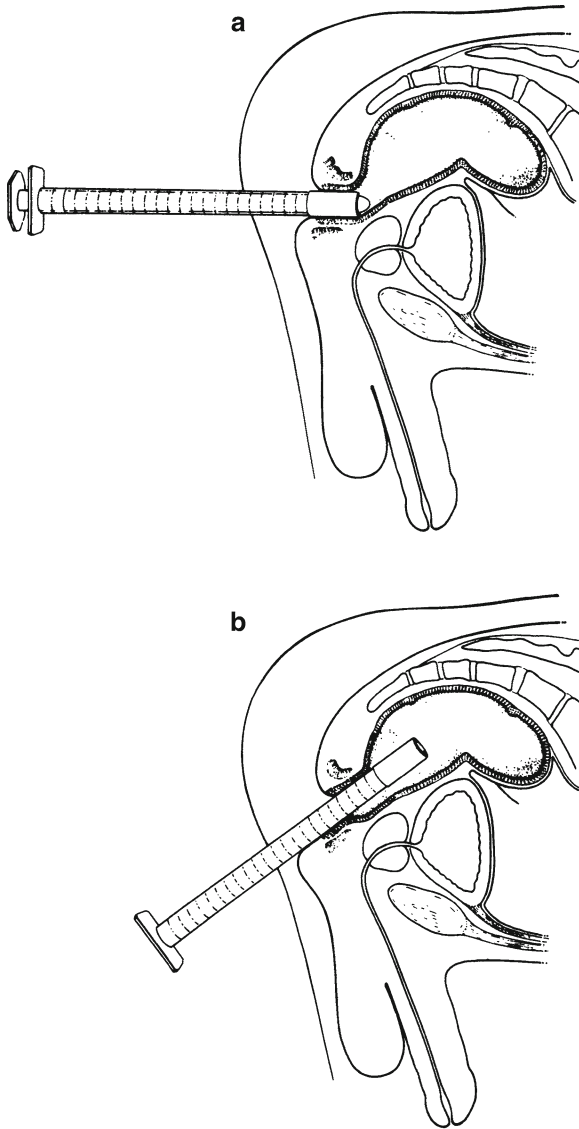


Figure 12.67. Sigmoidoscopic examination (a). The instrument is directed toward the umbilicus. The tip is just past the anorectal ring (b). With obturator removed, the instrument is passed by direct observation. The *tip* shown here is almost up to the middle rectal valve (By permission of JE Skandalakis, SW Gray, and JR Rowe. *Anatomical Complications in General Surgery*. New York: McGraw-Hill, 1983).

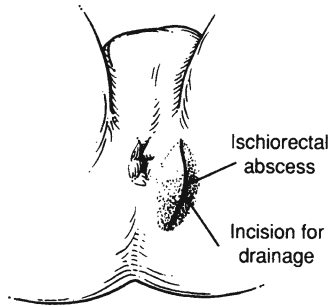


Figure 12.68. Incision at swelling.

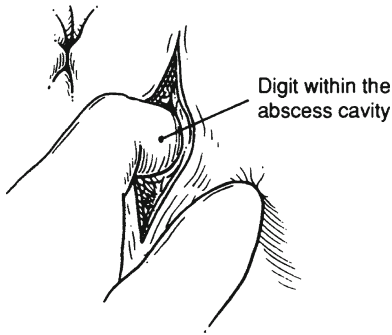


Figure 12.69. Intracavitary digital examination.

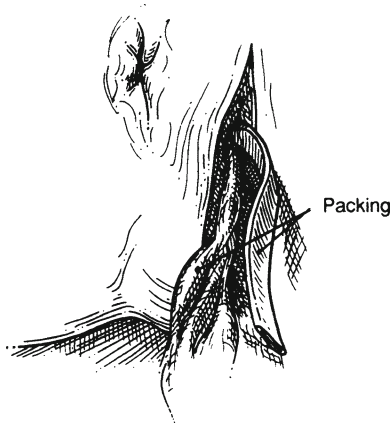


Figure 12.70. Gauze packing.

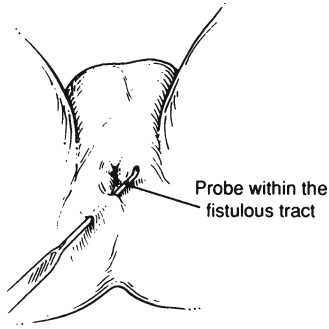


Figure 12.71. Probing internal fistula opening.

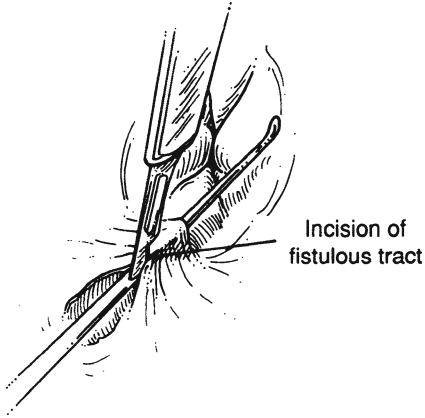


Figure 12.72. Excision of fistulous tract.

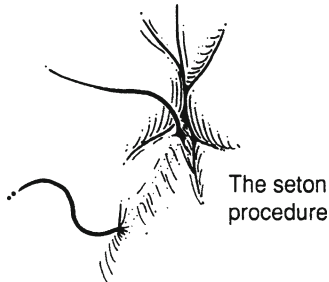


Figure 12.73. Seton placement.



Figure 12.74. Fibrin plug.

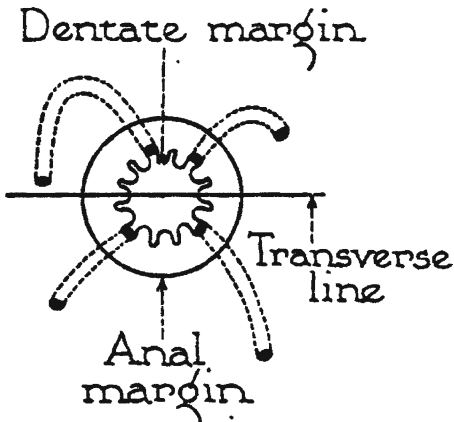


Figure 12.75. Goodsall-Salmon's rule of fistulas (see text) (From Nesselrod JP. Anal, perianal, perineal and sacrococcygeal sinuses. *Am J Surg* 1942;56:154-165; copyright Elsevier, with permission).

PROCEDURE: If the fistula is simple and not deep, excise the fistulous tract in toto, leaving the wound open. Fistulectomy involves pulling the tract and dissecting around it to “core” it out of the tissue, separating the tract out from surrounding tissue; this is particularly useful for suprasphincteric fistulas. Fistulotomy involves inserting a probe gently through the entire tract and cutting the tissue “roof” over the tract using electrocautery or scalpel blade.

Note:

- ✓ The subcutaneous and superficial external sphincters can be divided with impunity, but be very careful with the deep external sphincter and the puborectalis.

502 12. Colon and Anorectum

- ✓ If the fistula is deep or if there is concern that there is too much muscle within the fistula (a high fistula), the seton procedure is the treatment of choice. The seton (thin silastic vessel loop) may be tied around the probe and threaded through the tract (Figs. 12.73 and 12.74).
- ✓ An alternative to fistulectomy is insertion of a fibrin plug into the fistula.
- ✓ Most of the fistulas in ano are midline posterior.
- ✓ Learn Goodsall–Salmon’s rule of fistulas (Fig. 12.75), which relates the internal location of the fistula to its external opening:
 - If the external opening of the fistula is anterior to an imaginary transverse line across the anus, the most probable tract of the fistula is a straight line terminating into the anal canal. If the external opening is located more than 3 cm anterior to the line, the tract may curve posteriorly, terminating in the posterior midline.
 - If the external opening of the fistula is posterior to the imaginary transverse line, the most likely tract is a curve, terminating into the posterior midline wall of the anal canal.
- ✓ Horseshoe fistula is a U-shaped connection of multiple external openings around the anus, with an internal opening usually found in the posterior midline. The fistula can be intersphincteric or transsphincteric. The internal opening is excised, while the external openings debrided for adequate drainage.

Ligation of Intersphincteric Fistula Tract (LIFT)

Identify the intersphincteric or transsphincteric fistula tract to divide and ligate the tract in the intersphincteric groove. This avoids division of any sphincter muscle.

PREOPERATIVE PREPARATION: 1–2 enemas; seton already in place for weeks prior to surgery to mature the fistula tract.

POSITION: Prone jackknife.

ANESTHESIA: General or spinal.

PROCEDURE: As described above in anal fistulectomy/fistulotomy, identify the fistula tract. Use an anoscope to place the anal sphincter on tension. Leave the fistula probe in the fistula (Fig. 12.76a). Palpate the intersphincteric groove and create a curvilinear incision over the groove above the fistula tract. Dissect in the intersphincteric groove to dissect out the fistula tract, which lies perpendicular to the groove (Fig. 12.76b). Place ties on both sides of the tract (next to the internal and external sphincter). Divide the tract (with or without removing excess tract). Suture ligate each side in the intersphincteric groove to ensure complete closure (Fig. 12.76c, d). Test with peroxide from the external and internal openings of the fistula. Irrigate, and close the cavity with absorbable

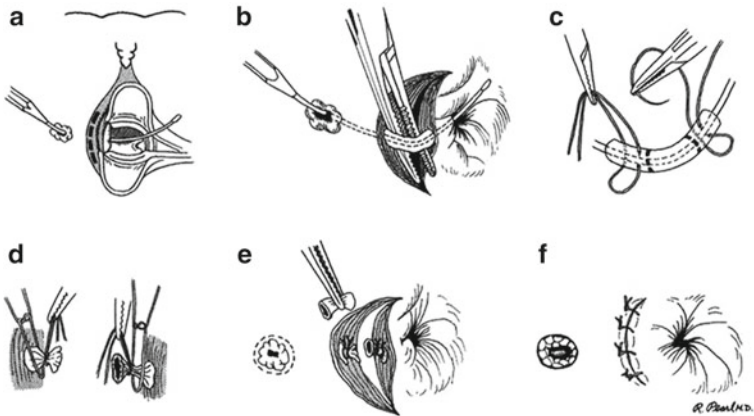


Figure 12.76. (a) Introduction of fistula probe through the tract. (b) Dissection of intersphincteric groove and identification of fibrotic fistula tract. (c) Suture ligation of fistula tract proximally, distally. (d) Additional ligature reinforcing tract closure. (e) Division of fistula tract; if tract is quite long, a segment of the tract is excised. (f) LIFT wound is closed loosely, and external opening of the tract is enlarged to facilitate drainage (From AM Abcarian, JJ Estrada, J Park, C Corning, V Chaudhry, J Cintron, L Prasad, H Abcarian. Ligation of intersphincteric fistula tract: Early results of a pilot study. *Dis Colon Rectum* 2012;55(7), with permission).

sutures (Fig. 12.76e, f). Both external and internal openings are gently curetted to remove any granulation tissue and then left open for drainage.

Anal Fissure

PREPARATION: Enemas as tolerated.

POSITION: Prone jackknife.

ANESTHESIA: General. Local block with bupivacaine with epinephrine is recommended to relax the sphincter and for postoperative analgesia.

PROCEDURE: Lateral internal sphincterotomy.

- ✓ Anterior or posterior midline sphincterotomy can lead to a “keyhole” deformity.

The anal fissure is examined with an anoscope to determine its length into the anal canal and its relation to the dentate line. With the anal sphincter on tension using a Pratt bivalve or Hill-Ferguson retractor, the surgeon palpates the intersphincteric groove with the finger, and the top of the anal sphincter is also palpated. Along the lateral position, the internal anal sphincter is dissected in the intersphincteric groove and in the submucosal plane. To prevent fistula formation, care is taken to avoid dis-

504 12. Colon and Anorectum

rupting the mucosa. Under direct vision, the distal portion of the internal anal sphincter is transected perpendicularly for the length of the fissure or up to the dentate line. The wound is irrigated and the mucosa checked for any holes. The wound is then closed loosely with absorbable suture.

- ✓ Hypertrophied edges of the anal fissure and the base of the fissure can be debrided to facilitate fissure healing. Sentinel anal tags can be excised.

Hemorrhoidectomy (Figs. 12.77, 12.78, 12.79, 12.80, and 12.81)

PREPARATION: Repeated enemas.

POSITION: Lithotomy or prone jackknife.

ANESTHESIA: General. Local block with bupivacaine with epinephrine is recommended to relax the sphincter and for postoperative analgesia.

- Step 1.** Perform digital rectal examination, anal dilatation, and anoscopic evaluation.
- Step 2.** Insert a gauze sponge into the lower rectum to prevent downward fecal leakage. Withdraw sponge and identify the prolapsing hemorrhoids (Figs. 12.77 and 12.78).
- Step 3.** Use a medium or large Hill-Ferguson anoscope. With a clamp of your choice, gently grasp the prolapsing hemorrhoid. Minimize the width of anoderm to be excised to avoid stenosis.
- Step 4.** Make an elliptical-shaped incision, including the skin of the anal verge up to the base of the hemorrhoid. Avoid the anal sphincters by elevating the hemorrhoidal tissue and pushing the sphincter muscles downward and away. Excision of the hemorrhoid can also be performed with the Harmonic scalpel or bipolar cautery device (see below).

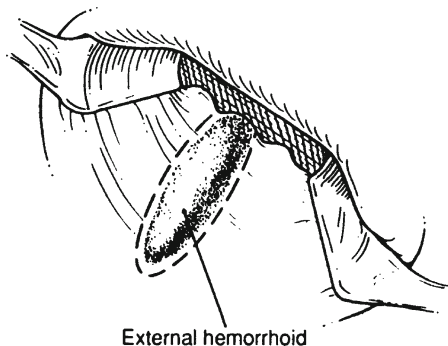


Figure 12.77. Prolapsing hemorrhoid.

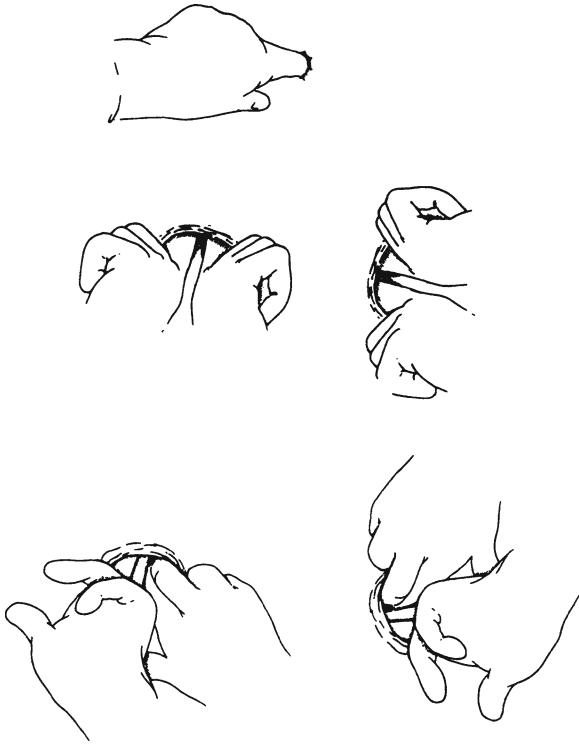

Figure 12.78. Digital rectal examination and anal dilatation.

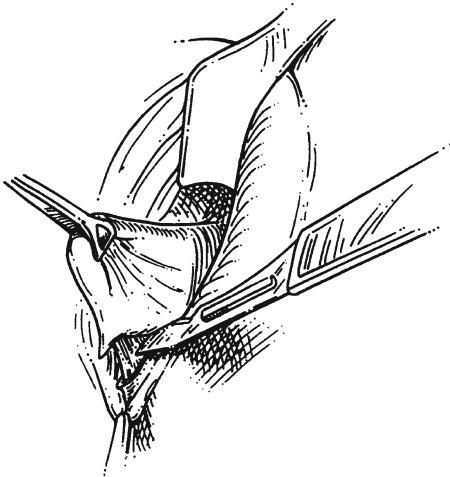


Figure 12.79. Grasping the prolapsing hemorrhoid.

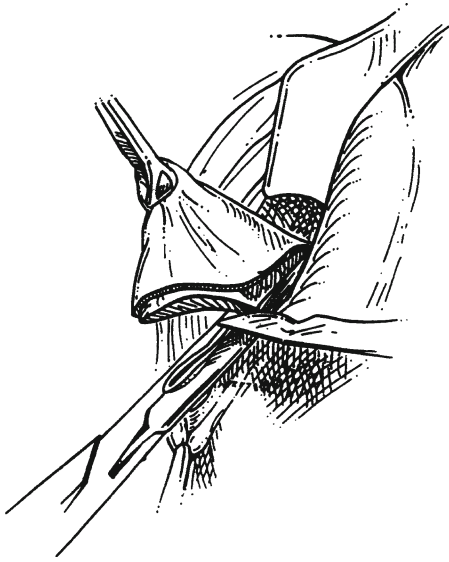


Figure 12.80. Excision of hemorrhoid.

Step 5. Clamp the dissected hemorrhoid and apply tension to visualize the mucocutaneous junction. Excise it using a scalpel (Fig. 12.79), scissor, or monopolar electrocautery. Suture ligate the apex of the hemorrhoidal bundle. Close the mucosal wound with absorbable suture (0 chromic, 2-0 Vicryl) to the anal verge in a running locking fashion. If the external wound is large, it can be loosely reapproximated with interrupted absorbable sutures. The external skin can be left open for drainage to heal by secondary intention. Be sure to save enough mucosa and anoderm between the excised hemorrhoids to prevent anal stenosis (Fig. 12.80).

Step 6. Occasionally an internal hemorrhoid has a polyp-like formation and may be excised in toto. The floor should be sutured with continuous 3-0 chromic (Fig. 12.81).

- ✓ Alternatively, the Harmonic scalpel or a bipolar cautery device (Ligasure, Enseal) can be used to excise the hemorrhoidal tissue. Typically these devices divide and coagulate tissue simultaneously. In comparison with monopolar electrocautery, use of bipolar devices leads to faster operating times and less postoperative pain, due to decreased thermal injury. Absorbable sutures can be used to oversee the excision sites as needed.

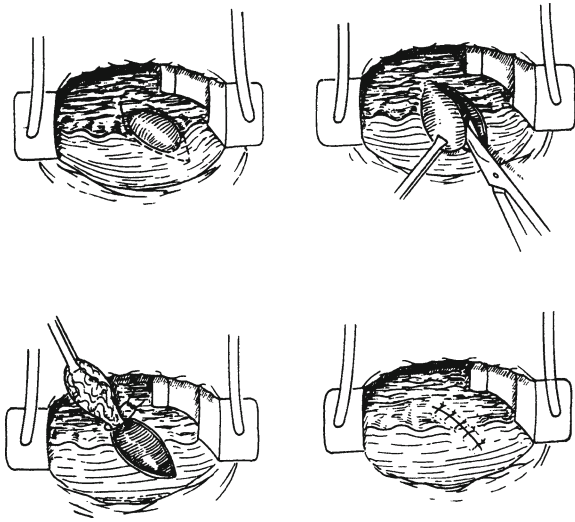


Figure 12.81. In toto excision of internal hemorrhoid.

Procedure for Prolapse and Hemorrhoids (PPH) Stapled Hemorrhoidopexy

PREPARATION: Repeated enemas.

POSITION: Prone jackknife.

ANESTHESIA: General. Local block with bupivacaine with epinephrine is recommended to relax the sphincter and for postoperative analgesia.

- Step 1.** Perform digital rectal examination, anal dilatation, and anoscopic evaluation.
- Step 2.** Gradual digital anal dilation to allow placement of the circular anal dilator (CAD) and obturator. With four 2-0 silk sutures, secure the CAD to the perianal skin. Remove the obturator. The dentate line should be visible through the CAD.
- Step 3.** Insert the open-sided anoscope and place a running 2-0 monofilament submucosal purse-string suture 3–4 cm from the anal verge, staying superficial to the rectal muscle. Placing the purse-string too close to the dentate line increases postoperative pain and can impair sensation. Placing the purse-string too high above the hemorrhoids may not reduce the hemorrhoids. Involving the rectal muscle can lead to sepsis or incontinence.
- Step 4.** Remove the anoscope. Insert the stapler with the anvil head through the purse-string suture using the CAD as a guide. Tie the purse-string around the anvil head. If using the Ethicon PPH stapler, bring

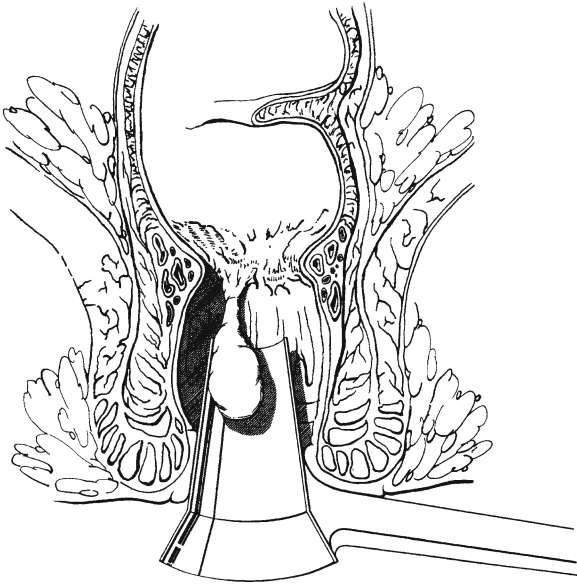


Figure 12.82. Anoscopic evaluation.

the monofilament suture ends through the stapler. Tie a loose knot in the suture outside the stapler. If using the Covidien stapler, the anvil is placed through the purse-string. The purse-string is tied around the anvil head with the suture ends brought through the holes of the anvil spike, and then the stapler mechanism is attached to the anvil spike.

- Step 5.** Apply traction on the suture and close the stapler. In females, perform a digital vaginal exam to confirm that the rectovaginal wall has not been incorporated into the closed stapler. Allow the stapler to remain completely closed for several minutes prior to and after firing.
- Step 6.** Remove the stapler. Inspect the staple line for hemostasis with the anoscope while the CAD is in place. Remove the CAD and reinspect for hemostasis with the anoscope alone. Any bleeding should be oversewn with 3-0 Vicryl suture. Electrocautery is not advised.

Band Ligation of Internal Hemorrhoids

Important note: Avoid banding patients who may require anticoagulation within 2 weeks.

POSITION: Prone jackknife or lateral decubitus.

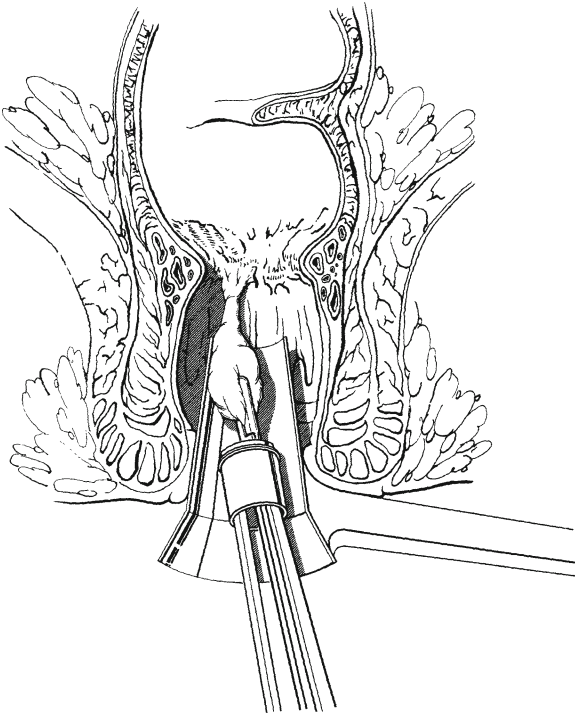


Figure 12.83. Examination of lower rectum.

- Step 1.** Digitally examine the anus for masses and to reduce any prolapse (Figs. 12.82, 12.83, 12.84, and 12.85). Ensure that there is only hemorrhoidal prolapse (not full thickness rectal prolapse).
- Step 2.** Insert an anoscope and examine the entire lower rectum for thrombosis, hypertrophied anal papillae, polyps, radiation proctitis, or Crohn's disease. Identify the major areas of hemorrhoid enlargement and prolapse.
- Step 3.** Using a McGivney ligator, clamp the midportion of the hemorrhoid and retract it into the bander. Avoid the sensitive distal mucosa. Apply the band. If using a McGowan band ligator, apply suction to the hemorrhoid. If there is sensation, release and suction more proximally. Apply the band.
- Step 4.** The hemorrhoidal tissue within the band may be infiltrated with lidocaine or dibucaine in small amounts to decrease slippage of the band and for local analgesia.

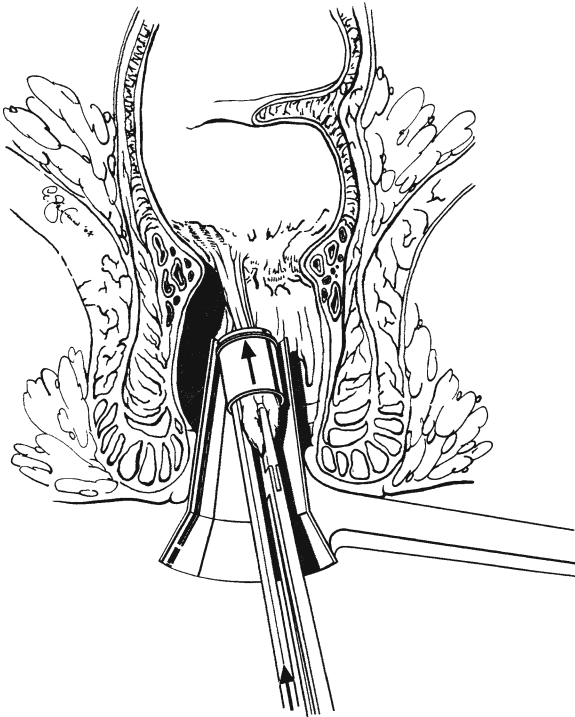


Figure 12.84. Hemorrhoid is clamped.

Thrombosed External Hemorrhoids

POSITION AND PREPARATION: As described for hemorrhoids

ANESTHESIA: Local anesthetic around the base of the thrombosed external hemorrhoid (TEH)

PROCEDURE: INCISION and DRAINAGE

Incise at the hemorrhoidal apex and evacuate the thrombus by pressure at the base of the hemorrhoid or by instrument (curette or curved hemostat).

PROCEDURE: EXCISION

Using sharp scissors or a scalpel, create an elliptical incision closely around the base of the thrombosed external hemorrhoid. Start distally and elevate TEH away from the base, removing the thrombus in toto up to the anal verge. Achieve hemostasis with direct pressure, silver nitrate, or electrocautery. If the wound is very large, loosely reapproximate the wound with 3-0 absorbable suture, leaving enough of the wound open for drainage.

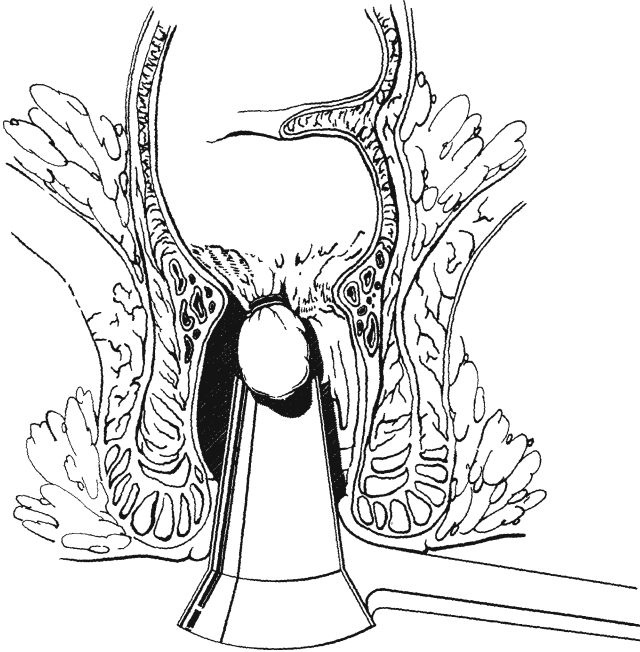


Figure 12.85. Retraction into bander.

Excision of Pilonidal Cyst

POSITION: Jackknife.

PREPARATION AND ANESTHESIA: General. Local block with bupivacaine with epinephrine is recommended to relax the sphincter and for postoperative analgesia.

- Step 1.** Fix extra-large adhesive tape to both lower gluteal areas and perineum. Anchor the tape to the operating room table, separating the intergluteal fold (Fig. 12.86).
- Step 2.** Probe the sinus gently, since occasionally it may travel laterally (Fig. 12.87). With an ovoid incision down to the fascia (Fig. 12.88), remove the cyst and the sinuses en bloc and in toto, including subcutaneous tissue.

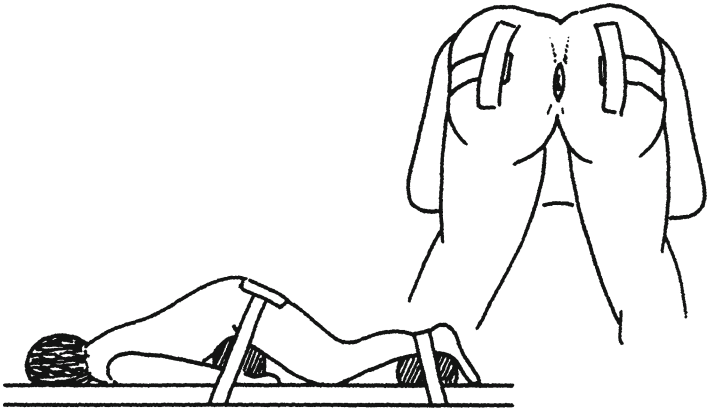


Figure 12.86. Positioning the patient.

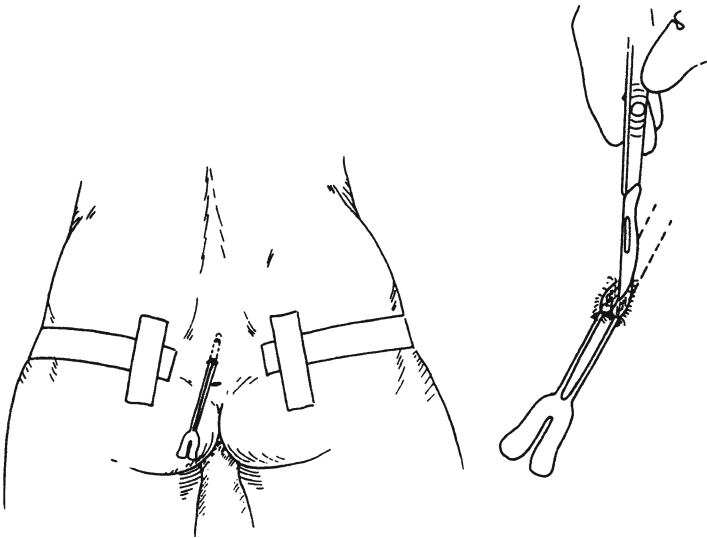


Figure 12.87. Probing the sinus. Incising the cyst.

Step 3. After good hemostasis is established, the skin edges of the wound can be marsupialized with a running locking suture or interrupted sutures. Pack the wound with iodoform gauze to heal by secondary intention. If there is no infection, the wound can be closed in one layer using 3-0 nylon with interrupted vertical mattress sutures, including the fascia, as demonstrated in Fig. 12.89.




Figure 12.88. Cyst is incised and removed.

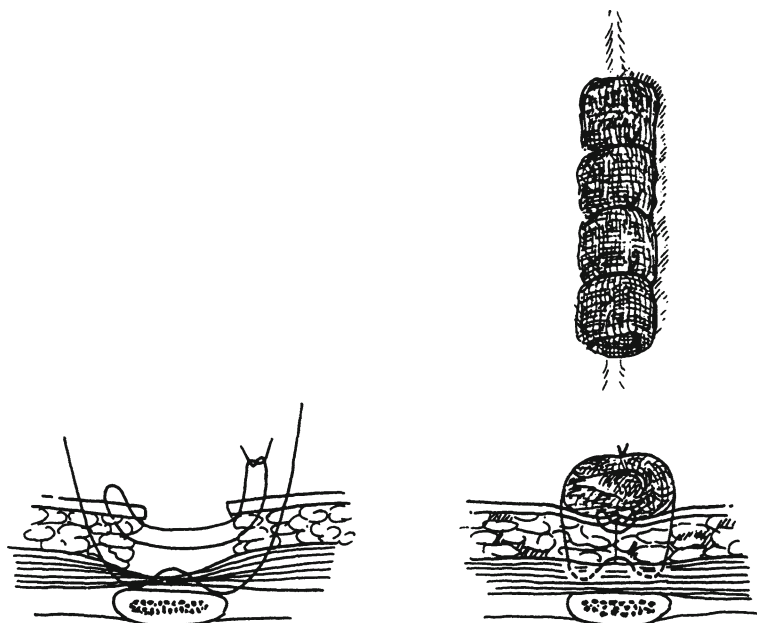


Figure 12.89. Marsupialization and packing of wound.

ANATOMY

■ TOPOGRAPHIC ANATOMY OF THE LIVER

Diaphragmatic Surface Relations

For descriptive purposes, the diaphragmatic surface of the liver is divided into superior, posterior, anterior, and right portions:

- The superior portion is related to the diaphragm and, from right to left, right pleura and lung, pericardium and heart (cardiac impression), and left pleura and lung.
- The posterior portion is related to the diaphragm and lower ribs. It contains the greater part of the bare area and the sulcus of the inferior vena cava (IVC).
- The anterior part is related to the diaphragm and costal margin, xiphoid process, the abdominal wall, and the sixth to tenth ribs on the right.
- The right portion is related to the diaphragm and the seventh to eleventh ribs. It is a lateral continuation of the posterior portion.

Anteriorly, the inferior border of the liver is marked by two notches to the right of the median plane. These are a deep notch accommodating the ligamentum teres and a shallow notch allowing space for the gallbladder.

Visceral Surface Relations

The visceral surface of the liver is related to the following organs from right to left:

- The hepatic flexure of the colon and part of the right transverse colon are related to the anterior one-third of the visceral surface of the right lobe, passing behind the sharp, anterior inferior margin of the liver. The colic impression begins at the right lobe and ends at the quadrate lobe.

- Behind the colic impression is the renal impression, produced by the right kidney and right adrenal gland. Fat, connective tissue, and peritoneum intervene between these organs and the liver. The right adrenal gland is in contact with the bare area of the liver.
- The gallbladder lies in a fossa just beneath the anterior inferior border of the liver.
- To the left of the gallbladder is a depression for the first and second portions of the duodenum. Posterior to the gallbladder fossa is the fossa for the IVC.
- Posteriorly and to the left of the ligamentum venosum (the posterior limb of the “H”), one can see a small impression for the abdominal esophagus.
- Almost the entire visceral surface of the left lobe is in contact with the stomach, forming the gastric impression.

■ PERITONEAL REFLECTIONS AND LIGAMENTS OF THE LIVER

The liver is attached to the anterior abdominal wall and the inferior surface of the diaphragm by the falciform, round, and coronary ligaments. The peritoneum covering the liver is reflected onto the diaphragm as two separate leaves—the anterior and posterior coronary ligaments. Between these is an area in which the diaphragm and the liver are in contact without peritoneum. This is the “bare area.” On the left, the two leaves of the coronary ligament approach and join to form the left triangular ligament; on the right, their apposition forms the right triangular ligament (Fig. 13.1).

Anteriorly, the anterior layer of the coronary ligament forms a fold that extends over the superior surface of the liver and is reflected over the anterior abdominal wall. This fold is the falciform ligament. Between the two layers of the fold, the remnant of the embryonic left umbilical vein forms the round ligament (ligamentum teres) of the liver. The falciform and round ligaments extend into the liver to form the obvious fissure that separates the apparent left and right “lobes” of the liver (which in reality are the two segments of the left lobe). On the visceral surface, the fissure for the round ligament extends posteriorly on the fissure for the ligamentum venosum. Between the fissure and the bed of the gallbladder lies the quadrate “lobe.” It is separated from the more posterior caudate “lobe” by the transverse fissure or porta hepatis (Fig. 13.2).

At the porta hepatis, the peritoneum of the liver forms the lesser omentum, which extends to the lesser curvature of the stomach as the hepatogastric ligament and to the first inch (2.54 cm) of the duodenum as the hepatoduodenal ligament (Fig. 13.3). The right margin of the lesser omentum contains the hepatic artery, the portal vein, and the common bile duct. The bile duct is usually on the right, in the free edge of the omentum.

The surgeon should remember the approximate rib levels of the liver, lungs, and pleurae, as shown in Table 13.1.

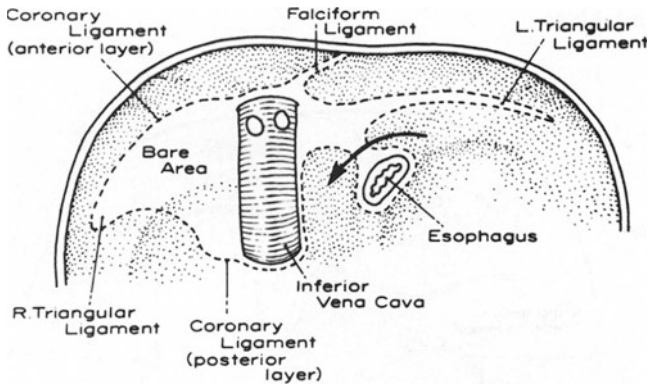


Figure 13.1. The inferior surface of the diaphragm showing the peritoneal attachments of the liver (*broken lines*). Within the boundaries of these attachments is the “bare area” of the liver and the diaphragm. The *arrow* passes through the posterior layer of the coronary ligament (from Gray SW, Rowe JS Jr, Skandalakis JE. *Surgical Anatomy of the Gastroesophageal Junction*. *Am Surg* 45(9):575–587, 1979. Redrawn from Hollingshead WH. *Anatomy for Surgeons*. Harper & Row, 1956. Reprinted by permission of JB Lippincott Co.).

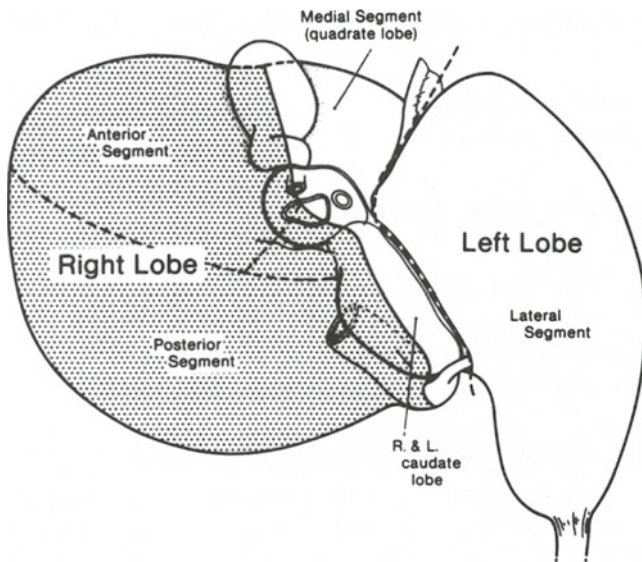


Figure 13.2. Visceral surface of the liver. The plane between the left medial and left lateral segments is variously referred to as the umbilical fissure, the fissure of the ligamentum teres, or the fissure of the falciform ligament (By permission of JE Skandalakis, SW Gray, and JR Rowe. *Anatomical Complications in General Surgery*. New York: McGraw-Hill, 1983).

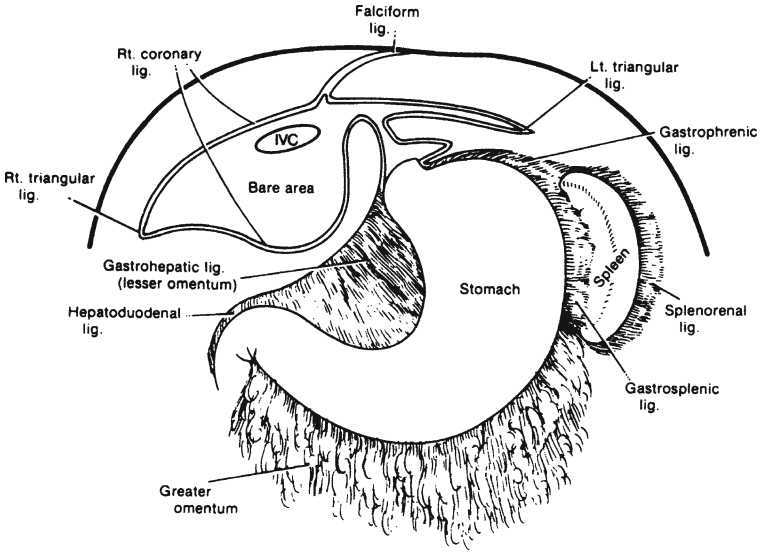


Figure 13.3. Peritoneal reflections of the liver: the lesser omentum (hepatogastric and hepatoduodenal ligaments) and its relation to the coronary ligament of the liver and diaphragm (By permission of JE Skandalakis, SW Gray, and JR Rowe. *Anatomical Complications in General Surgery*. New York: McGraw-Hill, 1983).

Table 13.1 Approximate rib levels of liver, lungs, and pleura

	<i>At the lateral sternal line</i>	<i>At the midaxillary line</i>	<i>At the vertebral spine line</i>
Liver	5	6	8
Lung	6	8	10
Pleura	7	10	12

By permission of Lockhart RD, Hamilton GF, Fyfe FW. *Anatomy of the Human Body*. Philadelphia: JB Lippincott, 1959, p. 549

■ MORPHOLOGY OF THE LIVER

Injection and corrosion preparations of the bile ducts, hepatic arteries, and portal veins have shown conclusively that there are true right and left lobes of the liver, approximately equal in size (Fig. 13.4). Remember that hepatic veins do not follow this division.

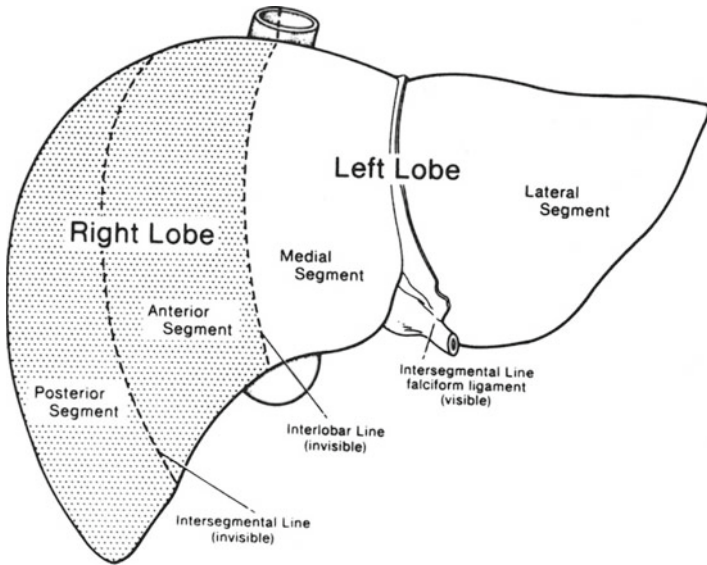


Figure 13.4. The true lobulation and segmentation of the liver: diaphragmatic surface (By permission of JE Skandalakis, SW Gray, and JR Rowe. *Anatomical Complications in General Surgery*. New York: McGraw-Hill, 1983).

On the visceral surface of the liver, the plane separating the right and left lobes passes through the bed of the gallbladder below and the fossa of the IVC above. On the diaphragmatic surface, there is no visible external mark. The line of separation is an imaginary line that passes from the notch of the gallbladder anteriorly, parallel to the fissure of the round ligament, to the IVC above (Fig. 13.2). The true left lobe thus consists of a left medial segment and a left lateral segment. The latter is the “left lobe” of older anatomic descriptions. Each of these two segments can be further divided into superior and inferior subsegments on the basis of the distribution of the bile ducts, hepatic arteries, and portal veins.

The true right lobe is divided by the right fissure into anterior and posterior segments. The plane of this fissure corresponds to the line of the eighth intercostal space. Each segment of the right lobe can be subdivided into superior and inferior subsegments.

The caudate lobe is a separate region divided by the interlobar plane into right and left subsegments. Its bile ducts, arteries, and portal veins arise from both right and left main branches. The caudate lobe is drained by two small, fairly constant hepatic veins that enter the left side of the vena cava. Names such as caudate and quadrate “lobes” are mentioned for convenience. They are not true lobes.

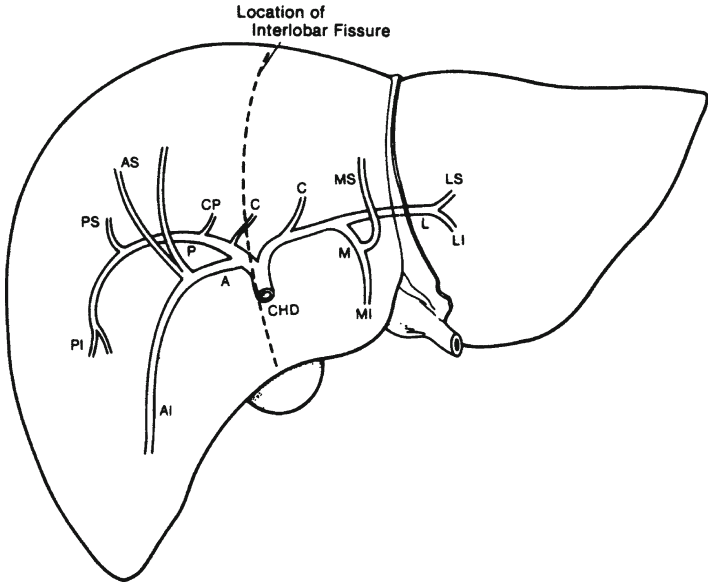


Figure 13.5. Diagram of the intrahepatic distribution of the bile ducts. The segmental branches are labeled: *A* anterior, *C* caudate, *I* inferior, *L* lateral, *M* medial, *P* posterior, *S* superior, *CHD* common hepatic duct, *CP* caudate process (By permission of JE Skandalakis, SW Gray, and JR Rowe. *Anatomical Complications in General Surgery*. New York: McGraw-Hill, 1983).

The quadrate “lobe” is a portion of the inferior half or so of the medial segment of the left lobe. It lies to the right of the falciform ligament, anterior to the hilum, and to the left of the gallbladder. It is related to the pylorus and the first part of the duodenum.

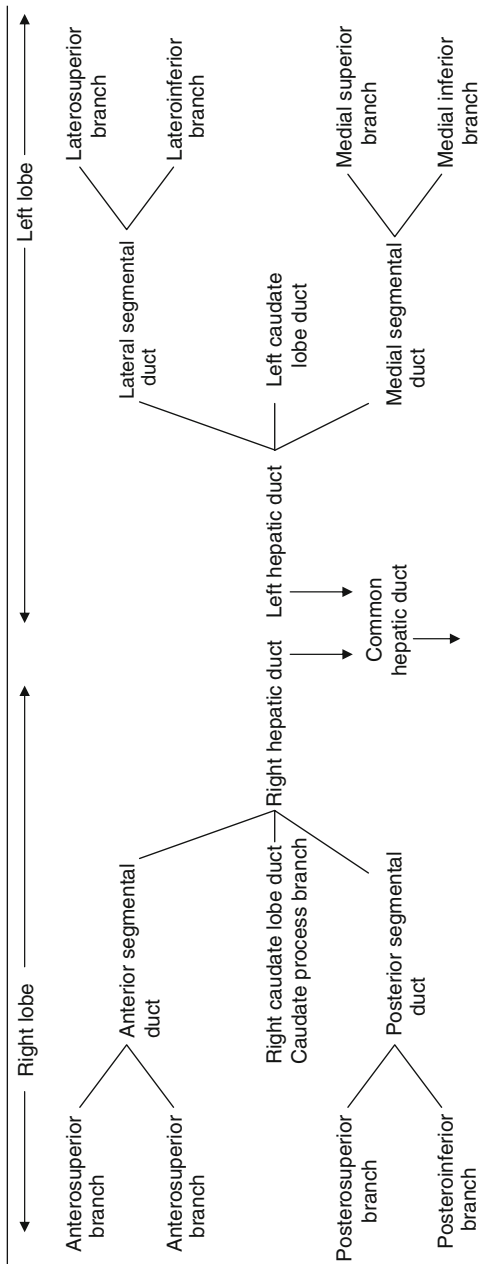
At the present time, we believe that there are interlobar anastomoses between the right and left lobes. In other words, there is communication between the right and left arteries, veins, and ducts.

Clinically, hepatic artery ligation is effective and feasible, and interruption of a lobar bile duct usually produces only transitory jaundice. In spite of these findings, we must remember Michel’s dictum that “the blood supply of the liver is always unpredictable.” Possible collateral pathways are not always *actual*.

Intrahepatic Duct System

The usual pattern of intrahepatic ducts is shown in Fig. 13.5 and Table 13.2. The most frequent variations are those in which the right anterior or posterior segmental duct crosses the midline to enter the left hepatic duct (Fig. 13.6).

Table 13.2 Terminology and pattern of intrahepatic bile ducts



Source: By permission of JE Skandalakis, SW Gray, and JR Rowe, *Anatomical Complications in General Surgery*, New York McGraw-Hill, 1983.

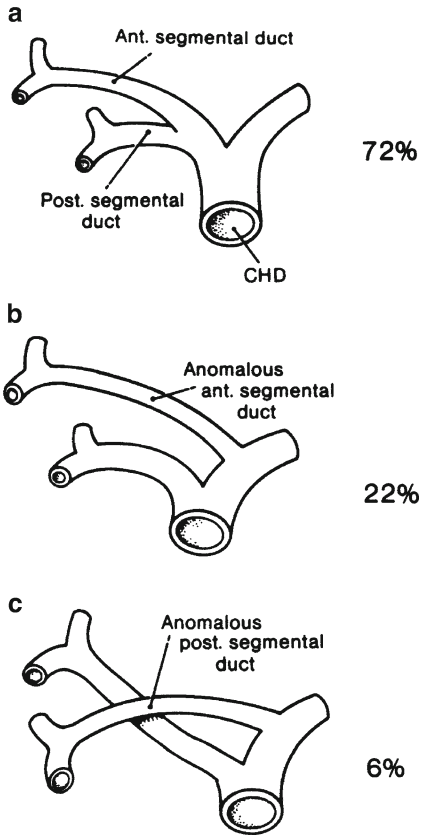


Figure 13.6. Intrahepatic segmental ducts. (a) Usual pattern. (b) Anomalous origin of right anterior duct. (c) Anomalous origin of right posterior duct. Both ducts cross the midline to reach their destinations (By permission of JE Skandalakis, SW Gray, and JR Rowe. *Anatomical Complications in General Surgery*. New York: McGraw-Hill, 1983).

Notice that the caudate lobe has a right and a left drainage. Only the caudate process can be considered to be asymmetric. An aberrant biliary duct, moreover, may occasionally be found in the left triangular ligament. The ligament should always be incised between clamps and ligated.

■ ANOMALIES

The most common hepatic anomaly is diminished size of the left “lobe.” Small accessory lobes attached to the liver or to a mesentery are often reported. The most striking of these is Riedel’s lobe, an elongated tongue of liver extending from the right “lobe” to or below the umbilicus (Fig. 13.7).

■ VASCULAR SYSTEM OF THE LIVER

The liver receives blood from two sources: the hepatic artery and the portal vein. The hepatic artery provides about 25 % of the hepatic blood supply and 50 % of the oxygen. The hepatic portal vein contributes about 75 % of the blood flow and 50 % of the oxygen.

Hepatic Artery

In the usual pattern, the common hepatic artery arises from the celiac trunk. After giving origin to the gastroduodenal artery, the hepatic artery continues as the proper hepatic artery in the hepatoduodenal ligament. In this ligament, the

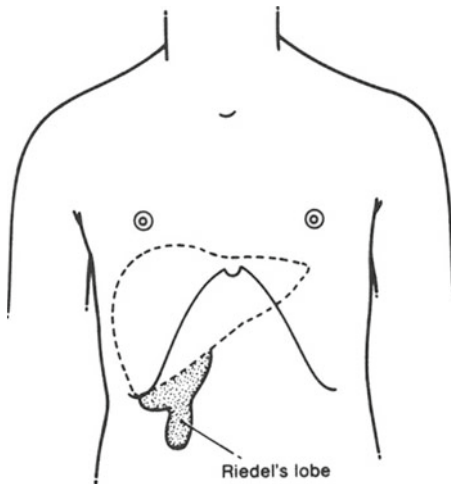


Figure 13.7. Riedel’s lobe of the liver. This anomalous lobe is found usually in middle-aged women and presents as an asymptomatic but unexplained mass (By permission of JE Skandalakis, SW Gray, and JR Rowe. *Anatomical Complications in General Surgery*, New York: McGraw-Hill, 1983).

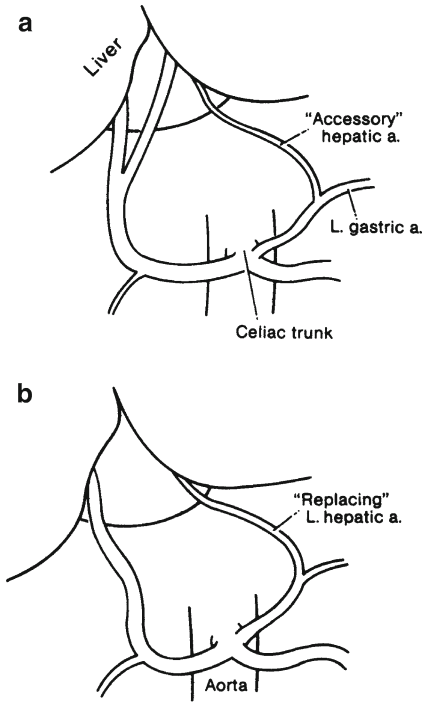


Figure 13.8. Aberrant hepatic arteries. (a) Accessory type. (b) Replacing type (By permission of JE Skandalakis, SW Gray, and JR Rowe. *Anatomical Complications in General Surgery*, New York: McGraw-Hill, 1983).

proper hepatic artery lies to the left of the common bile and hepatic ducts and anterior to the portal vein. It divides into right and left hepatic (lobar) arteries before it enters the porta.

An aberrant hepatic artery is one that arises from some vessel other than the celiac trunk and reaches the liver by an abnormal course. Such an aberrant artery is *accessory* if it supplies a segment of the liver that also receives blood from a normal hepatic artery (Fig. 13.8a). It is *replacing* if it is the only blood supply to such a segment (Fig. 13.8b).

At the porta hepatis, the right hepatic artery passes to the right, usually posterior to the hepatic duct, but occasionally anterior to it. The cystic artery gener-

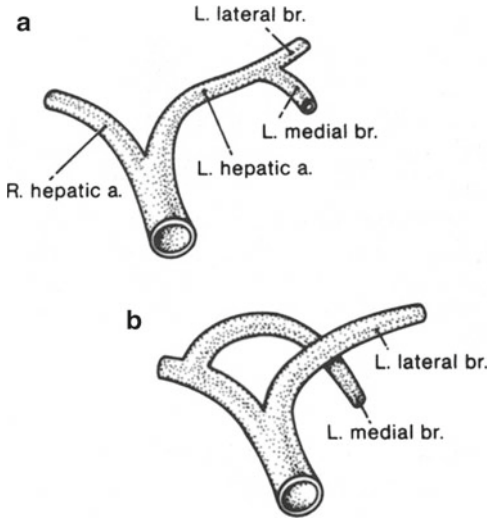


Figure 13.9. Hepatic arteries. (a) Usual pattern of segmental hepatic arteries. (b) Anomalous origin of the left medial segmental artery from the right hepatic artery, crossing the midline to reach the medial segment of the left lobe. This may be encountered in 25 % of individuals (By permission of JE Skandalakis, SW Gray, and JR Rowe. *Anatomical Complications in General Surgery*. New York: McGraw-Hill, 1983).

ally arises from the right hepatic in the hepatocystic triangle located between the cystic duct and the common hepatic duct. The left hepatic artery usually supplies the entire left lobe of the liver (Fig. 13.9a). However, in some individuals the left artery supplies only the left lateral segment, with the left medial segment being supplied by a branch of the right hepatic artery that crosses the midline (Fig. 13.9b).

Within the liver, the arteries follow the course of the bile ducts, dividing into anterior and posterior branches in the right lobe and into lateral and medial branches in the left lobe (Fig. 13.10).

Ligation of the right or left hepatic artery results in ischemia for about 24 h, after which translobar and transsegmental collateral vessels restore arterial blood to the deprived segment. With arteriography in patients, the existence of an interlobar arterial net following ligation of one hepatic artery has been appreciated.

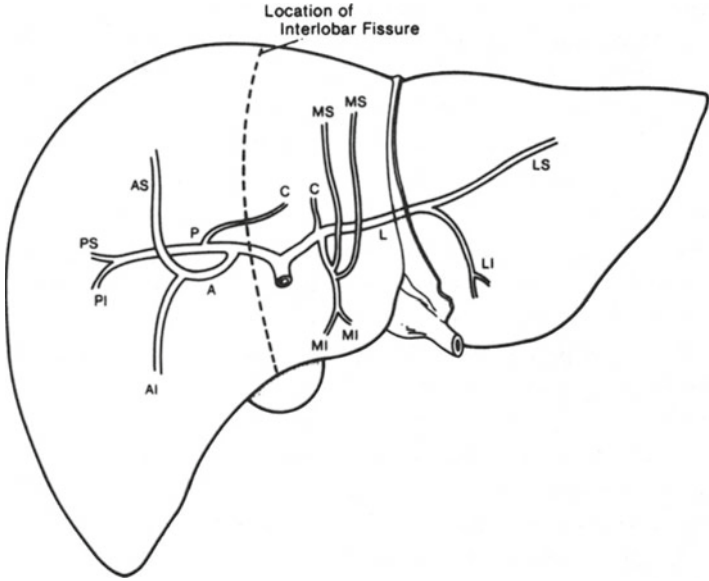


Figure 13.10. Diagram of the intrahepatic distribution of the hepatic artery. Abbreviations as in Fig. 13.5 (By permission of JE Skandalakis, SW Gray, and JR Rowe. *Anatomical Complications in General Surgery*, New York: McGraw-Hill, 1983).

Remember:

- ✓ Hepatic arteries are not end arteries *in vivo*; ligation of the right or left hepatic artery results in translobar and subcapsular collateral circulation within 24 h.
- ✓ After proximal ligation of the common hepatic artery, the right gastric and gastroduodenal arteries will maintain hepatic blood flow.
- ✓ Hepatic artery ligation is well tolerated. Death following such ligation is not usually the result of ligation.
- ✓ Cholecystectomy must always accompany hepatic artery ligation.

Portal Vein

The portal vein originates with the confluence of the superior mesenteric and splenic veins behind the pancreas. In about one-third of individuals, the inferior mesenteric vein enters at this confluence; in the rest, it enters either the superior mesenteric vein or the splenic vein below the junction.

In its upward course, the portal vein receives the left gastric and several smaller veins before dividing into right and left branches at the porta hepatis. Here it lies beneath the hepatic duct and the hepatic artery (Fig. 13.11).

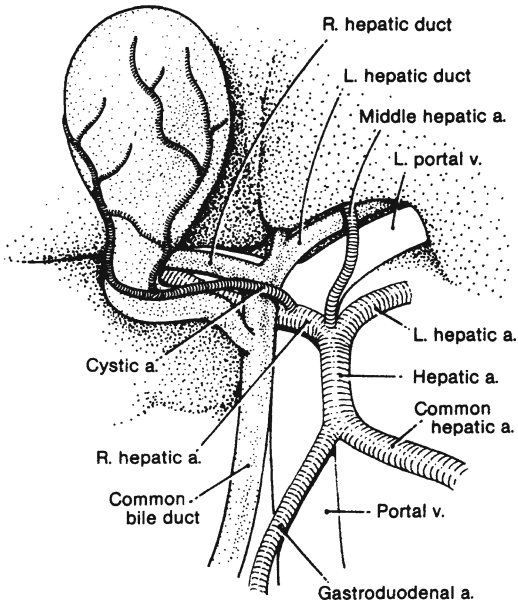


Figure 13.11. Relationship of the hepatic ducts, the hepatic artery, and the portal vein at the porta hepatis (By permission of JE Skandalakis, SW Gray, and JR Rowe. *Anatomical Complications in General Surgery*. New York: McGraw-Hill, 1983).

On the right, the portal vessels follow the pattern of the hepatic arteries and the bile ducts. The right portal vein divides into anterior and posterior vessels, each dividing further into superior and inferior branches. Near its origin, the right vein sends a branch to the right side of the caudate lobe.

The left portal vein is longer and smaller than the right vein. It divides into medial and lateral vessels, each with superior and inferior branches, and it gives a branch to the left side of the caudate lobe. The medial vessel contains a dilatation, the pars umbilicus, which represents the orifice of the obliterated embryonic ductus venosus (Fig. 13.12).

Remember:

- ✓ Portal veins may be ligated without fatality. Intersegmental communication is from hepatic sinusoids of adjacent lobules. There are few true anastomoses between venous branches.
- ✓ Reduction in portal blood flow increases hepatic artery blood flow. The reverse is not true.
- ✓ Atrophy follows portal vein ligation.
- ✓ Ligation of both the lobar hepatic artery and the portal vein will result in atrophy without necrosis.

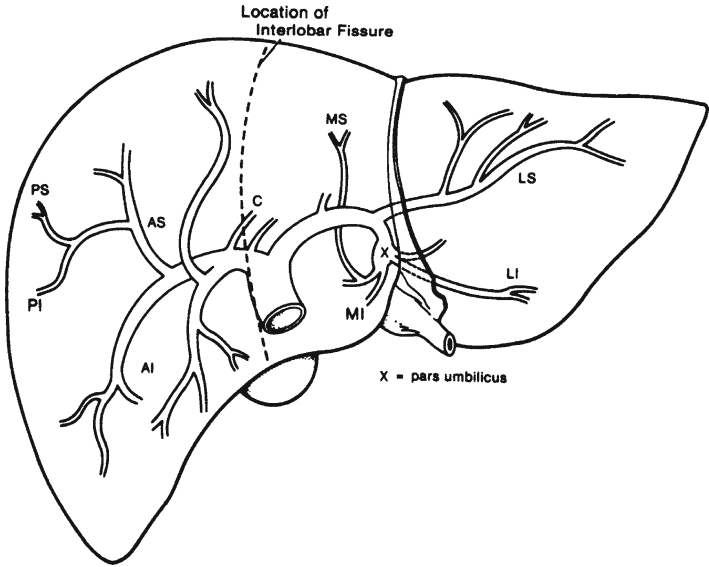


Figure 13.12. Diagram of the intrahepatic distribution of the portal vein. *AI* anteroinferior, *AS* anterosuperior, *C* caudate, *LI* lateroinferior, *LS* laterosuperior, *MI* medioinferior, *MS* mediasuperior, *PI* posteroinferior, *PS* posterosuperior, *X* pars umbilicus (By permission of JE Skandalakis, SW Gray, and JR Rowe. *Anatomical Complications in General Surgery*. New York: McGraw-Hill, 1983).

- ✓ Following a radical pancreaticoduodenal resection, the portal vein should not be ligated. Portal blood flow must be restored by a shunt or a replacement graft.

Hepatic Veins

Unlike the bile ducts, hepatic arteries, and portal veins—all of which serve lobes and segments of the liver—the hepatic veins lie in the planes between the lobes and segments. The veins are thus intersegmental and drain parts of adjacent segments. The presence of the hepatic veins requires the line of resection for a right lobectomy to be placed just to the right of the interlobar plane; for a left lobectomy, the line should be just to the left. The usual pattern of the hepatic veins is as follows (Fig. 13.13):

- The right hepatic vein (RHV) drains both posterior segments and the anterosuperior segment. It is located in the right segmental fissure.
- The middle hepatic vein (MHV) drains the anteroinferior segment and the medial inferior segment. It is located in the main lobar fissure.

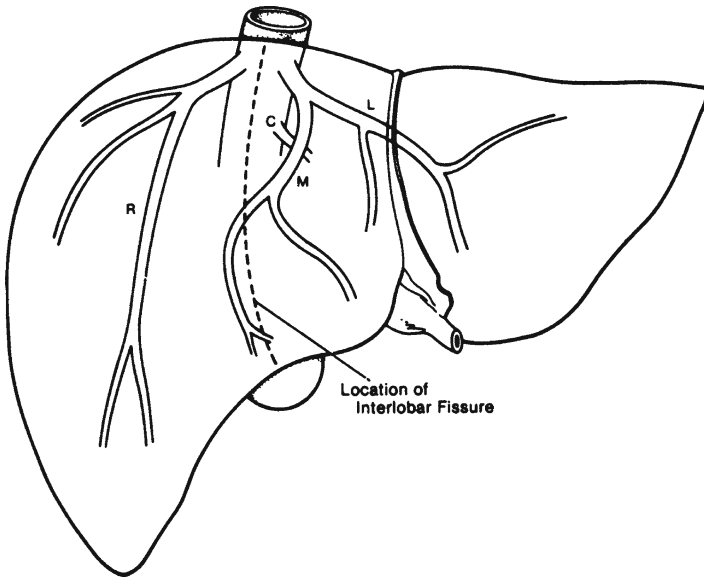


Figure 13.13. Diagram of the intrahepatic distribution of the hepatic veins. Note that they are interlobular rather than lobular. *C* caudate, *L* left, *M* medial, *R* right (By permission of JE Skandalakis, SW Gray, and JR Rowe. *Anatomical Complications in General Surgery*. New York: McGraw-Hill, 1983).

- The left hepatic vein (LHV) drains the ductus venosus (in the fetus), the left lateral segment, and the medial superior segment. It is located in the upper portion of the left segmental fissure.
- The MHVs and LHVs approach one another and often form a common trunk as they enter the vena cava less than 1 cm below the diaphragm. In addition to three major veins, there are as many as 50 smaller veins (dorsal hepatic veins), most of which are of insignificant size. The three major veins can be divided into types based on length of vein, tributaries or lack of tributaries, and availability for ligation; 1 cm of vein can be assumed to be adequate for successful ligation.

Remember:

- ✓ Lobar or segmental hepatic vein ligation is feasible.
- ✓ Hepatic resection following ligation of a hepatic vein is not necessary.
- ✓ Ligation of the RHV is possible prior to transection of the liver in the majority of cases; the MHVs and LHVs should not be ligated.

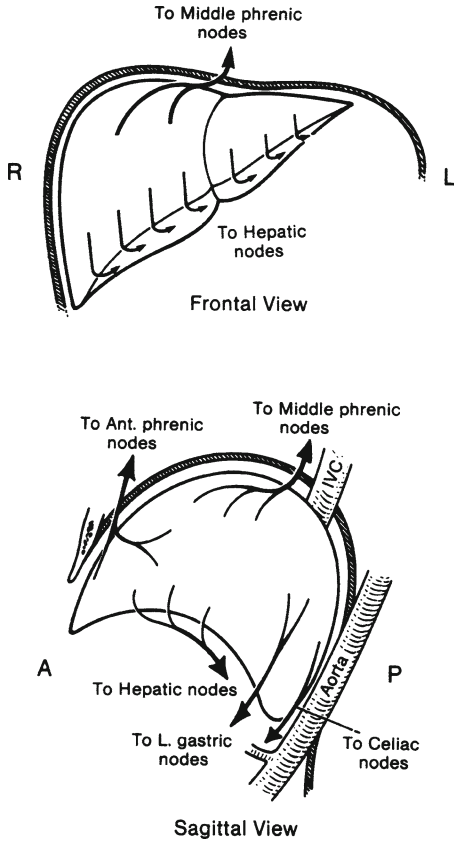


Figure 13.14. Diagram of the superficial lymphatic drainage of the liver: frontal and sagittal views (By permission of JE Skandalakis, SW Gray, and JR Rowe. *Anatomical Complications in General Surgery*. New York: McGraw-Hill, 1983).

Lymphatic Drainage

Superficial Lymphatics

The superficial lymphatics lie near the surface of the liver beneath the serosa and within the Glisson's capsule (Fig. 13.14).

Deep Lymphatics

The pathways of the deep lymphatics drain to (1) the middle (lateral) phrenic nodes of the diaphragm and (2) nodes of the porta hepatis following portal vein branches. The deep lymphatics carry the greater part of lymphatic outflow. There is free communication between the superficial and deep lymphatic systems.

■ PERIHEPATIC SPACES

The perihepatic spaces (subphrenic and subhepatic) and the collection of fluid within may be appreciated surgicoanatomically from Figs. 13.15, 13.16, 13.17, 13.18, 13.19, 13.20, 13.21, and 13.22.

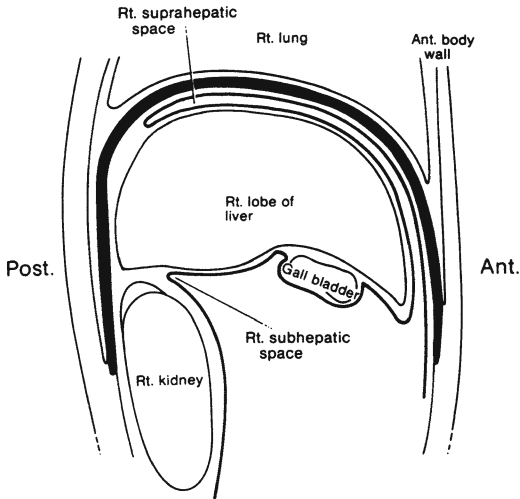


Figure 13.15. Diagrammatic parasagittal section through the upper abdomen showing the potential right suprahepatic and subhepatic spaces. The thick black line represents the diaphragm (By permission of JE Skandalakis, SW Gray, and JR Rowe. *Anatomical Complications in General Surgery*. New York: McGraw-Hill, 1983).

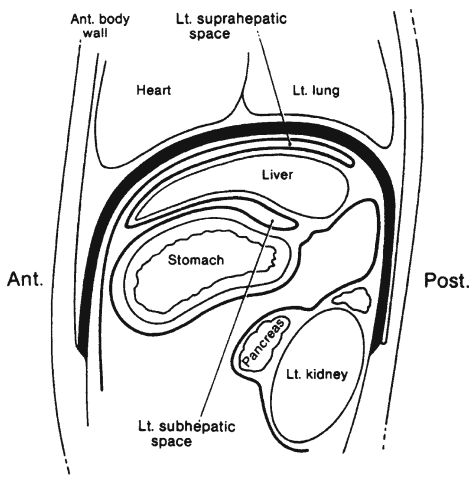


Figure 13.16. Diagrammatic parasagittal section through the trunk showing the potential left suprahepatic and subhepatic spaces (By permission of JE Skandalakis, SW Gray, and JR Rowe. *Anatomical Complications in General Surgery*. New York: McGraw-Hill, 1983).

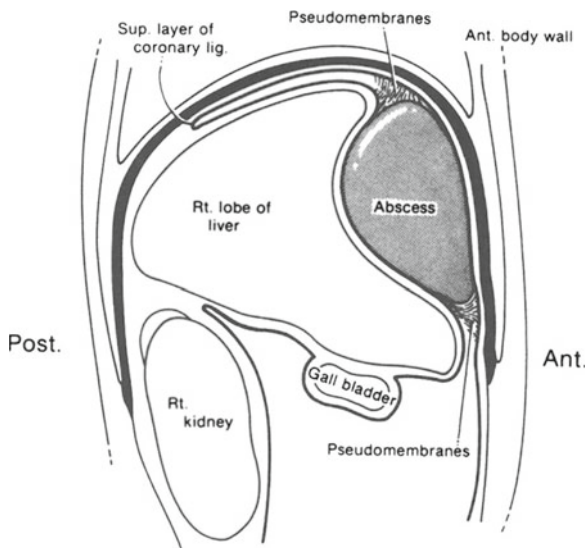


Figure 13.17. Relations of an abscess in the anterior portion of the right suprahepatic space (By permission of JE Skandalakis, SW Gray, and JR Rowe. *Anatomical Complications in General Surgery*. New York: McGraw-Hill, 1983).

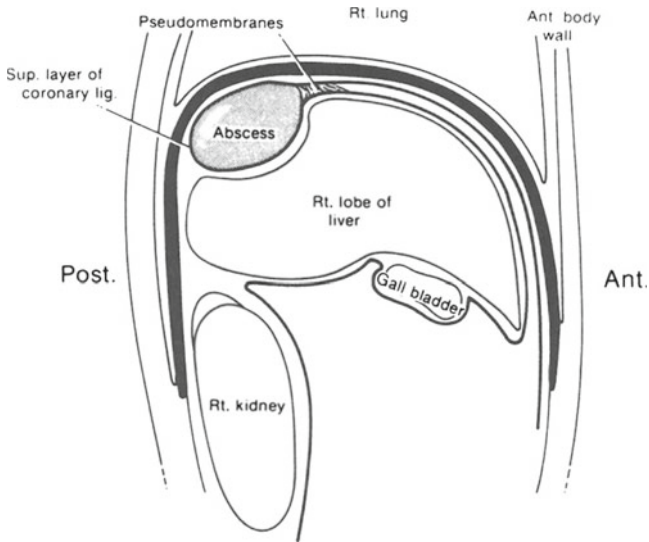


Figure 13.18. Relations of an abscess in the posterior portion of the right suprahepatic space (By permission of JE Skandalakis, SW Gray, and JR Rowe. *Anatomical Complications in General Surgery*. New York: McGraw-Hill, 1983).

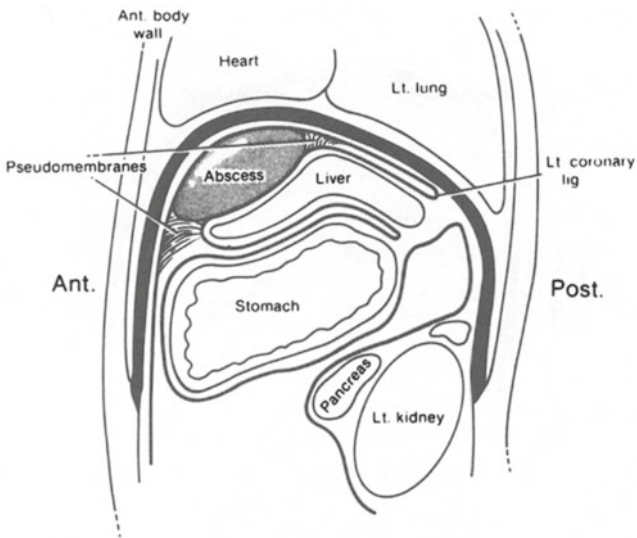


Figure 13.19. Relations of an abscess in the anterior portion of the left suprahepatic space (By permission of JE Skandalakis, SW Gray, and JR Rowe. *Anatomical Complications in General Surgery*. New York: McGraw-Hill, 1983).

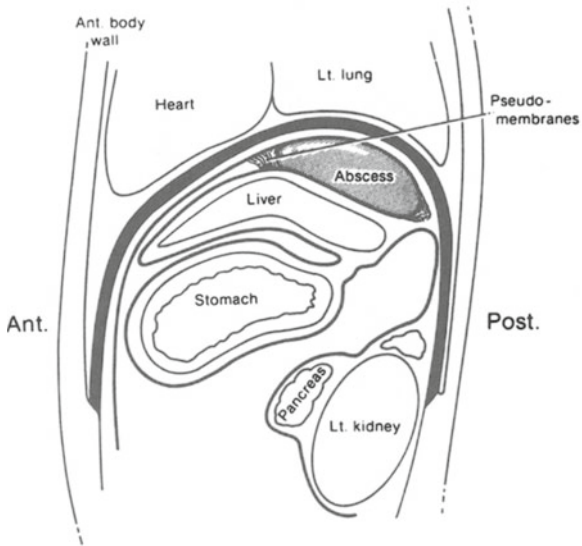


Figure 13.20. Relations of an abscess in the posterior portion of the left suprahepatic space (By permission of JE Skandalakis, SW Gray, and JR Rowe. *Anatomical Complications in General Surgery*. New York: McGraw-Hill, 1983).

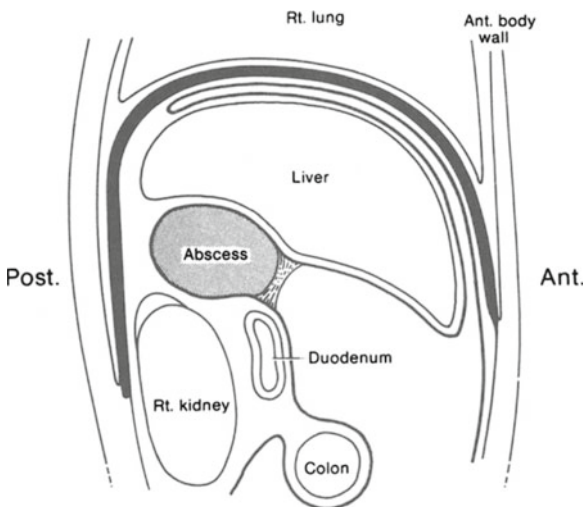


Figure 13.21. Relations of an abscess in the right infrahepatic space (By permission of JE Skandalakis, SW Gray, and JR Rowe. *Anatomical Complications in General Surgery*. New York: McGraw-Hill, 1983).

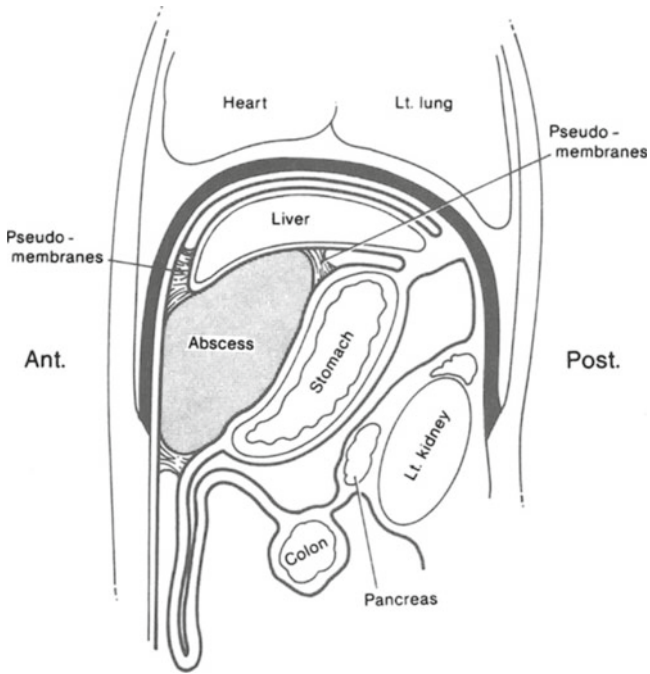


Figure 13.22. Relations of an abscess in the left infrahepatic space (By permission of JE Skandalakis, SW Gray, and JR Rowe. *Anatomical Complications in General Surgery*. New York: McGraw-Hill, 1983).

TECHNIQUE

■ NEEDLE BIOPSY

Use a Tru-Cut needle, then Bovie the liver capsule where it is bleeding.

■ EXCISIONAL BIOPSY

There are two excisional biopsy procedures: wedge type and nonwedge type (circumferential type).

Wedge-Type Biopsy

- Step 1.** With 0 chromic catgut or synthetic absorbable, place mattress sutures 1½–2 cm from the periphery of the lesion (Fig. 13.23).
- Step 2.** Remove the lesion with at least 1 cm healthy liver tissue. Proceed using electrocautery or argon Bovie.
- Step 3.** Send specimen to the lab to confirm that margins are clean.
- Step 4.** After obtaining good hemostasis by cautery, gently approximate with catgut sutures.

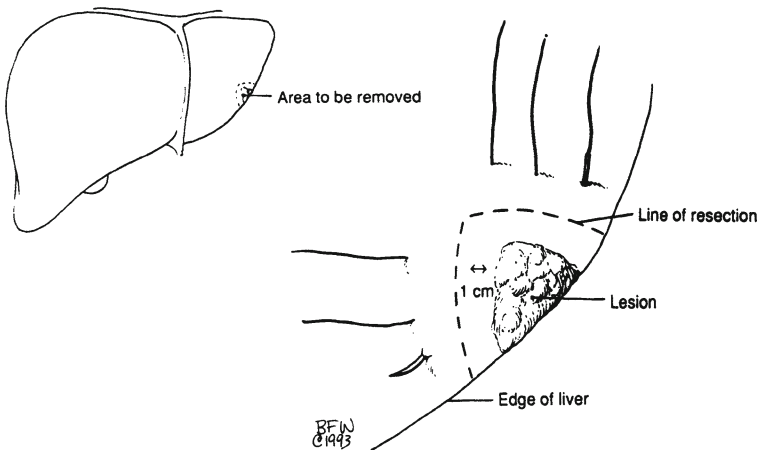


Figure 13.23. Wedge biopsy. Placement of sutures. *Inset:* resection site.

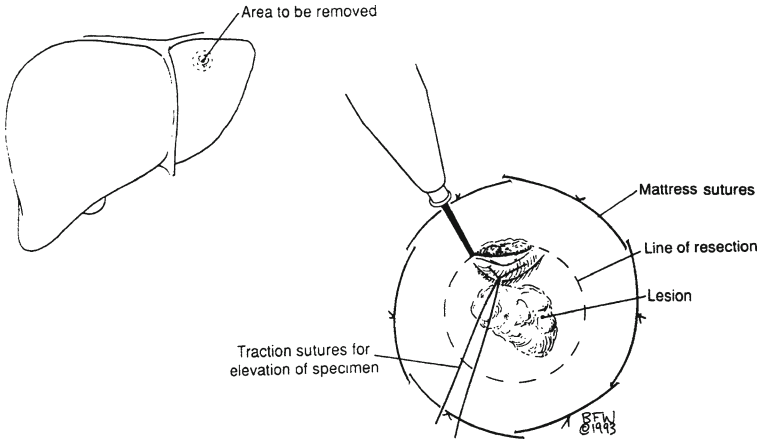


Figure 13.24. Circumferential (nonwedge) biopsy. Placement of sutures. *Inset*: resection site.

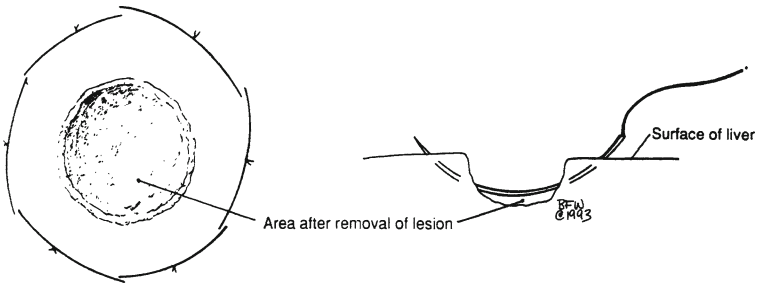


Figure 13.25. Wound suturing.

Nonwedge- or Circumferential-Type Biopsy

- Step 1.** Place deep hemostatic sutures, as in step 1 of wedge-type excisional biopsy, at least 1½–2 cm from the periphery of the lesion (Fig. 13.24).
- Step 2.** Remove lesion by electrocautery. Suction cautery or argon laser will be very helpful for controlling bleeding of liver parenchyma.
- Step 3.** Approximate with sutures (Fig. 13.25). Occasionally a gelatin sponge within the cavity helps.

■ HEPATIC RESECTIONS

Anatomical Landmarks for Liver Resection

Except for the sulcus, which divides the lateral and medial segments of the left lobe, the diaphragmatic surface of the liver gives little indication of its internal lobulation. In spite of this, at least four types of lobar and segmental resections can be performed. The four most common types are shown in Fig. 13.26.

The basic plan of the blood vessels within the liver is subject to many variations; hence, preoperative aortic, celiac, or selective hepatic arteriography must be performed and the films studied carefully before any surgical procedure is attempted. The main arterial trunk to the medial segment arises from the right hepatic artery and passes to the left across the midline in about 25 % of individuals (Fig. 13.9). Ligation of any arterial branch should be preceded by manual occlusion and observation of the limits of color change in the tissue.

Because the interlobar and intersegmental spaces are occupied by the hepatic veins (Fig. 13.13), it is necessary to transect the liver in a paralobular or parasegmental plane. This must be to the right of the vein for a right lobectomy or trisegmentectomy and to the left of the vein for a left lobectomy or a lateral segmentectomy (Fig. 13.27). This is especially important in the true interlobar (umbilical) fissure, where vessels and bile ducts may lie in the fissure and return to the medial lobe more distally.

Note:

- ✓ In all hepatic resections, the Cavitron ultrasonic surgical aspirator (CUSA) dissector facilitates the exposure and ligation of the arteries, veins, and ducts within the liver parenchyma. The argon laser is useful for parenchymal bleeding from smaller vessels that are not ligated.

Left Lobectomy

If the left lobe is to be resected, the left hepatic artery, the portal vein, and the bile duct should be ligated. Section of the triangular ligament will permit mobilization of the left lobe. Transection should follow a line from the left side of the fossa of the gallbladder to the left side of the fossa of the IVC (Fig. 13.27). The LHVs and MHVs should be exposed and ligated within the liver.

In most cases, the LHVs and MHVs form a common trunk before emerging from the liver. It is best to ligate the hepatic veins at the end of the dissection to be sure that only the veins from the resected segments are ligated. A left resection may be lobar, segmental, or even wedge shaped for a superficially located tumor.

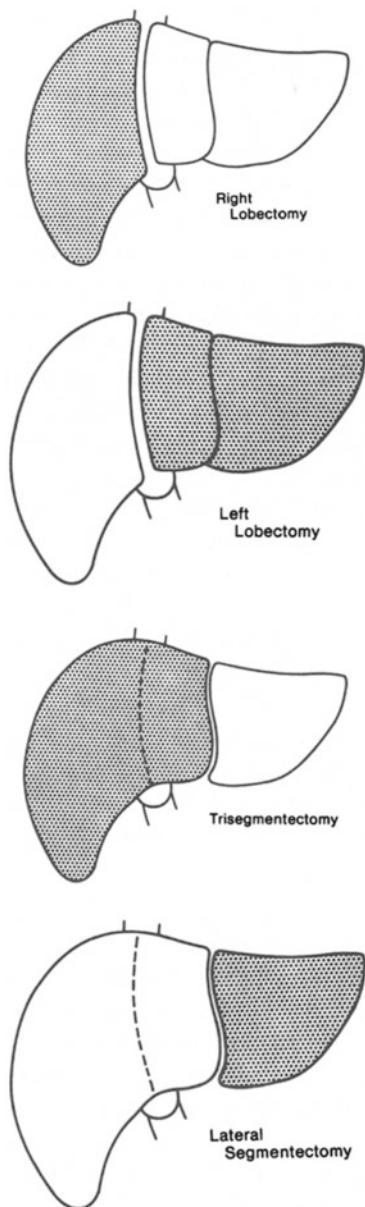


Figure 13.26. Types of lobar and segmental liver resections (By permission of JE Skandalakis, SW Gray, and JR Rowe. *Anatomical Complications in General Surgery*. New York: McGraw-Hill, 1983).

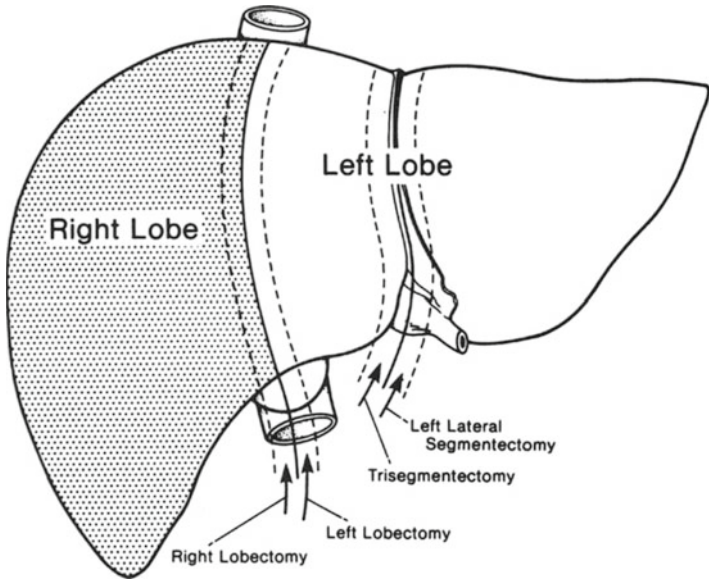


Figure 13.27. Planes of transection of the liver for lobectomy and segmentectomy. Trisegmentectomy includes the anterior and posterior segments of the right lobe and the medial segment of the left lobe (By permission of JE Skandalakis, SW Gray, and JR Rowe. *Anatomical Complications in General Surgery*. New York: McGraw-Hill, 1983).

Left Hepatic Lobectomy (Fig. 13.27)

- Step 1.** Perform cholecystectomy.
- Step 2.** Carefully dissect and isolate the left hepatic duct, left hepatic artery, and left portal vein (Fig. 13.28).
- Step 3.** Divide the left triangular, left coronary, and falciform ligaments (Fig. 13.29).
- Step 4.** With 2–0 silk, doubly ligate the left hepatic duct and left hepatic artery. The left portal vein should be clamped proximally and distally and, after division, oversewn with 5–0 synthetic nonabsorbable suture or silk (Fig. 13.30).
- Step 5.** Prepare and isolate the LHV. Clamp, divide, and oversew the vein as described in step 4 for the left portal vein. If the LHV is intrahepatic, proceed with lobar division (Fig. 13.31).
- Step 6.** By very superficial electrocoagulation, indicate the line of Rex on the Glisson's capsule of the liver. Start division of the hepatic parenchyma using the CUSA, and ligate vessels and ducts with 0 or 2–0 silk (Fig. 13.32). Further hemostasis is obtained with the argon laser.

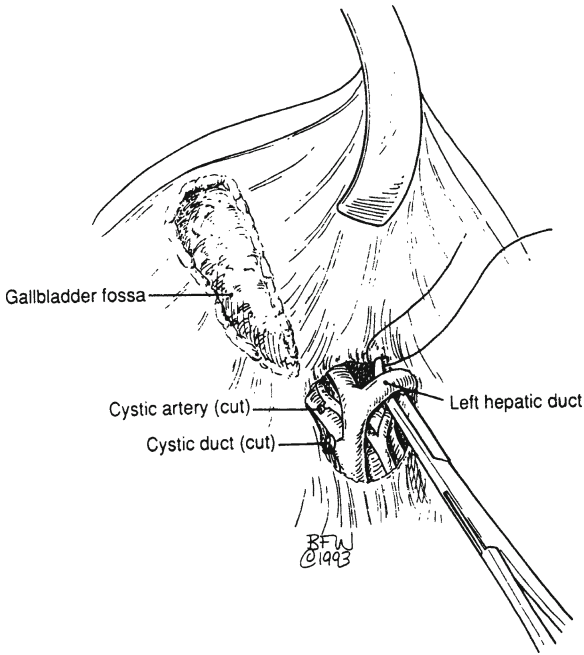


Figure 13.28. Ligation of vessels.

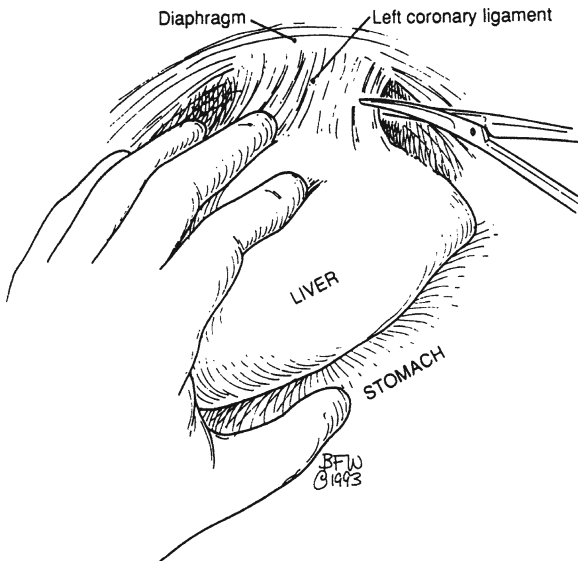


Figure 13.29. Division of ligaments.

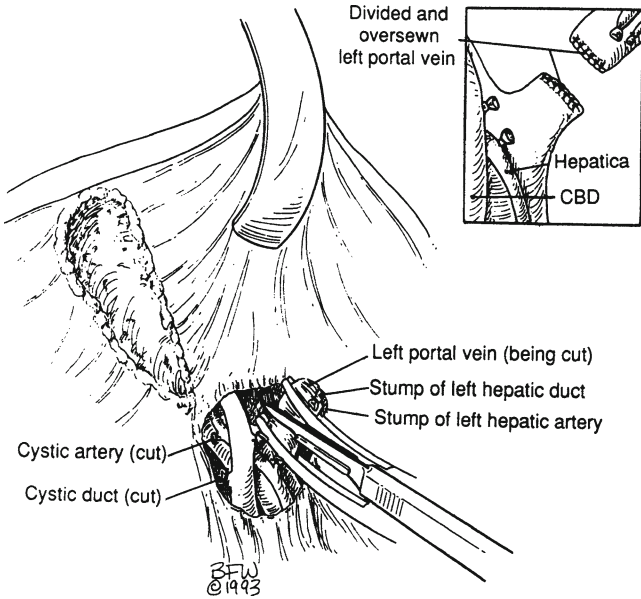


Figure 13.30. Division of left portal vein. *Inset*: detailed view.

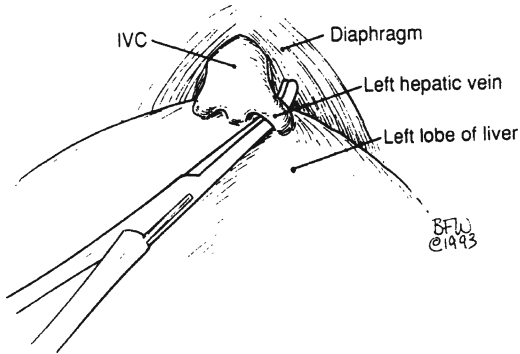


Figure 13.31. Division of parenchyma.

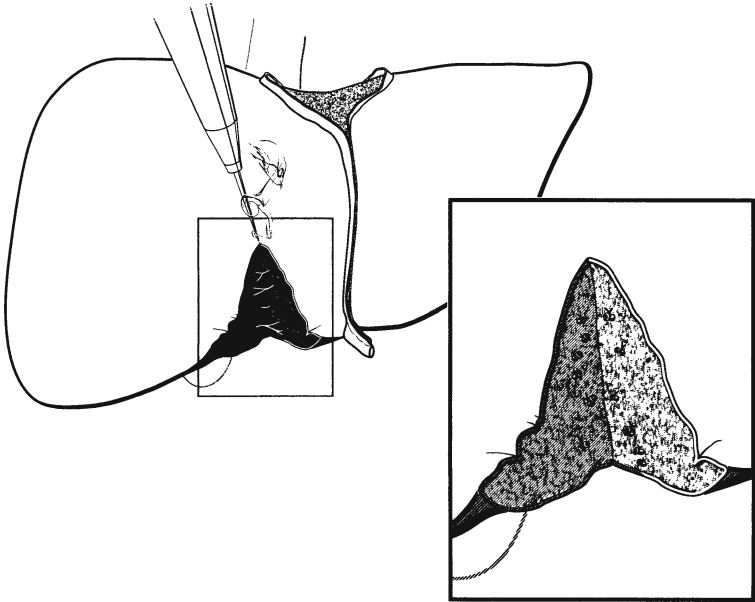


Figure 13.32. Lobar division.

Step 7. Insert Jackson–Pratt drains.

Step 8. Close abdominal wall in layers.

Left Lateral Segmentectomy (Fig. 13.4)

Step 1. With scissors, carefully section the right triangular and coronary ligaments (Fig. 13.29). Be sure to avoid injuring the LHV.

Step 2. With the electrocautery, score the line of resection 1–1½ cm lateral to the falciform ligament (Fig. 13.33).

Step 3. Proceed as in step 6 of left hepatic lobectomy (above).

Right Lobectomy

For a right lobectomy or trisegmental lobectomy, a right subcostal incision is used. It may be continued upward into the thorax or to the right if necessary.

The right triangular and coronary ligaments are incised so that the right lobe may be retracted. The round and falciform ligaments are preserved. In a “true” right or left lobectomy, the gallbladder must be sacrificed.

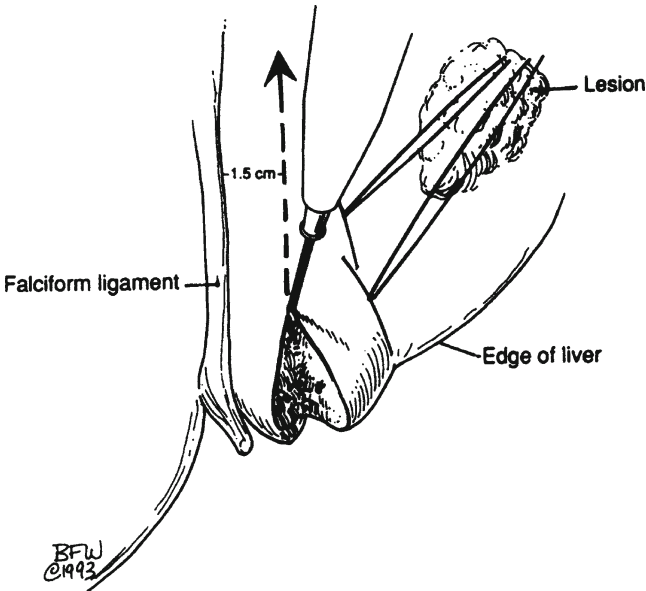


Figure 13.33. Line of resection.

Dissection begins at the hilum. Branches of the hepatic artery, the portal vein, and the bile duct of the lobe to be removed are ligated, and the interlobar hepatic veins are preserved. Blunt dissection must be used throughout.

The line of the interlobar fissure extends from the gallbladder fossa below to the IVC above. The dissection must pass to the right of the MHV to preserve drainage of the medial segment of the left lobe (Fig. 13.27). The RHV may be ligated extrahepatically before transection of the liver.

A right “extended” lobectomy (trisegmentectomy) is similar, but the liver is transected just to the right of the falciform ligament. The MHV must be ligated, since the medial segment is to be removed.

Right Hepatic Lobectomy (Fig. 13.27)

- Step 1.** Perform cholecystectomy.
- Step 2.** Divide the falciform, right anterior, posterior coronary, and right triangular ligaments. Be careful not to sever the RHV (Fig. 13.34).
- Step 3.** Rotate the right lobe medially.
- Step 4.** Identify, isolate, and doubly ligate the right hepatic duct and right hepatic artery. The right portal vein should be treated very carefully with the same technique used in step 5 of the left hepatic lobectomy (Fig. 13.35).

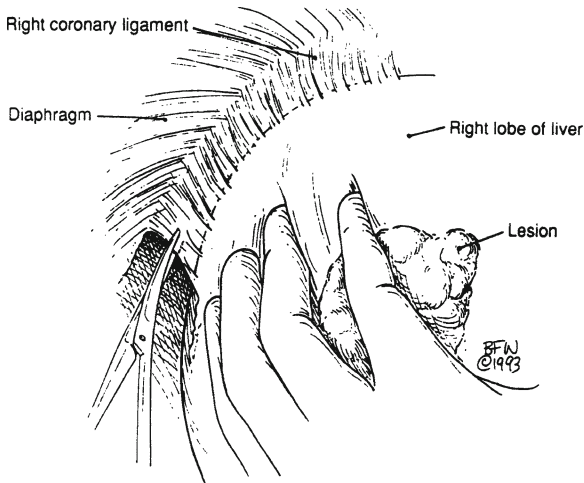


Figure 13.34. Incising the right coronary ligament.

- Step 5.** Dissect and carefully prepare the retrohepatic IVC and its small multiple parenchymal branches, which should be ligated doubly using 4–0 or 5–0 silk (Fig. 13.36).
- Step 6.** If the RHV was not ligated previously, it should be dissected very carefully, mobilized, clamped doubly, divided, and oversewn as described in the procedure for left hepatic lobectomy.
- Step 7.** If discoloration and demarcation are present between the right and left lobes at this time, divide the two lobes through the previously marked area, as in step 6 of the procedure for left hepatic lobectomy.
- Step 8.** For hepatic stabilization, approximate the falciform ligament (Fig. 13.37).
- Step 9.** Insert Jackson–Pratt drain.

Liver Resection and Trauma

In contrast to elective operations on the liver, the surgeon may be faced with traumatic liver injury that does not follow segmental lines. In such cases, the surgeon must decide whether to debride and repair the wound or convert it into an anatomical segmental resection. The problem is that most injuries occur to the right lobe. The choice lies between repair and right lobectomy. If the injury is minor, lobectomy is not justified. If the injury would leave grossly devascularized areas of the liver, then formal lobectomy is necessary.

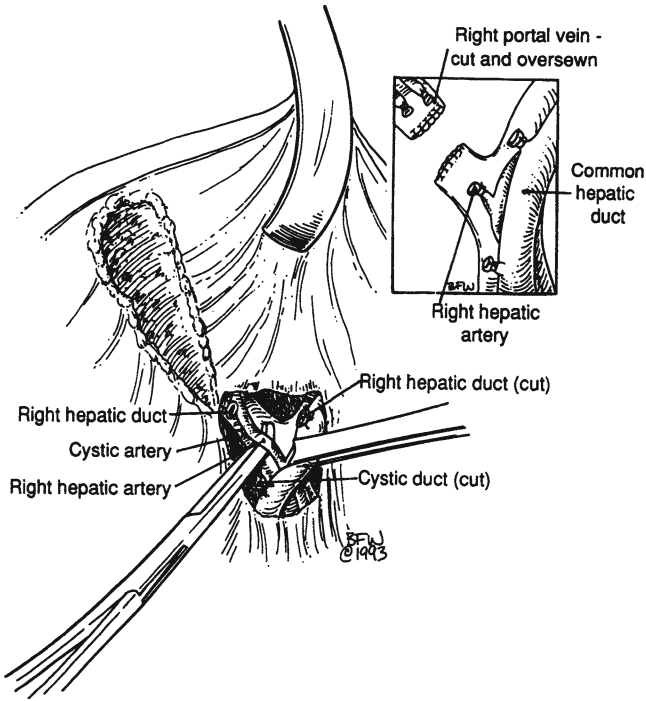


Figure 13.35. Right hepatic duct. *Inset:* right portal vein.

When there is doubt about the severity of the injury but lobectomy is contemplated, operative cholangiograms and aortography can be used to further delineate the area of destruction.

In severe trauma there may be no time for angiograms or even for careful hilar dissection. The surgeon must rely on knowledge of the interlobar plane to expose vessels that must be ligated.

Two indications for formal lobectomy have been proposed:

- Blunt or penetrating injuries resulting in extensive devitalization of a major portion of the right lobe
- Damage to the hepatic veins or the vena cava requiring right lobectomy for visualization and repair

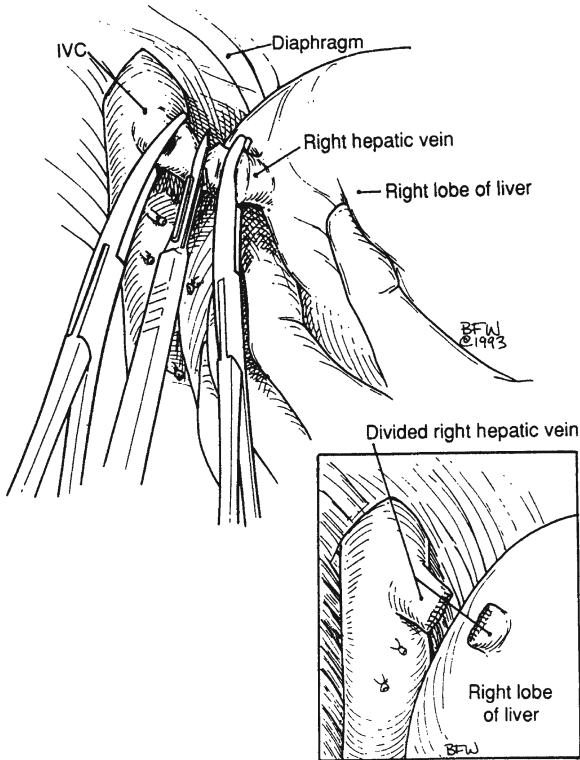


Figure 13.36. IVC and its branches. *Inset:* RHV.

Liver Trauma

- Step 1.** Make a long midline incision. Suction all blood from the peritoneal cavity.
- Step 2.** Mobilize the liver by incising the falciform, triangular, and coronary ligaments on both lobes (see Fig. 13.29).
- Step 3.** Explore the hepatic wound for evaluation and hemostasis. Debride and remove devascularized liver parenchyma. To control bleeding, it is very helpful to use the argon laser simultaneously with high suction (Fig. 13.38).

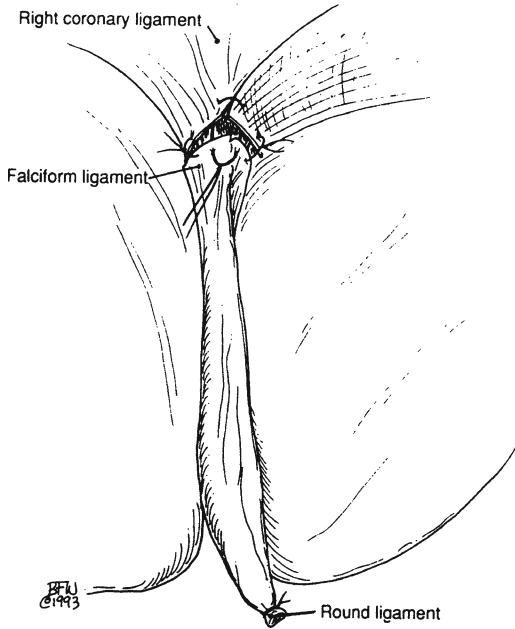


Figure 13.37. Stabilizing the falciform ligament.

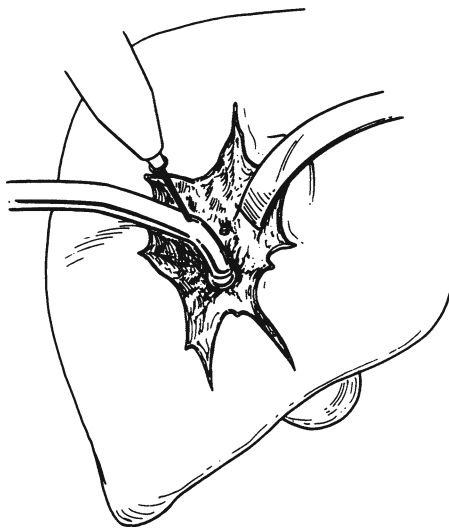


Figure 13.38. Exploring the hepatic wound.

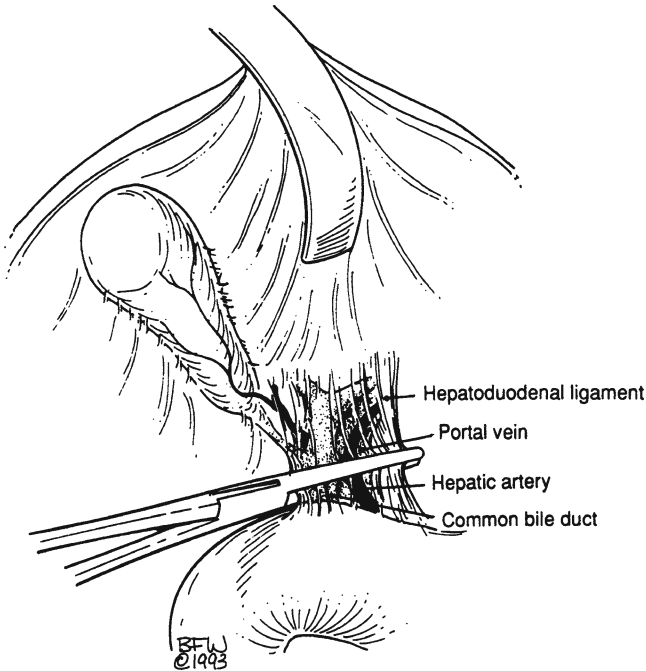


Figure 13.39. Hepatic triad is clamped.

Step 4. If required, clamp the hepatic triad with a noncrushing clamp (Fig. 13.39).

Step 5. If bleeding cannot be controlled, ligate the right or left hepatic artery. Perform a cholecystectomy if the right hepatic artery is ligated.

Options or alternatives (use only if absolutely necessary):

- Pack the hepatic wound for hemostasis and re-operate in 48 h.
- Clamp the aorta just below the diaphragm.
- Isolate the IVC using Cameron “keepers” (umbilical tape) above the renal veins and within the pericardium. With both ends of the tape threaded into an 18-French catheter, pull them taut by clamping with a Kelly clamp. If this procedure is necessary, a median sternotomy should be performed (Fig. 13.40).
- Occasionally it is necessary to place a shunt into the IVC.

For more details, read the excellent book by John L. Cameron, *Atlas of Surgery*, vol I. Philadelphia: Decker, 1990.

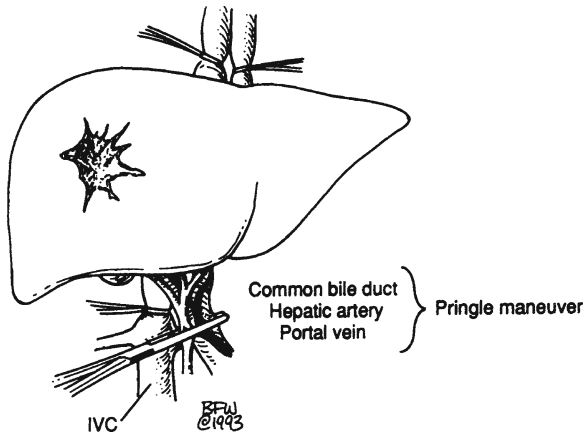


Figure 13.40. Hepatic salvage.

■ SEGMENT-ORIENTED LIVER RESECTION

Terminology

In order to internationally standardize terminology for the reporting of anatomic resections, a consistent terminology (Brisbane Liver Terminology) was adopted in 2000. This terminology, including references to Couinaud segments, is depicted in Fig. 13.41; a more complete description can be found at <http://www.ahpba.org> and <http://www.ihpba.org>.



Our description of segment-oriented liver resection will refer to Couinaud's 8 segments (Fig. 13.42). Depending upon the cephalocaudal location of the portal vein, segment 4 is further subdivided into 4A and 4B, with segment 4A superior and 4B inferior. An unambiguous description of a resection will specify the segments removed (e.g., bisegmentectomy 2,3). As long as the size of the future liver remnant is adequate, each Couinaud segment can be safely resected individually or in any combination with other segments.

Liver tumors often arise in the setting of chronic liver disease/cirrhosis; metastatic tumors are often multifocal and involve multiple segments. Segment-oriented resection permits expansion of historic resectability criteria while still adhering to the principles of parenchymal preservation and tumor clearance. Combined with the increased effectiveness of systemic therapy for micrometastatic disease (especially in colorectal carcinoma), the ability to resect individual liver segments provides unprecedented hope for patients with malignant liver tumors. Knowledge of segment-oriented liver resection is a must for a liver surgeon's armamentarium to be complete.

The author's preferred intraoperative technique is referred to as the *Glissonian approach*. The Glissonian approach takes advantage of the fact that the hepatic artery, portal vein, and bile duct divisions within the substance of the liver are maintained in a sheath of fibrous tissue (pedicle) that is palpably distinct from softer surrounding parenchyma. This distinction is apparent even in fibrotic/cirrhotic livers.

With knowledge of the intraparenchymal branching pattern of the main pedicle into right and left pedicles and their further branching into second- and third-order divisions, useful identification of separate segment-specific pedicles becomes possible. In the right hemiliver, clamping third-order pedicles while allowing blood flow to the rest of the liver makes possible the surface delineation of the segment supplied by that pedicle. If a second-order pedicle in the right hemiliver is clamped, the demarcation encompasses two contiguous segments (e.g., clamping the right anterior pedicle demarcates both segments 5 and 8).

a

1 <i>First-order division</i>			
Anatomical Term	Couinaud segments referred to	Term for surgical resection	Diagram (pertinent area is shaded)
Right Hemiliver OR Right Liver	Sg 5-8 (+/-Sg1)	Right Hepatectomy OR Right Hemihepatectomy (stipulate +/-segment 1)	
Left Hemiliver OR Left Liver	Sg 2-4 (+/-Sg1)	Left Hepatectomy OR Left Hemihepatectomy (stipulate +/-segment 1)	





Border or watershed: The border or watershed of the first order division which separates the two hemilivers is a plane which intersects the gallbladder fossa and the fossa for the IVC and is called the midplane of the liver.

Figure 13.41. Brisbane liver terminology (reproduced from Terminology Committee of the International Hepato-Pancreato-Biliary Association. The Brisbane 2000 terminology of liver anatomy and resections. *HPB* 2000;184:413. Copyright 2002 Taylor & Francis, with permission from John Wiley and Sons).



b

2

Second-order division (second-order division based on bile ducts and hepatic artery)

Anatomical Term	Couinaud segments referred to	Term for surgical resection	Diagram (pertinent area is shaded)
<i>Right Anterior Section</i>	Sg 5,8	Add (-ectomy) to any of the anatomical terms as in <i>Right anterior sectionectomy</i>	
<i>Right Posterior Section</i>	Sg 6,7	<i>Right posterior sectionectomy</i>	
<i>Left Medial Section</i>	Sg 4	<i>Left medial sectionectomy</i> OR <i>Resection segment 4</i> (also see Third order) OR <i>Segmentectomy 4</i> (also see Third order)	
<i>Left Lateral Section</i>	Sg 2,3	<i>Left lateral sectionectomy</i> OR <i>Bisegmentectomy 2,3</i> (also see Third order)	

Other "sectional" liver resections

Sg 4-8 (+/-Sg1)	<i>Right Trisectionectomy</i> (preferred term) or <i>Extended Right Hepatectomy</i> or <i>Extended Right Hemihepatectomy</i> (stipulate +/-segment 1)	
Sg 2,3,4,5,8 (+/-Sg1)	<i>Left Trisectionectomy</i> (preferred term) or <i>Extended Left Hepatectomy</i> or <i>Extended Left Hemihepatectomy</i> (stipulate +/-segment 1)	



Border or watershed: The borders or watersheds of the sections are planes referred to as the *right and left intersectional planes*. The left intersectional plane passes through the umbilical fissure and the attachment of the falciform ligament. There is no surface marking of the right intersectional plane.

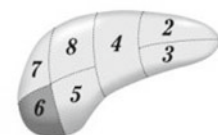Figure 13.41. (continued)

C

3

Third-order division

Anatomical Term	Couinaud segments referred to	Term for surgical resection	Diagram (pertinent area is shaded)
Segments 1-9	Any one of Sg 1 to 9	Segmentectomy (e.g. segmentectomy 6)	
2 contiguous segments	Any two of Sg 1 to Sg 9 in continuity	Bisegmentectomy (e.g. bisegmentectomy 5,6)	



For clarity Sg. 1 and 9 are not shown. It is also acceptable to refer to ANY resection by its third-order segments, eg. right hemihepatectomy can also be called resection sg 5-8.

Border or watersheds: The borders or watersheds of the segments are planes referred to as intersegmental planes.

Figure 13.41. (continued)

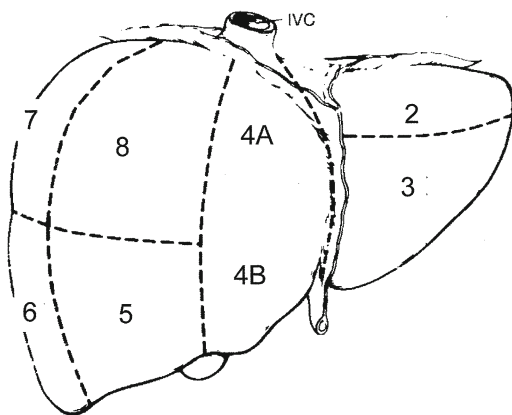


Figure 13.42. Liver lobes. Terminology of Couinaud (By permission of JE Skandalakis, LJ Skandalakis, PN Skandalakis, and P Mirilas. Hepatic surgical anatomy. *Surg Clin N Am.* 2004;84:413).

General Principles

All liver resections must balance the principle of maximum preservation of non-tumorous parenchyma with the necessity of obtaining adequate tumor clearance. These goals are more consistently achieved through segment-oriented (anatomic) resection than by nonanatomic resection. Even for benign lesions where margins are less critical, segment-oriented resection is associated with less blood loss.

After the abdomen is entered through either a “hockey stick,” “Mercedes-type,” or bilateral subcostal incision, all liver resections begin with intraoperative assessment of the size and quality of the future liver remnant. Ongoing communication is maintained with the anesthesia staff to maintain a low (0–5 mmHg) central venous pressure (CVP), which minimizes blood loss during the parenchymal transection. The liver is visually, manually, and sonographically inspected to assess for lesions not known preoperatively. Given the quality of current preoperative imaging it is unusual to find additional disease, but inspection is an obviously important step. Depending on the planned resection, the falciform, left triangular, hepatogastric, and/or right triangular ligaments are divided. The gallbladder, if present, is removed. Beginning caudad and proceeding cephalad, the liver is mobilized off the retrohepatic IVC by ligation and division of several small venous tributaries until the major hepatic veins (right, middle, left) are encountered. Occasionally, a large accessory right inferior hepatic vein (draining segments 6 and/or 7) is encountered. This accessory vein can be ligated (depending on tumor location) unless there is concern that the RHV may have to be sacrificed. If segment 1 (caudate) is to be resected, its venous drainage to the IVC is also carefully sacrificed. Because these veins are broad based and have almost no extra-parenchymal component, sacrificing them is more involved than sacrificing the other direct IVC tributaries. Adequate mobilization of the liver facilitates all subsequent steps; its importance cannot be overemphasized.

Parenchymal Transection Technique

In addition to maintenance of a low CVP, Pringle maneuvers are utilized to minimize blood loss during parenchymal transection. Most transections can be performed with less than 20–30 min of total Pringle clamping by experienced surgeons. If parenchymal transection is expected to take longer than 20 min, intermittent clamping lasting 10–15 min alternating with 5 min of unclamping is an effective strategy. Patients with well-compensated cirrhosis and patients with moderately steatotic livers are able to tolerate intermittent ischemia, as long as the cumulative clamp time is not excessive.

A detailed analysis of techniques and devices commonly employed during segment-oriented liver dissection is beyond the scope of this chapter. An incomplete list of transection techniques includes hydrojet dissection, clamp-crushing technique, and precoagulation of the transection plane. Instrumentation includes

ultrasonic aspirators, vessel sealing devices, and vascular staplers. Even if not used during the parenchymal transection, vascular staplers are useful devices for ligating/dividing pedicles and hepatic veins. To summarize, all the above-mentioned techniques and devices are effective; the experience of the surgeon with each modality dictates the appropriate method.

Operations on the Right Hemiliver

Right Hemihepatectomy

The liver is mobilized as described above and the gallbladder removed. A Pringle maneuver is performed. Hepatotomies are made anterior (incision #3, Fig. 13.43) and posterior (incision #4, Fig. 13.43) to the porta hepatis, taking care to avoid any recently ligated venous tributaries. Hepatotomies in the gallbladder fossa (incision #2, Fig. 13.43) and in the caudate process parallel to and immediately to the right of the IVC (incision #1, Fig. 13.43) also provide good access to the right main pedicle and its branches. Glisson's capsule is incised immediately anterior to the hepatoduodenal ligament (lowering of the hilar plate). This step allows the parenchyma immediately anterosuperior to the plate to be gently pushed away, exposing the portal triad bifurcation into right and left main pedicles. With the surgeon on the patient's right side, the right index finger is inserted into the posterior hepatotomy and the right thumb into the anterior hepatotomy until they meet around the right main pedicle sheath (Figs. 13.44 and 13.45), around which an umbilical tape is passed (Fig. 13.46).

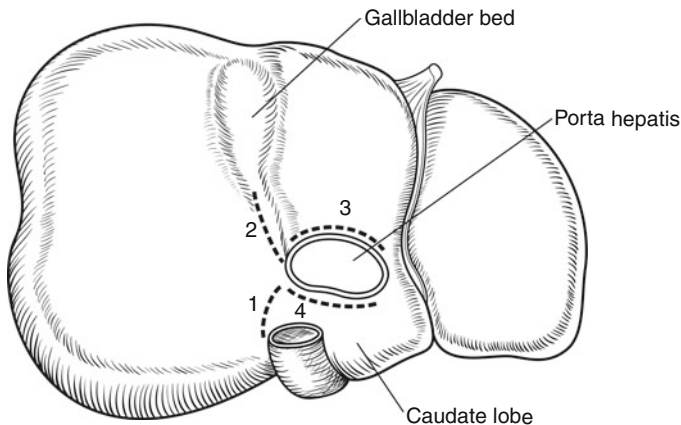


Figure 13.43. Incisions used for the posterior intrahepatic approach: (1) through the caudate process, (2) through the gallbladder bed, (3) in front of the porta hepatis, (4) behind the porta hepatis.

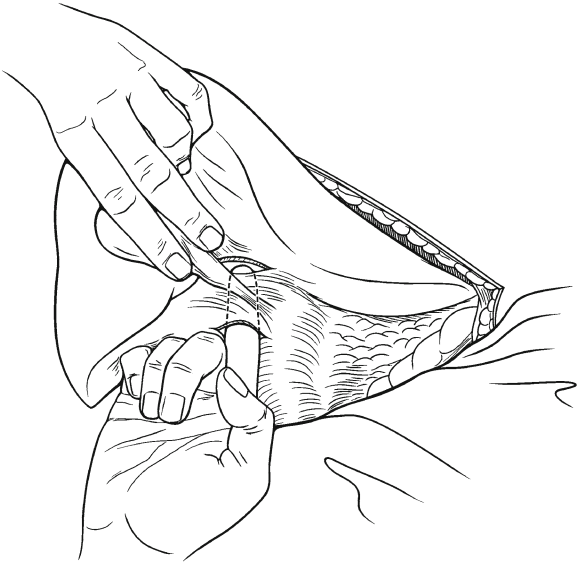


Figure 13.44. The index finger passes behind the hilar structures and emerges above the confluence of the right and left Glissonian sheaths.

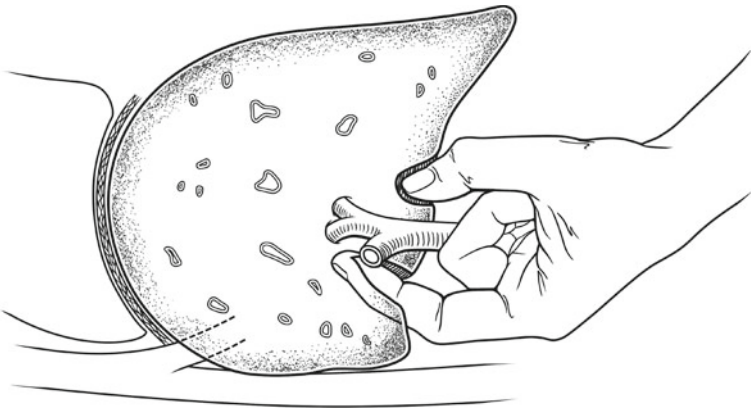


Figure 13.45. Sagittal view of the posterior approach.

Leftward traction on this tape protects the left-sided structures when the right main pedicle is clamped and ligated. (Note: placement of tapes around both main sheaths allows retraction of them into an almost extrahepatic location, facilitating further dissection.)

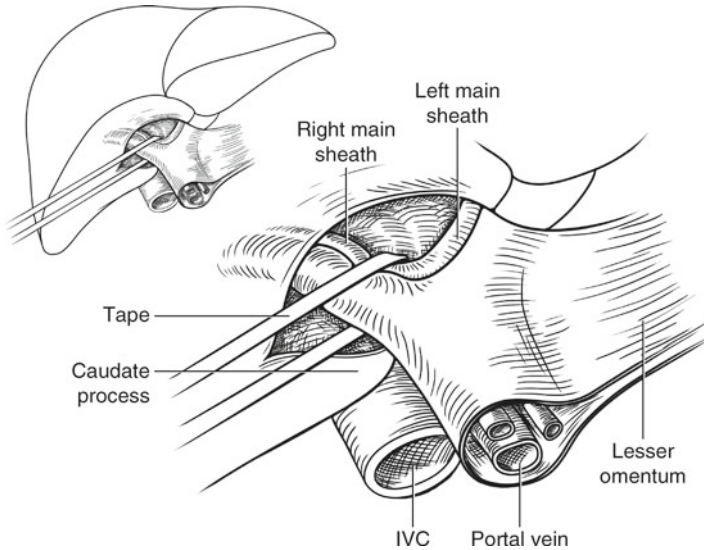


Figure 13.46. Posterior approach, showing tape around the confluence of the Glissonian sheaths.

A right hemihepatectomy is begun by clamping/ligating the right main pedicle, resulting in surface demarcation of the midplane of the liver. After the liver surface is scored with diathermy along this line, parenchymal transection proceeds via one or a combination of the techniques mentioned above. The RHV can be encircled and ligated/divided prior to beginning the transection or as the last component of the resection.

Right Hemihepatectomy Using the Glissonian Approach

- Step 1.** Divide the falciform and right triangular ligaments (dividing the hepatogastric and left triangular ligaments is sometimes useful as well).
- Step 2.** Perform cholecystectomy.
- Step 3.** Perform hepatic ultrasound (if applicable).
- Step 4.** Mobilize the liver off the IVC; include segment 1 mobilization as appropriate.
- Step 5.** Apply Pringle maneuver.
- Step 6.** Make hepatotomies in appropriate locations (Fig. 13.43).
- Step 7.** Isolate and clamp/ligate right main pedicle (Figs. 13.44 and 13.45).

- Step 8.** Release Pringle and score liver along ischemic demarcation (midplane of liver).
- Step 9.** Ligate RHV extrahepatically; alternatively, the RHV can be ligated during the parenchymal transection.
- Step 10.** Reapply Pringle, then perform parenchymal transection; intermittently release Pringle as necessary.
- Step 11.** Place drain if appropriate (i.e., biliary anastomosis, diaphragm resection, bile staining). These 3 occasions mandate placing a drain and are the only times one is indicated.
- Step 12.** Reattach falciform and/or left triangular ligaments, if previously divided, to prevent torsion of liver remnant.
- Step 13.** Close the incision. We use a 2-layer running #1 PDS in the muscle/fascia and staples on the skin—but this is entirely a matter of surgeon preference (there is no right/wrong way to close the incision as long as general surgical principles are applied).

Segmental Resections of the Right Hemiliver

The right main pedicle is isolated as described above. The sheaths surrounding the right anterior and posterior pedicles are identified by dissecting distally along the right main sheath. Clamping of selective pedicles delineates surface boundaries of corresponding segments, allowing their individual removal. Although some surgeons utilize intraoperative ultrasound to facilitate identifying segmental boundaries, we have not found this step to be necessary.

If segment 6 only is to be removed, its pedicle is usually easily identified by performing hepatotomies through the caudate process and through the gallbladder bed (incisions #1 and #2, Fig. 13.43). The segment 6 pedicle is found approximately 2 cm deep to the gallbladder fossa.

As seen in Fig. 13.47, the segment 7 pedicle is deeper and directed superoposteriorly; therefore, it is more difficult to isolate singly. In our experience, the surface boundary of segment 7 is more easily identified by temporarily clamping the segment 6 pedicle. The inferior boundary of segment 7 is identical to the superior boundary of segment 6; its medial boundary is always the RHV. Therefore, a straight line from the visible extrahepatic (superior) aspect of the RHV to the medial boundary of segment 6 practically identifies the medial boundary of segment 7.

The (second-order) right anterior pedicle shortly divides into (third-order) pedicles to segments 5 and 8, with the segment 5 pedicle being easier to isolate singly. Clamping of the entire anterior sheath or either third-order sheath delineates segments 5 and/or 8 from the rest of the liver, allowing their removal together or separately. For the sake of surgical simplicity, segment 8 often is not removed alone; segment 5 is usually removed with it. However, adoption of our approach allows segment 8-only resections to be performed when advisable.

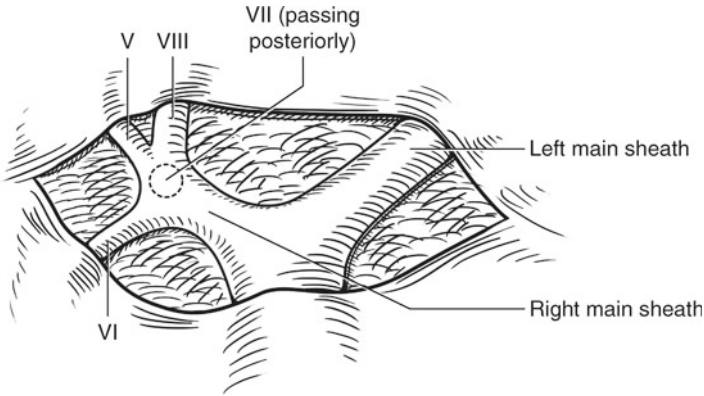


Figure 13.47. Posterior approach showing the sheaths that are usually exposed on the right side.

It is noteworthy that the inferior aspect of segment 5 is occasionally V-shaped and, therefore, may not extend far (if at all) to the right of the gallbladder fossa. This finding is relevant in anatomic resections done for gallbladder cancer (which minimally include segments 4B and 5) and indicates that segment 6 will also need to be included in the resection.

Unless an accessory inferior hepatic vein is first encountered and preserved, the RHV must be preserved during a right anterior sectionectomy (bisegmentectomy 5,8). Because the right anterior section is also drained by tributaries to the MHV, the RHV can be sacrificed in a right posterior sectionectomy (bisegmentectomy 6,7). Our routine practice is to preserve the RHV in right-sided resections other than hemihepatectomies. If preservation of the vein compromises oncologic clearance, then a right hemihepatectomy is likely more advisable than attempting to spare the RHV by a less comprehensive resection.

Right-Sided Segment-Oriented Resections Using the Glissonian Approach

- Step 1.** Divide the falciform and right triangular ligaments (dividing the hepatogastric and left triangular ligaments is sometimes useful as well).
- Step 2.** Perform cholecystectomy.
- Step 3.** Perform hepatic ultrasound (if applicable).
- Step 4.** Mobilize the liver off the IVC; include segment 1 mobilization as appropriate.
- Step 5.** Apply Pringle maneuver.
- Step 6.** Make hepatotomies in appropriate locations (Fig. 13.43).

- Step 7.** Isolate and clamp/ligate pedicle(s) to segments to be resected.
- Step 8.** Release Pringle and score liver along ischemic demarcation.
- Step 9.** Reapply Pringle, then perform parenchymal transection; intermittently release Pringle as necessary.
- Step 10.** Place drain if appropriate (biliary anastomosis, diaphragm resection, bile staining).
- Step 11.** Close the incision.

Operations on the Left Hemiliver

The left main pedicle extends leftward and anteriorly into the umbilical fissure. It can be isolated, and an umbilical tape can be passed around it as described above, using hepatotomies in front of and behind the porta hepatis (incisions #3 and #4, Fig. 13.43). Rightward traction on the tape protects right-sided vessels/ducts upon clamping/ligation of the left main pedicle.

The (second-order) pedicles to segments 2, 3 and 4A/4B originate within the umbilical fissure. Segments 2 and 3 pedicles pass leftward and 4A/4B pedicles pass rightward; therefore, the umbilical fissure and falciform ligament mark the boundary between segments 2 and 3 (left lateral section) and segment 4 (Note: this is the only surface anatomic feature that designates segmental boundaries). A bridge of tissue of varying size usually spans superficial to and across the ligamentum teres within the umbilical fissure. The tissue bridge (if present) can be divided with impunity to access the second-order pedicles or to facilitate any left-sided resection where segments 2, 3, and 4 are not removed in unison.

Left Hemihepatectomy

The liver is mobilized as described above and the gallbladder removed. A Pringle maneuver is performed. Hepatotomies are made anterior (incision #3 in Fig. 13.43) and posterior (incision #4 in Fig. 13.43) to the porta hepatis, taking care to avoid any recently ligated venous tributaries. The left main pedicle is isolated intrahepatically and clamped/ligated, resulting in surface delineation of the midplane of the liver. Since the MHVs and LHVs usually converge before emptying into the IVC, extrahepatic isolation of either or both is not as easy as isolation of the RHV; therefore, these veins usually are sacrificed intrahepatically during the transection. The liver surface is scored with diathermy along the ischemic line, followed by parenchymal transection utilizing one or a combination of the above-mentioned techniques. For reasons noted above, the LHV and/or MHV is usually sacrificed within the parenchyma during the parenchymal transection.

Removal of Segments 2 and/or 3

Mobilization of the liver off the IVC is not necessary for removal of segments 2 and 3 (left lateral sectionectomy) or either segment separately; a Pringle maneuver is not always necessary. To perform a bisegmentectomy 2,3, Glisson's capsule is scored with diathermy immediately to the left of the falciform ligament. The pedicles to segments 2 and/or 3 can be taken during (standard technique) or before (Glissonian approach) the parenchymal transection, depending on the ease of access. If either segment 2 or 3 only is to be removed, clamping the appropriate pedicle and scoring the liver along the ischemic demarcation precedes the parenchymal transection.

Bisegmentectomy 2,3 Using the Glissonian Approach

- Step 1.** Divide the falciform, left triangular, and hepatogastric ligaments.
- Step 2.** Perform hepatic ultrasound (if applicable).
- Step 3.** Apply Pringle maneuver (not always necessary). Intermittently release Pringle as necessary.
- Step 4.** Score liver immediately to the left of the falciform ligament.
- Step 5.** Isolate and clamp pedicles to segments 2 and 3.
- Step 6.** LHV can be ligated/divided extrahepatically or during parenchymal transection (more common).
- Step 7.** Perform parenchymal transection.
- Step 8.** Place drain if appropriate (biliary anastomosis, diaphragm resection, bile staining).
- Step 9.** Close incision.

(Mono)segmentectomy 2 or 3 Using the Glissonian Approach

- Step 1.** Divide the falciform, left triangular, and hepatogastric ligaments.
- Step 2.** Perform hepatic ultrasound (if applicable).
- Step 3.** Apply Pringle maneuver.
- Step 4.** Isolate and clamp/ligate appropriate pedicle.
- Step 5.** Release Pringle and score liver along line of ischemic demarcation.
- Step 6.** Perform parenchymal transection (more common).
- Step 7.** Place drain if appropriate (biliary anastomosis, diaphragm resection, bile staining).
- Step 8.** Close incision.

Segmentectomy 4A and/or 4B

It is unusual to remove segments 4A and/or 4B only. The midplane of the liver and the falciform ligament will mark the right and left resection boundaries, respectively. Following the procedures described above, the pedicles to segments 4A and/or 4B can be taken during or before the parenchymal transection, depending on the ease of access.

Segmentectomy 4A and/or 4B Using the Glissonian Approach

- Step 1.** Divide falciform, left triangular, right triangular, and gastrohepatic ligaments.
- Step 2.** Perform cholecystectomy.
- Step 3.** Perform hepatic ultrasound (if applicable).
- Step 4.** Mobilize liver off IVC; include segment 1 mobilization as appropriate.
- Step 5.** Score liver immediately to the right of the falciform ligament.
- Step 6.** Apply Pringle maneuver.
- Step 7.** Perform hepatomies (incisions #3 and #4, Fig. 13.43).
- Step 8.** Isolate and clamp left main pedicle (do NOT ligate pedicle).
- Step 9.** Release Pringle and score liver along ischemic demarcation (midplane of liver).
- Step 10.** Unclamp left main pedicle.
- Step 11.** Reapply Pringle, followed by parenchymal transection; intermittently release Pringle as necessary.
- Step 12.** Perform parenchymal transection, during which the MHV will be sacrificed.
- Step 13.** Place drain if appropriate (biliary anastomosis, diaphragm resection, bile staining).
- Step 14.** Close incision.

Segment 1 (Caudate Lobe) Resection

Caudate lobe resection is rarely indicated but deserves special mention due to its complexity. Segment 1 is not solely part of the right hemiliver or left hemiliver; it receives blood supply from and drains bile into both sides. The short and broad-based nature of its venous drainage requires special care to avoid injury and major hemorrhage during mobilization of segment 1 off the IVC. Once this segment is disconnected from the IVC, the parenchyma overlying the plane (dorsal fissure, denoted by the insertion of the hepatogastric ligament) between segment 1 posteriorly and segments 4 and 8 anteriorly is scored. The pedicles supplying segment 1 are sacrificed during the ensuing parenchymal transection.

Central Liver Resections

Central liver resections involve removal of segments 4A, 4B, 5, and/or 8. The details as outlined above will allow the surgeon to combine all of these segments in a single resection (“mesohepatectomy” or trisegmentectomy 4,5,8) or in any combination. Therefore, with knowledge of intrahepatic segmental anatomy, tumors in the central portion of the liver can be removed without unnecessarily sacrificing the parenchyma in a right or left trisectionectomy. The ability to perform these types of resections is crucial during operations on patients with chronic fibrotic liver disease or with evidence of chemotherapy-induced steatosis. During these operations, adherence to the principle of non-tumorous parenchymal preservation lessens the chances of postoperative liver failure.

Intrahepatic isolation and clamping of the appropriate pedicles through the techniques outlined delineates the surface boundaries of the resection to be performed, thereby allowing parenchymal transection to be performed in a segmental fashion. The MHV usually joins the LHV before entering the IVC as a common orifice; thus, isolating it extrahepatically is not usually feasible or safe. Therefore, the MHV is sacrificed when it is encountered during the parenchymal transection. When only segments 4A and/or 4B or segments 5 and/or 8 are to be removed, the vein can be preserved, as it marks the right or left boundary, respectively, of the resection. However, because of redundant venous drainage, sacrifice of the MHV when necessary will not lead to significant congestion of any the remnant liver.

Final Note

The intrahepatic approach outlined above for right- and left-sided and central liver resections is inappropriate for potentially malignant tumors located close to the main portal bifurcation; use of this approach would violate the principle of tumor clearance. In these cases, the vessels and bile duct corresponding to the side to be removed must be ligated extrahepatically (see “Hepatic Resections”).

■ REFERENCES¹

- Launois B, Jamieson GG. The posterior intrahepatic approach for hepatectomy or removal of segments of the liver. *Surg Gynecol Obstet.* 1992;174:155.
- Launois B, Jamieson GG. *Modern operative techniques in liver surgery.* New York: Churchill Livingstone; 1993.
- Strasberg SM. Nomenclature of hepatic anatomy and resections: a review of the Brisbane 2000 system. *J Hepatobiliary Pancreat Surg.* 2005;12:351.

¹References are suggested reading for anyone desiring a more thorough description of segment-oriented liver resections.

Extrahepatic Biliary Tract

ANATOMY

■ RIGHT, LEFT, AND COMMON HEPATIC DUCTS

The right and left hepatic ducts join soon after emerging from the liver to form the common hepatic duct (Fig. 14.1b). The junction lies 0.25–2.5 cm from the surface of the liver. The left duct is longer (1.7 cm, average) than the right duct (0.9 cm, average). In some cases, intrahepatic junction of the hepatic ducts is the result of liver enlargement (Fig. 14.1a); retraction of the liver may then be necessary to expose the junction.

Measurements of the common hepatic duct are highly variable. The duct is said to be absent if the cystic duct enters at the junction of the right and left hepatic ducts (Fig. 14.1c). In most individuals, the duct is between 1.5 and 3.5 cm long.

Three types of cystohepatic junction have been described: angular (Fig. 14.1a, b), parallel (Fig. 14.2a), and spiral (Fig. 14.2b, c).

■ ANOMALOUS HEPATIC DUCTS: SURGICALLY SIGNIFICANT SOURCES OF BILE LEAKAGE (FIG. 14.3)

An aberrant hepatic duct is a normal segmental duct that joins the biliary tract just outside the liver instead of just within; it drains a normal portion of the liver. Such a duct passing through the hepatocystic triangle is important because it is subject to inadvertent section with subsequent bile leakage (Fig. 14.3).

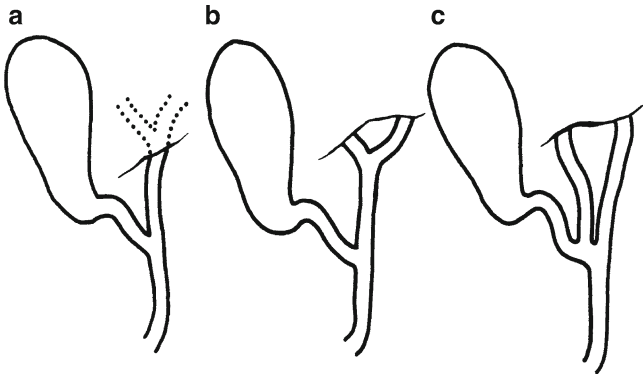


Figure 14.1. Variations of the hepatic ducts. (a) Intrahepatic union of left and right hepatic ducts; (b) usual extrahepatic union of left and right hepatic ducts; (c) distal union of hepatic ducts producing absence of the common hepatic duct (By permission of JE Skandalakis, SW Gray, RR Ricketts, et al. The extrahepatic biliary ducts and the gallbladder. In: JE Skandalakis and SW Gray. *Embryology for Surgeons*, 2nd ed. Baltimore: Williams & Wilkins, 1994).

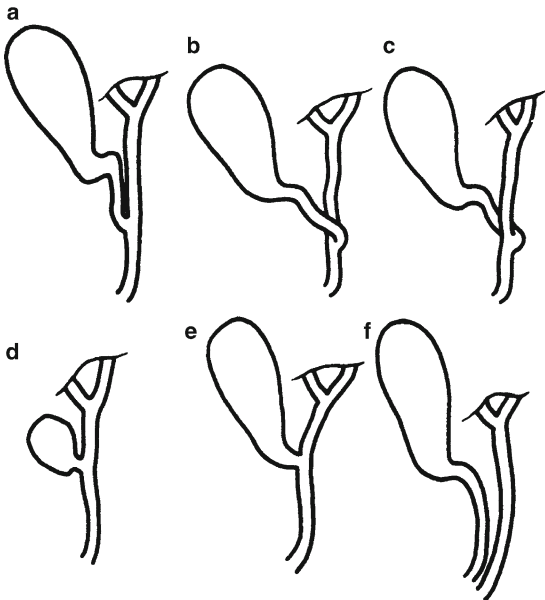


Figure 14.2. Types of cystohepatic junction. (a) Parallel type. (b, c) Spiral types. (d, e) Short cystic ducts. (f) A long cystic duct ending in the duodenum. This may also be called “absence of the common bile duct” (By permission of JE Skandalakis, SW Gray, RR Ricketts, et al. The extrahepatic biliary ducts and the gallbladder. In: JE Skandalakis and SW Gray. *Embryology for Surgeons*, 2nd ed. Baltimore: Williams & Wilkins, 1994).

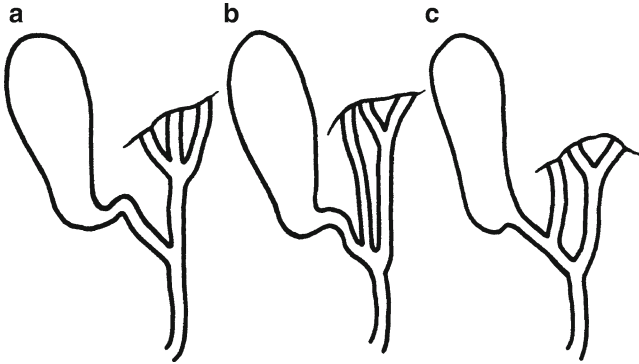


Figure 14.3. Accessory hepatic ducts. (a) Accessory duct joins the common duct along with the usual left and right hepatic ducts. (b) Accessory duct joins at the intersection of the cystic duct. (c) Accessory duct enters the cystic duct directly. Additional, minute hepatic ducts are not unusual (By permission of JE Skandalakis, SW Gray, RR Ricketts, et al. *The extrahepatic biliary ducts and the gallbladder*. In: JE Skandalakis and SW Gray. *Embryology for Surgeons*, 2nd ed. Baltimore: Williams & Wilkins, 1994).

Subvesicular bile ducts, found in approximately 35 % of individuals, are small blind ducts emerging from the right lobe of the liver and lying in the bed of the gallbladder. They do not communicate with the gallbladder.

Hepatocystic ducts drain bile from the liver directly into the body of the gallbladder or into the cystic duct.

Occasionally, the right, left, or even both hepatic ducts enter the gallbladder. This is an argument in favor of removing the gallbladder at the fundus, from above downward.

■ CYSTIC DUCT

The cystic duct is about 3 mm in diameter and about 2–4 cm long. If surgeons are unprepared for a short duct (Fig. 14.2e), they may find themselves inadvertently entering the common bile duct. If they underestimate the length, they may leave too long a stump, predisposing to the cystic duct remnant syndrome.

Very rarely, the cystic duct is absent and the gallbladder opens directly into the common bile duct. In such a case, the common bile duct might be mistaken for the cystic duct.

■ GALLBLADDER

The gallbladder is located on the visceral surface of the liver in a shallow fossa at the plane dividing the right lobe from the medial segment of the left lobe (the GB-IVC line). The gallbladder is separated from the liver by the connective tissue of Glisson's capsule. Anteriorly, the peritoneum of the gallbladder is continuous with that of the liver, and the fundus is completely covered with peritoneum.

The body of the gallbladder is in contact with the first and second portions of the duodenum. The body is also related to the transverse colon. Only in the rare presence of a mesentery (wandering gallbladder), a prerequisite for acute torsion, is the body completely covered by peritoneum. Several other anomalous peritoneal folds connected with the body of the gallbladder—cholecystogastric, cholecystoduodenal, and cholecystocolic—are redundancies of the lesser omentum.

The infundibulum is the angulated posterior portion of the body between the neck and the point of entrance to the cystic artery. When this portion is dilated, with eccentric bulging of its medial aspect, it is called a Hartmann's pouch. When this pouch achieves considerable size, the cystic duct arises from its upper left aspect rather than from what appears to be the apex of the gallbladder. The pouch is often associated with chronic or acute inflammation due to lithiasis and often accompanies a stone impacted in the infundibulum.

The neck of the gallbladder is S-shaped and lies in the free border of the hepatoduodenal ligament. The mucosa lining the neck is a spiral ridge said to be a spiral valve, but not to be confused with the spiral valve of the cystic duct (the valve of Heister).

A deformity of the gallbladder seen in 2–6 % of individuals is the Phrygian cap (Fig. 14.4a). Hartmann's pouch (Fig. 14.4b) is probably a normal variation rather than a true deformity.

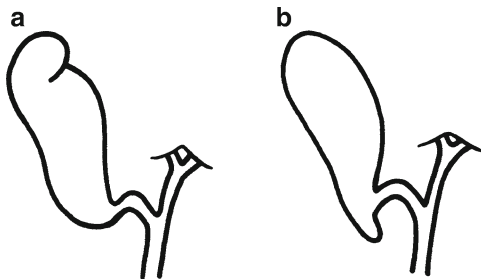


Figure 14.4. Deformities of the gallbladder. (a) "Phrygian cap" deformity; (b) Hartmann's pouch (By permission of JE Skandalakis, SW Gray, RR Ricketts, et al. The extrahepatic biliary ducts and the gallbladder. In: JE Skandalakis and SW Gray. *Embryology for Surgeons*, 2nd ed. Baltimore: Williams & Wilkins, 1994).

■ COMMON BILE DUCT

The length of the common bile duct begins at the union of the cystic and common hepatic ducts and ends at the papilla of Vater in the second part of the duodenum. It varies from 5 to 16 cm depending on the actual position of the ductal union. The duct can be divided into four portions (Fig. 14.5): supraduodenal, retroduodenal, pancreatic, and intramural (intraduodenal).

The supraduodenal portion lies between the layers of the hepatoduodenal ligament in front of the epiploic foramen of Winslow, to the right or left of the hepatic artery, and anterior to the portal vein.

The retroduodenal portion is between the superior margin of the first portion of the duodenum and the superior margin of the head of the pancreas. The gastroduodenal artery lies to the left. The posterior superior pancreaticoduodenal artery lies anterior to the common bile duct. The middle colic artery lies anterior to the duct and other arteries.

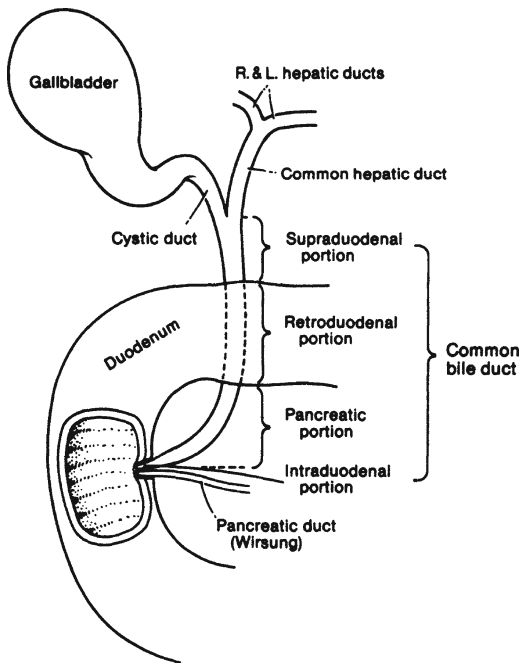


Figure 14.5. The extrahepatic biliary tract and the four portions of the common bile duct (By permission of JE Skandalakis, SW Gray, and JR Rowe. *Anatomical Complications in General Surgery*. New York: McGraw-Hill, 1983).

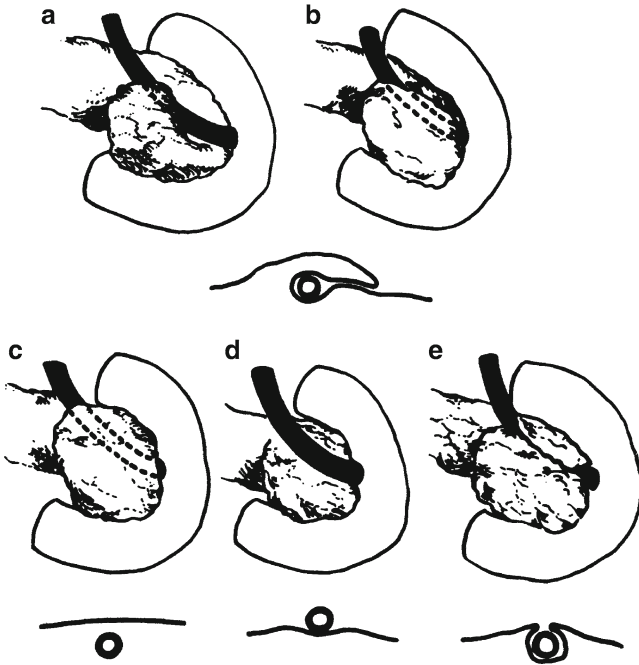


Figure 14.6. Relation of the pancreas and the common bile duct. (a, b) The duct is partially covered by a tongue of pancreas (44 %). (c) The duct is completely covered by the pancreas (30 %). (d) The duct lies free on the surface of the pancreas (16.5 %). (e) The duct is covered by two tongues of pancreas with a cleavage plane between (By permission of JE Skandalakis, SW Gray, JS Rowe, et al. *Contemp Surg* 15(5):17–40, 1979).

The common bile duct may be partly covered by a tongue of pancreas (44 %) (Fig. 14.6a, b); completely within the pancreatic substance (30 %) (Fig. 14.6c); uncovered on the pancreatic surface (16.5 %) (Fig. 14.6d); or completely covered by two tongues of pancreas (9 %) (Fig. 14.6e). Even when completely covered, the groove or tunnel occupied by the duct may be palpated by passing the fingers of the left hand behind the second part of the duodenum after mobilization with the Kocher maneuver.

The normal outside diameter of the first three regions of the common bile duct is variable, but a common bile duct more than 8 mm in diameter is definitely enlarged and, therefore, pathological.

The fourth, or intramural (sometimes called intraduodenal), portion of the common bile duct (see Fig. 9.9) passes obliquely through the duodenal wall

together with the main pancreatic duct. Within the wall, the length averages 15 mm. As it enters the wall, the common duct decreases in diameter. The two ducts usually lie side by side with a common adventitia for several millimeters. The septum between the ducts reduces to a thin mucosal membrane before the ducts become confluent (see Chap. 9).

■ HEPATOCYSTIC TRIANGLE AND TRIANGLE OF CALOT

The hepatocystic triangle is formed by the proximal part of the gallbladder and cystic duct to the right, the common hepatic duct to the left, and the margin of the right lobe of the liver superiorly (Fig. 14.7). The triangle originally described by Calot defined the upper boundary as the cystic artery. The area included in the triangle has enlarged over the years. Within the boundaries of the triangle as it is now defined are several structures that must be identified before they are ligated or sectioned.

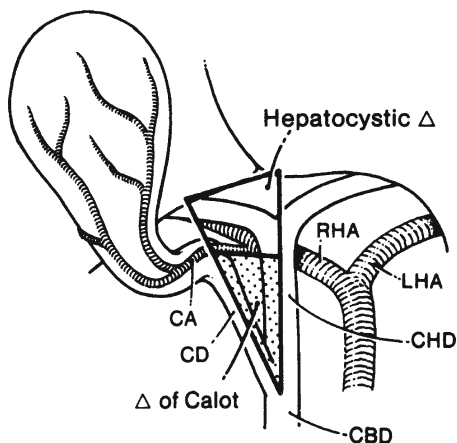


Figure 14.7. The hepatocystic triangle and the triangle of Calot. The upper boundary of the hepatocystic triangle is the margin of the liver; that of the triangle of Calot is the cystic artery; the triangle of Calot is stippled. CA cystic artery, CD cystic duct, CBD common bile duct, RHA right hepatic artery, LHA left hepatic artery, CHD common hepatic duct (By permission of JE Skandalakis, SW Gray, RR Ricketts, et al. The extrahepatic biliary ducts and the gallbladder. In: JE Skandalakis and SW Gray. *Embryology for Surgeons*, 2nd ed. Baltimore: Williams & Wilkins, 1994).

Table 14.1 Origin of the cystic artery

<i>Origin</i>	<i>Percent</i>
Right hepatic artery	
Normal	61.4
Aberrant (accessory)	10.2
Aberrant (replacing)	3.1
Left hepatic artery	5.9
Bifurcation of common hepatic artery	11.5
	<hr/> 92.1
Common hepatic artery	3.8
	<hr/> 95.9
Gastroduodenal artery	2.5
Superior pancreaticoduodenal artery	0.15
Right gastric artery	0.15
Celiac trunk	0.3
Superior mesenteric artery	0.9
Right gastroepiploic artery	Rare
Aorta	Rare
	<hr/> 99.9

From BJ Anson. Anatomical considerations in surgery of gallbladder. *Q Bull Northwest Univ Med School* 30:250, 1956

The hepatocystic triangle contains the right hepatic artery (and sometimes an aberrant right hepatic artery), the cystic artery, and sometimes an aberrant (accessory) bile duct.

In 87 % of individuals, the right hepatic artery enters the triangle posterior to the common hepatic duct, and in 13 % it enters anterior to it. In one study of cadavers, the right hepatic artery could have been mistaken for the cystic artery 20 % of the time. As a rule of thumb, any artery more than 3 mm in diameter within the triangle will probably not be a cystic artery.

In 18 %, there was an aberrant right hepatic artery. In 83 % of these specimens, the cystic artery arose from the aberrant artery within the triangle. In 4 %, the aberrant artery was accessory to a normal right hepatic artery, and in 14 %, it was a replacing artery, the only blood supply to the right lobe of the liver (see Fig. 13.8).

The cystic artery usually arises from the right hepatic artery or an aberrant right hepatic artery within the hepatocystic triangle. At the neck of the gallbladder, the cystic artery divides into a superficial and a deep branch (Table 14.1).

In 16 %, there were aberrant (accessory) bile ducts within the hepatocystic triangle that may cause bile to leak into the abdominal cavity.

■ VASCULAR SYSTEM OF THE EXTRAHEPATIC BILIARY TRACT

Arterial Supply

In general, the major blood vessels in the area of the extrahepatic biliary tree are posterior to the ducts, but in a number of cases they may lie anteriorly. The surgeon must recognize and preserve these arteries. Table 14.2 shows the frequency with which specific arteries are found anterior to segments of the biliary tract.

The gallbladder is supplied by the cystic artery.

The bile ducts are supplied by branches of the posterior superior pancreaticoduodenal, retroduodenal, and right and left hepatic arteries. Do not devascularize more than 2–3 cm of the upper surface of the duct (Fig. 14.8).

The blood supply of the supraduodenal common bile duct is essentially axial. The major supply comes from below (60 % from the retroduodenal artery), and 38 % comes from above (from the right hepatic artery). The bile ducts in the hilum and the retropancreatic bile duct have an excellent blood supply.

Ischemia of the bile duct can be avoided with a high or low transection, but bleeding of the edges should be checked prior to anastomosis.

Table 14.2 Segments of the biliary tract and the frequency of arteries lying anterior to them

<i>Segment</i>	<i>Artery anterior</i>	<i>Percent frequency</i>
Right and left hepatic ducts	Right hepatic artery	12–15
	Cystic artery	<5
Common hepatic duct	Cystic artery	15–24
	Right hepatic artery	11–19
	Common hepatic artery	<5
Supraduodenal common bile duct	Anterior artery to common bile duct	50
	Posterior superior pancreaticoduodenal artery	12.5
	Gastroduodenal artery	5.7–20 ^a
	Right gastric artery	<5
	Common hepatic artery	<5
	Cystic artery	<5
	Right hepatic artery	<5
	Retroduodenal common bile duct	Posterior superior pancreaticoduodenal artery
	Supraduodenal artery	11.4

^aIn another 36 %, the gastroduodenal artery lay on the left border of the common bile duct. Data from Johnson and Anson. *Surg Gynecol Obstet* 94:669, 1952 and Maingot (ed.), *Abdominal Operations*, 6th ed. Norwalk, CT: Appleton & Lange, 1974

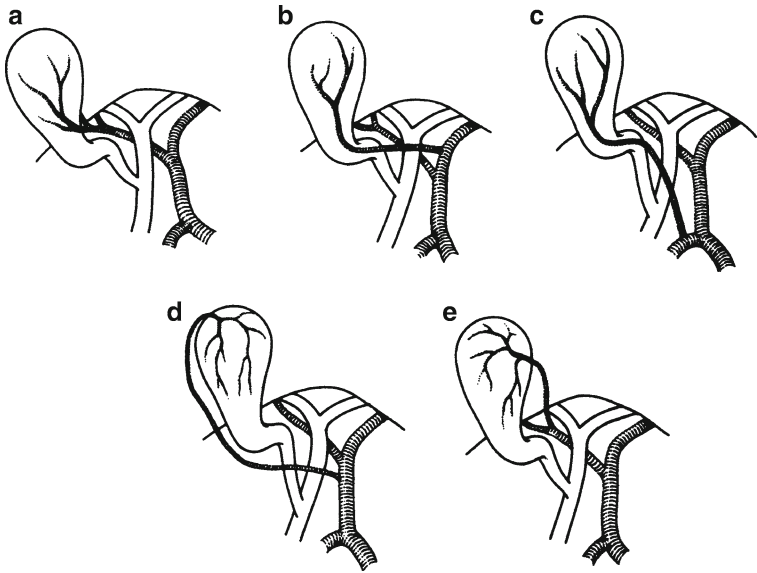


Figure 14.8. Some possible origins of the cystic artery. (a) Usual pattern (74.7 %) from the right normal or aberrant hepatic artery. (b) Origin from the common hepatic artery, its bifurcation, or from the left hepatic artery and crossing in front of the common hepatic duct (20.5 %). (c) Origin from the gastroduodenal artery (2.5 %). The remainder arise from a variety of sources. (d, e) Very rarely the cystic artery reaches the gallbladder at the fundus or body (“recurrent” cystic artery) (By permission of JE Skandalakis, SW Gray, RR Ricketts, et al. The extrahepatic biliary ducts and the gallbladder. In: JE Skandalakis and SW Gray. *Embryology for Surgeons*, 2nd ed. Baltimore: Williams and Wilkins, 1994).

Venous Drainage

Several cystic veins, rather than one, enter the hepatic parenchyma (Fig. 14.9).

An epicholodochal venous plexus helps the surgeon identify the common bile duct. Remember that stripping of the common bile duct is not permissible.

Lymphatic Drainage

Collecting lymphatic trunks from the gallbladder drain into the cystic node in the crotch of the junction of the cystic and common hepatic ducts to the “node of the hiatus” and posterior pancreaticoduodenal nodes (Fig. 14.10).

The pericholedochal nodes receive lymphatics from the extrahepatic bile ducts and from the right lobe of the liver.

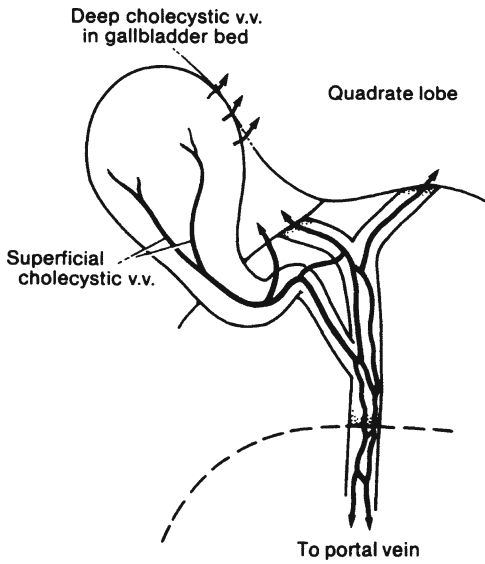


Figure 14.9. Venous drainage of the biliary tract. Most of the drainage is from the gallbladder bed into the quadrate lobe of the liver. Veins of the duct system drain upward to the liver and downward to the portal vein (By permission of JE Skandalakis, SW Gray, and JR Rowe. *Anatomical Complications in General Surgery*. New York: McGraw-Hill, 1983).

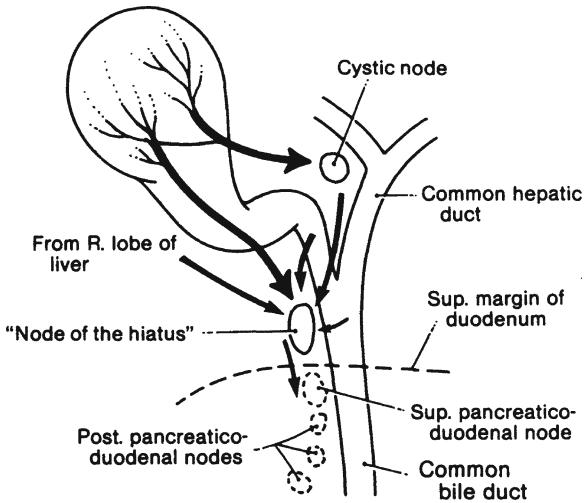


Figure 14.10. Lymphatic drainage of the biliary tract. The cystic node and the node of the hiatus are relatively constant. Drainage from the gallbladder, the cystic duct, and the right lobe of the liver reaches the posterior pancreaticoduodenal nodes (By permission of RB Fahim et al. *Ann Surg* 156(1):114-124, 1962).

TECHNIQUE

■ CHOLECYSTECTOMY

Three procedures for cholecystectomy are presented: (1) removal of the gallbladder from above downward, (2) removal of the gallbladder from below upward, and (3) laparoscopic cholecystectomy (at end of chapter).

PREOPERATIVE PREPARATION:

- Prior to incision, intravenous antibiotic of choice

ANESTHESIA: General

POSITION: Supine on a special X-ray operating room table

INCISION: Right subcostal or other incision of choice

Cholecystectomy from Above Downward

- Step 1.** Dissect the area of the cystic duct and the common duct. Identify the cystic duct and double pass a 2-0 silk around it. Identify the cystic artery. Ligate proximally and distally with 2-0 silk and divide. If there is any doubt about the identity of the cystic artery, do not divide yet.
- Step 2.** Using the Bovie, carefully dissect the gallbladder from the liver from above downward until you reach the hepatoduodenal ligament. Inspect the gallbladder fossa for leakage of bile or bleeding and treat using electrocautery (Fig. 14.11).
- Step 3.** If the cystic artery has not yet been divided, divide it. It should be located near and parallel to the cystic duct (Fig. 14.12).
- Step 4.** Isolate the cystic duct. Decide whether to perform a cholangiogram. If not, carefully clamp the cystic duct proximally and distally between two clamps. Divide the cystic duct between the clamps and ligate (Fig. 14.13).
- Step 5.** Remove the specimen and irrigate the gallbladder fossa and right upper quadrant.
- Step 6.** Decide whether to drain the area. If so, use a Jackson-Pratt drain, bringing it out through a stab wound. Close in layers.

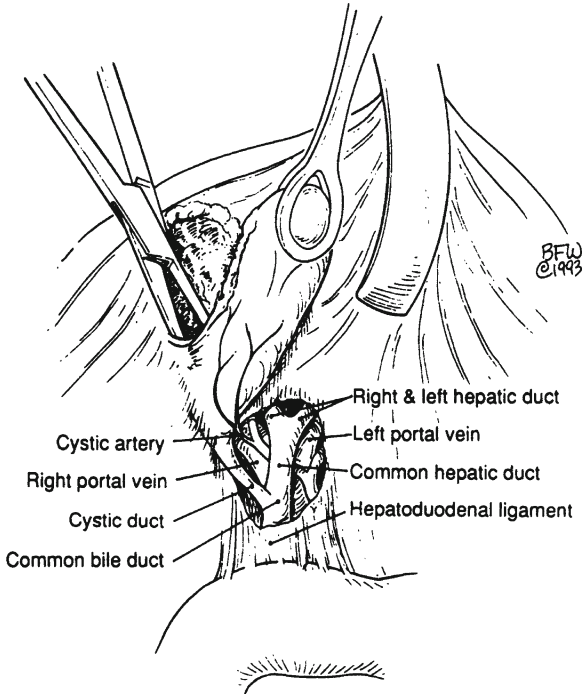


Figure 14.11. Area of cystic duct and cystic artery is dissected.

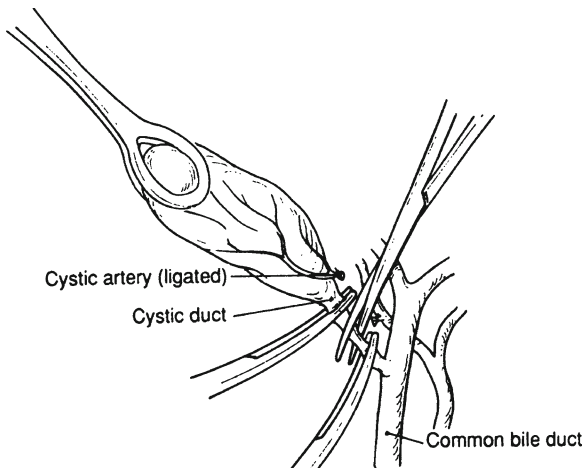


Figure 14.12. Division of cystic artery.

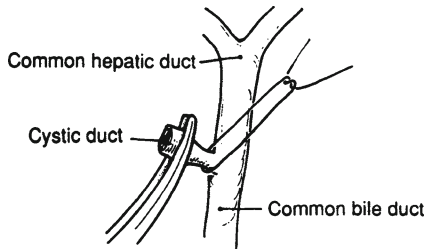


Figure 14.13. Division of cystic duct.

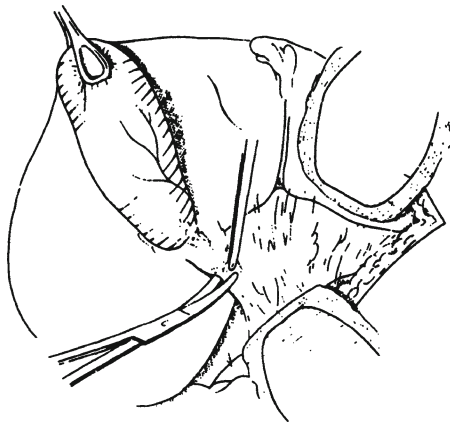


Figure 14.14. Dissecting area of cystic and common ducts.

Cholecystectomy from Below Upward

- Step 1.** Dissect the area of the cystic and common ducts and identify these structures as well as the cystic arteries (Figs. 14.14 and 14.15).
- Step 2.** Doubly ligate the cystic duct and cystic artery with 2-0 silk. Incise all around the serosa of the gallbladder approximately 1-1½ cm from the liver edge. Using the Bovie and right-angle clamp, dissect the gallbladder from the liver. Upward traction by placing a clamp near the cystic duct (on the gallbladder) is helpful.
- Step 3.** Remove the gallbladder and electrocoagulate the gallbladder fossa to stop bleeding or bile leakage (Fig. 14.16).

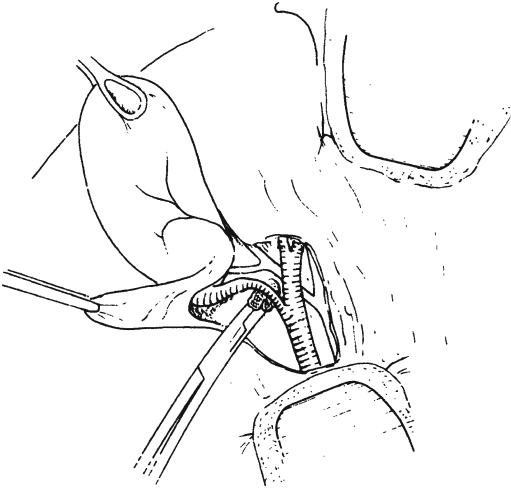


Figure 14.15. Bed of cystic arteries.

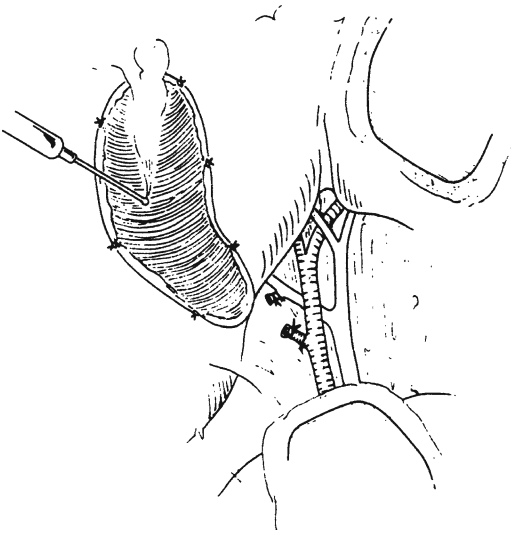


Figure 14.16. Electrocoagulation of gallbladder fossa.

Note:

- ✓ The anterior leaf of the hepatoduodenal ligament is routinely incised over the hepatocystic triangle and the underlying structures are revealed. In more difficult cases, where adhesions from inflammation or previous surgery have obscured normal relationships, greater efforts are required:
 - The hepatic flexure of the colon and the duodenum may be mobilized to the left.
 - The liver may be retracted to the right. This will put slight tension on the biliary ducts and open the epiploic foramen (Winslow's foramen), providing better orientation of the field.
 - In dissecting the gallbladder away from the liver bed, the cystic artery may be exposed by the rotation of the gallbladder to the left. This will also expose the common hepatic duct, the right and left hepatic ducts, and the cystic duct. Being able to perform this maneuver is one of the advantages of removing the gallbladder from the fundus downward.
 - Use suction and Bovie for the bleeding bed. The gallbladder bed may be filled with omentum and a drain placed over the omentum (not between the bed and the omentum).
 - The subserous excision of the gallbladder uses the lamina propria of loose connective tissue as the plane of dissection.
 - Another approach is to identify the cystic artery and duct and then ligate and transect them. The gallbladder may then be dissected from its bed from below upward.
 - Another option is to begin at the fundus of the gallbladder and dissect downward toward the neck with the following steps: (1) dissection of the gallbladder, (2) exposure of the cystic duct and its union with the common bile duct, (3) an operating room cholangiogram, and (4) dissection and ligation of the cystic duct and removal of the gallbladder.
 - Regardless of the direction of the procedure, the junction of the cystic and common hepatic ducts should be identified.

■ OPERATING ROOM CHOLANGIOGRAM

To perform an adequate operative cholangiogram, the volume of the biliary tract is more important than the length or the diameter. The capacity is between 12 and 20 ml. Obviously, the presence of stones will markedly reduce the capacity.

If a cholangiogram is performed, the patient should be rotated slightly to the right so that the common bile duct is rotated off the spine and becomes clearly visible.

An operative cholangiogram will be of great assistance to the surgeon passing a probe through the common bile duct. There is a potential danger if the surgeon passes a probe and expects it to take a straight line to the ampulla and encounters instead a 90-degree turn as the duct enters the duodenum. If the duct is fixed by disease or prior surgery, and if the surgeon is a little too rough, perforation can result.

- Step 1.** For traction, use mild tension on the proximal ligation of the cystic duct (which, though ligated, is still connected to the gallbladder). Make a minute opening into the anterior wall of the cystic duct with a No. 11 blade (Fig. 14.17). Through this opening, insert a Reddick balloon catheter. It is secured by inflating the balloon.
- Step 2.** Take two X-rays: the first after injecting 7 cm³ of 30 % Renografin and the second using 14 cm³ of contrast. Have the anesthesiologist stop ventilating the patient during exposure.

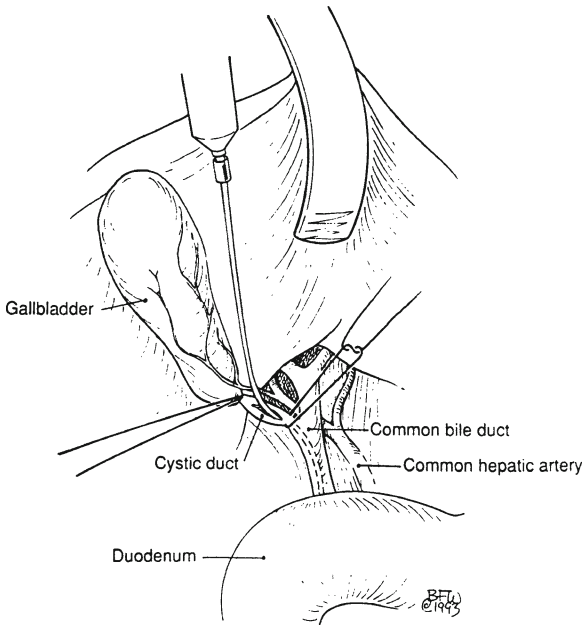


Figure 14.17. Cystic duct is entered.

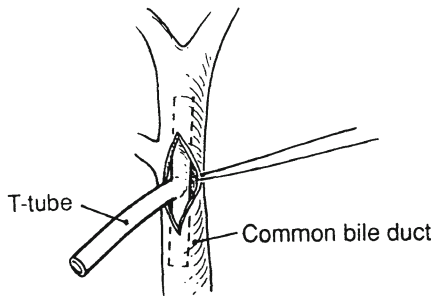
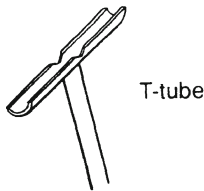


Figure 14.18. T-tube drainage. *Inset:* T-tube.

Step 3. If there is no pathology, remove the catheter and doubly ligate the cystic duct. If choledocholithiasis or other pathology is found, proceed with common duct exploration. Occasionally, choledochoscopy is helpful.

Step 4. T-tube draining is essential (Fig. 14.18).

Note:

- ✓ If the common bile duct is not completely filled, the patient can be placed in a slight Trendelenburg position and 20 cm³ of 30 percent Renografin used.

■ COMMON BILE DUCT EXPLORATION

Step 1. Perform duodenal Kocherization by careful incision of the lateral peritoneum and palpation of the duodenum, head of the pancreas, and distal common bile duct (Figs. 14.19 and 14.20).

Step 2. Dissect tissue overlying the common bile duct no more than 1–2 cm distal to the cystic stump. Skeletonization of more than 2½ to 3 cm can result in ischemia to the duct.

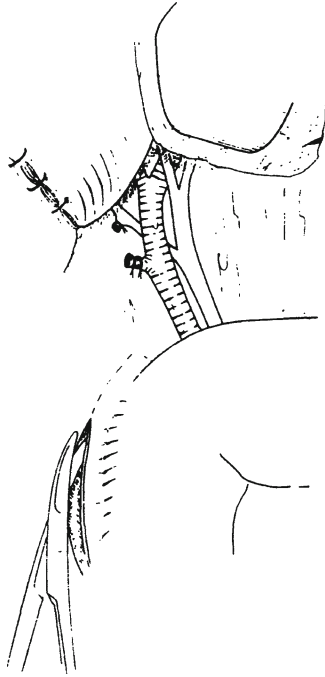


Figure 14.19. Dissecting the lateral peritoneum.

- Step 3.** Place 4–0 Vicryl stay sutures medial and lateral to the cleaned common bile duct area. Aspirate the common bile duct to make sure you are in the right place. Incise the elevated anterior wall of the common bile duct to a length of 1 cm or less (Figs. 14.21, 14.22, 14.23, and 14.24).
- Step 4.** Remove stones by instrumentation (Randall stones forceps, scoops of several types and sizes, irrigation catheter, biliary Fogarty catheter) or extrinsic pressure by milking the stones to the upward choledochotomy (Figs. 14.25 and 14.26).
- Step 5.** Demonstrate ampullary patency using a small French catheter. If doubt about patency remains, use a Bakes No. 3 dilator very carefully to avoid false passage. Choledochoscopy may be helpful. Conduct repeated irrigation of the biliary ducts to remove small stones or sludge. If stones are impacted in the ampulla, papillotomy for their removal will be necessary (Figs. 14.27, 14.28, 14.29, and 14.30).

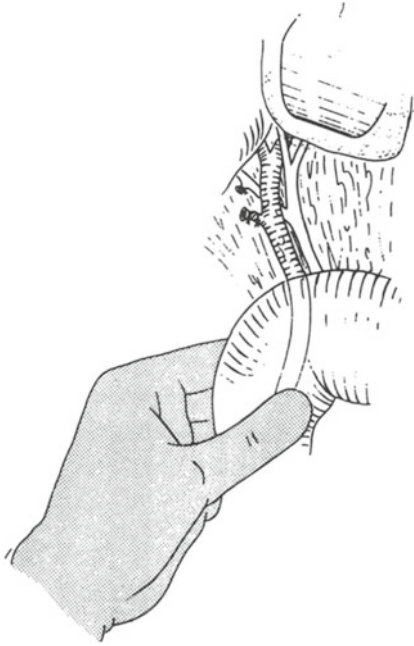


Figure 14.20. Palpation.

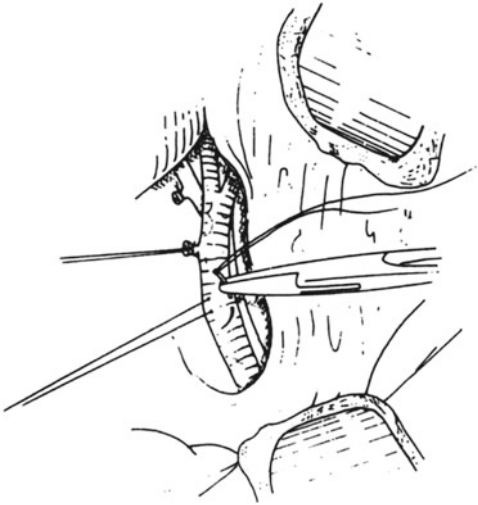


Figure 14.21. Stay sutures.

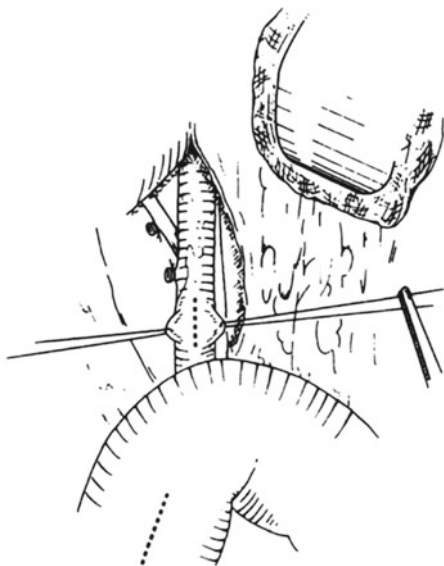


Figure 14.22. Incision site.

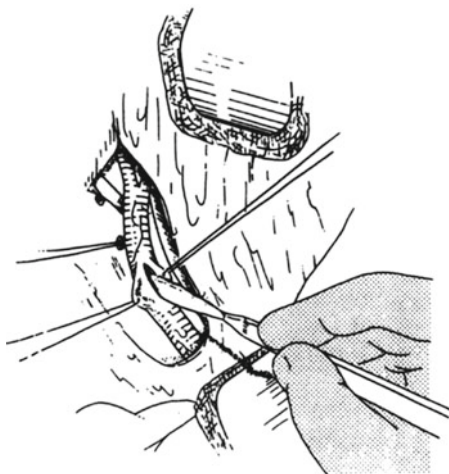


Figure 14.23. Incision.

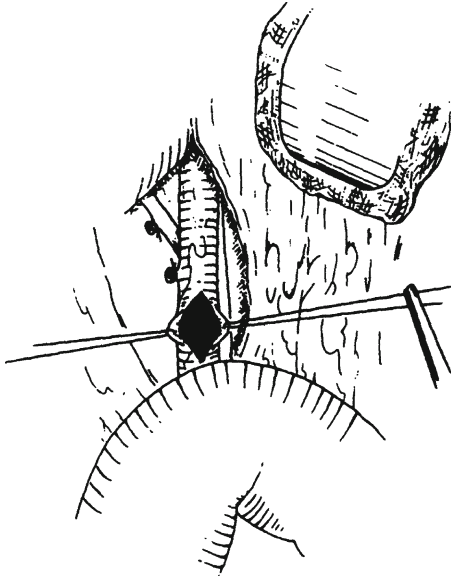


Figure 14.24. Opening for stone removal.

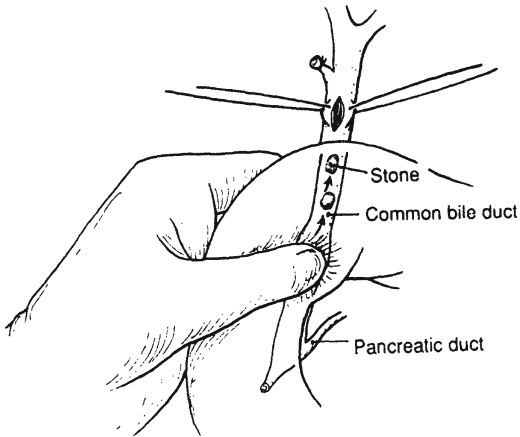


Figure 14.25. "Milking" the stones.

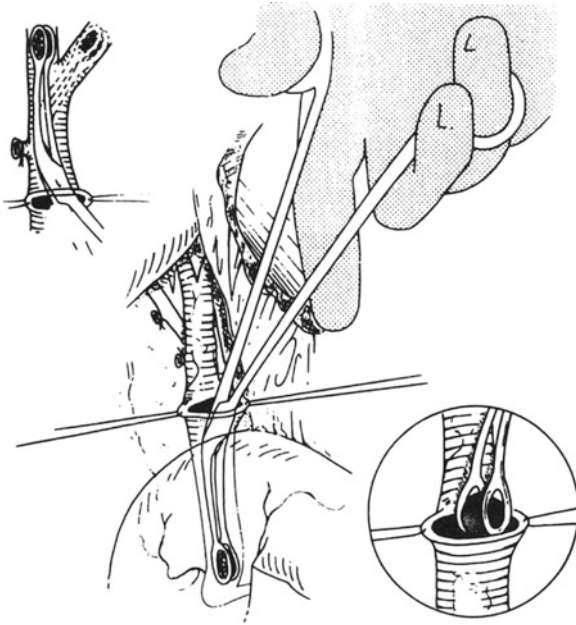


Figure 14.26. Stones removed by instrumentation. *Left inset:* forceps grasps stone. *Right inset:* stone is extracted.

- Step 6.** Insert a T-tube and close the common bile duct with 4-0 interrupted Vicryl (Figs. 14.31 and 14.32).
- Step 7.** Carry out T-tube cholangiography and bring T-tube straight out through the abdominal wall by a minute stab wound. Secure to skin with 2-0 silk.
- Step 8.** Close abdominal wall.

Remember these indications for exploration of the common bile duct:

- ✓ Presence of a palpable stone in common bile duct.
- ✓ Failure of stone extraction by ERCP.
- ✓ Positive intraoperative cholangiogram.
- ✓ Jaundice in absence of ERCP.
- ✓ Cholangitis.

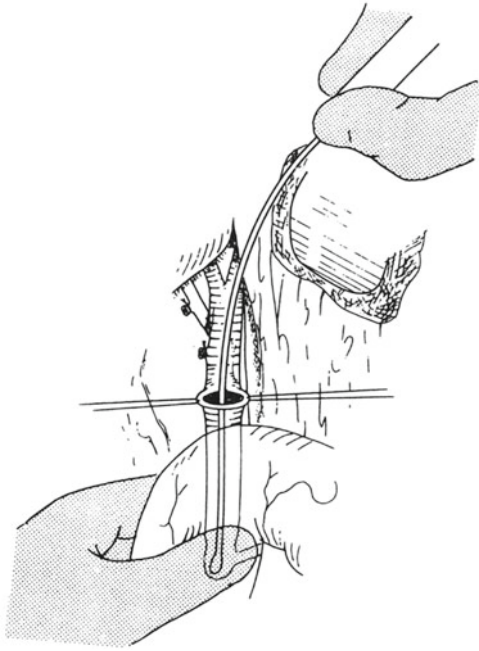


Figure 14.27. Demonstrating patency.

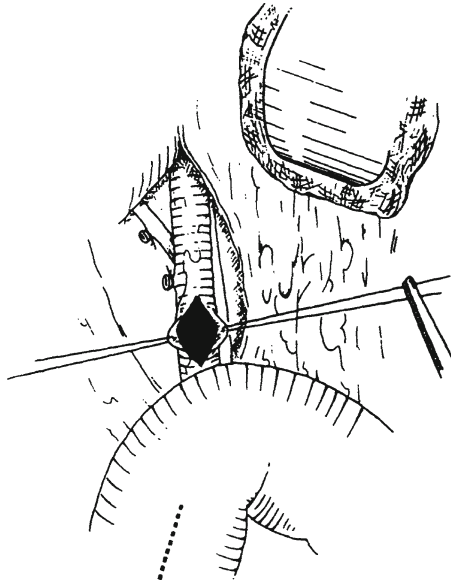


Figure 14.28. Incision site for duodenotomy.

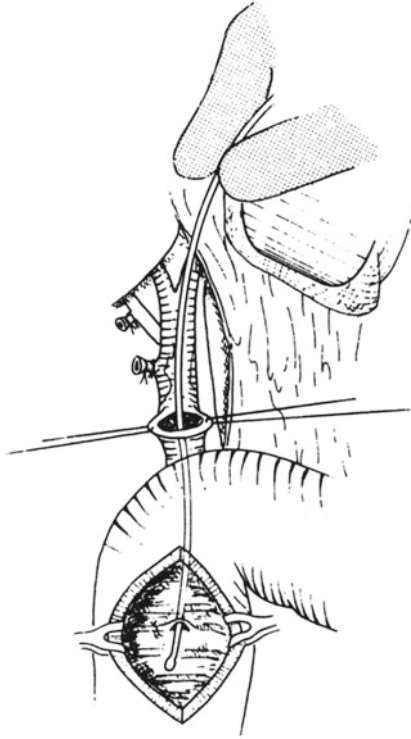


Figure 14.29. Perform the duodenotomy only if it is necessary.

- ✓ When in doubt, explore! Exposure and mobilization of 2–5 cm in length may be obtained by mobilizing the distal common bile duct from the undersurface of the pancreas. Because the duct may be intrapancreatic (Fig. 14.6c), the pancreas and duodenum should be mobilized (Fig. 14.6b, d, e).

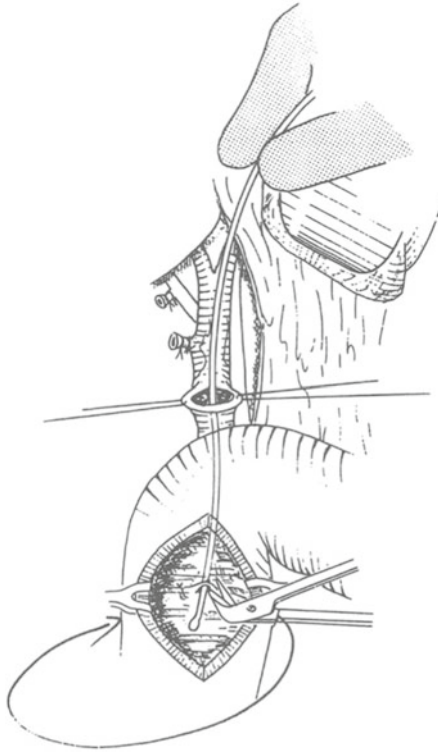


Figure 14.30. Papillotomy.

■ SPHINCTEROPLASTY

Step 1. Perform cholecystectomy and operating room cholangiogram.

Step 2. Carry out duodenal kocherization (Fig. 14.33) and choledochotomy. Insert balloon catheter all the way down through the ampulla. Place stay sutures of 4-0 silk at the duodenal wall in the area of the palpable balloon. Perform duodenotomy using electrocautery (Fig. 14.34).

Step 3. Localize the ampulla.

Step 4. At the 3 and 9 o'clock positions in the periampullary area, place 5-0 silk stay sutures (Fig. 14.35).

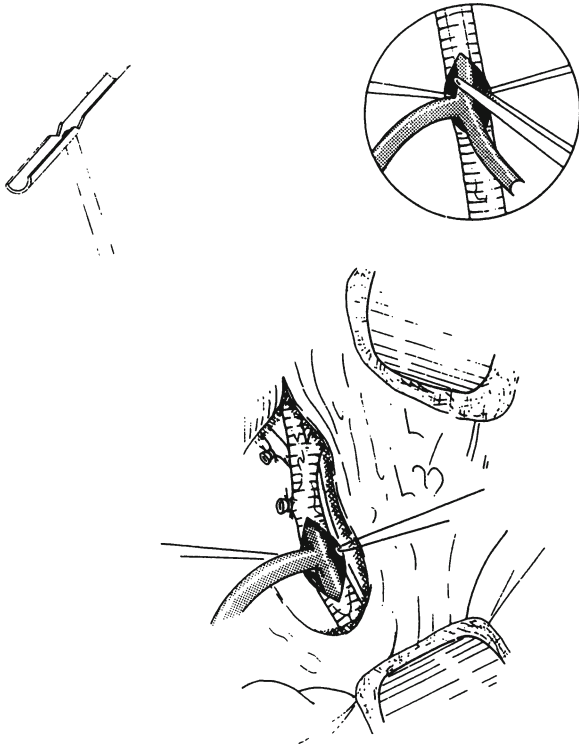


Figure 14.31. Site of T-tube insertion.

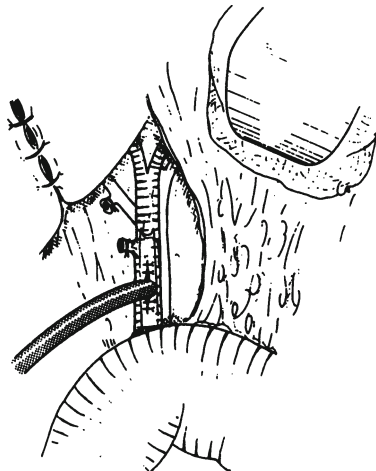


Figure 14.32. Closure.

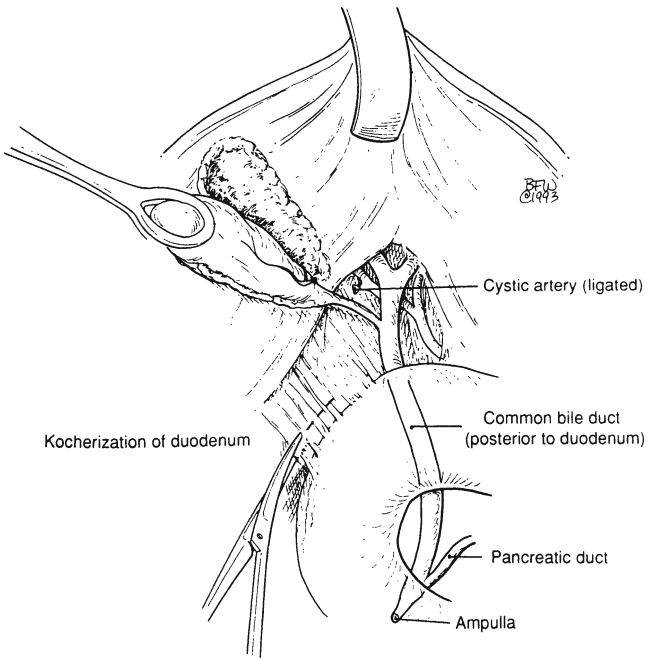


Figure 14.33. Duodenal kocherization.

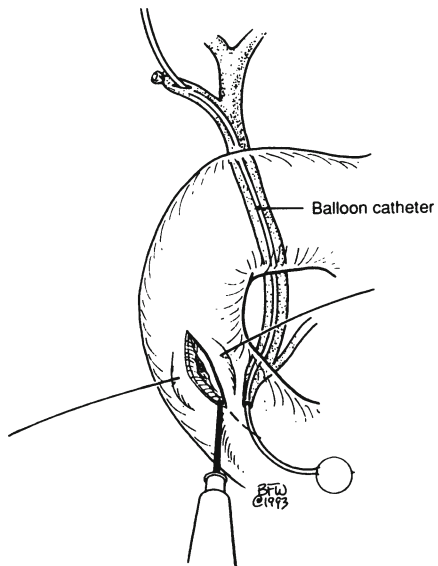


Figure 14.34. Duodenotomy with electrocautery.

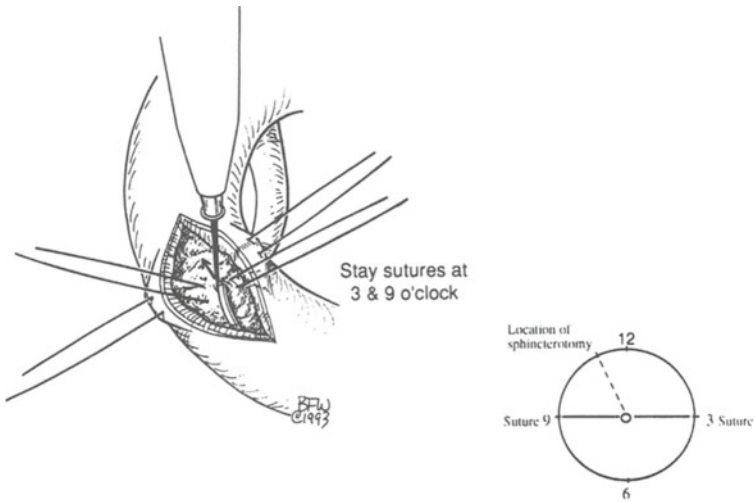


Figure 14.35. Placement of stay sutures. *Inset:* schema.

- Step 5.** Perform a sphincterotomy between the 10 and 11 o'clock positions to a depth of 2–3 mm using electrocautery (Fig. 14.36).
- Step 6.** Approximate the ductal and duodenal mucosa with interrupted 5–0 synthetic absorbable sutures (Figs. 14.36 and 14.37).
- Step 7.** Localize the pancreatic duct opening, insert a probe, and carefully perform a septotomy to a depth of 2–4 mm by knife or Pott's scissors.

Note:

- ✓ Wirsung's ductoplasty by interrupted sutures, as in step 6, is optional. If the ductal orifice is not found, secretin injection will be very helpful: one unit per kilogram of body weight.

- Step 8.** Execute duodenorrhaphy in two layers. Place a T-tube into the common bile duct and insert a Jackson–Pratt drain (Fig. 14.38).

■ CHOLEDOCHODUODENOSTOMY

- Step 1.** Establish good mobilization of the common bile duct and duodenum to avoid anastomotic tension. Anchor the duodenum to the common bile duct by placing a row of 4–0 Vicryl sutures posteriorly (Fig. 14.39).

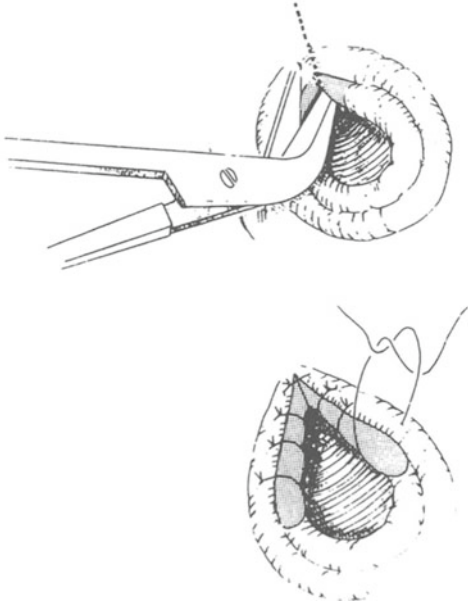


Figure 14.36. *Above:* sphincterotomy. *Below:* mucosa is approximated.

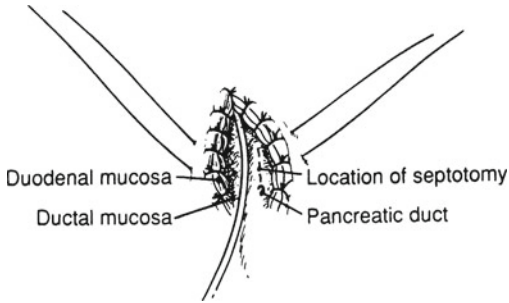


Figure 14.37. Septotomy site.

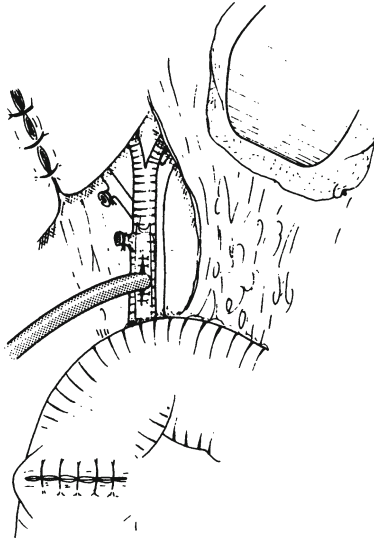


Figure 14.38. Duodenorrhaphy. Drain and T-tube placed.

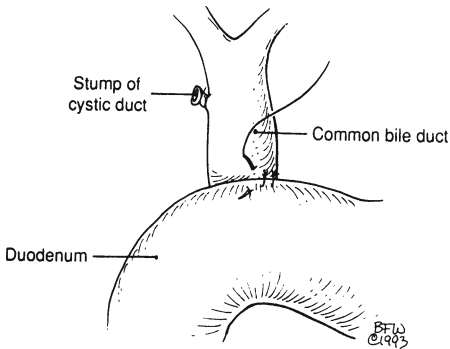


Figure 14.39. Duodenum is anchored.

Step 2. Make a 1.5- to 2-cm transverse incision of the duodenum just below the suture line and a vertical or transverse incision of the common bile duct just above the suture line (Fig. 14.40).

Step 3. Perform the anastomosis in a single layer using interrupted 4-0 Vicryl sutures, full thickness, to the common bile duct and duodenum (Figs. 14.40, 14.41, and 14.42).

Note:

- ✓ Alternatively, a side-to-side anastomosis can be performed.

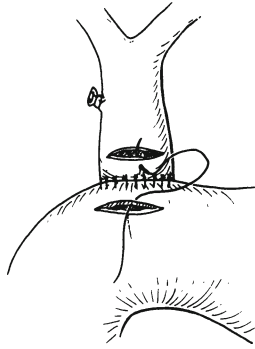


Figure 14.40. Duodenum and common bile duct are incised.

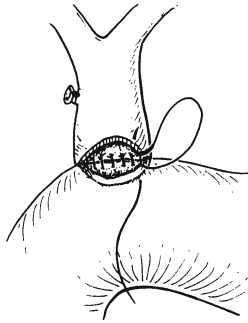


Figure 14.41. Placement of sutures.

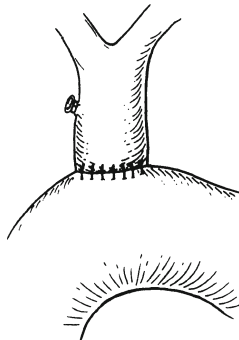


Figure 14.42. Anastomosis of common bile duct and duodenum.

■ CHOLEDOCHOCYSTECTOMY

- Step 1.** Evaluate the extent of the cyst (Fig. 14.43).
- Step 2.** Execute lysis of pericystic adhesions (Fig. 14.43).
- Step 3.** Perform cholecystectomy and choledochocystectomy (Fig. 14.44).
- Step 4.** Perform internal drainage by a 60-cm Roux-en-Y jejunal loop.
- Jejunal interruption at approximately 60 cm using GIA.
 - Small opening in transverse mesocolon.
 - Distal jejunal Roux-en-Y loop up through the transverse mesocolon opening.
 - End-to-side hepaticojejunal anastomosis in one layer with interrupted 4-0 absorbable sutures (Fig. 14.45).
 - Secure the jejunum to the transverse mesocolon opening.
 - End-to-side jejunojejunal anastomosis in two layers (Figs. 14.46 and 14.47).

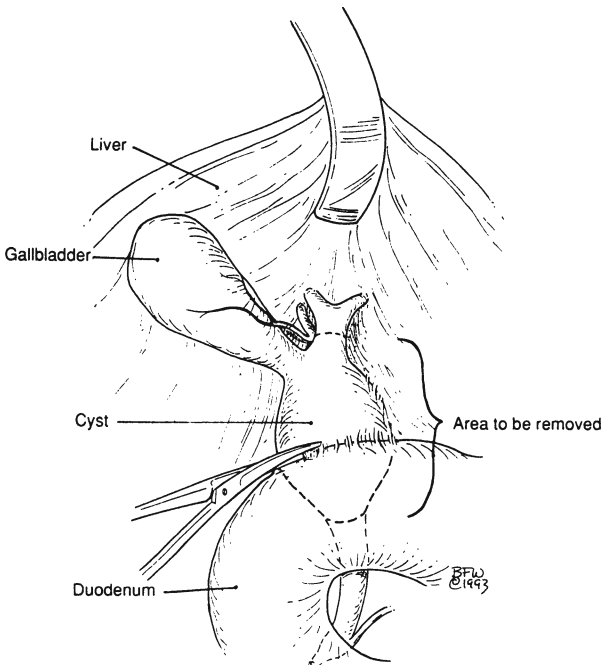


Figure 14.43. Evaluation and lysis.

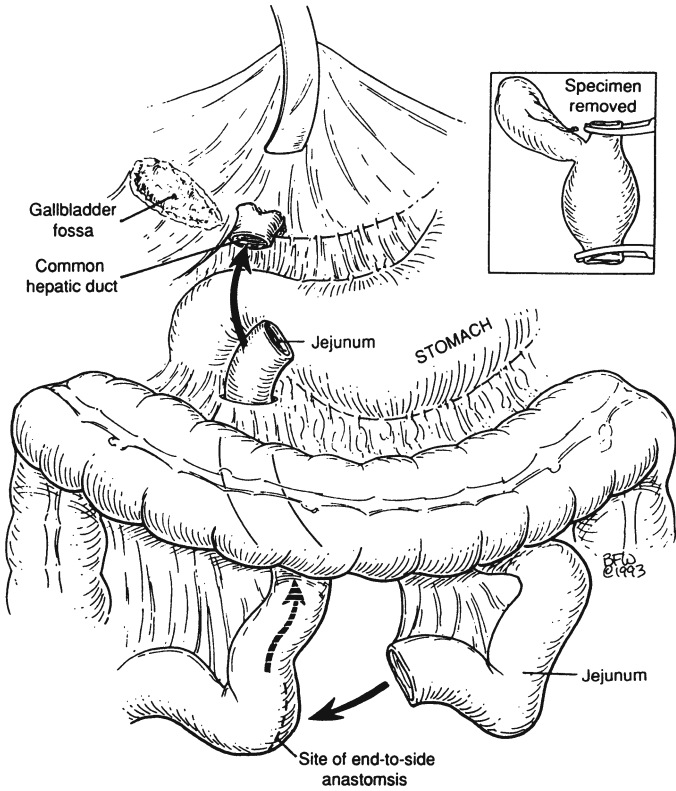


Figure 14.44. Creation of Roux-en-Y. *Inset* the specimen.

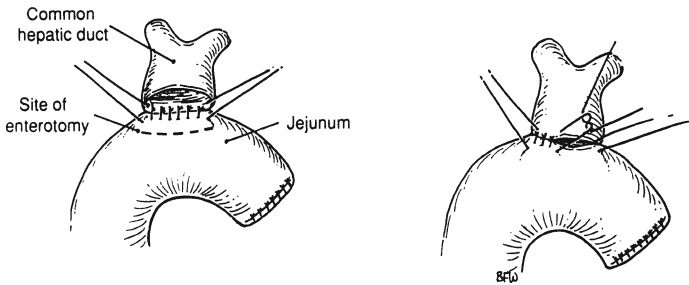


Figure 14.45. Hepaticojejunal anastomosis.

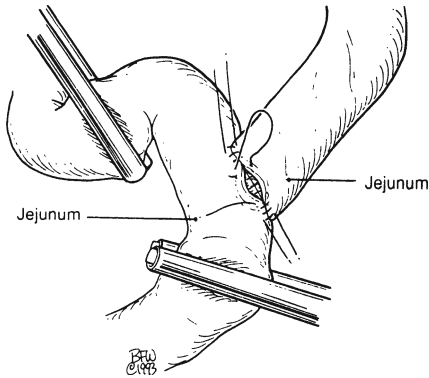


Figure 14.46. Site of end-to-side jejunojejunal anastomosis.

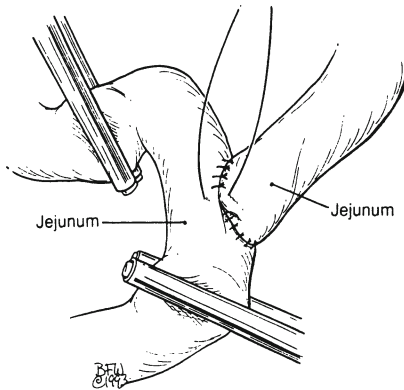


Figure 14.47. Completed two-layer anastomosis.

- g. Be sure to secure the Roux-en-Y loop to the vicinity of the gallbladder fossa with two or three interrupted 3-0 silk sutures to avoid possible herniation as well as weight tension.
- h. If there is room, it is advisable to insert a T-tube into the common hepatic duct (Fig. 14.48).

Step 5. Insert Jackson-Pratt drain and close abdominal wall.

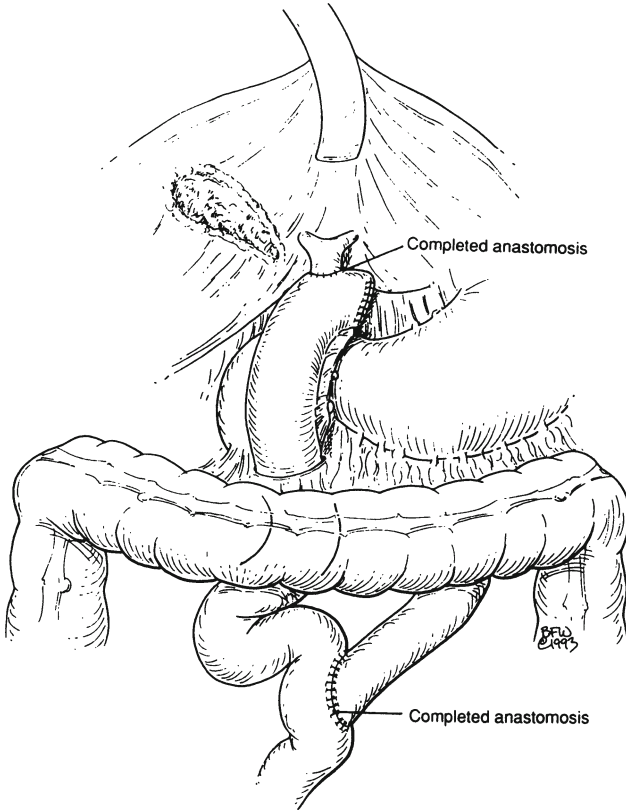


Figure 14.48. The ana.

■ LAPAROSCOPIC CHOLECYSTECTOMY

Figure 14.49 shows port placement. Functions of each port follow:

<i>Umbilical</i>	Laparoscopic examination of the peritoneal cavity; gallbladder localization; removal of the gallbladder
<i>Upper midline</i>	Surgical dissection of the gallbladder and partially of the hepatic triad at the hilum; clips may be accommodated through this port
<i>Right anterior axillary line</i>	Retraction of the gallbladder
<i>Right midclavicular line</i>	Retraction of the gallbladder

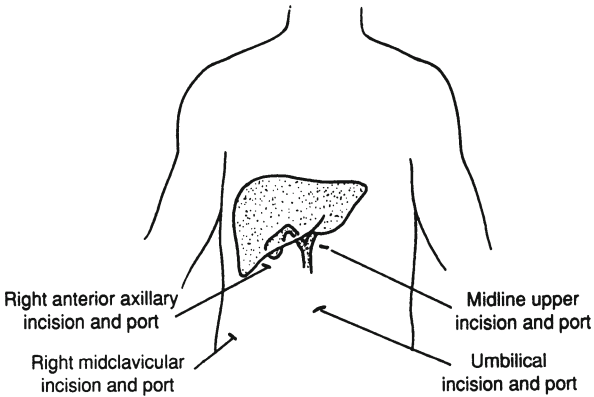


Figure 14.49. Sites of incisions and ports.

Procedure:

POSITION: Supine on X-ray operating room table.

ANESTHESIA: General.

OTHER: Place Foley catheter, nasogastric tube, and knee-high pneumatic apparatus.

- Step 1.** Using a No. 10 scalpel blade, make a longitudinal 5-mm incision in the umbilical area long enough to permit the entrance of a 5-mm trocar.
- Step 2.** Insert a Veress needle into the peritoneal cavity at a 45-degree angle toward the pelvic cavity. This may be facilitated with upward traction of the abdominal wall using two towel clamps on each side of the incision. Aspirate with a 10–20-cm³ syringe, and if there is no return with the aspiration, inject normal saline through the syringe.
- Step 3.** If normal saline is easily injected, insufflate CO₂.

Remember:

- ✓ During insufflation, the intraperitoneal pressure should be 0–5 mm, except when the Veress needle is not well placed. With obesity, initial pressure may be a little higher.

- Step 4.** If abdominal distention is satisfactory, proceed with the following “trocar steps”:
 - a. Insert a 5-mm trocar at the umbilical area at a 45-degree angle cephalad.
 - b. Insert the laparoscope with the attached camera.

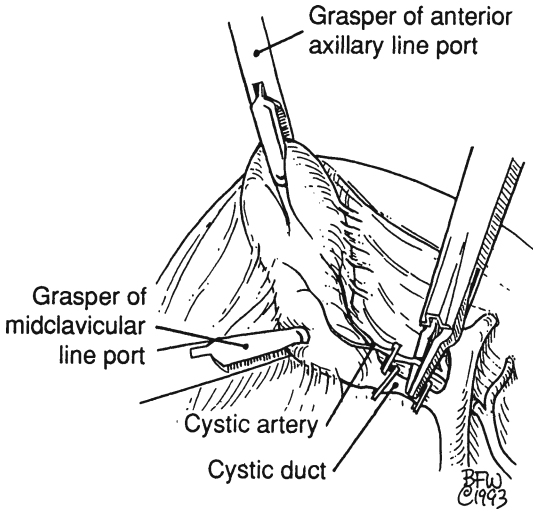


Figure 14.50. Gallbladder is raised. Hartman's pouch is retracted laterally.

- c. Perform laparoscopic inspection and begin exploration for any gross pathology.
 - d. Visualize the gallbladder.
 - e. Under direct vision, insert a 5-mm trocar through the incision at the upper midline or to the right of the midline or a similar incision. The need for narrow or wide costal margins and the patient's length of trunk should be considered because low placement will clash with the laparoscope, while in high placement the liver will interfere with dissection.
 - f. Also under direct vision, place the remaining two 5-mm trocars at the right anterior axillary line and the right midclavicular line.
 - g. Set the table in reverse Trendelenburg with rolling to the left.
- Step 5.** Retract the dome of the gallbladder anteriorly and upward by grasping the fundus with the port of the anterior axillary line. Grasp Hartmann's pouch with the port at the midclavicular line and retract laterally (Fig. 14.50).
- Step 6.** Dissect and visualize the cystic duct and common bile duct. If a cholangiogram is required, it may be done through the cystic duct prior to its ligation.
- Step 7.** Carefully ligate the cystic artery and cystic duct by proximal and distal clipping. Divide both entities (Figs. 14.50 and 14.51).

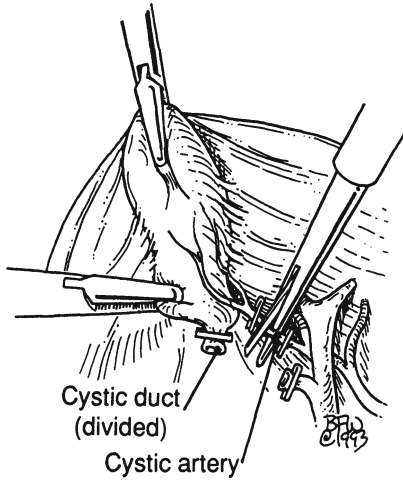


Figure 14.51. Ligation and division of cystic artery and cystic duct.

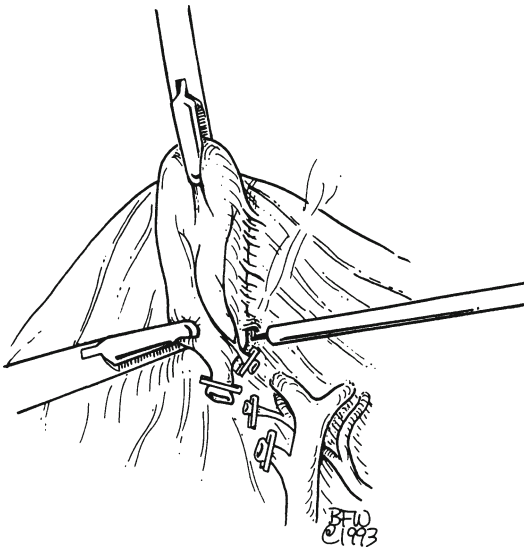


Figure 14.52. Dissection of gallbladder from the liver (used with permission of Ross Products Division, Abbott Laboratories, Columbus, OH 43216. Flexiflo Lap G. © 1992 Ross Products Division, Abbott Laboratories).

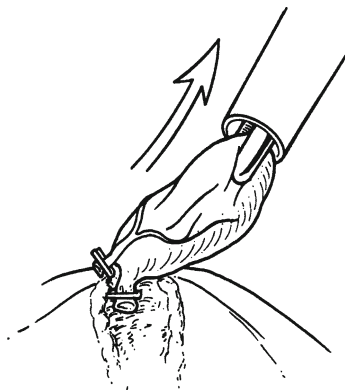


Figure 14.53. Separating gallbladder from its bed.

- Step 8.** Dissect the gallbladder from the liver using the “hook” electrocautery (Fig. 14.52).
- Step 9.** Slowly and carefully separate the gallbladder from its bed. Obtain hemostasis. Perform repeated irrigations (Fig. 14.53).
- Step 10.** Remove the gallbladder through the umbilical port. The umbilical incision may be enlarged to permit the cholecystic exodus.
- Step 11.** After ascertaining that there is no bleeding, remove all trocars under direct vision.
- Step 12.** Close the umbilical incision by suturing the fascia and the skin. Close the skin of the other ports.

15

Spleen

ANATOMY

■ GENERAL DESCRIPTION OF THE SPLEEN

The spleen is concealed at the left hypochondrium and is not palpable under normal conditions. It is associated with the posterior portions of the left 9th, 10th, and 11th ribs—separated from them by the diaphragm and the costodiaphragmatic recess (Fig. 15.1).

If one divides the spleen into three parts, the upper third is related to the lower lobe of the left lung, the middle third to the left costodiaphragmatic recess, and the lower third to the left pleura and costal origin of the diaphragm.

For all practical purposes, the spleen has two surfaces: parietal and visceral (Fig. 15.2). The convex parietal surface is related to the diaphragm, and the concave visceral surface is related to the surfaces of the stomach, kidney, colon, and tail of the pancreas. On the concave hilar surface, the entrance and exit of the splenic vessels at the splenic portals in most specimens form the letter S, which is evident if one connects the upper polar, hilar, and lower polar vessels.

A double layer of peritoneum covers the entire spleen, except for the hilum (Fig. 15.3).

■ CHIEF SPLENIC LIGAMENTS

At the hilum, the visceral peritoneum joins the right layer of the greater omentum and forms the gastrosplenic and splenorenal ligaments, the two chief ligaments of the spleen (Figs. 15.4 and 15.5). These two ligaments form the splenic pedicle. The splenic capsule is formed by the visceral peritoneum; it is as friable as the spleen itself and as easily injured (Fig. 15.4).

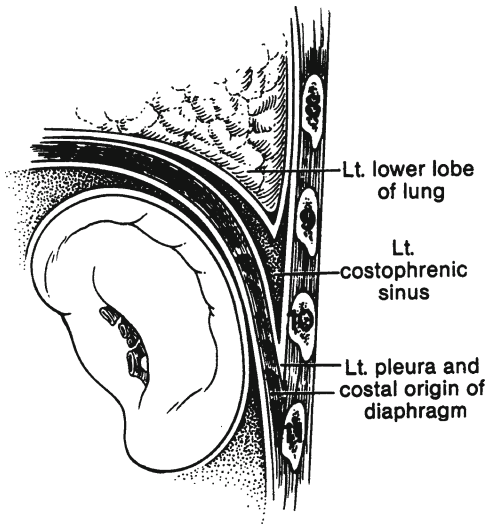


Figure 15.1. Location of the spleen. Reproduced from JE Skandalakis, GL Colborn, LB Pemberton, et al. *Prob Gen Surg* 7(1):1–17, 1990. With permission from Wolters Kluwer Health.

The superior pole of the spleen lies close to the stomach and may be fixed to it. The inferior pole lies 5–7 cm from the stomach. The gastrosplenic ligament contains the short gastric arteries above and the left gastroepiploic vessels below; it should be incised only between clamps or preferably after the vessels are ligated one by one. Transfixion sutures may be used.

The splenorenal ligament envelops the splenic vessels and the tail of the pancreas. The outer layer of the splenorenal ligament forms the posterior layer of the gastrosplenic ligament. Careless division of the former may injure the short gastric vessels. Bleeding from these vessels may be the result of too-enthusiastic deep posterior excavation by the index and middle fingers of an operator seeking to mobilize and retract the spleen to the right. The splenorenal ligament itself is nearly avascular and may be incised, but the fingers should stop at the pedicle (Fig. 15.6).

■ MINOR SPLENIC LIGAMENTS

The spleen has several minor ligaments, and their names indicate their connections (Fig. 15.5): the splenophrenic, splenocolic, pancreaticosplenic, pancreaticocolic, and phrenicocolic ligaments and the presplenic fold. The splenophrenic ligament (Fig. 15.5) is the reflection of the leaves of the mesentery to the

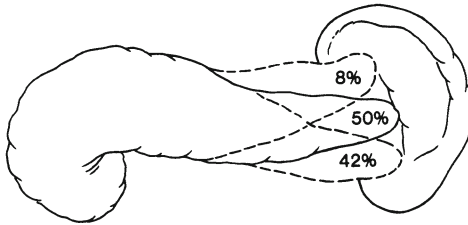
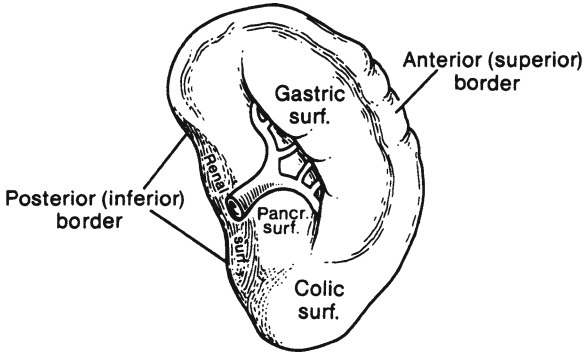


Figure 15.2. Splenic borders. (Top) Anterior and posterior border. (Bottom) Relations of the tail of the pancreas to the spleen. Reproduced from JE Skandalakis, GL Colborn, LB Pemberton, et al. *Prob Gen Surg* 7(1):1–17, 1990. With permission from Wolters Kluwer Health.

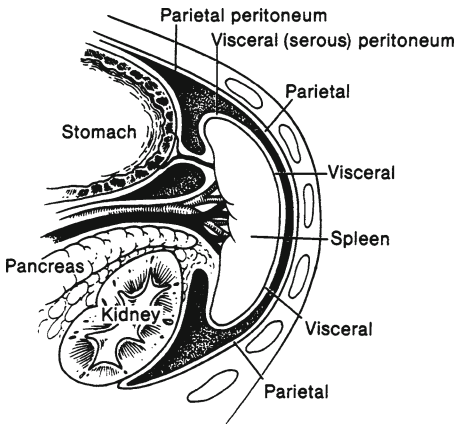


Figure 15.3. Sagittal view of peritoneum covering the spleen. Reproduced from JE Skandalakis, GL Colborn, LB Pemberton, et al. *Prob Gen Surg* 7(1):1–17, 1990. With permission from Wolters Kluwer Health.

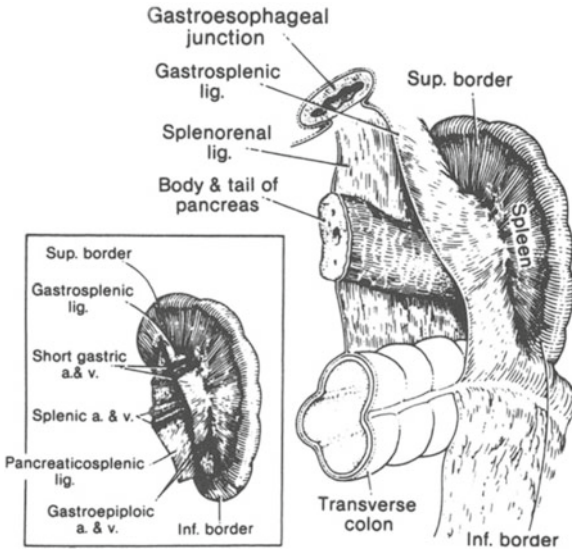


Figure 15.4. The peritoneal attachments of the spleen. (*Inset*) The hilum of the spleen showing the short gastric and gastroepiploic vessels in the gastrosplenic ligament (By permission of JE Skandalakis, SW Gray, and JR Rowe. *Anatomical Complications in General Surgery*. New York: McGraw-Hill, 1983).

posterior body wall and to the inferior surface of the diaphragm at the area of the upper pole of the spleen close to the stomach. It is usually avascular, but it should be inspected for possible bleeding after section.

Tortuous or aberrant inferior polar vessels of the spleen or a left gastroepiploic artery can lie close enough to the splenicocolic ligament to be injured by careless incision of the ligament, possibly resulting in massive bleeding. The ligament should be incised between clamps.

The pancreaticosplenic ligament (Fig. 15.5) is said to be present when the tail of the pancreas does not touch the spleen.

The pancreaticocolic ligament (Fig. 15.5) is the upper extension of the transverse mesocolon and is somewhat of a bridge from the tail or body of the pancreas to the splenic flexure of the colon (Fig. 15.7).

The “phrenicocolic ligament” is not a splenic ligament; i.e., it is not connected to the spleen, but the spleen rests upon it. It extends between the splenic flexure of the colon and the diaphragm and constitutes the “splenic floor” (Fig. 15.5).

The presplenic fold is a peritoneal fold anterior to the gastrosplenic ligament (Fig. 15.5), often containing the left gastroepiploic vessels. Excessive traction on this fold during upper abdominal operations can result in a tear in the splenic capsule.

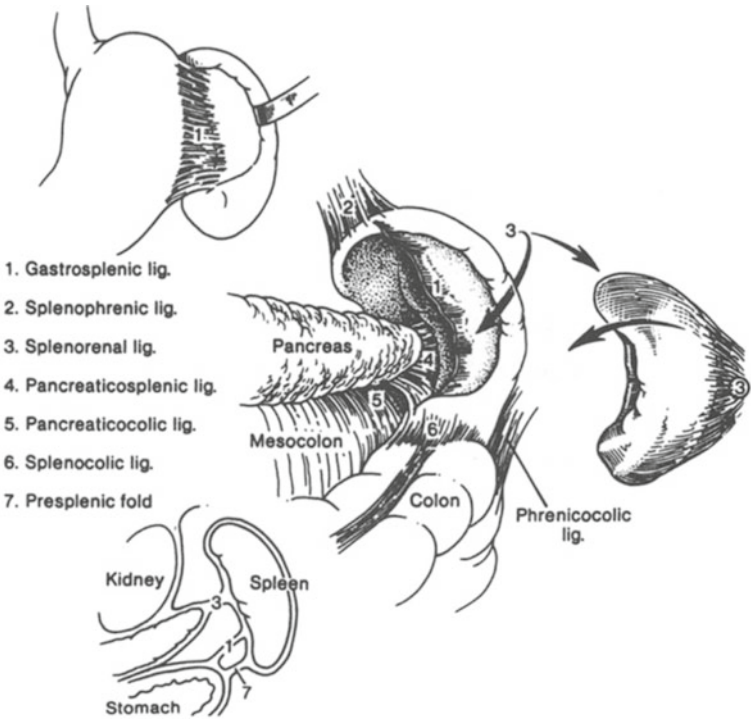


Figure 15.5. Chief and minor splenic ligaments. Reproduced from JE Skandalakis, GL Colborn, LB Pemberton, et al. *Prob Gen Surg* 7(1):1-17, 1990. With permission from Wolters Kluwer Health.

■ VASCULAR SYSTEM OF THE SPLEEN

Splenic Artery and Its Branches

The splenic artery, in most people, is a branch of the celiac trunk, arising together with the common hepatic and left gastric arteries. The splenic artery varies in length from 8 to 32 cm and in diameter from 0.5 to 1.2 cm. The normal course of the splenic artery crosses the left side of the aorta, passes along the upper border of the pancreas reaching the tail in front, and then crosses the upper pole of the left kidney.

The left gastroepiploic artery arises most often from the splenic trunk. Less often it arises from the inferior terminal splenic branch or its branches and rarely from the middle splenic trunk or the superior terminal branch.

610 15. Spleen

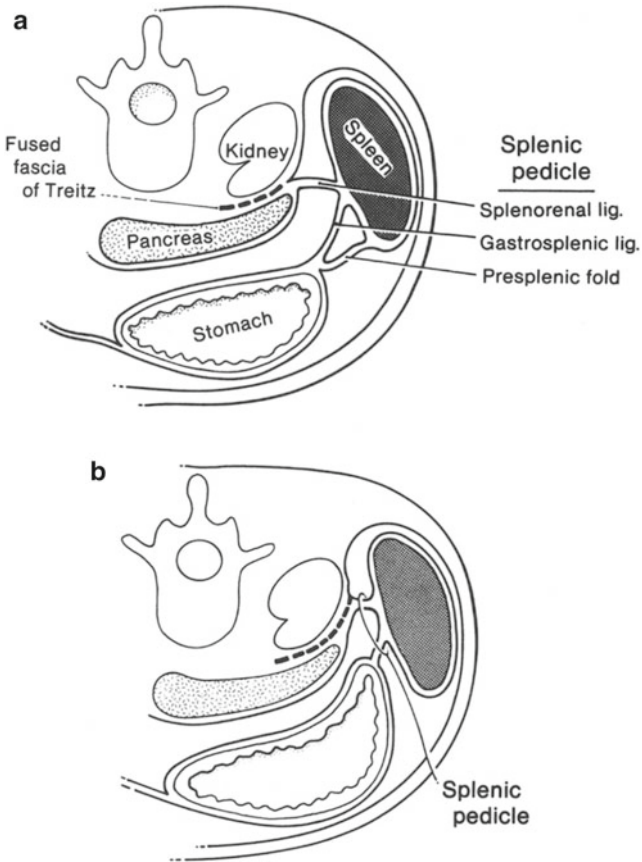


Figure 15.6. The splenic pedicle. (a) Long pedicle with a presplenic fold. (b) Short pedicle (By permission of JE Skandalakis, SW Gray, and JR Rowe. *Anatomical Complications in General Surgery*. New York: McGraw-Hill, 1983).

There is no question that the spleen can tolerate ligation of the splenic artery because of the available collateral circulation. Therefore, the spleen can be saved if necessary. Surgeons should remember that ligation of the splenic artery near its origin can result in hyperamylasemia resulting from deterioration of the pancreatic blood supply. Preoperative splenic arterial embolization as an adjunct to high-risk splenectomy has been advised.

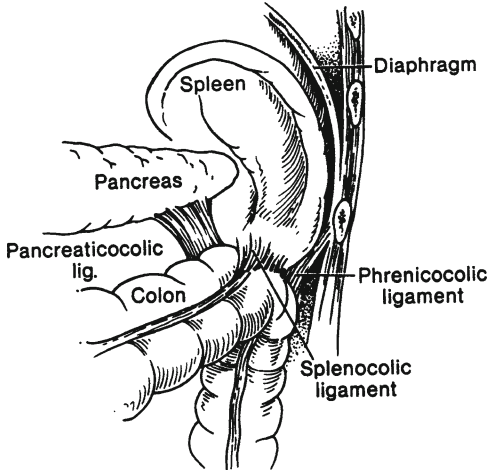


Figure 15.7. Relation of the pancreaticocolic, phrenicocolic, and splenocolic ligaments to the transverse mesocolon. Reproduced from JE Skandalakis, GL Colborn, LB Pemberton, et al. *Prob Gen Surg* 7(1):1–17, 1990. With permission from Wolters Kluwer Health

Splenic Vein and Its Branches

The splenic vein travels with the splenic artery (Fig. 15.8), sometimes crossing over or under it. The anatomy of the splenic vein is summarized in Fig. 15.9. The patterns are highly variable, and as in the arteries, no one vein resembles the next. The single characteristic of most of the short gastric veins is that they communicate directly with the spleen, entering at its upper part, rather than through the extrasplenic venous vessels. The left gastroepiploic venous drainage is into the splenic veins.

Lymphatic Drainage

One of the peculiarities of the spleen is the lack of provision for lymphatics for the splenic pulp. The splenic lymphatic chain (Fig. 15.10) is reported to be formed by suprapancreatic nodes, infrapancreatic nodes, and afferent and efferent lymph vessels.

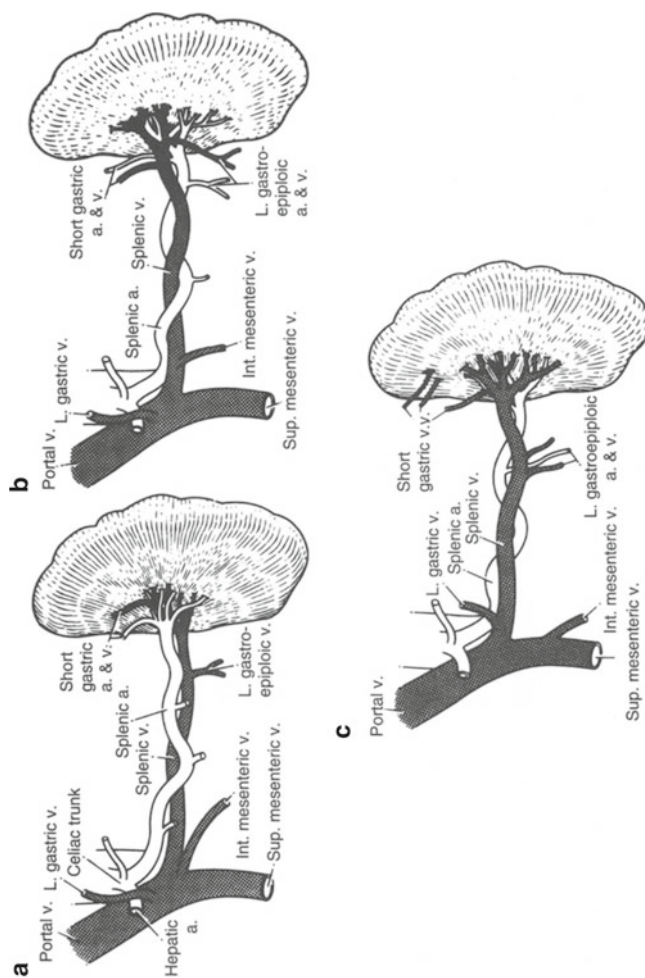


Figure 15.8. Relation of splenic artery and splenic vein. (a) Artery anterior to vein (usual pattern). (b) Artery both anterior and posterior to vein. (c) Artery posterior to vein (least common configuration) (By permission of JE Skandalakis, SW Gray, and JR Rowe. *Anatomical Complications in General Surgery*. New York: McGraw-Hill, 1983)

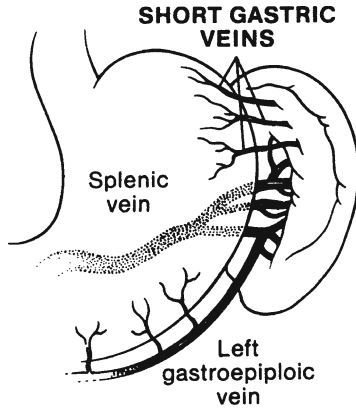


Figure 15.9. Anatomy of the splenic vein. Reproduced from JE Skandalakis, GL Colborn, LB Pemberton, et al. *Prob Gen Surg* 7(1):1–17, 1990. With permission from Wolters Kluwer Health.

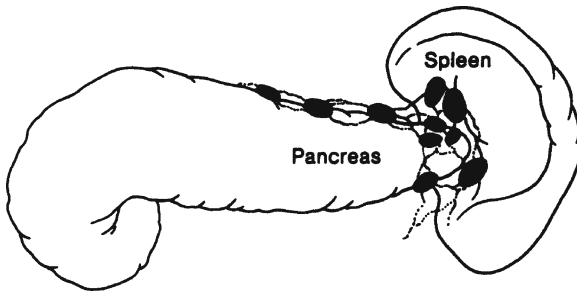


Figure 15.10. Lymphatic drainage of the spleen. Reproduced from JE Skandalakis, GL Colborn, LB Pemberton, et al. *Prob Gen Surg* 7(1):1–17, 1990. With permission from Wolters Kluwer Health.

■ SEGMENTAL ANATOMY

We propose that the term *segments* be used when referring to splenic parts separated by avascular planes, elsewhere called *lobes*. Studies indicate that the majority of the population has two splenic segments—superior and inferior. However, three and more segments have been reported in the literature.

■ ACCESSORY SPLEENS

The reported incidence of accessory spleens in autopsies varies from approximately 20 to 30 %. In approximately 60 % of affected patients, only one accessory spleen is present. In 20 %, two such spleens are present, and in 17 %, there are three or more splenic structures. Two-thirds to three-fourths of accessory spleens are located at or near the hilum of the normal organ, and about 20 % are embedded in the tail of the pancreas. The remainder are distributed along the splenic artery, in the omentum, in the mesentery, or beneath the peritoneum (Fig. 15.11). They range from 0.2 to 10 cm in size, resembling lymph nodes or miniature spleens.

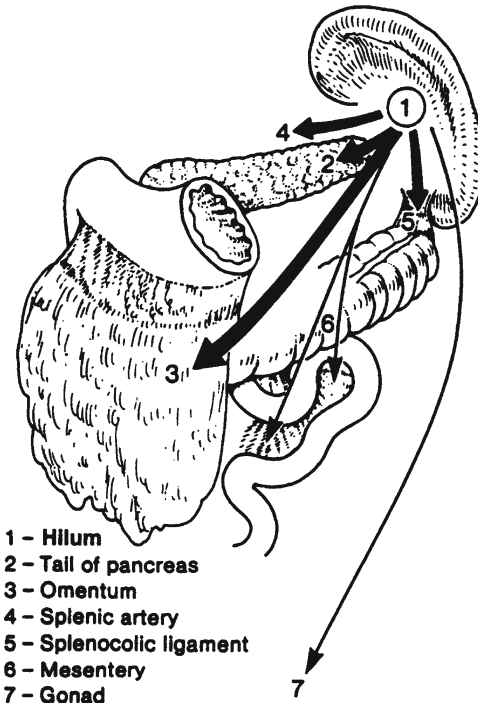


Figure 15.11. Sites of accessory spleens in order of frequency: (1) near the splenic hilum; (2) tail of the pancreas (these contain 86–95 % of all accessory spleens); (3) omentum; (4) along the splenic artery; (5) splenocolic ligament; (6) mesentery; and (7) testis or ovary (3–7 are unusual locations) (By permission of JE Skandalakis, SW Gray, and JR Rowe. *Anatomical Complications in General Surgery*. New York: McGraw-Hill, 1983).

Note:

- ✓ Patients with fractures of the left 9–11th ribs should be observed closely for splenic rupture.
- ✓ In splenomegaly, the spleen is always located in front of the splenic flexure of the colon. Adhesions are almost always present and sometimes vascular. Often an enlarged spleen has extensive adhesions to the colon.
- ✓ In elective splenectomies, if splenomegaly is present, intestinal preparation is essential.
- ✓ After radiologic evaluation of the topography of both the upper splenic pole and the left costodiaphragmatic recess, a left thoracotomy tube should be introduced above the upper pole of the spleen.

TECHNIQUE

■ SPLENECTOMY

A splenectomy is usually performed for one of the following four reasons: hemorrhage, hypersplenism, Hodgkin's disease staging (diagnostic laparotomy), or a problem such as an abscess, cyst, or tumor.

Splenectomy Due to Hemorrhage Secondary to Trauma

- Step 1.** Make an incision.
- Step 2.** Mobilize the spleen.
- Step 3.** Ligate the vessels.
- Step 4.** Divide the hilum.
- Step 5.** Obtain hemostasis.
- Step 6.** Provide drainage.
- Step 7.** Close the wound.

Splenectomy Due to Hematological Disorders (Hypersplenism)

- Step 1.** Make an incision.
- Step 2.** Ligate the arteries.
- Step 3.** Mobilize the spleen.
- Step 4.** Divide the hilum.
- Step 5.** Obtain hemostasis.
- Step 6.** Search for accessory spleens.
- Step 7.** Provide drainage.
- Step 8.** Close the wound.

Ligation of the Splenic Pedicle: Anterior Approach

- Step 1.** Incision (Fig. 15.12).
- Step 2.** Clamp, incise, and ligate the left part of the gastrocolic ligament and the gastroepiploic artery and vein. This will provide access to the lesser sac (Fig. 15.12).
- Step 3.** Locate the splenic artery at the superior border of the body of the pancreas. Carefully ligate the artery in continuity and doubly, with ligatures being placed as distally as possible (Fig. 15.13).

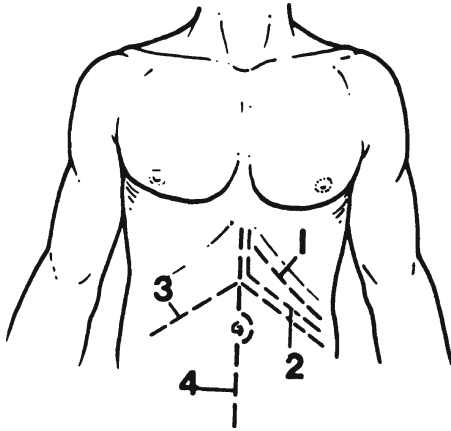


Figure 15.12. Incision for total splenectomy by the anterior approach and access to the lesser sac. (1) subcostal; (2) Kehr subcostal; (3) bilateral subcostal; (4) midline. Reproduced from LB Pemberton, LJ Skandalakis. *Prob Gen Surg* 7(1):85–102, 1990. With permission from Wolters Kluwer Health.

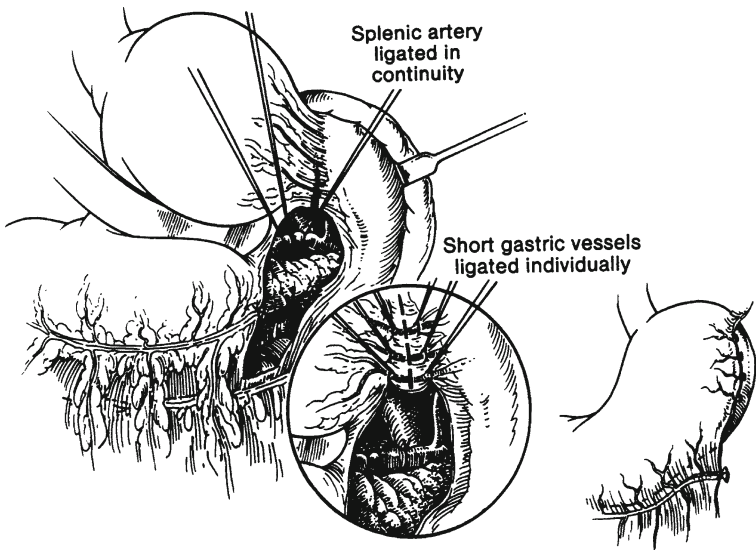


Figure 15.13. Ligation of the splenic artery and the short gastric arteries and vein. Reproduced from Pemberton LB, Skandalakis LJ. *Prob Gen Surg* 7(1): 85–102, 1990. With permission from Wolters Kluwer Health.

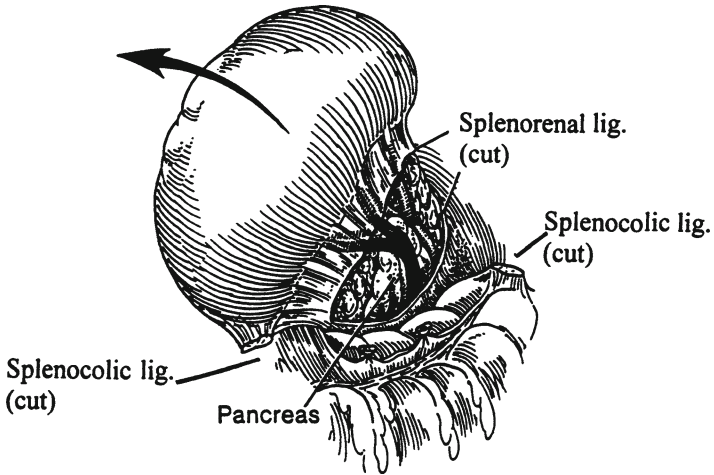


Figure 15.14. Division of the ligaments and delivery of the spleen to the outside of the peritoneal cavity. Reproduced from Pemberton LB, Skandalakis LJ. *Prob Gen Surg* 7(1):85–102, 1990. With permission from Wolters Kluwer Health.

- Step 4.** Clamp, divide, and ligate the short gastric arteries and veins, one at a time (Fig. 15.13).
- Step 5.** Mobilize the spleen by dividing the several ligaments with scissors. Insert the index finger deeply to separate the spleen from the renal covering. With the use of sharp and blunt dissection, clamp, divide, and ligate the splenocolic and splenophrenic ligaments.
- Step 6.** Elevate the spleen, tail, and part of the body of the pancreas, being particularly careful with the tail of the pancreas. The spleen is now outside the peritoneal cavity and is attached only by one of the branches of the splenic arteries and veins.
- Step 7.** Close to the hilum, clamp, divide, and ligate all branches of the splenic artery. The splenic vein and its branches are easily torn and should not be clamped. Ligate and divide the splenic vein and branches in continuity with 2–0 silk. The spleen is now free and should be removed (Figs. 15.14 and 15.15). All of the above can be accomplished with the endoscopic GIA with vascular loads.
- Step 8.** Inspect the site for bleeding, beginning with the diaphragm and continuing to the greater curvature of the stomach, pancreatic tail, gastrosplenic ligament, splenorenal ligament, splenocolic ligament, and splenic bed and other ligaments.

Splenic vein ligated in continuity



Figure 15.15. Ligation of the splenic vein. Reproduced from Pemberton LB, Skandalakis LJ. *Prob Gen Surg* 7(1):85–102, 1990. With permission from Wolters Kluwer Health.

Remember:

- ✓ Complete hemostasis is essential. After complete inspection for bleeding, search for accessory spleens.

Ligation of the Splenic Pedicle: Posterior Approach

- Step 1.** Hold the spleen medially (Fig. 15.16).
- Step 2.** Divide the splenorenal, splenophrenic, and splenocolic ligaments (Fig. 15.16).
- Step 3.** Lift the spleen outside the peritoneal cavity, being particularly careful with the tail of the pancreas.
- Step 4.** Dissect rapidly and mobilize the bleeding spleen immediately. Bleeding can be controlled by manually compressing the splenic artery and vein and the tail of the pancreas between the thumb and index finger or with a noncrushing clamp (Fig. 15.17).
- Step 5.** Ligate the arterial and venous branches close to the hilum using 2–0 and 3–0 ligatures. Doubly ligate the splenic artery (Fig. 15.18).

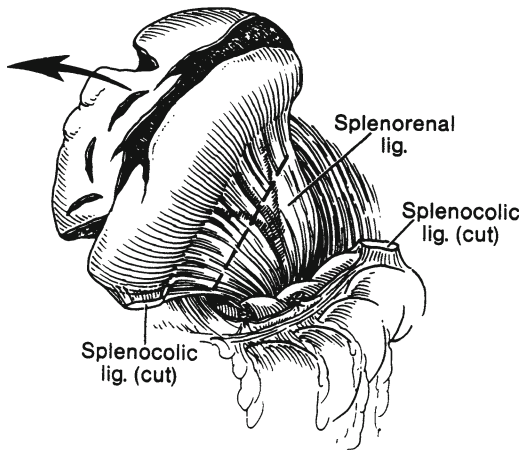


Figure 15.16. Medial position of the spleen during the posterior approach to splenectomy, showing division of the splenicocolic ligaments. Reproduced from Pemberton LB, Skandalakis LJ. *Prob Gen Surg* 7(1):85–102, 1990. With permission from Wolters Kluwer Health.

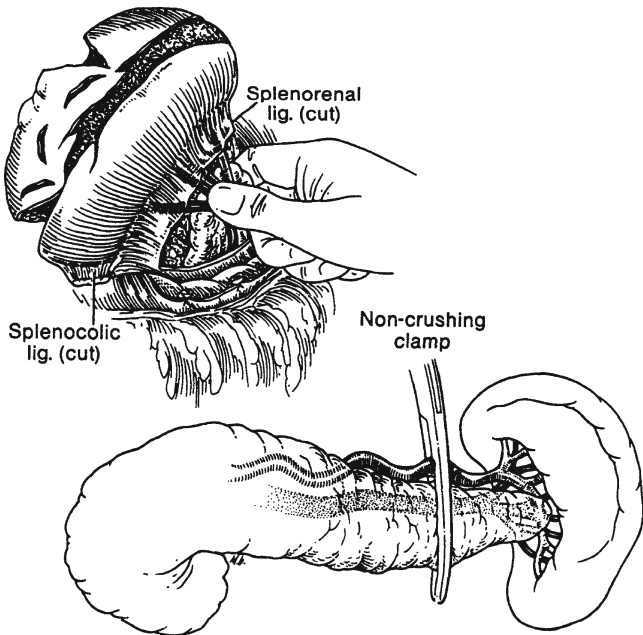


Figure 15.17. Compression of the splenic artery and vein. Reproduced from Pemberton LB, Skandalakis LJ. *Prob Gen Surg* 7(1):85–102, 1990. With permission from Wolters Kluwer Health.

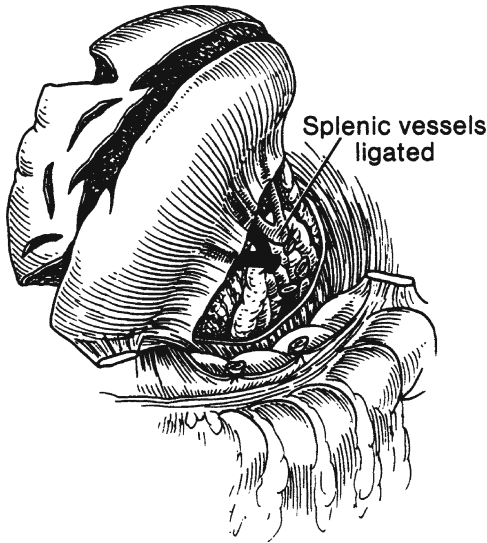


Figure 15.18. Ligation of the splenic artery. Reproduced from Pemberton LB, Skandalakis LJ. *Prob Gen Surg* 7(1):85–102, 1990. With permission from Wolters Kluwer Health.

Step 6. Ligate the short gastric vessels.

Step 7. Remove the spleen and secure any bleeding points.

Step 8. Close the abdominal wall.

Note:

- ✓ A GIA stapler with a vascular load can be used to divide the splenic artery and vein together at the hilum. The Harmonic Scalpel can be used to divide the short gastric vessels.

Partial Splenectomy

The major indication for partial splenectomy is trauma to the spleen; it is sometimes performed for nonparasitic splenic cysts, in Gaucher's disease, etc. An effort to save the spleen is paramount. However, it is our opinion that, if there is any doubt, the spleen should be removed. Detailed evaluation of the trauma must be done. Decisions must be made about the procedure of choice:

- Splenorrhaphy
- Splenorrhaphy with omental fixation (Fig. 15.19)
- Debridement, perhaps with partial splenectomy and omental fixation

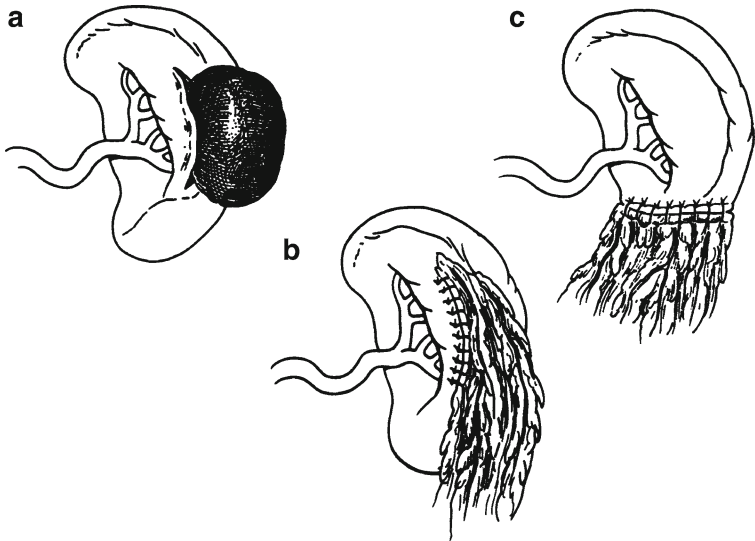


Figure 15.19. (a) Splenic rupture with hematoma. (b) Splenorrhaphy with omental fixation. (c) Partial splenectomy with omental fixation. Reproduced from Pemberton LB, Skandalakis LJ. *Prob Gen Surg* 7(1):85–102, 1990. With permission from Wolters Kluwer Health.

- Splenic mesh wrap (Fig. 15.20)
- Autotransplantation (Fig. 15.21)

Technique of Intrasplenic Dissection

With scalpel (not cautery), make a superficial anterior incision (not circumferential) of the splenic capsule on the viable side of the line of demarcation. Using the scalpel handle, gradually deepen the incision until the entire spleen has been divided.

Ligate all vessels with hemoclips or with figure-of-eight 4–0 silk. If oozing occurs, apply a hemostatic substance.

An alternative technique for treating the raw splenic remnant is placement of interlocking mattress sutures of 2–0 chromic catgut, 0.5–1 cm from the divided edge, compressing the splenic parenchyma for hemostasis. Tie these over pledgets of Gelfoam (absorbable gelatin sponge) or Surgicel (oxidized regenerated cellulose). A topical hemostatic agent may be applied for capsular avulsions or to arrest hemorrhage of very superficial lacerations.

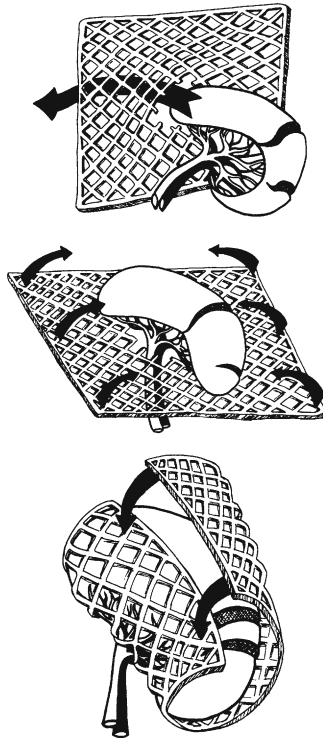


Figure 15.20. Splenic mesh wrap. (Top) Passage of injured spleen through hole in center of mesh. (Middle) Wrapping spleen in mesh. (Bottom) Sewing opposite edges of mesh to each other to create tamponade (By permission of DA Lange, P Zaret, GL Merlotti, et al. *J Trauma* 28(3):269–275, 1988).

Both an ultrasonic surgical aspirator (Cavitron) and an argon laser (which produces heat coagulation of blood vessels) have been used for identification and control of the intrasplenic vessels.

In partial splenectomy or a deeply lacerated spleen, use absorbable mesh. Observe the splenic remnant for 10 min to ascertain the completeness of hemostasis. The surgeon should determine whether drainage is required.

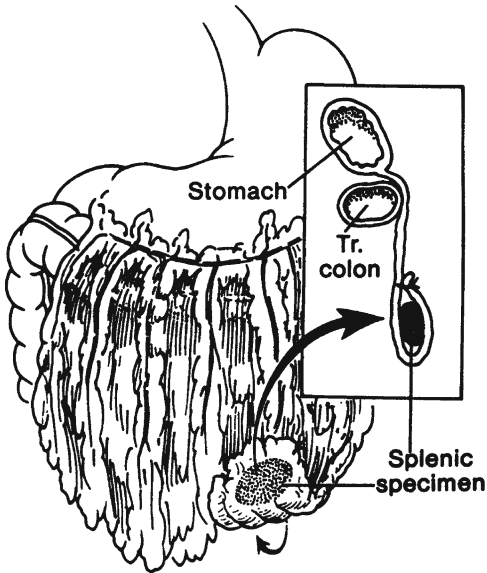


Figure 15.21. Autotransplantation. Reproduced from Pemberton LB, Skandalakis LJ. *Prob Gen Surg* 7(1):85–102, 1990. With permission from Wolters Kluwer Health.

■ OCCLUSION OF THE SPLENIC ARTERY

Step 1. Perform temporary occlusion of the main splenic artery.

Step 2. Remember that the splenic vasculature is segmental and highly variable; isolate the segmental branches. The superior polar artery is, however, quite constant, generally arising approximately 1–3 cm from the splenic hilum. At or near the splenic hilum, the splenic artery branches further into three to five major branches and into several large and small branches. The splenic veins follow the pattern of the arterial distribution more consistently in the smaller branches than in the larger ones.

Once the segment chosen for preservation is delineated, begin a systematic, stepwise ligation and division of the branches to the segment to be removed. As the ligation proceeds, evidence of the devascularization of the spleen will become increasingly obvious as segment after segment undergoes a color change ranging from dark bluish-purple to bluish-black.

Remove the devascularized splenic parenchyma. The remnant should be of normal color, size, and consistency, indicating adequate arterial inflow and venous outflow.

Remember:

- ✓ The splenorenal ligament is almost avascular, but small veins can cause problems.
- ✓ Perisplenic adhesions are vascular.
- ✓ The terminal splenic vessels are fragile and easily torn.
- ✓ The splenic capsule also is friable.
- ✓ Dissection of the splenic artery close to the celiac artery through the gastrocolic omentum can be done if moderate splenomegaly and adhesions are present. However, to avoid sudden, large loss of blood, the surgeon must be aware of the highly fragile splenic vein, which can coil around the artery.
- ✓ For huge spleens with multiple vascular adhesions, the artery can be ligated along the upper pancreatic border after the gastrocolic ligament is opened.
- ✓ A healthy ruptured spleen can be delivered easily from the abdomen.
- ✓ A large, diseased spleen requires careful dissection of the pre-hilar area and ligation of the vessels.
- ✓ In thrombocytopenic purpura, the abdomen should be explored after the spleen is removed to avert unnecessary bleeding.
- ✓ In idiopathic thrombocytopenic purpura, the splenic artery should be ligated as soon as possible.
- ✓ In the presence of hemolytic anemia, transfusions should not be given before the operation. Platelets should be transfused after splenic artery ligation.
- ✓ The splenic artery is the most unpredictable artery of the human body. If it is ligated proximally, it should also be ligated distally close to the hilum.
- ✓ The pancreatic tail should be handled gently at the hilum, especially when it is located posterior to the pedicle.
- ✓ Handle the renocolosplenic area gently to avoid bleeding and/or injury to the spleen, kidney, or colon.
- ✓ If the splenic pedicle is ligated en masse, the hilar vessels should be religated. The pedicle should be ligated twice with heavy silk.
- ✓ The pancreas should be separated from the spleen by division of the splenic artery and vein distal to the tip of the pancreas. The spleen survives on the short gastric vessels, if carefully preserved.
- ✓ When there is splenomegaly, heavy adhesions are present between the spleen and the diaphragm above and laterally, the stomach medially, and the splenic flexure below.
- ✓ Adhesions associated with splenomegaly may contain large neoplastic vessels, which can produce tremendous bleeding if not ligated and secured before their division.
- ✓ If a patient has a hemorrhagic disorder, a nasogastric tube should be inserted in the operating room, not in the patient's room, by an anesthesiologist.

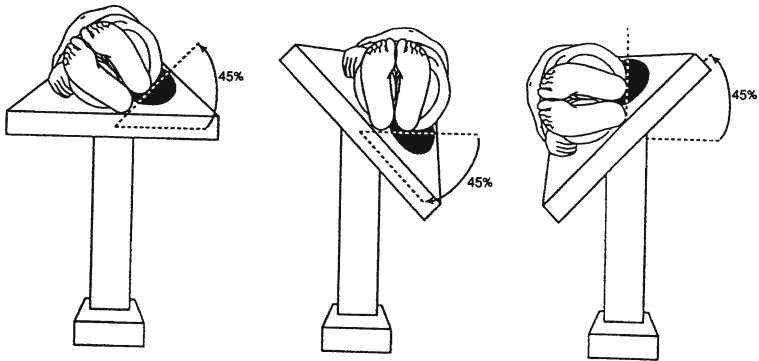


Figure 15.22. Patient positioning for lateral approach laparoscopic splenectomy. A rotating table that allows the patient's position to be changed from supine to true lateral facilitates a combined anterior/posterior approach to splenectomy (from CD Smith. *Laparoscopic Splenectomy*. In WC Wood and JE Skandalakis, eds. *Anatomic Basis of Tumor Surgery*. St. Louis: Quality Medical Publishing, Inc. 1999, pp. 670–679, with permission).

- ✓ In elective splenectomy with a large spleen, intravenous preoperative antibiotics and occlusion of the splenic artery are advisable. Preoperative splenic embolization should be considered. With such a procedure, the surgeon is committing to a total splenectomy.
- ✓ Monitor the patient closely for 24 h.
- ✓ Perform repeated hematocrit readings.
- ✓ If splenorrhaphy or splenic preservation has been performed, the patient should avoid sports for 3 months.
- ✓ If the patient has been on steroids, give a dose on induction.

■ LAPAROSCOPIC SPLENECTOMY

Splenectomy has traditionally been performed through a left subcostal or upper midline incision. More recently, splenectomy is performed using minimally invasive techniques. Because of the spleen's unique anatomical feature of possessing both anterior and posterior peritoneal attachments (Fig. 15.3), the laparoscopic approach to splenectomy uses lateral patient positioning (Fig. 15.22) to allow performance of both anterior and posterior approaches (previously described in this chapter). The supine position provides an anterior approach for safe visualization, exposure, and control of the short gastrics and the splenic artery through the lesser sac, while the lateral position facilitates a posterior approach for mobilization and final excision of the spleen. This minimally invasive procedure has been termed the “leaning spleen” technique of laparoscopic splenectomy.

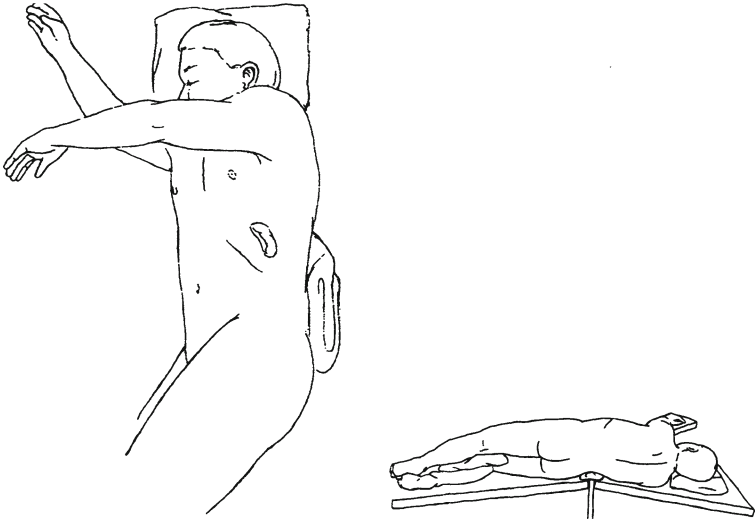


Figure 15.23. Modified left lateral decubitus positioning with iliac crest at table break and kidney rest elevated (from CD Smith. Laparoscopic Splenectomy. In WC Wood and JE Skandalakis, eds. *Anatomic Basis of Tumor Surgery*. St. Louis: Quality Medical Publishing, Inc, 1999, pp. 670–679, with permission).

PREOPERATIVE: Administration of polyvalent pneumococcal vaccine at least 2 weeks before operation; mild laxative evening before surgery (e.g., one bottle of magnesium citrate orally)

Note:

- ✓ Patients with ITP and critically low platelet counts (< 20,000 U/dl) should receive preoperative IgG to raise the immediate preoperative platelet levels to a safe range.
- ✓ Several units of packed red cells are cross-matched. In patients with ITP, platelets are crossed for administration after the splenic artery has been ligated intraoperatively.
- ✓ Patients who have been receiving corticosteroids within 6 months of surgery are given stress doses of intravenous corticosteroids.

POSITION: Modified left lateral decubitus; iliac crest at table break; kidney rest elevated (Fig. 15.23)

ANESTHESIA: General

OTHER: Foley catheter, orogastric tube, pneumatic compression hose; all pressure points well padded

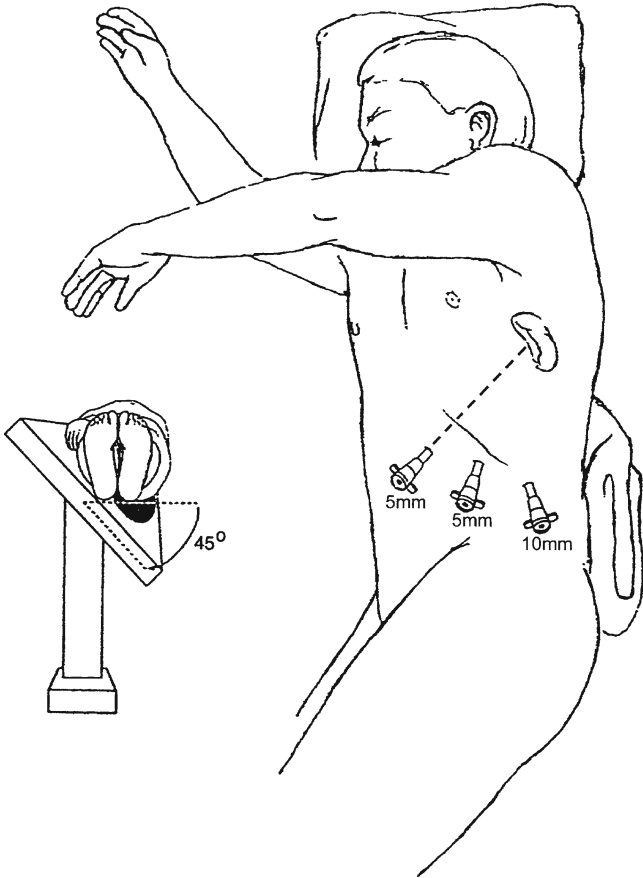


Figure 15.24. Cannula sites and their uses for laparoscopic splenectomy (from CD Smith. Laparoscopic Splenectomy. In WC Wood and JE Skandalakis, eds. *Anatomic Basis of Tumor Surgery*. St. Louis: Quality Medical Publishing, Inc, 1999, pp. 670–679, with permission).

- Step 1.** Prep and drape the patient so that either laparoscopy or open surgery can be performed.
- Step 2.** Establish carbon dioxide pneumoperitoneum to 15 mmHg with a Veress needle inserted at either the umbilicus or the midclavicular line below the left costal margin (cannula site for the camera).
- Step 3.** Insert cannulas as shown in Fig. 15.24.
- Step 4.** Visually explore for accessory splenic tissue (Fig. 15.11).

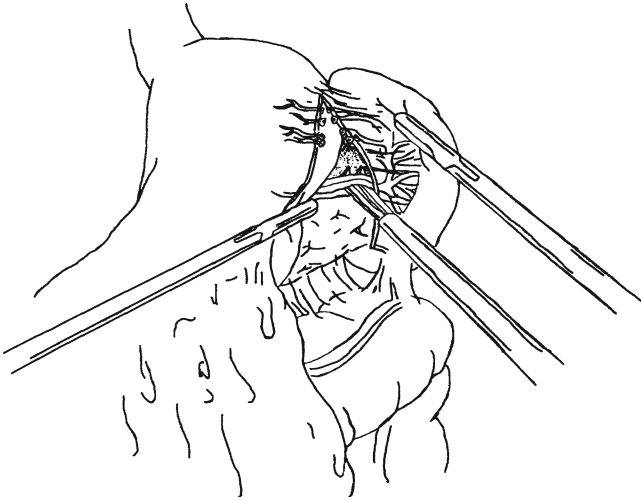


Figure 15.25. The short gastric vessels are divided. The lesser sac is entered and the splenic artery isolated with a blunt-tipped right angle (from CD Smith. Laparoscopic Splenectomy. In WC Wood and JE Skandalakis, eds. *Anatomic Basis of Tumor Surgery*. St. Louis: Quality Medical Publishing, Inc, 1999, pp. 670–679, with permission).

- Step 5.** Tilt the operating table to place the patient in the supine position. Enter the lesser sac by isolating and dividing the short gastrics.
- Step 6.** Using the Harmonic Scalpel, carefully divide the gastrosplenic and splenocolic ligaments (Fig. 15.25).

Note:

- ✓ If indicated, platelets are transfused after splenic artery ligation.
- Step 7.** The tail of the pancreas and splenic hilum will begin to come into view. Carefully isolate the hilum of the spleen with blunt dissection using a combination of dissection with a Kittner (peanut) and a blunt-tipped dissector.
- Step 8.** Rotate the operating table into the near-lateral position, thereby allowing gravity to “hang” the spleen from its lateral and posterior peritoneal attachments.
- Step 9.** Continue this mobilization from caudad to cephalad until the spleen is fully mobilized laterally, and the left hemidiaphragm is visualized from behind and above the spleen.

Note:

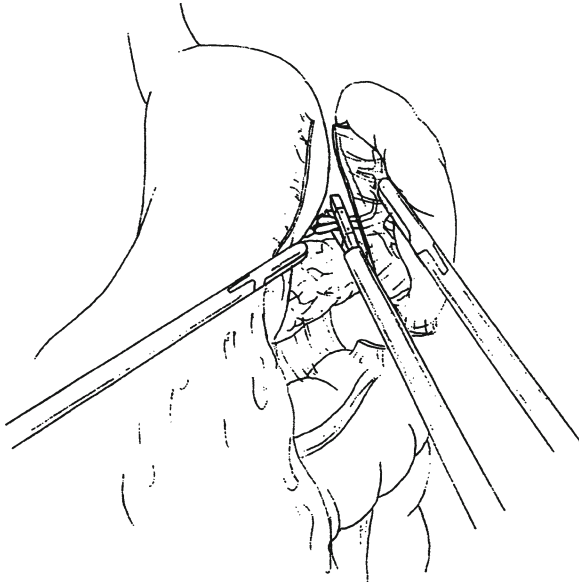


Figure 15.26. The splenic hilum is the only remaining attachment of the spleen. This is easily controlled and divided with a vascular stapler (from CD Smith. Laparoscopic Splenectomy. In WC Wood and JE Skandalakis, eds. *Anatomic Basis of Tumor Surgery*. St. Louis: Quality Medical Publishing, Inc, 1999, pp. 670–679, with permission).

- ✓ The gravity-facilitated dissection allows the spleen to fall medially, providing complete visualization of the tail of the pancreas and the splenic hilum.
- ✓ Use great care when manipulating the spleen. This will avoid capsular disruption which could lead to splenosis and recurrent hematologic disease.

Step 10. The splenic artery and vein are now easily ligated and divided using a vascular linear cutting stapler (Fig. 15.26).

Note:

- ✓ Care should be taken to identify and avoid the tail of the pancreas during this final hilar dissection and division.

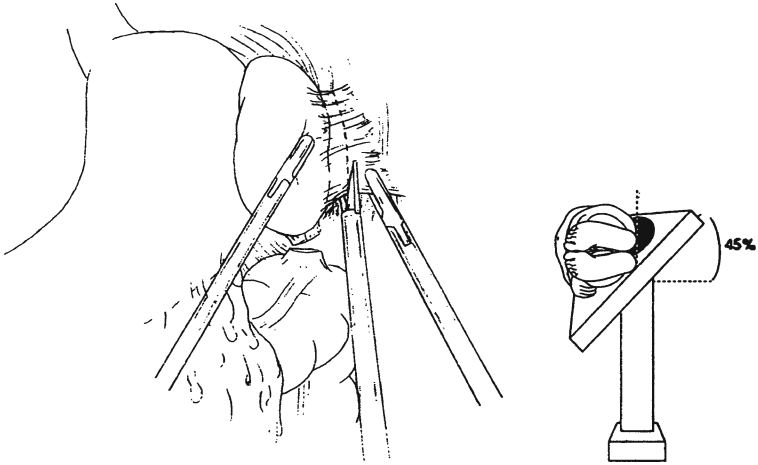


Figure 15.27. By rotating the operating table, the patient is placed in a true lateral position. The suspended spleen is mobilized by dividing the splenocolic and splenorenal ligaments (from CD Smith. Laparoscopic Splenectomy. In WC Wood and JE Skandalakis, eds. *Anatomic Basis of Tumor Surgery*. St. Louis: Quality Medical Publishing, Inc, 1999, pp. 670–679, with permission).

Step 11. Splenorenal ligament is divided (Fig. 15.27).

Step 12. Gently push the disconnected spleen medially and out of the left upper quadrant. Position a nylon-reinforced specimen retrieval sac in the left upper quadrant. With the help of gravity, gently push the spleen into the sac using perisplenic attachments or the hilar pedicle (Fig. 15.28).

Note:

✓ The bag must be stout enough not to rupture during extraction; a ruptured bag could cause splenosis.

Step 13. Pull the mouth of the specimen retrieval sac out through the mid-clavicular cannula site. Enter the sac extracorporeally and morcellate the spleen, removing it piecemeal from the sac with ring forceps until the sac can be extracted (Fig. 15.29).

Step 14. Inspect the operative site for hemostasis.

Step 15. Remove cannulas and allow carbon dioxide insufflation to entirely escape the abdominal cavity.

Step 16. Close the fascia of the 10 mm incision with an absorbable 0 suture and the skin with a subcuticular 4–0 absorbable suture.

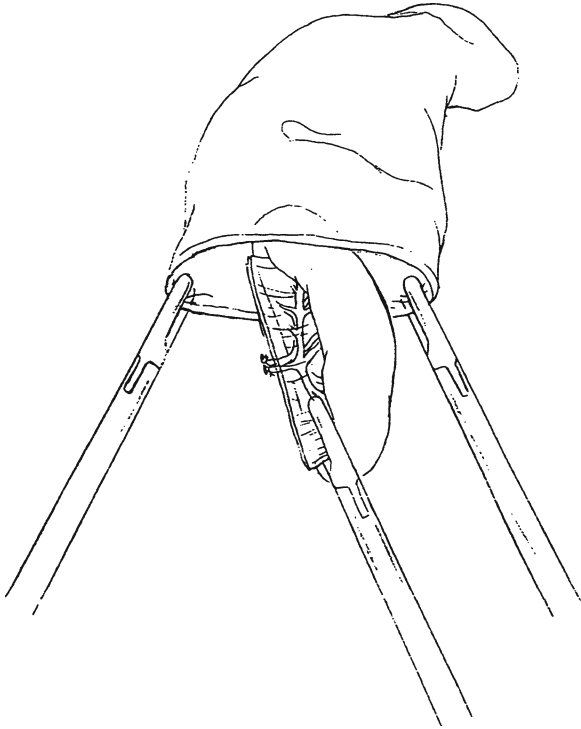


Figure 15.28. The excised spleen is placed in a specimen retrieval sac (from CD Smith. Laparoscopic Splenectomy. In WC Wood and JE Skandalakis, eds. *Anatomic Basis of Tumor Surgery*. St. Louis: Quality Medical Publishing, Inc, 1999, pp. 670–679, with permission).

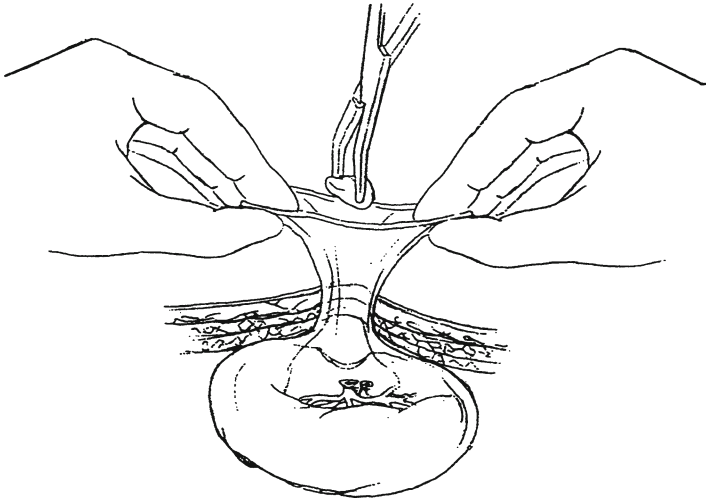


Figure 15.29. The mouth of the retrieval sac is pulled through one of the 10 mm cannula sites. The spleen is morcellated within the sac with ringed forceps until the sac can be removed (from CD Smith. *Laparoscopic Splenectomy*. In WC Wood and JE Skandalakis, eds. *Anatomic Basis of Tumor Surgery*. St. Louis: Quality Medical Publishing, Inc, 1999, pp. 670–679, with permission).

Adrenal Glands

ANATOMY

■ GENERAL DESCRIPTION OF THE ADRENAL GLANDS

Each adrenal gland, together with the associated kidney, is enclosed in the renal fascia (of Gerota) and surrounded by fat.

The glands are firmly attached to the fascia, which is in turn attached firmly to the abdominal wall and the diaphragm. A layer of loose connective tissue separates the capsule of the adrenal gland from that of the kidney. Because the kidney and the adrenal gland are thus separated, the kidney can be ectopic or ptotic without a corresponding displacement of the gland. Fusion of the kidneys, however, is often accompanied by fusion of the adrenal glands.

Occasionally the adrenal gland is fused with the kidney so that separation is almost impossible. If individuals with such a fusion need a partial or total nephrectomy, they also require a coincidental adrenalectomy.

The medial borders of the right and left adrenal glands are about 4.5 cm apart. In this space, from right to left, are the inferior vena cava, the right crus of the diaphragm, part of the celiac ganglion, the celiac trunk, the superior mesenteric artery, the other part of the celiac ganglion, and the left crus of the diaphragm.

■ RELATIONS OF THE ADRENAL GLANDS

Each adrenal gland has only an anterior and a posterior surface. Some of the relationships to other structures can be seen in Fig. 16.1.

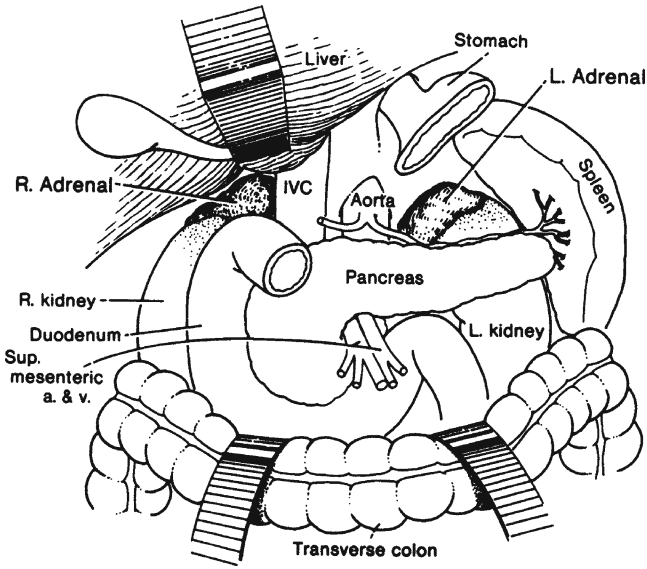


Figure 16.1. The relations of the adrenal glands from the anterior approach (By permission of JE Skandalakis, SW Gray, and JR Rowe. *Anatomical Complications in General Surgery*. New York: McGraw-Hill, 1983).

Right Adrenal Gland

- Anterior surface
 - a. Superior: “bare area” of liver
 - b. Medial: inferior vena cava
 - c. Lateral: “bare area” of right lobe of the liver
 - d. Inferior: peritoneum (very rarely, if ever) and first part of the duodenum (occasionally)
- Posterior surface
 - a. Superior: diaphragm
 - b. Inferior: anteromedial aspect of right kidney

Left Adrenal Gland

- Anterior surface
 - a. Superior: peritoneum (posterior wall of omental bursa) and stomach
 - b. Inferior: body of the pancreas

- Posterior surface
 - a. Medial: left crus of diaphragm
 - b. Lateral: medial aspect of the left kidney

■ VASCULAR SYSTEM OF THE ADRENAL GLANDS

Arterial Supply

The arterial supply of the adrenal glands arises, in most cases, from three sources: (Fig. 16.2)

- The superior adrenal arteries. A group of six to eight arteries arises separately from the inferior phrenic arteries.
- The middle adrenal artery arises from the aorta just proximal to the origin of the renal artery. It can be single, multiple, or absent. It supplies the perirenal fat only.
- One or more inferior adrenal arteries arise from the renal artery, an accessory renal artery, or a superior polar artery. Small twigs may arise from the upper ureteric artery.

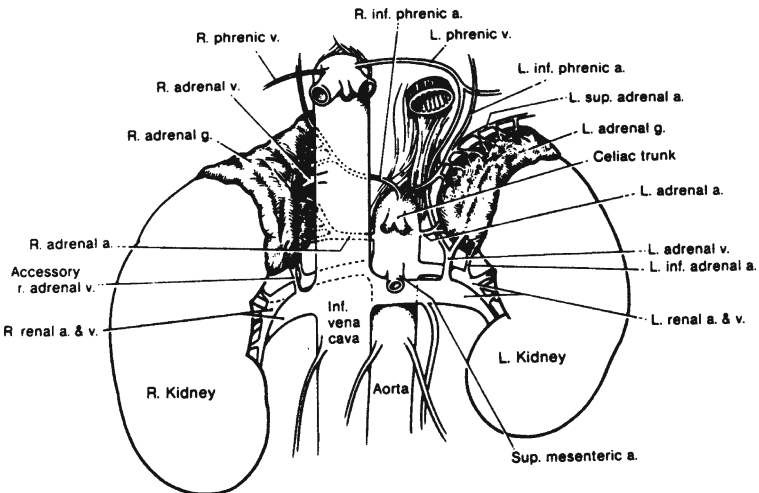


Figure 16.2. The arterial supply and venous drainage of the adrenal glands. As many as 60 arterial twigs may enter the adrenal gland. One or, occasionally, two veins drain the adrenal gland (By permission of JE Skandalakis, SW Gray, and JR Rowe. *Anatomical Complications in General Surgery*. New York: McGraw-Hill, 1983).

638 16. Adrenal Glands

All these arteries branch freely before entering the adrenal gland, so 50–60 arteries penetrate the capsule over the entire surface.

Venous Drainage

The adrenal venous drainage does not accompany the arterial supply and is much simpler (Fig. 16.2). A single vein drains the adrenal gland, emerging at the hilum. The left adrenal vein passes downward over the anterior surface of the left adrenal gland. This vein is joined by the left inferior phrenic vein before entering the left renal vein. From the right adrenal gland, the right adrenal vein passes obliquely to open into the inferior vena cava posteriorly.

Occasionally an adrenal gland has two veins, one following a normal course and the other being an accessory vein that enters the inferior phrenic vein.

When the posterior approach to the adrenal gland is used, the left adrenal vein is found on the anterior surface of the gland. The right adrenal vein is found between the inferior vena cava and the gland. Careful mobilization of the gland is necessary for good ligation of the vein.

Remember:

- ✓ The adrenal glands vie with the thyroid gland for having the greatest blood supply per gram of tissue.

Lymphatic Drainage

The lymphatics of the adrenal gland are usually said to consist of a profuse subcapsular plexus that drains with the arteries and a medullary plexus that drains with the adrenal veins. Drainage is to renal hilar nodes, lateral aortic nodes, and nodes of the posterior mediastinum above the diaphragm by way of the diaphragmatic orifices for the splanchnic nerves (Fig. 16.3). Lymphatics from the upper pole of the right adrenal gland may enter the liver. The majority of capsular lymphatic vessels pass directly to the thoracic duct without the intervention of lymph nodes.

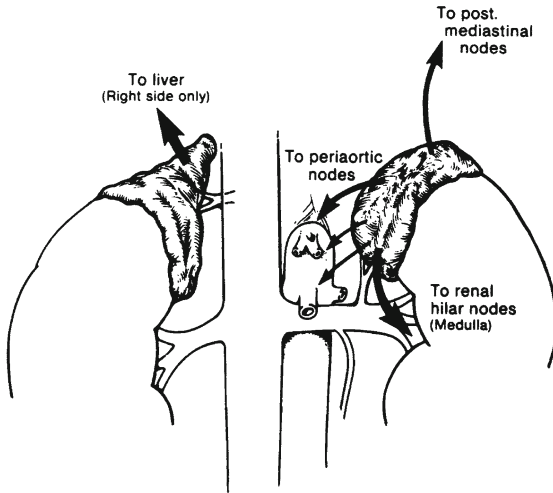


Figure 16.3. The lymphatics of the adrenal glands (By permission of JE Skandalakis, SW Gray, and JR Rowe. *Anatomical Complications in General Surgery*. New York: McGraw-Hill, 1983).

TECHNIQUE

■ ADRENALECTOMIES

Anterior Approach

The anterior approach is preferred when (1) the adrenal disease is bilateral (10 %), (2) the tumor is over 10 cm in size, or (3) the tumor has invaded surrounding structures. Using the anterior approach, both glands can be inspected, palpated, or biopsied. (In spite of this advantage, the use of the posterior approach has increased because of improvements in preoperative diagnosis, such as CT and selective adrenal angiography.)

The incision for an anterior approach may be vertical, midline or paramedian, transverse, or chevron (Fig. 16.4).

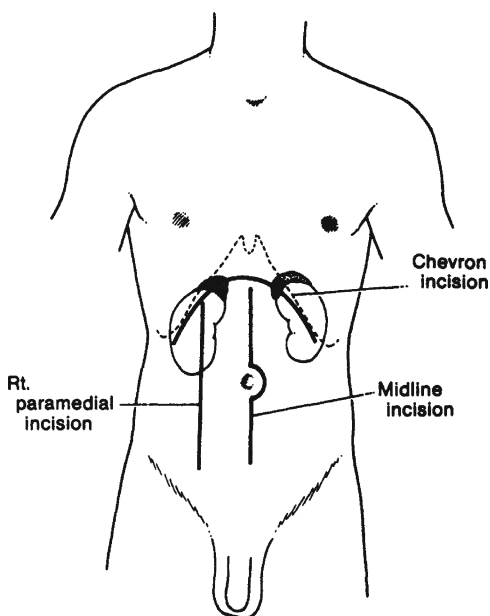


Figure 16.4. Incisions for anterior exposure of the adrenal glands. The chevron transabdominal incision provides bilateral exposure (By permission of JE Skandalakis, SW Gray, and JR Rowe. *Anatomical Complications in General Surgery*. New York: McGraw-Hill, 1983).

Exposure and Mobilization of the Left Adrenal Gland

Exposure of the left adrenal gland begins with the incision of the posterior parietal peritoneum lateral to the left colon. The incision is carried upward, dividing the splenorenal ligament (Fig. 16.5). Avoid injury to the spleen, splenic capsule, splenic vessels, and the tail of the pancreas, which are enveloped by the splenorenal ligament.

Another approach to the left adrenal is to open the lesser sac through the gastrocolic omentum. The incision should be longitudinal outside the gastroepiploic arcade (Fig. 16.6). Care must be taken to avoid traction on the spleen or the splenocolic ligament. The ligament may contain tortuous or aberrant inferior polar renal vessels or a left gastroepiploic artery.

In both approaches, the peritoneum under the lower border of the pancreas should be incised halfway along the tail and the incision extended laterally for about 10 cm. By gently retracting the pancreas upward, the left adrenal gland on the superior pole of the left kidney will be exposed. Both the kidney and the gland are covered with renal fascia (of Gerota). The gland will lie lateral to the

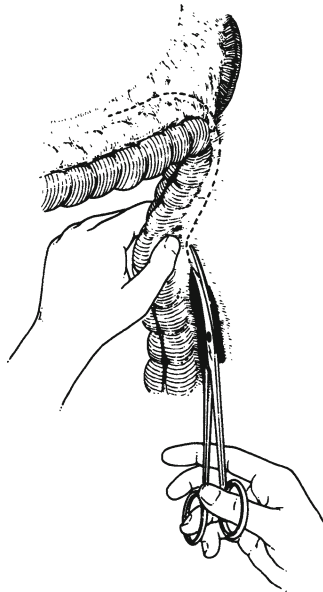


Figure 16.5. Incision of the parietal peritoneum lateral to the left colon. The incision divides the splenorenal ligament (By permission of JE Skandalakis, SW Gray, and JR Rowe. *Anatomical Complications in General Surgery*. New York: McGraw-Hill, 1983).

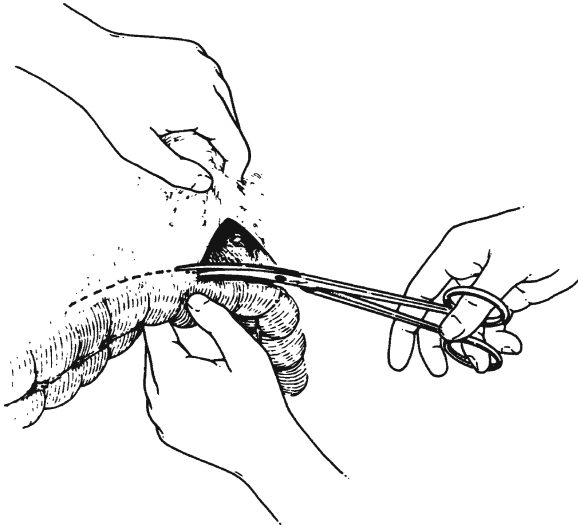


Figure 16.6. Approach to the left adrenal through the gastrocolic omentum opening the lesser sac (By permission of JE Skandalakis, SW Gray, and JR Rowe. *Anatomical Complications in General Surgery*. New York: McGraw-Hill, 1983).

aorta, about 2 cm cranial to the left renal vein. By incising the renal fascia, the adrenal gland is completely exposed and the adrenal vein is accessible.

If the operation is for pheochromocytoma, the adrenal vein should be ligated at once to prevent the release of catecholamines into the circulation during subsequent manipulation of the gland. If it is impossible to refrain from using retractors in this area, place them gently to avoid tearing the inferior mesenteric vein from the splenic vein.

In patients whose left adrenal lesion is anterior, a third approach is useful. The gland is exposed by an oblique incision of the left mesocolon (Fig. 16.7). The arcuate vessels may be divided, but the major branches of the middle and left colic arteries must be preserved. Injury to the wall of the left colon can be avoided by minimizing retraction.

In primary aldosteronism, meticulous attention to hemostasis is essential because the adrenal gland is hypervascular and friable. Hematomas from operative trauma may disguise or mimic adenoma. Use part of the adjacent peri-adrenal fascia to handle the gland. For manipulation, use only fine forceps. The numerous arteries can be clipped or electrocoagulated to maintain hemostasis.

The dissection starts at the inferolateral aspect of the left adrenal gland and proceeds superiorly (Fig. 16.8). Remaining alert to the possible presence of

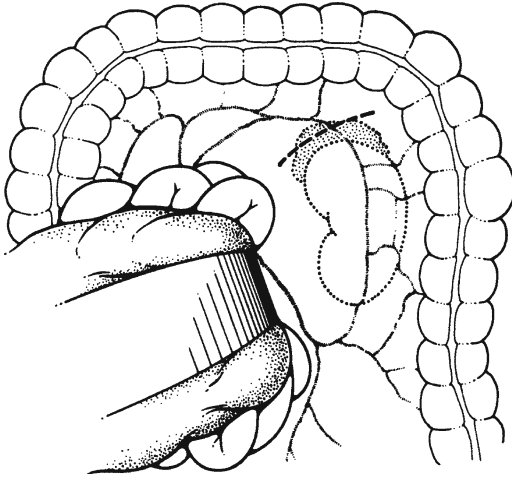


Figure 16.7. Approach to the left adrenal by incision of the left mesocolon near the splenic flexure. The major branches of the middle and left colic arteries must be spared, but the marginal artery may be sectioned (By permission of JE Skandalakis, SW Gray, and JR Rowe. *Anatomical Complications in General Surgery*. New York: McGraw-Hill, 1983).

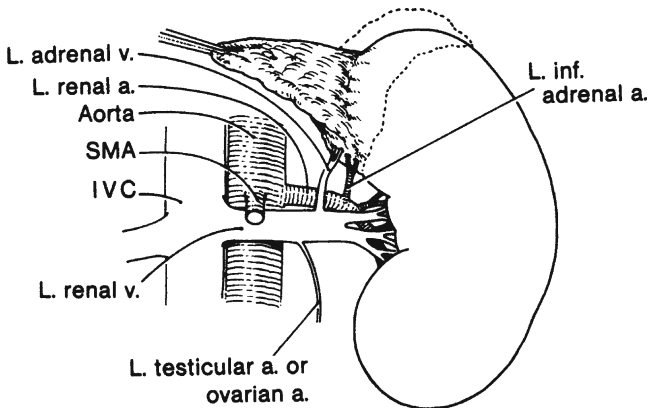


Figure 16.8. Direction of dissection of the left adrenal gland. Note the position of the left adrenal vein (By permission of JE Skandalakis, SW Gray, and JR Rowe. *Anatomical Complications in General Surgery*. New York: McGraw-Hill, 1983).

644 16. Adrenal Glands

a superior renal polar artery, the surgeon should retract the gland superiorly. Remember that the left adrenal gland extends downward, close to the left renal artery and vein.

After the adrenal gland has been removed, inspect its bed for bleeding points. Check surrounding organs, especially the spleen, for injury. If injuries exist, they may be repaired with sutures over a piece of retroperitoneal fat, Gelfoam, or Avitene. More severe injuries may require partial or even total splenectomy.

Exposure and Mobilization of the Right Adrenal Gland

The anterior approach to the right adrenal gland begins with the mobilization of the hepatic flexure of the colon. Posterior adhesions of the liver to the peritoneum are divided by sharp dissection. Keep in mind that medial attachments may contain hepatic veins.

The duodenum is exposed by mobilizing the colon. The second portion of the duodenum is freed by incision of its lateral, avascular peritoneal reflection. After separating it from retroperitoneal structures, reflect it forward and to the left (Kocher maneuver) (Fig. 16.9). The vena cava, right adrenal gland, and upper pole of the right kidney are now exposed (Fig. 16.10). The surgeon

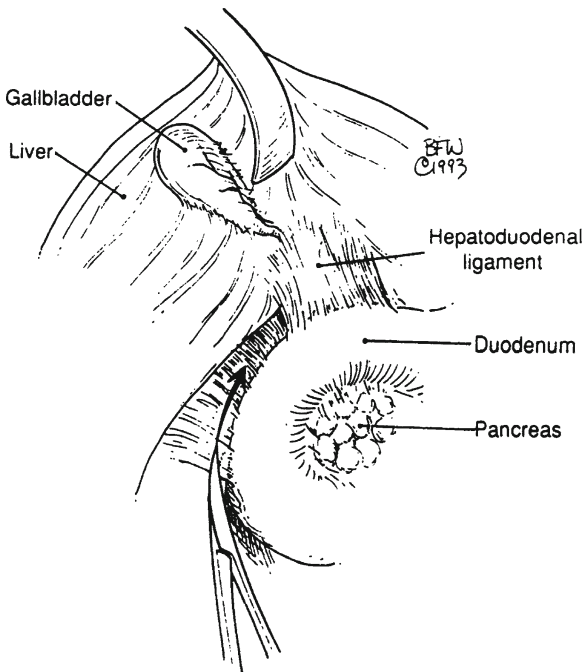


Figure 16.9. Path of midline incision.

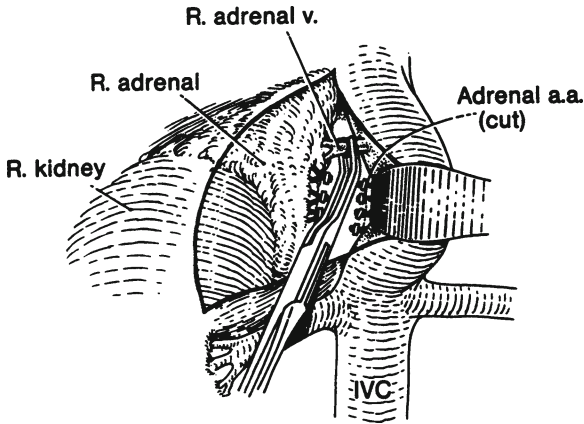


Figure 16.10. Following a Kocher maneuver, the right adrenal gland and upper pole of the right kidney are exposed. Note the position of the right adrenal vein (By permission of JE Skandalakis, SW Gray and JR Rowe. *Anatomical Complications in General Surgery*. New York: McGraw-Hill, 1983).

must remember that the common bile duct and the gastroduodenal artery are in this area.

Unlike the left adrenal gland, the right adrenal gland rarely extends downward to the renal pedicle. Usually the right adrenal vein leaves the gland on its anterior surface close to the cranial margin and enters the vena cava on its posterior surface (Fig. 16.10). To prevent release of catecholamines and to avoid stretching the vein, place hemostatic clips as soon as both borders of the vein are visible. Hemorrhage from the vena cava may follow if the vein is stretched and avulsed.

Unilateral or Bilateral Adrenalectomy

Right Anterior

- Step 1.** Patient should be in supine position.
- Step 2.** Make a long midline incision from the xiphoid process to the lower midline or bilateral subcostal. If exploring for pheochromocytoma, use a longer midline (Fig. 16.4).
- Step 3.** Perform lysis of the hepatocolic, hepatoduodenal, and hepatogastric ligaments with downward and left mobilization of the hepatic flexure and upward retraction of the right lobe of the liver.
- Step 4.** Kocherize the duodenum, which is retracted medially (Fig. 16.9).
- Step 5.** Visualize the adrenal gland, kidney, and inferior vena cava (Fig. 16.10).

646 16. Adrenal Glands

Step 6. Gently and carefully dissect the adrenal gland downward with the finger. Maintain good hemostasis and apply downward retraction to the kidney (Fig. 16.11).

Step 7. Remember:

- ✓ The adrenal vein empties into the lateral surface of the inferior vena cava and should be clipped or ligated carefully.
- ✓ Arterial supply, from branches of the inferior phrenic artery superiorly, renal artery inferiorly, and aorta medially, is very rich. Perform careful ligation and lysis of any adhesions (Fig. 16.10).

Step 8. The surgeon decides whether a Jackson–Pratt drain is required. Close in layers.

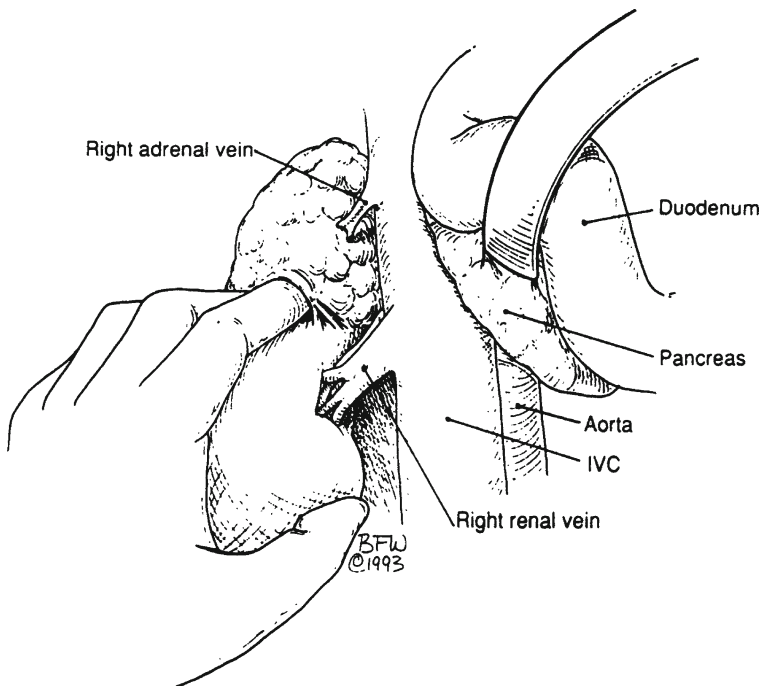


Figure 16.11. Downward retraction.

Left Anterior

Study the previous notes on left anterior adrenal mobilization and then proceed. If the left adrenal tumor involves the pancreatic tail, the splenic portae, or the splenic flexure of the colon, en bloc resection is advised. For large adrenal tumors, bowel preparation is a wise step prior to surgery.

Posterior Approach

Use the posterior approach for any adrenalectomy that precludes a laparoscopic or anterior approach. This may occur if the patient has had multiple abdominal operations.

With the patient prone, make a curvilinear incision through the latissimus dorsi muscle to the posterior lamella of the lumbodorsal fascia. The sacrospinalis muscle is exposed and the lumbar cutaneous vessels must be ligated or cauterized. Because dissection of the pleural fold at the 11th rib may result in pneumothorax, the surgeon must be sure to be over the 12th, not the 11th, rib. However, some surgeons prefer to remove the 11th rib on the right.

By detaching the sacrospinalis muscle attachments to the dorsal aspect of the 12th rib, the rib is exposed. It must be removed subperiosteally to avoid damaging the underlying pleura. Periosteum should be stripped on the superior surface from medial to lateral and on the inferior surface from lateral to medial. Be careful not to injure the 12th intercostal nerve bundle at the inferior angle of the rib. The nerve is separate from, but parallel to, the blood vessels, which may, if necessary, be ligated.

Separate the pleura from the upper surface of the diaphragm and incise the diaphragm from lateral to medial. Open the fascia and identify the upper pole of the kidney. The adrenal gland usually can be brought into the field with inferior retraction of the kidney. Avoid tearing the renal capsule or stretching any artery that might be the superior polar artery.

Left Adrenalectomy

Begin dissection of the left adrenal gland on the medial aspect, clipping the arteries encountered. Remember that the pancreas lies just beneath the gland and is easily injured. Identify the left adrenal vein, which usually emerges from the medial aspect of the gland and courses obliquely downward to enter the left renal vein. Avoid undue traction on the gland, so that the renal vein will not be torn.

Right Adrenalectomy

Approach the right adrenal gland by retracting the superior pole of the right kidney inferiorly; the posterior surface of the adrenal gland can then be dissected free from fatty tissue. When the apex of the gland is reached, retract the liver upward. After freeing the lateral borders, the only attachments are the medial margins.

648 16. Adrenal Glands

Retract the right adrenal gland laterally and ligate the arterial branches from the aorta and the right renal artery to the gland. Also ligate the right adrenal vein. Because of the possibility of hemorrhage from the vena cava or the adrenal vein, we recommend freeing up the vena cava far enough to ensure room for an angle clamp. After removing the gland and inspecting for air leaks and bleeding, the incision is closed.

Unilateral or Bilateral Adrenalectomy

- Step 1.** Place patient in prone position with flexion of hips and shoulders and rolls underneath.
- Step 2.** Incise the skin and subcutaneous fat along the length of the 11th rib, using knife or electrocautery (Fig. 16.12).
- Step 3.** Divide the latissimus dorsi and serratus posterior muscles with electrocautery (Fig. 16.13).
- Step 4.** Perform subperiosteal resection of the 11th rib (Fig. 16.14).

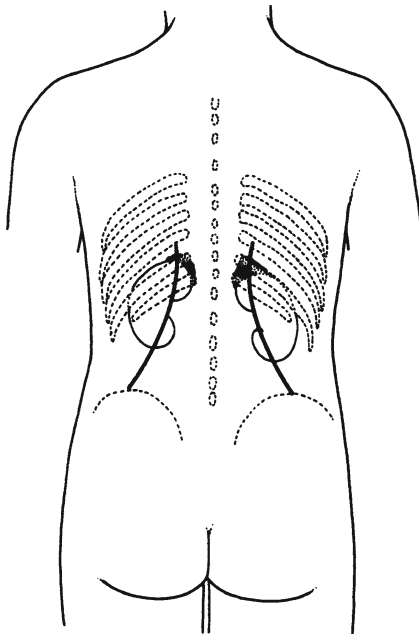


Figure 16.12. Incisions for a posterior approach to the adrenal glands (By permission of JE Skandalakis, SW Gray, and JR Rowe. *Anatomical Complications in General Surgery*. New York: McGraw-Hill, 1983).

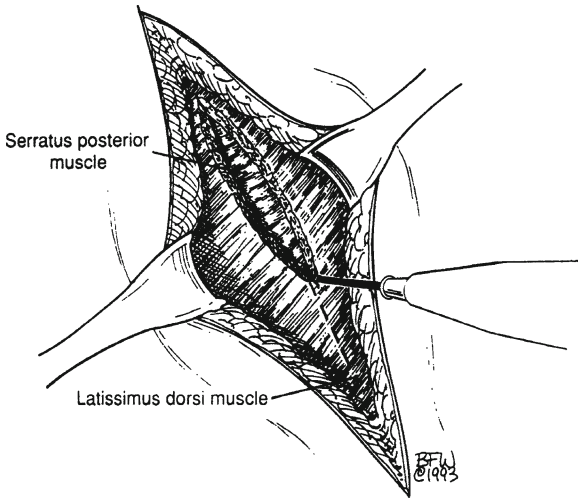


Figure 16.13. Dividing latissimus dorsi and serratus posterior muscles.

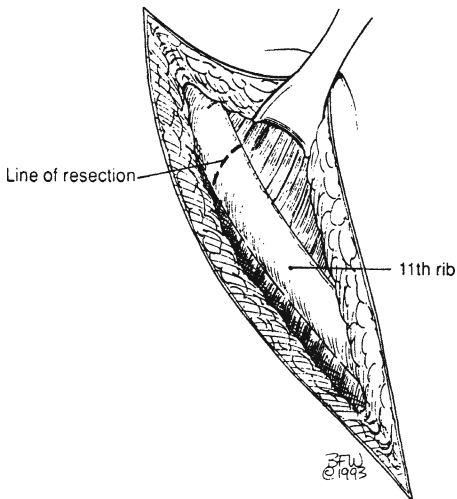


Figure 16.14. Resecting 11th rib.

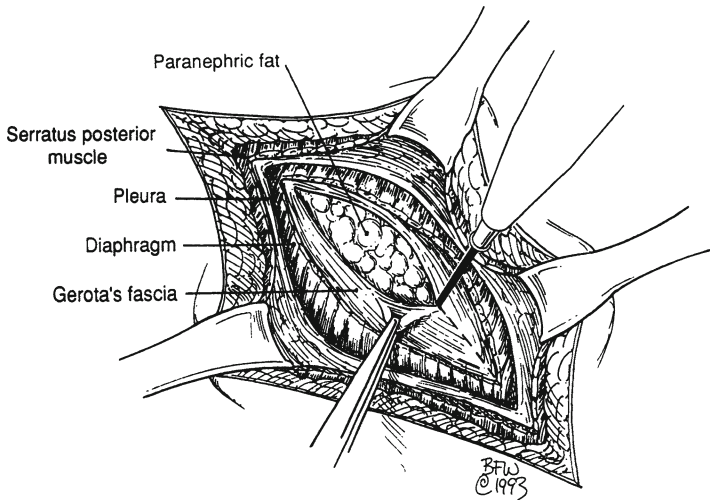


Figure 16.15. Incising Gerota's fascia.

- Step 5.** Carefully push the pleura upward or, if necessary, incise the pleura and the diaphragm.
- Step 6.** Incise Gerota's fascia and carefully push the kidney downward (Fig. 16.15).
- Step 7.** Perform very careful finger dissection of the adrenal gland. Any palpated cordlike formation should be clipped (Fig. 16.16).
- Step 8.** After good mobilization, divide the adrenal vein between clips (Fig. 16.17).

Remember:

- ✓ The adrenal vein on the right is very short and, in most cases, drains into the inferior vena cava; but on the left side the adrenal vein is, in most cases, long and drains into the left renal vein.
- Step 9.** If the pleura and diaphragm are incised, close the diaphragm with interrupted nonabsorbable sutures. Use a thoracotomy tube through a stab wound and close the wound in layers. The surgeon determines whether a Jackson–Pratt drain is required.

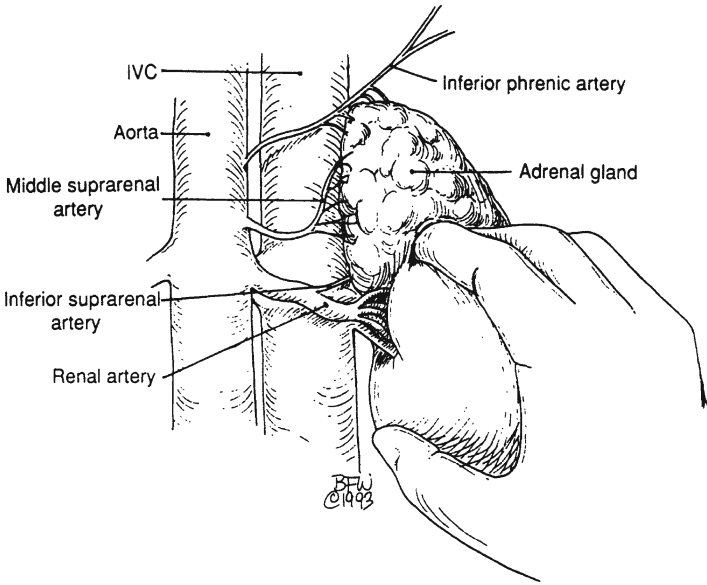


Figure 16.16. Finger dissection.

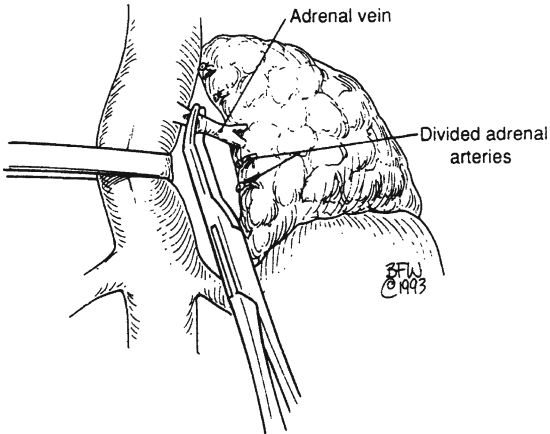


Figure 16.17. Dividing adrenal vein.

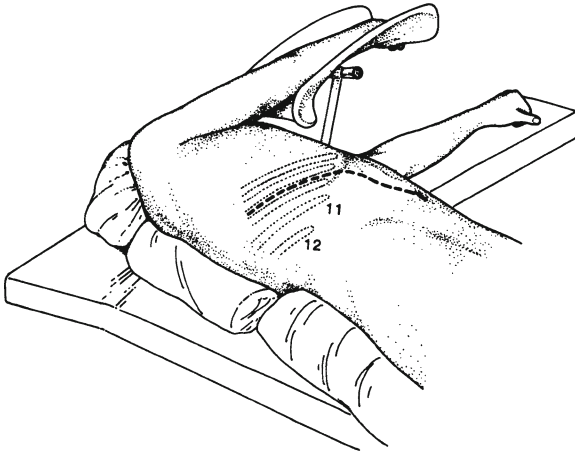


Figure 16.18. Incision for a thoracolumbar approach to the adrenal gland (By permission of JE Skandalakis, SW Gray, and JR Rowe. *Anatomical Complications in General Surgery*. New York: McGraw-Hill, 1983).

Thoracoabdominal Approach

Better exposure for large tumors of a single adrenal gland is achieved through the thoracoabdominal approach. It facilitates removal of the spleen and distal pancreas should they be involved with the adrenal tumor. Splenectomy is to be avoided whenever possible.

Start the incision at the angle of the eighth to the tenth ribs and extend it across the midline to the midpoint of the contralateral rectus muscle just above the umbilicus (Fig. 16.18). Remove the tenth rib, open the pleura, and incise the diaphragm from above. Follow the anterior approach procedure to complete the surgery.

■ LAPAROSCOPIC ADRENALECTOMY

Laparoscopic adrenalectomy results in enhanced recovery and shorter hospital stay when compared to open adrenalectomy. For most patients, laparoscopic adrenalectomy has become the gold standard for adrenalectomy.

This success is not surprising considering the similarities between laparoscopic adrenalectomy and laparoscopic cholecystectomy and the overwhelming success of laparoscopic cholecystectomy. Both approaches avoid an upper abdominal incision, both are ablative and therefore do not require any

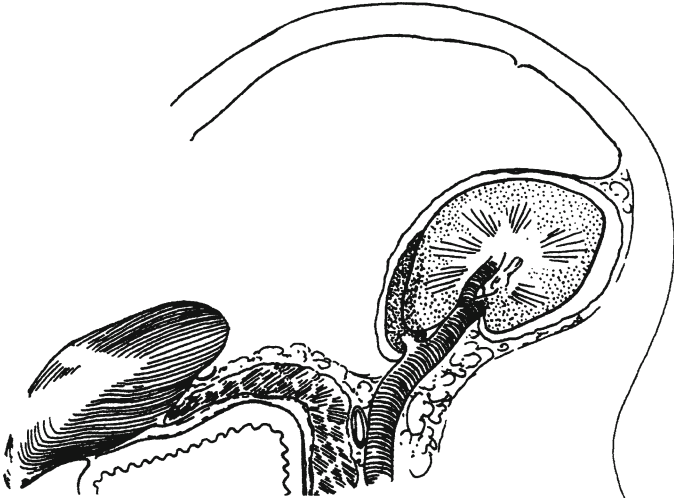


Figure 16.19. Cross section of patient in left lateral decubitus position demonstrating gravity-facilitated mobilization of spleen and distal pancreas to expose the left adrenal.

reconstructive techniques that remain problematic (e.g., anastomosis), both benefit from the magnification and clarity of view provided by the laparoscope (these anatomically dangerous regions are otherwise difficult to widely expose and visualize), and both are most commonly performed for benign disease and involve small, readily extractable specimens. From the standpoint of outcomes, laparoscopic adrenalectomy parallels cholecystectomy in nearly every way.

The transabdominal approaches continue to provide the best overall view of the areas of dissection and surrounding structures. Of the transabdominal approaches, the lateral approach offers many advantages over the anterior approach and has been the technique of choice for most surgeons performing laparoscopic adrenalectomy. The transabdominal *lateral* approach to adrenalectomy places the patient in lateral decubitus position to allow a gravity-facilitated exposure of the adrenals (Fig. 16.19). In this way, tissue and organs overlying the adrenals do not need to be manipulated with laparoscopic instruments, and the complications and bleeding associated with such manipulation are avoided.

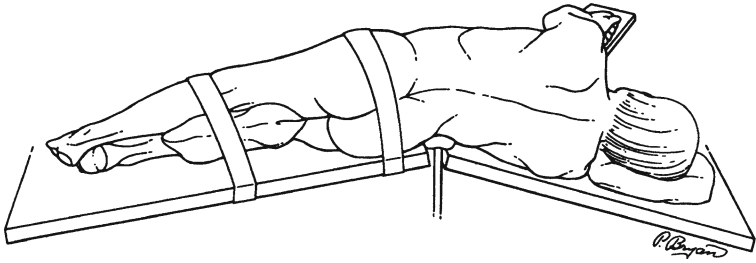


Figure 16.20. Patient positioning in left lateral decubitus position with kidney rest and table break at iliac crest. (From Smith CD, Weber CJ, Amerson JR. Laparoscopic adrenalectomy: new gold standard. *World J Surg* 23(4):389–396, 1999. Reprinted with permission from Springer).

Laparoscopic Left Adrenalectomy

PREOPERATIVE: Mild laxative the evening before surgery (e.g., one bottle of magnesium citrate orally)

POSITION: Left lateral decubitus; iliac crest at table break; kidney rest elevated (Fig. 16.20)

ANESTHESIA: General

OTHER: Foley catheter, orogastric tube, pneumatic compression hose; all pressure points well padded

- Step 1.** Prep and drape the patient so that either laparoscopy or open surgery can be performed (Fig. 16.21).
- Step 2.** Insert cannulas as shown in Fig. 16.22.
- Step 3.** Establish carbon dioxide pneumoperitoneum to 15 mmHg with a Veress needle inserted at the midclavicular line below the left costal margin (cannula site for the camera).
- Step 4.** Using a laparoscopic dissector and shears, incise the splenorenal ligament and mobilize the spleen laterally (Fig. 16.23). The decubitus positioning facilitates this dissection and mobilization. With gravity pulling the spleen medially and away from the anterior surface of the kidney, dissect the spleen and tail of the pancreas away from the retroperitoneum as the superior pole of the kidney and the adrenal are exposed.

Note:

- ✓ This dissection plane is relatively avascular. If excessive bleeding is encountered, the wrong plane of dissection is being developed.

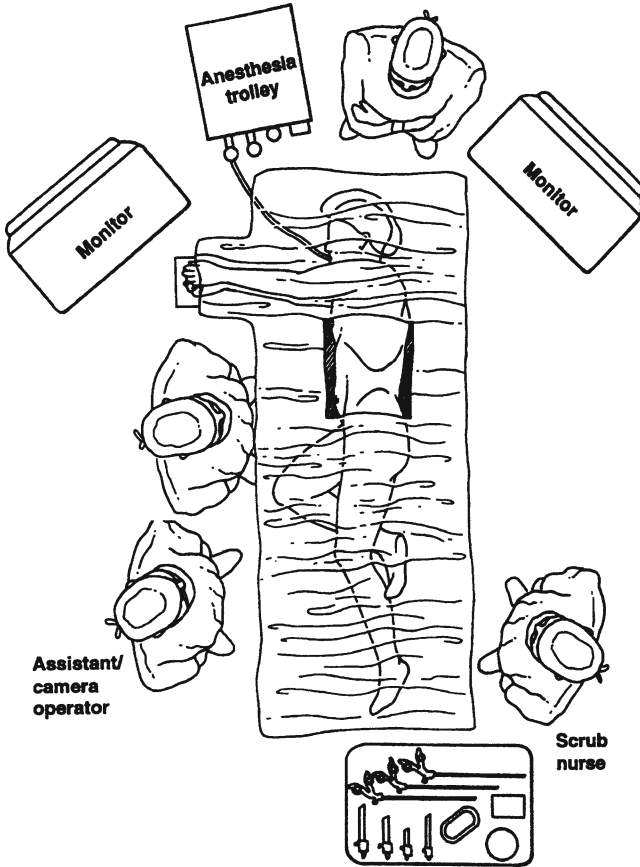


Figure 16.21. Operating room setup. (From Smith CD, Weber CJ, Amerson JR. Laparoscopic adrenalectomy: new gold standard. *World J Surg* 23(4):389–396, 1999. Reprinted with permission from Springer).

Step 5. Continue the dissection along the anterior surface of the kidney and adrenal until the inferior pole and medial border of the adrenal are exposed. It is important to continue this mobilization up to the diaphragm and close to the greater curve of the stomach and short gastric vessels. In this way, the exposure is analogous to opening a book, with the pages of the book being the spleen/pancreatic tail and the anterior surface of the kidney/adrenal, and the spine of the book being a line just beyond the medial edge of the adrenal gland (Fig. 16.24).

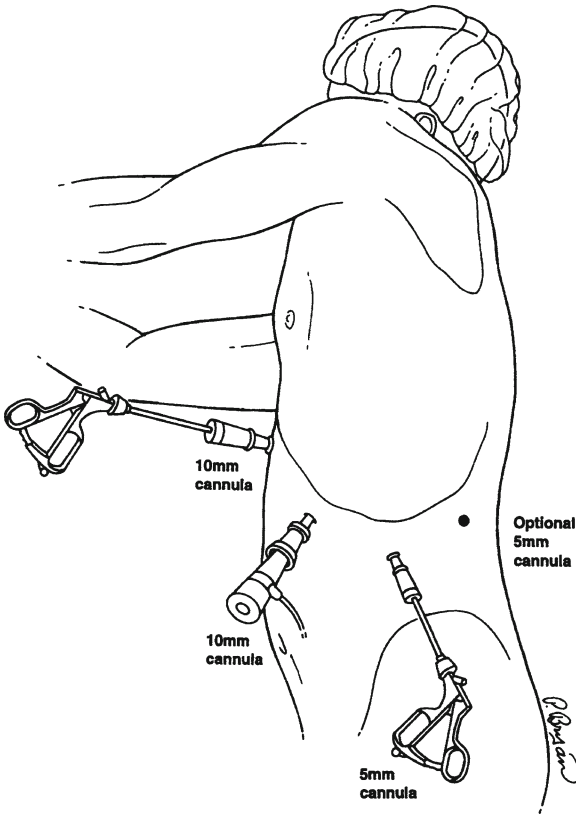


Figure 16.22. Cannula sites and uses. (From Smith CD, Weber CJ, Amerson JR. Laparoscopic adrenalectomy: new gold standard. *World J Surg* 23(4):389–396, 1999. Reprinted with permission from Springer).

Note:

- ✓ DO NOT mobilize the adrenal gland along its lateral edge too early in the exposure. If this mistake is made, gravity will allow the mobilized adrenal to fall medially and prevent visualization and access to the medial and inferior edges of the gland, where the left adrenal vein most likely will be encountered.

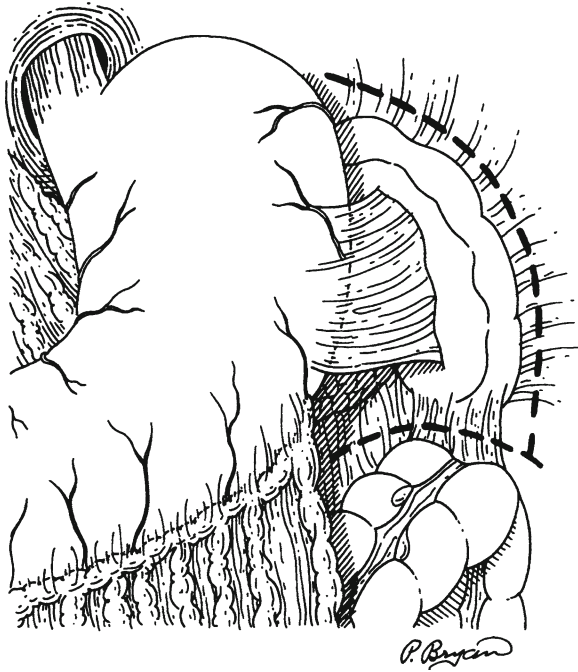


Figure 16.23. Initial incision along splenorenal and splenocolic ligaments. (From Smith CD, Weber CJ, Amerson JR. Laparoscopic adrenalectomy: new gold standard. *World J Surg* 23(4):389–396, 1999. Reprinted with permission from Springer).

Step 6. Isolate and clip the left adrenal vein (Fig. 16.25).

Note:

- ✓ Risk of injuring the left renal vein is minimized by staying close to the adrenal gland during this dissection. A right angle dissector greatly facilitates this exposure and isolation.

Step 7. Transect the adrenal vein.

Step 8. Excise the adrenal gland from inferior and medial to superior and lateral following the anterior surface of the kidney. Clip small feeding vessels as they are encountered.

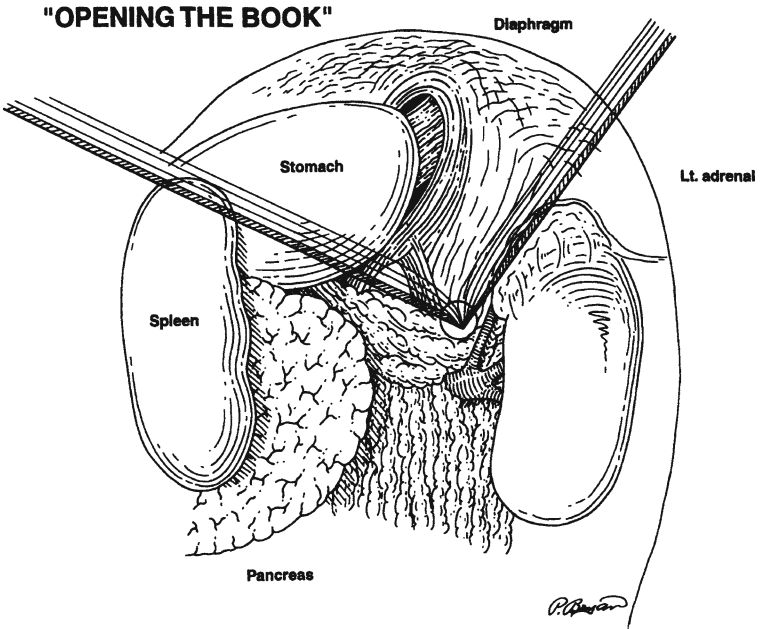


Figure 16.24. "Opening the Book." Mobilized spleen and tail of pancreas rotated off the kidney and adrenal. (From Smith CD, Weber CJ, Amerson JR. Laparoscopic adrenalectomy: new gold standard. *World J Surg* 23(4):389–396, 1999. Reprinted with permission from Springer).

Step 9. Place the adrenal in a specimen retrieval sac and remove (Fig. 16.26).

Note:

- ✓ The bag must be stout enough not to rupture during extraction (Fig. 16.27).
- ✓ To facilitate removal, the fascia of the cannula site of extraction may need to be stretched with a Kelly clamp.
- ✓ For large tumors, the entire incision may need to be extended.
- ✓ The adrenal should not be morcellated.

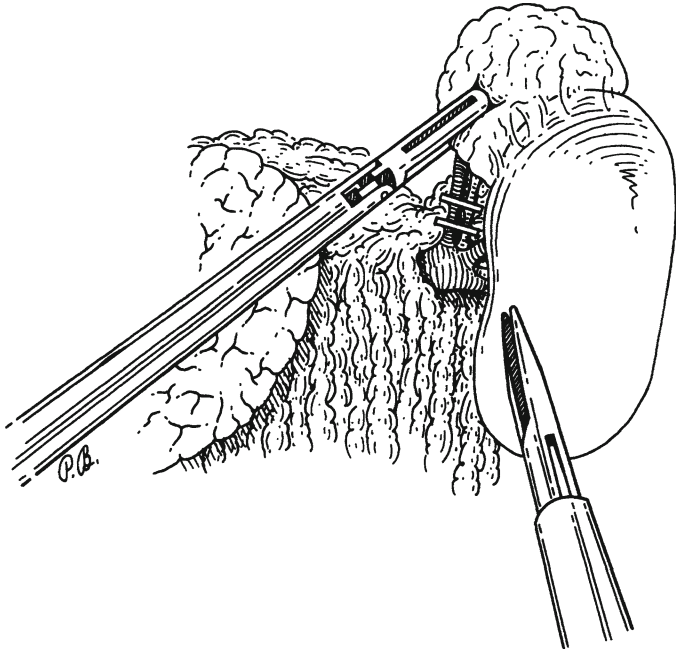


Figure 16.25. Isolation and control of the left adrenal vein. (From Smith CD, Weber CJ, Amerson JR. Laparoscopic adrenalectomy: new gold standard. *World J Surg* 23(4):389–396, 1999. Reprinted with permission from Springer).

- Step 10.** Irrigate and suction the operative field dry and carefully inspect for hemostasis.
- Step 11.** Remove cannulas and allow carbon dioxide insufflation to entirely escape the abdominal cavity.
- Step 12.** Close the fascia of the 10 mm incisions with an absorbable 0 suture and the skin with a subcuticular 4–0 absorbable suture.

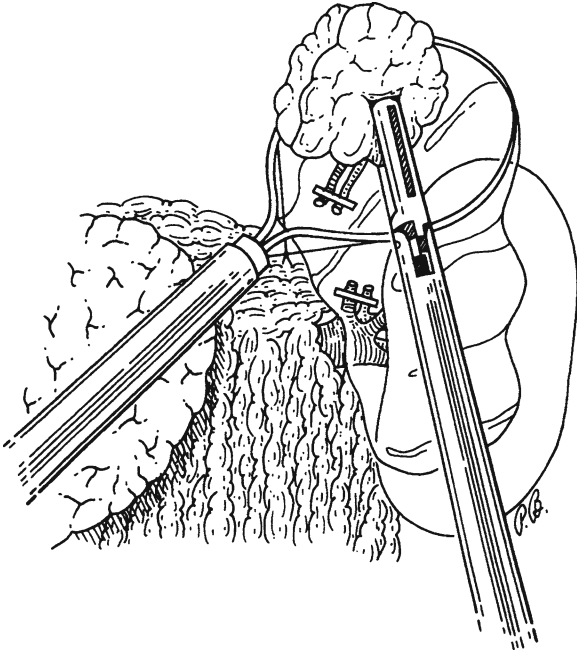


Figure 16.26. The excised adrenal gland is placed in the specimen retrieval sac. (From Smith CD, Weber CJ, Amerson JR. Laparoscopic adrenalectomy: new gold standard. *World J Surg* 23(4):389–396, 1999. Reprinted with permission from Springer).

Laparoscopic Right Adrenalectomy

PREOPERATIVE: As for left adrenalectomy

POSITION: As for left adrenalectomy except right lateral decubitus (Figs. 16.20 and 16.21)

ANESTHESIA: General

OTHER: As for left adrenalectomy

Step 1. Prep and drape the patient as described for left adrenalectomy.

Step 2. Insert cannulas as shown in Fig. 16.28.

Note:

✓ A fourth cannula in the epigastrium is necessary for a retractor to elevate the right lobe of the liver.

Step 3. Establish carbon dioxide pneumoperitoneum to 15 mmHg with a Veress needle inserted at the midclavicular line below the right costal margin (cannula site for the camera).

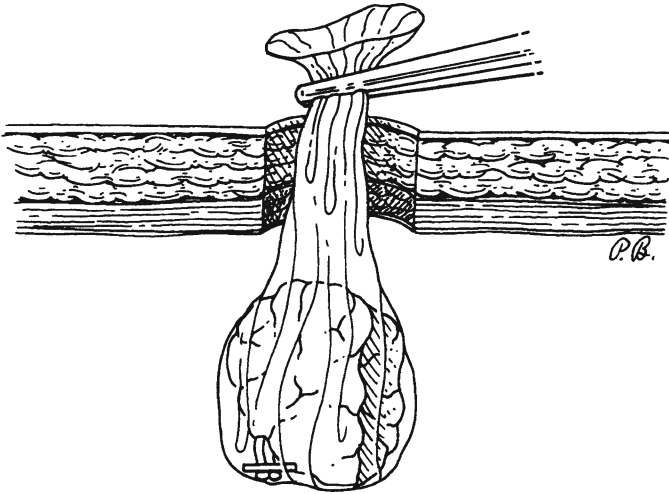


Figure 16.27. Specimen retrieval sac is extracted from the abdomen through 10 mm cannula site. (From Smith CD, Weber CJ, Amerson JR. Laparoscopic adrenalectomy: new gold standard. *World J Surg* 23(4):389–396, 1999. Reprinted with permission from Springer).

Step 4. With the liver retractor positioned, the anterior surface of the right kidney and the lateral edge of the inferior vena cava can be seen clearly. Begin dissection by creating a hockey-stick-shaped incision along the retroperitoneal attachment of the right lobe of the liver and the medial border of inferior vena cava (Fig. 16.29).

Note:

- ✓ This maneuver mobilizes the right lobe of the liver posteriorly and allows exposure of the anterior surface of the adrenal as the liver is pushed cephalad.
- ✓ The lateral positioning of the patient facilitates exposure of this area. Gravity holds the hepatic flexure of the colon and the omentum away from the operative field.
- ✓ It is rarely necessary to dissect the hepatic flexure or perform a Kocher maneuver to complete the dissection of the right adrenal.

Step 5. Carefully dissect the medial border of the inferior vena cava looking for the right adrenal vein (Fig. 16.30).

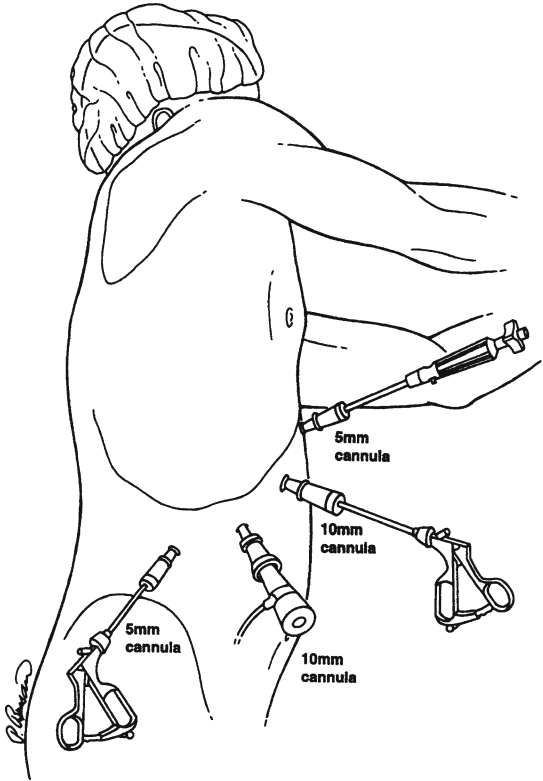


Figure 16.28. Cannula sites and uses for laparoscopic right adrenalectomy. (From Smith CD, Weber CJ, Amerson JR. Laparoscopic adrenalectomy: new gold standard. *World J Surg* 23(4):389–396, 1999. Reprinted with permission from Springer).

Note:

- ✓ The right adrenal vein is typically broad, short, and enters the vena cava slightly posteriorly.
- ✓ It is commonly found cephalad to the initial retroperitoneal incision along the right lobe of the liver.
- ✓ A blunt-tipped right-angle dissector is best for isolating the adrenal vein.

Step 6. Ligate the adrenal vein with three medium-large Ligaclips proximally and two distally (Fig. 16.31).

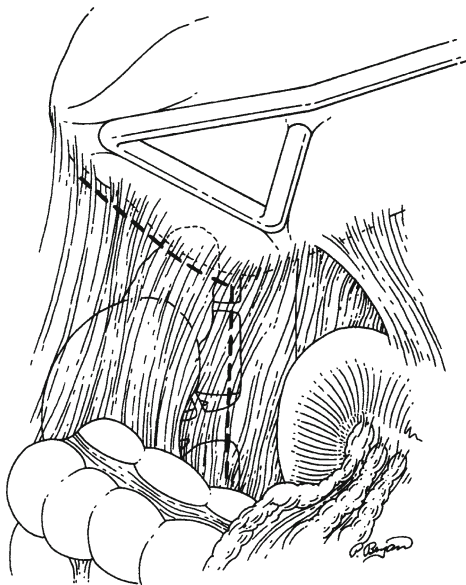


Figure 16.29. Hockey-stick incision for initial dissection of the right adrenal. (From Smith CD, Weber CJ, Amerson JR. Laparoscopic adrenalectomy: new gold standard. *World J Surg* 23(4):389–396, 1999. Reprinted with permission from Springer).

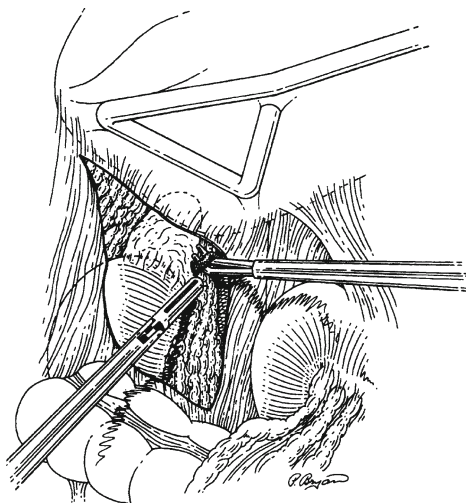


Figure 16.30. Exposure and isolation of the vena cava and right adrenal vein using blunt-tipped right-angle dissector. (From Smith CD, Weber CJ, Amerson JR. Laparoscopic adrenalectomy: new gold standard. *World J Surg* 23(4):389–396, 1999. Reprinted with permission from Springer).

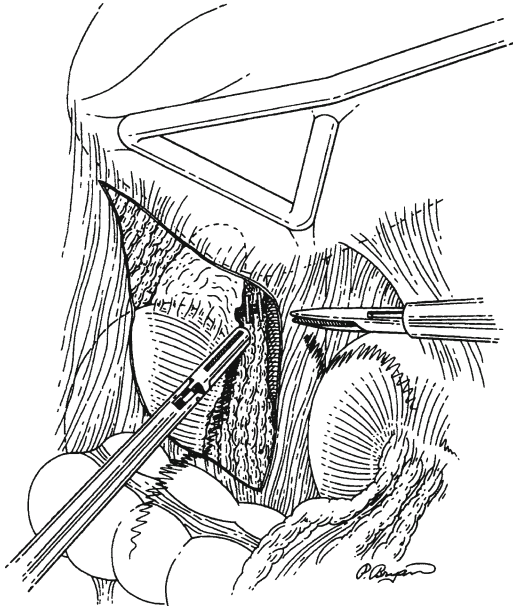


Figure 16.31. Ligation of the right adrenal vein with Ligaclips. (From Smith CD, Weber CJ, Amerson JR. Laparoscopic adrenalectomy: new gold standard. *World J Surg* 23(4):389–396, 1999. Reprinted with permission from Springer).

Note:

- ✓ Because of the short length of the vein, the proximal-most clip should be immediately at the edge of the cava.

Step 7. Transect the adrenal vein.

Step 8. Excise and remove the adrenal gland as described for left adrenalectomy.

Laparoscopic Bilateral Adrenalectomy

Bilateral laparoscopic adrenalectomies are performed in the manner already described for each individual side. Because right adrenalectomy has a higher risk of conversion to open adrenalectomy as a result of the immediate consequences of an adrenal vein/caval injury, left adrenalectomy should be performed first. In this way, the patient will have the greatest likelihood of benefiting from a laparoscopic approach. Before repositioning for right adrenalectomy the entire left adrenalectomy is completed, including wound closure and abdominal desufflation (minimizing duration of CO₂ pneumoperitoneum).

Vascular System

ANATOMY

■ ANATOMY FOR CAROTID ENDARTERECTOMY

The vagus nerve descends from the jugular foramen posteriorly between the internal jugular vein and the internal carotid artery. The ansa hypoglossi comes off the vagus nerve anteriorly and supplies the strap muscles. The facial vein enters the internal jugular vein. To expose the carotid bifurcation, division and ligation of the ansa hypoglossi and facial vein may be required. The hypoglossal nerve is often encountered as it descends from the jugular foramen in the carotid sheath traveling over the internal carotid artery and anterior to the external carotid artery toward the tongue.

■ ANATOMY FOR ABDOMINAL AORTIC ANEURYSM REPAIR

The abdominal portion of the aorta extends from the diaphragmatic hiatus to the level of the fourth lumbar vertebra (Fig. 17.1). It terminates as the left and right common iliac arteries, and the middle sacral artery. The abdominal aorta gives off visceral branches as the celiac, superior, and inferior mesenteric arteries and the suprarenal, spermatic, and renal arteries. Originating anteriorly from the aorta are the celiac, superior mesenteric, and inferior mesenteric arteries. The parietal branches off the abdominal aorta include the paired inferior phrenic arteries arising near the aortic hiatus and the multiple lumbar arteries, which divide into ventral and dorsal branches at the border of the psoas muscle.

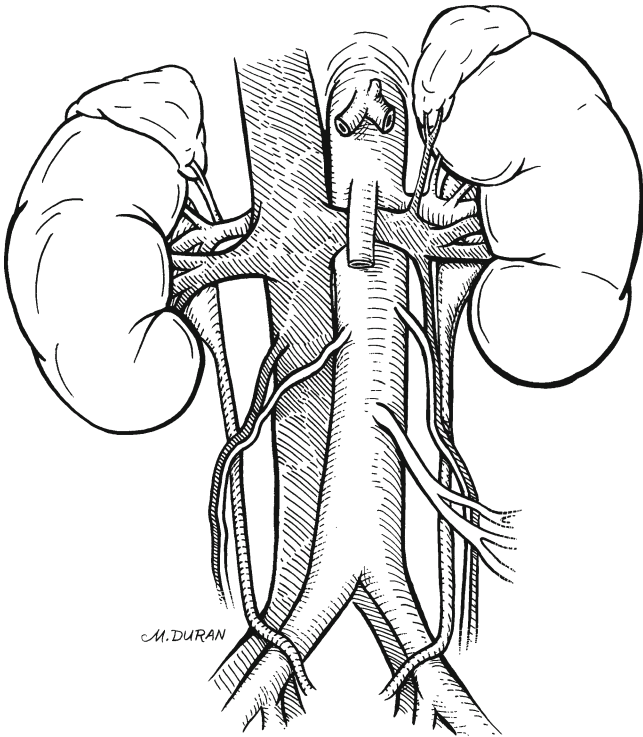


Figure 17.1. The abdominal aorta as it extends from the diaphragmatic hiatus to the common iliac bifurcation.

■ ANATOMY FOR LOWER EXTREMITY BYPASS

The infrainguinal region is bounded medially by the pectineus muscle and laterally by the tensor fascia lata muscle. Its superior border is the inguinal ligament, which is a strong, fibrous band that stretches from the anterior superior iliac spine to the pubic tubercle.

The external iliac artery becomes the common femoral artery as it emanates from a point under the middle of the inguinal ligament. The artery is relatively superficial proximally, but somewhat deeper where it terminates. Approximately 5 cm below the inguinal ligament, the profunda femoral branch takes origin from the common femoral artery, usually arising posterolaterally.

The femoral artery continues down the thigh as the superficial femoral artery (Fig. 17.2). The profunda femoris artery passes beneath the adductor longus

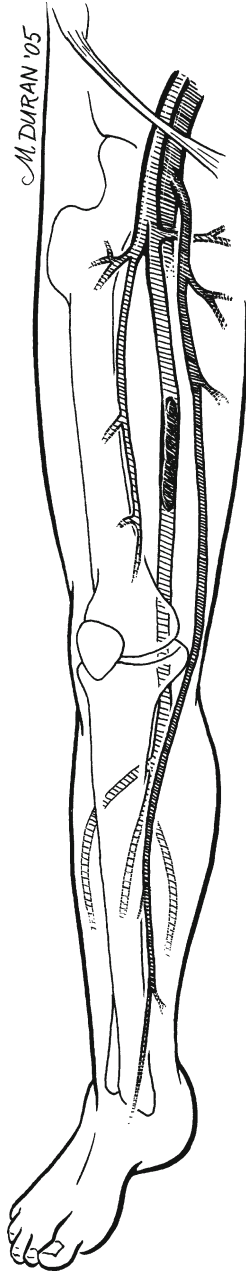


Figure 17.2. Vascular anatomy of the lower extremity. Note occlusion of the distal superficial femoral artery.

muscle, while the superficial femoral artery remains above it. The profunda femoris tends to remain patent in patients with superficial femoral artery occlusive disease and thus provides a source of collateral circulation. It has several important branches: lateral and medial circumflex femoral arteries (though they may occasionally arise from the common femoral artery) and the supreme geniculate artery. Distally, the superficial femoral artery courses under the sartorius muscle and into the adductor (Hunter's) canal.

From superficial to deep, the adductor canal is composed of the following muscles: adductor longus, adductor brevis, and adductor magnus. The superficial femoral artery becomes the popliteal artery as it emerges anterior to the adductor magnus. The popliteal artery then courses anterior to the semimembranosus, gastrocnemius, plantaris, and soleus muscles; this depth often makes palpating a popliteal pulse difficult.

Distal to the popliteus muscle, the popliteal artery bifurcates into the anterior tibial artery and the tibioperoneal trunk. The anterior tibial continues down the leg, anterior to the tibia, and becomes the dorsalis pedis artery in the foot. The peroneal and posterior tibial arteries arise from the tibioperoneal trunk, approximately 2 cm below the tendon of the soleus muscle. The peroneal artery divides into calcaneal branches as it passes behind the inferior tibiofibular articulation. The posterior tibial artery travels along the medial aspect of the leg and posterior to the medial malleolus.

The great saphenous vein starts on the medial side of the foot, just anterior to the medial malleolus. It continues along the medial aspect of the calf and thigh and courses anteriorly as it enters the femoral vein just below the inguinal ligament. The great saphenous is an ideal conduit for use in bypass surgery because of its convenient location next to the femoral artery and its superficial course in the subcutaneous tissue exterior to the investing fascia.

TECHNIQUE

■ CAROTID ENDARTERECTOMY

PRIOR TO SURGERY: On preoperative imaging, locate the carotid bifurcation to assist in correct placement of the incision. If there is a history of neck surgery, perform preoperative laryngoscopy to ascertain and document status of vocal cords; the recurrent laryngeal nerve may have been injured during the past procedure.

POSITION: Patient's head turned away from the operative side; neck extended.

ANESTHESIA: General or local (Fig. 17.3).

- Step 1.** Make an incision along the anterior border of the sternocleidomastoid muscle (SCM). Incise the platysma.
- Step 2.** Locate the external jugular vein and greater auricular nerve, which rest atop the SCM. Divide the vein to facilitate exposure, but preserve the nerve intact.
- Step 3.** Dissect around the relatively avascular anterior border of the SCM until the internal jugular vein is identified within the carotid sheath. Take care not to injure the vagus nerve.
- Step 4.** Divide and ligate the ansa hypoglossi and facial vein to expose the carotid bifurcation (Fig. 17.4).
- Step 5.** Dissect the carotid sufficiently to identify the internal and external carotid branches. Proximal arterial control is accomplished by encircling the common carotid artery in an area relatively free of

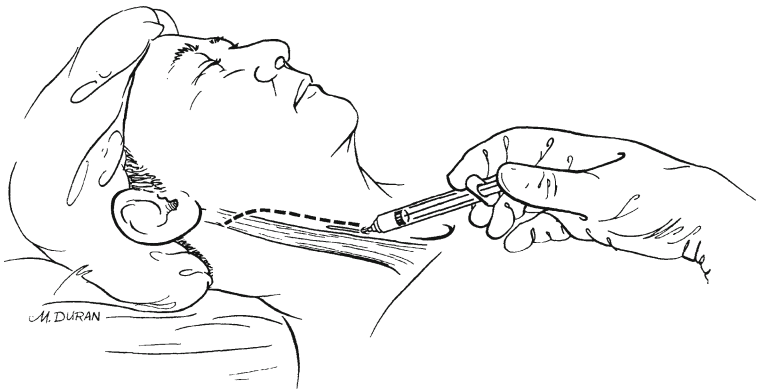


Figure 17.3. Infiltration of local anesthesia along the planned line of incision.

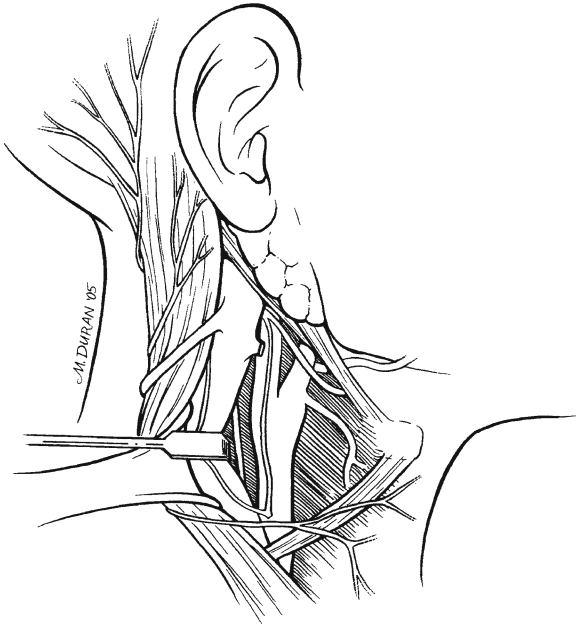


Figure 17.4. Exposure of the carotid bifurcation and adjacent nerves.

atherosclerosis. Distal arterial control is achieved by encircling the internal carotid artery at the most superior aspect of the wound where normal, non-atherosclerotic artery is encountered.

- Step 6.** If an additional 1–2 cm of distal exposure is needed, divide the posterior belly of the digastric muscle. Be alert for the hypoglossal nerve.
- Step 7.** Free the external carotid artery and facilitate vascular control of the three arterial trunks with Rummel's tourniquets (Fig. 17.5).
- Step 8.** Identify and isolate the superior thyroid artery.
- Step 9.** Systemically anticoagulate the patient with heparin.
- Step 10.** Clamp the distal internal carotid artery, then the common carotid artery and the external carotid artery.
- Step 11.** Control the superior thyroid artery by the loose application of a metallic clip or silk tie (which is removed at the end of the procedure).
- Step 12.** With a sharp knife and Potts scissors, perform an arteriotomy from the distal common carotid artery to the proximal internal carotid artery (Fig. 17.6).

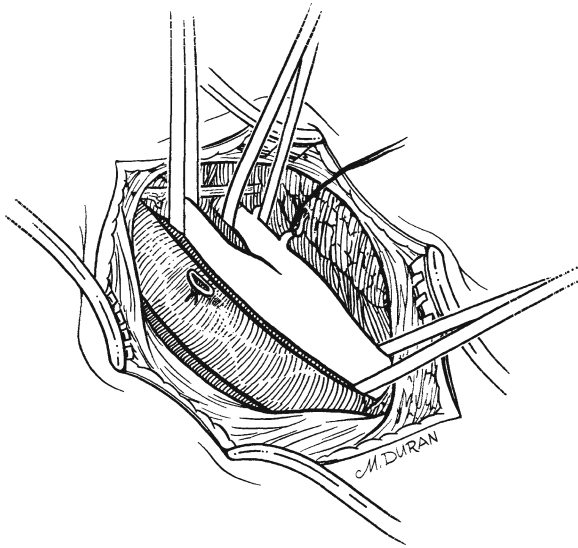


Figure 17.5. Arterial control of common carotid, internal carotid, and external carotid arteries with umbilical tape. Arterial control of superior thyroid artery with 3-0 silk tie.

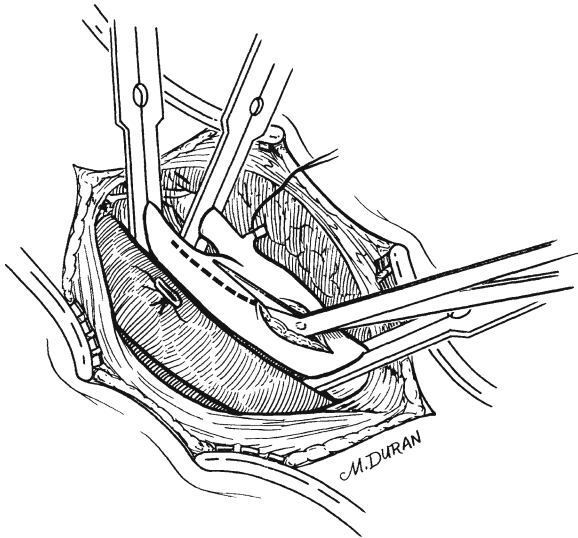


Figure 17.6. An arteriotomy is made with a scalpel and extended with Potts scissors.

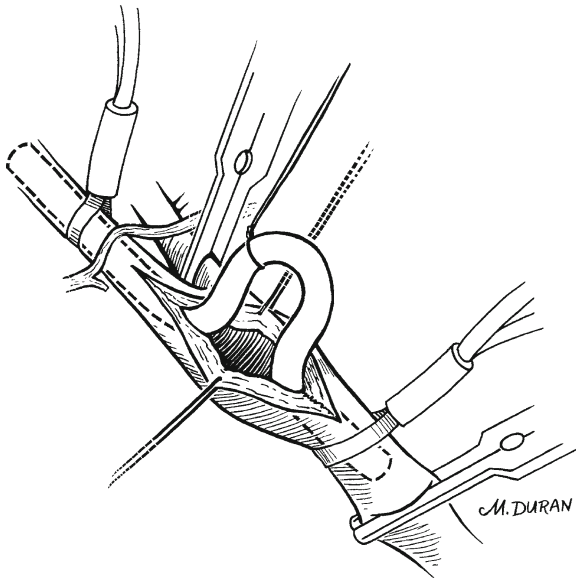


Figure 17.7. Placement of an indwelling shunt from the internal carotid artery to the common carotid artery.

- Step 13.** To maintain adequate blood flow, place an indwelling shunt first into the internal carotid artery and then into the common carotid artery (Fig. 17.7).
- Step 14.** Begin the endarterectomy in a deep plane between the plaque and the adventitia using a spatula (Fig. 17.8). Proceed proximally down the common carotid artery until the plaque thins; at this point sharply transect it.
- Step 15.** Tease the plaque from the external carotid artery using the endarterectomy spatula or a fine hemostat.
- Step 16.** As the atheromatous plaque thins distally in the internal carotid, there is transition to a more superficial plane at which point it usually breaks away from the very thin normal intima.
- Step 17.** Flush the inside of the artery with heparinized saline. Inspect.
- Step 18.** If the end-points of the dissection are not adequately visualized, extend the arteriotomy.
- Step 19.** If the distal end-point requires tacking, use simple sutures to make the intima adherent.
- Step 20.** Flush with heparinized saline to detect loose tags of circumferentially oriented media. Grasp with fine forceps and remove.

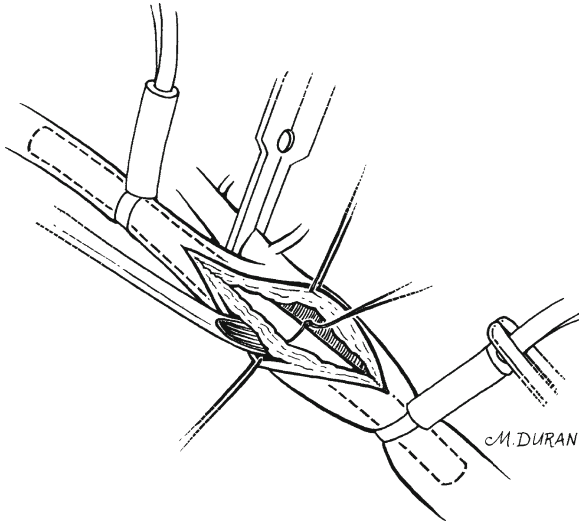


Figure 17.8. An endarterectomy spatula is used to lift plaque off the adventitia.

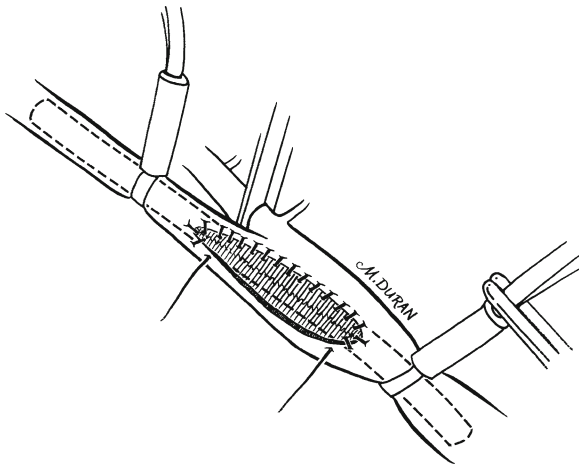


Figure 17.9. Closure of arteriotomy with a polyester patch using 6-0 monofilament suture.

Step 21. Close the arteriotomy by applying a collagen-impregnated polyester patch using a continuous layer of 6-0 monofilament suture (Fig. 17.9). Prior to completing the closure, remove the shunt and then vent the artery so that clot, debris, and air escape completely.

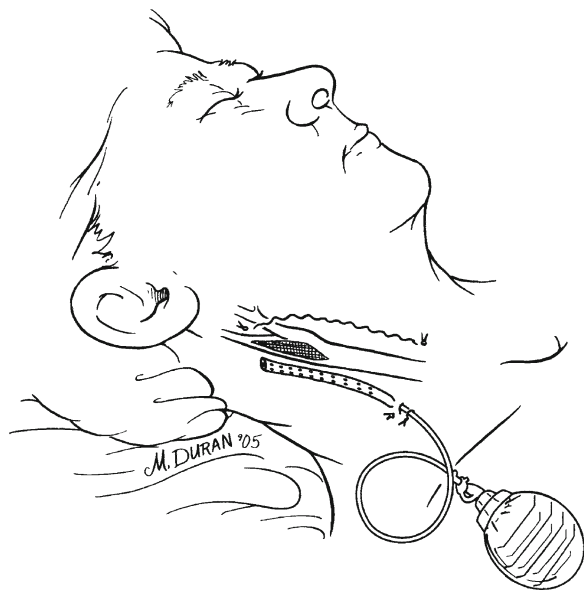


Figure 17.10. Placement of a Jackson–Pratt drain through a separate incision, and skin closure

- Step 22.** Remove clamps first from the external carotid artery, followed by the common carotid artery, and then the internal carotid artery.
- Step 23.** Place a suction drain through a stab wound low in the neck (Fig. 17.10).
- Step 24.** Close the platysma with a running absorbable suture; close the skin with a monofilament suture.

Remember:

- ✓ The diseased artery is not dissected from the patient, but rather the patient is dissected away from the artery. In other words, during maneuvers near the carotid, the artery should be minimally disturbed. This is based on the premise that undue manipulation of the vessel increases the risk of embolization of stroke-producing thrombus.
- ✓ Beware of the nonrecurrent laryngeal nerve in patients with an abnormal aortic arch, because the nerve may leave the carotid sheath in the neck.
- ✓ Avoid damage to cranial nerves during dissection by properly placing retractors or vascular clamps and by precise use of electrocoagulation current.

■ ELECTIVE INFRARENAL ABDOMINAL AORTIC ANEURYSM REPAIR

PRIOR TO SURGERY: Document lower extremity pulse examination.

POSITION: Supine.

ANESTHESIA: General.

- Step 1.** Make a midline incision from the xiphoid process to the symphysis pubis to provide excellent exposure.
- Step 2.** Reflect upward the transverse colon and mesocolon; reflect the small bowel to the right and upward.
- Step 3.** Incise the ligament of Treitz and the superior and medial duodenal attachments.
- Step 4.** If the inferior mesenteric vein cannot be laterally displaced, divide it to facilitate exposure.
- Step 5.** Open the retroperitoneum distally to expose the common iliac artery bifurcations (Fig. 17.11).
- Step 6.** Superiorly, perform retroperitoneal dissection to expose and encircle the infrarenal aortic wall.

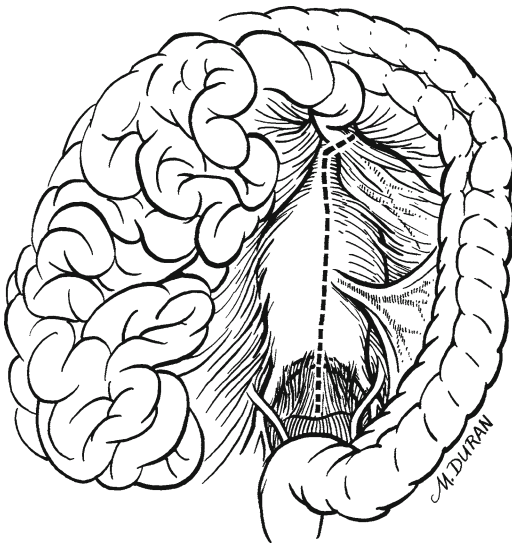


Figure 17.11. A vertical incision is made in the posterior parietal peritoneum to provide exposure from the infrarenal aorta to the common iliac arteries.

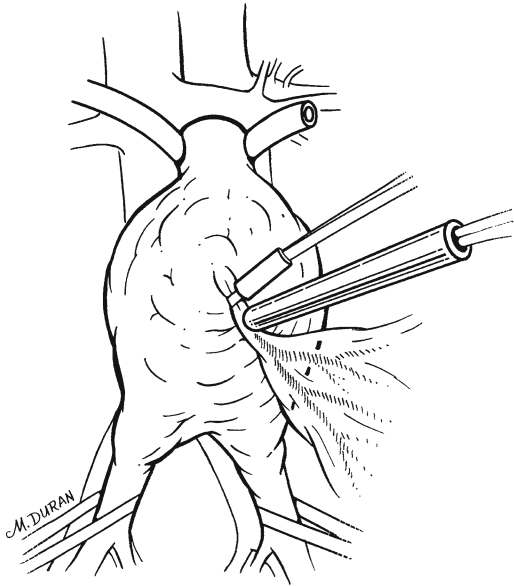


Figure 17.12. Doppler ultrasound interrogation of the inferior mesenteric artery.

- Step 7.** Assess patency and flow status of the inferior mesenteric artery by palpation and Doppler probe interrogation (Fig. 17.12).
- Step 8.** After adequate exposure has been achieved, give systemic heparin in a dose of 0.6–1.0 mg/kg of body weight.
- Step 9.** Clamp the iliac arteries, then the infrarenal aorta.
- Step 10.** Incise the aortic wall vertically (Fig. 17.13).
- Step 11.** Remove loose, laminated thrombus.
- Step 12.** If lumbar arteries are back-bleeding into the aneurysm, ligate with interrupted figure-of-eight sutures (Fig. 17.14).
- Step 13.** Cut to length a bifurcated, collagen-impregnated polyester graft (18 to 22 mm in size) and suture it end-to-end to the proximal aortic stump with running continuous 3-0 polypropylene suture (Fig. 17.15). This suture-line should be started on the back wall and carried anteriorly around the aorta from each side.
- Step 14.** Distally, make an anastomosis to each iliac artery in end-to-end fashion using 4-0 continuous suture (Fig. 17.16). Exercise caution in the circumferential dissection of the iliac arteries to avoid injuring the iliac veins or ureters.

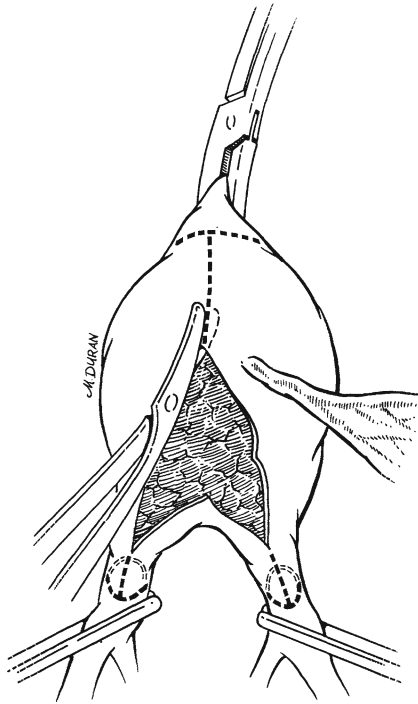


Figure 17.13. Incision of the aortic wall and common iliac arteries, facilitating removal of thrombus.

- Step 15.** Prior to completing the final anastomosis, flush the aorta and graft.
- Step 16.** Remove occlusion clamps stepwise and ascertain hemostasis at the suture lines.
- Step 17.** If the inferior mesenteric artery shows minimal back-bleeding, reimplant its orifice onto the aortic graft (Fig. 17.17). A side-biting vascular clamp allows for flow through the graft during reimplantation.
- Step 18.** After heparin reversal, inspect the field for hemostasis and close the aneurysm sac around the prosthesis with a single layer of running suture (Fig. 17.18).
- Step 19.** Suture the posterior parietal peritoneum to prevent adherence of the small bowel to exposed graft material.

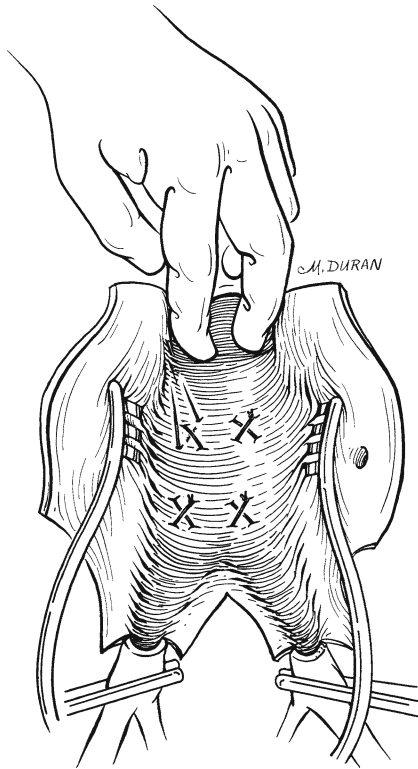


Figure 17.14. Ligation of back-bleeding lumbar arteries with figure-of-eight sutures.

Remember:

- ✓ During dissection it is possible to dislodge thrombus material from the aneurysm sac, which may embolize distally. Thus, it is important to demonstrate good back-bleeding intraoperatively and to confirm the presence of distal pulses immediately postoperatively.
- ✓ In 5 % of the population, there exists a retroaortic renal vein. Therefore, the course of the left renal vein should be demonstrated to prevent injury during cross-clamping.
- ✓ If preoperative imaging suggests that the inferior mesenteric artery is an important visceral collateral, or if intraoperative Doppler interrogation shows inadequate blood flow, the vessel should be reimplemented.

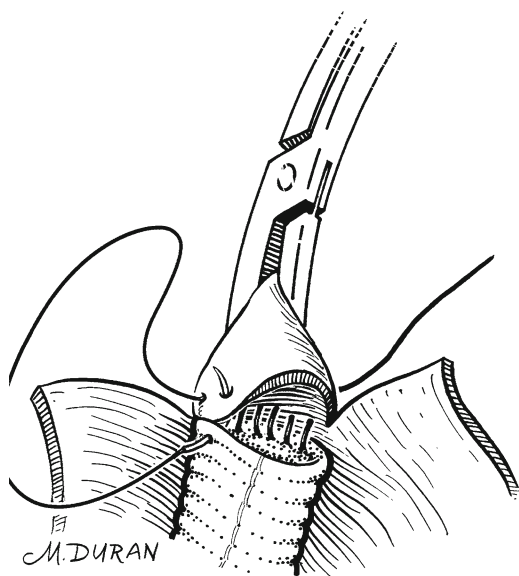


Figure 17.15. The proximal suture line is started on the back wall and brought anteriorly from each side with a continuous running suture.

■ FEMOROPOPLITEAL BYPASS, BELOW KNEE, WITH SAPHENOUS VEIN

PRIOR TO SURGERY: Imaging studies (angiogram, MRA, arterial duplex ultrasound mapping) are vitally important to proper preoperative planning. Preoperative duplex ultrasound vein mapping will assist in identifying the presence (or absence) of adequate venous conduit.

POSITION: Supine.

ANESTHESIA: General or spinal.

- Step 1.** Make a vertical incision overlying the femoral pulse.
- Step 2.** Identify the saphenous vein and dissect it out. Follow it down the medial aspect of the leg with either one incision or skip incisions along its course (Fig. 17.19).
- Step 3.** With 4-0 silk ligate venous tributaries flush with the main trunk. Their distal aspect may be either clipped or tied off in a similar manner (Fig. 17.20).

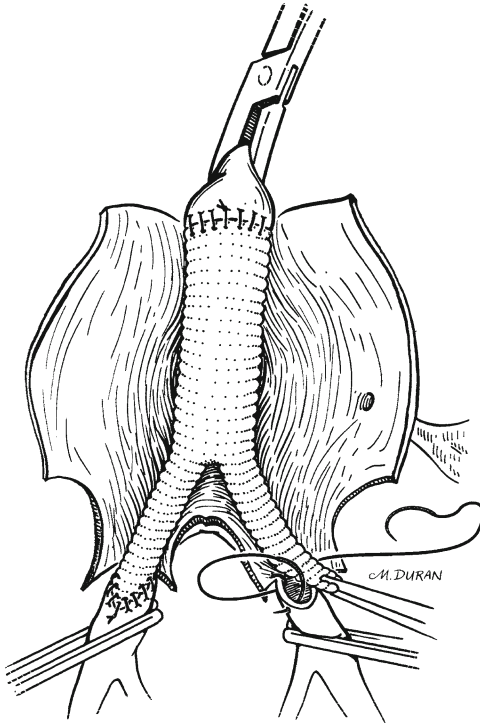


Figure 17.16. End-to-side anastomosis is fashioned to each iliac artery using a continuous running suture.

- Step 4.** Gently irrigate the saphenous vein with saline solution containing heparin.
- Step 5.** Ligate missed tributaries with silk sutures. The harvested vein can then be stored in a similar heparin solution, until ready for use.
- Step 6.** Expose the below-knee popliteal artery through an incision 2 cm behind the tibia on the medial aspect of the leg.
- Step 7.** Reflect the gastrocnemius muscle posteriorly and incise the fascia overlying the popliteal artery and vein.
- Step 8.** The origin of the soleus muscle that arches across the below-knee popliteal artery may have to be incised to allow for exposure.
- Step 9.** Dissect the distal popliteal artery away from its accompanying vein. Proximal and distal control of the vessel is obtained via vessel

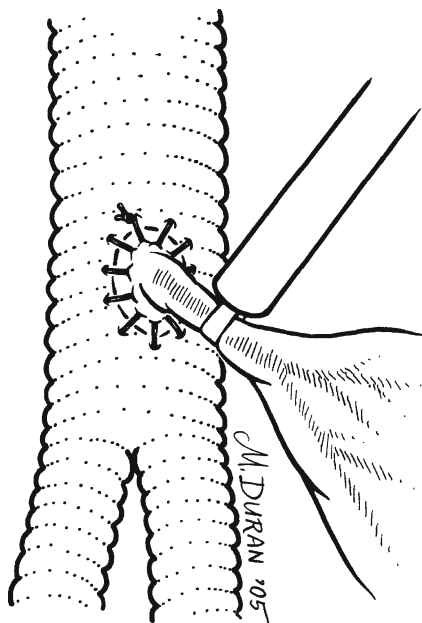


Figure 17.17. Reimplantation of the inferior mesenteric artery onto the aortic graft.

loops around the proximal popliteal, tibioperoneal, and anterior tibial arteries (Fig. 17.21).

- Step 10.** Expose the common femoral artery through the original femoral incision. Obtain proximal and distal control via vessel loops around the proximal common femoral, superficial femoral, and profunda femoral arteries, respectively.
- Step 11.** Create a tunnel from the below-knee popliteal space passing directly behind the knee joint and then medially through the subcutaneous tissue to the groin inflow site.
- Step 12.** Anticoagulate the patient systemically with heparin.
- Step 13.** Perform an end-to-side anastomosis by suturing the spatulated, reversed saphenous vein to an arteriotomy in the below-knee popliteal artery with continuous 6-0 monofilament polypropylene suture (for calcified vessels, 5-0 suture material is more suitable) (Fig. 17.22).
- Step 14.** Draw the saphenous conduit through the prepared tunnel to the groin, taking care to avoid kinking or twisting of the vein graft (Fig. 17.23).

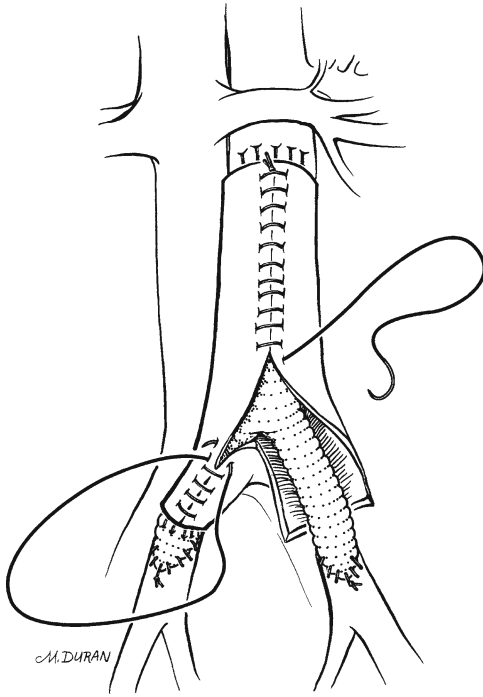


Figure 17.18. Closure of the aneurysm sac around the prosthesis.

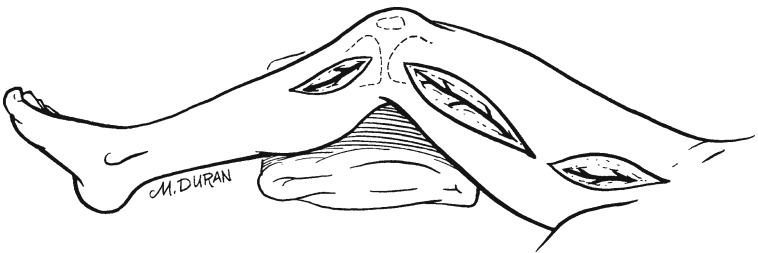


Figure 17.19. Incisions along the medial aspect of the leg facilitating dissection of the femoral and popliteal arteries, as well as harvest of the saphenous vein.

- Step 15.** Perform the femoral anastomosis in an end-to-side manner (Fig. 17.24).
- Step 16.** Close incisions in layers.
- Step 17.** Use of closed suction drainage is optional.




Figure 17.20. Venous tributaries are ligated with 4-0 silk flush with the main trunk. Their distal aspect may be clipped or tied off in a similar manner.

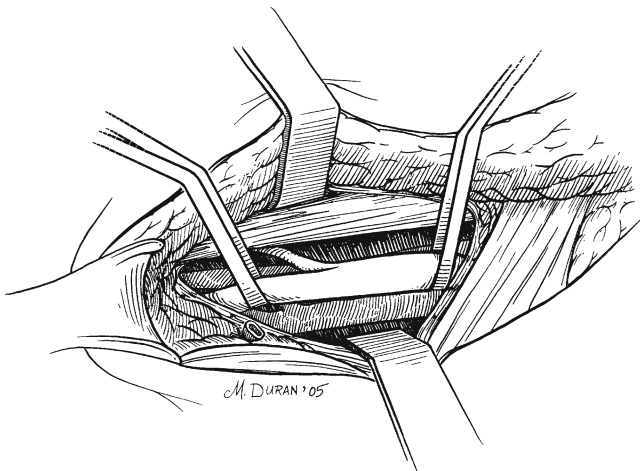


Figure 17.21. The below-knee popliteal artery exposure showing branching of the anterior tibial artery.

Remember:

- ✓ Good arterial inflow, suitable outflow, and an adequate conduit are the three requirements for a successful bypass.
- ✓ Complete hemostasis and avoidance of tissue desiccation are essential.

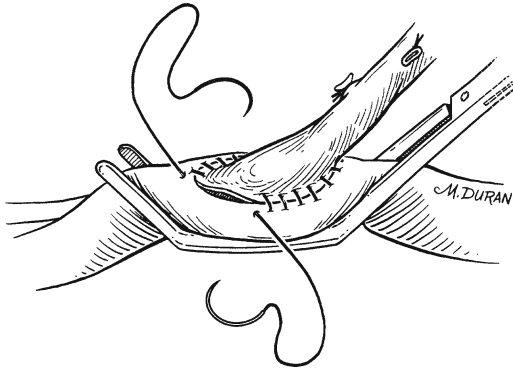


Figure 17.22. End-to-side anastomosis of spatulated vein to below-knee popliteal artery.

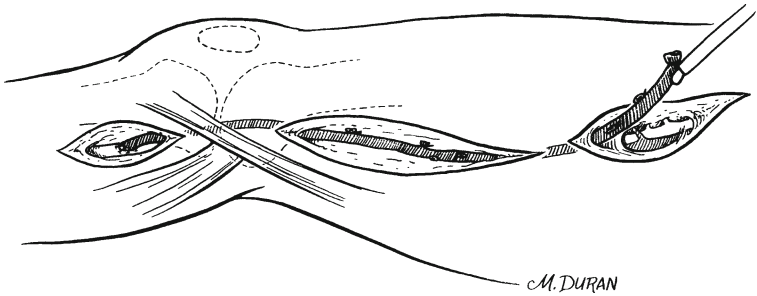


Figure 17.23. Completed distal anastomosis and reversed greater saphenous vein situated in anatomic tunnel.

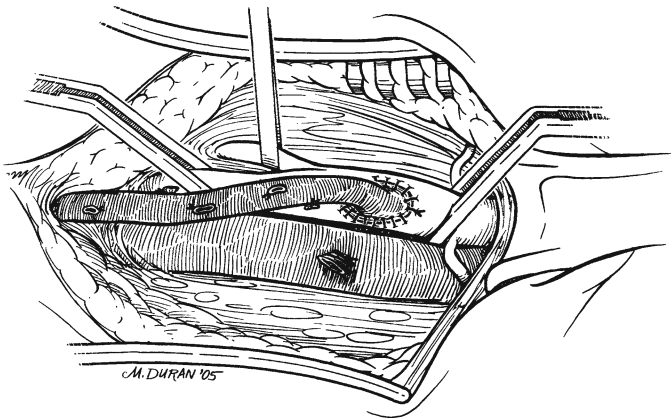


Figure 17.24. End-to-side femoral anastomosis.

■ ARTERIOVENOUS FISTULA (AVF)

Preoperative assessment must include evaluation of patient's history with regard to previous catheters, superficial venous thrombosis (SVT), and deep vein thrombosis (DVT) in the upper extremities. Determine the patient's handedness and, if possible, use the nondominant arm first.

Examine the patient's veins with a tourniquet in place. Examine arterial pulses from the axillary distally and verify a brisk Allen's test (assessment of collateral circulation).

Obtain ultrasound vein mapping of the upper extremities. Consider obtaining a venogram in cases where the patient has had multiple prior access procedures and/or central vein catheters that may impede a successful access.

If the patient in question is already on hemodialysis, consideration should be given to performing the procedure on a "non-dialysis" day. Immediately prior to a dialysis, the patient may experience volume overload and electrolyte imbalance. In addition, the patient may be hypovolemic immediately after dialysis and tend toward hypotension while under sedation during the procedure.

Generally, dialysis access operations can be performed under local anesthesia with mild sedation, although this decision must be modified individually based on the anticipated length and complexity of the procedure.

Radiocephalic AVF

- Step 1.** Prep the entire arm circumferentially from the shoulder to the hand. Cover the hand itself with a sterile towel and use adhesive bandage or a towel clamp to affix the towel in place.
- Step 2.** Make a short incision axially along the radial artery just proximal to the wrist.
- Step 3.** Initially identify the cephalic vein by undermining toward the dorsal surface of the wrist. Dissect the cephalic vein distally and proximally; free a sufficient length to allow the vein to reach the radial artery easily without tension. Ligate and divide branches with 4-0 silk.
- Step 4.** Ligate the cephalic vein distally and spatulate its open end. Flush the vein with heparinized saline. Inflate the vein gently.
- Step 5.** Proceed to expose the radial artery. Take great care to avoid injury to the adjoining structures. Encircle the radial artery proximally and distally with vessel loops.
- Step 6.** At this time you may heparinize the patient. Some operators choose not to administer systemic heparin and instead locally flush the artery with a heparinized saline solution. Both approaches are acceptable.

686 17. Vascular System

- Step 7.** Clamp the artery with vessel clamps such as angled Debaquey clamps.
- Step 8.** Create an arteriotomy with an 11 blade and extend it with Potts scissors.
- Step 9.** Sew the vein to the radial artery with standard vascular anastomosis technique using one or two 6.0 prolene suture.
- Step 10.** Once the anastomosis is completed, release the clamp on the proximal radial artery and the cephalic vein first so as not to flush any inadvertently retained debris to the hand. Finally, release the clamp on the distal radial artery. Examine the pulse in the fistula. You should feel a thrill and hear a bruit with Doppler. Examine the fistula where it is visible in your operative field. Make sure that there are no kinks in the AVF and that the fistula is not tethered in any way. Release any tethering bands of soft tissue.
- Step 11.** Approximate the subcutaneous fascia over the fistula. Close the skin with a subcuticular suture.

Note:

- ✓ Consider using ultrasound intraoperatively to mark the course of the cephalic vein and its major tributaries.

Brachiocephalic AVF

- Step 1.** Make a transverse incision just distal to the antecubital crease.
- Step 2.** In the subcutaneous fat, identify the medial cubital vein and the cephalic vein to which it drains.
- Step 3.** Mobilize the cephalic vein sufficiently so that it will reach the brachial artery without tension.
- Step 4.** Divide the bicep aponeurosis axially. Identify the underlying brachial artery. The brachial vein generally lies over the artery. Take great care not to injure the vein and the adjacent median nerve.
- Step 5.** Encircle the brachial artery proximally and distally.
- Step 6.** Heparinize the patient.
- Step 7.** Create a short arteriotomy in the brachial artery.
- Step 8.** Assess the correct length of cephalic vein needed to reach the artery and proceed to spatulate the vein.
- Step 9.** Sew the anastomosis with 6.0 prolene suture.
- Step 10.** Flush the anastomosis with heparinized saline and complete it.
- Step 11.** Examine the portion of the fistula visible in your incision and small skin flap. The vein should lie tension-free. Release any restrictive soft tissue bands.

Step 12. Close the incision with 3.0 Vicryl for the subcutaneous fascia and 4.0 Monocryl for the skin.

Note:

- ✓ Reestablish flow first to the fistula and then to the distal brachial artery. Expect an easily palpable thrill.

■ BRACHIO-AXILLARY ARTERIAL VENOUS GRAFT

- Step 1.** Make a short axially oriented incision just proximal to the antecubital crease over the brachial artery pulse.
- Step 2.** Sharply dissect the artery proximally and distally and encircle with vessel loops.
- Step 3.** Make another short axially oriented incision in the proximal upper arm in the axilla. Identify the axillary vein. Dissect vein free; avoid injury to neighboring structures. Encircle the vein proximally and distally.
- Step 4.** Use a large clamp or tunneler to create a subcutaneous tunnel between the two incisions. Do not make the tunnel any wider that it needs to be in order to pass the graft through it snugly. Orient the tunnel in an arched course and make sure that the majority of the graft will lie over the anterior portion of the bicep muscle.
- Step 5.** Pass a 4–7 mm tapered polytetrafluoroethylene (PTFE) graft in the tunnel with the 4 mm end toward the artery. Do not trim the 4 mm segment, because it provides resistance to flow and thereby reduces the risk of steal syndrome.
- Step 6.** Heparinize the patient.
- Step 7.** Clamp the brachial artery and create an arteriotomy.
- Step 8.** Sew the PTFE graft to the open brachial artery in an end-to-side fashion.
- Step 9.** Clamp the graft and reestablish flow in the brachial artery.
- Step 10.** Clamp the axillary vein.
- Step 11.** Make a venotomy in the vein.
- Step 12.** Trim the graft to length for a tension-free anastomosis.
- Step 13.** Sew the graft to the open vein in an end-to-side fashion with a 6–0 prolene.
- Step 14.** Flush the graft and vein prior to completion of the anastomosis.
- Step 15.** Complete the anastomosis and establish flow in the graft. You should expect a palpable thrill in the graft.
- Step 16.** Close the incisions. Use 3.0 Vicryl suture for the subcutaneous fascia and 4.0 Monocryl for the skin.

18

Uterus, Tubes, and Ovaries

ANATOMY

■ RELATIONS AND POSITIONS OF THE UTERUS, TUBES, AND OVARIES

The uterus lies in the pelvis between the bladder and rectum. The normal position of the uterus—whether anteverted, midplane, or retroverted—is maintained by the round ligaments. The ligaments insert laterally, anterior to the fallopian tubes, and then plunge into the pelvic sidewall. The round ligaments may be viewed as the roof of the broad ligament. The broad ligament contains the blood supply, lymphatic channels, and nerves of the corpus uteri.

The ureter courses just below the insertion of the uterine artery into the lower uterine segment, and it should be identified clearly to avoid injuring it. The lower uterine segment and cervix are bordered anteriorly by the bladder and posteriorly by the rectum. Moving downward, the surgeon encounters the uterosacral ligaments, which provide critical support to the uterus. Laterally and downward the broad ligament joins the cardinal ligament until the cervical/vaginal junction is reached.

The fallopian tubes emerge from the fundus and are in close proximity to the ovaries. The mesosalpinx descends from the tubes. The ovaries are joined to the uterus via the utero-ovarian ligament and to the pelvic sidewall by the infundibulopelvic ligament. The infundibulopelvic ligament contains the ovarian vessels.

■ VASCULAR SYSTEM OF THE UTERUS, TUBES, AND OVARIES

Arterial Supply

The uterine artery arises from the internal iliac artery, as do the cervical, vaginal, and other collateral vessels.

Venous Supply

The veins follow a course analogous to the internal iliac vein. The ovarian artery and vein course in a cephalad direction and have no pelvic origin.

Lymphatic Drainage

Coursing parallel to the internal iliac vessels, the drainage from the corpus uteri and cervix ends in the deep pelvic lymph nodes. The drainage from the ovaries is in a cephalad and midline direction, coursing to the periaortic nodes, adjacent to the inferior vena cava and aorta.

TECHNIQUE

■ ABDOMINAL HYSTERECTOMY AND BILATERAL SALPINGO-OOPHORECTOMY

In addition to understanding the surgical technique of hysterectomy, the surgeon should realize the significance of the procedure to the patient. Removal of the uterus will, under usual circumstances, sterilize the patient. Removal of the ovaries will result in castration of the patient. The possible need for estrogen replacement therapy, with all its attendant controversies, might then develop. It is beyond the scope of this chapter to consider these issues, but the surgeon is encouraged, when possible, to clearly understand the patient's wishes and perspective.

The incision for hysterectomy is often determined by the indications for the procedure. When cancer is suspected, a midline incision is performed from the umbilicus to the symphysis pubis. For large fibroids or extensive endometriosis, a Maylard incision (muscle-cutting transverse incision) might be performed. A tubo-ovarian abscess can be approached with either a Maylard or a midline skin incision. For benign disease of limited dimension, a Pfannenstiel incision (low transverse muscle-spreading incision) is often performed.

The following general technique of hysterectomy is suitable when there is no significant disruption of the normal anatomy; modifications are needed according to disease processes encountered.

PREOPERATIVE: Prepare the vagina carefully with a Betadine solution; administer antibiotics.

- Step 1.** Make incision. Generally a transverse muscle-splitting or muscle-cutting incision is performed. This choice of incision is associated with less postoperative pain and a more desirable cosmetic result. For a transverse incision, the skin is cut approximately 2 cm above the symphysis pubis and 3–4 cm to each side of the midline.
- Step 2.** Incise the rectus abdominis fascia and extend this incision laterally. Grasp the superior edge and sharply dissect the underlying muscle away from the fascia with Metzenbaum scissors. Bleeding from perforated vessels can be controlled with electrocautery.
- Step 3.** Take a Kelly clamp and identify the midline of the muscle. Gently separate the bellies and extend the incision superiorly and inferiorly, reaching the limits of your previous dissection.
- Step 4.** Grasp a peritoneal fold. Enter cautiously to avoid injury to underlying bowel. Extend the peritoneal incision superiorly and inferiorly.
- Step 5.** If a neoplasm is suspected, take pelvic washings and submit for cytology. If an infectious process is apparent, take fluid for culture.

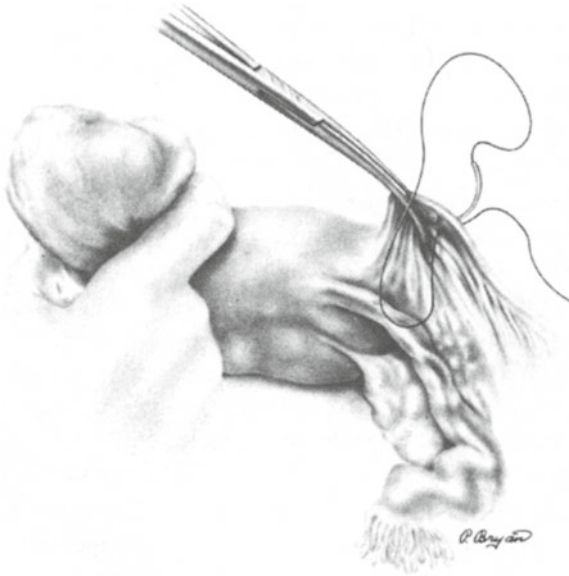

Figure 18.1. Round ligament is clamped, ligated, and cut. Broad ligament is opened (from HW Jones III. *Hysterectomy*. In: JA Rock and HW Jones III, eds. *TeLinde's Operative Gynecology*, 9th ed. Philadelphia: Lippincott Williams & Wilkins, 2003, p. 810, with permission).

- Step 6.** Place Kelly clamps on each corner of the uterus encompassing the round ligaments, utero-ovarian ligaments, and fallopian tubes.
- Step 7.** Place gentle traction on the clamps. With a curved Heaney, Zeppelin, or Masterson pelvic clamp, clamp the round ligament approximately 2 cm lateral to its uterine insertion. Cut the round ligament with a scalpel, leaving a pedicle approximately 3 mm distal to the clamp. Secure the pedicle with a 0 or 2-0 Vicryl suture ligature. All subsequent sutures are the same unless otherwise indicated (Fig. 18.1).
- Step 8.** Use Metzenbaum scissors to open the anterior and posterior leaves of the broad ligament (Fig. 18.2).
- Step 9.** Place two curved clamps on the utero-ovarian and fallopian tubes, approximately 1–2 cm lateral to the uterus. Cut the pedicle and secure with a free tie around the most lateral clamp. Remove the clamp as the surgeon stitches down on the knot. Place a second ligature below the remaining clamp before removing it (Fig. 18.3).

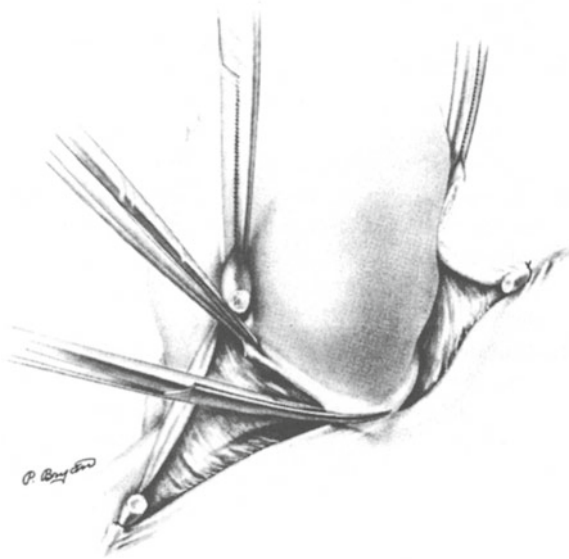


Figure 18.2. Leaves of the broad ligament are incised. To avoid unnecessary blood loss, the bladder is not dissected away from the uterus at this point (from JD Thompson and J Warshaw. Hysterectomy. In: Rock JA and JD Thompson, eds. *TeLinde's Operative Gynecology*, 8th ed. Philadelphia: Lippincott-Raven, 1997, p. 802, with permission).

Note:

- ✓ If performing bilateral salpingo-oophorectomy (BSO): Place two clamps across the infundibulopelvic ligament 1–2 cm from the ovary. Secure the pedicles as above. Therefore, the placement of the clamp either in front of or behind the ovary will determine whether the adnexa are removed or preserved.

Step 10. Use the Metzenbaum scissors to open the broad ligament until the uterine vessels are viewed and skeletonized. With the scissors pointing away from the bladder and toward the cervix, carefully dissect the bladder away from the cervix and lower uterine segment (Fig. 18.4).

Step 11. At the level of the internal cervical os, perpendicular to the cervix, place the first clamp. Place the second clamp immediately above it, and the third clamp above that, leaving enough of a gap to cut an adequate pedicle. Use the scalpel to cut to the tip of the clamp. Place a suture ligature at the tip of the bottom clamp and secure the

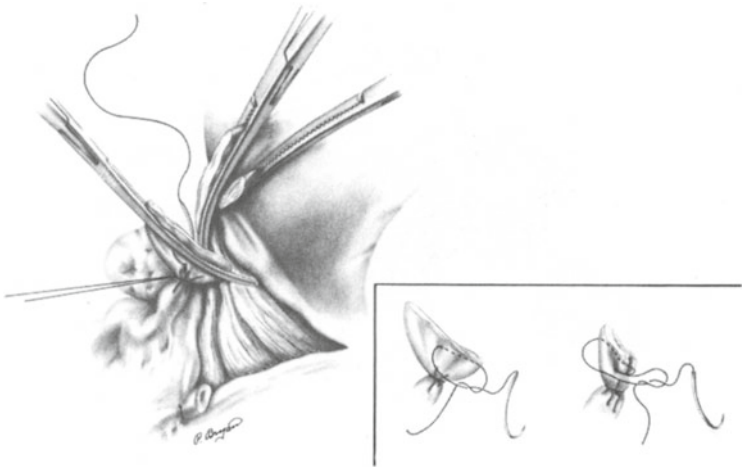


Figure 18.3. Double clamping. The lateral clamp is replaced with a free tie that surrounds the pedicle and occludes the vessels (inset: *left*). The middle clamp is replaced by a transfixion suture ligature (inset: *right*) (from JD Thompson and J Warshaw. Hysterectomy. In: JA Rock and JD Thompson, eds. *TeLinde's Operative Gynecology*, 8th ed. Philadelphia: Lippincott-Raven, 1997, p. 804, with permission).

bottom of the pedicle. Remove the bottom clamp. Place a second suture at the tip of the remaining bottom clamp. When the suture is secure, remove the pedicle. The third clamp is used to control any resultant back bleeding (Fig. 18.5).

- Step 12.** Between the uterus and the vascular pedicle above, advance straight clamps approximately 1 cm. It is important that the heel of this clamp be in direct contact with the secured previous pedicle. If it is not, tissue will be cut that is not encompassed by a ligature. Later attempts to arrest resultant bleeding are associated with an increased risk of injury to the ureter. Cut the pedicle and secure with a suture ligature (Fig. 18.6).
- Step 13.** Sequentially advance straight clamps: clamp, cut, and suture ligate until the uterosacral ligaments are encountered.
- Step 14.** With a straight clamp, clamp the uterosacral ligament 1 cm from the cervix. Cut and secure with a ligature.
- Step 15.** Using a scalpel, make a superficial incision between the uterosacral ligaments; usually 1–2 mm must be cut. Try to ensure that the entirety of the cervix is felt between the fingers and then apply a

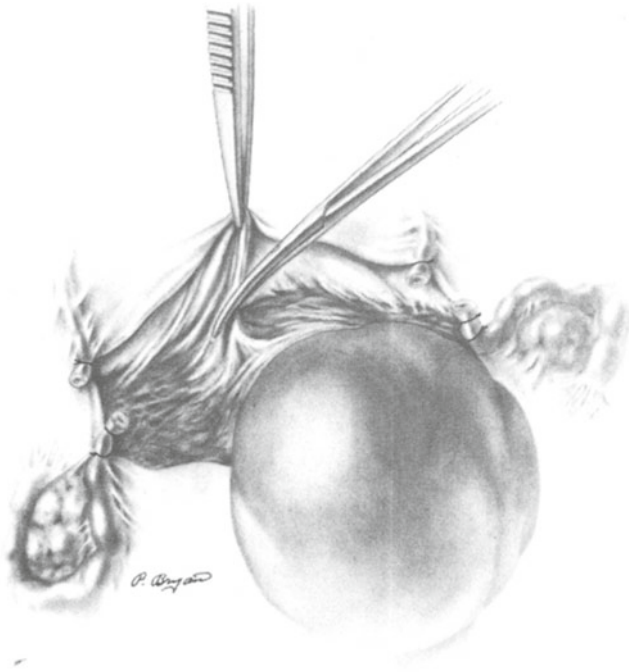


Figure 18.4. Mobilization of bladder (from HW Jones III. Hysterectomy. In: JA Rock and HW Jones III, eds. *TeLinde's Operative Gynecology*, 9th ed. Philadelphia: Lippincott Williams & Wilkins, 2003, p. 812, with permission).

curved clamp at the cervical-vaginal junction. Cut the pedicle, and the vagina is entered. Suture ligate the pedicle and secure it with a Kelly clamp.

- Step 16.** On the opposite side, repeat all these steps sequentially.
- Step 17.** Using Jorgensen scissors or a scalpel, cut the entire cervix away while removing as little vagina as possible (Fig. 18.7).
- Step 18.** Following a hysterectomy, the most common site for postoperative bleeding is the vaginal cuff. Carefully close the vagina in an anterior-to-posterior fashion with figure-of-eight stitches. If too much tissue is incorporated into a ligature, the risk of cellulitis increases.
- Step 19.** Carefully place a suture through the uterosacral pedicle close to the previous ligature, the posterior wall of the vagina, and the opposite uterosacral ligament. Caution is required to avoid injury

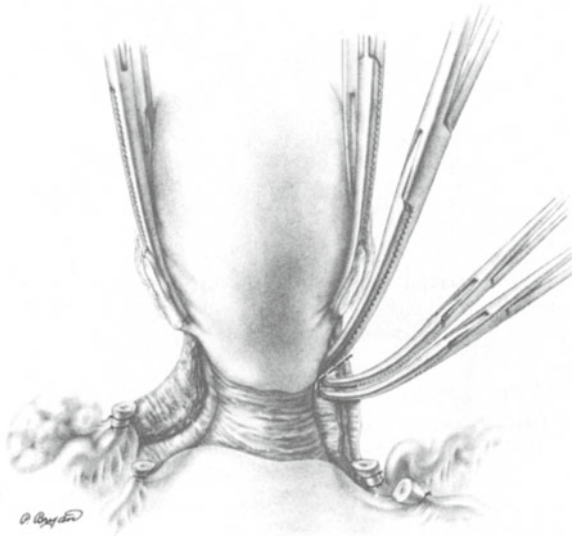


Figure 18.5. Skeletonization of uterine vessels and placement of suture ligatures (from HW Jones III. Hysterectomy. In: JA Rock and HW Jones III, eds. *TeLinde's Operative Gynecology*, 9th ed. Philadelphia: Lippincott Williams & Wilkins, 2003, p. 814, with permission).

to the ureters. This suture diminishes the likelihood that enterocele or vaginal vault prolapse will develop (Fig. 18.8).

- Step 20.** If there is evidence of pelvic infection, the vagina is not closed. Secure the vaginal edges with a continuous interlocking stitch. Before closing the retroperitoneal space, a drain may be placed with a running 3–0 Vicryl suture.
- Step 21.** Carefully irrigate the pelvis with normal saline and inspect all pedicles for complete hemostasis. The visceral or parietal peritoneum may be closed, but this is not mandatory.
- Step 22.** If the muscles have not been cut, typically they fall back together. After placing one interrupted 2–0 Vicryl suture at the midline, close the fascia with a 2–0 Vicryl running suture.
- Step 23.** Carefully irrigate the subcutaneous tissues and observe for hemostasis. The skin may be closed with a 3–0 or 4–0 subcuticular closure. Standard bandages may be applied.

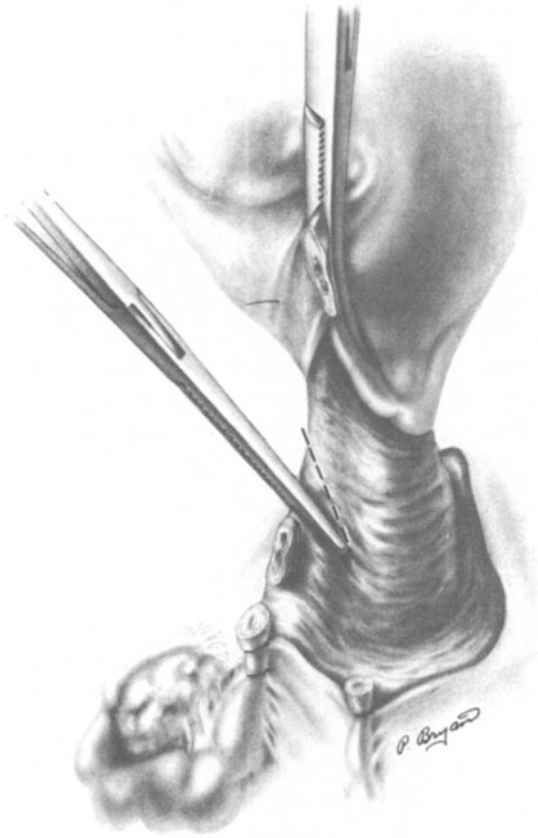


Figure 18.6. Line of incision (from HW Jones III. Hysterectomy. In: JA Rock and HW Jones III, eds. *TeLinde's Operative Gynecology*, 9th ed. Philadelphia: Lippincott Williams & Wilkins, 2003, p. 814, with permission).

Remember:

- ✓ Postoperative infection is a common complication following hysterectomy. Incidence can be reduced with the use of preoperative antibiotics; first-generation cephalosporins are usually used and should be administered before the incision is made.
- ✓ The wise surgical technique of limiting pedicle size will minimize the necrotic tissue left behind.
- ✓ Injury to the ureter is a rare but serious mishap. The surgeon performing a hysterectomy must know the course of the pelvic ureter. Once the

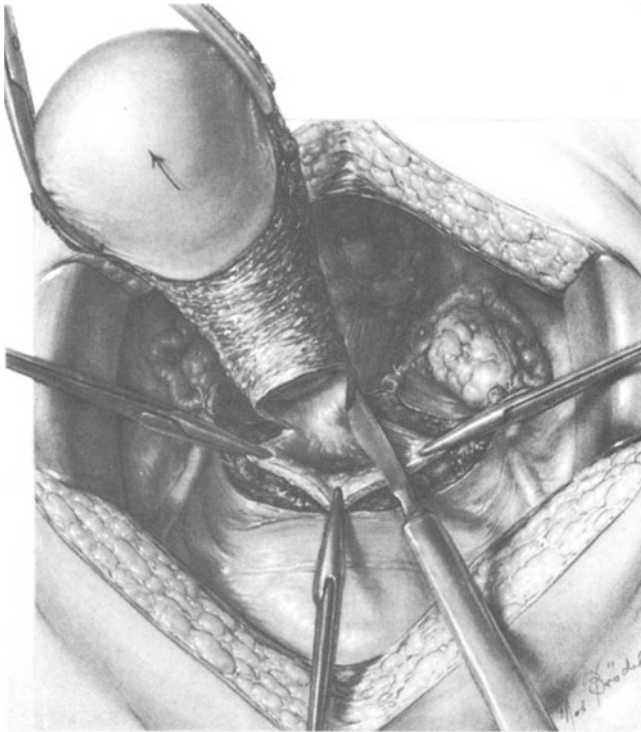


Figure 18.7. Cervix is removed. From EH Richardson. A Simplified Technique for Abdominal Panhysterectomy. *Surg Gynecol Obstet* (now *J Am Coll Surg*) 48:248–256, 1929. Reprinted with permission from Elsevier Limited.

broad ligament has been opened, careful dissection will reveal the presence of the ureter below the uterine vessels.

- ✓ Postoperative ileus is not always preventable, but the likelihood of its development can be reduced by avoiding irritation to the bowel. In particular, avoid packing away the intestines unless absolutely necessary and then always use moistened lap pads.
- ✓ Use of cautery and other newer energy-dependant devices should be avoided when the vascular pedicle is reached. Collateral thermal injury may put the ureter at risk.

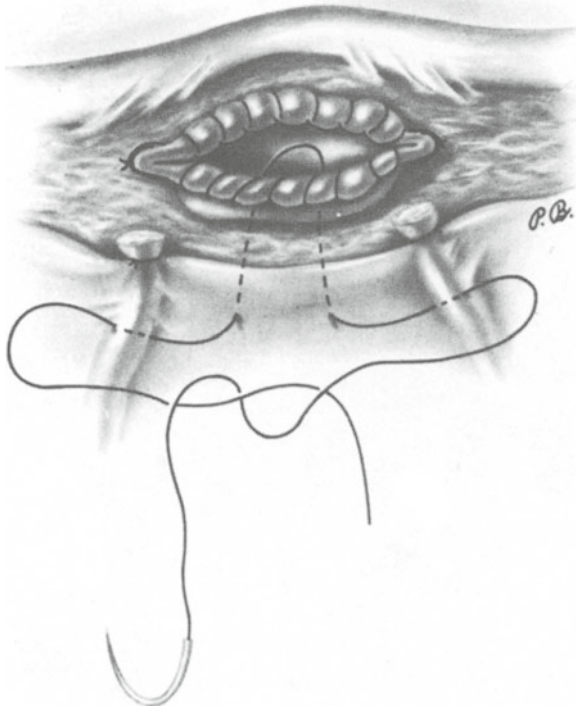


Figure 18.8. Open cuff is created (from JD Thompson and J Warshaw. Hysterectomy. In: JA Rock and JD Thompson, eds. *TeLinde's Operative Gynecology*, 8th ed. Philadelphia: Lippincott-Raven, 1997, p. 813, with permission).

■ OVARIAN CYSTECTOMY

In this era of extensive use of imaging, it would be unlikely for a surgeon to be surprised by the presence of an ovarian cyst (Fig. 18.9a). Nevertheless, the surgical management of these entities is relevant to all who enter the abdomen.

The ovary has the capacity to produce many benign and malignant tumors. In general, maximal effort should be focused on the preservation of useful function when the presumed histology is benign (Fig. 18.9a). When a ruptured, bleeding cyst is encountered, the surgeon should perform careful dissection with Metzenbaum scissors to excise the cyst from the surrounding ovarian parenchyma (Fig. 18.9b). The dissection plane becomes obvious as the cyst

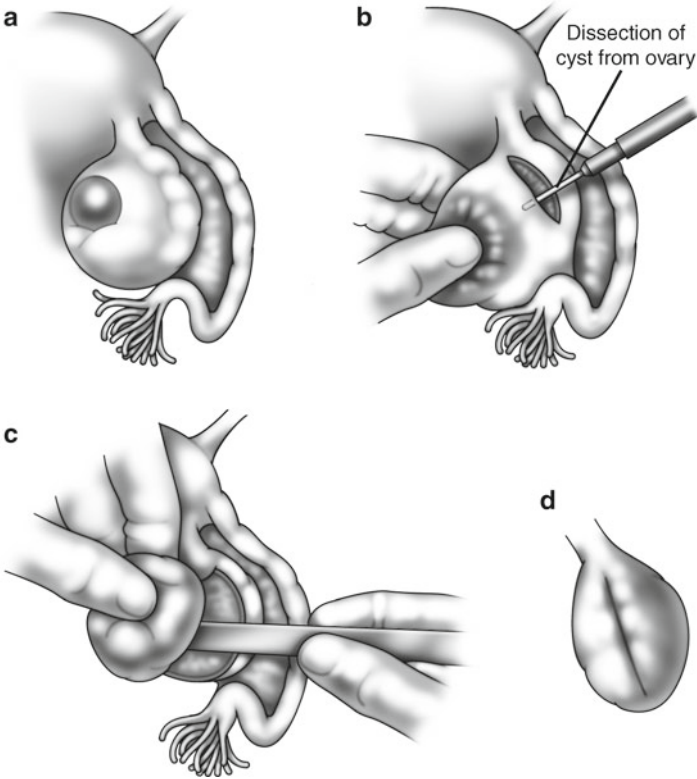


Figure 18.9. Resection of benign cyst.

wall is peeled away from the residual ovarian tissue (Fig. 18.9c). The ovary may be stabilized with a Babcock clamp and the cyst pulled away with smooth forceps. Deep stitches of 3-0 or 4-0 Vicryl are used cautiously to close the inner ovarian stroma. The ovarian cortex is then closed with interrupted 4-0 Vicryl (Fig. 18.9d) or a continuous baseball stitch (Fig. 18.10).

Care should be taken to remove as little ovarian stroma or cortex as possible. Hemostasis is improved by cautious use of the needlepoint Bovie prior to closure on obvious bleeding sites. Care should be taken not to compromise the ovarian blood supply by overly zealous cautery use. Copious irrigation with lactated Ringer's solution will diminish adhesion formation. Adhesion barriers on the repaired ovary have not conclusively demonstrated benefit and are not recommended.

When an unruptured cyst is encountered in a premenopausal patient, size will suggest management. In general, cysts less than 7 cm should be left undisturbed. Larger cysts can be removed using the procedure for ruptured cysts.

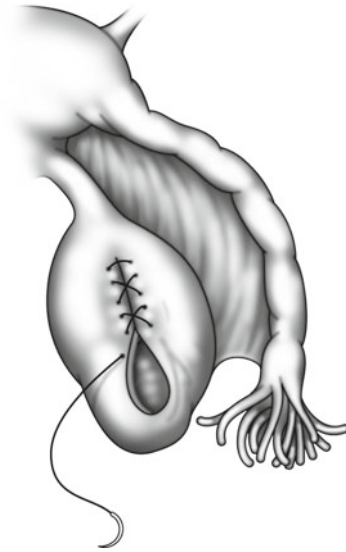


Figure 18.10. Closure of the ovary with a baseball stitch.

Care should be taken to avoid rupturing an intact cyst. If the surgeon encounters an asymptomatic cyst, it is best left undisturbed; most asymptomatic cysts are functional and will resolve spontaneously.

The presence of an ovarian cyst in a postmenopausal patient has a higher association with malignancy. If the cyst must be removed, peritoneal washings and omental biopsies should be obtained before oophorectomy. The infundibulopelvic ligament is isolated 1–2 cm next to the ovary, clamped, cut, and secured with 2–0 Vicryl sutures. The utero-ovarian ligament and fallopian tube are similarly clamped, cut, and ligated. If frozen section analysis confirms malignancy, a full staging operation of total abdominal hysterectomy, BSO, and pelvic and aortic lymphadenectomy should be performed by an appropriately trained surgeon.

Remember:

- ✓ Be careful to avoid injury to the ureter when clamping the infundibulopelvic ligament.
- ✓ Always adhere to the “golden rule” of gynecologic surgery—preservation of useful function. Never remove an ovary unless it is absolutely necessary.
- ✓ Careful attention to hemostasis decreases adhesion formation.
- ✓ Ovarian surgery is associated with a significant risk of infertility. Often the best approach is not to disturb the ovary.

Carpal Tunnel

ANATOMY

The surgical anatomy and anatomical entities related to the carpal tunnel syndrome are presented through illustrations and tables (Figs. 19.1, 19.2, 19.3, 19.4, and 19.5; Tables 19.1, 19.2, and 19.3).

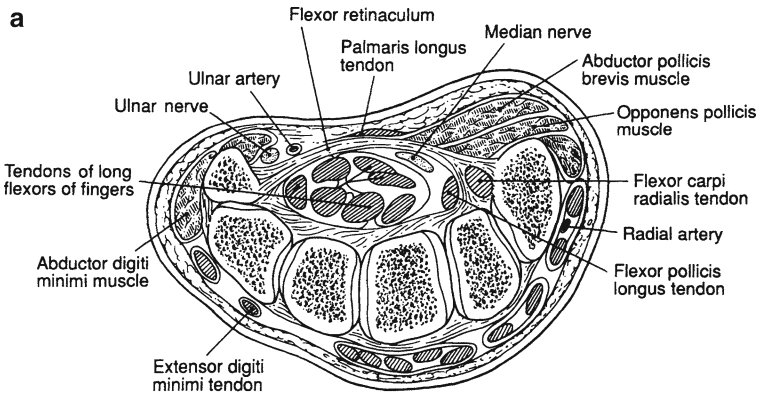
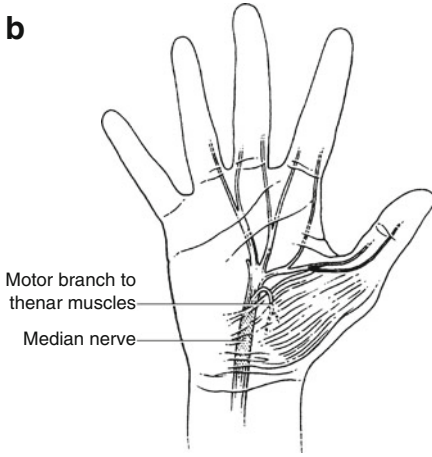


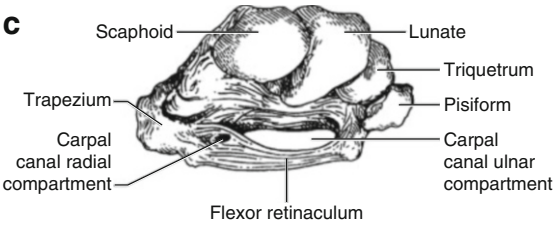
Figure 19.1. (a) Cross section of the wrist. (d) The tunnel and its relations. From JE Skandalakis, GL Colborn, PN Skandalakis, et al. The carpal tunnel syndrome: Part I. *Am Surg* 58(1):72–76, 1992. Reprinted with permission from American Surgeon.

704 19. Carpal Tunnel

b



c



d

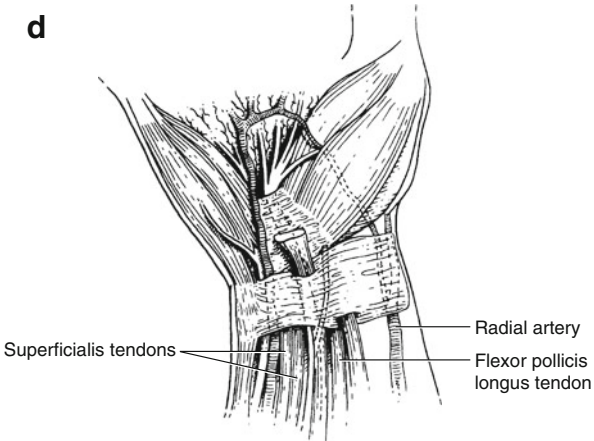


Figure 19.1. (continued).

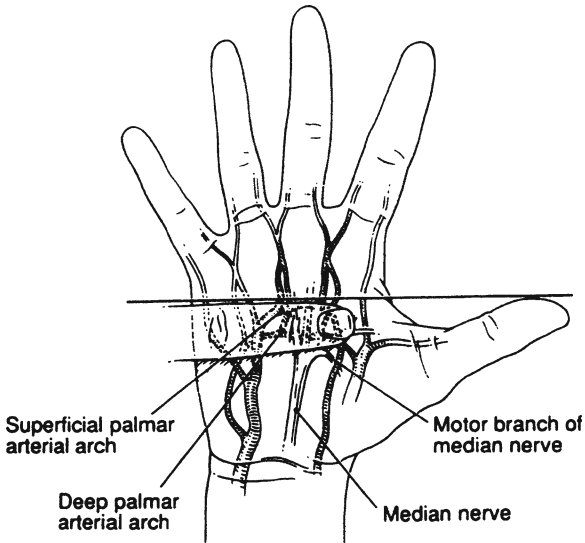


Figure 19.2. The superficial and deep palmar arches and the topography of the motor branches of the median nerve. From JE Skandalakis, GL Colborn, PN Skandalakis, et al. The carpal tunnel syndrome: Part I. *Am Surg* 58(1):72-76, 1992. Reprinted with permission from American Surgeon.

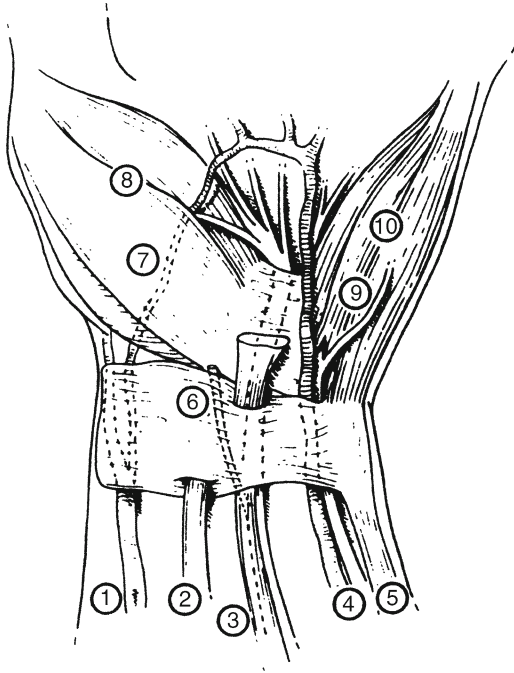


Figure 19.3. Superficial relations of the flexor retinaculum. (1) Radial artery, (2) flexor carpi radialis tendons, (3) palmaris longus tendon, (4) ulnar artery and nerve, (5) flexor carpi ulnaris tendon, (6) palmar cutaneous branch of median nerve, (7) palmar branch of radial artery, (8) three thenar muscles, (9) palmar cutaneous branch of ulnar nerve, and (10) three hypothenar muscles. Modified from JE Skandalakis, GL Colborn, PN Skandalakis, et al. The carpal tunnel syndrome: Part II. *Am Surg* 58(2):77–81, 1992 with permission from American Surgeon.

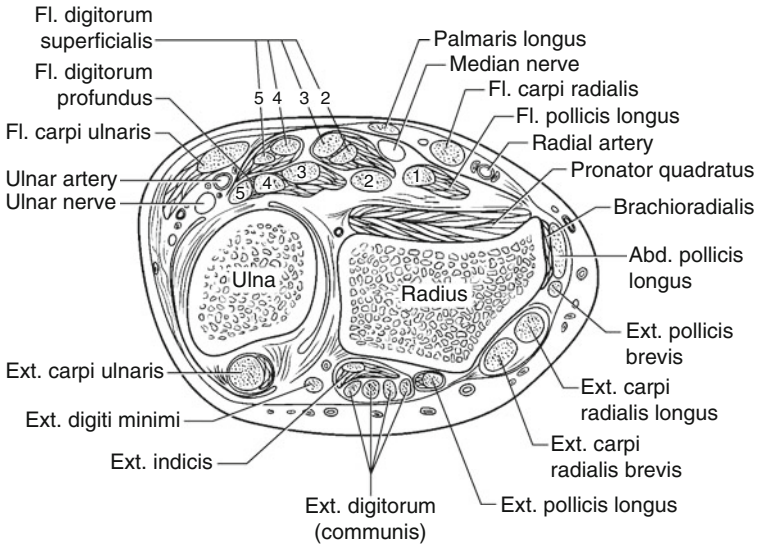


Figure 19.4. The proximal surgical zone.

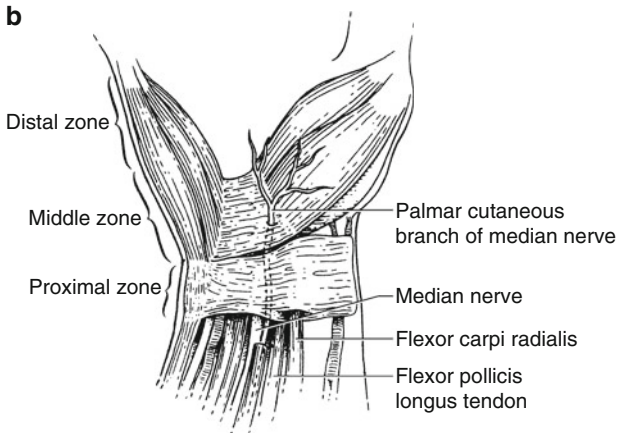
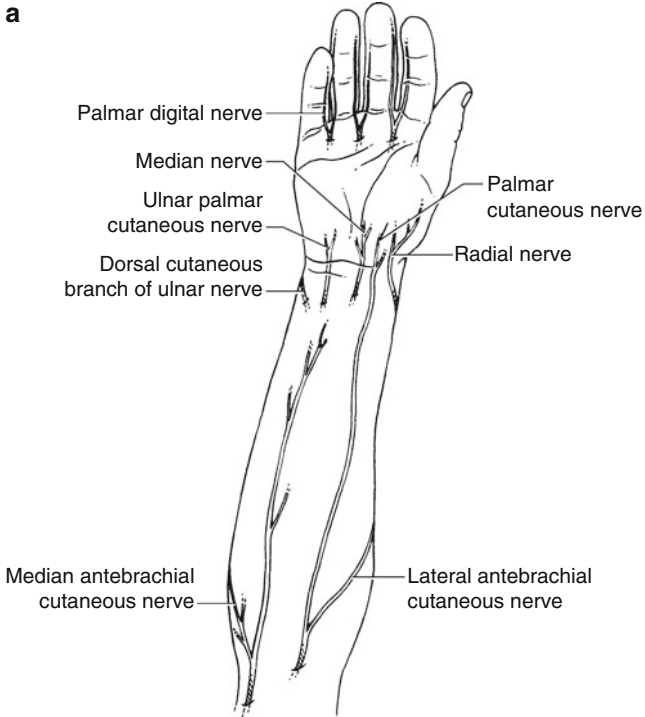


Figure 19.5. (a) Palmar cutaneous branches of the ulnar, musculocutaneous, radial, and median nerves. (b) Palmar cutaneous branch of the median nerve. From JE Skandalakis, GL Colborn, PN Skandalakis, et al. the carpal tunnel syndrome: Part III. *Am Surg* 58(3):158–166, 1992. Reprinted with permission from American Surgeon.

Table 19.1 Upper proximal zone divisions

Ulnar side	
Ulnar trio	Flexor carpi ulnaris Ulnar nerve Ulnar artery
Central (median) area	
Ulnar bursae with flexor digitorum superficialis and profundus tendons	
Median duo	Palmaris longus Median nerve
Radial side	
Radial trio	Radial artery Flexor carpi radialis Flexor pollicis longus within the radial bursa

From JE Skandalakis, GL Colborn, PN Skandalakis, et al. The carpal tunnel syndrome: Part II. *Am Surg* 58(2):77–81, 1992. Reprinted with permission from American Surgeon

Table 19.2 Central zone (carpal tunnel) divisions

Ulnar side
Ulnar bursa: eight tendons (sublimis and profundus)
Central area
Median nerve and its branches (with possible variations)
Radial side
Radial bursa and flexor pollicis

From JE Skandalakis, GL Colborn, PN Skandalakis, et al. The carpal tunnel syndrome: Part II. *Am Surg* 58(2):77–81, 1992. Reprinted with permission from American Surgeon

Table 19.3 Distal zone divisions

Ulnar side
Ulnar nerve branches
Ulnar artery and superficial arch
Ulnar bursa: four profundus tendons
Ulnar bursa: four superficialis tendons
Central (median) side
Median nerve branches
Recurrent branch thenar muscles
One or two digital nerves for thumb
Four or five digital nerves for index, middle, and radial side of ring finger
Radial side
Flexor pollicis longus with radial bursa
Median nerve palmar cutaneous branch

From JE Skandalakis, GL Colborn, PN Skandalakis, et al. The carpal tunnel syndrome: Part II. *Am Surg* 58(2):77–81, 1992. Reprinted with permission from American Surgeon

TECHNIQUE

■ SURGICAL TREATMENT OF CARPAL TUNNEL SYNDROME

Patients with chronic carpal tunnel syndrome may benefit from a number of different nonsurgical and surgical treatments. Often surgical release of the carpal canal is necessary to alleviate the majority of the patient's symptoms. Surgical decompression of the nerve works by increasing the space available for the median nerve, giving the nerve better opportunity to conduct impulses more normally.

While multiple surgical variations have been reported, none has been shown to be superior to a traditional open carpal tunnel release. The purpose of the chapter is to present the method of open carpal tunnel release for the purpose of treating chronic carpal tunnel syndrome. Because the surgical anatomy of the palm is complex, thorough knowledge of the local anatomy is crucial to optimize the outcome. Surgical complications often are related to anatomic variants that go unrecognized at the time of the procedure.

Surgery is usually performed on an outpatient basis using a regional or local anesthetic block, a sterile facility, and an optical magnification. Routine prophylactic antibiotics are not necessary to perform a surgical timeout with the patient.

- Step 1.** Tourniquet management. The procedure can be performed with the use of a well-padded brachial or antebrachial tourniquet, which is inflated to a pressure 100 mm/hg over the patient's systolic blood pressure (but not to exceed 250 mm/hg).
- Step 2.** Generate anesthesia for the procedure. For OR procedures done under local anesthesia, I use 0.5 % plain Marcaine. Perform a proximal median and ulnar nerve block with 10 cc, then infiltrate the line of the incision. The block is best done approximately 20 min prior to incision time.
- Step 3.** Make a curving incision that is in line with the ring finger metacarpal (Fig. 19.6).
- Step 4.** Blunt subcutaneous dissection allows for identification and preservation of the crossing cutaneous nerves. These nerves may originate from either the palmar cutaneous branch of the median nerve or the palmar cutaneous branch of the ulnar nerve (Fig. 19.7). Longitudinally incise the longitudinal fibers of the palmar aponeurosis.
- Step 5.** Identify the transverse carpal ligament. The ligament is thick and the fibers are transverse. The origin of the thenar muscles is found on the radial margin; the hook of the hamate can be palpated on

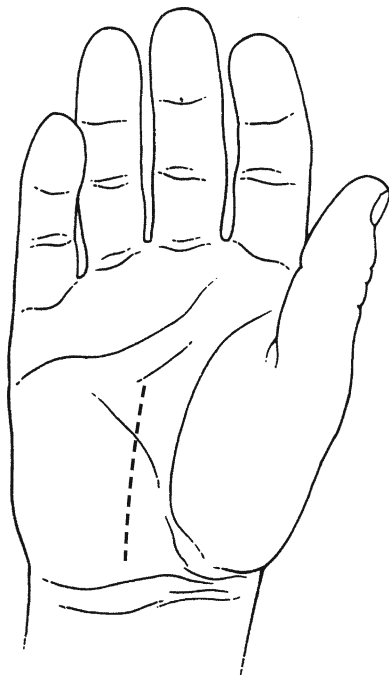


Figure 19.6. Preferred skin incision to avoid underlying neurovascular structures. Modified from JE Skandalakis, GL Colborn, PN Skandalakis, et al. the carpal tunnel syndrome: Part III. *Am Surg* 58(3):158–166, 1992 with permission from American Surgeon.

the ulnar aspect (Fig. 19.8). The ulnar artery and nerve are housed beneath the thick fibers of the palmar carpal ligament, just ulnar and palmar to the transverse carpal ligament. Distally, the palmar fat pad will mark the distal extent of the transverse carpal ligament. Proximally, the ligament will become confluent with the thinner, distal antebrachial fascia.

- Step 6.** Use a 15 blade to sharply release the transverse carpal ligament along the line of the ring finger metacarpal. Release along this line should be just ulnar to the position of the median nerve.
- Step 7.** Close the wound, skin only, with interrupted 4–0 or 5–0 nylon. A volar plaster splint is applied for 2 weeks.
- Step 8.** Under direct vision, release the distal antebrachial fascia in the proximal end of the incision.

712 19. Carpal Tunnel

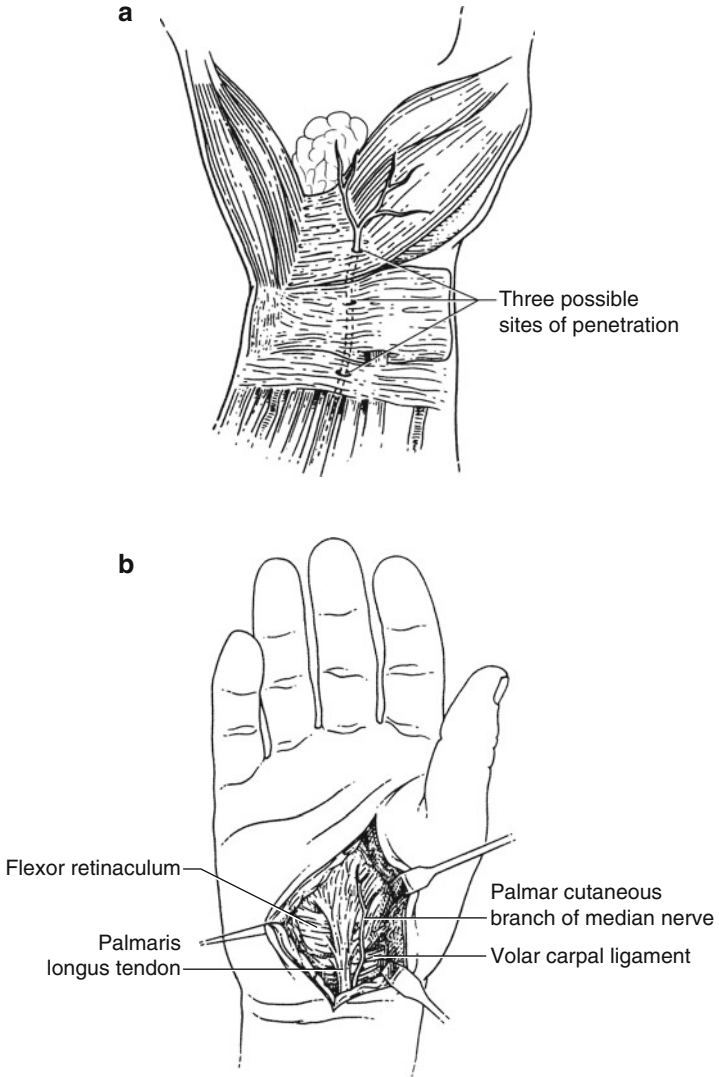


Figure 19.7. Superficial dissection to identify the distal palmaris longus tendon insertion into the palmar fascia and the distal palmar fat pad. (a) Three possible sites of penetration of the palmar cutaneous nerve. (b) Note the palmar cutaneous branch of the median nerve that parallels the palmaris longus tendon. Modified from JE Skandalakis, GL Colborn, PN Skandalakis, et al. the carpal tunnel syndrome: Part III. *Am Surg* 58(3):158–166, 1992 with permission from American Surgeon.

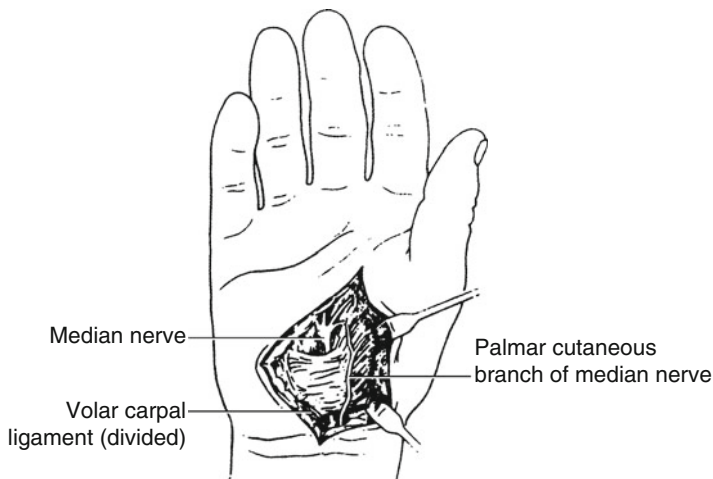


Figure 19.8. Identification of the transverse carpal ligament. Release of the ligament near its ulnar insertion limits risk to variant branches of the recurrent motor branch of the median nerve. From JE Skandalakis, GL Colborn, PN Skandalakis, et al. the carpal tunnel syndrome: Part III. *Am Surg* 58(3):158–166, 1992. Reprinted with permission from American Surgeon.

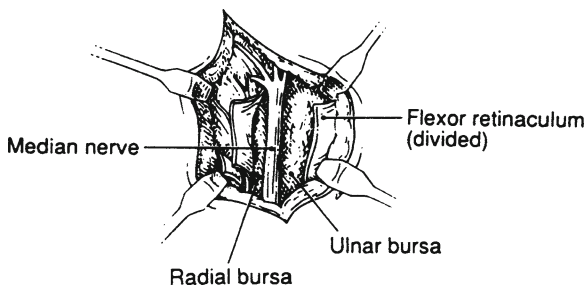


Figure 19.9. Division of the flexor retinaculum. Inspect the carpal tunnel contents. From JE Skandalakis, GL Colborn, PN Skandalakis, et al. the carpal tunnel syndrome: Part III. *Am Surg* 58(3):158–166, 1992. Reprinted with permission from American Surgeon.

Step 9. Inspect the cut edge of the ligament to ensure that the entire ligament is released. Inspect the carpal tunnel contents for anatomical abnormality, degenerative elements, and/or inflammatory conditions that may require additional treatment (Fig. 19.9). Make note of the condition of the median nerve (Fig. 19.10).

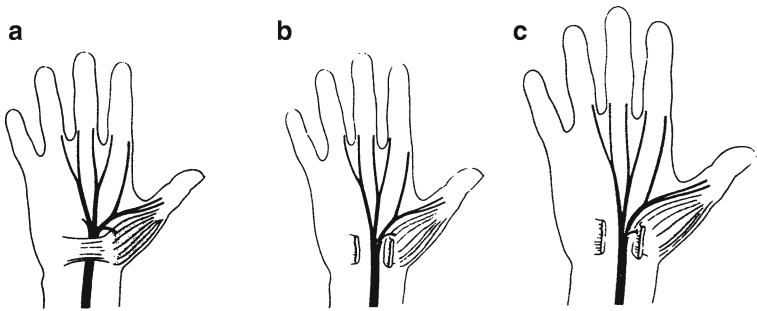


Figure 19.10. Anatomical variations of the median nerve in the carpal tunnel. (a) Regular branching of the median nerve, 55 percent. (b) Thenar branch leaving the median nerve within the carpal tunnel (subligamentous), 31 percent. (c) Transligamentous course of the thenar branch, 14 percent. From JE Skandalakis, GL Colborn, PN Skandalakis, et al. the carpal tunnel syndrome: Part III. *Am Surg* 58(3):158–166, 1992. Reprinted with permission from American Surgeon.

Step 10. Irrigate. Close the wound with a subcuticular absorbable suture.

Step 11. Apply a sterile soft dressing that allows for full finger range of motion.

Microsurgical Procedures

■ INTRODUCTION

The era of microsurgery, which followed the introduction of ultrafine, nonreactive sutures, precision surgical instrumentation, and improved optical magnification, led to digital replantation, free tissue transfer, vascularized bone grafting, and other procedures. This chapter provides basic information about microsurgical procedures, techniques, and the equipment needed to perform them.

■ MICROSURGICAL INSTRUMENTATION

Because of the exacting requirements of microsurgical procedures, high-quality instrumentation is crucial. Microsurgical tools require specialized storage conditions and individual cleaning, as well as regular inspections, repair, and replacement to ensure that they are ready for use by the surgical team.

A basic set of instruments should include microsurgical forceps (4, 5A), vessel dilating forceps, curved scissors, straight scissors, and vascular clamps (single and double for both arteries and veins). For more advanced procedures, surgical background with color contrast, microsutures, and microirrigation syringes are needed. Some complex cases may be facilitated by custom instruments.

■ METHODS OF MAGNIFICATION

Operating loupes—easily used and customized to each surgeon—work well for procedures in which lower levels of optical magnification (2.5–6.5×) are sufficient. The disadvantage of loupes is that magnification and depth of field are fixed.

An operating microscope is necessary for surgeries that require higher levels of magnification. This larger instrument provides exceptional image clarity and vibrant light. The operating microscope can be set up for use by a single operator or two surgeons. Newer microscopes have the capability for in-room televised display and recording of the operation. However, operating microscopes are more cumbersome to use than loupes, are expensive, and require significant maintenance.

Procedures often done with loupe magnification include:

- Pediatric hernia repair
- Hypospadias
- Discectomy
- Coronary artery bypass graft
- Arterial bypass graft using reversed saphenous vein interpositional graft
- Larger nerve repair
- Blepharoplasty
- Tendon repair

Procedures often done with use of the operating microscope include:

- Replantation
- Free tissue transfer
- Hand aneurysm resection and repair
- Smaller vessel repair (digital artery)
- Smaller nerve repair (digital nerve)
- Vascular repair

■ PSYCHOMOTOR SKILLS TRAINING

Like most surgical skills, precision techniques for microsurgery are best taught in a laboratory setting; standardized instruction is available in a number of centers. Typically students begin with simple methods for arterial repair. As their skills improve they advance to more difficult procedures, such as interpositional vein grafting. Because live animals are used, surgeons obtain direct feedback on the outcome. The significant learning benefit from this method is that students know their success rate for various procedures prior to taking them to a clinical setting.

■ SURGICAL SETUP

The setup for each case varies, but planning the procedure is time well spent. For most orthopedic and hand surgeries the microscope should be set up for “opposing” use, i.e., surgeon and assistant across from one another. For some ENT procedures, the surgeon and assistant may be oriented at right angles.

■ SUTURE MATERIALS

Surgeons generally prefer 7-0 to 11-0 monofilament, nonabsorbable sutures. Our preferences are for nylon and prolene.

■ PROCEDURE FOR VASCULAR REPAIR

Dissection/Preparation

For arterial repair in the limbs, regional or general anesthesia can be administered. The initial dissection should allow both proximal and distal control of the vessel. Usually this dissection is done with a broad pneumatic tourniquet inflated to a pressure that is 100 mmHg above the patient’s systolic blood pressure.

End-to-End Arterial and Venous Repair

The segment for repair (Fig. 20.1) is dissected free and the arterial ends are sharply trimmed using optical magnification. Using straight, sharp scissors, cut the vessel at right angles to the long axis of the artery. Gently dilate the artery,

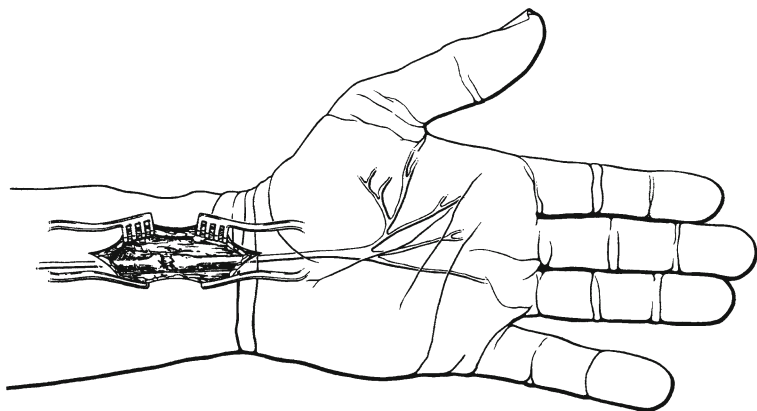


Figure 20.1. Vascular segment is dissected free.

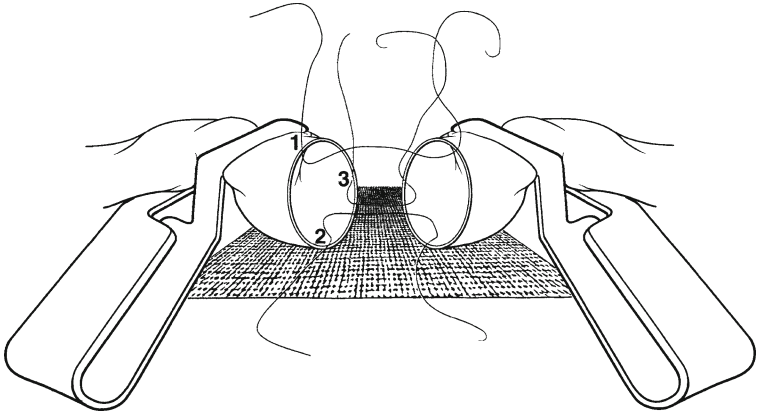


Figure 20.2. Interrupted suture technique.

clean the artery's interior of clot, and irrigate with a heparinized saline solution. With the tourniquet deflated, confirm satisfactory inflow and then apply a vascular occlusion clamp to the proximal artery. The two arterial ends are then positioned within the double clamp, leaving a small gap. For visual contrast, place a colored plastic background or suction mat behind the artery.

Suture the artery using an interrupted technique, everting the vessel edges. Place the initial two sutures 180° apart; then place the third suture halfway between them (Fig. 20.2). Each subsequent suture should again be placed halfway between the adjacent sutures until the vessel repair is complete (Figs. 20.3 and 20.4).

Turn the vessel over (180°) in the clamp. By opening the back wall with forceps, the surgeon can inspect the first half of the repair for accuracy. Again irrigate the vessel with a heparinized saline solution.

Assessing Patency

Next, remove first the distal clamp, then the proximal clamp. Inspect the repair for leakage and insert additional sutures as necessary. The surface of the vessel can be irrigated with Xylocaine to facilitate vessel dilation.

Begin assessment of patency of the repair. Inspect the distal color and capillary refill and feel for a distal pulse. Use a sterile Doppler to listen to the flow and perform a "milking test" of the repair: use two smooth forceps and place them side by side over the artery several centimeters proximal to the repair; occlude the artery with both forceps; gently slide the distal forceps distally across the repair site to a position well distal to the anastomosis so that

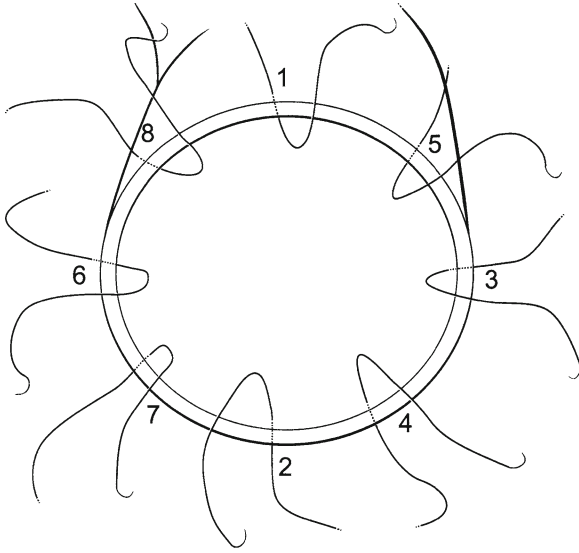


Figure 20.3. Intermediate suture placement.

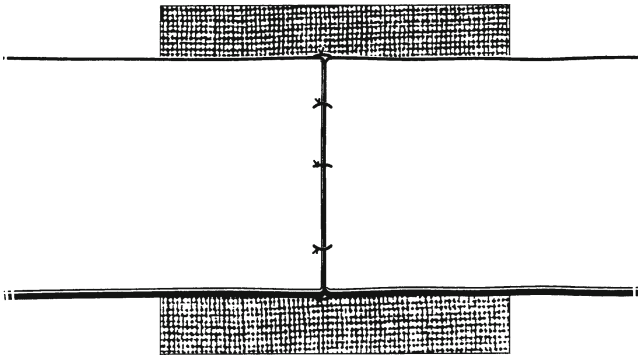


Figure 20.4. Back wall of sutured vessel.

the artery is “milked” flat. Release the arterial forceps proximal to the repair site and document anterograde flow that crosses the anastomosis in the artery. When possible, design a wound closure that places normal (or nearly normal) skin over the site of vascular repairs.

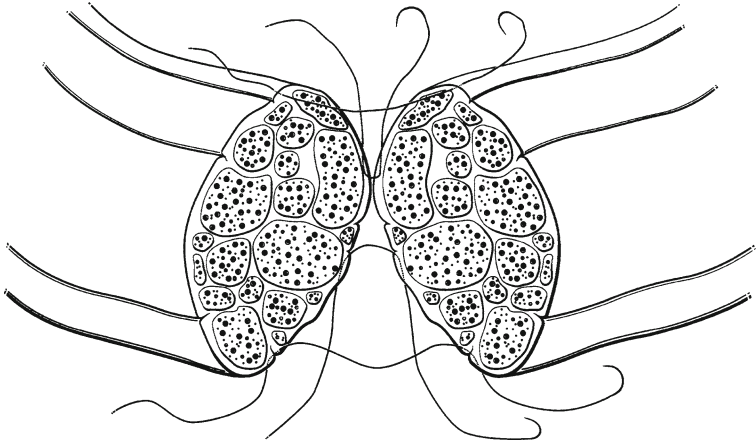


Figure 20.5. Nerve is oriented and first sutures are placed.

■ PROCEDURE FOR NERVE REPAIR

For nerve repair, clamps and positioning devices are usually not needed. Primary peripheral nerve repair is done using an interrupted epineurial suture method. For repair of traumatic injury, the proximal and distal ends of the artery are carefully identified and then mobilized by longitudinal dissection. When the nerve ends are mobilized sufficiently for end-to-end repair, the nerve must be oriented. Orientation will be facilitated by:

- A general working knowledge of the internal topography of the nerve
- Epineurial surface vessels that may be aligned in the repair
- Inspection of the internal fascicular array of the nerve

With the nerve oriented, the surgeon begins the repair by placing two sutures 180° apart in the external epineurium. Additional sutures are placed to bisect the distance between adjacent sutures until the repair is complete (Figs. 20.5 and 20.6).

Recommended suture gauges for specific nerves are as follows:

- Median, ulnar, and radial nerves: 7–0 to 10–0
- Common digital and proper digital nerves: 9–0 to 10–0

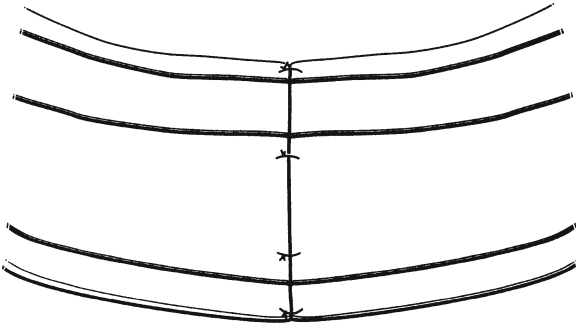


Figure 20.6. Intermediate sutures are placed.

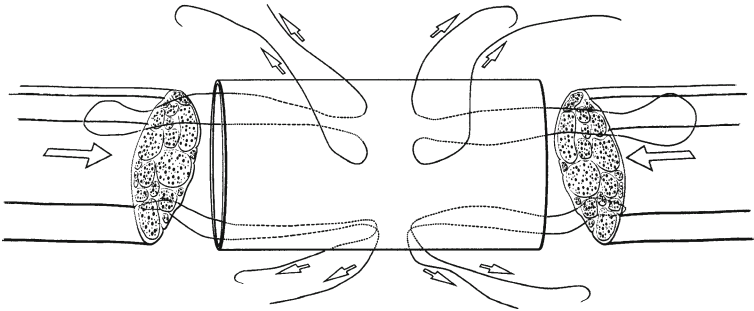


Figure 20.7. Neuroentubulation.

■ PROCEDURE FOR NEUROENTUBULATION

Neuroentubulation is an alternate method of nerve repair. It positions the transected nerve ends within 2–3 mm of each other, then allows repair to occur in the protected environment of the nerve tube. Previously, neuroentubulation was done with autogenous vein. There are now a number of commercially available devices for nerve entubulation. Initial dissection mobilizes the cut nerve ends. The cut ends are freshened with a sharp, straight scissors. With a suture method, the ends are advanced into the tube (Fig. 20.7).

Alternatively, the tube may be split, the nerve ends are laid into the tube (Fig. 20.8), and the tube is sutured closed with a running suture. The tube diameter should be slightly larger than the nerve to allow for postoperative edema in the nerve.

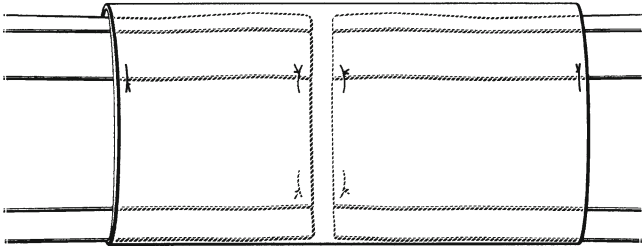


Figure 20.8. Tube split, nerve ends laid in, tube closure with running suture.

■ SUMMARY

Optical magnification and other improvements in instrumentation have expanded the surgeon's ability to treat a wide variety of difficult conditions. Appropriate tools and training enable the surgeon to repair vessels of less than 1 mm satisfactorily.

Miscellaneous Procedures

TECHNIQUE

■ DEVICE INSERTION

Subclavian Vein Catheter Insertion

- Step 1.** Place the patient in Trendelenburg position.
- Step 2.** Prep and drape the subclavian area. Make sure that the sternal notch is visible.
- Step 3.** Infiltrate the skin with a local anesthetic just underneath the clavicle at a point approximately halfway to two-thirds out from the sternal notch. While doing this, make sure that the needle gently touches the clavicle. Then, step down the injection so that the position of the needle is underneath the clavicle. Do not go deep enough to access the subclavian vein.
- Step 4.** Use the Seldinger technique to access the subclavian vein. Access is accomplished by using the needle that has been provided in the kit. The needle punctures the skin and is directed underneath the clavicle and aimed towards the sternal notch. As the needle is advanced, gentle back pressure is placed on the syringe. As the needle is advanced when the vein is accessed, the syringe will easily fill with blood. If on the way in the vein is not accessed, slowly withdraw the syringe, keeping gentle negative pressure. Quite often the vein will be accessed as the needle is withdrawn.
- Step 5.** Once the vein is accessed, insert the guide wire through the needle and advance into the vein. Remove the needle and continue advancing the guide wire (15 cm should be adequate).

724 21. Miscellaneous Procedures

Step 6. Place the introducer sheath over the guide wire and advance.

Step 7. Remove the inner rigid portion leaving the peel-away introducer sheath and insert the catheter into the introducer. Advance approximately 15 cm and then peel away the introducer sheath, leaving the catheter in place.

Step 8. Identify and isolate the superior thyroid artery. Flush all ports and secure the catheter to the skin with a 20 silk suture.

Remember:

- ✓ It is important not to change the orientation of the needle during insertion. Whatever angle you choose to insert the needle should be maintained until the needle is removed. Changing that angle when the needle is underneath the clavicle could injure the vein or artery.
- ✓ If the patient is being monitored, make sure that there are no premature ventricular contractions during insertion of the guide wire, which could be in too far and stimulating the heart. If the patient feels pain in the ear during insertion of the guide wire, the guide wire has likely traveled up the internal jugular vein.
- ✓ Avoid damage to cranial nerves during dissection by properly placing retractors or vascular clamps and by precise use of electrocoagulation current. If you are unable to access the vein with this technique, then try changing the angle of the needle insertion. I would suggest insertion so that the needle is aimed towards the sternoclavicular joint and aimed down approximately 30° to 45°.
- ✓ Make sure chest X-ray is obtained after this procedure to check placement of the line and to ensure that a pneumothorax has not occurred.

Chest Tube Insertion

Step 1. Place patient in a semi-decubitus position.

Step 2. Prep and drape chest at the level of the fourth intercostal space at the anterior axillary line.

Step 3. Infiltrate the skin with a local anesthetic of your choice approximately 2 cm distal to the fourth intercostal space. Infiltrate the tissue around and over the fifth rib. Step the needle up the fifth rib into the fourth intercostal space just above the rib.

Step 4. Make your incision through the skin with scalpel. Extend into the subcutaneous tissue.

Step 5. Using either a 6 or 8 in. Kelly clamp, begin blunt dissection, spreading with the clamp up towards the fourth intercostal space.

- Step 6.** Spread the tissue just above the fifth rib. With the clamp closed, push into the chest; once in, spread the clamp. At this point the index finger is inserted.
- Step 7.** Choose an appropriately sized chest tube depending on indications: larger for blood evacuation and smaller for pneumothorax or thin fluid. Using the Kelly clamp, grasp the end of the chest tube with the clamp so that the end of the clamp is even with the end of the tube.
- Step 8.** Insert the chest tube through the incision and direct posteriorly towards the apex of the thorax.
- Step 9.** Secure the chest tube to the skin using a 0 silk suture. It may be necessary to approximate the skin edges at one end or the other to get a good seal and prevent air from being sucked in.

Remember:

- ✓ The incision is made a little distal to the fourth intercostal space so that when the tube is eventually pulled, there will be a good seal and less chance for pneumothorax. It will also help to prevent air from being sucked around the tube when it is connected to the suction.
- ✓ The intercostal neurovascular bundle travels just inferior to each rib. It is for this reason that the tube is inserted over the rib and not under the rib.

■ BIOPSY

Sural Nerve Biopsy

INDICATIONS: Sural nerve biopsy is a well-established diagnostic procedure for peripheral neuropathies.

- Step 1.** Prep and drape the area of the lateral malleolus.
- Step 2.** Infiltrate the skin with a local anesthetic of your choice between the lateral malleolus and the Achilles tendon. This incision should be approximately 4 cm in length. If necessary extend the incision distally, following the curvature of the lateral malleolus and approximately 1 cm distal to the lateral malleolus.
- Step 3.** Commence blunt dissection when you have entered through the skin. The nerve, a glistening white structure approximately 3 mm in diameter, will be easily found.
- Step 4.** Infiltrate the nerve proximally and distally with a local anesthetic. Using scissors, transect the nerve proximally and distally. Try to obtain at least a 2 cm segment.
- Step 5.** Close the wound in layers. Use a 30 Vicryl for the subcutaneous tissue and a 40 nylon for the skin.

Muscle Biopsy

INDICATIONS: Muscle biopsies can be useful to help diagnose patients who present with symptoms such as weakness, muscle pain, cramps, and fatigue with activity. These symptoms in the presence of a neuropathy would also suggest a nerve biopsy. The muscle with pain or weakness is the one to biopsy.

- Step 1.** Prep and drape the anterolateral thigh.
- Step 2.** Infiltrate an area approximately 4 cm in length with a local anesthetic of your choice. This area will likely be over the rectus femoris. Infiltrate the local anesthetic into the subcutaneous tissue and muscle.
- Step 3.** Using Metzenbaum scissors, perform blunt dissection down to the muscle investing sheath.
- Step 4.** Score the investing sheath with a 15 blade.
- Step 5.** Grasp the underlying muscle with an Allis clamp.
- Step 6.** Remove a segment of muscle measuring approximately 3×2 cm. This is usually sent to pathology as a fresh specimen on ice.
- Step 7.** Close the wound in layers with 30 and 40 Vicryl.

Remember:

- ✓ Prior to removing the specimen the Bovie is not to be used because it can destroy and alter the histology of the specimen.

Bariatric Surgery

■ GENERAL DESCRIPTION OF GASTRIC BYPASS

The roux-en-Y gastric bypass has taken on many forms over the last five decades. While it is still performed as an open procedure across much of the country, the laparoscopic variant has enjoyed increasing popularity among bariatric surgeons and patients since Clark and Wittgrove first described their technique in 1994. The advancement of the roux limb may be performed in an antecolic/antegastric, retrocolic/antegastric, or retrocolic/retrogastric fashion. While each of these techniques has its own merits, it is advantageous for the practitioner to understand and be facile with each one; variations in patient anatomy as the situation presents may require the surgeon to diverge from his or her preferred approach.

What is described below is our technique for a laparoscopic retrocolic roux-en-Y gastric bypass. We recognize that there are many ways to “skin a cat,” with each resulting in an excellent outcome. While not described in this manuscript, we will often employ an antecolic approach based on the patient’s body habitus. We recognize, as well, that the use of a circular stapler placed trans-abdominally in order to create a stapled gastrojejunostomy is perfectly acceptable. However, this technique is not used in our practice. Furthermore, we now employ the DaVinci surgical robot for this procedure with the added advantage of enhanced visualization and intracorporeal dexterity. The technique of the procedure as described below, however, is the same regardless of the surgical approach.

ANATOMY

Gastric anatomy is presented in Chap. 7, stomach.

TECHNIQUE

■ RETROCOLIC ROUX-EN-Y GASTRIC BYPASS

DIET PRIOR TO SURGERY: We employ a two-week modified protein liquid diet in order to reduce the size of the liver, which aids in the visualization of the gastroesophageal junction.

TESTS PRIOR TO SURGERY: *H. pylori* testing is mandatory. Postoperative gastric ulcers in the remnant stomach are not only quite morbid but also can be a diagnostic and treatment dilemma. We have not found bowel prep to be beneficial preoperatively.

ENDOSCOPY: Routine preoperative upper endoscopy to rule out gastroduodenal lesions which will not be approachable endoscopically once the remnant stomach has been bypassed. Preoperative endoscopy also will help to define posterior herniation of the fundus that may not be evident at the time of the operation and which can lead to suboptimal pouch construction.

- Step 1.** The surgeon stands on the patient's right side with an assistant on the left.
- Step 2.** Prep and drape patient widely in anticipation of conversion to an open procedure if necessary.
- Step 3.** Establish pneumoperitoneum in the normal manner. We prefer introduction of a Veress needle just below the left subcostal margin.
- Step 4.** Enter the abdomen using a 5- or 10-mm optical viewing trocar 15–18 cm below the xiphoid and just to the left of the midline.
- Step 5.** Place two ports on the patient's right side: one just below the tip of the right lobe of the liver and the other in a line midway between the first port and the umbilicus. The second port should be a 12-mm port in order to accommodate a linear stapler.
- Step 6.** Place one or two more assistant ports in the left upper quadrant.
- Step 7.** Retract the left lobe of the liver anteriorly, using a Nathanson liver retractor placed through a small incision just below the xiphoid process.
- Step 8.** Inspect the entire abdomen. Any adhesions should be carefully taken down.
- Step 9.** Creation of roux loop prior to the creation of the gastric pouch.
- Step 10.** Identify the ligament of Treitz by retracting the greater omentum and transverse colon cephalad.

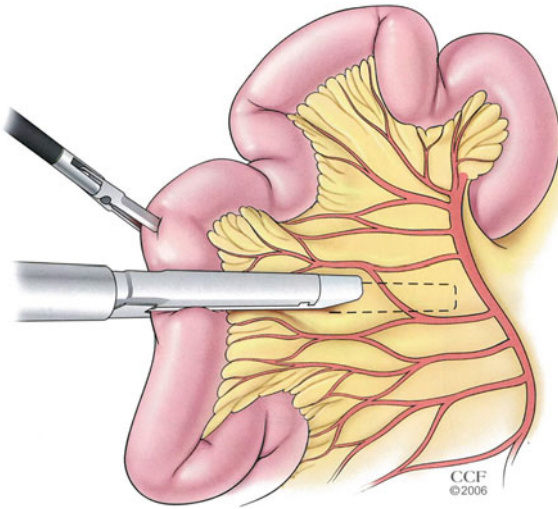


Figure 22.1. The small bowel is divided using a linear stapler. Two more firings of the stapler are used to divide the mesentery. This provides additional mobility for the roux limb (By permission of the Cleveland Clinic Foundation).

- Step 11.** Using a linear stapling device, divide the small bowel 40 cm distal to the ligament of Treitz. A vascular load is preferred when stapling the small bowel in order to reduce the incidence of staple line bleeding.
- Step 12.** To avoid ischemia of the two stapled ends, divide the mesentery for 4–5 cm in a direction perpendicular to the bowel (Fig. 22.1).
- Step 13.** Create the roux limb from the distal stapled bowel. We prefer a 120-cm roux limb for patients with a BMI less than 50 and a 150 cm roux limb for patients with a BMI greater than 50 kg/m² (Fig. 22.2).
- Step 14.** An energy device is used to create an enterotomy on the antimesenteric border of the base of the roux limb and near the stapled end of the proximal biliopancreatic limb.
- Step 15.** Create a side-by-side isoperistaltic anastomosis by placing a linear stapler into these enterotomies. After deploying the stapler, it is wise to slightly close it while it is being removed from the

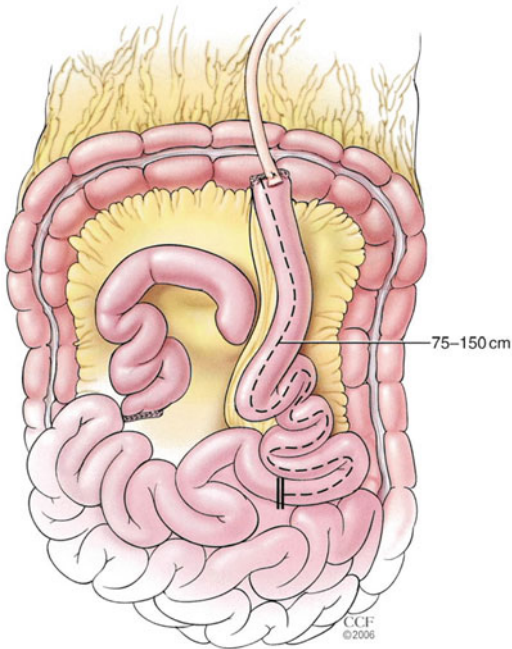


Figure 22.2. Creation of the roux limb (By permission of the Cleveland Clinic Foundation).

bowel lumen to avoid unnecessarily widening the common defect (Fig. 22.3).

- Step 16.** Close the common defect by aligning the edges of the bowel and deploying another staple load externally, or by oversewing the defect with a single layer of running 2-0 absorbable suture.
- Step 17.** The mesenteric defect must then be closed in order to prevent internal bowel herniation, which can be catastrophic. Close with a single running layer of nonabsorbable suture from the base of the mesenteric defect to the bowel. Care should be taken to avoid ligation of the small arterioles which may cause ischemia of the anastomosis (Fig. 22.4).
- Step 18.** For a retrocolic roux limb, the transverse mesocolon is held upright. A dimple can usually be seen just to the left of the middle colic vessels anterior to the ligament of Treitz. An energy device

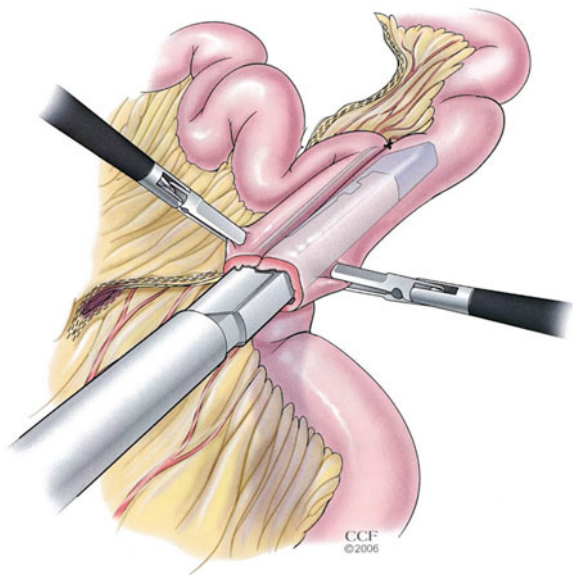


Figure 22.3. After the roux limb is measured, it is approximated to the biliopancreatic limb. Enterotomies are made. A linear stapler is used to create the anastomosis (By permission of the Cleveland Clinic Foundation).

is used to open the mesocolon for about 2.5 cm and to create a window into the lesser sac.

- Step 19.** Place the roux limb into the lesser sac, with care taken to avoid twisting. This is best achieved by keeping the divided end of the mesentery oriented to the left.
- Step 20.** Place the greater omentum and transverse mesocolon back into anatomic position.
- Step 21.** Inspect the gastroesophageal junction. Excise the anterior fat pad with an energy device so that the angle of His can be dissected.
- Step 22.** If a hiatal hernia exists, it is wise to dissect out the entire GE junction and repair it in the standard manner.
- Step 23.** Construct the pouch by creating a defect in the lesser omentum 6 cm distal to the GE junction. Enter the lesser sac from the lesser curvature of the stomach (Fig. 22.5).

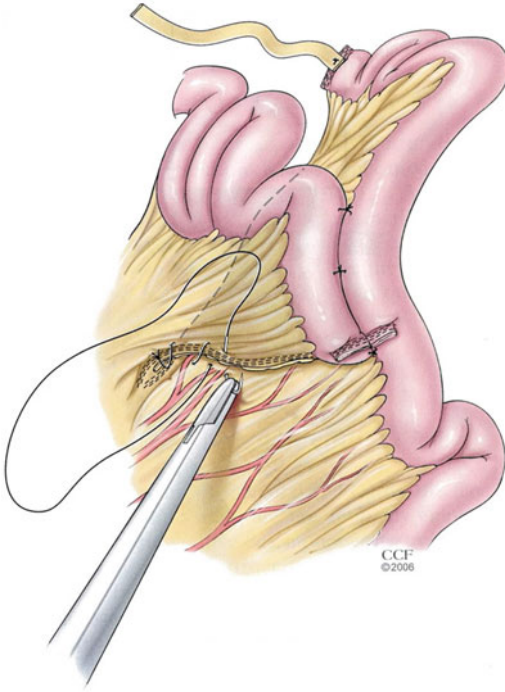


Figure 22.4. Closure of mesenteric defect (By permission of the Cleveland Clinic Foundation).

- Step 24.** After ensuring that all transoral intragastric devices have been removed by the anesthesia team, create a horizontal staple line with a 45-mm standard GI load linear stapler 6 cm distal to the GE junction.
- Step 25.** Inspect the posterior stomach. Take down any adhesions to the posterior lesser sac.
- Step 26.** The anesthesia team places a 36 French bougie transorally to the level of the staple line. It will be used to protect the esophagus and to calibrate the size of the gastric pouch.
- Step 27.** Carry the staple line cephalad through the angle of His. A complete division of the stomach must be ensured, because a gastro-gastric fistula can lead to weight regain.

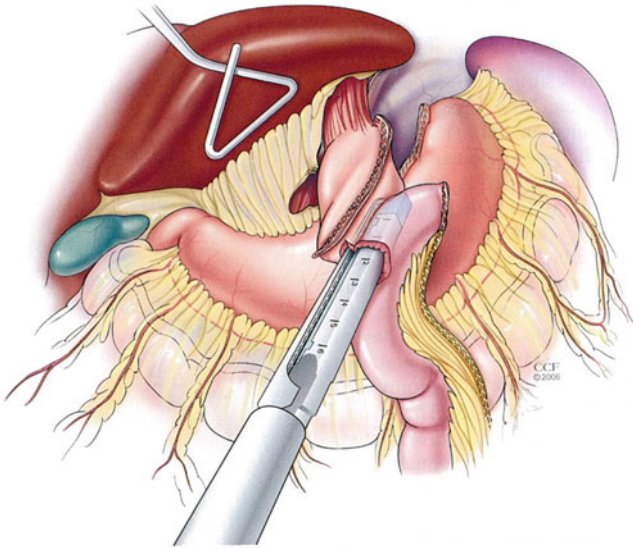


Figure 22.5. Creation of gastric pouch (By permission of the Cleveland Clinic Foundation).

- Step 28.** The roux limb is brought out through an opening in the gastrocolic ligament in an antegastric fashion, or brought out from behind the divided remnant stomach in a retrogastric fashion. Approximate the antimesenteric border near the stapled tip to the lower end of the gastric pouch
- Step 29.** Use a single layer of running 2–0 absorbable suture to approximate the base of the pouch to the antimesenteric border of the roux limb (Fig. 22.6).
- Step 30.** Use an energy device to create 1 cm mirroring defects in the lower edge of the gastric pouch and the roux limb anterior to the suture line.
- Step 31.** Run a posterior layer of running 2–0 absorbable suture to approximate the posterior edges of the gastrojejunostomy.
- Step 32.** Run the anterior inner layer of the gastrojejunostomy with a second 2–0 absorbable suture. Advance the 36 French bougie across the anastomosis into the small bowel in order to calibrate the size of the stoma (Fig. 22.7).

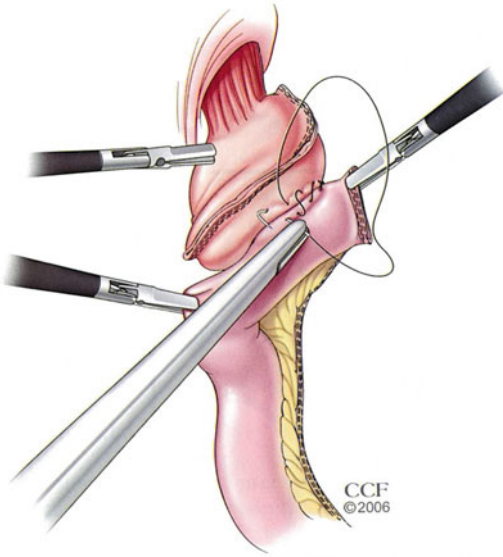


Figure 22.6. The roux limb is approximated to the gastric pouch (By permission of the Cleveland Clinic Foundation).

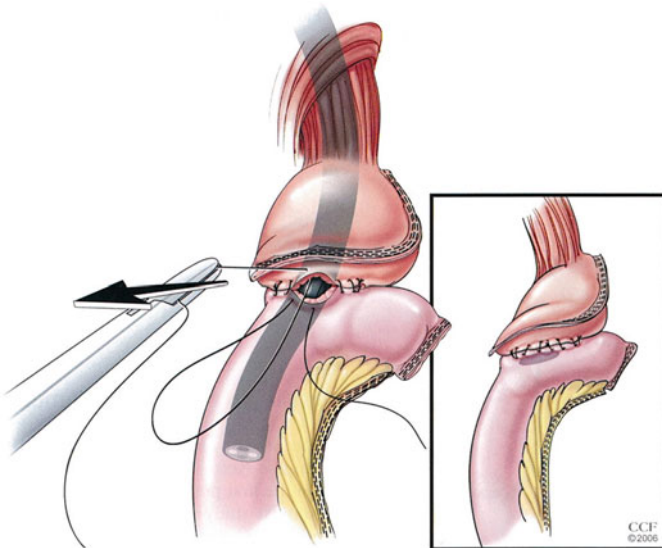


Figure 22.7. Completing the anastomosis. *Inset:* Common opening is closed (By permission of the Cleveland Clinic Foundation).

- Step 33.** Finally, a second anterior layer of running 2–0 absorbable suture is run in a Lembert fashion to complete the two-layer anastomosis.
- Step 34.** Test the integrity of the anastomosis. Clamp the roux limb just distal to the anastomosis. With the anastomosis submerged in saline, either infuse methylene blue through an orogastric tube or perform upper endoscopy to insufflate the pouch. The latter technique allows the surgeon to rule out an intraluminal anastomotic bleed, which can be immediately controlled by oversewing.
- Step 35.** With a competent anastomosis, surgical drains are typically not left in place unless there is a concern with the tissue's ability to heal.
- Step 36.** In the case of a retrocolic roux limb, the underside of the transverse mesocolon is again inspected. In order to prevent problems with poor emptying, gently reduce any redundant bowel back below the mesocolic defect. Close the defect by running a 2–0 permanent suture to approximate the cut edges of the transverse mesocolon the bowel. Take care to include the entire Peterson defect, which can be found on the patient's right side just below the site of entrance of the bowel through the mesocolic defect.
- Step 37.** The greater omentum and transverse mesocolon are again placed back in anatomic position. In order to prevent injury to the spleen or the newly formed gastrojejunostomy, carefully remove the liver retractor under direct visualization
- Step 38.** Remove the trocars. The carbon dioxide is completely expelled from the abdominal cavity (Fig. 22.8).

Postoperative:

- ✓ Pain control is generally not an issue postoperatively. Pain is generally well controlled with a PCA (patient-controlled analgesia) device that can be removed the morning following surgery and replaced with a liquid narcotic for a few days.
- ✓ A Foley catheter, placed after induction of anesthesia, is left overnight to monitor urine output. It is removed the morning following surgery.
- ✓ Unless there is concern about the anastomosis, patients are allowed ice chips on the night of surgery and started on a sugar-free clear liquid diet on the morning of post-op day 1.
- ✓ We do not employ swallow studies routinely. There is a well-published 50 % false negative rate for these studies. Intraoperative testing of the anastomosis should be all that is needed to ensure a competent suture line.

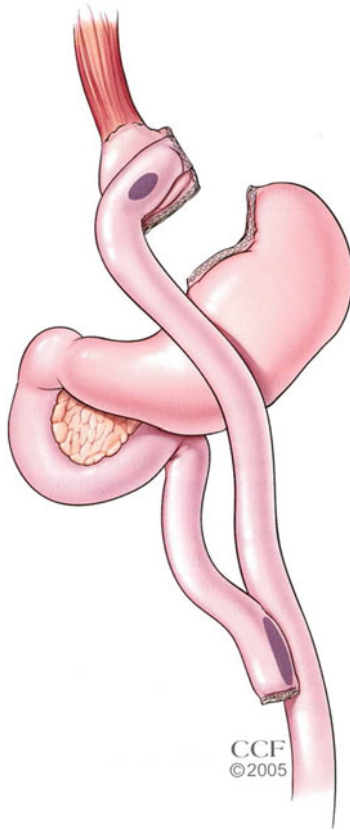


Figure 22.8. Completed roux-en-Y gastric bypass (By permission of the Cleveland Clinic Foundation).

- ✓ Patients should ambulate as early as the night of surgery and be kept on subcutaneous DVT (deep vein thrombosis) prophylaxis throughout the hospital stay.
- ✓ In our practice, any patient with a history of DVT, pulmonary embolism, or with a BMI of 50 kg/m^2 or greater is sent home on subcutaneous anticoagulation for one week.
- ✓ Patients who are tolerating liquids without nausea and ambulating may be discharged home on postoperative day 1 or 2.

738 22. Bariatric Surgery

- ✓ Patients are kept on a liquid diet for one to two weeks post-op. This diet consists of liquid protein supplementation, sugar-free fluids, and chewable vitamins.

■ LAPAROSCOPIC VERTICAL SLEEVE GASTRECTOMY

ANESTHESIA: General

PATIENT POSITIONING:

1. Patient in the supine position with both arms out.
2. Footboard secured to bed.
3. Care is taken to ensure that the patient's heels are on the footboard with toes out, to minimize the risk of ankle subluxation when in the standing position.
4. Surgeon stands on the patient's right with assistant on the left.

OTHER: Foley catheter, orogastric tube, sequential compression devices.

- Step 1.** Prep and drape in standard fashion for either open or laparoscopic access
- Step 2.** Administer perioperative cephalosporin and low molecular weight heparin in the preop holding area.
- Step 3.** Establish carbon dioxide pneumoperitoneum to 15 mm Hg with a Veress needle inserted in the left subcostal margin.
- Step 4.** Enter abdomen with a 12-mm optical viewing trocar just left and superior to the umbilicus.
- Step 5.** Port position as shown: Assistant 5-mm port in the left mid abdomen, 15 mm port in the right mid abdomen, 5 mm port in the right upper quadrant. Sub-xiphoid incision for the hook liver retractor.
- Step 6.** Once trocars are in position, patient placed in slight reverse Trendelenburg. The liver retractor is fixed to the bed with a mechanical arm.
- Step 7.** Dissection begins on the greater curve of the stomach 5 cm proximal to the pylorus. This is usually in the area of the insertion of the right gastroepiploic artery.
- Step 8.** All of the gastrocolic, gastrosplenic (short gastric vessels), and gastrophrenic attachments are divided using a harmonic scalpel, ligasure, or enseal device depending upon surgeon preference. The most cephalad aspect of the dissection on the greater curve is complete when the left crus is identified.
- Step 9.** Inspect the hiatus for a hiatal hernia.

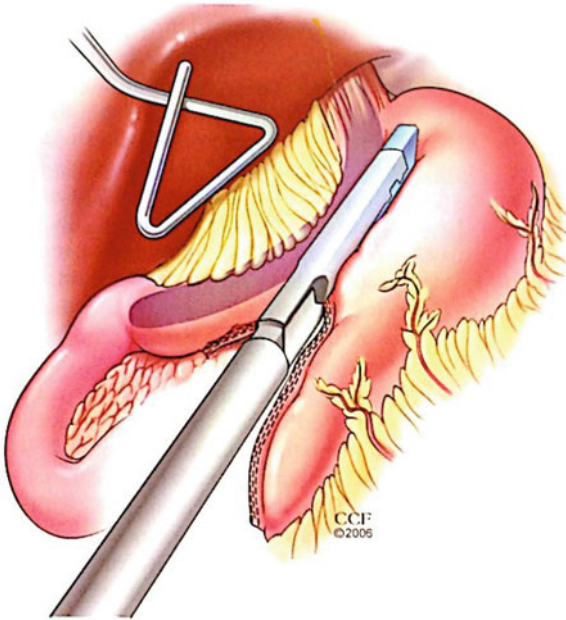


Figure 22.9. The stapler is fired successively from the antrum to the angle of His adjacent to an intragastric bougie (By permission of the Cleveland Clinic Foundation).

- Step 10.** If a hiatal hernia is encountered, the hiatus is circumferentially mobilized and a posterior cruroplasty is performed with interrupted 0-Ethibond sutures. Use a 60 Fr bougie to calibrate the posterior cruroplasty (if performed)
- Step 11.** A 36 Fr round, non-tapered tip bougie is advanced and situated along the lesser curve of the stomach. Take care to ensure that there is no orogastric tube or esophageal temperature probe in the patient's mouth at this time to eliminate the risk of accidental division of these tubes when the stomach is divided.
- Step 12.** Starting 5 cm proximal to the pylorus on the greater curve of the stomach use a surgical stapler to begin the vertical gastrectomy. We routinely start with the 4.1 mm thick tissue loads and transition to the 3.8 or 3.5 mm tissue loads. Often, we also use tissue reinforcement (although this is still debatable) (Fig. 22.9).
- Step 13.** The vertical gastrectomy continues, using the bougie as a guide. Care is taken to avoid narrowing the gastric pouch at the incisura. Care is also taken at the most cephalad aspect approaching the

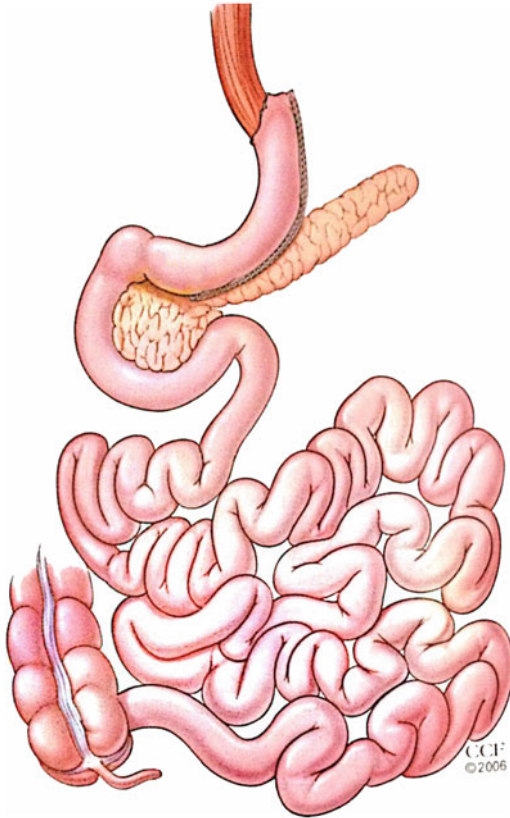


Figure 22.10. Completed laparoscopic sleeve gastrectomy (By permission of the Cleveland Clinic Foundation).

gastroesophageal junction to not hug the bougie, in order to avoid an inadvertent side bite on the distal esophagus.

- Step 14.** Perform an on-table leak test. Options include an air leak test using an endoscope, a saline submersion leak test, or a dye leak test. If the leak test is negative, we do not routinely perform a post-op day 1 upper GI series, unless it is clinically indicated.
- Step 15.** The portion of the stomach to be removed is placed in an endocatch bag and removed via the 15-mm trocar site.
- Step 16.** Remove all trocars under direct vision. Close the 15-mm fascial incision with 0 vicryl (Fig. 22.10).

Postoperative:

- ✓ Patients begin ambulating the evening of surgery.
- ✓ Ice chips are allowed immediately following surgery.
- ✓ The patient is advanced to a liquid diet postoperative day 1. Patients are discharged home if they are able to tolerate at least 4 ounces of liquids per hour.

Index

A

- Abdominal aortic aneurysm repair, 665–666
- Abdominal esophagus. *See* Gastroesophageal junction
- Abdominal wall
 - anterior, 113–115
 - blood supply
 - arterial, 131–133
 - venous drainage, 133
 - fossae, lower anterior, 117–118
 - groin (*see* Groin)
 - incisions
 - lower abdomen (Pfannenstiel incision), 154–155
 - lower midline, 152
 - McBurney, 156
 - pararectus, 152, 154
 - principles, 150
 - rectus (paramedian), 152–153
 - subcostal, 156
 - upper abdomen, 154
 - upper midline, 151–152
 - varieties, 150–151
 - inguinal area, laparoscopic cadaveric anatomy
 - anatomical entities, 144, 145
 - bladder and anterior abdominal wall, 138
 - circle of death, 147
 - diagrammatic presentation, 136
 - iliopubic tract and ligament of Cooper, 143
 - inferior epigastric vessels, 142
 - inguinal venous system, vasculature variations, 141
 - laparoscopic topographic anatomy, 137
 - myopectineal orifice, Fruchaud, 142
 - spermatic cord and iliac vessels, 143
 - transversalis fascia and femoral sheath, 139
 - triangle of doom, 146
 - triangle of pain, 146
 - vasculature, inguinal, 140
 - vessels and nerves, 144
 - lower anterior body wall, 117
 - nerve supply, 133–135
 - posterior (lumbar) body wall
 - inferior hernia, Petit triangle, 149

- Abdominal wall (*cont.*)
 inferior lumbar triangle
 (Petit), 148
 muscle layers and fascia,
 147–148
 superior lumbar triangle
 (Grynfeltt), 148
 umbilical region, 115–116
- Abdominoperineal resection
 abdominal phase, 480
 incision, perianal, 481, 482
 perineal phase, 481
 rectum, 481, 483
 sharp dissection, 481, 482
 sigmoid colon, 480
- Accessory spleen, 614–615
- Achalasia/cardiospasm
 bougie insertion and myotomy
 continuation, 273, 274
 dissection, stomach
 curvature, 272
 exposure, mucosal surface,
 272, 273
 suturing, gastric fundus, 273, 274
- Adrenalectomy
 anterior approach
 dissection direction, 642–643
 downward retraction, 646
 gastrocolic omentum opening,
 641–642
 incisions, 640
 Kocher maneuver, 644–645
 left adrenal gland, 641–644
 left mesocolon, incision,
 642–643
 midline incision, 644
 parietal peritoneum, incision,
 641–642
 right, exposure and
 mobilization, 644–645
 unilateral/bilateral, 645–646
 anterior, left, 647
 left, 646
 posterior approach, 647
 right, 647–648
 thoracoabdominal approach, 651
 unilateral/bilateral
 adrenal vein, division,
 650–651
 finger dissection, 650–651
 Gerota's fascia, incision, 650
 latissimus dorsi and serratus
 posterior muscles,
 division, 649
 resection, 11th rib, 649
- Adrenal gland
 description, 635
 relations, 635–637
 vascular system
 arterial supply, 637–638
 lymphatic drainage, 638–639
 venous drainage, 637–638
- Aldosteronism, 642
- Allen's test, 685
- Anal canal
 surgical
 mucosa, 439
 pectinate line and changes,
 439, 441
 rectal columns, 440
 wall, musculature
 external anal sphincter,
 437–438
 and rectum, 437–438
 surgical, 439
- anal canal
 surgical and perianal regions
 anal fistulectomy (*see* Anal
 fistulectomy)
 anatomy, 494
 distal interphalangeal joint,
 495, 496
 gauze packing, 495, 499
 incision, swelling, 495, 499
 intracavitary digital
 examination, 495, 499

- LIFT (*see* Ligation of intersphincteric fistula tract (LIFT))
- metacarpophalangeal joint, 494–495
- sigmoidoscopic examination, 494, 495, 498
- Anal fissure, 503–504
- Anal fistulectomy
- description, 497
 - excision, fistulous tract, 497, 500
 - fibrin plug, 497, 501
 - Goodsall–Salmon’s rule, fistulas, 497, 501
 - horseshoe fistula, 502
 - internal fistula opening, 497, 500
 - seton placement, 497, 500
- Anatomy
- nail, 6
 - scalp, 3
 - skin, 2
- Anorectum. *See* Colon
- Antrum
- antrum–body junction, “average stomach”, 319
 - distal pyloric, 316
 - and fundus, 295
 - gastric, 297
- Anus
- J-pouch, 480
 - rectum, 453–454
- Aorta
- abdominal portion, 665
 - and graft, 677
- Appendectomy
- appendix and mesentery, 422, 424
 - closing, layers, 425, 427
 - closing, skin, 425, 428
 - division, 425, 426
 - incision, fibers, 422, 423
 - inversion, 424, 426
 - laparoscopic, 428–430
 - ligation, 424, 425
 - location, McBurney’s point, 422, 423
 - packing, wound, 425, 427
 - preparation, peritoneum, 422, 424
 - site, ligation, 424, 425
- Appendicular artery
- lymphatic drainage, 421
 - single, 420
 - and vein, 420
- Appendicular vein, 420
- Appendix
- appendectomy (*see* Appendectomy)
 - mesentery, 419
 - vascular system, 420
- Arteriae rectae, 348
- Arteriovenous fistula (AVF)
- brachiocephalic, 686–687
 - radiocephalic, 685–686
- Autotransplantation, 622, 624
- AVF. *See* Arteriovenous fistula (AVF)
- Axilla
- artery, 97, 98
 - contents evacuation, 106, 110
 - dissection, 106, 108
 - exposed, 106, 108
 - lymph nodes, 98–99
 - structures, 104–105
 - topography, 93
 - vein and artery, 106, 109
 - walls, 91–92
- B**
- Bard plug and patch repair
- mesh insertion, 207–209
 - onlay patch, 207, 211
 - sac dissection, 207–208
 - securing mesh, internal oblique, 207, 210
 - suturing mesh, conjoined area, 207, 211

- Bariatric surgery
 anatomy, 728
 gastric bypass, 727
 laparoscopic vertical sleeve
 gastrectomy (*see*
 Laparoscopic vertical
 sleeve gastrectomy)
- Benign, skin lesions
 excision, cyst, 7–8
 incision, cyst removal, 7
 subcutaneous tissue, dissection, 7
- Bilateral salpingo-oophorectomy
 (BSO), 701
- Billroth
 Billroth I
 angle of sorrow, 327, 328
 division, stomach, 325, 326
 gastric and duodenal walls,
 325, 326
 transection, distal
 stomach, 325
 Billroth II
 elevation, transverse colon,
 328, 331
 four-layer anastomosis, 328,
 332–333
 method, anastomosis,
 328, 334
 partial closure, gastric
 opening, 328, 330
 proximal loop insertion,
 mesocolon, 328, 332
 specimen removal and
 closing, duodenal opening,
 328, 330
 and stomach mobilization,
 328, 329
 suture, mesocolon, 328, 331
 transection and removal, distal
 stomach, 328, 329
- Biopsy
 muscle, 730
 sentinel lymph node, 10
 sural nerve, 725
- Blepharoplasty, 716
- Branchial cleft
 excision
 fistula inset, 75–76
 fistulous tract exposure, 75–76
 location, incision, 75
 remnants, anatomy
 cysts, 49–51
 fistulas, 48
 incomplete closure, 51
 sinuses, 48–50
- Breast
 axilla, 93
 deep fascia, 91–92
 description, 91
 excisional biopsy
 creation, flaps, 103
 defect suturing, 104
 Langer's lines, incision, 103
 morphology, 94
 muscles and nerves, 94–96
 vascular system
 arterial supply, 94–98
 lymphatic drainage, 98–100
 lymph nodes, 98–99
 venous drainage, 98
- BSO. *See* Bilateral salpingo-
 oophorectomy (BSO)
- C**
- Cardiospasm. *See* Achalasia/
 cardiospasm
- Carotid artery
 and facilitation, vascular
 control, 670
 internal, 674
- Carotid endarterectomy
 arterial control, 670, 671
 arteriotomy, 670, 671
 bifurcation and adjacent nerves,
 669–670
 description, 665
 endarterectomy spatula, 672–673

- indwelling shunt placement, 672
- infiltration, local anesthesia, 669
- monofilament suture, 673
- suction drain, 674
- Carpal tunnel
 - central zone divisions, 703, 709
 - divisions, distal zone, 703, 709
 - flexor retinaculum, 703, 706
 - palmar arches, 703, 705
 - palmar cutaneous branch, 703, 708
 - proximal surgical zone, 703, 707
 - surgical treatment
 - anatomical variations, median nerve, 713–714
 - flexor retinaculum, 713
 - skin incision, 710, 711
 - superficial dissection, 710, 712
 - transverse carpal ligament, 710, 713
 - upper proximal zone divisions, 703, 709
 - wrist cross section, 703, 704
- Catecholamine, 642, 645
- Catheter
 - placement, 306, 307
 - subclavian vein, insertion, 723–724
- Caudate lobe
 - drainage, 522
 - resection, 562
 - subsegments, 519
 - transverse fissure/porta hepatis, 516, 517
- Cecopexy
 - colostomy (*see* Colostomy)
 - mobile cecum, 455, 456
 - teniae, 455, 456
- Cecum
 - appendix, 419
 - description, 431
 - identification, 422
 - inferior ileocecal fossa, 431–432
 - reinsertion, 422, 424
- Cervix
 - bladder, 693
 - esophagus, 256–257
 - submandibular triangle
 - basement, 21–22
 - contents, 20
 - floor, 21
 - lymphatic drainage, 22
 - neural “hammocks”, 19
 - roof, 17–19
 - subdivision, 18
 - triangle
 - carotid, 18, 23
 - muscular, 18, 23
 - posterior, 24–25
 - submental, 18, 22
 - and uterine segment, 689, 693
- Chest tube insertion, 724–725
- Cholangiogram
 - cystic duct, 581
 - T-tube drainage, 582
- Cholecystectomy
 - cystic
 - and common ducts, 576, 578
 - duct and artery, 576–577
 - electrocoagulation, gallbladder fossa, 578, 579
 - laparoscopic
 - cystic artery and duct, 602, 603
 - gallbladder, 602
 - liver, gallbladder, 603, 604
 - port placement, 600–601
 - procedure, 601
 - separating gallbladder, 604
 - procedures, 576
- Choledochocystectomy
 - ana, 597, 600
 - anastomosis, 597, 599
 - evaluation and lysis, 597
 - hepaticojejunal anastomosis, 597, 598
 - jejunojejunal anastomosis, 597, 599

Choledochoduodenostomy

- anastomosis, common bile duct and duodenum, 595, 596
- common bile duct, 595, 596
- duodenum, 593, 595
- placement, sutures, 595, 596

Colectomy

- colon, 459, 461
- colorectal anastomosis, 490
- distal colon fixation, 459, 462
- fixation sutures, 457, 458
- incision, transverse, 455, 457
- insertion, fingers, 459, 461
- laparoscopic and hand-assisted
 - right
 - periumbilical incision, 490–491
 - transverse colon and ileum, 491
 - laparoscopic hand assisted, 483–484

left

- closure alignment, 467, 470
- lateral approach, 466
- omentectomy, 467
- splenicocolic, phrenicocolic and pancreaticocolic ligaments, 467, 469
- ureter location, 467, 470
- loop, 455, 457–458
- operating room arrangement, splenic flexure
 - mobilization, 486, 488
- rectus muscle fibers, 459–460
- resection, sigmoid, 484–485

right

- alignment, colon and ileum, 464, 468
- anastomoses, 465, 468
- division, colon and ileum, 464, 467
- omentectomy, 463, 466
- resection line, 463, 465
- stapler insertion, 465, 468
- vascular division, 463, 464

sigmoid colectomy and low

- anterior resection, 489
- site, stoma, 459, 461
- skin level, stoma, 459, 462
- splenic flexure and left colon, 486–487
- stapler, 489
- stoma, 458–459
- transverse, 457, 458
- trocar placement, 485, 486

Colon

- anus, 453
- artery and lesion, 448–451
- ascending mesocolon, 432
- cecopexy (*see* Cecopexy)
- cecum, 431–432
- decatalogue, surgery, 455
- descending, 434
- description, 431
- fascial relations and tissue spaces, 440–442
- large intestine wall (*see* Large intestine wall)
- low anterior resection and triple stable procedure, 471–477
- lymphatic drainage, 448
- mesocolon, sigmoid, 433, 435
- mobile cecum, 432, 433
- pelvic diaphragm and continence, 442–443
- peritoneal reflections, 440 and rectum (*see* Rectum)
- rectum and anal canal, 434, 436
- resection
 - description, 462–463
 - left colectomy, 466, 467, 469–470
 - right colectomy, 463–468
- right, abdominal wall, 432, 433
- sigmoid, 452
- surgical anal canal and perianal regions (*see* Anal canal)
- transverse, 432

- Colostomy
- colon loop, 457, 458
 - distal colon fixation, 462
 - fat separation, 459, 460
 - fingers insertion, 459, 461
 - fixation sutures, 457, 458
 - incision, transverse, 457
 - loop, 455, 457
 - loop, transverse, 457, 458
 - site, stoma, 459, 461
 - skin level, 462
 - stoma, 458–459
 - transverse, 456
- Common bile duct
- diameter, 570
 - exploration
 - closure, 587, 591
 - demonstrating patency, 583, 588
 - duodenotomy, incision site, 583, 588
 - incision site, 583, 585
 - lateral peritoneum, 582, 583
 - “milking” stones, 583, 586
 - opening, stone removal, 583, 586
 - palpation, 582, 584
 - papillotomy, 583, 590
 - performance, duodenotomy, 583, 589
 - stay sutures, 583, 584
 - stones removal, instrumentation, 583, 587
 - T-tube insertion, 587, 591
 - and extrahepatic biliary tract, 569
 - length, 569
 - and pancreas, 570
 - retroduodenal portion, 569
- Common hepatic ducts
- cystohepatic junction, 565, 566
 - right and left, 565
 - variations, 565, 566
- Component separation
- external oblique muscle and rectus sheath, 163–164
 - ventral hernia, 163
- Crura
- origins, 217
 - pattern, 217–219
- Cystic duct, 567
- Cystogastrostomy
- aspiration, 397, 399
 - incision site, 397–399
 - suture, cyst wall, 397, 400
 - suture site, 397, 400
- Cysts, 49–51
- D**
- Deep fascia
- axillary, 28
 - buccopharyngeal, 27
 - carotid sheath, 26
 - investing, anterior/superficial layer, 25–27
 - pretracheal/middle layer, 26
 - prevertebral, posterior/deep layer, 26
 - walls, axilla, 91–92
- Diaphragm
- anatomy, 217
 - diaphragmatic-mediastinal relations (*see* Mediastinum)
 - esophageal hiatus (*see* Esophagus)
 - hernia
 - hiatus (*see* Hiatus)
 - laparoscopic nissen fundoplication (*see* Fundoplication)
 - sliding (*see* Sliding hernia)
 - traumatic, 243
 - nerve supply, 228, 230

Diaphragm (*cont.*)

- openings
 - aortic opening, 220, 222
 - esophageal hiatus, 218–223
 - hiatus, 218, 223
 - median arcuate ligament, 222–223
 - paraesophageal hernia (*see* Paraesophageal hernia)
 - traumatic diaphragmatic hernia, 243
 - vascular system
 - arterial supply, 226–227
 - lymphatic drainage, 227, 229
 - venous drainage, 227–228
- Direct inguinal hernia, 176, 179–181
- Distal pancreatectomy
- division, head of pancreas, 380, 381
 - exploration, pancreas, 380
 - laparoscopic
 - dissection, 393
 - EBVS device, 393
 - fibrin glue, 394
 - insufflate, abdomen, 392
 - LPR, 390–391, 394, 395
 - mobilization, pancreas, 393
 - pancreatic resection
 - instrumentation, 392
 - splenic preservation, 393
 - trocar placement, 392–393
 - ligated vessels, 380, 383
 - partial, 379
 - preparation
 - splenectomy, 380, 381
 - splenic vein tributaries, 380, 382
 - splenic artery division, 380, 382
 - with/without splenectomy
 - end-to-end
 - pancreaticojejunostomy, 384

- transection, pancreas, 382, 383

Diverticulum. *See*

- Pharyngoesophageal diverticulum

Duodenal papilla

- entities, sphincter of Boyden, 366, 368
- minor and major, 357
- musculature, 366
- relations, pancreatic and common bile ducts, 369
- T arrangement, mucosal, 367, 368

Duodenojejunal junction, 346

Duodenojejunostomy, 357, 360

Duodenotomy, 353

Duodenum

- configurations, Treitz suspensory ligament, 346, 347
- exposure and mobilization
 - accessory pancreatic duct, 356
 - bile duct, 357
 - Cattell maneuver, 354, 356
 - medial retraction, right colon, 354, 355
 - right colon, incision, 354
- sagittal section, 345, 346
- surgical applications, 353
- vascular compression repair
 - dilated proximal and duodenojejunostomy, 357, 360
 - duodenum crossess, spine, 357, 358
 - ligament, Treitz, 357, 359
 - sagittal section, 357, 359
 - superior mesenteric artery, 357, 358
- vascular system (*see* Vascular system)

E

- Elective infrarenal abdominal aortic aneurysm repair
 aneurysm sac closure, 677, 682
 aortic wall and common iliac arteries, 676–677
 back-bleeding lumbar arteries, 676, 678
 end-to-side anastomosis, 676, 680
 inferior mesenteric artery reimplantation, 676, 677, 681
 infrarenal aorta, 675
 proximal suture line, 676, 679
- Epigastric hernia
 fat dissection, 165–166
 linea alba, 165
 midline occurrence, 165
 small defect closure, 165–166
- Epineurium, 720
- Esophageal hiatus and crura
 peritoneal reflections, 262–263
 phrenoesophageal ligament, 261–262
 surgical considerations, 261
- Esophagectomy
 abdominal portion
 division, short gastric and left gastroepiploic vessels, 277
 midline upper abdominal and oblique left cervical incisions, 273, 275
 mobilization, stomach, 278, 279
 penrose drain, 276
 retractors *in situ*, 273, 276
 cervical portion
 anterior and posterior esophageal mobilization, 279, 281
 esophagus division, GIA stapler, 279, 282
 oblique incision, 279, 280
 postoperative care, 285
 preparation, gastric conduit and anastomosis
 end-to-side technique, single-layer, 283, 284
 linear GIA 75 stapler, 280, 282
 position, intrathoracic stomach, 283
- Esophagus
 abdominal and gastroesophageal junction (*see* Gastroesophageal junction)
 achalasia/cardiospasm, 272–274
 colon interposition
 colocolonic end-to-end anastomosis., 291, 293
 segments, 291, 292
 constrictions, 253–254
 curves, 254
 gastrophrenic ligament (*see* Gastrophrenic ligament, esophagus)
- hiatus
 attachments, 219, 223
 diaphragm, apertures, 219, 221
 inferior vena cava (IVC), 219, 222
 narrowing methods, 220, 224
 structures, 228–229, 231, 232
 hiatus and crura, 261–263
- Ivor Lewis approach (*see* Ivor Lewis approach)
- Ivor Lewis-McKeown (Three-Stage) esophagectomy, 290
- left thoracoabdominal esophagectomy, 290
- length, 253
- pharyngoesophageal diverticulum, 268–271
 junction (*see* Pharyngoesophageal junction)

- Esophagus (*cont.*)
 skeletonization, 229
 transhiatal esophagectomy
 (*see* Esophagectomy)
- Excision
 biopsy
 nonwedge/circumferential-
 type, 536–537
 wedge-type, 536
 branchial cleft cyst/fistula, 75–77
 breast biopsy
 creation, flaps, 103
 defect suturing, 104
 Langer's lines, incision, 103
- External supravescical hernia, 185
- Extrahepatic biliary tract
 aberrant hepatic duct, 565
 accessory hepatic ducts, 565, 567
 cholangiogram (*see*
 Cholangiogram)
 cholecystectomy, 576–580
 choledochocystectomy, 597–600
 choledochoduodenostomy (*see*
 Choledochoduo-
 denostomy)
 common bile duct (*see* Common
 bile duct)
 common hepatic ducts (*see*
 Common hepatic ducts)
 cystic duct, 567
 gallbladder (*see* Gallbladder)
 hepatocystic triangle (*see*
 Hepatocystic triangle)
 laparoscopic cholecystectomy,
 600–604
 sphincteroplasty (*see*
 Sphincteroplasty)
 vascular system, 573–575
- F**
- Facial nerve, identification, 48
- Fallopian tube, 689, 692, 701
- Fasciae
 deep fascia, 25–28
 superficial fascia, 25
- Fascia of Gerota, 635, 641, 650
- Femoral artery
 adductor canal, 668
 external iliac, 666
- Femoral hernia
 aberrant obturator arteries,
 locations, 185–186
 repair
 above inguinal ligament,
 187–188
 below inguinal ligament,
 188–191
 incision site, 188–189
 inguinal hernia, 187–188
 inguinal ligament, suturing,
 190–191
 sac manipulation, 187
 sac opened and contents,
 inspection, 188–189
 typical and atypical pathways, 185
- Femoropopliteal bypass
 anastomosis, femoral, 682, 684
 below-knee popliteal artery
 exposure, 681, 683
 distal anastomosis, 681, 684
 femoral and popliteal arteries,
 679, 682
 spatulated vein, 681, 684
 venous tributaries, 679, 683
- Finger, 710, 711, 714
- Finney pyloroplasty, 316
- Fistulas, 48
- Flexor
 carpi radialis, 708
 pollicis, 704
 retinaculum, 704
- Fundoplication
 crura approximation, 250–251
 dissection, crura, 247–248
 fundic wrap, 244–245

- gastric fundus mobilization, 249–250
 - hepatogastric omentum opening, 245–247
 - operating room setup and trocar placement, 245–246
 - Penrose drain, 247–248
- G**
- Gallbladder**
- deformities, 568
 - description, 568
 - infundibulum, 568
 - neck, 568
- Gastrectomy**
- Billroth (*see* Billroth)
 - cancer
 - abdominal esophagus and duodenum, 337, 338
 - blunt penetration, 335
 - duodenal closure, 337, 339
 - elevation, greater omentum, 335, 336
 - omentum relationship, transverse colon, 335, 336
 - placement, stay sutures, 337, 338
 - removal, lesser omentum, 337
 - resection site, 334, 335
 - transverse mesocolon, 338, 339
 - determination, anatomical boundaries
 - arbitrary landmarks, 316, 317
 - gastric resection, guidelines, 317
 - guidelines, antrectomy, 317–318
 - gastric remnant, ischemia, 320
 - hemorrhage control,
 - gastroduodenal artery, 321
 - ischemia, duodenal cuff, 321, 322
 - location, antral boundary, 318–319
 - middle colic artery, 322–323
 - mobilization, duodenum, 320
 - posterior gastric artery, 323–324
 - stomach mobilization, 319–320
 - T-closure, stomach/duodenum, 320–321
- Gastric bypass, 727
- Gastric ulcers, 313
- Gastric units**
- distal surgical
 - duodenum, 297
 - gastric antrum, 297
 - pylorus, 297
 - relations, 297–298
 - proximal surgical unit, 295–296
- Gastric wall, 298
- Gastroduodenal junction, 346
- Gastroesophageal junction**
- and abdominal esophagus
 - “cardiac sphincter”, 261
 - external junction, 259–260
 - internal junction, 260–261
 - lymphatic drainage, 267
- Gastrojejunostomy**
- antecolic, 308, 311
 - retrocolic
 - clamps placement, lesser curvature, 307, 308
 - enterotomy and gastrotomy, 308, 310
 - location, avascular area, 308, 309
 - posterior gastric wall, 308, 310
 - suture, mesentery, 308, 309
- Gastrophrenic ligament, esophagus**
- blood supply, 265, 266
 - lymphatics
 - drainage, gastroesophageal junction, 267
 - groups, lymph nodes, 265, 267

Gastrophrenic ligament,
 esophagus (*cont.*)
 nerve supply, 265
 structure, wall
 adventitia, 264–265
 mucosa, 263
 muscularis externa, 264
 submucosa, 264

Gastrosplenic ligament,
 606, 608, 618

Gastrostomy
 incisions, 320, 321
 Stamm, 306–307

Giant prosthetic reinforcement of
 visceral sac (GPRVS),
 198–199

Goodsall–Salmon's rule, 497, 501

GPRVS. *See* Giant prosthetic
 reinforcement of visceral
 sac (GPRVS)

Graft
 full-thickness, 11
 split-thickness (epidermis plus
 partial dermis), 11

Groin
 anatomical entities
 aponeurosis, external oblique
 muscle, 119
 conjoined area, 121–122
 falx inguinalis (Henle
 ligament), 122
 femoral canal and
 its sheath, 131
 Hesselbach triangle, 121, 126
 iliopectineal arch, 126
 iliopubic tract, 123
 inguinal canal, 126–129
 inguinal ligament (Poupart),
 119–120
 interfoveolar ligament
 (Hesselbach), 122
 lacunar ligament (Gimbernat),
 120–121

pectineal ligament
 (Cooper), 121
 reflected inguinal ligament
 (Colles'), 122
 superficial fascia, 118–119
 surgical ellipse, 130–131
 transversalis fascia, 123–125
 transversus abdominis,
 arch of, 122

hernias, 174

mesh hernia
 anterior approach, repair
 (*see* Mesh groin hernia)
 posterior approach, repair
 (*see* Mesh groin hernia)

non-mesh hernia, repairs
 Cooper ligament repair,
 174–178
 direct, 179–181
 external suprapubic
 hernia, 185
 Femoral hernia (*see* Femoral
 hernia)
 indirect inguinal hernia,
 174–178
 relaxing incision, 184
 sliding, 178–179

H

Hamate, 710

Heineke–Mikulicz pyloroplasty, 315

Hemihepatectomy
 bisegmentectomy, 561
 caudate lobe resection, 562
 central liver resections, 563
 liver, 560
 MHVs and LHV's, 560
 mono segmentectomy, 561
 pringle maneuver, 561

Hemiliver
 left hemihepatectomy
 gallbladder, 560

- Glissonian approach, 561
 - segmentectomy, 562
- right hemihepatectomy (*see* Right hemihepatectomy)
- Hemorrhoidectomy
 - excision, 504, 506
 - prolapsing hemorrhoid, 504
 - rectal examination and anal dilatation, 504, 505
 - in toto excision, internal, 504, 507
- Hepatic artery
 - aberrant, 523, 524
 - accessory type, 524
 - intrahepatic distribution, 525–526
 - lymphatic drainage, 530–531
 - portal vein, 526–528
 - right/left, 525
 - veins, 528–529
- Hepatic resections, liver
 - blood vessels, 538
 - left lobectomy (*see* Left lobectomy)
 - lobar and segmental resections, 539
 - lobectomy and segmentectomy, 538, 539
 - resection and trauma, 545–550
 - right lobectomy (*see* Right lobectomy)
- Hepatocystic triangle
 - cystic artery origin, 571, 572
 - and triangle of Calot, 571–572
- Hiatus
 - hernia
 - congenital short esophagus, 235, 237
 - esophageal hiatus, 233–234, 236
 - paraesophageal, 235
 - sliding hernias, 233, 237–240
 - inferior vena cava, 218
- Hydrocele, 211–212
- Hypersplenism, 616
- Hysterectomy
 - bladder mobilization, 693, 695
 - broad ligament, 692, 693
 - cervix, 695, 698
 - double clamping, 693–694
 - incision line, 694, 697
 - open cuff, 696, 699
 - round ligament, 692
 - technique, 691
 - uterine vessels skeletonization, 694, 696
- I**
- Ileocecal valve
 - anatomy, 407
 - benign disease, 411
 - Meckel's diverticulum, 409
- Ileum
 - and end-to-end anastomosis, 410, 411
 - and jejunum, 405
 - location, 409
 - Meckel's diverticulum, 409
 - terminal, 415
- Incisional hernia
 - defects
 - dissection around ring, 158–159
 - herniation, left rectus incision, 158–159
 - Kugel patch, tacking, 162
 - transversalis fascia,
 - deep layer to posterior surface, 161
 - trunk, paramedial sagittal cross section, 158, 160
 - wall, horizontal cross section, 158, 160–161
 - etiology and pathogenesis, 157
 - location, 157
 - operating room strategy, 158
 - preoperative evaluation
 - and care, 157

Infertility, 701

Inguinal canal

anterior wall, 127–128

female, 126–127

Fruchaud's myopectineal orifice,
127, 129

male, 126–127

posterior wall, 127

strong posterior, 127–128

surgical ellipse, 130–131

weak posterior wall, 127, 129

Inguinal hernia

direct, 176, 179–181

indirect, Cooper ligament repair
direct hernia, bulging, 175–176
electrocoagulation, 174
femoral canal, closure,
177–178

inguinal canal floor, 175

sutures placement, 175–176

transition suture,
placement, 177

Inguinal hernia repair

laparoscopic repair

aberrant obturator artery, 204

fascia closure, 205

Fruchaud's myopectineal
orifice, 200

myopectineal orifice, mesh
coverage, 200–201

operating room setup and
cannula sites, 202–203

placement, mesh behind
defect, 200–201

preperitoneal dissection
balloon, insertion, 202–203

preperitoneal space,
operating, 204

Intercostal

arteries, 97–98

connective tissue, 100

veins, 98

Internal thoracic artery, 94, 98

Interrupted suture technique, 718

Intrahepatic duct system

caudate lobe, 522

left hepatic, 520, 522

terminology and pattern, 520–521

Intussusception

reduction, 415–416

surgical anatomy, 410–411

Ivor Lewis approach

abdominal portion, 285–287

operative approach, 285

thoracic portion

intrathoracic esophagogastric
anastomosis, 289

mobilization, mid-esophageal
tumor, 288

right thoracotomy, 287

Ivor Lewis–McKeown (Three-Stage)
esophagectomy, 290

J

Jejunostomy

feeding, 418

Witzel, 416–418

Jejunum

and ileum, 405

loop, proximal, 416

prevention, torsion, 418

K

Kocher maneuver, 644–645

Kugel hernia repair

dissection area, 196–197

muscle-splitting incision,
195–196

patch insertion, 197–198

patch, position, 198–199

L

Laparoscopic adrenalectomy

bilateral, 664

and cholecystectomy, 652

lateral decubitus position, 653

- left
 - cannula sites and uses, 654, 657, 660, 664
 - excised adrenal gland, placement, 658, 660
 - Hockey-stick incision, initial dissection, 661, 664
 - inferior vena cava, dissection, 661, 663
 - lateral decubitus position, patient, 653
 - left adrenal vein, 657, 659
 - ligation, right adrenal vein, 662, 664
 - “opening a book”, 655, 658
 - operating room setup, 654, 655
 - patient positioning, 654
 - specimen retrieval sac, 658, 661
 - splenorenal and splenicocolic ligaments, initial incision, 654, 657
 - right, 660–664
 - transabdominal approaches, 653
- Laparoscopic appendectomy
 - division, mesoappendix, 428, 429
 - location, incision and port placement, 428, 429
 - removal, appendix, 428, 430
- Laparoscopic vertical sleeve gastrectomy
- Foley catheter, orogastric tube, sequential compression devices
 - closure, mesenteric defect, 731, 733
 - completed roux-en-Y gastric bypass, 736, 737
 - completion, anastomosis, 734, 735
 - creation, roux limb, 730, 731
 - gastric pouch, creation, 734, 735
 - ice chips, 741
 - on-table leak test, 740
 - roux limb, 730, 731, 734, 735
 - stapler, fired, 731, 732, 739
 - patient positioning, 738
- Large intestine wall
 - anal canal, 437–441
 - and colon
 - epiploic appendages, 434
 - transverse colon, 434, 436
 - rectum, 437
- Left hepatic vein (LHV)
 - and MHVs, 529, 538, 560
 - preparation and isolation, 540
- Left lobectomy
 - ligaments division, 540, 541
 - lobar division, 540, 543
 - parenchyma, 540, 542
 - portal vein, 540, 542
 - resection line, 540, 544
 - and segmentectomy, 539–540
 - vessels ligation, 540, 541
- Lesion
 - benign (*see* Benign, skin lesions)
 - malignant (*see* Malignant, skin lesions)
- Lichtenstein tension-free herniorrhaphy, 206–207
- LIFT. *See* Ligation of intersphincteric fistula tract (LIFT)
- Ligament of Treitz
 - configurations, suspensory, 346, 347
 - duodenum, 357, 359
 - and inferior mesenteric vein, 346, 353
- Ligation of intersphincteric fistula tract (LIFT)
 - intersphincteric groove, 502, 503
 - probe, 502–503
 - wound, 502, 503
- Liver
 - anomalies, 523
 - excisional biopsy, 536–537

Liver (*cont.*)

- hepatic resections (*see* Hepatic resections, liver)
 - morphology
 - caudate lobe, 519
 - hepatic artery ligation, 520
 - intrahepatic duct system, 520–522
 - left lobe, 519
 - true lobulation and segmentation, 518–519
 - needle biopsy, 536
 - perihepatic spaces (*see* Perihepatic spaces)
 - peritoneal reflections and ligaments, 516–518
 - resection and trauma
 - elective operations, 545
 - formal lobectomy, 546
 - hepatic salvage, 545, 550
 - hepatic triad, 545, 549
 - hepatic wound, 547, 548
 - segment-oriented liver resection (*see* Segment-oriented liver resection)
 - topographic anatomy
 - diaphragmatic surface relations, 515
 - visceral surface, 515–516
 - vascular system (*see* Vascular system, liver)
- Lobectomy
- left (*see* Left lobectomy)
 - right (*see* Right lobectomy)
- Loupes, 716
- Low anterior resection
- connectors, 475–476
 - presacral fascia, 471–472
 - proximal colon and distal rectum, 475, 476
 - resection sites, 472–473
 - stable line, 473, 475
 - triple stable procedure, 473, 475
 - vessels ligation, 471

- Lower extremity bypass
- infrainguinal region, 666
 - popliteal artery, 667
 - profunda femoris, 666–667
 - saphenous vein, 668
 - vascular anatomy, 666–667
- Lumbar hernia
- gluteal fascia flap, securing, 214–215
 - muscles approximation, 214–215
 - sites, 213
 - suturing patch, 214
- Lumpectomy, 111–112
- Lymphatic drainage
- deep lymphatics pathways, 531
 - superficial, 530
- Lymphatics and left thoracic ducts, 28–31

M

- Malignant, skin lesions
- incision, removal, 8–9
 - melanoma
 - lesion thickness and regional lymph node staging, 10
 - regional lymphadenectomy, 9
 - staging, 9
 - tumor thickness, 9
 - resection, 8–9
- Malleolus, 725
- Mammary
- node, 99
 - tissue, 104, 111
- Mastectomy
- long thoracic nerve, 102
 - medial anterior thoracic nerve, 102
 - modified radical
 - axillary vein and artery, 106, 109
 - bed of, 106, 110
 - breast contour, 104–105
 - dissection, axillary, 106, 108

- drains placement, 106, 111
 - evacuation, axillary contents, 106, 110
 - exposed axilla, 106, 108
 - flap formation, 104–107
 - Jackson–Pratt drains, 106, 111
 - pectoralis minor, 106, 109
 - structures, 104–105
 - pectoralis major and minor muscles, atrophy, 102
 - thoracodorsal nerve, 101
 - triangular bed of modified radical, anatomy, 100–102
 - McBurney incision, 156
 - Meckel's diverticulum
 - location, ileum and frequency, 409
 - resection, 414, 417
 - types, 409, 410
 - Median arcuate ligament, 222–223
 - Mediastinum
 - left, 224, 225
 - right, 223, 225
 - thorax, 224, 226
 - Mesentery
 - appendix, 419
 - length, 405, 419
 - thrombosis, 411
 - Mesh groin hernia
 - anterior approach, repair
 - Bard plug and patch repair, 207–211
 - Lichtenstein tension-free herniorrhaphy, 206–207
 - posterior approach, repair
 - Kugel hernia repair, 195–198
 - laparoscopic inguinal hernia, 200–205
 - Nyhus procedure, 192–195
 - recurrent hernias, 195
 - stoppa procedure, 198–199
 - Mesoappendix
 - division, 422, 424, 429
 - ligation site, 424, 425
 - Meso-esophagus, 259
 - Metacarpal, 711
 - MHV. *See* Middle hepatic vein (MHV)
 - Microirrigation syringes, 715
 - Microsurgery
 - instruments, 715
 - methods, magnification, 716
 - neuroentubulation (*see* Neuroentubulation procedure)
 - procedure, nerve repair, 720–721
 - psychomotor skills training, 716
 - surgical setup, 717
 - suture materials, 717
 - vascular repair (*see* Vascular repair procedure)
 - Microsutures, 715
 - Middle hepatic vein (MHV)
 - and LHV's approach, 529
 - and RHV, 559
 - “Milking test”, 718
 - Modified radical mastectomy. *See* Mastectomy
 - Muscle biopsy, 730
- N**
- Nail
 - bed, 6
 - ingrown toenail
 - conservative treatment, 13
 - definition, 12
 - partial excision, 14–16
 - radical excision, 16
 - total excision (avulsion), 14
 - structures, 6
 - Neck
 - branchial cleft (*see* Branchial cleft)
 - facial nerve, identification, 48
 - fasciae
 - deep fascia, 25–28
 - superficial fascia, 25

Neck (*cont.*)

- lymphatics and left thoracic ducts, 28–31
- masses, 52
- parathyroid
 - gland, anatomy, 42
 - reoperation, 70–71
- parathyroidectomy, 68–69
- parotidectomy, 52–57
- parotid gland (*see* Parotid gland)
- radical neck dissection (*see* Radical neck dissection)
- spaces, 28
- submaxillary gland, resection, 57–60
- thyroid
 - gland (*see* Thyroid gland)
 - reoperation, 69–70
- thyroidectomy, 60–68
- trachea
 - anatomic landmarks, 43
 - nervous system, 43
 - vascular system, 42
- tracheostomy, 86–89
- Nerve repair procedure, 720–721
- Nerve supply, pancreas, 371–372
- Neural “hammocks”, 19
- Neuroentubulation procedure, 721–722
- Neuropathy, 725
- Nyhus procedure
 - direct, indirect and femoral inguinal hernias, 194–195
 - groin hernias, sites, 192–193
 - posterior inguinal wall, 192
 - preperitoneal space, operative approach, 192–193
 - transverse fascial incision, 194

O

- Oophorectomy, 701
- Ovary
 - adhesion barriers, 700

- Babcock clamp, 700
- cyst
 - baseball stitch, 700, 701
 - benign, 699, 700
 - dissection plane, 699–700
 - postmenopausal patient, 701
- infundibulopelvic ligament, 693

P

- Palm, 710
- Pancreas
 - anterior relationships, 361, 362
 - bare areas, duodenum, 361, 362
 - body, 365
 - drainage, pancreatic pseudocyst (*see* Pancreatic pseudocyst)
 - ducts (*see* Pancreatic ducts)
 - ectopic and accessory, 372
 - evaluation, resectability, 373
 - exploration, 373–374
 - head, 363–364
 - neck, 365
 - nerve supply, 371–372
 - pancreatectomies (*see* Pancreatectomy)
 - posterior relationships, 362, 363
 - puestow procedure (*see* Puestow procedure, pancreas)
 - tail, 365–366
 - transduodenal-pancreatic biopsy, 395, 396
 - uncinate process, 364
 - vascular system (*see* Vascular system)
- Pancreatectomy
 - distal (*see* Distal pancreatectomy)
 - total pancreatectomy (with/without splenectomy), 384
 - Whipple procedure (*see* Whipple procedure)
- Pancreatic arcades, 370
- Pancreatic ducts

- duodenal papilla (*see* Duodenal papilla)
- variations, 366, 367
- Pancreaticoduodenectomy. *See* Whipple procedure
- Pancreaticojejunostomy
 - end-to-end, 384
 - side-to-side, 375, 377
- Pancreatic pseudocyst
 - external drainage, 403
 - internal drainage
 - cystoduodenostomy, 401
 - cystogastrostomy (*see* Cystogastrostomy)
 - cystojejunostomy, 401–402
 - roux-en-Y, 396–398
- Paraduodenal fossae, 345, 353
- Paraesophageal hernia
 - anterior approximation, 240, 242
 - excision of sac, 240–241
 - fundic wrap, 243, 244
 - posterior approximation, 241, 242
 - reduction, stomach and esophagus, 240–241
 - suturing, fundus, 243
- Parasympathetic nerves
 - division
 - anterior gastric, 303–304
 - celiac, 305
 - hepatic, 304, 305
 - posterior gastric, 304
 - vagal structure identification, hiatus
 - relation, anterior and posterior vagal trunks, 302, 303
 - truncal vagotomy, 302, 304
 - vagal structures, thorax and abdomen, 301, 302
- Parathyroid
 - gland, anatomy, 42
 - reoperation, 70–71
- Parathyroidectomy, 68–69
- Parenchymal transection technique, 554–555
- Parotidectomy
 - deep lobe, resection, 55–56
 - facial nerve identification, 54–55
 - formation, flaps, 52–53
 - inverted T-incision, 52–53
 - modified Y incision, 52–53
 - radical, 57
 - superficial lobe, resection, 55–56
- Parotid gland
 - relations, 43–44
 - structures traversing
 - arteries, 45
 - auriculotemporal nerve, 47
 - facial nerve, 44–45
 - great auricular nerve, 46
 - lymphatics, 46
 - parotid bed, 47
 - veins, 45–46
- Pectoralis
 - major and minor muscles, atrophy, 102
 - minor, 106, 109
- Pedicle
 - anterior and posterior, 558
 - falciform ligament, 561
 - and hepatic veins, 555
 - right and left, 551
- Pelvis, 689, 696
- Peptic ulcers
 - attachment, omental plug, 311, 312
 - closure, layers, 311, 312
- Perforated ulcers
 - gastric, 313
 - peptic (*see* Peptic ulcers)
- Perihepatic spaces
 - abscess, anterior portion, 531, 532
 - anterior portion, left suprahepatic, 531, 533
 - left infrahepatic, 531, 535
 - posterior portion, left suprahepatic, 531, 534
 - right infrahepatic, 531, 534

Perihepatic spaces (*cont.*)
right suprahepatic, 531, 533
suprahepatic and subhepatic,
531, 532
upper abdomen, 531

Peritoneal reflections and ligaments,
liver
anterior abdominal wall, 516
duodenum, 516, 518
rib levels, 516, 518
triangular ligament, 516, 517
visceral surface, 516, 517

Pharyngoesophageal diverticulum
clamping, 268, 270
and cricopharyngeal muscle
closure, 268, 270
division
omohyoid muscle, 268, 269
subcutaneous fascia, 268
elevation, 268, 269
exposure, periesophageal space,
269, 271

Pharyngoesophageal junction
cervical, 256–257
formation, muscular pharyngeal
wall, 254, 255
musculature, 255, 256
thoracic (*see* Thoracic esophagus)

Pheochromocytoma, 642, 645

Phrenoesophageal ligament
coronal section, 261, 262
development, 262

Pilonidal cyst
incised and removed, 511, 513
marsupialization and packing,
wound, 512, 513
positioning, patient, 511–512
sinus, 511, 512

Porta hepatis
hepatotomies, 560
right hepatic artery, 524–525

Portal vein
hepatic duct and artery, 526–527
intrahepatic distribution, 527–528

PPH. *See* Procedure for prolapse and
hemorrhoids (PPH)

Precision techniques, 716

Procedure for prolapse and
hemorrhoids (PPH)
anoscopic evaluation, 507–508
hemorrhoid, 510
lower rectum examination, 509
retraction, bander, 510, 511

Proctocolectomy
anastomosis, 478, 479
description, 477
ileoileal pouch, 478–479
J-pouch construction, 477, 478
resection site, 477–478
“Proximal gastric surgical unit”, 295

Psychomotor skills training, 716

Puestow procedure, pancreas
completion, 378
division, jejunum, 375, 376
exposure, lesser sac, 374
incision
electrocautery, 375
transverse mesocolon, 375, 376
jejunojejunostomy, 378
side-to-side
pancreaticojejunostomy,
375, 377
suture, jejunal loop, 375, 377

Pyloromyotomy, 346

Pyloroplasty
Finney, 316
Heineke–Mikulicz, 315

Pylorus
definition, 297
incision, 320, 321
stenosis, 314
T-closure, 320

R

Radical neck dissection
anterior triangle, 77, 79
deep cervical fascia, 77

- posterior triangle, 79–80
 procedure
 anterior triangle, dissection, 83, 85
 carotid sheath removal, 83, 85
 incision, 80–82
 omohyoid muscle, transection, 82, 84
 overlying fascia, exploration, 82, 84
 posterior triangle, exploration, 82–83
 specimen removal, 83, 86
 superficial cervical fascia, 77
 synopsis, 78
- Radius, 707
- Rectum
 and anal canal
 arterial supply, 444, 446
 median sacral artery, 446–447
 and anus
 nerve supply, 453–454
 venous drainage, 447
 arteries
 inferior mesenteric, 443
 marginal, 444–445
 middle colic, 443
 superior mesenteric, 443, 444
- Recurrent hernias, 195
- Relaxing incision, 184
- Renal fascia, 635, 641–642
- Replantation, 715, 716
- Retrocolic roux-en-y gastric bypass
 diet, 729
 endoscopy, 729–738
 postoperative, 736–738
 tests, 729
- RHV. *See* Right hepatic vein (RHV)
- Right hemihepatectomy
 Glissonian sheaths, 555, 557
 hemihepatectomy (*see* Hemihepatectomy)
 hepatomies, 555
 hilar structures, 555, 556
 operations, left hemiliver, 560
 posterior approach, 555, 556
 right-sided segment-oriented resections, 559–560
 sheaths, 558, 559
- Right hepatic vein (RHV)
 ligation, 529, 558
 preservation, 559
- Right lobectomy
 hepatic duct, 544, 546
 IVC, 545, 547
 ligaments
 coronary, 544, 545
 falciform, 545, 547
 triangular and coronary, 543
- S**
- Salpinx, 689
- Saphenous vein
 anatomic tunnel, 684
 arteriotomy, 681
- Scalp
 nerves, 4–5
 structures, 2–3
 vascular system
 arterial supply, 3–4
 lymphatic drainage, 4–5
 venous drainage, 3–4
- Segmentectomy
 4A and 4B, Glissonian approach, 562
 left lateral, 543
 lobectomy, left, 538
- Segment-oriented liver resection
 brisbane terminology, 550–553
 Couinaud, 550, 553
 Glissonian approach, 551
 parenchymal transection technique, 554–555
 principle, 554
 right hemihepatectomy (*see* Right hemihepatectomy)
- Seldinger technique, 723

- Short esophagus, 233, 235, 237
- Shouldice technique
 approximation
 deep part, 181–183
 pubic tubercle, internal ring, 182–183
 posterior wall, incision, 181
- Sinuses, 48–50
- Skin
 nervous system, 1–2
 structures, 1–2
 vascular system, 1
- Sliding hernia
 fundic wrap, 237, 239
 hiatus, repair of, 237–238
 indirect inguinal
 excess tissue, trimming, 179–180
 hernia sac, location, 179–180
 repair, 178–179
 types, 178–179
- Penrose drain, placement, 237–238
- suturing wrap, 240
- Small intestine
 anatomy, ileocecal valve, 407
 exposure and mobilization, 411
 feeding jejunostomy, 418
 intussusception (*see* Intussusception)
 layers, wall, 406
 length, 405
 Meckel's diverticulum (*see* Meckel's diverticulum)
 mesentery, 405
 small bowel resection, tumor
 ligation, vessels, 412, 413
 orientation, GIA stapler, 414
 position, noncrushing
 clamps, 412
 transection and stapling, 412, 413
 vascular system (*see* Vascular system, small intestine)
- Witzel Jejunostomy, 416–418
- Sphincteroplasty
 duodenal Kocherization, 590, 592
 duodenorrhaphy, 593, 595
 duodenotomy, electrocautery, 590, 592
 septotomy site, 593, 594
 sphincterotomy and mucosa, 593, 594
 stay sutures placement, 590, 593
- Spigelian (lateral ventral) hernia
 anterior abdominal wall
 hernias, 170
 closure, defect, 171, 173
 entities, 170–171
 transversus abdominis broken, 171–172
- Spleen
 accessory spleens, 614–615
 chief ligaments
 and minor, 605, 609
 pedicle, 606, 610
 peritoneal attachments, 605, 608
 location, 605, 606
 lymphatic drainage, 611, 613
 minor ligaments
 pancreaticosplenic, 606, 608
 splenic flexure, colon, 606, 611
 peritoneum, 605, 607
 segmental anatomy, 613
 splenectomy (*see* Splenectomy)
 splenic
 artery, 609, 610
 borders, 605, 607
 vein, 611–613
- Splenectomy
 autotransplantation, 622, 624
 hematoma, 621–622
 hemorrhage secondary, trauma, 616
 hypersplenism, 616
 intrasplenic dissection, 622, 623

- laparoscopic
 - cannula sites, 628
 - excised spleen, 631, 632
 - gastric vessels, 629
 - lateral approach, 626
 - left lateral decubitus, 627
 - retrieval sac, 631, 633
 - splenic hilum, 630
 - splenorenal ligament, 630–631
- splenic
 - mesh wrap, 622–623
 - pedicle (*see* Splenic pedicle)
- trauma, 621
- Splenic artery
 - description, 609, 610
 - temporary occlusion, 624
- Splenic pedicle
 - gastric arteries and vein, 616, 617
 - incision, 616, 617
 - ligation, splenic vein, 619
 - peritoneal cavity, 618
 - posterior approach, 619, 620
 - splenic artery and vein, 620–621
- Splenic porta, 647
- Splenic vein
 - anatomy, 611, 613
 - and splenic artery, 611–612
- Splenicocolic ligament, 641, 654, 657
- Splenomegaly, 615, 625
- Splenorenal ligament, 365, 605, 606, 618, 625, 630, 641, 654, 657
- Splenorrhaphy
 - omental fixation, 621, 622
 - partial splenectomy, 621–624
- Stamm gastrostomy
 - placement, catheter, 306, 307
 - purse-string sutures, anterior wall, 306
- Stomach
 - gastrectomies (*see* Gastrectomy)
 - gastric units (*see* Gastric units)
 - gastrojejunostomy, 307–311
 - gastrostomy, 306–307
 - ligaments
 - gastrocolic, 299
 - gastrophrenic, 299
 - gastrosplenic, 299
 - hepatoduodenal, 298
 - hepatogastric, 298
 - parasympathetic nerves (*see* Parasympathetic nerves)
 - perforated ulcers (*see* Perforated ulcers)
 - pyloric stenosis, 314
 - pyloroplasty (*see* Pyloroplasty)
 - sympathetic nerves, 305
 - vagotomies (*see* Vagotomy)
 - vascular system (*see* Vascular system)
 - wall, gastric, 298
- Stoppa procedure, 198–199
- Subclavian vein catheter insertion, 723–724
- Submammary, 94
- Submaxillary gland, resection
 - blunt dissection, 60, 61
 - exposure, 60
 - facial artery, vein and nerve, 59
 - sternocleidomastoid muscle (SCM), 57
 - superficial fascia, incision, 58
 - surgical field, 58
- Subscapular
 - identification and protection, 106
 - posterior wall, 93
 - scapular nodes, 100
 - thoracodorsal nerve, 101
 - triangular bed formation, 100
- Superficial fascia, 25
- Sural nerve biopsy, 725
- Surgery
 - benign lesion, excision, 11–12
 - malignant lesion, excision, 12

Surgery (*cont.*)

- temporal artery, biopsy
 - anatomical landmarks, 12, 13
 - arterial segment removal, 12, 14
 - incision, 12, 13

Sympathetic nerves, 305

T

Thenar muscles, 704, 710

Thoracic duct, 28–31

Thoracic esophagus

- anatomic weak areas, 259
- contents disposition, 257, 258
- surgical considerations, 259

Thoracoabdominal approach, 651

Thyroglossal duct

- cystectomy
 - closure, defect, 74–75
 - cyst dissection, 71–72
 - locations, 71–72
 - resection, 73–74
 - surgical field preparation, 73–74
- tract, diagrammatic
 - presentation, 71, 73
- persistent remnants, 41

Thyroidectomy

- breaking, attachments, 64
- deep fascia opening, 62–63
- flaps elevation, 62
- gland, exposure and mobilization, 65
- incision, superficial fascia, 61–62
- location, incision, 61
- separation and division, 65
- sternohyoid muscles, 64
- strap muscles elevation, 63–65
- total lobectomy
 - exposure, 66
 - ligation, 67
 - retraction, 67
 - subtotal, 68

Thyroid gland

- arterial supply and parathyroid glands, 34–36
- capsule, 33–34
- recurrent laryngeal nerves
 - branching, 40
 - exposure, 37–38
 - internal and external branches, relation, 41
 - postoperative hoarseness, 39
 - sympathetic ganglion, 39–40
 - vulnerability, 39
- thyroglossal duct, persistent remnants, 41
- venous drainage, 36
- vestiges, 33

Thyroid reoperation, 69–70

Total abdominal laparoscopic

colectomy

- description, 492
- synopsis, 492–493

Trachea

- anatomic landmarks, 43
- nervous system, 43
- vascular system, 42

Tracheostomy

- incising trachea, 88
- incision, 87
- position, 86
- skin preparation, 86
- thyroid isthmus, 87
- tracheal opening, 88–89

Transduodenal-pancreatic biopsy,

395, 396

Traumatic diaphragmatic hernia, 243

Triple stable procedure, 473

Trisegmentectomy, 538, 540,

544, 563

U

Ulna

- artery and nerve, 706
- palmar, 708

- Umbilical hernia
 herniorrhaphy, 167–168
 insertion, patch, 168–169
 large, 168–169
 straps, 168–169
 suturing, 168–169
- Uncinate process, 364
- Uterus, tubes and ovaries
 hysterectomy and BSO, 691–699
 ovarian cystectomy, 699–701
 relations and positions, 689
 vascular system
 arterial supply, 690
 lymphatic drainage, 690
 venous supply, 690
- V**
- Vagotomy
 extended proximal, 342–343
 parietal cell, 341, 344
 selective, 340
 truncal, 340, 343–344
- Vagus nerve. *See* Parasympathetic nerves
- Vascular repair procedure
 assessment, patency, 718–719
 dissection/preparation, 717
 end-to-end arterial and venous
 back wall, sutured vessel,
 718, 719
 intermediate suture placement,
 718, 719
 interrupted suture
 technique, 718
 vascular segment, 717
- Vascular system
 abdominal aortic aneurysm repair,
 665–666
 arteries
 blood supply, 348–349
 pancreaticoduodenal arcades,
 348, 350
- AVF, 685–686
 brachio-axillary arterial venous
 graft, 687
 branches, splenic artery, 370
 carotid endarterectomy, 665,
 669–674
 caudal pancreatic artery, 370
 dorsal pancreatic arcade, 370
 elective infrarenal abdominal
 aortic aneurysm repair,
 675–682
 extrahepatic biliary tract
 arterial supply, 573–574
 lymphatic drainage,
 574, 575
 venous drainage, 574, 575
 femoropopliteal bypass (*see*
 Femoropopliteal bypass)
- liver
 blood, sources, 523
 hepatic artery, 523–526
 lower extremity bypass,
 666–668
 lymphatic drainage, 351, 352,
 371, 421
 nerve supply, duodenum, 351
 pancreatic arcades, 370
 small intestine
 arterial supply, 407, 408
 lymphatic drainage, 409
 venous drainage, 407
- stomach
 arterial supply, 299–300
 lymphatic drainage, 300–301
 venous drainage, 300
 supply, arterial, 420
 transverse pancreatic artery, 370
 venous
 drainage, 350, 351,
 370–371
 supply, 420
- Venous thrombosis, 685
- Volar, 711–713

W

Whipple procedure

- division, parenchyma, 387, 388
- duodenojejunostomy, 389, 391
- harvest, specimen, 387, 388
- placement, sutures, 389, 390
- position, 385
- preparation
 - common hepatic ducts, 387
 - surgery, 385

protection, head

- of pancreas, 386

specimen, 385

- tacking, jejunum, 389, 391

- uncinate process, 387–388

Witzel Jejunostomy

- catheter, 416, 417

- selection, loop, 416

- seromuscular tunnel, 416, 418

- wall, incision, 416, 417