

J. Fernando Arévalo, Janet L. Davis, Emilio Dodds,  
and David G. Zeballos

---

### Abstract

Endogenous endophthalmitis is the result of hematogenous spread of organisms to the eye from a site of infection elsewhere in the body or from contaminated catheters or needles. The prognosis in endophthalmitis is dependent on culture results, time of onset of the endophthalmitis, and the virulence of the pathogen. Biopsy of intraocular fluid/tissue is the only method that permits reliable diagnosis and treatment. Successful management of infectious endophthalmitis depends on timely diagnosis and institution of appropriate therapy. The different presenting clinical settings, a rational approach to diagnosis, and the treatment of infectious endophthalmitis are reviewed.

---

### Keywords

Biopsy • Endogenous endophthalmitis • Intravitreal antibiotics • Metastatic infection • Vitrectomy

---

J.F. Arévalo, M.D., F.A.C.S. (✉)  
Chief of Vitreoretinal Division, The King Khaled Eye  
Specialist Hospital, Riyadh, Kingdom of Saudi Arabia  
Professor of Ophthalmology, Wilmer Eye Institute,  
The Johns Hopkins University, Baltimore, MD, USA  
e-mail: arevalojf@jhmi.edu

J.L. Davis, M.D., M.A.  
Anne Bates Leach Eye Hospital, Bascom Palmer Eye  
Institute, 900 NW 17th Street, Miami, FL 33136, USA  
e-mail: jdavis@med.miami.edu

E. Dodds, M.D.  
Hospital Juan A. Fernandez and Consultores  
Oftalmologicos, Montevideo 1410, Buenos Aires  
1018, Argentina  
e-mail: emdodds@gmail.com

D.G. Zeballos, M.D.  
Department of Ophthalmology, Clínica Kennedy  
Alborada, Primer piso, Oficina 101, Alborada 12<sup>a</sup> Etapa,  
Calle Crotos y Av. Rodolfo Baquerizo Nazur, Guayaquil,  
Guayas, Ecuador  
e-mail: david\_zeballos@hotmail.com

---

## Introduction

Endophthalmitis is a rare but potentially devastating intraocular infection that can result from exogenous spread following intraocular surgery, a complication of ocular trauma, or from an adjacent ocular interface, resulting in a poor visual prognosis for the majority of patients [1]. Endophthalmitis is divided into endogenous endophthalmitis, resulting from hematogenous spread from a focus of infection elsewhere in the body, and exogenous endophthalmitis, resulting from primary inoculation of the eye. Few patients with endogenous endophthalmitis are able to maintain good visual acuity.

Endogenous endophthalmitis, also termed metastatic endophthalmitis, occurs when organisms reach the eye via the bloodstream and enter the internal ocular spaces by crossing the blood-ocular barrier. Endogenous bacterial endophthalmitis (EBE) is less common than exogenous bacterial endophthalmitis and accounts for only 2–6% of all cases of endophthalmitis [2]. Several large series estimate that endogenous endophthalmitis accounts for 2–15% of all cases of endophthalmitis [3].

The possible range of infectious agents is broad and includes gram-positive bacteria, gram-negative bacteria, and fungi. However, there is considerable variation in the frequency of these pathogens between different geographical areas. Previously published series of patients with endogenous endophthalmitis have reported the most common bacterial organism as *Staphylococcus aureus* and the most common fungal organism as *Candida* species [4].

Endogenous endophthalmitis has been associated with many systemic risk factors, including chronic immune-compromising illnesses (diabetes mellitus, renal failure), indwelling or long-term intravenous catheters, immunosuppressive diseases and therapy (malignancies, human immunodeficiency virus [HIV] infection, chemotherapeutic agents), recent invasive surgery, endocarditis, gastrointestinal procedures, hepatobiliary tract infections, intravenous drug abuse, organ transplantation, and genitourinary

and dental procedures [5]. In most cases, the diagnosis of endophthalmitis is made on clinical grounds, and treatment is usually initiated empirically while awaiting results from intraocular and/or blood cultures.

Advances in medical technology, a longer life span of patients with chronic diseases and a rising prevalence of long-term intravenous access, may lead to the disease becoming more common in clinical practice. Endophthalmitis is the most dreaded ocular infection and carries one of the worst visual prognoses of all ocular infections. Recognition of the different clinical settings in which endophthalmitis occurs and awareness of the highly variable presentation it may have facilitate timely diagnosis. Biopsy of intraocular fluid/tissue is the only method that permits reliable diagnosis and treatment.

In this chapter, we review the epidemiology, clinical findings, management, and prognosis of endogenous endophthalmitis.

---

## Clinical Settings, Causative Organisms, and Epidemiology

Endophthalmitis is the term used for a severe inflammation of the intraocular structures always involving the ocular fluids (either the vitreous or the aqueous humor or both). The cause of the inflammation may be infectious or noninfectious (also called sterile endophthalmitis).

Infectious endophthalmitis can be classified on the basis of the clinical setting and the time of onset of clinically apparent inflammation. General categories include postoperative endophthalmitis, posttraumatic endophthalmitis, endogenous endophthalmitis, and miscellaneous noninfectious causes of endophthalmitis, e.g., sterile uveitis, phacoanaphylactic endophthalmitis, and sympathetic ophthalmia. It most commonly occurs as a postoperative complication of cataract surgery and in 70% of cases is caused by coagulase-negative *Staphylococci*. Such infections are rare, with an incidence of 0.07–0.32% [6]. Postoperative fungal endophthalmitis is usually seen in clusters due to the use of contaminated intraocular irrigation solution, intraocular

**Table 10.1** Classification of endophthalmitis

<i>Infectious endophthalmitis</i>	
Postoperative	
•	Acute postoperative endophthalmitis
•	Delayed-onset endophthalmitis (onset > 6 weeks postoperatively)
•	Conjunctival filtering bleb-associated
Endogenous	
Posttraumatic	
<i>Noninfectious endophthalmitis</i>	
Sterile uveitis	
Phacoanaphylactic endophthalmitis	
Sympathetic ophthalmia	

lenses, ventilation system, and hospital construction activities (Table 10.1) [7].

Endogenous endophthalmitis comprises only a minority of endophthalmitis cases. Whereas endophthalmitis occurs at an average annual incidence of 5 in 10,000 hospitalized cases, only 2–15% are endogenous [7]. Endogenous endophthalmitis, also termed metastatic endophthalmitis, occurs when organisms reach the eye via the bloodstream and enter the internal ocular spaces by crossing the blood-ocular barrier. Endogenous endophthalmitis is associated with several medical conditions such as diabetes, lymphoproliferative disease, malignancy, immunosuppression, parenteral alimentation, recent extended surgical procedure, alcoholism, or intravenous drug abuse [8, 9].

Endogenous bacterial endophthalmitis is a rare but a visually devastating disease. It may occur at any age and has no sexual predilection. The right eye is involved twice as often as the left eye because of the more proximal and direct blood flow to the right carotid artery [10]. Bilateral involvement occurs in approximately 25% of cases. Organisms spread hematogenously to the eye from a site of infection elsewhere in the body or from a contaminated catheter in the body. Retinal damage is caused partly by microbial toxins and exacerbated by the ischemia caused by septic emboli. Immunocompromised states such as diabetes mellitus, malignancy, and chemotherapy are associated with a reduced host defense and constitute risk factors for developing endogenous endophthalmitis.

The most common causes of bacterial endogenous endophthalmitis include *Streptococcus* species, *S. aureus*, and, in some studies, *B. cereus*. Whereas *B. cereus* was being increasingly recognized in exogenous, posttraumatic endophthalmitis, numerous cases of endogenous endophthalmitis relating to *B. cereus* had already been reported in the literature. The infections were linked with the transfusion of contaminated blood products and the use of illicit intravenously administered drugs [11].

*Streptococcus pneumoniae* and *S. viridans* are common causes of bacterial endogenous endophthalmitis secondary to meningitis and endocarditis, respectively, but other *Streptococcus* species have been isolated as well. Group G streptococcal endophthalmitis has been reported in elderly patients with skin wounds or malignant neoplasms, and group B streptococcal endophthalmitis has been noted in neonates with meningitis and in immunocompromised adults [12, 13]. *Acinetobacter baumannii* is emerging as a common cause of hospital-acquired infections especially in the very ill patients. Fortunately, *Acinetobacter* endogenous bacterial endophthalmitis is still a rare occurrence [14]. Other infrequently encountered organisms include *Citrobacter* [15], *Aeromonas hydrophila* [16], and nontuberculous *mycobacteria* [17].

Gram-positive bacteria are the most common cause of bacterial endogenous endophthalmitis. *Listeria monocytogenes* has been described as causing a fairly indolent infection that is characterized by a brownish hypopyon and should be considered if this finding is present without corneal involvement. Endophthalmitis caused by anaerobic *Clostridium* species has also been reported in association with bowel carcinoma, and because of its particularly aggressive nature, this infection often results in enucleation [18].

Enteric gram-negative microorganisms (e.g., *Escherichia coli*, *Klebsiella pneumoniae*, *H. influenzae*, *P. aeruginosa*, and *Serratia* species) are the most common causes of gram-negative bacterial endogenous endophthalmitis. *Pseudomonas aeruginosa* is an especially virulent organism that may result in an accelerated presentation with rapid vision loss. *Pseudomonas aeruginosa* endophthalmitis has

been reported in few cases since 1935 [19]. The age range is variable with cases reported in a 21-day-old infant and in an 86-year-old man. Males appear to be more commonly affected than females. Predisposing factors for *Pseudomonas aeruginosa* endogenous endophthalmitis appear to be endocarditis [20], bacteremia from any source, immunosuppression [21], and cystic fibrosis [22].

*Neisseria meningitidis* was a common cause of bacterial endogenous endophthalmitis, but it is rarely the cause today. *Haemophilus influenzae* infection can present in a manner similar to that of meningococcus with bacteremia, meningitis, and eye infection. *Nocardia asteroides* is an acid-fast bacterium that may lead to bacterial endogenous endophthalmitis secondary to dissemination from a pulmonary focus and has increasingly been associated with endogenous endophthalmitis in immunocompromised patients [23]. Among other acid-fast bacteria, *Actinomyces* species and *Mycobacterium tuberculosis* have also been reported infrequently [24].

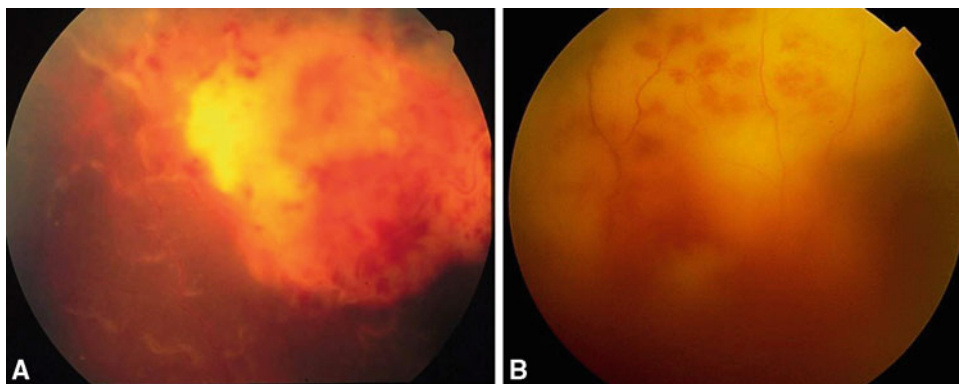
The most common organisms responsible for endogenous bacterial endophthalmitis differ in different parts of the world. In Western countries, the proportion of gram-positive organisms is about six times that of gram-negative organisms [25]. On the other hand, *Klebsiella pneumoniae*, which is an uncommon cause of endogenous bacterial endophthalmitis in the West [26], continues to be an important causative organism in Asia especially in Taiwan, being responsible for about 80% of the endogenous bacterial endophthalmitis cases [27].

Wong et al. [28] reported the East Asian experience of predominantly gram-negative organisms, in particular *Klebsiella pneumoniae*. In East Asia, endogenous bacterial endophthalmitis was overwhelmingly caused by gram-negative organisms, particularly *Klebsiella* spp. Cases reported from outside that region were more likely to be caused by gram-positive organisms. Unusual organisms may be more likely to get reported, but Wong's own case series considered all patients presenting with endogenous bacterial endophthalmitis and found that gram-negative organisms were responsible for 70% of infections. *Klebsiella* spp. accounted for about 90% of

endogenous bacterial endophthalmitis cases from that region, and 80% of cases in that review were from East Asian hospitals. The reason for this apparent predisposition to *Klebsiella* endogenous bacterial endophthalmitis is not clear, but there is also a high incidence of *Klebsiella* liver abscesses in this population. Patients with *Klebsiella* liver abscess have a 3% risk of developing endogenous bacterial endophthalmitis [29]. A comparable large series from North America found that only 32% of cases were caused by gram-negative organisms [30]. Most cases of *Klebsiella pneumoniae* endophthalmitis also occur secondary to urogenital and respiratory tract infections or, less commonly, in association with brain abscesses or meningitis [28].

Gram-positive organisms are responsible for 40% of cases. The most common gram-positive organisms were *Staphylococcus aureus*, group B streptococci, *Streptococcus pneumoniae*, *Listeria monocytogenes*, *Nocardia asteroides*, and group G streptococci [4]. In the West, gram-positive organisms such as *Staphylococcus aureus* and *Streptococcus pneumoniae* are responsible for most cases [30]. *N. asteroides* choroidal abscesses (Fig. 10.1a, b) may also be mistaken for fungal endophthalmitis or, alternatively, neoplastic choroidal metastases. All three conditions may have a similar fundal appearance, abnormal cells in the vitreous, and extraocular manifestations of disease. In this setting, transvitreal fine needle aspiration of a choroidal abscess has been used to establish the diagnosis [31].

Endogenous fungal endophthalmitis has emerged as a visually threatening complication in intravenous drug abusers and in patients with immune deficiency of various causes. In immunocompromised patients, intraocular infection represents dissemination of invasive diseases caused by *Candida* species, *Aspergillus* species, *Fusarium* species, *Cryptococcus neoformans*, *Pseudallescheria boydii*, *Coccidioides immitis*, and others [32, 33]. Among these, *Candida* species is the most common, and *Candida albicans* is the most frequent cause and accounts for 75–80% of cases of fungal endophthalmitis, followed by *Aspergillus* infection.



**Fig. 10.1** *Nocardia asteroides* choroidal abscesses. (a) Fundus photography demonstrating yellowish appearance of subretinal abscess with overlying retinal hemorrhages. Moderate vitritis and vasculitis are present. (b) Fundus

photography demonstrating yellowish appearance of subretinal abscess with overlying retinal hemorrhages. Moderate vitritis is present

**Table 10.2** Causative organisms of endogenous endophthalmitis

Bacteria	Fungi
<i>Streptococcus</i> sp.	<i>Candida albicans</i>
<i>Staphylococcus</i> sp.	<i>Aspergillus</i> sp.
<i>Clostridium septicum</i>	<i>Histoplasma</i>
<i>Bacillus aureus</i>	<i>Coccidioides</i>
Coagulase-negative <i>Staphylococcus</i>	<i>Blastomyces</i>
<i>Escherichia coli</i>	<i>Cryptococcus</i>
<i>Klebsiella pneumoniae</i>	<i>Sporothrix</i>
<i>Serratia marcescens</i>	<i>Pseudallescheria boydii</i>
<i>Pseudomonas aeruginosa</i>	<i>Bipolaris hawaiiensis</i>
<i>Neisseria meningitidis</i>	
<i>Listeria monocytogenes</i>	

*Candida albicans* is the most common cause of endogenous endophthalmitis. Other *Candida* species such as *C. tropicalis*, *C. glabrata*, and *C. parapsilosis*, as well as other fungi such as *Aspergillus*, *Coccidioides*, *Cryptococcus*, *Blastomyces*, and *Sporothrix*, also may cause an endogenous intraocular infection (Table 10.2) [34]. The prevalence of endogenous chorioretinitis and/or endophthalmitis in patients with *Candida* fungemia is reported to range from 2.8% to 45% [35].

Risk factors associated with intraocular *Candida* infection include *Candida albicans* species' multiple positive blood cultures, indwelling

catheters, parenteral hyperalimentation, hemodialysis, chronic exposure to antibiotics, immunosuppression, surgery, intravenous (IV) drug use, liver disease, malignancies, and states of debilitation [36].

*Aspergillus* endophthalmitis, a relatively rare condition, has a devastating course, with blindness as its usual outcome. *Aspergillus* endophthalmitis has been reported to occur following ocular surgery, trauma, and, less frequently, from hematogenous spread from extraocular sites. Disseminated aspergillosis occurs typically in patients with a compromised immune system related to organ transplantation, hematologic malignancy, or use of immunosuppressive agents [37]. In addition, there have been several case reports of *Aspergillus* endophthalmitis in intravenous drug abusers [38]. The diagnosis of *Aspergillus* endophthalmitis should be entertained in all patients with a systemic predisposition or *Aspergillus* disease elsewhere in the body. The help of ancillary investigations such as ultrasonography, lactate dehydrogenase activity of aqueous and serum, aqueous humor cytology, and fungal culture should be utilized to establish a diagnosis.

*Cryptococcus* spores can survive up to 2 years in pigeon droppings. Spores gain access to the human body through inhalation. From the lungs, the fungus is disseminated hematogenously and

preferentially affects the central nervous system. It is the most common cause of fungal meningitis. *Cryptococcus* organisms reach the eye through either direct extension from the optic nerve sheath or hematogenously from a distant focus. Cryptococcal endophthalmitis is a rare condition that is most often diagnosed by examining enucleated specimens or at autopsy [39].

*Coccidioides* endophthalmitis results from the inhalation of *C. immitis* arthroconidia, which are found in the dust of endemic areas such as the San Joaquin Valley of central California, Arizona, New Mexico, Texas, and in parts of Venezuela, Honduras, and Colombia. Agricultural workers and construction crews are at particular risk. In most patients, the inhalation of the spores leads to a self-limited respiratory disease. In a few patients who are reexposed to the fungus, a chronic respiratory disease ensues. Hematogenous dissemination to the eye can occur in both immunocompetent and immunocompromised patients [40].

---

## Clinical Findings

A high degree of suspicion is necessary to make an early diagnosis of endogenous endophthalmitis. Blurred vision is the most common symptom at presentation, occurring in 94.3% of patients. It has been suggested that pain is an important indicator of endophthalmitis, but only 74.3% of patients presented with pain, indicating that the absence of pain does not rule out the diagnosis of endophthalmitis. Hypopyon (Fig. 10.2a, b) is the most common sign of endophthalmitis, occurring in 85.7% of patients; but as is the case with pain, its absence does not preclude the diagnosis of endophthalmitis. Poor media clarity is the next best indicator, with 79.1% of patients having no view of any retinal vessels and 68% having no red reflex. Second-order retinal vessels were seen in only 10% of patients. Earlier signs include retinal changes such as Roth's spots and retinal periphlebitis. Slit lamp examination and ocular ultrasonography should be performed to look for anterior vitreous haze echoes and retinochoroidal thickening. Patients who present at a later stage

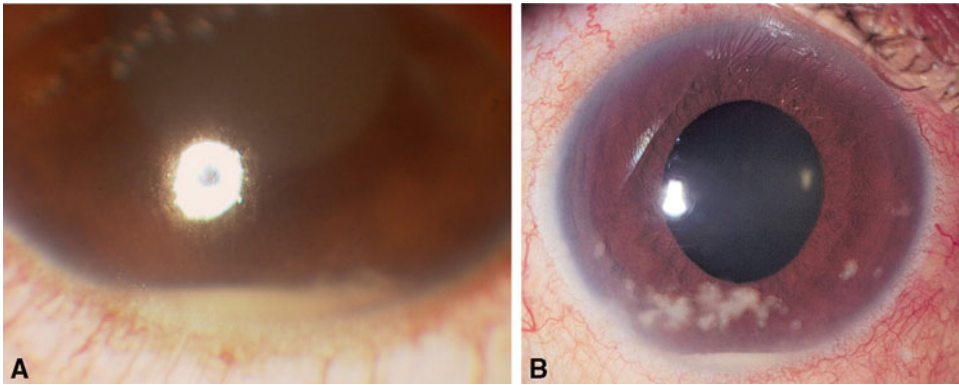
in the disease may have obvious signs such as chemosis, proptosis, and hypopyon.

Endogenous bacterial endophthalmitis generally occurs within a week after the onset of systemic illness, but may occasionally develop a month or more after the onset of sepsis [28]. The systemic symptoms of sepsis are often nonspecific and include malaise, nausea, loss of appetite or weight, and abdominal discomfort. Endogenous bacterial endophthalmitis may be classified as anterior, posterior, or panophthalmitis. The anterior and posterior forms may further be subdivided into focal or diffuse [10]. Anterior focal disease, where the infection is confined to one or more discrete foci that may appear as iris nodules or microabscesses, is rare. The anterior segment inflammation is mild to moderate. In the diffuse type, the inflammation tends to be more severe, with chemosis, lid swelling, corneal edema, fibrin in the anterior chamber, and hypopyon. The intraocular pressure (IOP) is often elevated.

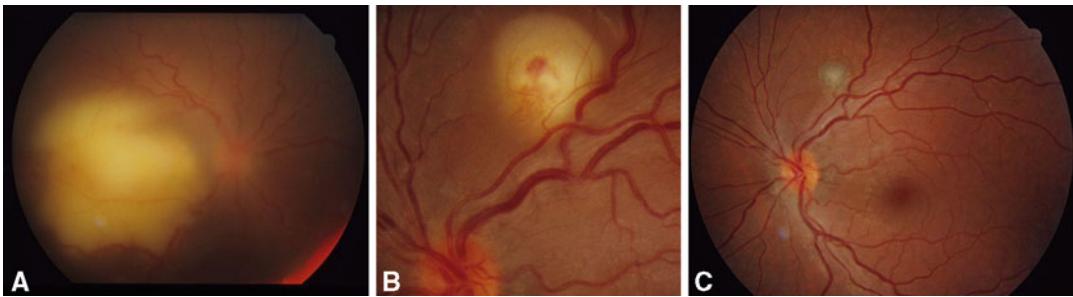
Posterior focal disease manifests as whitish nodules or plaques, usually in the choroid, that rapidly involve the retina. Infections caused by gram-positive organisms such as *Staphylococcus aureus* may be multifocal, associated with Roth's spots and retinal vasculitis, and tend to be severe (Fig. 10.3a, b, c). Gram-negative infections usually cause a single large choroidal abscess involving the posterior pole. There may only be minimal injection of the conjunctiva with a relatively clear cornea and mild to moderate anterior chamber reaction.

Diffuse disease is a more severe condition characterized by intense vitreous inflammation, which usually obscures the fundus. This may arise from virulent organisms such as Group B *Streptococcus* or from posterior focal infection, especially if these are misdiagnosed as autoimmune uveitis and treated with periocular steroid injections. Perivascular hemorrhages, inflammatory infiltrates, and arterial emboli [41] have been noted in cases where the fundi could be visualized. Ultimately, retinal necrosis occurs. Globe perforation may occur at the site of an abscess, especially if the infection is accompanied by a marked rise in IOP. In panophthalmitis, the infection involves the entire globe and may spread to the orbital tissues resulting in lid edema,





**Fig. 10.2** *Candida* endophthalmitis. (a) Clinical features of a 22-year-old woman with endogenous endophthalmitis. Marked intraocular inflammation with hypopyon and conjunctival congestion. (b) Anterior focal endophthalmitis



**Fig. 10.3** (a) *Staphylococcus aureus* abscess diagnosed by transvitreal biopsy. (b) *Staphylococcus aureus* abscess in the contralateral eye. (c) *Staphylococcus aureus* abscess in the contralateral eye resolved after antibiotic treatment

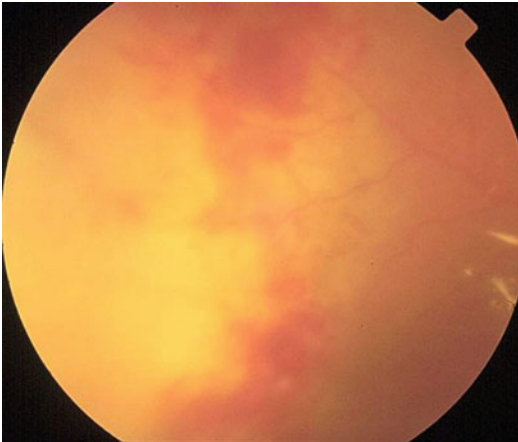
chemosis, proptosis, and limited ocular movements. This may be caused by *Klebsiella* (Figs. 10.4 and 10.5) and *Pseudomonas* species.

O'Day and colleagues outlined three features common to cases of exogenous *B. cereus* endophthalmitis. Firstly, there was a penetrating injury with vitreous involvement. Secondly, perforation was caused by a low velocity metallic fragment. Finally, there was the possibility of soil contamination. The interval between injury and deterioration of vision was typically less than 48 h. Severe pain often develops within 24 h. This occurs in conjunction with a drastic reduction in visual acuity, chemosis, periorbital swelling, and proptosis. Classically, a corneal ring abscess develops in association with the reduction of vision. Some authors have indicated that this is pathognomonic; however, it has been described in other cases of endophthalmitis including those caused by *Pseudomonas* and *Proteus* species [42].

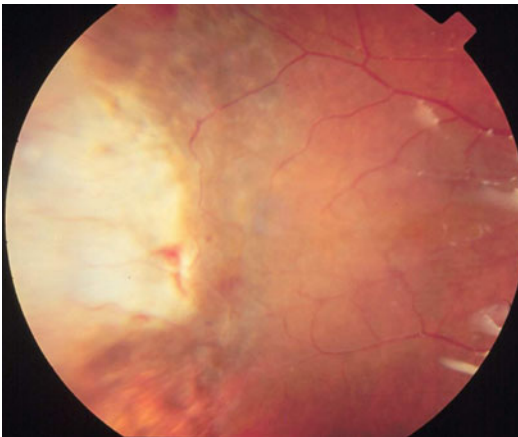
The other important distinguishing feature is that *B. cereus* endophthalmitis often produces associated systemic symptoms. The patient develops fever, leukocytosis, and malaise.

*Candida* chorioretinitis is the most common cause of endogenous endophthalmitis with a characteristic clinical ocular appearance. Endogenous *Candida* endophthalmitis often starts as a focal choroiditis, and then the infection spreads into the retina and breaks into the vitreous. The presence of white vitreous opacities forming a string-of-pearls appearance is a very typical feature (Fig. 10.6a, b). Among the mechanisms postulated to explain the predilection of *C. albicans* to infect the eye is the ability to form germ tubes in serum that embolize and lodge in the choriocapillaris.

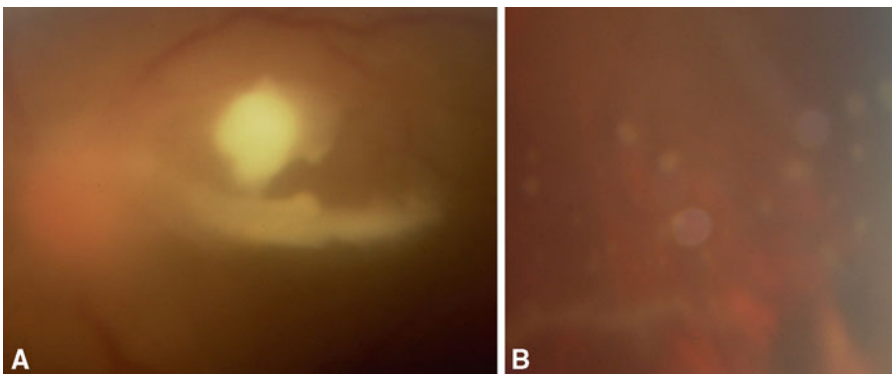
*Aspergillus* infections of ophthalmic interest usually cause keratitis or orbital cellulitis, and less commonly conjunctivitis and canaliculitis.



**Fig. 10.4** *Klebsiella pneumoniae* endophthalmitis. Fundus photo depicting a unilateral subretinal mass at the posterior pole



**Fig. 10.5** Same patient as in Fig. 10.4. The unilateral mass has resolved after treatment



**Fig. 10.6** Same patient as in Fig. 10.2a with *Candida* endophthalmitis. (a) Fundus photography shows a central macular yellow-white preretinal abscess or "fluffy ball"

[43] On review the authors found that the presenting complaint in the cases reported so far was a diminution of vision in 16 cases, a red eye in seven, ocular pain in four, and acute proptosis in two. Clinically, 12 cases presented with signs of iritis, five of whom had a hypopyon, and 18 showed marked chorioretinitis. A yellowish white mass with an abscess in the posterior segment was seen in 15 cases, while superficial retinal hemorrhages were present in three and a retinal detachment was observed in four. One case [44] presented with an anterior chamber mass, quite akin to the picture presented in the left eye by the same patient.

*C. neoformans* usually presents intraocularly as a multifocal chorioretinitis characterized by discrete yellow-white lesions of different sizes [39]. The inflammatory reaction is somewhat mild, in contrast to *Candida* or *Aspergillus*. Retinal vessels may be sheathed, and vitritis of variable intensity may develop [45]. Retinal necrosis accompanied by retinal hemorrhage and exudative retinal detachments also have been known to occur. If the central nervous system is involved, papilledema is present. A mild inflammatory reaction is usually present in the anterior segment.

In *Coccidioides* endophthalmitis, the uvea is the most common site of intraocular infection [46]. A granulomatous uveitis can ensue, with mutton-fat keratic precipitates and iris nodules with or without posterior involvement. Multifocal choroiditis with small yellow-white lesions

extending into the vitreous chamber. Vitreous chamber haze resulted in reduced fundus view. The retina was attached. (b) Snow balls in the inferior periphery of the same patient



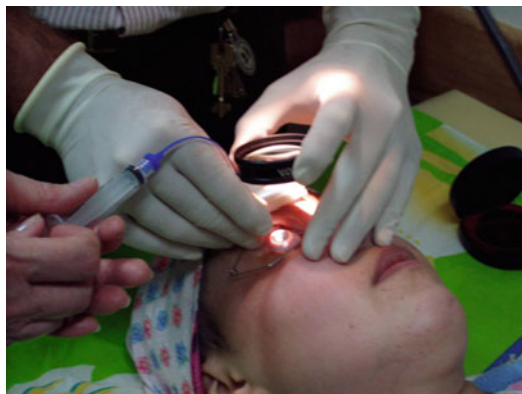
measuring less than a disk diameter in size and most commonly located in the peripapillary area has been described. Occasionally, vascular sheathing, vitreous haze, serous retinal detachment, and retinal hemorrhage may also be seen [47].

## Diagnosis

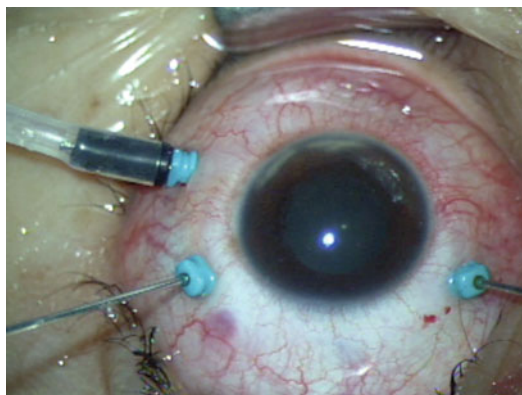
In addition to initial diagnostic laboratory tests, testing for HIV infection should be considered in otherwise healthy persons with endophthalmitis. Routine radiographs may reveal a primary pulmonary infection. Echocardiography is also warranted to assess the possibility of endocarditis. Other tests like chest radiographs, echocardiography, and ultrasonography or computed tomography (CT) scan of the abdomen may be useful to help locate the source of infection. In addition, a Gallium-67 scan may help to reveal foci of inflammation [48]. Computed tomography and magnetic resonance imaging of the orbits have been proposed both for the diagnosis as well as monitoring of response to treatment of endogenous bacterial endophthalmitis in eyes with opaque media. However, this may not be an economically viable option in developing countries, and ultrasonography is an equally sensitive and specific but more cost-effective diagnostic imaging tool [49]. Cultures obtained from blood (72%), urine (28%), and cerebrospinal fluid (50%) allow for early and reliable identification of microorganisms in at least 80% of cases of endogenous bacterial endophthalmitis [30] and should preferably be obtained before initiation of antibiotic therapy.

## How to Culture

When any type of endophthalmitis is suspected, intraocular cultures and gram stains should be performed. Both vitreous and aqueous humor from the anterior chamber should be cultured because occasionally organisms are isolated from one but not the other. Aqueous material can be obtained with a 5/8-in. 30-gauge needle attached to a tuberculin syringe through a limbal stab incision, and

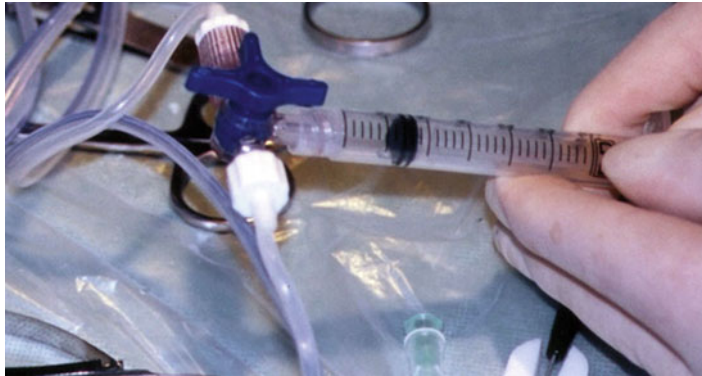

**Fig. 10.7** Aqueous material can be obtained with a 5/8-in. 30-gauge needle attached to a tuberculin syringe through a limbal stab incision, and 0.1–0.2 ml of fluid should be aspirated



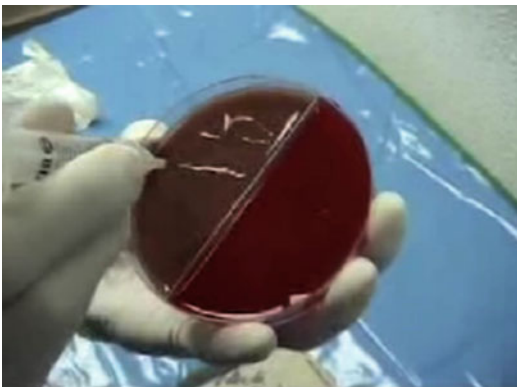**Fig. 10.8** After insertion of the first microcannula, the infusion cannula is directly inserted into the external opening of the microcannula. The infusion cannula should be close (turned off), and two other microcannulas are inserted in the superotemporal and superonasal quadrants

0.1–0.2 ml of fluid should be aspirated (Fig. 10.7). Vitreous biopsy is best performed via a 25-gauge transconjunctival sutureless pars plana one-, two-, or three-port vitrectomy (Figs. 10.8, 10.9, and 10.10) [50]. A single-port vitreous biopsy can be performed in the office with a 23-gauge vitrectomy probe. If an automated vitrectomy probe is not available, a biopsy specimen of the vitreous can be obtained with a 5/8- to 1-in., 25–27-gauge needle attached to a tuberculin syringe. Use of a vitrectomy probe probably results in less vitreo-retinal traction than aspiration with a syringe, and it does not increase the likelihood of obtaining



**Fig. 10.9** A 10-ml syringe is spliced via a three-way stopcock into the aspiration line. The vitrectomy hand-piece is placed in mid-vitreous cavity with the infusion turned off. Automated cutting and manual aspiration of

the vitreous without concurrent infusion is then performed. The vitrector is withdrawn from the eye, and the vitreous specimen is aspirated into the syringe



**Fig. 10.10** At least 1 ml of undiluted vitreous is aspirated into the collection syringe and distributed for studies

false-positive culture results [51]. Vitreous specimens (0.1–0.2 mL for aspirate, 0.5 mL for vitrectomy probe-assisted vitreous biopsy, 1 mL for three-port vitrectomy) should be sent to the laboratory undiluted to increase the yield. If a two- or three-port vitrectomy is done, one should consider submitting the cassette fluid for culture.

## Polymerase Chain Reaction

Polymerase chain reaction (PCR) is becoming increasingly utilized in the diagnosis of endophthalmitis and has a number of potential advantages [52]. PCR greatly amplifies the quantity of bacterial DNA available for analysis, and

this may enable the detection of a single organism [53]. The process of DNA replication can also be performed within a few hours.

Although PCR is a rapid and highly sensitive test, it also has disadvantages. The high sensitivity may lead to false-positive results, and specimens need to be carefully collected and processed to avoid exogenous or cross-contamination. False-negative results are also possible, particularly with unusual organisms [54]. Careful control experiments are therefore required if the results of PCR are to be meaningful. PCR may be used to rapidly establish the presence of bacterial infection but may take 48–72 h for final species identification [55], and unlike traditional culture techniques, it does not detect the ability of an organism to replicate, or its antibiotic sensitivity. In addition, PCR is not yet routinely available and is of limited use in mixed infections. For these reasons, PCR is likely to become a useful adjunct to microbiology and culture, rather than replacing it.

## Treatment

A patient with hand motions or better vision should have an immediate tap or biopsy, followed by injection of antibiotics. It is reasonable to perform vitreous taps because they can be done more quickly, decreasing delay in administration of antibiotics. Specimens should be obtained

from both the vitreous and the anterior chamber. If an adequate specimen is not obtained, vitreous biopsy should be performed. Undiluted vitreous provides the best specimen for cultures, but a specimen should also be obtained from the anterior chamber because 4.2% of patients in the Endophthalmitis Vitrectomy Study (EVS) had positive cultures from an anterior chamber specimen only [56].

Patients with light perception vision should have immediate vitrectomy. At the beginning of the procedure, a 0.3–0.5-mL specimen of undiluted vitreous should be obtained. After turning on the infusion, an anterior chamber tap should be done, and the specimens should be plated immediately. The vitrectomy is then completed. Often, there is a fibrin membrane covering the anterior surface of an intraocular lens; it is necessary to manipulate the vitreous cutter into the anterior chamber and remove the fibrin membrane, which can markedly improve visualization. Once the vitrectomy is completed, the fundus should be examined with indirect ophthalmoscopy and scleral depression to rule out any retinal breaks. After closing the sclerotomies, antibiotics are injected.

---

### Systemic Antibiotics

Prompt administration of antibiotic therapy is key in the acute management of endogenous endophthalmitis. This condition is particularly responsive to intravenous antibiotics. Systemic antibiotics also treat distant foci of infection and prevent continued bacteremia, thereby reducing chances of invasion of the unaffected eye. Intravenous benzylpenicillin is indicated in cases of suspected meningitis in children and young adults. Subsequent therapy can be tailored according to culture and sensitivity results and response to treatment. In all cases, prolonged intravenous therapy is usually required for 2–4 weeks to ensure complete eradication of the systemic infection. Empiric broad-spectrum antibiotic therapy with vancomycin and an aminoglycoside or a third-generation cephalosporin is warranted (Table 10.3) [57].

**Table 10.3** Treatment of endogenous bacterial endophthalmitis

- 
- Admit the patient to the hospital
  - Broad-spectrum IV antibiotics including vancomycin and an aminoglycoside or third-generation cephalosporin
  - Consider adding clindamycin in IV drug users until *Bacillus* infection can be ruled out
  - Intravitreal antibiotics are indicated
  - Cycloplegics may be administered
  - Topical steroids may be considered
  - Vitrectomy may be needed for virulent organisms
- 

#### IV Intravenous

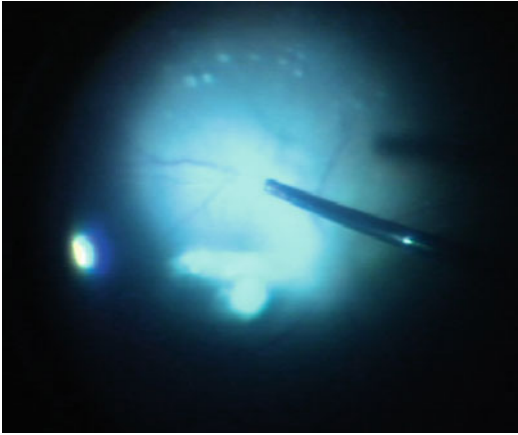
Third-generation cephalosporins penetrate ocular tissues and are effective against gram-negative organisms. The nature of the clinical presentation, as well as the presumed (or confirmed) source of infection, can be used to guide the decision about which antibiotic to use. In cases of documented gastrointestinal or genitourinary infection, second- or third-generation cephalosporins and aminoglycosides are considered the drugs of choice. Vancomycin should be given to patients known to abuse drugs, covering the possibility of infection with *Bacillus*. In the presence of wounds, oxacillin or a first-generation cephalosporin should be used. If the patient's history, stains, or culture results suggest a fungal infection, amphotericin B, fluconazole, or itraconazole should be included in the regimen [57].

Confirmation of a presumptive diagnosis of fungal endophthalmitis frequently implies a pars plana vitrectomy (Figs. 10.8, 10.9, and 10.11). Vitrectomy has the advantage of eliminating microorganisms and inflammatory mediators from the vitreous cavity and provides material for microbiological examinations. Because patients frequently carry a variety of yeasts, culture from the ocular tissue is the only sure method of establishing the etiology of endophthalmitis.

---

### Intravitreal Antibiotics

At the outset of the Endophthalmitis Vitrectomy Study (EVS), it was recognized that severe retinal vascular nonperfusion could result from



**Fig. 10.11** Same patient as in Fig. 10.6. After the undiluted sample is taken, the therapeutic three-port vitrectomy can then be completed if necessary

intraocular injection of gentamicin and that the macula was frequently involved, resulting in severe loss of vision [58].

The organizers of the EVS, however, apparently believed that amikacin did not cause the same sort of toxicity, and, therefore, 0.4 mg of amikacin and 1 mg of vancomycin were selected for intravitreal injections. Other investigators believed that this was an assumption because amikacin, like gentamicin, was known to have neurotoxicity, and amikacin had been implicated in cases of macular infarction [59]. The EVS organizers considered switching from amikacin to ceftazidime but decided against it because patients who developed macular infarction after intravitreal amikacin had also received a subconjunctival injection of gentamicin, and they remained unconvinced that amikacin was toxic [60]. Subsequently, several cases of unequivocal amikacin-induced retinal nonperfusion were reported, and it was demonstrated that decreased visual acuity could range from mild to severe, depending on the location and amount of retinal nonperfusion [61].

Some investigators continue to doubt the potential toxicity of amikacin apparently because in their personal experience they have never recognized such toxicity. They continue to use amikacin and cite the results of the EVS to justify their position, because only one case of macular

infarction was recognized out of 392 eyes treated with amikacin [62]. Based upon *in vitro* sensitivity studies in the EVS, ceftazidime was found to be equally efficacious as amikacin [63], and because ceftazidime has a better safety profile, Campochiaro [64] strongly recommends that ceftazidime be used instead of amikacin for intravitreal injections.

As the organisms that cause endophthalmitis and its virulence are not known, initially we always recommend taking a vitreous sample for culture and antibiogram; after that, we inject ample spectrum antibiotic combination in the cavity vitreous: vancomycin 1 mg in 0.1 ml + amikacin sulfate 0.4 mg in 0.1 ml or vancomycin 1 mg in 0.1 ml + ceftazidime sodium 2.25 mg in 0.1 ml. Antibiotics are sometimes injected into the vitreous cavity as the only intravitreal therapy, whereas on other occasions they are combined with pars plana vitrectomy.

Given the low permeability of pigmented epithelium to systemically administered drugs, intravitreal antifungals are used in cases in which systemic treatment is ineffective or following procedures such as vitrectomy and vitreous tap. For antifungal treatment, we include intravitreal amphotericin B (5  $\mu$ [mu]g/0.1 mL). Other primary antifungal treatments include intravitreal injection of voriconazole (100  $\mu$ [mu]g/0.1 mL), intravitreal injection of fluconazole (10  $\mu$ [mu]g/0.1 mL), intravitreal injection of miconazole (25  $\mu$ [mu]g/0.1 mL), and a combination of oral (amphotericin B 20 mg/day, fluconazole 400 mg/day, fluconazole 200 mg/day, or itraconazole 200 mg/day), topical, and subconjunctival antifungal agents, up to 6 months for endogenous fungal endophthalmitis. Despite poor vitreous penetration, systemic therapy of amphotericin B, fluconazole, or itraconazole may help in endogenous endophthalmitis.

The outcome of posterior diffuse endophthalmitis or panophthalmitis is frequently blindness, regardless of treatment measures. Vitrectomy and intravitreal antibiotics may, however, prevent ocular atrophy or the necessity for enucleation. Some damage may also be related to inflammatory mediators.



---

## Corticosteroid Therapy

To reduce the destructive effect of the significant inflammation that coexists with infection in endophthalmitis, many ophthalmologists use systemic, topical, subconjunctival, and intravitreal corticosteroids in combination with antibiotics, provided that no contraindications exist (e.g., diabetes mellitus, tuberculosis, fungal infection).

The use of intravitreal and systemic steroids in the management of endophthalmitis remains controversial, with systemic steroids being contraindicated in patients with inadequately controlled sepsis. Intravitreal steroids, however, may have a protective effect on the retina in curbing the severe inflammation induced by destruction of the bacteria within the eye [65].

We commonly prescribe prednisone, 1 mg/kg orally each morning for 3–5 days. In addition, we recommend intravitreal dexamethasone (400 µg/0.1 mL) [66]. It is given at the time of vitreous biopsy or vitrectomy. It is important to use preservative-free drugs to avoid potential retinal toxicity. Vancomycin, ceftazidime, and dexamethasone are physically incompatible and, if mixed in the same syringe, may precipitate. Therefore, separate slow injections to ensure proper mixing in the vitreous cavity are advised [67].

---

## Vitrectomy

The theoretical advantages of vitrectomy include removal of the infecting organisms, endotoxins, exotoxins, and vitreous membranes that could lead to retinal detachment, clearing of vitreous opacities, collection of abundant material for culture, and possibly better distribution of intravitreal antibiotics. The disadvantages of vitrectomy include the added cost and inconvenience, and the risk of anesthetic and surgical complications, such as cataract formation.

The role and timing of vitrectomy remains unclear in endogenous bacterial endophthalmitis. Some reports suggest that combining medical

therapy with early surgical intervention is beneficial [68]. Other studies found no significant benefit in performing vitrectomy [69]. However, all these studies have all been limited by the small number of cases and the variability with respect to multiple other factors including timing of surgery and the offending organisms. Vitrectomy will be useful in posterior diffuse disease as adequate material can be obtained for microbiology and it may have additional beneficial effects by reducing the number of organisms. Endogenous bacterial endophthalmitis complicated by retinal detachment is another indication for vitrectomy combined with scleral buckling. Silicone oil fill is usually necessary in these eyes. However, operating on a severely inflamed eye with an ischemic and necrotic retina increases the risk of hypotony, retinal breaks, and phthisis bulbi. When the infection has been controlled by systemic and or intravitreal antibiotics, vitrectomy is also useful in removing residual vitreous opacity and hastening visual rehabilitation

---

## Prognosis

The visual outcome of endogenous bacterial endophthalmitis has not improved in 55 years. Review of the literature from 1976 to 1985 showed that 41% of patients had count fingers vision or better, 26% were blind, and 29% required evisceration or enucleation [10]. Similar figures were reported over the preceding 30 years [70]. Review of the literature since 1986 also indicates a poor outcome, with equivalent figures of 32% (count fingers vision or better), 44% (blind), and 25% (evisceration or enucleation). The studies that investigated prognostic factors in endogenous bacterial endophthalmitis (EBE) [11] were retrospective, and although selection bias cannot be excluded, they identified several factors that adversely affect prognosis. These included delay in diagnosis [10]; use of inappropriate antibiotics [71]; diffuse infection of the vitreous and retina, or panophthalmitis; infection with virulent organisms [30]; and gram-negative infection [70].



Fungal endophthalmitis may occur as a complication of intraocular surgery; as a manifestation of systemic fungal infection, secondary to trauma; or as an extension of an adjacent focus of infection. Its diagnosis requires a high degree of suspicion. PCR testing may reduce the delay in making the diagnosis. The prognosis of fungal endophthalmitis depends on the virulence of the organism, the extent of intraocular involvement, and the timing and mode of interventions. Prompt therapy with systemic antifungals, pars plana vitrectomy, and intravitreal antifungals following early diagnosis helps to reduce significant visual loss in all forms of fungal endophthalmitis.

---

## Controversies and Perspectives

Intravitreal antibiotic therapy has become a commonly utilized standard for endophthalmitis treatment [3]. The intraocular concentration of antibiotics after intravitreal injection is far greater than that achieved by any other modality [62]. Therefore, intravitreal antibiotics are the most important component of therapy in eradicating infection in an eye with endophthalmitis. In the EVS, all patients received intravitreal amikacin (0.4 mg/0.1 cc) and vancomycin (1.0 mg/0.1 cc), but other antibiotics combinations have been suggested.

In the treatment of endophthalmitis, intraocular vancomycin is considered to be the drug of choice for gram-positive organisms and is non-toxic in the clinically recommended dose of 1 mg/0.1 cc [72]. In the EVS, all gram-positive organisms were susceptible to vancomycin, including methicillin-resistant *Staphylococcus aureus* (MRSA) [62]. Prior to vancomycin, cefazolin was used as a first-line choice for the treatment of gram-positive organisms, but frequent resistance to cefazolin made it a less desirable choice [73]. Among gram-positive organisms causing endophthalmitis, resistance to vancomycin is rare.

Continued controversy remains regarding the best antimicrobial against gram-negative organisms. Most clinicians have been using either an aminoglycoside, such as gentamicin or amikacin,

or ceftazidime, a third-generation cephalosporin. Intravitreal aminoglycosides are a reported cause of macular toxicity [59]. Aminoglycoside-induced macular infarction is thought to be partially due to the gravity-induced settling of drugs on the macula in a supine patient. This may result in a higher concentration of drug locally at the macula [61].

Ceftazidime has been suggested as an alternative antibiotic to cover gram-negative organisms because of its broad therapeutic index, lower risk for retinal toxicity, and its in vitro sensitivities that are as effective as the aminoglycosides.

The EVS found that only patients with perception of light or worse visual acuity benefited from formal vitrectomy, although it should be noted that a significant selection bias existed in the EVS patients. All EVS patients also received intensive topical steroid and cycloplegia, and because significant anterior segment inflammation exists, higher doses of topical steroids are needed than would normally be given after cataract surgery. In fact the EVS visual results were even better than the Moorfields results quoted [74], with 53% of patients achieving 6/12 or better and 74% achieving 6/30 or better [62]. This reinforces the fact that with prompt and effective treatment endophthalmitis patients can achieve a reasonable result, and unless other contraindications exist, all patients should be given systemic steroids. There has been one paper that reported poorer visual outcomes following the use of intravitreal steroids (albeit a retrospective review) [4]. If intravitreal steroids are contemplated, then the dosage typically recommended for dexamethasone is 0.4 mg in 0.1 mL [75].

One author of a recent paper [76] suggested the use of a 21-G needle, which might not leave a self-sealing wound via pars plana along with potential for vitreous incarceration. It is often possible to obtain an adequate sample using a 23-G needle. Direct visualization of pars plana sampling as suggested by one author is also not necessary [76]. Most eyes do not require anterior chamber washout or other intraocular manipulations that may delay the injection of the relevant antibiotics while a more complex surgical procedure is organized. Similarly changing syringes to

inject antibiotics via the same needle can be technically difficult, and it is typically easier to inject antibiotics as two separate injections. Half-inch 27-G or 30-G needles are sufficient for this purpose, and the shorter length means that damage to intraocular structures is less likely in a soft eye setting.

## Focal Points

- The outcome of endogenous endophthalmitis can be optimized by maintaining a high index of suspicion, especially in susceptible patients. However, the possibility of endogenous endophthalmitis in healthy patients and iatrogenic endogenous endophthalmitis also must be borne in mind.
- Poor prognostic factors include infection by more virulent organisms; poor host defense; misdiagnosis; and delayed, inappropriate, or inadequate treatment.
- Prompt diagnosis and intensive intravenous antibiotics are the most critical steps in the treatment of endogenous bacterial endophthalmitis. An important feature of this disease that needs emphasis is the potential risk to the unaffected eye. This means that intravenous antibiotics need to be administered very quickly, and patients should not be treated as if they have a unilateral eye problem.
- Current recommendations for empirically treating suspected bacterial endophthalmitis involve combination therapy targeting both gram-positive and gram-negative organisms. Therapeutic combinations of antibiotics should be tailored to the clinical scenario in which endophthalmitis develops and should target the most common causative organisms. Fungal therapy is considered when clinical history and ocular features justify this approach.
- Due to the low permeability of pigmented epithelium to systemically administered drugs, intravitreal antibiotics or antifungals are used in cases in which systemic treatment is ineffective or following procedures such as vitrectomy and vitreous tap. Regarding optimized

therapy in such patients, further studies are required.

- Intravitreal therapy and vitrectomy are effective treatment modalities in fungal and bacterial infections.

**Acknowledgments** The authors have no financial or proprietary interest in any of the products or techniques mentioned in this chapter.

Supported in part by the Arévalo-Coutinho Foundation for Research in Ophthalmology, Caracas, Venezuela.

## References

1. Hassan IJ, MacGowan AP, Cook SD. Endophthalmitis at the Bristol Eye Hospital: an 11-year review of 47 patients. *J Hosp Infect.* 1992;22:271–8.
2. Shrader SK, Band JD, Lauter CB, et al. The clinical spectrum of endophthalmitis: incidence, predisposing factors, and features influencing outcome. *J Infect Dis.* 1990;162:115–20.
3. Puliafito CA, Baker AS, Haaf J, Foster CS. Infectious endophthalmitis. Review of 36 cases. *Ophthalmology.* 1982;89:921–9.
4. Jackson TL, Eykyn SJ, Graham EM, Stanford MR. Endogenous bacterial endophthalmitis: a 17-year prospective series and review of 267 reported cases. *Surv Ophthalmol.* 2003;48:403–23.
5. Binder MI, Chua J, Kaiser PK, Procop GW, Isada CM. Endogenous endophthalmitis: an 18-year review of culture-positive cases at a tertiary care center. *Medicine (Baltimore).* 2003;82:97–105.
6. Kresloff MS, Castellarin AA, Zarbin MA. Endophthalmitis. *Surv Ophthalmol.* 1998;43:193–224.
7. Anand AR, Therese KL, Madhavan HN. Spectrum of etiological agents of postoperative endophthalmitis and antibiotic susceptibility of bacterial isolates. *Indian J Ophthalmol.* 2000;48:123–8.
8. Augsten R, Konigsdorffer E, Strobel J. Endogenous endophthalmitis in severe generalized diseases. *Ophthalmology.* 1997;94:397–400.
9. Michelson JB, Friedlaender MH. Endophthalmitis of drug abuse. *Int Ophthalmol Clin.* 1987;27:120–6.
10. Greenwald MJ, Wohl LG, Sell CH. Metastatic bacterial endophthalmitis: a contemporary reappraisal. *Surv Ophthalmol.* 1986;31:81–101.
11. Bouza E, Grant S, Jordan C, Yook RH, Sulit HL. *Bacillus cereus* endogenous panophthalmitis. *Arch Ophthalmol.* 1979;97:498–9.
12. Tan JH, Newman DK, Burton RL. Endogenous endophthalmitis due to group G *Streptococcus*. *Eye.* 1999;13:116–7.
13. Nagelberg HP, Petashnick DE, To KW, Woodcome Jr HA. Group B streptococcal metastatic endophthalmitis. *Am J Ophthalmol.* 1994;117:498–500.

14. Chen KJ, Hou CH, Sun MH. Endophthalmitis caused by *Acinetobacter baumannii*: report of two cases. *J Clin Microbiol.* 2008;46:1148–50.
15. Chen KJ, Sun MH, Hwang YS, et al. Endophthalmitis caused by citrobacter species. *Ocul Immunol Inflamm.* 2008;16:147–53.
16. Khan MI, Walters G, Metcalfe T. Bilateral endogenous endophthalmitis caused by *Aeromonas hydrophila*. *Eye.* 2007;21:1244–5.
17. Lalitha P, Rathinam SR, Srinivasan M. Ocular infections due to non-tuberculous mycobacteria. *Indian J Med Microbiol.* 2004;22:231–7.
18. Ormerod LD, Paton BG, Haaf J, Topping TM, Baker AS. Anaerobic bacterial endophthalmitis. *Ophthalmology.* 1987;94:799–808.
19. Ellenberger Jr C, Sturgill BC. Endogenous *Pseudomonas* panophthalmitis. *Am J Ophthalmol.* 1968;65:607–11.
20. George G. Bacterial endocarditis due to *Pseudomonas aeruginosa*. *J Am Med Assoc.* 1958;168:1929–30.
21. Sheares BJ, Prince AS, Quittell LM, Neu NM, Bye MR. *Pseudomonas aeruginosa* endophthalmitis after lung transplantation for cystic fibrosis. *Pediatr Infect Dis J.* 1997;16:820–1.
22. Detering K, Jenney A, Hall A, Fuller A, Pickles R, Snell G. Metastatic choroidal abscess due to *Pseudomonas aeruginosa* in patients with cystic fibrosis. *Clin Infect Dis.* 1997;24:525–6.
23. Srinivasan M, Sundar K. Nocardial endophthalmitis. *Arch Ophthalmol.* 1994;112:871–2.
24. Grenzebach UH, Busse H, Tötsch M, Dockhorn-Dworniczak B. Endophthalmitis induced by atypical mycobacterial infection. *Ger J Ophthalmol.* 1996;5:202–6.
25. Leibovitch I, Lai T, Raymond G, et al. Endogenous endophthalmitis: a 13-year review at a tertiary hospital in South Australia. *Scand J Infect Dis.* 2005;37:184–9.
26. Karama EM, Willerman F, Janssens X, et al. Endogenous endophthalmitis complicating *Klebsiella pneumoniae* liver abscess in Europe: case report. *Int Ophthalmol.* 2008;28:111–3.
27. Sheu SJ, Chou LC, Hong MC, et al. Risk factors for endogenous endophthalmitis secondary to *Klebsiella pneumoniae* liver abscess. *Zhonghua Yi Xue Za Zhi (Taipei).* 2002;65:534–9.
28. Wong JS, Chan TK, Lee HM, Chee SP. Endogenous bacterial endophthalmitis. An East Asian experience and a reappraisal of a severe ocular affliction. *Ophthalmology.* 2000;107:1483–91.
29. Chang FY, Chou MY, Fan RL, et al. A clinical study of *Klebsiella* liver abscess. *J Formos Med Assoc.* 1988;87:282–6.
30. Okada AA, Johnson RP, Liles WC. Endogenous bacterial endophthalmitis. Report of a ten-year retrospective study. *Ophthalmology.* 1994;101:832–8.
31. Gregor JR, Chong CA, Augsberger JJ, et al. Endogenous *Nocardia asteroides* subretinal abscess diagnosed by transvitreal fine-needle aspiration biopsy. *Retina.* 1989;9:118–21.
32. Graham DA, Kinyoun JL, George DP. Endogenous *Aspergillus* endophthalmitis after lung transplantation. *Am J Ophthalmol.* 1995;119:107–9.
33. Sheu SJ, Chen YC, Kuo NW, Wang JH, Chen CJ. Endogenous cryptococcal endophthalmitis. *Ophthalmology.* 1998;105:377–81.
34. Deutsch D, Adler S, Teller J, Savir H. Endogenous candidal endophthalmitis. *Ann Ophthalmol.* 1989;21:260–5.
35. Edwards Jr JE, Foos RY, Montgomerie JZ, Guze LB. Ocular manifestations of *Candida* septicemia: review of seventy-six cases of hematogenous *Candida* endophthalmitis. *Medicine (Baltimore).* 1974;53:47–75.
36. Parke DW, Jones DB, Gentry LO. Endogenous endophthalmitis among patients with candidemia. *Ophthalmology.* 1982;89:789–96.
37. Naidoff MA, Green WR. Endogenous *Aspergillus* endophthalmitis after kidney transplants. *Am J Ophthalmol.* 1974;79:502–9.
38. Doft PH, Clarkson JG, Robell G, Forster RK. Endogenous *Aspergillus* endophthalmitis in drug abusers. *Arch Ophthalmol.* 1980;98:859–62.
39. Crump JR, Elnor SG, Elnor VM, Kauffman CA. Cryptococcal endophthalmitis: case report and review. *Clin Infect Dis.* 1992;14:1069–73.
40. Cutler JE, Binder PS, Paul TO, Beamis JF. Metastatic coccidioidal endophthalmitis. *Arch Ophthalmol.* 1978;96:689–91.
41. Chee SP, Jap A. Endogenous endophthalmitis. *Curr Opin Ophthalmol.* 2001;12:464–70.
42. O'Day DM, Smith RS, Gregg CR, Turnbull PCB, Head WS, Ives JA, et al. The problem of *Bacillus* species infection with special emphasis on the virulence of *Bacillus cereus*. *Ophthalmology.* 1981;88:833–8.
43. Brightbell FS, Fraser LK. Unilateral keratoconjunctivitis with canalicular obstruction by *Aspergillus fumigatus*. *Arch Ophthalmol.* 1974;91:421–2.
44. Paradis AJ, Roberts L. Endogenous ocular aspergillosis: report of a case in an infant with cytomegalic inclusion disease. *Arch Ophthalmol.* 1963;69:765–9.
45. Custis PH, Haller JA, de Juan Jr E. An unusual case of cryptococcal endophthalmitis. *Retina.* 1995;15:300–4.
46. Blumenkranz MS, Stevens DA. Endogenous coccidioidal endophthalmitis. *Ophthalmology.* 1980;87:974–84.
47. Zakka KA, Foos RY, Brown WJ. Intraocular coccidioidomycosis. *Surv Ophthalmol.* 1978;22:313–21.
48. Kao PF, Tzen KY, Tsai MF, et al. Gallium-67 scanning in endogenous *Klebsiella* endophthalmitis with unknown primary focus. *Scand J Infect Dis.* 2000;32:326–8.
49. Seale M, Lee WK, Daffy J, Tan Y, et al. Fulminant endogenous *Klebsiella pneumoniae* endophthalmitis: imaging findings. *Emerg Radiol.* 2007;13:209–12.
50. Arévalo JF, Sanchez JG, Freeman WR. 25-gauge transconjunctival sutureless vitrectomy for vitreous and retinal/choroidal biopsy. In: Rizzo S, Patelli F, Chow DR, editors. *Vitreo-retinal surgery.* Berlin Heidelberg: Springer; 2009. p. 147–56.

51. Donahue SP, Kowalski RP, Jewart BH, Friberg TR. Vitreous cultures in suspected endophthalmitis. Biopsy or vitrectomy? *Ophthalmology*. 1993;100:452–5.
52. Van Gelder RN. Applications of the polymerase chain reaction to diagnosis of ophthalmic disease. *Surv Ophthalmol*. 2001;46:248–58.
53. Okhravi N, Adamson P, Matheson MM, et al. PCR-RFLP mediated detection and speciation of bacterial species causing endophthalmitis. *Invest Ophthalmol Vis Sci*. 2000;41:1438–47.
54. Knox CM, Cevallos V, Margolis TP, et al. Identification of bacterial pathogens in patients with endophthalmitis by 16S ribosomal DNA typing. *Am J Ophthalmol*. 1999;128:511–2.
55. Okhravi N, Adamson P, Lightman S. Polymerase chain reaction in the diagnosis of bacterial endophthalmitis. *Br J Ophthalmol*. 1999;83:378–80.
56. Barza M, Pavan PR, Doft BH, et al. Evaluation of microbiological diagnostic techniques in post-operative endophthalmitis in the endophthalmitis vitrectomy study. *Arch Ophthalmol*. 1997;115:1142–50.
57. Romero CF, Rai MK, Lowder CY, Adal KA. Endogenous endophthalmitis: case report and brief review. *Am Fam Physician*. 1999;60:510–4.
58. Conway BP, Campochiaro PA. Macular infarction after endophthalmitis treated with vitrectomy and intravitreal gentamicin. *Arch Ophthalmol*. 1986;104:367–71.
59. Campochiaro PA, Conway BP. Aminoglycoside toxicity—a survey of retinal specialists: implications for ocular use. *Arch Ophthalmol*. 1991;109:946–50.
60. Doft BH, Barza M. Ceftazidime or amikacin: choice of intravitreal antimicrobials in the treatment of endophthalmitis. *Arch Ophthalmol*. 1994;112:17–8.
61. Campochiaro PA, Lim JJ. Aminoglycoside toxicity in the treatment of endophthalmitis. The aminoglycoside toxicity study group. *Arch Ophthalmol*. 1994;112:48–53.
62. Endophthalmitis Vitrectomy Study Group. Results of the endophthalmitis vitrectomy study. A randomized trial of immediate vitrectomy and of intravenous antibiotics for the treatment of postoperative bacterial endophthalmitis. *Arch Ophthalmol*. 1995;113:1479–96.
63. Han DP, Wisniewski SR, Wilson LA, et al. Spectrum and susceptibilities of microbiologic isolates in the endophthalmitis vitrectomy study. *Am J Ophthalmol*. 1996;122:1–17.
64. Campochiaro PA, Green WR. Toxicity of intravitreal ceftazidime in primate retina. *Arch Ophthalmol*. 1992;110:1625–9.
65. Yang CS, Tsai HY, Sung CS, et al. Endogenous *Klebsiella* endophthalmitis associated with pyogenic liver abscess. *Ophthalmology*. 2007;114:876–80.
66. Kwak HW, D' Amico DJ. Evaluation of the retinal toxicity and pharmacokinetics of dexamethasone after intravitreal injection. *Arch Ophthalmol*. 1992;110:259–66.
67. Fiscella RG. Physical incompatibility of vancomycin and ceftazidime for intravitreal injection. *Arch Ophthalmol*. 1993;111:730.
68. Yoon YH, Lee SU, Sohn JH, et al. Result of early vitrectomy for endogenous *Klebsiella pneumoniae* endophthalmitis. *Retina*. 2003;23:366–70.
69. Liang L, Lin X, Yu A, et al. The clinical analysis of endogenous endophthalmitis. *Yan Ke Xue Bao*. 2004;20:144–8.
70. Shamma HF. Endogenous *E. coli* endophthalmitis. *Surv Ophthalmol*. 1977;21:429–35.
71. Wang LS, Lee FY, Cheng DL, et al. *Klebsiella pneumoniae* bacteremia: analysis of 100 episodes. *J Formos Med Assoc*. 1990;89:756–63.
72. Pflugfelder SC, Hernandez E, Fleisler SJ, et al. Intravitreal vancomycin. *Arch Ophthalmol*. 1987;105:831–7.
73. Flynn Jr HW, Pulido JS, Pflugfelder SC, et al. Endophthalmitis therapy: changing antibiotic sensitivity patterns and current therapeutic recommendations. *Arch Ophthalmol*. 1991;09:175–6.
74. Okhravi N, Towler H, Hykin P, Matheson M, Lightman S. Assessment of a standard treatment protocol on visual outcome following presumed bacterial endophthalmitis. *Br J Ophthalmol*. 1997;81:719–25.
75. Shah G, Stein J, Sharma S, et al. Visual outcomes following the use of intravitreal steroids in the treatment of postoperative endophthalmitis. *Ophthalmology*. 2000;107:486–9.
76. Elder M, Morlet N. Endophthalmitis. *Clin Experiment Ophthalmol*. 2002;30:394–8.