

Richard A. Gosselin
David A. Spiegel
Michelle Foltz
Editors

Global Orthopedics

Caring for Musculoskeletal
Conditions and Injuries in
Austere Settings

 Springer

Global Orthopedics

Richard A. Gosselin • David A. Spiegel
Michelle Foltz
Editors

Global Orthopedics

Caring for Musculoskeletal
Conditions and Injuries
in Austere Settings

 Springer

Editors

Richard A. Gosselin, MD, MPH, MSc,
FRCS(C)
Department of Orthopaedic Surgery
Institute for Global Orthopedics
and Traumatology
University of California San Francisco
San Francisco, CA, USA

David A. Spiegel, MD
Division of Orthopaedic Surgery
Children's Hospital of Philadelphia
Associate Professor of Orthopaedic
Surgery
University of Pennsylvania School
of Medicine
Philadelphia, PA, USA

Honorary Consultant in Orthopaedics
and Rehabilitation
Hospital and Rehabilitation Centre
for Disabled Children
Janagal, Kavre, Nepal

Michelle Foltz, MD
Columbus, MT, USA

ISBN 978-1-4614-1577-0 ISBN 978-1-4614-1578-7 (eBook)
DOI 10.1007/978-1-4614-1578-7
Springer New York Heidelberg Dordrecht London

Library of Congress Control Number: 2014934421

© Springer Science+Business Media New York 2014

This work is subject to copyright. All rights are reserved by the Publisher, whether the whole or part of the material is concerned, specifically the rights of translation, reprinting, reuse of illustrations, recitation, broadcasting, reproduction on microfilms or in any other physical way, and transmission or information storage and retrieval, electronic adaptation, computer software, or by similar or dissimilar methodology now known or hereafter developed. Exempted from this legal reservation are brief excerpts in connection with reviews or scholarly analysis or material supplied specifically for the purpose of being entered and executed on a computer system, for exclusive use by the purchaser of the work. Duplication of this publication or parts thereof is permitted only under the provisions of the Copyright Law of the Publisher's location, in its current version, and permission for use must always be obtained from Springer. Permissions for use may be obtained through RightsLink at the Copyright Clearance Center. Violations are liable to prosecution under the respective Copyright Law.

The use of general descriptive names, registered names, trademarks, service marks, etc. in this publication does not imply, even in the absence of a specific statement, that such names are exempt from the relevant protective laws and regulations and therefore free for general use.

While the advice and information in this book are believed to be true and accurate at the date of publication, neither the authors nor the editors nor the publisher can accept any legal responsibility for any errors or omissions that may be made. The publisher makes no warranty, express or implied, with respect to the material contained herein.

Printed on acid-free paper

Springer is part of Springer Science+Business Media (www.springer.com)

To Sherry and Pearl who made all of it possible – RAG

*To Maryam and Sophie, my partners, and all my colleagues at
HRDC – Drs. Ashok Banskota, Bibek Banskota, Om Shrestha,
Tarun Rajbhandary, Ishor Pradhan, Prakash Sitoula,
Abhiram Singh, Saroj Rijal, and Babu Kaji Shrestha – DAS*

To Orty with respect and love – MF

Preface

The burden of musculoskeletal diseases and conditions in low and middle income countries (LMICs) has increased substantially over the past 15 years, while the resources to address this are grossly inadequate. In particular, the development-fueled epidemic of injuries primarily affects young males during their most productive years, and the resulting disabilities have a profound impact on the individuals, their families, and society as a whole.

The aging of populations in these same countries has unleashed the musculoskeletal co-morbidities of chronic diseases, further increasing stresses on limited health care resources. The consequences can be social, economic, and/or political. Despite evidence of an “epidemiologic transition”, in which non-communicable diseases are eclipsing communicable diseases, only 10 % of global resources for health care are allocated for conditions that account for 90 % of the world’s disease burden. Funding for musculoskeletal conditions is negligible when compared with the resources directed to other health problems such as the infectious diseases.

Access to health services is limited for large segments of the population in developing countries, and many of those who present for care do so at a late stage in their disease. This makes the treatment of these “neglected” conditions more challenging, requires more complex and less cost-effective solutions, and often results in undesirable outcomes. In many cases, salvage treatments are all that can be offered. For every orthopedic patient who reaches a clinic or hospital, many more will have first been seen by a traditional healer or bonesetter. Even in district and provincial hospitals, most orthopedic problems are handled by nurses, orthopedic technicians, general practitioners, and general surgeons; orthopedic surgeons are usually found only in tertiary centers in major cities.

The general standards and use of technology in orthopedics in LMICs rarely match those in richer parts of the world, and health services are dependent on the available human, material, monetary, and institutional resources. Wide variations in access to and utilization of health services are seen both between and within developing countries, especially when comparing rural and urban communities. Disparities often reflect a growing gap between the rich and the poor within each setting, rather than a “north-south”, “developed-underdeveloped”, or “1st-3rd world” division.

Globalization has changed the dynamics of health care and has increased awareness of the inequities in services available in austere environments. This has led to a great interest in global health and international volunteerism,

as evidenced by the extraordinary response to recent natural disasters. In addition, institutions from high income countries have developed and promoted programs and initiatives that aim to improve education and services in LMICs. Enhanced access to travel and communication offers unprecedented opportunities to improve orthopedic services worldwide.

Given this information, how can interactions between practitioners from resource rich and resource poor settings lead to better care for patients throughout the world? We cannot overemphasize the value of the exchange of information and experiences between colleagues from these different environments, encouraging the concept of a “two way street”. Surgeons from places in which resources are readily available must necessarily adapt their knowledge and skills in a relevant manner when working in austere environments. Challenges include evaluating and treating familiar conditions, such as trauma and infections that present late or with complications that are rarely seen in the West, and unfamiliar conditions such as osteoarticular tuberculosis, the residua of poliomyelitis, and the sequelae of untreated congenital deformities. Colleagues practicing in resource constrained environments will be exposed during these interactions to problem solving skills and technologies from resource rich environments, and they must determine to what extent the information can be adapted to their needs.

Contextual variables must be recognized and addressed when choosing among treatments. Management must be individualized and adapted to the local environment, taking into account the desires of the patients and their families, the anticipated needs for activities of daily living, and the physical demands of work, the local resources, and the potential for rehabilitation. What may seem an obvious treatment in one setting may be inappropriate or harmful in another, and the differences are often subtle.

Our goal is to create a text book that is unique in scope, based on the experiences and insights of authors from a wide variety of settings around the world. This shared endeavor pairs surgeons from resource rich settings who have experience working in austere environments, with surgeons who work daily in difficult conditions in LMICs to make a balanced text that will be beneficial to all practitioners treating orthopedic conditions where resources are limited. This book does not pretend to address all musculo-skeletal conditions, but rather explores an array of commonly seen problems and solutions. There is not much “evidence” on which to base some of the recommendations, other than experience, but more importantly, we hope the principles implied by these recommendations will guide the practitioner to a rational approach. Not one of the authors will be in 100 % agreement with what is written. Rather, we have tried to tap into the cumulative experience of all authors, which totals well over 500 years.

The word “surgery” has been omitted from the title, recognizing that the management of musculoskeletal conditions and injuries in austere settings is largely non-operative. While some surgical techniques and approaches are described, this is not the main focus of the book. The primary aim is to provide volunteers or others engaged in elective or relief work in teaching and/or service provision with sound, basic principles and tools for the appropriate and effective management of orthopedic conditions. The needs are great, and a

surgeon working in a resource constrained setting will have his or her perceptions regarding the field of orthopedic surgery expanded and enhanced in ways that few other learning experiences offer. We hope in the end, the reader will appreciate the limitations of austere environments, and have acquired the knowledge to address both familiar and unfamiliar conditions in these settings.



A child with paraplegia wanted to play badminton, so a custom frame was constructed in the workshop. While some conditions cannot be cured, something can always be done to improve the lives of our patients (Courtesy of the Hospital and Rehabilitation Centre for Disabled Children, Janagal, Kavre, Nepal)

What Do We Call this Place?

There is no one set of terms that reflects the economic and human realities on the ground that can be used for every situation where a volunteer orthopedic surgeon might travel.

Some divisions that were used in the past are politically outdated, such as third world—a term previously used for countries aligned with neither free-market economies nor the communist second world. Most were poor countries and the term remains in the lexicon in an off-hand manner.

The division into developed and developing—the latter sometimes qualified as economically under-developed—has been commonly used and plays into the idea of development as it is practiced by governmental and non-governmental aid agencies working to upgrade infrastructure, build capacity, and generally improve the lives of people. A variety of spin-offs, such as, “still developing” add nuance, but little concrete information. We use these terms in this text primarily out of habit and for simplicity’s sake.

Low and middle income countries (LMICs) is a broad economic term defined by specific country-wide income brackets.¹ It is unfreighted with ambiguous or pejorative meaning, but is clumsy and encompasses a wide range of countries and situations that are difficult to place into groups to allow worthwhile comparisons.

Sometimes it is more useful not to talk about countries but to refer to settings or environments. Resource challenged, limited resources, under-resourced, transitional, and under-served are useful descriptive terms of more local conditions. Another term that has gained traction is austere environment. It seems a particularly appropriate term as for most of the countries or settings discussed in the book, austerity particularly affects the surgical fields.

Resources are not limited in the same manner or extent everywhere. Medical practice in LMICs is changing rapidly, and what used to be a rather standard lack of just about everything is being replaced piecemeal with an often unbalanced accumulation of resources that may have little to do with expectations based on gross national income per capita or need, but more on the vagaries of development money, the level and impact of corruption, the strength or weakness of the medical education system, or the presence of a few insightful and diligent people.

¹Based on gross national income (GNI) per capita in US \$, low-income is $\leq 1,025$; lower middle income is 1,025–4,035; and upper middle income is $\geq 4,036$.

Every chapter of this book starts off stating that the particular problem addressed is a challenge. It is possible that challenge isn't a word orthopedic surgeons working in the West use or think about on a daily basis. In this book the use is not hyperbole. A normally simple fracture that one would take care of as routine can transform itself in an austere setting into a significant logistics, social, economic, medical, and sometimes political problem. The approach to the fracture has to answer questions we have not been taught to ask.

Every chapter has somewhere embedded the simple caveat: 'when available'. Sometimes it reads like a Greek chorus. This phrase is intrinsically connected to the challenge one is warned about at the beginning of every chapter. In many places this simple fact of unavailability will stop the visiting surgeon cold. Other times it will be an inconvenience and the surgeon will find an answer. Often the answer lies in the basics we take for granted but rarely think about in our daily Western practices. Another way around is by consulting and listening to others. We hope this book provides options that expand the envelope of availability, while providing information to help the surgeon meet the challenge.

Richard A. Gosselin, MD
David A. Spiegel, MD
Michelle Foltz, MD

San Francisco, CA, USA
Philadelphia, PA, USA
Columbus, MT, USA

Contents

Part I Introduction

1 A History of Orthopedics in Austere Settings	3
Michelle Foltz, Geoffrey Walker, and James C. Cobey	
2 Global Burden of Musculoskeletal Conditions	9
Manjul Joshipura, Charles Mock, and Richard A. Gosselin	
3 Emerging Orthopedic Conditions	13
Richard A. Gosselin and El Hadji Ibrahima Diop	
4 Cost-Effectiveness of Orthopedic Surgery in Austere Environments	19
Richard A. Gosselin	
5 Barriers to the Delivery of Orthopedic Care.	23
David A. Spiegel and Stephen W. Bickler	
6 Teaching and Educational Resources.	27
Michelle Foltz and Kaye E. Wilkins	
7 Equipment and Supplies	31
Richard C. Fisher and Dominic Awariyah Adondaa	
8 Ethics	39
Michael Krosin	
9 Culture Shock and Traditional Healing	43
Michelle Foltz and Geoffrey Walker	

Part II General Clinical Topics

10 Coexisting Medical Conditions	51
Michelle Foltz and Richard A. Gosselin	
11 Tropical Diseases and Orthopedics	57
Richard A. Gosselin, Stephen W. Bickler, and Ali A. Ahmed Al-Iedan	
12 Rickets and Angulatory Bone Deformity	69
J. Norgrove Penny	

13	Nonsurgical Principles of Fracture and Injury Management	75
	Richard C. Fisher, Richard A. Gosselin, and Michelle Foltz	
14	Basic Plastic Surgery for Orthopedic Surgeons	99
	Nadine B. Semer	
15	HIV and Orthopedic Surgery	111
	William James Harrison	
16	Anesthesia for Orthopedic Surgery in Austere Environments. . . .	115
	K.A. Kelly McQueen, Ercan Türeci, and Errol Peter Lobo	

Part III Adult Trauma

17	Introduction to Trauma in Austere Environments	125
	Michelle Foltz, Nadine B. Semer, Richard A. Gosselin, and Geoffrey Walker	
18	Trauma of the Shoulder and Humeral Shaft.	139
	Richard C. Fisher and Sonam Dorji	
19	Trauma of the Elbow and Forearm	151
	Robert P. Hoffman and Sonam Dorji	
20	Trauma of the Hand and Wrist.	165
	Michelle Foltz, Tour Phot Sin, and Robert Derkash	
21	Trauma of the Pelvis and Acetabulum	177
	Richard A. Gosselin and Anand Sobhraj Devnani	
22	Trauma of the Hip and Femoral Shaft.	187
	Richard A. Gosselin, Faruque Quasem, and Lewis G. Zirkle	
23	Trauma of the Knee, Tibia, and Fibula	203
	Richard A. Gosselin and David O. Oloruntoba	
24	Trauma of the Ankle and Foot	221
	R. Richard Coughlin and Raphael Kumah-Ametepey	
25	Trauma of the Spine and Spinal Cord	235
	Dheera Ananthakrishnan and Gilbert E. Cauilan	

Part IV Pediatric Trauma

26	General Principles of Pediatric Trauma	247
	David A. Spiegel and Bibek Banskota	
27	Management of Upper Extremity Fractures.	255
	David A. Spiegel, Bibek Banskota, and Kaye E. Wilkins	
28	Management of Lower Extremity Fractures.	275
	David A. Spiegel, Bibek Banskota, and Kaye E. Wilkins	

Part V Musculoskeletal Infections

- 29 Introduction to Musculoskeletal Infections** 293
Jacques L. D'Astous and William James Harrison
- 30 Neglected Septic Arthritis in Children** 303
David A. Spiegel, Ashok Kumar Banskota,
and Bibek Banskota
- 31 Chronic Osteomyelitis in Children** 315
J. Norgrove Penny and David A. Spiegel
- 32 Osteomyelitis and Septic Arthritis in Adults** 325
William James Harrison and John L. Esterhai Jr.
- 33 Tuberculosis** 335
Z. Deniz Olgun, Muharrem Yazici, David A. Spiegel,
Syed Muhammad Awais, and Binod Bijukachhe

Part VI Non-infectious Pediatric Conditions

- 34 Clubfoot Etiology, Pathoanatomy, Basic Ponseti Technique,
and Ponseti in Older Patients** 357
Alaric Aroojis, Shafique Pirani, Bibek Banskota,
Ashok Kumar Banskota, and David A. Spiegel
- 35 Algorithm for Neglected Clubfoot** 369
J. Norgrove Penny
- 36 Limb Deficiencies** 377
Anna V. Cuomo and Hugh G. Watts
- 37 Evaluation and Treatment of Angular Deformities** 385
Sanjeev Sabharwal, Richard M. Schwend,
and David A. Spiegel
- 38 Developmental Dysplasia of the Hip** 397
Richard M. Schwend
- 39 Injection Injuries and Polio** 405
J. Norgrove Penny, John Ekure, David A. Spiegel,
and Hugh G. Watts
- 40 Cerebral Palsy and Other Neuromuscular Conditions** 423
Bibek Banskota, Michelle Foltz, Richard A. Gosselin,
and David A. Spiegel

Part VII Additional Considerations

- 41 Adult Reconstruction** 431
Richard A. Gosselin, Harry E. Jergesen,
and Daniel-John Lavaly

42 Bone and Soft Tissue Tumors	469
Nyengo Mkandawire and John P. Dormans	
43 Amputations	481
Richard A. Gosselin and Douglas G. Smith	
44 Orthopedics in Conflicts and Natural Disasters	493
Paul F. Ley, Thamer A. Hamdan, Marco Baldan, and Richard A. Gosselin	
Appendix 1	505
Appendix 2	507
Appendix 3	509
Appendix 4	515
Index	517

Contributors

Dominic Awariyah Adondaa, MD Trauma/Orthopedics, Komfo Anokye Teaching Hospital, Kumasi, Ashanti Region, Ghana

Ali A. Ahmed Al-Iedan Orthopedic Surgery, Basrah General Hospital, Basrah, Iraq

Dheera Ananthkrishnan, MD, MSE Orthopaedic Surgery, Emory University, Atlanta, GA, USA

Alaric Aroojis, MS (ORTHO), D'ORTHO, DNB (ORTHO) Department of Bone Surgery, Kokilaben Dhirubhai Ambani Hospital & Bai Jerbai Wadia Hospital for Children, Mumbai, Maharashtra, India

Syed Muhammad Awais, MBBS (Pb), MCPS-Surgery (CPSP), M.S.-Orth (Pb), MSc BioEng (Dun) Department of Orthopaedics, Spine and Traumatology, King Edward Medical University and Mayo Hospital, Lahore, Punjab, Pakistan

Marco Baldan Senior Surgeon, International Committee of the Red Cross, Geneva, Switzerland

Ashok Kumar Banskota, MBBS, MD FACS Department of Orthopaedics, Hospital and Rehabilitation Center for Disabled Children, Kavre, Banepa, Nepal

Bibek Banskota, MBBS, MRCS, MS Department of Orthopedics, Hospital and Rehabilitation Center for Disabled Children (HRDC), Janagal, Kavre, Nepal

Stephen W. Bickler, MD, DTM&H, FACS Pediatric Surgery, Rady Childrens Hospital, University of California San Diego, San Diego, CA, USA

Binod Bijukachhe, MBBS, MS (Ortho.), AO Fellow – Spine Spine Services, Department of Orthopedics, Grande International Hospital Limited, Kathmandu, Bagmati, Nepal

Gilbert E. Cauilan, MD, FPOA Department of Orthopedics, Southern Philippines Medical Center, Davao Medical School Foundation Hospital, Davao City, Philippines

James C. Cobey, MD, MPH, FACS Johns Hopkins Bloomberg School of Public Health, Department of International Health, Washington, DC, USA

R. Richard Coughlin, MD, MSC Department of Orthopaedic Surgery, Orthopaedic Trauma Institute, San Francisco General Hosp, University of California, San Francisco, San Francisco, CA, USA

Anna V. Cuomo, MD Department of Orthopedic Surgery, Shriners Hospital for Children, Los Angeles Unit, Los Angeles, CA, USA

Jacques L. D'Astous, MD, FRCS(C) Department of Orthopaedic Surgery, University of Utah, Salt Lake City, UT, USA

Orthopaedic Surgery Shriners Hospital, Salt Lake City, UT, USA

Robert Derkash, MD Orthopedic Surgery, Valley View Hospital, Glenwood Springs, CO, USA

Anand Sobhraj Devnani, M S (Orth) Department of Orthopaedics, Level 4, Medical Faculty (FPSK), University Putra Malaysia at Serdang Hospital, Serdang, Selangor, Malaysia

El Hadji Ibrahima Diop, FWACS, FAAOS, FAAS, FSICOT Orthopedics Surgery, St Christopher Iba Mar Diop Medical School, Ueiu University Dakar Senegal, Dakar, Senegal

Sonam Dorji, MBBS Department of Orthopaedics, JDW National Referral Hospital, Thimphu, Bhutan

John P. Dormans, MD Department of Orthopaedic Surgery, Children's Hospital of Philadelphia, University of Pennsylvania School of Medicine, Philadelphia, PA, USA

John Ekure, MBChB, MMed (Ortho), Mak, FCS Department of Orthopaedic Surgery, Kumi Orthopaedic Center, Kumi, Uganda

John L. Esterhai Jr, MD Department of Orthopaedic Surgery, Hospital of the University of Pennsylvania, Philadelphia, PA, USA

Richard C. Fisher, BA, MD, MS-Health Admin. Orthopaedic Surgery, University of Colorado Health Science Center, Aurora, CO, USA

Michelle Foltz, MD Columbus, MT, USA

Richard A. Gosselin, MD, MPH, MSc, FRCS(C) Department of Orthopedic Surgery, Institute for Global Orthopedics and Traumatology, University of California, San Francisco, CA, USA

Thamer A. Hamdan, MD, FRCS, FICS, FACS, FRCP Spine Surgery, Basrah General Hospital – University of Basrah, Basrah, Iraq

William James Harrison, BM BCh, MA(Oxon), FRCS (Trauma & Orthopaedics), FCS ECSA Trauma and Orthopaedics, Countess of Chester NHS Foundation Trust, Chester, UK

Robert P. Hoffman, MD Department of Orthopedic Surgery, Alameda County Medical Center, Oakland, CA, USA

Harry E. Jergesen, MD Orthopaedic Surgery, University of California, San Francisco, San Francisco, CA, USA
Orthopaedic Surgery, San Francisco General Hospital, San Francisco, CA, USA

Manjul Joshipura, MBBS, MS Department of Injury and Violence Prevention, World Health Organization, Geneva, Switzerland

Michael Krosin, MD Department of Surgery, Alameda County Medical Center, Oakland, CA, USA

Raphael Kumah-Ametepey, MD, Fach (Trauma/Orthopedics) Department of Trauma/Orthopaedics, Komfo Anokye Teaching Hospital, Kumasi, Ashant Region, Ghana, Africa

Daniel-John Laval, MBChB Orthopaedic Trauma, Emergency Surgical Centre, Freetown, Freetown, Western Area, Sierra Leone

Paul F. Ley, MD Orthopaedic Surgery, Emergency NGO, Milan, Italy

Errol Peter Lobo, MD PhD Perioperative Services, University of California San Francisco, San Francisco, CA, USA

Department of Anesthesia and Perioperative Care, Moffit- Long Hospital, San Francisco, CA, USA

K.A. Kelly McQueen, MD, MPH Department of Anesthesiology, Vanderbilt Anesthesia Global Health and Development, Vanderbilt Institute of Global Health, Vanderbilt University Medical Center, Nashville, TN, USA

Nyengo Mkandawire, BMBS, MCh(ORTH), FCS(ESCA), FRCS Department of Surgery, Queen Elizabeth Central Hospital, College of Medicine, Blantyre, Malawi

Charles Mock, MD, PhD, FACS Department of Surgery, University of Washington, HIPRC, Seattle, WA, USA
Harborview Medical Center, Seattle, WA, USA

Z. Deniz Olgun, MD Department of Orthopaedics and Traumatology, Dortyol State Hospital, Hatay, Turkey

David O. Oloruntoba Department of Orthopedics, Nelson Mandela Academic Hospital, Mthatha, Eastern Cape Province, Republic of South Africa

J. Norgrove Penny, CM, MD, FRCS(C) Department of Orthopaedic Surgery, University of British Columbia, CBM International, Canada

Shafique Pirani, MBBS FRCS(C) Division of Paediatric Orthopaedics, Department of Orthopaedics, University of British Columbia, New Westminster, BC, Canada

Faruque Quasem, MBBS, MS(Orth.) Orthopedic Surgery Department,
Sir Salimullah Medical College (SSMC) Mitford Hospital, Dhaka,
Bangladesh

Sanjeev Sabharwal, MD, MPH Division of Pediatric Orthopedics,
University of Medicine and Dentistry, New Jersey Medical School, Newark,
NJ, USA

Richard M. Schwend, MD Department of Orthopaedics, Children's Mercy
Hospital, Kansas City, MO, USA

Nadine B. Semer, MD, MPH, FACS Plastic Surgery, Kaiser Permanente
Downey Medical Center, Downey, CA, USA

Tour Phot Sin, MD Surgical Department, Sihanouk Hospital Center
of Hope, Phnom Penh, Cambodia

Douglas G. Smith, MD Department of Orthopedic Surgery,
Harborview Medical Center, University of Washington, Seattle, WA, USA

David A. Spiegel, MD Division of Orthopaedic Surgery, Children's
Hospital of Philadelphia, Associate Professor of Orthopaedic Surgery,
University of Pennsylvania School of Medicine, Philadelphia, PA, USA

Honorary Consultant in Orthopaedics and Rehabilitation,
Hospital and Rehabilitation Centre for Disabled Children,
Janagal, Kavre, Nepal

Ercan Türeci Department of Anaesthesiology and Reanimation,
Cerrahpaşa Medical Faculty, Istanbul University, Istanbul, Turkey

Geoffrey Walker, FRCS (Eng and Ed), FCS (Hon), ESCA World
Orthopaedic Concern, London, UK

Hugh G. Watts, MD Department of Orthopedic Surgery, Shriners
Hospitals for Children, Los Angeles Unit, Los Angeles, CA, USA

Kaye E. Wilkins, DVM, MD Department of Orthopedics and Pediatrics,
University of Texas Health Science Center at San Antonio, The Children's
Hospital of San Antonio, formerly Christus Children's Hospital, San
Antonio, TX, USA

Muharrem Yazici, MD Department of Orthopaedics, Hacettepe University
Faculty of Medicine, Sıhhiye, Ankara, Turkey

Lewis G. Zirkle, MD Orthopedic Surgery, Richland, Washington, USA

Part I

Introduction

A History of Orthopedics in Austere Settings

1

Michelle Foltz, Geoffrey Walker, and James C. Cobey

With the growth of their specialty after the Second World War, orthopedic surgeons have worked to develop, expand, and improve orthopedic care and teaching in resource-poor countries. Nongovernmental and governmental organizations, religious and secular charities, and individuals have played, and continue to play, a role in the developing world, establishing and strengthening training programs and providing service. The primary nature of orthopedic injuries and disease, the significant increase in orthopedic trauma as the world relentlessly develops, and the “can-do” attitudes that shape the profession all point to an increasing involvement of Western surgeons in international work.

The history of American organized orthopedic volunteering started in the late 1950s with two groups: Medical International Cooperative Organization (Medico) and the Orthopaedic Letters Club Overseas Program. This was a time of widespread soul-searching by Americans

after the 1958 publication of the political novel *The Ugly American*. The stories of official ignorance, arrogance, and misbehavior did not sit well with Americans’ notions of themselves. As a counter to this bleak picture, the inspirational books and engaging lectures of Dr. Tom Dooley, one of the founders of Medico, showed that the citizen-doctor-diplomat could change this negative perception.

In 1960 Medico became the medical arm of Cooperative for American Relief Everywhere (CARE), a broad-based development and disaster relief organization. (In the 1980s the organization became international, changing its name to Cooperative for Assistance and Relief Everywhere.) The two orthopedic organizations interested in international work merged their efforts in the early 1960s, becoming a subgroup of Medico called Orthopaedics Overseas (OO) with their own board and earmarked donations for their international programs. The core of dedicated surgeons in OO set up service and training programs in Tunisia, Indonesia, and Afghanistan, among other countries, with the goal of attaining local self-sufficiency in orthopedic care and training.

The seeds for World Orthopaedic Concern (WOC) were planted in 1970 during Dr. Ronald Huckstep’s world lecture tour to advise on the treatment of children crippled by polio in the developing world. His colleagues agreed that there was a need to improve orthopedic care and training in low-resource countries and envisioned setting up programs similar to those of Orthopaedics Overseas under a global

M. Foltz, MD (✉)
172 Stillwater Loop Road,
Columbus, MT 59019, USA
e-mail: michellefoltz@gmail.com

G. Walker, FRCS (Eng and Ed), FCS (Hon), ESCA
World Orthopaedic Concern, 9d The Grove,
Highgate Village, London N6 6JU, UK
e-mail: geoffreyf2.walker@gmail.com

J.C. Cobey, MD, MPH, FACS
Johns Hopkins Bloomberg School of Public Health,
Department of International Health, 4440 Garfield
St., Washington, DC 20007, USA
e-mail: cobey@att.net

umbrella. The first formal meeting of WOC was held in Lagos, Nigeria, in 1977. In 1986 Orthopaedics Overseas and the Committee on Orthopaedics Overseas of the Canadian Orthopaedic Association became affiliated with WOC but have retained their national identities.

During its 1978 meeting in Alma-Ata, The World Health Organization (WHO) made the case that primary care programs, rather than specialty programs, would bring the most good for the highest number of people in developing countries. In turn, CARE/Medico decreased support for its specialty training programs, such as OO, to emphasize primary care.

This was not a new controversy. From the start, the founders of Medico differed about whether to promote specialty or primary care programs in developing countries. Today it remains an issue within and among nongovernmental organizations (NGOs) and the funding bodies and foundations that support them. With the increasing sophistication of surgeons in developing countries because of the training and collaboration from many groups and individuals as well as the availability of cost-effective and useful instruments, many aspects of orthopedics, particularly trauma, are now viewed—even by the WHO—as primary care.

Since no small group of surgeons can realistically tackle all the orthopedic needs in the developing world, many organizations and individuals have concentrated their efforts on teaching and training. Besides developing capacity to meet orthopedic needs locally, the personal relationships have fostered continued interaction and have been a major factor in the strong global orthopedic network.

This brings up the questions of who to teach, what to teach, and where to teach. The answers to these questions depend on the particular country and the philosophy of the volunteer or organization.

Some of the most useful and long-term advances in delivering trauma care have occurred by teaching nurses and primary care workers at the middle and lower levels of the health system. Trained to properly manage basic trauma, they can save lives by working through systems, such as Advanced Trauma Life Support (ATLS), proceeding with ABCs,

giving fluids, and recognizing life-threatening and limb-threatening situations. In most developing country hospitals general surgeons are the major providers of orthopedic care, and some training programs concentrate on providing them with the orthopedic expertise to handle common musculoskeletal problems. In some countries, such as Malawi or Mozambique, with a limited population of surgeons, nonphysician orthopedic clinical officers are trained to deliver basic orthopedic care, including surgery.

If an organization wants to provide specialized orthopedic training and care, one of the first questions is where to train. In the beginning OO brought candidates for training to the USA. These highly trained surgeons returned home but rapidly became frustrated by the lack of equipment and ancillary help. Governments did not pay for specialized care, and colleagues were mistrustful of the new ideas brought from the outside. Not able to put their skills to use, the newly trained surgeons often returned to the West.

Teaching in the local environment with locally available equipment to care for local conditions seemed a better alternative. This usually involves building training programs from scratch with curricula to address the existing limitations or working within existing institutions. Good programs evolve, increasing in their self-sufficiency as more and more individuals are trained to higher standards.

Another decision is where in a country to train. Most often, and by default, this takes place in the capital, the seat of government, the home of the university or medical school, and the site of the largest hospital with the greatest number of ancillary specialists. But sometimes the government gets in the way and has its own agenda, the university is filled with outsized egos, and the largest hospital in the country becomes a sanctuary of specialty care, out of reach for the average patient with simple but debilitating orthopedic problems.

As more surgeons are trained and as the speed of development accelerates, the substance of what to teach is rapidly evolving. The idea that only nonoperative techniques that were current 40 or 50 years ago are the most appropriate for developing countries has come under

Fig. 1.1 The bright, clean, welcoming entrance to CURE's Pediatric Orthopedic Hospital in Kijabe, Kenya



considerable debate in the last decade. However, proper reduction and casting techniques as well as the principles of treatment in traction remain the mainstays of most fracture work in developing countries. As Western surgeons increasingly lose their skills to perform such nonoperative treatments, they have much to learn from their peers in developing countries, and volunteering becomes a network of teaching *and* learning.

No matter one's philosophy of how best to treat specific injuries and orthopedic conditions, teaching the basics of clinical orthopedics is the purpose of most training programs. Teaching by example that diligence, compassion, and communication along with a thorough knowledge of the problem and the various solutions is an essential component of orthopedics everywhere.

The history of orthopedics in resource-poor environments is not solely the work of organizations. Individuals—through necessity, the ability to look at problems from novel angles, and unconventional single-mindedness—have made a huge impact in the way orthopedics is practiced in countries with few resources.

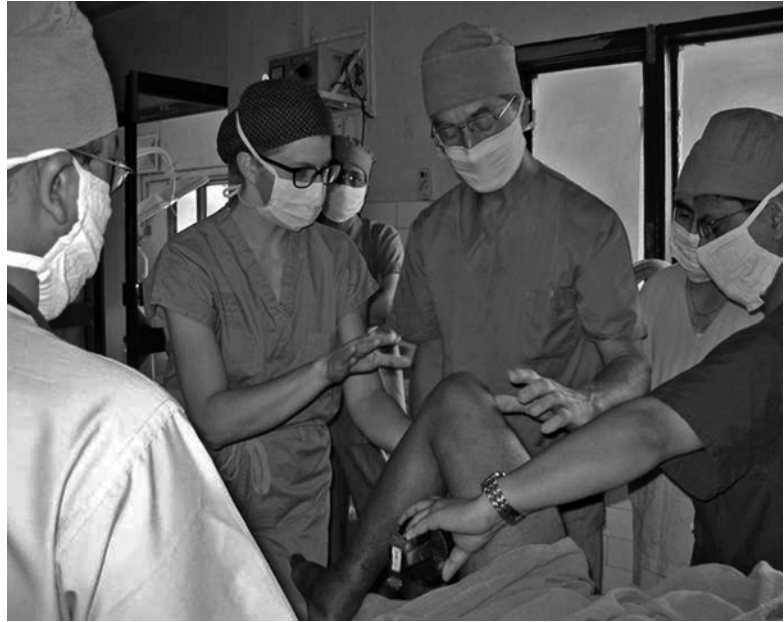The bicycle spokes and locally manufactured rings and bars that Dr. Gavriil Ilizarov ingeniously fashioned into his external fixateurs in Siberia in the 1950s and 1960s were the result of having little else to work with. These instruments

and protocols have given orthopedic surgeons a new approach to previously poorly understood problems. The Ilizarov system is an important disruptive technology that can be equally as useful in the most sophisticated high-tech center as in the most rudimentary clinic.

When in East Africa and faced with large numbers of joint contractures and deformities in children and young adults from polio in the 1960s, Dr. Ronald Huckstep not only devised a series of successful surgeries to deal with the problems but established workshops and taught people—including those whom he had helped with his surgeries—to make low-cost braces. Despite all attempts to eradicate the disease, polio and its residua remain a problem in some developing countries, and many of the principles of Dr. Huckstep's surgeries are the basis of polio treatment today.

Another approach to orthopedic needs in resource-poor countries is exemplified by Dr. Scott Harrison, through his foundation, CURE International. Combining his expertise as a surgeon, his faith, and his organizational abilities as a businessman, CURE has established orthopedic pediatric hospitals in many poor, developing countries, making them centers of excellence through the specialized training they offer and the surgery they provide (Fig. 1.1).

Fig. 1.2 US orthopedic volunteer, Carla Smith, introducing SIGN instruments and technique to surgeons in Nepal



The history of Western practitioners working in resource-poor countries cannot be separated from the question of equipment. Some surgeons make it a point to take no donated equipment with them, knowing the problems of sustainability or the lack of experience in treating the complications that such techniques may bring, especially if used without adequate training. Most donations are made with the best intentions, but any volunteer who has walked through a gauntlet of irreparable C-arms crowding already limited space in an operating theater knows that donations have to be realistically considered from many angles.

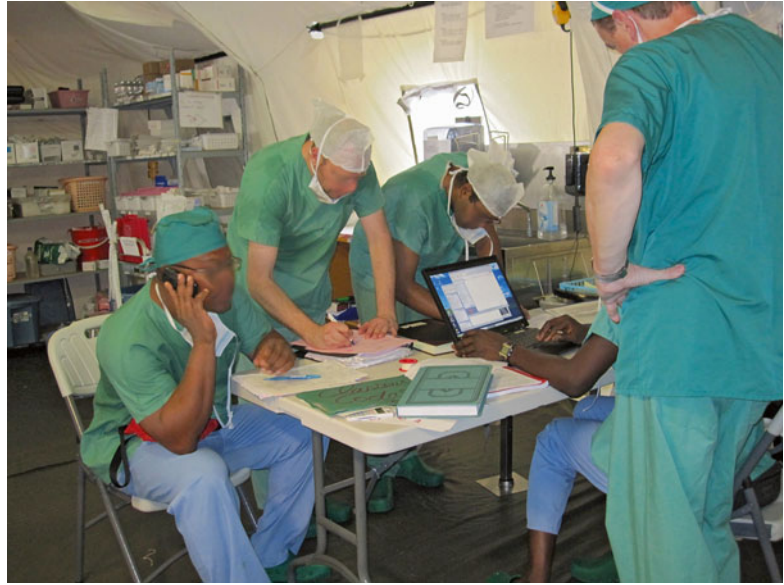SIGN (SIGN Fracture Care International) has shown that high-quality implants to treat long-bone fractures can be reliably used by developing country surgeons, working in less than ideal situations, if they are given a sustainable supply and are taught how to use them. SIGN's program combining feedback, mentoring, and networking has produced a new paradigm that has been especially useful in situations where poverty makes effective treatment of certain debilitating fractures extremely difficult (Fig. 1.2).

Providing disaster relief has been a major idea behind orthopedic work in developing countries, but it is one of the most difficult to put into useful action. Few volunteer orthopedic organizations

have been able to build, maintain, and put into action all the components that would allow a reasonably equipped orthopedic disaster-assistance team to become immediately operative in the field. Such an organization could be readily staffed by willing volunteers, but only government agencies, the military, and one NGO, Médecins sans Frontières (MSF or Doctors without Borders), have the necessary logistics to manage such a team. The surgery needed in disaster situations is similar to war surgery, demanding strict adherence to specialized protocols and triage principles that are unfamiliar to many volunteer orthopedic surgeons (Fig. 1.3).

Volunteer orthopedic programs have evolved over the last 50 years. Besides secular, nonprofit programs interested in training, like OO, volunteer programs with various agendas and goals have expanded the field. In organizations whose main goal is teaching, some specialize, teaching surgeons, residents, or nonsurgical clinicians. Some limit their programs to a specific region or country, such as focusing on the orthopedic problems of West Africa or Southeast Asia. Others concentrate on a specific area of orthopedics such as trauma or pediatrics or joint replacement surgery. Some NGOs are religiously affiliated, and many religious charities support programs or

Fig. 1.3 Surgeons from Haiti, Denmark, and Ghana working together under the auspices of MSF, Doctors without Borders, after the 2010 earthquake in Haiti



hospitals. Some organizations build hospitals or refurbish existing hospitals in order to maintain control. Different philosophies and goals provide a field wide enough for any volunteer to find a place to match her or his needs and skills.

The strength of the past 50-year history of orthopedics in developing countries rests on the work and determination of many surgeons who did not believe that limited resources meant limited results. As more surgeons rise to the challenge of improving orthopedic care in

developing countries, this attitude will continue to shape the future and change the face of global orthopedics.

Further Reading

- Derkash RS, Kelly N. The history of orthopaedics overseas. *Clin Orthop Relat Res.* 2002;396:30–5.
- Coughlin RR, Kelly N. Nongovernmental organizations in musculoskeletal care. *Clin Orthop Relat Res.* 2008;466:2438–42.

Manjul Joshipura, Charles Mock,
and Richard A. Gosselin

The Burden of Musculoskeletal Injuries

Injury is a major cause of death and disability globally. This is true in countries at all economic levels. There is a misperception that injuries are primarily a health problem of high-income countries. However, injury mortality rates are considerably higher in low- and middle-income countries (LMICs), as can be seen from Table 2.1. Globally the rates of death from all types of injury combined are 76/100,000/year. This is lowest in high-income countries (52/100,000), rises in middle-income countries, and is highest in low-income countries (103 deaths/100,000), where rates of death are twice those in high-income countries.

These high rates of death are in part due to the rising rates of injuries from increased use of

motorized transport and less developed trauma care systems [2]. Rates of injury have been coming down in high-income countries due to injury prevention schemes and improved trauma care. At the same time, rates of injury-related death and disability have been steadily rising in most LMICs and account for 90 % of the global injury deaths. As most of the world's people live in these countries, these trends have led to increasing rates of injury globally [2, 3].

For every person who dies from injury, many more suffer from nonfatal injury, leading to temporary or permanent disability. We do not have as comprehensive, global data for these nonfatal injuries as we do for death. However, the existing data show a significant burden of disability from musculoskeletal injuries affecting all economic strata, but it is especially heavy for LMICs [3].

Data on the burden of musculoskeletal injury come from several sources including hospital records and household surveys. Data from the National Health Interview Survey in the United States showed a rate for all extremity injuries of 68/1,000 persons/year. This included many minor cases that received outpatient treatment only, but excluded strains, sprains, and contusions, which did not receive medical treatment or which did not cause more than a half day of disability [4].

Data on more serious musculoskeletal injuries were obtained from the Healthcare

M. Joshipura, MBBS, MS
Department of Injury and Violence Prevention,
World Health Organization, 20 Avenue Appia,
Geneva 1211, Switzerland
e-mail: joshipuram@who.int

C. Mock, MD, PhD, FACS
Department of Surgery, University of Washington,
HIPRC, Box 359960, Seattle, WA, USA
Harborview Medical Center,
325 Ninth Avenue, Seattle, WA 98104, USA
e-mail: cmock@uw.edu

R.A. Gosselin, MD, MPH, MSc, FRCS(c) (✉)
Department of Orthopedic Surgery, Institute for
Global Orthopedics and Traumatology, UCSF, 1001
Potrero Ave, 3A-36, San Francisco, CA 94110, USA
e-mail: froggydoc@comcast.net

Manjul Joshipura is an employee of the WHO and has signed Springer's WHO Consent Form. WHO will hold the copyright to his work.

Table 2.1 Numbers and rates of death from injury by economic status of countries

Economic stratum	Number of injury deaths (000)	Population (000)	Rates (deaths/100,000/year)
Low	850	826,417	103
Lower middle	2,903	3,834,641	76
Upper middle	816	999,625	82
High	561	1,076,797	52
Total	5,130	6,737,480	76

Source of data: 2008 Global Burden of Disease Study [1]

Cost Utilization Project – Nationwide Inpatient Sample (HCUP-NIS). This showed an incidence of hospitalization (for at least 24 h) for musculoskeletal injuries of 3.5/1,000/year (2.7/1,000/year for lower extremity injuries and 0.8/1,000/year for upper extremity injuries). 50 % of these injuries were due to falls and 20 % to road traffic injuries. Similar data have been reported from other high-income countries [4].

Data from LMICs is limited to a few studies from a few countries; however, even these data are instructive. A survey from Ghana showed a rate of serious musculoskeletal injury (disability time of ≥ 30 days) of 17/1,000/year. It is difficult to draw comparisons due to different methodology, and it is likely that many of these serious injuries would have been treated as inpatients in high-income countries, but injury rates in Ghana are far higher than in the United States [4, 5].

Due to difficulties accessing medical care in LMICs, many of the musculoskeletal injuries go on to poor outcomes. The Ghana survey showed that 0.83 % of Ghanaians had an injury-related disability that had lasted longer than 1 year and was likely to be permanent. Seventy-eight percent of these disabilities were due to extremity injuries. Such disabilities should be readily amenable to low-cost improvements in orthopedic care and rehabilitation, in contrast to the more difficult to treat neurological injuries that are relatively more frequent causes of disability in high-income countries [6].

Utilizing the available data from high-income countries and LMICs, the global burden of disease (GBD) study has provided some global estimates for musculoskeletal injuries. The GBD study evaluated rates of hospital admission for various nonfatal injuries from road

Table 2.2 The 20 leading nonfatal injuries sustained^a as a result of road traffic collisions, world, 2002

Type of injury sustained	Rate per 100,000 population	Proportion of all traffic injuries
Intracranial injury ^b (short term ^c)	85.3	24.6
Open wound	35.6	10.3
Fractured patella, tibia, or fibula	26.9	7.8
Fractured femur (short term ^c)	26.1	7.5
Internal injuries	21.9	6.3
Fractured ulna or radius	19.2	5.5
Fractured clavicle, scapula, or humerus	16.7	4.8
Fractured facial bones	11.4	3.3
Fractured rib or sternum	11.1	3.2
Fractured ankle	10.8	3.1
Fractured vertebral column	9.4	2.7
Fractured pelvis	8.8	2.6
Sprains	8.3	2.4
Fractured skull (short term ^c)	7.9	2.3
Fractured foot bones	7.2	2.1
Fractured hand bones	6.8	2.0
Spinal cord injury (long term ^d)	4.9	1.4
Fractured femur (long term ^d)	4.3	1.3
Intracranial injury ^b (long term ^d)	4.3	1.2
Other dislocation	3.4	1.0

Reproduced from Peden et al. [7], Table 2.8

^aRequiring admission to a health facility

^bTraumatic brain injury

^cShort term=lasts only a matter of weeks

^dLong term=lasts until death, with some complications resulting in reduced life expectancy

traffic crashes. Table 2.2 shows that the majority of these are musculoskeletal injuries. As with fatal injuries, nonfatal musculoskeletal injuries primarily affect those in LMICs. The GBD estimated that the combined rates of extremity

injury from falls and road traffic crashes range from 1,000 to 2,600/100,000/year in LMICs compared with 500/100,000/year in high-income countries [3, 4].

Although we have some global data on rates of nonfatal injuries, it is limited, and the data that exist, especially those from hospital sources, likely underestimate the significance of the problem, due to both underreporting and the large number who do not receive formal medical care. There are ongoing efforts to develop better global data on nonfatal injuries, including musculoskeletal injuries, through the work of the GBD study and the Bone and Joint Decade.

The Burden of Nontraumatic Musculoskeletal Conditions

There are fewer studies on the burden of non-injury-related musculoskeletal (MSK) conditions. The initial GBD study [8], in 1990, showed an estimated worldwide burden of 26,842 DALYs (disability-adjusted life years) for osteoarthritis, rheumatoid arthritis, spina bifida, leprosy, and polio. This represented 16 % of the burden attributable to injuries and 2 % of the entire global burden of disease. Updated data from 2004 showed a worldwide burden of 34,017 DALYs, which was still only around 16 % of the injury-related burden, but represented 2.5 % of the entire global burden [9]. The most recent data suggest that in 2010, non-injury-related MSK conditions accounted for 4.4 % of the global burden of disease, more than doubling in 20 years [10]. Conditions that were not included in the initial study, such as neck and back pain, account for a significant portion of this increase.

Bone and joint conditions with a significant incidence or prevalence, such as malignancies and infections, congenital abnormalities, developmental abnormalities, and nonrheumatoid inflammatory arthropathies, have not been

included in the GBD. Though unaccounted for, it is likely their combined contribution to the global disease burden is significant. An overall aging population and the epidemiologic transition toward noncommunicable diseases will likely see a continuation of this trend for the foreseeable future.

Disclaimer: One of the authors is a staff member of the World Health Organization. He and the other authors are responsible for the views expressed in this publication, and they do not necessarily represent the decisions or the stated policy of the World Health Organization.

References

1. World Health Organization. Global burden of disease 2008 data. 2011. Available from http://www.who.int/gho/mortality_burden_disease/global_burden_disease_DTHInc_2008.xls. Accessed 23 May 2012.
2. Mock C, Quansah R, Krishnan R, Arreola-Risa C, Rivara F. Strengthening the prevention and care of injuries worldwide. *Lancet*. 2004;363:2172–9.
3. Mock C, Cherian M. The global burden of musculoskeletal injuries: challenges and solutions. *Clin Orthop Relat Res*. 2008;466:2306–16.
4. World Health Organization. The burden of musculoskeletal conditions at the start of the new millennium, report of a WHO Scientific Group, WHO Technical Report Series, vol. 919. Geneva: WHO; 2003.
5. Mock CN, Abantanga F, Cummings P, Koepsell TD. Incidence and outcome of injury in Ghana: results of a community-based survey. *Bull World Health Organ*. 1999;77:955–64.
6. Mock C, Boland E, Acheampong F, Adjei S. Long-term injury related disability in Ghana. *Disabil Rehabil*. 2003;25:732–41.
7. Peden M, Scurfield R, Sleet D, Mohan D, Hyder A, Jarawan E, Mathers C. World report on road traffic injury prevention. Geneva: World Health Organization; 2004.
8. Murray CJL, Lopez AD, editors. The global burden of disease. Boston: Harvard University Press; 1996.
9. Lopez AD, Mathers CD, et al. Global burden of disease and risk factors. New York: Oxford University Press; 2006.
10. Murray CJL, Vos T, Lozano R, Naghavi M, et al. Disability-adjusted life years (DALYs) for 291 diseases and injuries in 21 regions, 1990–2010: a systematic analysis for the Global Burden of Disease Study 2010. *Lancet*. 2012;380(9859):2197–223.

Richard A. Gosselin and El Hadji Ibrahima Diop

Introduction

As populations in developing countries become more wealthy and live longer, the patterns and types of diseases affecting them also change. Musculoskeletal infections, unaddressed pediatric conditions, and injuries remain the most common problems seen today in orthopedic clinics, as they have in the past. However, successful development and better overall nutrition are significantly modifying the incidence, severity, and underlying causes of these orthopedic conditions. This is most evident in the epidemic of road traffic, farming, and industrial injuries in low- and middle-income countries (LMICs). These injuries, both fresh and neglected, are addressed elsewhere in this book. The other trend is an increase in those conditions less often seen previously: age-related and lifestyle-related problems. These may look superficially like the same problems encountered in a Western practice, but for

many reasons they present as more severe and complex problems and take a greater toll on individuals, their families, and health systems.

Inflammatory Diseases

Inflammatory musculoskeletal conditions in developing countries have been present, most likely, forever. Since most are chronic, slowly progressive conditions, they were seldom seen and have had low priority. An aging population and relatively easier access to health care are bringing forth an increasing number of patients with rheumatoid arthritis, ankylosing spondylitis, gout, lupus, and seronegative spondylarthropathies [1]. A clinical examination is rarely sufficient for a definitive diagnosis, although certain findings such as tophi or windswept deformities of MCP joints can be highly suggestive. Plain radiographs, showing classic changes, may help point the clinician in the direction of a specific diagnosis. Most often only nonspecific laboratory tests, such as sedimentation rate or C-reactive protein, are available.

The more sophisticated and expensive serologic and pathologic tests necessary for a precise diagnosis are inaccessible except for the very few who can afford them. The services of a rheumatologist are unlikely to be available. For most patients, this makes little difference since the affordable treatments are usually aspirin, paracetamol/acetaminophen, early generation NSAIDs, and corticosteroids. Targeted medical treatment with

R.A. Gosselin, MD, MPH, MSc, FRCS(c) (✉)
Department of Orthopedic Surgery,
Institute for Global
Orthopedics and Traumatology, UCSF,
1001 Potrero Ave, 3A-36, San Francisco,
CA 94110, USA
e-mail: froggydoc@comcast.net

E.H.I. Diop, FWACS, FAAOS, FAAS, FSICOT
Orthopedics Surgery, St Christopher Iba Mar Diop
Medical School, Ueiu University Dakar Senegal,
BP 10309 Dakar Senegal, BP 25978 Dakar Senegal,
Dakar 12500, Senegal
e-mail: ibhdiop@gmail.com

interferon or newer-generation NSAIDs and surgeries such as spinal fusion and joint replacement are unavailable to the vast majority.

Degenerative Diseases

Degenerative joint disease (DJD) can be seen as an almost unavoidable consequence of aging, but can also occur prematurely secondary to trauma, congenital conditions such as developmental dysplasia of the hip (DDH), hereditary dysplasias, joint infections, and avascular necrosis. It commonly results from unrecognized or neglected intra-articular fractures or severe ligamentous injuries. When major weight-bearing joints are involved, the disability can be severe and prevent farming or manual labor, with dire economic consequences for an extended family. Severe involvement of the lower spine can be crippling.

The incidence of low-back pain, although still less than the epidemic numbers seen in rich countries, is steadily on the rise [2]. As with many other health conditions, patients tend to present late and in advanced stages of debility, at which time conservative management of weight loss, an exercise regimen, and bracing and/or judicious use of rest and walking aids are less successful. Most patients will have to rely on nonspecific symptomatic management and curtail their activity accordingly. The costs of prosthetic components are usually prohibitive, so arthrodesis may be of benefit in selective cases, by alleviating pain and providing stability (see Chap. 41). This option is rarely attractive to patients because of social or religious considerations.

Metabolic Diseases

Aging directly impacts the incidence and extent of two metabolic conditions: osteoporosis and diabetes. Osteoporosis is more common in

postmenopausal women, a group that represents a steadily increasing proportion of the population in developing countries [3]. Screening and prevention are usually absent, and most commonly the initial presentation is an insufficiency fracture after relatively trivial trauma. Upper extremity, pelvic, or spinal fractures will eventually heal on their own, with or without long-term disability. However, when the hip is involved, the morbidity can be significant since most such fractures are treated with prolonged bed rest in traction. The 1-year mortality can be well over 20 %. Pain, shortening, and the need to use a walking aid are common sequelae of malunions or nonunions. Secondary DJD is also common [4].

The incidence of type-2 diabetes is also increasing worldwide and reaching epidemic status in regions such as the Middle East [5]. Ironically this is related to a relatively new nutritional problem in poorer countries: overnutrition and a change from a diet of whole grains, fruits, and vegetables to one with more meat and refined sugars. These dietary changes contribute not just to abnormal glucose metabolism that can lead to infectious and neuropathic complications of the musculoskeletal system but also to obesity, which in turn accelerates the wear on weight-bearing joints [6] (Fig. 3.1).

Poor patients with diabetic foot sores often present late, when osteomyelitis is already present and conservative wound management unlikely to succeed. A Syme or below-knee amputation (BKA) is all too often the end result, after multiple ray resections and partial foot amputations fail. A similar problem is seen with neuropathic arthropathies (Charcot joints), particularly around the foot and ankle where progressive joint destruction leads to bony deformities producing chronic pressure wounds that lead to osteomyelitis (Fig. 3.2). Fusion of neuropathic joints has a high failure rate, but should be considered before the wounds develop. Otherwise a BKA is a common outcome.

Fig. 3.1 In many LMICs, those in the middle class, including health professionals, have a high incidence of obesity

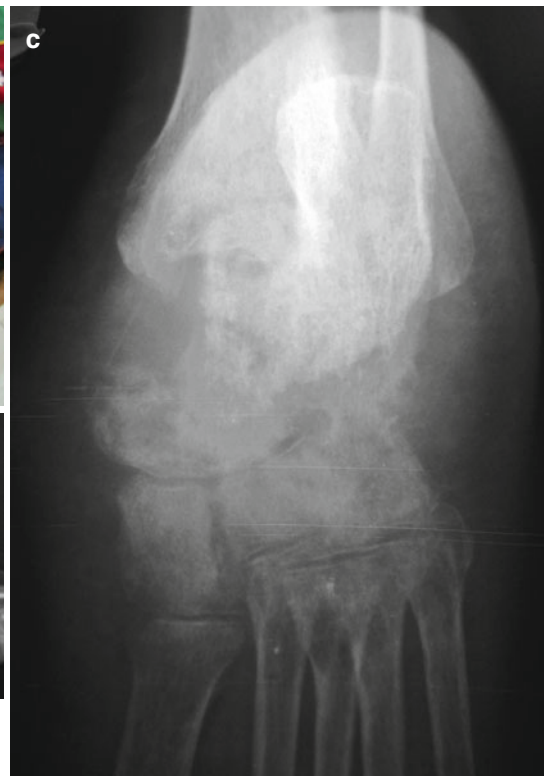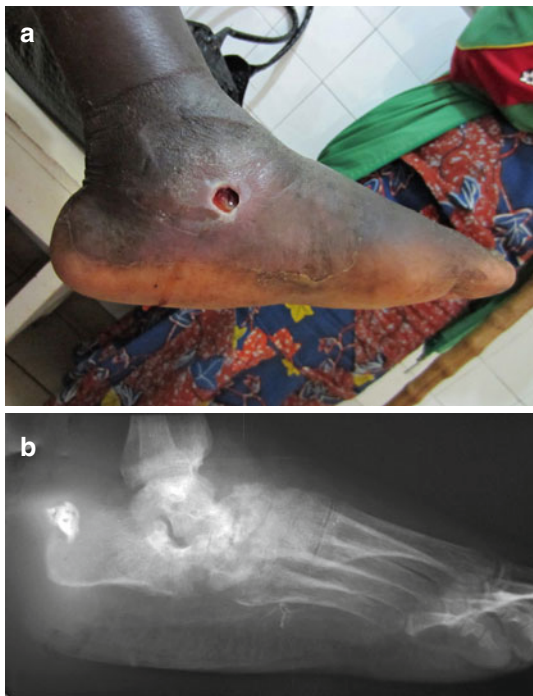

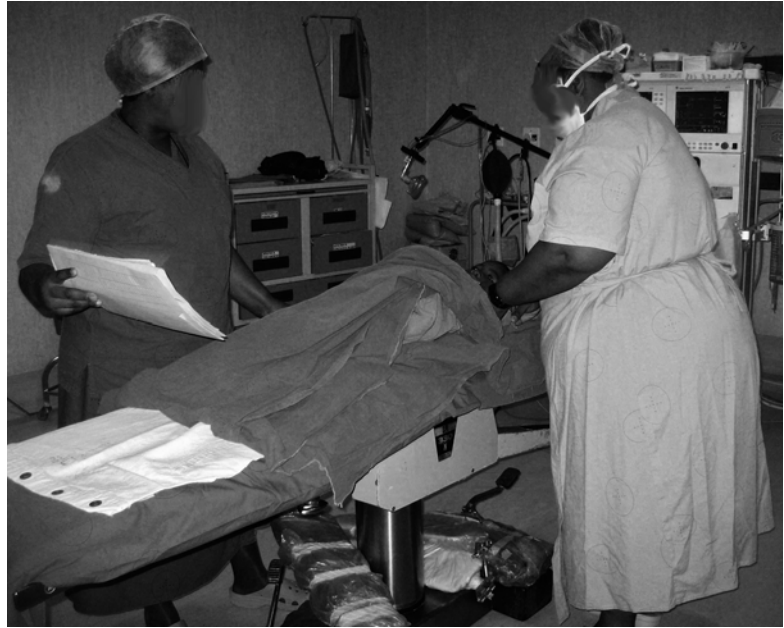
Fig. 3.2 (a) Chronic draining sinus of hind- and midfoot Charcot joints from diabetes. (b) Lateral X-ray showing destruction of talonavicular, calcaneocuboid, and midtarsal

joints with flattening of the longitudinal arch. (c) AP X-ray showing osteoporosis and joint destruction

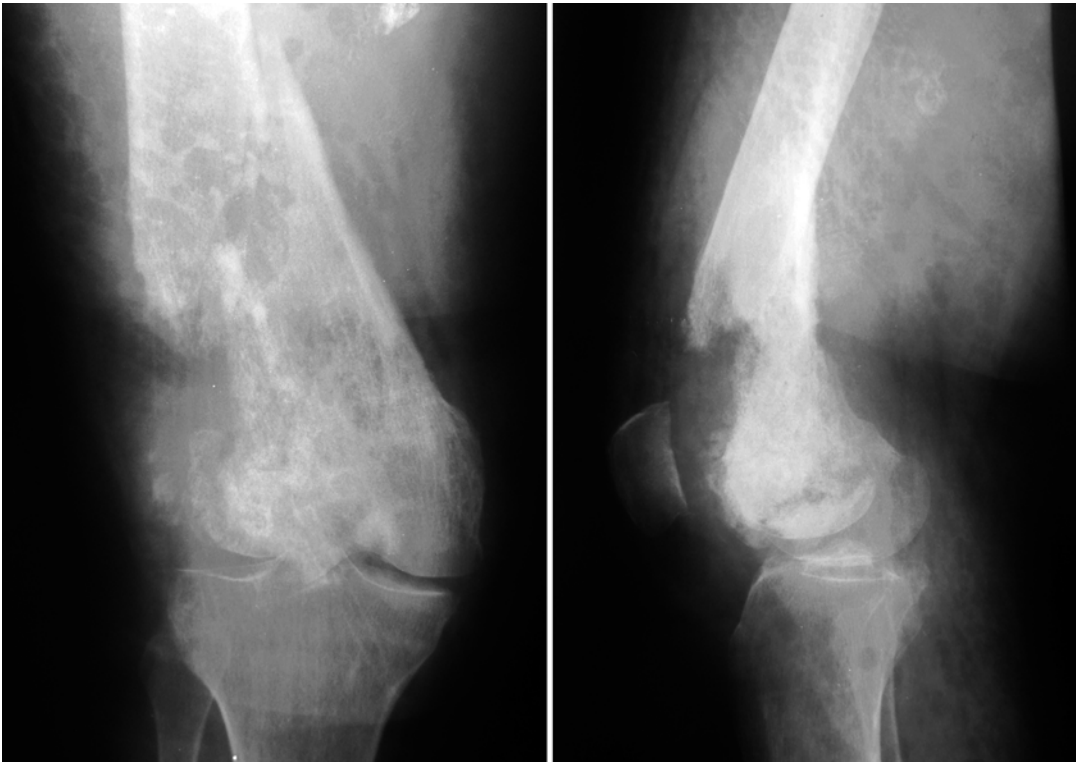


Fig. 3.3 This patient with medullary carcinoma of the thyroid presented with a pathological fracture of the distal femur for which only a knee immobilizer and palliative therapy could be provided

Neoplastic Disease

Primary or secondary (metastatic) neoplasias of the musculoskeletal system increase with age (see Chap. 42). Again, because of late presentation, the vast majority of patients are beyond hope of cure (Fig. 3.3). The unavailability of adjuvant treatments, such as chemo- and radiation therapy, compounds the problem. Metastatic disease is the most common of the bony neoplasms, and the habitual primaries from lung, breast, and prostate all increase with age.

A pathologic fracture is a common presentation. Faced with the lack of adjuvant modalities and since the fracture has no intrinsic potential to heal, palliative surgery for pain control is usually the only treatment option. As methyl methacrylate is rarely available, internal fixation without

curettage or bone graft is the next best option. The fixation should be rigid enough to last longer than the patient's anticipated life expectancy, not always an easy assessment. This is best achieved by one, sometimes two long plates or a statically locked IM nail of the largest possible diameter. Some surgeons object to nailing because of the possibility of seeding neoplastic cells distally in the canal, but for most patients presenting late, this is a moot point. If bone cement is available, the lesion should be curetted and the void filled with cement before internal fixation.

It is clear that the burden of age-related musculoskeletal conditions is rising and will continue to do so for the foreseeable future. This will impact heavily on the decision-making process when planning future allocation of scarce resources.

References

1. Woolf A, Brooks P, Mody GM. Prevention of musculoskeletal conditions in the developing world. *Best Pract Res Clin Rheumatol.* 2008;22(4):759–72.
2. Mody GM, Cardiel MH. Challenges in the management of rheumatoid arthritis in developing countries. *Best Pract Res Clin Rheumatol.* 2008;22(4):621–41.
3. Handa R, Ali Kalla A, Maalouf G. Osteoporosis in developing countries. *Best Pract Res Clin Rheumatol.* 2008;22(4):693–708.
4. Dhanwal DK, Dennison EM, Harvey NC, Cooper C. Epidemiology of hip fracture: worldwide geographic variation. *Indian J Orthop.* 2011;45(1):15–22.
5. Seidell JC. Obesity, insulin resistance and diabetes—a worldwide epidemic. *Br J Nutr.* 2000;83 Suppl 1:S5–8.
6. Hu FB. Globalization of diabetes: the role of diet, lifestyle, and genes. *Diabetes Care.* 2011;34(6):1249–57.

Cost-Effectiveness of Orthopedic Surgery in Austere Environments

4

Richard A. Gosselin

It has long been the global public health mantra that surgery is too expensive and relies on resources that are too specialized to be part of the basic health-care package for low- and middle-income countries (LMICs). Economic development has brought about a general increase in life expectancy with its attendant chronic diseases, while the rapid motorization of transport and mechanization of farming and industry have fueled an epidemic of high-energy injuries. Because of these irreversible changes, the need for surgical care is growing globally and will likely accelerate, although the true unmet need is unknown [1].

Part of the reason surgery remains the neglected stepchild of global health is the commonly accepted and unquestioned notion that it is not cost-effective compared to better-studied problems such as malnutrition, infectious diseases (HIV, malaria, TB), or maternal and child health (at-risk pregnancy, vaccination) [2]. This concept is increasingly challenged in new studies that use the same methodologies and metrics that are used to show the benefits of other interventions and that were previously used to exclude surgical care [3–5].

A cost-effectiveness analysis (CEA) is, as its name implies, an analytical technique or

tool that correlates the effectiveness of a health intervention to its costs. It is but one tool that health systems managers and public health policy makers use for the allocation of scarce health-care resources, as they are also bound by specific and local political, moral, and ethical imperatives. The technical advantage of a CEA is that it allows comparisons of different interventions using the same units of measurement, also called metrics. Many such metrics exist. Simple examples are dollars spent per life saved or dollars spent per complication averted, while more complex examples might add quality of life (QoL) components.

Composite metrics aim to capture different dimensions of a given condition into one summary measure and are widely used in cost-effectiveness analysis. Quality-adjusted life year (QALY), health-adjusted life expectancy (HALE), and disability-adjusted life year (DALY) are such measures. The Global Burden of Disease study (GBD) from the WHO, World Bank, and Harvard School of Public Health introduced the concept of DALY and used it as their metric of choice to give some order in determining the health burden of dissimilar diseases and conditions. The DALY is the most widely used metric within the political, economic, and social arenas of global health [6]. It is beyond the scope of this text to analyze its pros and cons, except to say that it does not meet with unanimous approval by all actors.

The DALY, like other composite metrics, is applied to populations not individuals and is the equivalent of 1 year of life lived in less than

R.A. Gosselin, MD, MPH, MSc, FRCS(c)
Department of Orthopedic Surgery, Institute for
Global Orthopedics and Traumatology, UCSF, 1001
Potrero Ave, 3A-36, San Francisco, CA 94110, USA
e-mail: froggydoc@comcast.net

perfect health. It measures a condition that is to be avoided or minimized, as opposed to a QALY, which measures a positive goal or outcome. The DALY summarizes into one measure the two fundamental components of any disease or condition: mortality and morbidity. Premature mortality is measured in years of life lost (YLL) attributed to a given disease or condition, and morbidity is measured in years lived with disability (YLD) attributed to said disease condition. DALYs are the sum of YLLs and YLDs for a particular condition and thus represent its health burden.

As stated above, DALYs measure disease within a population. In the example of diabetes, an individual cannot be both dead and blind from it. However, to give a more accurate idea of the health burden of diabetes within a population, those living with the various disabilities caused by the disease are measured and added to the number who died prematurely from the disease. DALYs allow global or regional burdens of disparate diseases such as TB, ischemic heart disease, melanoma, or clubfeet to be measured and compared.

Other composite metrics, such as QALYs and HALEs, are used for different purposes by different organizations, seeking answers to specific questions, in various settings. For example, insurance companies, hospital management, or NGOs might measure their respective levels of success or failure in any one setting by a different metric.

Using these metrics, cost-effectiveness analysis refers to the amount of burden from condition X that can be averted by intervention Y at cost Z. In short, a CEA correlates the costs to achieve effectiveness of treatment Y on condition X and is calculated in dollars, (euro, yen, etc.) per DALY averted. This levels the playing field, making CEAs of such diverse programs as immunizations, tobacco prevention, or cataract surgery comparable since they are all measured using the same metric: dollar per DALY averted. The reader is referred to the GBD study for methodological details.

Only with the second edition of the *Disease Control Priorities in Developing Countries* (www.dcp2.org) textbook in 2006 were surgery

and its cost-effectiveness deemed deserving of a chapter [7]. Estimates of DALYs averted for the studied surgical interventions varied by region, but were in the same ballpark: between \$35 and \$90 per DALY averted in LMICs at the district hospital level. These numbers came as a big surprise to most analysts and earned the unexpected “very good buy” recommendation from health economists.

Since then an increasing body of evidence has been published, supporting this recommendation: \$11/DALY averted in a general hospital in Bangladesh performing general surgical and obstetric procedures [3]; \$38/DALY averted in a general surgical, orthopedic, and pediatric hospital in Sierra Leone [4]; \$78/DALY averted in a district trauma hospital in Cambodia [5]; \$9/DALY averted for cataract surgery in India; and \$13/DALY averted for hernia surgery in Ghana. Though these costs are slightly more than the \$10/DALY averted for measles immunization or the \$15/DALY averted for insecticide-impregnated mosquito nets for malaria prevention, they compare favorably with antiretroviral therapy for HIV at \$400/DALY averted or the \$500/DALY averted for tobacco prevention programs.

Certain surgeries in developing country settings turn out to be not only more cost-effective than many of the widely supported and politically correct public health initiatives, but when compared with procedures done in the USA—estimated \$3,800/DALY averted for a tibial nailing of a 20-year-old male or \$48,000/DALY averted for total hip replacement in a 60-year-old male—they look to be veritable bargains.

More research is under way, and new methodologies are being developed to further define the surgical procedures that are cost-effective in resource-poor environments. This is a good example of how a CEA can make a strong argument for those advocating the inclusion of basic surgical care into the primary health-care armamentarium in developing countries, especially considering the need for surgical treatment of various acute and chronic conditions that will continue to increase for the foreseeable future.

References

1. Weiser TG, Regenbogen SE, Thompson KD, Haynes AB, Lipsitz SR, Berry WR, et al. An estimation of the global volume of surgery: a modelling strategy based on available data. *Lancet*. 2008;372(9633):139–48.
2. Farmer PE, Kim JY. Surgery and global health: a view from beyond the OR. *World J Surg*. 2008; 32(4):533–6.
3. McCord C, Chowdhury Q. A cost effective small hospital in Bangladesh: what it can mean for emergency obstetric care. *Int J Gynaecol Obstet*. 2003; 81:83–92.
4. Gosselin RA, Thind A, Bellardinelli A. Cost/DALY averted in a small hospital in Sierra Leone: what is the relative contribution of different services? *World J Surg*. 2006;30:505–11.
5. Gosselin RA, Heitto M. Cost-effectiveness of a district trauma hospital in Battambang, Cambodia. *World J Surg*. 2008;32(11):2450–3.
6. Murray CJL, Lopez AD, editors. *The global burden of disease*. Boston: Harvard University Press; 1996.
7. Debas H, Gosselin RA, McCord C, Thind A. Surgery. In: Jamison D et al., editors. *Disease control priorities in developing countries*. Washington: Oxford University Press; 2006. p. 1245–60.

David A. Spiegel and Stephen W. Bickler

Introduction

Inadequate access to surgical care results in considerable morbidity and mortality, especially for marginalized segments of the population in low- and middle-income countries (LMICs). Surgery continues to be neglected as a public health strategy due to the perception that it is costly, resource intensive, and benefits few within a population, despite a rapidly growing body of evidence to the contrary.

While most visiting surgeons will interact with colleagues practicing at the tertiary level, the majority of the population receives health services from traditional healers and nonsurgical practitioners, making awareness of the variables affecting access to and utilization of health services important.

D.A. Spiegel, MD (✉)
Division of Orthopaedic Surgery,
Children's Hospital of Philadelphia,
Associate Professor of Orthopaedic Surgery,
University of Pennsylvania School of Medicine,
Philadelphia, PA, USA

Honorary Consultant in Orthopaedics and Rehabilitation,
Hospital and Rehabilitation Centre for Disabled Children,
Janagal, Kavre, Nepal
e-mail: spiegeld@email.chop.edu

S.W. Bickler, MD, DTM&H, FACS
Pediatric Surgery, Rady Childrens Hospital,
University of California San Diego,
3030 Children's Way Suite 107,
San Diego, CA 92123, USA
e-mail: sbickler@ucsd.edu

A Conceptual Framework

In general, barriers are grouped according to (1) social/cultural, (2) financial, and (3) structural restraints [1]. Barriers may also be categorized according to WHO's conceptual framework for health systems, which focuses on the relationship between people (demand side) and six building blocks of the system (supply side) [2]. The demand side reflects an individual's utilization of services; the supply side is subdivided into governance, financing, service delivery, human resources, medicines and technologies, and information [2]. Interventions directed towards one building block will impact the others and are highly contextual (Table 5.1).

With respect to governance, few developing country health ministries include surgical care in their national health plans, and a lack of political support hampers efforts to improve surgical care. Regulations and/or guidelines for surgical training and scope of practice, certification and maintenance of certification, and continuing medical education are often lacking.

Neither morbidity and mortality nor the availability of cost-effective interventions explain the variance and the levels of local attention particular health issues receive [3, 4]. The political priorities for global health issues may be related to the power of the actors, the political contexts, the power of the ideas behind the issues, and the nature of the issues themselves [3, 4].

Service delivery, human resources, and medicines and technologies are tightly interrelated

Table 5.1 Barriers to the delivery of orthopedic surgical services

	Potential barriers				
Individual	Age				
	Gender				
	Education				
	Religious or cultural beliefs				
	Financial concerns		Direct costs (out-of-pocket expenses)		
			Indirect costs (time off work)		
		Cost of travel to health facility			
Fear of anesthesia or surgery					
Health system	Governance	Policies			
		Oversight			
		Regulation			
		Resource allocation			
	Service delivery	Lack of human resources	Insufficient numbers		
			Inadequate distribution (urban vs. rural)		
			Education and training	Orthopedic surgeons	
	Other providers	General surgeon			
		General MD			
				Paraprofessionals	
	Medicines and technologies	Inadequate infrastructure			
		Inadequate physical resources and supplies			
		Inadequate mechanisms for transportation and referral			
	Financing	Insufficient governmental allocation of funding			
		Dependence on out-of-pocket expenses			
		No protection from catastrophic spending			
		No risk pooling or insurance schemes			
Information	Inadequate data on the burden of orthopedic diseases (local, regional, national, global)				
	Inadequate information on availability of services (infrastructure, human, physical resources) at the facilities level				
	Lack of monitoring capability (disease burden, service availability, quality/outcomes)				
	Inadequate communication between central and peripheral levels of health system				

when considering access to surgical care. Deficiencies in infrastructure and physical resources or supplies may limit the availability of services [5–7]. Recognizing that the expectations for service delivery will vary depending on the level of health facility (district vs. secondary vs. tertiary), a package of “essential” surgical services should be universally accessible. These services should be aimed at conditions or diseases for which (1) there is a large public health burden, (2) the treatment is highly successful, and (3) the treatment is cost-effective [8]. Examples of “essential” orthopedic services might include irrigation and debridement for osteomyelitis and open fractures, nonoperative treatment of common fractures and dislocations, splinting and

casting, application of skin or skeletal traction, and amputation. The World Health Organization (WHO) has promoted essential surgical services, including orthopedics, through their Emergency and Essential Surgical Care Project (EESC); and a Global Initiative [9–11].

Deficiencies in human resources include an inadequate number and imbalance in the distribution of trained surgical providers, and variables in training and education. Task shifting, in which surgical care is delegated to non-surgeon doctors or health professionals without a medical degree, has become a popular strategy.

A critical link within the health system building blocks is the health information system (HIS), which is responsible for data collection,

data analysis, and the dissemination of information. HIS deficiencies include limited information on the burden of surgical diseases and the availability of surgical services, the absence of data for both evaluation and monitoring surgical diseases and outcomes, and the lack of strategies for monitoring and treatment. This knowledge is essential to understand the orthopedic needs of a population, the unmet surgical needs, educational requirements of caregivers, gaps in service availability, and quality of services delivered.

With regard to financing, both the direct and indirect costs (lost work time, transportation costs) of medical care can stress a family's resources, and countless families are pushed below the poverty line each year due to out-of-pocket expenses. Many low-income countries are unable to allocate sufficient funds to cover even the most basic health package, let alone curative services. As such, a large percentage of curative services are provided by the private sector at high prices.

Improving access to and utilization of orthopedic services requires a multidisciplinary, multi-sectoral effort. Increasing the awareness of the burden of musculoskeletal diseases will only happen through advocacy networks, including those formed by surgeons from resource rich areas who, while working in resource-limited areas, see firsthand the need for change and take action.

References

1. Grimes CE, Bowman KG, Dodgion CM, et al. Systematic review of barriers to surgical care in low-income and middle-income countries. *World J Surg.* 2011;35:941–50.
2. World Health Organization. Everybody's business: strengthening health systems to improve health outcomes: WHO's framework for action. Geneva: World Health Organization; 2007.
3. Shiffman J. A social explanation for the rise and fall of global health issues. *Bull World Health Organ.* 2009;87:608–13.
4. Shiffman J, Smith S. Generation of political priority for global health initiatives: a framework and case study of maternal mortality. *Lancet.* 2007;370:1370–9.
5. Irfan F, Irfan B, Spiegel DA. Barriers to accessing surgical care in Pakistan: healthcare barrier model and quantitative systematic review. *J Surg Res.* 2012; 176:84–94.
6. Spiegel DA, Choo S, Cherian M, Orgoi S, Kehrer B, Price RR, Govind S. Quantifying surgical and anaesthetic availability at primary health facilities in Mongolia. *World J Surg.* 2011;35:272–9.
7. Kushner AL, Cherian MN, Noel LPJ, Spiegel DA, Groth S. Addressing the millennium development goals from a surgical perspective: deficiencies in the capacity to deliver safe surgery and anesthesia in 8 low and middle-income countries. *Arch Surg.* 2010; 145:154–60.
8. Mock CN, Cherian MN, Juillard C, Donkor P, Bickler S, Jamison D, McQueen K. Developing priorities for addressing surgical conditions globally: furthering the link between surgery and public health policy. *World J Surg.* 2010;34:381–5.
9. Spiegel DA, Gosselin RA. Surgical services in low-income and middle-income countries. *Lancet.* 2007; 370:1013–5.
10. Bickler SW, Spiegel DA. Improving surgical care in low- and middle-income countries: a pivotal role for the World Health Organization. *World J Surg.* 2010; 34:386–90.
11. World Health Organization. Global initiative for emergency and essential surgical care. 2005. Available at: <http://www.who.int/surgery/globalinitiative/en/>. Accessed 25 Feb 2012.

Michelle Foltz and Kaye E. Wilkins

Teaching

Any orthopedic outreach situation in a resource-limited environment provides a number of opportunities for teaching, and few of them require the volunteer to be an academic. The wards, OPD, and operating rooms are great venues not only for teaching but are opportunities to better understand the local surgical problems and the barriers faced at all levels in delivering orthopedic care. Discussions of relevant topics at the bedside often leave lasting impressions with all members of the team. The audience includes not just surgeons and residents but also nurses and techs and even the cleaners. In some countries nursing is a step to medical school, and in his home village, the cleaner is the local doctor.

How things are discussed is as important as what is discussed. Open discussions in which all questions are considered and going through decision-making steps out loud are productive ways of teaching. Colleagues learn by exposure

to different ways of thinking. Showing respect for the patients and members of the team, as well as their opinions, opens the discussion further. Manners count.

Many volunteers think teaching means trying to pass on a vast amount of detailed knowledge, and the more facts given, the bigger and better the impact. Our greatest impacts often come from simple gestures and the seemingly inconsequential. Anyone who has worked with young surgeons, even in a non-teaching position, knows they watch and judge everything a volunteer does. A few days after showing and explaining some small maneuver to facilitate a fracture reduction, it is probable this young surgeon will put your methods into action and explain it to another colleague, using your same words and reasoning. This sort of teaching may well improve patient care better than any lecture detailing a classification system that cannot be put to use in the present setting and is immediately forgotten.

Teaching organizational skills seems far removed from a typical orthopedic volunteer agenda, but such skills are sorely lacking to some degree and at various levels in most hospitals or orthopedic departments in developing countries. In some cultures people do not think they have any control over events and never devise systems to prevent untoward consequences. Hospitals may lack the structures that demand organization or the existing processes are ineffective. We can help them organize their OR sets, make forms, and construct protocols that suit their needs. Those would truly be lasting contributions.

M. Foltz, MD (✉)
172 Stillwater Loop Road,
Columbus, MT 59019, USA
e-mail: michellefoltz@gmail.com

K.E. Wilkins, DVM, MD
Department of Orthopedics and Pediatrics,
University of Texas Health Science Center at San
Antonio, The Children's Hospital of San Antonio,
formerly Christus Children's Hospital,
7703 Floyd Curl Drive, Mail Code 7774,
San Antonio, TX 78229-3900, USA
e-mail: drkwilkins@aol.com

When volunteers are tasked with formal teaching, they need to find out the level of instruction expected and what information or skills are needed and wanted. Some organizations have training programs directed at a specific level of provider, with syllabi and approved teaching materials. Discussion with previous volunteers or the administrators of the volunteer organization will help determine what might be useful. Canned PowerPoint presentations copied from the Internet are usually irrelevant and show a lack of imagination and effort. Instructive, entertaining and pertinent lectures—PowerPoint or sprawled on a white board—given with humor and knowledge are another story.

Most volunteers from high-resource countries have been exposed to different ways of teaching by numerous, enthusiastic teachers. We value teaching and lifelong learning. Among the limited resources in most developing countries are good teachers and productive, uncorrupt systems of teaching. In some countries and cultures, teaching is fraught with ambivalence: if too much information is given to the student, he will surpass the teacher and steal the patients. Knowledge is power in such a zero-sum world and is best if not shared too widely. In such places there is little opportunity to learn how to teach. Surgeons are taught by watching, often becoming skillful operators, but may be unable to put the ideas of why, how, and when, not to mention judgment, within reach of a resident or trainee. Volunteers can help teach the teachers by framing each patient encounter into a teaching and learning situation.

Good teachers listen. Good teachers ask for advice, are humble, and secure enough to say they do not know what to do and are not comfortable doing a certain procedure. By such examples of professionalism, they will teach more than just orthopedics.

The ultimate in teaching is an exchange of ideas, not simply a one-way dissemination of information. Even in programs that are strictly service oriented, skills and ideas will be left behind, and the volunteer will have learned aspects of orthopedics he or she had not expected. Just as important are the personal, professional relationships one establishes. They

become a conduit for further exchange that can last a lifetime.

Educational Resources

Donated books are welcome teaching aids, but bring the right ones and make sure they go to the right person. In many centers and hospitals, textbooks are limited in number at both the private and institutional levels due to the expense of medical publications, coupled with low wages or lack of funds to support libraries. Books are prime targets for theft. As a consequence libraries may be locked with limited access. At some universities—where books are not readily available and the professor is the authority whose views become standard practice for the institution—the culture of referring to books or journals or looking things up for oneself is weak or nonexistent.

In settings where books or journals are limited, the culture of how to read scientific literature, evaluate its validity, and put it to use may have never had the opportunity to grow. Fostering such intellectual rigor by a limited journal club with discussions can open new approaches for interested colleagues. A volunteer can bring classic or review articles or download them from the Internet and distribute copies for discussion.

The Internet is open at a more egalitarian level than guarded libraries or pricy textbooks. In many areas computers are still expensive and access is limited, but the Internet's potential in resource-poor areas is vast and growing. YouTube (www.youtube.com) and iTunes U (www.apple.com/itunes) are both free and filled with surgical technique videos and useful information. The younger surgeons may be able to maneuver around the Web with ease, leaving older surgeons and those who are not easily conversant in a major global language, with the sense that it is a confusing technology and the information spurious. A volunteer spending a couple of hours at an Internet café with a technophobe colleague can open his mind to the professional and personal uses of this marvelous tool.

In 2002 the World Health Organization realized the Internet's potential to increase access to biomedical and health literature in low-resource countries. It convinced major book and journal publishers to join it in creating HINARI, Health InterNetwork Access to Research Initiative (www.who.int/hinari/). National universities, research institutes, professional schools, teaching hospitals, government offices, and national medical libraries in most low-income and some middle-income countries are eligible to apply for free or low-cost access. HINARI's goals are to promote intellectual rigor through the wide scope of available material, provide the basic materials for research, improve clinical treatment and in turn patient health, and support the global expansion of knowledge.

Ptolemy (www.ptolemy.ca) is a partnership involving the University of Toronto, the Association of Surgeons of East Africa (ASEA), the College of Surgeons of East, Central and Southern Africa (COSECSA), and the Canadian Institutes of Health Research (CIHR). Through its website the medical library of the University of Toronto is accessible to the participating organizations and their members.

Where available, HINARI and Ptolemy are widely used and are making a significant impact in providing access to literature such that surgeons and medical personnel are not limited by the expense of publication, the paucity of well-stocked libraries, or self-appointed authority.

Global Help Organization (GHO) (www.global-help.org) has taken a different tack in making literature accessible through the Internet. Its mission is to provide free or affordable health-care publications primarily for use in underserved countries. This is based on studies showing that low-cost educational material may be the most cost-effective method of improving sustainable health care in such areas [1]. Their publications primarily focus on orthopedics and pediatric problems. This is motivated by the large number of children in LMICs and the potential such knowledge has to prevent disability and provide long-term benefits by the effective management of pediatric and orthopedic problems. Currently over 100 titles are available as free downloads from its website. Over the past decade GHO has provided more than a million PDF publications and tens of thousands of printed publications and DVD libraries to users in more than 200 countries. Some publications have been translated into multiple languages. GHO's publications are specifically selected for their pertinence to teaching and learning in low-resource environments, making them extremely useful and accessible teaching aids for any volunteer.

Reference

1. Pakenham-Walsh N, Priestley C, Smith R. Meeting the information needs of health workers in developing countries. *BMJ*. 1997;314(7074):90.

Richard C. Fisher and Dominic Awariyah Adondaa

Introduction

Orthopedics is a gadget-rich specialty. The list is long: dressings, plaster and fiberglass casts, traction equipment, pins, intramedullary rods, plates and screws, prosthetic joints, prosthetic limbs, and crutches.

In 2003, a grant administered through Health Volunteers Overseas provided funds to send an experienced operating room technician to large teaching hospitals in five different developing countries. He inventoried the orthopedic instruments and implants and set up an inventory control system with the local operating room personnel. The goal was to establish a method of guiding both equipment purchases and donations to maintain functional sets of compatible instruments and implants that would be available when needed. He spent 3 months on the project, but by the end of the following year, little evidence remained of his efforts.

Maintaining a constant supply of functioning orthopedic equipment is a challenge in all environments, just more so in those with limited resources, where the logistics are difficult and distances long with poor transport. Operating room personnel are often non-specialized or are rotated between services. This breaks the continuity of the system and the knowledge chain needed to manage the large number of orthopedic implants and instruments. Technically, complex equipment handled by untrained personnel leads to frequent breakage, rendering it useless when repair and maintenance services are unavailable (Fig. 7.1). When instrument sets are kept in wrapped sterilized packs, it is impossible to know if the contents are complete without breaking the sterility (Fig. 7.2). Opening them only as the case begins, it is often too late to make changes. In places where the patient must purchase implants in an off-site location, there is little control of the quality or availability.

Hospital budgets routinely underfund orthopedic departments and may postpone purchases until another funding cycle. Purchasing departments are not run by surgeons or medical personnel, and the agent often chooses lower cost suppliers who sell equipment that is not compatible with current systems or buys inappropriate items from friends, pocketing a kick-back. Guiding donations is difficult as it may

R.C. Fisher, BA, MD, MS-Health Admin. (✉)
Orthopaedic Surgery, University of Colorado Health
Science Center, 12631 East 17th Ave,
Mailstop B202, Aurora, CO 80045, USA
e-mail: richard.fisher@ucdenver.edu

D.A. Adondaa, MD
Trauma/Orthopedics, Komfo Anokye Teaching
Hospital, Harper Str. 73, Adum,
Kumasi, Ashanti Region, 1934, Ghana
e-mail: ddrawariyah@yahoo.com




Fig. 7.1 (a) Instruments are jumbled together in a pan for washing and (b) dumped on the table without regard for preserving the sharp cutting edges or preventing them from bending and breaking



Fig. 7.2 Instrument and implant sets are often wrapped and sterilized in a location remote from the operating room. These sets cannot be inspected without breaking sterility. (a) Cloth wrapped (b) in somewhat more accessible metal containers


Fig. 7.2 (continued)

require saying “no” to some inappropriate items while waiting for more useful ones, which may never arrive. Equipment, whether purchased or donated, without local maintenance availability usually has a short lifespan. Items such as power drills, arthroscopy sets, and x-ray machines end up with other useless equipment

as baggage, clogging hallways or equipment rooms (Fig. 7.3).

These are some of the problems. This chapter will consider possible solutions including acquisition of local supplies, the ethics of donations, recent initiatives addressing the problem, and sources of purchased supplies.

Fig. 7.3 Useless and broken equipment becomes a burden



Local Acquisition

Simple supplies can be arranged from local sources in most countries. Common things like rope and pulleys for traction, plaster of Paris, razor blades, and common bleach are usually available. Plaster rolls can be made from gauze strips covered with dry plaster of Paris and then rolled up ready for use. Although dangerous, razor blades have been used as scalpel blades. Dakin's solution for dressing changes on open wounds is marketed under that trade name or can be made by diluting common bleach (see Chap. 14 for recipe).

In the past, implants have been made on-site using 316 stainless steels in a local machine shop, but without quality control, this is unsafe for the patient and should not be attempted. The exception is perhaps external fixation devices. While many ex fix frames are a common donation, informally fashioned frames are a reliable substitute and some can be reused. Simple solutions include pins and plaster, pins attached to a wooden bar, or more sophisticated metal devices (Fig. 7.4). They will, at least, serve in an emergency to gain fracture stability and wound access.

Centers with functioning prosthetic/orthotic workshops or training schools have access to a range of locally made splints, braces, and artificial limbs. While these vary in quality, a local source is invaluable. Often, physical therapy departments are able to fashion simple splints and braces; however,




Fig. 7.4 One type of locally made external fixation device copied from the old French Army fixateur

these will usually be not lightweight devices made from thermoplastic materials. Prepackaged elastic splints with Velcro closure are rarely available or are expensive. Simple wooden crutches made locally function well (Fig. 7.5), though many patients in Africa prefer to use a single, long walking stick, which they use in a poling maneuver and which may be more stable in mud than crutches.

Prosthetic manufacture requires special training. International Committee of the Red Cross, Handicap International, the Cambodia Trust, and the International Society for Prosthetics and Orthotics are organizations that conduct training programs throughout the world targeted for developing countries. To be most effective, there should be interaction between patient, surgeon,



Fig. 7.5 Wooden crutches made at a hospital in Ghana

prosthetist, and physical therapist, making location important, as patients must travel far and remain for the lengthy process of prosthetic manufacture, fitting, and training. There is a great need worldwide for prosthetic expertise.

The Ethics of Donations

Donated orthopedic equipment and supplies are a potentially valuable resource in developing countries. Although it seems as if any donation would be helpful in areas where there is great need, one should look carefully at the cost, sustainability, and ethics before shipping or carrying equipment to an overseas hospital [1].

While the equipment might be obtained for free, the costs involved with shipping, possible customs fees, or added baggage fare could be substantial. Consider whether those funds might have a better use. Much donated material turns out to be unusable once it reaches the country and ends up as a burden rather than a benefit. There are numerous reasons for this such as voltage differences and limited or expired shelf life (Fig. 7.6). Orthopedic donations are often incomplete, having either



Fig. 7.6 Two unusable, donated C-arms clutter the limited hall space in a Cambodian hospital. They cannot be fixed or disposed of locally due to the radioactive components

instruments without implants or vice versa. The following is a list of ethical and sustainability standards that will make a donation more effective:

- Be sure the material being donated is known and agreed upon by the recipient.
- Match the needs of the recipient country with the material being sent. The sets should either be complete in themselves or compatible with existing equipment. Be certain the instruments match the implants.
- The recipient should know how to use the equipment appropriately and safely. If not, include a training period as part of the donation.
- It should be sustainable, by either continued donations or local purchase.
- If it has a shelf life, it should not be outdated. The donated supplies should be as safe to use in the recipient as in the home country.
- In general, donations should be made available to all patients regardless of ability to pay.
- The donated material should not interfere with currently available purchased equipment and supplies. It should not compete economically with local markets.¹

When hospitals switch implants or remodel or equipment manufacturers market a new brand, the unwanted items become a ready source of donated supplies. These typically are given to individuals, sent to overseas programs, or filtered through a host of nongovernmental organizations (NGOs). The NGOs Medshare and doc2doc accept general supplies for redistribution. Others, such as Remedy, collect unused, unopened equipment and supplies in prepackaged sets and reassemble them into donor packs. World Access Project collects used wheelchair components,

¹For example, if donated rice is given away, it decreases demand and lowers the price for locally grown rice. This decreases production and encourages food dependency instead of developing food independence. A similar concept applies to equipment donations. Free material donations reduce the development of a sustainable local supply system, which is more important than short-term availability. Donations should serve as a foundation for maintenance of the service.

refurbishes them with volunteer help, and supplies them to developing countries. The US section of the International Society for Prosthetics and Orthotics (ISPO) acts as a clearing house for new and “gently” used prosthetics and new orthotic products. Along those lines, the NGO Orthopaedic Link has been working with orthopedic equipment manufacturers to receive their unwanted equipment sets and match them to specific overseas hospitals, creating a sustainable line of dependable products.

A different approach was developed by SIGN Fracture Care International. This NGO manufactures an FDA-approved, intramedullary, locking nail system that does not require fluoroscopy or a special fracture table for insertion. A supply of implants is provided with a training program. As the implants are used, they are replaced without charge if certain details of the case are provided to an Internet data bank. SIGN also supplies ongoing training through on-site visits and their yearly conference.

Purchased Equipment

Besides US, European, and Japanese manufacturers, orthopedic equipment is manufactured by firms in India, China, and many middle-income countries. The specific availability is primarily dependent on costs but also on geography. Several of the large US- and European-based corporations have regional offices and manufacturing facilities within reach of Africa and Asia, but their products are expensive for resource-poor hospitals.

A plethora of Indian companies manufacture and distribute orthopedic devices. These are available to countries in the region and the cost is reported to be lower than similar goods from the USA or Europe. Quality is more difficult to measure, but since 2006, India has a regulatory and licensing process for medical instruments and implants and many firms provide certification. There seem to be fewer customs problems in some countries neighboring India, making distribution easier. Orthopedic

supplies such as plaster, fiberglass, dressing materials, and splints from Indian firms are available in many developing countries and competitive in price.

Indian equipment and supplies are frequently imitated and fraudulently produced by bogus companies to appear as equipment from reputable Indian firms, creating problems due to lower quality. Some items that are considered obsolete in European countries are shipped to Africa at reduced costs. Health administrators are not medical professionals and will therefore opt for cheaper supplies, hence encouraging the flow of these products into the region. These supposed “cheap supplies” might be more expensive in the long term. Medical professionals need to play a more active role in acquiring medical consumables for their facilities to make sure appropriate systems are available.

Conclusion

Solutions include fashioning products from local sources, donated or recycled equipment, and purchased equipment and supplies when

funding is available. With all these options, it is imperative to monitor the quality of the product and be certain the providers are trained in its use. In the end, patient safety is most important.

Reference

1. Phillips JJ, Coughlin R, Gosselin RA. Socially responsible orthopaedic donations. AAOS NOW, American Academy of Orthopaedic Surgeons. 2010.

Websites

- doc2doc. www.dr2dr.org.
MedShare. www.medshare.org.
Orthopaedic Link. www.orthopaediclink.org.
Remedy. www.remedyinc.org.
SIGN Fracture Care International. www.signfracturecare.org.
U.S. National Member Society of the International Society for Prosthetics and Orthotics (U.S. ISPO). www.usispo.org.
World Access Project. www.worldaccessproject.org.

Michael Krosin

Typically, international work will take place in a setting with different resources from one's home country and in unfamiliar medical and cultural environments. This combination presents ethical considerations one should be aware of prior to embarking and includes patient-centered issues of safety and culture, host country physician issues, host country systems issues, and the special situations of either disaster relief or investigative research.

The foremost priority for any physician is patient safety. Surgery in austere environments that might be standard in one's home country may ultimately create more harm than good. Lack of certain technologies, implants, and a proper sterile environment may create risks that outweigh the benefits. Overly aggressive treatments, which result in poor outcomes, can create lasting mistrust and erode relationships.

There are situations where proper implants and environments exist and difficult procedures may be done safely. However, the aftercare, particularly in the face of complications, may be absent. The availability of aftercare should play a major consideration as to whether a procedure should be performed.

Lastly, proper record keeping should be prioritized by the visiting surgeon. Every effort should be made to establish an accurate, comprehensible, and accessible medical record. While most country's records are paper-based, it is a good idea for the visiting surgeon to keep an electronic file of implants and procedures in the event the paper chart is unrecoverable.

Patient autonomy in decision-making and other cross-cultural issues can present unforeseen challenges. Time, patience, and alternative methods of communication should overcome these barriers. It is important to set realistic expectations and clearly define the risks of a procedure, and in turn, it is helpful to have the patient verbalize his understanding. Patient and family expectations of physician paternalism may lead them to minimize the risks and overestimate the benefits of intervention. Cultural expectations may discourage the patient from asking questions or exercising his right to either decline or discuss treatments. The host country physician may also discourage questions. In certain cultures, other family members may decide on behalf of a patient. It is up to the visiting physician to make sure that a standard of informed consent and dialogue commensurate with the surgeon's own standard is maintained while respecting local culture (Box 8.1).

Distinct cultural and societal considerations should be considered prior to therapeutic interventions. For example, cultures that squat and kneel for basic hygiene and in the course of

M. Krosin, MD
Department of Surgery, Alameda County Medical
Center, 1411 E31st St., Oakland, CA 94602, USA
e-mail: mkrosin@acmedctr.org

Box 8.1 Pointers for Informed Consent

- Prior to talking with the patient, discuss the consent with the translator and resolve any issues of understanding or translation.
- When possible, use pictures or graphics or electronic devices.
- Describe percentages, odds, and risks using locally accessible analogies. In developing countries, there may be a therapeutic misconception that a foreign doctor will not encounter any problems and everything will be “normal” again.
- Include the patients’ family in the consent process if appropriate, but be aware that family members may prevent the patient from asking questions.
- Pause often and allow plenty of time for questions.
- Have the patient repeat back “in their own words” the critical risks, recovery time, immobilization, or rehabilitation parameters and likely deficits of function so that you are sure he understands. Explain that it is important to ask questions and that no question is bad or silly. Let the patient and/or family start by asking questions to get a background understanding even before the consent process begins.

everyday life may preclude certain elective procedures.

In many instances, the visiting surgeon will be partnered with a host country physician. It is likely that conversations comparing different medical systems and standards of care will arise. Talk of “better” methods or standards is liable to foster feelings of inferiority. By describing certain methods as superior, the visiting surgeon can undermine local physician confidence and risk shaming certain members of the medical

hierarchy. Always present any method or system as one of many good options.

The visiting surgeon should appreciate rank and seniority and understand that by spotlighting junior physicians, he may be creating problems for them with their superiors at a later date. The visiting surgeon may encounter host country physicians genuinely criticizing the local medical system and standard of care. Voicing agreement may create resentment and at the same time perpetuate further feelings of inadequacy. The visiting surgeon should remain neutral or complimentary regarding the host country’s medical care (Box 8.2).

One should be aware of issues regarding favoritism for members of certain religions, political parties, and ethnicities. The visiting surgeon should make every effort to encourage a fair and equitable distribution of resources. The host country may have become reliant on visiting medical personnel and equipment, and while this is understandable in the setting of scarce resources, it can also stifle the development of a sustainable local health delivery system. The visiting surgeon can help the host country’s physicians advocate for greater resources by encouraging data collection. This can later be used to justify additional investments.

International research and disaster relief introduce a complex set of ethical considerations. International research subjects are most often considered vulnerable populations, and it is mandatory to adhere to the basic principles of respect, justice, and beneficence as outlined in the Belmont Report on Human Subjects Research [1]. During disaster relief, resource distribution, patient triage, and the appropriateness of certain procedures should be considered in the greater context of the disaster. The lack of infrastructure and support may make certain types of volunteer relief work inappropriate and a detrimental strain on scarce resources. International work in these situations should be undertaken only with a coordinated and experienced team.

Box 8.2 Ethics: A Case Study

You are a member in a team of visiting volunteer surgeons at a site. This is the first time this site has hosted surgeons, and it is not clear if you will be returning for further volunteer trips. One of the patients you evaluate is a young farmer with a femoral hypertrophic nonunion after closed treatment. He has had the problem for over a year and been unable to work. Your team has appropriate implants and equipment (minus a c-arm) to treat the nonunion, but the infection rate for internal fixation at this site is 10 %. The junior local surgeon has experience with intramedullary nails and would like to proceed with the case with you as an assistant. The senior local orthopedic surgeon is willing to proceed with the case, but you sense he is somewhat tentative.

Considerations to think about:

- Patient safety and risk vs. benefit
- Technical and technological capability of follow-up and management of infection
- Patient informed consent
- Respect for local seniority

Resolution 1: Following a lengthy discussion in private with the senior orthopedist, you learn that in the past he has had some very poor outcomes with infected femoral nonunions and feels uncomfortable in their management but did not want to voice this. Following a discussion, he is willing to go along with fixation if there is a plan in place in case of infection. You discuss the plan with the senior surgeon first and then with both local surgeons to do a nail removal and washout in the case of infection and leave the patient hopefully no worse off. You also will leave a larger diameter nail if a washout and repeat nailing are needed. They have appropriate hand

reamers. A thorough informed consent with the patient occurs with translator, both local surgeons, and visiting surgeon present. The likelihood of a complication is expressed in terms the patient understands and his comprehension of this is verified to a degree you feel confident in his understanding. He agrees to proceed with the surgery.

Reference

1. The Belmont Report. Ethical principles and guidelines for the protection of human subjects of research. 1979. U.S. Department of Health and Human Services. <http://www.hhs.gov/ohrp/humansubjects/guidance/belmont.html>. Accessed 1 July 2012.

Suggested Reading

- Benatar SR, Singer PA. A new look at international research ethics. *BMJ*. 2000;321:824–6.
- Bernstein M. Ethical dilemmas encountered while operating and teaching in a developing country. *Can J Surg*. 2004;47(3):170–2.
- Bergler JH, Pennington AC, Metcalfe M, Freis ED. Informed consent: how much does the patient understand? *Clin Pharmacol Ther*. 1980;27:435–40.
- Molyneux CS, Peshu N, Marsh K. Understanding of informed consent in a low income setting: three case studies from the Kenyan coast. *Soc Sci Med*. 2004;59:2547–59.

Michelle Foltz and Geoffrey Walker

Culture Shock

There is no guaranteed way to prepare completely for cross-cultural encounters. Talking with people who have had similar experiences often builds the excitement that accompanies such journeys, but what others felt and how they dealt with problems will seldom match what one finds on arrival. Reading about the politics and current events and exploring the literature provide a perspective, but sometimes, the perspective is wide of the reality on the ground. Though every volunteer develops an individual approach to deal with each situation, common threads to successful adaptation include a willingness to communicate, a genuine receptivity to new ideas, and a ready sense of humor—all coupled with a healthy dose of humility.

The initial shock may come from the bombardment to all senses by unfamiliar levels of poverty, hygiene, and sanitation. People impinge on one's space, shout, push and shove, or bow their heads and whisper without making eye contact. Their

answers to questions may not make sense and the response to a friendly greeting and “thank you” can be a quizzical stare. Arriving ill or fatigued magnifies the sense of strangeness.

The concept of culture shock was formalized in the 1950s and has proved to be a common and predictable evolution of variably timed stages that a person goes through when first arriving in an alien culture. The initial fascination with one's new surroundings gives way to more unpleasant feelings, associated with heightened anxiety as the differences are brought into sharper contrast. In the next stage, one finds ways to adjust and eventually reaches a balanced *modus vivendi* [1].

For orthopedic surgeons, the adjustment to working in an austere setting, with all the manifestations of life lived close to survival mode, is further complicated by professional culture shock. All diseases have a social component, but in the face of limited resources, the complications and variables due to those social components carry added weight (Fig. 9.1). Patients present late and may not follow instructions for a 100 reasons. They take risks we do not understand and show a fatalism that is both admirable and self-defeating (Fig. 9.2). Their histories do not follow a time frame or idea of cause and effect we assume to be universal (Fig. 9.3). They do not return for follow-up as appointed, but show up a month late with smiles and a destroyed cast barely covering an infected surgical wound. They do not always tell what we consider the truth—reality

M. Foltz, MD (✉)
172 Stillwater Loop Road,
Columbus, MT 59019, USA
e-mail: michellefoltz@gmail.com

G. Walker, FRCS (Eng and Ed), FCS (Hon), ESCA
World Orthopaedic Concern, 9d The Grove,
Highgate Village, London N6 6JU, UK
e-mail: geoffreyf2.walker@gmail.com



Fig. 9.1 Patients arrive at the hospital or clinic by many different means. (a) This patient was picked up on an unlit street after being run over in Kabul. His leg was splinted with available materials; he was thrown into the back of a bystander's pickup and brought to the hospital. There are

no EMT services in many countries. (b) Families carry their injured or ill. (c) They use whatever is available, such as a wheelbarrow. (d) The buffalo ambulance must stop to eat and rest on the way to the clinic



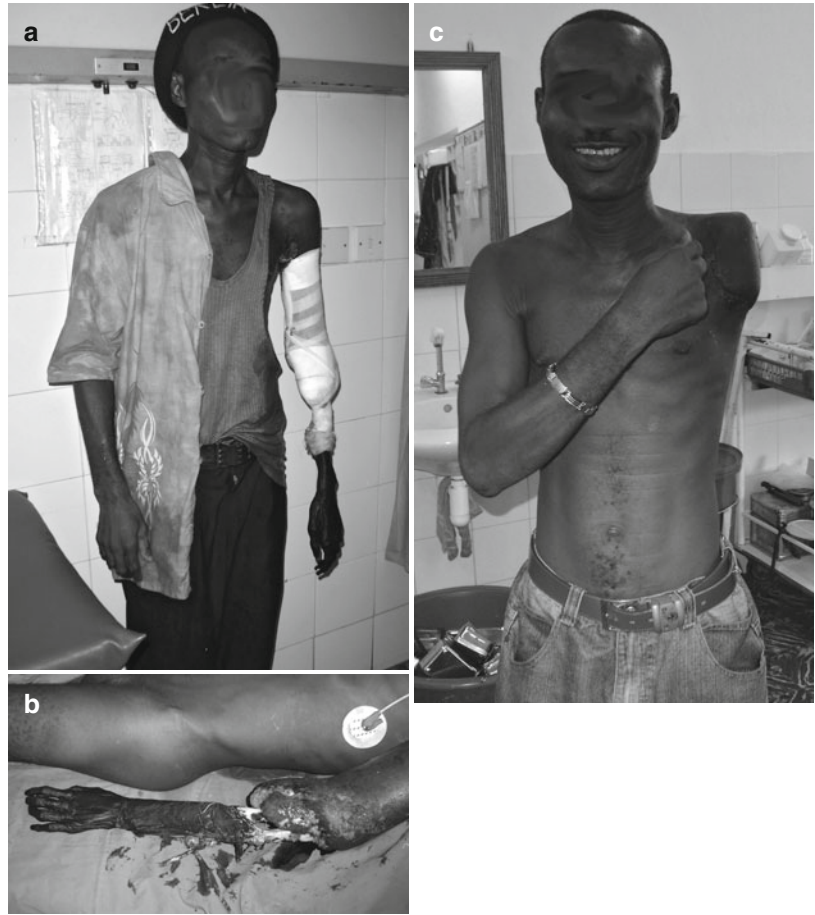Fig.9.2 Unsafe and frankly bizarre forms of transportation are immediately evident on arrival in most low- and middle-income countries. (a) Overcrowded, (b) unconventional use

of space, and (c) dangerous equipment. The long handlebars on this *kolyn* make it difficult to turn (d) passenger ignorant of the dangers



Fig.9.3 This mentally disturbed West African woman was sure her external fixateur was the source of the “bad medicine” that was preventing her fracture from healing and she took the situation into her own hands

Fig. 9.4 (a) This young Sierra Leonean man had been treated by a tradition healer for a couple of months before he arrived in an NGO hospital septic, anorexic, and malnourished with pus draining from his axillary lymph nodes and a mummified hand and forearm. (b) His arm when unwrapped in the operating room. The surgeon performed an open shoulder disarticulation with delayed primary closure 1 week later. (c) Patient a few months later



is sorted out differently when one lives on a dollar a day. The limitations within the local system seem endless and unexpected—of beds, operating time, dressing gauzes, and anesthesia. The brand new hospital constructed with aid money is already falling apart; the hospital has instruments to treat spinal fractures but no soap. Time is fluid and drags due to inexplicable delays. Learning to cope with such dissonance can be frustrating, but it can also be the most interesting aspect of volunteering in austere environments. At all levels, the local doctors know the limits; follow their advice.

Traditional Healers

The practices of traditional healers, bonesetters, and witch doctors, and the beliefs that make them a major contributor to medical care globally, are

very much a part of orthopedics in the developing world. Hospital-based surgeons see the mishaps of traditional bonesetters in the form of mal-unions and nonunion of fractures and at its most extreme, bonesetter's gangrene (Fig. 9.4). They also see their own patients leave the hospital to be treated by traditional methods. It is important to realize that the majority of orthopedic patients seeking traditional care unite their fractures and heal their injuries, though maybe not as well as we think we could have done (Fig. 9.5). People patronize traditional bonesetters because they are local and readily available, are less expensive than care in a government or private hospital, and are known and trusted entities that satisfy the patient's and the patient's family's cultural beliefs. Fear of amputation is another reason people seek care from traditional healers instead of hospitals [2].

Fig. 9.5 An Afghan traditional bonesetter made this comfortable and purposeful splint for a closed tibia fracture

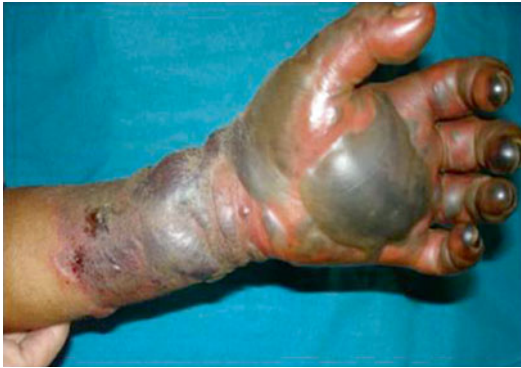
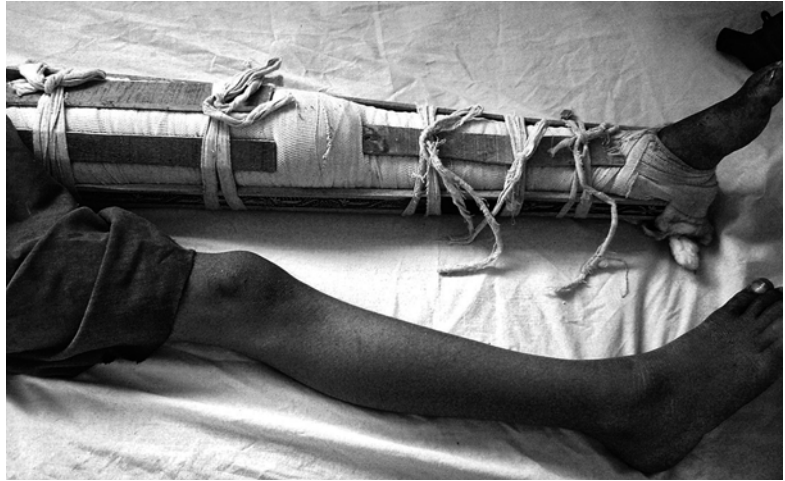
Fig. 9.6 The devastating results of a splint applied too tightly

Bonesetter methods are similar in many different settings and rely on immobilization with or without manipulation, achieved with a splint of bamboo or wood, which is applied tightly to the extremity with cloth or rope. Traditional bonesetters don't often recognize the damage caused by tight splints or how to deal with increasing pain after their application (Fig. 9.6). Herbs, powders, or unguents that irritate and blister the skin may be used as a dressing under the splints (Fig. 9.7) and heat is a common element in traditional treatments. Recognizing the cultural barriers, some enterprising surgeons have lowered amputation rates with short courses aimed to educate and share ideas with traditional bonesetters [3].

Some traditional methods such as scarification, rubbing metal on the skin to induce inflammation, or cupping are common throughout the world in

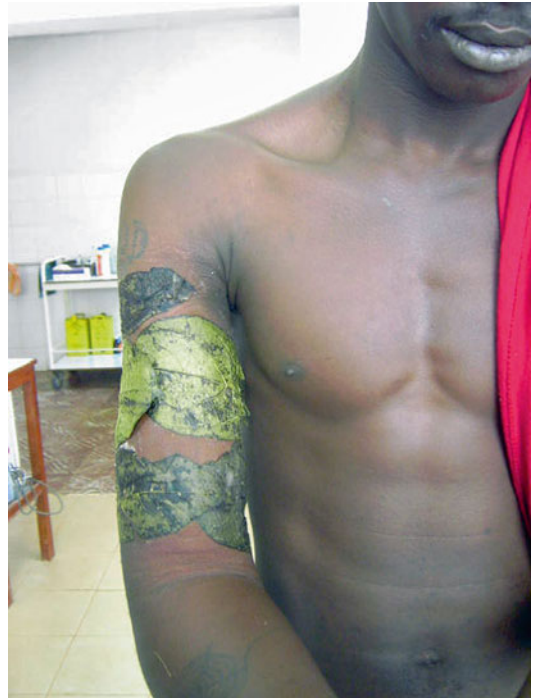

Fig. 9.7 Medicinal leaves wrapped around a fractured humerus were uncovered when the bamboo "Chinese splint" was removed

dealing with aches or pain (Fig. 9.8). Local plants or ash from plants is often used in conjunction with these physical modalities. Some patients try to hide that they first sought consultation from a traditional healer; others are open and freely discuss the efficacy of the treatment.

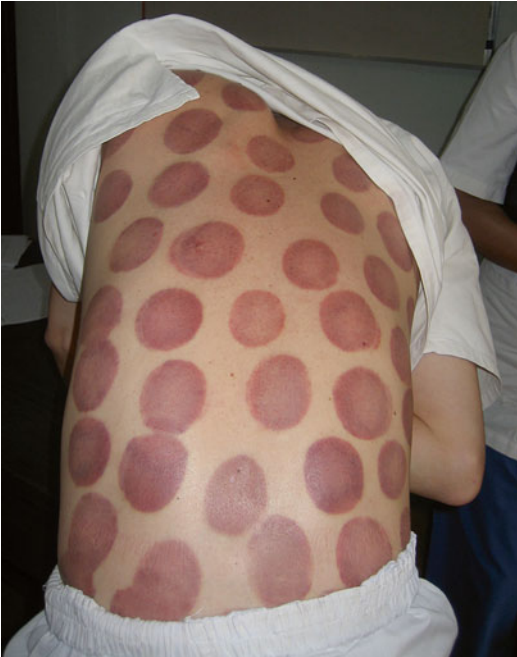

Fig. 9.8 The discolored cupping welts on the back of a Cambodian surgical trainee after he sought care from a traditional healer for nonspecific complaints of malaise

Traditional medicines—like all treatment modalities—rely on the faith that both the patient and healer bring to the situation. It is normal to be sickened at the sight of a child's dead arm because of a bandage applied too tightly and for too long, but there are many treatments that do little harm. Think of Western patients who increasingly use the unproven remedies that make alternative medicine a multibillion dollar business. Remain open. We are there to help, not to judge.

Reverse Culture Shock

Preparing for culture shock on return to one's home might seem nonsensical, but volunteers often talk about the unexpected disorientation and irritation that overtakes their homecoming—reverse culture shock. The adrenaline that made the foreign situation uniquely immediate is no longer present. The few weeks learning to work within limitations and find solutions have been lived fully and much was learned. Few friends or colleagues at home will understand the experience or how and why it left such an indelible impression. The old life seems dull and superficial, maybe too easy. A similar adjustment of attitudes and acceptance that allowed one to work in an austere environment will smooth the way home and in turn prepare one for the next volunteer opportunity.

References

1. Oberg L. Culture shock and the problem of adjustment to new cultural environments [Internet]. 2012. Available from: http://www.worldwide.edu/travel_planner/culture_shock.html. Cited 14 July 2012.
2. Ogunlusi JD, Okem IC, Oginni LM. Why patients patronize traditional bone setters. *Internet J Orthop Surg* [Internet]. 2007;4(2).
3. Eshete M. The prevention of traditional bone setter's gangrene. *J Bone Joint Surg Br*. 2005;87(1):102–3.

Suggested Reading

Walker G. Traditional healers—how can we improve their treatments? *SICOT e-Newsletter* [Internet]. 2012;(49). Available from: <http://www.sicot.org>. Cited 21 Dec 2012.

Part II

General Clinical Topics

Michelle Foltz and Richard A. Gosselin

Chronic Diseases or Illnesses

The self-reinforcing constellation of the chronic noncommunicable diseases and conditions – diabetes, obesity, hypertension, and respiratory and cardiac disease – that adversely affect the management of orthopedic conditions in high-resource countries present more varied and complex problems in the developing world. Besides occurring at a younger age and being poorly controlled, patients may not be aware of the extent of their medical problems, may fail to understand the need for long-term medication to control the pathology, or may not have the resources to buy necessary drugs. The expensive tests, therapies, and consulting expertise found in Western health systems to prepare patients for elective surgery are lacking in resource-poor settings. Managing trauma in the face of unaddressed and unmanaged comorbidities can transform already complicated situations into complex life-threatening ones [1, 2].

Western diet, a sedentary urban lifestyle, and increasing longevity due to improvements in

public health contribute to the ongoing increase in cardiac disease. The greater availability of antibiotics, even when inappropriately used, has seen a decrease in rheumatic heart disease, but it still remains a relatively common medical problem in developing countries, especially among the young and young adult populations. Unrecognized diminution in cardiac reserve and the lack of drugs outside the basics can compromise anesthesia and recovery.

Seventy percent of the over 280 million people with diabetes live in low- and middle-income countries (LMICs). It is one of the fastest growing chronic diseases, both in incidence and prevalence. The majority is type II diabetes, often undiagnosed for years leading to the additional burden of diabetic retinopathy, renal disease, and neuropathy that compromise orthopedic outcomes [3].

The world's burden of chronic respiratory disease falls disproportionately among the poor in developing countries. Households that depend on open fires for food preparation often have poor ventilation, or the fuel incompletely combusts, causing high levels of chronic indoor particulate and toxic chemical pollution. Growing levels of air pollution in urban areas – caused by an increase in motorized transport, traffic jams of idling cars, spewing fumes from poorly tuned vehicles, using inadequately processed petrol – increase the amount of low-grade, unaddressed chronic pulmonary pathology that can increase postoperative complications [4].

Ophthalmologic disease is widespread in developing countries and is often unrecognized

M. Foltz, MD (✉)
172 Stillwater Loop Road,
Columbus, MT 59019, USA
e-mail: michellefoltz@gmail.com

R.A. Gosselin, MD, MPH, MSc, FRCS(c)
Department of Orthopedic Surgery,
Institute for Global Orthopedics and Traumatology,
UCSF, 1001 Potrero Ave, 3A-36,
San Francisco, CA 94110, USA
e-mail: froggydoc@comcast.net

or untreated. Trachoma, a highly contagious Chlamydia infection scarring eyelids, cornea, and conjunctiva, is endemic in many parts of the developing world and, like most infectious diseases, is associated with poor sanitation and hygiene and disproportionately affects the poor. With an increase in both life span and the incidence of diabetes, untreated cataracts are a common cause of blindness or poor vision. Many public health systems lack formal visual screening programs.

Many public health workers consider tobacco as the number one health problem in the developing world. Its association with the increased incidence of cardiac and respiratory diseases and diabetes makes it a particularly lethal problem. Few smokers in developing countries fully understand the deleterious health effects of tobacco. Governments have little money or incentives for education campaigns and “Big Tobacco” actively lobbies to limit anti-smoking legislation or proposed tax increases that could potentially curb tobacco use. The idea that smoking adversely affects a wide range of health issues, including fracture healing, is laughable to many smokers in developing countries [5].

Nutrition

Malnutrition is difficult to assess clinically. Even in families with apparently well-nourished or frankly obese individuals, some members, especially women and children, may have unrecognized severe malnutrition. The deficiencies can be in calories, protein, vitamins, micronutrients, or any combination. Few developing country laboratories are equipped to sort out the specific deficiencies, while supplements may be beyond the means of the system and the individuals. Eating is highly cultural with certain food combinations prohibited or prescribed for the sick and ill that may not conform with a Western-trained physician’s idea of proper nutrition. High-protein meals are recommended for trauma and burn patients and those with catabolic complications. Multiple trauma patients can require up to 6,000 cal/day. Families should be encouraged to provide supplemental proteins and calories in the form of eggs, milk products, meat, and legumes.

Deficiencies in vitamin D and calcium leading to osteoporosis and osteomalacia are common in women, including young women, living in societies that demand all parts of the body be covered. Osteoporosis is further compounded in the same populations by restrictions of physical activity. The lack of safe streets and areas for exercise further enforces a sedentary lifestyle among the growing middle class. Walking for exercise and enjoyment appears to many who have recently purchased a car to be a step backward in personal economic development. Supplemental calcium, vitamin D3, and vitamin C in sufficient and bioavailable doses may improve fracture healing and, if available, should be encouraged. (Rickets is discussed in Chap. 12.)

Some areas have a high incidence of iodine-deficiency goiter, though most such individuals are euthyroid. In severe cases, hypothyroidism may develop and complicate orthopedic treatment.

Anemia and Hemoglobinopathies

Chronic anemia is a widespread problem in developing countries, especially in women following multiple pregnancies and in children after repeated bouts of malaria. A hemoglobin (Hb) level below 6 g compromises the body’s ability to heal acute injuries, infections, and chronic conditions. Such patients require blood transfusions before even minor surgery, such as skin graft. Some surgeons will not do skin grafting if the Hb is below 10 g [6], but more important than the Hb value is the quality of the granulation tissue, itself dependent on good tissue oxygenation. We would not hesitate to skin graft on a good granulation bed with an Hb of 8 g. Organized blood banks may not be present or reliable, making family members a common source of transfused blood, often with only rudimentary cross matching. Local doctors are usually adept at “conjunctivagrams” – correlating the color of the conjunctiva of the lower eyelid with an Hb estimate, or observing the color of the tongue or palm – but a finger-stick Hb is more reliable.

Though hardly a disease, pregnancy as a “comorbidity” needs to be assessed in young

women. The attendant anemia, potential hypertension, and cultural restrictions may complicate orthopedic treatments. It is wise to assume that all women of childbearing age are pregnant and ask a colleague how best to verify this.

Hereditary coagulopathies, such as hemophilia A or B, are severe diseases and not commonly seen in low-income countries, because of the short life expectancy. In middle-income countries, the diagnostic and therapeutic resources may be available for treatment, and one might see a child or adolescent with a musculoskeletal complication, such as a chronic arthropathy, with stiffness or ankylosis. Any procedure, including closed manipulation, is at high risk for complications and should be considered only if hematology expertise is present and replacement factors are available in adequate supply. Milder forms of coagulopathies are often undiagnosed and may present as significant postoperative bleeding [7].

Hereditary hemoglobinopathies such as sickle cell disease or thalassemia are common in LMICs. They are recessive diseases. The heterozygotes are healthy carriers of the trait, which is said to be protective against certain diseases such as malaria. The many forms of thalassemia are seen in Asia, the Middle East, and some parts of Africa. They are relevant to orthopedic care only because they are associated with chronic anemia. Sickle cell disease on the other hand has significant, sometimes dramatic musculoskeletal manifestations. It is common in West Africa and to a lesser degree around the Mediterranean basin. It should be part of the routine differential diagnosis for musculoskeletal pain and/or infection.

Sickle cell crisis manifests with acute abdominal and/or long bone pain, which can be multifocal and severe. Both proximal humerus and femur and vertebrae are common sites, leading to avascular necrosis with degenerative joint disease or acute and subsequent chronic osteomyelitis, usually with a visible sequestrum on x-ray. The differential diagnosis between a sickle crisis and acute osteomyelitis is not easy, especially in children. In general, acute osteomyelitis will give a slightly higher fever and a more elevated white count. Older patients who have had crises before can usually say if their symptoms are the same or different compared to previous episodes.

The cornerstones of treatment are transfusion for anemia and aggressive PO or IV hydration. If there is no significant improvement at 24 h, empirical use of antibiotics should be considered. X-ray changes are late findings and the decision to decompress a suspected infection should be based on other factors (see Chap. 29).

Sequestrectomy, after correction of the anemia, is the treatment of choice for chronic osteomyelitis in association with sickle cell disease. We have found no evidence in the literature to support the idea that use of a tourniquet will precipitate a crisis [8]. We have undoubtedly and unknowingly performed many procedures on sicklers using a tourniquet without obvious deleterious effects. The benefits of a clear and dry field outweigh the risks, if any, in our opinion.

Infectious and Parasitic Diseases

High incidences of hepatitis A, B, and C are found in many developing countries leading to acute and chronic liver disease that may impinge on healing orthopedic injuries and infections. Poor sanitation and lack of controls regarding food processing lead to hepatitis A. A history of widespread, poorly controlled past public health policies that allowed programs to reuse unsterilized needles for vaccinations and injections have spread hepatitis B and C.

The patterns of incidence for HIV/AIDs (see Chap. 15), the hepatitises, and TB (see Chap. 33) vary among countries and even within the regions of a country. One's local colleagues should be able to give an idea of prevalence and specific signs and symptoms to help make these diagnoses.

Over half a billion of the world's people are infected with malaria. The plasmodium species account for between one and two million deaths per year, primarily in children under 5 years. The stress of trauma and/or surgery may set off a recurrence of the chronic illness. Patients who have had previous episodes will often self-diagnose their condition. Malaria should be considered in the differential for any fever in endemic areas, but it is mandatory that postoperative wound infection be ruled out as a cause of fever even while treating the parasite. As with TB, the

diagnosis of malaria requires some human and laboratory resources that are not always available. The tests yield a fair number of false negatives and it is common for local providers to start malaria treatment without a confirmed diagnosis. A rapid clinical improvement is a reliable sign that the diagnosis is correct.

Parasitic helminths are widespread and highly correlated with poverty, poor community sanitation, and ignorance of hygiene. 1.3 billion people worldwide have *Ascaris* infestation [9]. Even moderate infections in children can lead to undernutrition. Over 20,000 people per annum, primarily children, die of such infestations, usually due to bowel or biliary obstruction. The prevalence of hookworm stands at one billion and is a common cause of anemia due to chronic blood loss from the intestine [9]. These and other roundworm infestations are treated with a short course of albendazole or mebendazole. In highly endemic areas, routine treatment on admission may be warranted.

The blood fluke causing schistosomiasis is endemic in the bodies of still freshwater of many tropical and subtropical developing countries. Two hundred million people worldwide are infected with over 20 million having chronic illness due to persistent infection or irreversible damage to the GI and GU systems [9]. A large proportion of those infected are aged 14 and under. It is rated the second most important socioeconomic/public health problem after malaria and can compromise orthopedic treatment.

Other Comorbidities

Alcohol and mind-altering drugs are a growing problem in LMICs, because of an increase in disposable income. Alcohol is known to interfere with fracture healing and cocaine is well known to cause anesthetic complications. The local substance of preference may be one that is unfamiliar to a visiting surgeon, producing a confusing constellation of signs and behaviors, especially in the face of shock and trauma. The local emergency room or outpatient department

personnel will usually have experience with specific local products and are the best source of information. Substance abuse is highly associated with both non-intentional injuries, such as road traffic injuries, and intentional injuries caused by violence. It is estimated that worldwide around 15 % of the burden of trauma is alcohol related, even higher in certain areas [10]. Complications of chronic alcoholism, such as clotting disorders or withdrawals, should be kept in mind when preparing for surgery.

In some populations, gout is a significant problem leading to severe disability. Tophi in unusual areas and inflammation masquerading as soft tissue infection or osteomyelitis can make diagnosis difficult, especially during a perioperative flare-up.

Though diabetes is rapidly becoming the world's leading cause of peripheral neuropathy, in tropical and subtropical areas where leprosy is common, it is still a significant source of hand and foot deformity due to motor loss and imbalance and sensory loss (see Chap. 11).

Some populations are predisposed to dental caries due to the mineral composition of their teeth or the limitations of diet, which when combined with poor oral hygiene can lead to severe periodontal infections which may seed operative or injury sites. Loss of teeth or loose teeth interferes with adequate nutrition. Although outside the realm of orthopedics, tooth abscess may lead to maxillary or mandible osteomyelitis. Basic knowledge of tooth extraction and drainage of facial bone infections can come in handy in areas where resources are limited.

Populations in developing countries are not immune to depression. According to the World Health Organization, major unipolar depression is a significant contributor to the global burden of ill-health. Dealing with a limb- or life-threatening orthopedic disease or injury is stressful even though patients may not display depression in ways Western surgeons are used to. Local health staff can identify such patients and help provide culturally sensitive care and counseling.

Many patients will not be aware of having comorbidities that can complicate their orthope-

dic management or know that past illnesses have left residual health problems. Besides the chronic systemic impairments common in high-resource medical practice, many of the comorbidities are tropical diseases for which most volunteers will have little experience. Many of these conditions have characteristic clinical presentations, making it especially important to complete a thorough exam, including a diligent dermatological inspection. Diseases such as leishmaniasis, Chagas disease, hydatid disease, typhoid fever, and amebiasis may be common in limited areas. Ask the local doctors what coexisting morbidities they typically encounter, the clinical presentations, and how they are best treated.

References

1. The maladies of affluence—globalization and health. *The Economist*. 11 Aug 2007. p. 49–50.
2. Growing pains – chronic diseases in developing countries. *The Economist*. 24 Sept 2011. p. 72–3.
3. Hossain P, Kowar B, El Nahas M. Obesity and diabetes in the developing world—a growing challenge. *N Engl J Med*. 2007;356:213–5.
4. Ait-Khaled N, Enarson D, Bousquet J. Chronic respiratory diseases in developing countries: the burden and strategies for prevention and management. *Bull World Health Organ*. 2001;79(10):971–9.
5. How to save a billion lives—smoking. *The Economist*. 9 Feb 2008. p. 65–6.
6. Agarwal P, Prajapati B, Sharma D. Evaluation of skin graft take following post-burn raw area in normovolaemic anaemia. *Indian J Plast Surg*. 2009;42(2): 195–8.
7. Rodriguez-Merchan EC, Herim M. Hemophilia orthopedic management with emphasis on developing countries. *Semin Thromb Hemost*. 2005;31(5): 518–26.
8. Fisher B, Roberts CS. Tourniquet use and sickle cell hemoglobinopathy: how should we proceed? *South Med J*. 2010;103(11):1156–60.
9. Pearson RD. *The Merck manual*. 19th ed. Whitehouse Station: Merck Sharp & Dohme Corp.; 2011. Nematodes and Trematodes; p. 1343, 1348, 1358.
10. Shield KD, Gmel G, Patra J, Rehm J. Global burden of injuries attributable to alcohol consumption in 2004: a novel way of calculating the burden of injuries attributable to alcohol consumption. *Popul Health Metr*. 2012;10(1):9.

Richard A. Gosselin, Stephen W. Bickler,
and Ali A. Ahmed Al-Iedan

Introduction

Some musculoskeletal diseases and conditions are seen almost exclusively in tropical environments. This is due to the tropical climate but also to associated conditions such as poverty, malnutrition, or overcrowding [1, 2]. Although “tropical medicine” is often considered synonymous with “tropical infections,” a broader scope includes all ill effects on health from exposure to a tropical environment. The majority of western surgeons will have had little exposure to most of these conditions during their training.

As with other conditions discussed in this book, most patients will present in advanced stages of disease, and diagnostic resources will be limited. Local surgeons and other providers are usually knowledgeable about conditions endemic to their area, and seeking their input in the diagnosis and

management is crucial. The following is a brief overview of orthopedically relevant tropical diseases and conditions one might encounter. They will vary across geographic areas, sometimes even according to seasons.

Bacterial Infections

The bacteria that commonly cause bone, joint, and soft tissue infections are the same all over the world for the same age groups; however, volunteers might encounter unfamiliar presentations of familiar infections and infections caused by unusual organisms.

In many places, cultures and sensitivity, even Gram stains, are unavailable or unreliable or may take such a long time to obtain that they serve little use. Antibiotic therapy is often dictated as much by what is available as what is efficient and often started empirically [3]. Although newer antibiotics such as the quinolones are available worldwide, in many places older antibiotics such as chloramphenicol, cloxacillin, and ampicillin, which are not widely used in high-resource settings, are still commonly employed. Hospitals have oversight on the quality of antibiotics they purchase, but outside “pharmacies” often provide cheaper medications of indeterminate quality. One must assume that most patients will not be fully compliant, stopping their medication as soon as they feel better, and keeping the rest for “later.” So it is not uncommon to see a patient return to the outpatient clinic who is not “responding well” to treatment.

R.A. Gosselin, MD, MPH, MSc, FRCS(c) (✉)
Department of Orthopedic Surgery,
Institute for Global Orthopedics and Traumatology,
UCSF, 1001 Potrero Ave, 3A-36,
San Francisco, CA 94110, USA
e-mail: froggydoc@comcast.net

S.W. Bickler, MD, DTM&H, FACS
Pediatric Surgery, Rady Childrens Hospital,
University of California San Diego,
3030 Children’s Way Suite 107,
San Diego, CA 92123, USA
e-mail: sbickler@ucsd.edu

A.A.A. Al-Iedan
Orthopedic Surgery, Basrah General Hospital,
Saad Ameen Street, Al Baradgia, Basrah, Iraq
e-mail: draliedan@yahoo.com

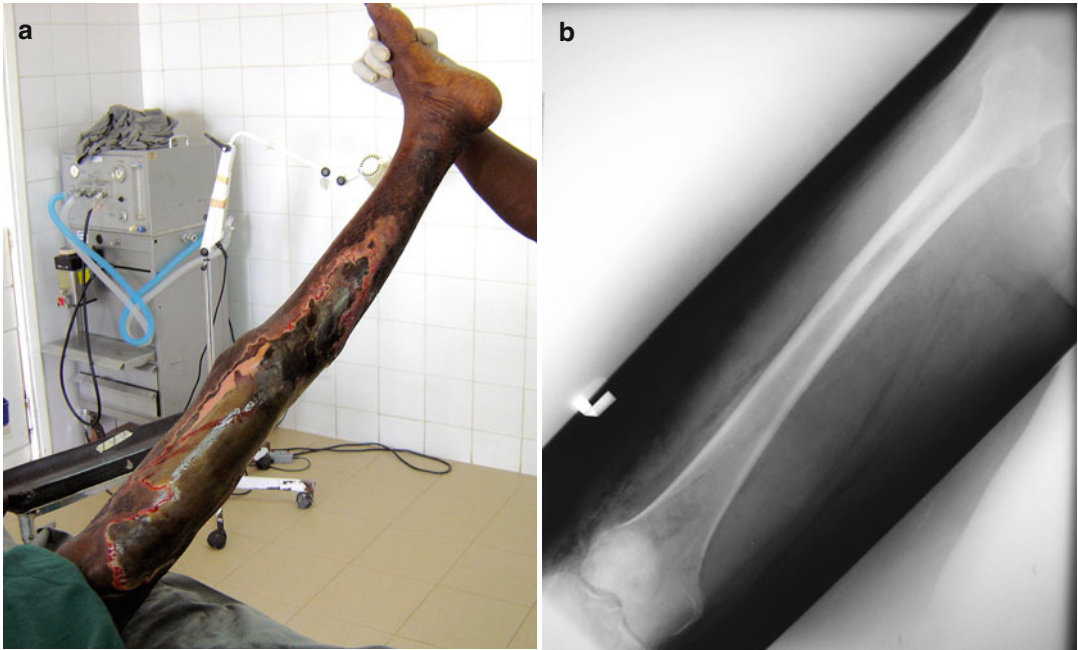


Fig. 11.1 (a) Gas gangrene involving the entire lower extremity of the young male patient who died of sepsis shortly after hip disarticulation. (b) X-rays show gas in the soft tissues and dissecting between muscle planes

Gas Gangrene

Gas gangrene most commonly results from a wound infected by *Clostridium perfringens*, a Gram-positive anaerobic bacillus, but also, on occasion, from some group A streptococci (so-called flesh-eating disease) or *Staphylococcus aureus* (Fournier's perineal gangrene). A high index of suspicion is necessary for the rare patient seen in the early stages of a foul-smelling, crepitating wound, when aggressive surgical debridement might still be limb or life saving. Whether the underlying pathology is a necrotizing myositis, fasciitis, or dermatitis is clinically irrelevant. They all need surgery, and high doses of penicillin, combined with clindamycin if available. Metronidazole, chloramphenicol, and rifampin are acceptable second choices. Most patients present late, with severe systemic manifestations, extensive limb involvement, and only a proximal amputation or disarticulation may be lifesaving (Fig. 11.1). If the infection reaches the trunk, only palliative measures are indicated (Fig. 11.2).

Tetanus

Tetanus is not a surgical condition per se, but it is surprisingly common in many parts of Africa, and a volunteer may have to help with the medical management. The inoculation of the spores of *Clostridium tetani*, another Gram-positive anaerobic bacillus, in a wound causes the release of the neurotoxin, tetanospasmin. The adult form occurs after contamination of a traumatic wound and the neonatal form comes from indigenous umbilical cord dressings made with mud or dung. In the adult, the disease appears after a 1–3 week incubation period. One of the first signs is trismus or lockjaw, which should alert the clinician to the underlying diagnosis. This progresses rapidly to more generalized contractions (tetani) and systemic involvement with mortality around 30 % if untreated (Table 11.1).

In the newborn, incubation is 3–7 days. Generalized contractions appear after a period of irritability and inability to suckle. Mortality is above 70 % if untreated [4]. Treatment for both

Fig. 11.2 Extensive gas gangrene of the entire left upper extremity of an elderly woman, with visible typical copper discoloration of the skin extending to the supraclavicular area. Even a forequarter amputation would not have saved her life

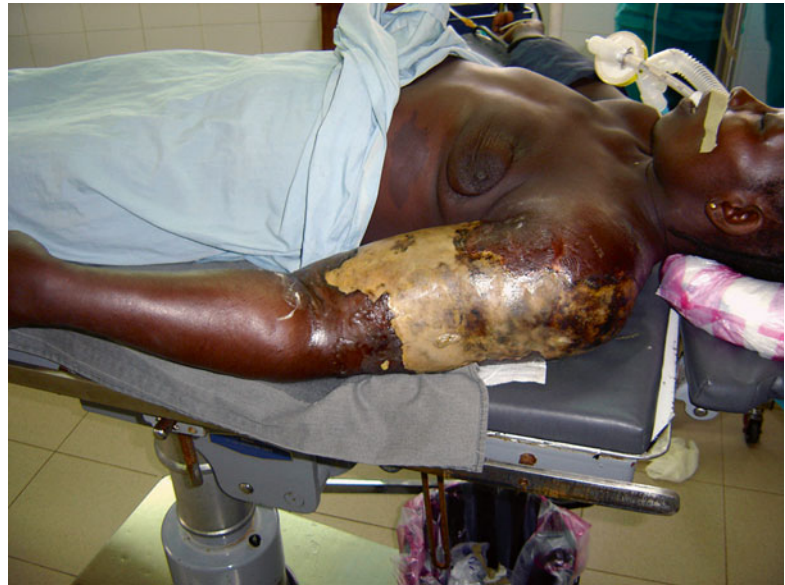

Table 11.1 Management of tetanus-prone wounds

Types of wounds likely to favor the growth of tetanus organisms include:

- Compound fractures
- Deep penetrating wounds
- Wounds containing foreign bodies (especially wood splinters)
- Wounds complicated by pyogenic infections
- Wounds with extensive tissue damage (e.g., contusions or burns)
- Any wound obviously contaminated with soil, dust, or horse manure (especially if topical disinfection is delayed more than 4 h)
- Reimplantation of an avulsed tooth is also a tetanus-prone event, as minimal washing and cleaning of the tooth is conducted to increase the likelihood of successful reimplantation

Wounds must be cleaned, disinfected, and, if appropriate, treated surgically

History of tetanus vaccination		Type of wound	Tetanus vaccine booster	Tetanus immunoglobulin
Three or more doses	<5 years since last dose	All wounds	No	No
	5–10 years since last dose	Clean minor wounds	No	No
		All other wounds	Yes	No
>10 years since last dose	All wounds	Yes	No	
<Three doses or uncertain	Clean minor wounds	Yes	No	
	All other wounds	Yes	Yes	

forms of tetanus requires nonspecific supportive measures, including a dark and quiet environment, antibiotic therapy with metronidazole and penicillin, surgical debridement if the patient’s condition permits, and sedation with benzodiazepines. If available, human immunoglobulin should be used; antitoxin is controversial in the neonatal form.

Brucellosis

Brucellosis, caused by aerobic Gram-negative coccobacilli, occurs from contact with animal parts or ingestion of unpasteurized dairy products. One of the disease’s most common manifestations is a monoarticular, chronic, indolent, often severe arthralgia. It also mimics spinal TB

both clinically and radiographically. Treatment is with streptomycin and doxycycline.

Ulcers

Ulcers are annoyingly common in tropical environments [5]. Both *Tropical (phagedenic) ulcers* and *Buruli ulcers* (see next section) are manifestations of infections. Tropical ulcers are seen almost only in adults and occur below the knee [6] (Fig. 11.3). They start frequently after an innocuous injury with a painful indurated patch of skin that becomes a pustule over 5–10 days. When this bursts, a full thickness round or oval ulcer is visible. This grows for 4–6 weeks, at which time, the pain subsides. The borders are regular, without undermining.

The ulcer will either heal on its own over the next weeks to months or become chronic, typically showing a poorly vascularized bed and secondary infection. Late underlying osteomyelitis or carcinomatous degeneration is common. The most common infecting microbe is *Bacillus fusiformis*, but spirochetes are also found. Antibiotics are helpful in the acute phase (penicillin, erythromycin, fluoroquinolones), or to manage secondary infections, but proper wound care using daily nonadherent dressing and sharp removal of necrotic tissue is the cornerstone of treatment. Attention to the patient's nutritional status and treatment of anemia are important adjuncts. Long-standing ulcers require surgical

debridement, often more than once, and split-thickness skin grafting, if and when the bed is adequate. The debridement does not need to be aggressive at the edges as there is little undermining. Many patients live for years with an ulcer, as it is painless and does not affect function. The chronic foul-smelling drainage is a common reason for consultation; by which time, chronic osteomyelitis or squamous cell carcinoma is common and amputation the only option.

Mycobacteria

Tuberculosis is addressed in Chap. 33. The other common mycobacterial diseases are the *Buruli ulcer* and *leprosy*.

Buruli Ulcer

Buruli ulcer is caused by *Mycobacterium ulcerans* (Fig. 11.4). It affects all ages and any body part in children, but primarily the extremities in adults [4, 7, 8]. It usually starts as a painless nodule that progresses rapidly to a painless ulceration. The edges of the ulcer are irregular and always show some undermining, which is often extensive. The skin margins are indurated and the ulcer can progress to involve a significant portion of the limb or trunk. It eventually reaches below the deep fascia and can involve the muscle, tendon, and even bone. Significant deformities and

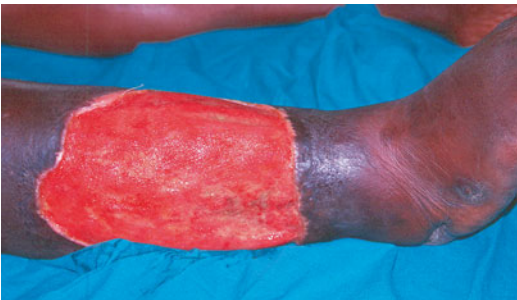

Fig. 11.3 Typical location and appearance of a tropical (phagedenic) ulcer. Note: the edges are not elevated, and the granulation tissue is of poor quality

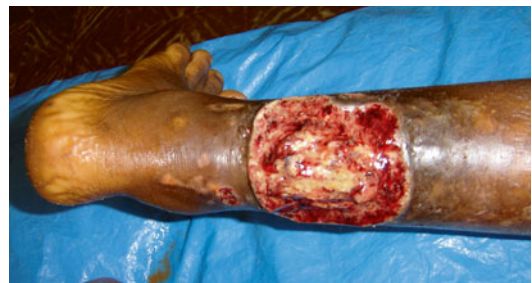

Fig. 11.4 Typical location and appearance of a Buruli ulcer, with elevated edges and centrifugal skin changes

contractures affecting function are common. The earlier treatment is started the more successful it is, making a high index of suspicion important. The WHO recommends 6–8 weeks of rifampin and streptomycin, but surgery is often necessary. The debridement needs to be aggressive, the margins widely excised through healthy skin—at least a couple centimeters beyond the undermining—and the wound later skin grafted. An overly conservative excision almost guarantees a recurrence, with loss of the skin graft. Overall, the results of treating Buruli ulcers are much better than those for tropical ulcers.

Leprosy

Leprosy is caused by *Mycobacterium leprae* and, although in overall decline, is surprisingly common in poor countries, with around 250,000 new cases/year. Historically, and to this date, it carries a high stigma [9]. It is less contagious than TB, but like TB, it is a disease of poverty. Overcrowding, malnutrition, chronic diseases affecting the immune system, and illiteracy are all risk factors. The chronic inflammatory response affects primarily the skin, eyes, and peripheral nerves.

Although infectious in nature, the disease behaves like a chronic, progressive peripheral neuropathy affecting both sensory and motor nerves [10]. Loss of proprioception and temperature sensation combine to create chronic wounds of the hands and feet that lead to secondary infection, necrosis, and in the late stages, amputations. Progressive loss of motor function, particularly in ulnar and median nerves, creates deformities and contractures of the hand (Fig. 11.5). Medical treatment with a combination of rifampicin, clofazimine, and dapsone is highly effective, but many patients present late, with irreversible musculoskeletal sequelae. Surgery can benefit selected patients under medical treatment: nerve transposition or decompression, tendon transfers, or even arthrodeses. Malignant degeneration of chronic lesions most often requires disarticulation at the level of the proximal joint.

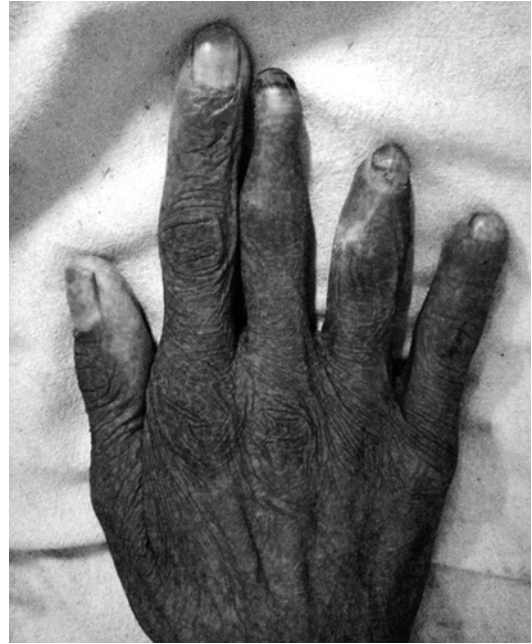

Fig. 11.5 Moderately advanced lepromatous involvement of the ulnar 3 fingers, with classic dystrophic “tapering” (Courtesy of Dr. Sam Baker)

Fungi

Deep soft tissue involvement can be seen with almost all fungal infections, but unless the patient is immunocompromised, bone and joint involvement is rare [11]. Histoplasmosis, candidosis, aspergillosis, cryptococcosis, and coccidioidomycosis should be part of the differential diagnosis of bone infections in HIV-positive patients. The more common fungi that affect musculoskeletal structures are:

Blastomycosis

Blastomyces dermatitidis can present as multifocal soft tissue abscesses and chronic osteomyelitis (Fig. 11.6). Oral itraconazole is the recommended treatment, with surgical drainage if necessary.

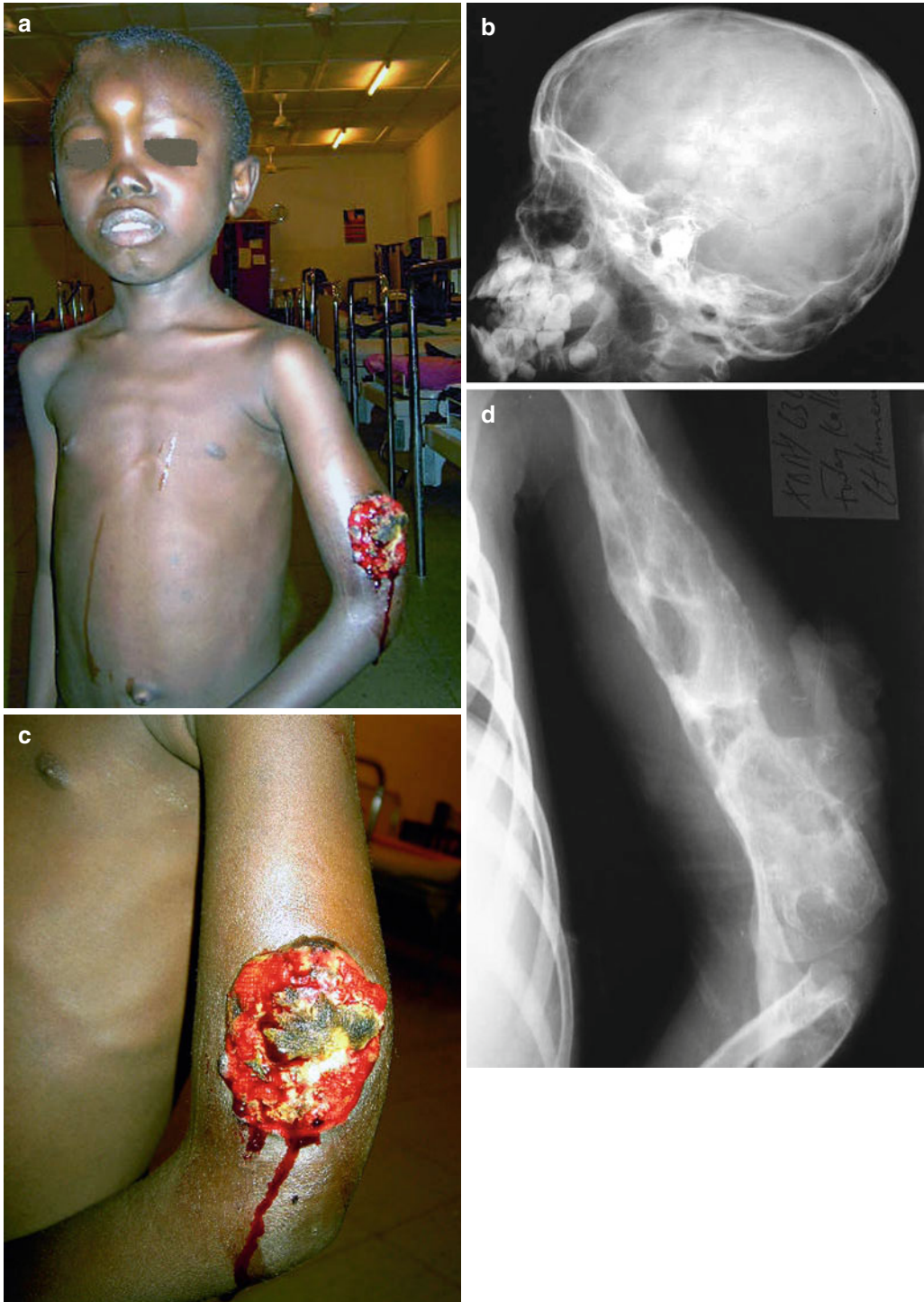

Fig. 11.6 (a) Craniofacial deformity and ulceration of left arm in child with blastomycosis. (b) X-ray of the skull shows no involvement of the frontal bones. (c, d)

and X-ray appearance of chronically ulcerated and fungating lesion secondary to underlying chronic blastomycosis osteomyelitis

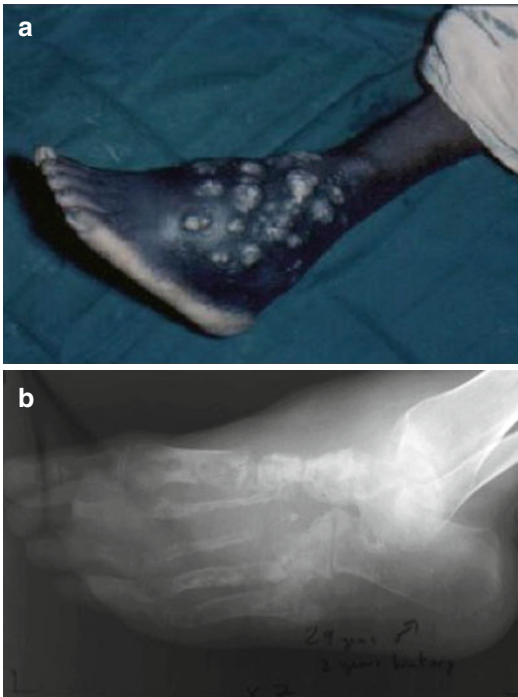


Fig. 11.7 (a) Typical appearance of the left foot, chronically infected with mycetomas (Madura foot), with multiple draining sinuses. (b) X-ray shows advanced destruction of the entire bony architecture of the foot

Mycetoma or Madura Foot

Mycetoma or Madura foot (Fig. 11.7) is a chronic soft tissue infection of the feet, usually seen in male farm workers, most often following a penetrating injury, which culminates in chronic osteomyelitis. Mycetomas are caused by actinomycetes bacteria (actinomycetomas) or fungi (eumycetomas). They are endemic in Africa, the Indian subcontinent, Central America, and northern South America. Lesions can be present for many years. Depending on the severity of the disease and the amount of bone involvement, treatment includes oral itraconazole, surgical debridement, or BKA.

Parasites

As with fungal diseases, parasitic diseases of bones and joints are uncommon, but unlike fungi, they are not as readily associated with immunosuppression. Common forms include:

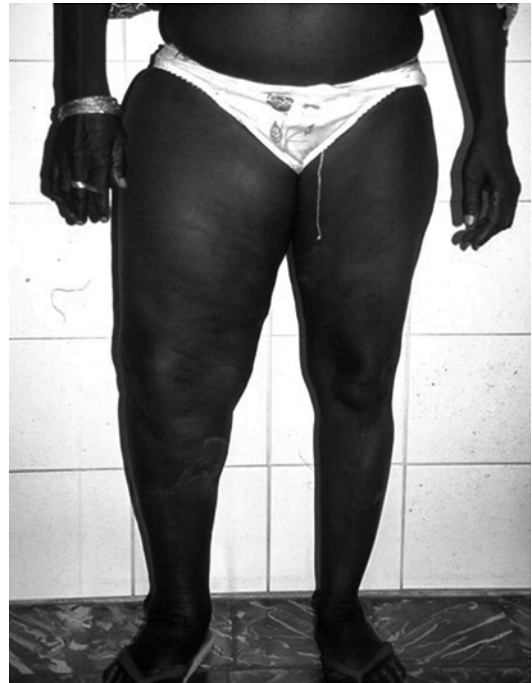

Fig. 11.8 Clinical appearance of chronic lymphatic filariasis involving the right lower extremity

Lymphatic Filariasis

Nematodes (roundworms) are transmitted to humans via insect bites, and the microfilariae eventually shut down the limb's lymphatic return, causing chronic edema and skin thickening, ultimately leading to elephantiasis. In early stages, knee pain is a common symptom, before the lymphatic changes are visible. Medical treatment with a combination of albendazole and ivermectin is curative. Once elephantiasis develops, it is irreversible, but with treatment the condition stops worsening (Fig. 11.8).

Dracunculiasis

Dracunculiasis or guinea worm: The nematode, *Dracunculus medinensis*, infects humans who drink stagnant, larval-infested water. A year later, a painful vesicular lesion appears, most often near or below the knee joint. Eventually it ulcerates, exposing one end of the worm. The only

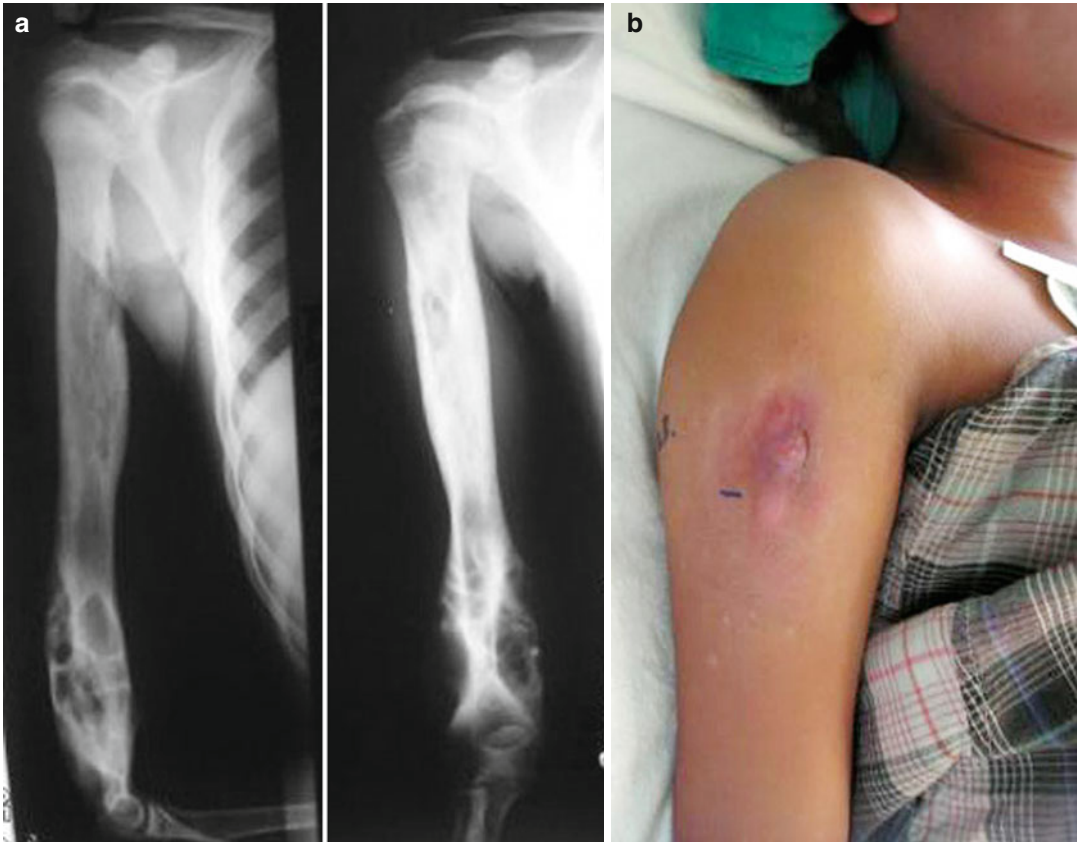


Fig. 11.9 (a) X-ray of hydatid osteomyelitis of the right humerus. (b) Chronically draining sinus of hydatid osteomyelitis

treatment is to wrap the end of the worm around a stick or match and progressively “roll it out.” This painful process can take hours or months. There is no medical or surgical treatment, unless the ulcer becomes secondarily infected, which is not uncommon.

Trichinosis

The parasitic nematode *Trichinella spiralis* is ingested in undercooked or raw pork, game, or bush meat, and forms cysts in striated muscle. Occasionally the cysts cause myalgias, but most are probably asymptomatic. Mebendazole

is the treatment of choice and surgery is rarely needed.

Hydatid Disease (Echinococcosis)

Humans are accidental intermediate hosts that become infected by handling soil, dirt, or animal hair that contains eggs of the tapeworm echinococcus. The musculoskeletal system is rarely targeted, but the polycystic form can create cysts in the metaphyses of long bones (Fig. 11.9). Medical treatment with mebendazole is usually sufficient, but cysts jeopardizing the structural integrity of the bone need to be curetted and bone grafted.

Venomous Injection Injuries

The musculoskeletal system can also be involved with venomous bites or stings—of varying degrees of severity—from snakes, lizards, fish, marine invertebrates, scorpions, spiders, and insects (Fig. 11.10). Local providers are usually experienced in these matters and their advice should be sought and followed. Envenomation by snakebite in particular can be life or limb threat-

ening, and knowing the type of snake is helpful. Not every snakebite requires surgical debridement or fasciotomy, so a careful clinical examination is of utmost importance. In doubt, it is better to decompress than miss a treatable compartment syndrome. However, there is no indication to decompress the muscles of a patient who presents late, with a well-established compartment syndrome of 2–3 days. This only creates wounds that will become infected.

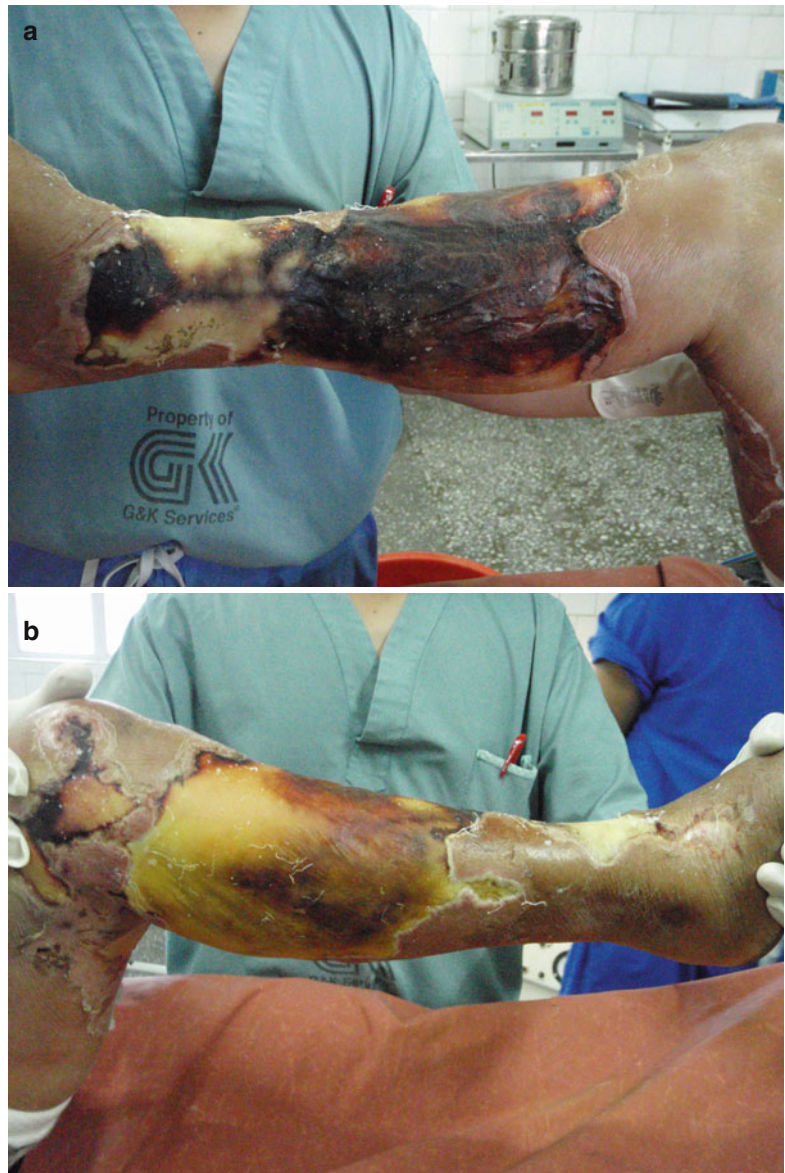
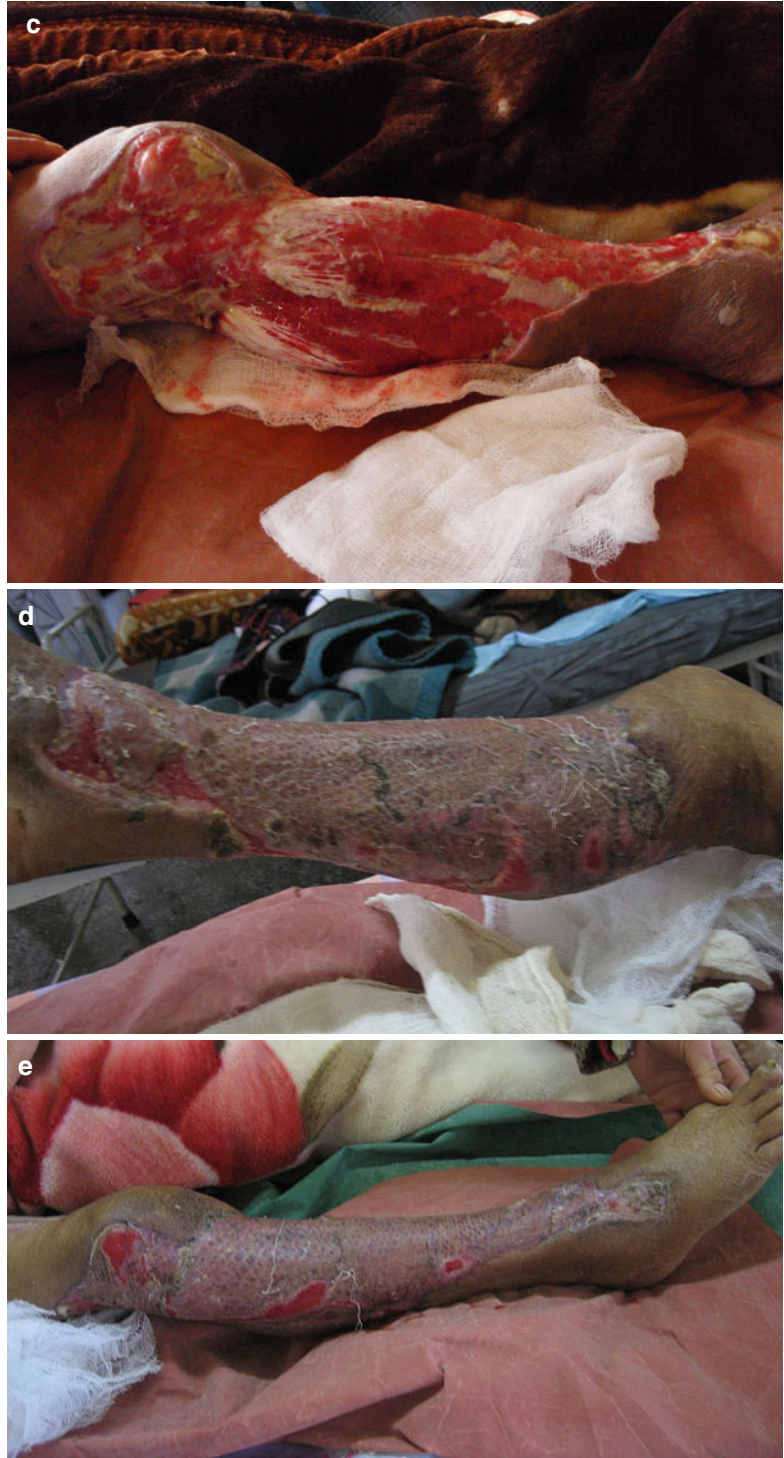
Fig. 11.10 (a, b) Clinical appearance of a progressive necrotizing dermatitis in an elderly Bhutanese woman about a week after being bitten by a spider. (c) Appearance of the leg after multiple debridements. (d, e) Leg after extensive meshed STSGs (Courtesy of Dr. Sam Baker)

Fig. 11.10 (continued)



References

1. Hotez PJ, Fenwick A, Savioli L, Molyneux DH. Rescuing the bottom billion through control of neglected tropical diseases. *Lancet*. 2009;373(9674):1570–5.
2. Hotez PJ, Molyneux DH, Fenwick A, Kumaresan J, Sachs SE, Sachs JD, Savioli L. Control of neglected tropical diseases. *N Engl J Med*. 2007;357(10):1018–27.
3. Lupi O, Madkan V, Tying SK. Tropical dermatology: bacterial tropical diseases. *J Am Acad Dermatol*. 2006;54(4):559–78.
4. Bickler S, Ameh E. *Surgical care for children*. Macmillan Publications; London, England. 2011.
5. MacDonald P. Tropical ulcers: a condition still hidden from the western world. *J Wound Care*. 2003;12(3):85–90.
6. Robinson DC, Adriaans B, Hay RJ, Yesudian P. The clinical and epidemiologic features of tropical ulcers (tropical phagedenic ulcer). *Int J Dermatol*. 1988;27(1):49–53.
7. Merritt RW, Walker ED, Small PL, et al. Ecology and transmission of Buruli ulcer disease: a systematic review. *PLoS Negl Trop Dis*. 2010;4(12):e911. Published online 2010 December 14.
8. Radford AJ. The surgical management of lesions of ulcerans infections due to mycobacterium ulcerans. *Trans R Soc Trop Med Hyg*. 2009;103(10):981–4.
9. van Brakel WH, Sihombing B, Djarir H, et al. Disability in people affected by leprosy: the role of impairment, activity, social participation, stigma and discrimination. *Glob Health Action*. 2012;5.
10. Van Brakel WH. Peripheral neuropathy in leprosy and its consequences. *Lepr Rev*. 2000;71(Suppl):S146–53. Review.
11. Meier JL, Beekmann SE. Mycobacterial and fungal infections of bone and joints. *Curr Opin Rheumatol*. 1995;7:329–36.

J. Norgrove Penny

Introduction

Angular deformities of the lower limbs are very common in pediatric orthopedic practice in lower-income countries. In a cross-sectional population-based study performed in Rwanda, angular deformities of the lower limbs were the most common cause of musculoskeletal impairment in children [1]. Limited access to services and delayed treatment often result in severe deformity not commonly seen in higher-income countries (Fig. 12.1). The prevalence is increased in certain geographic locations, particularly rural environments, and raises the question of a nutritional or genetic cause. But few epidemiologic studies have been done. Deformities can originate at the physis, metaphysis, or diaphysis and include genu varum, genu valgum, and wind-swept deformities. Practitioners must identify the etiology of the deformity prior to planning limb realignment.

Differential Diagnosis

The differential includes (1) posttraumatic or post-infectious, (2) Blount's disease, (3) vitamin D-resistant rickets, (4) nutritional (calcium

deficiency) rickets, (5) skeletal dysplasias, and (6) idiopathic.

Posttraumatic or Post-infectious

Inadequate access to primary treatment of osteomyelitis and fractures results in diaphyseal malunion or deformity, or asymmetric physal arrest (Fig. 12.2). The deformity is almost always unilateral and often accompanied by leg-length discrepancy.

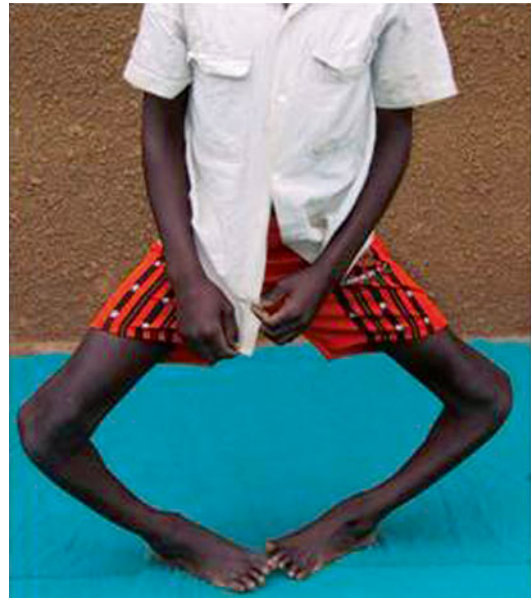

Fig. 12.1 Severe genu varum deformities from Blount's disease

J.N. Penny, MD, FRCS(C)
Department of Orthopaedic Surgery,
University of British Columbia, Vancouver, Canada
e-mail: norgroveanne@hotmail.com

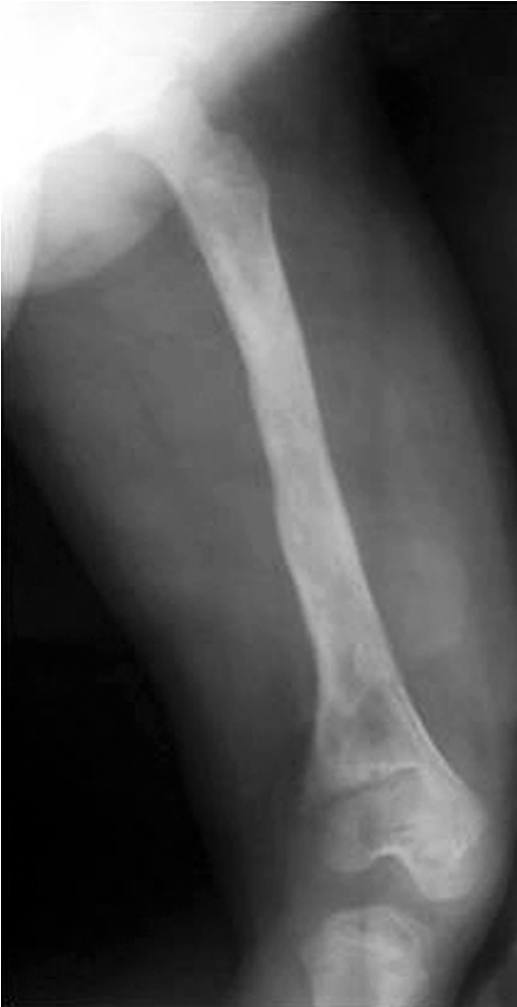

Fig. 12.2 Healed osteomyelitis of the femoral diaphyses with physeal growth arrest and varus angulation in a 7-year-old

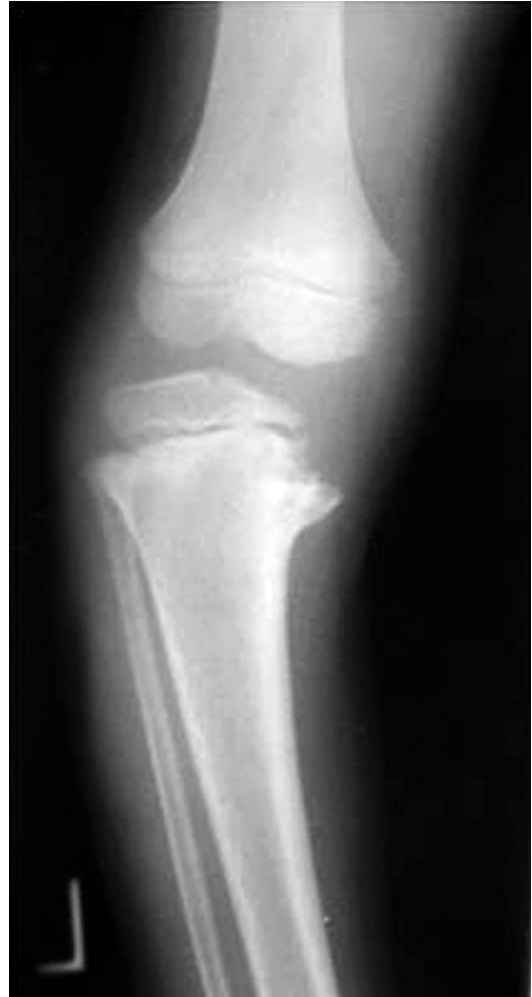

Fig. 12.3 X-ray of a knee with the typical bony changes of Blount's disease: medial tibial physeal changes with adaptive valgus at the distal femur

Blount's Disease

This condition is more common in children of African origin and must be distinguished from the Blount's seen in higher-income countries in patients who are obese. It is most commonly bilateral and is seen in both its infantile and adolescent forms. Careful evaluation of the radiograph reveals typical physeal changes confined to the medial half of the proximal tibial physis (Fig. 12.3). The distal femoral physis is often normal, but in some cases an adaptive valgus

deformity of the distal femur is seen. An alternate diagnosis should be sought if varus deformity is seen in the distal femur.

Vitamin D-Resistant Rickets

True vitamin D-deficiency rickets is rare in tropical countries due to the abundant sunlight, but may occur in cultures where children are covered. The more likely etiology is vitamin D-resistant rickets from genetic causes. Children

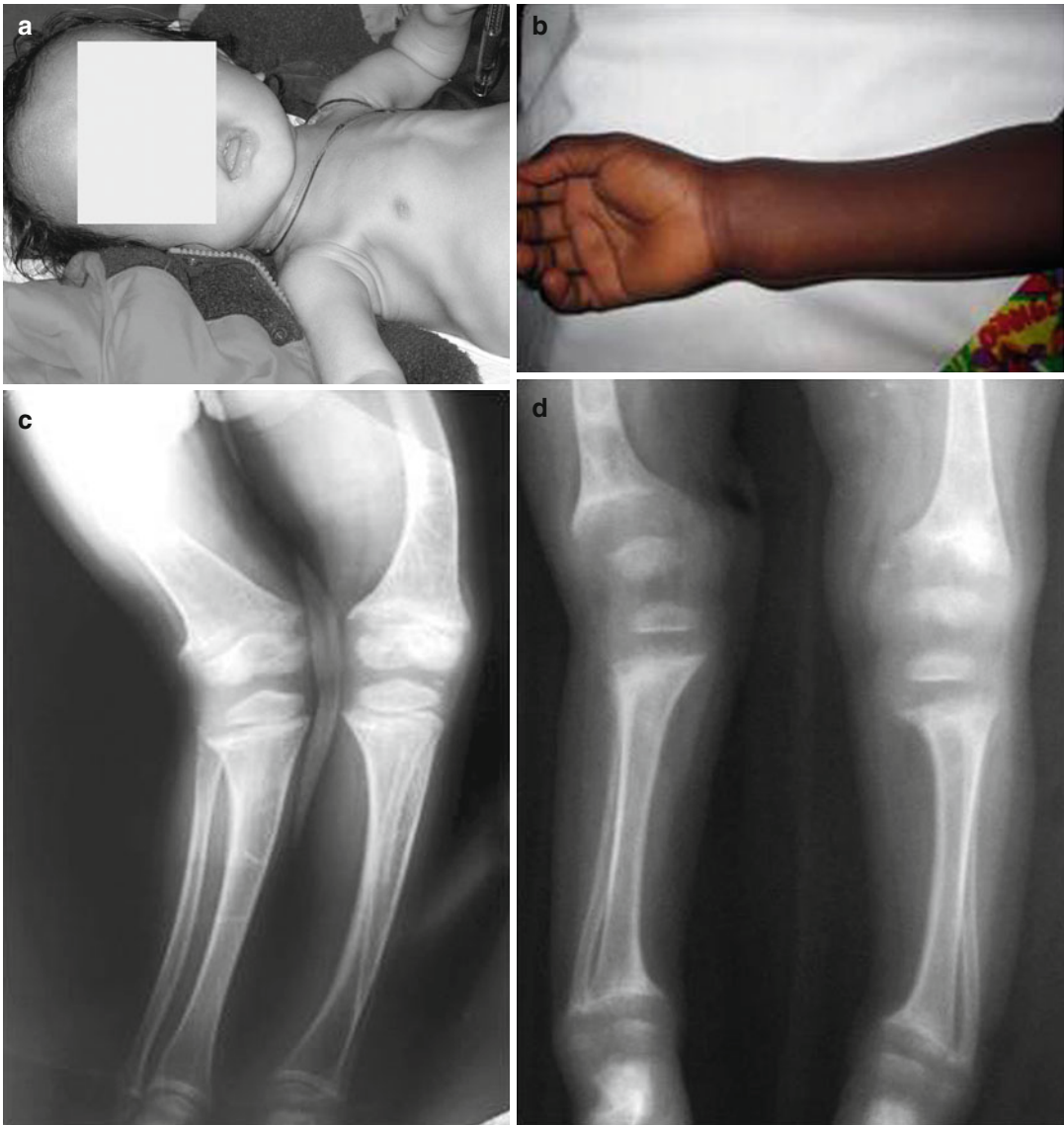

Fig. 12.4 (a) This infant presented with delayed motor milestones and was noted to have swelling at the costochondral junction (“rachitic rosary”). (b) A 4-year-old child with rickets and wrist swelling, a clinical sign of

active rickets, (c) also had bowing of the lower extremities. (d) Classic radiographic findings in rickets include widening of the physes and flaring of the metaphyses

present as toddlers with weakness and delayed walking, angular deformities, and enlarged epiphyses. Enlarged epiphyses are seen at the wrists, ankles, knees, and ribs (rachitic rosary). These children are invariably “sick” and malnourished. Biochemical screening to differentiate nutritional from vitamin D-resistant rickets

should be done if available. All children should be treated with vitamin D and calcium supplements as a trial. Radiographic evaluation reveals widened epiphyses at multiple locations. A wrist x-ray should be taken as other forms of angulatory bone deformity seldom affect the wrist (Fig. 12.4).

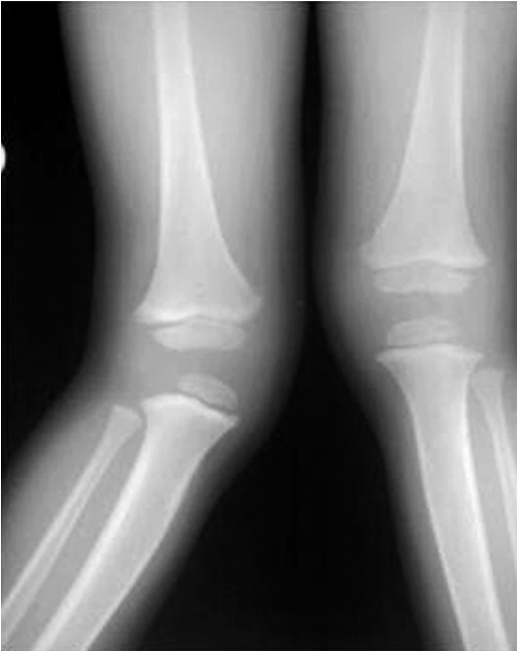

Fig. 12.5 Probable calcium-deficiency rickets in a toddler as angulation involves both the metaphyses and the diaphyses

Calcium Deficiency

Calcium-deficiency rickets, or “nutritional rickets,” is probably the most common cause of angular deformity in lower-income countries, yet is the least understood and is probably underdiagnosed [2, 3]. Many such cases have been classified as idiopathic. Studies in Nigeria, South Africa, Bangladesh, and other countries have elucidated this condition. It is often accompanied by the significant malnutrition of a monotonous carbohydrate diet deficient in micronutrients used as weaning food. It presents as genu valgum, genu varum, or windswept knees. Large deformities are common. Radiographs may show some widening or flaring of the metaphyses, but these changes are not as profound as in vitamin D-resistant rickets. Angular deformities occur in the metaphyses and diaphyses of long bones, especially at the knee. Upper extremity and other weight-bearing joint involvement is rare. The presentation of windswept deformity should create a high index of suspicion of calcium deficiency. Biochemical analysis will be normal (Fig. 12.5).

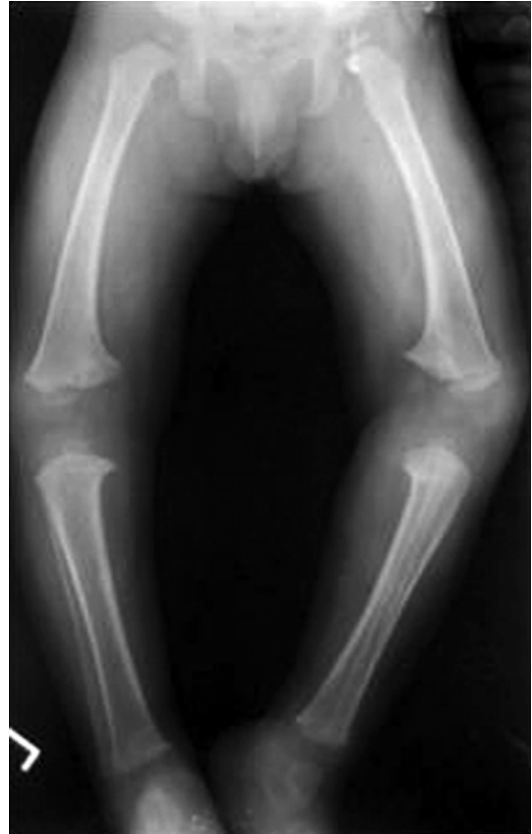

Fig. 12.6 Genu varum in a 3-year-old. Note the abnormal physes and metaphyseal changes at the proximal and distal femur and the proximal tibia. The diagnosis is epi-metaphyseal dysplasia

Skeletal Dysplasias

These are a relatively rare but large and diverse group of genetic disorders, and there is often a positive family history. Patients are typically of short stature, and multiple physes or bones are involved in symmetric fashion (Fig. 12.6). Treatment needs to be individualized with the aim to maintain the mechanical axis.

Idiopathic Deformity

Where none of the above categories can be defined, the condition can be considered idiopathic. These are usually mild deformities and are symmetric genu varum or valgum.



Fig. 12.7 Small whole fish from Uganda. Ground into a paste called *Kitobero* is a weaning food rich in protein, calcium, and vitamin D

Treatment

All children suspected of having a vitamin D or nutritional rickets should be treated by nutritional supplementation including vitamin D and calcium. Foods rich in these elements should be encouraged. The role of whole small fish with their intact livers and skeletons cannot be overestimated. Crushed and made into a paste or porridge (Fig. 12.7), they are better than any pharmaceuti-

cal product and are readily and cheaply available in many under-resourced countries.

Angular deformities of the knees can improve dramatically in small children before the age of five or six if given nutritional supplementation [4]. The use of long leg orthoses is controversial and difficult to implement. Those deformities remaining after treating the metabolic problem can be corrected either by “guided growth” strategies if mild, i.e., temporary hemi-epiphysiodesis by physeal stapling or plating techniques, or by osteotomies if more severe (see Chap. 37).

References

1. Atijosan O, Rischewski D, Simms V, Kuper H, Nuhi A, Foster A, Lavy C. A National Survey of Musculoskeletal Impairment in Rwanda: prevalence, causes and service implications. *PLoS ONE*. 2008;3:1–7.
2. Thacher TO, Fischer PR, Strand MA, Pettifor JM. Nutritional rickets around the world: causes and future directions. *Ann Trop Paediatr*. 2006;25:1–16.
3. Craviari T, Pettifor JM, Thacher TD, Meisner C, Arnaud J, Fischer PR, Rickets Convergence Group. Rickets: an overview and future directions, with special reference to Bangladesh. *J Health Popul Nutr*. 2008;26:112–21.
4. Arnaud J, Pettifor JM, Cimma JP, Fischer PR, Craviari T. Clinical and radiographic improvement of rickets in Bangladeshi children as a result of nutritional advice. *Ann Trop Paediatr*. 2007;27(3):185–91.

Richard C. Fisher, Richard A. Gosselin,
and Michelle Foltz

Introduction

Over the past couple of decades, younger generations of orthopedic surgeons in HICs have had a significant decrease in their exposure to nonsurgical treatments of musculoskeletal injuries. Surgeons in middle-income countries are experiencing a rapid transition from nonoperative to internal fixation of fractures. The current epidemic of road traffic injuries has helped push the speed of this transition as overcrowded hospitals cannot cope with the 6–10 week stays needed for adequate treatment of traction patients. But in more austere environments, nonoperative treatment remains the cornerstone of musculoskeletal injury management and provides an invaluable safety net [1, 2]. The following section is a brief reminder of basic principles of conservative techniques such as casting and traction.

R.C. Fisher, BA, MD, MS-Health Admin.
Orthopaedic Surgery, University of Colorado Health
Science Center, 12631 East 17th Ave, B202,
Aurora, CO 80045, USA
e-mail: richard.fisher@ucdenver.edu

R.A. Gosselin, MD, MPH, MSc, FRCS(c)
Orthopedic Surgery, Institute for Global Orthopedics
and Traumatology, UCSF, 1001 Potrero Ave, 3A-36,
San Francisco, CA 94110, USA
e-mail: froggydoc@comcast.net

M. Foltz, MD (✉)
172 Stillwater Loop Road,
Columbus, MT 59019, USA
e-mail: michellefoltz@gmail.com

Casting

A cast immobilizes the fracture by preventing motion at the joints above and below the fracture and maintains reduction by providing external 3-point fixation to counteract the inherent deforming forces. A fresh injury, particularly if the fracture is displaced, is always associated with some degree of swelling. The soft tissue injury takes precedence in treatment with attention directed to preventing neurovascular compromise. Prompt reduction, if indicated, is followed by the RICE principle of rest, immobilization, cold, and elevation to minimize the inflammatory responses of pain and edema.

In high-income countries initial injuries are usually splinted or placed in traction before definitive surgical treatment. In resource-poor areas acute injuries are usually splinted before final treatment in a cast, though there will be situations requiring definitive treatment at the initial visit. If a circumferential cast is applied, particularly after manipulation, we cannot emphasize enough that the patient should be admitted for elevation and observation, or if discharged, the cast should *always* be bivalved, with crystal-clear and simple instructions to the patient and his accompanying entourage about the indications and technique for removal, as well as the usual instructions for elevation and cast maintenance. Most everyone has access to scissors or knives to remove a splint or bivalved cast; no one has cast



Fig. 13.1 Window edema visible in the proximal window of this useless cast

cutters or spreaders to remove a circumferential plaster.

Ideally the patient will return in 3–4 days to have the bivalved cast closed, by applying a few rolls of plaster. For patients presenting late with fractures that do not require manipulation, definitive casting can be done initially if further swelling is unlikely. However, if in doubt, follow the above protocol for recent fracture immobilization. Postoperative patients may also require immobilization. A well-padded back slab, gutter splint, or one half of a bivalved cast can be used for a few days until the limb is ready for definitive casting, either by closing the bivalved cast or applying a new one. A new cast is necessary if

stress molding—stress applied while the cast is setting to prevent or correct an angulatory deformity—is necessary.

Small wounds or stitch removal can be managed through a window in the plaster. Windows have received a bad name because they are often improperly made or the window was not replaced at the time of dressing or stitch removal leading to window edema (Fig. 13.1). The edema can lead to wound complications and permanently discolor the skin. Making and cutting a window is explained in Fig. 13.2.

Writing the date of injury, date the cast was applied, and date of removal will avoid confusion if records are inadequate or lost. Unless contraindicated, the wound or incision under a cast should be closed with resorbable sutures in the pediatric population.

In spite of all precautions, and with the best of instructions, ultimately the patient's compliance will determine the success of cast treatment. It is surprisingly common to see at follow-up casts that are totally ineffective because of poor POP quality (Fig. 13.3), overuse (Fig. 13.4), or self-customization (Fig. 13.5).

Materials

Fiberglass is lighter, more rigid per unit of weight, and relatively water resistant compared to traditional plaster of Paris (POP, gypsum plaster, calcium sulfate hemihydrate). It is rarely available in austere environments, whereas POP is universally available, in rolls of different sizes. It can be of uneven quality, depending on the amount of plaster/roll, age of the roll, and manufacturer. In hot, humid environments, plaster's half-life may be limited depending on how and where it is stored. It is bulkier, takes longer to set and to dry (up to 48 h), and softens if wet. If fiberglass is available, but only in limited quantities, it can be used as a strengthening outer layer over POP, lessening the cast's weight and making it more durable.

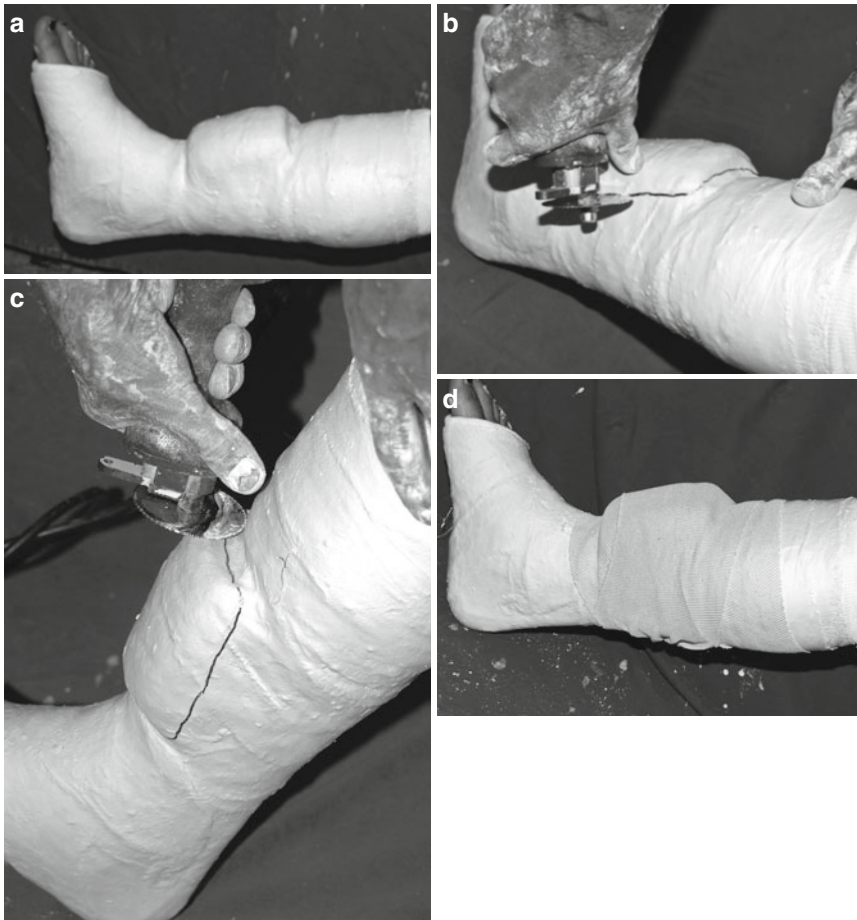

Fig. 13.2 (a) A thick, mounded underlying dressing clearly marks the area to be windowed. (b) Correct way to cut the window, tangentially to the cast. (c) Incorrect way

to cut window, perpendicularly to the cast. (d) Window, once opened, is closed and secured with an elastic wrap

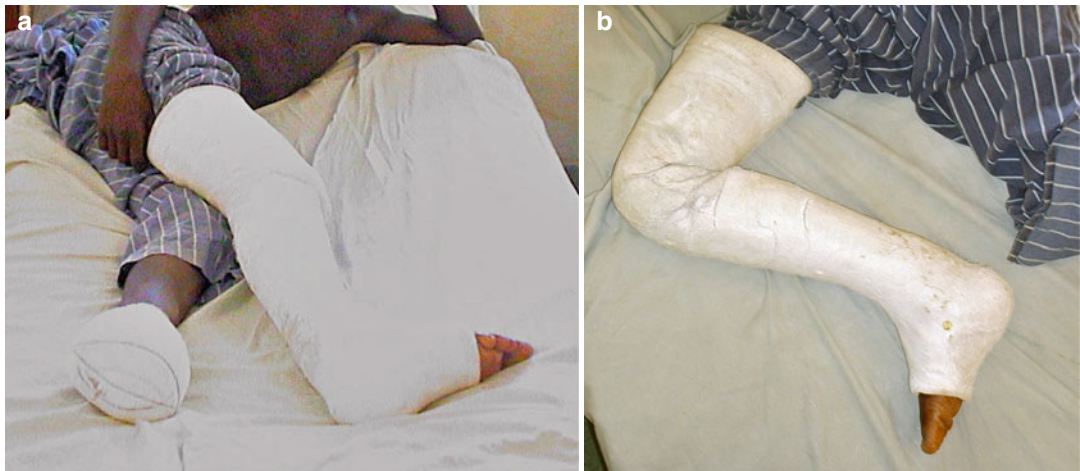


Fig. 13.3 (a, b) Poor quality POP allows movement of the joint it is supposed to immobilize

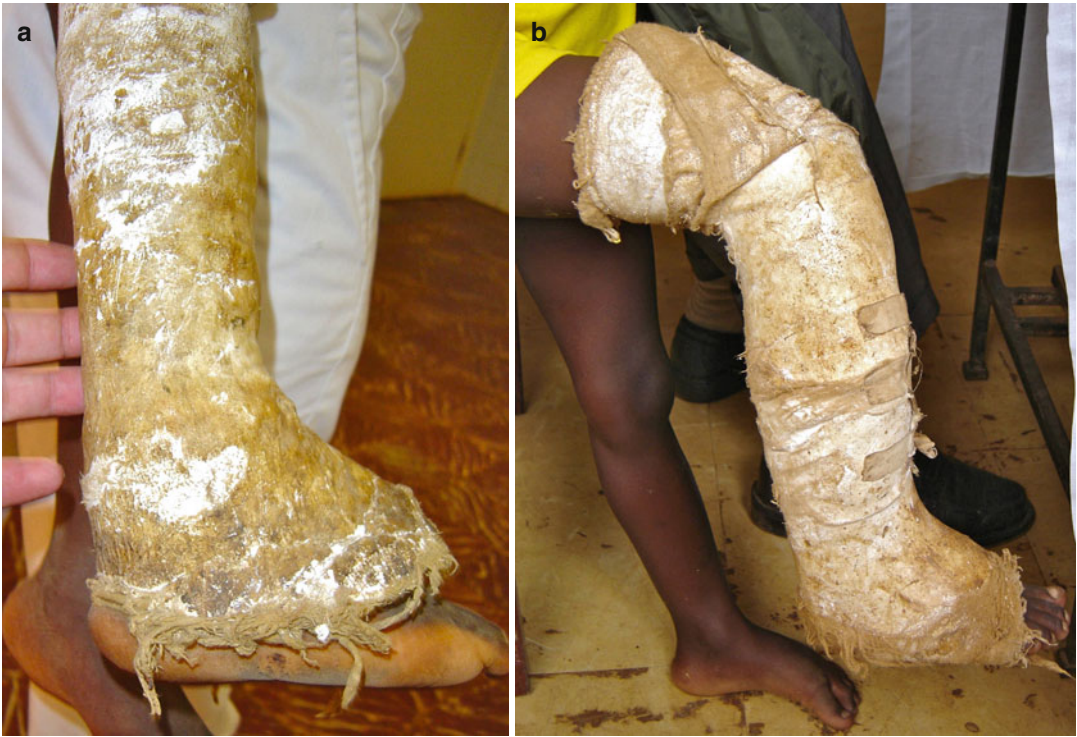

Fig. 13.4 (a, b) Examples of well-worn POP casts with the foot plates completely gone

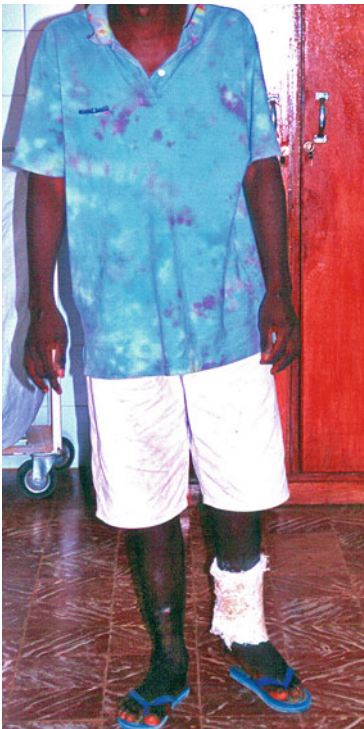

Fig. 13.5 This patient customized his BK POP down to barely more than an ankle brace

Casting Technique

Stockinette should be used under the cast when available. It protects the skin and hair and helps prevent saw blade cuts or burns on cast removal. Leave excess stockinette at both ends of the cast. Avoid wrinkles or creases at joints by cutting the stockinette tube transversely and overlapping the cut edges.

Specialty under-cast padding of cotton or synthetic may be available, but occasionally there are only large rolls of cotton batting. These are more difficult to use, as the layers must be separated and they tear more easily and more unevenly. Cast padding should be rolled firmly but without tension, usually from distal to proximal, overlapping the previous layer by half its width, to achieve a uniform 6–8 mm layer—better slightly too thick than too thin. Extra cotton is used over prominences such as the fibular head or the malleoli; over areas particularly sensitive to pressure sores, such as the posterior heel; and under weight-bearing areas. The padding, like the cast itself, should be applied with all the joints

in the desired position, to avoid creases and bunching that can cause pressure areas. Chinese finger traps or clove hitch loops of bandage to help immobilize and hold an extremity can prove useful to the unassisted surgeon.

Completely submerge a roll of plaster in a container of skin-temperature water. When bubbling has ceased, gently squeeze it to the point where it is barely, but still, dripping. Pressure at each end of the roll will prevent “bananaing” and if the leading edge of the roll is first folded back on itself, it is easier to find when wet, saving time. Cast heating problems can occur if the water is too warm and with certain types of quick-drying plaster, excessively thick plaster layers, or when a damp cast is placed directly on the plastic covers of pillows and mattresses and covered with a thick blanket.

The plaster is rolled in a manner similar to the cast padding, holding the roll against the patient with gentle tension but not pulling the roll away from the limb or bunching the padding. Unroll the plaster using the thenar side of the palm, smoothing each turn of the roll to remove air bubbles that lead to delamination. Take small tucks when moving between different circumferences and crossing over flexed joints. The desired thickness of the cast will vary according to patient age, anatomical site of the injury, and proposed usage, but it should be uniform. Reinforcement slabs can be applied over areas of high stress such as the front and back of the knee.

After the penultimate roll has been smoothed, mold the plaster to conform to the anatomical contours, e.g., a forearm or leg cast should be oval, not round. Three-point pressure is gently applied with the moving palms, never the finger tips, to maintain fracture reduction until the plaster is set. Trimming excess plaster can usually be done with scissors, cast saw, or a scalpel blade. Take care that the plaster does not dig into the first web of the thumb and the distal palmar flexion crease is visible, allowing finger MP flexion. The dorsum of all toes, including the fifth, should be free of plaster to the MTP joints to prevent sores caused by rubbing on the plaster with toe dorsiflexion. Turn the stockinette or remaining cotton over the plaster edges with a last layer of POP to give the cast a finished appearance.

When no assistant is available, it is easier to apply long-leg casts by completing the below-knee part first and proceeding with the above-knee section after the lower leg and ankle molding have been completed and the plaster has semi-set enough to maintain its position. Make sure the junction between the two cast segments is well padded and smooth with no sharp or bent edges to dig into the skin. Unless contraindicated, plaster the knee in 20–30° of flexion. With enough knee flexion it is impossible—even for the most noncompliant patient—to bear weight. The cast can be bivalved after it has reached a leathery state and the two halves secured with an ace-wrap before discharge. In spite of all precautions, many patients will come back with broken, wet, painful pressure points, or a foul-smelling cast. Do not disregard patients’ complaints. It is better, albeit time-consuming, to redo a cast than to have potential limb-threatening complications.

Take care when removing the cast. Injuries from the saw blade are possible, particularly in children and in paralyzed or anesthetized patients. Cast saw blades are often extremely worn and generate a lot of heat, creating possible thermal injury. Inserting two fingers between the skin and cast while cutting should avoid accidental cuts. A metal or plastic “protector”—looking like a long, thin, and more flexible ribbon retractor—may be available or can be made from local materials (finger splints or tongue depressor). This is slipped under the stockinette or cast padding to protect the skin from contact with the saw blade.

Wedging Casts

Depending on the age of the injury, some malalignment or loss of reduction can be salvaged with POP wedging or gypsotomy, most often without anesthesia. Because fewer fractures in HICs are treated non-operatively, cast wedging is becoming a lost art but is a useful technique for salvaging angulated forearm and tibial fractures in all ages and femur fractures in the pediatric population managed in spicas [3].

Opening wedges are made on the concave side of the deformity. They present fewer possibilities of pinching the skin than closing wedge

gypsotomies on the convex side. Whether wedging a plaster of Paris or fiberglass cast, the principles are the same: identify the apex of the deformity, mark the proposed wedge line on the cast, and make sure it covers more than half the circumference.

Identifying the site where the cast needs to be cut for wedging is made easier by taking an x-ray with a metallic marker taped on the cast at the presumed site *before* the gypsotomy (Fig. 13.6). Use a penny or paper clip taped to the cast to identify the apex before the gypsotomy. If on first applying the cast you think it might need future wedging, tape the metal marker on for the first postreduction x-ray and mark this with a sharpie for later wedging when the plaster is set or after the fracture has become sticky.

Prepare precut wood, cork, or plaster spacers. Start by making ± 10 cm perpendicular cuts at both extremities of the proposed wedge to prevent crack propagation. Then proceed with the gypsotomy. With one hand above as counterpressure, firmly and gradually apply distal pressure to open the plaster cut. Once in the proposed corrected position—usually calculated at 1 mm opening for each degree of desired correction, though one seems to always need a wider opening than anticipated—insert the spacer without allowing it to touch or put pressure on the underlying skin or curling the cut cast edges and take the appropriate x-rays. More manipulation may be indicated, using a larger spacer, or the cast can be closed by applying a few rolls of material over the wedged

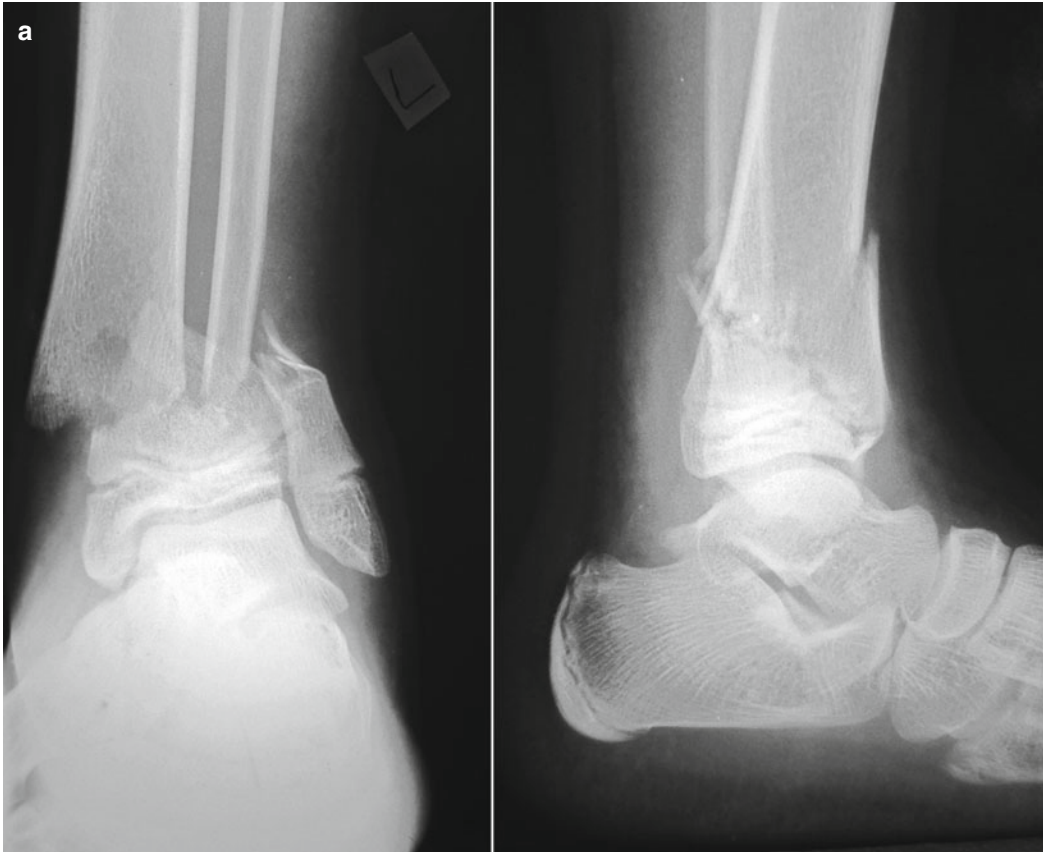


Fig. 13.6 (a) AP and lateral x-ray of displaced distal tibia-fibula fracture. (b) Residual angulation post-casting will be corrected with an anterolaterally based opening wedge. A metallic marker was placed immediately after casting to identify the optimal site for gypsotomy when the initial reduction was noted to be inadequate. (c) Gypsotomy line

marked, in this case going beyond half the circumference. Small longitudinal cuts at both ends of the line are marked and cut first to prevent crack propagation. (d) The gypsotomy is kept open with precut pieces of wood that do not put pressure on the skin. (e) X-rays confirm an acceptable reduction *before* the cast is closed with one to two more rolls of POP

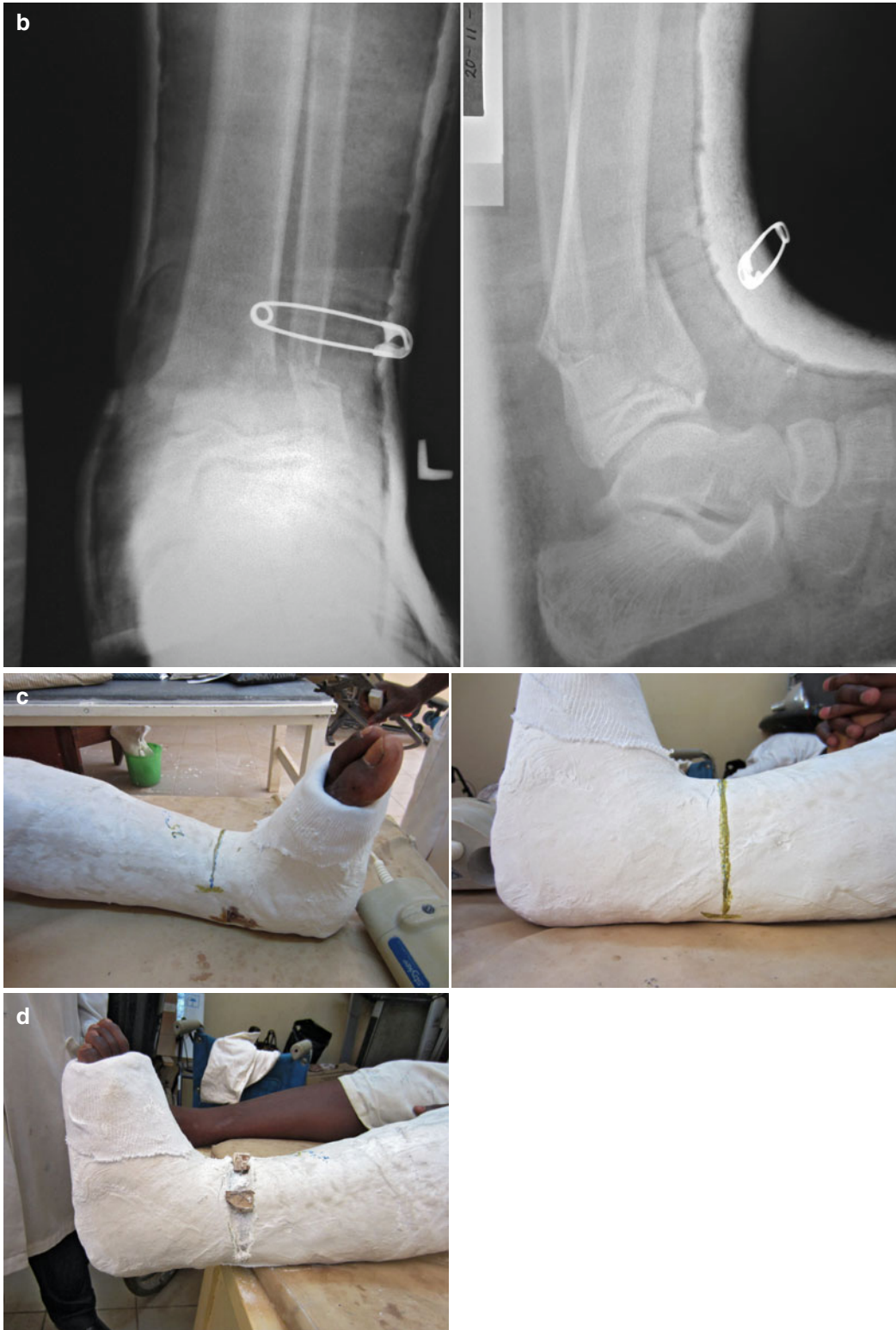

Fig. 13.6 (continued)

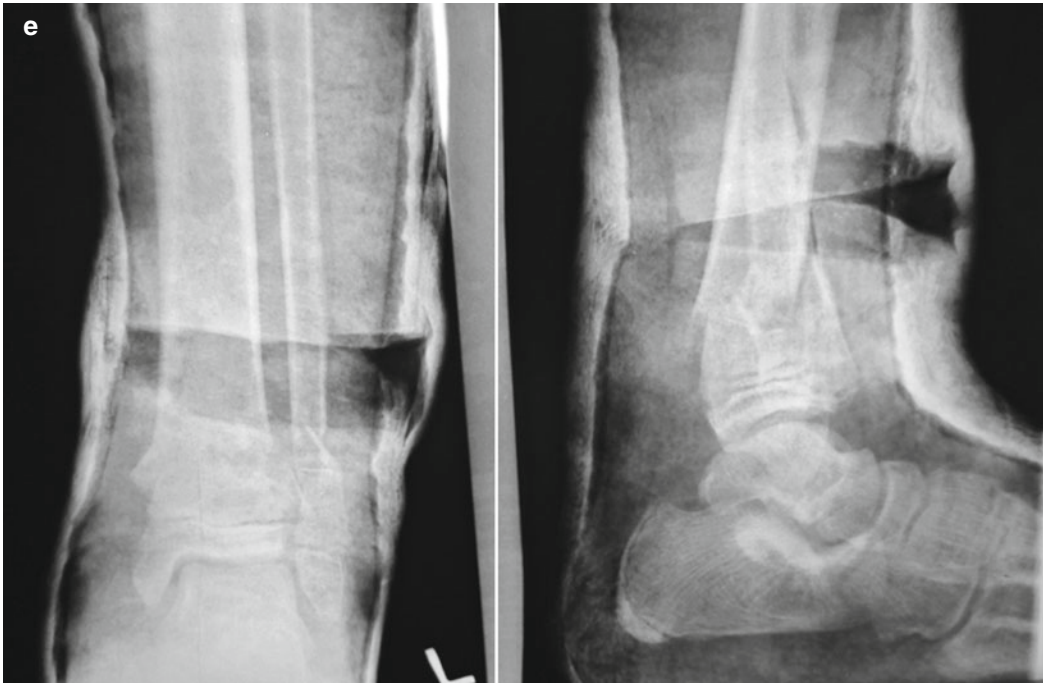


Fig. 13.6 (continued)

area. Sequential wedging over several days to a week for progressive correction is possible, by using progressively bigger spacers and closing the cast when the desired correction is achieved.

Special Casts

Hip Spica

Hip spicas are uncomfortable and unwieldy for adults but are useful to rest the extremity after removal of a femoral ex-fix when a patient cannot be admitted for traction or in salvage situations. In most cases the patient will be able to stand during application while supported by two drip-stands or crutches with the casted leg resting on a stool or box while applying a single-leg cylinder cast with a waist band. Pointers: cast the hip slightly abducted and flexed about 30–45°, to allow ground clearance. Knee flexion will depend on the weight-bearing status of the injury. Reinforce the connection between the pelvis and leg with extra plaster or fiberglass, and pad well sacral and other bony prominences. Hip spicas do not do well on obese patients.

Hip spicas for femur fractures are standard treatment and better tolerated in the pediatric

population—up to about 25 kg body weight—whether applied as the initial postfracture treatment or after a period of traction to allow early stabilizing callus (Fig. 13.7). Most hospitals have management protocols based on bed availability, personality of the fracture, proximity of the patient to the hospital, ease of transportation, and the philosophy of the local doctors. Variations include as follows: the type and length of traction, timing to spica application, type of spica—1½ or single leg, where the spica is applied, type of anesthesia used, or other forms of treatment.

When available, fiberglass is preferred as it is lighter, but the edges are sharp and should be covered with felt or extra cotton after trimming to allow rollback to produce rounded edges before the last rolls are applied. Spicas look neater and the edges wear better if stockinette is used. Prominences, especially around the sacrum, should be well padded.

A frame is usually available on which the child's buttock can rest and allow easy access for cast application (Fig. 13.8). If not, a makeshift one can be assembled with boxes, pillows, an up-turned medicine cup, or the OR table's arm board. Place a small bag of IV fluid, folded towel, or sheet between the stockinette and the skin of the

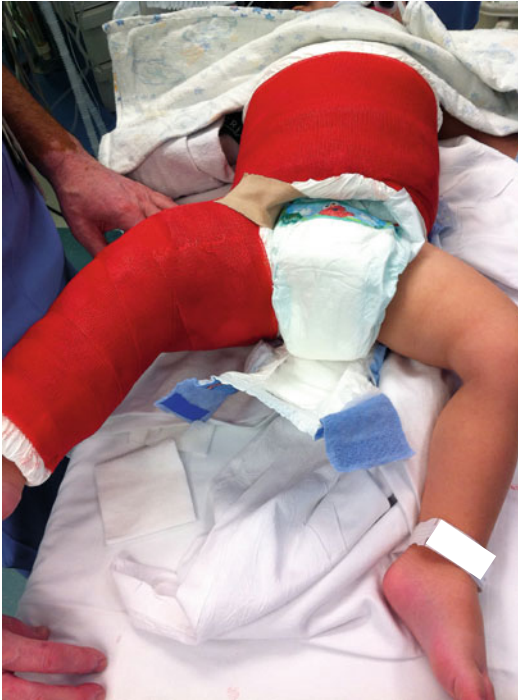

Fig. 13.7 Right hemi-spica for femur fracture. Notice the foot is free, the edges have been well padded to prevent skin problems, and the diaper is tucked underneath the cast


abdomen for chest expansion. One or two people, depending on the size of the child, need to hold the legs and maintain proper joint positions. This is particularly important after hip surgery, and a designated person (preferably the surgeon) is responsible to keep the limb in the desired position at all times throughout the casting.

A spica can be applied in one piece or in sections, beginning with splints and rolls around the thorax/pelvis from the xiphoid process and progressing distally to incorporate the hips. When this is set the rest of the leg section is applied.

Hips are casted between 45° and 90° flexion with abduction, enough to allow perineal care. Knees are casted at $45\text{--}90^\circ$. The amount of flexion depends on the location of the femur fracture (proximal fractures require greater flexion), how many legs are involved in the spica, and whether the child is allowed to walk. Mold the thigh into a few degrees of valgus as femur fractures often drift into varus. The foot is left free, as the sole pushing against the foot plate can shorten the femur. A seven to ten layer thick splint is applied laterally across the hip joint prior to the final roll



Fig. 13.8 (a) Example of a homemade portable spica table that holds the components and can be easily carried into the field. (b) Different sized buttock support plates



are easily exchangeable. (c) The length from edge of the chest support to the buttock plate is adjustable

to strengthen the cast, especially in a single-leg design. A bar between both legs strengthens the construct of a 1½ or double spica.

Precautions: (1) Do not first apply a short-leg cast and then apply manual traction, as there is risk of popliteal compression and compartment syndrome. (2) If a long-leg cast is first applied, and converted to the spica, it is difficult to mold the femur, and the upper edge of the long-leg cast may cause focal pressure against the skin of the lateral thigh.

With the child off the frame, the buttock and perineal areas are trimmed with a cast knife, scalpel blade, or cast saw, the edges rolled, and secured with casting material or later with tape. A small diaper must be tucked inside and under the cast edges before the child leaves the casting venue. A second diaper may be placed around the outside to support the first.

It is extremely important that the care giver understands that the diaper—disposable or cloth and rubber outer pants—be stuffed up and inside the cast, otherwise the cast will become soiled, potentially causing skin breakdown. In small children a sanitary napkin can be used as the first diaper layer, especially in situations where disposable nappies are expensive. A rare but serious complication of spica casting is superior mesenteric artery syndrome, with duodenal obstruction or even occlusion. Many clinicians prefer to discharge spica patients only after they have had a bowel movement, especially if they live far away.

Minerva Cast

Where there are no halos or other braces, a Minerva cast can immobilize stable cervical fractures immediately post-injury or unstable fractures after 4–6 weeks in traction or surgery. They should not be used in patients with sensory loss in the areas that are under the cast. Patients should be able to sit comfortably on a stool to provide 360° access while the cast is applied. A soft cervical halter attached to a weight over an IV pole can be used to help stabilize the patient. If “body-sized” stockinette is not available, a T-shirt turned inside out—so the inside seams do not rub on the skin—will do. Pad well the bony prominences.

Place pre-formed plaster slabs longitudinally down the back of the head, neck, and thorax and

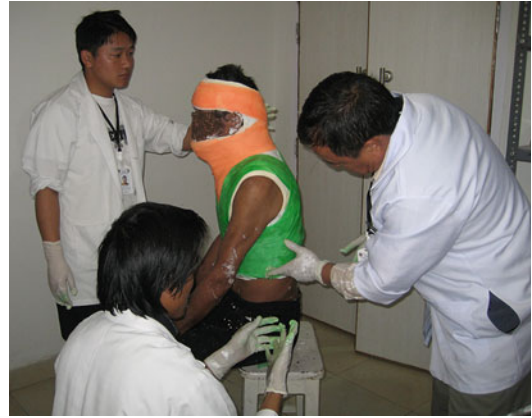

Fig. 13.9 Application of a Minerva jacket. The chin support should not interfere with chewing, but should support the mandible to prevent cervical motion

around the neck and thorax and over the shoulders. Additional slabs are crossed, or spicaed, from the head to chest. Make sure the mandible is secure and the jaw cannot slip inside the cast's neck, but that the cast does not inhibit chewing. Trim to allow full ROM of the shoulders and make sure the pinna of the ears are free. For female patients, the cast may need to extend more distally, allowing a cutout for the breasts. The cast controls cervical motion by 3-point fixation between the sternum, occiput, and mandible (Fig. 13.9).

Hyperextension Cast

For thoracic fractures without neurologic injury a hyperextension cast can be applied when the patient's pain allows mobilization. It is easiest to place the patient prone between two trolleys, exam tables, or beds such that he feels secure and there is enough room for the plasterers to work. A spotter is advised to monitor and help hold the patient's position. To obtain true hyperextension with 3-point fixation, the cast must come proximally to the manubrium and distally to the pubis using slabs and rolls of plaster. Trim the cast when the patient is supine or standing, making sure the axillae are free and he can flex the hips for personal activities. A cutout in the upper abdomen may help to relieve any feelings of claustrophobia and improve breathing (Fig. 13.10).

The greatest disadvantage of cast immobilization is joint stiffness. Elbows and knees should be freed from plaster immobilization as soon as

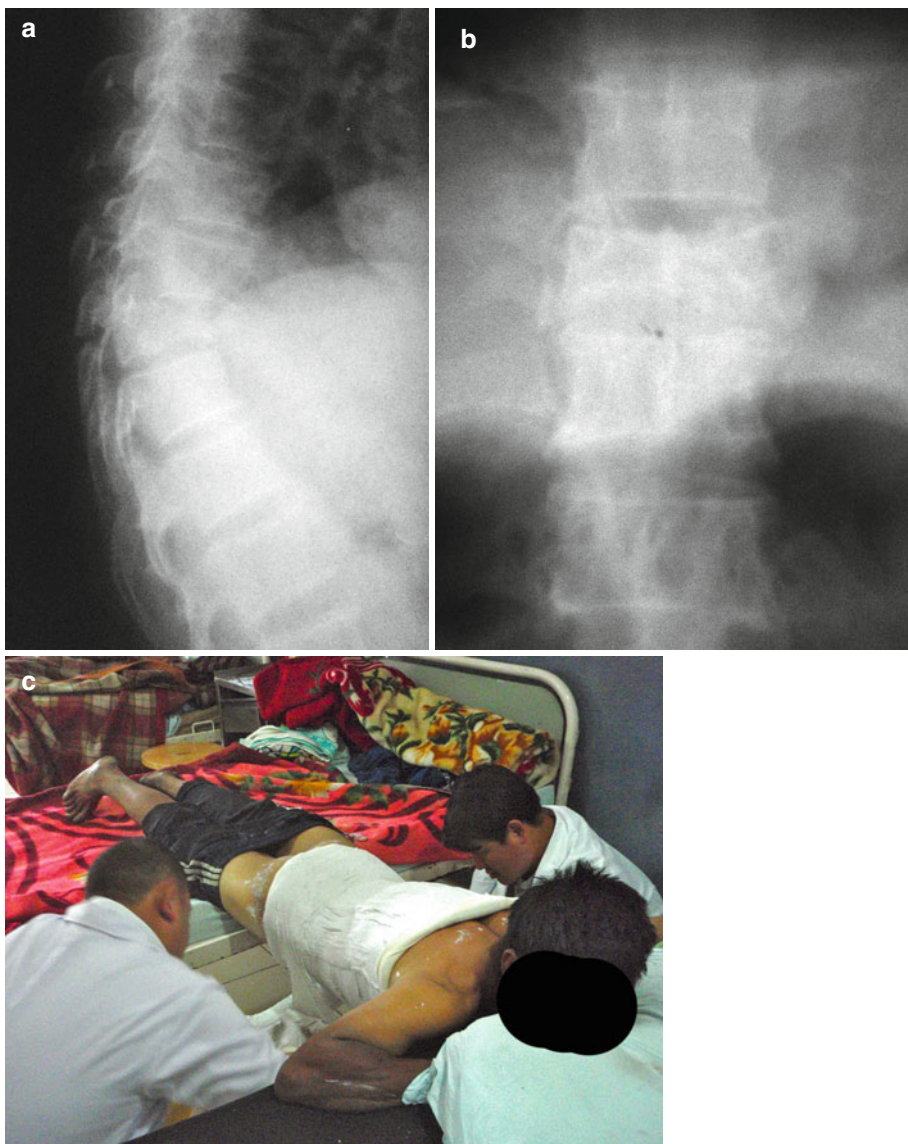


Fig. 13.10 (a, b) X-rays of an unstable flexion injury to the lower thoracic spine without neurological involvement in a Bhutanese farmer who fell out of a tree. (c)

Application of a thoracolumbar cast in extension with the patient prone between two beds (Courtesy of Dr. Sam Baker)

possible. Applying a Munster or patellar tendon-bearing (PTB) cast is a good alternative to a below-elbow or below-knee cast. The basic principle is good molding around anatomical prominences to prevent distal rotation at the fracture site.

Munster Cast

The forearm is put in the desired position of pro-supination, the cotton is rolled to a thinner thickness than normal to allow better plaster

molding. A short above-elbow cast is applied, making sure the internal shape around the distal forearm is oval, or what is called a “screw driver fit,” and that the cast is well molded over both sides of the olecranon and around and over both epicondyles. When dry or in the leather state, the cast is trimmed as shown just above the intercondylar line posteriorly, proximal to the epicondyles on each side, and 5–6 cm distal to the flexion crease anteriorly. This cast usually allows

near full extension, full flexion, and no or minimal pro-supination. The more distal the forearm fracture is, the better the immobilization with this cast (Fig. 13.11).

PTB Cast (Sarmiento)

A short above-knee cast is applied with around 20° of knee flexion, well molded around the leg,

and contoured snugly along both sides of the patellar tendon and around the entire patella. It is trimmed to just above the proximal pole of the patella anteriorly and 8–10 cm below the popliteal flexion crease posteriorly. It is important that the ankle remains in neutral position and the foot-plate extends beyond the metatarsal heads. Full unimpeded knee flexion should be possible, as

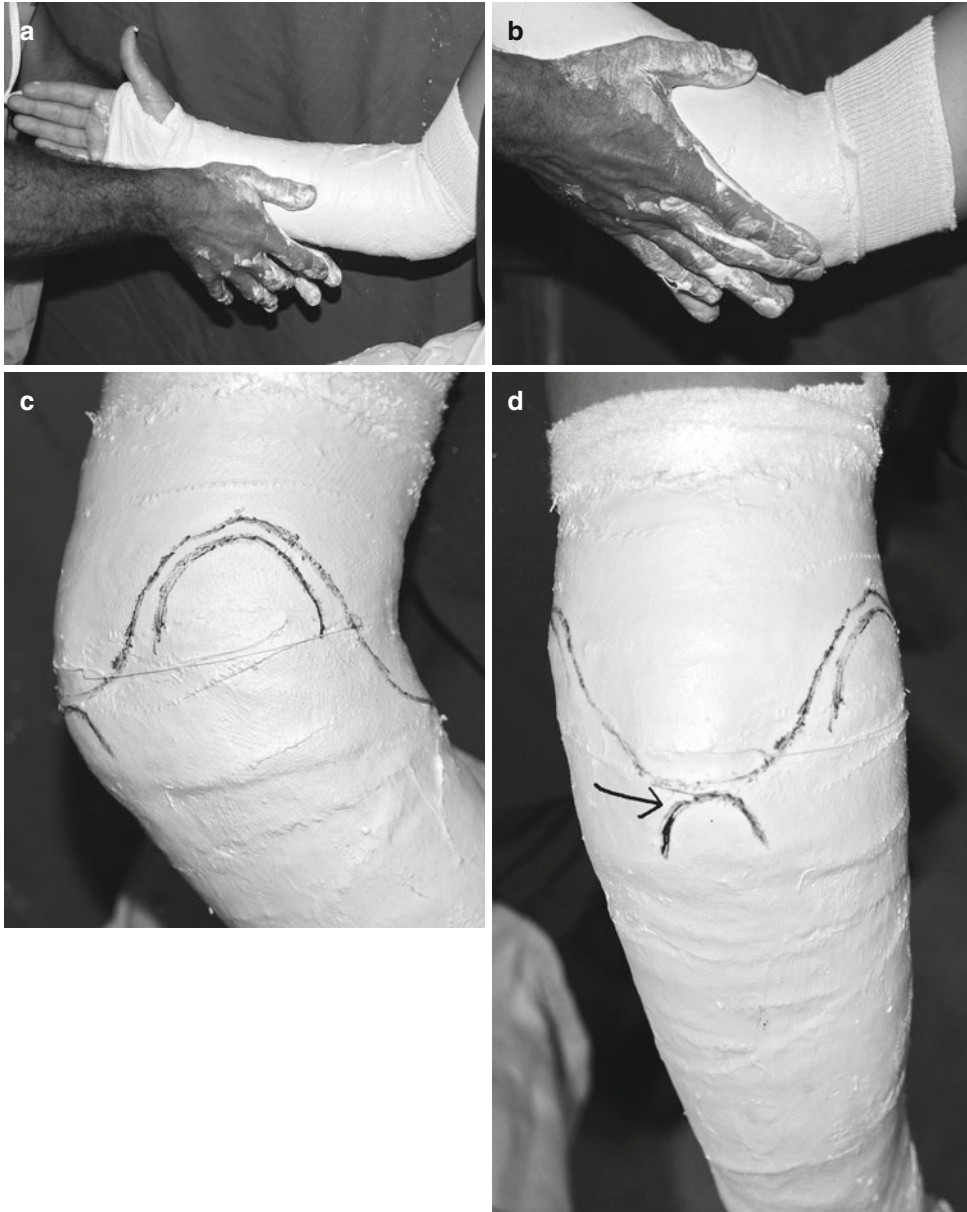

Fig. 13.11 (a, b) The Munster cast starts with a short above-elbow cast well molded around the forearm, along the olecranon, and over the epicondyles. (c) Trimming is done just above and around the epicondyles, (d) just prox-

imal to the tip of the olecranon, and (e) 8–10 cm distal to the elbow flexion crease anteriorly. (f, g) Near full flexion/extension is possible, while (h) supination and (i) pronation are severely restricted

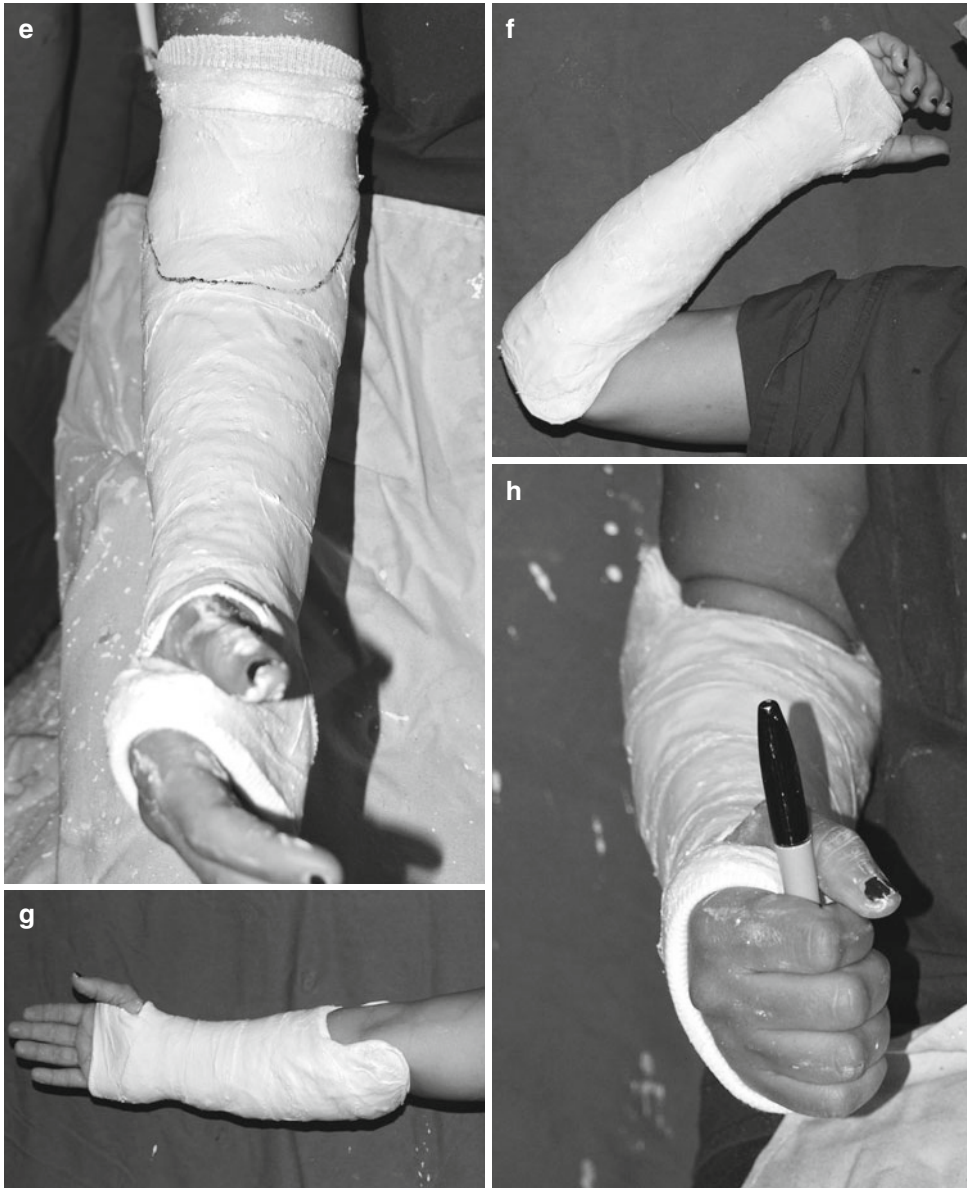

Fig. 13.11 (continued)

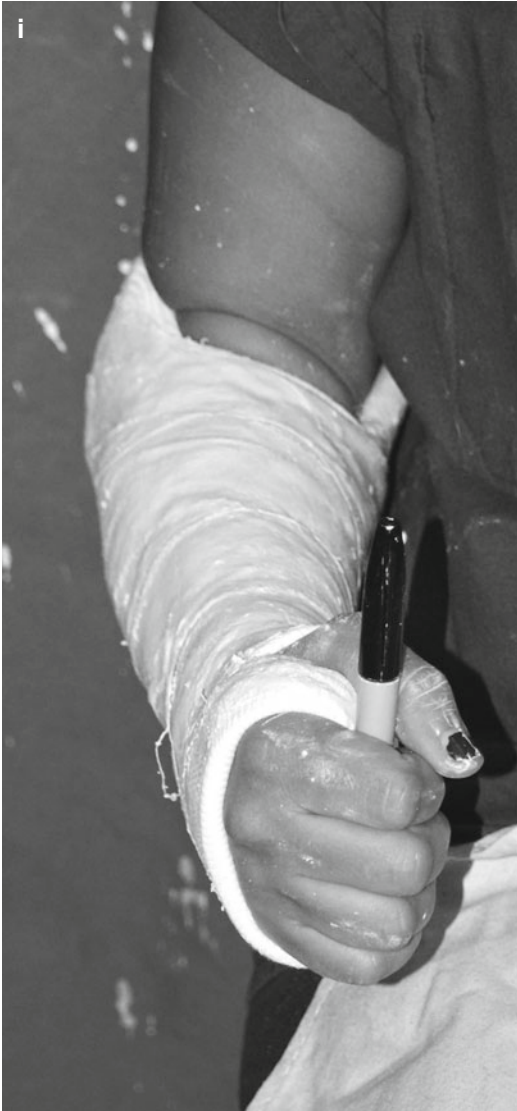

Fig. 13.11 (continued)

well as full extension, before the cast is finished. As for every walking cast, a rubber heel, centered over the anterior tibial crest, should be used if available. A “flip-flop” is a good “poor man’s” alternative walking rubber. Although called a patellar tendon-bearing cast, the weight is borne by the two leg bones rather than the patellar tendon. The proximal extension and snug molding confer rotational control (Fig. 13.12).




Fig. 13.12 The patellar tendon-bearing (PTB, Sarmiento) cast starts with a (a) low above-knee cast well molded over the calf, both sides of the patella tendon and around the patella. (b) The cast is trimmed just above the superior pole of the patella and distal to the popliteal flexion crease to allow unimpeded flexion and (c) extension

Traction

The purpose of traction is to provide a counterforce to the deforming muscle contractions across the fracture, making it possible to control motion, alignment, shortening, and pain [4]. The fracture position is maintained or altered by manipulating the traction apparatus. The traction force is applied through the skin or the skeleton via a trans-osseous pin. The decision of which method to use is based upon the traction weight needed to control the fracture position. Skin will tolerate about 3–4 kg. Greater weight is likely to cause skin shear with superficial ulceration, painful blistering, and can compromise the deep circulation leading to a compartment syndrome. The tightness of the skin wrapping to hold the strapping in place and the quality of the adhesive on the strapping limit this sort of traction to children or as a method to simply keep an adult's limb comfortable (Fig. 13.13).

Tincture of benzoin applied to the skin will help prevent blisters by keeping the strapping from pulling differentially on the skin. The bandage is wrapped in a figure of eight fashion with just enough compression to hold the strapping in place when weight is applied. Use ample padding and minimal compression over bony prominences and the peroneal nerve as it curves around the fibular neck. Avoid contact of the adhesive part of the strapping and compressive wrapping around the malleoli. Prepackaged strapping for skin traction is manufactured to leave these areas free of adhesive with wide spreader bars to prevent pressure.

If one must devise their own skin traction, using wide tape, face the area of the stirrup over the malleoli with a reversed layer of tape and make sure the spreader bar is wide enough so the tapes do not touch these sensitive areas. When in traction the heel should be free from pressure. A non-sterile glove half filled with water will elevate and cushion the heel from the underlying surface. Heels often roll off the glove and family members and the patient are recruited to maintain it in place.

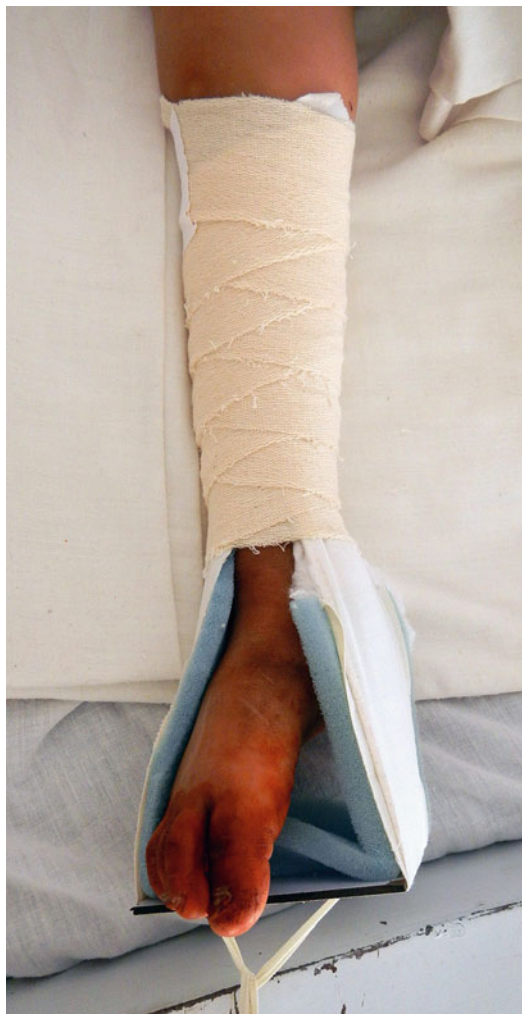

Fig. 13.13 Well-applied skin traction. Note the Figure of eight application of the bandage without pressure on the malleoli. The spreader bar is well away from the foot and its width prevents pressure on the malleoli. This type of skin traction in an adult is for temporary comfort only, not as definitive treatment

Skeletal traction is *not* synonymous with skillful neglect. Successful outcomes can be maximized by paying close attention to every step of the process: patient selection, pin insertion site and technique, and fracture and patient monitoring.

Pins come in many sizes and types: smooth and fully threaded (Steinmann) and centrally

threaded (Denham). Threads afford better purchase in bone, particularly in metaphyseal or cancellous bone. However, given enough time every pin will loosen and eventually become infected. This occurs more rapidly with smooth pins. Threaded pins should be used when available, and they need to be well identified as such, as they must be unscrewed for removal, not just pulled or hammered out. In general, the biggest pin should be used, as long as it is less than one third the diameter of the bone at the site of insertion—the same principle for choosing the size of ex-fix pins. An alternative still seen is a K-wire and tensioner stirrup, using the same principle as for an Ilizarov-type apparatus.

Pins for skeletal traction are easily placed in the outpatient department using sterile technique and local anesthesia. In many sites, pins are reused: they might not be perfectly straight and the tips are often blunt. The use of power for insertion is discouraged, as it creates thermal necrosis and may lead to premature loosening, infection, and formation of a ring sequestrum. Gently tapping the pin at the point of bony contact, even if using a hand drill or T-handle, can ease insertion and avoid slipping off the bone. Where pins are disposable, removal should be done by cutting one side close to the skin and generously painting the skin and tip with Betadine or chlorhexidine. Where pins are reused, the whole pin needs to be prepped and care taken during removal, especially if the pin is slightly bent. Grossly bent pins should be cut and discarded, no matter the general protocols on pin salvage.

Pin Placement

For lower extremity injuries the preferred sites for traction pins are the distal femur, proximal tibia, or calcaneus and for upper extremities the olecranon. In children there are epiphyses at these locations and care is needed to stay well clear of the cartilaginous growth plate and perichondral ring. The general principle is to put the pin in the middle of the bone, perpendicular to

the axis of traction, and starting at the “danger” side and ending at the “safe” side.

For femur, pelvis, and acetabular injuries, a proximal tibial pin is commonly used. Always rule out an associated knee injury before inserting the pin. In adults the proximal tibial traction pin is started from the lateral side and placed about 2–3 cm distal and posterior to the tibial tubercle. The lateral start prevents injury to the peroneal nerve by an exiting pin. After a sterile prep anesthetize the skin and periosteum on both sides. Make a 1-cm incision with a #11 blade. The pin should be parallel with the bed while the leg is in neutral rotation and at 90° to the long axis of the limb. These relationships may be difficult to evaluate by the operator, and the observations and guidance of an assistant from the foot of the patient, as well as moderate traction and stabilization of the extremity, will help keep the pin from going askew.

A hand drill or T-handle works well to advance a Steinman pin or Kirschner wire through the bone. In most institutions drills of any sort are rarely present in the OPD or ED, making a mallet a common insertional tool. If the pin exit misses the area initially anesthetized, inject more local in the appropriate location. When the skin becomes taut over the advancing pin tip, use the #11 blade to make a small exit wound. Place a sterile dressing on the entrance and exit sites and attach the stirrup. Because of similar concerns for nerve or arterial injury, place femoral and olecranon pins from medial to lateral.

Traction pins in the distal femur are commonly used in children and placed at the level of the beginning flare of the condyles, opposite the upper pole of the patella and slightly anterior to the longitudinal sagittal midline of the femur. They are safer than tibial traction pins as growth changes in the proximal tibia can occur following even well-placed pins. The greater bulk of soft tissue in the distal femur in adults makes such placement more problematic.

Calcaneal traction can be useful for short-time treatment of tibial fractures, especially those with significant soft tissue injury when external

fixateurs are not available. These pins are placed 1 cm distal and posterior to the tip of the lateral malleolus. In this position and placed parallel to the sole of the foot, the pin is well away from the posterior tibial nerve and vessels. Pins in this area often become loose and should not be in place more than 2–3 weeks. Pay particular attention that the heels are well protected from pressure.

Lower Extremity Traction

The simplest and most commonly used traction is Buck's traction, also called Buck's extension, and is employed mainly as temporary immobilization and pain control for abnormalities proximal to the knee using skin traction or a foam boot. Using the same skin traction attachment, this can be converted to Russell's traction (Fig. 13.14), which is useful in treating femoral fractures in children up to the age of about 10 years, or 22 kg weight. It has a complex geometry which doubles the pulling force for a given weight and is easily adjustable to maintain alignment [5].

Bryant's or gallows' traction is used in infants or children up to 2 years of age or 10 kg but entails the risk of vascular compromise to both the injured and non-injured leg and is not used in the USA. However, it is still commonly employed in austere environments because it is cheap and easy to monitor (Fig. 13.15). Local nursing staff and practitioners are usually familiar with this technique. Whether with a fixed or balanced arrangement, both legs are placed in traction until the infant's buttocks are elevated just off the bed. Both limbs need vascular checks hourly during the first 24 h. Never cover the feet so that they can be directly observed. Regularly monitor the traction for skin blisters. Complaints of pain or other concerns voiced by the child or caregiver need to be addressed. Early spica casting is indicated as soon as the fracture is sticky, usually before the end of the second week. In less austere environments where premade splints are available, the Pavlik harness as a "soft" spica

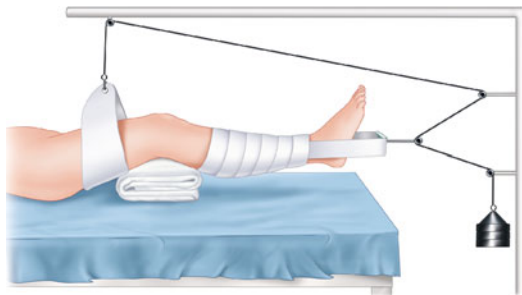


Fig. 13.14 Setup for Russell's traction

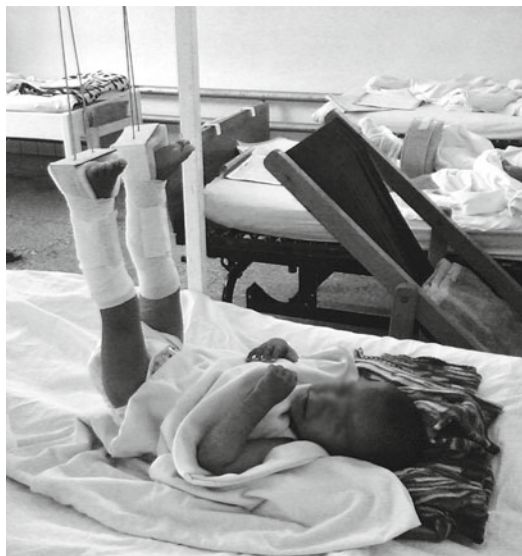

Fig. 13.15 Child in Bryant's (gallows) traction. The buttocks are barely elevated from the bed

can be used for femoral fractures in this age group.

When more weight is needed for older children, skeletal traction is used. 90–90 traction (Fig. 13.16) works for children up to about 8–10 years old, but adolescents or adults tolerate it poorly. Balanced suspension traction is useful for older children and adults and can be set using slings or a Thomas splint with a Pearson attachment (Fig. 13.17).

90–90 traction is particularly useful for controlling subtrochanteric or high femoral fractures to overcome the flexion pull of the iliopsoas on the proximal fragment. In young children one

Fig. 13.16 Adolescent in 90–90 traction with proximal tibial pin. Distal femoral pin is also an option

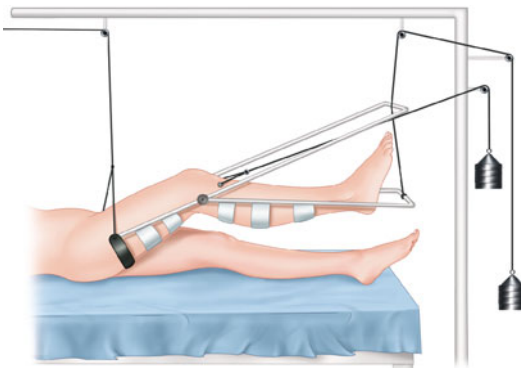


Fig. 13.17 Setup for Thomas-Pearson traction

can apply this using skin traction on the thigh combined with a sling or a lightweight below-knee POP supporting the lower leg. In the heavier child a femoral traction pin is used with the lower leg in a sling. For adolescents and adults who do not tolerate the 90–90 traction, a compromise—such as a Bohler-Braun frame and pulling along the long axis of the thigh—will often produce the necessary hip flexion. Angular malalignment can sometimes be corrected by adding a second skeletal pin, pulling in a different vector (Fig. 13.18).

As a general rule of thumb for adult femoral shaft fractures, traction should start at about 10–15 % of body weight. Traction in the 10–12 kg range is often needed, requiring at the outset larger pins to prevent bending and causing skin problems and difficulty in removal [6]. X-rays taken in the radiology suite are usually done without traction, and therefore useless and unnecessarily painful. When portable x-rays are available, AP and lateral views should be taken after 48–72 h and weekly for the next 3 weeks. Overriding by 1–1.5 cm is acceptable as long as alignment in both the frontal and sagittal planes is adequate (less than 10° of varus/valgus and 15° of anterior/posterior angulation). Distraction leads to nonunion and should be avoided, decreasing weights as needed.

Without x-ray, alignment is judged on a clinical basis and length determined by comparison to the non-injured side with a tape measure. After 3–4 weeks, the fracture is sticky enough that tinkering with weights will have little beneficial effect. Before removing the traction pin—usually at 6–8 weeks, the patient should have palpable painless callus, no motion at the fracture site on manipulation, the ability to lift the leg from the bed without pain, and x-ray evidence of ample bony callus.

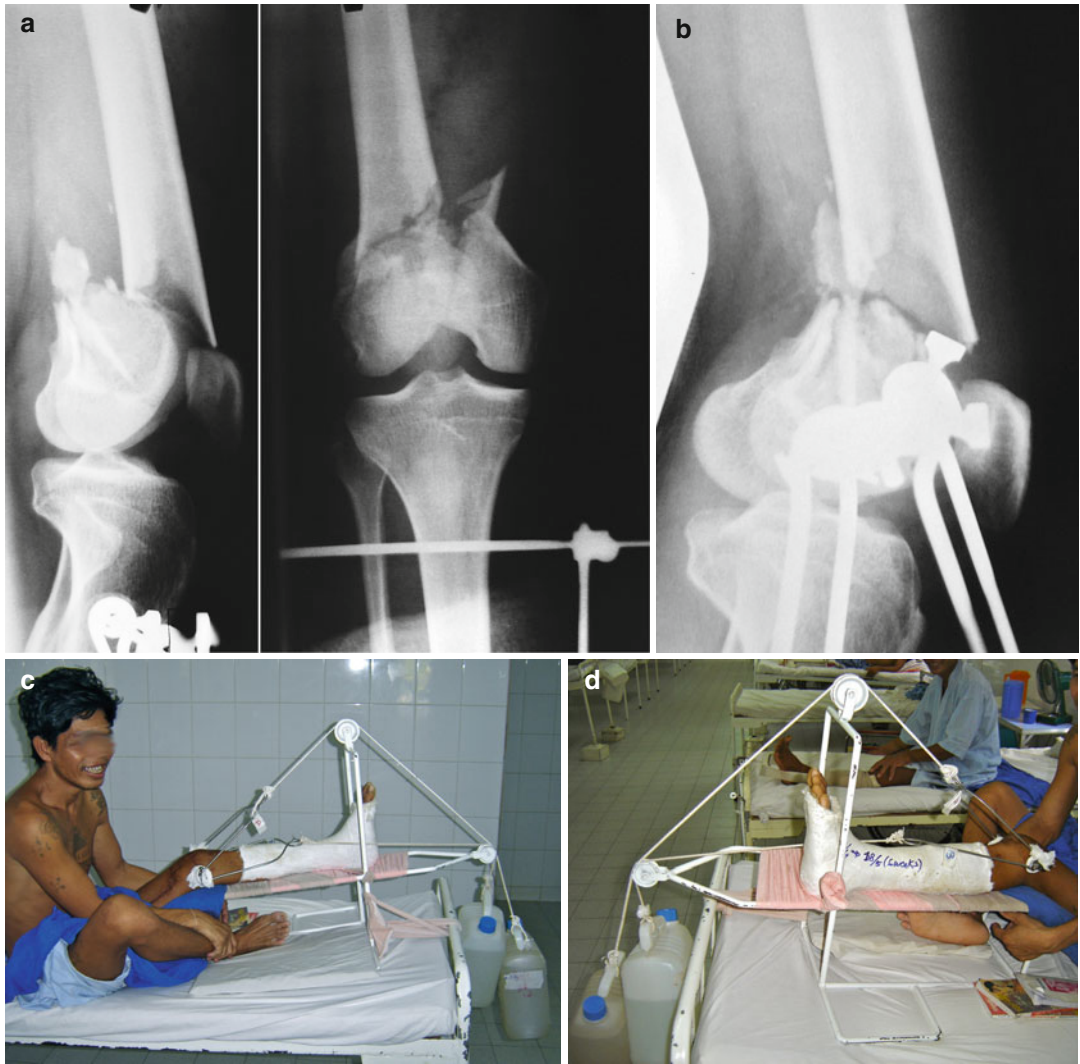
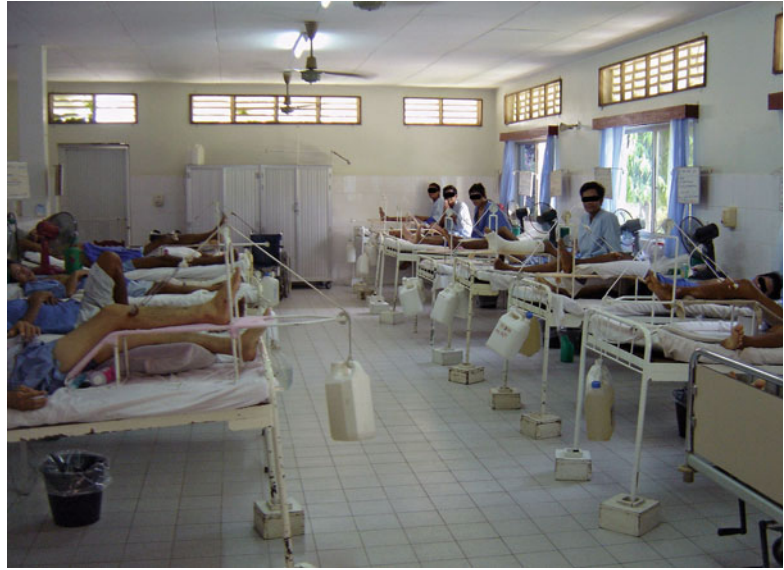
Fig. 13.18 (a) A comminuted supracondylar femur fracture with minimally displaced intercondylar component (T-type) treated initially with proximal tibial traction. The residual posterior angulation was unacceptable. (b) Two Steinmann pins were inserted in the distal fragment, to keep the intercondylar component reduced and allow trac-

tion using different vectors to correct the angulation. (c, d) Traction setup, with the patient comfortable on Boehler-Braun frame. The short-leg cast immobilizes an ankle fracture. Notice date and duration written on the POP and the water jugs used as weights

Fig. 13.19 Typical adult male ward with most patients in skeletal traction and on Boehler-Braun frames. Note the bed blocks elevating the foot end of the beds



In many places Boehler frames are used almost as a routine (Fig. 13.19). They can be used with skin, skeletal, or no traction, as a place simply to elevate and rest the leg. Unless the hospital is supplied with various sized frames, it is not easy to control a fracture in this nonadjustable frame, and it has a high complication rate with knee stiffness, skin breakdown about the buttocks, thigh and heel, and equinus contracture. If used, it requires close monitoring.

Perkin's traction is one of the most versatile and functional traction setups (Fig. 13.20). Traction is applied with a proximal tibial pin. It uses no external frames or splints but requires a bed in which the distal third of the mattress and frame can be removed or folded out of the way while maintaining tibial traction, to allow the patient to sit and do exercises. The flexed knee position helps to control the femur in the correct rotation. It is useful for femoral fractures from the supracondylar to intertrochanteric areas.

The first few days of exercises in Perkin's traction are painful and may require analgesia and "encouragement," but pain is replaced by discomfort more rapidly than one would expect. This method is time demanding on physiotherapy as the exercises should be supervised, at least at the beginning, and done twice a day for at least 30 min. When it is used to its full advantage, it is not uncommon to see patients with 90° of knee

flexion by the fourth week. This method is thought to promote earlier and stronger callus, but possibly at the expense of a slightly higher pin tract infection rate [6].

Most lower extremity fractures treated in traction will benefit from elevation of the foot of the bed on bed blocks or stacked bed blocks to gain sufficient elevation. These are blocks of wood that raise the end of the bed. They can easily be made in the hospital's workshop or in the local bazaar, and their use should be part of nursing routine.

Few hospitals will have calibrated weights that fit onto a weight hanger. Some hospitals use bags of IV fluid, with easy calibrations of 1 liter equaling 1 kg. Empty water bottles filled with sand can also be used. Pre-weighed sand bags are another option, but local rocks—pre-weighed, labeled, and hung in a canvas bag—are the most common weights. In spite of all precautions, some resourceful noncompliant patients will find ways to negate the discomforts of prolonged traction (Fig. 13.21). Properly rotating traction pulleys and other components are often old, missing, and substitutions abound (Fig. 13.22).

The general principles applicable to patients on prolonged bed rest apply to those in traction: good nutrition, DVT prophylaxis, avoid pressure sores (particularly heel and sacral areas), standard daily pin management, active and passive mobilization of all joints, and in particular,

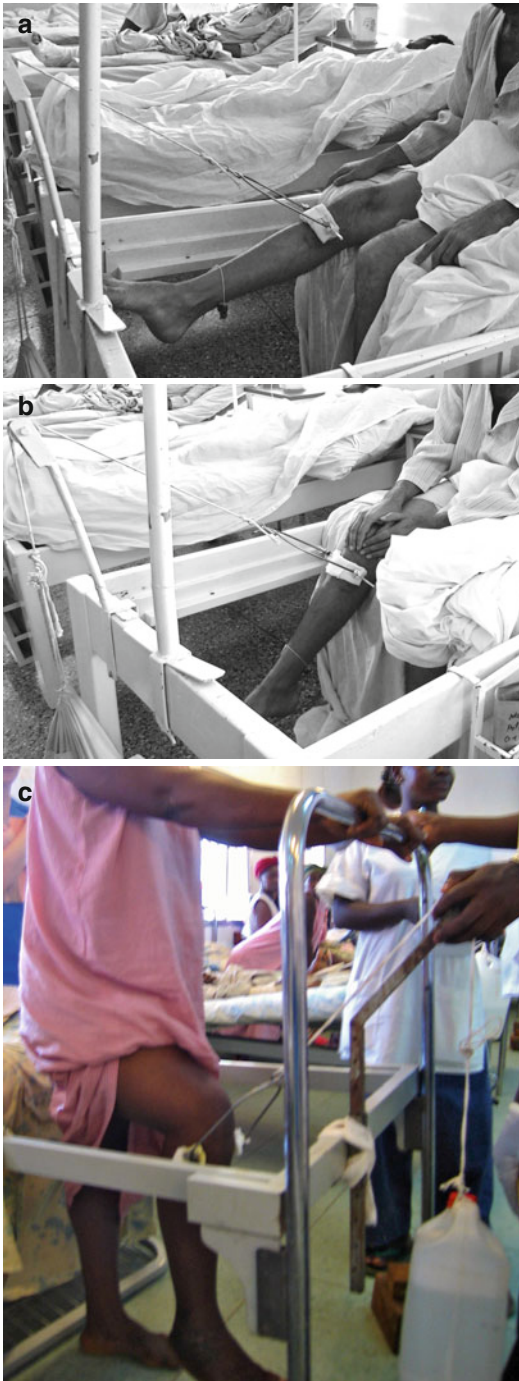


Fig. 13.20 (a, b) Perkin's traction setup, with patient doing active flexion/extension exercises. (c) In time the exercises can be done with the patient standing

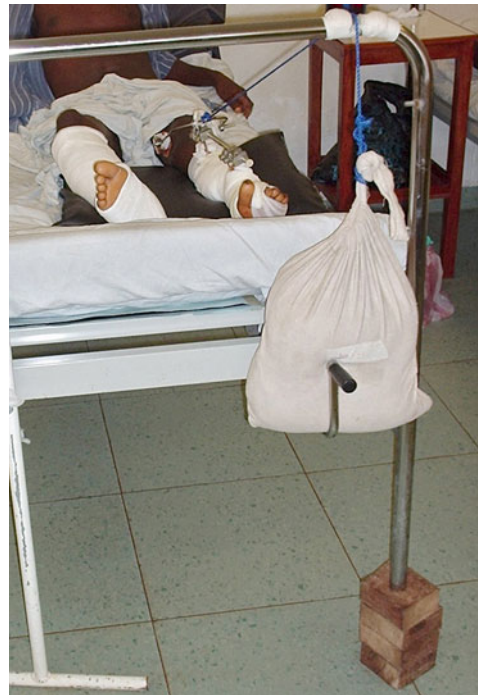

Fig. 13.21 This patient had a family member put the traction weight on the bed handle. Note the improvised "runner" to keep the traction rope abducted, the bag of rocks and the bed blocks

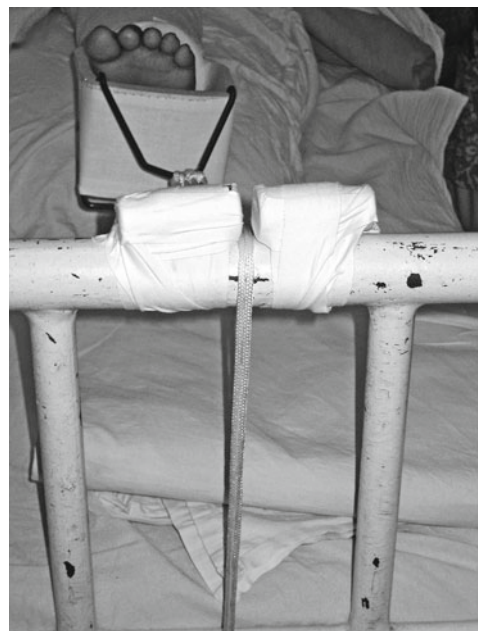
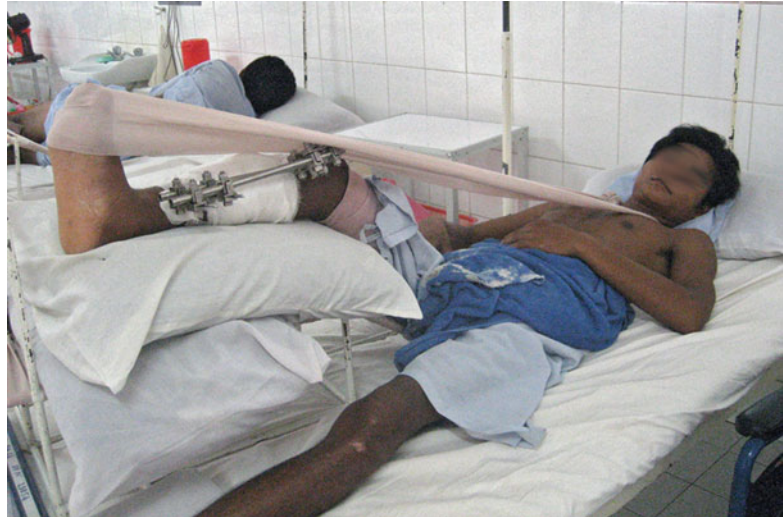
Fig. 13.22 Makeshift anti-sliding pulley apparatus

Fig. 13.23 Patient actively preventing equinus deformity with leg elevated on pillows and a Bohler-Braun frame



prevention of equinus deformity (Fig. 13.23). Exercises in traction are extremely important and an active physical therapy team will increase the success of this treatment modality. Patients should be taught isometrics, bed push-ups from a sitting position, bridging, and range of motion of all joints for which there is no contraindication. An overhead trapeze or ropes attached to a Balkan frame or the ceiling will go a long way to improving a patient's general physical condition. A program of upper extremity exercises using weights, heavy stones, or bricks will help occupy patients' long hours and prepare them for crutches. Just as using traction to treat fractures is not a license for benign neglect, a traction ward is not a lifeless space of patients waiting in endless boredom. Well-run traction wards should be vibrant with patients active in their rehabilitation.

Upper Extremity Traction

Upper extremity traction is used much less often than lower extremity traction. It might be useful on occasion as Dunlop's traction (Fig. 13.24) for elbow injuries in children, but care must be taken to avoid vascular compression with a tight skin wrap. Neurovascular status should be continually monitored. Skeletal olecranon traction is useful for elbow and distal humeral injuries in

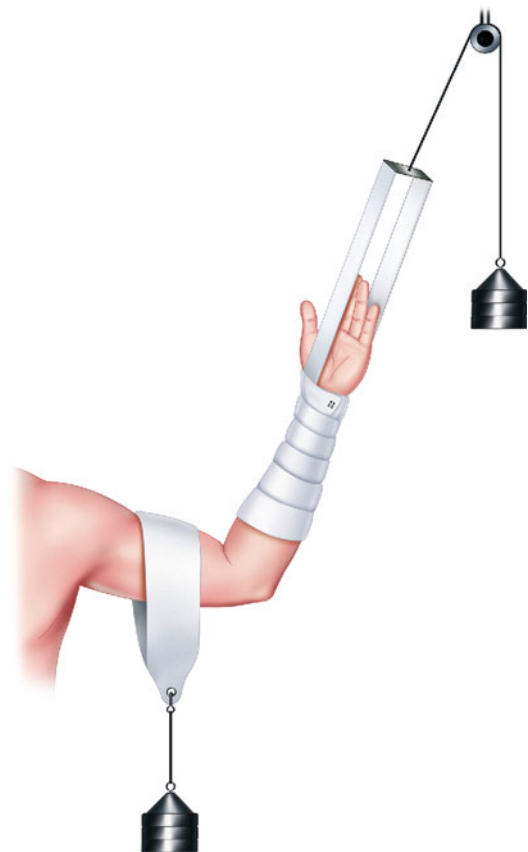


Fig. 13.24 Dunlop's traction

adults (Fig. 13.25). It can be arranged so the pull is horizontal, with the forearm hanging from an IV pole, or overhead, with just enough

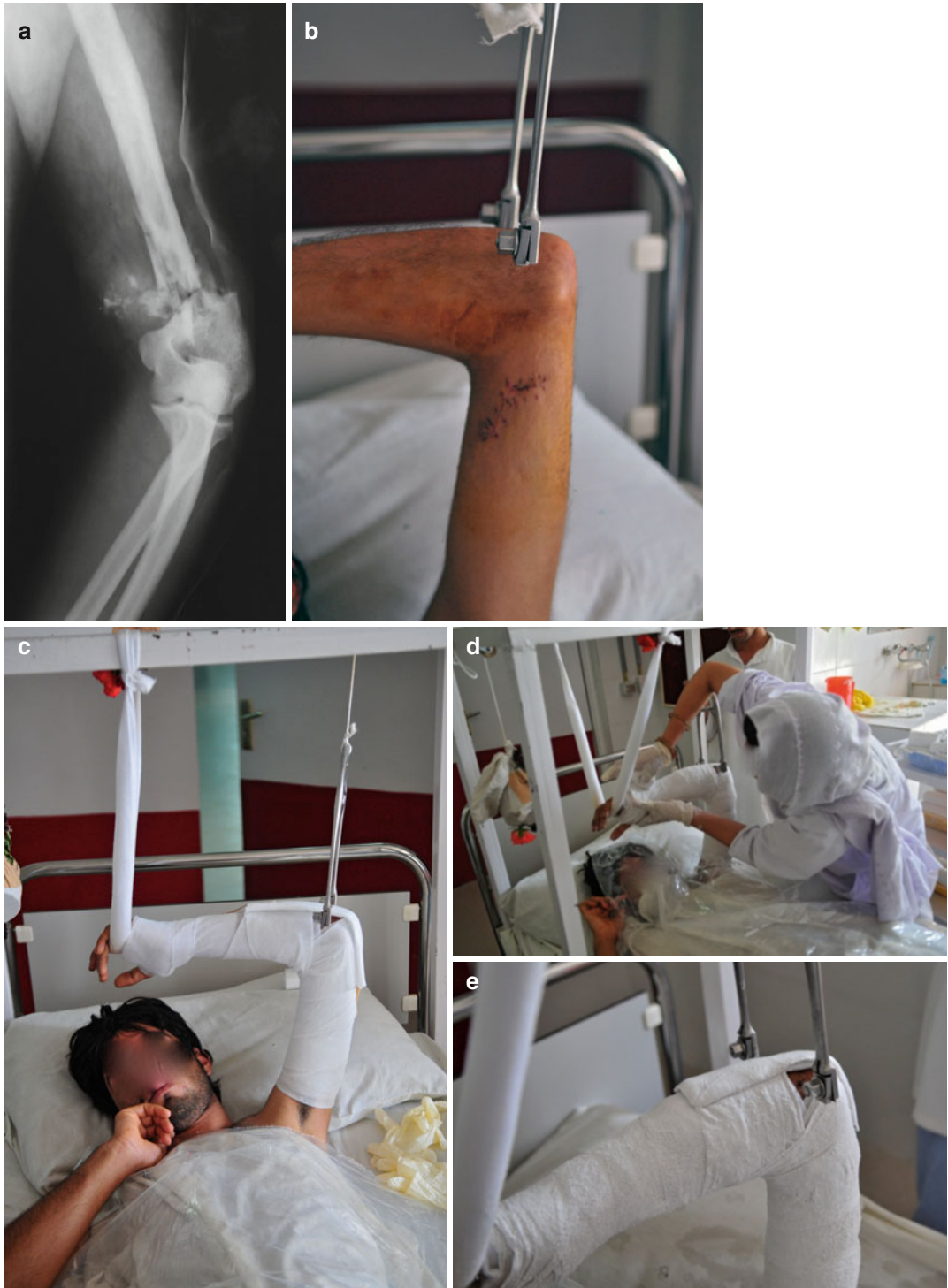

Fig. 13.25 (a) X-ray of GSW with comminuted distal humerus fracture. (b) Trans-olecranon traction. (c, d) At around 2–3 weeks, the fracture is sticky enough to be immobilized in an above-elbow POP, which is applied

while the patient is still in traction. (e) Once the POP is partially applied and set, the pin can be removed and the cast completed

weight to slightly lift the shoulder from the bed and the forearm resting at 90° in a sling. Active elbow motion while in traction should be encouraged.

References

1. Batta V, Dwyer AJ, Gulati A, Prakash J, Mam MK, John B. No difference in the long term final functional outcome after nailing or cast bracing of high energy displaced tibial shaft fractures. *J Trauma Manag Outcomes*. 2012;6(1):5.
2. Toivanen JA, Honkonen SE, Koivisto AM, Järvinen MJ. Treatment of low-energy tibial shaft fractures: plaster cast compared with intramedullary nailing. *Int Orthop*. 2001;25(2):110–3.
3. Bebbington A, Lewis P, Savage R. Cast wedging for orthopedic surgeons. *Injury*. 2005;36:71–2.
4. Byrne T. Traction handbook, Zimmerbooks. 9th ed. 2005. Available at: http://www.zimmer.com/web/enUS/pdf/200080500_TractionHandbook.pdf.
5. Gates DJ, Alms M, Cruz MM. Hinged cast and roller traction for fractured femur. A system of treatment for the Third World. *J Bone Joint Surg Br*. 1985;67(5):750–6.
6. Gosselin RA, Lavalley DJ. Perkins traction for adult femoral shaft fractures: a report on 53 patients in Sierra Leone. *Int Orthop*. 2007;31(5):697–702.

Nadine B. Semer

Wounds

Wounds are a common problem throughout the developing world and closure options are often a source of confusion. The history for a wound should include the following: causative event, chronicity of the wound, clinical course, and current treatment as well as a history of diabetes, tobacco use, malnutrition, HIV, and tetanus immunization. Examination of the wound will determine if it is clean, healthy, infected, or necrotic. All infected and necrotic tissues need to be debrided and the infection under control before closure.

Primary Closure

Primary wound closure requires the fewest long-term resources and the shortest wound healing time and is usually appropriate for patients who present within 6–8 h after injury (up to 24 h for face and some scalp wounds). If the wound cannot be closed without tension, it is better to leave it open to heal by secondary intention, create a flap, or skin graft.

N.B. Semer, MD, MPH, FACS
Plastic Surgery, Kaiser Permanente Downey
Medical Center, 9333 F. Imperial Hwy,
Downey, CA 90242, USA
e-mail: nadinesemer@yahoo.com

Delayed Primary Closure

Delayed primary closure is appropriate for wounds that are best treated by primary closure, but are over 6 h old, have questionably viable tissue at their base, or would have a very tight skin closure if closed primarily.

The wound is cleaned, packed open, and in 48–72 h reevaluated to be closed or re-debrided. It is useful to pre-place the skin sutures at the time of the first procedure. If closure is possible at the dressing change, the pre-placed sutures obviate the need for a second anesthetic. In austere environments, late presentation of wounds is common, making delayed primary closure a useful tool.

Secondary Closure

If the patient shows up many hours after injury or there is evidence of significant wound contamination, ongoing infection, or tissue necrosis such that primary closure is not possible or would be done under tension, it is best to clean the wound, debride the nonviable tissues, and leave it open to heal secondarily with regular dressing changes.

Local Care and Dressings

Studies show that wounds heal best in a moist environment [1] and there are many synthetic dressings and gels for wound care, these are

expensive and unlikely to be available. Wet to dry saline or dilute Dakin's solution dressings work well. Availability of gauze can also be a challenge. Dressings are best changed twice a day, though daily may be all that is possible (Boxes 14.1 and 14.2).

Box 14.1 Saline Solution

Boil a liter of water for 15 min in a covered pot. Add 1 tsp (5 ml) of table salt or cooking salt to this solution. Allow to cool, then store in a container with a tight lid. *NB:* this solution should not be used as an eyewash solution.

Dakin's Solution (*dilute sodium hypochlorite solution*)

For ¼ strength solution:

To a liter of NS, add 1.5 tsp of Clorox (sodium hypochlorite solution 5.25 % or plain household liquid bleach not concentrated). For ½ strength, double the Clorox. The container should be protected from light by wrapping it in aluminum foil and used within 3 days.

Box 14.2 Sugar Dressings

Sugar, as well as honey, has been used on open wounds including burns for centuries. It may work by decreasing wound pH, promoting epithelialization, or decreasing tissue edema through osmotic effects. In many areas it is cheap and readily available.

Place gauze moistened with betadine or saline onto wound. Coat this with sugar (~0.5–0.75 cm thickness). As the sugar draws moisture from the wound—an important component of the antibacterial properties of this dressing—the sugar will liquify. When this occurs, bacterial growth is promoted, so it is critical to change the dressing or add more sugar several times/day.

Vacuum-assisted closure (VAC) devices are frequently used in high-income countries to deal with problem wounds without resorting to flaps or grafts. Though presently expensive or nonexistent in low-income countries, the technology is changing such that they will become more readily available. Box 14.3 gives instructions for making a VAC from locally available materials.

Box 14.3 Do-It-Yourself Negative Pressure Wound Therapy

Supplies

Flexible tubing—similar to Jackson-Pratt drain tubing

Adhesive dressing such as Op-site or multiple layers of Saran wrap

Absorbent dressing material—gauze, foam prep sponges, OR towels, Kerlix, and kitchen sponges

Suction apparatus—requires access to wall suction or portable suction machine or a strong “hemovac-type” suction device.

Instructions

Place absorbent dressing material onto wound

- Place tubing within or on top of this material, not directly on the wound
- Cover with adhesive dressing or layers of Saran wrap
- Connect to suction (75–100 mmHg if you have a way to measure it, if not consider intermittent suction)
- Change every few days as needed [2, 3]

Skin Grafts

The following wounds will need a skin graft or flap because secondary closure will result in scar contracture that can severely limit function or cause significant disability:

- Wounds that will take more than several weeks to heal
- Wounds with exposed tendons, bone, and nerves

- Wounds in creases—antecubital fossa, dorsum of the ankle, back of the hand, and axilla

A split-thickness skin graft (STSG) is a partial thickness graft that preserves some of the dermis at the donor site, allowing it to heal on its own. A full-thickness skin graft (FTSG) takes the full thickness of the skin for the graft, requiring the donor site to be closed primarily.

Skin grafts receive their circulation from the recipient bed, making it critical that the wound is clean and the graft sutured in place. To prevent shear forces and promote vascular ingrowth at the graft-bed interface, the graft must be secured with a tie-over bolster, bulky dressing, or plaster splint and left undisturbed for 5–7 days. An STSG has a better chance for successful take on less than optimal surfaces than a thicker FTSG. An STSG can be used on wounds with exposed bone or tendons only if the thin, vascular overlying periosteum or peritenon is intact.

STSG

Most hospitals in austere settings have Humby or Watson knives to harvest an STSG (Fig. 14.1). The thickness setting should be 0.011–0.015 inch (0.25–0.4 mm); however, the dialed-in calibration on the knives is rarely reliable. To ensure

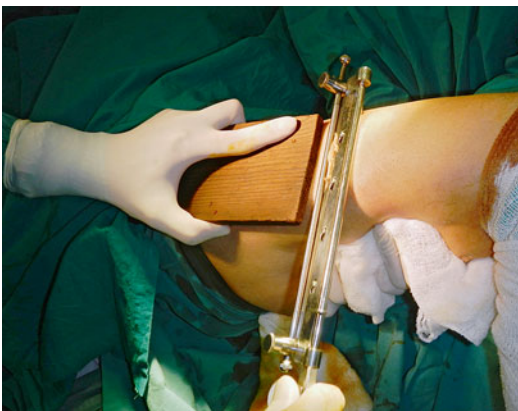

Fig. 14.1 The operator is holding a Humby knife at a 45°-angle while taking the STSG. A broad sterile wooden board puts pressure on and flattens the skin ahead of the knife

proper graft thickness, adjust the opening of the blade so that the beveled edge of a #10 blade fits snugly into the opening.

The most common donor site is the thigh. Wipe off any antibacterial solution that was used to prepare the site. Apply a sterile lubricant, such as mineral oil or vaseline from vaseline gauze to both the donor site and the instrument used to harvest the graft.

Technique

1. Have an assistant flatten the donor site, by placing tension on the skin with gauze or a wide flat object.
2. Hold the Watson or Humby knife with the sharp edge at a 45° angle to the skin.
3. With a back-and-forth motion, run the knife slowly over the tight skin.
4. As the graft skin is being taken, look at the wound. If fat is seen, the graft is too thick. If no pinpoint areas of bleeding are seen (paprika sign), it may be too thin (Fig. 14.2).
5. When enough graft has been harvested, cut the skin graft from the donor site with scissors.

Care of Donor Site

If local with epinephrine was not used at the start, apply a gauze wet with epinephrine solution (add 500 ml of saline to 1 ampule of 1:1,000 epi) to the donor site to control bleeding. Treat the donor site like a superficial burn, covering

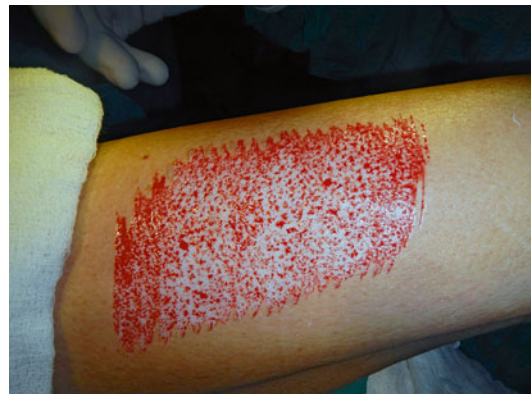

Fig. 14.2 The Paprika sign of small punctate bleeding vessels on the surface of an STSG donor site

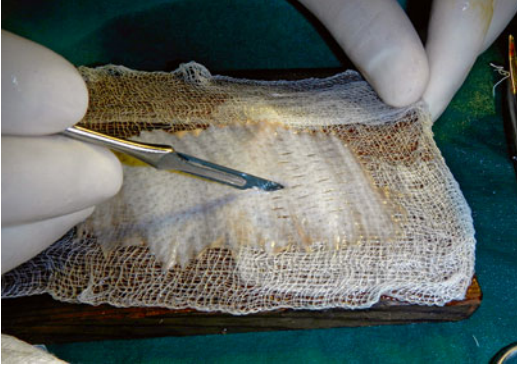

Fig. 14.3 Meshers are often unavailable. Many small cuts, made in a precise, concerted fashion will help expand the graft size. A wooden “cutting board” helps control the depth and size of the cuts

it with an adherent plastic dressing or a single piece of xeroform gauze and cover with a dressing. Remove the dressing at 24 h, leaving the xeroform open to air. It will form an eschar that will separate over the next 2–3 weeks.

FTSG

Primary donor sites for FTSG are the mobile skin of the lower abdomen, inner upper arm, and the preauricular area where the donor site can be closed primarily. Cut through the full thickness of the skin, and when the graft is free, place the epidermis side down, draped over a gauze-covered finger, and using sharp, curved scissors remove the underlying fat. This is critical, as fat will impede vessel ingrowth and the graft will not take.

Preparation of the Skin Graft

Place the graft on the wound dermis side down. Cutting holes in the graft with an 11 blade or scissors, pie crusting, helps it to cover a larger area, but without a true mesher, one must place a lot of cuts in the graft for it to significantly expand in size (Fig. 14.3). Pie crusting allows egress of serum or blood that prevents the graft's take. Suture from the graft to the edge of the recipient wound edge to keep the graft from displacing (Fig. 14.4). The graft can be secured with a tie-over bolster by

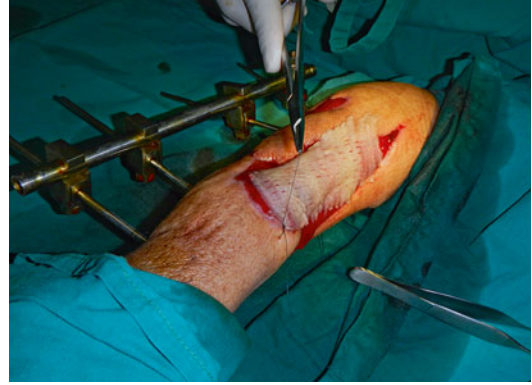

Fig. 14.4 STSG being sewn in place. Suturing from the graft to the wound edge stabilizes the graft and prevents it from displacement

leaving 6–8 cm lengths of suture spaced radially around the graft. These are tied over a mounded dressing of xeroform, Vaseline, or damp gauze to stabilize the graft. Plaster splints are helpful for immobilization and elevation to decrease swelling and promote healing.

Flaps

Wounds that require flap coverage are usually those with exposed bone or tendon or are in an area where a skin graft is not sturdy enough for long-term coverage, such as a pressure sore. A flap is a vascularized tissue, usually skin, fascia, or muscle, or a combination. A local flap can be created if there is sufficient tissue around the wound that can be moved into the defect. When local tissue is not available, a distant flap must be created. Initially the circulation to the flap comes from the donor tissue with gradual ingrowth of vessels from the recipient wound bed. Use of distant flaps needs to take into consideration the position of the parts and comfort for the patient to prevent joint stiffness due to immobility.

General Principles

To optimize circulation and reliability of a skin flap, heed the 3:1 rule: the flap should not be longer than three times its width. Proximally based flaps are more reliable than those based on dis-

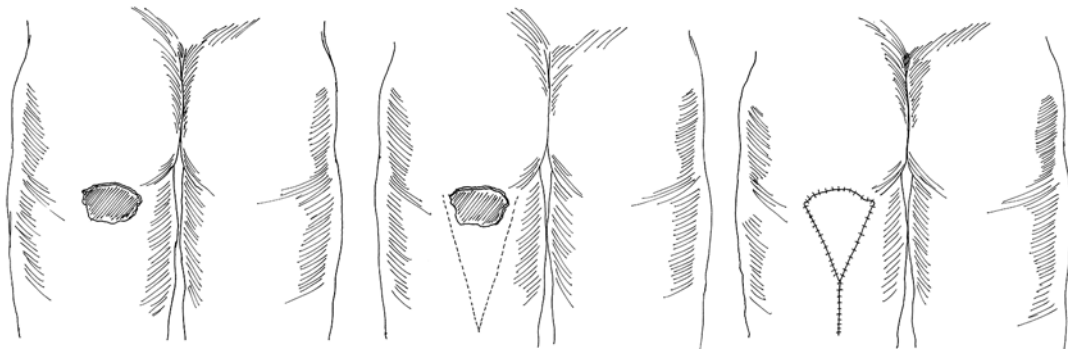


Fig. 14.5 Line drawing of V-Y plasty flap for covering an ischial pressure sore (Courtesy of Nadine Semer)

tal circulation. Delaying the flap—whereby the flap is incised and freed from all attachments except the pedicle and then loosely sutured back in place—will improve circulation by opening vessels within it. Wait 2–3 weeks to move the tissue into the defect. Close the flap defect with an STSG when a primary closure would result in undue tension.

Local Flaps

V-Y Advancement Skin Flap

A V-Y advancement skin flap is useful for covering ischial pressure sores and other wounds with lax surrounding tissues. They are commonly used for fingertip injuries when secondary healing is impractical. This flap counts on the deep tissue underlying the flap and the laxity of the surrounding tissues for its blood supply.

Procedure (Fig. 14.5)

1. Determine the site where the surrounding skin laxity is greatest.
2. Draw out the flap by marking the open part of the V at the widest edge of the wound, tapering gradually to a point.
3. Incise the skin edges through the subcutaneous tissue down to, but not into, the underlying fascia and muscle. The flap remains attached to the deep tissues.
4. Advance the flap into the wound defect.
5. Close the defect at the narrow point of the V, creating the vertical or tail component of the Y.

6. Suture the flap under no tension. It is better to have small gaps in the skin closure, which will eventually heal, than a tight closure and have part of the flap necrose.

Gastrocnemius Muscle Flap

A gastrocnemius muscle flap can cover exposed bone or a fracture site involving the proximal one-third of the tibia or the knee. It is best to do this flap within the first couple of weeks after injury before chronic inflammation in the surrounding tissues makes it difficult to mobilize the muscle. The best strategy is to move muscle alone and place an STSG over it.

The gastrocnemius muscle is the most superficial muscle of the posterior compartment of the leg. It originates from the distal femur and joins the underlying soleus muscle forming the Achilles tendon. The blood supply is a single dominant vessel that enters the muscle proximally, near the posterior knee joint. The medial muscle is most often used because it has a better arc of rotation to reach the front of the tibia.

Procedure

1. If available, use a tourniquet for the dissection.
2. Remove all dead bone and other tissue. If in doubt, debride, dress, and return in 3–5 days.
3. Extend the open wound onto the medial calf to visualize the underlying muscle. Try not to

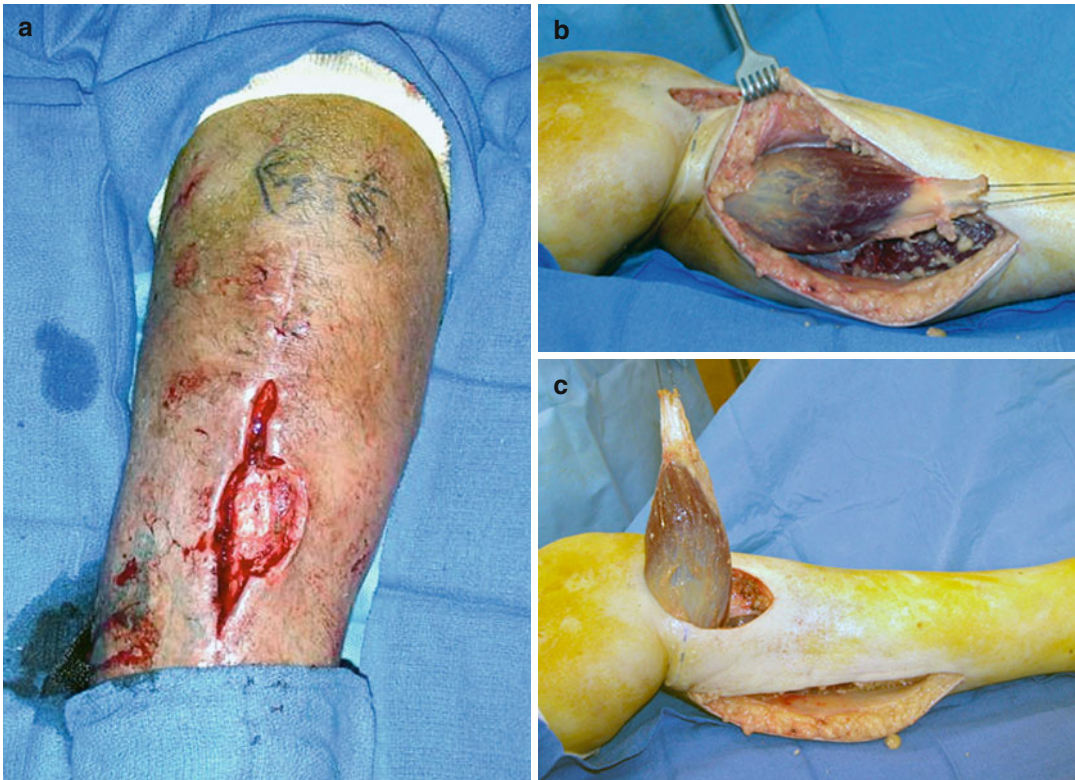

Fig. 14.6 (a) An exposed proximal tibia from a shrapnel wound that has been debrided. (b) The medial gastrocnemius is harvested through a separate incision. (c) The muscle has been tunneled under the fasciocutaneous

bridge to cover the exposed bone and will be sutured in place. Definitive closure is obtained with immediate or delayed (5–7 days) STSG

- leave intact skin bridges that can compress and necrose the muscle (Fig. 14.6).
4. Separate the gastrocnemius muscle from the overlying skin and underlying soleus muscle. This can often be done with blunt dissection.
 5. In the back of the calf, the two heads of the muscle come together at the central raphe, identified by the presence of the sural nerve. Divide the muscle along the raphe, transferring one-half of the muscle, and divide the muscle distally from the Achilles tendon.
 6. Bring the muscle around to the defect. Release proximal attachments as needed for length. Usually the origin of the muscle does not require division, but if additional length is required for the muscle to rotate into the defect, divide the origin with care to protect its vascular supply.

7. Once the muscle is freed, release the tourniquet and control bleeding.
8. The muscle should look pink when the tourniquet is removed. If it remains dark or does not bleed, the vascular pedicle has been injured and the muscle is unusable.
9. Suture the muscle loosely to the wound edges. If it cannot completely cover the wound, cover the important structures for which the flap is being made. An STSG can cover the soft tissues now or at a second procedure in 4–5 days.
10. Be sure the muscle is still pink after being sutured in place and is under no tension.
11. Close the skin extension primarily if possible and place a suction or Penrose drain in the defect.
12. Place the leg in a posterior splint, with instructions for bed rest and gentle elevation.

Keep the leg immobilized and elevated for at least 2 weeks after the operation. If the skin graft and all wounds look healthy at that time, the patient can dangle the leg, for a few minutes at a time, gradually increasing over the next few weeks. Gently wrap the leg with a compression bandage for several months to prevent swelling.

Soleus Muscle Flap

The soleus muscle flap is most useful for wounds in the middle of the tibia. This muscle has a segmental blood supply making it less reliable than the gastrocnemius flap. It is also deeper than the gastrocnemius, lying against the tibia, and can be severely damaged in injuries that particularly need coverage, such as open, comminuted, mid-shaft tibial fractures. The dominant vessel enters the soleus muscle in the top half of the muscle with smaller vessels feeding the muscle distally.

There may be cases where the need for tibial coverage exceeds the possibility of either a gastrocnemius or a soleus. When half of each muscle is used, both gastrocnemius and soleus can be used together without jeopardizing the function of ankle plantar flexion.

Procedure

1. If available, use a tourniquet for the dissection.
2. Be sure the wound is adequately debrided and that all the dead tissue and bone are removed.
3. Extend the wound onto the medial calf skin to visualize the underlying muscles. Try not to leave skin bridges, which will compress and diminish the circulation, necrosing the muscle. Identify the gastrocnemius muscle, the most superficial muscle in the calf. The plane of dissection is between the gastrocnemius muscle and the underlying soleus muscle. This can usually be done bluntly or with electrocautery when in the correct plane. Do not separate the gastrocnemius muscle from the skin. Any crossing vessels should be tied off.
4. Bluntly separate the soleus muscle from the muscles of the deep posterior compartment of the leg, taking care to avoid damage to the perforator vessels coming from the posterior tibial artery.
5. Release the tourniquet and control bleeding.
6. Determine whether the vascular supply to the muscle is sufficient to supply the flap by placing a small non-crushing clamp across the vessels that you plan to divide, before the division. If the muscle turns purple when the clamp is placed, the blood vessel you are basing the flap on will *not* supply enough circulation to the flap.
7. Divide the vessels not needed for flap viability.
8. Divide the muscle. If the flap is proximally based, divide the muscle from the Achilles tendon; if the flap is distally based, divide the muscle's origin. Bring the muscle to the exposed fracture or wound site.
9. Suture the muscle loosely to the wound edges. If the muscle cannot completely cover the wound, have it cover the exposed bone or tendons. Soft tissues can be covered with an STSG.
10. Place suction or Penrose drains under the muscle flap and from the donor area.
11. Place an STSG over the muscle at this time or in 2–5 days.
12. Place the leg in a splint and keep the leg gently elevated.

Post-op: Same as for gastrocnemius flap.

Excellent descriptions, pictures, and surgical technique for gastrocnemius and soleus flaps are available at GlobalHelp.org and can be downloaded as PDF files.

Fasciocutaneous Flap

Fasciocutaneous flap (Fig. 14.7) provides safe, simple coverage, requiring no special equipment or expertise. Using the 3:1 length to width ratio, skin, subcutaneous tissue, and deep fascia are raised from adjacent tissue and rotated to cover the defect. This random flap relies on the rich vascular network of the deep fascia.

Procedure

1. The flap is outlined allowing sufficient length to rotate it into position.
2. Starting at the end—distal if the flap is proximally based—cut through skin, subcutaneous, and deep fascia, keeping the three layers the same length.
3. Elevate the flap by dissecting in the subfascial plane.
4. Using fine sutures secure the fascia to the subcutaneous to prevent shearing of the layers.
5. The flap can be inset into the wound or if there is any question about its viability, it can be returned and sutured to its bed and inset in 2–3 weeks.

6. Apply STSG to the donor bed and other parts of the wound uncovered by the flap now or at a later date. A drain is advised.

Even with an ex-fix, a plaster back slab will help to prevent motion and equinus contracture.

Distant Flaps

Flaps to cover upper extremity wounds can be taken from the chest or abdomen. They require preop planning to map out a position that allows mobilization of the shoulder, the joints adjacent to the wound, and edema control. Initial postoperative immobilization must be secure enough to prevent the flap from kinking or pulling free when

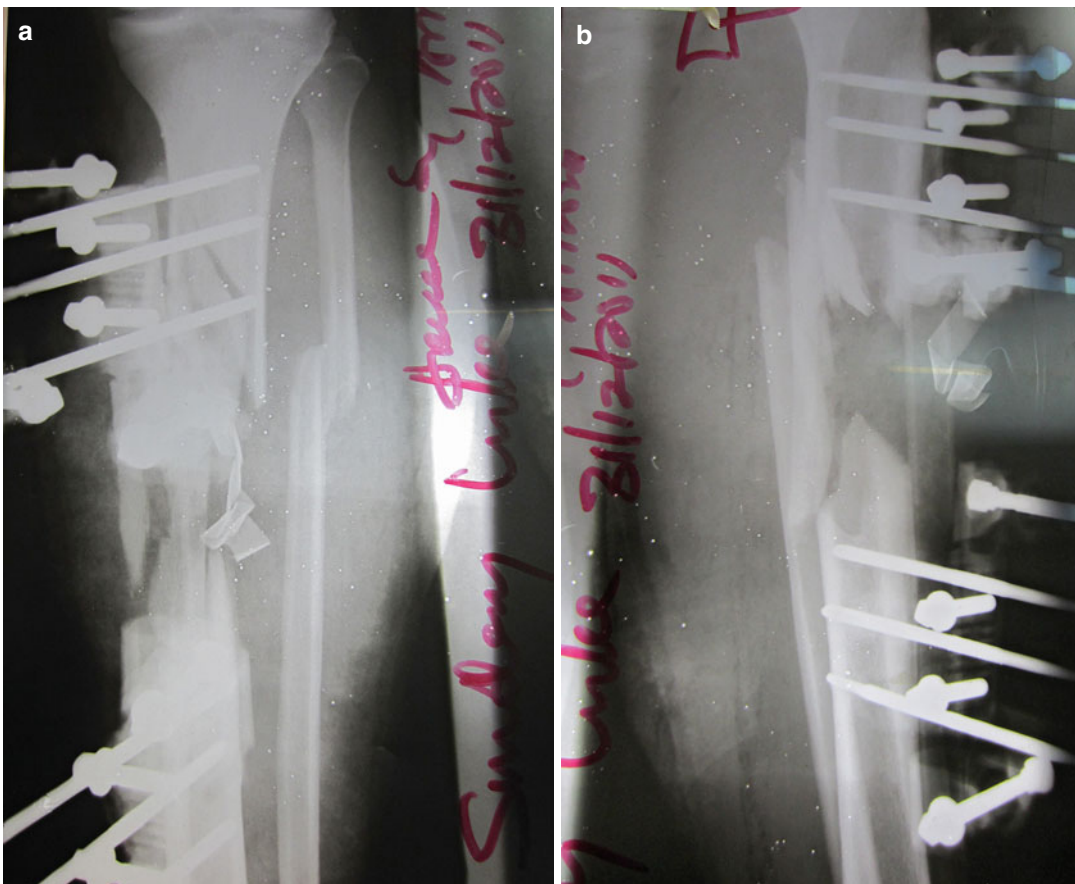

Fig. 14.7 (a, b) X-rays of a comminuted Gustilo IIIB tibial fracture with anterior bone loss. (c, d) A fasciocutaneous flap has been mobilized from the well-muscled lateral

side to cover the bone. Notice exposed lateral (c) and medial (d) soft tissues uncovered by the flap. (e) Five days later medial and lateral STSGs are placed

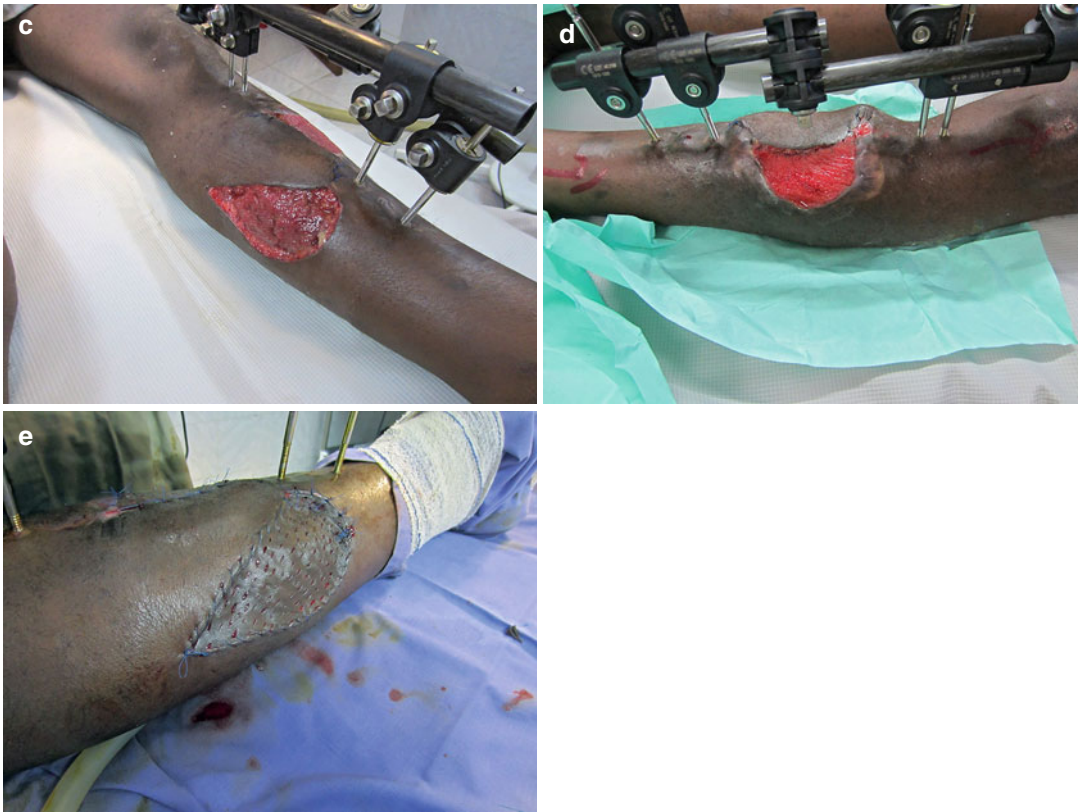

Fig. 14.7 (continued)

the patient awakens from anesthesia. Depending on the wound, these flaps can be done under general, regional, or local anesthesia

Procedure

1. Ask the awake patient to position the injured hand over the chest or abdomen in the most comfortable position. Stay away from breast tissue.
2. Mark this area. The flap should be drawn so that the hand can be comfortably attached and not kink the pedicle. Usually base the pedicle inferiorly, but any orientation can work. Avoid scars from previous injuries.
3. Design the flap so it is slightly larger than the defect.
4. Incise the skin, subcutaneous tissue, and underlying fascia. Do not incise muscle. The fascia contributes to the blood supply to the flap so keep it with the flap whenever possible.
5. Elevate the flap off the deep underlying tissues.
6. Loosely suture the three free sides of the flap in place. Leave small gaps if necessary to prevent a tight closure. Place a drain.
7. If unable to close the donor site, close with an STSG or allow it to heal secondarily.
8. Be sure you can see the flap through your dressings, so its circulation can be evaluated.

Groin Flap

See Fig. 14.8.

Cross-Leg Flap

This is a useful fasciocutaneous flap for complex wounds or fractures involving the distal third

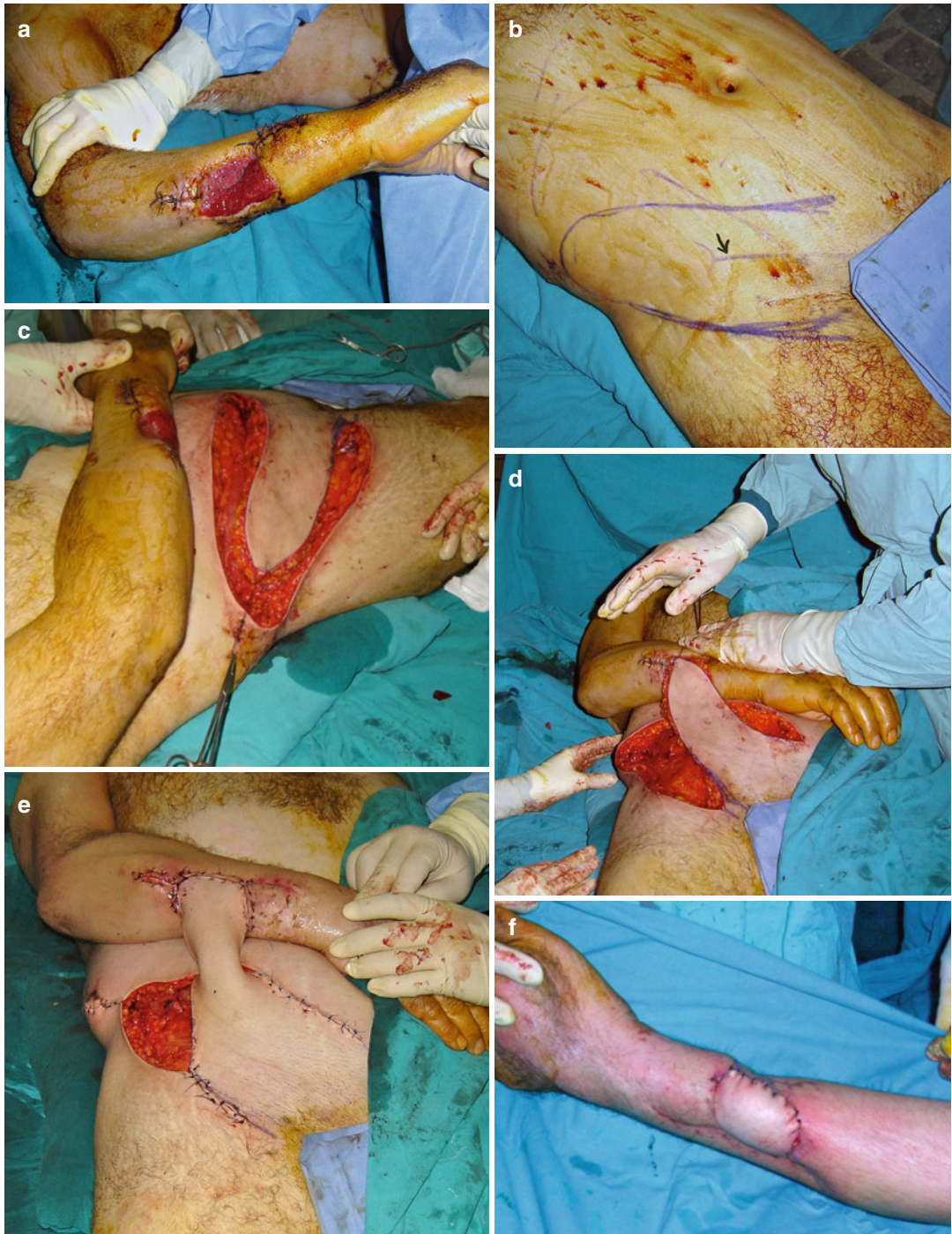


Fig. 14.8 (a) A shrapnel wound over the ulnar border of the right forearm, with exposed ulna. (b) Drawing of proposed flap, based on the superficial circumflex iliac artery (arrow). (c) Flap is elevated and (d) rotated to cover the

defect. (e) The flap is tubed and sutured to the recipient site. The donor site is partially closed primarily; the rest will be covered with STSG. (f) Appearance after the flap was detached at 3 weeks

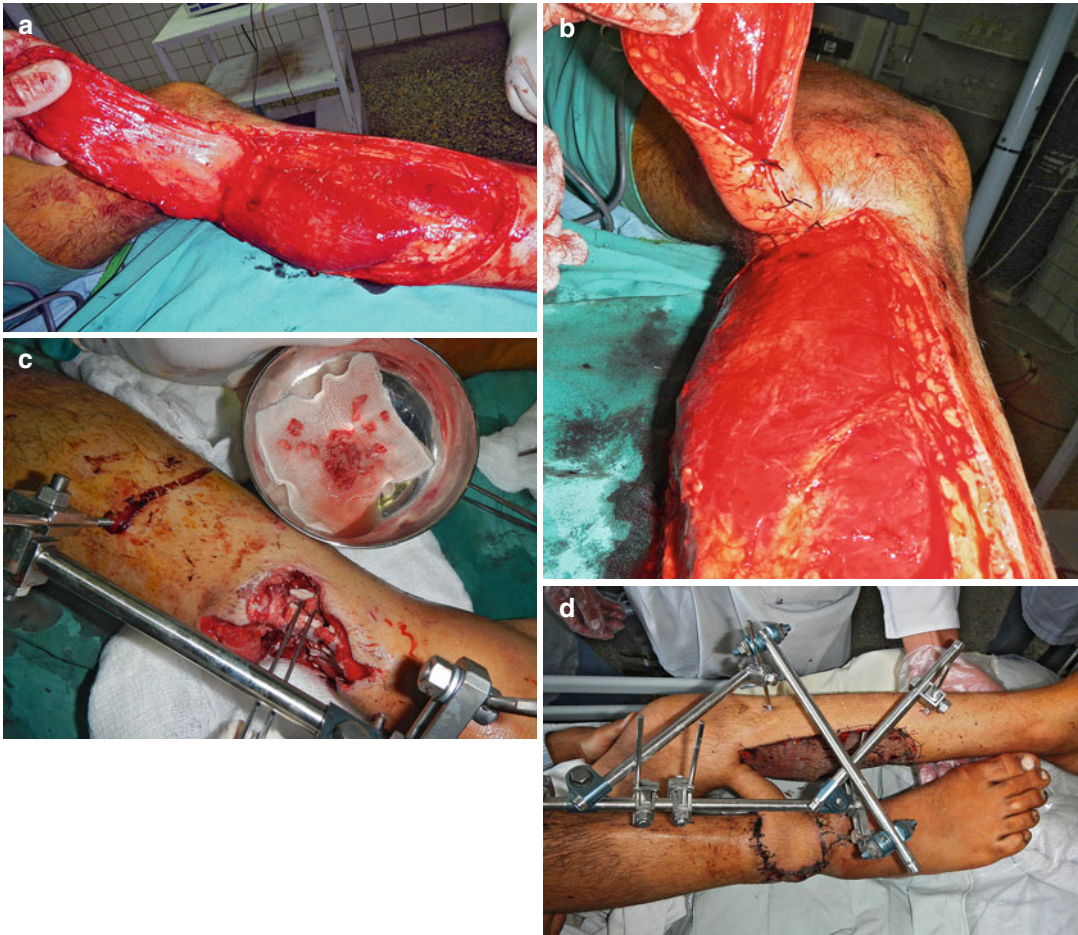

Fig. 14.9 Cross-leg flap. (a) A fasciocutaneous flap following the 3:1 length to width rule is raised. (b) The base of the flap is tubed to improve maneuverability. (c) Cancellous bone chips are placed in the distal tibial defect

before the flap is set. (d) Appearance 2 weeks after flap inset. Note: an external fixateur or plaster must maintain the legs in position

of the calf, ankle, or foot with exposed tendons or bone. The patient's legs must be immobilized together, in a relatively awkward position for 3–4 weeks, which can result in significant and permanent hip stiffness in adults, making it more useful in patients younger than ~25 years (Fig. 14.9).

Procedure

1. With the patient awake, determine the optimal leg position so that a flap of tissue taken from the non-injured posteromedial calf will lie easily over the defect with the least discomfort.
2. Draw the flap, slightly larger than the defect, with the pedicle based superiorly.
3. Incise the skin, subcutaneous tissue, and fascia as described above for fasciocutaneous flap.
4. Loosely suture the three free sides of the flap in place and place a drain.
5. Cover the donor site with STSG.
6. Immobilize the legs together. In children use a plaster hip spica cast with a bar connecting the legs. Window the plaster over the flap so it can be observed and cleaned. In adults, the plaster can often be loosened or removed after a few

days, but children will need to remain immobilized. An external fixateur will hold the position and also allow good access to the wounds.

General post-op care for all flaps involves cleaning the suture lines with saline or gentle soap and water. Apply antibiotic ointment if available.

Postoperative Troubleshooting

If any of the above mentioned flaps become swollen or bluish within a few hours of the operation, the circulation has been compromised—usually a venous, outflow problem.

1. Check positioning, especially if a distant flap, make sure the pedicle is not kinked.
2. Loosen the dressings.
3. Remove a few sutures.
4. Be sure no hematoma lies under the flap.
5. Be sure the patient is warm and has adequate pain control.

Flap division for distant flaps can usually be done ~4 weeks after the initial flap creation. If occlusion of the pedicle with fingers or an atraumatic clamp for 30 s creates pallor or loss of capillary refill, the flap should not be completely divided at that time.

Scar Modalities

Complete wound healing and scar maturation takes many months. Prevention of scar contracture is critical for optimal outcomes, especially when dealing with hand injuries. Simple scar massage is highly effective and can be done by the patient or family or a traditional healer. Two to three times each day, gentle massage to the scar will gradually soften the tissues and improve range of motion. Moisturizing lotions are useful and rural communities have local plant products that can be used. Massage needs to continue for months after the injury to limit tightness and contracture that can lead to decreased mobility and disability.

Tight, immobile scars unfortunately are common in patients who sustain deep burns to the

hand, antecubital fossa, axilla, and neck. The best treatment is prevention by splinting, range of motion exercises, early skin grafting, and scar modalities. However, when contractures are present, morbidity can be extreme. Z-plasty is a technique whereby the scar tissue is rearranged to lengthen the scar and improve mobility. Due to the geometry of creating the Z-plasty flaps, the gain in length is coupled with a loss of width, which can be problematic. In general, a more reliable way to treat scar contractures is to cut into or resect the tight scar to allow full range of motion at the joint and cover the resultant defect with a full-thickness skin graft. Be sure to use splints to immobilize the area and promote graft “take,” as well as prevent contracture recurrence. For fingers K-wires will keep the fingers in proper position; for children casting may also be necessary.

References

1. Field FK, Kerstein MD. Overview of wound healing in a moist environment. *Am J Surg* [Internet]. 1994 [cited 2012 Aug 13];167(1A):2S–6. Available from: <http://www.ncbi.nlm.nih.gov/pubmed/8109679>.
2. Bui TD, et al. Negative pressure wound therapy with off-the-shelf components. *Am J Surg*. 2006;192: 235–7.
3. Richards B. Negative pressure wound therapy. In: Richards B. *An orthopedist's workbench* [Internet]. 2010 [cited 2012 Aug 2]. Available from: <http://orthopodsworkbench.blogspot.com/2010/05/negative-pressure-wound-therapy.html>.

Suggested Reading from global-help.org as Free Downloads

- Kelleher J. Abdominal pedicle flaps to the hand and forearm. 2004. http://global-help.org/products/abdominal_pedicle_flaps_to_the_hand_forearm/.
- McCraw JB, Arnold PG, McCraw and Arnold's atlas of muscle and musculocutaneous flaps. 1986 and 2007. http://global-help.org/products/mccraw__arnolds_atlas_of_muscle_and_musculocutaneous_flaps/.
- Semer N. Basics of wound care. 2003. http://global-help.org/products/basics_of_wounds_care/.
- Semer N. Practical plastic surgery for non-surgeons. 2011. http://global-help.org/products/practical_plastic_surgery_for_nonsurgeons/.

William James Harrison

Introduction

Visiting clinicians need to be aware of the special considerations for orthopedic surgical care in patients with HIV/AIDS and the appropriate measures to prevent and treat occupational exposures. The human immunodeficiency virus (HIV) is a retrovirus that hides within the RNA of host cells. It targets T-helper (CD4) cells, depleting them in number and effectiveness, reducing host defenses and surveillance, and increasing the risk of infections and certain tumors. There are an estimated 33.4 million HIV-positive individuals worldwide, approximately two thirds in sub-Saharan Africa (22.4 million, prevalence 5.2 %) [1] and a higher prevalence in southern Africa. Trauma patients have a higher seroprevalence rate compared with national averages [2]. The South and South-East Asian region have approximately 3.8 million persons infected. While new diagnoses have decreased globally since 2001, the number of deaths remains static.

Combination drug therapy, highly active anti-retroviral therapy (HAART), has become increasingly available in resource-poor settings since 2003. HAART is effective in prolonging life, restoring activity levels, preventing maternal-fetal transmission, reducing infectivity, and generally

improving quality of life. Indications for HAART include (1) progression to AIDS (Pneumocystis carinii pneumonia), (2) CD4 count of ≤ 250 cells/mm [3], and (3) prevention of maternal-fetal transmission. These drugs are associated with side effects, some of which affect the musculoskeletal system.

Relevant Issues for Orthopedics and Traumatology

The author has identified several common associations between musculoskeletal diseases and HIV. Arthropathies are seen in adults and children—most commonly Reiter's syndrome and psoriatic arthropathy—and the clinician must differentiate inflammatory arthropathy from acute septic arthritis. While septic arthritis in association with HIV is unusual until immunity has been substantially reduced, inflammatory joint problems can occur at any stage.

Avascular necrosis (AVN), especially of the femoral head, occurs with HIV, though the pathogenesis remains unclear. AVN has been identified in patients on protease inhibitors, but many patients are symptomatic before starting HAART. Recently, osteoporosis associated with treatment has received attention in the Western literature, particularly after prolonged use of HAART. In sub-Saharan Africa this entity is not well described, perhaps because the use of HAART has been limited until recently. Infection with HIV/AIDS must always be suspected when adults are

W.J. Harrison, BM BCh, MA(Oxon),
FRCS (Trauma & Orthopaedics), FCS ECSA
Trauma and Orthopaedics,
Countess of Chester NHS Foundation Trust,
Liverpool Road, Chester CH2 1UL, UK
e-mail: jim.harrison1@nhs.net

diagnosed with septic arthritis. The association in children is not as strong [4]. Other conditions seen with frequency include infections (tuberculosis [5] and pyomyositis) and malignancies (Kaposi's sarcoma, non-Hodgkin's lymphoma). The association between HIV and TB is quite common and of particular interest to the orthopedic surgeon, as tuberculous musculoskeletal infections are much more frequent in HIV infected patients.

Those providing surgical care to patients with HIV/AIDS should be aware of how outcomes can be influenced, and misperceptions are common. The optimal method of fracture stabilization depends on the time of presentation, severity of soft tissue and other injuries, and local resources. There is no increased risk of wound infection following internal fixation of closed fractures in patients with HIV/AIDS [3, 6, 7] and no need for prolonged antibiotic coverage. However, the risk of infection following an open fracture is greater in HIV patients [3, 6, 7], and in the author's experience this risk can be reduced by aggressive debridement, early soft tissue reconstruction, and negative-pressure wound therapy where available [7]. Pin-track infections following external fixation are more common but are manageable [8].

While some reports suggest that fracture union rates are lower in patients with HIV/AIDS due to an impaired inflammatory response [4, 7], our experience does not support this. Delayed sepsis of an existing implant has been described, but it is unclear whether this represents reactivation of latent infection or a recent hematogenous seeding. In our experience this is an uncommon complication, and it is unnecessary to routinely remove implants. Patients with HIV/AIDS may be candidates for joint replacement, particularly total hip arthroplasty. The limited information shows that patients have satisfactory results at early follow-up with both uncemented and cemented implants; however, late sepsis remains a concern [9].

Occupational Hazards

The risk of seroconversion after an occupational exposure depends on the size of inoculation (higher in open injuries, hollow needles) and the patient's viral load (highest at initial

seroconversion and in late, untreated disease). Current information indicates that the overall risk after exposure is approximately 0.3 %, and this can be reduced up to tenfold by post-exposure prophylaxis (PEP) [10]. HAART reduces the patient's viral load dramatically, reducing the risk to health providers. The risk from exposure through local contact with mucous membranes is less than from a needle or bone spike stick.

Prevention is better than cure, and clinical staff must make every effort to reduce their exposure to HIV. In the author's practice, preoperative screening is only used to optimize patients for surgery and occasionally to guide decision-making or inform prognosis. We prefer to view all patients as potentially infected. This awareness should also reduce the exposure risks of hepatitis B and C. In the operating room, all personnel should wear protective eye wear or face shields and double glove. Sharp instruments (scalpels, needles) should be passed via a kidney basin. Needles are not re-sheathed, but kept in the kidney dish until disposal in a sharps bin. The author generally favors longer wounds to give better visualization and avoids blind finger probing around sharp bony edges. Instruments are used to reduce and hold bone fragments rather than fingers. Care must be taken to avoid excessive force, and tissues should not be devitalized when gaining exposure.

A hospital policy for PEP should be in place, and all staff need to be familiar with the protocol. The injury is immediately washed with soap and water and allowed to bleed, and mucous membranes flushed with water. The clinician and patient should immediately be tested for HIV, and the patient counseled regarding the event. In our experience, PEP is indicated when the patient is HIV positive and the clinician is HIV negative, although protocols vary between institutions and will evolve over time. The regime chosen depends on judged exposure risk, and treatment should be commenced as early as possible after exposure. Ideally, the results of blood tests are available within a few hours, and if not, the decision to begin PEP is based on clinical circumstances. This typically involves a 1-month course of antiretroviral therapy, though the specific

regimes often change, depending on local variables. Physicians travelling to endemic regions where PEP is unavailable should consider carrying a starter pack for PEP.

References

1. UNAIDS update. 2009. www.unaids.org/en/dataanalysis/epidemiology/2009aidsepidemicupdate/.
2. Harrison WJ, Lewis CP, Lavy CBD. Wound healing following implant surgery in HIV positive patients. *J Bone Joint Surg Br.* 2002;84-B:802–6.
3. Aird J, Noor S, Lavy C, Rollinson P. The effect of HIV on early wound healing in open fractures treated with internal and external fixation. *J Bone Joint Surg Br.* 2011;93B:678–83.
4. Lavy CBD, Thyoka M, Pitani AD. Clinical features and microbiology of 204 cases of septic arthritis in Malawian children. *J Bone Joint Surg Br.* 2005;87B:1545–8.
5. Govender S, Harrison WJ, Lukhele M. Impact of HIV on bone and joint surgery. *Best Pract Res Clin Rheumatol.* 2008;22(4):605–19.
6. Harrison WJ. HIV/AIDS in trauma and orthopaedic surgery. *J Bone Joint Surg Br.* 2005;87B:1178–81.
7. Harrison WJ, Lewis CP, Lavy CBD. Open fractures of the tibia in HIV-positive patients – a prospective, controlled, single-blind study. *Injury.* 2004;35:852–6.
8. Norrish AR, Lewis CP, Harrison WJ. Pin-track infection in HIV positive and HIV negative patients with open fractures treated by external fixation. *J Bone Joint Surg Br.* 2007;89B:790–3.
9. Brijlall S. Arthroplasty in HIV infected patients – a 5 year follow-up. *J Bone Joint Surg.* 2008;90B Suppl 111:473.
10. Lemaire R, Masson J-B. Risk of transmission of blood-borne viral infection in orthopaedic and trauma surgery. *J Bone Joint Surg Br.* 2000;82B:313–23.

K.A. Kelly McQueen, Ercan Türeci,
and Errol Peter Lobo

Introduction

The recognition that anesthesia is an essential component of health care in the developing world parallels the increased need for surgery in these countries. Armed conflicts, natural disasters, and the epidemic of traumatic injuries from motor vehicle crashes are the root of this increasing need, coupled with the shift in obstetric care from the home to clinic or hospital.

While anesthesia practice in high resource countries is fairly standard, in the developing world it varies from country to country and within countries from urban to rural. In most low-income countries, and many lower middle-income coun-

tries, one must assume that human resources, anesthetic medications and supplies, monitoring equipment, and medicines for resuscitation are scarce and preventable anesthesia death rates will be unacceptably high. When resources are doubly challenged by disaster or conflict, the balance tips further against the survival of the patient. However, even in the most austere setting, it is possible to deliver a safe anesthetic, relying on basic clinical skills of observing, touching, and listening to the patient.

This chapter outlines the anesthesia options and the constraints an orthopedic surgeon is likely to find in a resource limited environment. Instructions for some useful blocks are included.

K.A.K. McQueen, MD, MPH (✉)

Department of Anesthesiology,
Vanderbilt Anesthesia Global Health and Development,
Vanderbilt Institute of Global Health, Vanderbilt
University Medical Center, 1301 Medical Center Drive,
#4648 TVC, Nashville, TN 37232, USA
e-mail: kamcqueen@gmail.com

E. Türeci

Department of Anaesthesiology and Reanimation,
Cerrahpaşa Medical Faculty, Istanbul University,
Cerrahpaşa, Fatih, Istanbul 34097, Turkey
e-mail: etureci@yahoo.com

E.P. Lobo, MD, PhD

Perioperative Services, University of California San
Francisco, San Francisco, CA, USA

Department of Anesthesia and Perioperative Care,
Moffitt-Long Hospital, 505 Parnassus Avenue,
Room M175, San Francisco, CA 94143, USA
e-mail: loboe@anesthesia.ucsf.edu

Settings

In most district, provincial, NGO, and mission hospitals, anesthesia is given by nurses who have had additional training in the basic anesthesia possibilities particular to that setting. Often the anesthetist works alone without the assistance of an MD anesthesiologist or anesthesia technician.

Anesthesia usually means a combination of regional or spinal anesthesia and ketamine. In many instances the anesthetists are remarkably competent in handling routine cases with few drugs and are experts at giving spinals under difficult conditions. Volunteer orthopedic surgeons may attempt to do more complicated and demanding cases than the anesthetists are used to, making it important that the surgeon recognize the

extra burden he or she adds to the system. During such cases, the surgeon needs to be present in the operating room for the times of potential complications—induction and awakening—and to offer general assistance in a supportive role throughout the case.

The WHO Surgical Safety Checklist is becoming the standard operating room procedure globally, and surgeons should not be surprised to find it in use—or at least taped to the walls—even in austere settings. The checklist does much to encourage the teamwork necessary for handling problems or complications

when working in an unfamiliar environment. It is an especially useful facilitator for communication between the anesthesia personnel and the surgeon. If working in a setting where the checklist is not being used, a volunteer surgeon can make a major impact by initiating its use (Box 16.1).

Box 16.1 WHO Surgical Safety Checklist

1. Before anesthesia:
 - (a) Identity, site, and procedure confirmed
 - (b) Site marked
 - (c) Anesthesia checklist complete
 - (d) Pulse oximeter on and working
 - (e) Assessment done for:
 - Allergies
 - Difficult airway, aspiration risk
 - Risk of blood loss >500 mL (7 mL/kg for children)
2. Before incision:
 - (a) Identify all the team members
 - (b) Confirm site and nature of procedure
 - (c) Check if prophylactic antibiotics given
 - (d) Anticipated critical events:
 - Estimated duration and blood loss
 - Anticipated non-routine steps
 - Patient-specific anesthesia concerns
 - Sterility or equipment issues
 - (e) Essential imaging displayed
3. Before patient leaves the operating room:
 - (a) Procedure confirmed
 - (b) All counts complete
 - (c) Specimen labeled
 - (d) Address any equipment problems
 - (e) Anticipated recovery and management issues

Adapted from WHO safety checklist available at: http://www.who.int/patient-safety/safesurgery/ss_checklist/en/

Perioperative Management

Pre-op

When preparing a patient for surgery, follow the hospital guidelines concerning time requirements for NPO, necessary blood work, and preoperative testing. If blood replacement is anticipated, make sure it is available either through an existing banking system or a community living blood bank. While blood typing is easily completed, and rapid assays are available for HIV, there are many stigmas surrounding blood donation in low-income countries, and blood is often unavailable.

Comorbidities may be unknown and the hospital will unlikely have the facilities for a thorough medical assessment, but a finger stick Hb, fasting blood sugar, and routine pre-op blood pressure monitoring are usually possible. Any questions or possible problems should be discussed with the anesthesia personnel the day before, or at least before the patient arrives in the OR, to make sure the patient is adequately assessed and everyone is comfortable. While emergencies must be responded to emergently, the urgent or semi-elective patient must be properly evaluated before surgery is considered.

Preoperative NPO can be culturally difficult to translate and understand. However, the consequences of a full stomach are universally known and cannot be compromised outside of emergencies.

Post-op

Postoperative care is a crucial point in the perioperative continuum and may need to be addressed by the surgeon. The absence of a recovery room or an ICU must be planned and compensated for. Post-op vital signs, airway control, mental status

evaluation, and monitoring are the responsibility of the surgeon as part of the operating team. Postoperative orders must include O₂ support (if oxygen is available), IV fluids and urinary output, antibiotics, and analgesia.

Approaches for the Pediatric Patient

Children are not small adults, and the anatomy and physiology as well as the emotional state of children must be known to those who care for them. The pediatric features which are unique include the airway, higher O₂ consumption with a tendency towards hypoxia, decreased blood loss tolerance, increased likelihood of metabolic and electrolyte disorders, greater sensitivity to drugs, and loss of body heat (Table 16.1).

Neuroaxial Anesthesia

Regional anesthesia—epidural, spinal, regional intravenous anesthesia (RIVA) and nerve blocks—is effective and safe for extremity surgery when working in areas of limited resources. If sterile

conditions can be provided, regional blockade can be used for postoperative analgesia. Local wound or surgical site infiltration combined with analgesia or ketamine can provide adequate anesthesia and analgesia for many orthopedic procedures and as pain control for injuries. Perineural, intra-articular, and surgical site infiltration of a local anesthetic will help decrease the need for postoperative pain medication (Table 16.2).

Specific Nerve Blocks

Blockade of a neuroplexus (axillary block of the brachial plexus) or a specific nerve (femoral block) or group of nerves (interscalene block) is a good option for orthopedic patients in settings where adequate monitoring is possible, oxygen is available, and the potential for neurotoxicity can be treated. Wrist and ankle blocks are easy to do (Figs. 16.1 and 16.2). Lidocaine and bupivacaine are the most commonly available local anesthetics. For fingers/toes, nose, or ears, *never* use solutions with adrenaline. Use 5 or 6 mL of the anesthetic per nerve and for each subcutaneous “field block” for a total of no more than 30–40 mL of local anesthetic.

Table 16.1 IV fluid need in pediatric cases

Body weight (kg)	Hourly	Daily
0–10	4 mL/kg/h	100 mL/kg/day
10–20	40 mL + 2 mL for every kg above 10	1,000 mL + 50 mL for every kg above 10
20 ↗	60 mL + 1 mL for every kg above 20	1,500 mL + 20 mL for every kg above 20

Fasting time fluid is calculated and ½ of it is given additionally in the first hour, then ¼ at the second, and ¼ at the third

Anesthesiologist should know the exact age and weight of the child

Table 16.2 Anesthetic agents for local and regional anesthesia

	Lidocaine		Bupivacaine	
	Concentration	Volume	Concentration	Volume
General local infiltration	1 % with adrenaline	30 mL	0.25 %	
Infiltr. of fingers, toes	1 % without adren.	20 mL	0.25 %	
Digital block (ring)	1–2 % without adrenaline	2–4 mL per digit	0.25–0.5 %	
Interscalene block	2 % without/with adrenaline	40 mL 30 mL	0.25–0.5 %	40 mL
Axillary block	2 % without/with adrenaline	40 mL 30 mL	0.25–0.5 %	40 mL
Intercostal block (flail chest)			0.5 %	2 mL for each
Spinal block			0.5 % (hyperbaric)	1.5–2 mL

Halve the dose in children under 1 year because of the risk of respiratory arrest

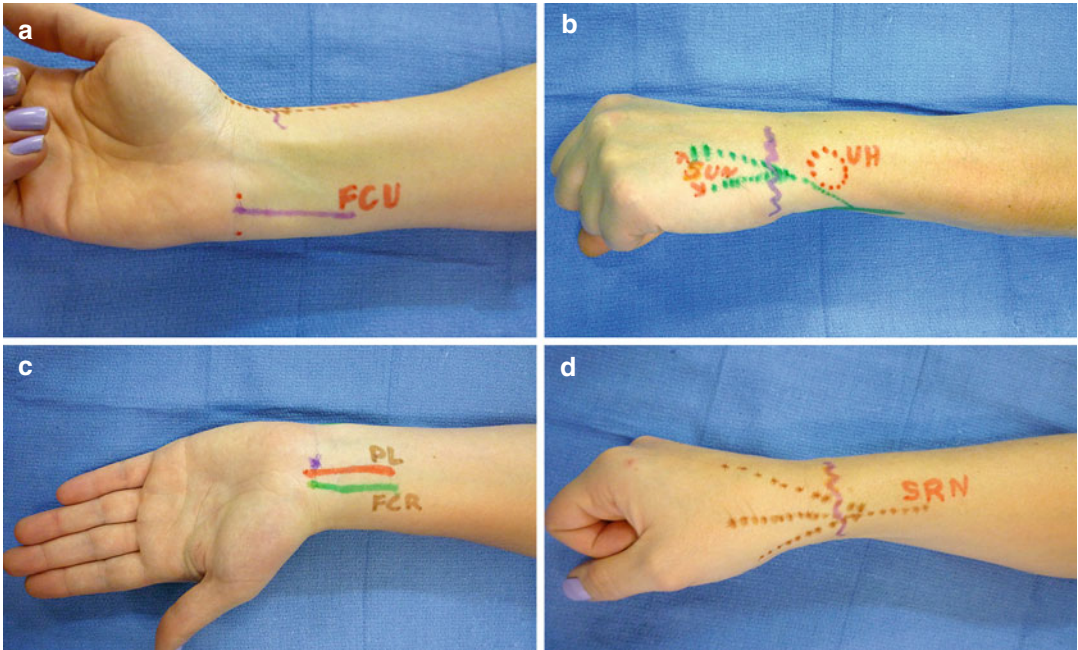


Fig. 16.1 Wrist block. (a) The ulnar nerve lies beneath the flexor carpi ulnaris (*FCU*) tendon and is reached by inserting a needle under the tendon just proximal to its carpal insertion. (b) The sensory branch of the ulnar nerve (*SUN*) is anesthetized with a “fan” or “field” subcutaneous block on the dorso-ulnar side of the wrist (*purple wavy line*), just distal to the ulnar head (*UH*). (c) The

median nerve usually lies between palmaris longus (*PL*) and flexor carpi radialis (*FCR*) tendons and can be reached from either side of the *PL* tendon. (d) The sensory branch of the radial nerve (*SRN*) emerges subcutaneously just dorsal to the tip of the radial styloid and is addressed with a transverse field block (*purple wavy line*)

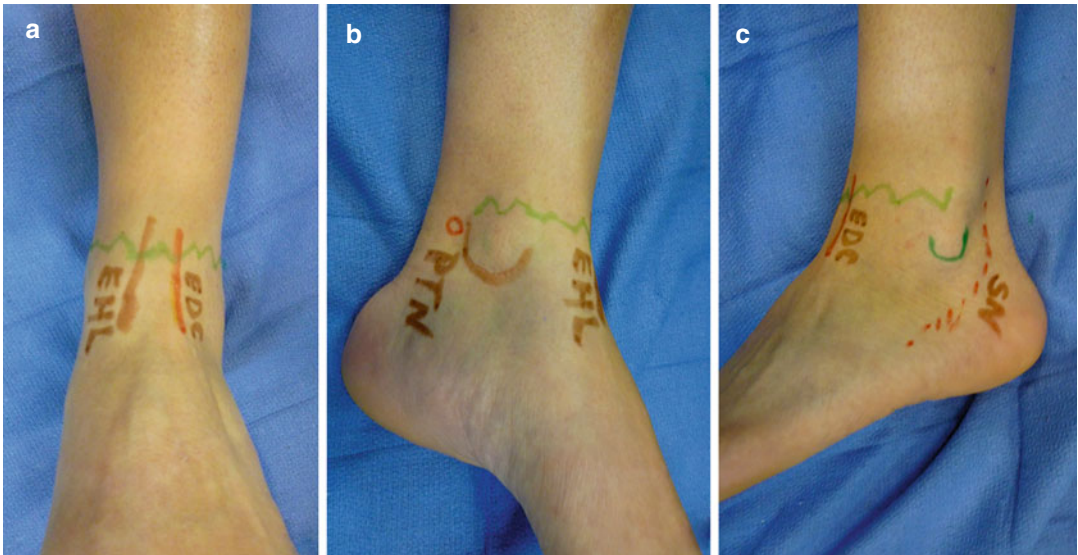


Fig. 16.2 Ankle block. (a) A “ringlike” field block can be done subcutaneously (*green wavy line*), blocking the saphenous nerve anterior to the medial malleolus and the superficial peroneal nerve lateral to the extensor digitorum communis (*EDC*) tendon. The deep peroneal nerve is blocked in the groove between extensor hallucis longus

(*EHL*) and *EDC* tendons. (b) The posterior tibial nerve (*PTN*) is blocked approximately 1 cm above and behind the tip of the medial malleolus. (c) The sural nerve (*SN*) is blocked at the midpoint between the Achilles tendon border and the tip of the lateral malleolus. The ring block should be continued circumferentially

Commonly Used Medicines

Anesthetic and pain medicines are often in limited and unpredictable supply in developing countries. Countries are obligated to have the drugs available that are listed in the World Health Organization (WHO) Essential Medicine List, but this is often compromised due to expense and supply chains. When used in combination, the main anesthetics on the essential list (halothane, ketamine, and morphine) can be safely used for most situations.

The following section is a review of some of the essential drugs useful in providing anesthesia in austere settings.

Opioids

Opioids mediate analgesia through a complex interaction of opioid receptors in the supraspinal central nervous system and provide reliable analgesia and some sedation and euphoria. They do not impair myocardial contractility but do reduce sympathetically mediated vascular tone and depress ventilation. Opioids given at recommended doses do not reliably produce unconsciousness but may decrease bowel motility and cause biliary spasm, nausea, and pruritus.

Morphine is relatively hydrophilic and has a slower onset with a longer clinical effect. Only a small amount of administered morphine gains access to the central nervous system, but it accumulates rapidly in the kidneys, liver, and skeletal muscles. Profound venous vasodilatation may be induced due to histamine release and reduction of sympathetic nervous system tone.

Meperidine (Demerol, pethidine) has one-tenth the potency of morphine and a shorter duration of action. In low doses it decreases shivering associated with rewarming after surgery and amphotericin-B administration. Several of its metabolites, including ones that cause seizures, may accumulate in the presence of renal disease.

Tramadol is a complex opioid analog of codeine that is available in many developing countries. It behaves in a similar fashion to tricyclic antidepressants. It is only one-seventh as potent as morphine and has a greater safety index

as it causes less respiratory depression. Nevertheless, it may produce seizures when used with MAO inhibitors, neuroleptic agents, and other drugs that lower the seizure threshold.

Non-opioid Analgesics

Diclofenac (*Voltaren*) is a nonsteroidal anti-inflammatory drug (NSAID) used for the treatment of mild to moderate pain, fever, and inflammation. It is available in most developing countries and can be used as an adjunct to opioids and other analgesics. Diclofenac is efficiently absorbed from the gastrointestinal tract. The starting dose is 25 mg orally three times daily, with a maximum dose of 150 mg/day

Paracetamol (*acetaminophen*) is widely available in developing countries—in the oral form or suppository form. It is available in 1,000 mg tablets with the daily dose not to exceed 4,000 mg. For infants and children, the recommended dose is 10–15 mg/kg, repeated every 4–6 h. Take care not to overdose in children.

Benzodiazepines

Benzodiazepines produce anxiolysis and sedation by facilitation of the inhibitory actions of GABA (gamma-aminobutyric acid) on nerve conduction in the cerebral cortex. They are used to produce sedation, amnesia, facilitate cooperation with medical care, attenuate alcohol withdrawal syndrome, treat seizures, and relieve muscle spasm. They have no analgesic properties and may cause a transient decrease in blood pressure, but have little effect on cardiac contractility. Respiratory depression is usually well tolerated in clinical doses, but may be accentuated in the elderly and those with COPD. Diazepam, midazolam, and lorazepam (Ativan) are three of the more commonly used benzodiazepines.

Diazepam (Valium) has a long clinical duration due to the long half-life of several active metabolites. It is not water soluble and therefore irritating when given intravenously or intramuscularly. It should not be used for patients with acute hepatitis. In musculoskeletal diseases,

diazepam is used as a “muscle relaxant” especially after contracture release or during fracture and dislocation reduction.

Midazolam (Dormicum, Hypnovel, Versed) is water soluble with a short clinical duration and few active metabolites. Its rapid onset with a greater degree of amnesia makes it a good choice for orthopedic procedures.

Other Drugs

Barbiturates have no analgesic effect and cause dose-related CNS, cardiac, and respiratory depression. Doses must be carefully monitored due to the increased likelihood of respiratory and hemodynamic depression especially in elderly patients. Medium-acting pentobarbital IV/PO and long-acting phenobarbital PO are used for violent agitation, such as status epilepticus that is refractory to other agents and the induction of barbiturate coma to treat increased intracranial pressure.

Propofol (Diprivan) is an ultrashort-acting intravenous anesthetic agent. It has potent sedative hypnotic activity with unconsciousness induced in less than 30 s followed by rapid awakening in 4–8 min with minimal residual sedative effects and good antiemetic qualities. It decreases systemic blood pressure as a result of myocardial depression and vasodilatation. When used in low doses—10–50 mcg/kg/min—as a continuous infusion for sedation, these effects are minimal. It has no analgesic effects but decreases narcotic requirements.

Ketamine produces a dissociative state along with intense analgesia. Agitated patients can be given an IM injection (3–5 mg/kg) or titration with 10 mg IV boluses to produce a cataleptic state in which the eyes remain open with a slow nystagmic gaze.

Ketamine’s amnesic, analgesic, and dissociative effects make it suitable for both induction and anesthesia maintenance. Additional advantages include maintenance of airway reflexes, cardiovascular stimulation, and bronchial relaxation. Disadvantages include increased airway secretions, transient increases in intracranial pressure, and an association with unpleasant visual or audi-

tory illusions. Addition of benzodiazepines may attenuate these untoward sensory effects. Ketamine is widely available in developing countries and is commonly used in the induction and maintenance of general anesthesia.

Induction can be achieved with an intravenous dose of ketamine, 2 mg/kg. The onset of action starts within 1 min and lasts 10–15 min. In some situations—particularly in older children and noncooperative patients—an intramuscular dose of ketamine, 7–10 mg/kg, may be used, with an onset of 3–5 min and will last about 15–30 min. Ketamine can be used as a maintenance anesthetic by continuous infusion at 2–4 mg/kg/h. In children under 1 year, halve the dose because of the risk of respiratory arrest. Medical staff should be aware of the catatonic unpleasant dreams associated with ketamine.

Anesthetic Vapors or Inhalational Agents

These agents are unpredictably available, as are their delivery systems. However, it is likely that they exist in many developing countries.

Management of Acute and Chronic Pain in Low Resource Settings

The role of pain in healing, disability, physical, and psychological well-being is only now beginning to be addressed in developing countries, and few doctors have been trained to appropriately dose narcotics and provide neuroaxial blockade and adequate local anesthesia for acute pain. Fewer physicians are comfortable providing treatment for chronic pain, while the medications needed for long-term chronic pain treatment are rarely available in low-income countries.

Acute Postoperative Pain Management

In low resource settings cost may be the main deterrent to proper pain management. Acute post-op pain management is often best managed

with a combination of local anesthesia given as infiltration or neuroaxial blocks, narcotics, and NSAIDs. Early in the postoperative period, there is little concern for significant side effects of narcotics or NSAIDs, and recent study has shown no evidence of NSAIDs interfering with bone healing [1]. Patients should be given the maximum per kilo dosage or dosed on a demand basis until comfortable. Ketamine [2] should be considered a potential adjuvant for narcotics for immediate postoperative pain. For any limb trauma, part of the pain treatment plan should include a neuroaxial block with a long-lasting local anesthetic or local perineural or incisional infiltration.

The surgeon has the responsibility at the end of the case, for incisional, intra-articular, or perineural infiltration. Most surgeons will be used to an anesthesiologist making the suggestion, giving them the dose, even drawing up the correct combination of meds. In many low resource settings, the surgeon may be working with a locally trained nurse anesthetist who won't make that suggestion or isn't as attuned to pain control.

Chronic Pain Management

Chronic pain is an unappreciated problem in low-income countries and leads to an unknown burden of disease, for which the long-term disability is likely large. Recognition of chronic pain is the first step in treating the common pain syndromes

that are associated with trauma and untreated cancer. Once identified, a treatment plan should be customized for the individual patient. Narcotics are rarely appropriate for chronic pain management, but NSAIDs and antiseizure medicines that decrease the transmission of painful signals to the cortex are appropriate for chronic use.

Neurontin—gabapentin, a GABA agonist—is commonly used as adjuvant therapy for chronic pain. This important drug is not included in the WHO Essential Medicine List and may be unknown to the practitioners treating chronic pain patients in low-income countries. The combination of Neurontin, NSAIDs, and local anesthetic blocks can be highly effective in treating chronic pain, including reflex sympathetic dystrophy (RSD) and phantom limb pain.

Conclusions

Providing safe anesthesia and pain control in low resource or unpredictable settings is essential, but is not intuitive. Specifically, orthopedic surgeons must be aware of the limitations and be flexible.

References

1. Kurmis A, Kurmis T, et al. The effect of nonsteroidal anti-inflammatory drug administration on acute phase fracture-healing: a review. *J Bone Joint Surg Am.* 2012;94:815–23.
2. Craven R. Ketamine. *Anesthesia.* 2007;62 Suppl 1: 48–53.

Part III
Adult Trauma

Michelle Foltz, Nadine B. Semer, Richard A. Gosselin,
and Geoffrey Walker

Introduction

Until recently, injuries were considered accidental events, occurring randomly—unpredictable and unavoidable. The 1996 Global Burden of Disease study (GBD) showed that at the population level, injuries, and their sequelae are like all other diseases and conditions that lead to premature death or ill health. Many people were surprised to learn that traumatic injuries accounted for 15 % of the total global burden of disease. No surgeon with experience in low- and middle-income countries (LMICs) would be surprised, as today, injuries in general—and road traffic

injuries (RTI) in particular—are widely acknowledged as the “neglected epidemic” of the developing world.

Vulnerable road users—children, pedestrians, and cyclists—are common victims. Besides the absolute increase in road traffic crashes in LMICs, there are more deaths and injuries per crash than in high-income countries (HICs), as each vehicle carries many more passengers. In the USA, drivers account for more than 60 % of vehicular deaths; in LMICs they account for less than 10 % (GBD). Considering the poor quality of road infrastructure, the number of unroadworthy vehicles, the lack of road safety laws or their enforcement, the paucity of prevention strategies, the poor quality of prehospital care, and often the hospital care itself, it comes as no surprise that the burden of vehicular injuries is increasing exponentially.

The lack of any social net is another significant difference between HICs and LMICs directly affecting orthopedic trauma care. There are few mechanisms by which an injured worker, even when injured on the job, is compensated for the injury, missed time, or wages. Because of these social hardships and other true or hidden costs, patients are reluctant to seek treatment unless absolutely necessary and often object to surgical treatments that involve prolonged hospitalization and extensive rehabilitation. For patients coming from remote areas, even if treatment is free, time away from fields and transportation costs are barriers to care, and certainly barriers to follow-up and many patients do not return for follow-up

M. Foltz, MD (✉)
172 Stillwater Loop Road, Columbus,
MT 59019, USA
e-mail: michellefoltz@gmail.com

N.B. Semer, MD, MPH, FACS
Plastic Surgery, Kaiser Permanente Downey
Medical Center, 2409 Cloy Ave,
Venice, CA 90201, USA
e-mail: nadinesemer@yahoo.com

R.A. Gosselin, MD, MPH, MSc, FRCS(c)
Department of Orthopedic Surgery,
Institute for Global Orthopedics and Traumatology,
UCSF, 1001 Potrero Ave, 3A-36,
San Francisco, CA 94110, USA
e-mail: froggydoc@comcast.net

G. Walker, FRCS (Eng and Ed), FCS (Hon), ESCA
World Orthopedic Concern,
9d The Grove, Highgate Village,
London N6 6JU, UK
e-mail: geoffreyf2.walker@gmail.com



Fig. 17.1 (a) This patient arrived in the OPD with an IV line in place and bottle strapped to a wooden pole wrapped in cloth for easier grip. Note bamboo splint over a swath of material protecting her left closed femur fracture. Local

clinics and first aid posts often have slatted bamboo splints readymade for immediate use. (b) Child arriving in hospital from clinic on *moto* taxi with IV line in place

unless there is a problem. All these elements need to be factored in when considering treatments, and whenever possible, serious consideration should be given to a “one-shot” treatment approach.

Acute Care

Due to distances between facilities, poor roads, lack of emergency transport, and systems, volunteers should not expect the sort of emergency room trauma resuscitation common in Western hospitals. When treating the injured in an emergency setting in a foreign country, it is beneficial to have a local doctor, nurse, or even an orderly interpret language and culture. They can help deal with the family in light of social expectations and in accordance with hospital requirements.

All acute trauma cases require evaluation using the Advanced Trauma Life Support protocols. Even if a patient presents late and has received treatment elsewhere, a brief but thorough ATLS exam should be completed.

Dehydration is common and often unrecognized. Even if the patient arrives with an intravenous line in place and fluids hanging, check the type of fluid and that the lines are open (Fig. 17.1). A Foley catheter for serial determination of urine output and color, as well as heart rate, respiratory rate, and blood pressure, may be the only clinical parameter for ongoing assessment. If the emergency department has a pulse oximeter, use it or share it with another patient. An initial Glasgow Coma Scale assessment should be recorded, even without indication of head injury (see Appendix 2).

Remove previously applied bandages and splints; sutures should be removed if there is any

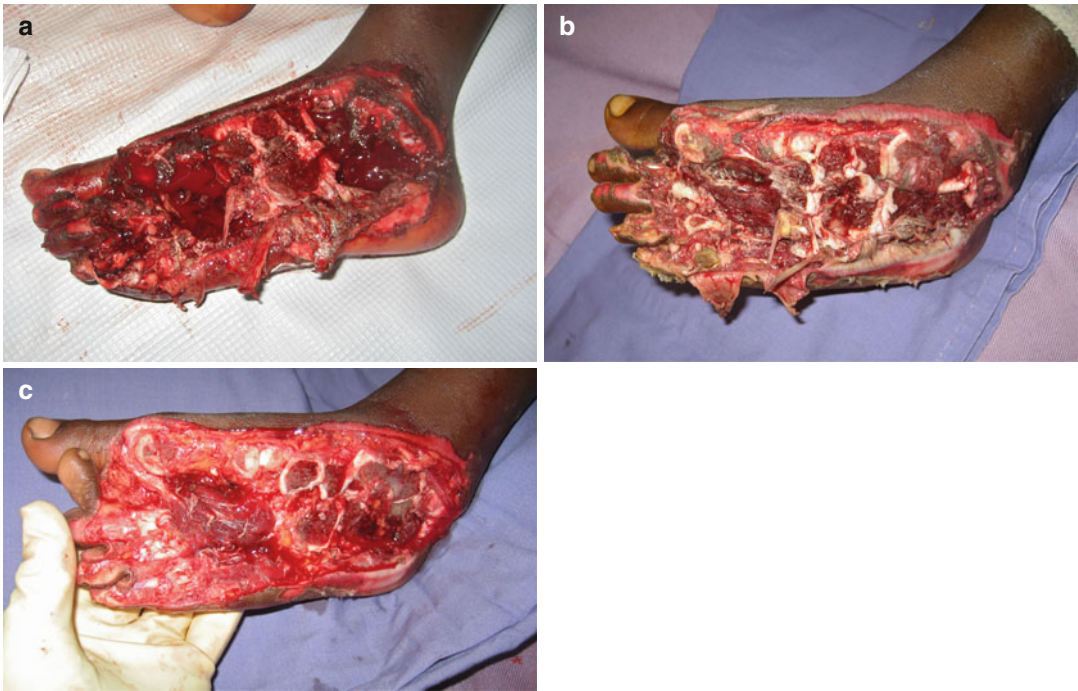

Fig. 17.2 (a) Avulsion of dorsum of foot—traction injury from a car’s tire running over child after she was knocked down. (b) Appearance after cleaning. (c) Appearance

after sharp debridement. In children these wounds often develop enough granulation to accept an STSG. Soft tissues that have lost bone can be used as a fillet flap

doubt concerning the cleanliness, tension, suitability of the repair, or the extent of the underlying injury, especially with the possibility of an open fracture. Complete disrobing may be difficult due to crowding, lack of curtains or private exam rooms, and culture. In certain societies, examining female patients, even by a female doctor, can lead to misunderstandings. A female staff member should be present; ask what is appropriate; explain what you plan to do and why. Families and patients used to offhand treatment in autocratic health systems usually respond positively when treated with respect and given thoughtful explanations [1].

Pay attention to the feet during the physical exam. Rubber flip-flops are common footwear and children often go barefoot, making crush and deep avulsion wounds common (Fig. 17.2). Foot wounds often have a distally based degloved, flap component. A minor but unaddressed foot injury can give more long-term disability than an open femur fracture.

X-rays, if the facilities are available, should be taken, but do not let the lack of advanced imaging or inadequate pictures interfere with clinical judgment. Patients with suspected femur fractures are often given one proximal femur x-ray and a distal femur x-ray in another plane (Fig. 17.3). A full complement of trauma films is unlikely while the logistics of obtaining additional views after admission can be extremely complicated. Digital films and processors are rare except in the private setting (Fig. 17.4). View boxes are few in number and x-rays are often viewed and assessed while held up to a window or light (Fig. 17.5), leading to faulty readings and missed subtleties. A white lab coat taped to the window will improve the detail (Fig. 17.6).

Many middle-income countries are developing trauma systems, but few hospitals in low-income countries have the staff and facilities for good triage. Emergency departments (ED) can be chaotic (Fig. 17.7) with triage based on the demands of a powerful family or the perceived

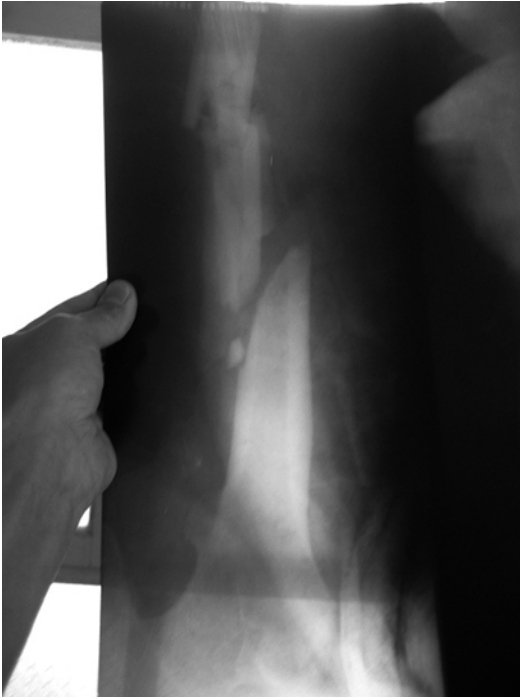

Fig. 17.3 A surgeon holding an x-ray up to light from a window because there is no view box in the operating theater. Note x-ray is inadequate to assess hip, proximal femur, or knee

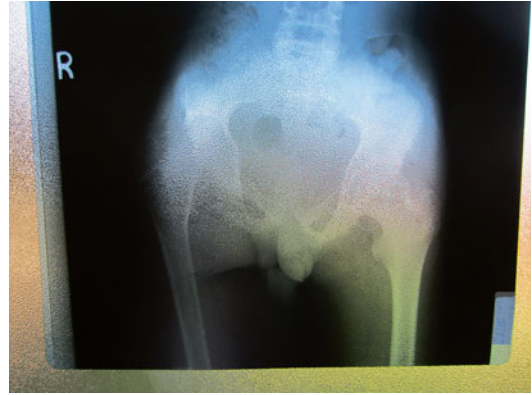


Fig. 17.5 Pelvic x-ray of child with AVN of R hip due to sickle cell disease read through window light

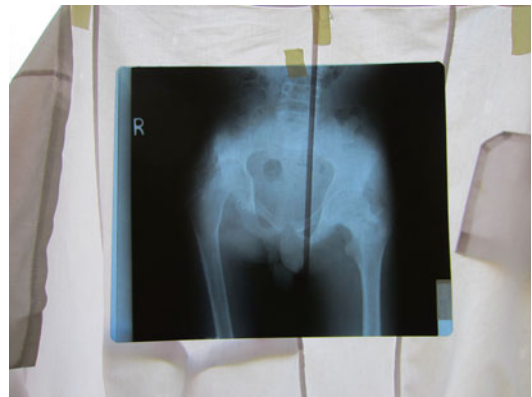

Fig. 17.6 The detail of the x-ray shown in Fig. 17.5 is improved when a white lab coat is interposed between the window and x-ray



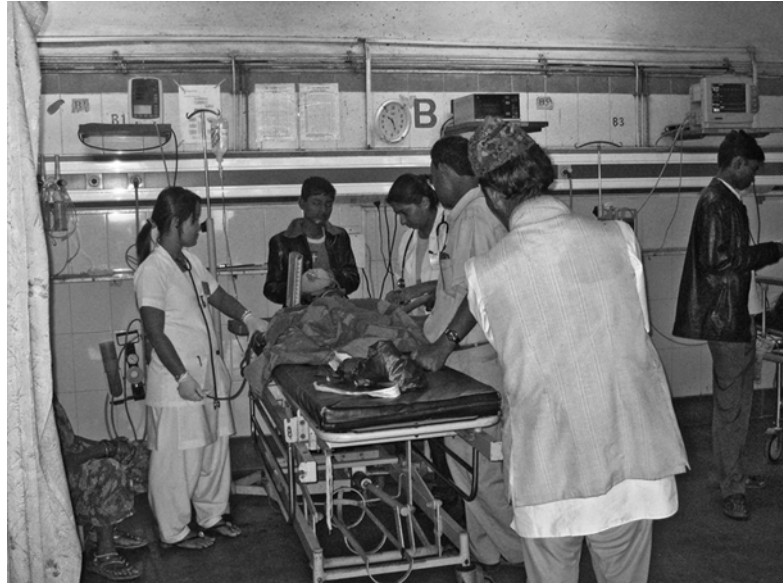Fig. 17.4 X-rays drying outside

importance of the hospital staff hierarchy. It may not make medical sense.

Hospitals may not have staff for night cases or obstetrics may take precedence, leaving trauma cases until the next morning, the next afternoon, or a couple days later. Hospitals that require payment up-front for services or overcrowded facilities in which the patient cannot obtain a bed can delay the initial surgical treatment. To avoid unnecessary frustration, try to find a modus operandi that will give the patient the best treatment within the systemic limitations. Remember, there is often more than one way to treat an injury that gives a good outcome.

If the injured patient is unable to go to the operating room in a timely manner, clean the wound in the emergency department with whatever sedation, systemic analgesia, or local

Fig. 17.7 A family member has been given the task to manually ventilate his relative while a nurse and doctor perform medical chores and other family members observe



anesthetic is available, using the cleanest fluid. Apply a bulky sterile or clean dressing. Splinting and elevation of all extremity injuries help relieve pain and prevent further local injury. Hospitals may have Steinmann pins and frames for traction, but do not be surprised if handed a mallet with which to hammer in the pin. Due to lack of equipment and supplies, improvisation is common.

Upper Extremity Injury with Tendon or Nerve Involvement

If appropriate sutures or instruments are not present to repair injured tendons or nerves, it is best to clean the wound, loosely close the skin, and apply a splint to avoid further injury. These repairs can be completed weeks later with good results if there is no infection and the soft tissues are stable. Poor, inadequate, or overly aggressive initial care can make a functional outcome impossible.

If one is comfortable repairing tendons and nerves and has the equipment, do not be heroic. Weigh the risks of equipment challenges and availability of hand therapy against hope for good outcome and be realistic. With multiple flexor tendon injuries, concentrate on repairing the flexor pollicis longus, one wrist flexor, and the profundus tendons.

Unless trained physiotherapists are available, it is usually best to splint patients for 6 weeks

post repair. Only in carefully selected patients is early motion a good option.

Degloving Injuries

Degloving injuries—whereby large swathes of skin are lifted, avulsed, or abraded from the underlying muscle—often include a significant crush as well as a shearing element. The tissue damage is often more extensive than it initially appears (Fig. 17.8).

Degloving injuries with flaps need to be closely evaluated. Explore and clean under all exposed undermined tissue, removing nonviable components. If the skin appears viable and the edges bleed, try to tack it loosely back in place but under no tension. Dress the extremity with loose splinted dressings and recheck in 1–2 days in the operating room to assess tissue demarcation. Even with optimal treatment, patients with degloving wounds are difficult to treat. The dead space under the flap and dying, damaged tissue make a great culture media and patients can become ill very quickly (Fig. 17.9).

Open Fractures

In countries where the motorbike and bicycle are the usual form of transport, open fractures are common, with open tibial fractures the most

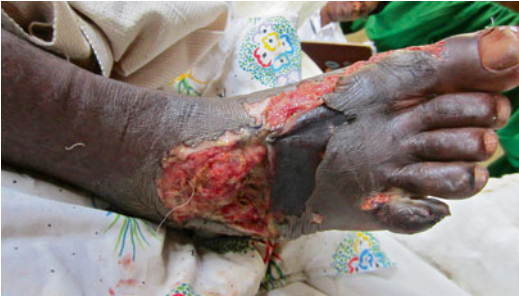

Fig. 17.8 On initial debridement, the extent of damage of this distally based flap was unrecognized. The tissue under the distally based flap was not explored and the flap was reattached under tension

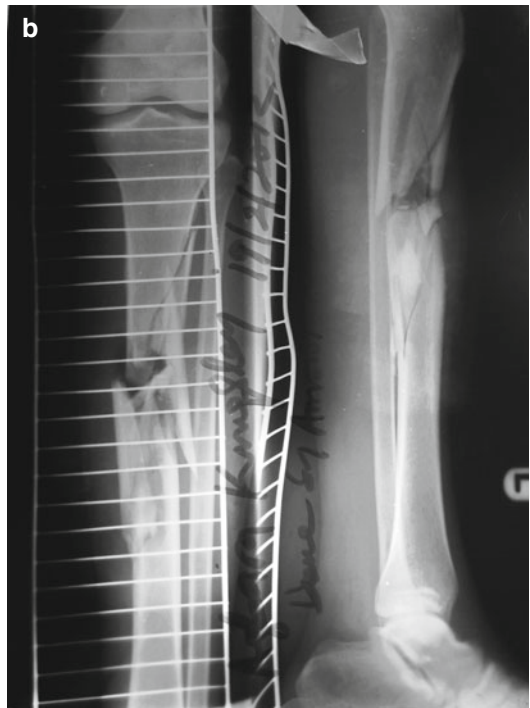
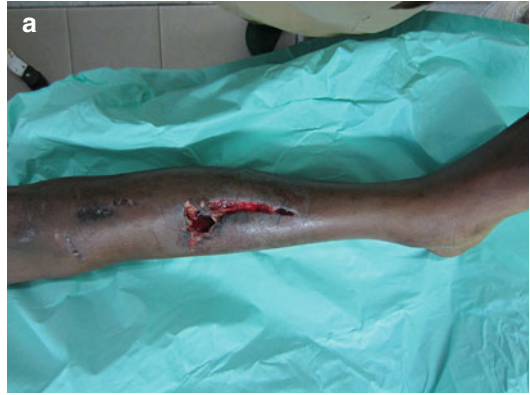
Fig. 17.10 (a) This patient was a passenger on a motorcycle taxi. He spent 2 days in another hospital without treatment. At the time of his presentation, the wound had a foul odor and the soleus muscle was necrotic. (b) The major bone fragments seen in his x-ray had no soft tissue attachments

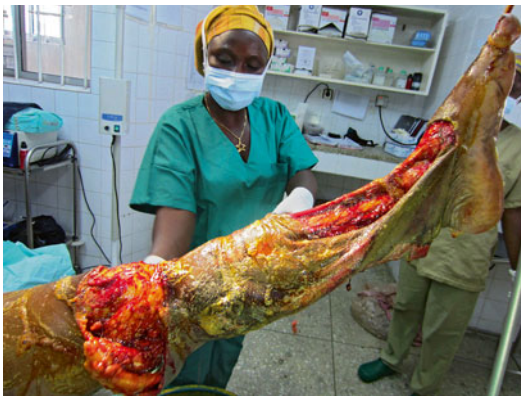

Fig. 17.9 Circumferential degloving injury of left leg, with loss of skin from mid-thigh to midfoot after the leg was run over by a heavy vehicle at work. The patient was hypertensive and diabetic and the leg was not salvageable

common. Patients often present after 2–3 days without treatment or with inadequate treatment, making good outcomes difficult or impossible (Fig. 17.10).

Prophylactic IV antibiotics appropriate to the injury, local availability, or hospital protocols are a mainstay in open fracture treatment and need to be given as early as possible. First- or second-generation cephalosporins are the frontline antibiotics with an aminoglycoside added for higher grade open fractures and penicillin, Flagyl, or clindamycin added to cover specific contamination [2]. The incidence of drug resistance in developing countries is unknown but appears to be lower than that experienced in the West. Pay attention to tetanus immunization and cover

aggressively, as patients often do not remember if or when they were vaccinated.

The Gustilo classification of open fractures is widely used globally. Classification is most accurate when done at the end of debridement in the operating room (OR), though an assessment in the ED helps set the parameters for the initial treatment (Box 17.1).

**Box 17.1 Gustilo and Anderson
Classification of Open Fractures**

Type I

Clean wound smaller than 1 cm in size.

Assumes a simple fracture pattern

Type II

Soft tissue injury >1 cm but <10 cm without extensive soft tissue damage.

Assumes minimal degloving and periosteal stripping and not more than moderate contamination or comminution

Type III

High-energy injuries, with substantial soft tissue injury, periosteal stripping, and/or some degree of crush. Segmental fractures, bone loss, farmyard injuries, high velocity GSW

Type IIIA

Large soft tissue injury or flap, though usually less than 10 cm. Adequate soft tissue remains to cover the bone

Type IIIB

Extensive soft tissue injury, bone loss, devascularization, and/or massive contamination. Inadequate soft tissue to cover bone without a flap

Type IIIC

Fractures with major arterial injury requiring repair

As in other open injuries, clean and splint the open fracture in the ED following local protocols. The controversy in the West concerning the appropriate time frame open fractures should be taken to the OR exists in developing countries, with the addition of rules and protocols that can prolong the time to debridement.

In the OR, apply an inflatable tourniquet, if available, even if you do not think you will use it. Prepping and draping procedures are often a matter of faith and precedent with nursing staff, who may resist well-meaning suggestions. If the prep appears substandard, ask to prep again, even a third time, until the wound and extremity are as clean as the situation allows. Due to lack

of draping material, the initial washout may take place using a non-sterile rubber drape and a plastic apron.

After removal of gross contamination, copious irrigation, and wound excision, re-prep and drape the patient. Enlarge and expose the deeper tissues underlying the wound. Remove all muscle that is discolored, of mushy consistency, fails to contract when irritated, and does not bleed when cut.

If the skin injury does not appear to be full thickness, it is sometimes safe to leave moderately damaged skin for further consideration at an early second OR visit, as it can be quite resilient. Pieces of bone unattached to soft tissue should be removed. No matter how large or structurally important a piece of cortical bone is, if it is devitalized and has no blood supply, it should be removed. The goal of debridement is to reestablish a healthy, vascularized soft tissue bed so the injured bone or the bone defect can be covered.

The surgical incisions made to enlarge the wound can be closed without tension at the end of the debridement, but the original wound must be left open and covered with a sterile dressing. Even if it appears that the wound can be closed, do not close it. Flaps of skin sutured under tension in an attempt to cover bone will fail, leading to further soft tissue loss, increased risk of infection, more severe disability, and extended hospitalization (Fig. 17.11). Initial debridements are rarely totally satisfactory, especially if done by a surgeon who is inexperienced with trauma in that particular setting.

Antibiotic impregnated beads as an adjunct to wound treatment are valuable in open fracture care. If polymethylmethacrylate cement is available, even outdated, any thermostable and water-soluble antibiotic in doses of between 2 and 4 g can be added to cement powder to make beads or spacers. Inexpensive liquid gentamicin is usually available, as opposed to expensive tobramycin. Six 80-mg vials of gentamicin added to the liquid monomer will give satisfactory antibiotic levels [3].

An external fixateur is a useful tool after debridement to treat the soft tissues of an open tibial fracture. Pin placement should remain

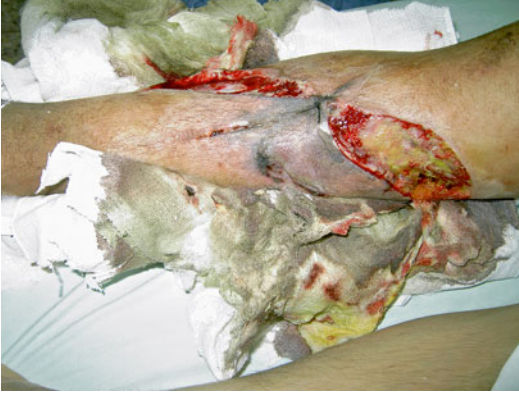

Fig. 17.11 Appearance of a leg 4 days after the initial debridement of a Grade IIIB open tibia fracture from RTI. It is unlikely that the entire anterolateral distally based flap would have survived, but the solitary stitch placed under tension to cover the bone has made the situation worse

outside the zone of injury and take into consideration anticipated flaps or skin grafts. Fixateur pins are often of poor quality or if reused, out of true. Unless the local surgeon following the case is comfortable with the long-term treatment of fractures in external fixateurs and familiar with the system at hand, it is best to remove external fixateurs when they are no longer needed to treat the soft tissue injury and convert the immobilization to either short-term or definitive treatment in plaster of Paris or traction (Fig. 17.12).

Open femur fractures, with a thicker and more vascular soft tissue envelope than tibial or forearm fractures, may allow earlier and more consistently successful delayed primary closure and definitive treatment by traction or internal fixation and can initially be treated with high tibial or calcaneal traction as opposed to external fixation.

Open humerus and forearm fractures, if unstable or with significant soft tissue loss, may benefit from short-term external fixation. Elbow stiffness and nerve impalement are potential problems. Splinting a severely injured forearm in neutral rotation leaves the extremity in the most functional position.

Plaster of Paris has many uses in the emergency setting after debridement. A robust back slab, U-slab, or three-sided gutter splint may

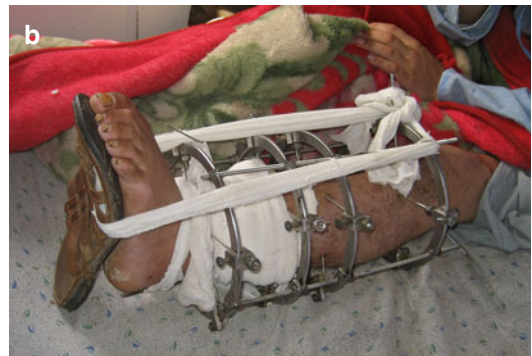
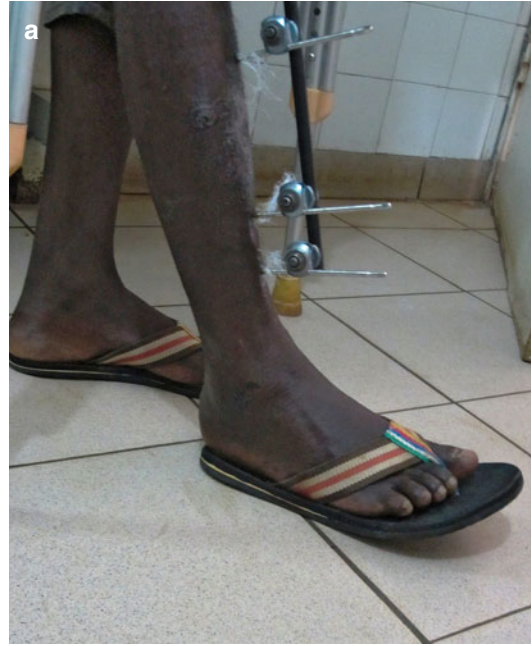
Fig. 17.12 (a) The maximum right ankle dorsiflexion after 6 weeks in an external fixateur. Equinus contracture is preventable by paying attention to splinting and directed exercises. (b) One of any number of makeshift solutions

offer better and quicker initial immobilization than an external fixateur conjured from a jumbled set of leftover clamps and bars with a surgical team that is unfamiliar with orthopedic cases.

Grade one open fracture wounds will heal by secondary intention and do not necessarily need to return to the operating room for closure after initial debridement. Grade 2 and 3 wounds should be returned to the operating room in 2–5 days for re-debridement, skin closure, skin graft, or flap. Repeat visits to the OR should continue as needed until the bone and soft tissues provide a clean,

stable vascular bed that can be covered with healthy tissue.

Inviting a colleague to look during debridement is good policy, especially if the wound will require extensive reconstruction or there is any question of limb or tissue viability. Though it is expensive and time consuming for the patient to return to the operating room, resist the temptation to do early dressing changes on the ward or to close wounds under tension, since these will increase the possibility of infection and may lead to more expensive and complex surgery in the future.

A short-term volunteer is unlikely to be present throughout the entire lengthy treatment of most open long bone fractures. Written communication over and above that given in the Gustilo classification—such as wound size and depth in cms, projected ability to close the wound and how, degree of periosteal stripping, presence of degloving or vascular injury, extent of muscle damage, type of initial contamination, detailed history of procedures done, and a proposed plan—provides useful information for continuity of care. Write details about the injury on the cast with a Sharpie. Digital photos left on a hospital computer or a flash drive and sketches in the chart will add to the written description.

Hardware and Its Removal

The volunteer surgeon will be asked when plates, screws, or nails will be removed. Explain that the fixation needs to remain in place until the bone is healed clinically and radiographically, usually 12–18 months. At the same time inform the patient and the family that hardware removal is usually not necessary. However, there are instances when it is (Fig. 17.13). If a patient requests removal on the advice of another practitioner, the history, exam, and x-ray should clarify if this is a ploy on the part of the practitioner for financial gain. Unfortunately, in some areas this is common practice.

Without fluoroscopy, metal removal can be difficult. Screws break or their heads become overgrown with bone, and retrieving the buried

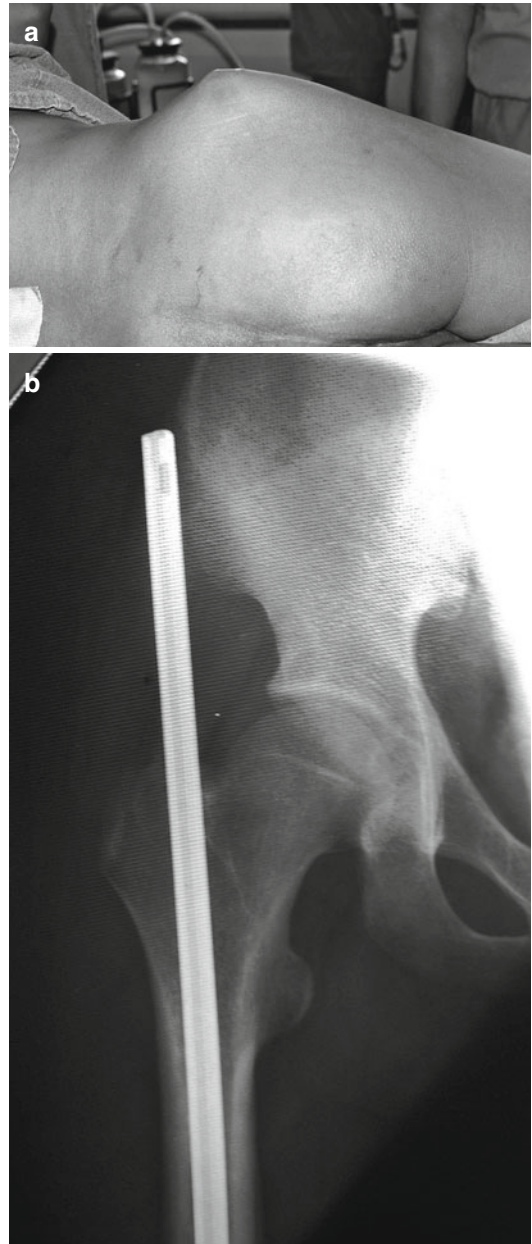

Fig. 17.13 (a) Compromised skin of right lateral buttock tented over a proximally protruding K-nail. (b) X-ray of long K-nail

end of an IM nail can be a frustrating procedure, with the potential for damaging the surrounding tissues. Make sure the x-rays on which one is basing the metal removal are recent, since hardware can be removed piecemeal, and patients are not always aware of what is present.

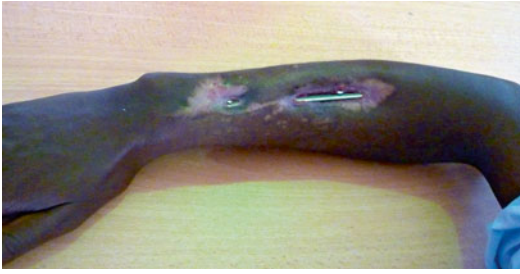

Fig. 17.14 This patient's radius fracture is healed and his wounds are amazingly clean despite the exposed plate. However he has no money to pay for the metal removal

In situations where patients must pay and will not be admitted until payment is made, they may have had the money for the implant and the OR expenses to insert it but not for its removal (Fig. 17.14).

K-wires used for percutaneous or open fixation, especially in pediatric fractures that will need the pins for only 3–6 weeks, should be left protruding far enough outside the skin so they can be bent back on themselves for easy removal in the OPD. A pin cut off at skin level will cause irritation and infection and be difficult to remove. Removing a buried pin will usually require a general anesthetic. Adults may tolerate a small incision under local anesthesia for buried pin removal but there may be no sterile pliers or pin removal set in the OPD. Using “simple” K-wires without evaluating how they will be removed is another instance in which the short-term volunteer must be aware of what he or she is leaving behind.

Compartment Syndrome

Surgeons should be aware of the possibility of compartment syndrome when dealing with *all* low- and high-energy traumas, open or closed fractures, and especially injuries with a crush component. Tibial fractures are commonly associated with compartment syndrome followed by forearm and elbow injuries. In the developing world compression from traditional treatments involving tight bandages and splints or irritating topical remedies and snakebite injuries are not uncommon causes.

The swelling due to compartment syndrome is clinically difficult to differentiate from that caused by the underlying injury, especially in the

face of internal degloving. Deep pain that is more intense and out of proportion to normal expectations or pain that increases despite elevation and immobilization should alert the surgeon.

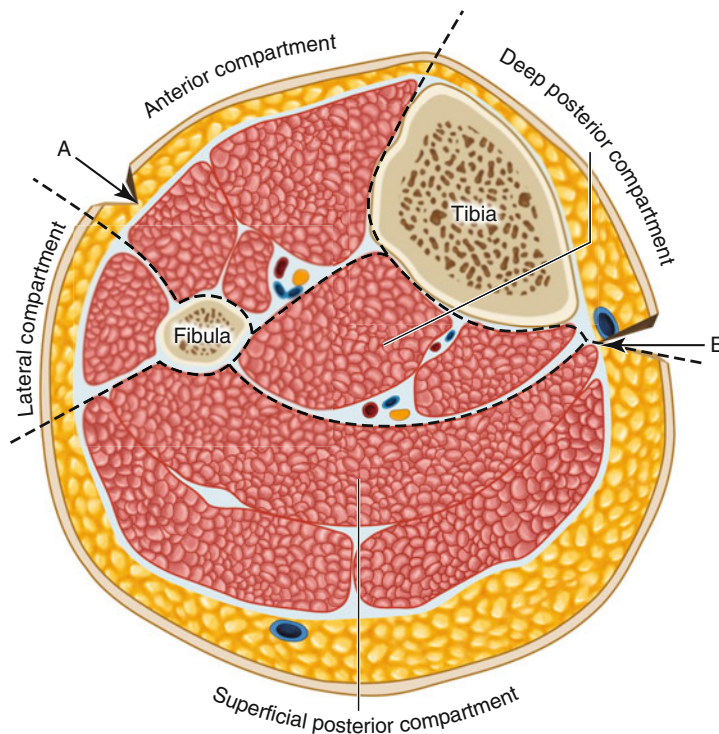
Pain on passive muscle stretch, with the fracture stabilized, is a reliable sign of increased compartment pressure especially in situations where cultural barriers make interpretation of pain difficult. Paresthesias may be a relatively early indicator but are hard to assess. Pallor and paralysis are late signs and limited in early diagnosis, while distal pulses can be present in the face of dead muscle.

At the first indication of possible compartment pressure elevation, all constricting bandages should be released while maintaining fracture stability. If bivalving or removing half of a plaster cast, splitting the cast padding along its entire length, and release of blood-soaked bandages or tight wrappings do not reverse the abnormal clinical signs, the patient needs emergency surgical decompression. Early administration of adequate intravenous fluids may prevent the concentration of metabolic by-products that can lead to renal failure of crush injuries, and supplemental oxygen will help maintain tissue oxygenation. Though the times given for ischemia to cause irreversible damage are 6 h for nerve and 8 h for muscle, do not wait, hoping for improvement.

Situations in which pain is difficult to evaluate—such as head injury, previous anesthesia, alcohol, or mind-altering drugs—can make the clinical diagnosis especially difficult. If in doubt, proceed with fasciotomy.

Surgical release of a compartment syndrome caused by a lower leg injury requires release of all four muscle compartments surrounding the tibia. This is most easily and thoroughly done using a 2-incision approach with a tourniquet in place but *not* inflated. A longitudinal medial incision placed about 2 cm posterior to the medial border of the tibia gives access to the superficial posterior and deep posterior compartments. An anterolateral longitudinal incision half way between the tibial crest and the fibula allows release of the anterior extensor and peroneal muscles. All individual fascial compartments need to be released, and any muscle that is discolored, of poor consistency, fails to contract when irritated, or does not bleed when cut should be considered nonviable and debrided (Fig. 17.15).

Fig. 17.15 Cross section of tibia showing the four compartments: anterior, lateral, superficial, and deep posterior—that should be released at the time of fasciotomy. *Arrow A*—place incision half way between anterior tibial crest and fibula to release the anterior and lateral compartments. *Arrow B*—place incision just behind the posterior-medial border of the tibia to allow access to both superficial and deep posterior compartments



Upper extremity impending compartment syndrome is approached through a straight or curvilinear volar incision that releases the median nerve in the carpal canal and may be extended proximally above the elbow. The dorsal compartments are decompressed by a longitudinal straight dorsal incision, taking care to release the fascia over the wrist extensors in the mobile wad.

The skin and fascial wounds are left open and covered with non-constricting bulky dressings supplemented with an external fixateur or robust plaster of Paris back slab or gutter splint to stabilize the fracture and prevent further soft tissue damage. The limb should be elevated just above heart level to prevent swelling from venous congestion. Fasciotomy wounds should be treated like wounds after debridement of an open fracture and reevaluated in the operating room in 2–5 days for possible skin closure, re-debridement of muscle, or skin grafting. If only one of the two wounds in the leg can be closed, leave open the one with the best soft tissue bed for later skin grafting. Most often this is the anterior lateral wound. Rows of short relaxing incisions on both sides of the wound may allow skin closure without tension. Rubber bands laced through skin staples, loops of suture, or along K-wires threaded

at the edges of the wound can be used to gradually close a wound over several days [4]. Better to skin graft a fasciotomy than close it under tension.

If an operating room is not available, there is no anesthesiologist, and timely transfer is not a viable option, proceed with the fasciotomy under local anesthesia in the ED or at the bedside.

Fat Embolism and Deep Venous Thrombosis

Patients with multiple long bone fractures and/or severe thoracic injury are noted candidates for fat embolism syndrome, but this complication can occur with any trauma. Hypoxia, pulmonary distress, petechiae on the upper anterior chest and upper arms, and non-focal neurological deterioration are the classic signs. Primary supportive therapies to prevent respiratory compromise include fluids and oxygen while maintaining adequate urine output.

Safe methods to protect trauma patients from deep vein thrombosis (DVT), such as low molecular weight heparin or compression boots, are usually too expensive or unavailable in austere

settings. The lab tests necessary for monitoring other forms of anticoagulation may be beyond the means and capabilities of the patients and the health system. Aspirin may be all that is available and should be used. Ask how the local surgeons handle this problem and take cues from them, realizing that the prevalence of DVT is unknown and little studied in most resource-limited situations, and the staff may not be attuned to this complication. The best preventive solution is early mobilization.

Burns

Due to heating and cooking with open fires or poorly constructed stoves, severe burns are common in developing countries. Other medical personnel are usually available to resuscitate these patients. But if not, the main treatments are tetanus prophylaxis, generous analgesia, vigorous fluid management with adequate hydration, and nutritional support (Box 17.2).

Box 17.2 Parkland Formula for Fluid Management for Burn Patients

The total fluid requirement in the first 24 h after injury (not after admission) is:

- $4 \text{ ml} \times \text{TBSA} (\%)^1 \times \text{body weight (kg)}$
- 50 % given in first 8 h after injury, not admission
- 50 % given in next 16 h

Children receive maintenance fluid in addition, at an hourly rate of:

- 4 ml/kg for the first 10 kg of body weight plus
- 2 ml/kg for the second 10 kg of body weight plus
- 1 ml/kg for >20 kg of body weight

¹TBSA—total body surface area of second and third burns only. Determine the extent of injury by “rule of 9 s.” The head, each entire arm, and the entire front or the entire back of each leg individually makes up 9 % TBSA. The anterior trunk and posterior trunk make up 18 % each.

A visiting orthopedic surgeon’s most important role may be preventing contractures. Gentle elevation of a burned extremity will decrease swelling and can prevent a relatively superficial burn from becoming full thickness. Circumferential burns, especially on extremities, may require escharotomy and early excision and grafting of large burns can prevent severe contracture. Early functional splints and ROM exercises will reduce disability.

Strategies When There Is No...

When there is no fluoroscopy, do not hesitate to open closed fractures for fixation, assuming all other conditions for open treatment are met. When done cleanly with careful soft tissue handling there should be no increase in infection rate. Even if fluoro is present but is temperamental, it might be best to teach a technique where it is not required, so that your local colleague will be able to do a similar case in the future when the fluoro does not work.

When CT scan is not available, try oblique views or axial views. Go to the x-ray room; help the technician position the patient. The combination of images from these less often used views when combined with one’s knowledge of anatomy should allow the generation of an “internal CT scan” image.

Accept clinical judgment. Solving problems by using the clinical skills learned in medical school, but often lying dormant since, is one of the most rewarding aspects of working in developing countries.

Have the hospital make equipment. Most hospitals in developing countries have workshops that can sharpen osteotomes, make lead hands, fabricate triangles for IM tibial nailing, or frames for elevating extremities. Welders and carpenters in local bazaars are happy to help solve problems (Fig. 17.16). Tailors are inexpensive and can follow most patterns or sketched ideas. Many hospitals have their own tailoring unit. A couple hundred dollars spent on local materials to make drapes and OR clothes will go a long way in improving the infection rate, even if they are not

water impermeable (Fig. 17.17). Locally made items are less expensive, improve the local economy, and help establish self-reinforcing pathways for the local surgeons to solve their own problems. Or, when you see a need, make it yourself (Fig. 17.18).




Fig. 17.16 Drip stand made in the hospital workshop of wood and nails

When stuck with a particular problem that you cannot solve, take a picture and send it by smartphone along with a description to a colleague, or the resident on call at your home hospital. Use the surgical videos on YouTube or iTunes U.

The goals in treating trauma—whether simple or complex, involving bone or not—boil down to restoration of function. Formal rehabilitation through physical or occupational therapy may be rudimentary and a visiting orthopedic surgeon often needs to take on the added task of rehabilitation from the time of admission.

Rehabilitation does not require high-tech equipment—a simple rubber ball works for hand therapy. When that is not available, three or four tightly wadded up plastic bags can serve as a ball. A deep bowl of sand or uncooked rice makes a good medium in which patients can exercise their fingers. Much post-injury stiffness and deformity can be prevented by paying attention to the basic principles of splinting, elevation, and strategically timed and purposeful exercise and massage. Teach the patient exactly what he should do.

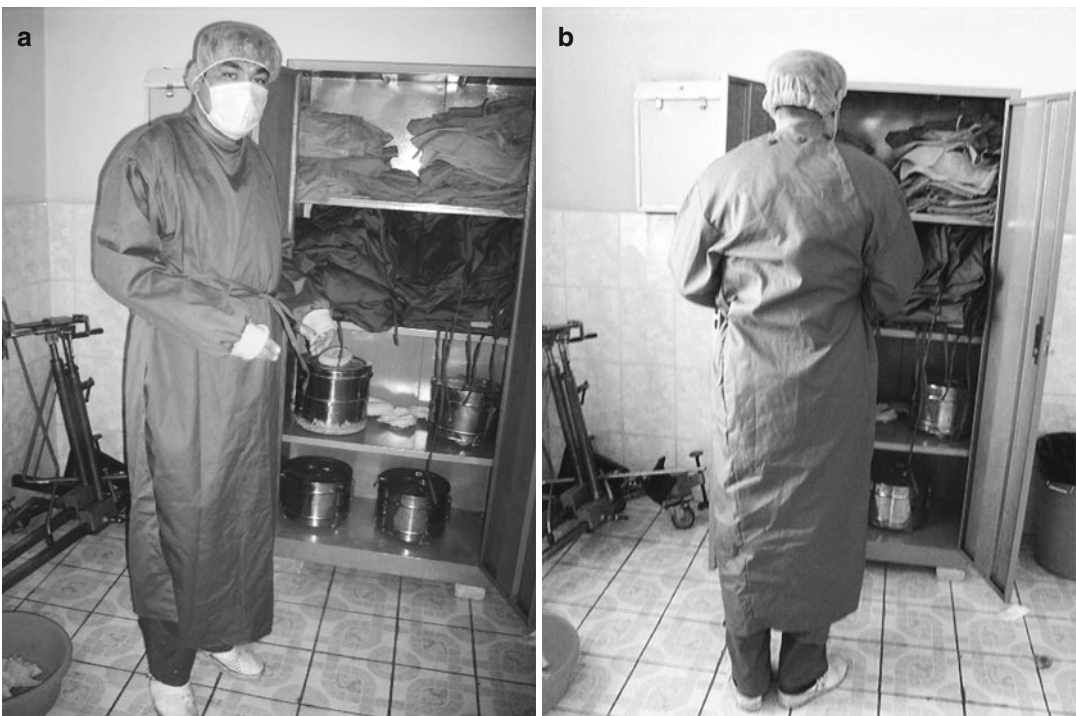

Fig. 17.17 (a, b) Operating room gowns with back flap made by an Afghan provincial hospital's tailoring department. Though not waterproof, they provide adequate coverage

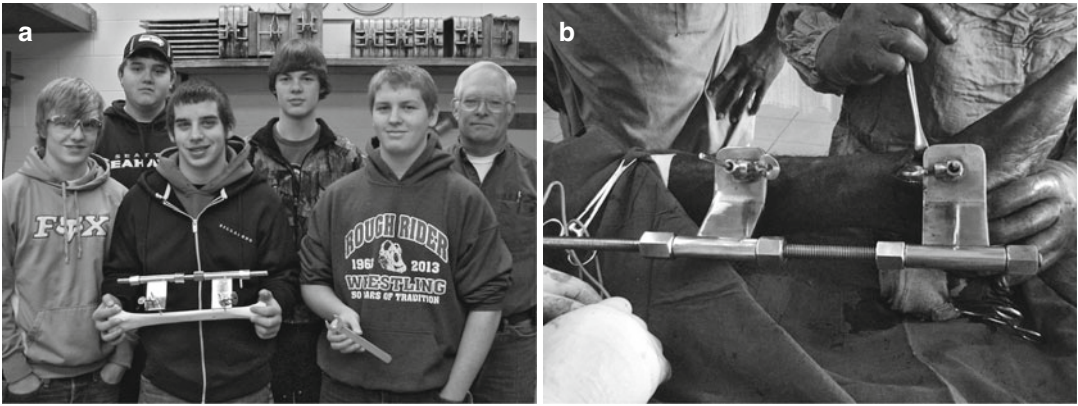


Fig. 17.18 Seeing a need and a challenge, two US orthopedic surgeons asked (a) the Port Angeles, Washington, high school machine shop students and their instructor to make an inexpensive fracture distractor. The <\$100

distractor was made from scrap stainless steel. (b) The distractor in use for an ankle arthrodesis in Cameroon (Courtesy of Dr. Sam Baker)

When language is a barrier, make sure someone who speaks a common language explains so that the patient can demonstrate what he is to do. Involve the families; they are critically important allies.

When stuck, ask for help. This does not have to be from another surgeon. The anesthesiologist and the nurses have spent many hours observing from the other side of the drapes and they are aware of what is possible within the system. Follow “best practices” as you understand them, keeping to the basics and doing no harm. Remember, you are part of a medial team. Almost any skill or equipment deficiency can be covered by a cohesive team prepared to listen and work together.

References

1. Hussain W, Hussain H, Hussain M, et al. Approaching the Muslim orthopaedic patient. *Topics in training. J Bone Joint Surg.* 2010;92-A(7):e2 1–7.
2. Holtom P. Antibiotic prophylaxis: current recommendations. *J Am Acad Orthop Surg.* 2006;14(10): S98–100.
3. Seldes R, et al. Liquid gentamicin in bone cement: a laboratory study of a potentially more cost-effective cement spacer. *J Bone Joint Surg.* 2005;87-A(2):268–72.

4. Ismavel R, Samuel S, et al. A simple solution for wound coverage by skin stretching. *J Orthop Trauma.* 2011;25(3):127–32.

Suggested Reading

- Adult trauma life support. 8th ed. Chicago: American College of Surgeons; 2004.
- Bucholz R, Court-Brown C, Heckman J, Tornetta P. Rockwood and Green’s fractures in adults, vol. I and II. Philadelphia: Lippincott Williams and Wilkins; 2010.
- Cook J, Sankran B, Wasunna A. Surgery at the district hospital: obstetrics, gynaecology, orthopaedics, and traumatology. Geneva: World Health Organization; 1991.
- Crenshaw AH. Campbell’s operative orthopaedics. 7th ed. St. Louis: C.B. Mosby Company; 1987.
- Hoppenfeld S, deBoer P, Buckley R. Surgical exposures in orthopaedics, the anatomic approach. Philadelphia: Lippincott Williams and Wilkins; 2009.
- King M, Bewes P, editors. Primary surgery, Trauma, vol. 2. Oxford Medical Publications. 2003. Available from: www.primary-surgery.org or <http://www.primary-surgery.org/start.html>. Cited 30 June 2012.
- Stannard JP, et al. Surgical treatment of orthopaedic trauma. New York: Thieme Publishers; 2007.
- Templeman D, Anglen J, Schmidt A. The management of complications associated with tibial fractures. In: Ricci W, Tornetta P, editors. Instructional course lectures trauma 2. Rosemont: AAOS; 2012. p. 243–56.

Richard C. Fisher and Sonam Dorji

Introduction

The shoulder and humerus are common sites of injury from simple falls to high-energy road traffic crashes. The primary goal is to restore a stable and comfortable range of motion to permit lifting, pushing, pulling, and most importantly positioning the hand. With serious injuries and limited resources, it is not necessary to achieve “perfection” to reach the above goals. Often simple, predictable solutions are preferable to more risky and costly alternatives.

Since radiology services are variable in developing countries, emphasis is placed on the history and physical examination, so that treatment can be initiated while awaiting a definitive X-ray. If surgery plans involve fluoroscopy, it is best to have a backup plan before beginning the case. Where CT and MRI are available, they can be helpful in appropriate circumstances.

R.C. Fisher, BA, MD, MS-Health Admin (✉)
Orthopaedic Surgery, University of Colorado Health
Science Center, 12631 East 17th Ave, B202,
Aurora, CO 80045, USA
e-mail: richard.fisher@ucdenver.edu

S. Dorji, MBBS
Department of Orthopaedics, JDW National Referral
Hospital, Thimphu, Bhutan
e-mail: drsonam2003@yahoo.com

Clavicle and Scapula Injuries

The scapuloclavicular complex provides the base support for the shoulder joint and the attachments for the controlling muscles. This complex is mobile on the trunk, supported only by muscle and a single bony attachment at the sternoclavicular joint, making injuries to this area common.

The Sternoclavicular Joint

Dislocations of the sternoclavicular joint occur from a medially directed force on the lateral shoulder or, rarely, a direct anterior blow. Anterior dislocations present with swelling and tenderness around a palpable bump over the medial clavicle. The dislocation is unstable and patients do well with symptomatic treatment only.

Posterior sternoclavicular dislocations can potentially impinge on the brachiocephalic vessels, brachial plexus, esophagus, and trachea. Patients may present with a palpable indentation about the medial clavicle, although swelling may obscure this. Swelling, venous congestion of the arm, and difficulty breathing or swallowing signal a significant injury. Reduction is usually necessary and should be performed in the operating room with resources to perform an open reduction and life-saving vascular repair if the vessels are torn and bleed when the pressure is removed. If closed reduction is not possible, an open reduction with resection of a centimeter or less of the medial clavicle and ligament repair is indicated [1].

Clavicle Injuries

In its position as strut between the arm and thorax, the clavicle is frequently injured from a lateral or direct anterior force. The mid-shaft is the most common site (80 %) followed by the lateral one-third [1]. Medial fractures are rare and often secondary to a space-occupying lesion in the bone. Most fractures can be treated closed with a sling or sling and figure eight dressing. While the healing time might be prolonged, nonunion is unusual. Open fractures, neurovascular injury, or displacement that compromises the overlying skin may require surgery. High-energy injuries causing a flail chest or an accompanying fracture in the shoulder suspensory ring might best be treated by stabilizing the clavicle fracture with a 3.5 mm dynamic compression plate and screws or a threaded intramedullary device. Smooth pins can migrate and should not be used in this region.

The treatment of lateral third fractures depends upon the relation of the fracture to the coracoclavicular ligaments. Most have minimal displacement and will heal using a sling. If the fracture disrupts or is medial to the ligaments, the displacement may preclude healing and require stabilization with a plate or ligament reconstruction.

The Acromioclavicular Joint

Intrinsically unstable, the acromioclavicular joint is held in place by soft tissue structures that are easily injured by a force applied to the tip of the acromion. The acromioclavicular (AC) ligaments resist anterior and posterior motion and are not as strong as the coracoclavicular (CC) ligament complex that resists upward displacement of the clavicle. A third restraint, the conjoined fascia of the deltoid and trapezius muscles, limits the displacement of the clavicle when the more inferior ligaments are torn.

Type I, II, and III injuries follow disruption of the AC and/or CC ligaments with displacement ranging from a few millimeters to several centimeters proximal displacement of the distal clavicle. These can be treated with a sling and range of motion exercise. The vast majority of Type III injuries will heal with a fully functional and pain-free shoulder

but with a visible bump. Surgery in acute cases is best reserved for those whose skin is at risk from underlying pressure. Surgery for chronic cases is never indicated for cosmesis but only if residual pain is disabling and should consist of excision rather than attempt at repair.

In Type IV injuries the clavicle is dislocated posteriorly through the trapezius muscle, and in Type V, the displacement is superior through the disrupted deltoid–trapezius fascia. Type VI injuries occur when the tip of clavicle becomes trapped inferior to the coracoid process and behind the conjoined tendon (short head of biceps and coracobrachialis). The latter three injury patterns usually need surgical treatment to place the distal clavicle in a functional position.

Scapula Fractures

Fractures of the scapula are usually the result of high-energy blunt trauma either from a direct blow or an axial load. Seventy-five percent are secondary to road traffic crashes [1]. While infrequent, they are important because of the potential for associated injuries to the brachial plexus and chest. Recognition of either severe chest trauma or a scapula fracture should prompt a careful examination for the other.

Scapular fractures are classified by region: body, spine, glenoid neck, glenoid fossa, acromion, and coracoid process. In general isolated fractures in these locations with minimal displacement can be treated successfully with a sling, gradually progressing to ROM exercises, and finally muscle strengthening as healing occurs.

The most significant injury pattern involves the superior shoulder suspensory complex (Fig. 18.1) that provides the support base for shoulder joint function. It includes the glenoid, coracoid, CC ligaments, AC joint, and acromion, with the major bony support from the clavicle and scapular neck. Injury of two or more structures in the ring can potentially cause instability. The concept of the “floating shoulder” involves fractures of the scapular neck, the mid-clavicle, and the humerus.

Treatment of this injury is controversial but fractures with minimal displacement, <5 mm in

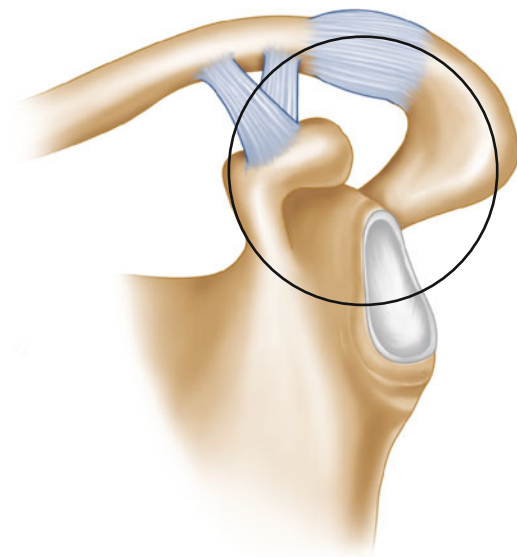


Fig. 18.1 Anatomy of the superior shoulder suspensory ring

the scapula and up to 10 mm in the clavicle, will reportedly do well with nonoperative care [2, 3]. Fractures with greater displacement should be considered for surgical stabilization. Clavicle fixation with a plate and screws is often sufficient to reduce the glenoid displacement and stabilize the ring. It has been suggested that both fractures in the ring need internal fixation but each case must be evaluated individually [3].

The most severe form is the scapulothoracic dissociation, in which the entire scapula–humerus–clavicle complex is “avulsed” from the chest wall, either through disruption of the bone or soft tissues. This requires high energy, and the clinical diagnosis is not always easy but is important to recognize, as there is a high incidence of associated neurovascular injuries. Close monitoring for vascular complications is necessary. Unless arterial repair is needed, the treatment is conservative.

Glenohumeral Dislocations

Anterior Dislocations

Anterior dislocations outnumber posterior dislocations by about 8:1 and the two can be distinguished by both history and physical exam.

The initial anterior dislocation usually follows trauma with forced abduction and external rotation of the arm [4]. The patient maintains his arm in slight abduction and external rotation; internal rotation is blocked and there is a “squared off” appearance to the shoulder. Anterior shoulder dislocations may have associated axillary nerve or brachial plexus injuries, making an initial neurovascular exam necessary.

Appropriate X-ray views including a scapular AP, trans-scapular lateral (or Y), and axillary lateral should be done, if possible, to confirm the diagnosis and rule out associated fractures before closed reduction. The humeral head is seen anterior to the “Mercedes Benz sign” in the trans-scapular view.

Posterior Dislocations

Posterior dislocations result from trauma in about 2/3 of cases but the remainder occurs during seizures or electrical injuries. Since the dislocation is directly posterior, the shoulder deformity is not as obvious as with anterior dislocation and is often missed. The classic findings are shoulder pain with loss of external rotation and fullness over the coracoid. X-rays often appear normal in the anterior–posterior view, making axillary or scapular lateral views necessary. Closed reduction for acute posterior dislocations is usually successful.

Chronic Dislocations

Shoulder dislocations presenting late are common in low resource environments and more challenging. The usual definition of “acute” is within 3 weeks of injury [4]. Dislocations seen in this time period will often reduce with closed treatment, although as time goes on more muscle relaxation might be needed, including general anesthesia. A closed reduction can be successful up to 4 weeks but be gentle and take increased care to avoid fracturing the humerus, especially avoid forced rotation (Fig. 18.2).

Advice from surgeons in developing countries suggests that beyond 3 months open reduction is

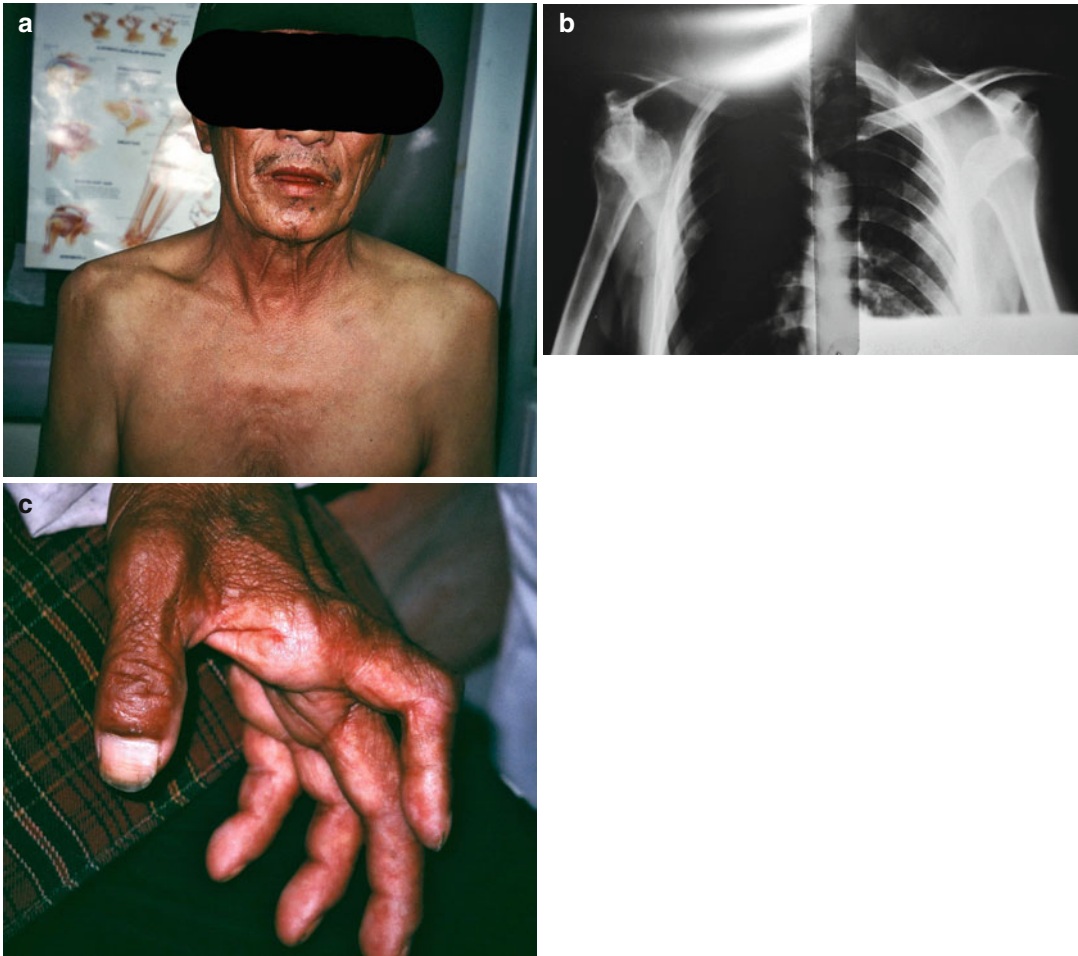

Fig. 18.2 (a) This farmer fell out of a tree in his orchard 6 weeks before and sustained right and left anterior shoulder dislocations. (b) Shoulder X-rays. He came to the orthopedic clinic because he was having some difficulty doing his farm work due to limited motion and traditional

therapy had not helped. He had no pain and therefore no surgery was offered. (c) He also had a complex dislocation of his left index MP 8 years previously and had no complaints regarding it (Courtesy of Dr. Sam Baker)

extremely difficult and should not be attempted. It is better to begin physical therapy for range of motion and muscle strengthening. The patient will not regain full abduction or forward elevation but will have satisfactory function otherwise as the case illustrates (Box 18.1).

Box 18.1 Case Illustration

A 26 year-old male came to the orthopedic clinic with a chief complaint of inability to use his right upper extremity to reach or perform activities at or above shoulder level.

He had injured his shoulder 7 years before and was told later that it was dislocated but he had not been treated. The right shoulder had an active range of motion of 30° abduction, 40° forward elevation, and full internal and external rotation. This appeared to be performed with minimal discomfort. Elbow and hand function were normal. X-rays showed an anterior glenohumeral dislocation. Although he wanted to have improved “use” of his shoulder, he was employed and stated that pain was not a problem. The clinic staff felt that no further treatment was indicated

If closed reduction is not possible, the two remaining options are open reduction or early rehabilitation allowing the shoulder to remain dislocated. While many surgical approaches have been described [5, 6], all report difficulty replacing the humeral head into the glenoid and having it stay. Some have used pins through the head into the glenoid to secure the reduction. Most report limited range of motion post-op, while injury to the axillary nerve is common. Results are worse the longer the shoulder has been dislocated.

We advise against simple humeral head resection as a flail shoulder is not functional. Patients with a chronically displaced shoulder usually adapt fairly well from a functional point of view, but if residual pain is truly disabling, two surgical options remain. Arthrodesis is technically challenging if the displacement is long standing. The second option, “shoulder Girdlestone” or Laurence Jones procedure, is a trade-off between pain and weakness/instability but may allow better function (see Chap. 41).

Fractures associated with shoulder dislocations commonly involve the glenoid rim, the humeral head (Hill–Sachs and reverse Hill–Sachs lesions), the greater tuberosity, the humeral neck, and the shear injuries of the humeral head. Glenoid and impression fractures of the head are associated with recurrent dislocations but rarely need immediate treatment. Tuberosity fractures usually reduce when the dislocation is reduced and will heal spontaneously. If the residual displacement is more than 3–4 mm, they may cause impingement symptoms and need surgical correction [4]. Shoulder dislocations associated with humeral neck and articular surface fractures are usually treated initially with attempted closed reduction. If successful the fractures are treated individually as described in the next section. If unsuccessful the options are the same as for isolated dislocations.

Proximal Humeral Fractures

Proximal humeral fractures account for about 5 % of all fractures and have two peaks of occurrence: high-energy fractures in young adults and low-energy injuries in the elderly [1, 7].

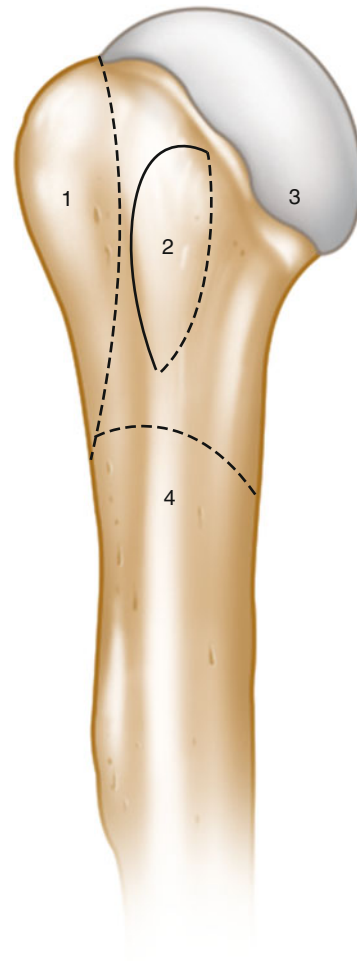


Fig. 18.3 The four major fragments used to classify proximal humeral fractures are 1 greater tuberosity, 2 lesser tuberosity, 3 humeral head, 4 humeral shaft

The fracture patterns follow the epiphyseal lines of the greater tuberosity, lesser tuberosity, humeral head, and humeral shaft (Fig. 18.3). The Neer classification system is based on the relative displacement of these four fragments [8]. A displaced fragment is separated by at least 1 cm or angled more than 45°. Fractures become more unstable as the pattern advances from 2 to 3 to 4 parts. Valgus impacted fractures are encountered most frequently in older adults. Though there is often some deformity, they are stable regardless of the number of fracture lines present.

The majority of proximal humeral fractures are impacted or minimally displaced and will

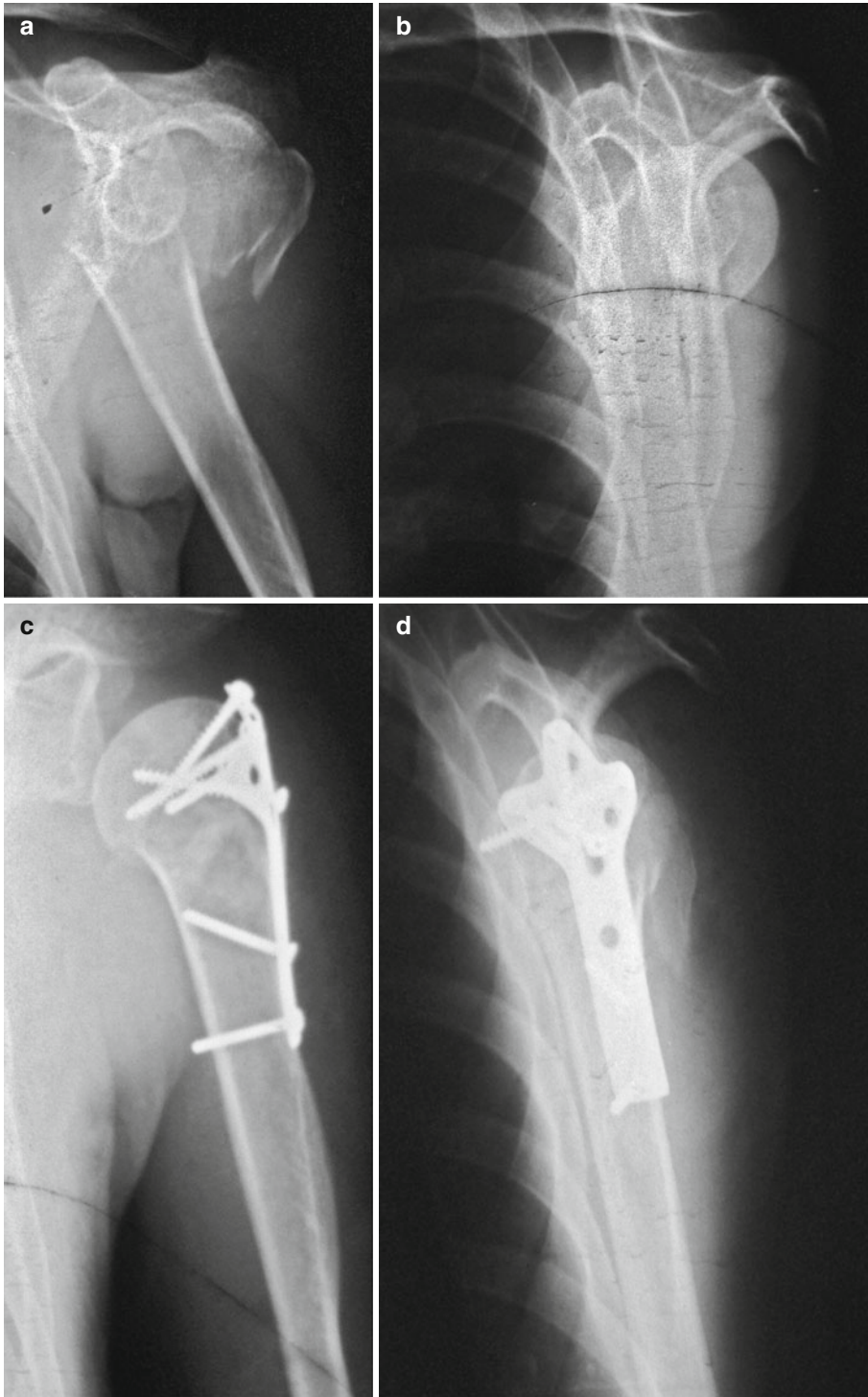


Fig. 18.4 (a, b) Preoperative X-rays of the right shoulder showing a four-part fracture of the proximal humerus. (c, d) X-ray taken 4 months after open reduction and application of a buttress plate. The patient had some

limitation of external rotation but otherwise full motion. She had symptoms of impingement, which improved after removal of the plate

heal with a functional ROM and near normal upper extremity function with closed treatment in a sling and early rehabilitation [7]. Unstable 2-, 3-, or 4-part fractures remain a challenge wherever encountered. Surgical treatment is often considered necessary for these fractures and includes percutaneous pins, suture stabilization, plates and screws, intramedullary rods, humeral head replacement, and total shoulder arthroplasty. Reported complications occur with all of these techniques [1]. In most developing countries angular blade plates, locking plates, and shoulder prostheses are not available.

The most common choices for treating displaced fractures are percutaneous K-wire pinning, flexible intramedullary rods, such as Rush rods, or cloverleaf buttress plates (Fig. 18.4). Percutaneous pin fixation is best done with plain X-ray or fluoroscopy. If closed reduction is not possible or X-ray is not available, open reduction with multiple pin fixation is a satisfactory option with good results reported. Suture reinforcement is useful to supplement buttress plate fixation when adequate screw purchases are not possible due to comminution or osteoporosis. A figure of eight wire can stabilize 2- and 3-part fractures especially if heavy suture is unavailable. Displaced humeral head fractures pose a risk for avascular necrosis but the rate decreases if the head retains at least 8 mm of the calcar. Recently described straight lateral approaches to the humeral head with dissection and protection of the axillary nerve have allowed a more direct approach with less forceful retraction of the swollen deltoid and less overall dissection [9].

Humeral Shaft Fractures

Diaphyseal fractures of the humerus account for about 3 % of all fractures and occur from high-energy injuries in young adults and low-energy falls in older adults [10]. The simple designation of spiral, oblique, transverse, segmental, and comminuted will help guide therapy (Fig. 18.5) [10]. Other considerations include the status of the radial nerve, the presence of an open wound, the type of

trauma (penetrating/blunt, high or low energy), the age of the patient, and the associated injuries.

The diagnosis can be suspected clinically from the history and physical examination, but when possible, obtain humerus X-rays in two planes that include the shoulder and elbow. Confirm the radial nerve function initially and during each stage of treatment.

Standard treatment options include closed management with a functional brace or coaptation splint and surgical treatment with plates and screws, an intramedullary rod, or external fixation. The limits of acceptable deformity are 20° anterior–posterior angulation, 30° varus–valgus angulation, 20° malrotation, and 3–4 cm shortening [10]. The goal of treatment is a solid fracture union within these parameters with a functioning radial nerve.

Treatment with a functional brace following a closed reduction has a reported success greater than 90 % in both open and closed fractures [11]. Treatment is usually begun with a coaptation splint for 7–10 days followed by an adjustable brace or a cast brace until fracture consolidation, about 12 weeks. The brace can be made from locally available materials or by shortening the coaptation splint. Wrist, elbow, and pendulum exercises are begun when tolerated. The splint needs frequent adjustment to keep it snug, and the patient should remain in an upright or semi-sitting position for 4–6 weeks in order to maintain fracture alignment. Hanging casts rely on gravity for reduction by ligamentotaxis but are often too heavy and too short and have a higher rate of nonunion, so should be considered a distant alternative to a well-applied coaptation splint.

Stable internal or external fixation is indicated in patients with head trauma, multiple injuries that preclude remaining in a semierect position, vascular injuries, and concomitant fractures of the shoulder or forearm. Rigid plate fixation in a good bone with screws crossing six cortices may have an advantage over locked IM nails of allowing partial early weight. Flexible rods work well but require a compliant patient to avoid nonunion (Fig. 18.6). External fixation is indicated if there

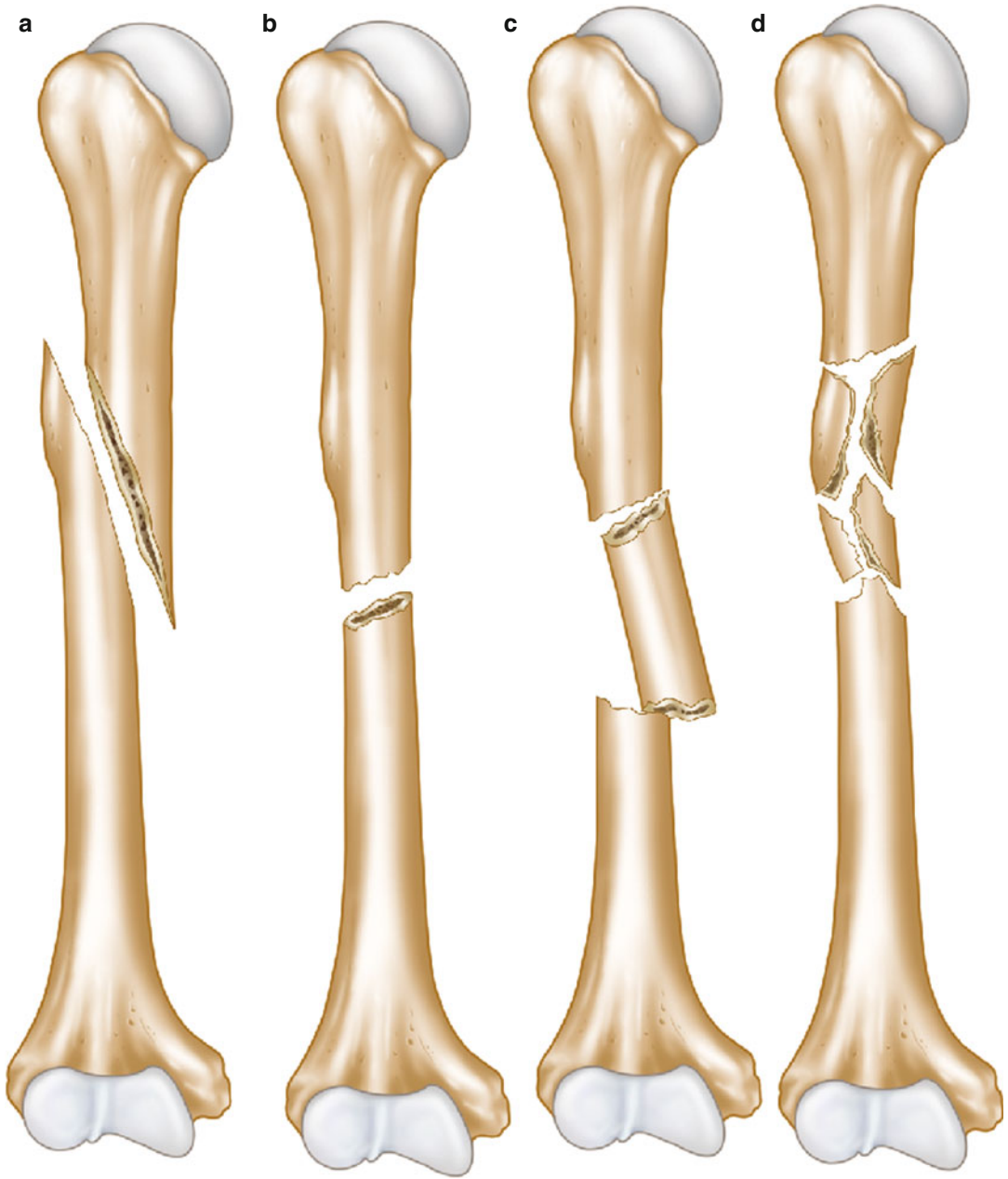


Fig. 18.5 Functional classification of humeral shaft fractures to help with treatment decisions. (a) Oblique/spiral, (b) transverse (c) segmental, and (d) complex comminuted

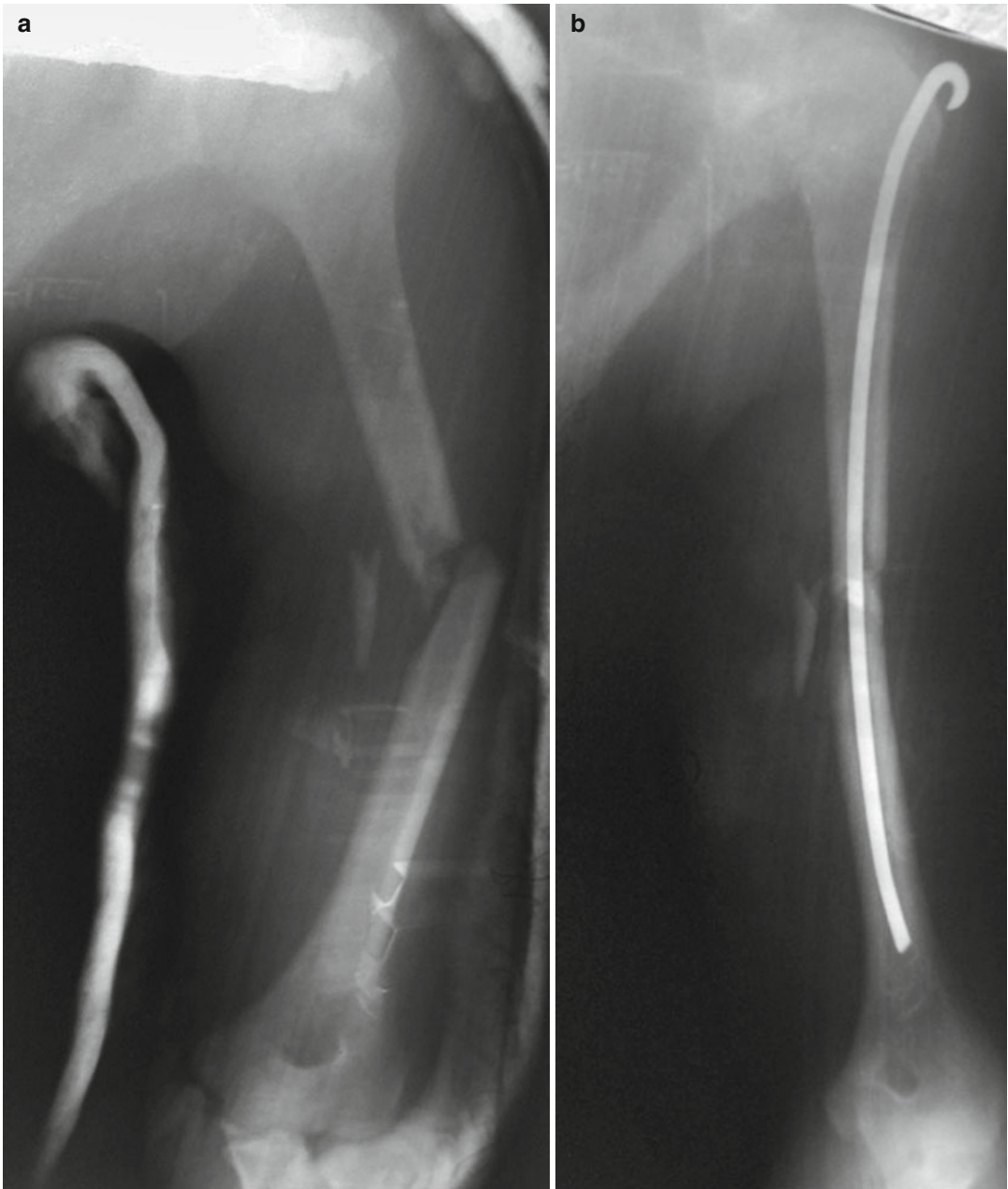


Fig. 18.6 Rush rod fixation of a mid-shaft humerus fracture in which the angulation could not be controlled with a coaptation splint. (a) Persistent angulation in the splint. (b) Postoperative X-ray after Rush rodding

are open wounds or as temporary fixation (Figs. 18.7 and 18.8). If the fracture extends near the distal metaphysis, the ex-fix should cross the elbow joint by placing two lateral pins in the humerus and two pins in either the radius or ulna. Proximity of the underlying nerves requires insertion of the pins through small incisions with dissection to bone and not percutaneously.

Management of radial nerve paralysis related to this fracture is no different in developing countries except electrical studies will unlikely be available, making a careful sensory and motor examination of radial nerve most important initially and periodically. If the nerve is not working when the patient is first seen and surgery is needed either for debridement of an open wound or fracture fixation, explore the nerve during the procedure. If the injury is closed and the nerve is not functioning initially or if function is lost during treatment, place the patient in an extension wrist splint and monitor. Initial signs of functional recovery can be seen by 2 months with complete return expected by 6 months. If there is no neurologic recovery by 3–4 months, consider nerve exploration. Muscle transfers for a nerve that has not returned in 6 months are a good option.

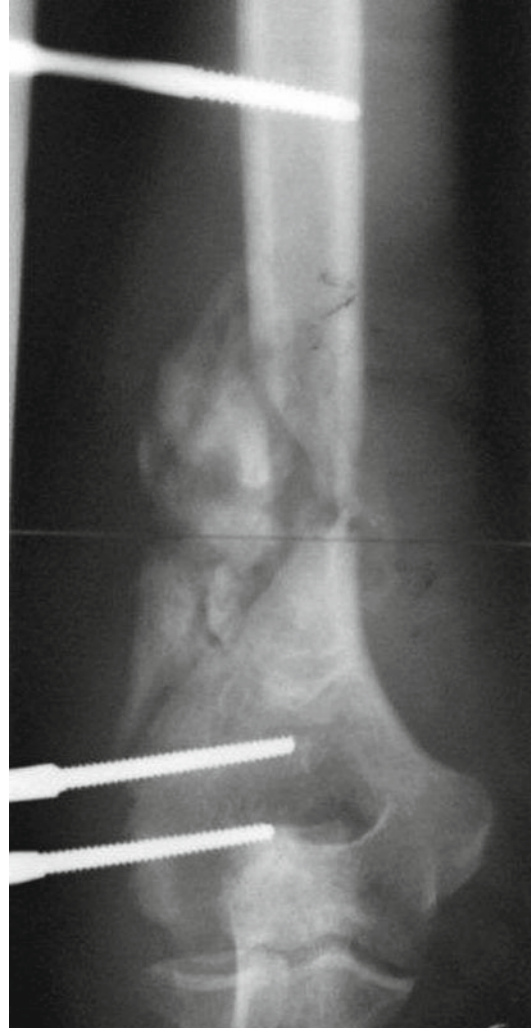


Fig. 18.7 External fixation device used to stabilize a comminuted distal humeral shaft fracture

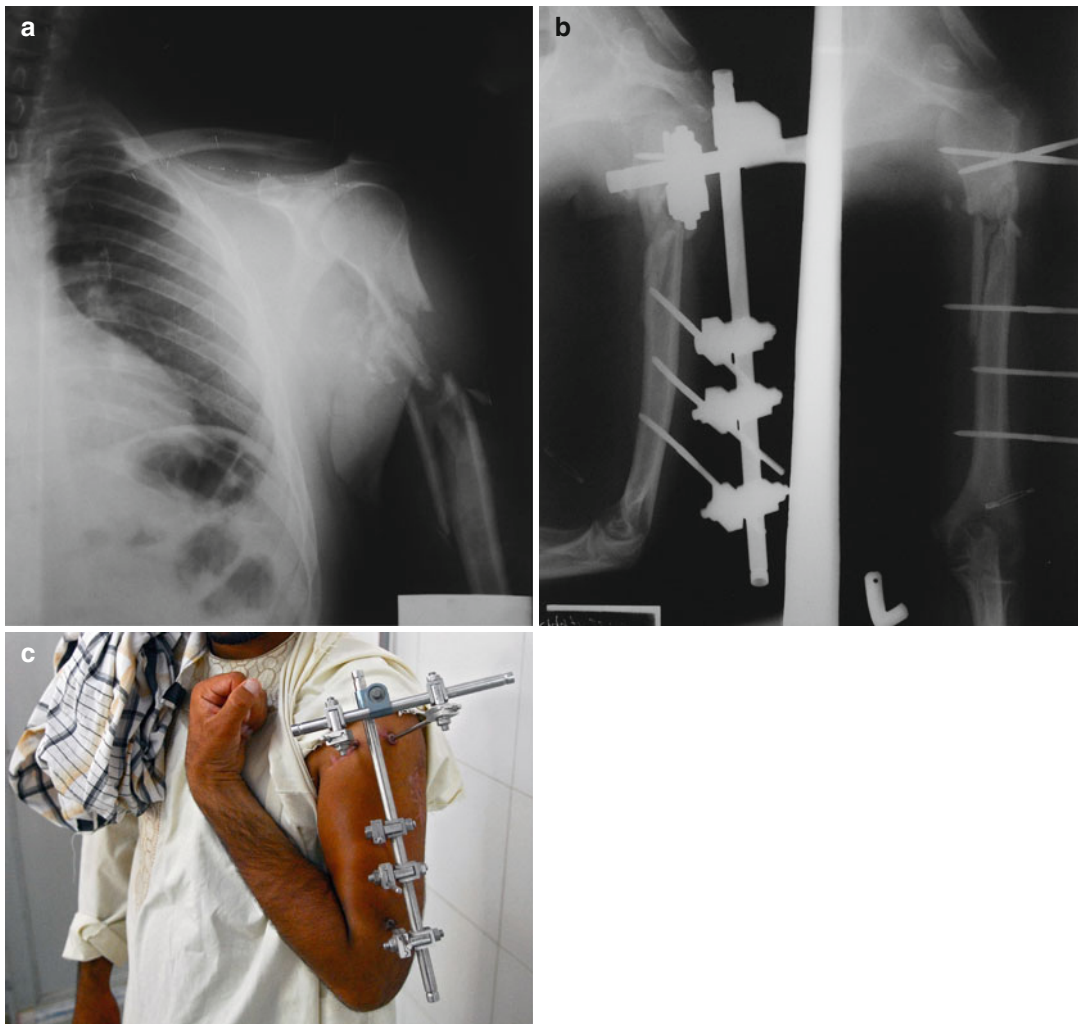


Fig. 18.8 (a) X-ray of GSW proximal left humerus. (b) X-ray with external fixation. (c) Lateral placement of the pins allows near full active elbow flexion

Conclusion

The shoulder and humerus are common sites for injury and often occur not in isolation but in conjunction with injuries of the ipsilateral elbow, forearm, and hand and also as a component of the multiply injured patient. Treatment needs to be prioritized and strict protocols are not applicable. Emphasis has been placed on simple, safe regimes for areas with scarce resources but it is assumed that as more complex treatment methods become safely available, they will be employed.

References

1. Green A. Traumatic conditions of the shoulder. In: Lieberman JR, editor. AAOS comprehensive orthopaedic review. Rosemont: American Academy of Orthopaedic Surgeons; 2009. p. 843–58.
2. Edwards SG, Whittle AP, Wood II GW. Nonoperative treatment of ipsilateral fractures of the scapula and clavicle. *J Bone Joint Surg Am.* 2000;82:774–80.
3. Goss TP. Scapula fractures and dislocations: diagnosis and treatment. *J Am Acad Orthop Surg.* 1995;3: 22–33.
4. Spang JT, Mazzocca AD, Arciero RA. The unstable shoulder. In: Lieberman JR, editor. AAOS comprehensive

- orthopaedic review. Rosemont: American Academy of Orthopaedic Surgeons; 2009. p. 805–15.
5. Neviaser JS. An operation for old dislocations of the shoulder. *J Bone Joint Surg Am.* 1948;30:997–1000.
 6. Rowe CR, Zarins B. Chronic dislocations of the shoulder. *J Bone Joint Surg Am.* 1982;64:494–505.
 7. Koval KJ, Gallagher MA, Marsicano JG, Cuomo F, McShinawy RS, Zuckerman JD. Functional outcome after minimally displaced fractures of the proximal part of the humerus. *J Bone Joint Surg Am.* 1997;79:203–7.
 8. Neer II CS. Displaced proximal humeral fractures. Part I. Classification and evaluation. *J Bone Joint Surg Am.* 1970;52:1077–89.
 9. Zlotolow DA, Catalano LW, Barron OA, et al. Surgical exposures of the humerus. *J Am Acad Orthop Surg.* 2006;14:754–66.
 10. Liporice FA. Fractures of the humeral shaft and distal humerus. In: Lieberman JR, editor. *AAOS comprehensive orthopaedic review.* Rosemont: American Academy of Orthopaedic Surgeons; 2009. p. 563–75.
 11. Sarmiento A, Zagorski JB, Zych GA, et al. Functional bracing for the treatment of fractures of the humeral diaphysis. *J Bone Joint Surg Am.* 2000;82:478–86.

Robert P. Hoffman and Sonam Dorji

Introduction

The elbow is a fascinating and important joint for proper upper extremity function. Useful elbow motion ranges from -30° extension to 130° flexion with 50° each supination and pronation. Post-injury restoration of function depends on early, progressive range of motion. In low- and middle-income countries (LMIC), old, poorly treated, or untreated elbow trauma is the common presentation. For these, early motion is impossible, and elbow stiffness is the normal end result. With this reality in mind, this chapter will touch on practices and procedures to help surgeons approach and treat some of the more common acute and chronic traumatic problems in the elbow and forearm, with a brief review of heterotopic ossification and inflammatory, degenerative, and post-traumatic elbow arthroses.

R.P. Hoffman, MD (✉)
Department of Orthopedic Surgery,
Alameda County Medical Center,
1411 E. 31st. Street, Oakland, CA 94602, USA
e-mail: rp.hoffman@comcast.net

S. Dorji, MBBS
JDW National Referral Hospital,
HQ/1/1A/25, Thimphu, Bhutan
e-mail: drsonam2003@yahoo.com

Acute Traumatic Conditions

Dislocations

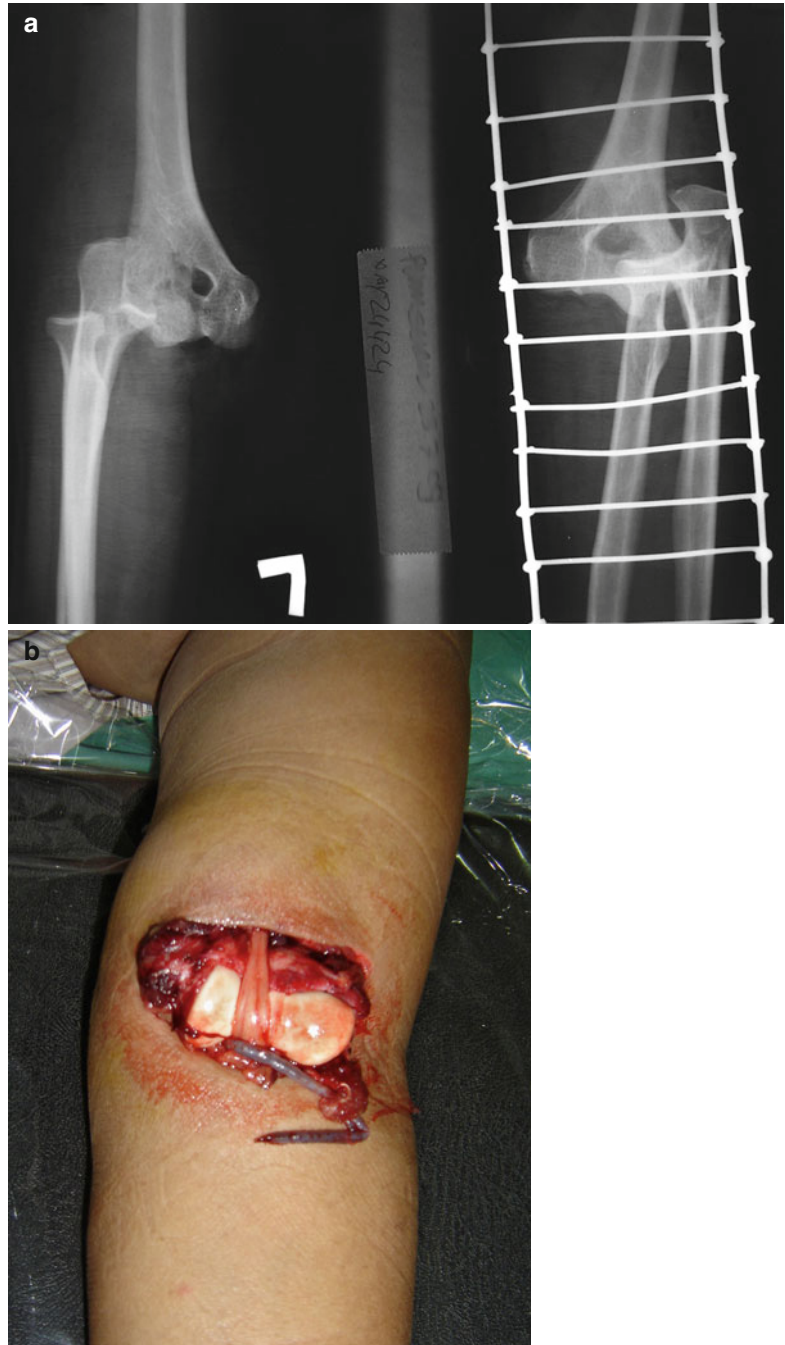
In austere environments, timing is the challenging issue. If the dislocation is seen acutely, it can be managed as one would in high-resource environments. Without hinged splints allowing protected motion, the injury may require longer initial immobilization than ideal, but this will produce a stable elbow. If the dislocation is combined with radial head trauma, NSIADs can minimize the high risk of heterotopic bone (Fig. 19.1).

Physical therapy will improve the final results, but many patients either live too far away or have trouble following simple instructions. The surgeon can play a vital role if reliable therapy is not available, by taking the time to teach and make sure the patient and his caregivers know what and what not to do.

Fracture/Dislocation: Terrible Triad

This fracture/dislocation—torn collateral ligaments and fractures of the radial head and coronoid process—produces an unstable elbow that is best treated by open reduction and fixation. The results are less than ideal under the best

Fig. 19.1 (a) X-rays of an open posteromedial elbow dislocation. (b). The exposed median nerve tented over the trochlea



circumstances, and without radial head implants, small headless compression screws, suture anchors, and small surgical instruments, results are compromised. ORIF of the radial head with whatever is available should be attempted. Even

if excised later, a damaged radial head provides the necessary acute stability to prevent valgus deformity and distal radioulnar problems. Even without a coronoid fracture, the lateral ulnar collateral ligament may have to be repaired if the

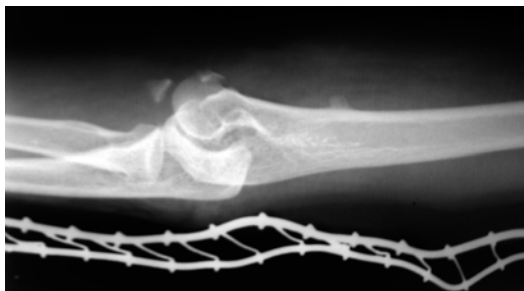

Fig. 19.2 Lateral view of terrible triad with type I coronoid fracture

elbow remains unstable. The medial collateral ligament rarely needs acute repair.

Dislocation with Coronoid Fracture

Type I coronoid fractures—avulsions of the tip that do not adversely affect elbow stability—need not be fixed, and dislocations with such fractures need a well-thought-out rehabilitation program to prevent stiffness. Type II fractures, involving approximately 50 %, and type III, involving greater than 50 % of the coronoid, are usually unstable and require open stabilization (Fig. 19.2). Exposure of the coronoid can be difficult. With a radial head fracture that is deemed fixable, a lateral Kocher interval incision can be used. Once the elbow is reduced and the radial head repaired, stability should be rechecked. If the elbow is stable at 30° flexion, the coronoid need not be repaired. If unstable, the lateral ulnar collateral ligament is taken down from its humeral origin to visualize the joint. If large enough, the coronoid fragment is fixed with a small fragment screw or a suture around or through the fragment and tied on the posterior surface of the olecranon.

For coronoid fractures with a sagittal component or medial extension, fixation with a small plate may be necessary. Without the need for a lateral approach to the radial head, the coronoid can be approached medially. Care must be taken to protect the ulnar nerve and the anterior fibers of the medial collateral ligament.

If the elbow is stable after repair, early motion at 7–10 days will lead to better long-term function than longer immobilization. A removable long arm splint can be used between exercise periods. If the repair is not stable, casting or splinting for 3–4 weeks is necessary. In this situation, stiffness is likely.

Fractures About the Elbow

Distal Humerus Fractures

In the developing world, these fractures can be a real test of the abilities and judgment of the surgeon. Basic principles used in resource-rich environments should be applied as possible. Most locations will have a small fragment system. Reconstruction plates placed in a 90°/90° fashion are the best choice, and DC plates contoured to fit are the second choice. Two semi-tubular plates stacked together to improve the implants' strength will also work. For isolated one-column fractures, a single plate may be adequate if screw fixation is secure (Fig. 19.3).

For both column and intra-articular fractures, a 90°/90° plate positioning is recommended. The medial plate is contoured to the medial supracondylar ridge and may extend as distal as the ulnar groove. Identify and mobilize the ulnar nerve early. If the nerve ends up lying over hardware without soft tissue interposition, transposition may be indicated. The preferred technique is the simplest: subcutaneous anterior transposition, securing the position with a couple of nonrestrictive sutures or fascial slings in the subdermal-fascial plane.

The lateral plate is applied posteriorly and contoured so its distal end abuts the articular surface of the capitellum. Intra-articular fractures usually require an olecranon osteotomy for adequate exposure. The intra-articular component of distal humeral fractures can be provisionally fixed with K-wires that are later incorporated into the plate construct with appropriate screws across the distal end of the humerus. Other than accurately reconstructing the articular components of

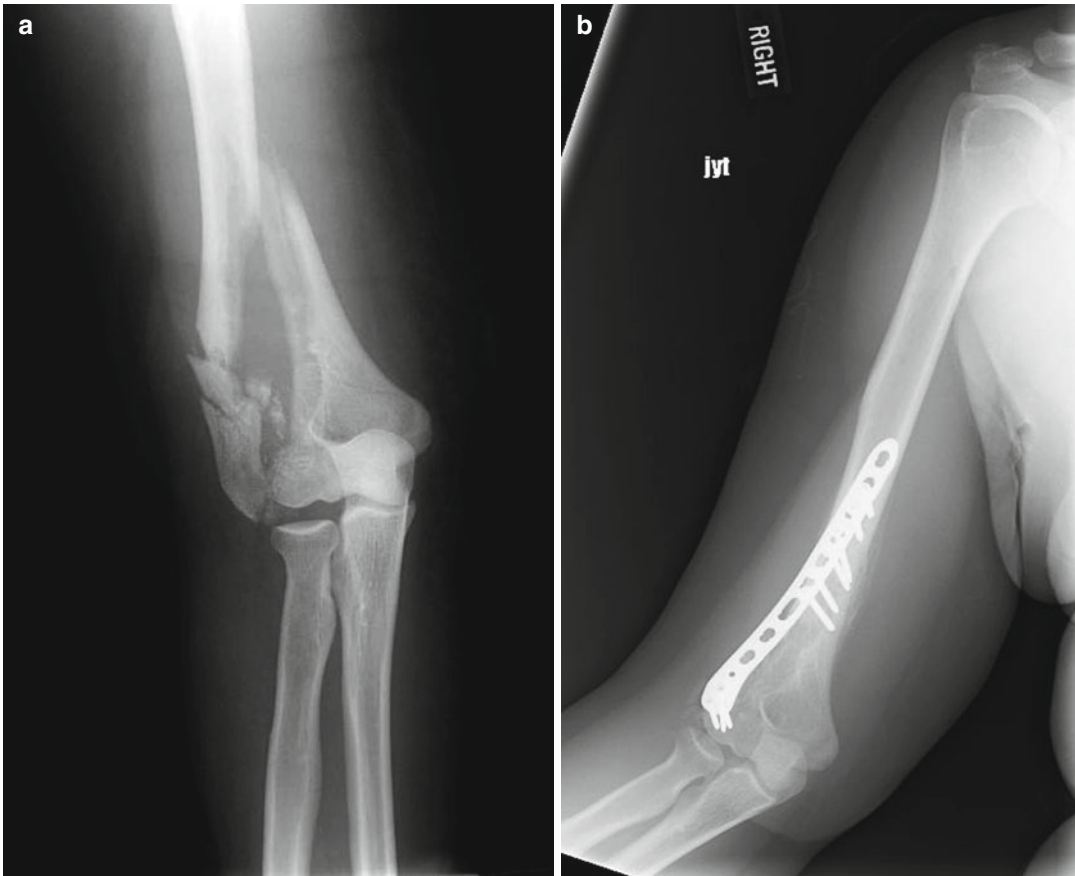


Fig. 19.3 (a) Comminuted lateral column fracture with high medial column involvement. (b) Fracture can be well fixed with only a lateral column plate as long as adequate

inter-fragmentary fixation is used for the articular surface and the large medial condylar fragment

the joint, it is important, especially in very comminuted fractures, to maintain the proper width of the distal humerus (Fig. 19.4).

If an olecranon osteotomy is performed for better exposure of the distal humerus, an intra-articular chevron or straight osteotomy gives good visualization of the humeral articular surface. Bicortical drill holes are made in the olecranon at the proposed osteotomy, taking care not to damage the distal humerus articular cartilage. An osteotome or power saw connects the holes in an incomplete cut, allowing the far cortex to be cracked open, again, minimizing damage to the articular cartilage. The osteotomy is repaired using a tension band technique—a 6.5 cancellous screw and washer with predrilling or two parallel K-wires.

Over the years, many of these fractures have been fixed with only K-wires if either surgeon skill or equipment is lacking. This is a risky technique since loss of fixation, early and late stiffness, infection, reoperation to remove motion-obstructing pins, nonunion, and post-traumatic arthritis are common results (Fig. 19.5). In severely comminuted distal humerus fractures, the nonoperative “bag of bones” approach may give better results while limiting iatrogenic disaster. This is especially useful in elderly patients with highly comminuted osteopenic fractures. This can be accomplished using an olecranon pin or winged screw overhead or lateral traction if the patient and hospital are geared for lengthy stays and such traction setups are available. Traction is kept for 3–4 weeks, allowing early elbow ROM as

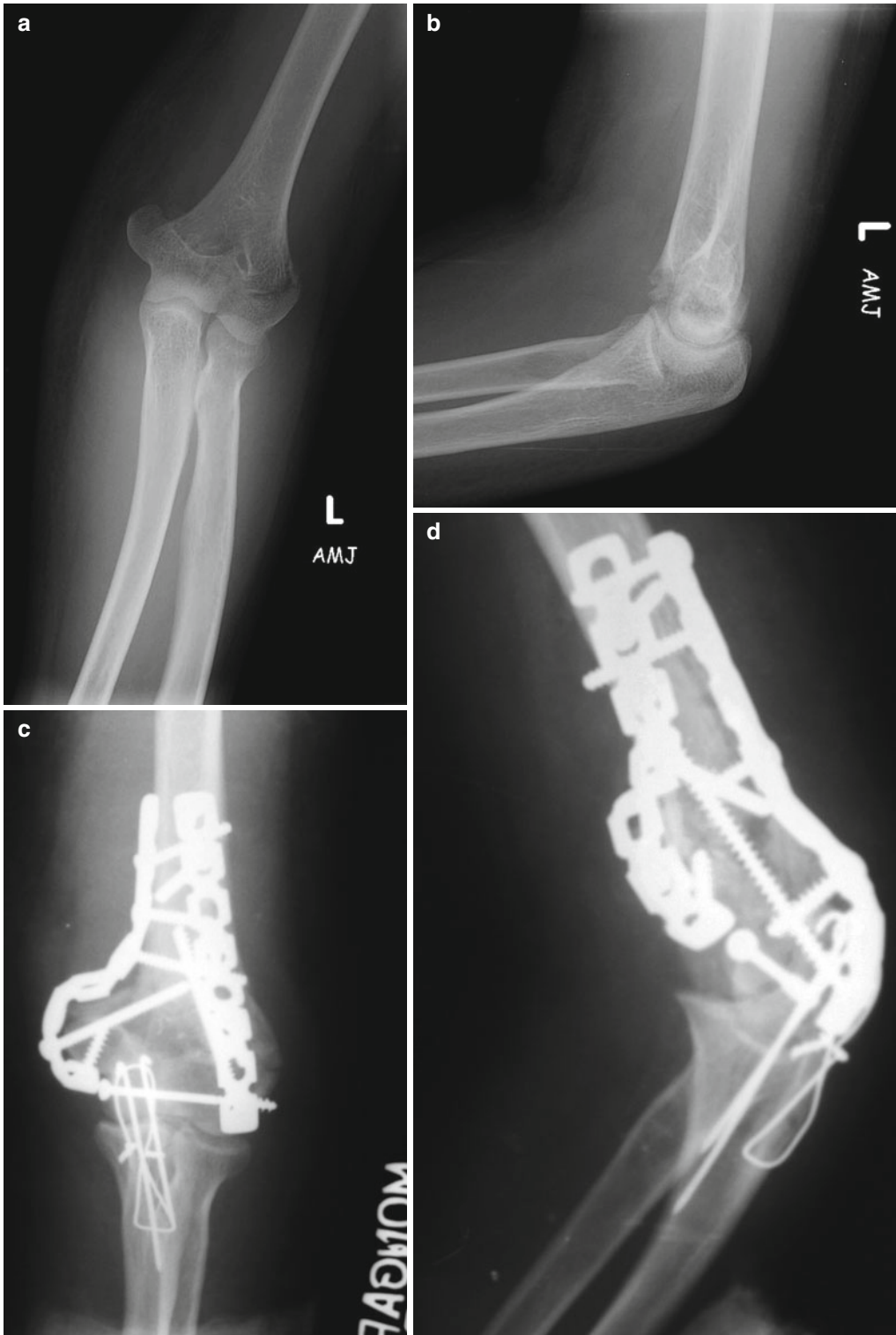

Fig. 19.4 (a) AP x-ray of a low bicondylar distal humeral fracture. (b) Lateral of same. (c) Postoperative AP x-ray. Note the 90/90 position of the plates with the lateral plate posterior and the medial plate contoured around the medial epicondyle. Non-locking, contoured, reconstruction

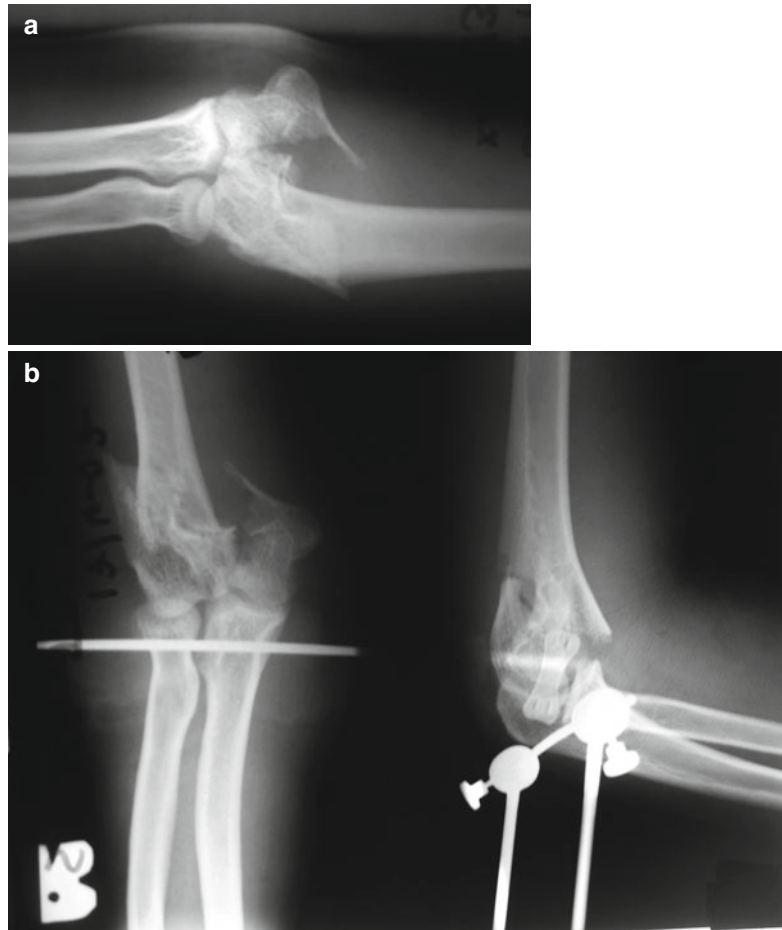
plates were used here. Note the inter-fragmentary screw used to fix the intra-articular fragments. The olecranon osteotomy was fixed with K-wires and tension band wiring. (d) Lateral x-ray view emphasizes the 90/90 plate placement

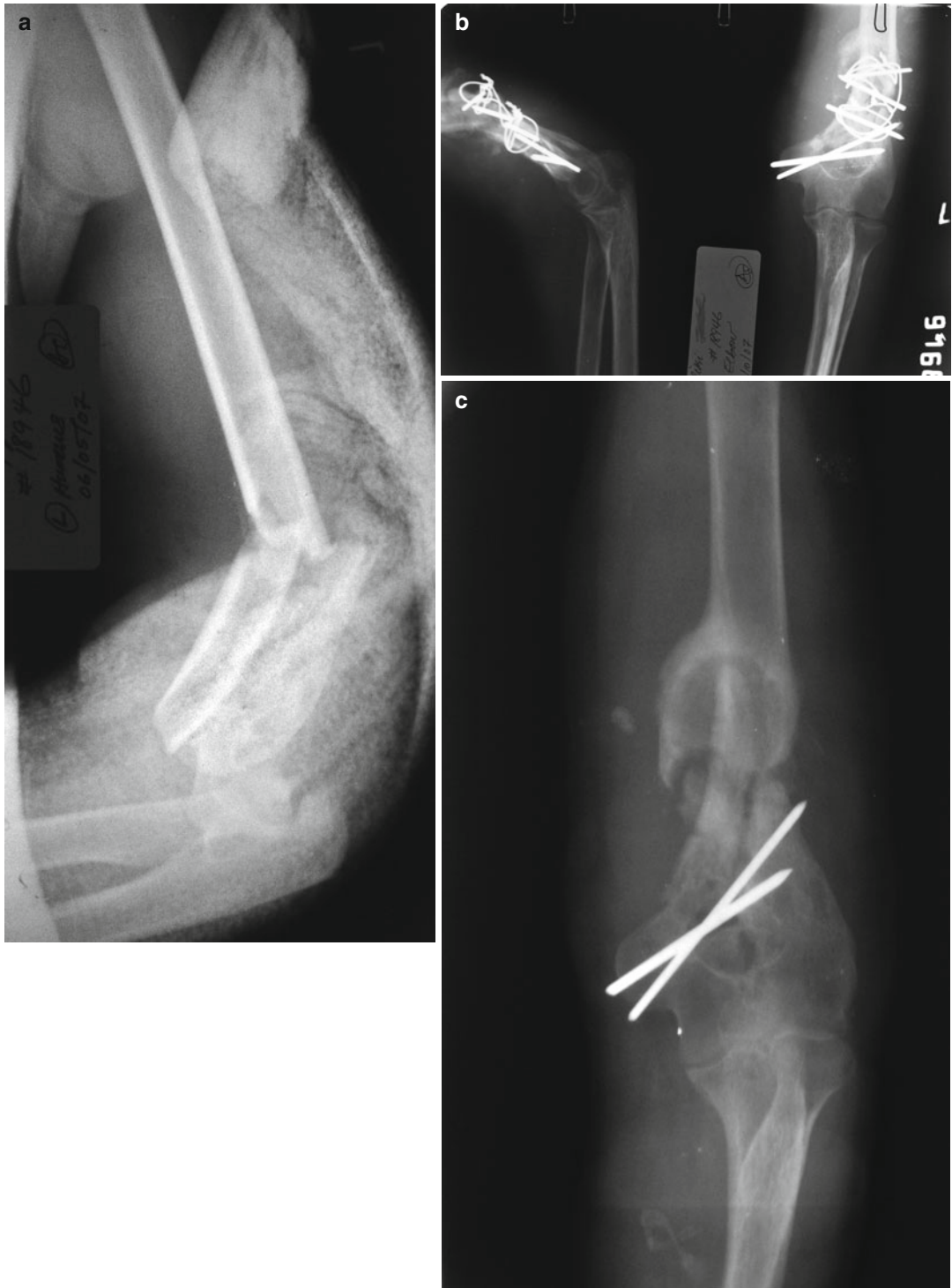

Fig. 19.5 (a) X-ray of comminuted intra-articular distal humerus fracture. (b) X-rays show early, inadequate proximal callus in the face of unstable fixation with K-wires

and cerclage wires. (c) The end result is nonunion with more motion at the nonunion than the elbow

Fig. 19.6 (a) X-ray of comminuted, bicondylar, intra-articular fracture of the distal humerus. (b) Olecranon pin is used for traction in a nonoperative “bag of bones” treatment



tolerated. When the fracture is sticky, traction is discontinued and a splint or cast is applied, until there is enough stability for ROM (Fig. 19.6).

For patients who cannot tolerate or afford bed rest, the elbow can be stabilized in a back slab for 7–10 days until gentle active and passive range of motion is initiated, hoping eventually for a painless nonunion. The elbow is very prone to stiffness even in the face of minor injuries and short immobilization times. Whatever technique is selected to treat these injuries, the surgeon should aim for motion as early as possible.

Capitellum

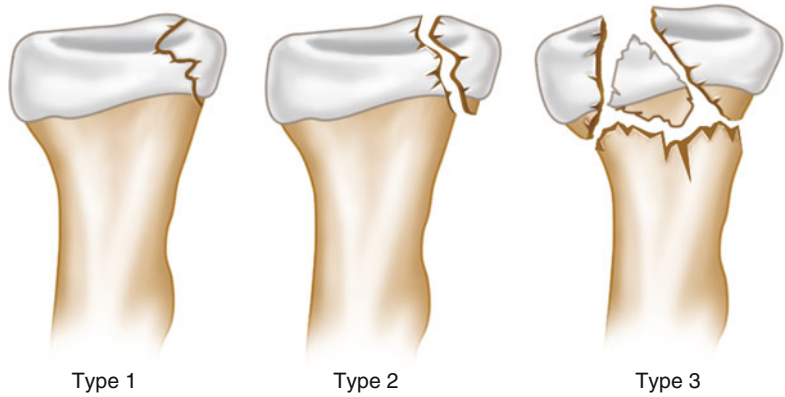
With a large capitellum fragment, ORIF with a headless screw is ideal, but rarely available.

Burying a headed screw or fixation from the posterior aspect of the lateral column is a viable alternative. Temporary K-wire fixation is a mechanically poor alternative and requires at least 3 weeks immobilization in neutral position before the wires can be removed. In a worst-case scenario, excision of the capitellum may be the only option. The results of this approach are mixed just as excision of the radial head. Proximal migration of the radius will produce pain in the wrist with either capitellar or radial head excision in about 1/3 of patients.

Radial Head

Most radial head fractures can be treated with conservative management (Mason I and even II

Fig. 19.7 Mason classification of radial head fractures. Type IV is any radial head fracture combined with an elbow dislocation



types). Radial head excision with prosthetic replacement for fractures with comminution greater than four components or inability to achieve an accurate articular reduction is the general recommendation (Mason type III) (Fig. 19.7). But without such replacements, ORIF, even if not perfect, may be a better option using buried K-wires, intraosseous wiring, or intraosseous sutures. Some authors have reported good results with late excision of Mason type IV fractures (any radial head fracture combined with an elbow dislocation), and this may be a reasonable approach for certain situations. Take care to examine the wrist for pain in the face of a radial head injury—the Essex–Lopresti lesion—as the distal radioulnar joint may be disrupted. When there is associated medial instability, the radial head should be reconstructed as best as possible to serve as a spacer, to prevent valgus displacement while the soft tissues are healing. It can be excised later.

Olecranon

Non-comminuted olecranon fractures can usually be treated with standard tension band technique as detailed above. In comminuted fractures, inter-fragmentary fixation and neutralization plating with a small fragment reconstruction or DC plate are preferred, taking care that the joint volume is maintained.

Radius and Ulna Fractures

Shaft fractures of the radius and ulna are approached in the same fashion whether in high- or low-income environments. X-rays need to show the elbow and wrist to rule out commonly associated injuries. Small fragment plates are usually available, and results with these in adults are far superior than other treatments in achieving fracture alignment, bone length, and preservation of the interosseous space. In the event that plates and screws are unavailable, either closed reduction and a long arm cast, percutaneous or open fracture fixation with one or two K-wires, or IM K-wires can be used.

IM nailing with small Ender nails, Steinmann pins, or stacked K-wires requires open reduction if there is no C-arm or the fracture is old. This technique is usually only successful in controlling length and axial alignment while providing no rotational stability. The radius is nailed starting from the styloid, the ulna from the olecranon tip. These wiring techniques are less than ideal and should be used only when appropriate internal fixation is not available. Post-op, an above elbow cast with interosseous molding is necessary. This can be converted to a Munster cast at 3 weeks (see Chap. 13). In fractures proximal to the insertion of the pronator teres, the forearm should be immobilized in supination to accommodate the position of the proximal fragment. In fractures distal to the pronator teres insertion, the

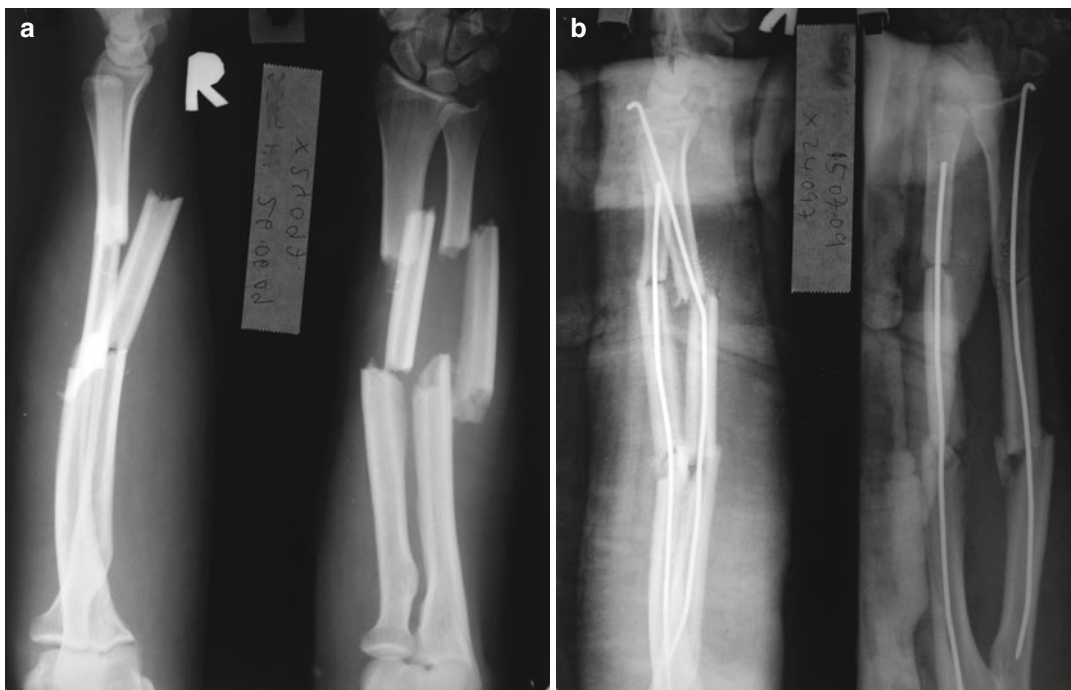


Fig. 19.8 (a) X-rays of a segmental both-bone forearm fracture. (b) Repaired with thin Rush rods opening the fracture site

forearm is better aligned in neutral rotation (Fig. 19.8).

For plating, the ulna can be approached along its entire length on the subcutaneous border. Plates can usually be placed beneath the flexor carpi ulnaris making plate irritation and the need for later removal less likely. For radial fractures in the distal 2/3 of the shaft, the volar Henry approach is the easiest and safest. For more proximal fractures, there is disagreement as to whether the dorsal Thompson approach, with its potential for posterior interosseous nerve injury, or the Henry approach, with many vessels in the way and a much deeper location of the radius, is the better choice. The surgeon's training and comfort level will make the decision.

Many forearm fractures will be seen late. Six weeks is not uncommon. Even at several months, it is often possible to find the callus and take down a potential malunion before a formal osteotomy is required. In these cases, with

rounded fracture ends, some shortening may be required of both bones in order to obtain good coaptation.

Isolated ulnar shaft fractures such as a "night stick" fracture can often be successfully treated with a short arm cast or locally made coaptation splints. As long as a good interosseous space is maintained, results are usually acceptable.

Monteggia and Galeazzi fracture/dislocations require anatomic reduction with plate fixation for good results in adults. Without anatomic reduction of a Monteggia fracture, radial head subluxation or dislocation may persist, and long-term results will be poor (Fig. 19.9). If Galeazzi fractures are not reduced anatomicly and there is disruption in the distal radioulnar ligaments, a poor result can be expected. The most reliable treatment is plating the radial fracture and testing stability of the distal radioulnar joint (DRUJ) in supination, where the DRUJ is the tightest. If stable, cast in supination for 6 weeks. If the DRUJ is still unstable in supination, reduce the

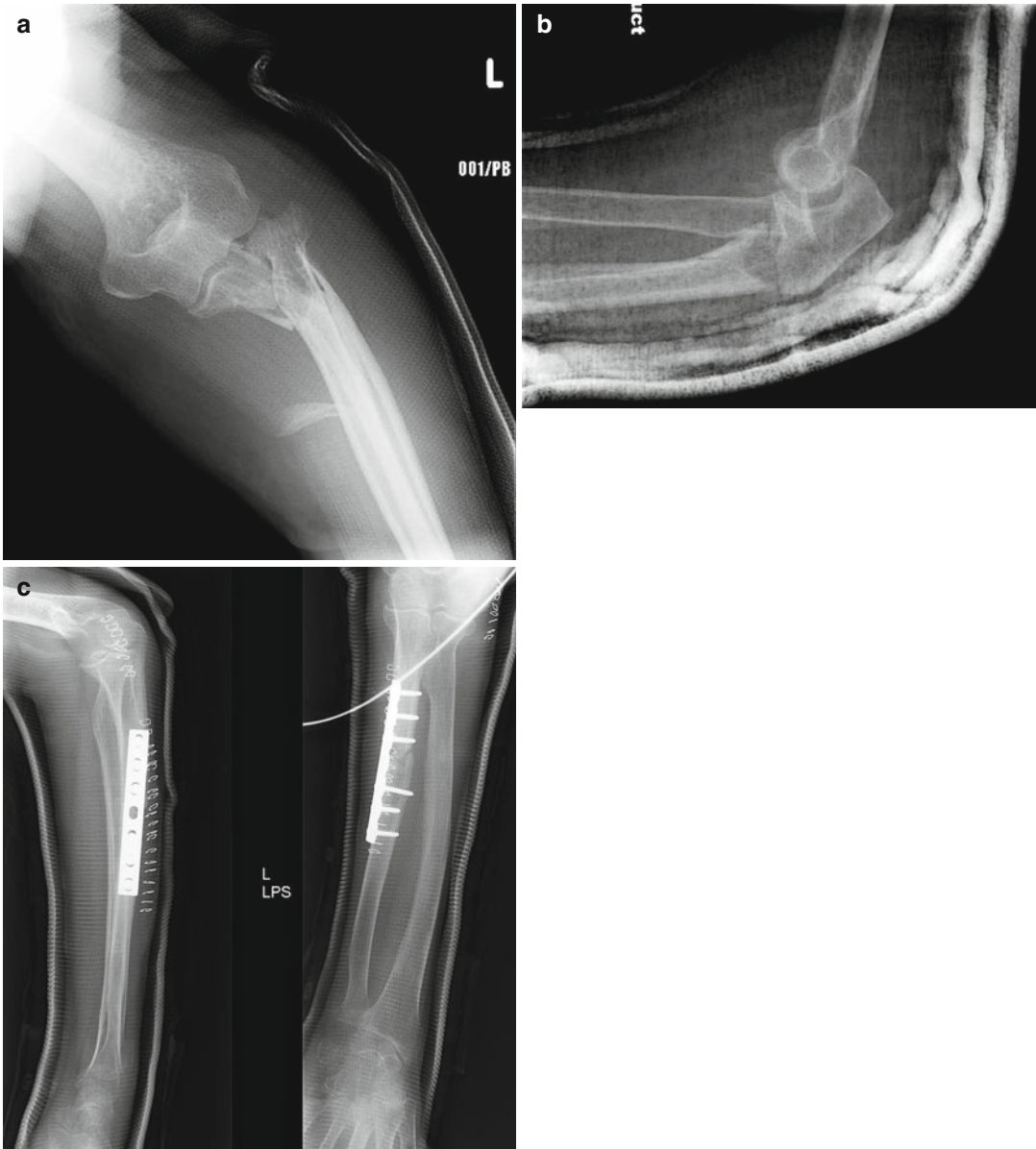


Fig. 19.9 (a) AP x-ray of a Monteggia fracture with clear dislocation of radial head. (b) Lateral view; (c) On this x-ray of a different patient with a Monteggia fracture, the

radial head is well reduced after plating the ulna (non-locking DC plates or reconstruction plates can be used in place of the locking plate shown here)

joint and transfix it with a 1.6 mm K-wire for 6 weeks.

Galeazzi fractures are often initially placed in ill-fitting below-elbow casts by technicians, nurses, or physios who recognize only the single bone fracture and not the complex injury pattern. A K-deformity with nonunion of the radius is common, requiring ORIF, occasionally with bone graft.

Ruptured Distal Biceps Tendon

A ruptured distal biceps tendon will compromise the strength of supination more than flexion. In the developing world, these can affect a patient's ability to do heavy labor but will not be incapacitating. Careful thought should be given whether repair is necessary. If repair is chosen, suture anchors are

typically not available, requiring a two incision technique, Boyd–Anderson. The incidence of heterotopic bone is high in this approach during ulnar exposure when passing the end of the biceps tendon posteriorly to the second incision.

Compartment Syndrome

Forearm compartment syndrome can be a devastating complication of supracondylar humerus fractures, radius and ulna fractures, or any upper extremity crush injury. The rate of muscle death is proportional to the compartment pressure and duration. A high index of suspicion and timely volar and dorsal compartment releases are necessary to prevent catastrophic complications. In the developing world, many potential compartment syndromes will arrive at the hospital days after the original injury. If loss of active muscle function or numbness has been present for over 24–48 h, one can assume that the muscles are dead and will not respond to fasciotomy. Ill-advised late fasciotomies almost always lead to poor wound healing, infection, and late amputation, making it safer to leave the situation alone and treat any contractures that develop on an elective basis. This is particularly true of crush injuries seen in natural disasters.

Chronic Traumatic Conditions

Old Dislocations

In the developing world, many elbow dislocations will either be untreated or poorly treated. Local bone setters will often place the elbow in full extension and splint it for weeks. When presented with an old dislocation or subluxation greater than 1 month, several important questions regarding treatment need to be asked:

1. Will the soft tissues allow a reduction even with a major ligamentous release?
2. Is pain a factor? Some old, chronic dislocations may have limited motion but retain stability and are minimally painful, especially when in the nondominant extremity. In this situation, consider whether overall function

can be improved, i.e., making the risk of the procedure worth the benefit.

3. If the elbow can be reduced, how will it be maintained? Is a hinged external fixateur available? Usually not. A static ex-fix or a large Steinmann pin through the olecranon into the humerus may be the only options.
4. Chronic dislocations require much therapy to regain useful function. Is it available and will the patient cooperate?

All these potential pitfalls make this a difficult problem to treat. In general, an open reduction may be attempted if the above issues are found to be acceptable.

Stiffness

Given the paucity of physical therapy, poor patient compliance, and long periods of immobilization, stiffness is a problem that is often the rule, not the exception. As with chronic dislocations, great care must be taken when making a decision to operate. Even with significant stiffness, elbow function can be reasonably good. A functional range of motion is considered to be -30° extension to 130° flexion and 50° each of supination and pronation. This is ideal but less motion can still be useful, especially with normal shoulder and wrist/hand function. It takes about 110° of elbow flexion—with a mobile wrist—for the fingers to reach the mouth.

In the developed world, stiffness is often dealt with arthroscopically, but lack of equipment and experience makes this technique virtually absent in the developing world. If open release is selected, intense and frequent therapy must be available to maximize postoperative range of motion. Static, progressive splinting can also help to regain motion after an extensive elbow release.

Heterotopic Bone and Synostosis

Ulnohumeral Synostosis

Heterotopic ossification (HO), with or without synostosis, is a significant and not rare complication of elbow injury. Any fracture around the

elbow can produce HO, but fracture dislocations have the highest incidence, approaching 35 %. With heterotopic ossification and stiffness, all of the previously mentioned problems surrounding surgical release apply. A localized excision for an isolated HO is often an effective treatment. The distal humerus, coronoid, and tip of olecranon are the most common locations. All of these can usually be reached through an extended lateral approach. One needs to take care to protect the lateral ulnar collateral ligament. It is easily identified and an approach to the tip of the olecranon posterior to the ligament is straightforward. Postoperative therapy is critical to maintain the range obtained at surgery.

In the case of a formal synostosis, the same approach can be used, but more aggressive excision of bone is often needed.

In the face of HO with or without synostosis, one must consider prevention of recurrence. Radiation therapy is the most predictable method (one dose, 750 cgy) with NSAIDs, the only other proven preventive therapy. Indomethacin is the gold standard, but other NSAIDs can be effective. Determine preoperatively if the patient has any contraindications to such drugs. If one of these two methods cannot be employed, recurrence and failure are expected.

Radioulnar Synostosis

Treatment of radioulnar HO and synostosis follows the same principles as ulnohumeral. It is difficult on plain radiographs to determine the location and extent of the HO. Without CT, additional plain films of the forearm may be necessary to adequately determine the extent and best approach for excision. A posterior approach between the ulna and radius is usually adequate. When very proximal HO causing synostosis cannot be removed, excision of a 1 cm segment of radius distal to the synostosis is a good alternative. This may produce instability but can often restore a functional arc of rotation.

Arthritis

Inflammatory Arthritis

The most common inflammatory arthritis globally is rheumatoid arthritis. In the developing world, medical management is often inadequate or absent. As total elbow replacement is not an option, the mainstay of surgical treatment will be radial head excision and possibly synovectomy. Radial head excision is straightforward, and the results usually justify the risks. Synovectomy should be considered carefully, as intensive therapy along with a compliant patient is needed for a satisfactory result.

Post-traumatic Arthritis and Osteoarthritis

In the elbow, these two conditions have similar presentations and treatment options for one can often be applied to the other. Without the aid of the arthroscope, surgical approaches will be open. If conservative measures fail, careful consideration of functional needs must be done before undertaking this route. Stiffness often accompanies arthritis, and the concerns regarding stiffness mentioned above need to be answered before attempting any surgery. The most common procedures are debridement, removal of loose bodies, excision of impinging spurs, and possibly radial head excision. As in other problems with the radial head, the risks of wrist pain after excision must be weighed. In chronic radial head excisions, around 30 % of patients will have some degree of wrist pain. Salvage procedures for inflammatory, post-traumatic, and osteoarthritis are considered in Chap. 41.

Infection

Penetrating injuries, hematogenous spread, and surgery are also common causes of elbow infections. In LMIC, bacterial cultures and sensitivities

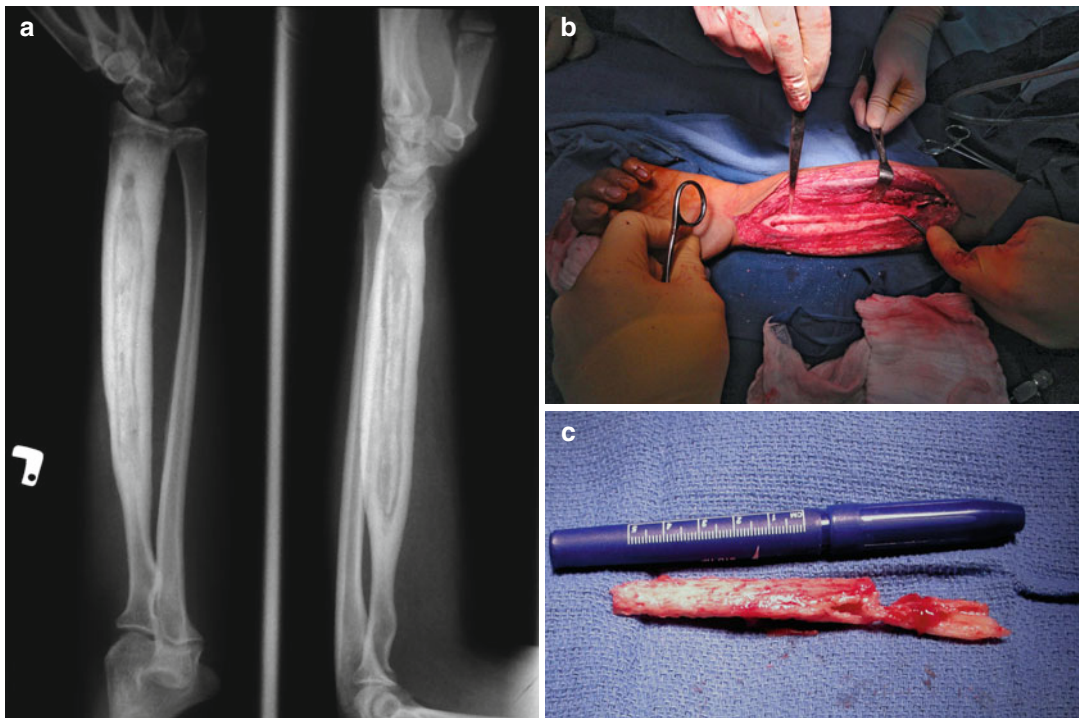


Fig. 19.10 (a) Large sequestrum of radius surrounded by newly formed involucrum. (b) Large intraosseous window was needed to remove entire sequestrum and residual dead bone within the involucrum. (c) The excised sequestrum

can be misleading, imprecise, or not available. In other regards, this is one area where a similar approach for all economic and resource levels can be applied, using standard techniques of open irrigation and debridement. A lateral approach to the elbow through a small Kocher incision is usually sufficient to wash out a joint infection. In the presence of osteomyelitis, a more extensive approach is required. Repeat washouts, debridement of avascular bone and cartilage, and appropriate antibiotics are the hallmark of treatment.

Osteomyelitis in either the radius or ulna requires long-term intravenous antibiotics with adequate debridement of all dead bone, including shortening of one or both bones. Shortening can produce weakness of the extrinsic muscles crossing the wrist joint, but this is often an acceptable trade-off in the face of chronic osteomyelitis with or without nonunion (Fig. 19.10).

Salvage/Reconstructive Procedures

Chronic proximal radial dislocations are challenging. In general, pain is the main indication for surgical treatment, typically radial head excision. In the absence of pain, poor motion is usually not improved with radial head excision.

For chronic dislocations of the ulnar head, disabling pain is the indication for shortening the distal ulna with plate fixation and immobilization in supination. Excision of the distal ulna, Darrach procedure, gives poorer functional results than an osteotomy with shortening and should be considered only where internal fixation is not possible.

For patients with severe elbow pain—usually the result of post-traumatic arthritis—few options exist. In a small number of patients, isolated radial head excision for lateral compartment involvement may be helpful. Remember to consider the possible morbidity due to proximal

radial migration and its potential for secondary wrist pain. The only other reasonable alternatives may be interposition arthroplasty or arthrodesis, as described in Chap. 41.

Suggested Reading

- Abalo A, Dossim A, Assiobo A, Walla A, Ouderaogo A. Intramedullary fixation using multiple Kirschner wires for forearm fractures: a developing country perspective. *J Orthop Surg (Hong Kong)*. 2007;15(3):319–22.
- Bach O. Musculo skeletal trauma in an East African public hospital. *Injury*. 2004;35(4):401–6.
- Bach O, Hope MJ, Chaheka CV, Dzimbiri KM. Disability can be avoided after open fractures in Africa-results from Malawi. *Injury*. 2004;35(9):846–51.
- Bucholz R, Heckman JD, Court-Brown C, Tornetta P. *Rockwood and Green's fractures in adults*. 7th ed. Philadelphia: Lippincott, Williams and Wilkins; 2010.
- Canale ST, Beaty JH. *Campbell's operative orthopaedics*. 11th ed. Philadelphia: Mosby; 2008.
- Laufer WE. Some tips on the treatment of fractures. *Trop Doct*. 1998;28(1):49–51.
- Morrey BF, Sanchez-Sotelo J. *The elbow and its disorders*. 4th ed. Philadelphia: Saunders/Elsevier; 2009.
- Musa AA. Functional cast bracing in the management of open forearm fractures: a preliminary report. *Niger Postgrad Med J*. 2006;13(2):143–6.
- Saati AZ, McKee MD. Fracture-dislocation of the elbow: diagnosis, treatment, and prognosis. *Hand Clin*. 2004;20(4):405–14.
- Wal A. Long-term results of intramedullary pinning of forearm fractures in a developing country. *Aust N Z J Surg*. 1997;67(9):622–4.

Michelle Foltz, Tour Phot Sin, and Robert Derkash

Introduction

Two major factors account for the increase in the number of hand and wrist injuries in austere settings: (1) the rapid, recent increase in motorization and mechanization in populations for which safety measures are unrecognized, nonexistent, or ignored and (2) increased longevity that has increased the number of fragility fractures [1].

Traditionally, the majority of these injuries have been treated nonoperatively. Utilizing proper casting and splinting techniques in conjunction with knowledge of the patient's needs and the natural history of the injury while paying attention to detail and follow-up, a volunteer surgeon can, in most cases, expect decent results with what are considered low-tech solutions.

M. Foltz, MD (✉)
172 Stillwater Loop Road,
Columbus, MT 59019, USA
e-mail: michellefoltz@gmail.com

T.P. Sin, MD
Surgical Department,
Sihanouk Hospital Center of Hope,
Street 134 Sangkat Vealvong Khan 7 Makara,
Phnom Penh, Cambodia
e-mail: tourphot@yahoo.com

R. Derkash, MD
Orthopedic Surgery, Valley View Hospital,
1618 Lincolnwood Drive,
Glenwood Springs, CO, 81601, USA
e-mail: rderkash@hotmail.com

General Considerations

Edema is a major problem in all hand and wrist injuries, and preventing it is best accomplished if injuries are seen and treated early and the affected part elevated. N.B: a sling holding the hand and wrist at waist level is not elevation. After reduction and splinting or casting, explain to the patient and family the need for elevation by holding the arm at the elbow so the injured part is above the heart or resting the forearm on top of the head.

A length of tubular stockinette is a useful elevator, but make sure it is not used as a sling. If the patient is admitted, the elevation order needs to be specific and the patient checked in the ward to make sure it is being carried out. Elevation can be done using an IV pole, pillows, or folded garments. ROM within the limits of the splint or cast accompanies elevation as an important edema reduction measure. Make sure the patient can demonstrate a full range of motion, preferably active, but passive will still help. Give the patient and family a specific number of times each day to do the exercises and for how long (Fig. 20.1). Many cultures use massage in traditional treatments, and patients and family are often receptive to edema reduction massage in both the acute and rehabilitation stages.

Rings, bracelets, and arm bands are common jewelry and need to be removed after any upper extremity injury. It is unlikely one will find a ring cutter, and sometimes the only instrument is a bolt cutter. In many cultures, religious strings or braids are worn around an extremity. Patients usually object to their removal. Local staff can help explain the need for

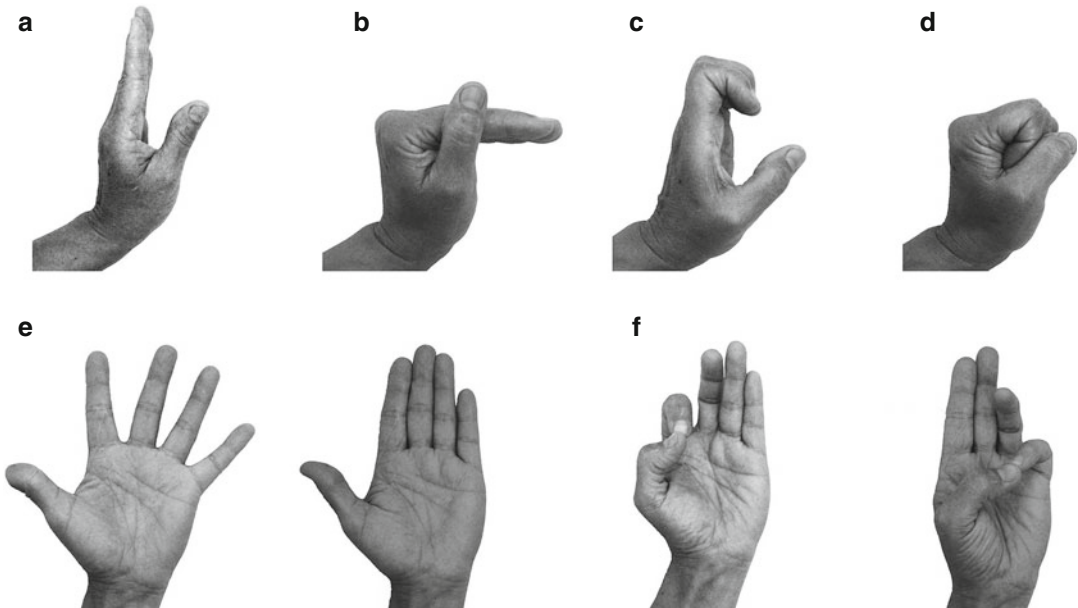


Fig. 20.1 Useful active or passive exercises to teach a patient and his family after hand or wrist injury for ROM and edema reduction. **(a)** Fully extend MP and IP joints

(b) Flex MP joints with IP joints extended. **(c)** Extend MP joints with IP joints flexed. **(d)** Make a fist. **(e)** Abduct and adduct fingers. **(f)** Touch thumb to tips of fingers

removal and the patients usually comply, especially if the talisman is retied around the cast.

One of the major drawbacks to nonoperative treatment is the need for frequent early checks to determine the position of the fracture or adjustment of the immobilization as swelling subsides. For patients who live far from the hospital and for whom lengthy inpatient treatment is not possible, reduction with pinning of a fracture may be a more conservative approach than simply reduction and casting.

The good outcomes hand and upper extremity surgeons enjoy in high-resource countries depend in large part on hand therapists. With few therapists in developing countries, the surgeon must take on this added role. The surgeon needs to think creatively about how to solve the immediate problems for the patient's advantage.

Equipment and Instruments

Pneumatic Tourniquet

Check if one is present, is the right size for upper extremity work, and functions. Esmarch bandages

are often used both to exsanguinate and to wrap proximally as tourniquets. They must be used with extreme caution as they can cause severe nerve injury as there is no control over the pressure.

Finger Traps

If not available, a simple long gauze made into a "rope" and looped around two fingers with a counterweight on the upper arm substitutes well (Fig. 20.2).

C-Arm

The presence of one in the operating theater does not mean it functions. Assess the quality of the image before planning cases that are dependent on fluoroscopy. Make sure lead protection is available for everyone in the room.

Hand Instruments

Make sure suitable small instruments are available and that they function, e.g., the tips of the forceps

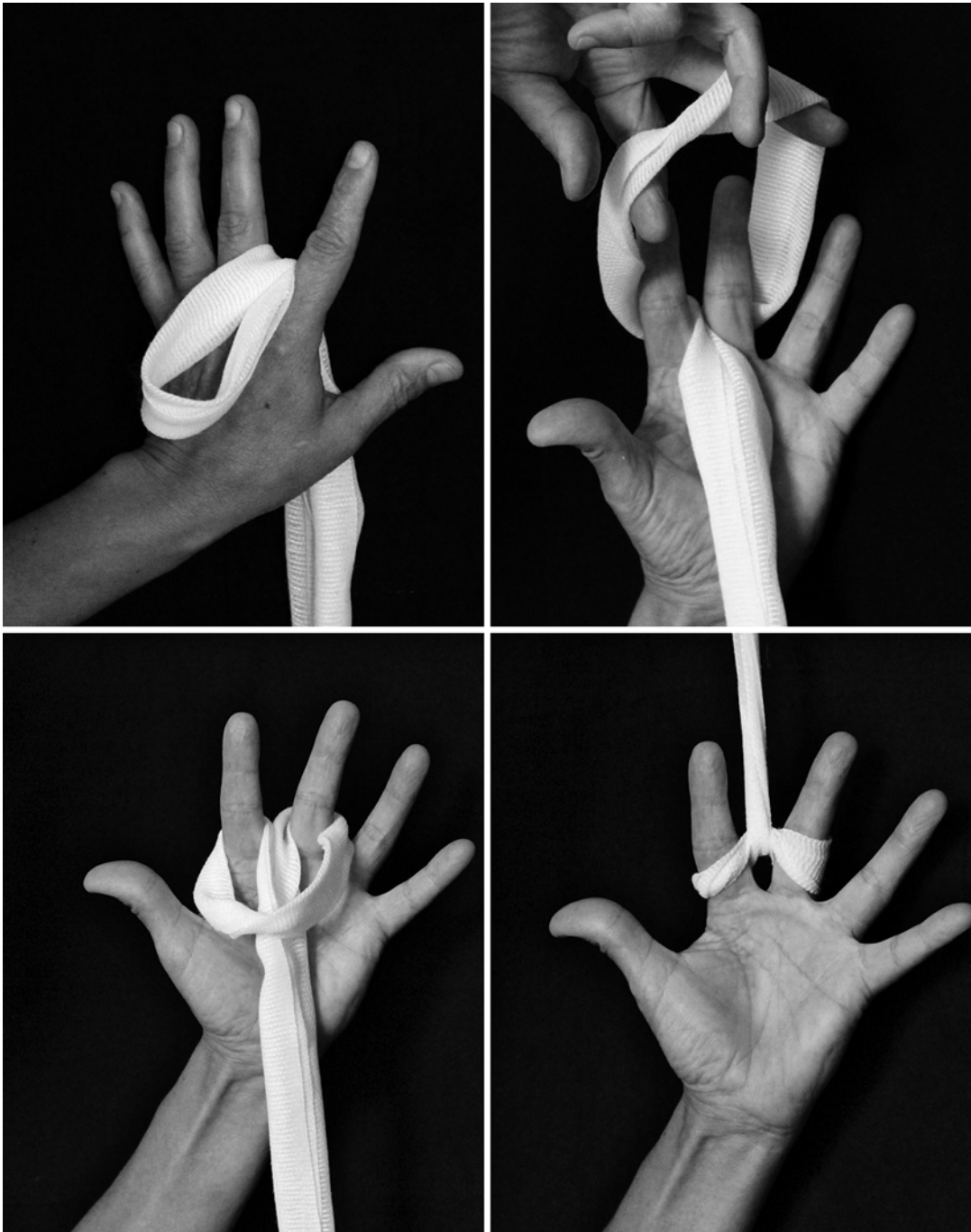


Fig. 20.2 Makeshift elevator made of Kerlix or long bandage gauze to assist in fracture reduction and casting

meet and the tenotomy scissors actually cut. Hospital staff are often reluctant to discard unusable instruments, knowing they won't be replaced, and return them in the instrument tray for "completeness."

K-Wires

Hospitals often buy K-wires in long lengths, allowing the surgeons to cut off what they

need. When cut with a dull pin cutter and the incomplete cut is repeatedly worked to complete the cut, the pin is generally out of true. Check the size, trueness, and tip points of K-wires before starting a case.

Power Drills

These are expensive and rarely present or are broken or have no wire driver attachment. Sometimes the chuck only accepts large pins. It is

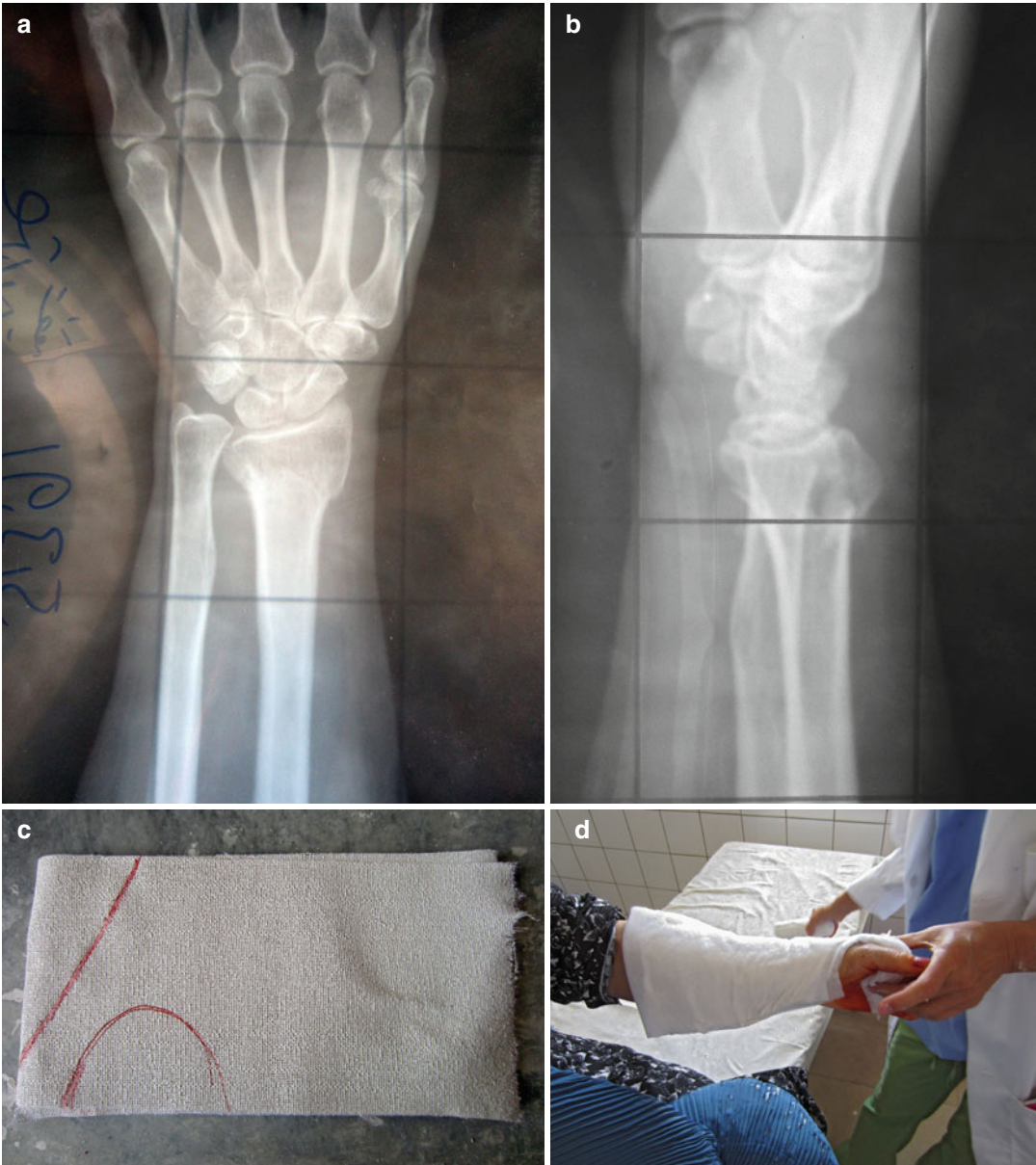

Fig. 20.3 Dorsal-radial splint. (a, b) X-ray of distal radius fragility fracture. (c) Outline of proposed splint on a 6" wide plaster slab. This is faced with cotton and can be used for either left or right injuries. (d) Splint applied on

the dorsal and radial sides of the forearm and wrist and (e) wrapped with a bandage, which can be resecured and tightened as swelling subsides

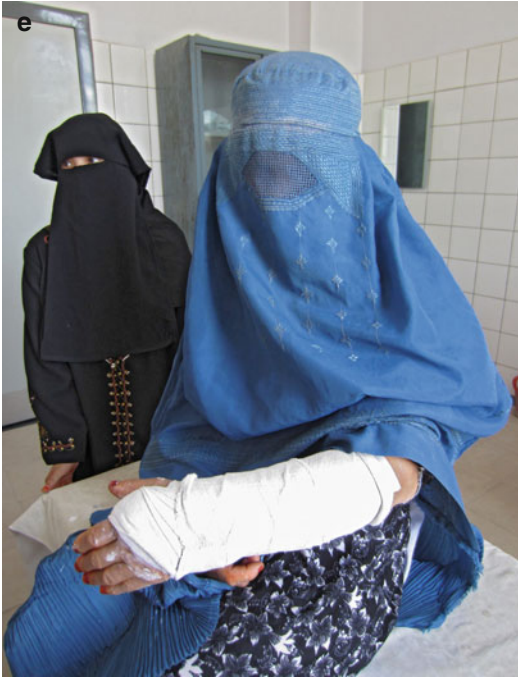

Fig. 20.3 (continued)

thought by some staff that the bones in the hand are small, making power unnecessary. A manual drill is difficult for someone used to working only with power, especially when trying to pin and, at the same time, hold small bone fragments in position. A Jacobs Chuck on a T handle may be more useful.

Lead Hand

Most hospitals in low-resource countries have workshops where a sheet of lead can be cut to make a lead hand or one can be made in the local bazaar.

Fractures of the Distal Radius and Ulna

Colles-type fractures in which the distal fragment is dorsally displaced with apex volar angulation can usually be treated with closed reduction. The Charnley dorsal-radial splint controls both the

dorsal and radial deformities (Fig. 20.3). It can be used as part of a sugar tongs or a below-elbow splint throughout the 4–6 weeks of treatment, by periodically adjusting the bandages as swelling decreases, or it can be converted into a circumferential POP (plaster of Paris). It is especially useful in elderly patients whose loose skin makes edema problematic.

Unstable fractures or those that lose reduction may benefit from percutaneous pinning. Intraoperative C-arm control helps with pin placement, but two-part extra-articular fractures can be pinned without C-arm using the Kapandji technique of intra-focal pinning. A small dorsal-radial incision allows fracture identification. One or two 0.62 K-wires are introduced into the fracture so they both reduce the fracture and buttress the distal fragment to hold the reduction. Once the K-wire is placed into the fracture, it can be drilled or tapped into the metaphyseal bone and cortex of the proximal fragment. If percutaneous pins are supported with a circumferential POP, ensure that the pin-skin interface is well padded and the pins do not press directly on the skin. Extending the plaster over the thumb MP joint prevents irritation due to thumb motion near a radial pin.

Wrist-spanning external fixateur can be used to maintain alignment and length, with or without percutaneous pinning of the fracture. In their absence, pins and plaster can produce similar results but without the ease of future adjustment. For reduction and fixing comminuted intra-articular distal radius fractures, a C-arm is necessary for percutaneous technique and is helpful for open reduction, but not mandatory.

Smith-type fractures—apex dorsal angulation—can usually be held in a POP with volar distal molding, taking care that no pressure is placed along the median nerve. Adding a short thumb spica to the cast will give a broader molding platform to control the distal fragment. A 0.62 K-wire will hold the fracture if a POP doesn't.

Certain intra-articular radius fractures are fracture/dislocations (Fig. 20.4). Postreduction and follow-up x-rays need to confirm capitellar-lunate

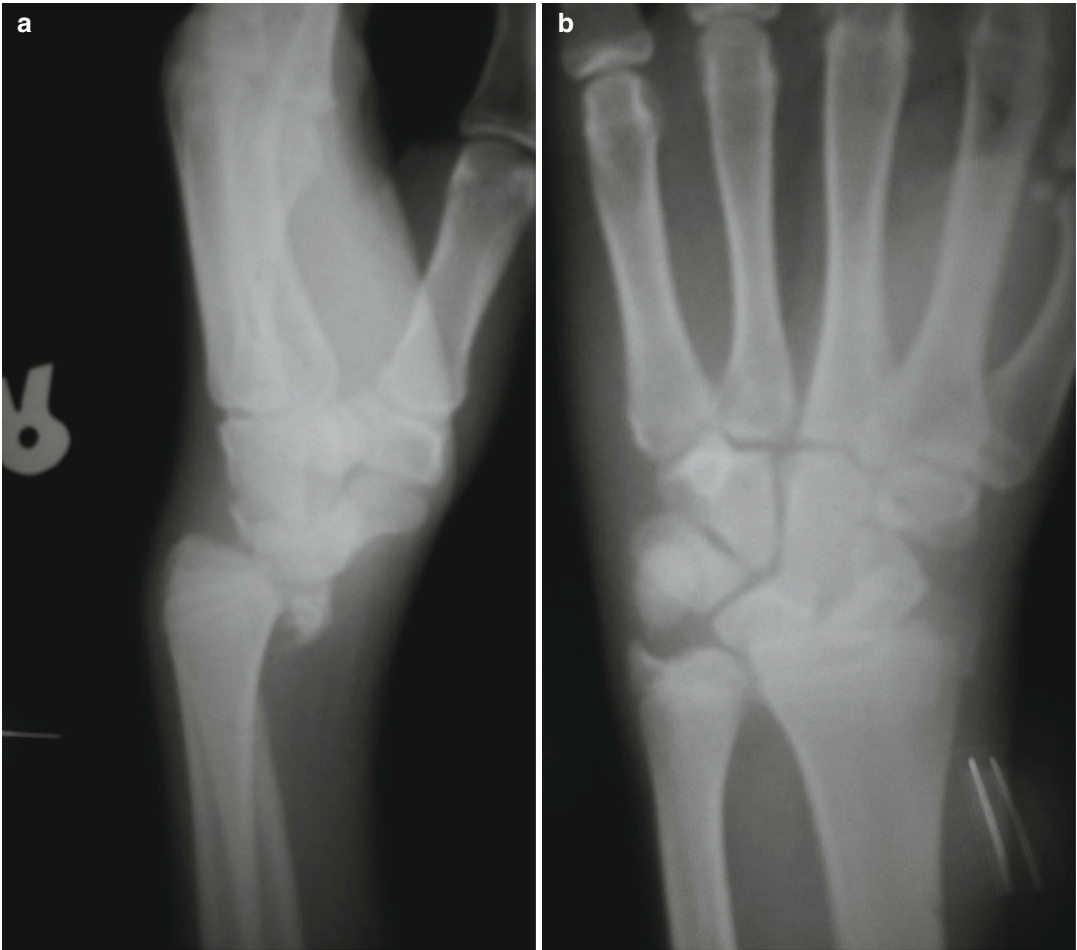

Fig. 20.4 (a, b) X-rays of an unstable volar Barton's fracture dislocation

alignment with the long axis of the radius. If the fracture fragments or the wrist alignment can't be reduced and held with a percutaneous pin, an open reduction and pinning is needed. Instability or dislocation of the distal radial ulnar joint often accompanies distal radius fractures. Most often, the distal ulnar subluxation or dislocation is dorsal and can be reduced by forearm supination. Examination under anesthesia to confirm rotational stability may be necessary.

A treatment that maintains radial length, reproduces the normal 12–15° volar tilt and 23° radial inclination, and reconstitutes articular congruity gives the best possibility for satisfactory post-injury function [2].

In many developing countries, the majority of distal radius fractures are handled by local healers,

and they often present to the OPD or clinic with striking deformities and x-ray irregularities. A careful history and exam focusing on the patient's specific complaints will help determine the course of action. Younger patients and those needing full function may benefit from surgical correction or reconstruction (see Chap. 41). However, patients with limited demands may only need reassurance and mobilization exercises (Fig. 20.5).

Scaphoid Fracture

If presenting early and with minimum displacement, these fractures can be treated in a thumb spica cast, above or below elbow, as the surgeon chooses. Due to minimal swelling, lack of

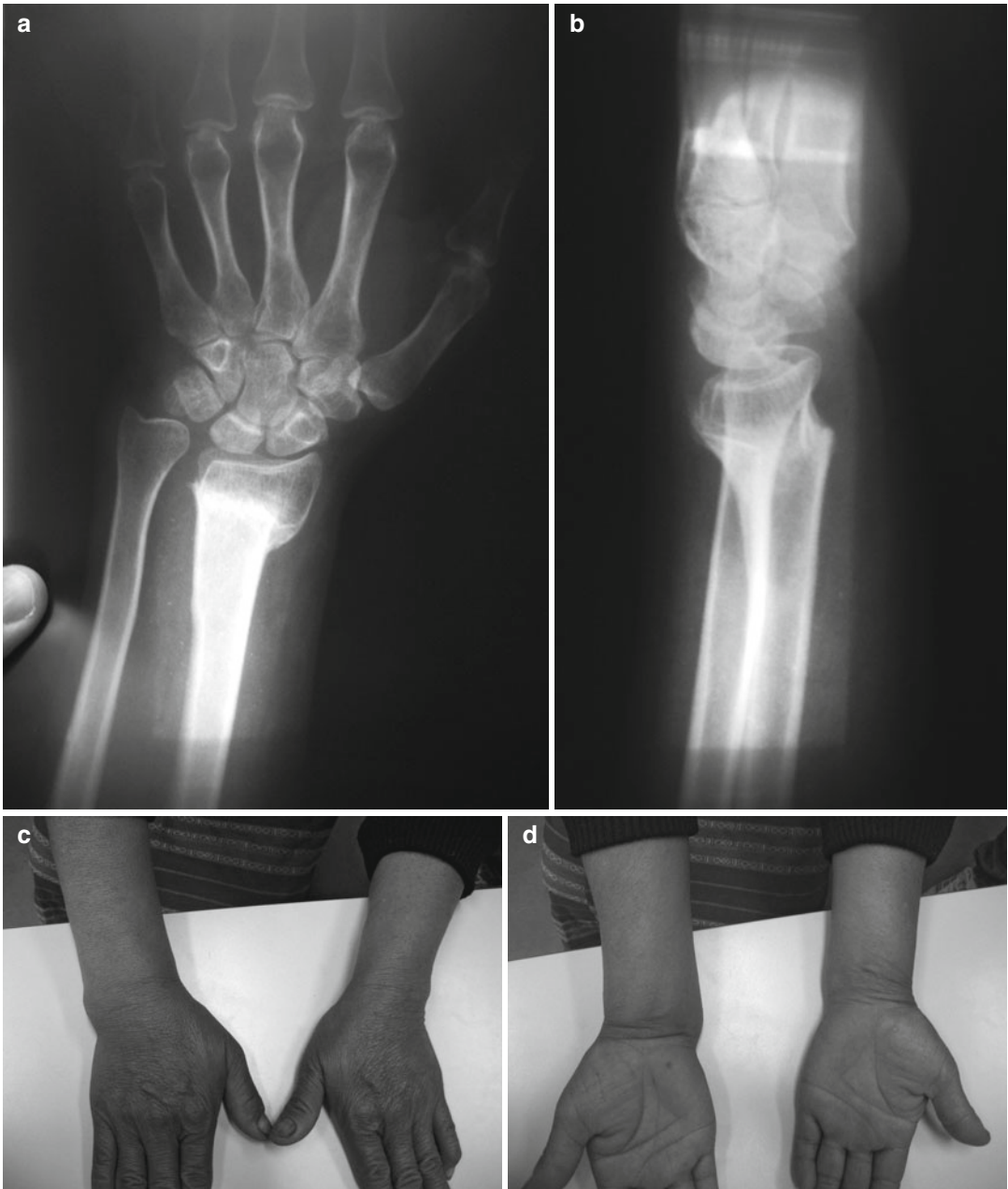

Fig. 20.5 (a, b) X-rays of a right distal radius fracture healed with the distal fragment shortened, dorsiflexed, radially displaced, distal R-U separation, and scapholu-

nate disruption. (c, d) Prominent ulnar head and widening of the wrist are present, but the patient has no limitation in supination and pronation and no pain

deformity, and early resolution of pain, many patients consider the injury a sprain and only present after the fracture has progressed to a painful nonunion. Open treatment by the volar or dorsal approach with local or iliac bone graft

to correct the deformity or shortening and held with two parallel K-wires should give satisfactory healing but may not resolve the pain associated with intracarpal incongruity and instability or arthritic changes in adjacent joints.

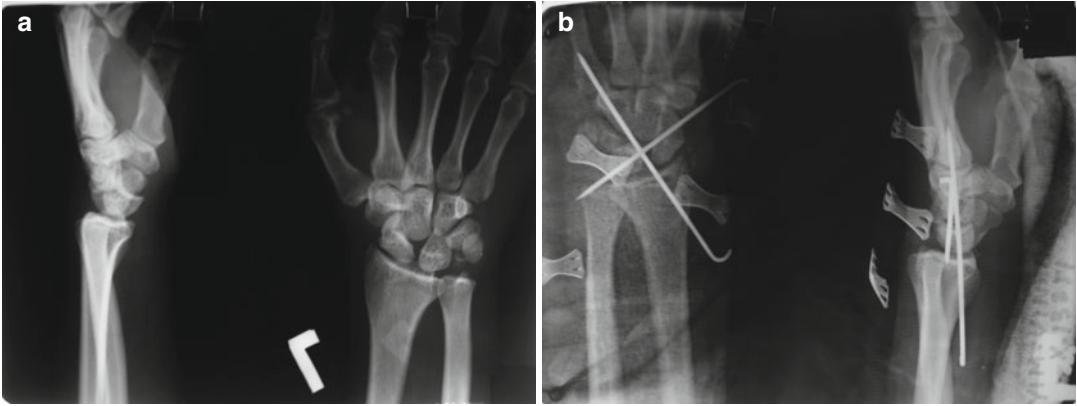


Fig. 20.6 Perilunate dislocation (a) x-ray presentation (b) after closed reduction and crossed pinning. Scapholunate dissociation persists, but carpal alignment is restored

Other Injuries and Conditions about the Wrist and Hand

Lunate Dislocations, Perilunate Dislocations, and Transscaphoid Perilunate Fracture/Dislocations

Lunate dislocations, perilunate dislocations, and transscaphoid perilunate fracture/dislocations are not common. Patients usually present fairly early, and the correct diagnosis depends on the quality of the x-rays and the ability to identify each carpal bone and its relationship with the rest of the carpus and the distal radius on true PA and lateral x-rays. Oblique films and fluoroscopy can be helpful. Sometimes these injuries can be reduced closed with relaxing anesthesia using either manual manipulation or hanging in finger traps. Using a C-arm, they can be pinned closed. Otherwise, they need to be opened, reduced, and pinned volarly—through an extended carpal tunnel incision—or dorsally, usually between the third and fourth dorsal compartments. The exposure depends on which side the major pathology appears to be located. Sometimes both approaches are needed for reduction in complex or late presenting cases. If the carpus is opened, carefully repair the capsule and ligaments. Twelve weeks immobilization is recommended (Fig. 20.6).

Bennett Fracture Dislocations

Bennett fracture dislocations can usually be reduced and held in a short-arm thumb spica POP that extends distal to the thumb IP joint. Radially applied pressure on the base of the first metacarpal with ulnar counterpressure on the neck of first metacarpal (not the proximal phalanx) should reduce the fracture dislocation. If maintenance of the position isn't possible in a cast, a K-wire from the proximal first MC to the second MC or to the trapezium will hold the reduction. A true AP x-ray of the thumb basilar joint to check the reduction can be obtained if the patient maximally pronates his hand to place the dorsum of the first metacarpal against the x-ray plate.

Complex Dislocations of the MP Joints

Complex dislocations of the MP joints by definition require an open reduction. Most often, the index, little finger, or thumb is involved. Dislocations presenting early can be reduced through a volar, dorsal, or lateral incision. They are usually stable with the flexed MPs splinted in a dorsal slab that allows active volar flexion of MP and IP joints but restricts MP extension (Fig. 20.7).

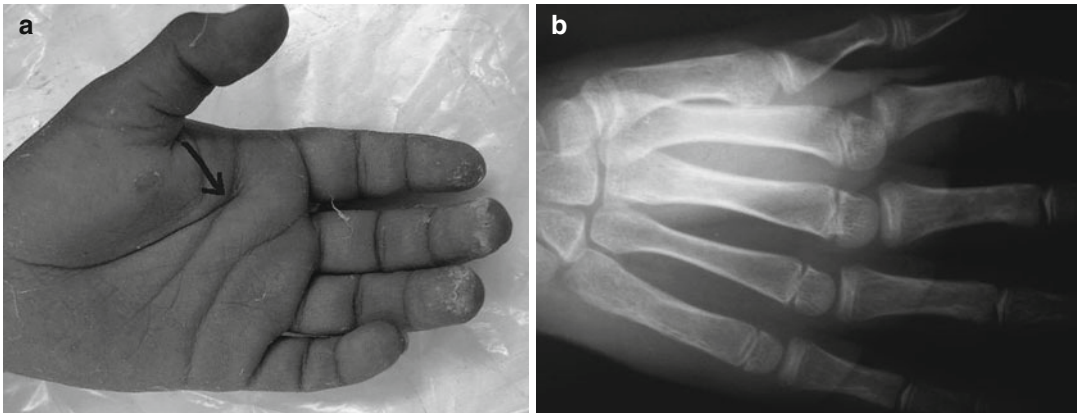


Fig. 20.7 Complex index MC dislocation. (a) Arrow points to characteristic palmar pucker. (b) X-ray showing index MCP incongruity

Late presenting cases may require both dorsal and volar open approaches and occasionally release of a portion of the collateral ligament in order to reduce the joint. These may be unstable, requiring K-wire pinning in MP flexion. Vigorous postoperative IP motion is encouraged, but often the fingers remain permanently stiff from the scarred and shortened soft tissues.

Metacarpal Fractures

Metacarpal fractures can usually be treated with closed reduction and splinting. Rotational correction can be maintained by selectively buddy taping the fingers, making sure the finger nails align and the flexed finger tips point to the scaphoid. Unstable MC fractures can often be successfully stabilized if both dorsal and volar slabs are applied as two separate splints to control the deforming forces [3].

If external splinting doesn't hold the reduction, percutaneous pinning with a longitudinal K-wire acting as an internal splint should hold the reduction. Buddy taping the adjacent fingers may be necessary if the K-wire does not control rotation. Alternatively, K-wires placed proximal and distal to the fracture and drilled into the adjacent, non-fractured metacarpal will hold the fracture aligned and to length while it heals. Make sure the fracture isn't distracted.

Boxer's Fracture

Boxer's fracture of the fifth or fourth metacarpal neck is common and often presents late. Angulation up to 45° of flexion is usually well tolerated. But if the flexed and/or rotated deformity leads to a painful grip, especially in manual laborers, closed or open reduction held with K-wires will improve the alignment.

Clenched Fist Injury

A clenched fist injury from a human tooth, with or without a fracture, requires surgical exploration, debridement, and inpatient IV antibiotics. Penicillin will cover *Eikenella corrodens*, with additional coverage for staphylococcal, streptococcal, and anaerobic bacteria.

Fractures of the Phalanges

Fractures of the phalanges, though often open and involving the joints, are usually treated with splinting. Aluminum-foam or specialized plastic splints are rarely available. For treatment of a fracture involving one finger, e.g., a mallet finger, middle phalanx, or distal phalanx fracture, wrap a dry plaster bandage around the

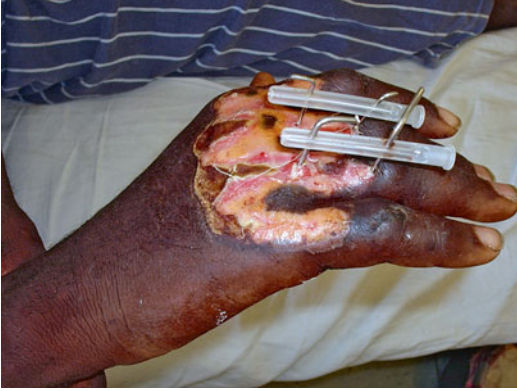

Fig. 20.8 External fixation of open fractures of middle and ring finger proximal phalanges using K-wires drilled through plastic needle caps that provide external stability and alignment

finger, submerge it in water, and mold the POP into the desired position. A small “nubbin” of the plaster end left on the dorsum of the POP acts as a focus for unraveling the cast when it is no longer needed.

For more unstable fractures or those involving multiple fingers, the broken finger(s) can be buddy taped and immobilized in volar, dorsal, or both volar and dorsal splints extending proximal to the wrist. The goal is to allow the fractures to heal in a functional position. Often these injuries present late and, if intra-articular, are best served with a fusion.

Open phalangeal fractures can be treated with an external fixateur made of K-wires drilled through a plastic syringe needle cap to maintain position until the soft tissues heal (Fig. 20.8).

High-Pressure Injection Injuries

High-pressure injection injuries usually present as puncture wounds in a digit or palm, along with swelling, pain, and redness. The patient and his family must be counseled about the seriousness of the injury as they often appear benign to the casual observer, but the injected material is often irritating or toxic and can extend proximally in the arm and cause a compartment syndrome.

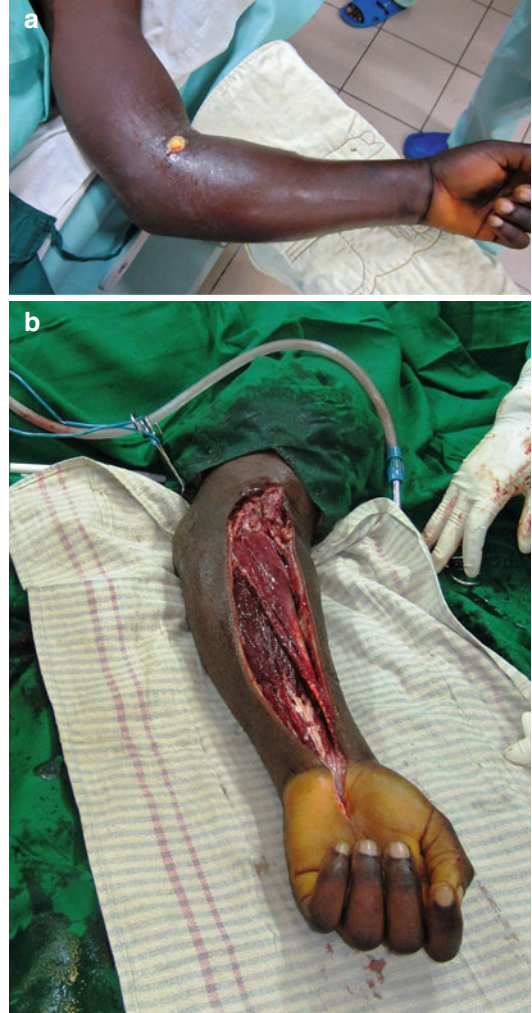


Fig. 20.9 Though not a true high-pressure injection injury, this patient injected insecticide into his antecubital area, which caused a painful chemical reaction. (a) Pre-op appearance of left arm. (b) The insecticide had liquefied and necrosed the fascia, leaving most of the muscle intact but, as the picture shows, abnormally colored

These injuries require urgent decompression and debridement, supplemented with antibiotics, splinting, and elevation. Wounds should be left open, and the patient returned to the operating room in 24–48 h for further debridement as needed until closed or skin grafted. Intraoperative pictures are helpful, as these injuries can lead to amputation (Fig. 20.9).

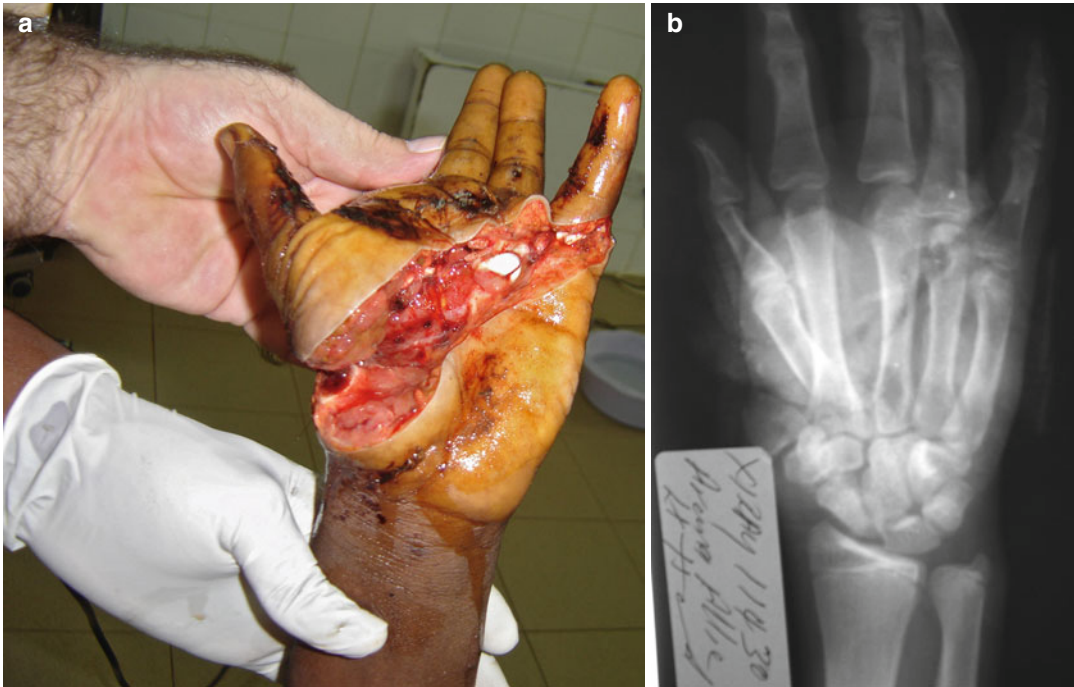


Fig. 20.10 (a, b) Machete injury to the hand cutting across the base of 1st MC, palmar soft tissues, including nerves, arteries, tendons, and scoring the distal 4th MC

Pyogenic Flexor Tenosynovitis

Pyogenic flexor tenosynovitis in austere environments most often presents late as a full-blown infection after a minor puncture wound. Kanavel's signs of semi-flexed finger, fusiform swelling, exquisite tenderness along the flexor tendon, and pain on passive extension of the digit are often all present. The flexor tendon sheath is usually full of thick pus and needs an extensive open debridement, generally through a mid-lateral incision with drainage catheters left in place, elevation, splinting, multiple antibiotics, and often repeat visits to the operating room. Even under the best circumstances, good functional results are rare.

Machete Injuries

Machete injuries to the hand and wrist are common in countries where these knives are used as an all-purpose tool. Though the wounds may be contaminated, the cuts are often clean with little

soft tissue crush. The circumstances will dictate how and what tissues to approximate. The goal is to leave a functional hand, not a specific complement of digits (Fig. 20.10).

The Mangled Hand

These high-energy injuries involve multiple structures and are usually due to industrial, farm, or motor vehicle trauma. Injuries can be segmental and often have a significant crush or degloving component as well as gross and ground-in contamination, all of which make the initial OPD determination of viable structures difficult. Early tetanus and antibiotic coverage are important as with any open injury (Fig. 20.11).

A thorough evaluation can usually only be done after cleaning in the OR, but the motor and sensory exams must be done before anesthesia is given. Debridement should be thorough, yet conservative. Viable skin, even without underlying bone, can be preserved, since it may be

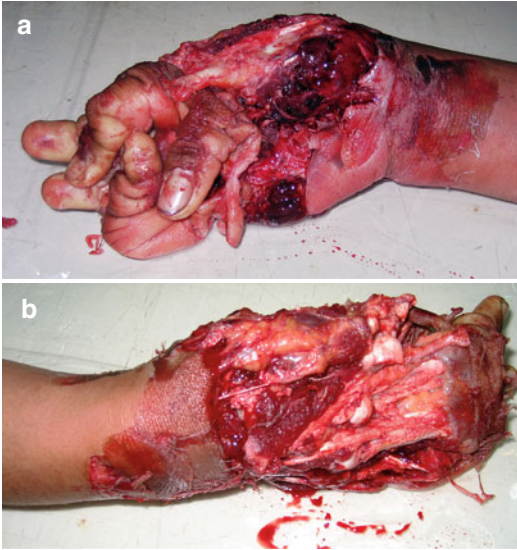


Fig. 20.11 (a, b) Hand mangled in an agricultural machine with degloving and crush components

useful as a fillet flap. Unstable fractures may need to be pinned, but the most important goal of the initial surgery is debridement. External splinting with plaster splints is usually satisfactory as the initial procedure. Tendons and nerves should be tagged for later repair. Intraoperative pictures are helpful for patient and family education and in seeking consultation from colleagues.

The decision making for such injuries is complex. For a short-term volunteer surgeon who doesn't know if anyone will be able to carry on at his or her departure, or one who is uncomfortable doing hand surgery, these injuries can be anxiety provoking. Reconstructive possibilities

are limited. The main goals are to prevent infection, remove all nonviable tissue, preserve useful function, elevate the hand to prevent edema, and splint the hand and wrist in a functional position: wrist dorsiflexion, MP flexion, and IP extension. Consultation with the local doctors, nurses, and therapists will help produce the most useful result within the local restrictions.

Conclusions

Hand and wrist injuries are common and can usually be treated nonoperatively except in specific injury configurations that have been shown to benefit from either open or open and stabilization procedures. The goals are to preserve function and limit pain.

References

1. Ihekire O, Salawu SA, Opadele T. International surgery: causes of hand injuries in a developing country. *Can J Surg.* 2010;53(3):161–6.
2. Batra S, Gupta A. The effect of fracture-related factors on the functional outcome at one year in distal radius fractures. *Injury.* 2002;33:499–502.
3. Bernstein ML, Chung KC. Hand fractures and their management: an international view. *Injury.* 2006;37(11):1043–8.

Suggested Reading

- Charnley J. Closed treatment of common fractures. Golden Jubilee edition. Cambridge: Cambridge University Press; 2007.
- Wolfe SW, Hotchkiss RN, Pederson WC, Kozin SH. *Green's operative hand surgery.* 6th ed. Philadelphia: Churchill Livingstone; 2011.

Richard A. Gosselin and Anand Sobhraj Devnani

Introduction

Simple pelvic fractures such as avulsion or rami fractures are rarely seen in orthopedic clinics of developing countries. Most heal on their own with symptomatic treatment and little functional sequelae. More complex fractures can heal with shortening or rotational malunions that affect gait and/or limb length, causing changes in hip joint mechanics, chronic pain, and degenerative joint disease. Occasionally, patients present with symptomatic nonunion involving the pubic symphysis or the sacroiliac joint. Non-orthopedic complaints include neurovascular deficits, urogenital and rectal problems, sexual dysfunction, and psychological problems. As most patients present late, some of these non-orthopedic sequelae may be the reasons for consultation.

R.A. Gosselin, MD, MPH, MSc, FRCS(c) (✉)
Department of Orthopedic Surgery,
Institute for Global Orthopedics and Traumatology,
UCSF, 1001 Potrero Ave, 3A-36,
San Francisco, CA 94110, USA
e-mail: froggydoc@comcast.net

A.S. Devnani, MS (Orth)
Department of Othopaedics, Level 4, Medical Faculty
(FPSK), University Putra Malaysia at Serdang
Hospital, Serdang, Selangor 43400 UPM, Malaysia
e-mail: anandsdevnani@yahoo.com

Examination

A trauma patient with a suspected pelvic injury should be assessed according to ATLS protocols, paying particular attention to head, chest, and abdominal injuries. A good history from the patient and bystanders is important and could help determine the amount of energy and the position of the patient at the time of impact. Inspection may show suspicious skin lesions such as small open wounds or tire marks on the skin, deformed or asymmetric iliac crests, or swelling and ecchymosis of the genitalia. Palpation, including the sacroiliac area, can reveal crepitation and localized pain. A visible deformity of the lower limb—such as shortening, malrotation, or abduction/adduction of the thigh—is strongly suggestive of an associated fracture of the hip or femur or a hip dislocation (Fig. 21.1).

Anteroposterior and latero-lateral compression maneuvers may help determine stability but are usually quite painful and may displace the fracture or dislodge any protective blood clot [1]. They should be done only once, in the operating room if surgery is planned for something else, and by the person making treatment decisions. The same applies to the cephalocaudal push-pull maneuver, which is best performed under sedation in the x-ray suite or under fluoroscopy. When gentle passive rotation of the hip is painful, a fractured proximal femur or acetabulum should be suspected rather than a

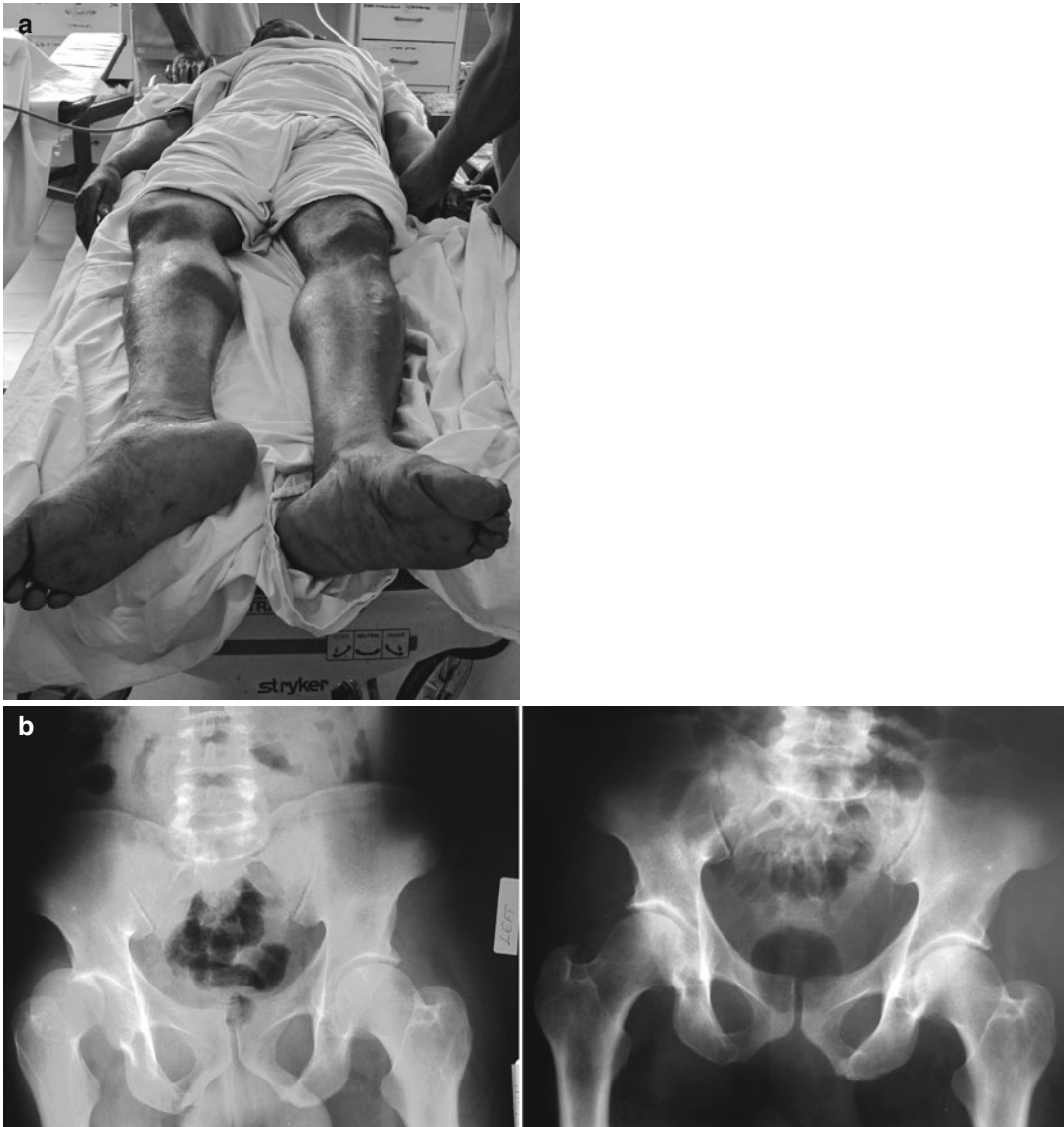


Fig. 21.1 (a) The shortened, externally rotated right leg in an anterior dislocation of the hip caused when the farmer slipped and hyperextended his right leg 5 days before. (b) Pre- and postreduction x-rays of the pelvis

pelvic fracture. These are often not easy to tell apart clinically.

A patient should be asked to urinate spontaneously and the urine examined for gross hematuria. For those who cannot urinate or who are unconscious, it is mandatory to look for blood at the urethral meatus and do a rectal examination, feeling for a “floating prostate” or a perforating spike of bone, *before* inserting a Foley catheter [2] (Fig. 21.2).

If a urethral tear is suspected, a retrograde urethrogram is easy to do with any available contrast

medium. If not possible, a suprapubic cystostomy should be placed without an attempt to insert a retrograde catheter, which could complete a partial urethral tear.

A comprehensive neurovascular examination of the extremities is necessary with results recorded in the chart. When a patient is hemodynamically borderline or unstable, the pelvis should be wrapped in a 15–20 cm wide sling centered over the greater trochanters, using a bed sheet or a large towel, which is then tightened and

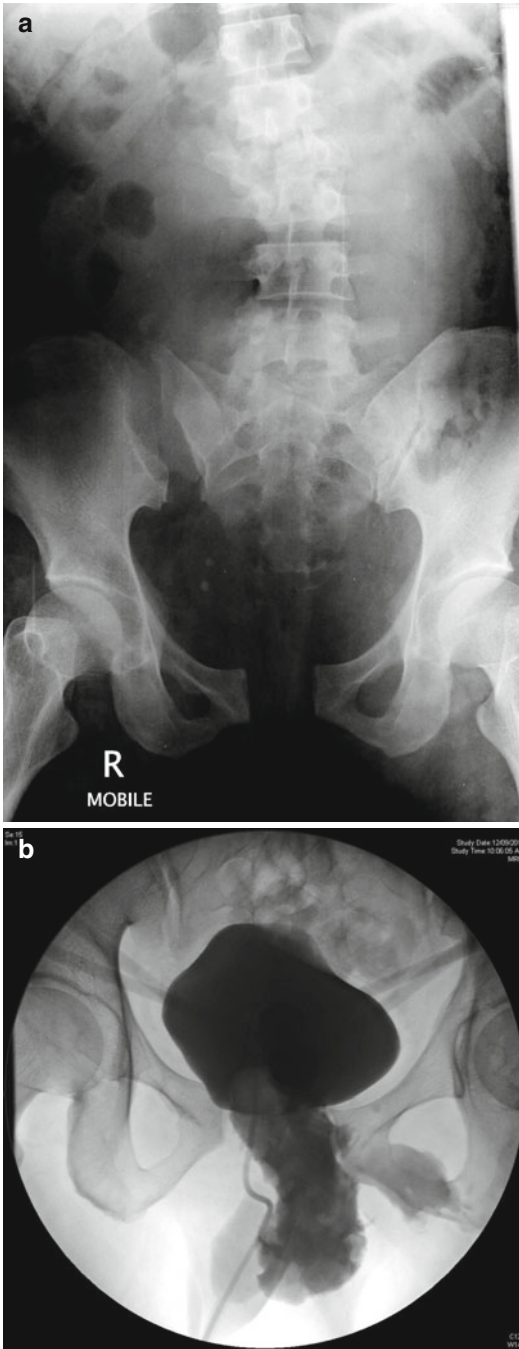


Fig. 21.2 (a) X-ray showing disruption of R hemipelvis at symphysis and R SI joint. (b) Cystogram showing extravasation of dye through tear in urethra

clamped [3] (Fig. 21.3). Binders control bleeding by compressing and stabilizing the fracture, rather than by reducing pelvic volume. They can be used in all patterns of fractures. This simple

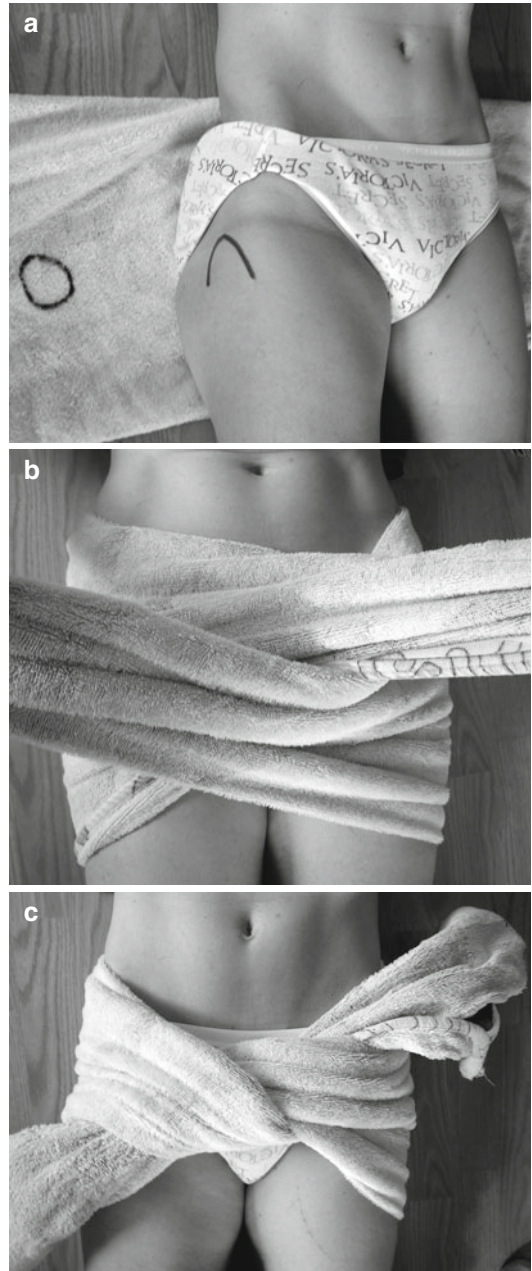


Fig. 21.3 (a) Compression wrapping of the pelvis using a towel or a sheet centered over the greater trochanters. (b, c) Tightening secured with a knot or clamps

maneuver has proved to be as effective as other more expensive and sometimes more dangerous devices, such as the MAST suit.

Only in the rare case—in which a patient remains hemodynamically unstable in spite of

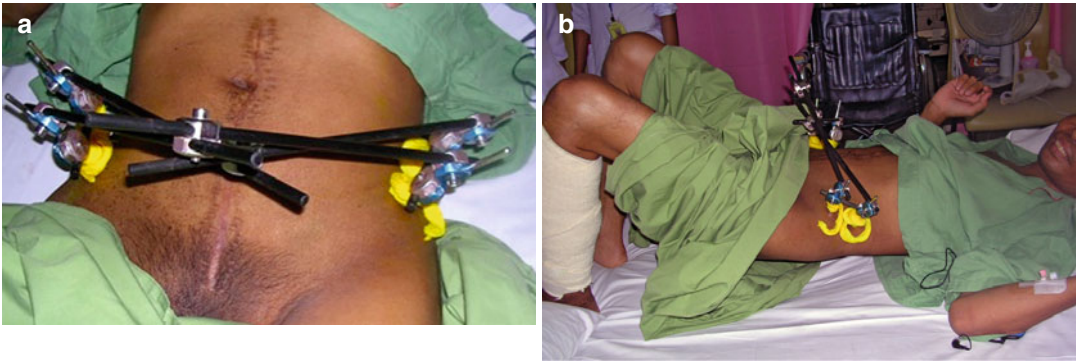


Fig. 21.4 (a) Simple external fixateur configuration for pelvic ring compression. (b) Patient is able to lift himself from bed

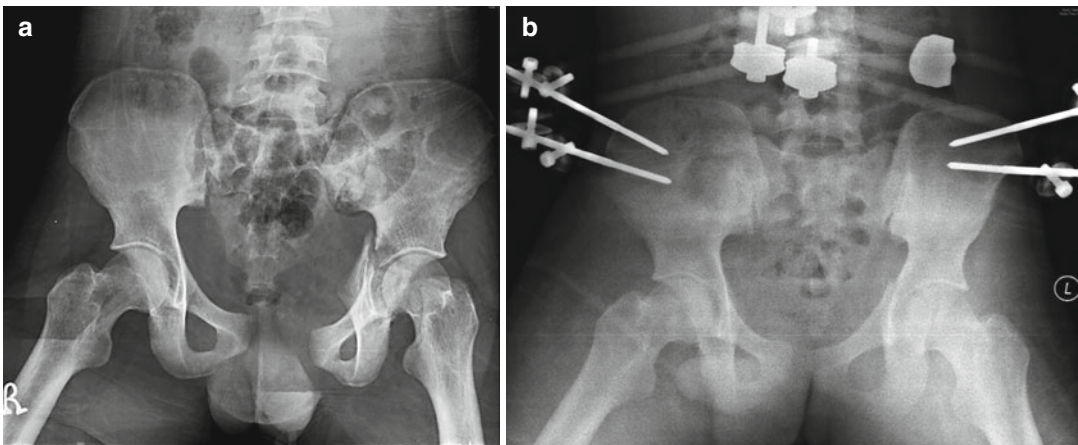


Fig. 21.5 (a) AP pelvis x-ray showing significant pubic diastasis, transverse or T-type fracture of the left acetabulum, and probable involvement of the left sacroiliac joint (asymmetric ala and fracture of left fifth transverse process).

(b) Acceptable reduction of the pelvic ring after application of anterior external fixateur in compression. The acetabular fracture is still slightly displaced, but the femoral head is concentrically reduced under the acetabular dome

proper resuscitation and the application of a pelvic sling or binder and where the surgeon is skilled with the use of external fixation, a set is available, and anesthesia resources are comfortable with this type of patient—should acute anterior external fixation be contemplated for hemorrhage control [4].

This is best done through incisions large enough to allow the thumb and index finger to feel both the inner and outer tables to facilitate the insertion of two pins in each anterior crest. A 2- or 3-bar frame is then loaded in firm but not excessive compression, with the midline bar-to-bar connector or spanning middle bar low enough to permit access to the abdomen if needed for a laparotomy, and far enough anteriorly so the belly does not rest on it when sitting (Fig. 21.4). Although a life-saving procedure, the ex-fix often becomes the definitive manage-

ment of the pelvic ring injury, and reduction should be assessed with appropriate x-rays and, if needed, adjusted once the patient is hemodynamically stable (Fig. 21.5). A patient can usually tolerate 24–48 h of pelvic wrapping, but high blood transfusion demand (often a scarce resource) can mitigate towards external fixation. Arterial embolization is rarely an option, and iliac artery ligation should be considered a heroic maneuver for a patient already undergoing a laparotomy for something else [5].

Diagnostic Investigations

Radiographic investigation is often limited to an AP pelvis x-ray [6]. It is important to compare the damaged hemipelvis with the intact opposite

side. Usually enough of the lower lumbar spine is included to confirm if the AP view is true or the patient was rotated by noting the alignment of the spinous processes and the pedicles.

Start with evaluation of the pubic rami and measure any separation of the symphysis pubis. Widening less than 2.5 cm is managed nonoperatively, while a diastasis of more than 2.5 usually means associated sacroiliac involvement, increasing the possibility of instability. Perform a systematic assessment of the symmetry of the inferior sacroiliac joints, iliac wings, obturator foramina, pelvic inlet, and teardrop. Evaluation of the teardrop is especially helpful in excluding an acetabular fracture. Aspherical incongruity of the hip joint needs to be particularly assessed to rule out a fracture and/or dislocation. Radiographic landmarks for the acetabulum include anterior and posterior wall, ilio-innominate and ilio-ischial lines, the acetabular dome, and the teardrop (Fig. 21.6).

Indirect x-ray signs of pelvic instability and ligamentous tears include avulsion fractures of the ischial spine, medial border of the ischium, lateral border of the sacrum, and lower lumbar transverse processes [7]. Remember, the

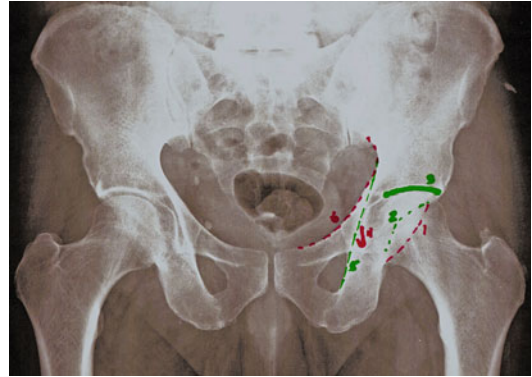


Fig. 21.6 AP pelvic x-ray showing symmetry of the sacroiliac joints, iliac wings, obturator foramina, and symphysis pubis and radiographic landmarks of the acetabulum: 1 posterior wall, 2 anterior wall, 3 acetabular dome, 4 tear drop, 5 ilio-ischial line, and 6 ilio-innominate line

x-ray shows the position the pelvis has “sprung back” to after injury, not the amount of initial displacement. Inlet (Fig. 21.7) and outlet views (Fig. 21.8) (Pennal) are easy to obtain since there is no need to move the patient and they are helpful in determining the degree of instability. Iliac oblique and obturator oblique views (Judet)

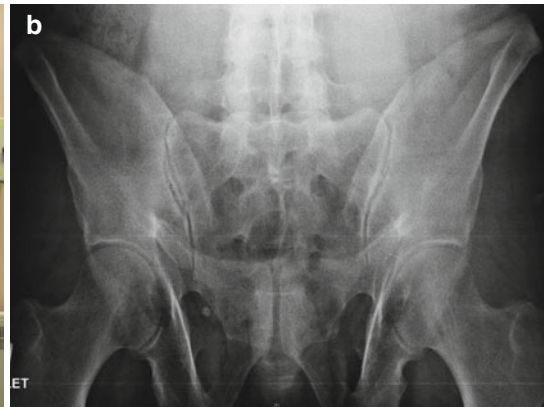
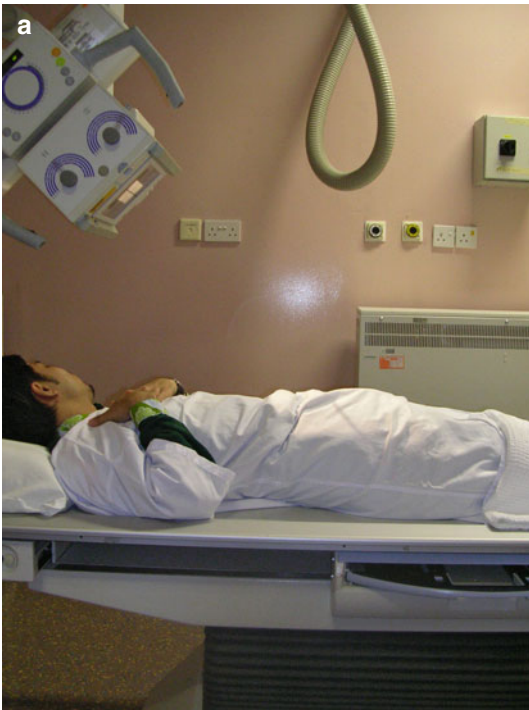
Fig. 21.7 (a, b) Inlet (cephalocaudal) view is particularly useful to detect rotation in the transverse plane and antero-posterior translation

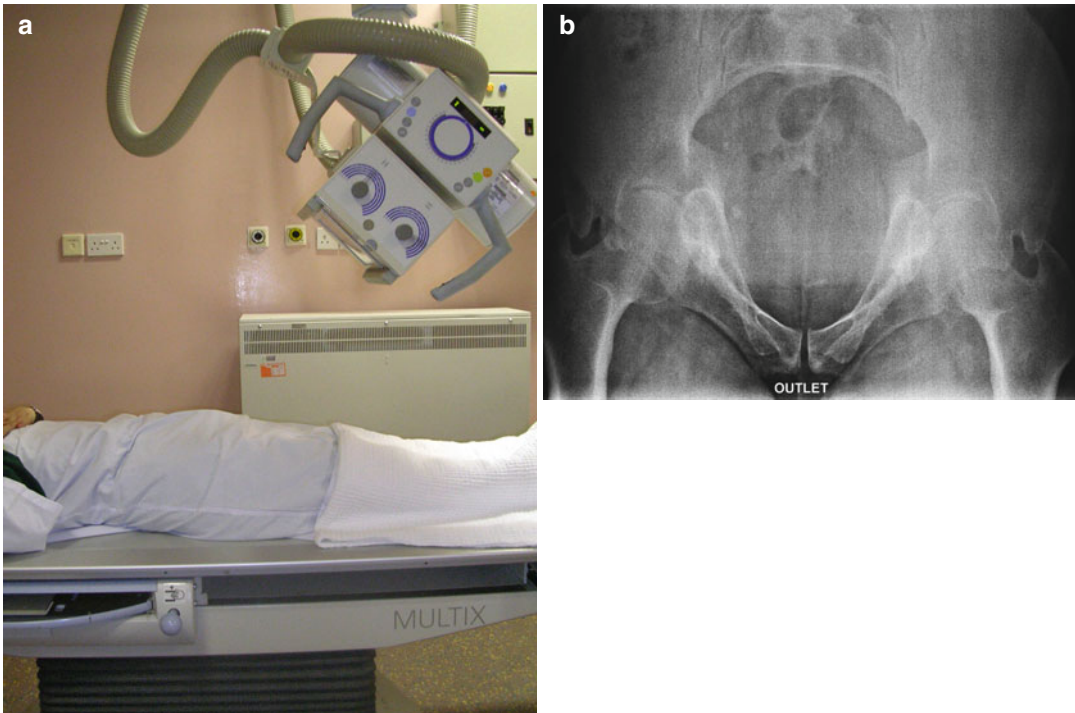


Fig. 21.8 (a, b) Outlet (caudocephalic) view is particularly helpful for evaluating rotation in the sagittal plane and cephalocaudal translation

(Fig. 21.9) are only helpful if surgery is contemplated. Otherwise, they are of academic interest only and are painful for the patient, so should not be done routinely. CT scans are helpful if available.

Pelvic Ring Injuries

The proper assessment of the stability of the pelvic ring is the key element to management [8]. Stability can be defined as the ability of the pelvic ring to withstand physiologic forces without abnormal deformation. The bony pelvis has no intrinsic stability, but when pelvic ligaments are intact, the sacrum acts as a reverse keystone in the pelvic arch. The posterior sacroiliac ligaments are by far the most important structures to this end. For the sake of simplicity, all injuries involving the posterior sacroiliac ligamentous complex are considered unstable. All others are stable or partially stable.

Although the Young-Burgess classification is widely used in the West, its level of sophistication is beyond the practical needs of most resource-poor centers. In these environments, the Bucholz classification is most helpful: Bucholz type 1 injuries are rotationally and vertically stable, type 2 injuries are rotationally unstable but vertically stable, and type 3 injuries are both rotationally and vertically unstable [9] (Fig. 21.10).

Many stable or partially unstable injuries are overtreated with prolonged bed rest (4–8 weeks) as per conventional wisdom. This commonly leads to associated complications of pressure sores, pin tract infections, thromboembolic disease, disuse atrophy, and stiffness, particularly where nursing care is lacking. Weight bearing does not affect *Bucholz type 1* injuries: stable avulsions, rami fractures, and low-grade compression fractures. These should be treated symptomatically with minimal bed rest, early mobilization, and ambulation as tolerated.

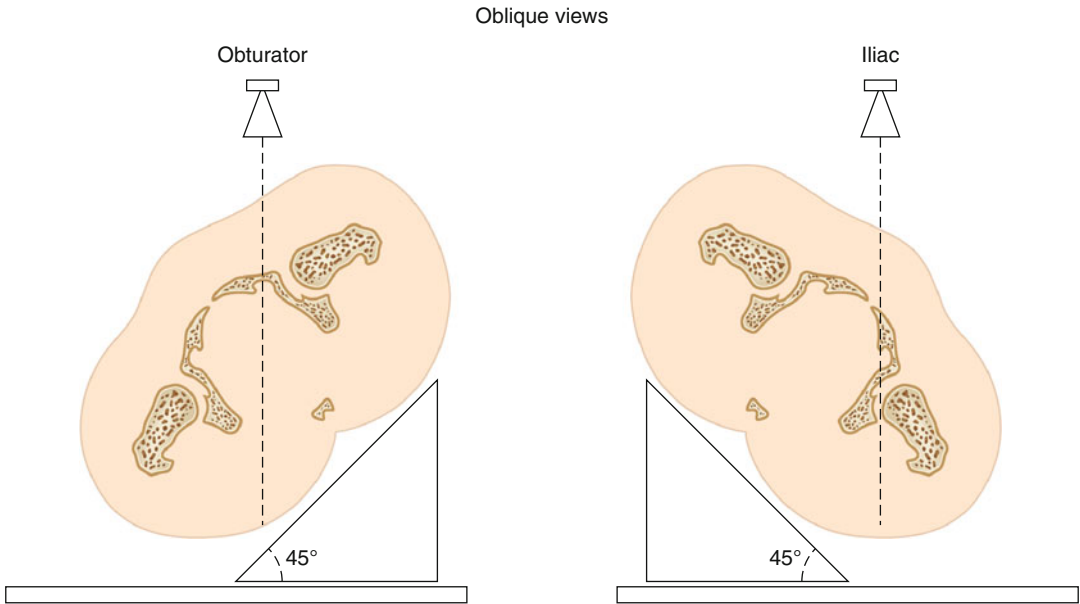


Fig. 21.9 Judet iliac and obturator oblique views

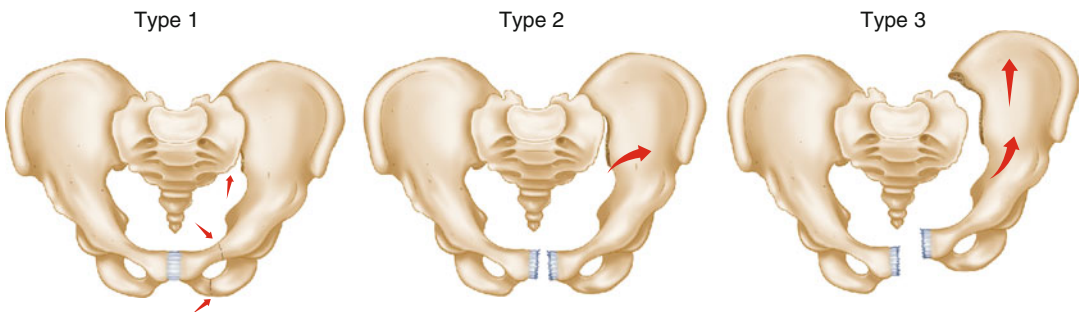


Fig. 21.10 Bucholz classification: type 1, stable fractures; type 2, rotationally unstable but vertically stable (usually open-book or lateral compression); type 3, both rotationally and vertically unstable (usually shear)

Bucholz type 2 injuries are commonly of the open-book or bucket-handle type—unstable in rotation but stable in translation. They require longer bed rest, but should still be mobilized as soon as pain allows. Reduction of an open-book deformity can be achieved by gravity, with the patient lying on either side. Skin traction for comfort should be sufficient and only necessary for 7–10 days. The patient is encouraged to sit at the side of the bed and progressed to ambulation with a walker or crutches bearing weight as tolerated. Residual pubic diastasis of up to 3 cm is well tolerated in the long run.

When skilled hands and appropriate hardware for internal or external fixation are available, surgery should be considered if there is a residual diastasis of >3 cm or for the polytrauma patient who requires early mobilization [10, 11]. Surgery for patients with Bucholz type 2 injuries is elective, after an attempt at closed reduction with lateral decubitus positioning. Internal fixation is through a Pfannenstiel incision, with an inflated Foley catheter balloon in place to help identify the bladder. The fixation should be rigid enough—usually one DC plate or reconstruction plate with six cortices on each side—to allow immediate mobilization.

Meticulous repair of the abdominal wall is necessary to avoid incisional hernias.

Bucholz type 3 injuries involve the disruption of the posterior sacroiliac bone and ligament complex. These can be purely ligamentous, as in SI joint dislocation; purely bony, as in fractures through the sacral foramina or a Malgaigne-type lesion through the sacral ala or iliac wing; or in combination trans-sacroiliac lesions. A bony and/or ligamentous disruption of the anterior ring accompanies the posterior injury, and there is always a translational component, either a cephalocaudal shear displacement or an anteroposterior displacement. The result is a hemipelvis that is both rotationally and vertically unstable.

X-ray findings are usually obvious but can be subtle, showing only asymmetry of the inferior sacroiliac joints and mild deformity of the anterior ring. Associated fractures of the lower lumbar transverse process, ischial spine, or ischial border should increase the level of suspicion. Inlet and outlet views will show the direction of the most severe displacement. A push-pull maneuver under sedation, with stress x-rays or fluoroscopy, can confirm the diagnosis. In the rare case where it is available, a CT scan can add valuable information but only if it will affect management decisions that can be acted upon.

Bucholz type 3 fractures are completely unstable and require prolonged bed rest if treated non-

operatively. Straight skeletal traction through the distal femur or proximal tibia is indicated, more to prevent further displacement than to reduce that existing and most importantly for comfort. The patient is encouraged to mobilize actively in bed as tolerated. Anticoagulants should be given if available. Progressive sitting is permitted as allowed by pain. When direct palpation of the posterior sacroiliac area, sitting upright, and a gentle push-pull maneuver without traction are all painless, the traction is superfluous and should be removed, usually around 3–4 weeks. Progressive mobilization out of bed is started with crutches or walker, but the patient should remain non-weight bearing for a minimum of 6 weeks, at which time x-rays should show some signs of consolidation. Residual shortening >2 cm can be addressed early with a shoe lift. But many patients will still prefer to go barefoot.

Surgical management is reserved for skilled and experienced surgeons, who are properly equipped and working in an appropriate surgical environment, including access to a blood bank. Both anterior and posterior rings need to be reduced and stabilized if the patient is to be mobilized early; otherwise, the purpose of surgery is defeated (Fig. 21.11).

External fixateurs have a limited roles in the definitive management of unstable pelvic fractures, but in combination with skeletal traction,

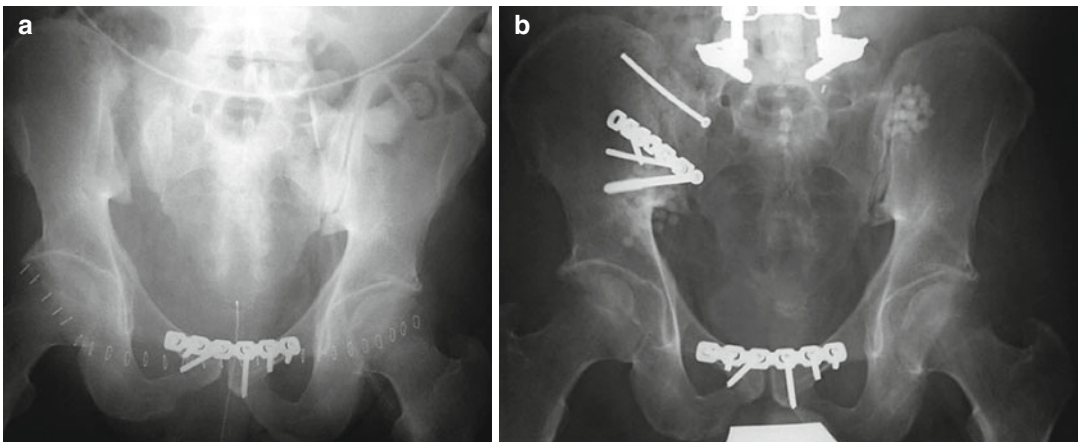


Fig. 21.11 (a) First procedure: ORIF with plate and 6 screws of symphysis pubis, through a Pfannenstiel approach. The right sacroiliac joint is still dislocated. (b) Second procedure: ORIF of right sacroiliac joint with

multiple screw and a small plate, with near anatomic restoration of the pelvic ring. Note also the presence of the distal end of spinal hardware to internally fix a lumbar spine fracture

they can be a safe alternative for vertical shear injuries in situations that lack specialized surgical facilities or if the patient's condition is too unstable to undergo more extensive internal fixation [12].

Acetabular Fractures

Complex fractures of the acetabulum (central dislocation of the hip) are usually beyond the scope and ability of most surgeons at home, let alone in an unfamiliar setting with limited resources [13].

The most common fracture of the acetabulum is a posterior wall fracture associated with a posterior hip dislocation (see Chap. 22) and is most commonly visible on the prereluction x-ray. It is important to assess hip stability after reduction, while still under anesthesia, and record the results.

An entrapped fragment is a different matter. Depending on its size, the piece or pieces need to be removed or fixed, usually through a posterior approach, with the patient in the lateral decubitus position. The joint is explored and the fragments removed. Impaction lesions at the margin of the fracture should be reduced. Posterior wall pieces large enough to be fixed should be reduced and maintained with screws or threaded K-wires if they are the only available implants. Smooth K-wires will eventually migrate and should be avoided, or at least bent if used.

Simple acetabular fractures involving the anterior wall or column rarely affect hip mechanics.

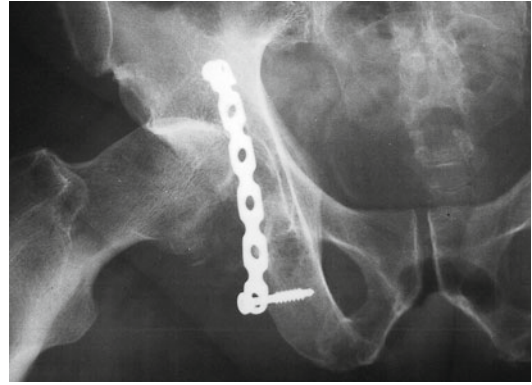


Fig. 21.12 Inadequate ORIF of posterior wall fracture, with subsequent re-dislocation of the hip

Treatment should be as for partially unstable pelvic ring fractures. All other fractures are complex, and unless near anatomic reduction is achieved, most will ensure premature degenerative changes of the hip. Bad surgery is worse than no surgery (Fig. 21.12). In austere environments, creating a decent bed for a future joint replacement is not a valid surgical indication. Unless *expert* hands are available, acetabular fractures should be managed conservatively with the goal of keeping the femoral head under the acetabular dome (Fig. 21.13). This is best achieved by longitudinal traction in extension. Lateral traction with a “screw-type” device inserted through the greater trochanter or into the femoral head and neck is not helpful, in our experience. It is difficult to insert in the proper position, an effective traction

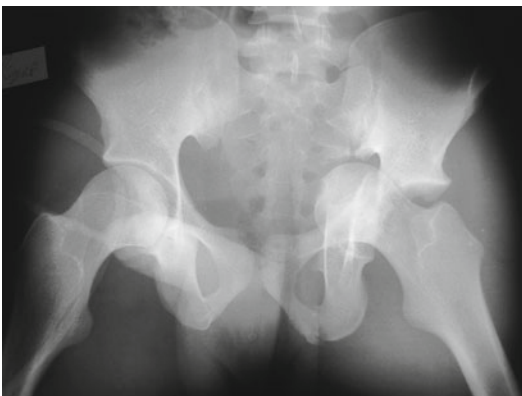
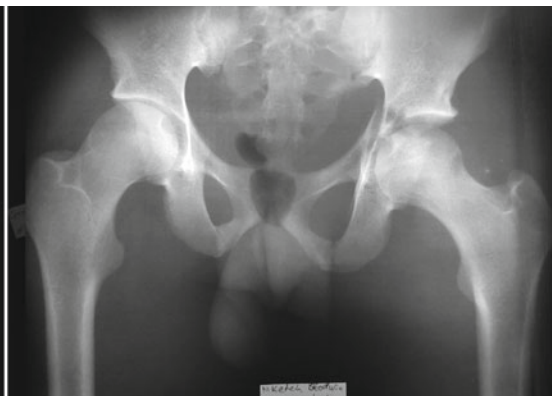
Fig. 21.13 This T-type acetabular fracture with “central dislocation” occurred when the young motorcyclist's leg was hit head on by another motorcyclist (*left*). The post-reduction x-ray (*right*) without traction shows residual



incongruity, and though no CT or films in traction are available, the best results will be with 6–8 weeks of skeletal traction, increasing ROM as tolerated to “mold” the joint

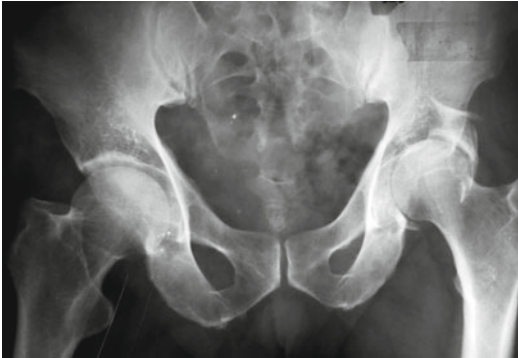

Fig. 21.14 Malunion of a displaced posterior wall fracture, with residual subluxation, and significant narrowing of the medial joint line, with medial osteophyte formation

apparatus is difficult to achieve and maintain, and it confines the patient to a prolonged supine position, rarely recreates an anatomic dome-head relationship, and quickly gets “soupy.” The disadvantages far outweigh the benefits.

Special mention is made for the “both-column” fracture pattern, where there is no intact acetabulum remaining in continuity with the intact proximal pelvis. Spontaneous “neo-congruency” can be seen, in which the displaced acetabular fragments mold around the femoral head. This usually occurs after 6 weeks of straight skeletal traction. But if traction makes the “neo-congruency” worse, as shown by a simple AP pelvis x-ray in traction, it is contraindicated, and the patient should be left at bed rest without traction for 6 weeks at which time a “neo-acetabulum” has formed around the head. Gentle range of motion is started early in bed, whether in traction or not, to promote molding, but the patient should not start weight bearing before 3 months.

Some patients will do well in spite of poor-looking x-rays, others the opposite. Premature DJD of the hip is unfortunately a common outcome (Fig. 21.14). Symptomatic treatment

including medication and walking aids are all that most patients will ever receive. Surgical options include arthrodesis (rarely accepted), Girdlestone arthroplasty (rarely accepted), and joint replacement (rarely accessible) (see Chap. 41).

References

1. Sagi HC, Coniglione FM, Stanford JH. Examination under anesthetic for occult pelvic ring instability. *J Orthop Trauma*. 2011;9:529–36.
2. Hanson PB, Milne JC, Chapman MW. Open fractures of the pelvis. *J Bone Joint Surg Br*. 1991;73-B:325–9.
3. Krieg JC, Mohr M, Ellis TJ, Simpson TS, Madey SM, Bottlang M. Emergent stabilization of pelvic ring injuries by controlled circumferential compression: a clinical trial. *J Trauma*. 2005;59(3):659–64.
4. Majeed SA. External fixation of the injured pelvis: the functional outcome. *J Bone Joint Surg Br*. 1990;72-B:612–4.
5. van Vugt AB, van Kampen A. Review article – an unstable pelvic ring – the killing fracture. *J Bone Joint Surg Br*. 2006;88-B:427–33.
6. Young JW, Burgess AR, Brumback RJ, Poka A. Pelvic fractures: value of plain radiography in early assessment and management. *Radiology*. 1986;160(2):445–51.
7. Starks I, Frost A, Wall P, Lim J. Is a fracture of the transverse process of L5 a predictor of pelvic fracture instability? *J Bone Joint Surg Br*. 2011;93-B:967–9.
8. Guthrie HC, Owens RW, Bircher MD. Review article – fractures of the pelvis. *J Bone Joint Surg Br*. 2010;92-B:1481–8.
9. Buchholz RW. Injuries of the pelvis and hip. *Emerg Med Clin North Am*. 1984;2:331–46.
10. Keel M, Trentz O. In mini symposium: pelvic fractures – part II – acute management of pelvic ring fractures. *Curr Orthop*. 2005;19:334–44.
11. Majeed SA. Grading the outcome of pelvic fractures. *J Bone Joint Surg Br*. 1989;71-B:304–6.
12. Lindhal J, Hirvensalo E, Bostman O, Santavirta S. Failure of reduction with external fixator in the management of pelvic ring injuries. *J Bone Joint Surg Br*. 1999;81-B:955–62.
13. Letournel E, Judet R. Fractures of the acetabulum. 2nd ed. Berlin: Springer; 1993.

Richard A. Gosselin, Faruque Quasem,
and Lewis G. Zirkle

Hip Dislocations

Posterior Hip Dislocations

Hip dislocations are usually high-energy injuries. Posterior dislocations are the most common and often associated with sciatic nerve injury. The classical clinical picture includes pain, shortening, and a flexion/adduction/internal rotation posture. A plain AP pelvis x-ray will confirm the diagnosis and rule out associated bony injuries. Anesthesia or sedation, preferably with muscle relaxation, is necessary for reduction. Trolleys and OR tables are narrow and unstable, making it safer to place the patient on a mattress on the floor for reduction, while an assistant applies downward pressure on the ASISs. Traction in line with the axis of the femoral displacement—the Allis maneuver—will reduce the dislocation,

usually with a clunk after which the leg is extended and externally rotated.

A “grinding” sensation on attempted postreduction hip motion suggests an entrapped osteoarticular fragment or missed fracture. If repeated attempts at closed reduction are unsuccessful, interposition or buttonholing is likely, requiring open reduction through a posterior approach.

A postreduction AP x-ray of the pelvis (not just the involved hip) is essential to confirm a concentric and congruent reduction with bilaterally comparable joint spaces (Fig. 22.1). For congruent joints, the degree of instability will dictate further management. A hip stable at 90° can be treated symptomatically, with weight bearing as tolerated and instructions to avoid excessive flexion, adduction, and internal rotation for 2 months. If the hip re-dislocates between 60° and 90°, straight skin traction in external rotation is indicated for at least 2 weeks. External rotation can be maintained by placing the leg in a stockinette tied to the side of bed or a derotation bar incorporated in a slipper cast. The patient should be allowed to lie supine, prone, and on the involved side, but not on the contralateral side to avoid adduction. Traction can be relaxed while the patient is awake but should remain in place at night. Sitting is allowed as tolerated within the safe zone. Inlet/outlet or iliac/obturator oblique views can be helpful, but CT is rarely available.

Another management option involves placing the leg in a straight knee cylinder POP, with or without a derotation bar, to keep the hip in external rotation and an abduction pillow.

R.A. Gosselin, MD, MPH, MSc, FRCS(c) (✉)
Orthopedic Surgery, Institute for Global Orthopedics
and Traumatology, UCSF, 1001 Potrero Ave, 3A-36,
San Francisco, CA 94110, USA
e-mail: froggydoc@comcast.net

F. Quasem, MBBS, MS (Orth.)
Orthopedic Surgery Department, Sir Salimullah
Medical College (SSMC) Mitford Hospital,
Mitford Road, Dhaka 1100, Bangladesh
e-mail: mfquasem@yahoo.com

L.G. Zirkle, MD
SIGN Fracture Care International,
Surgery, Kadlec Hospital,
2548 Harris Ave Richland,
Washington 99354, USA
e-mail: lewis.zirkle@signfracturecare.org

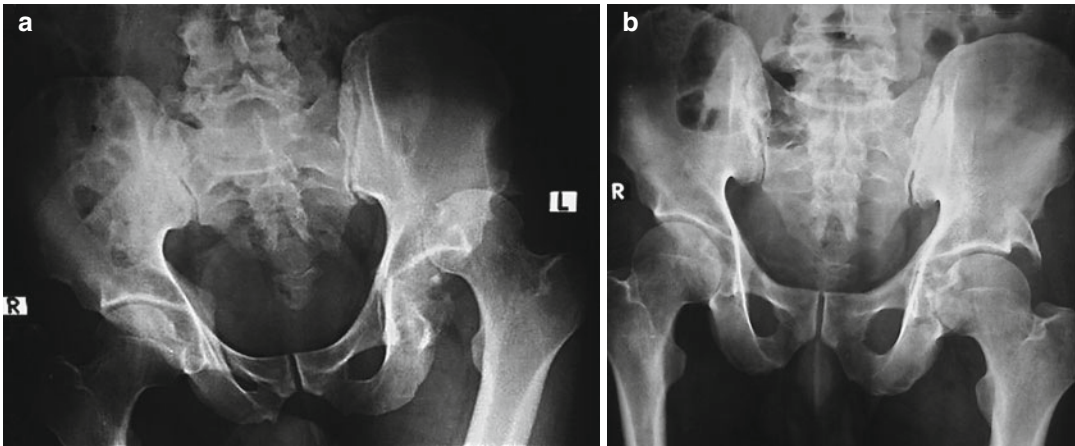


Fig. 22.1 (a) AP x-ray of a posterior dislocation of left hip with fracture of the posterior wall. (b) Postreduction x-rays show concentric reduction of femoral head, but the

posterior wall fragment remains displaced. Further management depends on clinical stability

The cast-enforced knee extension prevents hip flexion.

Recurrent dislocation of a concentrically reduced hip is rare.

A hip that re-dislocates at 45° flexion or less usually indicates a sizeable fracture of either the posterior wall or femoral head. Large posterior wall fragments should be fixed (see Chap. 21). Large femoral head fragments—from the weight-bearing area, between 10 and 2 o'clock—should be fixed, otherwise excised, with the ligamentum teres. Ideal fixation is with 2 lag screws starting from the femoral neck. For small fragments, a screw head can be countersunk below the articular surface or small threaded K-wires cut flush with the articular surface. The hip is reduced and assessed for stability and the posterior capsule repaired. A non-weight-bearing gait with range of motion starts early and continues for 6–8 weeks. In selected cases, 2–3 weeks traction may be beneficial. In theory, surgery is indicated for more than 2–3 mm of residual displacement of the posterior wall or dome fragment, and the hip is unstable. But this is only true if appropriate resources are available; otherwise, the patient is best treated conservatively as outlined above.

The incidence of AVN increases with the duration of the dislocation, but it is unclear at which point the curve flattens [1]. If the dislocation is relatively fresh, the patient usually presents with only mild discomfort at rest, pain

on passive motion, shortening, and inability to bear weight. AVN may or may not be present or visible on x-rays. Potential benefits of regaining length and the ability for painless ambulation must be weighed against risks of creating or exacerbating AVN or neurovascular injury. Open reduction is not indicated if the head is already deformed.

For long-standing dislocations with severe shortening, it is safer to put the patient in skeletal traction for 2 weeks and evaluate the position of the head on x-ray. Or perform a complete hip release and place the patient in straight leg skeletal traction, with the added risks of a second anesthetic or infection. A successful reduction may still lead to AVN or a painful, stiff hip. Fusion or Girdlestone excisional arthroplasty (see Chap. 41) are the only other surgical options. Patients seen after 6 months have adapted to a large extent and should be left alone.

Anterior Hip Dislocations

These are much less common than posterior dislocations (Fig. 22.2). The hip is usually slightly flexed, abducted, and externally rotated, and the head is often palpable in the groin. Closed reduction is by traction in the axis of the dislocation, followed by internal rotation and extension. The hip should be examined for instability and joint

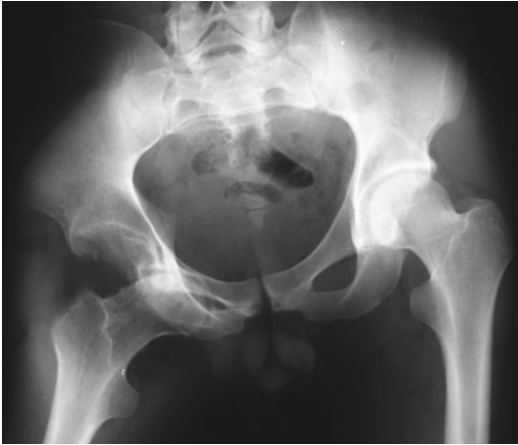

Fig. 22.2 Chronic obturator dislocation with neo-acetabulum. The patient walked with an abduction contracture and relative shortening, but no pain

incongruity or retained fragments as described above for posterior dislocations.

Stable hips can be placed in skin traction for comfort for a few days, avoiding external rotation. Instability in extension is usually due to an associated fracture, with or without fragment entrapment. An open reduction through an anterior approach is indicated, but fixing a fractured anterior wall or column is technically more demanding than the posterior wall, sometimes requiring a separate ilioinguinal approach.

Fractures of the Proximal Femur

The incidence of these fractures in austere environments is increasing as population ages [2]. They are challenging and remain “unsolved fractures” due to lack of fluoroscopy and fracture tables, delayed presentation, poor implants, and few viable alternatives such as prosthetic replacement [3]. Painful nonunions condemn the patient to use walking aids or a wheelchair.

Femoral Neck Fractures

Intracapsular fractures with varying degrees of compromise to the femoral head circulation. Valgus impaction or undisplaced fractures (Garden 1 and 2) have a better prognosis of

healing and less AVN than fractures with varus or total displacement (Garden 3 and 4). Nonoperative management of fractures impacted in valgus can be considered, but all other fresh fractures are candidates for internal fixation, particularly in younger patients.

If fluoroscopy and a fracture table are available, percutaneous compression screw fixation is routine. With fluoroscopy but no fracture table, percutaneous treatment is still possible with a radiolucent table and good assistants by slightly elevating the patient’s involved buttock on a cushion so that the femoral neck is roughly parallel to the ground. One scrubbed assistant provides traction on the leg, while an unscrubbed assistant gives countertraction over the contralateral shoulder via a folded sheet passed under the patient and over the perineum. The difficulty with this technique is the lack of lateral projection, requiring the surgeon to go by feel along the anterior neck to determine reduction and implant placement.

Regular short-threaded 6.5 mm cancellous screws can be used when cannulated screws are unavailable. Overdrill the lateral cortex with a 4.5 drill bit and advance the blunt tip of a K-wire in a push-pull fashion. This maximizes the tactile information as one crosses the fracture and prevents neck perforation. Positioning and depth can be assessed on a through-table AP view. A second or third K-wire should be inserted as parallel to the first as possible, replacing the wires one by one with the screws. Even divergent screws will provide some compression. Fluoroscopy will confirm that the construct moves as a unit, supplemented with a partial frog-leg position or a portable lateral.

When no intraoperative x-rays are available or the fracture is so old that it cannot be reduced closed, the only surgical option is an open reduction through an anterior approach. The anterior neck is rarely comminuted, making the reduction assessable both visually and palpably. A 3.2 mm drill bit can be advanced blindly in the axis of the neck, and parallel to the floor, in a push-pull fashion as described above to a depth as measured on the pre-op x-ray. A second drill bit of equal length is helpful in determining the screw length and is used to drill a second path parallel to the first.

The screw is inserted with the first drill bit still in place to prevent the head spinning. The 2 screws are compressed, and the construct is tested for stability in movement with no adventitious grinding sensation. A third screw is an option, but the risks of misplacement are higher with this blind technique.

Established painful nonunions without AVN and head deformity may benefit from open reduction, curettage, and compressive fixation, with or without a Judet/Myers procedure (see Chap. 41) [4]. An alternative, especially for neck fractures presenting after 10 days at which point an open reduction may cause more harm than good, is an extra-articular valgus osteotomy at or below the level of the lesser trochanter, to avoid the risk of iatrogenic AVN. Our choice is a 10–20° valgus correction that when fixed with a sliding hip screw, cephalic nail, or regular short-threaded screws should allow compression at the nonunion and the osteotomy with weight bearing. Temporarily pinning the head to the acetabulum before reaming and taping avoids spinning the proximal fragment.

Hemiarthroplasty is the treatment of choice when available. If degenerative changes in the acetabulum are already present, it should be reamed to subchondral bone and to the size of the selected prosthetic head. When head sizes are limited, reaming to the next size up is a better alternative than using too small a head.

Many elderly, low-demand patients with months-old fractures do well with the use of a walking aid, and the western surgeon needs to resist his or her training reflexes and avoid surgery based on x-rays and ingrained habits.

Intertrochanteric (Pertrochanteric) Fractures

These fractures are extracapsular and less likely to develop AVN. They are common insufficiency fractures in the elderly, but significant energy is required for a similar fracture in young adult bone. Patients present with pain, shortening, and external rotation of the limb. Nonoperative management with skeletal traction is usually successful

in treating this fracture but requires 6–8 weeks bed rest before patients can be mobilized without significant discomfort and often leads to malunion with shortening, varus, and rotation. Complications related to bed rest may require earlier mobilization at 3–4 weeks, with an increased incidence of malunion or nonunion. It is not easy to find the delicate balance between what is best for the fracture and best for the patient. Patients who present late may benefit from a shoe lift, as most patients accommodate well to the malunion.

Where fluoroscopy, fracture table, and appropriate implants are available, treatment is closed reduction and internal fixation with a sliding hip screw device or a cephalic nail. Cephalic nails are mechanically better for unstable fractures—those with posterior-medial comminution. Nails with larger proximal diameters risk added comminution at the entry site, making trochanteric entries preferred to piriformis fossa entry.

The proximal locking screws of an antegrade SIGN nail (SIGN Fracture Care International) can engage the head and neck fragment of more stable intertrochanteric fractures with the added stability of directed screws running up into the head and neck (Fig. 22.3). SIGN's hip fracture construct increases the precision of screw placement (Fig. 22.4). As with a DHS-type device, this allows impaction of the fracture with early weight bearing. The lack of a fracture table is compensated by manual traction/countertraction as described above. The lack of fluoroscopy makes reduction and fixation more difficult but can be overcome by partially detaching or splitting the vastus lateralis. This allows direct finger access to the fragments anteriorly and medially. A pilot K-wire introduced at the desired angle from an overdrilled entry site on the distal fragment can be advanced in a push-pull fashion and repositioned as needed, until it reaches a depth grossly corresponding to that templated preoperatively. The same technique of “semi-open reduction” is also helpful for determining the depth of insertion for a cephalic nail and its rotation for proximal interlocking.

When comminution is severe, a stable construct is more important than near-anatomical reduction. The distal fragment can be medialized,

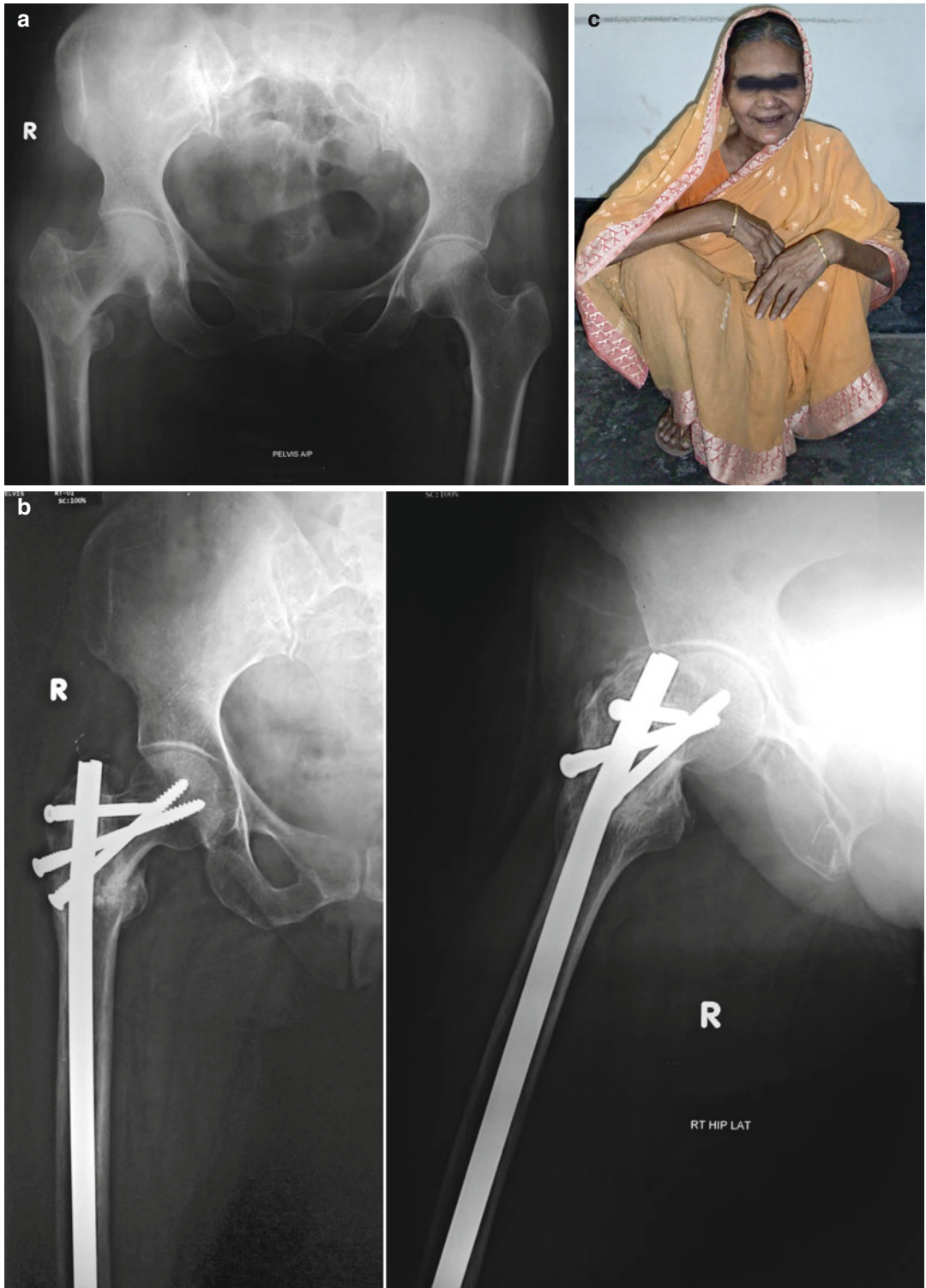


Fig. 22.3 (a) X-ray of a 2-part intertrochanteric fracture. (b) ORIF with the antegrade SIGN nail, with free screws secured into femoral neck and head. (c) The patient after surgery, able to independently walk and perform ADLs

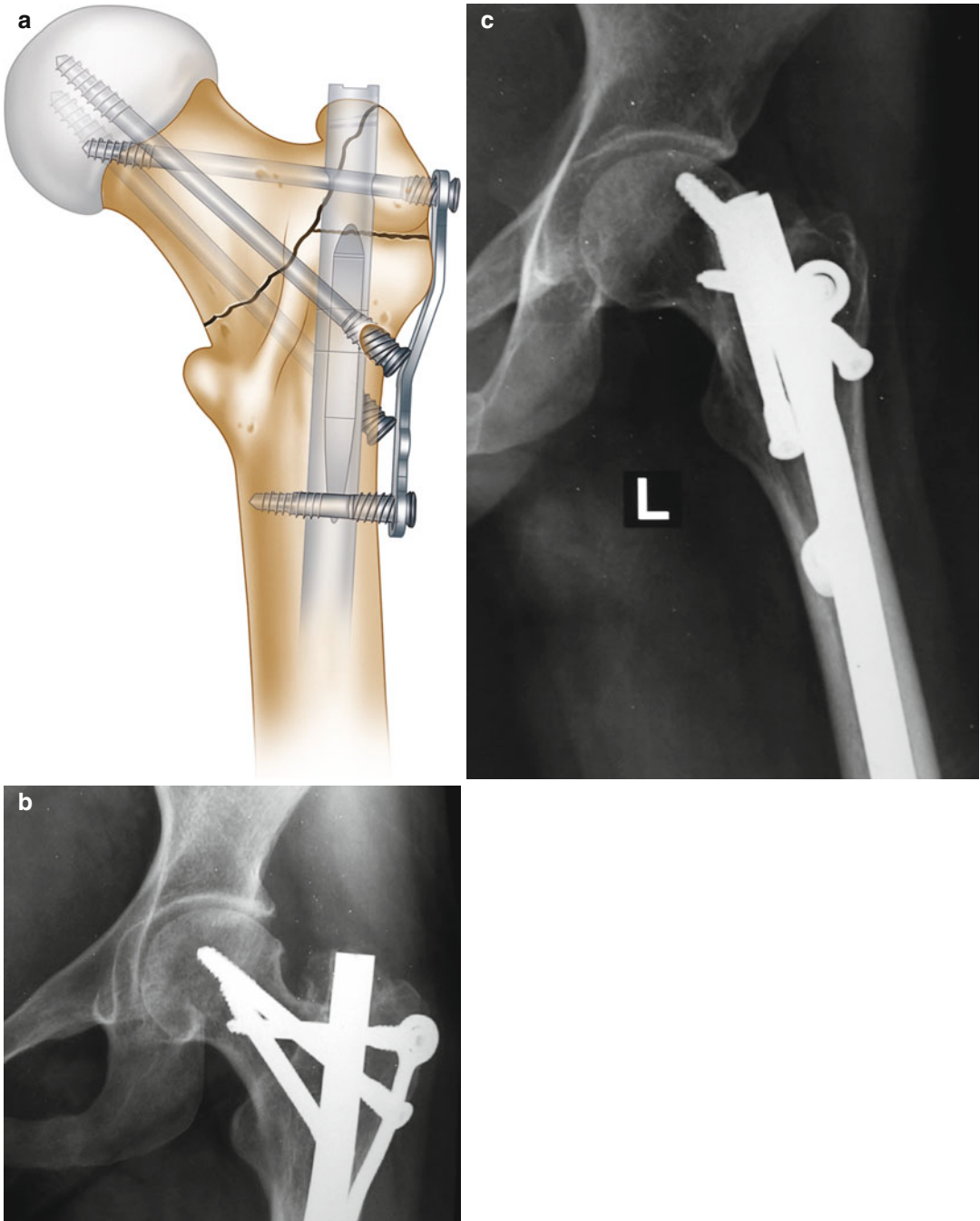


Fig. 22.4 (a) Engineer's drawing of the SIGN Hip Construct Device. The orientation of the device and its attachment to the proximal locking screw of the SIGN

nail allow placement of the remaining screws by a "miss a nail" technique. (b, c) X-rays of Hip Construct Device in use

and the spike of inferior cervical cortex impacted into the medullary cavity (Dimon-Hughston or pushover technique) (Fig. 22.5). The sliding

screw can be inserted under direct vision in the neck and the plate secured to the distal fragment. Once the fixation is completed, the surgeon

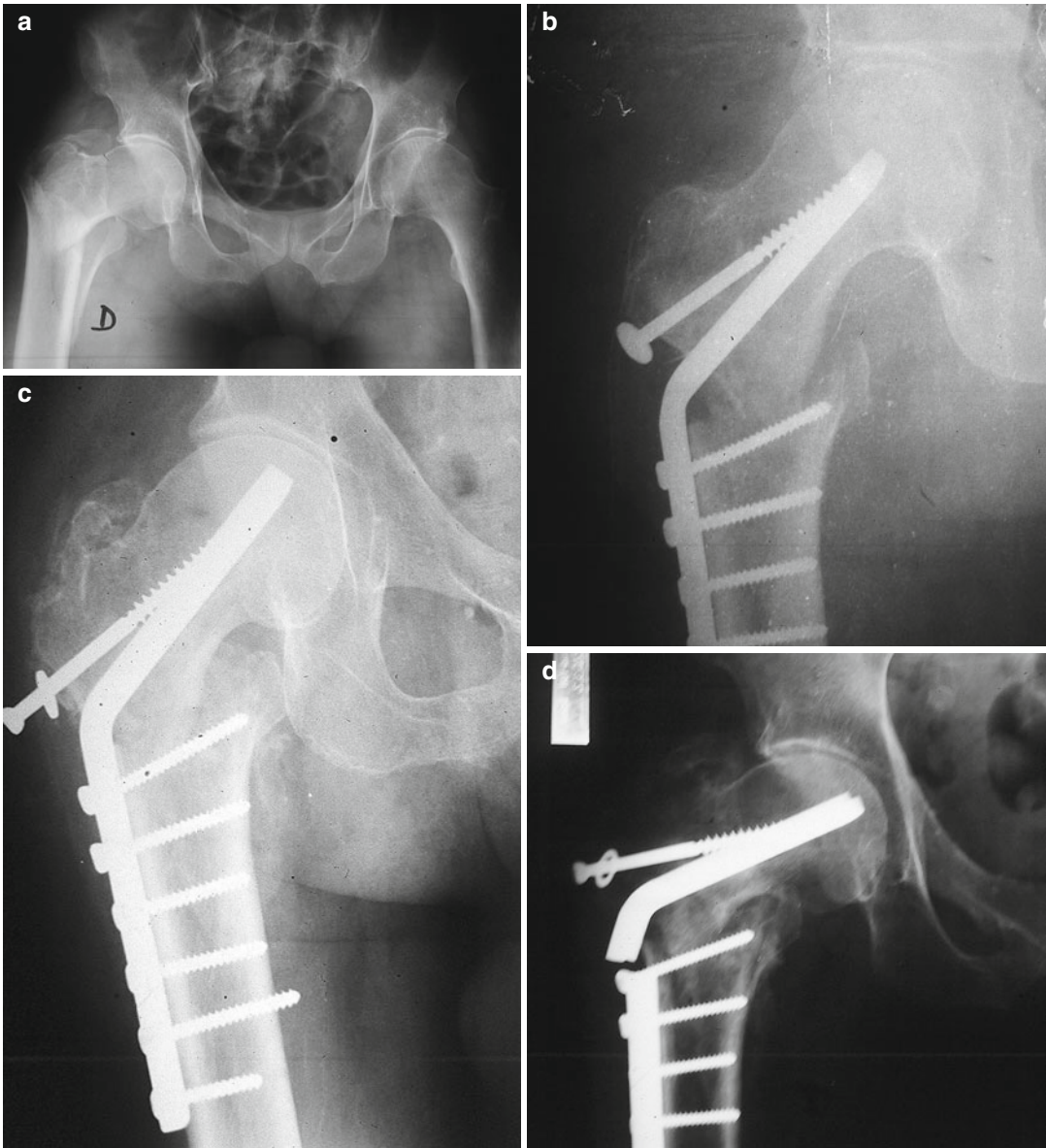


Fig. 22.5 (a) X-ray of comminuted intertrochanteric fracture with posteromedial instability (b) ORIF with blade plate and medialization of distal fragment (Dimon-Hughston). (c) The blade plate allows for only limited

impaction at the fracture site, and the proximal fragment has slid as far as it will go on the rigid blade, defeating the purpose of the impaction. (d) The race of bone healing against hardware failure is lost

verifies that the construct moves as a unit, confirmed by portable x-rays if available. This gives a stable construct that allows early weight bearing. The healing rate is high, and shortening is treated with a shoe lift.

External fixation in distraction between iliac crest and distal femoral fragment is a poor

alternative to internal fixation, only to be considered for wounds on the proximal/lateral thigh.

Painful nonunion of pertrochanteric fractures is not as common as in neck fractures and should be treated with internal fixation, with or without bone grafting, or osteotomy.

Femoral Shaft Fractures

Fractures of the femoral shaft require significant energy. The clinical presentation is usually self-evident, though a comprehensive clinical exam to rule out associated injuries is necessary. Isolated femoral shaft fractures rarely cause hypovolemic shock, but many patients in LMICs are borderline anemic before the injury and can quickly decompensate. We cannot overemphasize the importance of seeing the *entire* bone on x-rays, as associated fractures of the femoral neck need to be systematically ruled out. Articular fractures of the distal femur, patella fractures, and/or ligamentous damage should be suspected in the presence of a knee effusion.

Associated Femoral Neck and Shaft Fractures

Whether the femoral shaft fracture is treated surgically or conservatively, the presence of an ipsilateral neck fracture affects the treatment, as well as the functional prognosis. A missed undisplaced neck fracture will displace with skeletal traction or with the manipulation and traction needed for internal fixation. Surgical treatment of both fractures is the best option. The neck should be fixed first, after reduction if necessary, with compression screws that are positioned (usually anteriorly) so as not to impede nailing of the shaft fracture. Temporary Steinmann pins can be used and replaced with screws after shaft nailing. Proximal interlocking screws can also be used to complement neck fixation, depending on the nail design.

Associated Intertrochanteric and Shaft Fractures

This combination of fractures represents a particularly challenging combination. There is little bone in the proximal femur fragment for secure purchase of an implant. Rigid fixation most often requires long implants such as DHS-type devices or blade plates, or IM nails that allow proximal

interlocking in the femoral neck and head. If the segment between the two fractures is long enough, each can be treated with separate implants, the hip component as described above and the shaft component with a separate plate or a short retrograde nail.

The SIGN hip system can also be used for this problem in an antegrade fashion with static interlocking. Unless rigid fixation can be achieved, these patients should be treated in traction. Nonrigid fixation, such as flexible nailing, should be avoided as it exposes the patient to the same surgical risks without the benefits, as postoperative traction is usually necessary.

Subtrochanteric Fractures

These are usually high-energy injuries, with the proximal fragment displacing in flexion and external rotation from pull of the psoas muscle. When skeletal traction is the only option, it should be done through the distal femur and the limb put in the 90–90 position (90° of flexion at both hip and knee), with the calf suspended in a sling or lightweight POP boot to prevent equinus. Russell's traction at 45° hip flexion is an acceptable compromise. Healing requires prolonged bed rest, which poses significant nursing challenges. Whenever possible, ORIF should be performed, ideally with an interlocked IM nail. Plating is mechanically weaker, and medial comminution ensures a high nonunion rate and hardware failure. Using implants with cervical purchase can be difficult without fluoroscopy (Fig. 22.6). Autogenous iliac crest bone grafting is recommended, adding little to the acute morbidity.

Femoral Shaft Fractures

Skeletal traction remains the only treatment option in many austere environments. Unless there are significant wounds, external fixation is a poor substitute for sound internal fixation. Acceptable alignment is difficult to obtain and maintain, pins loosen or become infected, and knee stiffness is common, often with functional

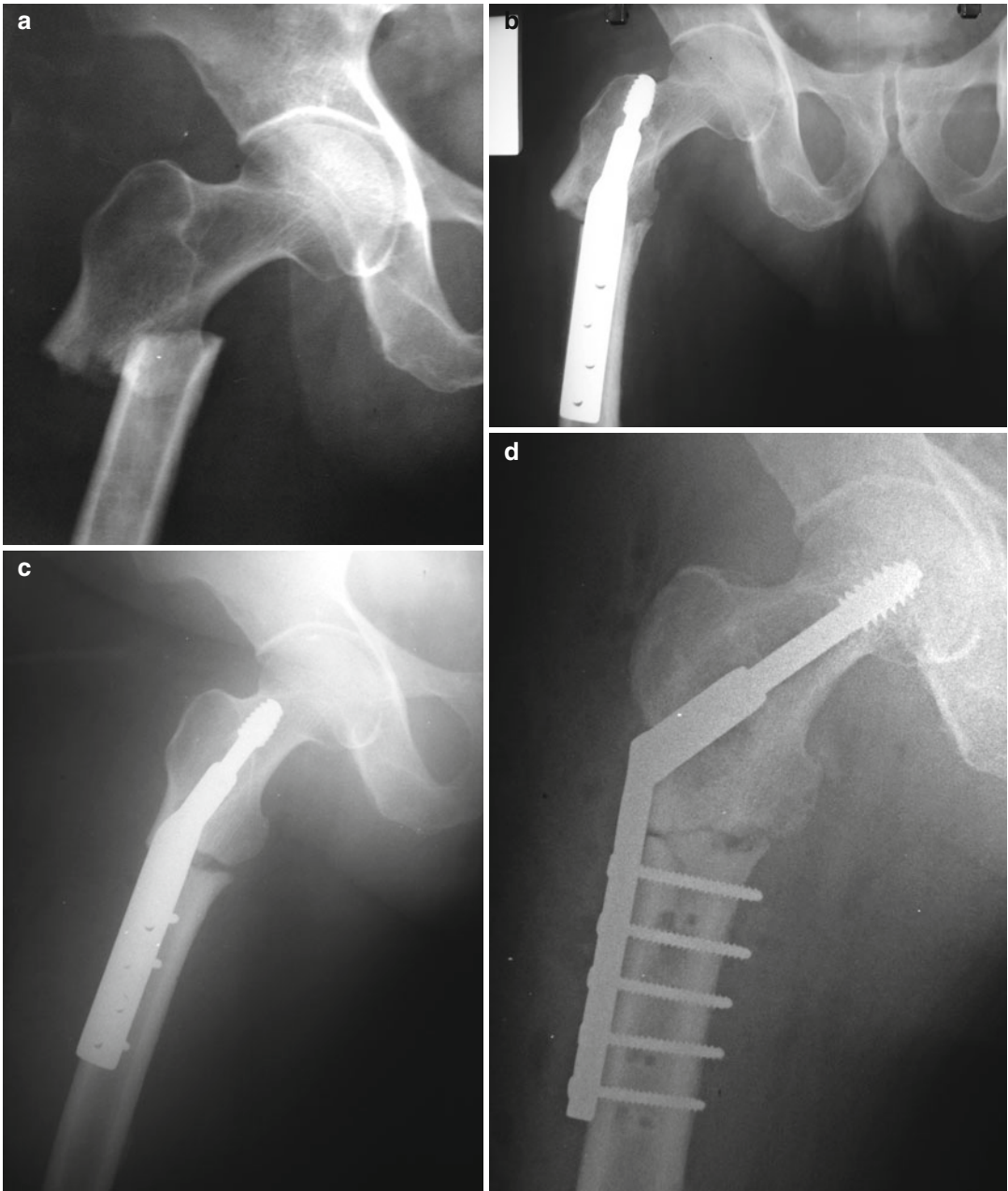


Fig. 22.6 (a) X-ray of transverse subtrochanteric fracture (b, c) attempt at blind use of DHS. The compression screw is likely located on or in the superior neck.

(d) Salvage required an open reduction and direct visualization of the anterior neck. Note the anteroposterior direction of the previous screw holes

disability long after the bone has healed. In most cases, these negatives override the main benefit of early mobilization that external fixation potentially provides. If an ex-fix is used, insert the pins with the knee in flexion, to minimize tethering

the vastus lateralis, and once the fixation is secure, the knee should be maximally flexed while under anesthesia.

Skeletal traction applied as temporizing treatment should always be applied as if it is the

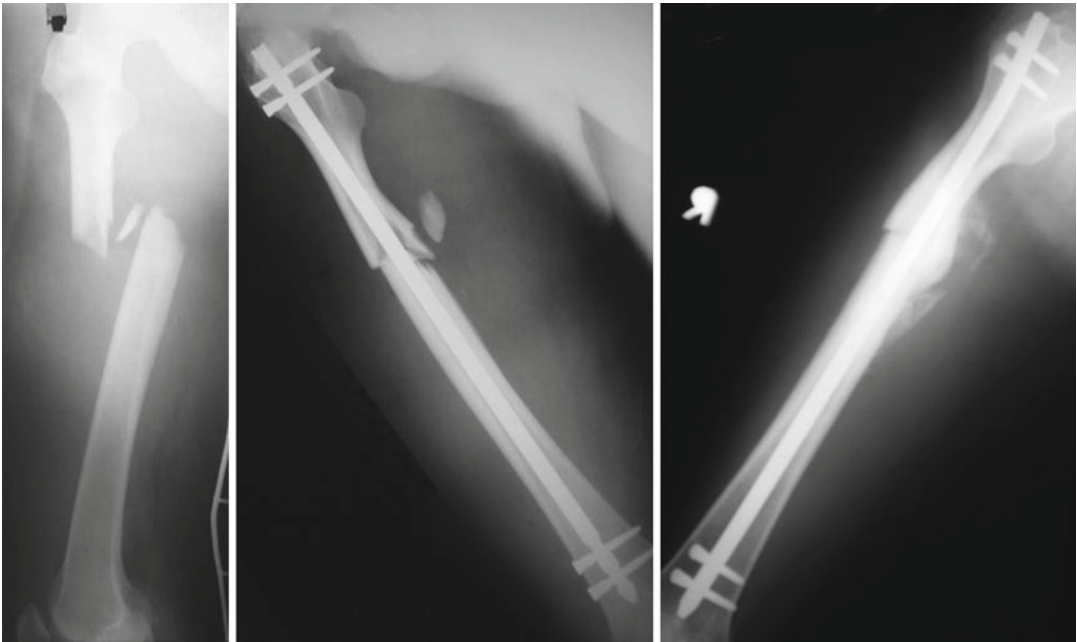


Fig. 22.7 Closed moderately comminuted femur fracture (*left*), fixed with SIGN nail (*middle*) and allowed full early weight bearing as tolerated. (*Right*) Patient is fully independent without limp at 5 months

definitive treatment, as it is common that surgery is delayed indefinitely and traction becomes the definitive treatment by default (for a discussion on femoral shaft fractures treated in traction, refer to Chap. 13).

Whenever possible, internal fixation is the treatment of choice for femoral shaft fractures. Many fractures present late, making a closed reduction impossible. Open reduction of a femur fracture, particularly if old, bleeds copiously, and blood should be available. Many of these patients have underlying chronic anemia before the fresh blood loss from the fracture, and careful monitoring of hemoglobin is mandatory. Prophylactic antibiotic coverage should be routine, according to available wide-spectrum antibiotics.

Intramedullary devices are the implant of choice for most diaphyseal fractures (Fig. 22.7). Traditional open nailing with a Kuntscher nail or other non-interlocked nail relies on 3-point fixation to prevent shortening and rotation. This can be achieved in very few fracture patterns. The same applies to flexible nailing with multiple Ender nails or Rush rods (Fig. 22.8). Nonrigid fixation serves mainly as “alignment” fixation,

and postoperative traction may still be necessary, obviating some of the benefits of surgery. In such situations, a well-molded cylinder POP may be needed to hold the proper rotation. In general, unless the patient can benefit from rigid fixation and early mobilization, nonoperative treatment is safer. However, if one is certain from the time elapsed, the position of the fracture ends on x-ray, and the clinical exam that the fracture is incapable of healing without surgical intervention, the surgeon needs to weigh the options.

Interlocking or stacked K-nails with multiple interference screws proximally and distally have been described, but the technique is unreliable and should only be attempted when this is all that is available and nonoperative methods have failed. It is possible to use a generic interlocking nail without fluoroscopy (technique in Appendix 3). The interlocking screws may have little purchase on both the far and near cortices, but the construct is usually strong enough to maintain rotational alignment and length.

The SIGN system was developed to allow locked IM nailing without power, fracture table, or fluoroscopy [5]. The system uses a solid nail

with no arc of radius but a 9° proximal bend with 1 screw hole and 1 slot proximally and 2 slots distally with all screws placed in one plane perpendicular to the nail. The same nail and targeting system are used for femur, tibia, and humerus fractures, keeping inventory to a minimum. Interlocking is achieved with a rigid external target arm and a system of sleeves and slot finders. The reduction is usually open and reaming is done by hand, using sharp T-handle reamers, which are part of the system. The femur can be

nailed in an antegrade fashion, using a trochanteric entry, or retrograde fashion through the knee. It is found in multiple austere environments, and its user base is expanding [6]. Replacement nails and screws are provided gratis to the hospital, as long as patient data are entered in an online data bank. It has the unique advantage to be free of charge to the patient. Volunteer surgeons are likely to be exposed to this system, and local surgeons are usually proficient in its use and excellent teachers [7].

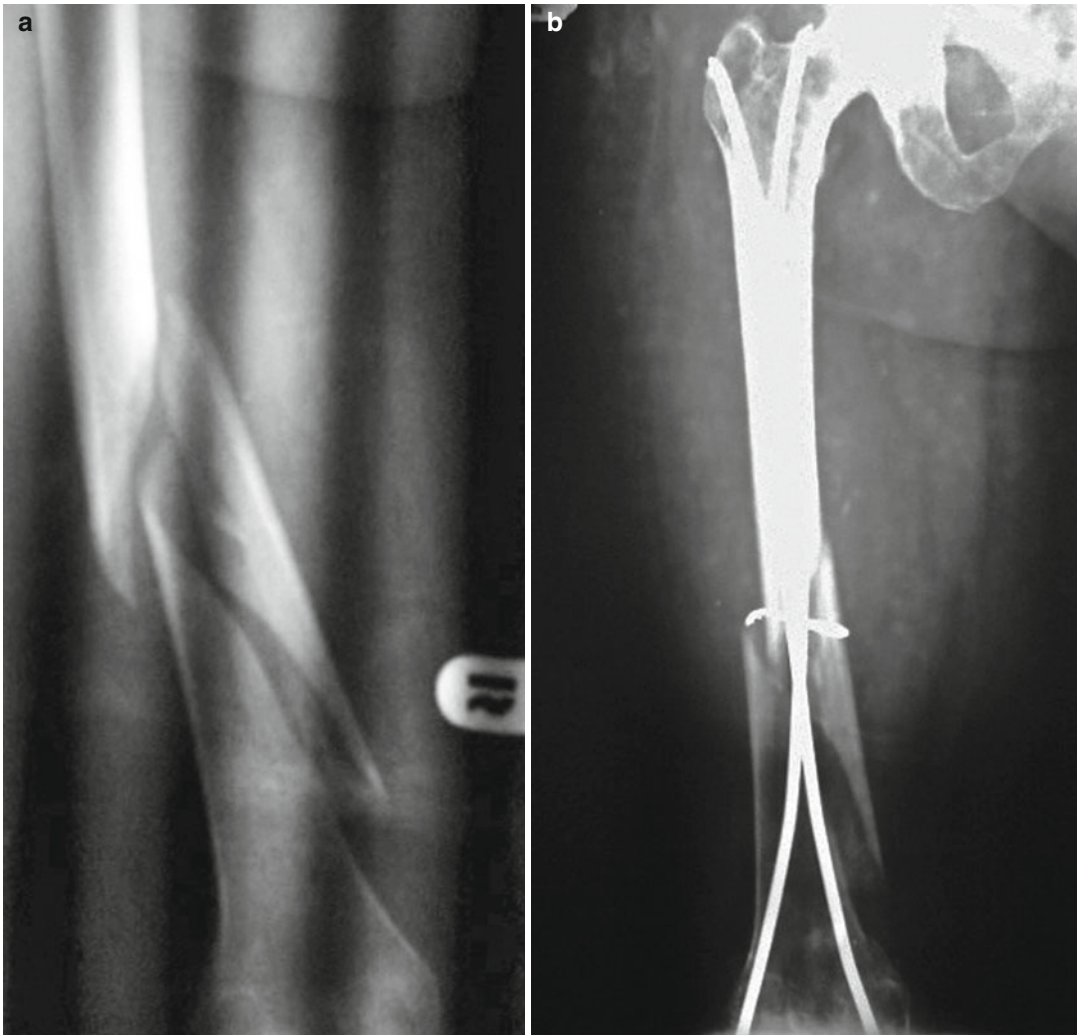


Fig. 22.8 (a) X-ray of a comminuted, unstable fracture of the distal femoral shaft. (b) ORIF with cerclage wire and 2 Ender nails, a construct without sufficient rigidity and stability. Note that one of the rods already protrudes

through the femoral neck. (c) Predictable malunion with shortening and external rotation. Note migration of the nails distally at their point of insertion. (d) Protrusion of the lateral nail through the skin

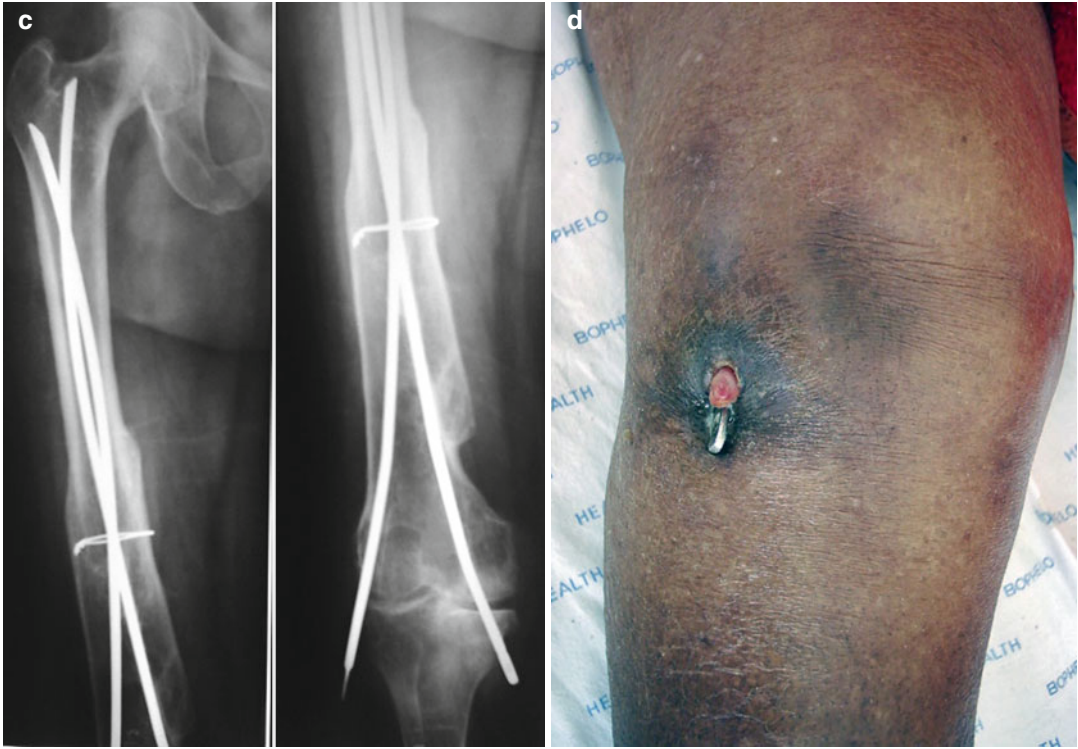


Fig. 22.8 (continued)

The fracture age, pattern, and location will dictate the type of nailing: antegrade or retrograde and static or dynamic. Fresh fractures may require a small opening at the fracture so the finger can feel as reamers and the nail engage the distal fragment. The periosteum should be disturbed no more than necessary. Older fractures require a more extensive exposure. An intact isthmus allows some degree of 3-point fixation, particularly for straight nails. Nails placed retrograde should end above the level of the lesser trochanter or more than 6 cm below it. The area in between is a high-stress area, and the patient may refracture at the level of the end of the nail or the interlocking screws. Dynamic nailing can be considered for simple, non-communited fractures of a stable pattern. Proximal shaft fractures should be done in an antegrade fashion, and vice versa. Comminuted, isthmic, long oblique, or segmental fractures should be nailed statically. Antegrade nailing is done in the lateral or semi (floppy)-lateral position; retrograde nailing is done with the patient supine.

Bilateral femur fractures can be done in the same session in the supine position (Fig. 22.9). Ipsilateral femur and tibia fractures can both be nailed through a single medial parapatellar or transpatellar tendon approach. If a “triangle” (easily made in the hospital workshop) is available to support the femur, the closed tibia fracture can be nailed first, followed by the femur. If the tibia fracture is open and external fixation will be the initial treatment, the ex-fix can be used for traction while fixing the femur. In this case, it is safer to redrape the ex-fix out of the field and reprep the thigh. If the femur fracture cannot be secured by these methods, it should be addressed first. Once the femur is nailed, it is always possible to revisit the tibial reduction and adjust the external fixateur as needed.

When the tibia will also be nailed, it can be temporarily immobilized with a 2-pin single-bar ex-fix, a cast, or back slab draped out of the field and removed later or by tightly rolling 2 or 3 nails or long plates in sterile towels and securing them

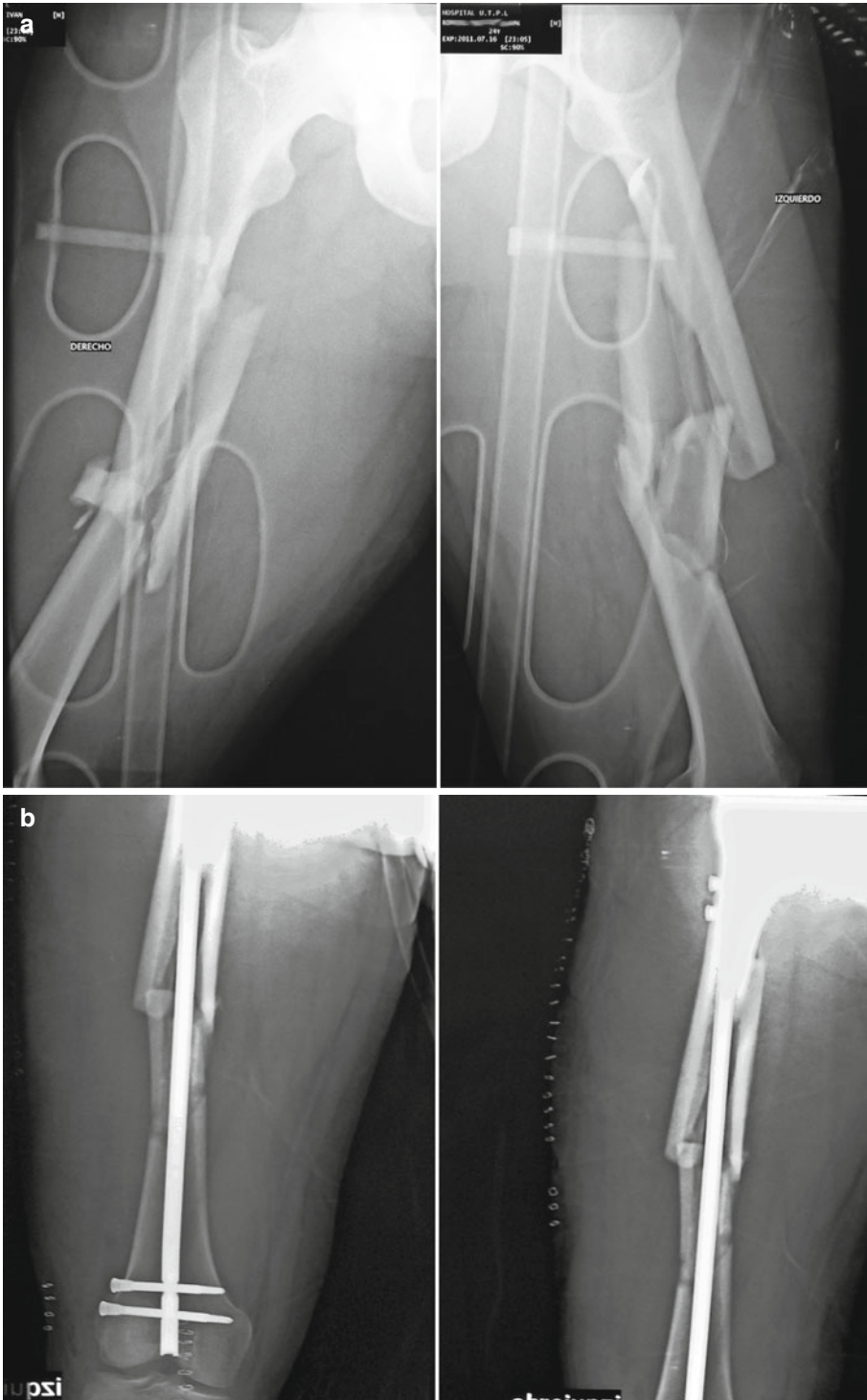
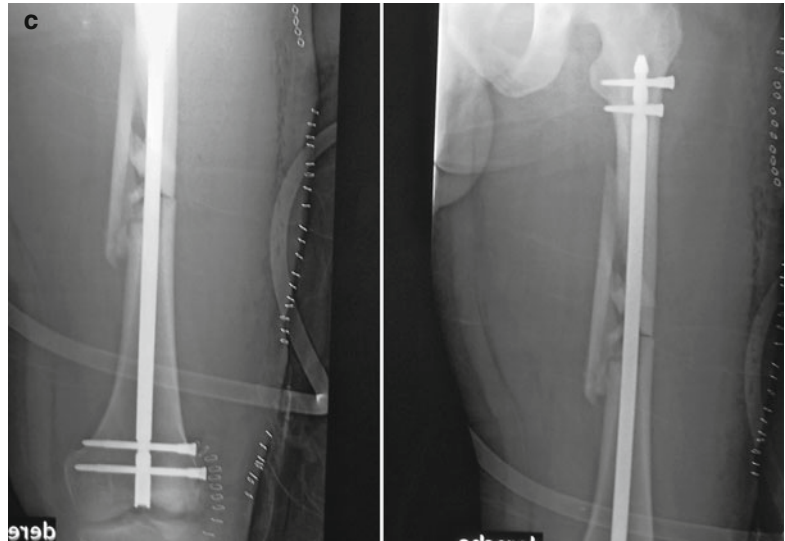


Fig. 22.9 (a) Bilateral closed femur fractures. (b, c) Bilateral retrograde SIGN nailing was done in the supine position

Fig. 22.9 (continued)



to each side of the leg with an Esmarch band or ace wrap to act as a stabilizing splint. A dried back slab can also be “dropped” in a sterile Mayo stand cover, secured on the leg, and removed after the femoral nailing is secured.

Intramedullary devices are not always available or affordable, and in many places plate and screws are the only surgical option. Inexpensive implants are available almost everywhere, and it is not unusual for a patient to buy a plate and screws at a local pharmacy. More commonly, semi-standard large fragment sets are available in the hospital, although often with a hodgepodge of plates and screws of different sizes or metallic composition. The surgeon should be aware of available implants *before* surgery. Do not accept the word of the OT supervisor. Plates and screws that are too long can be cut, but the reverse is not true. The same is true for any hardware removal—make sure you have the appropriate screwdriver *before* you embark in what may be an extremely frustrating endeavor.

Newer technologies such as locking plates are almost never available. Still, principles of minimal periosteal stripping, indirect reduction, and sub-muscular sliding of the plate should apply when there is a large comminuted fragment. Standard DC plates are hard to contour properly without plate benders. Pliers, or ideally a vise grip, and a screwdriver or small curette or elevator placed

through a screw hole along with a strong assistant and a healthy dose of enthusiasm will usually suffice. Large bone fragments can be fixed with lag screws, but cerclage wire is detrimental to the periosteal blood supply and should be avoided.

Postoperative management depends on many factors, not the least of which is patient compliance and collaboration [8]. Early weight bearing, at least partial, is rarely contraindicated when using an IM nail, and we encourage weight bearing depending on pain in most fractures that are interlocked. Active ROM of joints above and below the fracture is encouraged. A static nail that shows no or poor callus formation at 3 months could be dynamized distally, although no one agrees that it is effective or makes any difference. Many such fractures heal with more time. Established non-unions at 6 months require re-intervention: hardware removal and exchange, unless infection is present or suspected, in which case a few strategies need to be considered (see Chap. 41) [9].

References

1. Dwyer AJ, John B, Singh SA, Mam MK. Complications after posterior dislocation of the hip. *Int Orthop*. 2006;30(4):224–7.
2. Dhanwal DK, Dennison EM, Harvey NC, Cooper C. Epidemiology of hip fracture: worldwide geographic variation. *Indian J Orthop*. 2011;45(1):15–22.

3. Jamal Sepah Y, Umer M, Khan A, Ullah Khan Niazi A. Functional outcome, mortality and in-hospital complications of operative treatment in elderly patients with hip fractures in the developing world. *Int Orthop*. 2010;34(3):431–5.
4. Gupta A. The management of ununited fractures of the femoral neck using internal fixation and muscle pedicle periosteal grafting. *J Bone Joint Surg Br*. 2007; 89(11):1482–7.
5. Sekimpi P, Okike K, Zirkle L, Jawa A. Femoral fracture fixation in developing countries: an evaluation of the Surgical Implant Generation Network (SIGN) intramedullary nail. *J Bone Joint Surg Am*. 2011;93(19):1811–8.
6. Young S, Lie SA, Hallan G, Zirkle LG, Engesaeter LB, Havelin LI. Low infection rates after 34,361 intramedullary nail operations in 55 low- and middle-income countries: validation of the Surgical Implant Generation Network (SIGN) online surgical database. *Acta Orthop*. 2011;82(6):737–43.
7. Young S, Lie SA, Hallan G, Zirkle LG, Engesaeter LB, Havelin LI. Risk factors for infection after 46,113 intramedullary nails operation in low- and middle-income countries. *World J Surg*. 2013;37(2):349–55.
8. Pearson CA. Early protected weight bearing in African patients with fractures of the femur. *Injury*. 1977;9(2):89–92.
9. Yokoyama K, Itoman M, Shindo M, Kai H, et al. Deep infection and fracture healing in immediate and delayed locked intramedullary nailing for open femoral fractures. *Orthopedics*. 1999;22(5):485–90.

Richard A. Gosselin and David O. Oloruntoba

Fractures of the Distal Femur

Extra-articular Fractures

Isolated extra-articular fractures at or below the diaphyseal-metaphyseal junction of the distal femur are common. The management is challenging, and the results depend on the surgeon's experience and available resources. Rigid internal fixation of extra-articular fractures is the only way to allow early mobilization of both the knee joint and the patient, with all the known benefits.

Locking plates are rarely available. If a surgeon, by chance, has brought a set and uses it, the appropriate screwdrivers need to be left behind for the local surgeon. Even dynamic condylar screws (DCS) are rare. Old, often incomplete blade plate sets are more common, and our preferred technique for using these is described in Appendix 3. Depending on the amount and quality of bone in the distal fragment,

an eight- to ten-hole large DC plate can be bent through the fourth hole at a 90–95° angle, fashioning a blade plate—a challenging exercise if a plate bender is unavailable. If the bone quality of the distal fragment is adequate and the piece is large enough to accommodate three holes of a large DC plate, contouring it to fit the lateral cortex might suffice. A smaller second plate on the medial side can be added if the rigidity of the construct is in doubt.

Temporary fixation with crossed Steinmann pins can supplement the plate fixation. The pins are incorporated in a long-leg cast with the knee at 30–40° flexion to prevent weight bearing. The pins and cast are removed at 6 weeks, at which time gentle active range of motion (ROM) is started if fracture consolidation is progressing. Otherwise, continue the cast another 4–6 weeks before beginning knee ROM. Resume weight bearing at 10–12 weeks post-fixation.

Another older, but still relevant, fixation method uses first-generation smooth malleable IM nails, such as Ender and Rush nails. Their advantage is availability. They don't provide rigid fixation, but in stable reductions early knee motion can be instituted, and in unstable situations 3–6 weeks of plaster or traction may be needed. Two implants are inserted via openings in the medial and lateral femoral condyles and advanced simultaneously across the fracture. Take care to prevent nail back out which may lead to skin and soft tissue erosion. Ender nails have an eyelet near their tip where a small screw

R.A. Gosselin, MD, MPH, MSc, FRCS(c) (✉)
Orthopedic Surgery, Institute for Global Orthopedics
and Traumatology, UCSF, 1001 Potrero Ave, 3A-36,
San Francisco, CA 94110, USA
e-mail: froggydoc@comcast.net

D.O. Oloruntoba
Department of Orthopedics, Nelson Mandela
Academic Hospital, House 6, Mthatha General
Hospital, Mthatha, Eastern Cape 5099,
Republic of South Africa
e-mail: yinka.oloruntoba@gmail.com

can be used for “interlocking.” Burying the tips of the nails under the cortex makes removal more difficult.

When available, interlocked nails, such as the SIGN system described in Chap. 22, can be used in a retrograde fashion for both extra- and intra-articular fractures, provided there is enough bone stock. If there is an articular component, it is reduced and fixed first, followed by insertion of the nail which is interlocked in the distal fragment. If interlocking is not possible in the proximal femur fragment, the nail should be long and thick enough to provide 3-point fixation through the isthmus (Fig. 23.1).

When hardware for rigid or semirigid internal fixation is unavailable, there are three options: external fixation, skeletal traction, or pins and plaster. If sound external fixation can be achieved without spanning the joint, it should be considered. Spanning the joint is no better than cast immobilization, with the added risk of pin track infection.

When there is no or minimal comminution, temporary nonrigid fixation with pins incorporated in a long-leg cast—as detailed above, but without the plates—is another alternative, provided fixation is secure enough to maintain acceptable alignment. Removing pins and cast at 6 weeks is only done if early callus is visible. If in doubt, continue the pins and cast or hinged cast bracing another 4–6 weeks.

Proximal tibial skeletal traction is the last resort. It should be done on a Bohler frame, if available, to reduce the deforming forces of the gastrocnemii. This confines the patient to bed for 4–6 weeks, at which time the fracture should be clinically “sticky” and amenable to cast treatment for another 6 weeks.

An alternative to conventional traction is the Perkins traction technique, in which active knee ROM exercises are started as soon as 3–4 days after the fracture and progressed as pain allows (see Chap. 13).

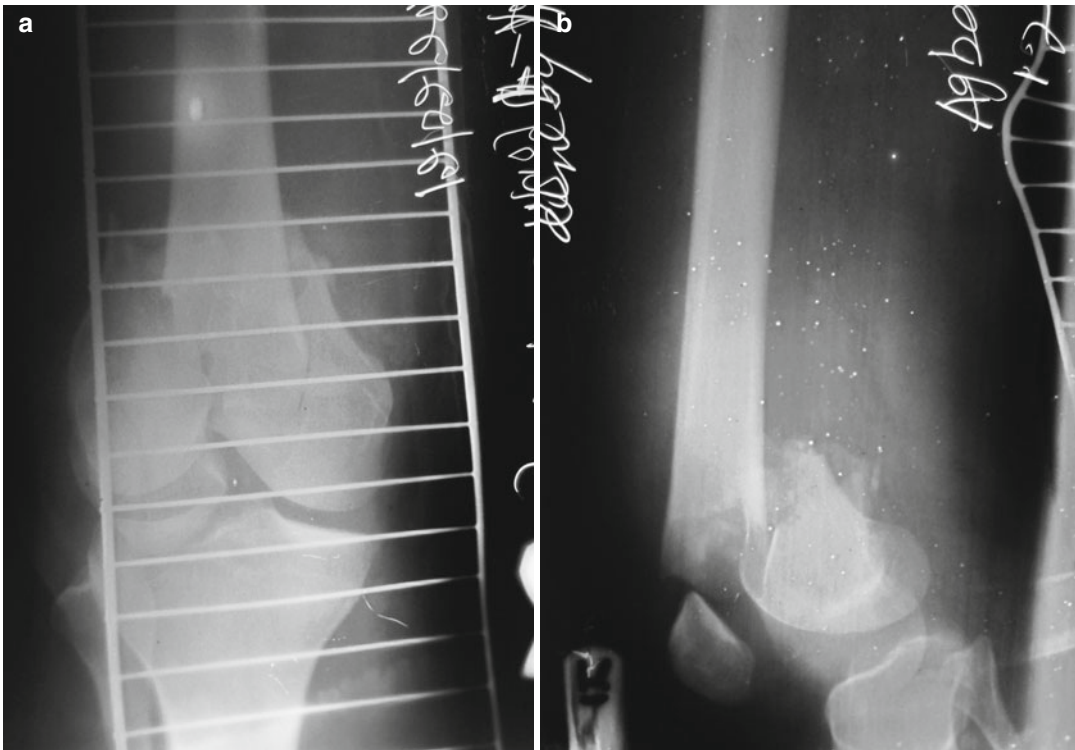


Fig. 23.1 (a, b) X-rays of a closed low Y-type intra-articular distal femur fracture. (c, d) ORIF by reestablishing the condyles with 2 compression screws and gentle

insertion of a retrograde SIGN nail. Only one locking screw could be placed. Patient can do ROM exercises, but weight bearing is limited by the intra-articular fracture

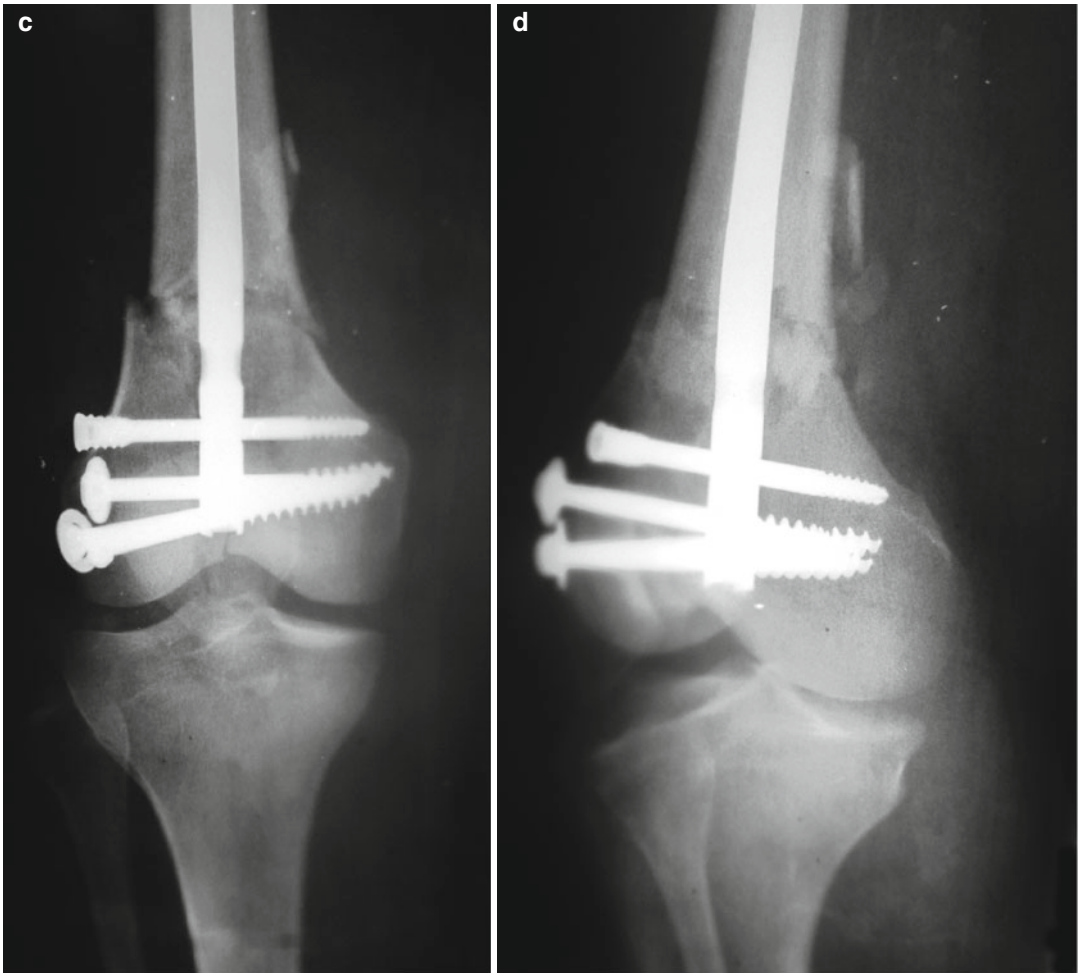


Fig. 23.1 (continued)

Intra-articular Distal Femur Fractures

Intra-articular distal femur fractures involve one or both condyles and are difficult to diagnose, particularly with poor-quality x-rays. A high index of clinical suspicion mandates obtaining good-quality imaging. A knee hemarthrosis with fat droplets can give additional information, especially in undisplaced fractures. The principle of anatomic restoration of joint surfaces applies to the treatment of these fractures, and any step-off >2 mm should be treated. Hardware availability will determine the rigidity of the fixation and thus the post-op regimen.

Since screws, wires, and pins are almost always available, one can at least reduce and fix the joint surface as anatomically as possible and

convert the fracture to an extra-articular one, to be managed as described above. Even if technically and biomechanically unsatisfying, a good articular reduction with lag screws and/or pins, even if not a rigid fixation, will significantly improve the long-term functional prognosis (Fig. 23.2).

Injuries of the Patella and Ligaments About the Knee

Patella Fractures

Management of patella fractures depends on the age of the injury, the amount of comminution or displacement, associated soft tissue injuries, and

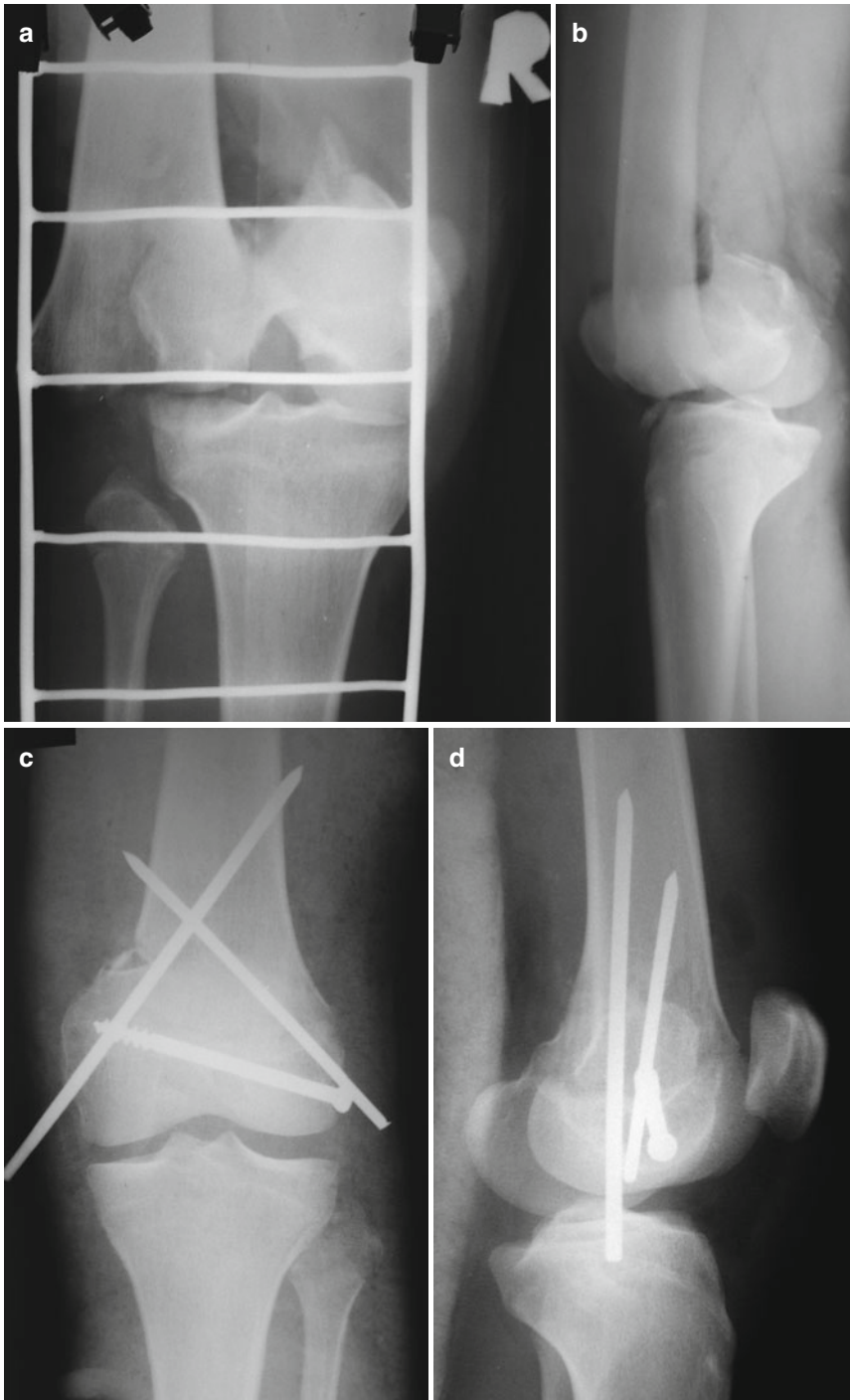


Fig. 23.2 Another way to treat a distal intra-articular fracture. (a, b) Admission AP and lateral x-rays (c, d). Postoperative AP and lateral views showing interfragment compression of the articular components with

one lag screw and temporary fixation of the extra-articular components with 2 crossed Steinmann pins that will be incorporated in a long-leg cast and removed at 6–8 weeks

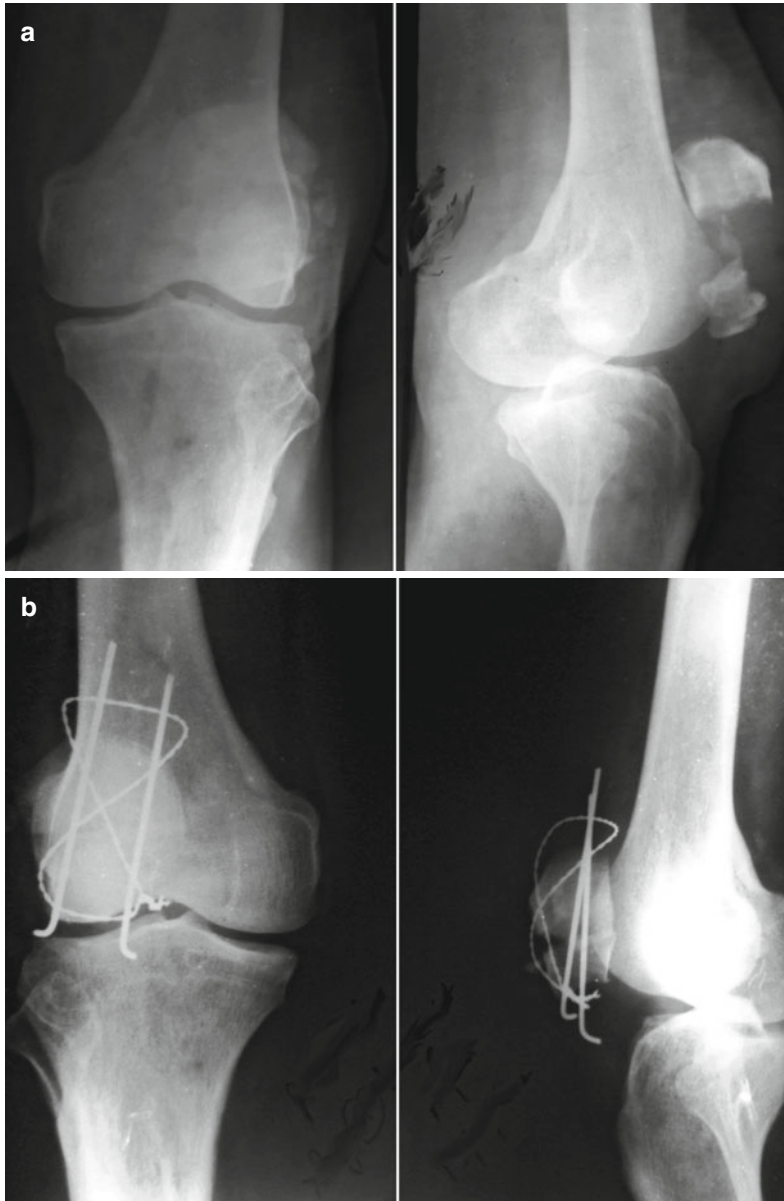


Fig. 23.3 (a) X-ray of displaced comminuted transverse fracture of patella. (b) ORIF with figure-of-8 tension banding, after excision of small comminuted fragments.

Dental wire was the only wire available; 2 strands were braided together

availability of hardware. Undisplaced patellar fractures can be treated in a well-molded, full-weight-bearing, cylinder cast for 6 weeks.

Articular step-offs ≥ 2 mm should be treated surgically. Figure-of-eight tension banding over 2 parallel K-wires remains the gold standard (Fig. 23.3). When wire is not available, braiding

3 strands of heavy non-resorbable suture can provide a cerclage strong enough for tension banding. Be sure to test it intraoperatively.

Using the plastic sleeve from a 14 or 16 French Jelco IV catheter facilitates passing the tension band wire under the tendons, instead of through them. The K-wires should be bent at one end for ease of later

removal under local anesthetic. Early active ROM and full weight bearing (WB) are encouraged.

When one pole is comminuted beyond repair, a partial patellectomy with reattachment of the quadriceps or patellar tendon to the remaining patella with transosseous sutures is a good solution. Fresh, completely comminuted (“blown-up patella”) fractures of the entire patella should be treated initially by K-wire fixation of the main fragments and “containment cerclage” of the patella, to prevent further displacement. A cylin-

der cast is used for 3 weeks, after which gentle active ROM is started. Many patients will do well clinically despite radiographic evidence of some degree of mal-/nonunion. Total patellectomy can always be done later if patients are symptomatic. But they must be aware that pain may persist, and there will be residual weakness—a significant impairment for people living close to the floor.

Whenever surgery is done, the surgeon should meticulously repair any associated lesions of the medial and/or lateral retinaculum (Fig. 23.4).

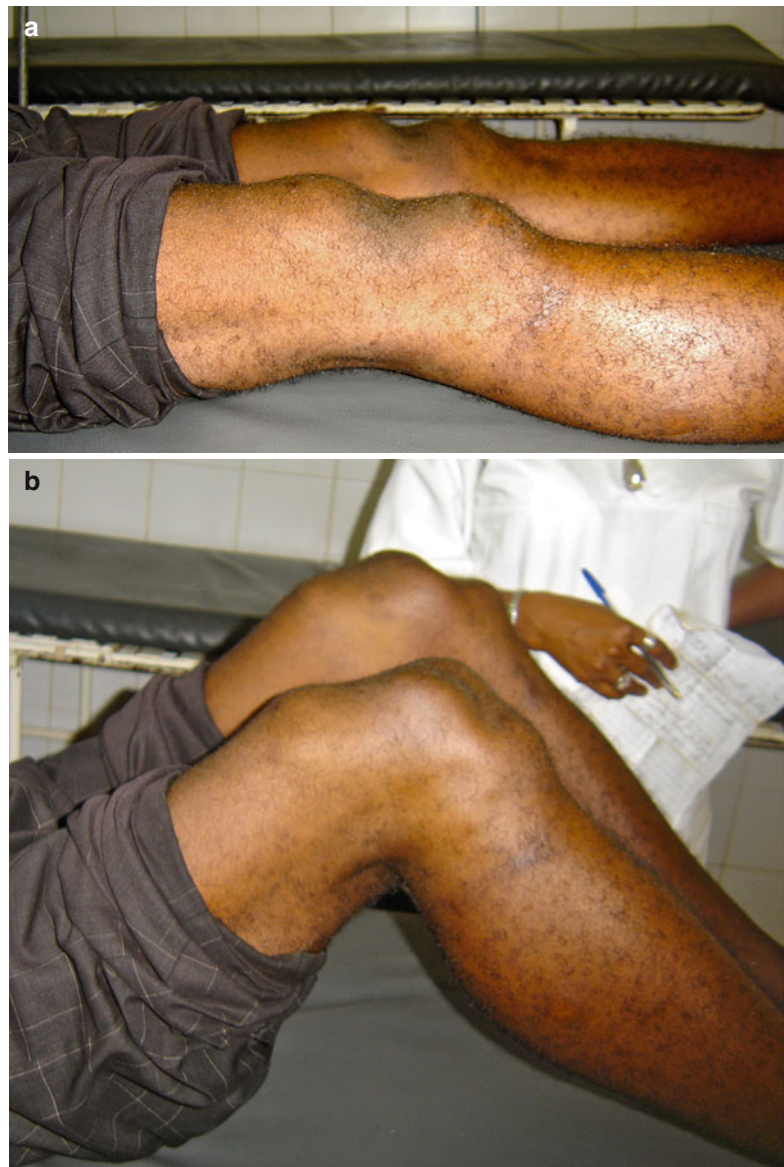

Fig. 23.4 (a, b) Clinical appearance of bilateral chronic patella nonunions with significant patella alta. X-ray appearance of (c) right and (d) left distal patellar pole nonunions with impressive proximal migration of the patellar body. This patient had the problem for years and had no pain but was unable to kneel or get up from the kneeling position without support. No surgery was offered

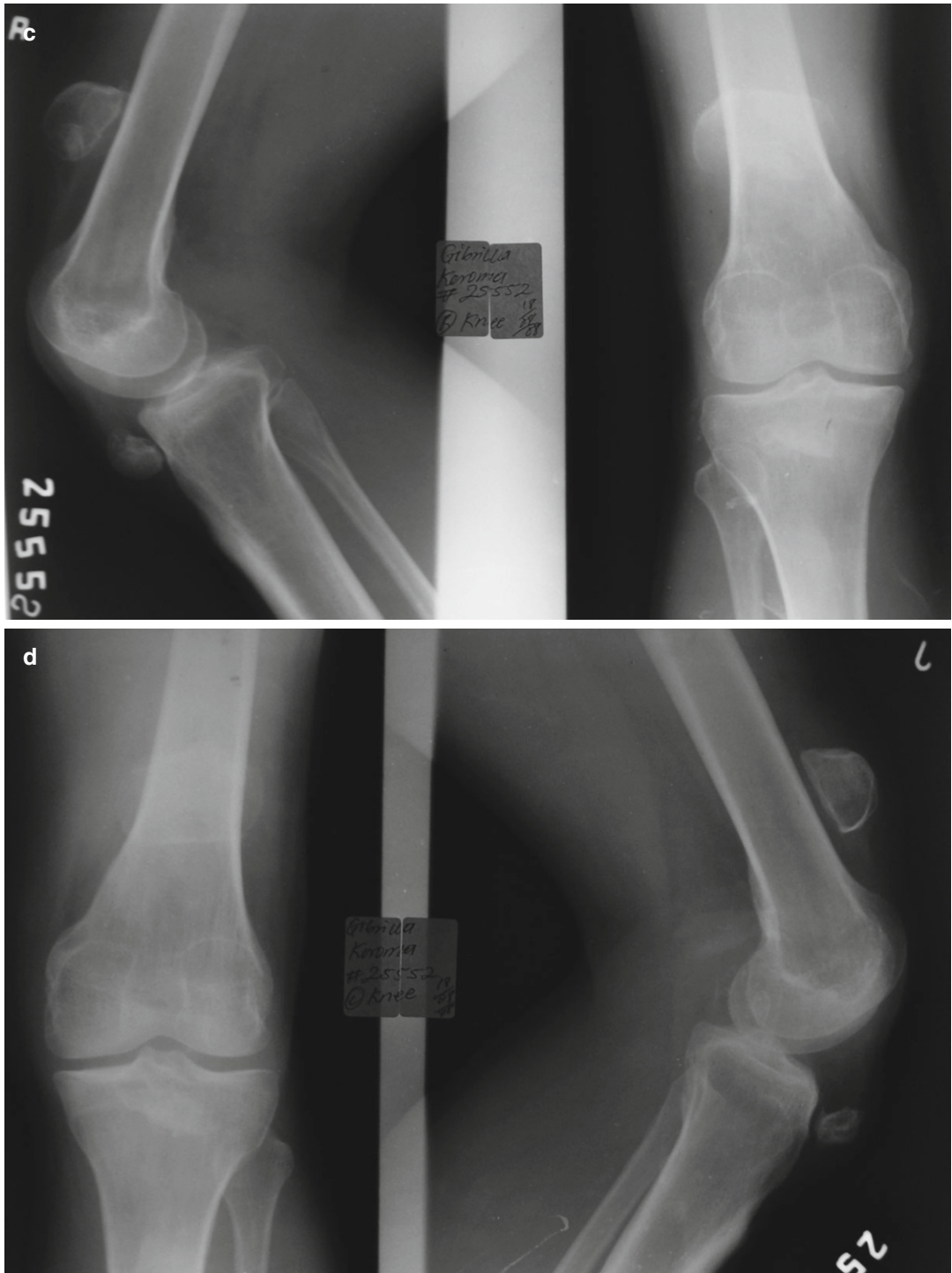

Fig.23.4 (continued)

Quadriceps and Patellar Tendon Ruptures

Acute (up to 6 weeks old) rupture of the quadriceps or patellar tendons should be repaired surgically. Depending on the location of the rupture, transosseous sutures may be required. The repair should be protected in a well-molded cast in extension for 6 weeks, allowing full WB. Chronic ruptures require soft tissue mobilization, often tendon grafting, and extensive rehabilitation. Patients need to understand that there will be a trade-off between instability and stiffness.

The repaired construct may be augmented (our preferred technique) with a tendon or fascial graft tunneled transversally through the patella and woven through the tendinous remnant. The peroneus brevis (with proximal myo-tenodesis to the longus), palmaris longus tendon, or a strip of fascia lata can be used as graft. When doing an augmentation, it is preferable to tighten both the repair and the augmentation with the knee in maximum extension, tying the repair sutures first. The patella itself can be temporarily skewered to the distal femur or proximal tibia with a small Steinmann pin to relieve tension on the repair. A long cylinder non-weight-bearing cast is worn for 6 weeks after which time the Steinmann pin is removed and ROM started. If no Steinmann pin transfixes the joint, WB can start early in the cast. All these bone procedures on a weakened patella may create an iatrogenic fracture, which requires repair as described above.

Special consideration needs to be given to femur fractures undergoing internal fixation after prolonged traction. Knee stiffness is common and often worsened by the relative lengthening of the extensor mechanism with the open reduction. Rigid fixation allows the knee to be manipulated, but this should be done with great care and the goal should be modest. Any sudden “giving way” is suspicious of an extensor mechanism rupture, and clinical signs such as a palpable defect or lack of patellar motion warrant immediate surgical exploration and repair.

Patellar Dislocations

Acute dislocations of the patella usually do well with nonsurgical management in a cylinder cast for 3 weeks. If on assessing postreduction stability, re-dislocation occurs spontaneously with knee flexion between 45° and 90°, surgical repair of the medial retinaculum and release of the lateral retinaculum will likely be needed. Patellae dislocated for more than 6–8 weeks do not relocate by manipulation alone.

Chronic patellar dislocations usually present with an extension lag, inability to independently squat or rise from the kneeling position, and varying degrees of pain. Instability and weakness may improve with surgical relocation that includes extensive lateral release, medial plication, and advancement of the vastus medialis. Although strength of the extensor mechanism will never be normal, the residual stiffness is usually better tolerated than the preoperative weakness and instability. Chondromalacia sets in early when the patellar cartilage has been damaged, and even a stable open reduction of a chronic patellar dislocation does not guarantee pain-free function. When pain is a major problem, a total patellectomy with realignment of the extensor mechanism might be the only option. Long-standing dislocations where the main symptom is weakness, not pain, and the patient is able to function adequately are better left alone (Fig. 23.5).

Ligamentous Injuries of the Knee

The results of surgical repair of acute or chronic tears of knee ligaments are highly dependent on postoperative rehabilitation and bracing, both of which are rarely present in LMICs. Acute injuries with displaced bony avulsions of the origin or insertions of ACL or PCL or the biceps tendon or lateral ligament from the fibular head are best treated by open surgical fixation. Associated meniscal lesions should be resected or repaired depending on the site and type. The knee should

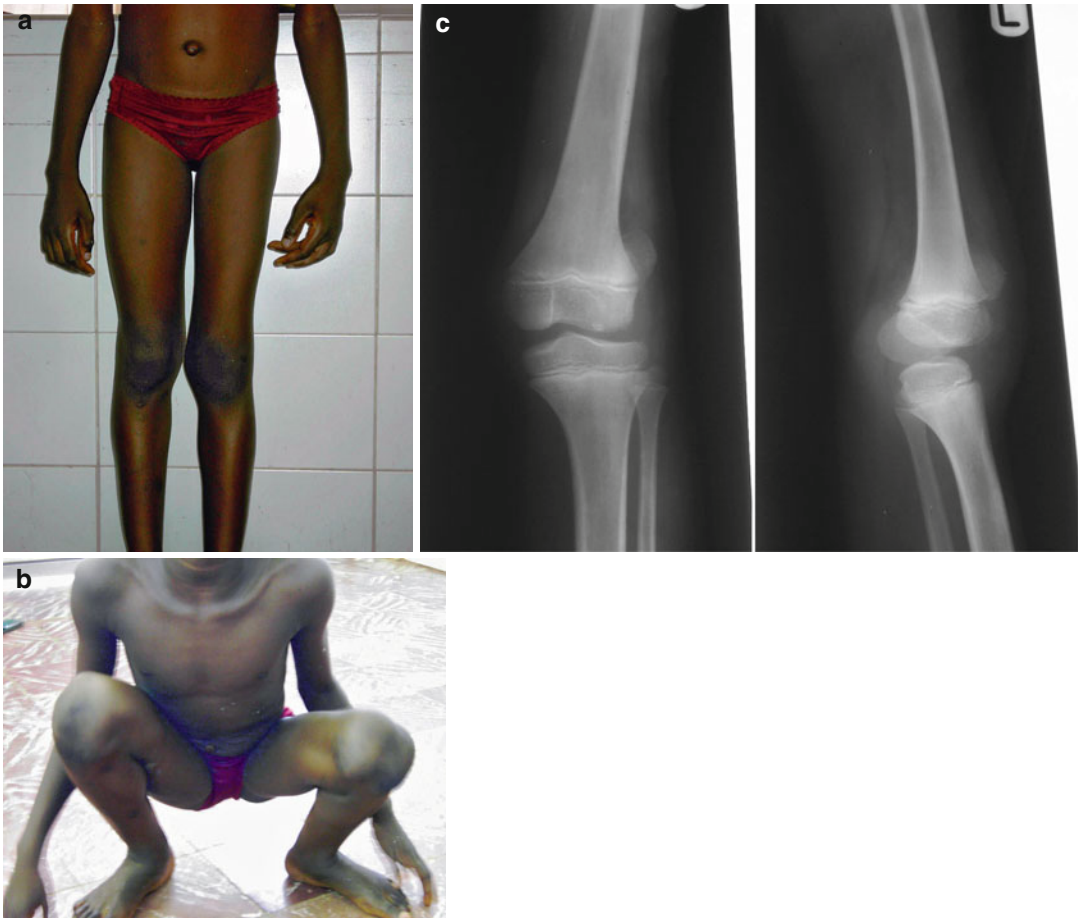

Fig. 23.5 (a) Clinical appearance of a chronic dislocation of the left patella. (b) This young man is able to squat independently. Note that right thigh is better muscled than

the left. (c) X-ray appearance of chronic left lateral patellar dislocation. No surgery was offered

be immobilized in a non-weight-bearing long-leg cast for 3–4 weeks at 30–40° flexion, after which time active rehabilitation is started. Progressive weight bearing can begin 2–3 weeks later. Commonly, patients are instructed on an exercise regimen to do at home and will never be seen again. This regimen leaves a knee that is initially stiff, but young, determined patients will have regained most of their pre-injury function at 1 year. Pure ligamentous injuries are usually better left alone, unless the ideal circumstances are all present. The same applies to chronic ligamentous instabilities.

Dislocations of the Knee

Acute Knee Dislocations

Acute knee dislocations should be reduced as soon as possible after the aseptic evacuation of any hemarthrosis. The patient must be kept under observation for frequent and regular monitoring of the neurovascular status since a compartment syndrome can appear even after reduction, and an intimal tear of the popliteal artery can quickly lead to acute thrombosis and distal ischemia. A vascular injury will most often require surgery, and unless a vascular

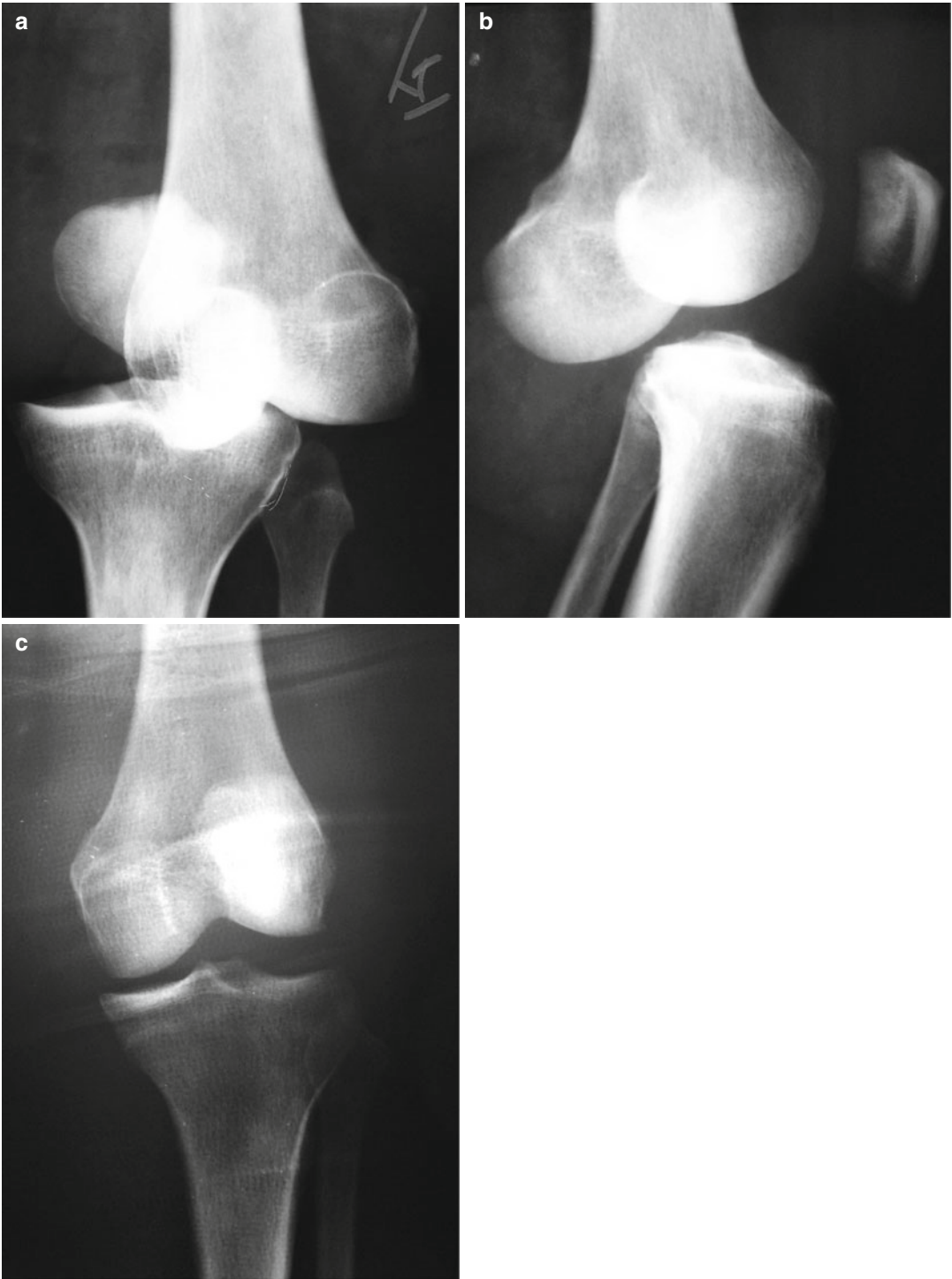


Fig. 23.6 (a, b) X-rays of fresh posteromedial dislocation of the left knee. (c) Unacceptable residual opening of the lateral compartment after closed reduction. This

required a repeat closed reduction and temporary joint transfixion with 2 Steinmann pins for 6 weeks

surgeon is quickly available or the orthopedic surgeon has the skills and equipment necessary, these injuries often lead to an above-knee amputation.

Subacute Knee Dislocations

Subacute knee dislocations are usually posterior and present beyond the period of vascular risk. They can often be reduced closed under anesthesia. Beyond 3 weeks and up to 3 months, open reduction is usually necessary, and care should be taken not to injure the popliteal neurovascular bundle posteriorly. On rare occasions, a closed reduction is possible, but it is necessary to confirm anatomic reduction with good

AP and lateral views, as residual subluxation is not uncommon and should be dealt with surgically (Fig. 23.6). Residual instability is often complex and cannot be handled by casting only. Temporary transfixion with 2 crossed Steinmann pins for 6 weeks can avoid the knee healing in a subluxed position. The knee should be immobilized in slight flexion to reduce traction on the popliteal vessels. With dislocations older than 3 months, the amount of shortening and scarring usually precludes a safe reduction, and a knee fusion is preferable (Fig. 23.7).

All knee dislocations require an aggressive physical therapy regimen with an emphasis on strengthening the stabilizing musculature, not just regaining range of motion.

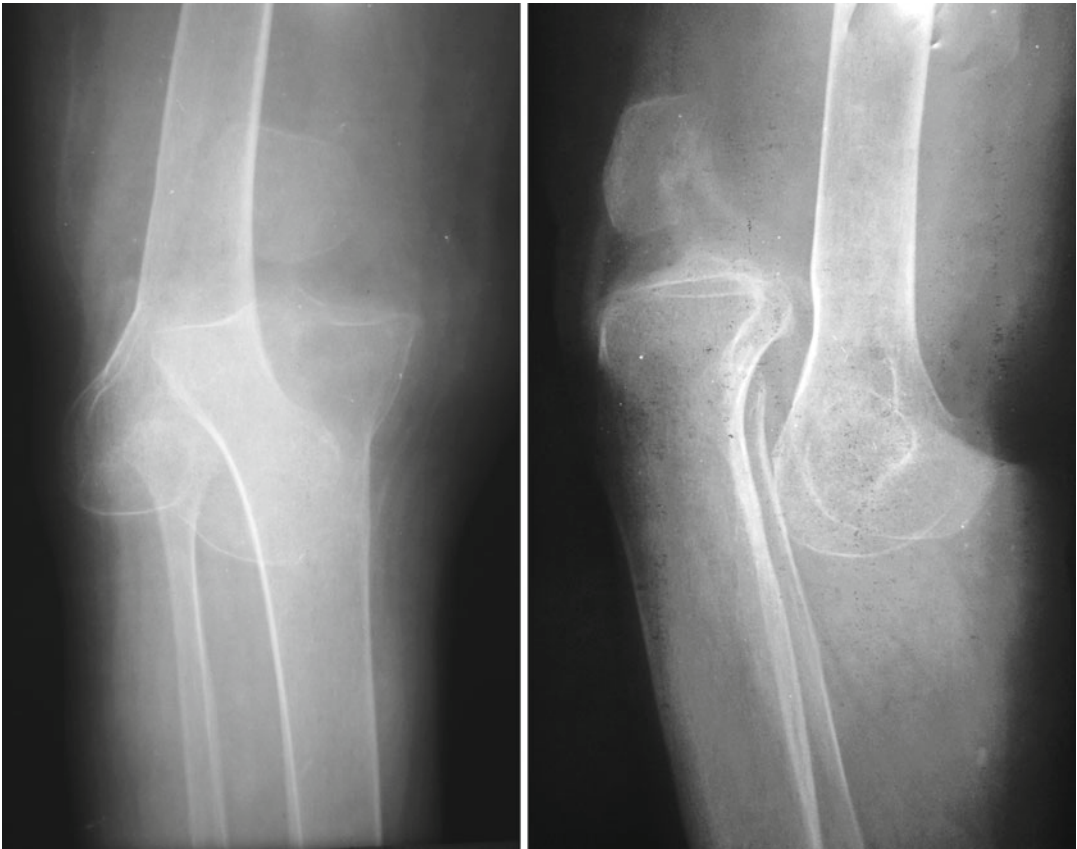


Fig. 23.7 AP and lateral x-rays of a 2-year-old dislocation of the knee without neurovascular loss. The patient was able to hobble with one pole

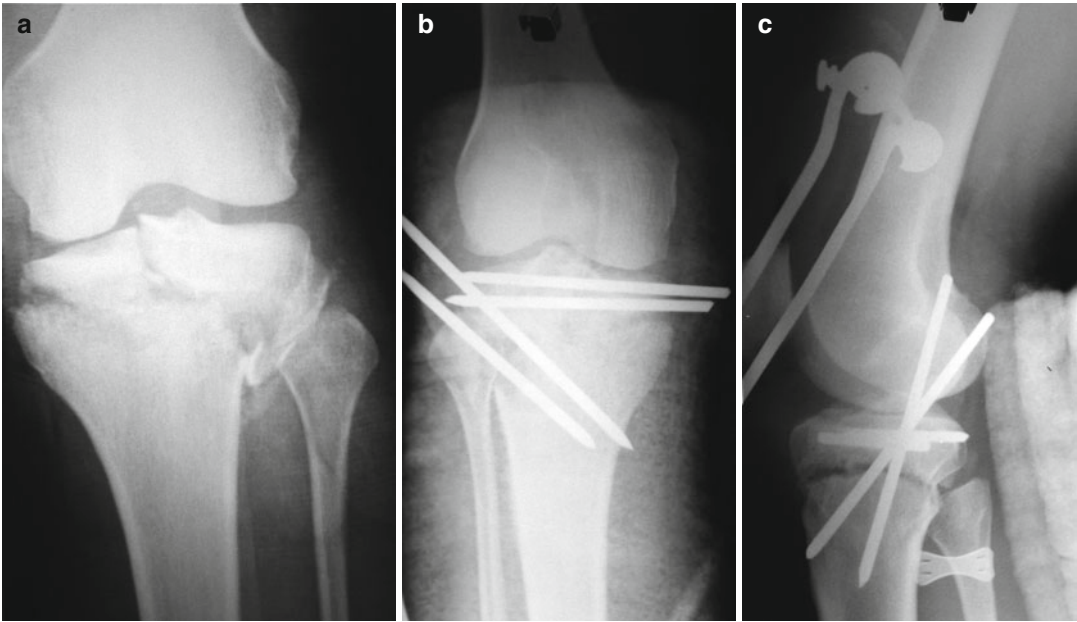


Fig. 23.8 (a) A comminuted T-type fracture of the proximal tibia, (b, c) treated with Steinmann pins to reduce and fix both intra- and extra-articular components. The distal

femoral traction pin (which was inserted too proximally) is used to treat an associated femoral shaft fracture

Fractures of the Tibia and Fibula

Tibial Plateau Fractures

Undisplaced tibial plateau fractures can be treated nonoperatively, after sterile evacuation of the hemarthrosis, in a non-weight-bearing long-leg cast in 20–30° flexion for 6 weeks, followed by an additional 6-week non-weight bearing accompanied with ROM and strengthening exercises. Compliance might be an issue as by the time the cast is removed, there is little pain and patients are eager to resume normal activities.

Fresh fractures displaced ≥ 2 mm should be treated according to the universal principles of anatomic reduction, rigid internal fixation, and \pm subchondral graft support. With fluoroscopy, simple non-comminuted fractures can be treated percutaneously with cancellous screws. Most often, open reduction, lag-screw fixation with one or occasionally 2 neutralization plates is needed. Fixation should ideally be rigid enough to allow early joint mobilization. ACL/PCL bony avulsions should be secured with tunneled sutures or lag screws. Meniscal lesions should

be repaired or excised; mid-substance ligament tears can be repaired primarily but generally not augmented.

Where plates are not available, the only option may be to restore the articular surface with screws or even pins and treat the now extra-articular fracture in a long-leg cast (Fig. 23.8). If restoring length is needed, one can use pins in plaster in distraction from distal femur to tibial shaft. Pins remain for 4–6 weeks, but weight bearing is delayed at least 6 weeks and gradually progresses to full WB over the next 6 weeks. Neglected fractures with malunions and articular incongruence rapidly lead to degenerative changes, often with some angular deformity (Fig. 23.9). On occasion, varus or valgus realignment osteotomies are indicated, but more often the only option is a knee fusion as replacements are rarely available and/or affordable (see Chap. 41).

Fibula Fractures

Isolated fractures of the fibula occur from a direct blow to the lateral aspect of the leg and are rare.

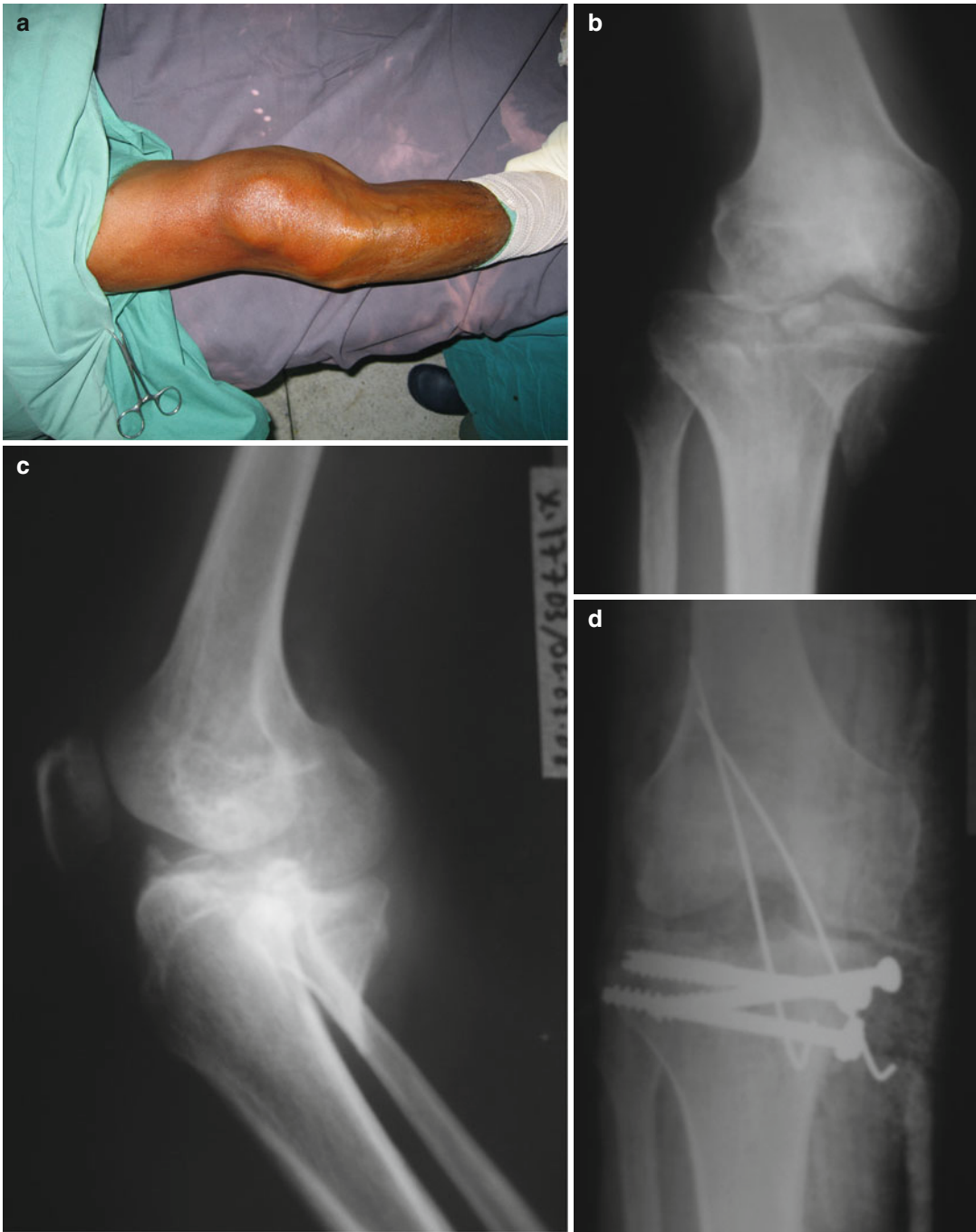

Fig. 23.9 (a) Clinical appearance of varus right knee secondary to 1-year-old untreated and malunited medial tibial plateau fracture. (b, c) Pre-op x-rays showing joint irregularity and deformity. (d, e) Post-op x-rays of knee showing reconstitution of tibial articular surface, with

slight central step-off, and pinning of joint (Steinmann pins would have been preferable to K-wires) to hold position. Note narrowing of medial side of joint and early changes consistent with DJD

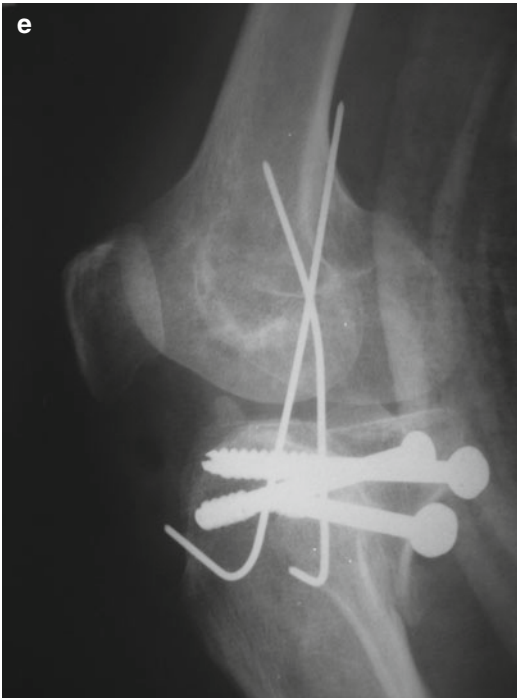

Fig. 23.9 (continued)

Once a compartment syndrome has been ruled out clinically, treatment is symptomatic. It is mandatory to examine the ankle joint to rule out an injury around the medial malleolus, suggestive of a Maisonneuve type of injury (so-called high ankle sprain). Tears of the deltoid ligament and syndesmosis lead to instability and widening of the mortise which can be demonstrated with stress x-rays in valgus (pronation, abduction). Mortise widening ≥ 2 mm is an indication for a syndesmosis screw. The alternative is a long-leg cast with the foot in varus and a few degrees of equinus. At 3 weeks, the cast is converted to a full-weight-bearing PTB-type cast for 3 more weeks with the foot in a neutral position.

Tibial Shaft Fractures

Conservative management with casts and functional bracing has become a lost art in rich countries, as internal fixation has demonstrated significant early personal and societal benefits.

Long-term advantages of surgical treatment in developing countries are more debatable [1].

In LMICs, conservative management remains the treatment cornerstone of closed and Gustilo type 1 open fractures. With acceptable reduction, most patients will heal and recover full function. Criteria for acceptability are not universally accepted, but most surgeons agree that at least 50 % bony contact in both AP and lateral projections and no more than 5° angulation in the sagittal and coronal planes are acceptable [2].

Undisplaced transverse mid-shaft fractures can initially be treated in a weight-bearing PTB or BK cast.

A satisfactory closed reduction of an initially displaced fracture can be immobilized in a non-weight-bearing well-molded long-leg cast (LLC) with 20–30° knee flexion. With fluoroscopy, reduction can be done under direct vision. When there is no assistant to help and the fracture is unstable, temporary fixation with a percutaneous Steinmann pin frees the surgeon's hands to apply the cast. The pin is removed once the cast has hardened—the “disappearing or vanishing pin” trick.

Fracture alignment is monitored regularly with sequential x-rays. Unacceptable displacement requires a repeat reduction and new cast or cast wedging. For surgeons who rarely use non-operative treatment, cast wedging can be a remarkably useful technique to maintain or correct unacceptable angulation (see Chap. 13).

At 6 weeks or when the fracture is clinically “sticky,” the LLC is converted to a below-knee weight-bearing cast, preferably a patellar-tendon-bearing type to limit rotation and give added stability against varus and valgus stresses (see Chap. 13). X-rays and clinical examination out of the cast after 6 more weeks will determine the need for longer immobilization. Muscle atrophy in the cast is reduced by static exercises in plaster.

This generic management scenario will vary according to many factors: fracture pattern and degree of comminution, high- vs. low-energy mechanism, associated injuries, and comorbidities. Fractures at the proximal tibial metaphyseal-diaphyseal junction, especially when comminuted, are notoriously slow to heal and may require extended immobilization in a weight bearing,

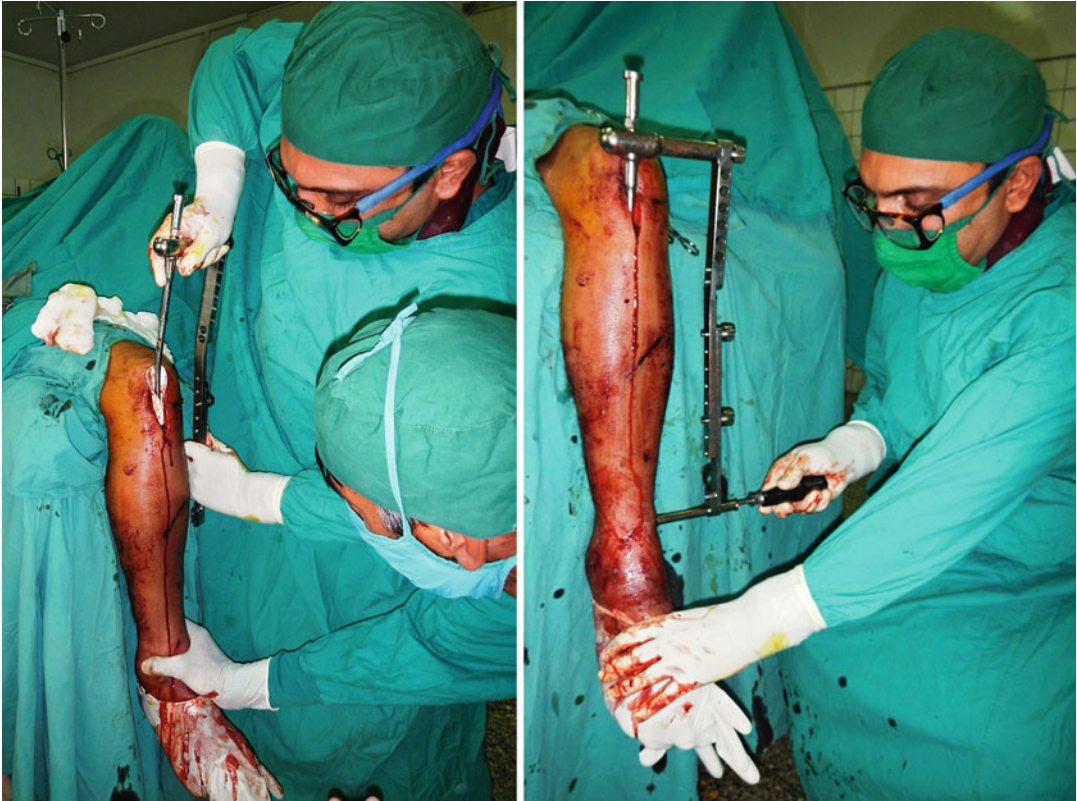

Fig. 23.10 (Left) Surgeons inserting a SIGN nail in a closed fashion using gravity assistance. (Right) Inserting a distal screw through the rigid target arm

above-knee cast. X-rays are important indicators of healing but are costly. Examination for tenderness, mobility or a rubbery feeling when the fracture is stressed, and the ability to bear full weight without a limp or hesitation are important parameters when assessing cast removal.

The drawbacks of cast immobilization—joint stiffness, muscle atrophy, and weakness—can be minimized with internal fixation, but at a higher risk of infection. Classical closed interlocked nailing is difficult without fluoroscopy (see technique in Appendix 3).

The SIGN nailing system is designed for use in environments with limited resources [3]. It uses a solid nail that can be inserted with the patient on a regular table, opening the medullary canal with hand reamers. Proximal and distal interlocking is achieved using the rigid external target arm (Fig. 23.10). As many if not most tibial

shaft fractures present late, an open reduction is usually necessary. Fresh fractures on the other hand pose more of a dilemma, giving the surgeon choices of blind closed nailing, open nailing, or nonsurgical management. Potential risks and benefits of these options are well known, but financial and educational considerations, or operating room status, need to be factored in.

If forced to nail a fresh fracture without fluoroscopy, small access incisions can be used to insert elevators and achieve reduction before passing the SIGN nail. Rotational reduction can be assessed by “eyeballing” the ASIS—patella—second metatarsal alignment.

Ender and Rush nails offer alternative internal fixation. They can be inserted using smaller incisions than plates and are easy to remove. They need precise bending as they provide fixation by three-point contact. A minimum of two implants

should be used. Because of their poor rotational control, postoperative plaster support with a PTB is needed for the first 3–6 weeks.

In most cases, plates and screws are a poor alternative to IM nailing. But as they are usually more readily available, they are sometimes the only surgical option. Large fragment plates are big and bulky and too prominent to be applied on the medial border of the tibia. In applying them laterally, the surgeon should be careful to avoid unnecessary periosteal stripping.

In the rare instance where no internal fixation is available and the fracture too unstable for cast treatment, the only other option is some form of external fixation. This can be achieved with a true external fixateur or with pins and plaster, poor man's ex-fix, where transfixing Steinmann pins are inserted above and below the fracture site, the fracture reduced, and the pins incorporated in a cast. Some surgeons prefer to use a third pin in one of the fragments to better control rotation.

Fractures of the distal tibia can be treated by "pins and plaster" using an ankle-spanning calcaneal pin. The cast is first applied from the tibial tuberosity to just below the malleoli, to secure the pins, and then completed above the knee and distally with the foot in neutral position.

Fresh open fractures are surgically debrided, but neglected small open fractures with quiescent, scabbed wounds are left undisturbed. Wounds can be managed by windowing or bivalving the cast. After the wound has closed, the windowed or bivalved cast can be sealed.

Most grade 2 and all grade 3 fresh open fractures should be treated with surgical debridement and external fixation. Often the "external fixation set" is a hodgepodge mixture of pins, clamps, and rods from different sets, and the surgeon's improvisational skills may be put to the test. When possible, pins should be inserted through healthy skin, keeping in mind that they should not interfere with flaps or skin grafts. The pins and plaster technique can also be used for some type 2 injuries and the cast windowed over the wound. If external fixation is not possible, large wounds are best managed in calcaneal traction with a posterior back slab on a Bohler frame.

Whatever the indication for the use of external fixation, it is important to realize that its main role is to manage the soft tissue injury, not the bone. As soon as soft tissues are healed, by whatever means, the external fixateur becomes superfluous. It should be removed before pin tracts become infected, and definitive treatment of the bone injury continues in a cast with or without weight bearing. If an additional surgical procedure is needed, it is safer after a "pin holiday" of 10–14 days and after surgical debridement of any suspicious pin tracts [4]. White cell counts, ESR, and CRP measurements after the "pin holiday" may help assess the potential risk for infection in anticipation of an ORIF.

The surgeon should pay particular attention throughout the entire period of external fixation to prevent equinus deformity of the foot and ankle. Unfortunately, this is seen far too often and significantly complicates the rehabilitation and often affects the final outcome more than the index injury. It is unfortunate as it is easily preventable with active exercises; active-assisted exercises with straps, belts, stockinet, or elastic bandage or bands; the passive use of a footplate connected to the ex-fix with string or elastic bands; or even a full BK back slab. Early ex-fix removal and replacement by a cast with the foot in neutral position is extremely important in preventing this debilitating complication.

Bumper Injuries

Pedestrians are major victims in austere environments. What often look like minor bumper injuries without bone involvement can become nasty wounds, especially if a degloving component is present. These injuries must be handled aggressively (Fig. 23.11).

The Severely Mangled Leg

Such injuries are a challenge at home, where resources in vascular and plastic surgery, VAC wound systems, and sophisticated rehabilitation

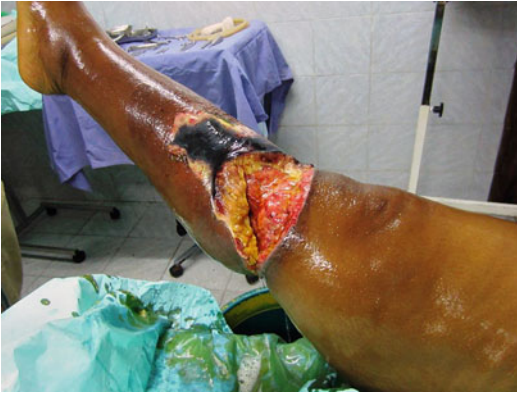

Fig. 23.11 A low-energy bumper injury of the anterior tibia with necrosis of skin and fat. These injuries can be very difficult to treat, especially in obese patients and when thorough debridement is delayed

are all available. In LMICs, prolonged disability and pain, requiring multiple, staged surgeries, are much more incapacitating than a good amputation with a good prosthesis. Many trauma patients are young males feeding extended families with blue-collar work or subsistence farming, who cannot afford years of inactivity. Most places now have some access to prosthetic facilities through NGOs, albeit not always timely or convenient. Sociocultural attitudes towards amputation need to be factored in and often take precedence over

pure clinical considerations. Nevertheless, in general, surgeons working in resource-poor environments should be more aggressive with amputation of dysfunctional limbs than they might be at home.

References

1. Batta V, Dwyer AJ, Gulati A, Prakash J, Mam MK, John B. No difference in the long term final functional outcome after nailing or cast bracing of high energy displaced tibial shaft fractures. *J Trauma Manag Outcomes*. 2012;6(1):5–11.
2. Duan X, Al-Qwbani M, Zeng Y, Zhang W, Xiang Z. Intramedullary nailing for tibial shaft fractures in adults. *Cochrane Database Syst Rev*. 2012;1:CD008241.
3. For technique manual. www.signfracturecare.org. Accessed 2 July 2012.
4. Gordon WT, Grijalva S, Potter BK. Damage control and austere environment external fixation: techniques for the civilian provider. *J Surg Orthop Adv*. 2012; 21(1):22–31.

Suggested Reading

- Brueckmann FR. *The art of effective fixation with rush pins*. New York: Thieme Medical Publishers; 1990.
- Rush LV. *Atlas of rush pin technics*. Meridian: Berivon Company; 1955.

R. Richard Coughlin and Raphael Kumah-Ametepey

Introduction

The incidence of lower leg, foot, and ankle fractures, dislocations, and injuries present an enormous challenge to orthopedic clinicians and practitioners especially in less-resourced countries [1]. Fortunately, the vast majority of these injuries are low energy and can be treated successfully with closed methods of splinting or plaster of Paris (POP). As many of these fractures are intra-articular, inadequate or poor treatment may result in significant morbidity, disability, and loss of livelihood. Due to the lack of robust soft tissue coverage to the lower leg, foot, and ankle, well-intentioned operative procedures may result in disastrous infections or wound healing problems. The most important principle of treatment is to achieve a stable plantigrade foot while avoiding complications.

R.R. Coughlin, MD, MSc (✉)
Department of Orthopaedics,
Orthopaedic Trauma Institute,
San Francisco General Hosp, University of California,
San Francisco, 2550 23rd Street, Building 9,
San Francisco, CA 94110, USA
e-mail: coughlin@orthosurg.ucsf.edu

R. Kumah-Ametepey, MD, Fach (Trauma/Orthopedics)
Department of Trauma/Orthopaedics,
Komfo Anokye Teaching Hospital,
1934, Kumasi, Ashant Region, Ghana, Africa
e-mail: raphael.kumah@gmail.com

General Treatment Principles

The early and timely reduction of fractures and dislocations about the ankle and foot cannot be overstated. The soft tissue envelope is not tolerant of displacement or deformity, and expedient reduction will limit any swelling and skin pressure. A well-applied, well-padded back slab, U-splint, or bivalved POP with elevation is frequently the most important early management for the vast majority of these injuries.

The ultimate goal of treatment is to attain a plantigrade foot—without gait-disturbing varus, valgus, or equinus deformities (Fig. 24.1)—while preserving a healthy soft tissue envelop. A stable ankle mortise is essential for long-term ankle function. Instability from a shortened fibula, widen mortise, or translation/angulation of the talus will ultimately lead to posttraumatic arthrosis. In this regard, the most important parameter is maintenance of the talus in line with the mechanical axis of the tibia in both AP and lateral planes.

If the position cannot be held by external splinting, casting, or cast modification by wedging or serial casting, open reduction and internal fixation can be considered after swelling has subsided and the skin shows fine wrinkles over the foot dorsum, fracture blisters have dried, and the soft tissue envelope has reached its optimal condition. The time until these changes occur depends on the time from injury to first hospital treatment, previous traditional treatments, the energy of the injury, and patient and

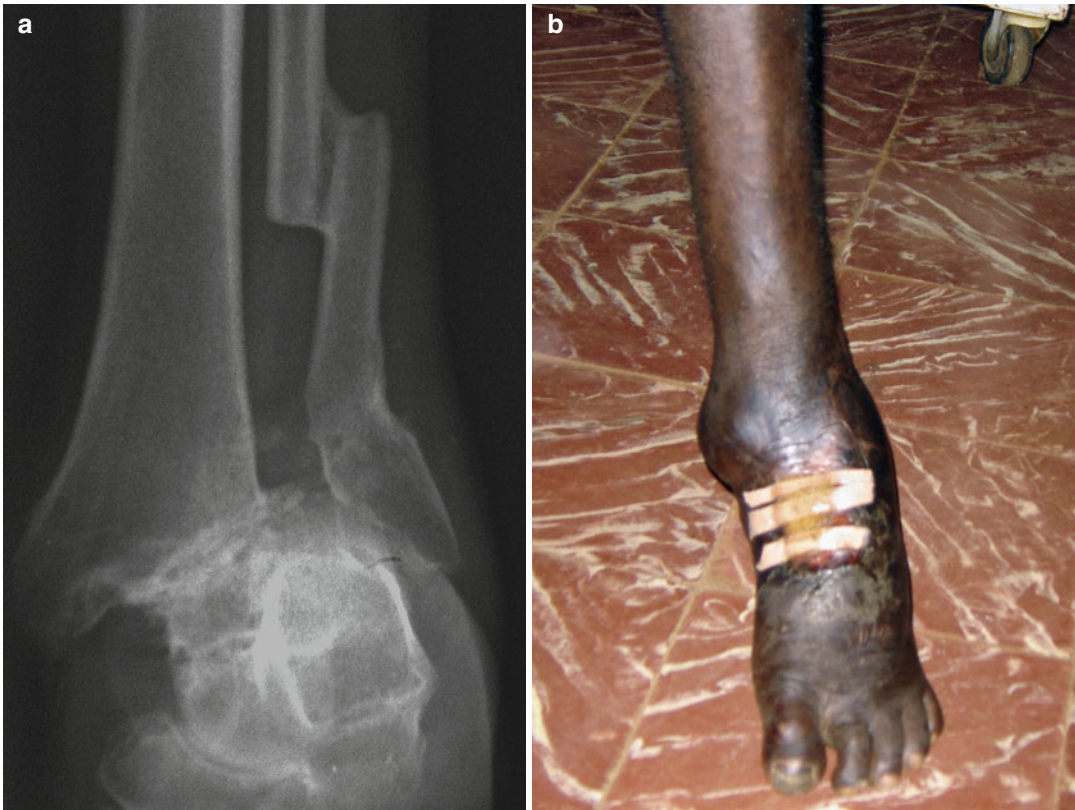


Fig. 24.1 (a) Malunion of a fracture/subluxation of the left ankle with lateral subluxation of the talus and valgus deformity of the hindfoot. (b) Clinical appearance of the

foot with a chronic wound on the dorsum secondary to ill-fitting shoes

nursing compliance. Wound dehiscence and infections around the foot and ankle are poorly tolerated in any environment, making it safer to wait. In less-resourced locales, lack of plastic surgeons and many antibiotics preclude effective management of wound complications (Box 24.1).

If open reduction and internal fixation is not possible in the face of uncontrolled instability, percutaneous pinning, especially in an attempt to hold alignment, can be considered. Its major drawback is the requirement of C-arm.

Box 24.1 Principles for Foot/Ankle Trauma

Early/timely reduction of fractures and dislocations

Immobilization with POP/cast

Ultimate goal

Plantigrade foot

Stable ankle mortise

Consider traction, ex-fixateur, or percutaneous pins

Intra-articular Distal Tibia Fractures (Pilon or Plafond Fractures)

By definition, intra-articular distal tibia fractures or pilon fractures infer a high energy mechanism of injury, with soft tissue compromise and the potential for significant soft tissue and joint complications and long-term disability. The prudent approach in less-resourced environments should be avoidance of complications while addressing the basic principles of ending with a stable, plantigrade foot, and acceptable alignment. Calcaneal pin traction with elevation

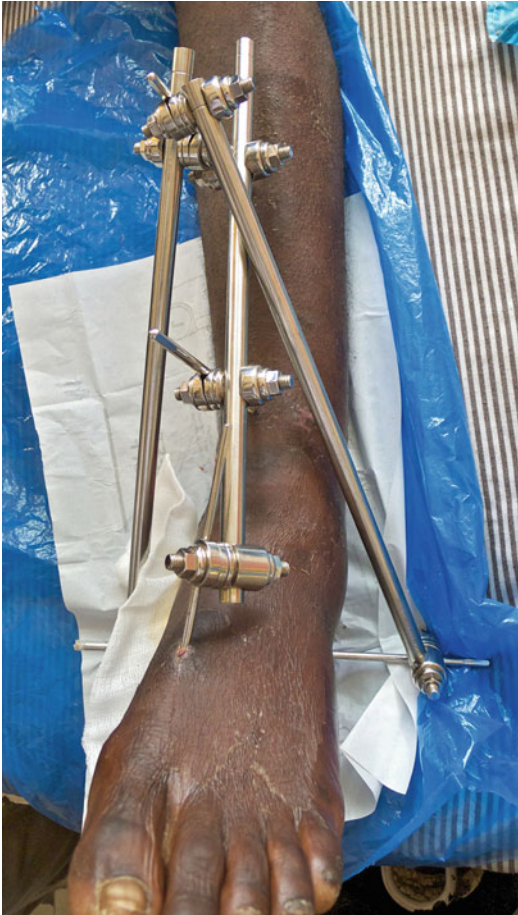

Fig. 24.2 Typical spanning external fixateur, with a trans-calcaneal pin and a pin in the first metatarsal, maintaining the foot and ankle in neutral alignment

on a Bohler-Braun frame provides a safe and effective treatment without the unacceptably high soft tissue complications of open reduction and internal fixation with nonspecific plates. This technique, while relieving the deforming force of the Achilles tendon, utilizes ligamentotaxis to realign the major fragments and restore an acceptable ankle mortise. Direct access to blisters, open wounds, or other soft tissue injury allows observation and dressings.

After 2–4 weeks, this approach can be converted to pins and plaster or a spanning external fixateur (Fig. 24.2). In certain fracture patterns or clinical situations, small incision approaches may be used with the addition of K-wires, Rush rods, or small plates in order to optimize the position or stability of major fracture fragments

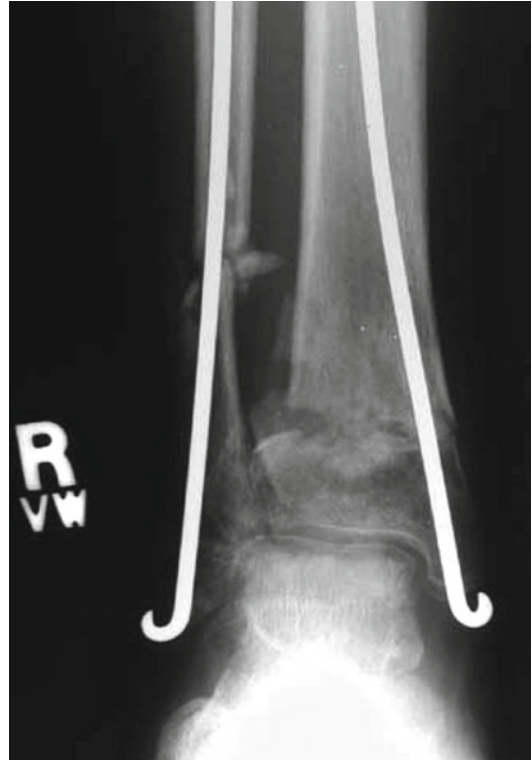


Fig. 24.3 Fracture of distal tibia and fibula fixed with Rush rods

or malleoli (Fig. 24.3). The decision to proceed with more rigid fixation and larger exposures to achieve anatomic reduction should be taken with trepidation, but the results of neglected displaced pilon fractures are also well known [2].

Ankle Fractures and Dislocations

Lower energy rotational ankle fractures and fracture-dislocations are common, and the majority can be adequately treated with closed methods (Fig. 24.4). Conversely, malalignment or mismanagement of these fractures result in pain, stiffness, or deformity, leading to severe functional disability. There are multiple classification systems (Lauge-Hansen, Weber), but the majority of displaced ankle fractures can be divided into (1) abduction-external rotation and less commonly (2) supination-adduction. Early reduction maneuvers are based on reversing the mechanism of injury and deformity. A prompt reduction will

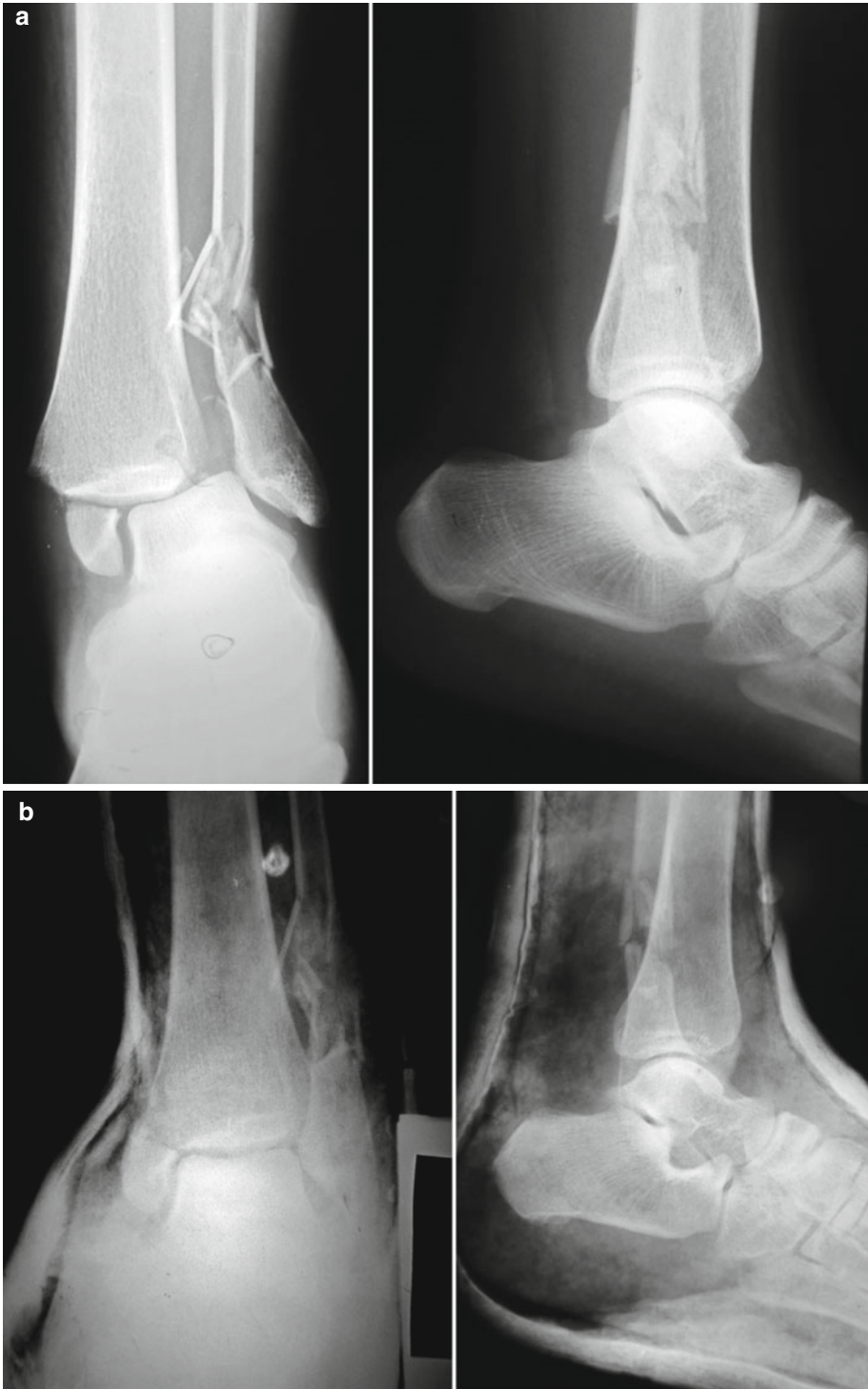

Fig. 24.4 (a) X-ray of closed bimalleolar fracture-dislocation after RTC. (b) Post reduction X-ray. (c) The appearance of the plaster cast showing molding distal to the lateral malleolus, proximal to the medial malleolus,

and proximally around the fibula to produce 3-point fixation (*arrowheads*). The heel is molded by lifting it in a plantar and forward motion to prevent equinus and maintain talo-tibial alignment (*arrowheads*)

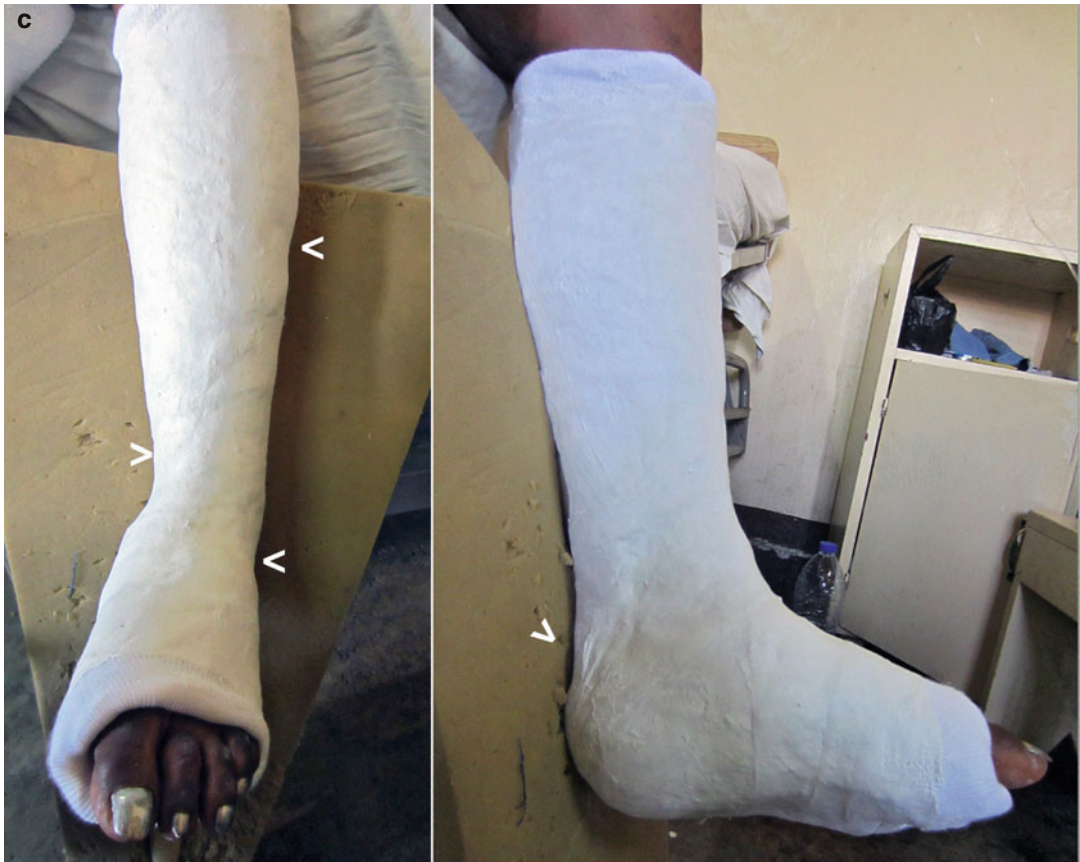

Fig. 24.4 (continued)

significantly reduce the pain, relieve neurovascular compromise, restore the plafond, and markedly reduce soft tissue swelling. Early reduction has a higher likelihood of success.

In less-resourced countries, many of these injuries will present in a delayed fashion with significant swelling. An excellent approach to this problem is Quigley stockinette traction for those fracture deformities that arise from abduction-external rotation forces (the vast majority). The elevation and stockinette traction allow the swelling to resolve, and while in the stockinette, the foot and ankle fall into adduction, internal rotation, and supination by simple gravity (Fig. 24.5). After 5–7 days, this technique can be followed by a more securely molded cast for maintenance of reduction after the swelling has subsided.

The reduction of malleolar fractures is eloquently described by Sir John Charnley in

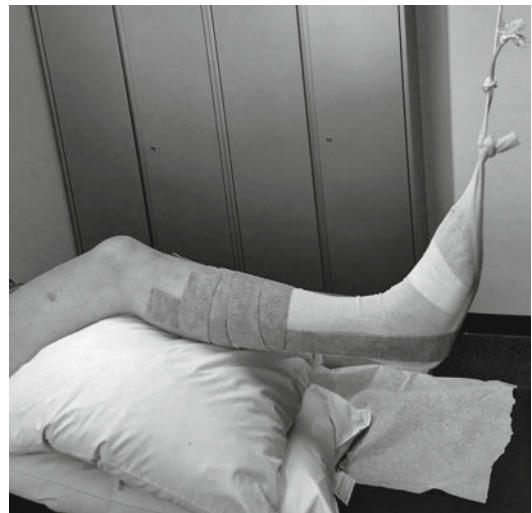

Fig. 24.5 Quigley stockinette technique for reduction and suspension of ankle injuries. Definitive operative or nonoperative management can be done when the swelling is reduced

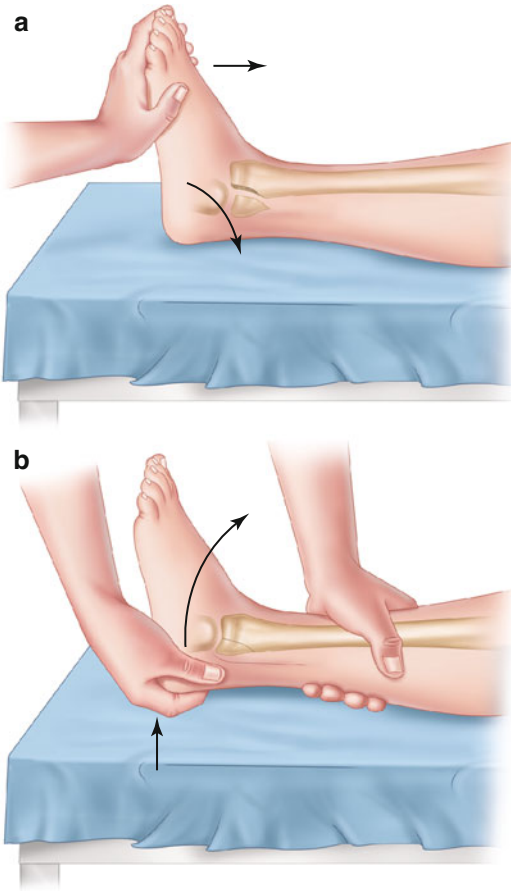


Fig. 24.6 Dorsiflexion of ankle fracture-dislocation with posterior injury is best performed by grasping heel and pulling it forward while dorsiflexing. (a) Reduction of an ankle fracture-dislocation with posterior injury will fail if the ankle is simply dorsiflexed. (b) Grasping the heel and pulling it forward with ankle dorsiflexion will produce a congruent reduction

The Closed Treatment of Common Fractures, and we recommend that surgeons, especially those who haven't treated ankle fracture-dislocations by other than open means, review his chapter on Pott's fracture. He lists three common sources of error when attempting a reduction:

1. Keeping the foot at right angles to the leg by dorsiflexing the forefoot in order to secure a plantigrade foot. This simply pushes the talus posteriorly, especially if the Achilles tendon is tight. Lifting the heel and bringing the hind-foot into a plantigrade position will correct this error (Fig. 24.6).



Fig. 24.7 Correction in the coronal plane is distal to the lateral malleolus and proximal to the medial malleolus

2. Compressing the mortise in an attempt to reduce the diastasis and realign the talus will simply put pressure on the soft tissues. To reduce a bimalleolar fracture-dislocation, lateral pressure must be applied distal to the lateral malleolus, and medial pressure must be directed proximal to the medial malleolus, forcing the talus medially (Fig. 24.7).
3. Incorrect rotation of the foot. The fracture forces produce external rotation, making it essential to keep the foot internally rotated to achieve a good reduction. Clinically check the alignment of the line connecting the patella with the second ray.

In environments with no intraoperative or portable X-rays, let alone fluoroscopy and CT scan, the surgeon requires a sensitive touch and keen eye.

If unable to achieve and maintain an acceptable reduction, open reduction and internal fixation of ankle and foot fractures may be considered

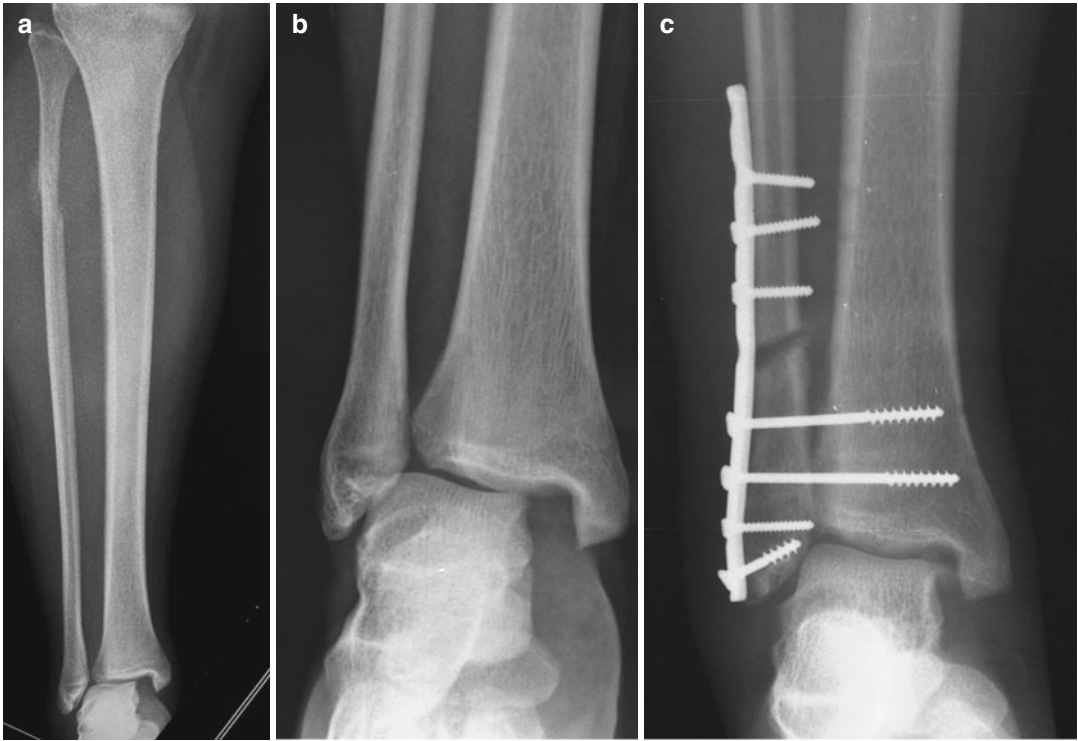


Fig. 24.8 (a) Residual syndesmotic widening at 6 weeks after a Maisonneuve-type injury. Note callus present at the proximal fibular fracture. (b) Close-up of mortise widen-

ing. (c) Postoperative appearance after fibular osteotomy and fixation with plate and 2 syndesmotic screws. The mortise has reduced to its normal width

if an adequate host, appropriate operating room facilities, and reasonable hardware are present. Good visualization is necessary as intraoperative fluoroscopy or X-rays will probably be a luxury. With syndesmotic injuries, good exposure is required to assure reduction. Visual reduction of the fibula in the anatomic position while placing the syndesmotic screws with the talus dorsiflexed will assure no narrowing of the ankle mortise. Even with late presentation, displaced syndesmotic injuries can benefit from ORIF (Fig. 24.8). Removal of syndesmotic screws or ankle hardware, although elective, is frequently requested on a cultural basis, and adequate time for ligamentous and bony union should be allowed—3 and 6 months, respectively.

The neglected, malunited, and late presenting ankle fracture should also be considered for operative management if the above criteria are met. Lengthening of the fibula and osteotomy of the medial malleolus to realign the talus beneath

the weight-bearing axis of the tibia, even in the presence of some arthritis, can significantly decrease symptoms of malalignment and slow the progress of arthritis. Some residual anterior subluxation is functionally better tolerated than posterior subluxation, but both will accelerate the onset of posttraumatic arthritis. An ankle arthrodesis can salvage an arthritic malunion (see Chap. 41).

Fractures and Fracture-Dislocations of the Foot

Although, fractures and fracture-dislocations of the foot are common and range in severity and degree of displacement, the majority, as for ankle injuries, can be managed successfully by closed methods through skillful reduction and casting with the occasional need for percutaneous pins or external fixateurs to maintain satisfactory

positions. The basic goal is a painless plantigrade foot. Some hindfoot valgus will unlock the transverse tarsal joints and achieve a more functional foot, while a stiff varus hindfoot or marked rocker bottom foot is poorly tolerated. Any cast should mold the transverse and longitudinal arches. Earlier weight-bearing will lessen edema, stiffness, and osteopenia.

Fractures of the Talus

Non-displaced articular or nonarticular talus fractures result from low-energy mechanisms and are amenable to cast management.

Talar neck fractures with associated disruption of the subtalar joint (Hawkins type 2) or neck fractures with disruption of both the subtalar and ankle joints (Hawkins type 3) are produced with more energy and have more soft tissue damage and higher AVN rates. They require adequate anesthesia to perform the appropriate plantarflexion maneuver to reduce the talar body at the subtalar and ankle joints. The midfoot-forefoot must be everted to disengage and reduce the fracture fragments from their usual varus position. A traction pin through the calcaneus to increase the joint space can help reduction. If unsuccessful, open reduction is worth the soft tissue risks; otherwise, the functional results are predictably poor. Peri-talar dislocations are relatively easy to reduce with adequate sedation and knee flexion. If instability remains post reduction (unusual), the addition of percutaneous pinning is warranted.

Fractures of the Calcaneus

Most fractures of the calcaneus are nonarticular, non- or minimally displaced, and amenable to cast management. The exceptions are the joint-depression type with significant varus position of the tuberosity or the “tongue type,” with or without skin compromise (Fig. 24.9). When there is significant widening of the hindfoot and the heel is in varus with significant loss of Bohler’s angle, adequate anesthesia is required to perform closed treatment that results in a more functional

hindfoot position, i.e., regaining as much height, narrowing the width, and improving alignment. The use of a traction pin, Schanz pin, or screw through the tuberosity as described by Essex-Lopresti can be utilized to correct and, in conjunction with a cast, maintain the position [3].

The “tongue-type” fracture with skin at risk is an urgent situation that should be splinted or casted in plantarflexion if palpably reducible or taken to the operating room for an Essex-Lopresti maneuver and pinning and casting. The cast should be changed from its plantarflexion position at 3–4 weeks to avoid Achilles shortening and disabling equinus contracture.

Calcaneal fractures are probably best treated with casting and early weight-bearing to allow earlier return of function rather than protracted non-weight bearing with or without a cast that will lead to disuse atrophy. Alternatively, an initial Jones dressing (large, bulky, moderately compressive dressing of thick cotton batting secured with elastic bandages), elevation and active range of motion followed by a cast for weight-bearing comfort can be employed, while avoiding prolonged non-weight bearing.

Midfoot Fractures and Fracture-Dislocations of Navicular, Cuboid, and Cuneiforms

These injuries frequently involve significant energy mechanisms of axial load or crushing forces. When significantly displaced or foreshortened, the use of finger traps with adequate sedation or anesthesia will help achieve acceptable reduction. Percutaneous pin fixation, pins and plaster, or external fixation are necessary for unstable fractures.

Lisfranc Fracture-Dislocations

These injuries come in various forms and degrees of ligamentous and bony disruption but should be amenable to closed reduction in the majority of cases with finger traps, or tensioned K-wires through the metatarsals followed by percutaneous

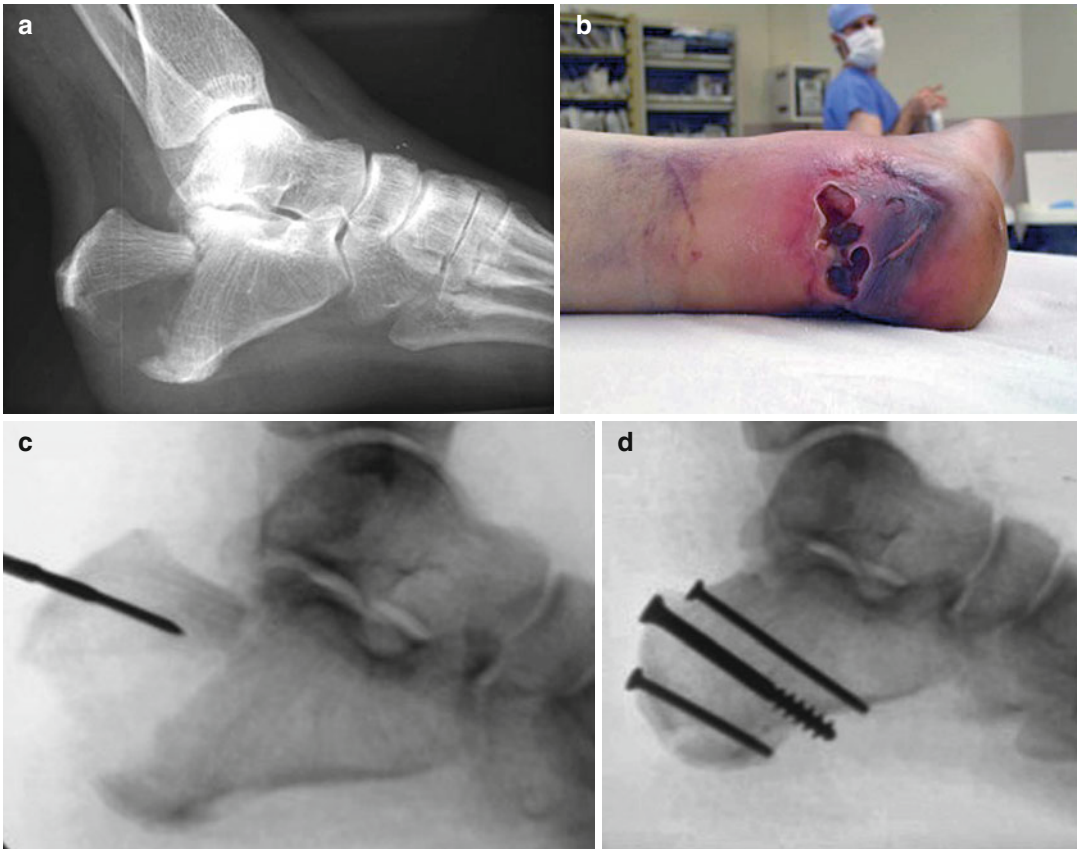


Fig. 24.9 (a) Typical displaced tongue-type fracture of the os calcis, with (b) ischemic changes of the overlying skin. (c) Reduction of the tongue fragment with a

temporary Schanz screw performing an Essex-Lopresti maneuver. (d) Definitive fixation using percutaneous screws (Courtesy of Stephen K. Benirschke)

stabilization with crossed K-wires. Two to three months casting is adequate for the soft tissues to stabilize.

Metatarsal Fractures

The vast majority of metatarsal fractures will heal with or without treatment. Nevertheless, significant displacement and the resultant deformity can leave the patient with permanent disabling pain, and every effort should be made to provide adequate closed approximation of the fracture fragments. Finger traps or KERLIX looped between and around 2 toes are ideal for providing traction to gain length and alignment for the majority of these injuries. Wire traction pins through the phalanges and tensioned to a bar attached to a cast have creatively worked in

the past with certain patterns. A situation with highly unstable and significant angulation that would alter the weight-bearing forefoot should be considered an indication to openly reduce and pin when the swelling has resolved (Fig. 24.10). Old injuries will likely need ORIF or bone resection.

Other Foot Injuries and Conditions

Mangled Feet are clinically challenging to manage, as many places in the developing world find amputation culturally unacceptable, and the access to or availability of prosthetics may be limited. Thorough debridement—plus or minus pinning—while allowing the tissues to demarcate for later debridement or partial foot removal may be the most prudent approach.

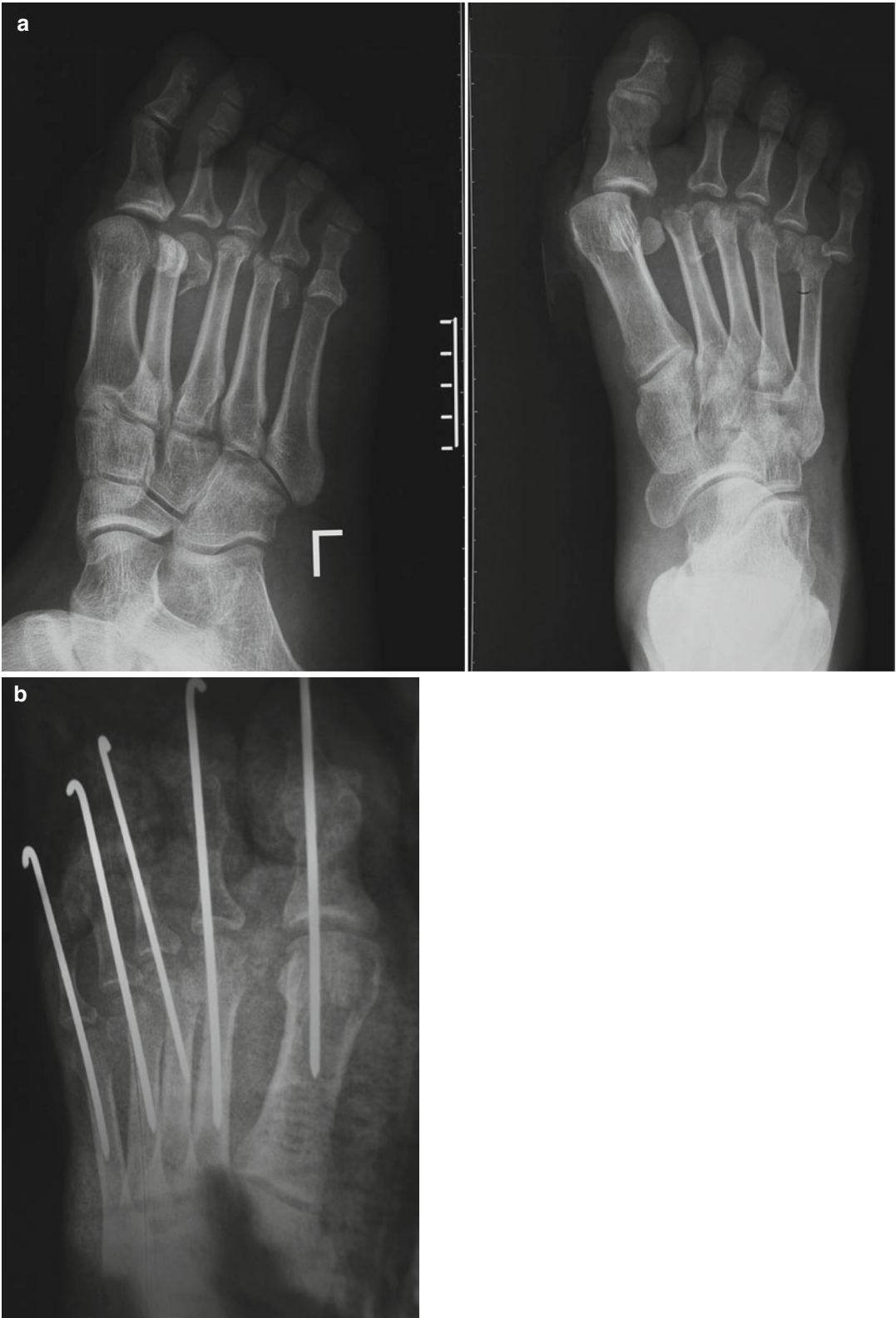

Fig. 24.10 (a) Fracture/dislocations of all metatarsophalangeal joints. (b) Postoperative X-ray showing result of retrograde pinning of all 5 rays

Degloving injuries of the foot are common in populations that wear sandals or flip flops. Distally based skin and soft tissue flaps often necrose, making coverage problematic (Fig. 24.11).

Charcot Fracture and Neuroarthropathy. With the epidemiologic transition occurring in many developing countries with increasing life expectancy and the emerging pandemic of obesity and type 2 diabetes, Charcot neuropathic fractures will present with increasing frequency. Total contact casting with limited padding except over the bony prominences and limited weight-bearing until the consolidation stages of the process are the mainstays of management. A plantigrade

foot, without varus, will give the patient the best chance of avoiding the sequelae of insensate plantar ulcerations, infections, and amputation.

Achilles Tendon Rupture. The loss or weakening of the triceps surae function by Achilles tendon rupture or laceration can be especially debilitating to manual labor or farming livelihoods in the resource-poor settings. If presenting within the first month, the majority can be adequately managed through equinus casting, as surgical results are fairly equivalent [4]. If presenting late as a neglected Achilles rupture, a V-Y advancement should be considered to restore the

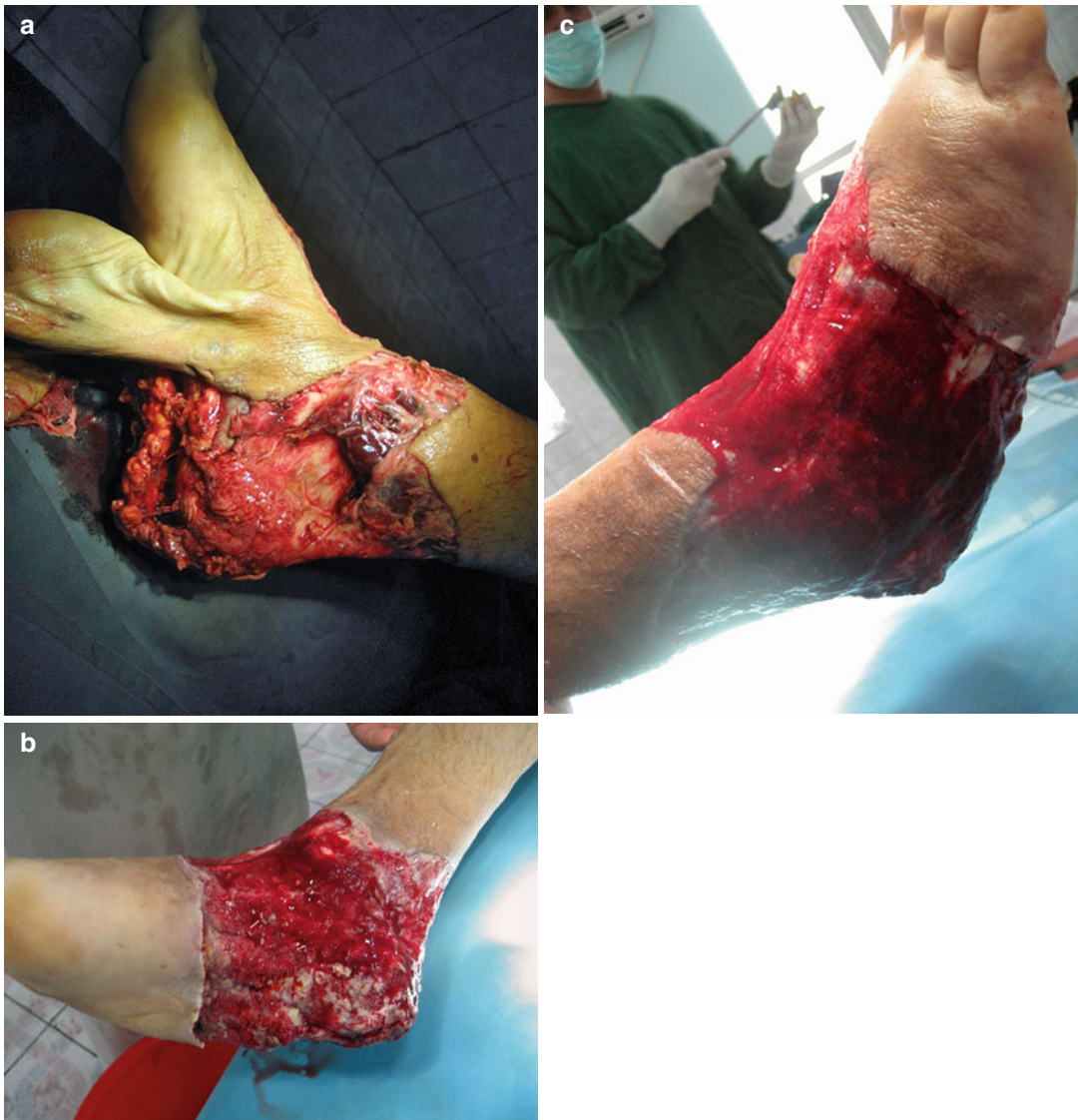

Fig. 24.11 (a) Superficial degloving injury of ankle and hindfoot. (b) Foot after debridement. (c) At time of STSG

essential function of this muscle group for normal gait, power, and strength.

Tips and Tricks for Management of Foot/Ankle Injuries in the Less-Resourced Environments

Closed, manipulative, functional, percutaneous, and less-invasive methods should all be considered the primary tools in the treatment armamentarium when managing lower leg, ankle, and foot injuries in less-resourced environments. They usually provide acceptable functional results with far less risk in the majority of cases while avoiding the significant and disastrous complications of wound healing, infections, or even loss of limb and life.

Rush Pin Technics

Certain displaced distal tibial, malleolar, or even calcaneal fractures not able to be reduced and maintained in a cast may be addressed with the use of minimal incisions and Rush pins.

Simple (Poor Man's) External Fixation Technique

This technique can maintain a foot plantigrade to the tibia, especially in situations of significant soft tissue injury or burns. Steinmann pins are drilled retrograde through the first and fifth metatarsal metaphyses at a 45° angle exiting the foot dorsum to engage the distal tibia through small stab wounds while maintaining foot and ankle alignment [5] (Fig. 24.12).

Percutaneous Steinmann Pins

Axial Steinmann pins can help maintain talar-tibial alignment, especially in the face of significant posterior malleolar comminution and instability. Manipulate the ankle to relocate the talus under the tibia as best as possible and secure the reduction with a retrograde Steinmann pin drilled through the calcaneus, talus, and up in the

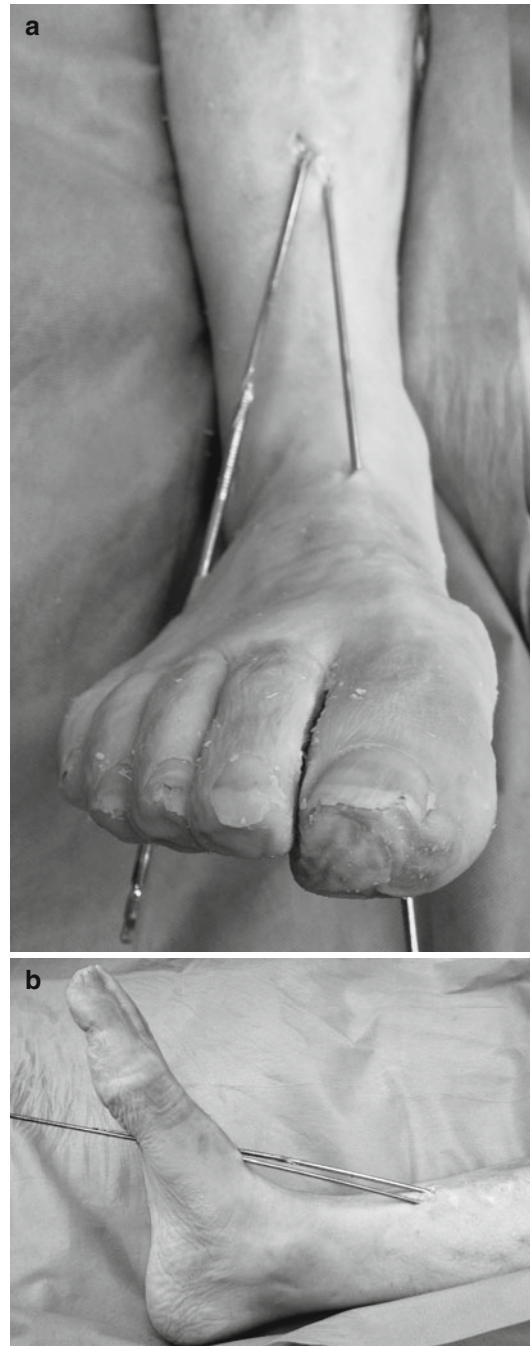

Fig. 24.12 (a) “Poor man’s” fixation when nothing else is available, using two Steinmann pins from first and fifth metatarsals to the anterior tibial crest. (b) Lateral view showing neutral position of the ankle joint

tibial shaft; incorporate it in a below-knee non-weight-bearing cast; and remove the pin after 6–8 weeks. Or, for questionably compliant patients, use a long leg cast.

References

1. Tadros AM, Eid HO, Abu-Zidan FM. Epidemiology of foot injury in a high-income developing country. *Injury*. 2010;41(2):137–40.
2. Tong D, Ji F, Zhang H, Ding W, Wang Y, Cheng P, Liu H, Cai X. Two-stage procedure protocol for minimally invasive plate osteosynthesis technique in the treatment of the complex pilon fracture. *Int Orthop*. 2012;36(4):833–7.
3. Rammelt S, Amlang M, Barthel S, Zwipp H. Minimally-invasive treatment of calcaneal fractures. *Injury*. 2004;35 Suppl 2:SB55–63.
4. Jiang N, Wang B, Chen A, Dong F, Yu B. Operative versus nonoperative treatment for acute Achilles tendon rupture: a meta-analysis based on current evidence. *Int Orthop*. 2012;36(4):765–73.
5. Pedrini G, Cardi M, Landini A, Strada G. Management of severe open ankle-foot trauma by a simple external fixation technique: an alternative during war and in resource-poor and low-technology environments. *J Orthop Trauma*. 2011;25(3):180–7.

Dheera Ananthkrishnan and Gilbert E. Cauilan

Introduction

The high health, social, and economic impact of spinal injuries is disproportionate in developing nations, as with all trauma, and a high index of suspicion for these injuries is key to assessment and treatment [1, 2]. Trauma protocols in the developed world have become highly sophisticated and include requisite CT scans of the cervical spine as well as the chest, abdomen, and pelvis. This is not possible in a resource-poor atmosphere, but following the tenets of thorough examinations of the spine and the neurologic systems will alert the surgeon to these injuries with the potential for limiting disabilities [3].

Evaluation

Whether a trauma patient is examined in the OPD, the ER, or the ward, the system of evaluation should be the same. An initial neurologic exam should be performed looking first for gross

deficits and then in more depth as allowed by the patient's clinical state. For example, a patient who has been thrown from a scooter is brought in by family for evaluation of a mangled leg. Observation alone should determine the gross motor function of the three other extremities.

In general, a thorough motor and sensory examination is necessary and should be recorded. It is mandatory to perform a rectal exam, assess the bulbocavernosus reflex, and document both of these. Perineal sensation needs to be assessed, looking for any sacral sparing, and the results noted. If a bulbocavernosus reflex is not yet present, the patient's spinal injury may still be evolving. Once the reflex has returned, the examiner can be reasonably sure that any neurologic injury present is real and likely fixed. Any high-energy injury requires inspection and palpation of the spine by log rolling the patient and palpating the entire spine, from occiput to sacrum. Localized pain and tenderness, as well as ecchymoses, can direct the radiographic exam to be specific, which is imperative in any setting, but particularly in an austere one. Patients who are seen late should also be examined for pressure sores.

Injury to the content (the cord) is assessed clinically; injury to the container (the bone-soft tissue complex of the spine) is assessed radiographically. Lateral and AP cervical spine x-rays should be obtained if the patient is obtunded or if indicated from the initial evaluation. The C7–T1 level should be well visualized on the lateral film. It may be necessary to pull the arms caudally while the x-ray is being taken for maximum

D. Ananthkrishnan, MD, MSE (✉)
Orthopaedic Surgery, Emory University,
59 Executive Park South, Suite 3000,
Atlanta, GA 30329, USA
e-mail: dananth@emory.edu

G.E. Cauilan, MD, FPOA
Department of Orthopedics,
Southern Philippines Medical Center,
Davao Medical School Foundation Hospital,
Davao City 8000, Philippines
e-mail: gecauilan@hotmail.com

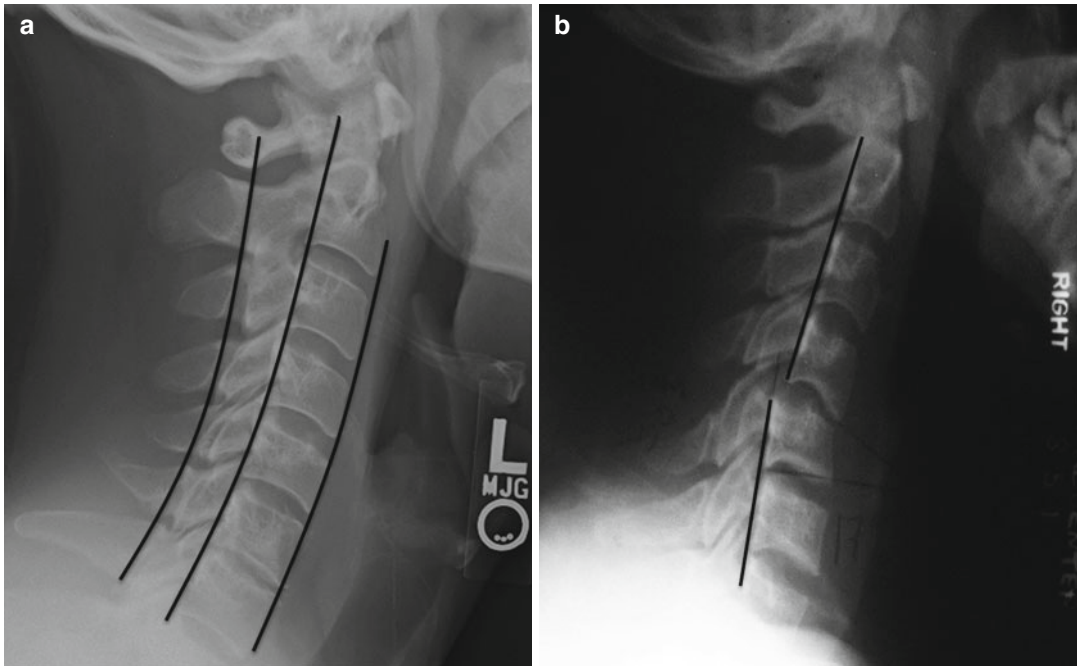


Fig. 25.1 (a) Normal lateral C-spine x-ray showing anterior spinal line, posterior spinal line, and spinolaminar line. (b) C-spine x-ray after trauma. Note break in posterior spinal line indicating C4–5 facet disruption and instability

visualization. If the cervicothoracic junction is still unable to be adequately assessed, a swimmer’s view is required. If possible, the patient’s neck should be immobilized with a cervical collar or taped across the forehead and secured to the backboard or bed during the clinical and radiographic evaluation. Sandbags on either side of the head as well as a support under the head can keep the head and cervical spine in neutral alignment. Log roll precautions should be used until the patient has been neurologically cleared.

Key Radiographic Points

- Cervical spine: visualize C7–T1.
- Cervical spine: evaluate continuity of the “three spinal lines,” looking for incongruities at the anterior border of vertebral body, posterior border of the vertebral body, and junction of the laminae (Fig. 25.1).
- Thoracolumbar spine (AP view): look for vertebral height loss, widening of the pedicles, and increased distance between spinous processes when compared to those above and below (Fig. 25.2).

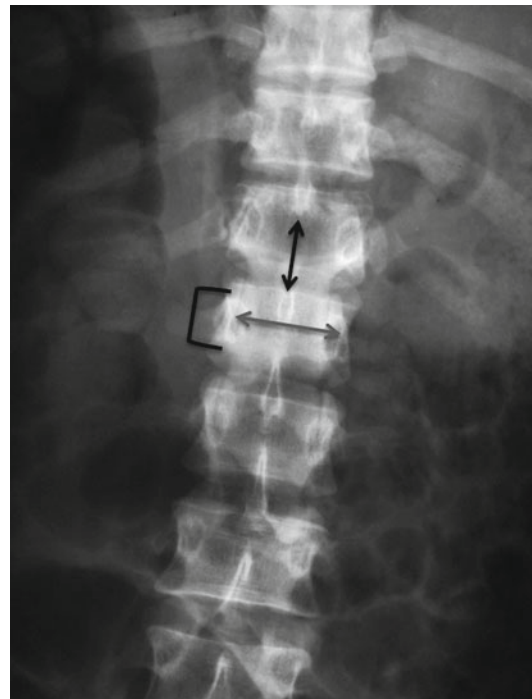


Fig. 25.2 AP x-ray of TL spine demonstrating key parameters. Interspinous distance (*vertical arrow*), interpedicular distance (*horizontal arrow*), and vertebral height (*bracket*)

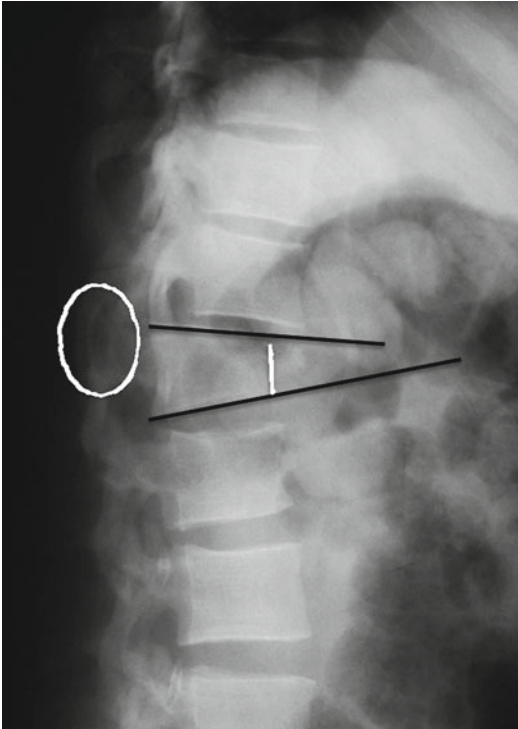


Fig. 25.3 Lateral x-ray after T11–12 trauma showing kyphosis and loss of vertebral body height and facet disruption (circle)

- Thoracolumbar spine (lateral view): look for vertebral body height loss and kyphosis; facet disruption is usually more evident on the lateral than the AP (Fig. 25.3).

Knowledge of the mechanism of injury enables further scrutiny of key areas and injury patterns:

Axial load (Fig. 25.4): burst fractures with variable involvement of all three columns

Flexion load (Fig. 25.5): anterior column compression with disruption of posterior column in tension

Extension load (Fig. 25.6): anterior column tension failure with compression of posterior column

Instituting a protocol for evaluating these patients in the resource-poor setting is likely to be challenging, but the visiting orthopedist should make it a point to follow a consistent and thorough pattern of evaluation. At hospitals that see a fair amount of trauma, an initial evaluation of current processes is a good idea. This can be followed by an in-service for junior physicians, nurses, and radiology personnel on the implementation of a basic spine trauma screening

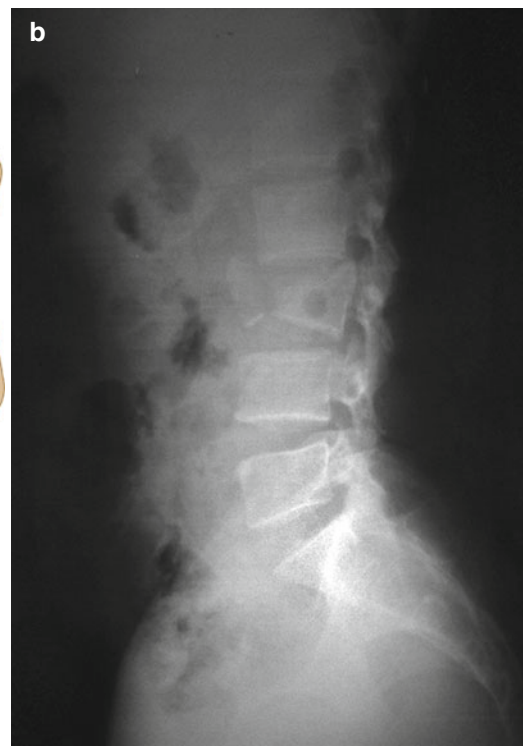
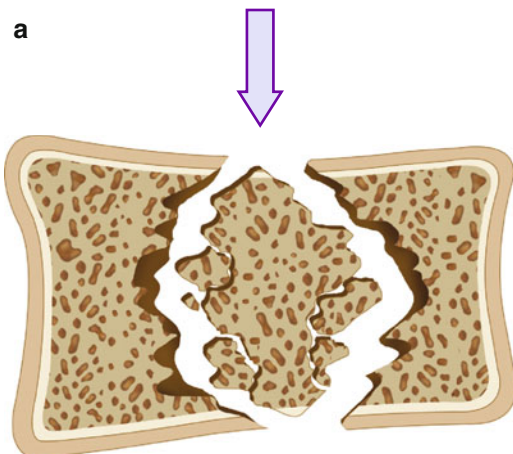


Fig. 25.4 (a) Axial load leads to compression or burst fracture. (b) Lateral x-ray of burst fracture of L3

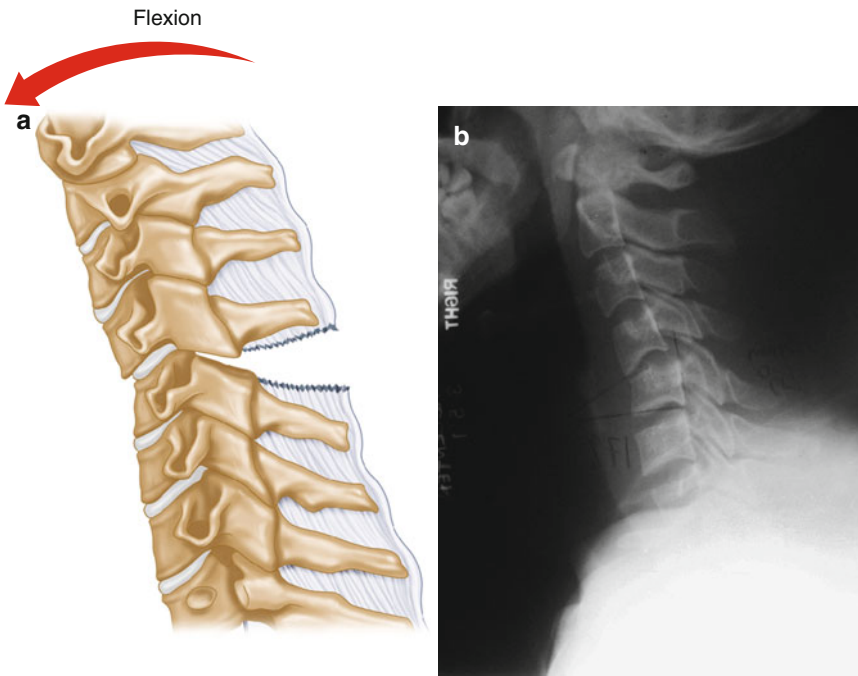


Fig. 25.5 (a) Flexion injury leads to compression injury of anterior elements and tension injury of posterior elements. (b) Lateral x-ray of flexion injury of C-spine

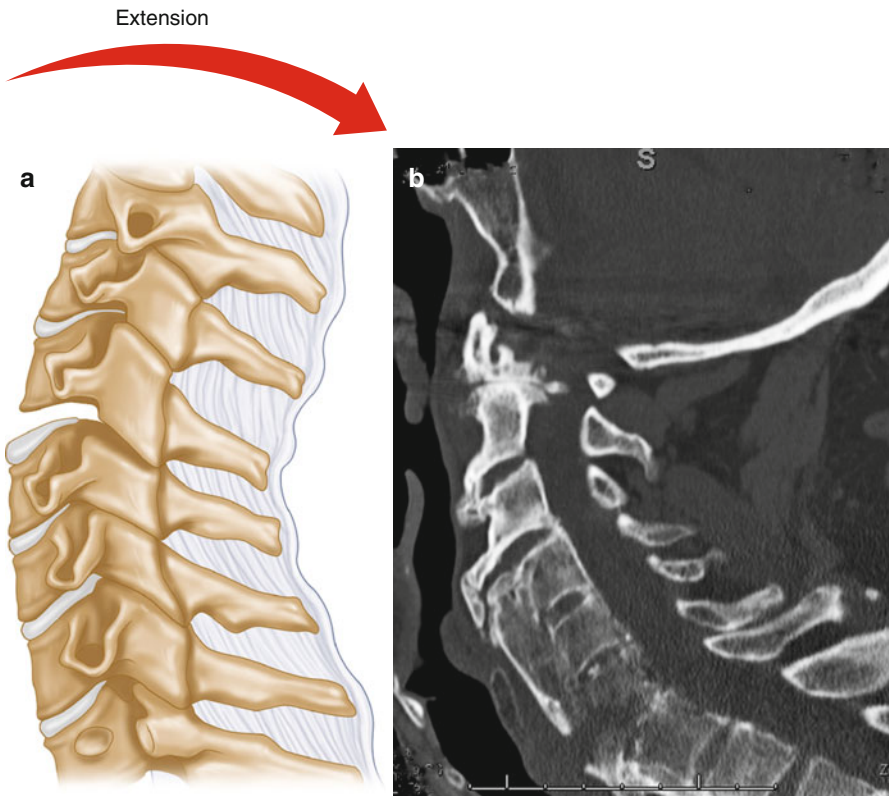


Fig. 25.6 (a) An extension load leads to anterior tension injury and posterior compression. (b) Lateral CT image of extension injury of C-spine

protocol. Leaving the site with such a protocol for clinical and radiographic evaluation will go a long way toward both patient care and education.

Assessment of the Injury

Once an injury has been identified, the surgeon needs to assess its stability and, to a lesser degree, the acuity of the treatment needed. With regard to the second point, most of these patients will have had a significant delay between their injury and the time of evaluation, and it is unlikely that a progressive neurologic deficit will present itself at a point at which an urgent decompression is necessary.

Just as everywhere else, the issue of stability is of paramount importance when determining a treatment plan. Distinctions should be made between acute structural instability and the potential for late structural instability, as well as between neurologically stable and unstable lesions. An instability checklist to assist with treatment algorithms is shown below. At least three should be present for the injury to be considered unstable:

- Anterior elements unable to function
- Posterior elements unable to function
- Sagittal plane translation
- Sagittal plane rotation
- Positive stretch test (neural tension sign, radicular pain with elongation of nerve root)
- Spinal cord involvement

Stability

Although there is some controversy regarding classification of spinal injuries, the three-column concept is one that all visiting orthopedists should be able to apply when evaluating a spinal injury. The spine is divided into anterior, middle, and posterior columns (Fig. 25.7). Generally, an injury involving three columns is said to be an acutely unstable one, and in resource-rich environments these patients will often be treated surgically. The concept of acute versus late

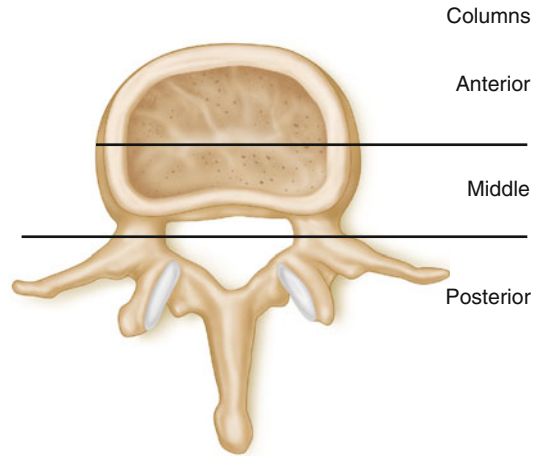


Fig. 25.7 The three columns of the spinal unit

instability becomes an issue with two-column injuries. Often the indication for stabilization of these injuries is the potential for delayed onset or late onset deformity. A one-column injury is unlikely to need any type of stabilization, either with an orthosis, cast, or surgery.

A patient who is losing neurologic function is considered to be neurologically unstable. For the vast majority of neurologically unstable spine trauma patients in resource-poor settings, there is little to be done. Axial imaging with CT and MRI, if available, can give greater detail about the area in question, leading to consideration of a surgical decompression if the resources are available. Such expensive tests are helpful only if they will alter management.

Treatment

The most common injury patterns seen and their treatments in resource-poor settings are noted in the table below. If Gardner-Wells tongs are available for reduction of cervical fracture dislocations, the sterile pins should be placed at 60 lb. inches of torque just above the external auditory meatus and below the equator of the skull (Fig. 25.8). Traction up to half of the patient's body weight is sometimes needed to achieve an awake reduction of facet dislocations, which can be difficult for both the tongs and the patient to tolerate.

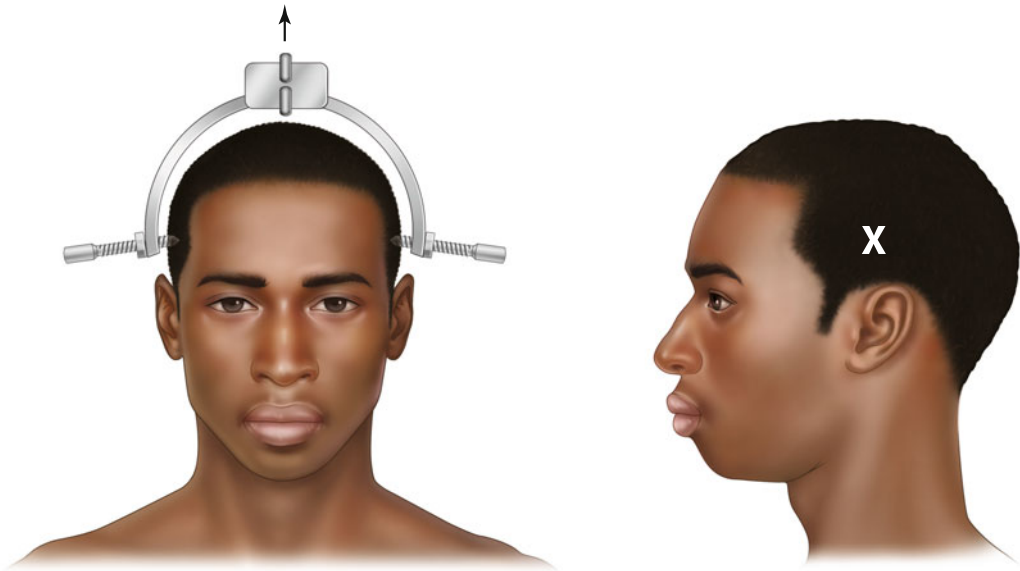


Fig. 25.8 Placement of Gardner-Wells tongs for reduction and traction of cervical spine injuries

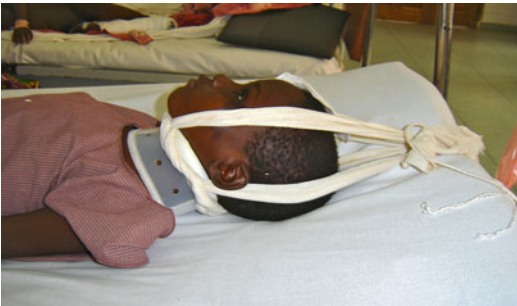

Fig. 25.9 Head halter traction made from stockinette. Note that the patient is also wearing a neck collar

Alternatively, 10–20 lb of traction can be hung via stockinette head halter traction around the occiput and mandible (Fig. 25.9). This traction is less robust, and the patient may need to be in traction for 48–72 h to obtain a reduction.

Thoracolumbar fractures can be treated with log rolling at bed rest. Extension casting with delayed mobilization will usually give better results. However, it is difficult to place adults in an extension cast even in the developed world, as a special table and general anesthesia are usually needed (see Chap. 13).

In general, if instrumentation and a surgeon skilled in using it are not available, surgery is not advisable. Any non-instrumented decompression in a fracture setting is likely to fail, resulting in a late deformity and possibly worse neurologic function than that preoperatively. The one exception to this is an anterior cervical discectomy with iliac crest bone graft in a cervical fracture dislocation. In conjunction with a cervical collar, this can be an extremely effective treatment when performed by a trained surgeon.

Upper Cervical Injuries (Occiput to C2)

- Rarely seen due to high mortality rate and if seen are usually neurologically intact due to the large amount of space available for the spinal cord.
- Plain films with odontoid view, possible flexion/extension films.
- CT likely unnecessary, but helpful if available.
- Short period (3 weeks) of traction may be useful for C1–C2 injuries.
- Treatment in collar for C1–C2 injuries, halo may be used as well if available (Fig 25.10).
- Surgery: not recommended in austere environments.

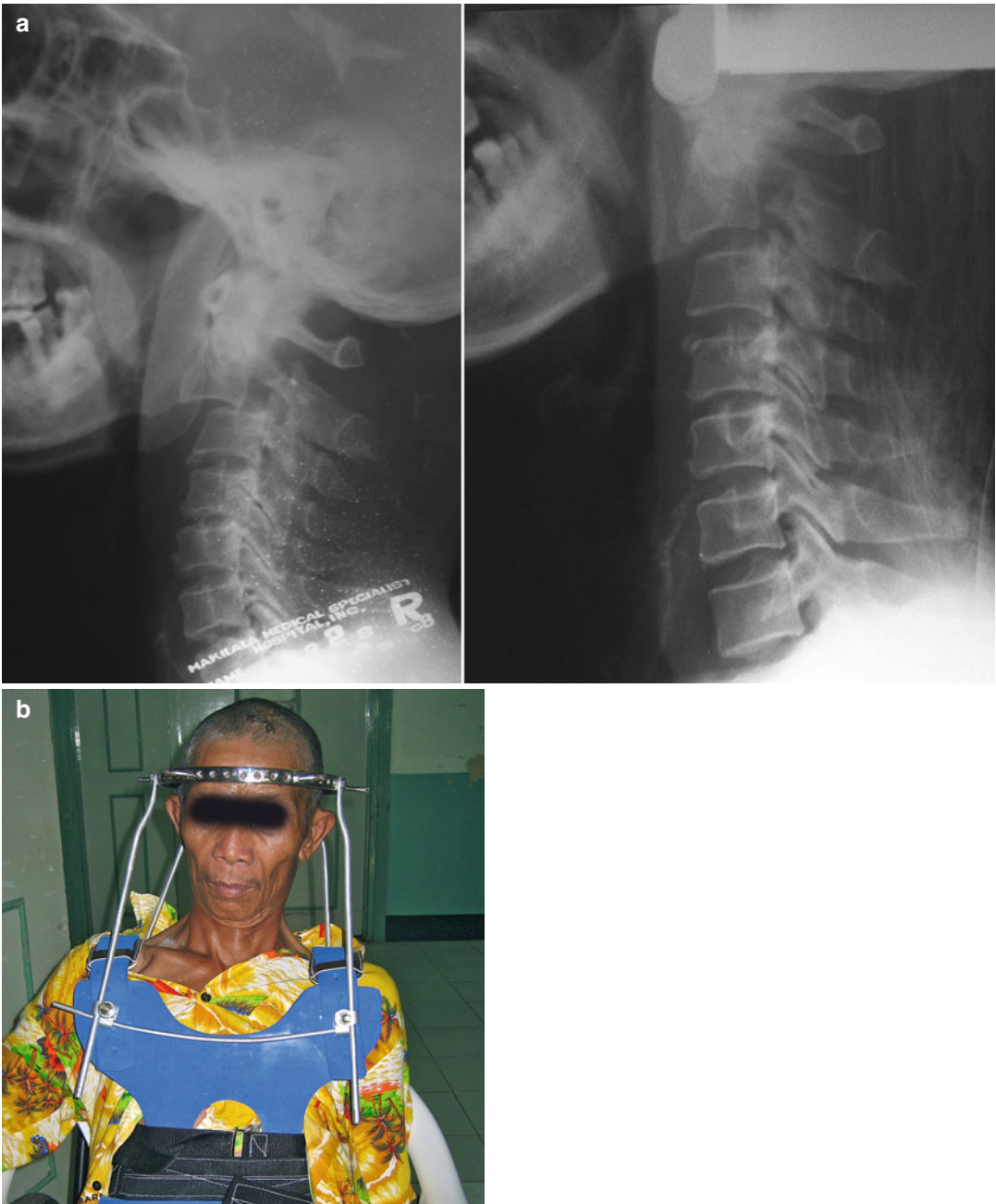


Fig. 25.10 (a) *Left:* lateral x-ray of C2 hangman's fracture with spondylolisthesis of C2 on C3. *Right:* acceptable reduction in halo vest. (b) Patient comfortable in halo

Lower Cervical Injuries

- Cervical fracture dislocations with facet subluxation or dislocation are common.
- Upright films, CT if possible.
- If no facet fracture, can attempt closed reduction with Gardner-Wells tongs (or halo) in an awake patient (follow neuro exam during reduction).

- Reduction will be difficult with a facet fracture present.
- Surgery: anterior or posterior reduction and fusion.
- NB: many of these injuries will be stable in a dislocated position. If the injury appears stable and the neurologic status is stable, it could be advisable to let the patient heal in a dislocated position.
- Patients should be immobilized and evaluated with plain x-rays if: unconscious, high-energy injury, pain in the spine, focal tenderness, abnormal neurologic examination, transient neurologic dysfunction, obvious neck trauma (ecchymoses, skin compromise, swelling, deformity), head/face trauma, or inconsolable child
- Radiographs in general are extremely difficult to evaluate, and the surgeon should have a low tolerance for prolonged immobilization with a collar or bed rest and repeat examinations.

Thoracolumbar Injuries

- Thoracolumbar burst fractures and compression fractures are most common.
- Upright films, CT if possible.
- 6–12 weeks of bed rest with extension casting or TLSO for 2- and 3-column injuries.
- Late kyphosis can be a problem even with 2-column injuries.
- Surgery: neurologic deficits may improve with a decompression, but this must be done in the setting of a fusion to prevent kyphosis, posterior fusion \pm anterior fusion [4].

Pediatric Spine Trauma in the Resource-Poor Setting [5]

Eighty percent of spinal trauma in children occurs in the cervical spine:

- Four injury patterns occur: fracture, subluxation, fracture with subluxation, and SCIWORA (spinal cord injury without radiographic abnormality).
- Increased elasticity of ligamentous structures, incomplete ossification of the spinal column, and large head size with respect to body contribute to the high incidence of cervical trauma.
- Below the age of 8, injuries tend to be in the upper cervical spine. As the child ages, the fulcrum of the spine moves distally, and subaxial injuries are more common.
- Positioning the child on a backboard with pads under the torso should accommodate the relatively large head size.
- Radiographic evaluation is difficult due to the normal anatomy of pediatric spine, such as wedge-shaped vertebrae and pseudosubluxation of C2–3 and C3–4.

Conclusion

Any spinal cord injury is a life-altering event. This is particularly true of patients in the developing world [6]. Even if the patient is at a hospital with the infrastructure, skills, knowledge, and material resources to provide modern surgical care for the unstable spine injury, the lack of rehabilitation can condemn the patient to a shortened life of dependence and infirmity [7]. When these patients are the breadwinners of the family, the impact of this injury is magnified exponentially. Any paralyzed patient at home becomes an extra mouth to feed and requires attendance for proper management, often taking a child away from school or from farmwork.

Unless the orthopedic volunteer has extensive experience in spinal surgery and is working within a solid surgical and perioperative infrastructure, operative management of these injuries should not be undertaken. It can be easy for the visiting orthopedist to be anxious and discouraged when faced with a spine trauma injury; however, approaching these injuries in a methodical manner can allow for the best care possible in an unfortunate situation.

References

1. Eid HO, Barss P, Adam SH, Torab FC, Lunsjo K, Grivna M, Abu-Zidan FM. Factors affecting anatomical region of injury, severity, and mortality for road trauma in a high-income developing country: lessons for prevention. *Injury*. 2009;40(7):703–7.
2. Naci H, Chisholm D, Baker TD. Distribution of road traffic deaths by road user group: a global comparison. *Inj Prev*. 2009;15(1):55–9.
3. Chadha M, Bahadur R. Steffee variable screw placement system in the management of unstable thoracolumbar fractures: a Third World experience. *Injury*. 1998;29(10):737–42.
4. Burns AS, O’Connell C. The challenge of spinal cord injury care in the developing world. *J Spinal Cord Med*. 2012;35(1):3–8.
5. Chiu WT, Lin HC, Lam C, Chu SF, Chiang YH, Tsai SH. Review paper: epidemiology of traumatic spinal cord injury: comparisons between developed and developing countries. *Asia Pac J Public Health*. 2010;22(1):9–18.
6. Jones TM, Anderson PA, Noonan KJ. Pediatric cervical spine trauma. *J Am Acad Orthop Surg*. 2011;19(10):600–11.
7. Gosselin RA, Coppotelli C. A follow-up study of patients with spinal cord injury in Sierra Leone. *Int Orthop*. 2005;29(5):330–2.

Part IV

Pediatric Trauma

David A. Spiegel and Bibek Banskota

Introduction

While image intensification has revolutionized children's fracture care in economically developed regions by facilitating minimally invasive techniques for reduction and fixation, such technology is rarely available in resource-challenged environments. However, the majority of fractures and dislocations in the pediatric population can be managed nonoperatively. To achieve adequate results the surgeon must have an understanding of the fracture's remodeling potential, an appreciation for the mechanism of injury, meticulous casting technique, and close follow-up during early healing to correct minor incongruities and deformities (Fig. 26.1).

The most common anesthetic technique for reduction is the hematoma block, performed using the *barbotage technique*. Approximately half the local anesthetic is injected into the

fracture, and the hematoma is aspirated to restore the initial fluid volume within the syringe. This process is repeated several times to distribute the anesthetic. After the final aspiration the volume of the hematoma should be unchanged. Ketamine is also useful when available.

A subset of fractures—displaced intra-articular and irreducible fractures—require open surgical treatment and/or fixation to achieve the best results, recognizing that open approaches increase the risk of infection (Fig. 26.2). A prompt diagnosis and early referral are essential if the resources and/or expertise are unavailable locally. Fracture fixation can usually be done with Kirschner wires or Steinmann pins. Without an image intensifier, “blind pinning” may be necessary, after which alignment and pin placement are assessed with portable radiographs. Open reduction via small incisions can facilitate minimally invasive fixation techniques such as intramedullary nailing of diaphyseal fractures.

D.A. Spiegel, MD (✉)

Division of Orthopaedic Surgery,
Children's Hospital of Philadelphia,
Associate Professor of Orthopaedic Surgery,
University of Pennsylvania School of Medicine,
Philadelphia, PA, USA

Honorary Consultant in Orthopaedics and Rehabilitation,
Hospital and Rehabilitation Centre for Disabled Children,
Janagal, Kavre, Nepal
e-mail: spiegeld@email.chop.edu

B. Banskota, MB BS, MRCS, MS
Department of Orthopedics,
Hospital and Rehabilitation Center for Disabled
Children (HRDC), Janagal, Kavre 6757, Nepal
e-mail: bibekbanskota@gmail.com

Fracture Healing and Remodeling

The inflammatory stage of fracture healing begins immediately after the injury and involves hematoma formation around the fracture ends. In the second or reparative phase, random bone is laid down by the endosteum (endochondral) and the periosteum (intramembranous). The last stage involves remodeling, the extent of which is determined by (1) skeletal age, (2) the specific bone involved, (3) fracture location within the bone, (4) distance of the fracture

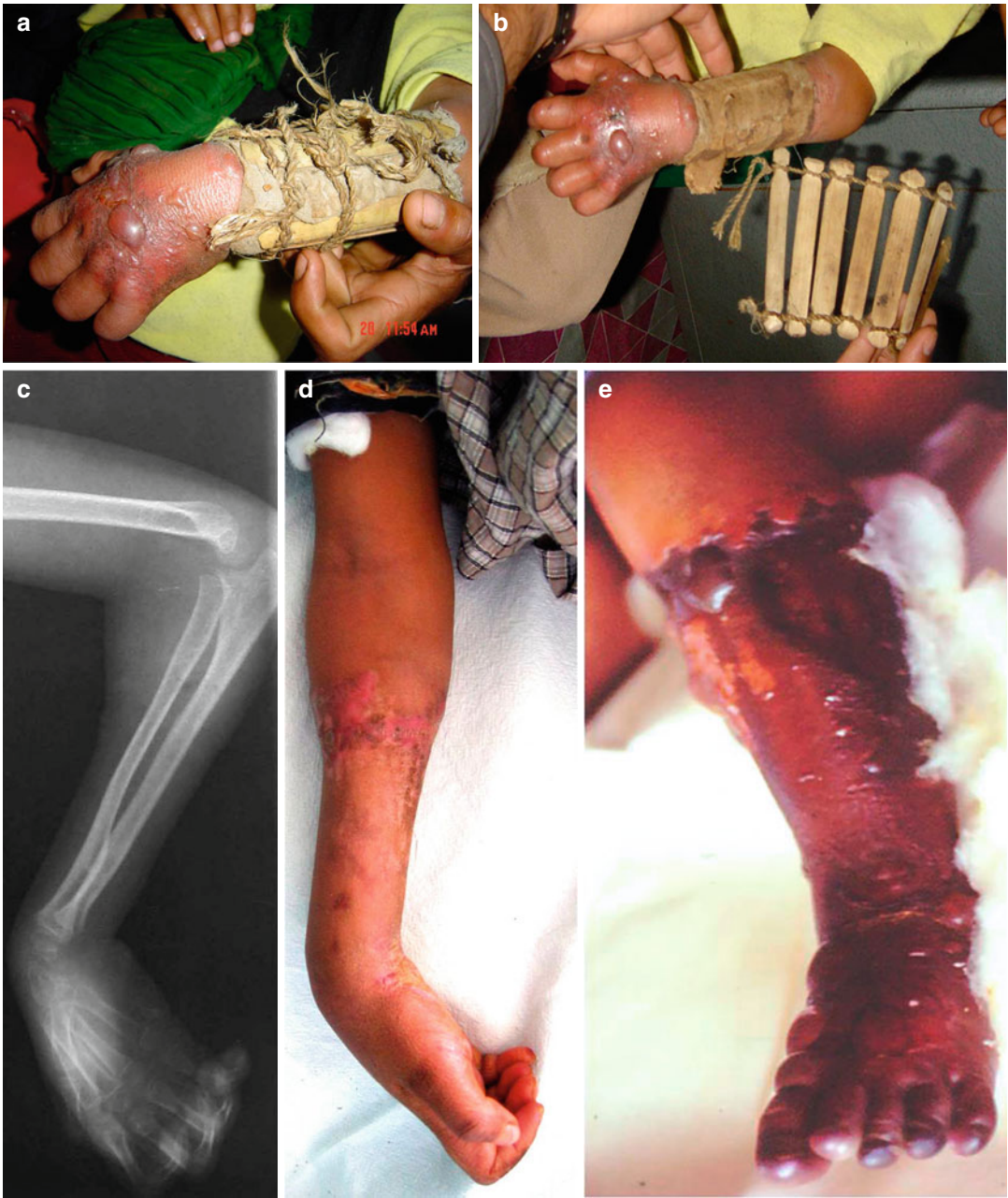

Fig. 26.1 (a, b) This forearm fracture was treated by a locally made splint. (c) In a similar case, the fracture healed in excellent alignment; (d) however, the treatment

was complicated by compartment syndrome and a Volkmann's ischemic contracture. (e) Gangrene can complicate casting

from a joint, and (5) whether the angulation occurs in the plane of motion of the neighboring joint.

The remodeling potential is greater when more than 2 years of growth remain and is especially good in children less than 8–10 years of age and in metaphyseal fractures. Seventy-five percent

of remodeling occurs from asymmetric physal growth, while 25 % is due to a combination of appositional bone growth on the concavity and resorption of bone on the convexity. General guidelines for acceptable alignment are illustrated in Table 26.1.

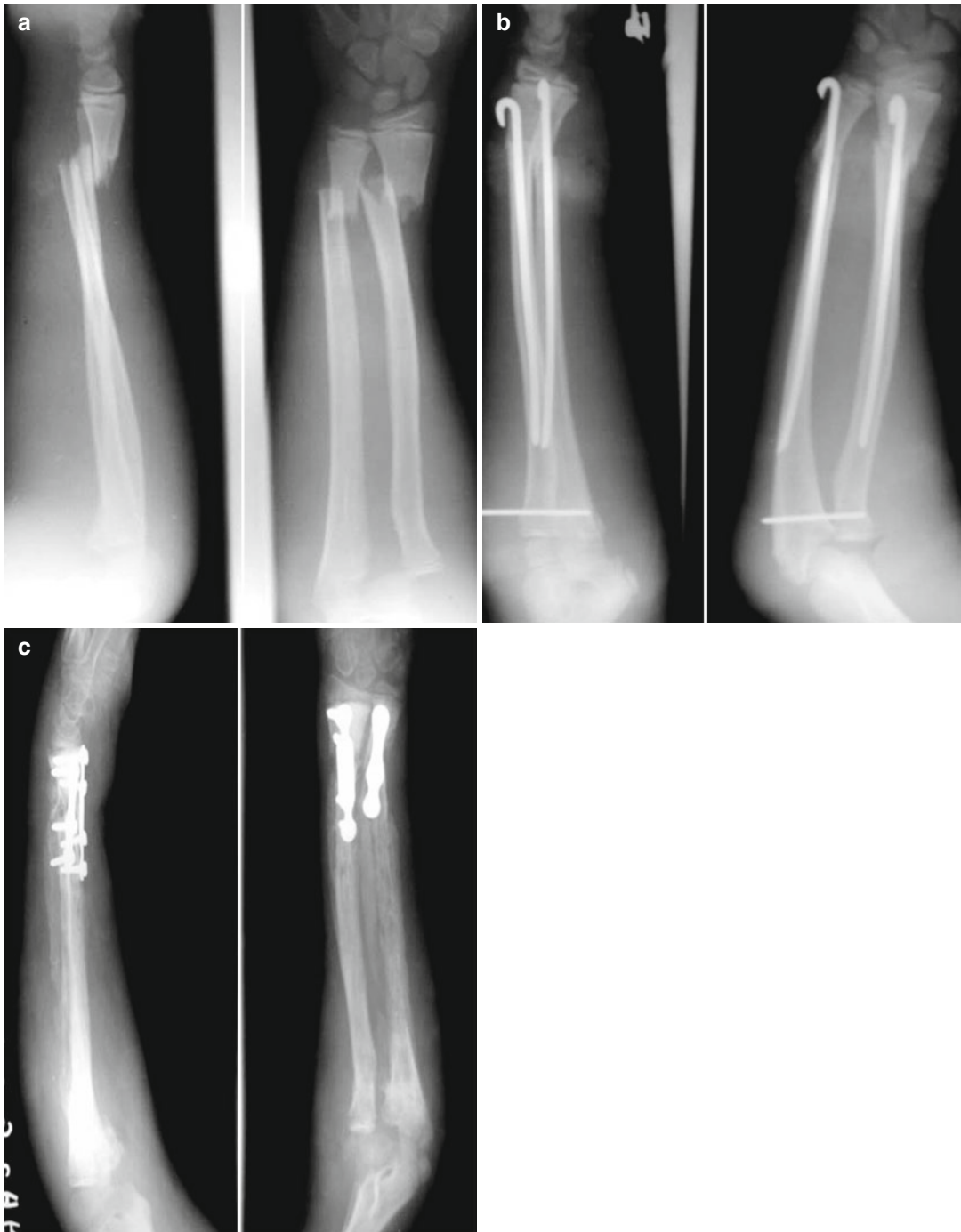


Fig. 26.2 (a) X-rays of a distal radius and ulna fracture with dislocation of proximal radius (Monteggia variant) was (b) initially treated by open reduction and nailing. The patient developed an infection which was (c) treated

by irrigation and debridement followed by plating. This was complicated by extensive osteomyelitis, a difficult problem to solve

Table 26.1 General guidelines for acceptable alignment of fractures in children and adolescents

General guidelines for acceptable alignment of common children's fractures

Lower extremity

Femoral shaft	Age (years)	Varus/valgus (°)	Ant/post-angulation (°)	Shortening (mm)
	Birth–2	30	30	15
	2–5	15	20	20
	6–10	10	15	15
	>11	5	10	10
Tibia and fibular shaft			≤8 years	>8 years
	Valgus		≤5°	≤5°
	Varus		≤10°	≤5°
	Anterior angulation		≤10°	≤5°
	Posterior angulation		≤5°	0°
	Shortening		10 mm	5 mm
	Rotation		≤5°	≤5°

Adapted from Beaty JH, Kasser JR, editors. Rockwood and Wilkins' fractures in children. 7th ed. Philadelphia: Lippincott, Williams and Wilkins; 2010

Box 26.1 Bone Age Differences

In sub-Saharan Africa it is common to find patients in their late teens or early 20s with epiphyseal fractures. From a study from Malawi, in 85.6 % of 119 patients the skeletal ages trailed chronological ages by a mean of 20 months [1]. Anthropological studies from the 1950s showed similar results when comparing East and West African populations to the Western middle class subjects of the commonly used bone atlases. Whether similar differences exist in other populations is unknown.

Physical anthropologists and forensic experts agree that the variations in the rates and times of human maturity are multifactorial and include genetic and environmental factors. Nutrition contributes to growth and developmental potential, and poor nutrition is commonly associated with stunted growth and delayed development. Chronic low dietary intake usually presents as a slow growth during childhood and adolescence, a late adolescent growth spurt, and a prolonged period of growth [2]. The specific effects of prenatal nutrition and the roles of caloric vs. protein malnutrition are not well understood.

Environmental stress also influences physiological age, but how this occurs is controversial. Chronic diseases may have a role on their own or by the accompanying malnutrition, especially in the young. And all of these factors may affect growth through alterations in the immune system.

Genetic factors affecting skeletal maturation are sure to play a role, as populations differ in average skeletal size, degree of sexual dimorphism, and proportions, while the variations within a population can be great.

Not all patients presenting in their late teens or early 20s with epiphyseal fractures are short or classically malnourished in appearance. The main points for the orthopedic surgeon are to be aware that physeal fractures occur in this older age group and to take care in planning any procedures dependent on remaining bone growth or giving medical legal statements about age. This latter can be problematic as birth certificates are often lacking and knowledge of date of birth vague. At the same time, having an extended growth potential to remodel a fracture can be an advantage.

Physeal Injuries

Physeal injuries can be due to fractures, infections (osteomyelitis or septic arthritis), tumors, irradiation, vascular insults, and other injuries (thermal, electrical). Physeal fractures are usually classified according to Salter and Harris (Fig. 26.3a). Peterson has added two additional types, (1) a metaphyseal fracture which extends into the physis (Fig. 26.3b) and (2) partial loss

of the physis, for example, medial malleolar loss from a lawn mower injury. The most common complication of physeal injuries is growth disturbance, which results in an angular deformity and/or limb length discrepancy. Growth disturbance is associated with partial or complete physeal arrest, or physeal growth deceleration without full arrest.

The consequences of physeal injuries are more profound for younger children with considerable

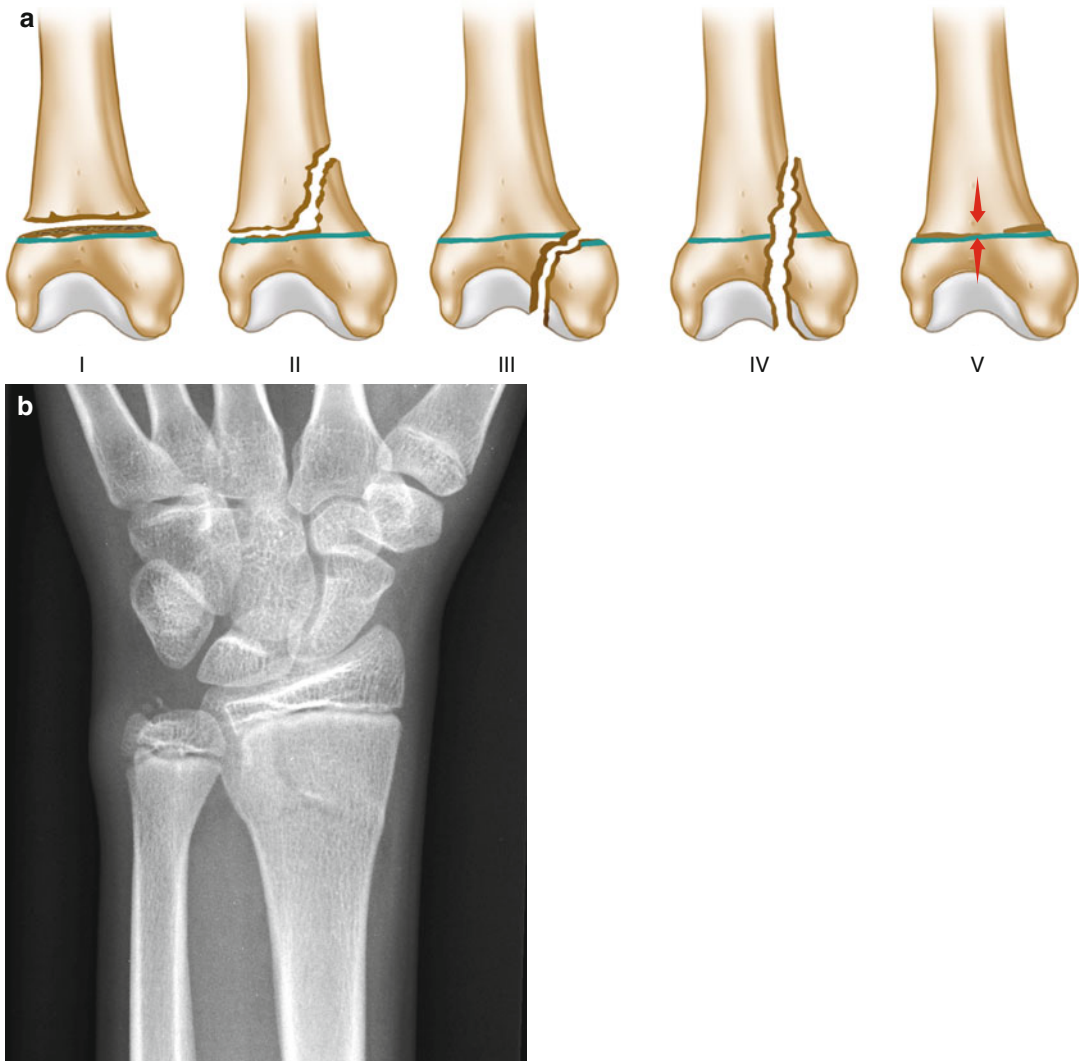


Fig. 26.3 (a) Salter-Harris classification of fractures. Type I fractures extend through the physis, while the Type II patterns travel through the physis and then exit through the metaphysis, leaving a metaphyseal component termed the “Thurston-Holland” fragment. Type III fractures extend through the physis and then exit the epiphysis, creating

displacement at both the physis and the joint surface. Type IV fractures extend from the metaphysis, across the physis and epiphysis, exiting in the joint. The rare Type V fracture is a compression injury that is not readily diagnosed on injury films but later presents with growth disturbance. (b) A metaphyseal fracture extending into the physis

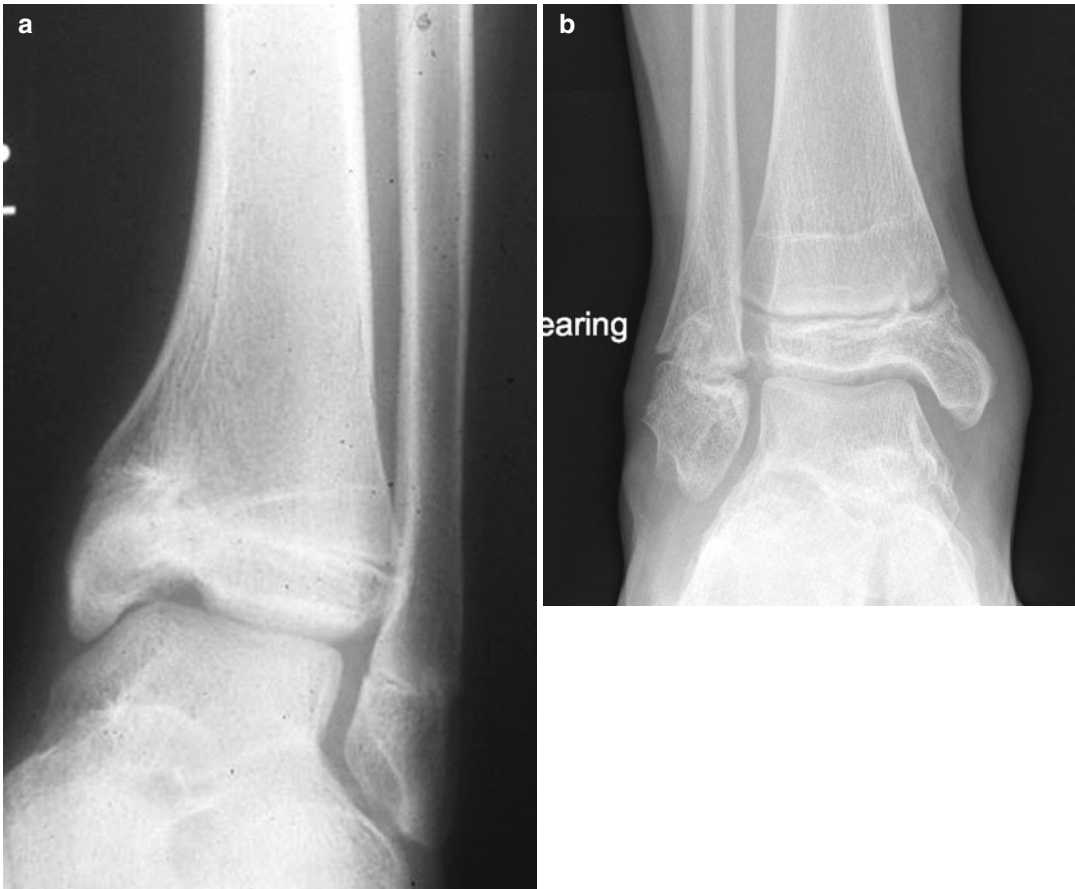

Fig. 26.4 (a) A healed physeal fracture of the medial malleolus with a varus deformity. Note the asymmetric growth arrest line. (b) Symmetric growth arrest lines suggest resumption of normal growth

growth remaining, high-energy injuries, and in selected physes such as the distal femur, due to its large surface area and undulations. The risk of iatrogenic injury can be reduced by treatment within 7 days after injury, gentle manipulation, and avoiding multiple or repeat reductions.

In the absence of advanced imaging, the diagnosis of growth arrest must be made on plain radiographs, and findings include the loss of the normal physeal contour and asymmetric Harris growth arrest lines (Fig. 26.4). While it may be impractical to provide long term follow-up for most patients with physeal fractures, that subset of injuries with the highest risk—Salter-Harris III and IV, high-energy mechanism, late manipulation, or reduction—should be followed closely. It is critical to educate patients and their families about the possibility of growth disturbance, by indicating the possible clinical

features, such as development of an angular deformity and the time over which such changes might occur. For example, rapidly growing physes such as the distal femur might show a disturbance within 2–4 months, while a slower growing physis such as the distal tibia might not show clinical signs until a year or more after the injury. While routine radiographic follow-up within the first few months might identify a growth disturbance before a clinical deformity has occurred, it remains a challenge for many patients to return to a health facility for follow-up. The best option may be to teach families how to evaluate limb lengths and symmetry. Community based rehabilitation workers can be taught to identify complications at an early stage.

If a physeal fracture is malaligned and healing has progressed beyond 7–10 days, several

options exist. If the degree of malalignment is within the expected remodeling potential of that physis and the patient is asymptomatic, observation is the best choice. When alignment is beyond the limits of remodeling and/or the patient's function is compromised, consider an open realignment and stabilization, recognizing and accepting that a physeal arrest will likely occur. Future plans for maintaining limb lengths within an acceptable range must then be discussed.

The predicted discrepancies after complete physeal arrest are based on the growth potential of the individual physis and the number of years of growth remaining. If a complete growth arrest is diagnosed, an epiphysiodesis of the contralateral physes may prevent a limb length discrepancy from developing. In younger children, the degree of anticipated discrepancy or the loss of adult height associated with contralateral epiphysiodesis may be unacceptable to the family, and limb lengthening may be the only alternative. For partial growth arrest, both progressive angular deformity and limb length inequality have to be managed, and a number of reconstructive options can be considered. Estimates for the absolute growth in millimeters and percentage growth of each physis have been gathered from the most recent edition of Rockwood and Wilkins' *Fractures in Children* and are shown in Table 26.2.

Management of Neglected Fractures and Dislocations

Fractures and dislocations presenting weeks to months following injury are common and challenging. Treatment decisions are based on symptoms and their impact on the patient's activities of daily living, the local resources, and the availability of rehabilitation. Outcomes following treatment of neglected fractures and dislocations are often inferior to those for the same injuries presenting acutely, especially when intra-articular and/or physeal. However, utilizing appropriate principles, improvements in symptoms, and/or function can be expected in most patients.

Table 26.2 Estimated growth of individual physes as a percentage within each bone and also in millimeters per year

Physis	Estimated % of growth	Estimated growth (mm/year)
Proximal humerus	80	7
Distal humerus	20	2
Proximal radius	25	1.8
Distal radius	75	5
Proximal ulna	80	5
Distal ulna	20	1.5
Proximal femur	30	3.5
Distal femur	70	9
Proximal tibia	55	6
Distal tibia	45	3–5
Proximal fibula	60	6.5
Distal fibula	40	4.5

From Rathjen KE, Birch JG. Physeal injuries and growth disturbances. In: Beaty JH, Kasser JR, editors. *Rockwood and Wilkins' fractures in children*, 7th ed. Philadelphia: Lippincott, Williams and Wilkins; 2010. p. 95

Fractures with symptomatic malalignment after complete healing require an osteotomy. When fractures present up to 3–4 weeks post-injury, but prior to complete union, osteoclasia can “loosen up” the fracture and facilitate realignment. Osteoclasia can be performed by closed manipulation, percutaneous drilling, or by open techniques. Angulation is easier to correct than shortening. Either skeletal traction or an external fixateur can gradually restore length and alignment after osteoclasia. An alternative is to perform an open, acute shortening and realignment.

Neglected intra-articular fractures and joint dislocations are more difficult to manage, especially in weight bearing joints, and often require salvage strategies. While much of the available information in the literature focuses on adults, the same principles can be adapted to children and adolescents, taking into account the potential for remodeling and growth.

References

1. Lewis CP, Lavy CBD, Harrison WJ. Delay in skeletal maturity in Malawian children. *J Bone Joint Surg Br.* 2002;84-B(5):732–4.
2. Fresancho AR. Human adaptation and accommodation. Ann Arbor: University of Michigan Press; 1993. p. 370–2.

Suggested Reading

- Beaty JH, Kasser JR, editors. Rockwood and Wilkins' fractures in children. 7th ed. Philadelphia: Lippincott, Williams and Wilkins; 2009.
- Gasco J, de Pablos J. Bone remodeling in malunited fractures in children. Is it reliable? *J Pediatr Ortho B*. 1997;6:126–32.
- Peterson HA. Physeal fractures: part 2. Two previously unclassified types. *J Pediatr Orthop*. 1994;14:431–8.
- Wenger DR, Pring ME, editors. Rang's children's fractures. 3rd ed. Philadelphia: Lippincott Williams and Wilkins; 2005.
- Wilkins KE. Principles of fracture remodeling in children. *Injury*. 2005;36:SA3–11.

David A. Spiegel, Bibek Banskota,
and Kaye E. Wilkins

Proximal Humerus

The majority of proximal humerus fractures, including those with considerable angulation, can be managed nonoperatively with a simple sling or collar and cuff as long as 2 years of growth remain (Fig. 27.1).

D.A. Spiegel, MD (✉)
Division of Orthopaedic Surgery,
Children's Hospital of Philadelphia,
Associate Professor of Orthopaedic Surgery,
University of Pennsylvania School of Medicine,
Philadelphia, PA, USA

Honorary Consultant in Orthopaedics and Rehabilitation,
Hospital and Rehabilitation Centre for Disabled Children,
Janagal, Kavre, Nepal
e-mail: spiegeld@email.chop.edu

B. Banskota, MB BS, MRCS, MS
Department of Orthopedics,
Hospital and Rehabilitation Center for Disabled
Children (HRDC), Janagal, Kavre 6757, Nepal
e-mail: bibekbanskota@gmail.com

K.E. Wilkins, DVM, MD
Department of Orthopedics and Pediatrics,
University of Texas Health Science Center
at San Antonio, The Children's Hospital
of San Antonio, formerly Christ Children's
Hospital, Mail Code 7774, 7703 Floyd Curl Drive,
San Antonio, TX 78229-3900, USA
e-mail: drkwilkins@aol.com

Supracondylar Humerus

Supracondylar humerus fractures, especially those with complete displacement, can be a challenge in settings with limited resources. No remodeling of coronal malalignment—varus or valgus—can be expected. However some remodeling in the sagittal plane will occur as the deformity lies in the plane of elbow motion. Non-angulated translation in either the coronal or sagittal plane will typically remodel. Cubitus varus, with or without hyperextension, is the most common deformity and is largely cosmetic, seldom interfering with function.

Non-displaced fractures (Type I) can be treated by a posterior splint or “back slab” or a long arm cast for 3 weeks, after which a removable splint or sling protects the elbow for several additional weeks.

Type II fractures have posterior angulation (apex anterior) with an intact posterior cortex and greenstick deformation but no displacement. They should be reduced so the anterior humeral line falls through the center of the capitellar ossification center (Fig. 27.2). The reduction is easily achieved by fully flexing the elbow, and these fractures are stable in rotation due to the intact posterior hinge. They can be stabilized by percutaneous pinning or managed in a cast. If hyperflexion is required to secure the reduction, once the bone ends are interdigitated, immobilization at 90° will usually hold the reduction without need for continued hyperflexion.

The goal of treating completely displaced supracondylar fractures (Type III) is to obtain

Fig. 27.1 (a, b) This 11-year-old female was (a) treated in a sling and (b) after 8 weeks demonstrated early remodeling with a full range of motion

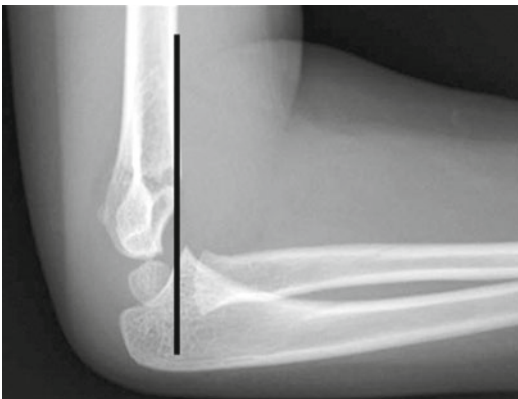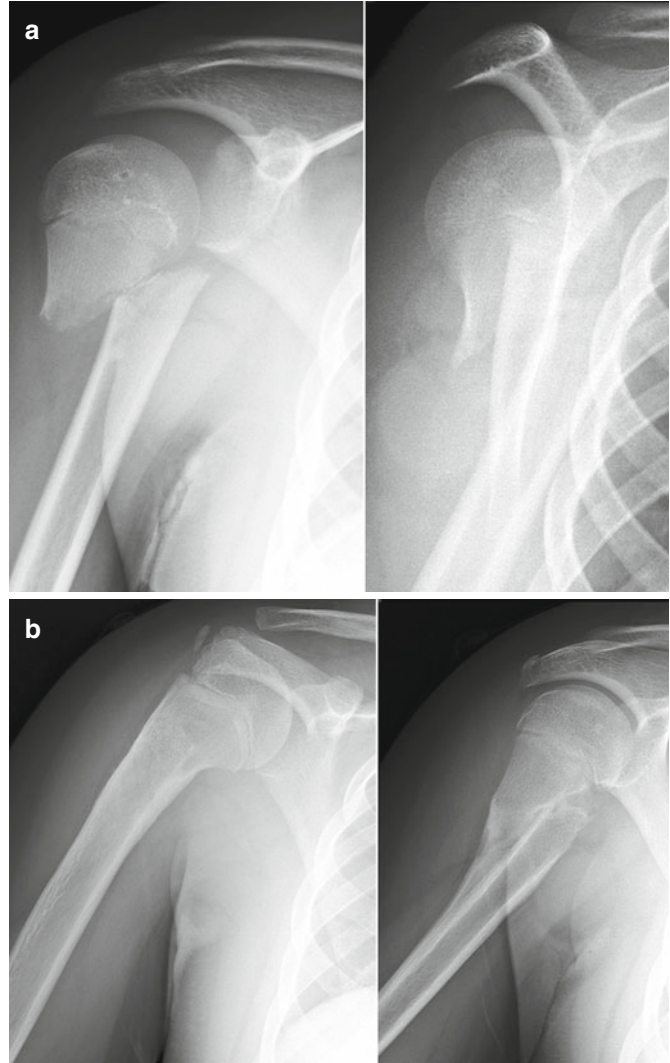


Fig. 27.2 Type II supracondylar humerus fracture with mild extension. Note the anterior humeral line falls anterior to the capitellar ossification center

an adequate functional result while avoiding complications. Ninety-five percent of Type III fractures are the extension type (Fig. 27.3). About 5 % are flexion type injuries, which are recognized by flexion of the distal fragment relative to the proximal (Fig. 27.4). Another clue is severe rotational deformity, for example, an AP x-ray view of the proximal fragment and a lateral of the distal fragment. These are typically globally unstable, have no distinct periosteal hinge to assist in the reduction, and often require an open reduction.

Type III fractures are unstable, and a reduction cannot be maintained in a cast. Furthermore, extension type fractures must be casted in

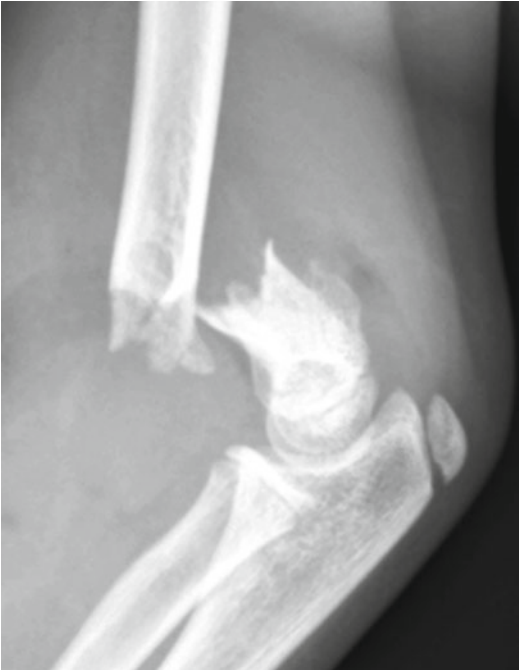

Fig. 27.3 Type III fractures are displaced and have no cortical continuity

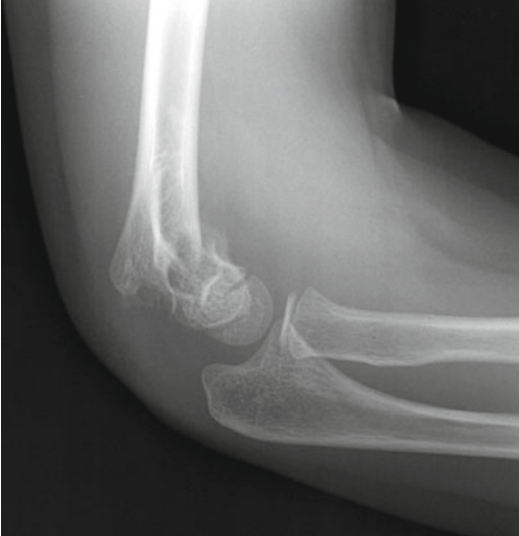

Fig. 27.4 Flexion-type supracondylar humerus fracture

hyperflexion, and this position increases the risk of vascular complications and compartment syndrome. In the rare circumstance that an image intensifier is available, closed reduction and percutaneous pinning can be attempted up to 5–7 days following injury. Reduction involves

applying gentle traction with the elbow in mild flexion and first correcting any varus or valgus deformity. The elbow is then gently and progressively flexed while applying a force from posterior to anterior on the distal fragment and simultaneously pushing the proximal fragment (humeral shaft) from anterior to posterior. Extension fractures usually have an intact periosteal hinge posteriorly, and the reduction is locked by fully flexing the elbow. Three divergent laterally placed bicortical K-wires are sufficient fixation (Fig. 27.5). With medial comminution or impaction, a medial K-wire may help prevent collapse into varus and should be inserted via a small incision over the medial epicondyle to prevent injury to the ulnar nerve. The extremity is placed in a posterior splint with the elbow in 60–70° flexion and the patient observed for 24 h for swelling and neurovascular function.

In some cases of Type III extension fractures, the proximal fragment is impaled through the brachialis muscle with the tip palpable under the skin. Often these show extensive bruising over the antecubital fossa (Fig. 27.6). A “milking maneuver” should dislodge the fragment prior to reduction. For the uncommon flexion pattern, extending the elbow after coronal correction will reduce the fracture.

Other options for the management of acute injuries include traction, closed reduction and “blind pinning,” and open reduction with percutaneous pinning. Dunlop’s side arm traction or olecranon traction can be utilized as a temporary measure in cases of severe swelling, or as the definitive treatment (Fig. 27.7). After 2–3 weeks and after adequate callus has formed, the traction is converted to a splint or cast.

Performing an open reduction may increase the risk of elbow stiffness and/or heterotopic ossification, especially in cases presenting after 5–7 days.

Nerve injuries are seen in up to 20 % of patients with displaced supracondylar humerus fractures. The most commonly injured nerve is the anterior interosseous branch of the median nerve, tested by asking the patient to make a circle between the tips of the thumb and the index finger—an “OK” sign. Radial nerve function is assessed by extending the interphalangeal joint of the thumb, and the ulnar nerve is tested by crossing the index and middle fingers.

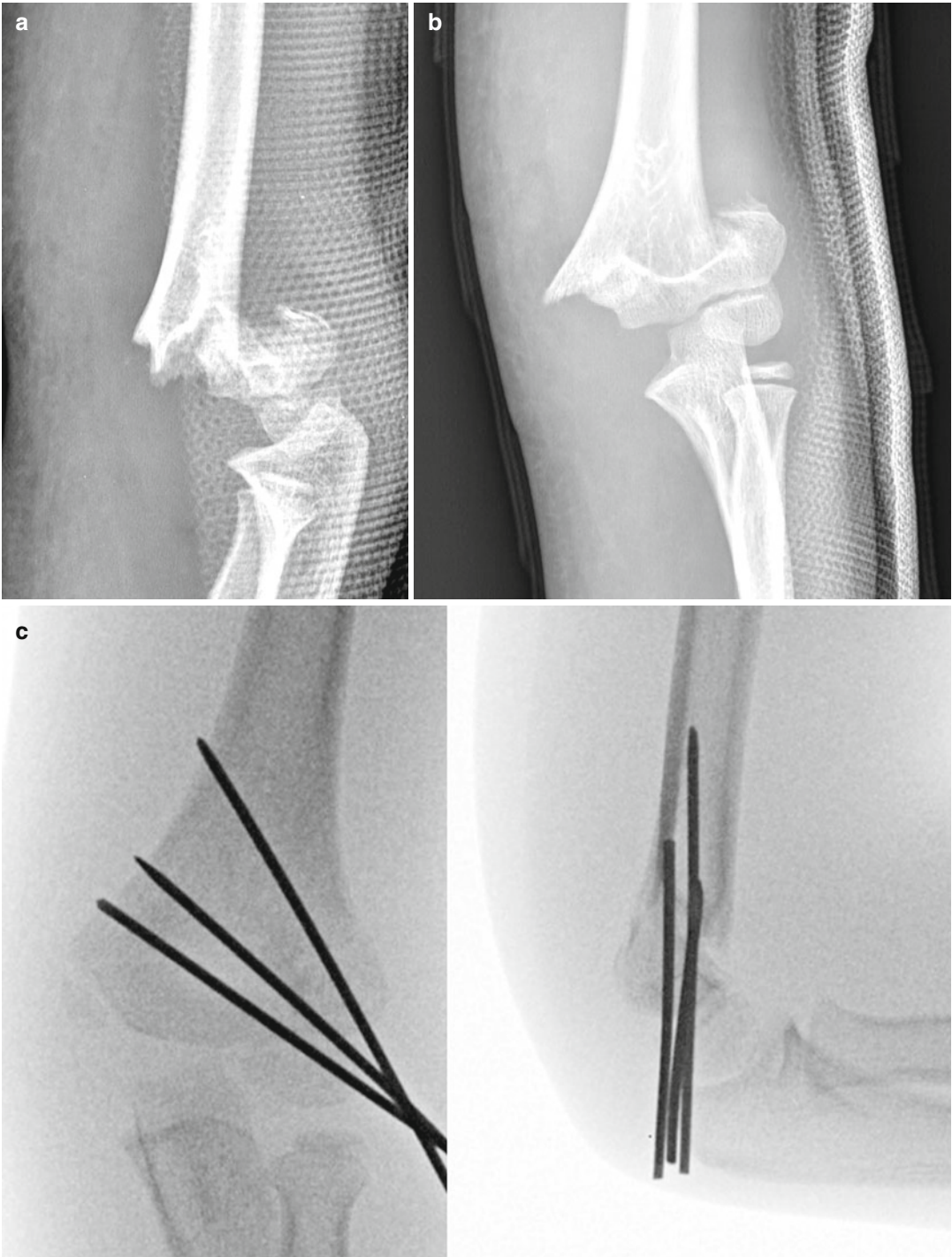


Fig. 27.5 (a, b) Displaced fractures are treated by open reduction and pinning or (c) percutaneous fixation

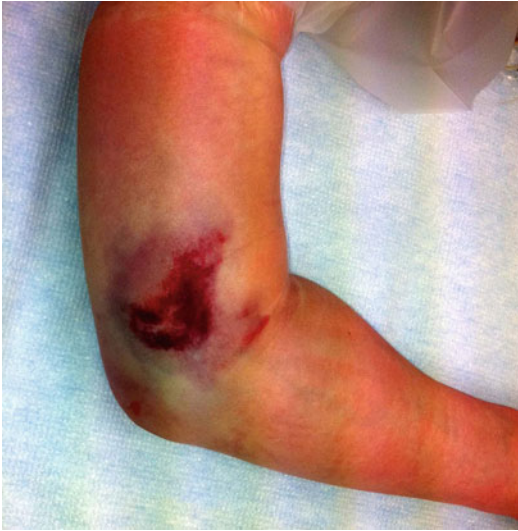

Fig. 27.6 Echymosis over the distal and medial aspect of the upper arm is common when the proximal fragment pierces the brachialis

When a nerve injury is identified at the time of presentation, the fracture is reduced and stabilized by closed or open means. In most cases the nerve will recover fully. If the fracture cannot be adequately reduced, an open exploration is suggested as the nerve and/or soft tissues may be trapped in the fracture. When a nerve palsy is diagnosed *after* the fracture is closed reduced and stabilized, nerve exploration should be considered, especially if an anatomic reduction was not achieved.

Vascular injuries occur in approximately 5% of cases. Patients presenting with inadequate tissue perfusion—typically a pulseless and pale hand—are treated by urgent reduction of the fracture. If an excellent pulse and adequate perfusion are restored, the limb is splinted in 60–70° flexion at the elbow and the patient is observed for 24–48 h. The pain associated with an evolving compartment syndrome may be diminished or masked in the presence of a median nerve palsy.

The management of the pulseless but well-perfused extremity after reduction requires close observation. If there is any concern about the adequacy of tissue perfusion, exploration is recommended as the vessel may be within the fracture site or tethered to the bone. Exploration is via a transverse incision across the antecubital fossa

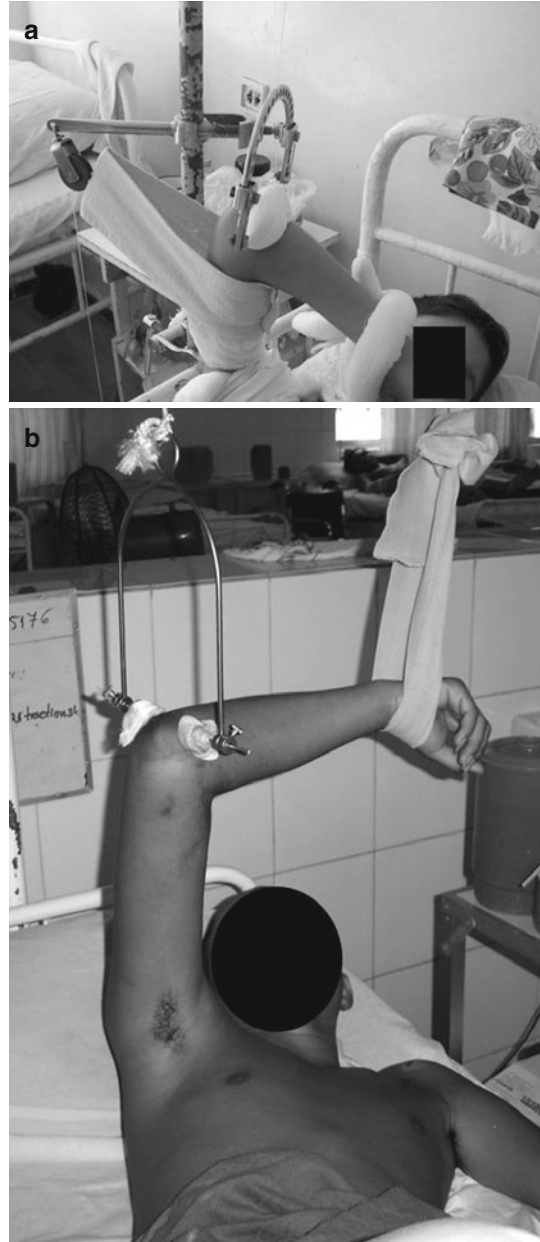


Fig. 27.7 (a) Skeletal traction is an excellent option for supracondylar fractures when an image intensifier is not available. (b) Several traction variations can be used (a Courtesy of Jonathan Phillips, M.D.)

that curves proximally on the medial side. Pulse oximetry may assist with monitoring during the postoperative period, but this device measures skin oxygenation and not muscle perfusion, making the clinical examination of muscle function

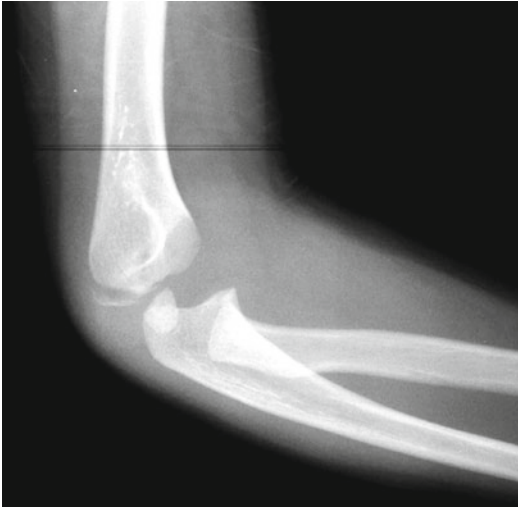

Fig. 27.8 Displacement of a lateral condyle fracture is often best appreciated on an internal oblique radiograph

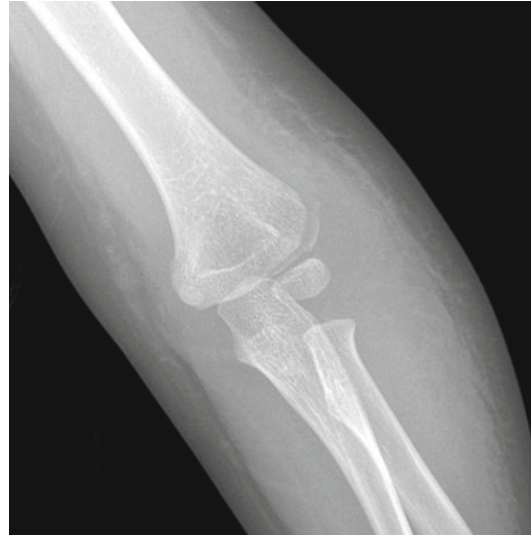

Fig. 27.9 Minimally displaced lateral condyle fracture

essential, especially in the diagnosis of a coexisting compartment syndrome.

Lateral Condyle Fractures

Fractures of the lateral humeral condyle are due to a fall on the outstretched arm, with traction on the forearm extensor wad origin. In contrast to a supracondylar fracture, which presents with circumferential soft tissue swelling, lateral condyle fractures have isolated swelling over the lateral elbow. When the diagnosis is in doubt, the fracture is best visualized on an internal oblique radiograph (Fig. 27.8). Fractures with 1–2 mm displacement can be managed in a long arm cast, recognizing that weekly radiographs for up to 3–4 weeks are required to ensure that progressive displacement of the fragment does not occur (Fig. 27.9).

Some fractures are angulated/displaced but not rotated, indicating an intact cartilaginous hinge in which the fracture does not extend into the elbow joint. If an image intensifier is available, an arthrogram can be useful to determine if the fracture is intraarticular. These fractures can either be managed in a cast or percutaneously pinned. Fractures with complete displacement require an open reduction and fixation with 2–3 K-wires, to

control the displacement at both the physis and the joint surface. The wires are removed at 3–4 weeks, after which a long arm cast is applied for an additional 2–4 weeks depending on the age of the child and the degree of healing (Fig. 27.10). Healing of lateral condyle fractures is often delayed with a risk of nonunion.

Monteggia Lesions

Monteggia lesions involve a fracture of the ulna with a dislocation of the radial head. Four types are described based on the direction of the dislocation. A line drawn through the center of the proximal radius, parallel with the radial shaft, should intersect the capitellum or capitellar ossification center in all x-ray projections. Reestablishing ulnar length and alignment is critical in maintaining radial head reduction in all Monteggia lesions. This must be confirmed by weekly x-rays for the first 3 weeks. Ulnar fixation is necessary when ulnar length and/or stability cannot be achieved. An intramedullary Steinmann pin suffices for short oblique fractures (Fig. 27.11); however, a plate may be required if the fracture is comminuted or length unstable.

In *Type I* lesions, the most common, the radial head, is dislocated anteriorly with an oblique

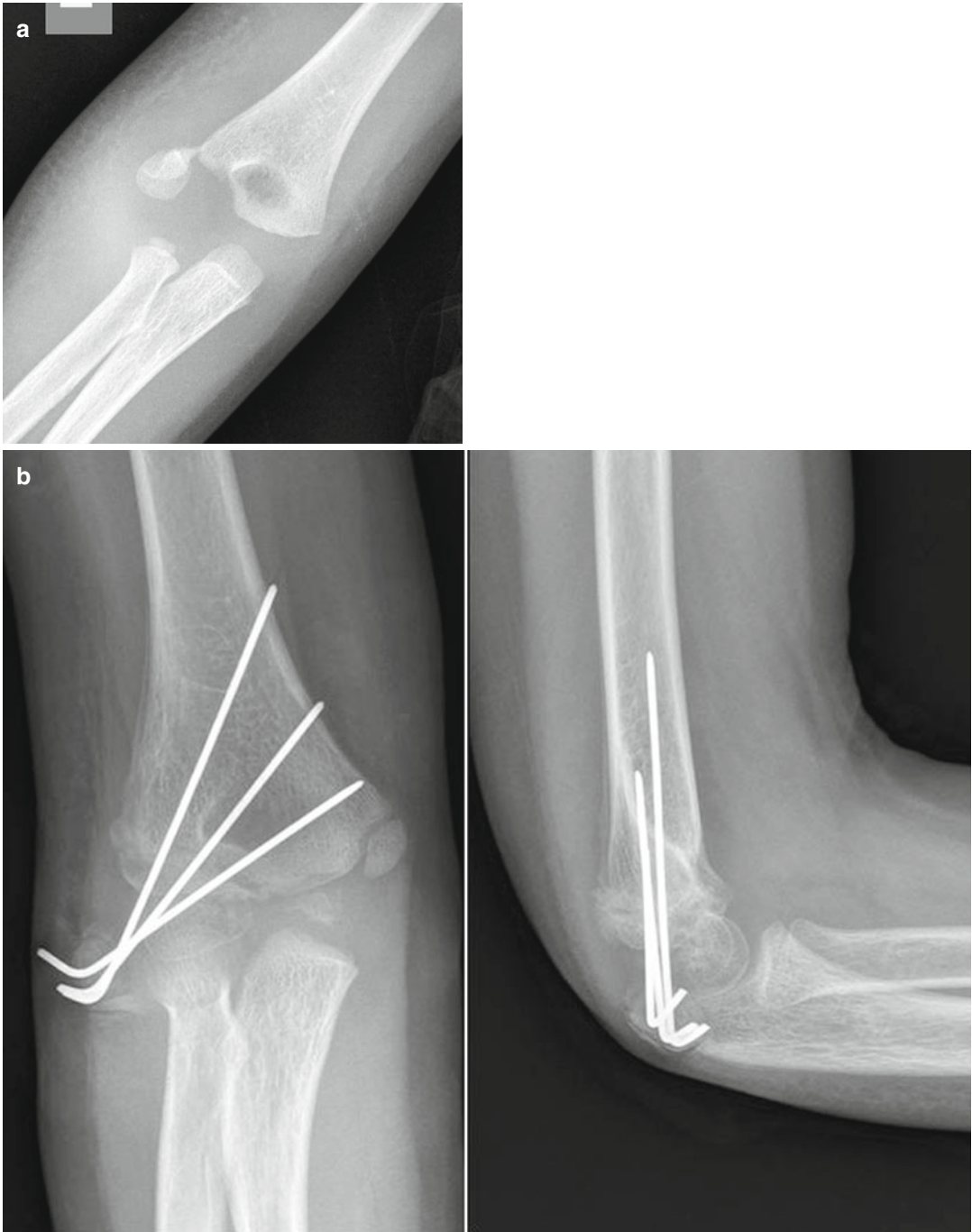


Fig. 27.10 (a) Displaced lateral condyle fracture treated by (b) open reduction and percutaneous fixation

greenstick or displaced fracture of the ulna, due to a fall on the outstretched arm with an extension stress at the elbow. Reduction involves (1) reestablishing ulnar length by correcting the

angular deformity and (2) reducing the radial head, usually by flexing the elbow and occasionally applying a posteriorly directed force to the proximal radius. The patient is immobilized in a

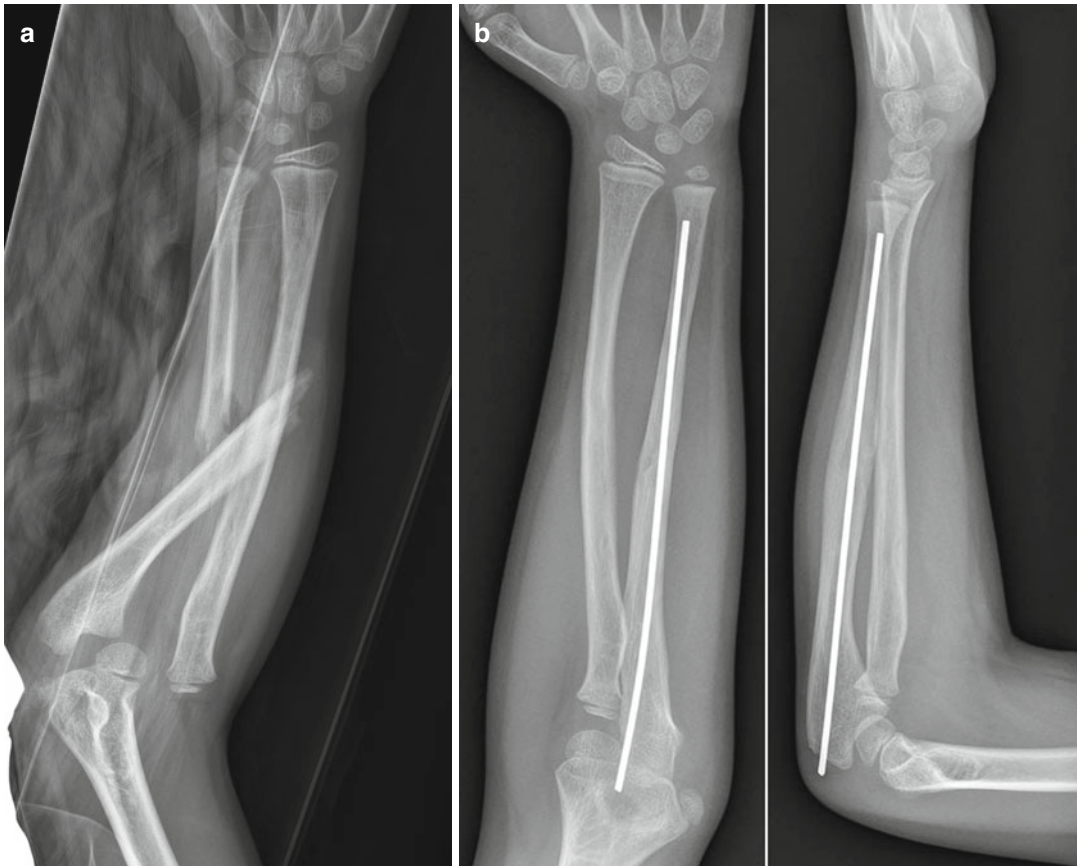


Fig. 27.11 (a) Monteggia fracture (Type I) with a widely displaced, oblique ulnar shaft fracture and anterior dislocation of the radial head (b) treated by closed

reduction of radius and ulna and intramedullary fixation of the ulna with a Steinmann pin

long arm cast in 110–120° flexion and neutral to mid-supination, which at 3 weeks is transitioned to a long arm splint and ROM exercises are begun.

The *Type II* lesion is rare and involves a posteriorly angulated proximal ulna fracture and posterior dislocation of the radial head. Reduce these by extending the elbow to reduce the ulna fracture, with or without digital pressure on the proximal ulna. The radial head will usually reduce spontaneously. A long arm cast with the elbow in extension is applied.

The *Type III* pattern is a greenstick varus fracture of the olecranon and a laterally dislocated radial head. Reduce this by a valgus stress with the elbow in extension. If the reduction is stable, the elbow can be immobilized in a long

arm cast with the elbow in 90° flexion. Recommendations for forearm rotation vary between pronation, semi-supination, and neutral. If the reduction is unstable or the fracture re-angulates, immobilize the extremity in a long arm cast with the elbow in extension and the forearm supinated.

The *Type IV* pattern consists of fractures of both the radial and ulnar shafts and radial head dislocation. Without a lever arm to help reduce the radial head, reduction requires ORIF. If surgical facilities and immediate referral are not possible, the best choice may be to treat both shaft fractures closed, addressing the radial head dislocation with open reduction and annular ligament reconstruction, usually with an ulnar osteotomy, at a later time.

Radial Neck and Olecranon

Fractures of the radial neck can be metaphyseal or physeal (Salter-Harris II) and angulated, translated, or both. Complications are frequent and include loss of motion, avascular necrosis, and radial head overgrowth. Up to 30° angulation and only 3–5 mm of translation are acceptable due to the risk of loss of forearm rotation. The authors favor reduction by the flexion-pronation maneuver, in which the elbow is held in 90° flexion, with the surgeon's thumb pressed against the radial head while the forearm is forcefully pronated. A long arm cast in 90° flexion and neutral rotation is worn for 3 weeks. An alternate technique involves placing a varus stress on the extended elbow while thumb pressure reduces the radial head. Open reduction should be avoided, if possible, owing to the high risk of stiffness, nonunion, and avascular necrosis. If an image intensifier is available, percutaneous manipulation with the blunt end of a Steinmann pin can be considered, or an intramedullary Kirschner wire with an angulated tip can be advanced across the fracture site and rotated to achieve reduction (Metaizeau technique).

Olecranon fractures may involve either the apophysis or the metaphysis. Non-displaced fractures are managed in a long arm cast with the elbow in extension, and those with more than 2-mm displacement and/or joint step-off require open reduction and fixation. While a wire tension band is required in adolescents and adults, in children a heavy nonabsorbable suture may be utilized for the figure of eight loop.

Diaphyseal Fractures of the Radius and Ulna

These fractures have less potential for remodeling than more distal fractures and require additional time for healing. Fractures are classified according to the completeness of the fracture, as (1) plastic deformation, (2) greenstick deformity, and (3) complete fractures. The reduction maneuver depends upon (1) location, (2) degree of

completeness, and (3) direction of deformity. Cast molding is essential and wedging may be required.

Plastic deformation presents as an angular deformity without an obvious fracture line. Reduction is achieved by placing a gradual and sustained force across the apex of the deformity. The end point occurs when alignment is restored clinically and forearm rotation is full. The reduction requires full general anesthesia or a good block. The above elbow cast must be well molded and is worn for 6 weeks.

In *greenstick fractures*, the cortex on the tension side fails completely, but the compression side cortex has only an incomplete fracture with plastic deformation. These fractures typically have both angular and rotational malalignment. In cases with apex volar angulation, the distal fragment is supinated relative to the proximal fragment, and pronation is required to reduce the fracture. In the opposite circumstance, an opposite maneuver is necessary. Correction of rotational malalignment usually corrects any angular deformity. Care must be taken to keep the elbow flexed to 90°, with good posterior molding along the distal humerus and proximal ulna to prevent the forearm sliding back into the cast. It is unclear whether the opposite cortex should be deliberately fractured during the reduction as the risks of creating an unstable fracture must be balanced against a possible reduction in the rate of refracture.

Complete forearm fractures tend to be unstable in angulation, rotation, and length. Intact muscle forces are an important factor in producing deformity and need to be taken into consideration during reduction and reduction maintenance. To assess rotation on an AP radiograph, the bicipital tuberosity is oriented 180° opposite the radial styloid, and the coronoid process should be 180° opposite the ulnar styloid. A difference in diaphyseal widths at the two ends of the fracture also indicates rotational malalignment. These fractures need to be immobilized in a long arm cast for at least 4 weeks, followed by an additional 2–4 weeks in a shorter cast. Shortening of less than 1 cm is acceptable, as is bayonet apposition (Fig. 27.12).

The main indications for surgical intervention are (1) open fractures, (2) inability to achieve or

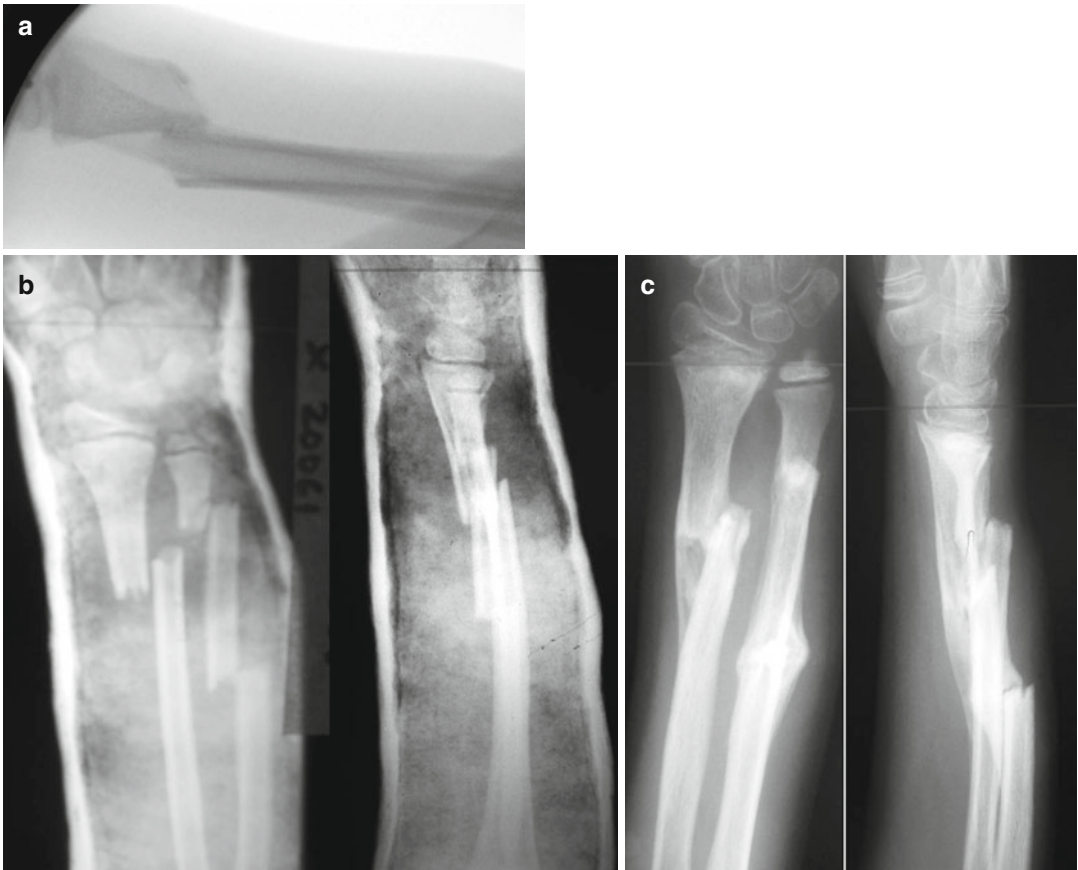


Fig. 27.12 (a) Bayonet apposition is acceptable as long as alignment is adequate. (b, c) Complete segmental diaphyseal radius and ulna fractures with bayonet apposition treated by closed reduction and casting

maintain an acceptable closed reduction, and (3) a second, ipsilateral fracture, especially supracondylar humerus. Options for stabilization include intramedullary fixation with flexible nails, K-wires, Steinmann pins or plate fixation. Open reduction is required in the absence of image intensification (Fig. 27.13).

The ulnar IM wire can be placed via a small incision along the lateral aspect of the proximal ulna, or from distal to proximal through a small opening in the distal ulnar metaphysis. The radial implant is inserted into the distal metaphysis either via a dorsal (between the second and third compartment) or radial approach (between the first and second dorsal compartments). Avoid injuring the distal radial physis and superficial radial nerve. The ulnar implant should be more

rigid than the radial implant, and the radial implant should be pre-contoured to maintain the normal radial bow.

Distal Radius Fractures

Both volar and dorsal fractures, involving the metaphysis or physis, can be expected to remodel approximately 0.9° of sagittal malalignment per month and 0.8° of radial deviation. The majority can be managed nonoperatively, with the exception of (1) open fractures, (2) displaced intra-articular fractures, (3) irreducible fractures due to interposed tissues, (4) an associated ipsilateral fracture, and (5) acute carpal tunnel syndrome. While there is no conclusive evidence to support

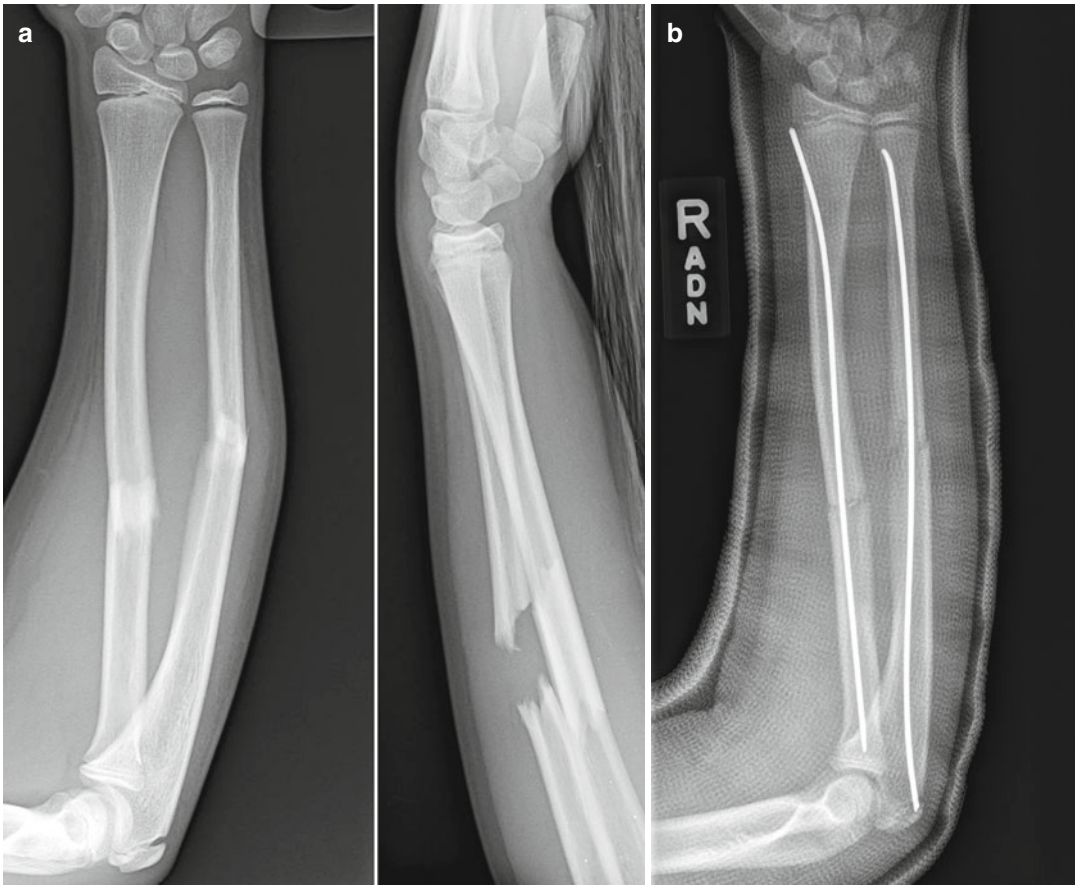


Fig. 27.13 (a) Unstable diaphyseal forearm fracture treated by (b) nailing

the use of a long versus short arm cast initially, some surgeons prefer a long arm cast for the first 2–3 weeks transitioning to a short arm cast once early healing is observed.

Distal radius physeal fractures with up to 50 % displacement have an excellent potential for remodeling, as long as one and one half years of growth remain. Major concerns with displaced physeal fractures are carpal tunnel syndrome and growth arrest. Distraction with finger traps or gentle counter traction can often reduce these fractures, and in some cases it is necessary to apply dorsal pressure on the distal fragment. The risk of growth disturbance is increased substantially when reduction is performed more than 1 week following injury or with repeated attempts.

Displaced distal radial metaphyseal fractures are less stable than distal physeal or greenstick fractures and are prone to re-displace after reduction especially when the ulna remains intact. Reduce them by hyperextending the distal fragment and apply traction to restore length. Once length is reestablished, angulation is corrected by volar flexing the distal fragment on the proximal fragment. The fracture is casted for at least 6 weeks. Dorsal bayonet apposition of both radius and ulna can be expected to remodel in children less than 12 years of age, but adequate alignment must be maintained.

Displaced *distal ulnar physeal* fractures are complicated by growth arrest in up to 50 % of cases, and patients should be followed for at least 1 year. Growth arrest can result in ulnar negative

variance and subsequent deformity of the distal radius and ulna.

Torus or buckle fractures are incomplete metaphyseal fractures and can be treated by simple immobilization for 3–4 weeks.

Neglected Upper Extremity Fractures/Dislocations

Displaced *supracondylar humerus fractures* are difficult to manage after more than a few days and soft callus has formed. The management of cases in which closed treatment is no longer possible, but healing is incomplete and remains controversial. Traction is most successful when

started within the first week but may be effective in some patients at 2–3 weeks following injury. Skeletal traction is preferable to skin traction as greater weight can be used.

The risk of complications such as stiffness and heterotopic ossification is increased when open reduction is done during the early, inflammatory phase of fracture healing (Fig. 27.14), and it may be prudent to perform a corrective osteotomy after the fracture has completely healed.

An alternative is “early” corrective osteotomy, performed after the initial hyperinflammatory state, usually after 4 weeks but before complete healing/remodeling. Removal of an anterior bone block, cheilectomy, can be considered when the primary problem is lack of flexion due to

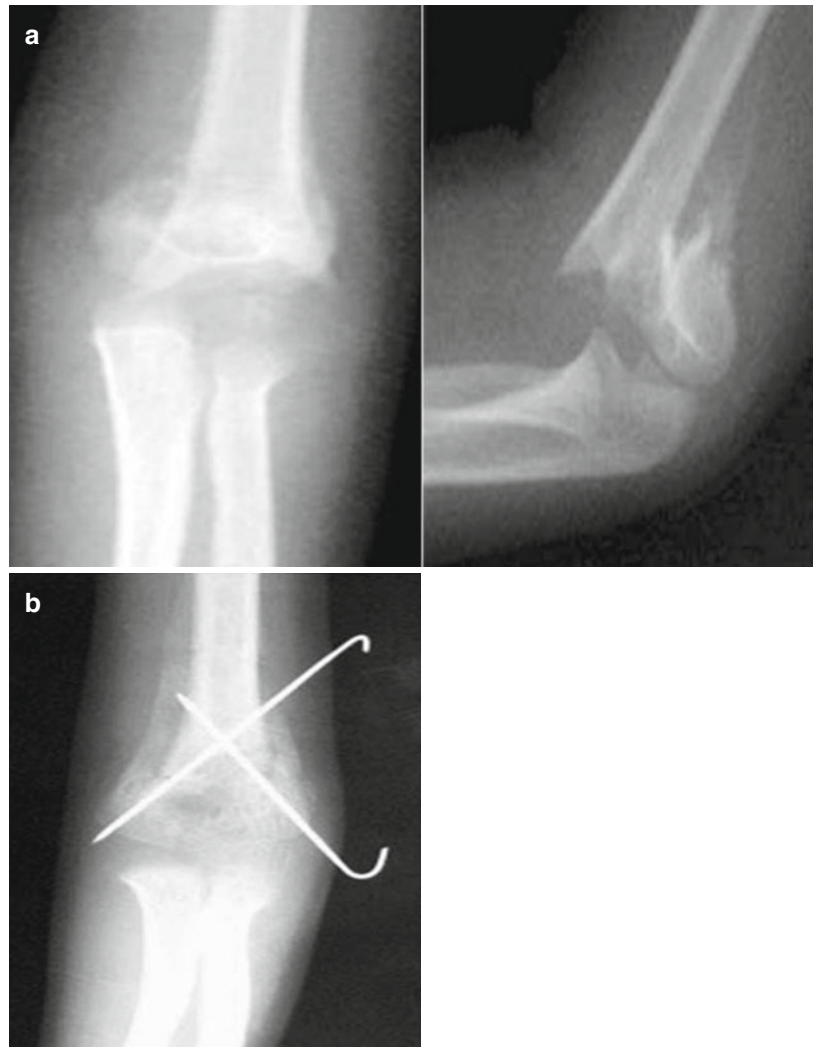

Fig. 27.14 This child (a) presented for treatment 12 days following Type III supracondylar fracture with early callus and was treated by (b) open reduction and percutaneous fixation. There is an increased risk of heterotopic ossification and stiffness with open treatment at this stage of fracture healing

impingement (Fig. 27.15). Approaches to open reduction have included anterior, medial, lateral, posterior, and combined medial and lateral. An anterior approach is advantageous in the presence of neurovascular pathology.

Untreated fractures of the *lateral humeral condyle* can result in chronic pain, loss of motion, instability, and cubitus valgus with or without tardy ulnar nerve palsy. Surgical treatment should be directed to relieving symptoms and/or

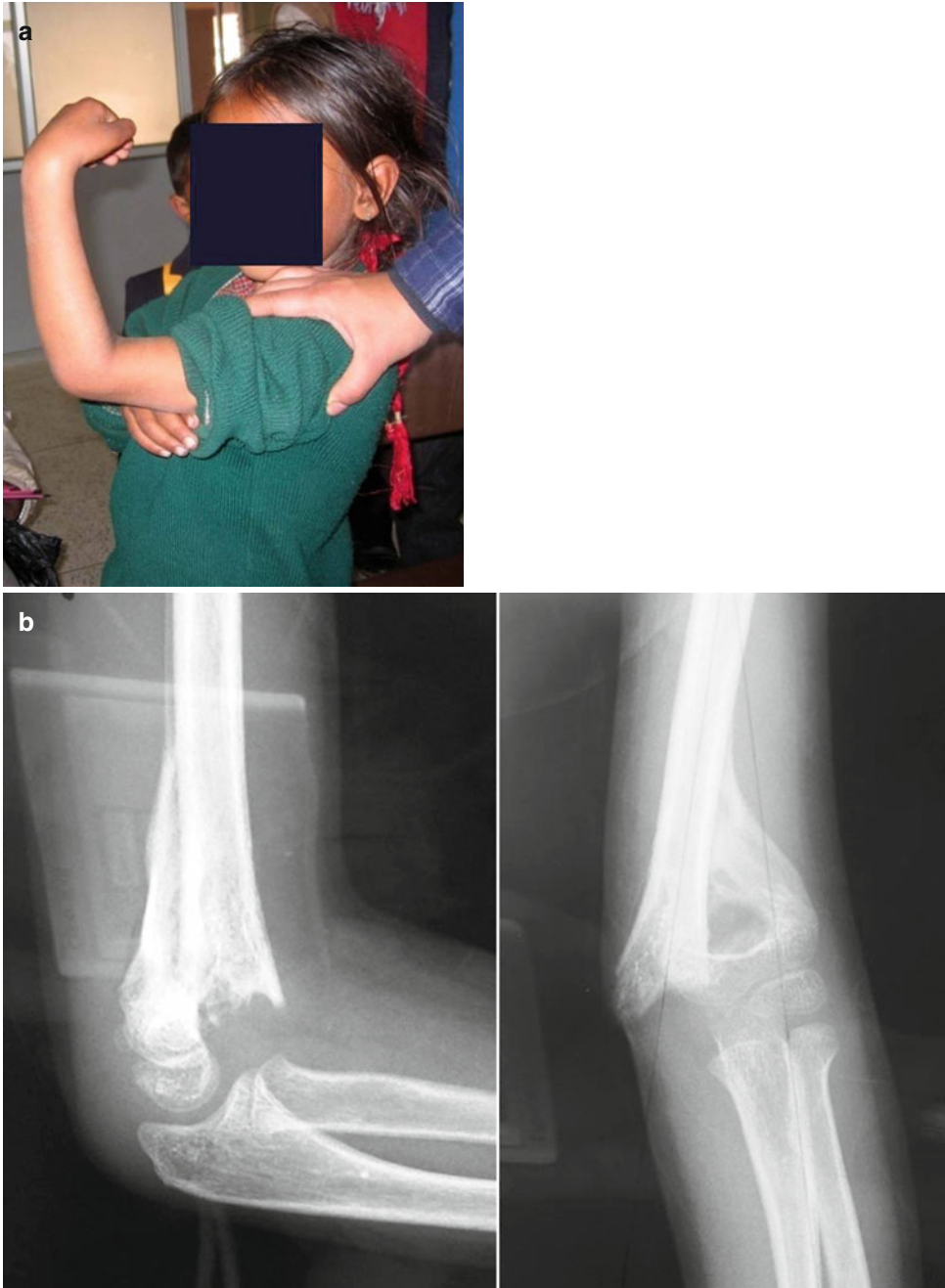

Fig. 27.15 (a–c) A common problem associated with untreated displaced supracondylar fractures is an osseous flexion block. (d) Cheilectomy is one treatment option. (e) Increased flexion on the table. (f) Post-op x-ray

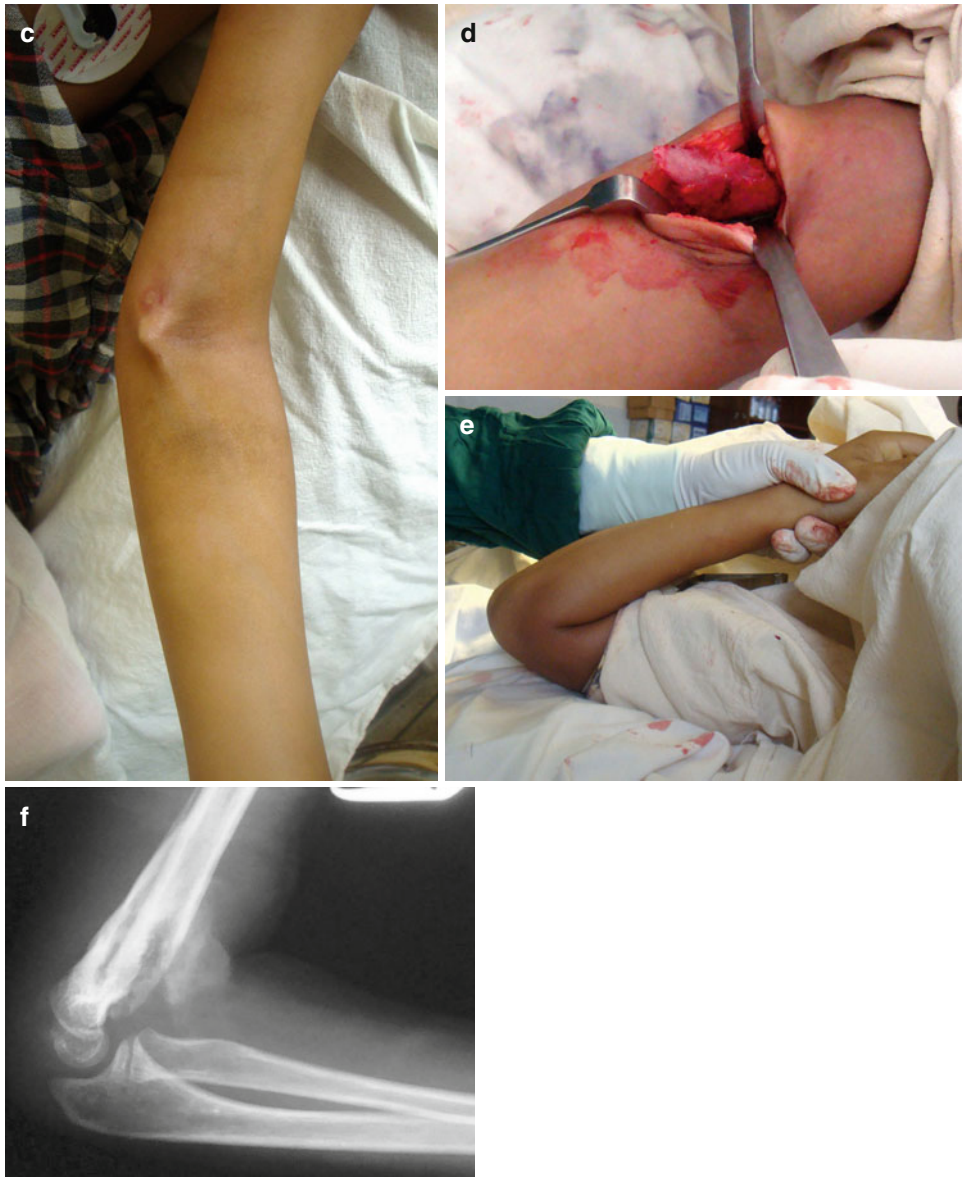

Fig. 27.15 (continued)

improving function, given the surgical risks of stiffness, avascular necrosis, and persistent nonunion. Observation may be appropriate for asymptomatic patients with normal function, recognizing that valgus deformity and/or discomfort can develop over time.

An anatomic reduction is unrealistic given the associated soft tissue contractures and remodeling. Any excessive dissection, especially posteriorly, may de-vascularize the fragment leading to avascular necrosis and persistent nonunion. Rather

than an anatomic reduction, the goal is union in a position that maximizes range of motion and provides the best carrying angle.

A posterolateral approach is used, with either local or iliac crest bone graft. Triceps lengthening can improve flexion. Fixation is with K-wires, a tension band, or screw, avoiding the physis (Fig. 27.16a–c). A varus producing distal humeral osteotomy and/or ulnar nerve transposition may be required to correct cubitus valgus and tardy ulnar nerve palsy, and consideration can be given

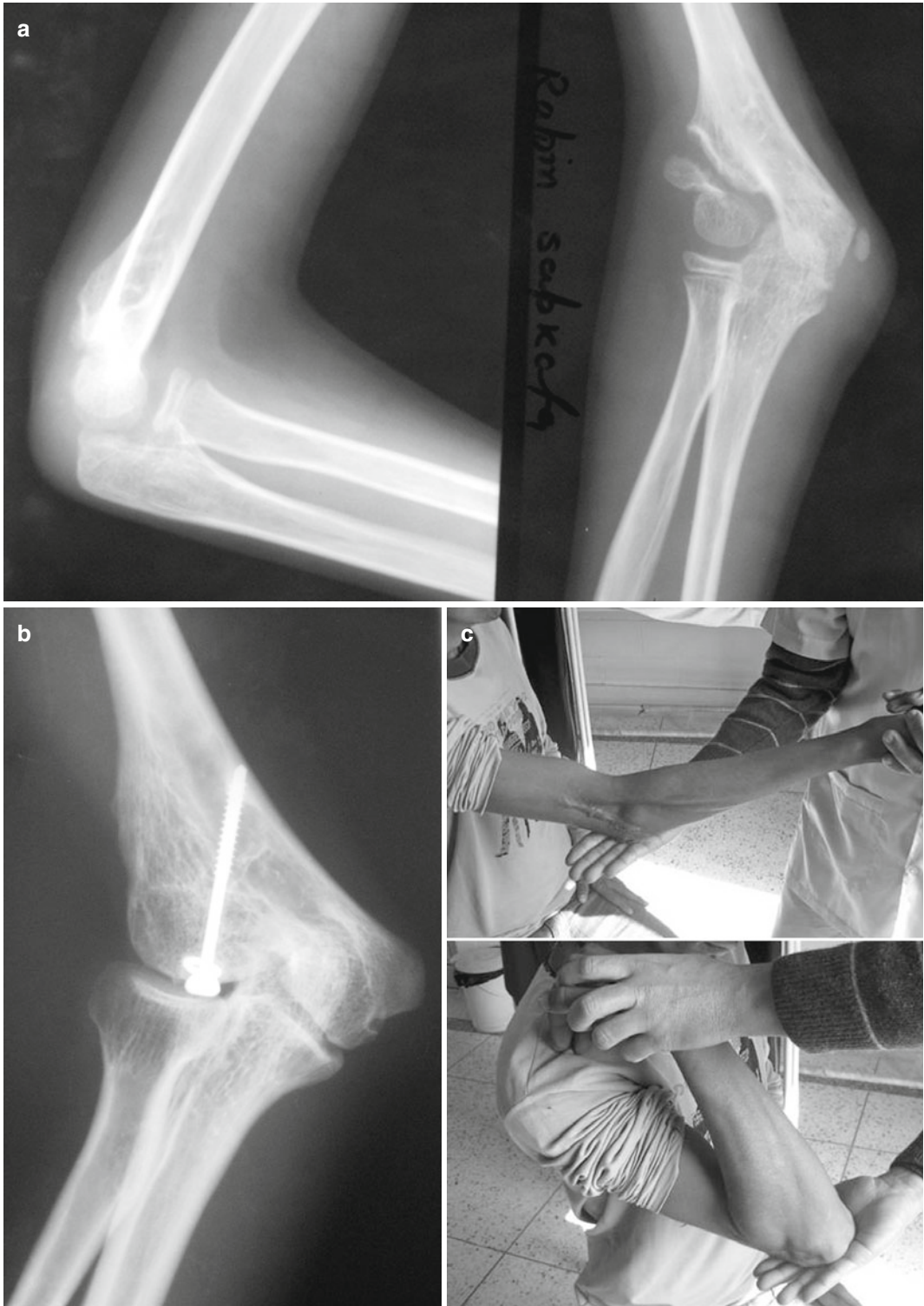

Fig. 27.16 This (a) untreated lateral condyle fracture went on to a painful nonunion and was treated by (b) in situ stabilization with a screw and local bone graft. Valgus

was present but was not of concern to the patient. (c) The fracture healed and the patient was asymptomatic despite some loss of motion

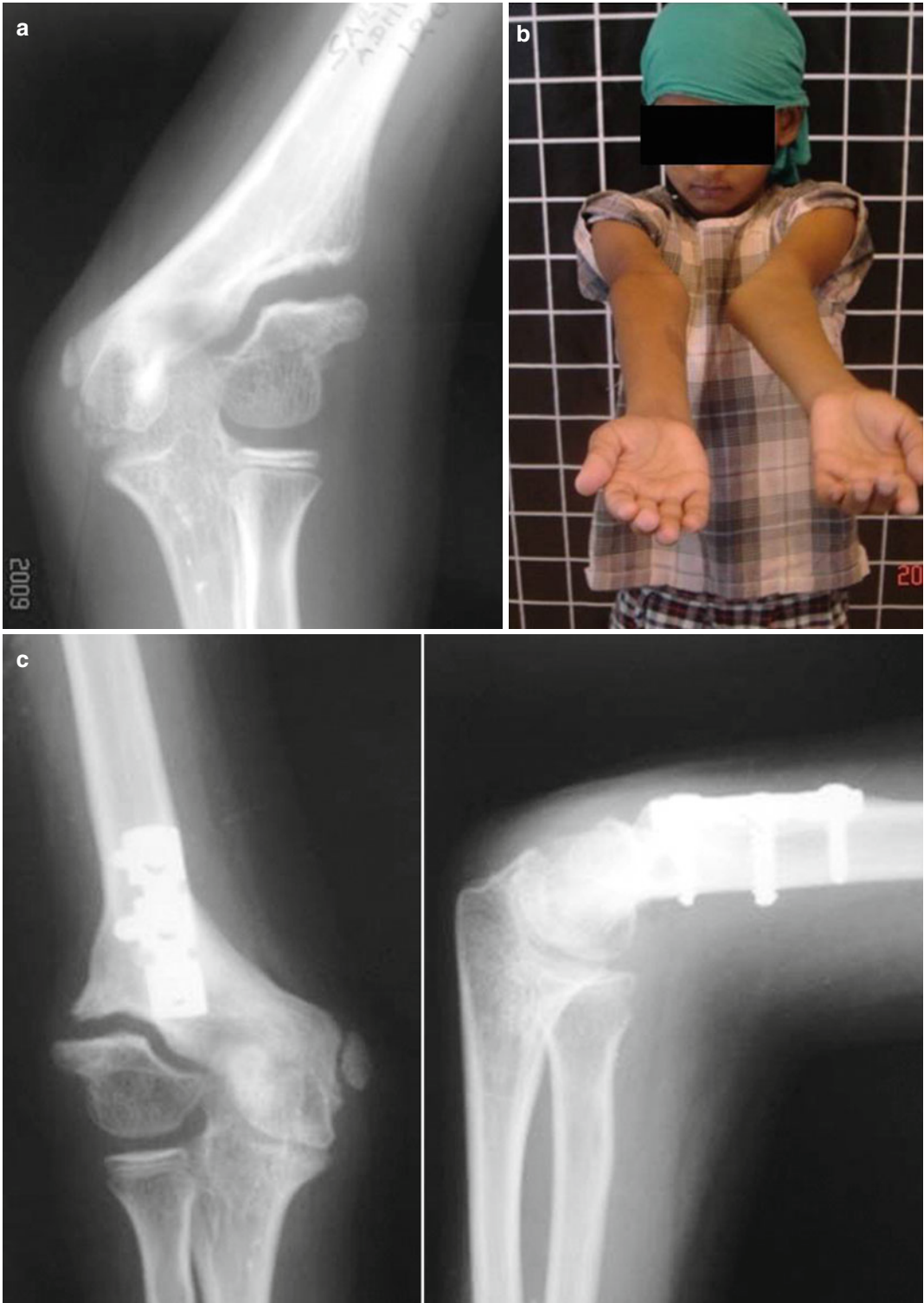

Fig. 27.17 Another approach to the (a, b) ununited lateral condyle fracture associated with significant valgus alignment is to perform a (c) corrective osteotomy without an attempt to achieve union of the fracture fragment

to performing a realignment osteotomy without an attempt at union (Fig. 27.17). There are no guidelines to suggest a time after which surgical treatment should not be considered.

While untreated *Monteggia lesions* may present with reasonable motion and function, requiring only observation, they more commonly present with pain, decreased range of motion, deformity, and/or elbow instability. Satisfactory outcomes after reconstruction have been achieved up to 3 years post-injury. The surgery involves

open reduction of the radial head with or without annular ligament reconstruction and an ulnar osteotomy for realignment and lengthening (Fig. 27.18).

Reestablishing ulnar alignment and length are critical in maintaining reduction of the radial head. An osteotomy of the radius is rarely required. Annular ligament reconstruction can be done using fascia from the triceps, a free tendon or fascial graft, or non-resorbable suture. The K-wire or Steinmann pin used to maintain

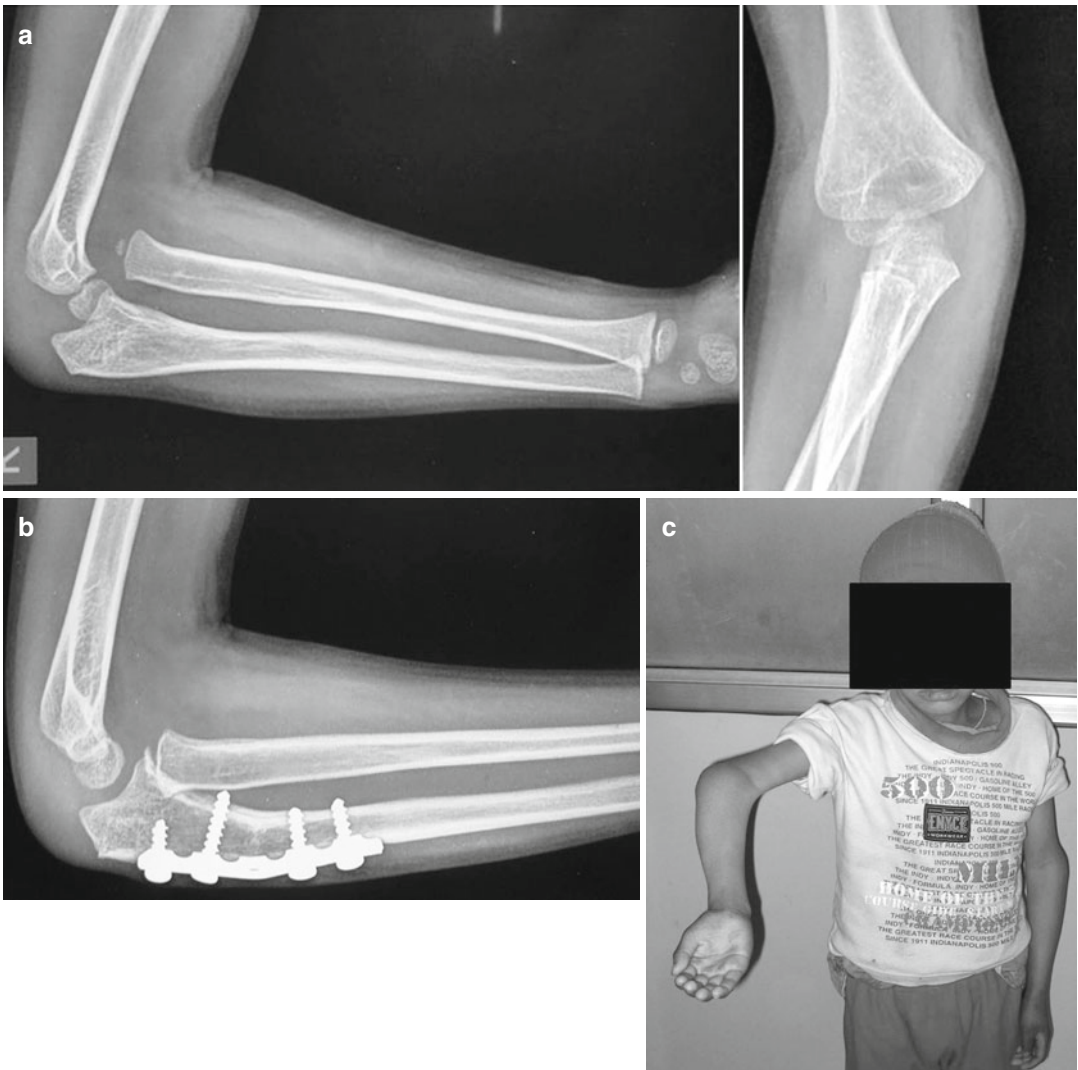


Fig. 27.18 This (a) untreated Type I Monteggia lesion underwent (b) corrective osteotomy to restore ulnar length, followed by open reduction of the radial head and

annular ligament reconstruction. This patient presented with a (c, d) neglected Type III Monteggia fracture, a very difficult treatment challenge

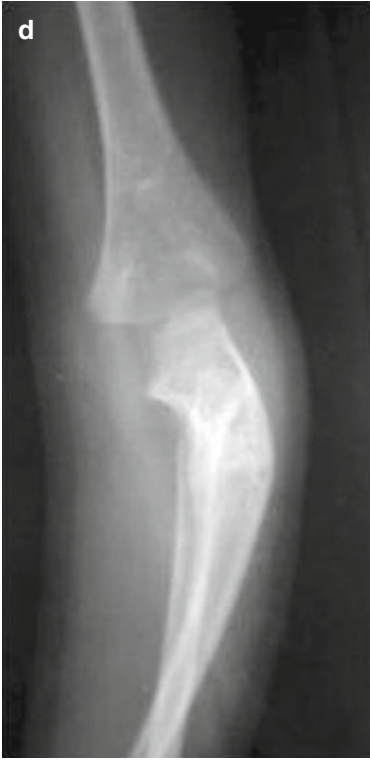

Fig. 27.18 (continued)

radiocapitellar reduction is removed after 2 weeks. Rarely, the radial head may reduce with restoration of ulnar length and alignment alone. Another option is an external fixateur to lengthen the ulna following osteotomy, with or without open reduction of the radial head.

Symptomatic chronic radial head dislocations can be treated by excision when reconstruction is not feasible, for example, when deformity of the radial head results in an incongruous relationship with the capitellum. Complications of these procedures include re-subluxation or dislocation of the radial head, ulnar neuropathy, nonunion, compartment syndrome, and stiffness, especially loss of pronation.

Patients with a neglected *elbow dislocation* commonly present with pain, restricted motion, and limitation of function (Fig. 27.19). Treatment options include primary open reduction, external fixateur with or without open reduction, and salvage procedures such as excisional arthroplasty or arthrodesis. Open reduction is the most common treatment. Barriers to reduction include contracture of the periarticular soft tissues and

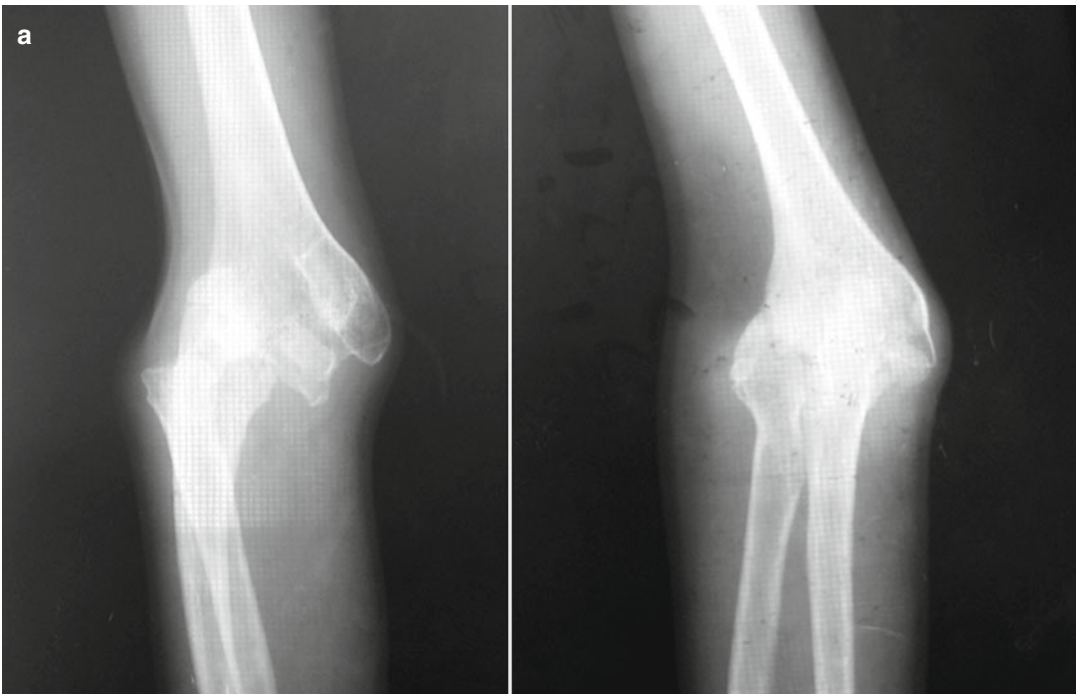


Fig. 27.19 This patient with a (a) neglected elbow dislocation presented with (b) loss of motion but without any pain or restrictions in activities of daily living

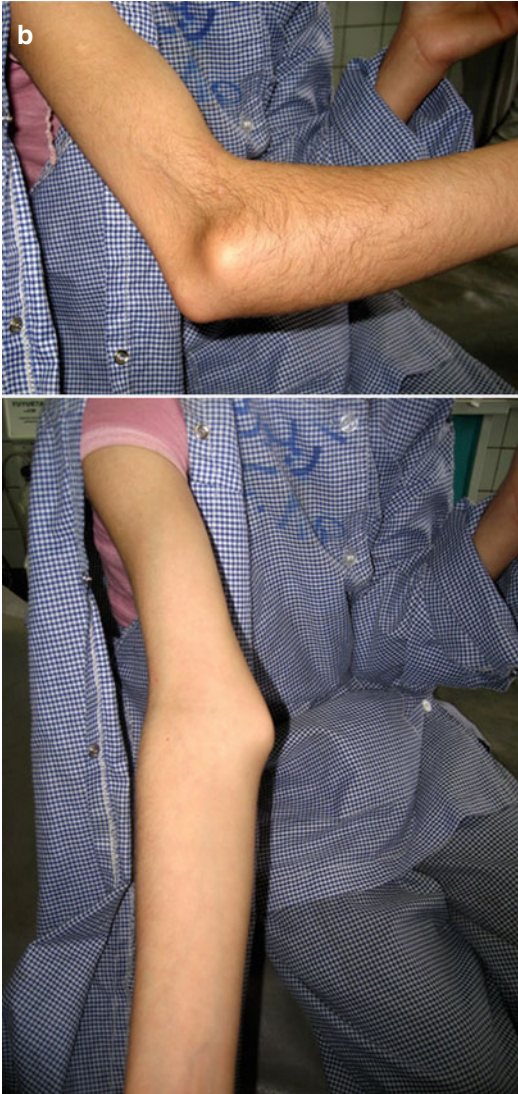


Fig. 27.19 (continued)

collateral ligaments, soft tissue calcification, and intra-articular fibrous tissue.

Careful dissection is required as osteopenia and articular cartilage softening make tissue differentiation difficult, risking joint damage. A posterior approach with triceps V-Y lengthening and isolation of the ulnar nerve remove the barriers

to reduction. A K-wire crossing the ulno-humeral joint holds the reduction. Active assisted range of motion exercises are started at 2 weeks when the K-wire is removed. Complications include transient ulnar nerve palsy, contracture, infection, and heterotopic ossification. The results are less satisfactory when a coexisting fracture is present. Joint space narrowing and signs of early arthritis are often observed on radiographic follow-up; however, it is unknown if and when these findings impact the clinical results.

Suggested Reading

- Devnani AS. Late presentation of supracondylar fracture of the humerus in children. *Clin Orthop Relat Res.* 2005;431:36–41.
- Elzohairy MM. Neglected posterior dislocation of the elbow. *Injury.* 2009;40:197–200.
- Hui JH, Sulaiman AR, Lee HC, Lam KS, Lee EH. Open reduction and annular ligament reconstruction with fascia of the forearm in chronic Monteggia lesions in children. *J Pediatr Orthop.* 2005;25:501–6.
- Kim HT, Park BG, Suh JT, Yoo CI. Chronic radial head dislocation in children, part 2: results of open treatment and factors affecting final outcome. *J Pediatr Orthop.* 2002;22:591–7.
- Lai GM, Bhan S. Delayed open reduction for supracondylar fractures of the humerus. *Int Orthop (SICOT).* 1991;15:189–91.
- Mahaisavariya B. Late treatment of displaced supracondylar fractures of the humerus using early wedge osteotomy. *Tech Orthop.* 2006;21:150–7.
- Mahaisavariya B, Laupattarakasem W. Neglected dislocation of the elbow. *Clin Orthop Relat Res.* 2005; 431:21–5.
- Rodgers WB, Waters PM, Hall JE. Chronic Monteggia lesions in children. Complications and results of reconstruction. *J Bone Joint Surg Am.* 1996;78:1322–9.
- Shimada K, Masada K, Tada K, et al. Osteosynthesis for the treatment of non-union of the lateral humeral condyle in children. *J Bone Joint Surg Am.* 1997;79:234–40.
- Toh S, Tsubo K, Nishikawa S, Inoue S, Nakamura R, Harata S. Long-standing nonunion of fractures of the lateral humeral condyle. *J Bone Joint Surg Am.* 2002;84A:593–8.
- Wilkins KE. Nonoperative management of pediatric upper extremity fractures or don't throw away the cast. *Tech Orthop.* 2005;20:115–41.

David A. Spiegel, Bibek Banskota,
and Kaye E. Wilkins

Femoral Shaft Fractures

A variety of options are available for managing femur fractures, and treatment is based on the age of the child, mechanism and energy of the injury, personality of the fracture, and local resources. Choices include (1) immediate spica casting, (2) traction followed by spica, (3) closed or open reduction and intramedullary fixation, (4) open reduction and plating, and (5) external fixation. An average of 9 mm overgrowth is commonly

observed in children between 3 and 8 years, and shortening up to 2 cm is commonly accepted in children less than 10 years. Both overlap and angulation can contribute to limb shortening, and the amount of shortening is best evaluated on lateral radiographs.

Management in Children Less than 6 Years Old

In general, femur fractures in children less than 6 years of age can be managed by closed reduction and immediate double- or single-leg spica casting (Fig. 28.1). A single-leg spica affords greater mobility and increased ease of care, and many patients will ambulate once early healing allows. High energy mechanism, comminuted, and short oblique fractures can be length unstable and require skeletal traction for 10–21 days before application of a spica. Proximal shaft fractures must be casted in 70–90° hip flexion as the proximal fragment is pulled into flexion by the psoas muscle. If traction is used, 90–90° traction is required (Fig. 28.2). Midshaft fractures can be casted in the midrange of hip flexion. The authors' preference is to leave the foot out of the cast.

Without portable imaging when the patient is treated in traction, limb lengths must be evaluated by clinical examination, taking care to avoid distraction. Ideally the affected limb will be shortened 1–1.5 cm to account for the expected overgrowth. When the fracture can be gently squeezed without pain, healing is sufficient for casting.

D.A. Spiegel, MD (✉)
Division of Orthopaedic Surgery,
Children's Hospital of Philadelphia,
Associate Professor of Orthopaedic Surgery,
University of Pennsylvania School of Medicine,
Philadelphia, PA, USA

Honorary Consultant in Orthopaedics and Rehabilitation,
Hospital and Rehabilitation Centre for Disabled Children,
Janagal, Kavre, Nepal
e-mail: spiegeld@email.chop.edu

B. Banskota, MB BS, MRCS, MS
Department of Orthopedics, Hospital and
Rehabilitation Center for Disabled Children (HRDC),
Janagal, Kavre 6757, Nepal
e-mail: bibekbanskota@gmail.com

K.E. Wilkins, DVM, MD
Department of Orthopedics and Pediatrics,
University of Texas Health Science Center at San
Antonio, The Children's Hospital of San Antonio,
formerly Christus Children's Hospital,
Mail Code 7774, 7703 Floyd Curl Drive,
San Antonio, TX 78229-3900, USA
e-mail: drkwilkins@aol.com

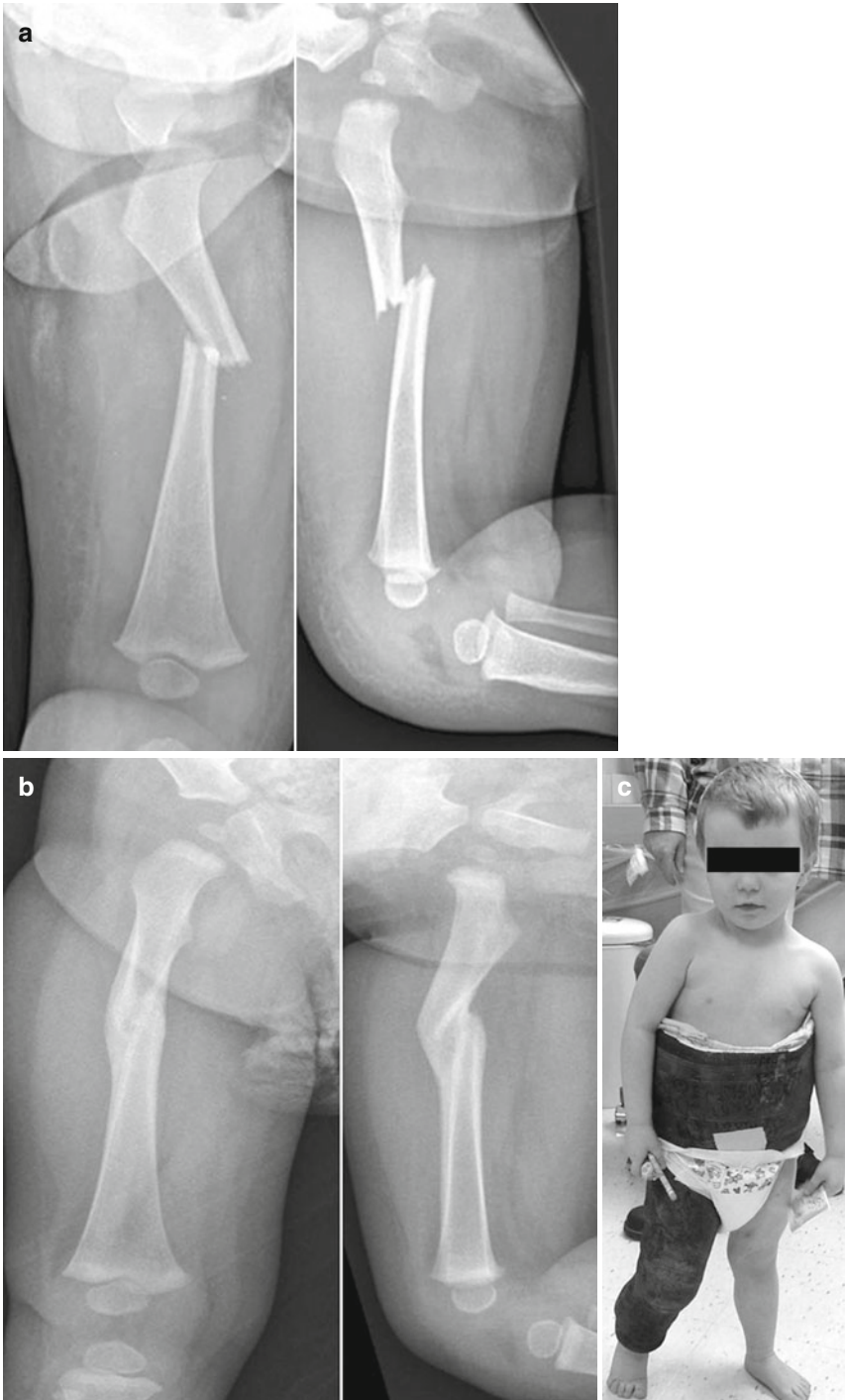


Fig. 28.1 (a, b) A proximal femoral diaphyseal fracture treated by closed reduction and immediate spica casting healed in adequate alignment, anticipating future remod-

eling. (c) Child walking in single-leg “walking spica” cast. The patient is wearing 2 diapers, one totally inside the cast

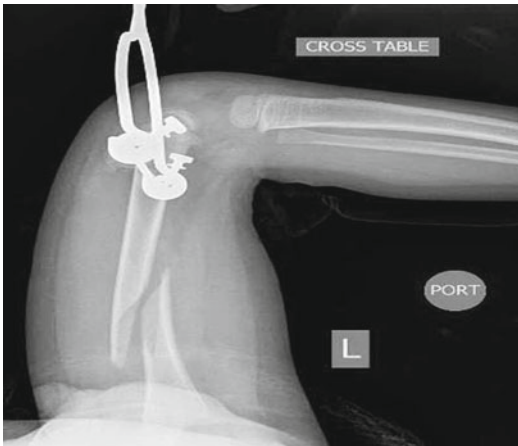


Fig. 28.2 90–90 traction is considered for 14–21 days in length unstable fractures, aiming for 1–1.5 cm of shortening in children between 3 and 8 years of age

Six Years Through Skeletal Maturity

Controversy surrounds the optimal management of patients from 6 years through skeletal maturity, and the best approach depends on the availability of a suitable environment for open surgery, portable radiographs or an image intensifier, and implants. Traction is an acceptable choice for any age. Proximal shaft fractures require 90–90 traction, and midshaft fractures can be treated in balanced skeletal traction with the hip in less flexion. Distal shaft fractures are more difficult to manage in traction, as the pull of the gastrocnemius on the distal fragment results in posterior sag. In addition to a longitudinal traction vector, a second traction pin may be needed in the distal fragment with the force vector directed anteriorly to counter the pull of the gastrocnemius. Some distal shaft fractures may be amenable to fixation with crossed Kirschner wires or Steinmann pins, but the two wires should not cross the fracture at the same point as stability will be inadequate.

The majority of length-stable fractures—transverse and mid-diaphyseal, in patients less than 50 kg—can be treated with an intramedullary implant. While flexible nails may rarely be available (Fig. 28.3), a Rush rod can be used, recognizing that a spica cast is often required for rotational stability. An open reduction is usually required in the absence of an image intensifier,

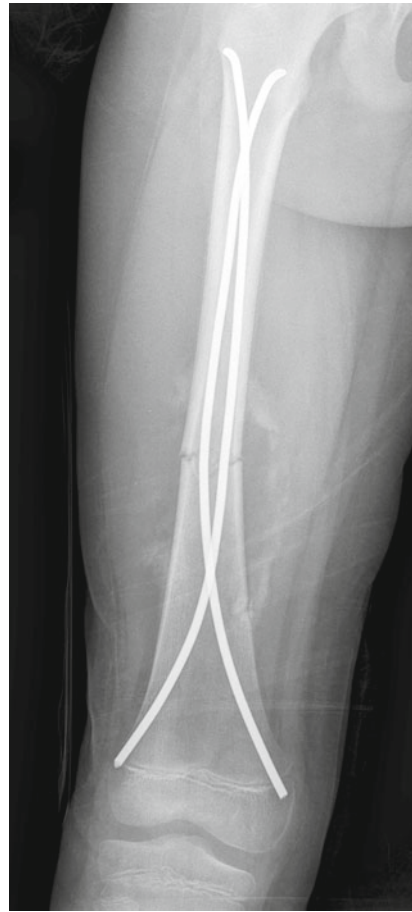

Fig. 28.3 Flexible nailing for a diaphyseal femur fracture

and a single Rush rod can be inserted through the tip of the greater trochanter and advanced across the fracture. Piriformis entry should be avoided as it is associated with AVN of the hip. Alternatively, two pre-contoured rods can be inserted from the distal metaphysis and advanced proximally. Even when available, rigid nails which enter the piriformis fossa must be avoided in the skeletally immature.

External fixateurs can be viewed as portable traction and are especially beneficial for open fractures needing wound care. Use fewer half pins, 2 half pins per fragment, and place them at least 3–4 cm from the fracture (Fig. 28.4). The resulting semirigid fixation allows micromotion, which stimulates callus. When more rigidity is needed external fixation principles for adult

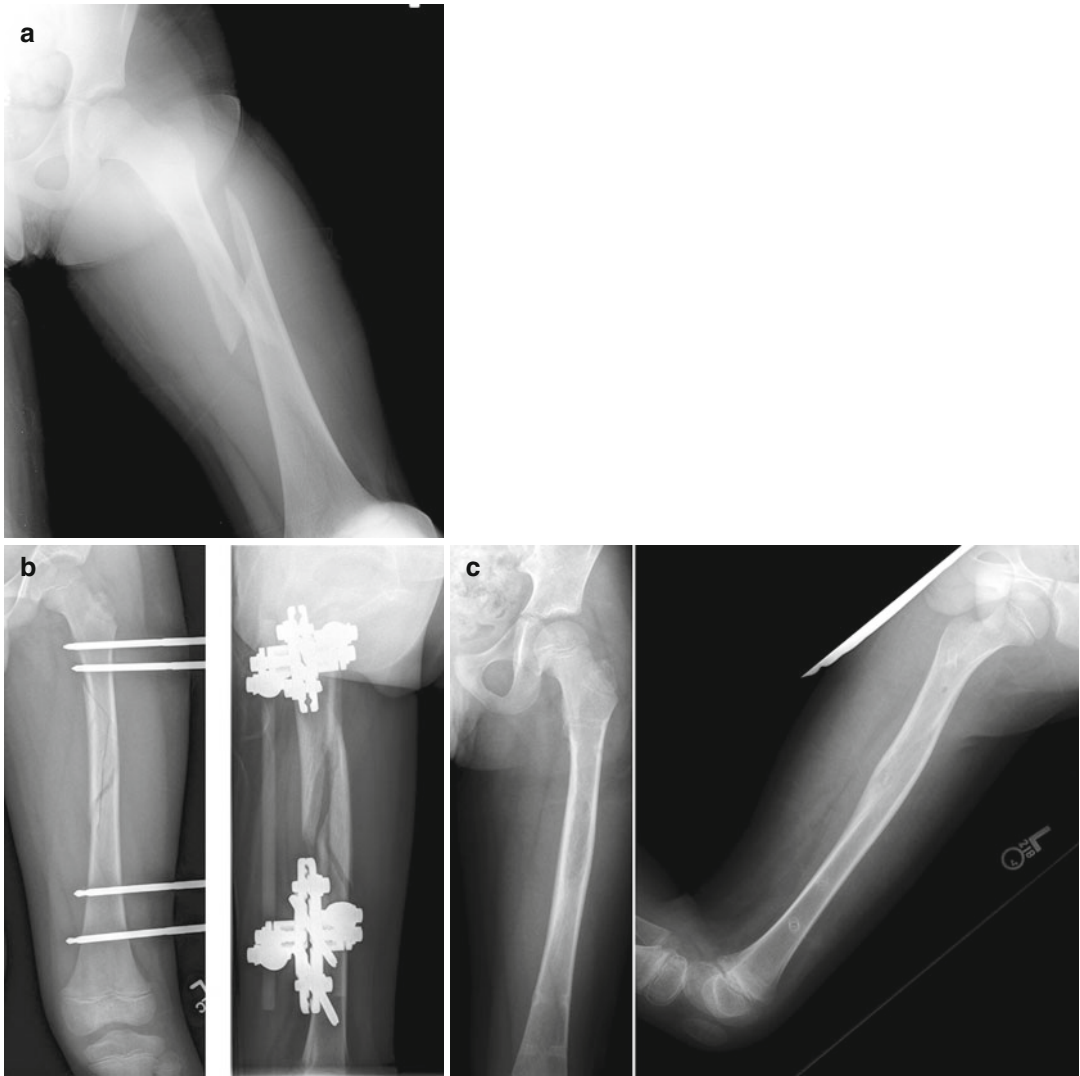


Fig. 28.4 (a) This length-unstable diaphyseal fracture was treated by (b) external fixation and (c) healed in satisfactory alignment

fractures can be used based on individual experience and judgment. Disadvantages of external fixation include the risk of refracture, especially in transverse fractures; pin tract infection or sepsis if adequate hygiene cannot be provided when the patient returns home; and the need for a second procedure to remove the fixateur.

Open reduction and plating is an option, but carries a greater risk of deep infection.

Tibia and Fibula Fractures

The majority of tibial shaft fractures, with or without fibular fracture, are amenable to closed management. These fractures are at risk for valgus angulation due to the pull of the anterior compartment muscles, and the remodeling potential is more limited for fractures with valgus and/or apex posterior angulation. Shortening up to 1 cm is acceptable, recognizing that the average

overgrowth is 5 mm in children between 2 and 10 years. Fifty percent apposition of the fragments is acceptable (Fig. 28.5). Unstable fractures requiring reduction are commonly managed in a long leg cast for the first few weeks, with transition to a short leg weight-bearing cast once early callus has formed. Weekly radiographs are required for 2–3 weeks or until callus is present. At any time in the early treatment, cast wedging may be necessary to maintain alignment (see Chap. 13).

The risk of compartment syndrome is increased for direct, blunt trauma, as well as high energy injuries. In austere settings compartment syndrome must be diagnosed clinically, and the index of suspicion is heightened by increasing requirements for pain medicine.

Indications for operative management include open injuries, inability to achieve or maintain a closed reduction, neurovascular injury, compartment syndrome, and floating knee injuries. Treatment options include traction, closed reduction and percutaneous fixation with a K-wire or Steinmann pin in proximal or distal metaphyseal fractures (Fig. 28.6), external fixation, intramedullary fixation, and open reduction and plating. Traction is rarely required when an external fixateur is available but can be delivered via a calcaneal or distal tibial pin. External fixation is ideal for open fractures requiring wound management, recognizing that the time to union is increased, and complications are frequent especially following open fractures. The fixateur should be either

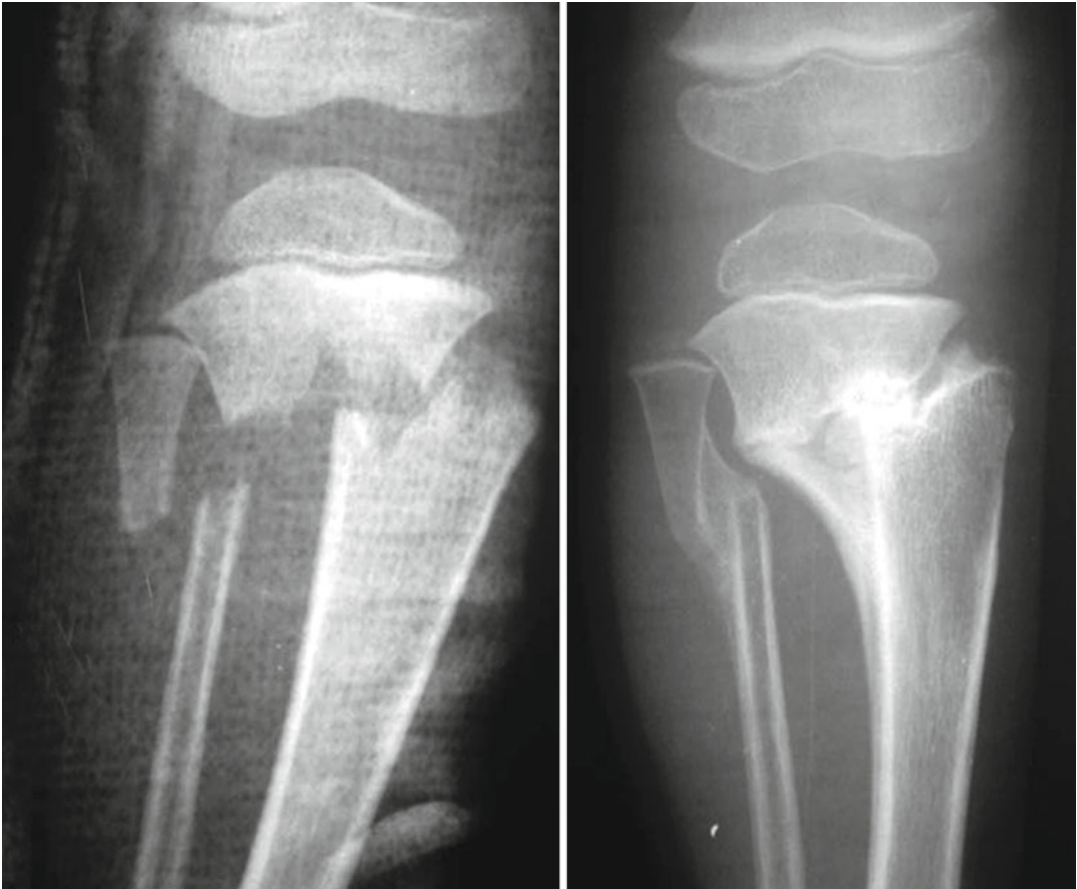

Fig. 28.5 This proximal tibia fracture was treated closed after manipulation to correct the valgus and healed in acceptable alignment although translation was >50 %. The patient was asymptomatic

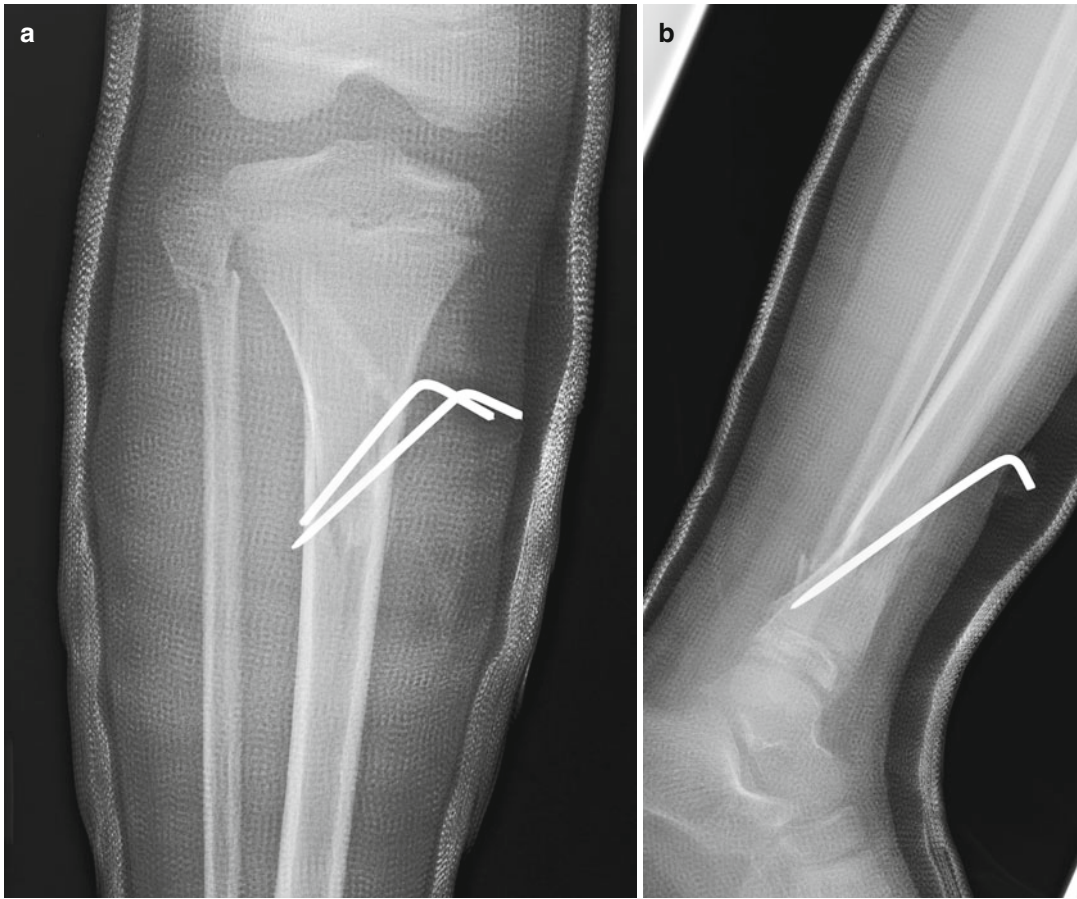


Fig. 28.6 (a) Percutaneous fixation can be used to maintain alignment in unstable proximal or (b) distal tibia fractures

dynamized or removed as soon as soft tissue healing allows.

When available, intramedullary fixation with a flexible nail or a Rush rod can be considered for both closed fractures and grade 1 or 2 open fractures (Fig. 28.7). Pre-contoured flexible nails, each less than 40% of the diameter at the isthmus, are inserted through two small incisions over the proximal tibial metaphysis and advanced across the fracture into the distal metaphysis but not across the physis. An open reduction is often required in the absence of an image intensifier. Procurvatum, anterior apex bowing, is common with standard nail positioning, and we recommend that the tips of the nails be rotated anteriorly to avoid this. Time to union is reduced when compared to treatment with external fixation,

and complications are less frequent. Open reduction with extensive subperiosteal stripping and plate fixation should be avoided if at all possible due to the risks of delayed union, nonunion, and wound sepsis.

Ankle Fractures

Ankle fractures are most commonly classified according to Dias and Tachdjian as (1) supination-inversion, (2) pronation-eversion-external rotation, (3) supination-external rotation, and (4) supination-plantar flexion.

In the supination-inversion pattern (Fig. 28.8), the lateral side fails first in tension, resulting in a Salter-Harris type I or II fracture of the distal

Fig. 28.7 (a) Unstable tibial shaft fracture (b) treated by flexible intramedullary nailing

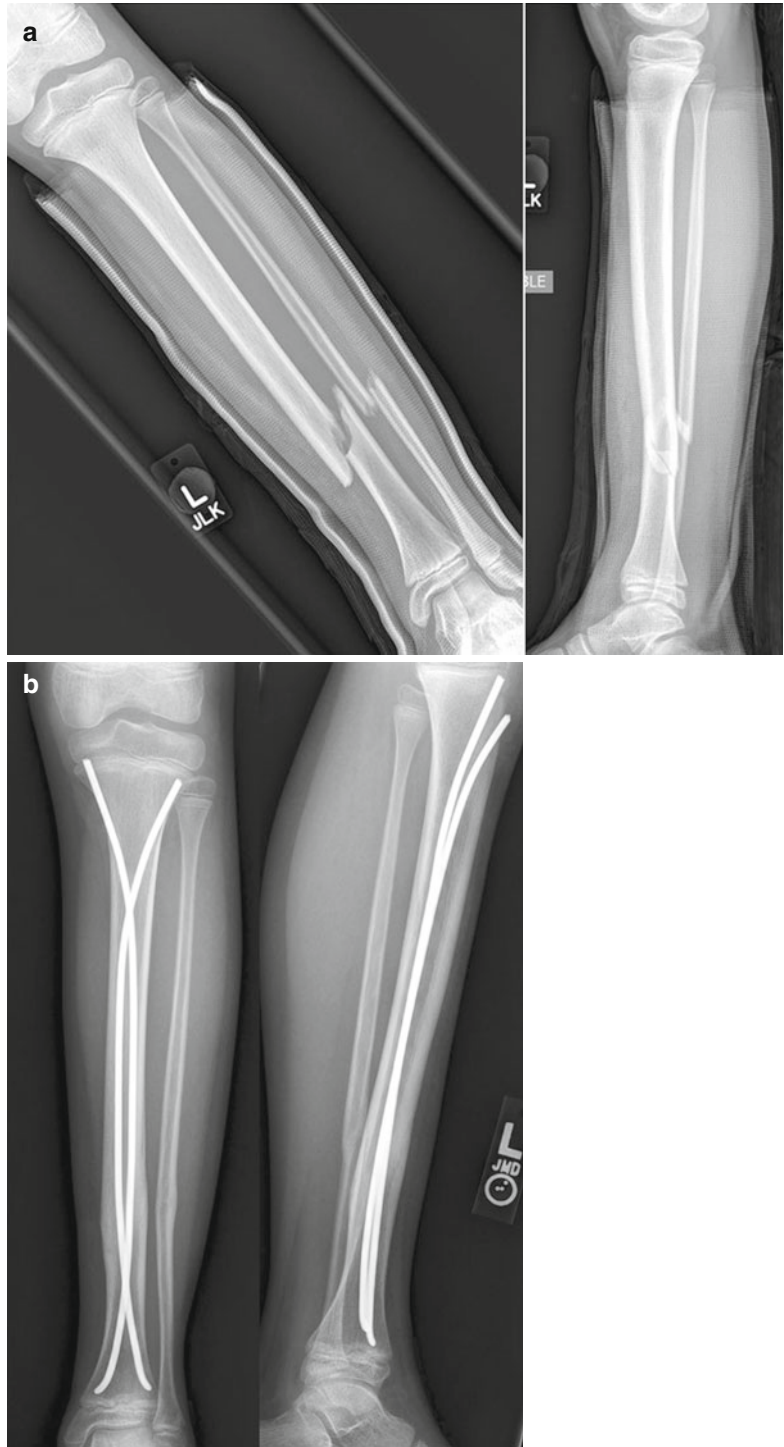

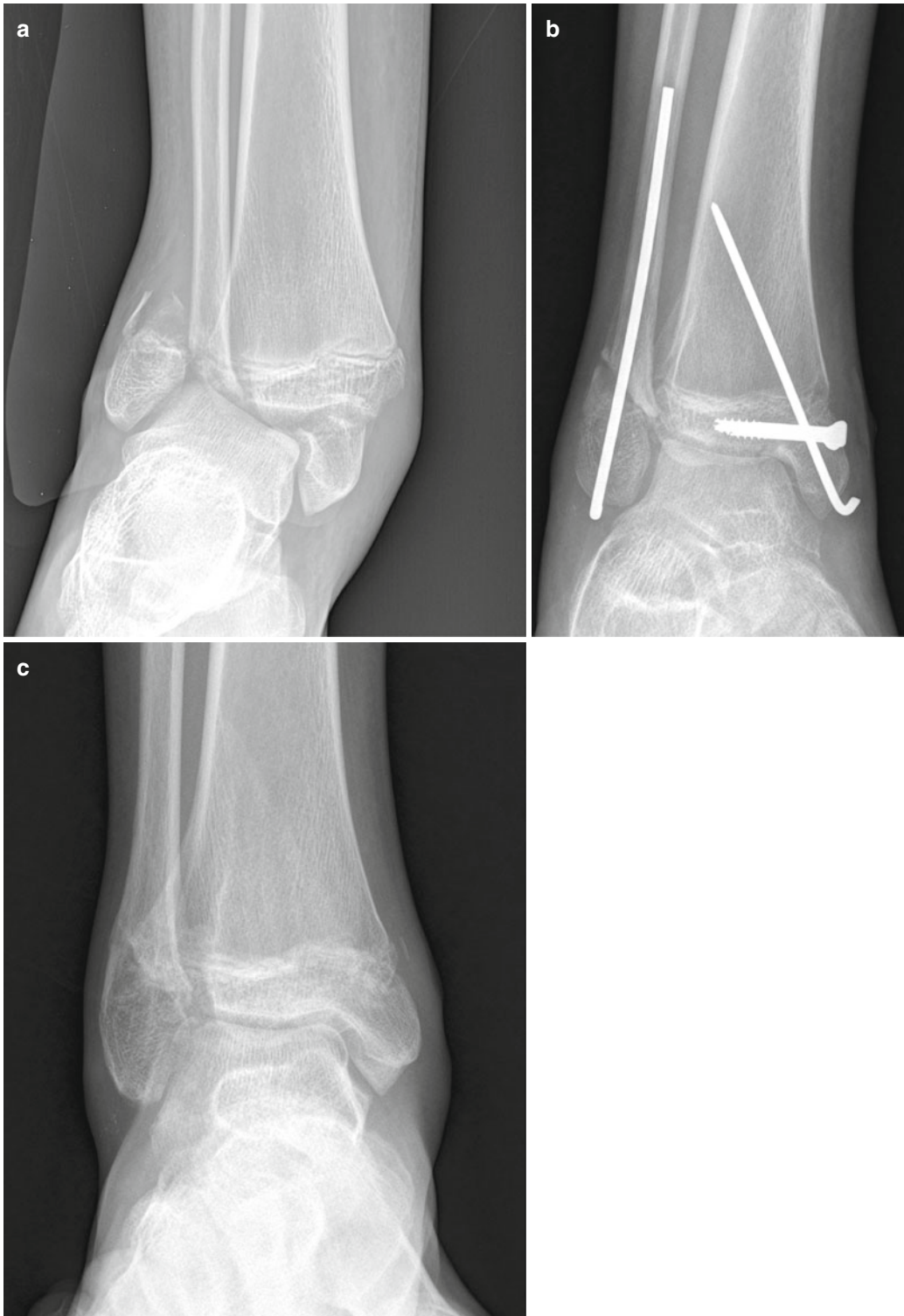


Fig. 28.8 (a) The supination-inversion fracture pattern involving Salter-Harris IV fracture of the medial malleolus and a Salter-Harris I or II fracture of the lateral malleolus (b) was treated by open reduction and fixation. (c) X-ray after removal of implants

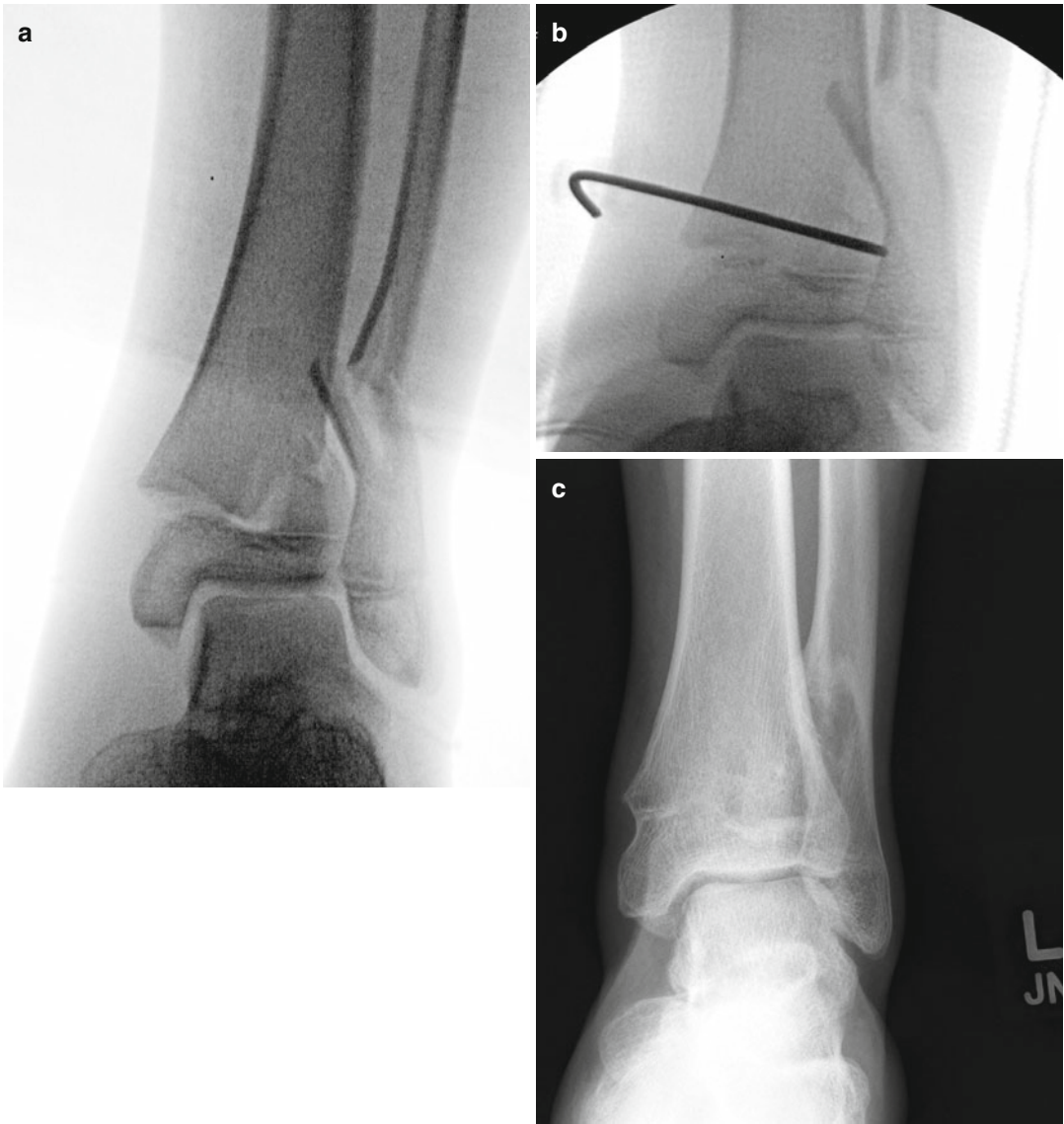

Fig. 28.9 (a) This pronation-eversion-external rotation fracture in an adolescent near epiphyseal closure was (b) reduced and stabilized with a percutaneous wire. (c) Final X-rays show acceptable ankle alignment

fibula. With greater force the talus is driven into the medial malleolus, producing an oblique fracture (Salter-Harris III or IV). There may be comminution and/or impaction of the distal tibial articular surface. Open reduction of these intra-articular malleolar fractures is required if displaced >2 mm. The risk of growth disturbance is significant.

In the pronation-eversion-external rotation pattern, the medial side fails in tension, resulting

in a Salter-Harris type I or II fracture of the distal tibia, associated with a transverse or oblique fracture of the distal fibula above the syndesmosis (Fig. 28.9). These present with valgus angulation. Periosteum may be trapped within the distal tibial fracture resulting in physeal widening. It is unclear whether routine removal of the periosteum is required to reduce the risk of growth disturbance; however, it should be removed if it prevents an adequate reduction.

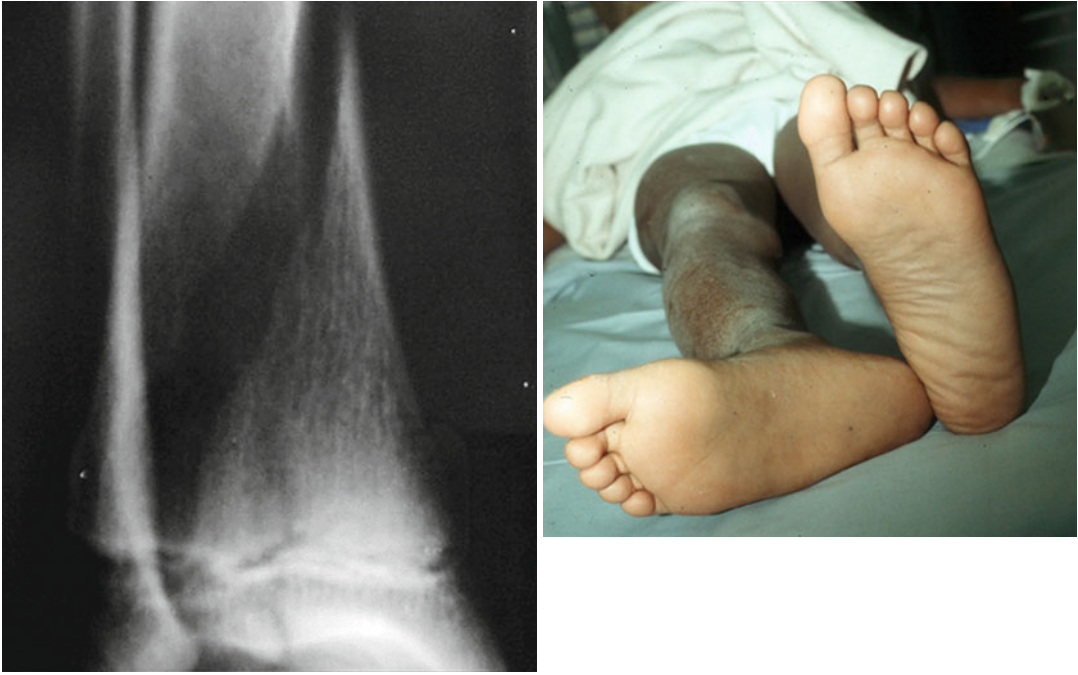

Fig. 28.10 The supination external rotation pattern may clinically present with obvious rotational deformity of the distal lower extremity

The supination-external rotation pattern involves a Salter-Harris I or II fracture of the distal tibia associated with an oblique fracture of the distal fibular metaphysis (Fig. 28.10). The major clinical deformity is external rotation, and the reduction is secured by internally rotating the distal fragment. If the fracture is unstable, a screw can be used to maintain the reduction.

The supination-plantar flexion pattern results in a Salter-Harris type I or II fracture of the distal tibia with the distal fragment displaced posteriorly and a greenstick fracture of the fibula (Fig. 28.11). These fractures are reduced by longitudinal traction with the ankle plantar flexed, while the distal fragment is pushed anteriorly. Periosteum is commonly interposed at the fracture site and may require removal. Inadequate

reduction results in loss of ankle dorsiflexion with or without impingement. If unstable, these are held with metaphyseal tibial screws placed from anterior to posterior.

Closure of the distal tibial physis is asymmetric, starting on the medial side and progressing to the lateral side. The Tillaux fracture results in avulsion of the anterolateral corner of the distal tibial epiphysis—the portion of physis that is last to close—by the anterior inferior tibiofibular ligament (Fig. 28.12). The triplane fracture is a more complex variant of the Tillaux in which fracture lines are identified in the coronal, sagittal, and axial planes (Fig. 28.13). Both of these injuries require reduction if there is more than 1 mm joint step-off or more than 2 mm displacement. While closed reduction can be attempted, many require open reduction and fixation.

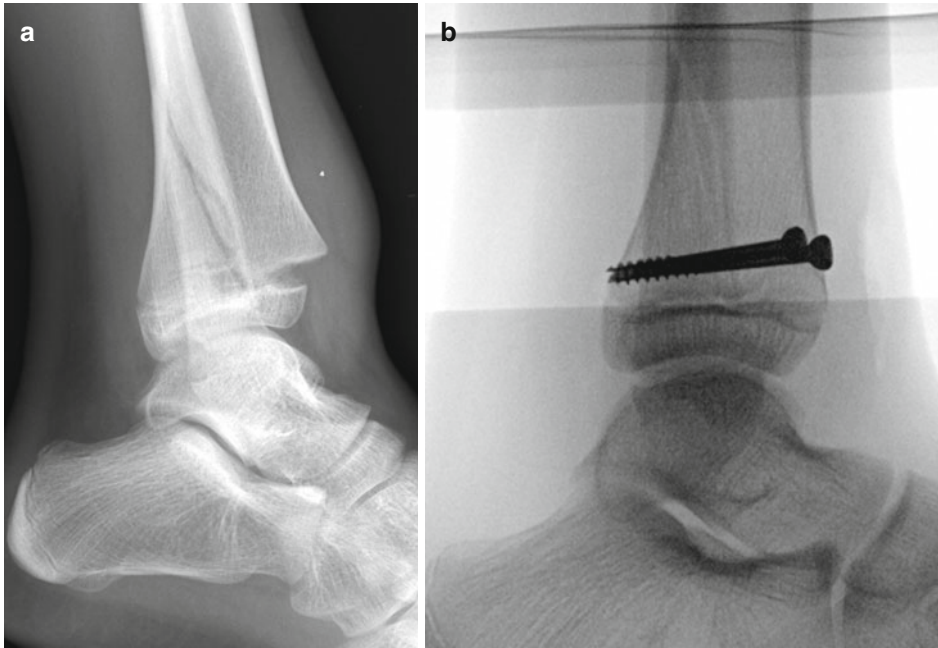


Fig. 28.11 (a) This supination-plantar flexion injury was treated by (b) reduction and screw fixation

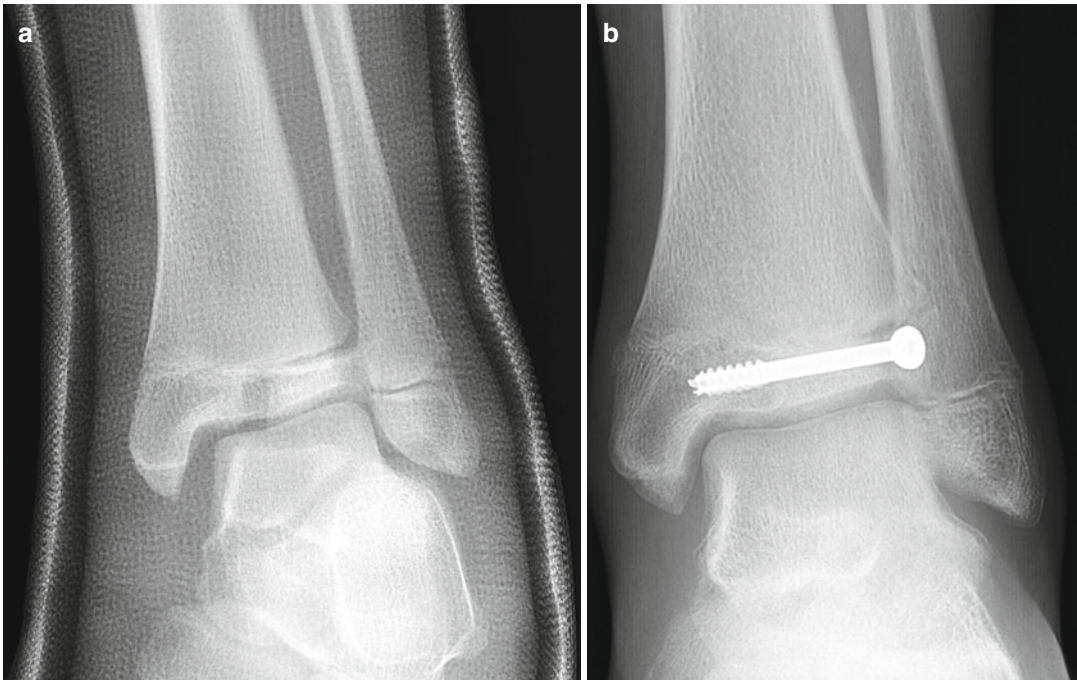


Fig. 28.12 (a) A juvenile Tillaux fracture treated by (b) open reduction and fixation

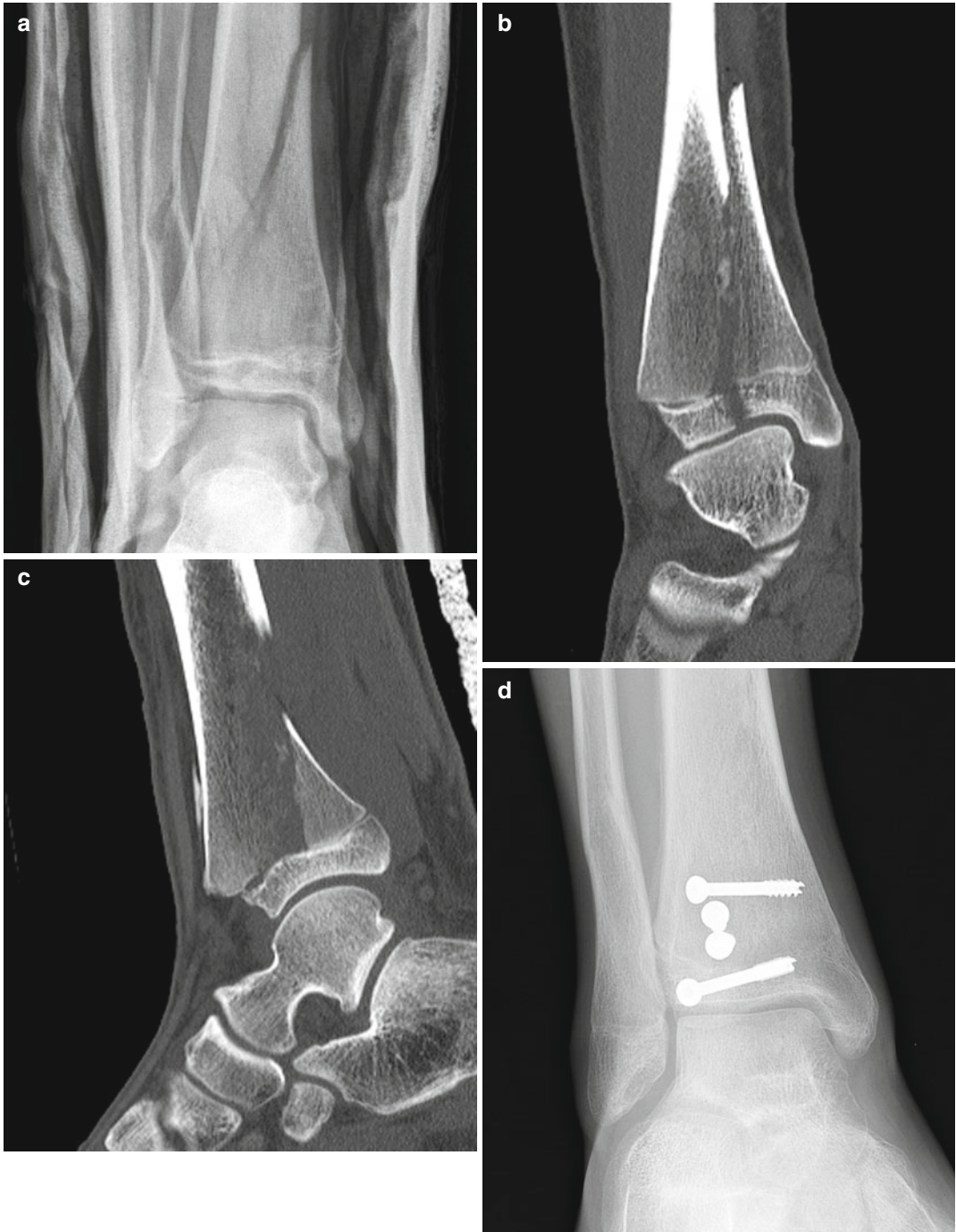


Fig. 28.13 An example of a displaced triplane fracture. (a) AP X-ray and (b, c) CT clearly showing the fracture configuration, (d) treated by closed reduction and screw fixation through a small anterolateral incision

Neglected Lower Extremity Fractures and Fracture/Dislocations

Malunited diaphyseal fractures are treated by percutaneous or open osteoclasis or osteotomy, followed by traction/casting or fixation. Limb length discrepancies may require additional treatment after union. The basic principles of angular correction must be followed (see Chap. 37). Malunited intra-articular fractures are more challenging and require individualized treatment.

The management of *neglected femoral shaft fractures* centers on restoring limb alignment and length caused by angulation and/or overriding fragments. Soft tissue contractures develop rapidly, making it difficult to restore length while correcting the deformity. An acute correction is possible, but lengthening more than 4 cm increases the risk of neurovascular complications, making some shortening necessary. In fractures associated with osteomyelitis shortening may occur during debridement (Fig. 28.14).

A staged approach can be used, in which mobility of the fracture is achieved by osteoclasis, and length is restored by either 5 or 10 days of skeletal traction or distraction with an external fixateur. Osteoclasis can be performed manually, by percutaneous drilling with a K-wire or Steinmann pin, or by an open procedure to remove callus or bone. Definitive stabilization is carried out once length has been restored, either by spica casting, internal fixation, or external fixation. Bone grafting with local callus or bone and/or iliac crest is recommended.

Femoral neck fractures are rare in children when compared with adolescents or adults, and neglected injuries are prone to malunion or non-union and avascular necrosis. While low energy injuries are observed in children, higher energy injuries predominate in adolescents and young adults. Primary strategies aim for union with preservation of the femoral head. Options include (1) bone grafting with internal fixation or (2)

osteotomy and internal fixation, with or without bone grafting (Fig. 28.15).

Most traumatic *hip dislocations* in children are the result of low energy injuries and coexisting fractures are infrequent. Patients present with pain, stiffness, instability, gait disturbance, and leg length discrepancy. While observation may be appropriate for the rare case in which the hip is asymptomatic and functioning well, options to achieve reduction include the “heavy traction” method or an open reduction, with or without preliminary traction and/or femoral shortening. Other treatments to salvage a chronically painful, dislocated hip include excisional arthroplasty, arthrodesis, and pelvic support osteotomy (see Chap. 41).

The “heavy traction” method employs distal femoral skeletal traction starting at 10 % of body weight and advancing as tolerated between 3 and 6 weeks until the femoral head reaches the level of the acetabulum. The hip is abducted to achieve a concentric reduction and a hip spica is worn for 6 weeks. Even though reduction is achieved in fewer than 50 % of patients, preliminary traction stretches the soft tissues, making any operative intervention easier and less likely to cause avascular necrosis.

Open reduction can be performed via an anterior, lateral, or posterior approach, with or without preliminary skeletal traction (Fig. 28.16). A posterior approach has a higher risk of AVN and our experience suggests that displacement of the femoral head through the joint capsule, or “buttonholing,” is uncommon in children compared to adults—perhaps due to greater soft tissue laxity and the lower energy associated with the injury. A femoral osteotomy may be required for shortening, depending on soft tissue tension at the time of reduction. If unstable a K-wire across the joint will maintain the reduction, and a spica cast is worn for 6 weeks. This method has been successful in dislocations up to 2 years and though AVN is common it does not seem to impact the results at short to midterm follow-up. A failed open reduction does not preclude any of the salvage treatment options.

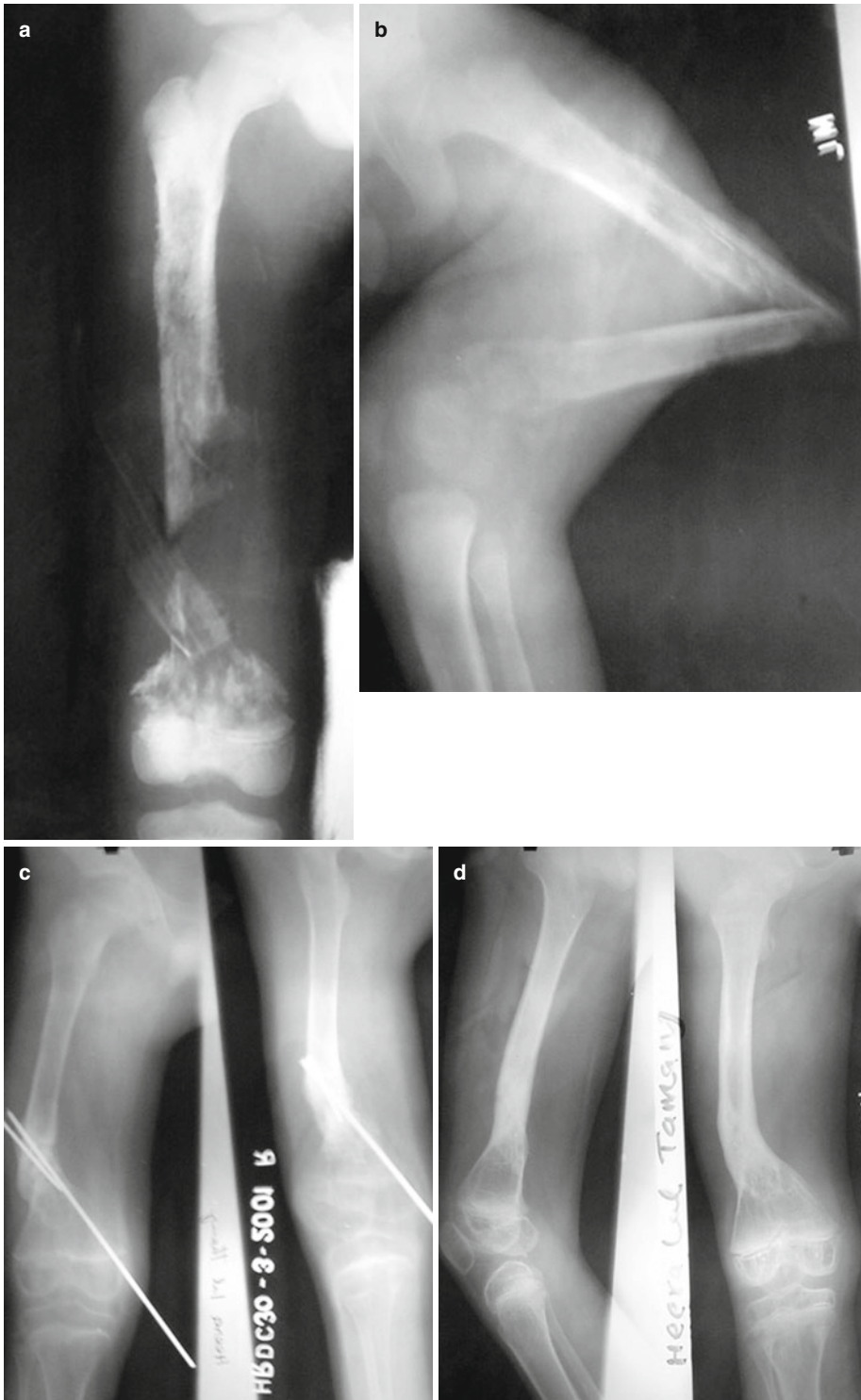


Fig. 28.14 (a, b) This pathologic open femoral shaft fracture due to osteomyelitis was (c) treated by debridement, antibiotics, and fixation with Kirschner wires.

(d) The fracture healed with moderate varus and shortening, but no evidence of persistent infection

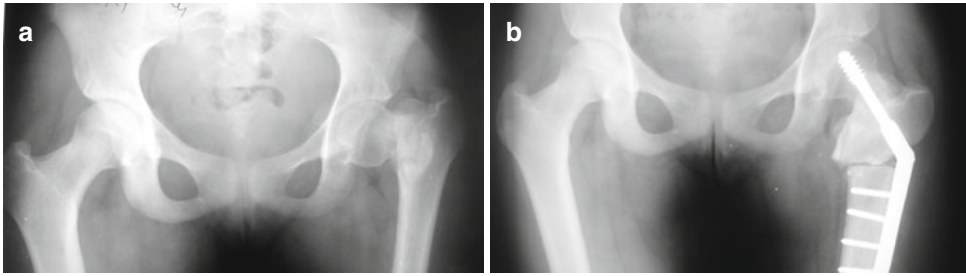


Fig. 28.15 (a) This neglected femoral neck fracture was (b) treated by a subtrochanteric valgus osteotomy

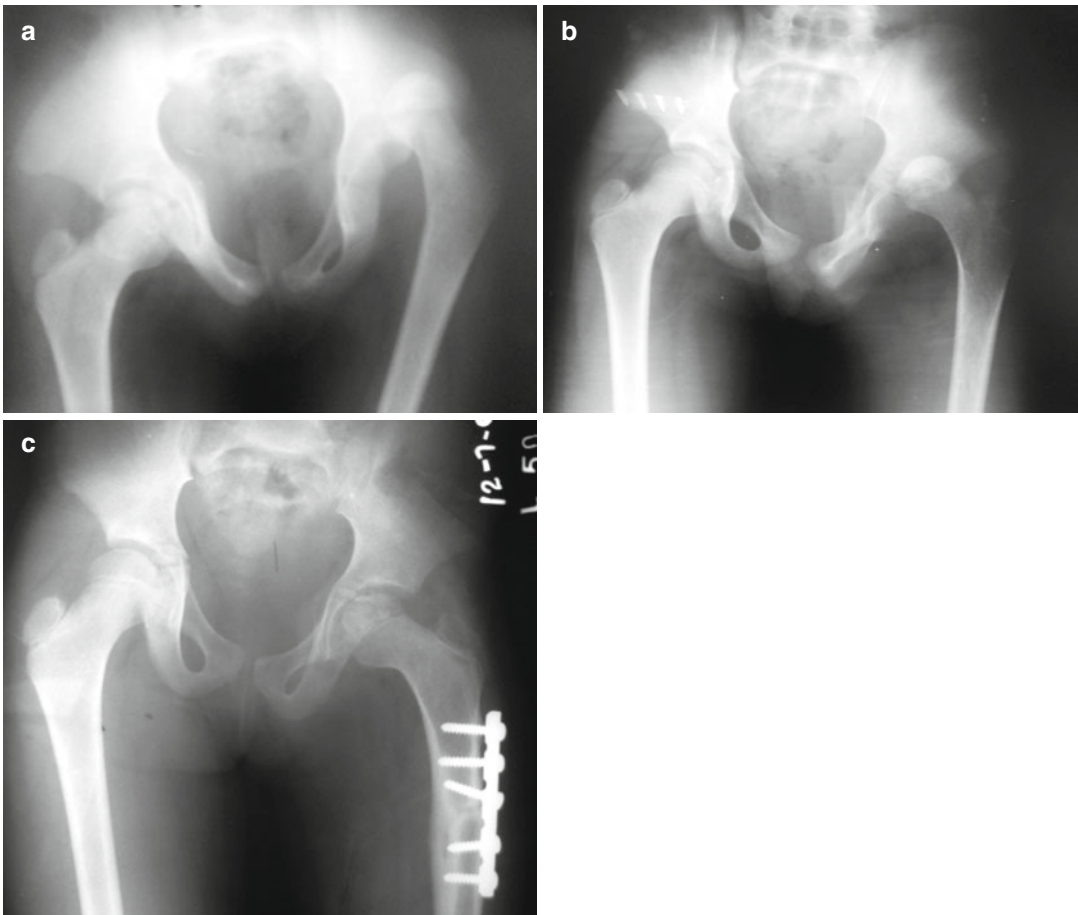


Fig. 28.16 (a) A neglected posterior dislocation of the hip was first treated by (b) skeletal traction with a distal femoral pin. (c) An open reduction and femoral shortening were required to reduce the joint and avoid excessive tension

Suggested Reading

- Abraham LM, Te CV, Cruz FD. Delayed open intramedullary nailing of femoral shaft fractures. *Tech Orthop* 2006;21:88–98.
- Banskota AK, Spiegel DA, Shrestha OP, Shrestha OP, Rajbhandary T. Open reduction for neglected traumatic hip dislocation in children and adolescents. *J Pediatr Orthop*. 2007;27:187–91.
- Gahukamble A, Nithyananth M, Venkatesh K, Amritanand R, Cherian VM. Open intramedullary nailing in neglected femoral diaphyseal fractures. *Injury*. 2009;40:209–12.
- Kumar S, Jain AK. Open reduction of late traumatic posterior hip dislocation in 12 children. *Acta Orthop Scand*. 1999;70:599–602.
- Magu NK, Singh R, Sharma AK, Ummat V. Modified Pauwels' intertrochanteric osteotomy in neglected femoral neck fractures in children: a report of 10 cases followed for a minimum of 5 years. *J Orthop Trauma*. 2007;21:237–43.
- Mahaisavariya B, Laupattarakasem W. Late open nailing for neglected femoral shaft fractures. *Injury* 1995;26:527–29.
- Roshan A, Ram S. The neglected femoral neck fracture in young adults: review of a challenging problem. *Clin Med Res*. 2008;6:33–9.

Part V

Musculoskeletal Infections

Jacques L. D'Astous and William James Harrison

Introduction

Musculoskeletal infections are a common cause of disability in economically underdeveloped regions. Their management is challenging owing to the usual delayed or neglected mode of presentation and limitation of available resources. Plain radiographs are often the only imaging at hand, laboratory services and infectious disease consultation may be deficient, and only a limited number of antibiotics may be available. Challenges include not only eradicating the infection but also managing other orthopedic complications such as destructive joint changes, bone loss, pathological fracture, angular deformities, and limb length discrepancy. The importance of nutritional supplementation as an adjunct in the treatment of all infections cannot be overemphasized as patients are often malnourished at baseline, reducing the effectiveness of their immune systems.

J.L. D'Astous, MD, FRCS(C) (✉)
Department of Orthopaedic Surgery,
University of Utah, 1275 Fairfax Rd. at Virginia St.,
Salt Lake City, UT 84108, USA

Orthopaedic Surgery, Shriners Hospital,
Salt Lake City, UT USA
e-mail: jdastous@shrinenet.org

W.J. Harrison, BM BCh, MA(Oxon),
FRCS (Trauma and Orthopaedics), FCS ECSA
Trauma and Orthopaedics,
Countess of Chester NHS Foundation Trust,
Liverpool Road, Chester, CH2 1UL, UK
e-mail: jim.harrison1@nhs.net

In this chapter we outline the basic treatment principles for septic arthritis; acute, subacute, and chronic osteomyelitis; and pyomyositis. Subsequent chapters focus on specific management principles for neglected joint sepsis, chronic osteomyelitis, osteomyelitis and septic arthritis in adults, and musculoskeletal tuberculosis.

Septic Arthritis

Septic arthritis can be caused by bacteria, mycobacteria (TB), or fungi. The etiology is most often hematogenous seeding of the synovium, but can also be due to extension of a metaphyseal osteomyelitis, following surgery, or rarely from direct traumatic inoculation. Septic arthritis associated with bacterial pathogens typically evolves rapidly, while the damage associated with tuberculous arthritis progresses slowly over months to several years.

After approximately 18 months of age, the physis typically serves as an effective barrier to the spread of infection from the bone into the joint. But in those younger, a metaphyseal osteomyelitis can decompress directly into the joint in locations where the metaphysis is intraarticular, namely the proximal humerus, radius and femur, and the distal fibula. Multiple joint sepsis can be seen in neonates, resulting in severe joint destruction and limb length inequality.

Acutely, patients present with joint pain, especially pain with motion, fever, and often a history of other infections. Limp or refusal to bear weight

is common, and pseudoparalysis of an extremity is often observed in infants or younger children. Neonates and toddlers may not exhibit a febrile response and may also have normal laboratory studies. A high index of suspicion is warranted, and any joints suspected of having septic arthritis should be aspirated and the specimen sent (if laboratory services are available) for a cell count and differential (WBC > 50,000 in acute pyogenic infection), gram stain, aerobic and anaerobic culture and sensitivity, acid fast bacilli, and fungal stains and cultures. Blood cultures are positive in 30–60 % of cases. Delayed treatment can lead to permanent joint damage, resulting in stiffness, deformity, and long-term disability.

Bacterial septic arthritis most commonly affects the large weight-bearing joints—hip and knee. Patients with hip sepsis usually hold the hip in flexion, abduction, and external rotation to minimize intracapsular pressure. Plain radiographs may show soft tissue swelling, loss of soft tissue planes, and occasionally bony changes consistent with an adjacent osteomyelitis. Joint space widening and subluxation or dislocation of the hip can be seen in neonates or infants with hip sepsis.

Typically, an excellent result can be expected with prompt diagnosis, surgical drainage, and antibiotics. While repeated aspiration may be appropriate in concert with antibiotics in the management of smaller joint infections in certain clinical situations, in most austere environments emergent surgical drainage is required in large weight-bearing joints, especially the hip and knee. Complications of delayed or inadequate treatment include avascular necrosis, joint ankylosis and/or degeneration, loss of motion, malpositioning of the limb, limb length inequality, and chronic pain.

Patients with joint infection due to mycobacteria or fungal sources will have a more indolent clinical course and pathological behavior similar to juvenile arthritis (see Chap. 33).

Osteomyelitis

Osteomyelitis can be caused by bacteria, mycobacteria (tuberculosis or other), fungi, or parasites. Organisms gain access to the bone through

a hematogenous route in the majority of cases, especially in children. Other sources include direct inoculation by a penetrating injury or following surgery, open fracture, or local spread of disease. Osteomyelitis can be classified by duration (acute, subacute, and chronic), route of infection (hematogenous, direct), anatomic location, and age group.

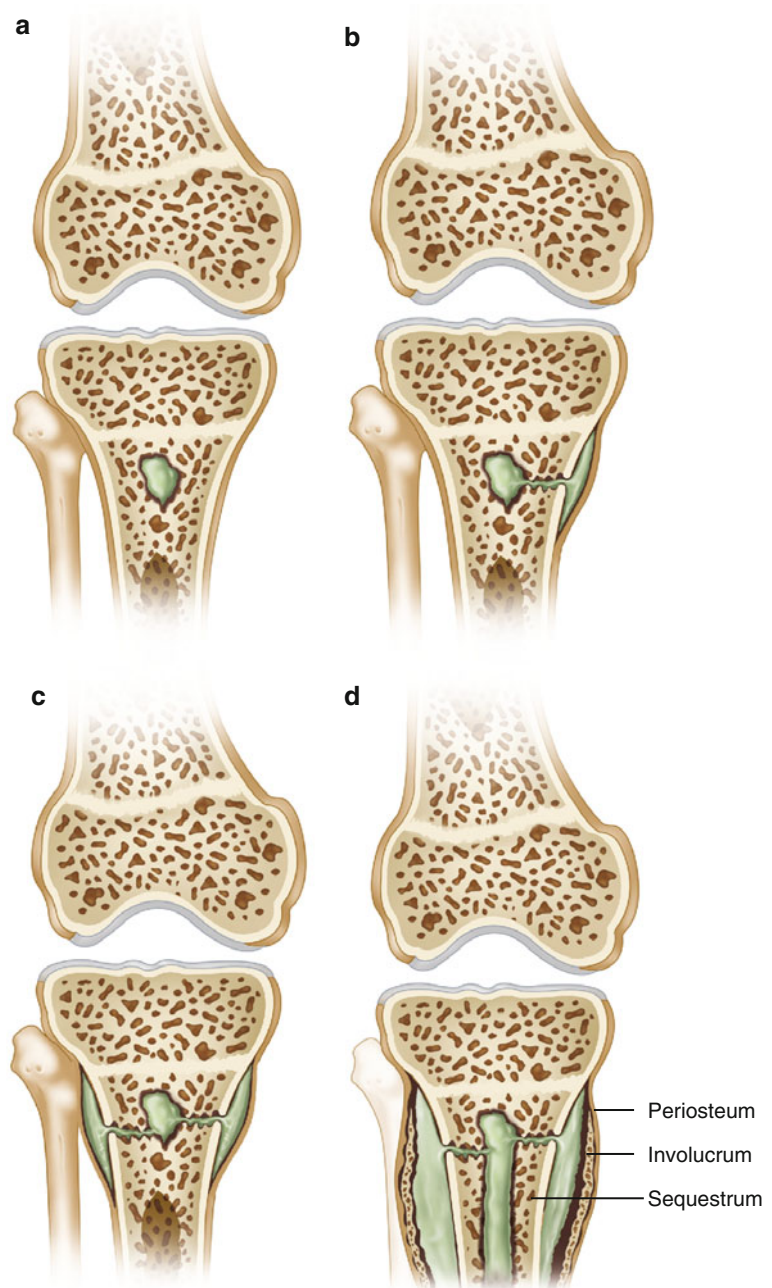
Acute Hematogenous Osteomyelitis

Acute hematogenous osteomyelitis is more common in children than adults and presents with localized pain, fever, lethargy/malaise, and limp or refusal to bear weight or use a limb. The signs and symptoms of acute osteomyelitis may be similar to acute septic arthritis, making a differential diagnosis difficult. Infants can present with pseudoparalysis of the limb, and fever may be absent. Physical findings include tenderness to palpation (especially in the metaphysis), swelling, warmth, and erythema, and often a sympathetic effusion or coexisting septic arthritis of an adjacent joint. When laboratory studies are available, the WBC count is elevated in 25–75 %, except in neonates or infants where the WBC counts are often normal. The C-reactive protein (CRP) becomes elevated within 6 h of infection, making it most useful for an early diagnosis. The erythrocyte sedimentation rate (ESR) becomes elevated within 24–48 h of onset.

Radiographs demonstrate soft tissue swelling and loss of soft tissue planes; however, bony changes, such as periosteal reaction and osteolysis, may not appear for 10–14 days. When the diagnosis is suspected clinically, aspirate the area of maximum tenderness with an 18 or 20 gauge needle under local anesthesia. If no purulent material is aspirated at the periosteum, the needle should be advanced through the thin metaphyseal bone. The natural history is shown in Fig. 29.1.

In hematogenous osteomyelitis, organisms typically lodge in the metaphyseal region because of sluggish blood flow in venous sinusoids adjacent to the physis. The organisms proliferate, and the intramedullary pressure increases due to the host inflammatory response. The infected material breaks through the thin metaphyseal cortex, resulting in a subperiosteal abscess. This subperiosteal

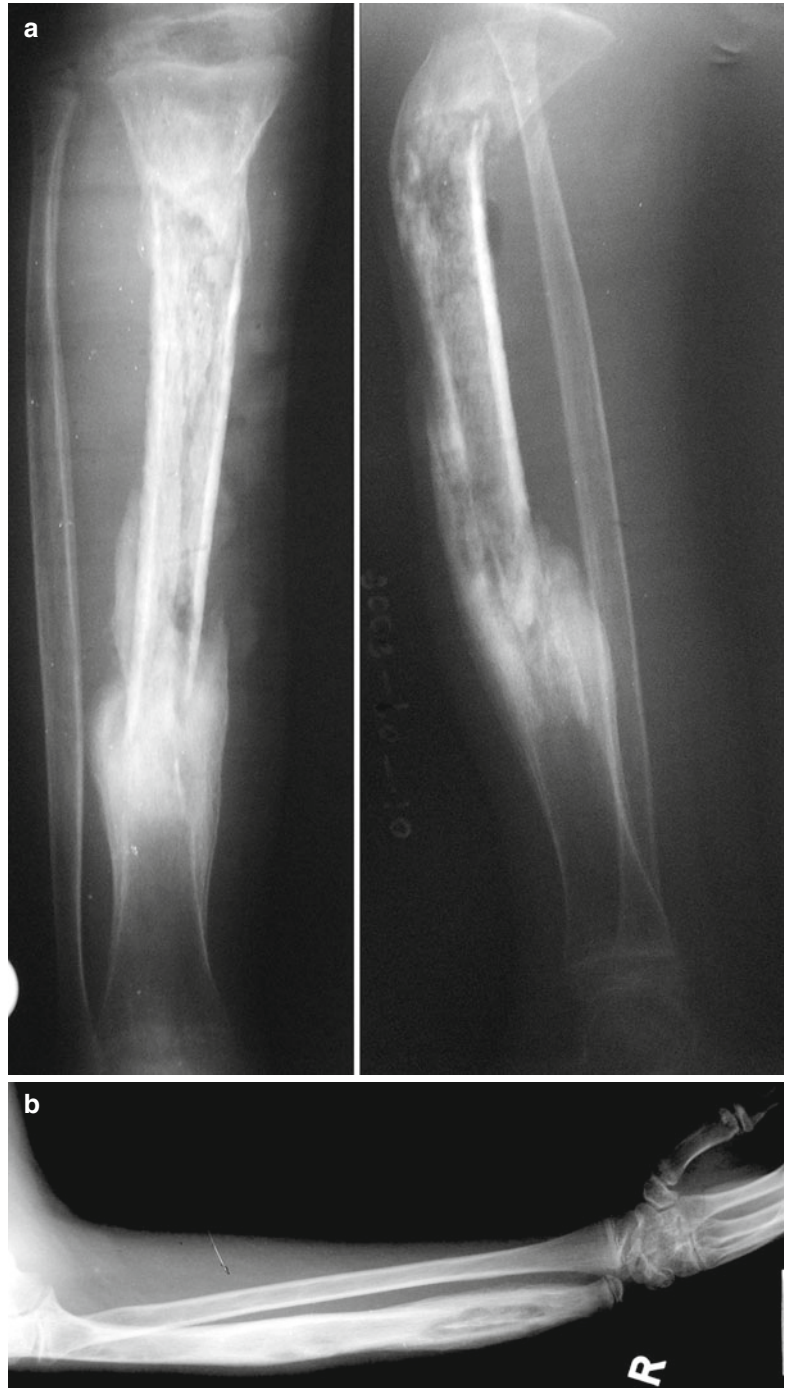Fig. 29.1 Natural history of pediatric hematogenous osteomyelitis of the tibial metaphysis. (a) The infection begins in the metaphysis, forming an intraosseous abscess that (b) decompresses through the thin metaphyseal cortex to become a subperiosteal abscess. (c) The abscess elevates the periosteum, stripping the blood supply to the bone. (d) One or more areas of bone become necrotic (sequestrae). The host periosteal response of new bone formation, involucrum, stabilizes the mechanical environment, partially or completely resorbs sequestrae and reconstitutes bone loss



abscess can expand, elevate the periosteum, and deprive the cortical bone of its blood supply, resulting in bone necrosis and the development of a sequestrum or sequestrae (Fig. 29.2). The entire shaft may become sequestered. Sequestrae are less common in adults than in infants and children. The communication between the medullary canal and a subperiosteal abscess is called a “cloaca.” Eventually, the abscess can break through

the skin, forming a sinus tract. The host response, as seen in the periosteum, is an attempt to reestablish stability by new bone formation and this is referred to as an involucrum (Fig. 29.3). The involucrum is typically much less robust in adults than it is in children. Where the metaphysis is intracapsular (proximal femur, proximal radius, proximal humerus, distal fibula), there is a risk of coexisting septic arthritis.

Fig. 29.2 (a–d) Examples of sequestrae and involucra. (a, d) The involucra of the tibia and metatarsals are partial, weak, and poorly demarcated from the indistinct sequestrae. (b, c) The involucra are complete and robust around the well demarcated sequestrae in the ulnar shaft and the proximal femur



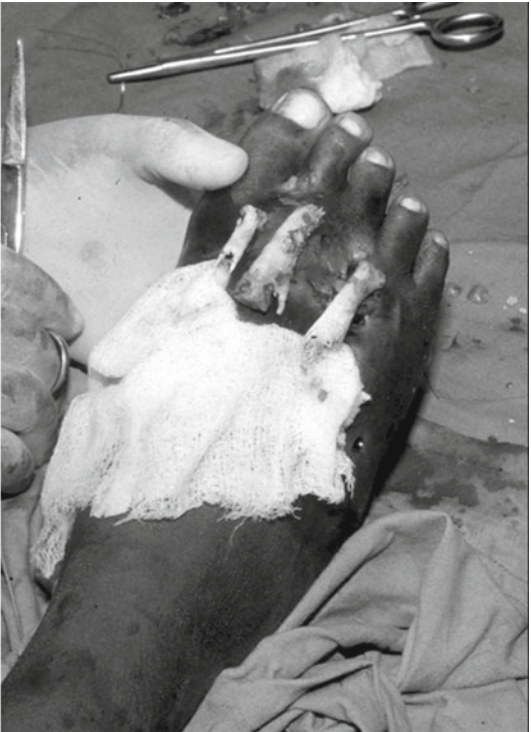
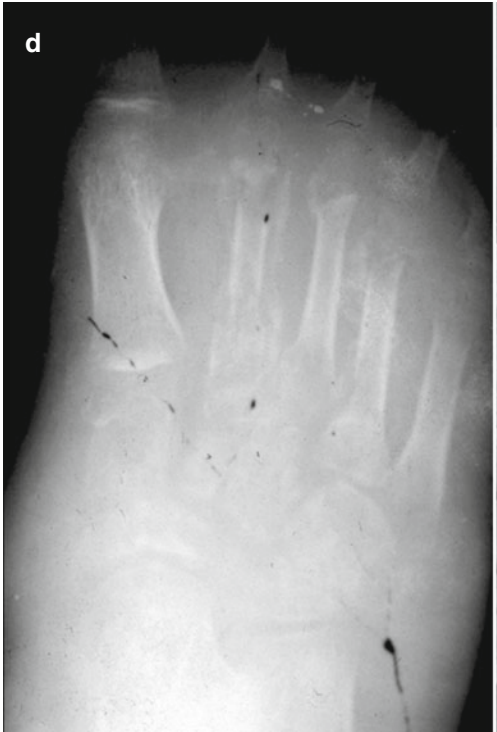
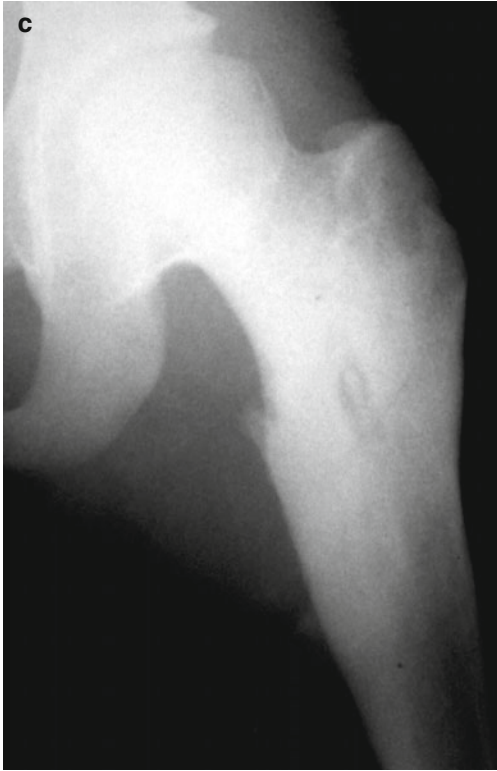Fig. 29.2 (continued)

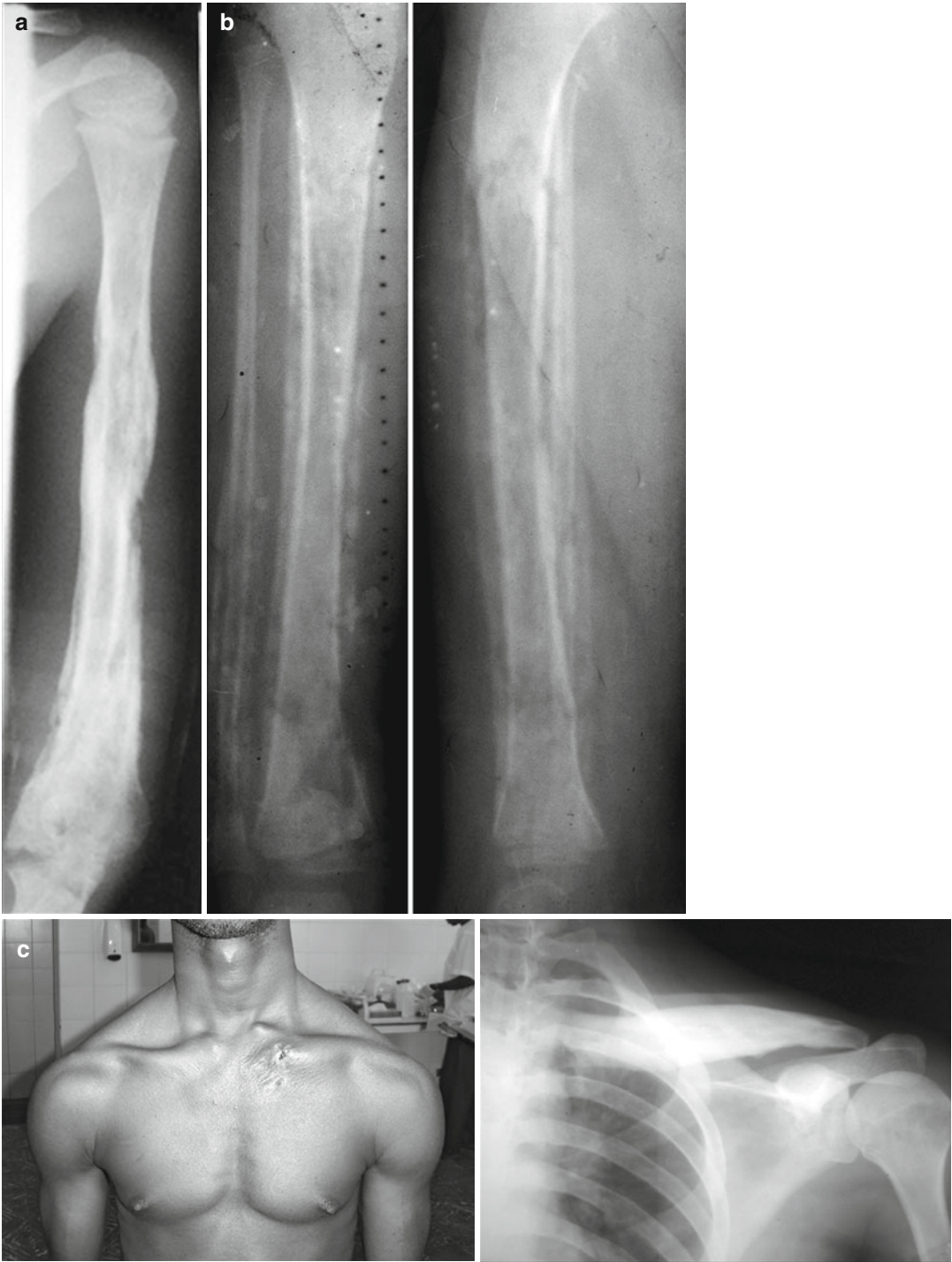
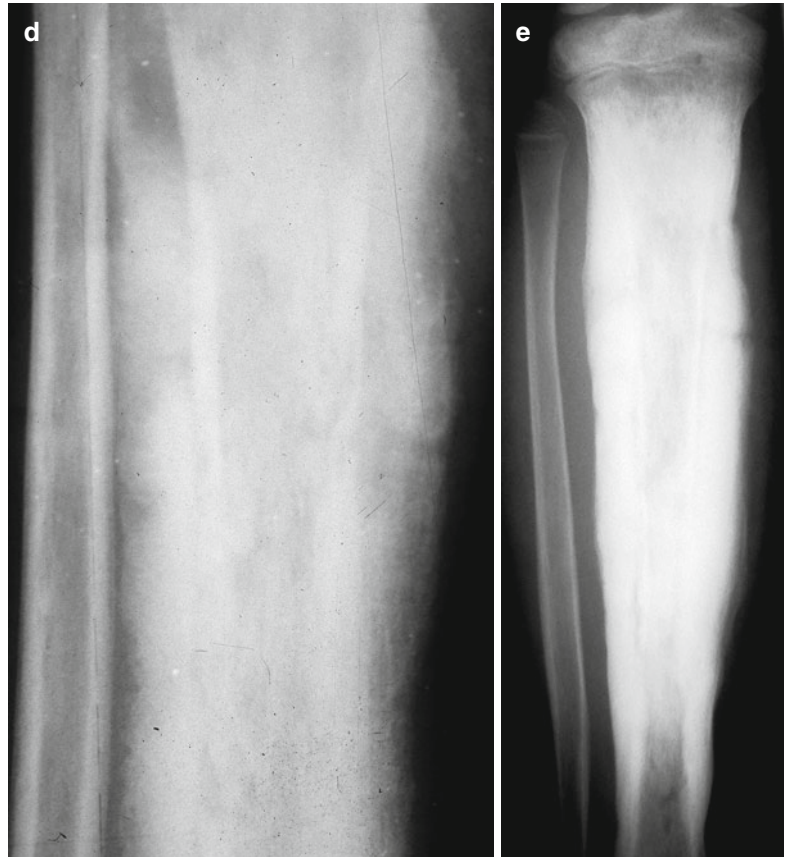


Fig. 29.3 The involucrum varies considerably in appearance. It may appear as a (a, b) smooth periosteal density as seen here in the midshaft of the humerus and both sides of the tibia. (c, d) As a smooth and sclerotic reaction from the addition of multiple layers of new bone

in this patient with clavicular osteomyelitis and a draining sinus over the medial clavicle. (d) A fluffy appearance to the new bone formation as seen on both sides of the tibia, and (e) As a thickened, densely sclerotic reaction

Fig. 29.3 (continued)

Subacute Osteomyelitis

Subacute osteomyelitis presents with intermittent bone pain, usually at night, which is often exacerbated by activity and with few or no systemic signs or symptoms. The symptoms of local discomfort to palpation or mild soft tissue swelling have often been present for at least 2 weeks before the patient arrives in the clinic or OPD. This is due to the combination of an indolent organism and strong host defenses. Laboratory studies are usually normal, although inflammatory markers may be slightly elevated. Staphylococcal species are most often cultured.

The radiographic features vary from a well-circumscribed lytic metaphyseal lesion with a sclerotic rim (Brodie's abscess) that can cross the physis, to a diaphyseal lesion with an aggressive periosteal reaction. The differential diagnosis includes benign or malignant bone tumors and tuberculous osteomyelitis. A biopsy is often

required to establish the diagnosis. Empiric antibiotics can be considered when characteristic x-ray features are present, such as a sclerotic rim to the lucency, a lucency that crosses physis, has a serpentine shape or multiple cavities, is epiphyseal, and is not associated with changes in the surrounding bone, and the patient has no systemic symptoms.

Chronic Osteomyelitis

The evolution from acute osteomyelitis to chronic osteomyelitis is highlighted in previous sections outlining the development of sequestrae, and the host's reaction in the form of involucra. At the chronic stage there is persistence of dead bone and/or debris which has been incompletely resorbed, and essentially represents a "standoff" between the immune system and the infectious focus or foci. Patients with chronic osteomyelitis present with a history of intermittent bone pain extending over

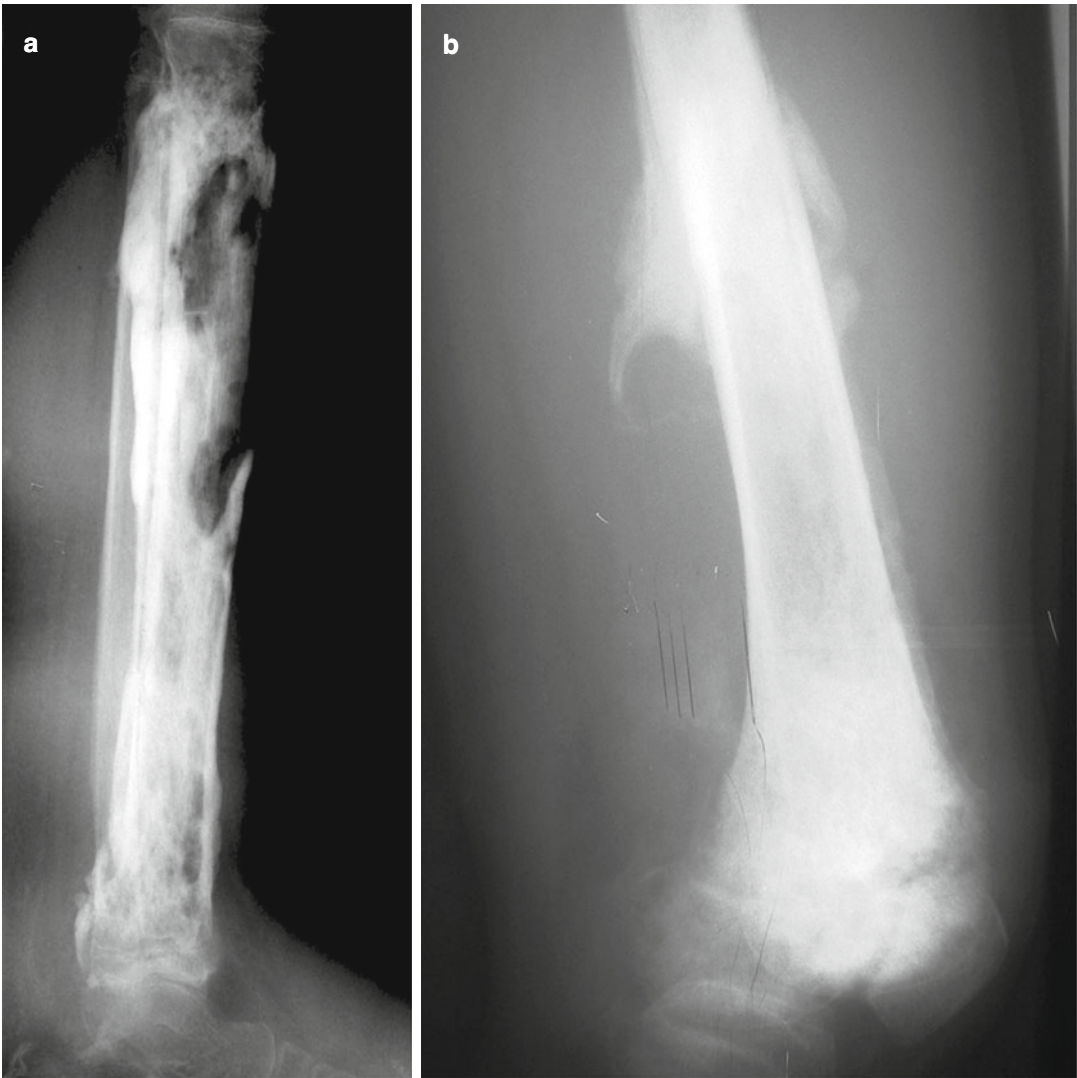


Fig. 29.4 Chronic osteomyelitis can present with radiographic findings similar to malignancy, with (a) extensive bone destruction with minimal host response, or (b) the involucrum can appear radiographically similar to a Codman's triangle

months to years, localized tenderness, and usually a draining sinus. Foci of dead bone and/or devitalized tissue harbor microorganisms, causing intermittent episodes of infection. Some patients may have exposed bone. Other findings at presentation can include pathological fracture, limb length discrepancy, or angular deformity. Plain radiographs are sufficient for evaluation. Laboratory tests are usually normal unless active infection is present. Since neoplasia can mimic chronic infection (Fig. 29.4), a biopsy should be obtained in selected cases. The treatment involves removal of all infected material (similar to tumor surgery), followed by reconstruc-

tion of any bone loss and correction of any other sequelae such as angular deformity. Antibiotics are an adjunct (see Chap. 31).

Mycobacterial Musculoskeletal Infections

Mycobacterial or fungal infections can also result in septic arthritis and osteomyelitis, and are most commonly observed in the setting of a compromised host, such as malnutrition, HIV/AIDS, and chronic comorbidities. These

infections have a more indolent or subacute presentation than bacterial infections. The routes of infection include hematogenous seeding from a visceral source, direct inoculation, or spread from a neighboring site. Up to one third of the world's population have been exposed to *Mycobacterium tuberculosis*, and musculoskeletal manifestations (<10 % of TB infections) include arthritis (45 %), osteomyelitis (5 %), and spondylitis (50 %) (see Chap. 33).

TB mimics a host of diseases both clinically and radiographically. The differential diagnosis includes brucellosis and fungal organisms such as *Candida*, *Blastomyces dermatitidis*, *Coccidioides immitis*, *Histoplasma capsulatum*, and *Cryptococcus neoformans*. In echinococcal osteomyelitis, parasite ova ingested from contaminated vegetables or water release a larval tapeworm that invades the liver via the portal venous system and spreads to the bone via a hematogenous route. Areas most commonly involved in mycobacterial or fungal infections include the spine, pelvis, and long bones, especially the proximal femur. In the absence of advanced laboratory techniques, the diagnosis must be suspected based on local prevalence of the disease and familiarity with the unique presentation and imaging characteristics of these diagnoses. Empiric treatment is often instituted using clinical guidelines.

Pyomyositis

Pyomyositis represents a pyogenic intramuscular infection and is seen most commonly in tropical regions. The differential diagnosis includes muscle strain, hematoma, thrombophlebitis, osteomyelitis, and neoplasia. It is more common in

immuno-compromised patients, particularly those infected with HIV. The symptoms evolve over days to weeks, from the insidious onset of pain and swelling (invasive stage) to abscess formation and often systemic toxicity (suppurative stage). *Staphylococcus aureus* is the most common organism (80 %), and antibiotics alone may suffice during the early, invasive stage. Since abscesses are subfascial, aspiration is made with a large bore needle which must be inserted deep, and it is not unusual to need more than one attempt. Ultrasound can make the procedure easier. Abscesses should be drained, and a short course of intravenous antibiotics is followed by an additional period of oral antibiotics. The overall duration of treatment should be 3–6 weeks. Tuberculosis rarely leads to intramuscular abscesses.

Suggested Reading

- Beckles VL, Jones HW, Harrison WJ. Chronic haematogenous osteomyelitis in children: a retrospective review of 167 patients in Malawi. *J Bone Joint Surg Br.* 2010;92:1138–43.
- Cierny 3rd G. Surgical treatment of osteomyelitis. *Plast Reconstr Surg.* 2011;127:190S–204204.
- Copley LA. Pediatric musculoskeletal infection: trends and antibiotic recommendations. *J Am Acad Orthop Surg.* 2009;17:618–26.
- Forsberg JA, Potter BK, Cierny 3rd G, Webb L. Diagnosis and management of chronic infection. *J Am Acad Orthop Surg.* 2011;19 Suppl 1:S8–19.
- Jones HW, Harrison JW, Bates J, Evans GA, Lubega N. Radiologic classification of chronic hematogenous osteomyelitis in children. *J Pediatr Orthop.* 2009;29:822–7.
- Spiegel DA, Singh GK, Banskota AK. Tuberculosis of the musculoskeletal system. *Tech Orthop.* 2005;20:167–78.
- Tuli SM. General principles of osteoarticular tuberculosis. *Clin Orthop Relat Res.* 2002;398:11–9.

David A. Spiegel, Ashok Kumar Banskota,
and Bibek Banskota

Introduction

The sequelae of septic arthritis can result in considerable disability in children, especially when the infection occurs in a weight-bearing joint such as the hip. Recommendations must be individualized and depend upon whether stability or motion is the goal, as well as the resources and expertise available. While a stable and painless

joint may be the goal for some joints (ankle, wrist, or knee), treatments that preserve motion are often more desirable at the hip and elbow. Many of the alternatives in austere environments are for salvage rather than reconstruction as irreversible changes in the joint and surrounding tissues have occurred (Fig. 30.1a–c).

This section illustrates the principles as applied to the sequelae of septic arthritis of the hip. While many of the strategies described are technically demanding and require specialized training, experience, and equipment, most are commonly performed at the tertiary level in resource poor settings, and a visiting surgeon must assess whether his or her training and experiences are sufficient to tackle these challenging cases. While the long-term outcomes following these salvage procedures have not been well defined, the goals are to provide symptomatic relief and functional improvement and to delay the need for other interventions such as total joint arthroplasty.

D.A. Spiegel, MD (✉)
Division of Orthopaedic Surgery,
Children's Hospital of Philadelphia,
Associate Professor of Orthopaedic Surgery,
University of Pennsylvania School of Medicine,
Philadelphia, PA, USA

Honorary Consultant in Orthopaedics and Rehabilitation,
Hospital and Rehabilitation Centre for Disabled Children,
Janagal, Kavre, Nepal
e-mail: spiegeld@email.chop.edu

A.K. Banskota, MBBS, MD FACS
Department of Orthopaedics, Hospital and
Rehabilitation Center for Disabled Children,
Adhikari Gaon, Janagal, Ugratara VDC,
Kavre, Banepa, Nepal
e-mail: Ashokbanskota@gmail.com

B. Banskota, MBBS, MRCS, MS
Department of Orthopedics, Hospital and
Rehabilitation Center for Disabled Children (HRDC),
Janagal, Kavre 6757, Nepal
e-mail: bibekbanskota@gmail.com

Sequelae of Hip Sepsis

The sequelae of hip sepsis include a wide range of morphologic abnormalities of the proximal femur, including coxa magna and/or growth disturbance from hyperemia or avascular necrosis (Fig. 30.2a–d), femoral neck pseudarthrosis (Fig. 30.3a, b), septic dislocation with the femoral

Fig. 30.1 (a) X-rays and (b) appearance of a child who presented with the residua of ankle septic arthritis and osteomyelitis. (c) A plantigrade foot was salvaged by fusing the distal tibia and fibula to the calcaneus, recognizing that limb lengthening would be required at a later date to treat leg length discrepancy

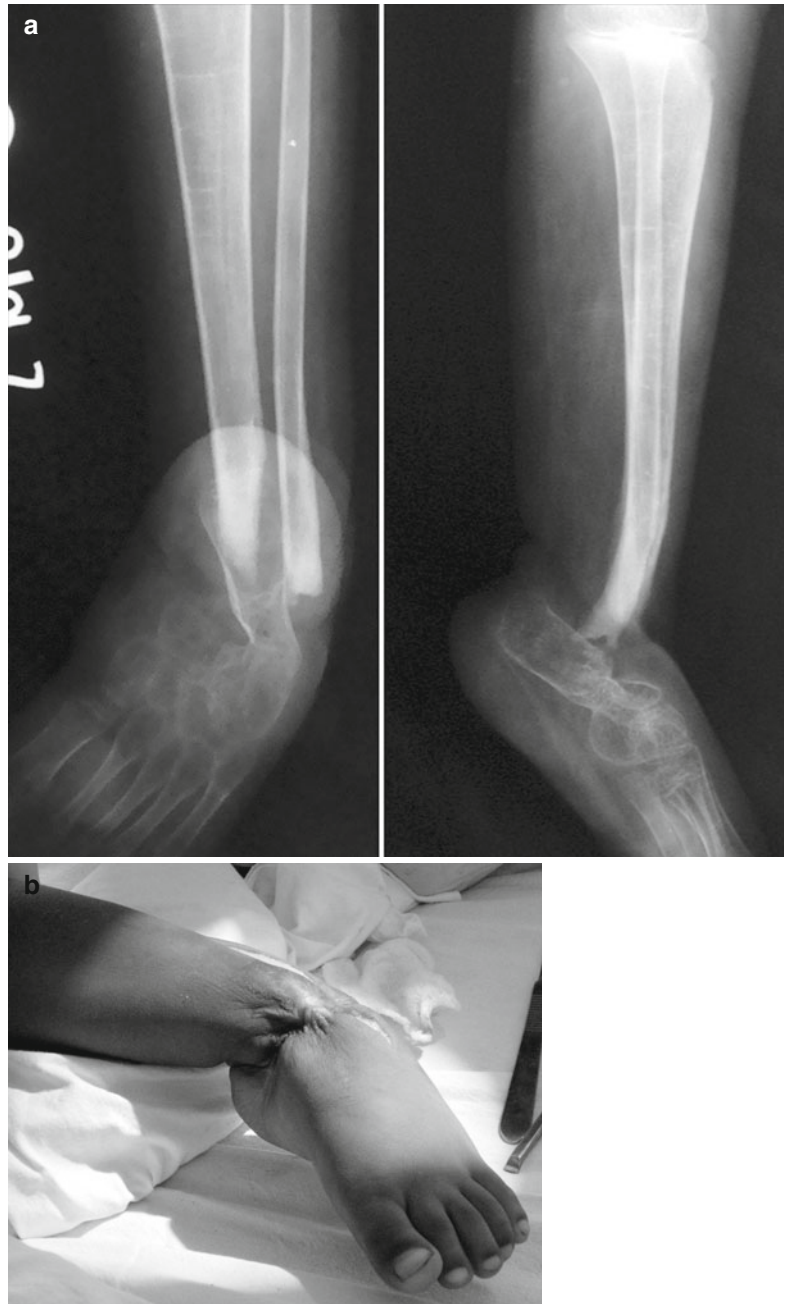


Fig. 30.1 (continued)

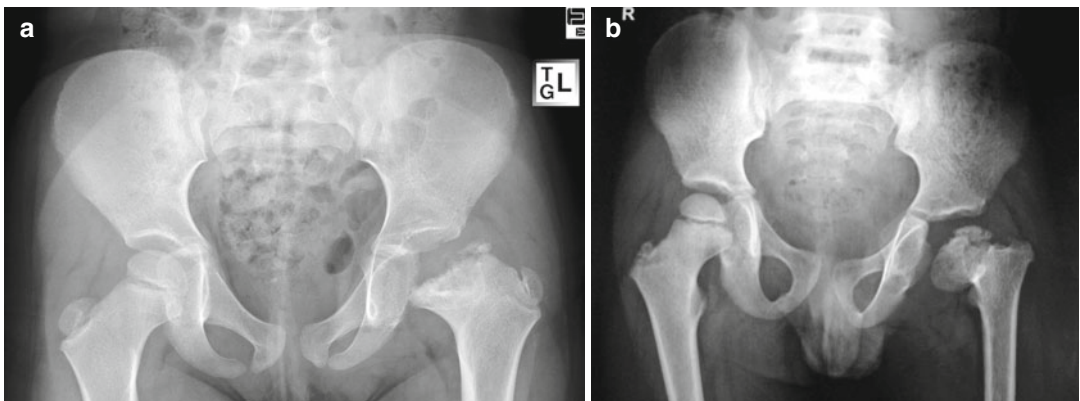
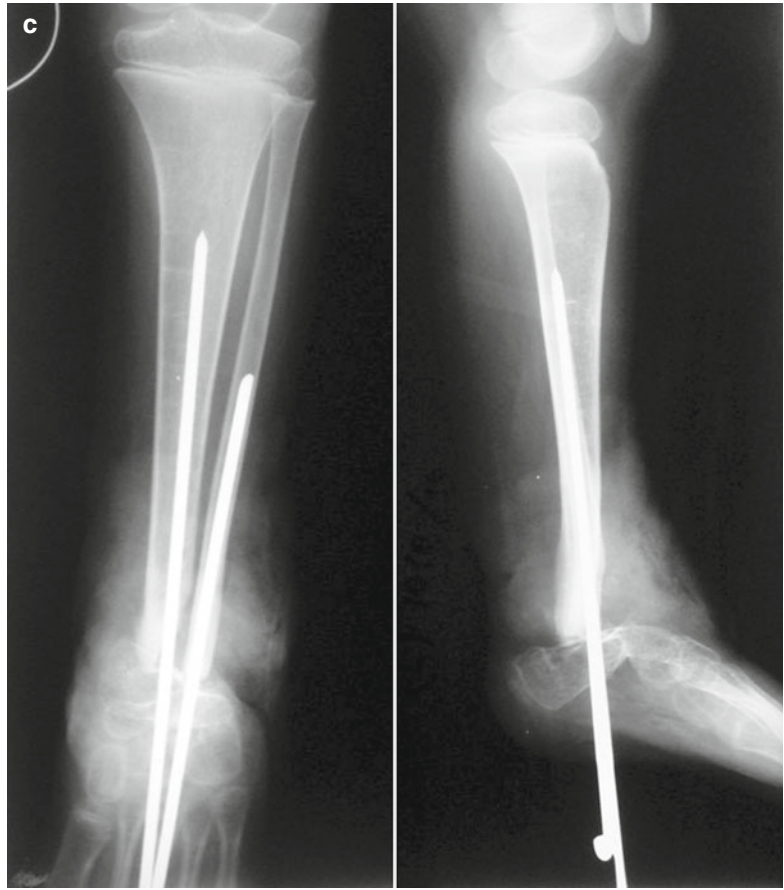


Fig. 30.2 Sequelae of hip sepsis. (a, b) In addition to proximal femoral varus or valgus deformities and rotational deformities, coxa magna and coxa breva are commonly observed due to hyperemia or AVN. (c) Septic

arthritis can be associated with proximal femoral osteomyelitis. (d) Multiple joint sepsis often results in significant limb shortening and joint abnormalities

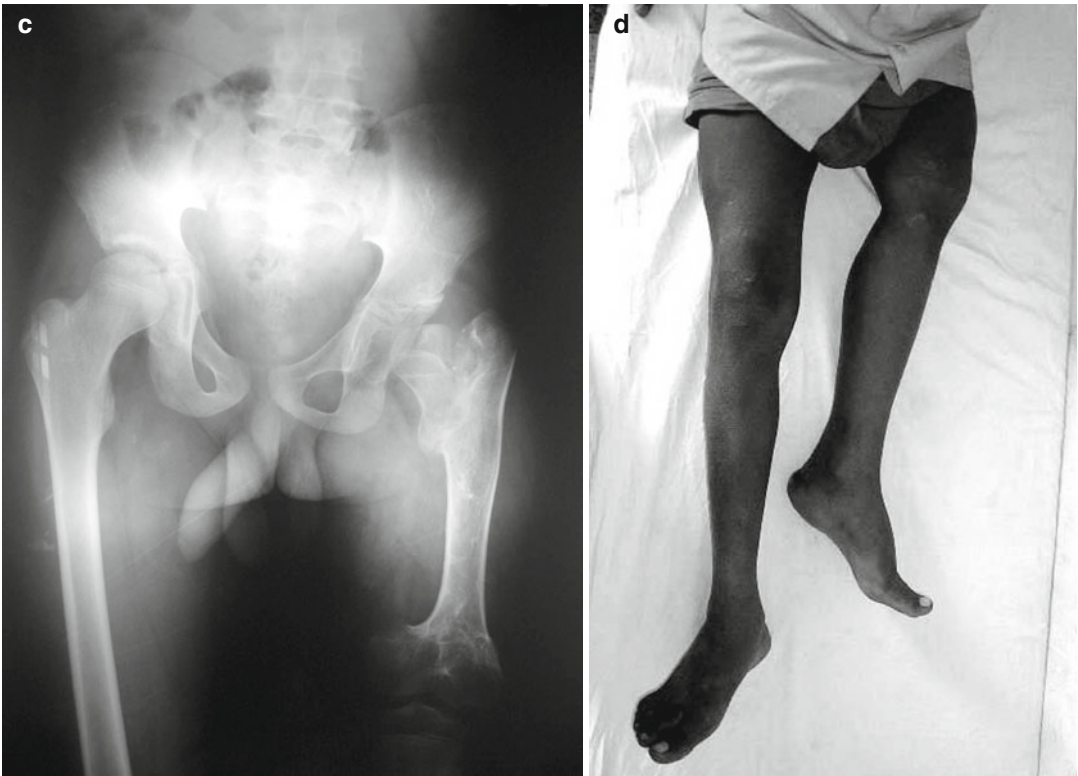

Fig. 30.2 (continued)

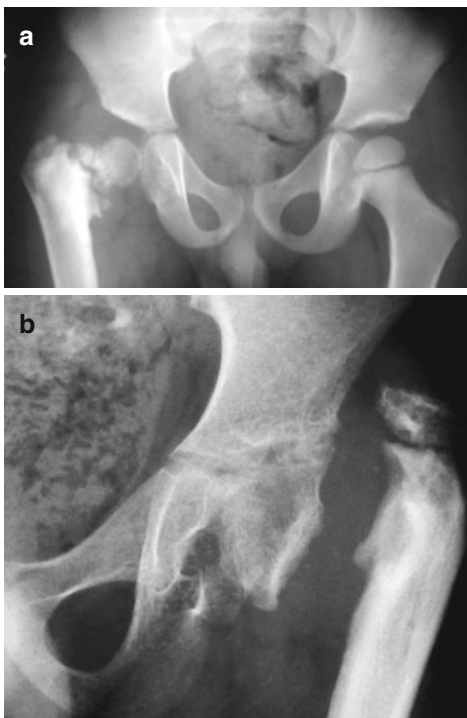


Fig. 30.3 (a, b) Pseudoarthrosis of the femoral neck

head present or absent (partial or complete), or post-septic fusion (Fig. 30.4a–e). Clinical findings include pain, instability (pistoning during ambulation), leg length discrepancy, and loss of motion.

The history focuses on the impact the symptoms have on activities of daily living. The examiner should note the presence, location, and intensity of pain, and which activities or positions precipitate or relieve the discomfort. The source of pain may be intra-articular from damage to the articular cartilage or impingement, or extra-articular due to soft tissue contracture or abductor insufficiency. The physical examination focuses on range of motion, limb alignment and lengths, and presence of pain when the hip is placed in certain positions. Plain radiographs may be the only imaging available, and arthrography or direct inspection may be required to delineate the status of articular cartilage and the relationship between the proximal femur and the acetabulum (Fig. 30.5a–b).

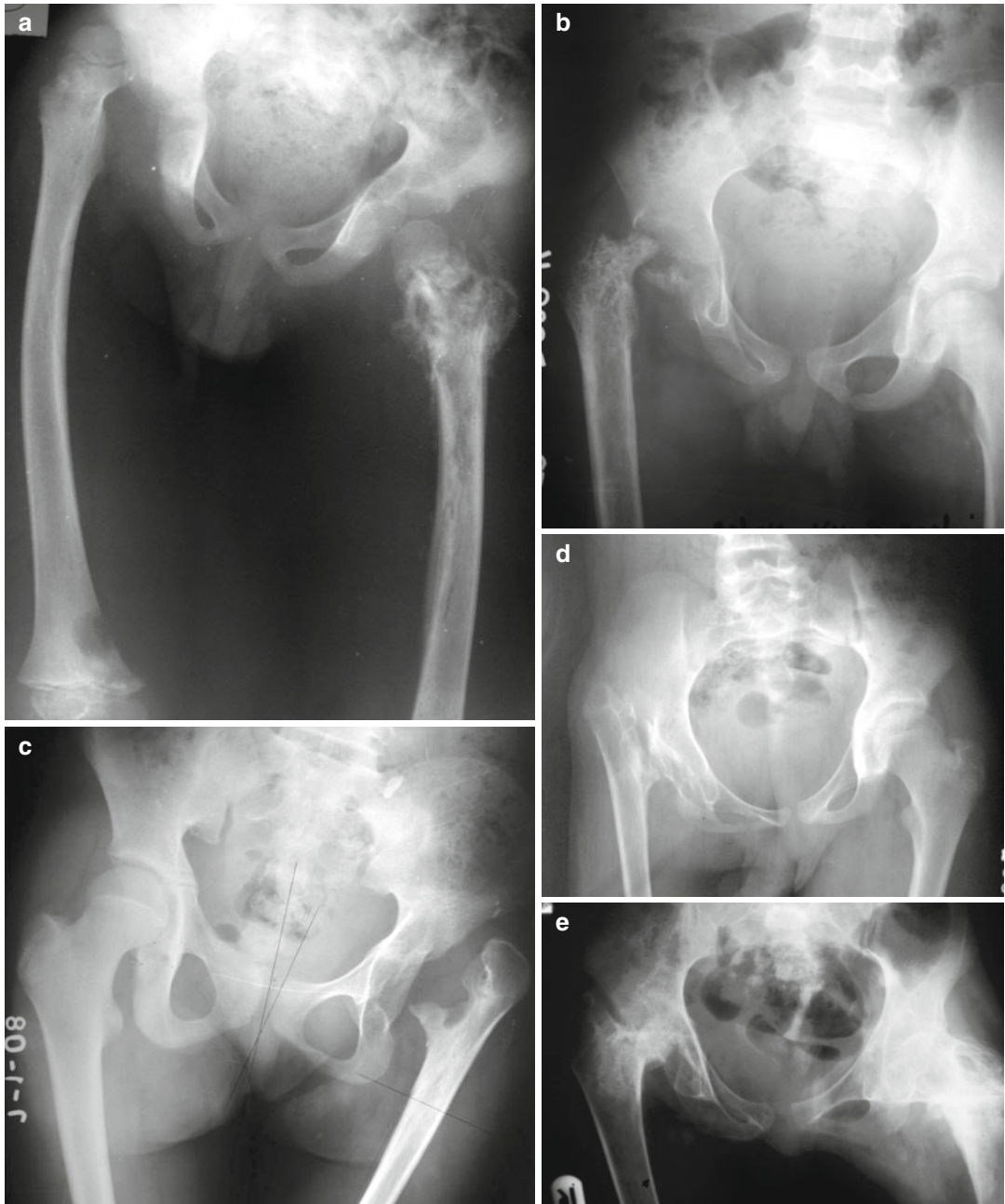


Fig. 30.4 A spectrum of abnormalities may complicate septic arthritis of the hip and its treatment, including (a) septic dislocation, (b) destruction of the femoral head with proximal migration, (c) loss of the femoral head and neck without proximal migration, (d) destruction of the head and neck with proximal migration, and (e) spontaneous fusion

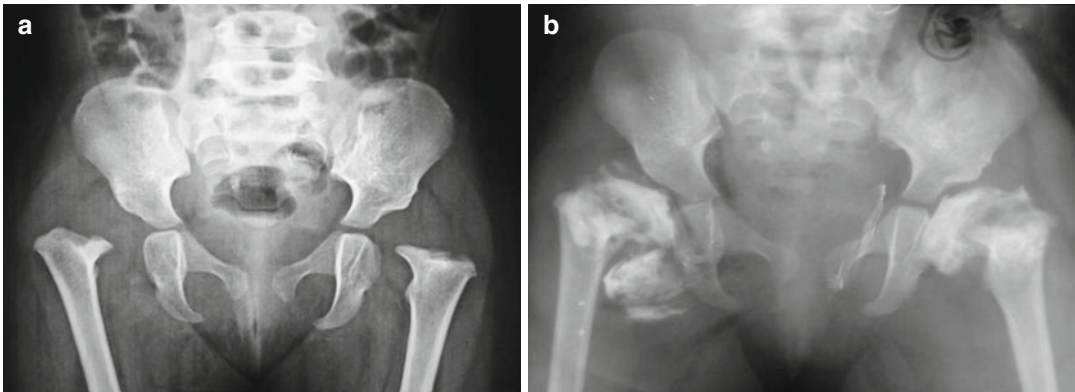


Fig. 30.5 (a, b) Arthrography, if available, is an excellent way to better visualize the anatomy of the proximal femur and acetabulum. In this case there is subluxation

with interposed material in the acetabulum, with flattening or an oblong shape to the femoral head (Courtesy of Premal Naik)

Treatment

The goals are pain relief, improve the absolute range of motion or the functional arc of motion, improve abductor mechanics, restore stability, and correct leg length discrepancy. Treatment must be individualized, focusing on symptoms, physical findings, and the pathoanatomic changes in the femoral head and acetabulum.

The classification presented by Forlin et al is simple, practical, and helps plan treatment [1]. The scheme focuses on (1) instability and (2) the degree of destruction of the proximal femur. The four categories are:

- IA Femoral head present and reduced
- IB Femoral head/neck absent but remaining proximal femur has not migrated superiorly (Fig. 30.4b)
- IIA Femoral head present but dislocated (Fig. 30.4a)
- IIB Femoral head/neck absent and remaining proximal femur is dislocated or superiorly migrated (Fig. 30.4c).

Forlin et al identified a better prognosis for those hips that were reduced and a poor prognosis for hips that were dislocated, whether or not the femoral head was present.

For cases in which the *femoral head is present and the hip is reduced* (Forlin IA), treatments include femoral osteotomies to correct abnormalities in the neck-shaft angle (coxa vara or valga) and/or rotational abnormalities (anteversion or retroversion). Pelvic osteotomies such as Salter, Dega,

or Shelf can be used alone or with a femoral procedure to improve coverage. For patients with inadequate abductor mechanics, transfer of the greater trochanter may improve abductor insufficiency.

Infants and toddlers in whom the *femoral head is present but the hip is dislocated* (Forlin IIA) are treated by an exam under anesthesia and an attempt at closed reduction and spica casting. An arthrogram can delineate the shape of the femoral head and the relationship between the femoral head and the acetabulum. If available, and ultrasound examination may also confirm if the hip can be reduced and whether or not the reduction is stable. If a closed reduction is unsuccessful, an open reduction with or without a shortening, varus femoral osteotomy and/or pelvic osteotomy is required. Johari et al found that closed reduction and percutaneous adductor tenotomy were only successful in 9/21 patients, and the remaining patients required a variety of procedures to reduce the hip [2]. Factors associated with a poor result included preoperative stiffness, avascular necrosis, and premature fusion of the triradiate cartilage. The authors suggested that closed reduction be attempted for all patients under 2 years of age, with open surgical treatment for those who fail closed reduction or are older than 2 years.

In Forlin IB patients, *femoral head/neck absent but remaining proximal femur has not migrated proximally*, consideration should be given to open reduction and capsulorrhaphy to keep the residual femoral neck well reduced in the acetabulum, along with a femoral and/or pelvic osteotomy as

needed to enhance stability, recognizing that additional procedures will likely be required.

Cases in which *the femoral head and neck are absent* (Forlin IIB) are associated with proximal migration of the residual femur. Treatment depends on the age of the patient, with the goal to restore stability, limb alignment, and length. Options include greater trochanteric arthroplasty, pelvic support osteotomy, and arthrodesis. The first two are motion sparing techniques, recognizing that arthrodesis may be unacceptable in cultures where hip mobility is required for activities of daily living.

Trochanteric arthroplasty involves placing the apophyseal cartilage of the greater trochanter within the acetabulum, with the expectation that remodeling will lead to a relatively congruent

relationship. The joint capsule is opened by an iliofemoral approach to confirm the absence of the femoral head and perform a debridement of any residual neck remnant and/or fibrous tissue in the acetabulum. An adductor tenotomy and/or psoas release may be required to restore motion. The trochanteric apophysis is placed into the acetabulum, and the gluteus medius is advanced and sutured to the lateral aspect of the femur. A varus subtrochanteric osteotomy of the proximal femur may facilitate placement of the trochanter into the acetabulum. In the modified Albee arthroplasty, the medial portion of the greater trochanter is angulated via an incomplete osteotomy to produce a 135° neck-shaft angle [3]. A wedge graft from the iliac crest is placed in the osteotomy to maintain correction (Fig. 30.6a–e).

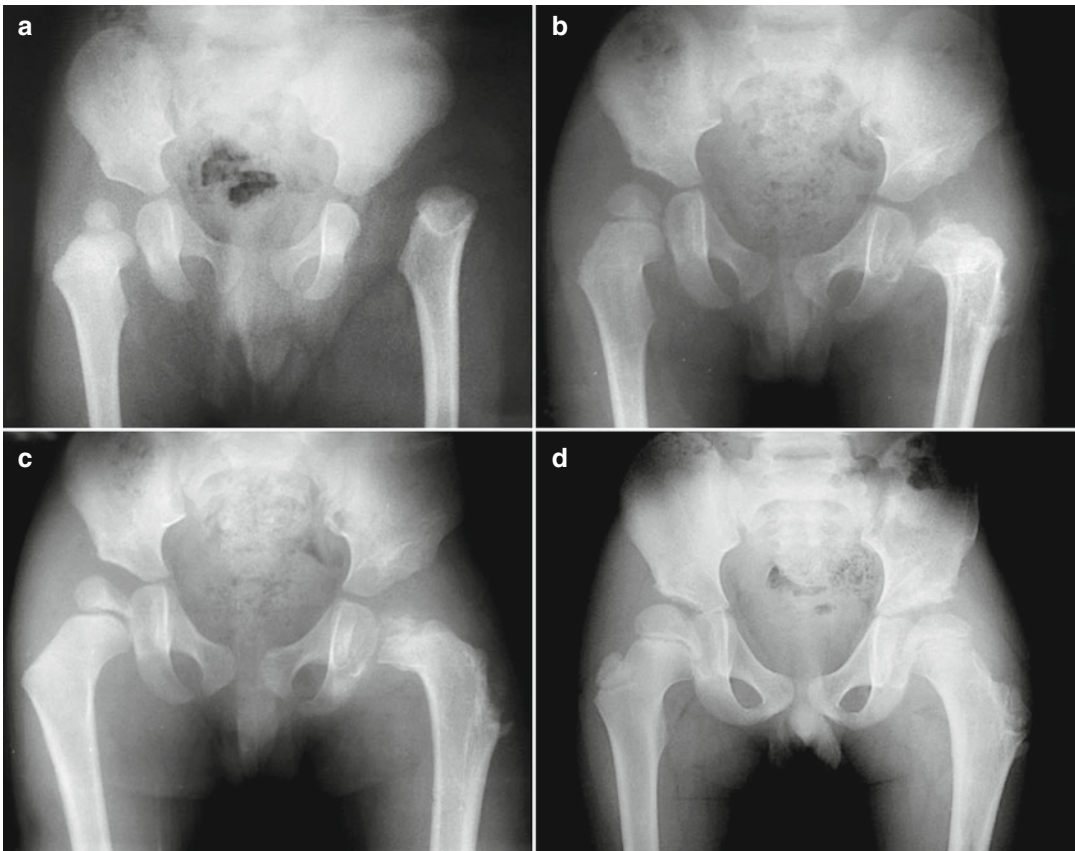


Fig. 30.6 (a–d) Greater trochanteric arthroplasty (Reprinted with permission from Wang EB, Ji SJ, Zhao Q, Zhang LJ. Treatment of severe sequelae of infantile hip sepsis with trochanteric arthroplasty. *J Pediatr Orthop.* 2007;27:165–70) (e, f). The modified Albee arthroplasty

involves placing a segment of the trochanter into the acetabulum by splitting the proximal femur vertically and inserting a wedge graft (Reprinted with permission from Li XD, et al. *J Bone Joint Surg [Am].* 2010;92:1373)

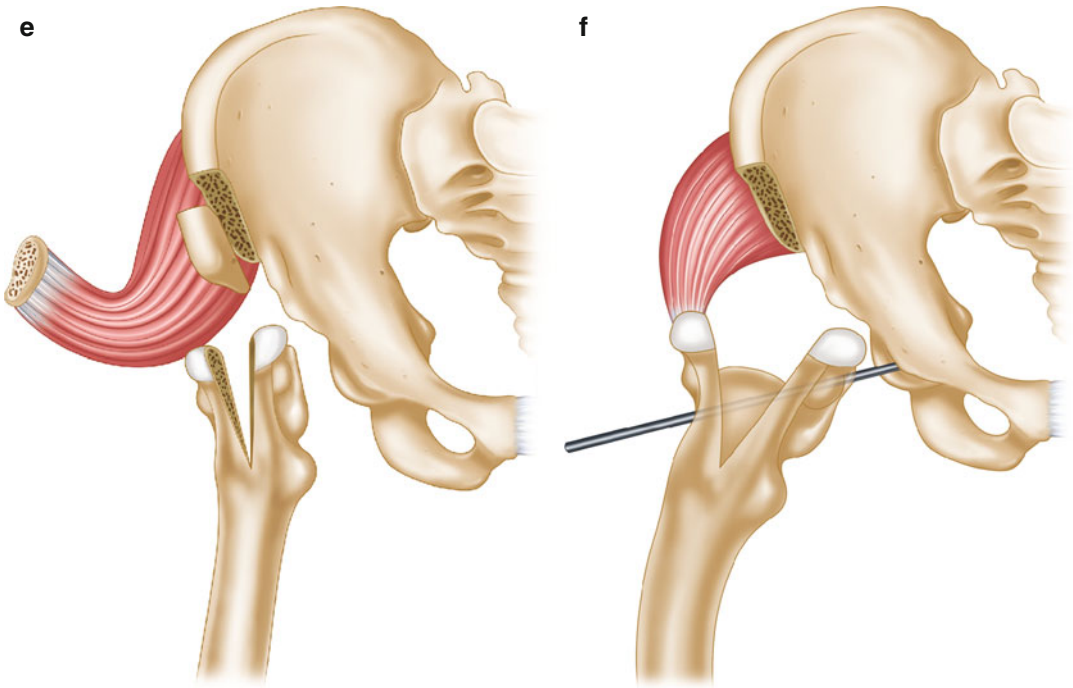


Fig. 30.6 (continued)

Pelvic support osteotomy addresses instability (pistoning), leg length discrepancy, and abnormalities in limb alignment. Most studies have concerned skeletally mature young adults with a variety of diagnoses (hip sepsis, DDH, polio) and have reported significant improvements in pain relief, range of motion, leg length equalization, and gait. Studies in children are limited, and remodeling can be expected in children and early adolescents, making repeat procedures necessary.

While a detailed analysis of the preoperative assessment and the surgical technique are beyond the scope of this chapter, pelvic support is provided by a proximal femoral valgus osteotomy, which positions the upper femoral shaft underneath the pelvis. Preoperatively, a standing AP radiograph of both lower extremities allows assessment of limb alignment and lengths, and an AP radiograph in maximum adduction is also obtained. Some authors also use a view in which the patient stands with all his weight on the

affected limb—“pelvic drop view” or “Trendelenburg” view. The location of the proximal femoral valgus osteotomy is determined on the maximum adduction x-ray view as the point of intersection between the femoral shaft and the ischium, and the degree of adduction may be calculated on a maximum adduction view, adding approximately 15° to ensure slight overcorrection (Fig. 30.7a–c). It is also important to achieve 5° of extension at the osteotomy.

Limb alignment and length are restored through a second, more distal osteotomy (Fig. 30.8a, b). Some internal rotation may be required based on the anticipation that the valgus will induce some external rotation of the limb. Stabilization of the osteotomies is most often by a ring, monolateral, or hybrid frame (Fig. 30.9a–c). Consideration can also be given to stabilizing the proximal osteotomy with a plate and using a fixateur for the distal osteotomy with lengthening. Another option for the treatment of bilateral septic sequelae is to realign the lower limbs relative to the pelvis (Fig. 30.10a–c).

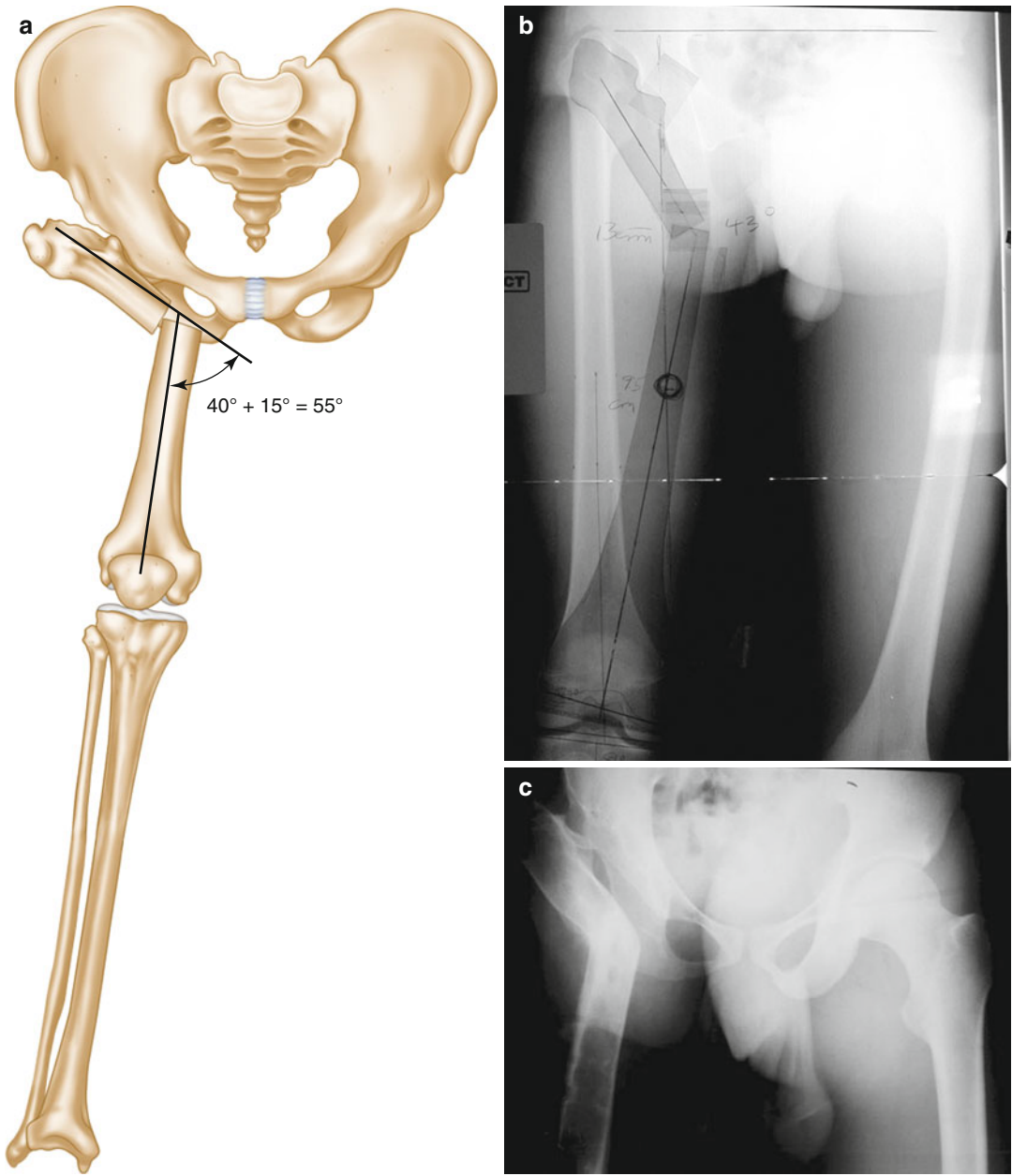


Fig. 30.7 (a) A maximum adduction view is important in preoperative planning for the proximal osteotomy and (b) preoperative templating may help as well. (c) Valgus osteotomy after healing (Case courtesy of J. Norgrove Penny, M.D.)

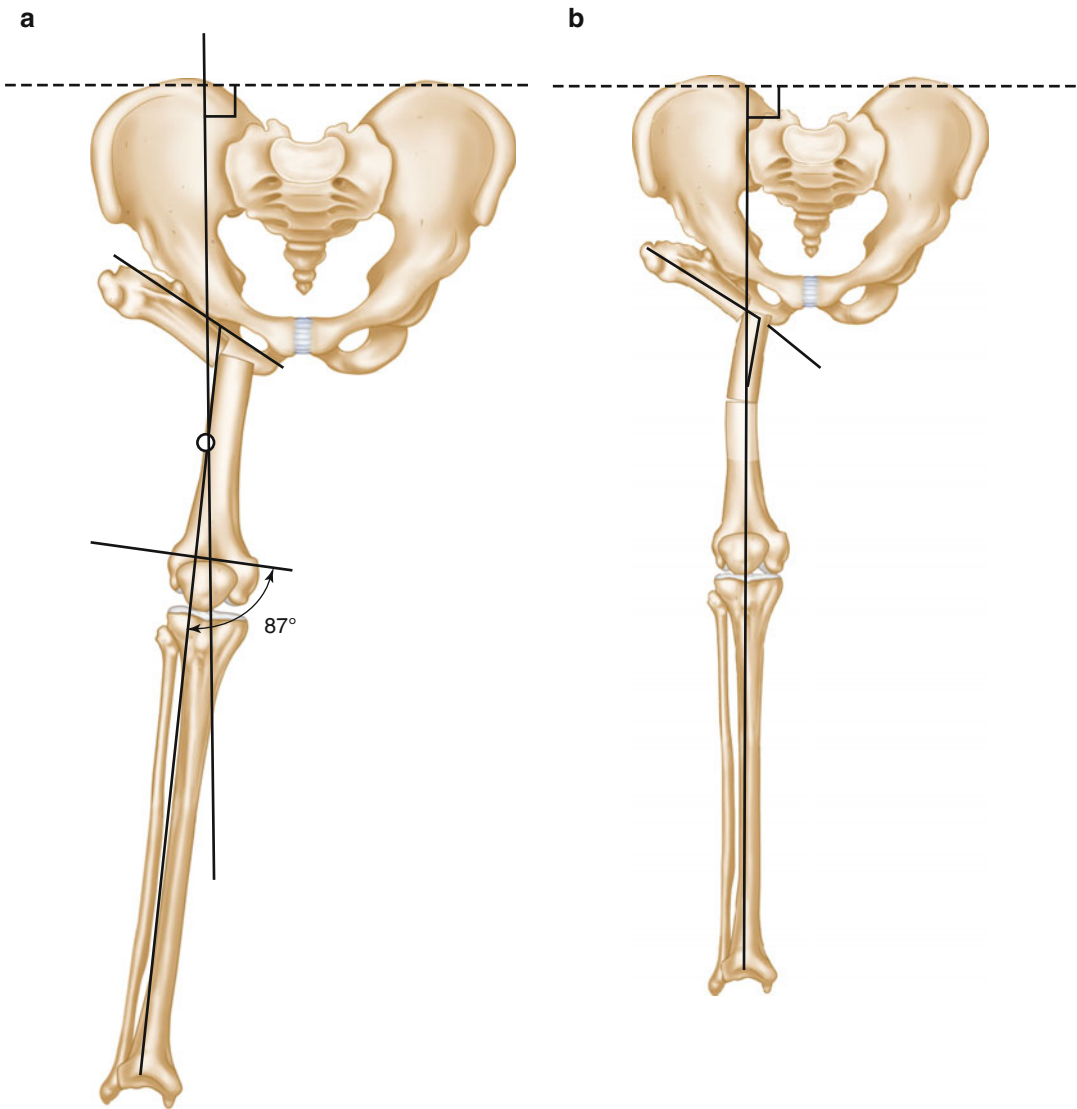


Fig. 30.8 The distal osteotomy (**a**) is performed in the femoral diaphysis at the junction of vertical line perpendicular to the pelvis and through the apex of the proximal osteotomy and the tibial mechanical axis (denoted as the small circle in this figure), and (**b**) allows realign-

ment of the mechanical axis and equalization of limb lengths (Reprinted with permission from Paley D. *Principles of deformity correction*. New York: Springer; 2002. p. 689–90, Figs. 19.21e–g)

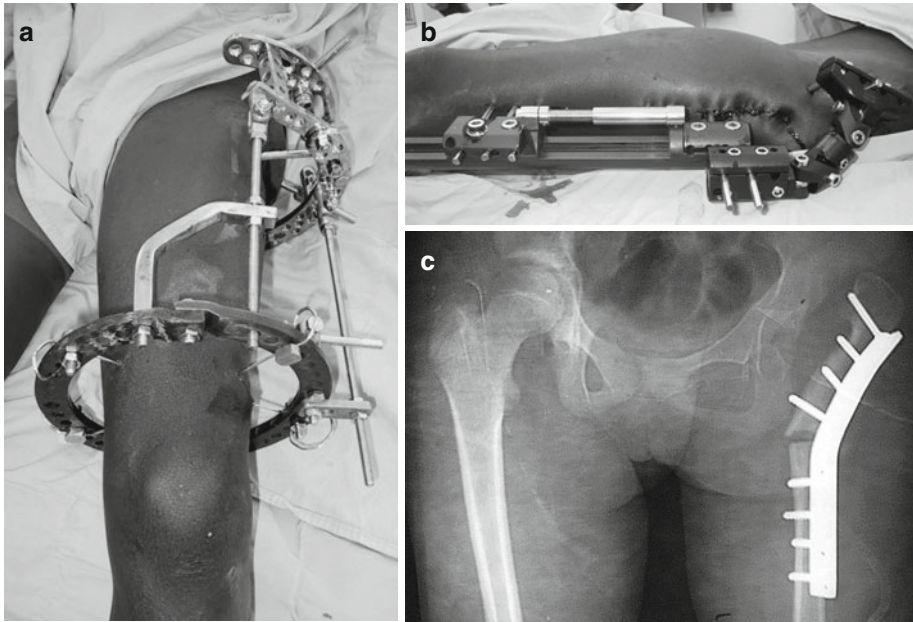


Fig. 30.9 Fixation can be achieved with a (a) ring construct, (b) hybrid or monolateral fixateur construct, or (c) a plate for the proximal osteotomy, and then a fixateur for

the distal osteotomy and lengthening (Case courtesy of J. Norgrove Penny, M.D.)

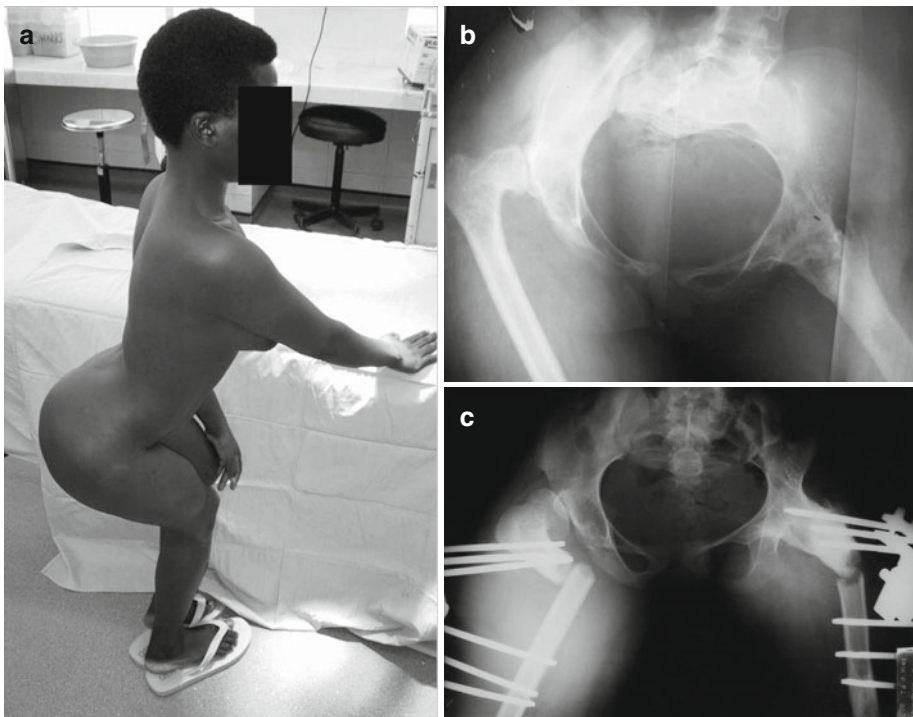


Fig. 30.10 (a) Appearance of a young woman with post-septic flexion/adduction contracture of the right hip and fusion on the left hip with flexion/abduction deformity. Notice the compensatory lumbar hyperlordosis. (b) AP

pelvis x-ray. (c) After discussing numerous options, the patient elected to have both limbs realigned relative to the pelvis by osteotomy and external fixation (Case courtesy of J. Norgrove Penny, M.D.)

References

1. Forlin E, Milani C. Sequelae of septic arthritis of the hip in children: a new classification and a review of 41 hips. *J Pediatr Orthop*. 2008;28:524–8.
 2. Johari AN, Dhawale AA, Johari RA. Management of post septic hip dislocations when the capital femoral epiphysis is present. *J Pediatr Orthop B*. 2011;20:413–21.
 3. Li XD, Chen B, Luo SW, Ji SJ, Du SX. Evaluation of the modified Albee arthroplasty for femoral head loss secondary to septic arthritis in young children: surgical technique. *J Bone Joint Surg Am*. 2011;93 Suppl 1:54–61.
-
- Suggested Reading**
- Choi IH, Shin YW, Chung CY, et al. Surgical treatment of the severe sequelae of infantile septic arthritis of the hip. *Clin Orthop Relat Res*. 2005;434:102–9.
- Choi IH, Yoo WJ, Cho TJ, Chung CY. Operative reconstruction for septic arthritis of the hip. *Orthop Clin North Am*. 2006;37:173–83.
- Inan M, Bowen RJ. A pelvic support osteotomy and femoral lengthening with monolateral fixator. *Clin Orthop Relat Res*. 2005;440:192–8.
- Manzotti A, Rovetta L, Pullen C, Catagni MA. Treatment of the late sequelae of septic arthritis of the hip. *Clin Orthop Relat Res*. 2003;410:203.
- Pafilas D, Nayagam S. The pelvic support osteotomy: indications and preoperative planning. *Strategies Trauma Limb Reconstr*. 2008;3:83–92.
- Rozbruch SR, Paley D, Bhave A, Herzenberg JE. Ilizarov hip reconstruction for the late sequelae of infantile hip infection. *J Bone Joint Surg Am*. 2005;87A:1007–18.
- Wada A, Fujii T, Takamura K, Yanagida H, Urano N, Suriyamorn P. Operative reconstruction of the severe sequelae of infantile septic arthritis of the hip. *J Pediatr Orthop*. 2007;27:910–4.
- Wang EB, Ji SJ, Zhao Q, Zhang LJ. Treatment of severe sequelae of infantile hip sepsis with trochanteric arthroplasty. *J Pediatr Orthop*. 2007;27:165–70.

J. Norgrove Penny and David A. Spiegel

Introduction

Children with osteomyelitis typically present at a more advanced stage in austere environments. As such, treatment strategies are more complex, lengthy, and less likely to achieve eradication of infection and adequate return of function. However, their capacity to repair and remodel diseased bone make children candidates for all efforts to eradicate this disabling condition. Acute osteomyelitis evolves into a chronic state in which there is persistent devitalized bone and/or debris with or without medical and/or surgical management. As such, the definition of “chronic” is somewhat arbitrary. Some of the clinical material presented in this chapter reflect different stages in this evolution between acute and chronic.

The patient’s general medical status is of crucial importance when assessing the chances for cure. Chronic infection results in a catabolic state, exacerbating long standing medical conditions such as HIV/AIDS, sickle cell disease, and malnutrition, which in turn compromise host immunity. These coexisting problems predispose patients to opportunistic infections such as malaria and tuberculosis, allowing both bacterial and tubercular osteomyelitis to occur in the same patient. Nutritional, vitamin, and mineral supplements are important adjuvants because malnutrition can be viewed as a type of reversible AIDS. Multifocal chronic osteomyelitis represents an extreme case in which host immunity is severely compromised, frequently involving multiple and/or unusual sites, such as the scapula, clavicle, ribs, or small bones of the feet and hands.

Tuberculous osteomyelitis can mimic sub-acute or chronic bacterial osteomyelitis, necessitating the inclusion of TB in the differential diagnosis and warranting a biopsy, especially in unresolved cases after proper surgical debridement. The bony changes in sickle cell disease are characteristically symmetrical, involving the central diaphyses of long bones and with a higher incidence of salmonella infection. The reason for this is unclear, but may have to do with otherwise innocuous salmonella having an affinity for the infarcted bone from previous sickle cell crises or from microinfarcts in the intestinal wall, allowing bacterial seeding. Neoplasia also needs to be in the differential.

J.N. Penny, MD, FRCS(C)
CBM International, Nibelungenstrasse 124,
Bensheim 64625, Germany
e-mail: norgroveanne@hotmail.com

D.A. Spiegel, MD (✉)
Division of Orthopaedic Surgery,
Children’s Hospital of Philadelphia,
Associate Professor of Orthopaedic Surgery,
University of Pennsylvania School of Medicine,
Philadelphia, PA, USA

Honorary Consultant in Orthopaedics and Rehabilitation,
Hospital and Rehabilitation Centre for Disabled Children,
Janagal, Kavre, Nepal
e-mail: spiegeld@email.chop.edu

Treatment

The goals of treatment are to eradicate the infection and treat a host of accompanying complications. The primary and most important treatment for children with chronic osteomyelitis is surgery. Surgery speeds healing and minimizes the risk of progressive bony destruction by removing necrotic tissue. Antibiotics are of no value in isolation.

Surgery involves a stepwise approach:

1. Pre-op planning—establish the correct diagnosis using a radiologic classification system that defines the natural history which in turn assists in planning surgical treatment.
2. Adequate debridement to remove all infected material.
3. Dead space management.
4. Rehabilitation and treatment of complications.

Pre-op Considerations

The patho-anatomic features in both the Penny [1] and Beit-CURE [2] classifications of chronic osteomyelitis help the surgeon judge the stability of the involved bony segment, determine the timing and extent of the proposed surgery, and

predict possible complications and/or the projected need for further procedures (Table 31.1). Both classifications describe a spectrum of radiographic findings related to the (1) extent of bony necrosis and the (2) host’s response. While there is significant overlap between these, the Beit-CURE classification also includes an assessment of physeal damage at the proximal and/or distal end of the bone, as well as a category for cases that cannot be classified based on their scheme.

Initially, the intramedullary abscess decompresses through the thin metaphyseal cortex, leading to a subperiosteal abscess. With both the endostial and subperiosteal blood supply compromised, one or more segments of the metaphysis and/or diaphysis become necrotic, a sequestrum (or sequestrae). When the infection drains through the skin, the systemic signs subside and the infection becomes localized, encapsulated, and chronic if untreated, and the periosteum lays down new bone around the sequestrum. In general the periosteum is resistant to infection and its response is to expel the dead bone and lay down appositional new bone or involucrum. Sequestrae may be partially or completely resorbed by the host response.

The following discussion will focus on management based on the scheme developed by the

Table 31.1 Penny and Beit-CURE classifications for pediatric chronic osteomyelitis

Classification	Description	Treatment	
Penny	I. Typical	Sequestrum and involucrum	Remove sequestrum
	II. Atrophic	No involucrum (periosteal death)	Observe for 3–6 months, if no involucrum then grafting or transport
	III. Sclerotic	Fusiform, dense cortical thickening, medullary canal may be obliterated, sequestrum may be hidden	Search for sequestrate, may be difficult to remove cortical window
	IV. Cortical	Localized sequestrum in cortex	Remove sequestrum
	V. Walled-off abscesses	Partial resorption of sequestrate, leaving well-defined lucencies in involucrum	Saucerization, look for sequestrae
	VI. Multiple microabscesses	Similar to walled-off abscesses, small and numerous	Difficult to remove, consider antibiotics and observation
	VII. Metaphyseal	Single or multiple abscesses with sclerotic margin	Saucerization and curettage
Beit-CURE	A. Brodie’s type	No sclerosis, one or more abscesses	
	B. Sequestrum and involucrum (B1–4)	B1. Localized cortical sequestrum	
		B2. Sequestrum with normal involucrum	
		B3. Sequestrum with sclerotic involucrum	
B4. Sequestrum without structural involucrum			
C. Sclerotic	Extensive sclerosis and abscesses		
Unclassifiable			
	Physeal damage: add “P” if proximal physis or “D” if distal physis is damaged		

primary author. In the *Type I presentation*, there is a well-defined sequestrum and an adequate involucrum (Type I, or Beit-CURE Type B2) (Fig. 31.1). The treatment involves surgical removal of the sequestrum or sequestrae at the appropriate time.

In the *Type II presentation* (Beit-CURE Type B4), one or more sequestrae may be identified;

however, there is an inadequate involucrum. The sequestrum can extravasate spontaneously leaving either focal bone loss or a large, segmental bone defect. The remaining bone is usually unstable, making more complex treatments likely (Fig. 31.2).

When the periosteal reaction shows a particularly robust vascular response, the sequestrum

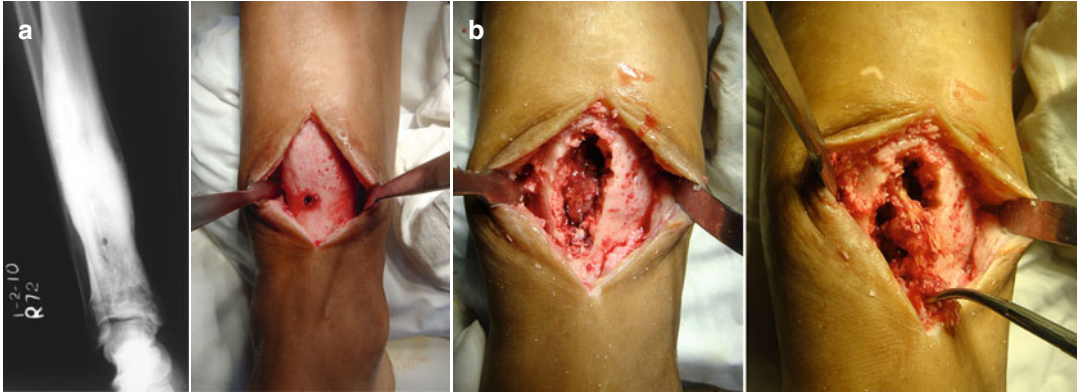


Fig. 31.1 Stages of sequestrectomy. (a) A sequestrum is identified distal to a sclerotic region, with a draining sinus. (b) An oval window facilitates sequestrectomy and

debridement (Images courtesy of the Hospital and Rehabilitation Centre for Disabled Children, Banepa, Nepal)

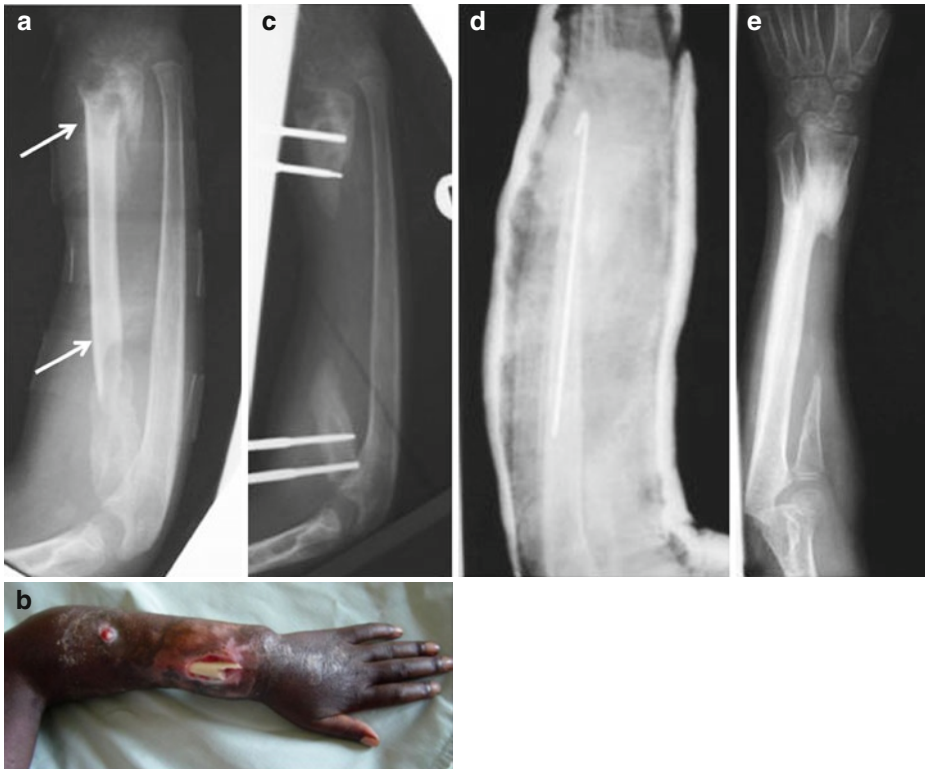

Fig. 31.2 (a) This patient developed sequestration of most of the radius (b) with a segment protruding through the skin. (c) Length was maintained after sequestrectomy

with an external fixateur. (d, e) Once sepsis was controlled, a single bone forearm was made. (f, g) Elbow flexion and extension were full, although forearm rotation was lost

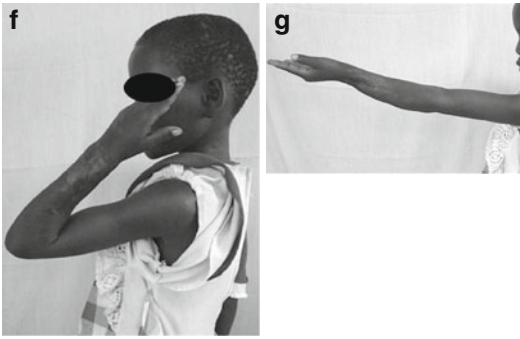


Fig. 31.2 (continued)

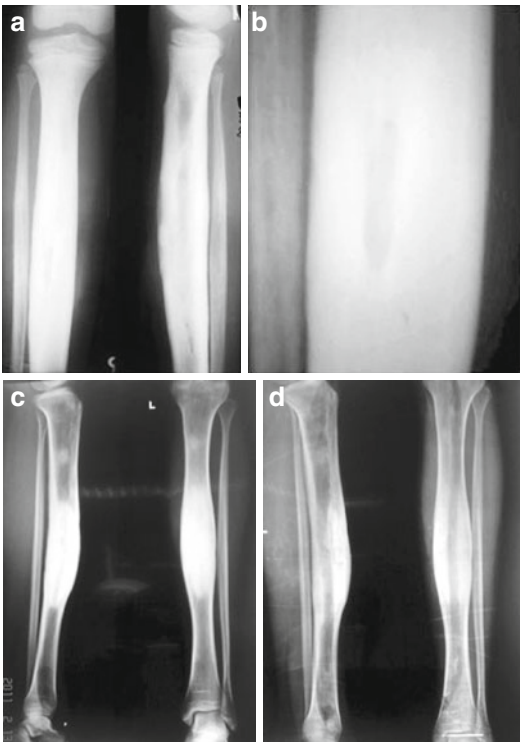


Fig. 31.3 (a) The sclerotic presentation (Type III) exhibits a thick, dense involucrum. (b) Sequestrae may be difficult to appreciate on plain radiographs when the involucrum is well developed, as in this image, and consideration should be given to obtaining over-penetrated views to try and identify sequestrae. If available, a CT scan can be helpful in identifying sequestrae. (c, d) In cases where no discreet sequestrum can be identified, and when technically possible, (d) diaphyseal reaming can be considered to decompress the medullary canal

becomes completely encased in bone and may be partially or completely resorbed. Three possible scenarios result: (1) the periosteal reaction is so prolific that the medullary canal is obliterated; (2) fusiform, hypertrophic appositional growth occurs,

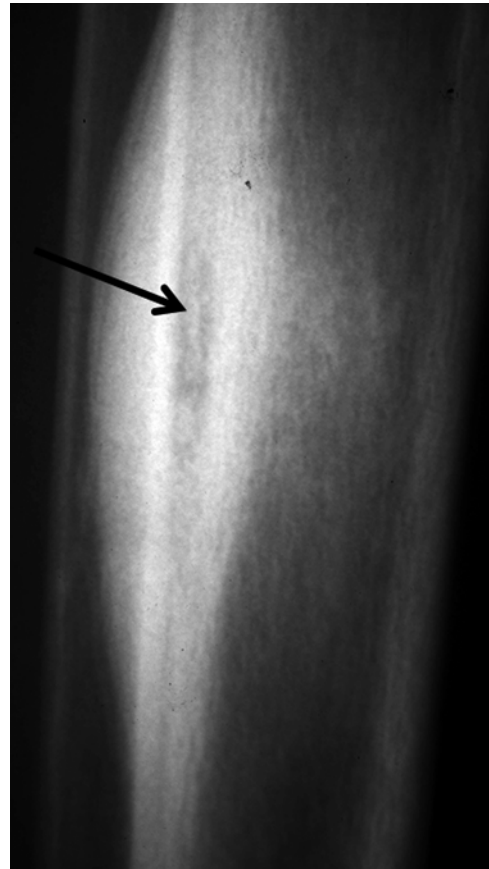


Fig. 31.4 In the cortical presentation, the sequestrum becomes walled off within the cortex of the bone, in this case the arrow points to a thin sclerotic sequestrum

resembling the “onion skin” periosteal reaction seen in Ewing’s sarcoma; or (3) the diaphysis of the bone becomes densely sclerotic. These are all descriptions of the various *sclerotic presentations, or Type III* (Beit-CURE Types B3 and C) (Fig. 31.3). Small sequestrae within the sclerotic bone can be difficult to identify and remove, and over-penetrated radiographs may help define them. Overgrowth of the involved bone is common from chronic hyperemia, as is angular deformity.

If the infection is not extensive and only a small amount of cortex dies, it may become walled off as a sequestrum entirely within the cortical bone. This is *Type IV, or the cortical presentation* (Beit-CURE Type B1) (Fig. 31.4). Cortical presentations are rare and represent a milder form of disease with isolated segmental cortical death.

Where the periosteal reaction is robust but not to the degree seen in the sclerotic presentation, a strong involucrum is formed with multiple

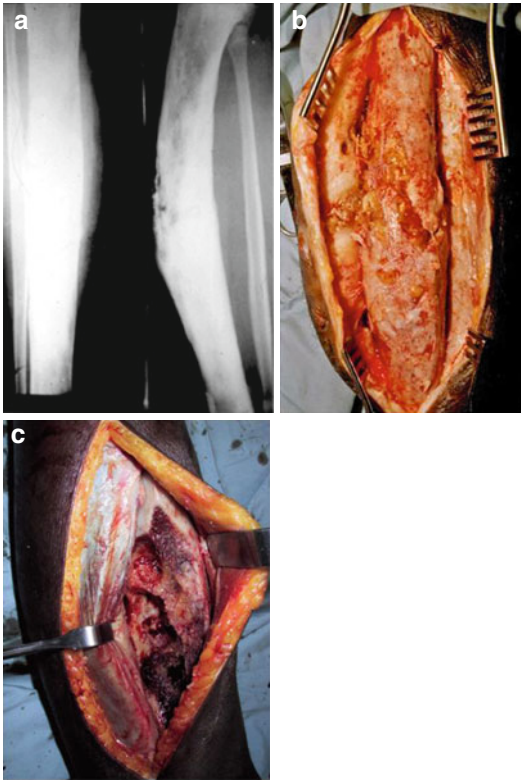


Fig. 31.5 This case illustrates the multiple walled-off abscesses presentation (Type V) with (a, b) extensive involvement of the tibial shaft. (c) A longitudinal partial diaphysectomy may facilitate debridement in such cases (Courtesy of Spiegel D, Penny J. Chronic osteomyelitis in children. *Tech Orthop.* 2005;20(2):142–52)

abscess cavities containing sequestrae, often associated with cloacae and multiple sinus tracts. This is *Type V or multiple walled-off abscesses presentation* (Fig. 31.5). A healthy vascular response by the involucrum may eventually resorb remnants of sequestrum, leaving multiple tiny abscesses and sequestrae called the *multiple microabscesses presentation, Type VI* (Fig. 31.6). In this type it is difficult to plan a surgical approach that does not remove excessive bone and compromise its structural integrity. Look for and begin with the locations with the most obvious sequestrae and those causing the most functional disability. Presumably, if left alone, these cases might progress to one of the sclerotic types or heal spontaneously as the last remnants of sequestrae are absorbed. Types V and VI may benefit from a watch and wait strategy along with long-term antibiotic therapy to reduce the bacte-

rial load while allowing the involucrum to mature. These patients require hospitalization preoperatively for antibiotics and nutritional support.

In some cases the infection is loculated in the metaphyses, *metaphyseal presentation, or Type VII* (Beit-CURE Type A) (Fig. 31.7). There are no

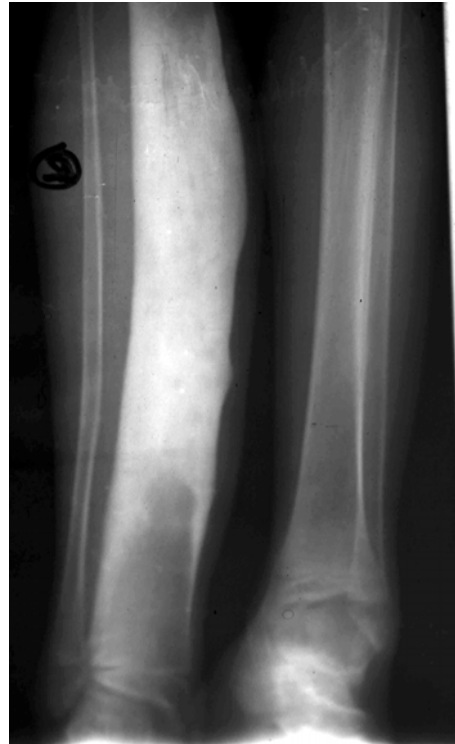

Fig. 31.6 Multiple microabscesses (Type VI)

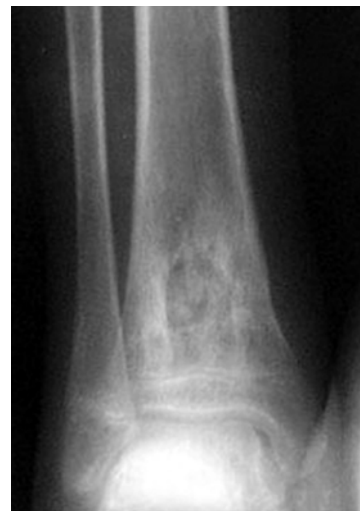

Fig. 31.7 Metaphyseal (Type VII)

typical cortical sequestrae, although microsequestrae can form from trabecular necrosis and the abscess cavity can be quite large due to the relative sponginess of the metaphyseal bone. The single or multiple walled-off abscesses may show a sclerotic margin or juxtacortical erosions. The surgical approach is limited saucerization and curettage, and the lesions usually reconstitute without requiring bone graft.

Adequate Debridement

Chronic osteomyelitis is associated with considerable hyperemia, and both the hypervascular involucrum and the surrounding soft tissues can bleed substantially during surgery. The hemoglobin should be checked preoperatively, and blood should be cross matched in anticipation of the need for a transfusion. Blood supplies are often

scarce or unobtainable, and blood-borne pathogens remain a concern.

The femur, hip, and humerus are the most troublesome locations for significant bleeding, making control of intraoperative blood loss a challenge. Suggestions to control blood loss include working quickly and efficiently, using a tourniquet (even in the face of sickle cell disease), placing the patient in Trendelenburg during lower extremity surgery, packing cavities with sponges when they are not being worked on, having your assistant elevate the limb straight-up if necessary, and elevating the extremity postoperatively. Elevation of the foot or head of bed on bed blocks is more effective than using pillows.

The timing of debridement is of paramount importance. As sequestrae may partially or completely resorb (Fig. 31.8), care must be taken to ensure the presence of adequate involucrum to

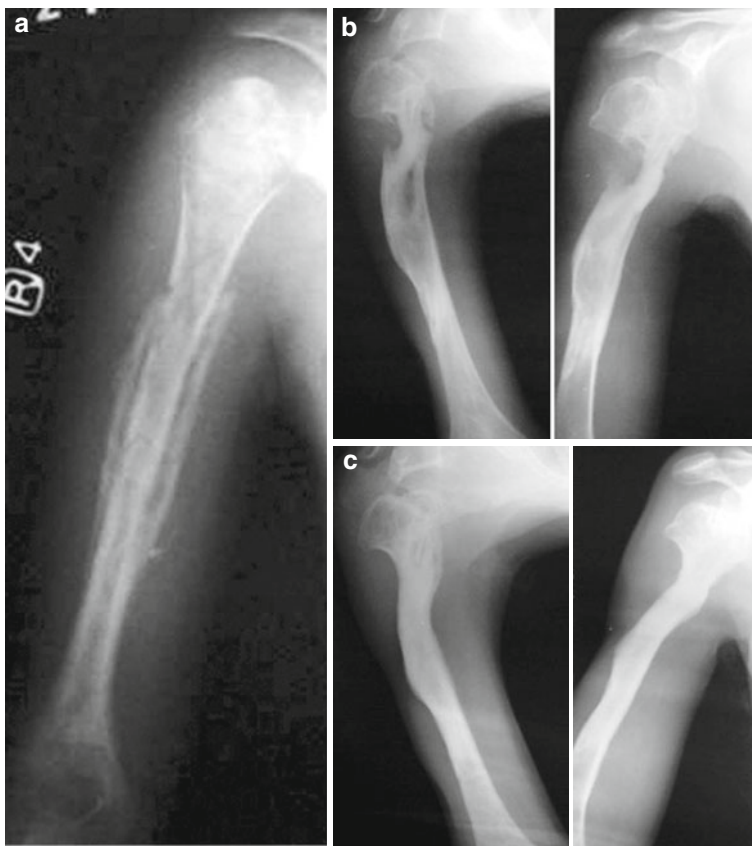


Fig. 31.8 Resorption of sequestrae. This case of proximal humeral osteomyelitis was initially treated by drainage of the abscess and antibiotics. (a) The upper segment of the humeral shaft became sequestered, (b) but the involucrum

matured over time and (c) only a small sequestered fragment in the upper metaphysis persisted (Images courtesy of the Hospital and Rehabilitation Centre for Disabled Children, Banepa, Nepal)

avoid complications such as segmental bone loss. This may entail waiting at least 3–6 months prior to definitive surgical care.

Plan the incision based on the location of draining sinuses, which suggest the location of cloacae any sequestrae. The skin incision should be placed over muscle, avoiding subcutaneous borders. If possible approach the bone in the area where the involucrum is weakest to avoid compromising its structural stability. Minimize subperiosteal stripping, which may further reduce the local blood supply. Use a drill to map an oval window in the cortex. Be aware that there is often no medullary canal. Remove the sequestrum in one piece, excavating the involucrum as necessary and curetting the intramedullary canal proximal and distal to remove any retained fragments. Feel and listen to the texture of the bone: sequestrae sound sharp and metallic on contact with a curette, while involucrum sounds woody and muffled.

Dead Space Management

Begin the closure by beveling the edges of the cortical window and if available, mobilize healthy muscle to lay in the defect. In Fig. 31.9, the incision has been made laterally and the anterior compartment muscles have been mobilized and

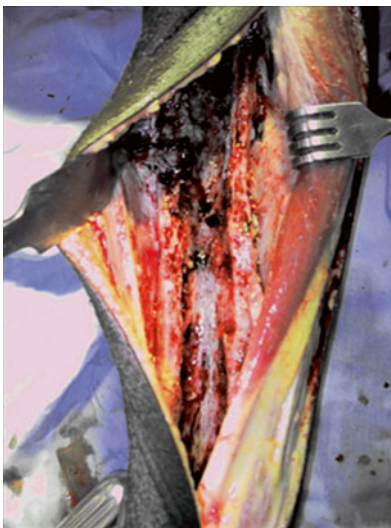

Fig. 31.9 Uniform punctate bleeding was observed, and the anterior compartment muscles (retracted in this photo) were sutured into the bony defect prior to loose reapproximation of the skin edges

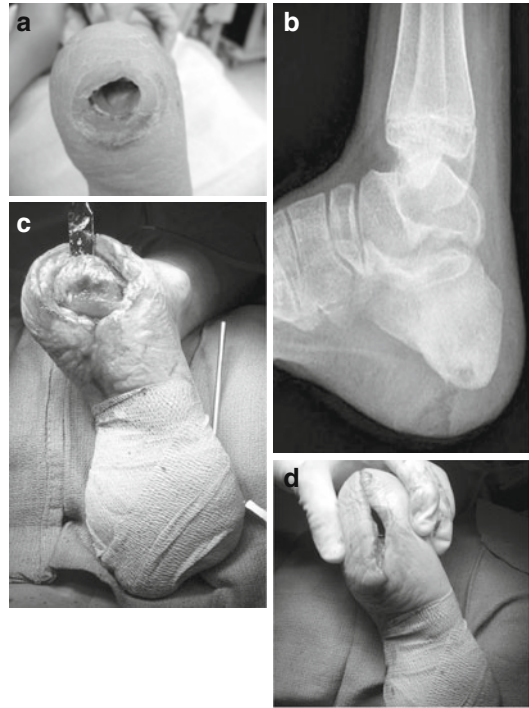


Fig. 31.10 For chronic calcaneal osteomyelitis, the heel splitting approach can be used for debridement. (a, b) This adolescent had an open wound for more than 1 year, and (c, d) underwent excision of the sinus tract and wide resection of the infected focus, followed by loose reapproximation of the wound edges

laid into the defect created by the sequestrectomy. This fills the dead space and enhances vascularity. Suture the muscle to holes drilled in the involucrum with absorbable sutures. Avoid closing the subcutaneous tissues, but loosely re-approximate the skin edges with nonabsorbable sutures, preferably monofilament (Fig. 31.10a–d). Leave a drain—even gauze packing—in the wound.

In the chronic stage of osteomyelitis, the infection is walled off and antibiotics cannot penetrate the tissues, making them ineffective alone in eradicating the infection. However, they may be indicated in patients presenting with systemic symptoms, used briefly to cover the surgical phase, and temporarily relieve local pain, swelling, and drainage, allowing easier surgical resection. Experience in Africa has shown that antibiotics are seldom necessary at the time of surgery or in the postoperative recovery in order to obtain a cure or good result.

Malaria treatment and prophylaxis is important in malarial endemic regions. Subclinical

malaria exacerbates anemia and malnutrition, and flares with the stress of surgery. A high postoperative fever in endemic locations is more likely to be an exacerbation of malaria than an exacerbation of osteomyelitis. If drainage recurs, think of loculated or hidden sequestrae.

lized. A much neglected but vitally needed facility in many under-resourced countries is the step-down rehabilitation hostel in the local community, and surgeons should encourage community-based rehabilitation programs to institute hostel care.

Rehabilitation and Reconstruction

Postoperative recovery can be prolonged, requiring dedicated nursing care and physiotherapy. Protected weight bearing may be necessary if the involucrum is not well established. For many patients it is impossible to accomplish this care on an outpatient basis, and long-term hospitalization is necessary. Wherever rehabilitation wards and facilities are available, they should be uti-

Long-Term Complications of Chronic Osteomyelitis and Their Treatments

Complications associated with chronic osteomyelitis include, but are not limited to, focal or segmental defects in bone, angular deformities, leg length discrepancy, physeal disturbance, and pathologic fracture, osteonecrosis, and squamous cell carcinoma from chronic sinus tracts (Fig. 31.11). When focal bone loss is observed,

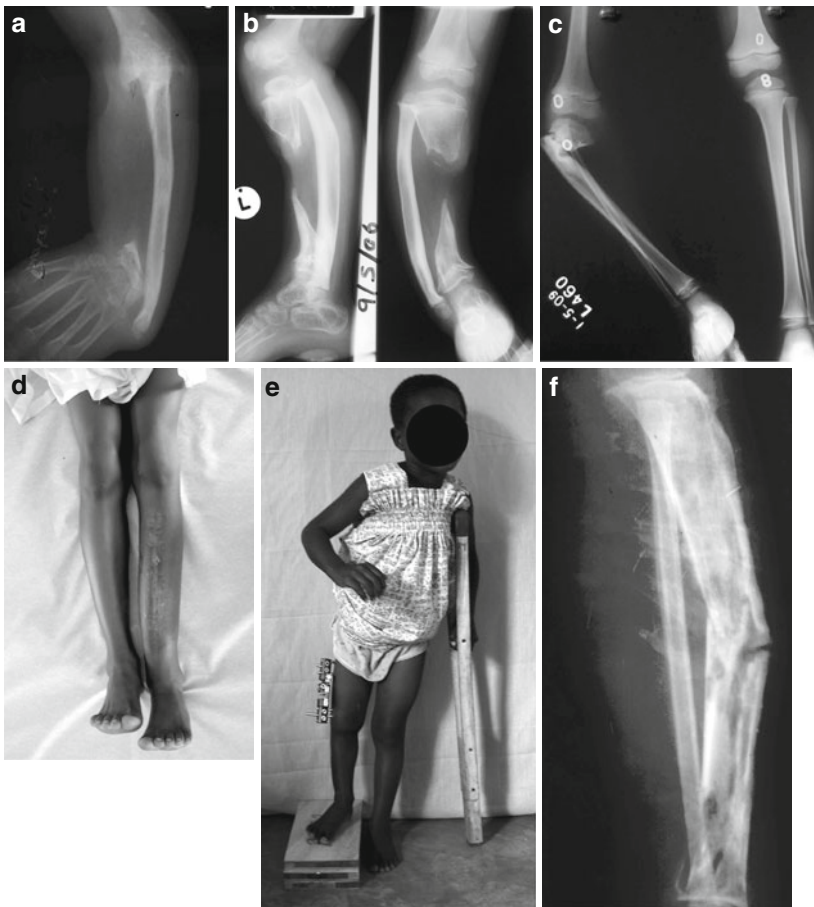

Fig. 31.11 Complications of osteomyelitis include (a, b) segmental bone loss, (c) angular deformities from physeal damage and growth disturbance, (d) limb overgrowth (leg

length discrepancy) from chronic hyperemia, (e) limb shortening, and (f) pathologic fracture

conventional grafting may suffice, and an open cancellous bone grafting technique (Papineau) may be considered (see Chap. 41).

Bypass procedures are a salvage option for segmental defects in the forearm (Fig. 31.12) or lower leg (Fig. 31.13); however, segmental defects in the femur or humerus are very difficult to manage (Fig. 31.14). Bone transport, unifocal or bifocal, is an excellent choice if the technology and experience are available. Angular deformities are managed by osteotomy for realignment, with either an acute correction for deformities $\leq 20^\circ$ or gradual correction with an external fixateur for more severe deformities. If growth remains an epiphysiodesis of the contralateral side may

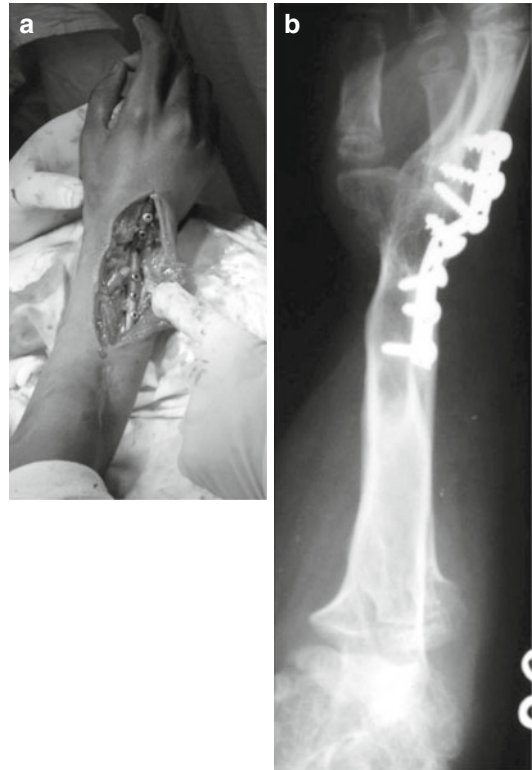

Fig. 31.12 (a, b) Segmental bone loss and wrist instability treated by creation of a single bone forearm and wrist fusion as there was insufficient distal radial bone stock to synostose the distal ulna to the distal radius

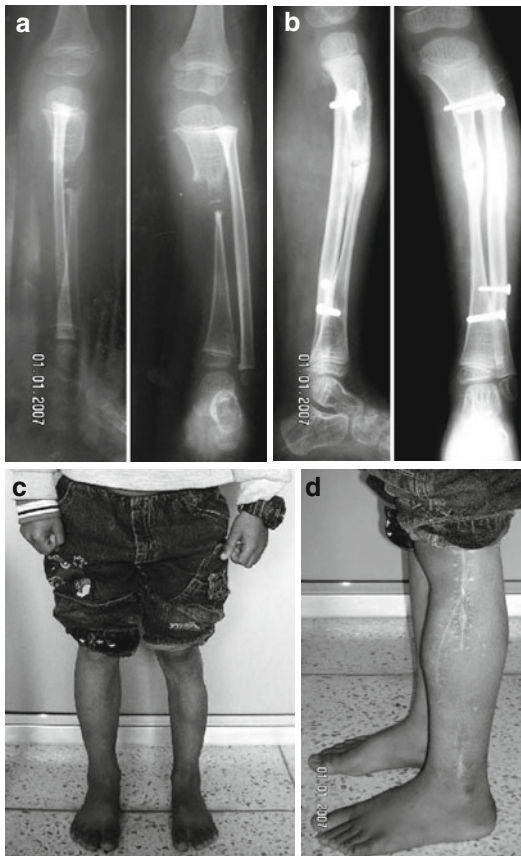

Fig. 31.13 Numerous techniques have been described for using the fibula to bypass segmental defects in the tibia from nonunion or infection. (a–d) In this case, following debridement, a bypass procedure was performed in which a side to side union of the tibia and fibula was achieved following bone grafting and fixation. Fibular bypass procedures can be performed in one or two stages, with or without translation of the fibular shaft under the mechani-

cal axis of the tibia (centralization). (e, f) show other examples of synostosis without centralization. (g) The fibula is capable of significant hypertrophy when centralized under the tibia. This radiograph was obtained at 8 years followup, and while there was no reactivation of infection, the case was complicated by ankle valgus and the patient elected to have a procedure for realignment

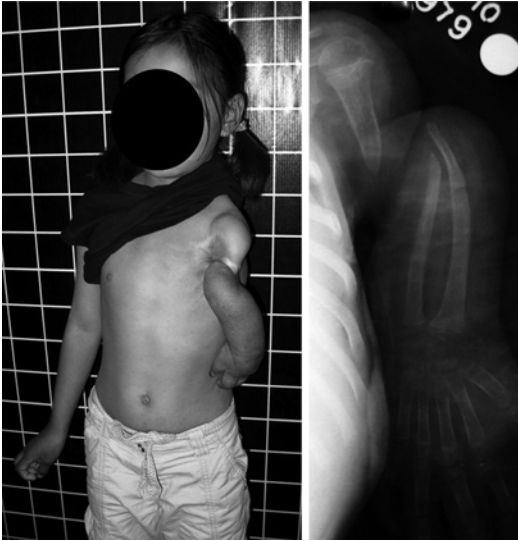

Fig. 31.14 Segmental loss in the humerus is much more difficult to manage. This young girl had an early debridement and ended up with loss of the lower humerus and the proximal radius and ulna. Her neurovascular exam was normal distally, but she was unable to use the extremity in any activities of daily living. A very difficult problem to solve

be considered as an alternative to lengthening or in conjunction with lengthening, depending upon the circumstances.

References

1. Spiegel DA, Penny JN. Chronic osteomyelitis in children. *Tech Orthop.* 2005;20:142–52.
2. Jones HW, Harrison JW, Bates J, Evans GA, Lubega N. Radiologic classification of chronic hematogenous osteomyelitis in children. *J Pediatr Orthop.* 2009;29:822–7.

Suggested Reading

- Agiza AR. Treatment of tibial osteomyelitic defects and infected pseudarthroses by the Huntington Fibular Transference Operation. *J Bone Joint Surg.* 1981;63a:814–9.
- Beaso J. Treatment of tibial defects due to osteomyelitis by postero-lateral cortico-cancellous bone grafting. *Trop Doct.* 1996;26:118–20.
- Beckles VL, Jones HW, Harrison JW. Chronic hematogenous osteomyelitis in children: a retrospective review of 167 patients in Malawi. *J Bone Joint Surg Br.* 2010;92:1138–43.
- Cierny 3rd G. Surgical treatment of osteomyelitis. *Plast Reconstr Surg.* 2011;127:190S–204.
- Cierny G, Zorn K. Segmental tibial defects. Comparing conventional and Ilizarov methodologies. *Clin Orthop Relat Res.* 1994;301:118–23.
- Daoud A, Saighi-Bouaouina A. Treatment of sequestra, pseudarthroses, and defects in the long bones of children who have chronic hematogenous osteomyelitis. *J Bone Joint Surg.* 1989;71a:1448–68.
- Jones HW, Beckles VL, Akinola B, Stevenson AJ, Harrison WJ. Chronic hematogenous osteomyelitis in children: an unsolved problem. *J Bone Joint Surg Br.* 2011;93:1005–10.
- Marsh JL, Prokuski L, Biermann JS. Chronic infected tibial nonunions with bone loss. Conventional techniques versus bone transport. *Clin Orthop Relat Res.* 1994;301:139–46.
- Panda M, Ntungila N, et al. Treatment of chronic osteomyelitis using the Papineau technique. *Int Orthop.* 1998;22:37–40.
- Sachs B, Shaffer JW. A staged Papineau protocol for chronic osteomyelitis. *Clin Orthop Relat Res.* 1984;184:256–63.
- Simpson AHR, Deakin M, Latham JM. Chronic osteomyelitis. The effect of the extent of surgical resection on infection-free survival. *J Bone Joint Surg.* 2001;83B:403–7.
- Tetsworth K, Cierny G. Osteomyelitis debridement techniques. *Clin Orthop Relat Res.* 1999;360:87–96.

William James Harrison and John L. Esterhai Jr.

Osteomyelitis

Adults with osteomyelitis commonly present with subacute or chronic disease from (1) reactivation of childhood chronic osteomyelitis, (2) open fractures, or (3) as a complication of musculoskeletal surgery. The offending organisms attach to avascular structures and become covered in an extracellular biofilm matrix which shields them from host defenses and antibiotics. Chronic osteomyelitis originating in childhood may remain active into adult life or may go through periods of dormancy with later reactivation. Reactivation can be spontaneous or provoked by an insult such as impaired immunity, trauma, or surgery.

While bacteremia and malnutrition are more common in children, infection-enhancing comorbidities such as HIV, diabetes mellitus, vascular disease, malignancy, and alcohol/tobacco abuse are more common in adults. In developing countries, open fractures commonly become infected due to delay in care. ORIF of

closed fractures is often complicated by sepsis because of suboptimal facilities, poor sterile technique and tissue handling, unstable fixation, and unhygienic perioperative care. The most common infecting organism is *Staphylococcus aureus*. The history may provide clues to less common pathogens such as salmonella in sickle cell and HIV patients, and mixed pathogens from animal and human bites.

Diagnosis

The periosteal reaction to infection, involucrum, is less robust in adults when compared to that in children, and the structural integrity of the bone must be assessed to determine the risk of pathologic fracture. Routine blood tests such as a CBC, ESR, and CRP should be obtained if possible, but are often normal in chronic osteomyelitis in the absence of an acute exacerbation. Additional helpful tests include blood cultures and serum chemistries including glucose, HIV, and serum protein (albumin). Deep cultures of pus, bone, and tissue around implants should always be taken, as external cultures from the skin or sinus tracts often grow mixed species and are less helpful.

Treatment

In the early stage of acute osteomyelitis, <2 weeks duration, there is typically no bone death

W.J. Harrison, BM BCh, MA (Oxon), FRCS (Trauma & Orthopaedics), FCS ECSA (✉)
Trauma and Orthopaedics,
Countess of Chester NHS Foundation Trust,
Liverpool Road, Chester, CH2 1UL, UK
e-mail: aojimh@gmail.com; jim.harrison1@nhs.net

J.L. Esterhai, Jr., M.D
Department of Orthopaedic Surgery,
Hospital of the University of Pennsylvania,
3400 Spruce Street, Silverstein Two,
Philadelphia, PA 19104, USA
e-mail: john.esterhai@uphs.upenn.edu

or sequestration and it may be adequately managed by antibiotics and surgical drainage of abscesses.

Adult chronic osteomyelitis is a surgical disease, and antibiotics should be viewed as an adjunct. The surgical principles used to treat a locally aggressive neoplasm are the most appropriate when dealing with chronic osteomyelitis, with the goal of a wide resection of the infected tissues followed by reconstruction of soft tissues and bony defects. Treatment of other problems such as angular deformity and limb length discrepancy may be required in the reconstructive phase.

The importance of medical management in all stages of adult bone infection to enhance host defenses and maximize healing potential cannot be overemphasized. Patients seropositive for HIV should be staged according to the guidelines of the World Health Organization [1], and antiretroviral therapy should be started or modified if the CD4 count is 350 cells/mm³ or below.

The following is the revised WHO HIV clinical staging system:

I = Asymptomatic ± lymphadenopathy

II = Minor mucocutaneous findings or recurrent upper respiratory infections

III = Severe weight loss, persistent fevers, chronic diarrhea, pulmonary tuberculosis, and bacterial infections

IV (AIDS) = Toxoplasmosis of the brain, visceral candidiasis, disseminated mycosis, HIV encephalopathy, extrapulmonary TB, or Kaposi's sarcoma

Lifestyle changes such as cessation of smoking and ethanol ingestion are also recommended.

Adult osteomyelitis is most commonly staged according to Cierny and Mader [2] (Table 32.1). This system considers both (1) anatomic type of infection (medullary, superficial, localized, diffuse) and (2) host status (medical comorbidities). The "A" host is healthy and has the best chance of an excellent outcome with aggressive surgical therapy aimed at disease eradication and limb reconstruction. The "B" host has local (chronic edema, vascular disease) and/or systemic (diabetes, malnutrition, immune deficiency) comorbidities that increase the risk of treatment failure. Limb salvage is not an option in "C" hosts in

Table 32.1 Cierny-Mader classification of adult osteomyelitis

Anatomic type	Description	Initial surgical debridement and dead space management	Reconstruction
I: Medullary	Biofilm nidus in endosteum (scar, implant, dead bone)	Unroofing by corticotomy, canal reaming, or both ± Antibiotic depot (PMMA) ± Primary closure Protect if fracture risk (cast or Ex Fix)	Dead space in medullary canal managed by bone grafting
II: Superficial	Nidus is an exposed bony surface, no medullary involvement	Soft tissue loss is main concern Superficial bony debridement	Local transposition flap
III: Localized	Full thickness, cortical sequestrum, medullary involvement, soft tissue defect possible	Combination of Types I and II Bony and soft tissue defects Protect if fracture risk (cast or Ex Fix) ± Antibiotic depot (PMMA)	Local transposition flap Dead space in medullary canal managed by bone grafting
IV: Diffuse	Permeative bony destruction which is often circumferential, unstable	Most difficult, treatment is always staged Extensive debridement causes bony instability or segmental defect ± Antibiotic depot (PMMA) Protect if fracture risk (cast or Ex Fix)	Strategies used alone or in combination include (1) acute shortening, (2) bone transport, (3) bypass procedures, (4) osteotomy with or without lengthening

Source: Cierny [2]

whom the risks of treatment, except palliative therapy, are greater than living with a chronic bone infection. The anatomic type thus determines the appropriate surgical approach based on the anatomic pathology, whereas the host status governs whether an aggressive versus palliative approach is selected.

Decision making is facilitated by knowledge of the patient's clinical condition, expertise of the clinician, local facilities, economics, and socio-cultural factors. A visiting surgeon should be cautious and sensitive to all these issues, and ask for input from local caregivers. The visitor must also be sure that the treatment can be completed in his or her absence. There may be times that simply allowing dependent drainage is best. The primary goal is to improve the patient's quality of life, and on occasion the risks of limb salvage may outweigh the benefits.

While debridement of all infected tissues is necessary, dead space management and reconstructive needs vary. Some of the tools are resource intensive and impractical; however, the general principles are crucial and can be adapted for use when resources are limited. The place of incision for dependent drainage is the most important factor. While sinograms can be considered, we prefer to pass a probe or curette intraoperatively to define the sinus track. The biological environment must be respected by careful tissue handling and avoiding subperiosteal stripping and placement of circumferential retractors.

Both sequestrae and involucrum are harder to define in adults than in children. It is generally easier to perform the debridement with a tourniquet inflated and through an oval cortical window (Fig. 32.1). The tourniquet can be deflated to assess the adequacy of debridement. Exposed viable cortex bleeds in a uniform Haversian pattern, and cancellous bone bleeds in a sinusoidal pattern, termed the "paprika sign."

Dead space management may include polymethylmethacrylate spacers that provide local antibiotic delivery in high concentration and temporary structural support prior to definitive bony reconstruction. The role of intravenous or oral antibiotics is not well defined, and we recommend that they be considered as an adjunct

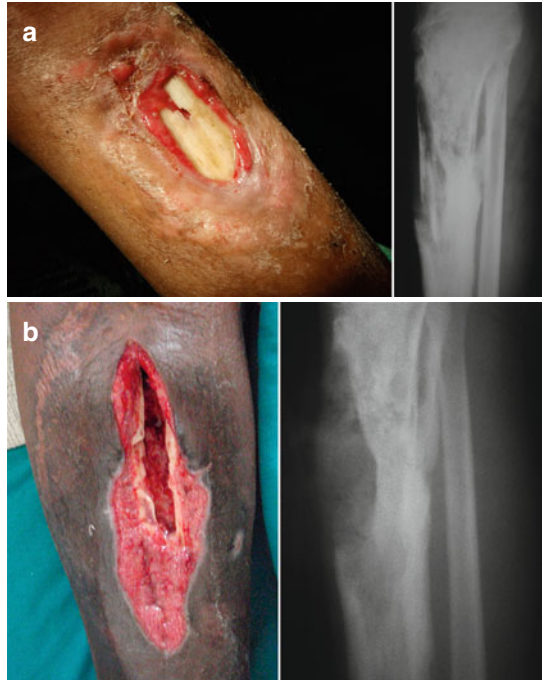


Fig. 32.1 (a) This case of tibial osteomyelitis with two thin sequestrae visible along the anterior open area of the cortex of the proximal tibia was (b) treated by sequestrectomy and debridement. Further management might include open cancellous bone grafting (Courtesy of Dr. Sam Baker)

to aggressive surgical care. A 24-h perioperative course will suffice for most patients, especially when access to antibiotics is limited. The need for long-term antibiotic therapy must be assessed on a case-by-case basis. Management of retained implants must be considered and depends on the degree of healing when the infection is diagnosed. In early infections, it may be best to perform an initial irrigation and debridement while retaining the implants if they are secure, followed by their removal once union has occurred. It is easier to treat an infected union than an infected nonunion.

Once the local environment has been sterilized by debridement and the sepsis controlled, options for the reconstruction of localized or segmental defects include (1) acute shortening, (2) cancellous bone graft, (3) structural free autograft, (4) structural allograft, (5) vascularized autograft, (6) bone transport, and (7) bypass procedures (forearm or lower leg).

Acute shortening up to 2 cm in the lower limb is generally well tolerated and can be offset by a shoe lift. A bigger challenge is how to stabilize and compress the site. External fixateurs may provide sufficient stability to promote union but are often difficult for patients to manage. Internal fixation may provide greater stability for bone healing, however there is an increased risk of local wound sepsis. Internal fixation can successfully treat septic nonunions if the biological and mechanical environments are optimized, for example, with an intramedullary implant. Internal fixation from both inside (intramedullary device) and outside (plate) will cause cortical necrosis, and this “dead bone sandwich” has a very high risk of becoming infected. Cerclage wiring almost guarantees necrosis of the segment and should be avoided at all costs.

Cancellous grafting is useful for localized bone defects. Structural free grafts, such as the fibula, are a concern since avascular bone is inserted into tissues which were previously infected. In addition, donor site morbidity should also be considered. Vascularized autografts are usually beyond the capabilities of austere environments.

Bone transport using a monolateral or ring fixateur is an option for defects greater than 2 cm in facilities with adequate equipment, expertise, and rehabilitation services, and in patients who can sacrifice the time and money involved (Fig. 32.2).

Soft tissue coverage can often be achieved with local fasciocutaneous or other flaps when primary or delayed primary closure is not an option. Vacuum assisted wound closure or negative pressure wound therapy is useful and can be made simply and economically (see Chap. 14).

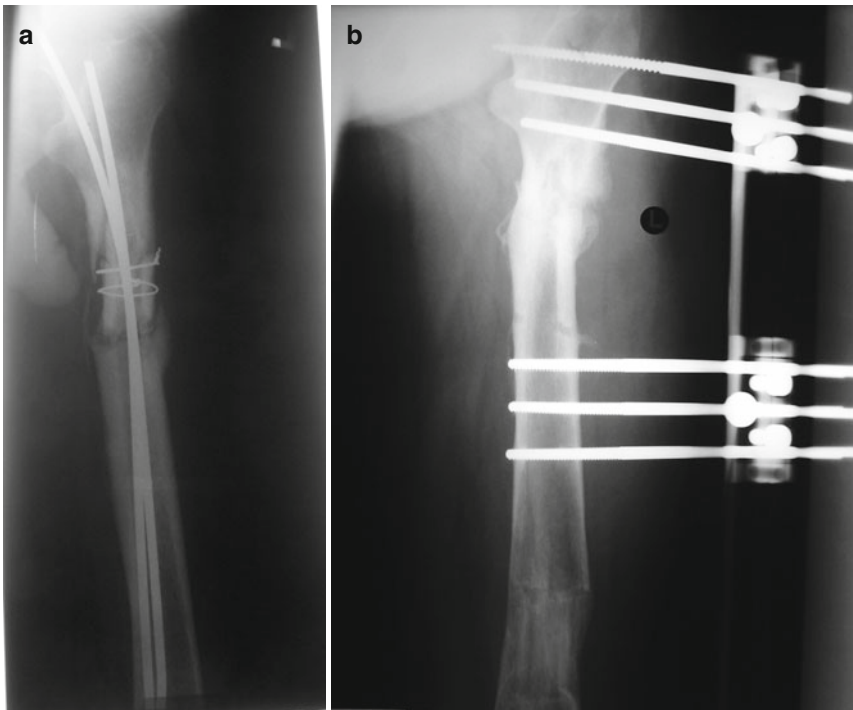


Fig. 32.2 (a) A 17-year-old male presented 6 months after sustaining an isolated closed fracture of his left femoral shaft in a road traffic crash that was treated surgically with two retrograde flexible nails and a cerclage wire. Cerclage wiring almost guarantees necrosis of the segment and should be avoided. He developed wound sepsis and his flexible nails had backed out and been hammered back up, transgressing the hip joint. At presentation he

had purulent drainage, scarred soft tissues, and stiffness of both the hip and knee. (b) He was treated by debridement of 6 cm of devitalized bone and removal of implants. The bone defect was filled with gentamicin beads, and a monolateral external fixateur was applied. The beads were removed after 2 weeks, and a third set of pins were inserted distally to facilitate corticotomy and bone transport

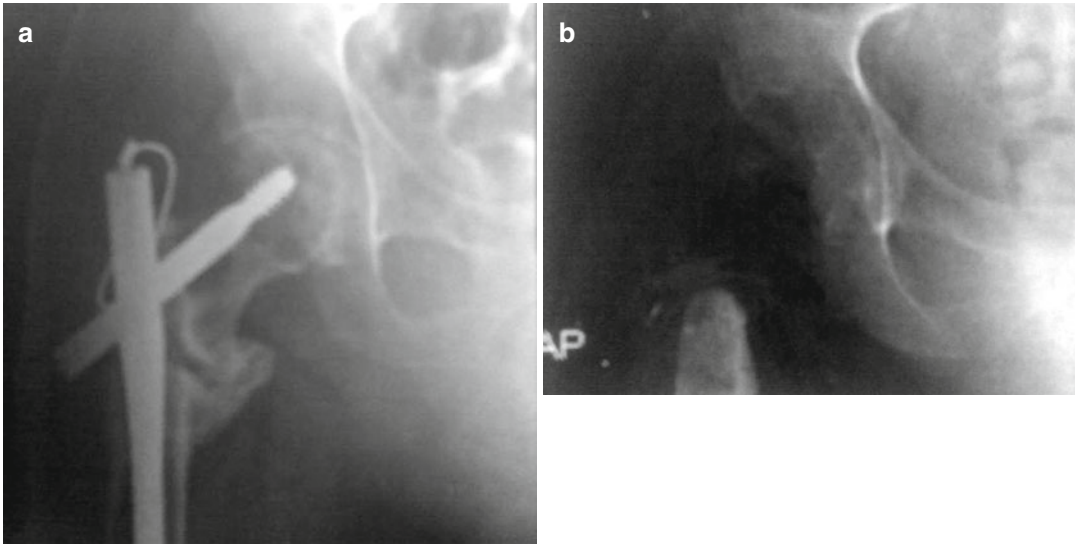


Fig. 32.3 (a) This 46-year-old multi-substance abuser sustained a closed subtrochanteric femur fracture, and treatment was complicated by nonunion. After several additional

surgeries, he developed a chronic MRSA osteomyelitis (b) which ultimately required an extensive Girdlestone arthroplasty with resection of the proximal femur

It is vital to think of rehabilitation and restoration of function from the outset of treatment, as muscle atrophy is common and ongoing sepsis exacerbates joint stiffness. An aggressive approach to infection control and stability management is required for rehabilitation (Fig. 32.3).

To justify the morbidity and risk of limb salvage, the expected outcome must offer distinct advantages over an amputation or observation alone. If treatment for cure in the given setting is contraindicated or excessive, the patient is classified as a C-host and offered palliation such as I&D, suppressive antibiotics, or ambulatory aides.

Finally, amputation is typically reserved as a salvage option but should also be considered in selected patients as the primary treatment to enhance outcomes and facilitate rehabilitation (Fig. 32.4). Amputations should include an adequate debridement, and wounds should be left open initially (see Chap. 43).

Adult Septic Arthritis

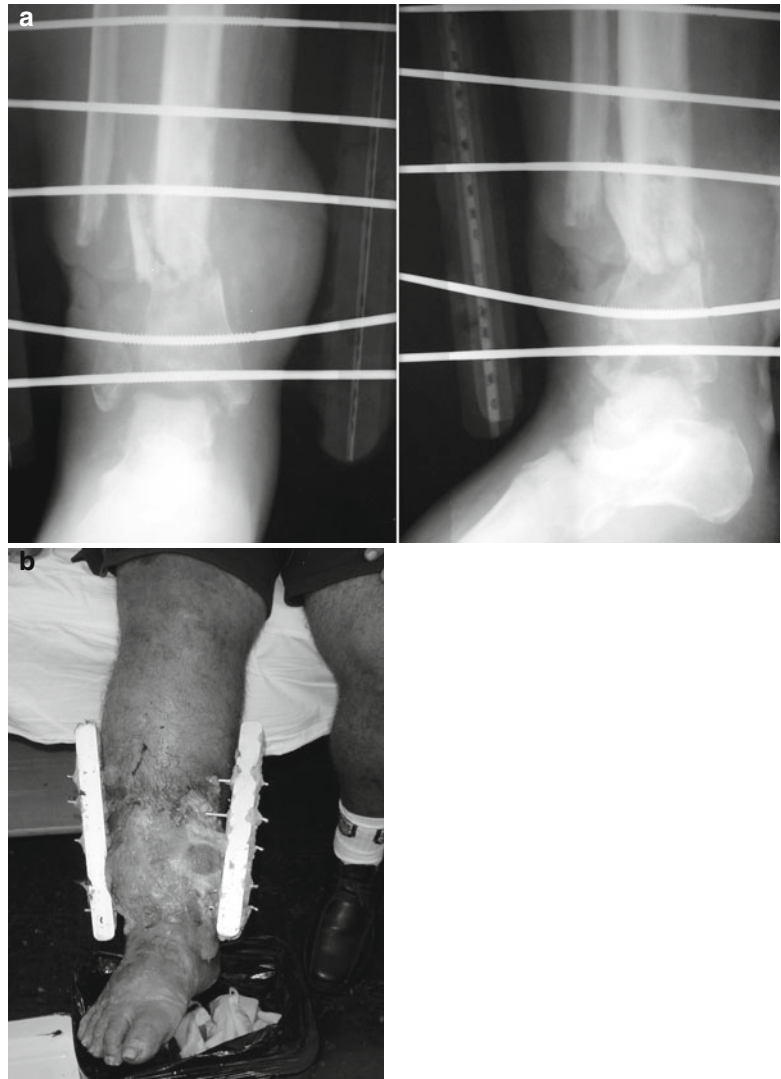
Septic arthritis can be due to bacteria, viruses, fungi, and parasites. The defense mechanisms of the host, properties of the invading organism, and

the premorbid condition of the joint play important parts in the pathophysiology of septic arthritis. Joint sepsis can result from hematogenous dissemination, direct inoculation, or contiguous spread from an adjacent osteomyelitis. Synovial fluid is an excellent growth medium for bacteria, has a relative lack of immunologic resistance, and there is no structural barrier to the spread of bacteria from the synovium to the joint. Transient bacteremia and trauma causing intra-articular hemorrhage can play a role in the pathogenesis of septic arthritis.

Risk factors for septic arthritis include systemic disorders (rheumatoid arthritis, diabetes, drug abuse, malignancies, HIV/AIDS, or immunocompromised status), local factors (trauma, osteoarthritis, surgery), age (elderly), and social factors (low income, exposure to animals). The differential diagnosis includes crystal-induced arthritis (gout, pseudogout), rheumatoid arthritis, chronic seronegative arthritis, Lyme disease, drug-induced arthritis, and seeding from infectious endocarditis.

Ninety percent of infections are monoarticular with primary knee sepsis accounting for 40–50 %, hip 20–25 %, and shoulder 10–15 %. Polymicrobial infections occur in 5–15 % of patients, often associated with an extra-articular polymicrobial infection or penetrating trauma,

Fig. 32.4 (a) This comminuted open fracture was treated with a locally made fixateur but (b) became infected, ultimately leading to a below-knee amputation



especially in immunocompromised patients. Staphylococcal species are most common, followed by streptococci. Gram-negative infections are more common in the elderly, intravenous drug users, and those with malignancy, diabetes, immunosuppression, or hemoglobinopathy. Host variables help predict the bacteria involved (Table 32.2).

Patients with joint infections secondary to *N. gonorrhoeae* are generally young, healthy adults. The most common clinical manifestation is a migratory polyarthralgia, with fever, tenosynovitis, and dermatitis commonly seen on initial

examination. Joint aspiration yields a positive Gram stain in only 25 % of the cases, and 50 % of cultures test negative. Synovial fluid white cell counts are less than those for nongonococcal septic arthritis, but are usually greater than 50,000 white blood cells (WBC)/mm. Urethral, cervical, rectal, and pharyngeal cultures have a much higher yield and should be taken from any sexually active patient suspected of having gonococcal arthritis. The infection shows a rapid response to ceftriaxone, and the arthritis generally resolves in 48–72 h. Surgical decompression is not needed in most cases, because joint destruction is rare.

Table 32.2 Septic arthritis complicating selected clinical settings

Clinical setting	Risk factors	Pathogen
Rheumatoid arthritis	Disabling arthritis Skin lesions Infected rheumatoid nodule	<i>Staphylococcus aureus</i> (40–60 %) <i>Streptococcus pyogenes</i> (10–20 %)
Advanced age	Diabetes mellitus, urinary tract infection, biliary tract infection, diverticulitis	<i>Staphylococcus aureus</i> (30–40 %) Gram negatives (10–20 %)
Immunosuppression, AIDS	Decreased humoral- and cell-mediated immunity	Atypical organisms (salmonella, <i>Agrobacterium</i> , fungi, atypical mycobacteria)
Hemoglobinopathy	Microinfarcts in intestinal wall	Salmonella, <i>Staphylococcus aureus</i>
Human and animal bites	Inoculation of indigenous mouth flora	<i>Pasteurella multocida</i> , <i>Eikenella corrodens</i> , <i>Streptobacillus moniliformis</i>
Intravenous drug use	Endocarditis, discitis	<i>Staphylococcus aureus</i> (60–80 %), <i>Pseudomonas aeruginosa</i> , <i>Candida</i> species
Plant thorns	Puncture wound, foreign body	Atypical organisms (<i>Pantoea agglomerans</i> , sporotrichosis, mycobacteria, nocardia, <i>Clostridium sordellii</i> , actinomycosis)
Aquatic environment		<i>M. marinum</i>

Patient Evaluation

Clinical signs and symptoms of septic arthritis are variable and imprecise. The key to diagnosis is a thorough clinical history and physical examination, which often shows intense joint pain even with very limited passive range of motion, along with laboratory studies of the synovial joint fluid.

The WBC count may be normal to slightly elevated and may not show a peripheral blood leukocytosis, while the ESR is consistently elevated. The CRP increases more rapidly than the ESR. Blood cultures should be obtained from all patients with clinical signs and symptoms of systemic sepsis.

Joint aspiration followed by synovial fluid analysis and culture is essential. On gross examination, the fluid is often thick, yellow, and cloudy. There may be a negative “string sign.” Values greater than 50,000 WBC/mm³ on the cell count are suggestive of bacterial arthritis, and values greater than 100,000 WBC/mm³ are rarely associated with other causes. The percentage of polymorphonuclear lymphocytes is typically more than 75 % in bacterial infections versus >50 % in inflammatory diseases and <25 % in noninflammatory conditions. Cultures

should include aerobes, anaerobes, fungi, and mycobacteria. In cases where *N. gonorrhoeae* is suspected, chocolate agar or Thayer-Martin plates should be used. Polarized microscopy may be helpful, recognizing that the presence of crystals does not rule out infection, because the two processes can coexist.

Plain radiographs are only occasionally helpful within the first 7–10 days and may show joint subluxation or soft tissue swelling, due to either joint effusion or synovial hypertrophy. Later in the infectious process, 40 % of patients will show abnormalities.

We classify adult septic arthritis based on the (1) site and extent of tissue involvement (four anatomic types), (2) host’s status (the same A, B, C classes used in the Cierny-Mader classification for osteomyelitis in adults), (3) duration of symptoms, and (4) virulence of the organism (Table 32.3).

Anatomic Type I is periarticular soft tissue infection without pyarthrosis, for example, a post-surgical superficial wound infection. Anatomic Type II occurs when the purulent material is confined within the capsule. Anatomic Type III exists when there is involvement of the joint and surrounding soft tissue, such as deep wound infection or septic bursitis, along with the joint

Table 32.3 Classification system for septic arthritis

Joint name (glenohumeral, elbow, hip, knee, etc.)
Anatomic type
I: Periarticular soft tissue infection without pyarthrosis
II: Isolated septic arthritis
III: Septic arthritis with soft tissue extension, but no osteomyelitis
IV: Septic arthritis with contiguous osteomyelitis
Host class
A: Normal immune system
B: Compromised host
B _L : Local tissue compromise
B _S : Systemic immune compromise
C: Risk associated with aggressive treatment unwarranted
Clinical setting
1: Less than 5 days of symptoms and non-virulent organism
2: Symptoms for 5 days or more, or a virulent organism
Clinical stage for a specific joint
Anatomic type + host class + clinical setting = stage

sepsis, but no bony involvement. When there is osteomyelitis contiguous with a joint infection, it is classified as Type IV.

The clinical setting takes into account the duration of symptoms and aggressiveness of the organism. We have grouped patients with less than 5 days of symptoms and infection with a less virulent bacterial strain into group 1. Those patients who are infected with a virulent organism or with symptoms for 5 days or greater fall into group 2. The cutoff was chosen at 5 days because animal studies have shown that irreversible joint damage occurs if septic arthritis persists beyond this time. The virulent organisms may vary between hospitals and geographic locations but generally include methicillin-resistant *S. aureus* (MRSA) and Gram-negative organisms.

Treatment

Empiric antibiotics—based on availability, the history, and the local prevalence of organisms—are instituted after a specimen is taken for the

appropriate studies. Usually, a penicillinase-resistant antistaphylococcal drug is the initial choice for the typical Gram-positive cocci infection. A more controversial issue is the use of oral versus parenteral antibiotics. Patients are typically started on intravenous therapy and converted to oral therapy if they exhibit an adequate clinical response, manifested by improved ROM of the joint, decreased pain, resolution of fever, as well as normalization of WBC and ESR.

The duration of antibiotic therapy varies with the pathogen, the patient's underlying condition, and adjuvant medical or surgical procedures. It is typically 2–6 weeks as long as an appropriate clinical response is observed. A 4- to 6-week course of antibiotics is required with more virulent organisms such as *S. aureus* or Gram-negative bacilli, immunocompromised patients, or those who show a slow clinical response.

The goals of treatment of septic arthritis include sterilization and decompression of the joint. In non-surgery-related infections, the preferred method of joint decompression remains controversial, and options include repeated needle aspirations (one to two times per day until effusion is gone) under sterile conditions with a large bore needle versus surgical drainage (open or arthroscopic). Recognizing the increased costs, morbidity, and recovery time following arthrotomy (versus aspiration), the authors' opinion is that open surgical drainage should be performed when:

- Patients present with >5 days of symptoms.
- Infection is caused by aggressive organisms (MRSA, Gram negatives).
- Host variables are poor (immunocompromised, coexisting diseases, elderly).
- Postsurgical cases.
- Cases in which a biopsy or synovectomy would be useful.
- Repeated arthrocentesis failed.

Cultures of synovial tissue may have a higher yield for fastidious organisms.

Although sterilization of a joint may be achieved with irrigation and antibiotics, residual bacterial products may contribute to a post-infectious synovitis. We usually start NSAIDs after initiation of antibiotic treatment to blunt

this synovitis. Finally, as articular cartilage is nourished by synovial fluid, active and passive range of motion should begin as soon as the acute symptoms subside.

References

1. World Health Organization. Revised WHO clinical staging of HIV/AIDS for adults and adolescents. 2005. Available at <http://www.who.int/hiv/pub/guidelines/clinicalstaging.pdf>. Accessed 14 Apr 2012.
2. Cierny 3rd G. Surgical treatment of osteomyelitis. *Plast Reconstr Surg*. 2011;127:190S–204.

Suggested Reading

Cierny G, Zorn K. Segmental tibial defects. Comparing conventional and Ilizarov methodologies. *Clin Orthop Relat Res*. 1994;301:118–23.

Garcia-De La Torre I. Advances in the management of septic arthritis. *Infect Dis Clin North Am*. 2006;20:773–88.

Marsh JL, Prokuski L, Biermann JS. Chronic infected tibial nonunions with bone loss. Conventional techniques versus bone transport. *Clin Orthop Relat Res*. 1994;301:139–46.

Mathews CJ, Kingsley G, Field M, et al. Management of septic arthritis: a systematic review. *Ann Rheum Dis*. 2007;66:440–4.

Ross JJ. Septic arthritis. *Infect Dis Clin North Am*. 2005;19:799–817.

Shah RK, Singh RP, Quasem MF, et al. Sign interlocking nail in the treatment of infected non union. *Tech Orthop*. 2009;24:289–96.

Smith JW, Chalupa P, Hasan MS. Infectious arthritis: clinical features, laboratory findings and treatment. *Clin Microbiol Infect*. 2006;12:309–14.

Weston V, Coakley G. Guidelines for the management of the hot swollen joint in adults with a particular focus on septic arthritis. *J Antimicrob Chemother*. 2006;58:492–3.

Z. Deniz Olgun, Muharrem Yazici, David A. Spiegel,
Syed Muhammad Awais, and Binod Bijukachhe

General Principles

Tuberculosis continues to be a major public health problem globally and is commonly encountered in areas with crowding, malnutrition, and poor sanitation and where access to preventive and curative health services is scarce or absent.

Mycobacterium tuberculosis is transmitted through inhalation of airborne droplets disseminated by individuals with pulmonary tuberculosis. The microorganisms are ingested by alveolar macrophages, and the infection is either contained or develops into active disease. Active disease is most common in children younger than 5 years

and adults with HIV/AIDS, and the incidence of extrapulmonary tuberculosis is increasing due to the increase in the prevalence of HIV/AIDS.

Musculoskeletal involvement is diagnosed in less than 10 % of all cases of tuberculosis, and 50 % of these patients have spinal involvement. Tissue destruction in tuberculosis is caused by a delayed hypersensitivity reaction, leading to inflammation, tissue exudation, and liquefaction, producing a cold abscess. These can migrate along tissue planes and exit the skin at sites remote from their origin, such as those from the spine draining through the inguinal or gluteal region (Fig. 33.1a, b). Though uncommon, multiple osseous and/or articular sites can occur in patients with significantly impaired host defenses. As the prognosis relates to the stage of disease at the time of presentation, early diagnosis and treatment improves patient outcomes.

Z.D. Olgun, MD
Department of Orthopaedics and Traumatology,
Dortyol State Hospital, Hatay 31500, Turkey
e-mail: orthodoc07@yahoo.com

M. Yazici, MD
Department of Orthopaedics,
Hacettepe University Faculty of Medicine,
Sihhiye, Ankara 06100, Turkey
e-mail: mimyazici@gmail.com

D.A. Spiegel, MD (✉)
Division of Orthopaedic Surgery,
Children's Hospital of Philadelphia,
Associate Professor of Orthopaedic Surgery,
University of Pennsylvania School of Medicine,
Philadelphia, PA, USA

Honorary Consultant in Orthopaedics and Rehabilitation,
Hospital and Rehabilitation Centre for Disabled Children,
Janagal, Kavre, Nepal
e-mail: spiegeld@email.chop.edu

S.M. Awais, MBBS (Pb), MCPS-Surgery (CPSP),
M.S.-Orth (Pb), MSc BioEng (Dun)
Department of Orthopaedics, Spine and Traumatology,
King Edward Medical University and Mayo Hospital,
8-Golf Lane, GOR-1, Lahore, Punjab 54000, Pakistan
e-mail: awais@kemu.edu.pk

B. Bijukachhe, MBBS, MS (Ortho.),
AO Fellow – Spine
Spine Services, Department of Orthopedics,
Grande International Hospital Limited,
Binayak Basti – 16, Balaju,
Kathmandu, Bagmati, Nepal
e-mail: binodbb@gmail.com

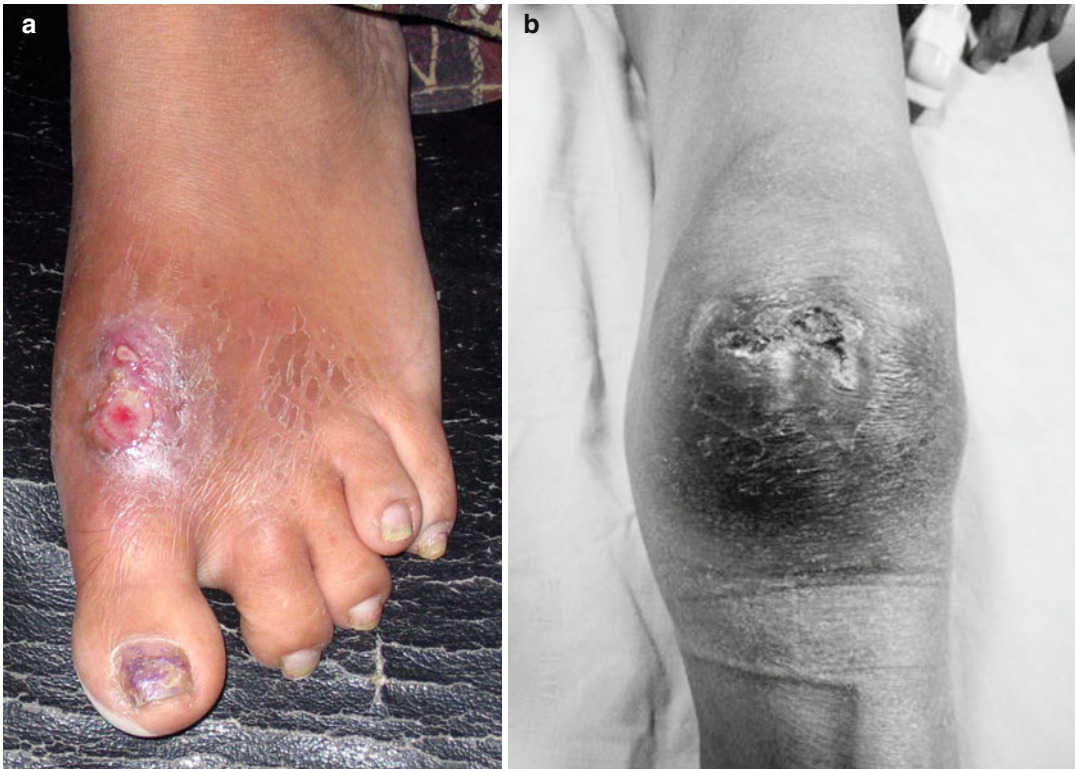


Fig. 33.1 (a, b) Sinuses often form as a complication of musculoskeletal tuberculosis (Reprinted with permission from Spiegel DA, Singh GK, Banskota AK. Tuberculosis

of the musculoskeletal system. *Tech Orthop.* 2005;20: 167–78)

Principles of Diagnosis

A high index of suspicion is required, especially in areas where the disease is not prevalent. Bone and joint tuberculosis is usually an indolent, slowly progressive disease, with patients often presenting with nonspecific constitutional symptoms such as low-grade fevers, night sweats, weight loss, anorexia, anemia, and malaise. Lymphadenopathy is common. Extremity involvement may present with localized pain and increased warmth, soft tissue swelling or effusion, loss of motion, and limp or gait disturbance. The initial evaluation includes a chest radiograph, a complete blood count, and an ESR. Normal acute phase reactants do not rule out the presence of tuberculosis. The purified protein derivative (PPD) tuberculin skin test is often positive in endemic areas or in patients who have received the BCG

vaccination and does not correlate with active disease.

The microbiologic diagnosis of tuberculosis in austere settings depends on the evaluation of sputum smears, and smears and cultures of biopsy specimens, using Ziehl-Neelsen and Auramine O stains. Acid fast bacilli and granulomas seen on direct microscopy lead to the fastest diagnosis but are present in less than 50 % of cases. A formal biopsy may be difficult to obtain especially in those with spinal involvement. Cultures are positive in up to 90 %, but often take 6–8 weeks to become positive.

Treatment Principles

Chemotherapy remains the mainstay of treatment for all forms of tuberculosis and is generally effective in 90 % of cases. Surgery is indicated

for (1) establishing the diagnosis and (2) treating complications of the disease. Ideally a biopsy and culture should guide therapy, but this is impractical in low resource environments. Empiric chemotherapy is provided in many cases when the characteristic clinical and radiographic features are present. In previously untreated adults without known drug susceptibility, rifampin and isoniazid should be used throughout the duration of therapy, and another first-line drug, streptomycin or ethambutol, is chosen for the first 2 months along with one second-line drug.

Most patients with active TB are treated with 6–9 months of therapy [1, 2], though some practitioners favor treating spinal disease for 12–18 months. The WHO treatment guidelines should be followed [2], and systems for monitoring compliance, such as DOTS – directly observed therapy, short course – should be in place. A longer duration of chemotherapy may be indicated with documented cases of relapse and in patients who exhibit signs of persistent inflammation, known as slow responders. Specific recommendations are available for patients with recurrent disease and active disease associated with HIV/AIDS. In contrast to abscesses associated with bacterial sepsis, cold abscesses may resolve with chemotherapy, and drainage is not routinely required. Bacterial superinfection should be suspected when a sinus track fails to close following an adequate course of chemotherapy.

Lack of adherence to treatment with chemotherapy commonly leads to the development of resistant strains that are more difficult and costly to treat. DOTS regimens have been developed to counter this but require intense resources, which are often lacking. Screening for drug toxicity is limited, and patient education about side effects and potential complications of treatment is crucial.

Multidrug-resistant TB is defined as resistance to isoniazid and rifampicin, while “extensively drug-resistant tuberculosis” describes resistance to isoniazid, rifampicin, and several second-line drugs [3]. Most of these resistant cases reflect the failure of the system to provide the correct medications and dosages and to monitor treatment. The incidences of these worrisome entities are on the rise.

Osteomyelitis

Osteomyelitis is the least common form of musculoskeletal TB (5 %), and the presentation is similar to subacute hematogenous osteomyelitis. Clinically, patients present with pain and soft tissue swelling, and both abscesses and sinuses are common. Most patients are adequately imaged with plain radiographs.

The differential diagnosis on plain radiographs is extensive and includes chronic osteomyelitis, Brodie’s abscess, benign and malignant tumors, and other granulomatous diseases. While a lytic lesion with or without a sclerotic rim is the most common presentation, lesions may be serpiginous, commonly cross the physis, and may readily invade neighboring joints (Fig. 33.2a–d). An aggressive periosteal response can also be observed, and in such cases a biopsy is mandatory.

Sequestrae are unusual but can be present. The entire diaphysis can become sequestered in children due to intraosseous thrombosis. Disseminated skeletal tuberculosis can be observed in compromised hosts, involving combinations of osseous and articular involvement. Tuberculous dactylitis, spina ventosa, occurs in the short tubular bones of the hands and feet. X-rays show multiple layers of subperiosteal new bone, a finding diagnostic for tuberculosis (Fig. 33.2d).

Given this diversity in plain radiographs, a biopsy is helpful in establishing the diagnosis, recognizing that under selected circumstances empiric treatment is considered. While curettage is recommended at the time of biopsy, bone grafting is rarely required as the lesions heal with chemotherapy.

Arthritis

The natural history of TB arthritis progresses over several years, beginning with synovial seeding or direct penetration from a metaphyseal focus and culminating with joint destruction. The host inflammatory response results in synovial hypertrophy and an effusion, although adult patients

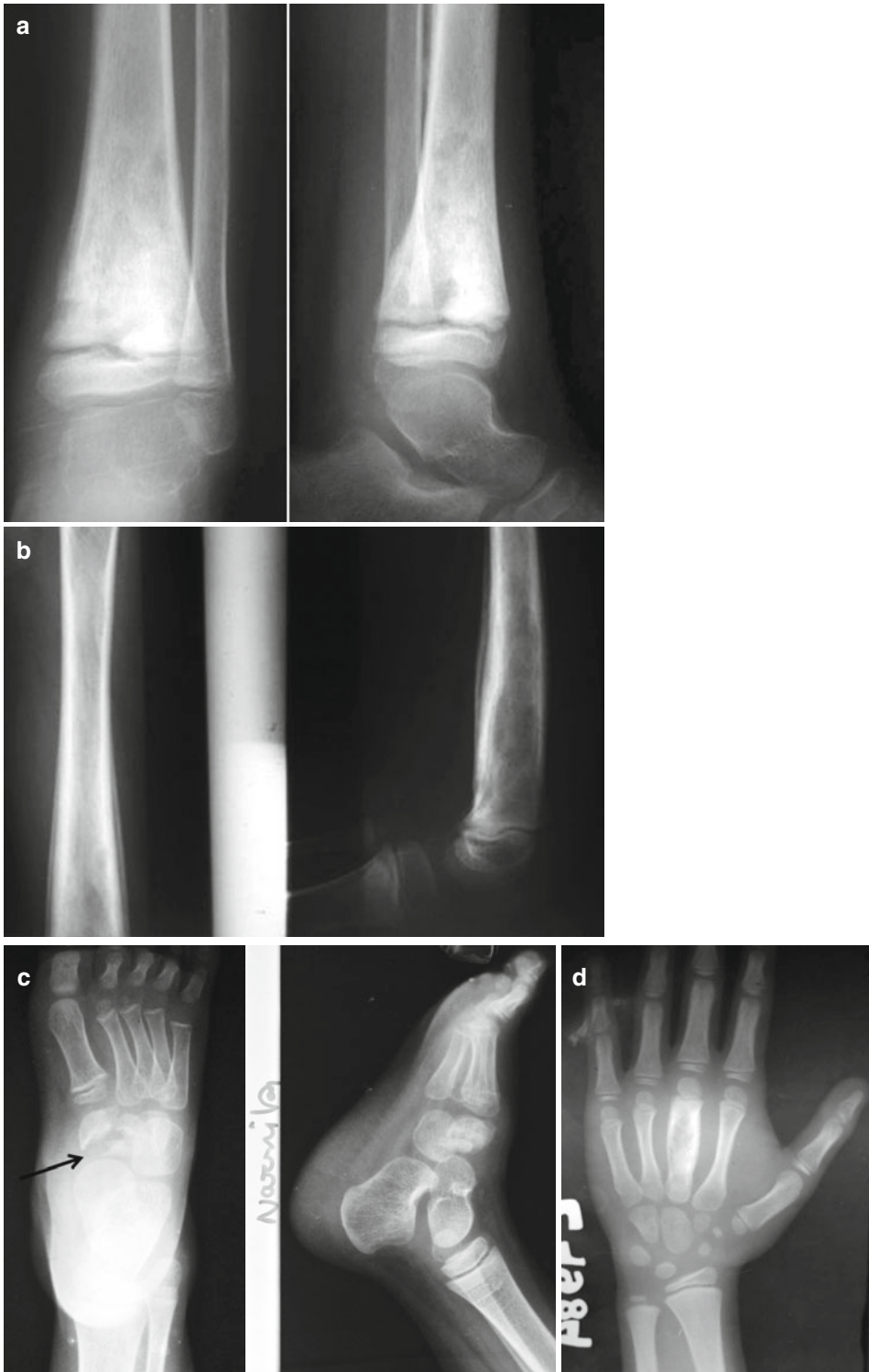

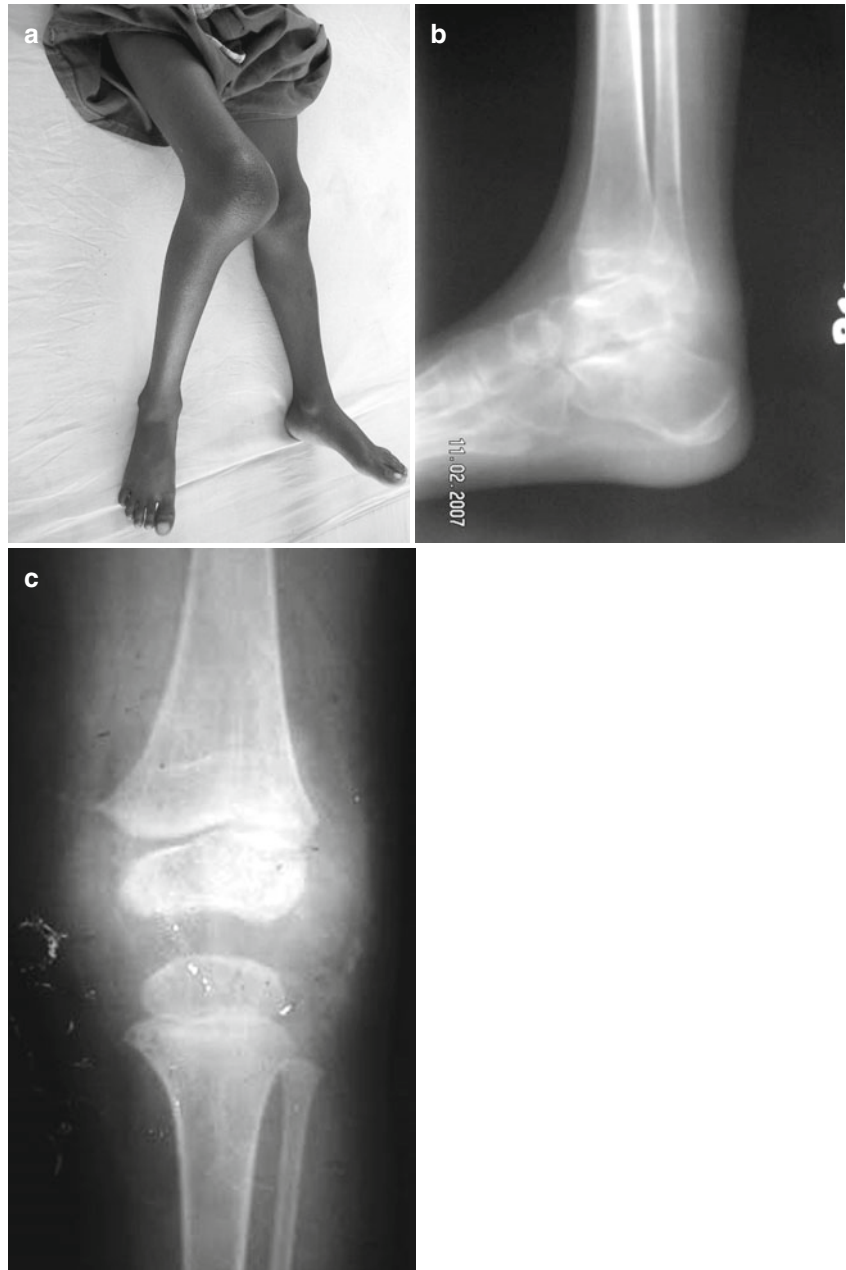Fig. 33.2 While TB osteomyelitis is variable in radiographic appearance, (a) one common presentation is an ill-defined metaphyseal lucency which crosses the physis. (b) In this example there is an expansile lesion with a smooth periosteal reaction. (c) TB in the foot typically involves both osseous and articular structures. In this case

there is involvement of the navicular, medial cuneiform, and lateral cuneiform, as well as the joints between these tarsal bones (d) Tuberculous dactylitis or spina ventosa (Reprinted with permission from Spiegel DA, Singh GK, Banskota AK. Tuberculosis of the musculoskeletal system. *Tech Orthop.* 2005;20:167–78)

may present with minimal effusion, called dry or “sicca” arthritis. At this point, plain radiographs demonstrate periarticular osteopenia due to the hyperemic inflammatory response (Fig. 33.3). Granulation tissue develops at the joint periphery leading to marginal erosions. As the disease progresses, this tissue extends across the joint surface

directly damaging the articular cartilage (Fig. 33.4a, b). Other osseous abnormalities include osteophytes, chondrocalcinosis, and loose bodies. Ultimately, destruction of the joint occurs with or without subluxation or dislocation (Fig. 33.5a–c). Joints may also become ankylosed, often in a nonfunctional position.

Fig. 33.3 Tuberculous arthritis. (a) Knee joint involvement during later stages is evidenced by significant synovitis with effusion, which may be complicated by flexion contracture and posterior subluxation of the tibia. Plain radiographs demonstrate (b) osteopenia and (c) soft tissue swelling early in the disease process



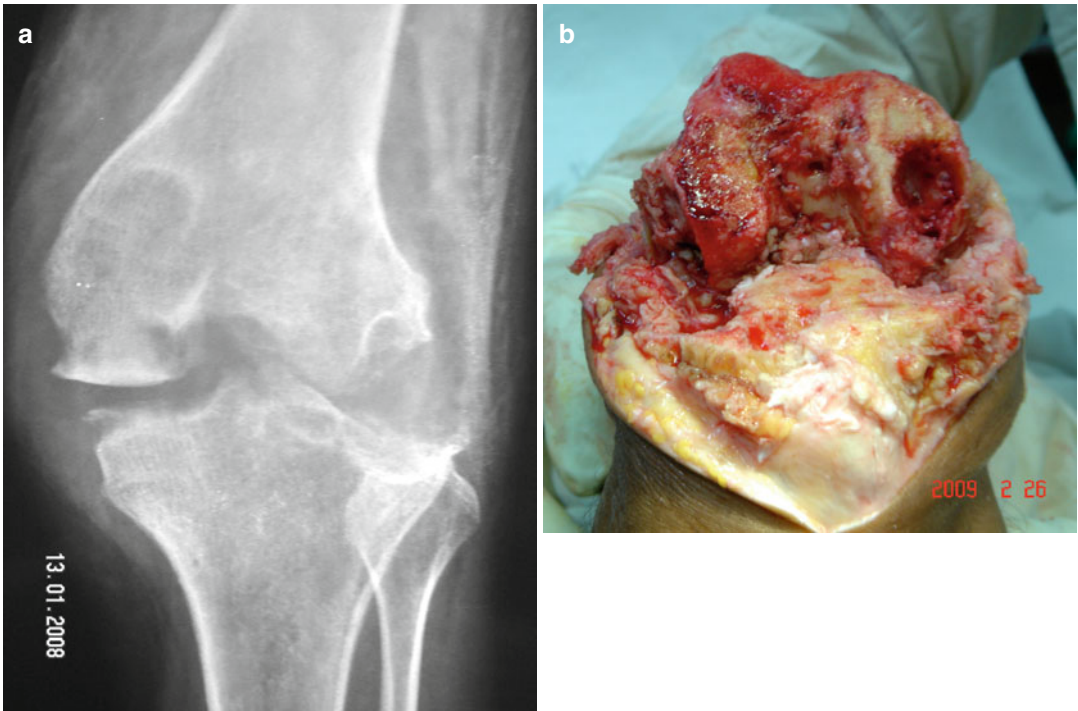


Fig. 33.4 (a, b) Proliferation of synovial granulation is followed by marginal erosions (Courtesy of the Hospital and Rehabilitation Centre for Disabled Children, Banepa, Nepal)

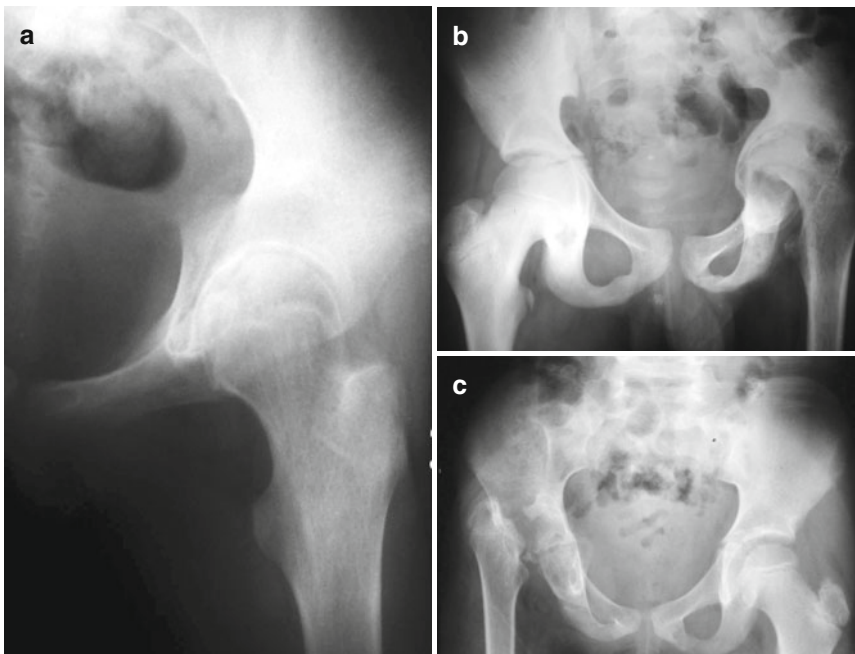


Fig. 33.5 Ultimately, there are destructive changes within the joint, for example, (a) narrowing of the joint space, (b) protrusion with destruction of the femoral head and acetabulum, and (c) loss of the femoral head and neck

The time course and evolution of pathologic changes is similar to that of an untreated chronic inflammatory arthropathy. Less common entities such as pigmented villonodular synovitis may also be confused with tuberculous arthritis, requiring a biopsy.

The clinical consequences are most profound in the larger, weight-bearing joints, especially the hip. Shanmugasundaram has classified the spectrum of morphologic abnormalities associated with hip disease into seven categories [4] (Fig. 33.6).

Other than biopsy, surgical intervention addresses complications of the disease, and procedures include synovectomy with or without joint debridement, osteotomy, arthrodesis, excisional arthroplasty, pelvic support osteotomy, and total joint arthroplasty.

During the early stages of TB arthritis, when there are no irreversible changes, treatment focuses on controlling discomfort with rest and restoring and maintaining ROM and strength. Adjunctive measures such as physical therapy,

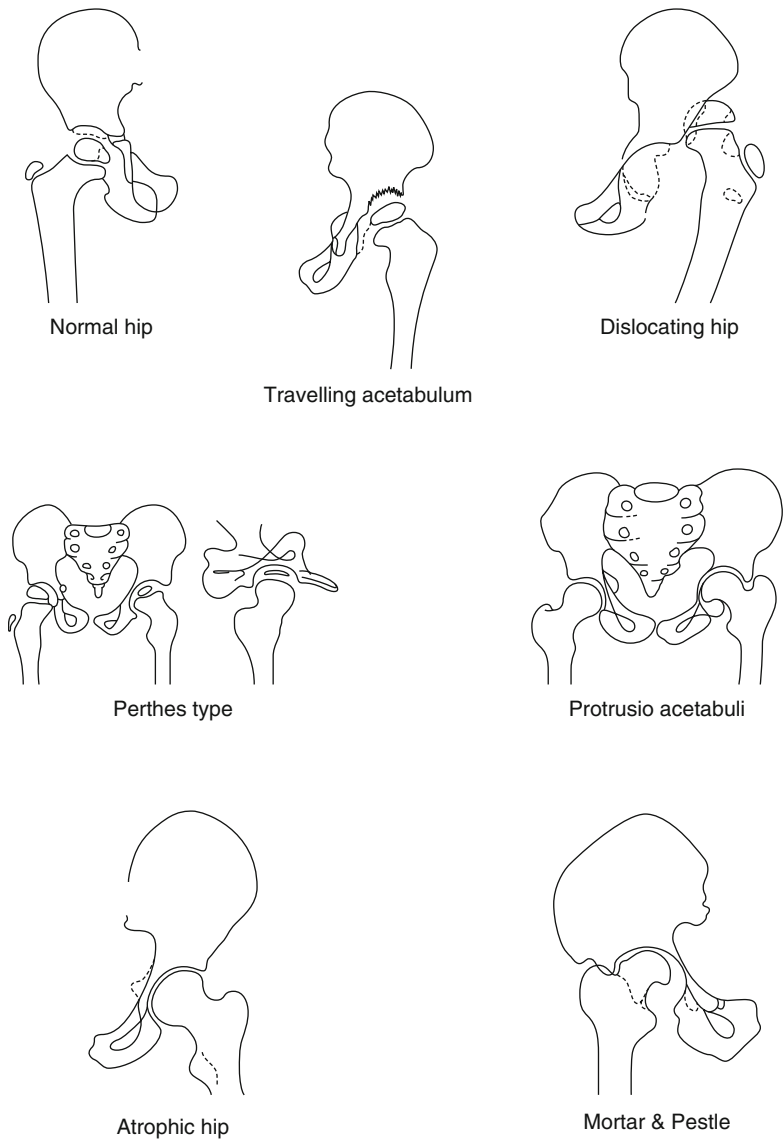


Fig.33.6 Shanmugasundaram has classified the spectrum of morphologic abnormalities associated with hip disease. Generalized hyperemia, likely associated with a mild form of avascular necrosis, presents as the “Perthes” type in which there is coxa magna. Involvement of the acetabular roof is classified as a “Travelling acetabulum,” while the “protrusio” type occurs with lesions in the acetabular floor. Destructive changes on both the femoral and acetabular sides of the joint commonly result in joint incongruity (“mortar and pestle”). The “atrophic” subtype involves symmetric thinning of the joint space and may be confused with rheumatoid arthritis. The joint may also become dislocated (“dislocating” subtype)

traction, serial casting, and/or splinting may help achieve and/or maintain motion, prevent deformity, provide comfort, and enhance strength. Weight bearing is encouraged when comfort and an adequate ROM allow. The prognosis is excellent in the early stages, and the indications for synovectomy, with or without joint debridement, remain controversial.

Irreversible changes in the joint occur in the later stages and salvage procedures can improve function. In cases where ankylosis is expected, the goal for some joints (wrist, knee, foot, and ankle) is to maintain a functional position by splinting or casting. When ankylosis would result

in a decrease in function, for example, in the elbow, an excisional arthroplasty can be considered (see Chap. 41). When a joint becomes ankylosed in a nonfunctional position, osteotomy can realign the limb.

With hip involvement, the context will determine whether the goal is stability or motion. Hip arthrodesis can reliably reduce pain and restore alignment, but produces increased stresses at the knee and lumbar spine that can lead to degenerative changes over the long term (Fig. 33.7a–d). Excisional arthroplasty will improve motion at the expense of stability, and the resulting gait disturbance can be significant.

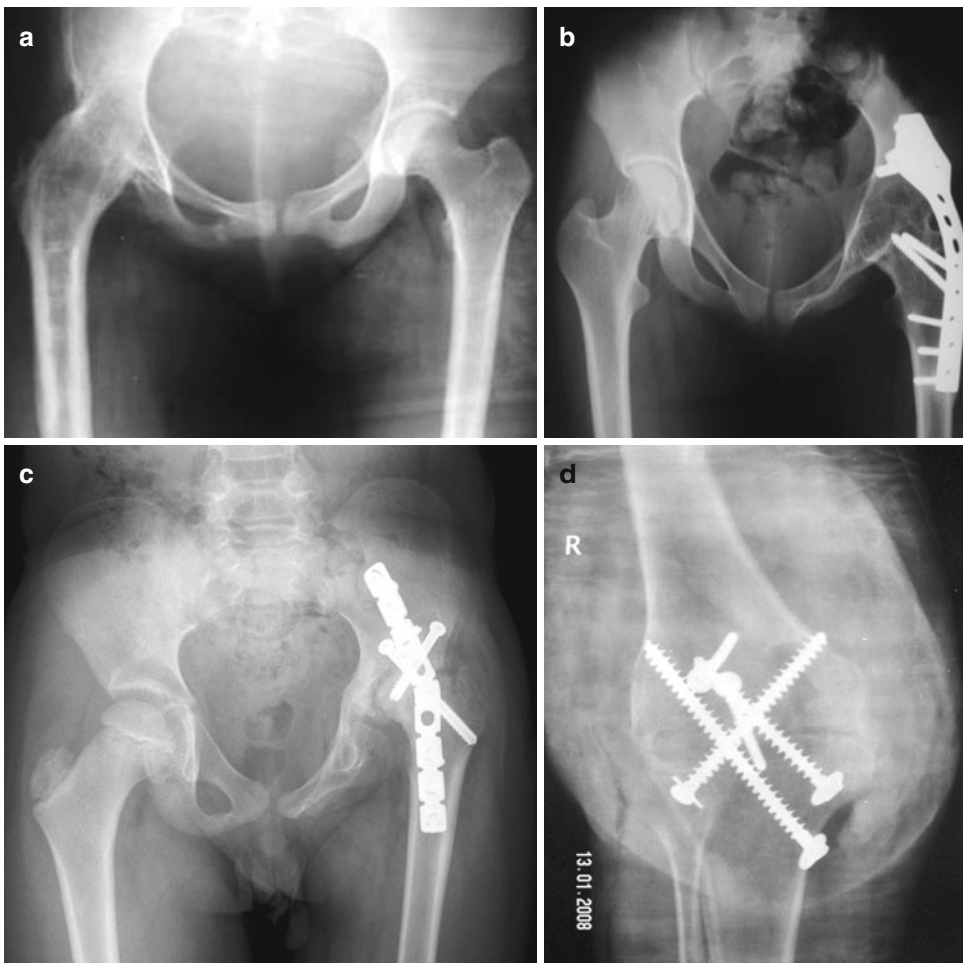


Fig. 33.7 Many options are available for salvage in the late stages of TB arthritis. (a) Arthrodesis provides excellent pain relief, but may be undesirable depending on the demands of daily living. Arthrodesis of the hip can be achieved with debridement and spica cast application in

younger children; fixation is required in adolescents and adults. (b) Internal fixation with a cobra plate via a posterior approach or (c) an anterior approach with screw and plate fixation. (d) This knee fusion was performed with screw fixation alone

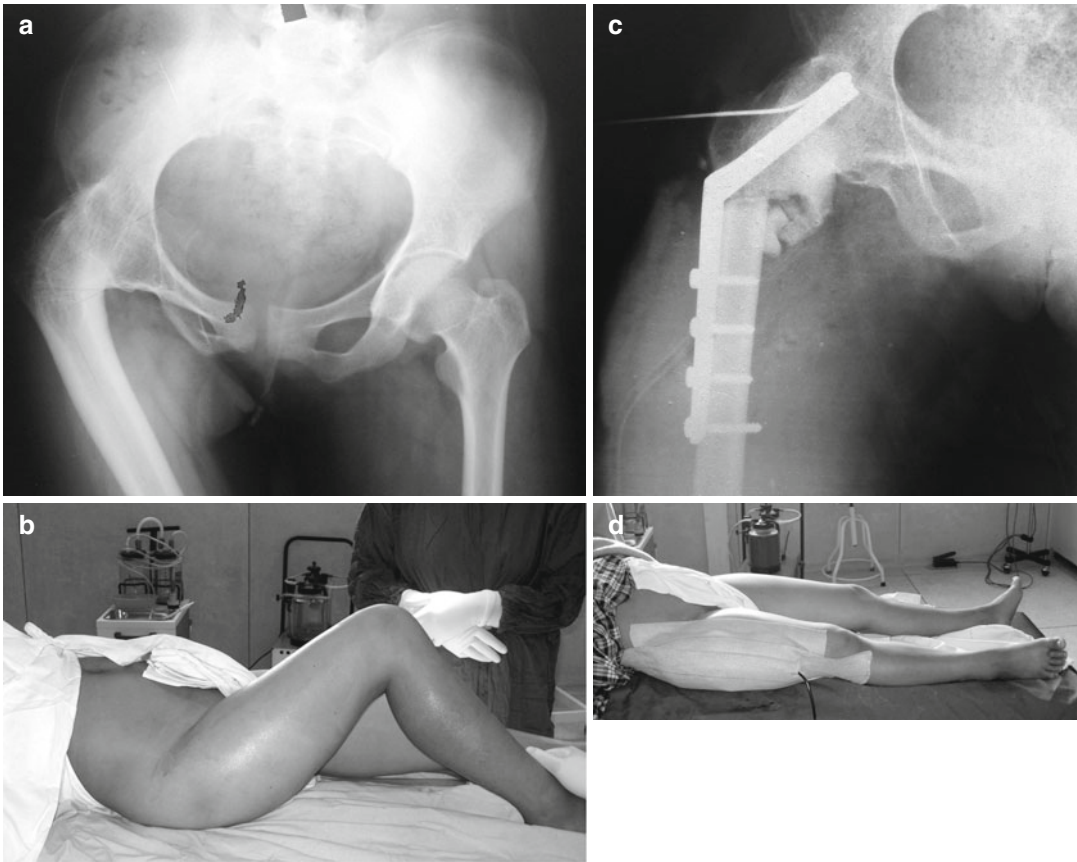


Fig. 33.8 (a, b) This adolescent presented with an awkward gait owing to spontaneous fusion of her right hip in severe flexion and adduction. (c, d) A realignment osteotomy was performed to place the extremity in a more

favorable position. The inequality in limb lengths can be addressed at a later stage if her discrepancy is symptomatic

When the hip has autofused in a nonfunctional position and arthrodesis is an acceptable solution, an osteotomy can reposition the limb (Fig. 33.8a–d). Pelvic support osteotomy should be considered when retention of motion is desirable. When the resources are available, total joint arthroplasty is an option, along with prophylactic chemotherapy to reduce the risks of disease reactivation.

TB arthritis of upper extremity joints is uncommon. Involvement of the shoulder results in a fixed adduction contracture. Arthrodesis can eliminate pain and instability. Surgical treatment options for the elbow include synovectomy, but once destructive changes are present, excisional or fascial arthroplasty, or rarely arthrodesis (in a heavy laborer), may be required (see Chap. 41). Wrist involvement often spreads to the carpal

bones and tendon sheaths, producing a flexion deformity. Early management includes splinting or immobilization. While synovectomy and debridement may be helpful before significant destructive changes have occurred in the wrist, most cases require arthrodesis for salvage.

Spondylitis

The spine is involved in approximately 50 % of cases of osteoarticular TB. The main surgical concerns are preservation of neurologic function and the prevention and treatment of kyphotic deformities. Much of the recent literature on this subject has come from centers with state-of-the-art capabilities, and the challenge is to adapt this knowledge to austere settings.

Pathophysiology and Natural History

Tuberculosis reaches the spine by hematologic dissemination from a pulmonary or genitourinary source, often through Batson's venous plexus, and commonly affects the thoracic or thoracolumbar spine. Direct extension from the lungs is rare. Three patterns of infection have been defined: paradiscal (most common), central, and anterior.

Bacilli lodge in the well-vascularized vertebral endplates and can spread beneath the anterior longitudinal ligament, the psoas sheath, or spinal canal, sparing the disk spaces early in the disease. While involvement of the anterior portions of the vertebral bodies results in multilevel spinal abscesses, involvement of the central portion of the vertebra can lead to loss of anterior column support and progressive collapse into kyphosis. Isolated posterior involvement is rare, as is panvertebral disease. Loss of stability may occur due to pathologic fracture or circumferential disease. Cold abscesses can present as a soft tissue mass in the axilla (Fig. 33.9), flank, groin,

or buttock and spontaneously exit the skin as a sinus.

The natural history of spinal disease is described in three stages [5]. Stage one lasts from 1 to 12 months. The second stage may last up to 3 years and is characterized by abscess formation and bony destruction. The third or healing stage occurs when the vertebrae ankylose (Fig. 33.10). Approximately 30 % of patients do not survive to this last stage. Nonunion suggests either recurrence of active disease or superinfection by pyogenic bacteria, both of which are associated with an unfavorable outcome.

Ten percent of patients present with neurologic involvement, most commonly Pott's paraplegia [6]. Cord compression in "early onset" paraplegia is due to pus, granulation tissue, and/or sequestrae. In contrast, "late onset" paraplegia is most often due to direct bony compression over the sharp internal gibbous, calcified caseous material, or fibrous tissue bands around the spinal

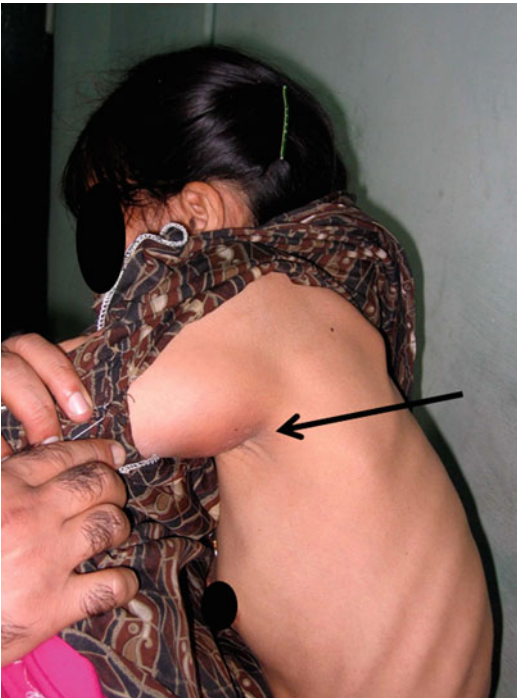

Fig. 33.9 This adult female developed a swollen lump in her left axilla that is mildly erythematous and nontender. It proved to be a cold abscess from spinal tuberculosis

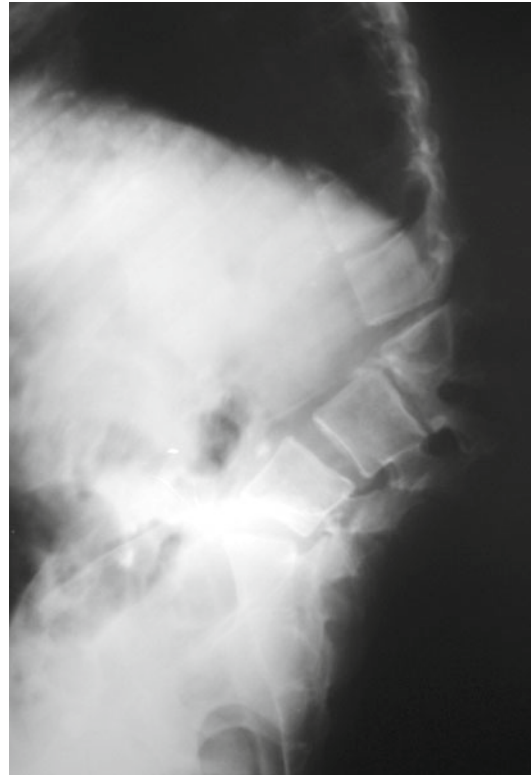


Fig. 33.10 This teenager was treated medically for TB but developed a severe kyphosis, with progressive collapse and fusion at the apex

cord. The prognosis is much better for early onset paraplegia, except when there is direct dural invasion. A kyphotic deformity may progress despite successful treatment of active disease, even after skeletal maturity, and lead to paraplegia.

Patient Evaluation

Back pain is the most common presenting symptom and is generally less severe when compared with pyogenic spondylitis. The pain follows an indolent course, often increasing noticeably at night and becoming gradually worse as the spine becomes mechanically unstable. Gait changes and subtle neurologic abnormalities due to myelopathy can be seen at the time of presentation. Constitutional symptoms are often present. The physical examination should include a meticulous neurologic examination; skin examination for masses, cold abscesses, enlarged lymph nodes, or sinuses; and the evaluation of spinal alignment.

Highly elevated white blood cell counts, CRP levels over 5 mg/dl, ESR levels over 40 mm/h, and levels of alkaline phosphatase (ALP) over 120 IU/l are more commonly associated with pyogenic spondylodiscitis, while the laboratory results for TB are both less marked and specific. This makes a high index of suspicion based on the presence of active TB of other organs, a history of longer diagnostic delays, and involvement of more than three spinal levels important in the differential diagnosis [7].

The radiographic differential diagnosis includes brucellosis, atypical mycobacteria, fungal, pyogenic discitis or vertebral osteomyelitis, and both primary and secondary spinal tumors. Plain radiographs are usually all that are available in austere settings.

Generally, two or three spinal levels are involved, and noncontiguous sites are reported. Localized osteopenia is the first sign and may be associated with loss of definition at the vertebral endplates. The disk space is commonly preserved early in the disease but becomes obliterated later. Scalloping of multiple anterior aspects of vertebral bodies, aneurysmal syndrome, can be observed. A loss of vertebral body height com-

monly occurs due to tissue destruction and collapse (Fig. 33.11). Radiologic findings suggestive of an abscess include fusiform soft tissue swelling (Fig. 33.12) or asymmetry or loss of the psoas shadow.

Destruction of the anterior vertebrae at multiple levels leads to a progressive kyphosis (Fig. 33.13a–c). Factors influencing kyphotic development include thoracic location, pediatric patients, and the pretreatment angle of kyphosis (Cobb angle). Rajasekaran et al. have identified four radiological features that may predict progression of kyphosis: (1) facet dislocation, (2) lateral translation, (3) retropulsion of the vertebral body, and (4) toppling of one vertebra over another [8, 9] (Fig. 33.14). They suggest that two or more findings require stabilization. Multilevel involvement with disk space sparing is seen with metastatic disease; however there are no paraspinous abscesses. It is difficult to distinguish tuberculous spondylodiscitis from that caused by atypical mycobacteria or fungi on radiologic and clinical findings alone.

Although rarely available in the settings where spinal TB is most common, MRI remains the most valuable imaging modality, showing abscess formation (Fig. 33.15a–d) and the involvement of structures around the spine. MRI is also the only modality that helps distinguish spondylitis of different etiologies.

Treatment

The goal of the treatment is to eradicate the disease, prevent or treat any deformity, and preserve or improve neurologic function. The prognosis depends on the timing of diagnosis and the efficacy of treatment.

Outpatient chemotherapy is as effective as surgical debridement in uncomplicated cases [10], even those with stable, mild paraparesis. There is no added benefit from bed rest or immobilization, as these are ineffective in preventing deformities when instability is already present. Adequate medical management may not prevent kyphotic deformities and the cosmetic, functional, and neurologic complications that follow. Radiographic changes can progress for more than

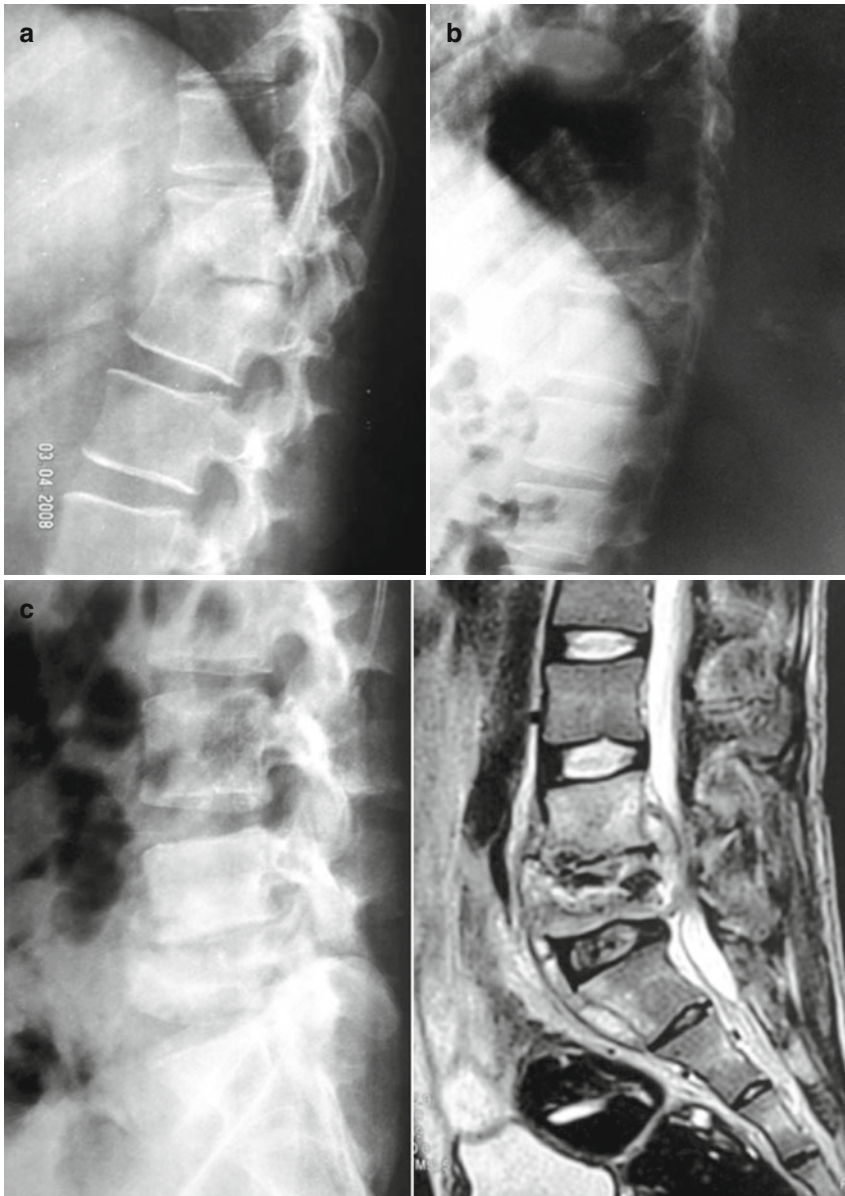


Fig. 33.11 (a) TB of the spine usually involves the anterior portion of the vertebra. Inflammation and bony resorption predispose to a progressive kyphotic deformity. (b) In some patients the central portion of the vertebra is more involved, resulting in central collapse, giving the

appearance of vertebra plana. (c) Collapse of the L4 vertebra into L5 (plain radiograph on *left*, MRI on *right*), with the MRI demonstrating abscesses and retropulsion of debris/caseous material

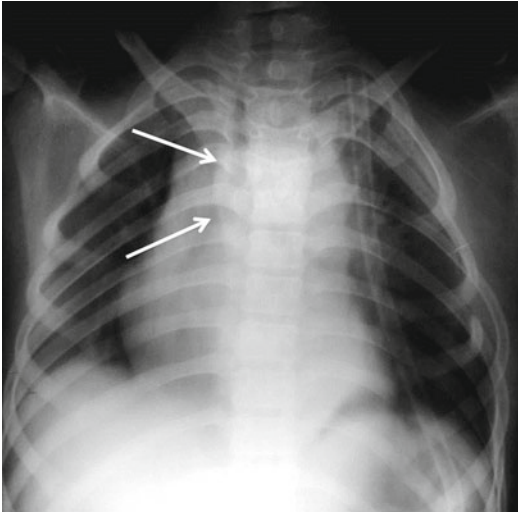


Fig. 33.12 Thoracic paraspinal abscesses appear as oval soft tissue densities adjacent to the spine on a chest radiograph (*arrows*), sometimes with calcifications within the wall of the abscess

a year after treatment is started and should not be mistaken for the failure of medical treatment.

Surgical treatment is reserved for establishing the diagnosis and treating complications of the disease, such as progressive or profound neurologic deficits, or patients with or at high risk for progressive kyphotic deformity. The current surgical treatment for TB spondylitis consists of thorough debridement of necrotic tissue; decompression of the neural elements; microbiologic assessment of specimens, if not done previously, and stabilization by instrumentation and fusion, which may be accomplished using a variety of approaches (Table 33.1). The original “Hong Kong” procedure involved anterior debridement and strut grafting (Fig. 33.16a–e), which restores anterior column integrity.

Most surgeons prefer a posterior stabilization extending two to three segments on each side of the pathology. In cases where bone destruction is not extensive and only drainage is required, an

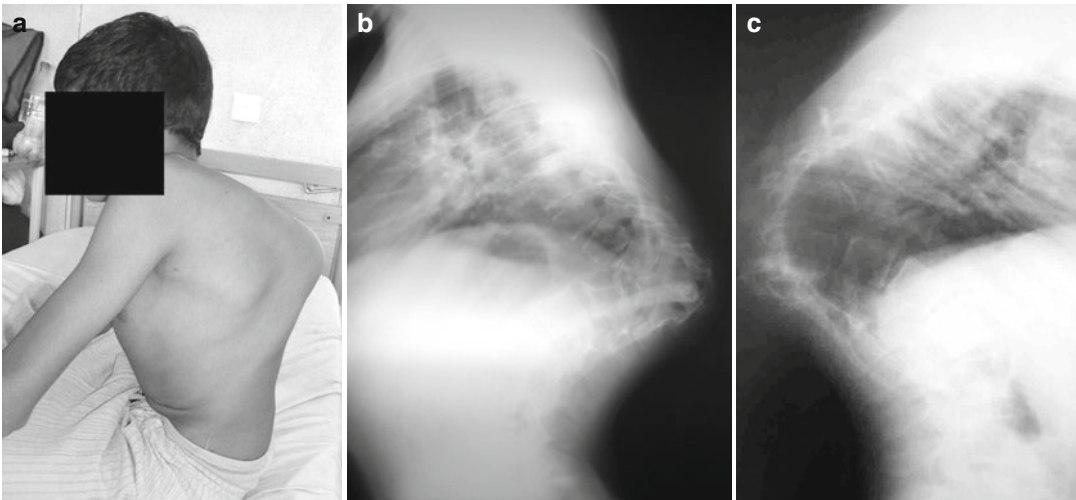


Fig. 33.13 (a–c) The treatment of severe kyphotic deformities is technically difficult and treatment is associated with a high risk of complications, especially in patients with “healed disease”

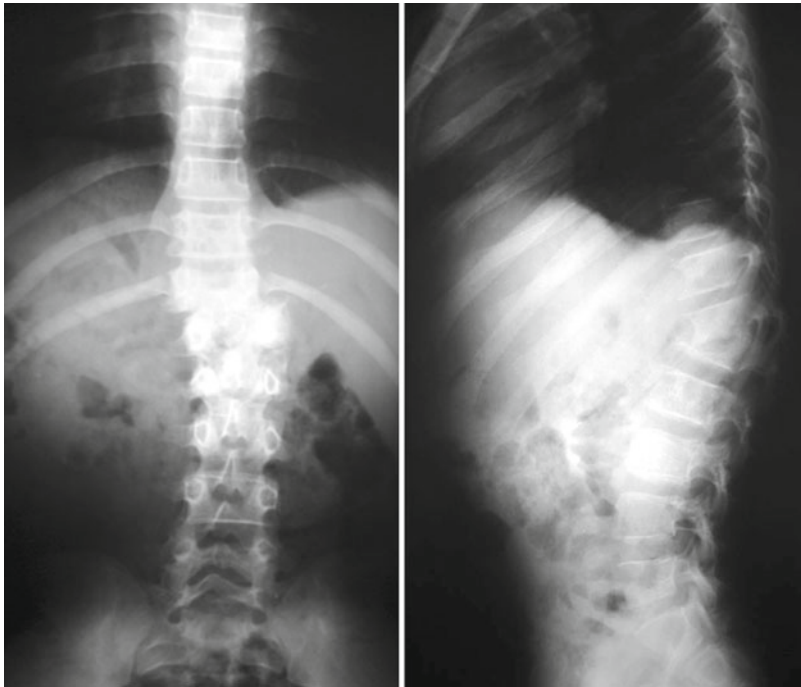


Fig. 33.14 This child developed spinal instability, including two of the four Rajasekaran criteria, lateral vertebral translation and “toppling over”

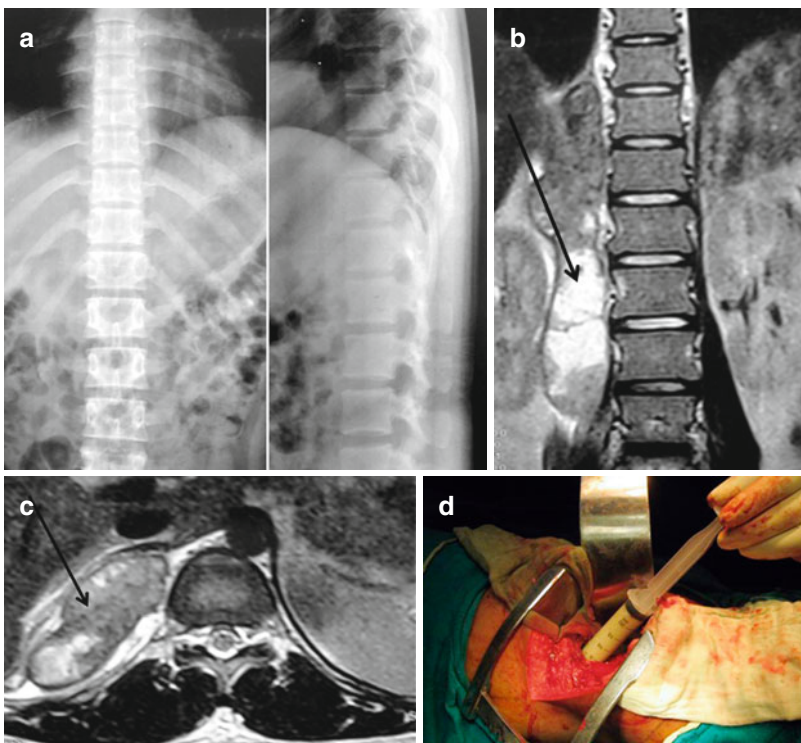


Fig. 33.15 (a) This patient had no evidence of an abscess or bony destruction on plain radiographs, however (b, c) an MRI scan revealed a large abscess adjacent to the lumbar spine, *arrows*. (d) An extraperitoneal approach was used to drain the abscess

Table 33.1 Surgical procedures utilized in the treatment of spinal tuberculosis

Surgical procedures	Indications/advantages	Disadvantages
Costotransversectomy	Abscess drainage in medically debilitated patients Less morbidity	Cannot decompress or perform an arthrodesis
Lateral extrapleural approach (extracavitary)	Decompression and fusion Extrapleural	Greater challenge if instrumentation is planned
Anterior decompression and fusion with or without instrumentation	Direct visualization Can perform wide decompression or debridement Does not destabilize posterior structures	Requires thoracotomy and/or taking down of the diaphragm Higher risk graft failure/nonunion if >2 segments spanned disk spaces and no instrumentation Difficult to visualize apex in sharp angular kyphosis
Anterior and posterior decompression and fusion	Circumferential disease	Higher morbidity and/or risk of complications
Posterior spinal fusion followed by anterior spinal decompression and fusion	Neurologically normal with high risk of future deformity progression Stabilize prior to debridement and grafting	Two stages required
Isolated posterior spinal fusion	Mild kyphosis with significant growth remaining	Posterior tethering, gradual restoration of alignment (reduction in kyphosis) with continued anterior spinal growth
Laminectomy	Isolated disease of posterior elements (rare) Extramedullary or intradural disease	Risks destabilizing the spine if with anterior involvement
Posterior approach for debridement, grafting, and instrumentation	Eliminates need for anterior procedure Shortens the spine	Technically demanding Higher risk of complications
Anterior +/- posterior release, traction, then instrumentation/fusion	Severe deformities with healed disease	High risk of complications Three to four procedures required Resource intensive
Resection of internal gibbus (apex of kyphotic deformity)	Severe deformities with healed disease, neurologic dysfunction	Very high risk of complications such as paralysis or neurologic deficit

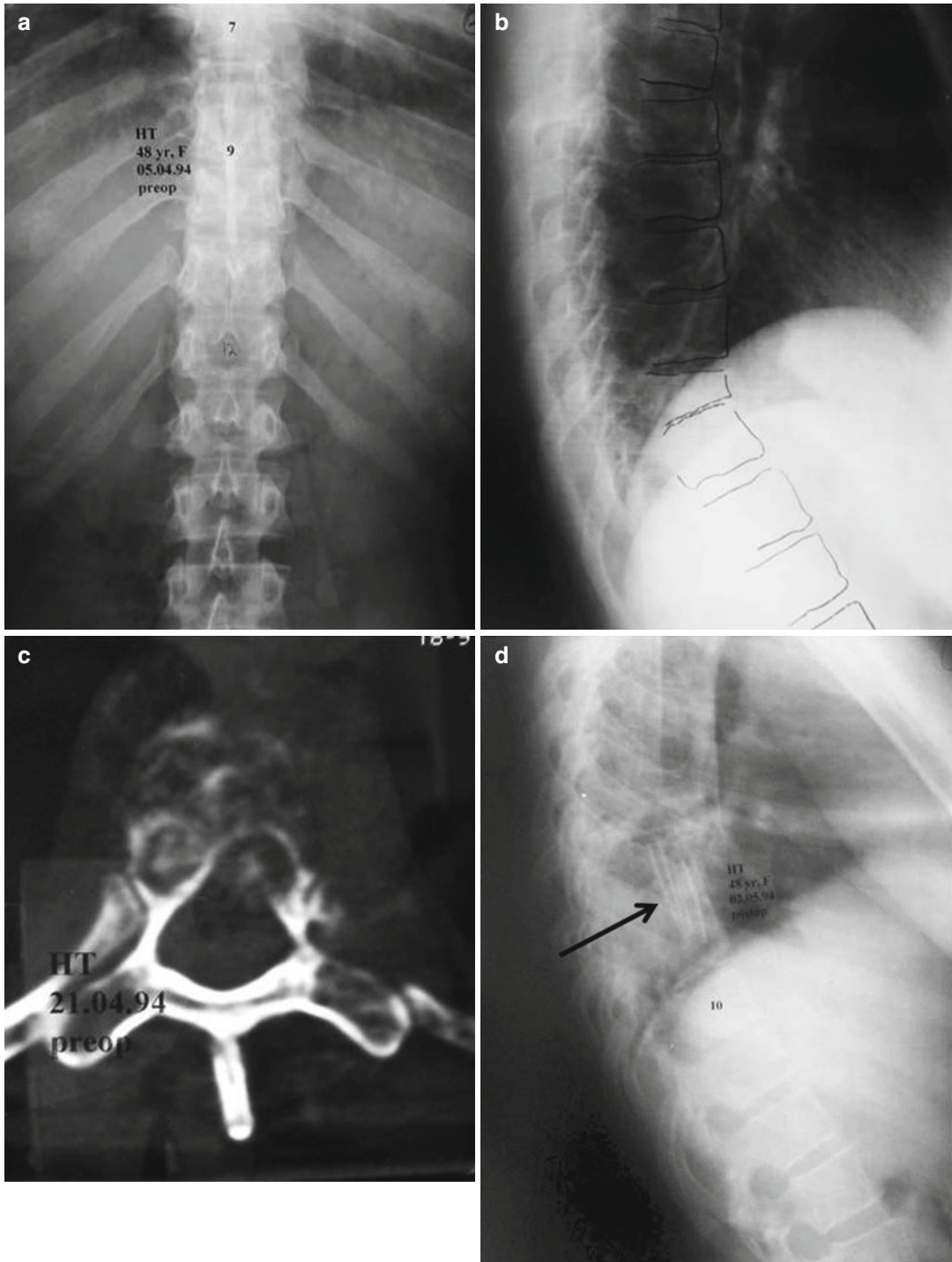


Fig. 33.16 Hodgson and colleagues popularized the anterior debridement and strut grafting for spinal tuberculosis. (a–c) This adult patient initially had involvement at three adjacent levels with mild collapse at a single level and (d, e) was treated by the Hong Kong procedure.

Several strut grafts (*black arrows*) were placed from T8-T9, across the diseased vertebrae, following spinal cord decompression and debridement of abscess and bony debris

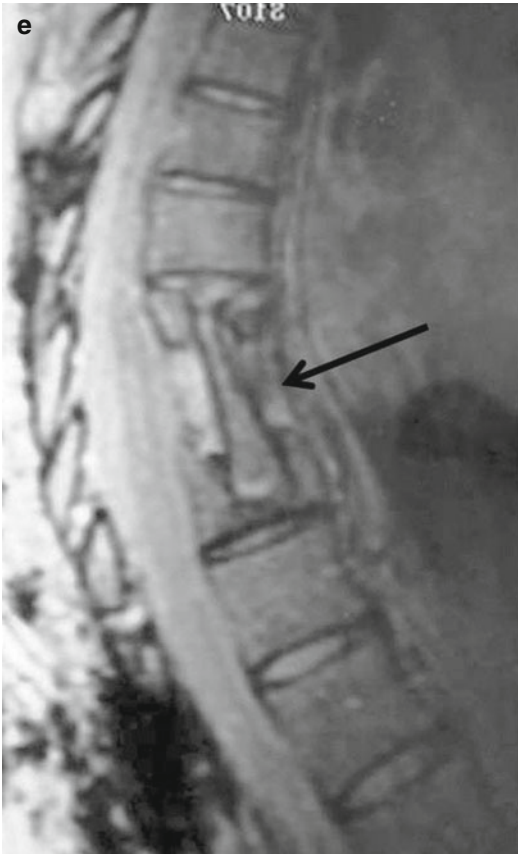

Fig. 33.16 (continued)

ultrasound or CT-guided biopsy can be performed, followed by posterior instrumentation and fusion. With extensive bone destruction and/or deformity, the authors favor a posterior-only technique for debridement, deformity correction, and an instrumented spinal arthrodesis with transpedicular fixation (Fig. 33.17a–c).

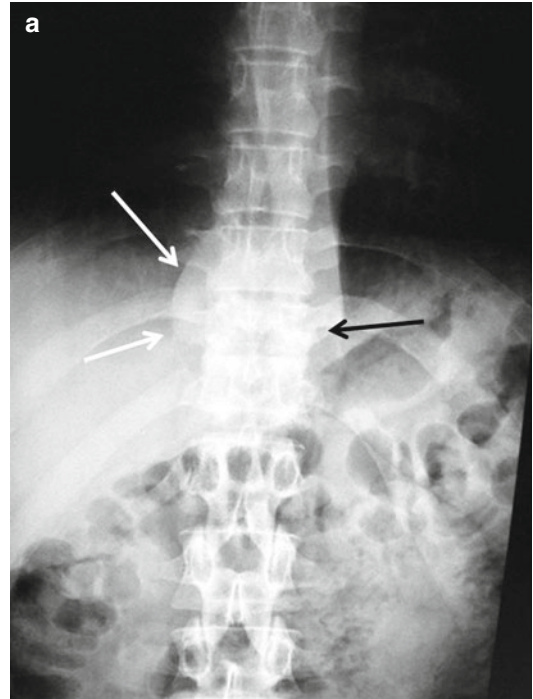


Fig. 33.17 (a, b) This 24-year-old male had severe collapse of a lower thoracic vertebra with relative preservation of the superior and inferior disc spaces (*black arrow*), a paraspinal abscess (*white arrows*), and was (c) treated by a posterior-only approach involving decompression/debridement, placement of a cage for anterior column support, and segmental posterior instrumentation extending two vertebrae above and two below the involved vertebra

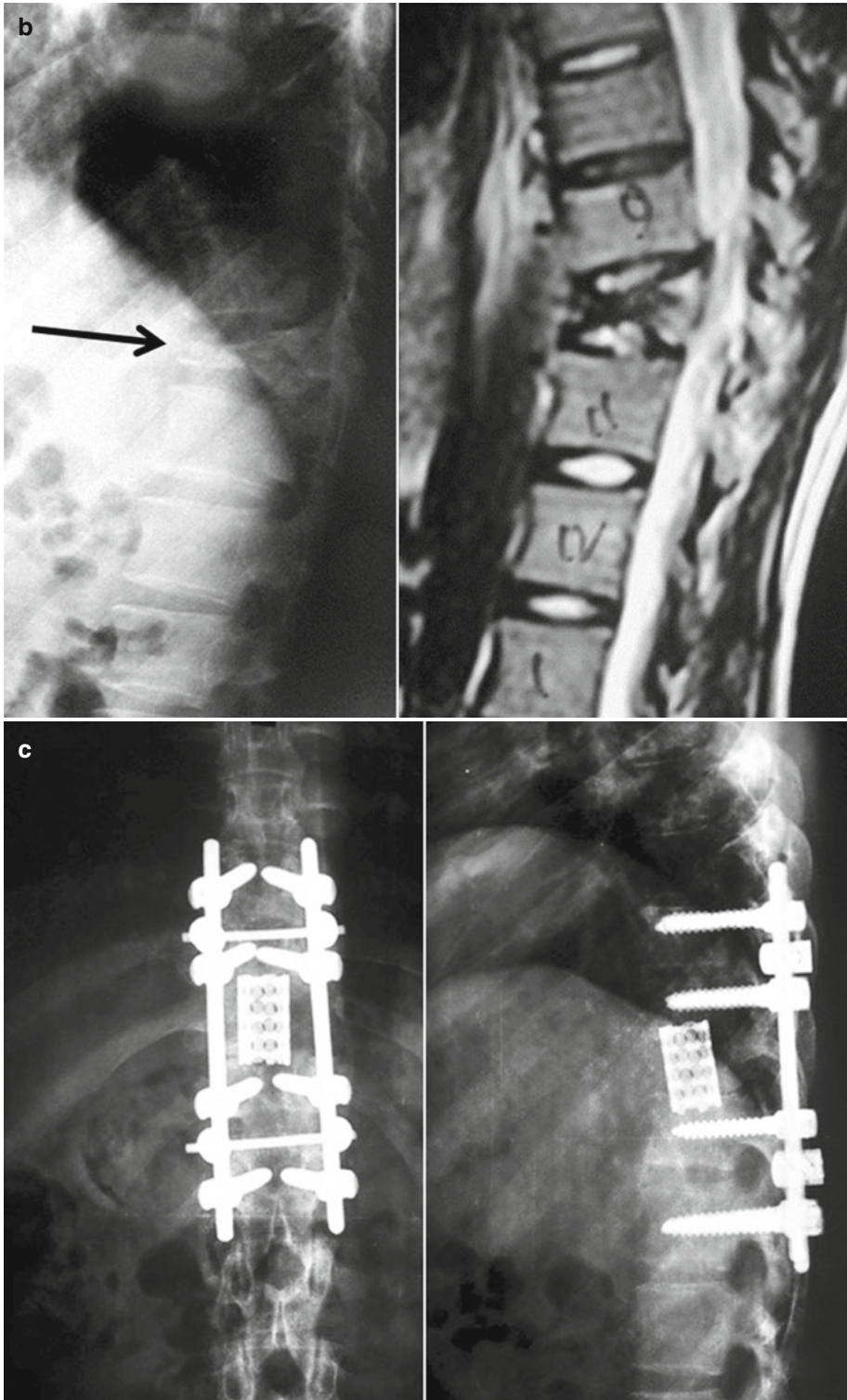


Fig. 33.17 (continued)

References

1. Parthasarathy R, Sriram K, Santha T, et al. Short-course chemotherapy for tuberculosis of the spine. A comparison of ambulant treatment and radical surgery: ten year report. *J Bone Joint Surg Br.* 2001;81B:464–71.
2. World Health Organization. Treatment of tuberculosis guidelines. 4th ed. Geneva: World Health Organization; 2010. Available at http://whqlibdoc.who.int/publications/2010/9789241547833_eng.pdf. Accessed 19 Apr 2012.
3. Holtz TH, Cegielski JP. Origin of the term XDR-TB. *Eur Respir J.* 2007;30:396.
4. Shanmugasundaram TK. Bone and joint tuberculosis. Madras: Kothandaram and Co.; 1983.
5. Tuli SM. Tuberculosis of the spine: a historical review. *Clin Orthop Relat Res.* 2007;460:29–38.
6. Hodgson AR, Skinsnes OK, Leong CY. The pathogenesis of Pott's paraplegia. *J Bone Joint Surg Am.* 1967;49:1147–56.
7. Kim CJ, Song KH, Jeon JH, et al. A comparative study of pyogenic and tuberculous spondylodiscitis. *Spine.* 2010;35:E1096–100.
8. Rajasekaran S. The natural history of post-tubercular kyphosis in children: radiological signs which predict late increase in deformity. *J Bone Joint Surg Br.* 2001;83:954–62.
9. Rajasekaran S, Shanmugasundaram TK. Prediction of the angle of gibbus deformity in tuberculosis of the spine. *J Bone Joint Surg Am.* 1987;69:503–9.
10. Jutte PC, Van Loenhout-Rooyackers JH. Routine surgery in addition to chemotherapy for treating spinal tuberculosis. *Cochrane Database Syst Rev.* 2006;25:(1):CD004532.

Suggested Reading

- Martini M, Adjrad A, Bouddjemaa A. Tuberculous osteomyelitis. A review of 125 cases. *Int Orthop.* 1986;10:201–7.
- Mehta JS, Bhojraj SY. Tuberculosis of the thoracic spine. A classification based on the selection of surgical strategies. *J Bone Joint Surg Br.* 2001;83:859–63.
- Spiegel DA, Singh GK, Banskota AK. Tuberculosis of the musculoskeletal system. *Tech Orthop.* 2005;20:167–78.
- Tuli SM. Tuberculosis of the skeletal system: bones, joints, spine and bursal sheaths. 3rd ed. Bangalore: Jaypee Brothers; 2004.

Part VI

Non-infectious Pediatric Conditions

Clubfoot Etiology, Pathoanatomy, Basic Ponseti Technique, and Ponseti in Older Patients

34

Alaric Aroojis, Shafique Pirani, Bibek Banskota,
Ashok Kumar Banskota, and David A. Spiegel

Introduction

Clubfoot or congenital talipes equinovarus (CTEV) is a hindfoot deformity caused by malalignment at the talocalcaneonavicular complex (Fig. 34.1). Clubfeet can be classified as idiopathic, postural, syndromic, and neurologic.

The incidence of clubfoot is approximately 1 in 1,000 live births worldwide. The etiology of idiopathic clubfoot remains debated, but the weight of evidence suggests a genetic etiology, though the inheritance pattern is unclear. A postural clubfoot is due to intrauterine positioning and either resolves spontaneously or is easily treated by gentle manipulation or several casts. Syndromes commonly associated with clubfoot

include arthrogryposis multiplex congenital and early amniotic rupture sequence or constriction band syndrome (Streeter's dysplasia). Clubfoot is also seen in a variety of neuromuscular conditions, most notably myelomeningocele. Clubfoot associated with syndromic and neuromuscular conditions tends to be more rigid and difficult to treat when compared with idiopathic clubfoot.

Pathoanatomy

The pathoanatomy of clubfoot primarily involves abnormalities in the talocalcaneonavicular complex with the calcaneus and navicular rotating

A. Aroojis, MS (ORTHO), D'ORTHO,
DNB (ORTHO)

Department of Bone Surgery, Kokilaben Dhirubhai
Ambani Hospital & Bai Jerbai Wadia Hospital for
Children, Four Bungalows, Andheri (w),
Mumbai, Maharashtra 400050, India
e-mail: alaric.aroojis@relianceada.com;
aroojis@gmail.com

S. Pirani, MBBS FRCS
Division of Paediatric Orthopaedics, Department
of Orthopaedics, University of British Columbia,
205-245 East Columbia Street,
New Westminster, V3L 3W4, BC, Canada
e-mail: spirani@me.com

B. Banskota, MBBS, MRCS, MS
Department of Orthopedics, Hospital and
Rehabilitation Center for Disabled Children (HRDC),
Janagal, Kavre, 6757, Nepal
e-mail: bibekbanskota@gmail.com

A.K. Banskota, MBBS, MD FACS
Department of Orthopaedics, Hospital and
Rehabilitation Center for Disabled Children,
Adhikari Gaon, Janagal, Ugratara VDC,
Kavre, Banepa, Nepal
e-mail: ashokbanskota@gmail.com

D.A. Spiegel, MD (✉)
Division of Orthopaedic Surgery,
Children's Hospital of Philadelphia,
Associate Professor of Orthopaedic Surgery,
University of Pennsylvania School of Medicine,
Philadelphia, PA, USA

Honorary Consultant in Orthopaedics and Rehabilitation,
Hospital and Rehabilitation Centre for Disabled Children,
Janagal, Kavre, Nepal
e-mail: spiegeld@email.chop.edu



Fig. 34.1 (a) An ambulatory child with untreated club-foot. (b) Walking on the lateral border of the foot can lead to excessive shoe wear and skin breakdown

around the talus. Both intraosseous (morphologic) and interosseous (alignment) abnormalities are present and are accompanied by soft tissue contractures. Abnormalities in alignment are illustrated using a model in Fig. 34.2a, b. Clinical findings include (1) midfoot cavus, (2) forefoot adductus, (3) hindfoot varus, and (4) hindfoot equinus (CAVE) (Fig. 34.2c).

The talus is smaller than normal, with medial and plantar deviation of the head and neck. The anteromedial surface articulates with the navicular, while the anterolateral surface is uncovered. Paradoxically, the talus is externally rotated within the ankle mortise. The calcaneus is adducted and inverted under the talus and has dysplastic facets, and the sustentaculum tali is underdeveloped. The navicular is flattened and medially displaced relative to the talar head and in severe cases articulates with the medial malleolus. The cuboid is medially displaced and inverted relative to the talus, with obliquity at the calcaneocuboid joint. At the ankle joint, the tibia articulates only with the most posterior part of the talus, and in severe deformities the posterior tuberosity of the calcaneus may touch the posterior surface of the tibia.

Soft tissue contractures accompany these abnormalities in bony morphology and alignment. The musculotendinous units of the deep posterior compartment (tibialis posterior, flexor digitorum longus, and flexor hallucis longus) are contracted, while the muscles of the anterior and lateral compartments (tibialis anterior, peroneus longus, and brevis) are elongated. The heel cord is thickened and contracted and is inserted slightly medial on the calcaneus. The deep plantar muscles of the foot are contracted, as well as the abductor hallucis. The distal tibiofibular joint, the posterior and medial aspects of the tibiotalar and subtalar joints, the talonavicular joint, and the calcaneocuboid joint become contracted over time. Contractures of multiple ligaments are seen, including the posterior tibiotalar, talofibular, calcaneofibular, deltoid, and those on the plantar aspect of the foot such as the spring ligament.

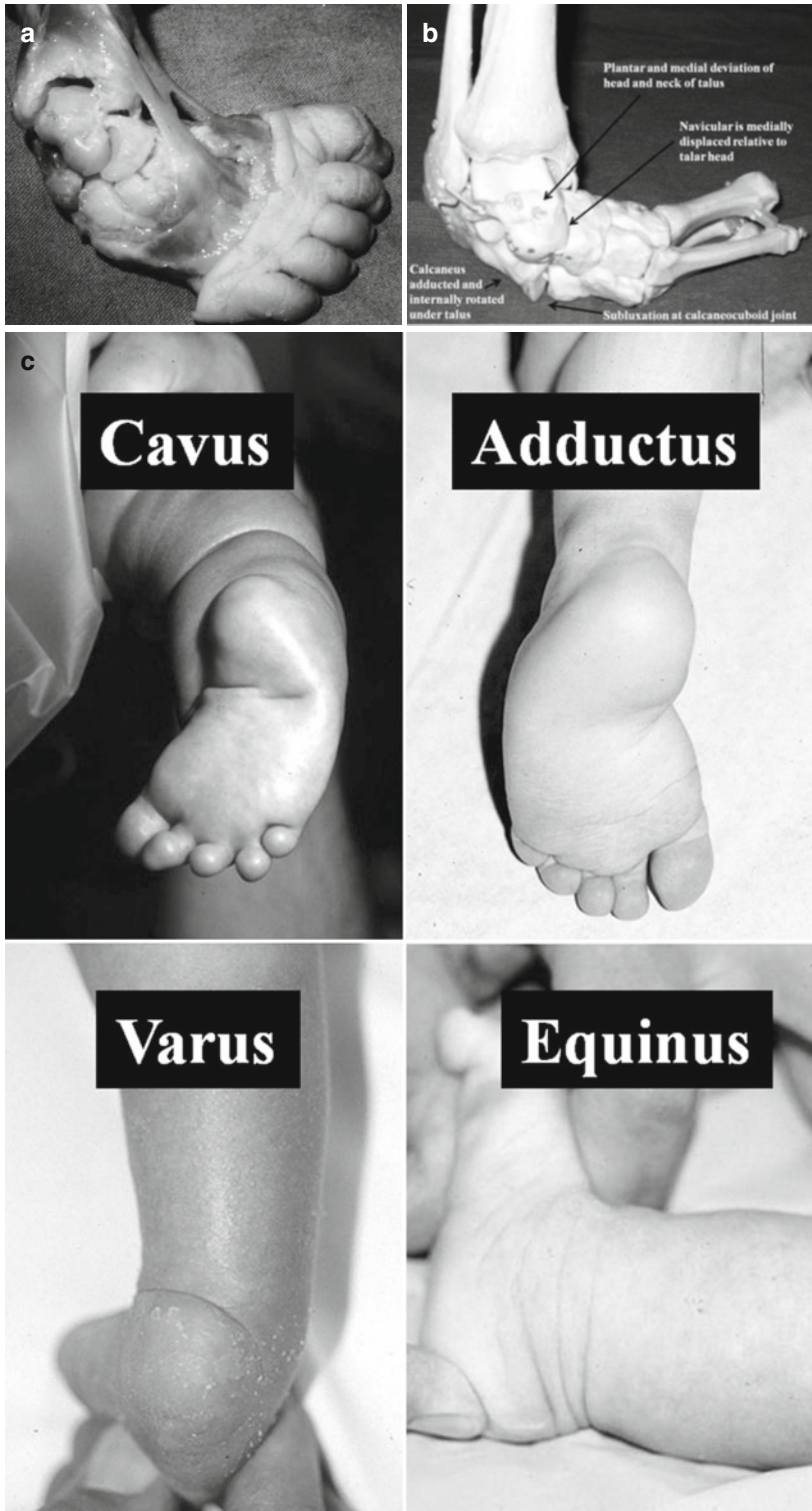


Fig. 34.2 (a) Clubfoot is a hindfoot deformity involving malalignment between the talus, calcaneus, and navicular (*Congenital Clubfoot, Fundamentals of Treatment* by Ponseti (1996) Fig. 9A p.18. By permission of Oxford University Press). (b) Osseous components of the

deformity are illustrated on this model. (c) Clinical components of the deformity include (1) cavus (midfoot), (2) adductus (midfoot), (3) varus (hindfoot), and (4) equinus (hindfoot)

Basic Ponseti Technique

The aim of clubfoot treatment is to obtain a functional, pain free, plantigrade foot with adequate mobility. Recognizing that extensive soft tissue releases often result in stiffness and the need for additional surgical procedures, the Ponseti method has achieved great popularity worldwide in recent years. This technique can be described as extra-articular and “minimally invasive” rather than nonsurgical. This method involves serial casting, with the majority of patients requiring a percutaneous tenotomy of the tendoachilles. Long-term bracing is essential to maintain the correction. Treatment is ideally started shortly after birth; however referral is often delayed in settings with limited resources. Evidence from both economically developed and developing countries suggests that the casts can be applied by non-orthopedic or even non-medical caregivers with good results.

The key concept is that the talar head serves as the fulcrum for correction, and the malalignment is corrected by rotation of the hindfoot bones around the talus, which remains fixed in space (Fig. 34.3a). In the initial cast, the first metatarsal is dorsiflexed to correct the cavus (Fig. 34.3b). Progressive abduction of the foot is used to simultaneously correct adductus and varus (Fig. 34.3c, d). Once full abduction is achieved, the ankle equinus is corrected, usually by a percutaneous tenotomy. Long leg casts are utilized at all stages of casting (Fig. 34.4).

The more relaxed the child, the easier the casting, and it is preferable to have the child breast feed immediately prior to and during casting. An assistant is helpful in holding the foot and upper thigh. With the patient supine, the person manipulating the foot stabilizes the leg at or above the malleoli without touching the calcaneus. There are two commonly used hand positions, depending on which hand is stabilizing the leg and which is holding the manipulation. In the first, the index finger puts pressure on the lateral side of the talar head while the tip of the thumb elevates the first ray and abducts the forefoot. In the second hand position, the thumb puts pressure on the head of the talus while the index finger dorsiflexes the first ray and abducts the foot (Fig. 34.5).

Because the navicular is medially displaced and its tuberosity is almost in contact with the medial malleolus, one can feel the prominent lateral part of the talar head as the first bony prominence, just anterolateral to the lateral malleolus. During the first casting, the midfoot cavus is corrected by dorsiflexing the first metatarsal, which supinates the forepart of the foot and aligns the forefoot with the hindfoot, which remains in varus. The foot should never be pronated as this increases the cavus and locks the calcaneus in varus.

During the next several casts, the forefoot is progressively abducted relative to the hindfoot, achieving simultaneous correction of the adductus and varus. Care should be taken to keep pressure on the region of the talar head during manipulation and casting; otherwise the talus will rotate laterally as the foot is abducted, pushing the lateral malleolus posteriorly, resulting in spurious correction. The foot is maintained in mild plantar flexion during this initial series of casts, leaving correction of equinus until later castings.

Initially, a below-knee cast is applied. After molding is completed, this is extended to an above-knee cast. The cast must extend to the groin, as short leg casts do not hold the calcaneus abducted and the foot will slip back in the cast. Removal of the cast should be done at the time of cast change and not the night prior. Soaking and unwrapping the plaster by the parent is more child-friendly than using a cast saw or cast knife (Fig. 34.6). The parents are taught to keep the plaster dry and clean and to examine the toes for any pallor or bluish discoloration that might indicate that the cast is too tight.

The goal is 70° abduction, which usually requires three to six casts. Once this is achieved and the heel is in valgus, the residual equinus is addressed. Attempts to correct the equinus before heel varus and forefoot supination are corrected will result in a rocker-bottom deformity. Take care to avoid external rotation of the tibial axis, which can achieve spurious correction by pushing the lateral malleolus posteriorly.

A tenotomy of the tendoachilles is required for residual equinus (ankle dorsiflexion <10°) in approximately 90 % of patients once the

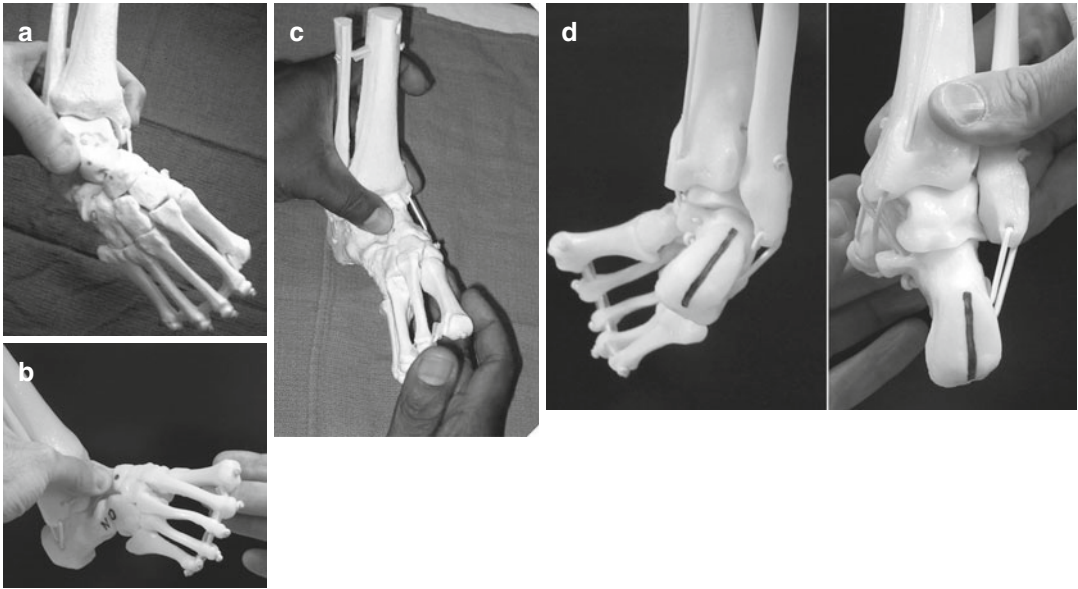


Fig. 34.3 (a) The talus must be fixed in space during manipulation and casting. (b) The first metatarsal is elevated to correct the midfoot cavus, and the (c) forefoot is abducted while maintaining pressure on the talus. (d)

Abduction simultaneously corrects adduction and varus, note the eversion of the calcaneus and the correction into valgus from varus

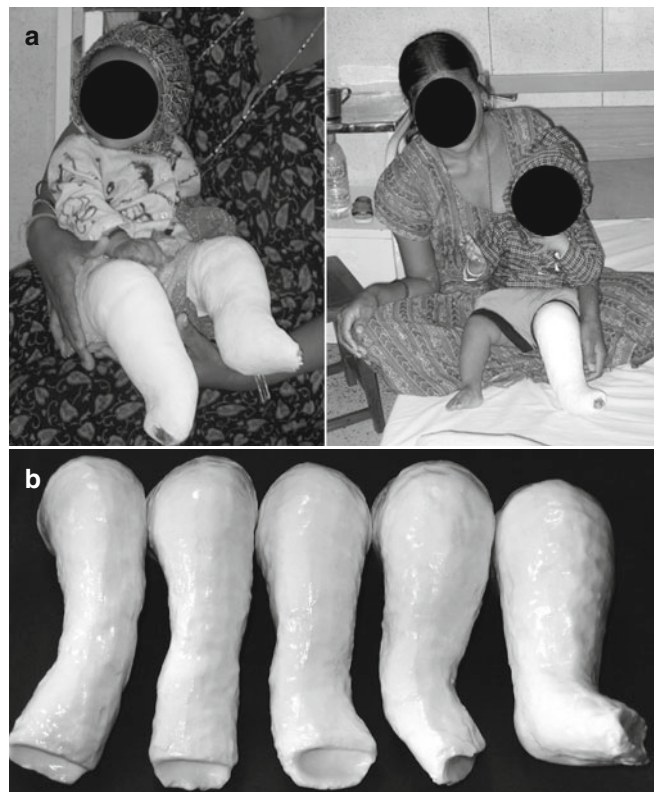

Fig. 34.4 (a) Long leg casts are applied with the foot (b) progressively abducted. Once full abduction is achieved, equinus is treated by casting or tendoachilles tenotomy

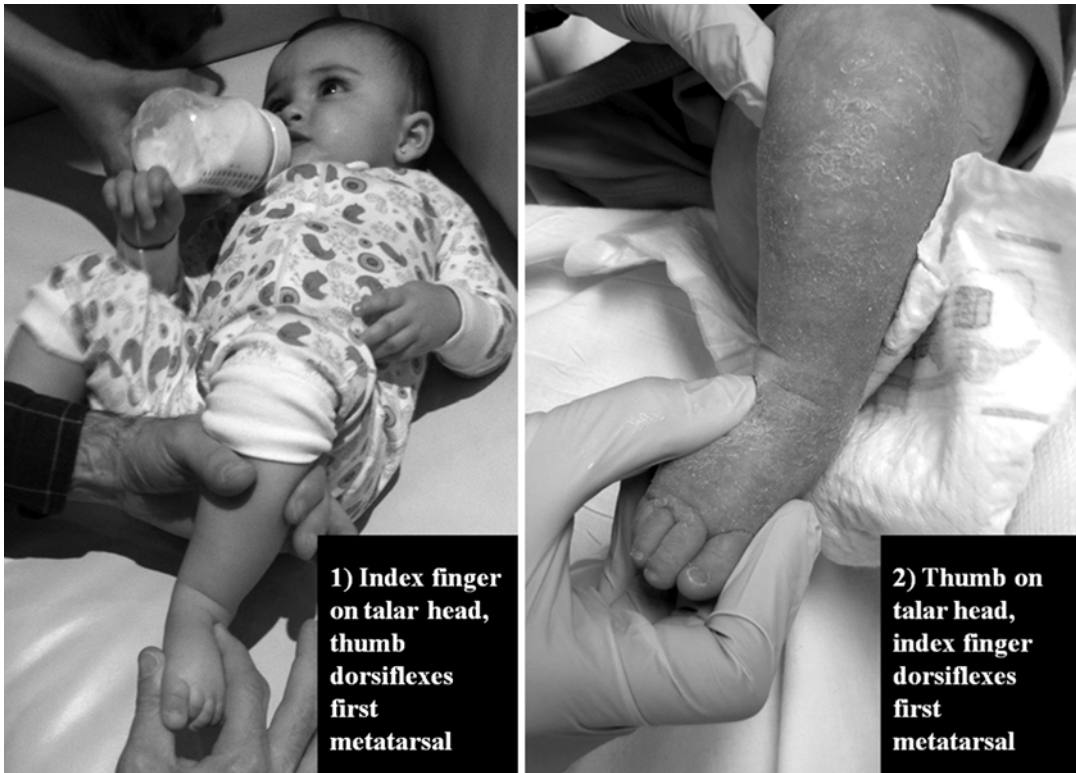

Fig. 34.5 Two different ways to hold the foot while applying the cast. The diaper should always be removed when applying the plaster to ensure that the cast will extend up to the groin



Fig. 34.6 The cast can be removed by first soaking in warm water and then gently unrolling the wet plaster

other components of the deformity are corrected (Fig. 34.7). Tendoachilles tenotomy can be performed under local or ketamine anesthesia in the outpatient clinic. The ankle is dorsiflexed by the assistant, keeping the knee in extension, making the tendon taut so it is easily palpated at its insertion. The scalpel blade is introduced approxi-

mately 1 cm above the insertion and directed from medial to lateral. The blade is turned 90° to remain horizontal on the anterior surface of the tendon, making the tenotomy from inside to out. A sudden pop is felt along with an increase in dorsiflexion. A dressing and compression bandage is applied, and the child is immediately handed to his/her mother for feeding. Once the child becomes pacified and the bleeding stops, a toe-to-groin cast is applied with the foot in maximum dorsiflexion (usually 15° or more but never normal) and 60° abduction. This cast is worn for 3 weeks, after which an abduction orthosis is applied.

Bracing is required to maintain correction and many brace designs are available. The most common is a pair of open-toed high-top straight-last shoes attached to a bar (Fig. 34.8). The brace is set at 60–70° abduction for the clubfoot side and 30–40° abduction on the normal side. The width of the bar is the same as the shoulder width. The bar should be bent 5–10° in the center, with the convexity away from the child, to hold the feet in 15° dorsiflexion. A small window cut at heel

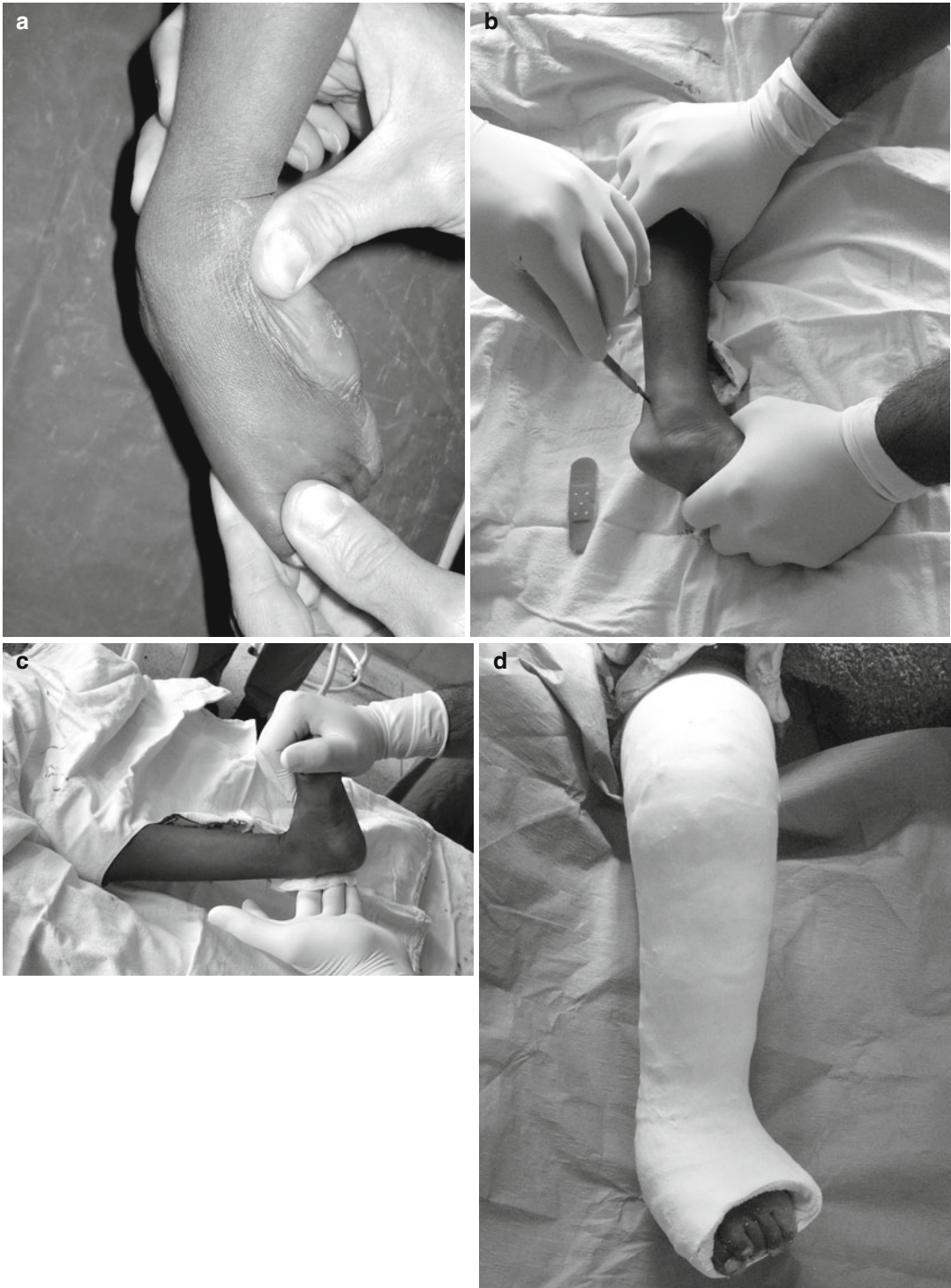



Fig. 34.7 (a) Before a percutaneous Achilles tenotomy is considered, the hindfoot must be able to be positioned in valgus with full passive abduction. (b) The tenotomy is

performed with an assistant dorsiflexing the foot to maintain tension on the tendon. (c) Dorsiflexion after the tenotomy. (d) The toe-to-groin cast is worn for 3 weeks

Fig. 34.8 (a, b) A foot abduction orthosis. Note the round window at the heel so parents can confirm that the heel is down in the brace



level allows the parents to see and feel that the heel does not rise up inside the shoe. Bracing works only as long as a full correction without residual equinus has been achieved, the brace is comfortable, and the parents develop and maintain a routine for its application.

It is often best to place the child in the brace prior to bedtime, rather than at the same time the child is put to sleep. The brace should be worn day and night for the first 3 months, and after that for 12 h at night and 2–4 h in the middle of the day for a total of 14–16 h a day. This protocol continues until the child is 4–5 years of age.

Relapses are seen in approximately 15 % of cases. Early relapses are treated by repeating the entire Ponseti casting, tenotomy, and brace sequence. Late relapses, typically after 2 years of age, often relate to muscular imbalance due to over pull of the tibialis anterior. In such cases, the Ponseti method is repeated, and once full abduction is achieved, patients typically require a repeat tenotomy and the tibialis anterior tendon is transferred to the third cuneiform (Fig. 34.9). Long-term bracing is not required following tibialis anterior transfer.

Ponseti in Older Patients

Thousands of children and adults in low- and middle-income countries (LMICs) face the burden of an untreated or “neglected” clubfoot because of deficiencies in access to or utilization of health services. While the physical consequences of an untreated clubfoot include inability to wear shoes, pain, and impaired ambulation, considerable social and cultural consequences add another dimension of disability. While successful results using the Ponseti method have been documented worldwide in patients less than 2 years of age, it remains unclear whether correction can be obtained in older patients or whether the method can reduce the magnitude of surgery required to achieve correction. While correction is achieved through progressive stretching of contracted soft tissues, concomitant remodeling of the chondro-osseous structures is required for permanent correction. Anecdotal experience suggests that remodeling of the osteoarticular surfaces is less reliable in patients older than approximately 8 years of age.

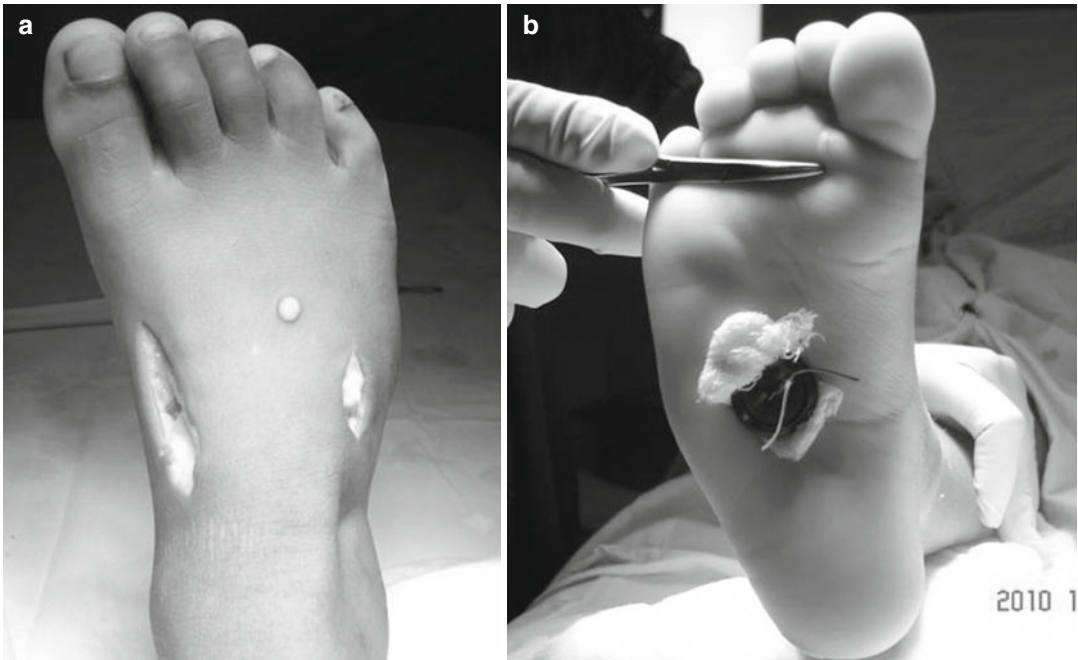


Fig. 34.9 (a, b) Subcutaneous transfer of the tibialis anterior to the lateral cuneiform

Recognizing that the Ponseti method was developed for babies, several adaptations have been utilized in older patients. Up to 12 casts may be required with each cast lasting 2 instead of 1 week. This requires a considerable time commitment. While 70° abduction is the goal when treating infants, only $20\text{--}50^\circ$ should be expected in older patients. The optimal treatment for equinus has yet to be established, and while percutaneous tenotomy has been successfully performed in patients up to 11 years, an open tendoachilles lengthening with or without posterior release may be required. When adequate dorsiflexion is not achieved after percutaneous release, serial casting may gain further correction. Severe mid-foot cavus is difficult to correct with casting and can require plantar fascia release.

Another issue surrounds the use of an orthosis to maintain correction in the older patients. While ambulatory patients will rarely adhere to full-time shoe and bar abduction splinting once the last cast is removed, most authors recommend some type of splinting (abduction splint, ankle foot orthosis) to prevent recurrence at least until the child is 4–5 years old, as advised in the original Ponseti method as applied to

infants. In patients older than 5 years, nighttime splinting for 1 year can be considered. Further study is required to address these technical concerns.

The few available reports concerning application of Ponseti principles in patients older than 2 years suggest that a plantigrade foot can be achieved in many patients up to 10 years of age (Fig. 34.10). Most patients have mild residual equinus, which may create the need for a “modified” squat in patients living in “floor cultures” (Fig. 34.11). The relapse rate can be as high as 25 % in these older patients (Fig. 34.12), and additional surgeries are often required.

Recognizing that avoiding extensive intra-articular surgery is the goal, long-term outcomes in these older patients must be assessed relative to alternative treatments, such as soft tissue releases with or without osteotomy, triple arthrodesis, and gradual correction using an external fixateur. Even if more extensive surgery will be required, our anecdotal experience suggests that casting reduces the extent of open surgical procedures, stretches the medial skin reducing the risk of skin breakdown, and allows for calluses and ulcers to heal. This is a work in progress.

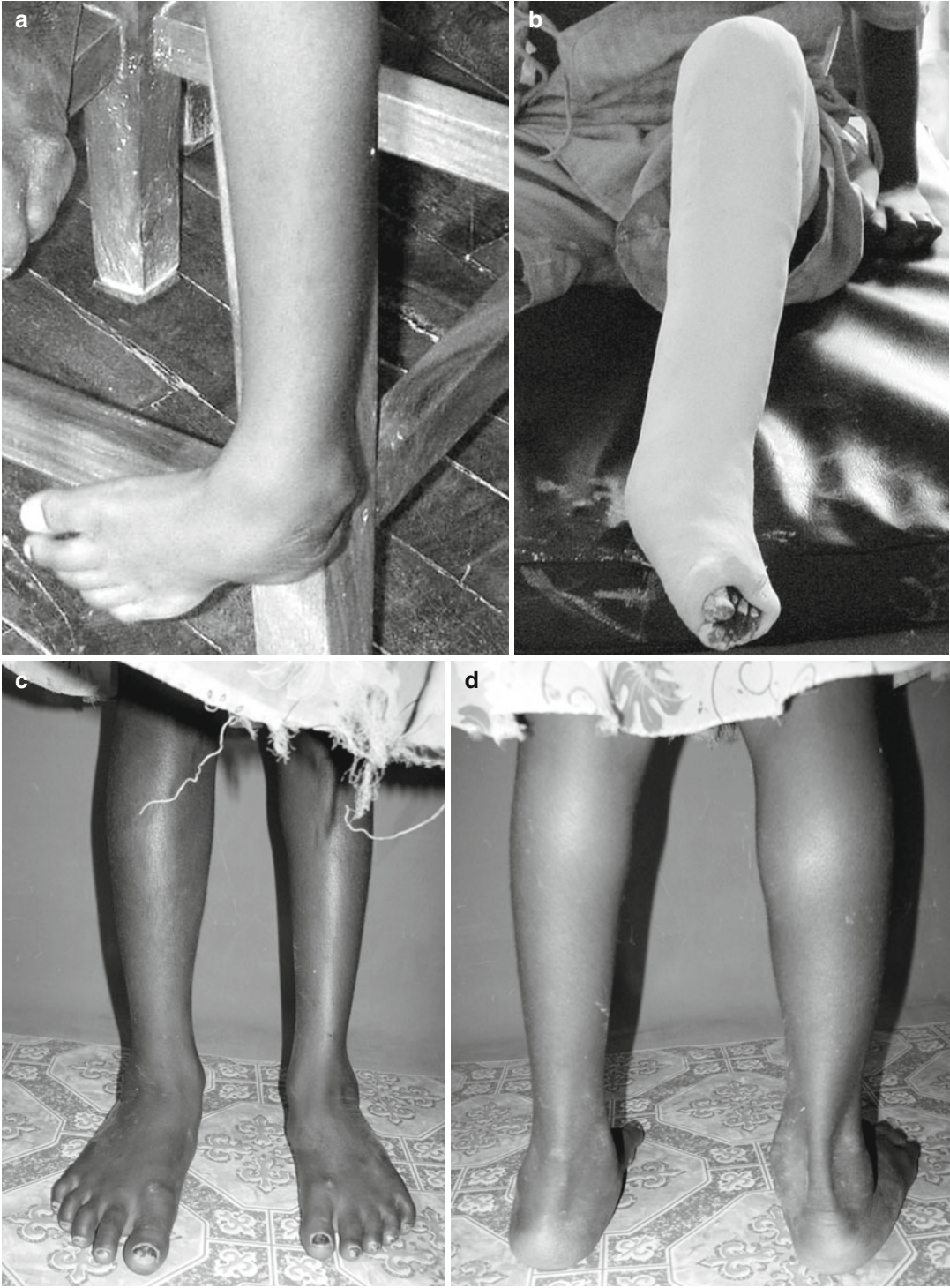

Fig. 34.10 (a) A 6-year-old with an untreated clubfoot was (b–d) successfully treated with the Ponseti technique

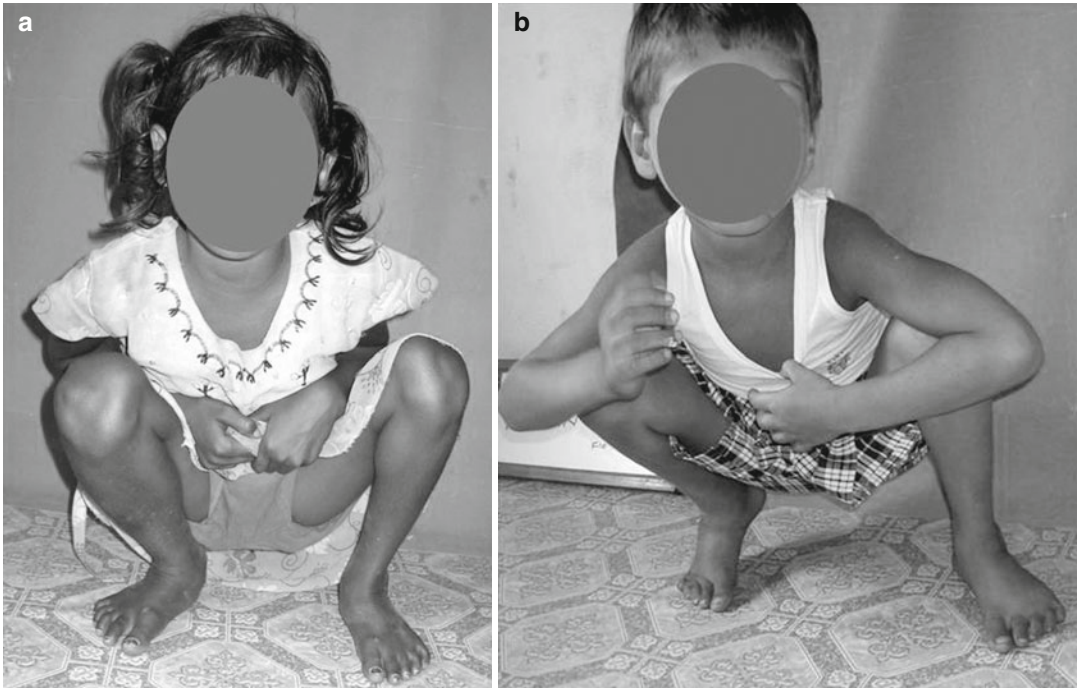

Fig. 34.11 While (a) this patient is able to squat normally following treatment, many have to utilize a (b) “modified” squat to accommodate persistent equinus, even when dorsiflexion is sufficient for normal ambulation

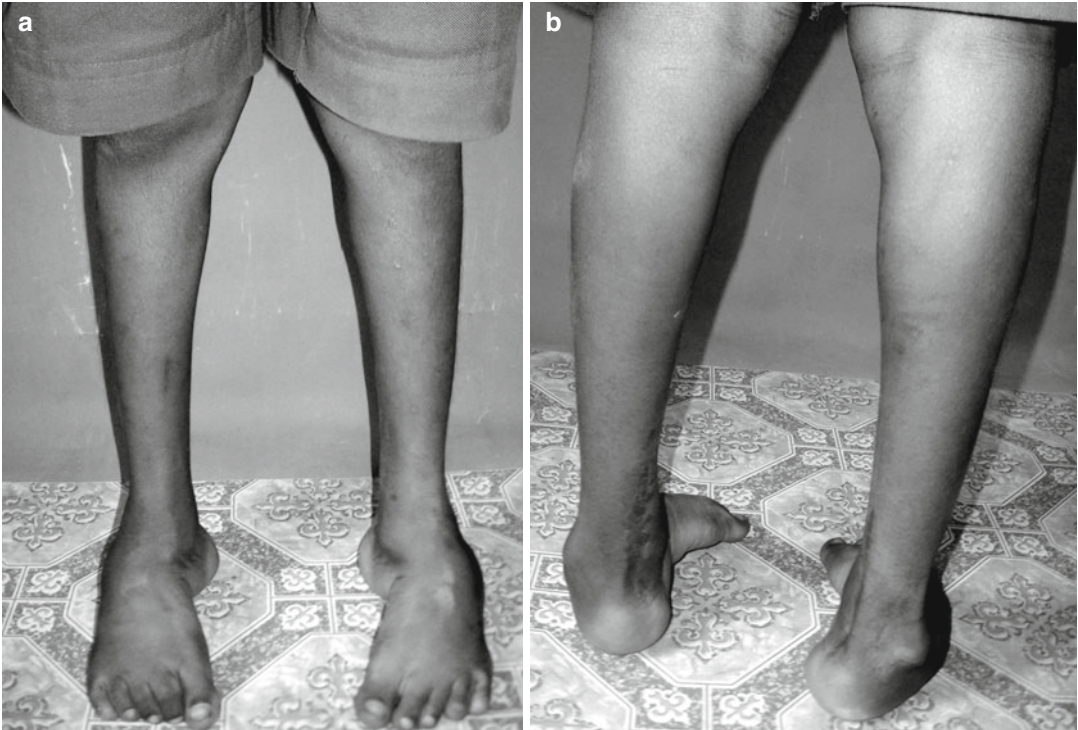


Fig. 34.12 (a, b) An older patient treated by the Ponseti method, including an open tendoachilles lengthening for severe equinus, had a relapse

Suggested Reading

- Banskota B, Banskota AK, Regmi R, Rajbhandary T, Shrestha OP, Spiegel DA. The Ponseti method in the treatment of children with idiopathic clubfoot presenting between five and ten years of age. *Bone Joint J* 2013;95-B:1721–25.
- Cooper DM, Dietz FR. Treatment of idiopathic clubfoot. A thirty-year follow-up note. *J Bone Joint Surg Am*. 1995;77:1477–89.
- Dobbs MB, Rudzki JR, Purcell DB, et al. Factors predictive of outcome after use of the Ponseti method for the treatment of idiopathic clubfeet. *J Bone Joint Surg Am*. 2004;86:22–37.
- Dobbs MB, Gurnett CA. Genetics of clubfoot. *J Pediatr Orthop B*. 2012;21:7–9.
- Khan SA, Kumar A. Ponseti's manipulation in neglected clubfoot in children more than 7 years of age: a prospective evaluation of 25 feet with long-term follow-up. *J Pediatr Orthop B*. 2010;19:385–9.
- Lourenco AF, Morcuende JA. Correction of neglected idiopathic clubfoot by the Ponseti method. *J Bone Joint Surg Br*. 2007;89B:378–81.
- McElroy T, Konde-Lule J, Neema S, Gitta S, Uganda Sustainable Clubfoot Care. Understanding the barriers to clubfoot treatment adherence in Uganda: a rapid ethnographic study. *Disabil Rehabil*. 2007;29:845–55.
- Pirani S, Naddumba E, Mathias R, et al. Towards effective Ponseti clubfoot care: the Uganda Sustainable Clubfoot Care Project. *Clin Orthop Relat Res*. 2009;467:1154–63.
- Ponseti IV. *Congenital clubfoot: fundamentals of treatment*. New York: Oxford University Press; 1996.
- Spiegel DA, Shrestha OP, Sitoula P, et al. Ponseti method for untreated idiopathic clubfeet in Nepalese patients from 1 to 6 years of age. *Clin Orthop Relat Res*. 2009;467:1164–70.
- Tindall AJ, Steinlechner CWB, Lavy CBD, Mannion S, Mkandawire N. Results of manipulation of idiopathic clubfoot deformity in Malawi by orthopaedic clinical officers using the Ponseti method: a realistic alternative for the developing world? *J Pediatr Orthop*. 2005;25:627–9.

J. Norgrove Penny

Introduction

With more than two-thirds of all children lacking access to specialized orthopedic care, neglected clubfoot is a common problem in resource poor environments (Fig. 35.1). While the pathoanatomy remains unchanged, the treatment becomes more complex with advancing age due to the severity of soft tissue contractures and the limited remodeling potential. As such, the surgeon needs to draw from a variety of treatment methods, to meet the challenges.

All neglected clubfeet are not the same; while the hindfoot is always rigid, there are varying degrees of rigidity of the midfoot and forefoot. If the forefoot remains relatively flexible (no rigid midfoot cavus), the child will bear weight on the lateral border of the foot with the foot pointing forward (Fig. 35.2). If there is a rigid midfoot cavus deformity, the foot will face backward with all the weight taken on the dorsum, and the prognosis for cast correction alone is poor (Fig. 35.3). The principle deformities—cavus, adductus, varus, and equinus—are illustrated using an adult-sized model of the foot in (Fig. 35.4).



Fig. 35.1 Father and son with neglected clubfoot

J.N. Penny, CM, MD, FRCS(C)
Department of Orthopaedic Surgery,
University of British Columbia,
CBM International, Vancouver, Canada
e-mail: norgroveanne@hotmail.com

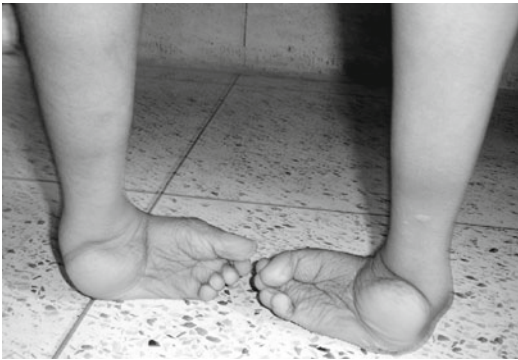

Fig. 35.2 Some neglected clubfoot point forwards during ambulation, suggesting that the midfoot cavus is flexible

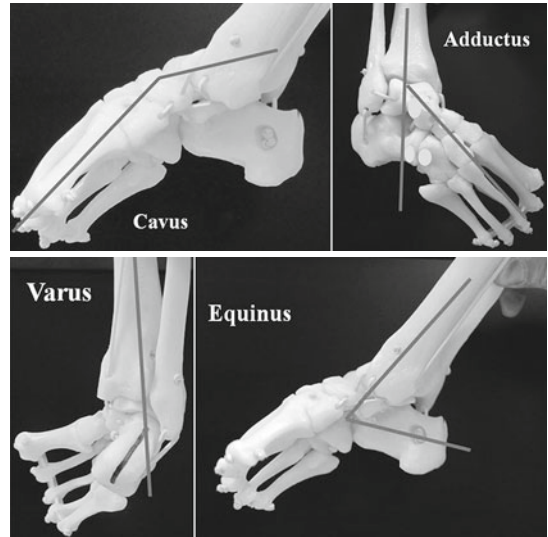


Fig. 35.4 The main components of clubfoot shown in an adult-sized model

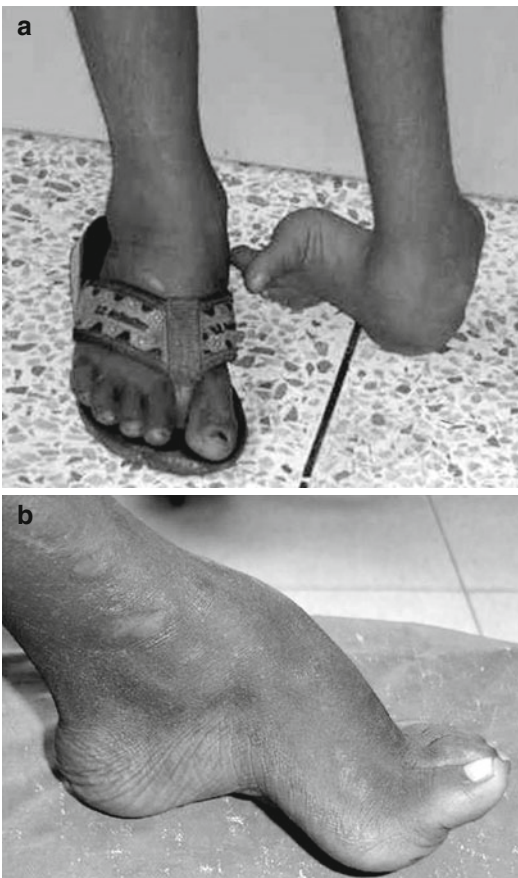


Fig. 35.3 (a) In patients with a rigid midfoot cavus, the foot points backward. (b) In less rigid cases the foot points forward (Courtesy of the Hospital and Rehabilitation Centre for Disabled Children, Banepa, Nepal)

Treatment Principles

Patients living in proximity to an organized treatment facility will have access to the full complement of treatment options, and treatment should ideally begin with casting using the Ponseti method. Where there are committed parents and no barriers to transport and clinic attendance, Ponseti casting can take place for as long as needed. Where there are committed parents but problematic transport logistics, notably due to poverty and rural living locations, hostel or hospital inpatient care should be made available. When organized services are absent or logistically impossible, primary surgical treatment may be a child’s only opportunity for correction. As a general surgical principle, children aged 8 and under require soft tissue release and a lateral column shortening osteotomy, while those over age 8 with a rigid foot respond best to a modified Lambrinudi triple arthrodesis [1, 2].

Suggested Surgical Algorithm
(Table 35.1)

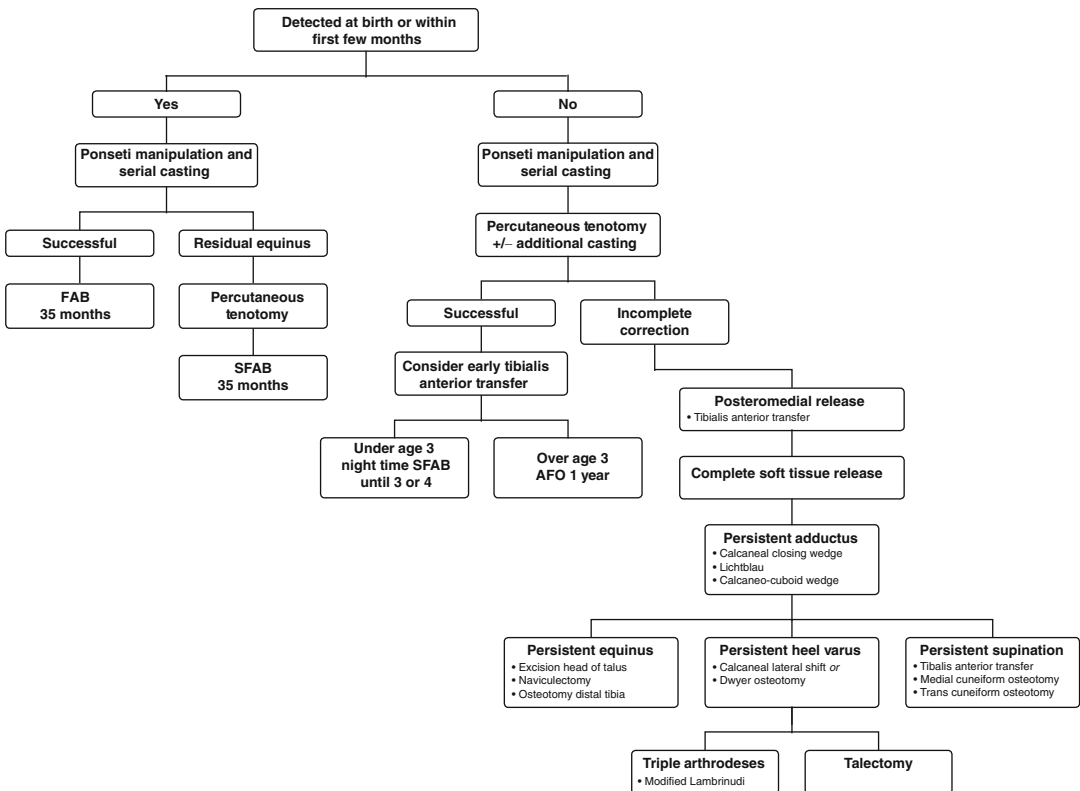
This progressive algorithm is applicable when an organized center is available and will necessarily be modified based on variables related to both the individual and the health system. The treatment begins with Ponseti casting and progresses to surgical procedures in an “à la carte” approach. Casting in walking-age children is more difficult and time-consuming, and a longer casting period can be expected. There is often little clinical improvement until after the first three or four casts. In older patients the casts are applied each week or two and continue until a plateau in correction is achieved. There should be a low threshold for extra-articular surgery (Achilles tenotomy, tibialis anterior transfer, plantar fascia release) and a high threshold for intra-articular surgery (capsular releases).

If persistent equinus is the main residual deformity, consider performing a percutaneous tenotomy using local anesthetic with sedation, ketamine, or general anesthesia. If the acceptable dorsiflexion of 15–20° is not obtained, a return to weekly casting after the tenotomy can facilitate full correction. An open release of the plantar fascia may be required if the midfoot cavus is rigid.

A soft tissue release (posterior, posteromedial, or posterior-medial-lateral) is needed if the tenotomy does not give enough correction (Fig. 35.5), with or without a lateral column shortening for persistent adduction deformity. Options include excision of the anterior process of calcaneus (Lichtblau procedure) [3] or the Evans calcaneocuboid wedge resection arthrodesis. Cuboid decancellation is not recommended since correction is achieved on the wrong side of the deformity and does not correct the obliquity at the calcaneocuboid joint.

The author prefers the Lichtblau procedure in children less than 6 years, hoping for a

Table 35.1 Algorithm for treatment of clubfeet in lower resource countries



FAB Steenbeek foot abduction brace, AFO ankle foot orthosis

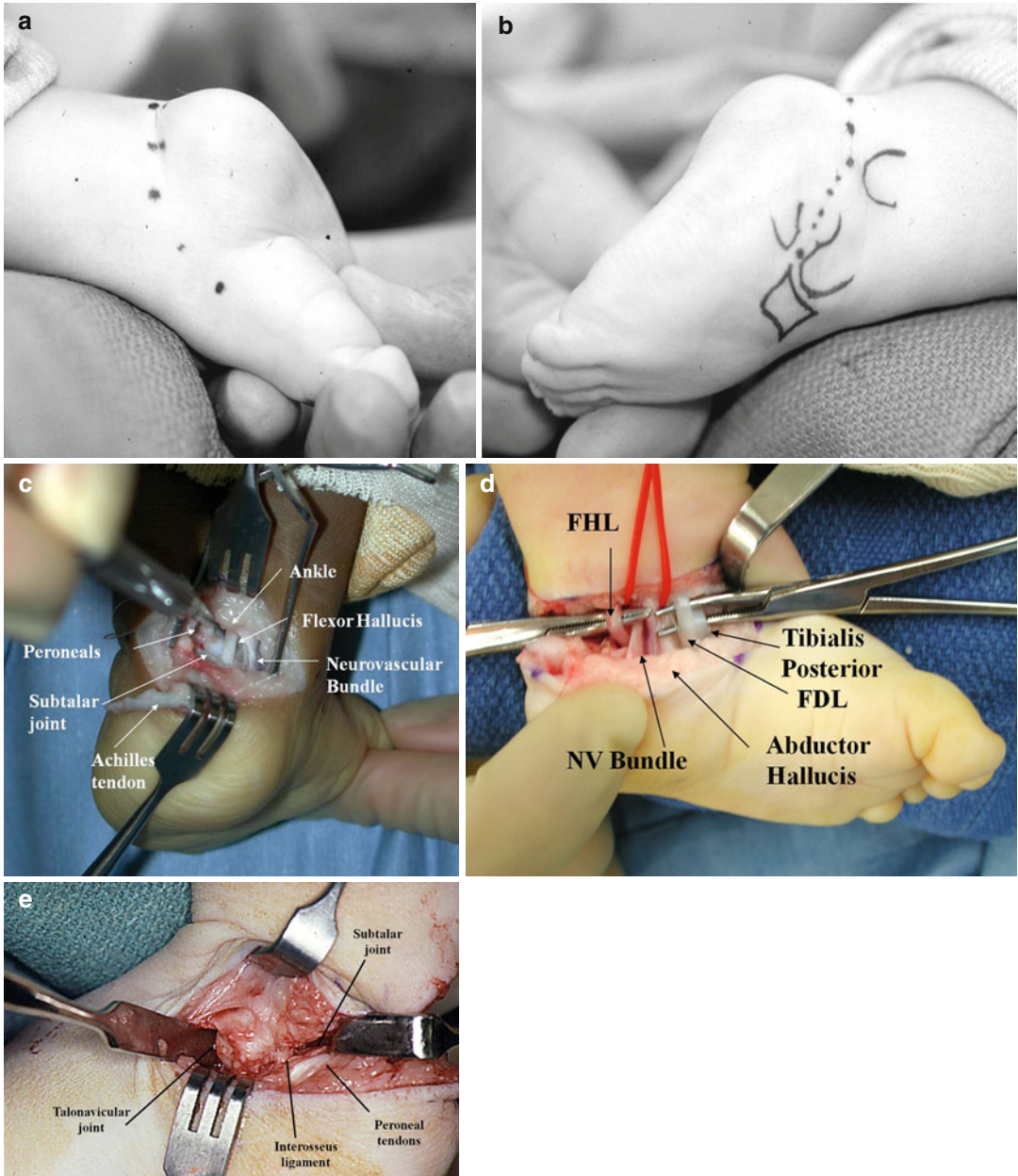


Fig. 35.5 (a, b) The skin incision for a posterior-medial-lateral release using a Cincinnati incision, as part of an “a la carte” approach, recognizing that in some cases not all of these structures require release or lengthening. (c) The posterior release involves tendoachilles lengthening, posterior capsulotomy of the ankle and subtalar joints. (d) The medial release involves tendon lengthenings (tibialis posterior, flexor digitorum longus, flexor hallucis longus,

abductor hallucis), and joint capsule releases (subtalar, talonavicular, calcaneocuboid), and sometimes a release of the plantar fascia and short toe flexors. When required, (e) the lateral release involves the lateral subtalar and talonavicular joint capsules. The talocalcaneal interosseous ligament should be left intact. A lateral column shortening can easily be performed as well (Courtesy of Richard S. Davidson, M.D.)

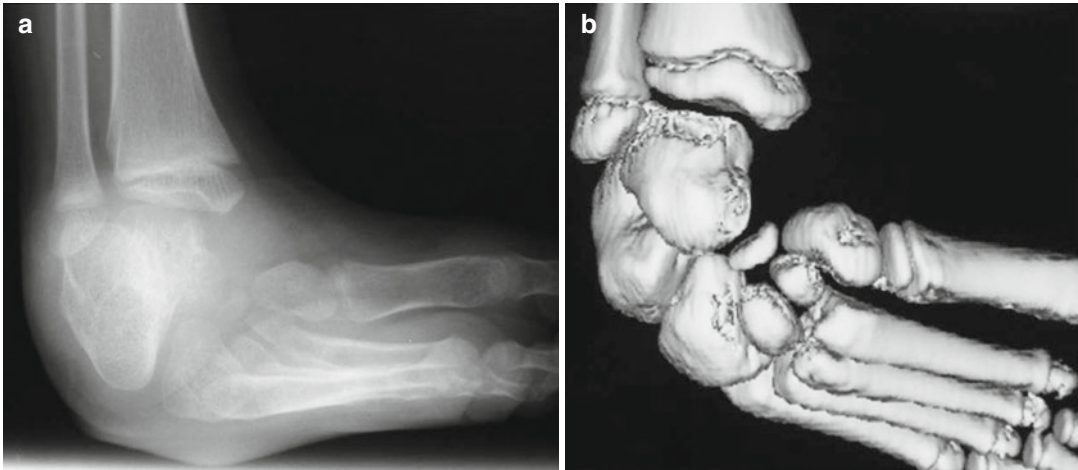


Fig. 35.6 (a, b) Neglected clubfeet always show considerable obliquity of the calcaneocuboid joint

mobile pseudoarthrosis to help preserve some joint motion. In children older than 6 years, a calcaneocuboid arthrodesis is performed, which provides adequate correction with less potential for relapse. In rare cases, particularly after previous surgery, there may be residual equinus, heel varus, and/or forefoot supination that require further correction. Lateral transfer of the tibialis anterior tendon (children older than 2 years) as a means to prevent recurrence should be considered. Complete subtalar release is seldom required if the preliminary casting to correct the forefoot has succeeded, but may be necessary in outreach situations, for example, a “surgical camp” in a remote location where there is only one chance to obtain a plantigrade foot.

Inadequate dorsiflexion is due to ankle equinus, with or without midfoot cavus (plantar flexion of midfoot on hindfoot). In severe midfoot cavus the navicular can impinge on the head of the talus. When this is seen, excision of the navicular may be helpful. The subsequent articulation between the head of the talus and the cuneiform joints is surprisingly congruous. Naviculectomy has been used successfully in the treatment of congenital vertical talus and other severe foot deformities in children [4, 5]. However, these are procedures of last resort. Where there is persistent hindfoot varus, a lateral closing wedge

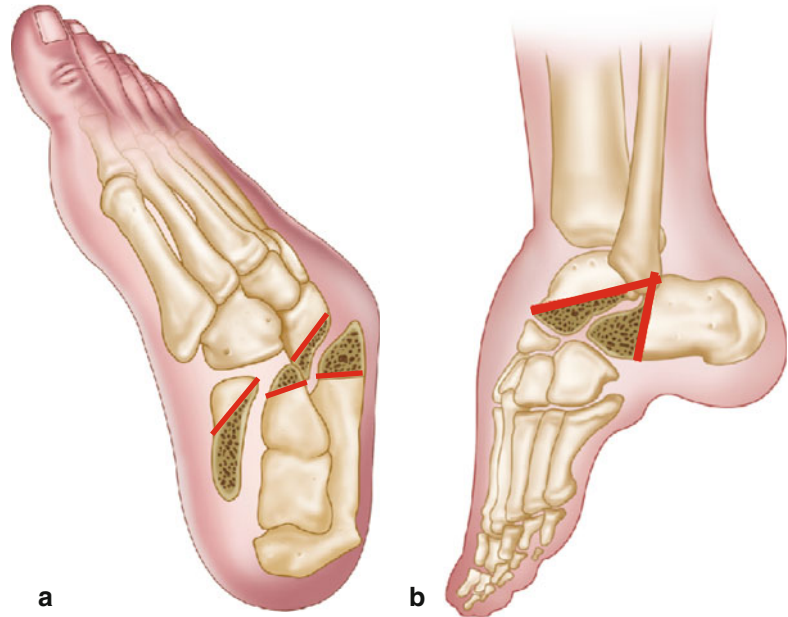
osteotomy of the calcaneus or a lateral calcaneal slide can be added.

Persistent forefoot supination is difficult to treat. Milder cases benefit from anterior tibial tendon transfer and a plantar flexion osteotomy of the medial cuneiform. More severe cases may require a trans-cuneiform osteotomy, but this procedure, when combined with rear foot osteotomies, results in a very rigid foot. It might be more appropriate to consider a triple arthrodesis in these cases.

For the older child or adolescent with a rigid clubfoot, when an extended treatment course is impossible, triple arthrodesis is the most expeditious way to gain correction with the fewest number of complications. Growth of the foot is not affected any more than with osteotomy procedures. The author prefers a modified Lambrinudi triple arthrodesis [1, 2] and has performed more than 100 for such clubfoot cases. Obliquity of the calcaneocuboid joint is usually pronounced and influences the orientation of the first osteotomy cut (Fig. 35.6). The technique is shown in (Fig. 35.7).

A standard Ollier lateral incision is made over the anterior calcaneus. The anterior process of the calcaneus is cut transversely with respect to the lateral border of the hindfoot and excised. A more conservative transverse osteotomy of the cuboid is made perpendicular to the lateral border of the forefoot. The head and neck of the talus

Fig. 35.7 (a, b) The first step is a lateral column shortening and calcaneocuboid fusion, removing more bone from the calcaneus than the cuboid. The orientation of the calcaneal cut is perpendicular to the long axis of the lower leg, and a triangular wedge is removed owing to the obliquity at the calcaneocuboid joint. The second cut removes the head and neck of the talus as well as the anterior portion of the calcaneus in the sagittal plane. The talonavicular resection is completed, followed by removal of the posterior facet of the subtalar joint



are excised obliquely beginning at the junction of the talar neck and the articular surface of the head of the talus, and an aggressive anterior wedge resection is taken at an oblique angle from the anterior process of calcaneus. This creates a dorsally based closing wedge osteotomy. The navicular is decorticated, and the posterior facet of the subtalar joint is excised. Correction is achieved by dorsal and lateral displacement of the forefoot on the hindfoot.

While fixation with staples, K-wires, or screws is desirable, careful cast correction without fixation gives an acceptable result (Fig. 35.8). Personal experience has shown that compared with triple arthrodesis, extensive soft tissue releases and osteotomies are associated with more complications, such as wound healing and infection, a longer operative time, and equivalent stiffness. Surgeons from the polio era considered triple arthrodesis a very adaptable and versatile procedure, and variations can correct a range of complex foot deformities [6]. While talectomy is an option for rigid clubfeet, especially those associated with arthrogryposis and myelodysplasia, the author agrees that the long-term results have been suboptimal [7].

An alternative surgical approach is gradual correction by differential distraction using an external fixateur (Ilizarov, Joshi, Taylor spatial frame, or similar devices) [8, 9] (Fig. 35.9). This requires knowledge and experience with the technology on behalf of the surgical team, committed parents and patient, and an inpatient rehabilitation hostel or hospital admission in most circumstances. Advantages include less open dissection and retention of foot length. The disadvantages are the long treatment course, a significant rate of stiffness and relapse, and feet that tend to be more painful over the long run.

The best use of a fixateur may be in the stiff neglected unilateral clubfoot, gaining preliminary length and skin stretching before proceeding to triple arthrodesis or midfoot osteotomy. This has been the experience of surgeons in India where the Joshi fixateur has been used extensively [8]. With severe and bilateral neglected clubfeet, asymmetric foot length is not an issue and triple arthrodesis or osteotomies become more practical. Our experience suggests that there is no significant difference in stiffness between patients treated with triple arthrodesis or distraction external fixation and soft tissue release with osteotomies.

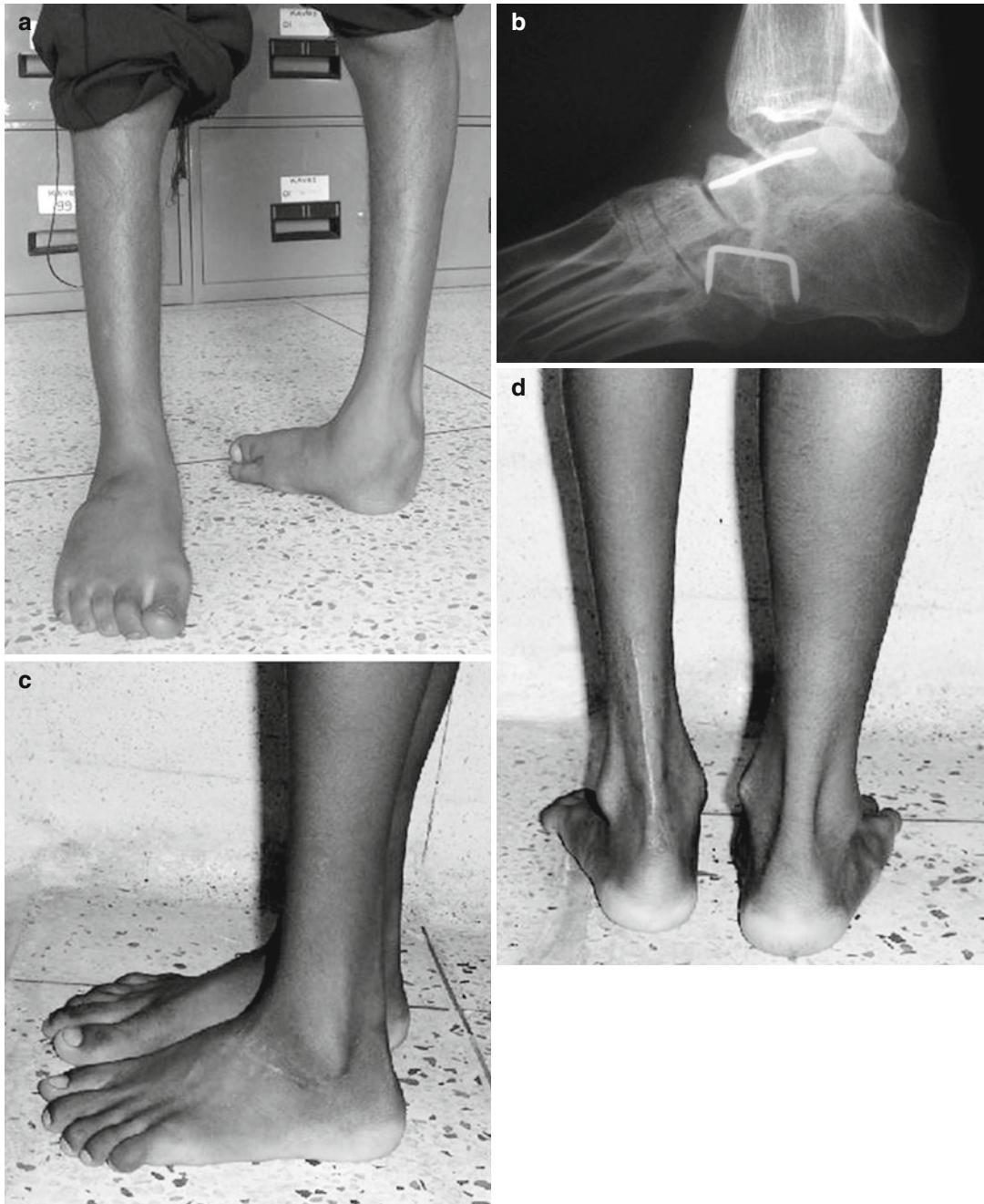

Fig. 35.8 Triple arthrodesis. (a) Preoperative appearance, and (b) postoperative lateral radiograph demonstrates fixation with K-wires fashioned into staples. (c, d)

Clinical appearance following triple arthrodesis. (Courtesy of the Hospital and Rehabilitation Centre for Disabled Children, Banepa, Nepal)

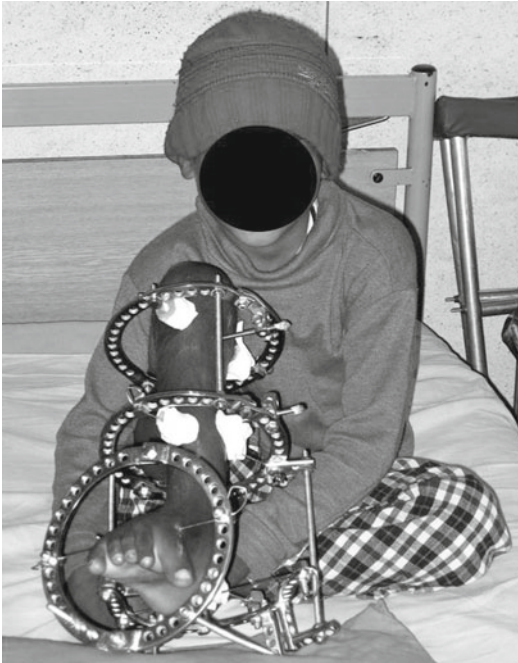

Fig. 35.9 Gradual correction with a ring fixateur. (Courtesy of the Hospital and rehabilitation Centre for Disabled Children, Banepa, Nepal)

Maintenance of Correction

In the Ponseti method, long-term bracing with a foot abduction orthosis is required as outlined in the previous chapter. Bracing is a logistic challenge in many environments, and lack of adherence to the bracing program is the most frequent cause of relapse after correction is obtained, at least in children under 2 years of age. Full-time bracing is impossible in children of walking age. The author's practice includes abduction bracing at night and naptime until the child is 3 or 4 years of age.

In children over age 3 at the time of correction and when operative facilities are available, a tibialis anterior tendon transfer should be considered

at the time of heel cord tenotomy, bypassing the need for foot abduction bracing. Postoperatively, 6 weeks of casting is followed with an ankle-foot orthosis (AFO) until outgrown. The AFO is used at night and part-time during the day allowing a few hours out of brace to facilitate mobility and strengthening. In children over age 3 where bony corrections have been performed and a tibialis anterior transfer done at the time of correction, an AFO is likewise used at night and part-time during the day until outgrown. Bracing is not required after triple arthrodesis.

References

1. Penny JN. The neglected clubfoot. *Tech Orthop.* 2005;20:153–66.
2. Shrestha OP, Spiegel DA, McCarthy JJ. Triple arthrodesis. In: Wiesel SW, editor. *Operative techniques in orthopaedic surgery.* Philadelphia: Lippincott, Williams and Wilkins; 2011. p. 1600–7.
3. Lichtblau S. Choices in surgical treatment of rigid neurogenic and arthrogryptic clubfeet. *Mt Sinai J Med.* 1989;56:17–22.
4. Clark MW, D'Ambrosia RD, Ferguson AB. Congenital vertical talus: treatment by open reduction and navicular excision. *J Bone Joint Surg Am.* 1977;59:816–24.
5. Mubarak SJ, Dimeglio A. Navicular excision and cuboid closing wedge for severe cavovarus foot deformities: a salvage procedure. *J Pediatr Orthop.* 2011;31:551–6.
6. Ryerson EW. The classic. Arthrodesing operations on the feet: Edwin W. Ryerson, M. D. *Clin Orthop Relat Res.* 1977;122:4–9.
7. Legaspi J, Li YH, Chow W, Leong JC. Talectomy in patients with recurrent deformity in club foot. A long-term follow-up study. *J Bone Joint Surg Br.* 2001;83:384–7.
8. Devadoss A, Devadoss S, Kapoor A. Differential distraction for relapsed clubfoot deformity in children. *J Orthop Surg (Hong Kong).* 2010;18:342–5.
9. Ferreira RC, Costo MT, Frizzo GG, da Fonseca Filho FF. Correction of neglected clubfoot using the Ilizarov external fixator. *Foot Ankle Int.* 2006;27:266–73.

Anna V. Cuomo and Hugh G. Watts

Overview

Limb deficiencies can result in functional disability and are often associated with significant social stigmas. Surgeons working in resource rich countries are part of a team that includes a prosthetist, physical therapist, and occupational therapist. In places with limited resources, failure to appreciate the limitations imposed by the absence of such professionals, or deficiencies in their skills, can result in a lack of functional improvement and unnecessary use of resources. Treatment must be individualized and tailored to personal or cultural beliefs. The purpose of this chapter is to equip the surgeon with some basic principles to guide management of limb deficient children in a variety of circumstances.

Most limb deficient children have a normal intellect and developmental milestones. Deficiencies may change the way a child crawls or walks, but interventions depend on functional and social circumstances. Acquired amputations will have normal bone, bone growth potential, and soft tissues proximal to the level of amputation.

Non-acquired amputations include early amniotic rupture sequence (congenital constrict-

tion bands) and congenital limb deficiencies. Femoral dysplasia or longitudinal deficiency of the fibula or tibia commonly require an amputation and prosthetic fitting to address the accompanying foot deformity, instability at the hip, knee and/or ankle, and limb length discrepancy (Table 36.1, Fig. 36.1). In these cases it is important to recognize any subtle deficiencies of the whole limb and also associated abnormalities such as scoliosis and congenital anomalies of the heart or kidneys. The surgeon may be the first person to recognize that other organ systems are affected and should refer the patient appropriately. Most cases of limb deficiency, except tibial deficiency, are thought to be spontaneous mutation and therefore not inheritable. It is important to address the family's fears of having similarly affected offspring in the future.

Both acquired and congenital amputations can have long bone overgrowth, requiring surgical capping of the bone ends with cartilage.

Patient Evaluation

The history focuses on limb function by asking the following questions:

- What are the missing segments and how do they affect function?
- Are there any muscle, nerve, fat, or skin abnormalities or dimples to suggest additional soft tissue involvement?
- What is the resting posture of the limb?

A.V. Cuomo, MD (✉) • H.G. Watts, MD
Department of Orthopedic Surgery, Shriners
Hospitals for Children, Los Angeles Unit,
3160 Geneva St, Los Angeles, CA 90020, USA
e-mail: ancuomo@shrinetnet.org; hwatts@ucla.edu

Table 36.1

Congenital limb deficiencies	Features	Treatment options
Femoral deficiencies	<ul style="list-style-type: none"> • <i>Congenital short femur</i> (femoral length >50 % of normal side) • <i>Proximal femoral focal deficiency (PFFD)</i> <ul style="list-style-type: none"> ◦ Stable hip (coxa vara, has proximal femur and acetabulum ± pseudarthrosis) ◦ Unstable hip or subtotal absence of proximal femur 	<ul style="list-style-type: none"> • Lengthen femur (or shorten contralateral femur) if congenital short femur • PFFD with stable hip, length <50 % = proximal femoral osteotomy, foot ablation, and knee fusion with fitting as a through-knee amputee • PFFD with unstable or subtotal absence = foot ablation and knee fusion or custom prosthesis
Longitudinal deficiency of the fibula	<ul style="list-style-type: none"> • Femoral deficiency common • Fibula absent or hypoplastic • Knee cruciate deficiency, patellar dysplasia • Tibia short with anteromedial bow • Equinovalgus foot with tarsal coalition, lateral deficiency 	<ul style="list-style-type: none"> • Foot reconstruction, epiphysiodesis versus lengthening for leg length inequality • Foot ablation and prosthetic fitting as a below-knee amputee if severe leg length discrepancy anticipated and/or severe foot deformity (<2 rays)
Longitudinal deficiency of the tibia	<ul style="list-style-type: none"> • 1/1 million births • Most sporadic, rarely genetic (AD, AR) • Hand anomalies most common, visceral rare • Femoral hypoplasia • Tibia can be (1) completely absent, (2) proximal tibia present with intact extensor mechanism, or (3) distal tibial deficiency with diastasis between tibia and fibula • Knee cruciate deficiency, patellar dysplasia • Fibula angulated, dislocated proximal tibiofibular joint • Equinovarus or equinus foot 	<ul style="list-style-type: none"> • Through-knee amputation and prosthetic fitting as through-knee amputee if no tibia present • If proximal tibia present, then foot ablation ± proximal tibiofibular synostosis and prosthetic fitting as a below-knee amputee • Distal diastasis is treated by foot ablation and prosthetic fitting as a below-knee amputee

- What muscle groups are used to effectively flex, extend, abduct, and adduct the limb?
- Which joints are stable or unstable?

Thoroughly examine both upper and lower extremities, look at the spine, and watch the child move around and do activities of daily living. Focusing the exam on the most severely involved limb is a common pitfall. If there is an associated scoliosis, determine how important spine flexibility is for gait and other activities.

For the lower limbs, determine the length inequality. The relative contribution of the femoral segment is determined with the hips and knees flexed with the child supine on a firm surface. The relative contribution from the leg and foot segments is determined with the child prone with the hips extended and the knees flexed. For children who can stand, the total discrepancy can be measured with the patient standing on wooden blocks or a measurable platform. Contractures at the hip, knee and/or ankle may contribute to the

functional discrepancy, as may shortening associated with a foot deformity, for example a clubfoot.

Additional Studies

X-rays supplement clinical information regarding the location of a bone deformity and the limb length discrepancy. If there is a joint contracture or the child is very young, lateral views of both lower limbs give a good idea of any relative discrepancy. Delayed ossification of the cartilage anlage can give the appearance of a missing joint. Look for secondary signs of joint formation by examining the more normal side of the joint. For instance, a well-defined acetabulum indicates the presence of a cartilaginous femoral head. An ultrasound can help identify the presence of an unossified or partially ossified cartilagenous anlage. If the local anatomy remains unclear, it may be wise to wait and reevaluate in 1 or 2 years.

General Treatment Considerations

Predicting future growth is essential and the surgeon should be prepared to predict the projected discrepancy.

For an infant or small child with a congenital non-acquired deficiency, the limbs will grow proportionally. An estimate of the projected discrepancy will determine if an amputation at a young age should be considered, such as for

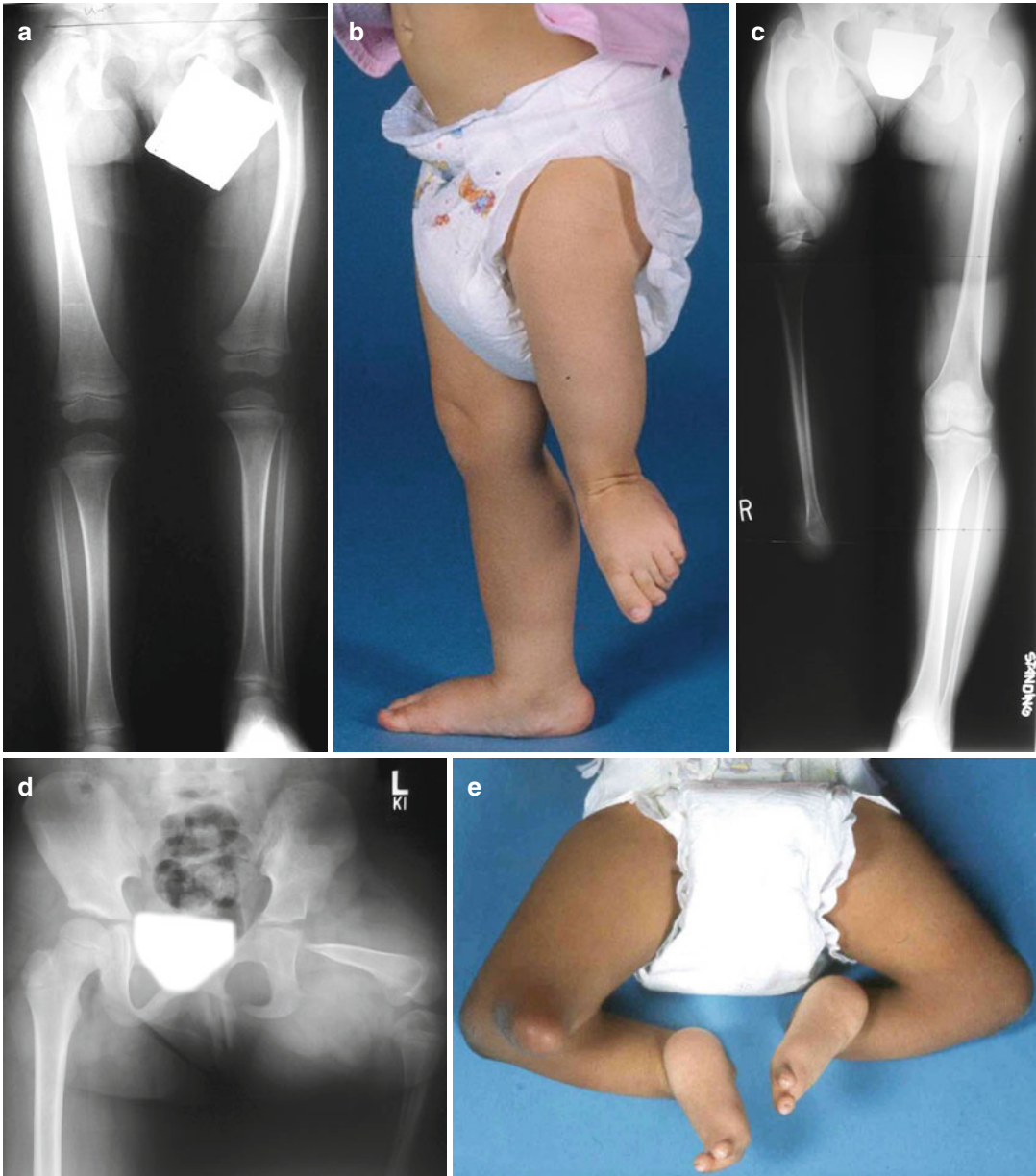


Fig. 36.1 A spectrum of abnormalities occurs in patients with longitudinal deficiencies of the femur, tibia, and fibula. Variations of femoral deficiency include (a) congenital short femur and (b–d) proximal focal femoral deficiency. Tibial deficiencies include (e, f) complete

absence of the tibia, (g, h) presence of an intact proximal tibia and extensor mechanism, and (i) distal deficiency with diastasis between the tibia and fibula. (j) An example of a fibular deficiency with a dysplastic fibula

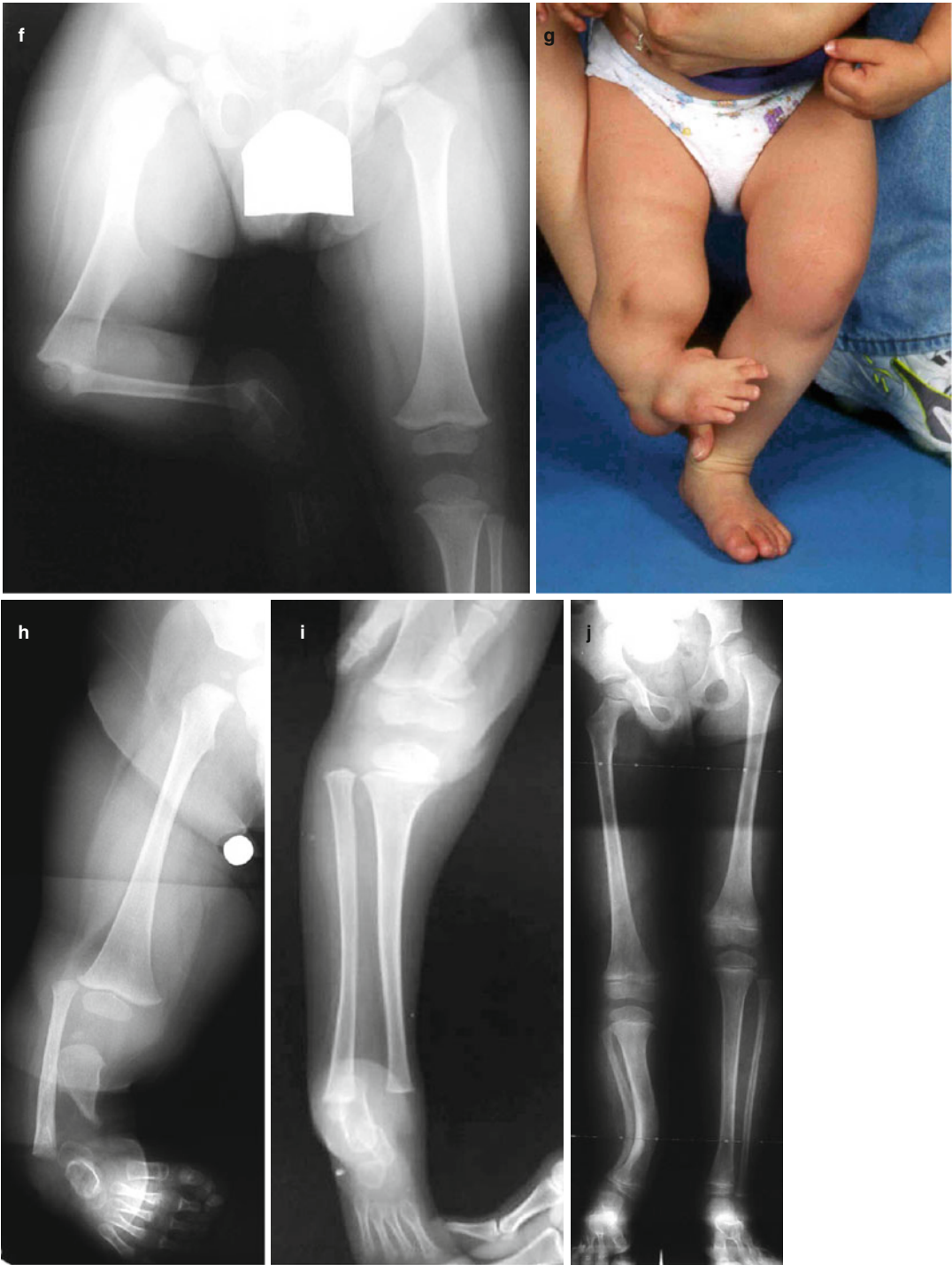


Fig. 36.1 (continued)

discrepancies of 10–20 cm, or if it is more reasonable to shorten the long limb with a timed epiphysiodesis.

At maturity, the average length of a femur is 41 cm for girls and 44 cm for boys [1, 2]. The average length of a tibia is 34 cm for girls and 37 cm for boys [1, 2]. As an example, if the affected femur measures 80 % of the length of the normal contralateral femur, a rough estimate of the discrepancy at maturity will be 20 % of 44, or 8.8 cm, for a boy.

Another rough guide: girls reach half their skeletal height by age 3 and boys by age 4. The discrepancy at these ages can be doubled for an estimate of final discrepancy. At ages 6 for girls and 8 for boys, the discrepancy can be multiplied by 1.5 [3].

For children age 8 and older with a congenital deficiency, while there is still future growth to consider, a large projected discrepancy at maturity will be obvious on clinical exam and management decisions can be made without detailed calculations. For projected discrepancies ≤ 10 cm, a more accurate assessment is important to consider timing of an epiphysiodesis or an acute shortening to better equalize the limb lengths. To project the final discrepancy and time for epiphysiodesis, the arithmetic method is simple and reasonably accurate [4, 5] (Table 36.2).

In the setting of growth arrest from trauma or infection, assume normal growth parameters per year until skeletal maturity. Add this value to the current discrepancy to project the final discrepancy. For children affected at a very young age—for example, neonatal sepsis with total physal ablation—it is useful to know the percentages of growth provided by each growth plate for the entire limb. These are roughly as follows:

proximal femur = 15 %, distal femur = 35 %, proximal tibia = 30 %, and distal tibia = 20 %. The yearly growth of individual physes has also been estimated (see Chap. 26, Table 26.2).

Determining the skeletal age of the child is the source of the greatest error in predicting limb length discrepancies. The calendar age is clearly the most convenient number to use; however, children undergo a prepubertal growth spurt at a variety of ages and growth can be severely affected by malnutrition.

Predicting future function is critical when planning treatment. One of the first considerations is the child's access to skilled prosthetic care. Anything other than a standard below- or above-knee prosthesis requires more skill to make, and a poorly fitting prosthesis will be painful and lead to pressure sores and infection. If the patient with a short lower limb can be fit for a prosthesis without changing the limb, for instance, a small foot is incorporated into the prosthesis, this may be a good first step for management. Though this avoids surgery and maintains a good weight-bearing end to the limb without the prosthesis, reliable access to a good prosthetist is the final determinant to success. If unsure of the skill of the prosthetist, ask what surgical modifications can be made to the limb to simplify the prosthesis and provide a better fit.

For acquired amputations, either from trauma or infection, effort should be made to preserve growth of the physis in young children. For instance, the bone and physis may be unaffected, but there may be inadequate distal soft tissue coverage for primary closure. Instead of amputating at a higher level, which would sacrifice the growth plate, the long bone can be shortened at

Table 36.2 Arithmetic method [3, 4]

This method is used in timing epiphysiodesis in patients older than 8 years, based on several assumptions
1. Distal femoral growth plate grows at 3/8 inch (9 mm) per year
2. Proximal tibial growth plate grows at 1/4 inch (6 mm) per year
3. Boys stop growing at 16 years of age
4. Girls stop growing at 14 years of age
5. If one of the growth plates is completely arrested, the discrepancy will increase at a rate corresponding to the normal rate of growth for that plate. Otherwise, it will increase at 1/8 inch (3 mm) per year
6. Calendar age is adequate in assessing growth and skeletal age need not be assessed

the metaphyseal diaphyseal junction, allowing the soft tissues to telescope for primary skin closure over the growth plate.

Avoid mid-diaphyseal amputations in children if at all possible because of bone overgrowth. If this cannot be avoided, the surgeon should cap the distal bone with an osteochondral graft, as described by Marquardt [6]. This can be taken from the amputated limb, such as a metatarsal head, or from the proximal fibula. The periosteum from both the donor and recipient bone should be approximated with suture after the bone is wedged into the canal with an interference fit. Cartilage capping is ideally performed at the time of amputation, but can be equally successful with a fibular head autograft to treat overgrowth that has already occurred (Fig. 36.2).

Avoid scars along the weight-bearing portion of the limb. Begin shrinking the stump as early as 2 weeks postoperatively to prepare for prosthetic fitting. Unlike adults, the skin and other soft tissues will often hypertrophy at the weight-bearing end of the stump.

Upper Extremity Deficiencies

The goal for the upper extremity is to assist activities of daily living. Do not take off nubbins unless they are problematic, as they provide traction and sensation. Patients with unilateral upper extremity deficiencies often compensate with the contralateral upper extremity, while those with bilateral deficiencies may be able to compensate with their lower extremities. When the deficiency is well compensated, it is inadvisable to recommend an upper extremity prosthesis that is insensate. Many children will reject upper extremity prostheses unless introduced before 1 year of age. In the rare circumstance when a child is poorly compensated, such as bilateral below elbow deficiencies, a useful surgical technique is the Krukenberg reconstruction [7], as described in Chap. 41. In addition, while a severe foot deficiency may make ambulation difficult, the foot may be used to substitute for the hands if the child is missing both upper extremities (Fig. 36.3). In this case, it would be shortsighted to amputate the feet.

Fig. 36.2 Modified Marquardt procedure. The periosteum is reflected off the distal aspect of the recipient bone, as well as off the proximal end of the “cap” (fibular head). The proximal aspect of the fibular graft is then placed into the recipient bone, and the periosteal sleeve from the fibular graft is repaired. The periosteal sleeve from the recipient bone is then wrapped around the graft and sutured to itself and to the periosteum over the distal aspect of the fibular graft

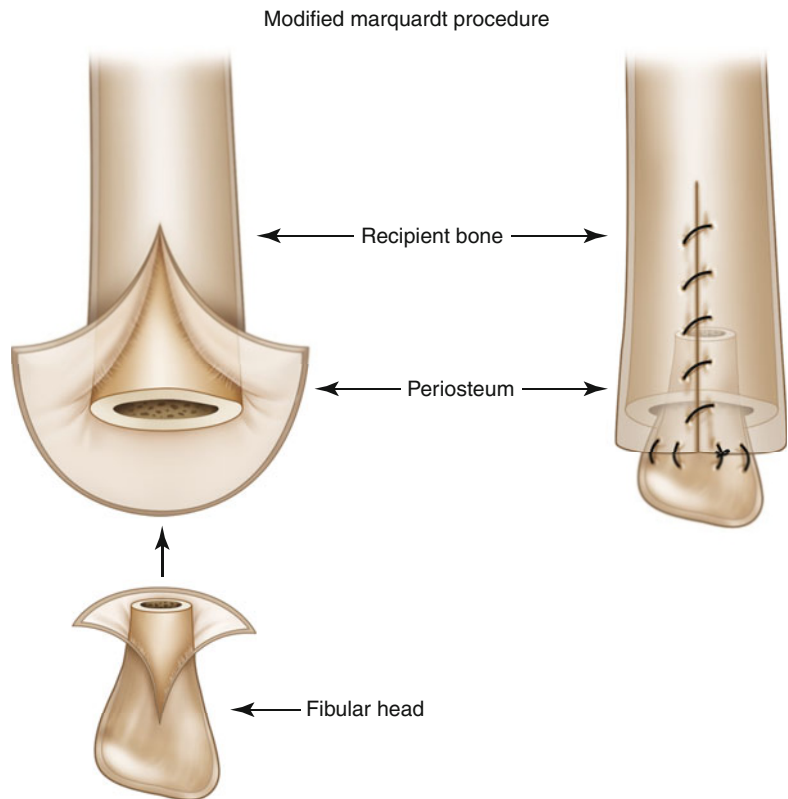

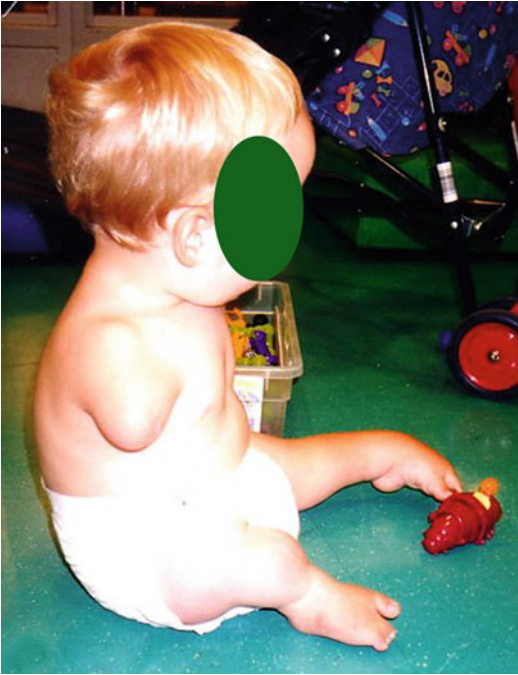


Fig. 36.3 This child with absence of both upper extremities will learn to use his feet for a variety of tasks

Lower Extremity Deficiencies

The most appropriate management depends on the severity of the foot deformity, knee and ankle joint stability, ongoing access to a prosthetist, and the social situation of the child. While longitudinal growth will usually remain proportional, it is important to recognize that angular deformities and contractures can increase, and the gait will change as the child matures. A deformed but functional joint in a child may become a painful, nonfunctional joint in an adult.

If possible, preservation of the knee joint is extremely important, as energy expenditures are considerably less for a below knee amputation versus a through or above knee amputation. However, an above knee amputation may be preferable in the absence of active knee extension. If the femur is more than 50 % the length of the contralateral side, consider a through-knee amputation. For the patient with an extremely short femur, <50 % of the length of the contralateral femur, consider combining a knee fusion with a foot ablation procedure, so the patient can be fitted as a through-knee amputee. The

authors prefer a Boyd amputation (excision of the ankle joint, including the distal tibial physis, with fusion of the calcaneus to the distal tibia) to a Syme amputation (ankle disarticulation) (see Chap. 43).

Any of these procedures may need to be combined with an epiphysiodesis to allow the mechanical knee to fall near the same level as the contralateral side at skeletal maturity. Large discrepancies in knee height lead to differences in swing phase duration and can yield an unusual compensatory gait pattern. The surgeon should plan for the femur to be shortened by 10 cm to accommodate the prosthesis, and an above-knee amputation should result in a stump that is about 5–6 cm proximal to the contralateral knee at skeletal maturity. A below-knee prosthesis requires about 10 cm for cosmetic appearing ankle and foot components, and the ideal stump length is between 15 and 25 cm at skeletal maturity.

The timing of surgical interventions depends on the projected limb length discrepancy and whether it is more reasonable to preserve the affected limb and shorten the long side or if an amputation on the affected side is best. Ideally, intervention is timed to allow the child to reach his normal motor milestones. Amputations are psychologically easier for the child the earlier they are performed. If the function of the limb is uncertain, particularly concerning hip and knee extension, it is best to wait until the child develops and the clinical picture clarifies. In the meanwhile, children can be fit with extension orthosis or a large external shoe lift to improve their gait (Fig. 36.4).

In most austere environments lengthening the short limb is not an option due to the high complication rate and need for ongoing monitoring and surgical intervention.

Although the concept has been popularized that a limb should not be shortened more than 5 cm, this has no basis other than concern for the appearance of a relatively long trunk relative to the limbs. If shortening a long limb by 10 cm will be a simple surgery to address a complicated problem, it is probably the right choice despite cosmetic concerns. A common error is to correct the current discrepancy and not the projected discrepancy at maturity. An acute shortening can be performed at any time; however, the surgeon is

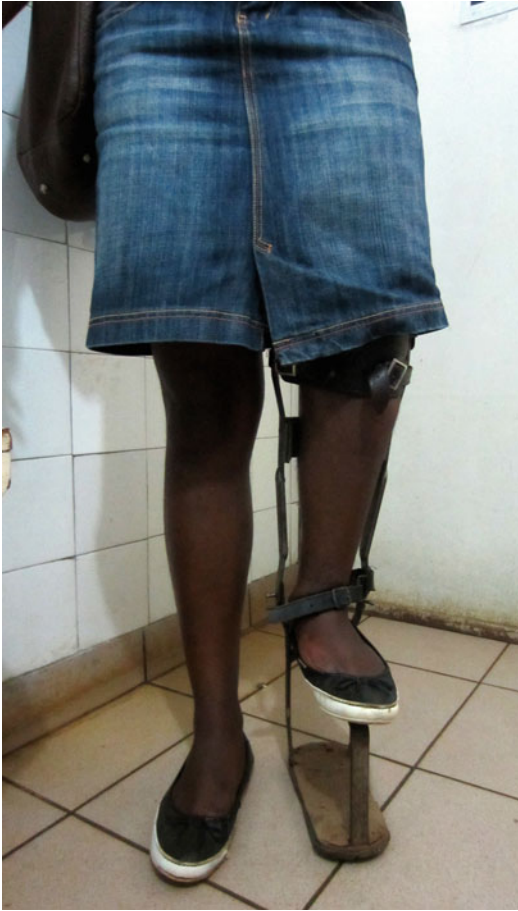

Fig. 36.4 An extension orthosis on an adolescent girl with a congenitally short femur

limited up to 5 cm in the femur and 3 cm in the tibia due to difficulty with soft tissue closure after the soft tissues telescope around the shortened segment. Acute shortenings can be staged once the soft tissues have shrunk to provide a larger magnitude of shortening.

References

1. Anderson M, Green WT, Messner MB. Growth and prediction of growth in the lower extremities. *J Bone Joint Surg Am.* 1963;45:1.
2. Anderson M, Messner M, Green W. Distribution of the normal femur and tibia in children from one to eighteen years of age. *J Bone Joint Surg.* 1964;46A:1197–202.
3. Paley D, Bhav A, Herzenberg J, Bowen R. Multiplier method for predicting limb-length discrepancy. *J Bone Joint Surg.* 2000;82:1432–46.
4. Menelaus M. Correction of leg length discrepancy by epiphyseal arrest. *J Bone Joint Surg.* 1966;48B:336–9.
5. Westh R, Menelaus M. A simple calculation for the timing of epiphyseal arrest: a further report. *J Bone Joint Surg.* 1981;63B:117–9.
6. Martini AK, Marquardt E. Stump plasty on congenital amputations. *Garyounis Med J.* 1980;3(Suppl):83–6.
7. Swanson AB, Swanson GD. The Krukenberg procedure in the juvenile amputee. *Clin Orthop.* 1980;148:55.

Sanjeev Sabharwal, Richard M. Schwend,
and David A. Spiegel

Introduction

The infant's lower limbs are aligned in varus from birth until approximately 18–24 months of age, after which they are in valgus. Valgus peaks between 3 and 4 years, and adult alignment (5–7° valgus) is achieved at approximately 7–8 years. When faced with a deformity, the surgeon must identify those that are patho-

logic and affect function or cosmesis, cause pain, or will have consequences later in life. Coronal plane deformities can be due to one or more of the following causes: angulation of the femur and/or tibia, intraarticular bony deficiencies at the knee, and ligamentous hyperlaxity. Physical examination along with full-length standing radiographs and other pertinent imaging modalities are used to individualize treatment (Fig. 37.1).

Limb bowing can be generalized or focal. The differential diagnosis of genu varum or genu valgum includes physiologic, posttraumatic (malunion, sequelae of physeal fractures), postinfectious, inflammatory (juvenile arthritides), systemic diseases (rickets), generalized bone disorders (skeletal dysplasias, osteogenesis imperfect, enchondromatosis, osteochondromatosis, neurofibromatosis), and congenital causes such as limb deficiencies. They are classified as anterolateral (apex anterior and lateral), anteromedial (apex anterior and medial), and posteromedial (apex posterior and medial).

Recognizing that many deformities are multiplanar and that planning for complex limb realignment is beyond the scope of this book, our goal is to provide a basic understanding of (1) lower limb malalignment, (2) how to identify components of the deformity, and (3) surgical options for achieving correction of these deformities.

S. Sabharwal, MD, MPH
Division of Pediatric Orthopedics,
University of Medicine and Dentistry,
New Jersey Medical School,
Suite 7300, Doctors Office Center,
90 Bergen Street, Newark, NJ 07103, USA
e-mail: sabharsa@umdnj.edu

R.M. Schwend, MD
Department of Orthopaedics,
Children's Mercy Hospital,
2401 Gillham Road, Kansas City,
MO 64108, USA
e-mail: rmschwend@cmh.edu

D.A. Spiegel, MD (✉)
Division of Orthopaedic Surgery,
Children's Hospital of Philadelphia,
Associate Professor of Orthopaedic Surgery,
University of Pennsylvania School of Medicine,
Philadelphia, PA, USA

Honorary Consultant in Orthopaedics
and Rehabilitation, Hospital and Rehabilitation
Centre for Disabled Children,
Janagal, Kavre, Nepal
e-mail: spiegeld@email.chop.edu

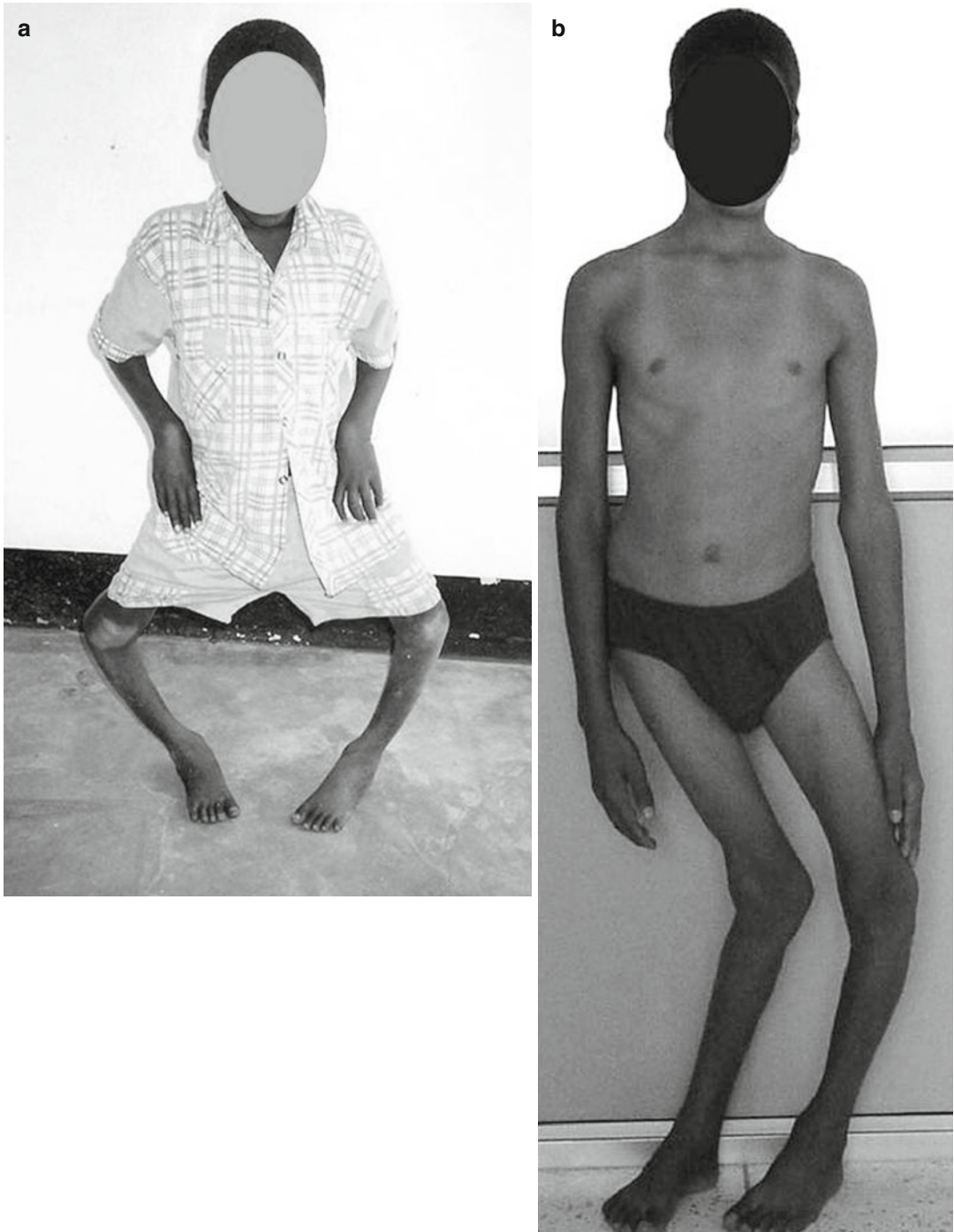

Fig. 37.1 Examples of (a) genu varum and (b) “windswept” limb deformities

Clinical Evaluation of Limb Deformities

The history should identify previous traumatic injuries or infections, and/or medical or nutritional issues, suggesting an underlying metabolic problem. The family history can identify similar limb malalignment in other family members and familial bone diseases. Ask how the patient and family perceive the “problem”: is this purely cosmetic, or is there pain or limitation in activities?

The physical assessment begins with general health and nutrition. Height and weight should be measured and compared with normative data. The lower extremity exam focuses on limb alignment and leg lengths, both assessed while standing with the patellae facing forward. Range of motion of the hip, knee, and ankle joints is measured, as contractures can be sources of apparent limb length discrepancy. Knee joint stability should be tested, as ligamentous laxity can contribute to a varus or valgus moment with weight bearing, often associated with a “thrust” during ambulation.

Radiographs are essential when evaluating a limb deformity, ideally as standing full-length AP (patella pointing forward) and lateral radiographs of both lower extremities. If long cassettes are unavailable, consider separate standing AP and lateral films of both the femur and the tibia/fibula, including the proximal and distal joints in each film. When weight-bearing views are unavailable, knee laxity must be inferred from the clinical exam. Look for physeal widening and other abnormalities seen in rickets or skeletal dysplasia.

Preoperative Planning

The *mechanical axis of the leg* passes from the center of the femoral head, through the medial tibial spine and the center of the ankle joint (Fig. 37.2). The *anatomic axes of the femur and tibia* are drawn parallel to the shaft of each bone. The *mechanical axis of the femur* is drawn as a line from the center of the femoral head to the center of the knee. The mechanical and anatomic axes of the tibia are identical. Tibiofemoral angles can either be anatomic—an angle formed by the intersection of the anatomic axes—or

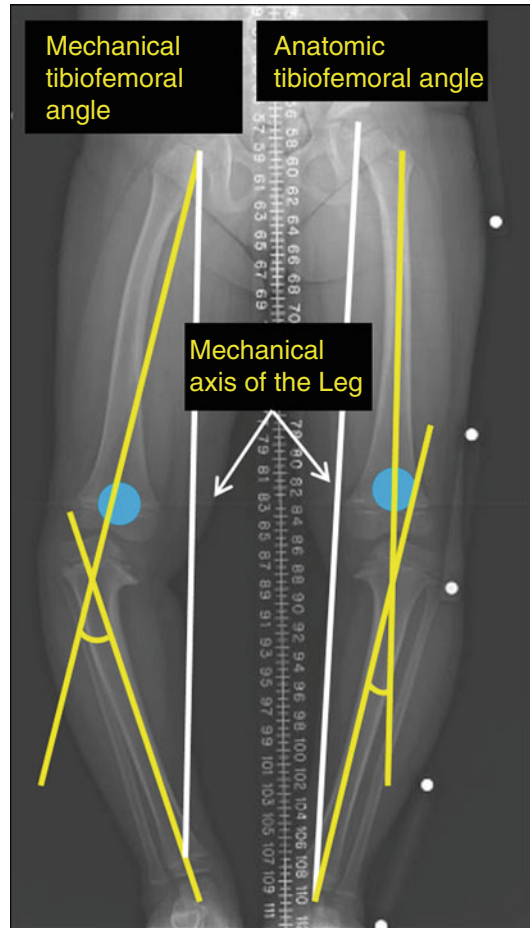


Fig. 37.2 A patient with Blount’s disease is shown to illustrate the mechanical axis and both the mechanical and anatomic tibiofemoral axes. Note that the left patella faces forward while the right is medial and the limb is slightly rotated. The blue circles indicate the location of the patellae

mechanical—an angle formed by the intersection of the mechanical axes. When using the anatomic axes, the value is normally 5–7° valgus. In the sagittal plane, the mechanical axis runs from the center of femoral head to the center of the ankle, passing anterior to the knee joint. This facilitates locking of the knee in extension during stance.

Preoperative planning should:

1. Identify the mechanical axis deviation (in mm from the center of the knee joint)
2. Determine the source of malalignment—femur, tibia, joint laxity, or any combination
3. Define the level of deformity

For simplicity, we will discuss coronal malalignment at the knee, recognizing that varus

or valgus deformities of the proximal femur or the ankle also play a role.

When a deviation in the mechanical axis has been identified, the location of deformity (femur, tibia, and/or joint) can be determined by comparing selected radiographic measurements with normative values or with the contralateral extremity in patients with unilateral involvement (Fig. 37.3a, Table 37.1). These include the tibiofemoral angle, the mechanical (or anatomic) lateral distal femoral articular angle (mLDFA, aLDFA), and the mechanical proximal tibial angle (MPTA). Normative values are also available for sagittal alignment about the knee (Fig. 37.3b), including the anatomic posterior distal femoral angle (aPDFDA) and the posterior proximal tibial angle (PPTA). Most deformities are in fact multiplanar.

Once the location of the deformity in the extremity has been determined, the second step identifies the location of the deformity within the femur or tibia or both. This employs the CORA, or center of rotation of angulation. The CORA is essentially the apex of the deformity and is identi-

fied by drawing both the proximal and distal axes (mechanical or anatomic) to determine their intersection (Fig. 37.4). If they intersect at the site of deformity as seen clinically, it is likely a uni-apical deformity, such as a malunited fracture, and correction would be performed at that location. If the lines do not intersect at the site of deformity, more than one CORA may exist, i.e., a multi-apical deformity or a uni-apical deformity with translation.

Coexisting metabolic problems should be treated before correcting the deformity to limit the chance of recurrence. Hypercalcemia can be a problem in patients with rickets if prolonged immobilization is required.

Surgical Correction of Angular Deformities

Angular deformity correction can be achieved by osteotomy, with acute or gradual correction, or by hemiepiphyseodesis, or guided growth. Most

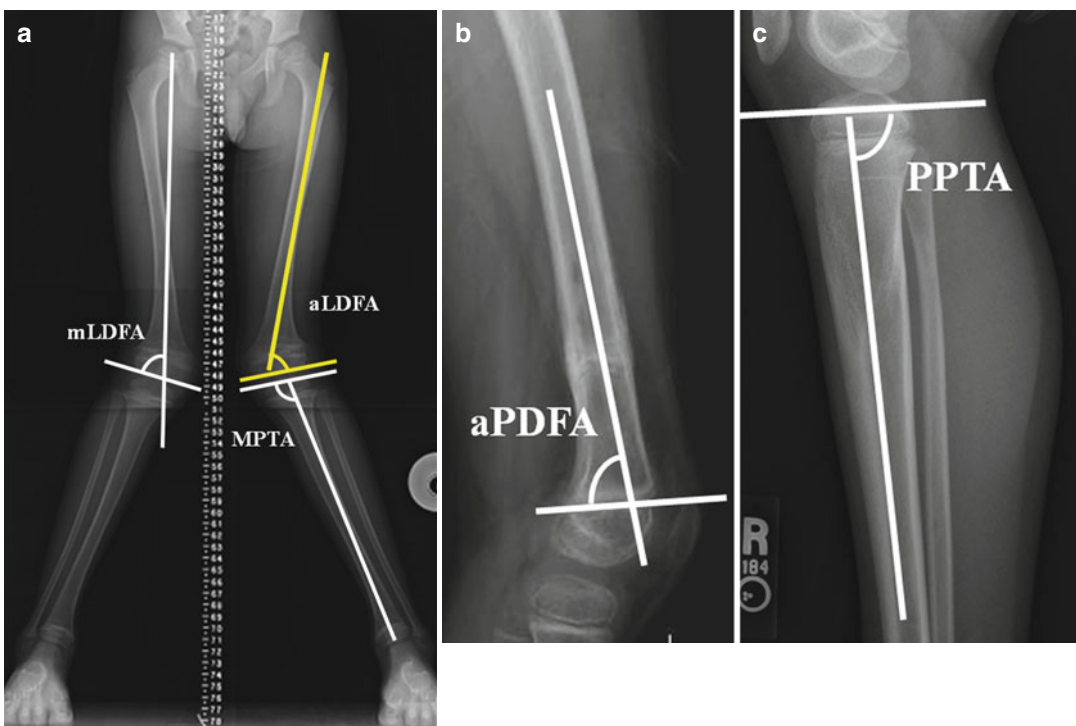


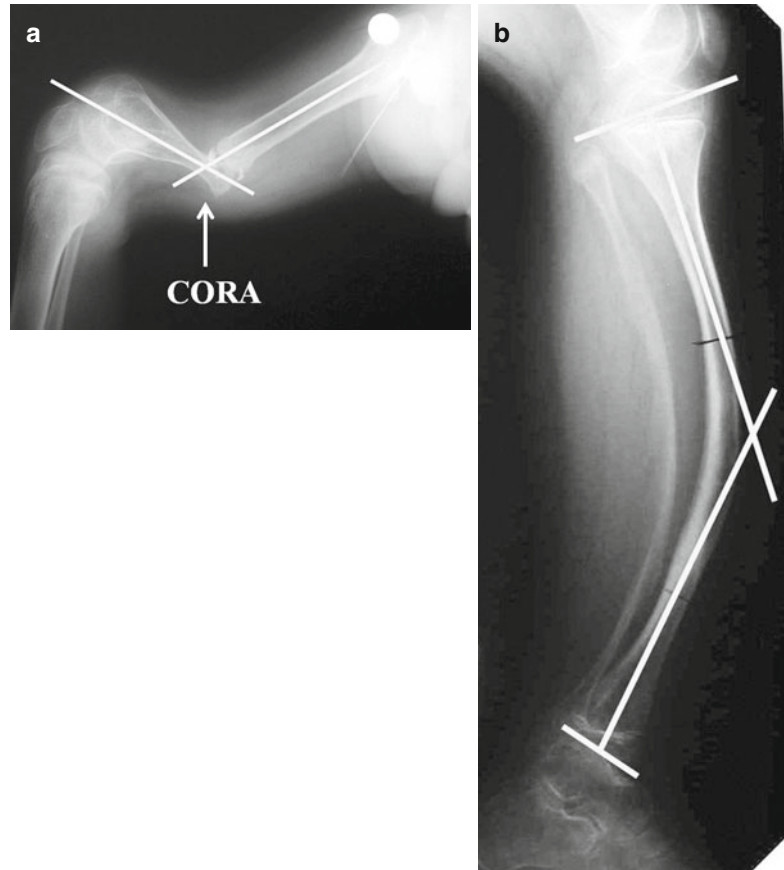
Fig. 37.3 (a) This radiograph of a patient with rickets demonstrates the anatomic (aLDFA) and the mechanical (mLDFA) distal femoral articular angles, as well as the mechanical medial proximal tibial angle (MPTA). (b)

Measurements used to assess deformity in the sagittal plane include the anatomic posterior distal femoral angle (aPDFDA) and the posterior proximal tibial angle (PPTA)

Table 37.1 Analysis of coronal and sagittal alignment

Joint	Measurement	Description	Normal values	Pathologic deviation
Coronal alignment	Mechanical lateral distal femoral angle (<i>mL DFA</i>)	Angle between the mechanical axis of the femur and a line drawn along the distal femoral condyles	88° (85–90°)	↑ = Femoral varus ↓ = Femoral valgus
	Anatomic lateral distal femoral angle (<i>aL DFA</i>)	Angle between the anatomic axis of the femur and a line drawn along the distal femoral condyles	81° (79–83°)	↑ = Femoral varus ↓ = Femoral valgus
	Mechanical medial proximal tibial angle (<i>mM PTA</i>)	Angle between tibial mechanical (anatomic) axis and a line drawn across the proximal tibial joint surface	87° (85–90°)	↑ = Tibial valgus ↓ = Tibial varus
	Joint line congruence angle (<i>JLCA</i>)	Angle between a line drawn along the distal femoral condyles and a line drawn along the proximal tibial joint surface	2° (1–3° medial)	↑ = Varus (wider laterally) ↓ = Valgus (wider medially)
	Anatomic posterior distal femoral angle (<i>aP DFA</i>)	Angle between the mid-diaphyseal line of the distal femur and the sagittal distal femoral joint line (physis or physeal scar)	83° (79–87°)	↑ = Recurvatum ↓ = Procurvatum
Sagittal alignment	Posterior proximal tibial angle (<i>PPTA</i>)	Angle between the proximal tibial articular surface and the mid-diaphyseal line of the tibia	81° (77–84°)	↑ = Recurvatum (more anterior slope) ↓ = Procurvatum (more posterior slope)

Fig. 37.4 The center of rotation of angulation (*CORA*). (**a**) The *CORA* for a transverse fracture lies at the site of deformity (fracture site) versus (**b**) A case of bowing in osteogenesis imperfecta in which the intersection of the mechanical axes of the proximal and distal tibia lies outside or away from the site of clinical deformity



deformities are multiplanar, making a comprehensive assessment of the transverse, sagittal, and axial planes necessary. For instance, a child with Blount's disease typically has genu varum, along with procurvatum and internal tibial torsion secondary to the relative growth inhibition of the posteromedial portion of the proximal tibial growth plate.

Osteotomy

An osteotomy can be made by percutaneous drilling and manual osteoclasis, open drilling, or with an oscillating saw, irrigating to minimize thermal necrosis. Fixation is with crossed K-wires or Steinmann pins, pins in plaster, staples, plating, or external fixation. An opening

wedge osteotomy with bone graft is useful when the limb is short, to gain limb length. Conversely, a closing wedge osteotomy will shorten the limb and does not require a graft. Oblique, dome, and step-cut osteotomies have also been described in chap. 41.

Acute correction $\geq 20\text{--}30^\circ$ carries a higher risk of neurovascular problems including compartment syndrome, especially when correcting genu valgum with a proximal tibial osteotomy. In such cases consider prophylactic release of the common peroneal nerve. Gradual correction by serial casting or external fixation lowers the risk of neurovascular complications.

If an osteotomy is made at the level of the *CORA*, ideally the deformity can be corrected by an opening or closing wedge osteotomy, as only angulation is required to restore the mechanical

axis, i.e., no additional translation is needed. An example is a malunited transverse diaphyseal fracture of the tibia where the osteotomy would be performed at the fracture site. In contrast, when the osteotomy is made away from the CORA, both angulation and translation are needed to restore the mechanical axis. An example is juvenile Blount's disease, in which the CORA is at the level of the physis, but the osteotomy is performed distal to the CORA to prevent iatrogenic physal arrest.

Hemiephysiodesis

An alternative to an osteotomy is either a permanent or reversible hemiephysiodesis. This option is for milder deformities and requires >1–2 years of remaining growth. A correction of 0.5–1° per month can be anticipated, but the speed of correction depends upon the growth potential of that particular physis, which may be less in patients approaching skeletal maturity and in those with skeletal dysplasias. Guided growth treatment can slow overall longitudinal growth of the affected bone, but limb lengths must be carefully monitored to achieve a satisfactory result.

Permanent hemiephysiodesis involves a partial surgical growth arrest by open or percutaneous techniques. A major challenge is predicting the most appropriate time to perform the procedure in younger patients. In the open technique (Phemister), the physis is exposed and a window of bone and physis is removed to 1 cm. depth. The segment is rotated 180° and replaced, or a segment of metaphyseal bone is placed in the defect. For patients with <2 years growth remaining, permanent partial physal closure may be more desirable than a reversible procedure.

Reversible hemiephysiodesis, or “guided growth,” involves an extra-periosteal tether, staple or plate, across the physis. This is removed once the deformity has been corrected. This makes the issue of timing less relevant as long as sufficient growth remains, although resumption of growth following implant removal can be

unpredictable. Gradual correction by “guided growth” has lower morbidity than osteotomy and can be performed as an outpatient. Follow-up must be assured, as the implant needs to be removed when correction has been achieved, and overcorrection is a risk especially in younger children.

Typically, three non-barbed staples are used, spanning the physis in the distal femur and/or proximal tibia, or a single plate perpendicular to the physis with one screw above and one below (Fig. 37.5). Screw lengths are generally less than 50% of the width of the bone at that level. Staples have a greater risk of fracture or migration than plates, especially with staples made of contoured Steinmann pins or K-wires. The plate must be oriented centrally in the anterior-posterior plane to avoid inducing a sagittal plane deformity. In austere environments, a small plate cut to two to three holes may suffice (Fig. 37.6). In the absence of an image intensifier, a K-wire or a needle, confirmed with an intraoperative X-ray, can localize the physis. Avoid direct exposure of the physis or the perichondral ring, as a permanent growth arrest can occur. Rebound growth must be anticipated, and overcorrection of 3–5° may be indicated in children with sufficient growth remaining.

Bowing of the Lower Leg

Anterolateral bowing of the tibia, in which the apex is directed anteriorly and laterally, is usually noted soon after birth and often leads to progressive angulation and a fracture that is recalcitrant to healing. More than half the patients with this deformity have type I neurofibromatosis, and other manifestations of this disease should be sought (Fig. 37.7). This type of tibial bowing carries a poor prognosis and the family should be counseled accordingly. Nonoperative management using a total contact brace with an anterior shell may delay or prevent a fracture. A tibial osteotomy pre-fracture should be avoided as there is a high likelihood of nonunion. Once there

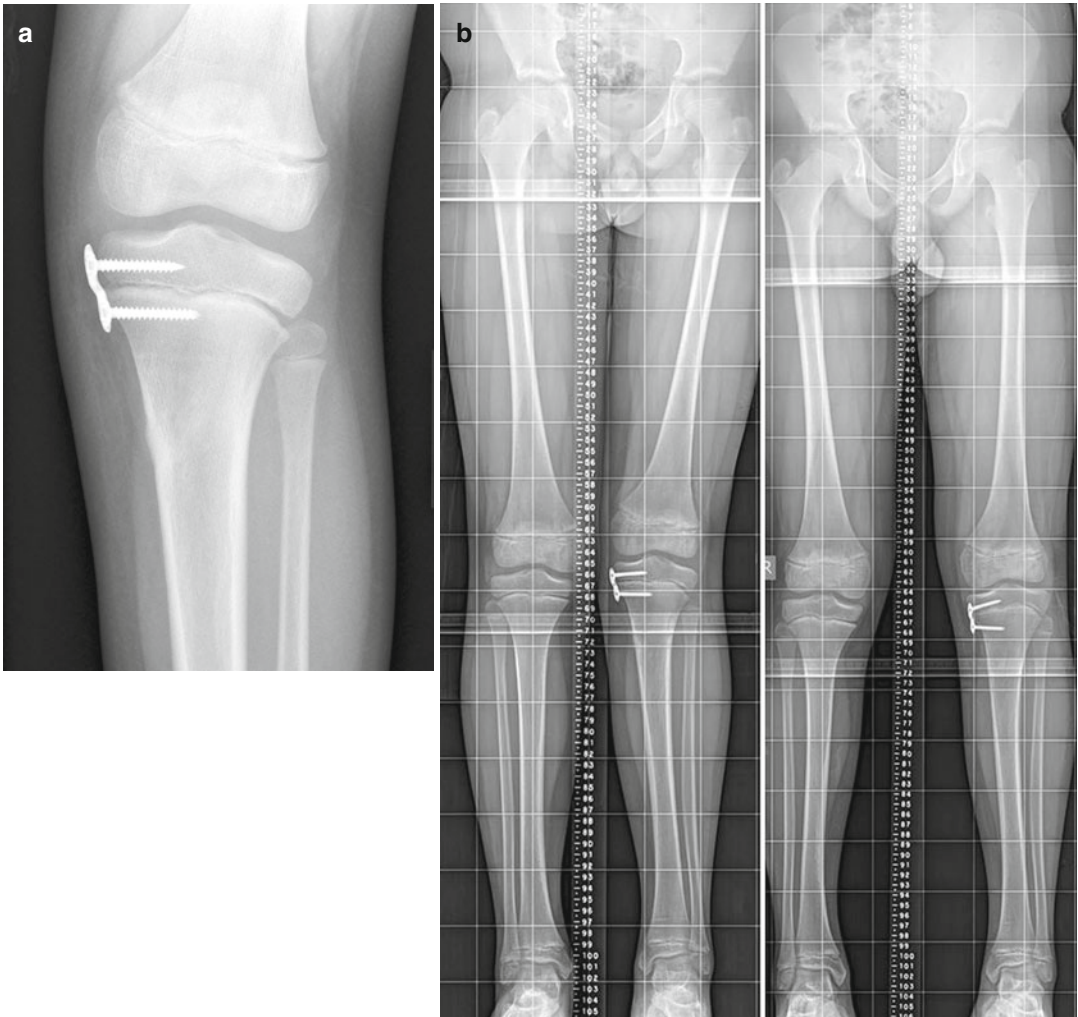


Fig. 37.5 A 12 year old male presented 10 months after a left proximal tibial metaphyseal fracture that developed progressive valgus angulation. (a) A growth tether was created by placing a small plate with 2 screws. (b) standing radiographs immediately after this “guided growth”

procedure, (left) and after 18 months (right) at which time the plate and screws were removed. Note the widened distance between screw tips, showing the differential growth and the resolution of the deformity

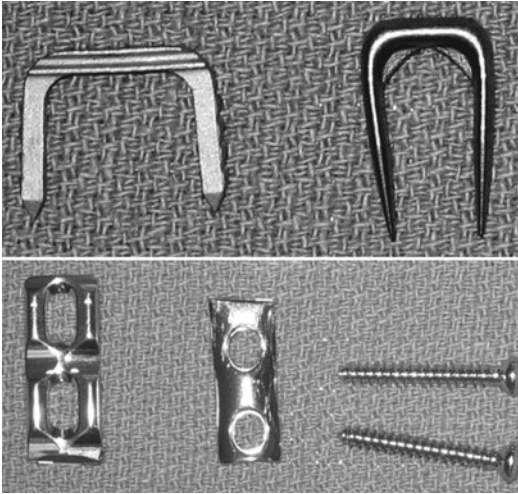


Fig. 37.6 Options for guided growth include staples and plates. In the absence of commercially available plates, implants such as a reconstruction or semi-tubular plate can be cut and secured with cortical screws

is an established fracture, the goal is to obtain and maintain union at the pseudarthrosis, using sound biologic and mechanical principles.

Commonly used surgical techniques include resection of the pseudarthrosis with realignment and/or stabilization using either intramedullary fixation with autologous bone graft, with or without a circumferential periosteal graft from the iliac crest, bone transport with distraction osteogenesis along with prophylactic intramedullary fixation, or vascularized fibular strut grafting. In some refractory cases, amputation may be necessary and the family should be informed of this possibility at the time of diagnosis.

A *posteromedial bowing* deformity, apex posterior and medial, of the tibia is almost always noted at birth and is associated with a calcaneovalgus foot deformity. This congenital anomaly has a relatively benign natural history with progressive improvement and mild residual angulation noted at skeletal maturity (Fig. 37.8). However, the affected tibia grows more slowly than the contralateral side, requiring treatment for leg length discrepancy with either a contralateral epiphysiodesis or an ipsilateral limb lengthening with or without deformity correction.

Anteromedial bowing of the lower leg is often associated with longitudinal deficiency of the fibula (Fig. 37.9). Further evaluation often reveals skin dimpling at the apex of the tibial deformity, absence of one or more lateral rays of the foot, hindfoot valgus, and limb shortening. Besides tibial radiographs, a full-length AP radiograph of both lower extremities is useful as the deformity is often associated with congenital shortening or bowing of the femur and hypoplasia of the lateral condyle. The tibial deformity and the leg length discrepancy tend to increase with growth. Based on the anticipated function of the foot and projected limb length discrepancy at skeletal maturity, as well as psychosocial factors and cultural norms, the limb can be lengthened with angular correction or amputated.

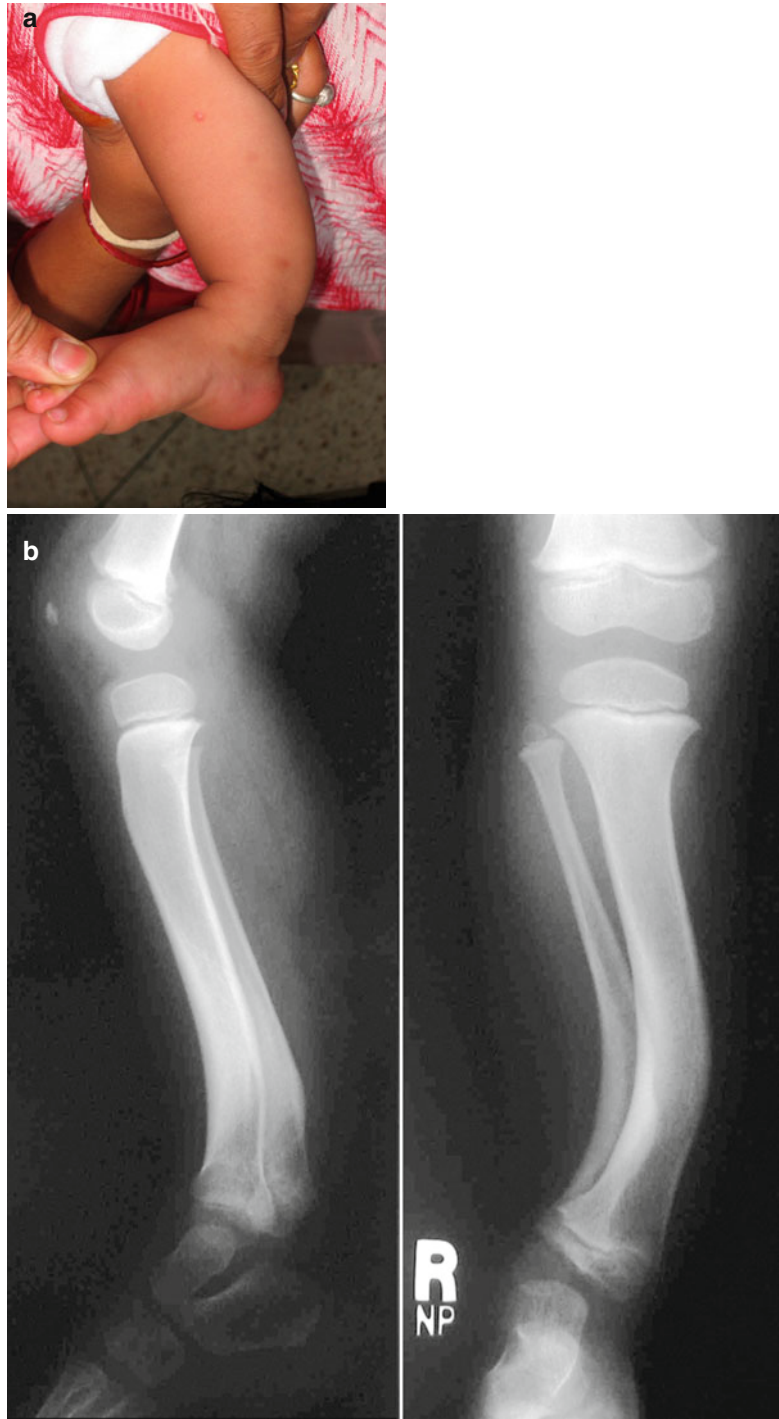
We must emphasize that reconstructive options are labor intensive and require months of active treatment. They should only be considered when adequate local capacity is present to continue the treatment and follow-up.

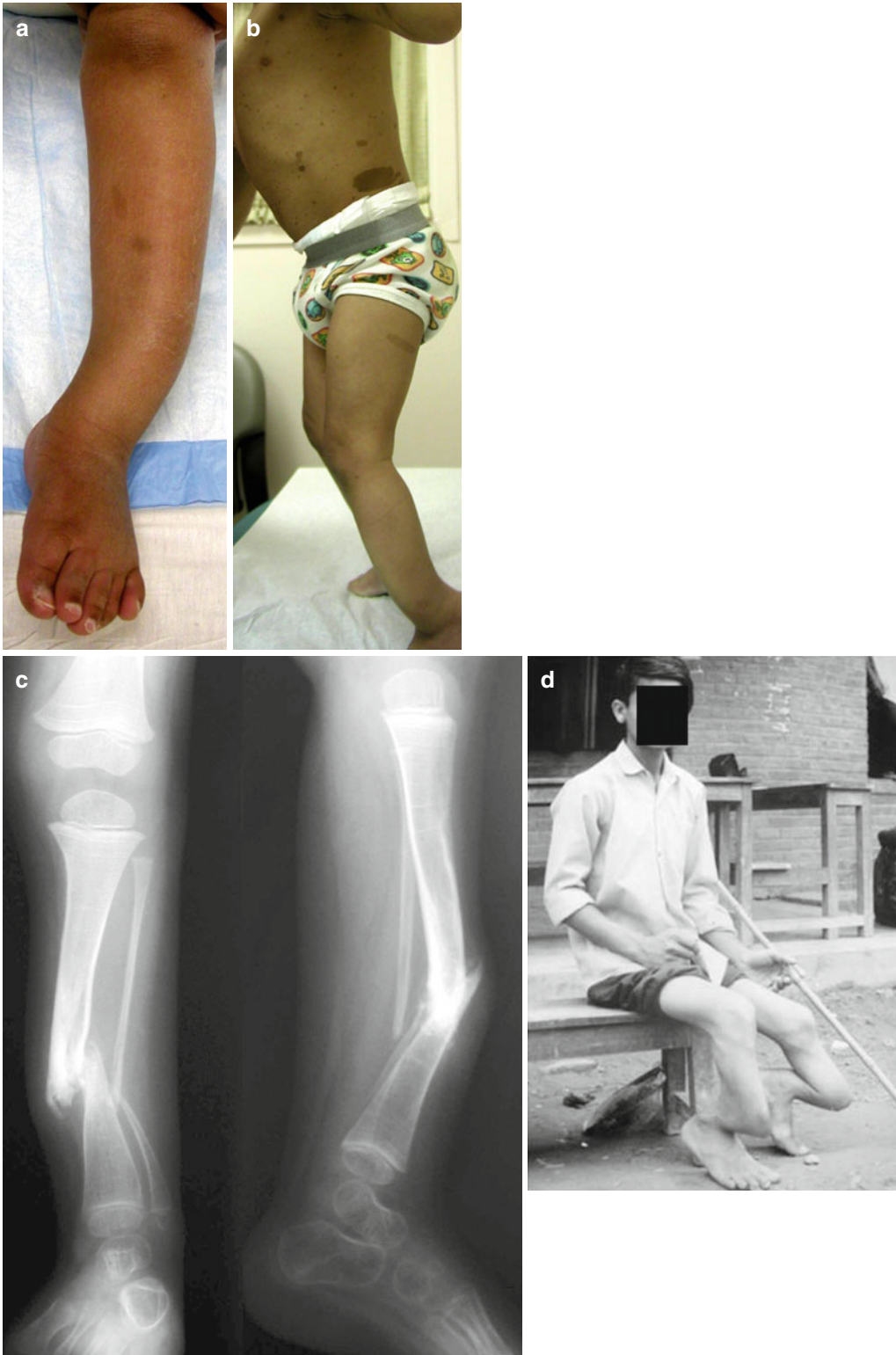

Fig. 37.7 (a) An 18-month-old with anterolateral bowing of the tibia had (b) multiple café au lait skin lesions on his trunk consistent with the diagnosis of type 1 neurofibromatosis. (c) X-ray findings in severe congenital pseud-

arthrosis of the tibia and fibula with fracture and (d) clinical example of a neglected bilateral congenital pseudarthrosis with severe angular deformity

Fig. 37.8 (a, b) Clinical and radiographic findings associated with posteromedial bowing of the tibia



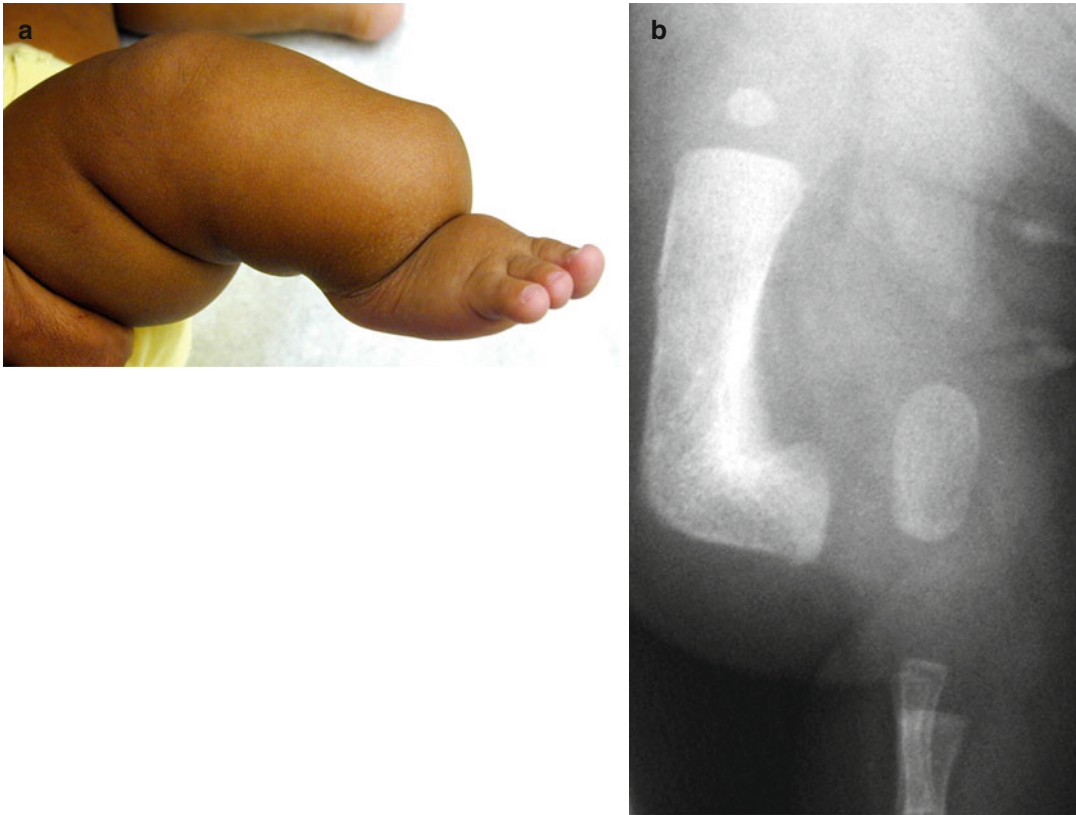


Fig. 37.9 (a, b) Clinical and radiographic appearance of a child with anteromedial bowing associated with longitudinal deficiency of the fibula

Suggested Reading

- Paley D. Principles of deformity correction. Heidelberg: Springer; 2002.
- Paley D, Herzenberg JE, Tetsowrth K, et al. Deformity planning for frontal and sagittal plane corrective osteotomies. *Orthop Clin North Am.* 1994;25:425.
- Sabharwal S. Blount disease. *J Bone Joint Surg Am.* 2009;91:1758–76.
- Sabharwal S, Zhao C. The hip-knee-ankle angle in children: reference values based on a full-length standing radiograph. *J Bone Joint Surg Am.* 2009;91:2461–8.
- Saran N, Rathjen KE. Guided growth for the correction of pediatric lower limb angular deformity. *J Am Acad Orthop Surg.* 2010;18:528–36.
- Stevens PM, Maguire M, Dales MD, et al. Physeal stapling for idiopathic genu valgum. *J Pediatr Orthop.* 1999;190:645–9.
- Wiemann 4th JM, Tryon C, Szalay EA. Physeal stapling versus 8-plate hemiepiphysiodesis for guided correction of angular deformity about the knee. *J Pediatr Orthop.* 2009;29:481–5.

Richard M. Schwend

Introduction

Developmental dysplasia of the hip (DDH) encompasses a spectrum of physical and imaging findings from mild instability to frank dislocation. DDH is usually asymptomatic during infancy and early childhood, making a careful and specific physical examination critical. An early diagnosis markedly improves the prognosis, and health workers caring for newborns and infants should be trained to screen their hips.

The incidence varies from 1.5 to 25 per 1,000 live births, and risk factors include breech position, female, first born, and positive family history. The risk is increased in cultures that tightly swaddle infants with their hips extended (Fig. 38.1). In Africa infants are routinely carried with their hips abducted and DDH is uncommon (Fig. 38.2).

The natural history of instability noted in the first few weeks of life is typically benign, and many cases resolve by 8 weeks. Conversely, the natural history of a child with a hip that is dysplastic or dislocated by walking age is poor. Looseness within the acetabulum is *instability*,

nonconcentric position is *subluxation*, and deformity of the femoral head and acetabulum is *dysplasia*.

With time, the child with DDH develops a limp, limb length discrepancy, and limited hip abduction. With bilateral dislocations the patient will have lumbar hyperlordosis in addition to an abductor lurch (Fig. 38.3). With maturity the patient can develop painful, early onset degenerative arthritis. Often subluxation is not as well tolerated as frank dislocation. Patients with balanced bilateral hip dislocations, or those

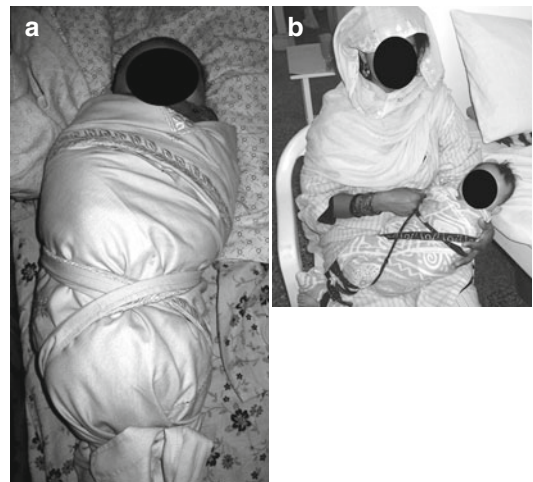


Fig. 38.1 (a, b) Tight swaddling, in which the hips are forcefully maintained in extension and adduction, increases the risk of DDH

R.M. Schwend, MD (✉)
Department of Orthopaedics,
Children's Mercy Hospital,
2401 Gillham Road, Kansas City, MO 64108, USA
e-mail: rmschwend@cmh.edu



Fig. 38.2 (a, b) Carrying an older infant or young child on the back with hips abducted encourages healthy development of the hip (b Courtesy of Byron McCord, MD)

who have not yet formed a false acetabulum, may have many years of pain-free ambulation.

Clinical Assessment

The physical exam in infants focuses on instability (Ortolani and Barlow maneuvers), whereas the exam in children older than 3 months identifies secondary changes including loss of passive abduction, shortening of the thigh with or without an extra thigh fold (Fig. 38.4), and leg length discrepancy or limp. The Ortolani maneuver gently reduces the subluxated or dislocated femoral head into the acetabulum by hip abduction. This

maneuver begins with the hip in an adducted position. The examiner's hand holds the thigh loosely, with the index and middle fingers on the area of the greater trochanter, and the thumb along the medial thigh. The hip is gently abducted while applying an anteriorly directed force through the trochanteric region, sensing whether the hip reduces. The Barlow maneuver assesses whether a reduced hip can be displaced by placing the hip in adduction and gently applying a posteriorly directed force to the proximal anterior thigh.

Plain radiography becomes useful by 4–6 months of age, when the femoral head's secondary center of ossification forms. Radiographic hip screening should be considered for the infant

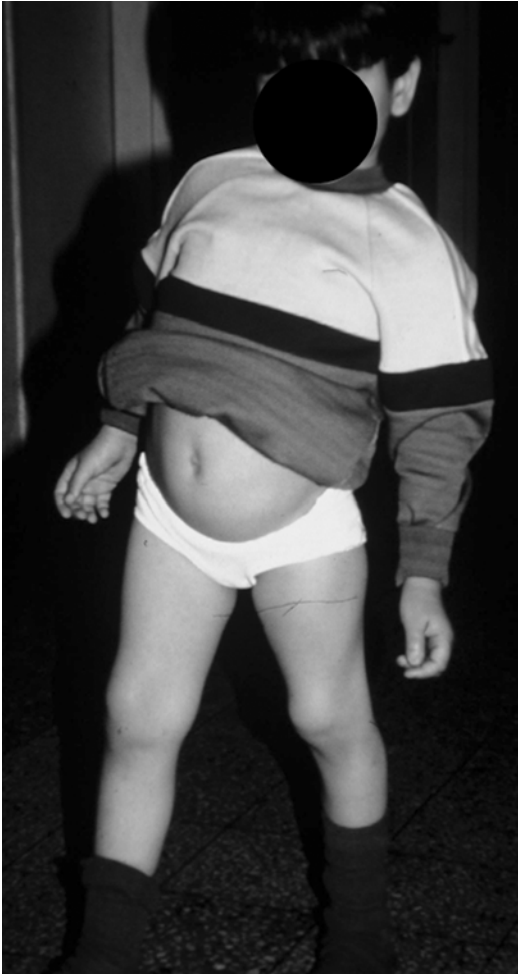

Fig. 38.3 This boy with bilateral DDH ambulates with an abductor lurch on both sides, in which his trunk shifts laterally over each hip during stance phase. He also has increased lumbar lordosis because of coexisting hip flexion contractures, noted by his protuberant abdomen

with risk factors for DDH or if diagnoses such as congenital short femur, proximal focal femoral deficiency, septic arthritis, or coxa vara are suspected. Ideally, screening suspected cases is by ultrasound.

Treatment

Early diagnosis and referral of DDH facilitates treatment by nonoperative measures. This is rarely achieved in austere environments, If

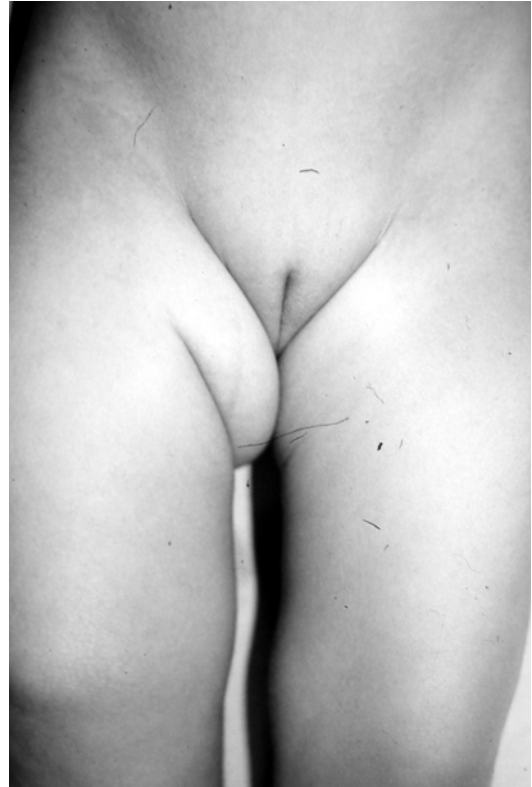

Fig. 38.4 Extra thigh fold on right from femoral shortening associated with dislocation

the diagnosis is established shortly after birth, treatment with a hip abduction device, such as a Pavlik harness, is recommended and can be used for infants up to 6 months. Bracing requires weekly monitoring, and is discontinued after 2-3 weeks if a reduction cannot be achieved. Forced abduction should be avoided given the high risk of avascular necrosis. If bracing fails, or if excessive abduction is required to achieve reduction, a closed or open reduction and casting should be considered.

Between 6 and 24 months, closed reduction with percutaneous adductor tenotomy and a spica cast is often effective. The cast is typically worn for 3 months, after which nighttime splinting is used for a variable period. Risks of bracing, casting, and surgical treatment include stiffness, avascular necrosis (AVN), nonconcentric reduction, redislocation, and femoral nerve palsy.

Patients in austere environments commonly present after walking age with a leg length

Fig. 38.5 (a) High bilateral hip dislocation with extreme acetabular and femoral head dysplasia in an older child should be left alone. (b, c) This unilateral dislocation in a younger child was treated surgically

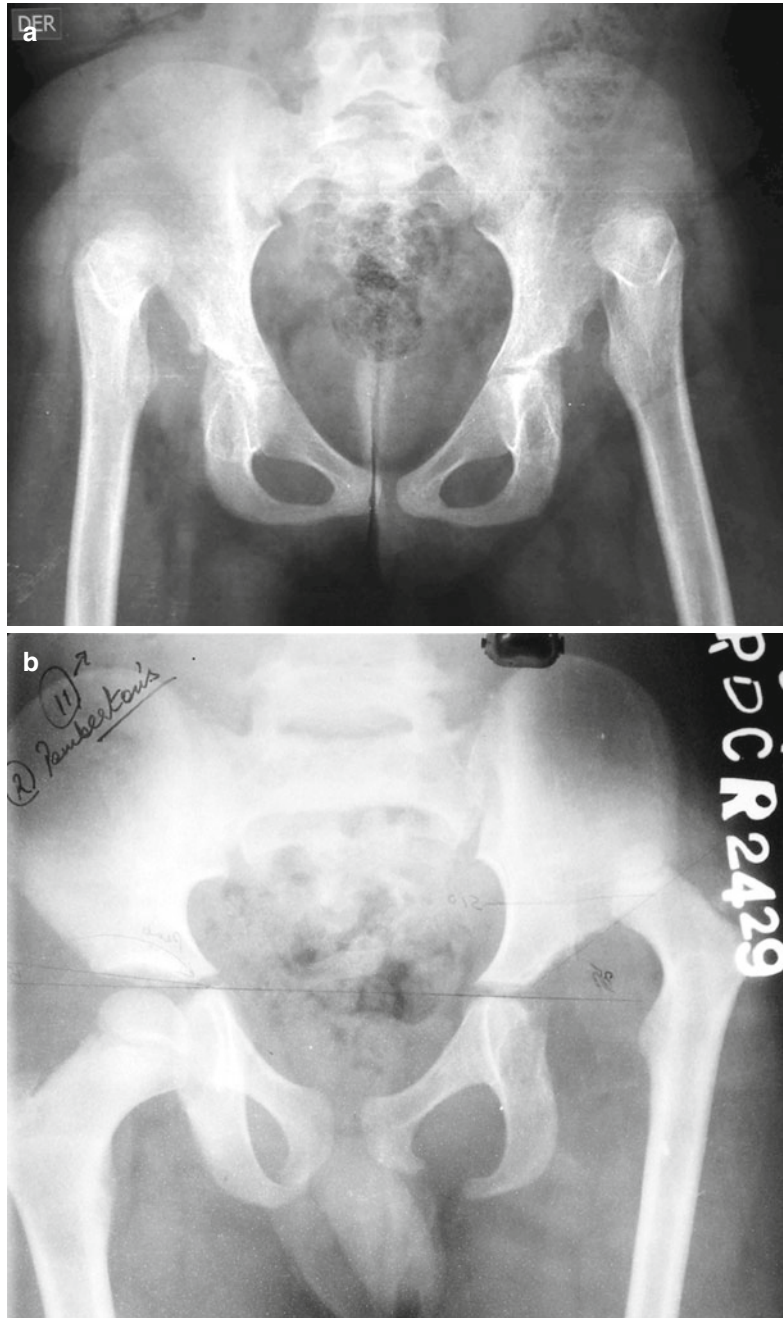
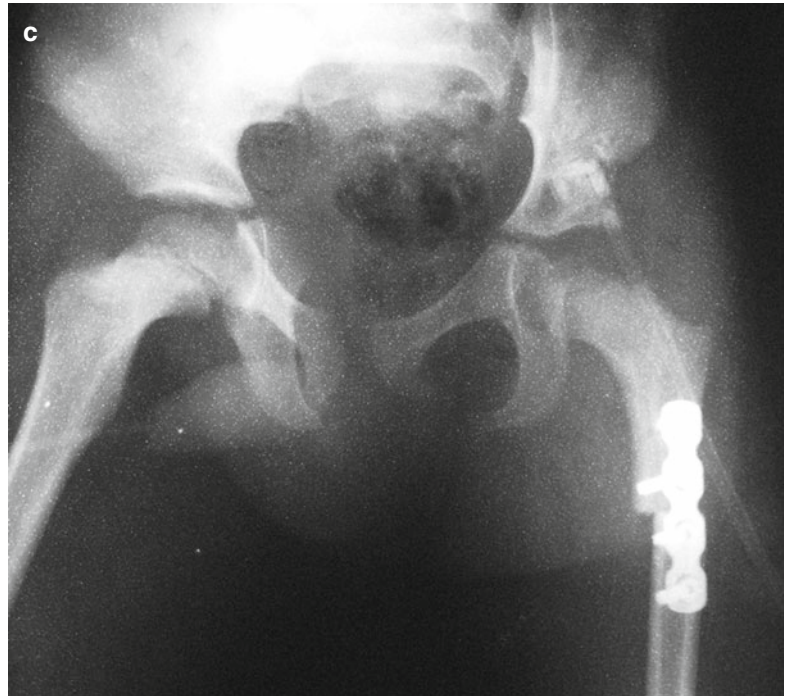


Fig. 38.5 (continued)

discrepancy and limp. At this point, an extensive surgical procedure is required. Usually this involves an open reduction of the hip with a capsulorrhaphy, femoral shortening osteotomy, and often a pelvic osteotomy (Fig. 38.5).

The open reduction component removes barriers to a concentric reduction of the femoral head within the acetabulum, and includes releasing the medial capsule and transverse acetabular ligament, and removing the ligamentum teres and any pulvinar. Femoral shortening reduces the risk of AVN, and an intraoperative assessment of the degree of femoral anteversion will determine whether, and to what degree, anteversion should be corrected. Femoral version varies considerably in patients with DDH, so no uniform recommendations can be made. Pelvic osteotomies include the Salter (redirectional) and the Pemberton (volume reducing). These procedures are technically demanding and complications such as stiffness, osteonecrosis, or redislocation can result in outcomes that are

inferior to observation alone (Fig. 38.6). Half of surgically reduced hips require further surgery, and repeat surgery in the older child is associated with poor results.

While there are no exact age criteria for when to surgically reduce a developmentally dislocated hip, we suggest that surgical reduction be avoided in patients older than 4–5 years with bilateral dislocations, and older than 7–8 years with a unilateral dislocation.

In settings with limited resources, lack of expertise, and inadequate followup, the volunteer surgeon should not perform this highly technical surgery in the older child with a dislocated hip, especially if there has been previous failed surgery or there is osteonecrosis. However, developing a trusting long-term relationship between an experienced visiting surgeon or organization and a committed and well-trained local surgeon can be an effective team to provide this high level of specialty care.

Fig. 38.6 (a) Open reduction and femoral shortening complicated by redislocation. (b) Successful closed reduction was complicated by avascular necrosis and deformity of the femoral head. (c) Chronic redislocation treated by pelvic support osteotomy

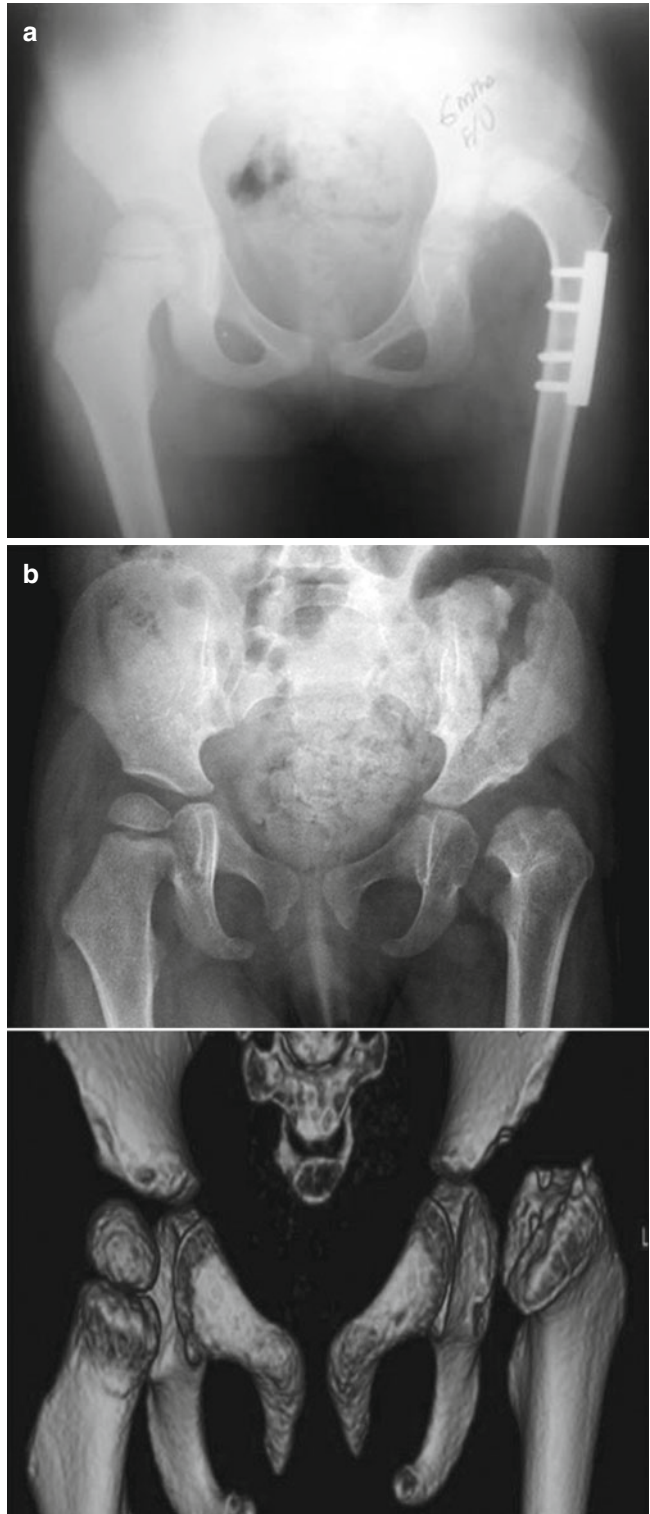
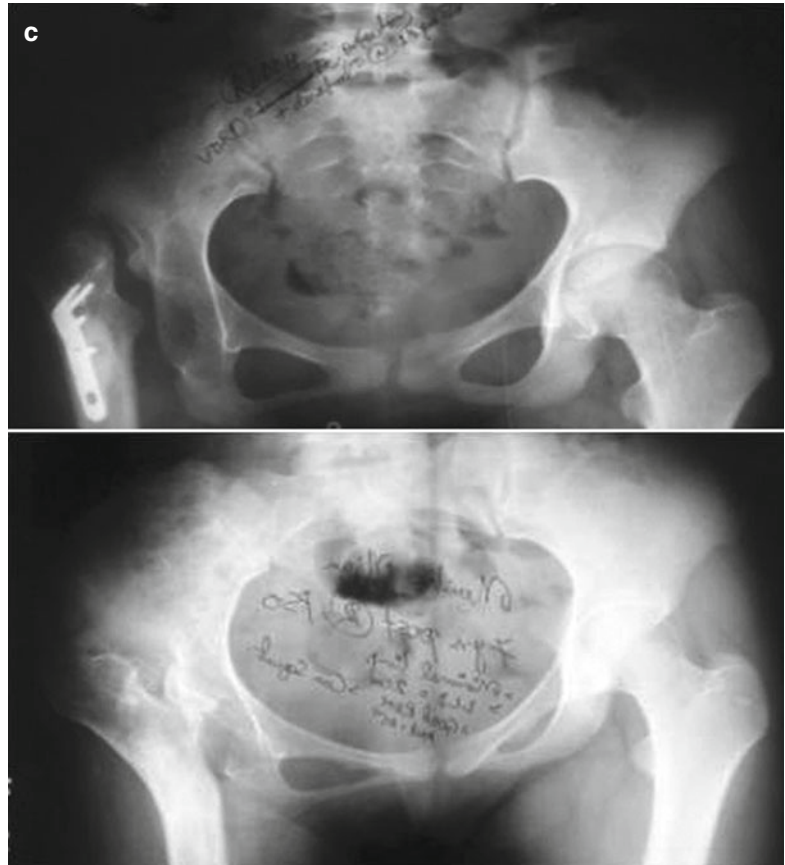


Fig. 38.6 (continued)

Suggested Reading

- Barlow TG. Early diagnosis and treatment of congenital dislocation of the hip. *J Bone Joint Surg Br.* 1962;44B:292–301.
- Holman J, Carroll KL, Murray KA, Macleod LM, Roach JW. Long-term follow-up of open reduction surgery for developmental dislocation of the hip. *J Pediatr Orthop.* 2012;32:121–4.
- International Hip Dysplasia Institute [Internet]. 2012. Available from: <http://www.hipdysplasia.org>.
- Jones DA. Neonatal hip stability and the Barlow Test. *J Bone Joint Surg Br.* 1991;73B:216–8.
- Moseley CF. Developmental hip dysplasia and dislocation. Management in the older child. *Instr Course Lect.* 2001;50:547–53.
- Scoles PV, Boyd A, Jones PK. Radiographic parameters of the normal infant hip. *J Pediatr Orthop.* 1987;7:656–63.

J. Norgrove Penny, John Ekure, David A. Spiegel,
and Hugh G. Watts

Postinjection Injuries

Introduction

Injection-induced injury (postinjection paralysis or PIP) during childhood is common, increasing in incidence, and has been called the “new polio” of Africa. The most common clinical scenarios are (1) foot drop, (2) equinovarus, (3) buttock abscess, (4) gluteal fibrosis, and (5) quadriceps fibrosis. Injection injury is more likely in newborns and small babies where the skin and nerve are in closer proximity than in older children. Many of the intramuscular injections given annually in developing

countries are unnecessary, yet are administered due to patient or family demand and caregiver overprescription. There is a prevalent belief in traditional settings that painful injections are more powerful and effective, even when adequate oral substitutes are readily available.

In most African languages the words for “fever” and “malaria” are identical, and all children with fevers are considered to have malaria. The usual history for PIP is of a young child presenting with a febrile illness who receives a quinine injection into the buttock for suspected malaria, even though the oral or rectal alternatives are equally as effective. Quinine is neurotoxic, can cause local tissue necrosis, and is painful when injected.

The child experiences immediate neurogenic pain, hypoesthesia, and weakness or paralysis of the foot on the side of the injection, or symptoms can develop gradually over a week. While recovery is possible and typically progresses slowly over several months, permanent residual paralysis is common. The peroneal branch of the sciatic nerve, which lies lateral to the popliteal branch, is more vulnerable.

The following muscles are affected, in the order from most common to least common: toe

J.N. Penny, MD, FRCS(C)
CBM International, Nibelungenstrasse 124,
Bensheim, 64625, Germany
e-mail: norgroveanne@hotmail.com

J. Ekure, MBChB, MMed (Ortho), Mak, FCS
Department of Orthopaedic Surgery,
Kumi Orthopaedic Center,
Malera Road, Plot 26-0, Kumi, Uganda
e-mail: drjohnekure@gmail.com;
kumiorthocenter@gmail.com

D.A. Spiegel, MD (✉)
Division of Orthopaedic Surgery,
Children’s Hospital of Philadelphia,
Associate Professor of Orthopaedic Surgery,
University of Pennsylvania School of Medicine,
Philadelphia, PA, USA

Honorary Consultant in Orthopaedics and Rehabilitation,
Hospital and Rehabilitation Centre for Disabled Children,
Janagal, Kavre, Nepal
e-mail: spiegeld@email.chop.edu

H.G. Watts, MD
Department of Orthopedic Surgery,
Shriners Hospitals for Children,
Los Angeles Unit, 3160 Geneva St,
Los Angeles, CA 90020, USA
e-mail: hwatts@ucla.edu

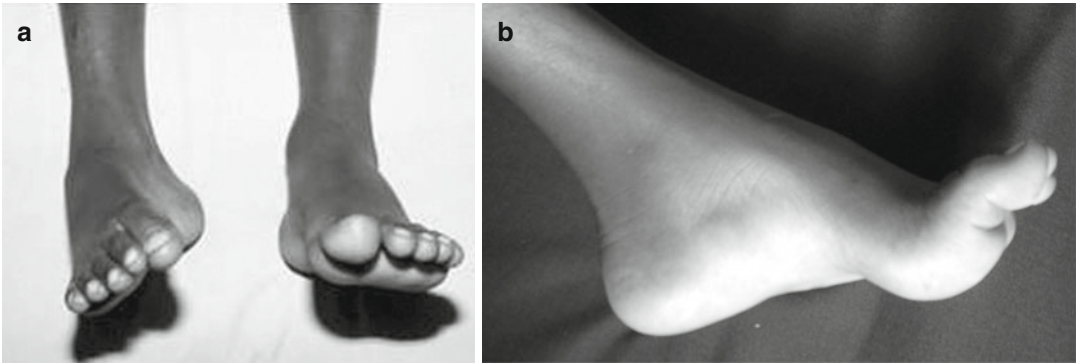


Fig. 39.1 (a, b) The typical appearance of foot drop following injection injuries. In these cases the deformities were mild and flexible on examination

extensors, tibialis anterior, peroneals, tibialis posterior, toe flexors, and gastrosoleus. There should be a sensory deficit in the first dorsal web space. Many children develop a buttock abscess after injection which can lead to muscle necrosis, fibrosis, and gluteal contracture.

Injection injury is most commonly confused with acute poliomyelitis. To differentiate, polio commonly retains function of the extensor hallucis longus, often shows weakness of quadriceps or glutei, and more importantly, has no sensory deficits.

Treatment of Foot Drop

Foot drop can be flexible or associated with varying degrees of fixed equinus contracture with or without varus (Fig. 39.1). Flexible deformities present as impaired clearance during swing phase. Patients with fixed equinovarus bear weight on the lateral or dorsal aspects of the foot. Trophic ulcers can develop on the insensate weight-bearing surfaces (Fig. 39.2). Varus is secondary to peroneal weakness or paralysis with normally functioning toe flexors, with or without a normally functioning tibialis posterior. The tibialis posterior strength must be carefully assessed before it is transferred.

A surgical algorithm has been developed by the first author (JNP) for postinjection foot drop, based on experience in Uganda (Table 39.1). Important pretreatment considerations include (1) state of heel varus, (2) presence of full pas-

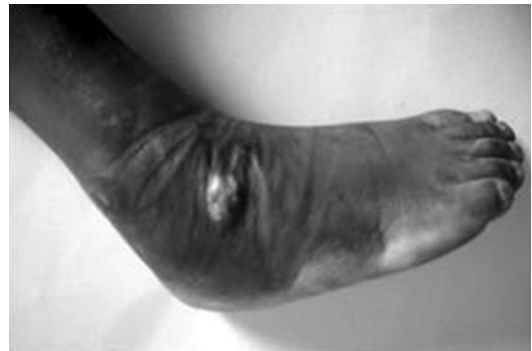

Fig. 39.2 Trophic ulcer in an insensate area of the foot in a patient with PIP

sive range of motion, and (3) function of tibialis posterior.

A *flexible foot drop* can be treated with an ankle-foot orthosis (AFO). Routine posterior tibial tendon transfer is recommended, if its strength is grade 4–5, to restore muscle balance and minimize or eliminate the need for an orthosis. We suggest that the posterior tibialis be brought subcutaneously to the dorsum and into a tunnel in the third cuneiform (Fig. 39.3) or sutured to the peroneus tertius. Transfer through the interosseous membrane is vulnerable to adhesions and may function as a tenodesis. When fixed deformity is present, preliminary soft tissue release, osteotomy, or arthrodesis may be necessary before tendon transfer.

Subtalar stabilization should be performed in all cases of tibialis posterior tendon transfer to prevent the foot from collapsing into

Table 39.1 Treatment options for common foot deformities associated with poliomyelitis

Deformity	Causes	Treatment options
Equinus	1. Weak DF (TA, EHL, EDC, PB) 2. Strong PF (GS, FHL, FDL)	1. Gastrosoleus lengthening
Equinovarus	1. Weak DF/EV (TA, EHL, EDC, peroneals) 2. Strong PF/IV (GS, FHL, FDL, TP)	1. TA transfer to middle cuneiform 2. TP transfer to third cuneiform 3. Subtalar stabilization
Equinovalgus	1. Weak DF/INV (TA) 2. Strong PF/EV (GS, TP, EHL, EDC, FHL, FDL, peroneals)	1. Gastrosoleus lengthening 2. Transfer of peroneal tendons to dorsum of foot 3. Subtalar stabilization
Calcaneus or calcaneocavus	1. Weak PF [GS] 2. Strong DF/INV or EV	1. Ankle-foot orthosis 2. GS weak or absent: consider transferring all available muscles to calcaneus (PL, PB, TP, FHL) 3. Tenodesis of the tendoachilles to the fibula 4. Calcaneal osteotomy or triple arthrodesis
Cavovarus	1. Weak DF/EV [TA, peroneals] 2. Strong PF/INV (GS, TP, FHL, FDL ± EHL, EDC)	1. STR (percutaneous TAL, PF release) 2. TP posterior transfer to dorsum of foot 3. Subtalar stabilization 4. Transfer EHL to first metatarsal neck (Jones)

Abbreviations: DF dorsiflexion, PF plantar flexion, INV inversion, EV eversion, TA tibialis anterior, PT tibialis posterior, GS gastrosoleus, PL peroneus longus, PB peroneus brevis, EHL extensor hallucis longus, FHL flexor hallucis longus, EDC extensor digitorum communis, FDL flexor digitorum longus, PF plantar fascia, STR soft tissue release

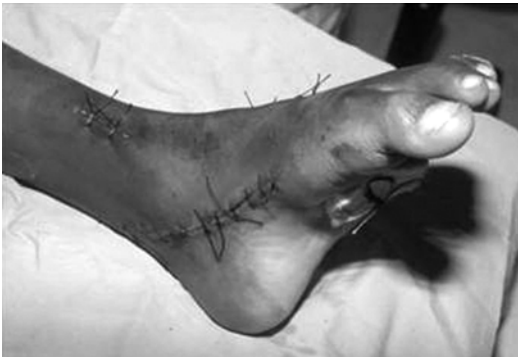

Fig. 39.3 The tibialis posterior is transferred subcutaneously, inserted through a drill hole into the third cuneiform, and secured with a suture through a button on the plantar surface of the foot

planovalgus. In children under about 10 years, we recommend an extra-articular technique (Grice-Green or Dennyson-Fulford). The Dennyson-Fulford, performed using cortico-cancellous graft with internal fixation, produces more predictable results in our experience. A full preoperative range of subtalar motion is needed; otherwise, a posteromedial soft tissue release is necessary. A triple arthrodesis should be performed in adolescents and adults,

with the advantage of making medial soft tissue release unnecessary and allowing superior correction in very stiff cases. If a bony procedure is needed, some surgeons prefer to stage the tendon transfer, to minimize disuse atrophy from prolonged casting.

With an isolated soft tissue release or tendon transfer, patients require 4–6 weeks cast immobilization followed by an AFO. Bony procedures require 8–12 weeks immobilization. Physiotherapy for tendon reeducation is necessary immediately after cast removal, and the AFO can often be discontinued when rehabilitation is completed, usually after 6 months.

Gluteal and Quadriceps Fibrosis

Fibrosis of the gluteal and/or the quadriceps muscles is caused by injections into the muscles, often multiple. Numerous drugs have been implicated, but quinine is a potent producer of muscle necrosis and subsequent fibrotic contracture.

Children with gluteal fibrosis show muscle wasting and walk with the hips externally rotated (Fig. 39.4). They cannot sit comfortably or squat

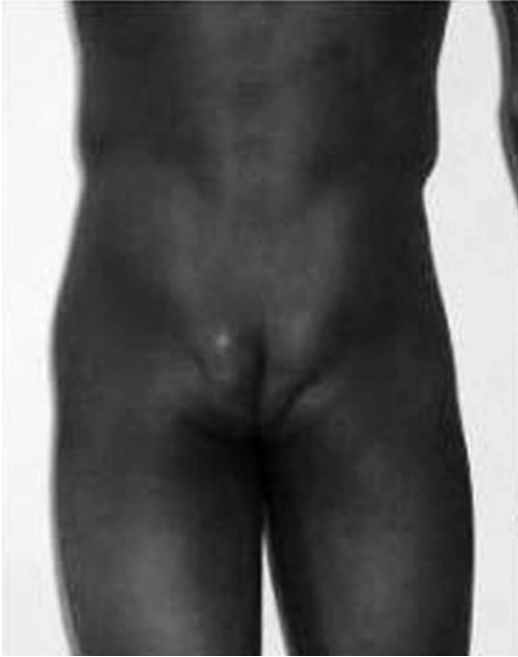

Fig. 39.4 Patient with gluteal fibrosis and marked muscle atrophy

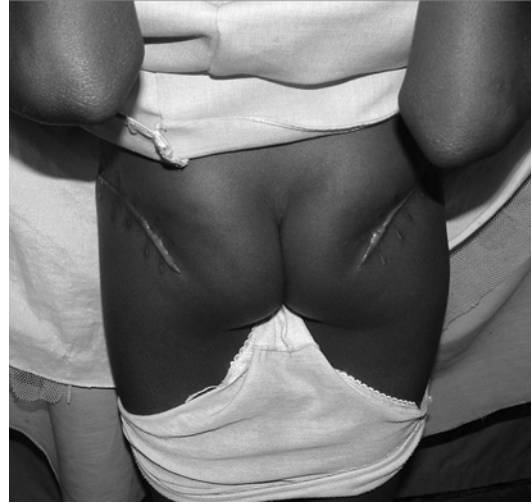

Fig. 39.6 The surgical scar following release of gluteal contracture

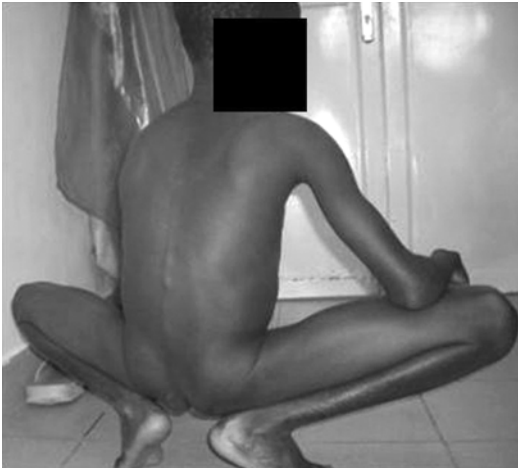

Fig. 39.5 Patient with gluteal fibrosis forced to squat in the “butterfly position” due to the contracture

except with the legs externally rotated (Fig. 39.5). The fibrotic tissue is resected with the patient in the lateral position. From the midpoint of a line connecting the anterior superior iliac spine and the tip of the greater trochanter, the incision extends toward the ischial tuberosity (Fig. 39.6).

The fibrotic tissues are released using diathermy while protecting the sciatic nerve. Complete release is achieved when hip flexion greater than 90° and internal rotation beyond neutral are possible. Range of motion exercises, crutch walking, and gait training are started as soon as possible; rehabilitation takes 2–3 months.

With quadriceps fibrosis and contracture, the child walks with a stiff knee gait. A modified Judet quadricepsplasty is recommended. Proximal release is a critical component, as distal release alone is less effective and has higher incidences of weakness, extensor lag, or quadriceps rupture. A lateral incision extends proximally from the distal femoral metaphysis. The vasti are released extra-periosteally, and multiple transverse incisions may be necessary in the ilio-tibial band and vastus fascia. The rectus femoris is released from the anterior inferior iliac spine through a separate anterior incision.

The contracture can be limited to just the rectus femoris, as demonstrated in the Duncan-Ely test (With the patient prone the knee is flexed, causing the pelvis to lift from the table). In this case the rectus femoris is released before considering quadricepsplasty. Postoperative therapy involves immediate passive range of motion and early active range of the knee.

Residua of Acute Poliomyelitis

Introduction

Besides the several hundred new cases of acute poliomyelitis each year, thousands of patients suffer from the residua of the disease. Infection occurs via a fecal-oral route, with most patients having a self-limited diarrhea. In only 1 % of cases, the virus spreads to the anterior horn cells of the spinal cord and brainstem. Following the acute illness, characterized by high fevers, muscle pain, and varying degrees of paralysis, recovery in function can be seen up to a year.

Polio presents as a nonprogressive, asymmetric flaccid motor paralysis or paraparesis. The diagnosis requires a history of a febrile illness, exam with normal sensation, no spasticity, and no bowel or bladder involvement. The differential diagnosis includes (1) post-cerebral malaria (spasticity, cognitive abnormalities); (2) Guillain-Barré or transverse myelitis (symmetric flaccid paralysis, sensory abnormalities); (3) konzo, lathyrism, and tropical myelopathy (spasticity, ataxia); (4) Burkitt's lymphoma of spine, spinal tumors, and spinal

tuberculosis (progressive, spasticity before flaccidity, bowel and bladder abnormalities, sensory involvement); and (5) postinjection paralysis.

Principles for polio treatment can be applied to other flaccid paralyses, remembering that the goal of surgery is functional restoration. Patient selection is critical, and surgical treatment must be complemented by rehabilitation and bracing.

Contractures are caused by muscle imbalance and positional or mechanical factors, but also by interstitial fibrosis from the inflammatory myositis during the initial viremic infection. Contracture of the tensor fascia femoris and iliotibial band (ITB) is frequent and all but pathognomonic for polio confirmed with the Ober test. This is performed with the patient lying on his uninvolved side, with the uninvolved knee and hip flexed. While stabilizing the pelvis the leg to be tested is extended, internally rotated, and adducted toward the table (Fig. 39.7). The abduction contracture prevents the leg from reaching the table.

The examination includes manual muscle testing of the upper and lower extremities and trunk

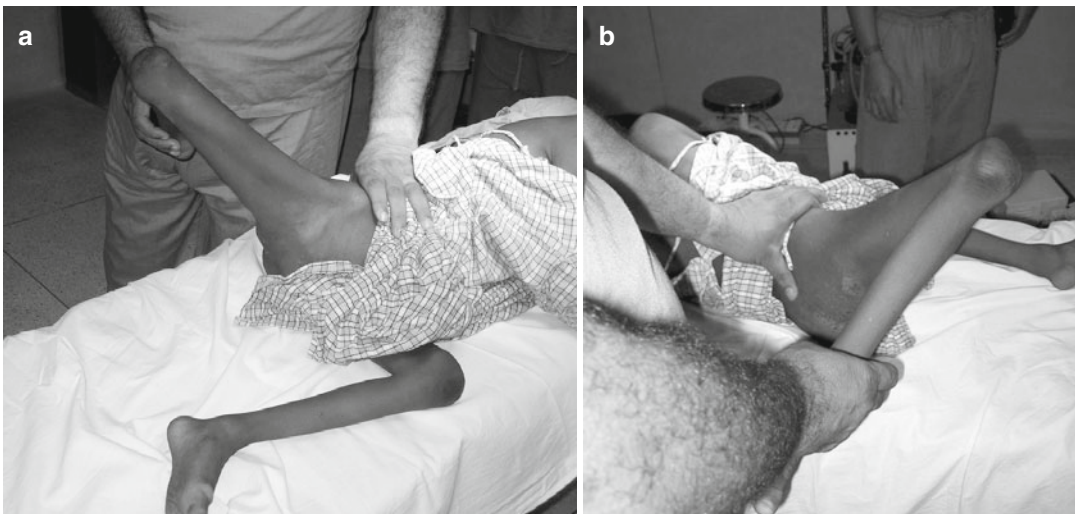


Fig. 39.7 The Ober test. (a) The patient is positioned on his/her side, with the leg to be tested facing upwards. The other leg is flexed maximally at the knee and the hip. The leg to be tested is extended, internally rotated, and

adducted. In this example (b) the thigh fails to adduct even down to neutral, suggesting a significant contracture of the iliotibial band

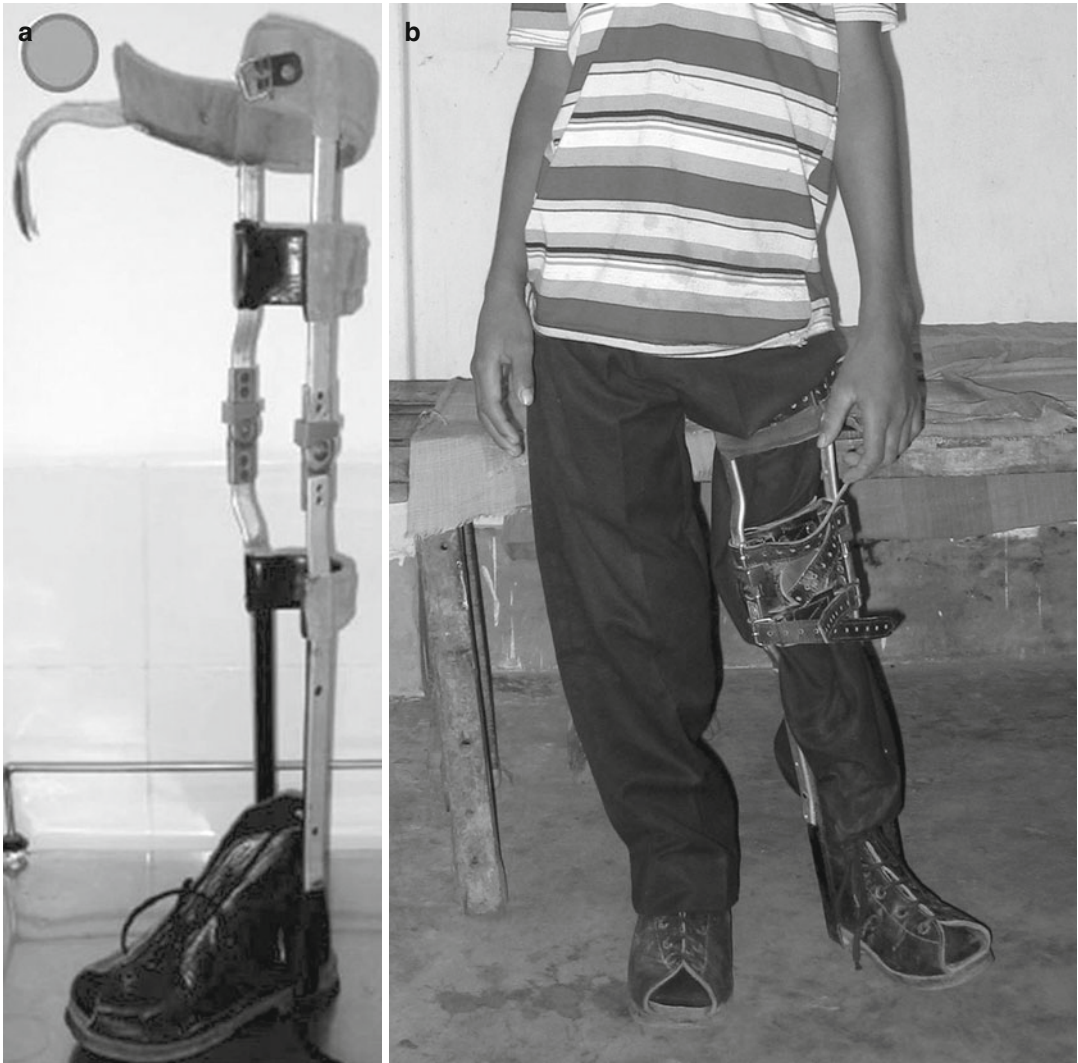

Fig. 39.8 (a) A knee ankle foot orthosis (KAFO), also called a caliper. (b) patient wearing a leather and metal caliper attached to an open-toed boot

and joint range of motion. Manual muscle testing uses a scale of 0–5.

0=No perceptible muscle contraction

1=Contraction palpable but no motion the categories of manual muscle testing need to be together, not on separate pages.

2=Motion with gravity reduced

3=Motion against gravity only

4=Full range of motion against some resistance

5=Full range of motion against full resistance

When resources are scarce, patients must be appropriately triaged to different levels of care. Some patients have the potential to be community ambulators, while others should be given a

wheelchair and other assistive devices rather than undergo complex orthopedic procedures (Fig. 39.8).

Common Patterns of Deformity

Though a broad spectrum and unique combinations of muscular weakness or paralysis are seen in patients with poliomyelitis, common patterns of deformity are (1) the crawler, (2) single-leg involvement (dangling leg syndrome), and (3) equinus (Fig. 39.9a–c). Severe cases with upper extremity weakness or trunk involvement with scoliosis are uncommon (Fig. 39.9d, e).

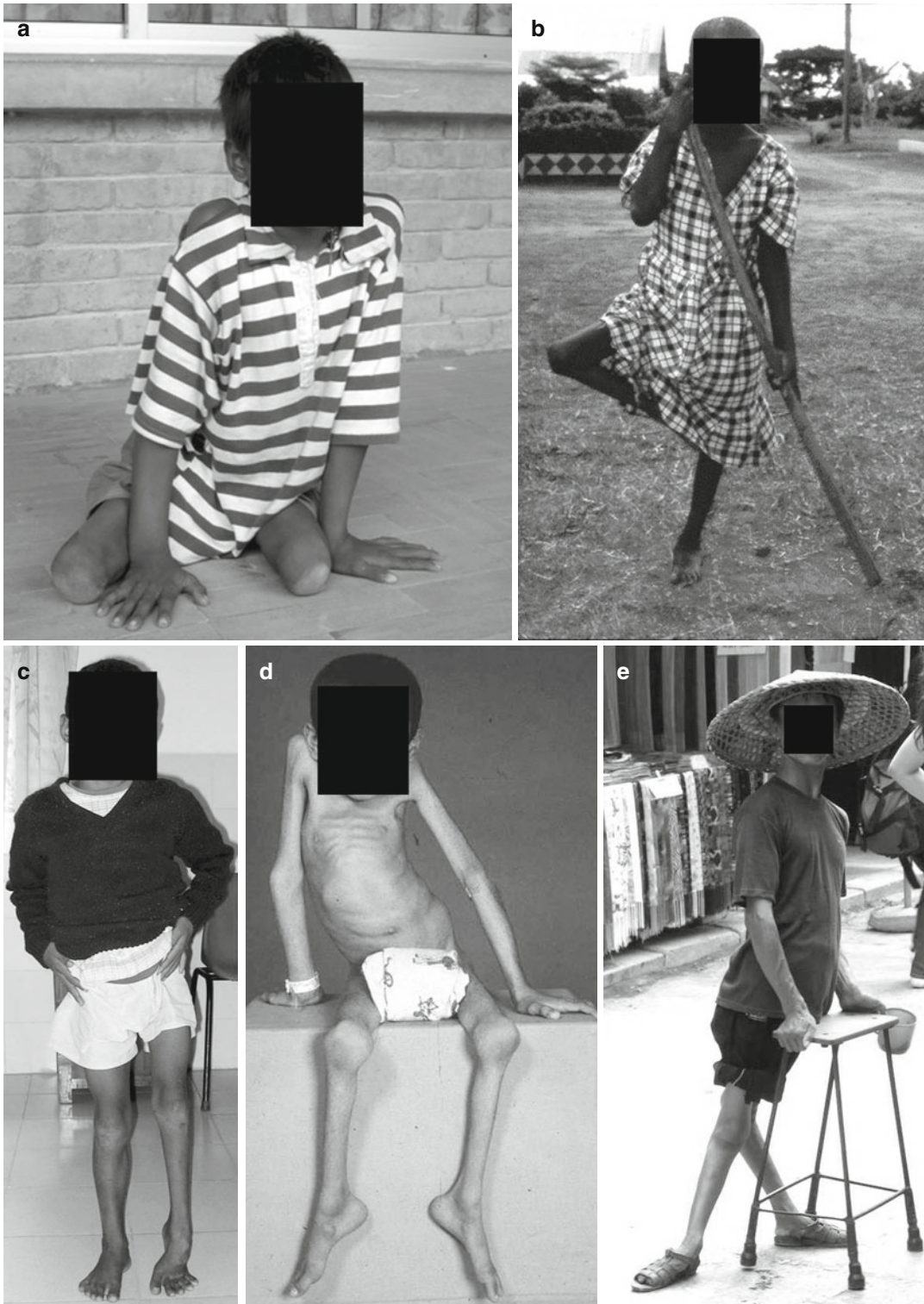

Fig. 39.9 The most common presentations are (a) the crawler, (b) dangling leg syndrome, and (c) equinus. (d) In cases with greater severity there may be significant weakness of the trunk and upper extremities that preclude

the use of crutches or assistive devices. (e) This man with flail lower extremities used a stool as an assistive device and locked both knees in hyperextension

Crawlers typically have bilateral severe lower extremity paralysis with minimal or no upper extremity involvement. Contractures include hip flexion/abduction, knee flexion (often with external rotation), and ankle equinus. This group of patients often carry a significant social stigma. For example, they have to use their upper extremities to maneuver into latrines that are often just holes in the ground, and their hands are chronically dirty which prevents them from having access to communal meals.

Patients with single-leg involvement typically have severe paralysis of one lower extremity, with weakness and contractures similar to those described for the crawler. They often walk with a stick, and the leg dangles.

Equinus deformity can be due to paralysis of the dorsiflexors with functional plantar flexors, giving a dynamic imbalance, or both muscle groups are paralyzed and there is a plantar flexion contracture. The extensor hallucis longus is often preserved, as innervation of this muscle originates from several root segments in the spine. Pure equinus is most common, but equinovarus or equinovalgus can occur.

Priorities for Treatment

The goals of treatment include (1) ambulation, (2) prevention of deformities during growth, (3) decreased bracing, (4) addressing the upper extremity, and (5) treatment of spinal deformity. If the arms are weak, or there is poor trunk control and scoliosis, provide a wheelchair. Adequate triceps and trunk strength are essential for crutch use and must be assessed preoperatively to define the patients who will benefit from lower extremity surgery. Assess triceps and deltoid strength by having the child raise his arms overhead and lifting his bottom off the chair by pushing down with both arms. If the child can kneel without using his hands, the hip extensors are at least grade 4 with a good potential for ambulation.

Typical treatments include the release of contractures around the hip, knee, and ankle,

followed by an AFO or KAFO (typically made from thermoplastic materials) or caliper, a KAFO made from leather and metal. Post-op rehabilitation is often begun with a walker, graduating to standard axillary crutches followed by forearm crutches (Lofstrand) as strength and confidence improve. Comfortable fitting with a caliper may require surgical treatment of foot deformities and correction of valgus knees and external tibial torsion. In some cases the goal is to reduce the need for bracing, and treatment of foot deformities by soft tissue release, tendon transfer, and osteotomy/arthrodesis is required. Procedures at the knee such as extension osteotomy and hamstring transfer may enable the caliper to be discontinued. However, hamstring transfer can weaken knee flexion and impair function of activities performed close to the floor, such as sitting or squatting at in-ground toilets.

As a child approaches skeletal maturity (>15–16 years), opportunities for correction diminish rapidly; complication rates are high and rehabilitation is long and difficult. Functional decline is a significant risk, limiting the ability to crawl, particularly after knee corrections. It is often pragmatic to accept the deformities and accommodate them with a wheelchair and tricycle.

Surgical Principles and Techniques

Correction of Hip and Knee Contractures

Methods to straighten the knee include passive stretching exercises, traction, surgical release of contracted soft tissues, osteotomy, or serial casting/cast wedging alone or in combination. Relative contraindications include knee contractures of more than 90°, marked external rotation (Fig. 39.10) posterior subluxation of the knee, or severe bilateral hip contractures.

Nonoperative measures should take care to counteract posterior subluxation of the tibia during manipulations and plastering

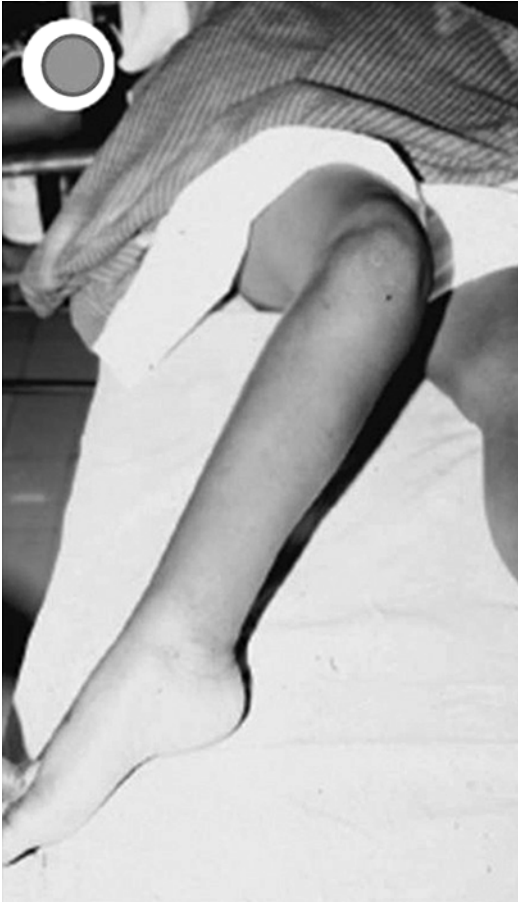

Fig. 39.10 Flexion contractures at the knee may be accompanied by external rotation at the knee joint and posterior subluxation of the proximal tibia

(Fig. 39.11). The first author (JNP) has developed a plaster wedging technique that allows the tibia to be translated anteriorly to prevent this (Fig. 39.12).

Indications for serial wedging include (1) patients <12 years old, (2) feet do not require surgery, (3) knee contractures less than 60°, and (4) no significant posterior subluxation or external tibial rotation.

Procedure: (1) Internally rotate the tibia to correct any external rotation, (2) apply a long leg cast with molding above the patella to gain extension while simultaneously translating the proximal tibia anteriorly, (3) wedge the cast

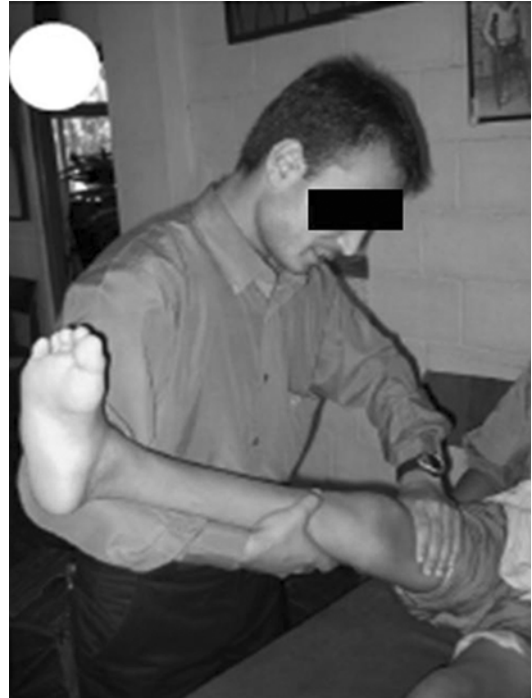

Fig. 39.11 When stretching or serial casting a fixed knee flexion contracture, care should be taken to simultaneously translate the proximal tibia anteriorly while pushing down on the distal femur to avoid posterior subluxation

after 1 week, and (4) after two wedgings apply a new cast. When serial casting is used to achieve further correction after surgical releases, the first cast is applied 2 weeks postoperatively, with repeat wedgings every 10–14 days thereafter. Each wedging corrects about 10°.

Contractures at the hip and knee typically require surgery, followed by stretching, traction, or serial wedging plasters, to achieve full correction. In general non-functional muscles are released and functional ones are lengthened. While release of hip and knee contractures can be completed in one setting, our opinion is that the knees and ankles should be treated first as residual knee flexion increases the risk of recurrent hip flexion contracture. While percutaneous techniques have been described by Huckstep, in this chapter we will focus on open surgical lengthenings.

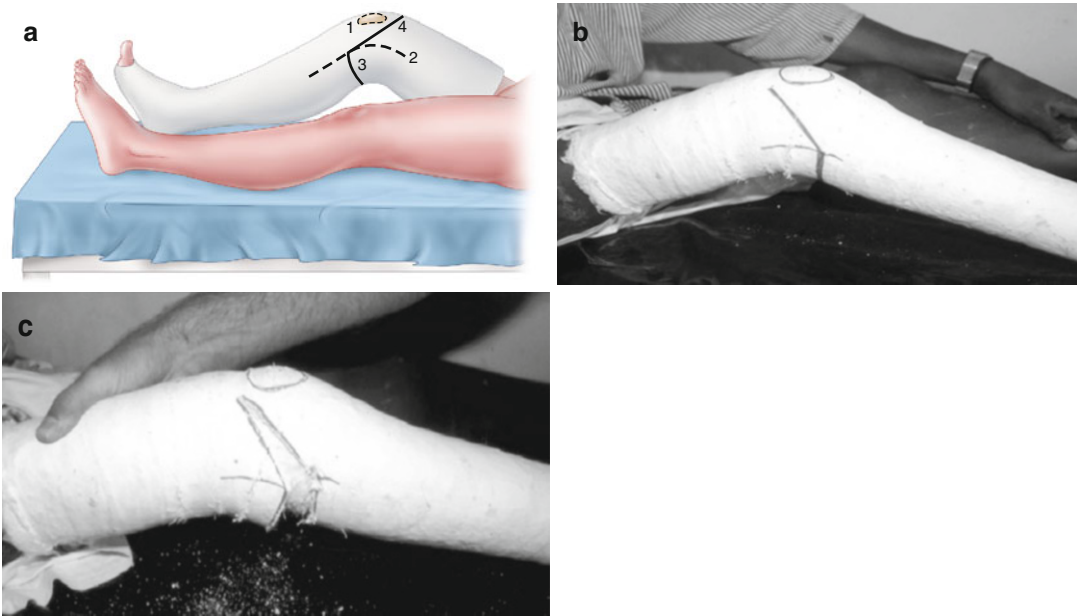


Fig. 39.12 Serial casting for knee flexion contractures. (a, b) Lines drawn on plaster for orientation and cutting. (1) Outline of the patella, (2) dotted line marks the midline on lateral and medial sides. (3) About 1 inch distal to the patella, draw a half circle around the posterior half of the plaster connecting the two midline markings. This line represents the posterior knee joint. (4) From both sides of the proximal pole of the patella and 2 inch apart, mark a line to meet line (3) at the midline. (c) Cut the plaster, leaving an intact hinge between the anterior cuts proximal to the

patella. This hinge serves as the center of rotation, proximal and anterior to the tibia. Gently straighten the knee/plaster, noting how the tibia shifts anteriorly, and fill the gap with cotton wool or cork. Overwrap with one or two rolls of plaster. After 5–10 days the plaster can be wedged again by removing the last rolls of plaster revealing the initial drawings. Never wedge the plaster more than two times, replace the cast instead. When the tibia is in extreme external rotation (as in polio), the center of rotation on the plaster should be positioned proximal and medial to the patella

Stage 1 Knee and Ankle Contractures: The equinus deformity is addressed by tendoachilles lengthening (TAL) performed percutaneously in mild deformities or by open lengthening with release of ankle and subtalar joints for more severe contractures. A Lambrinudi triple arthrodesis may be necessary when a TAL is insufficient. It is wise to leave a few degrees of residual equinus to help stabilize the knee by driving it backward during stance phase. If the leg is completely flail without good hip extensors, it is unlikely the

child will walk without a caliper, in which case the ankle can be brought to neutral. Residual equinus can also compensate for a short limb.

The knee release starts with excision of the iliotibial band and lateral intermuscular septum, the Yount procedure (Fig. 39.13). Sometimes the hip contracture will improve with sectioning the iliotibial band as part of this release. With marked external rotation and/or subluxation of the knee, the biceps is also released. Less commonly, releases or lengthenings of the semi-

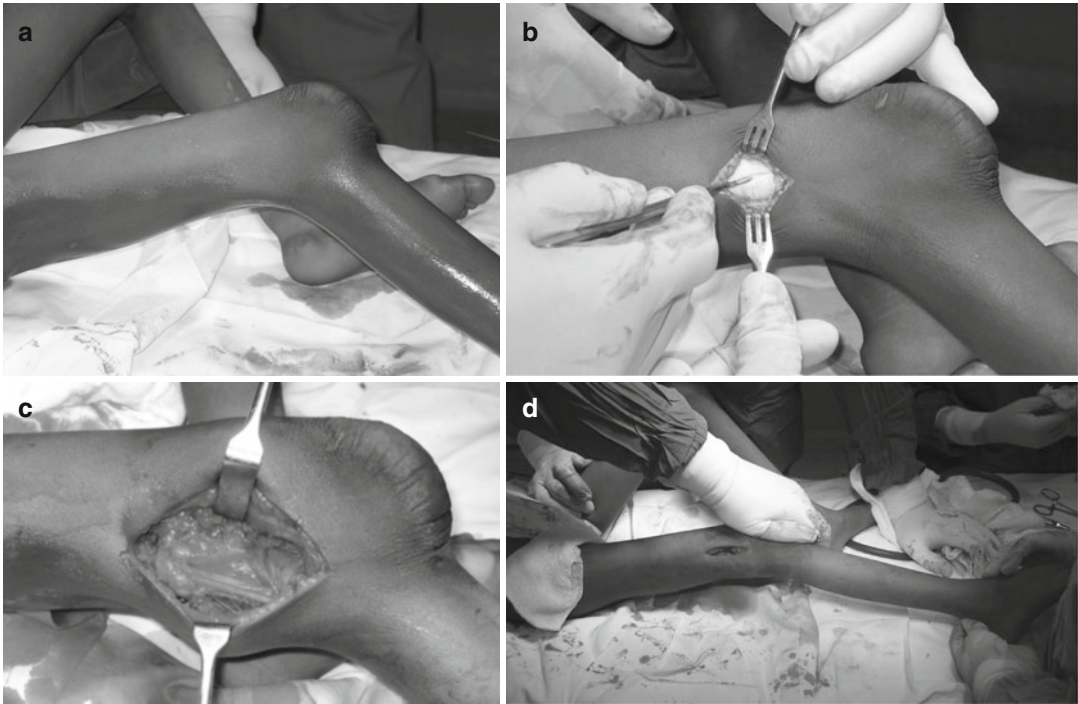


Fig. 39.13 (a) A fixed knee flexion contracture with mild posterior subluxation of the tibia. (b, c) The distal release (Yount procedure) begins with a longitudinal incision through which the iliotibial band and the intermuscular

septum are resected. (d) Correction achieved on the table. Residual deformity will be corrected by stretching or serial casting (courtesy of Hospital and Rehabilitation Centre for Disabled Children, Banepa, Nepal)

tendinosus, semimembranosus, and gracilis are performed through a medial incision. We do not recommend posterior capsulotomy, though one might consider releasing both heads of the gastrocnemius if the soleus is strong. When correcting a bilateral deformity $>20^\circ$ in older patients, femoral shortening or a distal femoral extension osteotomy with shortening may give the best results.

Stage 2: A hip flexion/abduction release is required if there is marked lumbar lordosis or an unstable forward pitched body position during stance. It can be done once the knee is straight

and the child is walking in calipers, usually 3–6 months after the first phase.

An open hip release, the Ober procedure, (Fig. 39.14) begins with a longitudinal incision in the interval between the sartorius and the tensor fascia lata. The lateral femoral cutaneous nerve is identified before releasing these two muscles and the anterior part of the glutei. The release should not extend posteriorly beyond the trochanter as this will weaken the hip extensors. The rectus femoris release follows; release of the anterior hip capsule is usually unnecessary. Full correction is rarely achieved at surgery.

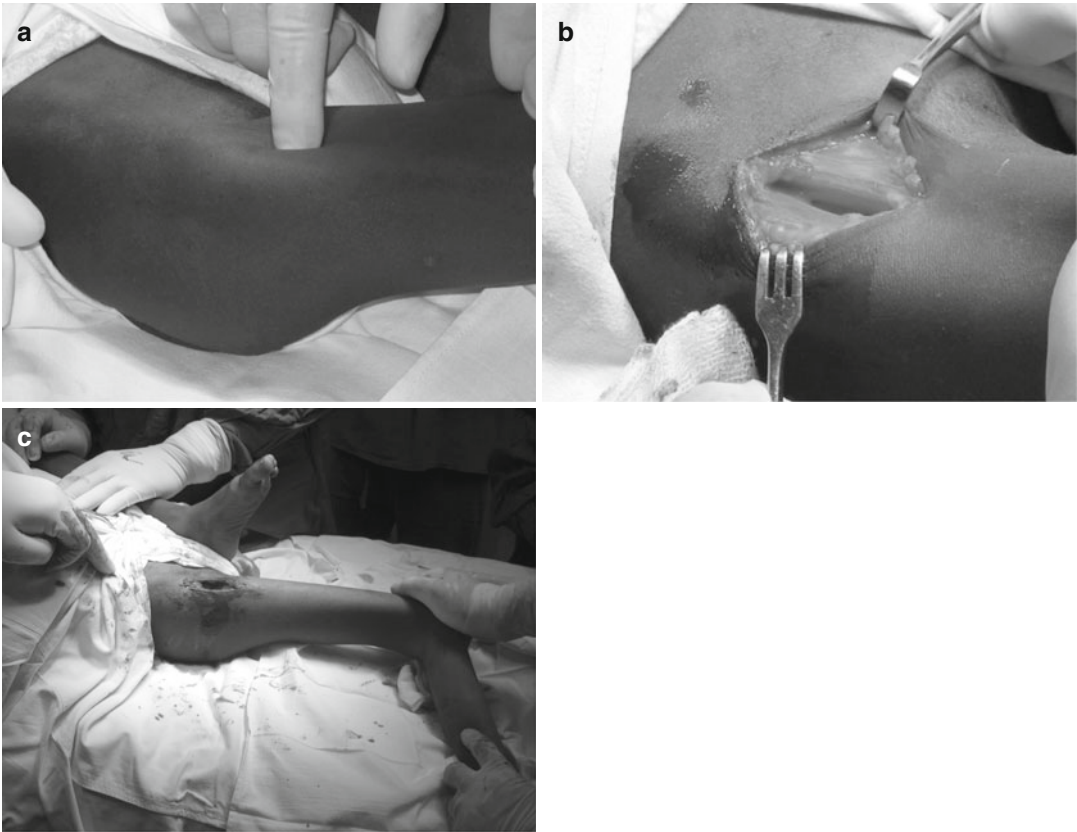


Fig. 39.14 The Ober procedure is a proximal release. (a) The interval between the sartorius and tensor fascia lata is palpated. (b) A longitudinal incision is made in the interval. The tensor and sartorius and the glutei, to the greater trochan-

ter, are released (but not posterior to the trochanter to preserve power of the hip extensors). (c) In this case correction was achieved on the table (courtesy of Hospital and Rehabilitation Centre for Disabled Children, Banepa, Nepal)

If the hip and knee releases are performed simultaneously, traction can be useful to gradually achieve full correction (Fig. 39.15). A distal tibial traction pin is placed for longitudinal traction and a proximal tibial traction pin for an anterior vector to counteract posterior subluxation of the tibia. Usually 3–6 weeks of traction is required, after which patients can be mobilized in calipers.

In association with hip and knee contractures, a variety of foot deformities occur depending

upon the pattern of weakness, the most common of which are equinus and equinovarus (Table 39.1, Fig. 39.16). The main principles are as follows:

1. Release contracted soft tissues.
2. Stabilize the subtalar joint.
3. Transfer muscles to balance the foot and ankle.

Achieving muscle balance is critical even when a triple arthrodesis is performed. The same procedures as described above in treatment of drop foot due to PIP are used.



Fig. 39.15 (a, b) This 18-year-old had severe flexion deformities at the hip and knee. (c) He was treated by proximal and distal soft tissue releases and skeletal traction. (d, e) The deformities corrected gradually and (f) he

was mobilized with calipers and a walking frame (courtesy of Hospital and Rehabilitation Centre for Disabled Children, Banepa, Nepal)

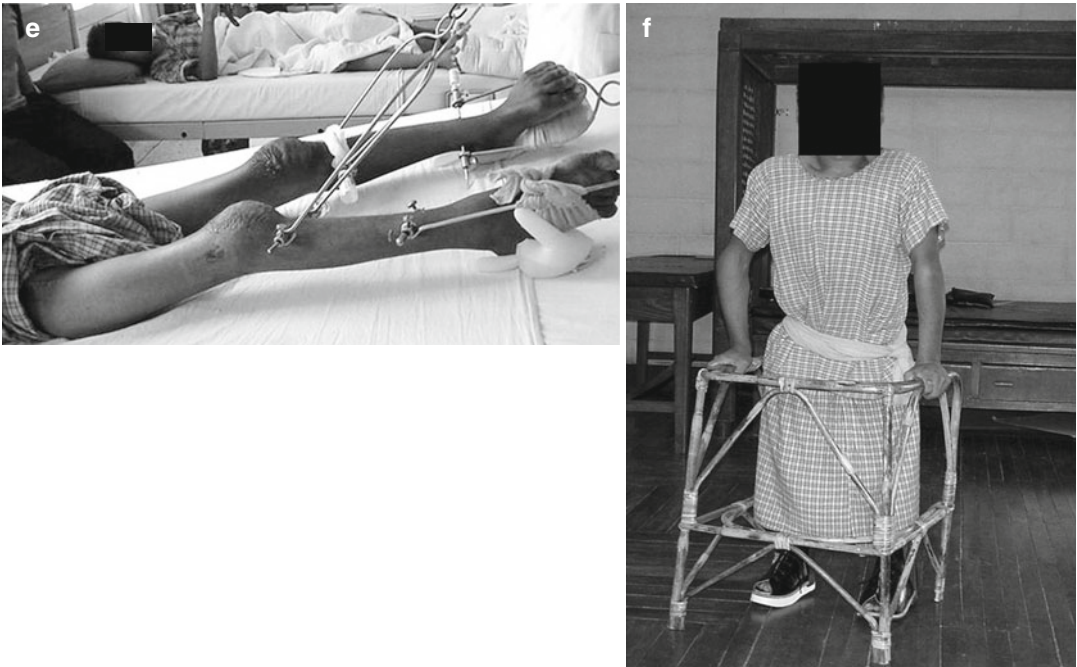

Fig. 39.15 (continued)

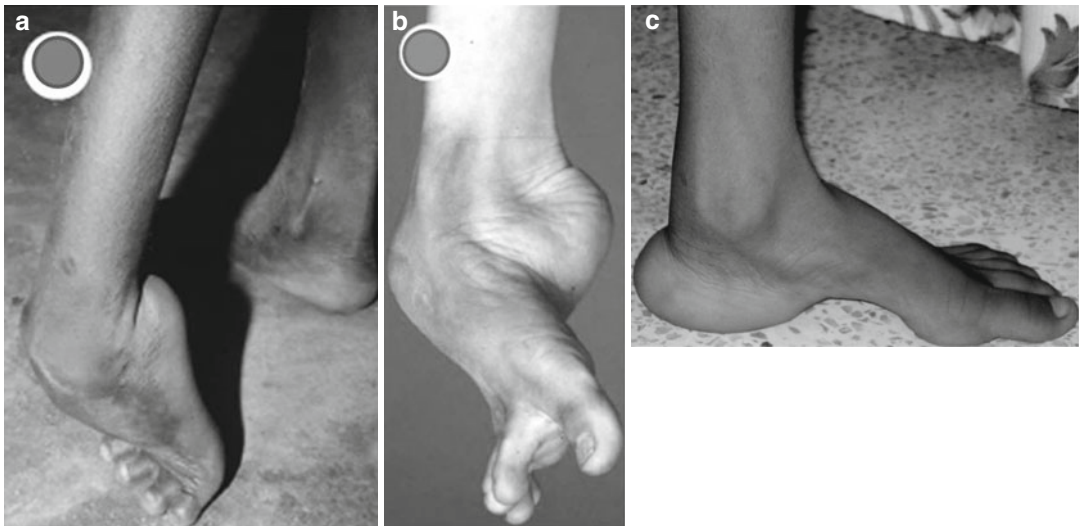


Fig. 39.16 Typical foot deformities include (a) equinus, (b) equinovarus, and (c) calcaneus

Miscellaneous Considerations

Quadriceps weakness or paralysis is common, and patients compensate with a “thigh-hand” gait, in which manual pressure on the anterior distal thigh facilitates knee extension (Fig. 39.17). A forward leaning trunk also compensates by

keeping the ground reaction force anterior to the knee. The presence of a fixed flexion contracture precludes locking the knee into a stable position. The most appropriate treatment depends on the degree of weakness and the strengths of the gastrosoleus and the gluteal muscles, and the presence of a fixed flexion deformity.



Fig. 39.17 The thigh-hand gait is a compensatory mechanism for quadriceps weakness or paralysis, to help lock the knee into extension during stance phase

Patients with mild to moderate weakness, no knee flexion contracture, and adequate strength of the hip and ankle muscles may compensate adequately. A caliper is an excellent choice when motion is full or flexion deformity is $<20^\circ$. A hamstring tendon transfer can be considered if there is full range of motion at the knee, at least 4/5 strength of the hip flexors and gastrocsoleus, normal patellofemoral mechanics, and normal limb alignment. The most successful technique is transfer of both semitendinosus and biceps femoris to prevent lateral patellar subluxation by pull of the biceps femoris. Patients will lose

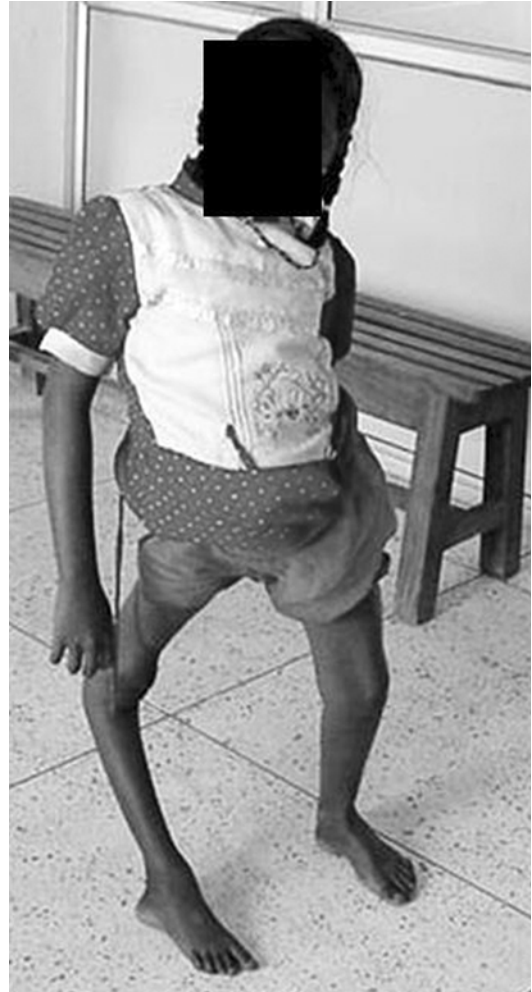

Fig. 39.18 Knee hyperextension may be due to soft tissue laxity or may be associated with recurvatum of the proximal tibia. Equinus is usually observed

active knee flexion, which can cause additional disability, especially with activities performed at ground level. In patients with a coexisting tendoachilles contracture, there is a risk of destabilizing the knee if the tendoachilles contracture is also corrected. It is typically safe to do a TAL when the quadriceps is grade 3 strength or better, but wise to leave some mild equinus when in doubt.

Genu recurvatum or hyperextension of the knee during stance phase can be secondary (Fig. 39.18) to excessive stretching of the posterior soft tissues and is commonly associated with weakness of the gastrocsoleus, quadriceps,

and hamstrings. The most common treatment is a KAFO or caliper and equinus correction.

Genu recurvatum also results from bony deformity, particularly an anterior slope of the tibial plateau. Typically gastrocsoleus and hamstrings are normal strength, quadriceps are weak, and equinus is present. The equinus prevents the tibia from advancing over the foot in stance phase, driving the knee into extension. While an orthosis will suffice in most cases, a flexion osteotomy of the distal femur may be necessary. Osteotomy of the proximal tibia carries an increased risk of neurovascular injury.

Leg length discrepancies are common, caused by absolute bony shortening, infrapelvic obliquity (hip abduction or adduction contracture), and/or suprapelvic obliquity (scoliosis) (Fig. 39.19). Slight shortening may be an advantage if the limb requires a brace, to provide clearance during swing phase. Treatment is individualized and can include contracture releases, epiphysiodesis, or limb lengthening. Epiphysiodesis may not be viewed favorably by the family as the surgery is done on the normal limb.

Hip instability, either subluxation or dislocation, can result from muscle imbalance or pelvic obliquity (infrapelvic or suprapelvic). When required, treatment should be directed to the primary pathology. Correction of hip abduction contracture by soft tissue releases may improve hip alignment and the compensatory scoliosis. For persistent hip instability, reconstruction by femoral and/or pelvic osteotomy with open reduction

can be considered, recognizing a significant risk of recurrence due to weakness of the surrounding muscles.

Upper extremity involvement is less common than lower extremity involvement and seldom requires surgery. Patients with a flail shoulder will benefit from a shoulder fusion, ideally between the ages of 6 and 8. The technique involves peeling off the articular cartilage, and fixing the joint with wires that are later removed, preserving the physis and longitudinal growth. The most common procedures at the elbow are to restore elbow flexion by appropriate tendon transfer. Release of a forearm pronation contracture may also improve function.

Scoliosis is seen in up to 25 % of polio patients, especially those with greater degrees of neurologic impairment. It may be due to asymmetric or global trunk weakness or as compensation for hip contractures. Progressive curves may impair sitting balance and ventilatory function. Non-ambulators typically have a collapsing C-shaped thoracolumbar or lumbar curve with pelvic obliquity. When a hip contracture and scoliosis coexist, we recommend correcting the hips first. A brace may serve as a temporizing measure to improve sitting balance and upper extremity function and possibly delay progression. Once a progressive, symptomatic curve is felt to warrant stabilization ($>40\text{--}60^\circ$ Cobb angle), an instrumented posterior spinal arthrodesis from T2 to the pelvis is required if the resources are available.

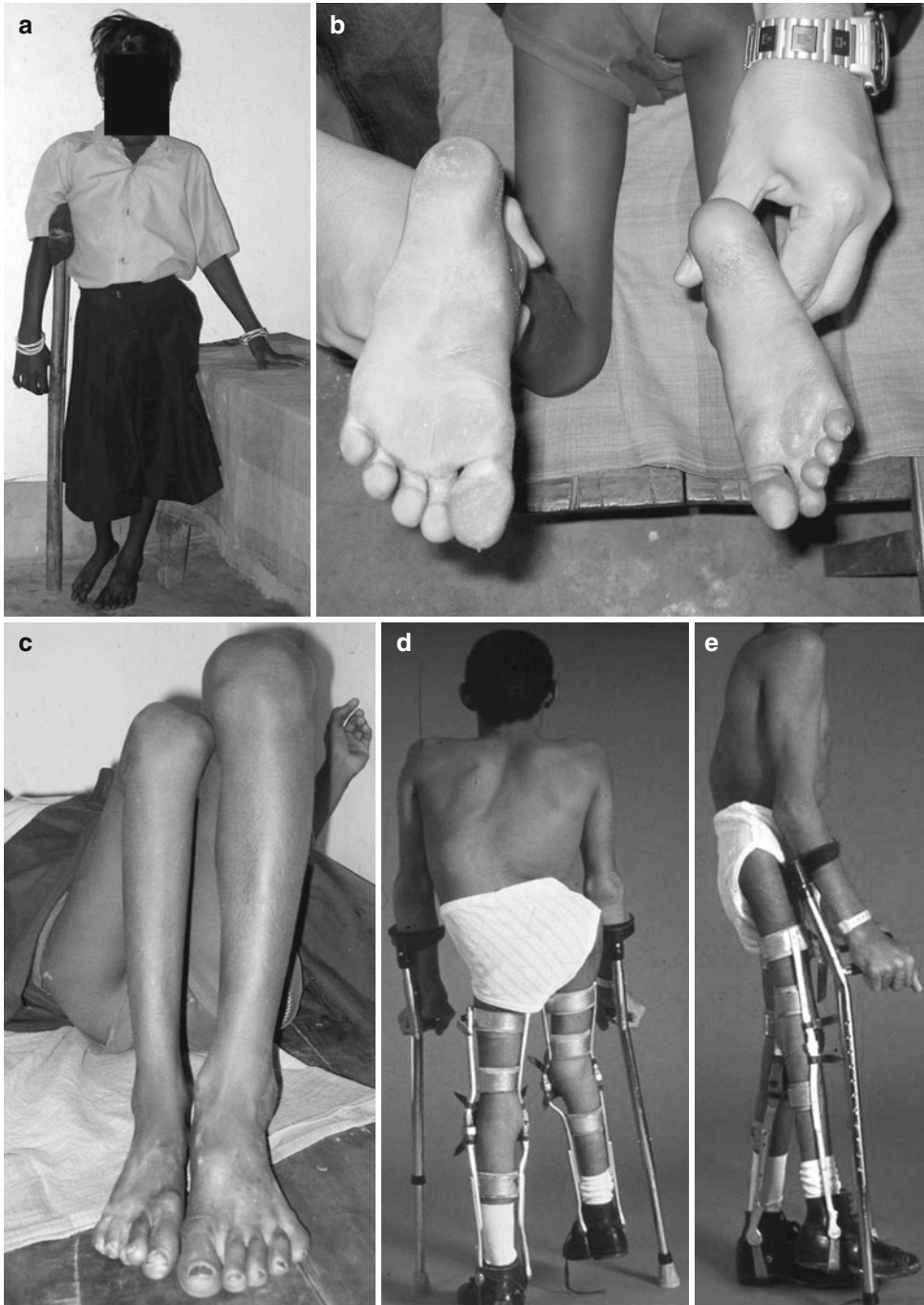

Fig. 39.19 Polio can be associated with a significant reduction in size of the involved extremity. (a–c) In this case of a flail right leg, there is significant leg length discrepancy due to bony shortening. Even the foot is smaller. (d, e) Leg length discrepancy can also be “apparent,” due to contractures and/or angular deformities. Components

might include absolute bony shortening, right hip adduction contracture (infrapelvic obliquity), left hip abduction contracture (infrapelvic obliquity), and left lumbar scoliosis (suprapelvic obliquity). The left lumbar curvature might also be compensating for the infrapelvic obliquity

Suggested Reading

- Barennes H. Intramuscular injections in Sub-saharan African children, apropos of a frequently misunderstood pathology: the complications related to intramuscular quinine injections. *Bull Soc Pathol Exot.* 1999;92:33–7.
- Herring JA, editor. Tachdjian's pediatric orthopaedics. 4th ed. Philadelphia: Saunders/Elsevier; 2008. p. 1483–583.
- Huckstep RL. Poliomyelitis, a guide for developing countries. Edinburgh: Churchill Livingstone; 1986.
- Huckstep RL. Appliances and surgery for poliomyelitis in developing countries. *Instr Course Lect.* 2000;49:593–601.
- Krul J, editor. Rehabilitation surgery for deformities due to poliomyelitis. Techniques for the district hospital. Geneva: World Health Organization; 1993.
- Naddumba EK, Ndoboli P. Sciatic nerve palsy associated with intramuscular quinine injections in children. *East Cent Afr J Surg.* 1999;4:17–20.
- Paley D. Knee extension contracture. Principles of deformity correction. New York: Springer; 2002. p. 563–9.
- Rose RE. Judet quadricepsplasty for extension contracture of the knee. *West Indian Med J.* 2005;54:238–41.
- Watts HG. Orthopaedic techniques in the management of the residua of paralytic poliomyelitis. *Tech Orthop.* 2005;20:179–89.

Bibek Banskota, Michelle Foltz, Richard A. Gosselin,
and David A. Spiegel

Introduction

Cerebral palsy and other conditions affecting the neuromuscular system remain largely undressed in low-resource settings.

News of a foreign surgeon or surgical team will often bring families with children who have neuromuscular and/or developmental problems, hoping for treatment or cure. Cerebral palsy (CP) is the most common entity and is a nonprogressive disorder of motion and posture arising from

injury to the immature brain. While the central nervous system (CNS) lesion remains static, progressive musculoskeletal abnormalities are due to spasticity and/or muscle imbalance.

CP presents on a spectrum from the mildly involved hemiplegic child to one with spastic quadriplegia who is unable to ambulate, has multiple contractures that interfere with positioning and ease of care, and may have scoliosis and coexisting medical problems (Fig. 40.1). Non-orthopedic abnormalities are common and often unrecognized.

In contrast to economically developed countries where CP is commonly associated with prematurity and low birth weight, most cases in the developing world are due to inadequate antenatal care, unsupervised home deliveries, and a lack of access to emergency obstetric interventions such as Cesarean section. Postnatal infections (encephalitis, meningitis) and kernicterus (neonatal jaundice) are also important causes.

B. Banskota, MBBS, MRCS, MS
Department of Orthopedics, Hospital and
Rehabilitation Center for Disabled Children (HRDC),
Janagal, Kavre, 6757, Nepal
e-mail: bibekbanskota@gmail.com

M. Foltz, MD (✉)
172 Stillwater Loop Road,
Columbus, MT 59019, USA
e-mail: michellefoltz@gmail.com

R.A. Gosselin, MD, MPH, MSc, FRCS(c)
Orthopedic Surgery, Institute for Global Orthopedics
and Traumatology, UCSF, 1001 Potrero Ave, 3A-36,
San Francisco, CA 94110, USA
e-mail: froggydoc@comcast.net

D.A. Spiegel, MD
Division of Orthopaedic Surgery,
Children's Hospital of Philadelphia,
Associate Professor of Orthopaedic Surgery,
University of Pennsylvania School of Medicine,
Philadelphia, PA, USA

Honorary Consultant in Orthopaedics and Rehabilitation,
Hospital and Rehabilitation Centre for Disabled Children,
Janagal, Kavre, Nepal
e-mail: spiegeld@email.chop.edu

Treatment

Priorities for treatment include improving the patient's communication skills and activities of daily living and only later mobility. While a host of physical impairments may be identified, the disability will depend on the patient's environment, the extent of financial and emotional support from family and community, and cultural and religious perceptions. Traditional beliefs and the family's opinions influence the




Fig. 40.1 (a) Ambulatory patient with spastic diplegia requires only a stick or pole for balance. (b) In contrast, a boy with spastic quadriplegia is barely able to crawl and requires complete support for activities of daily living. (c)

Transportation is a challenge for many rural non-ambulatory patients, and the child in this example is carried in the traditional Nepalese *doko*

perceived causes of the condition, the type of treatment sought, and expectations.

One of the most distressing aspects when asked to see such a child is the sense of impotence in the face of the family's hopes. However, the volunteer orthopedic surgeon has an important role, starting with a full and recorded history, including pregnancy, family history, and a record

of motor milestones. This can be a lengthy undertaking, as the history needs to address non-orthopedic and nonmedical questions from all parties. A sympathetic and knowledgeable interpreter is a helpful guide.

A careful medical examination can identify underlying and associated functional conditions that might point to a more specific and treatable

diagnosis. The musculoskeletal and neurological exams must be thorough, remembering that testing motor function and passive range of motion are unreliable in the face of spasticity. In ambulators, the physical examination focuses on passive range of motion, degree of spasticity, muscle strength and selectivity, bony alignment, and observational gait analysis. In non-ambulators, the assessment focuses on passive range of motion, trunk balance, and spinal alignment. Few lab tests are useful in helping to establish a diagnosis, and X-rays are more likely a confirmation of clinical findings.

Unfortunately, it often falls on the visitor's shoulders to explain to the family that some conditions have no cure and that the problem is in the CNS, not the limbs. Surgical management is only palliative in many cases and carries high rates of deformity recurrence. A delicate balance between realism and fatalism needs to be reached, requiring cultural sensitivity, best approached in tandem with a local counterpart. Having said that, surgical care will be beneficial when strict indications are met and adequate rehabilitation is available. Surgery is generally aimed at the complications of spasticity, namely muscle contractures and bony deformities. It should be avoided in patients with predominantly hyperkinetic or extrapyramidal findings, such as abnormal movements and fluctuating muscle tone.

A community based, family-centered strategy should be promoted. For example, the ICRC and Handicap International have rehabilitation programs that involve the family. When family members are educated in such a controlled setting and allowed to participate in the ongoing treatment, realistic goals can be set. In turn, trained family members can help influence and modify others' perceptions about the associated disabilities.

Surgical treatment is individualized and is aimed at improving function and requires adequate counseling, an experienced surgeon, realistic expectations, and the availability of rehabilitation services. Orthotics are often an essential component of the treatment plan and must be available and acceptable to the patient and his family. Counseling is essential to set goals, establish priorities, and instill appropriate expectations. While short muscles can be length-



Fig. 40.2 A simple, low-cost bamboo walker

ened and rotational abnormalities can be corrected, abnormal tone and movements, muscle weakness and imbalance, and deficiencies in the selectivity of motor control will all persist.

Patients who require an assistive device for balance will likely need one postoperatively (Fig. 40.2), and while orthoses may improve biomechanical function, they are often poorly tolerated in cultures where shoes are not worn. When setting functional goals, the patient's current functional level can be assessed by the Gross Motor Functional Classification System (GMFCS), as follows:

- 1 = Walks without limitations
- 2 = Walks with limitations—cannot do long distance, has abnormal balance
- 3 = Walks using a hand held mobility device
- 4 = Self-mobility with limitations—sitting requires support, needs wheelchair much of the time
- 5 = No head/trunk control or self-mobility, requires a wheelchair.

In addition, some “neglected” cases may be graded on first inspection as a GMFCS 4, but are truly GMFCS 2 or 3, which present as a GMFCS 4 due to lack of previous treatment.

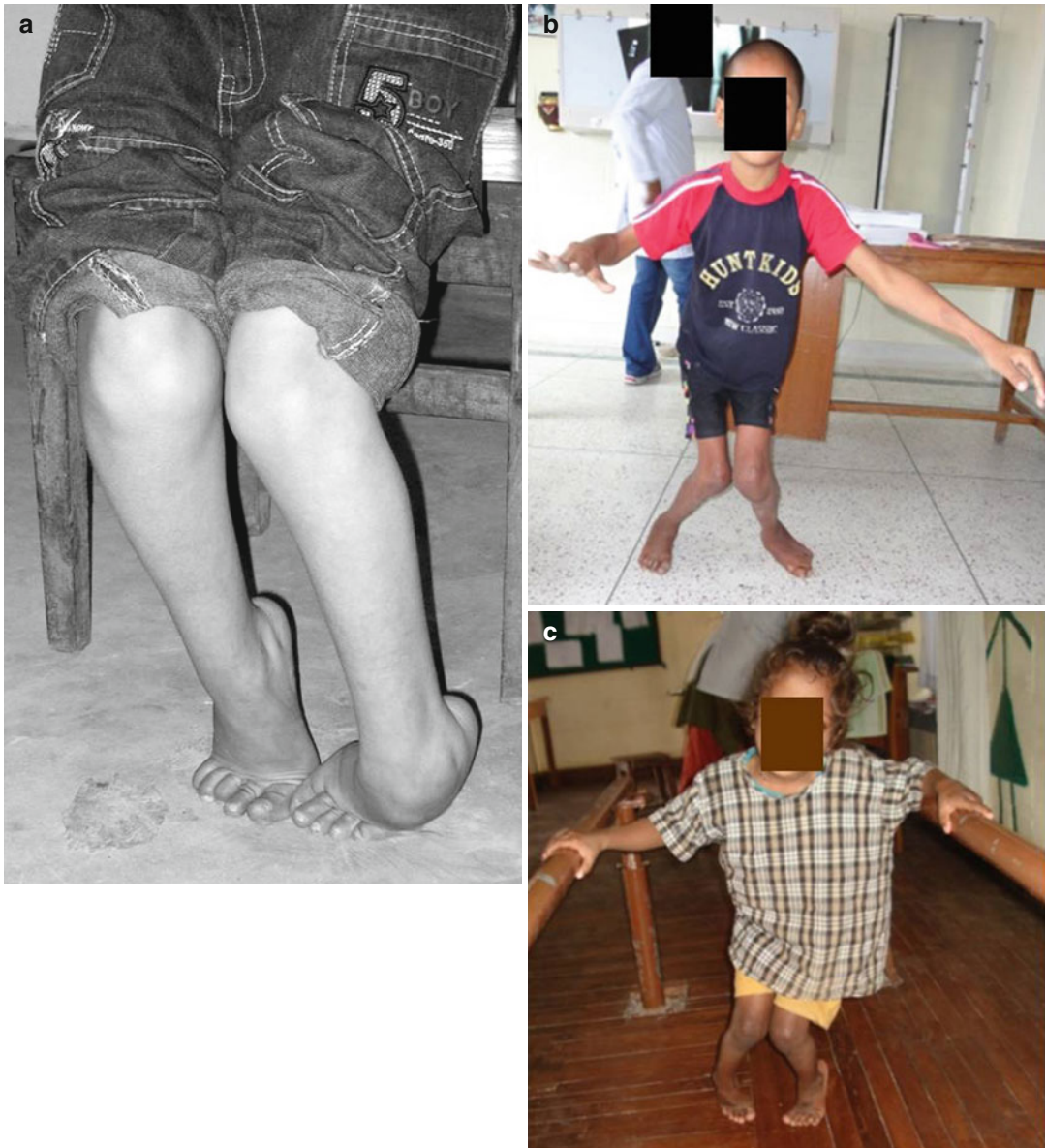

Fig. 40.3 Ambulatory patients have a host of musculo-skeletal problems in addition to their central nervous system impairment. **(a)** A patient with right-sided equinus, left equinovarus, bilateral knee and hip flexion with weight bearing (spasticity, weakness and/or contracture),

internal rotation of left greater than right thigh, and patella alta. **(b, c)** These children walk with a flexed knee gait. Orthopedic interventions can improve function; however, patient selection is critical, and pathology at multiple levels must be addressed simultaneously

Contractures can be dynamic from spasticity or myostatic due to fixed shortening of musculotendinous units. Contractures are most common in the biarticular muscles such as gastrocnemius, hamstrings, and iliopsoas. The moments generated across a joint are influenced by the force of the muscles crossing the joint and the skeletal levers across which they act. Coexisting bony rotational

abnormalities and joint malalignment, termed “lever arm disease”, may also impair biomechanical function (Fig. 40.3a–c). Due to the complexity and ongoing need for treatment over the years, there is always a risk that even simple procedures will result in suboptimal outcomes. In general, surgery is best done by experienced practitioners and only when adequate rehabilitation is available.

Surgical Treatment

Surgery is most commonly considered in community ambulators (GMFCS 1, 2) to preserve or improve function, recognizing that gait parameters may deteriorate into adulthood. Muscle weakness is common, and surgical lengthening will weaken the muscle further. Techniques such as musculotendinous recession are preferred.

The proposed benefits of any procedure must be weighed against the possibility of untoward effects, as simple surgical procedures can result in loss of function, including the cessation of ambulation, especially when there is inadequate access to rehabilitation. Orthoses are often essential and must be acceptable to the patient and the family. Pitfalls in surgical treatment include failure to identify treatable abnormalities at other levels, over-lengthening/weakening muscle groups, failure to treat bony “lever arm” problems, and failure to have realistic goals and/or appreciate the contribution from spasticity, muscle weakness, deficiencies in balance and proprioception, and the cognitive capacities and/or motivation of the patient and his or her family.

A simple case example is that of equinus contracture at the ankle, which is commonly associated with contractures at the knee and/or hip. Equinus contracture is assessed by the Silfverskiold test, in which the foot is inverted to lock the subtalar joint, and dorsiflexion assessed with the knee both flexed and extended. An isolated gastrocnemius contracture is identified when dorsiflexion is restricted with the knee in extension, but normal when the knee is flexed. Isolated tendoachilles lengthening in patients with spastic diplegia carries a high risk of over-correction, especially when the soleus is not contracted and when co-existing contractures are not simultaneously addressed. When performing a recession or a lengthening of the tendoachilles, it is best to aim for about 5 degrees of dorsiflexion, as mild residual equinus is preferable to a calcaneus posture.

The main clinical problems in patients with the greatest degree of neurologic impairment, namely spastic quadriplegia (GMFCS 4, 5) are hip dysplasia (progressive subluxation and dislocation), scoliosis, and lower extremity

contractures. Our impression is that these children do not usually survive in austere environments and often have medical comorbidities that increase the risk of anesthesia and postoperative complications. Surgical treatment is most often reserved for palliative muscle lengthening, for example, adductor or hamstring tenotomy, to improve positioning.

Other Neuromuscular Conditions

Children with other neuromuscular diseases or syndromes such as Duchenne muscular dystrophy, spinal muscular atrophy, myopathies, arthrogryposis, hereditary motor and sensory neuropathies such as Charcot-Marie-Tooth, and neurofibromatosis are often brought to a volunteer for evaluation. While it may not be possible to make a specific diagnosis based on history and physical examination alone, families should be counseled concerning the possibility of occurrence of a similar condition with future pregnancies. Treatment choices should be individualized and aimed at improving function.

Suggested Reading

- Bhatia M, Joseph B. Rehabilitation of cerebral palsy in a developing country: the need for comprehensive assessment. *Pediatr Rehabil.* 2000;4:83–6.
- Gladstone M. A review of the incidence and prevalence, types and aetiology of childhood cerebral palsy in resource-poor settings. *Ann Trop Paediatr.* 2010;30:181–96.
- Maloni PK, Despres ER, Habbous J, Primmer AR, Slatten JB, Gibson BE, Landry MD. Perceptions of disability among mothers of children with disability in Bangladesh: implications for rehabilitation service delivery. *Disabil Rehabil.* 2010;32:845–54.
- Morgan F, Tan BK. Rehabilitation for children with cerebral palsy in rural Cambodia: parental perceptions of family-centered practices. *Child Care Health Dev.* 2011;37:161–7.
- Nottidge VA, Okogbo ME. Cerebral palsy in Ibadan, Nigeria. *Dev Med Child Neurol.* 1991;33:241–5.
- Singhi PD, Ray M, Suri G. Clinical spectrum of cerebral palsy in north India—an analysis of 1,000 cases. *J Trop Pediatr.* 2002;48:162–6.
- Werner D. Disabled village children. A guide for community health workers, rehabilitation workers, and families. Berkeley: Hesperian Foundation; 2009.

Part VII

Additional Considerations

Richard A. Gosselin, Harry E. Jergesen,
and Daniel-John Lavalley

Introduction

This chapter deals with the sequelae of adult orthopedic conditions, neglected injuries, failed treatments, and end-stage degenerative joint disease as they are dealt with by osteotomies, arthrodeses, and/or arthroplasties.

In all cases a thorough general medical and specific orthopedic history is necessary with particular attention to nutrition, tobacco use, and coexisting medical diseases. Find out the patient's specific complaint, disability, and goals of treat-

ment to avoid disappointment. The exam includes neurologic and musculoskeletal assessments and must be recorded. Patients must also understand the surgeon's goals.

Reconstruction for Bone Healing Problems

Nonunions

Many patients present late after injury with an established malunion or nonunion. Pain, functional impairment, and anticipated premature joint deterioration are the indications for surgical management. Suboptimal cosmesis with near-normal function is not an indication for corrective osteotomy.

Nonunions are common, as most long bone fractures are treated nonoperatively [1]. When infected, especially after an attempt at surgical treatment, they represent a formidable challenge. Hypertrophic nonunions are generally due to inadequate immobilization, and the fracture often responds to rigid external immobilization and compression loading or rigid internal fixation. Oligo-atrophic and atrophic nonunions are attributed to an inadequate biologic environment, usually because of poor blood supply or nutritional status and/or tobacco use. They usually require internal fixation and bone grafting (Fig. 41.1).

R.A. Gosselin, MD, MPH, MSc, FRCS(c) (✉)
Department of Orthopedic Surgery,
Institute for Global Orthopedics
and Traumatology, UCSF, 1001 Potrero Ave, 3A-36,
San Francisco, CA 94110, USA
e-mail: froggydoc@comcast.net

H.E. Jergesen, MD
Orthopaedic Surgery, University of California,
San Francisco, San Francisco, CA, USA

Orthopaedic Surgery,
San Francisco General Hospital,
2550 23rd Street, Bldg. 9, 2nd Floor,
San Francisco, CA 94110, USA
e-mail: jergesen@orthosurg.ucsf.edu

D.-J. Lavalley, MBChB
Orthopaedic Trauma,
Emergency Surgical Centre, Freetown,
39 Lightfoot Boston Road, Off Wilkinson Road,
Freetown, Western Area, Sierra Leone
e-mail: djlav_sl@yahoo.com

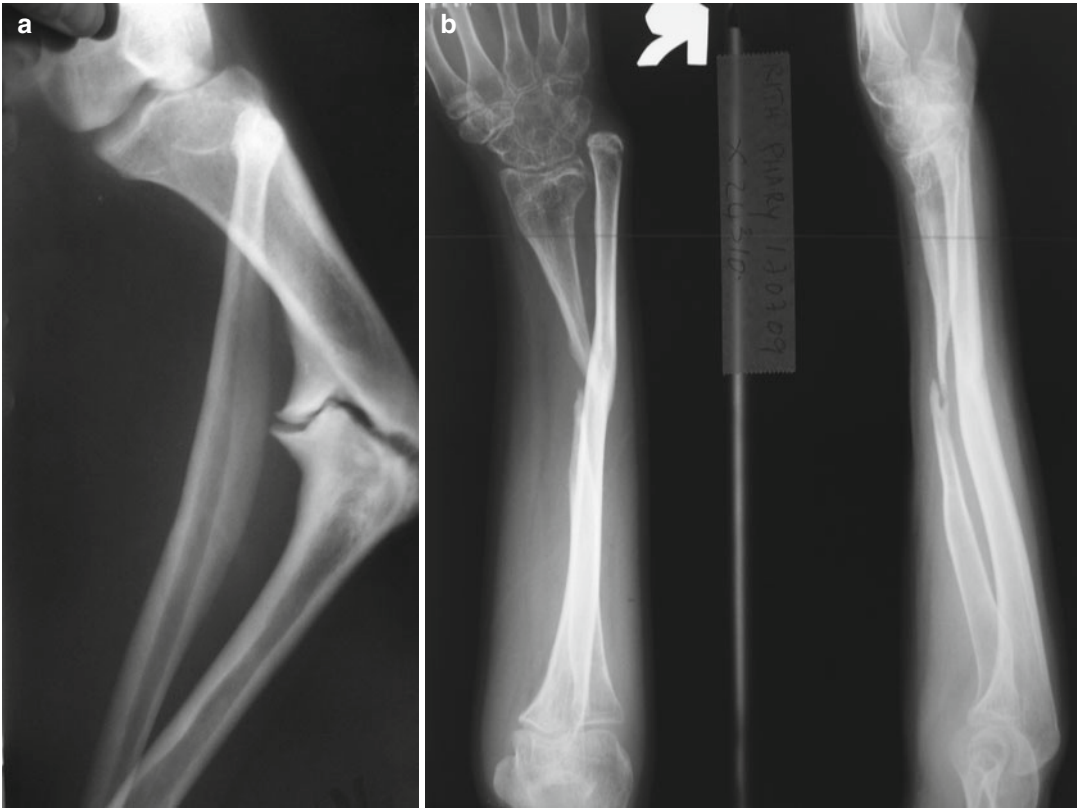


Fig. 41.1 (a) Hypertrophic nonunion of tibia. (b) An oligo-atrophic nonunion of radius

Humeral Shaft Nonunion

Humeral shaft fractures treated with hanging casts or coaptation splints can lead to nonunions, often of the oligo-atrophic type—particularly in the elderly and those with obese, flabby arms—or a true synovial pseudarthrosis, forming a “2nd shoulder” (Fig. 41.2).

These nonunions need rigid ORIF with a dynamic compression plate (DCP) or locked IM nail, with or without bone graft, usually through an anterolateral approach, or if the radial nerve needs exploration, a posterior approach. Bone ends are resected to bleeding bone and the medullary canals opened. Shortening up to 3 cm is well tolerated. A second plate can be added in the face of osteoporosis.

Radial and Ulnar Nonunion

Conservative management of both bone fractures and inadequate surgical fixation with Steinmann pins or K-wires as “alignment rods” often leads to

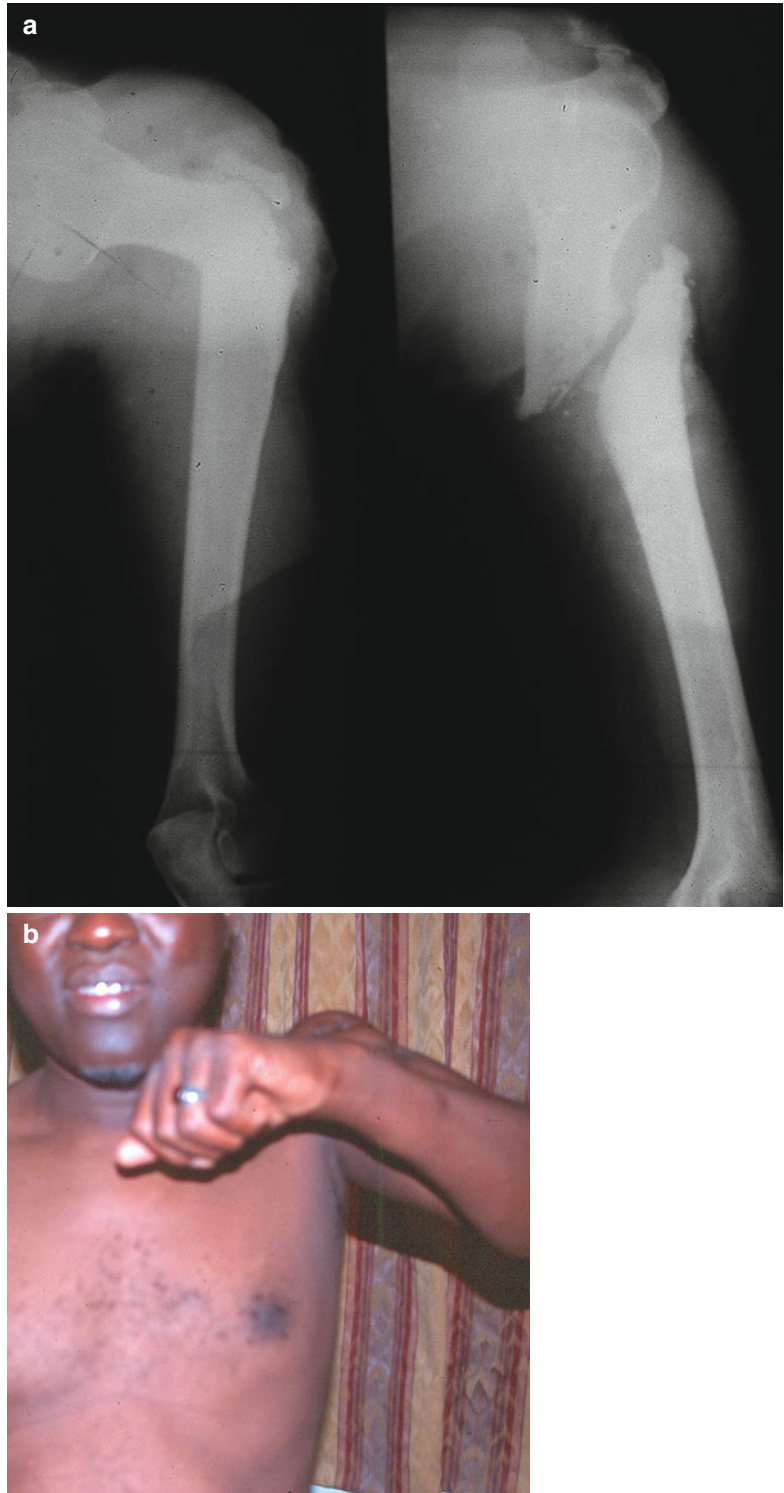
nonunion of one or both bones. No surgery is needed if one bone is healed, hand and elbow function is normal, and there is no pain on pronation, but this is rarely the case. Rigid internal fixation of both bones with plates and screws, with iliac crest bone grafting, that allows early mobilization, is the best option. Shortening up to 2 cm is acceptable, with both bones shortened the same amount. Reestablish the normal bow of the radius to maximize forearm pro-supination.

Nonunion of the distal radius and ulna is less common and, if symptomatic, should be taken down to bleeding viable bone and rigidly fixed (Fig. 41.3) with T plates or pinning and casting.

Scaphoid Nonunion

Scaphoid nonunions commonly present late with varying degrees of osteolysis, avascular necrosis, collapse, or carpal instability. If the bone has retained its anatomic contours, the treatment is surgical. Through a volar or dorsal approach, the

Fig. 41.2 (a) Hypertrophic pseudarthrosis of a proximal humerus fracture, (b) giving clinical appearance of “second shoulder”



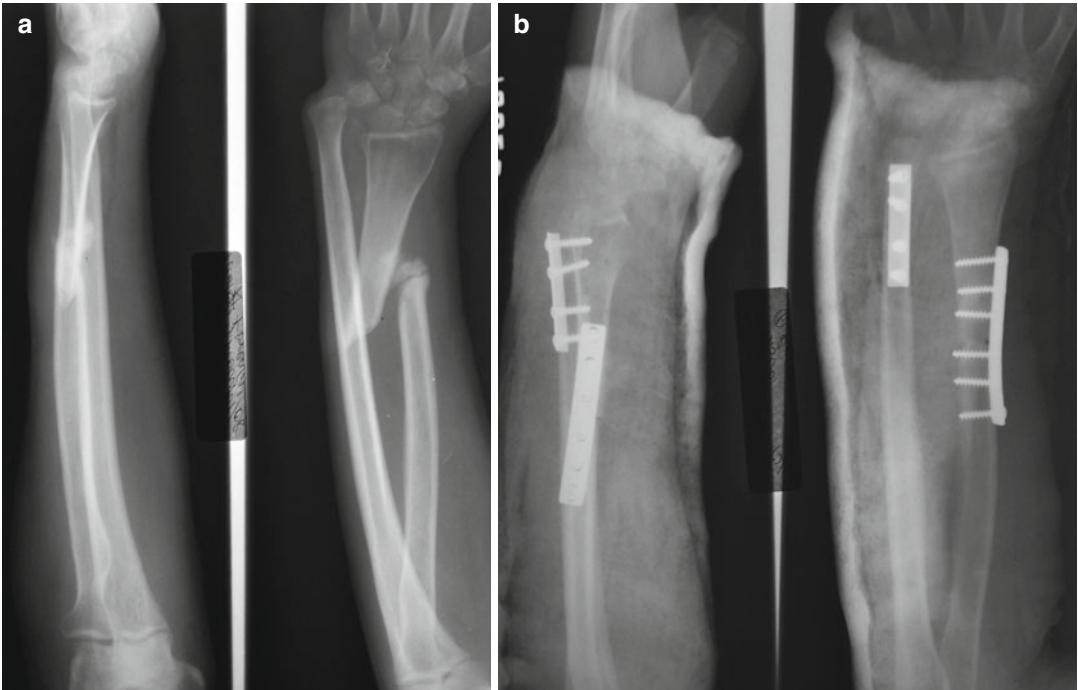


Fig. 41.3 (a) Oligo-atrophic nonunion of a Galeazzi fracture/dislocation. (b) Surgical treatment with internal fixation, bone grafting, and ulnar shortening. Note that the ulna is still 3–4 mm too long

nonunion is curetted and packed with cancellous bone from the distal radius, olecranon, or iliac crest. Self-compressing screws are rarely available, but two parallel K-wires are effective. Pins are removed at 6–8 weeks and casting is continued for another 6 weeks.

Femoral Neck Nonunion

Established nonunions of femoral neck fractures are usually painful and disabling. A cementless hemiprostheses is the best option. If fluoroscopy is available, percutaneous fixation with screws can be attempted in minimally displaced, relatively “fresh”—less than 3 months—fractures in younger individuals, but one should expect a high failure rate.

The only other option is an open reduction. The anterior approach is less likely to compromise the head’s vascular supply and should be used if only internal fixation is planned. A posterior approach is needed if one plans to add a pedicled corticocancellous pedicle bone graft based on the quadratus femoris muscle (Judet or Myers procedure) to the internal fixation [2].

In this procedure the femoral insertion of the quadratus femoris is exposed and osteotomized to include a segment of the intertrochanteric crest proximal to the quadratus insertion. The posterior hip capsule is T’ed open, the nonunion exposed, and fibrous tissue curetted from the nonunion site, creating a trough across the nonunion. The defect is filled with cancellous bone chips, and the graft is rotated on its muscle pedicle to cover the defect. It can be secured with a single screw.

Internal fixation of the femoral neck is achieved with three parallel, short-threaded 6.5 cancellous screws inserted in compression under direct vision from below the greater trochanter. The head can be temporarily pinned to the acetabulum with a Steinmann pin or drill bit, to avoid “spinning” during tapping or screwing. Six weeks non-weight-bearing is followed by progressive weight bearing as tolerated. This procedure is technically easier than it sounds, provides the added advantage of a vascularized graft, and is best reserved for younger patients. Although

intuitively appealing, no long-term outcome data exist from resource-poor environments.

Femoral Shaft Nonunion

Nonunions with minimal or no shortening can be exposed by sharply elevating a cortico-periosteal flap anteriorly and laterally, disrupting as little as possible the linea aspera posteriorly. Excising all fibrous tissue, the two ends of the canal are reopened and internally fixed with a statically locked IM nail (our preference), a dynamic nail with good 3-point fixation (Fig. 41.4), or a compression plate (Fig. 41.5).

Bone grafting is mandatory for oligo-atrophic nonunions with generous amounts of cancellous bone packed under the cortico-periosteal flap (Fig. 41.6). Hypertrophic nonunions most often heal with rigid fixation only, avoiding graft donor site morbidity.

Infected nonunions are appearing with increasing frequency after failed ORIF. The infection is addressed by a thorough debridement, removal of hardware if present and loose, and sequestrectomy to remove all nonviable bone and avascular segments. Hardware that is solid and still contributing to stability can be retained, until there is enough bone healing to allow it to be safely removed. Every effort should be made to mechanically remove as much of the biofilm as possible. Antibiotic beads or spacers can be made from 1.2 g of tobramycin, 2 g of vancomycin, or 6–80 ml vials of gentamycin per batch of cement. Dead space closure and bone coverage with healthy thigh muscle is usually possible.

Another option is temporary stabilization with an external fixateur, while the wound is left open to granulate from within. The wound is reassessed at 6 weeks, and if clean, the nonunion site is bone grafted and internally fixed. Suspicious fixateur pin tracts should be curetted, the patient put at bed rest, possibly in traction for 7–10 days, and treated with antibiotics before internal fixation.

Nonunion of Fractures About the Knee

Displaced fractures of the distal femur, proximal tibia, or patella lead to premature degenerative joint disease if not adequately reduced. They are commonly associated with ligamentous injuries, com-

pounding the problem. The decision to intervene surgically is based on the age and condition of the patient, activity level, time since injury, degree of comminution, amount of displacement, safety of the surgical environment, implant availability, and, importantly, the surgeon's comfort zone. Older fractures with already existing signs of degenerative arthritis are best left alone until symptoms are severe enough to warrant joint replacement or fusion.

Nonunion of the femoral condyles or tibial plateau is usually painful with weight bearing. A single large and undisplaced fragment can be fixed in situ with compression screws. With displacement greater than 2 mm, the fragment should be mobilized, reduced, and fixed, with supporting bone graft if needed, but only if the fragments can be reduced and fixed anatomically. A neutralization plate can improve the rigidity and allow early motion. Weight bearing is avoided for at least 6 weeks.

Meniscal lesions should be properly addressed. Ligamentous reconstruction beyond simple repair has a high risk of failure due to stiffness. Unless the secondary stabilizers—quadriceps and hamstrings—are also significantly damaged, most patients will develop satisfactory compensatory mechanisms.

Nonunion of the patella is addressed only if symptomatic. Occasionally a displaced, non-comminuted transverse fracture nonunion will benefit from mobilization, reduction, and fixation with tension banding or compression screws. Small, comminuted polar fragments can be excised and the patellar or quadriceps tendon reattached with heavy non-resorbable transosseous sutures. Some degree of residual stiffness and/or weakness will remain. Patellectomy may be the only solution to manage disabling pain, but weakness with running and stair climbing and an extension lag is almost unavoidable despite meticulous soft tissue reconstruction.

Nonunion of Tibia/Fibula Shaft Fractures

Nonunions that are not infected are approached in the same way as those in the femur (Fig. 41.7). Immediate weight bearing is encouraged, even if only partial. Some surgeons routinely perform a

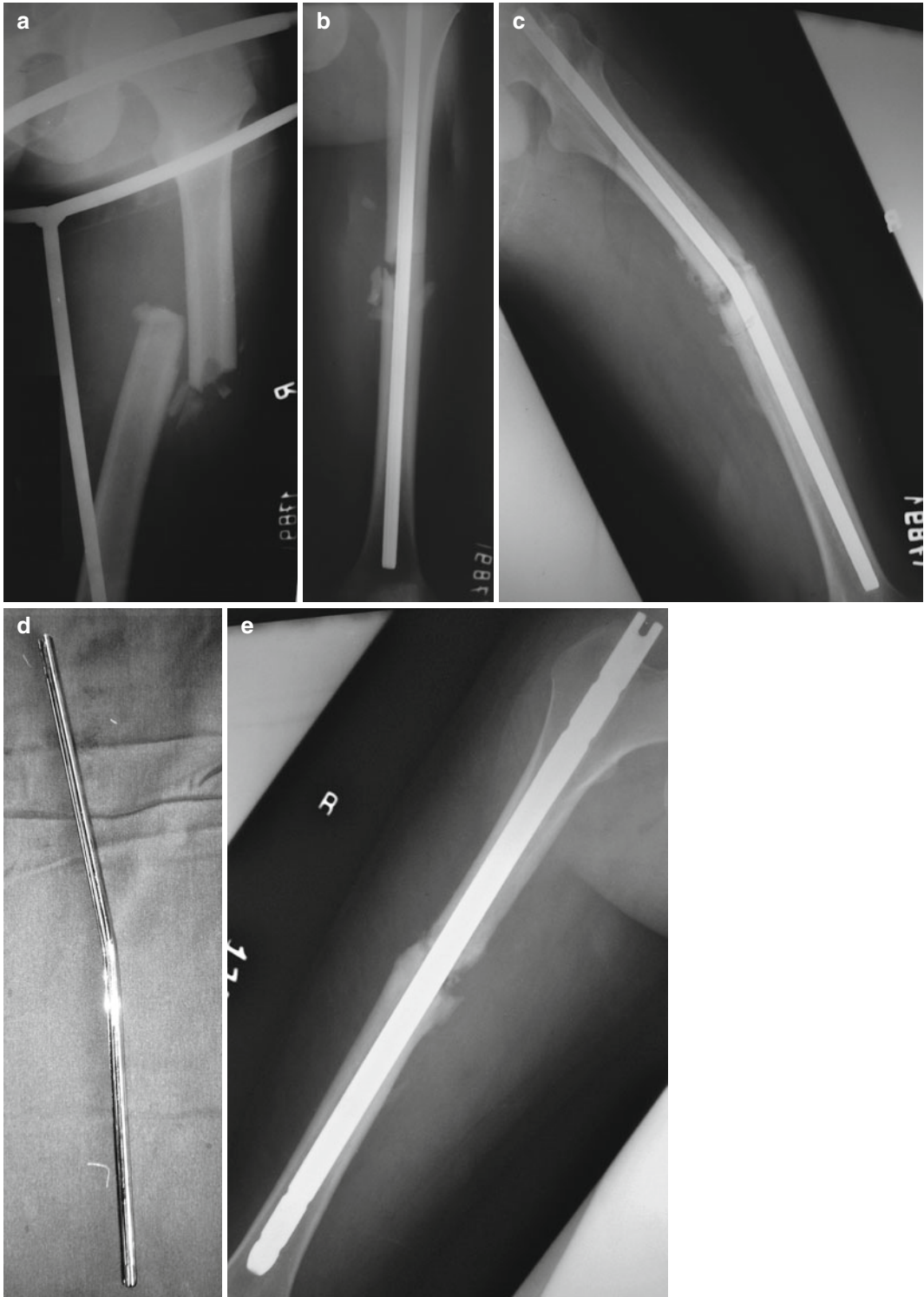


Fig. 41.4 (a) Comminuted transverse fracture of right femoral shaft. (b) ORIF with Kuntscher nail. (c) Nonunion at 6 months with the nail bending, but not broken yet. (d) The surgeon was lucky that the nail came out easily. (e) A bigger nail was inserted without opening the nonunion,

hoping that the reamings alone would provide sufficient bone graft and progressive weight bearing would encourage union. The nail was not interlocked because there was no fluoroscopy, and the proximal jig was broken

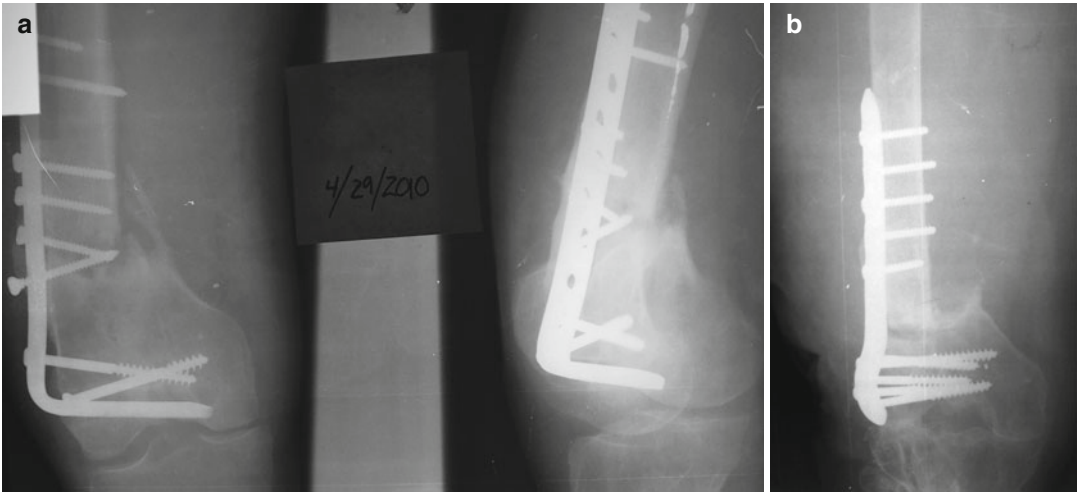


Fig. 41.5 (a) Nonunion of distal femur fracture with blade plate failure. (b) After debridement and shortening, the femur was fixed in compression, with medialization of the distal fragment, in a slightly varus position

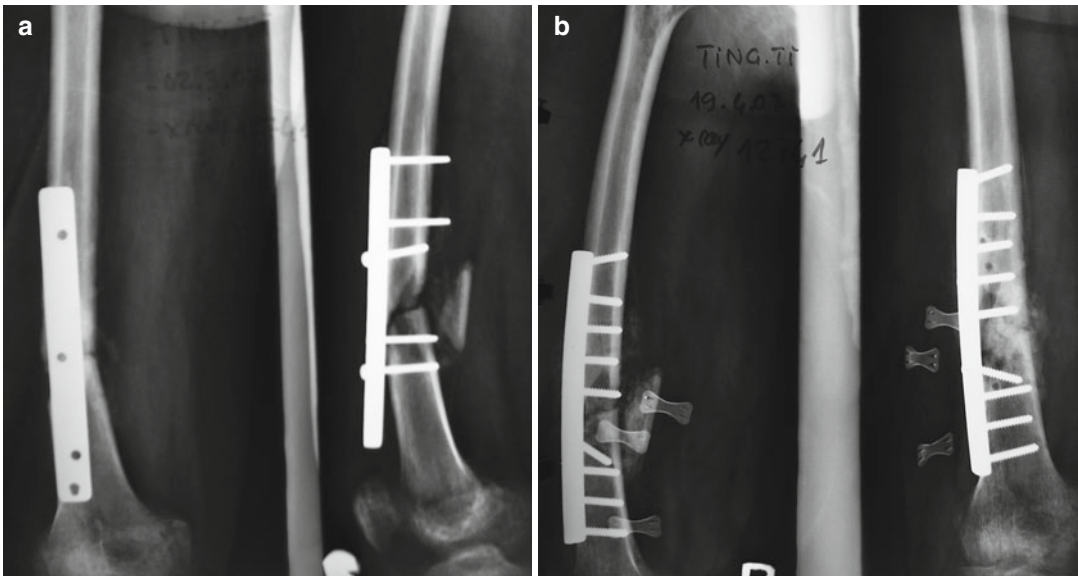


Fig. 41.6 (a) Delayed union 4 months after ORIF of a distal femoral shaft fracture. Unsatisfactory fixation has led to hardware failure. (b) Treated with re-plating and ample bone graft

fibular osteotomy (our preference), but this is not universally accepted (Fig. 41.8). Oligo-atrophic nonunions are bone grafted. Shortening of both segments should not exceed 1–1.5 cm. For nonunions near the ankle, a posterolateral approach is preferred to preserve the local blood supply.

Infected Tibial Nonunions

In resource-poor environments, management commonly involves multiple surgical procedures over long periods of time. The many constraints of this approach should be carefully weighed, and the patient made aware of the prolonged and costly process. Most patients are

willing to comply when they understand the severity of their disability and the alternative of amputation. The first objective in treating an infected, ununited tibia fracture is to control the infection (see Chap. 31, the same principles apply).

To address instability after debridement, the main fragments should be stabilized with an external fixateur or a bivalved or windowed cast. A saucerized bone that retains 2/3 of its

circumference does not need to be stabilized if the patient is compliant with non-weight-bearing. Depending on the available resources and expertise, the wound can be managed open or closed.

The Open Technique, Described by Papineau [3]

After thorough debridement, the wound is left open to granulate under a sterile dry dressing. The

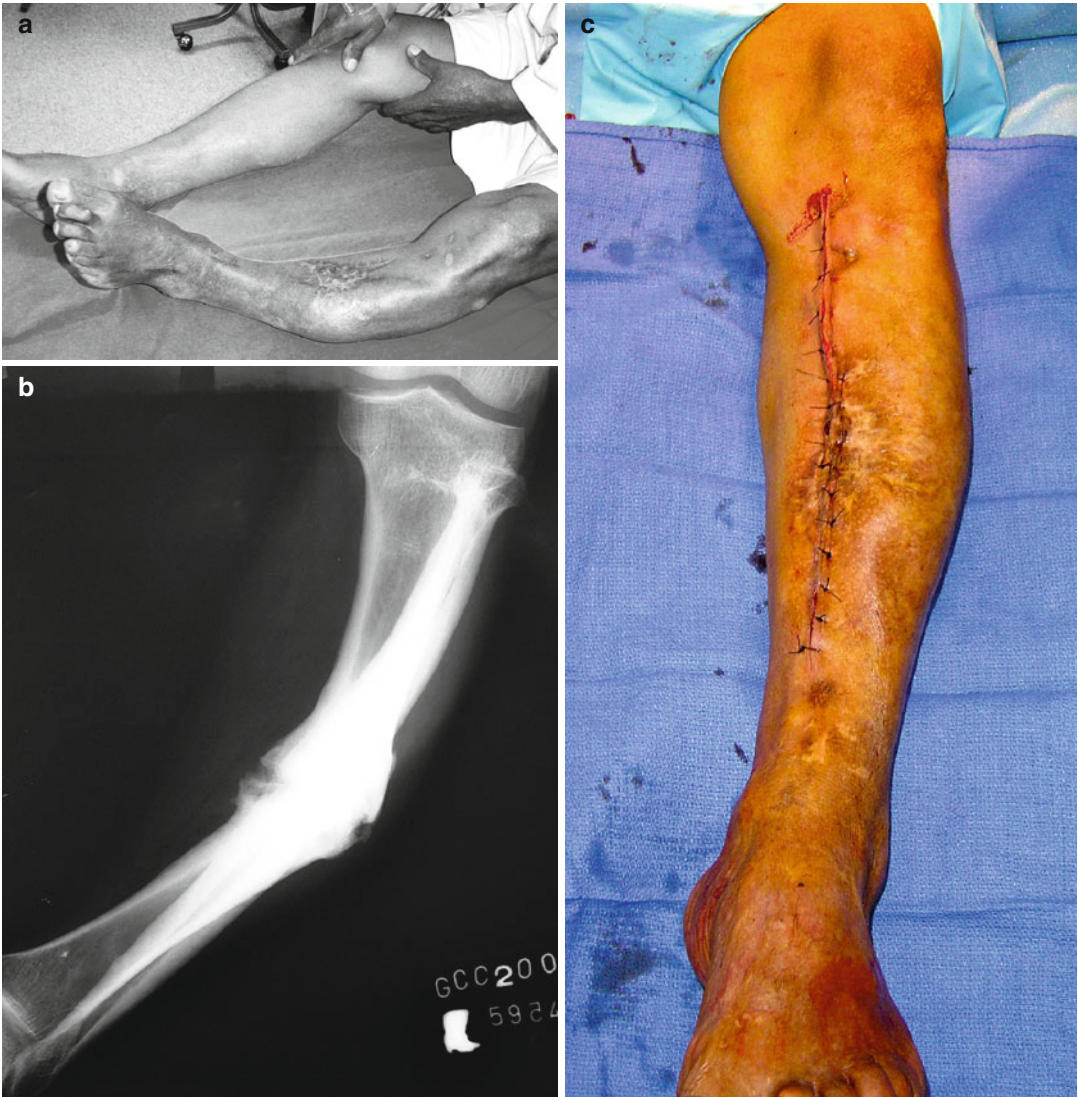
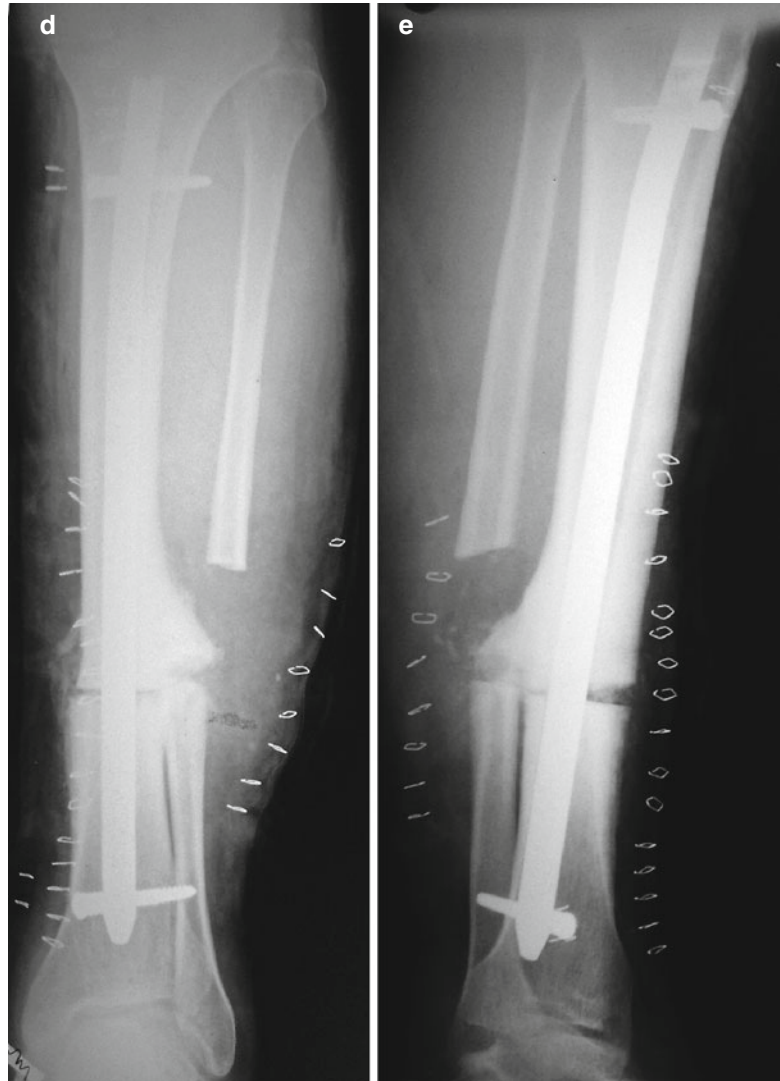


Fig. 41.7 (a, b) Clinical and radiographic appearance of a 55-year-old male with a hypertrophic nonunion of a 16-month-old mid-shaft tibia fracture. (c–e) Clinical and

radiographic appearance after segmental resection of fibula, nonunion takedown, bone graft, and statically locked IM nailing

Fig.41.7 (continued)

wound is irrigated in the shower before each daily dressing. Papineau believed that the mechanical action of direct irrigation promoted healthy granulation tissue and saw no difference in infection rates when comparing clean but non-sterile water to sterile saline. When the wound bed is completely covered with healthy granulation tissue, a generous amount of small chips of cancellous graft are tightly packed into the cavity. The first post-graft dressing is removed after 4–5 days, with the inevitable loss of some small chips, and gentle daily irrigation with saline solution or boiled tap water is performed until granulation

tissue “seeps-up” through the graft, at which time shower irrigation resumes. When granulation covers the graft, it can be covered with a STSG.

When skin and underlying soft tissues are healed and X-rays demonstrate sufficient bone consolidation, usually 4–8 weeks after skin grafting, the fixateur should be replaced with a patellar tendon-bearing cast. Progressive, protected weight bearing continues until clinical and radiographic consolidation is present. A fibular osteotomy is not routine but is considered if there is varus drifting or no progress to consolidation after 3 months. In open wound

techniques, local negative pressure systems, honey, sugar, or papaya paste have been described, with varying degrees of success. Follow local experience.

Closed Technique

The second option for wound management is wound closure with a muscle or fasciocutaneous rotation flap after it has been thoroughly debrided and clean. It is safer to delay skin grafting over a transferred muscle by 5–7 days, but anesthesia considerations should be factored in.

The medial gastrocnemius works well for nonunions in the proximal third of the tibia and

the soleus for the middle third. Wounds needing a soleus flap are often caused by high-energy trauma, with devitalization of the soleus, making this generally less reliable than a gastrocnemius flap. Distal third tibia nonunions remain a problem, as free flaps are rarely available. Fasciocutaneous flaps provide soft tissue coverage throughout the tibia except around the ankle. They do not bring in as robust a blood supply as a transposed muscle, but are easier for the less experienced surgeon. Cross-leg flaps in patients under 25–30 years; sural artery flaps and other local flaps are options for those experienced (see Chap. 14).

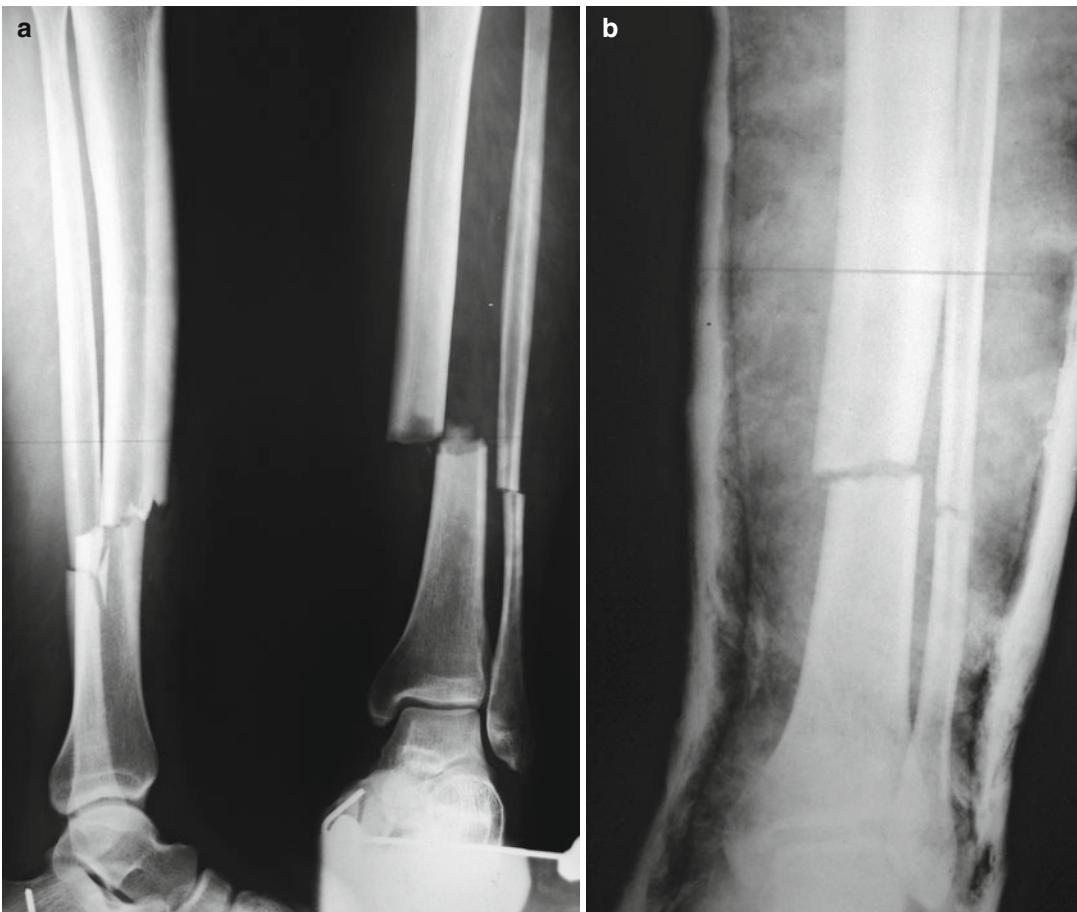


Fig. 41.8 Natural history of tibial fracture nonunion: (a) Initial X-rays shortly after injury involving both tibia and fibula. (b) Appearance after closed reduction and molding in AK POP. (c–e) Progressive varus angulation and hypertrophic nonunion over 6 months. (f) Treatment with ORIF

with dynamic interlocked IM nail, fibular osteotomy at malunion site and local bone graft. (g) Appearance 6 weeks later when patient was full weight bearing without pain

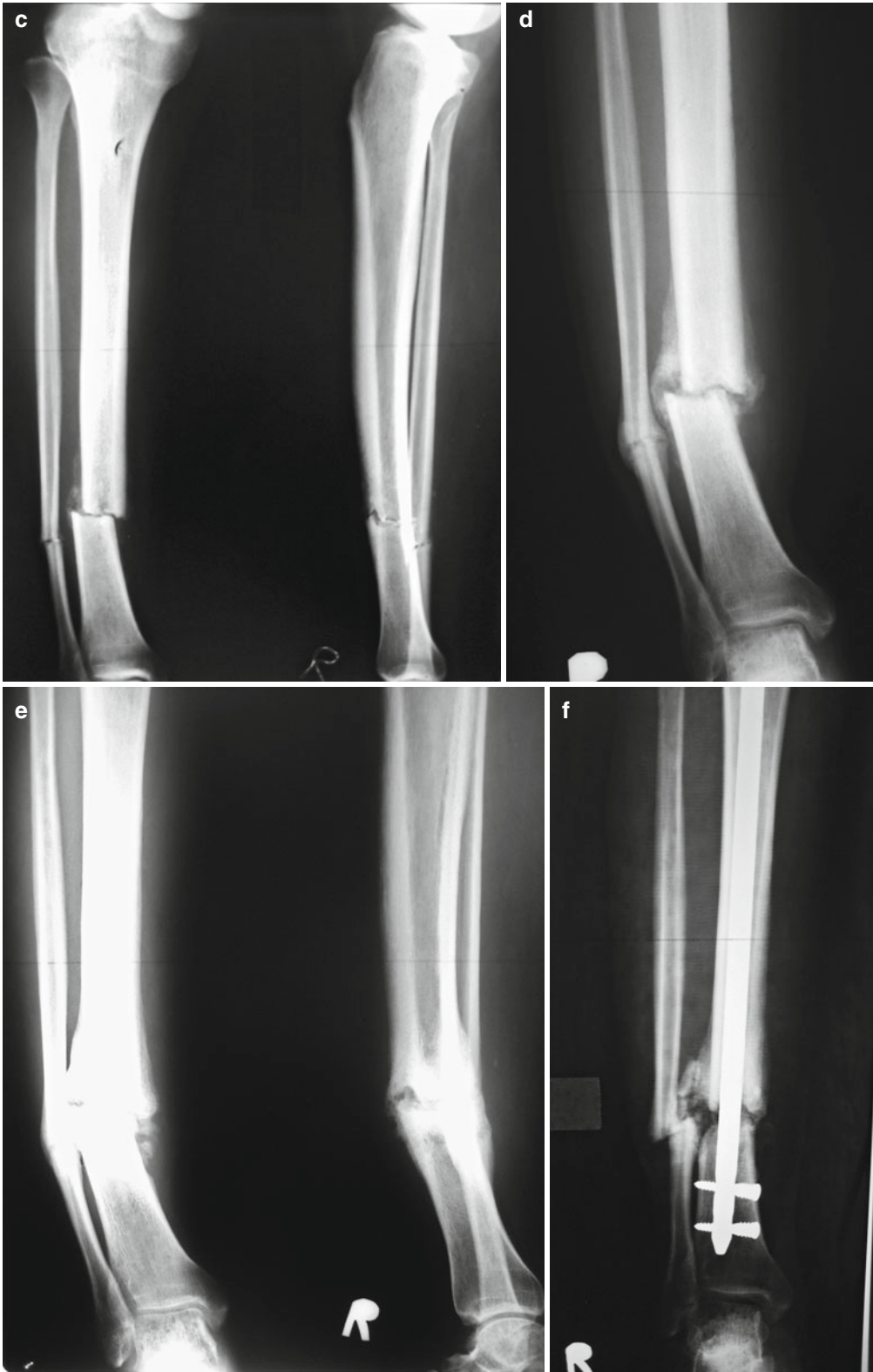


Fig. 41.8 (continued)

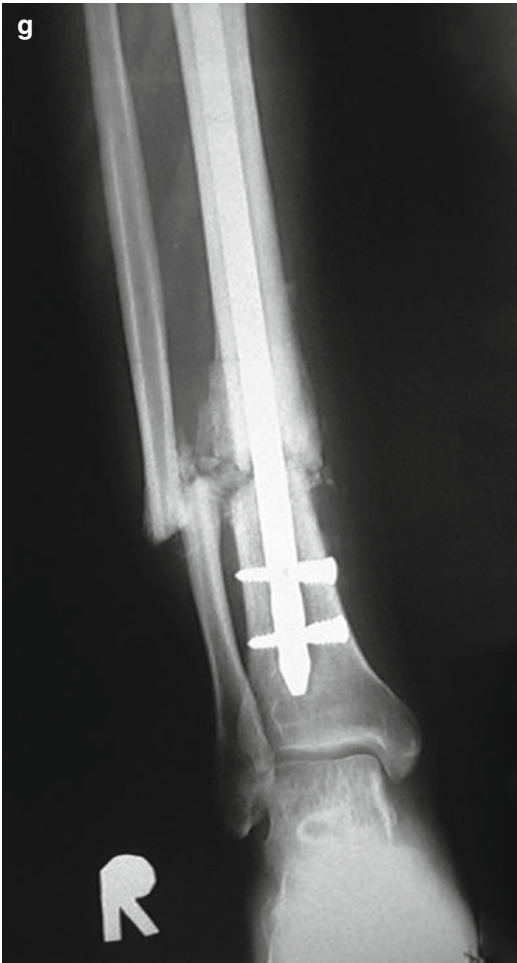

Fig. 41.8 (continued)

If methyl methacrylate is available, antibiotic impregnated, spacers can be shaped and left in the defect under the flap. The biomembrane that forms around the spacer provides a cellular environment that stimulates the incorporation of bone graft [4]. In this technique, the flap is elevated at 6 weeks, the spacer removed, and the gap filled with cancellous graft without disturbing the membrane. Further management is as above.

Another approach to managing infected tibial fractures in the pediatric or young adult population is to bypass the infected region by a tibiofibular synostosis proximal and distal to it (Fig. 41.9). This procedure is done through a posterolateral (Harmon) approach with the patient in a lateral or prone position, giving access to the posterior iliac

crest where bone graft can be harvested. This approach is useful when extensive anterior tibial soft tissue debridement is necessary to address the infection, a large bone defect is present, and/or when bone transport is not available. After the grafting a non-weight-bearing above-knee cast is applied and replaced at 6–8 weeks with a patellar tendon-bearing cast or brace that allows the intact fibula and adjacent bone graft to hypertrophy over the course of 12–24 months until full weight bearing commences.

Nonunion of Fractures About the Ankle

Intra-articular fractures of the distal tibia, or malleolar fractures, are common and often present late (Fig. 41.10). Patients assume the injury was a “bad sprain” and resume weight bearing as pain allows or are treated by a local healer and inadequately immobilized. In both scenarios, premature weight bearing tends to displace the fracture in the direction of the initial injury, most commonly in pronation and external rotation.

The goal of treatment is to reposition the talar body anatomically under the distal tibia, before secondary degenerative changes commence. Because residual displacement dramatically alters the area of contact in the tibiotalar joint, degenerative changes can occur rapidly, making a short window of opportunity for effective treatment. Absence of pain usually means that the young fracture has consolidated, but if pain is present, it is often difficult to determine if it is due to residual motion at the fracture site or synovitis from early articular cartilage wear. Any suspicion that there is motion at the fracture sites can be confirmed with fluoroscopy, stress X-rays, or differential anesthetic blocks.

Some malleolar and pilon fractures that are less than 8–10 weeks should be treated with open reduction and internal fixation (Fig. 41.11). Pilon fractures that are simple, with one large fragment involving more than 1/3 of the articular surface, are displaced more than 2 mm, and have no evidence of advanced consolidation on X-rays can be fixed with compression screws and/or plates. All other late pilon fractures are best handled nonoperatively, with treatment focused on functional rehabilitation, and surgery most likely a fusion.

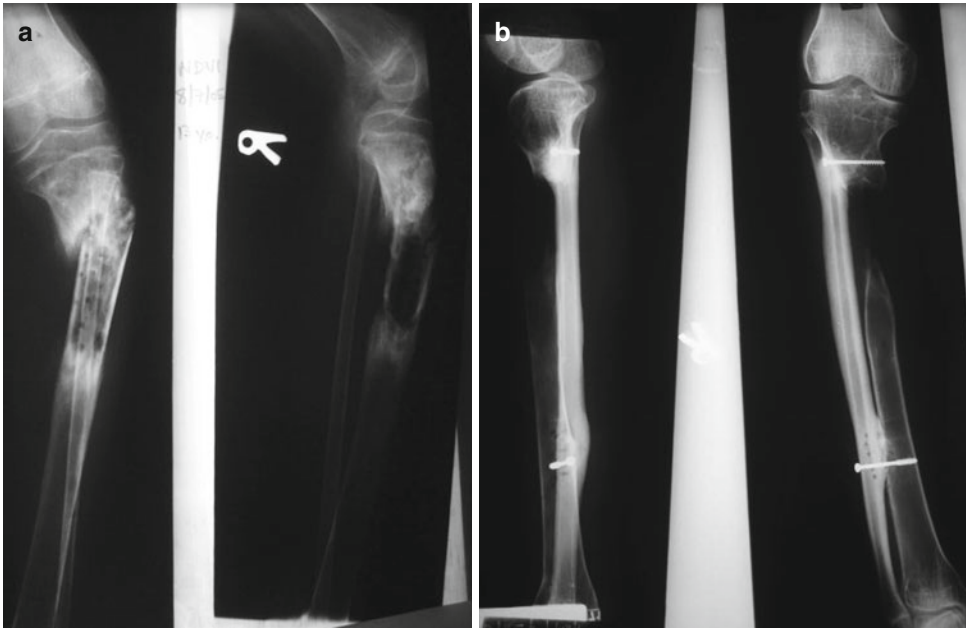


Fig. 41.9 (a) Infected nonunion of proximal tibia pathologic fracture secondary to chronic osteomyelitis. (b) Two years after debridement and tibiofibular synostosis

without osteotomizing the fibula. The fibula is visibly hypertrophied without signs of recurrent infection

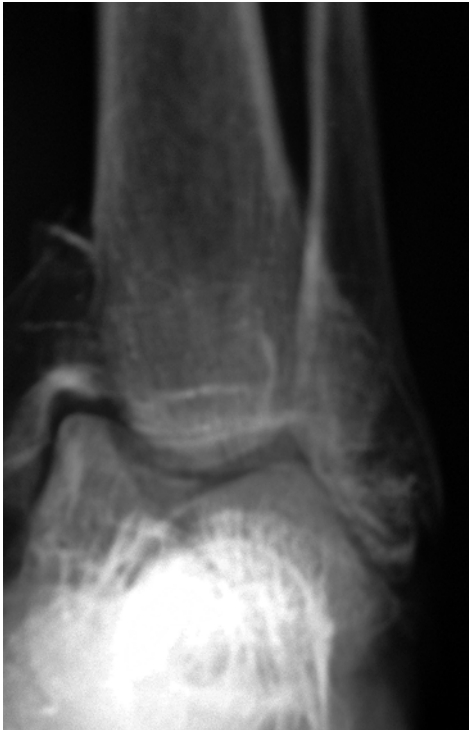

Fig. 41.10 Natural history of neglected displaced intra-articular ankle fracture, with impressive grooving of the talus. At this stage, arthrodesis is the only surgical option

Symptomatic undisplaced malleolar nonunions can be treated with compression fixation in situ by screws or plates. Displaced nonunions should be mobilized, reduced, and fixed so the talus sits as anatomically as possible under the distal tibia. In bimalleolar injuries, both malleoli must be mobilized and fixed to achieve this goal. Postoperative deforming forces can be temporarily neutralized by a sturdy Steinmann pin drilled from the calcaneus through the talus and into the distal tibia. The pin is left protruding at the plantar aspect of the heel and protected with a non-weight-bearing below-knee cast and removed after 6–8 weeks. Such pins should be used only in patients who can understand and comply with the non-weight-bearing status.

Malunion

Malunion of Humeral, Radial, or Ulnar Shafts

These rarely translate into a significant functional impediment. If so, a closing wedge osteotomy at

Fig. 41.11 (a) Displaced bimalleolar fracture/subluxation at 12 weeks. (b) Note the presence of callus laterally, but little medially. (c) The fracture was taken down and internally fixed with plate, screw, and pin, with an acceptable X-ray. The joint line is already narrowed with anterior beaking, and this patient may still need an arthrodesis

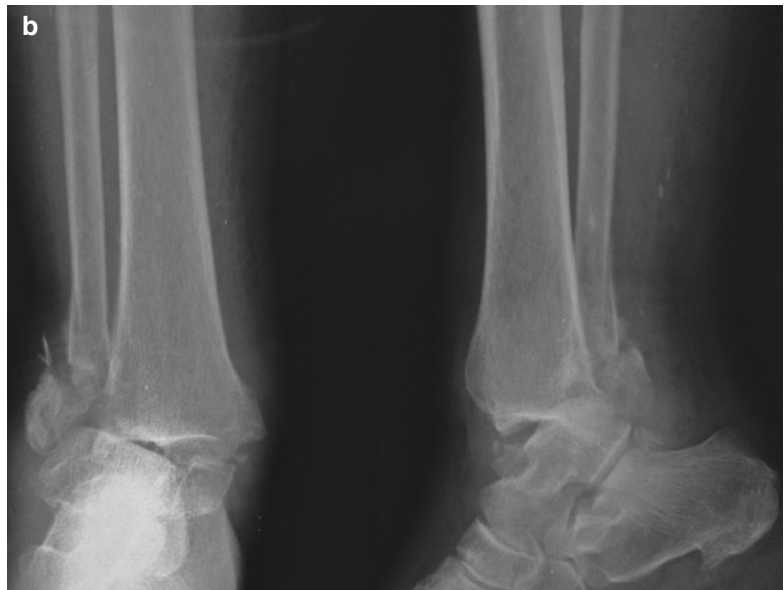
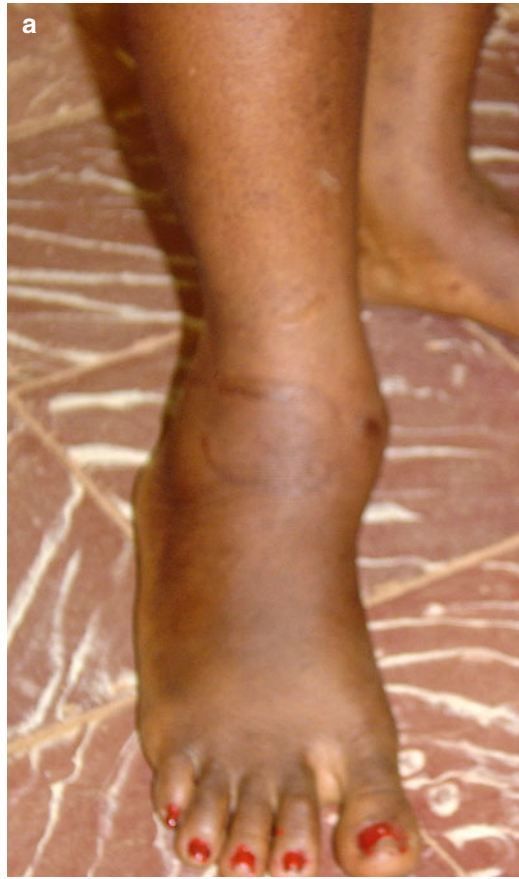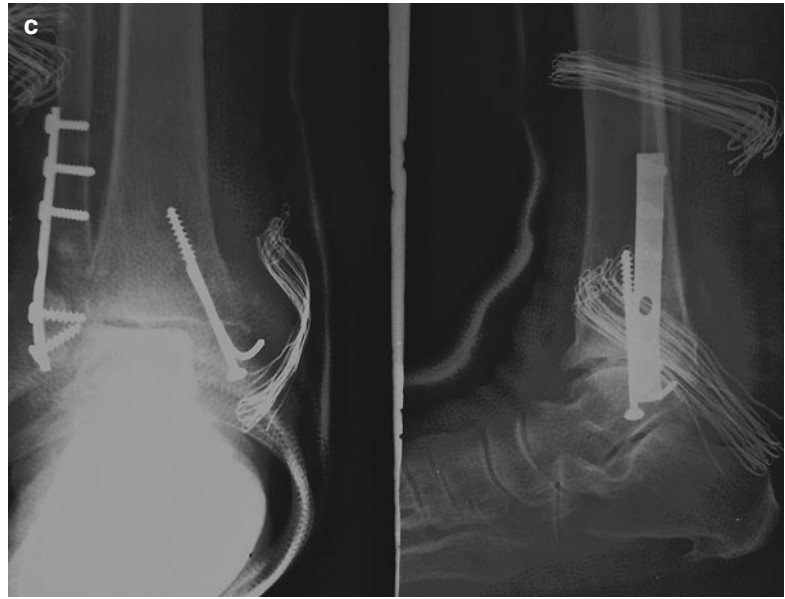


Fig. 41.11 (continued)

the apex of the malunion and internal fixation with or without grafting may be indicated.

Malunions of intra- or extra-articular fractures of the distal radius are more common. Shortening, radial deviation, and volar apex angulation, after a Colles fracture, are the most common presenting deformities and usually associated with a prominent, occasionally dislocated distal ulna. If there is a displaced intra-articular component, early degenerative changes with pain and stiffness can occur. The same is true for the rarer volar Smith fracture.

For those who complain of pain or disability, restoration of a more anatomic alignment may improve both function and cosmesis; however, it is often surprising how patients, particularly in the older age group, have much better clinical function than X-rays suggest.

The typical Colles deformity is approached dorsally, by a dorsal radially based open wedge osteotomy to restore the 10–15° of volar tilt and improve length and radial inclination. It is important to preserve a cortico-periosteal hinge at the apex of the osteotomy to prevent distraction and/or translation when the wedge is opened. A corticocancellous bone wedge from the iliac crest is press-fit into the opened osteotomy with cancellous chips filling the remaining gap. Internal fixation with a small plate is preferred, but bicortical

pinning with K-wires is also effective. A below-elbow cast is worn for 6 weeks, after which the pins are removed and a new cast applied for 6 more weeks. The deformity associated with a malunited Smith fracture is approached volarly, with a similar opening wedge technique.

If residual positive ulnar variance remains unacceptable—5 mm or more—or the ulnar styloid is too prominent, either ulnar shortening held with a small tubular plate, lag screws, or K-wire (preferred) or excision of the distal ulna, Darrach procedure, can be carried out.

Intra-articular malunions are technically more challenging, but sizeable single fragments can be mobilized, reduced, and pinned, using cancellous bone for support. This should be done before the corrective opening wedge is created.

Malunion of the Femoral Shaft

Osteotomy for malunion should be considered if the mechanical axis deviates by more than 10° in the frontal plane and 15° in the sagittal plane. Malrotation is more difficult to assess, but more than 15–20° of a rotational difference compared to the opposite side should probably be corrected. Deformities are usually multiplanar, requiring a comprehensive physical exam for surgical planning (Fig. 41.12).

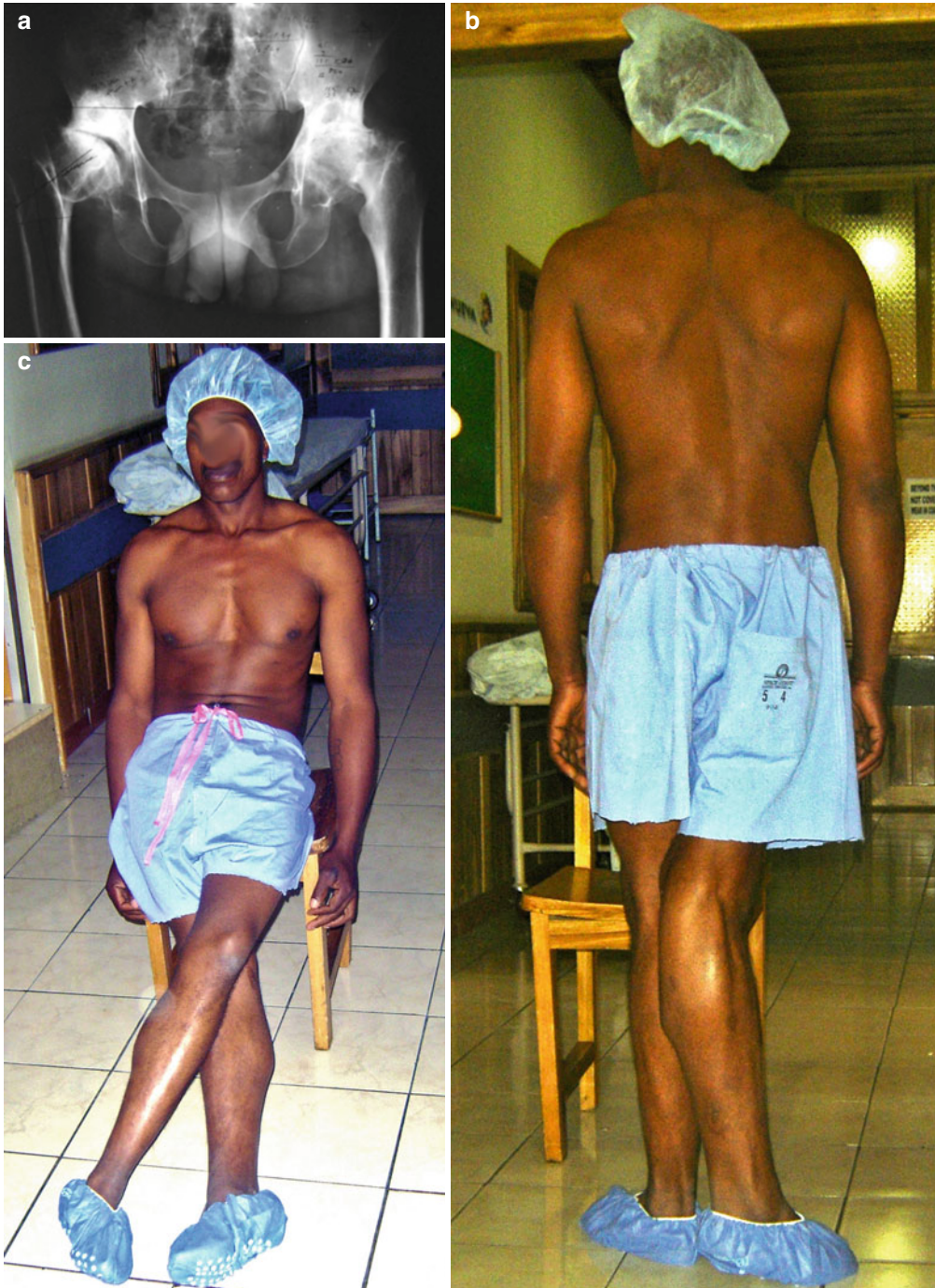

Fig. 41.12 (a) X-ray of 36-year-old male with bilateral fibrous ankylosis of the hips, which the patient said was due to a football injury in his early teens. He had no pain and no motion. (b, c) Standing and sitting appearance of the patient, demonstrating severe adduction/extension/external rotation of the right lower limb, with compensatory recurvatum of the knee. (d) As arthroplasty was not

an option, the patient underwent a flexion/abduction/derotation osteotomy, fixed with a DHS and a DC plate. (e) Clinical appearance the day following surgery. (f) X-ray taken the following year showing a healed osteotomy. The patient underwent a total hip replacement of the left hip at this time. He was doing well the third year and declined to have his osteotomy side converted to a total hip

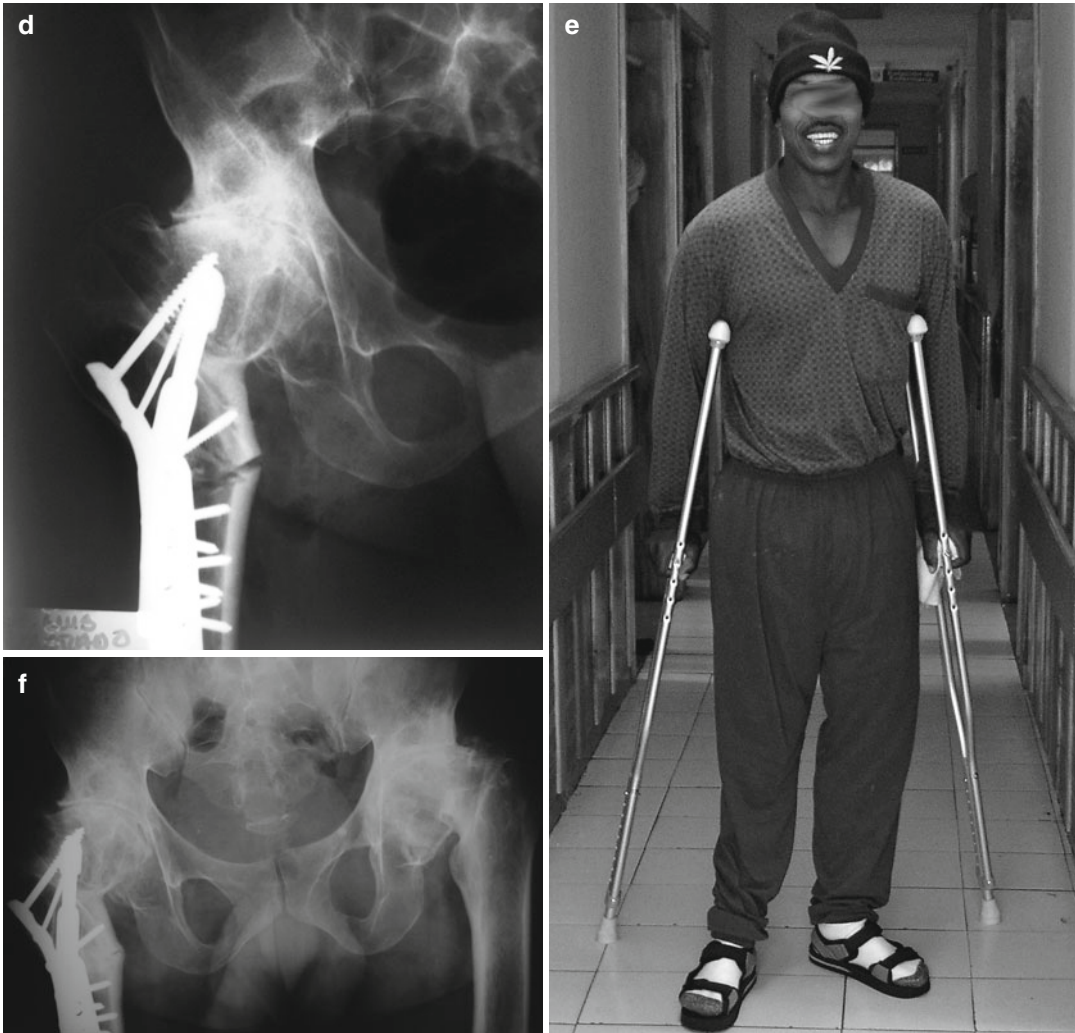

Fig. 41.12 (continued)

Femoral shortening less than 2 cm can be managed with a shoe lift. Up to 5 cm can be corrected with a single surgery, especially if a femoral distractor is available. Lengthening of more than 5 cm should not be attempted as a stretch injury to the sciatic nerve, or a thrombosis of the vasculature can result in a complication much worse than a leg length discrepancy.

If there is shortening due to healed overriding bone fragments and end-to-end reduction is not possible, the femur should be shortened and the residual length discrepancy addressed with a shoe lift. If regaining length is necessary, an alternative, after release, is distal femoral skeletal

traction with 10 kg for 2–3 weeks, followed by delayed internal fixation. The surgeon should weigh the increased risks of infection and bleeding using this 2-procedure technique. Proximal tibial traction might lessen the potential for infection caused with a distal femoral pin, but the traction weights across the knee ligaments can also cause injury. A third and safer option is slow and progressive correction and lengthening with osteoclasts and a distraction frame, as with the Ilizarov method, with the caveat that these should not be attempted by inexperienced surgeons and/or when no experienced surgeons will be present to handle the complications.

When the femoral length discrepancy and malunion can be handled at one sitting, it is approached laterally, and the fragments osteotomized and mobilized to regain the anticipated length. Angulatory malunions are addressed with the removal of appropriate bone wedges. The ends of the fragments are “refreshed” with a Gigli saw or rongeur, and the canal opened on both sides. Palpating the linea aspera helps preserve proper rotational alignment. A statically interlocked IM nail (our preference) or a large DCP with preferably eight cortices on each side can rigidly hold the osteotomy. Bone grafting is usually not required, but any excised bone can be used as local graft.

When there is no shortening, an elegant alternative to correcting multiplanar malunions with multiple complicated wedges is the “clamshell” osteotomy [5, 6]. The femur is osteotomized through healthy bone just above and just below the malunion, creating a malunion “segment.” This intermediate fragment is pre-drilled and bivalved with an osteotome from front to back, keeping intact as much soft tissue attachment as possible, especially posteriorly. A statically locked IM nail lies between the bivalved bone fragments, as in a segmental fracture. The shorter the segment, the closer it is to the midshaft, and the more normal the anatomy of the proximal and distal canals, the greater the likelihood that the nail will yield correction in all planes. Correction of malunited fractures at the metaphyseal junction is less predictable, particularly in rotation, and sound clinical judgment is necessary before attempting such surgery.

Malunions About the Knee

The same principles of accurate intra-articular reduction and fixation that are given above for nonunions about the knee apply to malunions. If pain is the presenting symptom, degenerative changes may well be worse than suggested on X-ray. Osteotomizing a healed intra-articular fragment through the old fracture line is more difficult than mobilizing an extra-articular nonunion and requires adequate exposure. When elevating a depressed fragment, bone grafting

should be used to fill the void and add support. Rigid internal fixation allows early mobilization, but when unavailable, temporary fixation with K-wires, Steinmann pins, and immobilization in a cast for 6–8 weeks is a viable alternative. Joint mobilization can be started after the pins are removed, but weight bearing waits for 3 months.

Malunions of Tibial Fractures

These are common and should be considered for correction if there is malalignment of more than 5–10° varus or valgus, or 10–15° or more of angulation in the sagittal plane. Shortening is rarely as great as that seen in the femur. When there is no shortening, the clamshell technique, as described for the femur or closed or open wedge osteotomies with nail or plate fixation can be used. Simple osteotomy at the malunion site—percutaneous when possible—fibular osteotomy, manipulation, temporary fixation with pins, and cast immobilization are effective when hardware is unavailable or the surgical environment precarious.

Malunions Around the Ankle

Unless degenerative changes are already visible on X-rays, malunions of malleolar fractures should be addressed in the same fashion as malleolar nonunions. This is technically more challenging as the precise level of medial osteotomy can be difficult to determine, especially if fluoroscopy is not available. Some degree of residual stiffness, even painless fibrous ankylosis, may yield acceptable outcomes. If pain becomes severe, a tibiotalar arthrodesis can be done and will be technically simpler if there has been some anatomical restoration of the joint.

Malunions of the Foot

A painful varus deformity of the hindfoot, seen after a displaced calcaneal fracture, may warrant a Dwyer osteotomy, described below. A diagnostic block will differentiate subtalar joint pain.

Localized metatarsalgia with a painful plantar callus can occur with metatarsal malunions. If symptomatic, an oblique osteotomy of the neck of the affected metatarsal is usually effective. The osteotomy is made from proximal-dorsal to

distal-plantar, and early weight bearing in a stiff-sole shoe allows the prominent metatarsal head to slide dorsally. Transfer metatarsalgia in neighboring metatarsals can occur. If the first metatarsal requires osteotomy, we recommend temporary internal fixation with K-wires in the desired position to prevent displacement.

Correction of Nontraumatic Deformities

Tibial Osteotomies

Tibial osteotomies are commonly indicated for nontraumatic deformities, such as genu varum or valgum arising from degenerative arthritis, rickets, dysplasias, or diaphyseal bowing. Severe deformities are often bilateral, and correcting only one side will achieve little. The second limb should be corrected, 4–6 months after the first, though both sides can be done safely at the same setting, with tourniquets used to restrict blood loss. This latter approach makes nursing difficult if prolonged non-weight-bearing is required.

In the case of severe deformities, the hip and ankle have usually compensated. Contractures around the hip are not uncommon, but this spherical joint usually adapts. The limitations of ankle anatomy make adapting to new mechanics less forgiving, particularly in the coronal plane. A plantigrade foot before correction indicates ankle joint adaptation and may require an additional distal tibial osteotomy. The patient should be made aware of the two-phased approach before the first procedure.

Genu Varum or Valgum Deformities

These are common and can be quite severe. Often the question is where to best perform the correction: femur, tibia, or both. If the site of malalignment can be easily identified, the site of correction is obvious. The ultimate goal is for knee and ankle joint lines to be parallel to the floor when standing. Prerequisites include adequate function of the ipsilateral hip and ankle joints (see Chap. 37 for further principles on correction of angular deformity).

Ask for the longest films possible of the entire leg, and from them estimate the precise amount of correction required to align the mechanical axis from the head of femur through the center of the knee and ankle joints. As a general rule, if the mechanical axis of the femur is 0° , all the correction should be obtained below the knee. If the mechanical axis of the tibia is 0° , the correction should be done above the knee. Otherwise the knee and ankle joints will lose their parallelism.

When X-rays are inadequate, angles can be estimated clinically, although less precisely, by the following: The center of the hip joint is identified and marked, one thumb breadth medial to the ASIS, or, as some advocate, one quarter of the distance between the tips of the greater trochanters [7]. The knee and ankle joints are also marked. An AP knee X-ray with metallic skin markers defines the joint more precisely. The mechanical axes of femur and tibia are drawn on the skin and the angles measured with a goniometer.

Varus deformity due to degenerative arthritis of the knee is usually corrected by means of a valgus-producing high tibial osteotomy with overcorrection up to 5° . Significant valgus deformity due to the same cause is managed by varus-producing distal femoral osteotomy. Varus or valgus deformity due to proximal tibial malunion is corrected at the malunion site itself to bring the knee joint parallel to the floor. Occasionally, deformities are so severe that osteotomies are needed on both sides of the joint.

Osteotomies can be dome or wedge type. In general, closing wedge osteotomies heal faster than opening wedge osteotomies, do not stretch neurovascular structures, allow early weight bearing, and should be preferred unless leg shortening is an issue. When osteotomies are done on both sides of the joint, an opening femoral wedge and a closing tibial wedge—with the tibial wedge used to prop open the femoral one—are much less at risk of winding up with a significant leg length discrepancy. This can be supplemented by a piece of fibula harvested at the time of osteotomy.

A sterile goniometer is valuable at the time of surgery. One solution is to create a makeshift one (see Appendix 3). The goniometer allows K-wire

insertion above and below the proposed osteotomy site at predetermined angles, so they will be parallel after the osteotomy. Positioning these wires parallel in the frontal or sagittal planes helps control rotation. These improvised markers are useful if a blade plate or DCS implant is used for internal fixation in the distal femur. Without fluoroscopy, proper positioning of hardware can be technically demanding, especially the blade plate. Our preferred technique is illustrated in Appendix 3.

If blade plates or DCS implants are not available, regular DCPs can be bent usually through the fourth or fifth hole of an 8–10-hole plate to make a blade plate. This is much easier with small fragment DCPs, in which case two plates can be used side by side if necessary. Unbent DCPs can also be used as condylar plates, but fixation in the distal fragment is usually limited to two screws. Fixation of the osteotomy can be achieved with Steinmann pins if no other implant is available. The pins are incorporated in a long-leg cast for 6–8 weeks, after which, knee motion is started, but weight bearing, particularly for open wedges with grafts, should wait until 3 months.

L- or T-shaped buttress plates are adequate for fixing high tibial closing wedge osteotomies. Blade plates can be contoured from small fragment DCPs or 1/3 tubular plates, stacking two together to increase their strength. If fixation is rigid, early knee motion is possible but not full weight bearing. Staples, compression screws, and even temporary pinning and casting are acceptable alternatives. Some surgeons recommend a well-molded cylinder cast and immediate weight bearing for their closing wedge osteotomies.

Dome Osteotomy

A dome osteotomy can be used for correction in the proximal tibia or distal femur. The healing time is faster due to the increased area of bone contact, and the correction may be more precise as the fragments can be “dialed in” at any desired angle. In theory, internal fixation should be on the concave side of the deformity, but when strong implants such as blade plates or condylar plates are available for the femur, lateral placement is adequate. In combined tibial and femoral dome osteotomies, a lazy S incision—starting laterally

over the distal femur, curving over the distal pole of patella, and following the posteromedial crest of the proximal tibia—affords better exposure to both bones than a classic anterior midline incision.

There should be no more than 2 cm of height between the dome apex and borders of the dome. For the femur we prefer a distal pointing (smile) dome at the metaphyso-diaphyseal junction, as there is more cortical bone stock in the distal fragment for fixation. Bicortical holes are drilled from anterior to posterior along the planned dome line and connected with a small osteotome. Well-positioned retractors and knee flexion prevent injury to the posterior neurovascular structures. The osteotomy is completed with forceful manipulation, leaving a posterior periosteal hinge. The osteotomy is temporarily fixed with two crossed Steinmann pins. The alignment is rechecked and the osteotomy internally fixed. The new knee center is used to assess how much correction is needed on the tibial side.

Different dome osteotomies have been described for the tibia (above or below the patellar tendon, smile or frown). We prefer to go through more cancellous bone, so we routinely use a proximal apex (frown) above the patellar tendon insertion. The technique is the same as above. All efforts are made to keep a posterior periosteal hinge at the osteotomy, and the distal fragment is rotated on the proximal one until the centers of the knee and of the ankle are in line. Temporary fixation with Steinmann pins allows for an assessment of the overall alignment, including a look from the foot of the table before definitive fixation.

Careful disruption of the proximal tibiofibular joint capsule is preferable to fibular osteotomy to avoid injury to the motor nerve of the extensor hallucis longus. Working a Cobb or Key elevator from distal to proximal between the lateral tibia and the fibular head will avoid injury to the interosseous vascular bundle distally. Rigid fixation is preferred as it allows earlier range of motion. If no hardware is available, temporary Steinmann pin fixation and a well-molded long-leg cast are acceptable alternatives. Even with rigid fixation, when both tibia and femur have been corrected, a posterior gutter splint or a bivalved long-leg cast is used for 7–10 days for comfort. The surgeon must

be on the lookout for a postoperative compartment syndrome. Weight bearing is started at 6 weeks.

Deformities of the Foot Requiring Osteotomies

Varus deformity of the hindfoot is common in under-corrected clubfeet, and occasionally from a displaced calcaneal fracture. A lateral closing wedge osteotomy of the calcaneus (Dwyer-type) is a simple and effective procedure and restores a more physiological mechanical environment.

A 5–6 cm oblique incision is made 2 cm below the tip of the lateral malleolus and centered on its posterior edge. Do not undermine the skin or violate anatomic planes, as wound healing can be compromised. Once the sural nerve is identified and protected, sharply incise the tissues down to bone. Expose the os calcis subperiosteally and insert retractors above and below the calcaneal body. A ± 1 cm wide laterally based bone wedge is removed, taking care to preserve a medial hinge. The wedge is closed and fixed with staples or with one or two short-threaded 6.5 screws. Secure internal fixation allows early range of motion and weight bearing at 3–4 weeks. Alternatively, a large Steinmann pin can hold the osteotomy within a well-molded short-leg non-weight-bearing cast for 6 weeks. Progressive weight bearing begins after pin removal.

Valgus deformity of the hindfoot can be seen in symptomatic flatfeet, in overcorrected clubfeet, tarsal coalition, or as a sequela of polio. Its management is similar to osteotomies done for lateral column lengthening.

Cavus deformity of the hind- and midfoot is often associated with central or peripheral neuromuscular conditions. A common associated complaint is metatarsalgia, especially with excessive pronation or supination of the forefoot. Depending on the location of the deformity, correction is with an anterior closing wedge osteotomy at either the talonavicular and calcaneocuboid joints or the naviculo-cuneiform-cuboid joints, accompanied by a thorough release of the plantar fascia. Fixation with screws or staples is preferred, but pins and/or wires and cast immobili-

zation are also effective. If, after correction, a “cock-up” deformity of the great toe MTP joint cannot be reduced passively, IP joint fusion and rerouting the EHL tendon through a tunnel in the neck of the first metatarsal will correct the deformity (Jones suspension procedure).

Salvage of Posttraumatic or Degenerative Joint Problems

Arthrodesis

Fusion of large joints is a rare salvage procedure in high-income countries because better alternatives are almost always available. This is not the case in poor countries, and surgeons should be comfortable with both the indications and techniques of arthrodesis, as this is often the only means to provide pain relief and stability.

Normal or near-normal motion of the joints adjacent to the arthrodesis is a prerequisite; near-normal function of the contralateral limb is desirable. As a general rule, distal joints tolerate the stress of a fusion better than proximal ones. It is essential that the patient understands that a successful fusion alleviates pain but results in complete and irreversible loss of motion with specific physical limitations. It is important to factor in the sociocultural context. Some surgeons advocate immobilizing the joint in question in plaster in the position of the anticipated fusion in order to confirm acceptance of the residual function allowed by the procedure. We insist that the patient, with the help of an interpreter if necessary, repeats to us exactly what will happen to him or her after surgery before we mutually agree to proceed. An iliac crest should always be prepped and available for bone harvest whenever any fusion of a major joint is attempted.

For many joints, the only alternative to arthrodesis is resection arthroplasty, which preserves some degree of motion, but may leave the patient with residual pain, weakness, and/or instability. It is usually technically more difficult to convert a failed resection arthroplasty to a fusion. Nonetheless, many patients prefer to take their chances with an elbow or hip resection arthroplasty than a fusion.

Shoulder

There is no universally accepted consensus on the best position for a glenohumeral arthrodesis, since residual motion will depend on scapulothoracic mobility. Rowe recommended 20° abduction, 30° flexion, and 40–50° internal rotation. The procedure is technically demanding, and since the upper extremity represents a long lever arm of deforming forces, rigid internal fixation is necessary, but may be difficult if disuse osteoporosis is present or the proper hardware lacking.

We prefer a two-incision technique, allowing better purchase on the scapular spine posteriorly with a neutralization plate. The patient is placed in a lateral position, and through a standard deltopectoral approach, the subscapularis and supraspinatus are detached from the humerus, and the capsule is widely opened. The joint is debrided and the articular surfaces of the glenoid and humeral head are prepared for maximum apposition in the desired position.

A transverse posterior incision is made along the scapular spine. Subperiosteally expose the superior aspect of the spine by mobilizing the belly of the supraspinatus superiorly, as far as the posterior acromion. The supraspinatus tendon is tagged, cut, and allowed to retract proximally, opening a tunnel between both wounds. Temporary fixation of the joint with large Steinmann pins allows the surgeon to assess the proposed position. A sterile pillow under the elbow is helpful during the entire fixation process. Long, short-threaded cancellous screws are used to compress the humeral to the glenoid bed. The strongest available large fragment DCP or small fragment DCP is molded to fit into the supraspinatus fossa and onto the anterolateral aspect of the proximal humerus. At least four screws are used in each fragment, with iliac crest graft as necessary. The supraspinatus tendon is reattached over the plate. When there is massive rotator cuff damage, an acromioplasty may be necessary to make room for the plate. Drainage is recommended.

Before being awakened from anesthesia, the patient is put in a shoulder spica splint. This is prepared 1 or 2 days prior to surgery by plac-

ing the arm in the anticipated fused position and making a shoulder spica cast, using two supporting struts between the arm and body segments of the cast. The spica is bivalved, connecting the medial half that supports the arm to the part around the torso. The borders are trimmed, padded, and taped for comfort. The shoulder abduction splint is secured after surgery using elastic bandages and should remain in place for 6 weeks. When removed for dressing change or personal hygiene, the elbow should be supported at all times. The patient is encouraged to move the wrist and fingers and do isometric exercises.

Elbow

Obtaining a solid elbow fusion is technically difficult: the bones are slender and the lever arm long. Most elbow fusions are performed for unilateral arthrofibrosis or ankylosis in a dysfunctional position (i.e., <90° flexion). The recommended position is 90° to 100° flexion [8]. It is important to maintain or regain as much pronation and supination as possible. For this reason, excision of the radial head is done through a separate, lateral anconeus approach. A straight posterior approach is used to reach the medial side of the joint and protect the ulnar nerve. The anterior, medial, and posterior aspects of the joint and distal humerus are exposed subperiosteally. The triceps tendon can be reflected by more than half its width to facilitate exposure or the olecranon osteotomized at the level of the posterior humeral cortex and the fragment used as bone graft. Retractors are positioned to reflect and protect the anterior structures. The joint is debrided, using valgus stress to facilitate the exposure.

The distal humerus is “squared off” and the olecranon articular surface is prepared to create a male/female fit. The elbow is placed in the desired position and bone apposition assessed. When joint destruction is severe, as after septic arthritis, we do not hesitate to shorten the distal humerus to above the olecranon fossa, to provide a sturdier bed. The medial epicondyle can be osteotomized and used as bone graft anteriorly with additional iliac graft as needed and

the radial head is excised. Pronation and supination may be impaired, as the radius often migrates proximally. This negative feature is offset by a higher likelihood of a successful fusion.

Fixation is secured with a 10-hole reconstruction plate or a small fragment DCP contoured to the posterior humeral cortex and the medial side of the proximal ulna. One or two screws inserted in compression outside the plate from the ulna into the distal humerus improve the construct. Alternatively a Steinmann pin can be inserted from the olecranon into the humeral medullary cavity and supplemented with screws, pins, or wires. This tenuous construct is made more secure by adding a 4-pin posterolateral external fixateur under compression for at least 3 months. A long arm cast is a poor alternative, and failure rates are high. When internal fixation is solid, a protective back slab can be used for the first 2 weeks, after which pronation-supination exercises are started.

Wrist

Wrist arthrodesis is indicated for pain following injury or infection, or as an alternative to tendon transfers for neurologic deficits. It does not rely on prolonged sophisticated rehabilitation. The desired position is about 20–30° dorsiflexion, lining the third metacarpal with the ulnar border of the radius. Through a straight longitudinal dorsal approach the articular surfaces of the distal radius, capitate and proximal second and third metacarpals are removed; the lunate and trapezoid can be “crumpled”—crushed but not excised—with a rongeur. Bone graft is from the distal radius or iliac crest. An 8–10-hole small fragment DCP is contoured to maintain the wrist in the desired position and secured over the bone graft (Fig. 41.13). It is desirable to protect the fusion in a short-arm cast for 6 weeks.

If plates are not available, a Steinmann pin can be inserted in a retrograde fashion from the space between second and third metacarpals into the shaft of the radius and supplemented with additional K-wires. With this fixation, a short-arm cast is mandatory for at least 6 weeks and can be continued for an additional 6 weeks. In rare

instances where bilateral fusions are indicated, the side responsible for personal hygiene, usually the left, should be fused at 10–20° flexion, the other side at 20–30° extension.

Thumb

Carpometacarpal (CMC) fusion is fixed in a position of near maximal opposition. Metacarpophalangeal (MCP) and interphalangeal (IP) joints should be fixed in 25–30° flexion. Condyles on both sides can be removed with small bone cutters and the opposing surfaces fixed in the desired position with small lag screws, K-wire and interosseous wiring, or crossed K-wires. A thumb spica is used for 6 weeks.

Fingers

MCP joint fusion of the index through little fingers is rarely indicated, as their mobility is essential for full finger function. However, if necessary, around 30° flexion is the recommended position. The proximal IP joints should be fused at 40–50° flexion, increasing flexion from the index to the little finger to maintain the normal cascade. The distal IP joints are fused at 15–20° flexion. Internal fixation is as described for the thumb.

Hip

Successful hip arthrodesis has a long track record of satisfactory pain relief. Secondary degenerative changes of the lower spine and ipsilateral knee are well-documented long-term ill effects. Females of reproductive age are particularly reluctant because of fear of obstetric complications. Because of sociocultural reasons, few patients agree to this procedure. Those who do are usually younger patients for whom pain is disabling and prevents gainful employment.

Many techniques are described, both intra- and extra-articular. The choice of technique depends on multiple factors: the surgeon's comfort zone and experience, the amount of remaining bone stock, and hardware availability. In tropical climates, it is preferred to use a technique requiring no external immobilization. The recommended position of fusion is about 30° flexion,

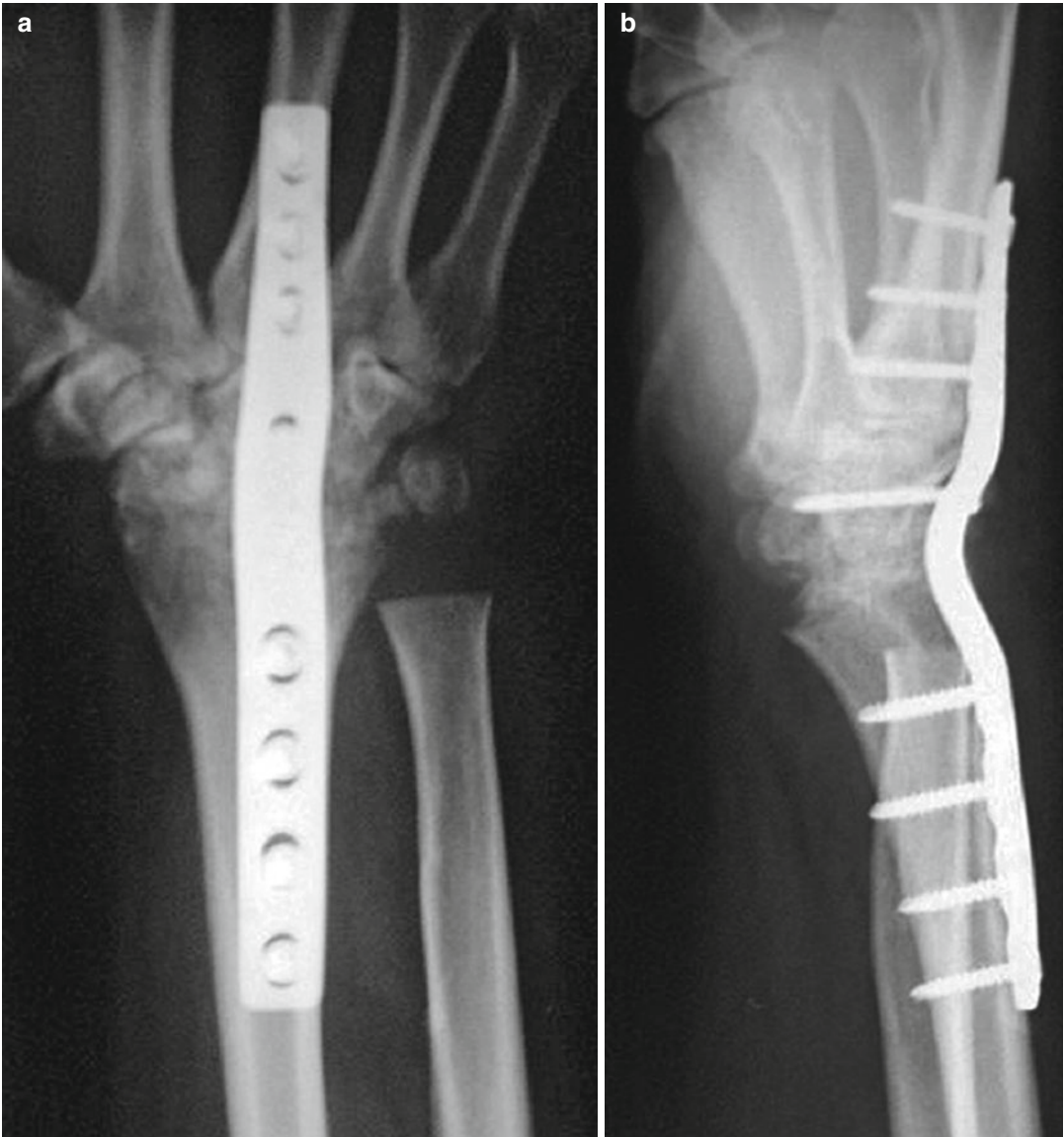


Fig. 41.13 (a, b) Wrist arthrodesis with fusion plate and screws in desired position of the wrist and of the hardware. A small DCP plate or a reconstruction plate work just as well

neutral abduction-adduction, and 5–10° external rotation.

Our preference is an intra-articular fusion with internal fixation through a posterolateral or anterolateral approach, with the patient in the lateral decubitus position and the iliac crest available for bone graft. A trochanteric osteotomy is made in line with the superior neck. The supra-acetabular area is exposed superiorly and posteriorly as far as

possible, avoiding neurovascular structures. The hip is dislocated on the side of the approach, using sharp instruments to remove the articular cartilage. Bone destruction may be so severe that little of the femoral head is left, in which case, the neck remnant is used for fusion, with generous quantities of corticocancellous graft.

Different techniques of bone graft supplementation have been described, including using a

sliding strip of corticocancellous bone from the supra-acetabular area (similar to the Blair ankle fusion), using the greater trochanter itself, or even a segment of fibula. Preoperative X-rays should alert the surgeon that bone loss might challenge any improvisational skills. The hip is reduced and maintained temporarily in the desired position with Steinmann pins. Sterile pillows are helpful in supporting the limb, while the surgeon assesses the limb position from all angles. Definitive fixation is achieved with three to four trans-articular short-threaded 6.5 cancellous screws in compression. It is important that a strong assistant supports and maintains the limb in the desired position throughout the entire internal fixation process—a tedious but necessary task.

Ideally, the construct is further fixed with a well-molded cobra plate from the supra-acetabular area to the lateral femoral cortex, including at least ten cortices on each side. One long DCP contoured and applied to the lateral femoral cortex is an acceptable alternative if proximal purchase is adequate. A second DCP can be used more anteriorly and is contoured to lie on the anterolateral femur. Rigid fixation is mandatory because of the large forces crossing the joint. Early knee joint motion is encouraged, but weight bearing should not start before 12 weeks.

In our experience, hip arthrodesis should not be attempted unless adequate internal fixation hardware is available. Steinmann pins, K-wires, screws alone, external fixation, and spica casts have a high failure rate, and salvage is difficult. An exception is in children, following acute or subacute septic arthritis with severe joint destruction, where spica cast immobilization can yield a spontaneous fusion or ankylosis in good position.

Knee

With normal adjacent hip and ankle joints, a knee fusion provides a stable painless limb for unassisted ambulation. With a knee fusion, kneeling for prayer, or the mobility to independently get up from and down to the floor is possible only if the opposite leg and both upper extremities are functionally normal. If poor knee function made

such motions difficult or painful before, not much is lost and patients may accept the procedure more easily. The desired position is about 0–10° flexion and 5° valgus.

Correction of severe flexion deformities or contractures, or chronic dislocations by shortening may put the neurovascular (NV) structures at risk. In these cases, in order to protect the neurovascular structures, it is safer first to perform a release, followed by skeletal traction, or serial casting aimed at achieving progressive correction before the definitive fusion. Careful neurovascular monitoring during the correction is mandatory.

Mild to moderate deformities can be corrected in a single setting. An anterior approach is preferred, everting the patella to debride the joint. The distal femoral condyles are removed with large osteotomes, while the knee is flexed and periosteal elevators are placed posteriorly to protect the NV bundle. The same is done with the proximal tibia, removing the cartilage to just below the subchondral line. Angular deformities are corrected by removing bone wedges, which further relax the posterior soft tissues.

Achieving good position and alignment is more difficult than it appears, and one or both bones often need a second cut. Temporary fixation with Steinmann pins allows assessment of the position. Definitive fixation is best achieved internally, with two large cancellous lag screws inserted in a crossing pattern from above the medial and lateral epicondyles with additional screws added from below the tibial plateaus. The construct is neutralized with a long large fragment DCP applied anteriorly on the femur and contoured to the anterolateral tibia (Fig. 41.14). Removing part of the anterior patella groove makes plate application easier. Alternatively two plates can be used, especially in poor quality bone, and the patella can be resected.

Rigid fixation in compression allows almost immediate partial weight bearing, with progression to full weight bearing after 6 weeks. External fixation in compression using frames such as the one described by Charnley can also

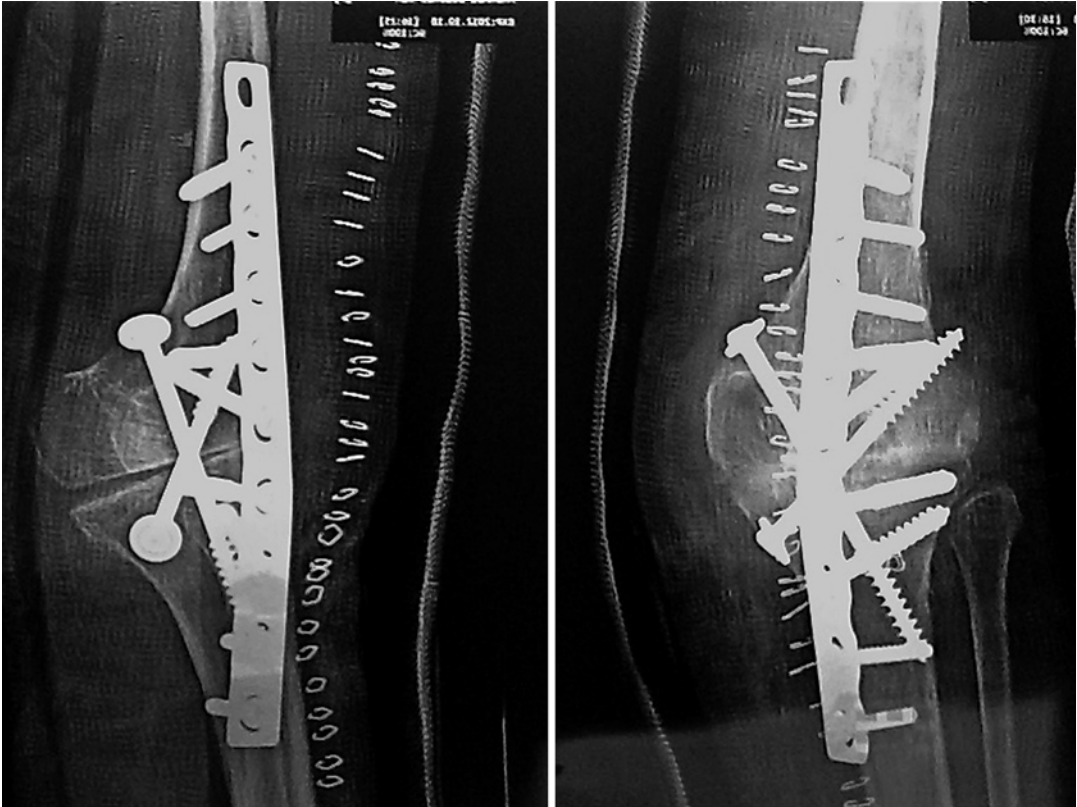


Fig. 41.14 Post-op X-rays of knee fusion with compression screws and anterior neutralization plate. The alignment is good in the frontal plane but there is some recurvatum in the sagittal plane, not the desired 5° of flexion. This 62-year-old woman had polio in both legs as a

child but was ambulatory with only a walking stick until she fell 3 years before. She was not able to resume walking because a quadriceps tendon tear was missed. She underwent knee fusion and returned to full WB at 6 weeks, with her stick, and without pain

give excellent results. When fixation is done with screws alone, staples, Steinmann pins, or any combination, a well-molded cylinder cast can permit early weight bearing and is another acceptable option (Fig. 41.15).

Ankle

The ankle tolerates fusion well. When malunion is the indication, corrective osteotomies or bone resections are indicated to restore normal alignment of the hindfoot. The approach is anterolateral and the desired position of arthrodesis is 0–5° plantar flexion, 0–5° external rotation, with the talus as posterior as possible under the tibia. The distal tibia and talar dome are removed with a wide osteotome, and the medial and lateral borders of the talus and the malleoli are shaved.

Excessive anterior subluxation of the talus under the tibia should be avoided since this reduces the contact area and changes the hindfoot contour posteriorly. The talus can be kept in the desired position with a temporary calcaneo-talotibial Steinmann pin. Two crossed lag screws directed from the tibia into the talar body and transverse screws from the malleoli into both the tibia and talus give good fixation. With severe joint destruction, additional bone graft can be harvested from the iliac crest.

A 1–1.5×3–4 cm cortical strut from the anterior tibia slid into a prefashioned trough in the talar dome and neck can add stability (Blair fusion) with cancellous bone harvested from the distal tibia as needed. Additional fixation can be added with a small contoured T plate or a 1/3 tubular plate anteriorly. A short-leg non-weight-bearing

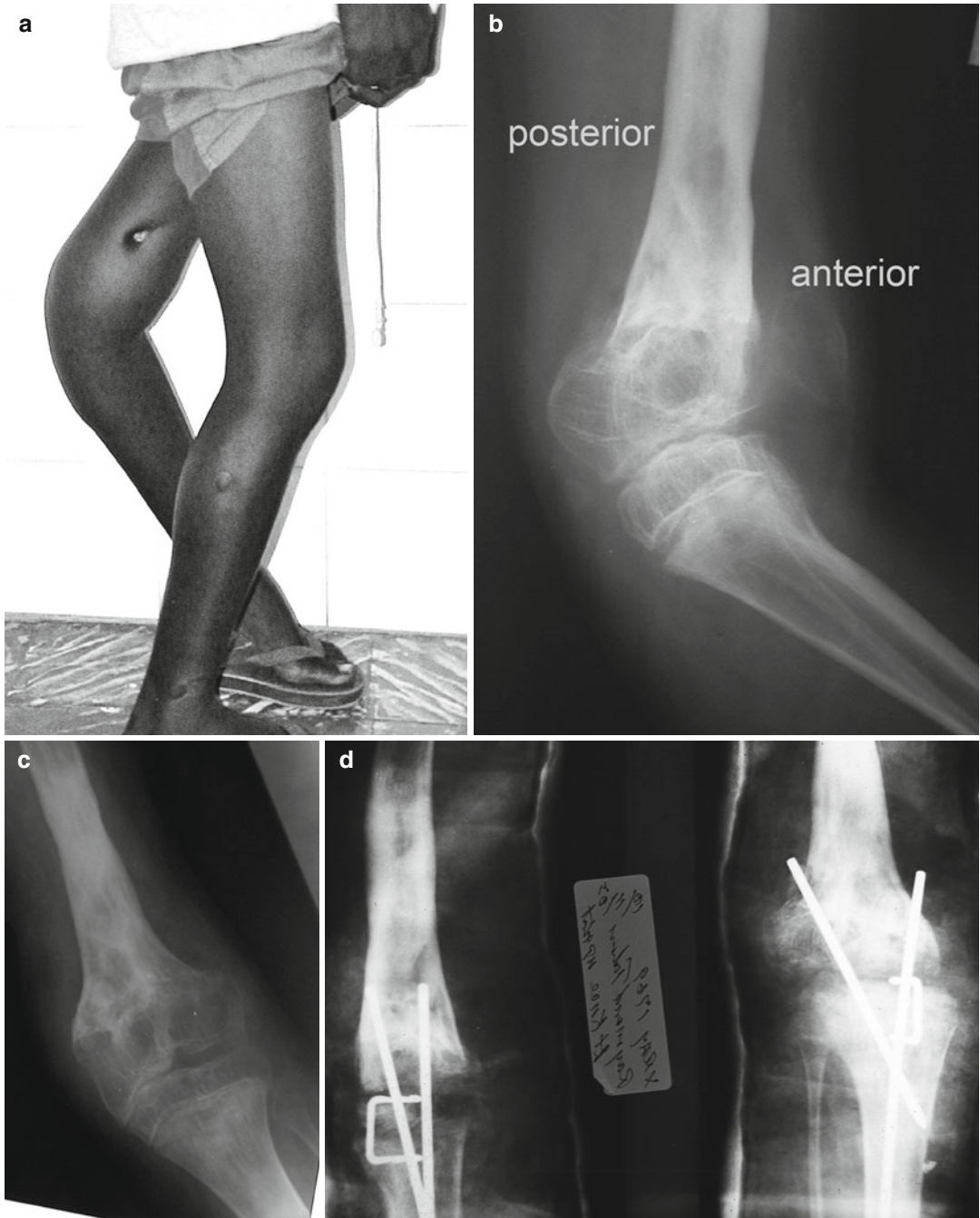

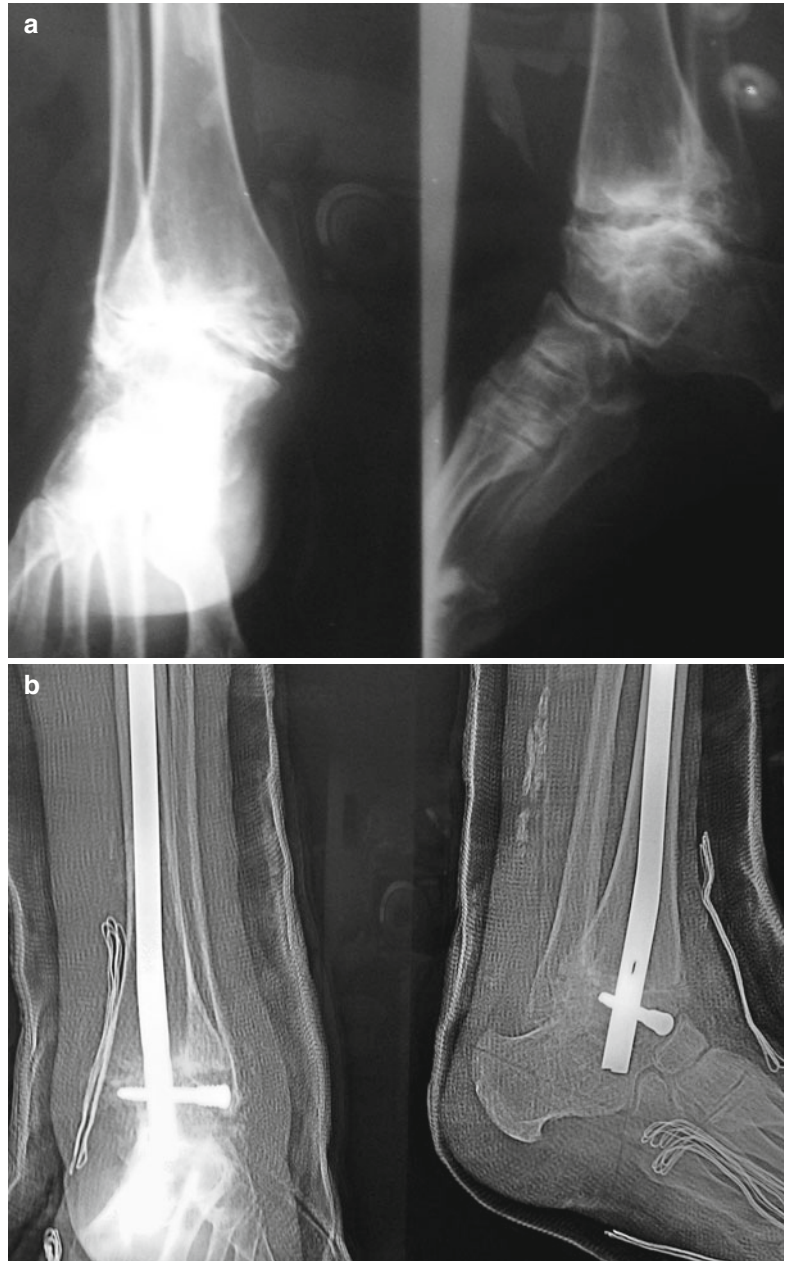
Fig. 41.15 (a) Clinical and (b, c) radiographic appearance of a 14-year-old boy with a fixed 65° recurvatum of his left knee, secondary to a septic arthritis. (d) Postoperative X-ray after arthrodesis and fixation with one staple and two Steinmann pins. (e) Clinical appearance in his postoperative cast. (f) X-ray appearance at

8 weeks, at which time, the pins were removed, and the patient put in a cylinder cast for three more months. (g, h) Clinical appearance at 1 year. The patient ambulated without pain or walking aids. A dressing is covering an unrelated injury. No X-rays were obtained, as there was a shortage of X-ray film

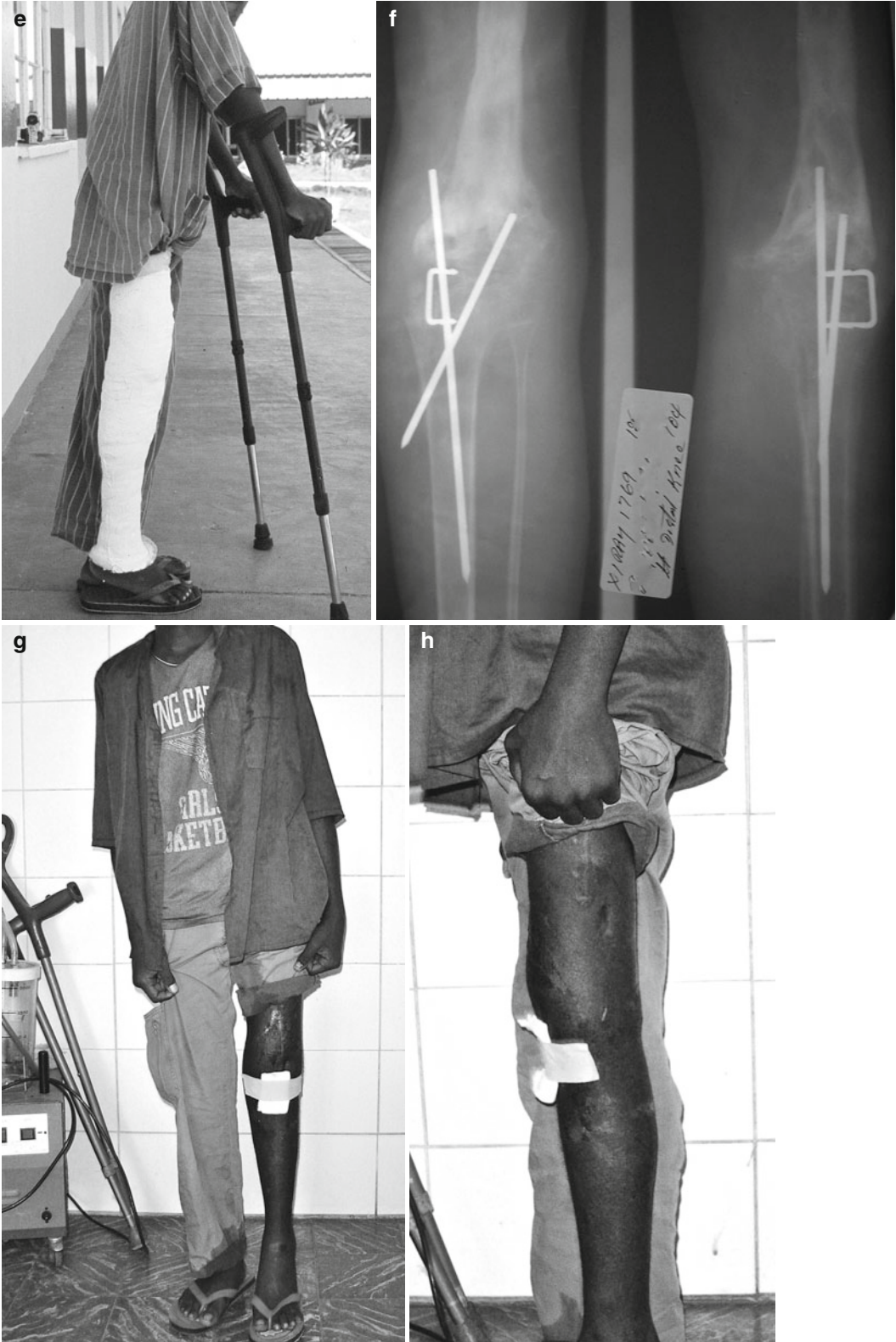

Fig.41.15 (continued)

Fig. 41.16 (a) Right ankle DJD secondary to posttraumatic avascular necrosis of the talus. There was also significant loss of subtalar motion. (b) A retrograde tibio-talo-calcaneus fusion was done with a dynamically interlocked IM nail



(NWB) cast is worn for 3 months until clinical consolidation.

When there is associated subtalar DJD, a tibio-talocalcaneal fusion is indicated. The ankle is approached anteriorly, debrided, and if necessary, corrective osteotomies performed. Retrograde nailing from the plantar aspect of the foot provides secure internal fixation (Fig. 41.16). Where

there are no nails, a stout Steinmann pin can be substituted and supplemented by a few screws from the distal tibia to the body of the calcaneus, or additional pins (Fig. 41.17). The subtalar joint will usually fuse spontaneously, and additional surgical exposure is not necessary. Pins can be removed at 6 weeks, with a NWB cast for another 6 weeks.

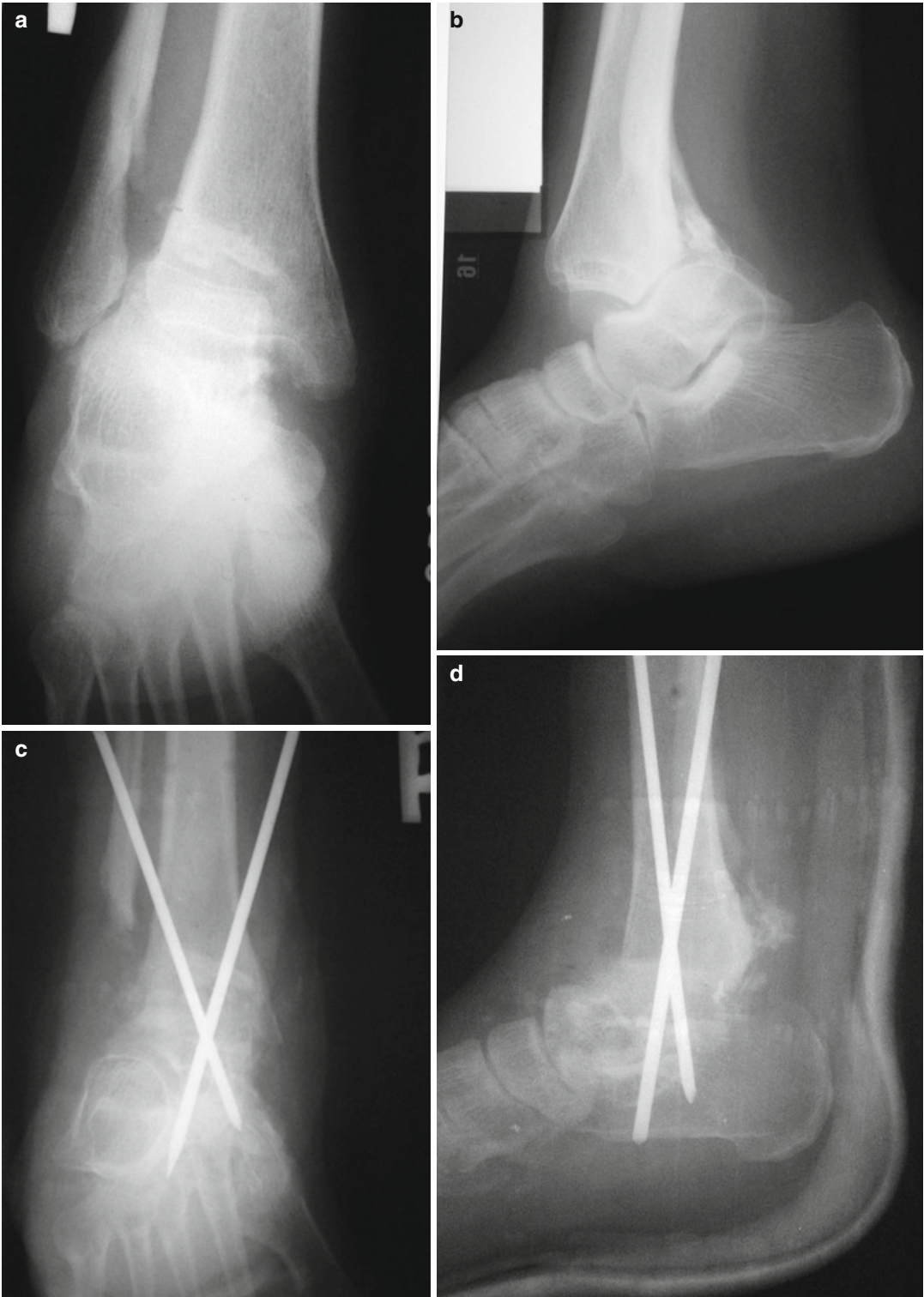


Fig. 41.17 (a, b) Posttraumatic ankle DJD requiring fusion. (c, d) In the absence of adequate implants, internal fixation is achieved with crossed Steinmann pins that will be removed at 12 weeks

Foot

Arthrodeses around the hindfoot are indicated for pain relief, deformity correction, or both. When pain without deformity is the indication, temporary relief with selective injections of local anesthetic in the suspected joint are good predictors of a favorable outcome. Most surgeons agree that fusing one of the three hindfoot joints functionally blocks the other two, commonly leading to premature DJD and making a triple arthrodesis preferable to a single-joint fusion.

We prefer the transverse Ollier approach, exposing the sinus tarsi and reflecting distally or removing the belly of the short extensor muscle. The peroneus brevis forms the margin of the exposure laterally, under which a retractor is inserted. The long extensor to the fifth toe forms the margin anteriorly. A retractor can be inserted under the dorsal soft tissues, all the way to the medial aspect of the foot, a maneuver more easily performed with the ankle in dorsiflexion. The talocalcaneal, talonavicular, and calcaneocuboid joints are opened and debrided. A small lamina spreader improves the exposure. As a general rule, whether the deformity is varus or valgus, under-correction is better than overcorrection. We prefer to remove the two anterior joints—talonavicular and calcaneocuboid—in one slice, with an oscillating saw or a wide osteotome.

The subtalar joint is more difficult to expose posteriorly. A lamina spreader in the sinus tarsi or even two Steinmann pins in the talus and calcaneus, used as joy sticks, allow easier exposure of the posterior facet which can be curetted or osteotomized. A varus deformity is corrected with a laterally based closing wedge osteotomy, with great care taken to avoid injury to the neurovascular bundle posteromedially. A valgus deformity can be corrected with an opening wedge osteotomy using resected bone or a small piece of fibula to maintain the open wedge. In this case, a lamina spreader or stacked osteotomes can help to keep the wedge open.

When correction is achieved, the joints are stabilized with staples, screws, pins, and/or K-wires and the foot is immobilized in a short-leg cast that is immediately bivalved and the leg is elevated. When swelling has resolved, the cast

can be completed. Pins and wires are removed at 6 weeks, a new cast applied, and the patient remains non-weight-bearing for a total of 3 months. Soft tissue releases such as Achilles lengthening, posterior release, tibialis posterior lengthening, plantar release, or a combination should not be overlooked.

Fixed equinus is addressed by combining a posterior release with an anterior (or dorsal) closing wedge osteotomy, with in situ fusion and fixation of the subtalar joint. Cavus deformities are corrected with an anteriorly based closing wedge osteotomy, performed more easily through a longitudinal anterior approach than an Ollier approach, in conjunction with an extensive plantar release.

Neglected displaced Lisfranc fracture-dislocations—tarsal-metatarsal—can be disabling. When a single ray is involved (usually the first), reduction is fairly easy, with appropriate soft tissue releases and joint excision. Displaced fracture-dislocations of the entire row (splayed or windswept) are more challenging. Most commonly some metatarsals are also displaced anteriorly, sometimes even overriding the cuneiforms. A single transverse incision disrupts the venous circulation, so we prefer two to three longitudinal incisions. Each joint is opened, debrided, mobilized, and shortened if needed. The base of the fifth metatarsal can be difficult to mobilize, due to retraction of the peroneus brevis tendon. This tendon can be lengthened or cut, if necessary, and sutured proximally to the peroneus longus tendon. Curettage of the articular surfaces is usually sufficient and bone graft is seldom needed. Each joint is reduced and fixed separately with screws and/or K-wires. Pins can be removed at 6 weeks, but weight bearing is allowed only at 3 months.

Fusion of the first metatarsophalangeal joint (MTP) may be indicated for management of hallux rigidus, failed hallux valgus surgery, posttraumatic DJD, or inflammatory conditions. Compared to a resection arthroplasty, a successful fusion may more reliably eliminate pain, but with some mild decrease in push-off strength. The ideal first metatarsal-phalangeal position is 25–30° extension and 10–15° valgus. These recommendations are made for patients in countries where shoes are

worn, such that the toe would be slightly extended with ambulation to prevent painful callus formation or IP joint arthritis. Most patients in poor countries walk barefoot or with sandals. If this is the case, the fusion should be done with less extension: 15–20° with respect to the first metatarsal to avoid a cocked-up toe. Internal fixation with a small plate or a screw inserted from the plantar aspect of the metatarsal neck into the medullary canal of the proximal phalanx or two crossed screws is preferred, but crossed K-wires and casting are also effective (Fig. 41.18).

is a procedure to reconstruct or replace a malformed or degenerated joint. The goals of these procedures are to reduce pain, preserve motion, and provide joint stability. In reality, not all these goals are equally achievable with the various techniques that will be discussed. In order to optimize the outcomes, the surgeon must first understand the needs and expectations of the patient and place these in the context of the disability being addressed. By setting realistic expectations at the outset and properly matching the procedure to the patient, the pathology, and the environment, outcomes can be maximized even when resources are limited.

Arthroplasty

Joint pain and stiffness in the developing world can frequently be traced to delays in initial management or improper early interventions. Arthroplasty

Resection Arthroplasty

Resection arthroplasty involves the removal of joint surfaces with varying amounts of bone in

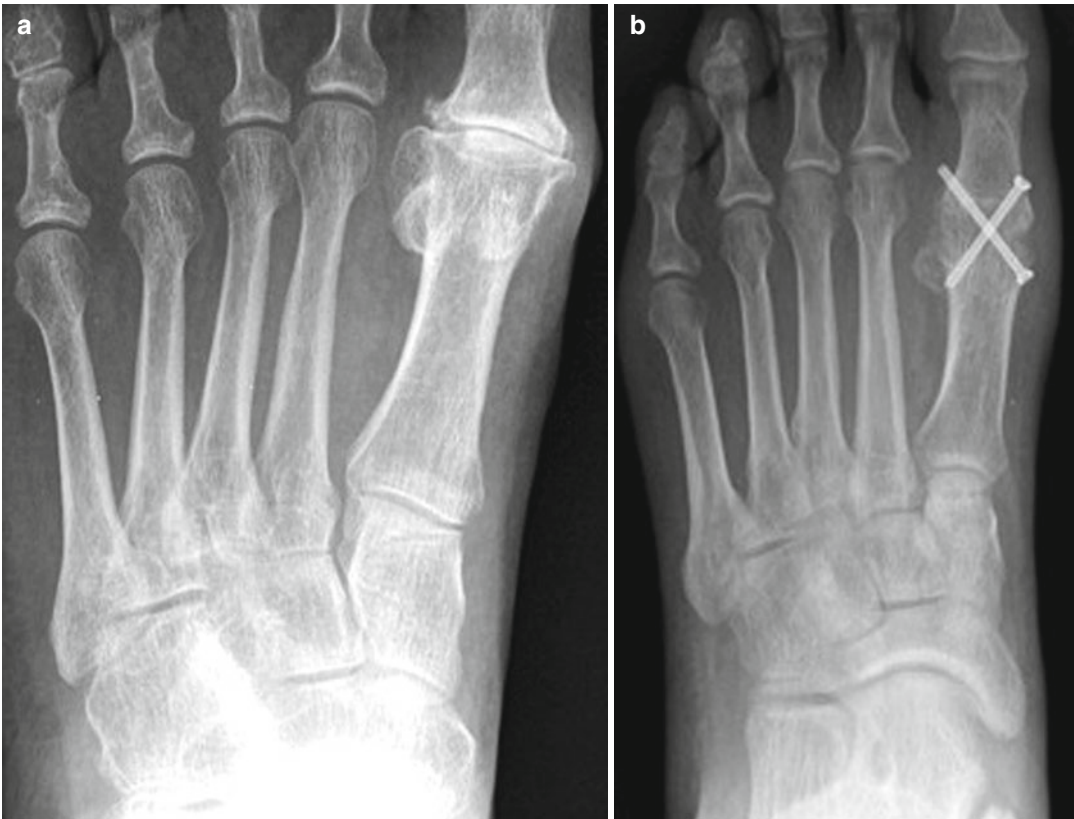

Fig. 41.18 (a) Symptomatic hallux rigidus. (b, c) AP and oblique views after arthrodesis with two crossed screws (Courtesy of Stephen K. Benirschke)

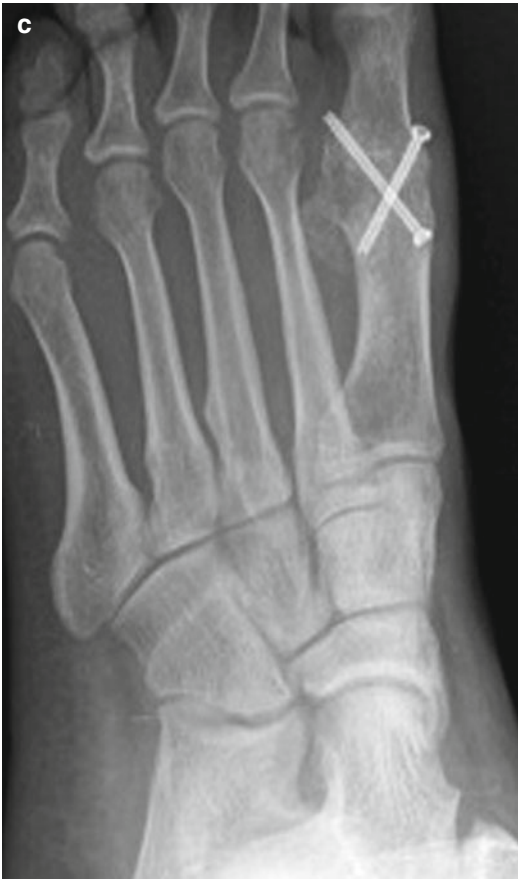

Fig. 41.18 (continued)

order to create a space between the bone ends. Goals are to decrease pain and maintain motion; however, stability is sacrificed. Resection arthroplasty is frequently used as a salvage procedure in chronically infected joints or in those where pain and stiffness prevent useful function.

Acromioclavicular Joint

Painful degenerative arthritis of the acromioclavicular joint, unreduced acromioclavicular dislocations, and malunited fractures of the distal clavicle are conditions amenable to distal clavicular resection. Remove at least 2–3 cm of bone from the distal clavicle, taking care to preserve the coracoacromial ligaments. Reconstruction of deficient coracoacromial ligaments to stabilize the distal clavicle is rarely indicated.

Shoulder

When there is inadequate bone stock for arthrodesis or shoulder stability is not a question, resection arthroplasty of the shoulder—Laurence Jones tenodesis—[9] can provide pain relief and active motion that is limited, but functional. Reattachment of the rotator cuff muscles to the proximal humerus in order to impart some active control improves this procedure.

Through a delto-pectoral approach, the subscapularis tendon, supraspinatus tendon, and conjoined tendon of the infraspinatus and teres minor are isolated with or without attached humeral bone, depending on the underlying pathology. The humeral head and, if necessary, a portion of the proximal humerus is resected and the bone surface smoothed. Decorticated and appropriately located grooves in the proximal humerus assist in reattaching the separate rotator cuff tendons or bone-tendon segments with heavy nonabsorbable suture. Any residual capsular tissue is plicated in the interval between the resected humerus and the glenoid. The deltoid is meticulously repaired to the acromion, and the arm is placed in 45° abduction and neutral rotation and immobilized for 4 weeks in a shoulder spica splint of the type previously described for shoulder arthrodesis. An additional 2–4 weeks of night splinting will further protect the repair if it is felt to be tenuous.

Wrist

Proximal row carpectomy (PRC) is the equivalent of a resection arthroplasty of the wrist. Where the primary goal is a stable, fixed, pain-free wrist joint, arthrodesis is more reliable. PRC is suited for the management of scaphoid non-unions and moderate radiocarpal arthritis. This straightforward procedure can be performed using a dorsal longitudinal incision through the third compartment. A capsular incision is made along the ulnar border of the extensor carpi radialis brevis tendon and the adjacent radius exposed subperiosteally. The scaphoid, lunate, and triquetrum are removed, in that order, taking care to preserve the volar radio-scaphoid-capitate ligament. After this excision, the proximal articular surface of the capitate articulates with the lunate

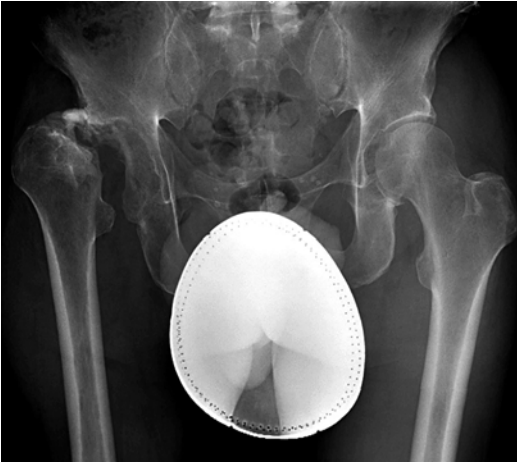

Fig. 41.19 Resection arthroplasty of the right hip, with greater trochanter abutting the acetabular rim

fossa. A short-arm cast is used for 3–4 weeks, followed by a volar wrist splint for 3–4 weeks while range of motion exercises are started. Grip strength will be reduced 20–30 % and motion reduced 40–50 % following this procedure, but pain relief with preservation of a functional range of motion is usually achievable.

Hip

Resection arthroplasty of the hip is often incorrectly termed the “Girdlestone procedure” [10]. As currently practiced [11], the head and neck of the femur are removed and the abductor muscles preserved. Plication of the joint capsule is carried out if sufficient tissue can be mobilized (Fig. 41.19). Any of the commonly described surgical approaches to the hip joint can be used. To our knowledge, post-op skeletal traction is not necessary.

Hip motion is encouraged within the limits of pain, and patients are started on partial weight bearing with crutches. Eventually, most patients are able to walk with only the use of a single crutch or cane. A 3–5 cm shoe lift partially corrects the resulting limb shortening. Pain relief and function can be surprisingly good.

Toes

Metatarsal head resection in the lesser toes is an effective intervention for severe forefoot defor-

mity arising from rheumatoid arthritis or trauma (Fig. 41.20). Resection of the proximal portion of the proximal phalanx of the great toe may restore pain-free motion when there is severe arthritis or infection in the MTP joint (Keller procedure). The advantage over MTP joint fusion is that no internal fixation is required, and there is no risk of a painful nonunion. The disadvantage of resection arthroplasty is shortening of the great toe and loss of push-off strength.

Interposition Arthroplasty

Interposition arthroplasty involves the placement of biologic or nonbiologic material between the surgically removed joint surfaces. The goal is to promote motion and prevent pain from direct bone-on-bone contact. Autogenous tendon, skin, and fascia are the materials most often used for interposition in austere settings.

Elbow

The ideal elbow motion to accomplish ADLs is a 100° arc of motion with no more than a 30° flexion contracture and at least 120–130° elbow flexion. To maintain some motion, interposition arthroplasty is sometimes chosen rather than arthrodesis as a salvage procedure for severe elbow afflictions. If successful, the procedure can result in elbow motion sufficient for self-care and light tasks. Bony ankylosis and gross instability are contraindications, and adequate bone stock in the distal humerus is a prerequisite.

Using a pneumatic tourniquet makes a long posterolateral incision over the distal humerus and proximal forearm [12]. Proximally, the lateral humeral shaft is exposed between the triceps and brachial radialis, and distally, the deep incision enters the interval between the anconeus and the extensor carpi ulnaris. The common extensor mechanism and lateral collateral ligament are detached from the lateral epicondyle and the anterior capsule released; if possible, the medial collateral ligament is preserved. The distal humerus is debrided of osteophytes and smoothed with rongeurs. The radial head is preserved, if

possible, but resected if necessary to achieve better forearm pronation and supination.

A cutis graft can be harvested from the bleeding bed created by raising a split thickness skin graft, removing a swath of underlying epidermal-dermis of up to 5–6 cm², and replacing the epidermal graft to cover the exposed subcutaneous tissue [13]. Alternatively, the cutis graft can be prepared from a full thickness ellipse of skin excised from the groin, where the defect is closed primarily as with a FTSG. The superficial, or skin, side of the cutis graft is placed against the cancellous surface of the humerus and sutured through small drill holes along the radial and ulnar margins, incasing the distal humerus. The extensor origin is reattached and the wound closed. A back slab is worn for 2 weeks at 90° flexion, followed by a hinged cast, brace, or back slab for another 4 weeks. Twice a day the splint is

removed and gentle passive range of motion exercises are done during the initial 2–4 weeks; at 4 weeks, gentle resisted muscle strengthening is started. While the outcome of interposition arthroplasty is acceptable in most low-demand patients, the results are unpredictable, and incomplete pain relief and stiffness remain in a sizeable minority. Residual instability of the joint can be addressed by the use of a brace to provide medial-lateral stability.

Thumb Carpometacarpal Joint

Painful CMC arthritis of the thumb can be managed by resection of the trapezium alone or by resection with interposition of a tendon graft, utilizing the palmaris longus or a distally based slip of the flexor carpi radialis tendon—the anchovy procedure. The joint is exposed through a longitudinal dorsoradial incision, the sensory branches

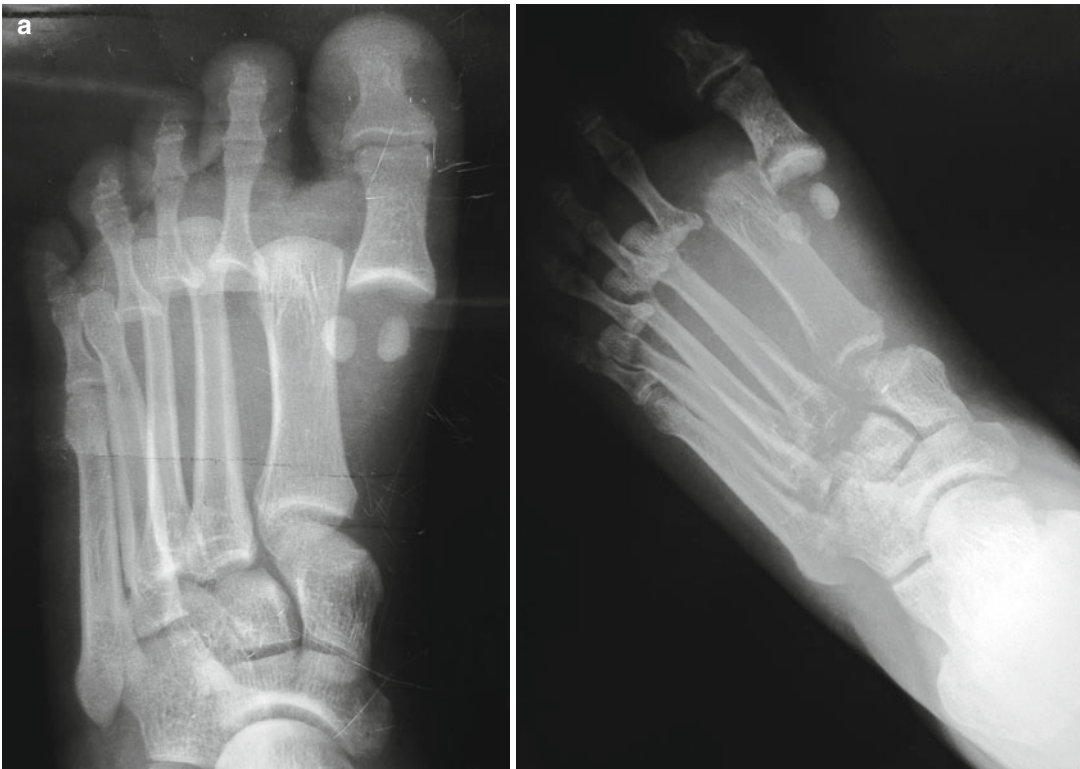

Fig. 41.20 (a) (*left*) X-ray of foot after being run over by the tire of a car with open plantar-medial dislocations of MT-P joints 1–4. X-ray on the *right* was taken 2 months later. Note periarticular osteoporotic midfoot changes. (b)

Appearance of the foot at time of surgery: wound still open but clean, swelling under control, but soft tissues deeply wrinkled and brawny. (c) X-ray post removal of MT heads and realignment of rays

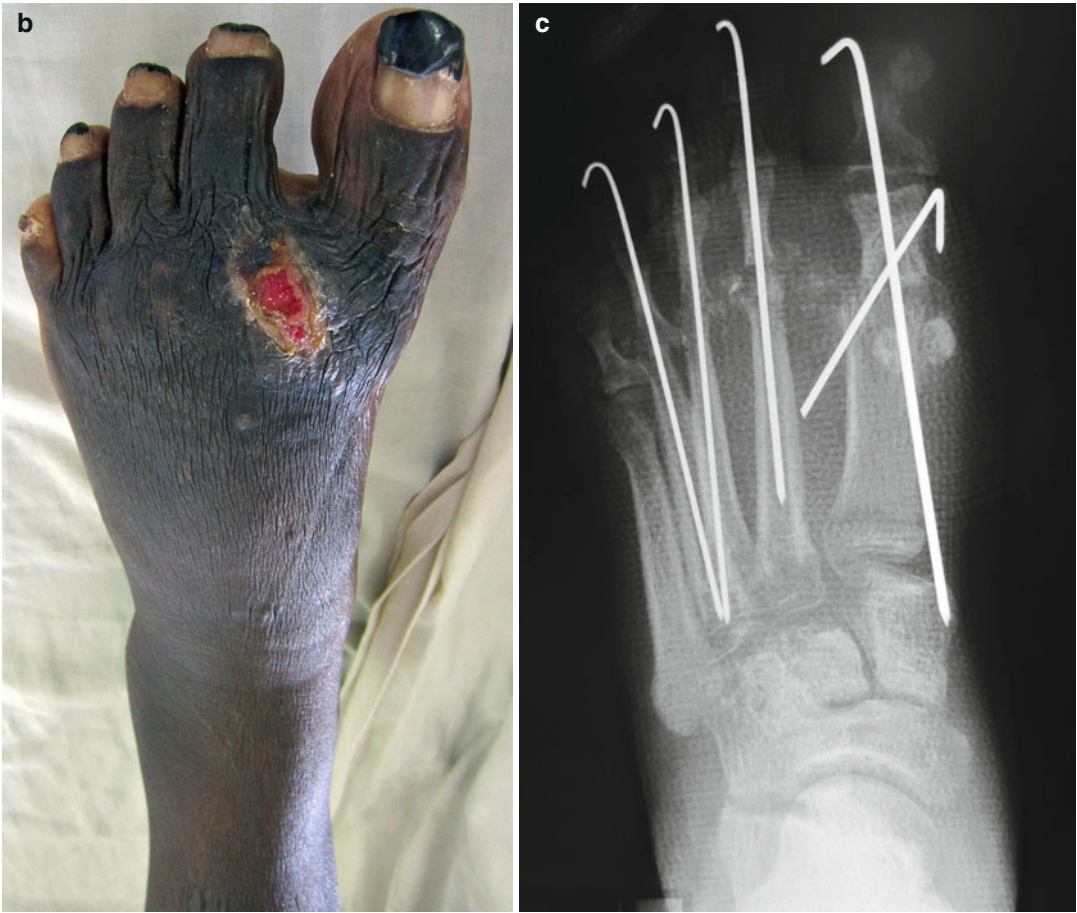

Fig. 41.20 (continued)

of the radial nerve protected, and the trapezium resected subperiosteally. The tendon graft is rolled and sutured into a ball with absorbable suture. The graft is sutured to the capsule and the capsule closed. A bulky dressing is applied with a thumb spica splint and heavy use of the hand is limited for 3 weeks, after which, gradual return to full use is encouraged.

Replacement Arthroplasty

Replacement arthroplasty involves replacing diseased joint surfaces with an orthopedic prosthesis. In comparison with resection and interposition arthroplasty, replacement arthroplasty is resource intensive. In high-income countries, this procedure is a cost-effective intervention. The potential benefits

of total joint arthroplasty are well known in the developing world. In many locales, surgeons are interested in learning these procedures, and visiting surgeons may be asked to perform them. However, for a variety of reasons enumerated below, including cost, replacement arthroplasty in the developing world should be undertaken with great caution. The one exception is unipolar hemiarthroplasty of the hip for femoral neck fracture [14].

Total joint replacement of the shoulder, hip, and knee are less well suited to austere settings due to suboptimal operating room environments, the high cost of implants and instruments, and a limited capability to address short- and long-term complications of these procedures. Prerequisites for a responsibly administered total joint arthroplasty program include a scrupulously sterile operating environment, access to prophylactic

antibiotics, focused postoperative rehabilitation, and the ability to manage short- and long-term postoperative complications.

Finally, access to low-cost implants with optimal long-term wear characteristics is required, as well as access to ancillary instrumentation, not only for the index procedure but also if there are complications requiring prosthetic removal. Visiting surgeons should not leave potential problems behind that the local surgeon is not equipped to address. Conversely, in less austere environments, total joint arthroplasties are being performed more frequently, usually in the setting of a lucrative private practice. The resources, knowledge, and skills to manage long-term complications such as aseptic loosening are often lacking, and some patients wind up with a situation as bad or worse than the index disease (Fig. 41.21). The same applies to early complications, where the visiting surgeon may feel pressure from peers and patient to “try something.” If surgery is contemplated, it should be kept as simple as possible (Fig. 41.22).

Hemiarthroplasty

Prosthetic replacement of the femoral head in patients with displaced femoral neck fractures is successful in some developing country settings [5]. Low-cost unipolar implants from middle-income country manufacturers can be implanted expeditiously with simple instrumentation, resulting in support-free, independent ambula-

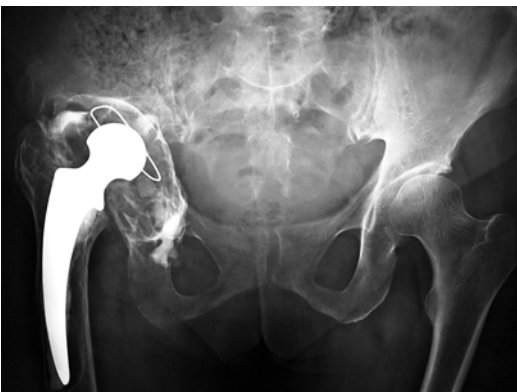

Fig. 41.21 Aseptic loosening of a right THR at 8 years, with impressive osteolysis on both sides of the joint. The patient could not bear weight, and there was no possibility for a revision

tion in the majority of patients. Whenever possible, cement fixation should be avoided, as it is expensive and difficult to remove. Some practitioners advocate an anterior or direct lateral surgical approach for this operation, in order to reduce the risk of postoperative dislocation with the posterior approach. Protected weight bearing is begun on the day after surgery in order to reduce the risk of pulmonary thromboembolism. Full weight bearing, with or without a stick, is

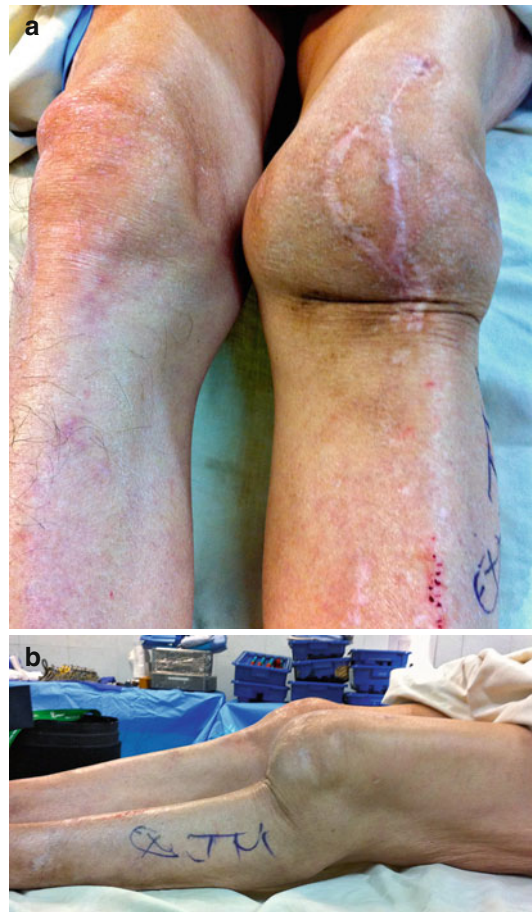

Fig. 41.22 (a, b) Clinical and (c) radiographic appearance of a 66-year-old patient with a chronically dislocated left TKR. This patient dislocated the first time 6 weeks post-op and underwent two more unsuccessful surgeries. He was in a wheelchair for almost 3 years. (d) Postoperative X-ray after open reduction, extensive lateral release, and medial reefing. The components were not loose, and there was no possibility of revision to a constrained configuration. The patient was immobilized in a cylinder cast in extension for 3 months and is still able to bear full weight at 2 years in a knee brace, but without any knee motion

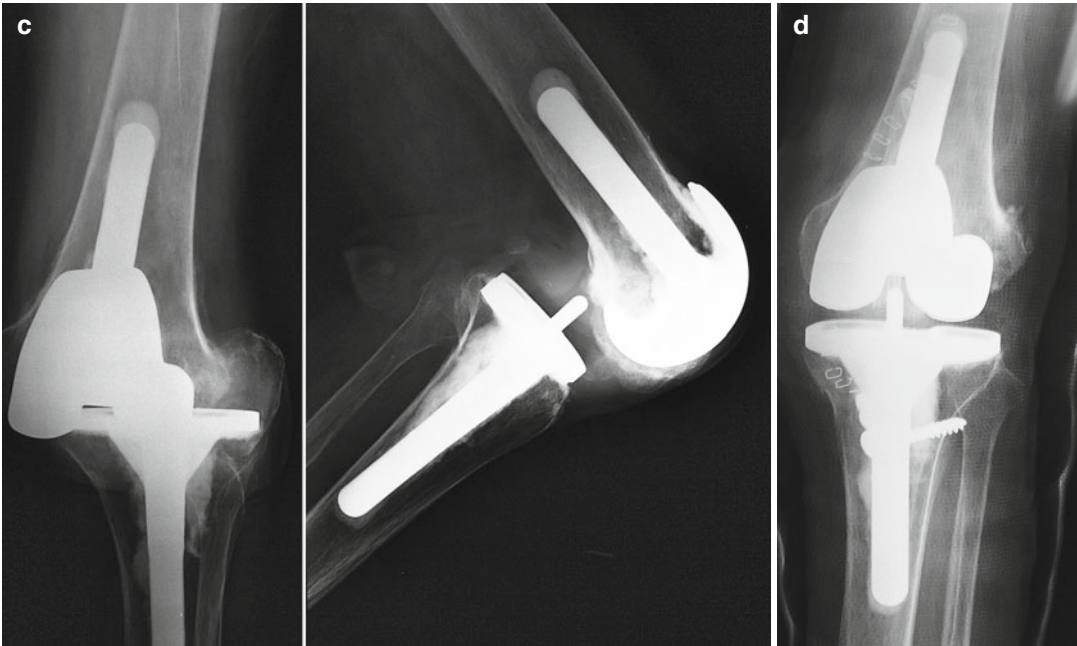


Fig. 41.22 (continued)

usually achieved by 6 weeks. Resection arthroplasty can be readily performed as a salvage procedure for management of adverse sequelae such as infection or prosthetic subsidence.

References

1. Bhandari M, Fong K, Sprague S, Williams D, Petrisor B. Variability in the definition and perceived causes of delayed unions and nonunions. *J Bone Joint Surg.* 2012;94(15):1367.
2. Vallamshetla VR, Sayana MK, Vutukuru R. Management of ununited intracapsular femoral neck fractures by using quadratus femoris muscle pedicle bone grafting in young patients. *Acta Orthop Traumatol Turc.* 2010;44(4):257–61.
3. Papineau LJ, Alfageme A, Dalcourt JP, Pilon L. Chronic osteomyelitis: open excision and grafting after saucerization. *Int Orthop.* 1979;3(3):165–76.
4. Masquelet AC, Begue T. The concept of induced membrane for reconstruction of long bone defects. *Orthop Clin North Am.* 2010;41(1):27–37.
5. Russell GV, Graves ML, Archdeacon MT, Barei DP, Brien GA, Porter SE. The clamshell osteotomy: a new technique to correct complex diaphyseal malunions. *J Bone Joint Surg Am.* 2009;91(2):314–24.
6. Tall M, Ouedraogo I, Nd Kasse A, Tekpa BJ, et al. intramedullary nailing in developing countries. *Orthop Traumatol Surg Res.* 2012;1:49–55.
7. Weinhandl JT, O'Connor KM. Assessment of a greater trochanter-based method of locating the hip joint center. *J Biomech.* 2010;43:2633–6.
8. Morrey BF, Askew LJ, Chao EY. A biomechanical study of normal elbow motion. *J Bone Joint Surg Am.* 1981;63:872–7.
9. Jones L. The shoulder joint-observations on the anatomy and physiology with analysis of reconstructive operation following extensive injury. *Surg Gynecol Obstet.* 1942;75:433.
10. Girdlestone GR. Acute pyogenic arthritis of the hip: an operation giving free access and effective drainage. *Lancet.* 1943;241:419–21.
11. Grauer JD, Amstutz HC, O'Carroll PF, Dorey FJ. Resection arthroplasty of the hip. *J Bone Joint Surg Am.* 1989;71(5):669–78.
12. Froimson AI, Morrey BF. Interposition arthroplasty of the elbow. In: Morrey BF, editor. *Master techniques in orthopedic surgery, the elbow -second edition.* Philadelphia: Lippincott Williams and Wilkins; 2002.
13. Akpuaka FC, Eze CB, Anyaehie UE. The use of the radial recurrent fasciocutaneous flap in interposition arthroplasty of elbow ankylosis: case report and review of literature. *Int Surg.* 2010;95(4):315–8.
14. Sie EJB, Kacou AD, Lambin Y. Austin Moore hemiarthroplasty for displaced femoral neck fractures in patients aged 55 years and above. An Ivorian experience. *Niger J Orthop Trauma.* 2006;5:8–13.

Nyengo Mkandawire and John P. Dormans

Introduction

The aim of this chapter is to outline the challenges of treating bone and soft tissue tumors in resource-limited environments and suggest an approach for management. The global cancer burden continues to rise and is projected to triple by 2030 [1]. In the West cancer survival has increased to more than 70 % with modern multidisciplinary oncology services, but without these, outcomes in developing countries remain poor. Patients often present late with advanced disease (Fig. 42.1) and palliative care, if available, may be the only treatment option.

Funding for cancer treatment remains a challenge, as even the basic health needs in LMICs are not being met. While 84 % of the world's population resides in LMICs, only 5 % of global resources to fight cancer go to them [2]. Palliative services are limited by both lack of trained health workers and access to essential drugs such as opioids.

N. Mkandawire, BMBS, MCh (ORTH), FCS (ECSA), FRCS (✉)

Department of Surgery, Queen Elizabeth Central Hospital, College of Medicine, Mahatma Gandhi Road, Blantyre, Malawi
e-mail: nmkandawire@medcol.mw

J.P. Dormans, MD

Department of Orthopaedic Surgery, Children's Hospital of Philadelphia, University of Pennsylvania School of Medicine, Philadelphia, PA, USA
e-mail: dormans@email.chop.edu

General Principles

In the absence of advanced technologies for staging and treatment, the clinician must rely on clinical features, basic imaging studies, and limited pathology services (Table 42.1, Fig. 42.2). Features suggestive of malignancy include non-mechanical pain, rapid increase in size, fever, malaise, and weight loss. The prognosis depends on the specific tumor grade, size, and depth; patient age; medical comorbidities; nutritional status; and available resources.

After a thorough history, physical exam, and plain radiographs, lesions suspected of being malignant should ideally be referred to a specialized center and staged prior to biopsy and definitive care, using the Musculoskeletal Tumor Society staging system. However, this relies on MRI to determine marrow extension, CT for local tumor extension and chest metastases, bone scintigraphy for skip lesions and mets, and reliable pathology, all of which are rarely available. In most resource poor environments, staging is limited to plain radiographs, a chest x-ray, and ultrasound to evaluate for abdominal, pelvic, or chest masses.

The biopsy of any lesion suspected of malignancy should be carried out at the treatment center where definitive services will be provided. One option is a core needle biopsy, which can be guided by x-ray, ultrasound, or CT. Open biopsies should be performed by the surgeon who will do the definitive surgery. Cultures should always

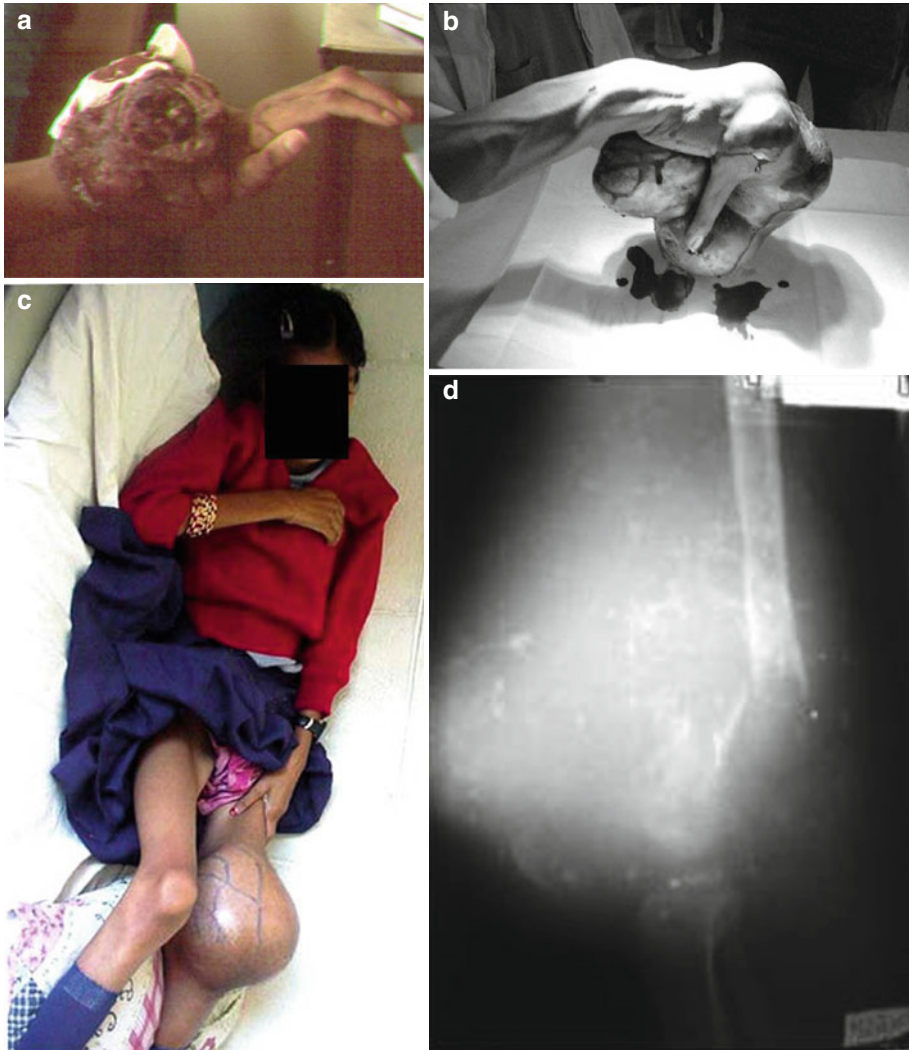

Fig. 42.1 (a–d) In austere settings tumors often present at an advanced stage, when palliative care is the only option

Table 42.1 Common musculoskeletal tumors based on age, location within the bone, and radiographic features

1. Patient age		Benign	Malignant
0–5 years		Langerhans cell histiocytosis (LCH), osteomyelitis	Fibrosarcoma, Ewing sarcoma, neuroblastoma, leukemia
5–10 years		Unicameral bone cyst (UBC), aneurysmal bone cyst (ABC), nonossifying fibroma, fibrous dysplasia, osteoid osteoma, osteoblastoma, LCH, osteomyelitis	Osteosarcoma, Ewing sarcoma, rhabdomyosarcoma
10–20 years		Fibrous dysplasia, osteoid osteoma, osteoblastoma, nonossifying fibroma, ABC, chondroblastoma, chondromyxoid fibroma, osteofibrous dysplasia	Osteosarcoma, Ewing sarcoma, adamantinoma, rhabdomyosarcoma
20 years		Giant cell tumor, enchondroma	Chondrosarcoma, lymphoma, leukemia, plasmacytoma, multiple myeloma, metastases (lung, renal, breast, thyroid, prostate)

Table 42.1 (continued)

2. Location	
Epiphyseal	Benign Chondroblastoma, subacute osteomyelitis, giant cell tumor (adult), osteochondroma, LCH Malignant Clear cell chondrosarcoma (adult), Paget's (adult)
Metaphyseal	giant cell tumor, unicameral bone cyst, aneurysmal bone cyst, nonossifying fibroma, osteochondroma, fibrous dysplasia, subacute osteomyelitis, Langerhans cell histiocytosis, chondromyxoid fibroma Osteosarcoma Fibrosarcoma Chondrosarcoma
Diaphyseal	Fibrous dysplasia, osteofibrous dysplasia, Langerhans cell histiocytosis, subacute osteomyelitis, enchondroma Ewing sarcoma, leukemia, lymphoma, adamantinoma, chondrosarcoma
Multiple locations	Multiple hereditary exostoses, LCH, fibrous dysplasia, enchondroma, hemangioma Leukemia, multiple myeloma, metastatic disease
Anterior spine	Eosinophilic granuloma, hemangioma, infection, giant cell tumor, chordoma, Paget's Leukemia, metastatic disease, multiple myeloma, osteosarcoma
Posterior Spine	Osteoblastoma, aneurysmal bone cyst, osteoid osteoma Metastatic (usually adults)
Pelvis	Aneurysmal bone cyst Langerhans cell histiocytosis Ewing sarcoma, osteosarcoma, chondrosarcoma, lymphoma

3. What is the lesion doing to the bone?

Lesional matrix	Ossification, mineralization (calcification), fibrous ("ground glass")	
Border of the lesion (wide or narrow zone of transition)	Circumscribed or geographic	Appears as though a line is drawn around the lesion Slow growing Narrow zone of transition
	Moth eaten	Small holes in bone Hard to define margin Wide zone of transition Rapid growth
	Permeative	Wide zone of transition Most aggressive, rapid growth

4. What is the bone doing to the lesion?

Cortical response	Slow-growing lesions are well contained, may expand cortex, but do not break through Rapidly growing lesions are not contained and break through cortex
-------------------	--

5. Periosteal reaction

Buttress – trying to build up support for bone stress

Spiculated – "hair on end," fast-growing/aggressive lesions

Solidification – thick periosteal new bone, slow process

Onion skin – several layers, fast-growing/aggressive lesions (Ewing sarcoma)

Interrupted – Codman triangle (triangular area of new bone formation from the periosteum)

be taken as chronic osteomyelitis can simulate malignancy, and vice versa.

The basic principles of open biopsy should be followed:

1. Longitudinal incision.
2. Direct approach to the lesion, avoiding contamination of surrounding tissues.
3. Adequate hemostasis.

4. If using a drain, place it in line with the skin incision.

The soft tissue component associated with a bony lesion should be sampled. Excisional biopsy is contraindicated in cases suspected of being locally aggressive or malignant. With few pathologists, samples are usually sent out and must include detailed clinical information.

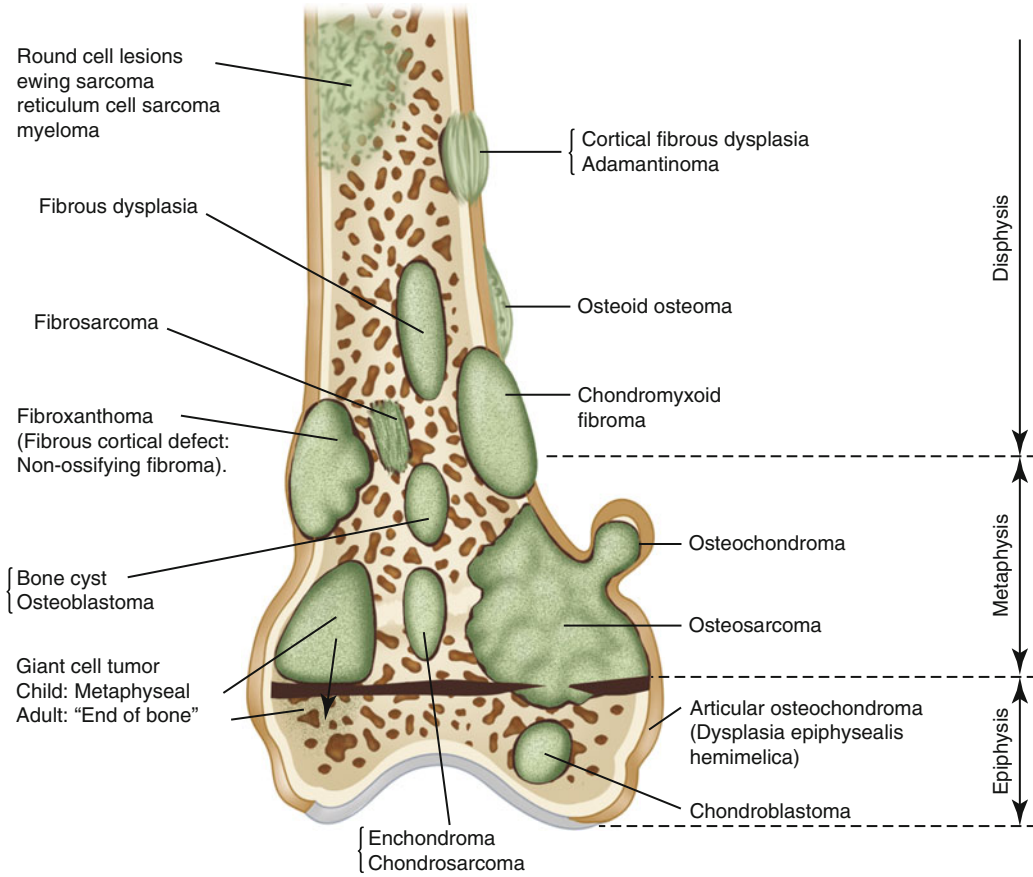


Fig. 42.2 Common bone tumors based on anatomic location

Treatment of Common Benign Bone Tumors

Benign bone tumors often present as incidental x-ray findings but can also cause localized discomfort or a pathologic fracture. The diagnosis

and management of common benign bone lesions are shown in Table 42.2, with examples of the typical radiographic findings in Fig. 42.3. Many of these can be managed outside specialized centers though referral for biopsy is appropriate when the diagnosis is unclear. Symptomatic

Table 42.2 Features of common benign bone tumors

Tumor	Description	Radiographic features	Treatment
Unicameral bone cyst	Fluid-filled cystic lesions	70 % in proximal humerus or proximal femur	Treat fracture first, then decide between observation and active treatment
	Metaphyseal	Centrally located; can be mildly expansile	Many techniques have been described, recurrence is common
	Single chamber versus multiloculated with septa	Radiolucent	Aspiration and injection with steroids
	Contain serous fluid	"Fallen fragment sign"	Curettage/bone graft
	Active if adjacent to the physis, latent if >0.5 cm from physis	Risk of fracture increased if diameter of cyst >85 % or cyst wall <5 mm width	Decompress into medullary space with Rush pin or other

Table 42.2 (continued)

Tumor	Description	Radiographic features	Treatment
Aneurysmal bone cyst	Benign but aggressive	Metaphyseal, eccentric, or central	Highly vascular
	Sponge-like collection of fibrous tissue, blood	Expansile, osteolytic	Simple curettage and bone grafting has high recurrence
	Destructive, elevates periosteum, but maintains thin osseous shell	Pathologic fracture heals, but ABC will persist and enlarge – recurrent fracture	Extensive curettage, bone grafting for larger lesions
Fibrous cortical defect (FCD)	Common in children	Metaphyseal	Observation, most regress spontaneously
	Distal femur or proximal tibia most common	Eccentric with thinned cortex 1–2 cm	
Nonossifying fibroma (NOF)	Same as FCD, but >5 cm	Metaphyseal	Treat pathologic fracture
	Multiple in one third	Eccentric, radiolucent	Occasionally consider surgery for large lesions (>50 % width of bone) which are painful or have refractured
	Regress spontaneously	Uniloculated or multiloculated Healing normal after fracture	Curettage and bone grafting
Fibrous dysplasia	Fibrous tissue proliferation in medullary canal	Lytic, “ground glass” appearance	Observation unless fractures or progressive bony deformities
	One or more sites may have diffuse involvement	Cortex may be thinned by endosteal erosion	Recurrence common
Osteoid osteoma	Night pain	Sclerotic reaction, central nidus	Surgical excision if chronic or severe symptoms and lesion is accessible
	Relief with aspirin or NSAIDs	CT scan helpful	
	Natural history is resolution		
Osteoblastoma	Similar pathology to osteoid osteoma	Lytic lesion often with a sclerotic rim	Observe if asymptomatic
	Benign but aggressive	Expansile, >2 cm	Resect if symptomatic
		Posterior elements of spine, numerous other sites	
Osteochondroma	Lump around knee, shoulder, or ankle	Metaphyseal	Remove if symptomatic
	Multiple hereditary form	Eccentric	Remove in adults if painful or growing (risk of malignant transformation)
	Grow in proportion to the growth of the child May occur in spine	Bony base with cartilaginous cap “Sessile” (flat, smooth) versus “pedunculated” (has a stalk)	
Enchondroma	Hands most common	Punctuate calcifications within lesions	Biopsy
	Usually not painful	May be expansile	Radiographic follow-up to confirm no growth Curettage if large and/or symptomatic
Langerhans cell histiocytosis	Wide variety of presentation	Radiolucent lesion of vertebral body, ilium, or long bone	Natural history is for improvement
	School-aged children for isolated LCH	“Punched out” at first, then periosteal reaction	Biopsy
	Look for multiple lesions		Chemotherapy only for disseminated/fulminant disease

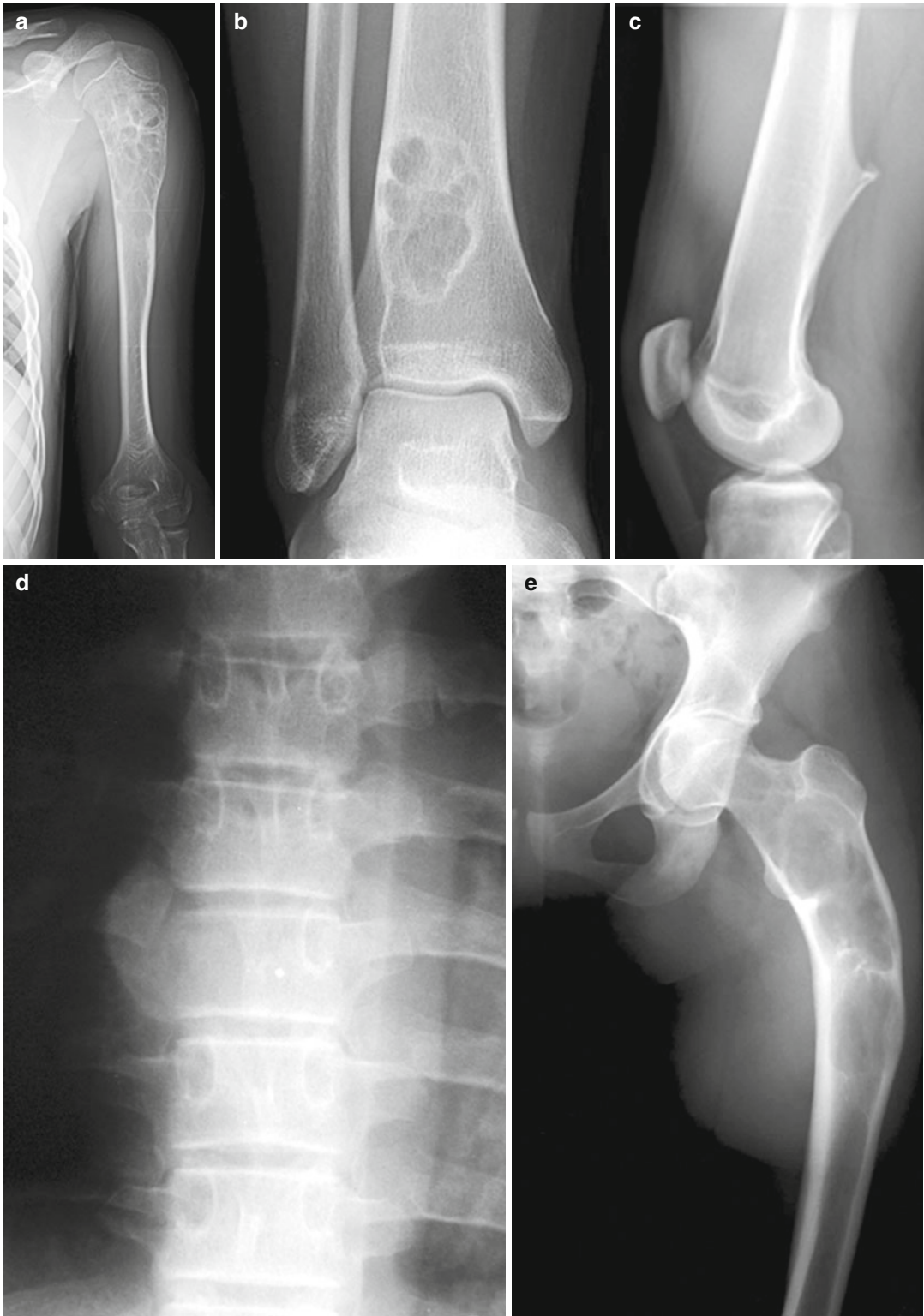
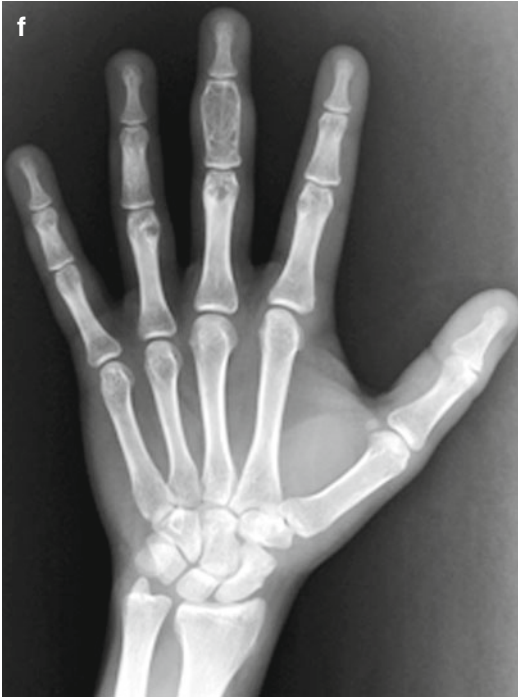
Fig. 42.3 Examples of benign tumors include (a) unicameral bone cyst, (b) nonossifying fibroma, (c) osteochondroma, (d) osteoblastoma, (e) fibrous dysplasia, and (f) enchondroma



benign lesions are often treated by marginal excision, with autogenous bone grafting to manage cavitory defects. Impending or pathologic fractures may require internal fixation. Curettage and bone cement (Fig. 42.4) can be considered for benign but aggressive lesions such as giant cell tumor. The risk of recurrence must be considered especially where the lesion extends into the soft tissues, and primary amputation may be a more realistic option for late presenting aggressive giant cell tumors around the knee joint.

Fig. 42.3 (continued)

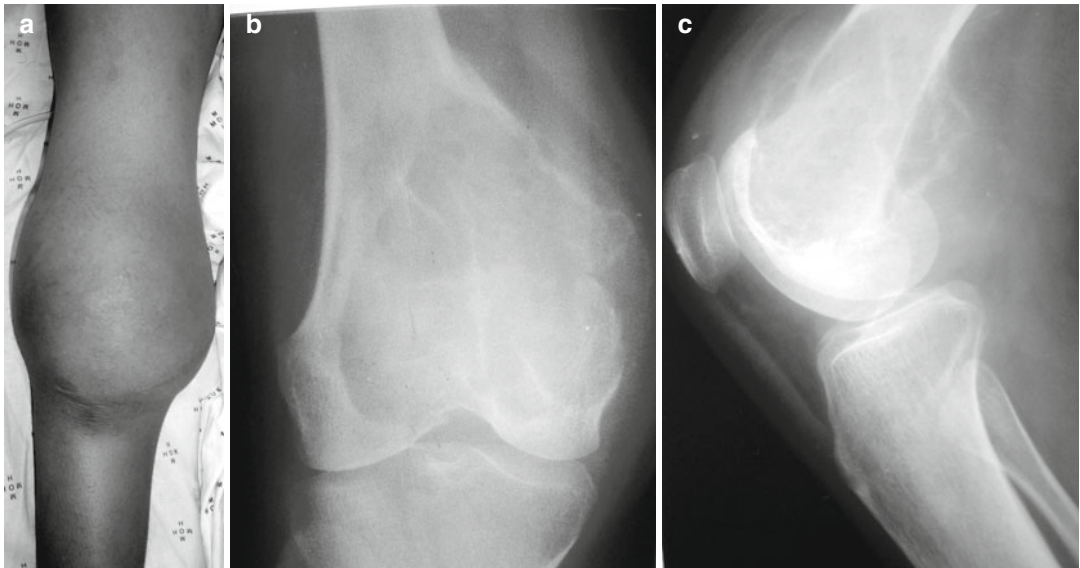


Fig. 42.4 (a–c) A giant cell tumor of the distal femur with soft tissue infiltration was (d) treated by curettage and bone cement. Subsequent tumor recurrence necessitated an above-knee amputation

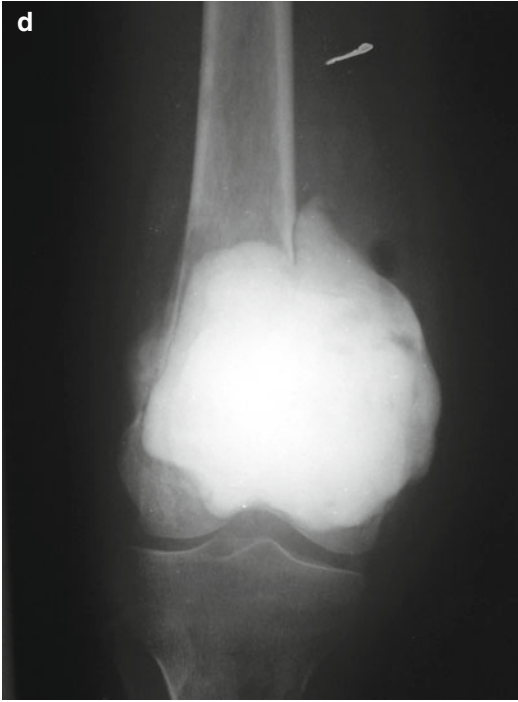

Fig. 42.4 (continued)

Treatment of Malignant Bone Tumors

When resources for comprehensive care are unavailable, it is often more practical to definitively treat a biopsy proven or clinicoradiologically diagnosed malignant lesion by radical excision or amputation. This is followed, where possible, by limited adjuvant chemotherapy. Limited resection or limb salvage procedures are rarely appropriate due to lack of capacity for reconstructive surgery and rehabilitation facilities. Where diagnostic and therapeutic resources are more abundant, proper management of both

benign and malignant lesions usually requires a staged approach and the casual volunteer should assist his national colleagues in the process, but refrain from starting what no one else will be able to finish.

Osteosarcoma is the most frequent primary bone cancer with a peak incidence in the second decade and usually involving metaphyses about the knee or the proximal humerus. Radiographs demonstrate a destructive lesion with both lytic and blastic areas, cortical destruction, and reactive periosteal bone at the margins. Poor prognostic factors include metastases, elevated alkaline phosphatase and lactate dehydrogenase, large tumor size, poor tumor necrosis following neoadjuvant chemotherapy, and location in the pelvis, proximal femur, or proximal humerus. A palliative amputation is sometimes offered (Fig. 42.5). Many patients are simply counseled and given limited palliative care, as the 5-year survival rate with surgery alone is only approximately 20% [3].

Ewing sarcoma belongs to the family of neuroectodermal tumors and is seen in adolescents and young adults. Approximately 50% of lesions are in the extremities. These lesions commonly present with a painful soft tissue mass and fever, and other constitutional features include weight loss and malaise. Findings on plain radiographs include diaphyseal location, “moth-eaten” or permeative pattern of destruction, and a characteristic “onion skin” periosteal response. Up to 10% may have multiple site involvement.

Chondrosarcoma commonly presents in patients 30–60 years of age (Fig. 42.6). These lesions arise in the metadiaphyseal region of long bones or the pelvis, scapula, or ribs. Some chondrosarcomas are secondary, arising in preexisting benign lesions such as osteochondromas.

Chondrosarcomas are usually managed by wide excision without the need for chemotherapy or radiotherapy.

Spindle cell sarcomas are a heterogeneous group including fibrosarcoma, malignant fibrous histiocytoma, leiomyosarcoma, and undifferentiated sarcoma. They account for 2–5 % of all

primary bone malignancies. Age at presentation is commonly 30–60 years with males more commonly affected. These sarcomas can arise in patients with Paget's disease or post irradiation. The treatment is similar to osteosarcoma.

Burkitt's lymphoma is the most common malignant disease of children in tropical Africa

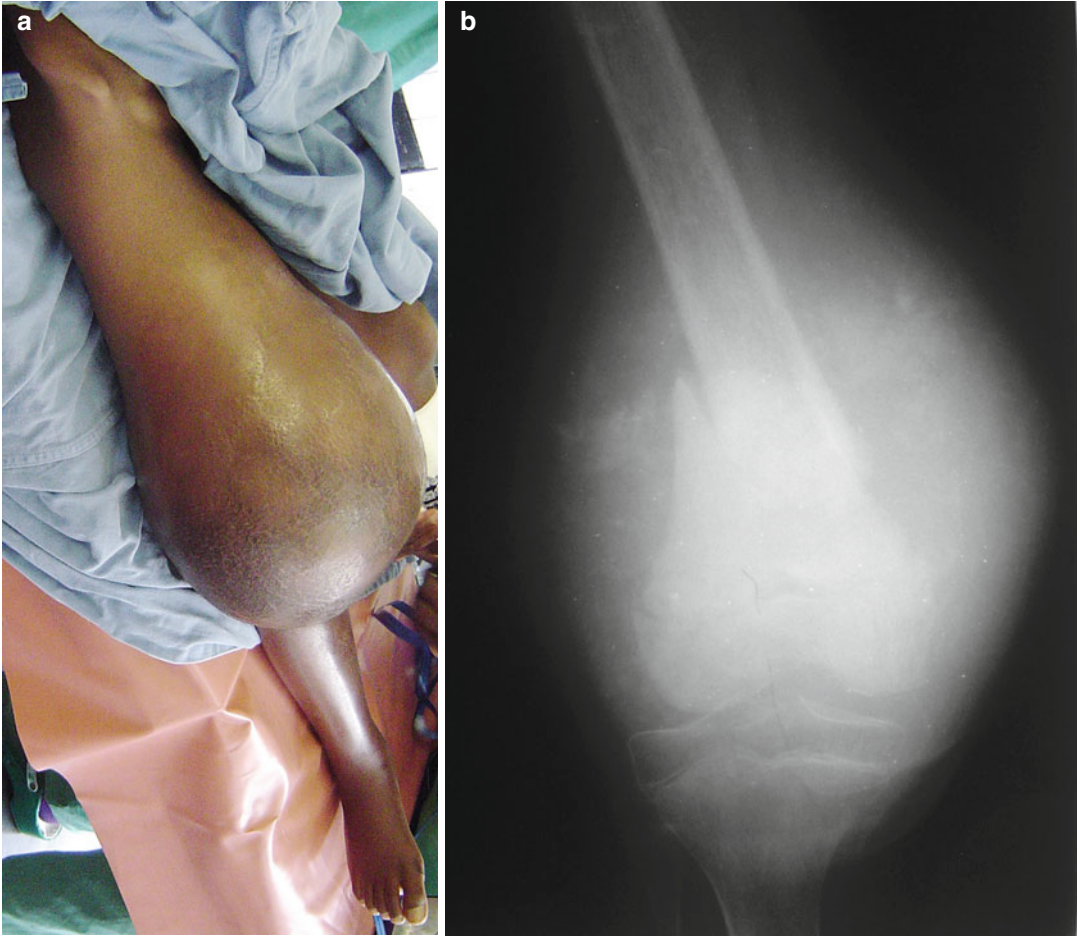


Fig. 42.5 (a, b) This osteosarcoma with pathologic fracture was treated by a (c) palliative hip disarticulation. Note the visible inguinal lymph nodes in photo (a)

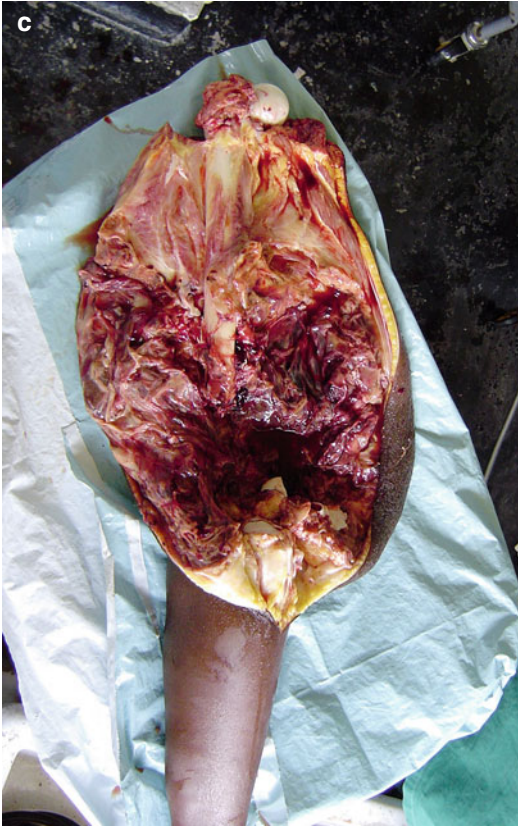

Fig. 42.5 (continued)

and is rapidly fatal if untreated [4, 5]. These tumors are associated with the Epstein-Barr virus and have a predilection for the mandible and maxilla. Only 3–7 % of cases have appendicular skeletal involvement, most commonly the femur, tibia, and humerus. The x-ray can mimic acute hematogenous osteomyelitis, chronic osteomyelitis, Ewing sarcoma, osteogenic sarcoma, acute leukemia, or congenital syphilis (Fig. 42.7). Most patients are under 10 years and have limited pain, tenderness, or local inflammation without regional lymphadenopathy, normal white cell count, and no systemic signs or symptoms. The tumor presents as a rapidly growing mass, and typical sites of involvement are the jaw, abdomen, and pelvis. The diagnosis is confirmed by

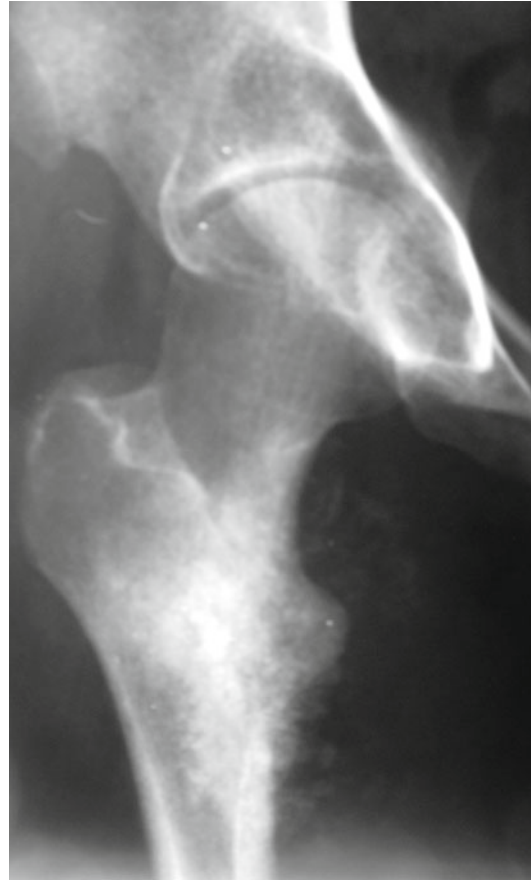

Fig. 42.6 Recurrent chondrosarcoma of the proximal femur

fine needle aspiration or open biopsy. The tumor responds well to cytotoxic drugs.

The role of surgery in Burkitt's lymphoma is limited to biopsy and rarely abdominal tumor debulking to improve the response to chemotherapy. Skeletal lesions, including pathologic fractures, usually heal without special treatment. Patients may present with paraplegia due to cord compression by extradural tumor deposits arising from a vertebral, retroperitoneal, or posterior mediastinal tumor mass, or cord ischemia. The paraplegia due to Burkitt's tumor is usually flaccid, is not associated with a kyphosis, and rarely involves the vertebral body or intervertebral disc.

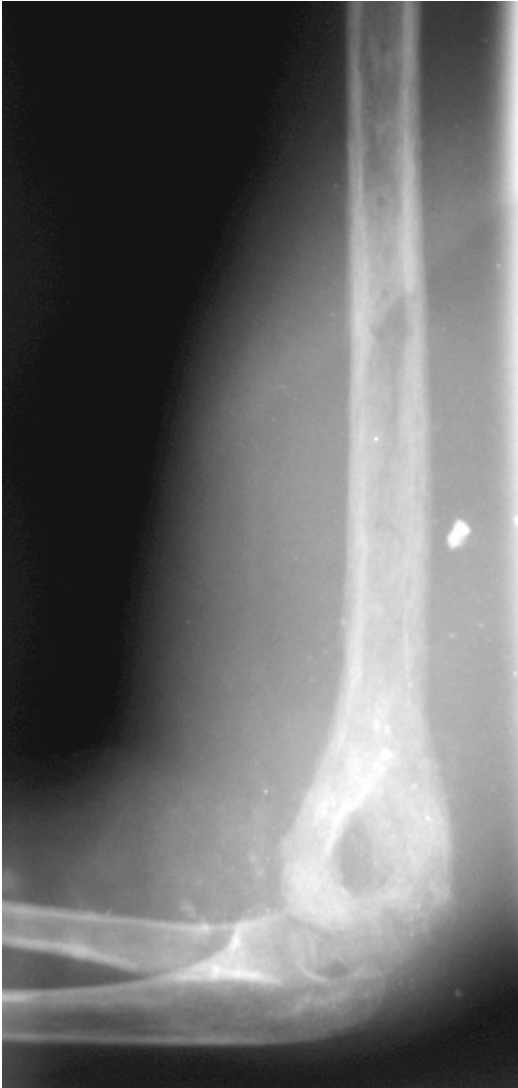


Fig. 42.7 Burkitt's lymphoma can mimic chronic osteomyelitis

nonmechanical pain, recurrence after previous excision, and evidence of bony involvement with lysis, new bone formation, and periosteal elevation. All high-risk lesions should be referred to the highest level of service possible and lesions with a low risk of malignancy can be treated by excisional biopsy.

Treatment of Metastatic Tumors

Pain due to impending or completed pathologic fracture is often the reason for consultation leading to the diagnosis of metastatic disease. Osteolytic metastases due to breast, lung, thyroid, kidney, or other primary cancers are common, as populations in LMICs are aging and tobacco use increasing. The goal of palliative care is to keep the patient pain free and functional for as long as possible. It is generally agreed that painful lesions eroding more than 50 % of the cortex in both planes should undergo prophylactic internal fixation. Without adjuvant therapies, the disease will inevitably progress, so fixation should be as robust as possible.

After a fracture has occurred, open fixation is required. Unless methyl methacrylate is available, the best approach is curettage of the tumor and internal fixation with a nail, single or double plating, or preferably both, using small screws and cerclage wire. Such constructs do not aim at bone healing, but rather at outlasting the patient before failure. Blood should always be available for transfusion and a pneumatic tourniquet used. A proximal disarticulation is a last option that few patients are willing to accept, especially when they understand the severity of their prognosis.

Treatment of Soft Tissue Tumors

Primary soft tissue tumors are rare, and there are numerous diagnoses, many of which have a spectrum of biologic potential. Factors suggestive of malignancy include size >5 cm, rapid increase in size, location deep to the fascia,

References

1. Boyle P, Bernard L. World cancer report. Lyon: International Agency for Research on Cancer; 2008. p. 5. <http://www.globalhealthfacts.org/data/topic/map.aspx?ind=66>. Accessed 1 May 2012.

2. A report from the Economist Intelligence Unit. The global burden of cancer—challenges and opportunities. 2009. http://graphics.eiu.com/marketing/pdf/EIU_LIVESTRONG_Global_Cancer_Burden.pdf.
3. Foster L, Dall GF, Reid R, Wallace WH, Porter DE. Twentieth century survival from osteosarcoma in childhood. Trends from 1933 to 2004. *J Bone Joint Surg Br.* 2007;89(9):1234–8.
4. Cockshott WP. Radiological features. In: Burkitt DP, Wright DH, editors. *Burkitt's lymphoma*. Edinburgh/London: E & S Livingstone; 1970. p. 23–33.
5. Fowles JV, Olweny CLM, Katongole-Mbidde E, et al. Burkitt's lymphoma in the appendicular skeleton. *J Bone Joint Surg Br.* 1983;65:464–71.

Suggested Reading

- Grimer RJ, Briggs TWR. Earlier diagnosis of bone and soft tissue tumours. *J Bone Joint Surg Br.* 2010;92-B:1489–92.
- Vlychou M, Athanasou NA. Pathology, radiological and pathological diagnosis of paediatric bone tumours and tumour-like lesions. *J Bone Joint Surg Am.* 2008;40:196–216.

Richard A. Gosselin and Douglas G. Smith

Introduction

In low-income countries (LICs), amputation for tumors, trauma, infections, and chronic diseases is a common surgical procedure and often remains the best or only option as limb salvage is rarely possible [1]. Surgeons working in low resource environments must therefore be very comfortable with a variety of amputation techniques [2].

Amputation surgery is a process—not just a procedure—and needs to address the gamut of physical, psychological, social, and rehabilitation issues affecting the patient and his or her family. Amputation surgery has two separate goals: removal of the disease and reconstruction of the residual limb. Whereas the first goal rests on the surgeon’s shoulders, the second requires a team of professionals, which will rarely be present in full. Ideally, the surgeon works pre- and postoperatively with the prosthetist, prosthetic technician, and physiotherapist or occupational therapist, who trains the patient in activities

of daily living and use and maintenance of the prosthesis.

The surgeon needs to be aware of the extent of available resources, expertise, and technologies, keeping in mind sustainability for the patient.

General Principles

The ideal upper extremity (UE) stump preserves as much distal function as possible as severely limited hand function is still better than having no hand. The stump should be painless, sensate, and without wounds, with the ability to provide assistive function as a paddle or claw. In LIC the majority of patients manage with only their stumps, using a prosthetic hand only for cosmesis.

The ideal lower extremity (LE) stump is painless, end-bearing, well padded, and balanced. A good prosthetic fitting ensures relatively equal leg lengths, with preservation of pelvic and spinal alignment for minimum energy expenditure during gait. Comorbidities such as malnutrition, anemia, or diabetes are common, must be considered, and can lead to wound healing problems.

An informed and properly translated consent form, signed by the patient or the decision maker, needs to be obtained, even in lifesaving situations, as some societies consider death preferable to amputation. Such decisions must be respected, even if the surgeon sees an amputation as a solution.

Once the decision to amputate is agreed upon, the surgeon should aim for the most distal level

R.A. Gosselin, MD, MPH, MSc, FRCS(c) (✉)
Orthopedic Surgery, Institute for Global Orthopedics
and Traumatology, UCSF, 1001 Potrero Ave, 3A-36,
San Francisco, CA 94110, USA
e-mail: froggydoc@gmail.com

D.G. Smith, MD
Department of Orthopedic Surgery, Harborview
Medical Center, University of Washington,
1959 N.E. Pacific St., Seattle, WA 98195-6500, USA
e-mail: dgsmith@u.washington.edu

that removes the disease and is compatible with sound wound healing and prosthetic fitting. Contrary to military wounds (see Chap. 44), where amputation surgery should err on the aggressive side of debridement, the surgeon facing a mangled extremity from a civilian injury should err on the conservative side and be prepared to remove more tissue or shorten the stump at the next surgical setting. Amputations for chronic conditions, particularly in dysvascular patients, should be at a level that provides the best chance of healing. As the prevalence of diabetes is increasing worldwide, amputations for “wet gangrene” will be more common [3]. Amputation in such conditions should almost never be closed primarily [4]. An initial more proximal level might be easier for a patient to accept than taking a chance at a more distal level that would lead to later revision, disappointment, and prolonged hospitalization.

Skin

The ideal scar is painless, pliable, and nonadherent to underlying tissues or bone. Conventional flaps can be planned for elective amputations and marked before cutting. When faced with “flaps of opportunity” after trauma, retain as much viable soft tissue as possible during the initial debridement and do not primarily close the wound. Delayed primary closure on the fifth day allows assessment for recontouring the flaps. Elective amputations for tumors or vascular disease can often be closed primarily. However, if there is any doubt about tissue viability, leave the stump open until delayed closure at 5 days. Under no condition, close a wound under tension.

As a good blood supply is essential for stump healing, avoid subcutaneous dissection by lifting a full fasciocutaneous flap wherever possible. Flaps should be generous as it is easier to trim excess skin than shorten the bone because of insufficient coverage. A tourniquet should be used and released before closure. To our knowledge there is no evidence to support not using a tourniquet in dysvascular or sickle cell patients.

Muscles

Muscle provides padding and balance between the agonist and antagonistic groups. A transected muscle belly bleeds and swells more than a muscle severed at or near its tendinous junction, making a bulky or unbalanced stump. Muscle should be cut obliquely—longer at the edge adjacent to the skin flap to shorter as the cut nears the bone. Muscles can be stabilized over the end of the cut bone in one of four ways:

Myofascial closure re-approximates the outer fascial envelope to the skin flap encasing the bone. Only the superficial layers of the muscle are involved, with the deeper layers retracting proximally, resulting in a “cone-head” stump, which is difficult to fit and should be reserved for cases with a high risk of ischemia.

Myoplasty closure is common in diaphyseal amputations, where muscle bellies are transected, leaving fascial and aponeurotic tissues unsuited for bony reattachment. Opposing muscle masses are sutured together over the bone end, providing distal padding. Unless they anchor themselves to bone with scar, they can act as an antagonistic sling, sliding over the bone end, creating a painful bursa and an unstable basis for the prosthesis.

Myodesis closure anchors the deep muscular layers to the periosteum or to bone through drill holes. The superficial muscle layers are re-approximated in a myoplasty fashion. This provides padding and balance, as deforming forces on the stump are counteracted by the myodesis. For example, an adductor myodesis of a transfemoral amputation prevents an abduction deformity from unopposed hip abductors.

Tenodesis closure secures the distal tendon directly to bone. It is the most physiologic technique, but usually feasible only in disarticulations.

Whatever the muscle closure technique, correct tensioning is important, dictated by clinical judgment. Experience suggests to err on the lax rather than the tight side.

Nerves

Many techniques have been proposed to prevent painful postoperative neuromas and phantom pain, the abnormal persistent or even worsening pain with time, as opposed to phantom sensation, which is a normal self-limited sensory phenomenon of the missing limb. None has proved superior. A simple sharp transection under gentle traction so the nerve retracts into a well-cushioned area away from scar and prosthetic pressure remains the technique of choice. Avoid excessive traction that can cause proximal axonotmesis and residual pain.

Preserve sensory nerves supplying the stump, particularly in the upper extremity. Named nerves need to be identified and separated from their accompanying vascular bundle and not incorporated in the vascular ligature, as this can cause “pulsatile” pain. Hemostasis of a vasa nervorum is by direct compression, not electrocoagulation.

Vessels

Named arteries and veins are identified and ligated separately, with double ligation for the arteries. Small bleeders can be coagulated after release of the tourniquet, and the rest managed by direct pressure before closure.

Bones

Most of the ground-to-body forces pass through the bony stump and are best distributed over the largest surface possible, making it important to avoid sharp bony prominences. Angles and corners need to be filed and rounded. The tibial stump needs to be beveled anteriorly at a 45° angle to prevent anterior skin problems. Extensive stripping of the bone should be avoided, as it can lead to irregular, painful exostoses. In adults, the canal will eventually seal itself with scar tissue, without bone wax or canal-filling procedures. In children, bone overgrowth is a common problem

prevented by capping the bone end with a periosteal flap or an osteochondral plug.

Wound Closure

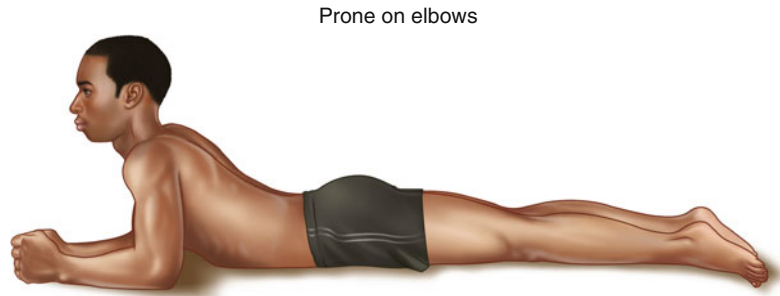
As for all wounds, dead space should be avoided and closure achieved under physiologic tension, with excess skin trimmed as necessary to avoid dog ears. We recommend drains, as hematomas impair stump healing. Delayed closure should always be the case for trauma patients. It may also be the case for some infected patients such as diabetics or patients with chronic ulcers. There is no role for guillotine amputations, except in the rare lifesaving extrication situation. There is no contraindication for a split-thickness skin graft over healthy muscle of a stump. It should be as thick as possible to minimize the risk of break down.

If the stump is closed primarily, a loose, bulky, compressive dressing is applied. The drain is removed at the first dressing change, in 24–48 h, and a new dressing applied that should be changed at suture removal (2–2.5 weeks) unless there is fever, drainage, foul odor, increased pain—all signs of potential infection. If the stump wound is left open at the initial surgery, it should be dressed with a bulky absorbent dressing using fluffed gauzes and light compression with elastic bandages. This dressing is only removed in the operating room at the time of delayed primary closure 4–5 days later. Subsequent management is the same as for a primarily closed stump.

Postoperative Management

POP back slabs for upper extremity and below-knee amputations are useful for comfort and preventing early contractures. Compressive dressings and distal elevation help control edema and pain. Avoid propping AKA stumps on pillows that lead to hip flexion contractures. For patients with BKAs, do not allow knee flexion over pillows, leading to knee flexion contractures. Patients with above-knee or through-knee amputations should spend time each day lying

Fig. 43.1 While in the prone position, gravity combats BKA flexion contracture of the knee and AKA flexion contracture of the hip. Elbow push-ups stretch the flexors even more. This should be done twice a day for 30 min



prone (Fig. 43.1). An active rehabilitation regimen will prevent joint contractures and stiffness; strengthen the antagonist muscles across the distal joint and proximal accessory muscles; and maximize active ROM. Adequate nutrition and cessation of smoking are important adjuncts.

After suture removal, compressive dressings will help the stump mold and mature until it is ready for the first fitting, usually around 3 months. Complete stump maturation takes around 12 months. In low resource environments, unless in expert hands, immediate or early rigid dressings should not be used. Early temporary prostheses are rarely available. The amputee needs training in the maintenance of his appliance, has access to necessary supplies such as socks or stockings, learns the signs and symptoms of impending stump problems, and has access for repair or replacement of the prosthesis.

An amputation is considered successful only when rehabilitation—uncomplicated wound healing, edema control, pain management, prevention of contractures and prosthetic fitting, and independence—is complete. Rehabilitation is an ongoing process, as regular prosthetic repair and replacement will be needed. An amputee is a patient for life.

Revision Amputations

Poor healing, inadequate length, contractures, wound complications, pressure sores, overgrowth, exostoses, and pain are reasons to revise an amputation. Problems usually stem from a recurrence of the disease, an incomplete initial excision, or the stump-prosthesis interface. Erosion through the skin of a poorly covered bony stump is not uncom-

mon, particularly in BKAs (Fig. 43.2). The same principles used in primary amputation surgery apply for revision surgery with the input of the prosthetist sought whenever possible. Scarring and atrophy make revisions technically more difficult, but they should be attempted, as the difference is often between using crutches for life and using a prosthesis. If pain can be clearly demonstrated to be from a neuroma—not easy—revision surgery with a proximal sharp neurotomy can provide dramatic relief.

Specific Amputations

Upper Extremity (UE)

It is important to preserve as many joints as possible, no matter how short the distal segment.

Scapulothoracic and Shoulder Disarticulations are mutilating procedures reserved for life-threatening situations or for “hygienic” management of chronic fungating tumors of the shoulder and proximal arm.

Arm Amputations should preserve as much humerus as safely possible. A stump that reaches the midline in adduction allows “paddle function.” An amputation through the proximal third of the humerus is functionally the same as a shoulder disarticulation and often has an abduction contracture due to an unopposed rotator cuff. An amputation through the distal third of the humerus allows a myodesis of the brachialis/biceps complex to the posterior humeral cortex. The triceps can be sutured to the flexors by myoplasty.

Elbow Disarticulation, after trimming the epicondyles, provides the longest lever arm in upper arm amputations and should be used, particularly in children.

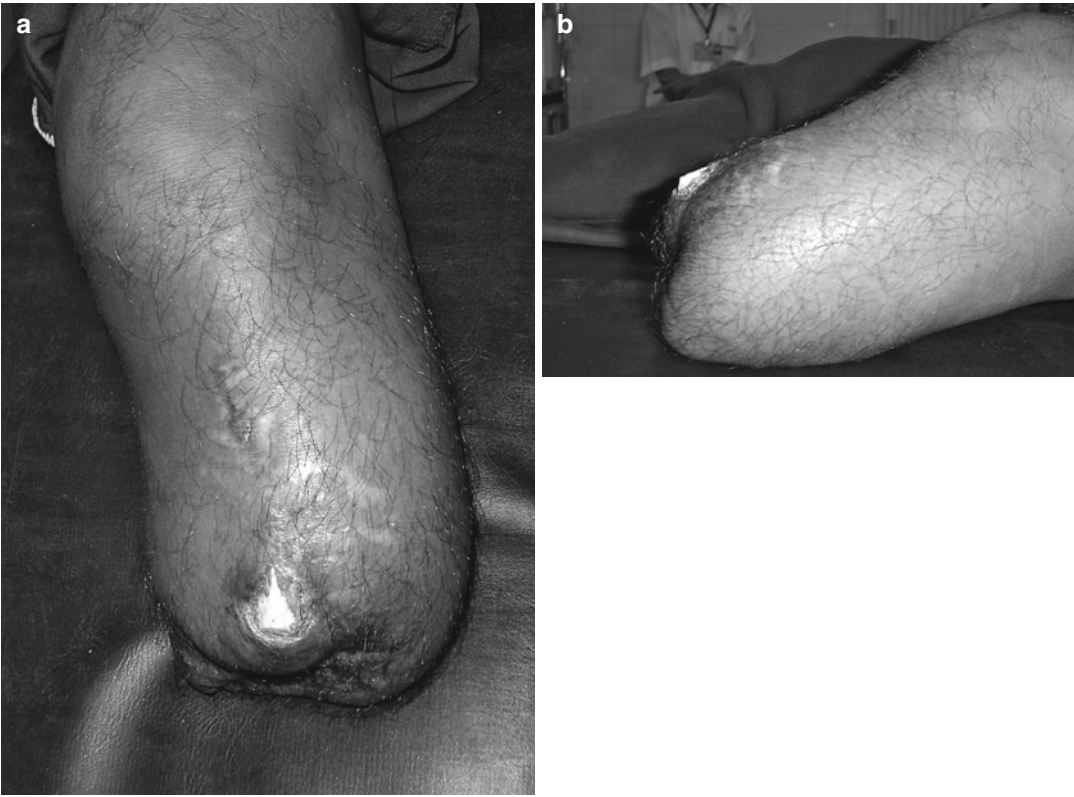

Fig. 43.2 (a, b) Ulceration of the skin over an ill-prepared and ill-covered tibial bony stump that was fortunately still salvageable with a proximal BKA

Forearm Amputations should be as long as possible to provide a sensate stump to use as a paddle, which can easily cross the midline with elbow flexion. Both bones should be cut at the same length. Proximal third amputations tend to have a supination contracture; those through the middle and distal third are more balanced. The distal half of the forearm is mostly tendinous, making padding of the bone ends difficult. Respect the sensory nervous distribution when designing the skin flaps.

The civil war in Sierra Leone revived interest in the Krukenberg procedure. It was initially described for blind bilateral forearm amputees, usually from mine blast injuries. The sensate 2-prong claw has no active pinch capacity, but the preservation of active pronation-supination, combined with shoulder abduction and rotation, allows better function than a simple paddle. This technique is demanding, reserved for bilateral amputees, doing one side at a time—the nondominant first—and the second only if the patient is satisfied with the first.

A disarticulation through the radiocarpal joint, preferably with a volar skin flap, is a good procedure, particularly in the pediatric population. Unless some rays are to be preserved, there is no benefit in retaining any of the carpal bones. The radial and ulnar styloids should be contoured to create a rounded, symmetrical stump.

Hand Amputations. Initial debridement of industrial or agricultural wounds should be as conservative as possible, as many of these injuries appear worse than they are. All tissues of questionable viability should be retained and left to declare themselves. They can be addressed at a second look, 48–72 h post-injury. Retain as many joints as possible as even a short sensate stub is more functional than a more proximal amputation. Immobilizing metacarpal and phalangeal fractures with k-wires stabilizes the bony architecture and promotes soft tissue healing (Box 43.1).

Box 43.1 General Principles for Upper Extremity Amputations

- Delayed primary closure is almost always preferable
- Preserve some prehension capability, either by key pinch or at least side-to-side pinch
- Stumps should be covered by sensate skin
- When a joint has lost antagonist balance, it should be pinned in a functional position to prevent contractures and allow delayed tendon transfer or arthrodesis
- A disarticulation is better than a more proximal trough-bone amputation. Even in adults, there is no need to remove the articular cartilage
- A bulky hand dressing can be stabilized with volar and/or dorsal POP slabs
- There are no indications for reimplantation
- Assume there will be no post-op hand rehabilitation
- Prostheses are rarely available, and then only for cosmetic purposes

Hand amputations for chronic conditions are done according to established techniques, such as ray resection. Primary or delayed primary closure using sensate skin without suture tension is preferable, but temporary flap coverage or split- or full-thickness skin grafting should be attempted if it allows preservation of more length or function.

Lower Extremity (LE)

The main goal for a LE amputation is to provide a well-healed stump that allows pain-free prosthetic use without the need for walking aids.

Hindquarter Amputation and Hip Disarticulation are reserved as heroic lifesaving maneuvers in severe open pelvic trauma, severe infection (gas gangrene), or tumors.

Above-Knee Amputation (AKA). As a general rule, longer femoral stumps serve better than short ones. Whenever feasible, proximal one-third amputations should leave at least 10 cm of

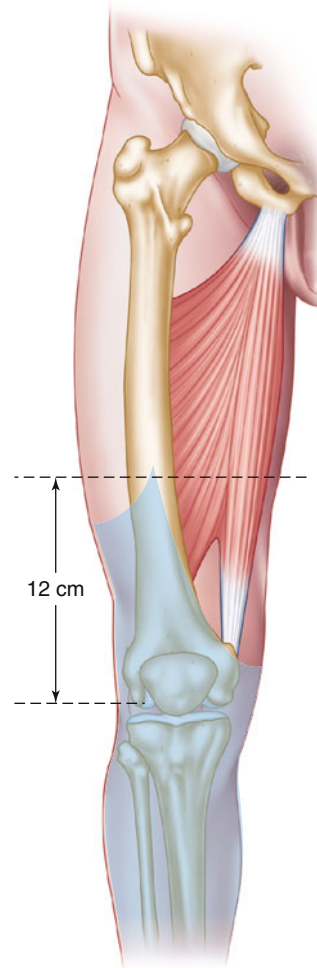


Fig. 43.3 Classic asymmetrical fish-mouth incision to prevent surgical scar at the tip of the stump. The bone is cut approximately 12 cm from the knee joint, just above Hunter's canal

bone below the lesser trochanter. Shorter stumps are almost impossible to fit with a prosthesis and develop a flexion/abduction contracture from muscular imbalance.

The conventional AKA is made at the junction of the middle and distal thirds, using a classic asymmetrical fish-mouth incision (Fig. 43.3). The apex of the anterior flap lies 8–10 cm distal to the proposed bone cut and is 2–3 cm longer than the posterior flap, so that the scar is slightly posterior to the end of the stump. The femoral artery is doubly ligated near the Hunter's canal and the femoral vein ligated separately. The

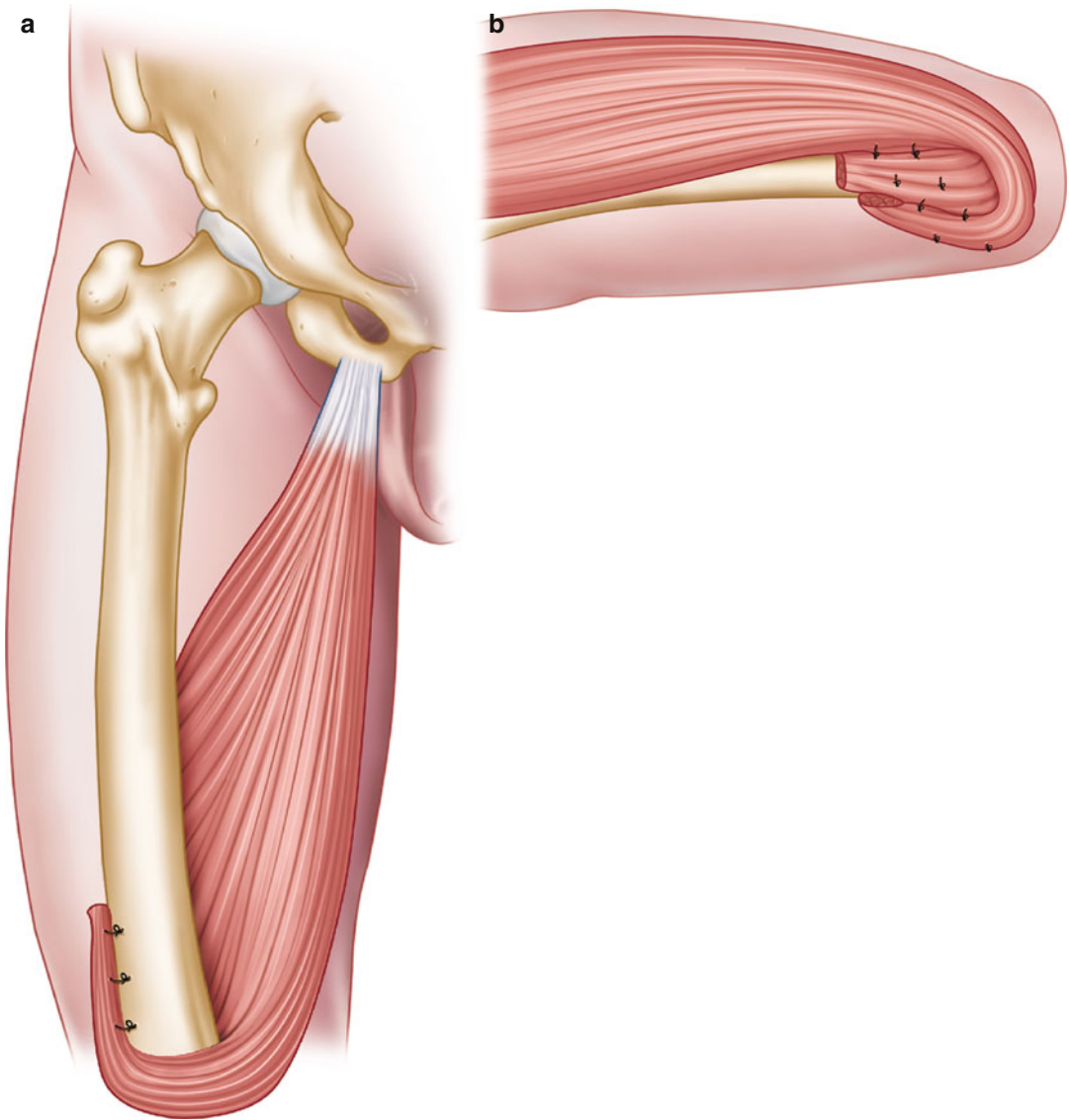


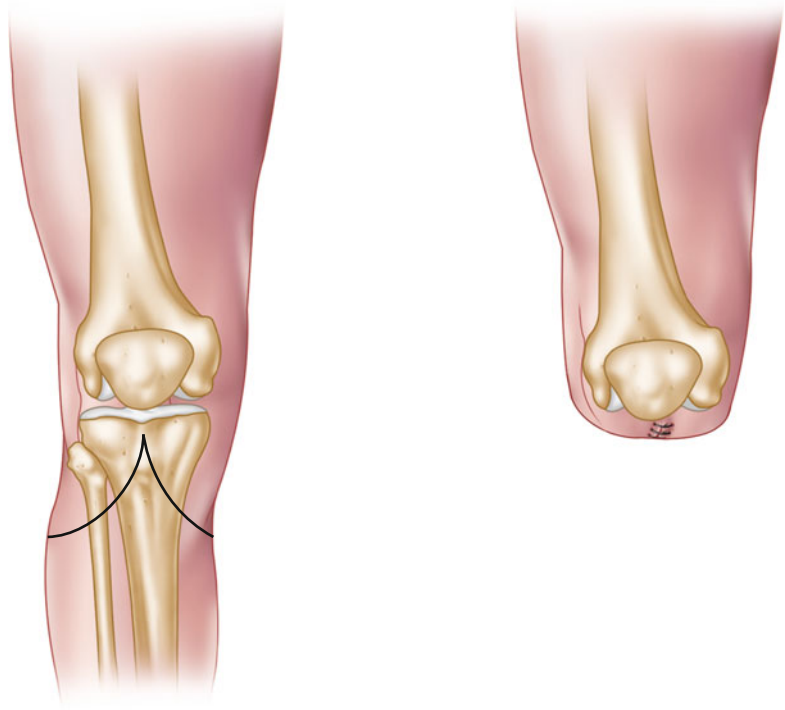
Fig. 43.4 (a) Myodesis of adductor magnus to the lateral femoral cortex using drill holes. (b) Myodesis of the quadriceps over the end of the stump and the adductor magnus over the end to attach to the linea aspera posteriorly

adductor magnus belly can be developed and myodesed to the lateral side of the rounded femoral bone stump (this counteracts the unopposed pull of the intact abductors on the greater trochanter). The quadriceps is cut obliquely in the coronal plane, and the available quadriceps tendon is myodesed posteriorly over the adductor, providing a well-padded and balanced stump (Fig. 43.4). The tourniquet is released, hemostasis

secured, and the skin closed without tension over a drain.

Knee Disarticulation. Before considering this procedure in adult patients who are likely to get a prosthesis, the surgeon needs to be absolutely sure that the skills and technology for this type of prosthesis are available. If not, a low AKA should be done, suturing the patellar tendon to the remaining PCL stump, and the wound is closed

Fig. 43.5 Incision for elective knee disarticulation



without removing articular cartilage or trimming the epicondyles. In patients who will not walk, a knee disarticulation can have advantages in better sitting support and an improved lever arm for transfers (Fig. 43.5).

Below-Knee Amputation (BKA) is the most common amputation and in austere settings is usually done because of trauma. If properly performed and the stump adequately fitted, the patient can retain a high level of function even with a low-tech prosthesis.

The level of the tibial cut is often dictated by the injury, but when done as an elective procedure, it is placed near the junction of the proximal and middle thirds, about 15 cm distal to the tuberosity or 2.5 cm for each 30 cm of patient height. Shorter stumps are more difficult to fit, and anything less than 5–6 cm tibial length is not functional. Amputations through the middle third are easy to fit, but there is no benefit to those in the distal third where good padding is difficult to achieve.

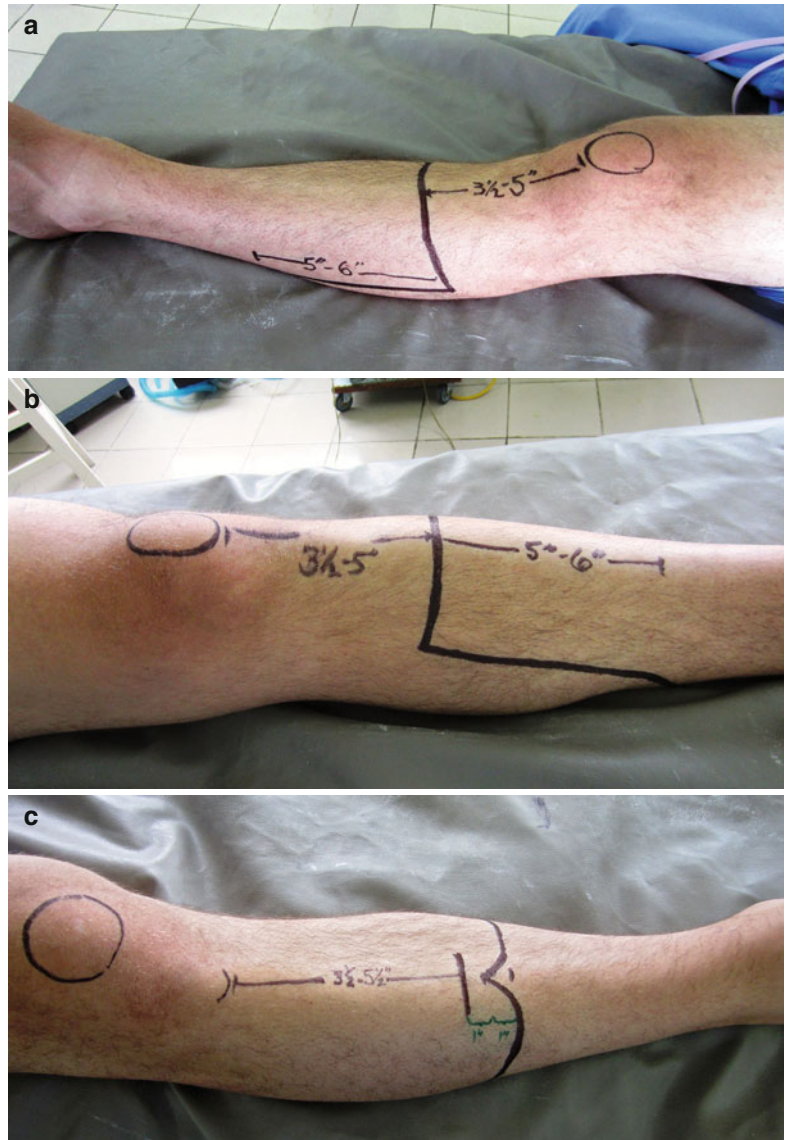
The Burgess “step” incision remains the classic approach, although more unconventional fish-mouth flaps, when properly designed, are also successful (Fig. 43.6). In the Burgess approach,

the anterior skin incision lies 1–2 cm distal to the proposed bone cut, and the posterior incision around 10 cm more distally to the anterior skin incision. The anterior and anterolateral compartments do not provide much padding and can be excised generously. The anterior tibialis neurovascular bundle is identified in the process and addressed accordingly. The saphenous vein is ligated, and the sural nerve sharply cut.

The tibia is cut with a Gigli saw, incorporating a 45° anterior bevel once through mid-bone. This is essential. The fibula is cut 1.5–2 cm proximal to the tibia, and both bones should be filed and rounded. An excessively long fibula creates wound and prosthetic fitting complications (Fig. 43.7). The specimen is flexed at the osteotomy, and the posterior muscle mass cut obliquely in line with the posterior incision, completing the amputation. The posterior tibialis neurovascular bundle is identified in the process and ligated.

Stable padding is assured by a myodesis of the posterior muscle mass through drill holes in the anterior tibial cortex or sutures in the periosteum. If the flap is too bulky, the soleus can be sacrificed. Primary closure is done without tension

Fig. 43.6 (a, b) Classic incision for “Burgess-type” BKA. (c) Distal fish-mouth incision, with bone cut proximal to the most proximal apex of the incision

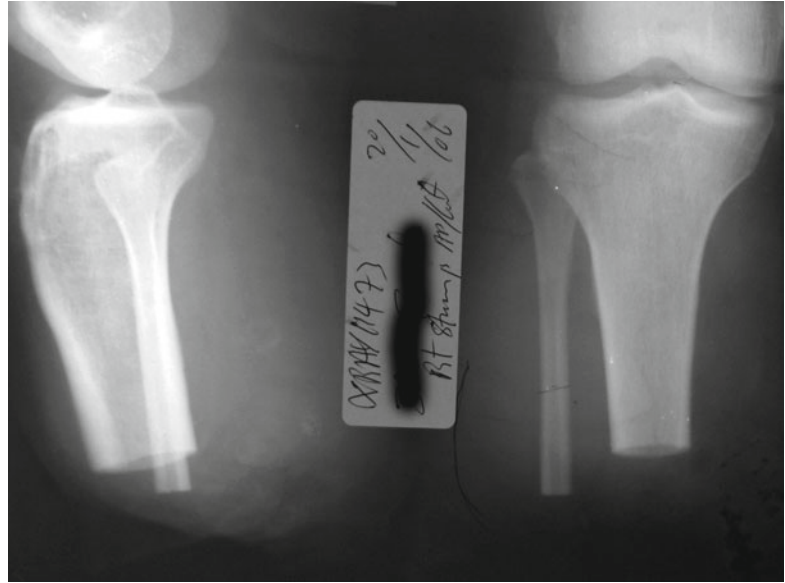


over a drain. The stump is immobilized in extension with a bulky dressing and posterior back slab. For trauma or any concerns about tissue health, apply an absorbent bulky dressing over the open wound and return in 4 or 5 days for a delayed primary closure.

Ankle Disarticulations. The Syme procedure provides an end-bearing stump if care is taken to preserve the fragile heel pad circulation arising from the posterior tibialis artery. It is less useful in trauma because a traumatized heel pad does not provide a pain-free distal end. A wide fish-

mouth incision is made so that the shorter horizontal anterior limb meets the longer vertical posterior limb at the malleoli. The anterior tibial bundle is ligated, and the hindfoot is dissected, cutting from front to back and staying close to the bone around the os calcis to minimize damage to the heel pad and its blood supply. The malleoli are removed at the level of the joint and can be trimmed obliquely to decrease their bulk. The heel pad is anchored to the distal tibia through drill holes. Any doubts about soft tissue viability should delay closure until a second look in

Fig. 43.7 The fibular stump is too long and needs to be revised to be 1.5–2 cm shorter than the tibia



4–5 days. The healed stump can be easily fitted with a prosthesis with a high level of function.

The Boyd procedure is beneficial in environments with limited resources, particularly in young trauma patients with good blood supply. The talus is excised, but the os calcis is retained and fused to the distal tibia in a calcaneus position with one or two retrograde Steinman pins. A percutaneous tenotomy of the Achilles tendon will remove the deforming force until the fusion is solid. The stump is protected in a non-weight-bearing below-knee POP for 3 months, after which the pins are removed and progressive weight bearing started if x-rays show consolidation. Inconclusive x-rays require additional casting. This gives an end-bearing stump with very little leg-length discrepancy and many patients can do without a prosthesis.

A Chopart disarticulation at the talonavicular and calcaneocuboid joints is rarely indicated. The authors prefer the Boyd technique with more predictable results and fewer late complications (Fig. 43.8).

Foot Amputations

- Disarticulation or amputation in the midfoot is little used. Equinus deformity is common, making tenodesis or tenotomy necessary.
- Transmetatarsal amputation may be indicated for multifocal osteomyelitis in diabetics or in crush injuries of the forefoot in younger patients. Prostheses are not necessary, but rebalancing by release of the Achilles tendon and stabilization of the anterior tendons should be performed.
- Ray resection may be indicated for chronic metatarsal osteomyelitis, tumor, or trauma. Delayed primary closure or closure by second intention can be effective if proper wound management resources are available. Transfer metatarsalgia is a common late complaint.
- Toe amputations or metatarsophalangeal disarticulations give very little functional disability, except for such procedures of the first ray, which may weaken push-off.

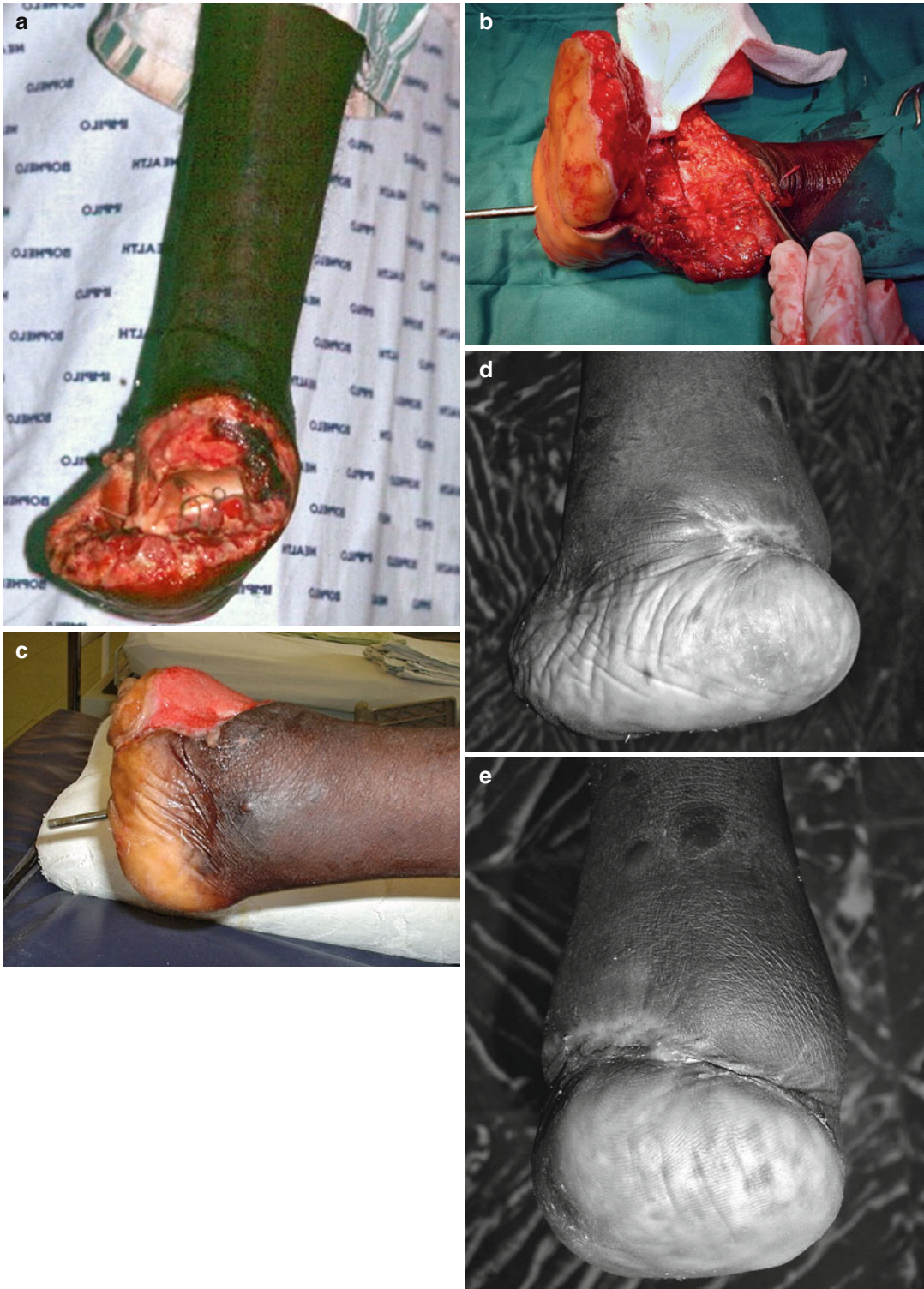
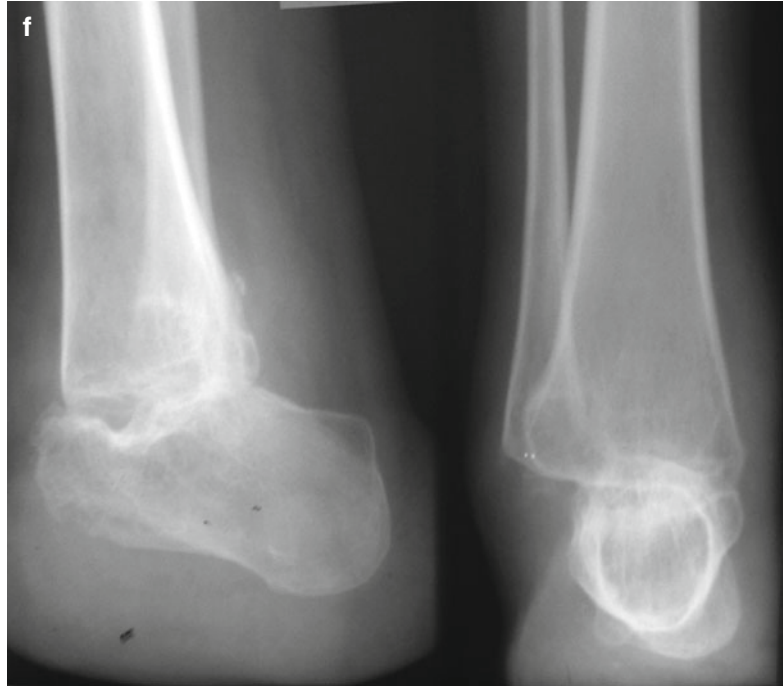


Fig. 43.8 (a) Appearance of the stump after initial debridement of a traumatic amputation. The dome of the talus is visible. (b) Repeat DBR at 5 days, at which time a talectomy was done, tibial and calcaneal articular surfaces removed, and calcaneus fixed to tibia with one stout retrograde Steinmann pin. The Achilles tendon was transected

and the wound partially closed. (c) The rest of the wound is granulating nicely without infection. (d, e) Clinical and (f) radiological appearance of the stump 6 months later. The pin was removed at 3 months, and the patient ambulated in a BK POP for 6 weeks. He was now full weight bearing without pain or complaints of shortening

Fig. 43.8 (continued)

References

1. Akiode O, Shonubi AM, Musa A, Sule G. Major limb amputations: an audit of indications in a suburban surgical practice. *J Natl Med Assoc.* 2005;97(1): 74–8.
2. Swann M, Walker GF. Amputations in developing countries. *Br Med J.* 1966;1(5494):1041–3.
3. Boulton AJ, Vileikyte L, Ragnarson-Tennvall G, Apelqvist J. The global burden of diabetic foot disease. *Lancet.* 2005;366(9498):1719–24.
4. Abbas ZG, Archibald LK, Abbas ZG, Archibald LK. Challenges for management of the diabetic foot in Africa: doing more with less. *Int Wound J.* 2007;4(4):305–13.

Suggested Reading

Smith DG, Michael JW, Bowker JH, editors. *Atlas of amputations and limb deficiencies: surgical, prosthetic, and rehabilitation principles.* 3rd ed. Rosemont: American Academy of Orthopedic Surgeons; 2004.

Paul F. Ley, Thamer A. Hamdan, Marco Baldan,
and Richard A. Gosselin

Orthopedics in Conflicts

Introduction

Wounded military personnel of national armed forces are managed successfully by military surgeons, according to well-established protocols, along with significant logistic and medical resources. The same is rarely true for civilian victims or the members of less structured armies. In the cross-border and civil wars of the developing world, the distinction between combatants and noncombatants is blurred, and civilian casualties far outnumber military ones. Civilian orthopedic

surgical practice in a conflict area is characterized by a lack of resources and a high proportion of ballistic trauma, alongside more conventional wounds.

Surgery was born on the battlefield and two problems were critical for military leaders: control of communicable diseases and treatment of wounded combatants. Every major war has “rediscovered” surgical lessons that had been forgotten or dismissed by the generation of surgeons practicing since the previous conflict [1, 2]. However, the systematic and thorough debridement of wounds, the principle of leaving wounds open, and the judicious use of blood products are some of the lessons that have been translated from the specialized body of war surgery to present-day surgical standards [3, 4].

The psychological impact of war—whether the individual sustains an injury, is a bystander, or perpetrates the injury—must be emphasized. Diagnoses such as posttraumatic stress disorder (PTSD) and psychoses require early diagnosis and appropriate treatment to lessen or avert long-term disability or suicide [5].

Gunshot Wounds

The frequency of gunshot injuries depends on the presence of conflict or civil strife, tribes or groups with a history of gun culture, and gun possession laws. Victims often know their assailants, and local medical staff are often aware of the level of strife in specific neighborhoods and the weapons commonly used. Security forces—police, army,

P.F. Ley, MD
Emergency ONG, Via Gerolamo Vida 11,
20127 Milan, Italy
e-mail: paulfley@libero.it

T.A. Hamdan, MD, FRCS, FICS, FACS, FRCP
Spine Surgery, Basrah General Hospital – University
of Basrah, Basrah 420001, Iraq
e-mail: thamerhamdan_170@yahoo.com,
thamerhamdan_170@hotmail.com

M. Baldan
Senior Surgeon, International Committee of the Red
Cross, Avenue de la Paix, 19, Geneva 1202,
Switzerland
e-mail: africanmarco@yahoo.it, mbaldan@icrc.org

R.A. Gosselin, MD, MPH, MSc, FRCS(c) (✉)
Orthopedic Surgery, Institute for Global Orthopedics
and Traumatology, UCSF, 1001 Potrero Ave, 3A-36,
San Francisco, CA 94110, USA
e-mail: froggydoc@gmail.com

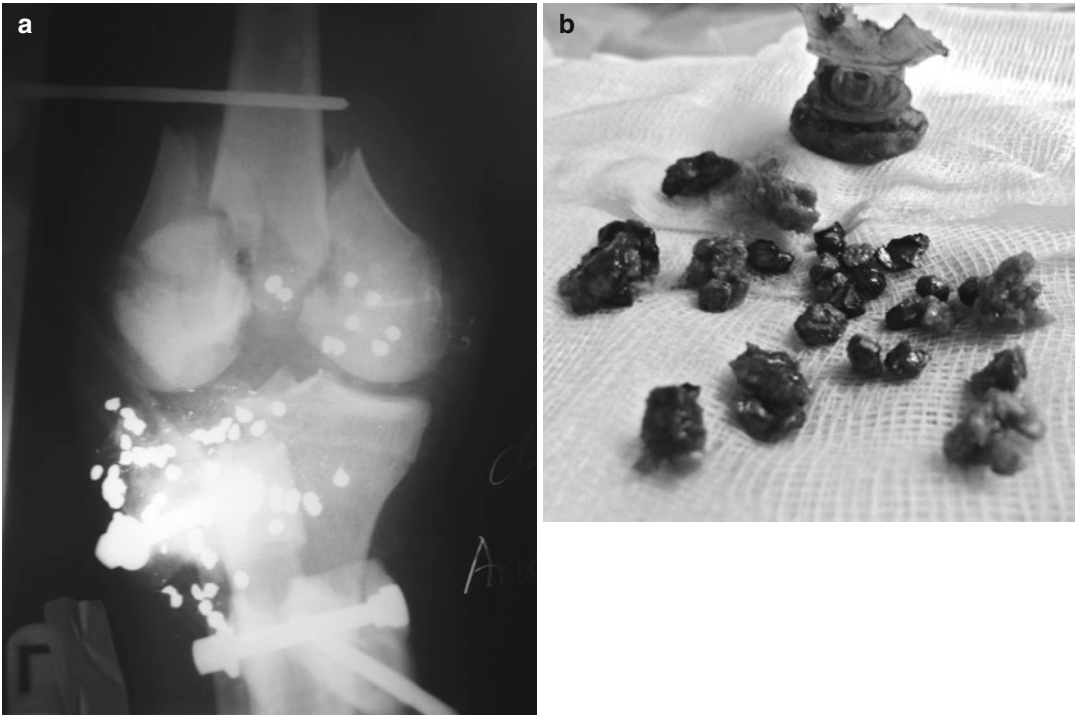


Fig. 44.1 (a) X-ray of GSW of the knee and (b) metal pellets and plastic casing retrieved only after the second debridement because of insufficient initial incisions (Courtesy of Tomoaki Atsumi, MD)

and civil patrol—are often involved, and sometimes for political reasons are not cooperative. In many war-torn countries, high-velocity firearms are inexpensive and available on the open market.

Discounting combat or gang violence, most injuries are from low- to medium-velocity firearms, and wound size does not predict the extent of internal damage. X-rays can help determine the energy imparted to the bone and reveal retained missile parts and the scatter pattern of shot gun pellets. These wounds need a thorough debridement to remove casing and the priming materials (Fig. 44.1).

The extent and nature of injury from any GSW is determined by the speed of the bullet at impact, mass of the missile, size and shape of the projectile, and characteristics of the tissues through which it travels. High-velocity missiles not only cut and crush tissues but also produce sonic waves with cavitation effects that produce microscopic damage at a distance from the bullet path. High-velocity gunshot wounds need to be addressed by the protocols of war injury treatment [6].

Blast Injuries

The tissue damage from blast injuries (bombs, land mines) depends on the type of munitions, distance from the target, and environment in which they detonate, such as open space, inside a building or underwater. The explosion causes injury in four ways [7, 8]:

- *Primary injury* is caused by the blast wave. All persons within the lethal zone die, while those outside it may sustain severe, non-penetrating injuries. Air-containing viscera are particularly sensitive to the damaging effects of the blast.
- *Secondary injury* is due to the direct effects of shrapnel or objects that become energized from the blast. Modern military munitions produce metallic fragments within a specific mass range to ensure consistent and effective damage over a large area.
- *Tertiary injury* from the blast wind can project human bodies against objects or propel objects that hit humans. The wave can collapse buildings, resulting in crush injuries.

- *Quaternary mechanism* or *flash injury* refers to the thermal wave, causing burns and inhalational injuries from smoke, including carbon monoxide.

Beyond these conventionally recognized mechanisms of blast injuries, biological contamination may take place purposely, such as a suicide bomber infected by hepatitis or HIV or by chance, if infected victims' parts contaminate survivors. Diethylenetriamine (DETA) sheet explosives contain pentaerythritol tetranitrate (PETN), which can cause a hyper-inflammatory syndrome.

Land Mines

Land mines are not designed to kill but rather to maim and destroy livelihoods. The majority of victims are civilians, and the toll is especially heavy among rural peasant farmers, nomads, livestock, children, and the poor who have little political voice. Despite huge efforts, clearing existing mines appears to be nearly impossible. Blast mines create damage through the blast wave, while fragmentation mines cause harm through propelled fragments.

Their clinicopathological effects have been grouped by ICRC into three patterns [4]. *Pattern 1* occurs when the victim steps on the mine, resulting in a traumatic amputation of some part of the triggering lower limb and variable degrees of penetrating injuries and burns to the other leg, genitalia, and body. This pattern produces the "umbrella effect" [4], in which the blast strips the soft tissue attachments from the tibia so they are spread apart as in opening an umbrella (Fig. 44.2). The soft tissue damage extends more proximally than the level of bone injury.

Pattern 2 occurs when the victim activates a fragmentation mine, spreading metallic fragments that randomly penetrate parts of the body. *Pattern 3* occurs when the victim manipulates the mine, usually children or deminers, resulting in injuries to the upper limbs, face, neck, and chest. More powerful mines are used to neutralize motorized vehicles (anti-tank mines, Improvised Exploding Devices, etc) and create a wide spectrum of injuries depending on location (inside vehicle or bystander) and distance from blast.

It is beyond the scope of this chapter to discuss injuries due to chemical, bacteriological or nuclear warfare.

Surgical Epidemiology of Conflicts

Generally, in conventional artillery warfare, guerilla warfare, and civil conflicts, the distribution of injuries includes superficial injuries requiring no hospitalization (40 %) and those requiring hospitalization (60 %). Sixty percent of those hospitalized will have limb injuries. The longer the delay to reach medical care, the more limb injury rates increase, as those with central wounds often die without immediate medical care. Longer delays increase the likelihood of infection. Therefore, longer delays result in more limb wounds, many with fractures, more infected wounds, more stable patients, less in-hospital mortality, and more need for orthopedic surgeons. This scenario is also true for natural disasters.

A wounding mechanism frequently overlooked is road traffic injuries (RTIs). These are frequent in conflict zones and after natural disasters, caused by disruption of road traffic control; absence of liability, especially for fighting parties not belonging to regular, disciplined armies; and vehicles and roads in a poor state of maintenance or damaged by the disaster.

Many of the following principles for treating injuries sustained in conflict situations are the same for dealing with the victims of natural disasters. The cause of the injuries may be different, and some of the ballistic-specific concerns are of less importance, but the specific principles are worthwhile to follow.

Treatment

For fresh injuries, effective treatment depends on prompt evacuation and transfer, triage of injuries, vigorous resuscitation, and aggressive exploration and debridement of wounds. Definitive management of orthopedic injuries is never considered in the initial stage (Fig. 44.3).

In urban warfare in middle-income countries, such as Iraq, transfer of the wounded to civilian hospitals can be quick and effective and injuries are seen while still fresh. In more austere environments such as Afghanistan and many sub-Saharan African countries, casualties often come from a distance. In theory, the site where civilian casualties are treated should be a safe and secure haven, but this is not always the case (Fig. 44.4).

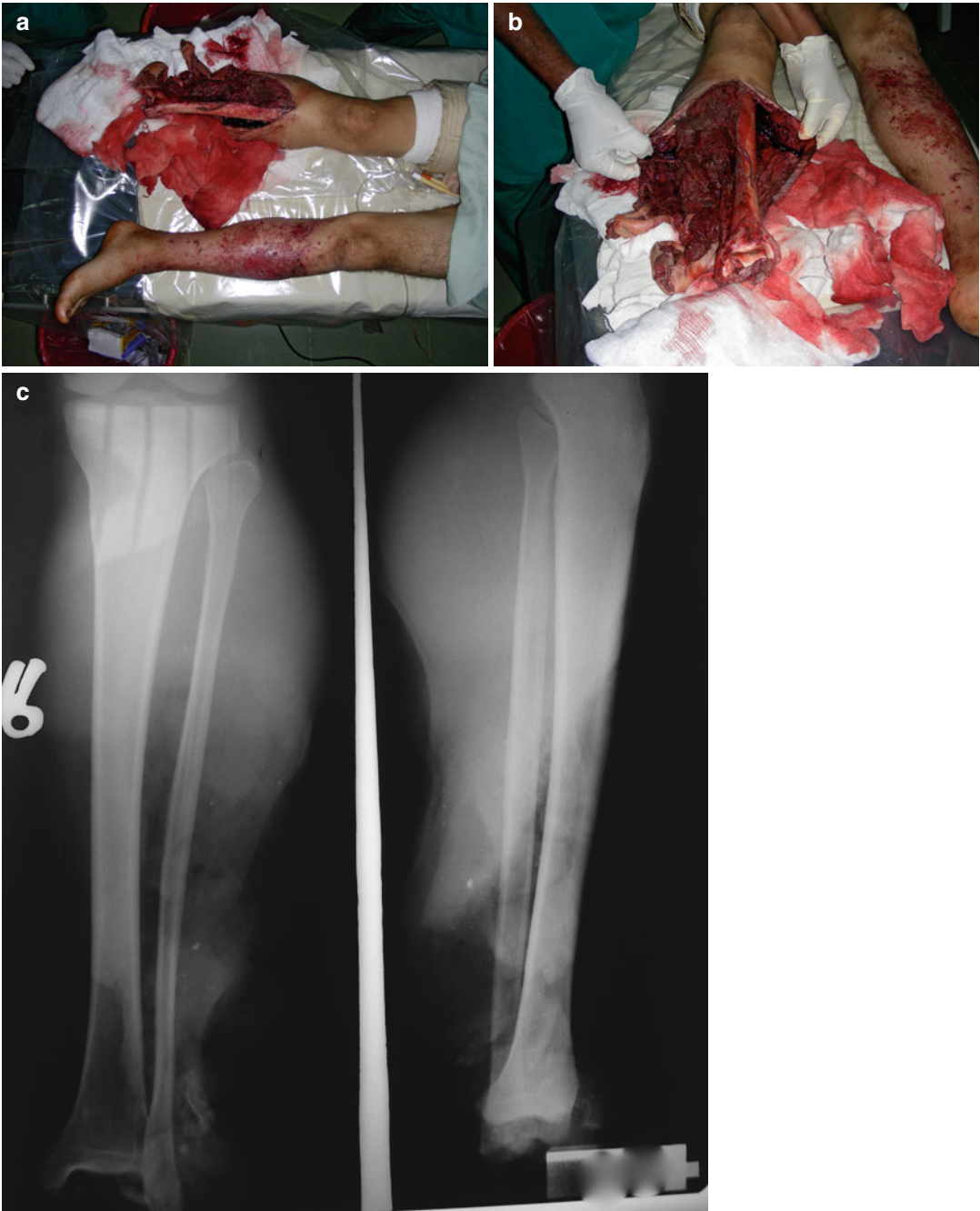

Fig. 44.2 (a) Typical land mine injury. (b) Umbrella effect with complete stripping of the tibia. (c) X-ray shows no fracture

Mass Casualty Event and Triage

A mass casualty situation involves a large number of casualties presenting over a short period of time and overwhelming the facilities and resources. The general treatment principle is to “do the best

for the most.” This is in contrast with the civilian practice of doing the “absolute best for every individual.” Triage, in a war surgery or natural disaster context, is a systematic way of placing patients into four groups (Box 44.1).



Fig. 44.3 (a, b) Triage tent of NGO hospital in Lashkargah, Afghanistan. (c) Patients ID tagged around the neck

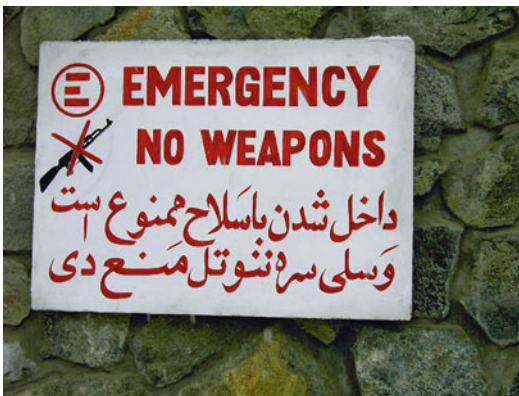

Fig. 44.4 “No weapons” sign at Emergency Hospital entrance, Kabul, Afghanistan

Box 44.1 ICRC Triage Categories

Category 1 injuries that have a reasonable chance of survival but require resuscitation and immediate surgery

Category 2 have the second priority for surgery

Category 3 have superficial wounds and can be managed as outpatients

Category 4 involves severe wounds with a poor prognosis and given supportive care

Assessment and Resuscitation

Whatever the mechanism of injury, it is essential to assess the patient according to ATLS principles of primary and secondary surveys. A common pitfall is concentrating on more evident and impressive wounds, and missing a small penetrating wound in a vital area. The physiologic reserve in younger patients can be misleading. They require particular attention and aggressive resuscitation with frequent reevaluations.

Land mine blast injuries in particular are associated with significant blood loss, making initial, aggressive resuscitation essential, particularly if the transfer time has been prolonged. Hemodilution will occur rapidly with crystalloid, and whole blood transfusion is usually required. Family members, friends, and fellow combatants are the best donor sources. The anticipation of a large transfusion requirement may be an indication for supportive treatment only.

Wound Debridement

Limb injuries account for around 60 % of all surgical injuries and are dealt with only once life-threatening injuries have been addressed. War wounds require extensive debridement, what the ICRC calls “wound excision” [4]. Adequate access is mandatory, requiring extensile skin incisions. All foreign material and necrotic tissues must be debrided [9, 10]. While only nonviable skin should be excised, subcutaneous tissue is sensitive to infection and requires generous excision. Avoid undermining the skin, which can compromise its blood supply. A fasciotomy is usually required to access deeper structures and reduce the chance of compartment syndrome. Muscle that does not appear viable must be excised based on color, absence of contractility, consistency, and lack of bleeding. Bone fragments without periosteal attachment should be removed no matter how large. Debridement may need to be repeated every 48–72 h until clean, viable tissue is observed.

Metallic fragments located in the wound or in pressure-sensitive areas such as palms or soles deserve removal, but leave the deeply seated fragments unless they are (1) intra-articular (impinging on joint function or a potential cause of lead-induced arthropathy) or (2) close

to the main vessels, where their sharp edges can erode the vessel wall and cause delayed bleeding.

All war wounds or wounds from natural disasters are contaminated and are *never* closed primarily no matter when they present or how “clean” they appear. Edema causes increased tissue pressure, leading to impaired vascularization and wound breakdown; residual contaminants and necrotic tissue left after debridement promote infection. Wounds can ideally be closed 4–7 days post debridement. Closure may be difficult if delayed beyond 7–10 days, at which time wound edges and flaps have retracted. However, if in doubt about the status of the wound or wound infection, a re-debridement should be performed and other plans made for closure. The routine use of a tourniquet in wound debridement has been debated, but has been promoted by the ICRC, especially in environments where blood replacement is an issue. Consider using a tourniquet in the presence of active bleeding, and it can be deflated later to reassess any “doubtful” tissues before applying a bulky dressing.

Dressings that absorb fluids, such as fluffed gauze held with a compression bandage and stabilized with a plaster slab or gutter splint, are simple and comfortable for the patient (Fig. 44.5). Extremity wounds need to be elevated using bed blocks to raise one end of the bed, pillows or Bohler frame or supporting an arm on pillows or suspended from an IV pole. Drains are unnecessary as all extremity wounds are left open.

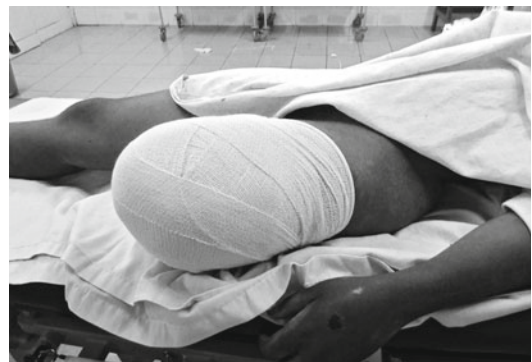

Fig. 44.5 Big, bulky, absorbent dressings are applied over limb wounds or stumps

The ICRC protocol for wound management involves dressing removal and wound evaluation in the operating room under anesthesia at 4–7 days, followed by re-debridement and/or primary closure, skin grafting, or leaving the wound to granulate. When the expertise is available, flaps can be helpful at this stage.

Vascular Injuries

Transected named arteries are usually visible and can be ligated or repaired, but often lead to amputation. Hypotension may mask vascular injuries, and multilevel vessel injuries can occur. Cavitation damage from high-velocity missile injuries can result in intimal injury, even at a distance from the wound, leading to ischemia. A high index of suspicion and close monitoring are essential during the first few days.

Peripheral Nerve Injuries

These may involve direct laceration or contusion, but are more often due to indirect mechanisms of the blast wave or extrinsic compression. The prognosis is poor when nerve injuries are associated with vascular damage. Spinal cord injuries have a poor prognosis, even if the spine is mechanically stable. Retained fragments should be removed from the spinal canal if possible.

Bones

Unless in the presence of a vascular repair, osseous injuries *never* require definitive management at initial debridement. All skeletal injuries can be treated initially with splinting or skeletal traction. External fixation can be applied at the return visit to the OR, in a sterile surgical field, and is of benefit only if it allows better wound care and early patient mobilization. As soon as wound coverage is successful and stable, many external fixateurs can be replaced by casts. There is no indication for internal fixation in the early stages because of the high risk of infection [10]. Internal fixation may be considered for displaced intra-articular fractures in the sub-acute phase.

In mass casualty or natural disaster situations, contrary to usual civilian practice, the surgeon needs to err on the aggressive side of the debride-

ment, which sometimes means amputation rather than an attempt at limb salvage. When there is no pressure on resource utilization, a more conservative approach can be taken and repeat debridements can be considered. In such conditions, prolonged treatment requiring multiple bone and soft tissue coverage procedures to save a limb might still not be in the patient's best interest, and a sound amputation with a good prosthetic fitting may be the best better option. Sociocultural determinants, consent issues, and availability of prosthetic services must all be factored when deciding to amputate (Fig. 44.6).

Natural Disasters

Introduction

Recent earthquakes in Pakistan, Iran, and Haiti have shown an unprecedented response from the international orthopedic community. Tsunamis, typhoons, or hurricanes do not generate the same number and severity of orthopedic injuries. The basic principles are the same as for war injuries: management of mass casualties, organization and coordination, and “best treatment for the most” in a given environment using available resources [11]. The uniqueness of a natural disaster lies in the fact that all injuries occur within a short period of time, such that time from injury does not usually factor in management prioritization.

Stages After a Natural Disaster

The aftermath of natural disasters can be classified into five stages:

Chaos

During the first 24–48 h, no significant medical or surgical treatment is generally available other than basic first aid. The health-care system is one of the first casualties. Life-threatening injuries will sort themselves out; the others will rapidly overwhelm what is left of existing structures and the new ones set up to handle the injured.

Initial Response

Massive efforts in organization, or reorganization and coordination, are set in motion. Essential logistical components are established to provide

transportation, communications, chain of command, security, power, hygiene and sanitation, water/food/shelter, and search and rescue. Medical intervention is the *last* component. It is important

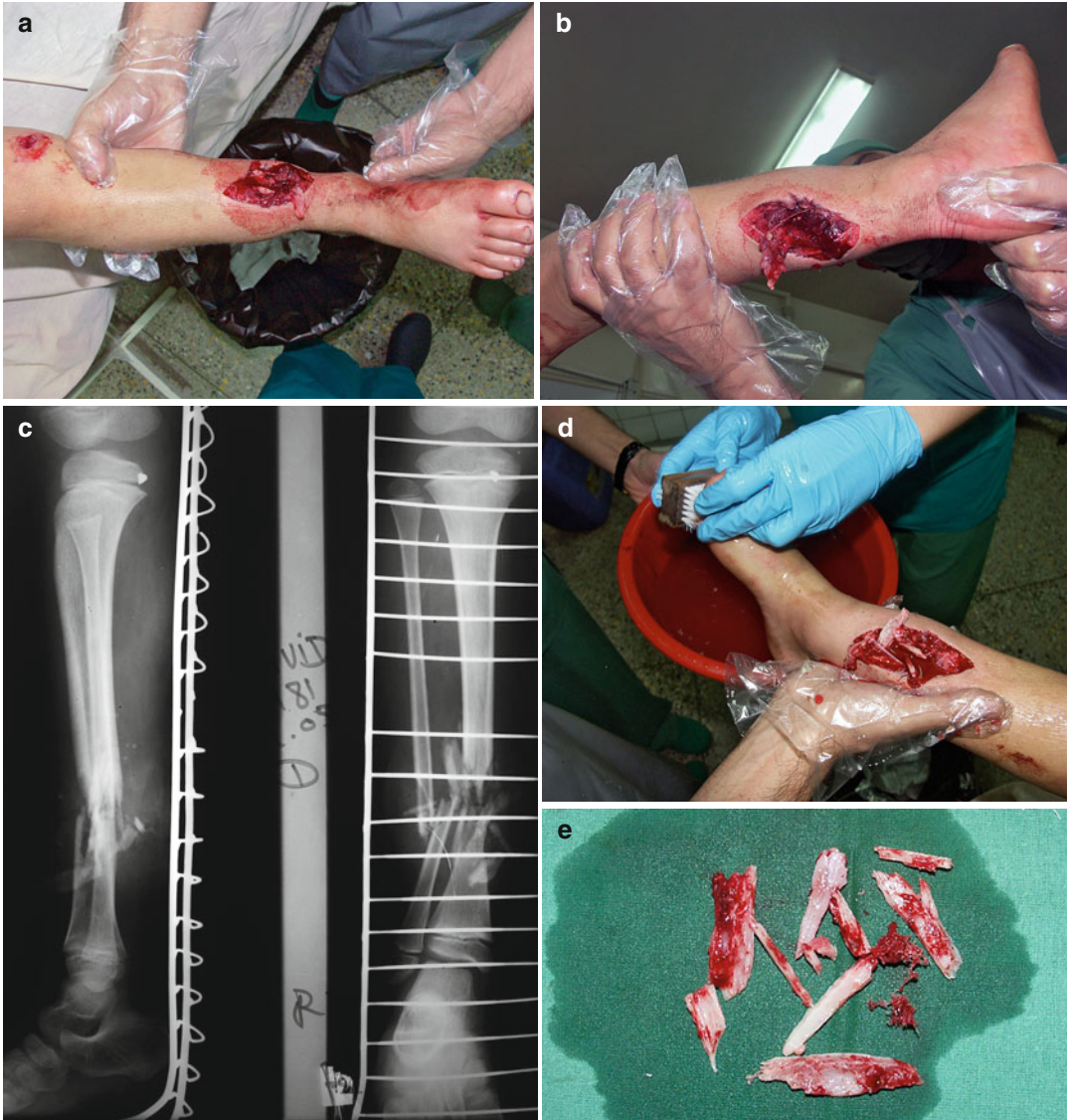

Fig. 44.6 Typical management of missile. (a, b) Anterior entry and posterior exit wound from metal fragments. (c) X-ray of right leg on admission. (d) Initial wash out with clean tap water before surgical debridement. (e) Devitalized bone fragments excised. (f) The patient post-op with ex-fix, leg elevated on frame, and heel protected. (g, h) X-ray in

external fixateur. (i) Anterior wound healed after delayed primary closure. (j) Posterior wound with good granulation (k) covered with STSG, and (l) the ex-fix removed and replaced with a weight-bearing POP as soon as the graft is mature

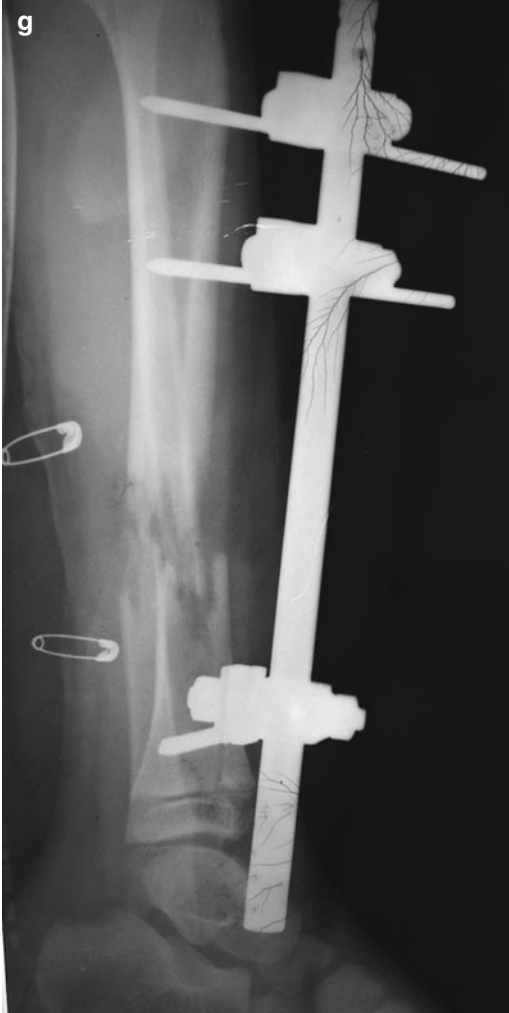
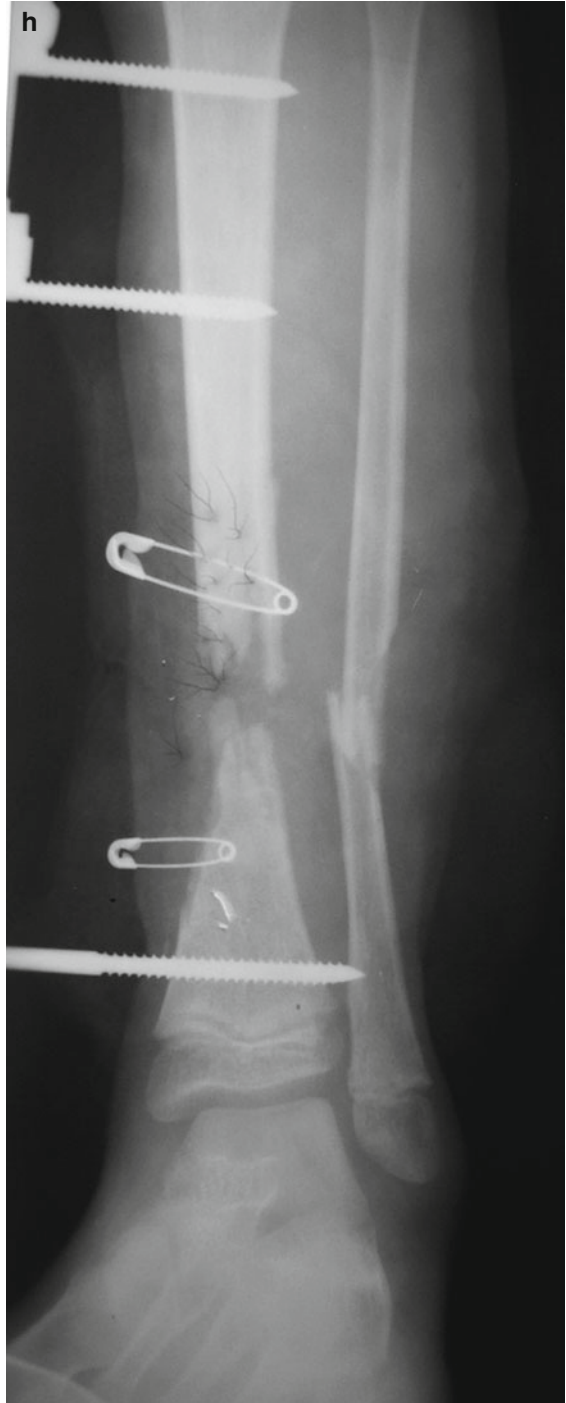
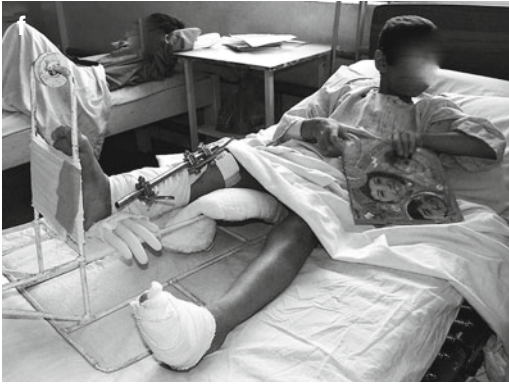

Fig.44.6 (continued)

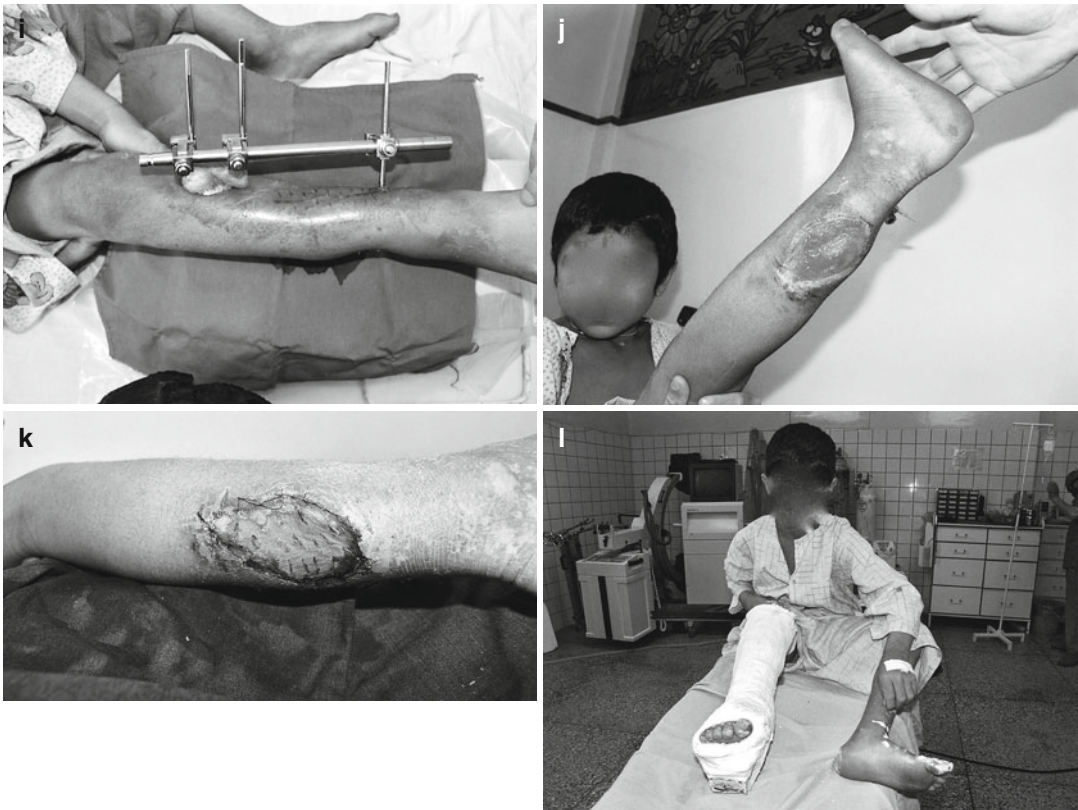

Fig. 44.6 (continued)

for a volunteer to keep a realistic perspective of where he or she fits in the overall priorities. Volunteers should not be a burden or nuisance. They should mobilize as part of a structured entity, such as government, NGO, or professional association, and not as spontaneous unaffiliated volunteers, “the dreaded” SUVs. Above all, they should not tap into resources dedicated to victims.

Most of the survivors will have orthopedic injuries, but during the first 10–14 days, the problems primarily involve wound management. Other than skeletal traction, external fixation, or amputation, no formal orthopedic interventions are done at this stage. *All* wounds should be left open, and *no* internal fixation can be safely performed [12].

Skeletal traction is effective only if weights can be suspended, which is difficult if the patient is lying on the ground. External fixation is a quick way to provide temporary fixation of open frac-

tures, their greatest benefit being access to wounds and early mobilization. There might be some indications for their use in closed pelvic or femur fractures, even if they need to be applied blindly, when early mobilization or evacuation of a patient is lifesaving. External fixation should not be viewed as the definitive treatment for the bone injury in such situations.

This is the stage where crush injuries are seen, and their management is controversial [13]. When a limb is “crushed” for more than 6 h, varying degrees of vascular compromise will be seen, depending on the amount of weight and duration of the crush (Fig. 44.7). If a limb does not reperfuse after crushing, it will require amputation. While closed injuries can often wait until demarcation, gangrenous limbs with open wounds require early, open amputation.

With reperfusion, toxic compounds such as potassium and cytokines are released into the

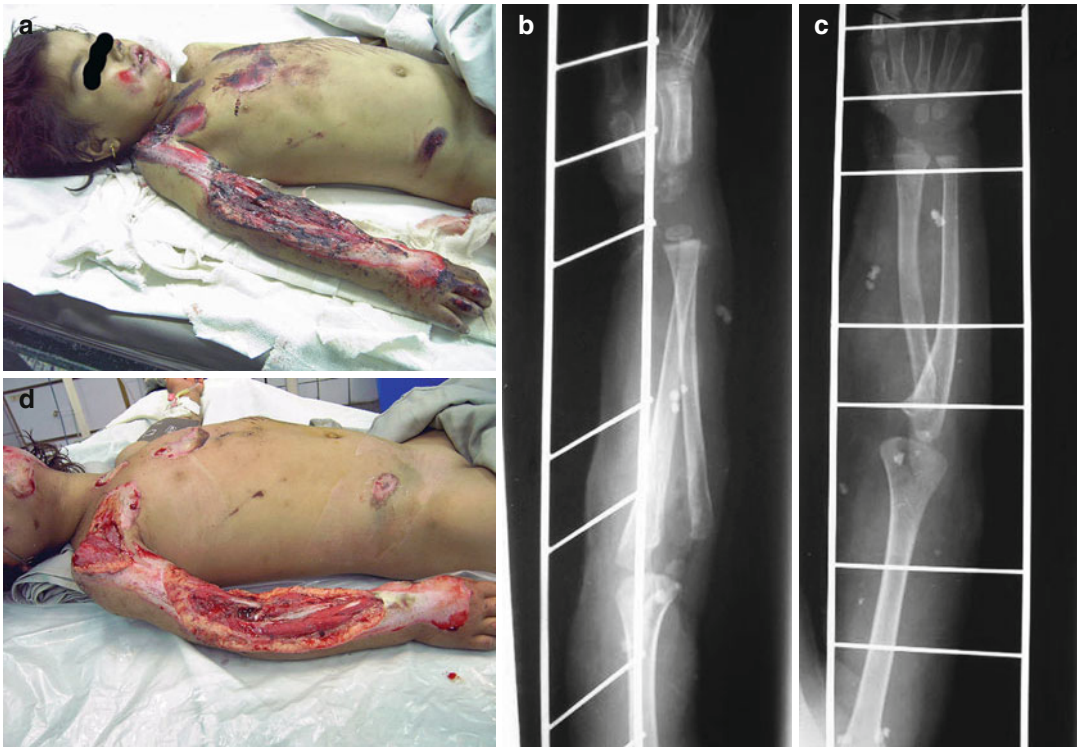


Fig. 44.7 (a) Child with crush injury to torso and right upper extremity before debridement. (b, c) X-ray showing proximal radial dissociation and radiodense particulate matter. (d) After debridement

circulation and may lead to systemic crush syndrome, a combination of one or more of the following: hypovolemia, hyperkalemia, sepsis, disseminated intravascular coagulation (DIC), adult respiratory distress syndrome (ARDS), renal failure, and eventually multiorgan failure and death [14]. The limb may develop compartment syndrome initially or as a result of reperfusion.

The indications for fasciotomy are also controversial. Contrary to civilian practice, almost 100 % of fasciotomies for crush injuries seen late will become infected. The benefits of fasciotomy need to be carefully weighed against the risk of sepsis, the main cause of death after 5 days. The surgeon needs to first differentiate between impending and established compartment syndrome. Impending compartment syndrome usually presents within 24 h of injury. The tense compartment is painful on palpation and has pain on passive stretching, but retains some sensory, motor, or vascular function. These compartments may benefit from release to prevent further compromise.

Established compartment syndrome usually presents after 24 h, with no function in the affected limb. Fasciotomies in such patients are contraindicated as they have no functional benefit and will always lead to wound infection. Medical management of crush syndrome might be necessary, but amputating a dead limb does not decrease the systemic effects of necrotic tissue and “prophylactic” amputation, as proposed by some, is a useless and hazardous endeavor. There is also no indication for a “guillotine” amputation, except maybe a disarticulation as a lifesaving maneuver to extirpate a trapped patient. Amputations should be done using standard flaps, or flaps of opportunity, and the wound left open, to be closed in a delayed fashion 4–7 days later, as per ICRC protocol.

Definitive Management of Injuries

After the first or second week, portable operating rooms have been deployed, some local infrastructure has been provided for “safe” surgery,

laboratory and x-ray are available, and treatment can be planned. Wound management still has high priority, but at this stage, definitive closure of clean wounds is possible with skin grafts and/or flaps. Closed fractures, particularly intra-articular ones, can usually be treated safely with internal fixation.

In appropriate surgical environments, IM nailing of long bones is also feasible. In open fractures, treatment of the underlying fracture may require a “pin holiday,” with or without traction, after ex-fix removal and before definitive ORIF. Open reduction is almost always necessary since more than a month has often passed since injury. Tibia fractures can often be treated by casting if alignment can be corrected by closed means.

Management of Complications

This stage overlaps the previous one as early complications of some injuries, and procedures may be seen before definitive management of others is started or in progress. Infections, with or without retained hardware, are the most common complications, along with nonunions and malunions. Appropriate surgical environments offer the possibility of ORIF. Stump problems are common and may require reshaping or revision at higher levels, as discussed in Chap. 43. At this stage, stump management should be done in concert with available prosthetic expertise and resources.

Rehabilitation

This stage overlaps all the previous stages, except chaos. Even in the early stages, the complex rehabilitation process needs to be kept in mind, as return to optimum function is the most important goal after life and limb are saved. Organizations such as Handicap International, ICRC, and Johanniter have extensive experience, expertise, and resources in the field of patient rehabilitation

in austere environments. The needs for systems rehabilitation, including health care and education, are more difficult to define, but an opportunity to share knowledge, experience, and resources with national colleagues should never be wasted.

References

1. DeBakey ME. History, the torch that illuminates: lessons from military medicine. *Mil Med.* 1996;161: 711–6.
2. Keogh B, Willett K. Lessons from war must be remembered. *J R Nav Med Serv.* 2012;98:3–4.
3. Rowley DI. War wounds with fractures: a guide to surgical management. Geneva: ICRC; 1996.
4. Giannou C, Baldan M. War surgery, Vol 1 and Vol 2. Geneva: ICRC; 2009, 2012.
5. Hamdan TA. Psychiatric aspects of orthopaedics. *J Am Acad Orthop Surg.* 2008;16:41–1646.
6. Swan KG, Swan RC. Principles of ballistics applicable to treatment of gunshot wounds. *Surg Clin North Am.* 1991;71:221–31.
7. Rawlins JSP. Physical and pathophysiological effects of blast. *Injury.* 1978;9:313–20.
8. Hamdan TA. Missile injuries of the limbs: an Iraqi perspective. *J Am Acad Orthop Surg.* 2006;14: S32–6.
9. Bosse MJ, Ficke JR, Andersen RC. Extremity war injuries: current management and research priorities. *J Am Acad Orthop Surg.* 2012;20 Suppl 1:viii–x.
10. Mamczak CN, Born CT, Obremskey WT, Dromsky DM. Evolution of acute orthopaedic care; extremity war injuries VII acute care panel. *J Am Acad Orthop Surg.* 2012;20 Suppl 1:S70–3.
11. Gosselin RA. War injuries, trauma and disaster relief. *Tech Orthop.* 2005;20:97–108.
12. Wolfson N. Amputations in natural disasters and mass casualties: staged approach. *Int Orthop.* 2012;36(10): 1983–8.
13. Bartal C, Zeller L, Miskin I, Sebbag G, et al. Crush syndrome: saving more lives in disasters: lessons learned from the early-response phase in Haiti. *Arch Intern Med.* 2011;171(7):694–6.
14. Sever MS, Vanholder R. Recommendation for the management of crush victims in mass disasters. RDRTF of ISN Work Group on Recommendations for the Management of Crush Victims in Mass Disasters. *Nephrol Dial Transplant.* 2012;27 Suppl 1:i1–67.

Appendix 1

List of Abbreviations

AC(J)	Acromioclavicular (joint)	DDH	Developmental dysplasia of the hip
ACL	Anterior cruciate ligament	DHS	Dynamic hip screw
ADLs	Activities of daily living	DIC	Disseminated intravascular coagulation
AE(A)	Above elbow (amputation)	DJD	Degenerative joint disease
AFO	Ankle foot orthosis	DOTS	Directly observed therapy, short course
AIDS	Acquired immunodeficiency syndrome	DRUJ	Distal radial ulnar joint
AK(A)	Above knee (amputation)	DVT	Deep vein thrombosis
AP	Anteroposterior	ED	Emergency department
ARDS	Adult respiratory distress syndrome	EHL	Extensor hallucis longus
ASIS	Anterior superior iliac spine	ESR	Erythrocyte sedimentation rate
ATLS	Advanced trauma life support	FDA	Food and Drug Administration
AVN	Avascular necrosis	FTSG	Full-thickness skin graft
BCG	Bacillus Calmette-Guerin	Fx	Fracture
BE(A)	Below elbow (amputation)	GBD	Global burden of disease
BK(A)	Below knee (amputation)	GCS	Glasgow Coma Scale
CAT	Computed axial tomography	GMFCS	Gross motor functional classification system
CBC	Complete blood count	GSW	Gunshot wound
CC	Coracoclavicular (ligaments)	HAART	Highly active antiretroviral therapy
CD-4	Cluster of differentiation 4	HALE	Health-adjusted life expectancy
CEA	Cost-effectiveness analysis	HB	Hemoglobin
CMC(J)	Carpal metacarpal (joint)	HIS	Health information systems
CNS	Central nervous system	HIV	Human immunodeficiency virus
CORA	Center of rotation of angulation	HO	Heterotopic ossification
CP	Cerebral palsy	ICRC	International Committee of the Red Cross
CRP	C-reactive protein	IM	Intramedullary
CT	Computed tomography	IP(J)	Interphalangeal (joint)
CTEV	Congenital talipes equinovarus	ITB	Iliotibial band
DALY	Disability- adjusted life year	IV	Intravenous
DBR	Debridement	KAFO	Knee-ankle-foot orthosis
DCP or DC plate	Dynamic compression plate	K-wire	Kirschner wire
DCS	Dynamic condylar screw	LE	Lower extremity
		LICs	Low-income countries
		LLC	Long leg cast
		LMICs	Low- and middle-income countries
		MCP(J)	Metacarpal-phalangeal (joint)

MC	Metacarpal	RIVA	Regional intravenous anesthesia
MRSA	Methicillin-resistant <i>Staphylococcus aureus</i>	ROM	Range of motion
MSK	Musculoskeletal	RSD	Reflex sympathetic dystrophy
MTP(J)	Metatarsal-phalangeal (joint)	RTC	Road traffic crash (preferred to RTA or road traffic accident)
NGO	Non-governmental organization	RTI	Road traffic injury
NSAIDs	Nonsteroidal anti-inflammatory drugs	SCIWORA	Spinal cord injury without radio- graphic abnormality
NV	Neurovascular	SIGN	Surgical implant generation network
NWB	Non-weight bearing	STSG	Split-thickness skin graft
OPD	Outpatient department	SUVs	Spontaneous unaffiliated volunteers
ORIF	Open reduction, internal fixation	TAL	Tendo-Achilles lengthening
PCL	Posterior cruciate ligament	TB	Tuberculosis
PEP	Postexposure prophylaxis	THR	Total hip replacement
PIP	Post-injection paralysis	TKR	Total knee replacement
PO	Per os (orally)	UE	Upper extremity
POP	Plaster of Paris	VAC	Vacuum-assisted closure
PPD	Purified protein derivative	WB	Weight bearing
PRC	Proximal row carpectomy	WBAT	Weight bearing as tolerated
PTB	Patellar tendon bearing	WBC	White blood cell count
PTSD	Post-traumatic stress disorder	WHO	World Health Organization
QALY	Quality-adjusted life year		

Appendix 2

Head Trauma and Basic Management of Brain Injury and Elevated Intracranial Pressure – Ercan Tureci

Primary traumatic brain injury occurs at the time of the impact. Secondary brain injury occurs with (1) intracranial insults such as elevated intracranial pressure, edema, hematoma, and seizure and

(2) systemic insults such as hypoxia, hypercapnia, hypotension, and electrolyte/metabolic disorders. The severity of the initial injury, as defined by the Glasgow Coma Scale (GCS), is predictive of eventual outcome. GCS 14–15 mild, 9–13 moderate, and 3–8 severe head injury. The correlation between GCS and survival is nonlinear, with a high rate of mortality for GCS 3–7 and a decline in mortality between GCS 8 and 15.

Glasgow Coma Scale (GCS)

Score	Infant <1 year	Child 1–4 years	Age 4–adult
<i>Eye opening</i>			
4	Spontaneously	<i>Spontaneously</i>	Spontaneously
3	To voice	To voice	To voice
2	To pain	To pain	To pain
1	No response	No response	No response
<i>Verbal response</i>			
5	Coos, babbles	Orientated, speaks, interacts, social	Orientated
4	Irritable cry, consolable	Confused speech, disorientated, consolable	Confused, disorientated
3	Cries persistently to pain	Inappropriate words, inconsolable	Inappropriate words
2	Moans to pain	Incomprehensible, agitated	Incomprehensible sounds
1	No response	No response	No response
VR for intubated age 4–adult patients: 5 appears able to converse, 3 questionable ability to converse, and 1 unresponsive			
<i>Motor response</i>			
6	Normal spontaneous movement	Normal, spontaneous movement	Obeys commands
5	Withdraws to touch	Localizes pain	Localizes pain
4	Flexion withdrawal	Flexion withdrawal	Flexion withdrawal
3	Abnormal flexion	Abnormal flexion	Abnormal flexion
2	Extension	Extension	Extension
1	No response	No response	No response

Management of head injured patients and control of intracranial pressure

- Airway management
- Elevate head of bed 15°–30°
- Oxygen SpO₂ 95%; Hb 8.5–10 g
- Sedation, if necessary and after initial assessment
- Osmotic diuresis: mannitol 0.25–1 g/kg every 4–6 h
- Lasix 0.5–1 mg/kg IV
- Seizure prophylaxis: phenytoin 15 mg/kg IV load, then 100 mg IV/PO/TID or 5–2 mg/kg. In children use with discretion
- Avoid hyperthermia and hyperglycemia
- Gastric ulcer prophylaxis
- Thromboprophylaxis: elastic stockings, *no* anticoagulants if suspect intracranial bleeding
- *No* role for parenteral corticosteroids
Young rule: adult dose X ($\text{age} \div (\text{age} + 12)$) = child's dose

Appendix 3

Tips, Tricks, and Pearls

Lower Extremity

Tibial nailing. Without a fracture table, tibial nailing can be done by “breaking” the OR table and hanging the leg over the end. With tables that do not “break,” a triangle is useful. Ex-fix rods clamped together and cushioned with drapes can be fashioned into a reasonable triangular support placed under the knee to maintain flexion while nailing.

Holding a closed reduction during tibial nailing is facilitated by wrapping an Esmarch or elastic bandage around the leg. Long broad DCPs or ex-fix bars wrapped against the leg give extra support while maintaining the alignment. NB check availability of Esmarch or other bandage the day before as many ORs do not keep them sterile.

Distal locking standard IM nails without fluoroscopy. A nail of equal length as that used in the patient is secured proximally close to the patient’s skin using two Steinmann pins, K-wires, or long drill bits through the cannulae in the proximal targeting jig. The distal femur/tibia is widely exposed with one incision in the vicinity of the distal interlocking holes. The lateral cortex is drilled under direct vision, and the hole made larger with bigger drill bits, T-handle reamers, curettes, or small rongeurs to expose the nail and hopefully the hole, if the nail has not deformed too much.

Good lighting and a small suction tip, preferably metal, with irrigation will help the process. The nail may need to be rotated to expose the hole, unless an IM interference fit prevents this.

Even with minimal lateral screw purchase, there should be enough purchase with engagement of the medial cortex to control rotation and shortening, even if the overall construct is obviously weak.

An alternative is to open a 2×3–4 cm window exposing the distal nail, drill the medial cortex under direct vision of the holes, and secure the window back in place with two screws that abut the nail, giving some increased contact. These techniques should be strong enough to allow early mobilization and active ROM, but weight bearing should be delayed.

Shaping templates for cutting known osteotomy angles. Using a sterile glove envelope, measure and mark on one side 1 unit from the corner. On the adjacent side, mark 3 units. Units can be the width of an osteotome (Fig. A.1), width of a maximally opened hemostatic or Kocher clamp, or anything that is handy. A line from the first of the 3 marks to the one mark has corner angles of 45°. A line from the second of the 3 marks to the one mark has a corner angle of 22° and a line from the 3rd mark to the one mark is 11° and so



Fig. A.1




Fig. A.2




Fig. A.3

forth (Fig. A.2). Wedges of desired angles can be cut from the glove envelope with reasonable accuracy.

Angles can also be estimated by opening a Kocher clamp so the jaws are at right angles and measuring the distance between the tips. Closing the distance by half yields an angle between the jaws of 45° . Halving the distance again gives an angle of about 22° and, again, about 11° .

How to use a blade plate. The blade entry site in the femur is selected below the epicondyle and marked. It should be 1.5–2 cm above the joint line and centered at the junction of the anterior 1/3 and posterior 2/3 (Fig. A.3). The plate part is positioned parallel to the shaft where it will lie. This is made easier by drilling K-wires through two proximal holes, clamped at the outer side of the plate so that they are equidistant from the cortex (Fig. A.4).

A third K-wire is inserted in line with the blade in the distal fragment (Fig. A.5). A plate (or an ex-fix bar or 2 bars acting as a sandwich) can be used to verify that the three K-wires are in the same sagittal plane. A fourth K-wire is drilled at the desired angle of correction at the blade entry

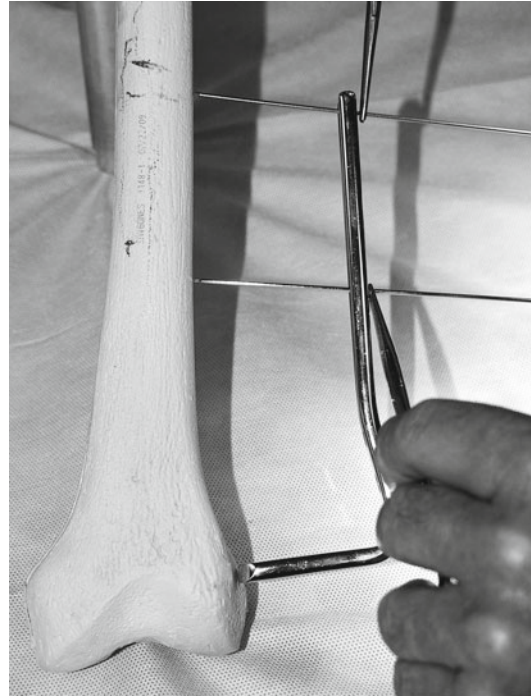


Fig. A.4

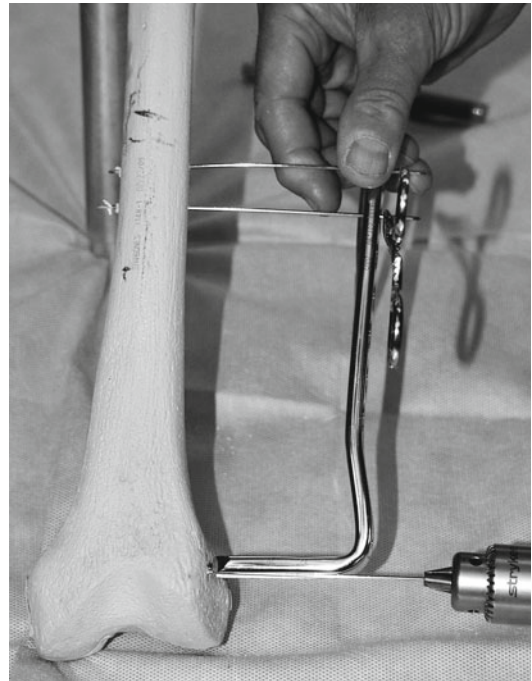


Fig. A.5

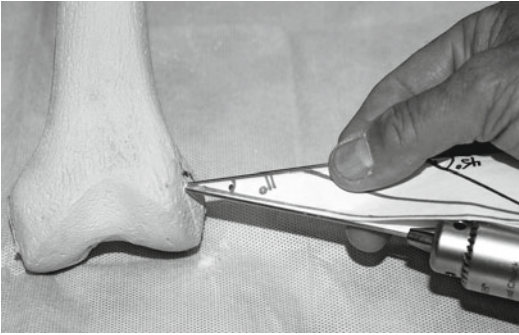


Fig. A.6

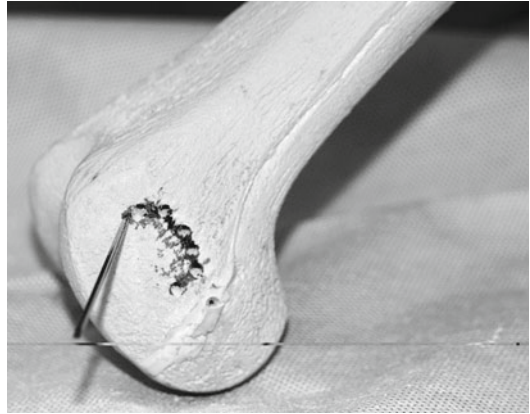

Fig. A.8

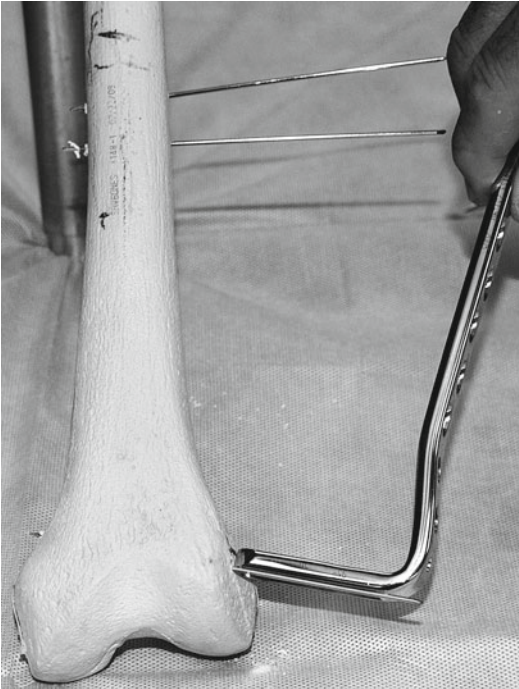

Fig. A.7

site, using the cut wedges as a guide (Fig. A.6). The third pin is removed.

The contours of the blade entry site are marked with pen or electrocautery (Fig. A.7). The entry site is predrilled with a small bit (Fig. A.8), and a narrow chisel or osteotome is used to tunnel the metaphysis, staying in line with the 4th K-wire and parallel to the blade plate in all planes. Without fluoroscopy, the appropriate depth needs to be gestimated, but a normal adult should be

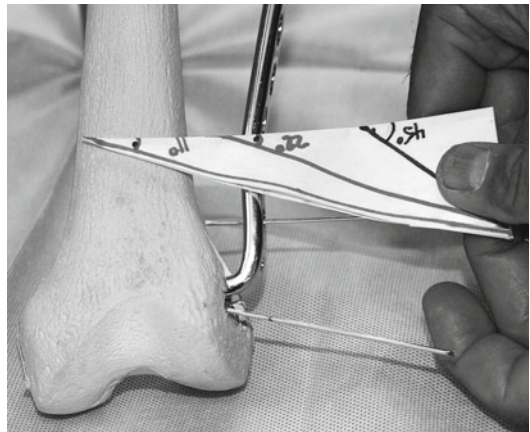

Fig. A.9

around 70–80 mm. Better too short than too long. The blade can be inserted at least halfway in (open wedge) or completely in (closed wedge) before doing the osteotomy.

The osteotomy site is marked, at least 1 cm proximal to the most distal screw in the blade plate, usually at the level of the offset (Fig. A.9). For an open wedge, a transverse osteotomy is done with a saw if available or with osteotomes connecting small drill holes using osteoclasts to keep a cortico-periosteal hinge on the opposite side. The blade is inserted and seated and the plate secured on the proximal fragment with a bone clamp.

A closed wedge requires the distal cut to be at the same location, with the proposed correction angle, and this is made easier by inserting the

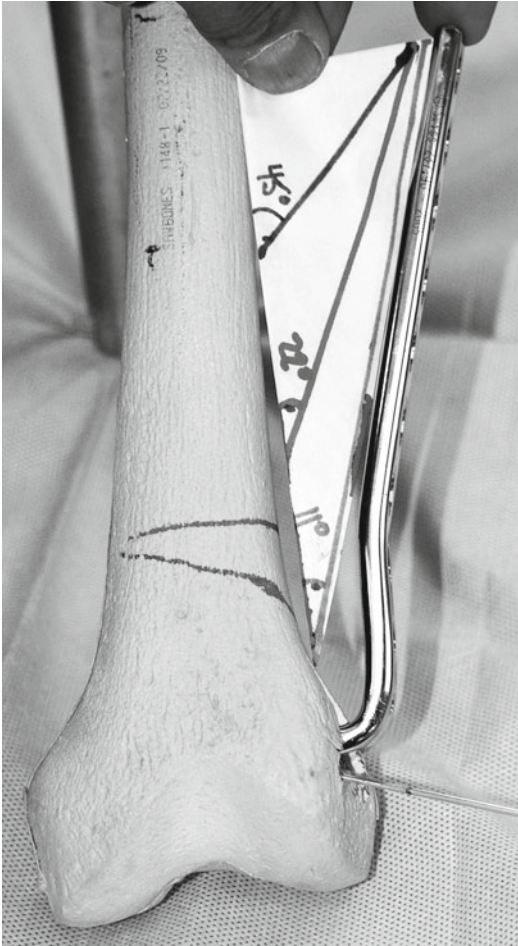

Fig. A.10

blade plate (Fig. A.10). The initial cut is done as above, and the second osteotomy is done proximally, perpendicular to the long axis of the bone, and triangulated to leave a cortico-periosteal hinge on the opposite side (Fig. A.11). The blade plate is inserted and fixed in compression proximally (Fig. A.12). If an opposite hinge has been preserved and the blade plate offset is adequate, translation should not be an issue (not the case in this example using a saw bone). Up to 1 cm is usually well tolerated, but more than that needs to

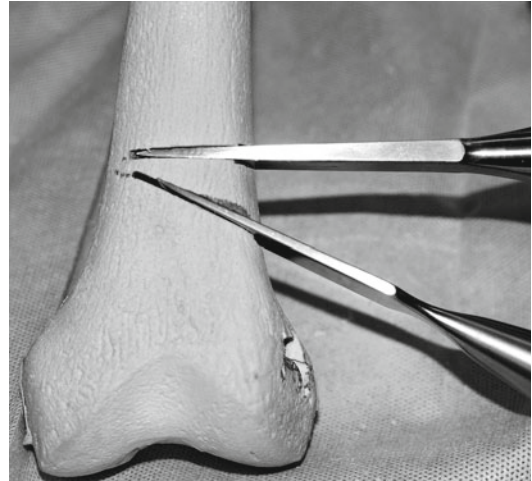

Fig. A.11

be addressed with a different plate offset. If contouring the plate is necessary, one needs to be acutely aware of not changing angles.

If ex-fix bars are not available. Large catheters or a medium-size chest drain can be prefilled with cement (bone if available, but more commonly dental) and inserted over the pins while still doughy.

Tips when casting without an assistant. For mid-shaft tibia or ankle fractures, place the patient supine with the leg hanging over the side and the thigh supported by a board. Loop a long swath of Kerlix or stockinette around the ankle and heel ending in a loop into which you can insert your foot to apply traction while rolling the cast. Stop the cast above the malleoli; remove the Kerlix traction when the POP has semi-set, making sure the undercast cotton padding is still intact without creases or bunching around the bony prominences; and finish the cast with the ankle and foot in their proper positions.

For a below cast when the fracture (tibia or ankle) is sticky and you are alone and need to keep the ankle at 90°. This technique requires a




Fig. A.12

piece of wood about 1 cm thick, 6 cm wide, and 40–50 cm long. Have the patient sit with his legs over the side of the table, adjust the stool so that you are sitting on one end of the piece of wood

and the other end is under the stockinette or cast padding and supporting the sole of the foot with the ankle in neutral position. When the cast is finished, pull out the piece of wood.

In the same situation of fracture stickiness and working alone, a below knee POP applied with the patient prone and the knee flexed 90° helps maintain neutral ankle position.

Miscellaneous

A wooden arm board can be used for spica table. If narrow and thin enough, a wooden arm board can be incorporated in the spica and the patient slid off after completion. More commonly, the board (or even the regular armrest) is too wide but can support the head and proximal trunk while assistants hold the lower part of the child. This allows the head to stay close to anesthesia.

Ex-fix for phalangeal fractures. K-wires drilled through the plastic cap of a syringe needle, through the bone, above and below the fracture make an ex-fix for open phalangeal fractures. Use one or two K-wires on each side of the fracture, depending on stability. Figure A.13a shows a near amputation of a thumb through the proximal phalanx from a sugarcane grinder, with 4 K-wires through a needle cap. Figure A.13b shows postreduction X-ray, with restoration of length.

Neatly splitting a tendon for Z-plasty. Using an 0 or 00 monofilament suture on a needle, penetrate the tendon in the middle and cut proximally and distally as needed, as if using a Gigli saw. Divide the tendon at the appropriate ends.

When putting on pelvic ex-fix. Use an incision long enough to put the thumb and finger on the inner and outer tables to sense pin placement. If a pin breaches the cortex, it needs to be the inner table, as these ex-fix are usually loaded in compression.

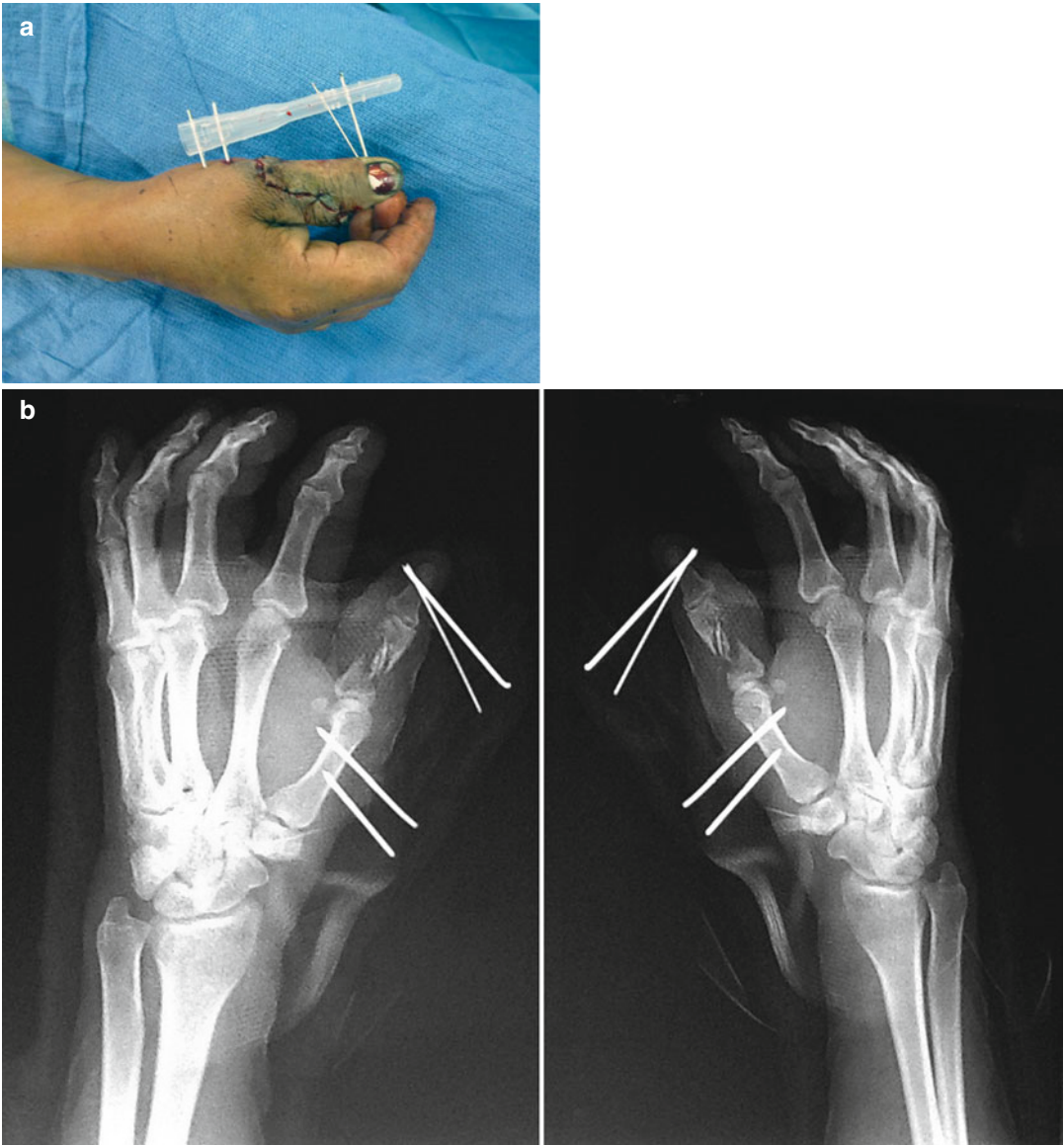


Fig. A.13

Portable instructions. With a sharpie or pen, mark on the cast, dressing, or even adjacent skin when it was done, when it needs to come off, or the date of the next planned procedure (Fig. A.14).

Skin hooks. These can be made from two syringe needles bent at the tips and held with hemostats.

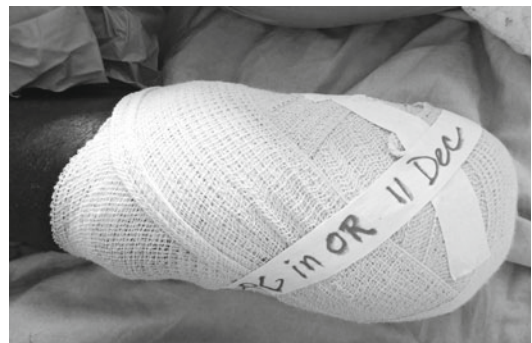

Fig. A.14

Appendix 4

What Do I Take?

Take your *passport, ticket, and yellow fever card*. Take copies of your passport, visa, yellow fever vaccine, and ticket but keep them in a part of your luggage separate from the originals. Take certified or notarized copies of medical licenses, diplomas, certificates, and your birth certificate or naturalization paper. E-mail copies or scans of all important documents to yourself so they can be easily retrieved.

Have all *contact numbers/addresses* readily available upon arrival, a charged and functional phone, and a plan B hotel, in case your pickup does not show up.

Drugs: bring what you would normally take at home, with some extra. Essential drugs: bring twice the amount needed for each, divided in two separate containers kept in different bags at all times. It is unlikely both bags will be lost or stolen.

Personal medicine bag:

- Site-specific medication (antimalarial, altitude sickness, etc.)
- Acetaminophen
- NSAID
- Cipro
- Lomotil
- Benadryl
- Bug repellent, antihistamine bite pen, or spray
- OTC cortisone cream
- Antacid
- Sleeping aid

Stuff:

- Headlight + batteries, as well as batteries for any other devices that need them
- Small LED flashlight to use in wards and OPD (they are almost always dark)

- Sharpies; extra pens
- Small camera
- Ear plugs—silicone, BioEars
- Moleskin-type notebooks to record cases and notes; 3 × 5 cards
- Business cards
- Large, sharp dressing scissors with a lead to attach to lab coat or fanny pack
- Spare glasses in an unbreakable case
- Loupes
- Protective eyewear
- Special sutures, gloves
- Goniometer
- Retractable measuring tape
- Stethoscope
- Reflex mallet
- Hand drill
- K-wires
- Downloaded technical books on computer, external hard drive, or flash drive
- Relevant PowerPoint talks
- Fluorescein (if a lot of osteomyelitis work is anticipated)
- Disposable Chinese finger traps
- Entertainment—books, Kindle, DVD player, and MP3 player
- Inexpensive cell phone that can accept local SIM cards and minutes
- Universal electrical adaptor and country-specific electrical plug
- Scrubs, lab coat, and cheap OR shoes to leave behind
- Microfiber towel
- Fanny pack or knapsack to carry instruments, camera, and flashlight
- Comfort food. A freshly unwrapped Snickers can ease any number of frustrations

Index

A

- Acetabular fractures. *See also* Pelvic fractures
 - ORIF, 185
 - T-type, central dislocation, 185
- Adult osteomyelitis
 - Cierny-Mader classification, 326
 - dead space management, 327
 - debridement, 327, 328
 - diagnosis, 325
 - localized/segmental defects reconstruction
 - acute shortening, 327
 - amputation, 329, 330
 - bone transport, 328–329
 - cancellous grafting, 328
 - soft tissue coverage, 328
 - structural free grafts, 328
 - vascularized autografts, 328
 - medical management, 326
 - rehabilitation, 329
 - treatment, 327
- Adult septic arthritis
 - anatomic type, 331
 - classification, 332
 - patient evaluation
 - clinical history and physical examination, 331–332
 - laboratory studies, 331–332
 - radiographs, 331
 - risk factors, 329
 - treatment, 332–333
- Adult trauma
 - acute care
 - avulsion wounds, 127
 - dehydration, 126
 - splinting and elevation, 128–129
 - ventilation, 127, 129
 - burns, 136
 - compartment syndrome, 134–135
 - degloving injuries, 129, 130
 - fat embolism and deep venous thrombosis, 135–136
 - open fractures
 - cephalosporins, 130
 - debridement of, 131, 132
 - external fixateur, 131–132
 - Gustilo classification, 130, 131
 - incisions, 131
 - polymethylmethacrylate cement, 131
 - tetanus immunization, 130
 - rehabilitation, 137
- Alcoholism, 54
- Amputation surgery
 - lower extremity, 481
 - above-knee amputation, 486–487
 - ankle disarticulations, 489–492
 - below-knee amputation, 488–490
 - foot amputations, 490
 - hindquarter amputation and hip disarticulation, 486
 - knee disarticulation, 487–488
 - muscle, 482
 - nerves, 483
 - postoperative management, 483–484
 - principles, 481–482
 - revision, 484, 485
 - skin, 482
 - upper extremity, 481
 - elbow disarticulation, 484
 - forearm amputations, 485
 - hand amputations, 485–486
 - principles, 486
 - scapulothoracic and shoulder disarticulations, 484
 - vessels, 483
 - wound closure, 483
- Anemia, 52–53
- Anesthesia
 - agents, 120
 - barbiturates, 120
 - benzodiazepines, 119–120
 - diclofenac (Voltaren), 119
 - ketamine, 120
 - opioids, 119
 - paracetamol (acetaminophen), 119
 - in pediatric patient, IV fluid need, 117
 - postoperative pain management, low resource settings, 120–121
 - propofol (Diprivan), 120
 - WHO surgical safety checklist, 116

Angular deformities

- coronal plane deformities, 385
- differential diagnosis
 - Blount's disease, 70
 - calcium-deficiency rickets, 72
 - idiopathic deformities, 72
 - posttraumatic or post-infectious, 69, 70
 - skeletal dysplasias, 72
 - vitamin D-resistant rickets, 70–72
- genu varum deformities, 69
- hemiepiphysiodesis, 391
- limb deformities
 - history, 387
 - physical assessment, 387
 - radiographs, 387
- lower leg bowing
 - anterolateral bowing, 391, 392
 - anteromedial bowing, 393, 396
 - posteromedial bowing, 391–394
- osteotomy, 390–391
- physical examination, 385, 386
- preoperative planning, 387–389
- treatment, 73

Ankle and foot

- achilles tendon rupture, 231–232
- bimalleolar fracture dislocation, 223, 224
- calcaneus fractures, 228
- degloving injuries, 231
- intra-articular distal tibia fractures, 222–223
- Lisfranc fracture-dislocations, 228–229
- management, tips and tricks for, 232
- mangled feet, 229
- metatarsal fractures, 229, 230
- midfoot fractures, 228
- Quigley stockinette traction, 225
- residual syndesmotic widening, Maisonneuve-type injury., 227
- talus fractures, 228
- treatment principles, 221–222

Ankle block, anesthesia, 117, 118**Ankylosing spondylitis, 13****Arthrodesis, 451**

- ankle, 456, 459–460
- fingers, 453
- foot, 461–462
- hip, 453–455
- knee, 455–457
- shoulder, 452
- thumb, 453
- wrist, 453

Arthroplasty

- acromioclavicular joint, 463
- hip, 464
- resection, 462–463
- shoulder, 463
- toes, 464
- wrist, 463–464

Avascular necrosis (AVN), 14, 111**B**

- Bacterial septic arthritis, 294
- Barriers to service delivery
 - health information system, 24–25
 - health system, 23, 24
- Below-knee amputation (BKA), 488–490
- Blast injuries, 494–495
- Blastomycosis, 61–62
- Blount's disease, 70
- Bone tumors
 - benign bone tumors
 - clinical features, 472–473
 - giant cell tumor, 475
 - radiographic findings, 472, 474–475
 - malignant bone tumors
 - Burkitt's lymphoma, 477–479
 - chondrosarcoma, 476–477
 - Ewing sarcoma, 476
 - osteosarcoma, 476
 - spindle cell sarcomas, 477
 - metastatic tumors, 479
 - open biopsy, 469, 471
 - soft tissue tumors, 479
- Boxer's fracture, 173
- Braces, polio, 5
- Brain injury management, 507–508
- Brucellosis, 59–60, 301, 345
- Bryant's (gallows) traction, 90, 91
- Buck's traction, 91
- Burkitt's lymphoma, 477–479
- Buruli ulcer, 60–61

C

- Calcium-deficiency rickets, 72
- Casting
 - bivalved, 75
 - hip spica, 82–84
 - materials, 76
 - minerva, 84
 - Munster cast, 85–86
 - patellar tendon-bearing (PTB), 86, 88
 - techniques, 78–79
 - wedging, 79–82
 - window edema, 76
- Cerebral palsy (CP)
 - biofunctional status assessment, 425–426
 - lab tests, 425
 - physical examination, 425
 - spastic quadriplegia, 423, 424
 - surgical treatment
 - assistive device, 425
 - benefits and pitfalls, 427
 - equinus and gastrocnemius contracture, 427
 - isolated tendoachilles lengthening, 427
- Charcot joints, 14, 15
- Chondrosarcoma, 476–477
- Chronic osteomyelitis

complications, 322–324
 differential diagnosis, 315
 multifocal, 315
 opportunistic infections, 315
 sequestrectomy, 317
 complications, 322
 dead space management, 321–322
 debridement, 320–321
 metaphyseal presentation, 319–320
 rehabilitation, 322
 stages, 317
 Cierny-Mader classification, 326
 Clenched fist injury, 173
 Clubfoot. *See also* Neglected clubfeet
 classification, 357
 clinical findings, 358
 etiology, 357
 incidence, 357
 pathoanatomy, 357–359
 Ponseti technique
 bracing, 362, 364
 casting, 360–364
 older patients, 364–367
 percutaneous achilles tenotomy, 360, 362, 365
 relapses, 364
 Conflicts and natural disasters. *See also* Natural disasters
 blast injuries, 494–495
 gunshot injuries, 493–494
 land mines, 495, 496
 surgical epidemiology, 495
 treatment
 assessment and resuscitation, 498
 bones, 499–501
 mass casualty event and triage, 496–497
 peripheral nerve injuries, 499
 vessel injuries, 499
 wound debridement, 498–499
 Cost-effectiveness analysis (CEA), 19–20
 Cross-leg flap, 107–110
 Crush injury, 502, 503
 Culture shock
 concept, 43
 poverty, 43
 reverse, 48
D
 Dangling leg syndrome, 411
 Degenerative joint disease (DJD), 14, 53, 177,
 186, 435, 459, 460
 Developmental dysplasia of the hip (DDH),
 14, 310, 397, 399, 401
 bilateral dislocations, 397–399
 clinical assessment
 physical exam, 398, 399
 radiography, 398–399
 incidence, 397, 398
 natural history, 397

 treatment
 age criteria, 401
 bilateral and unilateral hip dislocation, 399–401
 bracing, 399
 hip abduction device, 399
 open reduction and femoral shortening, 401–403
 Diabetes, 14, 51, 54
 Diazepam (Valium), 119–120
 Diclofenac (Voltaren), 119
 Disability-adjusted life year (DALY), 11, 19–20
 Dome osteotomy, 450–451
 Dracunculiasis, 63–64
 Dunlop's traction, 96

E

Educational resources, 27–29
 Elbow and forearm fractures
 arthritis, 162
 chronic traumatic conditions
 dislocations, 161
 stiffness, 161
 compartment syndrome, 161
 dislocations
 with coronoid fracture, 153
 NSIADs, 151, 152
 physical therapy, 151
 radial head, 151–153
 distal humerus fractures
 capitellum, 157
 comminuted lateral column
 fracture, 153, 154, 157
 low bicondylar distal humeral
 fracture, 153, 155
 olecranon, 158
 olecranon osteotomy, 153–154
 90°/90° plate positioning, 153
 heterotopic bone and synostosis
 radioulnar synostosis, 162
 ulnohumeral synostosis, 161–162
 infection, 162–163
 radius and ulna
 Galeazzi fractures, 159
 IM nailing, 158
 Monteggia fracture, 159, 160
 night stick fracture, 159
 plating, 158–159
 ruptured distal biceps tendon, 160–161
 salvage/reconstructive procedures, 163
 Emergency and Essential Surgical Care
 Project (EESC), 24
 Enchondroma, 473, 475
 Envenomation, 65
 Equipment and supplies
 donated equipment and supplies, 35–36
 local acquisition
 external fixation devices, 34–35
 prosthetic training, 35–36

- Equipment and supplies (*cont.*)
 rope and pulleys, plaster of Paris, razor blades,
 and bleach, 33
 wooden crutches, 35
 purchased equipment, 36–37
- Ethics
 cultural and societal considerations, 39–40
 favoritism, 40
 informed consent, 40
 patient autonomy, 39
 patient safety, 39
 record keeping, 39
- Ewing sarcoma, 318, 476, 478
- F**
- Fasciocutaneous flap, 103–104
 Fasciotomy, 503
 Femoral neck fractures, 189–190, 287
 Femoral shaft fractures
 antegrade/retrograde nailing, 198
 diaphyseal fractures, 196
 internal fixation, 196
 with intertrochanteric fractures, 194
 intramedullary devices, 200
 locking plates, 200
 multiple ender nails/rush rods, 196–198
 with neck fracture, 194
 Perkins traction technique, 204
 SIGN system, 196–197
 skeletal traction, 194–196
 subtrochanteric fractures, 194, 195
 tibial skeletal traction, 204
- Femoral shaft malunion
 femoral shortening and lengthening, 447–448
 osteotomy, 445
 physical examination, 445–446
 X-ray, 445–447
- Fibrous dysplasia, 473, 474
- Flaps
 cross-leg flap, 107–110
 distant flaps, 106–107
 fasciocutaneous flap, 103–104
 gastrocnemius muscle flap, 103–105
 general principles of, 102–103
 soleus muscle flap, 105
 V-Y advancement skin flap, 103
- Foot drop
 ankle-foot orthosis (AFO), 406, 407
 clinical appearance, 406
 physiotherapy, 407
 subtalar stabilization, 406–407
 treatment options, 406, 407
 triple arthrodesis, 407
 trophic ulcer, 406
- Forefoot adductus, 358
 Full-thickness skin graft (FTSG), 101
- Fungal infections
 blastomycosis, 61–62
 mycetoma/Madura foot, 63
- G**
- Gas gangrene, 58
 Gastrocnemius muscle flap, 103–105
 Giant cell tumor, 475–476
 Glasgow Coma Scale (GCS), 507
 Glenohumeral dislocations, 141
 Global Help Organization (GHO), 29
 Gout, 13
 Gross Motor Functional Classification System
 (GMFCS), 425
 Gunshot injuries, 493–494
- H**
- Hand and wrist injuries
 active/passive exercises, 165, 166
 Bennett fracture dislocations, 172
 complex dislocations, MP joints, 172–173
 distal radius and ulna
 Charnley dorsal-radial splint, 168, 169
 Smith-type fractures, 169
 unstable volar Barton's fracture dislocation, 169, 170
 wrist-spanning external fixateur, 169
 equipment and instruments, 166–169
 high-pressure injection injuries, 174
 lunate dislocations, 172
 Machete injuries, 175
 mangled hand, 175–176
 metacarpal fractures, 173
 perilunate dislocations, 172
 phalanges fractures, 173–174
 pyogenic flexor tenosynovitis, 175
 scaphoid fracture, 170–171
 transscaphoid perilunate fracture/dislocations, 172
- Head trauma management, 507–508
 Health-adjusted life expectancy (HALE), 19, 20
 Health InterNetwork Access to Research Initiative
 (HINARI), 29
- Hemiarthroplasty, 467–468
 Hemiepiphysiodesis, 391
 Hemophilia, 53
 Hepatitis, 53
 Hereditary coagulopathies, 53
 Hereditary dysplasias, 14
 Hindfoot equinus, 358, 359
 Hindfoot varus, 358, 359
- Hip dislocations
 anterior hip dislocations, 188–189
 posterior dislocations, 187–188
- Hip sepsis, sequelae
 femoral head dislocation, 303, 306, 307
 femoral neck pseudarthrosis, 303, 306
 morphologic abnormalities, 303, 305–306
 patient history, 306
 physical examination, 306
 plain radiographs, 306, 308
 treatment
 pelvic support osteotomy, 310
 post-septic flexion/adduction contracture, 310, 312
 trochanteric arthroplasty, 309

- Hip spica, 82–84
- Human immunodeficiency virus (HIV), 53
- avascular necrosis (AVN), 111
 - fracture union rates, 112
 - occupational hazards, 112–113
 - open fracture risk, 112
 - septic arthritis, 111
 - TB, 112
- Hydatid disease/Echinococcosis, 64
- I**
- Infected tibial nonunion management, 437–438
- open technique
 - fasciocutaneous flaps, 440
 - posterolateral (Harmon)
 - approach, 442, 443
 - soleus flap, 440
- Infectious diseases, 53–54
- Inflammatory diseases, 13–14
- Interposition arthroplasty, thumb carpometacarpal joint, 464–465
- Intertrochanteric (perthrochanteric) fractures
- cephalic nails, 190
 - complications, 190
 - with posteromedial instability, 192, 193
 - SIGN hip construct device, 190–192
- Intracranial pressure control, 508
- Iodine-deficiency, 52
- J**
- Joint infections. *See* Septic arthritis
- K**
- Knee ankle foot orthosis (KAFO), 410
- Knee arthrodesis, 455–457
- Knee injuries
- acute knee dislocations, 211
 - extra-articular fractures
 - DC plate, 203
 - IM nails, 203–204
 - Steinmann pins, 203
 - intra-articular distal femur fractures, 205, 206
 - ligamentous fracture, 210–211
 - patella injuries
 - dislocations, 210
 - figure-of-eight tension banding, 207
 - nonunions, 207–209
 - posteromedial dislocation, 212, 214
 - subacute knee dislocations, 213
- Kyphosis, 345, 349–350
- L**
- Leprosy, 61
- Limb deficiencies
- femoral dysplasia, 377, 378
 - longitudinal deficiency, 377, 378
 - lower extremity deficiencies, 383–384
 - patient evaluation
 - history, 377–378
 - length inequality determination, 378
 - ultrasound, 378
 - X-rays, 378
 - treatment considerations
 - amputations, 381–382
 - congenital deficiency, 379, 381
 - modified Marquardt procedure, 382
 - prosthetic care, child's access to, 381
 - upper extremity deficiencies, 382–383
- Lower extremity
- blade plate, 510–512
 - casting, 512–513
 - distal locking standard IM nails, 509
 - external-fixation, 513–514
 - neglected pediatric fractures/dislocations
 - femoral neck fractures, 287, 289
 - hip dislocations, 287,
 - malunited diaphyseal fractures, 287
 - osteotomy angles, 509–510
 - pediatric ankle injuries
 - displaced triplane fracture, 284, 286
 - juvenile Tillaux fracture, 284, 285
 - pronation-eversion-external rotation fracture, 283
 - supination-external rotation fracture pattern, 284
 - supination-inversion fracture pattern, 280, 282
 - supination-plantar flexion injury, 284, 285
 - pediatric femoral shaft fractures
 - closed reduction and immediate spica casting, 275, 276
 - external fixation, 277, 278
 - flexible nailing, 277
 - 90°–90° traction, 275, 277
 - pediatric tibia and fibula fractures
 - flexible intramedullary nailing, 280, 281
 - percutaneous fixation, 279, 280
 - tibial nailing, 509
 - traction (*see* Traction)
- Lupus, 13
- Lymphatic filariasis, 63
- M**
- Malaria, 53–54
- Malnutrition, 52
- Malunion
- ankle, 448
 - femoral shaft, 445–452
 - foot, 448–449
 - humeral and radial shafts, 443, 445
 - knee, 448
 - tibial fractures, 448
- Meperidine, 119
- Metabolic diseases, 14–15
- Midazolam, 120
- Midfoot cavus, 358, 359

- Minerva casting, 84
Morphine, 119
Multiple joint sepsis, 293
Munster cast, 85–88
Musculoskeletal infections
 mycobacterial, 300–301
 osteomyelitis (*see* Osteomyelitis)
 plain radiographs, 293
 pyomyositis, 301
 septic arthritis (*see* Septic arthritis)
 tuberculosis (*see* Mycobacterium tuberculosis)
- Musculoskeletal injuries
 incidence of hospitalization, 10
 mortality rates, 9–10
 nonfatal injuries, 10–11
 nontraumatic, 11
 outcomes, 10
- Musculoskeletal tumors, 470–471
Mycetoma/Madura foot, 63
Mycobacterial diseases
 Buruli ulcer, 60–61
 leprosy, 61
 tuberculosis (*see* Tuberculosis)
- Myodesis closure, 482
Myofascial closure, 482
Myoplasty closure, 482
- N**
Natural disasters
 amputations, 503
 crush injury, 502, 503
 fasciotomy, 503
 logistical components, 500
 management, 503–504
 medical intervention, 500, 502
 rehabilitation, 504
 reperfusion, 502–503
 skeletal traction, 502
- Neglected clubfeet
 pathoanatomy, 369
 surgical treatment
 “à la carte” approach, 371, 372
 correction maintenance, 376
 Lichtblau procedure, 371, 373
 modified Lambrinudi triple arthrodesis, 373–375
 naviclectomy, 373
 percutaneous tenotomy, 371
 Ponseti casting, 370, 371
 rigid midfoot cavus deformity, 369, 370
 ring fixateur, 374, 376
 trans-cuneiform osteotomy, 373
- Neuroaxial anesthesia, 117
Neurologic clubfoot, 357
Nonossifying fibroma, 473, 474
Nonsurgical principles. *See* Casting; Traction
- Nonunions
 ankle fractures, 442–445
 femoral neck nonunion, 434–435
 femoral shaft nonunion, 435–437
 humeral shaft fractures, 432, 433
 hypertrophic nonunions, 431, 432
 infected tibial nonunions, 437–438, 440, 442, 443
 knee fracture, 435
 oligo-atrophic and atrophic nonunions, 431, 432
 radial and ulnar nonunion, 432, 434
 scaphoid nonunions, 432, 434
 tibia/fibula shaft fracture, 435, 437, 440–442
- Nutrition, 52
- O**
Ober test, 409
Open fractures
 cephalosporins, 130
 debridement of, 131, 132
 external fixateur, 131–132
 femur fractures, 132
 Gustilo classification, 130, 131
 humerus and forearm fractures, 132
 inadequate treatment, 130
 incisions, 131
 polymethylmethacrylate cement, 131
 prepping and draping procedures, 131
 tetanus immunization, 130
- Ophthalmologic disease, 51–52
Orthopaedics Overseas (OO), 3, 4
Osteoblastoma, 473, 474
Osteochondroma, 473, 474
Osteomalacia, 52
Osteomyelitis
 acute hematogenous osteomyelitis
 involucrum, 295, 302–303
 laboratory studies, 294
 natural history, 294, 295
 physical findings, 294
 radiographs, 294
 sequestrum, 294–297
 signs and symptoms, 294
 in adults (*see* Adult osteomyelitis)
 in children (*see* Chronic osteomyelitis)
 chronic, 299–300
 etiology, 293
 subacute, 299
- Osteoporosis, 14, 52
Osteosarcoma, 476
Osteotomy
 angular deformities, 388–390
 dome osteotomy, 450–451
 femoral shaft malunion, 445
 pelvic support osteotomy, 310
 proximal osteotomy, 310, 311, 313
 tibial osteotomies, 449
 trans-cuneiform osteotomy, 373
- P**
Paracetamol (acetaminophen), 119
Parasitic diseases, 53–54
 dracunculiasis, 63–64
 helminths, 54
 hydatid disease/echinococcosis, 64

- lymphatic filariasis, 63
- trichinosis, 64
- venomous injection injuries, 65–66
- Pediatric trauma
 - fracture healing and remodeling
 - bone age differences, 250
 - guidelines for acceptable alignment, 250
 - inflammatory stage, 247
 - neglected fractures and dislocations, 253
 - open reduction and nailing, radius and ulna
 - fracture, 247, 249
 - physeal injuries
 - degree of malalignment, 253
 - growth disturbances, 252
 - Salter-Harris classification, 251
 - splint treatment, forearm fracture, 247, 248
- Pediatric upper extremity injuries
 - diaphyseal fractures, radius and ulna
 - Bayonet apposition, 263, 264
 - greenstick fractures, 263
 - plastic deformation, 263
 - unstable, 264, 265
 - distal radius fractures, 264–266
 - lateral condyle fractures, 260
 - Monteggia lesions, 260–262
 - neglected fractures/dislocations
 - elbow dislocation, 272–273
 - osseous flexion block, 267
 - untreated lateral humeral condyle
 - fracture, 267–268
 - untreated type I Monteggia lesion, 271–272
 - proximal humerus, 255, 256
 - radial neck and olecranon, 263
 - supracondylar humerus
 - capitellar ossification center, 255, 256
 - ecchymosis, 259
 - flexion-type, 256, 257
 - nerve injuries, 257, 259
 - open reduction and pinning, displaced
 - fractures, 257, 258
 - skeletal traction, 259
 - type III fractures, 256, 257
 - vascular injuries, 259
- Pelvic fractures
 - arterial embolization, 180
 - diagnostic investigations
 - CT scans, 182
 - inlet (cephalocaudal) view, X-ray, 181
 - Judet iliac and obturator oblique views, 181, 183
 - outlet (caudocephalic) view, 181, 182
 - external fixation, 178
 - pelvic ring injuries
 - Bucholz type 2 injuries, 183–184
 - Bucholz type 3 injuries, 184
 - complications, 182
 - external fixateurs, 184
 - stability assessment, 182
 - pelvic sling application, 180
 - physical examination
 - anteroposterior and latero-lateral compression
 - maneuvers, 177
 - cephalocaudal push-pull maneuver, 177
 - hip dislocation, 178,
 - urinary examination, 178, 179
 - pubic diastasis, 180
- Perkin's traction, 95
- Plastic surgery
 - delayed primary closure, 99
 - flaps (*see* Flaps)
 - local care and dressings
 - saline solution, 100
 - sugar dressings, 100
 - vacuum-assisted closure (VAC)
 - devices, 100
 - postoperative troubleshooting, 110
 - primary wound closure, 99
 - scar modalities, 110
 - secondary closure, 33
 - skin grafts (*see* Skin grafts)
- Poliomyelitis
 - contractures, 409
 - crawlers, 410–412
 - diagnosis, 409
 - differential diagnosis, 409
 - equinus deformity, 411, 412
 - knee ankle foot orthosis, 410
 - manual muscle testing, 409–410
 - Ober test, 409
 - single-leg involvement, 411, 412
 - treatment, 410
- Polymicrobial infections, 329–330
- Ponseti technique
 - bracing, 362, 364
 - casting, 360, 361
 - cast removal, 360, 362
 - older patients, 364–367
 - percutaneous achilles tenotomy, 360, 363
 - relapses, 364
- Postinjection paralysis (PIP)
 - affected muscles, 405–406
 - buttock abscess, 406
 - clinical history, 405
 - foot drop (*see* Foot drop)
 - gluteal and quadriceps fibrosis, 407–408
 - hip and knee contracture correction
 - distal tibial traction, 416–418
 - flexion contractures, 412, 413
 - foot deformities, 416, 418
 - hip flexion/abduction release, 415–416
 - Lambrinudi triple arthrodesis, 414
 - stretching or serial casting, 412, 413, 415
 - tendoachilles lengthening (TAL), 414
 - Yount procedure, 414
 - hip instability, 420
 - hyperextension, 419–420
 - intramuscular injections, 405
 - leg length discrepancies, 420, 421
 - prevalence, 405
 - quadriceps weakness, 418–419
 - recovery, 405
 - scoliosis, 420
 - upper extremity involvement, 420

Postural clubfoot, 357
 Proximal femur fractures, 189
 Proximal row carpectomy (PRC), 463
 Ptolemy, 29
 Pyomyositis, 293

Q

Quality-adjusted life year (QALY), 19, 20

R

Radioulnar synostosis, 166
 Reconstruction techniques for adults
 arthrodesis (*see* Arthrodesis)
 arthroplasty (*see* Arthroplasty)
 hemiarthroplasty, 467–468
 interposition arthroplasty
 elbow, 464–465
 thumb carpometacarpal joint, 465–466
 malunion (*see* Malunion)
 nontraumatic deformities
 dome osteotomy, 450–451
 foot deformity, 451
 genu varum/valgum deformities, 449–450
 tibial osteotomies, 449
 nonunions (*see* Nonunions)
 replacement arthroplasty, 466–468
 Respiratory disease, 51
 Reverse culture shock, 48
 Rheumatoid arthritis, 13
 Rickets
 calcium-deficiency, 72
 vitamin D-resistant, 70–71
 Russell's traction, 91

S

Scapula injuries, 139–141
 Schistosomiasis, 54
 Septic arthritis, 111
 acute, 293–294
 in adult (*see* Adult septic arthritis)
 bacterial, 294
 in children (*see* Hip sepsis, sequelae)
 etiology, 293
 metaphyseal osteomyelitis, 293
 multiple joint sepsis, 293
 X-rays findings, 303, 304
 Seronegative spondylarthropathies, 13
 Shoulder and humeral shaft
 acromioclavicular joint, 140
 chronic dislocations
 closed reduction, 141
 shoulder Girdlestone, 143
 tuberosity fractures, 143
 diaphyseal fractures, 145, 146
 external fixation device, 148
 functional brace/ coaptation splint, 145
 glenohumeral dislocations, 141

 history and physical examination, 145
 rush rod fixation, 145, 147
 scapula injuries, 139–141
 sternoclavicular joint, 139
 Sickle cell disease, 53
 SIGN Fracture Care International, 6, 36
 Silfverskiold test, 427
 Skeletal olecranon traction, 96–98
 Skin grafts
 full thickness skin graft (FTSG), 102
 preparation of, 102
 split-thickness skin graft
 (STSG), 101–102
 Smith-type fractures, 169
 Snakebite, 65
 Soft tissue tumors, 479
 Soleus muscle flap, 105
 Spinal cord and spine trauma
 assessment of the injury, 239
 evaluation
 cervical spine X-ray, 236
 perineal sensation, 235
 thoracolumbar spine, 236
 pediatric spine trauma, 241–242
 stability, 239
 treatment
 C2 hangman's fracture, 240, 241
 Gardner-Wells tongs placement, 239, 240
 head halter traction, 240, 241
 for lower cervical injuries, 241–242
 for thoracolumbar injuries, 242
 Spindle cell sarcomas, 477
 Split-thickness skin graft (STSG)
 care of donor site, 101–102
 donor site, 101
 Humby/Watson knives, 101
 Paprika sign, 101
 Sternoclavicular joint, 139
 Subacute osteomyelitis, 299
 Substance abuse, 54
 Syme procedure, 489
 Syndromic clubfoot, 357

T

Task shifting, 24
 Tetanus, 58–59
 Thalassemia, 53
 Thomas-Pearson traction, 91, 92
 Tibia and fibula
 bumper injuries, 218
 tibial plateau fractures, 214, 216
 tibial shaft fractures
 calcaneal pin traction, 218
 conservative management of, 216
 debridement and external fixation, 218, 219
 Ender and Rush nails, 217
 long-leg cast (LLC), 216
 SIGN nail, 217
 X-rays, 217

- Tibiofibular synostosis, 442, 443
Tobacco use, 52
Traction
 benzoin tincture, 89
 lower extremity
 Boehler frames, 94
 Bryant's (gallows) traction, 91
 Buck's traction, 91
 equinus deformity prevention, 96
 Perkin's traction, 94
 with proximal tibial pin, 92
 Russell's traction, 91
 Thomas-Pearson traction, 91, 92
 90°–90° traction, 92
 padding, 89
 pin placement, 90–91
 purpose of, 89
 skeletal traction, 89–90
 upper extremity
 Dunlop's traction, 96
 skeletal olecranon traction, 96–98
Traditional healers
 practices and belief, 46
 scarification, rubbing metal and cupping, 47, 48
Tramadol, 119
Trichinosis, 64
Tuberculosis (TB), 60, 112
 arthritis
 ankylosis, 342
 arthrodesis, 341–342
 clinical consequences, 341
 excisional arthroplasty, 341
 granulation tissue, marginal erosions, 339, 340
 hip disease, morphologic abnormalities, 339–340
 host inflammatory response, 337, 339
 joint destruction, 339, 340
 natural history, 337
 osteopenia and swelling, 339
 pelvic support osteotomy, 343
 synovectomy and debridement, 343
 musculoskeletal infections, 300–301
 mycobacterium
 diagnosis, 336
 osteomyelitis, 337, 338
 prognosis, 335
 sinuses, 335, 336
 tissue destruction, 335
 treatment principles, 336–337
 spondylitis
 outpatient chemotherapy, 345
 pathophysiology and natural history, 344–345
 patient evaluation, 345–348
 surgical treatment, 343, 347, 351–352
- U**
Ulcers, 60
Ulnohumeral synostosis, 161–162
Unicameral bone cyst, 472, 474
- V**
Vacuum-assisted closure (VAC) devices, 100
Venomous injection injuries, 65–66
Vitamin D-resistant rickets, 70–71
V-Y advancement skin flap, 103
- W**
WHO HIV clinical staging system, 326
World Orthopaedic Concern (WOC), 3–4
Wrist block, anesthesia, 117, 118
- Y**
Years lived with disability (YLD), 20
Years of life lost (YLL), 20
Yount procedure, 414