

Irina Melnik, Richard Derby, and Ray M. Baker

Key Points

- Discography is an invasive diagnostic procedure not intended to be an initial screening examination due to associated potential risk to a patient.
- It is a confirmatory test, which can reveal the true source of pain and thus leads to precise and effective treatment as well as might help patients to avoid unnecessary surgical interventions.
- The value of the test is not only in providing morphologic characteristics of the disc structure and degrees of internal annular disc disruption but also in providing unique clinical information by potentially evoking patients typical/concordant pain and confirming a specific level of the painful disc.
- As a provocative test, discography is liable to false-positive results, which can be potentially avoided by adherence to strict operational standards and interpretation criteria, including pain $\geq 7/10$, pressure < 50 psi a.o., concordant pain, \geq grade 3 annular tear, volume ≤ 3.5 mL, and the presence of a negative control disc.

- Technical challenges, potential complications, and interpretation mistakes can be avoided with proper selection of patients, including favorable psychological profiling, use of sterile technique, intravenous and intradiscal antibiotics, judicious use of sedation, and good technical training of a practitioner.
- Emerging alternative approaches including anesthetic discography and functional discography are gaining attention, as well as noninvasive MRI spectroscopy and other imaging tests, as an attempt to provide similar clinical information without putting patients at a potential short- or long-term risk.

Introduction

Discography was introduced in the 1940s to diagnose herniation and internal annular disruption of the lumbar and subsequently cervical and thoracic intervertebral discs [1, 2]. While the development of CT and MRI scans unquestionably provide the physician with invaluable information, discography combined with a post-discography CT scan remains the most accurate method of detailing internal annular disruption and disc morphology [3]. Unlike noninvasive imaging tests, pressurizing the disc adds critical information if significant concordant pain is reproduced; and more importantly, a negative response to provocation discography assists in identifying negative discs for which surgery is not recommended. Theoretically, speed- and pressure-controlled injection of contrast media into the disc nucleus stimulates nerve endings via two mechanisms: a chemical stimulus from contact between contrast dye and sensitized nociceptors and a mechanical stimulus resulting from the fluid-distending stress simulating loading [4]. In the outer one-third of the normal disc, dissections and histochemical analysis reveal innervation by branches of the sinuvertebral nerves, the gray rami communicantes, and the

I. Melnik, M.D.
Comprehensive Spine and Sports,
591 Redwood Highway, Suite 2300, Mill Valley, CA 94941, USA

Spinal Diagnostics and Treatment Center,
901 Campus Dr, Suite 310, Daly City, CA 94015, USA
e-mail: drmelnik@spinaldiagnostics.com

R. Derby, M.D. (✉)
Spinal Diagnostics and Treatment Center Medical Director,
901 Campus Dr, Suite 310, Daly City, CA 94015, USA
e-mail: rderby@spinaldiagnostics.com

R.M. Baker, M.D.
Evergreen Spine and Musculoskeletal Program,
Medical Director EvergreenHealth,
Kirkland, WA, USA
e-mail: rmbaker@evergreenhealthcare.org

ventral rami [5–8] which contain well-characterized nociceptive nerve fiber peptides such as substance P, VIP (vasoactive intestinal peptide), and CGRP (calcitonin-gene-related peptide) [9–11]. Distinct from normally aging discs, “pathologically painful” discs show a process of neo-innervation extending along annular fissures as well as to the inner annulus and nucleus pulposus which likely explains the pain of provocation discography [12–14].

Conceptually, provocation discography is an extension of the clinical examination, tantamount to palpating for tenderness [15]. In addition, post-discography CT findings suggest a firm correlation between a degree of a demonstrable annular disruption and reproduction of pain by disc stimulation [16, 17]. In a study by Vanharanta et al. greater than 75 % of painful discs on provocative discography (PD) had a grade 3 or greater annular tear. Provocation discography is particularly useful in challenging or inconclusive cases unresolved by MRI or myelography, such as in post-discectomy discs or recurrent disc herniations [18].

Provocative discography is an invasive diagnostic test, not intended to be an initial screening examination. Over the past decade, there have been debates challenging the validity and accuracy of discography, its long-term safety, and a need for alternative approaches such as functional anesthetic discography or innovative noninvasive biochemical imaging tests [19]. In this chapter, we discuss indications for provocative discography, technical considerations, and procedural descriptions as well as potential complications and future directions.

Indications and Contraindications

According to the position statement on discography by the North American Spine Society [3]:

Discography is indicated in the evaluation of patients with unremitting spinal pain, with or without extremity pain, of greater than 4 months’ duration, when the pain has been unresponsive to all appropriate methods of conservative therapy. Before discography, the patients should have undergone investigation with other modalities which have failed to explain the source of pain; such modalities should include, but not be limited to, either computed tomography (CT) scanning, magnetic resonance imaging (MRI) scanning and/or myelography.

The single purpose of discography is to obtain useful clinical information. The test endeavors to confirm or refute the hypothesis that a particular disc is a source of patient’s familiar or accustomed pain. Since it is a provocation test, disc stimulation is liable to false-positive results; however, a recent meta-analysis of asymptomatic subjects demonstrated that a false-positive rate of less than 10 % can be obtained [20] if the discographer adheres to ISIS/IASP operational standards and interpretation criteria: pain $\geq 7/10$, pressure < 50 psi a.o., concordant pain, \geq grade 3

annular tear, volume ≤ 3.5 mL, and the presence of a negative control disc [21, 22].

Since abnormal disc morphology alone is not diagnostic, as shown on CT and MRI scans of subjects asymptomatic of low back pain [23], the prime indication for discography is to help to distinguish which disc is symptomatic. A parallel application is to identify asymptomatic discs. When a single disc is found to be symptomatic in the presence of adjacent asymptomatic discs, focused surgical therapy can be entertained. Patients with symptomatic or abnormal discs at multiple levels constitute a greater surgical challenge. Identification of asymptomatic discs which do not require intervention is also clinically invaluable.

Indications and Inclusion Criteria

- Failed conservative treatment for low back pain of probable spinal origin.
- Ongoing pain for greater than 4 months.
- Other common pain generators have been ruled out (e.g., facets, sacroiliac joints).
- Symptoms are clinically consistent with disc pain.
- Symptoms are severe enough to consider surgery or percutaneous interventions.
- Surgery is planned and the surgeon desires an assessment of the adjacent disc levels.
- The patient is capable of understanding the nature of the technique and can participate in the subjective interpretation.
- Both the patient and physician need to know the source of pain to guide further treatments.

Contraindications

- Unable or unwilling to consent to the procedure or to cooperate
- Inability to assess patient response during the procedure
- Coagulopathy (INR > 1.5 or platelets $< 50,000/\text{mm}^3$)
- Known localized or systemic infection
- Pregnancy (to prevent fetal radiation exposure)

Relative Contraindications to Discography

- Allergy to contrast medium, antibiotics, or local anesthetics
- Congenital, postsurgical, and anatomical derangements or psychological problems that can compromise safety and success of the procedure (including spinal cord compression and myelopathy in case of cervical and thoracic procedures)

Preprocedural Evaluation and Patient Preparation

Preprocedural Evaluation

A thorough patient evaluation as well as patient education about the nature of the procedure is critical to ensure optimal performance and the utility of the test. The evaluation should include history, physical examination, previous medical conditions, prior surgeries, medications, and allergies. Information about pain is recorded, including onset of symptoms, nature, frequency, and distribution of pain as well as its intensity in 0–10 pain scale. In most cases of lumbar discography and all cases of thoracic and cervical discography, an MRI or CT scan should be reviewed prior to discography. Furthermore, since false-positive rates may increase with severe somatization disorder, psychometric testing should be included such as DRAM (Distress and Risk Assessment Method) [24]. Prior to the procedure, patients have to understand the importance of reporting and recognizing whether the test reproduces their usual or so-called concordant pain and be able to distinguish this pain from other pain. Concordant pain is necessary to determine a positive response. For this reason, it is advisable to have a trained observer independently monitor patient pain responses while the operator concentrates on the technical aspects of the procedure.

Patient Preparation

Since the disc is a relatively avascular structure, there is an increased risk of discitis – a rare but serious potential complication of the discography procedure. The most common pathogens are *Escherichia coli*, *Staphylococcus aureus*, or *Staphylococcus epidermidis*. Intravenous (IV) antibiotic prophylaxis should be administered within 15–60 min before the procedure using cephazolin 1 g, gentamicin 80 mg, or ciprofloxacin 400 mg. For patients allergic to penicillin, clindamycin 900 mg is a possible alternative [25–27]. In addition, many discographers add 2–6 mg/mL of a cephalosporin antibiotic to the nonionic contrast solution [28]. The procedure should be performed under sterile conditions with double gloves. It is recommended to handle and touch any needle only with sterile gauze or instruments, not a gloved hand. Many injectionists scrub, gown, and glove as for an open surgical procedure. The C-arm image intensifier should also be draped.

As a provocative test, discography is at best uncomfortable and at worst very painful. For this reason, it is recommended that patients be judiciously sedated to manage anxiety, opiate withdrawal, and possible extraneous pain related to disc access. Patient response should be

monitored with dosages titrated to establish a level of sedation permitting the patient to be conversant and responsive after needle placement. Short acting sedatives or analgesics are recommended, such as midazolam and fentanyl.

Technique of Lumbar Discography

Patient Position

Most lumbar discs can be safely and readily accessed using a postero-oblique, extrapedicular approach when patient lies in a prone oblique position on a fluoroscopy table. This technique, which has been described by Trosier [29] and modified by Aprill [30], prevents the potential complications associated with thecal puncture from a transdural approach [31]. Elevating the target side approximately 15° allows the fluoroscopy tube to remain in a more AP projection and reduces radiation scatter. If needed, a folded towel or soft wedge can be placed under the patient's flank to prevent side bending of the lumbar spine. A pillow or bolster can be placed under the patient's abdomen to slightly flex the spine and decrease the lumbar lordosis. Monitoring and light sedation are initiated. On the side selected for puncture, a wide area of the skin of the back is prepped and draped from the costal margin to the mid-buttock and from the midline to the flank. The puncture side should be opposite the patient's dominant pain to eliminate confusion between pain reproduced during contrast injection and the pain of penetrating the outer annulus fibrosus.

Disc Puncture

Prior to injection, a fluoroscopic examination of the spine is performed to confirm segmentation and to determine the appropriate level for needle placement. Using AP view, the beam should be parallel to the inferior vertebral endplate. After selecting the target disc using AP view, the fluoroscopic beam is axially rotated until the facet joint space is located midway between the anterior and posterior vertebral margins. In this view, the insertion point is 1 mm lateral to the lateral aspect of the superior articular process (SAP) and allows needles to be advanced parallel to the beam (Fig. 45.1).

Prior to needle placement, a skin wheal is made with lidocaine 1 % (~1 cc) using a 25-gauge 1.5-in. needle. To anesthetize the needle track, one can use a 25-gauge 3.5-in. needle advanced under to the level of the SAP. Excessive use of local anesthetic may obscure nerve root

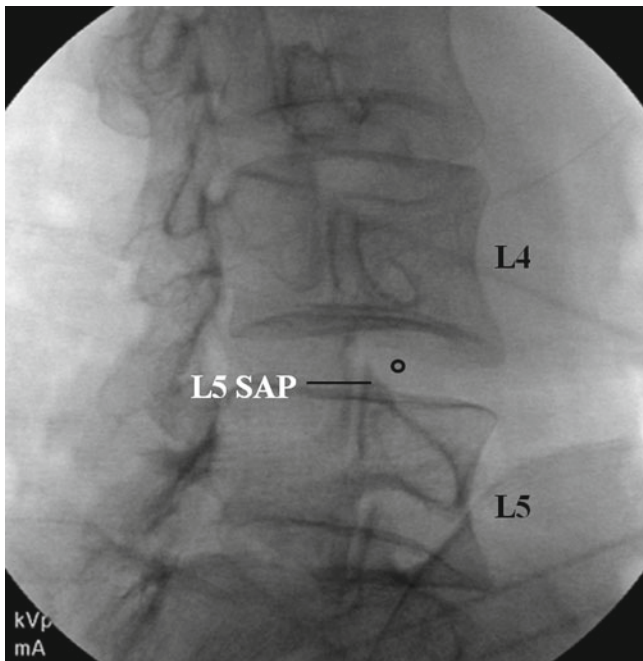


Fig. 45.1 In this view, the insertion point is 1 mm lateral to the lateral aspect of the superior articular process (SAP) and allows needles to be advanced parallel to the beam

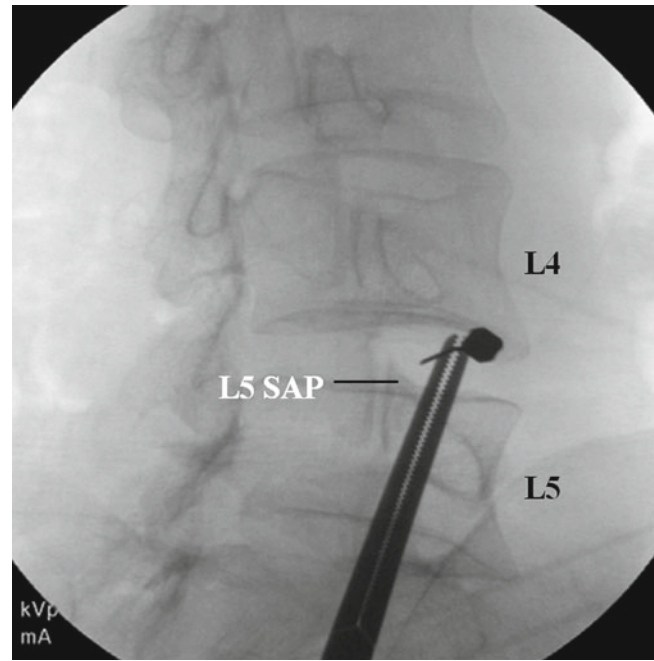


Fig. 45.2 The introducer needle is advanced parallel to the fluoroscopic beam using an oblique fluoroscope view

impairment and could potentially anesthetize the sinuvertebral and ramus communicans nerves, thus altering the evoked pain response during disc stimulation and creating a false-negative response. A single- or double-needle technique may be used; however, both the North American Spine Society and the International Spinal Injection Society recommend a double-needle approach due to lower risk of disc infection (although single-needle techniques have proved adequate and safe since the use of prophylactic antibiotics) [3, 25, 32].

Puncture of L1–L5 Intervertebral Discs

In the double-needle technique, a styletted 25-gauge, 6-in. needle is placed into each disc through a 20-gauge 3.5-in. introducer needle under fluoroscopic guidance. To protect the discographer's hand from radiation exposure, forceps may be used to grasp the introducing needle. The introducer needle is advanced parallel to the fluoroscopic beam using an oblique fluoroscope view (Fig. 45.2). If bony obstruction is encountered, the physician must confirm whether the needle has contacted the SAP or the vertebral body. If necessary, the needle may be slightly withdrawn and its trajectory modified. The introducer needle can be either advanced just over the lateral edge of the SAP or advanced to the margin of the disc. After confirming introducer needle position with a lateral view, a 25-gauge, 6-in. discogram needle is slowly advanced into the center of the disc through the introducer needle while

monitoring the lateral view. A slight bend placed on the end of the discogram needle facilitates navigation. When the needle contacts the disc, position should be checked using AP and lateral views, with the ideal positioning of the needle on the line between midpoint of pedicles on AP view and posterior vertebral margin on lateral view (Fig. 45.3a, b).

Contact with the annulus fibrosus is characterized by the perception of firm resistance and frequently the patient experiencing a momentary sharp or sudden aching sensation in the back or the buttock. The needle is then advanced to the center of the disc. This requires confirmation both in AP and lateral views (Fig. 45.4a, b). If the needle tip is in the midline of the disc on the AP view but anterior on the lateral view, the needle entered the disc too far laterally. If the needle tip is centered on the AP view but posterior on the lateral image, the needle entered the disc too far medially.

Puncture of L5-S1 Intervertebral Disc

Disc access at the L5-S1 interspace can be more challenging because of an overlying iliac crest and broader interfacetal distance at that level. In this case, a curved, double-needle technique is recommended. The fluoroscopy tube is rotated only far enough to bring the facet joint space approximately 25 % of the distance between the anterior and posterior vertebral margins. The introducer needle is inserted between the S1 SAP and the iliac crest (Fig. 45.5). The discography needle is advanced under

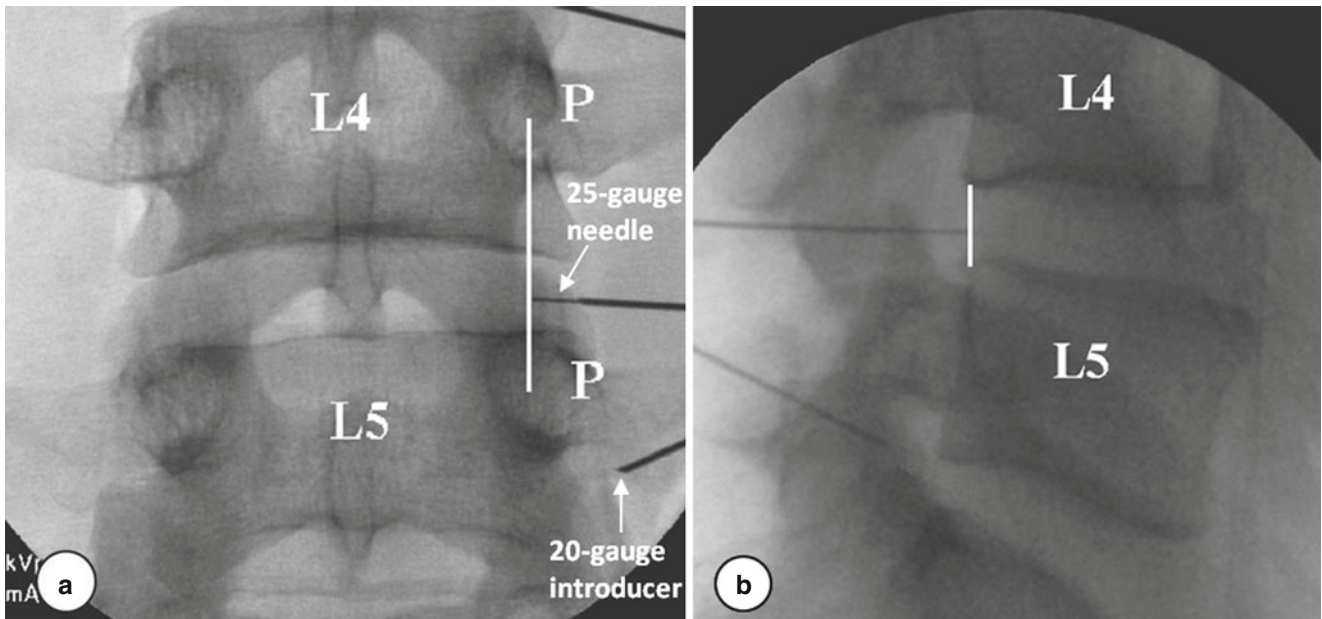


Fig. 45.3 (a, b) When the needle contacts the disc, position should be checked using AP and lateral views, with the ideal positioning of the needle on the line between midpoint of pedicles on AP view and posterior vertebral margin on lateral view

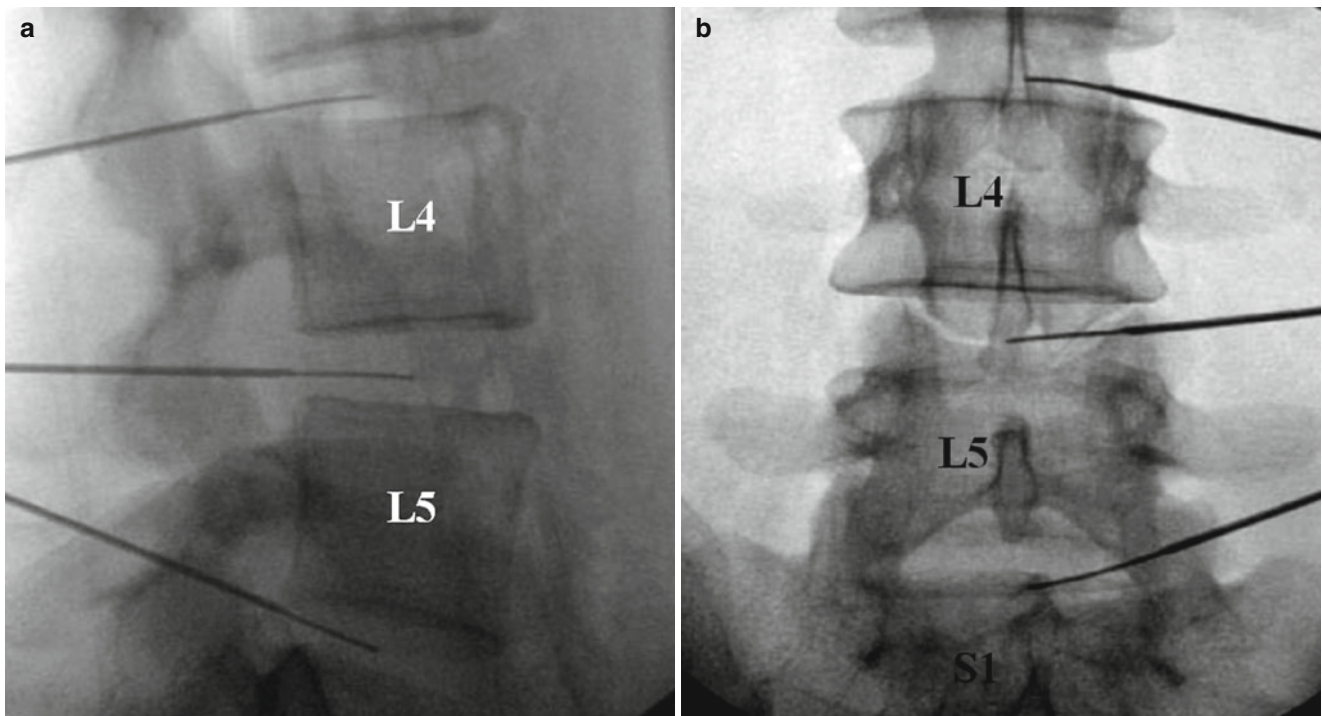


Fig. 45.4 (a, b) Contact with the annulus fibrosus is characterized by the perception of firm resistance and frequently the patient experiencing a momentary sharp or sudden aching sensation in the back or the

buttock. The needle is then advanced to the center of the disc. This requires confirmation both in AP and lateral views

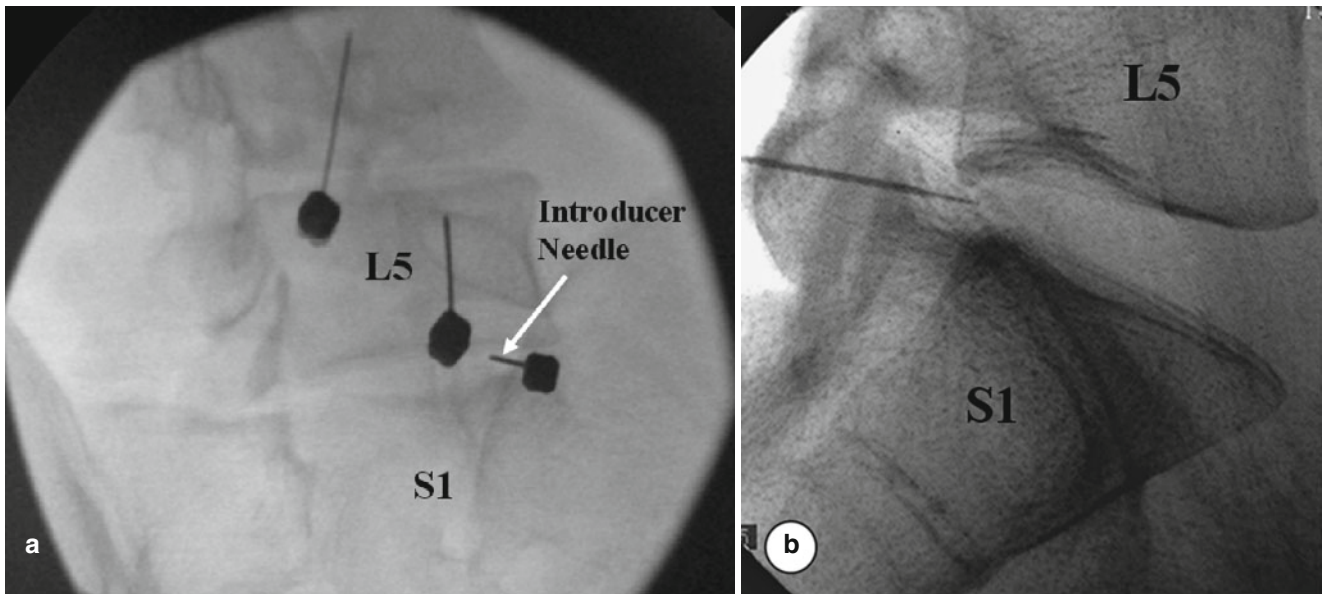


Fig. 45.5 (a, b) The fluoroscopy tube is rotated only far enough to bring the facet joint space approximately 25 % of the distance between the anterior and posterior vertebral margins. The introducer needle is inserted between the S1 SAP and the iliac crest

direct fluoroscopic vision, while the introducer needle is simultaneously retracted slightly. This unsheathes the discography needle, which should be turned so that the curve or bend bows the introducer needle in a medial and posterior direction through the “safe triangle.” If the needle fails to track medially and posteriorly, it will not pass toward the center of the disc and may strike the ventral ramus, in which case the needle should be removed and its curvature accentuated. If the needle is blocked by the SAP, the inner needle is retracted into the introducer needle, and the pair is advanced to the lateral edge of the S1 SAP. The inner discography needle may then be directed toward the center of the disc. Ideally, the needle should be within 4–5 mm of the center on AP and lateral fluoroscopy (Fig. 45.6a, b).

Provocation Using Pressure Manometry

Provocation

Once the needle tip is in the center of nucleus pulposus, nonionic contrast medium mixed with antibiotic is injected into each disc at slow velocity, using preferably a controlled injection syringe with digital pressure readout. The disc is slowly pressurized by injecting 0.5 mL increments through a syringe attached to a pressure measuring device, while recording the opening pressure, the injection pressure, the

location of contrast medium, and any pain response evoked. Injection continues until one of the following end points is reached: pain response $\geq 7/10$, intradiscal pressure >50 psi a.o. above opening in a disc with a grade 3 annular tear or 80–100 psi a.o. with a normal-appearing nucleogram, or a total of 3.5 mL of contrast has been injected. Typical opening pressures are 5–25 psi a.o., depending on the degree of nuclear degeneration; if it exceeds 30 psi a.o., this usually indicates that the needle tip is lodged within the inner annulus and needs to be repositioned.

Imaging

AP and lateral images of all injected discs are saved as part of the permanent record. A variety of fluoroscopic patterns may occur in abnormal discs: cotton ball, lobular, irregular, fissured, and ruptured (Fig. 45.7a) [33]. The appearance of the normal nucleus following the injection of contrast medium is classic: the contrast medium assumes either a lobular pattern or a bilobed “hamburger” pattern (Fig. 45.7b). Contrast medium may extend into radial fissures of various lengths but remain contained within the disc (Figs. 45.7 and 45.8). Contrast may escape into the epidural spaces through a torn annulus or through a defect in the vertebral end plate [34]. In other cases, the disc can look completely fissured and disrupted. However, none of these patterns alone are indicative of whether the disc is

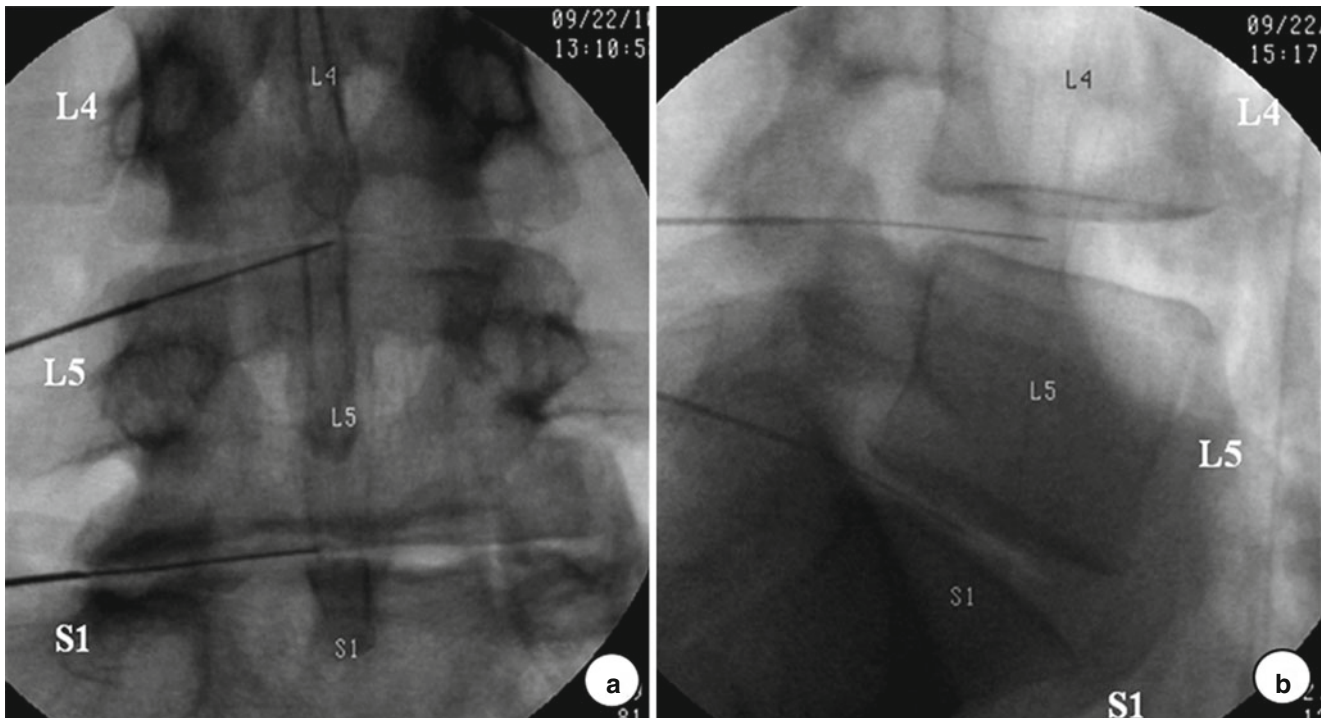


Fig. 45.6 (a, b) The inner needle may then be directed toward the center of the disc. Ideally, the needle should be within 4–5 mm of the center on AP and lateral fluoroscopy

painful; that can be ascertained only by the patient's subjective response to disc injection.

Post-discography axial CT scanning provides the most accurate depiction of internal disc architecture. The location of degeneration is described by dividing the disc into four quadrants [17]. If the contrast is confined to the nucleus, then no quadrant disruption is present; if the contrast is dispersed, then its location is described (e.g., single quadrant disruption, right posterior; two-quadrant disruption, left anterolateral and right posterior, etc.). The degree of radial and annular disruption is most commonly described [17, 35] using the modified Dallas discogram scale (Fig. 45.9) [32, 35–37]. Grade 0 describes contrast contained within the nucleus; grades 1–3 describe degree of fissuring extending to the inner, middle, and outer annulus, respectively; grade 4 describes a grade 3 annular fissure with a greater than 30° circumferential arc of contrast. A grade 5 annular tear indicates rupture or spread of contrast beyond the outer annulus (Fig. 45.8).

Interpretation

Discography is a provocative test which attempts to mimic physiologic disc loads and evoke the patient's pain

by increasing intradiscal pressure with an injection of contrast medium. Increased intradiscal pressure is thought to stimulate annular nerve endings, sensitized nociceptors, and/or pathologically innervated annular fissures. The intensity of the provocation stimulus must be carefully controlled through the skilled operation of a manometer syringe or an automated manometer, permitting more precise comparisons between patient discs and between discographers. Most abnormal discs will be painful between 15 and 50 psi a.o. [38] and are termed “mechanically sensitive” based on a four-type classification introduced in the 1990s by Derby et al. in respect to annular sensitivity [39]. Discs which are painful at pressures <15 psi a.o. are termed low-pressure positive or “chemically sensitive” discs [39]; if discs are painful between 15 and 50 psi a.o., they are termed “mechanically sensitive” discs. Indeterminate discs are painful between 51 and 90 psi a.o., and normal discs are not painful on provocation. An operator using manual “thumb” disc pressurization to 100 psi a.o. reported to have higher false-positive rate in asymptomatic subjects than other operators [24, 40]. If a disc is painful at >50 psi a.o., the response must be reported as indeterminate, because it is difficult to distinguish between a pathologically painful disc and the pain evoked from simply mechanically stimulating a normal or subclinically

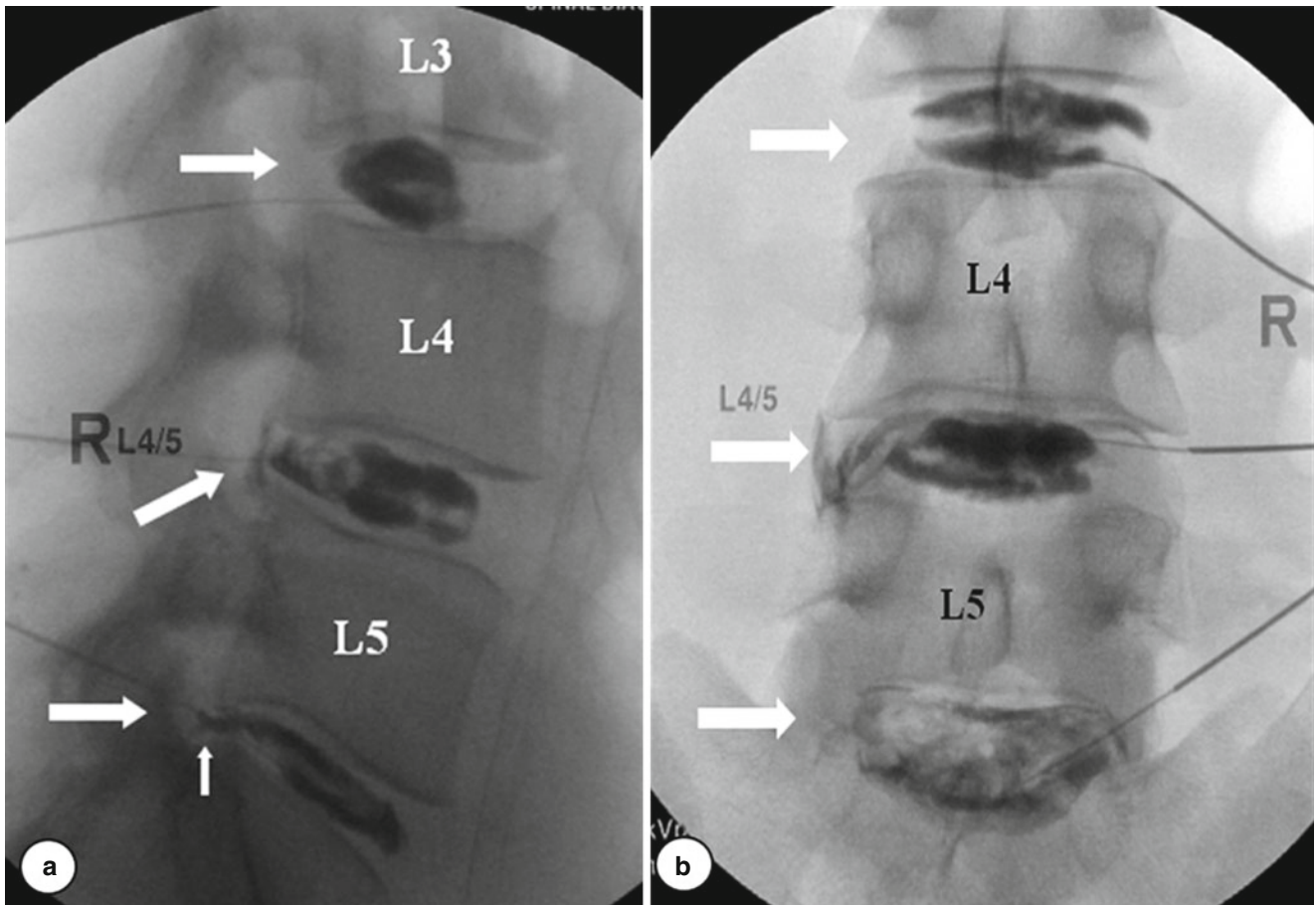


Fig. 45.7 (a) A variety of fluoroscopic patterns may occur in abnormal discs: cotton ball, lobular, irregular, fissured, and ruptured. (b) The appearance of the normal nucleus following the injection of contrast

medium is classic: the contrast medium assumes a either a lobular pattern or a bilobed “hamburger” pattern

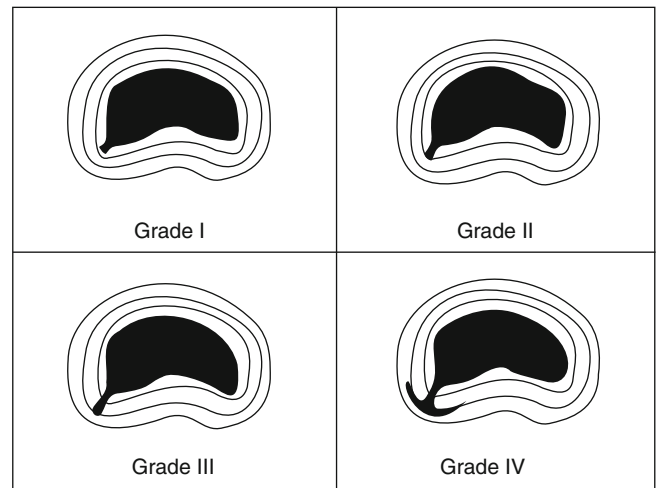
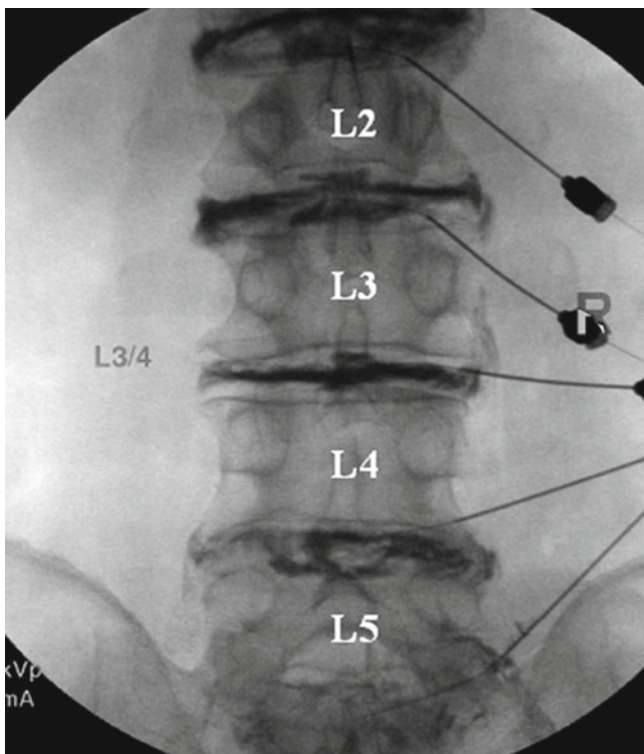
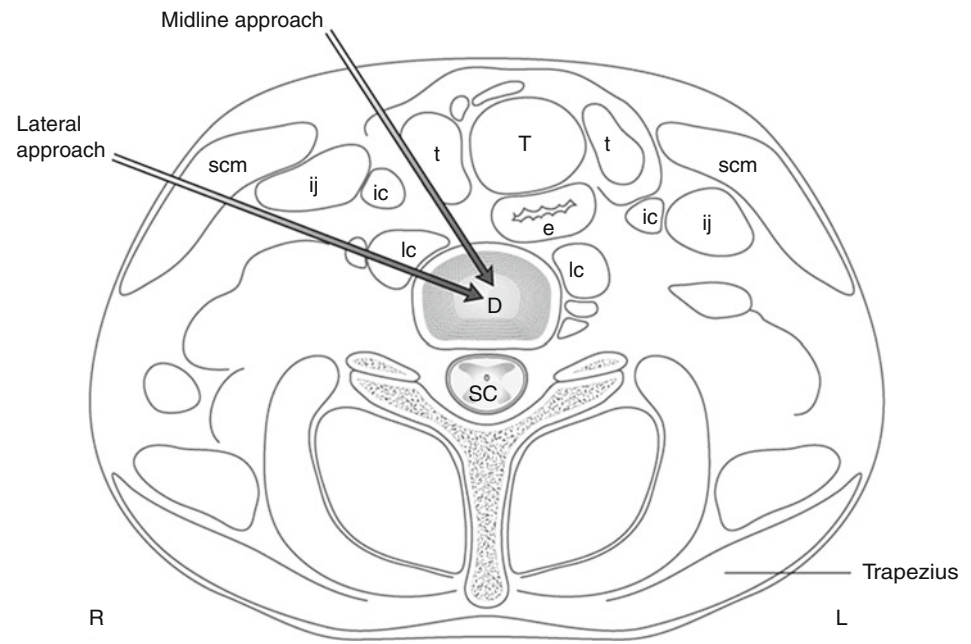


Fig. 45.9 The degree of radial and annular disruption is most commonly described [17, 35] using the modified Dallas discogram scale

Fig. 45.8 Contrast medium may extend into radial fissures of various degrees

Fig. 45.10 Pressure is applied with the index finger to the space between the trachea and the medial boarder of the sternocleidomastoid



symptomatic disc. To limit false-positive responses, the most up-to-date discography standards are set at a pressure criteria of <50 psi a.o. to define a positive response [32, 41].

Injection speed is also a confounding factor and may account for inter-operator variability in results and increased false-positive responses. At high injection speeds, the true intradiscal pressure (dynamic pressure) is higher than the recorded static pressure [42]. The dynamic pressure, measured only in research settings, is the actual pressure which would be recorded with an intradiscal pressure sensor. Currently, the pressure is measured indirectly via a manometric syringe which records plateau static pressures, postinjection. The pain during activities of daily living is more closely correlated to dynamic peak pressure [39]. Static pressure is reflective of dynamic pressure when recorded by needle sensor and manometer only at slower injection speeds (<0.08 mL/s) [42].

Pain assessment during the disc provocation is the most important information obtained from discography. If the patient's pain intensity, location, and character are similar to or the same as the patient's clinical symptoms, the criteria for concordant pain are satisfied. A true positive pain response is $\geq 7/10$, sustained for greater than 30–60 s; true discogenic pain is less likely to decrease rapidly. Pain which resolves within 10 s should be discounted. It is recommended to confirm all positive responses with manual repressurization with a small volume. If repressurization does not provoke concordant $\geq 7/10$ pain at <50 psi a.o., then the response is considered indeterminate. Clinically, patients with discogenic pain tend to have increased pain postoperatively and an exacerbation of symptoms lasting 2–7 days.

Technique of Cervical Discography

Patient Position

The patient is placed supine on the fluoroscopy table with a cushion placed under his or her shoulders to slightly hyperextend the neck, which may help to improve a disc access. While the side to be punctured in lumbar discography is that opposite the patient's dominant pain, a right-sided approach is used for cervical discography because the esophagus lies to the left in the lower neck. The patient's neck is prepared and draped in a sterile fashion.

Disc Puncture

Midline Approach

The disc level to be studied is identified on the AP view of fluoroscopy. The tube is rotated in a cephalad-caudal direction to bring the end plates parallel to the beam. Pressure is applied with the index finger to the space between the trachea and the medial boarder of the sternocleidomastoid muscle (Fig. 45.10). Firm but gentle pressure will displace the great vessels laterally and the laryngeal structures and trachea medially. Below C4, the right common carotid artery and the internal carotid artery above C4 are palpated. The fingers are insinuated until they encounter the anterior surface of the vertebral column. Since the carotid artery is manually displaced to allow safe needle passage into the disc, and the carotid body may be compressed, administration of IV atropine is therefore suggested to minimize the possibility of vasovagal response [43, 44]. The needle entry point should be medial to the medial border of the sternocleidomastoid muscle, thus avoiding the pharynx

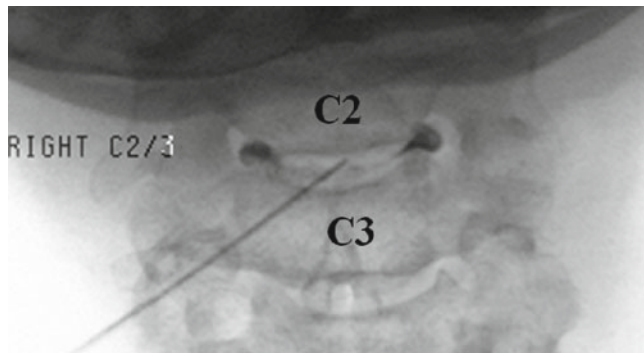


Fig. 45.11 The trachea is pushed medially by the fingernail of the index finger, and when the needle overlies the disc at 20–40° angle, the needle is introduced through the skin directed toward the anterior lateral aspect of the disc

superiorly and the apex of the lungs inferiorly. A shorter 25-gauge 2.5-in. needle is recommended for easier and safer handling. With the point of the needle just medial to or under the index finger, both the needle and the index finger can be moved in unison. The trachea is pushed medially by the fingernail of the index finger, and when the needle overlies the disc at 20–40° angle, the needle is introduced through the skin directed toward the anterior lateral aspect of the disc (Fig. 45.11). Once the needle is passed several millimeters into the disc, the lateral view is recommended to guide further advancement, taking precaution to not pass the needle through the disc and into the epidural space or spinal cord (Fig. 45.12). In order to gauge the depth of penetration, the needle may be directed to and touch the anterior disc body just above or below the disc margin before the insertion into the center of the disc.

Lateral Approach

In this approach, after aligning the vertebral end plates of the target level, the fluoroscopic beam is axially rotated until the anterior margin of the uncinat process is moved approximately one-quarter of the distance between the anterior and posterior lateral vertebral margins. In this view, the target insertion point is 1–2 mm medial to the anterior margin of the uncinat process (Fig. 45.13). The skin entry point will be over the lateral neck muscles and posterior to the great vessels or trachea. Pressure displacement of the great vessels is difficult and usually not done. This region is highly vascular, and patients have to be observed for signs of hematoma. Before and during the injection of contrast, the needle position within the center of a disc and a spread of contrast material inside the disc have to be confirmed with both AP and lateral fluoroscopic images (Fig. 45.14a, b). At C7-T1, the medial approach is preferred to avoid puncturing the apex of the lung.

Provocation and Interpretation

The clinical utility of provocative discography for solving puzzling presentations of atypical pain resulting from cervical

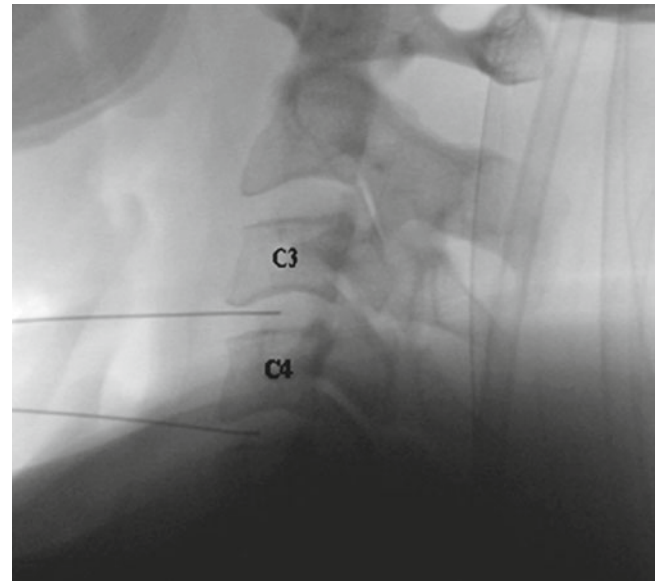


Fig. 45.12 Once the needle is passed several millimeters into the disc, the lateral view is used to guide further advancement, taking precaution to not pass the needle through the disc and into the epidural space or spinal cord

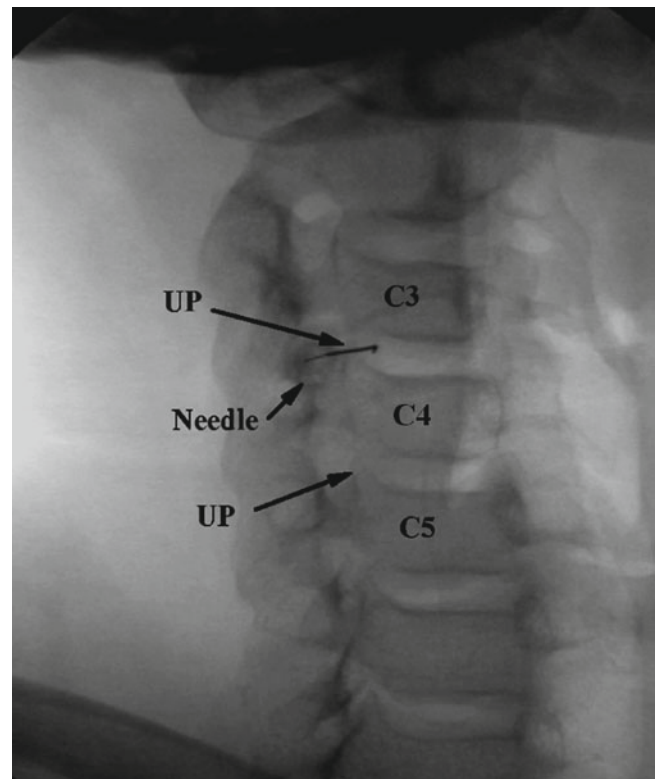


Fig. 45.13 In this approach, after aligning the vertebral end plates of the target level, the fluoroscopic beam is axially rotated until the anterior margin of the uncinat process (*UP*) is moved approximately one quarter of the distance between the anterior and posterior lateral vertebral margins. In this view, the target insertion point is 1–2 mm medial to the anterior margin of the uncinat process (*UP*)

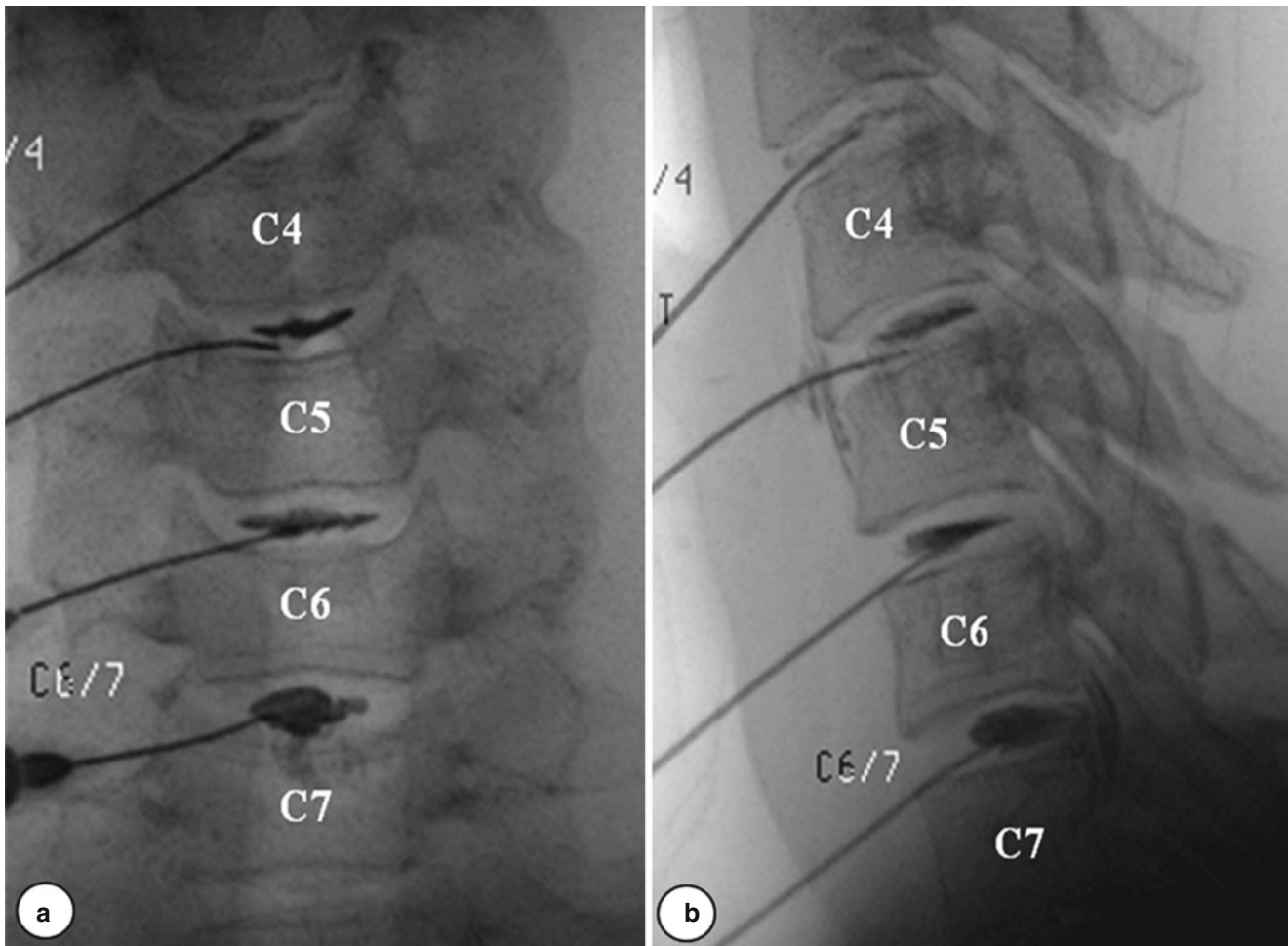


Fig. 45.14 (a, b) Before and during the injection of contrast, the needle position within the center of a disc and a spread of contrast material inside the disc have to be confirmed with both AP and lateral fluoroscopic images

discogenic lesions has been demonstrated. In a systematic review of the literature, Manchikanti showed a significant role for cervical discography in selecting surgical candidates and improving surgical outcomes, when strict criteria requiring a concordantly painful disc and two negative controlled discs, one above and one below the affected level, are utilized [45]. Normal cervical discs hold only 0.25–0.5 mL of fluid, and intradiscal injection of normal discs should not be painful. Schell et al. demonstrated an average pain response during disc stimulation in asymptomatic subjects as 2.2/10, whereas it was 5.2/10 in patients with neck pain. He showed that MRI cannot reliably identify the sources of neck pain and provocative discography results had better correlation between cervical discogenic pain and annular disc disruption compared to MRI [46, 47]. A 1–3-mL syringe with contrast media is attached to the needle. Manual syringe pressure is increased slowly until the intrinsic disc pressure is exceeded. Concordancy and pain intensity are recorded at 0.2 mL increments. A positive response requires provocation of significant

(>6–7/10) concordant pain during a confirmatory repeat injection of another 0.1–0.2 mL of contrast. Without an asymptomatic “control” disc, there is no evidence that the patient can discriminate between symptomatic and asymptomatic discs, especially in case of multiple concordant pain levels. It is observed that pressurization of the cervical discs will often cause separation of the end plates, and this movement may cause pain secondary to a symptomatic z-joint. It is recommended to rule out z-joint pain following an analgesic block protocol before performing cervical discography [48].

Technique of Thoracic Discography

Patient Positioning

The patient lies prone on the fluoroscopy table. Skin is prepared and draped in a sterile fashion. As a rule, the side to be punctured is that opposite the patient’s dominant pain.

Disc Puncture

The current standard technique of thoracic discography was described by Schellhas et al. in 1994 [49]. After the selection of the target disc on AP view and the alignment of vertebral endplates, the fluoroscopic beam is then rotated ipsilaterally until the corner of the intervertebral disc space is visualized between the superior articular process (SAP) and the costovertebral joint (CVJ). Typically, this degree of ipsilateral rotation will superimpose the tip of the spinous process (SP) on the edge of the contralateral vertebral body. In this view, the insertion point is just lateral to the interpedicular line (Fig. 45.15) and approximately 3 cm lateral to the spinous process. Most discographers prefer a single-needle technique using 23–25-gauge, 3.5-in. needle. A slight bend placed on the end of the needle will facilitate changing directions by needle rotation. The trajectory of the needle is roughly parallel and behind the rib as it passes anterior to attach to the spine at the costovertebral joints. Aiming point is a round to square section of the posterior lateral disc that can be seen through a 1–3-mm opening between the SAP and the rib (Fig. 45.15). The needle should be advanced in short increments and the direction changed as necessary by needle rotation. If one stays medial to the costovertebral junction and just lateral to the SAP, there is no chance of penetrating the lung. It may be hard to visualize thoracic SAP; however, it always projects above the pedicle, which is easily visualized. Although passage of the needle behind the rib is usually uneventful, passage of the needle between the rib and SAP might be difficult due to the small aperture, requiring correctional rotations of the bent needle. Once the needle has passed anterior to the SAP using lateral fluoroscopic view, the needle bend is turned posteriorly to facilitate advancing the needle in a more posterior direction (Fig. 45.16a, b).

Provocation and Interpretation

Nonionic contrast medium is slowly injected into each disc in 0.2–0.3 mL increments under direct fluoroscopic observation, while recording pain response, including behavior, pain intensity, and concordance as well as morphologic abnormalities such as grade 1–3 annular tears or end plate defects. The normal thoracic nucleus usually looks like either a diffuse, elongated homogenous or lobulated pattern (Fig. 45.17). The end point is reached if the pain is $>6/10$, intradiscal pressure reaches a firm end point, or a total of 2.5 mL of contrast has been injected. CT-discography is often performed to define the exact location and size of annular fissures and protrusions. The most important information obtained is if there is a presence of concordant pain with evoked pain intensity $>6/10$ in the presence of at least one negative control disc.

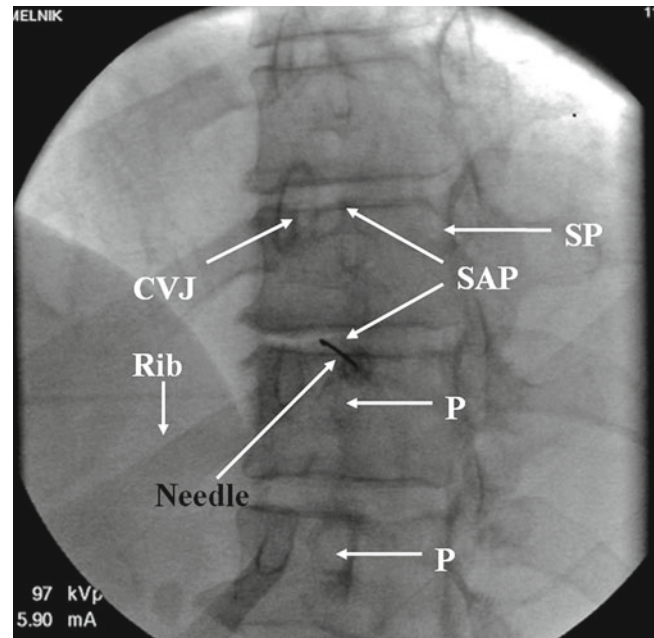


Fig. 45.15 Typically, this degree of ipsilateral rotation will superimpose the tip of the spinous process on the edge of the contralateral vertebral body. In this view, the insertion point is just lateral to the interpedicular line (P-pedicle) and approximately 3 cm lateral to the spinous process at the opening between the superior articular process (SAP) and the costovertebral joints (CVJ)

Postprocedural Care

After the procedure, patients are taken to the recovery room for vital signs and clinical status monitoring by nurses trained in spine injection management. The patient is checked immediately and 30 min postprocedure for any subcutaneous bleeding. Analgesic medications (oral, IV, or IM) are provided as needed. The patient is advised that he or she may experience an exacerbation of typical symptoms for 2–7 days and may experience postprocedure discomfort, including difficulty swallowing after cervical discography and lingering back pain after lumbar discography. The patient is instructed to contact the office if he or she develops fever, chills, or severe (or delayed) onset of pain. Patients are observed and discharged according to institutional protocol. Typically, the patient is discharged to the care of a responsible adult and instructed not to drive for the remainder of the day. Patients are contacted by phone 2–4 days postprocedure to screen for possible complications or adverse side effects.

Potential Risk and Complications

Lumbar Discography

Complications can result from the disc puncture itself, misadventures during needle placement, or medications

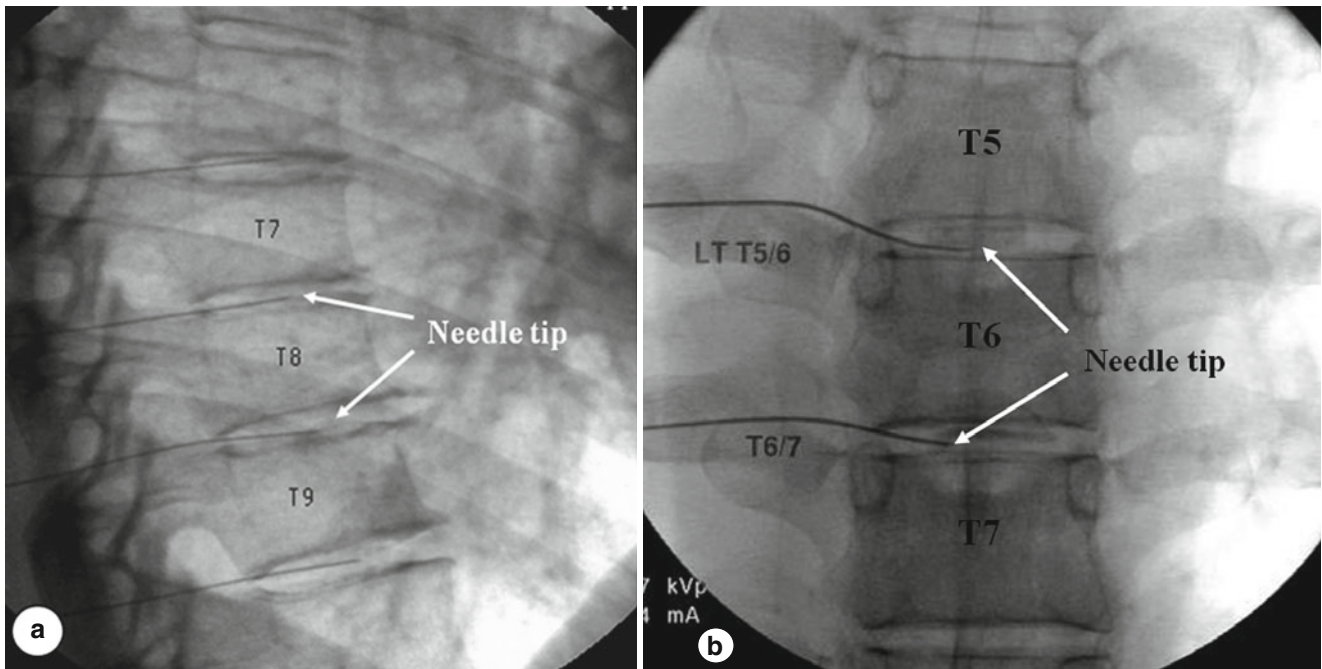


Fig. 45.16 (a, b) Once the needle has passed anterior to the SAP using lateral fluoroscopic view, the needle bend is turned posteriorly to facilitate advancing the needle in a more posterior direction

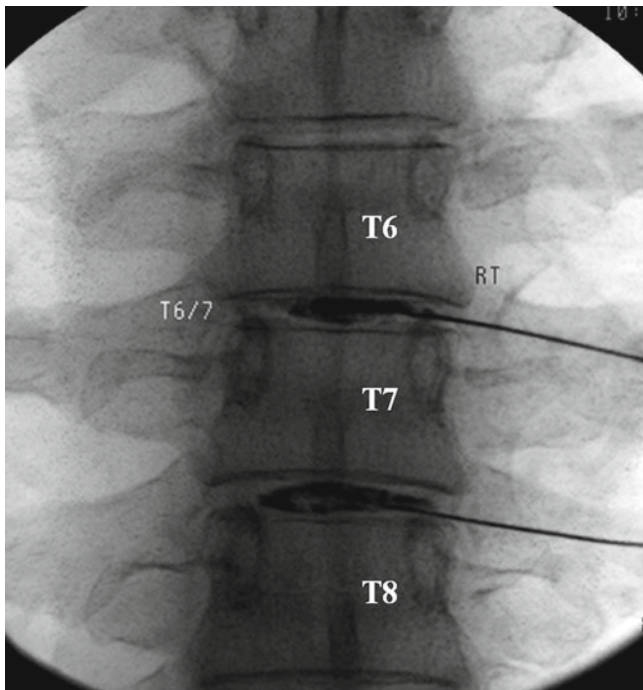


Fig. 45.17 The normal thoracic nucleus usually looks like either a diffuse, elongated homogenous or lobulated pattern

used during the procedure. Complications vary from minor (e.g., increased low back pain, nausea, headache) to major (discitis, seizures, permanent neurologic injury, and death)

[26, 50, 51]. Discitis is the most common serious complication of discography, reported to be less than 0.15 % per patient and 0.08 % per disc [3]. The incidence of discitis has been clearly diminished with the double- vs. single-needle technique [25]. Also, with careful preprocedure screening for infection (e.g., UTI or skin), aseptic skin preparation, styletted needles, and intravenous and intradiscal antibiotics, discitis is now very rare. However, even with prophylactic antibiotics, an epidural abscess after discography has been reported [52, 53].

Clinically, the patient with discitis presents with severe, unremitting, disabling axial pain beginning 5–21 days following the procedure, sometimes accompanied by fever and chills. Investigative tests may require blood work, including CBC, c-reactive protein (CRP), sedimentation rate (ESR), and blood cultures as well as a contrast-enhanced MRI and a disc biopsy. Empyema or abscess formation requires CT-guided drainage or surgical intervention [54–56]. Striking a ventral ramus is a potential hazard, but may be avoided by careful attention to correct technique. Other complications include spinal cord or nerve root injury, cord compression or myelopathy, urticaria, retroperitoneal hemorrhage, nausea, convulsions, headache, and, most commonly, increased pain [3]. An increase in the rate of disc degeneration over time following discography was also recently reported in a single small cohort study and requires further investigation [19]. Meanwhile, it is suggested to use smaller discography needles, gauges 25 or less.

Cervical Discography

Inadvertent passage of the needle through the cervical disc in the AP plane can cause spinal cord injury or post-theal puncture cephalgia, which can be avoided by using a shorter needle, using a lateral view during needle advancement and conformation of needle depth penetration by touching the anterior vertebral margin prior to passage into the disc [46]. Penetration of viscera such as the pharynx and esophagus is not a problem per se, but increases the risk of infection such as epidural and retropharyngeal abscess and discitis [56–59]. The reported incidence of discitis is 0.1–0.5 % [58, 60]. Needle passage through the carotid artery may result in a hematoma which could potentially cause an airway obstruction, especially in patients with coagulation problems [46].

Thoracic Discography

The main complications include pneumothorax, discitis, and neural injury. Pneumothorax can complicate cervical, thoracic, or lumbar discography, but more frequent in the thoracic spine. A small traumatic pneumothorax after percutaneous needle procedures can be treated conservatively and usually does not require chest tube insertion [61].

Discussion

The single purpose and objective of disc stimulation is to identify a painful intervertebral disc. As in the case of palpation for tenderness, provocation does not reveal pathology or the cause of pain; it only indicates the structure that when stressed, reproduces the patient's pain. If an explicit, patho-anatomical diagnosis is to be made, such as internal disc disruption, the discography must be supplemented by post-discography CT in order to reveal the fissures characteristic of this condition. Another, not least important value of discography is in identification of "negative discs" in response to a disc stimulation, thus limiting the number of levels requiring surgical intervention or a need for interventional disc procedures altogether. However, the diagnostic power of discography remains controversial [62]. As a provocative test, it has been criticized to have a potentially high false-positive rate [24]. The reasons for that can occur due to technical errors, due to neurophysiological phenomena, or due to psychosocial factors [32].

Correct technical performance is paramount to the accuracy of the discography results and has been underestimated over the past decades, leading to questionable medical outcomes and important legal implications.

Discography without strict standards for pressure, volume, speed of injection controls, and limits is unsupportable. Dynamic and static pressures, volumes, and pain responses must be gathered and documented using a consistent and reproducible technique, preferably using a controlled injection syringe with digital pressure readout rather than manual pressurization [63]. It was shown that speed-sensitive dynamic pressure is more liable to provoke a positive pain response, thus requiring a slow injection rate (0.05–0.1 mL/s), which most accurately reflects the pressures transferred to the outer annulus [63]. Many of the reported false-positive responses occurred at pressures of 50 psi a.o. or greater. In addition, provocation response should not be accepted as a positive unless it can be confirmed by a repeat pressurization, and pain does not decrease more than 50 % over 30 s. Transient pain provocation may occur when an asymptomatic fissure opens or a thin membrane sealing the outer annulus ruptures during disc pressurization.

Central hyperalgesia also has to be taken into account as a physiological phenomenon when the perception of stimuli from a receptive field is facilitated by ongoing nociceptive activity arising from adjacent or nearby but separate receptive fields. In this regard, formal studies have shown that in patients with no history and no symptoms of back pain, but with a painful donor site on the iliac crest, disc stimulation can evoke back pain [40], producing false-positive response.

Concerns have been raised regarding psychological comorbidity and psychosocial factors as significant confounding factors in patients undergoing discography, questioning the results of discography in patients with chronic pain or somatization disorders other than back pain [40]. Evidence indicates that patients with chronic or chronic intermittent low back pain respond similarly to disc stimulation as do asymptomatic volunteers undergoing discography, as was shown by Derby in a prospective controlled study of patients with grade 3 disc tears [64]. Shin also confirmed that a majority of patients with grade 4 tears could distinguish between "positive" and "negative discs" by magnitude of pain response, causing doubt on the argument that a majority of patients with chronic pain undergoing discography would overreport pain [65].

In addition, a randomized controlled trial comparing discography results of 25 patients with and without somatization disorder found no significant difference in positive responses between groups [66]. There was also no difference in positive responses in patients with depression and/or general anxiety disorder. That calls into question the results of a limited Carragee study of six somatization patients, where only four of six were able to complete their discography test because of pain [24]. Derby et al. [67] reported DRAM scores of 81 patients

undergoing discography: 15 % (12/81) were normal, 52 % (42/81) were at risk, and 33 % (27/81) were abnormal (distressed, depressive or somatic). The positive rates of discography were not statistically significant by subgroup ($p > 0.05$). In patients with chronic low back pain, no correlation was found between presenting DRAM score and discography result.

A recent meta-analysis of studies of asymptomatic subjects undergoing discography showed a high specificity of 0.94 (95% CI 0.89–0.98) and a relatively low false-positive rate of 6 % [20]. This critical examination of most studies in the literature since the 1960s showed that an acceptably low false-positive rate can be achieved when strict ISIS/IASP standards for a positive discography are utilized: pain $\geq 7/10$, concordant pain, pressure < 50 psi a.o., \geq grade 3 annular tear, volume limit ≤ 3.5 mL, and presence of a negative control disc.

In regard to post-discectomy subjects, it appeared that they have a slightly higher false-positive rate of 15 % per patient and 9.1 % per disc, as a group. Given our limited knowledge of discography in post-discectomy patients and the possibility that provocation may open previously healed granulation tissue along surgical planes, discographers have to consider pressure- and speed-controlled manometry and to use lower limits for pressure and volume when defining a positive value. Another recent concern raised by Carragee et al. [19] is a long-term risk that discography, as an invasive test, can potentially cause damage to punctured discs over time and result in accelerated disc degeneration. The authors showed a 21 % increase in the degree of disc degeneration using small gauge needles and an increase in the number of new disc herniations of all types in the discography vs. control group over 10 years. These results require attention and further investigation. It would be important to determine what proportion of those degenerative discs can be attributed to rather expected natural history of accelerated degeneration in this small cohort of patients with known cervical disc disease. Those patients might be already genetically predisposed to accelerated disc degeneration and multilevel spondylosis, compared to the normal population, as was shown in a well-designed twin study, when 74 % of degenerative findings at the lower lumbar levels were accounted for the heritability [68].

Even though the diagnostic power of discography remains controversial, it is a relatively safe and sensitive test for identifying painful discs, which may predict surgical outcomes. In a multicenter surgical and nonsurgical outcome study after pressure-controlled discography, Derby et al. [39] stated that precise prospective categorization of positive discographic diagnoses may predict treatment outcomes, surgical or otherwise, thereby greatly facilitating therapeutic decision-making.

Summary

Discography, when indicated and correctly performed, is a safe and sometimes powerful complement to the overall clinical context and is not intended to be a stand-alone test. Despite the controversy, this test can provide valuable information regarding the possible discogenic origin of pain and provide intricate details of inner disc morphology and annular disc disruption, when combined with a post-discography CT scan. It is not a screening procedure but rather a confirmatory one. Recent advances in discography technique, including use of pressure-controlled manometry and strict diagnostic criteria, helped to improved validity of this test significantly. In patients with chronic intractable neck or back pain but negative or indeterminate imaging findings who are being considered for surgical intervention, discography can help to localize the symptomatic level and potentially benefit the patients by surgical intervention or by avoiding it in case of “asymptomatic discs.” Newer noninvasive imaging technologies like magnetic resonance spectroscopy, measuring biochemical markers of inflammation that could potentially correlate with “painful disc” on discography, are gradually emerging. They have the potential to replace more invasive disc stimulation tests in the near future, but to this day, discography remains the criterion of standard for the diagnosis of discogenic pain.

References

1. Lindblom K. Technique and results in myelography and disc puncture. *Acta Radiol.* 1950;34:321–30.
2. Lindblom K. Technique and results of diagnostic disc puncture and injection (discography) in the lumbar region. *Acta Orthop Scand.* 1951;20:315–26.
3. Guyer RD, Ohnmeiss DD. Lumbar discography. Position statement from the North American Spine Society Diagnostic and Therapeutic Committee. *Spine.* 1995;20:2048–59.
4. O'Neill C, Derby R. Percutaneous discectomy using nucleoplasty. In: International 21st course for percutaneous endoscopic spinal surgery and complementary techniques. Spital zolikerberg, Zurich; 2003.
5. Bogduk N, Tynan W, Wilson AS. The nerve supply to the human lumbar intervertebral discs. *J Anat.* 1981;132:39–56.
6. Yoshizawa H, O'Brien JP, Smith WT, Trumper M. The neuropathology of intervertebral discs removed for low-back pain. *J Pathol.* 1980;132:95–104.
7. Groen GJ, Baljet B, Drukker J. Nerves and nerve plexuses of the human vertebral column. *Am J Anat.* 1990;188:282–96.
8. Malinsky J. The ontogenetic development of nerve terminations in the intervertebral discs of man. (Histology of intervertebral discs, 11th communication). *Acta Anat (Basel).* 1959;38:96–113.
9. Weinstein J, Claverie W, Gibson S. The pain of discography. *Spine (Phila Pa 1976).* 1988;13:1344–8.
10. Korkala O, Gronblad M, Liesi P, Karaharju E. Immunohistochemical demonstration of nociceptors in the ligamentous structures of the lumbar spine. *Spine.* 1985;10:156–7.

11. Konttinen YT, et al. Neuroimmunohistochemical analysis of peridiscal nociceptive neural elements. *Spine (Phila Pa 1976)*. 1990;15:383–6.
12. Peng B, et al. The pathogenesis of discogenic low back pain. *J Bone Joint Surg*. 2005;87:62–7.
13. Freemont AJ, et al. Nerve ingrowth into diseased intervertebral disc in chronic back pain. *Lancet*. 1997;350:178–81.
14. Coppes MH, Marani E, Thomeer RT, Groen GJ. Innervation of “painful” lumbar discs. *Spine*. 1997;22:2342–9; discussion 2349–50.
15. Bogduk N, Aprill C, Derby R, et al. Discography. In: *Spine care: diagnosis and conservative treatment*. St. Louis: Mosby; 1995. p. 219–36.
16. Moneta GB, et al. Reported pain during lumbar discography as a function of annular ruptures and disc degeneration. A re-analysis of 833 discograms. *Spine (Phila Pa 1976)*. 1994;19:1968–74.
17. Vanharanta H, et al. The relationship of pain provocation to lumbar disc deterioration as seen by CT/discography. *Spine*. 1987;12:295–8.
18. Greenspan A, Amparo EG, Gorczyca DP, Montesano PX. Is there a role for discography in the era of magnetic resonance imaging? Prospective correlation and quantitative analysis of computed tomography-discography, magnetic resonance imaging, and surgical findings. *J Spinal Disord*. 1992;5:26–31.
19. Carragee EJ, et al. Does discography cause accelerated progression of degeneration changes in the lumbar disc: a ten-year matched cohort study. *Spine (Phila Pa 1976)*. 2009;34:2338–45.
20. Wolfer LR, Derby R, Lee J-E, Lee S-H. Systematic review of lumbar provocation discography in asymptomatic subjects with a meta-analysis of false-positive rates. *Pain Physician*. 2008;11:513–38.
21. Bogduk N. Proposed discography standards. *ISIS newsletter*. Daly City: International Spinal Injection Society; 1994. p. 10–3.
22. Derby R. A second proposal for discography standards. *ISIS newsletter*. Daly City: International Spinal Injection Society; 1994. p. 108–22.
23. Jensen MC, et al. Magnetic resonance imaging of the lumbar spine in people without back pain. *N Engl J Med*. 1994;331:69–73.
24. Carragee EJ, et al. The rates of false-positive lumbar discography in select patients without low back symptoms. *Spine*. 2000;25:1373–80. discussion 1381.
25. Fraser RD, Osti OL, Vernon-Roberts B. Discitis after discography. *J Bone Joint Surg Br*. 1987;69:26–35.
26. Fraser RD, Osti OL, Vernon-Roberts B. Iatrogenic discitis: the role of intravenous antibiotics in prevention and treatment. An experimental study. *Spine*. 1989;14:1025–32.
27. Polk HC, Christmas AB. Prophylactic antibiotics in surgery and surgical wound infections. *Am Surg*. 2000;66:105–11.
28. Osti OL, Fraser RD, Vernon-Roberts B. Discitis after discography. The role of prophylactic antibiotics. *J Bone Joint Surg Br*. 1990;72:271–4.
29. Troiser O. Technique de la discographie extra-durale. *J Radiol*. 1982;63:571–8.
30. Aprill III C. Diagnostic disc injection. In: Frymoyer JW, editor. *The adult spine: principles and practice*. 2nd ed. Philadelphia: Lippincott-Raven; 1996.
31. Milette PC, Melanson D. A reappraisal of lumbar discography. *J Can Assoc Radiol*. 1982;33:176–82.
32. Bogduk N. Practice guidelines for spinal diagnostic and treatment procedures. San Francisco: International Spine Intervention Society; 2004.
33. Adams MA, Dolan P, Hutton WC. The stages of disc degeneration as revealed by discograms. *J Bone Joint Surg Br*. 1986;68:36–41.
34. Bogduk NC, Aprill C, Derby R, et al. Discography. In: White A, editor. *Spine care. Diagnosis and conservative treatment*. St. Louis: Mosby Co; 1995. p. 219–36.
35. Derby R, Kim B-J, Chen Y, Seo K-S, Lee S-H. The relation between annular disruption on computed tomography scan and pressure-controlled discography. *Arch Phys Med Rehabil*. 2005;86:1534–8.
36. Aprill C, Bogduk N. High-intensity zone: a diagnostic sign of painful lumbar disc on magnetic resonance imaging. *Br J Radiol*. 1992;65:361–9.
37. Sachs BL, et al. Dallas discogram description. A new classification of CT/discography in low-back disorders. *Spine*. 1987;12:287–94.
38. Derby R. Lumbar discometry. *Sci Newsl Int Spine Injection Soc Newsl*. 1993;1:8–17.
39. Derby R, et al. The ability of pressure-controlled discography to predict surgical and nonsurgical outcomes. *Spine*. 1999;24:364–71; discussion 371–62.
40. Carragee EJ, Tanner CM, Yang B, Brito JL, Truong T. False-positive findings on lumbar discography. Reliability of subjective concordance assessment during provocative disc injection. *Spine*. 1999;24:2542–7.
41. Derby R, Lee SH, Kim BJ. Discography. In: Slipman CW, Derby R, Simeone FA, Mayer TG, editors. *Interventional spine: an algorithmic approach*. Philadelphia: Saunders Elsevier; 2008. p. 291–302.
42. Seo K-S, et al. In vitro measurement of pressure differences using manometry at various injection speeds during discography. *Spine J*. 2007;7:68–73.
43. Singh V. The role of cervical discography in interventional pain management. *Pain Physician*. 2004;7:249–55.
44. Connor P, Darden BV. Cervical discography complications and clinical efficacy. *Spine*. 1993;18:2035.
45. Manchikanti L, et al. Systematic review of cervical discography as a diagnostic test for chronic spinal pain. *Pain Physician*. 2009;12:305–21.
46. Derby R, Melfi R, Talu G, Aprill C. Cervical discography: diagnostic value and complications. In: Curtis W, Slipman CW, Derby R, Simeone FA, Mayer TG, editors. *Interventional spine: an algorithmic approach*. New York: Saunders Publishers; 2007.
47. Schellhas KP, Smith MD, Gundry CR, Pollei SR. Cervical discogenic pain. Prospective correlation of magnetic resonance imaging and discography in asymptomatic subjects and pain sufferers. *Spine*. 1996;21:300–11.
48. Bogduk N, Aprill C. On the nature of neck pain, discography and cervical zygapophysial joint blocks. *Pain*. 1993;54:213–7.
49. Schellhas K, Pollei SR, Dorwart R. Thoracic discography. A safe and reliable technique. *Spine*. 1994;19:2103–9.
50. Thomas PS. *Image-guided pain management*. Philadelphia: Lippincott-Raven; 1997.
51. Vanharanta H, et al. Pain provocation and disc deterioration by age. A CT/discography study in a low-back pain population. *Spine*. 1989;14:420–3.
52. Tsuji N, Igarashi S, Koyama T. Spinal epidural abscess – report of 5 cases. *No Shinkei Geka*. 1987;15:1079–85.
53. Junila J, Niinimäki T, Tervonen O. Epidural abscess after lumbar discography. A case report. *Spine*. 1997;22:2191–3.
54. Baker AS, Ojemann RG, Swartz MN, Richardson EP. Spinal epidural abscess. *N Engl J Med*. 1975;293:463–8.
55. Ravicovitch MA, Spallone A. Spinal epidural abscesses. Surgical and parasurgical management. *Eur Neurol*. 1982;21:347–57.
56. Lownie SP, Ferguson GG. Spinal subdural empyema complicating cervical discography. *Spine*. 1989;14:1415–7.
57. Guyer RD, et al. Discitis after discography. *Spine*. 1988;13:1352–4.
58. Roosen K, Bettag W, Fiebach O. Complications of cervical discography (author’s transl). *ROFO Fortschr Geb Rontgenstr Nuklearmed*. 1975;122:520–7.
59. Vogelsang H. Cervical intervertebral discitis after discography (author’s transl). *Neurochirurgia (Stuttg)*. 1973;16:80–3.

60. Brodsky AE, Binder WF. Lumbar discography. Its value in diagnosis and treatment of lumbar disc lesions. *Spine*. 1979;4:110–20.
61. Johnson G. Traumatic pneumothorax: is a chest drain always necessary? *J Accid Emerg Med*. 1996;13:173–4.
62. Carragee EJ. Prevalence and clinical features of internal disk disruption in patients with chronic low back pain. *Spine*. 1996;21:776–7.
63. Derby R, Guyer R, Lee SH, Seo KS, Chen Y. The rational use and limitations of provocative discography. International Spine Intervention Society 13th annual meeting in NY, ISIS Newsletter. 2004;5:6–20.
64. Derby R, et al. Comparison of discographic findings in asymptomatic subject discs and the negative discs of chronic LBP patients: can discography distinguish asymptomatic discs among morphologically abnormal discs? *Spine J*. 2005;5:389–94.
65. Shin D, Kim H, Jung J, Sin D, Lee J. Diagnostic relevance of pressure-controlled discography. *J Korean Med Sci*. 2006;21:911–6.
66. Manchikanti L, et al. Provocative discography in low back pain patients with or without somatization disorder: a randomized prospective evaluation. *Pain Physician*. 2001;4:227–39.
67. Derby R, et al. The influence of psychologic factors on discography in patients with chronic axial low back pain. *Arch Phys Med Rehabil*. 2008;89:1300–4.
68. Derby R, Wolfer L, Summers J. Does discography cause accelerated progression of degeneration in the lumbar spine. *SpineLine*. 2010:Mar/Apr:26–30.