

Carol E.H. Scott-Conner and Jameson L. Chassin<sup>†</sup>

---

## Indications

Carcinoma of the pancreas (see Chap. 88)

---

## Contraindications

Distant metastases  
Absence of an experienced surgical team  
Patient who lacks alertness and intelligence to manage diabetes  
Invasion of portal or superior mesenteric vein

---

## Preoperative Preparation

See Chap. 89.

---

## Operative Strategy

Complete omentectomy is generally performed as part of a total pancreatectomy. Division of the splenic, short gastric, right gastric, and gastroduodenal arteries leaves the gastric pouch dependent on the left gastric artery for its blood supply. For this reason, do not divide the left gastric artery at its point of origin from the celiac axis. Rather, divide it along the lesser curvature distal to the point where the branches to the proximal stomach and esophagus arise. This chapter con-

centrates on the additional features necessary to complete the pancreatic resection and should be read in conjunction with Chap. 89.

---

## Documentation Basics

Findings

---

## Operative Technique

### Incision

Except for extremely stocky patients, we use a long midline incision from the xiphoid to a point 10 cm below the umbilicus.

---

## Evaluation of Pathology, Determination of Resectability, Initial Mobilization

The technique followed here is identical to that described in Figs. 89.2, 89.3, 89.4, 89.5, 89.6, and 89.7, except that the omentum is detached from the transverse colon and is removed with the specimen (Figs. 90.1 and 90.2).

---

## Splenectomy and Truncal Vagotomy

With the stomach and omentum retracted in a cephalad direction, identify the splenic artery along the superior surface of the pancreas. Open the peritoneum over the splenic artery at a point 1–2 cm distal to its origin at the celiac axis. With a right-angle Mixer clamp, free the posterior surface of the artery and apply a 2-0 silk ligature (Fig. 90.3). Ligate the vessel but do not divide it at this point.

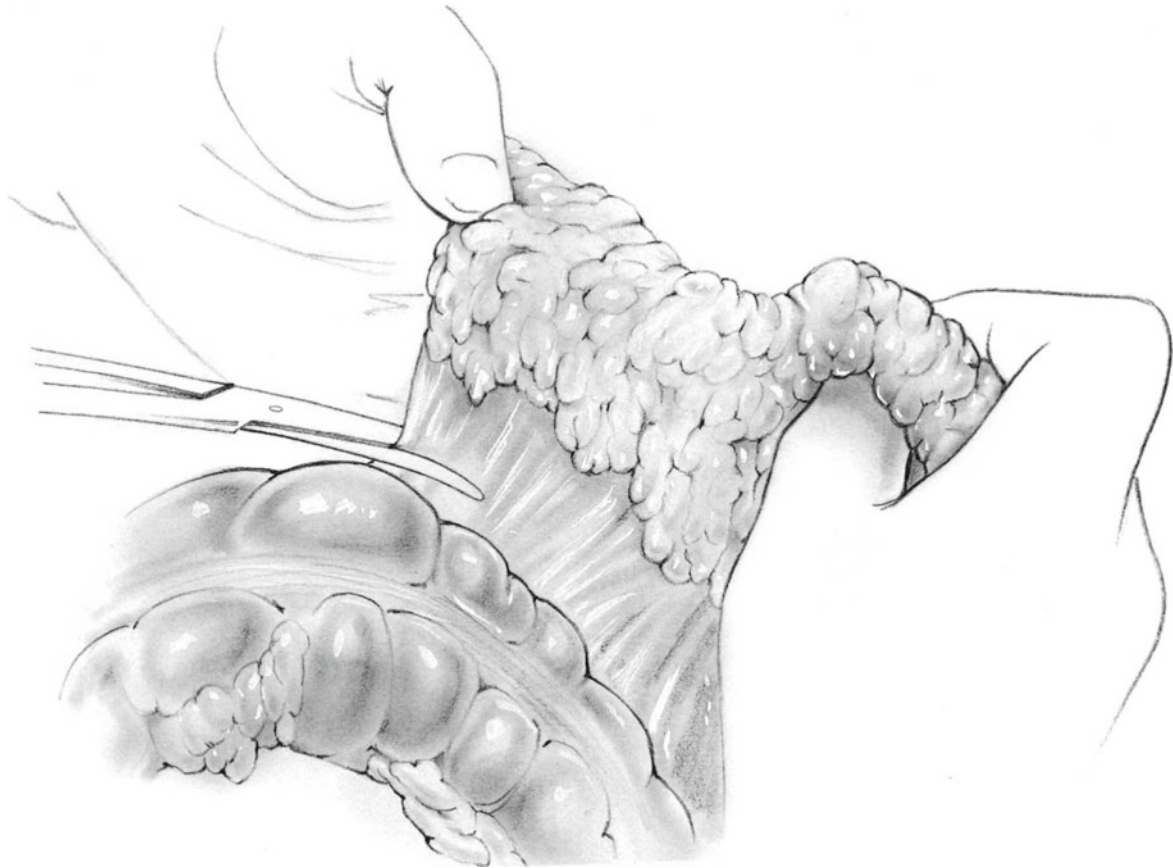---

<sup>†</sup>Deceased

---

C.E.H. Scott-Conner, MD, PhD (✉)  
Department of Surgery, Roy J. and Lucille A. Carver  
College of Medicine, University of Iowa,  
200 Hawkins Drive, 4622 JCP, Iowa City, IA 52242, USA  
e-mail: carol-scott-conner@uiowa.edu

J.L. Chassin, MD  
Department of Surgery, New York University  
School of Medicine, New York, NY, USA



**Fig. 90.1**

Apply a Thompson retractor to the left costal margin to improve the exposure of the spleen. Make an incision in the avascular lienophrenic fold of the peritoneum (Fig. 90.4a, b). Electrocoagulate any bleeding vessels. Elevate the tail of the pancreas together with the spleen. Divide the attachments between the lower pole of the spleen and the colon. Expose the posterior surface of the spleen and identify the splenic artery and veins at this point. If there is any bleeding, ligate these vessels. Insert moist gauze pads into the bed of the elevated spleen.

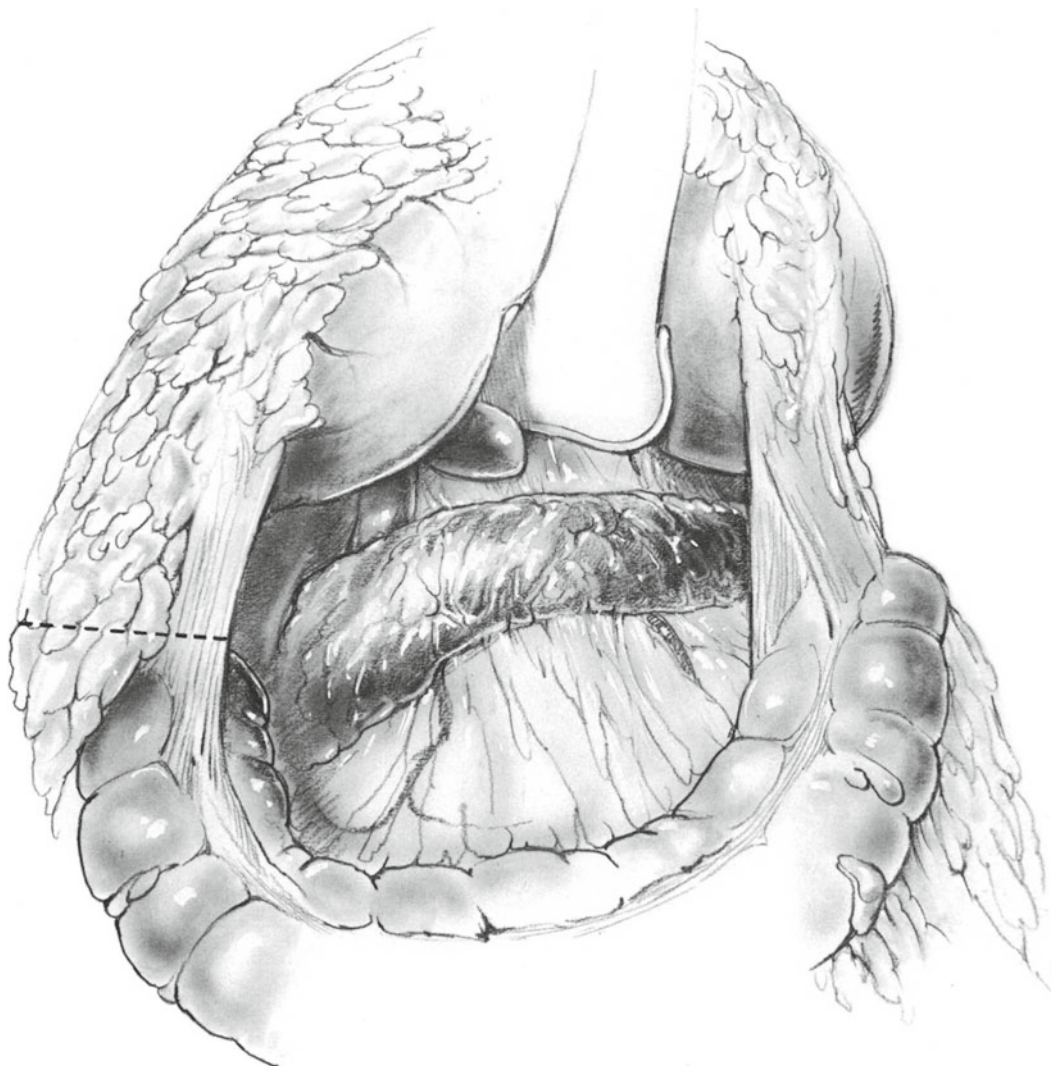
At this time remove the Thompson retractor from the left costal margin and place it in the region of the sternum. Apply traction in a cephalad and anterior direction, exposing the abdominal esophagus. Incise the peritoneum over the abdominal esophagus. Use a peanut gauze dissector to separate the crus of the diaphragm from the esophagus (Fig. 90.5) and perform a truncal vagotomy as described in Chap. 29.

### **Mobilizing the Distal Pancreas**

Identify the proximal short gastric vessel, and insert the left index finger underneath the gastrophrenic ligament.

Apply a hemostatic clip to the distal portion of the vessel. Ligate the gastric side of the vessel with 2-0 or 3-0 silk and divide it (Fig. 90.6). Continue the dissection in this manner until all of the short gastric vessels have been divided (Fig. 90.7).

Now redirect attention to the tail and body of the pancreas, which is covered by a layer of posterior parietal peritoneum. Incise this avascular layer first along the superior border of the pancreas and then again along the inferior border of the pancreas after elevating the tissue with an index finger (Fig. 90.8). As the pancreas is elevated from the posterior abdominal wall, follow the posterior surface of the splenic vein to the point where the inferior mesenteric vein enters; then divide this vessel between 2-0 silk ligatures (Fig. 90.9). Follow the splenic artery to its point of origin, where the previous ligature can be seen. Double-ligate the proximal stump of the splenic artery and apply a similar ligature to the distal portion of the splenic artery. Divide between these ties. Carefully dissect the junction of the splenic and portal veins away from the posterior wall of the pancreas. After 2 cm of the terminal portion of the splenic vein has been cleared (Fig. 90.10), divide the splenic vein between 2-0 silk ligatures.



**Fig. 90.2**

### **Antrectomy**

Divide the stomach as previously described (Fig. 90.11).

### **Cholecystectomy and Division of the Hepatic Duct**

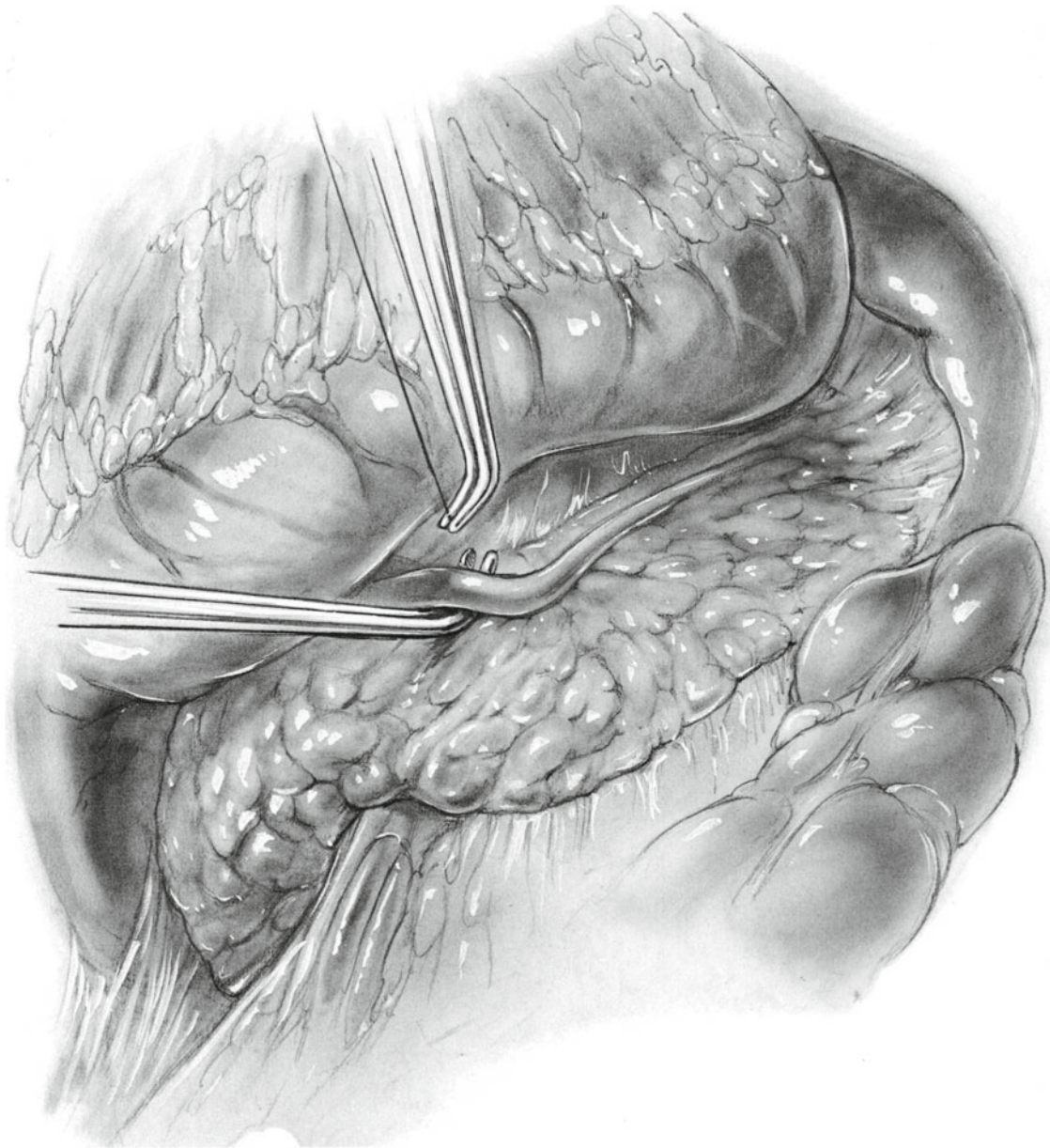
The hepatic duct, portal vein, and hepatic artery have already been stripped of overlying peritoneum and lymph nodes. At this time, divide and ligate the cystic artery. Remove the gallbladder by dissecting it out of the liver bed from above down (Fig. 90.12). Obtain complete hemostasis in the liver bed with electrocautery. Ligate the cystic duct. Divide it and remove the gallbladder.

Dissect the hepatic duct free from the portal vein at a point just above its junction with the cystic duct. Free about 1.5 cm

of hepatic duct. Apply a ligature to the distal end and an atraumatic bulldog clamp to the proximal end and divide the duct.

### **Freeing the Uncinate Process**

Retract the spleen, pancreas, and duodenum to the patient's right. Gentle dissection discloses three or four venous branches between the posterior surface of the pancreatic head and the portal-superior mesenteric veins (Fig. 90.13). Ligate each of these vessels with 3-0 silk and divide them. It is now possible gently to retract the portal vein to the right. At this point the superior mesenteric artery can generally be clearly identified. In some cases it is easy to identify several arterial branches that can be dissected free, divided, and individually ligated (Fig. 90.14). Divide the uncinete process as previously described (see Chap. 89).



**Fig. 90.3**

### **Mobilizing the Duodenojejunal Junction**

Expose the ligament of Treitz by elevating the transverse colon. Divide the jejunum as previously described and remove the specimen (Fig. 90.15; see also Fig. 90.14).

### **Hepaticojejunostomy**

Reconstruction is simpler because no pancreatic anastomosis is needed. The hepaticojejunostomy is performed first, as described in Chap. 89.

At a point about 50 cm downstream from the hepaticojejunostomy, construct a stapled gastrojejunostomy (Figs. 90.16 and 90.17). Bring the T-tube out through a stab

wound in the right upper quadrant. Irrigate the entire operative field with a dilute antibiotic solution. Be certain that hemostasis is complete. Insert a large Jackson-Pratt suction-drainage catheter in the right upper quadrant of the operative field, and bring it out through a stab wound in the abdominal wall. Close the midline incision in routine fashion. Close the skin with interrupted nylon sutures or staples.

---

### **Postoperative Care**

The principles of postoperative care described in Chap. 89 apply to total pancreatectomy except there is no possibility of a pancreatic fistula. The suction-drainage catheter is

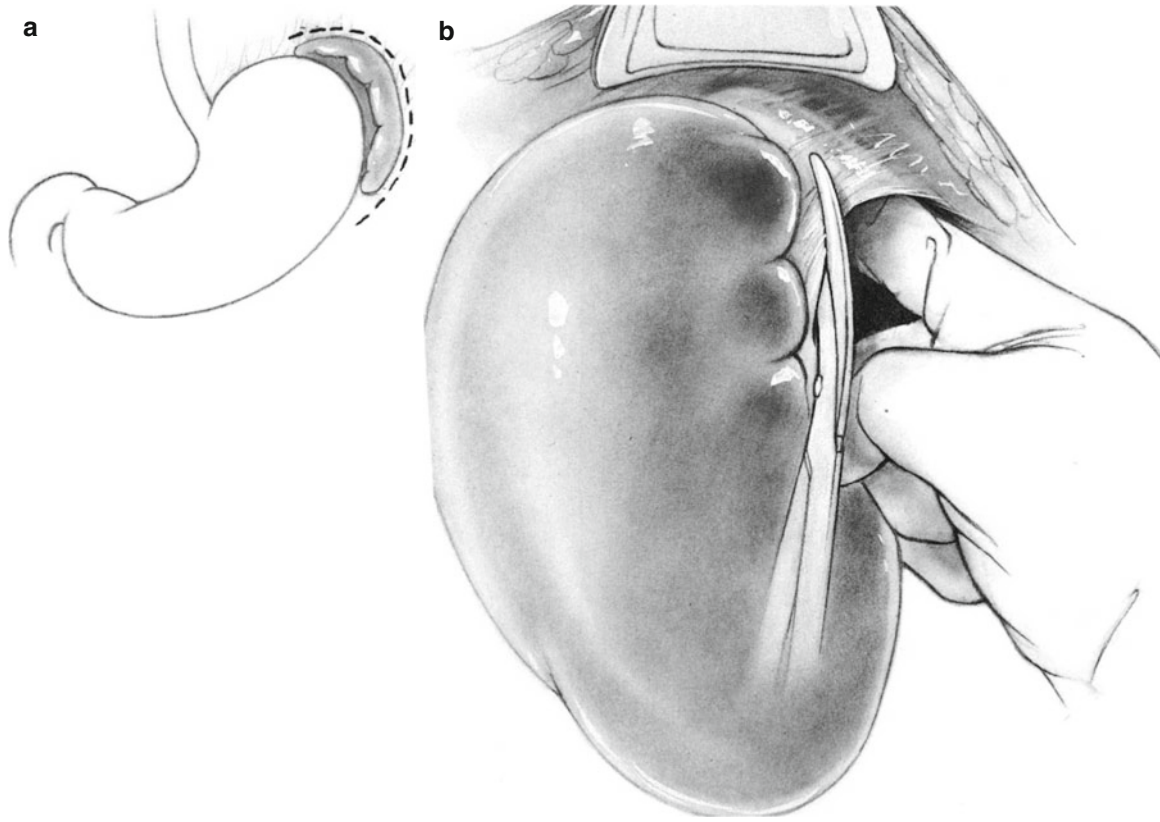


Fig. 90.4

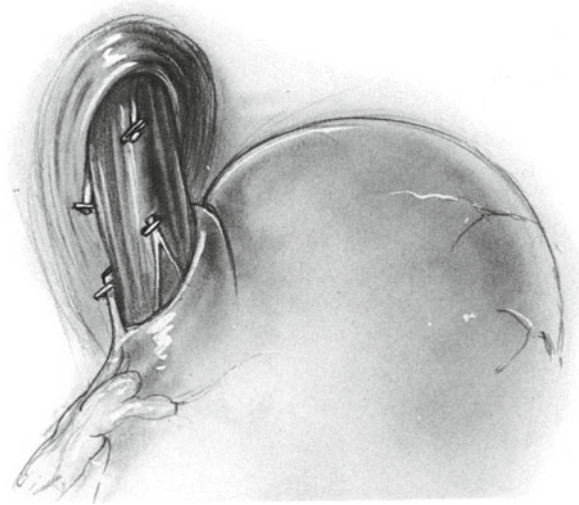


Fig. 90.5

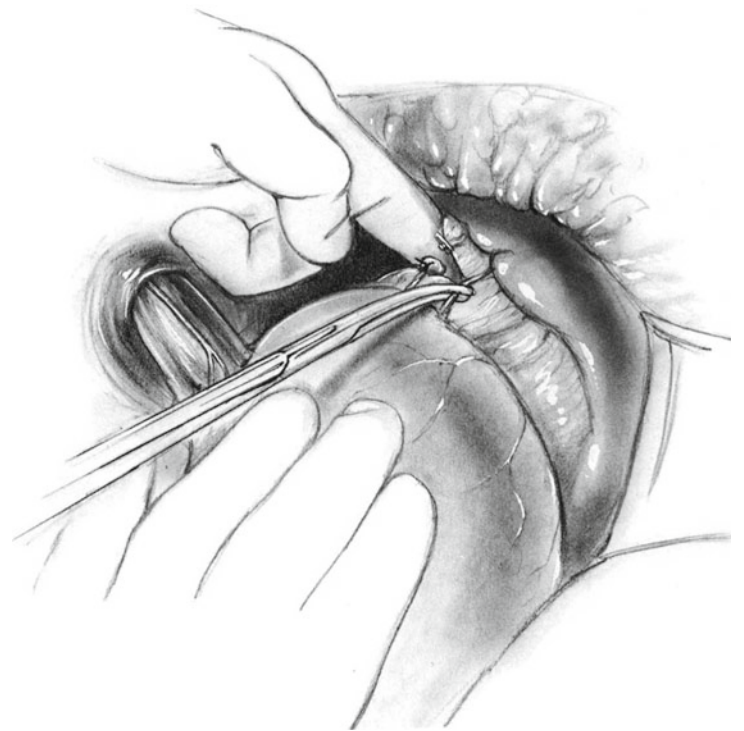


Fig. 90.6

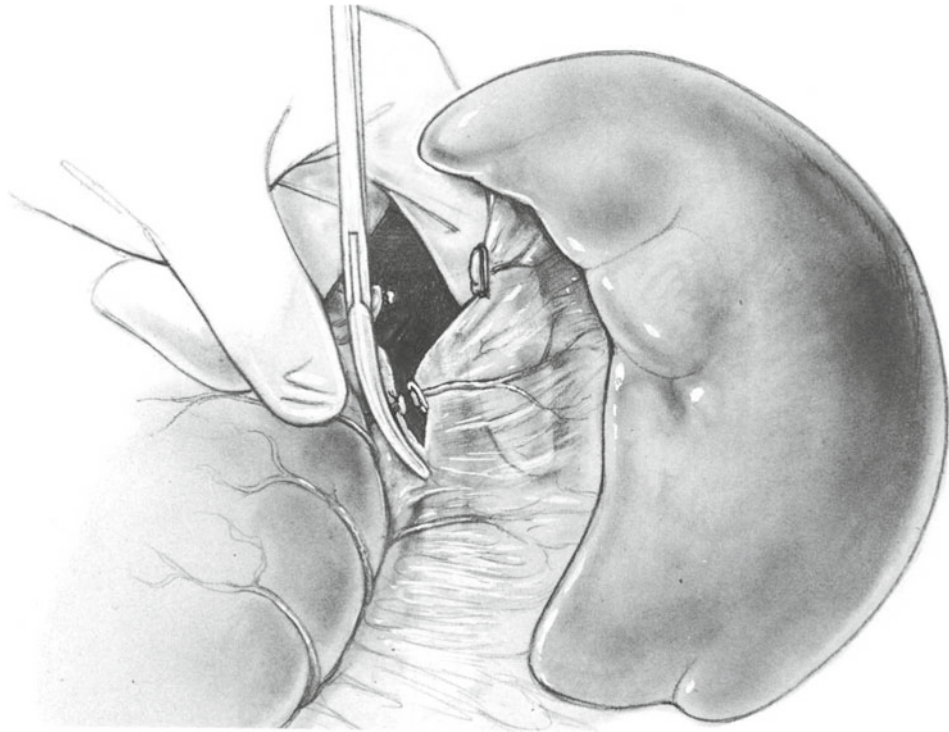


Fig. 90.7

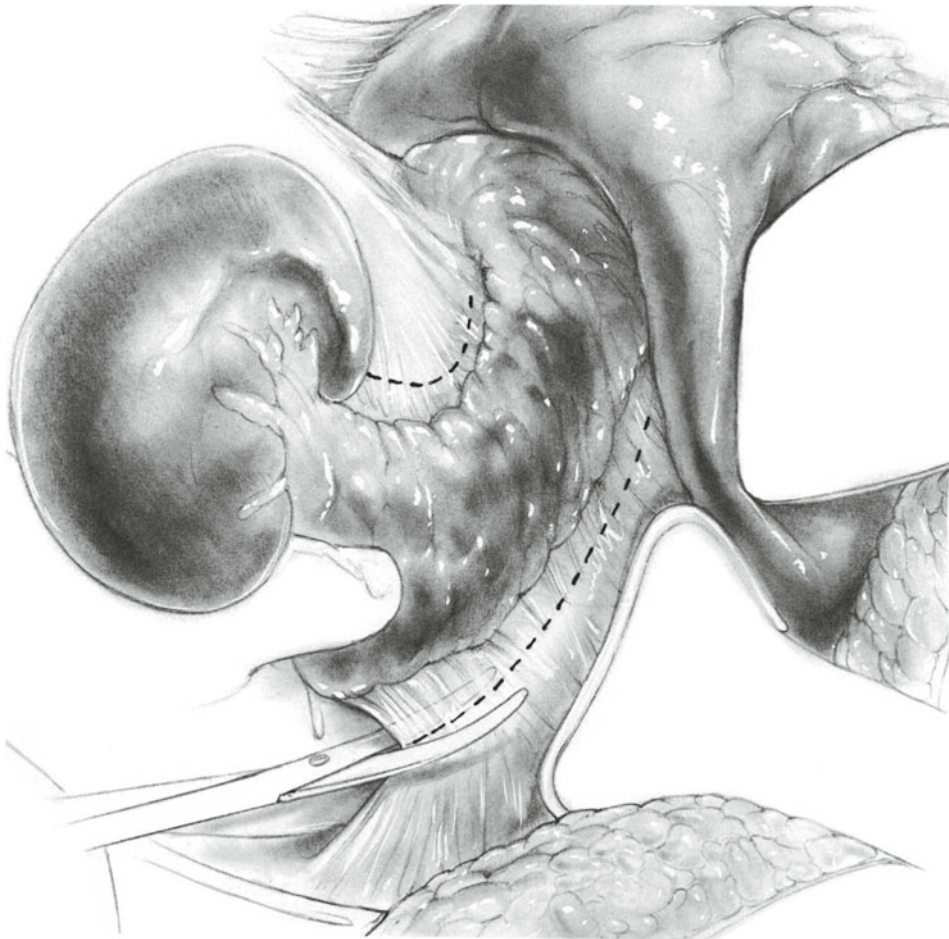


Fig. 90.8

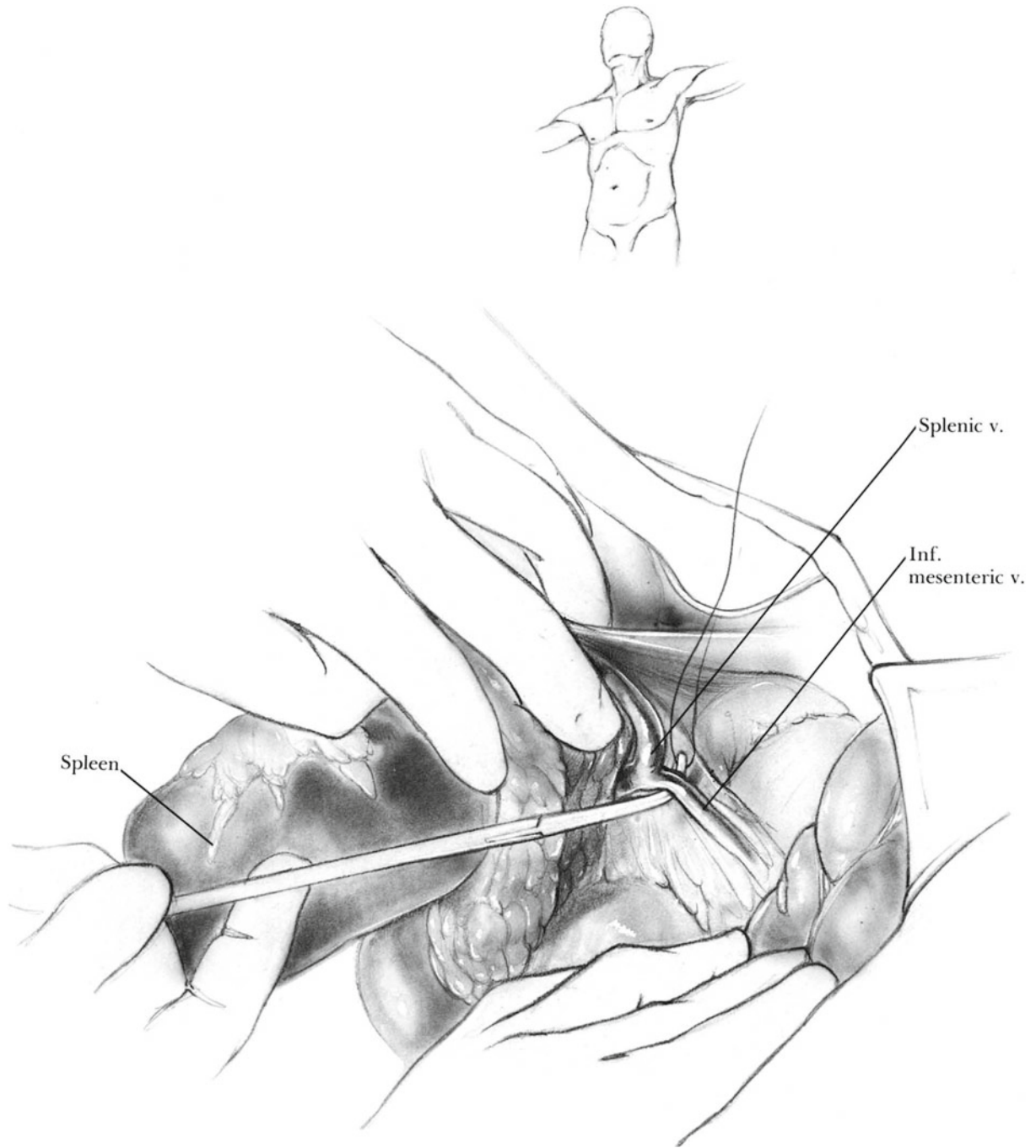
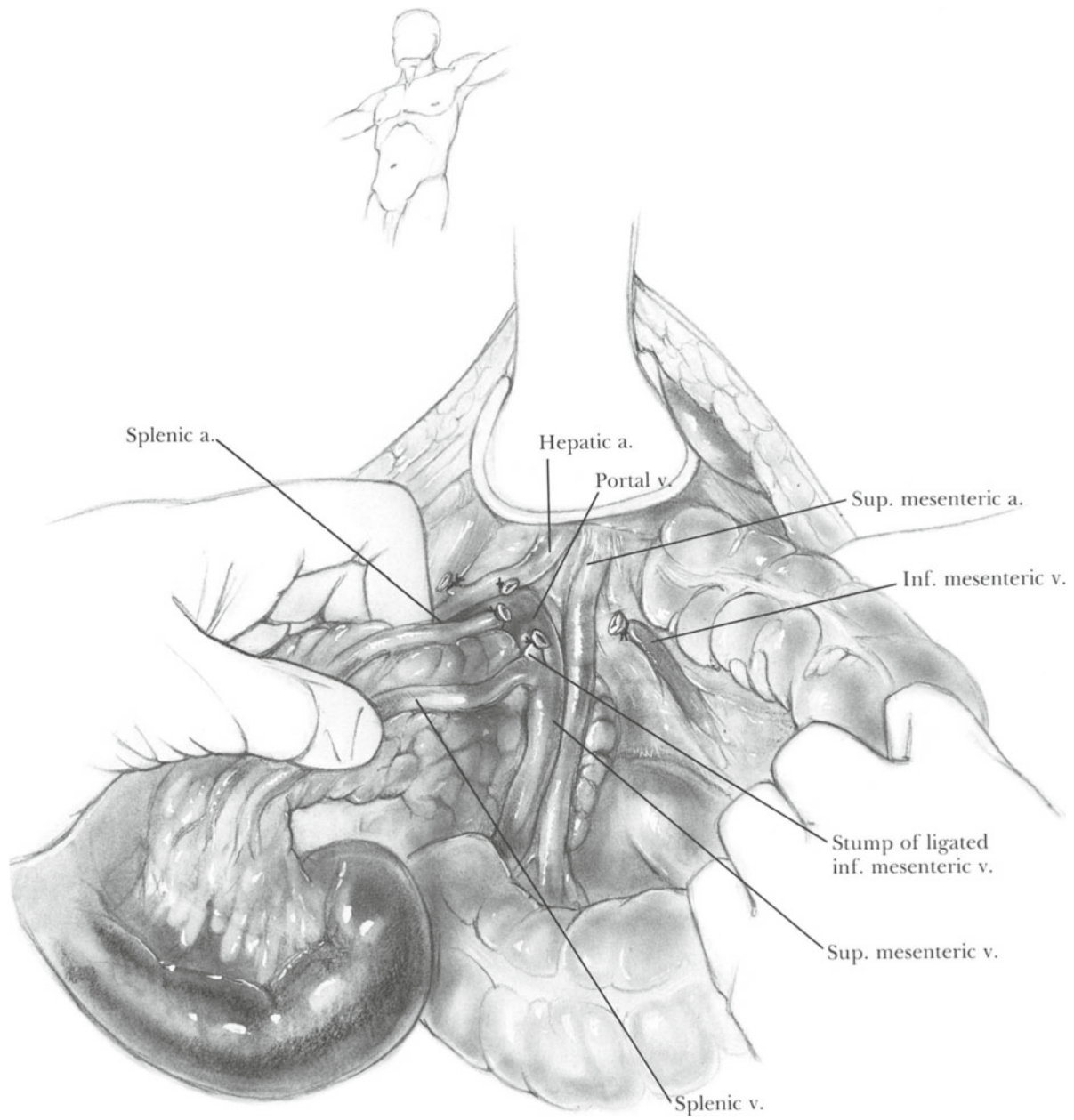


Fig. 90.9



**Fig. 90.10**



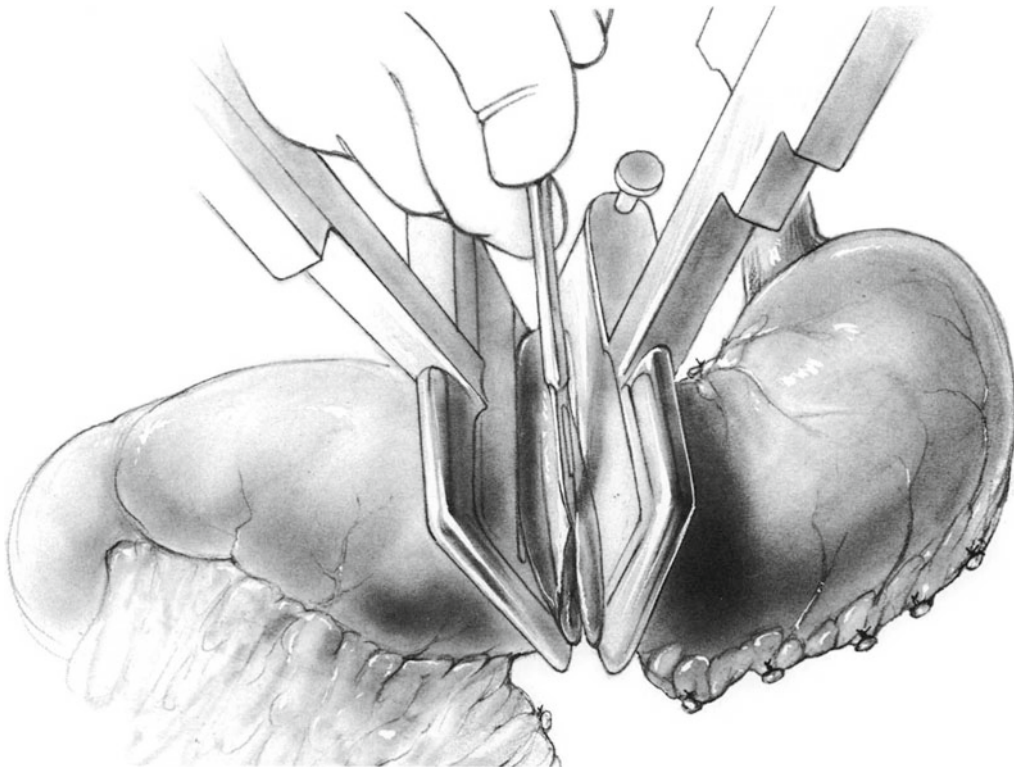


Fig. 90.11

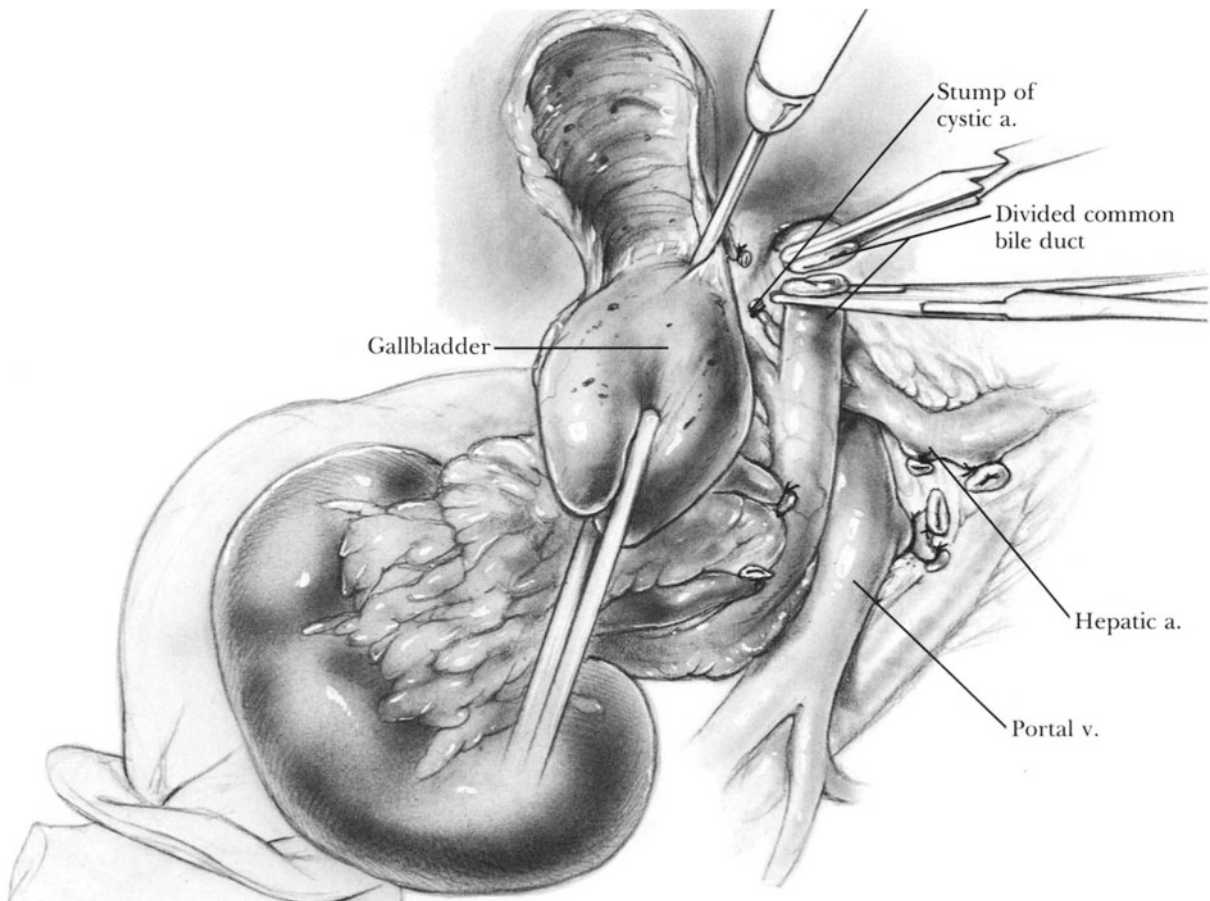
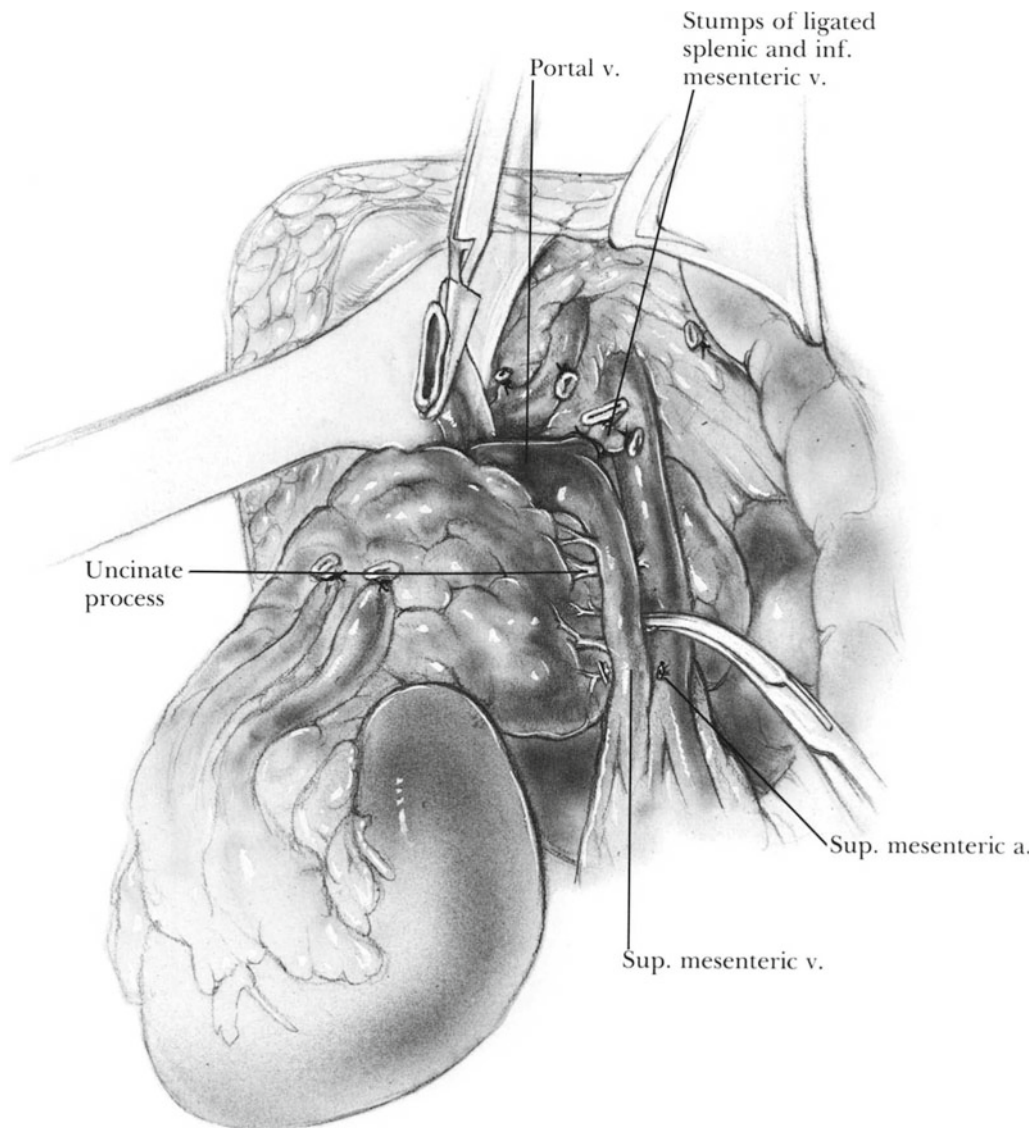


Fig. 90.12



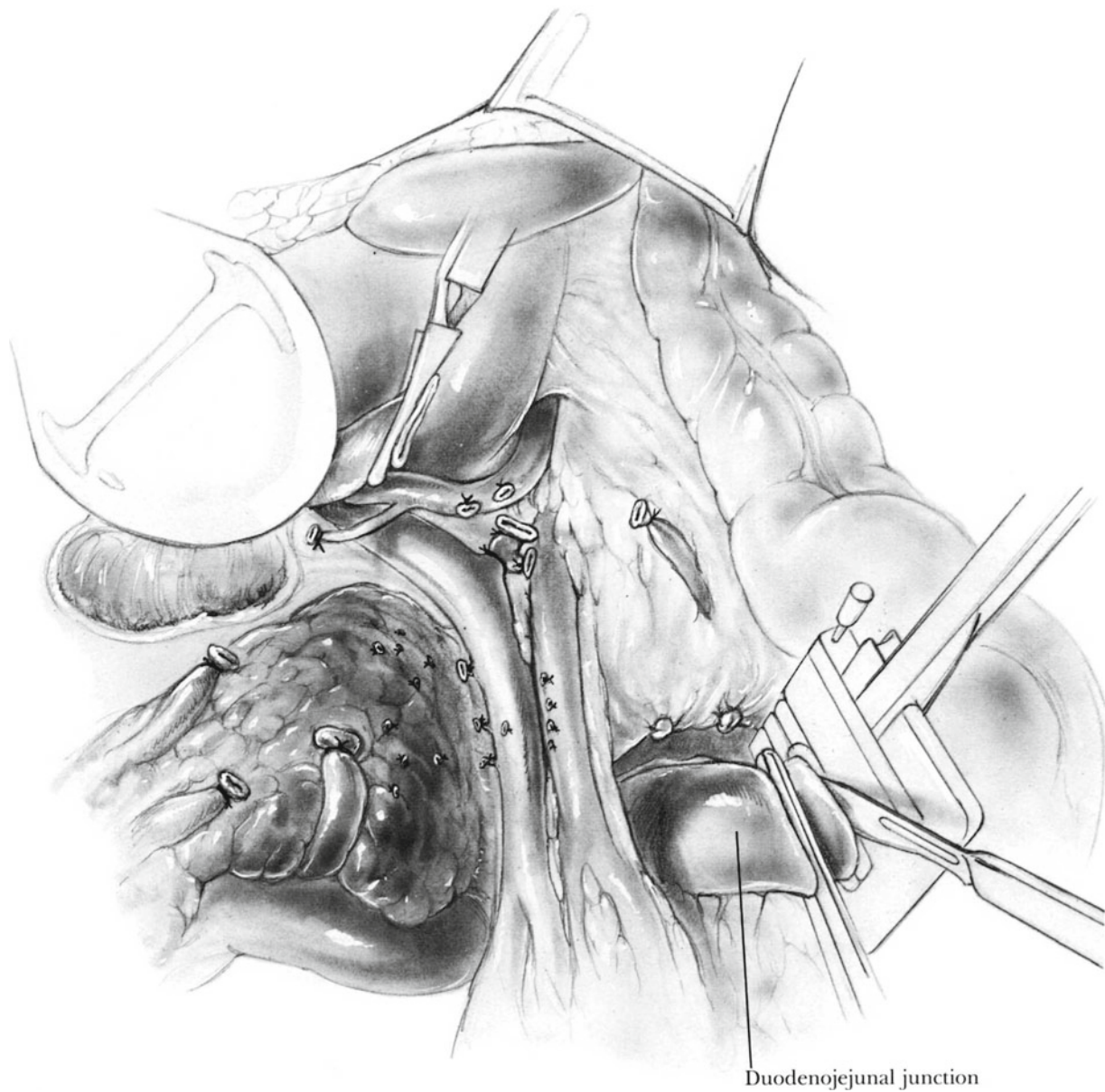
**Fig. 90.13**

removed sometime after the fourth postoperative day unless a significant amount of drainage persists. The T-tube is left in place for 21 days.

The most important element of postoperative care following total pancreatectomy is regulation of the resulting diabetes. The greatest danger is hypoglycemia due to administration of too much insulin. Perform blood glucose determinations every 3–4 h for the first few days. Do not try to keep the blood glucose level below 200 mg/dl. Especially during the early postoperative period, the diabetes is quite brittle, and an overdose of only a few units of insulin may

produce hypoglycemic shock. There is much more danger from hypoglycemia than from diabetic acidosis. Administer regular insulin in doses of 2–5 units every few hours as necessary. Frequently no more than 10–20 units are required per day. After patients begin to eat, they may be switched to one of the longer-acting insulin products. Patients and their relatives should be carefully instructed about the symptoms of hypoglycemia.

Repeated measurements of the gastric pH are vital to prevent postoperative gastric hemorrhage. Use intravenous  $H_2$  blockers to keep the gastric pH at 5 or above.



**Fig. 90.14**

A sufficient dose of pancreatic enzymes must be given to prevent steatorrhea. It may require three tablets of Pancrease before each meal.

### Complications

Hypoglycemia or hyperglycemia  
 Postoperative gastric bleeding due to stress ulceration or a marginal ulcer

Postoperative hemorrhage  
 Postoperative sepsis  
 Leakage from biliary anastomosis  
 Mesenteric venous thrombosis  
 Hepatic failure

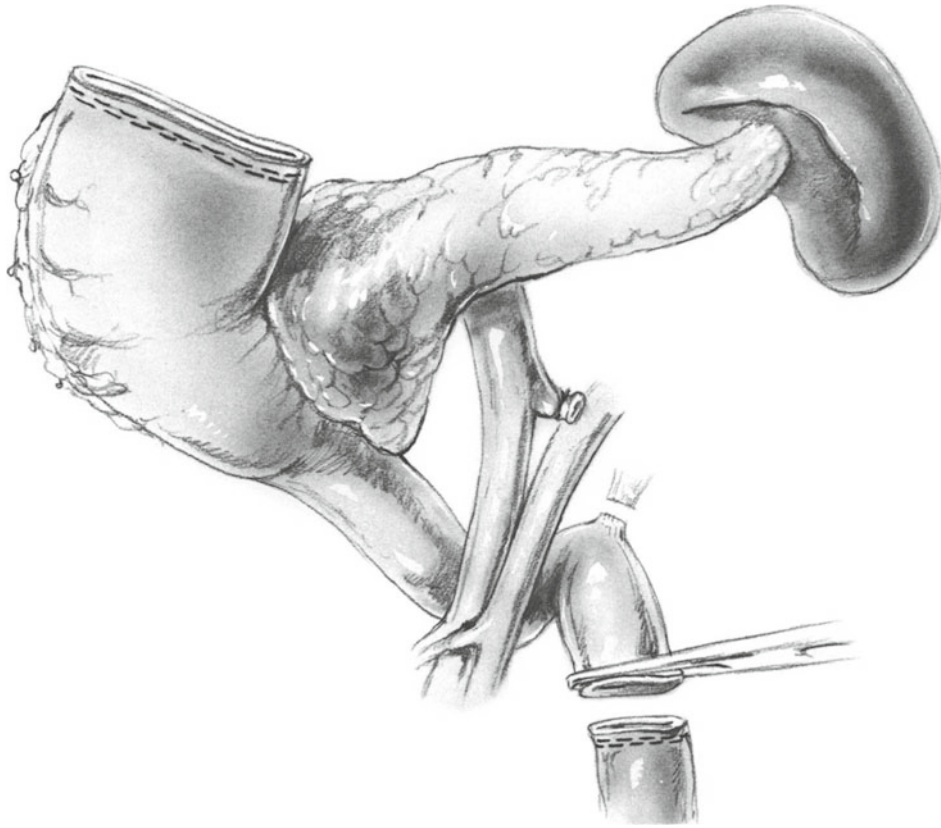


Fig. 90.15

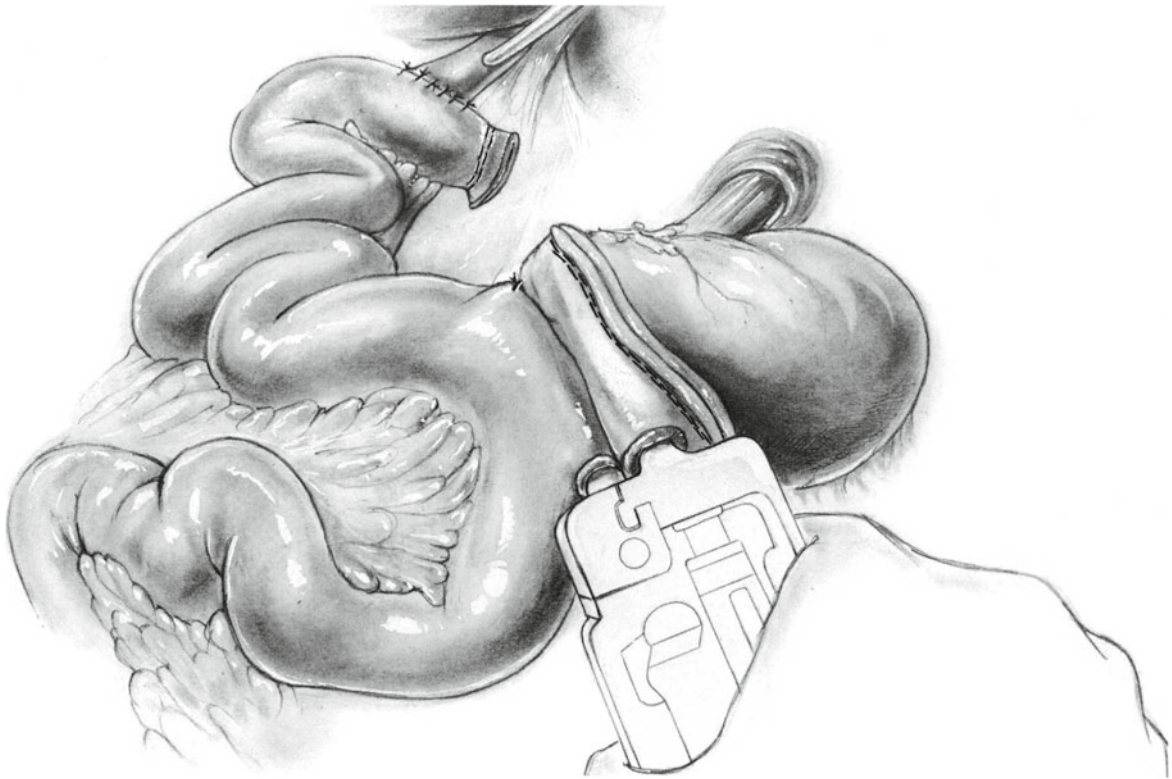
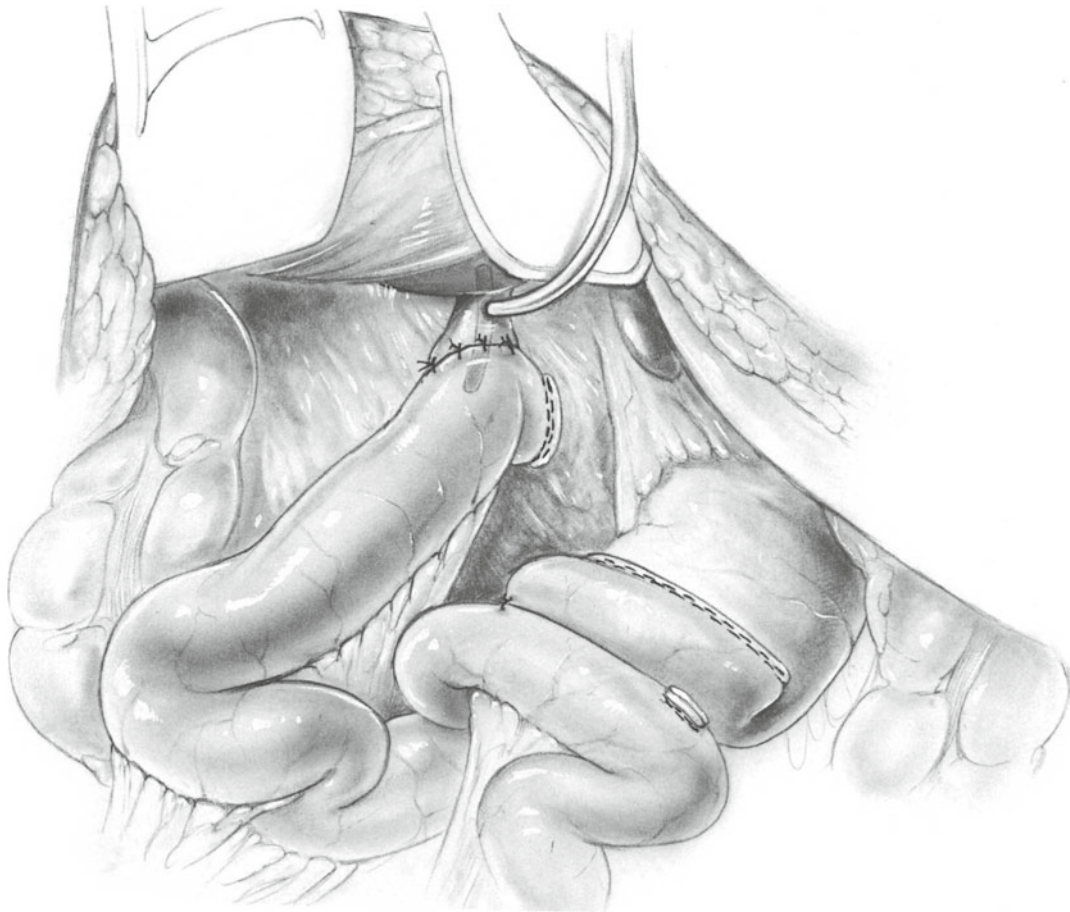


Fig. 90.16



**Fig. 90.17**

### Further Reading

- Bakkevold KE, Kambestad B. Morbidity and mortality after radical and palliative pancreatic cancer surgery: risk factors influencing the short-term results. *Ann Surg.* 1993;217:356.
- Brooks JR, Brooks DC, Levine JD. Total pancreatectomy for ductal cell carcinoma of the pancreas: an update. *Ann Surg.* 1989;209:405.
- Hidalgo M. Pancreatic cancer. *N Engl J Med.* 2010;362:1605.
- Sohn TA, Yeo CJ, Cameron JL, et al. Intraductal papillary mucinous neoplasms of the pancreas: an updated experience. *Ann Surg.* 2004;239:788.
- Swope TJ, Wade TP, Neuberger TJ, Virgo KS, Johnson FE. A reappraisal of total pancreatectomy for pancreatic cancer: results from US Veterans Affairs Hospitals 1987–1991. *Am J Surg.* 1994;168:582.