

Carol E.H. Scott-Conner and Jameson L. Chassin[†]

Indications

Persistent bleeding or protrusion
Symptomatic second- and third-degree (combined internal-external) hemorrhoids
Symptomatic hemorrhoids combined with mucosal prolapse
Strangulation of internal hemorrhoids
Early stage of acute thrombosis of external hemorrhoid

Contraindications

Portal hypertension
Inflammatory bowel disease
Anal malignancy

Preoperative Preparation

Advise patients to discontinue aspirin and other nonsteroidal antiinflammatory agents.
A sodium phosphate packaged enema (Fleet) is adequate cleansing for most patients.
Sigmoidoscopy, colonoscopy, or both are done as indicated by the patient's symptoms.
Routine preoperative blood coagulation profile (partial thromboplastin time, prothrombin time, platelet count) is performed if there is any suspicion of liver disease.
Preoperative shaving of the perianal area is preferred by some surgeons but is not necessary.

C.E.H. Scott-Conner, MD, PhD (✉)
Department of Surgery, Roy J. and Lucille A. Carver
College of Medicine, University of Iowa,
200 Hawkins Drive, 4622 JCP, Iowa City, IA 52242, USA
e-mail: carol-scott-conner@uiowa.edu

J.L. Chassin, MD
Department of Surgery,
New York University School of Medicine,
New York, NY, USA

Pitfalls and Danger Points

Narrowing the lumen of the anus, thereby inducing anal stenosis
Trauma to sphincter
Failing to identify associated pathology (e.g., inflammatory bowel disease, leukemia, portal hypertension, coagulopathy, squamous carcinoma of the anus)
Failure to manage postoperative bowel function

Operative Strategy

Avoiding Anal Stenosis

The most serious error when performing hemorrhoidectomy is failure to leave adequate bridges of mucosa and anoderm between each site of hemorrhoid excision. If a minimum of 1.0–1.5 cm of viable anoderm is left intact between each site of hemorrhoid resection, the risk of developing anal stenosis is minimized. Preserving viable anoderm is much more important than removal of all external hemorrhoids and redundant skin.

One method of preventing anal stenosis is to insert a large anal retractor, such as the Fansler or large Ferguson, after resecting the hemorrhoids. If the incisions in the mucosa and anoderm ("closed hemorrhoidectomy") can be sutured with the retractor in place, anal stenosis should not occur if good bowel function is maintained postoperatively.

Achieving Hemostasis

Traditionally, surgeons have depended on mass ligation of the hemorrhoid "pedicle" for achieving hemostasis. This policy ignores the fact that small arteries penetrate the internal sphincter and enter the operative field. Also, numerous vessels are divided when incising the mucosa to dissect the

[†]Deceased

pedicle. In fact, the concept of a “pedicle” as being the source of a hemorrhoidal mass is largely erroneous. A hemorrhoidal mass is not a varicose vein situated at the termination of the portal venous system. It is a vascular complex with multiple channels fed by many small vessels. Therefore it is important to control bleeding from each vessel as it is transected during the operation. A convenient method for accomplishing this goal is careful, accurate application of coagulating electrocautery. As pointed out by Goldberg and associates (Goldberg et al. 1980), much of the bleeding comes from the mucosal incision. Therefore, it is well to achieve perfect hemostasis before suturing the defect following hemorrhoid excision.

Associated Pathology

Even though hemorrhoidectomy is a minor operation, a complete history and physical examination are necessary to rule out important systemic diseases such as leukemia. Leukemic infiltrates in the rectum can cause severe pain and can mimic hemorrhoids and anal ulcers. Operating erroneously on an undiagnosed acute leukemia patient is fraught with the dangers of bleeding, failure to heal, and sepsis. Crohn’s disease must also be ruled out by history, local examination, and sigmoidoscopy, as well as biopsy in doubtful situations.

Another extremely important condition sometimes overlooked during the course of hemorrhoidectomy is squamous cell carcinoma of the anus. It may resemble nothing more than a small ulceration on what appears to be a hemorrhoid. Any hemorrhoid that demonstrates a break in the continuity of the overlying mucosa should be suspected of being a carcinoma, as should any ulcer of the anoderm, except for the classic anal fissure located in the posterior commissure. Before scheduling hemorrhoidectomy, biopsy all ulcerations and atypical lesions of the anal canal. It is prudent to submit label each hemorrhoid by location and submit for pathological examination.

Documentation Basics

Coding for anorectal procedures is complex. Consult the most recent edition of the AMA’s *Current Procedural Terminology* book for details (American Medical Association 2013). In general, it is important to document:

- Findings
- Internal versus external hemorrhoids
- Presence or absence of strangulation
- Ligation versus excision versus incision
- Closure of mucosa

Operative Technique

Closed Hemorrhoidectomy

Local Anesthesia

Choosing an Anesthetic Agent

A solution of 0.5 % lidocaine (maximum dosage 80 ml) or 0.25 % bupivacaine (maximum dosage 80 ml) combined with epinephrine 1:200,000 and 150–300 units of hyaluronidase is effective and has extremely low toxicity. Because perianal injection of these agents is painful, premedicate the patient 1 h before the operation with an intramuscular injection of some combination of narcotic and sedative (e.g., Demerol and a barbiturate or Innovar, 1–2 ml). Alternatively, give diazepam in a dose of 5–10 mg intravenously just before the perianal injection.

Techniques of Local Anesthesia

With the technique originally introduced by Kratzer (1974), the anesthetic agent is placed in a syringe with a 25-gauge needle. The needle should be at least 5 cm in length. Initiate the injection at a point 2–3 cm lateral to the middle of the anus. Inject 10–15 ml of the solution in the *subcutaneous* tissues surrounding the right half of the anal canal including the area of the anoderm at the anal verge. Warn the patient that this injection may be quite painful. Repeat this maneuver through a needle puncture site to the left of the anal canal. After placing a slotted anoscope in the anal canal, insert the needle into the tissues just underneath the anoderm and into the plane between the submucosa and the internal sphincter 3–4 cm deep into the anal canal (Fig. 69.1). If the injection creates a wheal in the mucosa similar to that seen in the skin after an intradermal injection, the needle is in a too-shallow position. An injection into the proper submucosal plane produces no visible change in the overlying mucosa. Inject 3–4 ml of anesthetic solution during the course of withdrawing the needle. Make similar injections in each of the four quadrants until the subdermal and submucosal tissues of the anal canal have been surrounded with anesthetic agent. It should require no more than 30–40 ml of anesthetic solution. Satisfactory relaxation of the sphincters is achieved without the need to inject solution directly into the muscles or to attempt to block the inferior hemorrhoidal nerve in the ischioanal space. Wait 5–10 min for complete relaxation and anesthesia.

In 1982, Nivatvongs described a technique to minimize pain (Nivatvongs 1982). It consisted, first, of inserting a small anoscope into the anal canal. Make the first injection into the *submucosal* plane 2 mm *above* the dentate line. Because of the difference in sensory innervation of the mucosa above the dentate line, injection here does not

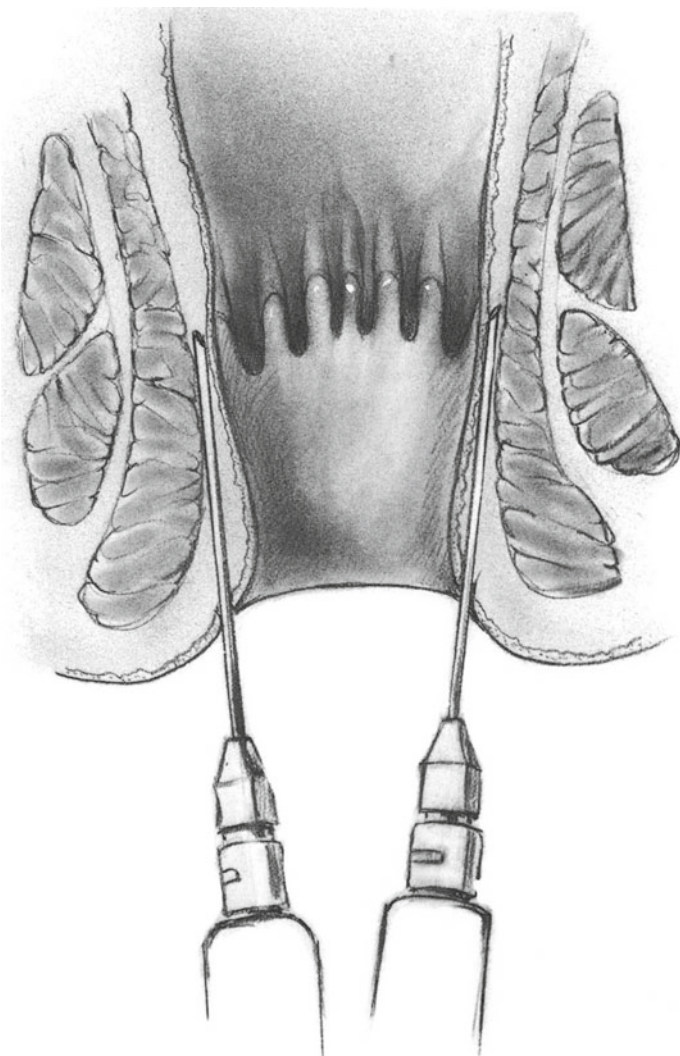


Fig. 69.1

produce acute pain. Inject 2–3 ml of anesthetic solution and then an equal amount of solution in each of the remaining three quadrants of the anus. Remove the anoscope and insert a well lubricated index finger into the anal canal. Use the tip of the index finger to massage the anesthetic agent from the submucosal area down into the tissues underneath the anoderm. Repeat this maneuver with respect to each of the four injection sites. By spreading the anesthetic agent distally, this maneuver serves to anesthetize the highly sensitive tissues of the anoderm just distal to the dentate line. When this has been accomplished, make another series of injections 2 mm *distal* to the dentate line. Inject 2–3 ml of solution underneath the anoderm and the subcutaneous tissues in the perianal region through four sites, one in each quadrant of the anus. Then use the index finger again to massage the tissues of the anal canal to spread the anesthetic solution

circumferentially around the anal and perianal area. In some cases additional anesthetic agent is necessary for complete circumferential anesthesia. An average of 20–25 ml of solution is required. Nivatvongs stated that this technique provides excellent relaxation of the sphincters and permits operation such as hemorrhoidectomy to be accomplished without general anesthesia. For a lateral sphincterotomy, it is not necessary to anesthetize the entire circumference of the anal canal when using this technique. Inject only the area of the sphincterotomy.

Intravenous Fluids

Because local anesthesia has few systemic effects, it is not necessary to administer a large volume of intravenous fluid during the operation. If large volumes of fluid are administered intraoperatively, the bladder becomes rapidly distended. In the presence of general anesthesia or even heavy sedation during local anesthesia, the patient is not sufficiently alert to have the desire to void. By the time the patient is alert, the bladder muscle has been stretched and may be too weak to empty the bladder, especially if the patient also has anal pain and some degree of prostatic hypertrophy. This can cause postoperative urinary retention, requiring catheterization. All of this can be prevented by avoiding general anesthesia and heavy premedication and by limiting the dosage of intravenous fluids to 100–200 ml during and after hemorrhoidectomy.

Positioning the Patient

We prefer to place the patient in the semiprone jackknife position with either a sandbag or rolled-up sheet under the hips and a small pillow to support the feet. It is not necessary to shave the perianal area; if the buttocks are hirsute, shave this area. Then apply tincture of benzoin. When this solution has dried, apply wide adhesive tape to the buttock and attach the other end of the adhesive strap to the operating table. In this fashion lateral traction is applied to each buttock, affording excellent exposure of the anus.

The alternative lithotomy position is preferred by some surgeons. This allows full access to the airway by anesthesia personnel. The surgeon generally sits to operate, and the operative field is vertical rather than horizontal.

Incision and Dissection

Gently dilate the anal canal so it admits two fingers. Insert a bivalve speculum such as the Parks retractor or a medium-size Hill-Ferguson retractor. One advantage of using the medium Hill-Ferguson retractor is that it approximates the diameter of the normal anal canal. If the defects remaining in the mucosa and anoderm can be sutured closed with the retractor in place following hemorrhoid excision, no

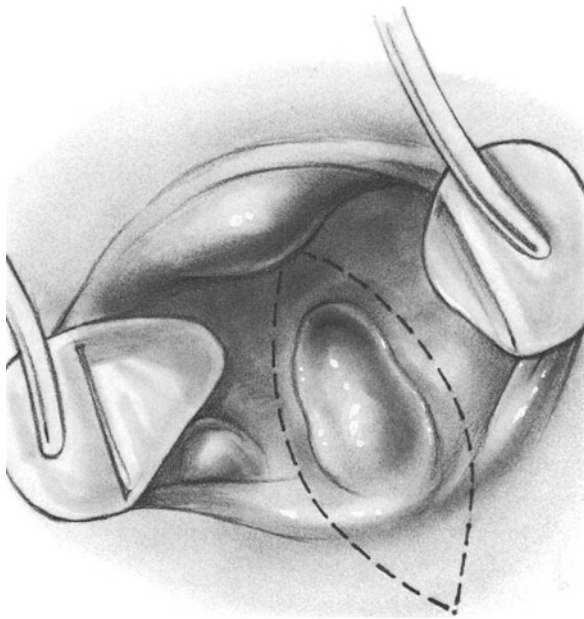


Fig. 69.2

narrowing of the anal canal occurs. Each of the hemorrhoidal masses can be identified by rotating the retractor and applying countertraction to the skin of the opposite wall of the anal canal. Generally, three hemorrhoidal complexes are excised: one in the left midlateral position, another in the right anterolateral position, and the third in the right posterolateral location. Avoid placing incisions in the anterior or posterior commissures. Grasp the most dependent portion of the largest hemorrhoidal mass in a Babcock clamp. Then make an incision in the anoderm outlining the distal extremity of the hemorrhoid (Fig. 69.2) using a No. 15 (Bard-Parker) scalpel. If the hemorrhoidal mass is unusually broad (>1.5 cm), do not excise all of the anoderm and mucosa overlying the hemorrhoid. If each of the hemorrhoidal masses is equally broad, excising all of the anoderm and mucosa overlying each of the hemorrhoids results in inadequate tissue bridges between the sites of hemorrhoid excision. In such a case incise the mucosa and anoderm overlying the hemorrhoid in an elliptical fashion. Then initiate a submucosal dissection using small, pointed scissors to elevate the mucosa and anoderm from the portion of the hemorrhoid that remains in a submucosal location. Carry the dissection of the hemorrhoidal mass down to the internal sphincter muscle (Fig. 69.3). After incising the mucosa and anoderm, draw the hemorrhoid away from the sphincter, using blunt dissection as necessary, to demonstrate the lower border of the internal sphincter. This muscle has whitish muscle fibers that run in a transverse direction. A thin bridge of fibrous tissue is often seen connecting the substance of the hemorrhoid to the internal sphincter. Divide these fibers with a scissors. Dissect the hemorrhoidal mass for a distance of about 1–2 cm above the dentate line where

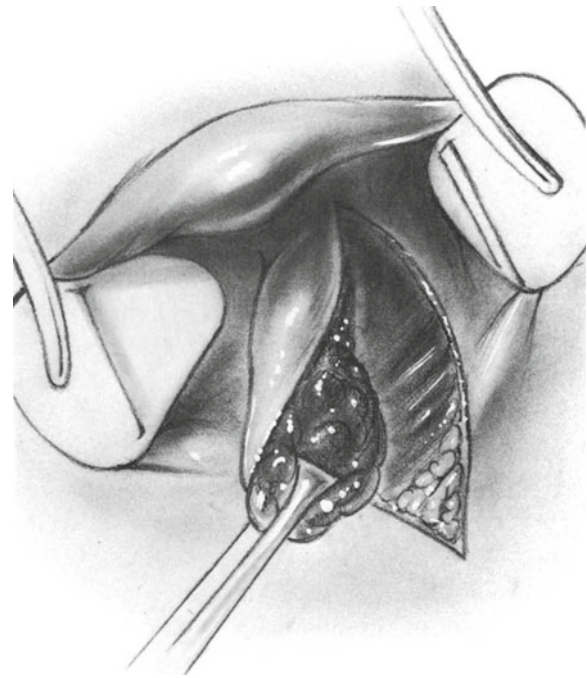


Fig. 69.3

it can be divided with the electrocoagulator (Fig. 69.4). Remove any residual internal hemorrhoids from underneath the adjacent mucosa. Achieve complete hemostasis, primarily with careful electrocoagulation. It is not necessary to clamp and suture the hemorrhoidal “pedicle,” although many surgeons prefer to do so (Fig. 69.5). It is helpful to remove all the internal hemorrhoids, but we do not attempt to extract fragments of external hemorrhoids from underneath the anoderm, as this step does not appear necessary. Most of these small external hemorrhoids disappear spontaneously following internal hemorrhoidectomy.

After complete hemostasis has been achieved, insert an atraumatic 5-0 Vicryl suture into the apex of the hemorrhoidal defect. Tie the suture and then close the defect with a continuous locking suture taking 2- to 3-mm bites of mucosa on each side (Fig. 69.6). Also include a small bit of the underlying internal sphincter muscle with each pass of the needle. This maneuver serves to force the mucosa to adhere to the underlying muscle layer and thereby helps prevent mucosal prolapse and recurrent hemorrhoids. Continue the suture line until the entire defect has been closed. Now repeat the same dissection for each of the other two hemorrhoidal masses. Close each of the mucosal defects by the same technique (Fig. 69.7). Be certain not to constrict the lumen of the anal canal. The rectal lumen should admit a Fansler or a large Ferguson rectal retractor after the suturing is completed. To avoid anal stenosis remember that the ellipse of mucosa-anoderm excised with each hemorrhoidal mass must be relatively narrow. Also remember that if the

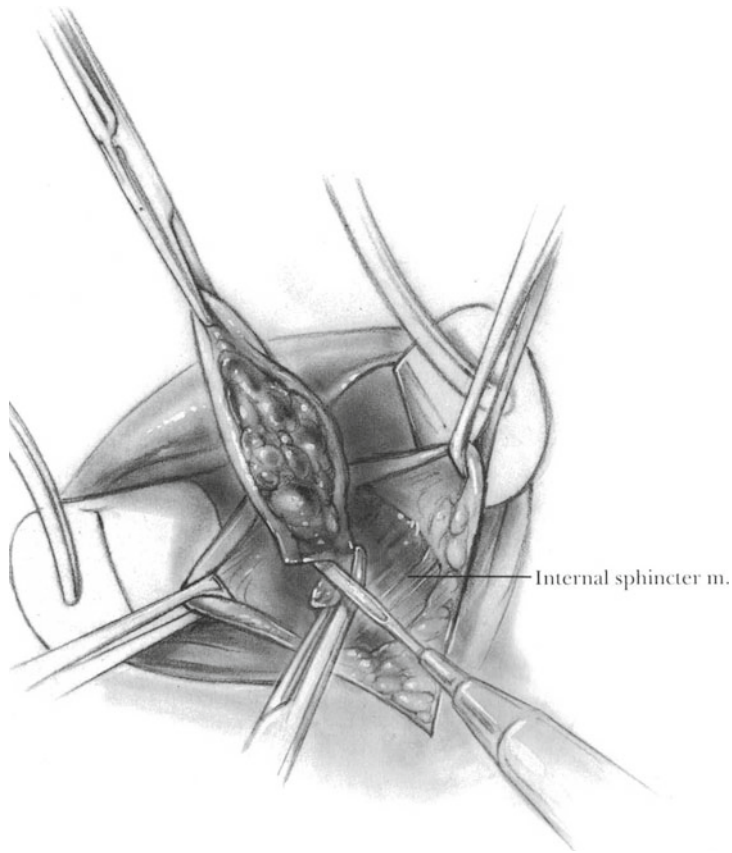


Fig. 69.4

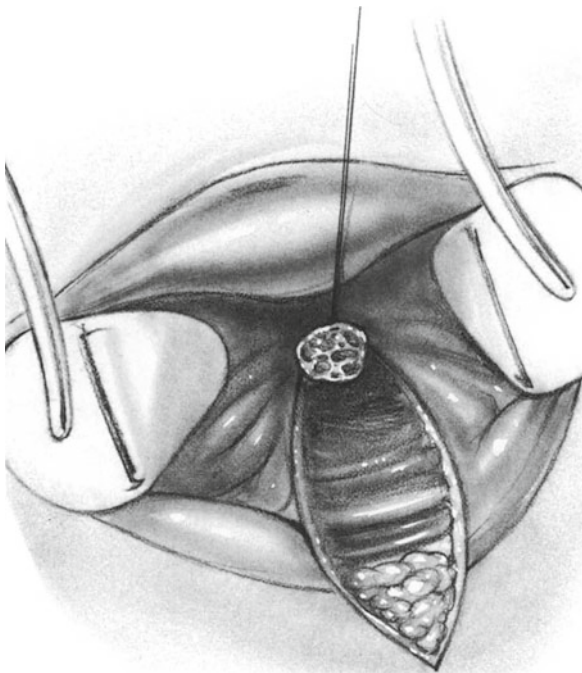


Fig. 69.5

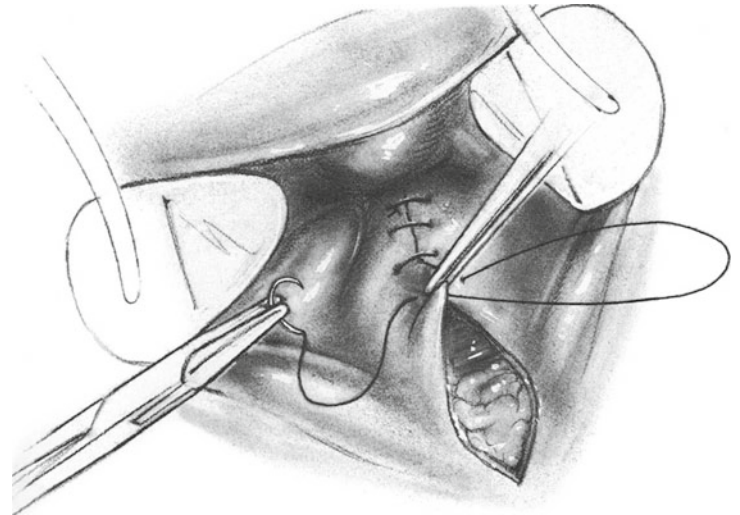


Fig. 69.6

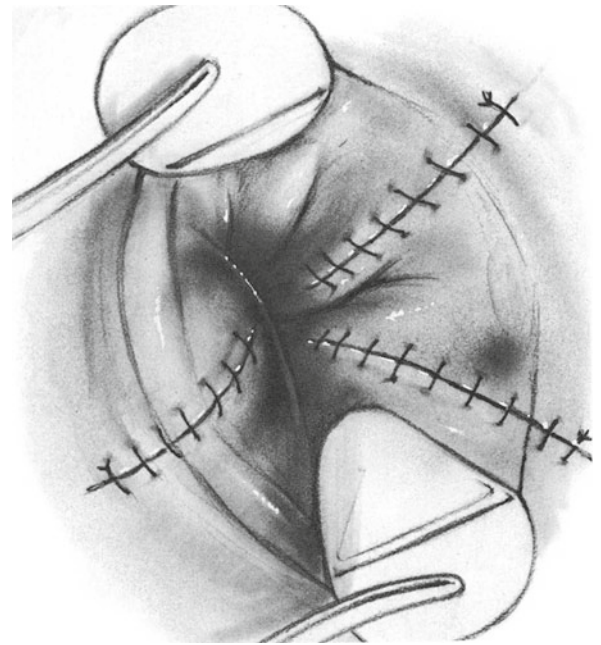


Fig. 69.7

tissues are sutured under tension, the suture line will undoubtedly break down.

A few patients have some degree of anal stenosis in addition to hemorrhoids. Under these conditions, rather than forcibly dilating the anal canal at the onset of the operation, perform a partial lateral internal sphincterotomy to provide adequate exposure for the operation. This is also true for patients who have a concomitant chronic anal fissure.

For surgeons who prefer to keep the skin unsutured for drainage, modify the above operative procedure by discontinuing the mucosal suture line at the dentate line, leaving the

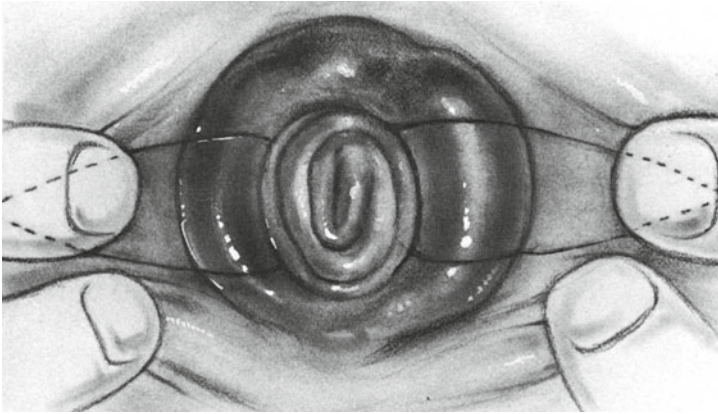


Fig. 69.8

defect in the anoderm unsutured. It is also permissible not to suture the mucosal defects at all after hemorrhoidectomy (see above).

Radical Open Hemorrhoidectomy

Incision

Radical open hemorrhoidectomy is restricted to patients who no longer have three discrete hemorrhoidal masses but in whom all of the hemorrhoids and prolapsing rectal mucosa seem to have coalesced into an almost circumferential mucosal prolapse. For these patients the operation excises the hemorrhoids, both internal and external, the redundant anoderm, and prolapsed mucosa from both the left and right lateral portions of the anus, leaving 1.5 cm bridges of intact mucosa and anoderm at the anterior and posterior commissures. With the patient in the prone position, as described above for closed hemorrhoidectomy, outline the incision on both sides of the anus as shown in Fig. 69.8.

Excising the Hemorrhoidal Masses

Elevate the skin flap together with the underlying hemorrhoids by sharp and blunt dissection until the lower border of the internal sphincter muscle has been unroofed (Fig. 69.9). This muscle can be identified by its transverse whitish fibers. Now elevate the anoderm above and below the incision to enucleate adjacent hemorrhoids that have not been included in the initial dissection (Fig. 69.10). This maneuver permits removal of almost all the hemorrhoids and still allows an adequate bridge of anoderm in the anterior and posterior commissures.

After the mass of hemorrhoidal tissue with overlying mucosa has been mobilized to the level of the normal location of the dentate line, amputate the mucosa and hemorrhoids with electrocautery at the level of the dentate line. This leaves a free edge of rectal mucosa. Suture this mucosa to the underlying internal sphincter muscle with a

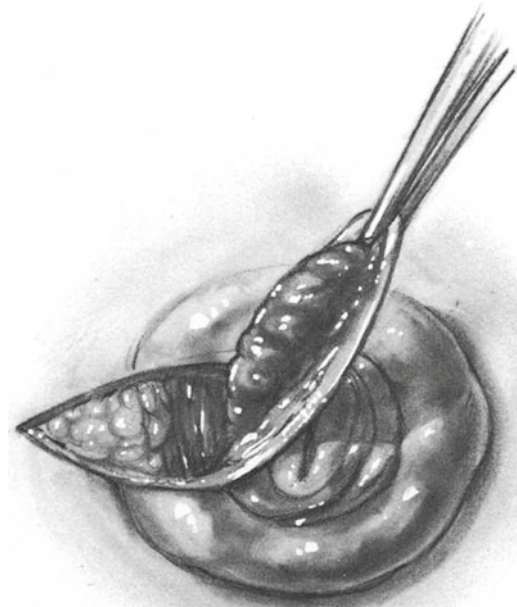


Fig. 69.9

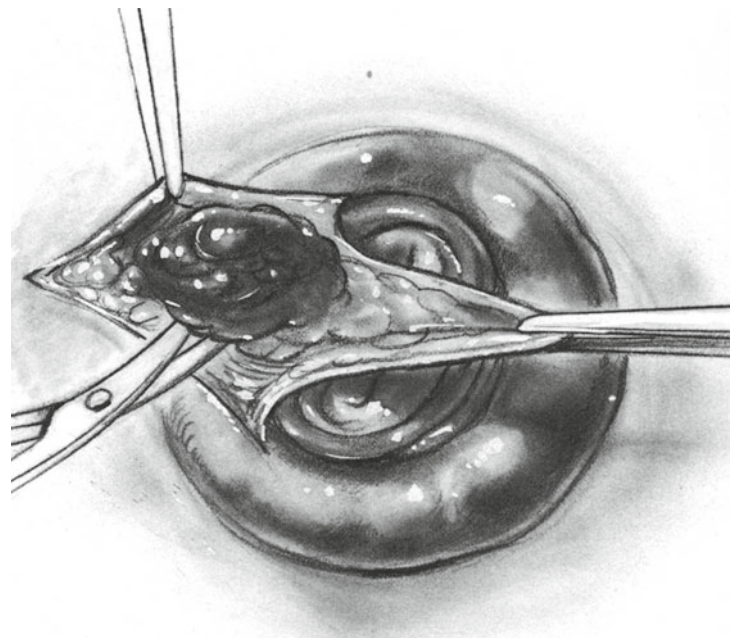


Fig. 69.10

continuous 5-0 atraumatic Vicryl suture, as illustrated in Fig. 69.11, to recreate the dentate line at its normal location. Do not bring the rectal mucosa down to the area that is normally covered by anoderm or skin, as it would result in continuous secretion of mucus, which would irritate the perianal skin.

Execute the same dissection to remove all of the hemorrhoidal tissue between 1 and 5 o'clock on the right side and

reattach the free cut edge of rectal mucosa to the underlying internal sphincter muscle, as depicted in Fig. 69.12. There may be some redundant anoderm together with some external hemorrhoids at the anterior or posterior commissure of the anus. Do not attempt to remove every last bit of external hemorrhoid as it would jeopardize the viability of the anoderm in the commissures. Unless viable bridges, about 1.5 cm each in width, are preserved in the anterior and posterior commissures, the danger of a postoperative anal stenosis far outweighs the primarily cosmetic ill effect of leaving behind a skin tag or an occasional external hemorrhoid.

Ensure that hemostasis is complete using electrocautery and occasional suture ligatures of fine PG or chromic catgut. Some surgeons also insert a small piece of rolled-up Gelfoam into the anus at the completion of the procedure. This roll, which should not be more than 1 cm in thickness, serves to apply gentle pressure and to encourage coagulation of minor

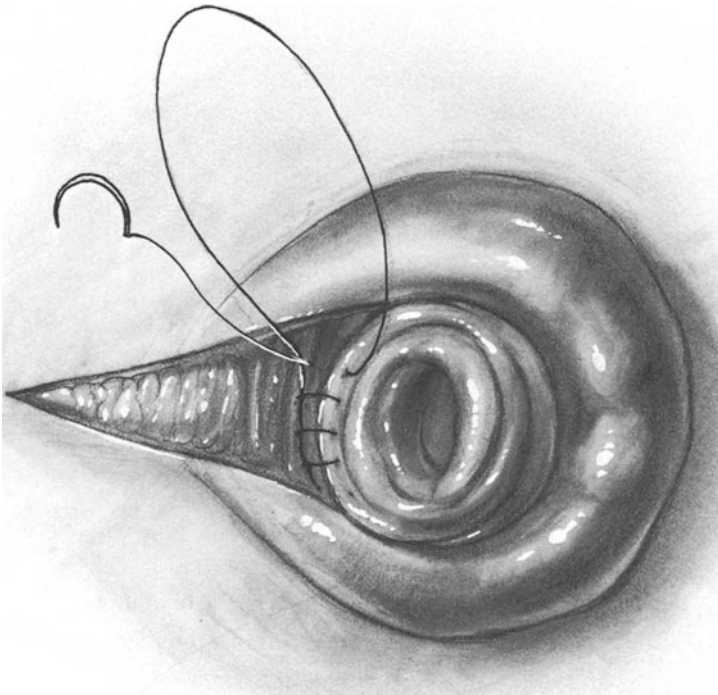


Fig. 69.11

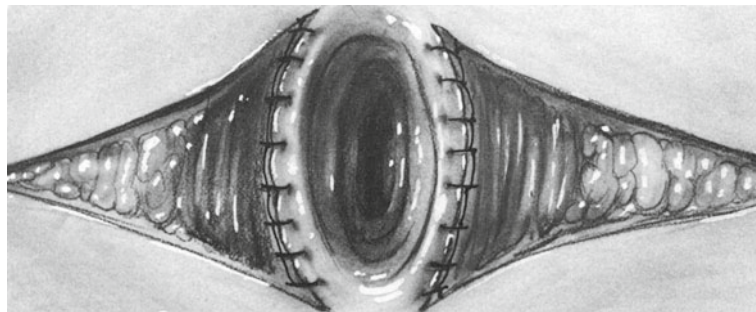


Fig. 69.12

bleeding points that may have been overlooked. The Gelfoam need not be removed, as it dissolves when the patient starts having sitz baths postoperatively. Apply a sterile dressing to the perianal area.

Anal packing with anything more substantial than the 1 cm roll of soft Gelfoam should not be necessary, as hemostasis with electrocautery should be meticulous. Large gauze or other rigid packs are associated with increased postoperative pain and urinary retention.

Postoperative Care

Encourage ambulation the day of operation.

Prescribe analgesic medication preferably of a nonconstipating type.

Prescribe Senokot-S, Metamucil, or mineral oil while the patient is in the hospital. After discharge, limit the use of cathartics because passage of a well formed stool is the best guarantee the anus will not become stenotic. In patients with severe chronic constipation, dietary bran and some type of laxative or stool softener is necessary following discharge from the hospital.

Order warm sitz baths several times a day, especially following each bowel movement.

Discontinue intravenous fluids as soon as the patient returns to his or her room and initiate a regular diet and oral fluids as desired.

If the patient was hospitalized for the hemorrhoidectomy, he or she is generally discharged on the first or second postoperative day. Most patients tolerate hemorrhoidectomy in the ambulatory outpatient setting.

Complications

Serious bleeding during the postoperative period is rare if complete hemostasis has been achieved in the operating room. However, if bleeding is brisk, the patient should probably be returned to the operating room to have the bleeding point suture ligated. Most patients who experience major

bleeding after discharge from the hospital have experienced a minor degree of bleeding before discharge. About 1 % of patients present with hemorrhage severe enough to require reoperation for hemostasis, generally 8–14 days following operation. If the bleeding is slow but continues or if no bleeding site is identified, the patient should be evaluated for coagulopathy, including that caused by platelet dysfunction.

If for some reason the patient is not returned to the operating room for the control of bleeding, it is possible to achieve at least temporary control by inserting a 30 ml Foley catheter into the rectum. The Foley balloon is then blown up, and downward traction is applied to the catheter. Reexploration of the anus for surgical control of bleeding is far preferable.

Infection occurs but is rare.

Skin tags follow hemorrhoidectomy in 6–10 % of cases. Although no treatment is required, for cosmetic purposes a skin tag may be excised under local anesthesia as an office procedure when the operative site has healed completely.

Goldberg SM, Gordon PH, Nivatvongs S. Essentials of anorectal surgery. Philadelphia: Lippincott; 1980.

Kratzer GL. Improved local anesthesia in anorectal surgery. *Am Surg.* 1974;40:609.

Nivatvongs S. An improved technique of local anesthesia for anorectal surgery. *Dis Colon Rectum.* 1982;25:259.

Further Reading

Corman ML. Hemorrhoids. In: *Colon and rectal surgery.* 3rd ed. Philadelphia: Lippincott; 1993. p. 54–115.

Ferguson JA, Heaton JR. Closed hemorrhoidectomy. *Dis Colon Rectum.* 1959;2:176.

Joshi GP, Neugebauer EE, PROSPECT Collaboration. Evidence-based management of pain after haemorrhoidectomy surgery. *Br J Surg.* 2010;97:1155.

Katdare MV, Ricciardi R. Anal stenosis. *Surg Clin North Am.* 2010;90:137.

Nienhuijs S, de Hingh I. Conventional versus LigaSure hemorrhoidectomy for patients with symptomatic hemorrhoids. *Cochrane Database Syst Rev.* 2009;(1):CD006761.

References

American Medical Association. Current procedural terminology: CPT®. Professional ed. Chicago: American Medical Association; 2013. <http://www.ama-assn.org/ama/pub/physician-resources/solutions-managing-your-practice/coding-billing-insurance/cpt.page>.