

S. Lustig, R. Badet, and Maad F. AlSaati

## Introduction

The theoretical aspects of computer-assisted total knee arthroplasty (TKA) were discussed at the end of the previous chapter, and we will consider in this chapter the practical applications of computer-assisted TKA. We have described conventional TKA in prior chapters and will discuss here a similar technique with computer assistance.

The use of “navigation” surgery using the computer has developed over the past 10 years since the first computer-assisted TKA in a human was performed under the direction of D. Saragaglia. The goal of this technique is to have more accurate and reproducible surgery (while at any time having the option of switching to a traditional guide system if needed). We use a PLEOS navigation system (Fig. 26.1), which allows us to use one of three surgical strategies:

- Performing cuts independently
- Performing cuts dependently
- Simulating the distal and posterior femoral cuts (after the tibial cut is made)



**Fig. 26.1** PLEOS navigation system

S. Lustig, MD, PhD (✉)  
Albert Trillat Center, Croix Rousse Hospital,  
103 grande rue de la Croix Rousse, Lyon 69004, France  
e-mail: [sebastien.lustig@gmail.com](mailto:sebastien.lustig@gmail.com)

R. Badet, MD  
Clinique Saint-Vincent-de-Paul,  
70 avenue du Médipôle, Bourgoin-Jallieu 38300, France  
e-mail: [badetr@roger-badet.fr](mailto:badetr@roger-badet.fr)

M.F. AlSaati, MD  
Saati Medical Center,  
88591, Riyadh 11672, Saudi Arabia  
e-mail: [maad.saati@gmail.com](mailto:maad.saati@gmail.com)

## Setup

Patient positioning and setup are the same as for a conventional knee arthroplasty

## Surgical Approach

There is no difference from the standard TKA approach. We perform an anteromedial approach in cases involving a varus knee and anterolateral approach in cases involving a valgus knee.

The cruciate ligaments are resected and the tibia dislocated forward with a Hohmann retractor. This maneuver is required for acquisition of all necessary landmarks.

## Introduction of the Sensors

One sensor is affixed to the tibia and one to the femur for detection by the camera. Both are placed percutaneously and in positions that will not interfere with access to the knee during the procedure.

The tibial sensor is positioned 10 cm below the skin incision so as not to interfere with the tibial cutting guide. The two threaded pins are introduced to the medial cortex of the tibia using a drill with spacing corresponding to the width of the sensor, which is then attached to the two pins. Two percutaneous femoral pins are similarly placed 10 cm above the skin incision to avoid impingement on the femoral cutting guide.

One then checks the positioning of the computer and the receiving antenna. The tibiofemoral sensors must be clearly visible to the cameras in both full extension and maximum flexion of the knee.

## Acquisitions

### Femur

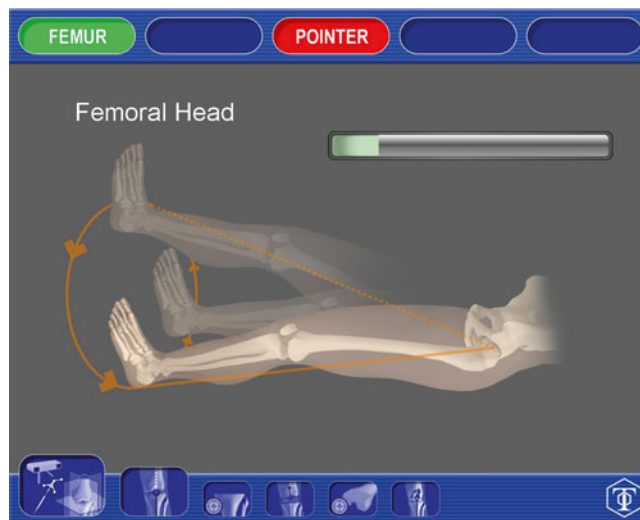
We start by identifying the center of the femoral head by putting the knee in extension and performing a slow, repeated circumduction movement with the entire lower limb. It is important to ensure that the pelvis is immobilized at this stage (Fig. 26.2).

The remaining points are acquired using a wand with an attached optical sensor. We identify first three points corresponding to the anterior cortex of the femur. It is important to identify the most anterior part of the cortex to avoid notching the femur during the anterior femoral cut (Fig. 26.3). Three points marking Whiteside's line are then marked with the use of the wand (Fig. 26.4).

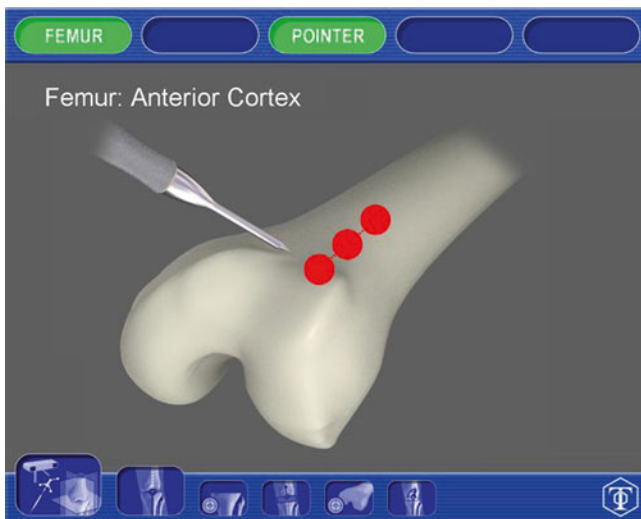
The knee center is identified as a point about 5 mm anterior to the femoral insertion of PCL (Fig. 26.5).

The most distal part of the medial and lateral condyles is marked by scratching on the corresponding areas (Fig. 26.6a, b). They give us the reference level (height) for the cuts.

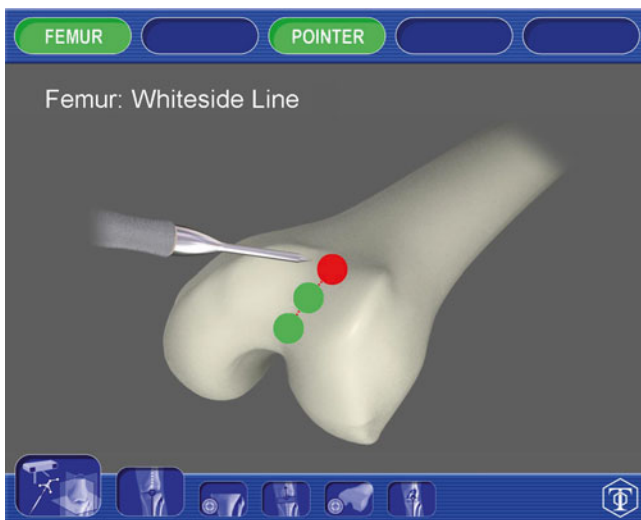
The posterior condyles are identified using special instruments that have two appendages that rest at the back of the condyles and in the bearing zone distally which are applied against the femur. The pointer is inserted in this instrument and the computer to indicate the flexion contracture or recurvatum positioning of the tool. It is positioned at 0° (or 3° depending on the surgeon's choice) to confirm the palpated zone on the posterior condyles.



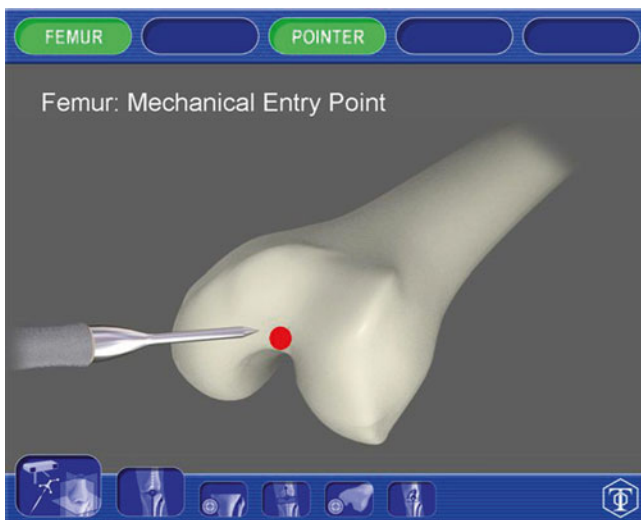
**Fig. 26.2** Acquisition of the center of the hip. We must make small rotary movements clockwise



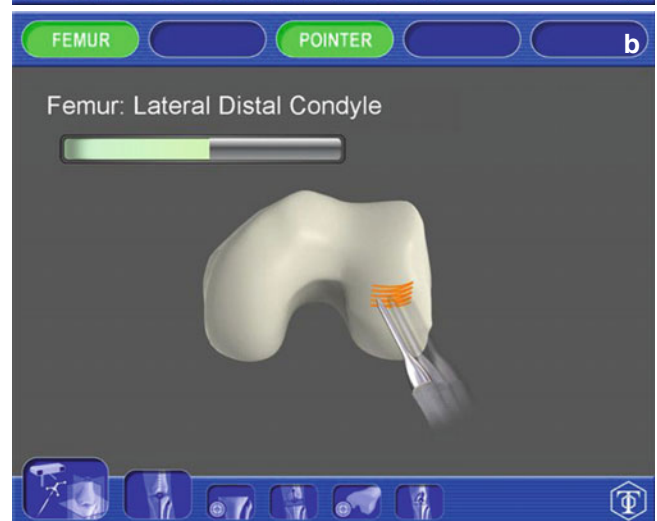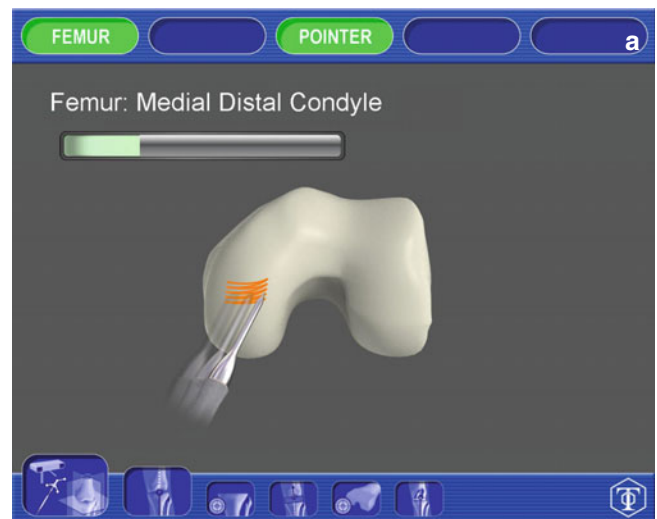**Fig. 26.3** Acquisition of the anterior femoral points



**Fig. 26.4** Acquisition of the bottom line of trochlea (Whiteside's line)



**Fig. 26.5** Acquisition of the femoral center, 5 mm above the femoral insertion of the PCL



**Fig. 26.6** Acquisition of the distal part of the femoral condyles (a medial, b lateral)

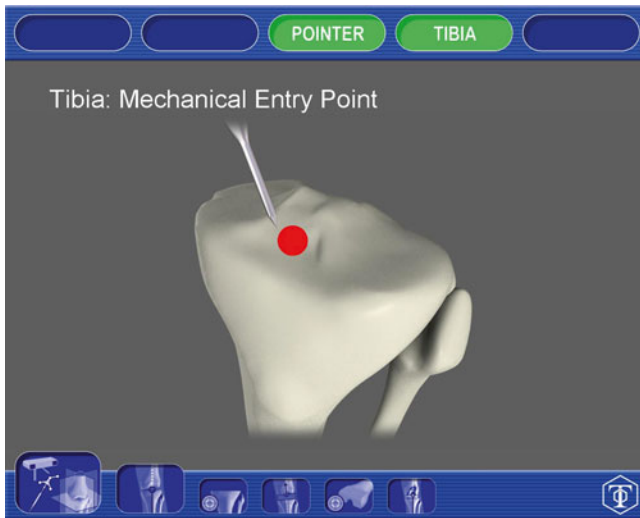
## Tibia

We first identify the ACL insertion site between the tibial spines (Fig. 26.7).

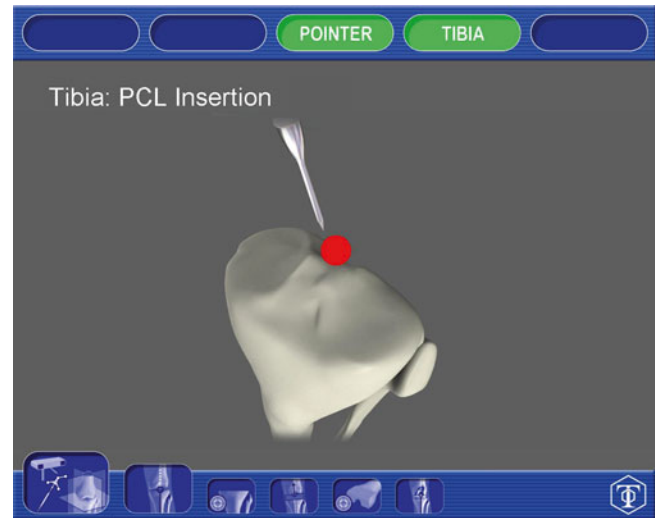
Then we locate:

- The deepest area of the medial tibial plateau and most prominent point on the lateral plateau, by scratching on the corresponding areas. They give us the reference for cutting levels (Fig. 26.8a, b).

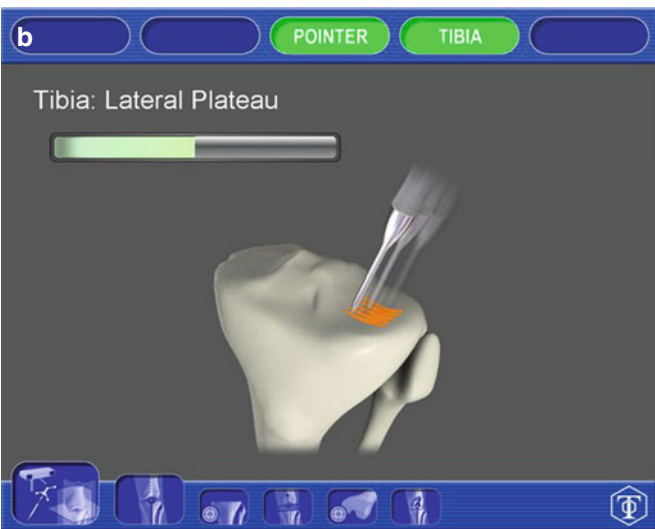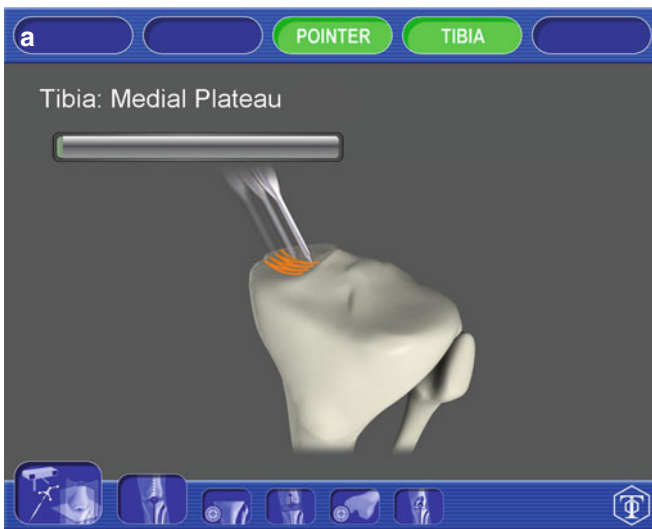- The area of insertion of the PCL at the back of the posterior tibial spine and the medial third of the ATT in front of the tibia (Fig. 26.9). The straight line joining insertion of the PCL and ATT gives the orientation of the tibial plateau.
- The medial and lateral malleoli of the ankle using the probe tip (Fig. 26.10).



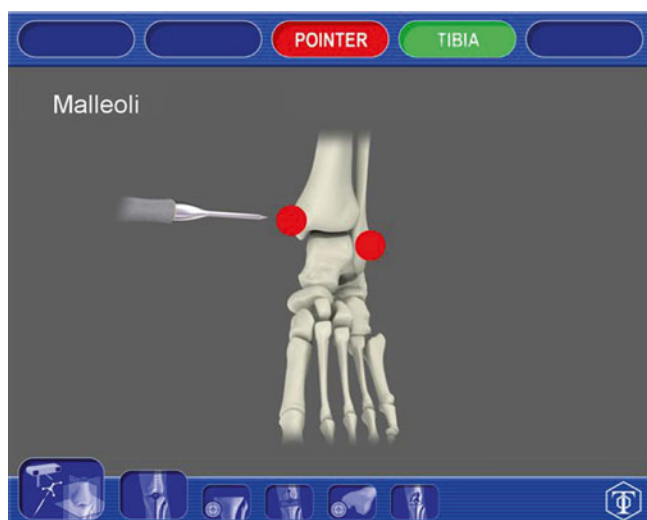**Fig. 26.7** Acquisition of the insertion zone of the ACL to the tibia



**Fig. 26.9** Acquisition of the insertion zone of the PCL to the tibia



**Fig. 26.8** Acquisition of the tibial plateau (a medial, b lateral)



**Fig. 26.10** Acquisition of the medial and lateral malleoli

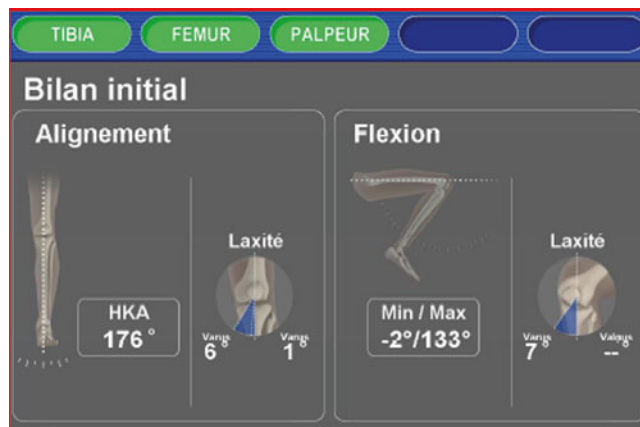## Axis and Ligaments

The overall axis of the lower limb is measured by the navigation system, at an angle close to full extension (Fig. 26.11).

We evaluate the varus and valgus laxity in extension. This measurement is performed by applying maximum stress in varus and valgus while the navigation system notes the maximum value in degrees.

The same measurements of laxity are carried out at 90° of flexion.

Finally, the maximum flexion is registered.

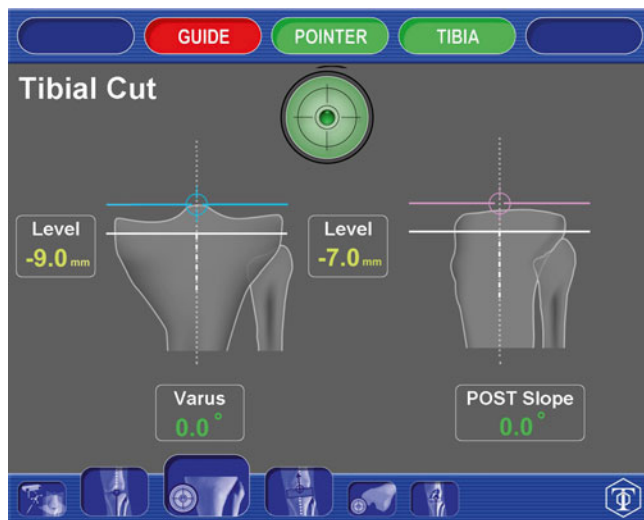


**Fig. 26.11** Initial assessment with measurement of the deformity (HKA angle), the laxity in extension/flexion and range of motion

## Tibial Cut

The knee is in 90° of flexion with the tibia dislocated anteriorly. A Hohmann retractor is positioned behind the tibia while another is applied to the lateral side of the lateral tibial plateau to maintain patellar eversion and provide visualization.

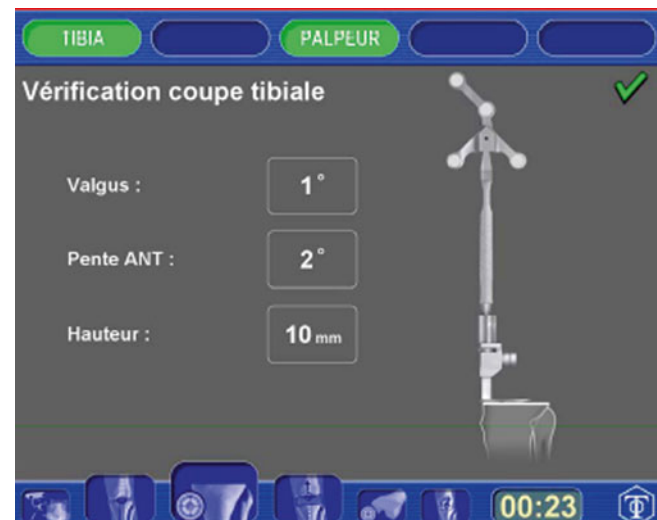The tibial guide is fixed by a pin that is placed at the center of the tibial epiphysis, in the insertion of the ACL. We control the correct positioning of the guide with the target sign on the screen (Fig. 26.12). The center of the target is the correct positioning for varus/valgus and the slope is set by the surgeon (for us 0° in the coronal and sagittal planes).



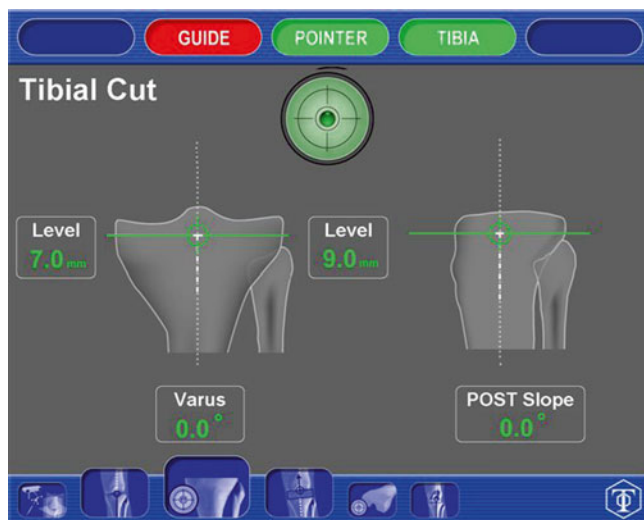
**Fig. 26.12** Introduction of the ancillary tibia

We then adjusted the height of the desired tibial cut (usually 9 mm with respect to the lateral tibial plateau in case of genu varum and 6 mm from the medial tibial plateau in case of genu valgum) (Fig. 26.13).

Once the parameters are validated, two pins are used to “save” the position of the tibial cutting guide that will then be removed. The pins enable the introduction of the “joker” for the tibial cut. The cut is carried out either through the tibial guide or on the pins (our choice). We check that the cut is made consistent with our prediction surgically by placing a sensor on the tibia after the cut has been performed (Fig. 26.14).



**Fig. 26.14** Verification of the tibial cut with the specific sensor positioned on the cut



**Fig. 26.13** Setting up the tibial cutting guide with control of the varus/valgus, slope and height of cut

## Balancing

The 9 mm tibial spacer is used to evaluate knee balance before making the femoral cuts.

We check the balance in flexion first (Fig. 26.15). The computer shows the medial and lateral spaces as well as the planned femoral cut. We need a minimum space of 19 mm (9 mm tibial space and 10 mm for the femoral cuts). We can perform if necessary a medial or lateral release to balance the space in flexion.

We then check the spaces in extension (Fig. 26.16). The computer shows the medial and lateral spaces as well as the planned femoral cut. We need a minimum space of 19 mm (9 mm tibial space and 10 mm for the femoral cuts).

The positioning is validated (varus/valgus and flexion contracture) and the size of the femoral implant needed to obtain the desired mechanical axis of the femur is selected.

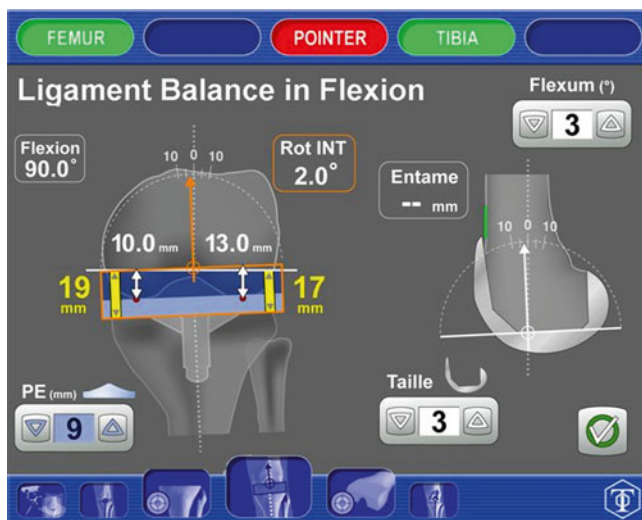


Fig. 26.15 Control spaces in flexion

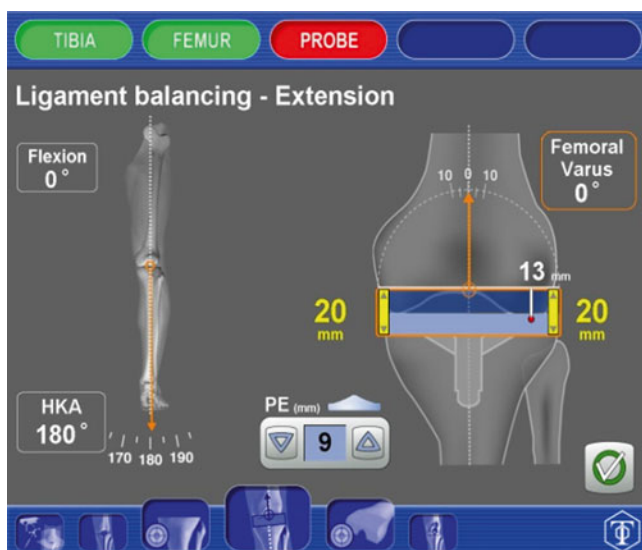


Fig. 26.16 Control spaces in extension

## Femoral Cut

The femoral guide is fixed by pins that are applied just above the intercondylar notch, above the insertion of the PCL. We control the proper positioning of the guide with a target sign on the screen. The center of the target is the correct positioning as defined in the previous step (varus/valgus and flexion contracture at 0°).

Then we adjusted the desired height of the femoral cut (usually 10 mm from the distal femur) (Fig. 26.17).

We can verify with the navigator that the cut performed is consistent with the programming (e.g., 0° flexion contracture and femoral mechanical axis of 90° by setting a specific device on the distal femoral guide).

The joker is then positioned to implement the two positioning pins of the 4-in-1 femoral cutting guide. It is applied to the distal femoral cut, and two hind legs are positioned in contact with both posterior condyles. Adjusting the rotation and especially the anterior-posterior positioning; according to the validated values at the time of equilibration. We can thus control the rotation, sizing, offset, and balancing in flexion without the use of compact multifunction cutting guide. Once positioning is controlled, we impact the two positioning pins and then remove the navigation, so we can apply the two pins on the 4-in-1 cutting guide, where four remaining femoral cuts are performed. The distal femoral cut is then controlled using the specific sensor (Fig. 26.18).

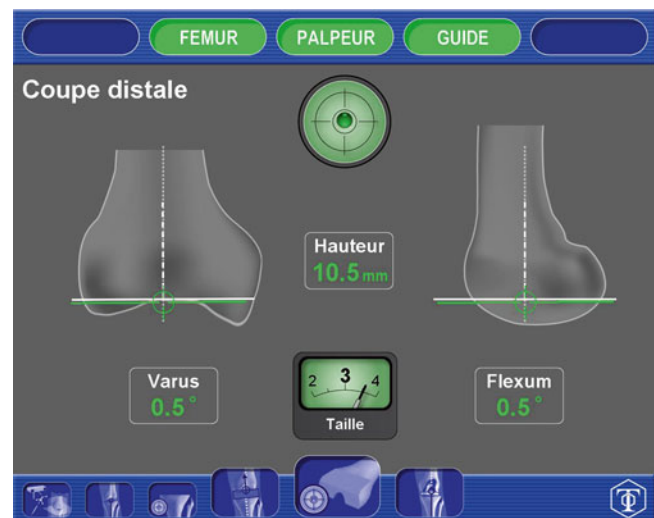
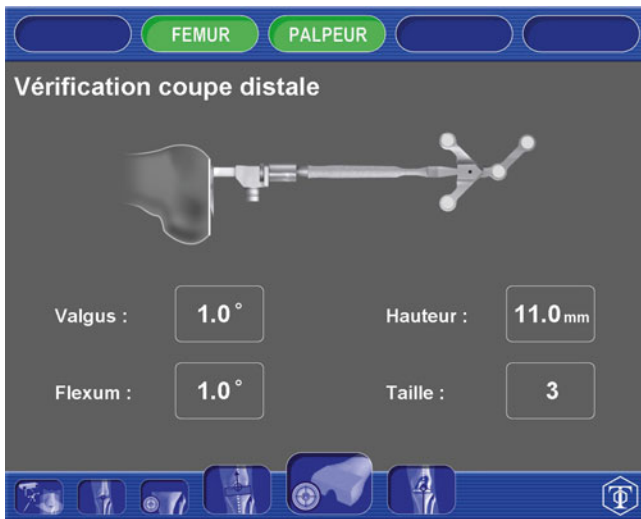

Fig. 26.17 Setting up the femoral cutting guide with control of the varus/valgus and of the flexion and the cutting height



**Fig. 26.18** Controlled femoral cut with the specific sensor positioned on the distal cut

## Trial

The trial parts are placed and we check the overall axis of the lower limb and laxity in flexion and extension (the same parameters at the beginning of the operation).

The patellar cut is not navigated.

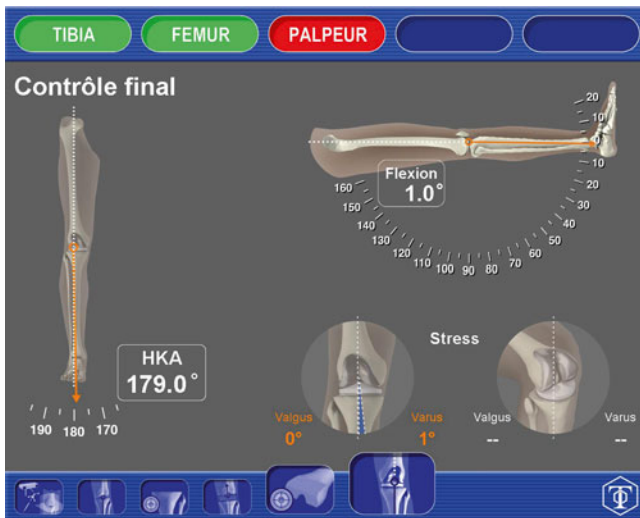

## Applying the Final Implants

The final implants are cemented in place. We can control the final positioning by the verification of the tibiofemoral axis, and once the cement hardens, we can evaluate the varus/valgus laxity (Fig. 26.19).

## Closure and Postoperative Care

All navigation pins are removed and closure and postoperative care proceed as for a non-navigated case.



**Fig. 26.19** Final check of the HKA angle, laxity in extension/flexion and maximal flexion