

Jacques Bernier
Editor

Head and Neck Cancer

Multimodality
Management

 Springer

Head and Neck Cancer

Jacques Bernier
Editor

Head and Neck Cancer

Multimodality Management

 Springer

Editor

Jacques Bernier, MD, PD
Department of Radio-Oncology
Genolier Swiss Medical Network
Geneva, Switzerland
and
Faculty of Medicine
University of Geneva
Geneva, Switzerland
jbernier@genolier.net

ISBN 978-1-4419-9463-9 e-ISBN 978-1-4419-9464-6

DOI 10.1007/978-1-4419-9464-6

Springer New York Dordrecht Heidelberg London

Library of Congress Control Number: 2011928238

© Springer Science+Business Media, LLC 2011

All rights reserved. This work may not be translated or copied in whole or in part without the written permission of the publisher (Springer Science+Business Media, LLC, 233 Spring Street, New York, NY 10013, USA), except for brief excerpts in connection with reviews or scholarly analysis. Use in connection with any form of information storage and retrieval, electronic adaptation, computer software, or by similar or dissimilar methodology now known or hereafter developed is forbidden.

The use in this publication of trade names, trademarks, service marks, and similar terms, even if they are not identified as such, is not to be taken as an expression of opinion as to whether or not they are subject to proprietary rights.

While the advice and information in this book are believed to be true and accurate at the date of going to press, neither the authors nor the editors nor the publisher can accept any legal responsibility for any errors or omissions that may be made. The publisher makes no warranty, express or implied, with respect to the material contained herein.

Printed on acid-free paper

Springer is part of Springer Science+Business Media (www.springer.com)

Preface

For the last two decades, the management of the head and neck cancers has been characterized by a number of profound mutations, both triggered by the willingness of oncologists to reshape significantly their conceptual approaches to locally advanced diseases and facilitated by the advent of new, more active drugs. Indeed, the potentialities of functional imaging, the significant progresses in conservative surgery and reconstruction, the acknowledged role of concurrent chemo-radiation, the investigational use of combined therapies for organ preservation, and the advent of targeted therapies are among the main tracks along which fundamental changes in philosophy of management have been recently observed. Coincident with this came the necessity to move progressively to a much more holistic approach, taking greater account of quality of life after treatment.

At the same time, it is important to remember that progress in head and neck cancer management is benefiting from an increasing understanding of all aspects involved in the development of these carcinomas, ranging from the molecular genetics of tumor growth to epidemiological and etiological factors, the role of which has been somewhat underestimated in the past, especially with respect to the natural history of the disease in individual patients.

Recently, intensive translational research in head and neck oncology yielded a large burden of significant laboratory discoveries and clinical breakthroughs. Paradoxically, these advances generated at the same time an often contradictory and confusing body of literature, which nevertheless emphasizes that, as red thread, the management of this disease must be *multidisciplinary*.

Therefore, there is room for a guide to contemporary management of head and neck cancer, and with this perspective, this textbook was designed and written with the intent of providing oncologists with a broad, comprehensive and balanced view of both consolidated and innovative concepts. Its objective is to help practitioners understand better the mechanisms that drive the development of head and neck cancer, as well as revisit the evidence-based data and complexities of decision-making in this field.

The first part of the textbook covers the vast domain that pertains to the scientific basis of head and neck oncology, ranging from epidemiology and etiology of these carcinomas to biomolecular mechanisms driving the cell malignant transformation and tumor growth. In particular, this book provides key information on those molecular analyses that are bound to pave the way, in head and neck oncology, for the eventual development of highly personalized future treatment strategies.

The second part reviews the key diagnosis modalities used in head and neck oncology, a field in which great progress is being made with not only a refinement of morphological imaging, but also an intensive preclinical and clinical research devoted to tumor metabolism. A greater understanding of the correlation between tumor types and patterns of spread will indeed allows clinicians to optimize combinations of treatments in each individual patient.

The book continues with a systematic account of the current management of individual cancers in function of their site of origin. The chapters of this third section of the textbook are organized to provide the readers with an exhaustive review of organ-oriented strategies. Each contribution explores the most recent evidence-based data and expert opinions, which reflect up-to-date diagnosis and treatment approaches.

The fourth and last part covers a number of issues worth considering in the comprehensive management of this disease, such as, quality assurance programs, patient rehabilitation, salvage treatments, and quality of life.

This textbook is aimed at showing how considerable are today's efforts toward improving treatment outcomes for head and neck cancer patients. This willingness to make significant and rapid progress probably derives from the fact that rarely in oncology are treatment failures more readily visible and functionally impairing than in these patients. This, together with the fact that head and neck cancer is a "big killer" worldwide, fully justifies the intensive translational and clinical research that fosters and optimizes our ways to plan and deliver treatments. Undoubtedly, these efforts allow investigators to take a number of significant steps forward, which foreshadow the implementation of treatment combinations *tailored* to each patient.

A timely account of our present knowledge of the principles and present day practice, this textbook reflects the considerable personal experiences of the experts who offer their contributions.

Without access to a multidisciplinary tumor board for guidance, many practitioners often remain confused about the appropriate therapy for patients with head and neck cancer. In this perspective too, we hope that this textbook will provide a source of knowledge and references not only to the established oncologist entrusted with the care of head and neck cancer patients, but also to the less experienced practitioner willing to get a better understanding of this multifaceted, complex field of oncology.

Geneva, Switzerland

Jacques Bernier

Contents

1	Epidemiology and Aetiology of Head and Neck Cancers	1
	Newell W. Johnson and Hemantha K. Amarasinghe	
2	Head and Neck Cancer Prevention	41
	Fausto Chiesa, Angelo Ostuni, Roberto Grigolato, and Luca Calabrese	
3	Cellular and Molecular Pathology of Head and Neck Tumors	57
	Adel K. El-Naggar	
4	Oncogenomics/Proteomics of Head and Neck Cancers	81
	Howard S. Moskowitz and Jennifer R. Grandis	
5	Genetics and Epigenetics of Head and Neck Cancer	93
	Richard J. Shaw and Jagtar Dhandra	
6	Immunology of Head and Neck Cancer	107
	Steve C. Lee and Robert L. Ferris	
7	HPV and EBV in Head and Neck Cancer	121
	Jeffrey Brumbaugh, Robert L. Ferris, and Shen Hu	
8	Head and Neck Cancer Staging and Prognosis: Perspectives of the UICC and the AJCC	135
	Brian O’Sullivan and Jatin P. Shah	
9	Biomarkers in Head and Neck Cancer	157
	John Wrangle, Shanthi Marur, and Arlene A. Forastiere	
10	Hypoxia in Head and Neck Cancers: Clinical Relevance and Treatment	169
	Yungan Tao and Jean Bourhis	
11	Translational Research in Head and Neck Oncology	179
	David S. Yoo and David M. Brizel	
12	Preclinical Models of Head and Neck Squamous Cell Carcinoma	191
	Michiel W.M. van den Brekel, C.L. Zuur, Stephen P. Malkoski, and Xiao-Jing Wang	
13	Morphologic Investigations in Head and Neck Cancer	201
	Suyash Mohan and Gaurang V. Shah	

14	Ultrasound Investigations in Head and Neck Cancer Patients	221
	Yolanda Y.P. Lee, K.T. Wong, Ann D. King, and Anil T. Ahuja	
15	Functional Imaging	235
	Ludwig G. Strauss and Antonia Dimitrakopoulou-Strauss	
16	Sentinel Node Biopsy for Head and Neck Cancer	241
	Lee Alkureishi and Gary L. Ross	
17	Approaches to Supportive Care	255
	Barbara A. Murphy	
18	Intensity-Modulated Radiation Therapy for Head and Neck Cancer	267
	Nancy Lee, Daniel Gomez, Edward J. Shin, and K.S. Clifford Chao	
19	Principles of Systemic Chemotherapy for Squamous Cell Head and Neck Cancer	281
	Cristina P. Rodriguez and David J. Adelstein	
20	Molecular Targeted Therapies in Head and Neck Cancer	293
	Vinai Gondi, Anne M. Traynor, and Paul M. Harari	
21	Phase I Study Methodology in Head and Neck Oncology	307
	Christophe Le Tourneau and Lillian L. Siu	
22	Evidence-Based Head and Neck Oncology: Principles and Pitfalls	317
	Søren M. Bentzen	
23	Programs of Organ and Function Preservation	327
	Jean-Louis Lefebvre	
24	Multidisciplinary Approach of Unresectable Head and Neck Cancer	333
	Ricardo Hitt, Blanca Homet, and Robert I. Haddad	
25	Laser Endoscopic Treatment	339
	Pierre R. Moreau and Pierre H. Demez	
26	Multidisciplinary Management of Skull Base and Superstructure Tumors	351
	Giulio Cantù, Carlo L. Solero, Stefano Riccio, Sarah Colombo, and Madia Pompilio	
27	Multidisciplinary Management of Oral Cavity and Maxillary Sinus Cancers	363
	Alexander D. Rapidis	
28	Management of Nasopharyngeal Carcinoma	381
	Anne W.M. Lee, Wai-Tong Ng, Tsz-Kok Yau, Stephen C.K. Law, and William I. Wei	
29	Multidisciplinary Management of Oropharynx Carcinomas	401
	Beth M. Beadle and David I. Rosenthal	
30	Multidisciplinary Management of Hypopharyngeal Carcinoma	431
	Marc Hamoir, Jean-Pascal Machiels, Sandra Schmitz, and Vincent Gregoire	

31 Cancers of the Larynx: Tis, T1, T2 Evaluation and Management	457
Carol M. Lewis, Ollivier Laccourreye, Randal S. Weber, and F. Christopher Holsinger	
32 Diagnosis and Multidisciplinary Treatment of Laryngeal Cancers	471
Nabil F. Saba, J. Trad Wadsworth, Jonathan J. Beitler, and Fadlo R. Khuri	
33 Principles and New Approaches in Surgical Reconstruction	483
Christina Kenney Magill and Bruce H. Haughey	
34 Multidisciplinary Treatment of the Neck	497
Remco de Bree, Johannes A. Langendijk, and C. René Leemans	
35 Postoperative Management of High-Risk Resectable Head and Neck Cancer	513
Jay S. Cooper	
36 Management of Salivary Gland Cancer	521
Laura D. Locati, Marco Guzzo, Patrizia Olmi, and Lisa Licitra	
37 Head and Neck Melanoma	533
Genevieve A. Andrews and Jeffery N. Myers	
38 Cervical Lymph Node Metastases of Squamous Cell Carcinoma from an Unknown Primary Site	547
Nicholas Pavlidis and George Plataniotis	
39 Management of Thyroid and Parathyroid Cancers	555
Ranee Mehra, Charu Aggarwal, and Roger B. Cohen	
40 Head and Neck Paragangliomas	569
Matthew O. Old and James L. Netterville	
41 Treatment of the Elderly Head and Neck Cancer Patient	581
Jean-Claude Horiot and Matti S. Apro	
42 Interstitial Radiation Therapy in Cancer of the Oropharynx and Oral Cavity	589
Peter C. Levendag, David N. Teguh, and Paul I.M. Schmitz	
43 Proton Beam Therapy for Head and Neck Cancer	605
Danielle N. Margalit, Judy A. Adams, and Annie W. Chan	
44 Normal Tissue Complications and Protection in Head and Neck Cancer Patients	613
Andy Trotti, Nikhil Rao, Avraham Eisbruch, and David I. Rosenthal	
45 Rehabilitation of Heavily Treated Head and Neck Cancer Patients	629
Rachael E. Kammer and JoAnne Robbins	
46 Salvage Therapy in Head and Neck Cancer Patients	641
Saba Aftab, Rod Rezaee, and Pierre Lavertu	

47	Systemic Treatment of Recurrent/Metastatic Squamous Cell Carcinoma of the Head and Neck	651
	Jan B. Vermorken	
48	Best Supportive Care for Palliative Treatment	665
	Michaela Salzwimmer	
49	Quality of Life in Head and Neck Cancer Patients	675
	Jolie Ringash	
50	Quality Assurance of Clinical Trials in the Management of Cancer in the Head and Neck	687
	Thomas J. FitzGerald, Maryann Bishop-Jodoin, Marcia M. Urie, Kenneth Ulin, Geoffrey S. Ibbott, James A. Purdy, Joel H. Saltz, Lester J. Peters, M. Giulia Cicchetti, Mitchell Schnall, Joseph Deasy, Walter R. Bosch, Michael V. Knopp, Lawrence H. Schwartz, Keith S. White, Richard Hanusik, Sandra K. Kessel, Karen Morano, and Fran Laurie	
	Index	695

Contributors

Matti S. Aapro, MD

IMO (Multidisciplinary Oncology Institute), Clinique de Genolier, Vaud, Switzerland

Judy A. Adams, CMD

Department of Radiation Oncology, Harvard Medical School, Massachusetts General Hospital, Boston, MA, USA

David J. Adelstein, MD

Department of Solid Tumor Oncology, Cleveland Clinic Taussig Cancer Center, Cleveland Clinic Lerner College of Medicine of Case Western Reserve University, Cleveland, OH, USA

Saba Aftab, MD

Department of Otolaryngology – Head and Neck Surgery, University Hospitals Case Medical Center, Cleveland, OH, USA

Charu Aggarwal, MD

Medical Oncology, Fox Chase Cancer Center, Philadelphia, PA, USA

Anil T. Ahuja, MD, FRCR

Department of Diagnostic Radiology and Organ Imaging, The Chinese University of Hong Kong, Hong Kong, China

Lee Alkureishi, MRCS, MBChB

Department of Plastic and Reconstructive Surgery, University of Chicago, Chicago, USA

Hemantha K. Amarasinghe, BDS, MSc, MD

School of Dentistry and Oral Health, University of Griffith, Southport, QLD, Australia

Genevieve A. Andrews, MD

Department of Head and Neck Surgery, UT MD Anderson Cancer Center, Houston, TX, USA

Beth M. Beadle, MD, PhD

Radiation Oncology Department, The University of Texas M. D. Anderson Cancer Center, Houston, TX, USA

Jonathan J. Beitler, MD, MBA, FACP

Department of Radiation Oncology and Otolaryngology, Emory University School of Medicine, Atlanta, GA, USA

Søren M. Bentzen, PhD, DSc

Department of Human Oncology, Medical Physics, and Biostatistics and Medical Informatics, University of Wisconsin–Madison, School of Medicine and Public Health, Madison, WI, USA

Jacques Bernier, MD, PD

Department of Radio-Oncology, Genolier Swiss Medical Network, Geneva, Switzerland;
University of Geneva, Geneva, Switzerland

Maryann Bishop-Jodoin, BS

Quality Assurance Review Center, Radiation Oncology, University of Massachusetts
Medical School, Lincoln, RI, USA

Walter R. Bosch, DSc

Quality Assurance Review Center, Radiation Oncology, University of Massachusetts
Medical School, Lincoln, RI, USA

Jean Bourhis, MD, PhD

Department of Radiotherapy, Institut Gustave Roussy, Villejuif, France

Remco de Bree, MD, PhD

Otolaryngology – Head and Neck Surgery Department, VU University Medical Center,
Amsterdam, The Netherlands

Michiel W.M.van den Brekel, MD, PhD

Otorhinolaryngology – Head and Neck Surgery Department, Netherlands Cancer Institute –
Antoni van Leeuwenhoek Hospital and Academic Medical Center,
University of Amsterdam, Amsterdam, The Netherlands

David M. Brizel, MD

Department of Radiation Oncology, Duke University Medical Center, Morris Building,
Science Drive, Durham, NC, USA

Jeffrey Brumbaugh

School of Dentistry, UCLA, Los Angeles, CA, USA

Luca Calabrese, MD

Department of Head and Neck Surgery, European Institute of Oncology, Milano, Italy

Giulio Cantù, MD

Department of Cranio-Maxillo-Facial Surgery, Fondazione IRCCS Istituto
Nazionale dei Tumori, National Cancer Institute, Via Venezian 1, Milano, Italy

Annie W. Chan, MD

Department of Radiation Oncology, Harvard Medical School, Boston, MA, USA

K.S. Clifford Chao, MD

Department of Radiation Oncology, Columbia University College of Physicians
and Surgeons, New York, NY, USA;
Division of Radiation Oncology, Weill Cornell College of Medicine, New York Presbyterian
Hospital, New York, NY, USA

Fausto Chiesa, MD

Department of Head and Neck Surgery, European Institute of Oncology, Milano, Italy

M. Giulia Cicchetti, MD

Quality Assurance Review Center, Radiation Oncology, University of Massachusetts
Medical School, Lincoln, RI, USA

Roger B. Cohen, MD

Medical Oncology, Fox Chase Cancer Center, Philadelphia, PA, USA

Sarah Colombo, MD

Department of Cranio-Maxillo-Facial Surgery, Fondazione IRCCS Istituto Nazionale
dei Tumori, National Cancer Institute, Milano, Italy

Jay S. Cooper, MD, FACR, FACRO, FASTRO

Maimonides Cancer Center, Brooklyn, NY, USA

Joseph Deasy, PhD

Quality Assurance Review Center, Radiation Oncology, University of Massachusetts Medical School, Lincoln, RI, USA

Pierre H. Demez, MD

Department of Otorhinolaryngology, University Hospital of Liege, Liege, Belgium

Jagtar Dhanda, BSc(Hons), MFDSRCS, MRCS

Oral and Maxillofacial Surgery, University Hospital Birmingham, Birmingham, UK

Antonia Dimitrakopoulou-Strauss, MD

CCU Nuclear Medicine, German Cancer Research Center, Heidelberg, BW, Germany

Avraham Eisbruch, MD

Department of Radiation Oncology, University of Michigan, Ann Arbor, MI, USA

Adel K. El-Naggar, MD, PhD

Department of Pathology, The University of Texas M.D. Anderson Cancer Center, Houston, TX, USA

Robert L. Ferris, MD, PhD

University of Pittsburgh Cancer Institute, Pittsburgh, PA, USA

Thomas J. FitzGerald, MD, BS

Department of Radiation Oncology, University of Massachusetts Medical School, UMass Memorial Medical Center, QARC, Suite 201, Lincoln, RI, USA

Arlene A. Forastiere, MD

Oncology Department, Johns Hopkins University, School of Medicine, Bunting/Blaustein Cancer Research Building, Baltimore, MD, USA

Daniel Gomez, MD

Radiation Oncology, The University of Texas MD Anderson Cancer Center, Houston, TX, USA

Vinai Gondi, MD

Department of Human Oncology, University of Wisconsin Comprehensive Cancer Center, Madison, WI, USA

Jennifer R. Grandis, MD

Eye & Ear Institute, Pittsburgh, PA, USA

Vincent Gregoire, MD, PhD, Hon. FRCR

Radiation Oncology, Centre du Cancer, Universite Catholique de Louvain – Cliniques Universitaires Saint-Luc, Brussels, Belgium

Roberto Grigolato

Department of Head and Neck Surgery, European Institute of Oncology, Milano, Italy

Marco Guzzo, MD

Board Certified in Otorhinolaryngology and Maxillo Facial Surgery, Department of Surgery, Fondazione IRCCS-Istituto Nazionale Dei Tumori, Milan, Italy

Robert I. Haddad, MD

Department of Medical Oncology, Dana-Farber Cancer Institute, Boston, MA, USA

Marc Hamoir, MD

Head and Neck Surgery, Université Catholique de Louvain,
St. Luc University Hospital and Cancer Center, Brussels, Belgium

Richard Hanusik, AB

Quality Assurance Review Center, Radiation Oncology,
University of Massachusetts Medical School, Lincoln, RI, USA

Paul M. Harari, MD

Department of Human Oncology, University of Wisconsin Comprehensive Cancer Center,
Madison, WI, USA

Bruce H. Haughey, MBChB

Department of Otolaryngology, Head and Neck Surgery,
Washington University School of Medicine, St. Louis, MO, USA

Ricardo Hitt, MD, PhD

Medical Oncology, 12 de Octubre Madrid, Madrid, Spain

F. Christopher Holsinger, MD

Department of Head and Neck Surgery, The University of Texas M.D. Anderson Cancer Center,
Houston, TX, USA

Blanca Homet, MD

Medical Oncology, 12 de Octubre Madrid, Madrid, Spain

Jean-Claude Horiot, MD, PhD

Clinique de Genolier, Institut Multidisciplinaire d'Oncologia, Genolier, Vaud, Switzerland

Shen Hu, PhD

School of Dentistry and Jonsson Comprehensive Cancer Center, UCLA,
Los Angeles, CA, USA

Geoffrey S. Ibbott, PhD

Quality Assurance Review Center, Radiation Oncology, University of Massachusetts
Medical School, Lincoln, RI, USA

Newell W. Johnson, MDS, PhD, FDSRCS, FRACDS, FCRPath, FFOP(RCPA), FMedSci

Griffith Health Institute and School of Dentistry and Oral Health, Griffith University,
Queensland, Australia

Rachael E. Kammer, MS, CCC-SLP, BRS-S

Department of Surgery, University of Wisconsin, Madison, WI, USA

Sandra K. Kessel, BA

Quality Assurance Review Center, Radiation Oncology, University of Massachusetts
Medical School, Lincoln, RI, USA

Fadlo R. Khuri, MD

Department of Hematology and Medical Oncology, Emory University, Atlanta, GA, USA

Ann D. King, MRCP, FRCR

Department of Diagnostic Radiology and Organ Imaging, The Chinese University
of Hong Kong, Hong Kong, China

Michael V. Knopp, MD, PhD

Quality Assurance Review Center, Radiation Oncology, University of Massachusetts
Medical School, Lincoln, RI, USA

Ollivier Laccourreye, MD

Serviced'Oto-Rhino-Laryngologie et Chirurgie Cervico-Faciale, Hôpital Européen
Georges-Pompidou, Assistance Publique des Hôpitaux de Paris, Paris, France

Johannes A. Langendijk, MD, PhD, MSc

Department of Radiation Oncology, University Medical Center Groningen, Groningen, The Netherlands

Fran Laurie, BS

Quality Assurance Review Center, Radiation Oncology, University of Massachusetts Medical School, Lincoln, RI, USA

Pierre Lavertu, MD, FRCS©, FACS

Department of Otolaryngology, Head and Neck Surgery, University Hospitals Case Medical Center, Cleveland, OH, USA

Stephen C.K. Law, MBBS, DMRT, FRCR, FHKCR, FHKAM(Radiology)

Clinical Oncology, Queen Elizabeth Hospital, Hong Kong, China

Anne W.M. Lee, MD, FRCR

Clinical Oncology, Pamela Youde Nethersole Eastern Hospital, Chai Wan, Hong Kong, China

Nancy Lee, MD

Radiation Oncology, Memorial Sloan-Kettering Cancer Center, New York, NY, USA

Steve C. Lee, MD, PhD

Otolaryngology – Head and Neck Surgery, Loma Linda University, Loma Linda, CA, USA

Yolanda Y.P. Lee, MBChB, FRCR

Department of Diagnostic Radiology and Organ Imaging, The Chinese University of Hong Kong, Hong Kong, China

C. René Leemans, MD, PhD

Otolaryngology/Head and Neck Surgery, VU University Medical Center, Amsterdam, The Netherlands

Jean-Louis Lefebvre, MD

Head and Neck Department, Centre Oscar Lambret, Lille, France

Peter C. Levendag, MD, PhD

Department of Radiation Oncology, Erasmus MC – Daniel den Hoed Cancer Center, Rotterdam, The Netherlands

Carol M. Lewis, MD, MPH

Department of Head and Neck Surgery, The University of Texas M.D. Anderson Cancer Center, Houston, TX, USA

Lisa Licitra, MD

Department of Medical Oncology, IRCCS Fondazione Istituto Nazionale Tumori, Milan, Italy

Laura D. Locati, MD

Department of Medical Oncology, Fondazione IRCCS-Istituto Nazionale Dei Tumori, Milan, Italy

Jean-Pascal Machiels, MD, PhD

Medical Oncology, Centre du Cancer Université Catholique de Louvain – Cliniques Universitaires Saint-Luc, Brussels, Belgium

Christina Kenney Magill, MD

Department of Otolaryngology, Head and Neck Surgery, Washington University School of Medicine, St. Louis, MO, USA

Stephen P. Malkoski, MD, PhD

Division of Pulmonary Sciences and Critical Care Medicine, University of Colorado Anschutz Medical Center, Aurora, CO, USA

Danielle N. Margalit, MD, MPH

Department of Radiation Oncology, Harvard Medical School,
Massachusetts General Hospital, Boston, MA, USA

Shanthi Marur, MD, MBBS

Oncology Department, Johns Hopkins University, School of Medicine, Baltimore, MD, USA

Ranee Mehra, MD

Medical Oncology, Fox Chase Cancer Center, Philadelphia, PA, USA

Suyash Mohan, MD

Radiology Department, University of Michigan, Ann Arbor, MI, USA

Karen Morano, CMD

Quality Assurance Review Center, University of Massachusetts Medical School,
Lincoln, RI, USA

Pierre R. Moreau, MD, PhD

Department of Otorhinolaryngology, University Hospital of Liege, Liege, Belgium

Howard S. Moskowitz, MD, PhD

Otolaryngology Department, University of Pittsburgh Medical Center, Pittsburgh, PA, USA

Barbara A. Murphy, MD

Pain and Symptom Management Program, Internal Medicine, Vanderbilt Ingram Cancer
Center, Nashville, TN, USA

Jeffrey N. Myers, MD, PhD, FACS

Department of Head and Neck Surgery, UT MD Anderson Cancer Center,
Houston, TX, USA

James L. Netterville, MD

Otolaryngology and Hearing & Speech Sciences, Vanderbilt Bill Wilkerson Center,
Nashville, TN, USA

Wai-Tong Ng, MD, FRCR

Clinical Oncology, Pamela Youde Nethersole Eastern Hospital, Chai Wan,
Hong Kong, China

Brian O'Sullivan, MD, FRCPC, FRCPI, FFRFRC SI (Hon)

Head and Neck Oncology Program, Department of Radiation Oncology,
Princess Margaret Hospital, Toronto, ON, Canada

Matthew O. Old, MD

Department of Otolaryngology – Head and Neck Surgery, The James Cancer Hospital
and Solove Research Institute at the Ohio State University Comprehensive Cancer Center,
Columbus, OH, USA

Patrizia Olmi, MD

Radiotherapy Unit, Imaging Diagnostic, Nuclear Medicine and Radiation Therapy
Department, Fondazione IRCCS-Istituto Nazionale Dei Tumori, Milan, Italy

Angelo Ostuni, MD

Department of Head and Neck Surgery, European Institute of Oncology, Milano, Italy

Nicholas Pavlidis

University of Ioannina, Av. S. Niarchos, Ioannina, Greece

Lester J. Peters, MD

Quality Assurance Review Center, Radiation Oncology, University of Massachusetts
Medical School, Lincoln, RI, USA

George Plataniotis, MD, PhD

Oncology Department, Aberdeen Royal Infirmary, Aberdeen, UK

Madia Pompilio, MD

Department of Cranio-Maxillo-Facial Surgery, Fondazione IRCCS Istituto Nazionale dei Tumori, National Cancer Institute, Milano, Italy

James A. Purdy, PhD

Quality Assurance Review Center, Radiation Oncology, University of Massachusetts Medical School, Lincoln, RI, USA

Nikhil Rao, MD

Radiation Oncology Department, H. Lee Moffitt Cancer Center and Research Institute, Tampa, FL, USA

Alexander D. Rapidis, MD, DDS, PhD, FACS

Eastman Dental Institute, University College London, London, UK;
Department of Head and Neck/Maxillofacial Surgery, Greek Anticancer Institute, Sant Savvas Hospital, Athens, Greece

Rod Rezaee, MD, FACS

Department of Otolaryngology – Head and Neck Surgery, University Hospitals Case Medical Center, Cleveland, OH, USA

Stefano Riccio, MD

Department of Cranio-Maxillo-Facial Surgery, Fondazione IRCCS Istituto Nazionale dei Tumori, National Cancer Institute, Milano, Italy

Jolie Ringash, BSc, MD, MSc, FRCP©

Department of Radiation Oncology, The Princess Margaret Hospital, Toronto, ON, Canada

JoAnne Robbins, PhD

Department of Medicine, University of Wisconsin, Madison, WI, USA;
Geriatric Research Education and Clinical Center (GRECC),
William S. Middleton Memorial Veterans Hospital, Madison, WI, USA

Cristina P. Rodriguez, MD

Taussig Cancer Institute, Cleveland Clinic, Cleveland, OH, USA

David I. Rosenthal, MD

Radiation Oncology Department, The University of Texas M. D. Anderson Cancer Center, Houston, TX, USA

Gary L. Ross, MBChB, MD, FRCS(Plast)

Plastic Surgery Department, The Christie, Manchester, UK

Nabil F. Saba, MD, FACP

Department of Hematology and Medical Oncology, Emory University School of Medicine, Atlanta, GA, USA;
Aerodigestive Malignancies Program, Winship Cancer Institute, Emory University, Atlanta, GA, USA

Joel H. Saltz, MD, PhD

Quality Assurance Review Center, Radiation Oncology, University of Massachusetts Medical School, Lincoln, RI, USA

Michaela Salzwimmer, MD

Department of General ORL, H&NS, Medical University of Graz, Graz, Austria

Paul I.M. Schmitz, PhD

Biostatistics, Erasmus MC – Daniel den Hoed Cancer Center, Rotterdam, The Netherlands

Sandra Schmitz, MD

Head and Neck Surgery, Universite Catholique de Louvain, St Luc University Hospital and Cancer Center, Brussels, Belgium

Mitchell Schnall, MD, PhD

Quality Assurance Review Center, Radiation Oncology, University of Massachusetts Medical School, Lincoln, RI, USA

Lawrence H. Schwartz, MD

Quality Assurance Review Center, Radiation Oncology, University of Massachusetts Medical School, Lincoln, RI, USA

Gaurang V. Shah, MD

Radiology Department, University of Michigan, Ann Arbor, MI, USA

Jatin P. Shah, MD, PhD (Hon.), FACS, FRCS (Hon.), FRACS (Hon.), FDSRCS (Hon.)

Head and Neck Service, Department of Surgery, Memorial Sloan-Kettering Cancer Center, New York, NY, USA

Richard J. Shaw, MD, FRCS, FDS

Head and Neck Surgery, University of Liverpool, Liverpool, UK;
Oral & Maxillofacial Surgery, University Hospital Aintree, Liverpool, UK

Edward J. Shin, MD

Otolaryngology, New York Eye and Ear Infirmary, New York, NY, USA

Lillian L. Siu, MD

Division of Medical Oncology and Hematology, Princess Margaret Hospital, Toronto, ON, Canada

Carlo L. Solero, MD

Neurosurgery, Fondazione IRCCS Istituto Neurologico “C. Besta”, Milan, Italy

Ludwig G. Strauss, MD

CCU Nuclear Medicine, German Cancer Research Center, Heidelberg, BW, Germany

Yungan Tao, MD, PhD

Department of Radiotherapy, Institut Gustave Roussy, Villejuif, France

David N. Teguh, MD

Department of Radiation Oncology, Erasmus MC – Daniel den Hoed Cancer Center, Rotterdam, The Netherlands

Christophe Le Tourneau, MD

Division of Medical Oncology, Institut Curie Paris, France

Anne M. Traynor, MD

Department of Human Oncology, University of Wisconsin Comprehensive Cancer Center, Madison, WI, USA

Andy Trotti, MD

Radiation Oncology Department, H. Lee Moffitt Cancer Center and Research Institute, Tampa, FL, USA

Kenneth Ulin, PhD

Quality Assurance Review Center, Radiation Oncology, University of Massachusetts Medical School, Lincoln, RI, USA

Marcia M. Urie, PhD

Quality Assurance Review Center, Radiation Oncology, University of Massachusetts Medical School, Lincoln, RI, USA

Jan B. Vermorken, MD, PhD

Medical Oncology Department, Antwerp University Hospital, Edegem, Belgium

J. Trad Wadsworth, MD

Otolaryngology – Head and Neck Surgery, Emory University, Atlanta, GA, USA

Xiao-Jing Wang, MD, PhD

Department of Pathology, University of Colorado, Denver, Aurora, CO, USA

Randal S. Weber, MD, FACS

Department of Head and Neck Surgery, The University of Texas M.D. Anderson Cancer Center, Houston, TX, USA

William I. Wei, MS, FRCS, FRCSE, FRACS(Hon), FACS, FHKAM(ORL)(SURG)

Surgery, The University of Hong Kong, Queen Mary Hospital, Hong Kong, China

Keith S. White, MD

Quality Assurance Review Center, Radiation Oncology, University of Massachusetts Medical School, Lincoln, RI, USA

K.T. Wong, MBChB, FRCR

Department of Diagnostic Radiology and Organ Imaging, The Chinese University of Hong Kong, Hong Kong, China

John Wrangle, MD, MPH

Oncology Department, Johns Hopkins University, School of Medicine, Baltimore, MD, USA

Tsz-Kok Yau, MD, FRCR

Clinical Oncology, Pamela Youde Nethersole Eastern Hospital, Chai Wan, Hong Kong, China

David S. Yoo, MD, PhD

Department of Radiation Oncology, Duke University Medical Center, Durham, NC, USA

C.L. Zuur, MD, PhD

Head and Neck Surgery, Oncology, The Dutch Cancer Institute – Antoni van Leeuwenhoek Hospital, Amsterdam, The Netherlands

Chapter 1

Epidemiology and Aetiology of Head and Neck Cancers

Newell W. Johnson and Hemantha K. Amarasinghe

Abstract Malignant neoplasms of the head and neck are among the most common in the world and constitute a major public health problem in most countries. Over 90% of these are squamous cell carcinomas arising in the mucous membranes of the upper aerodigestive tract (UADT). Their epidemiology and aetiology are considered in detail. We separate nasopharyngeal cancer, because it has a specific aetiology related to Epstein-Barr Virus (EBV) infection and dietary carcinogens. We then add those sites with the common major risk factors of alcohol, tobacco (including betel quid/areca nut habits) and diets poor in antioxidants and vitamins, and a minor role for Human Papillomavirus (HPV). Collectively, these UADT sites of oral cavity (including tongue), other pharynx, and larynx have a male incidence/mortality of 15.2/8.1 and for females of 4.6/2.4 cases per 100,000 pa. This ranks UADT cancer as the sixth most common site for men, eighth for women. Adding nasopharynx pushes head and neck cancer higher up the scale. If oesophagus were to be included as another alcohol and tobacco-related cancer, the rates add to 28.6/18.9 and 10.1/6.8 respectively. These cancers – which might be termed cancers of the mouth, throat and gullet – then rank second only to lung cancer in men, and fourth after breast, uterine cervix and large bowel in females, worldwide.

Detailed data are presented on geographical, ethnic, gender and time differences. The highest rates in the world are found in Melanesia, South Asia, parts of France, and much of Eastern Europe and the former Soviet republics. Many of these areas are showing rising trends, with a shift to involvement of younger individuals. This, and the fact that survival rates have improved little or not at all in much of the world over several decades, emphasises the need for effective primary and secondary prevention strategies – and for improved public policy to implement these.

N.W. Johnson (✉)
Griffith Health Institute and School of Dentistry and Oral Health,
Building GO5, Room 3.22a, Gold Coast
Campus, Griffith University, Queensland 4222, Australia
e-mail: n.johnson@griffith.edu.au

Keywords Cancer • Head and neck • Upper aerodigestive tract • Mouth • Larynx • Nasopharynx • Tobacco • Alcohol • Nutrition • Human papillomavirus (HPV)

Introduction and Scope

The term *Head and Neck [H&N] Cancer* is usually taken to cover the range of malignant neoplasms of soft tissue origin that develop in the oral cavity including the lips, nasal cavity, paranasal sinuses, pharynx, larynx and salivary glands. The skin will be included in many descriptions, but not usually ocular and intracranial neoplasms, nor those of endocrine or lymphatic origin – thus excluding thyroid and parathyroid cancers, and lymphomas. Sarcomas, though more rare, must be included among these soft tissue neoplasms of the head and neck, be they of connective tissue, neural or vascular origin.

Summary data will be given on primary bone “tumours” and on those of odontogenic origin, though their pathology and management are not covered in detail in this volume. Readers are referred to the several excellent modern textbooks of surgical pathology and of oral and maxillofacial pathology: especially recommended are Fletcher DEM, Ed, *Diagnostic Histopathology of Tumours*, 3rd Edn., Elsevier 2007 and Gnepp DR, Ed., *Diagnostic Surgical Pathology of the Head and Neck*, 2nd Edn. Elsevier 2009. Reliable concise accounts created by a team of international experts appear in the series of WHO “blue books”, viz: *Pathology and Genetics of Head and Neck Tumours*, Brown L et al. Eds., IARC Press, 2005.

Metastases from distant primaries to the jaws (and occasionally to mucous membranes), must always be considered.

Most head and neck cancers, indeed 95% or more, are squamous cell carcinomas (SCC) and variants thereof, originating from the epithelium of the mucosal lining of the upper aerodigestive tract (UADT), and adenocarcinomas from associated secretory glands. Carcinomas everywhere in the head and neck spread readily to the lymph nodes of the neck, and this is often the first (and sometimes only) manifestation of the disease at the time of presentation. Head and neck

SCC is strongly associated with certain environmental and lifestyle risk factors, notably tobacco use, smoked and “smokeless”, heavy alcohol consumption, diets poor in antioxidant vitamins and minerals, UV light and occupational exposures to radiation or chemical carcinogens and, increasingly to certain viruses, perhaps sexually transmitted, notably “high-risk” genotypes of the human papillomavirus family (particularly HPV 16 and 18, and particularly when originating in the tonsil and elsewhere in the oropharynx), and some human herpes viruses (HHVs: Epstein-Barr virus with nasopharyngeal carcinoma and HHV-8 with Kaposi sarcoma at all sites): there is a modest inherited susceptibility.

SCC of the H&N are frequently aggressive in their biologic behaviour: patients with many of these types of cancer have very destructive disease above the clavicle, develop local (cervical) lymph node metastases early, develop distant metastases over time – even following effective local therapy, and a high proportion have recurrence of the primary lesion and/or develop a second primary neoplasm. This is especially so if risky life-styles continue: UADT cancers ought in fact to be considered systemic diseases; not only is there “field of change” with molecular lesions involving much or all of the regional mucosae, but also damage to the immune system and host defenses generally, and damage to key organs especially the liver. Indeed co-morbidities are common – especially respiratory and cardiovascular – resulting from common risk factors, especially tobacco and alcohol abuse, and poor nutrition.

H&N SCC is curable if detected early, usually with some form of surgery. For more advanced lesions, in modern best practice, surgery is usually accompanied by preceding or subsequent radiotherapy, with or without adjuvant chemotherapy. We are now entering an era of individualised biotherapies for many cancers, based on understanding of the precise molecular aberrations within a given neoplasm, and of the patient’s individual genetic polymorphisms, though such approaches have not yet been extensively trialled.

The evidence base as it was earlier this decade, with a focus on oral cancer, is exhaustively presented in Shah JP, Johnson NW & Batsakis JG, *Oral Cancer*, Martin Dunitz London/Thieme New York, 2003.

History

Evidence of head and neck malignancies has been found in ancient skulls. The oldest known tumour is contained in a fossil found in East Africa by Leakey that dates back more than 500,000 years. Some historians speculate that a high incidence of nasal cancer may have been present in some ancient populations because of the inhalation of wood smoke

in poorly ventilated huts. In approximately 400 BC, Hippocrates described a common chronic ulcer at the edge of the tongue that he attributed to the presence of sharp teeth rubbing against the tongue: a challenge to differential diagnosis which is still real today!

The ancient Indian physician Sushruta described the removal of tumours and developed great skill in plastic surgery, partly from defects created by frequent amputations of the nose and ears for punishments. Modern Western Medicine received its foundation from early Roman medical writings. Little medical advancement was made for head and neck cancers until the advent of anaesthesia and surgical excision in the eleventh century.

Cancer Registries

Cancer registries play a vital role in monitoring the incidence of and mortality from cancers. However, the quality of data available in many registries can be far from ideal. Furthermore, many parts of the world produce no data at all, in others (often among the most populous), the data may come from localised, atypical regions. Hospital-based cancer registries naturally gather biased information – those cases which present to hospital only; thus, in many developing countries, cases may not come to attention at all, either because of fear or the inability of poor people to access hospital services. Data may be even more unreliable because in many developing countries follow-up, even of treated cases, is impossible. Death certification is not always compulsory and there is limited international standardisation in the categories for cause of death, let alone calibration of those signing death certificates.

Fortunately, many nations have high quality national, often incorporating regional, population-based cancer registries, with compulsory reporting of all malignancies. These are guided by, and quality-assured by, both national authorities and the positive influence of the World Health Organisation (WHO), mostly through its constituent body, the International Agency for Research on Cancer headquartered in Lyon, France. Data from all over the world are collated and are available from the websites of both these bodies: this includes free access to programmes that allow online interrogation of the databases. Many of the tables and graphs in this chapter have been generated in this way. Within the USA, the SEER website provides similar sophisticated opportunities to registered users (SEER is the Surveillance, Epidemiology and End Results program of the National Cancer Institute. It is based on data from, nowadays, 18 population-based registries described at <http://seer.cancer.gov/registries/list.html>).

Why Collect Detailed Epidemiological Data?

Cancer epidemiology is a demanding but essential science. Some acquaintance with epidemiological method and data is required by all who participate in cancer care, from politicians, public health officials, hospital managers, individual clinicians in both general and the wide range of specialist practitioners concerned with diagnosis and treatment, palliative carers, nurses, speech and swallowing therapists, dieticians, social workers to spiritual advisors. *Descriptive epidemiology* provides the fundamental evidence base, but its value is dependent on the accuracy and completeness of the information therein: reliable, sufficiently detailed and safely stored hospital-based information is *sine qua non*. Increasingly, hospital records contain information on lifestyle and other known or suspected risk factors: the growth of biological “tumour banks” or “tissue banks” from which molecular markers and indeed molecular mechanisms can be researched is encouraging, but needs much more co-ordinated international action.

Population-based registries, as described above, are of even greater value. These permit *analytical epidemiology*, and thus the ability to address essential questions such as: Why is the incidence of a particular type or site of neoplasm rising or falling over time or in a particular ethnic group or age group? How should this inform government and public health policy? Are existing public awareness and screening campaigns effective and efficient? How do different treatment modalities compare? How does my hospital or my personal clinical practice compare to the national average or

world best practice? In respect of the latter, there is an ethical imperative for every clinician to keep detailed records, using standardised measures, of the outcomes of his or her care. Guidelines for Care Pathways and “Minimum Data-Sets” to facilitate quality control and recording of outcomes are available: those from the British Association of Head and Neck Oncologists (<http://www.bahno.org.uk/docs/>) and from the American Head and Neck Society (<http://www.headandneckcancer.org/>) can be recommended. In many countries, cancer is a notifiable disease and both the registration of all cases, and the provision of information on the patient, on the care provided, and on the outcomes – not just survival rates but information on complications and on quality-of-life measures – is mandatory.

The Global Scenario of Head and Neck Cancer: Differences by Country

Head and neck cancer is the sixth most common type of cancer, representing about 6% of all cases and accounting for an estimated 650,000 new cases and 350,000 cancer deaths worldwide every year [1]. Figure 1.1 compares several H&N cancers with cancers affecting other body sites: age-adjusted global incidence and mortality rates are given for males and females; males predominate in all H&N sites.

Head and Neck Cancers are among the Top Ten in the World: We separate nasopharyngeal cancer, because it has a specific aetiology related to EBV infection and dietary

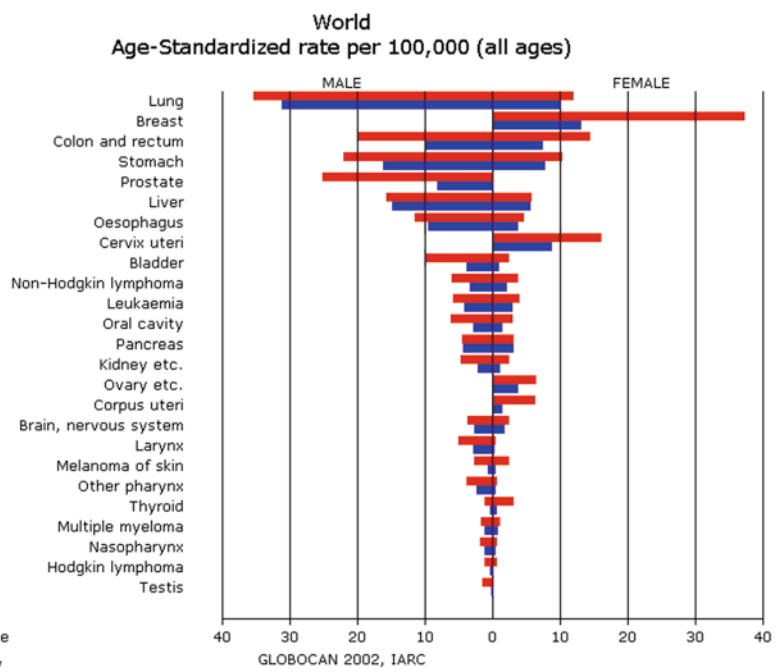


Fig. 1.1 Global scenario of age-standardised cancer incidence and mortality rates per 100,000 population

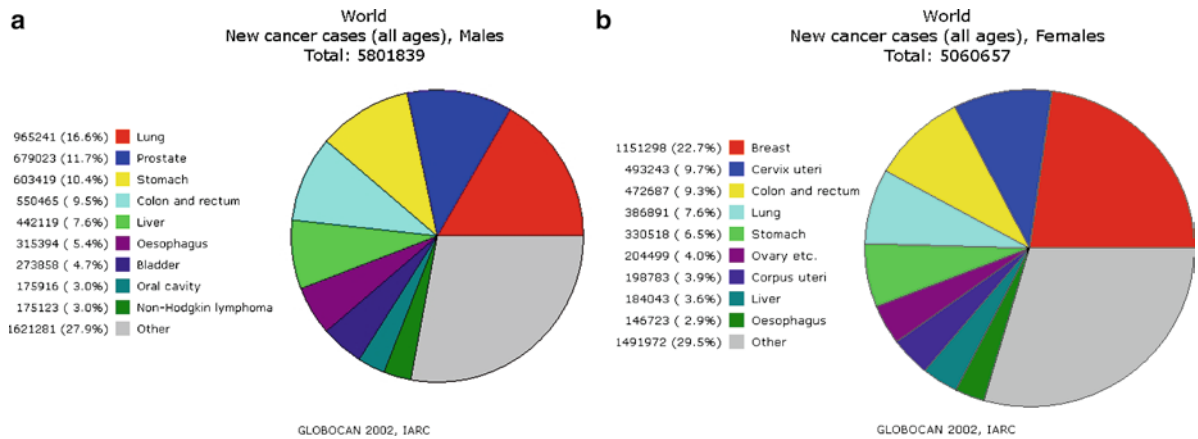


Fig. 1.2 Simple pie charts of the estimated number of new cases of cancer in the world in 2002, derived from the Globocan 2002 database, divided into the nine most common sites in males (a) and females (b). Note that oral cavity appears in eighth place for males

carcinogens. We then add together those sites with the common major risk factors of alcohol, tobacco and diets poor in antioxidants and vitamins, and a minor role for HPVirus – collectively termed *upper aerodigestive tract cancer (UADT)*: these sites are oral cavity (including tongue), other pharynx, and larynx. Male incidence/mortality is then 15.2/8.1 and female 4.6/2.4 cases per 100,000 pa. This would rank men approximately sixth in the table; women approximately eighth. Adding nasopharynx pushes head and neck cancer higher up the scale. If oesophagus were to be included as another alcohol and tobacco-related cancer, the rates add to 28.6/18.9 and 10.1/6.8, respectively. These cancers – which might be termed *cancers of the mouth, throat and Gullet* – then rank second only to lung cancer in men, and fourth after breast, uterine cervix and large bowel in females worldwide (Fig. 1.2a, b).

The geographical patterns of oral cancers are indicative of differences in the prevalence of risk factors among countries; tobacco and alcohol consumption, and quality of diet, in particular. Two-thirds of these malignancies occur in developing countries; and a high incidence continues to be observed in the Indian Subcontinent.

According to GLOBOCAN 2002, the highest incidence of oral cancer is found in Melanesia (astounding rates of 31.5 per 100,000 in men and 20.2 per 100,000 in women) [2]. In India alone, over 100,000 cases of oral cancer are registered every year. Though men predominate overall, among females, a very high incidence is found throughout southern Asia (8.3 per 100,000). In terms of countries, Sri Lanka has the highest incidence of oral cancer in the South Asia region. Poor access to health services contributes to high mortality.

Data extracted from the Cancer Incidence in Five Continents Database for the period 1998–2002 [3] also facilitate a global overview. When considering oral and pharyngeal cancer, the annual estimated incidence is around

275,000 cases for oral and 130,300 for pharyngeal cancers *excluding nasopharynx*: two-thirds of these cases occurring in developing countries [2]. There is a wide geographical variation in the incidence of oral cancer, nasopharyngeal cancer, other pharynx and larynx (Table 1.1).

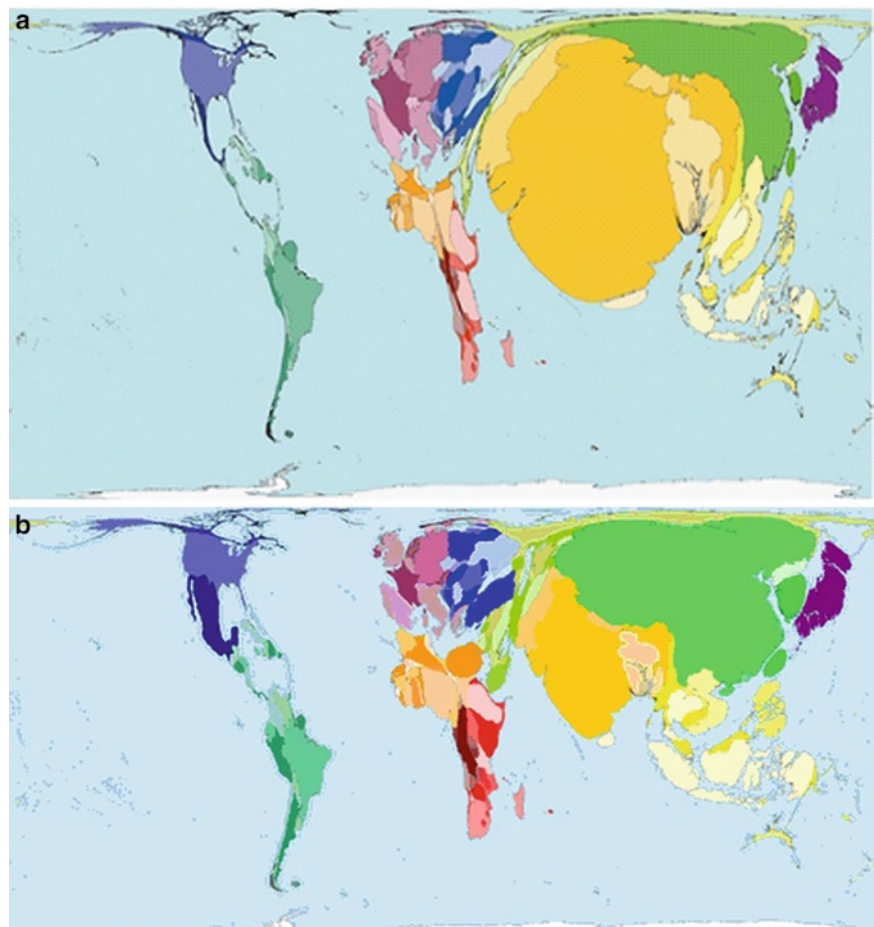
For oral cancer, the highest crude rates in the world are found in Melanesia, Hungary, France, Sri Lanka and Croatia [2]. There are marked differences among countries in the same geographical region [4, 5]. The extremely high rates in the relatively small populations of the Melanesian Islands have not been comprehensively researched, but good data from Papua New Guinea (see below) define the importance of areca nut (betel) chewing (called Buai in PNG) and smoking habits as the major risk factors.

The World maps reproduced below (Figs. 1.3–1.9), though simplifying data by aggregation to national averages, contain important information. As with the tables, maps are shown for each of the important head and neck sites. It has been apparent for decades that the global picture for head and neck cancer is dominated by the incidence of oral cancer in southern Asia and of oral cavity plus nasopharyngeal cancer in East Asia. In the 1980s, in India, Bangladesh, Pakistan and Sri Lanka, oral cancer was the most common site and accounted for about one-third of all cancers [6–8]. However, this proportion has fallen, mainly due to increased detection of other cancers by more extensive screening programmes and improved techniques [8]. Even within the subcontinent, there are striking differences in incidence rates. The highest rate for tongue and mouth is reported for men living in South Karachi, Pakistan; the second highest in Trivandrum city, Kerala, India. Extremely high rates for women are seen in the Tamil community in Malaysia – higher even than in Tamil Nadu itself: UADT sites in Indian females in Peninsular Malaysia are the second most common cancer, behind breast and above uterine cervix [9].

Table 1.1 World standardised *incidence* rates per 100,000 for H&N cancers. Data derived from the Globacan 2002 database: anatomic descriptors derived therefrom [2]

Country	Oral cavity		Nasopharynx		Other pharynx		Larynx	
	Male	Female	Male	Female	Male	Female	Male	Female
World	6.3	3.2	1.9	0.8	3.8	0.8	5.1	0.6
More developed	7.9	2.4	0.7	0.2	5.1	0.8	6.9	0.7
Less developed	5.7	3.5	2.4	1.0	3.4	0.8	4.3	0.6
Eastern Africa	5.9	4.8	2.3	0.9	1.6	0.5	3.5	0.7
Middle Africa	4.4	2.2	0.8	0.2	1.2	1.1	2.6	0.8
Northern Africa	3.1	1.5	2.7	1.1	1.0	0.2	4.0	0.6
Southern Africa	11.1	3.1	1.6	0.4	2.0	0.4	6.5	0.9
Western Africa	2.5	1.3	1.7	0.7	0.8	0.2	2.0	0.3
Caribbean	5.6	2.3	0.6	0.2	4.3	1.2	7.3	1.2
Central America	2.5	1.4	0.4	0.2	1.7	0.6	5.0	0.4
South America	6.1	1.8	0.3	0.1	3.5	0.7	7.2	0.7
Northern America	7.8	3.3	0.6	0.2	4.2	0.9	5.8	1.2
Eastern Asia	1.5	1.0	3.3	1.5	0.7	0.1	2.0	0.3
Southeastern Asia	3.6	2.5	5.8	2.1	2.2	0.7	3.7	0.5
South Central Asia	12.7	8.4	0.7	0.3	8.8	2.0	6.9	1.0
Western Asia	3.7	2.3	1.6	0.6	0.7	0.4	7.2	1.2
Central and eastern Europe	8.6	1.6	0.6	0.2	5.4	0.5	9.2	0.4
Northern Europe	5.3	2.6	0.4	0.2	2.6	0.7	4.3	0.7
Southern Europe	9.2	2.0	1.1	0.5	5.3	0.5	10.9	0.7
Western Europe	11.3	2.7	0.8	0.2	9.7	1.7	7.2	0.8
Australia	11.1	4.7	0.8	0.3	3.4	0.9	3.9	0.5
New Zealand	5.6	3.3	0.6	0.3	3.6	0.4	2.2	0.4
Melanesia	31.5	20.2	0.3	0.2	1.8	0.7	3.2	0.9
Micronesia	4.4	2.7	7.1	2.5	1.6	0.6	3.7	0.0
Polynesia	5.2	0.7	3.9	1.7	0.7	0.0	0.0	0.0

Fig. 1.3 Mouth Cancer Deaths, IARC 2002 International Classification of Diseases-10 codes: C00-C14. http://www.worldmapper.org/display_extra.php?selected=419. Accessed January 2010. These two maps (shown only for males here) distort countries on the basis of the number of deaths by mouth and pharynx cancer (a), and the number of smokers (b). They show that the public health burden is borne by Eastern Europe, Central and Eastern Asia and South Asia. China is the major storehouse of tobacco-related morbidity and mortality in the world, a nation where more than half the population continues to smoke. Yemen, Indonesia and Mongolia = Armenia, followed by Kenya are the top five-ranked countries for smoking prevalence, at 77%, 69%, 68% and 67%, respectively. *Territory size shows the proportion of men who smoke and live there*



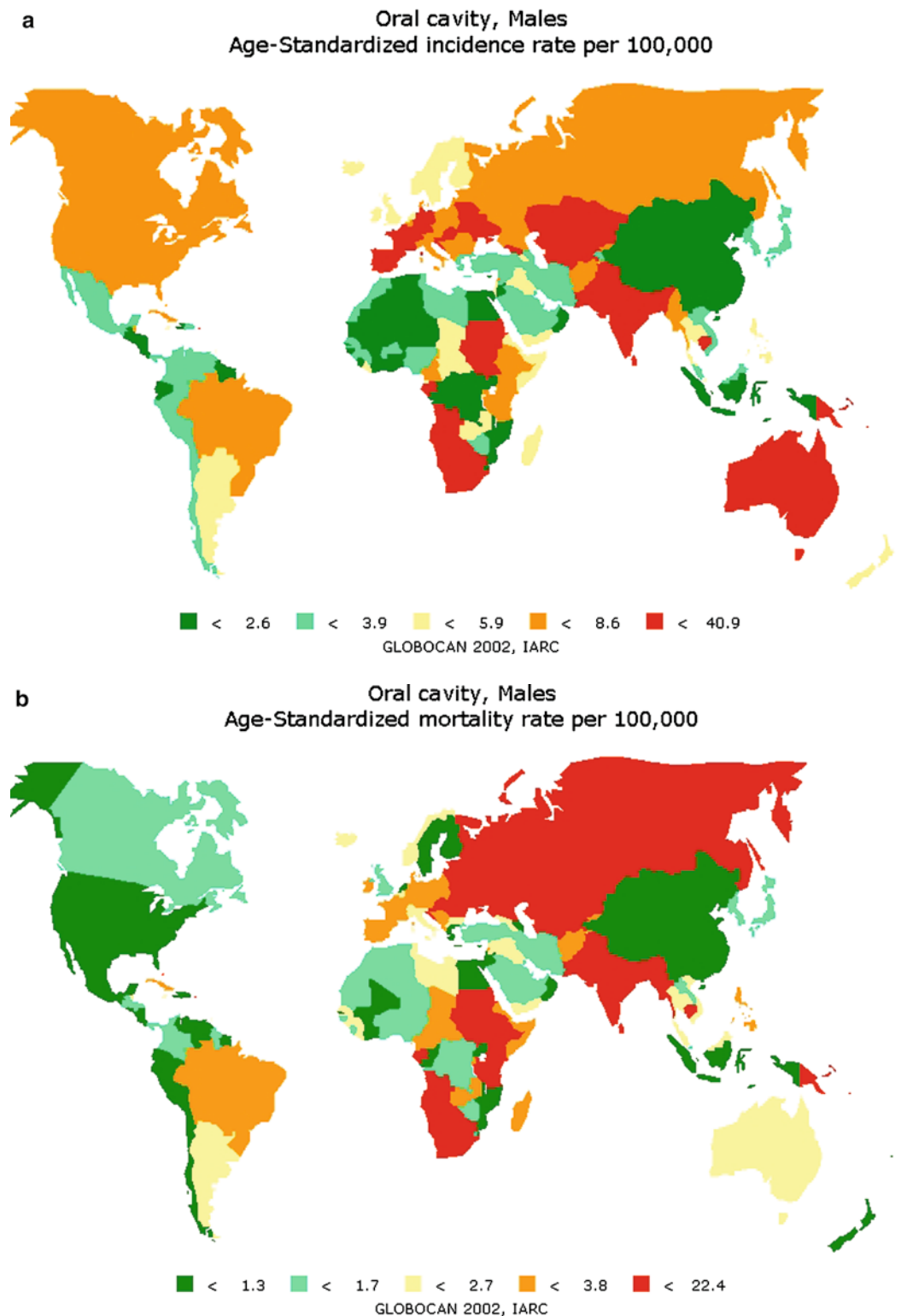


Fig. 1.4 Incidence (a) and mortality (b) rates for oral cavity cancer in males, in quintiles, by country. A quick comparison of these maps makes a number of points. The “traditional” high incidence areas of central Asia and the Indian sub-continent stand out: much of this is due to betel quid use, with or without smokeless tobacco, plus smoking, sometimes alcohol abuse, and poor diet. Note that parts of both Western and Eastern Europe remain in the top quintile – see text. The African data are not particularly robust. Australia shows a high incidence, due to ultraviolet light-induced lip cancer in a fair-skinned population:

mortality rates are not comparably high because lip cancer is comparatively easily treated. Eastern Europe and the former Soviet republics have high mortality, partly related to low socio-economic status, limited treatment facilities and the fact that many patients have substantial co-morbidities. As already mentioned, Papua New Guinea and surrounding Melanesian islands of the Western Pacific are in the top quintile both in incidence and mortality: indeed Melanesia has the highest recorded rates in the world at the beginning of this millennium – associated with chewing of areca nut and tobacco use

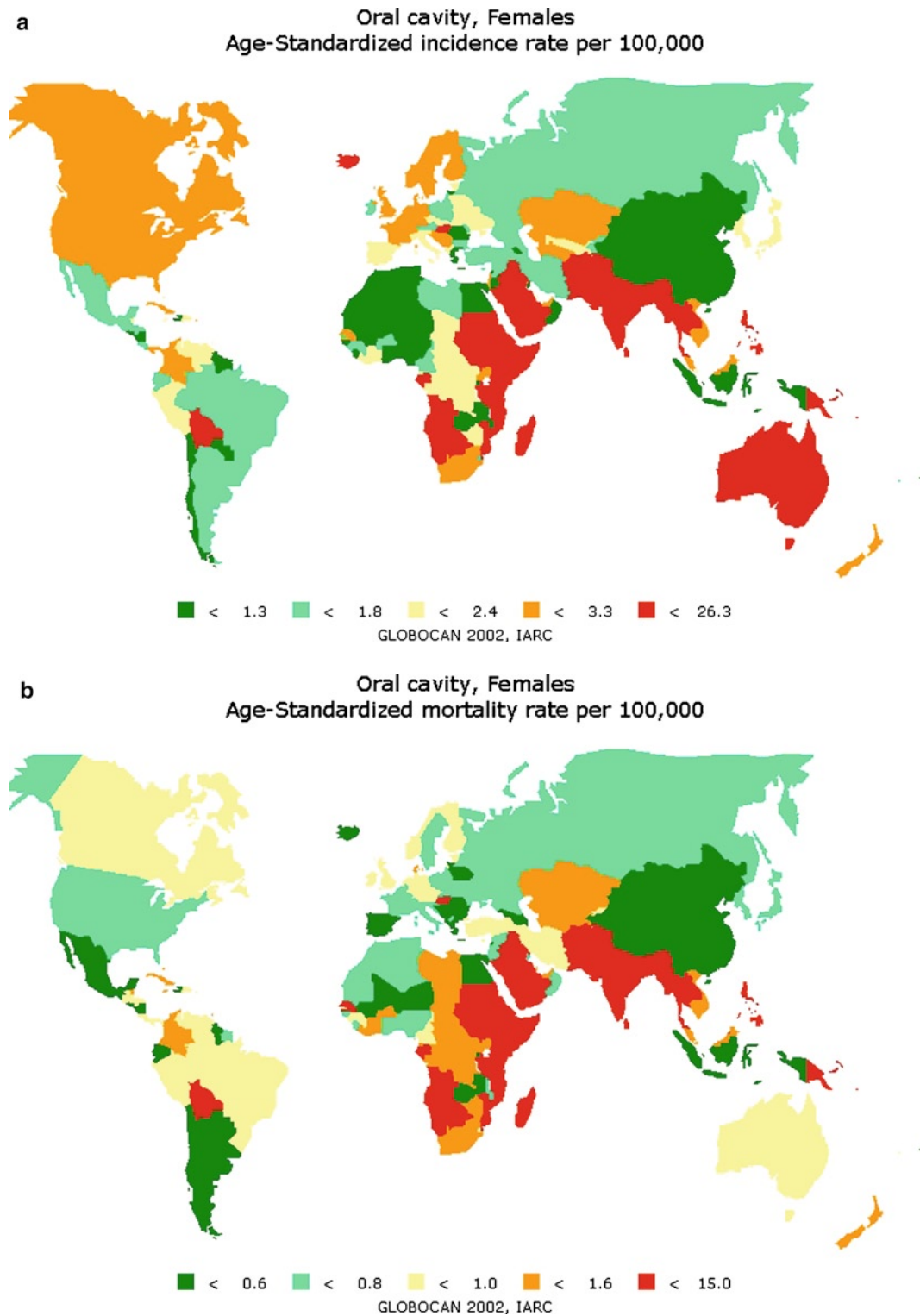


Fig. 1.5 Similar explanations relate to the national incidence (a) and mortality (b) data for women. Note the serious situation in the Indian Subcontinent and parts of SE Asia. In parts of India, oral cancer is the

leading cancer among women, because of heavy use of betel quids. Indeed emigrant Tamil women working on rubber and palm oil estates in Malaysia have among the highest rates, by population group, in the world

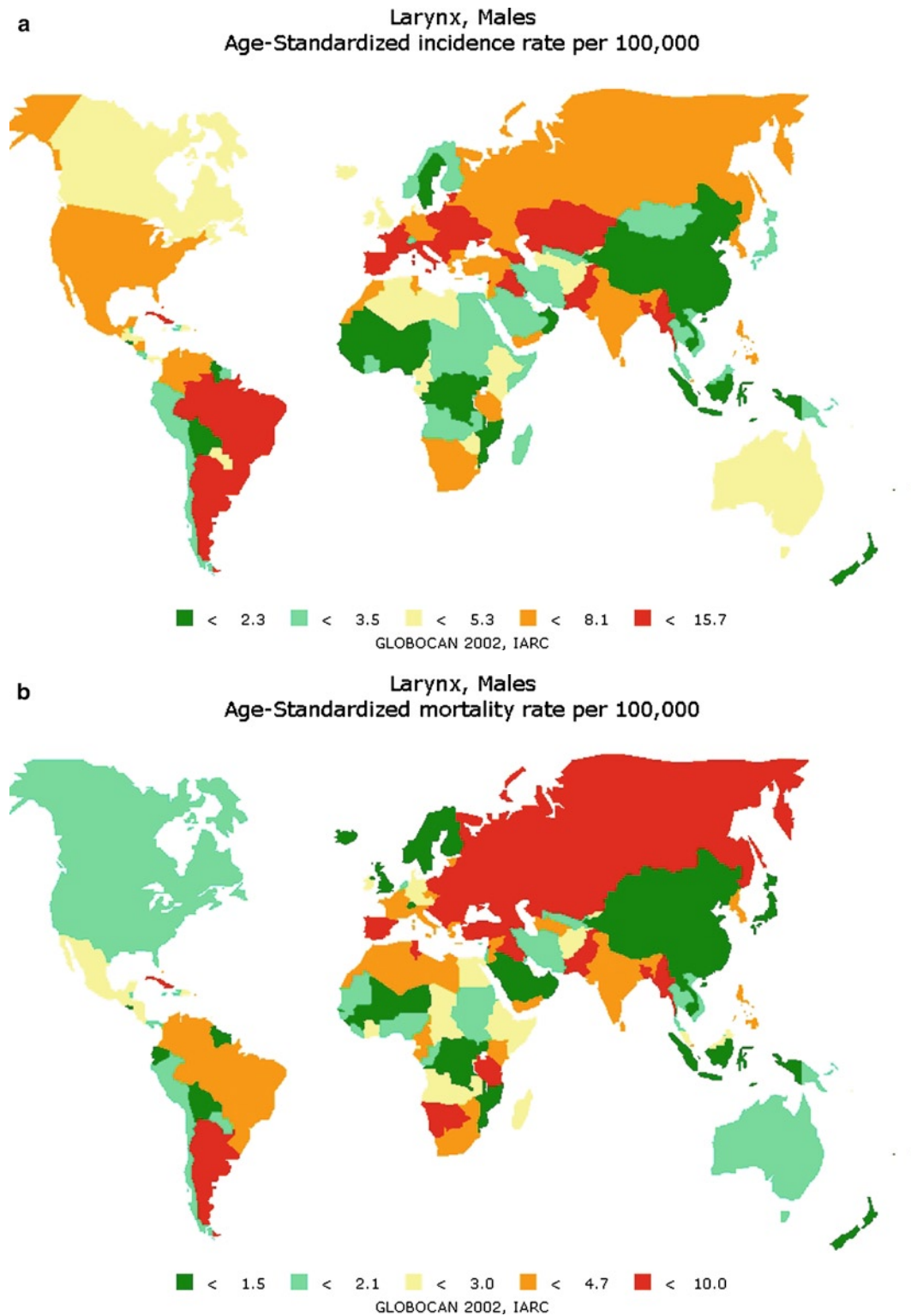


Fig. 1.6 Rates of laryngeal cancer largely reflect smoking rates around the globe, with the surprising exceptions of China and Japan who have comparatively low incidence (a) and mortality (b), in spite of male smoking prevalence being 50% or above: however as noted earlier

Japanese rates are on the rise. The proportionately higher death rate in Eastern Europe, Russia and the former Soviet Republics is again related to late stage at diagnosis and high co-morbidities associated with low socio-economic status and difficulties with access to care

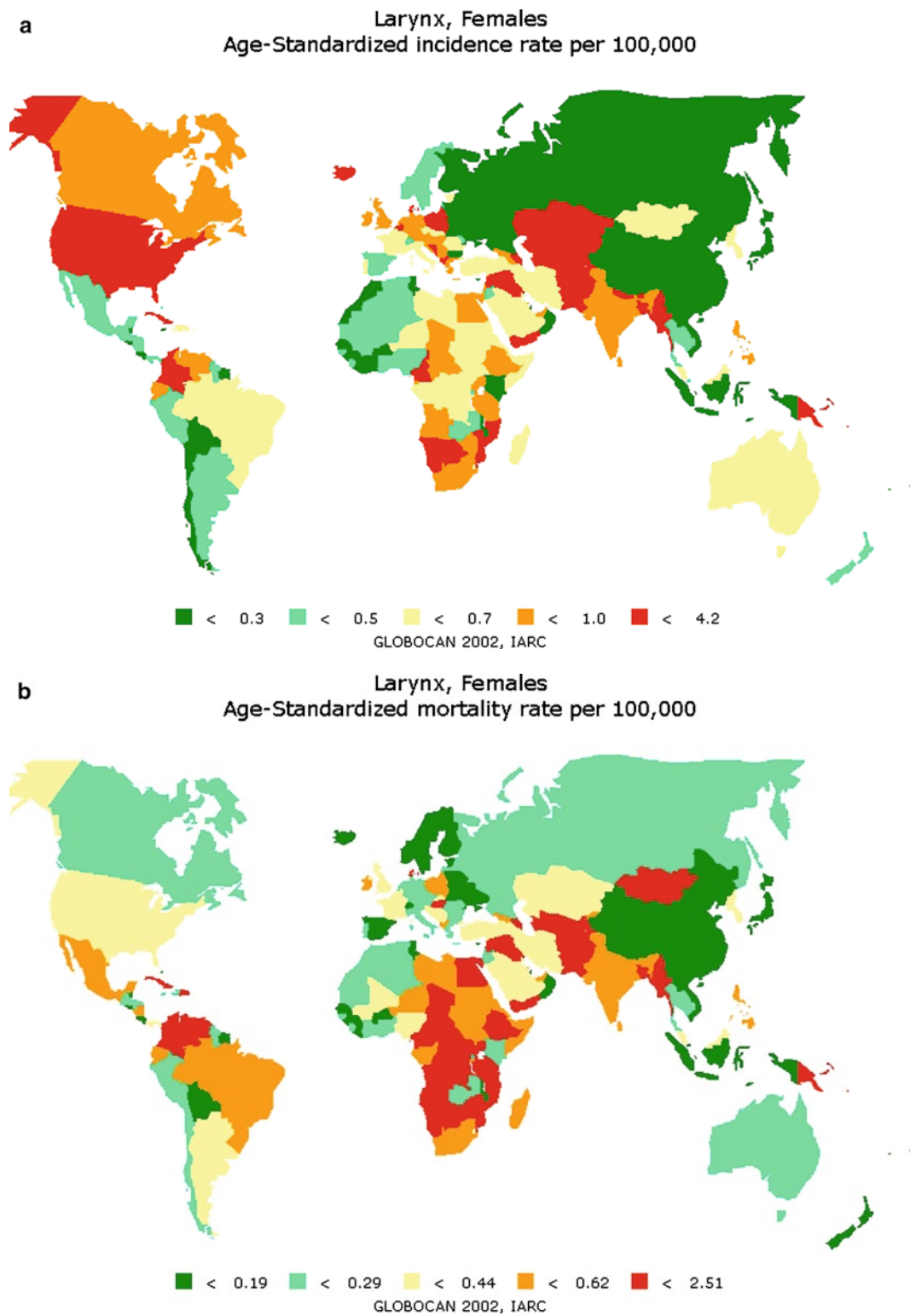


Fig. 1.7 (a and b) Because smoking is far less prevalent in women than men in most societies, the laryngeal cancer rates are low worldwide, and little can be read into this aspect of “geographical pathology”

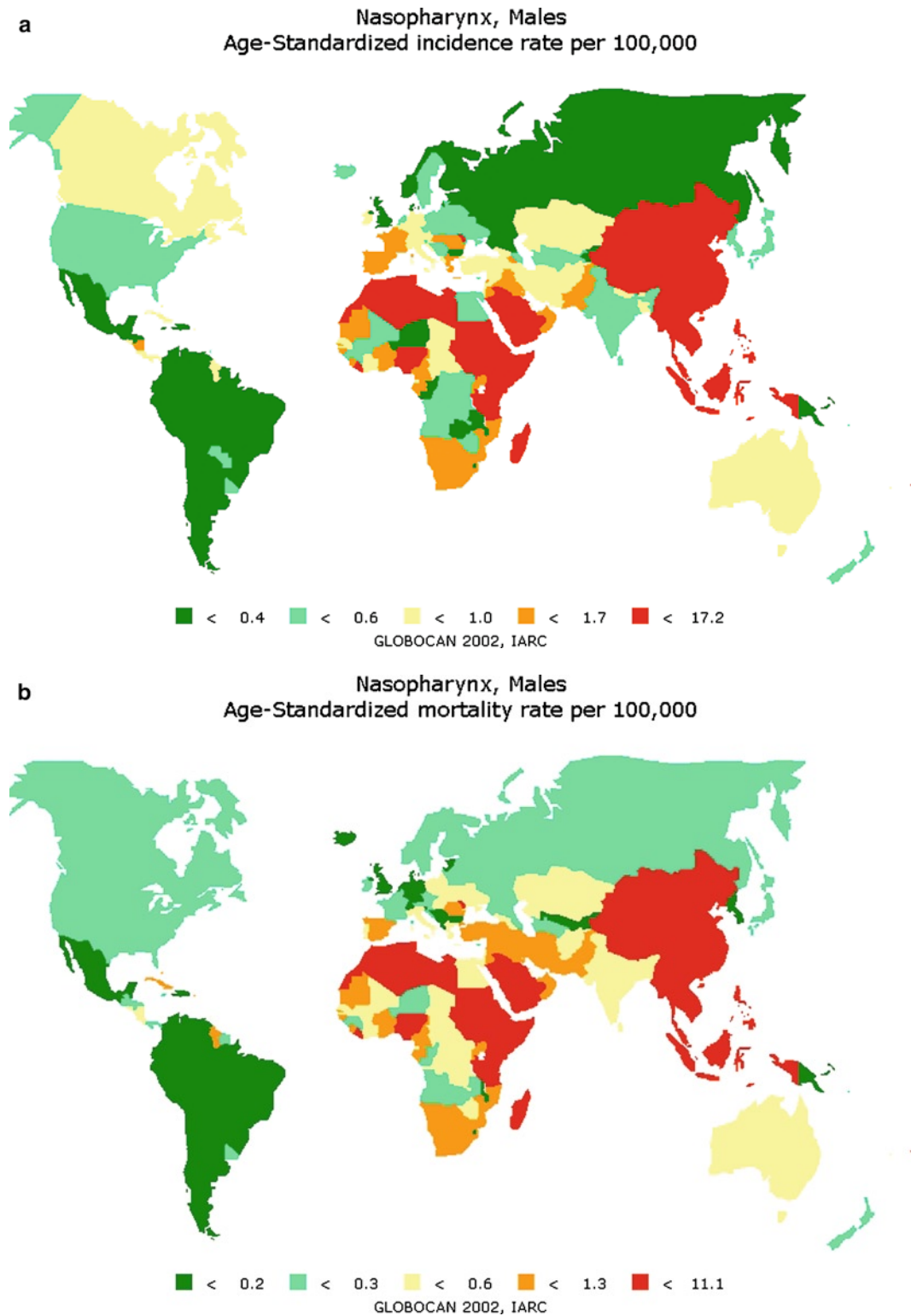


Fig. 1.8 Risk factors for nasopharyngeal cancer are comparatively well understood. It is a biologically distinct disease, driven by Epstein-Barr virus, in subjects with genetic susceptibility, compounded by toxins in particular cultural dietary practices. Both incidence (a) and

mortality (b) rates are historically high in North Africa and in China – particularly Guangdong Province, the Hong Kong SAR and emigrant communities there from

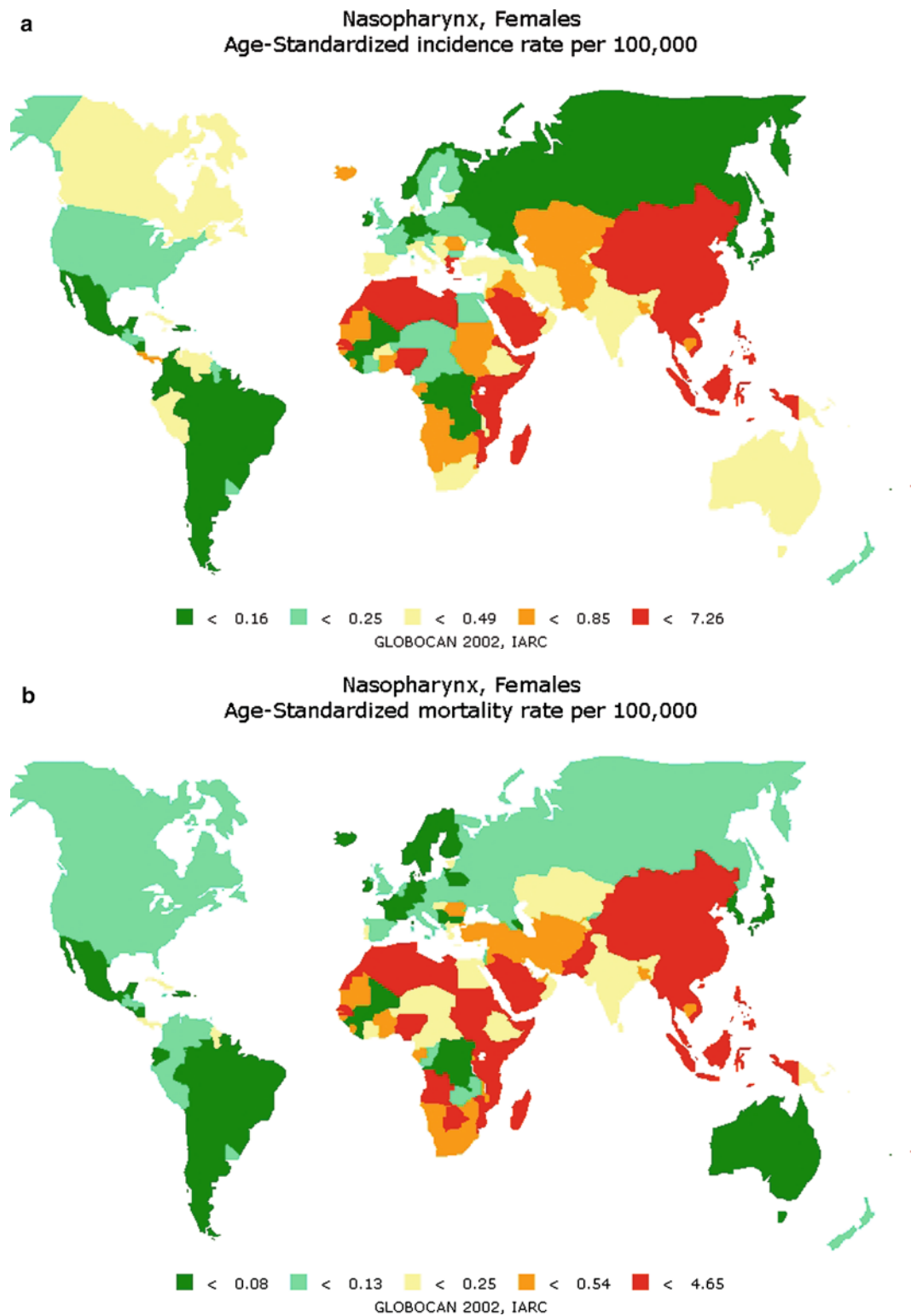


Fig. 1.9 (a and b) Female rates for NPC are lower than for men, but show the same geographical distribution

More than 180,000 cases of oral cancer occur every year in South and South-East Asia alone, with poor prospect of survival: about 90% of these cases are attributable to smoking and chewing habits [7]. It is encouraging that overall rates in India are showing a decreasing trend in successive birth cohorts, declining trends were observed for mouth (ICD10 C03–C06) and tongue (C01–C02) cancers among females and tongue cancers among males between 1982 and 2000 [10]. However, there is growing concern that commercial areca nut and tobacco products will contribute to future rises in the incidence of oral submucous fibrosis and of subsequent oral cancer [11].

Data from Japan show a dramatic increase in oral and pharyngeal cancer incidence (ICD10 C01–C14) for both sexes; there is a 4.4-fold increase for males and 3.8-fold increase for females in the total numbers between 1965 and 1999 – noted from the data retrieved from Osaka Cancer Registry's database [12]. There is also an upward trend for both males and females in Australia and among the non-Maori population in New Zealand. Lip cancer in fair-skinned populations, particularly due to ultraviolet light, is a growing problem [13]. In Europe, Hungary has the highest incidence and mortality of oral and pharyngeal cancer for both sexes [14]. Between 1984 and 1994, the Hungarian mortality rates for oral cancers rose by 83.5 and 72.3% in males and females, respectively. Trends in the mortality rate among Italian and French males peaked in the 1980s and have decreased after 1990 [15]. However, some persisting upward trends were registered for Belgium, Denmark, Greece, Portugal, and Scotland [16].

In the USA, the estimated number of incident cancer cases for tongue, mouth and other oral cavity in 2008 was 15,250 cases for men and 7,650 for women; for the pharynx, the number of incident cases for men is 10,060 and 2,350 for women (3% of all cancer cases in men). For cancer of the larynx, 12,250 incident cases were estimated, of which 9,680 were men. In the USA, the mortality rates per 100,000 population pa for cancer of the oral cavity and pharynx for men was 5.61 in 1990 and 3.98 in 2004, the absolute decrease being 1.63 per 100,000, contributing to a 3% reduction in mortality of all sites. For women, the decrease across the same period was 0.56 contributing to a 2.5% reduction of all sites [12]. The incidence rates of cancers of the oral cavity and pharynx-throat were stable or declining for men and women in most age groups during the period 1973–2003 in the USA, probably related to changes in tobacco and alcohol consumption. This is a highly pleasing situation, common to many countries with advanced care facilities but not reflected in most of the high incidence countries elsewhere in the world. Furthermore, as described below, black citizens of the USA fare comparatively badly.

Cancer of the larynx has always been a serious public health problem in nations with high smoking prevalence, and

this remains a disaster in China and eastern Europe and the former Soviet Republics. Differences among selected countries are shown in detail in the time and birth cohort trends reproduced below.

For cancers of the oropharynx and tonsils, the highest combined rate is currently seen in France and for laryngeal cancer, it was Spain. For hypopharyngeal cancer specifically, the highest rate in men was in France. For women, the highest ASR(W) for mouth and tongue specifically was in Pakistan, almost the same as that for men [17].

Differences by Sex

As already noted, worldwide, the incidence of head and neck cancers overall is higher for males than females. According to the International Agency for Research on Cancer [2], the age-specific incidence of “oral cavity”, plus “nasopharynx” plus “other pharynx” cancers totalled 12 per 100,000 population for males in 2002 and 4.8 for females (see Table 1.1). This may be because of their greater indulgence in the most important risk factors, such as heavy alcohol and tobacco consumption for intra-oral cancer and sunlight for lip cancer in those who work outdoors. However, oral cancer in females is increasing in some parts of the world. For instance, a study from Argentina showed the male/female ratio to be 1.24:1 for the period 1992–2000 compared to 7.1:1 for the 1950–1970 period [18]. The incidence of tongue and other intra-oral cancers for women can be greater than or equal to that for men in high incidence areas such as India, where betel quid/areca nut chewing (and sometimes smoking) are common among women, although this varies considerably from region to region.

Within Europe, the incidence of oral cavity and pharyngeal cancers (C00–14) among males in the most recent period varied substantially between 5.9 (Finland) and 32 (France) per 100,000 pa [19]. Incidence rates among females were highest in northern and western Europe but were consistently lower than those for males. The male-to-female ratio decreased during the last 10 years and recently varied between 1.5 and 2.5 in northern Europe and 7.7 in Lithuania. Between 1990 and 1999, the UK incidence rates for oral cancers rose in males of all ages from 6.5 to 8.3 per 100,000 (an increase of 18%) and in females from 2.6 to 3.6 per 100,000 (an increase of 30%) [20].

In the USA, the death rate due to cancer of the oral cavity and pharynx per 100,000 population in 2005 was 3.8 for males and 1.4 for females, down from 6.9 to 2.3, respectively in 1975. This substantial improvement is not reflected in most of the rest of the world.

Apart from the traditional risk factors, it has been suggested that oestrogen deficiency may influence susceptibility to oral cancer in women: Significantly, younger mean age at

menopause and higher rates of hysterectomy may influence the higher rates of oral cancer seen among younger females [21]. Data presented in this chapter are, whenever possible, separated by sex.

Ethnic Variations

Variations by ethnicity are largely due to the social and cultural practices, and the influence of dietary and genetic factors, though the latter are less well quantified. Variations in outcome are also contributed to by differences in access to healthcare. Where cultural practices represent risk factors, their continuation by immigrants from high incidence regions to other parts of the world results in comparatively high cancer incidence in immigrant communities. This can also affect the sub-sites of oral cancer most commonly affected, as shown in a recent study from California [22]. The highest age-adjusted oral cancer rates in the USA are found among non-Hispanic black men (4.86/100,000) followed by non-Hispanic black women (4.71/100,000), with Asian and Hispanic populations showing intermediate incidence rates compared with white (Caucasian) ethnic groups. Tongue cancer was the most common type of oral cancer among every ethnicity. Asians were more likely to develop their malignancy in the buccal mucosa, a reflection of continuing areca and tobacco chewing habits. Another study showed that American Indians and Alaskan Natives overall had significantly lower incidence rates than non-Hispanic whites [23]. Several studies from the USA have demonstrated that black patients with oral cancer have poorer overall and disease-specific survival than whites, mainly because of their comparatively poor access to health care [24, 25]. This is especially concerning because the incidence of oral plus pharyngeal cancer for black men in the USA is so high, and is the sixth most common site for malignant disease among this group [26].

The age-adjusted incidence rate for oral and pharyngeal cancers is higher for South Asians than for other residents in England, particularly among females [27]. Interestingly, this study showed that British South Asian males have significantly better survival than their non-South Asian peers in the south east of England, possibly a reflection of the more indolent progress of tobacco/areca nut-induced lesions [27].

Worldwide there are four times more men who smoke than women. In 2002, there were 941 million male smokers, which was 43% of all men aged over 15 years old. The largest population of male smokers lives in China – where men are more likely to smoke than not to smoke. Even Puerto Rico and Sweden, with the lowest percentages of men who smoke still have 17% who are smokers (Fig. 1.3a, b).

When smoking is widespread, smokers not only just damage their own health, but also collectively damage the health of

people around them. Passive smoking by children can increase the risks of asthma, cot deaths and chest infections.

The prevalence of smoking increased dramatically during the world wars, mainly due to the policy of providing free cigarettes to allied troops as a “morale boosting” exercise.

The Cancer Council, 2006.

Age Distributions

Oral cancer is usually a disease that occurs in males after the fifth decade of life. The mean age at presentation is in the fifth and early sixth decades in Asian populations compared with the seventh and eighth decades in the North American population [28–33]. Statistics in the USA for 2001–2005 show that the median age at diagnosis for cancer of the oral cavity and pharynx was 62 years [34].

Several studies suggest that 4–6% of oral cancers now occur at ages younger than 40 years [35]. An alarming increase in incidence of oral cancers among younger people has been reported from many parts of the world [36–39], a trend that appears to be continuing. There was a significant increase in the incidence of cancers in the tongue and tonsil among 20–40 year olds in the USA between 1973 and 2001 [40]. In Germany, Czechoslovakia and Hungary, there has been an almost tenfold rise in mortality from oral cancer in men aged 35–44 [41], within one generation. Robinson and Macfarlane showed a dramatic increase in incidence rates for younger males in Scotland from the 1980s to the 1990s [42]. In the high prevalence areas of the world, in many cases patients are less than 40 years old, probably owing to heavy lifetime use of various forms of tobacco, although some recent Indian data have not shown this [43].

It is also clear that a number of cases of squamous cell carcinoma occur in both young and old patients, often in the absence of traditional alcohol and tobacco risk factors, and in which the disease may pursue a particular aggressive course. A study conducted in Southern England concluded that a substantial proportion of cases of younger people diagnosed with oral cancer occur in the absence of known risk factors [44]. This, together with the relatively short duration of exposure in users suggests that factors other than tobacco and alcohol are implicated in the development of oral cancer in a significant minority of cases. Diets poor in fresh fruits and vegetables were identified as conferring significant risk. HPV infections may also be relevant in a proportion of these cases. It is also suggested that greater attention should be paid to familial antecedents of malignant neoplasms in younger patients with oral cancer [45].

Age distribution curves for the major head and neck cancer sites are given for deliberately selected countries in Figs. 1.10–1.15.

Mouth & Pharynx, CO1-14 exc lip, saliv gland and nasopharynx, Male

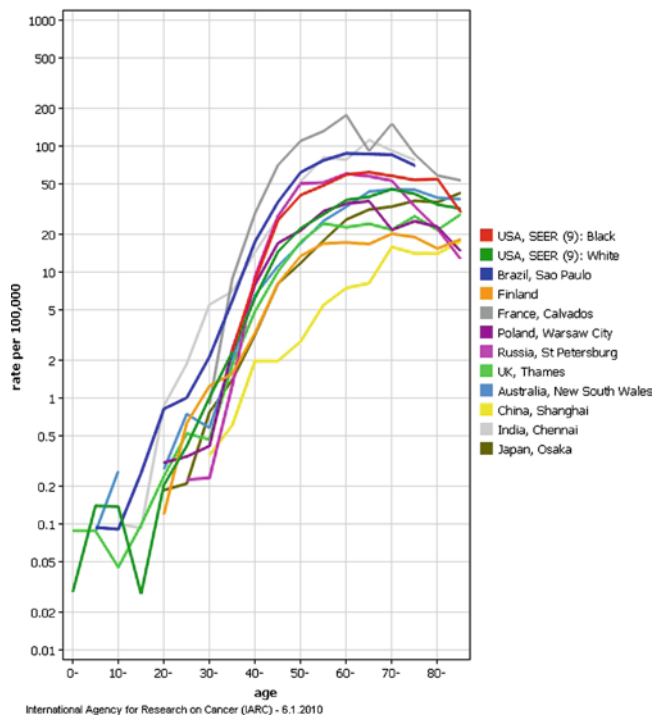


Fig. 1.10 Male age-specific incidence curves for mouth and pharynx for selected countries. All UADT cancers show a similar distribution. Most cases occur in the fifth to seventh decades of life, presumably because decades of exposure to tobacco, alcohol and poor nutrition take time to synergise with other agents in triggering malignant transformation – or in allowing this to survive the host response!! There are, nevertheless, a significant minority of cases appearing in the third and fourth decades of life: these attract much interest as, although associations with early commencement of smoking, and with unsafe alcohol use can be demonstrated, a substantial minority of cases arise without exposure to traditional risk factors: here dietary inadequacies and HPV infection are thought to be important, as may inherited predisposition. In the high incidence age bands there is a ~40–100-fold difference in incidence with, among the countries selected here, disturbingly high rates in NW France, Brazil and South India. Note the much worse situation in American blacks cf. whites, explained by a mixture of risk-factor and socio-economic reasons. Finland does comparatively well – not surprising in view of that nation’s success in reducing the prevalence of smoking, though alcohol abuse remains a social problem. What is surprising are the low rates recorded for Shanghai, in spite of high smoking prevalence in this large city. China is in the early stages of developing a comprehensive, nation-wide Cancer registry system and caution is necessary in interpreting some of the current data

Mortality Rates and Trends over Time

Table 1.2 gives mortality data again extracted from the Cancer Incidence in Five Continents Database for the period 1998–2002 [3], for comparison with the incidence data in Table 1.1. Trends of age-standardised (world population) mortality rates for the head and neck cancer sites of interest,

Mouth & Pharynx, CO1-14 exc lip, saliv gland and nasopharynx, Female

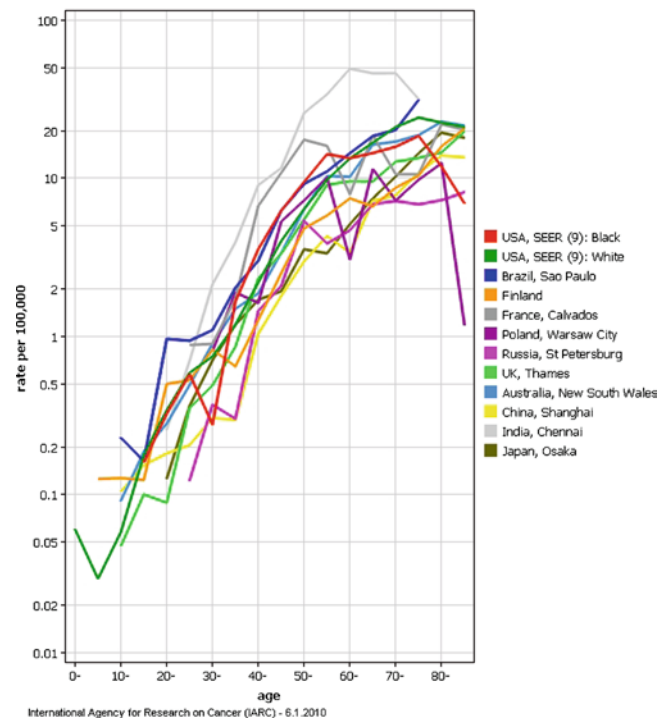


Fig. 1.11 Rates for females are lower and international differences are less marked. Women in South India stand out – related to use of betel quid and tobacco, together with low SES

within selected countries over the past three to six decades, are presented in Figs. 1.16–1.21.

Current male death rates for oral and pharyngeal cancer around the world are seen vividly in Fig. 1.16. There was a steady rise in oral cancer mortality in men from the 1950s to late 1980s in most Western European countries [46], but this trend has since declined, in France, China and Hong Kong, which had exceedingly high rates in the past. Unfortunately, in most countries in central and eastern Europe, oral cancer mortality in men has continued to rise, reaching exceedingly high rates in Hungary, Slovakia, Slovenia and the Russian Federation. Hungary, Ukraine, Estonia and Bulgaria show more than a 100% increase in mortality rates for men during the 20-year period up to the turn of the Millennium. Even though the rates of oral cancer are comparatively low among women, there is a steady increase in some countries in Europe (notably Hungary, Belgium, Denmark and Slovakia). Hungary also shows a 98% increase in mortality rates for women Fig. 1.17. These disturbing trends are thought to relate to high drinking and smoking patterns in these societies, together with poor diet in lower socio-economic groups.

Trends for laryngeal cancer reflect continuing high rates of tobacco consumption in many societies (Figs. 1.18 and 1.19). Trends for naso-pharyngeal cancer, both good and bad, are shown for high-incidence countries (Figs. 1.20 and 1.21).

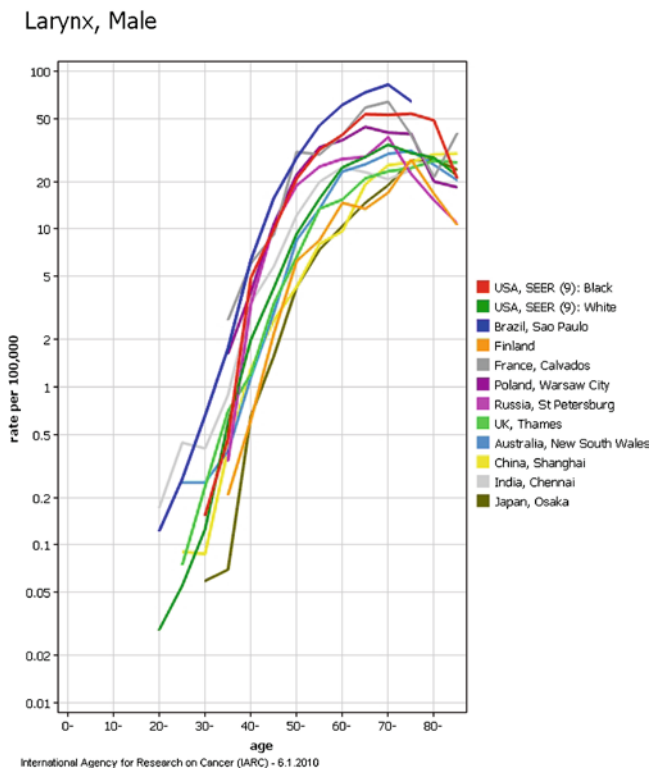


Fig. 1.12 Many of the differences between populations are likely to be explained by smoking and other traditional risk factors. Serious public health challenges exist in the Brazilian example. Poland and the Russian example are consistent with the major concerns we have for Eastern Europe, Russia and the former Soviet republics as a whole. Blacks do poorly in the USA. Finland provides encouragement: indeed this was the first country in the world to reach the WHO target for the year 2000 of having less than 20% of the adult population smoking. Japan and China remain enigmas

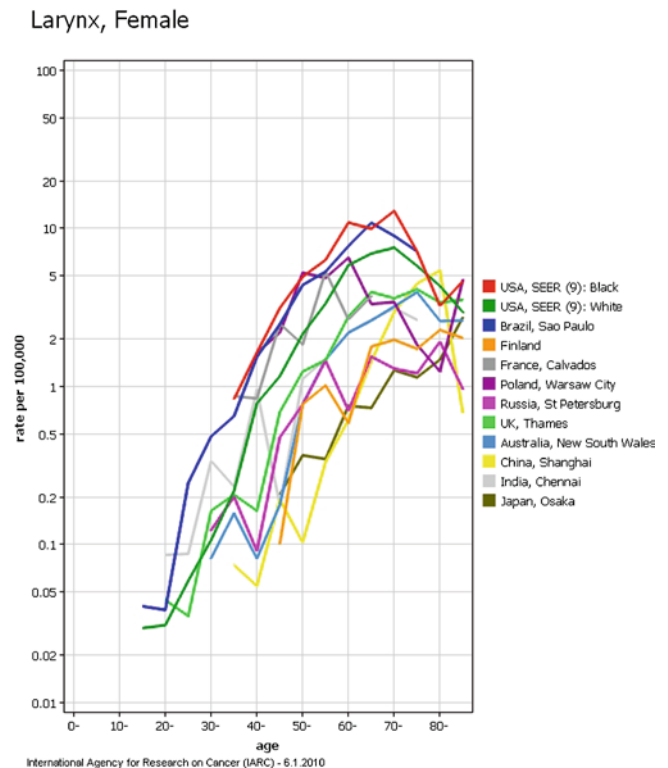


Fig. 1.13 Although at first glance the spread for women looks larger, the rates are much lower than for men. Again, however, Brazil and American blacks stand out

Mortality Trends by Birth Cohort

This is a valuable way for determining time trends. Cases of particular cancers are transformed back, in 5-year age groups, to the date of birth of the affected individuals. Curves for particularly instructive countries are given below. In general these show that for most UADT cancers, in most developed countries, rates fell in the latter part of the nineteenth and the first part of the twentieth centuries. This has been continued in, for example, the USA (Fig. 1.22) and the UK (Fig. 1.23). However in Hungary (Fig. 1.24: and the same is true for most of eastern Europe, Russia and the former Soviet republics), those born in the first half of the twentieth century showed alarming rises in death rates. All of these birth cohorts have now passed on, or they are in the highest risk age groups: in these countries, we have thus seen a growing epidemic of UADT cancer. The curves provide limited hope that Hungary at least, may be showing some control in younger people.

France (Fig. 1.25) is an interesting case: again the data show that this nation has “turned the corner” with a rise, and now a downturn for cohorts born since the end of the Second World War.

The SEER programme in the USA has reported an overall fall in the mortality from oral and pharyngeal cancer, between 1975 and 2004, of 1.87% per annum Table 1.3.

Table 1.3 shows a fall in all mortality rates for oral and pharyngeal cancer in the USA between 1975 and 2004. There is a considerable fall in mortality among both white and black women under 65 years of age (APC of -3.12 and -3.21 , respectively). Furthermore, the SEER data show higher 5-year relative survival rates for whites (61.8%) and blacks (39.5%), who were diagnosed during the period 1995–2001, than rates for those who were diagnosed during the period 1974–1976 (when rates for whites and blacks were 55 and 36.3%, respectively) [47]. The 5-year survival rates in the SEER Registries range from a high of 72.1% for white women in Utah to a low of 24.8% for black men in metropolitan Atlanta. These striking differences are likely to be explained by a number of factors including socio-economic condition, age, stage at diagnosis, continued presence or absence of environmental risk factors and access to

Nasopharynx, Male

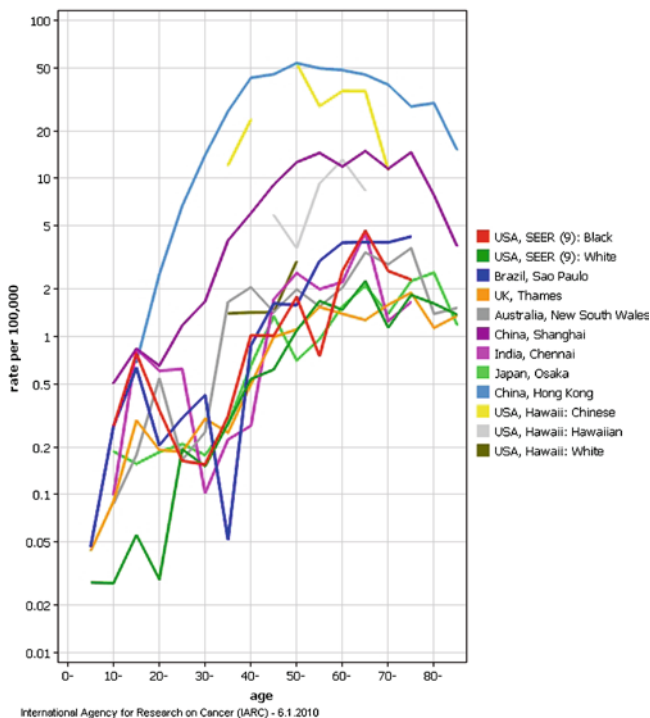


Fig. 1.14 NPC is a distinct disease. These countries have been chosen to reflect the differences by population. As mentioned in the legend to the cancer map, southern Chinese men are particularly susceptible: hence the alarming data from Hong Kong and to a lesser extent from Shanghai. Although the data are fragmentary, the markedly higher rates in Chinese Hawaiians than other racial groups there is consistent with the ethnic bias

hospital services. African-American patients have consistently poorer survival outcomes [48].

A study in Mumbai, India, indicated a decreasing trend in oral cancer incidence among Indian men, which it was suggested may be due to a decrease in the use of betel quid/pan and associated oral smokeless tobaccos over this period [49]. However, there continues to be a high prevalence of smokeless tobacco use among young adult men and women, especially in the form of Pan Parag/Gutka-type products, and cigarette smoking is increasing. Overall, UADT cancers are not likely to decrease.

Population-based survival rates around the world show little evidence of improvement over recent decades, despite vast improvements in treatment modalities. Cure rates and survival rates have improved with advances in surgical and other techniques in highly specialised, high-volume treatment institutions. Regrettably, such highly expert management is not yet uniformly available and it will be many more decades before these results are reflected in population trends.

Nasopharynx, Female

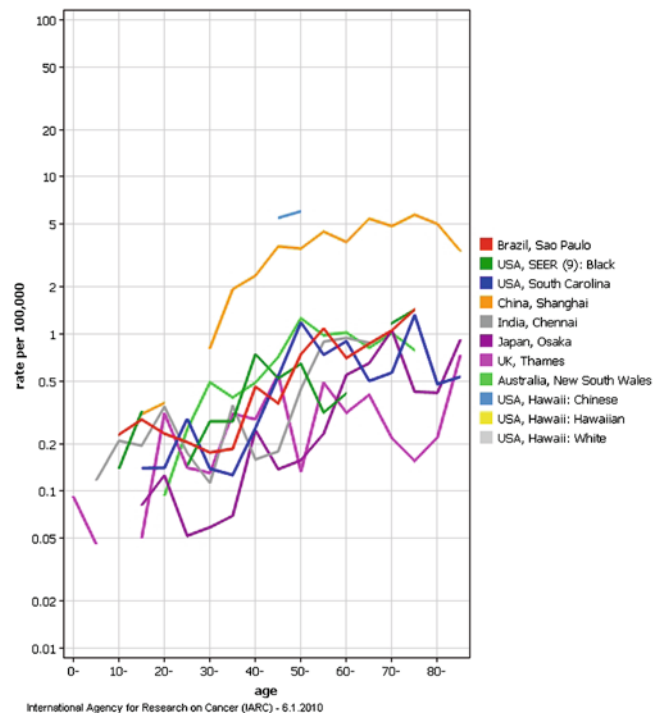


Fig. 1.15 The highest rates of NPC in women are again in Chinese – though only a tenth of those in males

Aetiology of Head and Neck Cancer

The majority of oral SCC are related to tobacco in various forms, betel quid chewing, heavy alcohol drinking and dietary micronutrient deficiency. In the developing world, tobacco and areca nut, used either alone or in combination, accounts for the vast majority of oral cancers and oral potentially malignant disorders (OPMD) [50]. The WHO has classified areca nut, a common component of many different chewing habits, as carcinogenic to humans [51]. UV radiation is relevant to lip cancer and there is an increasing evidence for a role for “high risk” genotypes of the HPV family, especially for tonsillar and other oropharyngeal sites.

Betel Quid

A betel quid generally contains betel leaf, areca nut and slaked lime, and may contain tobacco. Other substances, particularly spices, including cardamom, saffron, cloves, aniseed, turmeric, mustard or sweeteners, are added according to local preference [51].

Table 1.2 World standardised global mortality rates per 100,000 for H&N cancers. Data derived from the Globocan 2002 database: anatomic descriptors derived therefrom [2]

Country	Oral cavity		Nasopharynx		Other pharynx		Larynx	
	Male	Female	Male	Female	Male	Female	Male	Female
World	2.7	1.5	1.2	0.5	2.5	0.5	2.9	0.4
More developed	2.7	0.7	0.3	0.1	2.5	0.4	3.3	0.3
Less developed	3.0	1.9	1.6	0.7	2.5	0.6	2.7	0.4
Eastern Africa	3.5	2.9	1.7	0.7	1.2	0.4	2.9	0.6
Middle Africa	2.7	1.3	0.6	0.2	0.9	0.8	2.1	0.7
Northern Africa	1.9	0.9	2.0	0.8	0.7	0.1	3.3	0.5
Southern Africa	6.3	1.7	1.1	0.3	1.5	0.3	4.2	0.5
Western Africa	1.5	0.8	1.2	0.5	0.6	0.2	1.6	0.3
Caribbean	2.7	1.0	0.5	0.1	2.4	0.7	4.5	0.8
Central America	1.0	0.5	0.2	0.1	1.0	0.3	2.5	0.4
South America	2.3	0.8	0.2	0.1	2.3	0.4	3.9	0.6
Northern America	1.4	0.6	0.3	0.1	1.3	0.4	1.7	0.3
Eastern Asia	0.7	0.4	2.1	0.9	0.3	0.1	1.0	0.2
Southeastern Asia	1.9	1.3	3.8	1.3	1.7	0.5	2.3	0.3
South Central Asia	7.0	4.6	0.5	0.2	6.7	1.5	4.5	0.6
Western Asia	1.8	1.1	1.0	0.4	0.5	0.3	4.4	0.7
Central and eastern Europe	5.1	0.7	0.4	0.1	3.9	0.3	6.8	0.3
Northern Europe	1.9	0.8	0.2	0.1	1.3	0.3	1.6	0.3
Southern Europe	2.7	0.6	0.4	0.1	2.5	0.3	4.8	0.2
Western Europe	2.9	0.8	0.2	0.1	4.0	0.6	2.9	0.3
Australia	1.8	0.9	0.3	0.1	1.5	0.3	1.6	0.2
New Zealand	1.3	1.0	0.3	0.1	1.0	0.2	0.9	0.2
Melanesia	17.3	11.7	0.2	0.2	1.4	0.5	1.9	0.7
Micronesia	2.4	1.5	4.9	1.6	1.2	0.5	2.1	0.0
Polynesia	2.8	0.3	2.5	1.1	0.6	0.0	0.0	0.0

Note again the stand-out rates for Melanesia! All head and neck cancers are highly morbid and lethal. Taking oral cavity, as defined in these tables, Death to Registration ratios (D/R) are 0.34 for males and little better at 0.29 for females in the more-developed countries: an appalling 0.52 and 0.54, respectively, in less-developed countries where they come late to diagnosis, where there are significant co-morbidities and where quality care is less available. *This means that in most of the world, more than half of the individuals diagnosed with an oral cancer die of their disease*

Fig. 1.16 Trends in mortality over time are important to track, and to understand. Hungary is a disaster, though hopefully the rise has been arrested. Russia remains a concern. France demonstrates what can be achieved, overall, in spite of the concerns shown by the Calvados registry data above. The overall downward trend in the other countries illustrated is encouraging

Mortality from Lip, oral cavity and pharynx Cancers
Age-standardized rate (World), Male all ages

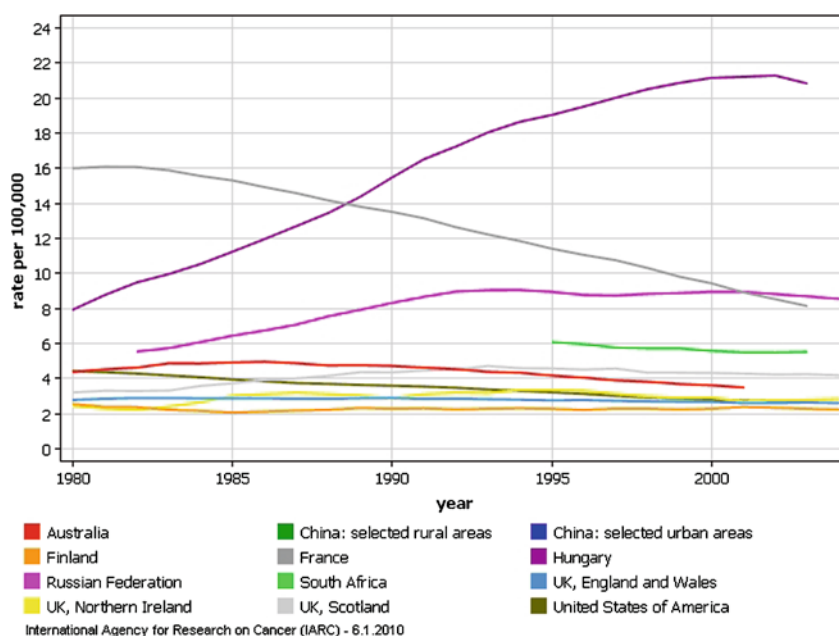


Fig. 1.17 Although only approximately a tenth of the male rate, Hungarian females remain a challenge

Mortality from Lip, oral cavity and pharynx Cancers
Age-standardized rate (World), Female all ages

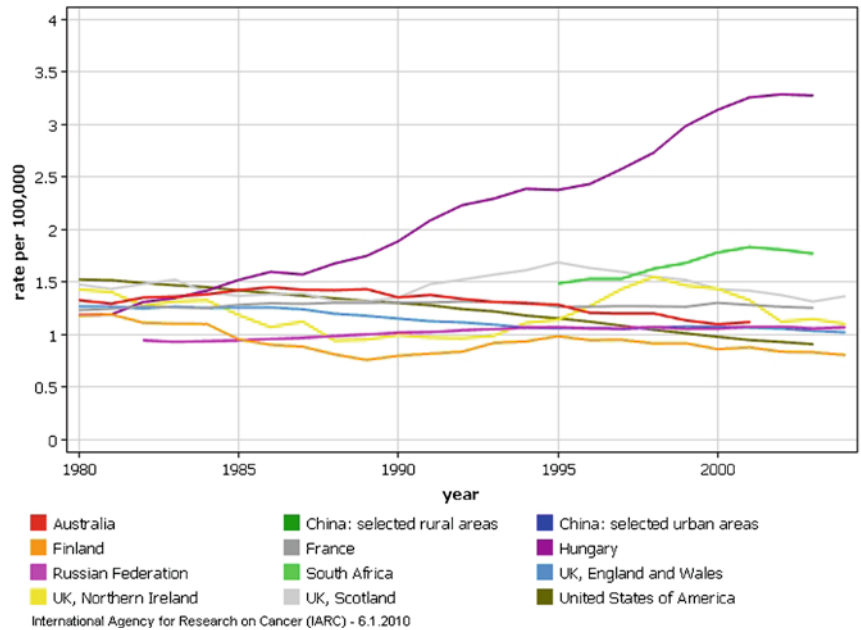


Fig. 1.18 Another success demonstrated for France. Have Russia and Hungary genuinely turned the corner?

Mortality from Larynx Cancer
Age-standardized rate (World), Male all ages

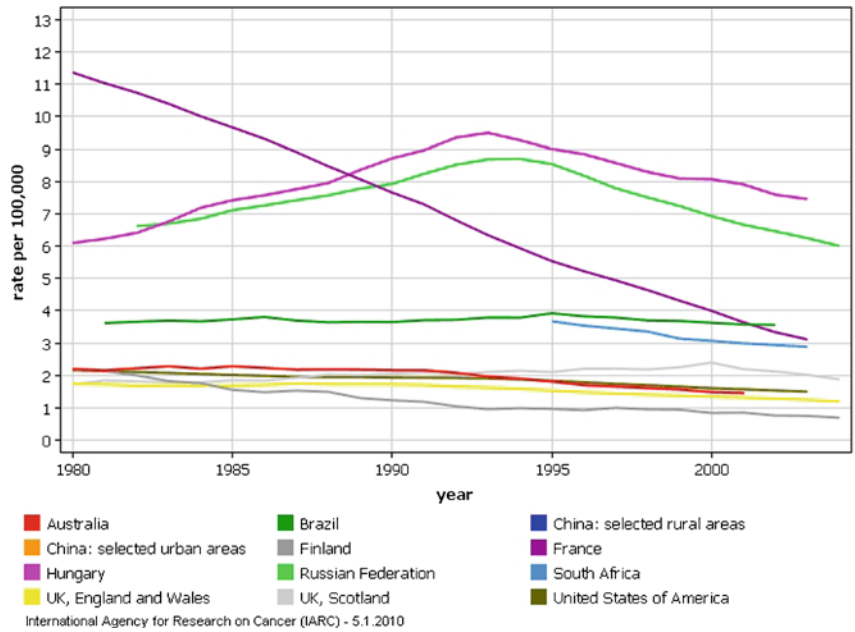


Fig. 1.19 This is a “noisy” curve because of the comparatively low mortality rates in women. Worryingly, but not surprisingly, it suggests an upward trend in Hungary

Mortality from Larynx Cancer Age-standardized rate (World), Female all ages

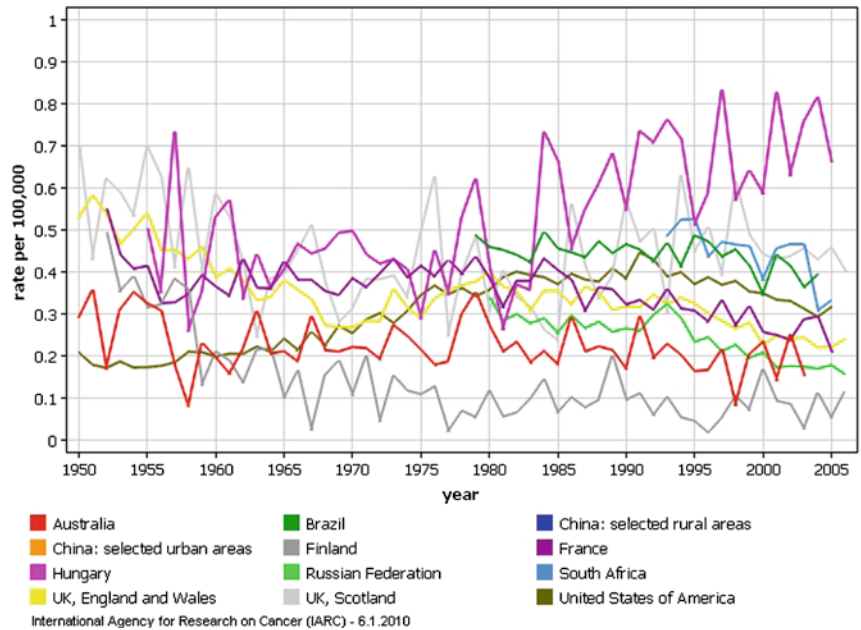


Fig. 1.20 One hopes the successes in Hong Kong can be replicated in other high risk groups

Mortality from Nasopharynx Cancer Age-standardized rate (World), Male all ages

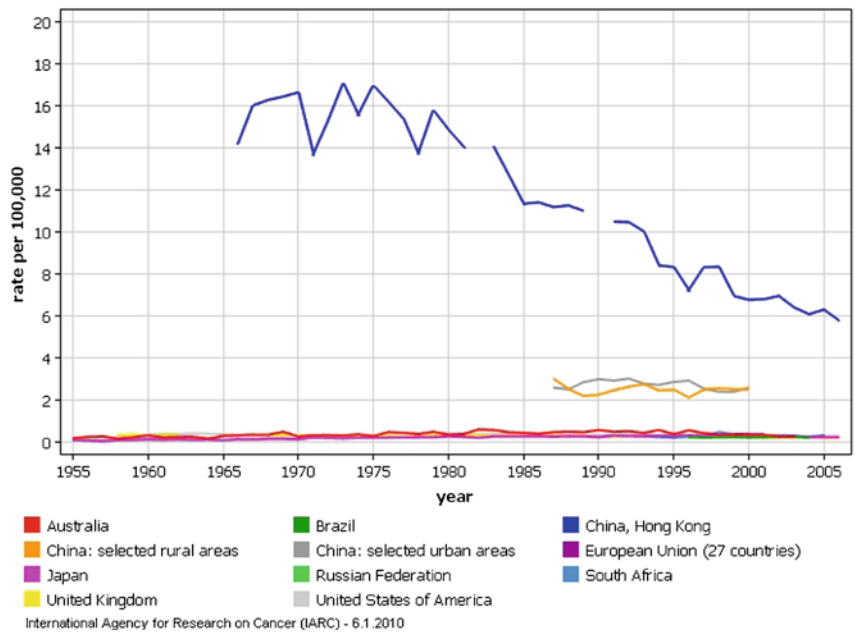
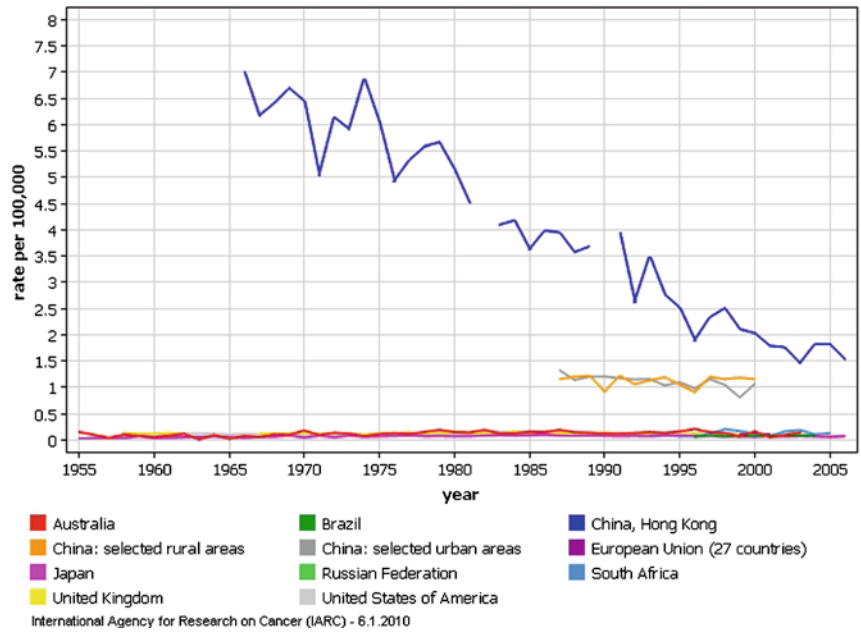
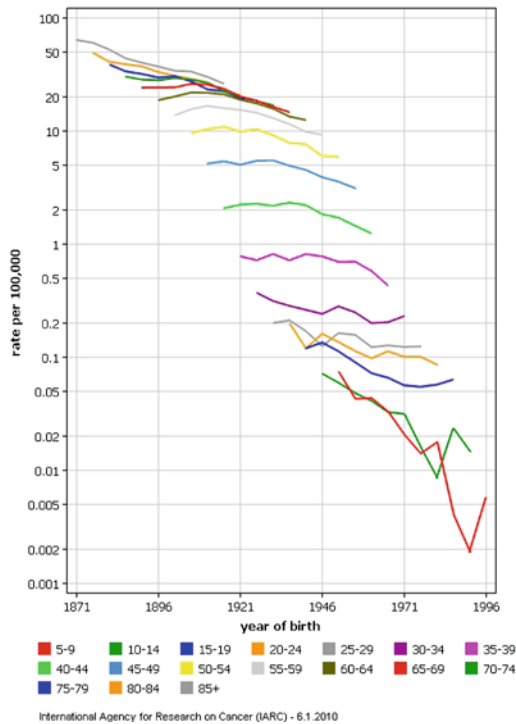


Fig. 1.21 From a lower initial base, Hong Kong women share this success story

Mortality from Nasopharynx Cancer Age-standardized rate (World), Female all ages



a
United States of America: Male
Mortality from Lip, oral cavity and pharynx Cancers



b
United States of America: Female
Mortality from Lip, oral cavity and pharynx Cancers

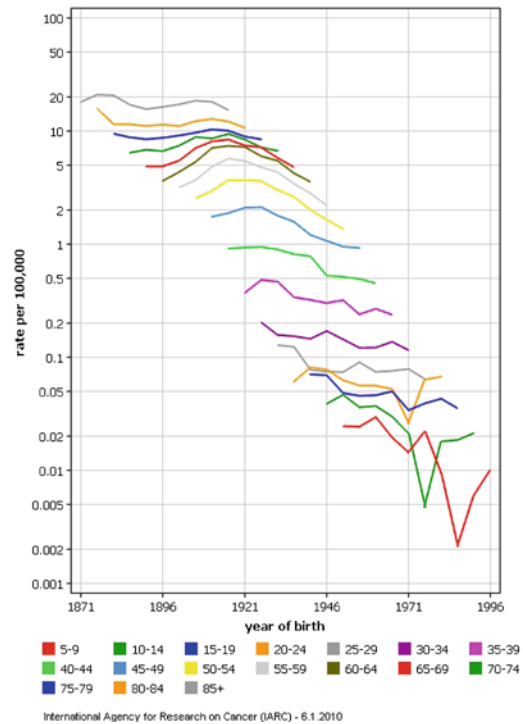


Fig. 1.22 Birth-cohort curves of the mortality rates for lip, oral cavity and pharyngeal cancers for USA males (a) and females (b)

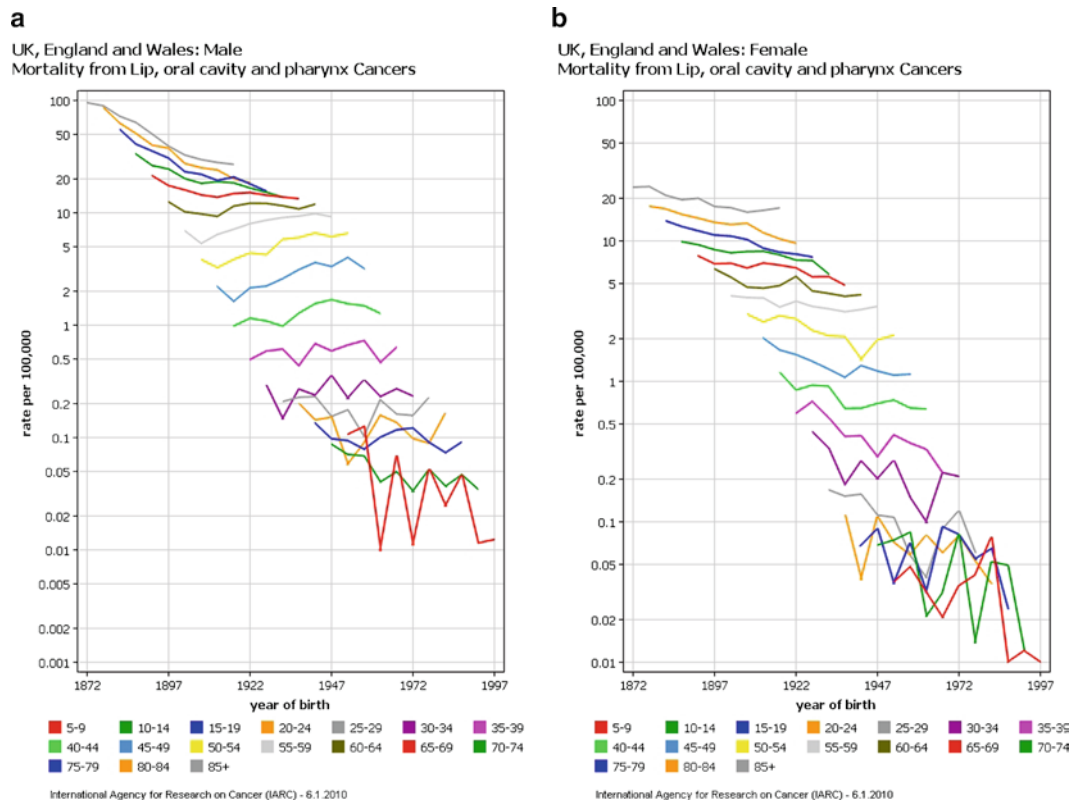


Fig 1.23 Birth-cohort curves of the mortality rates for lip, oral cavity and pharyngeal cancers for males (a) and females (b) England and Wales

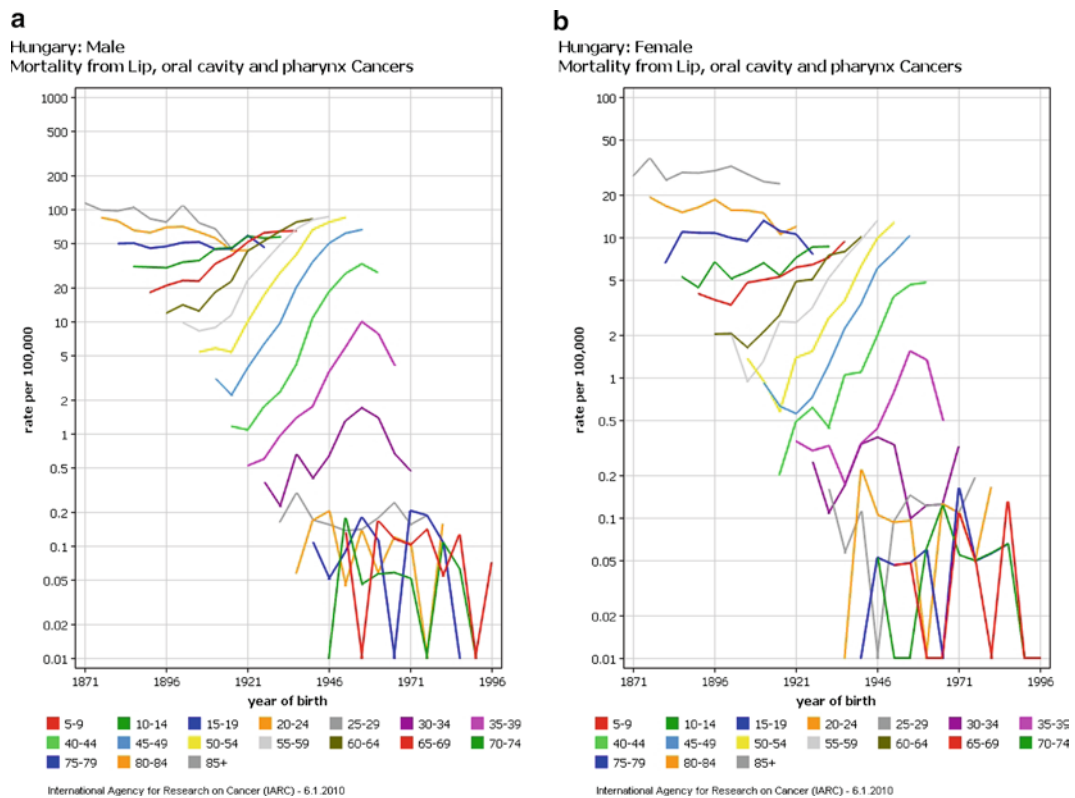


Fig. 1.24 Birth-cohort curves of the mortality rates for lip, oral cavity and pharyngeal cancers for males (a) and females (b), and for laryngeal cancer (c, d) in Hungary. The challenge for Hungary, apparent in other

curves, is confirmed here. Males born in the first half of the twentieth century had rising rates or death from oral and pharyngeal cancer. There are indications that those born after 1950 may be less at risk

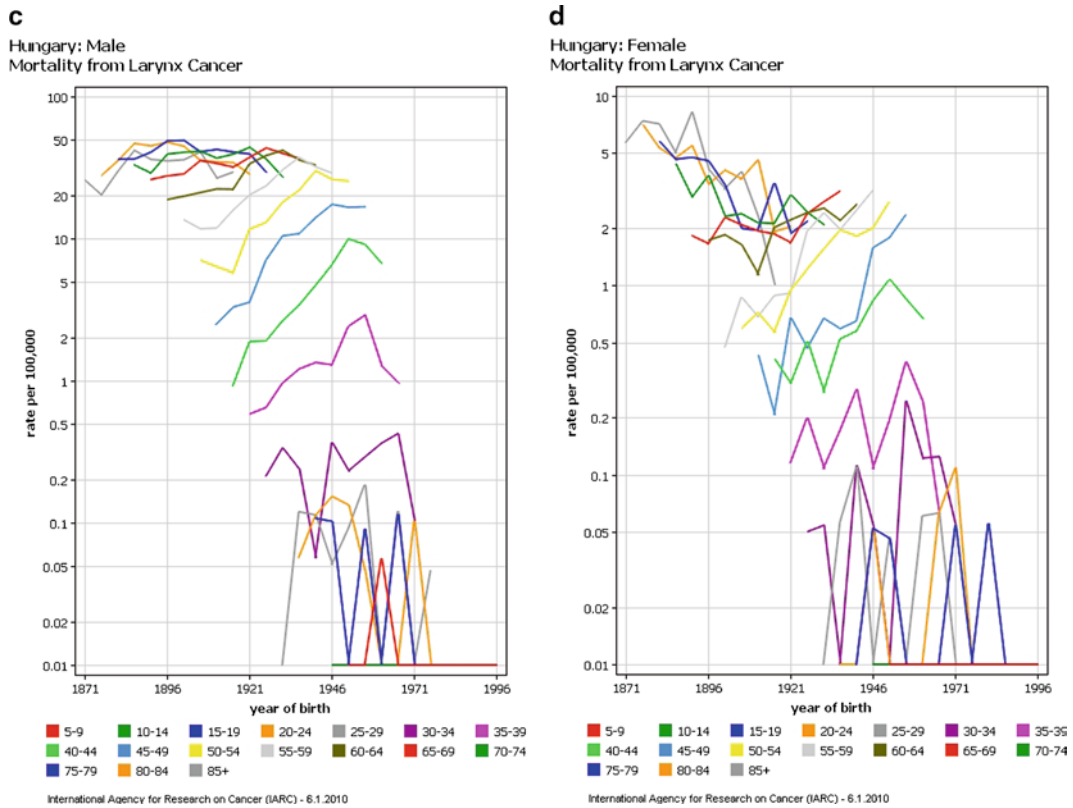


Fig. 1.24 (continued)

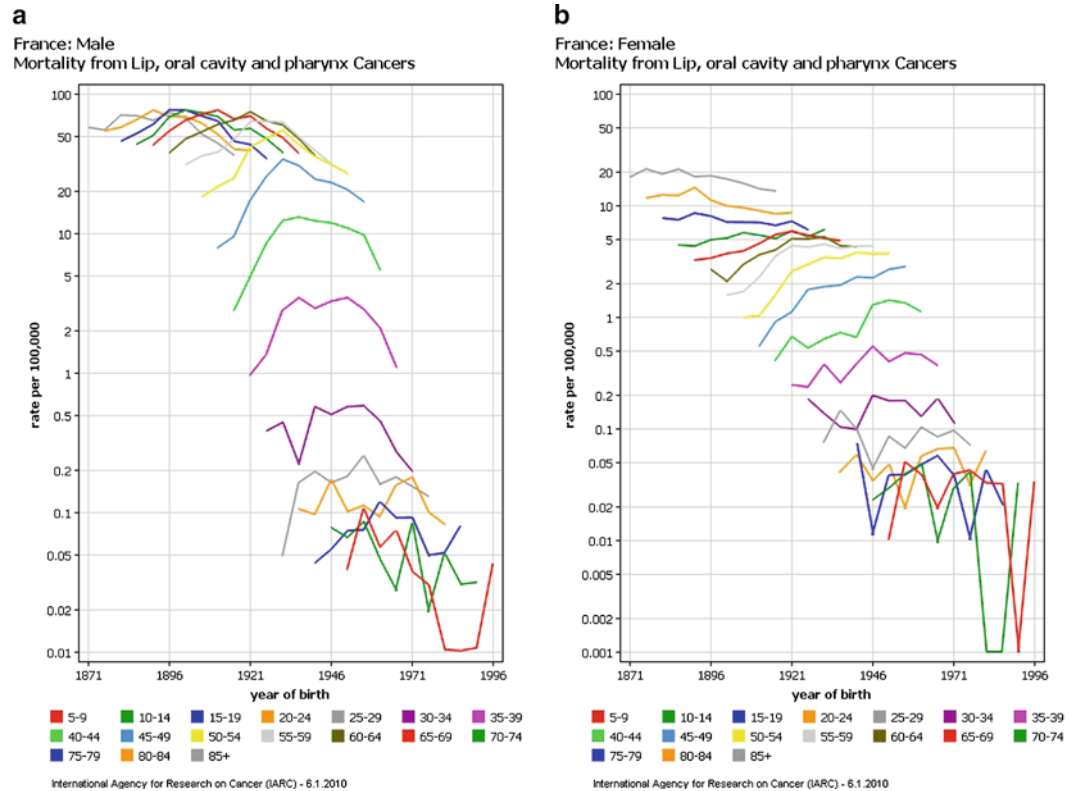


Fig. 1.25 Birth-cohort curves of the mortality rates for lip, oral cavity and pharyngeal cancers for males (a) and females (b), and for laryngeal cancer (c, d) in France. Birth cohort curves are instructive. For males born in the nineteenth century and the first few decades of the twentieth

century, death rates from oral and pharyngeal cancer were extremely high. Those born from around 1940 and later are generating the national average downward trends seen above

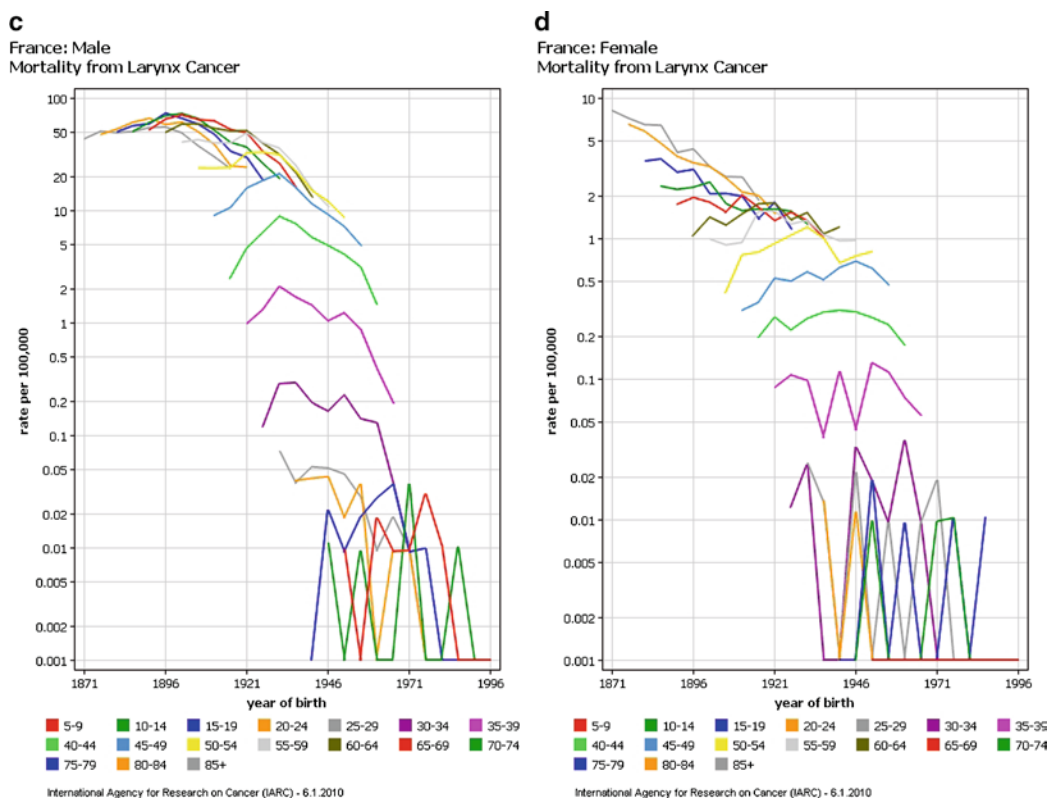


Fig. 1.25 (continued)

Table 1.3 Mortality trends (APC) for oral and pharyngeal cancer in the USA between 1975 and 2004, by race and sex. (SEER Cancer Statistics Review, 1975–2004) [34]

	All races			Whites			Blacks		
	Total	Males	Females	Total	Males	Females	Total	Males	Females
All ages	-1.87 ^a	-2.12 ^a	-1.63 ^a	-1.87 ^a	-2.15 ^a	-1.62 ^a	-1.94 ^a	-1.91 ^a	-1.71 ^a
Under 65	-2.41 ^a	-2.24 ^a	-3.06 ^a	-2.38 ^a	-2.18 ^a	-3.12 ^a	-2.88 ^a	-2.80 ^a	-3.21 ^a
65 and over	-1.45 ^a	-1.99 ^a	-0.75 ^a	-1.53 ^a	-2.14 ^a	-0.79 ^a	-0.46 ^a	-0.59 ^a	-0.26

APC annual percentage change

^aThe annual percentage change in rate is statistically significantly different from zero ($p < 0.05$).

Betel Leaf

The leaves of the *Piper betel* vine (a member of the pepper family) contain betel oil, a volatile liquid, which contains several phenols including hydroxychavicol, eugenol, betel phenol and chavicol. These compounds may, to some extent, be protective, sharing some of the antioxidant properties of many plant polyphenols. Vitamin C, a large amount of carotene and 36 trace elements have also been reported in the betel leaf, clearly beneficial micronutrients [52].

Betel Inflorescence

Apart from the leaf, other parts of the vine such as stem, inflorescence (the flowers or pods) or catkins are also consumed with areca nut. Consumption of the inflorescence is common in Melanesia and parts of Taiwan, and in China, and it is mostly added to the quid for its aromatic flavour [51]. Betel inflorescence contains a high concentration of phenolic compounds including hydroxychavicol, eugenol, isoeugenol, eugenol methyl ester and safrole. Safrole itself, a major

phenolic compound, is classified as a weak carcinogen in rats and is banned as a food and cosmetic additive by the FDA in the USA, *inter alia*, however, there is no direct evidence for its carcinogenicity in man.

Areca Nut

Areca nut is the seed of the fruit of the oriental palm *Areca catechu*. It is the basic ingredient of a variety of widely used chewed products. The consumption of areca nut is indigenous to India, Sri Lanka, Bangladesh, Myanmar, Taiwan and numerous islands in the South Pacific. It is also popular in parts of Thailand, Indonesia, Malaysia, Cambodia, Vietnam, Philippines, Laos and China, and in emigrant communities from these countries. It is believed that *Areca catechu* may be native to Sri Lanka, West Malaysia and Melanesia. Areca nut is used as a masticatory substance by approximately 600 million people worldwide. It is estimated that 10–20% of the world's population chew areca nut in some form, often mixed in betel quid (pan) [51].

The major constituents of the nut are carbohydrates, fat, proteins, fibre, polyphenols (flavonols and tannins), alkaloids and mineral matter. Among the chemical constituents, alkaloids are the most important chemical. The nut has been shown to contain at least six related alkaloids, of which four (arecoline, arecaidine, guvacine and guacoline) have been conclusively identified [53].

Nitrosamine derivatives from each of the four major arecal alkaloids are produced by nitrosation of the alkaloids in dried-stored nuts, in the mouth and especially in the acid conditions found in the stomach, in the presence of nitric oxide generated by bacterial action. Two of these derivatives are accepted as carcinogenic in animal studies, especially MNPN (methylnitrosaminopropionitrile). Endogenous nitrosation is significantly higher in subjects with poor oral hygiene as determined by volumes of dental plaque [54]. This implies that, on the basis of the availability of substrates from both areca nut and tobacco, there is a more extensive formation of nitrosamine in subjects with poor oral hygiene if they also chew tobacco [55]. Moreover direct evidence that reactive oxygen species, such as the hydroxyl radical (HO), are generated in the oral cavity due to auto-oxidation of polyphenols contained in areca nut and enhancement by the alkaline pH from slaked lime has been reported [51, 56].

Areca Nut-Based Industrial Packaged Products

A variety of packaged areca products are now available. These are mostly manufactured in India and Pakistan, and

exported worldwide where they are used by old and new habitués. The most common are *gutka* and *pan masala*. Gutka is a dry, relatively non-perishable commercial preparation containing areca nut, slaked lime, catechu, condiments and powdered tobacco. The same mixture without tobacco is called pan masala [57].

Damage to Oral Soft Tissues from the Chewing of Areca Nut and Related Products

(a) Lichenoid Lesions

Areca-induced lichenoid lesions, mainly on buccal mucosa and tongue, are recognised. This is considered to be a type IV contact hypersensitivity-type lesion that resembles oral lichen planus clinically [58].

(b) Betel Chewer's Mucosa

This condition was first described by Mehta et al. (1971), and is characterized by a brownish-red discoloration of the oral mucosa. It is often accompanied by encrustation of the affected mucosa with quid particles, which are not easily removed, and with a tendency for desquamation and peeling. Both chemical and traumatic effects of the betel quid are likely on the oral mucosa. The presence of tobacco in the quid is not essential for the development of chewer's mucosa [58].

(c) Oral Leukoplakia

A case control study conducted in Taiwan, where areca is chewed without tobacco, found the odds ratio for developing leukoplakia to be 7.43 (95% CI 1.94–156.27) for areca nut chewers. These authors demonstrated that the cessation of areca chewing resulted in regression of 62% of leukoplakias [59].

(d) Oral Submucous Fibrosis (OSF)

It is now accepted that chewing areca is the single most important etiological factor for the development of OSF [60], although the pathogenesis is not fully understood. In vitro studies have shown that areca nut alkaloids such as arecoline and its hydrolysed product arecaidine can stimulate cultured fibroblasts to proliferate and synthesise collagen. In addition, flavonoids from the nut have been shown to enhance the cross-linking of collagen, thereby increasing its resistance to degradation by collagenases, as part of normal tissue homeostasis. The copper content of areca nut is high and the possible role of copper as a mediator of fibrosis is supported by the demonstration of up-regulation of lysyl oxidase in OSF biopsies [61].

(e) Oral squamous cell carcinoma (OSCC)

Historical evidence dating back nearly a century indicates that areca nut is involved in the development of OSCC. Subsequently, many case-control studies [62, 63] have confirmed that betel quid chewing increases the

risk of developing OSSC, especially when the quid contains tobacco. A South African study found that 68% of cheek cancer and 84% of tongue cancers developed in subjects consuming areca *without* tobacco [64]. A large number of animal studies have confirmed that areca products and derivatives such as arecoline and areca-derived nitrosamines have the ability to induce neoplastic changes in experimental models, and the IARC has now formally designated areca and betel quids without tobacco as carcinogenic to man [51].

Slaked Lime

Slake lime (calcium hydroxide) is added to betel quids in most of South Asia. In coastal areas of Sri Lanka and the Pacific, it is obtained by heating sea shells or harvested from corals. In inland areas, it is quarried from limestone. When added to betel quids, it causes erosions of oral mucous membranes, which facilitate penetration of betel-quid carcinogens through the mucosa.

Smokeless or Chewing Tobacco

Tobacco is often added to the quid mixture. Edible tobacco in the Indian subcontinent is prepared from sun-dried and partly fermented, coarsely cut leaves of *Nicotiana rustica* and *Nicotiana tabacum* without further processing. Chewing tobacco results in a local exposure of oral mucosa to at least 16 carcinogens, including tobacco-specific nitrosamines (TSNA) and polycyclic aromatic hydrocarbons (PAH) [65]. Unusually high levels of carcinogenic TSNA (e.g. NNN – *N*-nitrosornicotine, and NNK) were reported in saliva of oral snuff users in the Sudan [66] and tobacco chewers in India [67]. NNK is a potent carcinogen and human buccal epithelial cells (in culture) have been shown to be to metabolise NNK: The formation of macromolecular DNA adducts following NNK metabolism is correlated with carcinogenesis in animal models [68].

Betel chewing also releases large amounts of a reactive oxygen species (ROS), especially while the betel quid is actually present. Both TSNA and ROS are major genotoxic agents involved in chewing tobacco-associated oral cancer [51]. Clear dose–response relationships between quid use and the risk of oral cancer and of potentially malignant oral disorders have been demonstrated in many epidemiological studies.

Most forms of oral smokeless tobacco – oral snuff – consumed in Scandinavia and in North America are not flue-cured, and contain relatively low amounts of TSNA. Although

the topic is controversial, many of these products are not highly carcinogenic and it has even been suggested that they have a role as nicotine replacement products in achieving smoking cessation [69]. It is, however, important to remember that there is no such thing as safe tobacco: most smokeless tobaccos have high levels of nicotine and are addictive; indeed, there is an evidence that they can be initiators of smoking [70]. Furthermore, they have significant cardiovascular effects [71] and certainly produce oral mucosal lesions and local damage to the periodontium [72].

Contaminants

Areca nut can be contaminated with fungi such as *Aspergillus flavus*, *A. niger* and *Rhizopus* spp. Almost 40% of samples of areca nut from India analysed using thin layer chromatography contained aflatoxins [73]. These are established carcinogens.

Tobacco Smoking

Tobacco is identified as the leading preventable cause of premature death worldwide. It is estimated that 4.9 million people died of tobacco-related illness in 2000, and by 2020, it is expected that this figure will rise to 10 million deaths per year, of which 70% will be in developing countries [68]. Tobacco is a major independent risk factor for the development of oral and pharyngeal cancer and other malignancies of the upper aerodigestive tract. Tobacco is consumed in different ways as a form of smoking: cigarettes, cigar, beedi, reverse smoking and smokeless tobacco like oral snuff or in moist pouches. Tobacco smoke contains more than 60 carcinogenic combustion products. In particular, NNK, NNN and polycyclic aromatic hydrocarbons (PAHs) have been causally linked to UADT cancer. The activity of carcinogens is generally exerted through DNA adducts [74, 75]. Both tobacco smoking and quid chewing cause oxidative stress to tissues, that is, the sustained presence of reactive oxygen species (ROS), which initiate free radical reactions. ROS can damage proteins, lipids, carbohydrates and DNA. Minor DNA damage can result in mutations that can be part of the causal chain for malignant transformation, while sustained DNA damage can result in further perturbations of cell cycle control [76].

In addition to an extensive literature on the carcinogenicity of tobacco smoke in cell and animal models, numerous case–control and cohort studies affirm its key role in man, and the super-multiplicative synergism with alcohol drinking [77]

Alcohol

Unsafe consumption of alcohol, including so-called binge drinking, is a major public health problem worldwide, for example, contributing between 5,000 and 40,000 deaths in the UK annually [78]. The possible beneficial effects of moderate alcohol consumption have been widely canvassed, because of the so-called J-shaped relationship between alcohol intake and all-cause mortality, as shown in a number of meta-analyses [79]. The upstroke of this J-curve is thought to be due to the cardio protective effect of moderate alcohol consumption: In particular, alcohol increases high density lipoprotein levels, inhibits platelet aggregation, and promotes fibrinolysis [80]. It has always been recognised that above an intake of around 10 g of alcohol per day the detrimental effects of alcohol predominate [79].

The recent increases in oral cancer reported in younger subjects in the UK were related, at least in part, to growing alcohol use/abuse in that society [44]. The difficulty of accurately quantifying the influence of alcohol in the aetiology of H&N cancer stems from the fact that most people who drink heavily also smoke. It is also difficult to obtain reliable information from individuals on their intake of alcohol.

The health education council in the UK recommends a weekly intake of no more than 14 units for women and 21 units for men. Using these criteria one in four men and one in ten women in that country are believed to be drinking over this limit, with the number of habitual heavy drinkers estimated at four million [81]. Although the legal age for drinking is 18 years, the average age at which drinking starts has fallen since the early 1970s from around 17 to around 11 years, in boys and girls. The recent emergence of “Alcopops” (alcoholic drinks that mimic the taste of non-alcoholic drinks) has resulted in wide uptake among those under 18.

Internationally there is a developing view that *any* consumption of alcohol is detrimental, and even the French government now publicly recommends severe constraint or even abstinence: the French National Cancer Institute has declared “there is no amount of alcohol, however small, which is good for you” [82]. WHO policy is to minimise the use of alcohol throughout all of society [83], and the 2009 Australian Guidelines to Reduce Health Risks from Drinking Alcohol summarises the science cogently [84].

Ethanol and water are the main components of most alcoholic beverages, which also contain volatile and non-volatile flavour compounds. The major alcohol metabolising enzymes are alcohol dehydrogenase that oxidises ethanol to acetaldehyde, and aldehyde dehydrogenase that detoxifies acetaldehyde to acetate. Acetaldehyde is responsible for the oral carcinogenic effect of ethanol, owing to its multiple mutagenic effects on DNA. Specific alcoholic beverages have been shown to contain specific impurities or contaminants

that can be carcinogenic. *N*-nitrosodiethylamine is present in some beer and whisky and has been associated with an increased risk of oral cancer. Polycyclic aromatic hydrocarbons, some of which are considered to be carcinogenic, are found in many brands of whisky [85].

Alcohol also acts in the following ways to promote oncogenesis [85].

Ethanol:

- Damages the phospholipids of cell membranes and increases permeability. It has been shown to enhance the penetration of tobacco-specific carcinogens across the oral mucosa [86].
- Impairs DNA repair mechanisms.
- Acts as a solvent, allowing the carcinogens from tobacco to penetrate into tissue.
- Perhaps catalyses the activation of tobacco carcinogens.
- Alcohol is highly calorific. It lessens the protective effect of beneficial foods such as fruits and vegetables by depressing hunger.
- Is hepatotoxic, thus reducing the effectiveness of those enzyme systems central to detoxification of carcinogens, especially the glutathione-*S*-transferases and cytochrome-p450 systems.

A case-control study in Uruguay conducted between 1992 and 1996 is worthy of note [87]. Histologically confirmed cases ($n=471$) of squamous cell carcinoma of the oral cavity and pharynx in males admitted to four major hospitals in Montevideo were matched with the same number of other patients admitted for a variety of non-smoking and non-drinking-related conditions as controls. Alcohol consumption was assessed by interview and the number of grams of ethanol consumed per day was calculated. Ever-drinking was associated with a 4.5-fold increased risk of oral-pharyngeal cancer compared to non-drinkers, though no clear dose-response relationship was observed. Consumption of hard liquor was associated with a 3.6-fold increased risk, whereas pure wine drinking showed only a 2.1-fold increased risk. When risks were analysed by sub-sites, the highest odds ratios were observed for oral cavity cancer.

Another case-control study conducted in Italy and Switzerland between 1992 and 1997 included 749 cases of oral/pharyngeal cancer and 1,772 hospital controls. Alcohol consumption was measured by the number of drinks consumed per day, one drink corresponding to ~125 ml of wine, 330 ml of beer or 30 ml of spirits (i.e. about 12 g of ethanol). Compared to light drinkers (1–2 drinks per day), the adjusted OR for 3–4 drinks was 2.1(95% CI 1.5–2.9) and 21.1(95%CI 14.0–31.8) for more than 12 drinks per day. Wine drinkers who consumed more than 12 drinks per day were at a 16.1-fold risk compared to the abstainers. Consumption of more than 3 beers per day resulted in a 2.3-fold risk compared to the non-beer drinkers. In contrast to the Uruguayan study,

there was only a 1.9-fold risk for consumption of spirits as compared to non-spirit drinkers [88].

There are many confounders in such studies. Most people drink a variety of beverages, and accurate controlling for tobacco, diet, socio-economic status and other variables is challenging.

Mouthwashes

There has been considerable interest in the possible risks of H&N cancer associated with use of alcohol-containing mouthwashes recently, leading some manufacturers to use “alcohol-free” as a marketing tool. Epidemiological findings have not been consistent and control for other major risk factors, including smoking, not always easy to ascertain from the published work [89]. Some reviews have argued that using mouthwash daily may be an independent cause of cancers of the head, neck and oesophagus [90, 91]. It is well established that ethanol increases the permeability of lining mucosa, allowing carcinogens to penetrate more freely. Acetaldehyde, the proximal metabolite of ethanol can accumulate in the mouth from bacterial action, and as explained above this is an established carcinogen. However, four case-control studies have shown non-significant, lower or similar oral cancer risks among self-reported mouth wash users compared to non-users [92, 93]. The most recent meta-analysis has not demonstrated excess risk for oral cancer from alcohol-containing mouthwashes [94, 95]. There is, however, a plausible biological basis for risk associated with alcohol-containing mouthwashes, especially in smokers and it is always prudent to remember that absence of evidence is not evidence for absence.

Diet and Nutrition in the Aetiology of Head and Neck Cancer

Dietary factors are estimated to account for approximately 30% of all cancers in Western countries [96]. This proportion is currently thought to be about 20% in developing countries and is projected to increase in the future [97]. Poor diet is a significant risk factor for all H&N cancers [98–104] and appears to be second only to tobacco as a cause of oral cancers worldwide [3]. A case-control study of laryngeal cancer in Italy and Switzerland between 1992 and 2000, revealed that a diet not only rich in, but also varied in, fruit and vegetables confers decreased risk of laryngeal cancer [101].

Evidence comes from case-control and cohort studies, from animal and from in vitro experiments. Protective and unhealthy foods are well understood, and form the basis of health

education messages in most countries. The micronutrients that confer these benefits are also well understood. Vitamin A and related carotenoids (in particular beta-carotene), vitamins C and E and selenium appear to be particularly protective against most epithelial cancers [105–107], and much of the effect is attributable to their antioxidant activities. Antioxidants act by reducing free radical reactions which can cause DNA mutations and changes in lipid peroxidation of cellular membranes [108]. Other protective roles of micronutrients are modulation of carcinogen metabolism, maintenance of appropriate cell differentiation, inhibition of cell proliferation and oncogene expression, maintenance of immune function and inhibition of formation of endogenous carcinogens [76].

A recent meta-analysis on oral cancer, based on 15 case-control studies and one cohort study, was able to utilise diet data from nearly 5,000 subjects: this estimated that each portion of fruit or vegetables consumed per day reduced the risk of oral cancer by around 50% [109]. These effects are also demonstrable with OPMD: In a population-based case-control study in Japan, where there were 48 cases of oral leukoplakia and 192 control subjects, serum levels of lycopene and beta-carotene were significantly lower in those with leukoplakia; logistic regression showed that high levels of beta-carotene were related to low risk of oral leukoplakia (OR=0.16) [110].

Intervention studies are also encouraging in this respect. In a major double-blind placebo-controlled trial in Kerala [111], up to one third of subjects showed regression of their oral leukoplakias after 12 months supplementation with oral beta-carotene. Extensive studies from the MD Anderson Cancer Centre in the USA are progressively identifying the most effective combinations of anti-oxidants in the regression of OPMD and the prevention of recurrences and second primary neoplasms in H&N cancer, although it has to be recognised that these agents do not always prevent the progression of an OPMD to overt cancer [112].

There is current interest in the protective effects of tea, especially green tea, which contains high levels of polyphenols [113]. These are powerful antioxidants able to counteract both initiation and promotion of carcinogenesis [108].

Genetic Predisposition

There is considerable evidence for a minor component of inherited, genetic predisposition in UADT cancers, related to polymorphisms in carcinogen-metabolising enzyme systems [114]. A recent extensive meta-analysis [91] pooled individual-level data across 12 case-control studies including 8,967 HNC cases and 13,627 controls. After adjusting for potential confounding factors a family history of H&N cancer in first-degree relatives increased the risk (OR=1.7, 95% CI 1.2–2.3).

The risk was higher when the affected relative was a sibling (OR=2.2, 95% CI 1.6–3.1) rather than a parent (OR=1.5, 95% CI 1.1–1.8) and for more distal H & N sites (hypopharynx and larynx). The OR rose to 7.2 (95% CI 5.5–9.5) among subjects with family history, who were alcohol and tobacco users. No association was observed for family history of nontobacco-related neoplasms and the risk of HNC (OR=1.0, 95% CI 0.9–1.1). Rare cancer syndromes can involve the H&N: Cowden syndrome, caused by mutations in the tumour suppressor gene PTEN; and dyskeratosis congenita, in which oral white lesions in young people have a risk of malignant transformation [115].

Microorganisms

Microorganisms have been implicated in the aetiology of oral leukoplakia for more than a century, beginning with the classic dorsal leukoplakia of syphilitic glossitis. Today tertiary syphilis is rare, but the fungus, *Candida albicans*, a common oral commensal, is frequently found invading the upper epithelium in histological sections of leukoplakia, more so in the mouth than pharynx or larynx [116], and this involvement is associated with a higher risk of malignant transformation [117]. The terms “candidal leukoplakia” and “hyperplastic candidiasis” have been used to describe such lesions.

It is now clear that high-risk HPV genotypes, particularly HPV 16 and 18, are important co-factors, especially in cancers of the tonsil and elsewhere in the oropharynx [118, 119]. The current state of knowledge is covered extensively in another chapter of the present volume.

The role of bacteria in the aetiology of UADT cancers is currently receiving more attention [120]. Endogenous production of acetaldehyde and reduction of nitrate to nitrites by oral flora is higher in drinkers with poor oral hygiene [121]. Understanding the role of the oral flora is certainly important in the management of the distressing mucositis associated with so much cancer therapy.

Air Pollution

Part of the urban/rural difference in the incidence of head and neck cancer has been related to atmospheric pollution. For example, mean sulphur dioxide and smoke concentrations in the atmosphere are positively correlated with squamous cancer of the larynx and, to a lesser extent, the pharynx in data collected some time ago from the West Midland region of England 1950–1990 [122].

Indoor air pollution resulting from the use of solid fuel such as wood, crop residue, animal dung and coal for cooking

and heating is a significant health problem in many developing countries, where a greater proportion of people use such fuels frequently in poorly ventilated areas. Many studies have been identified indoor air pollution as a risk factor for H&N cancer [123, 124] and a recent monograph by the International Agency for Research on Cancer has identified indoor air pollution from coal usage as a known human carcinogen, while that from biomass (primarily wood) as a probable human carcinogen [125]. Studies carried out in China and Brazil have reported exposure to wood smoke as a risk factor for oral cancer [126], nasopharyngeal cancer [127] and UADT cancer [128].

Solar Radiation

Prolonged exposure to sunlight represents an important risk factor for the development of squamous cell carcinoma of the lip in people with fair complexions, and those with outdoor occupations. Usually, the lower lip is involved because it receives considerably more direct sunlight than the upper lip [129]. Evidence comes from many countries, including those at latitudes with clean air through which ultraviolet light penetrates easily, such as Finland [130] or Sweden [131], and from countries closer to the equator with regular long hours of sunshine such as rural Greece where lip cancer can account for 60% of oral cancers [132] and in India, for example, in fishermen [6] – though some protection may exist in darker-skinned races or individuals. In Finland, the increased risk for lip cancer is confounded by smoking and social class, whereas that for oral cavity and pharynx is not; at these latter sites, alcohol was a much stronger confounder than tobacco [133]. A study from California shows that risk for women is strongly related to lifetime solar radiation exposure, but lipstick and other sunscreens are protective [134]. Although the observation goes back over a decade, there is a recent concern that modern cosmetic lip glosses may enhance UV damage to the lips, including increased risk of cancer [134].

Falls in the incidence of lip cancer have been interpreted as due to reduced occupational exposure to sunlight and to reduced pipe and cigar smoking [135, 136].

Global Scenario of Oral Potentially Malignant Disorders and Laryngeal Leukoplakia

The term Oral Potentially Malignant Disorders (OPMD) was recommended by an international Working Group convened by the WHO Collaborating Centre for Oral Cancer and Precancer in London in 2005 [135]. It conveys that not all

disorders described under this umbrella will transform to invasive cancer – at least not within the lifespan of the affected individual. Leukoplakia, Erythroplakia, Oral Submucous fibrosis, Lichen planus, Palatal lesions in reverse smokers, Actinic keratosis, Discoid lupus erythematosus, Dyskeratosis congenita, and Epidermolysis bullosa are described under the broad definition of OPMD [137, 138].

Global Prevalence of OPMD

Estimates of the global prevalence of OPMD range from 1 to 5% [139], although much higher prevalences are reported from Southeast Asia, usually with a male preponderance, for example, in Sri Lanka (11.3%) [50], Taiwan (12.7%) [140]

and Pacific countries like Papua New Guinea (11.7%) [141]. Wide geographical variations across countries and regions are mainly due to differences in socio-demographic characteristics, the type and pattern of tobacco use and clinical definitions of disease (see Table 1.4). In Western countries, the overall prevalence is low and a decreasing trend over time is observed.

Stefano [154], conducted a meta-analysis of 23 primary studies on oral leukoplakia, from international data published between 1986 and 2002. The point-prevalence estimates were 1.49% (95% CI 1.42–1.56%) and 2.6% (random effect, 95% CI 1.72–2.74%). Leukoplakia was significantly more prevalent among males (prevalence ratio 3.22), but no difference was found between geographical areas and between younger and older adults. Using these data, they calculated that the crude annual oral cancer incidence rate attributable

Table 1.4 Summary of the prevalence of OPMD reported in the literature

References	Country (year)	Sampling method	F/M ratio	Age group	Disease entity	Definition used	Prevalence %
[50]	Sri Lanka (2008)	MSSC	0.6/1.0	≥30	OPMD	WHO 1994	11.3 weighted for gender and geographical location.
[142]	Taiwan (2005)	Random	0.9/1.0	≥15	OPMD	Not given	12.7
					Leukoplakia		7.4
					Erythroplakia		1.9
					Lichen planus		2.9
					OSF		1.6
[143]	USA (2003)	MSSC	0.9/1.0	≥20	Leukoplakia	Kramer 1978, Kramer 1980	0.5–0.3
[144]	Sri Lanka (2003)	Multi-stage stratified cluster (MSSC)	–	35–44 years and 65–74 years	OPMD	WHO 1994	4.1
					Leukoplakia		2.6
					Erythroplakia		0.4
					OSF		1.6
[145]	Spain (2002)	Stratified, random	0.8/1.0	≥30	Leukoplakia	WHO 1978, Axell, T et al. 1984	1.6
[146]	Germany (2000)	Stratified, random	1.0/1.0	35–44 year	Leukoplakia	Axell 1976	1.6
			0.7/1.0	65–74 year	Leukoplakia	Zain 1995	1.0
						WHO-ICD-DA	
[147]	Japan (2000)	All invited	0.4/1.0	m >40, f >20	Leukoplakia	WHO 1980	0.19
					Lichen planus		0.21
[148]	Malaysia (1997)	Stratified, random	0.7/1.0	≥25	Leukoplakia	WHO 1978	0.96
					Erythroplakia	Axell, T et al. 1984	0.01
					OSF		0.06
					Lichen planus		0.38
[149]	Netherland (1996)	Waiting room	0.9/1.0	13–93 year	Leukoplakia	Axell 1984	0.6
						Axell 1996	
						Schepman 1995	
[150]	Hungary (1991)	Random	0.7/1.0	All age groups	Leukoplakia	Axell 1984	1.3
					Lichen planus		0.1
[151]	Japan (1991)	Factory workers	0.5/1.0	18–63 years	Leukoplakia	Axell 1984	2.5
[152]	Sweden (1987)	Stratified random	Not found	≥15	Lichen planus	Axell 1976	1.9
[153]	Sweden (1987)	All-invited residents	0.9/1.0	≥15	Leukoplakia	Axell 1976	3.6

to leukoplakia would be between 6.2 and 29.1 per 100,000 thus suggesting that the global number of oral cancer cases is probably under-reported.

Age and Gender Distribution of OPMD

This varies considerably, mainly dependent on lifestyle and thus on ethnicity and geographical location. In the developed world, leukoplakia is usually found between the fourth and seventh decades of life, in the developing world some 5–10 years earlier [155]. Females are less commonly affected, largely reflecting greater use of relevant habits by men.

Malignant Transformation of OPMD

Risk of malignant transformation varies from site to site within the mouth, from population to population and from study to study [156–158]. A classic study conducted in the 1970s with follow-up over 7 years of more than 30,000 Indian villagers, showed transformation rates from 10 to 24 per 100,000 per year [157]. Another classic study from the early 1980s, a hospital-based study in Californian patients with oral leukoplakia, with a mean follow-up period 7.2 years, revealed a malignant transformation rate of 17.5% [158]. Rates for hospital-based studies are, unsurprisingly, consistently higher than community-based studies because of sampling bias.

Petti [154] has estimated a mean global prevalence of 2.6% for leukoplakia, and a mean global transformation rate of 1.36% per year (95% CI 0.69–2.03). Extrapolating from these figures suggests that considerably more OSCC should have been reported in recent times, a possible reason being under-reporting of cases of oral cancer in the developing world.

Epidemiology of Laryngeal Leukoplakia

Epithelial precursor lesions of the larynx, clinically defined as leukoplakia and chronic laryngitis, are mostly seen in adults and affect men more often than women. This gender disparity is more pronounced after the sixth decade of life [159]. Epidemiological studies of laryngeal precursor lesions are scarce and the incidence differs worldwide and depends upon the amount, manner and types of exposure to relevant carcinogens. According to a recent review [160], 1,268 patients were clinically diagnosed as laryngeal leukoplakia and chronic laryngitis during the period from 1979 to 2004 in Slovenia. The incidence of patients, covering a region

with approximately 800,000 inhabitants or 40% of the population of Slovenia, varied for the benign group of precursor lesions (squamous hyperplasia and basal parabasal cell hyperplasia) from 0.84 to 4.62/100,000 inhabitants pa (mean value 2.61/100,000 inhabitants, SD=1.10). The incidence of patients for atypical hyperplasia ranged from 0.25 to 2.62/100,000 inhabitants pa (mean value 0.86/100,000 inhabitants, SD=0.49).

Aetiology of Laryngeal Leukoplakia

Laryngeal leukoplakic lesions are strongly associated with tobacco smoking and alcohol use, especially in combination [161–163]. Other risk factors are: industrial pollution, specific occupational exposures, nutritional deficiency, and hormonal disturbance [164–166]. A recent meta-analysis has shown a weak association between HPV-16 and laryngeal cancer [167]. Several authors have recently devoted much attention to the potential role of gastro-esophageal reflux disease, but the results are not conclusive [161, 168].

Salivary Gland Neoplasms

Epidemiology

Neoplasms arising in the salivary glands are relatively uncommon, yet they represent a wide variety of both benign and malignant histologic sub-types. The reported annual incidence, when all salivary gland tumours are considered, varies widely between countries and regions [169].

According to Globocan 2002, the world's highest incidence of salivary neoplasms was reported from the Northern Territory of Australia (though the number of cases in this thinly populated area was too small – only seven cases – to place credence on this value); the second highest from Croatia (Table 1.5). Within Japan, the highest rates are reported from the region of Nagasaki, regarded as long-term effects of the atomic bomb explosion in 1945. The estimated annual incidence in the USA is 1.5 cases per 100,000 population pa; here they constitute only about 6% of all head and neck neoplasms [170].

Site, Age and Sex Distribution

Nearly 80% of these tumours arise in parotid glands, 15% in submandibular glands, with the remainder distributed across the sublingual and minor salivary glands of the oral and

oropharyngeal mucosae [171]. In most series, benign neoplasms are the majority, representing 54–79% of cases described. Pleomorphic adenoma is by far the most common, accounting for about 50% of all salivary gland tumours. Warthin's tumour is second in frequency among benign neoplasms and, in most large studies, mucoepidermoid carcinoma is the most common malignancy [169].

Table 1.5 Incidence of salivary neoplasms: cases per 100,000 pa, standardised ASR(W)

Population	ASRW male	ASRW female
Australia, Northern territory	1.7	0.2
Croatia	1.6	0.6
Poland, Cracow	1.5	0.6
USA, District of Columbia white	1.4	0.4
USA, black	0.9	0.6
USA, white	1.1	0.8
UK, Oxford region	0.7	0.5
Canada	0.9	0.6
China, Hong Kong	0.7	0.5
India, Chennai	0.5	0.3
Japan, Nagasaki	0.7	0.5
France, Herault	0.8	0.7
Norway	0.7	0.6
Spain, Granada	0.6	0.5
Switzerland, Geneva	0.6	0.9

The average ages of patients with benign or malignant tumours are 46 and 47 years, respectively, with peak incidence of most of the specific types in the sixth and seventh decades. However, the highest incidence of pleomorphic adenomas, mucoepidermoid carcinomas and acinic cell carcinomas is significantly younger in the third and fourth decades. Salivary neoplasms are rare in young people and in patients under 17 years of age, a neoplasm of a major gland is as likely to be mesenchymal as epithelial in origin [172–175] (Figs. 1.26a, b).

Aetiology of Salivary Gland Neoplasms

The aetiology of salivary gland neoplasms is still poorly understood. Furthermore, especially with neoplasms that have mixed cellularity, notably pleomorphic adenomas and carcinomas arising therein, which show epithelial, myoepithelial and mesenchymal characteristics, controversy remains as to whether there is a single or more than one type of cancer stem cell [169].

Viruses: Studies have shown a strong association between EBV and lymphoepithelial carcinomas [176, 177], with geographical variations, as this shows a preponderance for Asian

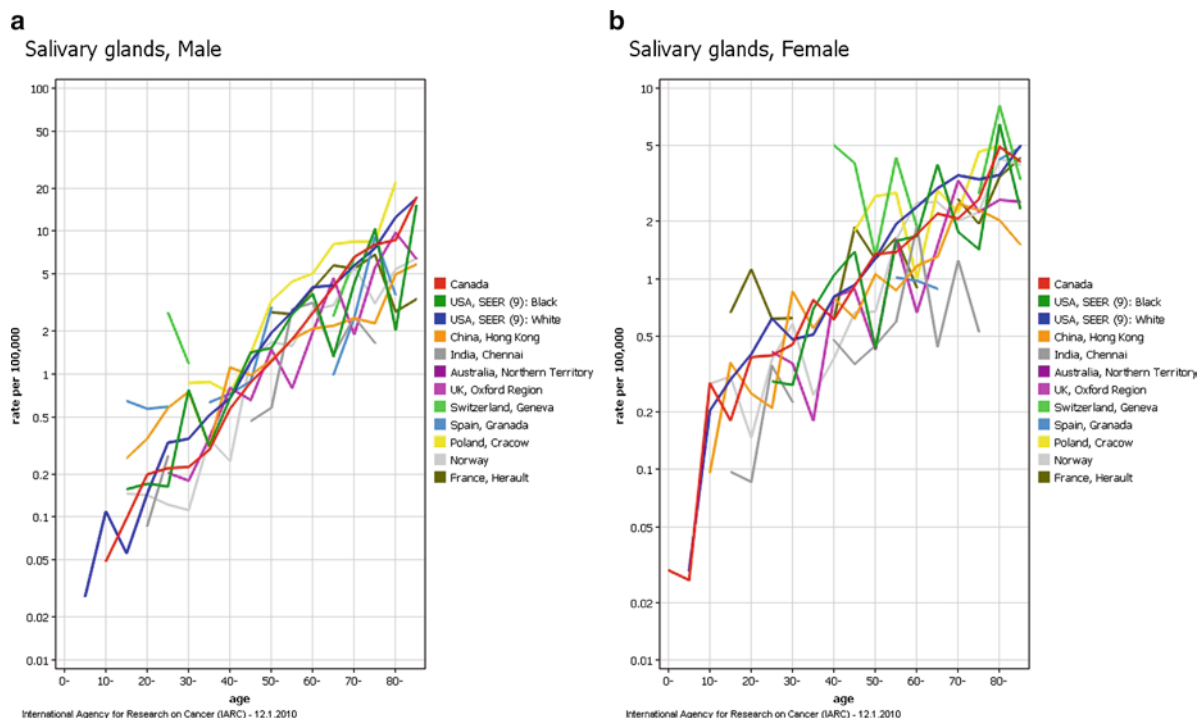


Fig. 1.26 The incidence of salivary gland neoplasms rises steadily, and linearly, with age. Data from selected countries are given in Fig. 1.26 (a, males; b, females). Note that the scales are, as usual with

such data presentations, logarithmic. Thus it is seen that across most of the life span there is no major sex predilection

patients [178] and Greenlandic Inuits [179]. Salivary tissue is an established reservoir for EBV, but a clear oncogenic role for EBV or for cytomegalovirus (CMV) has not been demonstrated in other salivary gland carcinomas or in benign parotid tumours [177]. SV40 sequences have been postulated in human pleomorphic adenomas [180], but there is no significant association between human salivary gland tumours and other viruses, including polyoma virus and papillomavirus (HPV).

Radiation: There is convincing evidence implicating exposure to ionising radiation and the development of salivary gland neoplasms. Long-term follow-up studies of the survivors of the atomic bomb explosions in Hiroshima and Nagasaki show an increased relative risk of 3.5 for benign, and 11 for malignant salivary neoplasms [181, 182]. The risk was directly related to the level of exposure to ionising radiation. There was a high frequency of both mucoepidermoid carcinoma and Warthin's tumours in these patients [183]. Therapeutic radiation, especially in the head and neck region, has been linked to significantly increased risk [184, 185]. Iodine 131, used in the treatment of thyroid disease, is thought to produce neoplasms, as the isotope is also concentrated in salivary glands [186].

Several studies have suggested that exposure to routine dental radiographs may be associated with an increased risk of salivary neoplasms, though the evidence is inconclusive [187, 188]. Exposure to ultraviolet radiation has also been implicated [189–191], though this seems biologically improbable. There appears to be no excess risk in those exposed to radon [192], or the microwaves of cellular telephones [193, 194].

Occupation: There is a literature relating salivary gland neoplasms to occupation. Suggested risks include rubber manufacturing [195], exposure to metal in the plumbing industry [196] and nickel compounds [195], woodworking in the automobile industry [197] and employment in hairdressing and beauty shops [198, 199]. An increased risk of salivary gland cancers was reported in people living in certain Quebec countries where asbestos was mined, and this risk was inversely proportional to distance from the mines [200].

Lifestyle and nutrition: Tobacco and alcohol, which are highly associated with head and neck squamous cell carcinoma, have not been shown to play a major role in the development of salivary malignancies [201]. However, tobacco smoking has been associated with the development of Warthin's tumour. Exposure to silica dust and kerosene as a cooking fluid increased the risk of salivary neoplasms in a Chinese population [202], and an increased risk of parotid neoplasms was associated with exposure to nickel, chromium, asbestos and cement dust [203]. An elevated level of risk has been described in those with a high cholesterol intake [204].

Hormones: Oestrogen activity or upregulation of oestrogen receptors have been described in pleomorphic adenomas in

some studies [205], but were absent in another [206]. Progesterone and androgen receptors are present in some salivary neoplasms [205, 207] and binding of hormones to these may influence tumour progression.

Other Important Cancers of the Head and Neck: Malignant Melanoma and Kaposi's Sarcoma (KS)

Malignant melanoma is recorded by cancer registries separately from mucosal and other cancers (Table 1.6). These data represent all skin sites but the management of melanoma often falls into the hands of head and neck clinicians, so the data are of interest. DNA damage from ultraviolet light, especially acute sunburn and especially early in life, is the major risk factor. This explains the high incidence rates in Australia, New Zealand, northern Europe and among white South Africans: for head and neck melanoma the risks associated with ultraviolet light are most marked at low altitudes [208]. Melanoma of UADT mucosa is a serious, usually fatal, disease: global epidemiological data will be "buried" in the graphs and tables above. Such data as available have been reviewed recently by van der Waal et al. [209].

Table 1.6 World standardised incidence rate per 100,000. Accessed from <http://www-dep.iarc.fr/> in December 2009

Country	Melanoma skin (C43)		Kaposi sarcoma (C46)	
	Male	Female	Male	Female
World	2.8	2.6	0.0	0.0
More developed	8.3	7.5	0.0	0.0
Less developed	0.7	0.7	0.0	0.0
Eastern Africa	1.2	2.3	23.0	9.5
Middle Africa	2.2	2.1	30.0	8.6
Northern Africa	0.7	0.5	0.3	0.1
Southern Africa	5.4	4.1	13.2	5.7
Western Africa	1.1	0.9	4.6	1.4
Caribbean	1.0	1.1	0.0	0.0
Central America	1.3	1.7	0.0	0.0
South America	2.4	2.3	0.0	0.0
Northern America	16.4	11.7	0.0	0.0
Eastern Asia	0.3	0.2	0.0	0.0
Southeastern Asia	0.5	0.5	0.0	0.0
South Central Asia	0.5	0.4	0.0	0.0
Western Asia	1.6	1.5	0.0	0.0
Eastern Europe	3.3	3.8	0.0	0.0
Northern Europe	8.4	10.0	0.0	0.0
Southern Europe	6.0	5.5	0.0	0.0
Western Europe	7.3	10.3	0.0	0.0
Australia	38.5	29.5	0.0	0.0
New Zealand	33.8	29.2	0.0	0.0
Melanesia	4.8	2.9	0.0	0.0
Micronesia	1.2	0.7	0.0	0.0
Polynesia	5.1	0.0	0.0	0.0

Kaposi's sarcoma (all sites) is an AIDS-defining lesion and is thus most common where HIV-disease is most rampant: it is a major problem in sub-Saharan Africa, in many countries of which KS is the most frequently diagnosed cancer [210]. In our series of 710 head and neck cancers in northern Nigeria, KS was the most common HIV-associated malignancy [211]. KS is seen less commonly in the current era of highly active anti-retroviral therapy in populations where such therapy is widely available. Many of the zero numbers in these tables reflect absence of data – or situations where KS is not separately registered.

The aetiology of KS was described in 1994 and is now clearly established as infection with Human Herpes Virus Type 8 (HHV-8, also known as Kaposi Sarcoma Herpes Virus – KSHV). It is a multifocal malignancy of lymphatic endothelial cells. Endemic KS in HIV-negative subjects still exists, especially in the Mediterranean where it has long been regarded as having an ethnic predilection – for certain Jewish groups. There is a puzzle with HIV/AIDS-related KS, however; the head and neck, especially the mouth, is a common site for KS in HIV-positive subjects; the oropharynx is the primary reservoir, and saliva/oral fluids are the major vehicle of transmission [212]. Transmission occurs via oral-genital contact and is more common in men who have sex with men. In India, which is currently the single nation of the world with the highest number of HIV infections, KS is almost never seen. Whether this is because of different social practices, differences in the strains of KS circulating in that country – with different pathogenicity – or differences in host response, remains unknown [213] (Table 1.7).

The Death to Registration Ratio (D/R) for melanoma can be readily calculated here. For ANZ this ranges from 0.09 to 0.18, whereas in northern Europe, the average approaches double this, viz 0.16 for women and 0.26 for men. Women do better all over the world, possibly because they seek treatment earlier. Note that these outcomes are substantially better than for oral cancer. In ANZ, there are highly effective public education campaigns regarding protection against sun damage, and many screening and treatment facilities. In spite of this, the comparatively poor outcomes perhaps reflect a degree of complacency towards the very common sun-induced lesions, many of which are benign.

Primary Neoplasms of the Jaws and Facial Bones

While to a large extent, these lesions constitute the “bread and butter” for many oral/maxillofacial pathologists and surgeons, such lesions are comparatively rare: they do not represent anything like the major public health problem of epithelial tumours of the head and neck. They are not, therefore,

Table 1.7 World standardised mortality rate per 100,000. Accessed from <http://www-dep.iarc.fr> in December 2009

Country	Melanoma skin (C43)		Kaposi sarcoma (C46)	
	Male	Female	Male	Female
World	0.8	0.6	0.0	0.0
More developed	1.8	1.2	0.0	0.0
Less developed	0.3	0.3	0.0	0.0
Eastern Africa	0.7	1.3	20.8	8.8
Middle Africa	1.3	1.3	25.3	7.8
Northern Africa	0.4	0.3	0.2	0.1
Southern Africa	2.9	2.2	12.4	5.4
Western Africa	0.7	0.5	4.0	1.3
Caribbean	0.4	0.3	0.0	0.0
Central America	0.6	0.5	0.0	0.0
South America	0.9	0.6	0.0	0.0
Northern America	2.5	1.3	0.0	0.0
Eastern Asia	0.1	0.1	0.0	0.0
Southeastern Asia	0.3	0.3	0.0	0.0
South Central Asia	0.3	0.2	0.0	0.0
Western Asia	0.7	0.6	0.0	0.0
Eastern Europe	1.6	1.2	0.0	0.0
Northern Europe	2.2	1.6	0.0	0.0
Southern Europe	1.6	1.1	0.0	0.0
Western Europe	1.8	1.3	0.0	0.0
Australia	5.1	2.6	0.0	0.0
New Zealand	6.1	3.6	0.0	0.0
Melanesia	2.5	1.5	0.0	0.0
Micronesia	0.6	0.3	0.0	0.0
Polynesia	2.5	0.0	0.0	0.0

a major thrust of this volume, but have excellent coverage in other modern textbooks including those referred to in the “Introduction” of this chapter.

It is not appropriate here to indulge in the favourite pastime of oral pathologists to debate the classification of such lesions, uniformity of which would be essential to the comparability of international epidemiological data. Furthermore, it is extremely difficult to mine international and national databases for detailed histological typing, so that the incidence and mortality associated with bone and odontogenic tumours might be reliably quantified. Recourse has to be made to case series and, while these are valuable, significant regional differences in epidemiology and risk factors are hard to quantify. A concise summary of the situation with odontogenic tumours is in the WHO “Blue Book” of 2005 [169].

Difficulties also arise because some databases/case series include benign neoplasms – and with odontogenic lesions, there are frequently grey areas regarding the behaviour of a particular diagnostic category or individual lesion. Strictly speaking, cancer registries should only record malignancy. Hamartomatous and benign lesions are very much more common than malignant odontogenic tumours [214]: Differences emerge between case series based on dental/oral-maxillofacial departments which are more likely to include the former, whereas cases handled in broader general hospitals or cancer hospitals will select for malignancies.

Ameloblastoma is clearly the most common malignant odontogenic tumour worldwide. An extensive series of 1,642 cases from Sichuan University [215] found that benign tumours comprised 97% of cases: ameloblastoma was the most common malignancy, followed by odontogenic keratocystic tumour. In a series of 1,088 cases from northern California [216], 76% were (benign) odontomas: ameloblastomas comprised 12% – a surprisingly high figure perhaps reflecting the specialised nature of this laboratory. This paper also tabulates data from case series all over the world describing the frequencies of the various types of odontogenic “tumour”.

There has long been an impression that odontogenic tumours are more common in Africa – perhaps because so many advanced lesions come late to diagnosis. A thoughtful analysis of the literature up to the early 1990s is given by Smith, [217]. In a more recent series, of 308 odontogenic tumours in Lagos, southern Nigeria, 97% of the tumours were benign and only 3.4% malignant; ameloblastoma with predilection for the mandible was the most frequent [218].

Among primary malignant bone tumours [219], most case series around the world contain very small numbers of patients, but indicate various types of osteo[genic] sarcoma to be most common. Osteosarcomas of all sites account for 40–60% of primary malignant bone tumours and ~10% of these occur in the head and neck, mostly in the jaws. These tend to be diagnosed approximately two decades later than their long bone counterparts, which have a peak incidence between 10 and 14 years. Head and neck osteosarcomas metastasise less frequently than those in long bones, and have a better 5-year survival rate, reported between 27 and 84%. The experience of one USA centre has recently been described [220], with a helpful review of the literature. Out of 2,830 biopsies of oral and jaw lesions diagnosed 1983–2003, in Lagos, 59 (2.08%) were primary malignant bone tumours, osteosarcoma again being most frequent (28.8%). Interestingly the mean age at presentation (27 ± 14 years) was lower than reports from other parts of the world.

Cancer Metastatic to the Head and Neck

Tumours metastatic to the H&N from distant sites are comparatively rare, representing about 1% of oral tumours. Most lesions are found in patients between the fifth and seventh decades of life. They affect the jaws more commonly than soft tissues in a ratio of 2:1 [221]. The most common primary tumours metastatic to the jaws are breast (20%), lung (13%), kidney (8%), adrenal (8%), bone (7%), colorectal (6%), prostate (5%), and liver (5%).

A review of cases revealed that 54% of the 218 metastatic tumours to oral soft tissues were located on the attached gingiva,

followed by 22% on the tongue: The role of inflammation in the attraction of metastatic cells to the gingiva has been suggested [222].

The Future of Head and Cancer Epidemiology

As with many aspects of life, global inequalities are increasing in the incidence rates of head and neck cancers, in the provision and quality of prevention and screening programmes, and in access to and quality of patient care. The drivers of these inequalities are socio-political: war, poverty, pestilence, climate change, lack of food and water security [223]. The problems do not derive primarily from ignorance of causes and mechanisms of disease, but from ineffective or absent implementation of the right policies, and from lack of resources to implement them. As scientists and clinicians devoted to head and neck oncology we all have a moral responsibility to contribute to these wider social and political challenges. The knowledge to apply world best practice is within the pages of this book. The leadership of many local and national bodies is acknowledged: these activities need to be in dialogue and synergy with global leadership through agencies such as the World Health Organisation, the International Agency for Research on Cancer, the UICC/International Union against Cancer, the International Federation of Head and Neck Oncologic Societies, the International Academy of Oral Oncology and others. The International Association for Dental Research launched an initiative in 2010 seeking to reduce global inequalities in oral cancer (and in other oro-facial diseases and disorders).

It is a truism that however sophisticated and effective our diagnostic and treatment armamentarium becomes, head and neck cancer rates around the world will never be reduced by such interventions – though, of course, hundreds of thousands of lives may be saved or improved. The emphasis must be on primary and secondary prevention, on the implementation of policies that work to these ends and on their continued evaluation and improvement.

References

1. Parkin DM, Bray F, Ferlay J, Pisani P. Global cancer statistics, 2002. *CA Cancer J Clin.* 2005;55:74–108.
2. Ferlay J, Bray F, Pisani P, Parkin DM. GLOBOCAN 2002. Cancer Incidence, Mortality and Prevalence Worldwide. IARC Cancer Base No. 5 Version 2.0, 2004.
3. IARC. Cancer incidence in five continents, vol 1X. Available from: <http://www-dep.iarc.fr>. Accessed on 10/08/2009.
4. Moore SR, Johnson NW, Pierce AM, Wilson DF. The epidemiology of mouth cancer: a review of global incidence. *Oral Dis.* 2000;6:65–74.

5. Moore SR, Johnson NW, Pierce AM, Wilson DF. The epidemiology of tongue cancer: a review of global incidence. *Oral Dis.* 2000; 6:75–84.
6. Sankaranarayanan R. Oral cancer in India: an epidemiologic and clinical review. *Oral Surg Oral Med Oral Pathol.* 1990;69: 325–30.
7. World Health Organization. Control of oral cancer in developing countries. A WHO meeting. *Bull WHO* 1984;62:817–30.
8. Ministry of Health. National Cancer Control Programme, Sri Lanka. Cancer incidence data: Sri Lanka year 2000. 6th Publication. Maharagama: NCCP; 2005.
9. Ministry of Health Malaysia. Second report of the National Cancer Registry, Cancer Incidence in Malaysia 2003. Available from <http://www.radiologymalaysia.org/Archive/NCR/2ndNCR.pdf>. Accessed on 09/12/2009.
10. Satyanarayana L, Asthana S. Life time risk for development of ten major cancers in India and its trends over the years 1982 to 2000. *Indian J Med Sci.* 2008;62:35–44.
11. Gupta PC, Nandakumar A. Oral cancer scene in India. *Oral Dis.* 1999;5:1–2.
12. Jemal A, Siegel R, Ward E, Hao Y, Xu J, Murray T, et al. Cancer statistics, 2008. *CA Cancer J Clin.* 2008;58:71–96.
13. Moore SR, Allister J, Roder D, Pierce AM, Wilson DF. Lip cancer in South Australia, 1977–1996. *Pathology.* 2001;33:167–71.
14. Nemes JA, Redl P, Boda R, Kiss C, Marton JJ. Oral cancer report from Northeastern Hungary. *Pathol Oncol Res.* 2008;14:85–92.
15. Tanaka S, Sobue T. Comparison of oral and pharyngeal cancer mortality in five countries: France, Italy, Japan, UK and USA from the WHO Mortality Database (1960–2000). *Jpn J Clin Oncol.* 2005;35:488–91.
16. Bosetti C, Bertuccio P, Levi F, Lucchini F, Negri E, La Vecchia C. Cancer mortality in the European Union, 1970–2003, with a joint-point analysis. *Ann Oncol.* 2008;19:631–40.
17. Curado MP, Edwards B, Shin HR, Storm H, Ferlay J, Heanue M, Boyle P. Cancer Incidence in Five Continents, Vol. IX IARC Scientific Publications No. 160, Lyon, IARC;2007. Available from <http://www-dep.iarc.fr/>. Accessed on 5th January 2010.
18. Brandizzi D, Chuchurru JA, Lanfranchi HE, Cabrini RL. Analysis of the epidemiological features of oral cancer in the city of Buenos Aires. *Acta Odontol Latinoam.* 2005;18:31–5.
19. Karim-Kos HE, de Vries E, Soerjomataram I, Lemmens V, Siesling S, Coebergh JW. Recent trends of cancer in Europe: a combined approach of incidence, survival and mortality for 17 cancer sites since the 1990s. *Eur J Cancer.* 2008;44:1345–89.
20. Conway DI, Stockton DL, Warnakulasuriya KA, Ogden G, Macpherson LM. Incidence of oral and oropharyngeal cancer in United Kingdom (1990–1999) – recent trends and regional variation. *Oral Oncol.* 2006;42:586–92.
21. Suba Z. Gender-related hormonal risk factors for oral cancer. *Pathol Oncol Res.* 2007;13:195–202.
22. Liu L, Kumar SK, Sedghizadeh PP, Jayakar AN, Shuler CF. Oral squamous cell carcinoma incidence by subsite among diverse racial and ethnic populations in California. *Oral Surg Oral Med Oral Pathol Oral Radiol Endod.* 2008;105:470–80.
23. Reichman ME, Kelly JJ, Kosary CL, Coughlin SS, Jim MA, Lanier AP. Incidence of cancers of the oral cavity and pharynx among American Indians and Alaska Natives, 1999–2004. *Cancer.* 2008;113:1256–65.
24. Nichols AC, Bhattacharyya N. Racial differences in stage and survival in head and neck squamous cell carcinoma. *Laryngoscope.* 2007;117:770–5.
25. Gourin CG, Podolsky RH. Racial disparities in patients with head and neck squamous cell carcinoma. *Laryngoscope.* 2006;116: 1093–106.
26. Suarez E, Calo WA, Hernandez EY, Diaz EC, Figueroa NR, Ortiz AP. Age-standardized incidence and mortality rates of oral and pharyngeal cancer in Puerto Rico and among Non-Hispanics Whites, Non-Hispanic Blacks, and Hispanics in the USA. *BMC Cancer.* 2009;9:129.
27. Moles DR, Fedele S, Speight PM, Porter SR, dos Santos Silva I. Oral and pharyngeal cancer in South Asians and non-South Asians in relation to socioeconomic deprivation in South East England. *Br J Cancer.* 2008;98:633–5.
28. Chhetri DK, Rawnsley JD, Calcaterra TC. Carcinoma of the buccal mucosa. *Otolaryngol Head Neck Surg.* 2000;123:566–71.
29. Diaz Jr EM, Holsinger FC, Zuniga ER, Roberts DB, Sorensen DM. Squamous cell carcinoma of the buccal mucosa: one institution's experience with 119 previously untreated patients. *Head Neck.* 2003;25:267–73.
30. Iyer SG, Pradhan SA, Pai PS, Patil S. Surgical treatment outcomes of localized squamous carcinoma of buccal mucosa. *Head Neck.* 2004;26:897–902.
31. Liao CT, Wang HM, Ng SH, Yen TC, Lee LY, Hsueh C, et al. Good tumor control and survivals of squamous cell carcinoma of buccal mucosa treated with radical surgery with or without neck dissection in Taiwan. *Oral Oncol.* 2006;42:800–9.
32. Lin CS, Jen YM, Cheng MF, Lin YS, Su WF, Hwang JM, et al. Squamous cell carcinoma of the buccal mucosa: an aggressive cancer requiring multimodality treatment. *Head Neck.* 2006;28:150–7.
33. Siczka E, Datta R, Singh A, Loree T, Rigual N, Orner J, et al. Cancer of the buccal mucosa: are margins and T-stage accurate predictors of local control? *Am J Otolaryngol.* 2001;22:395–9.
34. Surveillance Epidemiology and End Results (SEER). SEER Cancer Statistic Review 1975–2004. National Cancer Institute. Available from: <http://seer.cancer.gov/statfacts/html/oralcav.html>. Accessed on 10/08/2009.
35. Llewellyn CD, Johnson NW, Warnakulasuriya KA. Risk factors for squamous cell carcinoma of the oral cavity in young people—a comprehensive literature review. *Oral Oncol.* 2001;37:401–18.
36. Warnakulasuriya S, Mak V, Moller H. Oral cancer survival in young people in South East England. *Oral Oncol.* 2007;43:982–6.
37. Macfarlane GJ, Boyle P, Scully C. Rising mortality from cancer of the tongue in young Scottish males. *Lancet.* 1987;2:912.
38. Annertz K, Anderson H, Biorklund A, Moller T, Kantola S, Mork J, et al. Incidence and survival of squamous cell carcinoma of the tongue in Scandinavia, with special reference to young adults. *Int J Cancer.* 2002;101:95–9.
39. Schantz SP, Yu GP. Head and neck cancer incidence trends in young Americans, 1973–1997, with a special analysis for tongue cancer. *Arch Otolaryngol Head Neck Surg.* 2002;128:268–74.
40. Shiboski CH, Schmidt BL, Jordan RC. Tongue and tonsil carcinoma: increasing trends in the U.S. population ages 20–44 years. *Cancer.* 2005;103:1843–9.
41. Scully C, Bedi R. Ethnicity and oral cancer. *Lancet Oncol.* 2000; 1:37–42.
42. Robinson KL, Macfarlane GJ. Oropharyngeal cancer incidence and mortality in Scotland: are rates still increasing? *Oral Oncol.* 2003;39:31–6.
43. Elango JK, Gangadharan P, Sumithra S, Kuriakose MA. Trends of head and neck cancers in urban and rural India. *Asian Pac J Cancer Prev.* 2006;7:108–12.
44. Llewellyn CD, Johnson NW, Warnakulasuriya KA. Risk factors for oral cancer in newly diagnosed patients aged 45 years and younger: a case-control study in Southern England. *J Oral Pathol Med.* 2004;33:525–32.
45. Hirota SK, Braga FP, Penha SS, Sugaya NN, Migliari DA. Risk factors for oral squamous cell carcinoma in young and older Brazilian patients: a comparative analysis. *Med Oral Patol Oral Cir Bucal.* 2008;13:E227–31.
46. La Vecchia C, Lucchini F, Negri E, Levi F. Trends in oral cancer mortality in Europe. *Oral Oncol.* 2004;40:433–9.

47. Morse DE, Kerr AR. Disparities in oral and pharyngeal cancer incidence, mortality and survival among black and white Americans. *J Am Dent Assoc.* 2006;137:203–12.
48. Moore RJ, Doherty DA, Do KA, Chamberlain RM, Khuri FR. Racial disparity in survival of patients with squamous cell carcinoma of the oral cavity and pharynx. *Ethn Health.* 2001;6:165–77.
49. Sunny L, Yeole BB, Hakama M, Shiri R, Sastry PS, Mathews S, et al. Oral cancers in Mumbai, India: a fifteen years perspective with respect to incidence trend and cumulative risk. *Asian Pac J Cancer Prev.* 2004;5:294–300.
50. Amarasinghe HK, Usgodaarachchi US, Johnson NW, Laloo R, Warnakulasuriya S. Betel-quid chewing with or without tobacco is a major risk factor for oral potentially malignant disorders in Sri Lanka: a case-control study. *Oral Oncol.* 2010;46(4):297–301.
51. International Agency on Research on Cancer. IARC Monographs on the Evaluation of Carcinogenic Risk to Human. Betel-quid and areca-nut chewing and some areca-nut related nitrosamines. vol.85. Lyon: IARC 2004.
52. Zaidi JH, Arif M, Fatima I, Qureshi IH. Radiochemical neutron activation analysis for trace elements of basic ingredients of pan. *J Radioanal Nucl Chem.* 2002;253:459–64.
53. Lord GA, Lim CK, Warnakulasuriya S, Peters TJ. Chemical and analytical aspects of areca nut. *Addict Biol.* 2002;7:99–102.
54. Nair J, Ohshima H, Nair UJ, Bartsch H. Endogenous formation of nitrosamines and oxidative DNA-damaging agents in tobacco users. *Crit Rev Toxicol.* 1996;26:149–61.
55. Carossa S, Pera P, Doglio P, Lombardo S, Colagrande P, Brussino L, et al. Oral nitric oxide during plaque deposition. *Eur J Clin Invest.* 2001;31:876–9.
56. Nair U, Bartsch H, Nair J. Alert for an epidemic of oral cancer due to use of the betel quid substitutes gutkha and pan masala: a review of agents and causative mechanisms. *Mutagenesis.* 2004;19:251–62.
57. Gupta PC, Warnakulasuriya S. Global epidemiology of areca nut usage. *Addict Biol.* 2002;7:77–83.
58. Trivedy CR, Craig G, Warnakulasuriya S. The oral health consequences of chewing areca nut. *Addict Biol.* 2002;7:115–25.
59. Shiu MN, Chen TH, Chang SH, Hahn LJ. Risk factors for leukoplakia and malignant transformation to oral carcinoma: a leukoplakia cohort in Taiwan. *Br J Cancer.* 2000;82:1871–4.
60. Maher R, Lee AJ, Warnakulasuriya KA, Lewis JA, Johnson NW. Role of areca nut in the causation of oral submucous fibrosis: a case-control study in Pakistan. *J Oral Pathol Med.* 1994;23:65–9.
61. Trivedy C, Warnakulasuriya KA, Hazarey VK, Tavassoli M, Sommer P, Johnson NW. The upregulation of lysyl oxidase in oral submucous fibrosis and squamous cell carcinoma. *J Oral Pathol Med.* 1999;28:246–51.
62. Thomas SJ, Bain CJ, Battistutta D, Ness AR, Paissat D, Maclennan R. Betel quid not containing tobacco and oral cancer: a report on a case-control study in Papua New Guinea and a meta-analysis of current evidence. *Int J Cancer.* 2007;120:1318–23.
63. Subapriya R, Thangavelu A, Mathavan B, Ramachandran CR, Nagini S. Assessment of risk factors for oral squamous cell carcinoma in Chidambaram, Southern India: a case-control study. *Eur J Cancer Prev.* 2007;16:251–6.
64. van Wyk CW, Stander I, Padayachee A, Grobler-Rabie AF. The areca nut chewing habit and oral squamous cell carcinoma in South African Indians. A retrospective study. *S Afr Med J.* 1993;83:425–9.
65. Petti S. Lifestyle risk factors for oral cancer. *Oral Oncol.* 2009;45:340–50.
66. Idris AM, Nair J, Friesen M, Ohshima H, Brouet I, Faustman EM, et al. Carcinogenic tobacco-specific nitrosamines are present at unusually high levels in the saliva of oral snuff users in Sudan. *Carcinogenesis.* 1992;13:1001–5.
67. Nair J, Ohshima H, Friesen M, Croisy A, Bhide SV, Bartsch H. Tobacco-specific and betel nut-specific N-nitroso compounds: occurrence in saliva and urine of betel quid chewers and formation in vitro by nitrosation of betel quid. *Carcinogenesis.* 1985;6:295–303.
68. Warnakulasuriya S, Sutherland G, Scully C. Tobacco, oral cancer, and treatment of dependence. *Oral Oncol.* 2005;41:244–60.
69. Gartner C, Hall W. The potential role of snus in tobacco harm reduction. *Addiction.* 2009;104:1586–7.
70. Haddock CK, Weg MV, DeBon M, Klesges RC, Talcott GW, Lando H, et al. Evidence that smokeless tobacco use is a gateway for smoking initiation in young adult males. *Prev Med.* 2001;32:262–7.
71. Critchley JA, Unal B. Health effects associated with smokeless tobacco: a systematic review. *Thorax.* 2003;58:435–43.
72. Kallischnigg G, Weitkunat R, Lee PN. Systematic review of the relation between smokeless tobacco and non-neoplastic oral diseases in Europe and the United States. *BMC Oral Health.* 2008;8:13.
73. IARC Monographs on the Evaluation of Carcinogenic Risk to Humans, Some Traditional Herbal Medicines, Some Mycotoxins, Naphthalene and Styrene. Vol. 82, Lyon, IARC press. 2002. p. 171–4.
74. Hecht SS. Tobacco carcinogens, their biomarkers and tobacco-induced cancer. *Nat Rev Cancer.* 2003;3:733–44.
75. International Agency for Research on Cancer. Tobacco smoke and involuntary smoking. IARC Monographs on the Evaluation of Carcinogenic Risk to Human. vol.83. Lyon: IARC; 2004.
76. Zain RB. Cultural and dietary risk factors of oral cancer and precancer—a brief overview. *Oral Oncol.* 2001;37:205–10.
77. Shah JP, Johnson NW, Batsakis JG. Oral cancer. London/Thieme New York: Martin Dunitz; 2003.
78. Whent H, Sayers M, Morgan A, Hunt R. Health update Alcohol. 2nd Edition. London. Health Education Authority 1997.
79. Rehm J. Alcohol consumption and mortality. What do we know and where should we go? *Addiction.* 2000;95:989–95.
80. Goldberg DM, Soleas GJ, Levesque M. Moderate alcohol consumption: the gentle face of Janus. *Clin Biochem.* 1999;32:505–18.
81. World Health Organization. Department of Mental Health and Substance Abuse. Global status Report on Alcohol 2004. Geneva:WHO 2004.
82. Institute National Du Cancer. Alcohol and risk of cancer: \leq javascript:void(0) \geq current status of scientific data and recommendations for public health. 2007. Available from <http://www.e-cancer.fr/la-sante-publique/prevention/alcoolisme>. Accessed on 26/01/2010.
83. World Health Organization. Evidence for the effectiveness and cost-effectiveness of interventions to reduce alcohol-related harm. Available from \leq <http://www.euro.who.int/document/E92823.pdf> \geq . Accessed on 28/01/2010.
84. National Health and Medical Research Council. Australian Guidelines to Reduce Health Risk from Drinking Alcohol. Available from http://www.nhmrc.gov.au/_files_nhmrc/file/publications/synopses/ds10-alcohol.pdf. Accessed on 28/01/2010.
85. Ogden GR, Wight AJ. Aetiology of oral cancer: alcohol. *Br J Oral Maxillofac Surg.* 1998;36:247–51.
86. Howie NM, Trigkas TK, Cruchley AT, Wertz PW, Squier CA, Williams DM. Short-term exposure to alcohol increases the permeability of human oral mucosa. *Oral Dis.* 2001;7:349–54.
87. De Stefani E, Boffetta P, Oreggia F, Fierro L, Mendilaharsu M. Hard liquor drinking is associated with higher risk of cancer of the oral cavity and pharynx than wine drinking. A case-control study in Uruguay. *Oral Oncol.* 1998;34:99–104.
88. Altieri A, Bosetti C, Gallus S, Franceschi S, Dal Maso L, Talamini R, et al. Wine, beer and spirits and risk of oral and pharyngeal cancer: a case-control study from Italy and Switzerland. *Oral Oncol.* 2004;40:904–9.
89. Elmore JG, Horwitz RI. Oral cancer and mouthwash use: evaluation of the epidemiologic evidence. *Otolaryngol Head Neck Surg.* 1995;113:253–61.

90. McCullough MJ, Farah CS. The role of alcohol in oral carcinogenesis with particular reference to alcohol-containing mouthwashes. *Aust Dent J*. 2009;53:302–5.
91. Guha N, Boffetta P, Wunsch Filho V, Eluf Neto J, Shangina O, Zaridze D, et al. Oral health and risk of squamous cell carcinoma of the head and neck and esophagus: results of two multicentric case-control studies. *Am J Epidemiol*. 2007;166:1159–73.
92. Young TB, Ford CN, Brandenburg JH. An epidemiologic study of oral cancer in a statewide network. *Am J Otolaryngol*. 1986;7:200–8.
93. Winn DM, Diehl SR, Brown LM, Harty LC, Bravo-Otero E, Fraumeni Jr JF, et al. Mouthwash in the etiology of oral cancer in Puerto Rico. *Cancer Causes Control*. 2001;12:419–29.
94. La Vecchia C. Mouthwash and oral cancer risk: an update. *Oral Oncol*. 2009;45:198–200.
95. Warnakulasuriya S. Causes of oral cancer—an appraisal of controversies. *Br Dent J*. 2009;207:471–5.
96. Stewart BW, Kleihues P, Stewart Bernard W, Paul K. The cause of cancer In *World Cancer Report*. Lyon: IARC Press; 2003. p. 22–31.
97. World Health Organization. Cancer: diet and physical activity's impact. Available from www.who.int/dietphysicalactivity/publications/facts/cancer/en. Accessed on 02/02/2010.
98. De Stefani E, Boffetta P, Ronco AL, Correa P, Oreggia F, Deneo-Pellegrini H, et al. Dietary patterns and risk of cancer of the oral cavity and pharynx in Uruguay. *Nutr Cancer*. 2005;51:132–9.
99. De Stefani E, Oreggia F, Boffetta P, Deneo-Pellegrini H, Ronco A, Mendilaharsu M. Tomatoes, tomato-rich foods, lycopene and cancer of the upper aerodigestive tract: a case-control in Uruguay. *Oral Oncol*. 2000;36:47–53.
100. Llewellyn CD, Linklater K, Bell J, Johnson NW, Warnakulasuriya S. An analysis of risk factors for oral cancer in young people: a case-control study. *Oral Oncol*. 2004;40:304–13.
101. Garavello W, Lucenteforte E, Bosetti C, Talamini R, Levi F, Tavani A, et al. Diet diversity and the risk of laryngeal cancer: a case-control study from Italy and Switzerland. *Oral Oncol*. 2009;45:85–9.
102. Lucenteforte E, Garavello W, Bosetti C, La Vecchia C. Dietary factors and oral and pharyngeal cancer risk. *Oral Oncol*. 2009;45:461–7.
103. Garavello W, Lucenteforte E, Bosetti C, La Vecchia C. The role of foods and nutrients on oral and pharyngeal cancer risk. *Minerva Stomatol*. 2009;58:25–34.
104. Levi F, Pasche C, La Vecchia C, Lucchini F, Franceschi S, Monnier P. Food groups and risk of oral and pharyngeal cancer. *Int J Cancer*. 1998;77:705–9.
105. Schwartz J, Shklar G. Regression of experimental oral carcinomas by local injection of beta-carotene and canthaxanthin. *Nutr Cancer*. 1988;11:35–40.
106. Shklar G, Schwartz JL, Trickler DP, Reid S. Prevention of experimental cancer and immunostimulation by vitamin E (immunosurveillance). *J Oral Pathol Med*. 1990;19:60–4.
107. Schwartz JL, Shklar G, Flynn E, Trickler D. The administration of beta carotene to prevent and regress oral carcinoma in the hamster cheek pouch and the associated enhancement of the immune response. *Adv Exp Med Biol*. 1990;262:77–93.
108. Warnakulasuriya S. Food, nutrition and oral cancer. In: Michael Wilson, editor. *Food constituents and oral health*. Woodhead Publishing Limited: Oxford; 2009. p. 273–95.
109. Pavia M, Pileggi C, Nobile CG, Angelillo IF. Association between fruit and vegetable consumption and oral cancer: a meta-analysis of observational studies. *Am J Clin Nutr*. 2006;83:1126–34.
110. Nagao T, Ikeda N, Warnakulasuriya S, Fukano H, Yuasa H, Yano M, et al. Serum antioxidant micronutrients and the risk of oral leukoplakia among Japanese. *Oral Oncol*. 2000;36:466–70.
111. Sankaranarayanan R, Mathew B, Varghese C, Sudhakaran PR, Menon V, Jayadeep A, et al. Chemoprevention of oral leukoplakia with vitamin A and beta carotene: an assessment. *Oral Oncol*. 1997;33:231–6.
112. Papadimitrakopoulou VA, Lee JJ, William Jr WN, Martin JW, Thomas M, Kim ES, et al. Randomized trial of 13-cis retinoic acid compared with retinyl palmitate with or without beta-carotene in oral premalignancy. *J Clin Oncol*. 2009;27:599–604.
113. Tsao AS, Liu D, Martin J, Tang XM, Lee JJ, El-Naggar AK, et al. Phase II randomized, placebo-controlled trial of green tea extract in patients with high-risk oral premalignant lesions. *Cancer Prev Res (Phila Pa)*. 2009;2:931–41.
114. Tai J, Yang M, Ni X, Yu D, Fang J, Tan W, et al. Genetic polymorphisms in cytochrome P450 genes are associated with an increased risk of squamous cell carcinoma of the larynx and hypopharynx in a Chinese population. *Cancer Genet Cytogenet*. 2010;196:76–82.
115. Handley TP, McCaul JA, Ogden GR. Dyskeratosis congenita. *Oral Oncol*. 2006;42:331–6.
116. De Pasquale K, Sataloff RT. Candida of the larynx. *Ear Nose Throat J*. 2003;82:419.
117. Holmstrup P, Vedtofte P, Reibel J, Stoltze K. Long-term treatment outcome of oral premalignant lesions. *Oral Oncol*. 2006;42:461–74.
118. D'Souza G, Kreimer AR, Viscidi R, Pawlita M, Fakhry C, Koch WM, et al. Case-control study of human papillomavirus and oropharyngeal cancer. *N Engl J Med*. 2007;356:1944–56.
119. Andrews E, Seaman WT, Webster-Cyriaque J. Oropharyngeal carcinoma in non-smokers and non-drinkers: a role for HPV. *Oral Oncol*. 2009;45:486–91.
120. Meurman JH, Uittamo J. Oral micro-organisms in the etiology of cancer. *Acta Odontol Scand*. 2008;66:321–6.
121. Homann N, Tillonen J, Rintamaki H, Salaspuro M, Lindqvist C, Meurman JH. Poor dental status increases acetaldehyde production from ethanol in saliva: a possible link to increased oral cancer risk among heavy drinkers. *Oral Oncol*. 2001;37:153–8.
122. Wake M. The urban/rural divide in head and neck cancer—the effect of atmospheric pollution. *Clin Otolaryngol Allied Sci*. 1993;18:298–302.
123. Sapkota A, Gajalakshmi V, Jetly DH, Roychowdhury S, Dikshit RP, Brennan P, et al. Indoor air pollution from solid fuels and risk of hypopharyngeal/laryngeal and lung cancers: a multicentric case-control study from India. *Int J Epidemiol*. 2008;37:321–8.
124. Dietz A, Sennewald E, Maier H. Indoor air pollution by emissions of fossil fuel single stoves: possibly a hitherto underrated risk factor in the development of carcinomas in the head and neck. *Otolaryngol Head Neck Surg*. 1995;112:308–15.
125. International Agency for Research on Cancer. IARC monographs on the evaluation of the carcinogenic risk of chemicals to humans, Volume 95: Indoor air pollution from heating and cooking: some solid fuels and cooking oil fumes. Lyon: IARC Press; 2006.
126. Franco EL, Kowalski LP, Oliveira BV, Curado MP, Pereira RN, Silva ME, et al. Risk factors for oral cancer in Brazil: a case-control study. *Int J Cancer*. 1989;43:992–1000.
127. Zheng YM, Tuppin P, Hubert A, Jeannel D, Pan YJ, Zeng Y, et al. Environmental and dietary risk factors for nasopharyngeal carcinoma: a case-control study in Zangwu County, Guangxi, China. *Br J Cancer*. 1994;69:508–14.
128. Pintos J, Franco EL, Kowalski LP, Oliveira BV, Curado MP. Use of wood stoves and risk of cancers of the upper aero-digestive tract: a case-control study. *Int J Epidemiol*. 1998;27:936–40.
129. Baker SR, Krause CJ. Carcinoma of the lip. *Laryngoscope*. 1980;90:19–27.
130. Pukkala E, Notkola V. Cancer incidence among Finnish farmers, 1979–1993. *Cancer Causes Control*. 1997;8:25–33.
131. Wiklund K, Dich J. Cancer risks among male farmers in Sweden. *Eur J Cancer Prev*. 1995;4:81–90.
132. Antoniadis DZ, Styaniadis K, Papanayotou P, Trigonidis G. Squamous cell carcinoma of the lips in a northern Greek population.

- Evaluation of prognostic factors on 5-year survival rate-I. *Eur J Cancer B Oral Oncol.* 1995;31B:333-9.
133. Pukkala E, Soderholm AL, Lindqvist C. Cancers of the lip and oropharynx in different social and occupational groups in Finland. *Eur J Cancer B Oral Oncol.* 1994;30B:209-15.
 134. Pogoda JM, Preston-Martin S. Solar radiation, lip protection, and lip cancer risk in Los Angeles County women (California, United States). *Cancer Causes Control.* 1996;7:458-63.
 135. Levi F, La Vecchia C, Te VC, Franceschi S. Trends in lip cancer incidence in Vaud, Switzerland. *Br J Cancer.* 1993;68:1012-3.
 136. Alho OP, Keranen MR, Kantola S, Riihimaki S, Jokinen K, Alho P, et al. Lip cancer in Northern Finland: changing incidence and clinical characteristics. *J Oral Pathol Med.* 2000;29:299-302.
 137. Warnakulasuriya S, Johnson NW, van der Waal I. Nomenclature and classification of potentially malignant disorders of the oral mucosa. *J Oral Pathol Med.* 2007;36:575-80.
 138. van der Waal I. Potentially malignant disorders of the oral and oropharyngeal mucosa; terminology, classification and present concepts of management. *Oral Oncol.* 2009;45:317-23.
 139. Napier SS, Cowan CG, Gregg TA, Stevenson M, Lamey PJ, Toner PG. Potentially malignant oral lesions in Northern Ireland: size (extent) matters. *Oral Dis.* 2003;9:129-37.
 140. Chung CHYY, Wang TY, Shieh TY, Warnakulasuriya S. Oral precancerous disorders associated with areca quid chewing, smoking, and alcohol drinking in Southern Taiwan. *J Oral Pathol Med.* 2005;34:460-6.
 141. Thomas SJ, Harris R, Ness AR, Taulo J, MacLennan R, Howes N, et al. Betel quid not containing tobacco and oral leukoplakia: a report on a cross-sectional study in Papua New Guinea and a meta-analysis of current evidence. *Int J Cancer.* 2008;123:1871-6.
 142. Chung CH, Yang YH, Wang TY, Shieh TY, Warnakulasuriya S. Oral precancerous disorders associated with areca quid chewing, smoking, and alcohol drinking in southern Taiwan. *J Oral Pathol Med.* 2005;34:460-6.
 143. Scheifele C, Reichart PA, Dietrich T. Low prevalence of oral leukoplakia in a representative sample of the US population. *Oral Oncol.* 2003;39:619-25.
 144. Ministry of Health. National Oral Health Survey, Sri Lanka (2002/2003). 2009.
 145. Garcia-Pola Vallejo MJ, Martinez Diaz-Canel AI, Garcia Martin JM, Gonzalez GM. Risk factors for oral soft tissue lesions in an adult Spanish population. *Community Dent Oral Epidemiol.* 2002;30:277-85.
 146. Reichart PA. Oral mucosal lesions in a representative cross-sectional study of aging Germans. *Community Dent Oral Epidemiol.* 2000;28:390-8.
 147. Nagao T, Ikeda N, Fukano H, Miyazaki H, Yano M, Warnakulasuriya S. Outcome following a population screening programme for oral cancer and precancer in Japan. *Oral Oncol.* 2000;36:340-6.
 148. Zain RB, Ikeda N, Razak IA, Axell T, Majid ZA, Gupta PC, et al. A national epidemiological survey of oral mucosal lesions in Malaysia. *Community Dent Oral Epidemiol.* 1997;25:377-83.
 149. Schepman KP, van der Meij EH, Smeele LE, van der Waal I. Prevalence study of oral white lesions with special reference to a new definition of oral leukoplakia. *Eur J Cancer B Oral Oncol.* 1996;32B:416-9.
 150. Banoczy J, Rigo O. Prevalence study of oral precancerous lesions within a complex screening system in Hungary. *Community Dent Oral Epidemiol.* 1991;19:265-7.
 151. Ikeda N, Ishii T, Iida S, Kawai T. Epidemiological study of oral leukoplakia based on mass screening for oral mucosal diseases in a selected Japanese population. *Community Dent Oral Epidemiol.* 1991;19:160-3.
 152. Axell T, Rundquist L. Oral lichen planus- a demographic study. *Community Dent Oral Epidemiol.* 1987;15:52-6.
 153. Axell T. Occurrence of leukoplakia and some other oral white lesions among 20, 333 adult Swedish people. *Community Dent Oral Epidemiol.* 1987;15:46-51.
 154. Petti S. Pooled estimate of world leukoplakia prevalence: a systematic review. *Oral Oncol.* 2003;39:770-80.
 155. Napier SS, Speight PM. Natural history of potentially malignant oral lesions and conditions: an overview of the literature. *J Oral Pathol Med.* 2008;37:1-10.
 156. Reibel J. Prognosis of oral pre-malignant lesions: significance of clinical, histopathological, and molecular biological characteristics. *Crit Rev Oral Biol Med.* 2003;14:47-62.
 157. Pindborg JJ, Mehta FS, Daftary DK. Incidence of oral cancer among 30, 000 villagers in India in a 7-year follow-up study of oral precancerous lesions. *Community Dent Oral Epidemiol.* 1975; 3:86-8.
 158. Silverman Jr S, Gorsky M, Lozada F. Oral leukoplakia and malignant transformation. A follow-up study of 257 patients. *Cancer.* 1984;53:563-8.
 159. Bouquot JE, Kurland LT, Weiland LH. Laryngeal keratosis and carcinoma in the Rochester, MN, population 1935-1984. *Cancer Detect Prev.* 1991;15:83-91.
 160. Gale N, Michaels L, Luzar B, Poljak M, Zidar N, Fischinger J, et al. Current review on squamous intraepithelial lesions of the larynx. *Histopathology.* 2009;54:639-56.
 161. Vaezi MF, Qadeer MA, Lopez R, Colabianchi N. Laryngeal cancer and gastroesophageal reflux disease: a case-control study. *Am J Med.* 2006;119:768-76.
 162. Bosatra A, Bussani R, Silvestri F. From epithelial dysplasia to squamous carcinoma in the head and neck region: an epidemiological assessment. *Acta Otolaryngol Suppl.* 1997;527:47-8.
 163. Gallus S, Bosetti C, Franceschi S, Levi F, Negri E, La Vecchia C. Laryngeal cancer in women: tobacco, alcohol, nutritional, and hormonal factors. *Cancer Epidemiol Biomark Prev.* 2003;12:514-7.
 164. Fiorella R, Di Nicola V, Resta L. Epidemiological and clinical relief on hyperplastic lesions of the larynx. *Acta Otolaryngol Suppl.* 1997;527:77-81.
 165. Maier H, Tisch M. Epidemiology of laryngeal cancer: results of the Heidelberg case-control study. *Acta Otolaryngol Suppl.* 1997;527:160-4.
 166. Parnes SM. Asbestos and cancer of the larynx: is there a relationship? *Laryngoscope.* 1990;100:254-61.
 167. Hobbs CG, Sterne JA, Bailey M, Heyderman RS, Birchall MA, Thomas SJ. Human papillomavirus and head and neck cancer: a systematic review and meta-analysis. *Clin Otolaryngol.* 2006;31: 259-66.
 168. Lewin JS, Gillenwater AM, Garrett JD, Bishop-Leone JK, Nguyen DD, Callender DL, et al. Characterization of laryngopharyngeal reflux in patients with premalignant or early carcinomas of the larynx. *Cancer.* 2003;97:1010-4.
 169. Barnes L, Eveson JW, Reichart P, Sidransky D. World Health Organization classification of tumors: pathology and genetics of head and neck tumours. Lyon: IARC Press; 2005. p. 221-4.
 170. Surgical Pathology of the Salivary Glands. Eds. Ellis, GL, Auclair, PL, Gnepp, DR. Philadelphia, WB Saunders; 1991.
 171. Eisele DW, Johns ME. Salivary Gland Neoplasms. In: Bailey BJ, editor. *Head & Neck Surgery-Otolaryngology.* Philadelphia: Lippincott Williams & Wilkins; 2001. p. 1279-97.
 172. Kessler A, Handler SD. Salivary gland neoplasms in children: a 10-year survey at the Children's Hospital of Philadelphia. *Int J Pediatr Otorhinolaryngol.* 1994;29:195-202.
 173. Lack EE, Upton MP. Histopathologic review of salivary gland tumors in childhood. *Arch Otolaryngol Head Neck Surg.* 1988;114:898-906.
 174. Seifert G, Okabe H, Caselitz J. Epithelial salivary gland tumors in children and adolescents. Analysis of 80 cases (Salivary Gland

- Register 1965–1984). *ORL J Otorhinolaryngol Relat Spec.* 1986;48:137–49.
175. Shikhani AH, Johns ME. Tumors of the major salivary glands in children. *Head Neck Surg.* 1988;10:257–63.
176. Saw D, Lau WH, Ho JH, Chan JK, Ng CS. Malignant lymphoepithelial lesion of the salivary gland. *Hum Pathol.* 1986;17:914–23.
177. Tsai CC, Chen CL, Hsu HC. Expression of Epstein-Barr virus in carcinomas of major salivary glands: a strong association with lymphoepithelioma-like carcinoma. *Hum Pathol.* 1996;27:258–62.
178. Iezzoni JC, Gaffey MJ, Weiss LM. The role of Epstein-Barr virus in lymphoepithelioma-like carcinomas. *Am J Clin Pathol.* 1995;103:308–15.
179. Hamilton-Dutoit SJ, Therkildsen MH, Neilsen NH, Jensen H, Hansen JP, Pallesen G. Undifferentiated carcinoma of the salivary gland in Greenlandic Eskimos: demonstration of Epstein-Barr virus DNA by in situ nucleic acid hybridization. *Hum Pathol.* 1991;22:811–5.
180. Martinelli M, Martini F, Rinaldi E, Caramanico L, Magri E, Grandi E, et al. Simian virus 40 sequences and expression of the viral large T antigen oncoprotein in human pleomorphic adenomas of parotid glands. *Am J Pathol.* 2002;161:1127–33.
181. Belsky JL, Tachikawa K, Cihak RW, Yamamoto T. Salivary gland tumors in atomic bomb survivors, Hiroshima-Nagasaki, 1957 to 1970. *JAMA.* 1972;219:864–8.
182. Belsky JL, Takeichi N, Yamamoto T, Cihak RW, Hirose F, Ezaki H, et al. Salivary gland neoplasms following atomic radiation: additional cases and reanalysis of combined data in a fixed population, 1957–1970. *Cancer.* 1975;35:555–9.
183. Saku T, Hayashi Y, Takahara O, Matsuura H, Tokunaga M, Tokuoka S, et al. Salivary gland tumors among atomic bomb survivors, 1950–1987. *Cancer.* 1997;79:1465–75.
184. Mihailescu D, Shore-Freedman E, Mukani S, Lubin J, Ron E, Schneider AB. Multiple neoplasms in an irradiated cohort: pattern of occurrence and relationship to thyroid cancer outcome. *J Clin Endocrinol Metab.* 2002;87:3236–41.
185. Modan B, Chetrit A, Alfandary E, Tamir A, Lusky A, Wolf M, et al. Increased risk of salivary gland tumors after low-dose irradiation. *Laryngoscope.* 1998;108:1095–7.
186. Hoffman DA, McConahey WM, Fraumeni Jr JF, Kurland LT. Cancer incidence following treatment of hyperthyroidism. *Int J Epidemiol.* 1982;11:218–24.
187. Preston-Martin S, Thomas DC, White SC, Cohen D. Prior exposure to medical and dental x-rays related to tumors of the parotid gland. *J Natl Cancer Inst.* 1988;80:943–9.
188. Preston-Martin S, White SC. Brain and salivary gland tumors related to prior dental radiography: implications for current practice. *J Am Dent Assoc.* 1990;120:151–8.
189. Nagler RM, Laufer D. Tumors of the major and minor salivary glands: review of 25 years of experience. *Anticancer Res.* 1997;17:701–7.
190. Spitz MR, Sider JG, Newell GR. Salivary gland cancer and risk of subsequent skin cancer. *Head Neck.* 1990;12:254–6.
191. Spitz MR, Sider JG, Newell GR, Batsakis JG. Incidence of salivary gland cancer in the United States relative to ultraviolet radiation exposure. *Head Neck Surg.* 1988;10:305–8.
192. Miller AS, Harwick RD, Alfaro-Miranda M, Sundararajan M. Search for correlation of radon levels and incidence of salivary gland tumors. *Oral Surg Oral Med Oral Pathol.* 1993;75:58–63.
193. Auvinen A, Hietanen M, Luukkonen R, Koskela RS. Brain tumors and salivary gland cancers among cellular telephone users. *Epidemiology.* 2002;13:356–9.
194. Johansen C, Boice Jr J, McLaughlin J, Olsen J. Cellular telephones and cancer—a nationwide cohort study in Denmark. *J Natl Cancer Inst.* 2001;93:203–7.
195. Horn-Ross PL, Ljung BM, Morrow M. Environmental factors and the risk of salivary gland cancer. *Epidemiology.* 1997;8:414–9.
196. Milham Jr S. Cancer mortality pattern associated with exposure to metals. *Ann NY Acad Sci.* 1976;271:243–9.
197. Swanson GM, Belle SH. Cancer morbidity among woodworkers in the U.S. automotive industry. *J Occup Med.* 1982;24:315–9.
198. Swanson GM, Burns PB. Cancer incidence among women in the workplace: a study of the association between occupation and industry and 11 cancer sites. *J Occup Environ Med.* 1995;37:282–7.
199. Swanson GM, Burns PB. Cancers of the salivary gland: workplace risks among women and men. *Ann Epidemiol.* 1997;7:369–74.
200. Graham S, Blanchet M, Rohrer T. Cancer in asbestos-mining and other areas of Quebec. *J Natl Cancer Inst.* 1977;59:1139–45.
201. Muscat JE, Wynder EL. A case/control study of risk factors for major salivary gland cancer. *Otolaryngol Head Neck Surg.* 1998;118:195–8.
202. Zheng W, Shu XO, Ji BT, Gao YT. Diet and other risk factors for cancer of the salivary glands: a population-based case-control study. *Int J Cancer.* 1996;67:194–8.
203. Dietz A, Barne B, Gewelke U, Sennewald E, Heller WD, Maier H [The epidemiology of parotid tumors. A case control study]. *HNO.* 1993;41:83–90.
204. Horn-Ross PL, Morrow M, Ljung BM. Diet and the risk of salivary gland cancer. *Am J Epidemiol.* 1997;146:171–6.
205. Jeannon JP, Soames JV, Bell H, Wilson JA. Immunohistochemical detection of oestrogen and progesterone receptors in salivary tumours. *Clin Otolaryngol Allied Sci.* 1999;24:52–4.
206. Nasser SM, Faquin WC, Dayal Y. Expression of androgen, estrogen, and progesterone receptors in salivary gland tumors. Frequent expression of androgen receptor in a subset of malignant salivary gland tumors. *Am J Clin Pathol.* 2003;119:801–6.
207. Fan CY, Melhem MF, Hosal AS, Grandis JR, Barnes EL. Expression of androgen receptor, epidermal growth factor receptor, and transforming growth factor alpha in salivary duct carcinoma. *Arch Otolaryngol Head Neck Surg.* 2001;127:1075–9.
208. Chang YM, Barrett JH, Bishop DT, Armstrong BK, Bataille V, Bergman W, et al. Sun exposure and melanoma risk at different latitudes: a pooled analysis of 5700 cases and 7216 controls. *Int J Epidemiol.* 2009;38:814–30.
209. Meleti M, Leemans CR, Mooi WJ, Vescovi P, van der Waal I. Oral malignant melanoma: a review of the literature. *Oral Oncol.* 2007;43:116–21.
210. Sasco AJ, Jaquet A, Boidin E, Ekouevi DK, Thouillot F, Lemabec T, et al. The challenge of AIDS-related malignancies in sub-Saharan Africa. *PLoS ONE.* 2010;5:e8621.
211. Otoh EC, Johnson NW, Mandong BM, Danfillo IS. Primary head and neck cancers in Jos, Nigeria: a re-visit. *West Afr J Med.* 2006;25:92–100.
212. Webster-Cyriaque J, Duus K, Cooper C, Duncan M. Oral EBV and KSHV infection in HIV. *Adv Dent Res.* 2006;19:91–5.
213. Speicher D, Johnson NW. Improving the Detection of Human herpesvirus-8 in AIDS Patients. In: Rahmatulla M, Shah N, editors. *Research Priorities for Meeting Oral Health Goals in Developing Countries.* Hyderabad: International Association for Dental Research; Indian Academy for Advanced Dental Education & Paras Medical Books (P) Ltd; 2009. p. 66–79.
214. Daley TD, Wysocki GP, Pringle GA. Relative incidence of odontogenic tumors and oral and jaw cysts in a Canadian population. *Oral Surg Oral Med Oral Pathol.* 1994;77:276–80.
215. Jing W, Xuan M, Lin Y, Wu L, Liu L, Zheng X, et al. Odontogenic tumours: a retrospective study of 1642 cases in a Chinese population. *Int J Oral Maxillofac Surg.* 2007;36:20–5.
216. Buchner A, Merrell PW, Carpenter WM. Relative frequency of central odontogenic tumors: a study of 1,088 cases from Northern California and comparison to studies from other parts of the world. *J Oral Maxillofac Surg.* 2006;64:1343–52.

217. Smith CJ. Odontogenic Neoplasms and Hamartomas. In: Prabhu R, Wilson DF, Daftary DK, Johnson NW, editors. Chapter 33 in: *Oral Diseases in the Tropics*. New York: Oxford University Press; 1992.
218. Ladeinde AL, Ajayi OF, Ogunlewe MO, Adeyemo WL, Arotiba GT, Bamgbose BO, et al. Odontogenic tumors: a review of 319 cases in a Nigerian teaching hospital. *Oral Surg Oral Med Oral Pathol Oral Radiol Endod*. 2005;99:191–5.
219. Ogunlewe MO, Ajayi OF, Adeyemo WL, Ladeinde AL, James O. Osteogenic sarcoma of the jaw bones: a single institution experience over a 21-year period. *Oral Surg Oral Med Oral Pathol Oral Radiol Endod*. 2006;101:76–81.
220. Fernandes R, Nikitakis NG, Pazoki A, Ord RA. Osteogenic sarcoma of the jaw: a 10-year experience. *J Oral Maxillofac Surg*. 2007;65:1286–91.
221. Hirshberg A, Shnaiderman-Shapiro A, Kaplan I, Berger R. Metastatic tumours to the oral cavity – pathogenesis and analysis of 673 cases. *Oral Oncol*. 2008;44:743–52.
222. Hirshberg A, Buchner A. Metastatic tumours to the oral region. An overview. *Eur J Cancer B Oral Oncol*. 1995;31B:355–60.
223. Hobdell MH, Oliveira ER, Bautista R, Myburgh NG, Lalloo R, Narendran S, et al. Oral diseases and socio-economic status (SES). *Br Dent J*. 2003;194:91–6. discussion 88.

Chapter 2

Head and Neck Cancer Prevention

Fausto Chiesa, Angelo Ostuni, Roberto Grigolato, and Luca Calabrese

Abstract Head and neck cancer (HNC) represents a broad spectrum of diseases that involves the nasal and oropharyngeal cavities, the paranasal sinuses, the major and minor salivary glands, the larynx and the lymphatic tissues of the neck. The world-wide yearly incidence exceeds over half a million cases. Tobacco (smoking and smokeless) and alcohol use are the principal risk factors, however, a substantial and increasing proportion of head and neck tumors cannot be attributed to these. Recent evidence has shown that the incidence of oropharyngeal cancer among women and younger patients continues to grow and it is not related to alcohol or tobacco use but to human papillomavirus infection. Substantial advances in treatment regimens made over the last two decades have not improved the 5-year mortality rate that remains approximately 50%.

Prevention represents the best opportunity to improve oncologic results and it consists of three levels of intervention: primary prevention (considered the best) aims to avoid exposure to established risk factors; secondary prevention consists of early diagnosis; tertiary prevention involves active management of patients already treated for HNC.

In this chapter, we review the natural history of oral cavity and laryngeal cancer as well as the known mechanisms of carcinogenesis. Precancer and risk markers for cancer are discussed as they relate to prevention in all its forms (primary, secondary, and tertiary). Chemoprevention is the use of natural or synthetic chemicals to reverse, suppress, or prevent the conversion of a premalignant lesion to a true neoplasm. It spans all three forms of prevention and it can aim at both local and locoregional disease control. All of the major important chemoprevention clinical trials reported on in the scientific literature are presented and discussed critically and their impact on clinical practice is presented.

Attention is given to new directions in the field and how HNC prevention may progress through the search for new, sensitive, and specific biomarkers as well as an improved understanding of the biomolecular mechanisms of tumor invasion, metastasis, and the newly acquired data from the Human Genome Project.

Improvement in HNC prevention requires a multidisciplinary approach to face complex processes and multiple factors that may act concurrently in the etiology of disease. Future challenges remain in the correct interpretation of new findings and their wise and scientific application. Only then will we be able to impact the field of HNC, transforming prevention in the only form of cure.

Keywords Prevention • Early diagnosis • Chemoprevention • Precancerous lesions • Risk factors • HPV • Biomarkers • Molecular medicine • Multidisciplinary approach

Introduction

Head and neck cancer (HNC) represents a broad spectrum of diseases that involves the nasal and oropharyngeal cavities, the paranasal sinuses, the major and minor salivary glands, the larynx and the lymphatic tissues of the neck. The world-wide yearly incidence exceeds over half a million cases [1]. Tobacco (smoking and smokeless) and alcohol use are the principal risk factors, however, a substantial and increasing proportion of head and neck tumors cannot be attributed to these. Recent evidence has shown that the incidence of oropharyngeal cancer among women and younger patients continues to grow and it is not related to alcohol or tobacco use but to human papillomavirus (HPV) infection [1–5].

Substantial advances in treatment regimens made over the last two decades have not changed the 5-year mortality rate that remains approximately 50% [6–11]. The diagnosis of HNC is often dramatically delayed in spite of easy access for evaluation and screening [12–14]. Late diagnosis results in complex, aggressive, and often mutilating treatment with a

F. Chiesa (✉)

Department of Head and Neck Surgery, European Institute of Oncology, Via Ripamonti, 435, Milano 20141, Italy
e-mail: fausto.chiesa@ieo.it

high morbidity and significant functional compromise. Local disease control (e.g., minimizing metastases and managing recurrence) and development of a second primary tumor remain two of the most significant challenges [15, 16]. In fact, second primary tumors are among the major cause of morbidity and mortality among patients cured for head and neck squamous cell carcinomas (HNSCC).

Prevention of HNC could offer the best opportunity to improve oncologic results and it consists of three levels of intervention. Primary prevention aims at avoiding exposure to established risk factors. Approximately 80% of HNCs are tobacco and alcohol related [1–3]; this percentage is not so easy to reduce because of the addiction induced by their daily use and the powerful impact of advertising by the tobacco and liquor industry particularly on the younger population. The increased incidence of HPV-related cancers has been linked to a change in the sexual patterns in the overall population. Currently, other than monogamous sexual intercourse and avoidance of orogenital intercourse, no effective strategies exist to eliminate this risk factor.

Secondary prevention consists of early diagnosis. Early detection programs usually entail regular clinical evaluation of asymptomatic at-risk patients; consistent and reliable instrumental or serologic tools are currently unavailable. Even though screening is not equally successful for all HNCs, the premise is that early diagnosis could improve morbidity and mortality outcomes. Improved screening increases the overall number of diagnoses, however, in order to be truly effective, it must be associated with increased disease-free survival, a decreased mortality rate, and improvement in the effectiveness of treatments. If this is not possible, and the patient's quality of life does not improve, the cost–benefit ratio may be too high to be justified [17].

Tertiary prevention involves management of patients already treated for HNC. The interventions range from educational programs to smoking cessation for those patients who continue to smoke even with the diagnosis of a malignancy and include early diagnosis of recurrences and/or second primary tumors.

Natural History of Head and Neck Cancers

Head and Neck Carcinogenesis

The development of HNCs is generally related to field cancerization and multistep carcinogenesis. Field cancerization is a morphological concept arising from Slaughter's observation that in all resected oral tumors, the macroscopically

benign epithelium beyond the periphery of the primary tumor was microscopically abnormal [18]. Exposure of an epithelial field to repeated carcinogenic insults results in the development of genetic damage to normal-appearing mucosa. The entire field is susceptible to multifocal development of squamous intraepithelial neoplasia (SIN) and cancer [18–21]. A distinct but related concept is “the field of tissue injury,” which includes the molecular changes occurring throughout the tissue exposed to a carcinogen [22]. The field of injury reflects the host's response to and damage from the carcinogen; this may or may not be a precursor to premalignant lesions and frank malignancy. Field cancerization and the field of injury have both been implicated in many malignancies and potentially hold the keys for preventing and curing epithelial cancers and for understanding *in vivo* epithelial carcinogenesis. Target treatments to reduce cancer risk involve the whole field.

On a molecular level cancer is considered a disease of genetic, progressive, multistep mutation [23–29], however, carcinogenesis may take multiple paths and may be multifocal. This progression is heralded in tissues by the appearance of associated specific molecular and genotypic damage resulting in phenotypic changes that progress from normal histology to early dysplasia, continuing on to severe dysplasia, superficial cancers, and finally invasive disease [23, 24]. It has been estimated that four to six genetic events are required to progress from severe dysplasia to cancer and that one HNC could require up to 10–20 years to develop. The degenerative advance of cancer, however, is not always linear or sequentially additive: progression can occur away from clinically visible lesions, strongly suggesting that genetic aberrations may not always result in locally apparent disease and accumulation of mutations. Lesions that appear morphologically similar harbor often different molecular fingerprints, suggesting that a given phenotypic change can arise from diverse pathways. This absence of a direct, predictable, and consistent correlation between clinical and histological features of suspect lesions is well documented [23–29]. Recent microarray investigations of chromosomal aberration patterns of HPV-negative oral and oropharyngeal squamous cell carcinomas showed subclasses of cancer with unique genetic and clinical fingerprints. This observation, if confirmed in larger studies, could have important diagnostic and therapeutic implication in clinical practice [30].

Precancerous Lesions

Epidemiological, experimental, and clinical observations teach us that cancer may be preceded by a morphological tissue modification, a precancerous lesion, clinically manifest

as a white (leukoplakia), a red (erythroplakia), or a red-white lesion (erythro-leukoplakia).

Oral Cavity

Leukoplakias and Related Lesions

White lesions in the oral cavity were thought to be precancerous as early as 1870 by Paget, who described them as ichthyosis, smoker's patch, and leucokeratosis [31]. The term leukoplakia was first used by Schwimmer in 1877 [32]. In 1936, McCarthy described the microscopic features of oral leukoplakias, grading them as 1–4, where grade 4 referred to lesions showing microscopic evidence of significant dysplasia or early malignant changes [33].

Leukoplakia is a clinical term used to describe a range of white oral lesions; it implies a diagnosis of exclusion of common conditions with similar appearance and harbors intrinsic potential malignancy [34–37]. Microscopically, these lesions are characterized by simple orthokeratosis, parakeratosis with epithelial hyperplasia and minimal inflammation, hyperkeratosis, or varying degrees of dysplasia. The latter occurs in up to 16% of leukoplakias [34]. Leukoplakias and erythroplakias (less frequent than leukoplakias in the general population) may undergo malignant transformations with or without clinical evidence of such change. Only 5–36% of white lesions can transform into malignancy within 20 years, the annual transformation rate of oral leukoplakia is unlikely to exceed 1%, and there is no proven correlation between transformation and the degree of dysplasia [38–41]. In spite of the progresses in molecular biology, there is not yet a single reliable marker predictive of malignant transformation [36, 37]. Clinically, early stages may be mistaken for reactive lesions that appear either as painless, nonhealing, indurated ulcerations, or hypertrophic lesions. Differential diagnosis is based on the analysis of the risk factors, the natural history, the progression and, most importantly, the clinical features of the lesion. A definitive diagnosis, however, can only be obtained after histological confirmation. Only then can the appropriate therapy be selected. The clinical conundrum for lesions without features of malignancy remains whether the initial biopsy is representative of the entire lesion, especially when they present with nonhomogeneous features [38, 42]. Microscopic foci of malignant tissue may be present and can only be detected histologically. Unexpected carcinomas in resection specimen have been reported for oral lesions removed after the initial incisional biopsy had not shown the presence of malignant tissue [38–43]. This lack of correlation between the histopathologic examination of

initial biopsies and the examination of definitive surgical specimens may strongly influence the decision-making process when assessing and managing suspicious lesions [42, 44].

Conventional Treatment of Leukoplakias and Related Lesions

In consideration of the reported malignant transformation rate of 5–36% [38–41], the therapeutic goal for oral leukoplakias is secondary prevention. Treatment modalities include lifestyle modification and elimination of risk factors, such as tobacco and alcohol intake, medical therapy with retinoids or antimycotics, surgical excision, cryosurgery, laser evaporation, or laser excision. Surgical excision is widely accepted to be the most effective form of treatment [36–44]. A useful initial approach in the management of oral leukoplakias should be the removal of etiologic factors in conjunction with simultaneous anti-inflammatory and antimycotic therapy. If clinical improvement or resolution is not obtained within a few weeks, surgical excision of persistent oral leukoplakias, preferably laser resection, seems to be the most rational next step [45]. However, results of prospective [46] and retrospective studies [36–45] describing rates of malignant transformation in patients treated with surgical or laser excision of oral leukoplakias are hardly comparable because of differences in diagnostic and inclusion criteria, follow-up time intervals, patient characteristics, and surgical techniques employed. The inconclusive data leaves unproven the hypothesis that surgical removal of potentially malignant oral lesions can prevent the onset of oral cancer [37, 38, 41, 47–49] and formed the basis for pilot chemoprevention studies.

Larynx

Leukoplakias and Related Lesions

Analogies exist between laryngeal and oral precancerous lesions: the presence of dysplasia has clinical relevance for both, but in laryngeal lesions a better correlation seems to exist between the grade of dysplasia and the clinical evolution of the lesion [50–54]. The natural history of untreated laryngeal dysplasia is well described for mild and moderate dysplasia. Invasive cancer can develop in as many as 45% of patients with moderate dysplasia and some authors have recommended intervention. For lesions with mild dysplasia, the rate of progression is reported to be up to 11.5% [49, 53].

Conventional Treatment of Leukoplakias and Related Lesions

As for the oral cavity, the management of premalignant lesions of the larynx is controversial. The best opportunity for cure must not be missed because of inadequate treatment and therapy must be oncologically radical with maximal functional preservation. The available data on the treatment of laryngeal premalignancy mostly addresses severe dysplasia/carcinoma in situ [51–56]. A “wait-and-see” approach cannot be employed in these patients as some studies have indicated an unacceptably high rate of progression to invasive carcinoma. Intervention is recommended for all cases of severe dysplasia and/or carcinoma in situ [54]. Despite substantial recent advances there is significant morbidity associated with nonsurgical therapy sometimes used to treat these conditions [56] while laser surgery seems to be the best treatment modality to fulfill the requirements of oncologic radicality and organ as well as functional preservation [51, 52, 55].

Precancer and Risk Markers for Cancer

A biological marker (biomarker) is a parameter that can be objectively measured and evaluated as an indicator of normal biological and pathogenic processes, gauging the response to therapeutic (most often pharmacological) interventions [57]. A small subset of biomarkers that demonstrate a strong correlation with the desired clinical endpoint can serve as its substitute. These surrogate endpoints are expected to be reasonably likely to predict clinical benefit or harm (or lack thereof) based on epidemiologic, therapeutic, physiopathologic, or other scientific evidence.

The search for reliable biomarkers has an important impact on the evaluation of chemoprevention studies that goes beyond the potential changes to clinical practice. The evaluation of a marker linked to carcinogenesis requires the study of its expression in tumors; the presence of this marker (over-expressed, mutated, or masked) is analyzed in precancerous lesions or in normal tissue to assess if it is present as an indicator of a biologic process associated with the progression of a neoplasia [58]. In HNC chemoprevention trials, the search for reliable biomarkers focuses on identification of indicators of malignant transformation in clinically suspect lesions, those linked to second primary tumors and/or identification of individuals at greatest risk for the development of neoplasias [58]. SIN is defined as a noninvasive lesion with genetic abnormalities resulting in loss of cellular control functions with some phenotypic characteristics of invasive cancer [35, 59]. Preventive measures focus on evaluation and removal of its risk factors and surgical resection [45, 49, 51]. Epithelial tissues display SIN as moderate to severe dysplasia whose grade is determined by the degree of cellular abnormality above

the epithelial basement membrane [34–38, 59]. Accuracy in grading is dependent on the quality of the tissue sample, the biopsy site, and the experience of the pathologist. Several studies have shown great inter- and intra-examiner variability in the assessment of presence, absence, and grade of oral epithelial dysplasia [35, 37, 59]. SIN is believed to represent (with appropriate sampling) the total field of abnormal epithelium and to provide identifiable lesions that can be targeted to evaluate the efficacy of new therapeutic interventions [28]. However, only a small portion of these lesions progress to cancer and they are not always indicative of malignant transformations [38, 42]. A striking discordance between the genetic status and the clinical and histologic features has been reported, particularly as it relates to treatment response [60]. Molecular studies also suggest that dysplasia may not be considered a reliable biomarker for cancer because high risk modifications can be found in nondysplastic lesions [49, 58].

There currently is not a body of evidence substantially strong enough to advocate in clinical practice the use of biomarkers as prognostic indicators for HNC [58]. Research in the field continues particularly with gene expression and salivary proteomics studies [61, 62] and recently published reports identify Podoplanin [63, 64] and the genotype CD1 AA and AG [54] as promising new markers.

Chemoprevention

Chemoprevention is the use of natural or synthetic chemicals for the reversal, suppression, or prevention of conversion of a premalignant lesion to an invasive form [57]. In other words, chemoprevention includes all the interventions that employ agents aimed at preventing the development of cancer. Two basic concepts guide chemoprevention studies; the levels of acceptable toxicity must be much lower than in patients with cancers and the drug may only be administered orally [57, 65]. Premalignant lesions of the oral cavity represent an ideal model to study chemoprevention. Ready access allows easy monitoring and serial biopsies resulting in greater possibility of early intervention and faster data analysis [66, 67]. Only few studies have been conducted on laryngeal precancer because of limitations related to difficulty in access and monitoring [54, 68–70]. We can distinguish different forms of chemopreventive interventions: primary, adjuvant, and chemoprevention in high-risk population.

Primary Chemoprevention

This form of chemoprevention includes treatment of precancerous lesions (leukoplakias) with agents acting to reverse morphological precursors of malignancy and to assess their efficacy.

Table 2.1 Primary chemoprevention randomized trials

<i>Stich HF, 1988 [75]</i>	
Design	β -Carotene 180 mg/week (Group I), β -carotene+ vitamin A 100,000 IU/week (Group II), placebo (Group III)
Length of the study	6 months
Patients included in the study	130 tobacco/betel chewers
End points	Complete remission (RC) of lkp and reduction of micronucleated cells
Results	Group I = 15%, Group II = 27% ^a , Group III = 3%
Remarks	Nobody changed the risk habits
<i>Stich HF, 1988 [76]</i>	
Design	Vitamin A 200,000 IU/week vs. placebo
Length of the study	6 months
Patients included in the study	54 tobacco/betel chewers
End points	Complete remission (RC) of lkp and prevention of new lkp
Results	Intervention group = 57% RC, 0% New lkp; Placebo = 3% RC, 21% New lkp
Remarks	Nobody changed the risk habits
<i>Hong WK, 1986 [66]</i>	
Design	13- <i>cis</i> -RA (1–2 mg/kg/day) vs. placebo
Length of the study	3-month intervention; follow-up = 6 months
Patients included in the study	Intervention = 24; placebo = 20
End points	Clinical = remission of leukoplakia; pathological = reversion of dysplasia
Results	Clinical-intervention group = 67%, placebo = 10%, $p = 0.0002$; pathological-intervention group = 54%, placebo = 10%; $p = 0.01$
Remarks	Two severe toxicity; relapse of lkps in 56% of responding patients 2–3 months after intervention ended
<i>Lippman SM, 1993 [77]</i>	
Design	Phase I = 3-month high-dose 13- <i>cis</i> -RA (1.5 mg/kg/day) Phase II = 9-month low dose 13- <i>cis</i> -RA (0.5 mg/kg/day) (Group I); β -carotene (30 mg/day) (Group II)
Length of the study	12 months
Patients included in the study	Phase I (3 months) = 70; phase II (9 months) = 33 Group I, 26 Group II
End points	Remission of leukoplakia
Results	Phase I – remission of lkp = 36/66 (55%); progression of lkp = 7/66 Phase II – remission or stable disease 92% Group I vs. 45% Group II; $p = 0.001$ Group I = 8% progression, 1 Tis; Group II = 55% progression, 1 Tis, 5 SCC
Remarks	Mild, though greater toxicity in the high-dose 13- <i>cis</i> -RA evaluable patients after phase I (3 months) = 66; after phase II = 22 (Group I); 13 (Group II)

lkp leukoplakia, *is* in situ carcinoma, *SCC* squamous cell carcinoma

^aStatistically significant

Retinoids, β -carotene, and α -tocopherol are the main agents employed in chemoprevention studies of oral leukoplakias. More than 30 years have elapsed since the initial clinical studies of natural vitamin A in the management of oral leukoplakia, and several single-arm studies have been reported [71–74]. Table 2.1 shows the design and the results of the published randomized trials [66, 75–77]. These studies demonstrate response rates that vary from 44 to 83% but revealed the dermatologic and liver toxicity of natural vitamin A. The effectiveness of these interventions is limited to the duration of the drug intake: a few weeks or months after stopping the drug intake the leukoplakias recur. Topical application of a natural or synthetic retinoid also achieved a temporary complete remission in more than 50% of patients, but the severe local side effects and the necessity to apply the drug locally limited this form of treatment and it is no longer used [45, 74]. Several authors conducted chemoprevention trials for laryngeal precancerous lesions [68, 69, 78]. The efficacy of the chemopreventive agents was less (clinical and histologic) than in oral lesions while similarities were noted in the overall

response profile (variability of response rate, side effects). Among these studies particular attention should be given to the Almadori trial [78]: a chemoprevention study with folates in patients with oral and laryngeal leukoplakias based on the observation that serum folate levels are significantly lower in patients with cancerous and precancerous lesions than in at risk and control patients.

While there currently is no effective form of primary chemoprevention, its main role and goal remains to evaluate and test new agents that are effective and have a low side-effect profile.

Adjuvant Chemoprevention: Prevention of Second Primary Tumors

This form of chemoprevention consists of interventions on patients cured for HNC that employ a chemopreventive agent or a combination of agents in order to reduce the risk of second

primaries. Patients treated for HNC have a constant and continuing risk of developing a second primary that varies from 2.7 to 4% yearly in the aerodigestive tract as well as in other sites [15, 16, 20, 79, 80]. Adjuvant chemoprevention might modulate epithelial cell biology and this way halt the progression of carcinogenesis [17, 81].

The development of synthetic vitamin A analogs (all-*trans*-retinoic acid, 13-*cis*-retinoic acid, etretinate, and phenretinide)

with potentially greater therapeutic indexes allowed the rapid expansion of chemoprevention trials [66, 77, 82]. Design and results of the published randomized trials are reported in Table 2.2 [67, 82–89]: in most of these the treatment regimens synthetic retinoids are taken alone or in association with β -carotene. The reported protective effects are conflicting: in some studies retinoids seem to significantly reduce occurrence of second primaries [67, 82, 83], in others

Table 2.2 Adjuvant chemoprevention: results of the most significant randomized trials

<i>Hong WK, 1990 [82], Benner SE, 1994 [83]</i>	
Design	13- <i>cis</i> -RA (50–100 mg/m ² /day) for 12 months vs. placebo
Length of the study	Intervention = 12 months; follow-up = 54.5 months (median)
Patients included in the study	103 disease-free patients after primary treatment for a HNSCC
End point	Occurrence of second primaries
Results	Intervention = 4%; placebo = 24%; $p = 0.005$
Remarks	13- <i>cis</i> -RA does not prevent recurrences and progression of the original tumor Difference in developing a second primary between treatment group diminishes in time, however, persists reduction of occurrence of second primary within head and neck area and lung
<i>Bolla M, 1994 [84]</i>	
Design	Etretinate (50 mg/day first month, and 25 mg/day 23 months) vs. placebo
Length of the study	Intervention = 12 months; follow-up = 41 months (Median, range 0–81)
Patients included in the study	316 patients treated for T1/T2 N0/N1 ≤ 3 cm M0 HNSCC
End point	Occurrence of second primaries
Results	No differences between intervention group (28 second primaries) and placebo (29 second primaries)
Remarks	Multicentric study Treatment discontinued in 33% of patients due to toxicity vs. 23% in placebo, $p = 0.05$ Etretinate does not prevent recurrences and progression of the original tumor
<i>van Zandwijk N, 2000 [85]</i>	
Design	Group I – <i>N</i> -acetyl cysteine (600 mg/day/2 years); Group II – retinol palmitate (300,000 IU/day/1 year and 150,000 IU/day/1 year); Group III – both; Group IV – placebo
Length of the study	Intervention = 24 months; follow-up = 49 months (Median)
Patients included in the study	2,595 patients treated for curable HNSCC (60%) and lung cancer (40%)
End points	Occurrence of second primaries and recurrences of the treated tumor
Results	No differences between the four groups
Remarks	Multicentric study 93.5% of patients have smoked; 25% continued to smoke after cancer diagnosis
<i>Bairati I, 2005 [86], Meyer F, 2008 [87]</i>	
Design	α -Tocopherol (400 IU/day) and β -carotene (30 mg/day) + RT vs. Placebo + RT
Length of the study	Intervention = 36 months; follow-up = 52 months (Median)
Patients included in the study	400 with stage I–II HNSCC treated by radiation therapy
End points	Occurrence of second primaries and recurrences of the treated tumor
Results	α -Tocopherol higher risk than placebo of second primary (HR = 2.88) and recurrences (HR = 1.86) during the supplementation period, but lower rate when supplementation was discontinued (second primary HR = 0.41; recurrences HR = 0.33). Among smokers during RT highest risk of death for HNSCC (HR = 3.38)
Remarks	Multicentric study In the course of the trial β -carotene was discontinued after 156 patients had enrolled because of ethical concerns
<i>Khuri FR, 2006 [88]</i>	
Design	13- <i>cis</i> -RA (30 mg/m ² /day) vs. Placebo
Length of the study	Intervention = 36 months, monitored for up to 4 years
Patients included in the study	1,190 early stage (I–II) HNSCC
End point	Occurrence of second primaries and overall survival
Results	No statistical difference
Remarks	Smoking statistically significantly increased the rate of second primary (HR = 1.64) and death (HR = 2.51) than nonsmoking (HR = 2.52)

(continued)

Table 2.2 (continued)*Perry CF, 2005 [89]*

Design	Group I=high-dose isotretinoin (1 mg/kg/day for 1 year and 0.5 mg/kg/day for 2 years); Group II=moderate dose isotretinoin (0.5 mg/kg/day); placebo
Length of the study	3 years intervention
Patients included in the study	151 patients cured for a HNSCC
End points	Occurrence of second primary in head and neck are lung or bladder
Results	No significant difference in the occurrence of second primary, recurrence of primary disease or DFS
Remarks	Multicentric trial

Chiesa F, 2005 [67]

Design	Fenretinide 200 mg (1 year) vs. Placebo
Length of the study	Intervention = 12 months; follow-up = 60 months
Patients included in the study	170 after resection of oral leukoplakia
End points	Recurrences of leukoplakias and occurrence of new leukoplakias and cancer
Results	Protective effect of fenretinide
Remarks	The protective effect lasted significantly for 7 months after drug interruption

HNSCC head and neck squamous cell carcinoma, DFS disease-free survival

no protective effect was shown [84, 85, 88, 89]. The toxicity of etretinate is very high and many patients enrolled in the French study [84] discontinued treatment because of the side effects. The toxicity of high-dose isotretinoin was observed in all of the studies and its severity required many patients to discontinue therapy [83, 90–92]. On the contrary low-dose isotretinoin was well tolerated and was more effective than β -carotene. Several studies tested the effectiveness of another synthetic retinoid, N-(4-hydroxyphenyl) retinamide (fenretinide or 4-HPR) in preventing the clinical progression of oral leukoplakia via receptor-independent apoptosis and receptor-dependent effects [67, 93, 94]. These studies showed that fenretinide is a well-tolerated drug, able to prevent new occurrences of oral leukoplakias without improved efficacy at higher doses [93, 94]. After interruption of the pharmacotherapy, however, the protective effect of retinoids decreases over time and some patients can develop new leukoplakias and squamous cell carcinomas [66, 94]. In the Hong study [66, 83], the difference between the odds ratio of developing a second primary tumor at any site for isotretinoin-treated group diminishes over time and no statistically significant difference in survival has been observed. In the Chiesa study [67], the protective effect of fenretinide was shown to last significantly for 7 months after the completion of a 1-year intervention.

cancer of the upper aerodigestive tract because of lack of micronutrients and vitamin A in their diet, or of heavy alcohol and tobacco use. Intervention generally lasted several years and the results in term of reduced mortality from or reduced incidence of cancer were evaluated for at least 5 years after the end of the interventions. Table 2.3 shows the results of these trials [96–104]. Retinoid and micronutrient supplementation showed a protective effect in populations with low tissue levels of retinoids, but it was dangerous in individuals with normal retinoid levels, inducing a higher incidence of cardiovascular diseases and lung cancer. Two studies were stopped because of these results [98–103]. A relationship between lung cancer and serum levels of some carotenoids seem to show some gender predilection favoring males, with no apparent association observed among women [105]. These results and a critical review of the literature allow us to conclude that there is no evidence to support antioxidant supplementation for primary or secondary prevention, while Vitamin A, β -carotene, and Vitamin E may increase mortality [106–108]. Future randomized trials could evaluate the potential effects of Vitamin C and selenium for primary and secondary prevention with close monitoring for potential harmful effects. Antioxidant supplements need to be considered medicinal products and should undergo sufficient evaluation before marketing [109].

Chemoprevention in High-Risk Populations

This form of chemoprevention consists of dietary supplementation with vitamins, retinoids, and micronutrients in high-risk populations. During the final two decades of the last century several preventive studies have been conducted all over the world (China, Scandinavian countries, USA) [96, 97]. These trials included thousands of patients at risk for developing a

New Directions in Chemoprevention

Following the conflicting and intriguing results of the early chemoprevention trials, other therapeutic regimens (single drug or combination) have recently been evaluated [95, 110–115]. Most studies tested anti-inflammatory drugs, including COX-inhibitors and aspirin, because of the strong link between nonsteroidal anti-inflammatory drugs (NSAIDs) and the

Table 2.3 Chemoprevention trials in high-risk populations

<i>Blot WJ, 1993 [96]</i>	
Design	Diet supplementation with Retinol + zinc (Group A), riboflavin + niacin (Group B), Vitamin C + molybdenum (Group C), β -carotene + Vitamin E + selenium (Group D)
Length of the study	Diet supplementation = 5 years; follow-up = 2 more years
Patients included in the study	29,584 at risk for esophageal and gastric cancer
End point	Decrease of mortality for esophageal, and stomach cancer
Results	Significantly lower mortality for cancer was found in group D, evident after 1–2 years
Remarks	No significant effect on mortality rates for all causes was found in the other arms
<i>Li JY, 1993 [97]</i>	
Design	Diet supplementation with 12 minerals + 14 vitamins vs. placebo
Length of the study	6 years
Patients included in the study	3,318 subjects with esophageal dysplasia
End point	Decrease in cancer mortality and incidence
Results	No substantial short-term beneficial effect on incidence or mortality for esophageal cancer
Remarks	Cancer mortality 4% lower (RR = 0.96) and cerebrovascular disease 38% lower (RR = 0.62) in intervention group, not statistically significant
<i>ABTC Study Group, 1994 [98], Albanes D, 1996 [99], Virtamo J, 2003 [100]</i>	
Design	α -Tocopherol (50 mg/day) (Group I), β -carotene (20 mg/day) (Group II), both (Group III), placebo (Group IV)
Length of the study	5–8 years (Median 6.1 years)
Patients included in the study	29,153 Male Finnish, 50–69 years old, smokers ≥ 5 cigarettes/day
End point	Reduction in lung cancer incidence
Results	Multicentric study Higher incidence of lung cancer and ischemic heart disease in those receiving β -carotene No reduction in lung cancer in those receiving α -tocopherol
Remarks	Fewer prostate cancers, but more deaths from hemorrhagic stroke in the α -tocopherol group The beneficial and adverse effects of supplemental α -tocopherol and β -carotene disappeared during postintervention follow-up
<i>Omenn GS, 1996 [101, 102], Goodman GE, 2004 [103]</i>	
Design	β -Carotene 30 mg/day + Vitamin A 25,000 IU vs. Placebo
Length of the study	4 years (stopped 21 months early than planned)
Patients included in the study	18,314 smokers, former smokers and workers exposed to asbestos
End point	Decrease in lung cancer incidence
Results	Multicentric study Stopped due to higher incidence of lung cancers (RR = 1.28) and death for lung cancer (RR = 1.46) and for cardiovascular diseases (RR = 1.26) in the intervention group as compared with the placebo group The adverse effects persisted after supplementation was stopped (as of December 2004), although not statistically significant
<i>Lin J, 2009 [104]</i>	
Design	Vitamin C Group (ascorbic acid 500 mg/day), vitamin E group (α -tocopherol 600 IU/every other day), β -carotene group (50 mg/every other day), placebo
Length of the study	9.4 years (average)
Patients included in the study	7,627 women free of cancer before randomization
End point	Incidence and death from cancer
Results	No overall benefits in the primary prevention of total cancer incidence or cancer mortality
Remarks	Multicentric, double-blind, placebo-controlled $2 \times 2 \times 2$ factorial trial

reduction of cancer incidence demonstrated in human epidemiological studies. The NSAIDs family inhibits the cyclooxygenase (COX) family of enzymes. COX-2 has been shown to be upregulated as much as 150-fold in HNSCC and 50-fold in the normal appearing tissue of patients with HNSCC compared with normal subjects [116]. However, problems and results of the first multicentric studies using these agents are similar to those obtained with the retinoids [117–120]. Heath et al. [117] found that administration of 200 mg of celecoxib twice daily for 48 weeks of treatment

does not appear to prevent progression of Barrett's dysplasia to cancer. In a hospital-based case-control study (529 patients with HNSCC vs. 529 controls), Jayaprakash et al. concluded that aspirin use reduces the risk of HNC (25%; OR 0.75) [119]. This effect is more pronounced in women and in individuals with low to moderate exposure to cigarette smoke or alcohol consumption. Heavy smokers and alcohol drinkers did not benefit from the protective effect of aspirin.

Current basic science advances are swiftly followed by an inability to translate them into clinically relevant interventions,

to verify end-points and to establish adequate follow-up. As of September 2009 the National Institute of Health [120] reports six recruiting chemoprevention clinical trials using molecular agents (kinase or serin protease inhibitors), and anti-inflammatory drugs (COX-2 inhibitors, sulindac, or acetylsalicylic acid) as single agents or in combination. In addition to these, 11 other primary or adjuvant chemoprevention trials are currently active, but not yet in the recruiting phase: their purpose is to test the effectiveness of natural and synthetic retinoids (four trials), dietary supplementation (one study), anti-inflammatory (four studies), and antidiabetic drugs (two studies).

Chemoprevention trials are expensive because of the large study population needed and the necessary length of the studies. Cost analysis of these trials includes the sample size, the total number of study subjects and the necessary lengthy follow-up, the number of trial outcomes evaluated, possible delays in the accrual process, and cost effectiveness of particular retention activities. Based on the negative experiences made with the CARET study, the psychological effects of information relating to possible negative outcomes of the study (involving healthy population) should also be considered [121, 122].

The original promise HNC chemoprevention will be fulfilled only if putative biomarkers are validated with well designed and adequately funded long-term studies, that allow the creation of accurate molecular risk stratification models and translate into significant changes to clinical practice [17, 81, 93, 123, 124].

Prevention of Neck Metastases

One of the basic issues of secondary and tertiary prevention in HNC is linked to the possibility of prevention of neck metastases [125, 126]. The neck is the central point in the management of HNSCCs; once metastases become clinically apparent, extra-capsular spread (ECS), a known prognostic factor [125, 126, 132], is more likely than in occult metastatic disease where ECS is estimated to be more than 15–20% [126–128]. ECS does not depend on the quantity of tumor cells present in the metastatic nodes: up to 60% of micro-metastatic nodes (cN0 pN1) show ECS [129–131]. A study by Woolgar evaluating the treatment results in a series of patients with head and neck cancer [128] showed that, regardless of the T stage, the overall survival (OS) depends upon the pathological lymph node status: OS in pN0 patients was 73%, in pN+ without ECS=51%, and in pN+ with ECS was 29%. Distant metastases and local recurrences are also significantly related to the lymph node status [132]. Currently, the only specific predictive factors of lymph node metastases are the site, size, and thickness of the primary tumor [130, 133].

Identification of factors affecting invasion and metastasis, as well as the establishment of biomarkers to predict malignant potential and to identify different risk groups are of paramount importance. Cancer cell invasion and metastasis are a complex, multistep process involving interactions between invading cells, the extracellular matrix, and other stromal elements. In the initial phases of tumor progression, tumor cells undergo genetic changes, providing proliferative advantages such as the ability to resist growth-inhibiting signals, avoidance of programmed cell death (apoptosis), induction of blood vessel growth (angiogenesis), loss of cell adhesion and migration, lymphatic angiogenesis, and the ability to survive in the environment of the metastatic site [134–136]. When these metastatic capacities are acquired (early or late) in tumor progression remains unclear, however there is evidence suggesting, in contrast to common belief, early acquisition of this transformation [136]. Many of these competitive advantages may also vary in time. For example, cell adhesion should decrease to allow cells to migrate and metastasize, but cell adhesion is again needed to settle at the metastatic site [134].

Search for Additional More Sensitive Markers

Many biomarkers have been studied to establish correlation with the presence of nodal metastases in HNSCC with widely varying results and include matrix-metallo proteinases (MMP) [134, 137–145], podoplanin [63, 64], *p27*, *ki-67* [146–148], and vascular endothelial growth factor (VEGF) [149, 150]. Recently, new techniques centered upon gene-expression profiling and comparative genomic hybridization with microarray technology have been developed and have allowed reliable detection of predictors of behavior rather than single markers [134, 151–156]. The findings of these studies indicate that these markers identify a subset of patients with poor prognosis, requiring aggressive treatment modalities, including new molecular targeted therapies likely to act as anti-invasion and antimetastatic therapeutic agents [157].

HPV Infection

The HPV is part of a very heterogeneous family of viruses. It represents an important human carcinogen, causing the vast majority of cervical and anogenital tumors, and a variable number of cancers in other districts of the human body including the head and neck [158, 159]. HPV-positive SCCHN have been reported to share some epidemiological and biological characteristics with anogenital carcinomas [160, 161].

Risk Factors for HPV Infection, Oral, and Oropharyngeal Squamous Cell Carcinomas

HPV infection is thought to precede the development of an HPV-positive HNSCC. The presence of high-risk HPV infection in oral mucosa and seropositivity increases significantly the risk of development OSCC [162–166]. Therefore, risk factors for HPV oral infection are likely, by extension, to be risk factors for HPV-positive HNSCC. Patients with HPV-positive tumors appear to be distinct from HPV-negative patients. There is no gender predilection, patients are often nonsmokers and nondrinkers [167, 168] and younger than HPV-negative tumors [169]. The degree to which oral HPV infection may combine with tobacco and/or alcohol use to increase risk of cancer is unclear [160, 169]. In the majority of the studies OSCC related to HPV infection have a better outcome and a reduced risk of relapse and second tumors as compared with HPV-negative tumors [160, 170, 171].

Vaccination as a Form of Prevention

Vaccines designed strictly for prevention of cervical cancer and vulvar genital warts have recently been introduced. The existing vaccines are able to create a robust humoral immune response [172, 173] that is much more effective than the levels of antibodies acquired after a natural infection, and persist at least for a 60-month period [172]. Five-year follow-up demonstrates 100% effectiveness in prevention of persisting infection as well as HPV-16 and HPV-18 CIN 2/3 lesions in young women [173].

HPV-16 is found in the majority of HPV-positive oral cancer [173]. All vaccine trials reported to date have been designed to investigate the ability to generate protection against anogenital HPV infection in women. There is reason to believe that the existing vaccines may be effective against oral HPV infection, and prevent vaccine-type HPV-related HNC in both men and women [172, 174]. Data also suggests that therapeutic vaccines are effective against low-volume disease and could be used as adjuvant therapy following surgery or radiotherapy to clear microscopic residual disease [4]. Clinical trials to evaluate the efficacy of the quadrivalent HPV vaccine (against HPV 6, 11, 16, 18) in protecting against oral infection are currently being developed.

Conclusions

Improvement in the field of prevention requires a multidisciplinary approach. The development of cancer is a complex process, and multiple factors may be crucial in prevention.

A clear geographic variability in cancer risk and burden exists across countries and specific interventions are required in each region. Primary prevention is considered the best form of prevention. Implementation of a primary prevention program requires knowledge of the specific risk factors (tobacco, alcohol, HPV infection) and the ability to limit exposure and to remove them. Efforts to promote healthy lifestyle practices such as tobacco control and cessation programs, recommendation for dietary modification (including alcohol consumption reduction) and weight control have yielded mixed results without significant reduction in the incidence of new cases of HNSCC [41, 175]. This observation highlights the fact that achieving primary prevention is very difficult and has given greater relevance to secondary prevention. Early detection and diagnosis entails by definition the discovery of preneoplastic lesions and early carcinomas. Precancerous lesions and cancer are part of a clinical continuum making it difficult to define where one ends and the other begins. Consequently, it becomes difficult to definitively state what represents therapy for one end of the disease spectrum versus the other [157, 176]. Genetic aberrations do not always result in visible lesions and a large portion of all preneoplastic lesions remains clinically silent. Even recognizing preneoplastic alterations, currently there is no sufficient evidence suggesting that the surgical treatment of precancerous lesions reduces the incidence of cancer [41].

The rapid development of molecular biology, the identification of the fundamental cancer genes and signaling pathways, and the development of new functional diagnostic imaging techniques show renewed promise for early prevention. The stratification of patients in different subgroups based on etiology, genomic classification, and other parameters clearly has important implications. Other than showing promise, however, we have not been able to translate this new knowledge into clinically successful strategies for early detection or chemoprevention of cancer. We are again at the dawn of a new era with the conclusion of the Human Genome Sequencing Project and advances in molecular and cellular pathophysiology hold yet more promise that a deeper understanding of the fundamental disease mechanisms may result in improved prevention and cure. The challenges remain in the correct interpretation of these findings and in their wise and scientific application. Only then will we be able to impact the field of HNC, transforming prevention into the only form of cure.

References

1. Ferlay J, Bray F, Pisani P, Parkin DM. GLOBOCAN 2002: cancer incidence, mortality and prevalence worldwide, version 2.0. IARC Cancer Base No. 5. Lyon (France): IARC Press; 2004.
2. Conway DI, Stockton DL, Warnakulasuriya KA. Incidence of oral and oropharyngeal cancer in United Kingdom (1990–1999) recent trends and regional variation. *Oral Oncol.* 2006;46:586–92.

3. Hashibe M, Brennan P, Chuang SC, Boccia S, Castellsague X, Chen C, et al. Interaction between tobacco and alcohol use and the risk of head and neck cancer: pooled analysis in the International Head and Neck Cancer Epidemiology Consortium. *Cancer Epidemiol Biomarkers Prev.* 2009;18:541–50. Epub 2009 Feb 3.
4. Psyrri A, Gouveris P, Vermorken JB. Human papillomavirus-related head and neck tumors: clinical and research implication. *Curr Opin Oncol.* 2009;21:201–5.
5. zur Hausen H. Papillomaviruses in the causation of human cancers a brief historical account. *Virology.* 2009;384:260–5. Epub 2009 Jan 8.
6. Myers JN, Elkins T, Roberts D, Byers RM. Squamous cell carcinoma of the tongue in young adults: increasing incidence and factors that predict treatment outcomes. *Otolaryngol Head Neck Surg.* 2000;122:44–51.
7. Hinerman RW, Mendenhall WM, Morris CG, Amdur RJ, Werning JW, Villaret DB. Postoperative irradiation for squamous cell carcinoma of the oral cavity: 35-year experience. *Head Neck.* 2004;26:984–94.
8. Ribeiro KC, Kowalski LP, Latorre MR. Impact of comorbidity, symptoms, and patients' characteristics on the prognosis of oral carcinomas. *Arch Otolaryngol Head Neck Surg.* 2000;26:1079–85.
9. Sparano A, Weinstein G, Chalian A, Yodul M, Weber R. Multivariate predictors of occult neck metastasis in early oral tongue cancer. *Otolaryngol Head Neck Surg.* 2004;131:472–6.
10. Khuri FR, Kim ES. Primary head and neck cancer. In: Furie B, Cassileth PA, Atkins MB, Mayer RJ, editors. *Clinical haematology and oncology.* Philadelphia: Elsevier; 2003. p. 999–1011.
11. Stewart BW, Kleihues P. World cancer report: head and neck cancer. Lyon (France): IARC Press; 2003. p. 232–6.
12. Sargeran K, Murtomaa H, Safavi SM, Teronen O. Delayed diagnosis of oral cancer in Iran: a challenge for prevention. *Oral Health Prev Dent.* 2009;7:69–76.
13. Scott SE, Grunfeld EA, McGurk M. The idiosyncratic relationship between diagnostic delay and stage of oral squamous cell carcinoma. *Oral Oncol.* 2005;41:396–403.
14. Onizawa K, Nishihara K, Yamagata K, Yusa H, Yanagawa T, Yoshida H. Factors associated with diagnostic delay of oral squamous cell carcinoma. *Oral Oncol.* 2003;39:781–8.
15. Chuang SC, Scelo G, Tonita JM, Tamaro S, Jonasson JG, Kliever EV, et al. Risk of second cancer among patients with head and neck cancers: a pooled analysis of 13 cancer registries. *Int J Cancer.* 2008;123:2390–6.
16. Manikantan K, Rhode S, Dwivedi R, Palav R, Nutting CM, Rhys-Evans P, Harrington KJ, Kazi R. Making sense of post-treatment surveillance in head and neck cancer: the when and what of follow-up. *Cancer Treat Rev.* 2009;35(8):744–53. Epub 2009 Sep 9.
17. Boyle P, Macfarlane GJ, Blot WJ, Chiesa F, Lefebvre JL, Azul AM, et al. European School of Oncology Advisory report to the European Commission for the Europe Against Cancer Programme: oral carcinogenesis in Europe. *Eur J Cancer B Oral Oncol.* 1995;31B:75–85.
18. Slaughter DP, Southwick HW, Smejkal W. Field cancerization in oral stratified squamous epithelium: clinical implications of multicentric origin. *Cancer.* 1953;6:693–8.
19. Hong WK, Lippman SM, Wolf GT. Recent advances in head and neck cancer-larynx preservation and cancer chemoprevention: the seventeenth Annual Richard and Hinda Rosenthal Foundation Award lecture. *Cancer Res.* 1993;53:5113–20.
20. Leemans CR, Chiesa F, Tradati N, Snow GB. Messages from completed randomized trials in head and neck cancer. *Eur J Surg Oncol.* 1997;23:469–76.
21. Dakubo GD, Jakupciak JP, Birch-Machin MA, Parr RL. Clinical implications and utility of field cancerization. *Cancer Cell Int.* 2007;7:2.
22. Steiling K, Ryan J, Brody JS, Spira A. The field of tissue injury in the lung and airway. *Cancer Prev Res.* 2008;1:396–403.
23. Almadori G, Bussu F, Cadoni G, Galli J, Rigante M, Artuso A, et al. Multistep laryngeal carcinogenesis helps our understanding of the field cancerisation phenomenon: a review. *Eur J Cancer.* 2004;40:2383–8.
24. Almadori G, Bussu F, Cadoni G, Galli J, Paludetti G, Maurizi M. Molecular markers in laryngeal squamous cell carcinoma: towards an integrated clinicobiological approach. *Eur J Cancer.* 2005;41:683–963.
25. Marcu LG, Yeoh E. A review of risk factors and genetic alterations in head and neck carcinogenesis and implications for current and future approaches to treatment. *J Cancer Res Clin Oncol.* 2009;135:1303–14. Epub 2009 Jul 30.
26. Sidransky D. Emerging molecular markers of cancer. *Nat Rev Cancer.* 2002;2:210–9.
27. Le QT, Giaccia AJ. Therapeutic exploitation of the physiological and molecular genetic alterations in head and neck cancer. *Clin Cancer Res.* 2003;9:4287–95.
28. Spielmann PM, Palmer T, McClymont L. 15-Year review of laryngeal and oral dysplasias and progression to invasive carcinoma. *Eur Arch Otorhinolaryngol.* 2010;267(3):423–7. Epub 2009 Jun 20.
29. Vogelstein B, Kinzler KW. Cancer genes and the pathways they control. *Nat Med.* 2004;10:789–99.
30. Smeets SJ, Brakenhoff RH, Ylstra B, van Wieringen WN, van de Wiel MA, Leemans CR, et al. Genetic classification of oral and oropharyngeal carcinomas identifies subgroups with a different prognosis. *Cell Oncol.* 2009;31:291–300.
31. Bouquot JE, Whitaker SB. Oral leukoplakia: rationale for diagnosis and prognosis of its clinical subtypes or "phases". *Quintessence Int.* 1994;25:133–40.
32. Shklar G. Modern studies and concepts of leukoplakia in the mouth. *J Dermatol Surg Oncol.* 1981;7:996–1003.
33. McCarthy FP. Etiology, pathology and treatment of leukoplakia buccalis, with report of 316 cases. *Arch Derm Syph.* 1936;34:612–23.
34. World Health Organisation, Collaborating Centre for Oral Precancerous Lesions. Definition of leukoplakia and related lesions: an aid to studies on oral precancer. *Oral Surg.* 1978;46:518–39.
35. Gale N, Pilch BZ, Sidransky D, El-Naggar AK, Westra W, Califano J, et al. Tumours of the oral cavity and oropharynx (Epithelial precursor lesions). In: Barnes L, Eveson JW, Reichart P, Sidransky D, editors. *World health organization classification of tumours. Pathology & Genetics.* Lyon: IARC Press; 2005. p. 177–9.
36. Warnakulasuriva S, Johnson NW, van der Waal I. Nomenclature and classification of potentially malignant disorders of the oral mucosa. *J Oral Pathol Med.* 2007;36:575–80.
37. van der Waal I. Potentially malignant disorders of the oral and oropharyngeal mucosa; terminology, classification and present concepts of management. *Oral Oncol.* 2009;45:317–22. Epub 2008 Jul 31.
38. Chiesa F, Tradati N, Sala L, Costa L, Podrecca S, Boracchi P, et al. Follow-up of oral leukoplakia after carbon dioxide laser surgery. *Arch Otolaryngol Head Neck Surg.* 1990;116:177–80.
39. Scheifele C, Reichart PA. Is there a natural limit of the transformation rate of oral leukoplakia? *Oral Oncol.* 2003;39:470–5.
40. Napier SS, Speight PM. Natural history of potentially malignant oral lesions and conditions: an overview of the literature. *J Oral Pathol Med.* 2008;37:1–10.
41. Lodi G, Porter S. Management of potentially malignant disorders: evidence and critique. *J Oral Pathol Med.* 2008;37:63–9.
42. Holmstrup P, Vedtofte P, Reibel J, Stoltze K. Long-term treatment outcome of oral premalignant lesions. *Oral Oncol.* 2006;42:461–74.
43. van der Hem PS, Nauta JM, van der Wai JE, Roodenburg JL. The results of CO₂ laser surgery in patients with oral leukoplakia: a 25-year follow-up. *Oral Oncol.* 2005;41:31–7.
44. Lee JJ, Hung HC, Cheng SJ, Chiang CP, Liu BY, Jeng JH, et al. Factors associated with underdiagnosis from incisional biopsy of

- oral leukoplakic lesions. *Oral Surg Oral Med Oral Pathol Oral Radiol Endod.* 2007;104:217–25. Epub 2007 Jun 7.
45. Tradati N, Grigolati R, Calabrese L, Costa L, Giugliano G, Morelli F, et al. Oral leukoplakias: to treat or not? *Oral Oncol.* 1997;33:317–21.
 46. Schwarz F, Maraki D, Yalcinkaya S, Bieling K, Bocking A, Becker J. Cytologic and DNA-cytometric follow-up of oral leukoplakia after CO₂- and EnYAG-laser assisted ablation: a pilot study. *Lasers Surg Med.* 2005;37:29–31.
 47. Chiesa F, Boracchi P, Tradati N, Rossi N, Costa L, Giardini R, et al. Risk of preneoplastic and neoplastic events in operated oral leukoplakia. *Eur J Cancer Oncol.* 1993;29:23–8.
 48. Mehanna HM, Rattay T, Smith J, McConkey CC. Treatment and follow-up of oral dysplasia – a systematic review and meta-analysis. *Head Neck.* 2009;31(12):1600–9.
 49. O’Shaughnessy JA, Kelloff GJ, Gordon B, Dannenberg AJ, Hong WK, Fabian CJ, et al. Treatment and prevention of intraepithelial neoplasia: an important goal target for accelerated new agent development. *Clin Cancer Res.* 2002;8:314–46.
 50. Ricci G, Molini E, Faralli M, Simoncelli C. Retrospective study on precancerous laryngeal lesion: long term follow-up. *Acta Otorhinolaryngol Ital.* 2003;23:362–7.
 51. Sadri M, McMahon J, Parker A. Management of laryngeal dysplasia: a review. *Eur Arch Otorhinolaryngol.* 2006;263:843–52.
 52. Minni A, Barbaro M, Rispoli G, Diaferia F, Bernardeschi D, Filippo R. Treatment with laser CO₂ cordectomy and clinical implications in management of mild and moderate laryngeal precancerosis. *Eur Arch Otorhinolaryngol.* 2008;265:189–93.
 53. Roedel RM, Christiansen H, Mueller RM, Matthias C. Transoral laser microsurgery for carcinoma in situ of the glottic larynx. A retrospective follow-up study. *ORL J Otorhinolaryngol Relat Spec.* 2009;71:45–9. Epub 2008 Nov 26.
 54. Papadimitrakopoulou V, Izzo JG, Liu DD, Myers J, Ceron TL, Lewin J, et al. Cyclin D1 and cancer development in laryngeal premalignancy patients. *Cancer Prev Res.* 2009;2:14–21.
 55. Remijn EE, Marres HA, van den Hoogen FJ. Endoscopic laser treatment in pre-malignant and malignant vocal fold epithelial lesions. *J Laryngol Otol.* 2002;116:1019–24.
 56. Riquelme NR, Thankappan K, Cooper M, Sullivan MA, Dougherty T, Popat SR, et al. Photodynamic therapy for head and neck dysplasia and cancer. *Arch Otolaryngol Head Neck Surg.* 2009;135:784–8.
 57. Meyskens Jr FL. Biomarker intermediate endpoint and cancer prevention. *J Natl Cancer Inst Monogr.* 1992;13:177–81.
 58. Smith J, Rattay T, McConkey C, Helliwell T, Mehanna H. Biomarkers in dysplasia of the oral cavity: a systematic review. *Oral Oncol.* 2009;45:647–53. Epub 2009 May 12.
 59. Warnakulasuriya S, Reibel J, Bouquot J, Dabelsteen E. Oral epithelial dysplasia classification systems: predictive value, utility, weaknesses and scope for improvement. *J Oral Pathol Med.* 2008;37:127–33.
 60. Mao L, El-Naggar AK, Papadimitrakopoulou V, Shin DM, Shin HC, Fan Y, et al. Phenotype and genotype of advanced premalignant head and neck lesions after chemopreventive therapy. *J Natl Cancer Inst.* 1998;90:1545–51.
 61. Freed GL, Cazares LH, Fichlander CE, Fuller TW, Stack Jr BC, Schraff S, et al. Differential capture of serum proteins for expression profiling and biomarker discovery in pre- and posttreatment head and neck cancer samples. *Laryngoscope.* 2008;118:61–8.
 62. Leethanakul C, Knezevic V, Patel V, Amornphimoltham P, Gillespie J, Shillitoe EJ, et al. Gene discovery in oral squamous cell carcinoma through the Head and Neck Cancer Genome Anatomy Project: confirmation by microarray analysis. *Oral Oncol.* 2003;39:248–58.
 63. Chuang WY, Yeh CJ, Wu YC, Chao YK, Liu YH, Tseng CK, et al. Tumor cell expression of podoplanin correlates with nodal metastasis in oesophageal squamous cell carcinoma. *Histol-Histopathol.* 2009;24:1021–7.
 64. Kawaguchi H, El-Naggar AK, Papadimitrakopoulou V, Ren H, Fan Y-H, Feng L, et al. Podoplanin: a novel marker for oral cancer risk in patients with oral premalignancy. *J Clin Oncol.* 2008;26:354–60.
 65. Richtsmeier WJ. Biologic modifiers and chemoprevention of cancer of the oral cavity. *N Engl J Med.* 1993;328:58–59.
 66. Hong WK, Endicott J, Itri LM, Doos W, Batsakis JG, Bell R, et al. 13-cis-retinoic acid in the treatment of oral leukoplakia. *N Engl J Med.* 1986;315:1501–5.
 67. Chiesa F, Cavadini E, Formelli F, Costa L, Giardini R, Zurrida S, et al. Randomized trial of fenretinide (4-HPR) to prevent recurrences, new localizations and carcinomas in patients operated on for oral leukoplakia: long-term results. *Int J Cancer.* 2005;115:625–9.
 68. Issing WJ, Struck R, Naumann A. Positive impact of retinyl palmitate in leukoplakia of the larynx. *Eur Arch Otorhinolaryngol.* 1997;254(Suppl 1):105–9.
 69. Papadimitrakopoulou VA, Izzo JG, Mao L, Keck J, Hamilton D, Shin DM, et al. Cyclin D1 and p16 alteration in advanced premalignant lesion of upper aerodigestive tract: role in response to chemoprevention and cancer development. *Clin Cancer Res.* 2001;7:3127–34.
 70. Papadimitrakopoulou VA, Liu DD, Mao L, Shin DM, El-Naggar A, Ibarguen H, et al. Biologic correlates of biochemoprevention trial in advanced upper aerodigestive tract premalignant lesions. *Cancer Epidemiol Biomarkers Prev.* 2002;11:1605–10.
 71. Sporn MB. Approaches to prevention of epithelial cancer during the pre-neoplastic period. *Cancer Res.* 1976;36:2699–702.
 72. Koch AF. Biochemical treatment of precancerous oral lesions: the effectiveness of various analogues of retinoic acid. *J Maxillofac Surg.* 1978;6:59–63.
 73. Shah JP, Strong EW, DeCose JJ, Itri L, Sellers P. Effect of retinoids on oral leukoplakia. *Am J Surg.* 1983;146:466–70.
 74. Silverman S, Eisenberg E, Renstrup G. A study of the effects of high doses of vitamin A on oral leukoplakia (hyperkeratosis), including toxicity, liver function, and skeletal metabolism. *J Oral Ther Pharmacol.* 1965;2:9–23.
 75. Stich HF, Rosin MP, Hornby AP, Mathew B, Sankaranarayanan R, Nair MK. Remission of oral leukoplakias and micronuclei in tobacco/betel quid chewers treated with Beta-carotene and with Beta-carotene plus Vitamin A. *Int J Cancer.* 1988;42:195–9.
 76. Stich HF, Hornby AP, Mathew B, Sankaranarayanan R, Nair MK. Response of oral leukoplakias to the administration of Vitamin A. *Cancer Lett.* 1988;40:93–101.
 77. Lippman SM, Batsakis JG, Toth BB, Weber RS, Lee JJ, Martin JW, et al. Comparison of low-dose isotretinoin with beta carotene to prevent oral carcinogenesis. *N Engl J Med.* 1993;328:15–20.
 78. Almadori G, Bussu F, Galli J, Cadoni G, Zappacosta B, Persichilli S, et al. Serum levels of folate, homocysteine, and vitamin B12 in head and neck squamous cell carcinoma and in laryngeal leukoplakia. *Cancer.* 2005;103:284–92.
 79. Cooper JS, Pajak TF, Rubin P, Tupchong L, Brady LW, Leibel SA, et al. Second malignancies in patients who have head and neck cancer: incidence, effect on survival and implications based on RTOG experience. *Int J Radiat Oncol Biol Phys.* 1989;17:449–56.
 80. Licciardello JT, Spitz MR, Hong WK. Multiple primary cancers in patients with cancer of the head and neck; second cancer of the head and neck, esophagus and lung. *Int J Radiat Oncol Biol Phys.* 1989;17:467–76.
 81. Boyle P, Chiesa F, Scully C. Chemoprevention and oral cancer – (more) trials and (more) tribulations. *Eur J Cancer B Oral Oncol.* 1995;31B:1–2.
 82. Hong WK, Lippman SM, Itri LM, Karp DD, Lee JS, Byers RM, et al. Prevention of second primary tumors with isotretinoin in squamous cell carcinoma. *New Engl J Med.* 1990;323:795–801.
 83. Benner SE, Pajak TF, Lippman SM, Earley C, Hong WK. Prevention of second primary tumors with isotretinoin in patients with squamous cell carcinoma of the head and neck: long term follow-up. *J Natl Cancer Inst.* 1994;86:140–1.

84. Bolla M, Lefur R, Ton Van J, Domenge C, Badet JM, Koskas Y, et al. Prevention of second primary tumours with etretinate in squamous cell carcinoma of the oral cavity and oropharynx. Results of a multicentric double-blind randomised study. *Eur J Cancer*. 1994;30A:767–72.
85. van Zandwijk N, Dalesio O, Pastorino U, de Vries N, van Tinteren H. EUROSCAN, a randomized trial of vitamin A and N-acetylcysteine in patients with head and neck cancer or lung cancer. For the European Organization for Research and Treatment of Cancer Head and Neck and Lung Cancer Cooperative Group. *J Natl Cancer Inst*. 2000;92:977–86.
86. Bairati I, Meyer F, Gélinas M, Fortin A, Nabid A, Brochet F, et al. A randomized trial of antioxidant vitamins to prevent second primary cancers in head and neck cancer patients. *J Natl Cancer Inst*. 2005;97:481–8.
87. Meyer F, Bairati I, Fortin A, Gélinas M, Nabid A, Brochet F, et al. Interaction between antioxidants vitamin supplementation and cigarette smoking during radiation therapy in relation to long-term effects on recurrence and mortality: a randomized trial among head and neck cancer patients. *Int J Cancer*. 2008;122:1679–83.
88. Khuri FR, Lee JJ, Lippman SM, Kim ES, Cooper JS, Benner SE, et al. Randomized phase III trial of low-dose isotretinoin for prevention of second primary tumors in stage I and II head and neck cancer patients. *J Natl Cancer Inst*. 2006;98:441–50.
89. Perry CF, Stevens M, Rabie I, Yarker ME, Cochran J, Perry E, et al. Chemoprevention of head and neck cancer with retinoids: a negative result. *Arch Otolaryngol Head Neck Surg*. 2005;131:198–203.
90. Ellis CN, Krach KJ. Uses and complications of isotretinoin therapy. *J Am Acad Dermatol*. 2001;45:S150–7.
91. Campbell RM, DiGiovanna JJ. Skin cancer chemoprevention with systemic retinoids: an adjunct in the management of selected high-risk patients. *Dermatol Ther*. 2006;19:306–14.
92. Brelford M, Bedute TC. Preventing and managing the side effects of isotretinoin. *Semin Cutan Med Surg*. 2008;27:197–206.
93. Lippman SM, Hawk ET. Cancer prevention: from 1717 to milestones of past 100 years. *Cancer Res*. 2009;69:5269–84. Epub 2009 Jun 2.
94. William Jr WN, Lee JJ, Lippman SM, Martin JW, Chakravarti N, Tran HT, et al. High-dose fenretinide in oral leukoplakia. *Cancer Prev Res*. 2009;2:22–6.
95. Papadimitrakopoulou VA, Lee JJ, William Jr WN, et al. Randomized trial of 13-*cis* retinoic acid compared with retinyl palmitate with or without beta-carotene in oral premalignancy. *J Clin Oncol*. 2009;27:599–604.
96. Blot WJ, Li JY, Taylor PR, Guo W, Dawsey S, Wang GO, et al. Nutrition intervention trials in Lixian, China: supplementation with specific vitamin/mineral combinations, cancer incidence, and disease-specific mortality in the general population. *J Natl Cancer Inst*. 1993;85:1483–92.
97. Li JY, Taylor PR, Dawsey S, Wang GO, Ershow AG, Guo W, et al. Nutrition intervention trials in Linxian, China: multiple vitamin/mineral supplementation, cancer incidence, and disease-specific mortality among adults with esophageal dysplasia. *J Natl Cancer Inst*. 1993;85:1492–8.
98. The Alpha-Tocopherol, Beta-Carotene Cancer Prevention Group. The effects of vitamin E and beta-carotene on the incidence of lung cancer and other cancers in male smokers. *N Engl J Med*. 1994;330:1029–35.
99. Albanes D, Heinonen OP, Taylor PR, Virtamo J, Edwards BK, Rautalahti M, et al. Alpha-tocopherol and beta-carotene supplements and lung cancer incidence in the alpha-tocopherol, beta-carotene cancer prevention study: effects of base-line characteristics and study compliance. *J Natl Cancer Inst*. 1996;88:1560–70.
100. Virtamo J, Pietinen P, Huttunen JK, Korhonen P, Malila N, Virtanen MJ, et al. Incidence of cancer and mortality following alpha-tocopherol and beta-carotene supplementation: a post intervention follow-up. *JAMA*. 2003;290:476–85.
101. Omenn GS, Goodman GE, Thornquist MD, Balmes J, Cullen MR, Glass A, et al. Effects of a combination of beta-carotene and vitamin A on lung cancer and cardiovascular disease. *N Engl J Med*. 1996;334:1550–5.
102. Omenn GS, Goodman GE, Thornquist MD, Balmes J, Cullen MR, Glass A, et al. Risk factors for lung cancer and for intervention effects in CARET, the Beta-Carotene and Retinol efficacy Trial. *J Natl Cancer Inst*. 1996;88:1550–9.
103. Goodman GE, Thornquist MD, Balmes J, Cullen MR, Glass A, Keogh JP, et al. The Beta-Carotene and Retinol Efficacy Trial: incidence of lung cancer and cardiovascular disease mortality during 6-year follow-up after stopping beta-carotene and retinol supplements. *J Natl Cancer Inst*. 2004;96:1743–50.
104. Lin J, Cook NR, Albert C, Zaharris E, Graziano JM, Van Denburgh M, et al. Vitamins C and E and beta carotene supplementation and cancer risk: a randomized controlled trial. *J Natl Cancer Inst*. 2009;101:14–23. Epub 2008 Dec 30.
105. Ito Y, Wakai K, Ozasa K, Watanabe Y, Seki N, Ando M, et al. Lung cancer mortality and serum levels of carotenoids, retinol, tocopherols, and folic acid in men and women: a case control study nested in the JACC Study. *J Epidemiol*. 2005;15 Suppl 2:S140–9.
106. Huang HY, Caballero B, Chang S, Alberg AJ, Semba RD, Schneyer CR, et al. The efficacy and safety of multivitamin and mineral supplement use to prevent cancer and chronic disease in adults: a systematic review for a national Institutes of Health state-of-the-science conference. *Ann Intern Med*. 2006;145:372–85. Epub 2006 Jul 31.
107. Greenwald P, Anderson D, Nelson SA, Taylor PR. Clinical trials of vitamin and mineral supplements for cancer prevention. *Am J Clin Nutr*. 2007;85:314S–7.
108. Bardia A, Tleyeh IM, Cerhan JR, Sood AK, Limburg PJ, Montori VM. Efficacy of antioxidant supplementation in reducing primary cancer incidence and mortality: systematic review and meta-analysis. *Mayo Clin Proc*. 2008;83:23–34.
109. Bielakovic G, Nikolova D, Gluud LL, Simonetti RG, Gluud C. Antioxidant supplements for prevention of mortality in healthy participants and patients with various diseases. *Cochrane Database Syst Rev*. 2008;2:CD007176.
110. Erlotinib Prevention Oral Cancer (EPOC). <http://www.clinicaltrials.gov/ct2/results>. Accessed 9 Sept 2009.
111. Shin DM, Khuri FR, Murphy B, Garden AS, Clayman G, Francisco M, et al. Combined interferon- α , 13-*cis*-retinoic acid, and alpha-tocopherol in locally advanced head and neck squamous cell carcinoma: novel bioadjuvant phase II trial. *J Clin Oncol*. 2001;19:3010–7.
112. Armstrong WB, Wan XS, Kennedy AR, Taylor TH, Meyskens Jr FL. Development of the Bowman-Birk inhibitor for oral cancer chemoprevention and analysis of Neu immune-histochemical staining intensity with Bowman-Birk inhibitor concentrate treatment. *Laryngoscope*. 2003;113:1687–702.
113. Rudin CM, Cohen EE, Papadimitrakopoulou VA, Silverman Jr S, Recant W, El-Naggar AK, et al. An attenuated adenovirus, ONYX-015, as mouthwash therapy for premalignant oral dysplasia. *J Clin Oncol*. 2003;21:4546–52.
114. Papadimitrakopoulou VA, William Jr WN, Dannenberg AJ, Lippman SM, Lee JJ, Ondrey FG, et al. Pilot randomized phase II study of celecoxib in oral premalignant lesions. *Clin Cancer Res*. 2008;14:2095–101.
115. Mulshine JL, Atkinson JC, Greer RO, Papadimitrakopoulou VA, Van Waes C, Rudy S, et al. Randomized, double-blind, placebo-controlled phase I trial of the cyclooxygenase inhibitor ketorolac as an oral rinse in oropharyngeal leukoplakia. *Clin Cancer Res*. 2004;10:1565–73.
116. Gillespie MB, Moody MW, Lee FS, Poole LJ, Hornig JD, Lathers D, et al. Head and neck cancer recurrence and mortality in nonselective cyclooxygenase inhibitor users. *Arch Otolaryngol Head Neck Surg*. 2007;133:28–31.

117. Heath EI, Canto MI, Piantadosi S, Montgomery E, Weinstein WM, Herman JG, et al. Secondary chemoprevention of Barrett's esophagus with celecoxib: results of a randomized trial. *J Natl Cancer Inst.* 2007;99:545–57.
118. Bosetti C, Gallus S, La Vecchia C. Aspirin and cancer risk: an updated quantitative review to 2005. *Cancer Causes Control.* 2006;17:871–8.
119. Jayaprakash V, Rigual NR, Moysich KB, Loree TR, Nasca MA, Menezes RJ, et al. Chemoprevention of head and neck cancer with aspirin: a case control study. *Arch Otolaryngol Head Neck Surg.* 2006;132:1231–6.
120. Chemoprevention of head and neck cancers. <http://www.clinicaltrials.gov/ct2/results>. Accessed 15 Sept 2009.
121. Thornquist MD, Urban N, Tseng A, Edelstein C, Lund B, Omenn GS. Research cost analysis to aid in decision making in the conduct of a large prevention trial, CARET. Carotene and Retinol Efficacy Trial. *Control Clin Trials.* 1993;14:325–39.
122. Valanis B, Blank J, Glass A. Mailing strategies and costs of recruiting heavy smokers in CARET, a large chemoprevention trial. *Control Clin Trials.* 1998;19:25–38.
123. Szabo E. Assessing efficacy in early-phase cancer prevention trials: the case of oral premalignancy. *Cancer Prev Res.* 2008;1:312–5.
124. Khuri FR, Shin DM. Head and neck cancer chemoprevention gets a shot in the arm. *J Clin Oncol.* 2008;26:345–7.
125. Takes RP, Rinaldo A, Rodrigo JP, Devaney KO, Fagan JJ, Ferlito A. Can biomarkers play a role in the decision about treatment of the clinically negative neck in patients with head and neck cancer? *Head Neck.* 2008;30:525–38.
126. Greenberg JS, Fowler R, Gomez J, Mo V, Roberts D, El Naggar AK, et al. Extent of extracapsular spread: a critical prognosticator in oral tongue cancer. *Cancer.* 2003;97:1464–70.
127. Greenberg JS, El Naggar AK, Mo V, Roberts D, Myers JN. Disparity in pathologic and clinical lymph node staging in oral tongue carcinoma. Implication for therapeutic decision making. *Cancer.* 2003;98:508–15.
128. Woolgar JA, Rogers SN, Lowe D, Brown JS, Vaughan ED. Cervical lymph node metastasis in oral cancer: the importance of even microscopic extracapsular spread. *Oral Oncol.* 2003;39:130–7.
129. Brazilian Head and Neck Cancer Study Group. Results of a prospective trial on elective modified radical classical vs. supraomohyoid neck dissection in the management of oral squamous cell carcinoma. *Am J Surg.* 1998;176:422–7.
130. Woolgar JA. Pathology of the N0 neck. *Br J Oral Maxillofac Surg.* 1999;37:205–9.
131. Russolo M, Giacomarra V, Papanikolla L, Tirelli G. Prognostic indicators of occult metastases in oral cancer. *Laryngoscope.* 2002;112:449–52. Corrected and republished in: *Laryngoscope.* 2002;112:1320–1323.
132. Myers JN, Greenberg JS, Mo V, Roberts D. Extracapsular spread. A significant predictor of treatment failure in patients with squamous cell carcinoma of the tongue. *Cancer.* 2001;92:3030–6.
133. O'Brien CJ, Lauer CS, Fredricks S, Clifford AR, McNeil EB, Bagia JS, et al. Tumor thickness influences prognosis of T1 and T2 oral cavity cancer but what thickness? *Head Neck.* 2003;25:937–45.
134. Frech S, Hommann K, Riedel F, Gotte K. Lymphatic vessel density in correlation to lymph node metastasis in head and neck squamous cell carcinoma. *Anticancer Res.* 2009;29:1675–9.
135. Sugiura T, Inoue Y, Matsuki R, Ishii K, Takahashi M, Abe M, et al. VEGF-C and VEGF-D expression is correlated with lymphatic vessel density and lymph node metastasis in oral squamous cell carcinoma: implications for use as a prognostic marker. *Int J Oncol.* 2009;34:673–80.
136. Cabanillas R, Llorente JL. The Stem Cell Network model: clinical implication in cancer. *Eur Arch Otolaryngol.* 2009;266:161–70. Epub 2008 Sep 20.
137. MacDougall JR, Matrisian LM. Contributions of tumor and stromal matrix metalloproteinases to tumor progression, invasion and metastasis. *Cancer Metastasis Rev.* 1995;14:351–62.
138. Rosenthal EL, Matrisian LM. Matrix metalloproteinases in head and neck cancer. *Head Neck.* 2006;28:639–48.
139. Rosenthal EL, Johnson TM, Allen ED, Apel IJ, Punturieri A, Weiss SJ. Role of the plasminogen activator and matrix metalloproteinase systems in epidermal growth factor- and scatter factor-stimulated invasion of carcinoma cells. *Cancer Res.* 1998;58:5221–30.
140. O-charoenrat P, Sarkaria I, Talbot GS, Reddy P, Dao S, Ngai I, et al. SCCRO (DCUN1D1) induces extracellular matrix invasion by activating matrix metalloproteinase 2. *Clin Cancer Res.* 2008;14:6780–9.
141. O-charoenrat P, Rhys-Evans PH, Eccles S. Expression of matrix metalloproteinases and their inhibitors correlates with invasion and metastasis in squamous cell carcinoma of the head and neck. *Arch Otolaryngol Head Neck Surg.* 2001;127:813–20.
142. Peterson JT. Matrix metalloproteinase inhibitor development and the remodeling of drug discovery. *Heart Fail Rev.* 2004;9:63–79.
143. McIntyre JO, Fingleton B, Wells KS, Piston DW, Lynch CC, Gautam S, et al. Development of a novel fluorogenic proteolytic beacon for in vivo detection and imaging of tumour-associated matrix metalloproteinase-7 activity. *Biochem J.* 2004;377:617–28.
144. Bertini I, Calderone V, Cosenza M, Fragai M, Lee YM, Luchinat C, et al. Conformational variability of matrix metalloproteinases: beyond a single 3D structure. *Proc Natl Acad Sci USA.* 2005;102:5334–9.
145. Okada A, Bellocq JP, Rouyer N, Chenard MP, Rio MC, Chambon P, et al. Membrane-type matrix metalloproteinase (MT-MMP) gene is expressed in stromal cells of human colon, breast, and head and neck carcinomas. *Proc Natl Acad Sci USA.* 1995;92:2730–4.
146. Thomson PJ, Hamadah O, Goodson ML, Cragg N, Booth C. Predicting recurrences after oral precancer treatment: use of cell cycle analysis. *Br J Maxillofac Surg.* 2008;46:370–5. Epub 2008 Feb 20.
147. Pignataro L, Sambataro G, Pagani D, Pruneri G. Clinico-prognostic value of D-type cyclins and p27 in laryngeal cancer patients: a review. *Acta Otolaryngol Ital.* 2005;25:75–85.
148. Lothaire P, de Azambuja E, Dequanter D, Lalami Y, Sotiriou C, Andry G, et al. Molecular markers of head and neck squamous cell carcinoma: promising signs in need of prospective evaluation. *Head Neck.* 2006;28:256–69.
149. Joo KH, Jung CK, Kim MS, Sun DI. Relationship between vascular endothelial growth factor and Notch1 expression and lymphatic metastasis in tongue cancer. *Otolaryngol Head Neck Surg.* 2009;140:512–8.
150. Boonkitticharoen V, Kulapaditharom B, Leopairut J, Kraiphikul P, Larbcharoensub N, Cheewaruangroj W, et al. Vascular endothelial growth factor a and proliferation marker in prediction of lymph node metastasis in oral and pharyngeal squamous cell carcinoma. *Arch Otolaryngol Head Neck Surg.* 2008;134:1305–11.
151. Agra IM, Carvalho AL, Pinto CA, Martins EP, Filho JG, Soares FA, et al. Biological markers and prognosis in recurrent oral cancer after salvage surgery. *Arch Otolaryngol Head Neck Surg.* 2008;134:743–9.
152. Hensen EF, De Herdt MJ, Goeman JJ, Oosting J, Smit VT, Cornelisse CJ, et al. Gene-expression of metastasized versus non-metastasized primary head and neck squamous cell carcinoma: a pathway-based analysis. *BMC Cancer.* 2008;8:168–78.
153. Chen ZG. Exploration of metastasis-related proteins as biomarkers and therapeutic targets in the treatment of head and neck cancer. *Curr Cancer Drug Targets.* 2007;7:613–22.
154. Yang MH, Chang SY, Chiou SH, Liu CJ, Chi CW, Chen PM, et al. *Oncogene.* 2007;26:1459–67. Epub 2006 Aug 28.

155. Cromer A, Charles A, Millon R, Ganguli G, Chalmel F, Lemaine F, et al. Identification of genes associated with tumorigenesis and metastatic potential of hypopharyngeal cancer by microarray analysis. *Oncogene*. 2004;23:2484–98.
156. Carinci F, Lo Muzio L, Piattelli A, Rubini C, Chiesa F, Ionna F, et al. Potential markers of tongue tumor progression selected by cDNA microarray. *Int J Immunopathol Pharmacol*. 2005;18:513–24.
157. Lippman SM, Heymach JV. The convergent development of molecular-targeted drugs for cancer treatment and prevention. *Clin Can Res*. 2007;13:4035–41.
158. Walboomers JM, Jacobs MV, Manos MM. Human papillomavirus is a necessary cause of invasive cervical cancer worldwide. *J Pathol*. 1999;189:12–9.
159. Finch JT, Klug A. Papillomaviruses in the causation of human cancers – a brief historical account. *Virology*. 2009;384(2):260–5. Epub 2009 Jan 8.
160. Herrero R, Castellsague X, Pawlita M. Human papillomavirus and oral cancer: the International Agency for Research on Cancer multicenter study. *J Natl Cancer Inst*. 2003;95:1772–83.
161. Gillison ML, Koch WM, Capone RB. Evidence for a causal association between human papillomavirus and a subset of head and neck cancers. *J Natl Cancer Inst*. 2000;92:709–20.
162. Smith EM, Ritchie JM, Summersgill KF. Age, sexual behavior and human papillomavirus infection in oral cavity and oropharyngeal cancers. *Int J Cancer*. 2004;108:766–72.
163. Hansson BG, Rosenquist K, Antonsson A. Strong association between infection with human papillomavirus and oral and oropharyngeal squamous cell carcinoma: a population-based case-control study in southern Sweden. *Acta Otolaryngol*. 2005;125:1337–44.
164. Mork J, Lie AK, Glatte E. Human papillomavirus infection as a risk factor for squamous-cell carcinoma of the head and neck. *N Engl J Med*. 2001;344:1125–31.
165. D'Souza G. Case-control study of human papillomavirus and oropharyngeal cancer. *N Engl J Med*. 2007;356:1944–56.
166. Smith EM, Ritchie JM, Pawlita M, Rubenstein LM, Haugen TH, et al. Human papillomavirus seropositivity and risks of head and neck cancer. *Int J Cancer*. 2007;120:825–32.
167. Weinberger PM. Molecular classification identifies a subset of human papillomavirus-associated oropharyngeal cancers with favourable prognosis. *J Clin Oncol*. 2006;24:736–47.
168. Gillison ML. Human papillomavirus and prognosis of oropharyngeal squamous cell carcinoma: implications for clinical research in head and neck cancers. *J Clin Oncol*. 2006;24:5623–5.
169. Lindel K, Beer KT, Laissue J. Human papillomavirus positive squamous cell carcinoma of the oropharynx: a radiosensitive subgroup of head and neck carcinoma. *Cancer*. 2001;92:805–13.
170. Fakhry C, Westra WH, Li S. Improved survival of patients with human papillomavirus-positive head and neck squamous cell carcinoma in a prospective clinical trial. *J Natl Cancer Inst*. 2008;100:261–9.
171. Nichols AC, Faquin WC, Westra WH, Mroz EA, Begum S, et al. HPV-16 infection predicts treatment outcome in oropharyngeal squamous cell carcinoma. *Otolaryngol Head Neck Surg*. 2009;140:228–34.
172. Harper DM, Franco EL, Wheeler CM. Sustained efficacy up to 4.5 years of a bivalent L1 virus-like particle vaccine against human papillomavirus types 16 and 18: follow-up from a randomised control trial. *Lancet*. 2006;367:1247–55.
173. Mao C, Koutsky LA, Ault KA. Efficacy of human papillomavirus-16 vaccine to prevent cervical intraepithelial neoplasia: a randomized controlled trial. *Obstet Gynecol*. 2006;107:18–27.
174. Reisinger K, Block SL, Lazcano-Ponce E. Safety and persistent immunogenicity of a quadrivalent vaccine in preadolescents and adolescents: a randomized controlled trial. *Pediatr Infect Dis J*. 2007;26:201–9.
175. Greenwald P. The future of cancer prevention. *Semin Oncol Nurs*. 2005;21:296–8.
176. Abbruzzese JL, Lippman SM. The convergence of cancer prevention and therapy in early-phase clinical drug development. *Cancer Cell*. 2004;6:321–6.

Chapter 3

Cellular and Molecular Pathology of Head and Neck Tumors

Adel K. El-Naggar

Abstract Head and neck pathology encompasses a multitude of organs of diverse histogenesis. Malignancies arising from head and neck sites accordingly are diverse in origins, morphogenesis, and biological behavior. Excluding connective tissue and vascular entities, the main entities that are presented in this chapter include squamous mucosal sites, salivary, thyroid and sinonasal, and skull base tumors. The histopathological classification remains the main reference to the diagnosis and to a large extent, malignancy grading. Advances in immunohistochemical techniques and the development of reagents to cellular intermediate filaments and lineage markers have led to better diagnosis and categorization of undifferentiated entities with overlapping morphologic features. More recently, major strides have been achieved in the molecular genetic characterization and understanding of head and neck tumorigenesis. Although clinically applicable and validated molecular biomarkers have yet to be realized, it is important to address the recent discoveries and their potential integration with the phenotypic and pathologic features.

This chapter concisely presents the relevant pathomorphologic and molecular features of the tumors of the major head and neck sites for clinical management.

Keywords Head and neck squamous carcinoma • Molecular genetics • Squamous tumorigenesis • Tumor heterogeneity

Squamous Mucosal Carcinogenesis

Head and neck squamous carcinoma (HNSC) is the fifth most common cancer worldwide with approximately 500,000 new cases per year. They develop from the squamous mucosal

lining of the upper respiratory tract mainly in individuals with a history of abusing risk factors, including cigarette smoking, alcohol abuse, and human papillomavirus. Only 20% of individuals with these risk factors, however, develop squamous carcinoma [1, 2].

Head and neck mucosal sites are an ideal model of investigating the molecular genetic alterations leading to squamous carcinoma development because of their readily accessible location, association with known risk factors, and the presence of defined histopathologic progression stages. In contrast to other major cancer types, HNSC lacks familial inheritance, is difficult to cultivate and there are no faithful animal models to advance research and development in this field [1].

Squamous tumorigenesis is thought to result from successive accumulation of molecular genetic alterations in the squamous epithelium lining the upper aerodigestive tract [1, 2]. Although the temporal occurrence and the order of these events are largely unknown, some certainly precede the phenotypic changes associated with preinvasive dysplastic lesions. The progression of late stage dysplasia to invasive carcinoma is a complex one and comprised of both cellular and structural changes as a result of dysregulation of key pathways triggered by interaction of epithelium and the host stromal elements [3] (Fig. 3.1).

Histopathology

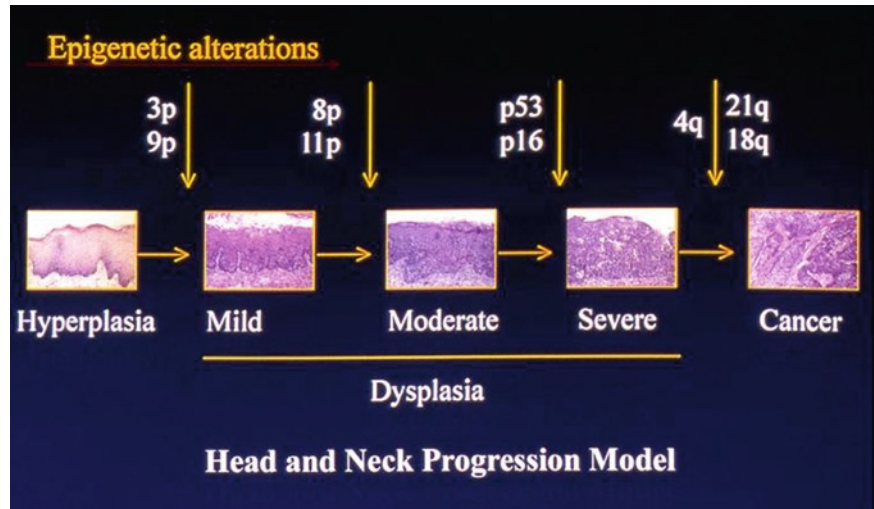
The diagnosis and management of head and neck mucosal lesions are based on the histopathologic assessment of biopsied or excised specimens.

Oral Premalignant Lesions

These lesions are recognized as grossly abnormal mucosa of no definitive etiology and can broadly be classified into leukoplakia (white) and erythroplakia (red). The risk of developing

A.K. El-Naggar (✉)
Department of Pathology, The University of Texas
M.D. Anderson Cancer Center, 1515 Holcombe Blvd., Unit 085,
Houston, TX 77030, USA
e-mail: anaggar@mdanderson.org

Fig. 3.1 Phenotypic and molecular progression model of head and neck squamous tumorigenesis



invasive carcinoma from these lesions varies greatly and range from 3 to 16% for leukoplakia and from 30 to 50% for erythroplakia [2].

Leukoplakia

Leukoplakia is defined as a persistent white area of unknown etiology. These lesions may present as either discrete homogenous or delimited nonhomogenous forms. Generally, the nonhomogenous lesions are associated with higher risk than their homogenous counterparts. The majority of leukoplakias develop in tobacco consuming individuals and their location and appearance varies according to the geographic location and the manner and nature of the tobacco consumption. A definitive diagnosis is based on the histopathological evaluation of lesional biopsy and serves to rule out mimics, such as Lichen Planus and to assess the presence or absence of dysplasia [2]. Histologically, leukoplakia is characterized by epithelial hyperplasia with hyperkeratosis and/or parakeratosis. The development of dysplasia in these lesions is heralded by progressive alteration of the squamous epithelium manifested by changes in basal cell polarity and cellular and nuclear features and is graded as mild, moderate, or severe based on the extent of the dysplastic cellular features.

Erythroplakia

Erythroplakia is defined as a grossly red squamous mucosa. They present as either homogenous or nonhomogenous red mucosa with and without leukoplakia association. Erythroplakia represents the end stage of dysplasia histologically and carries the highest risk of progression to invasive squamous carcinoma. Both severe dysplasia and microinva-

sive carcinoma (>3 mm) are generally treated with complete excision without neck dissection. Lesions with more than 5 mm invasion are eligible for neck dissection [2].

Squamous Carcinoma Variants

Squamous carcinoma manifests multiple, distinct phenotypes with variable site predilections and biological behaviors and include verrucous, papillary, basaloid, and sarcomatoid phenotypes [5].

Verrucous Hyperplasia

Verrucous hyperplasia grossly appears as a white, warty raised growth mainly in the oral cavity. Both verrucous hyperplasia and carcinoma share clinically and pathologically similar and overlapping features. Verrucous hyperplasia shows exophytic growth with minimal inward stromal involvement. A diagnosis can only be achieved by an excisional biopsy where the edges and the full depth of the lesion are represented. The histologic diagnosis, therefore, is generally arbitrary and the difference is essentially academic since both lesions should be completely excised [4].

Verrucous Carcinoma

This is a locally invasive squamous carcinoma with warty gross features and minimal cellular abnormalities. These lesions may frequently present in oral and laryngeal sites and in its pure form, has minimal metastatic potential.

Verrucous carcinoma typically affects the oral and laryngeal sites, is locally invasive and in pure form, rarely metastasizes. Histologically, these tumors are well differentiated and invade with broad pushing borders [5].

Conventional Squamous Carcinoma

This is the most common form of presentation and typically graded based on the degree of squamous epithelial alterations and state of keratinization into well, moderately and poorly differentiated carcinoma. The pattern of invasion of these lesions may also impact on the extent of invasion, metastasis, vascular, and perineural permeation. Generally, broad, invasive fronts are less ominous than finger-like invasive fronts [1].

Papillary Squamous Carcinoma

Papillary squamous carcinoma is typically laryngeal or nasal in origin and is exophytic in presentation with minimal tissue invasion. An association with HPV infection has been suggested, but remains uncertain. Papillary squamous carcinoma typically pursues less aggressive behavior than the other forms of squamous carcinoma, except the verrucous variant [5].

Basaloid Squamous Carcinoma

This is a unique high-grade variant of squamous carcinoma with a predilection for hypopharyngeal, tonsillar, and base of tongue sites. They are characterized by uniform, highly malignant basaloid cells with focal squamous differentiation and collagen-like deposition. Recently, an association with high-risk HPV infection has been reported. Morphologically, tumors are characterized by a proliferation of homogenous basaloid cells with necrosis and focal abrupt areas of luteinization. These tumors may be confused with solid adenoid cystic and neuroendocrine carcinomas [5, 6].

Sarcomatoid Squamous Carcinoma

Two forms of sarcomatoid squamous carcinoma are recognized: the exophytic form and the ulcerative invasive forms. The exophytic are usually found in laryngeal and hypopharyngeal sites and may or may not manifest areas of conventional squamous carcinoma. The distinction between this entity and pure sarcoma is based on combined morphologic and immunohistochemical staining for keratin intermediate filaments. Patients with the exophytic form may pursue a relatively better clinical course than the endophytic counterpart [7].

Viral Associated Squamous Carcinoma Subtypes

Oropharyngeal Carcinoma

Increasing evidence links HPV as an etiologic agent in the development of a subset of HNSC. Current data indicate that the majority of these cases are oropharyngeal, including the tonsils. This is further supported by the high risk of oropharyngeal carcinoma in seropositive HPV-16 and high risk of anogenital cancer patients. The exact prevalence of HPV in HNSC is not accurately known with figures ranging from 5 to >70%. These variations are related to several factors, including differences in population, tumor sites, method of HPV detection, and histological subtypes. It is clear, however, that HPV-16 is dominantly present in more than 50% of patients with oropharyngeal SCC. Integration of viral DNA into the nuclear genome is a critical step in the malignant transformation. Subsequent to viral integration, detection of early genes (E2) occurs and upregulation of E6 and E7 genes is noted. The E6 of the HPV-16 bind to the p53 suppressor genes, consequently, and lead to uncontrolled proliferation of the oropharyngeal squamous mucosa. It has also been shown that elevated expression of p16 is a surrogate marker in HPV infection. Approximately 10–60%, dependent on the population and the site of infection of HNSCs, are reported to harbor HPV. Patients with this type of tumor respond better, do not have traditional risk factors, and have better survival. E7 leads to inactivation of Rb protein and the release of the transcription factor E2F and the upregulation of both p14 and p16 proteins. Evidence for viral integration, especially in tonsillar carcinoma, in tumor cells is critical to the diagnosis. Also, the detection of p16 overexpression as an alternative/complimentary to the detection of HPV infection may be helpful. The contribution of viral load to variations in reporting these markers remains to be addressed. In one study, high viral load of <60 copies/cells was found to correlate positively with survival; however, a later subsequent larger study failed to confirm this finding [6, 8–13].

The traditional risk factors associated with conventional squamous carcinoma may play a secondary, but deleterious role in this demographic population. Only certain oncogenic subtypes of the papilloma virus, especially HPV-16 and 18, have been identified as etiologic factors in tumorigenesis of HNSC. The E6 and E7 genes of the HPV-16 genes bind to the p53 and Rb suppressor genes and upregulation of the p16-INK4 inhibitor leading to dysregulation of the cell cycle and tumor development. Interestingly, these tumors are less aggressive and more sensitive to conventional therapy than conventional squamous carcinoma.

Nasopharyngeal Carcinoma

This is a unique form of HNSC that develops in the nasopharyngeal region. They are classified based on their histological appearance into differentiated squamous carcinoma (WHO I) and undifferentiated carcinoma with lymphoid stroma (WHO II or III). The histologic features of type I are similar to well-differentiated squamous carcinoma, while the types II and III are highly undifferentiated carcinoma with integral lymphoid components. Nasopharyngeal carcinoma (NPC) is associated with Epstein–Barr virus infection especially in patients from the Orient and Middle East but less likely in patients from the Western hemisphere. These tumors are highly sensitive to radiation therapy [14].

Adverse Pathologic Features of Clinical Relevance

The following histopathologic factors are considered features associated with high risk of recurrence and failure to therapy response:

1. Poor histologic differentiation
2. Finger-like and single cell invasive pattern
3. Perineural invasion
4. Close surgical margins (<5 mm)
5. Presence of high-grade dysplasia
6. Extra nodal extension of lymph node metastasis [15]

Molecular Pathology

Cellular Concept

The molecular and biological analysis and understanding of squamous tumorigenesis of the head and neck is largely based on the concept of field characterization conceived by Slaughter et al. in 1953 [16]. This concept assumes that risk factors render the entire aerodigestive mucosal surface susceptible to the squamous carcinoma development. In the small subset of patients with no history of risk factors, and/or short temporal exposure to these factors, an inherent genetic susceptibility may play a role [1, 17, 18]. The cellular concept's premise for squamous carcinoma development and progress is that HNSC carcinoma results from molecular and/or biological alterations in the squamous epithelial cells.

DNA-Based Studies

LOH Findings

Microsatellites are short tandem repeat DNA sequences scattered throughout the genome. The vast majority of these repeats are polymorphic, inherited differently from each parent among different populations. Using constitutional DNA extracted from fresh or archived specimens as a standard, loss or shift in mobility in tumor microsatellite bands on gel electrophoresis, determines the presence or lack of microsatellites of alterations. In general, frequent loss of loci on chromosomes 3p, 9p, and 17p has been detected in premalignant squamous lesions and many constitute any early alterations that may be used in screening of high risk individuals for early detection of cancer. Other chromosomal alterations, including 4q, 6p, 8p, 11q, 13q, and 18q are typically more frequent in invasive and advanced squamous carcinomas. Chromosomal gains, in contrast, are infrequent in squamous tumorigenesis and limited to chromosomes 3q26 and 11q13 amplicons and generally are late events [18–22].

Specific Gene Findings

p53 gene: p53 is a tumor suppressor gene on chromosome 17p. It is the most frequently mutated gene in HNSC in approximately 50% of the cases. Tumors from patients with long histories of risk factor exposure are more frequently mutated. Most of the p53 mutations are transversion in type (G:T), but missense mutations can also be found and clustered between exons 5 and 9.

p16 gene: p16 is another tumor suppressor gene on chromosome 9p21. Loss of p16, a potent inhibitor of cell cycle, leads to uncontrolled proliferation. In contrast to p53, mutations of p16 are infrequent events in HNSC. Instead, hypermethylation of the p16 promoter and the first exon is the major mechanism for loss of function [23–25].

FHIT gene (Fragile histidine triad): FHIT, on the short arm of chromosome 3p14.2, has also been implicated in HNSC. However, the frequency and the temporal involvement of this gene in squamous tumorigenesis remain undefined [2].

Cyclin-D1 gene: Cyclin-D1, a critical cell cycle gene within chromosome 11p amplicon, has also been found to be highly amplified in advanced premalignant and invasive lesions. Polymorphism at this gene has been associated with high risk of developing squamous carcinoma [26].

p63 gene: P63 is a member of the p53 gene family and located on chromosome 3q29–29 region. P63 is a vital gene in normal epithelial development and has been implicated in

several epithelial tumor developments. P63 has two different promoters resulting in two different protein products, on retaining the transactivation domain (TA p63) and another lacking it ($\Delta(\delta)Np63$).

Both isotypes undergo alternative splicing at the carboxy terminal leading to six isoforms (three each) (α (alpha), β (beta), and ν (upsilon)). Studies of this gene and its main isotypes in HNSC indicate an important role in tumorigenesis, especially the ΔN isotypes. Overexpression of this isotype blocks differentiation and metastasis, promotes proliferation in HNS tumorigenesis, and may be an attractive target for therapeutic intervention in a subset of patients with these tumors [27, 28].

Epigenetic Alterations

Epigenetic alteration is the process of gene silencing by non-DNA alterations and includes cytosine methylation of the CpG islands at the promoter and/or chromatin modulation and histone acetylation. These epigenetic modifications are reversible and may be of future therapeutic value. Cytosine methylation of several tumor suppressor genes in HNSC has been the target of numerous studies. Genes that have been found to be highly methylated in HNSC include p16, MGMT, RARB, E-Cadherin, and DAPk [29, 30]. The diagnostic and therapeutic potential of these alterations remain to be achieved.

Genomic Studies

In genomic studies of HNSC using varied platforms, patient populations have recently been conducted. The inherent heterogeneity of these tumors complicates the interpretation and renders a clear conclusion difficult. Although results have shown evidence for segregating different responsive and aggressive behaviors, lymph node metastasis and tumor sites, the complexity of the analysis and the heterogeneity of tumors and biological behaviors limit the clinical utilization of these platforms [31–34].

MicroRNAs

MicroRNAs, highly conserved and ubiquitous short (18–22 nt) noncoding RNA sequences, were found to regulate gene expression posttranscriptionally by base pairing with 3'-UTR (untranslated region) of cognate RNA transcript. Dependent

on the extent of base pairing with target RNA, miRNA may lead to translational regression or degradation. Because of the partial complementarity between miRNAs and their targets, each miRNA may regulate several genes. A few recent studies of these molecules have recently been published. Several miRNAs, including miR-375 and miR-221, have been found to be significantly altered in HNSC [35, 36]. Another study of squamous carcinoma of the tongue identified 24 upregulated and 13 downregulated miRNAs. Of the most significantly upregulated, miR-184 was identified. Inhibition of the miR-184 cell lines led to decreased proliferation, downregulation of C-Myc, and induction of apoptosis. Further analysis of these molecules is warranted for their potential therapeutic use [37].

Growth Factors and Signal Transduction Pathways

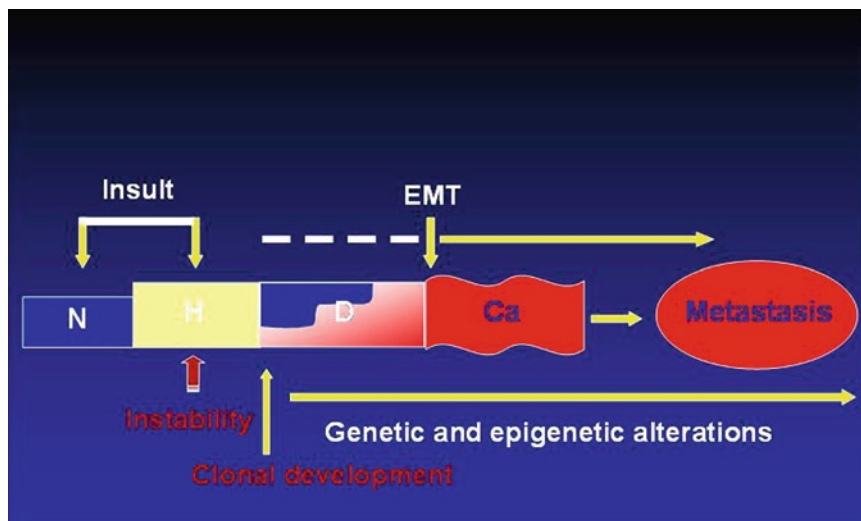
Understanding the signaling pathways, trafficking and regulation of fundamental, inter- and intracellular tumor/host interactions, will lead to understanding the biology of individual tumors and the development of effective targeted therapy in HNSC. Alterations in several growth factor receptor pathways play a critical role in the development and progression of HNSC. Several growth factors affecting signaling pathways in HNSC have been identified. These include the EGFR, Ras, NF κ B, TGF β , and PI3k/Akt/mammalian target of rapamycin (mTOR) pathways.

Epidermal Growth Factor

The epidermal growth factor (EGFR) gene is located on the short arm of chromosome 17 and encodes for a transmembrane tyrosine-kinase receptor expressed on several epithelial cells. EGFR activation is a critical early event in the development of squamous carcinoma. EGFR is a glycoprotein receptor with a cysteine-rich ligand-binding domain with short sequence and intracellular tyrosine kinase and carboxy-terminal scaffolding domains. The activation of EGFR family members is either through ligand dependence or independence.

The independent activation is the result of mutation or overexpression-induced homodimerization or heterodimerization with other Grb family members. Ligand-independent activation of EGFR in HNSC has been linked to a transition mutation, EGFR variant III (EGFRvIII). Ligand binding to the EGFR initiates phosphorylation and triggers a signal transduction cascade that result in the activation of

Fig. 3.2 Proposed model of epithelial to mesenchymal transition in squamous tumors



downstream molecules and increase in cell proliferation. Overexpression of EGFR has been amply reported in HNSC to be associated with aggressive behavior, poor progression and response to targeted anti-EGFR therapy [38–40]. Studies of mutations in the hot spot exons of this gene have yielded negative results. However, increased gene copy numbers have been reported in a subset of these tumors. Currently, immunohistochemical staining with anti-EGFR is the most commonly used method of assessment of this gene. It is unknown, however, whether the activated form (phosphorylated) or the total EGFR level correlates better with the activity and response to therapy in HNSC [41]. The interest and available data on EGFR have led to interest in the development of molecularly targeted small-molecule inhibitors in the treatment of HNSC. New anti-EGFR tyrosine-kinase activity has been used in clinical trials as single or multiple agents and modalities with limited success (response rate 10–15%). The binding by ligands (EGF, TGF2, amphiregulin, and heparin binding – EGF) leads to antiphosphorylation of multiple tyrosine residues at the carboxy terminus, where SRC and other proteins interact with transducer mitogenic signals [39].

VEGF and FGF

Elevated expression of VEGF and FGF and their receptors have been reported associated with angiogenesis and aggressive behavior in HNSC. The regulation of this growth factor is primarily through the hypoxia-inducible factor-1 α (HIF-1 α)-dependent and -independent processes and involves both PI3k and AkT pathways [42–47].

A humanized VEGF monoclonal antibody (Bevacizumab) has recently been tested and shown to inhibit angiogenesis [48, 49].

PI3k/AkT/mTOR Pathway Inhibitors

Activation of these pathways plays an important role in the development and progression of HNSC. Mutation of the PI3k gene leads to cellular transformation of HNSC. Restoration of this pathway may lead to inhibition of PI3k phosphorylation and expression, which is responsible for radio resistance in HNSCC [50]. Also, activation of the AkT pathway may lead to EGFR overexpression and enhance resistance to targeted treatment. The mTOR has been shown to regulate critical cellular processes, including motility, proliferation, survival, and transcription.

mTOR inhibition, however, may lead to negative feedback of the insulin-like growth factor, which may lead to activation of PF3k and AkT and potentially counteracting the mTOR inhibitor [51]. Multiple agents or single agents targeting multiple pathways may be an ideal strategy.

The complexity of the aberrant signaling in HNSCC underlines the difficulties in treating these patients (Fig. 3.2).

Structural Concept

Mesenchymal Epithelial Transformation

In the last two decades, minimal attention has been paid to the role of epithelial/stromal interactions of invasion, progression, and metastasis in HNSC. Recent investigations in several solid tumor models have shown that invasion and metastasis are associated with alteration in cell to cell and cell to matrix adhesion altered epithelial cell polarity and increased motility. Several studies have shown that this process is initiated in response to extracellular stimuli

and factors. Growth factors and their receptors play a central role in the transduction of key events associated with this process. Among the most important of these are the Ras, SRC, PI3k, and the MAP kinase pathways. The activation of these pathways have been shown to lead to downregulation of adhesion molecules (e.g., E-Cadherin) and elevation of surrogate mesenchymal markers (e.g., Vimentin) [3, 52, 53]. This process is highly relevant to squamous carcinoma invasion and metastasis, where E-Cadherin is a key adhesion molecule in squamous epithelial cells. E-Cadherin not only is important in cell to cell and cell basement adhesion, but also in mediating cell to cell cross-talk through Ca-dependent homotypic interactions [38, 54, 55]. Several growth factors, including TGF β , lead to downregulation of E-Cadherin and other cellular features associated with EMT. However, the manifestation of EMT in HNSC may vary considerably from tumor to tumor and within a given tumor. Not infrequently, minimal EMT changes are observed in well differentiated with broad invasive fronts while complete mesenchymal transformations is found in the sarcomatoid form of these tumors. In addition to the semiquantitative changes in these molecules, qualitative changes may also occur. This is clearly manifested in the phenotypic distribution of E-Cadherin from membranous to cytoplasmic localization.

EMT, therefore, is a dynamic and heterogeneous process that underlies the biology of a squamous carcinoma and that the degree and extent of these changes reflect their aggressive nature.

Biomarker Applications in Head and Neck Tumorigenesis

Early diagnosis in high risk individuals for HNSC is key to improving treatment and prognosis of this disease. Similarly, predicting the biological behavior, response to nonsurgical therapy and toxicity is important in stratifying patients for treatment and targeted therapy. Therefore, the identification of sensitive and reproducible markers is critical to the success of these efforts. The application of tissue-based assay requires that they accurately and reproducibly reflect the underlying pathological and biological processes. These processes are dynamically varied in and between individuals. Quantitation of lesional variabilities and confounding non-neoplastic processes is necessary for accurate interpretation and the exclusion of false positive and negative results. Integrating tissue assessment and biomarker results might ultimately be the best model of risk assessment for head and neck cancer patients [2, 24, 56].

Salivary Gland Tumors

Salivary gland tumors are rare and remarkably heterogeneous neoplasms of an uncertain histogenesis. They constitute only 2–3% of all head and neck neoplasms, with an overall incidence of approximately 2.5–3 per 100,000 persons per year [57, 58]. Major salivary glands are the most commonly afflicted sites, with 80% of tumors occurring in the parotid, 10–15% in the submandibular gland, and 5–10% in the sublingual and minor glands [59]. Most tumors (80%) of parotid gland origin are benign, whereas those arising in submandibular, sublingual, and minor glands are more often malignant. Primary malignant salivary gland neoplasms compose approximately 5–10% of all the head and neck carcinomas and 0.3% of all cancers [57]. Generally, salivary neoplasms present in middle and older age (mean age 56 years), with only 2–3% occurring in children under 10 years of age, and more commonly in males than in females [57, 60].

Salivary Tumors in Children

The majority of salivary neoplasms in children are nonepithelial and mainly of vascular origin. The most common is mucoepidermoid followed by acinic cell carcinomas forming approximately 60% of malignant neoplasms in this category. The most common benign epithelial neoplasm in this age group is pleomorphic adenoma (PA). It is worth noting that a rare congenital tumor known as embryoma or sialoblastoma occur prenatally. Histologically, these tumors represent a neoplastic growth of embryonic, primitive, basaloid epithelial cell of salivary gland. These lesions are considered low-grade malignancy. The differential diagnosis is basal cell adenocarcinoma and adenoid cystic carcinoma (ACC) [61–63].

Fine Needle Aspiration in the Evaluation of Salivary Masses

Fine needle aspiration (FNA) may be used in the initial evaluation of a salivary mass. The main indications of this procedure is to exclude lymphoreticular disorder, inflammatory and granulocytic reactive lesions and metastasis. FNA may not be recommended in the diagnosis of primary salivary gland tumors and cystic lesions. Not uncommonly, FNA may induce neurosis, reactive inflammatory, and reparative manifestations that may obscure the underlying neoplastic conditions. Occasionally, however,

especially in the planning of the extent of the operation, surgeons may utilize this technique to obtain a malignant diagnosis.

Pathologic features of clinical importance:

1. Tumor size
2. Histologic diagnosis
3. Malignancy grade (when applicable)
4. Margin status
5. Perineural involvement

Histopathology

Table 3.1.

Benign Tumors

Pleomorphic Adenomas

PAs are the most common benign salivary tumors that primarily occur in the parotid. Clinically, these tumors pursue a benign clinical course with a tendency for local recurrence due to mainly nodular extension. Rarely, some PAs may metastasize while retaining their benign phenotypic features. Histologically they manifest varied cellular components, comprising epithelial and myoepithelial cells in variable background of myxoid and/or chondroid stroma [57, 64–66].

Karyotypic analyses have identified recurrent and specific cytogenetic abnormalities, with t(3;8) (p21;q12) reported in more than 40%, and a small subset manifesting rearrangements of the 12q14-15 region [67]. The latter include translocation involving 12q14-15 with chromosome 9p12 or different partners and/or inversion of both chromosomes at the same breakpoint. Random clonal abnormalities have also been detected in more than 20% of PAs [68, 69]. Molecular studies using microsatellite repeat markers reported frequent

loss of heterozygosity at the long arm of chromosomes 8 and 12p loci [67, 70]. Two specific genetic markers have been consistently identified in PAs; the PLAG1 on chromosome 3p21 is the most frequent upregulated gene, but its biological significance in the development of pleomorphic adenoma remains uncertain [71].

The second recurrent and specific chromosomal alteration involving 12q14-15, leads to overexpression of the high mobility group A2 gene (HMGA2). The gene is an architectural factor that regulates transcription through binding to AT-rich DNA. Microarray analysis of PA and PLAG1-transfected cells have identified most of the unregulated genes to be growth factors, such as IGF, BDGF1, CRABP2, SMARCD1, and EFNBI [72]. Together these findings indicate that the PLAG1 gene contributes to oncogenesis through the induction of growth factors [73].

Warthin's and Oncocytic Tumors

Warthin's tumor (WT) is the second most common benign salivary gland tumor. It arises almost exclusively in intra- or periparotid lymphoid stroma. Histopathologically, the tumor manifests oncocytic epithelial cell proliferation within lymphoid stroma with and without cystic formation. A spectrum of oncocytic tumors ranging from nodular oncocytic hyperplasia, adenoma, and carcinoma have been described and most likely related to Warthin's tumors [74]. Current molecular and cytogenetic studies indicate that the majority of these lesions manifest a normal karyotype [75], while approximately 10% have cytogenetic abnormalities; the most common cytogenetic alteration identified is the t(11;19) (q21-22;p13) [76, 77]. The same translocation and its fusion gene product *CRTC1/MAML2* were also found in mucoepidermoid carcinoma (MEC). The finding of this abnormality in both tumors, along with their reported simultaneous occurrence, indicates a genetic link between these lesions. Collectively, the data support a clonal origin in a subset of these tumors with a propensity to transformation to MEC or oncocytic carcinoma.

Basal Cell Tumors

Both basal cell adenomas and carcinomas are rare and constitute approximately 2–3% of all salivary gland tumors. These tumors may not infrequently pose diagnostic difficulties due to their cytomorphologic similarities. They are typically formed of bland basal cell proliferation in nests and/or cords formation with intercellular eosinophilic homogenous material deposition [78]. Because of the infrequency of these tumors, only small numbers have been genetically analyzed; a common cytogenetic alteration in few tumors was a trisomy

Table 3.1 A simplified classification of salivary gland tumors

Myoepithelial/epithelial	Epithelial
Benign	
Myoepithelioma	Oncocytoma
Pleomorphic adenoma	Basal cell adenoma
Malignant (carcinoma)	
Myoepithelial	Mucoepidermoid
Epi-myoepithelial	Salivary duct
Basaloid salivary	Adenoid cystic, solid
Adenoid cystic	Basaloid salivary
Terminal duct	Acinic cell

8, but other sporadic cytogenetic alterations, including t(7;13) translocation, have also been reported [79]. CGH analyses of examples of these tumors showed loss of chromosomes 2, 6, and 7, gains of chromosomes 1 and 8, and amplification of 12q region. Molecular analysis of these tumors has reported frequent loss of heterozygosity at chromosome 16q12-13, a region that houses the cylindromatosis gene (CYLD) [79].

Canalicular Adenoma

Canalicular adenoma is characterized by columnar epithelial cells forming anastomosing bilayered cellular formations including nests and is trabecular in a vascular stroma. The lesions are typically well circumscribed and encapsulated [57, 65]. Differential diagnosis of canalicular adenoma from basal cell adenoma and ACC may occasionally be difficult, especially on biopsy specimens. Because of their rarity and benign nature, molecular studies of this entity are very rare.

Myoepithelial Tumor

Myoepithelial tumors are formed almost exclusively of myoepithelial cells, which are rare and are less than 1% of all salivary gland neoplasms. Some tumors may show focal areas of pleomorphic adenoma. They may manifest a variety of phenotypic forms, including plasmacytoid, spindle, clear, and/or epithelial features. Current molecular genetic data on these lesions are sparse and preclude any definitive findings that contribute to either their development or biology. Cytogenetic analyses of a few examples have reported nonspecific chromosomal abnormalities and were insufficient for comment on their contribution to these tumors [80, 81]. Upregulation of the WT1 mRNA has been detected in some benign and malignant myoepithelial tumors, but the oncogenic role of this event in their development is unknown [82].

Malignant Tumors

Mucoepidermoid Carcinoma

MECs compose approximately 30% of malignant salivary neoplasms and are most common in children and adolescents. MEC manifests three distinctive phenotypic grades based on the cellularity and architectural features of the tumors. Of all salivary neoplasms, MEC is the only entity in which both cytogenetic and molecular analyses have led to the identification of consistent unique alteration that may constitute an initiating event in the development of a subset of these tumors. Several cytogenetic analyses of MEC have shown translocation t(11;19) (q21;p13) either alone or with other nonspecific alterations [75, 83–85].

Cloning of this translocation has identified a fusion oncogene composed of exon 1 of the *MECT1* (*CRTC1/WAMTP*) gene (Fig. 3.3) on chromosome 19p13 and exons 2–5 of the *MAML2* gene on chromosome 11q21 regions [86]. *MAML2*, a member of the mastermind gene family, encodes a nuclear protein that binds to the CSL transcriptional factor and the intracellular domain of the Notch receptor to activate the Notch target gene. The fusion partner is the *CRTC1* (*MECT1*), a member of the highly conserved CRE β /cAMP coactivator gene family [87, 88]. Studies of this fusion transcript in a series of MEC have reported a correlation between fusion-positive tumors and low tumor grade and better behavior. Fusion-negative MEC may evolve from a different evolutionary pathway and may represent a biologically distinctive category. The results also suggest that tumors lacking the fusion transcript behave more aggressively. The finding of the fusion transcript in both sporadic Warthin's tumor and MEC and concomitant tumors supports an early or etiologic role in the development of a subset of these tumors. Epithelial ductal cells in heterotypic salivary tissue in intra- or paraparotid lymphoid stroma acquiring the t(11;19) fusion gene give rise to Warthin's tumor, while the same alteration in the salivary tissue gives rise to MEC in sporadic presentations.

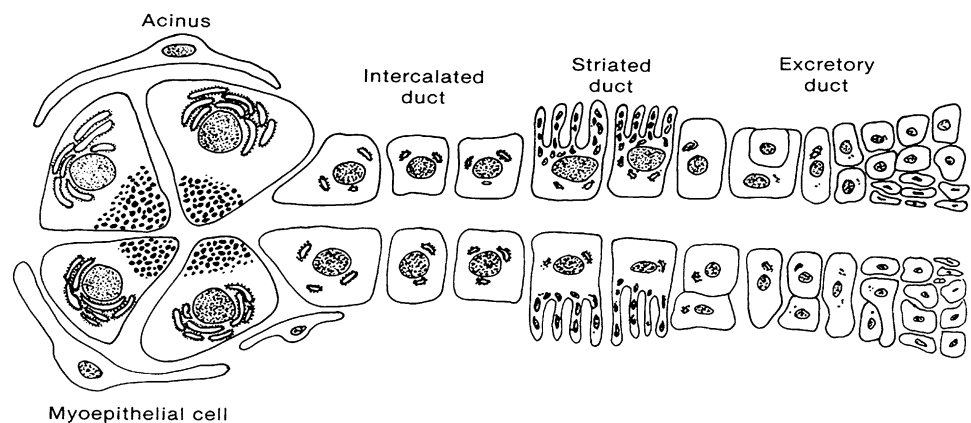


Fig. 3.3 Ductal structure and proposed origin of salivary gland tumors

The development of MEC in a Warthin's tumor may therefore result from metaplastic changes in ductal cells with the fusion transcript [89–92].

Salivary Duct Carcinoma and Adenocarcinoma Ex-Pleomorphic Adenoma

Salivary duct carcinoma (SDC) and adenocarcinomas present either de novo or in the setting of pleomorphic adenoma and manifest remarkable similarity to mammary duct carcinoma [93, 94]. Cytogenetic studies of some of these tumors have shown rearrangements of chromosome 8q12, alteration of chromosome 12q13-15 region, and amplification of both the HMG1C and MDM2 genes may be potentially associated with these tumors. Other studies have shown that translocations of chromosome 5(q22-23, q32-33) and t(10;12) (p15;q14-15) resulted in transportations of the entire HMG1C gene to chromosome 10 marker [57, 95–97].

Using microsatellite markers on microdissected benign and matching malignant components of salivary gland carcinoma ex-pleomorphic adenoma (Ca ExPA), have shown alterations at 8q and/or 12q in both components and restricted alterations at chromosome 17p loci in the malignant component [95, 96]. These findings suggest that alterations at 8q and 12q regions represent early events, whereas alteration at 17p is associated or coincident with the malignant transformation. Studies of specific genes and loci have also reported homozygous deletion of the p16 gene on chromosome 9p21 [98, 99], and p53 alterations and loss of heterozygosity at different loci on chromosome [73]. A subset of SDC, as in mammary ductal carcinoma express hormonal and growth factor overexpression that may be used in their biological and therapeutic stratification [98]. Overexpression of HER-2, EGFR, and androgen receptors are found in more than one-third of these tumors [100, 101].

Adenoid Cystic Carcinoma

ACC is the second most common malignant salivary gland tumor and the most clinically relentless malignancy. ACC is known for its indolent and persistent clinical behavior and propensity for perineural invasion. ACC manifests three phenotypic subtypes, which they nearly always present in the majority of tumors but with variable proportions [102]. These include tubular, cribriform, and the solid morphologic variants. In both the tubular and the cribriform phenotypes, the tumor units consist of myoepithelial and ductal epithelial cells. Cytogenetic studies of these tumors have reported frequent alterations at chromosomes 6p, 9p, and 17p, with the most consistent alteration at the 6q regions (Table 3.2) [99, 103].

Table 3.2 Adenoid cystic carcinoma (ACC)

Acinic cell carcinoma	Pleomorphic adenoma	Warthin's	Mucoepidermoid carcinoma
	Adenoid cystic carcinoma	Oncocytoma	Adenocarcinoma
	Monomorphic adenomas		
	Epithelial myoepithelial carcinomas		

Studies of ACC found a high frequency of loss of heterozygosity at 6q23-25, and this correlated with histologic grade and clinical behavior. Studies using microsatellite markers have also reported frequent loss at chromosomes 12q, 6q23-qter, 13q21-33, and 19q regions. These regions house two genes, PLAGL1 and LATS, that were not mutated in any of these tumors. A recent comparative genomic hybridization of ACCs identified a novel gain at chromosome 22q13 region in 30% of the tumors in addition to the loss of chromosome 6q and gains of chromosomes 16p and 17q regions [104–106]. Microarray analysis of a few examples of these tumors have shown amplification of MDM2, HMG1C, MYC, and other genes located on chromosomes 8q and 12q14 [107–109]. A frequent finding in these tumors is the overexpression of the C-Kit protein. C-Kit (CD117) is a transmembrane tyrosine kinase receptor encoded by the C-Kit gene on chromosome 4. The C-Kit ligand, a stem cell factor (also known as steel factor and mast cell growth factor) induces signal transduction pathways affecting development, cell growth, and migration of different cell functions [110–112]. The role and the cellular distribution of this gene product in the biology and as a target in these tumors remain to be determined.

Acinic Cell Carcinomas

Acinic cell carcinoma is a distinctive salivary malignancy that develops almost exclusively in the parotid gland. These tumors arise from acinar cells and manifest granular serous cellular features with variable and overlapping morphologic subtypes [113]. They are generally low-grade carcinomas, occasionally presenting as high-grade carcinomas with high mitotic figures, necrosis, and lymph node metastasis [114]. In addition, several examples of transformation into dedifferentiation or anaplastic carcinomas have been reported. Cytogenetic and molecular studies of these tumors are few and inconclusive. One study cites evidence for a frequent loss of heterozygosity at limited chromosomal regions [115], including 4p15-16, 6p25-qter, and 17p11, suggesting that these regions may contain critical genes related to their development. In another study of multiple samples of an ACC, variable clonal alterations were obtained, suggesting

multiclonal origin [116]. Studies of dedifferentiated acinic cell carcinoma have shown an association of such transformation with Cyclin D₁ upregulation. The lack of confirmatory and validation follow-up studies precludes any speculation on the role of these findings in this entity.

Polymorphous Salivary Adenocarcinoma (Terminal Duct Carcinoma)

This entity is characterized by intratumoral growth pattern variabilities and uniformed monotonous cellular composition. The hard palate is the most frequent site but they may rarely occur in major salivary glands. The tumor constitutes 19.6% of malignant minor gland tumors. Because of the lack of encapsulations, these tumors typically infiltrate adjacent tissue and are prone to perineural invasions. The recurrence rate for these tumors is approximately 17% and regional metastasis occurs in approximately 9% [117].

Epi-Myoepithelial Carcinoma

This rare entity represents a malignancy of low grade and indolent course that is composed of dual myoepithelial and ductal tumor cells. Histopathologically, the tumor forms duct and tubular formations of relatively prominent clear myoepithelial cells and inner cuboidal and uniform duct cells.

Rare Salivary Gland Neoplasms and Subjects

Squamous Carcinoma

Rarely squamous carcinoma may arise de novo in major salivary glands and if presented not underlined. The exclusion of metastasis from other sites must be proved. Rare carcinomas reported to be of primary origin include small cell and lymphoepithelial carcinoma.

Nonepithelial Neoplasms

Nonepithelial neoplasms form less than 5% of all salivary gland tumors. They represent lesions arising from salivary gland supporting connective tissue. The most common lesions are angioma, lipoma, neurofibroma, and hemangiopericytoma. The growth and microscopic features of these lesions are identical to those encountered in other sites.

Primary Lymphoma

Lymphomas are very rare and mainly found in the parotid gland. The majority of primary lymphomas are of the MALT

type. They may arise in either intraparotid lymph nodes or the parenchyma. The vast majority are of the follicular B-cell derivation with rare instances of T-cell origin.

Metastasis to Salivary Glands

The most common metastasis to major salivary glands, especially the parotid, is squamous carcinoma followed by melanoma of the skin. This is largely due to the lymphatic drainage of skin of the face. Hematogenous spread to the parotid originates primarily from kidney, breast, and lung carcinomas. Metastasis to the submandibular gland is very rare due to the lack of intraglandular lymph nodes. Epithelial neoplasms are rarer and disproportionately malignant [57].

Genomic and Proteomics of Salivary Gland Tumors

Proteomic analysis of solid tumors remains limited and difficult to execute. There is only a single study of ACC xenografts by fluorescent two-dimensional gel, electrophoresis, and matrix-assisted laser-desorption/ionization techniques. This study identified four upregulated and five downregulated proteins. Of these proteins, maspin and stathmin were confirmed to be highly expressed in human ACC. Similar attempts have been made in some salivary gland tumors. The results, however, should be considered preliminary or suspect until verified [72, 93, 118, 119].

Thyroid and Parathyroid Tumors

Thyroid

Thyroid nodules are one of the most common clinical conditions. The vast majority of these are reactive lesions or benign tumors and only 10% are malignant. Approximately 14,000 new cases of thyroid carcinomas are diagnosed per year in the USA [120]. The histologic subtypes of thyroid malignancies include papillary, follicular, poorly differentiated, anaplastic, and medullary carcinomas. Broadly, these tumors can be categorized into differentiated (papillary, follicular, and medullary) and undifferentiated (poorly differentiated and anaplastic) carcinomas [121, 122]. The papillary, follicular, poorly differentiated (insular), and the majority of anaplastic carcinomas arise from the follicular epithelial cells while the MTC is derived from parafollicular calcitonin-producing c-cells [123–126].

Etiology

The etiology of thyroid malignancies is largely unknown, although exposure to radiation during childhood (papillary) and iodine deficiency (follicular) have been linked to the development of certain carcinoma subtypes. Papillary thyroid carcinoma may affect any age, but especially children, young adults, and females. Carcinomas typically present as an enlarged mass with or without ipsilateral nodal involvement [127–130].

Initial radioscintigraphy is helpful in distinguishing between hot (benign) and cold (malignant) nodules [131].

Pathology

Cytology

Fine needle aspiration (FNA) is the first line of diagnostic techniques for thyroid tumor diagnosis. In general, an accurate diagnosis of papillary and medullary thyroid carcinoma can be readily made on FNA. The sensitivity and the specificity of FNA in diagnosing follicular lesions, including follicular variant of papillary carcinoma, however, is low. It is estimated that up to 30% of FNA-based diagnosis of follicular neoplasms are indeterminate [132, 133].

Histology

Thyroid neoplasms are generally classified based on their histogenesis from epithelial (follicular cell) and neuroectodermal (C-cell) neoplasms. Epithelial neoplasms are broadly benign follicular adenomas and differentiated neoplasms and poorly differentiated and anaplastic carcinomas.

Follicular Adenoma

Adenomas are characterized by a well-circumscribed nodular growth with thin encapsulation. They may present as solitary or multiple nodules at any age and gender. Microscopically, they may manifest microfollicular, trabecular, and macrofollicular forms. The main differential diagnoses for adenomas are follicular hyperplasia (Goiter) and follicular carcinoma. Oncocytic changes due to the high content of mitochondria are most likely secondary to respiratory cellular demands. The biological behavior of these neoplasms is similar to those of corresponding follicular tumors [134–136].

Differentiated Carcinomas

- *Follicular type*
Follicular carcinomas comprise approximately 5–10% of all thyroid malignancies. They generally afflict females in

their middle age than males. A high incidence of these tumors is reported in iodine deficient regions, suggesting a role for continuous TSH stimulation in the genesis of this entity. The diagnosis of this entity is based on the findings of a thick fibrous capsule and the presence of capsular and/or vascular penetration [134]. These tumors can be further classified as minimally invasive or encapsulated, if invasion did not extend beyond the capsule.

Follicular carcinoma is typically solitary and may present or be preceded by metastasis typical to bone, lung, and brain [125, 137–139].

Patients present with a single palpable cold mass with a high propensity for radioactive iodine uptake [140, 141].

- *Papillary type*
Papillary carcinoma is the most common of all thyroid carcinomas, accounting for more than 70% of these tumors. They may present at any age with peak incidence between 30 and 40 years of age. Females are far more affected than males, and young patients typically have a better and long protracted course than older patients, especially men. There is strong circumstantial evidence linking Hashimoto's thyroiditis to increased incidence of papillary thyroid carcinoma [142–144].

Papillary thyroid carcinomas are multifocal in more than 75% of the cases and total thyroidectomy is generally the treatment of choice. Papillary thyroid carcinoma may present as a thyroid mass (80%) or as a lymph node metastasis (20%). The hallmark of papillary carcinoma is finding papillary structures lined by cuboidal or columnar cells with clear and/or cleaved nuclei. The nuclear features are especially helpful in the diagnosis of the follicular variant of this entity. Not uncommonly present (40%) is the concentric calcification associated with this tumor (psammoma bodies). Several histopathologic variants of this entity have been described with some being associated with a more aggressive clinical course. However, the lack of prospective studies with long-term follow-up render the significance of these subtypes tenuous. The clinical aggressiveness of papillary thyroid carcinoma varies depending on the gender, age, and size of the tumor with older males having a more aggressive course as well as patients with large invasive tumors [120, 126].

- *Undifferentiated carcinomas*
 - (a) *Poorly differentiated*
This histologic variant represents a tumor that lacks follicular or papillary differentiation and the cellular anaplasia of anaplastic carcinoma. Tumors typically manifest cell nests or cords with monotonous cellular features. The differential diagnosis is mostly with medullary thyroid carcinoma. Tumor cells react positively to antithyroglobulin antibodies and they are negative for calcitonin. Their behavior is considered more aggressive than the fully differentiated tumors [122, 145].

(b) *Anaplastic*

Anaplastic thyroid carcinoma (ATC) is the most clinically aggressive neoplasm and accounts for 4–10% of all thyroid malignancies. This entity afflicts elderly individuals and is more common in females than males (3:1) [146, 147].

Clinically, patients present with rapidly progressive local disease. The majority of these tumors arise from preexisting differentiated thyroid carcinoma, most commonly the papillary phenotype. In resected specimens of these tumors, evidence for a differentiated carcinoma can be found. The etiology of ATC is unknown, but previous radiation of thyroid lesions has been linked to the development of these tumors. Histopathologically, these tumors manifest highly malignant tumor cell composition with heterogeneous features and tumor necrosis. The most common pathologic phenotypes are sarcomatous, giant cell, and squamous variants. The differential diagnoses of these tumors include sarcomatoid carcinoma of the upper aerodigestive tract, sarcoma, and melanoma [121, 148–150]. Immunostaining assists in excluding sarcoma and melanoma. The prognosis of these patients is very poor.

• *Medullary carcinoma*

Medullary thyroid carcinoma arises from the C-cell, a neuroectodermally derived cell, and accounts for 3–10% of thyroid cancer. The tumors present in two forms: sporadic, the most common, which accounts for 70–80% and the familial form, which represents the remaining 20–30%. The tumors affect both genders equally and patients in middle age.

The familial and the sporadic forms have mutation in the RET gene, the frequency and the type of these mutations vary. Tumors in the sporadic form present with a solitary mass with/without neck enlargement and paraneoplastic syndrome. Tumors in the familial form are generally multifocal and affect the younger age and children [151, 152].

The most common location of these tumors is the lateral aspect of the upper 2/3 of the thyroid lobes, where a high aggregation of C-cells can be found. Histopathologically, tumors consist of nests and cords and organized structures composed of small to medium-sized cells with uniform nuclei. Tumor clusters are encircled by delicate vessels and fibrous tissue. Not uncommonly, deposition of dense homogenous eosinophilic materials representing amyloid deposition is noted. The amyloid nature of these materials can be verified by either congo red staining or by light microscopic birefringence [52].

Immunostaining for calcitonin and other neuroendocrine markers may be used for confirmation. The most common sites of metastasis for MTC are regional lymph nodes, lung, liver, and bone. The prognosis of MTC depends on several factors, including age, gender, size,

and stage. Generally, the young and females have better outcomes. Patients with MEN-2B have a worse outcome.

The differential diagnosis of these tumors include metastasis from neuroendocrine carcinoma, renal cell carcinoma, and microfollicular thyroid neoplasm.

• *Sclerosing mucoepidermoid carcinoma*

This is a rare malignancy of the thyroid gland, typically in association with Hashimoto's thyroiditis. It is characterized by infiltrating sclerotic stroma with infiltrating nests of squamoid cells with occasional mucinous cells. The stroma is characteristically infiltrated by numerous eosinophils.

Molecular Analysis of Thyroid Neoplasms**Genetics**

RAS gene mutations were frequently found not only in thyroid carcinomas but also in adenoma [153]. Point mutations in RAS have been linked to early thyroid tumorigenesis. Whether adenomas with RAS gene mutations represent a biologically malignant lesion remains unknown [154–157]. Rearrangements of the PPAR γ /RAX8 translocation have also been reported in follicular carcinoma and adenomas suggesting that it may constitute an early event in their development [158–162].

Several studies have also shown mutation in the RAS gene RET/PTC rearrangements on chromosome 10 and BRAF oncogene mutations in thyroid carcinoma. The frequency and the biological significance of these events are the subject of debate and remain to be determined. The most frequent of these genetic alterations is the BRAF point mutation in Exon 15 at codon 600 [129, 163–166]. This mutation has been reported in up to 70% of PTC cases.

RET mutated MTC are characterized by early onset and metastasis to lymph nodes and distant organs [152, 167]. The RET proto-oncogene encodes a receptor tyrosine kinase (RTR) that is widely expressed in neuroendocrine cells. RET point mutation in the intracellular kinase domain or extracellular occur in medullary thyroid carcinoma [171, 172]. RET gene rearrangements; however, are associated with papillary thyroid carcinoma.

The common underlying denominator in tumor growth is the constitutive activation of the RET kinase [143, 168–170]. The molecular mechanisms that result in RET activation and the pathophysiology vary widely [87].

PTC with RET gene arrangements are heterogeneous and generally indolent and rarely present with metastasis. In these tumors, chromosomal rearrangements involving the RET gene fuse the 5' end and a promoter of a gene upstream of the RET kinase domain leading to the expression of a chimeric product, a RET/PTC. RET/PTCs are localized to the

cytoplasm since they lack the NH₂ terminal sequence and the transmembrane domain of the RET gene. All NH₂-terminal fusion partners identified to date contain homodimerization domains that mediate dimerization and activation of the kinase region in RET/PTC oncoproteins [168, 169, 172–174]. Recent studies have also established the anaplastic phenotypic transformation from differentiated thyroid carcinoma through the analysis of RAS, BRAF genes [146, 147, 156, 175–177]. Galectin-3 is an antiapoptotic molecule of the B-galactoside binding lectin family. Alteration in the expression of galectin-3 has been proposed as a diagnostic marker of thyroid malignancy [131, 133, 178, 179].

Genomics

Gene expression analysis of several thyroid neoplasms have been performed. Upregulation of MET, SGRPINA, FNI, CD44, and DPP4 and downregulation of TFF3 gene have been reported in some of these studies [160, 178, 180–183]. Genomic analysis although allowed for the identification of thyroid neoplasm and the biological categorization within carcinomas, the utilization of these assays in the clinical diagnosis is limited and impractical.

Parathyroid Lesions

Parathyroid glands are derived from the third and fourth pharyngeal pouches and are recognized by the fifth to the 6 weeks of gestation. The majority of humans have two pairs of parathyroid glands. Multiples up to 10 (13%), and as few as one, have been reported in humans.

Normal glands are encapsulated, small, soft, and tan to red-brown in color. Parathyroid cells are organized in lobules with fat cells and vascular stroma. The degree of fat in normal parathyroid varies but in general is approximately 60%. Although, literally a non-neoplastic process, evidence of clonality and evolution to adenoma and carcinoma based on clonality analysis has been documented [184–187].

Parathyroid Hyperplasia

Parathyroid hyperplasia is pathologically characterized by increased parathyroid cells with reduction of fat cells in parathyroid lobules. This may occur in all four glands with a variable degree. Generally, this may signify a systemic etiology such as calcium deficiency, vitamin D alterations, or kidney diseases. Hyperplasia of the parathyroid can also be a manifestation of MEN type I syndrome. Histopathologically, they manifest diffuse or nodular cellular proliferation. The cellular feature varies and may include clear and oncocytic cytoplasm [188].

Parathyroid Adenoma

Parathyroid adenoma is a benign parathyroid gland neoplasm and is the most common cause of hyperparathyroidism accounting for more than 80% of cases. Parathyroid adenoma affects more females than males in the middle age. These lesions are considered clonal in origin and present as a single well-circumscribed nodule with a peripheral rim of parathyroid tissue [127, 189]. Adenoma is typically homogenous and contains no adipose tissue cells. Although, they may arise in any gland, they are more frequently reported in the lower glands [120].

Locally Infiltrative Parathyroid Neoplasm (Atypical Parathyroid Adenoma)

Occasionally, parathyroid neoplasms with cytomorphic features identical to those of hyperplasia or adenoma and infiltrative growth into surrounding soft tissue with intersecting fibrous bands may be encountered. The lack of high and abnormal mitotic figures, necrosis and marked cellular pleomorphism preclude a definitive malignant diagnosis. These lesions are typically prone to local recurrence because of the difficulties to completely excise them. These lesions may also be called atypical parathyroid adenoma.

Parathyroid Carcinoma

Parathyroid carcinoma is a rare, highly malignant neoplasm accounting for less than 5% of patients with hyperparathyroidism. This entity may be hormonally active or inactive [190]. The inactive carcinoma has reportedly been more aggressive. These tumors present as a solid mass that are difficult to excise due to its infiltrative nature. Histopathologically, these tumors are characterized by a proliferation of markedly pleomorphic cells, high and abnormally mitotic figures, broad intersecting fibrous bands, vascular and soft tissue invasion and necrosis. This is a surgically treated disease but more than a third of these patients experience metastasis.

Molecular Analysis of Parathyroid Lesions

Alterations in overexpression of Cyclin D and chromosome 11q13 regions have been shown to characterize parathyroid nodular hyperplasia and adenoma. Other clonal and molecular findings support a clonal basis for the development of at least a subset of these lesions. The Cyclin D and retinoblastoma glue have frequently been found in parathyroid carcinoma alterations [120, 191–193]. Mutation at the MEN1 gene on chromosome 11q13 region has been reported in up

to 50%. Genome-wide studies have also shown loss of 11q region in addition to other chromosomes [194–196].

Molecular alterations of parathyroid carcinoma are rare and inconclusive, but alterations of the retinoblastoma and the MEN1 genes have been reported. Proteins have reported to be limited to these tumors. Loss of heterozygosity and mutation of the HRPT2 gene, which encodes for the parafibrinogen has also been documented in parathyroid carcinoma and are believed to be restricted to malignancy. If validated, may have a diagnostic and therapeutic implication [197–199]. Somatic mutations as well as germline mutations of the HPRT2 have been implicated to underlie primary hyperparathyroidism [200].

Sinonasal and Skull Base Tumors

A wide spectrum of malignant neoplasms arises from the sinonasal and skull base regions. The majority of these tumors are poorly or undifferentiated malignancies and manifests overlapping features resulting in diagnostic challenges [201, 202]. Excluding tumor-like lesions like hamartomas and teratomas, the most commonly encountered benign neoplasms are Schneiderian papillomas.

Schneiderian Papillomas

Schneiderian papillomas account for 0.4–5.0% of all sinonasal tumors and are classified based on their growth and histological features into exophytic, inverted and cylindrical subtypes. The exophytic form arises predominantly in the nasal septum, but they may also occur in the nasal cavity and the maxillary sinus. They are usually solitary and rarely associated with malignant transformations. Histologically, they manifest a fibrovascular core lined by hyperplastic nonkeratinizing squamous and/or transitional epithelium. The main differential diagnosis is papillary squamous carcinoma. The latter exhibits cellular features of malignancy and stromal invasion. These lesions are prone to recurrence in up to 22–40% of the cases. Inverted papillomas comprise approximately 45% of all papillomas and are characterized by inward growth due to invagination of the epithelial components into the stroma. They commonly arise in the nasal cavity and paranasal sinuses and rarely in the septum. These lesions are also known for high recurrence rate and progression into carcinoma [203]. The epithelial lining of the inverted papilloma is commonly nonkeratinizing, stratified, squamous epithelium with vacuolation, intraepithelial microcysts, and acute inflammatory cells. Malignant transformation may present as differentiated or poorly differentiated

squamous carcinoma with and without evidence of dysplasia. The presence of keratinization is always associated with carcinoma. The differential diagnosis of inverted papilloma includes other forms of Schneiderian papilloma. Recurrence rate is approximately 45–75%. Molecular studies of these lesions are rare. However, evidence for monoclonality has been reported, but no specific genetic alterations were linked to progression [203].

Salivary Type Neoplasms

Salivary tumors arising at these locations derived from minor glands and manifest identical morphologic features to those arising in major and minor salivary glands. The difference is their uncapsulated nature and the associated difficulties in assessing margin status. The most common benign tumor is pleomorphic adenoma and the most common malignancies are adenoid cystic, mucoepidermoid and acinic cell carcinomas in descending order and adenocarcinoma, not otherwise classified. The differential diagnosis is mainly from metastasis and nonsalivary seromucinous carcinoma [202].

Nonsalivary Type Adenocarcinoma

These adenocarcinomas are classified into seromucinous type and intestinal type. The seromucinous type most likely arise from the seromucinous glands lining, the respiratory epithelium of the nasal cavity. They are typically well-differentiated adenocarcinoma. The intestinal type is similar to adenocarcinoma of the colorectal sites. These tumors arise from the respiratory epithelium most likely due to intestinal metaplasia as a result of exposure to wood dust or leather chemical processing. These tumors affect middle and elderly individuals with the aforementioned risk factors. The tumors manifest identical phenotypic features to their intestinal counterparts, including mucinous production and signet-ring formation. The biological behavior of these tumors is generally aggressive with the majority of patients succumbing to their disease within 3 years. Molecular and phenotypic studies of this entity have shown evidence for shared molecular alterations with colonic adenocarcinoma [204–208].

Squamous Carcinoma

Carcinomas of the sinonasal cavity comprise approximately 3% of all malignant tumors. The majority (70%) are squamous in derivation. The vast majority occurs in the maxillary sinus

and a small subset occurs in other nasal sites. Several etiologic factors have been linked to the development of these tumors, among which nickel and thorotrast exposure were the most commonly incriminated. These tumors typically affect men in their 50s to 60s. Histopathologically, they may present as keratinizing squamous carcinoma or nonkeratinizing [201, 209].

Other forms of squamous carcinomas as verrucous and spindle cell and basaloid squamous carcinomas have been described. The differential diagnoses of these tumors include metastasis, ameloblastomas, and inverted papilloma. The biological behaviors of this entity depend on the site and degree of differentiation with the nasal carcinoma patients fairs better than those with paranasal tumors [202].

Undifferentiated Sinonasal Carcinoma

These tumors are characterized by their lack of differentiation and affects both males and females equally. Histologically, they manifest undifferentiated carcinoma similar to those of type III NPC. These tumors run an aggressive biological course and present in advanced stage. Because of the undifferentiated nature, they may be confused with a wide variety of undifferentiated neoplasms at these sites. These include poorly differentiated squamous carcinoma, NPC, neuroblastoma, melanoma, lymphoma, and small round cell tumors. Immunohistochemical and molecular markers are important in differentiating these tumors, especially on small pretreatment biopsies [202, 210, 211].

Neuroendocrine Carcinomas

Neuroendocrine carcinomas of the sinonasal region are uncommon relative to the larynx and are classified into typical (well-differentiated) and atypical carcinoid (moderately differentiated) and poorly differentiated (small and large cell) carcinoma. The most common subtype is the poorly differentiated subtype, which typically affects the nasal cavity with extension to the ethmoid and maxillary sinuses. They affect men and women equally with a wide range of age. The diagnosis and differential diagnosis is established by performing keratin and other neuroendocrine markers [212–214].

Small Round Cell Tumors and Neuroblastoma

A host of tumors that share a small rounded and basal-like tumor cell composition is not uncommonly presented at these sites. These include neuroblastoma, rhabdomyosarcoma, neuroendocrine carcinoma (small cell), and Ewing's/

neuroectodermal tumors [215–217]. Although younger age groups are more frequently affected, older ages may also be presented with these tumors. They occur equally in both sexes. There are no known predisposing factors associated with the development of these tumors and most likely familial and genetic factors may underlie their development. The diagnosis of these tumors, especially on initial biopsy, is challenging and is largely aided by ancillary immunohistochemical and molecular markers [201, 217–221].

Sinonasal Melanoma

Primary sinonasal melanoma is very rare and accounts for 1% of all melanomas and 2.4% of nasal malignancies. The most common sites for this entity is nasal cavity and the paranasal sinuses with the most frequent sites being the nasal septum, lateral nasal wall, and the middle and inferior turbinates. Histologically, cells are small, rounded and undifferentiated and commonly manifest melanin pigment. These tumors are highly aggressive and prone to recurrence. They are typically presented at middle or older age, but they may present at any age. The differential diagnosis of this tumor includes all small round undifferentiated tumors at these locations (Fig. 3.4) [216, 222–225].

Fibrous and Vascular Neoplasms

These tumors are divided into a benign, low-grade category and include fibromatosis, fibroma, myxoma, hemangioma, Schwannoma and hemangiopericytoma and solitary fibrous tumor and low-grade fibrosarcoma. Their diagnosis is based on the histopathologic features and their treatment is largely surgical [202].

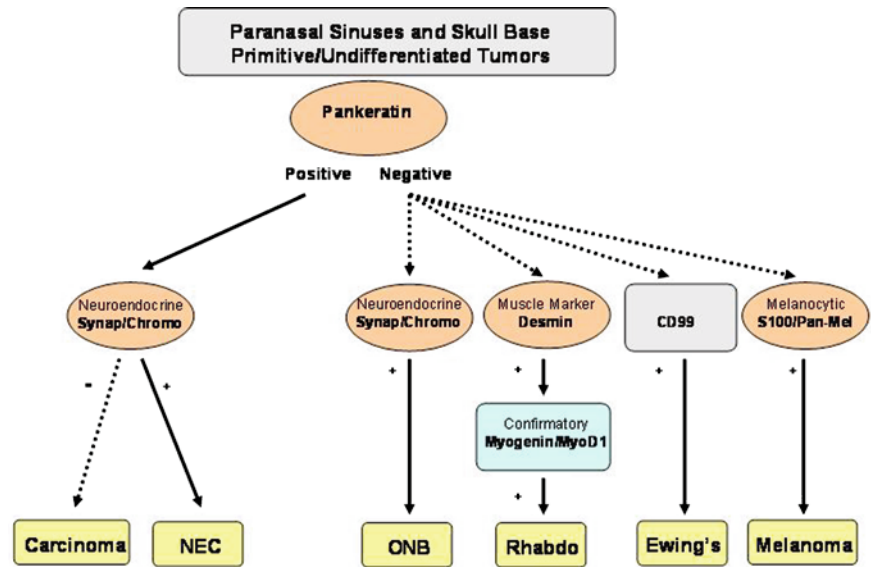
Odontogenic Tumors

Odontogenic lesions may also present in the sinonasal sites especially the maxillary sinus and includes calcifying odontogenic and tumor ameloblastoma. The most important differential diagnosis for these tumors is inverted squamous papilloma and squamous carcinoma. These tumors typically occur in young and middle age individuals and behave as benign or locally destructive tumors. Ameloblastoma may however, transform into more malignant ameloblastic carcinoma. Complete excision of these tumors is curative.

Teratocarcinosarcoma

Teratocarcinosarcoma is an extremely rare carcinoma that may lead to management difficulties. The histogenesis of

Fig. 3.4 Algorithmic marker applications for sinonasal undifferentiated neoplasms



this entity remains unsettled, but an origin from stem cell is possible. Histologically, these tumors are characterized by the presence of immature neural elements and malignant epithelial and mesenchymal tumors. The tumor affects mainly men in their middle and old age. These tumors are treated surgically with postoperative radiotherapy [226].

Lymphoproliferative Disorders

Non-Hodgkin lymphoma is the most common lymphoproliferative disease in the sinonasal tract. Of the different subtypes that represent this category, the Nk1 T-cell lymphoma is the dominant lymphoma at these sites.

T-cell lymphoma (natural killer) typically afflicts predominantly men in the middle or old age. The disease has been reported to be more common in Asians. The most common presentation is destructive mid-facial lesions with obstructive symptoms. The disease is strongly associated with EBV. Histologically, the disease is characterized by polymorphous cell infiltrate, including lymphocytes, plasma cells, histiocytes, and eosinophils with necrosis [227–231].

The differential diagnosis of this entity includes infectious conditions, especially fungal organisms, and especially Wegener's granulomatosis. The absence of EBV virus and antineutrophil cytoplasmic antibodies exclude the latter.

Molecular and Genetic

Advances in molecular genetic studies of skull-base neoplasms are limited to small round cell tumors, including Ewing's, synovial, and rhabdomyosarcomas. Specific trans-

location generating oncogenic fusion transcripts have been identified in some of these tumors and currently used in their diagnosis and management stratification. In Ewing's sarcoma and peripheral primitive neuroectodermal tumor, the EWS/FLI-1 gene resulting from the t(11;22) (q24;q12) is detected in 80% of tumors. The fusion gene has also been detected in neuroblastoma and rhabdomyosarcoma [220, 221, 232]. The PAX-FKHR fusion gene has also been used in the diagnosis and to guide treatments in alveolar rhabdomyosarcoma. Future identification of specific translocation will lead to better diagnosis and classification of other tumors.

References

1. El-Naggar AK. Pathobiology of head and neck squamous tumorigenesis. *Curr Cancer Drug Targets*. 2007;7:606–12.
2. Mao L, El-Naggar AK. Molecular changes in the multistage pathogenesis of head and neck cancer. In: Srivastava S et al., editors. *Molecular pathology of early cancer*. Amsterdam: IOS; 1999.
3. Mandal M, Myers JN, Lippman SM, et al. Epithelial to mesenchymal transition in head and neck squamous carcinoma: association of Src activation with E-cadherin down-regulation, vimentin expression, and aggressive tumor features. *Cancer*. 2008;112:2088–100.
4. Shear M, Pindborg JJ. Verrucous hyperplasia of the oral mucosa. *Cancer*. 1980;46:1855–62.
5. Choi HR, Roberts DB, Johnigan RH, et al. Molecular and clinicopathologic comparisons of head and neck squamous carcinoma variants: common and distinctive features of biological significance. *Am J Surg Pathol*. 2004;28:1299–310.
6. Begum S, Westra WH. Basaloid squamous cell carcinoma of the head and neck is a mixed variant that can be further resolved by HPV status. *Am J Surg Pathol*. 2008;32:1044–50.
7. Choi HR, Sturgis EM, Rosenthal DI, et al. Sarcomatoid carcinoma of the head and neck: molecular evidence for evolution and

- progression from conventional squamous cell carcinomas. *Am J Surg Pathol.* 2003;27:1216–20.
8. Dahlstrand H, Nasman A, Romanitan M, et al. Human papillomavirus accounts both for increased incidence and better prognosis in tonsillar cancer. *Anticancer Res.* 2008;28:1133–8.
 9. Dahlstrom KR, Adler-Storthz K, Etzel CJ, et al. Human papillomavirus type 16 infection and squamous cell carcinoma of the head and neck in never-smokers: a matched pair analysis. *Clin Cancer Res.* 2003;9:2620–6.
 10. Kumar B, Cordell KG, Lee JS, et al. Response to therapy and outcomes in oropharyngeal cancer are associated with biomarkers including human papillomavirus, epidermal growth factor receptor, gender, and smoking. *Int J Radiat Oncol Biol Phys.* 2007;69:S109–11.
 11. Nichols AC, Faquin WC, Westra WH, et al. HPV-16 infection predicts treatment outcome in oropharyngeal squamous cell carcinoma. *Otolaryngol Head Neck Surg.* 2009;140:228–34.
 12. Sand L, Jalouli J, Larsson PA, et al. Human papilloma viruses in oral lesions. *Anticancer Res.* 2000;20:1183–8.
 13. Westra WH, Taube JM, Poeta ML, et al. Inverse relationship between human papillomavirus-16 infection and disruptive p53 gene mutations in squamous cell carcinoma of the head and neck. *Clin Cancer Res.* 2008;14:366–9.
 14. Barnes L, Eveson JW, Reichart P, et al. World Health Organization classification of tumours. Pathology & genetics. Head and neck tumours. Lyon: IARC; 2005.
 15. Janot F, Klijanienko J, Russo A, et al. Prognostic value of clinicopathological parameters in head and neck squamous cell carcinoma: a prospective analysis. *Br J Cancer.* 1996;73:531–8.
 16. Braakhuis BJ, Tabor MP, Kummer JA, et al. A genetic explanation of Slaughter's concept of field cancerization: evidence and clinical implications. *Cancer Res.* 2003;63:1727–30.
 17. Forastiere A, Koch W, Trotti A, et al. Head and neck cancer. *N Engl J Med.* 2001;345:1890–900.
 18. Jang SJ, Chiba I, Hirai A, et al. Multiple oral squamous epithelial lesions: are they genetically related? *Oncogene.* 2001;20:2235–42.
 19. El-Naggar AK, Hurr K, Huff V, et al. Microsatellite instability in preinvasive and invasive head and neck squamous carcinoma. *Am J Pathol.* 1996;148:2067–72.
 20. El-Naggar AK, Hurr K, Huff V, et al. Allelic loss and replication errors at microsatellite loci on chromosome 11p in head and neck squamous carcinoma: association with aggressive biological features. *Clin Cancer Res.* 1996;2:903–7.
 21. El-Naggar AK, Hurr K, Luna MA, et al. Intratumoral genetic heterogeneity in primary head and neck squamous carcinoma using microsatellite markers. *Diagn Mol Pathol.* 1997;6:305–8.
 22. El-Naggar AK, Lai S, Clayman GL, et al. p73 gene alterations and expression in primary oral and laryngeal squamous carcinomas. *Carcinogenesis.* 2001;22:729–35.
 23. Coombes MM, Briggs KL, Bone JR, et al. Resetting the histone code at CDKN2A in HNSCC by inhibition of DNA methylation. *Oncogene.* 2003;22:8902–11.
 24. Papadimitrakopoulou VA, Izzo J, Mao L, et al. Cyclin D1 and p16 alterations in advanced premalignant lesions of the upper aerodigestive tract: role in response to chemoprevention and cancer development. *Clin Cancer Res.* 2001;7:3127–34.
 25. Wang D, Grecula JC, Gahbauer RA, et al. p16 gene alterations in locally advanced squamous cell carcinoma of the head and neck. *Oncol Rep.* 2006;15:661–5.
 26. Nakahara Y, Shintani S, Mihara M, et al. Alterations of Rb, p16(INK4A) and cyclin D1 in the tumorigenesis of oral squamous cell carcinomas. *Cancer Lett.* 2000;160:3–8.
 27. Thurfjell N, Coates PJ, Uusitalo T, et al. Complex p63 mRNA isoform expression patterns in squamous cell carcinoma of the head and neck. *Int J Oncol.* 2004;25:27–35.
 28. Weber A, Bellmann U, Bootz F, et al. Expression of p53 and its homologues in primary and recurrent squamous cell carcinomas of the head and neck. *Int J Cancer.* 2002;99:22–8.
 29. Maruya S, Issa JP, Weber RS, et al. Differential methylation status of tumor-associated genes in head and neck squamous carcinoma: incidence and potential implications. *Clin Cancer Res.* 2004;10:3825–30.
 30. Viswanathan M, Tsuchida N, Shanmugam G. Promoter hypermethylation profile of tumor-associated genes p16, p15, hMLH1, MGMT and E-cadherin in oral squamous cell carcinoma. *Int J Cancer.* 2003;105:41–6.
 31. Chen YJ, Lin SC, Kao T, et al. Genome-wide profiling of oral squamous cell carcinoma. *J Pathol.* 2004;204:326–32.
 32. Chung CH, Parker JS, Karaca G, et al. Molecular classification of head and neck squamous cell carcinomas using patterns of gene expression. *Cancer Cell.* 2004;5:489–500.
 33. Giri U, Ashorn CL, Ramdas L, et al. Molecular signatures associated with clinical outcome in patients with high-risk head-and-neck squamous cell carcinoma treated by surgery and radiation. *Int J Radiat Oncol Biol Phys.* 2006;64:670–7.
 34. Roepman P, Wessels LF, Kettelarij N, et al. An expression profile for diagnosis of lymph node metastases from primary head and neck squamous cell carcinomas. *Nat Genet.* 2005;37:182–6.
 35. Li J, Huang H, Sun L, et al. MiR-21 indicates poor prognosis in tongue squamous cell carcinoma as an apoptosis inhibitor. *Clin Cancer Res.* 2009;15:3998–4008.
 36. Ramdas L, Giri U, Ashorn CL, et al. miRNA expression profiles in head and neck squamous cell carcinoma and adjacent normal tissue. *Head Neck.* 2009;31:642–54.
 37. Wong TS, Liu XB, Wong BY, et al. Mature miR-184 as potential oncogenic microRNA of squamous cell carcinoma of tongue. *Clin Cancer Res.* 2008;14:2588–92.
 38. Hazan RB, Norton L. The epidermal growth factor receptor modulates the interaction of E-cadherin with the actin cytoskeleton. *J Biol Chem.* 1998;273:9078–84.
 39. Rubin Grandis J, Melhem MF, Gooding WE, et al. Levels of TGF- α and EGFR protein in head and neck squamous cell carcinoma and patient survival. *J Natl Cancer Inst.* 1998;90:824–32.
 40. Temam S, Kawaguchi H, El-Naggar AK, et al. Epidermal growth factor receptor copy number alterations correlate with poor clinical outcome in patients with head and neck squamous cancer. *J Clin Oncol.* 2007;25:2164–70.
 41. Ang KK, Berkey BA, Tu X, et al. Impact of epidermal growth factor receptor expression on survival and pattern of relapse in patients with advanced head and neck carcinoma. *Cancer Res.* 2002;62:7350–6.
 42. Gallo O, Franchi A, Magnelli L, et al. Cyclooxygenase-2 pathway correlates with VEGF expression in head and neck cancer. Implications for tumor angiogenesis and metastasis. *Neoplasia.* 2001;3:53–61.
 43. Janot F, El-Naggar AK, Morrison RS, et al. Expression of basic fibroblast growth factor in squamous cell carcinoma of the head and neck is associated with degree of histologic differentiation. *Int J Cancer.* 1995;64:117–23.
 44. Joo YH, Jung CK, Kim MS, et al. Relationship between vascular endothelial growth factor and Notch1 expression and lymphatic metastasis in tongue cancer. *Otolaryngol Head Neck Surg.* 2009;140:512–8.
 45. Lopez-Graniel CM, Tamez de Leon D, Meneses-Garcia A, et al. Tumor angiogenesis as a prognostic factor in oral cavity carcinomas. *J Exp Clin Cancer Res.* 2001;20:463–8.
 46. Montag M, Dyckhoff G, Lohr J, et al. Angiogenic growth factors in tissue homogenates of HNSCC: expression pattern, prognostic relevance, and interrelationships. *Cancer Sci.* 2009;100:1210–8.
 47. Raffi S, Avcilla ST, Jin DK. Tumor vasculature address book: identification of stage-specific tumor vessel zip codes by phage display. *Cancer Cell.* 2003;4:331–3.
 48. Schultz-Hector S, Haghayegh S. Beta-fibroblast growth factor expression in human and murine squamous cell carcinomas and its relationship to regional endothelial cell proliferation. *Cancer Res.* 1993;53:1444–9.

49. Williams JK, Carlson GW, Cohen C, et al. Tumor angiogenesis as a prognostic factor in oral cavity tumors. *Am J Surg*. 1994;168:373–80.
50. Qiu W, Schonleben F, Li X, et al. PIK3CA mutations in head and neck squamous cell carcinoma. *Clin Cancer Res*. 2006;12:1441–6.
51. Chan G, Boyle JO, Yang EK, et al. Cyclooxygenase-2 expression is up-regulated in squamous cell carcinoma of the head and neck. *Cancer Res*. 1999;59:991–4.
52. Avizienyte E, Wyke AW, Jones RJ, et al. Src-induced de-regulation of E-cadherin in colon cancer cells requires integrin signalling. *Nat Cell Biol*. 2002;4:632–8.
53. Batlle E, Sancho E, Franci C, et al. The transcription factor snail is a repressor of E-cadherin gene expression in epithelial tumour cells. *Nat Cell Biol*. 2000;2:84–9.
54. Christiansen JJ, Rajasekaran AK. Reassessing epithelial to mesenchymal transition as a prerequisite for carcinoma invasion and metastasis. *Cancer Res*. 2006;66:8319–26.
55. Maeda M, Shintani Y, Wheelock MJ, et al. Src activation is not necessary for transforming growth factor (TGF)-beta-mediated epithelial to mesenchymal transitions (EMT) in mammary epithelial cells. PP1 directly inhibits TGF-beta receptors I and II. *J Biol Chem*. 2006;281:59–68.
56. Papadimitrakopoulou VA, Hong WK. Biology of oral premalignant lesions: concepts and implications for chemoprevention. *Eur J Cancer Prev*. 1996;5 Suppl 2:87–93.
57. Day TA, Deveikis J, Gillespie MB, et al. Salivary gland neoplasms. *Curr Treat Options Oncol*. 2004;5:11–26.
58. Pinkston JA, Cole P. Incidence rates of salivary gland tumors: results from a population-based study. *Otolaryngol Head Neck Surg*. 1999;120:834–40.
59. Speight PM, Barrett AW. Salivary gland tumours. *Oral Dis*. 2002;8:229–40.
60. Pinto AE, Fonseca I, Martins C, et al. Objective biologic parameters and their clinical relevance in assessing salivary gland neoplasms. *Adv Anat Pathol*. 2000;7:294–306.
61. Luna MA, Batsakis JG, El-Naggar AK. Salivary gland tumors in children. *Ann Otol Rhinol Laryngol*. 1991;100:869–71.
62. Shapiro NL, Bhattacharyya N. Clinical characteristics and survival for major salivary gland malignancies in children. *Otolaryngol Head Neck Surg*. 2006;134:631–4.
63. Wu L, Aster JC, Blacklow SC, et al. MAML1, a human homologue of *Drosophila* mastermind, is a transcriptional co-activator for NOTCH receptors. *Nat Genet*. 2000;26:484–9.
64. Bradley PJ. Recurrent salivary gland pleomorphic adenoma: etiology, management and results. *Curr Opin Otolaryngol Head Neck Surg*. 2001;9:100–8.
65. Califano J, Eisele DW. Benign salivary gland neoplasms. *Otolaryngol Clin North Am*. 1999;32:861–73.
66. Stennert E, Guntinas-Lichius O, Klussmann JP, et al. Histopathology of pleomorphic adenoma in the parotid gland: a prospective unselected series of 100 cases. *Laryngoscope*. 2001;111:2195–200.
67. Gillenwater A, Hurr K, Wolf P, et al. Microsatellite alterations at chromosome 8q loci in pleomorphic adenoma. *Otolaryngol Head Neck Surg*. 1997;117:448–52.
68. Declercq J, Van Dyck F, Braem CV, et al. Salivary gland tumors in transgenic mice with targeted PLAG1 proto-oncogene overexpression. *Cancer Res*. 2005;65:4544–53.
69. El-Naggar A, Batsakis JG, Kessler S. Benign metastatic mixed tumours or unrecognized salivary carcinomas? *J Laryngol Otol*. 1988;102:810–2.
70. Schoenmakers EF, Kools PF, Mols R, et al. Physical mapping of chromosome 12q breakpoints in lipoma, pleomorphic salivary gland adenoma, uterine leiomyoma, and myxoid liposarcoma. *Genomics*. 1994;20:210–22.
71. Mark G, Dahlenfors R, Ekedahl C, et al. The mixed salivary gland tumor – a normally benign human neoplasm frequently showing specific chromosome abnormalities. *Cancer Genet Cytogenet*. 1980;2:231–41.
72. Leivo I, Jee KJ, Heikinheimo K, et al. Characterization of gene expression in major types of salivary gland carcinomas with epithelial differentiation. *Cancer Genet Cytogenet*. 2005;156:104–13.
73. Martins C, Fonseca I, Roque L, et al. PLAG1 gene alterations in salivary gland pleomorphic adenoma and carcinoma ex-pleomorphic adenoma: a combined study using chromosome banding, in situ hybridization and immunocytochemistry. *Mod Pathol*. 2005;18:1048–55.
74. Foschini MP, Malvi D, Betts CM. Oncocytic carcinoma arising in Warthin tumour. *Virchows Arch*. 2005;446:88–90.
75. Enlund F, Behboudi A, Andren Y, et al. Altered Notch signaling resulting from expression of a WAMTP1-MAML2 gene fusion in mucoepidermoid carcinomas and benign Warthin's tumors. *Exp Cell Res*. 2004;292:21–8.
76. Martins C, Fonseca I, Roque L, et al. Cytogenetic characterisation of Warthin's tumour. *Oral Oncol*. 1997;33:344–7.
77. Nordkvist A, Mark J, Dahlenfors R, et al. Cytogenetic observations in 13 cystadenolymphomas (Warthin's tumors). *Cancer Genet Cytogenet*. 1994;76:129–35.
78. Batsakis JG, Luna MA, El-Naggar AK. Basaloid monomorphic adenomas. *Ann Otol Rhinol Laryngol*. 1991;100:687–90.
79. Choi HR, Batsakis JG, Callender DL, et al. Molecular analysis of chromosome 16q regions in dermal analogue tumors of salivary glands: a genetic link to dermal cylindroma? *Am J Surg Pathol*. 2002;26:778–83.
80. el-Naggar AK, Lovell M, Callender DL, et al. Cytogenetic analysis of a primary salivary gland myoepithelioma. *Cancer Genet Cytogenet*. 1999;113:49–53.
81. Hungermann D, Roeser K, Buerger H, et al. Relative paucity of gross genetic alterations in myoepitheliomas and myoepithelial carcinomas of salivary glands. *J Pathol*. 2002;198:487–94.
82. Magrini E, Pragliola A, Farnedi A, et al. Cytogenetic analysis of myoepithelial cell carcinoma of salivary gland. *Virchows Arch*. 2004;444:82–6.
83. Bullerdiek J, Haubrich J, Meyer K, et al. Translocation t(11;19)(q21;p13.1) as the sole chromosome abnormality in a cystadenolymphoma (Warthin's tumor) of the parotid gland. *Cancer Genet Cytogenet*. 1988;35:129–32.
84. Dahlenfors R, Wedell B, Rundrantz H, et al. Translocation(11;19)(q14-21;p12) in a parotid mucoepidermoid carcinoma of a child. *Cancer Genet Cytogenet*. 1995;79:188.
85. El-Naggar AK, Lovell M, Killary AM, et al. A mucoepidermoid carcinoma of minor salivary gland with t(11;19)(q21;p13.1) as the only karyotypic abnormality. *Cancer Genet Cytogenet*. 1996;87:29–33.
86. Nordkvist A, Gustafsson H, Juberg-Ode M, et al. Recurrent rearrangements of 11q14-22 in mucoepidermoid carcinoma. *Cancer Genet Cytogenet*. 1994;74:77–83.
87. Komiya T, Park Y, Modi S, et al. Sustained expression of Mect1-Maml2 is essential for tumor cell growth in salivary gland cancers carrying the t(11;19) translocation. *Oncogene*. 2006;25:6128–32.
88. Kyakumoto S, Kito N, Sato N. Expression of cAMP response element binding protein (CREB)-binding protein (CBP) and the implication in retinoic acid-inducible transcription activation in human salivary gland adenocarcinoma cell line HSG. *Endocr Res*. 2003;29:277–89.
89. Bell DA, Thompson CL, Taylor J, et al. Genetic monitoring of human polymorphic cancer susceptibility genes by polymerase chain reaction: application to glutathione transferase mu. *Environ Health Perspect*. 1992;98:113–7.
90. Tirado Y, Williams MD, Hanna EY, et al. CRTCl/MAML2 fusion transcript in high grade mucoepidermoid carcinomas of salivary and thyroid glands and Warthin's tumors: implications for histogenesis and biologic behavior. *Genes Chromosomes Cancer*. 2007;46:708–15.

91. Tonon G, Gehlhaus KS, Yonescu R, et al. Multiple reciprocal translocations in salivary gland mucoepidermoid carcinomas. *Cancer Genet Cytogenet.* 2004;152:15–22.
92. Tonon G, Modi S, Wu L, et al. t(11;19)(q21;p13) translocation in mucoepidermoid carcinoma creates a novel fusion product that disrupts a Notch signaling pathway. *Nat Genet.* 2003;33:208–13.
93. Lewis JE, Olsen KD, Sebo TJ. Carcinoma ex pleomorphic adenoma: pathologic analysis of 73 cases. *Hum Pathol.* 2001;32:596–604.
94. Olsen KD, Lewis JE. Carcinoma ex pleomorphic adenoma: a clinicopathologic review. *Head Neck.* 2001;23:705–12.
95. El-Naggar AK, Callender D, Coombes MM, et al. Molecular genetic alterations in carcinoma ex-pleomorphic adenoma: a putative progression model? *Genes Chromosomes Cancer.* 2000;27:162–8.
96. el-Naggar AK, Hurr K, Kagan J, et al. Genotypic alterations in benign and malignant salivary gland tumors: histogenetic and clinical implications. *Am J Surg Pathol.* 1997;21:691–7.
97. el-Naggar AK, Lovell M, Callender DL, et al. Concurrent cytogenetic, interphase fluorescence in situ hybridization and DNA flow cytometric analyses of a carcinoma ex-pleomorphic adenoma of parotid gland. *Cancer Genet Cytogenet.* 1998;107:132–6.
98. Hellquist HB, Karlsson MG, Nilsson C. Salivary duct carcinoma – a highly aggressive salivary gland tumour with overexpression of c-erbB-2. *J Pathol.* 1994;172:35–44.
99. Johns 3rd MM, Westra WH, Califano JA, et al. Allelotype of salivary gland tumors. *Cancer Res.* 1996;56:1151–4.
100. Williams MD, Chakravarti N, Kies MS, et al. Implications of methylation patterns of cancer genes in salivary gland tumors. *Clin Cancer Res.* 2006;12:7353–8.
101. Williams MD, Roberts D, Blumenschein Jr GR, et al. Differential expression of hormonal and growth factor receptors in salivary duct carcinomas: biologic significance and potential role in therapeutic stratification of patients. *Am J Surg Pathol.* 2007;31:1645–52.
102. Batsakis JG, Luna MA, El-Naggar AK. Histopathologic grading of salivary gland neoplasms: III. Adenoid cystic carcinomas. *Ann Otol Rhinol Laryngol.* 1990;99:1007–9.
103. Kasamatsu A, Endo Y, Uzawa K, et al. Identification of candidate genes associated with salivary adenoid cystic carcinomas using combined comparative genomic hybridization and oligonucleotide microarray analyses. *Int J Biochem Cell Biol.* 2005;37:1869–80.
104. Fordice J, Kershaw C, El-Naggar A, et al. Adenoid cystic carcinoma of the head and neck: predictors of morbidity and mortality. *Arch Otolaryngol Head Neck Surg.* 1999;125:149–52.
105. Freier K, Flechtenmacher C, Walch A, et al. Copy number gains on 22q13 in adenoid cystic carcinoma of the salivary gland revealed by comparative genomic hybridization and tissue microarray analysis. *Cancer Genet Cytogenet.* 2005;159:89–95.
106. Holst VA, Marshall CE, Moskaluk CA, et al. KIT protein expression and analysis of c-kit gene mutation in adenoid cystic carcinoma. *Mod Pathol.* 1999;12:956–60.
107. Rutherford S, Yu Y, Rumpel CA, et al. Chromosome 6 deletion and candidate tumor suppressor genes in adenoid cystic carcinoma. *Cancer Lett.* 2006;236:309–17.
108. Sandros J, Mark J, Happonen RP, et al. Specificity of 6q- markers and other recurrent deviations in human malignant salivary gland tumors. *Anticancer Res.* 1988;8:637–43.
109. Stallmach I, Zenklusen P, Komminoth P, et al. Loss of heterozygosity at chromosome 6q23-25 correlates with clinical and histologic parameters in salivary gland adenoid cystic carcinoma. *Virchows Arch.* 2002;440:77–84.
110. Jeng YM, Lin CY, Hsu HC. Expression of the c-kit protein is associated with certain subtypes of salivary gland carcinoma. *Cancer Lett.* 2000;154:107–11.
111. Patel KJ, Pambuccian SE, Ondrey FG, et al. Genes associated with early development, apoptosis and cell cycle regulation define a gene expression profile of adenoid cystic carcinoma. *Oral Oncol.* 2006;42:994–1004.
112. Queimado L, Reis A, Fonseca I, et al. A refined localization of two deleted regions in chromosome 6q associated with salivary gland carcinomas. *Oncogene.* 1998;16:83–8.
113. Batsakis JG, Luna MA, El-Naggar AK. Histopathologic grading of salivary gland neoplasms: II. Acinic cell carcinomas. *Ann Otol Rhinol Laryngol.* 1990;99:929–33.
114. Lewis JE, Olsen KD, Weiland LH. Acinic cell carcinoma. Clinicopathologic review. *Cancer.* 1991;67:172–9.
115. el-Naggar AK, Abdul-Karim FW, Hurr K, et al. Genetic alterations in acinic cell carcinoma of the parotid gland determined by microsatellite analysis. *Cancer Genet Cytogenet.* 1998;102:19–24.
116. Edwards PC, Bhuiya T, Kelsch RD. Assessment of p63 expression in the salivary gland neoplasms adenoid cystic carcinoma, polymorphous low-grade adenocarcinoma, and basal cell and canalicular adenomas. *Oral Surg Oral Med Oral Pathol Oral Radiol Endod.* 2004;97:613–9.
117. Jin C, Jin Y, Hoglund M, et al. Cytogenetic and molecular genetic demonstration of polyclonality in an acinic cell carcinoma. *Br J Cancer.* 1998;78:292–5.
118. Kishi M, Nakamura M, Nishimine M, et al. Genetic and epigenetic alteration profiles for multiple genes in salivary gland carcinomas. *Oral Oncol.* 2005;41:161–9.
119. Maruya S, Kim HW, Weber RS, et al. Gene expression screening of salivary gland neoplasms: molecular markers of potential histogenetic and clinical significance. *J Mol Diagn.* 2004;6:180–90.
120. DeLellis R, Lloyd R, Heitz P, et al. Pathology and genetics of tumors of endocrine origin. Lyon: IARC; 2004.
121. Giuffrida D, Gharib H. Anaplastic thyroid carcinoma: current diagnosis and treatment. *Ann Oncol.* 2000;11:1083–9.
122. Pulcrano M, Boukheris H, Talbot M, et al. Poorly differentiated follicular thyroid carcinoma: prognostic factors and relevance of histological classification. *Thyroid.* 2007;17:639–46.
123. Kebebew E, Ituarte PH, Siperstein AE, et al. Medullary thyroid carcinoma: clinical characteristics, treatment, prognostic factors, and a comparison of staging systems. *Cancer.* 2000;88:1139–48.
124. Kondo T, Ezzat S, Asa SL. Pathogenetic mechanisms in thyroid follicular-cell neoplasia. *Nat Rev Cancer.* 2006;6:292–306.
125. LiVolsi VA, Baloch ZW. Follicular neoplasms of the thyroid: view, biases, and experiences. *Adv Anat Pathol.* 2004;11:279–87.
126. Lloyd RV, Erickson LA, Casey MB, et al. Observer variation in the diagnosis of follicular variant of papillary thyroid carcinoma. *Am J Surg Pathol.* 2004;28:1336–40.
127. Abboud B, Sleilaty G, Helou E, et al. Existence and anatomic distribution of double parathyroid adenoma. *Laryngoscope.* 2005;115:1128–31.
128. Assaad A, Voegtly L, Hunt JL. Thyroidectomies from patients with history of therapeutic radiation during childhood and adolescence have a unique mutational profile. *Mod Pathol.* 2008;21:1176–82.
129. Lima J, Trovisco V, Soares P, et al. BRAF mutations are not a major event in post-Chernobyl childhood thyroid carcinomas. *J Clin Endocrinol Metab.* 2004;89:4267–71.
130. Nikiforov YE. Radiation-induced thyroid cancer: what we have learned from chernobyl. *Endocr Pathol.* 2006;17:307–17.
131. Bartolazzi A, D'Alessandria C, Parisella MG, et al. Thyroid cancer imaging in vivo by targeting the anti-apoptotic molecule galectin-3. *PLoS One.* 2008;3:e3768.
132. Hofman V, Lassalle S, Bonnetaud C, et al. Thyroid tumours of uncertain malignant potential: frequency and diagnostic reproducibility. *Virchows Arch.* 2009;455:21–33.
133. Mehrotra P, Okpokam A, Bouhaidar R, et al. Galectin-3 does not reliably distinguish benign from malignant thyroid neoplasms. *Histopathology.* 2004;45:493–500.

134. Baloch ZW, LiVolsi VA. Our approach to follicular-patterned lesions of the thyroid. *J Clin Pathol.* 2007;60:244–50.
135. Bartolazzi A, Gasbarri A, Papotti M, et al. Application of an immunodiagnostic method for improving preoperative diagnosis of nodular thyroid lesions. *Lancet.* 2001;357:1644–50.
136. Vasko VV, Gaudart J, Allasia C, et al. Thyroid follicular adenomas may display features of follicular carcinoma and follicular variant of papillary carcinoma. *Eur J Endocrinol.* 2004;151:779–86.
137. Rosai J, Kuhn E, Carcangiu ML. Pitfalls in thyroid tumour pathology. *Histopathology.* 2006;49:107–20.
138. Sobrinho-Simoes M, Magalhaes J, Fonseca E, et al. Diagnostic pitfalls of thyroid pathology. *Curr Diagn Pathol.* 2005;11:52–9.
139. Suster S. Thyroid tumours with a follicular growth pattern: problems in differential diagnosis. *Arch Pathol Lab Med.* 2006;130:984–8.
140. Evans HL. Follicular neoplasms of the thyroid. A study of 44 cases followed for a minimum of 10 years, with emphasis on differential diagnosis. *Cancer.* 1984;54:535–40.
141. Hirokawa M, Carney JA, Goellner JR, et al. Observer variation of encapsulated follicular lesions of the thyroid gland. *Am J Surg Pathol.* 2002;26:1508–14.
142. Bongarzone I, Vigneri P, Mariani L, et al. RET/NTRK1 rearrangements in thyroid gland tumors of the papillary carcinoma family: correlation with clinicopathological features. *Clin Cancer Res.* 1998;4:223–8.
143. Castellone MD, Santoro M. Dysregulated RET signaling in thyroid cancer. *Endocrinol Metab Clin North Am.* 2008;37:363–74. viii.
144. Fonseca E, Soares P, Cardoso-Oliveira M, et al. Diagnostic criteria in well-differentiated thyroid carcinomas. *Endocr Pathol.* 2006;17:109–17.
145. Fagin JA, Matsuo K, Karmakar A, et al. High prevalence of mutations of the p53 gene in poorly differentiated human thyroid carcinomas. *J Clin Invest.* 1993;91:179–84.
146. Wang HM, Huang YW, Huang JS, et al. Anaplastic carcinoma of the thyroid arising more often from follicular carcinoma than papillary carcinoma. *Ann Surg Oncol.* 2007;14:3011–8.
147. Wiseman SM, Loree TR, Hicks Jr WL, et al. Anaplastic thyroid cancer evolved from papillary carcinoma: demonstration of anaplastic transformation by means of the inter-simple sequence repeat polymerase chain reaction. *Arch Otolaryngol Head Neck Surg.* 2003;129:96–100.
148. Collini P, Sampietro G, Pilotti S. Extensive vascular invasion is a marker of risk of relapse in encapsulated non-Hurthle cell follicular carcinoma of the thyroid gland: a clinicopathological study of 18 consecutive cases from a single institution with a 11-year median follow-up. *Histopathology.* 2004;44:35–9.
149. Cornett WR, Sharma AK, Day TA, et al. Anaplastic thyroid carcinoma: an overview. *Curr Oncol Rep.* 2007;9:152–8.
150. Hunt J. Understanding the genotype of follicular thyroid tumors. *Endocr Pathol.* 2005;16:311–21.
151. DeLellis RA. Pathology and genetics of thyroid carcinoma. *J Surg Oncol.* 2006;94:662–9.
152. Dvorakova S, Vaclavikova E, Sykorova V, et al. Somatic mutations in the RET proto-oncogene in sporadic medullary thyroid carcinomas. *Mol Cell Endocrinol.* 2008;284:21–7.
153. Namba H, Rubin SA, Fagin JA. Point mutations of ras oncogenes are an early event in thyroid tumorigenesis. *Mol Endocrinol.* 1990;4:1474–9.
154. Cheung L, Messina M, Gill A, et al. Detection of the PAX8-PPAR gamma fusion oncogene in both follicular thyroid carcinomas and adenomas. *J Clin Endocrinol Metab.* 2003;88:354–7.
155. Di Cristofaro J, Marey M, Vasko V, et al. Molecular genetic study comparing follicular variant versus classic papillary thyroid carcinomas: association of N-ras mutation in codon 61 with follicular variant. *Hum Pathol.* 2006;37:824–30.
156. Garcia-Rostan G, Zhao H, Camp RL, et al. ras mutations are associated with aggressive tumor phenotypes and poor prognosis in thyroid cancer. *J Clin Oncol.* 2003;21:3226–35.
157. Nakamura N, Erickson LA, Jin L, et al. Immunohistochemical separation of follicular variant of papillary thyroid carcinoma from follicular adenoma. *Endocr Pathol.* 2006;17:213–23.
158. Castro P, Rebocho AP, Soares RJ, et al. PAX8-PPARgamma rearrangement is frequently detected in the follicular variant of papillary thyroid carcinoma. *J Clin Endocrinol Metab.* 2006;91:213–20.
159. Kroll TG, Sarraf P, Pecciarini L, et al. PAX8-PPARgamma1 fusion oncogene in human thyroid carcinoma [corrected]. *Science.* 2000;289:1357–60.
160. Lui WO, Foukakis T, Liden J, et al. Expression profiling reveals a distinct transcription signature in follicular thyroid carcinomas with a PAX8-PPAR(gamma) fusion oncogene. *Oncogene.* 2005;24:1467–76.
161. Nakabashi CC, Guimaraes GS, Michaluart Jr P, et al. The expression of PAX8-PPARgamma rearrangements is not specific to follicular thyroid carcinoma. *Clin Endocrinol (Oxf).* 2004;61:280–2.
162. Nikiforova MN, Biddinger PW, Caudill CM, et al. PAX8-PPARgamma rearrangement in thyroid tumors: RT-PCR and immunohistochemical analyses. *Am J Surg Pathol.* 2002;26:1016–23.
163. Kebebew E, Weng J, Bauer J, et al. The prevalence and prognostic value of BRAF mutation in thyroid cancer. *Ann Surg.* 2007;246:466–70. discussion 470–1.
164. Lee JH, Lee ES, Kim YS. Clinicopathologic significance of BRAF V600E mutation in papillary carcinomas of the thyroid: a meta-analysis. *Cancer.* 2007;110:38–46.
165. Mitsiades CS, Negri J, McMullan C, et al. Targeting BRAFV600E in thyroid carcinoma: therapeutic implications. *Mol Cancer Ther.* 2007;6:1070–8.
166. Trovisco V, Vieira de Castro I, Soares P, et al. BRAF mutations are associated with some histological types of papillary thyroid carcinoma. *J Pathol.* 2004;202:247–51.
167. Elisei R, Cosci B, Romei C, et al. Prognostic significance of somatic RET oncogene mutations in sporadic medullary thyroid cancer: a 10-year follow-up study. *J Clin Endocrinol Metab.* 2008;93:682–7.
168. Fenton CL, Lukes Y, Nicholson D, et al. The ret/PTC mutations are common in sporadic papillary thyroid carcinoma of children and young adults. *J Clin Endocrinol Metab.* 2000;85:1170–5.
169. Fusco A, Chiappetta G, Hui P, et al. Assessment of RET/PTC oncogene activation and clonality in thyroid nodules with incomplete morphological evidence of papillary carcinoma: a search for the early precursors of papillary cancer. *Am J Pathol.* 2002;160:2157–67.
170. Gujral TS, van Veelen W, Richardson DS, et al. A novel RET kinase-beta-catenin signaling pathway contributes to tumorigenesis in thyroid carcinoma. *Cancer Res.* 2008;68:1338–46.
171. Soares P, Fonseca E, Wynford-Thomas D, et al. Sporadic rearranged papillary carcinoma of the thyroid: a subset of slow growing, less aggressive thyroid neoplasms? *J Pathol.* 1998;185:71–8.
172. Elisei R, Romei C, Cosci B, et al. RET genetic screening in patients with medullary thyroid cancer and their relatives: experience with 807 individuals at one center. *J Clin Endocrinol Metab.* 2007;92:4725–9.
173. Grieco M, Santoro M, Berlingieri MT, et al. PTC is a novel rearranged form of the ret proto-oncogene and is frequently detected in vivo in human thyroid papillary carcinomas. *Cell.* 1990;60:557–63.
174. Jhiang SM, Caruso DR, Gilmore E, et al. Detection of the PTC/retTPC oncogene in human thyroid cancers. *Oncogene.* 1992;7:1331–7.

175. Hunt JL, Tometsko M, LiVolsi VA, et al. Molecular evidence of anaplastic transformation in coexisting well-differentiated and anaplastic carcinomas of the thyroid. *Am J Surg Pathol.* 2003;27:1559–64.
176. Nikiforov YE. Genetic alterations involved in the transition from well-differentiated to poorly differentiated and anaplastic thyroid carcinomas. *Endocr Pathol.* 2004;15:319–27.
177. Wiseman SM, Griffith OL, Deen S, et al. Identification of molecular markers altered during transformation of differentiated into anaplastic thyroid carcinoma. *Arch Surg.* 2007;142:717–27. discussion 727–9.
178. Barden CB, Shister KW, Zhu B, et al. Classification of follicular thyroid tumors by molecular signature: results of gene profiling. *Clin Cancer Res.* 2003;9:1792–800.
179. Bartolazzi A, Orlandi F, Saggiorato E, et al. Galectin-3-expression analysis in the surgical selection of follicular thyroid nodules with indeterminate fine-needle aspiration cytology: a prospective multicentre study. *Lancet Oncol.* 2008;9:543–9.
180. Chevillard S, Ugolin N, Vielh P, et al. Gene expression profiling of differentiated thyroid neoplasms: diagnostic and clinical implications. *Clin Cancer Res.* 2004;10:6586–97.
181. Rodrigues RF, Roque L, Krug T, et al. Poorly differentiated and anaplastic thyroid carcinomas: chromosomal and oligo-array profile of five new cell lines. *Br J Cancer.* 2007;96:1237–45.
182. Vasko V, Espinosa AV, Scouten W, et al. Gene expression and functional evidence of epithelial-to-mesenchymal transition in papillary thyroid carcinoma invasion. *Proc Natl Acad Sci USA.* 2007;104:2803–8.
183. Zhu Z, Gandhi M, Nikiforova MN, et al. Molecular profile and clinical-pathologic features of the follicular variant of papillary thyroid carcinoma. An unusually high prevalence of ras mutations. *Am J Clin Pathol.* 2003;120:71–7.
184. Sanjuan X, Bryant BR, Sobel ME, et al. Clonality analysis of benign parathyroid lesions by Human Androgen Receptor (HUMARA) Gene Assay. *Endocr Pathol.* 1998;9:293–300.
185. Scarpelli D, D'Aloiso L, Arturi F, et al. Novel somatic MEN1 gene alterations in sporadic primary hyperparathyroidism and correlation with clinical characteristics. *J Endocrinol Invest.* 2004;27:1015–21.
186. Shan L, Nakamura M, Nakamura Y, et al. Comparative analysis of clonality and pathology in primary and secondary hyperparathyroidism. *Virchows Arch.* 1997;430:247–51.
187. Sinha S, Sinha A, McPherson GA. Synchronous sporadic carcinoma and primary hyperplasia of the parathyroid glands: a case report and review of the literature. *Int J Surg Pathol.* 2006;14:336–9.
188. DeLellis RA, Mazzaglia P, Mangray S. Primary hyperparathyroidism: a current perspective. *Arch Pathol Lab Med.* 2008;132:1251–62.
189. Carneiro-Pla DM, Romaguera R, Nadji M, et al. Does histopathology predict parathyroid hypersecretion and influence correctly the extent of parathyroidectomy in patients with sporadic primary hyperparathyroidism? *Surgery.* 2007;142:930–5. discussion 930–5.
190. Lumachi F, Basso SM, Basso U. Parathyroid cancer: etiology, clinical presentation and treatment. *Anticancer Res.* 2006;26:4803–7.
191. Cetani F, Pardi E, Viacava P, et al. A reappraisal of the Rb1 gene abnormalities in the diagnosis of parathyroid cancer. *Clin Endocrinol (Oxf).* 2004;60:99–106.
192. Cryns VL, Thor A, Xu HJ, et al. Loss of the retinoblastoma tumor-suppressor gene in parathyroid carcinoma. *N Engl J Med.* 1994;330:757–61.
193. Dotzenrath C, Teh BT, Farnebo F, et al. Allelic loss of the retinoblastoma tumor suppressor gene: a marker for aggressive parathyroid tumors? *J Clin Endocrinol Metab.* 1996;81:3194–6.
194. Dwight T, Nelson AE, Theodosopoulos G, et al. Independent genetic events associated with the development of multiple parathyroid tumors in patients with primary hyperparathyroidism. *Am J Pathol.* 2002;161:1299–306.
195. Miedlich S, Krohn K, Lamesch P, et al. Frequency of somatic MEN1 gene mutations in monoclonal parathyroid tumours of patients with primary hyperparathyroidism. *Eur J Endocrinol.* 2000;143:47–54.
196. Morrison C, Farrar W, Kneile J, et al. Molecular classification of parathyroid neoplasia by gene expression profiling. *Am J Pathol.* 2004;165:565–76.
197. Cetani F, Ambrogini E, Viacava P, et al. Should parafibromin staining replace HRTP2 gene analysis as an additional tool for histologic diagnosis of parathyroid carcinoma? *Eur J Endocrinol.* 2007;156:547–54.
198. Gill AJ, Clarkson A, Gimm O, et al. Loss of nuclear expression of parafibromin distinguishes parathyroid carcinomas and hyperparathyroidism-jaw tumor (HPT-JT) syndrome-related adenomas from sporadic parathyroid adenomas and hyperplasias. *Am J Surg Pathol.* 2006;30:1140–9.
199. Juhlin CC, Villablanca A, Sandelin K, et al. Parafibromin immunoreactivity: its use as an additional diagnostic marker for parathyroid tumor classification. *Endocr Relat Cancer.* 2007;14:501–12.
200. Cetani F, Pardi E, Ambrogini E, et al. Different somatic alterations of the HRPT2 gene in a patient with recurrent sporadic primary hyperparathyroidism carrying an HRPT2 germline mutation. *Endocr Relat Cancer.* 2007;14:493–9.
201. Cordes B, Williams MD, Tirado Y, et al. Molecular and phenotypic analysis of poorly differentiated sinonasal neoplasms: an integrated approach for early diagnosis and classification. *Hum Pathol.* 2009;40:283–92.
202. Wenig BM. Undifferentiated malignant neoplasms of the sinonasal tract. *Arch Pathol Lab Med.* 2009;133:699–712.
203. Califano J, Koch W, Sidransky D, et al. Inverted sinonasal papilloma: a molecular genetic appraisal of its putative status as a Precursor to squamous cell carcinoma. *Am J Pathol.* 2000;156:333–7.
204. Choi HR, Sturgis EM, Rashid A, et al. Sinonasal adenocarcinoma: evidence for histogenetic divergence of the enteric and nonenteric phenotypes. *Hum Pathol.* 2003;34:1101–7.
205. Luna MA. Sinonasal tubulopapillary low-grade adenocarcinoma: a specific diagnosis or just another seromucous adenocarcinoma? *Adv Anat Pathol.* 2005;12:109–15.
206. Orvidas LJ, Lewis JE, Weaver AL, et al. Adenocarcinoma of the nose and paranasal sinuses: a retrospective study of diagnosis, histologic characteristics, and outcomes in 24 patients. *Head Neck.* 2005;27:370–5.
207. Skalova A, Cardesa A, Leivo I, et al. Sinonasal tubulopapillary low-grade adenocarcinoma. Histopathological, immunohistochemical and ultrastructural features of poorly recognised entity. *Virchows Arch.* 2003;443:152–8.
208. Yom SS, Rashid A, Rosenthal DI, et al. Genetic analysis of sinonasal adenocarcinoma phenotypes: distinct alterations of histogenetic significance. *Mod Pathol.* 2005;18:315–9.
209. Stelow EB, Mills SE. Squamous cell carcinoma variants of the upper aerodigestive tract. *Am J Clin Pathol.* 2005;124(Suppl):S96–109.
210. Carbone A, Gloghini A, Rinaldo A, et al. True identity by immunohistochemistry and molecular morphology of undifferentiated malignancies of the head and neck. *Head Neck.* 2009;31:949–61.
211. Cerilli LA, Holst VA, Brandwein MS, et al. Sinonasal undifferentiated carcinoma: immunohistochemical profile and lack of EBV association. *Am J Surg Pathol.* 2001;25:156–63.
212. Lee DH, Cho HH, Cho YB. Typical carcinoid tumor of the nasal cavity. *Auris Nasus Larynx.* 2007;34:537–9.
213. Lin IH, Hwang CF, Huang HY, et al. Small cell carcinoma of the nasopharynx. *Acta Otolaryngol.* 2007;127:206–8.

214. Milroy CM, Ferlito A. Immunohistochemical markers in the diagnosis of neuroendocrine neoplasms of the head and neck. *Ann Otol Rhinol Laryngol*. 1995;104:413–8.
215. Bourne TD, Bellizzi AM, Stelow EB, et al. p63 Expression in olfactory neuroblastoma and other small cell tumors of the sinonasal tract. *Am J Clin Pathol*. 2008;130:213–8.
216. Fujimura Y, Ohno T, Siddique H, et al. The EWS-ATF-1 gene involved in malignant melanoma of soft parts with t(12;22) chromosome translocation, encodes a constitutive transcriptional activator. *Oncogene*. 1996;12:159–67.
217. Kumar S, Perlman E, Pack S, et al. Absence of EWS/FLI1 fusion in olfactory neuroblastomas indicates these tumors do not belong to the Ewing's sarcoma family. *Hum Pathol*. 1999;30:1356–60.
218. Babin E, Rouleau V, Vedrine PO, et al. Small cell neuroendocrine carcinoma of the nasal cavity and paranasal sinuses. *J Laryngol Otol*. 2006;120:289–97.
219. Brissett AE, Olsen KD, Kasperbauer JL, et al. Merkel cell carcinoma of the head and neck: a retrospective case series. *Head Neck*. 2002;24:982–8.
220. Gardner LJ, Ayala AG, Monforte HL, et al. Ewing sarcoma/peripheral primitive neuroectodermal tumor: adult abdominal tumors with an Ewing sarcoma gene rearrangement demonstrated by fluorescence in situ hybridization in paraffin sections. *Appl Immunohistochem Mol Morphol*. 2004;12:160–5.
221. Qian X, Jin L, Shearer BM, et al. Molecular diagnosis of Ewing's sarcoma/primitive neuroectodermal tumor in formalin-fixed paraffin-embedded tissues by RT-PCR and fluorescence in situ hybridization. *Diagn Mol Pathol*. 2005;14:23–8.
222. Chang AE, Karnell LH, Menck HR. The National Cancer Data Base report on cutaneous and noncutaneous melanoma: a summary of 84,836 cases from the past decade. The American College of Surgeons Commission on Cancer and the American Cancer Society. *Cancer*. 1998;83:1664–78.
223. Conley J, Pack GT. Melanoma of the mucous membranes of the head and neck. *Arch Otolaryngol*. 1974;99:315–9.
224. Lentsch EJ, Myers JN. Melanoma of the head and neck: current concepts in diagnosis and management. *Laryngoscope*. 2001;111:1209–22.
225. Medina JE, Ferlito A, Pellitteri PK, et al. Current management of mucosal melanoma of the head and neck. *J Surg Oncol*. 2003;83:116–22.
226. Smith SL, Hessel AC, Luna MA, et al. Sinonasal teratocarcinoma of the head and neck: a report of 10 patients treated at a single institution and comparison with reported series. *Arch Otolaryngol Head Neck Surg*. 2008;134:592–5.
227. Campo E, Cardesa A, Alos L, et al. Non-Hodgkin's lymphomas of nasal cavity and paranasal sinuses. An immunohistochemical study. *Am J Clin Pathol*. 1991;96:184–90.
228. Carbone A, Gloghini A, Dotti G. EBV-associated lymphoproliferative disorders: classification and treatment. *Oncologist*. 2008;13:577–85.
229. Chan J, Jaffe E, Ralfkiaer E. Extranodal NK/T-cell lymphoma, nasal type. Lyon: IARC; 2001.
230. Fellbaum C, Hansmann ML, Lennert K. Malignant lymphomas of the nasal cavity and paranasal sinuses. *Virchows Arch A Pathol Anat Histopathol*. 1989;414:399–405.
231. Vidal RW, Devaney K, Ferlito A, et al. Sinonasal malignant lymphomas: a distinct clinicopathological category. *Ann Otol Rhinol Laryngol*. 1999;108:411–9.
232. Hill DA, O'Sullivan MJ, Zhu X, et al. Practical application of molecular genetic testing as an aid to the surgical pathologic diagnosis of sarcomas: a prospective study. *Am J Surg Pathol*. 2002;26:965–77.

Chapter 4

Oncogenomics/Proteomics of Head and Neck Cancers

Howard S. Moskowitz and Jennifer R. Grandis

Abstract Head and neck cancer treatment has experienced great advances in surgical techniques, radiation therapy, chemotherapy, and molecular targeted strategies through the years. In addition, there has been explosive growth in our understanding of tumor biology through research focusing on individual genes and their gene products. However, poor overall survival persists despite this progress, in large part because treatment decisions continue to be based on traditional parameters, such as tumor size, tumor site, and presence of regional or distant metastases. Head and neck cancer represents an extremely heterogeneous disease with dysregulation of multiple interrelated cellular pathways, including differentiation, apoptosis, angiogenesis, and metastasis. The complexity of interactions between genes and proteins and the environment and the difficulty of finding the right combinations of targets to study pose fundamental problems with successful identification of therapeutic targets and predictive elements.

Oncogenomic and proteomic analyses offer the opportunity to accelerate the pace of discovery for clinically relevant targets. A variety of high-throughput technologies including expression profiling and mass spectrometry technologies are being used to analyze cancer genomes and proteomes with the ultimate goal of identifying new cancer genes and therapeutic targets. Potentially, the identification of disease-associated proteins and protein signatures could be used as tumor markers for early detection, response to therapy, or relapse. A greater understanding of the molecular events underpinning clinical outcomes will provide useful tools in the identification of new targets for future therapy. These advances have already begun to manifest in several key areas of treatment including early detection of cancer, evaluation of surgical margins, determination of necessary extent of surgery, and predictions of outcome and recurrence. In this chapter we review key technological advances leading to

these recent changes as well as many of the studies helping to implement these technologies and apply them to patients with head and neck cancer.

Keywords Oncogenomics • Proteomics • Microarray • Gene expression

Introduction

Head and neck squamous cell carcinoma (HNSCC) is the most common histology of cancers arising from the upper aerodigestive tract, comprising approximately 90% of all tumors. HNSCC encompasses a variety of subsites, but despite possessing similar histologic characteristics, the clinical behavior, such as metastatic rate and response to therapy, varies between subsites and even within an individual subsite, indicating biologic heterogeneity in the setting of common histology. Current treatment strategies rely on traditional clinical, radiologic, and histopathologic parameters to determine the stage of disease using the T (tumor), N (node), and M (metastasis) classification system. This system allows for the estimation of disease burden which is presumed to predict clinical outcomes and assist the clinician in making the most appropriate decision for patient management. However, the biologic heterogeneity of HNSCC is reflected by the dysregulation of multiple pathways, including cellular differentiation, angiogenesis, and apoptosis. Apparently, identical histologic tumors may have similar phenotypic characteristics, but develop through dysregulation of different pathways and can have different clinical courses.

Despite their intrinsic differences, all HNSCCs are treated similarly. Standard therapy for stage I/II tumors is surgical resection and/or radiation therapy. By contrast, treatment for advanced stage III/IV tumor requires the combination of chemotherapy, radiation therapy, and/or surgery. Given this relatively uniform treatment, clinical outcome after curative therapy varies greatly. The advent of new surgical techniques, radiation therapy, and chemotherapy have improved local

J.R. Grandis (✉)
Eye & Ear Institute, Suite 500, 200 Lothrop Street,
Pittsburgh, PA 15213, USA
e-mail: jgrandis@pitt.edu

control and overall quality of life, but survival rates for head and neck cancer have not increased significantly. It is likely that the diversity in outcome reflects intrinsic heterogeneity in the molecular components of individual tumors.

Clinical outcome has not been shown to be accurately predicted by clinical, radiographic, or histologic characteristics. A limited number of histologic features, such as perineural, perivascular, or nodal extracapsular spread are associated with increased tumor aggressiveness and may influence clinical care. Unfortunately, currently recognized individual markers associated with tumor development generally lack sensitivity or specificity and there is currently no single molecular marker that is used for patient management in HNSCC. Human papilloma virus (HPV) may ultimately serve as a putative marker for HNSCC as it is more common in nonsmokers and nondrinkers and these tumors have a better outcome independent of the specific therapy.

Given the variety of molecular changes found in these tumors, a greater understanding of the molecular basis of the biochemical pathways involved in carcinogenesis potentially can facilitate diagnosis, drug discovery, and therapy for affected patients. These molecular changes involve interacting networks that operate at the transcriptional, translational, and posttranslational levels. Traditional approaches have generally not been useful due to the complexity of interactions, the difficulty of finding the proper combinations of genes and proteins to investigate, and the reliance on techniques that examine one or only several genes or proteins at a time.

The application of novel unbiased discovery technologies offers the opportunity for comprehensive and systematic molecular analysis to capture the complex cascade of events underpinning the clinical behavior of tumors. Tumors are believed to have molecular footprints that can be identified through the combined application of high-throughput profiling techniques and sophisticated bioinformatics tools for complex data analysis and pattern recognition. The main underlying goal is the identification of new targets that may provide insights into the underlying mechanisms of cancer biology, which in turn can potentially lead to novel approaches to cancer diagnosis, prediction of clinical outcomes, and development of new therapeutic targets.

Oncogenomic Technologies

Cancer can be simplistically thought of as the overexpression of oncogenes and/or the silencing of tumor suppressor genes. However, in most cancers, including HNSCC, cancer development and progression is likely due to numerous genetic alterations involving a variety of different pathways. Although common alterations underlie many types of cancer,

an individual cancer often develops due to an accumulation of specific mutations in DNA. Since these mutations accumulate randomly, different combinations of mutations exist between different individuals with the same type of cancer. Through the years, the cytogenetic analysis of cells has evolved from the gross visual analysis of chromosomes to a detailed analysis of the regions of chromosomal gain, loss, and translocation. These techniques include comparative genomic hybridization (CGH) where normal and tumor DNA is labeled and hybridized to normal metaphase chromosomes and the fluorescence pattern is then analyzed for increased or decreased intensity representing copy number differences between genomes. Similarly, fluorescent in situ hybridization (FISH) utilizes labeled sequence specific probes, allowing for the detection of particular genes of interest as well as visualization of copy number per cell.

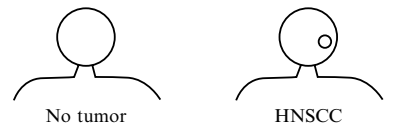
More localized and specific analysis has been made possible through the advent of high-throughput DNA sequencing facilities as well as novel approaches to look at genomic variability. Single nucleotide polymorphisms (SNPs) are areas in the genome with an altered DNA sequence that may be markers for disease predisposition or may be used to genetically identify patients. Microsatellites are tandem nucleotide repeats that are generally located in noncoding areas of the genome. They can have variable length and have been mapped to specific chromosomal regions, allowing for the detection of adjacent genes of interest. In addition, microRNAs are a noncoding family of genes involved in posttranscriptional gene regulation that are associated with cell proliferation, cell differentiation, cell death, and carcinogenesis. Each of these can be investigated through the use of array technology.

The most commonly utilized platform for oncogenomic analysis currently is DNA microarray technology, which offers the capacity for parallel measurement of relative gene expression levels (Fig. 4.1). These technologies are based on the selective mRNA or cDNA hybridization to DNA probes on the array surface. There are two general categories of microarrays, commercially available microarrays with defined content or microarrays produced with variable and customizable content. Microarray technology involves DNA sequence hybridization onto microscopic surfaces, which can be read by a laser able to detect the signal of minute fluorophores. These studies can incorporate nearly the entire known genome in a single experiment.

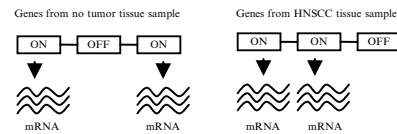
Each of these technologies generates large amounts of data that can be generated from a single sample, particularly from tumor lysate or serum. Bioinformatics technologies enable the statistical analysis of this data and address the issues of data management and generate prediction algorithms to shortcut the experimental process. These data can be examined via unsupervised analysis using data based only on gene expression pattern regardless of the specific

Fig. 4.1 Algorithm for using DNA microarray analysis to identify altered expression levels in HNSCC. After careful selection of patients, tissue samples are collected from study participants and mRNA is isolated. The mRNA represents the expression profile of the isolated cells as only active genes will produce mRNA. Microarray data from various tissues can be compared to generate differential expression patterns reflective of variations in gene expression between subjects. This data can be combined to define cancer signatures reflective of specific steps in tumorigenesis

1) Samples of tissue are collected from appropriate areas to be studied



2) mRNA is isolated



3) DNA copies are generated and labeled with various markers/probes

4) Labeled samples are applied to the microarray

5) Microarray is scanned and data is collected

6) Data processing, normalization, and differential expression analysis

7) Meta-profiles and cancer signatures

characteristics of the tissue being examined. This approach offers the potential to segregate different tumor types and allows identification of tumor subtypes that are not distinguishable by clinical, radiologic, or histologic characteristics. By contrast, supervised approaches select genes with parameters or conditions and the analysis is dependent on the supervising parameter to discriminate the groups or categories with highest prediction accuracy. A predictive gene list is generated from a training set and the results are then confirmed by cross validation and analysis by an independent cohort of patient samples.

Proteomic Technologies

Proteome analysis is complementary to DNA microarray technology. Some techniques of proteomic analysis are widely used and clinically applicable, such as enzyme-linked immunosorbent assay and immunohistochemistry, while others are used primarily as research tools, such as immunoblotting and immunoprecipitation. Most of these techniques are limited to the study of only one or a few proteins at a given time. More comprehensive screening is permitted through 2D gel electrophoresis (2-DE). 2-DE is the method with highest resolution for the separation of protein mixtures and is believed to be superior for pattern analysis of complex samples. However, 2-DE may be difficult to use with certain proteins such as membrane proteins and basic proteins and

has limited resolution of proteins in the low molecular weight spectrum. 2-DE separates proteins according to isoelectric points (isoelectric focusing) followed by separation according to molecular mass (SDS-PAGE). Peptide mass fingerprinting permits in-gel digestion of the protein spot of interest with a specific enzyme and resulting peptides are extracted from the gel and molecular weights of these peptides are measured. Alternatively, the peptides can be fragmented in a mass spectrometer yielding partial amino acid sequences from the peptides which act as sequence tags.

Fundamentally important to recent advances in proteomics have been improvements in the speed, accuracy, and sensitivity of mass spectrometry (MS) instruments for the analysis of complex protein mixtures or tissues (Fig. 4.2). MS analyzes proteins or peptides as ions which can be distinguished based on mass to charge ratio (m/z). Basic components of the instrument are the ion source which volatilizes and ionizes the proteins, mass analyzer which separates proteins based on m/z values, and the detector which detects the sample after separation. The two most commonly used MS approaches are matrix-assisted laser desorption ionization (MALDI) and surface-enhanced laser desorption ionization (SELDI). These new high-throughput methodologies have the ability to observe large numbers of protein events. Furthermore, as compared to 2-DE they permit improved speed, high-throughput capability, lower amounts of protein sample, effective resolution of low mass proteins, and direct application to assay development. Furthermore, sample loading and processing can be fully automated.

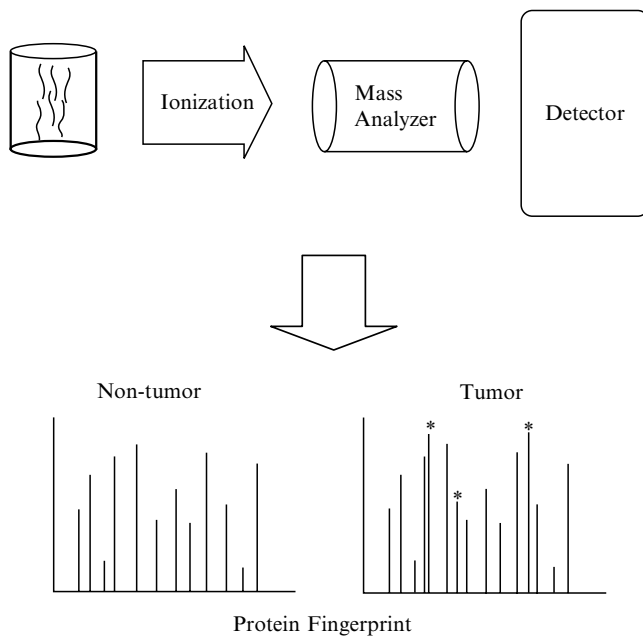


Fig. 4.2 Mass spectrometry approaches to biomarker analysis. Analysis begins with a protein or peptide mixture that is processed to maximize the number of detected differentially expressed proteins. The sample is subsequently ionized by a variety of instruments such as a laser and separated by a mass analyzer (TOF or ion trap) based on mass and charge. The resulting spectra are representative of the ionized proteins within the initial sample. Bioinformatics approaches are then utilized to compare the spectra to identify unique and differing protein components (*asterisk* indicates differentially expressed m/z species)

MALDI is commonly used for bioanalysis and employs laser energy to ionize and volatilize proteins. A matrix such as a UV absorbing organic acid is mixed with the sample to absorb laser energy and transfer it to the proteins to generate ions which are then transferred to the mass analyzer. Ionization is not uniform and depends on relative protein abundance and intrinsic chemical characteristics. MALDI is generally coupled with a time-of-flight (TOF) mass analyzer which separates proteins based on time to traverse a flight tube and strike a detector. MALDI-TOF-MS is a particle counting method that relies on molar abundance. It requires minimal sample preparation, can distinguish hundreds to thousands of proteins from a complex mixture, and can detect subtle protein modifications. However, MALDI has a limited mass range, limited sensitivity for low abundance proteins, and proteins with extremely high concentration can interfere with detection of proteins with similar m/z ratios.

SELDI utilizes a surface to capture and partially purify proteins from a complex sample based on physical and biochemical properties and is dependent on protein conformational stability for reliable detection. A variety of coated surfaces are presently available that bind proteins based on hydrophobicity, anionic or cationic charge, or binding to metals. SELDI also partially purifies the protein sample,

making it less complex than the similar unfractionated sample for MALDI. This partial purification may lose critical proteins, but theoretically generates fewer problems with highly abundant proteins. When the process is expanded to many hundreds of samples, population-specific protein expression profiles can be deduced that are characteristic of the assayed group. However, the identified mass spectrum does not enable protein identification and none of the interactions are specific.

Reverse phase protein arrays (RPPA) are another high-throughput platform for marker screening. RPPA utilizes lysed histopathologically relevant pure cell populations. The lysate is immobilized in an array configuration via a pin-based microarrayer onto nitrocellulose slides with each spot containing the whole cellular protein contents. Each slide is then probed with an antibody that can be detected by a variety of assays. Protein samples are arrayed in miniature dilution curves to ensure that the analyte of interest remains in the linear range of detection.

Finally, tissue microarray (TMA) technology applies advanced array-based approaches to data gathering with standardized medical pathology laboratory practices. A TMA block is loaded with freshly sectioned core biopsies from paraffin-embedded tissues from large cohorts of cancer patients on a single slide. Automated digital image capture is followed by pathologist scoring of the image. Further evolution in the analysis of stained TMA sections involves automated scoring of staining intensities and features on TMA slides using image analysis software. TMA provides the capability to perform rapid analysis of comprehensive panels of normal and disease specimens. TMA allows visualization of molecular targets in thousands of tissue specimens at a time and reveals cellular localization, prevalence, and clinical significance of candidate genes and gene products. However, TMA is limited by the availability of antisera, only provides a qualitative estimation of protein levels, and may miss important histologic areas due to the small size of the core biopsies utilized in these arrays.

Oncogenomics of HNSCC

Genomic Changes Underlying Malignant Transformation

Cancer develops from the accumulation of various genetic alterations. DNA microarrays have had a major impact on biomedical research and have emerged as a powerful tool for the parallel measurement of relative gene expression levels and have been widely studied in HNSCC (Table 4.1). The usage of DNA microarrays to generate clinically relevant molecular

Table 4.1 HNSCC studies incorporating DNA microanalysis

Authors	Tissue samples	Array platform
Jeon et al. [1]	25 HNSCC cell lines 1 immortalized oral keratinocyte line	Incyte Genomics Human GEM2 cDNA
Jarvinen et al. [3]	10 HNSCC cell lines 10 primary laryngeal tumors 5 LN+, 5 LN-	Agilent Human 1A
Jarvinen et al. [4]	18 oral tongue SCC cell lines	Agilent Human 1A and Human 1A (v2)
Mendez et al. [5]	19 primary, 7 recurrent OC 8 LN+, 18 LN- 2 premalignant lesions	Affymetrix Test-1 and HuGeneFL
Ha et al. [6]	7 primary HNSCC 7 H&N dysplastic lesions	Affymetrix Hu95A.v2
Chen et al. [7]	171 oral SCC 17 dysplastic lesions	Affymetrix U133 2.0 Plus
Ginos et al. [8]	25 primary, 16 locally recurrent 19 LN+, 21 LN-, 1 LN unknown	Affymetrix HG-U133A
Ziober et al. [9]	13 oral SCC 3 LN+, 10 LN-	Affymetrix HG-U133A
Kondoh et al. [10]	27 oral SCC 5 LN+, 21 LN-, 1 LN unknown 19 leukoplakias	IntelliGene HS Human
Schmalbach et al. [12]	20 primary OC/OP 13 LN+, 7 LN- 4 oral SCC cell lines	Affymetrix HG-U95Av2
Belbin et al. [13]	9 primary OC All LN +	Custom cDNA microarray
Roepman et al. [14]	Predictor set: 82 primary OC/OP Validation set: 22 primary OC/OP 55 LN+, 49 LN-	Qiagen Human Array-Ready Oligo set (version 2.0)
Hensen et al. [15]	22 primary HNSCC 11 LN+, 11 LN-	Qiagen Human Array-Ready Oligo set (version 2.0)
Rickman et al. [16]	186 primary HNSCC 132 LN+, 50 LN-, 4 LN unknown	Affymetrix HGU133_Plus2
Chung et al. [17]	55 primary HNSCC, 5 recurrent 26 LN+, 14 LN-, 20 LN unknown	Agilent Human 1
Cromer et al. [18]	34 primary HP SCC 30 LN+, 4 LN-	Affymetrix HG-U95A

signatures has grown in its acceptance. Early studies showed the heterogeneous nature of HNSCC tumors at the molecular level. However, direct comparison between studies has often proved difficult due to the variety of gene-expression arrays, platforms, and data analysis algorithms used.

Preclinical work in HNSCC cell lines provided initial insights into the genetic variations that may underlie the cancer phenotype. Cell lines offer relative homogeneity of samples for investigation, but may suffer from artifacts of immortalization and passage in vitro compared with human tumors. One microarray study analyzed 25 HNSCC cell lines and one immortalized human oral keratinocyte cell line and found wide alteration in the gene expression in cell cycle regulation, oncogenesis, cell proliferation, differentiation, and apoptosis [1]. Their work revealed two distinctive subtypes of gene expression patterns, but these patterns did not seem to correlate with the clinical staging or differentiation grade of the original tumors. A more recent study used SNP-array based loss of heterozygosity (LOH) profiling on whole-genome loss of 41 HNSCC cell lines and found several frequent LOH regions [2]. This study identified a region on chromosome 8 that exhibited the most frequent LOH (87.9%) and found that the mitochondrial tumor suppressor gene 1, a candidate tumor suppressor gene residing in this area, was consistently down regulated in expression, suggesting it may be a tumor suppressor in HNSCC.

Another report utilized genome-wide CGH and expression microarray analyses to reveal known and novel amplicons that showed concomitant increase of copy number and expression of target genes for both laryngeal SCC cell lines and primary tumors [3]. They found that the overexpression of 739 genes could be attributed to gene copy number alteration in cell lines, of which 325 genes showed the same phenomenon in primary tumors. Subsequently, this group analyzed oral tongue SCC cell lines and found that these cell lines exhibited similar genomic alterations as had been previously been found in their laryngeal SCC cell lines despite the differences in clinicopathologic features between these anatomic subsites [4]. A wide variety of genes were found to be altered including deletions of known tumor suppressor genes such as *FHIT*, *CSMD1*, and *CDKN2A*.

Other studies have attempted to provide a framework for improving our understanding of the molecular events underpinning various aspects of these tumors. The progression of normal epithelia through premalignancy to HNSCC is a multistep process that has been associated with distinct histologic characteristics at each stage. An early study analyzed invasive SCC lesions from the oropharynx and oral cavity and using hierarchical clustering analysis they were able to show that oral SCC was distinguishable from normal oral tissue, but there was heterogeneity among the tumors even of a particular histopathologic grade and stage [5]. This study identified 239 genes that were overexpressed and 75 genes that were down regulated, but could not find statistically significant differences in gene expression between metastatic and nonmetastatic tumors. Later, another group established

a transcriptional progression model of HNSCC in the progression from normal mucosa to dysplastic epithelium to invasive HNSCC [6]. Matched samples were analyzed using gene expression arrays, significance analysis of microarrays, hierarchical clustering, and principal components analysis to identify genes with differential expression patterns between the tissue groups. The progression from normal to premalignant was associated with altered expression of 334 genes (108 up regulated and 226 down regulated) while the progression of premalignant to malignant was only associated with altered expression of 18 genes (5 up regulated and 13 down regulated). This transcriptional model suggested that the majority of alterations occurred before the development of invasive cancer.

An alternative strategy was used in another study employing forward and stepwise logistic regression analyses to identify potential biomarkers for the early detection of oral SCC by comparing gene expression of primary oral SCC, oral dysplasia, and clinically normal oral tissue [7]. They identified combinations of genes which differentiated oral SCC from controls that included laminin-gamma2 chain, collagen type IV alpha1 chain, collagen type I alpha1 chain, and peptidyl arginine deiminase type 1. Another group analyzed 41 HNSCC tumors from various anatomic sites and compared them with normal oral mucosa with gene expression arrays [8]. They used statistical and data filtering criteria to identify 2,890 genes differentially expressed between the two groups and revealed functional gene expression signatures that were highly represented in HNSCC, including those involved in inflammatory response, epidermal differentiation, cell adhesion, and extracellular matrix functions. They suggested that the disease signature is an intrinsic feature of a HNSCC and may function as a predictor of early local treatment failure.

Several studies have attempted to build on the growing lists of putative biomarkers by generating gene sets which may be able to lead to useful predictions regarding the propensity for a given lesion to be or develop into a cancerous lesion. One study matched tumor and normal specimens from the oral cavity and analyzed microarray gene expression data with a supervised learning algorithm [9]. This study generated a 25-gene signature that could classify normal and tumor specimen that was highly accurate on independent validation test sets, but failed to predict nonoral tumors. Many of the genes in the predictor set had been previously implicated in oral SCC. The predictor set comprised several epithelial marker genes that had categories of potential interest including extracellular matrix components and cell adhesion molecules. Similarly, a different group attempted to generate a classifier set for oral SCC and leukoplakias and found differential expression of 118 marker gene candidates by complementary DNA microarray [10]. Further evaluation demonstrated an 11-gene predictor set that could distinguish the two groups with greater than 97% accuracy.

Genomic Changes Underlying Metastases

Metastasis is the principal cause of death in patients suffering from cancer, but the underlying molecular mechanisms are poorly understood. It is widely believed that the accumulation of genetic damage leads to the expression of a malignant phenotype that precedes metastasis formation. The reliable detection of the presence of metastases in local lymph nodes to distinguish metastatic from nonmetastatic tumors would be important for treatment planning. One study compared the gene-expression profiles of adenocarcinoma metastases of multiple tumor types to unmatched primary adenocarcinomas [11]. They found a gene-expression signature of 17 unique genes that could distinguish the two groups. Furthermore, an analysis of 279 independent primary solid tumors of diverse types and organ sites revealed that tumors carrying this signature were associated with metastasis and poor clinical outcome.

With specific regard to HNSCC, several groups have investigated differences in gene expression between primary tumors that had or had not metastasized. In one analysis of tumors from the oral cavity and oropharynx, 101 genes demonstrated significant expression differences between the metastatic and nonmetastatic tumors [12]. These genes included a variety of cellular functions putatively associated with cancer behavior and the gene with the greatest differential expression between the metastatic and nonmetastatic tumors was collagen type 11 alpha1. A different study used microarray analysis to measure gene-expression changes associated with tumor progression in patients with stage III or stage IV untreated oral SCC [13]. They identified 140 genes that consistently increased in expression during the progression from normal tissue to invasive tumor to metastatic node as well as 94 genes that decreased in expression in a similar progression, which revealed a distinct pattern of gene expression during the progression from histologically normal tissue to primary carcinoma to nodal metastasis.

In another study, 82 primary tumors located in the oropharynx or oral cavity regions were analyzed using DNA microarray gene-expression profiling [14]. This study established a set of 102 predictor genes for determining the presence of lymph node metastases. Many of the predictor genes they found were previously implicated in metastasis. The application of this gene set to a validation group gave an overall predictive accuracy of 86% as compared with 68% based solely on clinical diagnosis. A subsequent study implemented this dataset as a reference dataset and an independent gene expression dataset of metastasized and nonmetastasized HNSCC tumors as a validation dataset [15]. They utilized supervised gene-based and pathway-based analysis to evaluate differences in gene expression to enhance the understanding of the biological context of the results. The identified gene sets were involved in extracellular matrix remodeling

(including matrix metalloproteinases (MMPs) and their regulatory pathways) as well as hypoxia and angiogenesis.

Another group looked at 186 primary tumors and analyzed the samples with respect to whether the development of metastasis was the first recurrent event [16]. They collected transcriptome and array-CGH data followed by non-supervised hierarchical clustering to distinguish tumors differing in pathological differentiation. They were able to identify associated functional changes and created a four-gene model (*PSMD10*, *HSD17B12*, *FLOT2*, and *KRT17*), which predicted the metastatic status with 77% success in a separate validation group and the prediction was independent of clinical criteria. Similarly, another study revealed that gene expression patterns in 60 primary and previously untreated HNSCC allowed the tumors to be categorized into four distinct subtypes with statistically different recurrence-free survival [17]. Clinical nodal staging resulted in low prediction accuracy when used as the supervising parameter. However, supervised analyses using pathological staging to predict lymph node metastasis status improved the prediction accuracy of gene expression from the primary tumor which was further improved by analysis based on anatomic subsites leading to a prediction accuracy of 83%.

A large-scale gene expression analysis of the hypopharynx, a location associated with particularly aggressive behavior, found 119 genes that were highly differentially expressed between early and late tumors [18]. Furthermore, 164 differentially expressed genes were found that differentiated between relatively nonaggressive and aggressive tumors. Clustering of the associated probe sets defined the two groups of samples and correctly assigned 92% of the tumors. In a separate study, genome-wide analysis was performed looking for LOH and allelic imbalance (AI) on specimens of tumor stroma and tumor epithelium isolated by laser capture microdissection on 122 patients with HNSCC and a history of smoking [19]. They found nearly twice as many areas of LOH/AI within the stroma as was found in the epithelium, more than 40 areas in total. Furthermore, they found three stroma-specific loci that were significantly associated with tumor size and cervical lymph node metastasis, highlighting the importance of examining stromal and epithelial elements and suggesting that stromal alterations play an important role in HNSCC behavior.

Genomic Changes Underlying Variable Responses to Treatment

Treatment protocols often involve the use of chemotherapy and/or radiation therapy. Several recent studies have directed their attention toward the identification of genetic alterations that would give prognostic information regarding a given

tumor's likelihood of response to various treatment protocols. One study on HNSCC cell lines that exhibited relative radioresistance and radiosensitivity identified 167 genes that were significantly overexpressed in radioresistant cells, 25 of which included cancer-related genes involved in growth, proliferation, apoptosis, and adhesion [20]. Another study used significance analysis of microarrays for gene selection and a multivariate linear regression model for the prediction of radiosensitivity [21]. They identified three novel genes whose expression values correlated with radiation sensitivity and the overexpression of one of these genes, RbAp48, in cancer cells lines induced radiosensitization.

In another recent study, 92 biopsies were obtained from untreated HNSCC patients prior to treatment with cisplatin-based chemoradiation for advanced HNSCC [22]. This group utilized supervised analyses to predict locoregional control and disease recurrence and found several gene sets that were enriched in recurrences. Furthermore, they utilized a signature established by Chung et al. [17] for HNSCC defining a high-risk group and found it to be predictive for locoregional control and disease-free survival in their dataset. Finally, a more targeted analysis utilized a cDNA array consisting of genes associated with angiogenesis and/or metastasis [23]. Seventeen genes were correlated with locoregional failure, of which *MDM2* and *erbB2* were found to be predictors of locoregional failure in their population of patients treated with chemoradiation therapy.

Genomic Changes Found in Surrogate Tissues

An evolving area of investigation involves the use of surrogate tissues in the investigation of HNSCC. Using saliva from patients with primary T1/T2 oral SCC with matched control patients in terms of age, gender, and smoking history, one group used microarrays to profile the human salivary transcriptome [24]. They found 1,679 genes that were significantly differentially expressed between the groups including seven cancer-related mRNA biomarkers that exhibited at least a 3.5-fold elevation in oral SCC saliva (*IL8*, *IL1B*, *DUSP1*, *HA3*, *OAZ1*, *S100P*, and *SAT*). The combination of four of these biomarkers had a discriminatory power of 91% sensitivity and specificity for oral cancer detection. A subsequent study compared the clinical accuracy of saliva with that of blood by using RNA biomarkers for oral cancer detection [25]. Using four serum mRNA markers, a sensitivity of 91% and a specificity of 71% were obtained for distinguishing oral cancer. However, the four salivary mRNA markers had a higher receiver operating characteristic curve value demonstrating that for oral cancer detection, salivary transcriptome diagnostics may demonstrate a slight advantage as compared with serum.

Meta-Analyses of HNSCC Microarray Studies

Given the increasing number of studies of the HNSCC transcriptome, a recent analysis looked at the studies incorporating DNA microarray analysis to examine genetic expression changes associated with the development of HNSCC [26]. Eighty-four genes were identified with common alterations in transcriptional expression across multiple studies. Many of these had been reported to be involved with HNSCC, including MMPs, integrins, collagens, fibronectin, tenascin C, and cathepsin L, as well as many genes with less characterized roles in HNSCC. Only one gene, transglutaminase 3 was common to at least three of the reviewed studies. Overall, they found that genes encoding extracellular matrix and integral membrane proteins, cell adhesion molecules, and proteins involved in epidermal development and differentiation were most frequently identified in these studies. Furthermore, their results suggested a global down regulation of genes encoding ribosomal proteins and cholesterol biosynthesis enzymes and an up regulation of MMPs and inflammatory response genes.

Another study looked at 63 HNSCC transcriptomic studies in three categories of comparisons, premalignant vs. normal (Pre), primary tumors vs. normal (TvN), and metastatic or invasive vs. primary tumors (Meta) [27]. They used a systems-biology approach via network-based meta-analysis and verified that 82 genes, 1,260 genes, and 321 genes in the Pre, TvN, and Meta comparisons, respectively, were found reported at least twice. Overall, 1,442 unique genes were reported at least twice in the studies that they analyzed. In terms of the direction of fold changes of the verified genes, the least contradiction was found in the TvN group and the most contradiction was found in the Pre group. Furthermore, they found that few genes overlapped between the Pre and Meta groups although many genes overlapped between the other pairs of comparisons. Genes that were highly reported in prior studies across all three stages were *ECM1*, *EMPI*, *CXCL10*, and *POSTN*. Subsequently, they constructed knowledge-based networks which revealed that integrin signaling and antigen presentation pathways were highly enriched in the dataset and they found that chromosomal regions of 6p21, 19p13, and 19q13 had genomic alterations that were correlated with the nodal status of HNSCC.

Proteomics of HNSCC

Tumor Tissue Studies

High-throughput proteomic technologies have been utilized to detect biologically significant differences in protein expression of HNSCC in the same types of samples utilized in

gene-expression analysis. These studies have used a variety of techniques as outlined earlier in the chapter. One study utilized SELDI-TOF-MS to generate proteomic spectra and used the “Lasso algorithm” to extrapolate proteomic patterns that can best discriminate HNSCC patients from non-cancer controls which identified 65 significant data points to be used for discrimination [28]. Testing of these points yielded moderate sensitivity of 68% and specificity of 73% indicating that with further improvement and validation it may be useful as a screening test for HNSCC in the future. More recently, another study analyzed 113 HNSCC, 73 healthy, 99 tumor-distant, and 18 samples of tumor-adjacent squamous mucosa by SELDI-TOF-MS [29]. They found 48 protein peaks differentially expressed between healthy mucosa and HNSCC. A supervised prediction analysis revealed greater than 90% classification of healthy mucosa and tumor samples and 72% of the tumor-adjacent mucosa samples were predicted as aberrant, providing evidence for the existence of genetically altered fields with inconspicuous histology.

MALDI-TOF has also been successfully used in HNSCC proteomic studies. In one such investigation, MALDI-TOF was coupled with magnetic bead fractionation to analyze an HNSCC cohort consisting of matched pretreatment and 6–12 month posttreatment samples for analysis [30]. A set of approximately 200 spectral peaks was used and was able to largely correctly classify normal from pretreatment HNSCC samples, pretreatment from posttreatment, and normal from posttreatment samples. This showed the potential for use of this technology as a discovery platform in order to generate biomarker panels that potentially could be used for more accurate prediction of prognosis and treatment efficacies for HNSCC.

Another study used multidimensional LC-MS/MS to identify proteins that are differentially expressed in HNSCC for cancer biomarker discovery [31]. More than 811 proteins were identified, which included structural proteins, signaling components, and transcription factors. They utilized a panel of the three best performing biomarkers, YWHAZ, stratifin, and S100-A7, to discriminate cancerous from noncancerous head and neck tissue. Their differential expression was verified by immunohistochemistry, immunoblotting, and RT-PCR and achieved a sensitivity of 92% and specificity of 87% in an independent set of HNSCC in discriminating tissue types. More recently, an analysis of samples from HNSCC patients with 2-DE and MALDI-TOF-MS revealed 181 proteins with differential expression between pretreatment and posttreatment samples [32]. Classification by disease status revealed significant differential expression of 16 proteins including several protease inhibitors and other molecules with direct implications on tumor survival. Another study attempted to validate DNA microarray results on a subset of genes that could potentially

serve as biomarkers of oral SCC [33]. This group was able to validate five of six potential biomarkers by using qRT-PCR to examine expression changes in oral SCC and normal control tissues. TMA analysis then revealed that four of the six biomarkers (*SPARC*, *POSTN*, *TNC*, and *TGM3*) had differential expression and localization.

Surrogate Tissue Studies

Serum studies have been widely used in the investigations of HNSCC given the challenges in obtaining repeat tumor samples. One study used MALDI on sera from 99 HNSCC and 143 controls to obtain serum protein patterns [34]. The mass spectra and linear discriminant analysis were used to select the top 45 spectral features. The subsequent spectral profiles from the sera of the HNSCC patients statistically significantly differed from the sera of control subjects. In a separate study, samples were analyzed by SELDI-TOF and 80 common peaks or clusters were generated from the training set and used to create classification trees [35]. This algorithm correctly identified 91% of HNSCC sera in the training set and 83% of HNSCC samples in the test set, yielding an overall sensitivity of 83% and an overall specificity of 90%. Furthermore, they were able to identify a particular peak as the known biomarker metalloproteinase-1 based on mass and whose relative intensity consistently correlated with levels detected by radioimmunoassay.

More recent research has sought novel surrogate tissue sources, which may be convenient for investigation. Alterations in the levels of biomarkers have been investigated in other body fluids that are near or bathe tumor sites. Accordingly, saliva is an ideal complementary resource for developing HNSCC diagnostics and more recent study attempts have focused on the use of salivary proteomics for oral cancer biomarker discovery. One analysis collected saliva from 64 oral SCC and 64 healthy subjects and utilized subtractive proteomics to find that several salivary proteins were differentially expressed [36]. Five candidate biomarkers were validated and demonstrated high sensitivity (90%) and specificity (83%) in detecting oral SCC. Another recent study, found two proteins, alpha-1-B-glycoprotein and complement factor B proteins, to be present in patients with HNSCC but not in normal specimens, while cystatin S, parotid secretory factor, and poly-4-hydrolase beta-subunit proteins were detected in most normal saliva but not in HNSCC [37]. These results suggest that certain proteins are differentially found in saliva from patients with HNSCC and a small set of proteins may be useful for future validation for clinical investigation. Finally, another study built on prior data indicating that the expression of IL-6 and IL-8 are uniquely associated with oral SCC. They analyzed patients

with newly diagnosed T1 or T2 oral cavity or histologically confirmed oropharyngeal SCC. Their analysis revealed that IL-8 was detected at higher concentrations in saliva and IL-6 was detected at higher concentrations in serum of patients with oral SCC, indicating that these markers and tissues hold promise for biomarker analysis in oral SCC [38].

Challenges of Oncogenomics/Proteomics in HNSCC

The application of these novel technologies offers many opportunities for advanced analyses of HNSCC. With the completion of the Human Genome Project and advances in array technology, gene expression studies offer an opportunity to look at the full complement of genes expressed by a tumor. Gene expression profiling experiments have generated a tremendous amount of information regarding concomitant genetic events during disease. However, the functional consequences of disease are also regulated by the deregulation of protein products and protein networks so that the information flow cannot be ascertained from gene analysis alone.

Key Advantages and Limitations of DNA Microarrays:

Advantages:

- Provide insight into fluctuations in gene transcription.
- Capable of generating large amounts of expression data quickly.
- Current microarrays give expression data from essentially the entire genome.
- Technological advances have generated microarrays that can be implemented using automated, high-throughput strategies, at reduced costs.

Limitations:

- High quality RNA is required for the generation of good expression data.
- Changes in RNA expression may not correlate with changes in protein levels.
- Advanced biostatistics are necessary to process vast amounts of data generated.

Furthermore, there are a variety of potential pitfalls in microarray analysis that may obscure the quantification of genes of interest. One of the most important variables relates

to the quality of the transcripts utilized for the microarray which may relate to initial and long-term tissue handling as well as processing of the transcripts for use in the microarray studies. A recent report indicated that there may be a storage-time decrease in the predictive performance of tissue samples [1]. Other common causes of signal variations include errors with fluidics protocols, spoiled or omitted hybridization cocktail reagents, and inaccurate quantification of labeled samples. There are also a variety of factors inherent to the microarray technology such as intensity-dependent dye effect and spatial-dependent dye effect that can influence the quantification process. In addition, studies vary in the heterogeneity of the cell types included in the samples from 50% tumor cells to the pure isolation of single tumor cells.

By contrast, the study of disease-related protein changes provides unique challenges since these changes are dependent on highly regulated processes at the transcriptional, translational, and posttranslational levels.

Key Advantages and Limitations of Proteomic Approaches:

Advantages:

- Provide insight into fluctuations in transcribed and translated gene products as well as posttranslational modifications.
- Capable of using a variety of tissue sources with minimal processing to analyze variations.
- Increasingly offering high-throughput technologies.

Limitations:

- High abundance proteins may obscure data.
- Generally, only analyze a minority of proteins within the entire sample.
- Difficult to correlate individual spectral peaks/signatures with actual proteins.

Many of the standard proteomic approaches rely on the usage of complex protein mixtures and the indirect assignment of spectra to identify target proteins. These approaches are often hampered by the presence of large quantity proteins that may obscure quantification of the proteins of interest. Accordingly, there has been increasing interest in developing protein microarrays capable of identifying hundreds of protein events simultaneously; however, these arrays have a set of unique problems. Protein interactions are governed by complex associations between the target protein and the antigen-binding site on the antibody. Furthermore, proteins tend to denature with changes in pH or temperature and antibodies must exhibit strong affinities and specificity to each of their respective

substrates especially in the analysis of specific protein states, such as phosphorylation or proteolytic cleavage. In addition, the variation in protein concentration in cells may vary widely, so detection methods must exist that can quantify protein concentration over many orders of magnitude.

These studies also require careful experiment planning starting with the selection of appropriate controls. Many studies use matched “normal” epithelium, but this may confound interpretations of gene expression changes occurring in HNSCC tumorigenesis. Although logistically difficult to achieve, the theoretically ideal control tissue would match for patient age, gender, smoking and drinking history, and other variables to minimize further confounding factors.

Conclusion and Future Directions

The goals of oncogenomics and proteomics are to improve diagnosis, therapy, and cure rates for cancer patients. A patient’s genomic signature of a cancer may serve as the basis for choosing the most effective therapy for the individual patient to improve their chances of recovery and their quality of life. Oncogenomics and proteomics have progressed from molecular profiling to model systems, cancer pharmacology, and clinical trials. Although it is unlikely that a single biomarker accurately detects the presence of HNSCC, analyses that can detect multiple markers may have improved predictive value when used in combination. Imperfect biomarkers may still be clinically useful for serial testing of single individuals because acute changes in biomarker levels may signal the need for an aggressive search for the cause. An important challenge for biomarker validation is the considerable molecular heterogeneity of individual cancers and the low overall incidence of the disease in general population, making it difficult to validate the true prognostic potential of a biomarker or panel of biomarkers. Nonconcordance of predictive gene lists is common in many microarray studies using different platforms and data mining tools and may represent differences in experimental design or data analyses, but also may represent true differences in biology based on different subsites or other unknown factors.

Furthermore, although current oncogenomic and proteomic approaches may yield valuable information in the identification of novel diagnostic markers, gene- and protein-expression profiles may not be able to provide an alternative method of diagnosis on their own. It may become necessary to include other technologies, such as metabolomics, peptidomics, glycomics, and lipidomics for better isolation and identification of molecular targets. In order to obtain reliable prognostic markers, these technologies will need to be combined with advanced bioinformatics tools to integrate and mine the data from basic and clinical research. Once molecular signatures are successfully validated, it will also

be important to perform long-term clinical studies to determine the validity of using these signatures in independent cohorts of patients for the prediction of patient response to therapeutic options.

References

- Jeon GA, Lee JS, Patel V, et al. Global gene expression profiles of human head and neck squamous carcinoma cell lines. *Int J Cancer*. 2004;112:249–58.
- Ye H, Pungpravat N, Huang BL, et al. Genomic assessments of the frequent loss of heterozygosity region on 8p21.3-p22 in head and neck squamous cell carcinoma. *Cancer Genet Cytogenet*. 2007;176:100–6.
- Jarvinen AK, Autio R, Haapa-Paananen S, et al. Identification of target genes in laryngeal squamous cell carcinoma by high-resolution copy number and gene expression microarray analyses. *Oncogene*. 2006;25:6997–7008.
- Jarvinen AK, Autio R, Kilpinen S, et al. High-resolution copy number and gene expression microarray analyses of head and neck squamous cell carcinoma cell lines of tongue and larynx. *Genes Chromosom Cancer*. 2008;47:500–9.
- Mendez E, Cheng C, Farwell DG, et al. Transcriptional expression profiles of oral squamous cell carcinomas. *Cancer*. 2002;95:1482–94.
- Ha PK, Benoit NE, Yochem R, et al. A transcriptional progression model for head and neck cancer. *Clin Cancer Res*. 2003;9:3058–64.
- Chen C, Mendez E, Houck J, et al. Gene expression profiling identifies genes predictive of oral squamous cell carcinoma. *Cancer Epidemiol Biomarkers Prev*. 2008;17:2152–62.
- Ginos MA, Page GP, Michalowicz BS, et al. Identification of a gene expression signature associated with recurrent disease in squamous cell carcinoma of the head and neck. *Cancer Res*. 2004;64:55–63.
- Ziober AF, Patel KR, Alawi F, et al. Identification of a gene signature for rapid screening of oral squamous cell carcinoma. *Clin Cancer Res*. 2006;12:5960–71.
- Kondoh N, Ohkura S, Arai M, et al. Gene expression signatures that can discriminate oral leukoplakia subtypes and squamous cell carcinoma. *Oral Oncol*. 2007;43:455–62.
- Ramaswamy S, Ross KN, Lander ES, Golub TR. A molecular signature of metastasis in primary solid tumors. *Nat Genet*. 2003;33:49–54.
- Schmalbach CE, Chepeha DB, Giordano TJ, et al. Molecular profiling and the identification of genes associated with metastatic oral cavity/pharynx squamous cell carcinoma. *Arch Otolaryngol Head Neck Surg*. 2004;130:295–302.
- Belbin TJ, Singh B, Smith RV, et al. Molecular profiling of tumor progression in head and neck cancer. *Arch Otolaryngol Head Neck Surg*. 2005;131:10–8.
- Roepman P, Wessels LF, Kettelarij N, et al. An expression profile for diagnosis of lymph node metastases from primary head and neck squamous cell carcinomas. *Nat Genet*. 2005;37:182–6.
- Hensen EF, De Herdt MJ, Goeman JJ, et al. Gene-expression of metastasized versus non-metastasized primary head and neck squamous cell carcinomas: a pathway-based analysis. *BMC Cancer*. 2008;8:168.
- Rickman DS, Millon R, De Reynies A, et al. Prediction of future metastasis and molecular characterization of head and neck squamous-cell carcinoma based on transcriptome and genome analysis by microarrays. *Oncogene*. 2008;27:6607–22.
- Chung CH, Parker JS, Karaca G, et al. Molecular classification of head and neck squamous cell carcinomas using patterns of gene expression. *Cancer Cell*. 2004;5:489–500.
- Cromer A, Carles A, Millon R, et al. Identification of genes associated with tumorigenesis and metastatic potential of hypopharyngeal cancer by microarray analysis. *Oncogene*. 2004;23:2484–98.
- Weber F, Xu Y, Zhang L, et al. Microenvironmental genomic alterations and clinicopathological behavior in head and neck squamous cell carcinoma. *JAMA*. 2007;297:187–95.
- Ishigami T, Uzawa K, Higo M, et al. Genes and molecular pathways related to radioresistance of oral squamous cell carcinoma cells. *Int J Cancer*. 2007;120:2262–70.
- Torres-Roca JF, Eschrich S, Zhao H, et al. Prediction of radiation sensitivity using a gene expression classifier. *Cancer Res*. 2005;65:7169–76.
- Pramana J, Van den Brekel MW, van Velthuysen ML, et al. Gene expression profiling to predict outcome after chemoradiation in head and neck cancer. *Int J Radiat Oncol Biol Phys*. 2007;69:1544–52.
- Ganly I, Talbot S, Carlson D, et al. Identification of angiogenesis/metastases genes predicting chemoradiotherapy response in patients with laryngopharyngeal carcinoma. *J Clin Oncol*. 2007;25:1369–76.
- Li Y, St John MA, Zhou X, et al. Salivary transcriptome diagnostics for oral cancer detection. *Clin Cancer Res*. 2004;10:8442–50.
- Li Y, Elashoff D, Oh M, et al. Serum circulating human mRNA profiling and its utility for oral cancer detection. *J Clin Oncol*. 2006;24:1754–60.
- Choi P, Chen C. Genetic expression profiles and biologic pathway alterations in head and neck squamous cell carcinoma. *Cancer*. 2005;104:1113–28.
- Yu YH, Kuo HK, Chang KW. The evolving transcriptome of head and neck squamous cell carcinoma: a systematic review. *PLoS One*. 2008;3:e3215.
- Soltys SG, Le QT, Shi G, et al. The use of plasma surface-enhanced laser desorption/ionization time-of-flight mass spectrometry proteomic patterns for detection of head and neck squamous cell cancers. *Clin Cancer Res*. 2004;10:4806–12.
- Roesch-Ely M, Nees M, Karsai S, et al. Proteomic analysis reveals successive aberrations in protein expression from healthy mucosa to invasive head and neck cancer. *Oncogene*. 2007;26:54–64.
- Freed GL, Cazares LH, Fichandler CE, et al. Differential capture of serum proteins for expression profiling and biomarker discovery in pre- and posttreatment head and neck cancer samples. *Laryngoscope*. 2008;118:61–8.
- Ralhan R, Desouza LV, Matta A, et al. Discovery and verification of head-and-neck cancer biomarkers by differential protein expression analysis using iTRAQ labeling, multidimensional liquid chromatography, and tandem mass spectrometry. *Mol Cell Proteomics*. 2008;7:1162–73.
- Gourin CG, Zhi W, Adam BL. Proteomic identification of serum biomarkers for head and neck cancer surveillance. *Laryngoscope*. 2009;119:1291–302.
- Choi P, Jordan CD, Mendez E, et al. Examination of oral cancer biomarkers by tissue microarray analysis. *Arch Otolaryngol Head Neck Surg*. 2008;134:539–46.
- Sidransky D, Irizarry R, Califano JA, et al. Serum protein MALDI profiling to distinguish upper aerodigestive tract cancer patients from control subjects. *J Natl Cancer Inst*. 2003;95:1711–7.
- Wadsworth JT, Somers KD, Stack Jr BC, et al. Identification of patients with head and neck cancer using serum protein profiles. *Arch Otolaryngol Head Neck Surg*. 2004;130:98–104.
- Hu S, Arellano M, Boonthung P, et al. Salivary proteomics for oral cancer biomarker discovery. *Clin Cancer Res*. 2008;14:6246–52.
- Ohshiro K, Rosenthal DI, Koomen JM, et al. Pre-analytic saliva processing affect proteomic results and biomarker screening of head and neck squamous carcinoma. *Int J Oncol*. 2007;30:743–9.
- St John MA, Li Y, Zhou X, et al. Interleukin 6 and interleukin 8 as potential biomarkers for oral cavity and oropharyngeal squamous cell carcinoma. *Arch Otolaryngol Head Neck Surg*. 2004;130:929–35.

Chapter 5

Genetics and Epigenetics of Head and Neck Cancer

Richard J. Shaw and Jagtar Dhanda

Abstract Cancer is caused by a multi-step progression of genetic and epigenetic aberrations resulting in a clonal expansion of cells. These cells have a selective growth advantage characterised as the “hallmarks of cancer” including loss of control of the cell cycle, genomic instability, inhibition of apoptosis, insensitivity to growth signals and promotion of angiogenesis. A greatly increased understanding of the pathogenesis of the various underlying genetic and epigenetic lesions has accompanied the recent explosion of knowledge, coined the “omics” revolution. In a variety of cancer sites, we are already able to explain and classify much of the heterogeneity of tumour behaviour in terms of the underlying molecular lesions responsible. This capacity will increase with the scope of technologies becoming available, and being able to offer a corresponding tailored approach to therapy remains the ultimate goal.

Keywords Genetics • Epigenetics • Mutations • Carcinogenesis • Tumour suppressor genes • Oncogenes • DNA methylation • Histones

Introduction

Despite the many innovations in cancer management, it is increasingly apparent that new advances in cancer therapy will rely on a greater understanding of treatment at a molecular level. A new “omics” language has developed with genomics, proteomics and metabolomics, all fields of translational research and terms used to bridge together traditional pure and applied science into the clinical setting. The clinical behaviour of HNSCC varies greatly from patient to patient, site to site and even within individual sub-sites, and its intrinsic heterogeneity in biological properties, which is common

in solid tumours, is reflected in the diversity of outcomes. These differences in tumour properties are a consequence of differing genetic and epigenetic changes as well as differing host responses. A better understanding of the genetic mechanisms of carcinogenesis will help to target therapies to specific characteristics of a patient’s tumour, central to the modern concept of personalised medicine. One example with clear and clinically exploitable differences in genetic mechanism is that of Human Papilloma Virus (HPV) mediated HNSCC, although this will not further discussed here as it is covered specifically in Chapter 10. Much of what follows is essentially a discussion of HPV negative HNSCC.

Cancer results from the accumulation of molecular lesions which occur, and might be investigated, at the genetic, epigenetic, messenger RNA or protein level. The importance of genetic changes and frequency of the resultant disease have led to cancer being labelled the commonest human genetic disease. Often when we consider genetic diseases, we immediately think of inherited diseases. Fortunately inherited head and neck cancer syndromes are relatively uncommon, but there are several such entities predisposing to HNSCC which offer a valuable window on the events also critical to sporadic cancers. The great majority of sporadic cancers occur due to exposure to environmental mutagens. These mutagens cause genetic lesions that have a huge range of scale, from a single nucleotide to an entire chromosomal region being lost or gained. These genetic abnormalities occur more or less randomly rather than as an ordered sequence, and it is apparent that while some may be critical “drivers” to carcinogenesis, others are “bystander” events. Our ability to explore this disordered cancer genome is dependent on, and limited by, the availability of representative tumour models, high-quality tissue resource and the capacity of available technologies. Fortunately, there has been great progress in both areas in recent years and it is likely that this will significantly contribute to our understanding of cancer biology. Since the completion of the 15-year human genome project in 2003, the capability of the available “next-generation” sequencing techniques is such that an entire genome can be re-sequenced using a fraction of the resources previously required. It is now feasible to re-sequence individual tumours in attempt to

R.J. Shaw (✉)
Head and Neck Surgery, Oral & Maxillofacial Surgery, University
Hospital Aintree, University of Liverpool, Daulby Street, Liverpool
L69 3GA, UK
e-mail: Richard.Shaw@liverpool.ac.uk

highlight which mutations appear critical to carcinogenesis. In many respects, DNA is an excellent resource for clinical biomarkers. Not only do many of the critical events occur at the DNA level, but also it is a highly stable macromolecule which is simply extracted and less prone to degradation and artefact than the more labile RNA and protein alternatives.

One of the most consistent characteristics of cancer is genomic instability, resulting from loss of function in the DNA repair mechanisms. Each cell is daily subject to thousands of genetic insults which are generally repaired, or if beyond repair, the cell is destined for apoptosis. Inherited predisposition to cancer can either be those rare single gene autosomal recessive syndromes with a greatly increased risk (i.e. inherited cancer syndromes), or multiple polymorphisms more subtly affecting predisposition in the general population [i.e. single nucleotide polymorphisms (SNPs)]. In both cases, DNA damage and repair appear to be the common target. In exploring the results of comprehensive re-sequencing for sporadic human cancers, it has also become apparent that the commonest mutations seen are in also in the DNA repair machinery.

In the last decade, interest has also grown in the epigenetics of cancer. The role of promoter hypermethylation has become a focus for research in many tumour sites, including HNSCC. Silencing of certain tumour suppressor genes (TSGs), central to the development of many solid tumours, may occur in the absence of genetic change, via aberrant methylation of CpG islands. Several promising avenues exist in attempting to translate this research field into the clinical management of HNSCC. The discussion in this chapter will present the genetic and epigenetic basis of HNSCC. The advances in molecular techniques which have contributed to our understanding of the development of head and neck cancer are also summarised.

Genetic Principles in Carcinogenesis

Cancers arise from cells that have undergone heritable and non-heritable (somatic) genetic alterations which are then followed by clonal expansion. Theodore Boveri is generally credited as the father of this somatic mutation theory of carcinogenesis [1]. There is considerable evidence to support many of his predictions in his comprehensive theory on the origin of malignant tumours. These genetic alterations can involve activation of cancer promoting genes or inactivation of cancer suppressing genes. Multiple heritable changes are required for a normal cell to evolve into a cancer cell with evidence showing that this may involve between 3 and 10 genetic events, i.e. carcinogenesis is a multi-step and multi-factorial process that involves multiple genes [2]. This is supported by histopathological observations revealing multiple stages of tumour progression from pre-malignancy to overt carcinoma, animal models of carcinogenesis and

predisposition of cancer in individuals with heritable cancer syndromes. Mathematical models based on age-specific tumour incidence curves are consistent with 3–7 independent hits required for carcinogenesis [2]. These sequential accumulations of genetic abnormalities develop in a Darwinian fashion with those aberrations giving a selective advantage being propagated further.

Oncogenes and TSGs

The two main types of genetic alterations in the development of cancer are activation of cancer promoting genes, otherwise known as oncogenes, which when activated support cell survival and proliferation, or inactivation of cancer suppressing genes, or TSGs, which when inactivated promote tumour development. Oncogenes are derived from alteration of cellular proto-oncogenes, a term used to describe genes which encode for proteins normally expressed that mediate positive cell growth or survival signals, i.e. an oncogene is an abnormally activated proto-oncogene. Oncogenes give cancer cells dominant gain of function with a selective growth advantage due to promoting uncontrolled cell proliferation. They can be activated by a number of mechanisms such as mutations that cause overexpression from gene amplification, increased transcription or by structural changes such as chromosomal translocation [3–5]. Most of the products of oncogenes override the normal cell cycle checkpoints allowing abnormal cell proliferation [6]. Oncogenes can be classified into one of the five broad functional groups [7]. They represent the differing stages at which their products are involved in the growth signal cascade, from the extracellular proteins such as growth factors and their transmembrane receptors (EGFR and erbB), the subsequent intracellular signalling transducer (ras and raf) to the eventual intra-nuclear transcription factors (c-myc). Other oncogene products include cell cycle regulators (cyclin D1) and inhibitors of apoptosis (bcl-2).

The list of oncogenes associated with head and neck cancer is extensive. EGFR is commonly found to be overexpressed in HNSCC [8] and new treatments have arisen with cetuximab, a chimeric monoclonal antibody directed against EGFR. EGFR is a member of the ErbB protein family of cell surface receptors which works through the tyrosine kinase cascade. Downstream effects include activation of kinases and signal transducers [i.e. mitogen-activated protein kinase (MAPK), extracellular signal-regulated kinases (ERK) and the JaK/STAT pathway] which all result in activation of pathways involved in proliferation, apoptosis, invasion, angiogenesis and metastasis [9]. Genetic alterations in the EGFR pathway provide predictive biomarkers, as they correlate with response to therapy with cetuximab [10]. Interestingly, sensitivity to EGFR inhibition agents in other tumours has been shown to be accurately predicted by downstream RAS/RAF

mutations in many tumour types [11]. Other oncogenes in HNSCC include $\Delta(\text{delta})\text{Np}63\text{-}\alpha(\text{alpha})$ which belongs to the p53 family [12] and matrix metalloproteinases, which are involved in proliferation and migration [13].

TSG-encoded proteins have an inhibitory regulatory effect on growth, mediated via cell cycle, apoptosis, cell adhesion and DNA repair [14]. TSGs give cancer cells recessive loss of function and can be inactivated by genetic events such as mutation, deletions, or by epigenetic events such as DNA methylation or chromatin remodelling [15]. TSGs require both alleles to be altered before manifestation (i.e. homozygosity) unlike oncogenes, which can be activated by single allele activation (i.e. heterozygosity). This was first described by Knudson as the “double hit” theory for retinoblastomas [16, 17]. On inactivation of TSG cells lose their regulatory control leading to unchecked cell division and the development of cancer. p53, the “guardian of the genome,” was one of the earliest TSGs discovered in a broad range of cancers including head and neck cancer [18]. It is normally activated by stimuli that cause cellular stress such as radiation and carcinogenic toxins exposure. Such activation results in p53 regulating growth by influencing cell cycle control at the G1/S junction, a “checkpoint” in the cell cycle. Actively dividing cells pass such checkpoints to ensure that the progeny do not receive incomplete or damaged DNA. If the genetic impact of such stimuli is irreparable then it promotes apoptosis. p53 mutations are associated with a reduced survival in HNSCC patients with evidence for its role as a predictive biomarker [19–21]. Other important TSGs found in HNSCC include the CDKN2a locus which codes for p16 and p14 (ARF), discussed below. The DCC gene (deleted in colon cancer) on chromosome 18q21 is a conditional TSG [22] which mediates the growth effects by binding to netrin-1 and loss of the FAT gene [23] at 4p35 thought to play a role in cell–cell adhesion.

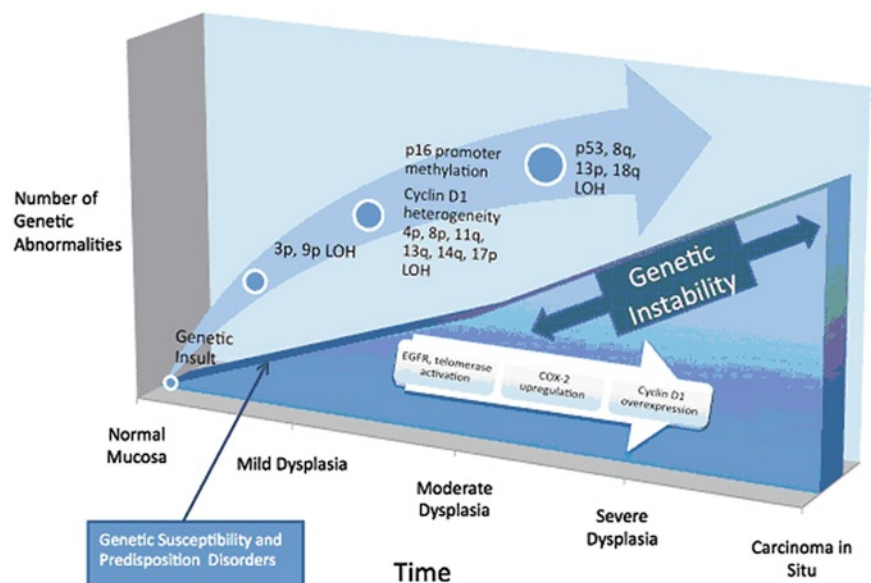
The Multi-step Process of Carcinogenesis: The Genetic Progression Model

The multi-step process of carcinogenesis reflects genetic alterations that drive the progressive transformation of normal cells to malignant cells and can be used to understand genetic events in terms of a timeline during the development of head and neck cancer. A genetic progression model in HNSCC has been postulated (Fig. 5.1) which demonstrate the common sequence of genetic losses [7, 24]. The frequency of genetic alterations in progressive lesions from dysplasia to carcinoma can correlate with the timing of such mutations along the progression axis. For example, there is a high frequency of loss of chromosomal material at loci 9p, 3p and 17p in dysplastic lesions indicating such events occur early in carcinogenesis. Loss of 13q and 8p are more frequently observed in carcinomas suggesting that they occur at later stages of carcinogenesis [24].

Early Events: Loss of 9p21 Region (CDKN2A Locus)

The most common early loss found in HNSCC is chromosomal region 9p21 with 71% loss in pre-invasive and invasive lesions suggesting an early event [25]. This region encodes p16 and p14^{arf}. The p16 gene encodes a cell cycle protein which inhibits cyclin-dependent kinases (CDK4 and CDK6); thereby preventing phosphorylation of Rb protein which would normally promote cell cycle progression from G1 to S phase [26–28]. p16 is frequently subject to epigenetic inactivation as well as loss.

Fig. 5.1 The progression model for HNSCC. As genetic abnormalities (LOH and oncogene activation) accumulate over time, a corresponding histological progression is found. The rate of accumulation of these genetic changes is increased once genomic instability is established. The first stages of this progression axis may be heritable (susceptibility and predisposition disorders)



Loss of 3p Region

Loss of chromosome 3p region is another early event in HNSCC found in oral dysplasia [29, 30]. The region includes the TSGs FHIT (fragile histidine triad gene) [37] and RSBF1A. RSBF1A may function in the effector molecule in the RAS-activated growth inhibition signalling pathway and is inactivated by hypermethylation and allelic loss [31].

Later Events: 17p Loss of Heterozygosity/p53 Mutation

p53 is located on chromosome 17p13 as discussed earlier and its loss of function results in transformation as genetic abnormalities are allowed to persist unrepaired through the cell cycle and passing on to progeny. Mutations or deletions of p53 are associated with increased genomic instability which itself may hasten the rate and effect of further genetic mutations.

11q13 Amplification/Cyclin D1 Overexpression

The oncogenes bcl-1, int-2, hst-1, EMS-1 and cyclin D1/PRAD1 are implicated in the frequent amplifications (33%) at this site [32]. Cyclins are proteins involved in cell cycle regulation, the cyclin D1 gene product which activates Rb by phosphorylation, leading to cell cycle progression from G1 to S phases resulting in proliferation [33].

There are many other examples of late genetic events in head and neck cancer including abnormalities detected at 3q26 amplification, 13q21, 14q23, 4q21-q25 and 5q13 deletion [24].

Hereditary Conditions Predisposing to HNSCC

Mutations may occur in the face of minimal exposure to carcinogens in a number of rare but mechanistically interesting inherited cancer syndromes (Table 5.1). During somatic mitosis, errors are observed in DNA replication. A failure in the regulatory cellular processes involved in correcting these replication errors contributes to carcinogenesis since accurate replication and repair of DNA is essential to genomic integrity. The regulatory processes involve systems to detect the abnormal DNA and mechanisms to repair them, which, if not possible, will lead to programmed cell death (or apoptosis) [34]. Defects in any part of this chain of events of recognition, repair or apoptosis result in unresolved genomic instability and can be demonstrated in hereditary conditions with a predisposition to cancer (Fig. 5.2).

Table 5.1 Hereditary conditions predisposing to HNSCC

Fanconis anaemia
Blooms syndrome
Ataxia telangiectasia
Xeroderma pigmentosum
Li-fraumeni syndrome
Lynch II syndrome

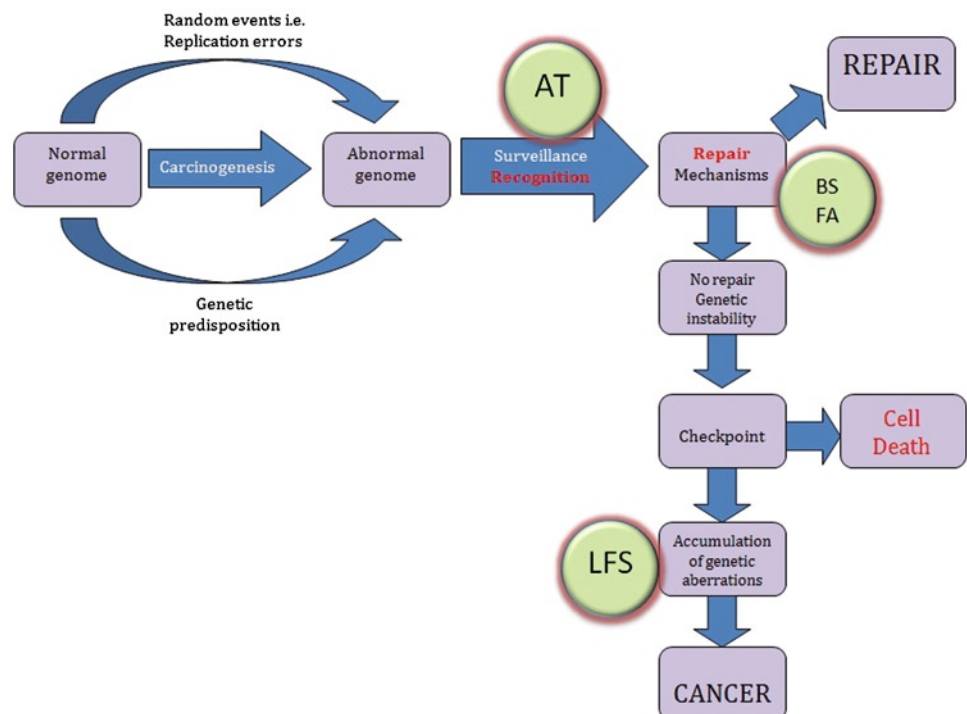


Fig. 5.2 Interaction of the hereditary conditions which predispose to HNSCC with the pathways of carcinogenesis (AT ataxia telangiectasia, BS Blooms syndrome, FA Fanconis anaemia, LFS Li-Fraumeni syndrome)

Fanconi Anaemia

Fanconi anaemia (FA) is a rare autosomal recessive disorder (incidence 1:350,000) that was first described in 1927 [35]. It is characterised by various congenital malformations, progressive bone marrow failure and tumour development [36]. The disease involves many organs and patients typically present with hyper-pigmentation, skeletal anomalies, growth retardation, learning disability and risk of secondary malignancies including HNSCC at a young age. The genes associated with FA have a caretaker role in the protection against carcinogenesis, i.e. they maintain the integrity of the genome by DNA repair mechanisms. FA is defined by its cellular hypersensitivity to DNA cross-linking agents and two genetic defects have been suggested that determine the development of cancer, defective chromosomal stability and immunodeficiency [37]. The genes associated with the FA including BRCA1, BRCA2 (also mutated in familial breast cancers), FANCD2 and FANCG are frequently also affected in sporadic HNSCC. This suggests that the process leading to early occurrence of oral cancer in FA patients follows a similar pathway of carcinogenesis to non-FA sporadic cancer patients, particularly in younger patients [38]. This is supported by differences in expression levels of Fanconi-related genes in OSCC of younger compared to older patients. It leads to the conclusion that sporadic tumours in younger patients also occur through defective carcinogen metabolism or DNA repair mechanisms (see below).

Blooms Syndrome

Bloom's syndrome (BS) is also an autosomal recessive disorder associated with Ashkenazi Jewish ancestry belonging to the "chromosomal breakage syndromes." It is characterised by marked genetic instability and is associated with a greatly increased risk of a wide range of cancers including head and neck malignancy. Features include growth retardation, hypersensitivity to sunlight, facial sun-sensitive telangiectatic erythema, skin pigmentation in non-sun-exposed skin and moderate to severe immunodeficiency. Patients are predisposed to develop either haematological or solid tumours. BS is characterised by a high level of sister chromatid exchanges, when two chromatids form during late prophase of mitosis, break and rejoin with one another and thereby physically switching positions on the chromosome. This increased frequency of chromosomal breakages or interchanges occurring spontaneously or following exposure to DNA damaging agents. The genetic instability arises through mutations in both copies of the BLM gene, located on chromosome 15q26. The BLM protein interacts with proteins involved in genomic maintenance and stability and

a super complex of BRCA1-associated proteins named BASC (BRCA1-Associated genome Surveillance Complex). This surveillance complex includes proteins involved in replication repair processes found in ataxia telangiectasia (ATM), hereditary non-polyposis colorectal carcinoma (HNPCC) (MLH1 and MSH2) [39] and some of the Fanconi complementation group of proteins (FANCA, FANCG, etc.) [40]. There are also interactions between the BLM protein and many other proteins including p53 [41].

Ataxia Telangiectasia

Ataxia telangiectasia (AT) is a debilitating and progressive neurodegenerative disease of childhood and characteristic defects include neurodegeneration, immune dysfunction, radiosensitivity and cancer predisposition. The underlying cause of the disease is mutation in the ATM (ataxia telangiectasia, mutated) gene located on 11q22-23 [42], a common deletion site in HNSCC [43]. Its product is a protein kinase involved in the cellular response to DNA damage [44]. ATM is also involved in immune system maturation and meiosis. Cancer predisposition is mainly of the lymphoreticular system and is also linked to head and neck malignancy in younger patients [45]. The ATM gene is involved in surveillance of DNA damage, activation of repair enzymes or apoptosis if such damage is irreparable. After DNA damage, it undergoes autophosphorylation initiating a signalling cascade involving cell cycle regulators including p53, BRCA1, p53-binding protein 1 (p53BP1) and the checkpoint kinase CHK2 [46].

Xeroderma Pigmentosum

Xeroderma pigmentosum (XP) is an autosomal recessive disease characterised by a severe predisposition to ultraviolet light-induced skin cancers. There are two major clinical forms, one involving progressive degenerative changes of the skin and eyes and the other also includes progressive neurological degeneration [47]. There is an extreme sensitivity to sunlight with cutaneous symptoms ranging from sunburn to overt carcinoma. The risk of squamous cell carcinoma is elevated by 100,000-fold with a median onset of skin cancer at 8 years of age. XP is the archetype of the family of nucleotide excision repair (NER) diseases [48] deficient in a gene product required in the excision of damaged DNA. The NER excises damaged single strands of DNA and replace them with a new sequence of bases using a template for base pairing the intact strand of DNA opposite the damaged site. Abnormalities in this repair system leads to high levels of specific modifications of crucial regulatory genes in skin cells leading to cancer as well as resulting in chromosomal breakage [48].

Li-Fraumeni Syndrome

Li-Fraumeni syndrome is a rare autosomal dominant syndrome characterised by a predisposition to cancers including sarcomas, leukaemia's and brain tumours. The early onset malignancy (<45 years), usually a sarcoma, is associated with a family history of multiple cancers. There is frequently a germline mutation of the TSG p53 [49] and other TSGs such as CHEK2. They have a 90% lifetime risk of developing cancer [50] and are at risk of developing both lung and laryngeal carcinomas.

Lynch Syndrome II

HNPCC is an autosomal dominant inherited familial cancer syndrome in which patients are susceptible to colorectal cancer without diffuse polyposis. Lynch Syndrome II has additional features to Lynch I and has an association with extracolonic cancers including laryngeal cancer [51]. These patients have a defect in the DNA mismatch repair enzyme hMSH2, an important enzyme in genetic instability and carcinogenesis of HNPCC [52].

Genetic Predisposition and Mutagen Sensitivity

Inherited chromosomal instability syndromes represent one end of a spectrum of DNA repair defects. There are individual variations in the efficiency of DNA repair systems within "normal" individuals who subsequently have an increased tendency for DNA damage from carcinogen exposure consequently increasing their susceptibility to cancers [53]. Environmental exposure to carcinogens implicated in head and neck carcinogenesis cannot fully account for the development of cancer alone since not all heavy smokers develop cancer and likewise not all cancer patients are exposed to alcohol or tobacco [53–55]. Individuals with an inherited genetic susceptibility to head and neck cancer can have defects in systems used to maintain DNA after exposure to such carcinogens [54]. Mutagen sensitivity and polymorphisms in DNA repair enzymes or carcinogen metabolising enzymes support the role of hereditary susceptibility for head and neck cancer and giving some explanation to the variable risk from carcinogen exposure. Studies have demonstrated odds ratios of 1.5–2.5 for cancer development in those predisposed by mutagen sensitivity polymorphisms. Greater predictive power is found when combining mutagen sensitivity tests with other risk factors

such as alcohol and smoking in head and neck cancer. Both epidemiological and molecular evidence support the role of heritable genetic susceptibility for head and neck cancer. Familial aggregation studies have demonstrated that family history is a significant risk factor for head and neck cancer [56]. Genetic polymorphisms in carcinogen metabolising enzymes (xenobiotic metabolising enzymes) frequently occur in the population, partially explaining this susceptibility. Both phase 1 and phase 2 enzymes have been implicated. Phase 1 enzymes include the cytochrome P450 enzymes CYP1A1, CYP1B1, CYP2D6 and CYP2E1. Phase II enzymes include Glutathione *S*-transferase enzymes GSTM1, GSTT1 and GSTP1. Metabolic polymorphisms such as those in the cytochrome P450 (CYP)1A1 gene are associated with oral cancer risks in some populations with cancer resulting from relatively lower smoking exposure than those with differing genotypes [57, 58]. A meta-analysis assessing the associations of oral cancer risk with CYP1A1 genetic variation suggested that it might not be a risk factor, whereas the GSTM1 null genotype significantly increased susceptibility to oral cancer in Asians but not in Caucasians [59]. Other polymorphisms have been found to be protective, e.g. GSTT1 null genotype among Indian tobacco users [60].

Techniques Used to Detect Genetic Changes in Cancer

See Table 5.2.

Cytogenetics

Cytogenetics, the study of chromosomal rearrangements, was one of the earlier methods of determining the site of genetic abnormalities related to the pathogenesis of cancer. With karyotype analysis, cultured cells are arrested in metaphase and a visual analysis made of gross genetic changes such as translocations, breakpoints and areas of gain

Table 5.2 Techniques used to detect genetic changes in cancer

Cytogenetics
Comparative/genomic hybridisation (CGH)
Fluorescent in situ hybridisation (FISH)
Microsatellite alterations
DNA microarray techniques
SNP arrays
Sanger sequencing
Next-generation sequencing

or loss. At metaphase, the chromosomes appear as long arms (p) and short arms (q) joined at the centromere. The disadvantage of such gross techniques is that alterations at a DNA base level are missed and abnormalities found are only a snapshot in time. The commonest areas of gain are on the short arm of chromosomes 1, 3, 8 and 15. The commonest areas of loss are on the long arms of chromosomes 8, 13, 14, 15 and 11q. Cytogenetics can be used as a screening technique to identify gross losses or gains but subsequent identification of specific genes requires functional studies to determine gene properties.

Fluorescent In Situ Hybridisation and Comparative Genomic Hybridisation

Techniques have developed over time to improve the resolution of karyotype analysis and molecular cytogenetic technology such as fluorescent in situ hybridisation (FISH) and comparative genomic hybridisation (CGH) have increased the ability to identify genetic alterations in cancer cells. These higher resolution techniques have found area of loss commonly in 1p, 3p, 4p, 5q, 8p, 10p, 11q, 13q and 18q and areas of gain at 1q, 3q, 5p, 7q, 8q, 9q, 11q, 12p, 14q and 15q [61, 62]. FISH is a technique in which sequence-specific fluorescent probes are detected after hybridisation using microscopy detecting gains (amplifications) or losses (deletions). It is an efficient and a reproducible approach for precise localisation of specific sequences and allows visualisation of copy number per cell. CGH is a fluorescence in situ technique developed to look at chromosome losses or gains which are unbalanced throughout the genome. It allows mapping of chromosome imbalances using total genomic DNA as a probe. In this technique, normal metaphase chromosomes are hybridised with differentially fluorescence labelled DNAs (tumour with green and normal with red) and fluorescence in different regions measured for increased or decreased intensity which would measure over or under expressed areas of tumour DNA. While cytogenetics have provided an insight into specific regions of tumour DNA, CGH enables comparisons of entire genomes of malignant and normal cells. It also allows retrospective studies with archival tissues overcoming the difficulties of conventional cytogenetic analysis of solid tumours. The most frequently observed changes are copy number changes on chromosomes 3 and 5. Examples of TSGs found at these locations include VHL on 3p [63] and FAP on 5q [33, 64]. These studies also identified the region 11q13 in a HNSCC with amplification of this region correlates with aggressive growth and a late event in the progression axis [65]. CGH arrays have been used in profiling HNSCC revealing previously unknown oncogenes as well as predicting chemoradiosensitivity [38].

DNA Microarray Techniques

Edwin Southern, a British biologist, first described in 1975 the use of labelled nucleic acids in a known DNA sequence (or a probe) to identify complementary DNA fragments through hybridisation of base pairs, a process known as Southern Blotting [66]. The DNA probes used were labelled with a radioisotope or a fluorescent tag. The methods of probe detection for DNA have been miniaturised into microarray techniques which enable detection of several thousands of DNA or RNA sequences at a time. The process is the reverse of Southern Blotting with the probe being placed on an immobile surface such as glass, silicone or nylon and exposed to free nucleic acid to be analysed [67]. It has developed CGH to several orders of magnitude hybridising normal and cancer DNA to several millions of probe sequences and allowing for a much finer map of genetic abnormalities [38]. This technology has been used to identify specific regions of gain such as 8q22 and the LRP12 gene [29].

SNP Arrays

Work on the human genome project led to the discovery of SNPs, scattered areas of altered DNA sequences which ultimately have no impact on protein expression and so no adverse effect in normal individuals. Since these SNPs cluster in populations they can be used as identification as well as markers for genetic predisposition if located in DNA repair genes or detoxifying enzymes for environmental toxins and can indirectly provide information on gain or loss of specific genomic regions [61].

Sequencing and Next-Generation Sequencing

Genomic sequencing has greatly progressed since dideoxy chain termination sequencing in 1970s [68]. The automated sequencer accelerated the process and subsequent development of the “shotgun” technique saved more time by splitting the genome into smaller segments. In the past few years, another generation of sequencers have been launched that can read as much DNA in a day that would previously taken years. Next-generation sequencing is a technique central to the emerging field of personalised medicine and produce large arrays of templates with each one read simultaneously so millions of templates can be read at once with thousands of times the throughput of Sanger’s technique. With the ever-reducing costs of the technology, there is the real prospect of developing biomarkers based on genome-wide mutational screens looking at patterns of mutations or genomic landscapes to stratify the risk of cancer rather than looking at individual genetic mutations.

The Epigenetics of Head and Neck Cancer: Epigenetics: The Role of DNA Methylation, Histone Modifications and the Nucleosome

As each cell in the body contains the same DNA code, but the morphology and behaviour of these cells differs greatly, it can readily be appreciated that much of this variation arises from the way that the DNA is interpreted. This change in interpretation is known as epigenetics, providing an extra layer of processing in addition to the basic genetic paradigm of DNA → RNA → protein proposed by Crick and Watson. Epigenetic changes are heritable modifications of DNA with information content that influence phenotype, but that are not associated with changes in nucleotide sequence. The regulation of gene expression is by the controlling influence of the proteins surrounding the DNA molecules known as histones. Chemical modifications of both histones (the “histone code”) and DNA (the “DNA methylome”), control the availability of genes for transcription, and in turn has a fundamental influence on cell differentiation. It is now beyond doubt that epigenetic dysregulation has a major part to play in carcinogenesis; however, before attempting to understand the changes seen in cancer, it is important to review the normal physiological role of epigenetics.

The most important aspects of epigenetic regulation are methylation of gene promoters and modification of histone proteins. Gene promoter regions are particularly interesting stretches of DNA usually leading up to the transcriptional start sites. From the four nucleotides seen in DNA (A, C, T and G), it might readily be assumed that the frequency of any particular dinucleotide combination in any particular stretch of DNA might be approximately 1/16th. However, one particular combination, CG, has a very characteristic pattern.

For much of the genome, the CG dinucleotide has been evolved out because it is highly mutation-prone. In contrast, the CG content within certain defined stretches of DNA is particularly high, upwards of 50%, and these regions are called CpG islands (the “p” merely refers to the phosphodiester bond seen between all nucleotides in DNA). Definitions of CpG islands vary, but typically refer to stretches of around 200 base pairs with >50% CpG content upstream of mammalian genes. Chemical modification of the cytosine by methylation tends to occur in concert along the gene promoter. This is associated with transcriptional silencing via conformational changes in the surrounding histones (Fig. 5.3).

The “default” CpG methylation pattern of humans is in two different states depending on the location. For scattered CpG not associated with gene promoters, almost all are methylated. Within CpG islands, most are normally unmethylated. Changes in methylation are brought about by a balance of two coordinating influences: first waves of de novo methylation [69] sweeping the genome and second active “resetting” demethylation, probably mediated through histone modifications [70]. This DNA methylome is reset early in embryogenesis and then re-established around the time of implantation. Further targeted alterations subsequently occur throughout differentiation and are associated with the loss of pluripotential state. The embryonic stem cell is principally characterised by its epigenetic signature.

The interplay between chromatin and DNA methylation is somewhat complex and currently the focus of much research. It appears that in some circumstances, the DNA methylation pattern creates changes in histones, but in others the reverse relationship is found. In a highly simplified model of transcriptional regulation, unmethylated DNA is found in association with acetylated histones with a relaxed chromatin

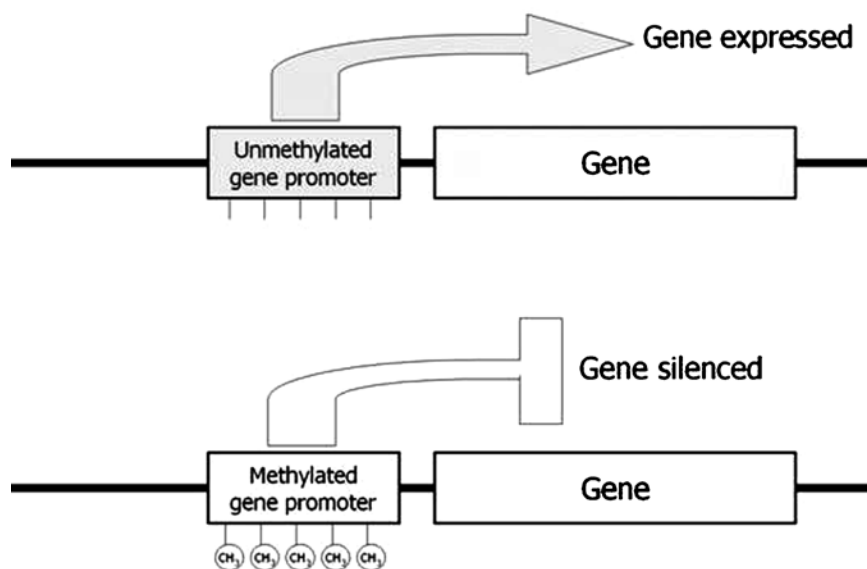


Fig. 5.3 Effect of gene promoter methylation on gene expression

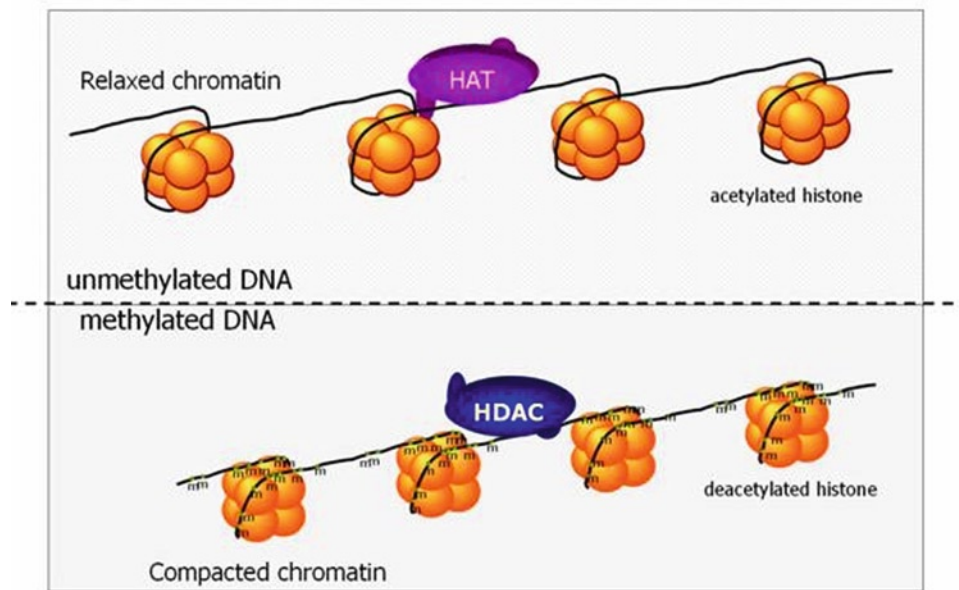


Fig. 5.4 Methylation and histone acetylation co-ordinate transcriptional availability. *HAT* histone acetyltransferase, *HDAC* histone deacetylase, *m* methylated CpG dinucleotide

structure amenable to transcription. In methylated DNA, histone deacetylase is recruited creating a much tighter conformation of deacetylated histones which are not available for transcription and hence the gene is silenced (Fig. 5.4).

A pair of each of the core histones (H2A, H2B, H3 and H4) make up an octamer in which DNA is wound around to form a nucleosome. The N-terminal tails of histones are subject to a wide variety of covalent modifications such as acetylation, methylation and phosphorylation, which have influence over conformation and subsequent gene expression. Heterochromatin is the term used to describe highly packed regions which are transcriptionally silenced. Methylation of histone H3 at lysine 9 (H3K9) and 27 (H3K27) are important modifications in heterochromatin. Gene repression induced by histone methylation and heterochromatin formation is readily reversible and common in cellular differentiation. Gene repression induced by DNA methylation leads to permanent gene silencing and is seen in various physiological and pathological processes such as imprinting and cancer [71]. It is likely that the DNA methylation pattern of a cell might be the template used to reconstitute the epigenetic programme following cell division. A third epigenetic mark worthy of consideration is nucleosome occupancy. Nucleosomes are known to be dynamic structures and tend to be depleted in promoter regions [72]. Removal of nucleosomes correlates with transcriptional activation, and often this can be related to only one or two nucleosomes near the transcriptional start site [73]. Presumably, this is because transcription binding sites become more accessible.

Epigenetic Drivers of Carcinogenesis: Challenging the Genetic Paradigm

It has become increasingly apparent that cancer is as much a disease of misdirected epigenetics as genetic mutations and losses. As an illustration, recent results suggest that as many as 5% of known gene promoters (i.e. 1,500–2,000 genes) are methylated in a typical solid tumour [74] compared with, typically, 11 gene mutations [75]. While it is now beyond dispute that silencing of many TSGs important to cancer occurs through DNA methylation, the models available to explain an overall contribution of epigenetics to cancer have evolved with the technologies available to study them. Initially, it was understood that the principal change in cancer was hypomethylation of genome-wide CpGs [76], but eventually it was realised that the functional significance of promoter methylation of a smaller number of TSGs [77] might have greater functional relevance. One model is that methylation patterns arise through a process of selection. Some evidence suggests that tumours have upregulation of DNA methyltransferase enzymes and that those cells gaining a growth advantage from the clones of cells primed for malignant transformation [78]. These epigenetic events may then occur in pre-invasive lesions, involving disruption or over-activation of key developmental pathways and cell-signalling properties. This, so called, “epigenetic addiction” [79] may then predispose to later genetic mutations and genomic instability ultimately causing malignant transformation. In this model, one may hypothesise that epigenetic

events may be the most valuable in predictive modelling in potentially malignant H&N lesions. Advances in genome-wide methylation technologies have, however, revealed that not all epigenetic events appear to occur in the TSGs expected. It is seen that many methylation events occur in gene promoters not previously implicated in cancer and with no obvious mechanistic links. An alternative hypothesis is that certain genes are earmarked for methylation and it has been shown that genes frequently methylated in cancer have specific tri-methylation of lysine 27 in histone H3 in their nucleosomes [80]. This suggests that cancer targeted *de novo* methylation may be programmed by a pre-ordained epigenetic code that physiologically has a role in marking embryonic genes for repression. Many hypermethylated genes in adult cancers are Polycomb group marked (H3K27me) in embryonic stem cells and there are many, and unexpected, similarities in higher-order chromatin conformation between stem cells and adult cancers [81].

Molecular Assay of Epigenetic Alterations in Cancer

As the technological platforms which support detection of methylation have generally lagged behind other genomic methods, the translational potential of the DNA methylome has remained relatively unexplored. Much of the previous HNSCC literature has concentrated on a known published cohort of methylated genes [82, 83], clearly limiting progress. Methylation assays have previously relied upon methylation-sensitive restriction enzymes or methylcytosine antibodies which greatly limit the number of samples analysed and precision of resulting data. Probably, the largest breakthrough in methylation assays was bisulphite conversion, in which the methylation code is converted to a C/T polymorphism. This then allows the creation of methylation-specific PCRs [84] and a similar process might be made semi-quantitative by using real-time PCR [85]. Methylation-specific PCR can be criticised as being only as specific as the primers and conditions allow, and without doubt some of the applications previously suggested push the envelope of reliable and reproducible performance of PCR. It must also be appreciated that the loss of sequence complexity accompanying bisulphite conversion also predates towards the loss of specificity. Methods previously described for SNIp analysis might then be “borrowed” for methylation assays, such as pyrosequencing [86–88]. Alternative methods use standard Sanger sequencing of bisulphite-converted DNA, but the impact of massive parallel sequencing has yet to be realised in epigenetics. Various multiplexed and array methods have been made available, either relying on modifications of SNIp arrays [89] for use with bisulphite conversion or using

restriction enzymes. In addition, more indirect methods have been improvised to detect potential methylation targets using pharmacological unmasking. It is possible to shortlist those genes upregulated by the use of demethylating agents in cancer cell lines using expression arrays [90, 91]. In order to detect histone modifications, where methods of chromatin immunoprecipitation predominate, effective scaled-up assays are not currently available.

Clinical Application of Epigenetics in Head and Neck Cancer

A comprehensive list of genes subject to promoter methylation in HNSCC is not yet available, and the previously published candidates [82, 83] are subject to regular additions. The genes and pathways subject to methylation are spread across the broad range of cellular functions. It may be that some of the methylation events seen as being relatively frequent in HNSCC are not critical mechanistic determinants of progression; however, others such as promoter methylation of p16 (CDKN2) [87, 92] appear to be highly likely to have functional relevance. Whether this is of importance to a suggested clinical application is highly dependent on the intended use of the assay and this brushes on broader issues concerning on molecular biomarkers are discussed below. Studies in several tumour sites (in particular, colorectal cancer [93]) highlight the significance of the CpG island methylation phenotype (CIMP), with distinct features of histology, biological aggression and outcome. A cluster of tumours with a greater degree of promoter methylation than would be predicted by chance alone are designated CIMP+ve. In HNSCC, initial studies suggest that this group had less aggressive tumour biology and elicit a greater host inflammatory response [94]. The exact mechanisms underlying CIMP remain obscure, one may now speculate that the affected genes are histone H3K27 targets for EZH2-containing Polycomb complex [80].

Epigenetic Biomarkers in HNSCC

The intended use of biomarkers can vary quite dramatically between assays. Biomarker research can resemble an uncertain navigation of the minefield between the discovery of an interesting observation in the research lab and the adoption of a proven biomarker for the benefit of patients in the clinic. Predictive biomarkers are designed to help make treatment decisions as they predict for response to certain treatments, whereas prognostic biomarkers give an indication of the likely outcome for survival. A further class of biomarkers predicts for the mere presence of disease in

surrogate specimens such as saliva, blood or surgical margins. In many regards, DNA methylation appears to be a very promising aberration for biomarker applications as it can be detected with great specificity and sensitivity in many biological specimens [95]. Further, it may be present in a relatively high proportion of tumours encountered (e.g. cyclin A1 methylation in 50% of HNSCC [87, 91]), which is in contrast to specific p53 mutations which are, individually, relatively uncommon. Although mutations are irreversible events, there is the possibility of pharmacological reversal of methylation and histone changes. The ability to detect tumour-specific methylation events with great sensitivity results from methylation-specific assays which can detect methylated DNA, certainly in 1:1,000 concentrations [85], and maybe in much lower proportions [96]. It is possible then, at least in theory, to screen populations for cancer-specific events in saliva, perhaps using panels of methylation events [97] or to offer surveillance to post-treatment patients using their previous cancer's epigenetic fingerprint [98]. It is also possible to search for tumour-specific methylation in histologically negative resection margins in order to optimise adjuvant treatment [99–101]. Management of the patient with dysplasia of the head and neck depends on accurate prediction of transformation and pathological grading fails in some regards. Bringing together the promise of epigenetic biomarkers within non-invasive sampling and also the mechanistic relevance of epigenetics in priming the molecular field for further genetic events seems logical in this setting. It has now been established that 3p and 9p losses represent very effective genetic biomarkers of progression within H&N dysplastic lesions [24]. Early evidence suggest that methylation may have some promise in this field [102] and one longitudinal study has found p16 methylation to be a specific predictor of malignant progression in oral dysplasia [103]. It may be possible to make a prognostic evaluation of a tumour prior to definitive treatment by epigenetic analysis of the biopsy. In this way, the patient's treatment may be individualised by methylotype. The full impact of genome-wide methylation profiling and its prognostic value has yet to be evaluated. Realising the potential in order for any of these applications to be clinic-ready is self-evidently a painstaking process.

Epigenetically Directed Therapy in HNSCC

Several suggestions have been made that promoter methylation of specific genes may indicate a particular tumour's sensitivity to a drug. Such studies have yet to make an impact in the treatment of HNSCC. In the treatment of gliomas, it has been found that MGMT promoter methylation is a useful predictor of the responsiveness to alkylating agents such as Temozolomide [104]. Perhaps of more relevance is

that CHFR methylation predisposes cancer to increased sensitivity to taxanes [105] which may be a useful line of investigation as TPF-induction chemotherapy gains ground in HNSCC. Epigenetic alterations are particularly interesting as characteristics of cancer as they can potentially be reversed in drug treatment. A great number of epigenetically directed drugs are now entering clinical trials, particularly in the field of haematological malignancy. Demethylation agents such as 5-azacytidine and decitabine are now licenced for the treatment of myelodysplasia. The use of histone deacetylase inhibitors as single agents has limited usefulness but shows promise in combination with demethylating agents. The emergence of drug-resistant clones accompanying loss of DNA mismatch repair with MLH1 hypermethylation has been identified as a frequent issue in treatment failure in ovarian cancer. At least in vitro, this has been addressed by combination therapy with both demethylating agents and standard chemotherapy [106]. Clearly this field is in its infancy, and provided epigenetic therapy can be administered with acceptable toxicity; methylation assays are readily available to demonstrate adequate pharmacodynamic effects.

References

1. Boveri T. Zur Frage der Entstehung Maligner Tumoren. Jena, Germany: Gustave Fischer; 1914.
2. Barrett JC. Mechanisms of multistep carcinogenesis and carcinogen risk assessment. *Environ Health Perspect.* 1993;100:9–20.
3. Alitalo K, Schwab M. Oncogene amplification in tumor cells. *Adv Cancer Res.* 1986;47:235–81.
4. Haluska FG, Tsujimoto Y, Croce CM. Oncogene activation by chromosome translocation in human malignancy. *Annu Rev Genet.* 1987;21:321–45.
5. Klein G, Klein E. Evolution of tumours and the impact of molecular oncology. *Nature.* 1985;315(6016):190–5.
6. Field JK. The role of oncogenes and tumour-suppressor genes in the aetiology of oral, head and neck squamous cell carcinoma. *J R Soc Med.* 1995;88(1):35P–9.
7. Sidransky D. Molecular genetics of head and neck cancer. *Curr Opin Oncol.* 1995;7(3):229–33.
8. Ishitoya J, Toriyama M, Oguchi N, Kitamura K, Ohshima M, Asano K, et al. Gene amplification and overexpression of EGF receptor in squamous cell carcinomas of the head and neck. *Br J Cancer.* 1989;59(4):559–62.
9. Chang SS, Califano J. Current status of biomarkers in head and neck cancer. *J Surg Oncol.* 2008;97(8):640–3.
10. Bonner JA, Harari PM, Giralt J, Azarnia N, Shin DM, Cohen RB, et al. Radiotherapy plus cetuximab for squamous-cell carcinoma of the head and neck. *N Engl J Med.* 2006;354(6):567–78.
11. Eberhard DA, Johnson BE, Amler LC, Goddard AD, Heldens SL, Herbst RS, et al. Mutations in the epidermal growth factor receptor and in KRAS are predictive and prognostic indicators in patients with non-small-cell lung cancer treated with chemotherapy alone and in combination with erlotinib. *J Clin Oncol.* 2005;23(25):5900–9.
12. Patturajan M, Nomoto S, Sommer M, Fomenkov A, Hibi K, Zangen R, et al. DeltaNp63 induces beta-catenin nuclear accumulation and signaling. *Cancer Cell.* 2002;1(4):369–79.

13. Rosenthal EL, Matrisian LM. Matrix metalloproteases in head and neck cancer. *Head Neck*. 2006;28(7):639–48.
14. Weinberg RA. Tumor suppressor genes. *Science*. 1991;254(5035):1138–46.
15. Choi S, Myers JN. Molecular pathogenesis of oral squamous cell carcinoma: implications for therapy. *J Dent Res*. 2008;87(1):14–32.
16. Knudson Jr AG. Genetics and etiology of human cancer. *Adv Hum Genet*. 1977;8:1–66.
17. Vogelstein B, Kinzler KW. The multistep nature of cancer. *Trends Genet*. 1993;9(4):138–41.
18. Levine AJ. p53, the cellular gatekeeper for growth and division. *Cell*. 1997;88(3):323–31.
19. Bradford CR, Zhu S, Ogawa H, Ogawa T, Ubell M, Narayan A, et al. P53 mutation correlates with cisplatin sensitivity in head and neck squamous cell carcinoma lines. *Head Neck*. 2003;25(8):654–61.
20. Poeta ML, Manola J, Goldwasser MA, Forastiere A, Benoit N, Califano JA, et al. TP53 mutations and survival in squamous-cell carcinoma of the head and neck. *N Engl J Med*. 2007;357(25):2552–61.
21. Temam S, Flahault A, Perie S, Monceaux G, Coulet F, Callard P, et al. p53 gene status as a predictor of tumor response to induction chemotherapy of patients with locoregionally advanced squamous cell carcinomas of the head and neck. *J Clin Oncol*. 2000;18(2):385–94.
22. Carvalho AL, Chuang A, Jiang WW, Lee J, Begum S, Poeta L, et al. Deleted in colorectal cancer is a putative conditional tumor-suppressor gene inactivated by promoter hypermethylation in head and neck squamous cell carcinoma. *Cancer Res*. 2006;66(19):9401–7.
23. Nakaya K, Yamagata HD, Arita N, Nakashiro KI, Nose M, Miki T, et al. Identification of homozygous deletions of tumor suppressor gene FAT in oral cancer using CGH-array. *Oncogene*. 2007;26(36):5300–8.
24. Califano J, van der RP, Westra W, Nawroz H, Clayman G, Piantadosi S, et al. Genetic progression model for head and neck cancer: implications for field cancerization. *Cancer Res*. 1996;56(11):2488–92.
25. van der Riet P, Nawroz H, Hruban RH, Corio R, Tokino K, Koch W, et al. Frequent loss of chromosome 9p21–22 early in head and neck cancer progression. *Cancer Res*. 1994;54(5):1156–8.
26. Lukas J, Parry D, Aagaard L, Mann DJ, Bartkova J, Strauss M, et al. Retinoblastoma-protein-dependent cell-cycle inhibition by the tumour suppressor p16. *Nature*. 1995;375(6531):503–6.
27. Serrano M, Hannon GJ, Beach D. A new regulatory motif in cell-cycle control causing specific inhibition of cyclin D/CDK4. *Nature*. 1993;366(6456):704–7.
28. Serrano M, Gomez-Lahoz E, DePinho RA, Beach D, Bar-Sagi D. Inhibition of ras-induced proliferation and cellular transformation by p16INK4. *Science*. 1995;267(5195):249–52.
29. Garnis C, Baldwin C, Zhang L, Rosin MP, Lam WL. Use of complete coverage array comparative genomic hybridization to define copy number alterations on chromosome 3p in oral squamous cell carcinomas. *Cancer Res*. 2003;63(24):8582–5.
30. Mao L, Lee JS, Fan YH, Ro JY, Batsakis JG, Lippman S, et al. Frequent microsatellite alterations at chromosomes 9p21 and 3p14 in oral premalignant lesions and their value in cancer risk assessment. *Nat Med*. 1996;2(6):682–5.
31. Dong SM, Sun DI, Benoit NE, Kuzmin I, Lerman MI, Sidransky D. Epigenetic inactivation of RASSF1A in head and neck cancer. *Clin Cancer Res*. 2003;9(10 Pt 1):3635–40.
32. Berenson JR, Yang J, Mickel RA. Frequent amplification of the bcl-1 locus in head and neck squamous cell carcinomas. *Oncogene*. 1989;4(9):1111–6.
33. Callender T, El-Naggar AK, Lee MS, Frankenthaler R, Luna MA, Batsakis JG. PRAD-1 (CCND1)/cyclin D1 oncogene amplification in primary head and neck squamous cell carcinoma. *Cancer*. 1994;74(1):152–8.
34. Cheng KC, Loeb LA. Genomic instability and tumor progression: mechanistic considerations. *Adv Cancer Res*. 1993;60:121–56.
35. Fanconi G. Familiäre infantile perniziösartige Anämie (perniziöses Blutbild und Konstitution). *Jahrbuch für Kinderheilkunde und physische Erziehung*. 1927;117:257–80.
36. Lustig JP, Lugassy G, Neder A, Sigler E. Head and neck carcinoma in Fanconi's anaemia – report of a case and review of the literature. *Eur J Cancer B Oral Oncol*. 1995;31B(1):68–72.
37. Kaplan MJ, Sabio H, Wanebo HJ, Cantrell RW. Squamous cell carcinoma in the immunosuppressed patient: Fanconi's anemia. *Laryngoscope*. 1985;95(7 Pt 1):771–5.
38. Sparano A, Quesnelle KM, Kumar MS, Wang Y, Sylvester AJ, Feldman M, et al. Genome-wide profiling of oral squamous cell carcinoma by array-based comparative genomic hybridization. *Laryngoscope*. 2006;116(5):735–41.
39. Wang Y, Cortez D, Yazdi P, Neff N, Elledge SJ, Qin J. BASC, a super complex of BRCA1-associated proteins involved in the recognition and repair of aberrant DNA structures. *Genes Dev*. 2000;14(8):927–39.
40. Meetei AR, Sechi S, Wallisch M, Yang D, Young MK, Joenje H, et al. A multiprotein nuclear complex connects Fanconi anemia and Bloom syndrome. *Mol Cell Biol*. 2003;23(10):3417–26.
41. Garkavtsev IV, Kley N, Grigorian IA, Gudkov AV. The Bloom syndrome protein interacts and cooperates with p53 in regulation of transcription and cell growth control. *Oncogene*. 2001;20(57):8276–80.
42. Gatti RA, Berkel I, Boder E, Braedt G, Charnley P, Concannon P, et al. Localization of an ataxia-telangiectasia gene to chromosome 11q22–23. *Nature*. 1988;336(6199):577–80.
43. Lazar AD, Winter MR, Nogueira CP, Larson PS, Finnemore EM, Dolan RW, et al. Loss of heterozygosity at 11q23 in squamous cell carcinoma of the head and neck is associated with recurrent disease. *Clin Cancer Res*. 1998;4(11):2787–93.
44. Savitsky K, Bar-Shira A, Gilad S, Rotman G, Ziv Y, Vanagaite L, et al. A single ataxia telangiectasia gene with a product similar to PI-3 kinase. *Science*. 1995;268(5218):1749–53.
45. Ai L, Vo QN, Zuo C, Li L, Ling W, Suen JY, et al. Ataxia-telangiectasia-mutated (ATM) gene in head and neck squamous cell carcinoma: promoter hypermethylation with clinical correlation in 100 cases. *Cancer Epidemiol Biomarkers Prev*. 2004;13(1):150–6.
46. Shiloh Y. ATM and related protein kinases: safeguarding genome integrity. *Nat Rev Cancer*. 2003;3(3):155–68.
47. Bootsma D. Nucleotide excision repair syndromes: xeroderma pigmentosum, Cockayne syndrome and trichothiodystrophy. In: Scriver CB, editor. *The metabolic and molecular basis of inherited disease*. New York: McGraw-Hill Book Co.; 2001. p. 677–703.
48. Cleaver JE. Cancer in xeroderma pigmentosum and related disorders of DNA repair. *Nat Rev Cancer*. 2005;5(7):564–73.
49. Santibanez-Koref MF, Birch JM, Hartley AL, Jones PH, Craft AW, Eden T, et al. p53 germline mutations in Li-Fraumeni syndrome. *Lancet*. 1991;338(8781):1490–1.
50. Akashi M, Koeffler HP. Li-Fraumeni syndrome and the role of the p53 tumor suppressor gene in cancer susceptibility. *Clin Obstet Gynecol*. 1998;41(1):172–99.
51. Trizna Z, Schantz SP. Hereditary and environmental factors associated with risk and progression of head and neck cancer. *Otolaryngol Clin North Am*. 1992;25(5):1089–103.
52. Fishel R, Lescoe MK, Rao MR, Copeland NG, Jenkins NA, Garber J, et al. The human mutator gene homolog MSH2 and its association with hereditary nonpolyposis colon cancer. *Cell*. 1993;75(5):1027–38.
53. Hsu TC, Johnston DA, Cherry LM, Ramkissoon D, Schantz SP, Jessup JM, et al. Sensitivity to genotoxic effects of bleomycin in

- humans: possible relationship to environmental carcinogenesis. *Int J Cancer*. 1989;43(3):403–9.
54. Field JK. Genomic instability in squamous cell carcinoma of the head and neck. *Anticancer Res*. 1996;16(4C):2421–31.
 55. Schantz SP, Zhang ZF, Spitz MS, Sun M, Hsu TC. Genetic susceptibility to head and neck cancer: interaction between nutrition and mutagen sensitivity. *Laryngoscope*. 1997;107(6):765–81.
 56. Foulkes WD, Brunet JS, Sieh W, Black MJ, Shenouda G, Narod SA. Familial risks of squamous cell carcinoma of the head and neck: retrospective case-control study. *BMJ*. 1996;313(7059):716–21.
 57. Sato M, Sato T, Izumo T, Amagasa T. Genetically high susceptibility to oral squamous cell carcinoma in terms of combined genotyping of CYP1A1 and GSTM1 genes. *Oral Oncol*. 2000;36(3):267–71.
 58. Tanimoto K, Hayashi S, Yoshiga K, Ichikawa T. Polymorphisms of the CYP1A1 and GSTM1 gene involved in oral squamous cell carcinoma in association with a cigarette dose. *Oral Oncol*. 1999;35(2):191–6.
 59. Zhuo W, Wang Y, Zhuo X, Zhu Y, Wang W, Zhu B, et al. CYP1A1 and GSTM1 polymorphisms and oral cancer risk: association studies via evidence-based meta-analyses. *Cancer Invest*. 2009;27(1):86–95.
 60. Anantharaman D, Chaulal PM, Kannan S, Bhisey RA, Mahimkar MB. Susceptibility to oral cancer by genetic polymorphisms at CYP1A1, GSTM1 and GSTT1 loci among Indians: tobacco exposure as a risk modulator. *Carcinogenesis*. 2007;28(7):1455–62.
 61. Ha PK, Chang SS, Glazer CA, Califano JA, Sidransky D. Molecular techniques and genetic alterations in head and neck cancer. *Oral Oncol*. 2009;45(4–5):335–9.
 62. Uchida K, Oga A, Okafuji M, Mihara M, Kawauchi S, Furuya T, et al. Molecular cytogenetic analysis of oral squamous cell carcinomas by comparative genomic hybridization, spectral karyotyping, and fluorescence in situ hybridization. *Cancer Genet Cytogenet*. 2006;167(2):109–16.
 63. Latif F, Tory K, Gnarr J, Yao M, Duh FM, Orcutt ML, et al. Identification of the von Hippel-Lindau disease tumor suppressor gene. *Science*. 1993;260(5112):1317–20.
 64. Kinzler KW, Nilbert MC, Vogelstein B, Bryan TM, Levy DB, Smith KJ, et al. Identification of a gene located at chromosome 5q21 that is mutated in colorectal cancers. *Science*. 1991;251(4999):1366–70.
 65. Williams ME, Gaffey MJ, Weiss LM, Wilczynski SP, Schuurin E, Levine PA. Chromosome 11Q13 amplification in head and neck squamous cell carcinoma. *Arch Otolaryngol Head Neck Surg*. 1993;119(11):1238–43.
 66. Southern EM. Detection of specific sequences among DNA fragments separated by gel electrophoresis. *J Mol Biol*. 1975;98(3):503–17.
 67. Southern E, Mir K, Shchepinov M. Molecular interactions on microarrays. *Nat Genet*. 1999;21(1 Suppl):5–9.
 68. Sanger F, Coulson AR. A rapid method for determining sequences in DNA by primed synthesis with DNA polymerase. *J Mol Biol*. 1975;94(3):441–8.
 69. Okano M, Bell DW, Haber DA, Li E. DNA methyltransferases Dnmt3a and Dnmt3b are essential for de novo methylation and mammalian development. *Cell*. 1999;99(3):247–57.
 70. Paroush Z, Keshet I, Yisraeli J, Cedar H. Dynamics of demethylation and activation of the alpha-actin gene in myoblasts. *Cell*. 1990;63(6):1229–37.
 71. Suzuki MM, Bird A. DNA methylation landscapes: provocative insights from epigenomics. *Nat Rev Genet*. 2008;9(6):465–76.
 72. Shivaswamy S, Bhinge A, Zhao Y, Jones S, Hirst M, Iyer VR. Dynamic remodeling of individual nucleosomes across a eukaryotic genome in response to transcriptional perturbation. *PLoS Biol*. 2008;6(3):e65.
 73. Fatemi M, Pao MM, Jeong S, Gal-Yam EN, Egger G, Weisenberger DJ, et al. Footprinting of mammalian promoters: use of a CpG DNA methyltransferase revealing nucleosome positions at a single molecule level. *Nucleic Acids Res*. 2005;33(20):e176.
 74. Schuebel KE, Chen W, Cope L, Glockner SC, Suzuki H, Yi JM, et al. Comparing the DNA hypermethylation with gene mutations in human colorectal cancer. *PLoS Genet*. 2007;3(9):1709–23.
 75. Sjoblom T, Jones S, Wood LD, Parsons DW, Lin J, Barber TD, et al. The consensus coding sequences of human breast and colorectal cancers. *Science*. 2006;314(5797):268–74.
 76. Feinberg AP, Vogelstein B. Hypomethylation distinguishes genes of some human cancers from their normal counterparts. *Nature*. 1983;301(5895):89–92.
 77. Sakai T, Toguchida J, Ohtani N, Yandell DW, Rapaport JM, Dryja TP. Allele-specific hypermethylation of the retinoblastoma tumor-suppressor gene. *Am J Hum Genet*. 1991;48(5):880–8.
 78. Jones PA, Baylin SB. The epigenomics of cancer. *Cell*. 2007;128(4):683–92.
 79. Baylin SB, Ohm JE. Epigenetic gene silencing in cancer – a mechanism for early oncogenic pathway addiction? *Nat Rev Cancer*. 2006;6(2):107–16.
 80. Schlesinger Y, Straussman R, Keshet I, Farkash S, Hecht M, Zimmerman J, et al. Polycomb-mediated methylation on Lys27 of histone H3 pre-marks genes for de novo methylation in cancer. *Nat Genet*. 2007;39(2):232–6.
 81. Tiwari VK, McGarvey KM, Licchesi JD, Ohm JE, Herman JG, Schubeler D, et al. PcG proteins, DNA methylation, and gene repression by chromatin looping. *PLoS Biol*. 2008;6(12):2911–27.
 82. Ha PK, Califano JA. Promoter methylation and inactivation of tumour-suppressor genes in oral squamous-cell carcinoma. *Lancet Oncol*. 2006;7(1):77–82.
 83. Shaw R. The epigenetics of oral cancer. *Int J Oral Maxillofac Surg*. 2006;35(2):101–8.
 84. Herman JG, Graff JR, Myohanen S, Nelkin BD, Baylin SB. Methylation-specific PCR: a novel PCR assay for methylation status of CpG islands. *Proc Natl Acad Sci USA*. 1996;93(18):9821–6.
 85. Easds CA, Danenberg KD, Kawakami K, et al. Methylight: a high-throughput assay to measure DNA methylation. *Nucleic Acids Res*. 2000;28:E32.
 86. Colella S, Shen L, Baggerly KA, Issa JP, Krahe R. Sensitive and quantitative universal Pyrosequencing methylation analysis of CpG sites. *Biotechniques*. 2003;35(1):146–50.
 87. Shaw RJ, Liloglou T, Rogers SN, Brown JS, Vaughan ED, Lowe D, et al. Promoter methylation of P16, RARbeta, E-cadherin, cyclin A1 and cytoglobin in oral cancer: quantitative evaluation using pyrosequencing. *Br J Cancer*. 2006;94(4):561–8.
 88. Shaw RJ, Hall GL, Lowe D, Liloglou T, Field JK, Sloan P, et al. The role of pyrosequencing in head and neck cancer epigenetics: correlation of quantitative methylation data with gene expression. *Arch Otolaryngol Head Neck Surg*. 2008;134(3):251–6.
 89. Bibikova M, Lin Z, Zhou L, Chudin E, Garcia EW, Wu B, et al. High-throughput DNA methylation profiling using universal bead arrays. *Genome Res*. 2006;16(3):383–93.
 90. Hoque MO, Kim MS, Ostrow KL, Liu J, Wisman GB, Park HL, et al. Genome-wide promoter analysis uncovers portions of the cancer methylome. *Cancer Res*. 2008;68(8):2661–70.
 91. Tokumaru Y, Yamashita K, Osada M, Nomoto S, Sun DI, Xiao Y, et al. Inverse correlation between cyclin A1 hypermethylation and p53 mutation in head and neck cancer identified by reversal of epigenetic silencing. *Cancer Res*. 2004;64(17):5982–7.
 92. El-Naggar AK, Lai S, Clayman G, Lee JK, Luna MA, Goepfert H, et al. Methylation, a major mechanism of p16/CDKN2 gene inactivation in head and neck squamous carcinoma. *Am J Pathol*. 1997;151(6):1767–74.
 93. Toyota M, Ahuja N, Ohe-Toyota M, Herman JG, Baylin SB, Issa JP. CpG island methylator phenotype in colorectal cancer. *Proc Natl Acad Sci USA*. 1999;96(15):8681–6.

94. Shaw RJ, Hall GL, Lowe D, Bowers NL, Liloglou T, Field JK, et al. CpG island methylation phenotype (CIMP) in oral cancer: associated with a marked inflammatory response and less aggressive tumour biology. *Oral Oncol.* 2007;43(9):878–86.
95. Laird PW. The power and the promise of DNA methylation markers. *Nat Rev Cancer.* 2003;3(4):253–66.
96. Shaw RJ, Akufo-Tetteh EK, Risk JM, Field JK, Liloglou T. Methylation enrichment pyrosequencing: combining the specificity of MSP with validation by pyrosequencing. *Nucleic Acids Res.* 2006;34(11):e78.
97. Righini CA, de Fraipont F, Timsit JF, Faure C, Brambilla E, Reyt E, et al. Tumor-specific methylation in saliva: a promising biomarker for early detection of head and neck cancer recurrence. *Clin Cancer Res.* 2007;13(4):1179–85.
98. Carvalho AL, Jeronimo C, Kim MM, Henrique R, Zhang Z, Hoque MO, et al. Evaluation of promoter hypermethylation detection in body fluids as a screening/diagnosis tool for head and neck squamous cell carcinoma. *Clin Cancer Res.* 2008;14(1):97–107.
99. Goldenberg D, Harden S, Masayeva BG, Ha P, Benoit N, Westra WH, et al. Intraoperative molecular margin analysis in head and neck cancer. *Arch Otolaryngol Head Neck Surg.* 2004;130(1):39–44.
100. Shaw RJ, Hall GL, Woolgar JA, Lowe D, Rogers SN, Field JK, et al. Quantitative methylation analysis of resection margins and lymph nodes in oral squamous cell carcinoma. *Br J Oral Maxillofac Surg.* 2007;45(8):617–22.
101. Tan HK, Saulnier P, Auferin A, Lacroix L, Casiraghi O, Janot F, et al. Quantitative methylation analyses of resection margins predict local recurrences and disease-specific deaths in patients with head and neck squamous cell carcinomas. *Br J Cancer.* 2008;99(2):357–63.
102. Lopez M, Aguirre JM, Cuevas N, Anzola M, Videgain J, Aguirregaviria J, et al. Gene promoter hypermethylation in oral rinses of leukoplakia patients – a diagnostic and/or prognostic tool? *Eur J Cancer.* 2003;39(16):2306–9.
103. Hall GL, Shaw RJ, Field EA, Rogers SN, Sutton DN, Woolgar JA, et al. p16 Promoter methylation is a potential predictor of malignant transformation in oral epithelial dysplasia. *Cancer Epidemiol Biomarkers Prev.* 2008;17(8):2174–9.
104. Esteller M, Garcia-Foncillas J, Andion E, Goodman SN, Hidalgo OF, Vanaclocha V, et al. Inactivation of the DNA-repair gene MGMT and the clinical response of gliomas to alkylating agents. *N Engl J Med.* 2000;343(19):1350–4.
105. Banno K, Yanokura M, Kawaguchi M, Kuwabara Y, Akiyoshi J, Kobayashi Y, et al. Epigenetic inactivation of the CHFR gene in cervical cancer contributes to sensitivity to taxanes. *Int J Oncol.* 2007;31(4):713–20.
106. Steele N, Finn P, Brown R, Plumb JA. Combined inhibition of DNA methylation and histone acetylation enhances gene re-expression and drug sensitivity in vivo. *Br J Cancer.* 2009;100(5):758–63.

Chapter 6

Immunology of Head and Neck Cancer

Steve C. Lee and Robert L. Ferris

Abstract The immune system plays a key role in the progression of head and neck cancer. A greater understanding of the important contribution of the dysregulation and evasion of the immune system in the development and evolution of head and neck cancers should lead to improved therapies and outcomes for patients. Head and neck cancer evades the host immune system through manipulation of its own immunogenicity, production of immunosuppressive molecules, and promotion of immunomodulatory cell types. Also, the immune system can be exploited to promote metastasis, angiogenesis, and growth. In this chapter, we review basic immunology as it relates to head and neck cancer and discuss the theory of cancer immunosurveillance and immune escape. Current research on cytokines as biomarkers, cancer stem cell tumor antigens, and immunotherapeutic strategies are presented.

Keywords Immunology • Immunotherapy • Head and neck cancer • Biomarkers • Immune evasion • Immune surveillance • Monoclonal antibodies

Introduction

The immune system plays a key role in the progression of head and neck cancer. A greater understanding of the important contribution of the dysregulation and evasion of the immune system in the development and evolution of head and neck cancers should lead to improved therapies and outcomes for patients. In this chapter, we review basic immunology as it relates to head and neck cancer and discuss the theory of cancer immunosurveillance and immune escape.

There has been a recent renaissance in the idea that nascent cancer cells are destroyed by the immune system before tumor formation can occur (termed immune surveillance).

R.L. Ferris (✉)
University of Pittsburgh Cancer Institute,
200 Lothrop Street, Suite 500, Pittsburgh, PA 15213
e-mail: ferrrl@upmc.edu

Derangements in the immune system or alterations in the transformed cells may allow immune escape that allows the cancer to become manifest. Once tumor is established, there are a myriad ways in which it interacts with the immune system. Transcription factors such as NFκ(kappa)B (nuclear factor kappa-light-chain-enhancer of activated B cells) and STAT3 (signal transducers and activators of transcription), which are usually dysregulated in tumor-promoting inflammatory states in response to cytokine stimuli, are aberrantly activated in tumor cells and are intensively studied as possible targets for therapeutic intervention. Tumors themselves produce cytokines such as TGF-β(beta), IL-6, and IL-10, which suppress cell-mediated antitumor immunity. In response to inflammatory stimuli, head and neck cancer cells also can express receptors which are involved in lymphocyte and dendritic cell migration. Expression of these receptors by tumor cells, such as CCR7 and CXCR4, constitute immune exploitation of established signals intended for immune cells and have been associated with tumor invasion, metastasis, and cell survival, leading to treatment resistance. Another recently espoused theory is the idea that tumors are comprised of a heterogenous cell population in the tumor microenvironment that includes a special subpopulation of cancer stem cells (CSC) that are able to recreate the entire tumor phenotype and potentially evade immune recognition. These cells appear to be more resistant to conventional chemotherapy and radiation, and may not possess the same tumor antigen expression or T-cell recognition as non-CSC.

In head and neck cancer patients, there appear to be global alterations in the functional state of the immune system, as evidenced by changes in serum cytokines, chemokines and other immune-related biomarkers in cancer patients. There is considerable investigation focusing on the identification of serum biomarkers to monitor cancer progression, prognosis, treatment response, and relapse. Finally, we describe various immunotherapeutic strategies designed to utilize the immune system to stimulate elimination of cancer. These include cancer vaccines using tumor peptide antigens or viral, bacterial, and DNA-based vectors as well as tumor antigen-specific monoclonal antibodies (mAb). The recent clinical efficacy of these FDA-approved mAb, including cetuximab

(anti-EGFR) and bevacizumab (anti-VEGF), has stimulated investigation into immunological mechanisms of action which may explain antitumor clinical activity.

Brief Overview of the Immune System

The immune system has traditionally been divided into two major arms: innate and adaptive immunity. This dichotomy is somewhat artificial since there is tremendous interaction between the two components. Innate immunity refers to the part of the immune system that provides antigen nonspecific, first-line protection. The effectors of innate immunity include NK cells and phagocytes such as neutrophils, macrophages, dendritic cells, and monocytes that ingest extracellular debris or pathogens. Innate immunity also utilizes pattern recognition systems that recognize molecules that are not normally present in the human body: double-stranded RNA, bacterial cell wall components, lipopolysaccharide, and microbial membranes. These pattern recognition systems can take the form of enzymes like lysozyme, antimicrobial peptides (defensins), soluble factors (complement, C-reactive protein, mannose-binding lectin), and cell surface receptors (Toll-like receptors, scavenger receptors). Innate immunity is static and nonspecific, and does not change in magnitude or efficacy after repeated exposure to antigenic challenges. However, innate immune signals effectively trigger the adaptive immune system. Dendritic cells (DC) and other antigen-presenting cells link the two systems. DC ingest and process tumor antigens, after effectors of innate immunity have destroyed the tumor cell. DC then present these antigens to cytolytic and helper T lymphocytes, causing clonal expansion of antigen-specific T cells. Activation of the adaptive immune system (T lymphocytes) provides immunologic memory responses against these antigens. Thus, key effectors in tumor immunology are NK cells, B cells, T cells, and DC.

B Lymphocytes

Early in the field of immunology, humoral immunity was believed to be the primary effector mechanism, in 1948 plasma cells were identified as the source of antibodies. Plasma cells are one of the two endpoints for B cells, the other being the memory B cell. B cells can be activated via T-cell-dependent or -independent antigens. Tumor antigens are T-cell dependent antigens which require binding of the antigen to the B cell receptor and a secondary activation signal via CD40 on an activated helper T cell. It is well established that B cells in cancer patients are capable of recognizing and producing antibodies to tumor antigens [1, 2]. In head and neck cancer, circulating serum antibodies have been

found against p53 [3], MUC1 [4], p40 [5], p73 [6], and HPV E6 and E7 [7]. However, levels of circulating antibody have not been correlated with clinical outcome other than high postoperative levels of anti-p53 antibody which have been correlated with poor prognosis [8]. Interestingly, it has been noted that there is an increased frequency of IgE subtype immunoglobulins in head and neck cancer [2, 9]. The significance of this finding, if any, is unclear.

T Lymphocytes

T lymphocytes were defined in the early 1960s when mice were thymectomized in an attempt to prevent lymphoma. When the initial experiments in adult mice failed to have any effect, neonatally thymectomized mice were found to have profoundly decreased lymphocyte numbers and were unable to generate antibodies despite having plasma cells. Based on these data, Miller theorized that the thymus must be the source of a “helper” cell that is required to produce antibody [10–12]. In later experiments, depletion of CD8 abolished this destruction which identified CD8 T cells as a primary effector of specific tumor/allograft rejection.

T lymphocytes are defined by the presence of T-cell receptors (TCR) on their cell surface. TCR are part of the immunoglobulin superfamily and undergo germline DNA rearrangement to produce diversity much like immunoglobulin genes in B cells. TCR recognizes tumor antigens which are short peptide fragments bound to or “presented by” major histocompatibility complexes (MHC). There are two main classes of MHC: MHC I molecules found on the cell surface of all nucleated cells and MHC II is found only on professional antigen-presenting cells such as macrophages and dendritic cells. MHC class I and II binds with peptides, which are derived from tumor proteins and “processed” within the cell, and MHC then bind or present these tumor peptides on the cell surface for recognition by T cells. The TCR can only recognize peptide antigen when presented by a particular self-MHC molecule, a phenomenon known as MHC restriction, which led to the Nobel Prize in 1996 to Doherty and Zinkernagel. Therefore, CD8 T cells can recognize syngeneic (self) but not allogeneic (from someone else) tumor cells. MHC I binding tumor peptides are usually eight to ten amino acids in length, derived from endogenous proteins processed via the proteasome, and are presented to CD8 T cells. MHC II peptides are longer (11–16 amino acids), derived from exogenous proteins taken in by endocytosis, and are presented to CD4 T cells [13].

T lymphocytes are generally divided into CD4⁺ or CD8⁺ T cells. While it remains unclear how T cells are selected to become CD4 or CD8 cells, there are usually twice as many CD4 T cells as CD8 T cells released. Once antigen is encountered along with the appropriate costimulatory signals,

T cells become activated and differentiated. CD4 T help (T_H) cells usually differentiate into one of two major subclasses, T_H1 and T_H2 , and this differentiation depends on the cytokine milieu in the environment at the time of activation. These two subsets of CD4 cells are differentiated by function and cytokine secretion profile. The T_H1 subset is responsible for most cell-mediated immune functions such as activation of CD8 T cells, inflammation, and delayed-type hypersensitivity as well as production of complement activating IgG antibodies. Macrophages or dendritic cells will produce IL-12 in response to intracellular pathogens. IL-12 along with IFN- γ (gamma) and IL-18 drive the T_H1 response. T_H1 cells secrete IL-2, IFN- γ , and TNF- α and are felt to be the most strongly antitumor subtype.

On the other hand, IL-4 drives a T_H2 response [14]. The T_H2 response drives B cells to produce IgM, IgE, and non-complement-activating IgG, as well as activating eosinophils, in response to parasitic invasion. T_H2 T cells are strongly implicated in allergy and are felt to be tumor permissive. T_H2 cells secrete GM-CSF, IL-3, IL-4, IL-5, IL-10, and IL-13. More recently, other subsets of CD4 T cells have been identified. T_H17 cells require TGF- β and IL-6 for differentiation and are defined by their production of IL-17. IL-17 is known to induce the production of several chemokines that attract proinflammatory cells and IL-17 expression is greatly increased in autoimmune diseases [15]. The final subset of CD4 T cells is the regulatory T cell (Treg) that was originally defined as a CD4⁺CD25⁺Foxp3⁺ T cells. Tregs are thought to be a reciprocal subtype to T_H17 cells in that both are induced by TGF- β , but Tregs are immunosuppressive as opposed to T_H17 cells which are proinflammatory. Tregs have recently been strongly correlated with disease status in SCCHN patients [16, 17].

Natural Killer Cells

NK cells were discovered in 1975 when experiments studying tumor lysis by lymphocytes from immunized animals found lysis that was independent of previous immunization or activation [18]. This was thought to be an artifact until the NK cell was isolated and given the name “natural killer” cell for its ability to kill tumors without previous activation. NK cells kill much in the same way as cytotoxic T cells, through the interaction Fas ligand on their surface with Fas on target cells inducing apoptotic cell death. They also constitutively possess perforin and granzyme granules and degranulate causing cytolysis. Unlike T cells that are self MHC restricted and require self MHC for activation, NK cells are suppressed by the presence of self MHC via KIR receptors that inhibit NK killing when bound by self MHC [19]. These inhibitory signals can inhibit killing even when activating receptors on the NK cell are bound and therefore presentation of self MHC on the target’s surface is protective. Activation receptors

on the NK cell include NKD2D and Fc γ III receptor. NKD2D binds ligands produced by cells stressed by DNA damage or infection. Fc γ III receptor is a high affinity receptor for IgG which provides a mechanism by which NK cells can recognize targets bound by antibody. Activating Fc γ receptors mediate antibody-dependent cell-mediated cytotoxicity (ADCC) by NK cells, macrophages, monocytes, neutrophils, and eosinophils.

Dendritic Cells

Dendritic cells (DC) are antigen-presenting cells and as such are potent initiators of the immune response. DC efficiently take up antigen via several mechanisms including phagocytosis, macropinocytosis, and adsorptive endocytosis. After uptake, antigen is shunted into lysosomes and degraded for presentation on MHC II. DC also possess B7 molecules on their surface that provide a necessary secondary activation signal to T cells after engagement of the MHC–peptide complex with the TCR. Because DC are such potent activators of T cells and initiators of adaptive immunity, they have been intensely studied as a possible therapeutic for cancer immunotherapy.

Another important process mediated by DC is cross presentation of antigen derived from tumor cells or shed tumor products/vesicles. Exogenous antigen is processed via the exogenous pathway and presented to CD4 cells by DC via MHC II. However, DC are able to move exogenous antigen to the endogenous pathway and present these antigen to CD8 cells via MHC I. This surrogate presentation of exogenous antigen to the endogenous pathway is defined as cross presentation. Cross presentation serves a very important function because it allows DC to activate cytotoxic T cells against virally infected cells and tumor cells and have recently been harnessed in cancer vaccine trials.

Cancer Immunosurveillance and Immunoediting

The idea of immune control of malignant cells was first proposed by Paul Ehrlich in 1908, but it was not until the 1950s that greater understanding of the immune system gave rise to a formalized hypothesis. This “cancer immunosurveillance” hypothesis was introduced by Burnet and Thomas and stated that tumor cells must have recognizably different antigens than normal cells and therefore have the potential for immune clearance. Also at that time, the phenomenon of allograft rejection via cellular immunity was observed. Because grafting of allogeneic tissue is not a naturally occurring event, Thomas proposed that the actual primary function of cellular immunity was not to protect against allografts but rather to

protect against tumors. Conflicting experimental results led many to abandon the idea of cancer immunosurveillance for several decades, until several key discoveries have led to a revival of the hypothesis. First was the discovery of the NK cell in the late 1970s which seemed to provide innate immune protection from tumor [20]. The discovery of IFN- γ and its proapoptotic effect on tumor growth gave additional support to the potential for immune clearance of cancer cells [21]. Mice lacking IFN- γ receptors produced more tumors with decreased latency after methylcholanthrene challenge and addition of IFN- γ was protective against transplanted, spontaneous, and induced tumors in another experiment. Studies in mice lacking perforin, a key component of cytolytic granules in T cells and NK cells, recapitulated the results in IFN- γ receptor knockout mice with more frequent tumors and lower latency of formation [22]. Mice with genetically induced immunodeficiency were found to be more susceptible to both spontaneous and chemically induced tumors. In humans, epidemiologic data from AIDS patients demonstrate increased risk of lymphoma, Kaposi's sarcoma, and virally induced carcinomas of the genitourinary tract. There also appears to be a higher risk of HPV-associated HNC in HIV+ patients [23]. These data confirm the unchallenged idea that immune protection from viral infections reduces risks of cancer associated with viruses.

But what of tumors without viral etiology? Data gathered from transplant patients who are immunosuppressed to avoid organ rejection demonstrate increased risk of many tumors with no known viral etiology such as lung, head, and neck [24],

pancreatic, endocrine, colon cancer, and melanoma [25]. The cancer immunosurveillance hypothesis has given rise to the theory of cancer immunoediting which is the idea that immune surveillance of cancers provides selective pressure on tumor cells and selects for cells that can evade the immune system. One study showed that many tumors grown in immunocompromised mice are rapidly cleared when injected into immunocompetent mice, whereas cancers from immunocompetent mice continue to grow when transplanted into immunocompetent mice, indicating a qualitative difference in the cancer cells that was dependent on the immune environment [26]. The theory contends that successful tumor formation can occur only after the cancer has discovered a means by which it can evade the immune system.

Immune Escape and Immunosuppression in Head and Neck Cancer

Cancer cells evade the immune system by two primary mechanisms: by reducing their innate immunogenicity or by suppressing the immune response (Fig. 6.1). Tumor cells can reduce T-cell-mediated recognition by altering HLA class I expression. It has been noted that some tumor cells have a complete loss of HLA expression due to defects in β_2 -microglobulin expression or function. Alternatively, chromosomal defects in the HLA-encoding genes themselves can cause selective loss of HLA expression. This process has been noted in approximately 50%

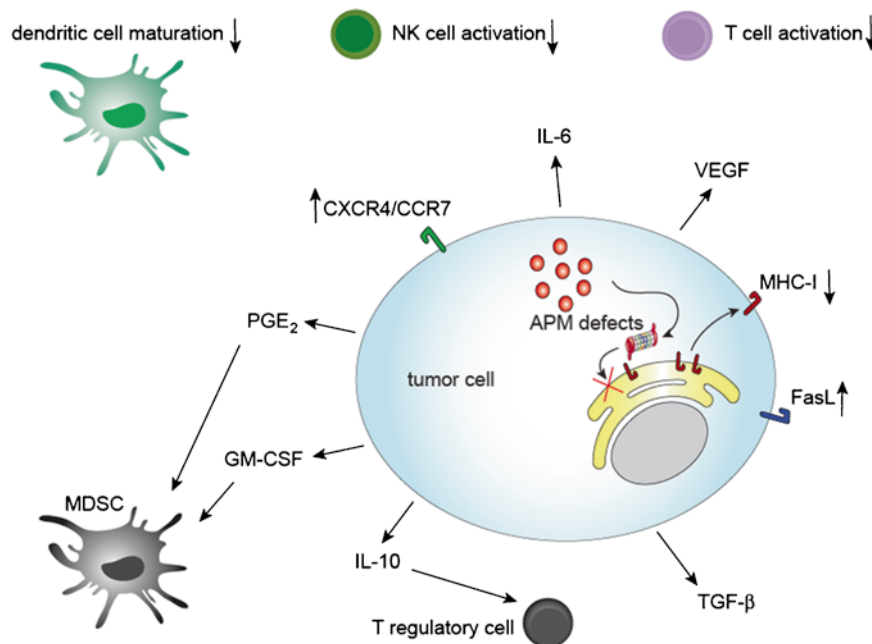


Fig. 6.1 Tumor cell immune evasion and exploitation. Tumor cells secrete several small molecules and cytokines that depress NK, DC, and T-cell function and induce immunosuppressive MDSC and regulatory T cells.

MHC downregulation and defects in the antigen presentation machinery impairs T-cell recognition. Fas ligand is expressed which kills T cells. Chemokine receptors aid in metastasis of the cancer cell to lymph nodes

of head and neck squamous cell carcinomas [27] and was correlated with poor prognosis in esophageal squamous cell cancer [28] and laryngeal squamous cell cancer [29]. In other cancers, there is ample expression of HLA and tumor antigen but without recognition by T cells. Because HLA loss variants are killed by NK cells, one proposed explanation for the lack of NK cell killing is that cancer cells possess defects in their antigen presentation machinery (APM). This would reduce selectively tumor antigen-HLA peptide completely without reduction in overall surface HLA density.

Endogenous antigens are processed through the cytoplasmic immunoproteasome which consists of various subunits including low molecular weight proteasome (LMP) 2, LMP7, and LMP10. Antigenic peptides are transported to the endoplasmic reticulum by the transporter associated with antigen processing (TAP) where they are associated with HLA class I heavy chains by tapasin [30]. Thus, SCCHN cells that express HLA I and whole tumor antigen can evade T-cell recognition through decreased expression of LMP2, TAP1, TAP2, and tapasin. The observation that T-cell recognition could be reconstituted with either exogenous peptide or upregulation of APM expression [31] confirms the biological significance of this immune escape mechanism. In addition to decreased expression of HLA, SCCHN tumor cells express Fas ligand which can interact with Fas and transduce a powerful apoptosis signal to activated T cells allowing immune evasion [32] by eliminating tumor-infiltrating T lymphocytes.

As mentioned, decreased expression of HLA molecules is protective against T cells but increases NK cell-mediated cytotoxicity as the absence of HLA removes a key inhibitory signal for NK cells. Therefore, tumor cells must employ multiple mechanisms to suppress NK cell-mediated antitumor immunity. MICA, a ligand of NKG2D in NK and T cells, can be released in a soluble form to act as a competitive antagonist [33]. Cytokines and other molecules that suppress immune function such as IL-10, TGF- β , IL-6, PGE₂, VEGF, and GM-CSF are known to be produced by SCCHN cells. IL-10 reduces activation of cytotoxic T cells and has been correlated with advanced stage head and neck cancer [34]. TGF- β suppresses T cell and NK activation and is a key cytokine in the differentiation of regulator T cells [35]. TGF- β production is increased in preneoplastic oral cavity lesions and promotes angiogenesis and a protumorigenic microenvironment linking it to early tumor formation [36]. IL-6 signals via STAT3 to inhibit DC maturation, NK cell, T cell, neutrophil, and macrophage activation [37] and has been correlated with recurrence and survival in SCCHN [38]. Reduced DC numbers and function have been observed in this disease (Mueller-Burghaus paper). STAT3 is a transcription factor that is also involved several other immunosuppressive pathways such as IL-10 signaling [39], suppression of dendritic cells [40], downregulation of IL-12 [41], and generation of regulatory T cells [42]. PGE₂ is a prosurvival, proangiogenic

molecule that is produced by many cancers including SCCHN [43, 44]. It is also a potent immunomodulator that decreases T-cell proliferation, inhibits Th1 T cells, decreases B-cell proliferation and inhibits maturation and antigen presentation of DC [45]. VEGF, which is primarily thought of as a promoter of angiogenesis, is overexpressed in 90% of SCCHN [46] and functions to increase the ratio of immature to mature DC in the tumor microenvironment which is thought to lead to T cell anergy [47]. GM-CSF when produced in large quantities by tumors recruit myeloid-derived suppressor cells (MDSC) [48, 49] which have been identified in SCCHN.

Myeloid-Derived Suppressor Cells

Myeloid-Derived Suppressor Cells (MDSC) are a diverse family of myeloid cells that are defined by Gr1⁺CD11b⁺ and in cancer patients they are usually also CD33⁺ and CD34⁺ [50]. They are increased in almost all cancer patients and, indeed, were first characterized in SCCHN [49] where their link to VEGF and GM-CSF was discovered. In addition to VEGF and GM-CSF, MDSC are induced by IL-6, IL-1 β , PGE₂, and complement C5a. Initial studies in SCCHN found that MDSC inhibit IL-2 secretion by activated T cells which is a key step in T-cell proliferation and escalation of cell-mediated immunity. Also, they deplete the tumor microenvironment of arginine and cysteine which are essential for T-cell activation. MDSC produce nitric oxide and reactive oxygen species that catalyze the nitration of the TCR which inhibits TCR – MHC interactions and subsequent activation. Downregulation of the TCR zeta chain which also interferes with T-cell activation is mediated by MDSC along with downregulation of L-selectin which is important for migration of naïve T cells to lymph nodes. Data on the effect of MDSC on NK cells has been conflicting with reports of both enhancing as well as suppressive action on NK cells which may be a function of the heterogeneity of MDSC populations. MDSC also promote induction of Tregs via production of IL-10, TGF- β , and arginase [50]. Treatments such as antibody depletion, retinoic acid, gemcitabine, and STAT3 blockade that diminish MDSC restore immune surveillance, increase T-cell activation, and improve efficacy of immunotherapy. The basal levels of MDSC increase with age and may contribute to increased tumor frequency and growth rate increase with age [51].

T Regulatory Cells

Though it was long suspected that a subset of T cells were immunosuppressive, their characterization occurred relatively recently when it was found that this subpopulation

were CD4⁺ cells that also expressed CD25 [52]. There are now four subtypes of regulatory T cells: naturally occurring thymus-derived CD4⁺CD25^{high}FoxP3⁺Tregs, antigen-induced IL-10-dependent Tregs (Tr1), IL-4-dependent Tregs (Th3), and antigen-specific Tregs [16]. There is also a CD8⁺CD25⁺ variant which also appears to have immunosuppressive ability but their biological significance is unclear and they are thought to be overshadowed by the much more abundant CD4⁺ Tregs [53]. Tregs cause anergy, apoptosis and cell cycle arrest of activated T cells via production of IL-10, TGF- β , and direct cell–cell contact [54]. They also inhibit the action of dendritic cells, NK cells, and B cells [55]. In SCCHN patients, Tregs are increased in frequency in peripheral blood and among T cells infiltrating the tumor and draining lymph nodes resulting in an immunosuppressed state [17, 56, 57]. Also, Treg numbers are inversely proportional to DC and CD8⁺ T-cell numbers in SCCHN [58, 59]. Treg frequency as a prognostic indicator is unclear as one study linked increased Tregs with better locoregional control [60] while another study found increased Tregs associated with early recurrence [61]. Also interesting was the finding that Treg numbers were greater in SCCHN patients after treatment than before treatment indicating that oncologic treatment increases Treg numbers [17].

These data indicate that SCCHN induces an immunosuppressed state via multiple potent mechanisms which is a barrier to effective cancer immunotherapy. They secrete immunosuppressive cytokines and molecules. Cytokine levels are aberrant in SCCHN patients indicating deregulation or dysregulation of cytokine pathways [62]. There is increased frequency of immunosuppressive regulatory immune cells and there is a global dysfunction of almost every facet of the immune system in SCCHN patients.

Inflammation and Cancer

The strong link between inflammation and cancer is manifested by aberrant immune signals. The fact that some cancers arise at sites of chronic inflammation was first noted by Virchow over a century ago. Since then, chronic inflammatory states have been linked to a myriad of tumors: *Helicobacter pylori* infection and gastric cancer, inflammatory bowel disease and colon cancer, chronic irritation, and inflammation of the aerodigestive tract by tobacco and alcohol and SCCHN. Studies of the tumor microenvironment demonstrate infiltration of inflammatory mediators and a complex milieu of cytokines. Many of these cytokines have been previously discussed – TGF- β , IL-6, IL-10, GM-CSF – but also include cytokines such as IL-1 β , IL-23, and TNF- α (alpha) as well as chemokines, which are “chemotactic cytokines” that direct immune cell migration.

Chemokines are a family of small heparin-binding cytokines that direct the movement and migration of leukocytes. There are four groups of chemokines based on the arrangement of cysteine residues near the N-terminus of the proteins: C, CC, CXC, and CX3C. The G-coupled transmembrane chemokine receptors are also divided into these four groups based on their cognate ligand [63]. SCCHN cells have aberrant expression of several chemokines. They overexpress CXCL1 which has been implicated in tumor angiogenesis, nodal metastasis, and leukocyte infiltration. CCL2 is also overexpressed in squamous cell cancer and is thought to have similar functions. CXCL5 is found in metastatic SCCHN and is involved in tumor migration and tumorigenesis. CXCL8, also found in metastatic SCCHN, promotes matrix metalloprotease secretion and subsequent extracellular matrix breakdown and tissue invasion.

Of the chemokine receptors, CXCR4 and CCR7 are of particular interest as these two receptors are overexpressed in malignant cells including SCCHN cells. Increased expression of CXCR4 and its ligand, CXCL12, in SCCHN cells is associated with nodal metastasis, tumor recurrence, and overall survival. Studies of CXCR4 activation have shown increased metastatic potential, induction of matrix metalloprotease and collagenase expression, decreased cell adhesion and increased cell mobility. CCR7 appears to have similar biological actions. High CCR7 expression is clinically associated with tumor stage, lymphatic invasion, nodal metastasis and poorer prognosis [64]. A study of chemokine receptor expression differences between primary and metastatic SCCHN cell lines found that only CCR7 was consistently upregulated in metastatic SCCHN [65]. CCR7 also provides tumor survival and invasion signals via the PI3 kinase signal transduction pathway [66]. These actions in tumor cells are similar to the action of CCR7 in dendritic and CD8⁺ cells where they mediate chemotaxis to lymph nodes and antiapoptotic signals and may explain the predilection of SCCHN to metastasize to lymph nodes where there is a high concentration of chemokines. The production of chemokines and their receptors by SCCHN tumor cells represents exploitation of the immune system to promote tumor survival and metastasis.

A key regulator of the inflammatory response in cancer is the transcription factor NF- κ B [67] which stimulates many cancer-promoting cytokines and chemokines in SCCHN [68]. NF- κ B sits downstream of several soluble factors including TNF- α , IL-1, and reactive oxygen species that are produced by macrophages and granulocytes that infiltrate tumor. Of interest in relation to SCCHN, NF- κ B activation can also be elicited by cigarette smoke condensate, betel nut extract, and EGFR signaling [69–71]. Activation of the NF κ B pathway induces several tumor-promoting processes in SCCHN [72]. NF- κ B is traditionally thought of as a stress response transcription factor because it controls expression of several prosurvival genes such as mdm2, TRAF1, TRAF2, IAP, and Bcl-XL. These act

as antiapoptotic signals for tumor cells and confer resistance to natural death pathways for aberrant cells. NF- κ B also promotes tumor cell proliferation and expansion through regulation of a key cell cycle modulator, cyclin D1. Angiogenesis is promoted by NF- κ B through VEGF production and several cytokines including TNF- α , IL-1, -6, and -8 are induced causing a positive feedback loop. Tissue invasion is promoted by the upregulation of heparinase, matrix metalloprotease, and urokinase. It has also been suggested that NF- κ B mediates resistance to treatment with chemotherapy and radiation via regulation of GADD (growth arrest DNA damage) and glutathione-S-transferase [73]. The activation of NF- κ B by inflammatory immune mediators demonstrates yet another subversion and exploitation of the immune system by cancer to promote key aspects of tumor formation and progression.

Cancer Stem Cells

Recently, there has been growing interest in the cancer stem cell hypothesis. Heterogeneity in tumor cells has long been accepted and this theory postulates the existence of a subpopulation of tumor cells that are pluripotent and are able to effectively recapitulate the entire heterogeneous tumor when transferred to another site. They are thought known to be more resistant than other tumor cells to chemotherapy as well as radiation [74]. Several defining markers of these stem cells have been proposed. The first marker proposed was CD44 [75], a cell surface glycoprotein which binds hyaluronate but may also inhibit the action of the p53 tumor suppressor in cancer cells [76]. However, CD44 expression is abundant in normal epithelia and its utility as a cancer stem cell marker is questionable [77]. Another proposed marker is aldehyde dehydrogenase 1 which is found in many embryonic stem cells and was identified as the responsible protein in conferring resistance to chemotherapeutic agents in stem cells [78]. Because these cancer stem cells are able to reconstitute the entire tumor, many believe that ultimately, it is treatment of this small population of resistant cells that determines the success or failure of oncologic therapy. If this is the case, it is important that these cells be addressed in any treatment regimen. Because aldehyde dehydrogenase 1 (ALDH1) is not highly expressed in normal tissues, its potential as a tumor antigen target has been recently explored [79].

Immune Mediators as Cancer Biomarkers

Because of the derangements in production of cytokines and other immunomodulatory molecules caused by cancer, there has been investigation into the possibility of using cytokine

profiles as biomarkers. Biomarkers are of considerable interest because they could be useful in early detection of cancer, determination of prognosis, as a marker of treatment response and selection of optimal treatment regimen. Cytokines as biomarkers have been investigated in SCCHN in several studies. An older study found that serum TNF- α was 100-fold higher in cancer patients than in disease free controls [80]. A subsequent study linking serum TNF- α levels to cancer status was published but that paper found IL-6 to be a more sensitive marker than TNF- α [81]. Another cytokine commonly cited in papers as a possible biomarker for detection of tumor is IL-8 which is elevated in recurrent or metastatic cancer [82]. In a study of over 300 subjects encompassing those with active disease, no evidence of disease and healthy smokers 60 cytokines were measured and a panel of 25 including IL-8, IFN- α , IFN- γ , IL-1, and RANTES could correctly identify active disease with a sensitivity of 84.5% and a specificity of 92% [83]. This provided a proof-of-principle that the immune system may serve as a biosensor of malignancy and disease status. In another study, IL-6, IL-8, VEGF, and hepatocyte growth factor were elevated in cancer patients and decreases over treatment correlated with improved survival. Interestingly, elevated pretreatment VEGF was a good prognostic factor [84]. This is in contrast to a studies in non-small-cell lung cancer [85] and head and neck cancer (ASCO 2009 A6035) which demonstrated low pretreatment VEGF as a predictor of better treatment response and longer progression free survival. A large study of 444 patients found that high pretreatment IL-6 is an independent predictor of poor prognosis [38].

Head and Neck Cancer Immunotherapy

There are several strategies for delivering tumor vaccines with each having inherent advantages and disadvantages. All methods depend on delivering an antigen to the host in an effort to elicit an adaptive cellular immune response to the tumor antigen. Most methods require the use of a specific known tumor antigen but some can use entire tumor cells as part of the vaccine to activate the immune system against multiple unspecified and unknown tumor antigens.

DNA vaccines utilize delivery of naked DNA encoding a known tumor antigen to the patient. This DNA is taken up by cells and the antigen is expressed for subsequent processing and presentation by DC. DNA vaccines are safe, inexpensive, easy to deliver, and do not induce the formation of neutralizing antibodies allowing repeated administration. However, they have a low transfection efficiency and elicit a very weak immune response and therefore are often engineered to encode proteins that target DC or are given with adjuvant agents that increase DC activation. Currently in SCCHN,

DNA vaccines encoding a HPV-16 E6/E7 fusion protein is under development for HPV positive SCCHN [86] and another vaccine encoding Hsp65 has been tested in a phase I trial [87] and demonstrated clinical response in 4 out of 14 patients with recurrent unresectable SCCHN.

Bacterial/viral vaccines can deliver tumor antigen as well as functioning as an immune adjuvant because the immune system responds to a perceived infection. They are very immunogenic, relatively inexpensive, and easy to manufacture but have the downsides of potential toxicity, preexisting neutralizing antibodies, or the formation of antibodies against the bacterial or viral vector limiting repeat dosing or effectiveness. Also, these tend to elicit a stronger humoral rather than cellular immune response which is less desirable. Several such vaccine are currently under development: HPV-16 E7 Listeria vaccine [88], Vaccinia-based E6/E7 vaccine [89], and a Vaccinia-based E2 [90].

Peptide vaccines consist of synthesized peptides that have been designed to correspond to an epitope on a tumor antigen that binds well to the cleft of an HLA molecule. They are similar to DNA vaccines in that they are safe and inexpensive with low immunogenicity but have the added drawback of being restricted to the HLA subclass for which they were designed. The popular HLA subclass used in vaccine design is HLA-A2 as this is the most common subclass found in Caucasians. Clinical trials are underway with a MAGE-A3/HPV-16 peptide (NCT00257738) and a LMP-2 peptide for EBV-related nasopharyngeal carcinoma (NCT00078494).

To circumvent HLA restriction, whole proteins can be used as a vaccine. Whole proteins can be processed by the antigen-presenting cells and presented on self MHC to cause activation of T cells. However, the vast majority of identified tumor antigen proteins are self proteins and therefore the patient's immune system is tolerant to these proteins. Therefore, there is tremendous difficulty in producing an effective immune response with protein vaccines.

Tumor cell vaccines are similar to whole protein vaccines in that they are not HLA restricted and specific epitopes need not be known for their use. Often the tumor cells are given with adjuvant agents or modified by viral infection to improve their immunogenicity. A Newcastle disease virus infected tumor cell vaccine was found to induce a specific T-cell response and [91] that correlated with better clinical outcome. These vaccines tend to be labor intensive because tumor has to be isolated and processed before it can be used as a vaccine.

Dendritic cells are the most potent activators of antigen-specific T cells and consequently, DC vaccines are the most widely studied cancer vaccine strategy. This is an extremely labor-intensive method in which dendritic cells are isolated from each patient and they are loaded with tumor antigen *ex vivo*. This loading can be in the form of peptides, proteins, DNA transfection, tumor cell lysates, apoptotic tumors, necrotic tumors, or cell fusion. After DC are loaded with

tumor antigen, they undergo maturation and activation with various cytokine cocktails to prime them for presenting the tumor antigen to T cells. These DC are then introduced to the patients usually into the tumor or into lymph nodes. Several DC-based vaccines are currently being developed for SCCHN: intratumoral injection of DC (NCT00492947), multivalent p53 DC vaccine [92], and lysyl oxidase like-4 transfected DC [93].

There are also efforts to reverse the immunosuppression associated with cancer. One method utilizes a cocktail of multiple cytokines delivered systemically to improve immune competence. Other strategies target specific inhibitory molecules. CTLA-4 is a receptor found on T cells which sends an inhibitory signal and leads to T-cell anergy. An anti-CTLA-4 antibody has been developed to block this inhibitory signal [94]. Another inhibitory cell surface protein on T cells is programmed death-1 [95] and antagonistic antibodies to this protein have demonstrated efficacy in phase II trials [96]. Anti-KIR antibodies remove the major inhibitory signal on NK cells. There are also monoclonal antibodies which act as agonists of various stimulatory receptors such as CD40, CD137, and glucocorticoid-induced tumor necrosis factor receptor [97–99] in various stages of development.

Monoclonal Antibody-Based Immunotherapy of SCCHN

Today the most widely used form of cancer immunotherapy is mAb therapy. Currently available mAbs that may have activity in head and neck cancer are listed in Table 6.1. The most extensively studied of these is cetuximab, a mouse–human chimeric IgG1 anti-epidermal growth factor receptor (EGFR) mAb [100]. EGFR is an attractive target in SCCHN because it is overexpressed in 80–90% of SCCHN and leads to tumor cell proliferation, invasion, angiogenesis, tumor survival, and consequently, poor survival and prognosis [101]. The one mAb which does not target EGFR listed in Table 6.1 is bevacizumab which is a humanized IgG1 specific

Table 6.1 Currently available mAbs for investigation or clinical use in head and neck squamous cell carcinoma

Antibody	Subtype	Target
Cetuximab	Chimeric IgG1	Domain III of EGFR
Panitumumab	Human IgG2	Domain III of EGFR
Matuzumab	Humanized IgG1	Domain III of EGFR
Zalutumumab	Human IgG1	Domain III of EGFR
IMC-11F8	Human IgG1	Domain III of EGFR
Bevacizumab	Humanized IgG1	VEGF-A

Reprinted from Lee, S., Lopez-Albaitero, A., and Ferris, R. L. (2009). Immunotherapy of head and neck cancer using tumor antigen-specific monoclonal antibodies. *Current Oncology Reports*. 11 (2), 156–162. With kind permission from Springer Science+Business Media

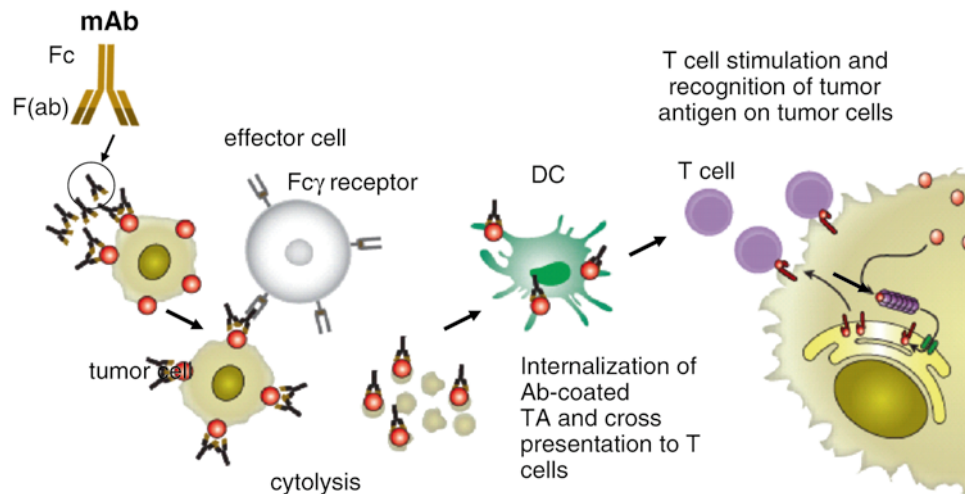


Fig. 6.2 Schematic representation of ADCC, the effector mAb has a constant fragment [Fc] that interacts with immune effector cells, and a variable fragment [F(ab)] that is antigen (EGFR) specific. During cross presentation, tumor antigens are degraded in the cytoplasm of dendritic cells (DC), and presented to T cells producing a cellular

immune response. Reprinted from Lee, S., Lopez-Albaiteo, A., and Ferris, R. L. (2009). Immunotherapy of head and neck cancer using tumor antigen-specific monoclonal antibodies. *Current Oncology Reports*. 11 (2), 156–162. With kind permission from Springer Science+Business Media

against VEGF-A. A phase II trial of a combination of bevacizumab and erlotinib in SCCHN demonstrated a response rate of 14.6% and an overall mean survival of 6.8 months [46] and several other phase II trials in combination with cetuximab and pemetrexed are pending. An Eastern Cooperative Oncology Group (ECOG) phase III trial studying bevacizumab in combination with chemotherapy is also currently underway.

It is becoming clear that anti-EGFR mAb mediate antigen-specific immune responses to targeted tumors (Fig. 6.2). There are two major mechanisms by which mAb can activate the immune system against a tumor target, direct killing via lytic immune cell (NK cell or monocytes) and complement fixation, or opsonization of tumor for phagocytosis and subsequent antigen processing. The latter would induce TA-specific cytotoxic T lymphocytes (CTL) to recognize and lyse tumor cells. One of the most direct methods by which antibodies can cause tumor lysis is via antibody-dependent cellular cytotoxicity (ADCC) mediated by NK cells and probably monocytes and neutrophils. Panitumumab and cetuximab both mediate ADCC [102] and the extent of ADCC is heavily influenced by genetic polymorphisms in FcγRIIIa, also known as CD16 [103]. Complement activation via the classical pathway is another major effector of humoral immunity and is activated by IgM, IgG1, IgG2, and IgG3. A combination of cetuximab and matuzumab can elicit complement-dependent cytotoxicity in vitro [104]. In addition to direct activation of NK cell lysis of tumor cells, TA-specific mAbs can elicit CD8⁺ T-cell responses to tumor-derived antigens through interaction with FcγRs on antigen-presenting cells (APC). In human cells, there are three activating FcγRs,

FcγRI, FcγRIIa, and FcγRIII and one inhibiting FcγR, FcγRIIB [105] with FcγRIIa being the dominant receptor on APC. This antigen-specific T-cell activation was noted in 78% of patients treated with trastuzumab for breast cancer and this activation seemed to correlate positively with clinical response [106]. Specific T-cell activation has recently been demonstrated in a model using glioma and cetuximab [107] and it is likely that similar T-cell activation also occurs in SCCHN patients treated with anti-EGFR mAbs (Lee, SC and Ferris, RL unpublished data).

The mechanism for TA-specific T-cell induction may actually be enhanced by ADCC and NK cell activation. In addition to their ability to mediate ADCC, activated NK cells, particularly CD56^{bright} NK cells [108] have also been shown to secrete cytokines, such as IFN-γ, TNF-α, and chemokines, such as macrophage inflammatory protein-1α, MIP-1β, and RANTES, that inhibit tumor cell proliferation, enhance antigen presentation, and aid in the chemotaxis of T cells [103, 109]. Indeed, NK cells can interact with other innate immune cells that are present during the early phases of inflammatory responses [110]. This so-called NK cell–DC cross-talk follows the recruitment of both NK cells and DC to sites of inflammation [110, 111], resulting in potent activating bi-directional signaling. NK cells in the presence of cytokines released by DC become activated, regulating both the quality and the intensity of innate immune responses. Also, activated NK cells release cytokines that favor DC maturation and select the most suitable DC for subsequent migration to lymph nodes and efficient T-cell priming. In addition, IFN-γ secreting NK cells can be recruited directly to the lymph nodes to enhance T-cell

induction [112]. Elevated levels of the NK cell-derived chemokines IL-8, macrophage inflammatory protein-1, and RANTES have been detected within the sera of trastuzumab responding cancer patients [109]. These NK cell factors could induce the chemotaxis of naive and activated T cells, as indicated by the correlation of their presence with the infiltration of tumor tissue by CD8⁺ CTL. These data suggest that NK cell cytokine and chemokine production may enhance DC cross presentation and T-cell induction, with the potential to spread it to other TA [113].

Conclusion

Cancer immunology is a rapidly evolving field and it is only recently that we have begun to understand the complex interaction between cancer and the host immune system. Tumor cells demonstrate several methods to exploit the immune system to help promote angiogenesis, derive prosurvival and proliferative signals, and induce metastasis and tumor progression. At the same time, cancers are able to cloak themselves from the immune system by self modification and by immunosuppression of the host. These insights and better understanding of the workings of the immune system have allowed the recent explosion of several promising immunotherapeutic agents that are currently in clinical use as well as under development.

References

- Vlock DR, Schantz SP, Fisher SG, Savage HE, Carey TE, Wolf GT. Clinical correlates of circulating immune complexes and antibody reactivity in squamous cell carcinoma of the head and neck. The Department of Veterans Affairs Laryngeal Cancer Study Group. *J Clin Oncol.* 1993;11:2427–33.
- Calenoff E, Cheever MA, Satam M, et al. Serum immunoglobulins specific for intracellular proteins of squamous cell carcinoma. *Archives of otolaryngology. Head Neck Surg.* 1995;121:183–91.
- Couch ME, Ferris RL, Brennan JA, et al. Alteration of cellular and humoral immunity by mutant p53 protein and processed mutant peptide in head and neck cancer. *Clin Cancer Res.* 2007;13:7199–206.
- Rabassa ME, Croce MV, Pereyra A, Segal-Eiras A. MUC1 expression and anti-MUC1 serum immune response in head and neck squamous cell carcinoma (HNSCC): a multivariate analysis. *BMC Cancer.* 2006;6:253.
- Yamaguchi K, Patturajan M, Trink B, et al. Circulating antibodies to p40(AIS) in the sera of respiratory tract cancer patients. *Int J Cancer.* 2000;89:524–8.
- Tominaga O, Unsal K, Zalzman G, Soussi T. Detection of p73 antibodies in patients with various types of cancer: immunological characterization. *Br J Cancer.* 2001;84:57–63.
- Zumbach K, Hoffmann M, Kahn T, et al. Antibodies against oncoproteins E6 and E7 of human papillomavirus types 16 and 18 in patients with head-and-neck squamous-cell carcinoma. *Int J Cancer.* 2000;85:815–8.
- Shimada H, Shiratori T, Takeda A, et al. Perioperative changes of serum p53 antibody titer is a predictor for survival in patients with esophageal squamous cell carcinoma. *World J Surg.* 2009;33:272–7.
- Neuchrist C, Kornfehl J, Grasl M, et al. Distribution of immunoglobulins in squamous cell carcinoma of the head and neck. *Int Arch Allergy Immunol.* 1994;104:97–100.
- Miller JF. Effect of neonatal thymectomy on the immunological responsiveness of the mouse. *Proc Roy Soc B.* 1962;156:2.
- Miller JF, Mitchell GF. Cell to cell interaction in the immune response. I. Hemolysin-forming cells in neonatally thymectomized mice reconstituted with thymus or thoracic duct lymphocytes. *J Exp Med.* 1968;128:801–20.
- Mitchell GF, Miller JF. Cell to cell interaction in the immune response. II. The source of hemolysin-forming cells in irradiated mice given bone marrow and thymus or thoracic duct lymphocytes. *J Exp Med.* 1968;128:821–37.
- Masopust D, Vezys V, Wherry EJ, Ahmed R. A brief history of CD8 T cells. *Eur J Immunol.* 2007;37 Suppl 1:S103–10.
- Mosmann TR, Coffman RL. TH1 and TH2 cells: different patterns of lymphokine secretion lead to different functional properties. *Annu Rev Immunol.* 1989;7:145–73.
- Korn T, Oukka M, Kuchroo V, Bettelli E. Th17 cells: effector T cells with inflammatory properties. *Semin Immunol.* 2007;19:362–71.
- Bergmann C, Strauss L, Wang Y, et al. T regulatory type 1 cells in squamous cell carcinoma of the head and neck: mechanisms of suppression and expansion in advanced disease. *Clin Cancer Res.* 2008;14:3706–15.
- Strauss L, Bergmann C, Gooding W, Johnson JT, Whiteside TL. The frequency and suppressor function of CD4⁺CD25^{high}Foxp3⁺ T cells in the circulation of patients with squamous cell carcinoma of the head and neck. *Clin Cancer Res.* 2007;13:6301–11.
- Herberman RB, Nunn ME, Holden HT, Lavrin DH. Natural cytotoxic reactivity of mouse lymphoid cells against syngeneic and allogeneic tumors. II. Characterization of effector cells. *Int J Cancer.* 1975;16:230–9.
- Miller JS. The biology of natural killer cells in cancer, infection, and pregnancy. *Exp Hematol.* 2001;29:1157–68.
- Herberman RB, Holden HT. Natural cell-mediated immunity. *Adv Cancer Res.* 1978;27:305–77.
- Dunn GP, Bruce AT, Ikeda H, Old LJ, Schreiber RD. Cancer immunoeediting: from immunosurveillance to tumor escape. *Nat Immunol.* 2002;3:991–8.
- Russell JH, Ley TJ. Lymphocyte-mediated cytotoxicity. *Annu Rev Immunol.* 2002;20:323–70.
- Gillison ML. Oropharyngeal cancer: a potential consequence of concomitant HPV and HIV infection. *Curr Opin Oncol.* 2009;21:439–44.
- Jain A, Reyes J, Kashyap R, et al. What have we learned about primary liver transplantation under tacrolimus immunosuppression? Long-term follow-up of the first 1000 patients. *Ann Surg.* 1999;230:441–8. discussion 8–9.
- Birkeland SA, Storm HH, Lamm LU, et al. Cancer risk after renal transplantation in the Nordic countries, 1964–1986. *Int J Cancer.* 1995;60:183–9.
- Shankaran V, Ikeda H, Bruce AT, et al. IFN γ and lymphocytes prevent primary tumour development and shape tumour immunogenicity. *Nature.* 2001;410:1107–11.
- Grandis JR, Falkner DM, Melhem MF, Gooding WE, Drenning SD, Morel PA. Human leukocyte antigen class I allelic and haplotype loss in squamous cell carcinoma of the head and neck: clinical and immunogenetic consequences. *Clin Cancer Res.* 2000;6:2794–802.
- Mizukami Y, Kono K, Maruyama T, et al. Downregulation of HLA Class I molecules in the tumour is associated with a poor prognosis

- in patients with oesophageal squamous cell carcinoma. *Br J Cancer*. 2008;99:1462–7.
29. Ogino T, Shigyo H, Ishii H, et al. HLA class I antigen down-regulation in primary laryngeal squamous cell carcinoma lesions as a poor prognostic marker. *Cancer Res*. 2006;66:9281–9.
30. Ferris RL, Whiteside TL, Ferrone S. Immune escape associated with functional defects in antigen-processing machinery in head and neck cancer. *Clin Cancer Res*. 2006;12:3890–5.
31. Lopez-Albaitero A, Nayak JV, Ogino T, et al. Role of antigen-processing machinery in the in vitro resistance of squamous cell carcinoma of the head and neck cells to recognition by CTL. *J Immunol*. 2006;176:3402–9.
32. Gastman BR, Atarshi Y, Reichert TE, et al. Fas ligand is expressed on human squamous cell carcinomas of the head and neck, and it promotes apoptosis of T lymphocytes. *Cancer Res*. 1999;59:5356–64.
33. Seliger B, Abken H, Ferrone S. HLA-G and MIC expression in tumors and their role in anti-tumor immunity. *Trends Immunol*. 2003;24:82–7.
34. Jebreel A, Mistry D, Loke D, et al. Investigation of interleukin 10, 12 and 18 levels in patients with head and neck cancer. *J Laryngol Otol*. 2007;121:246–52.
35. Moutsopoulos NM, Wen J, Wahl SM. TGF-beta and tumors—an ill-fated alliance. *Curr Opin Immunol*. 2008;20:234–40.
36. Lu SL, Reh D, Li AG, et al. Overexpression of transforming growth factor beta1 in head and neck epithelia results in inflammation, angiogenesis, and epithelial hyperproliferation. *Cancer Res*. 2004;64:4405–10.
37. Cheng F, Wang HW, Cuenca A, et al. A critical role for Stat3 signaling in immune tolerance. *Immunity*. 2003;19:425–36.
38. Duffy SA, Taylor JM, Terrell JE, et al. Interleukin-6 predicts recurrence and survival among head and neck cancer patients. *Cancer*. 2008;113:750–7.
39. Murray PJ. STAT3-mediated anti-inflammatory signalling. *Biochem Soc Trans*. 2006;34:1028–31.
40. Sun Y, Chin YE, Weisiger E, et al. Cutting edge: negative regulation of dendritic cells through acetylation of the nonhistone protein STAT-3. *J Immunol*. 2009;182:5899–903.
41. Kortylewski M, Xin H, Kujawski M, et al. Regulation of the IL-23 and IL-12 balance by Stat3 signaling in the tumor microenvironment. *Cancer Cell*. 2009;15:114–23.
42. Pallandre JR, Brillard E, Crehange G, et al. Role of STAT3 in CD4+CD25+FOXP3+ regulatory lymphocyte generation: implications in graft-versus-host disease and antitumor immunity. *J Immunol*. 2007;179:7593–604.
43. Snyderman CH, Milanovich M, Wagner RL, Johnson JT. Prognostic significance of prostaglandin E2 production in fresh tissues of head and neck cancer patients. *Head Neck*. 1995;17:108–13.
44. Camacho M, Leon X, Fernandez-Figueras MT, Quer M, Vila L. Prostaglandin E(2) pathway in head and neck squamous cell carcinoma. *Head Neck*. 2008;30:1175–81.
45. Harris SG, Padilla J, Koumas L, Ray D, Phipps RP. Prostaglandins as modulators of immunity. *Trends Immunol*. 2002;23:144–50.
46. Seiwert TY, Cohen EE. Targeting angiogenesis in head and neck cancer. *Semin Oncol*. 2008;35:274–85.
47. Johnson BF, Clay TM, Hobeika AC, Lyerly HK, Morse MA. Vascular endothelial growth factor and immunosuppression in cancer: current knowledge and potential for new therapy. *Expert Opin Biol Ther*. 2007;7:449–60.
48. Gabrilovich D. Mechanisms and functional significance of tumour-induced dendritic-cell defects. *Nat Rev Immunol*. 2004;4:941–52.
49. Pak AS, Wright MA, Matthews JP, Collins SL, Petruzzelli GJ, Young MR. Mechanisms of immune suppression in patients with head and neck cancer: presence of CD34(+) cells which suppress immune functions within cancers that secrete granulocyte-macrophage colony-stimulating factor. *Clin Cancer Res*. 1995;1:95–103.
50. Ostrand-Rosenberg S, Sinha P. Myeloid-derived suppressor cells: linking inflammation and cancer. *J Immunol*. 2009;182:4499–506.
51. Grizzle WE, Xu X, Zhang S, et al. Age-related increase of tumor susceptibility is associated with myeloid-derived suppressor cell mediated suppression of T cell cytotoxicity in recombinant inbred BXD12 mice. *Mech Ageing Dev*. 2007;128:672–80.
52. Sakaguchi S, Sakaguchi N, Asano M, Itoh M, Toda M. Immunologic self-tolerance maintained by activated T cells expressing IL-2 receptor alpha-chains (CD25). Breakdown of a single mechanism of self-tolerance causes various autoimmune diseases. *J Immunol*. 1995;155:1151–64.
53. Cosmi L, Liotta F, Lazzeri E, et al. Human CD8+CD25+ thymocytes share phenotypic and functional features with CD4+CD25+ regulatory thymocytes. *Blood*. 2003;102:4107–14.
54. Alhamarneh O, Amarnath SM, Stafford ND, Greenman J. Regulatory T cells: what role do they play in antitumor immunity in patients with head and neck cancer? *Head Neck*. 2008;30:251–61.
55. Ralainirina N, Poli A, Michel T, et al. Control of NK cell functions by CD4+CD25+ regulatory T cells. *J Leukoc Biol*. 2007;81:144–53.
56. Strauss L, Bergmann C, Szczepanski M, Gooding W, Johnson JT, Whiteside TL. A unique subset of CD4+CD25highFoxp3+ T cells secreting interleukin-10 and transforming growth factor-beta1 mediates suppression in the tumor microenvironment. *Clin Cancer Res*. 2007;13:4345–54.
57. Strauss L, Bergmann C, Whiteside TL. Functional and phenotypic characteristics of CD4+CD25highFoxp3+ Treg clones obtained from peripheral blood of patients with cancer. *Int J Cancer*. 2007;121:2473–83.
58. Sakakura K, Chikamatsu K, Takahashi K, Whiteside TL, Furuya N. Maturation of circulating dendritic cells and imbalance of T-cell subsets in patients with squamous cell carcinoma of the head and neck. *Cancer Immunol Immunother*. 2006;55:151–9.
59. Chikamatsu K, Sakakura K, Whiteside TL, Furuya N. Relationships between regulatory T cells and CD8+ effector populations in patients with squamous cell carcinoma of the head and neck. *Head Neck*. 2007;29:120–7.
60. Badoual C, Hans S, Rodriguez J, et al. Prognostic value of tumor-infiltrating CD4+ T-cell subpopulations in head and neck cancers. *Clin Cancer Res*. 2006;12:465–72.
61. Boucek J, Mrkvan T, Chovanec M, et al. Regulatory T cells and their prognostic value for patients with squamous cell carcinoma of the head and neck. *J Cell Mol Med*. 2009;14:426–33.
62. Lathers DM, Young MR. Increased aberrance of cytokine expression in plasma of patients with more advanced squamous cell carcinoma of the head and neck. *Cytokine*. 2004;25:220–8.
63. Koizumi K, Hojo S, Akashi T, Yasumoto K, Saiki I. Chemokine receptors in cancer metastasis and cancer cell-derived chemokines in host immune response. *Cancer Sci*. 2007;98:1652–8.
64. Ding Y, Shimada Y, Maeda M, et al. Association of CC chemokine receptor 7 with lymph node metastasis of esophageal squamous cell carcinoma. *Clin Cancer Res*. 2003;9:3406–12.
65. Wang J, Xi L, Hunt JL, et al. Expression pattern of chemokine receptor 6 (CCR6) and CCR7 in squamous cell carcinoma of the head and neck identifies a novel metastatic phenotype. *Cancer Res*. 2004;64:1861–6.
66. Wang J, Zhang X, Thomas SM, et al. Chemokine receptor 7 activates phosphoinositide-3 kinase-mediated invasive and prosurvival pathways in head and neck cancer cells independent of EGFR. *Oncogene*. 2005;24:5897–904.
67. Karin M. Nuclear factor-kappaB in cancer development and progression. *Nature*. 2006;441:431–6.
68. Van Waes C, Yu M, Nottingham L, Karin M. Inhibitor-kappaB kinase in tumor promotion and suppression during progression of squamous cell carcinoma. *Clin Cancer Res*. 2007;13:4956–9.

69. Anto RJ, Mukhopadhyay A, Shishodia S, Gairola CG, Aggarwal BB. Cigarette smoke condensate activates nuclear transcription factor-kappaB through phosphorylation and degradation of IkappaB(alpha): correlation with induction of cyclooxygenase-2. *Carcinogenesis*. 2002;23:1511–8.
70. Lin SC, Lu SY, Lee SY, Lin CY, Chen CH, Chang KW. Areca (betel) nut extract activates mitogen-activated protein kinases and NF-kappaB in oral keratinocytes. *Int J Cancer*. 2005;116:526–35.
71. Bancroft CC, Chen Z, Yeh J, et al. Effects of pharmacologic antagonists of epidermal growth factor receptor, PI3K and MEK signal kinases on NF-kappaB and AP-1 activation and IL-8 and VEGF expression in human head and neck squamous cell carcinoma lines. *Int J Cancer*. 2002;99:538–48.
72. Ferris RL, Grandis JR. NF-kappaB gene signatures and p53 mutations in head and neck squamous cell carcinoma. *Clin Cancer Res*. 2007;13:5663–4.
73. Allen CT, Ricker JL, Chen Z, Van Waes C. Role of activated nuclear factor-kappaB in the pathogenesis and therapy of squamous cell carcinoma of the head and neck. *Head Neck*. 2007;29:959–71.
74. Tang C, Ang BT, Pervaiz S. Cancer stem cell: target for anti-cancer therapy. *FASEB J*. 2007;21:3777–85.
75. Prince ME, Sivanandan R, Kaczorowski A, et al. Identification of a subpopulation of cells with cancer stem cell properties in head and neck squamous cell carcinoma. *Proc Natl Acad Sci USA*. 2007;104:973–8.
76. Godar S, Ince TA, Bell GW, et al. Growth-inhibitory and tumor-suppressive functions of p53 depend on its repression of CD44 expression. *Cell*. 2008;134:62–73.
77. Mack B, Gires O. CD44s and CD44v6 expression in head and neck epithelia. *PLoS One*. 2008;3:e3360.
78. Chen YC, Chen YW, Hsu HS, et al. Aldehyde dehydrogenase 1 is a putative marker for cancer stem cells in head and neck squamous cancer. *Biochem Biophys Res Commun*. 2009;385:307–13.
79. Visus C, Ito D, Amoscato A, et al. Identification of human aldehyde dehydrogenase 1 family member A1 as a novel CD8+ T-cell-defined tumor antigen in squamous cell carcinoma of the head and neck. *Cancer Res*. 2007;67:10538–45.
80. Soylu L, Ozcan C, Cetik F, et al. Serum levels of tumor necrosis factor in squamous cell carcinoma of the head and neck. *Am J Otolaryngol*. 1994;15:281–5.
81. Jablonska E, Piotrowski L, Grabowska Z. Serum levels of IL-1b, IL-6, TNF-a, sTNF-RI and CRP in patients with oral cavity cancer. *Pathol Oncol Res*. 1997;3:126–9.
82. Gokhale AS, Haddad RI, Cavacini LA, et al. Serum concentrations of interleukin-8, vascular endothelial growth factor, and epidermal growth factor receptor in patients with squamous cell cancer of the head and neck. *Oral Oncol*. 2005;41:70–6.
83. Linkov F, Lisovich A, Yurkovetsky Z, et al. Early detection of head and neck cancer: development of a novel screening tool using multiplexed immunobead-based biomarker profiling. *Cancer Epidemiol Biomarkers Prev*. 2007;16:102–7.
84. Allen C, Duffy S, Teknos T, et al. Nuclear factor-kappaB-related serum factors as longitudinal biomarkers of response and survival in advanced oropharyngeal carcinoma. *Clin Cancer Res*. 2007;13:3182–90.
85. Hanrahan EO, Ryan AJ, Mann H, et al. Baseline vascular endothelial growth factor concentration as a potential predictive marker of benefit from vandetanib in non-small cell lung cancer. *Clin Cancer Res*. 2009;15:3600–9.
86. Yan J, Reichenbach DK, Corbitt N, et al. Induction of antitumor immunity in vivo following delivery of a novel HPV-16 DNA vaccine encoding an E6/E7 fusion antigen. *Vaccine*. 2009;27:431–40.
87. Victora GD, Socorro-Silva A, Volsi EC, et al. Immune response to vaccination with DNA-hsp65 in a phase I clinical trial with head and neck cancer patients. *Cancer Gene Ther*. 2009;16:598–608.
88. Sewell DA, Pan ZK, Paterson Y. Listeria-based HPV-16 E7 vaccines limit autochthonous tumor growth in a transgenic mouse model for HPV-16 transformed tumors. *Vaccine*. 2008;26:5315–20.
89. Davidson EJ, Faulkner RL, Sehr P, et al. Effect of TA-CIN (HPV 16 L2E6E7) booster immunisation in vulval intraepithelial neoplasia patients previously vaccinated with TA-HPV (vaccinia virus encoding HPV 16/18 E6E7). *Vaccine*. 2004;22:2722–9.
90. Albarran YCA, de la Garza A, Cruz Quiroz BJ, et al. MVA E2 recombinant vaccine in the treatment of human papillomavirus infection in men presenting intraurethral flat condyloma: a phase I/II study. *BioDrugs*. 2007;21:47–59.
91. Karcher J, Dyckhoff G, Beckhove P, et al. Antitumor vaccination in patients with head and neck squamous cell carcinomas with autologous virus-modified tumor cells. *Cancer Res*. 2004;64:8057–61.
92. Andrade P, Deleo A, Visus C, Butterfield L, Argiris A, Ferris RL. Phase I adjuvant trial of multi-epitope p53 vaccine for patients with squamous cell carcinoma of the head and neck (SCCHN) a preliminary report. *J Clin Oncol*. 2009;27:Abstract 3012.
93. Weise JB, Csiszar K, Gottschlich S, et al. Vaccination strategy to target lysyl oxidase-like 4 in dendritic cell based immunotherapy for head and neck cancer. *Int J Oncol*. 2008;32:317–22.
94. Weber J. Overcoming immunologic tolerance to melanoma: targeting CTLA-4 with ipilimumab (MDX-010). *Oncologist*. 2008;13 Suppl 4:16–25.
95. Li B, VanRoey M, Wang C, Chen TH, Korman A, Jooss K. Anti-programmed death-1 synergizes with granulocyte macrophage colony-stimulating factor-secreting tumor cell immunotherapy providing therapeutic benefit to mice with established tumors. *Clin Cancer Res*. 2009;15:1623–34.
96. Brahmer JR, Topalian SL, Powderly J, et al. Phase II experience with MDX-1106 (Ono-4538), an anti-PD-1 monoclonal antibody, in patients with selected refractory or relapsed malignancies. *J Clin Oncol*. 2009;27:Abstract 3018.
97. Boczkowski D, Lee J, Pruitt S, Nair S. Dendritic cells engineered to secrete anti-GITR antibodies are effective adjuvants to dendritic cell-based immunotherapy. *Cancer Gene Ther*. 2009;16:900–11.
98. Zhang M, Yao Z, Dubois S, Ju W, Muller JR, Waldmann TA. Interleukin-15 combined with an anti-CD40 antibody provides enhanced therapeutic efficacy for murine models of colon cancer. *Proc Natl Acad Sci USA*. 2009;106:7513–8.
99. Murillo O, Arina A, Hervas-Stubbs S, et al. Therapeutic antitumor efficacy of anti-CD137 agonistic monoclonal antibody in mouse models of myeloma. *Clin Cancer Res*. 2008;14:6895–906.
100. Mendelsohn J, Baselga J. Epidermal growth factor receptor targeting in cancer. *Semin Oncol*. 2006;33:369–85.
101. Rubin Grandis J, Melhem MF, Gooding WE, Day R, Holst VA, Wagener MM, et al. Levels of TGF-alpha and EGFR protein in head and neck squamous cell carcinoma and patient survival. *J Natl Cancer Inst*. 1998;90:824–32.
102. Lopez-Albaitero A, Ferris RL. Immune activation by epidermal growth factor receptor specific monoclonal antibody therapy for head and neck cancer. *Archives of otolaryngology. Head Neck Surg*. 2007;133:1277–81.
103. Lopez-Albaitero A, Lee SC, Morgan S, et al. Role of polymorphic Fc gamma receptor IIIa and EGFR expression level in cetuximab mediated, NK cell dependent in vitro cytotoxicity of head and neck squamous cell carcinoma cells. *Cancer Immunol Immunother*. 2009;58:1853–64.
104. Dechant M, Weisner W, Berger S, et al. Complement-dependent tumor cell lysis triggered by combinations of epidermal growth factor receptor antibodies. *Cancer Res*. 2008;68:4998–5003.
105. Dhodapkar MV, Dhodapkar KM, Li Z. Role of chaperones and FcgammaR in immunogenic death. *Curr Opin Immunol*. 2008;20:512–7.

106. Taylor C, Hershman D, Shah N, et al. Augmented HER-2 specific immunity during treatment with trastuzumab and chemotherapy. *Clin Cancer Res.* 2007;13:5133–43.
107. Banerjee D, Matthews P, Matayeva E, Kaufman JL, Steinman RM, Dhodapkar KM. Enhanced T-cell responses to glioma cells coated with the anti-EGF receptor antibody and targeted to activating Fcγ3Rs on human dendritic cells. *J Immunother.* 2008;31:113–20.
108. Cooper MA, Fehniger TA, Fuchs A, Colonna M, Caligiuri MA. NK cell and DC interactions. *Trends Immunol.* 2004;25:47–52.
109. Roda JM, Joshi T, Butchar JP, et al. The activation of natural killer cell effector functions by cetuximab-coated, epidermal growth factor receptor positive tumor cells is enhanced by cytokines. *Clin Cancer Res.* 2007;13:6419–28.
110. Mailliard RB, Son YI, Redlinger R, et al. Dendritic cells mediate NK cell help for Th1 and CTL responses: two-signal requirement for the induction of NK cell helper function. *J Immunol.* 2003;171:2366–73.
111. Lucas M, Schachterle W, Oberle K, Aichele P, Diefenbach A. Dendritic cells prime natural killer cells by trans-presenting interleukin 15. *Immunity.* 2007;26:503–17.
112. Moretta L, Ferlazzo G, Bottino C, et al. Effector and regulatory events during natural killer-dendritic cell interactions. *Immunol Rev.* 2006;214:219–28.
113. el-Shami K, Tirosh B, Bar-Haim E, et al. MHC class I-restricted epitope spreading in the context of tumor rejection following vaccination with a single immunodominant CTL epitope. *Eur J Immunol.* 1999;29:3295–301.

Chapter 7

HPV and EBV in Head and Neck Cancer

Jeffrey Brumbaugh, Robert L. Ferris, and Shen Hu

Abstract The focus of this book chapter is to discuss the role of human papillomavirus (HPV) in head and neck squamous cell carcinoma (HNSCC) and Epstein-Barr virus (EBV) in nasopharyngeal carcinoma (NPC). We have summarized the main events of HPV & EBV life cycle, potential mechanisms of HPV- or EBV-mediated carcinogenesis, and the implications of HPV and EBV in head and neck cancer, with an emphasis on disease diagnosis, prognosis, and therapeutic treatment. The potential of proteomics for studying these virus-associated cancers has also been discussed. A mechanistic understanding of HPV-associated HNSCC or EBV-associated NPC would require profound analysis of these tumors using advanced molecular analysis technologies, which will then facilitate the development of preventive and therapeutic strategies for these diseases.

Keywords Human papillomavirus • Head and neck squamous cell carcinoma • Epstein-Barr virus • Nasopharyngeal carcinoma • Proteomics

Head and Neck Cancer

Cancer of the head and neck, including oral, laryngeal, and pharyngeal sites, is the sixth most common malignancy in the world. Each year, almost 650,000 patients worldwide receive the diagnosis of head and neck cancer and some 350,000 die from this disease [1]. Nearly 90% of these cancers are head and neck squamous cell carcinoma (HNSCC) in histology. HNSCC is causally associated with heavy smoking and alcohol abuse. In addition, many studies have suggested an etiological role for infection agents, such as human papillomavirus (HPV) and Epstein-Barr virus (EBV) in subsets of HNSCC, occurring mainly in the oropharynx

and nasopharynx, respectively [2, 3]. In this chapter, we will give an overview about HPV-associated HNSCC and EBV-associated nasopharyngeal carcinoma (NPC).

HPV and Its Life Cycle

HPV is known as the virus that causes common warts and a host of other more serious conditions, from anogenital and aerodigestive diseases, to cervical cancer and laryngeal papillomas. On a molecular level, HPVs are circular, non-enveloped, double-stranded DNA viruses, measuring about 7.9 kb in size. They belong to the Papillomaviridae family, all of whose members have a notable similarity in genomic organization [4], and were first isolated in rabbit papillomatosis in 1933 [5]. Early studies of the virus allowed researchers to observe its life cycle, most notably the transition of the benign papillomas in rabbits as they progressed towards malignancy [6]. Today, more than 200 different types of HPVs have been isolated and there are certainly additional types that have not yet been identified [7]. The many types of HPVs are categorized into several groupings, based on tropism for infection site – cutaneous or mucosal – and on their risk for malignancy – high, intermediate, or low. The mucosal subgroup of HPVs contains more than 40 identified subtypes, making it the largest subgroup, predominantly infecting the genital and respiratory tracts [4], while the cutaneous type is mostly benign. The risk level of an HPV reflects its association with malignancy, with low-risk HPVs inducing benign hyperplasias, such as papillomas or warts, and with high-risk HPVs strongly linked to malignancy and the possibility of carcinogenesis [8].

The life cycle of an HPV virion is greatly dependent on both its own genetic mechanisms as well as those of the host cells that it infects. The genome of HPV is comprised of nine open-reading frames, which are divided into seven early-phase genes (E) and two late-phase genes (L) [6]. The early-phase genes encode proteins that regulate viral DNA replication, RNA transcription, and cell transformation,

S. Hu (✉)
School of Dentistry and Jonsson Comprehensive Cancer Center,
UCLA, 10833 Le Conte Avenue, Los Angeles, CA 90095, USA
e-mail: shenhu@ucla.edu

while the late-phase genes encode proteins that are involved in viral spread, such as the structural components of the capsid [9]. During an infection, HPVs typically target the cells in the basal layer of the squamous epithelium, integrating its genome into a host cell, and eventually replicating. First, the virus enters and infects the basal cells of the epithelium through either a wound or micro-abrasions. As these epithelial cells divide and proliferate, the viral DNA also proliferates as a low copy number plasmid, maintained in the nuclei of the daughter cells. The virus then becomes latent, exhibiting no signs of infection, for an unspecified amount of time. This latency period can last anywhere from several months to the lifetime of the host patient, and the infected tissue is both clinically and histologically normal during this time. In a subset of infected host cells, the HPV may become active, depending on the host's stage of differentiation. Due to a strong association between the HPV and the stage of differentiation of the host cell, the HPV DNA replicates to a high copy number only when epithelial cells move from a basal position to a more suprabasal position and become terminally differentiated. It is also in these suprabasal epithelial cells that the L1 and L2 HPV proteins, which constitute the viral capsid, are synthesized and that the progeny are produced and released. Normally, the suprabasal epithelial cells would not be able to support such DNA replication, but the E1 and E2 proteins allow for productive viral DNA replication and, along with E5, papilloma formation [7, 10]. Once the dead squames of the host epithelium are sloughed off, the viral life cycle continues as the process begins anew.

Mechanisms of HPV-Mediated Carcinogenesis

After an HPV virion infects a host and begins to form benign papillomas, there is a small chance that a subset of these papillomas will turn malignant. The transformation from a benign papilloma to carcinoma is a rare event, but in the case that it does occur, HPV DNA replication is ceased, and the life cycle of the virus is effectively terminated [10]. From this point, the functioning of several E genes will affect differentiation of the host epithelium, and HPV-mediated carcinogenesis can occur. While the precise molecular mechanisms of HPV-mediated carcinogenesis are not fully understood, the genome of HPV contributes a vital component to the malignancy (Fig. 7.1).

Currently, high-risk HPVs are understood to contribute to carcinogenesis mainly through the actions of the two viral oncogenes E6 and E7 [11–13]. E6 and E7 are responsible for inactivating the human tumor-suppressing proteins p53 and pRb, respectively, thus allowing the potential for unchecked

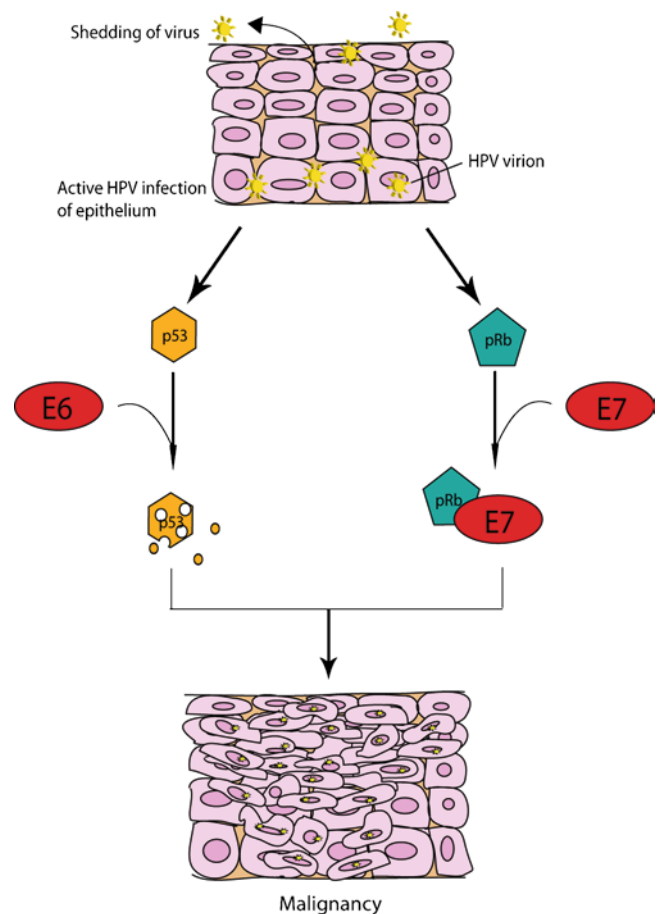


Fig. 7.1 Possible carcinogenic mechanisms of HPV in HNSCC. An active infection of HPV in the basal layer of the epithelium encodes the oncogenic proteins E6 and E7, which degrade the tumor-suppressing proteins p53 and pRb, respectively. E6 marks p53 for degradation by ubiquitination, and E7 binds and destabilizes pRb. The loss of p53 and pRb allow for unchecked growth and eventually to malignant carcinoma

growth and a pathway towards malignancy. It has been observed that E6 proteins of high-risk HPVs bind and form a complex with p53, subsequently marking the tumor suppressant for ubiquitination and degradation [12, 13]. Conversely, small interfering RNA (siRNA) knockdown of HPV-16 E6 results in accumulation of p53 [14]. E7, on the other hand, binds and destabilizes the Rb tumor suppressor protein and related proteins [11, 15]. Accordingly, it has been suggested that E6 is mainly responsible for offsetting the increased levels of p53 and E7 produces a necessary function in promoting cell-cycle progression and viral DNA replication in differentiated keratinocytes. It has also been theorized that E6 may not assist in complete p53 degradation, but merely diminish its effects [16].

Though the exact role of E4 has yet to be determined, its RNA has been detected most abundantly in benign HPV-induced papillomas, implying that it may play a significant role in the life cycle of the virus and perhaps in HPV-mediated

carcinogenesis [10]. The E4 protein is found exclusively in the differentiating layer of the host epithelial cells and promotes the collapse of the cytokeratin network. Similarly, the precise role of E5 in carcinogenesis is not completely clear, but it may have an important part in stimulating the transformation of HPV and promoting the proliferation of HPV-infected cells [4].

Low-risk HPVs have not been studied as thoroughly as high-risk types, due to their infrequent role in HPV-mediated carcinogenesis. The E6 and E7 oncogenes of low-risk HPV types also target p53 and pRb, but with less ability to perturb their host's cellular functions than high-risk types [16]. Consequently, they have less capability of inducing carcinogenesis.

By any means, the molecular mechanisms of HPV-mediated carcinogenesis are far from being completely understood, and additional studies are warranted. To compound this lack of knowledge, it may also prove difficult to separate the molecular mechanisms and etiological role of HPV in carcinogenesis from the many cofactors of the disease. Studies have suggested HPV is not a sufficient cause for cancer, only recognized as a necessary one [4, 17]. For instance, evidence suggests that the transformation of HPV-infected cells into malignancies require cellular mutations as an impetus, such as carcinogenic agents like tobacco or UV irradiation [10]. Several studies have even shown that HPV-transformed cells are non-invasive, implying the need for a cellular cofactor to be present in order for carcinogenesis to occur [4].

HPV in Head and Neck Precancer

Commonly, HPV itself is recognized in the context of carcinogenesis as the virus is associated with cervical cancers as well as several other anogenital carcinomas. However, recent clinical studies have presented convincing evidence for a causal role of the virus in a subset of HNSCCs [3, 18]. The HPVs of most concern in HNSCC are the mucosal, high-risk types that can infect the epithelium of the aerodigestive tract. Most frequently, HPV-16 and, to a lesser extent, HPV-18 have been detected and identified as two such types, playing important roles in head and neck carcinogenesis [19]. Since HPV infection of the cervix follows a genetic progression from benign papillomas to malignant lesions, the detection of HPV in the precancerous lesions of HNSCC may be an important indicator of the potential presence of the disease.

In the precancerous stages of HNSCC, dysplastic lesions undergo a series of molecular and genetic alterations that eventually lead to malignancy. In order to implicate HPV with an etiological role in head and neck carcinogenesis, it is important to know whether the prevalence of HPV DNA

present in early dysplastic lesions increases as malignancy develops. For this purpose, numerous studies have measured the HPV DNA in premalignant lesions and the reported results are conflicting, with HPV prevalence ranging from 0% to 88% [20–23]. The observed discrepancies may be attributed to the variation in examined samples and the sensitivity of the applied methodologies. Overall, HPV may in fact play a role in precancerous lesions, but to date this has not been histologically or morphologically defined.

HPV in Head and Neck Cancer

Though the evidence of HPV involvement in precancerous lesions is varied, the evidence of HPV in HNSCC is now well-established. HPV-positive HNSCCs comprise a heterogeneous group of squamous cell carcinomas (SCCs) of the oral cavity, pharynx, and larynx [24], each with varying biological/clinical characteristics and unique etiology. Specifically, oropharyngeal and tonsillar carcinomas have emerged as an area of particular interest due to their notably strong association to HPV.

A systematic review of the data from 60 published studies revealed an overall HPV prevalence of 25.9% in HNSCC based on a total of 5,046 cancer specimens examined. HPV prevalence was found significantly higher in oropharyngeal SCCs (35.6% of 969) than oral SCCs (23.5% of 2,642) or laryngeal SCCs (24.0% of 1,435). HPV16 accounted for a larger majority of HPV-positive oropharyngeal SCCs (86.7%) compared with HPV-positive oral SCCs (68.2%) and laryngeal SCCs (69.2%). HPV-18, on the other hand, was very rare in HPV-positive oropharyngeal SCC (2.8%) compared to other head and neck sites of oral SCCs (34.1%) and of laryngeal SCCs (17.0%) [25]. A recent case-control study of 100 patients with newly diagnosed oropharyngeal cancer and 200 control patients without cancer concluded that HPV-16 DNA was detected in 72% of 100 paraffin-embedded tumor specimens, and 64% of patients with cancer were seropositive for the HPV-16 oncoprotein E6, E7, or both [26]. To further separate HPV-positive oropharyngeal SCCs from other HNSCCs, known risk factors for the disease seem to be markedly absent [27]. Thus, increasing evidence suggests that HPV-associated oropharyngeal carcinomas are in fact a separate malignancy, distinct from other HNSCCs in terms of both risk factors and biology [27, 28].

The distribution of specific HPV type and infection sites in laryngeal papillomas and tonsillar infection in oropharyngeal SCC may suggest “specific virus-tissue interactions” that only allow for HPV infection in certain sites of the head and neck [25]. While HPV-16 and HPV-18 play a significant role in oropharyngeal carcinogenesis, HPV-6 and HPV-11 may play an analogous role in laryngeal papillomas [19].

Although more than one type of HPV can be found in tumor specimens, the low-risk types of HPV found in the majority of laryngeal papillomas differ from the high-risk HPVs in oropharyngeal SCCs. Similarly, the split between the types of HPV found in oropharyngeal and laryngeal SCCs is evidenced by the uneven distribution of HPV-16 and HPV-18 as previously mentioned. In addition, data collected from oropharyngeal SCC studies have shown that the tonsils are infected in particular more often than the rest of the oropharynx, though both contain HPV-16 as the dominant virus [25]. It seems that laryngeal papillomas and tonsillar SCC point towards a specific HPV-tissue interaction, but further investigations are required to determine a more precise distribution of HPV types in various HNSCC locations. High risk HPV subtypes may also possess more potent immune evasion capability, permitting malignant progression.

Today, more than 20 different types of HPVs have been reported in HNSCC, and as many as 14 have been identified as high-risk in cervical cancer [25]. In 2005, the International Agency for Research on Cancer (IARC) concluded that there was sufficient evidence to implicate HPV-16 in causing carcinomas of the oral cavity and of the oropharynx, limited evidence for HPV-18 in the oral cavity, inadequate evidence for other HPV types in the oral cavity and in the oropharynx, limited evidence for HPV-6, -11, -16, and -18 in the larynx, and inadequate evidence for the carcinogenicity of HPV in the esophagus [24].

Detection of HPV and Diagnosis of HPV-Positive HNSCC

In the study of HPV in human cancers, many detection techniques of HPV DNA have been established. One of the primary concerns when performing molecular detection of HPV DNA is the sensitivity and reliability of the applied techniques. Compared to other HPV-positive SCCs, such as cervical carcinomas, HPV-positive HNSCCs and related dysplasia seem to have a relatively low level of HPV DNA present. For instance, studies involving polymerase chain reaction (PCR) assays of HPV-positive HNSCCs have produced weaker results when using samples from both oral mucosa and cancerous lesions in the head and neck as opposed to cervical carcinomas, potentially due to saliva clearance of the virus [28].

A wide variety of methods are currently being used to detect HPV in HNSCC, including PCR assays, in situ hybridization, Southern blot, and antibody detection, which in turn may provide for early diagnoses and treatment of HNSCC. PCR is utilized as one of the most sensitive methods of detecting HPV DNA in both cancerous and precancerous lesions. However, one of the drawbacks of using PCR is also

one of its most pronounced strengths: its extreme sensitivity. As such, PCR is prone to contamination, and if contaminated, a sample of cancerous tissue analyzed using PCR may provide either an overestimation or underestimation of possible HPV positivity. Commonly, PCR detection of HPV relies on the amplification of the E6, E7, and L1 sequences of the viral genome. Compared to conventional PCR techniques, real-time quantitative PCR analysis is able to quantify the amount of HPV DNA in a tissue sample as well as greatly reduce the risk of contamination, thus providing more accurate results [17, 22, 29]. Recently, a “MassARRAY” assay based on coupling mass spectrometry with competitive PCR, was described for measuring HPV DNA in serum and/or peripheral blood fraction of individuals with cervical, head/neck, or bladder cancers. The technique may be more sensitive than real-time quantitative PCR-based assays, while specificity was maintained [30].

Before PCR was widely used, in situ hybridization (ISH) and Southern blot were prevalently used for detecting HPV DNA. In situ hybridization (ISH) involves the use of type-specific radioactively labeled DNA probes complementary to HPV sequences for detection. It is a clinically useful test to confirm the diagnosis of HPV and therefore has widespread applicability [8]. Southern blot, on the other hand, is known for its high specificity and low rate of contamination, even being able to distinguish between integrated and episomal HPV DNA [6].

Aside from the more classical methods of HPV detection, screening individuals for the presence of HPV antibodies or related proteins provides yet another way to detect the virus. HPV infections are in fact very commonplace among adults, and as a result, anticapsid antibodies are produced during the infection. Those exposed to harmless HPV infections and those exposed to high-risk carcinogenic HPVs, however, differ in the type of antibodies that the body produces. Serum antibodies to the viral capsid proteins, E6 and E7, are most frequently detected in individuals with HPV-positive cancer, as opposed to the anticapsid (L1) protein antibodies found in normal individuals. The detection of such specific immunologic biomarkers may provide evidence for the presence of the viral genome in patients as well as indicating a higher risk of developing HPV-mediated carcinoma. Similarly, immunohistochemical analyses of the expression of p16 may provide an important method of detecting productive HPV infection [27, 31, 32]. In many types of SCCs, the functional loss of p16 has been observed. In contrast, HPV-positive SCCs, including those of the head and neck, have shown a strong overexpression of p16, probably due to the impairment of the negative feedback control of pRb by the viral oncogene E7 among other mechanisms [27, 31]. Further investigation of p16 may support its potential application as a biomarker in standard screenings, reflecting HPV status in early dysplastic lesions [27].

Early diagnosis of HNSCC is critical for reducing the rate of mortality of the disease and is the focus of much ongoing research in the field. As such, the molecular detection of HPV serves a vital purpose. Often times, it may be difficult to appropriately diagnose HPV-positive HNSCC, since there are such a wide variety of molecular assays, sampling methods, and oral specimens available that standardization of methods is a difficult task [28]. Nevertheless, a positive detection of HPV infection does not necessarily indicate the development of head and neck cancer. In this regard, it is also important to develop new molecular biomarkers (in addition to HPV DNA and proteins) for an improved diagnosis of HPV-positive HNSCC.

Prognosis of HPV-Positive HNSCC and Therapeutic Treatment

Prospective clinical trials and large retrospective studies have shown that patients diagnosed with HPV-positive HNSCC have a more favorable prognosis than patients who have HPV-negative HNSCC [31, 33–36]. It has been estimated that HPV-positive tumors may reduce the risk of death by nearly 60–80% in HNSCC patients when compared to HPV-negative tumors [8]. Since HPV-positive HNSCCs are molecularly and clinically distinct from HPV-negative cases, many hypothesize that there are factors specific to HPV-positive tumors that can explain the reduced rate of mortality and that cause them to respond differently to treatment [31]. This certainly warrants further molecular analysis of HPV-positive HNSCC to understand the molecular mechanism responsible for favorable prognosis.

Within the past few years, vaccines have come to the forefront of the battle against virus-associated cancers. A vaccine that could potentially prevent HPV infection, suppress its viral effects, or both, would prove effective in treating HPV-positive HNSCC. Theoretically, a prophylactic vaccine should prevent HPV from infecting a host epithelium by completely neutralizing the virus upon exposure. Several prophylactic vaccines are already on the market (e.g., Gardasil and Cervarix) [7]. Such vaccines have the potential to prevent a significant number of anogenital carcinomas, most notably cervical cancer, but their effectiveness in preventing HNSCCs still remains to be evaluated [18]. In addition, the duration of protection that the vaccine offers is unknown, and they do not guard against all types of HPV that could potentially result in carcinogenesis [7].

If a patient has already been infected with the virus, a therapeutic vaccine should instead induce a cellular immunity in which mainly T-cells are primed against HPV antigen epitopes expressed by oncogenes E6 and E7 [9]. It may also be possible to develop a vaccine that provides both types

of protection from HPV: prophylactic and therapeutic. Chemotherapeutic vaccines targeting the viral oncogenes E6 and E7 are still under development today.

Similar to the idea of a therapeutic vaccine targeting E6 and E7, gene therapy for HPV-positive carcinomas provides another possible tool in combating HPV-mediated carcinogenesis. While certainly far from clinical use in humans at the moment, the potential implementation of gene therapy might entail the use of E6 short interfering RNA, antisense RNA to E6 and E7, and a mutated E2 protein that would induce apoptosis in cancer cells [9, 10, 28]. Other studies have even suggested that altering the metabolism of estrogen in the body could prevent some laryngeal papillomas and laryngeal cancers, since estrogen levels can affect the risk of cancer in some tissues sensitive to hormones [10].

Radiation therapy has proven to be rather effective in treating HPV-positive HNSCCs with significantly improved survival rates of HPV-positive carcinomas in the head and neck [37, 38]. Cidofovir is an antiviral drug used to treat HPV-induced laryngeal papillomatosis and other viral infections, with initial reports suggesting activity in cervical carcinoma cells. In the presence of Cidofovir, HPV-16-transformed HNSCC cells exhibit a pronounced sensitivity to irradiation, perhaps due to the induction of p53 expression by Cidofovir. Because p53 mediates pro-apoptotic effects of XRT, this provides a mechanistic explanation for Cidofovir as a radiation sensitizing agent [39].

Immunotherapy (e.g., targeting p53-derived or E7-derived peptides) may provide a potential approach to combating HPV-associated HNSCC [40, 41]. Wild-type sequence (wt) p53 peptides are attractive candidates because elevated levels of p53 protein occur in a high proportion of human carcinomas, including HNSCC. However, in HPV-associated HNSCC, increased proteasomal degradation of p53 may result in appreciable presentation of p53-derived peptides, despite low p53 expression. The requirement of p53 overexpression would visually exclude these individuals from wt p53-based immunotherapy. In fact, both wt and mutant p53 molecules were found sensitive to E6-mediated degradation in HPV-associated HNSCC and that this HPV-induced p53 degradation was correlated with increased T-cell recognition of the tumor cells *in vitro* and *in vivo*. These findings suggest that p53 peptides may be useful tumor antigens for HNSCC immunotherapy and T cell-mediated immunotherapy against wt p53 should not be restricted to tumors overexpressing p53 [41]. HPV-encoded oncogenic proteins, such as E7, are also promising tumor-specific antigens. T-cell frequencies against E7 derived peptides (HPV-16 E7_{11–20} and E7_{86–93}) were found significantly elevated in HPV-16 positive HNSCC patients compared with HPV-16-negative patients or healthy volunteers. In addition to the presence of HPV-specific effector T cells, successful tumor elimination requires that HPV-infected tumor cells function

as appropriate targets for CTL (cytotoxic T lymphocyte) recognition and elimination. The study also suggested endogenous E7-specific immunity exists even in the presence of ongoing virus-associated malignancy, perhaps due to immune escape of tumor cells from CTL recognition by downregulation of some antigen-processing machinery component expression. These findings support that E7-derived peptides are potentially useful targets to facilitate HPV-specific immunotherapy of HNSCC [40].

EBV and Its Life Cycle

Nearly 45 years ago, EBV was first discovered in 1964 from a patient with African Burkitt lymphoma (BL) [42]. As one of the most common human viruses, EBV is known today around the globe, infecting adults and children alike. Spread from person to person through close contact, EBV infection usually goes unnoticed by most, occurring as a subclinical illness or simple childhood sickness. The age at which a person becomes infected with the virus, however, depends on several factors, including living conditions, hygiene, and sexual behavior. By adulthood, over 90% of the population has been infected by EBV at some point in their lives [43].

EBV itself is a γ (gamma)-herpes virus and a member of the Herpesviridae family. The herpesviruses consist of generally large, complex DNA viruses, able to encode about 100 different proteins, and are one of the largest virus groups that significantly infects the pediatric population. After a primary infection, herpesviruses typically establish permanence in their host, in the form of a life-long infection. In the case of EBV, the virus perpetuates its existence by latently infecting circulating B-cells, which are subsequently shed into genital and salivary secretions. Instead of damaging or destroying the B-cells that it infects, EBV increases the number of B-cells in the host and extends their survival, causing a sudden growth of infected cells and ensuring the virus' permanence [43, 44].

The life cycle of EBV consists of two separate phases, which include an active, lytic form of infection and a latent state of infection. Most often, EBV resides in its host in a state of dormancy, infecting B lymphocytes in the blood. In this state, EBV expresses very few viral proteins and remains undetectable by the host immune system. Each B-cell carrier would contain around 2–5 copies of intact, circular viral DNA. But, as a highly infectious virus, EBV is capable of periodically reactivating and commencing the lytic phase of its life cycle. The lytic cycle then produces new progeny virions, infects more B-cells, and eventually returns to a state of latency. Since the life cycle of EBV so closely resembles the natural differentiation pathway of antigen-activated B-cells, the virus is able to guide infected B-cells through its various

stages of differentiation, essentially dictating whether EBV will exist in its latent or active form. It is in its ability to alter the various stages of B-cell differentiation, to permanently affect its growth transformation, that EBV has its pathogenic capacity, which in turn results in the numerous lymphomas and carcinomas for which EBV is responsible [44–46].

Mechanisms of EBV-Mediated Carcinogenesis

While it may seem counterintuitive, EBV poses the larger risk of becoming tumorigenic when in its latent state, rather than in its active state. When EBV induces growth transformation in its host cell, the production of progeny virions is ceased, and the virus undertakes a tumorigenic pathway of replication. The host B-cells propagate EBV's DNA by replicating it as an extrachromosomal episome, utilizing the host's own DNA polymerase. The tumorigenic properties of this type of latent infection largely come from a small set of latent genes, which include the latent membrane proteins (LMP1, LMP2A, and LMP2B) [47, 48], EBV nuclear antigens (EBNA1, EBNA2, and EBNA3) [49, 50], and the EBV encoded noncoding RNAs (EBERs) [46, 51, 52] (Fig. 7.2).

EBNAs play a major role in promoting the activities of the other proteins, primarily oncogenic LMPs. In particular, EBNA1 holds a great deal of significance since it is found universally in all EBV-associated tumors and the presence of EBNA1 enables the EBV genome to be replicated and passed along to the daughter cells of an activated, dividing host. In addition to EBNA1, EBNA2 is produced during an infection and acts as the major transcriptional regulator of both cellular and viral expression. It has been shown, by deletion of the gene encoding EBNA2, that the protein is crucial in the transformation of infected B-cells [46, 53, 54]. Functionally-speaking, EBNA2 upregulates the expression of several B-cell antigens, such as CD21 and CD23, plus the viral membrane proteins LMP1 and LMP2. Lastly, the EBNA3 family – which includes EBNA3A, EBNA3B, and EBNA3C – encode hydrophilic nuclear proteins. The EBNA3s, with the exception of EBNA3B, have been demonstrated to be indispensable in B-cell transformation in vitro [43, 46, 53, 54].

As the principal EBV oncogene, LMP1 is necessary for cell immortalization and has demonstrated transforming ability. This viral protein has a significant effect on epithelial cell growth and inhibits cell differentiation, often inducing growth transformation. LMP1-positive cells have increased mobility, which in turn leads to greater tumorigenic potential and faster disease progression. In addition, LMP1 is also involved in suppressing immunogenic responses through its capacity to downregulate T-cell response genes related to tumor antigen presentation. On the other hand, less is known

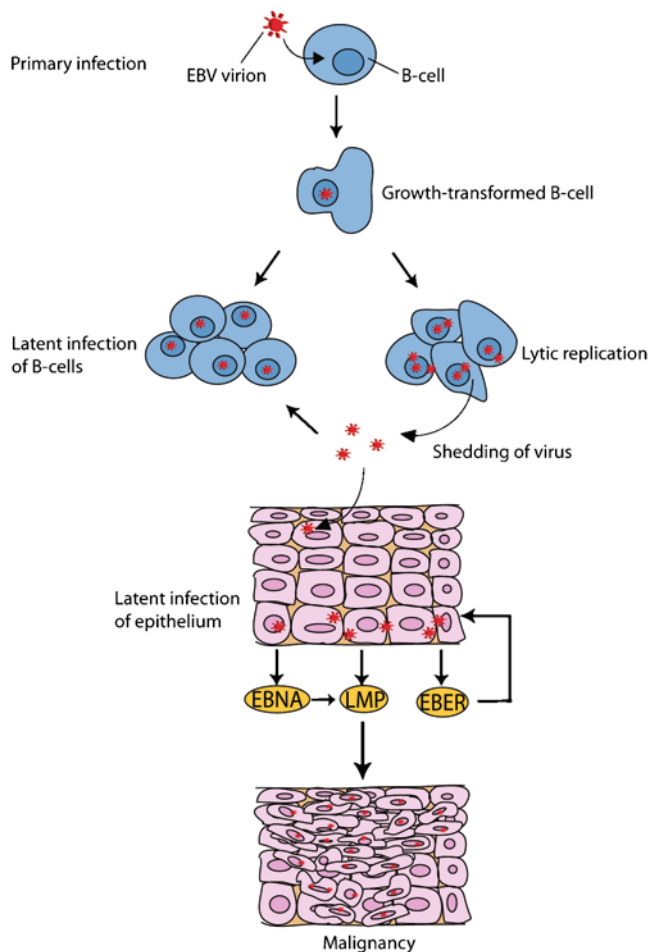


Fig. 7.2 Possible carcinogenic mechanisms of EBV in NPC. After the primary infection of a B-cell by EBV, the growth-transformed B-cell may undergo two different pathways. Usually, EBV will establish a latent infection in the B-cells, lying in a state of dormancy. On occasion, however, the lytic phase of its lifecycle may commence, and EBV will replicate in the B-cells, shedding EBV virions which can then latently infect either more B-cells or the epithelium of the nasopharynx. As the EBERs maintain viral latency, the EBNAs upregulate the LMPs – namely LMP1, the principal oncoprotein responsible for inhibiting cell differentiation and promoting malignancy

about LMP2A and LMP2B. Studies in rodent populations have suggested that LMP2A is a driving force behind the proliferation and survival of B-cells, thus maintaining EBV latency and preventing the activation of the EBV lytic cycle. Recent reports have also shown that LMP2A can transform epithelial cells. The role of LMP2B is less complex, and it is thought to regulate LMP2A function [43, 46, 54].

Lastly, the presence of EBERs is a characteristic of latent EBV infection, although they are not necessary for B-cell transformation. The EBERs are small, nuclear RNAs that are the most abundant RNAs in EBV-infected cells. They are present in all forms of latency and are thought to contribute to malignancy by maintaining viral latency. In some EBV-associated malignancies, such as BL, EBERs seem to

play a more critical part in contributing to pathogenesis, especially in initiating B-cell growth transformation [46, 53].

The EBNAs, LMPs, and EBERs have been identified as the molecules of most interest in EBV-associated tumorigenesis. However, to some extent, EBV infection appears to be necessary but not sufficient for tumorigenesis in NPC. Although there are many aberrations that contribute to tumorigenesis, the critical signals in NPC development are the Wnt pathway, transcription factors NF-kappa B and beta-catenin. Most NPC tumors exhibit Wnt pathway protein dysregulation and over-expression of beta-catenin and NF-kappa B [43]. As with any carcinoma, the loss of tumor suppressors is to be expected. In EBV-mediated tumorigenesis, however, levels of tumor suppressors are less predictable. While p16 and p27 activity is decreased in EBV-associated carcinoma, high levels of p53 are found. It is unclear whether increased p53 levels contribute to EBV malignancy or whether it is merely a natural response to infection. Another oncogene that may play a role in EBV-associated carcinomas is the *BARF1* gene, which has been demonstrated to play an important role in growth promotion. Since the BARF1 protein exists in serum, it may also prove to be a useful diagnostic biomarker in some patients with EBV-associated carcinoma [43, 55, 56].

EBV in Nasopharyngeal Precancer

NPC is an EBV-related malignancy found mainly in parts of Southeast Asia. Tumorigenic activities of EBV in NPC have been well studied and documented, but there is a glaring lack of evidence regarding the interaction of EBV and precancerous lesions of NPC. In contrast to many cancers, early manifestations of malignancy such as dysplasia, or carcinoma in situ are rare in the development of NPC. In one study, screening for dysplasia and carcinoma in situ, only 11 out of over 5,000 nasopharyngeal-biopsy samples displayed early malignant changes without adjacent invasive carcinoma. These 11 samples were then analyzed for the presence of EBV, and in all cases, the expression of EBV-DNA, EBERs, and LMP1 were detectable. These results seem to imply that the pre-invasive lesions serve as a focal point of EBV-induced cellular proliferation, and that EBV infection precedes the development of malignancy [57]. However, in a similar study, EBV-DNA was detected in only a portion of the cells of tissue samples with carcinoma in situ, as opposed to all of the cells [58]. This may suggest that EBV infection occurred after the initial neoplastic event, and that some preceding genetic change may affect viral infection, allowing for a latent EBV infection to establish and express oncogenic proteins. Another study highlights the loss of the p16 tumor suppressor as a potential contributor to the progression towards invasive

malignancy. A more recent study suggested that chromosomal losses, which affect the chromosome 3p occur at a preinvasive stage, early in the development of tumorigenesis. Early dysplastic lesions examined in this study supported the evidence that EBV infection in fact occurs after genetic alterations in the cell, allowing a latent EBV infection to develop [59]. Of course, these controversial results warrant further studies to investigate the role of EBV in precancerous lesions of the nasopharynx. Other cofactors in addition to EBV infection, including genetic modifications in tumor suppressors such as p53 and pRb or in *ras* genes, as well as environmental factors, may need to be considered as possible sources of preinvasive malignancy.

EBV in Nasopharyngeal Cancer

The association of EBV with NPC can be dated back to the early 1970s [60–62]. While NPC is often simply thought of as an EBV-related malignancy, it can be defined more precisely as a squamous cell carcinoma (SCC) that develops around the ostium of the Eustachian tube in the lateral wall of the nasopharynx. NPC tumors are comprised of malignant, EBV-infected epithelial cells that are surrounded by reactive lymphocytes [63]. The World Health Organization (WHO) classifies NPC into three categories, based on its histology. Type 1 – keratinizing SCC – is characterized by well-differentiated cells that produce keratin. Type 2 – nonkeratinizing SCC – is more varied in cell differentiation and does not produce keratin. Lastly, type 3 – also nonkeratinizing SCC – is undifferentiated with highly variable cell types. In NPC, types 2 and 3 are EBV-associated and have an overall better prognosis than type 1, which is typically EBV absent [43, 63]. Some studies suggest that regardless of subtype, all NPC show strong evidence of EBV as an etiological factor in the onset of the disease, whereas others maintain that the association of EBV with more than type 3 NPC is controversial at best [43, 64, 65].

EBV episomes and viral proteins are consistently detected in all cells of most tumors associated with the virus, implying the necessary nature of EBV in the development of these malignancies. Since a ubiquitous EBV virion can lead to such a wide range of cancers, it is clear that other factors aside from EBV must influence the development of these cancers as well. As such, EBV is recognized as a necessary, but insufficient, cause for NPC. EBV strain variation may play a part in determining the type of cancer that will arise, implying specificity in EBV strain and malignancy. Potential cofactors, including epidemiological patterns, genetic susceptibility, and environmental factors such as salted or pickled foods and exposure to fumes and chemicals from the occupational environment have also been associated with

the development of NPC [62, 64, 65]. In areas with high incidence, NPC clusters in families which suggests that both geography and genetics may influence disease risk. A genome-wide scan for familial NPC revealed evidence of a major susceptibility locus for NPC on chromosome 4 [66].

In type 3 NPC, EBV infects the epithelial cells of the posterior nasopharynx. To explain the infection of these specific cells by NPC, two mechanisms have been proposed. First, while an EBV-compatible receptor on epithelial cells has not been found, the CD21 receptor, which is a surface protein antigenically related to B-cells, could potentially be used as a point of virion entry. Alternatively, it has been suggested that EBV may gain entry into the nasopharyngeal epithelial cells through IgA-mediated endocytosis [67, 68]. In either case, the EBV genomes present in the epithelial cells are of clonal origin, and EBV is distinctly absent from surrounding tissues and invading T-lymphocytes.

Another point to consider when discussing the causality of EBV in NPC is the way in which EBV-infected cells can evade the immune response. EBV-infected epithelial cells in the nasopharynx possess normal antigen processing and are recognized by EBV-specific cytotoxic T-lymphocytes, but they are not destroyed [44, 64, 69]. One possible explanation involves the increased production of IL-1 α (alpha) and IL-1 β (beta) by the infected epithelial cells, which control the levels of lymphocytes and contribute to the growth of the tumor [70]. In addition, the over-expression of bcl-2 allows the infected cells to bypass apoptosis and this contributes to oncogenesis [71].

Overall, it has been well-established that EBV contributes to the development of NPC, although to which specific WHO classification is less clear. EBV has been consistently linked to the disease in epidemiological studies, serological analyses, and the expression of malignant viral products by EBV, implying an etiological role for the virus in NPC.

Detection of EBV and Diagnosis of EBV-Positive NPC

The detection methods for EBV mainly rely on the presence of EBV-DNA and its gene products [72, 73]. Depending on the type of latent infection present, different EBV-associated proteins may be detected in EBV-infected patients. Typically in NPC, type 1 and type 2 latency are observed [46, 74]. Namely EBER transcripts, as well as ENBA1 and LMP2A proteins, characterize type 1 latency, while type 2 latency additionally expresses LMP1 and LMP2B [73]. Lab testing of EBV can be accomplished in several ways, including in situ hybridization, Southern blot analysis, EBV-DNA amplification with PCR, and serological analysis, all of which may contribute to early detection and diagnosis of EBV-positive NPC [73].

EBER in situ hybridization is considered the gold standard for detecting and localizing latent EBV in tissue samples. EBER transcripts are expressed in virtually all EBV-related NPC tumor cells yet are notably absent in adjacent normal tissue. This localization appears to occur in the early stages of infection, and as such, becomes a valuable diagnostic tool. The main advantage of using in situ hybridization is its ability to localize EBV in the context of cytological and histopathological features of the tissue [56, 73]. Southern blot analysis is based on the variable number of terminal repeats at the ends of each EBV-DNA molecule. Since any cell is only infected once with EBV, each infected cell may contain up to 20 terminal repeats from the infecting genome of the virus. EBV-related NPCs harbor monoclonal EBV-DNA that can be detected with a clonality assay. After lesional EBV-DNA is subjected to *BAMHI* restriction enzyme, electrophoresis, and transfer, monoclonal patterns can be distinguished and the amount of linear EBV-DNA present can give some indication of active viral replication [73, 75].

EBV-DNA amplification with PCR provides yet another method for the detection of EBV-DNA in blood, fluid, or tissue samples [73, 76]. Since EBV-DNA is present to some degree even in healthy virus carriers, this detection method lacks the specificity of EBER in situ hybridization. The use of EBV-DNA amplification with real-time quantitative PCR, however, leads to the possibility of EBV viral load measurement. The assays are relatively quick, can be used as a screening method based on body fluid testing, and therefore appear to have advantages over other methods of viral detection [73, 77]. Since quantitative PCR permits precise measurement of EBV-DNA levels in clinical samples, EBV viral load assays might be able to distinguish low-level infection in carriers from higher levels associated with EBV disease. Serology remains the most accurate detection method for confirming acute versus remote EBV-related infections. EBV-specific serological assays through enzyme-linked immunosorbent assay or immunofluorescent assay are used for more precise indication of acute or recurring EBV infection [73, 78]. Since other diseases can present biomarkers similar to those associated with EBV-related NPC, additional detection methods are commonly used to confirm the presence of EBV, most notably quantitative DNA amplification assays.

The early detection of EBV in NPC is absolutely critical concerning the prognosis of a patient, since NPC exhibits an extraordinarily high cure rate for early stage disease. The detection of NPC is based on the clinical history of the patient and a physical examination, but a definitive diagnosis requires a biopsy of the lesion. A combination of radiologic assessments, including CT and MRI scans of the head and neck, are currently used to assess the tumor and stage of the

disease. Although there are mixed reviews of the usefulness of serology in predicting and diagnosing NPC, it is often a common technique to determine the status of EBV infection and site of the primary tumor [79].

Prognosis of EBV-Positive NPC and Therapeutic Treatment

Early diagnosis of NPC is vital in combating the disease, as it is much more effective when the tumors are treated at early stage. With traditional radiotherapy or chemotherapy, early stage NPC treatment has proven to be highly effective, while later stage treatment using the same therapies, targeting NPC that is already metastatic or recurrent, provides much less favorable results [80]. The prognosis for individuals with NPC recurrence or progression remain very dim, as about 85% of patients die within 1 year, and virtually all die within 3 years [81].

Considering the poor prognosis of individuals diagnosed with late-stage NPC, it is important to screen patients regularly for the presence of the disease in order to provide effective treatment. Similar to other carcinomas, the prognosis of NPC depends on the size of the tumor, lymph node involvement, and distant metastasis [43]. Several studies have attempted to characterize the prognoses of patients with EBV-positive NPC in relation to the presence of several different diagnostic biomarkers [82, 83]. One study has demonstrated that the presence of EBNA1 DNA in peripheral-blood cells is an important risk factor for patients with NPC, indicating a significantly higher risk of developing distant metastasis and an overall lowered survival rate [83]. Another study has suggested that the quantitative analysis of plasma EBV-DNA levels is a useful tool in screening and monitoring potential NPC patients [84].

The standard treatment for NPC is radiotherapy, but better prognoses are obtained when utilized in combination with adjuvant chemotherapy [43]. Since EBV infection in tumor cells is generally restricted to a latent form, switching from the latent form of viral infection into the lytic form may induce tumor cell apoptosis [85]. One potential tool for accomplishing this is the use of valproic acid (VPA), an anti-seizure drug that also has strong histone deacetylase inhibitory activity, for activating lytic viral gene expression in EBV-positive tumors [86]. Another line of study involves the use of a variety of chemotherapeutic agents, including cisplatin, 5-fluorouracil (5-FU), and taxol to induce the switch from the latent to lytic form of EBV infection in tumor cells. Because the lytic form of EBV infection converts the cytotoxic prodrug, ganciclovir (GCV), into its active form, the combination of GCV and chemotherapy has

been shown to be much more effective in the treatment of EBV-positive NPC than either agent alone [87]. A follow-up study of the metastatic NPC patients with chemotherapy indicates that a high percentage of the patients (~70%) can attain complete responses and long-term survival (disease-free for at least 36 months). The data confirms the promising potential of chemotherapy in treating NPC [82].

Cell therapy is another therapy that holds great promise for a specific treatment against EBV-positive NPC, targeting the viral aspect of the disease. EBV is present in virtually all poorly differentiated and undifferentiated nonkeratinizing NPCs, which makes it a reliable target in cell therapy. EBV expresses a restricted set of viral antigens, namely LMP1 and LMP2, in addition to EBNA1, all of which are immunogens that are capable of inducing a T-lymphocyte response. Because it has been shown that NPC cells are capable of immunologic processing for cytotoxic T-lymphocyte recognition, studies have been conducted to explore the possibilities of pulsing dendritic cells with EBV-peptides to enhance T-lymphocyte immunity. Generally, clinical responses to cell therapy have been well tolerated, although it does have its limitations in tumor specificity and targeting tumors with poorly expressed EBV antigens [80, 81].

Due to the involvement of EBV in NPC, there is also the potential for the use of prophylactic and therapeutic vaccines for treatment. However, due to the diversity of EBV-pathogenic mechanisms and EBV-related diseases, vaccines can only be designed for one disease entity, rather than all EBV-related malignancies [88]. Despite this shortcoming, a polyepitope-based vaccine has been developed for NPC that has numerous advantages over traditionally proposed vaccines that target EBV LMP antigens [89]. While still in the clinical stages of testing in humans, the vaccine has proven to be highly successful in mice populations.

Proteomics of HPV- and EBV-Associated Cancers

Proteomics is a powerful approach for biomedical research because it aims for a comprehensive, quantitative analysis of protein expression and its changes under biological perturbations such as disease or drug treatment. Recent studies on stably transfected cancer (cervical and colon) cell lines have indicated that proteomics is powerful to identify the target proteins of E6 or E7 modulation as well as the E7-interacting proteins [90–92]. Analysis of the protein alterations and E7 binding partners in the transfected cells suggested that HPV-16 E7-infected epithelial cells could evade immune surveillance or resist against apoptosis by inducing or binding to chaperones, cell signaling and cell-cycle regulatory proteins [90, 91]. Similar proteomic studies

can be performed to unveil the target proteins and binding partners of E6 and E7 in HNSCC, which can provide further insight on mechanistic understanding of HPVs in head and neck oncogenesis and facilitate the development of anti-viral or anti-cancer drugs based on these target molecules and protein–protein interactions. The best-known cellular targets of the HPV-16 E7 oncoprotein are the retinoblastoma tumor suppressor protein pRB and the related pocket proteins p107 and p130. However, there is ample evidence that E7 has additional cellular targets that contribute to its transforming potential. To identify cellular targets of HPV-16 E7, tandem affinity purification can be used to pull down HPV-16 E7 associated cellular protein complexes and subsequently mass spectrometry (MS) can allow for the identification of cellular targets of E7. Using this approach, a 600-kDa retinoblastoma protein associated factor, p600, has been identified as a cellular target of E7. The protein regulates cellular pathways contributing to anchorage-independent growth and cellular transformation [93].

When applied to studying HPV-positive and HPV-negative cancers, proteomics could reveal target proteins that have diagnostic or therapeutic implication in the diseases [94–96]. For example, proteomics has been successfully used to identify a novel target protein, retinoblastoma-binding protein 48 (RbAp48), as an important mediator controlling the transforming activity of HPV-16 in cervical cancer. The protein was found differentially expressed between HPV-positive and HPV-negative cell lines and cancer tissues based on 2-D gel electrophoresis and MS. Suppression of RbAp48 using small interfering RNA in cervical epithelial cells significantly stimulated cell proliferation and colony formation. Conversely, over-expression of RbAp48 significantly inhibited cell growth and tumor formation [96]. These results suggest that proteomics profiling followed by molecular biology validation is a powerful approach to elucidate signaling molecules in HPV-associated cancers.

Likewise, proteomics may have promising applications in EBV-positive NPC towards the mechanistic understanding of the disease and discovery of diagnostic/therapeutic targets [97]. Using proteomics and a phosphoprotein enrichment method, LMP1 was found to increase the quantity of total phosphoproteins by ~18%, and many proteins (e.g., annexin A2) showed significant changes in the degree of phosphorylation when LMP1 was expressed [98]. LMP1 increased the serine, but not tyrosine, phosphorylation of annexin A2 by activating the protein kinase C (PKC) signaling pathway [99]. EBV is able to efficiently immortalize primary B lymphocytes *in vitro*. The growth program of EBV-infected B cells is initiated and maintained by the viral transcription factor EBNA2, which regulates viral and cellular genes, including the proto-oncogene *c-Myc*. Proteomic analysis has proven to be a powerful approach to profile the target proteins of EBNA2, including both *c-Myc*-dependent or

c-Myc-independent ones [100]. EBV nuclear antigen leader protein (EBNA-LP) is a phosphoprotein suggested to play important roles in EBV-induced immortalization of B cells. One of the potential functions of EBNA-LP is a cooperative induction with EBNA-2 of viral and cellular gene expression, including that of the genes for viral LMP-1 and cellular cyclin D2. Based on MS analysis, the major phosphorylation sites of EBNA-LP were identified to be at serine residue of position 35 in the W2 repeat domain. These modification sites are critical for the protein to cooperate with EBNA-2 in upregulating the expression of LMP-1 in B-lymphoma cells [101].

Summary and Future Perspective

HPV infection has now been recognized as an important risk factor for a subset of HNSCC, particularly those arising from the oropharynx (base of tongue and tonsils). HPV-16 and HPV-18 represent the most prevalent viral types, and they show specific virus-tissue interactions in HNSCC. In addition, patients with HPV-positive HNSCC seem to have a better overall and disease-specific survival, as compared with the HPV-negative group. On the other hand, EBV has critical viral transforming functions in epithelial cells that may lead to the development of NPC, as evidenced by the consistent expression of EBV viral genes and latent membrane proteins in NPC. The tumorigenic activities of HPV in HNSCC and EBV in NPC have been well studied and documented, but there is a glaring lack of evidence regarding the interaction of HPV or EBV with precancerous lesions.

Early diagnosis of virus-associated cancers is vital in combating the diseases, as it is much more effective when the tumors are treated at the early stage before metastatic spread. However, a positive detection of viral infection does not necessarily mean the development of cancer. In this regard, it is also important to develop new molecular biomarkers, in addition to viral DNA and proteins, for a more precise diagnosis of HPV- or EBV-associated HNSCC. Prophylactic vaccines have the potential to prevent and treat virus-associated HNC. However, it is equally important to develop molecular targeted therapies for patients with the cancers so as to slow down the progression of transformed cells and improve the survival.

The mechanism of virus-associated tumorigenesis is complex, involving the aberrations of many signaling pathways and the alteration in expression of numerous proteins leading to immune escape by malignant cells. Although clinical studies have shown strong association between HPV/EBV and subsets of HNCs, the molecular mechanism regarding how these viruses facilitate the development of HNC remains largely unclear. Previous molecular studies on HPV-associated HNCs have focused on DNA and chromosomal

levels, but few on transcriptomic and proteomic profiles [29, 102]. An improved mechanistic understanding of the virologic basis for HNCs would require profound analysis of these tumors using high-content molecular analysis technologies (e.g., proteomics). This would facilitate the development of targeted therapies for treatment of these cancers if immune escape can be reversed. Meanwhile, molecular classification of tumors is likely to provide important translational information that will allow a better estimate of prognosis and may well influence treatment decisions if future HPV-stratified clinical trials support this approach.

References

1. Ferlay J, Bray F, Pisani P, Parkin DM. *Globocan 2002: cancer incidence and mortality worldwide*. IARC/WHO CancerBase no. 5, version 2.0. France: Lyon; 2004.
2. Gillison ML, Koch WM, Capone RB, et al. Evidence for a causal association between human papillomavirus and a subset of head and neck cancers. *J Nat Cancer Instit*. 2000;92:709–20.
3. Gillison ML, Shah KV. Human papillomavirus-associated head and neck squamous cell carcinoma: mounting evidence for an etiologic role for human papillomavirus in a subset of head and neck cancers. *Curr Opin Oncol*. 2001;13:183–8.
4. Renwei C, Leena-Maija A, Antti V. Human papillomavirus type 16 in head and neck carcinogenesis. *Rev Med Virol*. 2005;15:351–63.
5. Shope RE, Hurst EW. Infectious papillomatosis of rabbits: with a note on the histopathology. *J Exp Med*. 1933;58:607–24.
6. Ha PK, Califano JA. The role of human papillomavirus in oral carcinogenesis. *Crit Rev Oral Biol Med*. 2004;15:188–96.
7. Psyrri A, DiMaio D. Human papillomavirus in cervical and head-and-neck cancer. *Nat Clin Prac Oncol*. 2008;5:24–31.
8. Fakhry C, Gillison ML. Clinical implications of human papillomavirus in head and neck cancers. *J Clin Oncol*. 2006;24:2606–11.
9. Devaraj K, Gillison ML, Wu TC. Development of HPV vaccines for HPV-associated head and neck squamous cell carcinoma. *Crit Rev Oral Biol Med*. 2003;14:345–62.
10. Steinberg B, Auborn K. Papillomaviruses in head and neck disease: pathophysiology and possible regulation. *J Cell Biochem Suppl*. 1993;17F:155–64.
11. Dyson N, Howley PM, Munger K, Harlow E. The human papilloma virus-16 E7 oncoprotein is able to bind to the retinoblastoma gene product. *Science*. 1989;243:934–7.
12. Werness BA, Levine AJ, Howley PM. Association of human papillomavirus types 16 and 18 E6 proteins with p53. *Science*. 1990;248:76–9.
13. Scheffner M, Werness BA, Huibregtse JM, Levine AJ, Howley PM. The E6 oncoprotein encoded by human papillomavirus types 16 and 18 promotes the degradation of p53. *Cell*. 1990;63:1129–36.
14. Ferris RL, Martinez I, Sirianni N, Wang J, López-Albaitero A, Gollin SM, et al. Human papillomavirus-16 associated squamous cell carcinoma of the head and neck (SCCHN): a natural disease model provides insights into viral carcinogenesis. *Eur J Cancer*. 2005;41:807–15.
15. Boyer SN, Wazer DE, Band V. E7 protein of human papilloma virus-16 induces degradation of retinoblastoma protein through the ubiquitin-proteasome pathway. *Cancer Res*. 1996;56:4620–4.
16. MÜnger K, Howley P, DiMaio D. Human papillomavirus E6 and E7 oncogenes. In: Garcea R, DiMaio D, editor. *The papillomaviruses*. Springer, 2007. pp. 197–252.

17. Ming Z, Eli R, Andre Lopes C, Wayne K, WeiWen J, David S, et al. Feasibility of quantitative PCR-based saliva rinse screening of HPV for head and neck cancer. *Int J Cancer*. 2005;117:605–10.
18. Gillison ML, Lowy DR. A causal role for human papillomavirus in head and neck cancer. *Lancet*. 2004;363:1488–9.
19. Herrero R. Chapter 7: human papillomavirus and cancer of the upper aerodigestive tract. *J Natl Cancer Inst Monogr*. 2003;2003:47–51.
20. Jose VB, Yolanda J, Judith M, et al. Lack of association between proliferative verrucous leukoplakia and human papillomavirus infection. *J Oral Maxillofacial Surg*. 2007;65:46–9.
21. Fouret P, Dabit D, Sibony M, Alili D, Commo F, Saint-Guily JL, et al. Expression of p53 protein related to the presence of human papillomavirus infection in precancer lesions of the larynx. *Am J Pathol*. 1995;146:599–604.
22. Ha PK, Pai SI, Westra WH, Gillison ML, Tong BC, Sidransky D, et al. Real-time quantitative PCR demonstrates low prevalence of human papillomavirus type 16 in premalignant and malignant lesions of the oral cavity. *Clin Cancer Res*. 2002;8:1203–9.
23. Bouda M, Gorgoulis VG, Kastrinakis NG, et al. High risk HPV types are frequently detected in potentially malignant and malignant oral lesions, but not in normal oral mucosa. *Mod Pathol*. 2000;13:644–53.
24. Muñoz N, Castellsagué X, de González AB, Gissmann L. Chapter 1: HPV in the etiology of human cancer. *Vaccine*. 2006;24:S1–10.
25. Kreimer AR, Clifford GM, Boyle P, Franceschi S. Human papillomavirus types in head and neck squamous cell carcinomas worldwide: a systematic review. *Cancer Epidemiol Biomarkers Prev*. 2005;14:467–75.
26. D'Souza G, Kreimer AR, Viscidi R, et al. Case-control study of human papillomavirus and oropharyngeal cancer. *N Engl J Med*. 2007;356:1944–56.
27. Klussmann JP, Gultekin E, Weissenborn SJ, et al. Expression of p16 protein identifies a distinct entity of tonsillar carcinomas associated with human papillomavirus. *Am J Pathol*. 2003;162:747–53.
28. Campisi G, Giovannelli L. Controversies surrounding human papilloma virus infection, head & neck vs. oral cancer, implications for prophylaxis and treatment. *Head Neck Oncol*. 2009;1:8.
29. Slebos RJC, Yi Y, Ely K, et al. Gene expression differences associated with human papillomavirus status in head and neck squamous cell carcinoma. *Clin Cancer Res*. 2006;12:701–9.
30. Yang H, Yang K, Khafagi A, et al. Sensitive detection of human papillomavirus in cervical, head/neck, and schistosomiasis-associated bladder malignancies. *Proc Natl Acad Sci USA*. 2005;102:7683–8.
31. Fakhry C, Westra WH, Li S, Cmelak A, Ridge JA, Pinto H, et al. Improved survival of patients with human papillomavirus-positive head and neck squamous cell carcinoma in a prospective clinical trial. *J Natl Cancer Inst*. 2008;100:261–9.
32. Begum S, Gillison ML, Nicol TL, Westra WH. Detection of human papillomavirus-16 in fine-needle aspirates to determine tumor origin in patients with metastatic squamous cell carcinoma of the head and neck. *Clin Cancer Res*. 2007;13:1186–91.
33. Wei L, Carol HT, Christopher JOB, et al. Human papillomavirus positivity predicts favourable outcome for squamous carcinoma of the tonsil. *Int J Cancer*. 2003;106:553–8.
34. Hanna M, Signe F, Rolf L, Tina D, Eva M-W. Human papillomavirus (HPV) DNA in tonsillar cancer: clinical correlates, risk of relapse, and survival. *Int J Cancer*. 2000;89:300–4.
35. Harriet CH, Manni JJ, Haesevoets A, et al. Marked differences in survival rate between smokers and nonsmokers with HPV 16-associated tonsillar carcinomas. *Int J Cancer*. 2008;122:2656–64.
36. Weinberger PM, Yu Z, Haffty BG, et al. Molecular classification identifies a subset of human papillomavirus-associated oropharyngeal cancers with favorable prognosis. *J Clin Oncol*. 2006;24:736–47.
37. Chaturvedi AK, Engels EA, Anderson WF, Gillison ML. Incidence trends for human papillomavirus-related and -unrelated oral squamous cell carcinomas in the United States. *J Clin Oncol*. 2008;26:612–9.
38. Corvò R. Evidence-based radiation oncology in head and neck squamous cell carcinoma. *Radiother Oncol*. 2007;85:156–70.
39. Sirianni N, Wang J, Ferris RL. Antiviral activity of Cidofovir on a naturally human papillomavirus-16 infected squamous cell carcinoma of the head and neck (SCCHN) cell line improves radiation sensitivity. *Oral Oncol*. 2005;41:423–8.
40. Albers A, Abe K, Hunt J, et al. Antitumor activity of human papillomavirus type 16 E7-specific T cells against virally infected squamous cell carcinoma of the head and neck. *Cancer Res*. 2005;65:11146–55.
41. Sirianni N, Ha PK, Oelke M, et al. Effect of human papillomavirus-16 infection on CD8+ T-cell recognition of a wild-type sequence p53 264–272 peptide in patients with squamous cell carcinoma of the head and neck. *Clin Cancer Res*. 2004;10:6929–37.
42. Epstein M. The 1986 Walter Hubert lecture. Recent studies on a vaccine to prevent EB virus-associated cancers. *Br J Cancer*. 1986;54:1–5.
43. Chou J, Lin Y-C, Kim J, You L, Xu Z, He B, et al. Nasopharyngeal carcinoma – review of the molecular mechanisms of tumorigenesis. *Head Neck*. 2008;30:946–63.
44. Junker AK. Epstein-Barr virus. *Pediatr Rev*. 2005;26:79–85.
45. Pattle SB, Farrell PJ. The role of Epstein-Barr virus in cancer. *Exp Opin Biologic Ther*. 2006;6:1193–205.
46. Raab-Traub N. Epstein-Barr virus in the pathogenesis of NPC. *Sem Cancer Biol*. 2002;12:431–41.
47. Wang D, Liebowitz D, Kieff E. An EBV membrane protein expressed in immortalized lymphocytes transforms established rodent cells. *Cell*. 1985;43:831–40.
48. Laux G, Perricaudet M, Farrell PJ. A spliced Epstein-Barr virus gene expressed in immortalized lymphocytes is created by circularization of the linear viral genome. *EMBO J*. 1988;7:769–74.
49. Sample J, Hummel M, Braun D, Birkenbach M, Kieff E. Nucleotide sequences of mRNAs encoding Epstein-Barr virus nuclear proteins: a probable transcriptional initiation site. *Proc Nat Acad Sci USA*. 1986;83:5096–100.
50. Yates JL, Warren N, Sugden B. Stable replication of plasmids derived from Epstein-Barr virus in various mammalian cells. *Nature*. 1985;313:812–5.
51. Arrand JR, Rymo L. Characterization of the major Epstein-Barr virus-specific RNA in Burkitt lymphoma-derived cells. *J Virol*. 1982;41:376–89.
52. Swaminathan S, Tomkinson B, Kieff E. Recombinant Epstein-Barr virus with small RNA (EBER) genes deleted transforms lymphocytes and replicates in vitro. *Proc Nat Acad Sci USA*. 1991;88:1546–50.
53. Young LS, Murray PG. Epstein-Barr virus and oncogenesis: from latent genes to tumours. *Oncogene*. 2003;22:5108–21.
54. Murray PG, Young LS. Epstein-Barr virus infection: basis of malignancy and potential for therapy. *Exp Rev Mol Med*. 2001;3:1–20.
55. Seto E, Ooka T, Middeldorp J, Takada K. Reconstitution of nasopharyngeal carcinoma-Type EBV infection induces tumorigenicity. *Cancer Res*. 2008;68:1030–6.
56. Tsuchiya S. Diagnosis of Epstein-Barr virus-associated diseases. *Crit Rev Oncol Hematol*. 2002;44:227–38.
57. Pathmanathan R, Prasad U, Sadler R, Flynn K, Raab-Traub N. Clonal proliferations of cells infected with Epstein-Barr virus in preinvasive lesions related to nasopharyngeal carcinoma. *N Engl J Med*. 1995;333:693–8.
58. Yeung WM, Zong YS, Chiu CT, Chan KH, Jonathan STS, Damon TKC, et al. Epstein-barr virus carriage by nasopharyngeal carcinoma in situ. *Int J Cancer*. 1993;53:746–50.

59. Lo K-W, Teo PML, Hui AB-Y, et al. High resolution allelotyping of microdissected primary nasopharyngeal carcinoma. *Cancer Res.* 2000;60:3348–53.
60. Henle W, Henle G, Zajac BA, Pearson G, Waubke R, Scriba M. Differential reactivity of human sera with early antigens induced by Epstein-Barr virus. *Science.* 1970;169:188–90.
61. Hepeng J, Zeng YI Profile: a controversial bid to thwart the ‘Cantonese Cancer’. *Science.* 2008;321:1154–5.
62. Xiuchan G, Randall CJ, Hong D, et al. Evaluation of nonviral risk factors for nasopharyngeal carcinoma in a high-risk population of Southern China. *Int J Cancer.* 2009;124:2942–7.
63. Morrison JA, Gulley ML, Pathmanathan R, Raab-Traub N. Differential signaling pathways are activated in the Epstein-Barr virus-associated malignancies nasopharyngeal carcinoma and Hodgkin lymphoma. *Cancer Res.* 2004;64:5251–60.
64. Thompson MP, Kurzrock R. Epstein-Barr virus and cancer. *Clin Cancer Res.* 2004;10:803–21.
65. Pagano JS, Blaser M, Buendia M-A, Damania B, Khalili K, Raab-Traub N, et al. Infectious agents and cancer: criteria for a causal relation. *Semin Cancer Biol.* 2004;14:453–71.
66. Feng B-J, Huang W, Shugart YY, et al. Genome-wide scan for familial nasopharyngeal carcinoma reveals evidence of linkage to chromosome 4. *Nat Genet.* 2002;31:395–9.
67. Lin CT, Lin CR, Tan GK, Chen W, Dee AN, Chan WY. The mechanism of Epstein-Barr virus infection in nasopharyngeal carcinoma cells. *Am J Pathol.* 1997;150:1745–56.
68. Young LS, Dawson CW, Brown KW, Rickinson AB. Identification of a human epithelial cell surface protein sharing an epitope with the C3d/epstein-barr virus receptor molecule of B lymphocytes. *Int J Cancer.* 1989;43:786–94.
69. Bejarano MT, Masucci MG. Interleukin-10 abrogates the inhibition of Epstein-Barr virus-induced B-cell transformation by memory T-cell responses. *Blood.* 1998;92:4256–62.
70. Huang Y-T, Sheen T-S, Chen C-L, Lu J, Chang Y, Chen J-Y, et al. Profile of cytokine expression in nasopharyngeal carcinomas: a distinct expression of interleukin 1 in tumor and CD4+ T cells. *Cancer Res.* 1999;59:1599–605.
71. Lu Q-L, Elia G, Lucas S, Thomas JA. Bcl-2 proto-oncogene expression in Epstein-Barr-virus-associated nasopharyngeal carcinoma. *Int J Cancer.* 1993;53:29–35.
72. Wei W, Sham J. Nasopharyngeal carcinoma. *Lancet.* 2005;365:2041–54.
73. Gulley ML. Molecular diagnosis of Epstein-Barr virus-related diseases. *J Mol Diagn.* 2001;3:1–10.
74. Spano J-P, Busson P, Atlan D, Bourhis J, Pignon J-P, Esteban C, et al. Nasopharyngeal carcinomas: an update. *Eur J Cancer.* 2003;39:2121–35.
75. Raab-Traub N, Flynn K. The structure of the termini of the Epstein-Barr virus as a marker of clonal cellular proliferation. *Cell.* 1986;47:883–9.
76. Lo YMD, Chan ATC, Chan LYS, Leung S-F, Lam C-W, Huang DP, et al. Molecular prognostication of nasopharyngeal carcinoma by quantitative analysis of circulating Epstein-Barr virus DNA. *Cancer Res.* 2000;60:6878–81.
77. Fan H, Gulley ML. Epstein-Barr viral load measurement as a marker of EBV-related disease. *Mol Diagn.* 2001;6:279–89.
78. Hsu JL, Glaser SL. Epstein-Barr virus-associated malignancies: epidemiologic patterns and etiologic implications. *Crit Rev Oncol Hematol.* 2000;34:27–53.
79. Zhou X, Cui J, Macias V, Kajdacsy-Balla AA, Ye H, Wang J, et al. The progress on genetic analysis of nasopharyngeal carcinoma. *Comp Func Genomics.* 2007;2007:1–13.
80. Comoli P, Pedrazzoli P, Maccario R, et al. Cell therapy of stage IV nasopharyngeal carcinoma with autologous Epstein-Barr virus-targeted cytotoxic T lymphocytes. *J Clin Oncol.* 2005;23:8942–9.
81. Lin C-L, Lo W-F, Lee T-H, et al. Immunization with Epstein-Barr virus (EBV) peptide-pulsed dendritic cells induces functional CD8+ T-cell immunity and may lead to tumor regression in patients with EBV-positive nasopharyngeal carcinoma. *Cancer Res.* 2002;62:6952–8.
82. Fandi A, Bachouchi M, Azli N, et al. Long-term disease-free survivors in metastatic undifferentiated carcinoma of nasopharyngeal type. *J Clin Oncol.* 2000;18:1324–30.
83. Lin J-C, Chen KY, Wang W-Y, Jan J-S, Liang W-M, Tsai C-S, et al. Detection of Epstein-Barr virus DNA in the peripheral-blood cells of patients with nasopharyngeal carcinoma: relationship to distant metastasis and survival. *J Clin Oncol.* 2001;19:2607–15.
84. Lo YMD, Chan LYS, Lo K-W, et al. Quantitative analysis of cell-free Epstein-Barr virus DNA in plasma of patients with nasopharyngeal carcinoma. *Cancer Res.* 1999;59:1188–91.
85. W-h F, Kenney SC. Valproic acid enhances the efficacy of chemotherapy in EBV-positive tumors by increasing lytic viral gene expression. *Cancer Res.* 2006;66:8762–9.
86. Li J-H, Chia M, Shi W, Ngo D, Strathdee CA, Huang D, et al. Tumor-targeted gene therapy for nasopharyngeal carcinoma. *Cancer Res.* 2002;62:171–8.
87. Feng W-h, Israel B, Raab-Traub N, Busson P, Kenney SC. Chemotherapy induces lytic EBV replication and confers ganciclovir susceptibility to EBV-positive epithelial cell tumors. *Cancer Res.* 2002;62:1920–6.
88. Spring SB, Hascall G, Gruber J. Issues related to development of Epstein-Barr virus vaccines. *J Natl Cancer Inst.* 1996;88:1436–41.
89. Duraiswamy J, Bharadwaj M, Tellam J, et al. Induction of therapeutic T-cell responses to subdominant tumor-associated viral oncogene after immunization with replication-incompetent poly-epitope adenovirus vaccine. *Cancer Res.* 2004;64:1483–9.
90. Kyung-Ae L, Jung-Hyun S, Chang Won K, et al. Protein profiling and identification of modulators regulated by the E7 oncogene in the C33A cell line by proteomics and genomics. *Proteomics.* 2004;4:839–48.
91. Lee K-A, Kang J-W, Shim J-H, et al. Protein profiling and identification of modulators regulated by human papillomavirus 16 E7 oncogene in HaCaT keratinocytes by proteomics. *Gynecol Oncol.* 2005;99:142–52.
92. Yim E-K, Meoyng J, Namakoong S-E, Um S-J, Park J-S. Genomic and proteomic expression patterns in HPV-16 E6 gene transfected stable human carcinoma cell lines. *DNA Cell Biol.* 2004;23:826–35.
93. Huh K-W, DeMasi J, Ogawa H, Nakatani Y, Howley PM, Münger K. Association of the human papillomavirus type 16 E7 oncoprotein with the 600-kDa retinoblastoma protein-associated factor, p600. *Proc Natl Acad Sci USA.* 2005;102:11492–7.
94. Christian M, Günther E, Robert W, Bettina S, Jens Peter K, Claus W, et al. Proteomic analysis of human papillomavirus-related oral squamous cell carcinoma: identification of thioredoxin and epidermal-fatty acid binding protein as upregulated protein markers in microdissected tumor tissue. *Proteomics.* 2009;9:2193–201.
95. Lo W-Y, Lai C-C, Hua C-H, Tsai M-H, Huang S-Y, Tsai C-H, et al. S100A8 is identified as a biomarker of HPV18-infected oral squamous cell carcinomas by suppression subtraction hybridization, clinical proteomics analysis, and immunohistochemistry staining. *J Proteome Res.* 2007;6:2143–51.
96. Kong L, Yu X-P, Bai X-H, et al. RbAp48 is a critical mediator controlling the transforming activity of human papillomavirus type 16 in cervical cancer. *J Biol Chem.* 2007;282:26381–91.
97. Cho W. Nasopharyngeal carcinoma: molecular biomarker discovery and progress. *Mol Cancer.* 2007;6:1.
98. Yan G, Li L, Tao Y, et al. Identification of novel phosphoproteins in signaling pathways triggered by latent membrane protein-1 using functional proteomics technology. *Proteomics.* 2006;6:1810–21.

99. Yan G, Luo W, Lu Z, et al. Epstein-Barr virus latent membrane protein 1 mediates phosphorylation and nuclear translocation of annexin A2 by activating PKC pathway. *Cell Signal*. 2007; 19:341–8.
100. Schlee M, Krug T, Gires O, et al. Identification of Epstein-Barr virus (EBV) nuclear antigen 2 (EBNA2) target proteins by proteome analysis: activation of ebna2 in conditionally immortalized B cells reflects early events after infection of primary B cells by EBV. *J Virol*. 2004;78:3941–52.
101. Yokoyama A, Tanaka M, Matsuda G, et al. Identification of major phosphorylation sites of Epstein-Barr virus nuclear antigen leader protein (EBNA-LP): ability of EBNA-LP to induce latent membrane protein 1 cooperatively with EBNA-2 is regulated by phosphorylation. *J Virol*. 2001;75:5119–28.
102. Martinez I, Wang J, Hobson KF, Ferris RL, Khan SA. Identification of differentially expressed genes in HPV-positive and HPV-negative oropharyngeal squamous cell carcinomas. *Eur J Cancer (Oxford)*. 2007;43:415–32.

Chapter 8

Head and Neck Cancer Staging and Prognosis: Perspectives of the UICC and the AJCC

Brian O'Sullivan and Jatin P. Shah

Abstract The prognosis of head and neck cancer embodies numerous dimensions of outcome governed by a large array of factors within the patient and the tumor. These can be influenced by external factors that include access to an adequate standard of treatment for these tumors. For many outcomes, especially the key end-points of organ preservation, loco-regional control, occurrence of distant metastases, and survival, anatomic extent of disease remains one of the most powerful prognostic factors. This is embodied in the tumor-node-metastasis (TNM) classification which has provided a very effective enabling tool to facilitate many elements of cancer control. Traditionally, its contribution has been a codified classification and language to describe anatomic stage of disease for use in the clinic, determining eligibility and stratification for clinical trials and treatment protocols, and for comparison and surveillance of treatment results among centers and jurisdictions. More recently, a focus on nonanatomic factors has become very important, partly because it is recognized that traditional extent of disease does not embrace all dimensions of prognosis. In particular, this relates to the quest to understand the biological dimensions of cancer that are needed to achieve more personalized and/or biologically driven therapies. Increasingly, there is a need in head and neck cancer to exploit new biological discoveries to permit modification of treatment and interventions in the clinic for this heterogeneous group of tumors. Because of this, the TNM has been criticized due to a perception that it has not been adapted sufficiently to modern needs despite its worldwide adoption. This may stem from the fact that there is no alternative uniform functional framework available to classify nonanatomical predictive and prognostic factors. There seems to be a tendency to regard TNM as the optimal receptacle for these factors due to its uniform appeal and success. As the field evolves, both anatomic disease extent and other factors, especially those addressing biological

behavior of disease, need to be studied in their component domains as well as in combination using an agreed enabling taxonomy. An important strategy is to move toward constructing prognostic models, likely using prognostic nomograms, which will not only include the TNM staging information, but will also include other parameters of prognosis including comorbidities and biochemical or genetic markers. In addition, experts in one area (e.g., translational science or clinical trials methodology perhaps) who may rely on TNM may not always consider that the classification provides very different needs for others (e.g., health services research or screening and cancer control initiatives, etc.) and vice versa. Ignoring or dismissing one dimension of prognosis compared to another will not be fruitful and the true contribution of each will remain unappreciated, and the goals of the prognostic factor effort in head and neck cancer may be left unfulfilled.

Keywords Head and neck cancer • Staging • Prognosis • Prognostic models

Introduction

In oncology, “to stage” a patient implies two intentions. The first uses clinical examination and investigations to describe the extent of disease to permit a rational treatment strategy to be formulated. The second employs an agreed classification system to categorize the extent of disease within risk hierarchies that predict the outcome following conventional treatment strategies. For the latter, the foremost priority is given to the risk of death and is provided by the joint primary tumor-node-metastasis (TNM) classification of the Union for International Cancer Control (UICC) and the American Joint Committee on Cancer (AJCC), a discussion about which will comprise much of this chapter. A challenge is to also consider new methods to enhance prognostic information and determine if these can be incorporated into or complement the traditional anatomically based classification. A variety of candidate areas exist and include features relevant to the host (or patient), the environment of the patient’s

B. O'Sullivan (✉)
Head and Neck Oncology Program, Department of Radiation
Oncology, Princess Margaret Hospital,
610 University Avenue, Toronto, Ontario, M5G 2M9, Canada
e-mail: brian.osullivan@rmp.unh.on.ca

treatment setting, and finally, the assessment of the tumor itself which has tended to receive the most emphasis. For the latter, of particular emphasis is the biological character of an individual tumor or groups of tumors. In this chapter, we discuss the importance of anatomic staging in the management of head and neck cancer and provide some perspective on the scope and application of the TNM classification and how it continues to evolve since its inception more than 50 years ago. A second component will summarize the changes that were introduced in the recently published seventh edition TNM [1, 2]. The final sections of the chapter address newer concepts including the evolving tension between anatomic staging in its current form and the value of nonanatomic methods of prognostication that need to be considered (see the section on “The Future of TNM in Head and Neck Cancer”).

Achievements, Challenges/Limitations, and Opportunities of the TNM Staging System

1. Anatomic extent of disease remains one of the most powerful prognostic factors and is embodied in the TNM classification. TNM has provided an effective enabling tool to facilitate many elements of cancer control on a global basis. Anatomic features of loco-regional tumor extension are especially important in the head and neck since these underpin the management of these tumors.
2. A major dilemma in TNM staging is that frequent revisions would undermine the value conferred by the stability and universality of TNM, but a static formulation of TNM risks falling behind the state of the art in diagnostic techniques, biological concepts, and biomarkers.
3. Dimensions of prognosis are not uniform and the settings where some factors are useful to consider may not apply to other situations (e.g., early vs. advanced stage, or recurrence vs. first presentation, or important end-point in head and neck cancer such as survival vs. organ preservation).
4. The TNM remains essential so that newer biological findings can be evaluated in the context of its existing structure. Although it has significant limitations in the era of molecular oncology, it is also needed to provide the framework for advances in biological discoveries when cohorts of patients are evaluated for prognostic or predictive outcomes.
5. Future research should focus on the evolution of biology with advancing stage since this could open the door to the potential for a true molecular-based “staging system.” A major achievement of this type

(continued)

could override or complement traditional anatomic staging in some diseases or situations.

6. In considering prognosis in cancer, the UICC and AJCC are also focusing on *host* and *environmental* factors that may be as important as *tumor*-based prognostic factors in some settings.
7. The UICC and AJCC recognize an urgent need to achieve agreement on a new taxonomy and methodology to permit nonanatomic factors to be combined with traditional anatomic classifications while allowing the full impact of both to be explored, adopted, and used without compromise to the other. One ultimate goal is to move toward a prognostic nomogram, where the TNM anatomic staging will remain as an important component.
8. TNM serves many purposes in cancer care, research, and control, and dismissing one dimension compared to another will not be fruitful since the true contribution of each will remain unappreciated and the goals of the prognostic factor effort in head and neck cancer may be left unfulfilled.

The Principles of Staging in Head and Neck Cancer

The Importance of Anatomic Staging in Head and Neck Cancer

The challenge for oncologists who manage head and neck cancers is to achieve tumor control while maximizing the opportunities for preservation or restoration of form and function. A dominant pattern of treatment failure of head and neck tumors is loco-regional recurrence, making it important to have a clinical staging system that acknowledges this behavior and emphasizes the anatomic features of local tumor extension that underpin the management of these tumors. Clinical evaluation is a fundamental part of the assessment (i.e., palpation and observation of the head and neck that are almost unique to these sites because of their relative accessibility compared to other disease areas) and together with imaging studies informs a user friendly language for the extent of disease that can be applied uniformly and consistently on a worldwide basis [3]. This traditional need to classify the extent of disease remains a paramount component of the assessment of patients with head and neck cancer and the basis for many comparisons between groups of patients and the means to develop initial treatment approaches. Salvage of initial treatment failure also requires unique attention and diligence since selected patients may enjoy long-term control and cure if management is appropriately applied.

Therefore, disease description at recurrence is important so that the goals of treatment are achieved and includes the ability to plan treatment and compile results that can be compared among centers and jurisdictions separately from the description of the initial treatment. Here again, a codified language to describe treatment and protocol guidelines and permit orderly reporting of results of this adverse setting is needed and is provided by an anatomic stage classification that is tailored to the recurrent scenario which in the TNM system uses the “r” prefix described later.

The Evolution of the TNM Classification in Head and Neck Cancer

The TNM staging system was first proposed in 1944 by Pierre Denoix at Institute Gustave-Roussy, Paris, France [4]. The first formalization of the classification was developed by the Union for International Cancer Control (UICC) when it published the first of its brochures on cancer of the breast and larynx in 1958, to be followed by that on cancer of the buccal cavity and pharynx in 1963. This led to the classification of additional anatomic sites and their eventual compilation in 1968 as a single booklet, referred to as the *Livre de Poche*, which contained 22 body site classifications and represented the first edition of the TNM staging system [5]. Of central importance in the first edition of TNM were the classifications of head and neck cancer. These originally included buccal cavity, nasopharynx, hypopharynx, and larynx. All contained a common, though now outdated, regional lymph node classification that focused on whether lymph nodes in the neck were palpable or not, and used fixity as the criterion for N3. The buccal cavity was subdivided into seven regions and a number of subsites such as “lips (red borders)” with divisions into upper and lower components. Of interest also, the oropharynx was initially allocated as a region within the buccal cavity site and did not achieve independence as a region within the head and neck until the 1974 second edition [6]. Another interesting element was that fixation of the vocal cord was classified as T2 in the first edition and only became T3 in the 1974 second edition classification following a trial period of a new proposal. Also the first edition contained only a limited attempt to combine the three different anatomic components (T–N–M) into groups that might provide prognostic strata as stage-groups. This process was confined to breast and cervix cancer as it was deemed “...in the opinion of the Union an attempt to stage group all sites would at present be immature” [5]. Importantly, this was also modified in the second edition thereby representing the first formal international attempt to prognosticate in head and neck cancer using different elements of extent of disease grouped together.

The American Joint Committee (AJC) was founded in 1959 to complement this work in the USA. Joint classifications

were prepared by both organizations and distributed for trial periods before their formal adoption into the TNM classification. In 1977, the AJC introduced a TNM classification of its own [1] which had the potential for two separate classifications. This was recognized early on and a strong collaboration between both organizations (the AJCC renamed in 1980, and UICC) has continued since, so that both classifications resemble each other as closely as possible. Nowhere is this more apparent than in the classification of the head and neck sites stewarded by the authors of this chapter representing the UICC and the AJCC.

From the outset, the TNM was intended to be an anatomic stage classification describing the anatomic extent of the primary tumor as well as the involvement and extent of regional lymph nodes and distant metastasis. It describes the anatomic extent of cancer and is based on the hypothesis that the probability of survival and the choice of treatment are related to the anatomical extent of the tumor at the primary site (T), the presence or absence of tumor in regional lymph nodes (N), and the presence or absence of metastasis beyond the regional lymph nodes (M). At present, in the head and neck sites, T is almost always divided into four major categories (T1–T4), with a further subdivision into moderately advanced local disease (T4a) or very advanced local disease (T4b). A common lymph node classification represented by four categories (N0–N3) with some subcategories is used in almost all the head and neck sites. The T- and N-categories are also combined with the M-categories that indicate the presence or absence of distant metastases to form groups representing stages and that confer prognostic guidance. As noted earlier and continues to be the case, TNM has always needed to evolve with the availability of additional information about outcome, new treatments, or novel ways to evaluate disease and anatomy, including developments in imaging or emerging biological insights about disease behavior or etiology. Almost all clinical trials use anatomic extent, generally represented by the TNM or its elements, to define entry criteria or to control for prognostic imbalance between arms of randomized trials by employing stratification based on anatomic stage [7]. It is also a critical pathway to developing clinical practice guidelines such as those of the National Comprehensive Cancer Network (NCCN) [8], and is a key determinant in identifying patients to be treated by guidelines, and for monitoring compliance to guidelines [7].

The Place of Non-anatomic Prognostic Factors and Staging

It is important to recognize that the TNM classification was never intended to capture all elements that are important in determining prognosis or guiding treatment and that a variety of tumor, host, and external factors are also important and

are becoming increasingly so today. One of the ironies of the TNM classification is that it has been immeasurably successful in its goals and has enjoyed worldwide adoption but in recent times has become a target for criticism because of assertions that it has not adapted itself to modern needs [9]. This may stem from the fact that there is no uniform functional framework that can be used to classify nonanatomical predictive and prognostic factors. The tendency seems to have evolved to consider the TNM as the optimal receptacle for these factors presumably due its uniform appeal and success. This needs to be considered carefully since the problem is not straightforward. Dimensions of the elements of prognosis are not uniform and the settings where some factors are appropriate to consider may not apply to other situations of the disease. These concepts will be discussed later.

How TNM is Modified

As discussed already, changes continually take place in the TNM classification because of the need to maintain relevance with current management approaches and to respond to the availability of new data that may be considered in revisions to the classifications. This generally requires evidence of the need for modification and for the most part relies on published data in the literature. Thus, for example, the AJCC and UICC meticulously reviewed the overall TNM classification for all diseases in preparation for the recently published seventh edition. In considering change, it is important to reflect on the fact that any classification or staging system is a "compromise" between the "ideal" and the "practical." The more complex the system is, the less compliance we will observe. One of the basic tenets of the staging system is that it should be applicable and available worldwide, it should be user friendly, and it should have the ease to have maximum compliance from all parts of the world [10].

The process of revision involves collaboration between both organizations, and that is partly accomplished by a series of disease-specific task forces. A number of resources are available to the task forces which especially include a structured process for introducing changes to the TNM classification. The elements of the TNM process include the development of unambiguous criteria for the information and documentation required to consider changes in the classification, establishment of a well-defined process for the annual review of relevant literature, formation of site-specific expert panels, and the participation of experts from all over the world in the TNM review process [11]. In the preparation of the seventh edition, a number of anatomic areas were considered by the head and neck task forces and are summarized later (see the section on "Recent Modifications to TNM").

In addition some domains, including anatomically based issues, may seem relevant but are not included in

the modifications. This may arise because the data supporting the change are not sufficiently strong, or may lack the practicalities to permit its inclusion in a general way, or may not fit into the established structure of the TNM. In order to address the need for awareness of other elements that are not included in the formal classification, the UICC and the AJCC have initiated separate processes with different but complementary goals.

The UICC approach includes a separate publication, entitled the "TNM Supplement, A Commentary on Uniform Use" [12]. The "Supplement" now appears following each revision of TNM with the fourth edition currently in preparation. Its purpose is to provide explanations and examples to answer the numerous questions that arise during the daily use of TNM, particularly in unusual cases. It enumerates the recommended criteria for pathological classification (pT and pN). One example in the head and neck is a description of the superior and inferior boundaries of the glottis, since these are not elaborated in the UICC *Livre de Poche* though such items may be included in the more expansive AJCC Cancer staging manual. Another example concerns the reminder that pathological classification also uses clinical information. Thus in considering impaired mobility or fixation in the glottis, this information that is evaluated in the clinical T-category is also used to define the pathologic TNM (see Table 8.1) [12]. The "Supplement" also contains proposed classifications for new tumor sites and types not yet part of the official UICC and AJCC TNM system and that can be tested by interested investigators with a view to encouraging publication that may result in their subsequent inclusion in the formal classification if the data prove robust. Optional expansions of existing TNM categories are also included in the "Supplement" for those needing to record more detail. An added feature is the "Frequently Asked Questions" chapter, derived from the UICC and AJCC TNM web sites' Help Desks.

The AJCC has taken a different approach. First, the AJCC staging manual is a more expansive text. Consequently, it is less portable for consultation in the clinic by clinicians, though it provides the reference foundation for the work of cancer registrars in North America. A more compact version is available though is still not as brief and synoptic in presentation as the UICC *Livre de Poche*. In addition, the AJCC has implemented the "Collaborative Staging System" (CS), which acts as a repository of all available prognostic information for current and future use. This process commenced in 2004, and comprises a data collection tool across all US hospital and population registries for cancer staging information [13]. It uses a standardized data dictionary to collect information on T, N, M, and site-specific prognostic and predictive factors. The CS system is built into all cancer registry software systems in the USA. Areas identified for data collection in the head and neck sites include such factors as the

Table 8.1 Application of selected rules relevant to the TNM head and neck classification*General issues*

For each disease, there should be a clinical (obtained without resection) and a pathological (obtained after surgery) classification that contain equivalent descriptors

Pathological classification (pTNM) is based on evidence acquired before treatment, supplemented or modified by additional evidence acquired from surgery and from pathological examination

Because the designation is based on evidence acquired before treatment, a glottic cancer with a fixed vocal cord will remain a T3 lesion after surgery unless additional evidence of extension of disease is present to raise the category to the next (i.e., more advanced) level

The pathological assessment of pT and pN requires a resection adequate to evaluate the highest pT or pN category

If there is doubt about whether a tumor should be classified with a higher T- or N-category, it should be allotted to the lower category (i.e., less advanced) where the available criteria for that case can be reliably applied

The designation X is used for the T- or the N-categories, if there is inadequate information available to classify the lowest category when disease has been known to be present in that location. The term X is not used for the M-category since a clinical exam alone can permit assessment of distant metastases. It is also not used for the designation of unknown primary where T0 is the correct convention

T-category issues

Tumors overlapping adjacent areas should be classified according to the site where the bulk of the lesion is located

In the case of multiple primary tumors in one organ, the tumor with the highest T-category should be classified and the multiplicity or the number of tumors should be indicated in parenthesis, e.g., T2(m) or T2(5)

In simultaneous bilateral primary cancers of paired sites (e.g., tonsillar carcinomas), each tumor should be classified independently

In unknown primary cancer classification, the designation T0 should be used for the T-category. T0 is also used at the time of recurrence of a previous known head and neck cancer (e.g., regional lymph node or distant failure) if there is no evidence of disease recurrence at the primary site, preceded by the descriptor “r”

N-category issues

The regional lymph nodes are the cervical nodes. Midline nodes are considered ipsilateral nodes except in the thyroid

The definitions of the N-categories for all head and neck sites except nasopharynx, thyroid, and mucosal melanoma are the same

In oral cavity, larynx, pharynx, and thyroid cancers, metastases at level VII (those in the anterior superior mediastinum, cephalad to the innominate artery) are considered regional lymph node metastases. The remaining mediastinal lymph node metastases are considered distant metastases

Histological examination of a selective neck dissection specimen will ordinarily include 6 or more lymph nodes

Histological examination of a radical or modified radical neck dissection specimen will ordinarily include 10 or more lymph nodes

If the lymph nodes are negative, but the number ordinarily examined is not met, classify as pN0

When size is a criterion for pN classification, measurement is made of the metastasis, not of the entire lymph node

In unknown primary cancer classification, the designation T0 and the N-classification should use that of the site most likely to represent the origin of the tumor

actual size of lymph nodes, the location of lymph nodes (e.g., upper or lower neck involvement), human papillomavirus (HPV) status, the presence of extracapsular spread (ECS), and tumor thickness in oral cancers. Many of these are not reliably available by clinical evaluation, but their strength is apparent on pathological examination where they may influence practice in significant ways. For example, the presence of ECS is a singularly adverse factor [14] and drives the need for chemotherapy in addition to radiotherapy in the postoperative adjuvant management of cervical lymph node metastases [15]. Tumor thickness in oral cavity primary sites is one of the strongest predictors for the presence of lymph node involvement in the neck beyond the formal T staging system [16], thereby influencing the approach to neck management. Other important pathological issues that are not part of the TNM at present include the character of the tumor (e.g., endophytic vs. exophytic) and the nature of the host tumor interface (pushing vs. infiltrating) and the presence of perineural or lymphovascular invasion (LVI) that also impact on the treatment of patients. In addition to being implemented in some other jurisdictions beyond the USA, ongoing efforts involving the College of American Pathologists (CAP) and the Centers for Disease Control and Prevention (CDC) are revising the CAP Cancer Templates for reporting pathology on cancer specimens to collect core elements on tumor size, extension, nodal involvement, and metastases in the format needed for recording in the CS system. It is also expected that the CS system will be incorporated in the NCI's Cancer Bioinformatics Grid (caBIG) as the accepted standard for recording data on the extent of disease and stage [13]. In this way, the future potential exists for important elements that influence treatment and prognosis to be analyzed in order to develop prognostic groups that may be able to enhance the existing TNM stage classification.

Specific Designations and Rules in TNM

The staging of head and neck cancer requires the clinician and the cancer registrar to be familiar with an extensive assortment of anatomic sites and subsites. Practitioners and statisticians interested in how results from clinical trials are interpreted and received need to be familiar with the fundamental rules of the TNM classification. The same holds for everyone involved in interpreting and applying the general results of treatment or in maintaining and addressing consistency in how treatment guidelines are developed, used, and assessed. Depending on an individual's or a group's focus, some of these may seem arbitrary, cumbersome, or even unnecessary. Nonetheless, they embody a uniformity that is applicable to all oncologic disease sites, health professionals, and jurisdictions around the world [3].

A detailed discussion of the rules of TNM is not intended in this chapter. Some basic issues will be known to practitioners such as the fact that the TNM for most mucosal sites is designed for squamous cell carcinoma and minor salivary gland cancer. It is also acknowledged that head and neck oncologists are very familiar with the TNM system though they may not be aware of some of the recent changes described below. In addition, even experts may not be aware of all of the “fine print” that exists and a summary of some of the questions and problems that arise in day-to-day usage is provided (see Table 8.1). This is not intended to be exhaustive and the interested specialist should also consult additional sources mentioned earlier as well as the actual TNM classification publications [1, 2, 12]. Several broader issues merit comment, however. These concern the areas of clinical vs. pathological staging, some additional descriptors within the classification, and the use of grouping of elements to define prognosis.

Clinical vs. Pathological Staging

All cases should be confirmed microscopically and two classifications are described for each site, which includes a *Clinical classification* (the TNM or cTNM) that is based on evidence acquired before treatment and is essential to select and evaluate therapy. Physical examination, imaging, endoscopy, biopsy, and other relevant examinations including surgical exploration comprise the majority of this evidence. In contrast, *Pathological classification* (pTNM) is based on postsurgical histopathological classification, and is used to guide adjuvant therapy and provides additional data to estimate prognosis and to calculate end results. Both should be recorded and should not be mixed or considered equivalent since different selection criteria apply to each. In addition, they should contain the same elements.

Additional Descriptors Used in TNM

The clinical TNM and pTNM classification also contain specific terms to facilitate clinical situations faced by clinicians in the contemporary management of head and neck cancer. Thus, several symbols may be used to facilitate including the m, y, r, and R identifiers (see Table 8.2).

The suffix m, in parentheses, is used to indicate the presence of multiple primary tumors in a single site, whereby the tumor with the highest T-category should be classified and the multiplicity or the number of tumors should be indicated in parenthesis, e.g., T2(m) or T2(2) in the case of two tumors (see Table 8.1).

Table 8.2 Selected additional descriptors encountered in the TNM or pTNM of head and neck cancer

<i>m Symbol</i>	The suffix m, in parentheses, is used to indicate the presence of multiple primary tumors at a single site. See commentary in Table 8.1
<i>y Symbol</i>	In those cases in which classification is performed during or following multimodality therapy, the cTNM or pTNM category is identified by a y prefix The ycTNM or ypTNM categorizes the extent of tumor actually present at the time of that examination. The y categorization is not an estimate of the extent of tumor prior to multimodality therapy This convention should typically be used following neoadjuvant therapies and may be most applicable to induction chemotherapy
<i>r Symbol</i>	Recurrent tumors, when classified after a disease-free interval, are identified by the prefix r
<i>R-Classification</i>	The absence or presence of residual tumor after treatment is described by the symbol R as follows RX: Presence of residual tumor cannot be assessed R0: No residual tumor R1: Microscopic residual tumor R2: Macroscopic residual tumor In some situations, the R2 designation may interact with the “r symbol” if macroscopic (gross) residual represents recurrence of previous tumor (see text)

The y symbol is available to classify cases during or following multimodality therapy by identifying the clinical TNM or pTNM category identified by a “y” prefix that designates that the classification refers to the extent of tumor actually present at the time of that examination. Therefore, the y categorization is not an estimate of the extent of tumor prior to multimodality therapy, but is useful for description of TNM after the completion of neoadjuvant regimens [17].

The lower case “r” symbol is available to describe recurrent tumors and needs to be applied after a disease-free interval (usually in the order of 3–4 months). Such tumors are identified by the prefix “r” as rTNM or rpTNM and need to be distinguished from the upper case “R” designation used to describe residual disease following surgical resection as R0 for microscopically clear resections, R1 for microscopic residual disease, and R2 for macroscopic residuum. In some cases, confusion could arise between the upper case “R2” designation for gross residual disease vs. the lower case “r” designation that designates recurrent disease since one may eventually merge into the other if sufficient time evolves. This is especially prone during the time to referral to a cancer center for definitive treatment following an initially incomplete excision.

Lymph Node Classification for Micrometastasis and Sentinel Node Assessment

The regional lymph node classification has recently also been adapted to address subclinical disease. This is particularly relevant in the head and neck to sentinel lymph node assessment where the designation “Sn” has been introduced in the TNM classification (Table 8.3). Therefore, the following designations are applicable when sentinel lymph node assessment is attempted: pNX(sn), sentinel lymph node could not be assessed; pN0(sn), no sentinel lymph node metastasis; and pN1(sn), sentinel lymph node metastasis. Cases with morphological evidence of micrometastasis only, i.e., no metastasis larger than 0.2 cm, can be identified by the addition of “(mi),” e.g., pN1(mi) (see Fig. 8.1). A designation of morphologically evident isolated tumor cells (ITC) can also be used to designate single tumor cells or small clusters of cells not more than 0.2 mm in greatest extent that can be detected

Table 8.3 Refinement in description of subclinical disease (most applicable to regional lymph node evaluation using sentinel node biopsy) assessment

Cases with micrometastasis only, i.e., no metastasis larger than 0.2 cm, can be identified by the addition of (mi), e.g., pN1 (mi)

Isolated tumor cells (ITC) are single tumor cells or small clusters of cells not more than 0.2 mm in greatest extent are designated by the term “i+”

Molecular detection (nonmorphologic findings for ITC) of tumor presence is designated by the term “mol+”

Sentinel node assessment is described by the use of the suffix “sn” at the end of the classification of a given tumor as depicted below

The classifications for ITC and molecular detection of tumor should be used and designated as follows

pN0	No regional lymph node metastasis histologically; no examination for ITC
pN0(i−)	No regional lymph node metastasis histologically; negative morphological findings for ITC
pN0(i+)	No regional lymph node metastasis histologically; positive morphological findings for ITC
pN0(mol−)	No regional lymph node metastasis histologically; negative nonmorphological findings for ITC
pN0(mol+)	No regional lymph node metastasis histologically; positive nonmorphological findings for ITC

When sentinel lymph node assessment is attempted

pNX(sn)	Sentinel lymph node could not be assessed
pN0(sn)	No sentinel lymph node metastasis
pN1(sn)	Sentinel lymph node metastasis

Cases with or examined for ITC in sentinel lymph nodes can be classified as follows

pN0(i−)(sn)	No sentinel lymph node metastasis histologically; negative morphological findings for ITC
pN0(i+)(sn)	No sentinel lymph node metastasis histologically; positive morphological findings for ITC
pN0(mol−)(sn)	No sentinel lymph node metastasis histologically; negative nonmorphological findings for ITC
pN0(mol+)(sn)	No sentinel lymph node metastasis histologically; positive nonmorphological findings for ITC

by routine H and E stains or immunohistochemistry and is designated as (i+) (see Table 8.3). This overall approach has been validated recently by experts in sentinel lymph node assessment [18].

The approach has been similarly adapted to the situation where no morphological evidence of disease is apparent, but evaluation is based on a molecular assessment of the presence of disease by techniques such as flow cytometry or DNA analysis (see Table 8.3). The term “mol” is used to indicate that such a technique has been employed in the assessment; e.g., pN0(mol−) indicates that no regional lymph node metastasis is present histologically, and there is a negative assessment for nonmorphological findings for ITC. In contrast, pN0(mol+) indicates that no regional lymph node metastasis is identifiable histologically but there is a positive assessment for nonmorphological findings for ITC. Also, in the situation where these characteristics have been assessed but confined to a sentinel lymph node assessment, the term “Sn” may be used as follows: pN0(mol+)(sn), no sentinel lymph node metastasis histologically, but there are positive nonmorphological findings for ITC. In general, these terms are not commonly used in practice, but are available in the event that these assessments become more uniformly used in the future. It is apparent that the designations (i+) and (mol+) are considered N0 at this time.

Stage Grouping

For purposes of tabulation and analysis, it is useful to condense the T-, N-, and M-categories into stage groups. In general, in the TNM system, the groups are based on a hierarchy governed by the degrees of modification of prognosis. Most usually carcinoma in situ is categorized as Stage 0, tumors

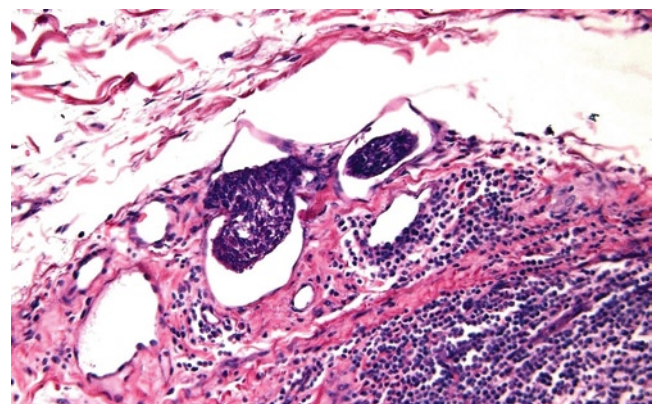


Fig. 8.1 Micrometastasis evident by small clusters of cells not more than 0.2 mm in greatest extent can be detected by routine H and E stains and are designated by the addition of “mi,” e.g., pN1(mi) for detection in a single lymph node. Single tumor cell can also be classified using the term isolated tumor cells (ITC) and designated by the use of (i+) (see Table 8.3)

localized to the organ of origin as Stages I and II, locally extensive disease and especially spread to regional lymph nodes as Stage III, and those with distant metastasis as Stage IV. In the classification of head and neck tumors, some unique differences exist and will be outlined in the sections that address specific anatomic sites in the head and neck region, most notably in the area of mucosal melanoma, where a new classification has been introduced for the first time, in anaplastic thyroid cancer and in the general head and neck classification where very advanced local disease (T4b) and extensive regional adenopathy (N2c and N3) will place the case at the highest level of adverse prognosis (Stage IV).

The stage groups are intended, as far as possible, to provide homogeneous groups with distinctive survival rates for the different cancer sites. In addition, there are pathological stage groups if sufficient tissue has been removed for pathological examination to evaluate the highest T- and N-categories. As discussed earlier, the Stage Groups have also evolved over time. Originally, in the first edition of the TNM classification, they did not exist and in the most recent edition, the AJCC and the UICC have introduced separate modified approaches in order to acknowledge the potential importance of nonanatomic factors (see "Combining Variables and Validation" section later).

Recent Modifications to "TNM"

The seventh edition of the TNM staging system has recently become available for wide usage [1, 2]. In the head and neck classifications, some additional fine tuning has been undertaken but significant changes were not necessary following the relatively substantial modifications previously introduced in the sixth edition [19, 20]. These had included similar T-category criteria for primary tumors of the oral cavity, oropharynx, salivary glands, and thyroid gland. However, some adjustments seemed necessary and are briefly outlined in the following paragraphs. In addition, there is one new classification that addresses mucosal melanoma of the head and neck. Broadly speaking, the changes are intended to reflect current practices of treatment, clinical relevance, and contemporary data as well as providing the opportunity for data to be collected with a uniform classification in situations where this may have been problematic previously.

Recent Modifications to the T-Classification

Very Advanced Local Disease (T4)

In the seventh edition, the terms "resectable" (T4a) and "unresectable" (T4b) that were introduced by the AJCC in the sixth edition [19], have been replaced by the words "moderately

advanced" (T4a) and "very advanced" (T4b). These changes were considered necessary since a significant proportion of advanced stage epithelial malignancies of the head and neck are being treated nonsurgically, and hence the terms "resectable" and "unresectable" were felt to be inappropriate for the selection of therapy. Moreover, criteria for resectability may be subjective and are often dependent on the quality of available imaging studies [21] that may not be universally available across the world. In addition, authors have reported that in some sites certain T4b cancers may be resectable with a favorable outcome, raising concern that the criteria may not be universally applied especially in retrospective series [22]. The anatomic criteria for the definitions of T4a and T4b, however, remain unchanged. For oropharynx, hypopharynx, larynx, nasal cavity, paranasal sinuses, and major salivary glands, T4 lesions have been divided into T4a (moderately advanced local disease) and T4b (very advanced local disease) leading to the stratification of Stage IV into Stage IVA (moderately advanced local/regional disease), Stage IVB (very advanced local/regional disease), and Stage IVC (distant metastatic disease). An exception is the nasopharynx. Here there is as yet insufficient data to permit a subdivision of the T4 category. In particular, there is evidence that minimal invasion of the skull base or minimal cranial nerve involvement is not uniformly prognostically detrimental when determined by imaging assessments [23], further emphasizing the rationale for the importance of clinical evaluation in staging assessments (e.g., of cranial nerves in this instance). Further information is needed to explore the cut-points of this heterogeneous T-category in addressing further revisions to the nasopharyngeal carcinoma (NPC) TNM.

Nonmelanoma Skin of the Head and Neck

Changes have also been introduced in the T-categories of nonmelanoma skin cancers that are also consistent with other cutaneous sites in the body. The 5 cm size breakpoint between the T2 and the T3 categories and invasion of extradermal structures as a criterion for T4 have been eliminated. Instead, a more clinically applicable approach for T3 includes invasion of peripheral facial and skull bones more readily amenable to safe ablative approaches, whereas the T4 category is confined to involvement of the skull base. Skin lesions in non-head and neck sites are similarly categorized according to relevant anatomic issues (e.g., axial skeleton in T4). Another novel feature is T1 tumors (<2 cm in size) can be upstaged to Stage II if they contain two or more defined high-risk criteria that include some pathologic features and location of the lesion, though in practice this will only apply to a small number of cases. The latter approach, using such high-risk features that contain pathological rather than anatomic factors, is unique to the AJCC version of the classification, but are still specified separately by the UICC without formally impacting the classification.

Other Changes in T-Categories

Relatively minor changes have been made in the remaining T-categories for various primary sites in the head and neck. The most apparent changes are in the nasopharynx (see Table 8.4), a site that underwent no change in the sixth edition TNM other than some minor wording. However, since the sixth edition, a relatively consistent finding has been the absence of a difference in outcome between T1 and T2a tumors leading to a recommendation for reclassification of patients with soft tissue disease involvement of the oropharynx and nasal fossa to the T1 category [24, 25]. Thus, T2a lesions will now be designated T1 and Stage IIA will therefore now be Stage I (see Table 8.4).

Table 8.4 Nasopharyngeal TNM clinical classification (revision in seventh edition)

<i>T – primary tumor</i>			
TX	Primary tumor cannot be assessed		
T0	No evidence of primary tumor		
Tis	Carcinoma in situ		
T1	Tumor confined to nasopharynx or extends to oropharynx and/or nasal cavity		
T2	Tumor with parapharyngeal extension ^a		
T3	Tumor invades bony structures of skull base and/or paranasal sinuses		
T4	Tumor with intracranial extension and/or involvement of cranial nerves, hypopharynx, orbit, or with extension to the infratemporal fossa/masticator space		
<i>N – regional lymph nodes</i>			
NX	Regional lymph nodes cannot be assessed		
N0	No regional lymph node metastasis		
N1	Unilateral metastasis, in cervical lymph node(s), and/or unilateral or bilateral metastasis in retropharyngeal lymph nodes, 6 cm or less in greatest dimension, above the supraclavicular fossa		
N2	Bilateral metastasis in lymph node(s), 6 cm or less in greatest dimension, above the supraclavicular fossa		
N3	Metastasis in lymph node(s) greater than 6 cm in dimension or in the supraclavicular fossa		
	N3a greater than 6 cm dimension		
	N3b in the supraclavicular fossa		
<i>M – distant metastasis</i>			
M0	No distant metastasis		
M1	Distant metastasis		
<i>Stage grouping (Nasopharynx)</i>			
Stage 0	Tis	N0	M0
Stage I	T1	N0	M0
Stage II	T1	N1	M0
	T2	N0, N1	M0
Stage III	T1, T2	N2	M0
	T3	N0, N1, N2	M0
Stage IVA	T4	N0, N1, N2	M0
Stage IVB	Any T	N3	M0
Stage IVC	Any T	Any N	M1

Note: The term “Stage Grouping” is termed “Anatomic Stage/Prognostic Groups” in the AJCC version of the classification [1]

^aParapharyngeal extension denotes postero-lateral infiltration of tumor. Adapted from Sobin LH, Gospodarowicz MK, Wittekind C. TNM classification of malignant tumors. 7th ed. New York: Wiley; 2010. Reprinted with kind permission from Wiley

As well, in the substantial series from Hong Kong that influenced the preceding recommendation concerning the T2a category, 1006 patients had T2b disease (those with parapharyngeal extension). Analysis of this subset indicated that they remain a distinct group with less favorable prognosis compared to the proposed T1 category. A significantly higher hazard of local and distant failure is evident with consequent significant impact on cancer-specific death. This effect was even more apparent when restricted to patients without lymph node involvement [24] and was confirmed in a separate large series from mainland China that included 309 patients with T2b disease [25]. Both series demonstrate a more even rise in the hazard ratio for adverse events with redistributed T-categories (i.e., T2a is reassigned to T1, and T2b remains as a T2 category). Therefore, this is adopted in the seventh edition TNM that includes the subcategory characterized by the presence of parapharyngeal extension without additional extension representing the T2 category alone. As a consequence, former Stage IIB of the sixth edition is now designated Stage II in the seventh edition (see Table 8.4).

For primary cancers of the thyroid gland, T1 tumors have been subdivided into T1a (≤ 1 cm) and T1b (> 1 cm, up to 2 cm), limited to the thyroid gland. This subdivision of T1 will allow gathering of data to clarify the much debated controversy in the literature about the management of primary tumors < 1 cm (microcarcinoma) and > 1 cm, up to 2 cm confined to the thyroid gland. In the formal TNM classification, both the AJCC and the UICC recommends to continuing the use of traditional descriptors of multifocality using the designation (m) (the largest determining of the classification), e.g., T2(m). In this context, the AJCC has also introduced a descriptor for solitary tumor (s) in addition to multifocal tumor (m) to permit users to subdivide the T-categories.

Recent Modifications to the N-Classification

Traditionally, the N-classification for cervical lymph node metastasis has been uniform for all sites except thyroid, nasopharynx, and skin. The N-classification for thyroid and nasopharynx is unique to those sites and is based on tumor behavior and prognosis. In NPC, retropharyngeal lymph nodes, regardless of unilateral or bilateral location, will now be considered N1. The basis for this decision reflects several issues. First, heterogeneous approaches to addressing retropharyngeal nodes have been used among centers. Some have considered them as N1 if unilateral, N2 if bilateral, N1 irrespective of laterality, N1 if discrete, or T2b if abutting adjacent soft tissue tissues or unclassified [24]. Some of these approaches reflect historic inadequacies in imaging prior to the era of cross-sectional imaging, especially MRI, and consistent principles have not been identified in TNM. Evidence from several studies shows that patients with retropharyngeal nodes alone have a risk of distant metastasis that is similar to

N1 disease [26, 27]. In addition, the proposal that they should correspondingly be classified as N1 disease and that this should be independent of laterality [27] forms the basis for revision of this element in the seventh edition of TNM.

An important change for nonmelanoma skin cancer in the seventh edition is the introduction of the N-classification used in the remaining head and neck sites and is justified based on a variety of studies that indicate that increasing extent of neck disease is associated with adverse outcome [28]. Indeed this compelling argument has influenced the complete nonmelanoma skin cancer classification to a degree that the head and neck N-classification is now also used for axillary and inguinal lymph nodes in the seventh edition TNM. For metastatic squamous cell carcinoma, from mucosal primary sites, no major changes were made in the N staging for any site, except that a descriptor has been added. As noted earlier, ECS of disease has been added as ECS+ or ECS– as a descriptor for capture in the CS of the AJCC. These descriptors will not influence the nodal staging system, but will permit gathering of data for potential future revisions of the N-classification.

A final point concerning the neck is that the new classification for mucosal melanoma (see below) uses a limited schema restricted to only designating absence (N0) or presence of regional lymph node involvement (N1) without additional categories (see Table 8.5).

Table 8.5 TNM classification for mucosal melanoma of the head and neck (a new classification in the seventh edition TNM)

<i>Primary tumor</i>			
T3	Mucosal disease		
T4a	Moderately advanced disease		
	Tumor involving deep soft tissue, cartilage, bone, or overlying skin		
T4b	Very advanced disease		
	Tumor involving brain, dura, skull base, lower cranial nerves (IX, X, XI, XII), masticator space, carotid artery, prevertebral space, or mediastinal structures		
<i>Regional lymph nodes</i>			
NX	Regional lymph nodes cannot be assessed		
N0	No regional lymph node metastases		
N1	Regional lymph node metastases present		
<i>Distant metastasis</i>			
M0	No distant metastasis		
M1	Distant metastasis present		
<i>Stage grouping</i>			
Stage III	T3	N0	M0
Stage IVA	T4a	N0	M0
	T3–T4a	N1	M0
Stage IVB	T4b	Any N	M0
Stage IVC	Any T	Any N	M1

Note: The term “Stage Grouping” is termed “Anatomic Stage/Prognostic Groups” in the AJCC version of the classification [1]

Adapted from Sobin LH, Gospodarowicz MK, Wittekind C. TNM classification of malignant tumors. 7th ed. New York: Wiley; 2010. Reprinted with kind permission from Wiley

The New Classification for Mucosal Melanoma of the Head and Neck

Mucosal melanoma of the head and neck warrants separate consideration and the approach to these lesions is outlined in a new chapter that introduces a TNM classification for the first time (see Table 8.5). Even small cancers behave aggressively with high rates of recurrence and death [29]. To reflect this aggressive behavior, even the smallest mucosal melanomas confined to the mucosa alone are designated as T3 and those with moderately advanced lesions (involving underlying cartilage or bone) are staged T4a. Very advanced primary tumors are staged T4b. In situ mucosal melanomas are excluded from staging, as they are extremely rare. There is also no T1 or T2 category. It is intended that the availability of a stage classification for this rare, unfavorable, and perplexing disease may facilitate research addressing its etiology, biology, and treatment.

The Future of TNM in Head and Neck Cancer

As implied and discussed earlier, the anatomic extent of disease remains one of the strongest and most consistent prognostic factors, especially in head and neck cancer. Multiple reasons for this exist and have been described. As also mentioned, however, its very success seems to have rendered it vulnerable since no alternative overarching strategy has emerged to amalgamate, administer, and process multiple prognostic elements for a given cancer. A major dilemma in TNM staging is that frequent revisions to include new biomarkers, for example, would undermine the value conferred by the stability and universality of TNM, but a static formulation of TNM risks falling behind the state of the art in diagnostic techniques, biological concepts, and biomarkers [30]. In fact, other techniques do exist and should be considered but a shift in attitude is probably needed to embrace other methods of classification in addition to the TNM system. In addition to the area of biomarker discovery, other areas of prognostic importance also exist and in many situations have the capability of equaling or even overcoming effects embodied by traditional areas of cancer classification in terms of disease biology and anatomic disease extent. For example, many nonanatomic factors address issues relevant to the host (i.e., patient) or the environment or setting where the patient is treated and particularly in the context of the availability of treatment or diagnostic assessments, but receive scant attention in the voluminous literature on prognosis that has emerged recently. Some of these issues will be discussed to introduce these concepts while recognizing that this field is evolving

and immediate solutions have not yet been developed or universally adopted. Broadly, prognostication in cancer can be classified into three domains that address the dimensions of the *Tumor*, the *Host*, and the *Environment*. This traditional classification has been used by the UICC in its publications “Prognostic Factors in Cancer” now in its third edition [31]. In addition, this text has also introduced a tabular format for each disease site throughout the body to address these three dimensions but, additionally, has allocated them into three hierarchy tiers to address whether these factors influence treatment of the disease at the present time (based on recommendations in published practice guidelines), whether they add valuable additional information to understand the disease setting without influencing treatment decisions, or finally whether they represent new and promising discoveries that have not yet found a place to put it in the assessment of the disease in the clinic. A modified example of one of the head and neck tabulations is shown in Table 8.6 [32].

Some of these areas will be discussed briefly in addition to some of the challenges in grouping data and using them to

prognosticate for the individual patient or in groups of patients. In addition, statistical assessments need ongoing understanding of concepts that address validation in particular.

The Importance of “Non-anatomic” Tumor Factors

Introduction of Biologic Prognostic Markers

A recent provocative editorial [33] noted that the power of the TNM staging system is largely derived from the observation that tumors demonstrating loco-regional or distant spread carry a worse prognosis than their less advanced counterparts. The problem is that, while this is true, and it is possible to predict survival based on a particular clinico-pathological stage, there are clearly some patients that beat the odds [33]. Unfortunately, the authors also point out that there is also evidence that small tumors can metastasize early in their course and that a surgically resected primary tumor may in fact harbor cells demonstrating metastatic potential. This suggests the possibility to differentiate virulent tumor cells capable of metastasis from nonvirulent tumor cells based on molecular profiling. Molecular evidence may then be used to predict the outcome and treatment needs for an individual patient better than TNM staging. This speaks to the inherent clinical and molecular heterogeneity of cancer we now know that exists and to our inability to predict the behavior of any particular tumor. And so the question can be legitimately posed: will TNM survive the molecular revolution [33]?

We feel that is unlikely to change for the foreseeable future. In large part, the place of TNM remains secure if only for the fact that newer biological findings will need to be evaluated in the context of an existing robust structure such as that provided by TNM, even if it remains imperfect. In addition, TNM is also a worldwide language, at least in head and neck cancer, and it is not possible to replace it in many areas of the world where complex molecular assays are unavailable. It also represents the basis for entry and stratification in many clinical trials [7] to permit the evaluation of new treatments and biomarkers in a manner that reduces the influence of treatment-selection bias.

In head and neck cancer, as in all other regions, we are confronted by a large group of potential factors, but their precise place in the management of the disease remains uncertain. Articles are appearing that address a bewildering multitude of potential molecular characterizations of head and neck cancers, often in studies containing only modest patient numbers [34–37]. It is not the purpose of this chapter to discuss these in detail but broad comments may be useful as we continue to search for the best use of potential biomarkers

Table 8.6 Prognostic factors in oral cavity, pharynx, and larynx cancer

Prognostic factors	Tumor related	Host related	Environment related
Essential	T-category N-category M-category Anatomic subsite	Performance status	
Additional	Resection margin Number of involved nodes Extracapsular nodal extension Perineural, lymphovascular invasion Tumor hypoxia HPV status	Comorbidities Age	Radiation dose Overall treatment time Quality of surgery and radiotherapy
New and promising	EGFR expression Surgical molecular margins Osteopontin DNA profiling		

Sources:

ESMO guidelines for management of SCC of the head and neck 2005 http://www.esmo.org/reference/referenceGuidelines/pdf/new_pdf/ESMO_16_SCCHN.pdf

National Cancer Institute: Lip and Oral Cavity (PDQ®): Treatment Guidelines 2005 <http://www.cancer.gov/cancertopics/pdq/treatment/lip-and-oral-cavity/healthprofessional/NCCN> Clinical Practice Guidelines in Oncology: Head and Neck Cancer 2005 http://www.nccn.org/professionals/physician_gls/PDF/head-and-neck.pdf

Modified from Bourhis J. Oral cavity, pharynx, and larynx cancer. In: Gospodarowicz MK, O’Sullivan B, Sobin LH, eds. *Prognostic Factors in Cancer*. 3rd ed. New York: Wiley; 2006:99–104

and explore how to incorporate these important elements that have the potential to profile these tumors in methods that take us beyond pure extent of disease. In the paragraphs that follow, for squamous cell carcinoma of mucosal origin, we have chosen two relatively well-recognized biomarkers, specifically the expression of the epidermal growth factor receptor (EGFR) and of HPV, that could be readily available if needed for clinical management of patients with head and neck cancer in the developed world. Both have been discussed by the head and neck task forces in the process of preparation of the seventh edition TNM. The situations surrounding both biomarkers will be discussed in relation to the proposition that they could replace or enhance the TNM or other prognostic models in the near future.

For some time, it has been recognized that EGFR expression is an independent determinant of survival and a robust independent predictor of loco-regional relapse, although not for distant metastasis that is capable of withstanding the scrutiny of rigorous multivariate analysis. However, in one of the original landmark correlative studies of a large series of patients treated with radiotherapy alone, EGFR expression varied considerably among head and neck squamous cell carcinomas, and the study was restricted to the investigation of higher stage patients (i.e., in excess of 95% of patients had UICC/AJCC Stage III or IV disease) [38]. Thus, the precise impact of this biomarker in the continuum of the different degrees of head and neck cancer disease extension remains unclear. This problem in fact exists in much of the prognostic factor literature, where different factors or prognostic models may be important in subsets of a disease that address issues such as advanced stage as compared to early disease, or in different scenarios (e.g., primary vs. recurrent presentations) but it becomes problematic when one wishes to apply them universally across the entire disease spectrum. An additional problem relating to EGFR expression concerns its true value in the clinic as matters stand today. The initial data suggested that EGFR expression might be considered for selecting patients for more aggressive combined therapies or enrollment into trials targeting EGFR signaling pathways [38]. Strong claims have persisted that it is a promising therapeutic target in head and neck cancer based on the proven efficacy of cetuximab, a monoclonal antibody against EGFR, when combined with radiotherapy in locally advanced cancer (Stages III and IV) [39]. This observation had led to the approval of the drug for this indication on a worldwide basis. However, the role of EGFR-targeting agents in other therapeutic modalities, such as combined chemoradiotherapy or induction chemotherapy, remains to be defined [40]. In addition, and perhaps more disheartening, is the knowledge that the useful effects of cetuximab appear to be divorced from the degree of EGFR expression [40, 41]. The reality is that the majority of squamous cell carcinomas in the head and neck overexpress EGFR, but the clinical responses to

EGFR-targeting agents have been modest, and molecular predictors for response to EGFR-targeted therapies have not been identified in the head and neck. Molecular marker studies have shown that mutations in the EGFR gene such as the L858R mutation in the tyrosine kinase portion of the receptor confer sensitivity to EGFR tyrosine kinase inhibitors in non-small cell lung cancer, but positive similar and additional studies in head and neck cancer have proven elusive to this point [40]. One opportunity is that emerging data suggest that cetuximab may have the ability to elicit immune responses such as antibody-dependent cell toxicity (ADCC), and the search for predictive biomarkers for cetuximab therapy may need to be redefined to include elements of the immune system. Certainly, the response to cetuximab appears to be multifaceted and involves more than a simple inhibition of the EGFR pathway [40], and until the situation becomes clearer and its role more certain the incorporation of this potentially important biomarker with elements of the TNM remains unresolved. It does seem clear, however, that its place in the prediction of prognosis in head and neck cancer should continue to be evaluated within the established framework of anatomic disease extent and failure to do so may lead to spurious findings.

In contrast, the AJCC has recently recommended that HPV status in tumor should be assessed in mucosal squamous cell carcinoma of head and neck sites because of the impact it has on the prognosis of some head and neck cancers [1]. These data, together with other factors not included in TNM, will be compiled in the CS for analysis in the future and in particular as it relates to prognostic models that take into account various factors. This is an encouraging opportunity since the HPV status could influence treatment decisions in the near future due to modifications in treatment intensity currently under consideration [42].

However, even HPV status needs to be viewed cautiously in the present discussion. In essence, the landscape of head and neck cancer has been dramatically altered in recent years by the emergence of this subgroup of cancers with a different oncogenesis compared to the traditional situation where tobacco and alcohol were almost the sole etiologic agents. Strong epidemiologic evidence exists for the rapidly increasing incidence of a specific subgroup of squamous cell carcinomas, predominantly in the tonsil and base of tongue regions of the oropharynx, that are associated with HPV oncogenesis [43]. These tumors seem to have significantly more favorable outcome compared to traditional squamous cell cancer in these locations [44]. This has been attributed to enhanced immunological response to HPV in the host or to an increased sensitivity to radiotherapy [42] though evidence suggests that outcome is also related to better response following both chemotherapy and surgery. These findings have led to HPV being widely accepted as a prognostic biomarker for oropharyngeal carcinomas.

An alternative interpretation is to regard this as an entirely different disease compared to traditional oropharynx cancer. In essence, it remains unresolved whether it should be considered separately from traditional smoking-related oropharyngeal cancer, and clinically trials are now being designed specifically with this in mind to tailor treatment strategies to these more favorable cancers. This potentially implies that a different TNM classification could even be considered in this disease and would be akin to the way a disease such as NPC is approached where its different etiology, also predominantly viral, and case profile set it aside from other head and neck cancer. Apart from their different etiology, other evidence for considering HPV-related oropharyngeal cancers uniquely includes the characteristic histological description of these tumors as poorly differentiated, often exhibiting minimal keratinization, basaloid features, and exhibiting clinical features that include noninvasive submucosal primary lesions, lymph nodes with palpable features that resemble those found in lymphoma patients, and that appear cystic on computerized tomography (CT) [45]. Recently, it has even been suggested that lymph node involvement carries dramatically less prognostic importance compared to traditional head and neck cancers emphasizing again that it is difficult to evaluate the influence of these important biomarkers unless the evaluation is undertaken within some framework that addresses the extent of disease. Indeed the evidence appears to be that, in this group of patients, a substantial percentage of whom have metastasis to cervical lymph nodes in less advanced primary tumors, the N status, is an unreliable prognostic indicator [46]. Again this is reminiscent of the NPC situation where different consideration to N-classification has been needed, although the direction of the effect was the opposite due to higher risk of distant metastases in NPC with advanced neck disease.

Additional complexity also exists in relation to racial differences in outcomes for oropharyngeal cancer and that is related to molecular basis of these tumors. Recent data suggests that the adverse outcome of black patients compared to white patients may be explained by the paucity of association with HPV expression in tumors among the black population [47]. The precise reason for the disparity in HPV expression remains unresolved but its absence appears strongly associated with significantly less favorable outcome of oropharyngeal cancer in blacks compared to patients where HPV is associated.

Finally, in considering the HPV situation, patients who have HPV-related oropharyngeal cancers but who are smokers appear to retain some of the adverse profile of more traditional head and neck cancer and do not fare as well as *never smoked* patients [36, 48]. Such “hybrid etiology” cancers appear to be complex, and in this situation the concept of a biomarker within the spectrum of regular and traditional oropharyngeal cancer may indeed apply. Complicated interplays exist, including additional adverse expression of EGFR

that appears to be expressed, possibly through increased hypoxia in the tumor tissues in smokers’ cancers [36]. In addition, in their modest cohort of 66 patients, Kumar et al. identified other unexplained variables including an adverse effect of female gender (although only 12 were female) and additional adverse biomarkers. The authors advised additional validation to understand the role of these findings in predicting and guiding therapies. This would also apply to how these findings could be incorporated with TNM staging. Again most of the patients had presented with relatively advanced regional node involvement or with fairly advanced T-category disease rendering it difficult to address the whole spectrum of the disease [36].

Serum Markers

Among mucosal head and neck cancers, NPC has additional uniqueness in possessing a robust circulating tumor marker that can be expected to be employed clinically. One of the uses is the correlation of circulating EBV DNA with disease staging using quantitative real-time polymerase chain reaction (PCR) technology [49]. By means of its production by NPC cells, EBV DNA level has been shown to be more powerful than existing staging system in predicting outcomes by providing an index of disease burden in the individual patient and has been investigated now by numerous authors [50]. In particular, Leung et al. showed that pretherapy circulating EBV DNA load is an independent prognostic factor for overall survival in NPC. Thus, patients with early stage disease can be segregated by EBV DNA levels into a poor-risk subgroup with survival similar to that of Stage III disease and a good-risk subgroup with survival similar to Stage I disease [51]. While this provides an attractive concept, it also faces challenges in whether it can be applied universally at this time, especially in regions where the disease is most prevalent and resources to make it universally available are not as plentiful as in the developed world. A possibility may be to use it presently as an additional tool within clinical trials to augment prognostic assessment and disease monitoring. Also importantly, while it is attractive to consider it as a molecular marker that provides characterization of disease for prognostication, it falls somewhat short of this. As is the case for prostate specific antigen in prostate cancer staging, or in the case of serum markers for testis cancer, both of which are incorporated in the TNM classification [1, 2], these blood assays are considered indicators of disease burden and, in reality, represent surrogates for disease bulk. The same probably applies in NPC since the influence of the circulating marker correlates with the full spectrum of disease extent and the disparity noted above from Leung et al. could be explained by imprecision in estimating the extent of disease in these complex tumors in the region of the skull base.

True biological serum markers that represent qualitative tumor characteristics are less common where expression is relevant to the oncogenic process (as opposed to the burden of disease) and is a complex area of research [30]. Some examples in the head and neck have proved unreliable, such as those available in thyroid cancer. Here the situation is aggravated by other dimensions of prognosis that need to be considered. Thus, in differentiated thyroid cancer, discrepancies between methods for the assessment of thyroglobulin may be problematic [52]. Also, more than 95% of papillary and follicular carcinomas are thyroglobulin positive, even those that are metastatic, and well-differentiated tumors generally express more thyroglobulin than poorly differentiated tumors [53]. This therefore means most patients with aggressive tumors and adverse prognosis may not necessarily manifest higher levels of thyroglobulin. On the other hand, in medullary thyroid cancer, biomarkers such as basal calcitonin; stimulated calcitonin, and carcinoembryonic antigen are powerful indicators of tumor activity. However, unlike EBV DNA levels in NPC, the levels of serum calcitonin may not necessarily reflect tumor burden (volume) accurately. Thus, in the view of the authors, they are not perfect [54]. Also, elevated but stable calcitonin levels seem not to portend unfavorable outcome after treatment and a more representative assessment may relate to calcitonin doubling times. These assessments are not available as baseline variables and while potentially prognostic in follow-up do not aid in addressing the needs of baseline assessment and staging [55]. Familial medullary carcinoma was one of the first tumor, where genetic predisposition to the development of cancer was confirmed, by the assessment of RET Protooncogene, in gene carriers. This powerful genetic marker accurately identifies gene carriers, and has facilitated the prevention of medullary carcinoma by early elective thyroidectomy during infancy and childhood.

Volume as a Predictor

Classification based on tumor volume instead of strict anatomic extent alone has been reported as a significant prognostic factor in the management of head and neck cancer. In turn, this has prompted investigators to suggest the incorporation of tumor volume into the TNM staging system. Indeed an extensive literature has now emerged that addresses this topic, but will not be discussed exhaustively. Much of this knowledge emanates from the treatment of NPC but has also been reported for other head and neck cancers [56, 57]. Nonetheless, if tumor volume is to be used as an independent prognostic factor, the methods for volume measurement need to be standardized [58]. Unfortunately, the technical challenges to implement this in the clinical setting routinely need to be resolved if it is to be used to classify patients

using a TNM system. Not only is the measurement of tumor volume a tedious process requiring the tumor to be outlined digitally on cross-sectional imaging, but also the results are prone to difficulties created by both intra- and interobserver discrepancy. To overcome this problem, several investigators have developed semiautomated systems to reduce inter-operator as well as intraoperator variability [58]. In order to overcome the technical and manpower considerations, alternative simpler methods have also been suggested including standard bidimensional measurements [59, 60]. While there seems to be no doubt that tumor volume provides a robust predictor of outcome in many head and neck cancers, including claims of superiority to TNM in the contemporary era of head and neck cancer treatment, problems with implementing this approach remain. Manpower issues and other problems have not yet been resolved, including the determination of agreed potential cutpoints that might be used to create a classification that meets the needs of the clinician and scientists. This is also particularly relevant in regions of the world where NPC is most prevalent. In the end it must also be acknowledged that while volume assessment could provide utility if it was introduced, it remains fundamentally a measure of the extent of disease. In addition, the tumor volume of a totally exophytic cauliflower-like cancer does not have the same prognostic implications, as a tumor of the same volume, which is nearly all endophytic. It has been a long-standing observation that exophytic tumors are quite radiosensitive, in contrast to endophytic tumors. Thus, tumor volume, such as assessment of serum markers, is not strictly divorced from the anatomic stage paradigm and does not address many of the problems discussed earlier and that seem to lie at the heart of many of the criticisms of TNM [33].

Evolution of Biology with Advancing Stage

Another complex problem involving interplay between anatomic disease extent and molecular characterization of disease concerns the potential that disease could evolve in its character as it progresses from early to more advanced stage. While undesirable for patients, and implying the need for more intensive treatment as disease evolves, investigators might readily embrace this concept. Thus, intensified treatment, while often used for anatomically more extensive tumors, could additionally be needed because the disease character has evolved to a more aggressive phenotype. In turn, this also could open the door to the potential for a true molecular-based "staging system." Unfortunately, while the proposal is attractive in concept, few useful examples are available in the head and neck region. Investigation into this important area will need robust translational science activities, grounded in the laboratory and the clinic, where

the anatomic stage classification and clinical parameters provide the framework for this evaluation. An example, in laryngeal cancer, is a study intended to address shortcomings in cancer prognostication and treatment due to a lack of methods to adequately address the complexity and diversity of disease. The authors of this study used multiparametric methods to identify specific patterns of disease progression. They investigated, on an exploratory basis, whether genome-wide alterations of loss and gain, using a panel of 122 gene probes (112 unique genes), discriminated between early stage (Stages I and II) and late stage (Stages III and IV) laryngeal squamous cell carcinomas. Significant differences between early vs. advanced stage were apparent for the following genes: ERBB4, CASP2, RECQL4, and BCL7A. Loss of ERBB4 ($P=0.045$) and BCL7A ($P=0.019$) significantly discriminated between early and advanced stages. Gain of RECQL4 copy number ($P=0.043$) was associated with advanced stage; gain of CASP2 ($P=0.043$) characterized early disease, but loss was associated with advanced stage. Problems with this approach include not only the isolated nature of this study, but also the multiple significance testing makes it important to validate the findings independently. The potential that the number of statistical assessments used could result in spuriously significant observations by chance alone appears to have also been recognized by the authors who identified their study as “exploratory” [61].

A related issue with a different application exists within the domain of head and neck cancer staging that embodies the concept of tumor evolution over time. In essence, this, as in the previous example, relies on the fact that carcinogenesis is a multistep process at both the phenotypic and genetic levels. A malignant neoplasm has several phenotypic attributes which commences with the benign and acquires genetic events that carry it through sequential steps that ultimately lead to excessive growth, local invasion, and the ability to form regional or distant metastases [62]. An application of this evolution with some practical clinical consequence relates to the potential to temporally model some of the key genetic events of a cancer and to identify whether different areas of cancer in the same patient could be related to each other or could have descended from each other. A very practical use for this is the potential to identify if pulmonary squamous cell carcinoma in a patient with head and neck squamous cell carcinoma might represent metastatic disease or a second primary. Depending on the approach taken for these two scenarios, it may have profound implications for a patient who may be denied potentially curative treatment when this might be possible if such a lesion is incorrectly declared metastasis. For some time, the ability has been available to achieve this diagnostic distinction using molecular tools for an important element of cancer staging, but as yet it seems not to have been translated actively to the clinic [63, 64].

The Importance of Host Factors

It has been well recognized that features of the host have significant prognostic impact in head and neck cancer. However, with the exception of differentiated thyroid cancer, where patient age is an important factor, the head and neck TNM classification does not take into account any host characteristics.

A consistent feature of the management of laryngeal cancer has been the demonstration that female gender is a powerful and independent favorable factor in addition to other more traditional factors. In a large retrospective series ($n=1,252$) from Aarhus University Hospital in Denmark, women had absolute improvements of approximately 10% compared to men for all cancer-specific outcomes including local control, loco-regional, disease-specific survival, and overall survival following curative radiotherapy [65]. Female gender seems to retain this favorable advantage in other sites as well, based on a very large recent series ($n=3,821$) from Germany [66]. For this reason, reports of adverse outcome in HPV-related oropharyngeal cancer in women compared to men is unexpected [36, 67]. While these represent small studies, they raise the possibility of host interactions with the biological process underlying the pathogenesis of head and neck cancer and the subsequent response to treatment. Earlier we have also noted the discrepancy in outcome between black vs. white patients with oropharyngeal squamous cell carcinoma and the fact that there is a dramatic difference in the association of cancers in these two groups with HPV oncogenesis, and the precise reasons underlying this remain speculative [47]. There is also evidence that the status of the host immune system may be relevant and may be an explanation for the unusually favorable outcome of HPV-related oropharyngeal cancer compared to traditional cancers in this location [68].

Another well-described host-related prognostic variable for outcome in head and neck cancer is comorbidity. Comorbidity is described as “the presence of one or more medical ailments, in addition to the primary tumor but not caused by the primary tumor” [69]. Risk factors for the development of head and neck squamous cell carcinoma, such as smoking and alcohol abuse, contribute to other diseases as well (e.g., cardiovascular, pulmonary, or hepatic diseases). Therefore, comorbidity is to be expected in these patient groups. This has been well established by early work from Picciliro [70] to more recent reporting of the influence of comorbidity for the first time in hypopharyngeal cancer [71]. Several established validated instruments designed to code and quantify comorbidity are available. These include, in historic order, the cumulative illness rating scale (CIRS) [72], the Kaplan Feinstein comorbidity index (KFI) [73], the Charlson comorbidity index (CCI) [74], and the index of coexistent disease (ICED) [75].

In a comparative study of these four instruments, the KFI was the most successful in stratifying patients with head and neck cancer [76] though the CIRS appeared to be uniquely robust in another report that addressed laryngeal cancer exclusively managed with surgery [77]. Whether this would apply to patients treated with organ preservation strategies is unclear and emphasizes the context-based nature of some of these analyses that are sometimes overlooked. Nevertheless, a very consistent finding throughout such literature of head and neck cancer is the observation that comorbidity, assessed in various ways, seems to have as significant effect as the stage in understanding the prognosis of patients with these cancers and needs to be considered in designing treatment approaches. These analyses may also provide a framework for amalgamation of the various elements of prognosis into usable prognostic models that may be applicable in a broader perspective. This is discussed below in the section on "Combining Variables and Validation."

The Importance of Environmental Factors

The relationship between outcome and the environment where the patient with head and neck cancer is treated can be profound and the reasons underpinning these can be complex. What sets these apart from other prognostic factors is that they exert influence external to the parameters of the host and tumor but their value relates to their ability to explain reasons for differential outcomes for treatments that might otherwise be expected to be similar. A classification is available and includes factors related to the physician, the health care system, and society [31]. Each can also be subdivided into treatment-related issues (e.g., expertise, access, and health care delivery processes), educational issues (e.g., participation in continuing education, development of practice guidelines, and access to information), or quality issues (e.g., quality of treatment, quality of the health care facility, and access to affordable health insurance). Interested readers should consult the original description for a more detailed discussion [31].

The problem of environment as a prognostic factor is well exemplified by the recent report of outcome in a large prospective randomized trial where the technical planning and radiotherapy parameters of almost 700 patients were evaluated by a team of expert head and neck radiation oncologists. This review was undertaken without knowledge of the outcome of the patient or of the arm of the trial on which the patient was treated. In patients who received at least 60 Gy, those with major deficiencies in their treatment plans had a markedly inferior outcome compared with those whose treatment was initially protocol compliant. The 2-year overall survival was 50% vs. 70% (hazard ratio 1.99; $P < 0.001$) and the 2 years freedom from loco-regional failure was 54% vs. 78% (hazard

ratio 2.37; $P < 0.001$) for deficient vs. compliant radiotherapy, respectively. A large variation in the percent of plans with major adverse impact was noted according to country. Even more striking was the correlation between the number of patients entered and the probability of receiving unsatisfactory radiotherapy. In centers enrolling fewer than five patients, 29.8% had a predicted major adverse impact compared with 5.4% in centers enrolling more than 20 patients [78].

Another recent interesting example relates to the availability of modern radiotherapy facilities in the form of access to intensity-modulated radiotherapy (IMRT). The use of IMRT has rapidly become widespread for the delivery of radiotherapy for patients with head and neck cancer in the USA. However, significant geographic variations are apparent in the utilization of IMRT, and patients in census tracts comprising the lowest socioeconomic quartile were less likely to receive IMRT than their more affluent counterparts [79].

Other recent reports also point out disappointing examples of environmental health care disparities associated with advanced head and neck presentations in the USA. These are much more likely to be evident in patients without adequate health care insurance, or individuals, especially blacks, residing in regions with low educational accomplishments or with low median household incomes. Similar findings were seen in patients with laryngeal cancer [80] and oropharyngeal cancer [81]. The authors indicate that it is important to consider the impact of insurance coverage on disease stage at diagnosis and associated morbidity, mortality, and quality of life.

Similar findings on stratified analysis and logistic regression were applied to two million incident cancers (1997–2000) from 32 states representing 57% of the US population. For a great many cancers, poverty as a factor independently predicts advanced stage cancer suggesting improved access and utilization of good medical care might facilitate earlier diagnosis and longer survival [82]. Consistent with these findings is the report of a large series ($n = 1,231$) of patients with primary squamous cell carcinoma of the oral cavity, pharynx, or larynx diagnosed or treated at the University of Pittsburgh by Kwok et al. [83] They report that patients with Medicaid/uninsured and Medicare disability were at increased risk of death after a diagnosis of SCCHN when compared with patients with private insurance, after adjustment for age, gender, race, smoking, alcohol use, site, socioeconomic status, treatment, and cancer stage. Similarly, Molina and colleagues studied 20,915 patients with head and neck cancer in the Florida Cancer Data System and showed that African American and poor patients have a dramatically worse prognosis although the disparity is not entirely explained by demographics, comorbidity, or undertreatment [84].

While numerous other factors are also associated with adverse outcome, space does not permit a more detailed discussion of this very important and often overlooked area.

Ironically, as implied by the examples shown above, these factors have the greatest potential for remediation with consequent improvement in outcome compared to other prognostic factors but this can only be accomplished if resource inadequacies and process deficiencies are addressed.

Combining Variables and Validation

The science of prognostic factor assessment is a nascent area that needs to be considered in a broader context. We have seen that the dimensions of prognosis in head and neck cancer cover a wide field, yet there remains uncertainty about how to proceed in our goals of using the extent of this knowledge to its full capability. It does appear that critical dismissal of one dimension as being less useful than another is probably not the solution, nor is it helpful to dismantle a system that is being used successfully worldwide, for over 40 years, to permit newer elements to be introduced if the framework was not designed to receive them. In general terms, some agreement on taxonomy and methodology is required. Perhaps the adoption of formal terms such as *Staging* to describe the anatomic extent of disease and *Profiling* to describe the qualitative characteristic of tumors may be a start. The use of the term *Prognostic models* could then permit them to be combined in a rational way that allows their full impact to be exploited. These concepts are under active discussion by the UICC and AJCC. Different aspects of these will be discussed below under different rubrics that address the traditional TNM groupings, the use of prognostic indexes, the use of nomograms, and the area of validation and comparison of prognostic models.

Handling Prognostic Groups Within TNM

In addressing the need to combine different prognostic elements into groups, the UICC and the AJCC have taken slightly different approaches in the seventh edition TNM classification. The AJCC has substituted the term “Anatomic Stage/Prognostic Groups” in place of what were previously termed “Stage Groups” when the elements of TNM are combined together within the TNM in the seventh edition [1]. However, the goal of the new terminology is the same as it was previously, i.e., to create a basic form of prognostic index. The UICC has approached this slightly differently in the seventh edition although the intent is identical to the AJCC, namely, to permit the incorporation of validated nonanatomical prognostic factors at present or in the future. The UICC’s approach is to use two forms of grouping of component elements [2]. The predominant one for this edition is termed “Stage Groups” and contains only anatomic factors

for virtually all sites within TNM and represents the same “Stage Groups” as were used in the former sixth edition. Certain diseases that traditionally used some nonanatomic factors, e.g., thyroid cancer where age has been incorporated, and sarcomas that included grade, are retained in the “Stage Groups” of the seventh edition to avoid disruption to a classification developed many years ago. However, the incorporation of newer nonanatomic factors is being addressed by the creation of a third dimension within the UICC’s version of TNM in the form of “Prognostic Groups.” In truth, these are identical to the AJCC’s “Anatomic Stage/Prognostic Groups” in the few diseases where this applies and for all other diseases the UICC “Stage Groups” are analogous. At present only two diseases have the new “Prognostic Groups” in the UICC version, namely, prostate and esophageal cancer, in both of which pathological grade was recently introduced in the classification. There are currently no head and neck sites included in this process. In time, it is possible that the UICC may also modify thyroid and sarcoma so that the anatomic and nonanatomic elements will only be aggregated together in the “Prognostic Groups,” and the “Stage Groups” will only contain anatomic extent of disease variables throughout TNM. In this way, anatomic disease extent can be addressed independently in “Stage Groups” or in combination with nonanatomic factors in the “Prognostic Groups,” the latter being analogous to the “Anatomic Stage/Prognostic Groups” of the AJCC.

A final and more sobering dimension in the area of “Prognostic Groups” or “Stage Groups” is the fact that these are generally developed in a pragmatic rather than pure scientific way. Hence, the literature contains numerous examples of the theme that the TNM stage group classifications, while successful in creating statistically distinct groups, often do not perform as well as other stage grouping systems [85]. Potentially, the future will require some attention to this area of research as well if the groups formulated within the classification are to be considered seriously. Detailed discussion of alternative staging systems is reported in the literature [86].

Prognostic Indexes

The head and neck literature contains a growing body of reports devoted to combining different elements of prognosis together. Generally, the intention is to focus on a particular setting (e.g., previously untreated patients, patients with recurrent cancer, patients with metastatic disease, early stage disease vs. more advanced disease, etc.). Usually, the intention is to facilitate decision-making in the management of patients, usually concerning some intervention that is typically treatment related. Behind most is the goal of generating

a quantified prognosis in the form of a score that may be of use to the patient, guiding clinical decisions, and may be useful for guiding eligibility for clinical trials tailored to specific treatments and patient types.

Some of the dimensions are appropriate to combine together, but some may be less so in the sense that they may contain elements that are not present at baseline time of diagnosis and treatment decision-making even though they may be characterized as such. A typical example is the inclusion of the status of resection margins in a model where this variable only becomes available after the first and often most important treatment has been administered (namely, surgery). Thus, it is not only unavailable at baseline, but it also automatically selects out cases with different prognosis based on their likelihood of undergoing a successful resection with clear margins. Cases with positive resection margins can be expected to be already having adverse prognosis from the stand-point of the anatomic extent of disease, but such classifications may still be highly useful in guiding decision-making for the use of adjuvant treatments once the primary treatment has been undertaken. This further illustrates the theme that disease extent must be considered in applying prognostic models, and one cannot necessarily extrapolate to another setting whether it concerns different stages of disease, different anatomic sites, or different scenarios (e.g., primary vs. recurrent cancer).

There is insufficient opportunity to explore the different models that have been developed in the head and neck arena but these include, among others, attention to parotid cancer [87, 88], metastatic nasopharyngeal cancer [89], laryngeal cancer [77], hypopharyngeal cancer [71], and various combinations of cancers of the larynx, oral cavity, and pharynx [69]. Some of these studies were mentioned earlier in the context of comorbidity in the section on "The Importance of Host Factors" where many have included comorbidity assessed in various ways combined with the TNM and other elements of anatomic disease extent and included other factors such as age, gender, and some pathological features. As yet there is no report that incorporates a robust model that combines molecular characterization of disease (or even host) with more traditional domains and this type of work is very inviting for the future. As noted some studies have combined different prognostic factors that include biological markers with more traditional parameters such as gender and smoking but they have not as yet been formulated into a prognostic index to guide decision-making for individual patients or even groups of patients [36, 48].

Nomograms

Nomograms are widely used for cancer prognosis, primarily because of their ability to reduce statistical predictive models

into a single numerical estimate of the probability of an event that is tailored to the profile of an individual patient. Often these use appealing graphical interfaces, commonly displayed by computer, that facilitate interaction with individual patients about their personal disease situation. While widely used in some areas of oncology, especially prostate cancer, there is very little published material concerning nomograms for head and neck cancer. Gross et al. developed a nomogram for guiding adjuvant treatment after surgery for oral cavity squamous cell carcinoma [90]. Notably, this was developed for relatively early stage resected oral cancer and this context must be remembered as it is easy to stray from the original basis of the nomogram when using it to discuss problems with patients. So far there is no evidence that this is happening in head and neck cancer but there may be such instances in other diseases.

The AJCC, in particular, is exploring the use of nomograms to address the potential goal of creating a "continuous prognostic nomogram" for each site and each patient, where the anatomic TNM staging will remain as the fundamental factor, but other important features, such as biomarkers as well as comorbidities, will be included with a weighted score to arrive at a "prognostic score," at any given point throughout the patient's life [10]. In this concept, the prognostic score will be a dynamic "staging and prognostic" tool to accurately reflect each patient's prognosis at the point of inquiry. The CS approach implemented by the AJCC will act as a repository of all available prognostic information for current and future use to support this approach. This ambitious project is potentially both welcome and problematic. Clearly, it is important to be able to encompass the multiple dimensions of prognosis in this way and the concept is certainly meritorious. On the other hand, a limitation is that it largely relates to individual prognosis at this time and additional development will be needed to address groups of patients since one of the goals of the stage classifications is to be able to compare results across groups, in trials, and among regions. Another challenge concerns the statistical underpinnings of these models that require careful scrutiny, including the degree of uncertainty surrounding the point estimates. This is thoroughly addressed in a recent review that includes cautionary language that the methodology underlying the construction of nomograms should be understood by clinical users so that prognostic estimates are appropriately communicated [91].

Validation and Comparison of Prognostic Models

An important aspect of the creation of prognostic indexes concerns the underlying statistical principles and the epidemiological basis for their creation. This area cannot be

addressed here but the reader should be aware of such principles as the generalizability of the index to patients outside the source population. It includes transportability of results beyond the domain where it was created such as transportability regarding geographic location, but also by time or era, which may be more difficult to address with different historical dimension to the data, its assembly, and its use. Other dimensions include clinical and statistical validation. The complex nature of these issues and the assumptions behind the models, including understanding their inherent weaknesses, require attention and are summarized more completely elsewhere [87, 88, 92, 93].

Other elements in understanding prognostic models, and especially when comparing models against each other, concern a variety of concepts in the evaluating process. These include hazard consistency (i.e., homogeneity within strata for the outcome of interest), hazard discrimination (i.e., each stratum chosen should have a statistically distinct prognosis compared to the stratum above and below it for the outcome), outcome prediction (i.e., maximizing prediction accuracy by techniques such as percent of variation in outcome explained by the scheme or by measuring the slope, or degree of separation in the mean probability predictions), and balance (where different prognostic strata or groups are relatively even and balanced). These are detailed elsewhere for the interested reader [86, 94].

References

- Edge SB, Byrd DR, Compton CC, Fritz AG, Greene FL, Trotti A. AJCC cancer staging manual. 7th ed. New York: Springer; 2010.
- Sobin LH, Gospodarowicz MK, Wittekind C. TNM classification of malignant tumors. 7th ed. New York: Wiley; 2010.
- Greene FL, Sobin LH. The TNM system: our language for cancer care. *J Surg Oncol*. 2002;80(3):119–20.
- Denoix PF. Tumor, node and metastasis (TNM). *Bull Inst Nat Hyg (Paris)*. 1944;1:1–69.
- International Union Against Cancer (UICC). TNM classification of malignant tumours. Geneva: G. de Buren; 1968.
- International Union Against Cancer (UICC). TNM classification of malignant tumours. 2nd ed. Geneva: Imprimerie G. de Buren; 1974.
- Mackillop WJ, O'Sullivan B, Gospodarowicz M. The role of cancer staging in evidence-based medicine. *Cancer Prev Control*. 1998;2(6):269–77.
- NCCN. National Comprehensive Cancer Network – Head and Neck. http://www.nccn.org/professionals/physician_gls/PDF/head-and-neck.pdf. Accessed June 2009.
- Ferlito A, Rinaldo A. The future of the TNM staging system in laryngeal cancer: time for a debate? *Eur Arch Otorhinolaryngol*. 2008;265(12):1441–3.
- Shah J. Concerning the editorial “The future of the TNM staging system in laryngeal cancer: time for a debate?” by Ferlito and Rinaldo. *Eur Arch Otorhinolaryngol*. 2009;266(1):155. author reply 157–158.
- Gospodarowicz MK, Miller D, Groome PA, Greene FL, Logan PA, Sobin LH. The process for continuous improvement of the TNM classification. *Cancer*. 2004;100(1):1–5.
- Wittekind C, Greene F, Hutter RVP, Sobin LH, Henson DE. TNM supplement: a commentary on uniform use. 3rd ed. New York: Wiley; 2003.
- Edge SB, Compton CC. The American Joint Committee on Cancer: the 7th edition of the AJCC cancer staging manual and the future of TNM. *Ann Surg Oncol*. 2010;17(6):1471–4.
- Shaw RJ, Lowe D, Woolgar JA, et al. Extracapsular spread in oral squamous cell carcinoma. *Head Neck*. 2010;32(6):714–22.
- Bernier J, Cooper JS, Pajak TF, et al. Defining risk levels in locally advanced head and neck cancers: a comparative analysis of concurrent postoperative radiation plus chemotherapy trials of the EORTC (#22931) and RTOG (#9501). *Head Neck*. 2005;27(10):843–50.
- Huang SH, Hwang D, Lockwood G, Goldstein DP, O'Sullivan B. Predictive value of tumor thickness for cervical lymph-node involvement in squamous cell carcinoma of the oral cavity: a meta-analysis of reported studies. *Cancer*. 2009;115(7):1489–97.
- Brierley JD, Greene FL, Sobin LH, Wittekind C. The “y” symbol: an important classification tool for neoadjuvant cancer treatment. *Cancer*. 2006;106(11):2526–7.
- Atula T, Hunter KD, Cooper LA, Shoaib T, Ross GL, Soutar DS. Micrometastases and isolated tumour cells in sentinel lymph nodes in oral and oropharyngeal squamous cell carcinoma. *Eur J Surg Oncol*. 2009;35(5):532–8.
- Greene FL, Page D, Norrow M, et al. AJCC cancer staging manual. 6th ed. New York: Springer; 2002.
- Sobin LH, Wittekind C. TNM classification of malignant tumors. 6th ed. New York: Wiley; 2002.
- Yousem DM, Gad K, Tufano RP. Resectability issues with head and neck cancer. *AJNR Am J Neuroradiol*. 2006;27(10):2024–36.
- Liao CT, Ng SH, Chang JT, et al. T4b oral cavity cancer below the mandibular notch is resectable with a favorable outcome. *Oral Oncol*. 2007;43(6):570–9.
- Nishioka T, Shirato H, Kagei K, et al. Skull-base invasion of nasopharyngeal carcinoma: magnetic resonance imaging findings and therapeutic implications. *Int J Radiat Oncol Biol Phys*. 2000;47(2):395–400.
- Lee AW, Au JS, Teo PM, et al. Staging of nasopharyngeal carcinoma: suggestions for improving the current UICC/AJCC Staging System. *Clin Oncol (R Coll Radiol)*. 2004;16(4):269–76.
- Liu MZ, Tang LL, Zong JF, et al. Evaluation of sixth edition of AJCC staging system for nasopharyngeal carcinoma and proposed improvement. *Int J Radiat Oncol Biol Phys*. 2008;70(4):1115–23.
- Tang L, Li L, Mao Y, et al. Retropharyngeal lymph node metastasis in nasopharyngeal carcinoma detected by magnetic resonance imaging: prognostic value and staging categories. *Cancer*. 2008;113(2):347–54.
- Tham IW, Hee SW, Yap SP, Tuan JK, Wee J. Retropharyngeal nodal metastasis related to higher rate of distant metastasis in patients with N0 and N1 nasopharyngeal cancer. *Head Neck*. 2009;31(4):468–74.
- Ch'ng S, Maitra A, Allison RS, et al. Parotid and cervical nodal status predict prognosis for patients with head and neck metastatic cutaneous squamous cell carcinoma. *J Surg Oncol*. 2008;98(2):101–5.
- Teppo H, Kervinen J, Koivunen P, Alho OP. Incidence and outcome of head and neck mucosal melanoma – a population-based survey from Northern Finland. *Int J Circumpolar Health*. 2006;65(5):443–7.
- Ludwig JA, Weinstein JN. Biomarkers in cancer staging, prognosis and treatment selection. *Nat Rev Cancer*. 2005;5(11):845–56.
- Gospodarowicz MK, O'Sullivan B, Koh E-S. Prognostic factors: principles and application. In: Gospodarowicz MK, O'Sullivan B, Sobin LH, editors. *Prognostic factors in cancer*. 3rd ed. New York: Wiley; 2006. p. 23–38.
- Bourhis J. Oral cavity, pharynx, and larynx cancer. In: Gospodarowicz MK, O'Sullivan B, Sobin LH, editors. *Prognostic factors in cancer*. 3rd ed. New York: Wiley; 2006. p. 99–104.
- Hodul PJ, Yeatman TJ. TNM staging is obsolete. *J Surg Oncol*. 2007;95(1):8–9.
- Giri U, Ashorn CL, Ramdas L, et al. Molecular signatures associated with clinical outcome in patients with high-risk head-and-neck

- squamous cell carcinoma treated by surgery and radiation. *Int J Radiat Oncol Biol Phys.* 2006;64(3):670–7.
35. Kong CS, Narasimhan B, Cao H, et al. The relationship between human papillomavirus status and other molecular prognostic markers in head and neck squamous cell carcinomas. *Int J Radiat Oncol Biol Phys.* 2009;74(2):553–61.
 36. Kumar B, Cordell KG, Lee JS, et al. EGFR, p16, HPV Titer, Bcl-xL and p53, sex, and smoking as indicators of response to therapy and survival in oropharyngeal cancer. *J Clin Oncol.* 2008;26(19):3128–37.
 37. Takes RP, Rinaldo A, Rodrigo JP, Devaney KO, Fagan JJ, Ferlito A. Can biomarkers play a role in the decision about treatment of the clinically negative neck in patients with head and neck cancer? *Head Neck.* 2008;30(4):525–38.
 38. Ang KK, Berkey BA, Tu X, et al. Impact of epidermal growth factor receptor expression on survival and pattern of relapse in patients with advanced head and neck carcinoma. *Cancer Res.* 2002;62(24):7350–6.
 39. Bonner JA, Harari PM, Giralt J, et al. Radiotherapy plus cetuximab for locoregionally advanced head and neck cancer: 5-year survival data from a phase 3 randomised trial, and relation between cetuximab-induced rash and survival. *Lancet Oncol.* 2010;11(1):21–8.
 40. Kim S, Grandis JR, Rinaldo A, Takes RP, Ferlito A. Emerging perspectives in epidermal growth factor receptor targeting in head and neck cancer. *Head Neck.* 2008;30(5):667–74.
 41. Egloff AM, Grandis JR. Improving response rates to EGFR-targeted therapies for head and neck squamous cell carcinoma: candidate predictive biomarkers and combination treatment with Src inhibitors. *J Oncol.* 2009;2009:896407.
 42. Mehanna H, Jones TM, Gregoire V, Ang KK. Oropharyngeal carcinoma related to human papillomavirus. *BMJ.* 2010;340:879–80.
 43. Hammarstedt L, Lindquist D, Dahlstrand H, et al. Human papillomavirus as a risk factor for the increase in incidence of tonsillar cancer. *Int J Cancer.* 2006;119(11):2620–3.
 44. Klussmann JP, Mooren JJ, Lehnen M, et al. Genetic signatures of HPV-related and unrelated oropharyngeal carcinoma and their prognostic implications. *Clin Cancer Res.* 2009;15(5):1779–86.
 45. Goldenberg D, Begum S, Westra WH, et al. Cystic lymph node metastasis in patients with head and neck cancer: an HPV-associated phenomenon. *Head Neck.* 2008;30(7):898–903.
 46. Straetmans JM, Olthof N, Mooren JJ, de Jong J, Speel EJ, Kremer B. Human papillomavirus reduces the prognostic value of nodal involvement in tonsillar squamous cell carcinomas. *Laryngoscope.* 2009;119(10):1951–7.
 47. Settle K, Posner MR, Schumaker LM, et al. Racial survival disparity in head and neck cancer results from low prevalence of human papillomavirus infection in black oropharyngeal cancer patients. *Cancer Prev Res (Phila Pa).* 2009;2(9):776–81.
 48. Maxwell JH, Kumar B, Feng FY, et al. Tobacco use in human papillomavirus-positive advanced oropharynx cancer patients related to increased risk of distant metastases and tumor recurrence. *Clin Cancer Res.* 2010;16(4):1226–35.
 49. Lo YM. Prognostic implication of pretreatment plasma/serum concentration of Epstein-Barr virus DNA in nasopharyngeal carcinoma. *Biomed Pharmacother.* 2001;55(7):362–5.
 50. Chan KC, Lo YM. Circulating EBV DNA as a tumor marker for nasopharyngeal carcinoma. *Semin Cancer Biol.* 2002;12(6):489–96.
 51. Leung SF, Zee B, Ma BB, et al. Plasma Epstein-Barr viral deoxyribonucleic acid quantitation complements tumor-node-metastasis staging prognostication in nasopharyngeal carcinoma. *J Clin Oncol.* 2006;24(34):5414–8.
 52. Schlumberger M, Hitzel A, Toubert ME, et al. Comparison of seven serum thyroglobulin assays in the follow-up of papillary and follicular thyroid cancer patients. *J Clin Endocrinol Metab.* 2007;92(7):2487–95.
 53. McLeod DS. Current concepts and future directions in differentiated thyroid cancer. *Clin Biochem Rev.* 2010;31(1):9–19.
 54. Machens A, Dralle H. Biomarker-based risk stratification for previously untreated medullary thyroid cancer. *J Clin Endocrinol Metab.* 2010;95(6):2655–63.
 55. Boostrom SY, Grant CS, Thompson GB, et al. Need for a revised staging consensus in medullary thyroid carcinoma. *Arch Surg.* 2009;144(7):663–9.
 56. Chong VF. Tumour volume measurement in head and neck cancer. *Cancer Imaging.* 2007;7 Spec No A:S47–49.
 57. Studer G, Lutolf UM, El-Bassiouni M, Rousson V, Glanzmann C. Volumetric staging (VS) is superior to TNM and AJCC staging in predicting outcome of head and neck cancer treated with IMRT. *Acta Oncol.* 2007;46(3):386–94.
 58. Chong VF, Ong CK. Nasopharyngeal carcinoma. *Eur J Radiol.* 2008;66(3):437–47.
 59. King AD, Zee B, Yuen EH, et al. Nasopharyngeal cancers: which method should be used to measure these irregularly shaped tumors on cross-sectional imaging? *Int J Radiat Oncol Biol Phys.* 2007;69(1):148–54.
 60. Lee CC, Ho HC, Su YC, et al. Bidimensional measurement of nasopharyngeal carcinoma: a simple method to predict outcomes. *Clin Otolaryngol.* 2009;34(1):26–33.
 61. Saglam O, Shah V, Worsham MJ. Molecular differentiation of early and late stage laryngeal squamous cell carcinoma: an exploratory analysis. *Diagn Mol Pathol.* 2007;16(4):218–21.
 62. Jones S, Chen WD, Parmigiani G, et al. Comparative lesion sequencing provides insights into tumor evolution. *Proc Natl Acad Sci USA.* 2008;105(11):4283–8.
 63. Geurts TW, Nederlof PM, van den Brekel MW, et al. Pulmonary squamous cell carcinoma following head and neck squamous cell carcinoma: metastasis or second primary? *Clin Cancer Res.* 2005;11(18):6608–14.
 64. Leong PP, Rezai B, Koch WM, et al. Distinguishing second primary tumors from lung metastases in patients with head and neck squamous cell carcinoma. *J Natl Cancer Inst.* 1998;90(13):972–7.
 65. Johansen LV, Grau C, Overgaard J. Laryngeal carcinoma – multivariate analysis of prognostic factors in 1252 consecutive patients treated with primary radiotherapy. *Acta Oncol.* 2003;42(7):771–8.
 66. Guntinas-Lichius O, Wendt T, Buentzel J, et al. Head and neck cancer in Germany: a site-specific analysis of survival of the Thuringian cancer registration database. *J Cancer Res Clin Oncol.* 2009.
 67. Hannisdal K, Schjolberg A, De Angelis PM, Boysen M, Clausen OP. Human papillomavirus (HPV)-positive tonsillar carcinomas are frequent and have a favourable prognosis in males in Norway. *Acta Otolaryngol.* 2010;130(2):293–9.
 68. Dahlstrand H, Dahlgren L, Lindquist D, Munck-Wikland E, Daliansis T. Presence of human papillomavirus in tonsillar cancer is a favourable prognostic factor for clinical outcome. *Anticancer Res.* 2004;24(3b):1829–35.
 69. Datema FR, Ferrier MB, van der Schroeff MP, Baatenburg de Jong RJ. Impact of comorbidity on short-term mortality and overall survival of head and neck cancer patients. *Head Neck.* 2010;32(6):728–36.
 70. Piccirillo JF, Feinstein AR. Clinical symptoms and comorbidity: significance for the prognostic classification of cancer. *Cancer.* 1996;77(5):834–42.
 71. Homma A, Sakashita T, Oridate N, et al. Importance of comorbidity in hypopharyngeal cancer. *Head Neck.* 2010;32(2):148–53.
 72. Linn BS, Linn MW, Gurel L. Cumulative illness rating scale. *J Am Geriatr Soc.* 1968;16(5):622–6.
 73. Kaplan MH, Feinstein AR. The importance of classifying initial co-morbidity in evaluation the outcome of diabetes mellitus. *J Chronic Dis.* 1974;27(7–8):387–404.
 74. Charlson ME, Pompei P, Ales KL, MacKenzie CR. A new method of classifying prognostic comorbidity in longitudinal studies: development and validation. *J Chronic Dis.* 1987;40(5):373–83.
 75. Cleary PD, Greenfield S, Mulley AG, et al. Variations in length of stay and outcomes for six medical and surgical conditions in Massachusetts and California. *JAMA.* 1991;266(1):73–9.

76. Hall SF, Rochon PA, Streiner DL, Paszat LF, Groome PA, Rohland SL. Measuring comorbidity in patients with head and neck cancer. *Laryngoscope*. 2002;112(11):1988–96.
77. Castro MA, Deditis RA, Ribeiro KC. Comorbidity measurement in patients with laryngeal squamous cell carcinoma. *ORL J Otorhinolaryngol Relat Spec*. 2007;69(3):146–52.
78. Peters LJ, O’Sullivan B, Giralt J, et al. Critical impact of radiotherapy protocol compliance and quality in the treatment of advanced head and neck cancer: results from TROG 02.02. *J Clin Oncol*. 2010;28(18):2996–3001.
79. Guadagnolo BA, Liu C-C, Cormier JN, Du XL. Evaluation of trends in the use of intensity-modulated radiotherapy for head and neck cancer from 2000 through 2005: socioeconomic disparity and geographic variation in a large population-based cohort. *Cancer*. 2010;116(14):3505–12.
80. Chen AY, Schrag NM, Halpern M, Stewart A, Ward EM. Health insurance and stage at diagnosis of laryngeal cancer: does insurance type predict stage at diagnosis? *Arch Otolaryngol Head Neck Surg*. 2007;133(8):784–90.
81. Chen AY, Schrag NM, Halpern MT, Ward EM. The impact of health insurance status on stage at diagnosis of oropharyngeal cancer. *Cancer*. 2007;110(2):395–402.
82. Greenlee RT, Howe HL. County-level poverty and distant stage cancer in the United States. *Cancer Causes Control*. 2009;20(6):989–1000.
83. Kwok J, Langevin SM, Argiris A, Grandis JR, Gooding WE, Taioli E. The impact of health insurance status on the survival of patients with head and neck cancer. *Cancer*. 2009;116(2):476–85.
84. Molina MA, Cheung MC, Perez EA, et al. African American and poor patients have a dramatically worse prognosis for head and neck cancer: an examination of 20,915 patients. *Cancer*. 2008;113(10):2797–806.
85. Hall SF, Groome PA, Irish J, O’Sullivan B. TNM-based stage groupings in head and neck cancer: application in cancer of the hypopharynx. *Head Neck*. 2009;31(1):1–8.
86. Patel SG, Lydiatt WM. Staging of head and neck cancers: is it time to change the balance between the ideal and the practical? *J Surg Oncol*. 2008;97(8):653–7.
87. Poorten VV, Hart A, Vauterin T, et al. Prognostic index for patients with parotid carcinoma: international external validation in a Belgian-German database. *Cancer*. 2009;115(3):540–50.
88. Vander Poorten VL, Hart AA, van der Laan BF, et al. Prognostic index for patients with parotid carcinoma: external validation using the nationwide 1985–1994 Dutch Head and Neck Oncology Cooperative Group database. *Cancer*. 2003;97(6):1453–63.
89. Toh CK, Heng D, Ong YK, Leong SS, Wee J, Tan EH. Validation of a new prognostic index score for disseminated nasopharyngeal carcinoma. *Br J Cancer*. 2005;92(8):1382–7.
90. Gross ND, Patel SG, Carvalho AL, et al. Nomogram for deciding adjuvant treatment after surgery for oral cavity squamous cell carcinoma. *Head Neck*. 2008;30(10):1352–60.
91. Iasonos A, Schrag D, Raj GV, Panageas KS. How to build and interpret a nomogram for cancer prognosis. *J Clin Oncol*. 2008;26(8):1364–70.
92. Harrell Jr FE, Lee KL, Mark DB. Multivariable prognostic models: issues in developing models, evaluating assumptions and adequacy, and measuring and reducing errors. *Stat Med*. 1996;15(4):361–87.
93. Justice AC, Covinsky KE, Berlin JA. Assessing the generalizability of prognostic information. *Ann Intern Med*. 1999;130(6):515–24.
94. Groome PA, Schulze KM, Mackillop WJ, et al. A comparison of published head and neck stage groupings in carcinomas of the tonsillar region. *Cancer*. 2001;92(6):1484–94.

Chapter 9

Biomarkers in Head and Neck Cancer

John Wrangle, Shanthi Marur, and Arlene A. Forastiere

Abstract Biomarker research provides the opportunity to risk stratify patients based on identified prognostic and predictive markers. The need for such biomarkers is evident to improve response and survival outcomes in head and neck cancer through more rational patient selection for intensive curative regimens as well as palliative treatments. Increasing numbers of molecularly targeted therapeutics are in preclinical and clinical evaluation in head and neck cancer. These compounds, added to current chemotherapy and radiotherapy regimens, are costly and potentially add to normal tissue toxicity. This chapter focuses on markers with potential for testing in large validation clinical trials. As yet, no one marker has validated predictive capacity of utility in the selection of therapy for individuals with head and neck cancer. HPV-16 appears to be prognostic for better outcome while high EGFR expression is prognostic for poor outcome. Validated diagnostic tests that are widely available and collaboration among investigators are additional future challenges in biomarker research for head and neck cancer.

Keywords Molecular biomarkers • Head and neck cancer • Therapeutic targets • Predictive and prognostic markers

Introduction

The management of patients with head and neck cancer has changed dramatically over the past 30 years from a surgically dominated specialty to a multidisciplinary decision-making approach. Nearly all patients presenting with locally advanced cancers now receive chemotherapy combined with radiotherapy as a part of their treatment, often as a strategy to preserve organ function or as an adjuvant following surgery. Advances have also occurred in radiation technology for treatment

planning and dose delivery to improve local control and reduce the volume of normal tissue treated and risk of late effects. The entrance of molecularly targeted therapeutics into the clinical arena offers an exciting opportunity to improve upon the outcomes achievable with standard cytotoxic regimens and radiotherapy. However, these therapies have high cost and may add to the existing toxicity risk profile of chemoradiation.

The current system of histopathologic and radiographic assessments of tumor stage and surgical margins has limited ability to stratify patients for specific risk of metastasis, local–regional recurrence or the development of a second primary. The identification of molecular predictive markers is a logical and rational next step to achieve more than a marginal improvement in outcome within the coming decade. This would allow tailoring of treatment based on risk – treatment associated with high morbidity would ideally be recommended for patients at the highest risk of dying from their cancer, thus limiting exposure. High cost novel biologic therapies would be utilized based on individual biomarker tumor characteristics. The underpinnings already exist for biomarker-driven research as great strides have been made in the understanding of carcinogenesis in head and neck cancer. Progression from early carcinogenesis, including premalignant lesions to invasive squamous cell carcinoma is known to be a multistep process of genetic alterations and has been studied extensively in tobacco-related head and neck squamous cell cancers (HNSCC) [1]. Alterations in cyclin D1, p53, and p16 tumor suppressor genes are early events of carcinogenesis. Alterations in signaling pathways, growth factors, angiogenesis, cell adhesion, and cell death characterize later events of carcinogenesis leading to invasion and metastasis.

Biomarker research is a critical next step in discovery. The ideal biomarker would have three characteristics. First, it would have the ability to accurately diagnose cancer and recurrence in asymptomatic populations. Second, the biomarker would be prognostic, that is, to have the ability to predict the risk of recurrence or survival or be predictive of response to a specific therapy. Third, the biomarker would also serve as a therapeutic target. Research has focused on molecular markers of cell-cycle control (cyclin D-1, Rb gene product, p16, p21, p27),

A.A. Forastiere (✉)
Oncology Department, Johns Hopkins University,
School of Medicine, Bunting/Blaustein Cancer Research Building,
1650 Orleans Street, Room G90, Baltimore, MD 21231, USA
e-mail: af@jhmi.edu

Table 9.1 Predictive markers

Predictive marker	Predicts	Study (year)	N	Lab method	OR (p-value)	HR for progression (CI)	HR for death (CI)	Response to CT (p-value)	Response to CT-RT (p-value)	PFS (p-value)	OS (p-value)	DFS (p-value)
EGFR	Cetuximab sensitivity	Burtness (2005) [8]	117	IHC	0.05	–	–	–	–	–	–	–
EGFR	Cetuximab sensitivity	Vermorken (2008) [9]	442	IHC	–	0.47 (0.37–0.61)	0.75 (0.59–0.95)	–	–	–	–	–
EGFR	Response to therapy	Kumar (2008) [44]	70	IHC	–	–	–	0.01	0.055	–	–	–
p16	Response to therapy	Kumar (2008) [44]	70	IHC	–	–	–	0.008	0.009	–	–	–
p53	Response to therapy	Temam (2000) [67]	99	IHC	–	–	–	0.002	–	–	–	–
p53	Larynx preservation	Kumar (2008) [44]	70	IHC	–	–	–	0.03	–	–	–	–
Bcl-xL	Larynx preservation	Kumar (2008) [44]	70	IHC	–	–	–	0.02	–	–	–	–
Bcl-xL	Complete response	Trask (2002) [60]	47	IHC	–	–	–	0.143	–	–	–	–
Bcl-xL	Larynx preservation	Trask (2002) [60]	47	IHC	–	–	–	0.06	–	–	–	–
Bcl-2	Local control	Wilson (1996) [59]	93	IHC	–	–	–	>0.0016	–	–	–	–
ERCC-1	Cisplatin sensitivity	Jun (2008) [75]	45	IHC	–	–	–	–	–	0.036	–	–
ERCC-1	Cisplatin sensitivity	Handra-Luca (2007) [70]	96	IHC	0.01	–	–	–	–	–	–	–
HPV	Response to initial chemotherapy	Worden (2006) [76]	42	PCR	–	–	–	0.001	–	–	–	–
HPV	Response to chemoradiotherapy	Worden (2006) [76]	42	PCR	–	–	–	0.005	–	–	–	–
RASSF1A/2A methylation	Response to radiation	Huang (2009) [73]	482	MSP	0.009	–	–	–	–	–	–	–
TIMP3 methylation	Response to radiation	De Schutter (2009) [77]	59	MSP	–	–	–	–	–	–	0.005	0.12
CDH1 methylation	Response to radiation	De Schutter (2009) [77]	43	MSP	–	–	–	–	–	–	0.002	0.007

Table 9.2 Prognostic markers

Study (year)	Prognostic marker	N	Lab method	DFS	OS	PFS	LP	HR for survival (CI)
Kumar (2008) [44]	↓HPV titer	–	–	–	0.008	–	–	–
Kumar (2008) [61]	↓p53/↑Bcl-xL	–	–	–	0.005	–	–	–
Akervall (1997) [51]	11q13 rearrangement	75	Cytogenetics	–	0.005	–	–	–
Marsit (2008) [54]	CCND1	444	Sequence detection	–	–	–	–	0.6 (0.4–1.0)
Akervall (1997) [51]	Cyclin D1	75	IHC	–	0.047	–	–	–
Marsit (2008) [54]	Cyclin D1	109	IHC	–	–	–	–	3.6 (1.0–13.0)
Michalides (1997) [53]	Cyclin D1	115	IHC	–	0.05	–	–	–
Namazie (2002) [55]	Cyclin D1	103	FISH	–	0.003	–	–	–
Ang (2002) [78]	amplification/p16 deletion	–	–	–	–	–	–	–
Ang (2002) [78]	EGFR	155	IHC	0.0016	0.0006	–	–	–
Chung (2006) [14]	EGFR	86	FISH	–	<0.01	<0.05	–	–
Kumar (2008) [44]	EGFR	–	–	–	0.001	–	–	–
Rubin Grandis (1998) [79]	EGFR	91	IHC	0.0001	0.0001	–	–	–
Temam (2007) [13]	EGFR	134	RT-PCR	0.0001	0.0001	–	–	–
Xia (1999) [80]	EGFR/HER-2/HER-3	47	IHC	–	<0.05	–	–	–
Xia (1999) [80]	HER-2	47	IHC	–	<0.001	–	–	–
Kumar (2008) [44]	p16	50	IHC	–	0.001	–	–	–
Kumar (2008) [44]	p53	50	IHC	–	–	–	0.03	–
Poeta (2007) [66]	p53	420	DNA microarray	–	–	–	–	1.7 (1.2–2.4)
Rubin Grandis (1998) [79]	TGFα	91	IHC	0.0001	0.0001	–	–	–
Pena (1999) [58]	Bcl-2	42	IHC	<0.05	–	–	–	–
Wilson (1996) [59]	Bcl-2	93	IHC	–	0.012	–	–	–
Kumar (2008) [44]	HPV	50	PCR	–	0.03	–	–	–
Gillison (2000) [33]	HPV	253	PCR	–	–	–	–	0.41 (0.20–0.88)
Licitra (2006) [81]	HPV	90	PCR	–	0.0018	–	–	–
Worden (2008) [76]	HPV	42	PCR	–	0.007	–	–	–
Marsit (2008) [74]	CDH-1 methylation	340	MSP	–	<0.02	–	–	–

apoptosis (p53, Bcl-x1, Bcl-2), growth regulation (HER family – EGFR and downstream pathways, Cox-2, Ki-67), and measures of hypoxia (CA9, HIF-1 α). Potentially useful molecular markers in head and neck cancer also include detection of viral DNA – the human papillomavirus (HPV), predominantly in oropharynx cancer and Epstein-Barr virus (EBV) associated with nasopharyngeal carcinoma. This chapter focuses on biomarkers specific to HNSCC, where there is a body of literature indicating clinical utility or high potential for clinical utility as prognostic or predictive markers (Tables 9.1 and 9.2).

Epidermal Growth Factor Receptor

The Epidermal Growth Factor Receptor (EGFR) is a transmembrane glycoprotein and a member of the ErbB family of receptors. This receptor is composed of an extracellular ligand-binding domain, a transmembrane region and an intracellular domain that includes the tyrosine kinase enzyme. Endogenous ligands, particularly transforming growth factor- α (TGF α), stimulate the external receptor to undergo conformational change and dimerization [2]. Dimerization results in activation of intracellular tyrosine kinase, protein phosphorylation and stimulation of various cell signaling pathways that mediate cell cycle progression, angiogenesis, inhibition of apoptosis, tumor invasion, and metastasis (Fig. 9.1).

EGFR is a prognostic marker for disease-free and overall survival of HNSCC. The majority of HNSCC (~90%) over-express EGFR relative to normal tissue; EGFR expression

level is associated with poor prognosis and decreased overall survival [3, 4]. Overexpression of EGFR's primary ligand, TGF α is associated with poor response to anti-EGFR therapy and overall poor prognosis [4, 5].

The most commonly used method of EGFR protein detection is immunohistochemistry (IHC), which is a practical diagnostic tool that can be performed in most laboratories. However, the limitations of IHC include inter- and intra-variability in scoring by pathologists and lack of standardization of IHC assays. A more informative method uses automated quantitative analysis (AQUA) of immunofluorescence. EGFR expression can be scored on membrane, cytosolic, and nuclear components. Using the AQUA immunofluorescence technique, investigators showed that both tumor EGFR and nuclear EGFR staining were independent prognostic factors [6].

EGFR is also a molecular target for therapeutic intervention in HNSCC as well as colorectal cancer, and nonsmall cell lung cancer. Two classes of drugs target the EGFR, antibodies bind to the extracellular ligand binding domain while small molecule tyrosine kinase inhibitors (TKI) bind to the intracellular tyrosine kinase domain. Cetuximab, a chimeric monoclonal IgG1 antibody directed against EGFR, is FDA-approved in combination with radiotherapy for locally advanced HNSCC [7]. Cetuximab, when combined with cisplatin, demonstrated modest activity in previously treated recurrent or metastatic head and neck cancer [8] and survival benefit when used as first line therapy in combination with platinum-based chemotherapy in metastatic or recurrent head and neck cancer [9]. As single agents, antibodies directed against EGFR, and small molecule TKI of EGFR have

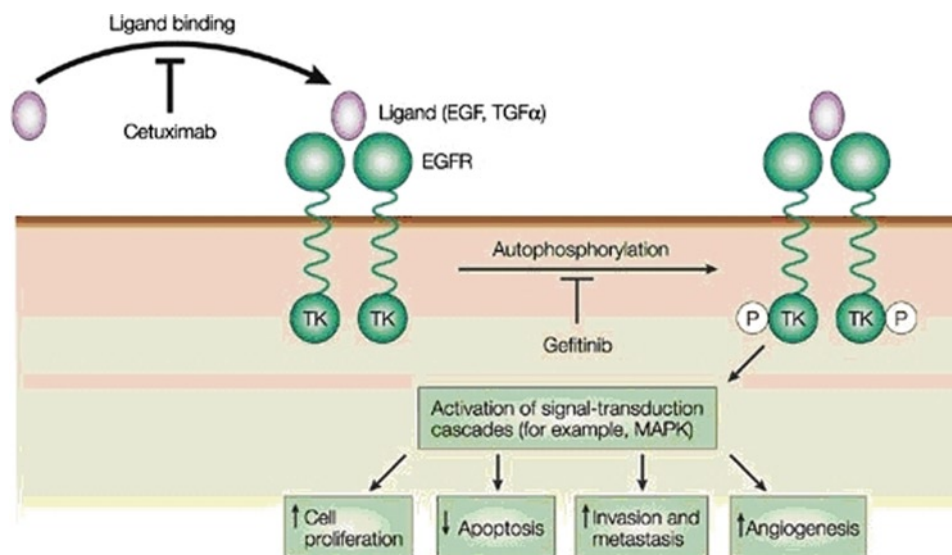


Fig. 9.1 EGFR and the mode of action of cetuximab. Binding of a ligand to EGFR causes receptor dimerization, either with another EGFR monomer or with another member of the erbB family, leading to tyrosine kinase activation. The resultant receptor autophosphorylation initiates signal-transduction cascades involved in cell proliferation and

survival. Cetuximab blocks binding of ligands to EGFR, inhibiting receptor phosphorylation and downstream events. Modified from Kirkpatrick P, Graham J, Muhsin M. Cetuximab. Nature Reviews Drug Discovery 2004;549–550. Adapted by permission from Macmillian Publishers Ltd. © 2004

modest activity as measured by standard clinical response criteria (partial response rate 4–10%) [10, 11]. EGFR overexpression has not been shown to correlate with the efficacy of EGFR-targeted therapy in HNSCC and therefore does not serve as a predictive biomarker [11, 12].

The mechanisms that believed responsible for the low response to EGFR inhibition provide insight into potential prognostic and predictive biomarkers and therapeutic targets. These include signaling pathways that are independent of EGFR, such as EGFR nuclear localization and direct transactivation of genes, ERK and AKT activation by the insulin growth factor receptor-1 (IGFR-1), Src/STAT-mediated transactivation of EGFR; gene mutations causing dysregulated cell cycle check points, such as EGFR variant III (EGFR vIII) mutation in the extracellular domain, and EGFR mutation of the kinase domain.

EGFR gene amplification is under evaluation as a prognostic factor in HNSCC. The EGFR gene is amplified in 10–58% of HNSCC and is measured by fluorescence in situ hybridization (FISH) and quantitative PCR. In two independent studies, EGFR gene amplification was associated with worse progression-free and overall survival [13, 14]. EGFR gene amplification is positively associated with response to EGFR-directed antibody therapies in nonsmall cell lung cancer and colon cancer [15] but as yet, there are no published

reports correlating gene amplification with response outcome to EGFR-targeted therapies in HNSCC.

Similarly, EGFR polymorphisms (on EGFR intron 1) in the extracellular domain have been found in nonsmall cell lung cancer and colon cancer [16, 17] and are associated with significantly improved PFS and OS in colon cancer [18]. This is another potential prognostic biomarker of interest in HNSCC. The most common mutation of the extracellular ligand binding domain is the inframe deletion of exons 2–7, known as EGFR variant III and is reported in about 42% of HNSCC. This mutation is detected by RT-PCR [19]. In preclinical studies, the EGFR vIII mutation was associated with poor response to anti-EGFR agents, but this is not yet a proven predictive marker in the clinical setting in HNSCC.

Upregulated EGFR-dependent pathways drive tumor proliferation and survival. Two main pathways are the RAS/RAF/MAP kinase signaling pathway for proliferation and the PI3K/AKT signaling pathway for cell survival. Activation of these pathways independent of EGFR is known to be a major cause of resistance to anti-EGFR agents. Three pathways that have been the focus of investigations as potential therapeutic targets, prognostic and predictive biomarkers are the PI3K-AKT/mTOR pathway, Src/STAT pathway, and IGFR pathway (Fig. 9.2) [20]. The protein products of these signaling intermediates can be measured to determine gene

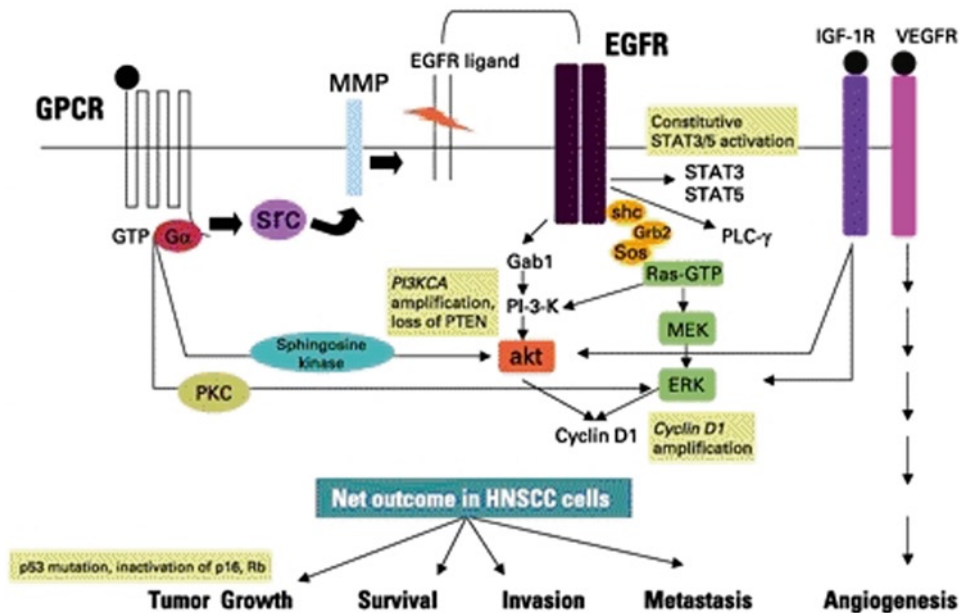


Fig. 9.2 Possible resistance to epidermal growth factor receptor (EGFR) inhibition in head and neck squamous cell carcinoma (HNSCC) as a result of EGFR-independent activation of oncogenes. In addition to oncogenic pathways activated by EGFR, EGFR-independent oncogenesis in HNSCC may result from activation of G protein-coupled receptors (GPCRs), other growth factor receptors, genetic aberrations, such as mutation and amplification of oncogenes, loss of tumor suppressor genes, and vascular endothelial growth factor

(VEGF) overexpression promoting angiogenesis. *MMP* matrix metallo-proteinase, *IGF-1R* insulin-like growth factor-1receptor, *VEGFR* VEGF receptor, *PKC* protein kinase, *STAT* signal transducer and activator of transcription, *Rb* retinoblastoma. From Kalyankrishna S, Grandis JR. Epidermal Growth Factor Receptor Biology in Head and Neck Cancer. *Journal of Clinical Oncology* 24:2666–2672, 2006. Reprinted with permission © 2006 American Society of Clinical Oncology. All rights reserved

activation or repression in response to anti-EGFR therapies and provide a rationale for the use of multitargeted biologic therapies.

PI3 Kinase/AKT Pathway and mTOR

Signaling through the PI3K/AKT pathway leads to activation of the mammalian target of rapamycin (mTOR). mTOR is represented by two structurally and functionally distinct multiprotein signaling complexes, mTORC1 (mTOR complex 1, rapamycin sensitive) and mTORC2 [21]. mTORC1 is mainly activated via the PI3 kinase pathway through AKT. mTORC2 is activated through a currently unknown mechanism, possibly by receptor tyrosine kinase (RTK) signaling. It has been suggested that mTORC2 phosphorylates and activates a different pool of AKT that is not upstream of mTORC1. mTORC2 is rapamycin insensitive. PI3K is inhibited by PTEN, and acts as a tumor suppressor by regulating the AKT pathway [22]. The PI3K/AKT/mTOR pathway is dysregulated by loss/mutation of the PTEN through PI3K mutation/amplification; through AKT/PKB overexpression/overactivation; mutation of PIK3CA is associated with reduced response rate following anti-EGFR therapeutics in metastatic colon cancer. These mutations are noted in a very small population approximately 8% in HNSCC [23]. Loss of PTEN expression either by hypermethylation or loss of heterozygosity (LOH) of PTEN occurs in 12% of HNSCC and could contribute to resistance seen with anti-EGFR agents [24]. Hence, mutation of PIK3CA and loss of PTEN and markers of PIK3/AKT pathway are biomarkers with predictive potential.

IGFR/AKT Pathway

The type I insulin-like growth factor receptor (IGF-IR) is a member of a family of transmembrane tyrosine kinases and is activated by two high affinity binding ligands, insulin-like growth factor I (IGF-I) and insulin-like growth factor II (IGF-II) [25]. Unlike many cell surface receptors, the IGF-IR exists as a preformed dimer; it requires domain rearrangements rather than receptor oligomerization for cell signaling. Upon ligand binding, the IGF-IR undergoes a conformational change, thereby activating its tyrosine kinase activity. The principal pathways for transduction of the IGF signal are the mitogen-activated protein kinase (MAPK) and phosphatidylinositol 3-kinase (PI3K)/AKT pathways [26].

There appears to be crosstalk between EGFR and IGF-1R and resistance to anti-EGFR agents is secondary to persistent IGF-1R mediated PIK3/AKT activation [27, 28]. Preclinical studies of IGF-1R TKI OSI868, alone and in combination

with an EGFR TKI (erlotinib), showed low response in cell lines with higher levels of pIGF-1R or EGFR expression exposed to single one inhibitor and significantly enhanced anti-proliferative effect to the combined EGFR TKI and IGF-1R TK [29]. Based on these observations, clinical trials combining biologic therapeutics to target both EGFR and IGF1R are in progress.

Src/STAT Pathway

The Src-STAT pathway is activated in response to EGFR activation [30]. Activated Src-kinases release RTK ligands that activate the Raf-ERK/MAPK pathway and represent another mechanism to circumvent EGFR inhibition. These pathways as with EGFR, influence cell adhesion, migration, angiogenesis, differentiation, proliferation, and cell apoptosis. Dysregulation and overexpression of Src leads to tumorigenesis, tumor progression, and metastasis. Increased phospho-Src (p-Src), and decreased E-cadherin in HNSCC was associated with more invasive aggressive tumors, poor differentiation, and more frequent lymph node metastases [31]. Dasatinib, a dual Src/Abl kinase inhibitor has shown inhibition of migration and invasion in HNSCC cell lines [32]. Clinical trials combining Src-targeted agents and EGFR-targeted agents for the treatment of metastatic HNSCC and combined with radiotherapy for an initial curative treatment are in progress. Correlative studies evaluating receptor activation status, downregulation by the targeted therapeutic and correlation with outcome variables provides insight into the potential utility of Src as a prognostic and predictive biomarker.

HPV

HPV is commonly associated with anogenital cancers and more recently has been associated with a subset of HNSCC [33]. There are over 100 types of HPV virus, but only about 15 are considered to have oncogenic potential. The HPV type that is most frequently associated with HNSCC is t HPV-16; it is also associated with cervical and vulvar cancers in women; anal and penile cancers in men and women [34]. Over the past decade, the incidence of oropharynx cancers has shown an upward trend in young men in the USA and Europe in the absence of exposure to two major risk factors, tobacco and alcohol [35]. HPV-16 is now recognized to be a prognostic factor for survival outcome. HPV-related cancers appear to show increased sensitivity to radiotherapy and chemotherapy, but HPV-16 has not been validated as a predictor of response to specific therapies.

HPV is a sexually transmitted virus. The major risk factors appear to be an increased number of lifetime oral sex and vaginal sex partners and possibly marijuana use. HPV-associated HNSCC has a distinct risk factor profile, clinical presentation, biology, and tumor morphology [36, 37]. The incidence of HPV-associated head and neck cancer varies geographically, worldwide. The highest rates are observed in Sweden with approximately 90% of oropharynx cancers associated with HPV, approximately 60% in the USA, 30–40% in Western Europe and very low, unchanging rates in Southeast Asia.

Patients with HPV positive head and neck cancer commonly present with large cystic neck nodes and a small primary (T1) in the tonsil or base of the tongue. Histologically, these cancers are usually nonkeratinized, poorly differentiated squamous cancers with basaloid features [38, 39].

HPV-16 detected by FISH or p16 detected by IHC have been shown in retrospective and prospective studies to be prognostic for a favorable outcome relative to patients with HPV negative oropharynx cancer. When treated with chemotherapy and radiation therapy, these HPV positive patients appear to be more responsive to these treatments translating to a significantly better overall survival and progression free survival outcome [40].

The biology of HPV-associated HNSCC is distinct from the tobacco-associated HNSCC and could explain the favorable outcomes observed with HPV-associated HNSCC [41]. The HPV virus integrates its DNA into the host cell nucleus, encodes for E6 and E7 genes and dysregulates the production of E6 and E7 oncoproteins. The E6 oncoprotein promotes

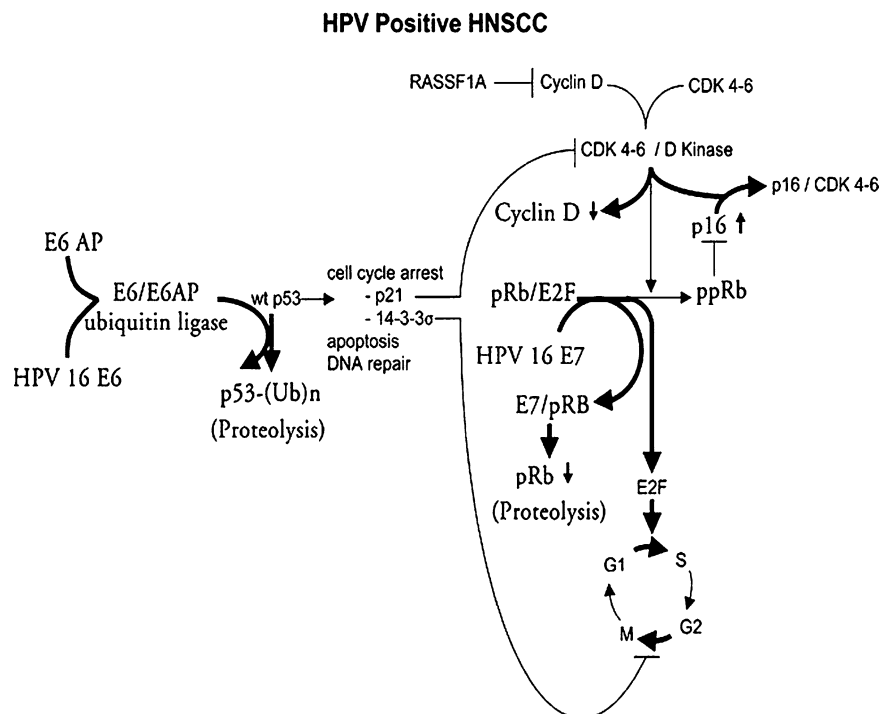
ubiquitination and degradation of p53 promoting cell survival. The E7 oncoprotein binds and inactivates the retinoblastoma tumor suppressor gene leading to upregulation of p16 and low expression of cyclin D1 cell cycle disruption, proliferation, and malignant transformation (Fig. 9.3).

The method preferred for HPV detection is FISH, instead of PCR which requires a sophisticated technology and fresh frozen tissue [42]. The prognostic impact of HPV-associated head and neck cancer has defined a distinct subset of oropharynx cancer and future clinical trials are stratified for this factor or there are separate trials designed for HPV positive and HPV negative oropharynx cancers.

Retrospective studies have explored the association between HPV status, p16, tobacco exposure and survival [43]. The survival outcomes for HPV-16 positive and p16 positive patients were similar. The pattern of failure revealed significantly lower rates of locoregional failure, in HPV positive HNSCC patients compared to HPV negative patients and no difference in the distant metastases between the two groups. When survival was assessed after adjusting for tobacco exposure the HPV positive <20 pack year smokers had a significantly better 2 year overall survival (95%) compared to HPV negative ≥ 20 pack year smokers (63%) suggesting that tobacco exposure altered the biology of HPV positive tumors.

Other investigators have reported a positive correlation between the combination of low EGFR expression, high p16 expression and improved survival outcome in contrast to patients who had high EGFR expression and low HPV titer or high EGFR and low p16 expression [44].

Fig. 9.3 HPV infection and cell cycle dysregulation. HPV DNA integrates into the host genome and produces oncoproteins E6 and E7. E6 inhibits wild-type p53 function through ubiquitination, releasing cell-cycle arrest. E7 upregulates p16 and downregulates Cyclin D1 via inactivation of retinoblastoma tumor suppressor to promote proliferation and malignant transformation. From Gillison M. Human papillomavirus-associated head and neck cancer is a distinct epidemiologic, clinical, and molecular entity. *Sem Oncol* 2004;31(6):11. Reprinted with kind permission from Elsevier



NF- κ B

The transcription factor Nuclear Factor- κ B (NF- κ B) is a protein complex that acts on promoter sites involved in many cellular processes, including survival and apoptosis, inflammation, migration, cell proliferation, and angiogenesis. It is present ubiquitously in human cells and serves as a point of convergence for several signaling pathways. As a rapid acting transcription factor, NF- κ B is normally converted from its inactive form to an active transcription factor in response to a cellular insult. The inactive state of NF- κ B is maintained by Inhibitor of Kappa Beta (κ B) and requires the activity of a proteasome for activation. In HNSCC, tobacco is a major risk factor, and there is evidence suggesting that cigarette smoke condensate activates NF- κ B via direct phosphorylation and subsequent degradation of κ B.

The list of inciting stimuli which lead to activation and subsequent homo- and heterodimerization of NF- κ B and its homologs are diverse and include bacterial lipopolysaccharide, viruses, and fungi as well as cytotoxic agents, DNA damage, and radiation. The activation of NF- κ B results in activation of receptors and signaling proteins, including IL-1/interleukin-1 receptor 1 (IL-1R1) and TGF α /EGFR in HNSCC [45]. Alterations in the PI3-K/Akt pathway, such as mutations of PI3-K or loss of PTEN, cause persistent activation of NF- κ B and ongoing oncogenesis. Hypoxia and ionizing radiation induce NF- κ B activity [46, 47]. Inhibition of activation by combining targeted therapy such as proteasome inhibitors and inhibitors of upstream targets that may contribute to aberrant NF- κ B activation or coactivated pathways may have therapeutic potential for HNSCC. In HNSCC cells, treatment with bortezomib down modulates expression of NF- κ B-regulated genes cyclin D1, Bcl-XL and IAP-1, inhibits cellular proliferation and angiogenesis, and promotes apoptosis [48, 49]. Biomarkers of NF- κ B activation, biomarkers of inhibition of NF- κ B, and inflammatory markers are under investigation in clinical trials that combine proteasome inhibitors with other targeted therapeutics, chemotherapy, and radiation therapy. In squamous cell cancer of the larynx, NF- κ B status as determined by IHC positively correlated with nodal status and T stage, and low expression was associated with poor outcomes [50]. The ultimate utility of NF- κ B may be in its predictive capacities. It may be useful not only for selecting therapies specifically targeting increased NF- κ B activation, but also predicting response to cytotoxic agents and radiation.

Cyclin D1

Studies of Cyclin D1 show that this regulator of cell cycle transition from G1 to S phase may have prognostic implications in HNSCC. Polymorphisms in CCND1, the gene

encoding Cyclin D1, have been associated with many aspects of the natural history of the disease, from the risk of developing HNSCC, grade of the tumor, risk for recurrence in operable disease, and overall survival [51–54]. Cyclin D1 acts after pairing with cyclin-dependant kinases 4 and 6 (CDK4, CDK6). This interaction may be further perturbed by inactivation of p16, an inhibitor of CDK4 and 6. Inactivation or deletion of p16 has been associated with poor prognosis and, conversely, relatively high levels of p16 are associated with greater response to therapy [44, 54, 55]. The activation of cyclin D and related complexes is important for cells to enter into S phase and for the G₁–S transition of the cell cycle. The Cyclin D Kinase (CDKN2A) locus, located on chromosome 9p21, encodes two functionally distinct tumor suppressor genes, p14ARF and p16INK4a, which play an active role in the p53 and Rb tumor suppressor pathways. Any alteration of p16 disrupts the expression of cyclin D1 causing abnormal proliferation of the cells.

In tobacco-related HNSCC, p16 loss is well documented and cyclin D1 is overexpressed and/or amplified and has been correlated with more advanced, aggressive disease, lymph node metastasis, and reduced survival [55, 56]. By contrast, patients with HPV-associated HNSCC, characterized by overexpression of p16 and low levels of cyclin D1, exhibit high response rates to chemotherapy and chemoradiation, and apparent longer progression-free and overall survival [57].

Bcl-2

Bcl-2 and Bcl-xL are members of the Bcl-2 family of 25 genes. Bcl-2 was the first gene described as having a role in apoptosis, or programmed cell death. Originally studied in B-cell lymphomas, hence its name, the Bcl-2 gene is placed next to the immunoglobulin heavy chain locus in a characteristic chromosomal translocation, [14, 18]. The juxtaposition results in dramatic overexpression of the Bcl-2 gene product resulting in dysregulation of the normal pro- and anti-apoptotic balance. Bcl-2 overexpression is noted in a variety of tumors, where this translocation does not occur and there are likely multiple other mechanisms involved. The way in which Bcl-2, Bcl-xL, and other members of this family exert their influence over apoptosis is not clear, though they may act by regulating the release of apoptotic factor by forming ion channels in the outer membrane of mitochondria. Programmed cell death occurs in response to a variety of insults, such as starvation, irreparable DNA damage, or viral infection and is intended to lead to an orderly elimination of a damaged cell in a way not hazardous to the organism it belongs to. A variety of soluble factors influence whether cells undergo apoptosis, some promoting and others inhibiting it. Bcl-2 and Bcl-xL are both considered

anti-apoptotic agents, and about 70% of all HNSCC upregulate one of the two [58]. Paradoxically, Bcl-2 overexpression has been associated with improved outcomes in a HNSCC tumor's response to therapy, local control, time to progression, and survival underscoring the lack of certainty [58–60]. Reduced expression of Bcl-xL was associated with better outcomes in larynx preservation [60, 61]. Like many other cellular pathways with no directed drug target, the bcl-2 family of genes has predictive value for therapies not known to act on them specifically.

p53 and DNA Damage Repair

Discovered in 1979 and characterized as a tumor suppressor in 1983, p53 is a highly studied, critical element of cell cycle regulation and is mutated in over half of all human malignancies [62]. The normal role of p53 is to respond to an enormous variety of stress signals, classically hypoxia and DNA damage [62, 63]. Bound to MDM2 p53 is inactive, but cleavage in response to these various stress signals may be induced, as well as decreased degradation. As a result, the quantity of p53 cell increases. Transcription of TP53, the gene encoding p53, is upregulated in response to stress signals from the MAPK family of protein kinases and many other kinases involved specifically in checkpoint integrity. Once activated, p53 initiates cell cycle arrest at the G1/S transition to allow for DNA repair [62, 63]. If DNA repair occurs, the cell is allowed to reenter the cell cycle. If this pause in cell division fails to restore the integrity of the DNA, cell death ensues.

Mutations of TP53 occur at high frequency in human cancer in general, and HNSCC in particular. Estimates of the prevalence of this mutation in HNSCC range from about 40% to 80%, and if the prevalence of aberrant p53 expression is estimated when including the nonmutational, downregulating effects of HPV E6 protein, the estimate approaches 100% [64]. Note, though, that p53 aberrations, whether by mutation or variation in expression level, may not be prognostically equivalent. Complicating this further, all mutations may not be equivalent, where certain nucleotide substitutions in certain exons of TP53 lead to a spectrum of inactivation from no effect on activity to total functional inactivation. For instance, a patient with a proline for arginine substitution at codon 72 of exon 4 may do worse than those with wild-type TP53 [65]. Mutational status in aggregate, however, has been studied both as a prognostic and predictive marker, and tumors with mutated p53 appear less likely to respond to neoadjuvant chemotherapy and associate with decreased overall survival [66, 67].

More recently, Perrone et al. looked retrospectively at banked tumor samples and showed that 40% of patients with wild-type p53 or mutations which left partial function had

complete response to chemotherapy with cisplatin/fluorouracil (no taxanes used) versus 10% in those with nonfunctional mutants [68]. The bewildering variety of potential prognostic and predictive significance of even a single gene is highlighted by p53 and highlights the need for well-designed validation studies and likelihood of complex interpretation of an individual's data, especially when paired with the many other markers that are obtained in tandem.

The role of p53 is that of cell cycle regulator, and as such is responsible for initiating important DNA damage repair mechanisms. An enzyme essential to repairing cross-linked DNA adducts created by alkylating agents, such as cisplatin is the excision repair cross-complementation group 1 (ERCC1). Having become the subject of intense interest since studies showed that its overexpression is associated with lack of response to cisplatin-containing regimens in nonsmall cell lung cancer, it has since been shown to be a potential marker for response to therapy and overall survival in HNSCC [69, 70].

Methylation

Epigenetic modifications are increasingly understood and of increasing prognostic and predictive relevance. Normally functioning DNA methyltransferases silence genes by methylating promoter regions. Thought to be an early step in carcinogenesis, abnormal methylation activity results in inactivation of tumor suppressor genes contributing to carcinogenesis, metastasis, invasiveness, and deregulation of the cell cycle. Methylation status has prognostic and therapeutic potential. The concept of demethylating therapy started in myelodysplastic syndrome and is being adapted to solid tumors trials.

Many tumors have well-characterized, high incidence of hypermethylation at specific promoter regions. Hypermethylation in HNSCCs has been demonstrated at many genes, including those of p16, E-cadherin, MGMT, DAPK1, RAR beta, and cyclin A1 among many [71, 72]. The Ras/P13K/AKT pathway is thought to be a major factor in radiation sensitivity, and hypermethylation of RASSF1A and RASSF2A in a study of 482 samples was correlated with response to radiation [73]. Methylation of the CDH-1 promoter may have prognostic significance having been observed to correlate with overall survival [74].

Conclusion

Current research and patient care are influenced by rapidly advancing knowledge of the molecular biology of head and neck cancer, and the complexity of interconnecting pathways

from cell surface receptors to transcriptional activation of genes mediating uncontrolled cellular proliferation and survival. Molecular target identification and an array of new therapeutics present challenges to the standard methodologies for clinical trial design, evaluation of efficacy and toxicity. Risk stratification based on molecular prognostic and predictive markers is next on the horizon for advancing the field. This chapter has focused on markers with potential for testing in large validation clinical trials. As yet, no one marker has validated predictive capacity of utility in the selection of therapy for individuals with head and neck cancer. HPV-16 appears to be prognostic for better outcome while high EGFR expression is prognostic for poor outcome. Validated diagnostic tests that are widely available and collaboration among investigators are additional future challenges in biomarker research for head and neck cancer.

References

- Haddad RI, Shin DM. Recent advances in head and neck cancer. *N Engl J Med*. 2008;359:1143–54.
- Harris RC, Chung E, Coffey RJ. EGF receptor ligands. *Exp Cell Res*. 2003;284:2–13.
- Dassonville O, Formento JL, Francoual M, et al. Expression of epidermal growth factor receptor and survival in upper aerodigestive tract cancer. *J Clin Oncol*. 1993;11:1873–8.
- Grandis JR, Melhem MF, Barnes EL, et al. Quantitative immunohistochemical analysis of transforming growth factor- α and epidermal growth factor receptor in patients with squamous cell carcinoma of the head and neck. *Cancer*. 1996;78:1284–92.
- Grandis JR, Twardy DJ. TGF- α and EGFR in head and neck cancer. *J Cell Biochem Suppl*. 1993;17F:188–91.
- Psyri A, Yu Z, Weinberger PM, et al. Quantitative determination of nuclear and cytoplasmic epidermal growth factor receptor expression in oropharyngeal squamous cell cancer by using automated quantitative analysis. *Clin Cancer Res*. 2005;11:5856–62.
- Bonner JA, Harari PM, Giralt J, et al. Radiotherapy plus cetuximab for squamous-cell carcinoma of the head and neck. *N Engl J Med*. 2006;354:567–78.
- Burtneß B, Goldwasser MA, Flood W, et al. Phase III randomized trial of cisplatin plus placebo compared with cisplatin plus cetuximab in metastatic/recurrent head and neck cancer: an Eastern Cooperative Oncology Group study. *J Clin Oncol*. 2005;23:8646–54.
- Vermorken JB, Mesia R, Rivera F, et al. Platinum-based chemotherapy plus cetuximab in head and neck cancer. *N Engl J Med*. 2008;359:1116–27.
- Soulieres D, Senzer NN, Vokes EE, et al. Multicenter phase II study of erlotinib, an oral epidermal growth factor receptor tyrosine kinase inhibitor, in patients with recurrent or metastatic squamous cell cancer of the head and neck. *J Clin Oncol*. 2004;22:77–85.
- Cohen EE, Rosen F, Stadler WM, et al. Phase II trial of ZD1839 in recurrent or metastatic squamous cell carcinoma of the head and neck. *J Clin Oncol*. 2003;21:1980–7.
- Agulnik M, da Cunha Santos G, Hedley D, et al. Predictive and pharmacodynamic biomarker studies in tumor and skin tissue samples of patients with recurrent or metastatic squamous cell carcinoma of the head and neck treated with erlotinib. *J Clin Oncol*. 2007;25:2184–90.
- Temam S, Kawaguchi H, El-Naggar AK, et al. Epidermal growth factor receptor copy number alterations correlate with poor clinical outcome in patients with head and neck squamous cancer. *J Clin Oncol*. 2007;25:2164–70.
- Chung CH, Ely K, McGavran L, et al. Increased epidermal growth factor receptor gene copy number is associated with poor prognosis in head and neck squamous cell carcinomas. *J Clin Oncol*. 2006;24:4170–6.
- Hirsch FR, Herbst RS, Olsen C, et al. Increased EGFR gene copy number detected by fluorescent in situ hybridization predicts outcome in non-small-cell lung cancer patients treated with cetuximab and chemotherapy. *J Clin Oncol*. 2008;26:3351–7.
- Nie Q, Wang Z, Zhang GC, et al. The epidermal growth factor receptor intron1 (CA) n microsatellite polymorphism is a potential predictor of treatment outcome in patients with advanced lung cancer treated with Gefitinib. *Eur J Pharmacol*. 2007;570:175–81.
- Tiseo M, Capelletti M, De Palma G, et al. Epidermal growth factor receptor intron-1 polymorphism predicts gefitinib outcome in advanced non-small cell lung cancer. *J Thorac Oncol*. 2008;3:1104–11.
- Graziano F, Ruzzo A, Loupakis F, et al. Pharmacogenetic profiling for cetuximab plus irinotecan therapy in patients with refractory advanced colorectal cancer. *J Clin Oncol*. 2008;26:1427–34.
- Sok JC, Coppelli FM, Thomas SM, et al. Mutant epidermal growth factor receptor (EGFRvIII) contributes to head and neck cancer growth and resistance to EGFR targeting. *Clin Cancer Res*. 2006;12:5064–73.
- Kalyankrishna S, Grandis JR. Epidermal growth factor receptor biology in head and neck cancer. *J Clin Oncol*. 2006;24:2666–72.
- Bjornsti MA, Houghton PJ. The TOR pathway: a target for cancer therapy. *Nat Rev Cancer*. 2004;4:335–48.
- Wullschlegel S, Loewith R, Hall MN. TOR signaling in growth and metabolism. *Cell*. 2006;124:471–84.
- Murugan AK, Hong NT, Fukui Y, et al. Oncogenic mutations of the PIK3CA gene in head and neck squamous cell carcinomas. *Int J Oncol*. 2008;32:101–11.
- Shin KH, Kim JM, Rho KS, et al. Inactivation of the PTEN gene by mutation, exonic deletion, and loss of transcript in human oral squamous cell carcinomas. *Int J Oncol*. 2002;21:997–1001.
- Adams TE, Epa VC, Garrett TP, et al. Structure and function of the type 1 insulin-like growth factor receptor. *Cell Mol Life Sci*. 2000;57:1050–93.
- Moschos SJ, Mantzoros CS. The role of the IGF system in cancer: from basic to clinical studies and clinical applications. *Oncology*. 2002;63:317–32.
- Pollak MN, Schernhammer ES, Hankinson SE. Insulin-like growth factors and neoplasia. *Nat Rev Cancer*. 2004;4:505–18.
- Chakravarti A, Loeffler JS, Dyson NJ. Insulin-like growth factor receptor I mediates resistance to anti-epidermal growth factor receptor therapy in primary human glioblastoma cells through continued activation of phosphoinositide 3-kinase signaling. *Cancer Res*. 2002;62:200–7.
- Morgillo F, Woo JK, Kim ES, et al. Heterodimerization of insulin-like growth factor receptor/epidermal growth factor receptor and induction of survivin expression counteract the antitumor action of erlotinib. *Cancer Res*. 2006;66:10100–11.
- Koppikar P, Choi SH, Egloff AM, et al. Combined inhibition of c-Src and epidermal growth factor receptor abrogates growth and invasion of head and neck squamous cell carcinoma. *Clin Cancer Res*. 2008;14:4284–91.
- Mandal M, Myers JN, Lippman SM, et al. Epithelial to mesenchymal transition in head and neck squamous carcinoma: association of Src activation with E-cadherin down-regulation, vimentin expression, and aggressive tumor features. *Cancer*. 2008;112:2088–100.
- Johnson FM, Saigal B, Talpaz M, et al. Dasatinib (BMS-354825) tyrosine kinase inhibitor suppresses invasion and induces cell cycle arrest and apoptosis of head and neck squamous cell carcinoma and non-small cell lung cancer cells. *Clin Cancer Res*. 2005;11:6924–32.

33. Gillison ML, Koch WM, Capone RB, et al. Evidence for a causal association between human papillomavirus and a subset of head and neck cancers. *J Natl Cancer Inst.* 2000;92:709–20.
34. Bosch FX, Manos MM, Munoz N, et al. Prevalence of human papillomavirus in cervical cancer: a worldwide perspective. International biological study on cervical cancer (IBSCC) Study Group. *J Natl Cancer Inst.* 1995;87:796–802.
35. D'Souza G, Kreimer AR, Viscidi R, et al. Case-control study of human papillomavirus and oropharyngeal cancer. *N Engl J Med.* 2007;356:1944–56.
36. Gillison ML, D'Souza G, Westra W, et al. Distinct risk factor profiles for human papillomavirus type 16-positive and human papillomavirus type 16-negative head and neck cancers. *J Natl Cancer Inst.* 2008;100:407–20.
37. Weinberger PM, Yu Z, Haffty BG, et al. Molecular classification identifies a subset of human papillomavirus-associated oropharyngeal cancers with favorable prognosis. *J Clin Oncol.* 2006;24:736–47.
38. Wilczynski SP, Lin BT, Xie Y, et al. Detection of human papillomavirus DNA and oncoprotein overexpression are associated with distinct morphological patterns of tonsillar squamous cell carcinoma. *Am J Pathol.* 1998;152:145–56.
39. Goldenberg D, Begum S, Westra WH, et al. Cystic lymph node metastasis in patients with head and neck cancer: an HPV-associated phenomenon. *Head Neck.* 2008;30:898–903.
40. Fakhry C, Westra WH, Li S, et al. Improved survival of patients with human papillomavirus-positive head and neck squamous cell carcinoma in a prospective clinical trial. *J Natl Cancer Inst.* 2008;100:261–9.
41. Wiest T, Schwarz E, Enders C, et al. Involvement of intact HPV16 E6/E7 gene expression in head and neck cancers with unaltered p53 status and perturbed pRb cell cycle control. *Oncogene.* 2002;21:1510–7.
42. Begum S, Cao D, Gillison M, et al. Tissue distribution of human papillomavirus 16 DNA integration in patients with tonsillar carcinoma. *Clin Cancer Res.* 2005;11:5694–9.
43. Gillison ML, Harris J, Westra W, et al. Survival outcomes by tumor human papillomavirus (HPV) status in stage III–IV oropharyngeal cancer in RTOG 0129. *Proc Am Soc Clin Oncol.* 2009;27.
44. Kumar B, Cordell KG, Lee JS, et al. EGFR, p16, HPV Titer, Bcl-xL and p53, sex, and smoking as indicators of response to therapy and survival in oropharyngeal cancer. *J Clin Oncol.* 2008;26:3128–37.
45. Allen CT, Ricker JL, Chen Z, et al. Role of activated nuclear factor-kappaB in the pathogenesis and therapy of squamous cell carcinoma of the head and neck. *Head Neck.* 2007;29:959–71.
46. Cummins EP, Taylor CT. Hypoxia-responsive transcription factors. *Pflugers Arch.* 2005;450:363–71.
47. Gupta AK, McKenna WG, Weber CN, et al. Local recurrence in head and neck cancer: relationship to radiation resistance and signal transduction. *Clin Cancer Res.* 2002;8:885–92.
48. Sunwoo JB, Chen Z, Dong G, et al. Novel proteasome inhibitor PS-341 inhibits activation of nuclear factor-kappa B, cell survival, tumor growth, and angiogenesis in squamous cell carcinoma. *Clin Cancer Res.* 2001;7:1419–28.
49. Chang AA, Chen Z, Ricker JL, et al. Induction of cell apoptosis and regulation of inhibitor of apoptosis protein-1 (IAP-1) and Cyclin D gene expression in head and neck cancer cell lines by PS-341/Bortezomib (VELCADE), a novel proteasome inhibitor. *Proc Amer Assoc Cancer Res.* 2004;45.
50. Huang C, Huang K, Wang C, et al. Overexpression of mitogen-activated protein kinase kinase 4 and nuclear factor-kappaB in laryngeal squamous cell carcinoma: a potential indicator for poor prognosis. *Oncol Rep.* 2009;22:89–95.
51. Akervall JA, Michalides RJ, Mineta H, et al. Amplification of cyclin D1 in squamous cell carcinoma of the head and neck and the prognostic value of chromosomal abnormalities and cyclin D1 overexpression. *Cancer.* 1997;79:380–9.
52. Holley SL, Matthias C, Jahnke V, et al. Association of cyclin D1 polymorphism with increased susceptibility to oral squamous cell carcinoma. *Oral Oncol.* 2005;41:156–60.
53. Michalides RJ, van Veelen NM, Kristel PM, et al. Overexpression of cyclin D1 indicates a poor prognosis in squamous cell carcinoma of the head and neck. *Arch Otolaryngol Head Neck Surg.* 1997;123:497–502.
54. Marsit CJ, Black CC, Posner MR, et al. A genotype-phenotype examination of cyclin D1 on risk and outcome of squamous cell carcinoma of the head and neck. *Clin Cancer Res.* 2008;14:2371–7.
55. Namazie A, Alavi S, Olopade OI, et al. Cyclin D1 amplification and p16(MTS1/CDK4I) deletion correlate with poor prognosis in head and neck tumors. *Laryngoscope.* 2002;112:472–81.
56. Okami K, Reed AL, Cairns P, et al. Cyclin D1 amplification is independent of p16 inactivation in head and neck squamous cell carcinoma. *Oncogene.* 1999;18:3541–5.
57. Pyeon D, Newton MA, Lambert PF, et al. Fundamental differences in cell cycle deregulation in human papillomavirus-positive and human papillomavirus-negative head/neck and cervical cancers. *Cancer Res.* 2007;67:4605–19.
58. Pena JC, Thompson CB, Recant W, et al. Bcl-xL and Bcl-2 expression in squamous cell carcinoma of the head and neck. *Cancer.* 1999;85:164–70.
59. Wilson GD, Grover R, Richman PI, et al. Bcl-2 expression correlates with favourable outcome in head and neck cancer treated by accelerated radiotherapy. *Anticancer Res.* 1996;16:2403–8.
60. Trask DK, Wolf GT, Bradford CR, et al. Expression of Bcl-2 family proteins in advanced laryngeal squamous cell carcinoma: correlation with response to chemotherapy and organ preservation. *Laryngoscope.* 2002;112:638–44.
61. Kumar B, Cordell KG, D'Silva N, et al. Expression of p53 and Bcl-xL as predictive markers for larynx preservation in advanced laryngeal cancer. *Arch Otolaryngol Head Neck Surg.* 2008;134:363–9.
62. Levine AJ. p53, the cellular gatekeeper for growth and division. *Cell.* 1997;88:323–31.
63. Foulkes WD. p53 – master and commander. *N Engl J Med.* 2007;357:2539–41.
64. Balz V, Scheckenbach K, Gotte K, et al. Is the p53 inactivation frequency in squamous cell carcinomas of the head and neck underestimated? Analysis of p53 exons 2-11 and human papillomavirus 16/18 E6 transcripts in 123 unselected tumor specimens. *Cancer Res.* 2003;63:1188–91.
65. Sullivan A, Syed N, Gasco M, et al. Polymorphism in wild-type p53 modulates response to chemotherapy in vitro and in vivo. *Oncogene.* 2004;23:3328–37.
66. Poeta ML, Manola J, Goldwasser MA, et al. TP53 mutations and survival in squamous-cell carcinoma of the head and neck. *N Engl J Med.* 2007;357:2552–61.
67. Temam S, Flahault A, Perie S, et al. p53 gene status as a predictor of tumor response to induction chemotherapy of patients with locoregionally advanced squamous cell carcinomas of the head and neck. *J Clin Oncol.* 2000;18:385–94.
68. Perrone F, Bossi P, Cortelazzi B, et al. TP53 mutations and pathological complete response to neoadjuvant cisplatin/fluorouracil chemotherapy in resected oral cavity squamous cell carcinoma. *J Clin Oncol.* 2009.
69. Reed E. ERCC1 measurements in clinical oncology. *N Engl J Med.* 2006;355:1054–5.
70. Handra-Luca A, Hernandez J, Mountzios G, et al. Excision repair cross complementation group 1 immunohistochemical expression predicts objective response and cancer-specific survival in patients treated by Cisplatin-based induction chemotherapy for locally advanced head and neck squamous cell carcinoma. *Clin Cancer Res.* 2007;13:3855–9.

71. Ha PK, Califano JA. Promoter methylation and inactivation of tumour-suppressor genes in oral squamous-cell carcinoma. *Lancet Oncol.* 2006;7:77–82.
72. Shaw RJ, Liloglou T, Rogers SN, et al. Promoter methylation of P16, RARbeta, E-cadherin, cyclin A1 and cytoglobin in oral cancer: quantitative evaluation using pyrosequencing. *Br J Cancer.* 2006;94:561–8.
73. Huang KH, Huang SF, Chen IH, et al. Methylation of RASSF1A, RASSF2A, and HIN-1 is associated with poor outcome after radiotherapy, but not surgery, in oral squamous cell carcinoma. *Clin Cancer Res.* 2009;15:4174–80.
74. Marsit CJ, Posner MR, McClean MD, et al. Hypermethylation of E-cadherin is an independent predictor of improved survival in head and neck squamous cell carcinoma. *Cancer.* 2008;113:1566–71.
75. Jun HJ, Ahn MJ, Kim HS, et al. ERCC1 expression as a predictive marker of squamous cell carcinoma of the head and neck treated with cisplatin-based concurrent chemoradiation. *Br J Cancer.* 2008;99:167–72.
76. Worden FP, Kumar B, Lee JS, et al. Chemoselection as a strategy for organ preservation in advanced oropharynx cancer: response and survival positively associated with HPV16 copy number. *J Clin Oncol.* 2008;26:3138–46.
77. De Schutter H, Geeraerts H, Verbeke E, et al. Promoter methylation of TIMP3 and CDH1 predicts better outcome in head and neck squamous cell carcinoma treated by radiotherapy only. *Oncol Rep.* 2009;21:507–13.
78. Ang KK, Berkey BA, Tu X, et al. Impact of epidermal growth factor receptor expression on survival and pattern of relapse in patients with advanced head and neck carcinoma. *Cancer Res.* 2002;62:7350–6.
79. Rubin Grandis J, Melhem MF, Gooding WE, et al. Levels of TGF-alpha and EGFR protein in head and neck squamous cell carcinoma and patient survival. *J Natl Cancer Inst.* 1998;90:824–32.
80. Xia W, Lau YK, Zhang HZ, et al. Combination of EGFR, HER-2/neu, and HER-3 is a stronger predictor for the outcome of oral squamous cell carcinoma than any individual family members. *Clin Cancer Res.* 1999;5:4164–74.
81. Licitra L, Perrone F, Bossi P, et al. High-risk human papillomavirus affects prognosis in patients with surgically treated oropharyngeal squamous cell carcinoma. *J Clin Oncol.* 2006;24:5630–6.

Chapter 10

Hypoxia in Head and Neck Cancers: Clinical Relevance and Treatment

Yungan Tao and Jean Bourhis

Abstract Tumor hypoxia, or the condition of low oxygen, is a key factor for tumor progression and treatment resistance. Hypoxic areas arise as a result of an imbalance between the supply and consumption of oxygen. Cellular responses to hypoxia are orchestrated through activation of the hypoxia-inducible factor family of transcription factors (HIFs). There are several approaches for detecting tumor hypoxia in head and neck cancers (HNC). Direct oxygen measurements in tissues with Eppendorf-pO₂ histography have been used, but this method is invasive. Recent studies have focused on molecular markers of hypoxia, such as HIF-1 and carbonic anhydrase isozyme IX (CA-IX), and on developing noninvasive imaging techniques. Hypoxia appears to be prognostic for outcome in HNC. Several studies have shown that low pO₂ in tumor, high HIF-1, Glut-1 and CA-IX expression, serum level of osteopontin correlated with treatment outcomes in HNC patients treated with RT or chemoradiotherapy.

Several strategies have been used to overcome hypoxia-induced treatment resistance in HNC, such as hyperbaric oxygen treatment, accelerated radiotherapy with carbogen and nicotinamide, hypoxic cell radiosensitizers: nitroimidazoles, erythropoietin manipulation, and hypoxic cell cytotoxin. More recently, Micro-Environment-Vascular Normalization, HIF-1 Targeting and 18F-FMISO positron emission tomography-based intensity-modulated radiotherapy are promising methods.

Keywords Hypoxia • Radiotherapy • Head and neck cancer • HIF-1

Tumor hypoxia, or the condition of low oxygen, is a key factor for tumor progression and treatment resistance. Hypoxia develops in solid tumors due to aberrant blood vessel formation, fluctuation in blood flow, and increasing oxygen

demands for tumor growth. Because hypoxic tumor cells are more resistant to ionizing radiation, tumor hypoxia has been recognized as a potential cause of failure when treating human solid tumors with ionizing radiation, both in experimental models and in patients with several type of cancer including head and neck cancers (HNC). The importance of hypoxia as a potential mechanism limiting the probability of cure rate in patients with HNC treated with radiation has been recognized [1].

Description of Factors Associated with Hypoxia and Potential Mechanisms of Resistance Related to Hypoxia

Hypoxic areas arise as a result of an imbalance between the supply and consumption of oxygen. In locally advanced solid tumors, the O₂ consumption rate of neoplastic cells may outweigh a restricted oxygen supply and results in the development of tissue areas with low or very low O₂ levels [2]. Other mechanisms are involved in the development of hypoxia in solid tumors: severe structural and functional abnormalities of tumor microvessels induce perfusion limited O₂ delivery; deterioration of diffusion geometry limits oxygen penetration; tumor-associated and/or therapy-induced anemia could lead to a reduced O₂ transport capacity [2].

As a consequence of these mechanisms tumor hypoxia is associated with the production of fewer radiation-induced cytotoxic free radicals, less radiation-induced DNA damage, and decreased tumor cell kill. This is called as oxygen enhancement effect. Damage to DNA is mainly induced by interaction with oxygen reacting free radicals formed by the ionization of water surrounding the DNA [3]. Typically, DNA strand breaks that are not repaired can lead to fatal chromosomal aberrations. It has been shown that oxygenated cells are 2.5–3 times more radiosensitive than hypoxic cells [3]. Hypoxic cells are also considered to be resistant to most anticancer drugs for several reasons [4]: first, hypoxic cells are distant from blood vessels and, as a result, may not be

J. Bourhis (✉)
Radiotherapy Department, Institut Gustave Roussy,
39 Rue Camille-Desmoulins, Villejuif 94805, France
e-mail: jean.bourhis@igr.fr

adequately exposed to some types of anticancer drugs [5]; second, cellular proliferation decreases as a function of distance from blood vessels, an effect that is at least partially due to hypoxia; third, hypoxia can select for cells that have lost sensitivity to p53-mediated apoptosis, which might lessen sensitivity to some anticancer agents; fourth, hypoxia can upregulate genes involved in drug resistance, including genes encoding P-170 glycoprotein.

Hypoxia is not only an important cause of treatment resistance but also a powerful stimulus of several critical tumor phenotypes. These discoveries have prompted to question whether the link between hypoxia and radioresistance is completely explainable by the oxygen enhancement effect as described above or, whether hypoxia also influences radiosensitivity through biological effects.

Molecular Pathways Involved in Hypoxia

Cellular responses to hypoxia are orchestrated through activation of the hypoxia-inducible factor family of transcription factors (HIFs) [6]. HIF-1 is a heterodimer that consists of the hypoxic response factor HIF-1 α and the constitutively expressed HIF-1 β [7]. The level of HIF-1 α expression is determined by the rates of protein synthesis and protein degradation. HIF-1 α protein synthesis is regulated via O₂-independent mechanisms, by the activation of the phosphatidylinositol 3-kinase (PI3K) and ERK-mitogen-activated protein kinase (MAPK) pathways [8]. These pathways can be activated by signaling via receptor tyrosine kinases, nonreceptor tyrosine kinases, or G-protein-coupled receptors.

HIF-1 α protein degradation is regulated by O₂-dependent prolyl hydroxylation, which targets the protein for ubiquitylation by E3 ubiquitin-protein ligases. These ligases contain the Von Hippel-Lindau (VHL) tumor-suppressor protein, which binds specifically to hydroxylated HIF-1 α . Ubiquitylated HIF-1 α is rapidly degraded by the proteasome. In the absence of oxygen, HIF-1 binds to hypoxia-response elements (HREs), thereby activating the expression of numerous hypoxia-response genes, such as the proangiogenic growth factor vascular endothelial growth factor (VEGF). The redox active apurinic/apyrimidinic endonuclease-1 has been shown to keep HIF-1 α in a reduced state that is necessary for its transcriptional function. HIF-1 can affect several intracellular processes, including glycolysis, cell proliferation, apoptosis, angiogenesis, and invasion/metastasis – which have been shown to influence the response to radiation and might, therefore, serve as a link between HIF-1 activity and tumor radiosensitivity.

Recently, two other pathways that independently influence gene expression and processes of importance for tumor

cell behavior have proved to be O₂-sensitive [9]. The first occurs through regulation of an important integrator of metabolic signals, the kinase mammalian target of rapamycin (mTOR, also known as FRAP1), and its downstream effectors that orchestrate the initiation of protein synthesis, autophagy, and apoptosis sensitivity. The second is through activation of the unfolded protein response (UPR), a program of transcriptional and translational changes that occurs as a consequence of endoplasmic reticulum (ER) stress. The UPR controls multiple downstream processes, including protein production, protein maturation and degradation, cell metabolism, and cell death. HIF-, mTOR- and UPR-dependent responses to hypoxia act in an integrated way, influencing each other and common downstream pathways that affect gene expression, metabolism, cell survival, tumorigenesis, and tumor growth.

Increased HIF-1 α protein synthesis was inhibited by treatment with rapamycin – a macrolide antibiotic inhibits mTOR. However, it is not known whether phosphorylation of these proteins by mTOR is necessary or sufficient for increased HIF-1 α synthesis. In addition to effects on HIF-1 α synthesis, activation of the RAF–MEK–ERK signaling pathway has also been shown to stimulate HIF-1 α transactivation-domain function. This effect is due at least in part to phosphorylation by ERK of the co-activator p300.

A recently characterized hypoxia-induced protein, that regulated in development and DNA damage 1 (REDD1), could negatively control mTOR activity. In head and neck squamous cell carcinoma (HNSCC) cell lines, the expression of the phosphorylated forms of the mTOR downstream targets S6 kinase and S6 (pS6) decreased after hypoxia. These events were associated with REDD1 upregulation. Inhibition of AMP-activated protein kinase (AMPK) before prolonged hypoxia prevented REDD1 expression, thereby sustaining mTOR activity. Reduced mTOR activity in response to hypoxia through AMPK/REDD1 was deregulated, which hence might contribute to the persistent activation of the mTOR pathway in HNSCC cells [10].

How to Detect Hypoxia in the Tumors: Techniques to Measure Tumor Hypoxia

There are several approaches for detecting tumor hypoxia in HNC. In a recent hypoxia workshop, convened by Cancer Imaging Program of the National Cancer Institute (NCI) [11], the conclusion was that, although hypoxia is an important aspect of tumor physiology and response to treatment, there is a lack of simple and efficient methods to measure hypoxia and image oxygenation hampers further understanding and limits their prognostic usefulness. There is no gold standard for measuring hypoxia. Briefly, techniques for

measuring tumor oxygenation can be categorized into two groups: direct invasive and indirect noninvasive methods. Direct oxygen measurements in tissues with Eppendorf- pO_2 histography have been used, but this method is invasive. Recent studies have focused on molecular markers of hypoxia, such as HIF-1 and carbonic anhydrase isozyme IX (CA-IX), and on developing noninvasive imaging techniques. The workshop report also presented a comprehensive review of different approaches for measuring tumor hypoxia.

Electrode pO_2 measurements have been used in several normal tissues, such as brain, breast, subcutis, and skeletal muscle, and these measurements have been used to develop profiles that can be illustrated by pO_2 histograms reflecting the oxygenation status of a given tissue. These pO_2 distribution profiles may reflect the efficacy of several oxygen supply determinants, such as blood flow rate, the blood's oxygen transport capacity, the availability of oxygen to the cells, rate of oxygen extraction from the blood, oxygen diffusion distances, microvascular density, and oxygen diffusion coefficients within the tissue, as well as the rate of oxygen consumption by the cells. Although the microelectrode technique directly measures tumor pO_2 , it suffers from several drawbacks that make it difficult for general use. These include invasiveness, tumor inaccessibility, pressure dependence, interobserver variability, failure to distinguish necrosis from hypoxia, and the lack of spatial information [12].

Endogenous and secreted molecular markers for tumor hypoxia represent proteins and genes whose expressions are induced by hypoxic exposure. One of the most studied oxygen response pathways is HIF-1 pathway, HIF-1 and several of its downstream targets, including Glut-1 (glucose transporter-1), CA-IX, and VEGF, have been widely investigated as prognostic markers in HNC patients with mixed results. One advantage of endogenous markers is that levels of these proteins can be assessed on archival materials, thereby allowing possible correlation with treatment outcomes. In addition, it requires neither the injection of a hypoxic marker drug used as an exogenous nor any additional invasive procedure except the need of a biopsy at diagnosis. A possible drawback of these approaches is that these proteins can be regulated by factors other than hypoxia. Another hypoxia-related marker, the serum level of osteopontin (OPN) has also been reported recently. Le et al. [13] investigated the relationship between OPN, tumor pO_2 , and prognosis in patients with HNSCC, and it has been shown that Plasma OPN levels appeared to correlate with tumor hypoxia in HNSCC patients and may serve as noninvasive tests to identify patients at high risk for tumor recurrence.

Indirect approaches use injectable molecular reporters of oxygen (exogenous marker), which include 2-nitroimidazole compounds, such as misonidazole (MISO), pimonidazole (1-(2-nitro-1-imidazolyl)-3-*N*-piperidino-2-propanolol) [14],

and EF5 (nitroimidazole [2-(2-nitro-1H-imidazol-1-yl)-*N*-(2,2,3,3,3-pentafluoropropyl) acetamide]) [15]. These compounds form stable adducts with intracellular macromolecules only in hypoxic regions ($pO_2 < 10$ mmHg) [16]. Detection of these adducts with antibodies can provide information on the relative oxygenation at the cellular level [17, 18]. In general, 2-nitroimidazole markers stain for areas of chronic hypoxia and are more sensitive at severe hypoxic conditions than the microelectrode [19]. This approach is limited by the requirement for exogenous drug administration, additional biopsies for staining, and quantification of staining [20].

MRI can provide a useful way to measure hypoxia. Absolute pO_2 can be measured on the basis of fluorocarbon reporter molecules. These may be introduced by direct intratumoral injection and they provide measurements consistent with electrodes (interstitial pO_2). A major advantage over electrodes is that maps of regional pO_2 may be measured at 50–150 individual locations simultaneously. MRI methods for interrogating tumor oxygenation are attractive since they avoid the complication of short-lived radioactivity and MRI equipment is widely available. Blood oxygen level dependent (BOLD) MRI is an imaging technique that distinguishes paramagnetic deoxy-Hb from O_2 Hb. BOLD MRI signal is related to vascular oxygenation and may allow direct estimates of pO_2 . However, the correlation becomes difficult for small blood vessels where partial-volume effects combine vessel and tissue in individual voxels and BOLD may also be confounded by flow effects [21]. Oxygen-sensitive MR reporter molecules have also been developed, generally based on perfluorocarbons (PFCs). Other MRI-based imaging such as, FREDOM (fluorocarbon relaxometry using echoplanar imaging for dynamic oxygen mapping) and PISTOL (proton imaging of silanes for tissue oxygen levels) are also under investigation [21].

Positron emission tomography (PET)-based hypoxia imaging has also been widely over the past 15 years. 18F-fluoro-misonidazole [1-(2-nitroimidazolyl)-2-hydroxy-3-fluoropropane; 18F-FMISO], is the most widely used PET agent for mapping regional hypoxia [21]. Because 18F-FMISO partitions nearly equally between octanol and water, normoxic tissues have tissue-to-blood ratio (T/B) pixel values of almost 1.0. When the O_2 supply is adequate, most tissues have relatively similar levels of 18F as in the blood. The hypoxic part of a tumor can be characterized by the maximum T/B value or by the total number of pixels with T/B greater than same threshold. 18F-FMISO PET could identify hypoxic tissue that is heterogeneously distributed within human tumors and can help to facilitate image-directed radiotherapy. 18F-FMISO imaging has also been used to identify postradiotherapy tumor recurrence by differential uptake of tracer. A significant correlation was found between hypoxic tissue identified by 18F-FMISO and both pimonida-

zole and CA-IX, detected by immunohistochemical staining techniques. Several other compounds have also been evaluated as imaging agents [21]. 18F-fluoro-erythro-nitroimidazole (18F-FETNIM) has been evaluated in HNC. A derivative that is more hydrophilic than 18F-FMISO, 18F-fluoro-azomycin-arabinofuranoside (18F-FAZA), has been shown to be promising for clinical use, as it is the 18F-fluoro-etanidazole (18F-FETA) and EF5. An alternative PET agent for hypoxia is based on a metal complex of radioactive copper with ATSM, diacetyl-bis(*N*4-methylthiosemicarbazone) [21]. Dithiosemicarbazones have antitumor properties that are enhanced when they are complexed with Cu(II). Because there are several advantageous imaging radionuclides of copper, this has led several laboratories to develop substituted ligands of dithiosemicarbazones as potential imaging agents. Cu-ATSM uptake is more rapid than 18F-FMISO uptake, and the reported hypoxic to normoxic ratio is greater. One concern is that, because of its lipophilicity, the early uptake and washout of Cu-ATSM is probably influenced by regional blood flow, which is a major confounder with hypoxia [21]. Nevertheless, Cu-ATSM is finding a useful role in several clinical settings.

Hypoxia and Clinical Outcomes in Head and Neck Cancers

Hypoxia appears to be prognostic for outcome in HNC, with data suggesting that hypoxia is prognostic for survival and local control. Several studies have shown that low pO_2 in tumor, defined by either the median value or the hypoxic fraction, correlated with treatment outcomes in HNC patients treated with RT or chemoradiotherapy [22–24]. Brizel et al. [24] reported 63 HNC patients with pretreatment tumor oxygen assessment, including primary site and lymph nodes. Hypoxia (tumor median pO_2 , 10 mmHg) adversely affected 2 year local–regional control, disease-free survival, and overall survival (35% vs. 83%). It was also found that tumor pO_2 predicted for pathologically persistent neck nodes in patients undergoing a neck dissection for clinical N2–3 necks after chemoradiation treatment [25]. In another study by Terris [26], only a small number of patients were assessed and hypoxia did not appear to be a prognostic factor. A multicenter study by Nordmark et al. [27] involving 397 patients with HNC provided further evidence that tumor pO_2 was an independent predictor for survival and tumor hypoxia was associated with a poor prognosis in patients with advanced HNC following primary radiotherapy. In HNC, hypoxia not only predicts for disease-free survival and overall survival but also for local control, suggesting hypoxia-induced radiation resistance as an important factor for local failure.

The prognostic impact of HIF-1 α and HIF-2 α expression has been the subject of numerous studies [28–31]. High HIF-1 expression has been correlated with a poorer survival in HNC treated with radiation with or without chemotherapy [28, 32]. Similar trends are observed in nasopharyngeal tumors [33]. Koukourakis et al. [28] assessed the expression of HIF-1 α and HIF-2 α in 75 cancer specimens from patients with HNSCC treated with concurrent chemoradiotherapy. HIF-1 α and HIF-2 α overexpression were shown in 52 and 33% of cancer samples, respectively. Bone/cartilage involvement was more frequent in tumors with high HIF-1 α expression. HIF-1 α and HIF-2 α overexpression were significantly associated with high microvessel density and with VEGF expression. High levels of HIF-1 α and HIF-2 α expression were associated with incomplete response to chemoradiation, poor local relapse-free survival, and poor overall survival. HIF-2 α expression was an independent prognostic factor in multivariate models. Aebbersold et al. [32] explored the predictive potential of HIF-1 α expression in 98 patients with oropharyngeal cancer treated by curative radiation therapy in which 94% of the primary tumors showed overexpression of HIF-1 α . The degree of HIF-1 α immunoreactivity correlated inversely with both the rate of complete remission of the primary tumor and lymph node metastases as well as with local failure, and overall survival. Winter et al. [34] investigated the role of expression of HIF-1 α and HIF-2 α in a series of 151 patients who underwent surgery for HNSCC. High HIF-1 α was expressed in 45 of 140 tumors (30%) and HIF-2 α was expressed in 21 of 139 tumors (14%). HIF-1 α alone was associated with a worse disease-free survival, and high HIF-1 α /high HIF-2 α expression was also an independent prognostic factor. The immunohistochemical detection of the HIF-1 α target gene Glut-1 has been shown to be correlated with a poorer survival in HNC [35]. Oliver et al. [36] investigated the relationship between Glut-1 expression and clinical outcome of a retrospective series of 54 cases of oral squamous cell carcinomas. There was a significant relationship between those tumors which demonstrated intense staining of Glut-1 and loco-regional recurrence. Kunkel et al. [37] analyzed retrospectively Glut-1 expression in 118 patients with oral squamous cell carcinoma. The survival rate of patients with a low Glut-1 labeling index was significantly longer compared with patients with a high Glut-1 labeling index (138 months vs. 60 months), and Glut-1 expression was found to be an independent prognostic marker.

The second target gene of HIF-1 α which has been extensively studied with regard to its prognostic significance is CA-IX [38]. As with HIF-1 α and Glut-1, most studies found a negative impact of high CA-IX expression in patient with HNC. In one study by Koukourakis et al. [39], HIF-2 α and CA-IX were assessed in a series of patients treated with radiotherapy in the frame of the continuous

hyperfractionated accelerated radiotherapy (CHART) randomized trial (54 Gy in only 12 days compared with conventional radiotherapy, 66 Gy in 6.5 weeks). Both high levels of HIF-2 α and CA-IX were correlated with loco-regional control and survival, suggesting the importance of tumor hypoxia in HNC. However, no benefit was found with the accelerated regimen in the group of hypoxic tumors. In another study [40], tumors with a nonhypoxic profile, as defined as low HIF-1 α and low CA-IX expression had significantly better local control.

A recent work by Overgaard et al. [41] used another hypoxia-related marker, the serum level of OPN, in a randomized trial that compared patients' radiotherapy with and without an hypoxic sensitizer (nimorazole). The patients who benefited the most from the hypoxic modification were in the group with high levels of serum OPN, strongly suggesting that measuring tumor hypoxia before radiotherapy help to individualize irradiation in a more rational way. Studies showing a prognostic significance of 2-nitroimidazole markers have also been reported for HNC [19].

Strategies to Overcome Hypoxia-Induced Treatment Resistance in Head and Neck Cancers

Hyperbaric Oxygen Treatment

The most straightforward strategy to overcome hypoxia is to administer oxygen at a pressure higher than room air (usually 3 atm), i.e., hyperbaric oxygen treatment. The largest clinical trial with hyperbaric oxygen has been conducted by the British Medical Research Council, which randomized 1,669 patients between radiotherapy with or without hyperbaric oxygen [42]. Hyperbaric oxygen significantly improved both survival and local control after radiotherapy for head-and-neck tumors and showed promising results in HNC patients. Some of the earliest work toward this end was done using hyperbaric oxygen to radiosensitize cervical [43] or HNC [44]. Though there was some initial success with this technique, recent studies have indicated that combining radiation with hyperbaric oxygen results in significant increase of normal tissue toxicities [45]. A meta-analysis of randomized trials suggests that the use of hyperbaric oxygen breathing during RT can improve local control by 10% and also improve 5-year survival for irradiated head and neck tumors, however, it has not gained general acceptance for clinical use due to inconsistent responses, safety issues, and the high cost for implementation and especially due to the increased incidence of severe radiation toxicity [46].

Accelerated Radiotherapy with Carbogen and Nicotinamide

Another promising approach to decrease hypoxia in HNC is to combine radiotherapy with both the vasodilator nicotinamide and carbogen breathing (95%O₂, 5%CO₂) to increase tumor pO₂. This strategy, so-called accelerated radiotherapy with carbogen and nicotinamide (ARCON) has produced excellent 3-year local control rates >80% for locally advanced stage T3–4 laryngeal and oropharyngeal cancers in a phase II study [47]. Following this promising result, a large randomized phase III clinical trial testing the efficacy of ARCON in laryngeal cancer patients has been performed in the Netherlands and should be presented in 2009 [48].

Improving Hemoglobin with Erythropoietin Manipulation

Early studies were also done using blood transfusion to increase the oxygen transport and, thereby, increase the tumor tissue pO₂. Despite some initial success [49] with this method transfusion failed to improve the local control in a randomized trial performed by the Danish Head and Neck Cancer (DAHANCA) group. Recently, blood transfusion has been supplanted by the administration of erythropoiesis-stimulating factors. Unfortunately, the combination of erythropoietin and radiotherapy is proved to be detrimental in several large randomized studies. Anemia is associated with a poorer outcome in patients treated with radiotherapy [50], possibly because it leads to low oxygen levels in tumors. Correction of anemia has been suggested to reverse this hemoglobin effect, thereby improving cancer control [51]. Recombinant human erythropoietin (EPO) can correct anemia and improve the quality of life in anemic patients with cancer. A phase III trial (ENHANCE study, 351 patients) was conducted to address the question whether anemia correction with erythropoietin could improve the outcome of curative radiotherapy among patients with HNSCC [52]. It showed that EPO corrected anemia, but tumor control, survival, and disease control rates were significantly worse when using EPO. This detrimental effect associated with EPO, when combined with RT in HNSCC was confirmed by the results of RTOG 99-03 [53] and DAHANCA-10 randomized studies (14th European Cancer Conference ECCO). In this later study, in a series of 515 patients eligible for analysis, a significantly poorer loco-regional control rates was observed for the patients who received erythropoietin compared to the control group in HNSCC patients treated with radiotherapy. However, the target hemoglobin range in that study was 14.0–15.5 g/dl, which is beyond the optimal range for tumor oxygenation.

The reason of the observed negative effect of EPO on tumor control could be that tumor oxygenation is decreased by both anemia and inappropriately high-hemoglobin levels. The latter are associated with an increased blood viscosity and a drop in nutritive perfusion. Hemoglobin concentrations between 12 and 14 g/dl could be optimal for maximum tumor oxygenation [51]. Thus, it is important to keep the hemoglobin concentrations within this range during radiotherapy. In addition, a retrospective analysis of a subset of patients from the ENHANCE study suggested that the expression of erythropoietin receptors on cancer cells can play an important role in HNSCC patients receiving erythropoietin during radiotherapy [54]. Loco-regional progression-free survival was substantially poorer if erythropoietin was administered to patients positive for the receptor expression compared with placebo, however, erythropoietin did not impair outcome in receptor-negative patients. Given these results, the use of EPO in HNC patients should not be considered outside controlled clinical trials [55].

Hypoxic Cell Radiosensitizers: Nitroimidazoles

A widely investigated hypoxia-targeted strategy is to use electron-affinic drugs (nitroimidazoles) to sensitize tumors to the effect of radiation. Xenograft studies showed significant radiosensitization with nitroimidazole compounds in tumors without enhancing normal tissue toxicity. These encouraging results led to the realization of several of clinical trials exploring the clinical radiosensitizing potential of misonidazole in the late 1970s. However, the results of these clinical trials have been generally disappointing. One of the possible factors to explain the failure of misonidazole to provide significant advantage is the low plasma concentrations achievable with the permitted dose of this neurotoxic drug. Nevertheless, some was seen in one randomized trial. In the DAHANCA 2 trial [56], 626 patients with head and neck carcinoma were randomized to two different split-course radiation regimens and given either misonidazole or placebo during the initial 4 weeks of treatment. Overall, the misonidazole-treated group did not have a significantly better control rate than the placebo group. However, some benefit was found in patients with pharynx carcinomas. Misonidazole induced significant peripheral neuropathy in 26% of the treated patients, whereas other drug-related side effects were minimal. In the DAHANCA 5 trial [57], a less toxic nitroimidazole compound, nimorazole (Naxogin®), was used. Four hundred and twenty-two patients with carcinoma of the supraglottic larynx and pharynx were randomized to receive nimorazole or placebo, in association with conventional primary radiotherapy. With a median follow-up of 112 months, the nimorazole group showed a significantly

better loco-regional control rate than the placebo group and a lower cancer-related death rate, without increasing the major side-effects.

Hypoxic Cell Cytotoxin: Bioreductive Drugs

Bioreductive agents can selectively kill hypoxic cells. The first bioreductive drug used in clinical trials was mitomycin-C [58]. Haffty et al. [59] showed that the addition of mitomycin-C to RT resulted in statistically significant improvement in loco-regional control and cause-specific survival in HNC. Another study by Dobrowsky et al. [60, 61] comparing conventional fractionated RT to the Vienna continuous hyperfractionated accelerated RT regimen (V-CHART) or to V-CHART plus mitomycin-C showed that the best survival and loco-regional control rates were observed for the V-CHART and mitomycin-C group. However, the use of mitomycin-C is limited by its significant toxicity making it unlikely to be the ideal drug for exploiting tumor hypoxia.

Recently, a new approach to tumor hypoxia has been developed using drugs that are preferentially cytotoxic to hypoxic cells [4], such as tirapazamine (TPZ). Preclinical studies have demonstrated that TPZ results in potentiation of both radiation and CDDP cytotoxicity [62]. In a phase I trial of TPZ, CDDP, and radiation (TPZ/CIS), impressive results were seen in locally advanced HNSCC [63]. This drug was then further evaluated in a randomized phase II trial Trans-Tasman Radiation Oncology Group (TROG) 98.02 [64], 122 previously untreated advanced HNSCC patients were randomized to receive RT concurrently with either CDDP plus TPZ (TPZ/CIS), or CDDP and 5-FU. The striking observation of this study was that tumor control probability was strongly related to the pretreatment level of hypoxia, as measured by PET misonidazole. Hypoxic tumors treated with tirapazamine had an excellent control rate (>90%) while hypoxic tumors receiving 5-FU instead of tirapazamine had a very poor control rate (<25%) [65]. On the other hand, Rischin et al. reported results of a phase III trial HeadSTART of TROG during ASCO 2008. Eight hundred and sixty-one patients with previously untreated Stage III or IV HNSCC were randomized to receive RT concurrently with either CDDP (100 mg/m² every 3 weeks) or CDDP (75 mg/m² every 3 weeks + tirapazamine). No benefit was found due to the addition of TPZ to CT-RT in the absence of selection for the presence of hypoxia. All together, these two randomized studies suggest that a key issue in this area is to detect hypoxia and adapt the treatment to the characteristics of each individual tumor.

In another phase II trial [66], 62 patients with lymph node-positive, resectable, stage IV HNSCC were randomized

to receive either two cycles of induction chemotherapy (TPZ, cisplatin, and 5-FU) followed by simultaneous chemoradiotherapy (TPZ, cisplatin, and 5-FU) or to receive the same regimen without TPZ. Patients who did not achieve a complete response at 50 Gy underwent surgical treatment. The addition of TPZ increased hematologic toxicity but did not improve outcomes in the small series of patients with resectable HNSCC.

Micro-Environment-Vascular Normalization

Jain [67] has proposed the concept of normalization of tumor vasculature through antiangiogenesis and antivascular targeted therapy [68]. Owing to high levels of proangiogenic molecules produced locally, such as VEGF, tumors become hypervascular, but the vessels are leaky and the blood flow is spatially and temporally heterogeneous. This leads to increased interstitial fluid pressure (IFP) and focal hypoxia, creating barriers to delivery and efficacy of therapeutics. The proposed mechanism of action of the VEGF-specific inhibitors, such as bevacizumab and sorafenib, is the inhibition of new-vessel formation and killing of immature tumor vessels, transient normalization of the remaining vasculature by decrease in macromolecular permeability (and thus the IFP) and hypoxia, and improvement of blood perfusion. The lowered IFP can lead to improved delivery of chemotherapeutics and molecularly targeted agents; the improved oxygenation sensitizes cancer cells to cytotoxic therapeutics and reduces the selection of more-malignant phenotype; and, finally, increased cellular proliferation around normalized vessels might increase the cytotoxicity of chemotherapeutics [69]. Normalization of the vasculature might also benefit the direct killing of cancer cells by bevacizumab, in synergy with the chemotherapeutics.

Combined effects of bevacizumab with erlotinib and irradiation have been observed using a preclinical study on a HNC orthotopic model [70]. A phase I dose escalation study [71] has been conducted to evaluate the combination of bevacizumab and chemoradiotherapy (5-FU, hydroxyurea, radiation) in a series of 44 poor-prognosis HNC patients. Bevacizumab was integrated with chemoradiotherapy at a dose of 10 mg/m² every 2 weeks. Some fistula formation/tissue necrosis were observed that could be bevacizumab-related. Erlotinib and bevacizumab combination has been investigated in 58 patients with recurrent or metastatic HNSCC in a phase I/II study [72]. The most common side effects of any grade were rash and diarrhea. A few patients could have benefit from this approach especially when the ratio of tumor-cell phosphorylated VEGF receptor-2 (pVEGFR2) over total VEGFR2 and endothelial-cell pEGFR

over total EGFR in pretreatment biopsies were associated with complete response.

A phase II trial of sorafenib has been conducted in a small series of 27 patients with recurrent or metastatic squamous cell carcinoma of the head and neck or nasopharyngeal carcinoma. Sorafenib was well tolerated with a few grade 3 and no grade 4 toxicities but had modest anticancer activity comparable to monotherapy with other targeted agents in this group of patients [73].

Targeting HIF-1

Given the role of HIF-1 α in response to hypoxia, there is a major interest to develop specific HIF-1 inhibition. In xenograft assays, manipulation of HIF-1 activity by genetic or pharmacological means has marked effects on tumor growth along with some effects on angiogenesis, glucose metabolism, and/or cell survival [74].

Topotecan, a topoisomerase I poison that reversibly binds to and stabilizes the topoisomerase I enzyme, inhibited HIF-1 protein translation by a proteasome- and DNA damage-independent mechanism. Currently, topotecan is being tested in a clinical trial at the National Cancer Institute for its ability to inhibit HIF-1 α protein expression and function in patients with advanced malignancies refractory to standard therapy [74].

Inhibitors of several upstream signaling pathways of HIF-1, such as EGFR and mTOR, have been extensively investigated in clinical trials in these recent years [7]. The mTOR inhibitors (everolimus and temsirolimus) that can suppress mTOR-dependent HIF-1 translation, and EGFR inhibitors (gefitinib, erlotinib) or antibodies (cetuximab, panitumumab) could inhibit HIF-1 induction by EGFR-dependent pathways [8].

Hsp90 is a molecular chaperone associated with a number of proteins, which include transcription factors (AhR, glucocorticoid receptor, p53) and signaling kinases (Akt, ErbB2, Raf-1, v-Src), and ensures the proper conformation, localization, and function of these client proteins. Hsp90 inhibitors were found to induce ubiquitination and proteasome-mediated degradation of HIF-1 α in a VHL-independent fashion, under both normoxic and hypoxic conditions [74].

Histone deacetylase (HDAC) inhibitors have also been tested recently [74]. The dynamic process of reversible acetylation of the lysine residue of histone, and nonhistone proteins is controlled by HDAC and histone acetyltransferases. Acetylation of histone proteins is important for DNA chromatin conformation and regulation of gene expression. Acetylation of nonhistone proteins has been implicated in protein stability and function and direct acetylation of HIF-1 α has been suggested.

PET-Based Intensity-Modulated Radiotherapy

Image fusion techniques and the use of intensity-modulated and image-guided radiotherapy can allow to delineate hypoxic radioresistant subtarget volumes for delivering a partial tumor boost. PET could detect hypoxia in tumors and a higher dose could be given to the hypoxic areas, using intensity-modulated radiotherapy (IMRT). The MSKCC experience with microboosts on hypoxic areas up to 100 Gy. This approach requires that PET imaging be sensitive and specific enough to image hypoxia. In this framework, a validation of PET imaging used for adaptive radiotherapy was undertaken in animal models by comparing small-animal PET images (2.7 mm resolution) with autoradiography (AR) (100 μ m resolution) in various tumors under various physiological situations [75]. Discrepancies were found between the PET images and the underlying microscopic reality represented by AR images. These differences, attributed to the finite resolution of PET, were important when considering small regions of the tumors. Dose painting based on PET images should be carefully considered and should take these limitations into account.

The feasibility of a Cu-ATSM-guided IMRT approach through coregistering hypoxia (^{60}Cu -ATSM PET) to the corresponding CT images for IMRT planning has been reported in HNC patients [76]. Radiation dose to the hGTV could be escalated without compromising normal tissue sparing (parotid glands and spinal cord). The plan delivered 80 Gy in 35 fractions to the ATSM-avid tumor subvolume and the GTV simultaneously receives 70 Gy in 35 fractions while more than one-half of the parotid glands were spared to less than 30 Gy.

Thorwarth et al. [77] investigated the feasibility of different hypoxia dose painting strategies in radiotherapy of 13 head and neck cancer patients. For each patient, three different treatment plans were created: a conventional IMRT plan, an additional uniform dose escalation (uniDE) of 10% to the fluorodeoxyglucose (FDG)-positive volume, and a plan in which dose painting by numbers (DPBN) was implemented. DPBN was realized according to a map of dose-escalation factors calculated from dynamic ^{18}F -FMISO PET data. For DPBN, the prescriptions could be fulfilled in larger regions of the target than for uniDE. DPBN seems to result in higher benefits for the patients regarding tumor control probability. If hypoxia could be adequately quantified with a simple imaging technique such as FMISO positron emission tomography, DPBN in head-and-neck cancer could substantially increase tumor control.

Lee et al. reported the results from a prospective study of pre-/midtreatment ^{18}F -FMISO PET scans in a series of locoregionally advanced HNC patients treated with concomitant chemotherapy and IMRT [78]. Each patient underwent four

PET scans: one pretreatment FDG PET/CT scan, two pretreatment ^{18}F -FMISO PET/CT scans, and a final ^{18}F -FMISO PET (midtreatment) scan performed 4 weeks after the start of chemoradiotherapy. An heterogeneous distribution of ^{18}F -FMISO was noted in the primary and/or nodal disease in 90% of the patients. The positive ^{18}F -FMISO findings of the midtreatment PET scan was not correlated with patient outcome.

Another study has evaluated the influence of changes in tumor hypoxia on the efficacy of IMRT dose painting, according to serial ^{18}F -FMISO PET imaging [79]. Seven patients with HNC were imaged twice with FMISO PET, separated by 3 days, before radiotherapy. IMRT plans were designed, on the basis of the first FMISO scan, to deliver a boost dose of 14 Gy to the hypoxic volume, in addition to the 70-Gy prescription dose. The changes in spatial distribution of tumor hypoxia, as detected in serial FMISO PET imaging added some complexity to define an adequate, coverage of hypoxic tumor volumes achievable by dose-painting IMRT and, dose painting potentially increased the EUD of the hypoxic volumes.

Other Methods

Hyperfractionation radiotherapy (HFRT) [80] was designed to improve radiotherapy effectiveness by delivering two to three fractions daily with a reduced dose per fraction, which may reduce late toxicity despite an increased total dose. In addition, hyperfractionation could induce reoxygenation and its use was associated with an 8% improvement in survival at 5 years [81]. Other radiotherapy techniques can be of interest to overcome tumor hypoxia, such as high linear-energy transfer (LET) radiation which is less oxygen dependent. For example, carbon ions could be used to decrease the radiation resistance induced by hypoxia, and is currently under investigation.

In conclusion, tumor hypoxia continues to be a therapeutic challenge in HNC. Nonetheless, the prospect of reducing its impact is looking brighter with improved ability of detecting hypoxia and better understanding of its molecular targets for therapeutic exploitation. Testing new leads from the laboratory will require clinical trials with innovative designs that incorporate serial novel noninvasive surrogate end points for hypoxia, such as molecular makers or imaging methods.

References

1. Bourhis J. Hypoxia response pathways and radiotherapy for head and neck cancer. *J Clin Oncol.* 2006;24:725–6.
2. Vaupel P, Mayer A. Hypoxia in cancer: significance and impact on clinical outcome. *Cancer Metastasis Rev.* 2007;26:225–39.

3. Moeller BJ, Richardson RA, Dewhirst MW. Hypoxia and radiotherapy: opportunities for improved outcomes in cancer treatment. *Cancer Metastasis Rev.* 2007;26:241–8.
4. Brown JM, Wilson WR. Exploiting tumour hypoxia in cancer treatment. *Nat Rev Cancer.* 2004;4:437–47.
5. Tannock IF. Conventional cancer therapy: promise broken or promise delayed? *Lancet.* 1998;351 Suppl 2:SI9–16.
6. Harris AL. Hypoxia – a key regulatory factor in tumour growth. *Nat Rev Cancer.* 2002;2:38–47.
7. Semenza GL. Targeting HIF-1 for cancer therapy. *Nat Rev Cancer.* 2003;3:721–32.
8. Giaccia A, Siim BG, Johnson RS. HIF-1 as a target for drug development. *Nat Rev Drug Discov.* 2003;2:803–11.
9. Wouters BG, Koritzinsky M. Hypoxia signalling through mTOR and the unfolded protein response in cancer. *Nat Rev Cancer.* 2008;8:851–64.
10. Schneider A, Younis RH, Gutkind JS. Hypoxia-induced energy stress inhibits the mTOR pathway by activating an AMPK/REDD1 signaling axis in head and neck squamous cell carcinoma. *Neoplasia.* 2008;10:1295–302.
11. Tatum JL, Kelloff GJ, Gillies RJ, et al. Hypoxia: importance in tumor biology, noninvasive measurement by imaging, and value of its measurement in the management of cancer therapy. *Int J Radiat Biol.* 2006;82:699–757.
12. Stone HB, Brown JM, Phillips TL, et al. Oxygen in human tumors: correlations between methods of measurement and response to therapy. Summary of a workshop held November 19–20, 1992, at the National Cancer Institute, Bethesda, Maryland. *Radiat Res.* 1993;136:422–34.
13. Le QT, Sutphin PD, Raychaudhuri S, et al. Identification of osteopontin as a prognostic plasma marker for head and neck squamous cell carcinomas. *Clin Cancer Res.* 2003;9:59–67.
14. Raleigh JA, Calkins-Adams DP, Rinker LH, et al. Hypoxia and vascular endothelial growth factor expression in human squamous cell carcinomas using pimonidazole as a hypoxia marker. *Cancer Res.* 1998;58:3765–8.
15. Evans SM, Hahn S, Pook DR, et al. Detection of hypoxia in human squamous cell carcinoma by EF5 binding. *Cancer Res.* 2000;60:2018–24.
16. Varghese AJ, Gulyas S, Mohindra JK. Hypoxia-dependent reduction of 1-(2-nitro-1-imidazolyl)-3-methoxy-2-propanol by Chinese hamster ovary cells and KHT tumor cells in vitro and in vivo. *Cancer Res.* 1976;36:3761–5.
17. Ljungkvist AS, Bussink J, Kaanders JH, et al. Dynamics of tumor hypoxia measured with bioreductive hypoxic cell markers. *Radiat Res.* 2007;167:127–45.
18. Evans SM, Koch CJ. Prognostic significance of tumor oxygenation in humans. *Cancer Lett.* 2003;195:1–16.
19. Kaanders JH, Wijffels KI, Marres HA, et al. Pimonidazole binding and tumor vascularity predict for treatment outcome in head and neck cancer. *Cancer Res.* 2002;62:7066–74.
20. Lee NY, Le QT. New developments in radiation therapy for head and neck cancer: intensity-modulated radiation therapy and hypoxia targeting. *Semin Oncol.* 2008;35:236–50.
21. Krohn KA, Link JM, Mason RP. Molecular imaging of hypoxia. *J Nucl Med.* 2008;49(2):129S–48.
22. Nordmark M, Overgaard J. A confirmatory prognostic study on oxygenation status and loco-regional control in advanced head and neck squamous cell carcinoma treated by radiation therapy. *Radiother Oncol.* 2000;57:39–43.
23. Rudat V, Stadler P, Becker A, et al. Predictive value of the tumor oxygenation by means of pO₂ histography in patients with advanced head and neck cancer. *Strahlenther Onkol.* 2001;177:462–8.
24. Brizel DM, Dodge RK, Clough RW, et al. Oxygenation of head and neck cancer: changes during radiotherapy and impact on treatment outcome. *Radiother Oncol.* 1999;53:113–7.
25. Brizel DM, Prosnitz RG, Hunter S, et al. Necessity for adjuvant neck dissection in setting of concurrent chemoradiation for advanced head-and-neck cancer. *Int J Radiat Oncol Biol Phys.* 2004;58:1418–23.
26. Terris DJ. Head and neck cancer: the importance of oxygen. *Laryngoscope.* 2000;110:697–707.
27. Nordmark M, Bentzen SM, Rudat V, et al. Prognostic value of tumor oxygenation in 397 head and neck tumors after primary radiation therapy. An international multi-center study. *Radiother Oncol.* 2005;77:18–24.
28. Koukourakis MI, Giatromanolaki A, Sivridis E, et al. Hypoxia-inducible factor (HIF1A and HIF2A), angiogenesis, and chemoradiotherapy outcome of squamous cell head-and-neck cancer. *Int J Radiat Oncol Biol Phys.* 2002;53:1192–202.
29. Kyzas PA, Stefanou D, Batistatou A, et al. Hypoxia-induced tumor angiogenic pathway in head and neck cancer: an in vivo study. *Cancer Lett.* 2005;225:297–304.
30. Beasley NJ, Leek R, Alam M, et al. Hypoxia-inducible factors HIF-1alpha and HIF-2alpha in head and neck cancer: relationship to tumor biology and treatment outcome in surgically resected patients. *Cancer Res.* 2002;62:2493–7.
31. Silva P, Slevin NJ, Sloan P, et al. Prognostic significance of tumor hypoxia inducible factor-1alpha expression for outcome after radiotherapy in oropharyngeal cancer. *Int J Radiat Oncol Biol Phys.* 2008;72:1551–9.
32. Aebersold DM, Burri P, Beer KT, et al. Expression of hypoxia-inducible factor-1alpha: a novel predictive and prognostic parameter in the radiotherapy of oropharyngeal cancer. *Cancer Res.* 2001;61:2911–6.
33. Hui EP, Chan AT, Pezzella F, et al. Coexpression of hypoxia-inducible factors 1alpha and 2alpha, carbonic anhydrase IX, and vascular endothelial growth factor in nasopharyngeal carcinoma and relationship to survival. *Clin Cancer Res.* 2002;8:2595–604.
34. Winter SC, Shah KA, Han C, et al. The relation between hypoxia-inducible factor (HIF)-1alpha and HIF-2alpha expression with anemia and outcome in surgically treated head and neck cancer. *Cancer.* 2006;107:757–66.
35. Jonathan RA, Wijffels KI, Peeters W, et al. The prognostic value of endogenous hypoxia-related markers for head and neck squamous cell carcinomas treated with ARCON. *Radiother Oncol.* 2006;79:288–97.
36. Oliver RJ, Woodwards RT, Sloan P, et al. Prognostic value of facilitative glucose transporter Glut-1 in oral squamous cell carcinomas treated by surgical resection; results of EORTC Translational Research Fund studies. *Eur J Cancer.* 2004;40:503–7.
37. Kunkel M, Reichert TE, Benz P, et al. Overexpression of Glut-1 and increased glucose metabolism in tumors are associated with a poor prognosis in patients with oral squamous cell carcinoma. *Cancer.* 2003;97:1015–24.
38. De Schutter H, Landuyt W, Verbeken E, et al. The prognostic value of the hypoxia markers CA IX and GLUT 1 and the cytokines VEGF and IL 6 in head and neck squamous cell carcinoma treated by radiotherapy +/- chemotherapy. *BMC Cancer.* 2005;5:42.
39. Koukourakis MI, Bentzen SM, Giatromanolaki A, et al. Endogenous markers of two separate hypoxia response pathways (hypoxia inducible factor 2 alpha and carbonic anhydrase 9) are associated with radiotherapy failure in head and neck cancer patients recruited in the CHART randomized trial. *J Clin Oncol.* 2006;24:727–35.
40. Schrijvers ML, van der Laan BF, de Bock GH, et al. Overexpression of intrinsic hypoxia markers HIF1alpha and CA-IX predict for local recurrence in stage T1–T2 glottic laryngeal carcinoma treated with radiotherapy. *Int J Radiat Oncol Biol Phys.* 2008;72:161–9.
41. Overgaard J, Eriksen JG, Nordmark M, et al. Plasma osteopontin, hypoxia, and response to the hypoxia sensitiser nimorazole in radiotherapy of head and neck cancer: results from the DAHANCA 5 randomised double-blind placebo-controlled trial. *Lancet Oncol.* 2005;6:757–64.
42. Report of a Medical Research Council Working Party. Radiotherapy and hyperbaric oxygen. *Lancet.* 1978;2:881–4.

43. Dische S, Anderson PJ, Sealy R, et al. Carcinoma of the cervix – anaemia, radiotherapy and hyperbaric oxygen. *Br J Radiol.* 1983;56:251–5.
44. Henk JM, Kunkler PB, Smith CW. Radiotherapy and hyperbaric oxygen in head and neck cancer. Final report of first controlled clinical trial. *Lancet.* 1977;2:101–3.
45. Bennett M, Feldmeier J, Smee R et al. Hyperbaric oxygenation for tumour sensitisation to radiotherapy. *Cochrane Database Syst Rev.* 2005;4:CD005007.
46. Overgaard J, Horsman MR. Modification of hypoxia-induced radioresistance in tumors by the use of oxygen and sensitizers. *Semin Radiat Oncol.* 1996;6:10–21.
47. Kaanders JH, Pop LA, Marres HA, et al. ARCON: experience in 215 patients with advanced head-and-neck cancer. *Int J Radiat Oncol Biol Phys.* 2002;52:769–78.
48. Kaanders JH, Bussink J, van der Kogel AJ. ARCON: a novel biology-based approach in radiotherapy. *Lancet Oncol.* 2002;3:728–37.
49. Evans JC, Bergsjø P. The influence of anemia on the results of radiotherapy in carcinoma of the cervix. *Radiology.* 1965;84:709–17.
50. Denis F, Garaud P, Bardet E, et al. Final results of the 94-01 French Head and Neck Oncology and Radiotherapy Group randomized trial comparing radiotherapy alone with concomitant radiochemotherapy in advanced-stage oropharynx carcinoma. *J Clin Oncol.* 2004;22:69–76.
51. Rades D. Erythropoietin administration during radiotherapy in anaemic head-and-neck cancer patients: is it still a reasonable option or too dangerous? *Oral Oncol.* 2009;45:91–3.
52. Henke M, Laszig R, Rube C, et al. Erythropoietin to treat head and neck cancer patients with anaemia undergoing radiotherapy: randomised, double-blind, placebo-controlled trial. *Lancet.* 2003;362:1255–60.
53. Machtay M, Pajak TF, Suntharalingam M, et al. Radiotherapy with or without erythropoietin for anemic patients with head and neck cancer: a randomized trial of the Radiation Therapy Oncology Group (RTOG 99-03). *Int J Radiat Oncol Biol Phys.* 2007;69:1008–17.
54. Henke M, Mattern D, Pepe M, et al. Do erythropoietin receptors on cancer cells explain unexpected clinical findings? *J Clin Oncol.* 2006;24:4708–13.
55. Bokemeyer C, Aapro MS, Courdi A, et al. EORTC guidelines for the use of erythropoietic proteins in anaemic patients with cancer: 2006 update. *Eur J Cancer.* 2007;43:258–70.
56. Overgaard J, Hansen HS, Andersen AP, et al. Misonidazole combined with split-course radiotherapy in the treatment of invasive carcinoma of larynx and pharynx: report from the DAHANCA 2 study. *Int J Radiat Oncol Biol Phys.* 1989;16:1065–8.
57. Overgaard J, Hansen HS, Overgaard M, et al. A randomized double-blind phase III study of nimorazole as a hypoxic radiosensitizer of primary radiotherapy in supraglottic larynx and pharynx carcinoma. Results of the Danish Head and Neck Cancer Study (DAHANCA) Protocol 5-85. *Radiother Oncol.* 1998;46:135–46.
58. De Ridder M, Van Esch G, Engels B, et al. Hypoxic tumor cell radiosensitization: role of the iNOS/NO pathway. *Bull Cancer.* 2008;95:282–91.
59. Haffty BG, Son YH, Papac R, et al. Chemotherapy as an adjunct to radiation in the treatment of squamous cell carcinoma of the head and neck: results of the Yale Mitomycin Randomized Trials. *J Clin Oncol.* 1007;15:268–76.
60. Dobrowsky W, Naude J, Widder J, et al. Continuous hyperfractionated accelerated radiotherapy with/without mitomycin C in head and neck cancer. *Int J Radiat Oncol Biol Phys.* 1998;42:803–6.
61. Dobrowsky W, Naude J. Continuous hyperfractionated accelerated radiotherapy with/without mitomycin C in head and neck cancers. *Radiother Oncol.* 2000;57:119–24.
62. Gandara DR, Lara Jr PN, Goldberg Z, et al. Tirapazamine: prototype for a novel class of therapeutic agents targeting tumor hypoxia. *Semin Oncol.* 2002;29:102–9.
63. Rischin D, Peters L, Hicks R, et al. Phase I trial of concurrent tirapazamine, cisplatin, and radiotherapy in patients with advanced head and neck cancer. *J Clin Oncol.* 2001;19:535–42.
64. Rischin D, Peters L, Fisher R, et al. Tirapazamine, Cisplatin, and Radiation versus Fluorouracil, Cisplatin, and Radiation in patients with locally advanced head and neck cancer: a randomized phase II trial of the Trans-Tasman Radiation Oncology Group (TROG 98.02). *J Clin Oncol.* 2005;23:79–87.
65. Rischin D, Hicks RJ, Fisher R, et al. Prognostic significance of [18F]-misonidazole positron emission tomography-detected tumor hypoxia in patients with advanced head and neck cancer randomly assigned to chemoradiation with or without tirapazamine: a sub-study of Trans-Tasman Radiation Oncology Group Study 98.02. *J Clin Oncol.* 2006;24:2098–104.
66. Le QT, Taira A, Budenz S, et al. Mature results from a randomized Phase II trial of cisplatin plus 5-fluorouracil and radiotherapy with or without tirapazamine in patients with resectable Stage IV head and neck squamous cell carcinomas. *Cancer.* 2006;106:1940–9.
67. Jain RK. Normalization of tumor vasculature: an emerging concept in antiangiogenic therapy. *Science.* 2005;307:58–62.
68. Winkler F, Kozin SV, Tong RT, et al. Kinetics of vascular normalization by VEGFR2 blockade governs brain tumor response to radiation: role of oxygenation, angiopoietin-1, and matrix metalloproteinases. *Cancer Cell.* 2004;6:553–63.
69. Jain RK, Duda DG, Clark JW, et al. Lessons from phase III clinical trials on anti-VEGF therapy for cancer. *Nat Clin Pract Oncol.* 2006;3:24–40.
70. Bozec A, Sudaka A, Fischel JL, et al. Combined effects of bevacizumab with erlotinib and irradiation: a preclinical study on a head and neck cancer orthotopic model. *Br J Cancer.* 2008;99:93–9.
71. Seiwert TY, Haraf DJ, Cohen EE, et al. Phase I study of bevacizumab added to fluorouracil- and hydroxyurea-based concomitant chemoradiotherapy for poor-prognosis head and neck cancer. *J Clin Oncol.* 2008;26:1732–41.
72. Cohen EE, Davis DW, Karrison TG, et al. Erlotinib and bevacizumab in patients with recurrent or metastatic squamous-cell carcinoma of the head and neck: a phase III study. *Lancet Oncol.* 2009;10:247–57.
73. Elser C, Siu LL, Winquist E, et al. Phase II trial of sorafenib in patients with recurrent or metastatic squamous cell carcinoma of the head and neck or nasopharyngeal carcinoma. *J Clin Oncol.* 2007;25:3766–73.
74. Melillo G. Targeting hypoxia cell signaling for cancer therapy. *Cancer Metastasis Rev.* 2007;26:341–52.
75. Christian N, Lee JA, Bol A, et al. The limitation of PET imaging for biological adaptive-IMRT assessed in animal models. *Radiother Oncol.* 2009;91:101–6.
76. Chao KS, Bosch WR, Mutic S, et al. A novel approach to overcome hypoxic tumor resistance: Cu-ATSM-guided intensity-modulated radiation therapy. *Int J Radiat Oncol Biol Phys.* 2001;49:1171–82.
77. Thorwarth D, Eschmann SM, Paulsen F, et al. Hypoxia dose painting by numbers: a planning study. *Int J Radiat Oncol Biol Phys.* 2007;68:291–300.
78. Lee N, Nehmeh S, Schoder H, et al. Prospective trial incorporating pre-/mid-treatment [(18)F]-misonidazole positron emission tomography for head-and-neck cancer patients undergoing concurrent chemoradiotherapy. *Int J Radiat Oncol Biol Phys.* 2009;75:101–8.
79. Lin Z, Mechalakos J, Nehmeh S, et al. The influence of changes in tumor hypoxia on dose-painting treatment plans based on 18F-FMISO positron emission tomography. *Int J Radiat Oncol Biol Phys.* 2008;70:1219–28.
80. Bourhis J, Lapeyre M, Tortochaux J, et al. Phase III randomized trial of very accelerated radiation therapy compared with conventional radiation therapy in squamous cell head and neck cancer: a GORTEC trial. *J Clin Oncol.* 2006;24:2873–8.
81. Bourhis J, Overgaard J, Audry H, et al. Hyperfractionated or accelerated radiotherapy in head and neck cancer: a meta-analysis. *Lancet.* 2006;368:843–54.

Chapter 11

Translational Research in Head and Neck Oncology

David S. Yoo and David M. Brizel

Abstract Translational research in head and neck oncology has evolved dramatically. Ongoing discoveries in basic mechanisms of cancer biology and technological advances in both diagnostic imaging and radiation delivery have enhanced the ability to improve treatment outcomes. The overarching goal for all translational research should be to enlarge the armamentarium from which clinicians can rationally select the most appropriate options for individual patients in ways that maximize therapeutic benefit and minimize toxicity.

Focusing on this goal will become more critical as the health care system deals with external economic, social, and political pressures and forces that will affect both bench and bedside. As these concerns encroach on the translational process, it is imperative to recognize that the research itself is best equipped to address them – more efficacious treatments, improved patient selection, decreased toxicity.

What also should not be lost in translation is the unpredictable and occasional serendipitous nature of research. Two cornerstones of head and neck cancer therapy, cisplatin [1, 2] and cetuximab, owe their existence to chance and fate. Meanwhile, the compelling story of tumor hypoxia has yet to result in any new additions to the therapeutic arsenal. This chapter will explore the meaning of translational research means, identify potential pitfalls on the horizon, and highlight common themes and new avenues of research using specific examples from both the head and neck and general oncology literature.

Keywords Translational research • Oncology • Targeted therapy • Cetuximab

Introduction

Translational research is not unlike world peace, the meaning of which depends upon whom is asked. But it sounds great, and everyone is for it. Unfortunately, success can be elusive, with many setbacks along the way. Progress requires seeking and forging of new relationships, many times between seemingly unrelated and disparate camps that speak different languages.

The concept of translational research in oncology evokes images of a bridge, spanning and connecting the separate worlds of basic bench research and clinical bedside investigation and treatment. Cellular and molecular discoveries in the laboratory yield clues to underlying mechanisms of disease, identifying novel targets for therapeutic intervention that ultimately improve cancer patient outcomes. The National Cancer Institute expands on this concept, defining translational research as that which “transforms scientific discoveries that arise from laboratory, clinical, or population studies into clinical applications to reduce cancer incidence, morbidity, and mortality” [3].

The discipline of head and neck oncology possesses a strong history of translational research and continues to expand and build upon its foundation of scientific discoveries. Several chapters in this textbook are singularly devoted to epidemiology, genetics, virology, proteomics, predictors and prognosticators, hypoxia, targeted therapies, and functional imaging. Other chapters discuss preclinical models and phase I study methodology. Translational research links these topics together and is ultimately responsible for writing and shaping the current and future chapters on patient management and evidence-based practice.

Roadblocks

One of the ironic aspects of cancer research today is that the sheer avalanche of data and knowledge generated may overwhelm the ability to ask the most appropriate clinical

D.M. Brizel (✉)
Department of Radiation Oncology, Duke University Medical Center,
Morris Building, Science Drive, Durham, NC 27710, USA
e-mail: david.brizel@duke.edu

questions. When the haystack is filled with needles, finding one gives way to the more challenging task of finding the right one. For example, at least 12 different agents target the epidermal growth factor receptor (EGFR) alone [4]. There are four downstream pathways associated with EGFR, and the number of potential therapeutic strategies to shepherd through from conception to daily practice expands geometrically along each signaling cascade [5]. The danger then becomes one of seeing a promising new treatment get lost in the translation.

The Clinical Research Roundtable at the Institute of Medicine (IOM) in their special communication to JAMA in 2003 highlighted an example of one of the dilemmas in translational research [6]. The IOM, comprised of individuals from the fields of nursing, medicine, basic science, public health, medical informatics, insurance companies, industry, and private foundations, described two translational roadblocks that “impede efforts to apply science to better human health in an expeditious fashion.” The first exists when trying to convert basic *in vitro* and *in vivo* laboratory discoveries into novel interventions for human studies. The second occurs in the process of applying the results of these human studies and attempting to integrate them into everyday clinical practice and decision-making. The culprits deemed to be responsible for both blocks including insufficient funding, insufficient infrastructure, lack of qualified personnel, lack of career incentives, and a dearth of willing research subjects.

Much of the emphasis and funding in medical research to date has been placed on trying to overcome the first block. Novel therapeutics and new diagnostic modalities generate great excitement and enthusiasm, translating well not only within the medical profession, but also to the general public as well. Many are now concerned, however, that the second translational block constitutes the greatest bottleneck and is most detrimental to the health outcomes of everyday patients. More people, it has been argued, can be better served by focusing on the appropriate delivery of already proven treatment strategies rather than inventing new ones [7]. For example, the expenditure of effort to develop new and incrementally more efficacious statins or antiplatelet drugs contributes less to the overall societal health than using those same resources to ensure delivery of already available drugs to all eligible patients [8].

US health care expenditures in 2007 totaled \$2.4 trillion, nearly 17% of the gross domestic product (GDP) [9]. Current projections are for this sum to increase to 20% of GDP by 2017. Historically, approximately 5% of this spending has been related to cancer therapy, although this percentage is also expected to rise with the aging US population and the adoption of newer, more expensive technologies and therapies [10]. How much should be spent and what level of care it should buy will require national debate and political intervention, meaning the probability of a rational solution is low.

The growing awareness of the extent to which new cancer treatments contribute to the escalating costs of health care has resulted in urgent calls to police within the oncology community before outside government agencies are mandated to do so. Such external intervention could set up more translational blocks, likely with less precision and more regulation. A recent report from the NIH reviewed four molecular targeted agents – cetuximab, bevacizumab, erlotinib, sorafenib – pinnacles of the translational research effort and compared their “purported” benefits and estimated costs [11]. They highlighted the recent multinational phase III FLEX (First-Line ErbituX) study comparing platinum-based chemotherapy with or without cetuximab as first-line therapy in EGFR-overexpressing nonsmall cell lung cancer patients with either wet stage IIIB or stage IV disease [12]. Patients randomized to the cetuximab arm received a loading dose of 400 mg/m², followed by weekly doses of 250 mg/m² concurrent with up to six cycles of chemotherapy and continuing weekly until disease progression or unacceptable toxicity. The primary endpoint was achieved with a statistically significant increase in median survival from 10.1 to 11.3 months with the addition of cetuximab. Ten percent developed grade 3 acne-like skin toxicity.

The cost of adding cetuximab to 18 weeks of chemotherapy (60 kg patient and \$11.52 per mg of cetuximab) was \$80,352 per patient [11]. Similarly, the addition of the small molecule tyrosine kinase inhibitor erlotinib to gemcitabine in advanced pancreatic cancer increased median survival by 10 days [13] for a cost of \$15,752 [11]. Similar examples were presented for the use of bevacizumab in metastatic breast cancer [14] and sorafenib in renal cell carcinoma [15], emphasizing the tension that exists reconciling the costs of these therapies and their limited impacts on overall survival and/or quality of life.

The EXTREME (ErbituX in first-line Treatment of REcurrent or METastatic head and neck cancer) trial had a very similar design to the FLEX study in lung cancer. In this trial, 442 patients with previously untreated recurrent or metastatic disease not amenable to local therapy were randomized to platinum and 5FU-based chemotherapy alone versus chemotherapy with weekly cetuximab [16]. Those patients with stable disease on concurrent therapy continued with weekly cetuximab until disease progression or unacceptable toxicity. The addition of cetuximab improved median survival from 7.4 to 10.1 months, along with improvements in progression-free survival and response rates.

This increase represented a significant achievement in the recurrent/metastatic setting, the first intervention shown to improve survival in this population since cisplatin over 30 years ago [17]. However, this 2.7-month improvement in EXTREME may face further scrutiny, given the shot across the bow from the NIH regarding the results of FLEX. A typical patient in the USA with a body surface area of 2 mg/m²

would have required 9,300 mg of cetuximab in 18 weeks in the experimental arm of the EXTREME trial at a cost of \$107,136 based on 2008 data. Weekly treatment for 12 months in the setting of stable disease would have received 26,300 mg, which would have cost \$302,976. Neither a privately run nor a publicly administered health care system can sustain this level of expense. A potential doomsday scenario for translational research could result if insurance companies and/or governments decide to offer patients a fraction of that cost to NOT take therapy.

The American Society of Clinical Oncology published the initial deliberations of its Cost of Care Task Force focusing on the perspectives of the different stakeholders in the oncology community – patients, industry, payers, and physicians – and highlighted the need to “define the value of specific cancer interventions” [18]. Some advocate funding restraints on research studies which would place cost limits on experimental interventions depending on their potential survival advantages [11]. In the same vein, some industry stakeholders may decide that certain disease entities, including head and neck cancers, lack the necessary patient numbers and potential market share for allocation of their resources in support of clinical trials.

Common Themes

The story of ICI 46,474, more commonly known as tamoxifen, is an instructive case study. This compound was first developed in the 1970s by Imperial Chemical Industries Ltd. Pharmaceuticals Division (now AstraZeneca) as a postcoital contraceptive [19]. The initial research that established tamoxifen as an antiestrogen capable of controlling hormone-dependent tumors almost did not happen. At the time, the company did not see a financial incentive to market a drug used for a short period of time by a small number of metastatic breast cancer patients, most of who were getting the latest and most promising therapy, cytotoxic chemotherapy combinations. It took the threatened resignation of the Head of Research, serendipity and years of preclinical data before the antitumor activity of tamoxifen was established. Moreover, testing in humans was originally performed in patients with advanced metastatic disease. Although somewhat effective, it was not until tamoxifen was studied in an adjuvant setting that the large benefits in reducing recurrence and improving overall survival were seen in estrogen receptor positive patients [20]. As stated by Dr. Jordan, the man who helped translate tamoxifen into clinical practice, “the key to success was targeting women with the right tumor with the correct duration of treatment at the right stage.”

The right woman, the right tumor, at the right stage – many parallels can be drawn from the tamoxifen story to the

targeted agents of today. Cetuximab’s origins can be traced back to a woman born in the late nineteenth century. What she did for the first eight decades of her life is not known, but at the age of 85, her squamous cell carcinoma of the vulva was harvested and transformed into the immortalized cell line A431 [21]. Eleven years later in 1984, her cell line provided the substrate for the creation of murine monoclonal antibodies against the EGF receptors over-expressed along the cell surface [22]. In 1991, one of these antibodies, mAb 225, was successfully injected and studied in human subjects [23]. By 1995, the chimeric antibody C225, aka cetuximab, was developed to overcome the human antimouse antibody phenomenon that limited the clinical utility of mAb 225 [24].

Head and neck cancer patients with over-expression of EGFR were noted to have a poorer prognosis, providing the rationale for targeted therapy with C225 [25, 26]. Cetuximab has been utilized in a variety of different clinical scenarios since – as a single agent in advanced chemorefractory disease [27], with chemotherapy in the recurrent/metastatic setting [16, 28], with radiation therapy alone in locally advanced but nonmetastatic patients [29], and with concurrent chemoradiation [30]. In refractory patients, single-agent cetuximab showed a median survival of 178 days [27]. The results of EXTREME in previously untreated recurrent/metastatic patients were outlined earlier, showing an increase in median survival from 7.4 to 10.1 months [16]. The phase III pivotal trial from Bonner et al., which compared radiation therapy alone in the definitive setting with or without cetuximab, showed significant improvements in both local control and survival, increasing median survival from 29.3 to 49 months and 3 year overall survival from 45 to 55% [29]. As with tamoxifen, the earlier utilization of cetuximab in the nonmetastatic and treatment-naïve setting demonstrated a more robust improvement in clinical outcomes. Building upon these findings, the RTOG has recently completed enrollment onto a phase III study evaluating whether the addition of cetuximab to definitive chemoradiation can further improve outcome.

The fate of cetuximab and other novel therapeutic agents as they progress through various phases of development highlights several important themes for current and future translational research efforts. As the specificity of these agents toward their molecular targets increases, so too should the process of patient selection in order to optimally use them in various clinical scenarios. The keys to success require several interrelated questions to be addressed: who gets therapy, what agent(s) gets tested, whether to give or not give therapy, scheduling, and sequencing, where is the primary tumor located, and why did things work or not work? Limitations on resources and competition for study patients will prevent all of these questions from being asked. The head and neck oncology community will need to prioritize which ones are most important.

Who Gets Treated

The standard approach for new investigational agents that survive the preclinical gauntlet is to first test them in patients that have failed all known conventional therapies, initially for dose-limiting toxicities and safety and then for efficacy. An exciting and challenging avenue for research is now asking how improvements in outcomes in the recurrent and refractory setting translate in treatment-naïve patients. Are the additional months in median survival outback simply reshuffled upfront? Or are there true qualitative and quantitative improvements in survival, with more cures and less patients going on to require therapy for recurrent or metastatic disease? In head and neck cancer, the EXTREME and Bonner studies suggest the latter.

This has not always been the case. In colorectal cancer, the addition of bevacizumab to irinotecan, bolus fluorouracil, and leucovorin in previously untreated metastatic patients resulted in a statistically significant improvement in survival (median duration 15.6 vs. 20.3 months, HR 0.66, $p < 0.001$) [31]. A similar benefit in overall survival was seen in a phase III ECOG study in patients with previously treated metastatic colorectal cancer. In this trial, the addition of bevacizumab to fluorouracil, leucovorin, and oxaliplatin (FOLFOX) improved median survival from 10.8 to 12.9 months compared to FOLFOX alone [32]. However, the survival benefits of adding bevacizumab to standard of care chemotherapy do not appear to automatically translate in the nonmetastatic setting. Preliminary results from NSABP C-08 showed no statistically significant improvement in disease-free survival with the addition of bevacizumab to FOLFOX in resected stage II–III colon cancer patients [33].

Another more ominous example is a phase III SWOG adjuvant lung cancer study. Patients received definitive concurrent thoracic chemoradiation and consolidation docetaxel chemotherapy with or without the addition of gefitinib, a small molecule EGFR tyrosine kinase inhibitor. Patients receiving gefitinib had a significant decrease in median survival (23 vs. 35 months) [34]. These findings further emphasize the importance that promising preclinical and early phase data for targeted agents must be validated in a rigorous phase III setting before they can be incorporated into widespread clinical practice.

Even then, the translation of successful randomized phase III trials in the phase IV practice setting can encounter unexpected hazards. Cetuximab is associated with an approximate 3–4% incidence of grade 3–4 infusion reactions in the USA. However, in certain geographic locations, the rate of severe anaphylactic hypersensitivity-type reactions approaches 20–25% [35]. In an illustrative example of bedside-to-bench reverse translation, these reactions have been linked to preexisting IgE antibodies that cross-react to a

galactose- α -1,3-galactose moiety that is tagged to the Fab portion of the mouse component of the cetuximab molecule during antibody production [36]. Moreover, preexisting IgE antibodies in the general population were found to be more prevalent in people from Tennessee, Arkansas, and North Carolina (20.8%) as opposed to northern California (6.1%) or Boston (0.6%). The potential increased risk for these severe reactions has limited the enthusiasm for and restricted utilization of cetuximab in pockets of the Southeast USA. It was perhaps serendipitous that C225 was developed in other parts of the country.

Parallels may be drawn to trials examining the addition of concurrent chemotherapy to radiation in nasopharyngeal carcinoma (NPC), a tumor known for significant geographic variability with regards to histology and EBV status. Following the positive results of the Intergroup 0099 trial [37], studies were undertaken throughout Asia to determine whether the significant survival benefit seen in North American patients with a concurrent chemoradiation strategy translated to the endemic form of NPC found more predominantly in that part of the world. Three phase III trials from Taiwan, Singapore, and Hong Kong confirmed a survival benefit with concurrent chemoradiation versus radiation alone [38–40]. However, preliminary results from a fourth study with nonkeratinizing/undifferentiated histology patients from Hong Kong and Canada showed no survival benefit but increased acute and late toxicity with concurrent chemoradiation [41]. Whether regional or demographic differences in efficacy and/or toxicity will be discovered with targeted therapies remains to be seen.

The question of who gets certain therapies is further complicated by the growing awareness of a likely causal association between certain subsets of head and neck cancers and the human papillomavirus (HPV) [42]. These double-stranded DNA viruses have survived millennia in the inhospitable terminally differentiated epithelia of higher level organisms, cleverly restarting their nondividing hosts' replication machinery by inactivating both the p53 and pRb tumor suppressors. The first suggestion of HPV involvement in head and neck cancer came in 1983 based on histopathologic findings seen in a subset of oral squamous cell carcinomas similar to those caused by HPV in the uterine cervix [43]. Detection of high risk HPV16 DNA in tonsil cancer specimens came in 1990 [44]. Multiple retrospective series and a subsequent meta-analysis suggested that patients with HPV-positive oropharyngeal tumors had improved disease-free and overall survival, with a 28% reduced risk of death compared to HPV-negative patients [45]. The prognostic significance of HPV status was demonstrated prospectively in 96 patients from a phase II ECOG study examining an induction chemotherapy regimen followed by chemoradiation [46]. Patients with HPV-positive tumors had higher response rates to chemotherapy and chemoradiation, as well

as a 2-year overall survival of 95% [95% CI=87–100%] versus 62% [95% CI=49–74%] for the HPV-negative patients.

The improved outcomes and atypical presentations (younger age, female, lack of prior tobacco and alcohol use) of HPV-positive head and neck cancer patients suggest these tumors may represent a distinct clinical entity [47]. Given the potential for confounding of clinical trial results, future translational studies in head and neck cancer will likely need to stratify patients according to HPV status [48]. RTOG 0619, discussed below, includes stratification of oropharyngeal primary tumors by HPV status. Moreover, the excellent prognosis of HPV-positive patients has further implications regarding the future direction of treatment strategies that incorporate novel translational therapies. The question arises whether intensive concurrent regimens using radiation, chemotherapy, and molecular targeted agents are necessary for optimal tumor control in HPV-positive patients or are they just more toxic. Therefore, strategies for deintensification of therapy in this subset of patients, including radiation dose reduction and/or combining radiation with lower doses of cisplatin chemotherapy or with well-tolerated targeted agents in lieu of chemotherapy, will likely be emphasized in the near future.

What

With more stratification and potential reclassification of HPV-positive patients into a separate disease entity, the already small pie of head and neck cancer eligible to participate in clinical trials could get sliced further, reducing the ability to definitively answer study questions. RTOG 9003, the largest trial in head and neck cancer, needed over 6 years to enroll 1,113 patients [49]. Already, the increasing number of investigational agents has likely outgrown the number of people available for enrollment in clinical trials and the resources available to conduct them. To date, the RTOG has opened four head and neck protocols with targeted agents. Three are closed to accrual, 0234 and 522 with cetuximab, and 0615 with bevacizumab in NPC. The open 0619 study examines the addition of vandetanib, a dual EGFR and VEGFR tyrosine kinase inhibitor, to cisplatin in high-risk postoperative patients with extracapsular extension and/or microscopic positive margins. During the initial conception of 0619, the authors tallied the number of ongoing phase I/II studies in head and neck cancer with targeted agents, noting 32 trials involving cetuximab, gefitinib, erlotinib, panitumumab, celecoxib, bevacizumab, and lapatinib.

The study of one agent at a time is challenging enough, with or without radiation, with or without chemotherapy. Another area of increasing interest involves targeting multiple signaling pathways at once, either with multiagent

cocktails or more promiscuous inhibitors such as vandetanib. The rationale for this approach has been the limited clinical utility seen with single targeted agents alone and the redundancy of signaling pathways. Despite the fact that a majority of head and neck tumors have EGFR over-expression, cetuximab with radiation therapy still showed a 50% local recurrence rate in the Bonner trial [29].

This fact is not surprising, given the complexity of the molecular signaling pathways involved in the pathogenesis of head and neck cancers [50]. Preclinical studies have shown significant cross-talk, with both direct and indirect associations between the various signaling cascades, providing alternative routes to bypass inhibition of one pathway [51]. Already, the simultaneous inhibition of the EGFR and VEGF pathways with erlotinib and bevacizumab has been studied in the recurrent/metastatic setting, showing the combination was well tolerated and potentially more efficacious in a subset of patients with molecular evidence of activated pathways [52]. At Duke University, a phase I/II trial examining the use of erlotinib, bevacizumab, and concurrent cisplatin with hyperfractionated radiation therapy in treatment-naïve, locally advanced nonmetastatic patients has recently completed accrual. Median follow-up is 2 years, and the results have been promising, with only 2 of the 28 patients having had a local recurrence. The trial design has also incorporated companion studies with serial functional imaging scans and serum samples collected at time points before, during, and after the completion of therapy. The goal is to help identify potentially predictive and/or prognostic factors that correlate with treatment outcomes, improving the selection of patients for targeted therapies in the future.

However, more is not always better. The Dutch CAIRO2 study in metastatic colorectal cancer found that the addition of cetuximab to capecitabine, oxaliplatin, and bevacizumab lead to a decrease in progression-free survival and quality of life [53]. The search for molecular rationales, including mechanisms of resistance, will require more bench research to help translate these unexpected bedside findings.

When

Clearly, not every patient benefits from the administration of targeted therapies. Even with the potential for more dramatic clinical improvements in the definitive and nonmetastatic setting, it does not appear economically feasible to incorporate one or two (or more) targeted therapies into the treatment regimen of every patient that presents de novo with locally advanced head and neck cancer. Finding biomarkers and molecular assays that can reliably predict who might respond favorably to certain agents and when they should be utilized is a key emphasis of ongoing studies. In colorectal

cancer, patients with EGFR expressing tumors and unresectable metastatic disease were randomized to FOLFIRI chemotherapy with or without cetuximab. Tumor KRAS gene mutation status was also examined. A progression-free survival benefit for cetuximab was limited to those patients with wild-type KRAS [54]. In the previously mentioned phase I/II study examining erlotinib and bevacizumab in recurrent/metastatic head and neck cancer, patients with increased phosphorylation of VEGFR in tumors and EGFR in endothelial cells were more likely to have complete responses [52]. Another study examining cisplatin and erlotinib in recurrent/metastatic head and neck patients found a correlation between improved treatment response and high EGFR gene copy number [55]. More robust and clinically applicable prognostic and/or predictive tools will be identified and validated. In fact, given the current climate, research that results in the more judicious use of novel therapies is mission critical to the viability and support of future translational studies.

The ability to identify responders versus nonresponders to targeted therapy early on in the treatment course would further improve patient selection and efficacy, providing guidance on when changes in therapy should be made. Recent trials with targeted agents have incorporated correlative studies with functional imaging modalities to noninvasively and serially assess the tumor microenvironment and monitor any possible treatment-related changes. Tools such as dynamic contrast-enhanced MRI (DCE-MRI) and PET-based assays attempt to capture novel information based on the underlying tumor biology, yielding potentially prognostic and predictive information to augment the anatomically based TNM staging system. For example, many antiangiogenic targeted agents exert their effects on tumor perfusion and vascular permeability, physiologic processes that can be quantitatively measured with DCE-MRI [56]. In breast cancer, early changes in tumor microvessel functionality as monitored by changes in DCE-MRI signaling predicted final clinical and pathologic response to neoadjuvant chemotherapy [57]. Other DCE-MRI parameters have also correlated with local control, disease-free, and overall survival in multiple tumor sites, including lung, cervix, and head and neck [58–63].

How

The question of how to optimally incorporate novel therapeutic agents in radiation-based treatment regimens is an active area of research. One limitation of the Bonner cetuximab trial that likely impacted widespread accrual and subsequent acceptance into clinical practice was the use of a control arm in the study that utilized radiation therapy alone in locally advanced patients. Based on the meta-analysis of Chemotherapy in Head and Neck Cancer (MACH-NC), which

examined updated patient data on 16,485 patients from 87 trials published between 1965 and 2000, the addition of chemotherapy to radiation provided an absolute benefit of 4.5% at 5 years with a hazard ratio of 0.88 [64]. This benefit was more pronounced (6.5% at 5 years, HR 0.81) with the concomitant use of chemotherapy and radiation as compared to induction or adjuvant strategies.

The RTOG is addressing in two phase III trials whether the addition of targeted agents to current standards of care in both locally advanced and high-risk postoperative patients provides further benefit. RTOG 0522 asks whether cetuximab improves outcome when added to concurrent chemoradiation in the definitive setting while RTOG 0619, as described previously, is testing whether vandetanib improves upon combined modality therapy in high-risk postoperative patients. How novel targeted agents are incorporated into subsequent treatment regimens will be a critical area of ongoing research. Potential improvements in efficacy will need to be balanced against any increases seen in acute and late toxicity. In this context, tools to improve patient selection will play increasingly more important roles to optimally match treatment regimens of varying intensities to individual patients in order to optimize their therapeutic ratio.

The addition of targeted agents to concurrent chemoradiation may represent the evolution of a new standard of care for patients with high-risk, poor prognosis disease. In other clinical scenarios, such as HPV-positive patients with better prognoses where chemotherapy may not be necessary or in elderly patients where the addition of chemotherapy may only increase toxicity, targeted agents may ultimately replace concurrent chemotherapy [65]. For example, the use of lapatinib with concurrent chemoradiation is being evaluated in locally advanced head and neck patients [66]. At the same time, others are examining lapatinib with radiation therapy alone in locally advanced patients who cannot tolerate chemoradiation [67].

One hypothesis-generating result from Bonner's pivotal trial arises from the differences in survival seen between those patients who received cetuximab with altered fractionation versus conventional daily treatment schedules. Subset analyses showed that patients treated with concomitant boost regimens had a hazard ratio (HR) of 0.62 while the hyperfractionation group had a HR=0.74. No difference in survival was seen in those patients who underwent conventional fractionation (HR=1.01) [29]. This suggests that a trial design that utilized only conventional radiation with cetuximab would have resulted in a negative study.

Determining the optimal radiation fractionation schedules to use with the various targeted agents may present an ongoing challenge. Sobering parallels may be drawn from the now nearly completed search for the ideal schedule to use with decades-old systemic agents. Results from the recently updated MACH-NC suggest that the survival benefit seen with concurrent chemotherapy is similar irrespective of the

radiation fractionation regimen utilized (conventional HR 0.83 [95% CI 0.78–0.88] vs. altered HR 0.73 [95% CI 0.65–0.82] $p=0.14$) [64]. The results of RTOG 0129, which tests conventional versus accelerated fractionation, will help to determine the optimal radiation fractionation scheme to use with platinum-based chemotherapy. To re-emphasize the fact that more does not always mean better, a GORTEC phase III study showed no difference in progression-free survival at 3 years between accelerated versus conventional radiation therapy with concomitant carboplatin and 5-FU [68].

Where

The location of the primary tumor site has been suggested to influence survival. A multivariate analysis of 492 patients showed better prognosis in patients treated for larynx and nasopharyngeal tumors compared to those with oropharynx, oral cavity, and hypopharyngeal primaries [69]. In another series of locally advanced patients treated with intra-arterial cisplatin and radiation (RADPLAT), those with hypopharyngeal primaries were more likely to develop distant metastases (odds ratio 2.8) compared to patients with oral cavity, oropharynx, or laryngeal tumors [70]. In the Bonner trial, 253 of the 424 patients in the study had oropharyngeal tumors. On subgroup analysis, these patients appeared to derive the greatest benefits in locoregional control and survival from the addition of cetuximab [29]. Whether or not this benefit reflects the influence of HPV-associated malignancy in the oropharynx is unknown.

These findings further underscore the complexities facing the successful translation of targeted agents into clinical practice. Future prospective trials will likely need to focus on specific head and neck cancer subsites to avoid potential dilution of successful outcomes by the inclusion of possibly “non-responding” patients. In the case of oropharyngeal tumors, these will need to be further subdivided according to HPV status. At the same time, excessive stratification and selection of patients may severely cripple study power and applicability of results to the general head and neck cancer population.

Why

The need to confirm hypotheses in prospective trials is highlighted by several pitfalls in the translation of the very logical and rational hypoxia story into clinical practice. Since 1912, when Swartz observed less severe skin reactions when a radiation source compressed the surrounding blood flow, careful clinical and laboratory research has subsequently

established the significant role hypoxia plays in cancer progression and increased resistance to radiation and chemotherapy [71, 72]. In head and neck cancer, studies directly measuring pretreatment intratumoral oxygenation levels in primary tumors and lymph node metastases using polarographic electrode techniques predicted for response to radiation therapy [73] and was prognostic for disease-free survival [74]. More recent studies have focused on less invasive methods such as hypoxia-related biomarkers and functional imaging studies to correlate tumor hypoxia with treatment-related outcomes [75]. Using tissue samples from RTOG 90-03 patients, expression of lysyl oxidase, a hypoxia-related protein, was shown to be strongly associated with increased metastases, disease progression, and death [76].

This rationale led to the testing of therapeutic strategies designed to ameliorate or target hypoxia. Anemia, which contributes to tumor hypoxia, is associated with inferior outcomes following both radiotherapy alone and concurrent chemoradiation [77–79]. However, correction of anemia has not improved treatment outcome in prospective trials. In one series of patients treated with sequential chemotherapy followed by chemoradiation, the use of blood transfusions to maintain hemoglobin levels >12 g/dL was associated with worse survival [80]. Two randomized DAHANCA studies that incorporated blood transfusions for low hemoglobin levels showed no benefit [81, 82].

Both erythropoietin [83] and darbepoietin alfa [84] reversed the effects of anemia on radiation response in pre-clinical models. Moreover, a retrospective study of patients treated with neoadjuvant chemoradiation and surgery for oral cavity/oropharyngeal cancers, the use of recombinant human erythropoietin completely abrogated the negative prognostic impact associated with hemoglobin levels <14.5 g/dL [85]. However, two randomized phase III trials showed no benefit to the addition of erythropoietin in anemic HNC patients undergoing radiation therapy [86, 87]. In fact, the Henke study resulted in poorer disease control and survival in patients randomized to receive erythropoietin [86]. A randomized study in cervix cancer patients was closed prematurely due to concern for increased thromboembolic events with erythropoietin [88]. A Cochrane review including 13,933 cancer patients in 53 trials showed that erythropoiesis-stimulating agents were associated with increases in on-study mortality and worse overall survival [89]. These unexpected clinical findings stimulated laboratory research that demonstrated expression of erythropoietin receptors on tumor cells in a variety of malignancies, including squamous cell carcinomas of the head and neck [90]. Potential erythropoietin-mediated signaling mechanisms responsible for increased cancer cell survival have been implicated [91, 92].

An alternate strategy of specifically targeting hypoxic cancer cells led to the study of bioreductive agents such as tirapazamine [93]. Preclinical data showed preferential

cytotoxicity to hypoxic tumor cells, and early phase I/II data demonstrated encouraging results when this agent was combined with chemotherapy and/or radiation [94–96]. However, two randomized phase III studies have shown no benefit from the addition of tirapazamine to radiation and chemotherapy. The HEADSTART trial showed no benefit in patients with locally advanced HNC treated to 70 Gy with three cycles of concurrent cisplatin [97]. The TRACE study, which used the same treatment scheme, was terminated early due to excessive mortality in the experimental tirapazamine arm [98]. Unfortunately, no systematic assessment of tumor hypoxia was performed in either of these trials. Studies using electrode and PET-based techniques suggest that approximately one third to one half of HNC patients do not have significant levels of tumor hypoxia [99, 100]. Therefore, it is possible that both of these trials were “biologically underpowered” to address the hypoxia question which was being investigated.

Translational studies using functional imaging modalities that correlate with tumor hypoxia may better identify candidates for hypoxia-targeted therapy [101]. A substudy of TROG-98.02 using 18-F misonidazole-PET to image tumor hypoxia found a significantly higher risk of locoregional failure in hypoxic patients who received concurrent chemotherapy compared to those who also received tirapazamine [100]. The ability to image hypoxia-specific regions with PET and/or functional MRI may further allow for physical targeting and treatment intensification with radiation techniques such as intensity-modulated radiation therapy [102]. However, significant daily fluctuations in tumor hypoxia imaging have been seen in as many as 30% of patients [103]. This suggests widespread clinical application will require further translational research into the dynamic nature of these processes studied by functional imaging modalities – vascular permeability, perfusion, and metabolism.

Conclusion

Successful translational research will help to define new standards of care by improving the therapeutic ratio between treatment efficacy and toxicity. Better prognostic tools and more robust predictive assays will help to improve patient selection, stratifying patients to appropriate intensifications or deintensifications of therapy, and identifying those most likely to benefit from various treatments. In future trials, enriching the study population with those most likely to need and respond to certain therapies will hopefully magnify any potential improvements in outcome, in turn lowering the number of subjects needed to detect statistically significant differences. This is especially critical for head and neck cancer where the eligible patient pool from which to draw is smaller than other disease sites.

New experimental therapies will need to be built on the foundation of prior successes, incorporating themselves into optimized standard of care regimens. Due to increasing economic constraints, leadership and guidance will likely need to come from the large umbrella cooperative groups such as the RTOG and EORTC regarding trial design and priorities. The design of trials should continue to combine treatment interventions with various correlative studies to identify and validate predictors that will help determine who benefits most from specific therapies. Strategic plans within RTOG have been discussed to improve the ability to perform more successful translational studies – tissue banking, seed grants, bioinformatics, and statistical support [104].

The war on cancer has seen decades of translational research create a new generation of targeted weapons with increasing specificity and accuracy. The danger now lies in using these agents to carpet-bomb entire patient populations, failing to commit the same level of resources to identifying the correct human targets.

References

1. Fricker SP. Metal based drugs: from serendipity to design. *Dalton Trans.* 2007 Nov 21; (43):4903–17.
2. Rosenberg B. Possible mechanisms for the antitumor activity of platinum coordination complexes. *Cancer Chemother Rep.* 1975;59(3):589–98.
3. National Cancer Institute. <http://www.cancer.gov/trwg/TRWG-definition-and-TR-continuum>. [cited July 20, 2009]; Available from: <http://www.cancer.gov/trwg/TRWG-definition-and-TR-continuum>. Accessed 2011.
4. Karamouzis MV, Grandis JR, Argiris A. Therapies directed against epidermal growth factor receptor in aerodigestive carcinomas. *JAMA.* 2007;298(1):70–82.
5. Egloff AM, Grandis JR. Targeting epidermal growth factor receptor and SRC pathways in head and neck cancer. *Semin Oncol.* 2008;35(3):286–97.
6. Sung NS, Crowley Jr WF, Genel M, et al. Central challenges facing the national clinical research enterprise. *JAMA.* 2003;289(10):1278–87.
7. Woolf SH. The meaning of translational research and why it matters. *JAMA.* 2008;299(2):211–3.
8. Woolf SH, Johnson RE. The break-even point: when medical advances are less important than improving the fidelity with which they are delivered. *Ann Fam Med.* 2005;3(6):545–52.
9. NCHC. Facts about Healthcare – Health Insurance Costs. [cited July 22, 2009]; Available from: <http://nchc.org/facts-resources/fact-sheet-cost>. Accessed 2011.
10. Institute NC. Cancer Trends Progress Report – 2007 Update. 2007 [cited August 1, 2009]; Available from: <http://progressreport.cancer.gov>. Accessed 2011.
11. Fojo T, Grady C. How much is life worth: cetuximab, non-small cell lung cancer, and the \$440 billion question. *J Natl Cancer Inst.* 2009;101(15):1044–8.
12. Pirker R, Pereira JR, Szczesna A, et al. Cetuximab plus chemotherapy in patients with advanced non-small-cell lung cancer (FLEX): an open-label randomised phase III trial. *Lancet.* 2009; 373(9674):1525–31.
13. Moore MJ, Goldstein D, Hamm J, et al. Erlotinib plus gemcitabine compared with gemcitabine alone in patients with advanced pancreatic cancer: a phase III trial of the National

- Cancer Institute of Canada Clinical Trials Group. *J Clin Oncol*. 2007;25(15):1960–6.
14. Miller K, Wang M, Gralow J, et al. Paclitaxel plus bevacizumab versus paclitaxel alone for metastatic breast cancer. *N Engl J Med*. 2007;357(26):2666–76.
 15. Escudier B, Eisen T, Stadler WM, et al. Sorafenib in advanced clear-cell renal-cell carcinoma. *N Engl J Med*. 2007;356(2):125–34.
 16. Vermorken JB, Mesia R, Rivera F, et al. Platinum-based chemotherapy plus cetuximab in head and neck cancer. *N Engl J Med*. 2008;359(11):1116–27.
 17. Wittes RE, Cvitkovic E, Shah J, Gerold FP, Strong EW. CIS-Dichlorodiammineplatinum(II) in the treatment of epidermoid carcinoma of the head and neck. *Cancer Treat Rep*. 1977;61(3):359–66.
 18. Meropol NJ, Schrag D, Smith TJ, et al. American Society of Clinical Oncology Guidance Statement: The Cost of Cancer Care. *J Clin Oncol*. 2009.
 19. Jordan VC. Tamoxifen: catalyst for the change to targeted therapy. *Eur J Cancer*. 2008;44(1):30–8.
 20. Early Breast Cancer Trialists' Collaborative Group. Tamoxifen for early breast cancer: an overview of the randomised trials. *Lancet*. 1998;351(9114):1451–67.
 21. Giard DJ, Aaronson SA, Todaro GJ, et al. In vitro cultivation of human tumors: establishment of cell lines derived from a series of solid tumors. *J Natl Cancer Inst*. 1973;51(5):1417–23.
 22. Masui H, Kawamoto T, Sato JD, Wolf B, Sato G, Mendelsohn J. Growth inhibition of human tumor cells in athymic mice by anti-epidermal growth factor receptor monoclonal antibodies. *Cancer Res*. 1984;44(3):1002–7.
 23. Divgi CR, Welt S, Kris M, et al. Phase I and imaging trial of indium 111-labeled anti-epidermal growth factor receptor monoclonal antibody 225 in patients with squamous cell lung carcinoma. *J Natl Cancer Inst*. 1991;83(2):97–104.
 24. Goldstein NI, Prewett M, Zuklys K, Rockwell P, Mendelsohn J. Biological efficacy of a chimeric antibody to the epidermal growth factor receptor in a human tumor xenograft model. *Clin Cancer Res*. 1995;1(11):1311–8.
 25. Rubin Grandis J, Melhem MF, Gooding WE, et al. Levels of TGF- α and EGFR protein in head and neck squamous cell carcinoma and patient survival. *J Natl Cancer Inst*. 1998;90(11):824–32.
 26. Ang KK, Berkey BA, Tu X, et al. Impact of epidermal growth factor receptor expression on survival and pattern of relapse in patients with advanced head and neck carcinoma. *Cancer Res*. 2002;62(24):7350–6.
 27. Vermorken JB, Trigo J, Hitt R, et al. Open-label, uncontrolled, multicenter phase II study to evaluate the efficacy and toxicity of cetuximab as a single agent in patients with recurrent and/or metastatic squamous cell carcinoma of the head and neck who failed to respond to platinum-based therapy. *J Clin Oncol*. 2007;25(16):2171–7.
 28. Burtneß B, Goldwasser MA, Flood W, Mattar B, Forastiere AA. Phase III randomized trial of cisplatin plus placebo compared with cisplatin plus cetuximab in metastatic/recurrent head and neck cancer: an Eastern Cooperative Oncology Group study. *J Clin Oncol*. 2005;23(34):8646–54.
 29. Bonner JA, Harari PM, Giralt J, et al. Radiotherapy plus cetuximab for squamous-cell carcinoma of the head and neck. *N Engl J Med*. 2006;354(6):567–78.
 30. Radiation Therapy Oncology Group. Head and Neck Cancer Protocols. [cited August 1 2009]; Available from <http://www.rtog.org/ClinicalTrials/ProtocolTable/StudyDetails.aspx?study=0522>. Accessed 2011.
 31. Hurwitz H, Fehrenbacher L, Novotny W, et al. Bevacizumab plus irinotecan, fluorouracil, and leucovorin for metastatic colorectal cancer. *N Engl J Med*. 2004;350(23):2335–42.
 32. Giantonio BJ, Catalano PJ, Meropol NJ, et al. Bevacizumab in combination with oxaliplatin, fluorouracil, and leucovorin (FOLFOX4) for previously treated metastatic colorectal cancer: results from the Eastern Cooperative Oncology Group Study E3200. *J Clin Oncol*. 2007;25(12):1539–44.
 33. Allegra CJ, Yothers G, O'Connell MJ, et al. Initial safety report of NSABP C-08: a randomized phase III study of modified FOLFOX6 with or without bevacizumab for the adjuvant treatment of patients with stage II or III colon cancer. *J Clin Oncol*. 2009;27(20):3385–90.
 34. Kelly K, Chansky K, Gaspar LE, et al. Phase III trial of maintenance gefitinib or placebo after concurrent chemoradiotherapy and docetaxel consolidation in inoperable stage III non-small-cell lung cancer: SWOG S0023. *J Clin Oncol*. 2008;26(15):2450–6.
 35. O'Neil BH, Allen R, Spigel DR, et al. High incidence of cetuximab-related infusion reactions in Tennessee and North Carolina and the association with atopic history. *J Clin Oncol*. 2007;25(24):3644–8.
 36. Chung CH, Mirakhur B, Chan E, et al. Cetuximab-induced anaphylaxis and IgE specific for galactose- α -1, 3-galactose. *N Engl J Med*. 2008;358(11):1109–17.
 37. Al-Sarraf M, LeBlanc M, Giri PG, et al. Chemoradiotherapy versus radiotherapy in patients with advanced nasopharyngeal cancer: phase III randomized Intergroup study 0099. *J Clin Oncol*. 1998;16(4):1310–7.
 38. Chan AT, Leung SF, Ngan RK, et al. Overall survival after concurrent cisplatin-radiotherapy compared with radiotherapy alone in locoregionally advanced nasopharyngeal carcinoma. *J Natl Cancer Inst*. 2005;97(7):536–9.
 39. Lin JC, Jan JS, Hsu CY, Liang WM, Jiang RS, Wang WY. Phase III study of concurrent chemoradiotherapy versus radiotherapy alone for advanced nasopharyngeal carcinoma: positive effect on overall and progression-free survival. *J Clin Oncol*. 2003;21(4):631–7.
 40. Wee J, Tan EH, Tai BC, et al. Randomized trial of radiotherapy versus concurrent chemoradiotherapy followed by adjuvant chemotherapy in patients with American Joint Committee on Cancer/International Union against cancer stage III and IV nasopharyngeal cancer of the endemic variety. *J Clin Oncol*. 2005;23(27):6730–8.
 41. Lee AW, Lau WH, Tung SY, et al. Preliminary results of a randomized study on therapeutic gain by concurrent chemotherapy for regionally-advanced nasopharyngeal carcinoma: NPC-9901 Trial by the Hong Kong Nasopharyngeal Cancer Study Group. *J Clin Oncol*. 2005;23(28):6966–75.
 42. Gillison ML, Koch WM, Capone RB, et al. Evidence for a causal association between human papillomavirus and a subset of head and neck cancers. *J Natl Cancer Inst*. 2000;92(9):709–20.
 43. Syrjanen K, Syrjanen S, Lamberg M, Pyrhonen S, Nuutinen J. Morphological and immunohistochemical evidence suggesting human papillomavirus (HPV) involvement in oral squamous cell carcinogenesis. *Int J Oral Surg*. 1983;12(6):418–24.
 44. Niedobitek G, Pitteroff S, Herbst H, et al. Detection of human papillomavirus type 16 DNA in carcinomas of the palatine tonsil. *J Clin Pathol*. 1990;43(11):918–21.
 45. Ragin CC, Taioli E. Survival of squamous cell carcinoma of the head and neck in relation to human papillomavirus infection: review and meta-analysis. *Int J Cancer*. 2007;121(8):1813–20.
 46. Fakhry C, Westra WH, Li S, et al. Improved survival of patients with human papillomavirus-positive head and neck squamous cell carcinoma in a prospective clinical trial. *J Natl Cancer Inst*. 2008;100(4):261–9.
 47. Vidal L, Gillison ML. Human papillomavirus in HNSCC: recognition of a distinct disease type. *Hematol Oncol Clin North Am*. 2008;22(6):1125–42. vii.
 48. Gillison ML. Human papillomavirus and prognosis of oropharyngeal squamous cell carcinoma: implications for clinical research in head and neck cancers. *J Clin Oncol*. 2006;24(36):5623–5.
 49. Fu KK, Pajak TF, Trotti A, et al. A Radiation Therapy Oncology Group (RTOG) phase III randomized study to compare hyperfractionation and two variants of accelerated fractionation to standard fractionation radiotherapy for head and neck squamous cell carcinomas: first report of RTOG 9003. *Int J Radiat Oncol Biol Phys*. 2000;48(1):7–16.

50. Molinolo AA, Amornphimoltham P, Squarize CH, Castilho RM, Patel V, Gutkind JS. Dysregulated molecular networks in head and neck carcinogenesis. *Oral Oncol.* 2009;45(4–5):324–34.
51. Matta A, Ralhan R. Overview of current and future biologically based targeted therapies in head and neck squamous cell carcinoma. *Head Neck Oncol.* 2009;1(1):6.
52. Cohen EE, Davis DW, Karrison TG, et al. Erlotinib and bevacizumab in patients with recurrent or metastatic squamous-cell carcinoma of the head and neck: a phase I/II study. *Lancet Oncol.* 2009;10(3):247–57.
53. Tol J, Koopman M, Cats A, et al. Chemotherapy, bevacizumab, and cetuximab in metastatic colorectal cancer. *N Engl J Med.* 2009;360(6):563–72.
54. Van Cutsem E, Kohne CH, Hitre E, et al. Cetuximab and chemotherapy as initial treatment for metastatic colorectal cancer. *N Engl J Med.* 2009;360(14):1408–17.
55. Agulnik M, da Cunha Santos G, Hedley D, et al. Predictive and pharmacodynamic biomarker studies in tumor and skin tissue samples of patients with recurrent or metastatic squamous cell carcinoma of the head and neck treated with erlotinib. *J Clin Oncol.* 2007;25(16):2184–90.
56. Hylton N. Dynamic contrast-enhanced magnetic resonance imaging as an imaging biomarker. *J Clin Oncol.* 2006;24(20):3293–8.
57. Ah-See ML, Makris A, Taylor NJ, et al. Early changes in functional dynamic magnetic resonance imaging predict for pathologic response to neoadjuvant chemotherapy in primary breast cancer. *Clin Cancer Res.* 2008;14(20):6580–9.
58. Baba Y, Yamashita Y, Onomichi M. Dynamic MR imaging and radiotherapy. *Magn Reson Med Sci.* 2002;1(1):32–7.
59. Hoskin PJ, Saunders MI, Goodchild K, Powell ME, Taylor NJ, Baddeley H. Dynamic contrast enhanced magnetic resonance scanning as a predictor of response to accelerated radiotherapy for advanced head and neck cancer. *Br J Radiol.* 1999;72(863):1093–8.
60. Loncaster JA, Carrington BM, Sykes JR, et al. Prediction of radiotherapy outcome using dynamic contrast enhanced MRI of carcinoma of the cervix. *Int J Radiat Oncol Biol Phys.* 2002;54(3):759–67.
61. Ohno Y, Nogami M, Higashino T, et al. Prognostic value of dynamic MR imaging for non-small-cell lung cancer patients after chemoradiotherapy. *J Magn Reson Imaging.* 2005;21(6):775–83.
62. Tomura N, Omachi K, Sakuma I, et al. Dynamic contrast-enhanced magnetic resonance imaging in radiotherapeutic efficacy in the head and neck tumors. *Am J Otolaryngol.* 2005;26(3):163–7.
63. Yamashita Y, Baba T, Baba Y, et al. Dynamic contrast-enhanced MR imaging of uterine cervical cancer: pharmacokinetic analysis with histopathologic correlation and its importance in predicting the outcome of radiation therapy. *Radiology.* 2000;216(3):803–9.
64. Pignon JP, le Maitre A, Maillard E, Bourhis J. Meta-analysis of chemotherapy in head and neck cancer (MACH-NC): an update on 93 randomised trials and 17, 346 patients. *Radiother Oncol.* 2009;92(1):4–14.
65. Pignon JP, le Maitre A, Bourhis J. Meta-analyses of chemotherapy in head and neck cancer (MACH-NC): an update. *Int J Radiat Oncol Biol Phys.* 2007;69(2 Suppl):S112–4.
66. Harrington KJ, El-Hariry IA, Holford CS, et al. Phase I study of lapatinib in combination with chemoradiation in patients with locally advanced squamous cell carcinoma of the head and neck. *J Clin Oncol.* 2009;27(7):1100–7.
67. Le QT, Raben D. Integrating biologically targeted therapy in head and neck squamous cell carcinomas. *Semin Radiat Oncol.* 2009;19(1):53–62.
68. Bourhis J, Sire C, Lapeyre M, et al. Accelerated versus conventional radiotherapy with concomitant chemotherapy in locally advanced head and neck carcinomas: results of a phase III randomized trial. *Int J Radiat Oncol Biol Phys.* 2008;72(1):S31–2.
69. Cerezo L, Millan I, Torre A, Aragon G, Otero J. Prognostic factors for survival and tumor control in cervical lymph node metastases from head and neck cancer. A multivariate study of 492 cases. *Cancer.* 1992;69(5):1224–34.
70. Doweck I, Robbins KT, Vieira F. Analysis of risk factors predictive of distant failure after targeted chemoradiation for advanced head and neck cancer. *Arch Otolaryngol Head Neck Surg.* 2001;127(11):1315–8.
71. Bernier J, Hall EJ, Giaccia A. Radiation oncology: a century of achievements. *Nat Rev Cancer.* 2004;4(9):737–47.
72. Vaupel P, Mayer A. Hypoxia in cancer: significance and impact on clinical outcome. *Cancer Metastasis Rev.* 2007;26(2):225–39.
73. Nordsmark M, Overgaard M, Overgaard J. Pretreatment oxygenation predicts radiation response in advanced squamous cell carcinoma of the head and neck. *Radiother Oncol.* 1996;41(1):31–9.
74. Brizel DM, Sibley GS, Prosnitz LR, Scher RL, Dewhirst MW. Tumor hypoxia adversely affects the prognosis of carcinoma of the head and neck. *Int J Radiat Oncol Biol Phys.* 1997;38(2):285–9.
75. Le QT, Kong C, Lavori PW, et al. Expression and prognostic significance of a panel of tissue hypoxia markers in head-and-neck squamous cell carcinomas. *Int J Radiat Oncol Biol Phys.* 2007;69(1):167–75.
76. Le QT, Harris J, Magliocco AM, et al. Validation of lysyl oxidase as a prognostic marker for metastasis and survival in head and neck squamous cell carcinoma: Radiation Therapy Oncology Group Trial 90-03. *J Clin Oncol.* 2009;27(26):4281–6.
77. Prosnitz RG, Yao B, Farrell CL, Clough R, Brizel DM. Pretreatment anemia is correlated with the reduced effectiveness of radiation and concurrent chemotherapy in advanced head and neck cancer. *Int J Radiat Oncol Biol Phys.* 2005;61(4):1087–95.
78. Fortin A, Wang CS, Vigneault E. Effect of pretreatment anemia on treatment outcome of concurrent radiochemotherapy in patients with head and neck cancer. *Int J Radiat Oncol Biol Phys.* 2008;72(1):255–60.
79. Rades D, Stoehr M, Kazic N, et al. Locally advanced stage IV squamous cell carcinoma of the head and neck: impact of pre-radiotherapy hemoglobin level and interruptions during radiotherapy. *Int J Radiat Oncol Biol Phys.* 2008;70(4):1108–14.
80. Bhide SA, Ahmed M, Rengarajan V, et al. Anemia during sequential induction chemotherapy and chemoradiation for head and neck cancer: the impact of blood transfusion on treatment outcome. *Int J Radiat Oncol Biol Phys.* 2009;73(2):391–8.
81. Overgaard J, Hansen HS, Overgaard M, et al. A randomized double-blind phase III study of nimorazole as a hypoxic radiosensitizer of primary radiotherapy in supraglottic larynx and pharynx carcinoma. Results of the Danish Head and Neck Cancer Study (DAHANCA) Protocol 5-85. *Radiother Oncol.* 1998;46(2):135–46.
82. Overgaard J, Hansen HS, Specht L, et al. Five compared with six fractions per week of conventional radiotherapy of squamous-cell carcinoma of head and neck: DAHANCA 6 and 7 randomised controlled trial. *Lancet.* 2003;362(9388):933–40.
83. Stuben G, Pottgen C, Knuhmann K, et al. Erythropoietin restores the anemia-induced reduction in radiosensitivity of experimental human tumors in nude mice. *Int J Radiat Oncol Biol Phys.* 2003;55(5):1358–62.
84. Ning S, Hartley C, Molineux G, Knox SJ. Darbepoietin alfa potentiates the efficacy of radiation therapy in mice with corrected or uncorrected anemia. *Cancer Res.* 2005;65(1):284–90.
85. Glaser CM, Milesi W, Kornek GV, et al. Impact of hemoglobin level and use of recombinant erythropoietin on efficacy of preoperative chemoradiation therapy for squamous cell carcinoma of the oral cavity and oropharynx. *Int J Radiat Oncol Biol Phys.* 2001;50(3):705–15.
86. Henke M, Laszig R, Rube C, et al. Erythropoietin to treat head and neck cancer patients with anaemia undergoing radiotherapy: randomised, double-blind, placebo-controlled trial. *Lancet.* 2003;362(9392):1255–60.

87. Machtay M, Pajak TF, Suntharalingam M, et al. Radiotherapy with or without erythropoietin for anemic patients with head and neck cancer: a randomized trial of the Radiation Therapy Oncology Group (RTOG 99-03). *Int J Radiat Oncol Biol Phys.* 2007; 69(4):1008–17.
88. Thomas G, Ali S, Hoebbers FJ, et al. Phase III trial to evaluate the efficacy of maintaining hemoglobin levels above 12.0 g/dL with erythropoietin vs above 10.0 g/dL without erythropoietin in anemic patients receiving concurrent radiation and cisplatin for cervical cancer. *Gynecol Oncol.* 2008;108(2):317–25.
89. Bohlius J, Schmidlin K, Brillant C, et al. Erythropoietin or Darbepoietin for patients with cancer – meta-analysis based on individual patient data. *Cochrane Database Syst Rev.* 2009;(3):CD007303.
90. Arcasoy MO, Amin K, Chou SC, Haroon ZA, Varia M, Raleigh JA. Erythropoietin and erythropoietin receptor expression in head and neck cancer: relationship to tumor hypoxia. *Clin Cancer Res.* 2005;11(1):20–7.
91. Pajonk F, Weil A, Sommer A, Suwinski R, Henke M. The erythropoietin-receptor pathway modulates survival of cancer cells. *Oncogene.* 2004;23(55):8987–91.
92. Winter SC, Shah KA, Campo L, et al. Relation of erythropoietin and erythropoietin receptor expression to hypoxia and anemia in head and neck squamous cell carcinoma. *Clin Cancer Res.* 2005;11(21):7614–20.
93. Zeman EM, Brown JM, Lemmon MJ, Hirst VK, Lee WW. SR-4233: a new bioreductive agent with high selective toxicity for hypoxic mammalian cells. *Int J Radiat Oncol Biol Phys.* 1986;12(7):1239–42.
94. Rischin D, Peters L, Hicks R, et al. Phase I trial of concurrent tirapazamine, cisplatin, and radiotherapy in patients with advanced head and neck cancer. *J Clin Oncol.* 2001;19(2):535–42.
95. Le QT, Taira A, Budenz S, et al. Mature results from a randomized Phase II trial of cisplatin plus 5-fluorouracil and radiotherapy with or without tirapazamine in patients with resectable Stage IV head and neck squamous cell carcinomas. *Cancer.* 2006;106(9):1940–9.
96. Lunt SJ, Telfer BA, Fitzmaurice RJ, Stratford IJ, Williams KJ. Tirapazamine administered as a neoadjuvant to radiotherapy reduces metastatic dissemination. *Clin Cancer Res.* 2005;11(11):4212–6.
97. Rischin D, Peters L, O'Sullivan B, et al. Tirapazamine, cisplatin, and radiation versus cisplatin and radiation for advanced squamous cell carcinoma of the head and neck (TROG 02.02, HeadSTART): a phase III trial of the Trans-Tasman Radiation Oncology Group. *J Clin Oncol.* 2010;28(18):2989–95.
98. Seiwert TY, Salama JK, Vokes EE. The chemoradiation paradigm in head and neck cancer. *Nat Clin Pract Oncol.* 2007;4(3):156–71.
99. Brizel DM, Dodge RK, Clough RW, Dewhirst MW. Oxygenation of head and neck cancer: changes during radiotherapy and impact on treatment outcome. *Radiother Oncol.* 1999;53(2):113–7.
100. Rischin D, Hicks RJ, Fisher R, et al. Prognostic significance of [18F]-misonidazole positron emission tomography-detected tumor hypoxia in patients with advanced head and neck cancer randomly assigned to chemoradiation with or without tirapazamine: a sub-study of Trans-Tasman Radiation Oncology Group Study 98.02. *J Clin Oncol.* 2006;24(13):2098–104.
101. Le QT. Identifying and targeting hypoxia in head and neck cancer: a brief overview of current approaches. *Int J Radiat Oncol Biol Phys.* 2007;69(2 Suppl):S56–8.
102. Lee NY, Le QT. New developments in radiation therapy for head and neck cancer: intensity-modulated radiation therapy and hypoxia targeting. *Semin Oncol.* 2008;35(3):236–50.
103. Lin Z, Mechalakos J, Nehmeh S, et al. The influence of changes in tumor hypoxia on dose-painting treatment plans based on 18F-FMISO positron emission tomography. *Int J Radiat Oncol Biol Phys.* 2008;70(4):1219–28.
104. Chung CH, Wong S, Ang KK, et al. Strategic plans to promote head and neck cancer translational research within the radiation therapy oncology group: a report from the translational research program. *Int J Radiat Oncol Biol Phys.* 2007;69(2 Suppl):S67–78.

Chapter 12

Preclinical Models of Head and Neck Squamous Cell Carcinoma

Michiel W.M. van den Brekel, C.L. Zuur, Stephen P. Malkoski, and Xiao-Jing Wang

Abstract Model systems are irreplaceable to study cancer. Although the best model system is human cancer in man, research in patients is restricted by ethical and financial restraints. Furthermore, experiments cannot be repeated and patient numbers are limited. Tumor cell cultures are the most versatile system to study cancer cells. They allow for repeated experiments in controlled conditions, are relatively inexpensive and are ideal to study genes, pathways, and tumor response. Mouse models enable to study cancer behavior and carcinogenesis in vivo and many different model systems are available. Apart from xenografts in immune compromised mice, transplantation of oral mice tumors in syngeneic mice, animals developing oral cancer using carcinogen exposure and genetically modified mice can be used. All these models, however, have advantages and limitations that will be discussed in this chapter.

Keywords Squamous cell cancer • Mouse • Model system • Xenograft • Cell culture • Head and neck • Transgenic

Head and neck squamous cell carcinomas (HNSCCs) represent 3–5% of all newly diagnosed cancers each year in the western world with 5-year survival rates in the order of 25–95% depending on disease site and stage. The limited survival rates in most patients indicate the need for novel treatment strategies with new potent drugs. In addition, these survival rates yield a widely divergent individual response of similar histopathological cancers to the applied treatment regimen. Currently, the decision on therapy relies mainly on the outcome of both retrospective data as well as various well-performed prospective trials and meta-analyses. However, so far no prospective trial has been conducted using biomarkers for treatment selection and thus we have

not been able to stratify patients based on individual tumor properties since knowledge regarding the biological basis of variations in tumor response to chemotherapeutics was and is still limited.

HNSCCs are characterized by a rather large genetic diversity, possibly caused by the long duration of carcinogenic exposure and the genetic instability of most head and neck carcinomas [1]. However, several pathways are almost always invariably involved in carcinogenesis, such as the P53 and INK4a pathways [2, 3]. The fact that these tumors are genetically highly heterogeneous and unstable has hampered the development of drugs specifically targeting pathways relevant in head and neck cancer. So far, only the inhibition of the EGFR receptor has proven to have clinical benefit for a subpopulation of head and neck cancer patients, especially when combined to radiotherapy [4]. However, in preclinical models, several other targeted therapies have shown promising results, such as drugs targeting phosphoinositol (PI)-3-kinase–AKT, insulin-like growth receptor, BCL2, MET, and several others [5–8].

Although the role of human papilloma virus (HPV) was postulated a long time ago, only recently it was recognized that HNSCCs can be divided really into those that are and those that are not associated with HPV [9]. The HPV16 papillomavirus oncogenes E6 and E7 have been detected in HPV genomes in HNSCC and its oncoproteins are known for their ability to bind and inactivate tumor suppressor proteins p53 and retinoblastoma (pRb) [10]. Tumors with HPV infection occur at a younger age, are less related to smoking and alcohol and do not have P53 mutations or loss of P16 (INK4a) function by mutations, deletions, or methylation. Instead, these pathways are deregulated by the E4 and E6 proteins expressed by the virus [11]. HPV status does not only predict treatment outcome, but likely, should also be used to guide treatment [12]. However, as stated above, at the moment we lack the knowledge and reliable trials to personalize treatment regimens in HNSCC.

Studying cancer in humans poses enormous ethical, financial, and practical hurdles, due to the limited number of patients and tumor material, the enormous costs, and the ethical dilemmas in clinical research. Therefore, preclinical

M.W.M. van den Brekel (✉)
Otorhinolaryngology – Head and Neck Surgery Department,
Netherlands Cancer Institute – Antoni van Leeuwenhoek Hospital
and Academic Medical Center, University of Amsterdam,
Plesmanlaan 121, Amsterdam 1066 CX, The Netherlands
e-mail: vd.brekel@nki.nl

models are an important tool for exploring tumor initiation and progression, cancer genetics, and novel therapeutic approaches. A variety of HNSCC model systems have been developed, including cancer cell lines derived from human HNSCC, exposure of animals to oral carcinogens, and genetically engineered mouse models (GEMMs). Each system has important strengths and weaknesses that must be appreciated to interpret data derived from these models. To maximize clinical relevance, model systems should resemble human HNSCC as closely as possible. For example, cell lines should harbor the genetic and epigenetic alterations common to HNSCC and carcinogen exposures should mimic the routes and chemicals associated with human HNSCC. Similarly, GEMMs should examine the genetic alterations frequently observed in human HNSCC. To overcome the intrinsic limitations of a given model, results should be validated by multiple approaches in different systems; however, ultimately, all results obtained in model systems must be validated in human samples or subjects.

HNSCC Cell Lines

Cancer cell lines are the most versatile model system wherein cancer cells can be characterized and even manipulated genetically. Genetic manipulation techniques have enabled us to study the influence of specific genetic abnormalities or correction of these abnormalities on tumorigenesis, tumor behavior, or treatment response [5]. Using these techniques, one can study human genes in mouse cell lines as, e.g., the influence of known mutagens on human P53 [13]. In addition, it has been shown that differences in response can be attributed to differences in the genetic make-up of HNSCC cell lines, them being either HPV positive or negative [8] and Li et al. showed that by blocking SRC kinase, cetuximab resistant tumors can become sensitive again [14]. Such experiments, that can only be done using well-characterized cancers, can give us insights that in the near future may lead to more individualized and more effective treatment protocols. Although in HNSCC the routine use of molecular markers for treatment selection is not established yet, in several other tumor types such as breast, colon, and lung, this molecular knowledge has already been translated into important predictive assays used in treatment selection [15, 16]. Currently, there is a strong urge to find, validate, and implement markers for a more individualized treatment selection in HNSCC.

A major advantage of cell lines is that experiments can be done within several days and are relatively inexpensive. Using cell lines, the same tumors can be tested over and over again with multiple new drugs, combinations of drugs, or genetic interventions. This enables testing numerous

radiotherapy doses or drugs on the same tumor as well as the mechanisms or conditions by which tumors become resistant to treatment. These mechanisms can then be targeted to avoid resistance. For instance, in human HNSCCs, ligand activation of the epidermal growth factor receptor (EGFR) leads to downstream signaling of several prosurvival cascades (pathways) eventually promoting cell proliferation, angiogenesis, invasion, and metastasis. Therefore, EGFR is one of the most promising molecular targets in cancer therapy. Recently, Li et al. described several mechanisms of acquired resistance of SCC to cetuximab (an EGFR-blocking antibody) and performed research to investigate the role of nEGFR (EGFR translocated from plasma membrane to nucleus) in this phenomenon using nonsmall cell lung carcinoma cell lines. In these cells, an increased Src family kinase (SFK) activity was found, linked to the translocation of the EGFR to the nucleus, suggesting that a combined modality treatment regimen of blocking SFKs together with cetuximab may be a future clinical trial treatment design for patients with EGFR resistant tumors [14]. In the field of studying radiotherapy and radiosensitization in head and neck cancer, much work has been done using cell lines [17]. It has been shown that hypoxia, DNA repair, and repopulation, as well as intrinsic tumor cell characteristics play an important role in radioresistance [18, 19].

The role of HPV has also been studied in head and neck cell lines. Mouse tonsil epithelial cell lines (MTECs) become immortalized by HPV 16 E6–E7 transfection and allow for extensive research to determine what viral genes are required for this immortalization and anchorage-independent growth and, eventually, malignant growth in vivo. Hoover et al. in 2007 reported that HPV viral oncogenes alone were indeed sufficient to induce anchorage-independent growth of MTECs in vitro, but additional H-ras oncogene expression was needed to form invasive cancers in vivo [20].

However, cancer cell lines also have critical limitations. Most importantly, they represent a homogeneous clonal population capable of growing in vitro; in fact, the majority of individual tumors and cancer cells within an individual tumor are incapable of growing in tissue culture. Hence, cultured cells typically fail to reflect the genetic heterogeneity of the native tumor from which they were derived. Interestingly, patients whose tumors can establish cell lines have worse clinical prognosis [21], suggesting that characteristics supporting in vitro growth are indicative of aggressive tumor behavior in vivo. Furthermore, as cells are passaged, there is increased selective pressure for in vitro growth and after many passages, cultured cancer cells may differ from the original tumor from which they were derived. For example, tumor lines and native tumors may exhibit different chemosensitivity patterns and this can be influenced by the number of in vitro passages [22–24]. Culture conditions can also influence the responses to cytotoxic therapies; e.g., cells

grown as anchorage-independent spheroids can have different responses to cytotoxic agents than the same cells grown as anchorage-dependent monolayers [25]. Accordingly, cell lines cannot be used to predict treatment response in individual patients [26]. Many of these issues have potentially been accentuated in HNSCC as there is a relative paucity of well characterized lines [21, 27], and a lack of standardized tissue culture techniques that can limit reproducibility [28–34]. A final important limitation of cultured cells is an inability to study the interactions between tumor epithelial cells and key components of the tumor stroma, including fibroblasts, immune cells, and the vasculature.

Despite these limitations, much of our basic mechanistic understanding of the roles of specific molecules has been derived from cell culture data. Perhaps the best successful example of basic biologic understanding directly improving cancer outcome occurred in chronic myelogenous leukemia (CML) where the observation that inhibition of the bcr–abl fusion protein reduced growth of leukemic cell lines led to the successful clinical deployment of imatinib [35, 36]. Unfortunately, because HNSCC appears to be more genetically heterogeneous than CML, HNSCC may not be susceptible to inhibition of a single oncogenic pathway [1]. It is probable that using a combination of drugs, inhibiting several pathways, such as EGFR inhibitors in combination with, e.g., blockade of the PI-3-kinase–AKT pathway, insulin-like growth factor receptor (IGFR), BCL2, or cMET holds promise for the future and has been studied in preclinical models [5–8].

Although cell lines are the optimal system to study pathways and the role of specific genes for carcinogenesis and treatment response, it has proven very difficult to find reliable markers from cell line experiments. We recently studied radioresistance in cell lines obtained from Grenman in Turku (Finland) and made a gene expression profile correlating with radiosensitivity [19, 37, 38]. Unfortunately, this expression profile was not predictive of local control after radiotherapy of laryngeal cancer in patients. This again shows the difficulty of extrapolating *in vitro* findings to clinical practice.

Short Term Cultures

As cell lines are difficult to establish, as they represent only a fraction of a tumor and as in every passage additional genetic changes occur, cell lines cannot be used to guide treatment of an individual patient. To augment individual treatment planning, short-term culturing techniques are used. In this technique, a small tissue biopsy sample that includes both tumor epithelial cells and tumor stromal cells (e.g., fibroblasts) is cultured and then tested for sensitivity to chemotherapeutic agents *in vitro*. In this setting, it appears that a single biopsy (100 mg) sample is representative of the

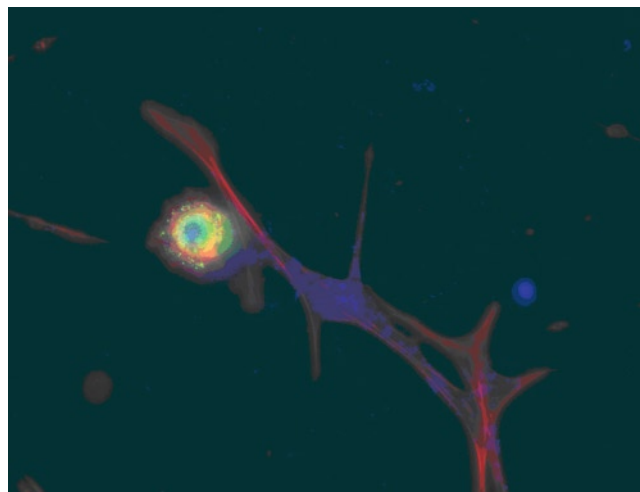


Fig. 12.1 Digital immunofluorescence of short-term cultured cells from an oropharyngeal carcinoma. A tumor cell and fibroblast are shown (64 \times). Staining: cell nucleus: Hoechst staining double-stranded DNA (blue); cell actin: Alexa Fluor[®] 568 phalloidin (red); SCC cytokeratin: Mouse anti-human pan Cytokeratin and Alexa Fluor[®] anti-mouse IgG 568 (green)

entire tumor with respect to chemoresponsiveness [39] and that coculture of tumor and stromal cells increases the predictive value of this assay [40] (Fig. 12.1). One technical difficulty of this approach is the overgrowth of the fibroblast subpopulation; however, this can be overcome by avoiding enzymatic digestion and allowing both tumor epithelial and stromal cells to grow out of multicellular tumor particles. Short-term cultures can also be grown on a collagen sponge-gel-supported matrix to maintain tissue architecture and facilitate cell–cell interactions that may be important in chemotherapy response. Using these systems, a culture sufficient for *in vitro* drug testing can be established 80% of the time [41, 42] and *in vitro* testing can occur within a few days. In addition, short-term cultures can be subsequently used to establish xenograft models if desired (see below) [43].

In these experiments, the typical read out is cell count or proliferation after treatment with a cytotoxic agent [40, 44, 45], however, qualitative data, such as cell cycle arrest, differentiation, and morphology can also be collected to assess the specific response of the tumor and stroma cells to the (cancer) drug applied. For mass screening the HTS immunofluorescent automated microscopy with high-content imaging is possible using the CellProfiler program [46].

The tumor clonogenic assay is one of the most intensely studied *in vitro* methods for chemosensitivity testing and evaluates colony formation of cancer (stem) cells with the potential for anchorage-independent growth in semisolid media in which individual cells develop into colonies. Comparing response to drugs in this clonogenic assay and in patients, Fiebig et al. found that 62% of the comparisons for drug sensitivity and 92% of the comparisons for drug resistance were

correct [41]. In further experiments in head and neck cancer using the histoculture drug-response assay, the correlation between clinical response to induction chemotherapy and the prediction in the assay was almost 78% [45].

An alternative method for short-term cultures is a collagen sponge-gel-supported histoculture in which tissue architecture is maintained. The architecture allows more cell–cell interaction which might be important in chemotherapy response. A histoculture drug response assay for individualizing chemotherapy has been developed and proved to be very predictive. As an end-point, the MTT assay can be used [40, 44, 45]. Comparison between all these culture methods has not been performed.

Although small patient numbers were used, primary tumor cell culture models have been shown to predict the individual tumor sensitivity for different cancer drugs [45, 47–49]. However, there are so far no phase III studies demonstrating a significant increase in survival rates compared to empirically determined standard chemotherapy regimens. Therefore, the tissue culture has not yet found a routine role in the individualization of patient therapy.

Xenograft Mouse Models

Another approach for amplifying, studying, and testing tumors *in vivo* is to subcutaneously implant human cancers into immunologically compromised nude or SCID mice. Depending on the original tumor subsite (oral cavity, oropharynx, larynx, and hypopharynx), 70–80% of the patient HNSCCs were successfully xenografted and short-term cultured in the mouse [43]. Once established, the system allows for *in vivo* testing of novel cancer drugs, as studying the response of human tumors in subcutaneous, e.g., ectopic tissue sites of the mouse to the various cancer drugs applied may produce relevant and predictive information to the clinic, provided that pharmacokinetic parameters (especially dosing) are employed. Alternatively, orthotopic transplantation is suggested to facilitate metastatic spread thereby increasing the models' clinical predictive value as various drugs can then be tested on either (or both) the primary tumor growing in a physiologically relevant site and distant metastatic disease, especially in case therapy is initiated at the point when metastases are macroscopic in nature [50].

To study the changes in gene expression with transformation and metastatic tumor progression of squamous cell carcinomas, oral tumors and cell lines derived from mice were transplanted into inbred syngeneic recipients [51]. Other examples include the oral SCC VII/SF cell line (from C3H/HeJ mice) and the transformed PAM 212 cell line (from BALB/c keratinocytes) [52] and similar models have been described using a hamster buccal pouch carcinoma of rat oral

carcinoma [53, 54]. In addition, tumor cell lines can be manipulated *ex vivo* then transplanted to study the roles of specific molecules or pathways during tumor progression and metastases. For example, while induction of HPV genes E6 and E7 can immortalize mouse tonsil epithelial cells *in vitro*, additional H-ras transduction is necessary to form invasive cancers [20].

Compared to cell lines, direct xenograft mouse models preserve key features that cells in culture derived from the same tumor samples irreversibly lose [55], perhaps by preserving the human stroma and immune cells important for tumor growth and metastases [56].

Xenografts derived directly from patient biopsies, with minimal *in vitro* manipulation, appear to retain better the morphological and molecular marker of the source tumors, despite serial passing across several generations of mice [57]. In addition, human tumors can be serially transplanted into other immunocompromised mice providing additional tumor material for downstream molecular or cellular analysis or additional tumor-bearing mice for *in vivo* testing of therapeutic compounds. These systems may be better suited for studying invasiveness and metastases than cell culture systems [58–60], particularly if coupled with evolving imaging techniques such as micro PET-CT.

However, because the xenograft model involves implanting human tumors cells, it cannot be used to study early stage carcinogenesis, tumor initiation, or chemoprevention. Also, when tumors are transplanted they will still require angiogenesis and supporting tumor stroma from the murine host, and as recipient mice are immunocompromised, this model is not suitable for evaluating tumor immunology. Moreover, agent metabolism and pharmacodynamics are different in mice, and, as with immortalized cell lines, serial passaging of tumor xenografts can change the tumor characteristics by selecting for tumor cell populations suited to growing in an immunocompromised host [61, 62]. Finally, compared to experiments with cell lines, xenografting experiments are more time-consuming and expensive.

Cancer Induction by Chemical Carcinogens

Mice, rats, and hamsters can be exposed to carcinogens to induce cancer. Although exposures can be laborious and time-consuming, these models are especially useful to study carcinogenesis and chemopreventive strategies as there is usually a long latency between exposure and tumor development and animals frequently develop premalignant lesions [63]. Depending on the mutagen, exposure route, and dose, oral tumors with different genetic alterations and behaviors can be produced. Like human HNSCC, chemically induced HNSCC harbor a variety of genetic lesions, however, chemically

induced tumors are typically more homogenous than their human counterparts as animals are only exposed to one carcinogen that produces characteristic genetic alterations as opposed to being exposed to a complex mixture of compounds each with different genotoxic effects (i.e., cigarette smoke) [64, 65]. Finally by applying carcinogenesis protocols to genetically engineered mice, the specific roles of molecules and pathways in promoting or inhibiting tumor initiation, growth, or metastases can be assessed.

One well-characterized HNSCC model is application of the H-ras mutagen 7,12-dimethylbenz(a)anthracene (DMBA) to the hamster buccal pouch [66, 67]. In this model, oral DMBA is applied three times weekly for 10–24 weeks. Squamous cell carcinomas will occur in the majority of the hamsters, and lymph node metastases are sometimes found [68]. Because these tumors are almost all H-ras initiated, they do not typically have the genetic instability seen in human HNSCC where chromosome breaks and aneuploidy are frequent. Nonetheless, this is a clinically relevant genetic alteration as HNSCC arising in Asian patients is frequently initiated by activated Ras signaling [69]. One downside of this model is that the tools and reagents for hamsters are more limited than those for mice, however, DMBA can also be used to induce skin SCC in mice (when combined with tumor promotion by a phorbol ester) or to induce oral SCC in genetically susceptible animals [70]. Although DMBA is not a tobacco carcinogen, it is a convenient way of introducing H-ras mutations to the oral epithelium to evaluate the interactions of other experimental systems on Ras-initiated tumors.

In a study of Chang et al. in 2000, *N*-methyl-*N*-benzyl nitrosamine (MBN) was applied to hamster buccal pouches to characterize the MBN-induced tumors with regard to the frequency of p53 and H-ras mutations, as these are among the specific molecular alterations observed in human HNSCCs [71]. In this analysis, the alterations in p53, H-ras, and telomerase activity observed in the model are similar in many respects to the analogous human lesions of the head and neck, suggesting that this model system may be particularly useful for the development of cancer chemoprevention regimens and cancer therapies.

Rats and mice also develop oral squamous cell carcinomas after application of the chemical carcinogen 4-nitroquinoline *N*-oxide (4-NQO) for 2–6 months in their drinking water or application in a concentrated solution to the oral cavity for 12–16 weeks [72]. 4-NQO, although not a natural tobacco derivative, causes a spectrum of DNA damage similar to that caused by tobacco-associated carcinogens. In addition, in p53 transgenic mice, the incidence of oral cancer was increased from 0 to 67% when treated with 4-NQO thrice weekly for 16 weeks and a maximum follow-up of 32 weeks [73]. Also in HPV16-transgenic mice treated with 4-NQO, the incidence of SCC was increased significantly compared

to their nontransgenic counterparts and histopathological analyses demonstrated progressive neoplastic disease in the oral cavity with remarkable similarities to human HPV-positive HNSCC. Using this model, the investigators reported to have identified a biomarker that distinguishes between HPV-positive and HPV-negative HNSCC [74].

The 4-NQO-induced cancer model has also been used to induce salivary gland cancer [75]. Furthermore, other carcinogens can be used, such as benzo[a]pyrene (B[a]P), *N*-nitroso-*N*-methylurea (NMU), 4-(methylnitrosamino)-1-(3-pyridyl)-1-butanone (NNK), or nitrosornicotine (NNN). The oral cavity of hamsters, rats, and mice or the skin of these animals can be used to induce cancer [65, 76, 77].

As these animals first develop premalignant lesions, these models are especially useful to study inhibitory (chemopreventive) or promoting stimuli. It has been shown that DMBA-induced carcinogenesis in the hamster cheek pouch can be counteracted by long-term (18 weeks) topical application of GW2974, a dual inhibitor of EGFR and ErbB2 tyrosine kinase, decreasing the incidence, number, and size of both visible tumors and microscopic lesions such as hyperplasia, dysplasia, and SCC significantly [78]. In another study, celecoxib (a highly selective inhibitor of cyclooxygenase (COX)-2, known to be overexpressed in human (pre)malignant oral lesions) was applied for 7 weeks in the oral cavity of hamsters after they were painted for 5 weeks with DMBA. Celecoxib was effective in delaying the onset of early lesions and able to slow down the growth of the oral tumor [79]. The antilipidperoxidative and antioxidant potential of curcumin and piperine were reported to be crucial in the biochemical mechanistic pathway of their chemoprevention in DMBA-induced oral carcinogenesis [80, 81].

A major improvement of using carcinogen induced cancer has been made by using these carcinogens in genetically predisposed mice of cell lines, such as the P53 knock-out mice, or the HPV 16 E–E7 transfected immortalized oral cell lines [73, 74, 82]. Using carcinogens in these models causes cancer or transformation in a much faster and controlled way [83]. Using this model system, one can study the role of different genes on carcinogenesis. Apart from P53, also Xeroderma pigmentosa A (XPA) knock-out or cyclin D1 overexpression have been shown to increase and accelerate oral cancer formation in 4-NQO-treated mice [84, 85].

Transgenic Mouse Models

GEMMs have been an enormous step forward for cancer modeling and allow evaluation of discrete genetic alterations in specific organs *in vivo* in an immunocompetent animal. Additional benefits of GEMMs include the ability to evaluate how multiple genetic defects interact to promote or inhibit

cancer and the opportunity to evaluate whether specific targeted therapies are active against tumors with a defined genetic composition. Drawbacks are that human cancers are more genetically complex and heterogeneous than tumors produced in mouse models and differences in the human and mouse immune systems may complicate studies of tumor immunology.

Advances in murine embryology and genetics initially facilitated targeted mutagenesis of the mouse germ line by homologous recombination in ES cells leading to the creation of classic “knock out” mice. If a genetic modification is not lethal during embryonic development, heterozygotes can be crossed to create mice homozygous for a particular gene deletion. While knockout mice can occasionally be used to study deletion of tumor suppressors, there are critical limitations to this approach. First, global gene deletion of putative tumor suppressors is frequently embryonic lethal and this prevents the assessment of many genes using this strategy. For similar reasons, it is difficult, if not impossible, to study combinations of genetic modifications using this technique [86]. In addition, because the genetic modification is present in all tissues, tumors can develop in multiple anatomic locations, potentially hindering study of the tumor of interest. Finally, the fact that tumor stromal cells (fibroblasts, immune cells, and vasculature) also harbor the same genetic modification can impact overall tumor behavior in unanticipated ways. So far, germ-line deletions have not provided HNSCC specific insight. A step toward conditional mutagenesis is to place oncogenes under control of a tissue-specific promoter. Examples are K14-HPV16 mice that express E6/E7 in K14 expressing cells. These mice develop hyperplasia and some strains also oral SCCs [87]. Recently, also AKT activation or Ras activation in combination with loss of P53 has been shown to induce oral cancer [88, 89].

With the development of conditional genetic manipulation systems, many of these problems have been overcome [90]. In these systems, a target gene is flanked by loxP restriction sites that are the target of the *Escherichia coli* bacteriophage P1 Cre recombinase; Cre recombinase then excises sequences between loxP sites, allowing conditional gene deletion. As animals harboring conditional alleles are phenotypically normal in the absence of genetic recombination mediated by Cre recombinase, this system avoids many of the problems of embryonic lethality or infertility associated with germ-line deletions. By placing a loxP-flanked stop codon upstream of an oncogene (e.g., *Kras*^{G12D}), this approach can also be used to “knock-in” tumor initiators [91, 92] or specific p53 mutations.

Tissue restricted genetic manipulation is achieved by delivery of Cre recombinase to the cells of interest. While this can be done with adenoviral vectors [91], this approach has largely given way to transgenic approaches that use a tissue-specific promoter to target Cre recombinase expression

to the cells of interest [93]. In this setting, genetic manipulation then occurs only in cells that express the targeted Cre recombinase transgene. The Epstein–Barr virus ED-L2 promoter as well as keratin 5 (K5) and keratin 14 (K14) promoters have been used to target gene manipulations to the oral epithelium [94–98], however, because keratins are robustly expressed in a variety of epithelial tissues, especially the skin and mammary tissue, an additional layer of control is required to restrict Cre recombinase expression to the head and neck epithelium. This is achieved by using a ligand-inducible Cre recombinase fusion protein whose expression is restricted by a K5 or K14 promoter. Currently available constructs include both tamoxifen-inducible truncated estrogen receptor fusions, such as K14CreER^T and K5CreER^{T2} [93, 95] (Figs. 12.2 and 12.3); and RU486-inducible truncated progesterone receptor fusions, such as K14CrePR or K5CrePR [99], although only the CrePR constructs have so far been used to generate mouse models of HNSCC [96]. Another system in which genes can be turned on and off is the tetracycline-inducible system (tet-on and tet-off receptor) targeted to epithelial cells combined with oncogene under the control of tet-regulated responsive elements. On doxycycline administration the oncogene can be expressed [100, 101]. The main advantage of ligand-dependent systems is that they allow tissue-specific, spatial, and temporal control of recombination. Because these systems can be used to introduce

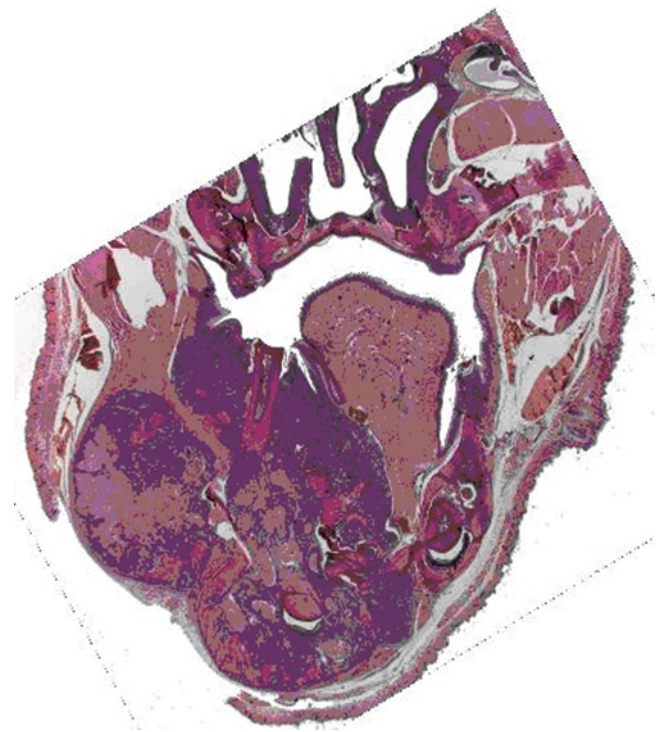


Fig. 12.2 Coronal histopathological section through the mouth and nose of a K14P53FF transgenic mouse (nonfunctioning P53 in all K14 expressing cells). Some of these animals develop oral squamous cancer as visible on the right side around the mandible

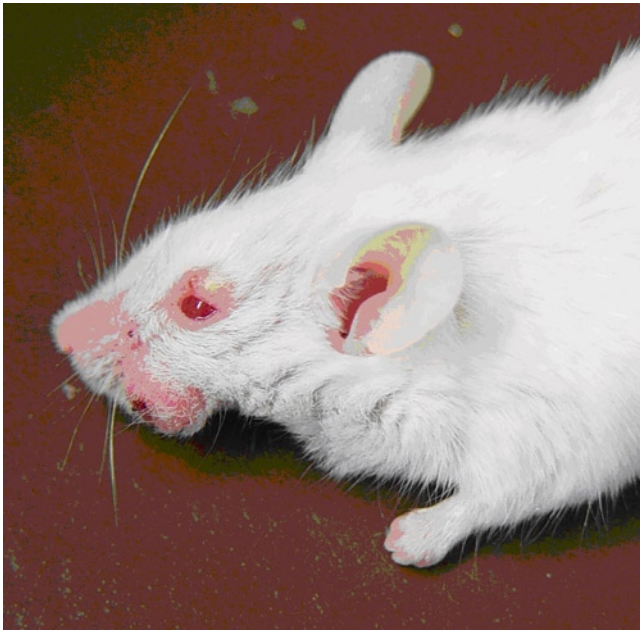


Fig. 12.3 Transgenic mouse with K14P53FF and P16 knockout with a cheek cancer

multiple somatic genetic alterations simultaneously into a target tissue interactions between different oncogenes and tumor suppressors can be evaluated *in vivo*. Disadvantages of this system are that most inducible Cre recombinase systems have some level of background activity and toxicity, and that there may be variability in recombination efficiency for different genes, partially related to the distance between LoxP sites [102, 103]. Apart from using tissue-specific promoters and ligands, an alternative is to use an adenoviral vector: adenoCre. This system is used in pulmonary cancer [91].

GEMMs can be used to test whether alterations in specific pathways or combinations of pathways are sufficient for HNSCC development and the mechanisms by which specific molecular alterations contribute to HNSCC development [96, 98, 104]. For example, although knock-in of oncogenic $Kras^{G12D}$ in the oral cavity causes benign papilloma formation [97], simultaneous deletion of transforming growth factor beta type II receptor (TGFbetaR2) with $Kras^{G12D}$ activation causes full penetrance HNSCC [70]. Thus it appears that $Kras$ activation functions as a tumor initiator while defective TGFbeta signaling causes tumor progression, especially as TGFbetaR2 deletion in the oral epithelium does not cause HNSCC. Interestingly, in contrast to TGFbetaR2, Smad deletion in the oral epithelium causes spontaneous HNSCC, suggesting that although both these molecules are components of the TGFbeta signaling pathway that they have distinct nonoverlapping functions in HNSCC [96, 104]. GEMMs can also be used to suggest novel therapeutic avenues. For example, HNSCC induced by Smad4 deletion have increased genetic instability and may hence be more susceptible to

either ionizing radiation or poly(ADP-ribose) polymerase (PARP) inhibitor-induced cell death. Given that Smad4 expression is frequently reduced in HNSCC this may have substantial clinical implications [96].

There is a great need to develop more reliable and different GEMMs for HNSCCs. When these are established, they should be validated for predicting treatment responses in human HNSCCs. Also the influence of different genetic make-up on tumor behavior and treatment response is an important aspect to be studied. So far HNSCC model systems are not as well developed as breast cancer models and pulmonary cancer models. It is a challenge for the next years to catch up with these research fields.

References

1. Reshmi SC, Saunders WS, Kudla DM, Ragin CR, Gollin SM. Chromosomal instability and marker chromosome evolution in oral squamous cell carcinoma. *Genes Chromosom Cancer*. 2004;41:38–46.
2. Leng K, Schlien S, Bosch FX. Refined characterization of head and neck squamous cell carcinomas expressing a seemingly wild-type p53 protein. *J Oral Pathol Med*. 2006;35:19–24.
3. Perez-Ordóñez B, Beauchemin M, Jordan RC. Molecular biology of squamous cell carcinoma of the head and neck. *J Clin Pathol*. 2006;59:445–53.
4. Bonner JA, Harari PM, Giralt J, et al. Radiotherapy plus cetuximab for squamous-cell carcinoma of the head and neck. *N Engl J Med*. 2006;354:567–78.
5. Crowe DL, Sinha UK. p53 apoptotic response to DNA damage dependent on bcl2 but not bax in head and neck squamous cell carcinoma lines. *Head Neck*. 2006;28:15–23.
6. Wilsbacher JL, Zhang Q, Tucker LA, et al. Insulin-like growth factor-1 receptor and ErbB kinase inhibitor combinations block proliferation and induce apoptosis through cyclin D1 reduction and Bax activation. *J Biol Chem*. 2008;283:23721–30.
7. Seiwert TY, Jagadeeswaran R, Faoro L, et al. The MET receptor tyrosine kinase is a potential novel therapeutic target for head and neck squamous cell carcinoma. *Cancer Res*. 2009;69:3021–31.
8. Gupta AK, Lee JH, Wilke WW, et al. Radiation response in two HPV-infected head-and-neck cancer cell lines in comparison to a non-HPV-infected cell line and relationship to signaling through AKT. *Int J Radiat Oncol Biol Phys*. 2009;74:928–33.
9. Park NH, Li SL, Xie JF, Cherrick HM. *In vitro* and animal studies of the role of viruses in oral carcinogenesis. *Eur J Cancer B Oral Oncol*. 1992;28B:145–52.
10. Chung CH, Gillison ML. Human papillomavirus in head and neck cancer: its role in pathogenesis and clinical implications. *Clin Cancer Res*. 2009;15:6758–62.
11. Hafkamp HC, Mooren JJ, Claessen SM, et al. P21 Cip1/WAF1 expression is strongly associated with HPV-positive tonsillar carcinoma and a favorable prognosis. *Mod Pathol*. 2009;22:686–98.
12. Fallai C, Perrone F, Licitra L, et al. Oropharyngeal squamous cell carcinoma treated with radiotherapy or radiochemotherapy: prognostic role of TP53 and HPV status. *Int J Radiat Oncol Biol Phys*. 2009;75:1053–9.
13. Liu Z, Muehlbauer KR, Schmeiser HH, Hergenbahn M, Belharazem D, Hollstein MC. p53 mutations in benzo(a)pyrene-exposed human p53 knock-in murine fibroblasts correlate with

- p53 mutations in human lung tumors. *Cancer Res.* 2005;65:2583–7.
14. Li C, Iida M, Dunn EF, Ghia AJ, Wheeler DL. Nuclear EGFR contributes to acquired resistance to cetuximab. *Oncogene.* 2009;29:3801–13.
 15. Zwart W, Griekspoor A, Rondaij M, Verwoerd D, Neeffjes J, Michalides R. Classification of anti-estrogens according to intramolecular FRET effects on phospho-mutants of estrogen receptor alpha. *Mol Cancer Ther.* 2007;6:1526–33.
 16. Gerber DE. EGFR inhibition in the treatment of non-small cell lung cancer. *Drug Dev Res.* 2008;69:359–72.
 17. Begg AC, van der Kolk PJ, Dewit L, Bartelink H. Radiosensitization by cisplatin of R1F1 tumour cells in vitro. *Int J Radiat Biol Relat Stud Phys Chem Med.* 1986;50:871–84.
 18. Begg AC, Vens C. Genetic manipulation of radiosensitivity. *Int J Radiat Oncol Biol Phys.* 2001;49:367–71.
 19. Eschrich SA, Pramana J, Zhang H, et al. A gene expression model of intrinsic tumor radiosensitivity: prediction of response and prognosis after chemoradiation. *Int J Radiat Oncol Biol Phys.* 2009;75:489–96.
 20. Hoover AC, Spanos WC, Harris GF, Anderson ME, Klingelutz AJ, Lee JH. The role of human papillomavirus 16 E6 in anchorage-independent and invasive growth of mouse tonsil epithelium. *Arch Otolaryngol Head Neck Surg.* 2007;133:495–502.
 21. Pekkola K, Raikka A, Joensuu H, Minn H, Aitasalo K, Grenman R. Permanent in vitro growth is associated with poor prognosis in head and neck cancer. *Acta Otolaryngol.* 2004;124:192–6.
 22. Engelholm SA, Vindelov LL, Spang-Thomsen M, et al. Genetic instability of cell lines derived from a single human small cell carcinoma of the lung. *Eur J Cancer Clin Oncol.* 1985;21:815–24.
 23. Ferguson PJ, Cheng YC. Phenotypic instability of drug sensitivity in a human colon carcinoma cell line. *Cancer Res.* 1989;49:1148–53.
 24. Kruczynski A, Kiss R. Evidence of a direct relationship between the increase in the in vitro passage number of human non-small-cell-lung cancer primocultures and their chemosensitivity. *Anticancer Res.* 1993;13:507–13.
 25. Griffon-Etienne G, Merlin JL, Marchal C. Evaluation of Taxol in head and neck squamous carcinoma multicellular tumor spheroids. *Anticancer Drugs.* 1997;8:48–55.
 26. Johnson JJ, Decker S, Zaharevitz D, et al. Relationships between drug activity in NCI preclinical in vitro and in vivo models and early clinical trials. *Br J Cancer.* 2001;84:1424–31.
 27. Spiegel J, Carey TE, Shimoura S, Krause CJ. In vitro sensitivity and resistance of cultured human squamous carcinoma cells to cisplatin and methotrexate. *Otolaryngol Head Neck Surg.* 1984;92:524–31.
 28. Masuda N, Fukuoka M, Takada M, Kudoh S, Kusunoki Y. Establishment and characterization of 20 human non-small cell lung cancer cell lines in a serum-free defined medium (ACL-4). *Chest.* 1991;100:429–38.
 29. Verschraegen CF, Hu W, Du Y, et al. Establishment and characterization of cancer cell cultures and xenografts derived from primary or metastatic Mullerian cancers. *Clin Cancer Res.* 2003;9:845–52.
 30. Liu B, Wang T, Qian X, Liu G, Yu L, Ding Y. Anticancer effect of tetrandrine on primary cancer cells isolated from ascites and pleural fluids. *Cancer Lett.* 2008;268:166–75.
 31. Mouriquand J, Mouriquand C, Petitpas E, Mermat MA. Long-term tissue cultures of human pleural effusions: a cytological follow-up. *In Vitro.* 1978;14:591–600.
 32. Lam DC, Girard L, Suen WS, et al. Establishment and expression profiling of new lung cancer cell lines from Chinese smokers and lifetime never-smokers. *J Thorac Oncol.* 2006;1:932–42.
 33. Ince TA, Richardson AL, Bell GW, et al. Transformation of different human breast epithelial cell types leads to distinct tumor phenotypes. *Cancer Cell.* 2007;12:160–70.
 34. Inagaki T, Matsuwari S, Takahashi R, Shimada KK, Fujie K, Maeda S. Establishment of human oral-cancer cell-lines (Kosc-2 and Kosc-3) carrying P53 and C-Myc abnormalities by geneticin treatment. *Int J Cancer.* 1994;56:301–8.
 35. O'Brien SG, Kirkland MA, Melo JV, et al. Antisense BCR-ABL oligomers cause non-specific inhibition of chronic myeloid leukemia cell lines. *Leukemia.* 1994;8:2156–62.
 36. Cohen MH, Williams G, Johnson JR, et al. Approval summary for imatinib mesylate capsules in the treatment of chronic myelogenous leukemia. *Clin Cancer Res.* 2002;8:935–42.
 37. Grenman R, Carey TE, McClatchey KD, et al. In vitro radiation resistance among cell lines established from patients with squamous cell carcinoma of the head and neck. *Cancer.* 1991;67:2741–7.
 38. de Jong MC, Pramana J, van der Wal JE, Lacko M, et al. CD44 expression predicts local recurrence after radiotherapy in larynx cancer. *Clin Cancer Res.* 2010;16:5329–38.
 39. Horn IS, Wichmann G, Mozet C, et al. Heterogeneity of epithelial and stromal cells of head and neck squamous cell carcinomas in ex vivo chemoresponse. *Cancer Chemother Pharmacol.* 2010;65:1153–63.
 40. Singh B, Li R, Xu L, et al. Prediction of survival in patients with head and neck cancer using the histoculture drug response assay. *Head Neck.* 2002;24:437–42.
 41. Fiebig HH, Maier A, Burger AM. Clonogenic assay with established human tumour xenografts: correlation of in vitro to in vivo activity as a basis for anticancer drug discovery. *Eur J Cancer.* 2004;40:802–20.
 42. Wichmann G, Horn IS, Boehm A, et al. Single tissue samples from head and neck squamous cell carcinomas are representative regarding the entire tumor's chemosensitivity to cisplatin and docetaxel. *Onkologie.* 2009;32:264–72.
 43. Law JH, Whigham AS, Wirth PS, et al. Human-in-mouse modeling of primary head and neck squamous cell carcinoma. *Laryngoscope.* 2009;119:2315–23.
 44. Furukawa T, Kubota T, Hoffman RM. Clinical applications of the histoculture drug response assay. *Clin Cancer Res.* 1995;1:305–11.
 45. Hasegawa Y, Goto M, Hanai N, et al. Evaluation of optimal drug concentration in histoculture drug response assay in association with clinical efficacy for head and neck cancer. *Oral Oncol.* 2007;43:749–56.
 46. Kuijl C, Savage ND, Marsman M, et al. Intracellular bacterial growth is controlled by a kinase network around PKB/AKT1. *Nature.* 2007;450:725–30.
 47. Dollner R, Granzow C, Werner JA, Dietz A. Is there a role for chemosensitivity tests in head and neck cancer? *Onkologie.* 2004;27:310–5.
 48. Dollner R, Granzow C, Helmke BM, Ruess A, Schad A, Dietz A. The impact of stromal cell contamination on chemosensitivity testing of head and neck carcinoma. *Anticancer Res.* 2004;24:325–31.
 49. Yoshimasu T, Ohta F, Oura S, et al. Histoculture drug response assay for gefitinib in non-small-cell lung cancer. *Gen Thorac Cardiovasc Surg.* 2009;57:138–43.
 50. Kerbel RS. Human tumor xenografts as predictive preclinical models for anticancer drug activity in humans: better than commonly perceived – but they can be improved. *Cancer Biol Ther.* 2003;2:S134–9.
 51. Dong G, Loukinova E, Chen Z, et al. Molecular profiling of transformed and metastatic murine squamous carcinoma cells by differential display and cDNA microarray reveals altered expression of multiple genes related to growth, apoptosis, angiogenesis, and the NF-kappaB signal pathway. *Cancer Res.* 2001;61:4797–808.
 52. OMalley BW, Cope KA, Johnson CS, Schwartz MR. A new immunocompetent murine model for oral cancer. *Arch Otolaryngol Head Neck Surg.* 1997;123:20–4.

53. Tezabwala BU, Nouri AME, Cannell H, Symes M. Local anergy rather than systemic anti-tumour immunity to explain tumour growth in an animal model of oral squamous cell carcinoma. *Oncol Rep.* 1997;4:883–8.
54. Thomas Dw, Matthews Jb, Patel V, Game Sm, Prime Ss. Inflammatory cell infiltrate associated with primary and transplanted tumors in an inbred model of oral carcinogenesis. *J Oral Pathol Med.* 1995;24:23–31.
55. Daniel VC, Marchionni L, Hierman JS, et al. A primary xenograft model of small-cell lung cancer reveals irreversible changes in gene expression imposed by culture in vitro. *Cancer Res.* 2009;69:3364–73.
56. De Wever O, Mareel M. Role of tissue stroma in cancer cell invasion. *J Pathol.* 2003;200:429–47.
57. Rubio-Viqueira B, Jimeno A, Cusatis G, et al. An in vivo platform for translational drug development in pancreatic cancer. *Clin Cancer Res.* 2006;12:4652–61.
58. Langdon SP, Hendriks HR, Braakhuis BJ, et al. Preclinical phase II studies in human tumor xenografts: a European multicenter follow-up study. *Ann Oncol.* 1994;5:415–22.
59. Shigeta T, Umeda M, Komatsubara H, Komori T. Lymph node and pulmonary metastases after transplantation of oral squamous cell carcinoma cell line (HSC-3) into the subcutaneous tissue of nude mouse: detection of metastases by genetic methods using beta-globin and mutant p53 genes. *Oral Surg Oral Med Oral Pathol Oral Radiol Endod.* 2008;105:486–90.
60. Henriksson E, Baldetorp B, Borg A, et al. p53 mutation and cyclin D1 amplification correlate with cisplatin sensitivity in xenografted human squamous cell carcinomas from head and neck. *Acta Oncol.* 2006;45:300–5.
61. Hashitani S, Noguchi K, Manno Y, et al. Changes of histological and biological features by serial passages in a human adenoid cystic carcinoma line transplantable in nude mice. *Oncol Rep.* 2005;13:607–12.
62. Kelland LR. Of mice and men: values and liabilities of the athymic nude mouse model in anticancer drug development. *Eur J Cancer.* 2004;40:827–36.
63. Frame S, Crombie R, Liddell J, et al. Epithelial carcinogenesis in the mouse: correlating the genetics and the biology. *Philos Trans R Soc Lond B Biol Sci.* 1998;353:839–45.
64. Mitsunaga SI, Zhang SY, Ruggeri BA, et al. Positive immunohistochemical staining of p53 and cyclin D in advanced mouse skin tumors, but not in precancerous lesions produced by benzo[a]pyrene. *Carcinogenesis.* 1995;16:1629–35.
65. Ruggeri BA, Bauer B, Zhang SY, Klein-Szanto AJ. Murine squamous cell carcinoma cell lines produced by a complete carcinogenesis protocol with benzo[a]pyrene exhibit characteristic p53 mutations and the absence of H-ras and cyclin D1 abnormalities. *Carcinogenesis.* 1994;15:1613–9.
66. Shklar G, Schwartz J, Grau D, Trickler DP, Wallace KD. Inhibition of hamster buccal pouch carcinogenesis by 13-cis-retinoic acid. *Oral Surg Oral Med Oral Pathol.* 1980;50:45–52.
67. Gimenezconti IB, Bianchi AB, Stockman SL, Conti CJ, Slaga TJ. Activating mutation of the Ha-ras gene in chemically induced tumors of the hamster-cheek pouch. *Mol Carcinog.* 1992;5:259–63.
68. Take Y, Umeda M, Teranobu O, Shimada K. Lymph node metastases in hamster tongue cancer induced with 9, 10-dimethyl-1, 2-benzanthracene: association between histological findings and the incidence of neck metastases, and the clinical implications for patients with tongue cancer. *Br J Oral Maxillofac Surg.* 1999;37:29–36.
69. Saranath D, Chang SE, Bhoite LT, et al. High frequency mutation in codons 12 and 61 of H-ras oncogene in chewing tobacco-related human oral carcinoma in India. *Br J Cancer.* 1991;63:573–8.
70. Lu SL, Herrington H, Reh D, et al. Loss of transforming growth factor-beta type II receptor promotes metastatic head-and-neck squamous cell carcinoma. *Genes Dev.* 2006;20:1331–42.
71. Chang KW, Sarraj S, Lin SC, Tsai PI, Solt D. P53 expression, p53 and Ha-ras mutation and telomerase activation during nitrosamine-mediated hamster pouch carcinogenesis. *Carcinogenesis.* 2000;21:1441–51.
72. Schoop RA, Noteborn MH, de Jong Baatenburg RJ. A mouse model for oral squamous cell carcinoma. *J Mol Histol.* 2009;40:177–81.
73. Zhang Z, Wang Y, Yao R, Li J, Lubet RA, You M. p53 transgenic mice are highly susceptible to 4-nitroquinoline-1-oxide-induced oral cancer. *Mol Cancer Res.* 2006;4:401–10.
74. Strati K, Pitot HC, Lambert PF. Identification of biomarkers that distinguish human papillomavirus (HPV)-positive versus HPV-negative head and neck cancers in a mouse model. *Proc Natl Acad Sci USA.* 2006;103:14152–7.
75. Ide F, Kitada M, Sakashita H, Kusama K. Reduction of p53 dosage renders mice hypersensitive to 7, 12-dimethylbenz(alpha)anthracene-induced salivary gland tumorigenesis. *Anticancer Res.* 2003;23:201–4.
76. Yuan B, Heniford BW, Ackermann DM, Hawkins BL, Hendler FJ. Harvey ras (H-ras) point mutations are induced by 4-nitroquinoline-1-oxide in murine oral squamous epithelia, while squamous cell carcinomas and loss of heterozygosity occur without additional exposure. *Cancer Res.* 1994;54:5310–7.
77. Tang XH, Knudsen B, Bemis D, Tickoo S, Gudas LJ. Oral cavity and esophageal carcinogenesis modeled in carcinogen-treated mice. *Clin Cancer Res.* 2004;10:301–13.
78. Sun Z, Sood S, Li N, et al. Chemoprevention of 7, 12-dimethylbenz[a]anthracene (DMBA)-induced oral carcinogenesis in hamster cheek pouch by topical application of a dual inhibitor of epidermal growth factor receptor (EGFR) and ErbB2 tyrosine kinases. *Oral Oncol.* 2008;44:652–7.
79. Feng L, Wang Z. Chemopreventive effect of celecoxib in oral precancers and cancers. *Laryngoscope.* 2006;116:1842–5.
80. Manoharan S, Balakrishnan S, Menon VP, Alias LM, Reena AR. Chemopreventive efficacy of curcumin and piperine during 7, 12-dimethylbenz[a]anthracene-induced hamster buccal pouch carcinogenesis. *Singapore Med J.* 2009;50:139–46.
81. Letchoumy PV, Mohan KV, Stegeman JJ, Gelboin HV, Hara Y, Nagini S. In vitro antioxidative potential of lactoferrin and black tea polyphenols and protective effects in vivo on carcinogen activation, DNA damage, proliferation, invasion, and angiogenesis during experimental oral carcinogenesis. *Oncol Res.* 2008;17:193–203.
82. Zhong LP, Pan HY, Zhou XJ, et al. Characteristics of a cancerous cell line, HIOEC-B(a)P-96, induced by benzo(a)pyrene from human immortalized oral epithelial cell line. *Arch Oral Biol.* 2008;53:443–52.
83. Attardi LD, Donehower LA. Probing p53 biological functions through the use of genetically engineered mouse models. *Mutat Res.* 2005;576:4–21.
84. Ide F, Kitada M, Sakashita H, Kusama K, Tanaka K, Ishikawa T. p53 haploinsufficiency profoundly accelerates the onset of tongue tumors in mice lacking the xeroderma pigmentosum group A gene. *Am J Pathol.* 2003;163:1729–33.
85. Wilkey JF, Buchberger G, Saucier K, et al. Cyclin D1 overexpression increases susceptibility to 4-nitroquinoline-1-oxide-induced dysplasia and neoplasia in murine squamous oral epithelium. *Mol Carcinog.* 2009;48:853–61.
86. Berns A. Cancer. Improved mouse models. *Nature.* 2001;410:1043–4.
87. Coussens LM, Hanahan D, Arbeit JM. Genetic predisposition and parameters of malignant progression in K14-HPV16 transgenic mice. *Am J Pathol.* 1996;149:1899–917.
88. Moral M, Segrelles C, Lara MF, et al. Akt activation synergizes with Trp53 loss in oral epithelium to produce a novel mouse model for head and neck squamous cell carcinoma. *Cancer Res.* 2009;69:1099–108.

89. Raimondi AR, Molinolo A, Gutkind JS. Rapamycin prevents early onset of tumorigenesis in an oral-specific K-ras and p53 two-hit carcinogenesis model. *Cancer Res.* 2009;69:4159–66.
90. Akagi K, Sandig V, Vooijs M, et al. Cre-mediated somatic site-specific recombination in mice. *Nucleic Acids Res.* 1997;25:1766–73.
91. Meuwissen R, Linn SC, van der Valk M, Mooi WJ, Berns A. Mouse model for lung tumorigenesis through Cre/lox controlled sporadic activation of the K-Ras oncogene. *Oncogene.* 2001;20:6551–8.
92. Chan IT, Kutok JL, Williams IR, et al. Conditional expression of oncogenic K-ras from its endogenous promoter induces a myelo-proliferative disease. *J Clin Invest.* 2004;113:528–38.
93. Bindels EM, van den Brekel MW. Development of a conditional mouse model for head and neck squamous cell carcinoma. *Adv Otorhinolaryngol.* 2005;62:1–11.
94. Opitz OG, Harada H, Suliman Y, et al. A mouse model of human oral-esophageal cancer. *J Clin Invest.* 2002;110:761–9.
95. Vasioukhin V, Degenstein L, Wise B, Fuchs E. The magical touch: genome targeting in epidermal stem cells induced by tamoxifen application to mouse skin. *Proc Natl Acad Sci USA.* 1999;96:8551–6.
96. Bornstein S, White R, Malkoski S, et al. Smad4 loss in mice causes spontaneous head and neck cancer with increased genomic instability and inflammation. *J Clin Invest.* 2009;119:3408–19.
97. Caulin C, Nguyen T, Longley MA, Zhou Z, Wang XJ, Roop DR. Inducible activation of oncogenic K-ras results in tumor formation in the oral cavity. *Cancer Res.* 2004;64:5054–8.
98. Lu SL, Herrington H, Wang XJ. Mouse models for human head and neck squamous cell carcinomas. *Head Neck.* 2006;28:945–54.
99. Matsumoto T, Kiguchi K, Jiang J, et al. Development of transgenic mice that inducibly express an active form of c-Src in the epidermis. *Mol Carcinog.* 2004;40:189–200.
100. Vitale-Cross L, Amornphimoltham P, Fisher G, Molinolo AA, Gutkind JS. Conditional expression of K-ras in an epithelial compartment that includes the stem cells is sufficient to promote squamous cell carcinogenesis. *Cancer Res.* 2004;64:8804–7.
101. Paillard F. “Tet-on”: a gene switch for the exogenous regulation of transgene expression. *Hum Gene Ther.* 1998;9:983–5.
102. Higashi AY, Ikawa T, Muramatsu M, et al. Direct hematological toxicity and illegitimate chromosomal recombination caused by the systemic activation of CreERT2. *J Immunol.* 2009;182:5633–40.
103. Leonhard WN, Roelfsema JH, Lantinga-van Leeuwen IS, Breuning MH, Peters DJ. Quantification of Cre-mediated recombination by a novel strategy reveals a stable extra-chromosomal deletion-circle in mice. *BMC Biotechnol.* 2008;8:18.
104. Opitz OG, Quante M, von Werder A, Heeg S, Blum HE. A mouse model of oral-esophageal carcinogenesis. *Onkologie.* 2005;28:44–8.

Chapter 13

Morphologic Investigations in Head and Neck Cancer

Suyash Mohan and Gaurang V. Shah

Abstract Head and neck cancer (HNC) is the fifth most common cancer worldwide and is traditionally associated with high morbidity and mortality. Patients with head and neck squamous cell cancer require a careful evaluation and a multidisciplinary team approach to determine optimal management. Treatment planning depends on TNM staging, which is evaluated with physical examination, endoscopies, and cross-sectional imaging. CT and MR imaging form the main stays of cross-sectional imaging and is extensively utilized in characterizing and staging of malignant tumors involving the head and neck which is critical for the selection of appropriate therapeutic regimens. The goal of imaging in patients with HNC are to establish tumor extent and size, to assess nodal disease, for possible perineural tumor spread, to distinguish recurrent tumor from posttreatment changes, and to monitor the result and response of treatment. Cross-sectional imaging supplements and compliments the physical examination by delineating the complex anatomic and pathological changes of the neck.

CT and MRI complement each other; certain conditions are better studied with one than the other. Various strengths and weaknesses of each modality should be carefully considered when selecting them for tumor assessment and follow up. Certain newer techniques, such as CT and MR perfusion, MR spectroscopy, facilitate the evaluation of functional parameters in oncologic patients, such as tissue perfusion, which can integrate the morphologic and metabolic information derived from conventional techniques and have the potential to identify the characteristics that could indicate malignant progression. Recently, functional imaging with ^{18}F -fluorodeoxyglucose (FDG) positron emission tomography (PET) was introduced and found to be superior to conventional imaging work-ups in the evaluation of patients with head and neck malignancies. It improves the detection of occult cervical lymphatic disease, distant metastasis, and assists in localization of unknown primary carcinoma of head and neck region or a synchronous second tumor. Combined

PET/CT scanners have improved anatomic localization of HNC, incorporating the anatomic accuracy of CT with functional data of ^{18}F FDG-PET. From methodological development, these morphologic investigations are making the critical transition to preclinical and clinical validating methods and eventually to widespread clinical tools.

Keywords Head and neck cancer • Staging • CT perfusion • MR perfusion • MR spectroscopy • PET/CT • Squamous cell cancer • Synchronous second tumor • Unknown primary

A head and neck cancer (HNC) accounts for 3–5% of all the malignant conditions worldwide and is the fifth most common cancer condition [1]. HNC encompasses a variety of cancers, 90% of which are head and neck squamous cell cancers (HNSCCs), arising from a variety of sites. The primary risk factors for HNSCC in American men and women are tobacco and alcohol use. In 2009, approximately 83,730 new diagnoses and 18,860 deaths were expected in United States due to HNC [2]. Patients with HNSCC require a careful evaluation and a multidisciplinary team approach to determine optimal management. Treatment planning depends to a large extent on TNM staging, which is evaluated with physical examination, endoscopies, and cross-sectional imaging [3].

Radiologic imaging with CT and MR imaging is extensively utilized to evaluate soft tissue masses of head and neck. These masses are diagnosed and staged primarily on the basis of physical examination and CT and MRI findings [4–6]. Imaging has become a vital and integral tool in characterizing and staging of malignant tumors involving the head and neck. CT and MRI provide essential information about the deep extension of clinically detected masses and also delineate additional clinically unsuspected masses [7, 8]. Accurate staging at the time of diagnosis is critical for the selection of appropriate treatment strategy. Precise prediction of the extent of primary tumors, cervical lymph node status, and distant metastatic spread is important for treatment planning and prognosis. The goal of imaging in patients with HNC is to establish tumor extent and size, to assess nodal disease, for possible perineural tumor spread, and to distinguish recurrent

G.V. Shah (✉)
Radiology Department, University of Michigan, B2A209, UM11S,
1500 E. Med Ctr Dr., Ann Arbor, MI 48109, USA
e-mail: gvshah@med.umich.edu

tumor from posttreatment changes [9]. Imaging is also essential to follow up the patients after various therapeutic options available for the treatment are exercised, including surgery with or without radical dissection, lymph node dissections of various severities, radiotherapy, chemotherapy, and various combinations of all these [10]. Accurate evaluation of all these factors prior to treatment helps guide surgical extent or radiation ports, minimizing locoregional treatment failure.

CT and MRI are the most commonly utilized imaging modalities for the assessment of primary malignant tumor, local extension, and lymph nodal involvement. They are also the first imaging modalities for monitoring the result and response of surgical intervention, radiation or chemotherapy, or combinations thereof. In this goal, cross-sectional imaging supplements and complements the physical examination by delineating the anatomy and pathological changes of the neck. Complex anatomic structures and regions, such as the orbit, skull base, paranasal sinuses, deep spaces of the suprahyoid and infrahyoid neck, larynx, and lymph nodes, require that the radiologist be familiar with the imaging modalities available and their appropriate applications.

CT and MRI complement each other; certain conditions are better studied with one than the other. Various strengths and weaknesses of each modality should be carefully considered when selecting them for tumor assessment and follow up [11]. The interpretation of CT and MRI should be based on the patient's history, physical findings, comorbidities, and previous procedures that may influence the structures visualized. Comparison with previous imaging is also essential to reliably understand the present condition.

Standard CT

Computerized tomography (CT) was introduced in the 1970s and revolutionized body imaging. It is inexpensive, fast, and ubiquitous in most medical centers. CT is quite good at delin-

ing tumor extent and nodal disease. In head and neck tumors including squamous cell carcinoma, CT helped in tumor staging, which dictated patient management and related to prognosis [8]. Helical multidetector computerized tomography (MDCT) with 16 and now 64 detector rings has rapidly become the new industry standard in CT imaging. This along with dynamic acquisition typically has resulted in reduced scan time, thinner sections, increased anatomic coverage and better resolution of reformatted images, and three-dimensional reconstruction. Section thickness as low as 0.5 mm can be achieved along with acquisition of up to eight images per second [12]. This has greatly enhanced the sensitivity and specificity of CT scan in HNC for primary staging as well as posttherapeutic follow-up (Fig. 13.1).

The anatomic coverage of a neck CT should include the base of the skull and should extend up to the medial end of the clavicles with 4-mm thick slices. Additionally, 2 mm slices and higher zoom factor may be employed at the region of interest using reconstructed spiral data. In patients with significant dental hardware, additional angulated images may also be obtained for better anatomic coverage avoiding streak artifacts.

CT has proved to be a modality of choice for initial work-up of a patient suspected of HNC and proved excellent for initial locoregional and lymph nodal staging and for posttherapeutic follow-up.

CT Perfusion

CT perfusion (CTP) facilitates the evaluation of functional parameters in oncologic patients, such as tissue perfusion, which can integrate the morphologic information derived from conventional CT techniques. It is a dynamic contrast-enhanced technique which is used for quantitative assessment of tissue microcirculation [13], and it has recently been rediscovered as a promising noninvasive tool for the evaluation

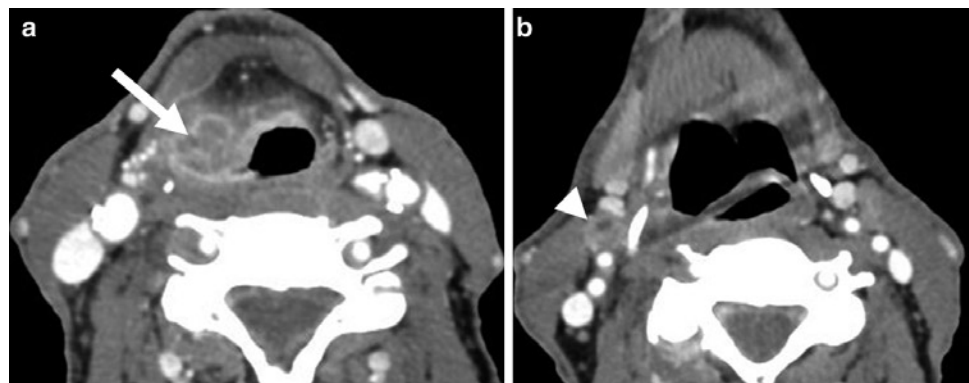


Fig. 13.1 Axial postcontrast CT scan showing T3 stage right aryepiglottic fold carcinoma (a) with transglottic extension (arrow) and metastatic right level 2 lymphadenopathy (b) consistent with N1 disease (arrowhead)

of the microcirculatory changes associated with several neoplasm, including cancers of the head and neck [14–17]. CTP technique is based on the central volume principle, which relates blood flow, blood volume, and MTT as: $\text{blood flow (BF)} = \text{blood volume (BV)} / \text{MTT}$. Faggioni et al. have shown that BV, BF, and permeability-surface area product are significantly higher, whereas MTT is significantly reduced in head and neck tumor (both primary neoplasm and lymph node metastases, whenever present) compared with normal tissue and with muscle taken as a reference ($p < 0.01$); moreover, the alteration of CTP parameters correlates with histopathologic diagnosis of adenocarcinoma in all cases [14]. Ash et al. have shown that CTP parameters of the neck (BF and BV) correlate positively with microvessel density (MVD) of endoscopic biopsy specimens obtained from primary tumor sites of HNSCC [18]. Although, it seems unlikely that CT perfusion will replace biopsy for pretreatment assessment of MVD, CTP has the potential to monitor treatment response by enabling noninvasive assessment of alterations in MVD and acting as a surrogate marker for tumor oxygenation.

Standard Magnetic Resonance Imaging

Magnetic resonance imaging (MRI) introduced in the 1980s was a quantum jump in diagnostic imaging of the head and neck pathologies. Some of the earliest investigations in head and neck imaging with MRI highlighted the ability of MRI to differentiate neoplastic from inflammatory lesions. MRI provides essential information about the deep extension of clinically detected masses and also delineates additional clinically unsuspected lesions [7]. It has added value for the detection of soft tissue extent, marrow involvement, and perineural spread [19]. The excellent tissue characterization and noninvasive multiplanar imaging capability of MR imaging result in more accurate diagnosis of neoplastic and benign tumors of the head and neck [20–24]. MRI is reported to be superior to CT in detecting tumor extensions, in separation of edema from the tumor, and in the evaluation of possible bone marrow invasion. Dynamic MRI is also utilized to plan and evaluate radiotherapy of HNC [25].

MRI of the neck should be tailored for the anatomic region and process under evaluation. A standard head coil usually suffices for relatively localized examinations of the suprahyoid region and base of the skull, whereas, the infrahyoid neck requires a neck coil. Axial, coronal, and sagittal sequences are essential. Unenhanced axial T1-weighted images display anatomic relationships and can detect lesions (e.g., lymph node lesions) embedded within fat. T1-weighted coronal images can define the false vocal cords, true vocal cords, laryngeal ventricle, and the floor of mouth [26, 27].

T1-weighted sagittal images provide helpful information about the preepiglottic space and nasopharynx. T2-weighted transaxial images characterize tissue, detect tumor within muscle, demonstrate cysts, and assist differentiation of post-therapy fibrosis from recurrent tumor [28].

Gradient moment nulling, flow compensation, cardiac gating, and presaturation pulses are some techniques used to minimize motion artifacts [26]. Gadolinium (Gd)-enhanced images improve delineation of margins in many lesions. Fat-suppression techniques, such as short tau inversion recovery (STIR) and frequency-selected fat suppression, may improve the conspicuity of soft-tissue lesions embedded in fatty tissue by selectively diminishing the hyperintensity of fat on T1-weighted images [29] (Fig. 13.2). Postcontrast T1-weighted images usually best delineate the tumor margins [30], and this may be further improved with fat saturation (fat-sat), which, however, frequently results in artifacts and image degradation [31]. However, the normal enhancement of the aerodigestive mucosa may conceal small mucosal tumors.

Early investigators credited MR imaging with greater precision in head and neck imaging than was warranted [32]. Conventional MR imaging did not have the last word in histological specificity, early detection of primary malignancy, and differentiating neoplastic from inflammatory lymph nodes. In spite of early enthusiasm, MR imaging did not eliminate the need for biopsies or aspirations of lesions. Spin echo imaging is still the mainstay of MR imaging, but now various new techniques hold promise for the future of head and neck imaging [33].

MR Diffusion

Although diffusion-weighted MRI (DWI) has been used for long for the evaluation of brain pathology, its potential utility for evaluating extracranial neoplastic disease has only recently been recognized. Hypercellular tissue within malignant tumors will show low ADC values [34, 35], while tissue changes such as edema, inflammation, fibrosis, and necrosis show low cellularity and hence higher ADC values [33] (Fig. 13.3). Diffusion weighted imaging of oropharynx can easily be performed at the time of MR conventional imaging and adds approximately only 1–2 min of additional time to the examination. Localization and extent of primary squamous cell cancer, one of the commonest malignant neoplasms of head and neck, is usually well defined by CT or conventional MRI. High sensitivities and specificities, better than CT or conventional MRI are also reported in staging of neck lymph nodes in squamous cell carcinoma [36, 37]. Whole body DWI at high b -values with ADC mapping is technically feasible and improves assessment of metastatic spread in routine

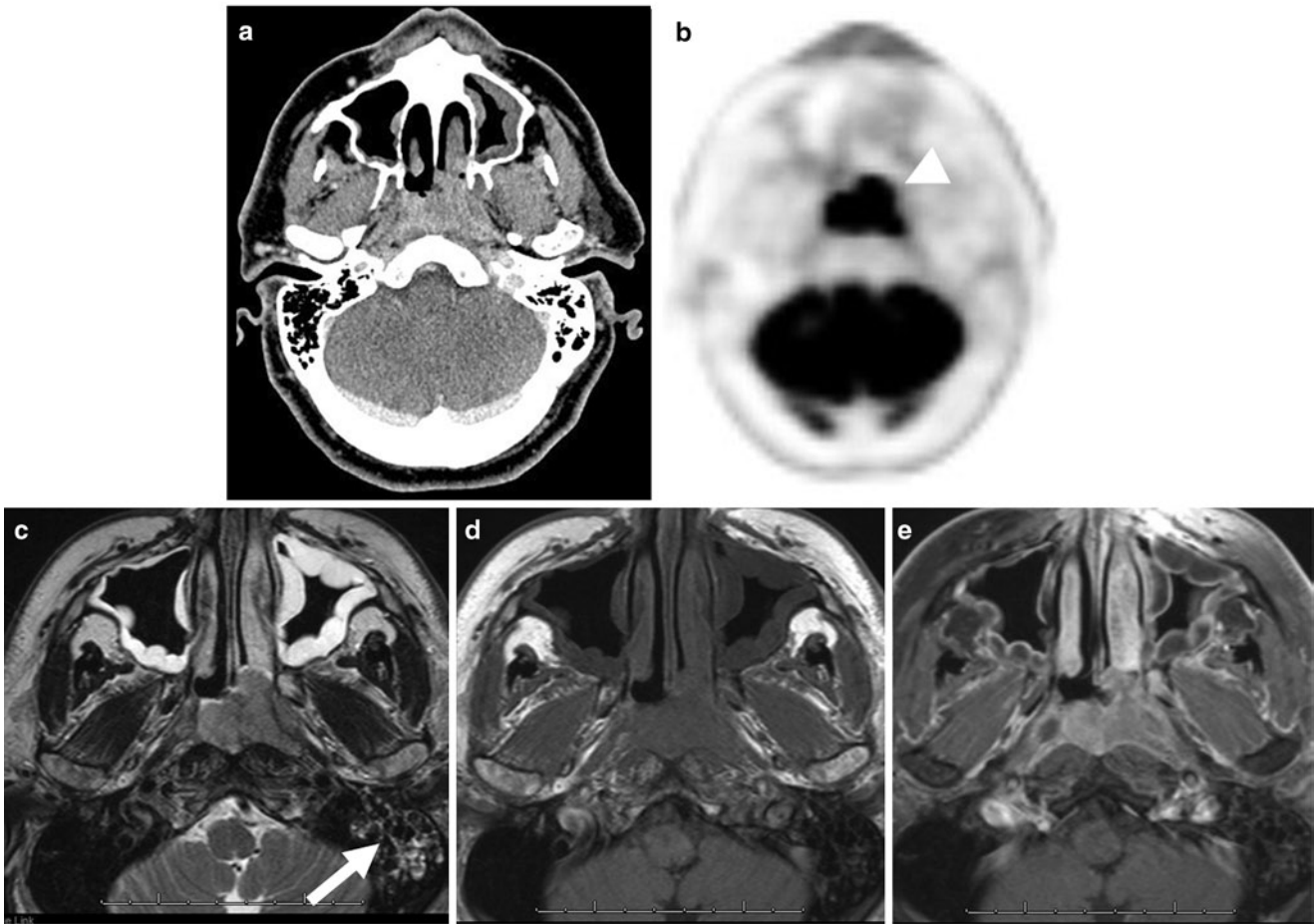


Fig. 13.2 CT-PET (a and b) images showing FDG avid nasopharyngeal mass (*arrow head*). Axial T2W (c) and pre- and postcontrast fat suppressed T1W images (d and e) showing enhancing mass within the

left posterior nasopharynx crossing to the right side. Fluid in the right mastoid air cells (*arrow*) secondary to Eustachian tube dysfunction

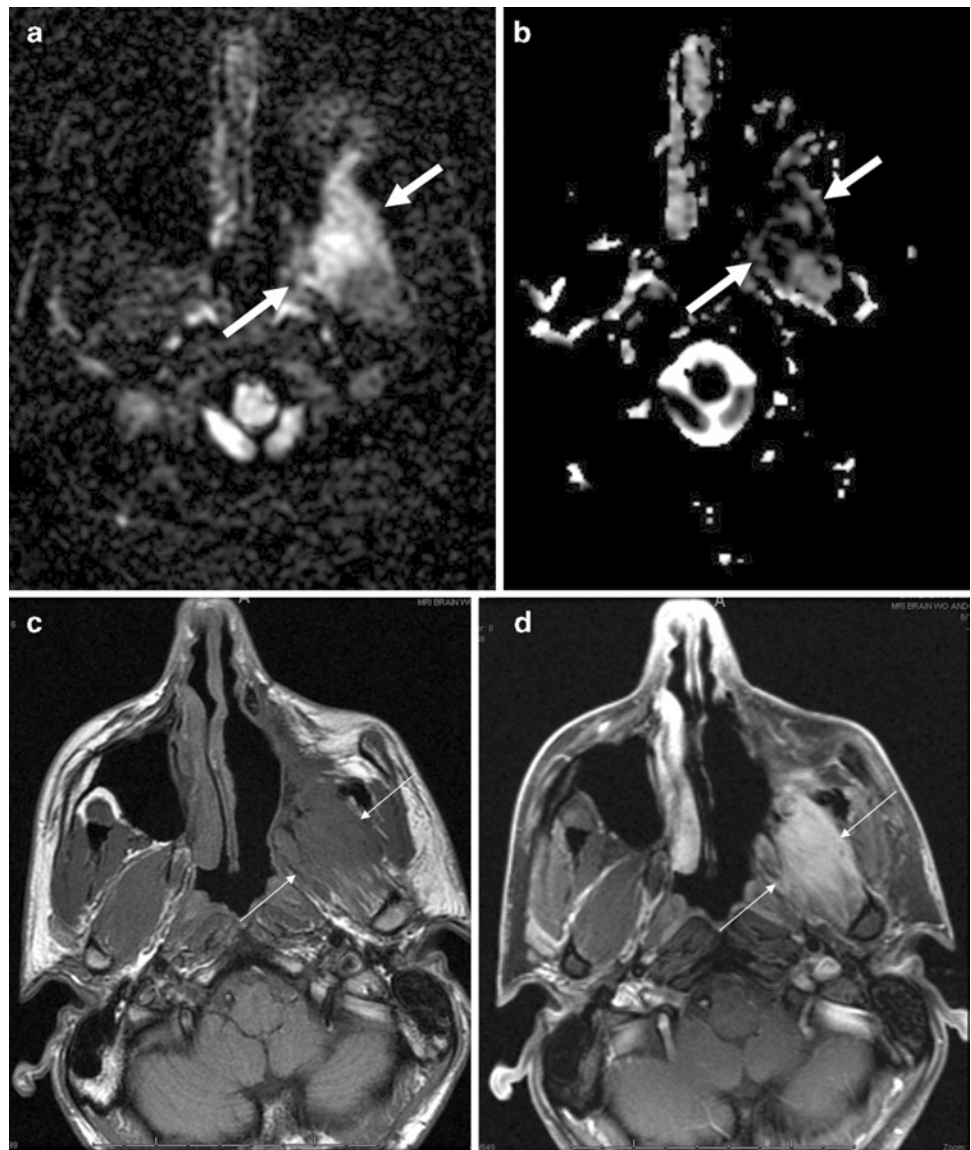
MR examinations. The characterization of neck lymph nodes remains a difficult issue with anatomy-based imaging methods, and DWI may be useful in this regard [38, 39]. DW imaging performed with ADC ($b_0=1,000$) values had higher accuracy than turbo spin-echo MR imaging in nodal staging, providing added value in the detection of subcentimeter nodal metastases [39].

MR Perfusion

Perfusion imaging evaluates dynamic microscopic blood flow changes through a region of interest. Changes in tissue signal intensity on MRI are measured during a dynamic contrast infusion. Blood flow, blood volume, and transit time parameters of tissue regions can be then generated. Perfusion characteristics of tissue demonstrate changes in blood flow

or volume of the head and neck lesions depending on underlying pathologic processes [33]. This technique has been previously studied in characterizing brain ischemia, particularly in identifying infarcted tissue versus tissue at risk [40]. Changes in perfusion characteristics are also demonstrated in neoplastic tissue (Fig. 13.4). Generally, these findings may not add substantial additional information regarding tumor extent at the diagnosis. However, such imaging may be of benefit in qualitative analysis of tumor tissue. Specifically, additional recent studies have demonstrated that squamous cell carcinomas of the upper aerodigestive tract with increased blood volume/flow are more chemosensitive than other lesions with relative decreased perfusion parameters. This is likely due to relative increased oxygenation and metabolism of such lesions [16]. Such perfusion techniques could be particularly useful in determining which patients would benefit from such medical treatment, as opposed to surgical therapies which may not always preserve organ function.

Fig. 13.3 Axial DWI (a) showing restricted diffusion in a left masticator space adenoid cystic cancer (arrows) with low ADC values (b) as seen on corresponding ADC maps (arrows)



An additional area of interest is in regard to tumor recurrence or regression. Conventional MRI or CT may simply demonstrate increased contrast enhancement within the treated neck. However, morphologic changes in tissue appearance (such as increase in size or nodularity) may not be well demonstrated on early posttreatment conventional imaging. Recent studies have concluded that for recurrent oral cavity and oropharyngeal carcinomas, perfusion parameters are altered. Specifically, BV and BF within recurrent tumor tissue are elevated in comparison to therapy-altered tissue, with corresponding decreases in transit time [41]. Perfusion imaging, such as diffusion imaging, adds little time to either conventional MRI or CT examinations and can also be obtained noninvasively [42].

MR Magnetization Transfer

Magnetization transfer (MT) technique may be useful for differentiating enhancing lesions from background tissue and defining poorly enhancing lesions. This technique is based on the principle that the selective magnetization of protons associated with macromolecules may be transferred to the water protons that constitutes the MT image. A strong MT effect is observed where an efficient transfer mechanism exists between the two proton populations. This is exploited to improve contrast between mass lesions that demonstrate an MT effect and background tissue like fat that does not [43]. Use of MT can improve contrast between head and neck lesions and background tissues. MT is shown to improve

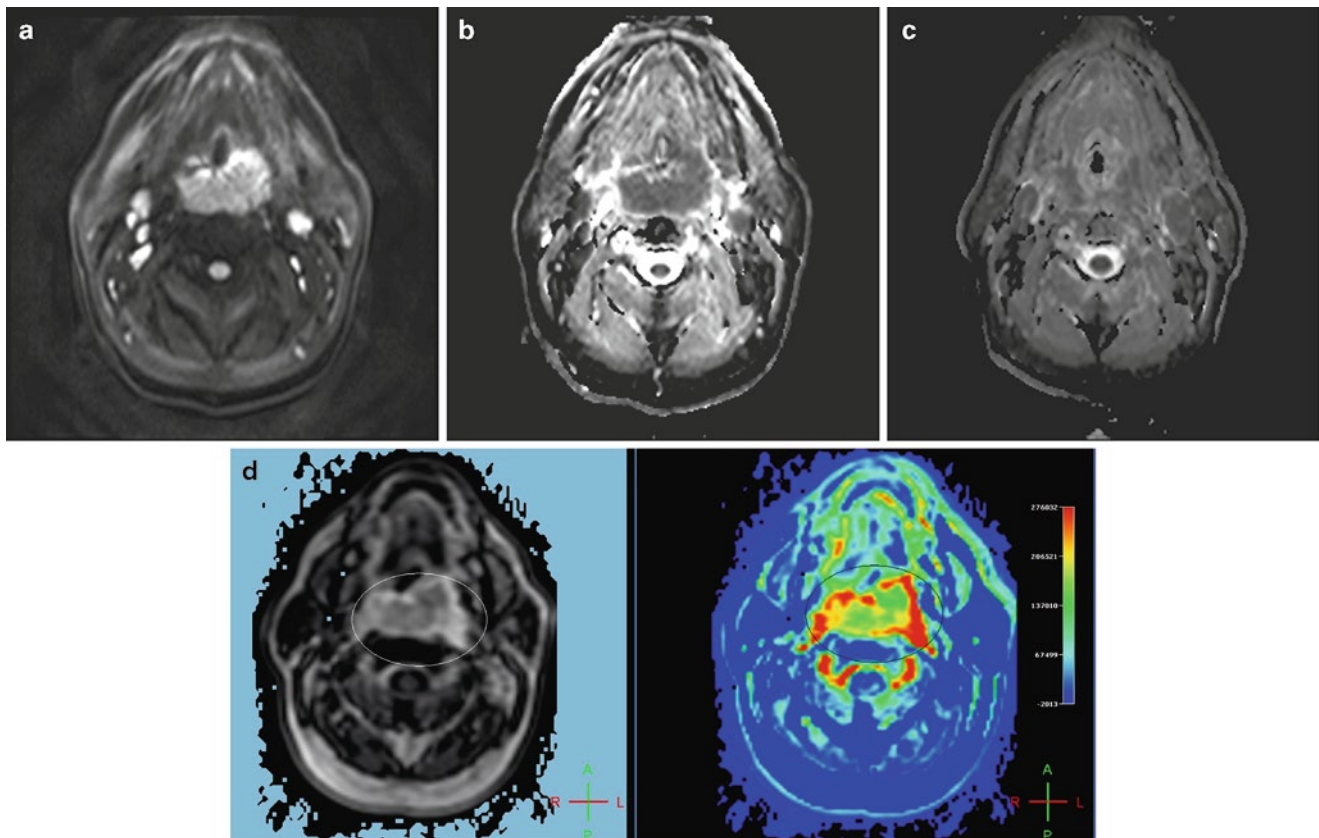


Fig. 13.4 (a, b, c) Large posterior oropharyngeal wall squamous cell carcinoma demonstrates increased DWI (a) and decreased ADC (b) signal intensity at presentation. Posttherapy, the lesion has decreased greatly in size (c). (d) Blood volume map of the same

patient as in images a–c demonstrates increased perfusion values of the lesion (*circled*) in comparison to the adjacent tissues at presentation (from [33], reprinted with permission from John Wiley and Sons)

depiction of enhancing lesions adjacent to tissues with a strong MT effect [44]. MT can also aid unenhanced MR imaging in the delineation of tumors or lymph nodes in the parotid gland. MT is not indicated for cystic lesions, because they are generally well shown on a T2-weighted image or for cervical lymphadenopathy within lipid tissue, because that has natural tissue contrast on conventional MRI [44].

However, MT has not enjoyed widespread application in head and neck imaging, partly because conventional imaging usually provides sufficient delineation of most primary lesions and lymphadenopathy.

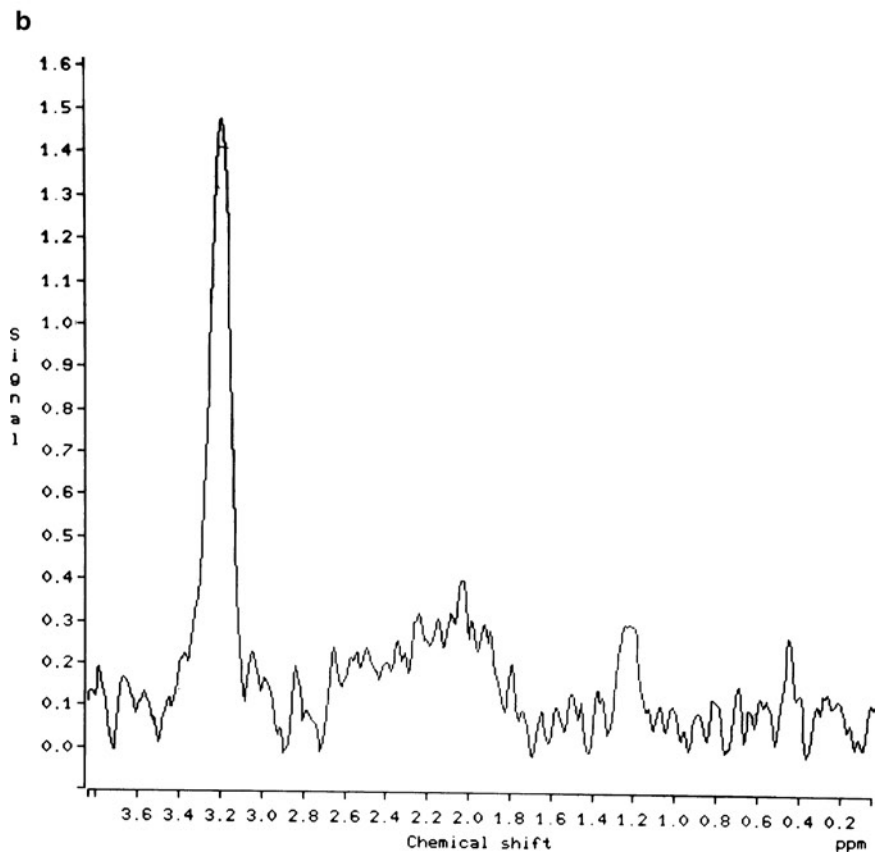
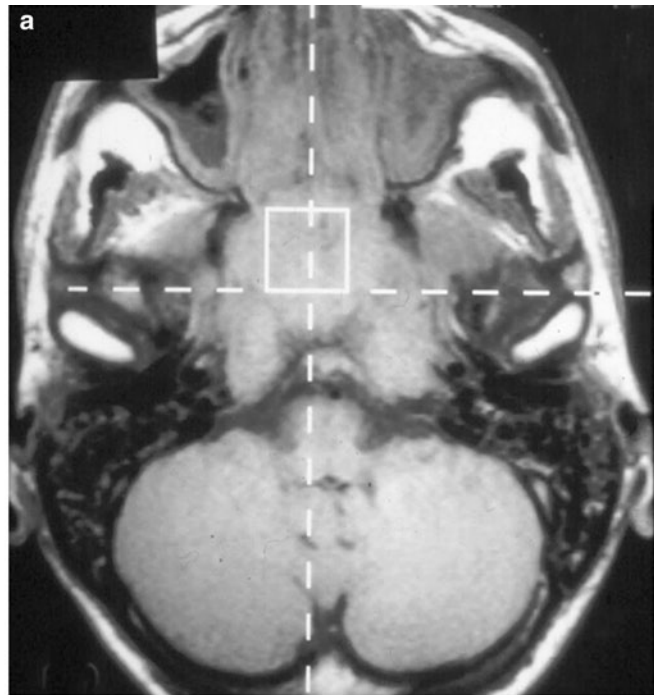MR Spectroscopy

It is now widely accepted that cancer progression is accompanied by intracellular biochemical changes. Magnetic resonance spectroscopy (MRS) provides a noninvasive method for evaluation of various diseases of head and neck independent

of the anatomic information provided by MRI [45]. ¹H-MR spectroscopy has the potential to assess biochemical composition and hence identify characteristics that could indicate malignant progression. It has the unique ability to analyze the tissue at the molecular level by evaluating the presence of specific metabolites. This is especially helpful to characterize lesions that have equivocal features on standard anatomic imaging. Early metastatic infiltration of nonenlarged lymph nodes or residual malignant disease in patients undergoing treatment for malignant process may also have normal or ambiguous appearance on routine anatomic CT or MR imaging [46].

In the case of HNSCC, it has been shown that ¹H-MR spectroscopy has the potential to differentiate between normal and malignant tissue with a high degree of sensitivity and specificity [45, 47–50] (Fig. 13.5). MR spectroscopy of HNC and lymph nodes helps to differentiate nonmalignant from malignant tumors and lymph nodes and also helps to differentiate between residual malignancies from postradiation changes. Elevation of the Cho/Cr ratio appears to be a consistent finding

Fig. 13.5 Patient with throat pain and dry cough exhibits a nasopharyngeal mass on MR imaging. **(a)** T1 axial images show a large nasopharyngeal midline soft tissue mass with nonspecific features and without frank aggression. **(b)** 1H-MRS reveals attenuation of *N*-acetyl aspartate peak, elevation of choline peak, and increased choline to creatine ratio compatible with malignant mass. This lesion was proved on biopsy to be a squamous cell carcinoma (from [45], reprinted with permission from Elsevier)



for HNSCCA and has also been identified in analysis of various SCCA cell cultures and SCCA containing cervical metastatic lymph nodes [47]. Higher levels of choline metabolites in tumors are believed to be due to increased cell proliferation

and biosynthesis, while reduced creatinine resonance likely reflect increased energy metabolism within tumors [51].

For prognostication, MR spectroscopy has the potential to contribute to an accurate and early prediction of tumor behavior

and response to treatment in squamous cell carcinoma of the head and neck region. Using the choline-to-creatine (3.2/3.0 ppm) and the 1.3/0.9 ppm spectral intensity ratios (signal due to lipid or lactic acid), a sensitivity of 83% and a specificity of 82% were obtained in predicting which HNC patients would fail treatment [52].

Tumor hypoxia is a common phenomenon in solid tumors and has been shown to adversely affect the treatment outcomes in patients with head and neck (HN) squamous cell carcinoma treated with conventional therapy [53–55]. Resonance from lactate (Lac, 1.3 ppm) may be a marker for tumor oxygenation and may help staging and was thought to have potential for staging and monitoring the treatment [56]. However, in a recent work the lactate SI did not correlate with tumor pO₂, treatment response, or locoregional control in a series of 62 patients with resectable stage IV HN squamous cell carcinoma undergoing induction chemotherapy [57]. Additional research is needed to refine this technique.

PET/CT

Conventional morphological imaging methods such as CT and MRI have been the mainstay of diagnostic work-up for diagnosis, staging and posttherapeutic follow-up in patients with HNC. Recently, functional imaging with ¹⁸F-fluorodeoxyglucose (FDG) positron emission tomography (PET) was introduced and found to be superior to conventional imaging work-ups in the evaluation of patients with head and neck malignancies [58–60]. ¹⁸FDG-PET has higher sensitivity and specificity for detecting lymph node

metastases than CT or MRI. It improves detection of occult cervical lymphatic disease, distant metastasis, and assists in localization of unknown primary carcinoma of head and neck region [61–65]. ¹⁸FDG-PET is considered superior to CT and MRI for local staging and detection of malignant characteristics in cervical lymph nodal enlargements [58, 59, 66–69]. It has a high negative predictive value (NPV) of approximately 90%, which is more than any other imaging modality. There is growing evidence that ¹⁸FDG-PET imaging is increasingly accepted as a valuable imaging tool in the evaluation of patients with head and neck carcinomas [61–64, 70–73]. The potential clinical applications include pretreatment staging, treatment monitoring, and evaluation of the previously treated patients [74] (Fig. 13.6).

Poor quality of anatomical localization of the primary tumor and metastases on ¹⁸FDG-PET can have negative impact on staging and management [75]. The poor spatial resolution of ¹⁸FDG-PET is a limiting factor, especially within the intricate anatomy of head and neck [68]. Combined PET/CT scanners overcome these limitations by fusing the anatomic data of CT with functional data of ¹⁸FDG-PET [76–78]. In PET/CT, the most relevant additional effect is that the CT data adds specificity to ¹⁸FDG-PET data [79, 80]. The utility of PET/CT has been evaluated extensively in head and neck neoplasm. Several of these studies showed that the integrated combination of CT and ¹⁸FDG-PET is more accurate than either of the modalities alone for detection and anatomic localization of HNC, thus enhancing the patient care [81–86]. The accuracy of integrated PET/CT is also more than ¹⁸FDG-PET and CT images viewed side by side [82, 87–90]. In one study, CT data improved the specificity of the images in approximately two-third of patients with lesions

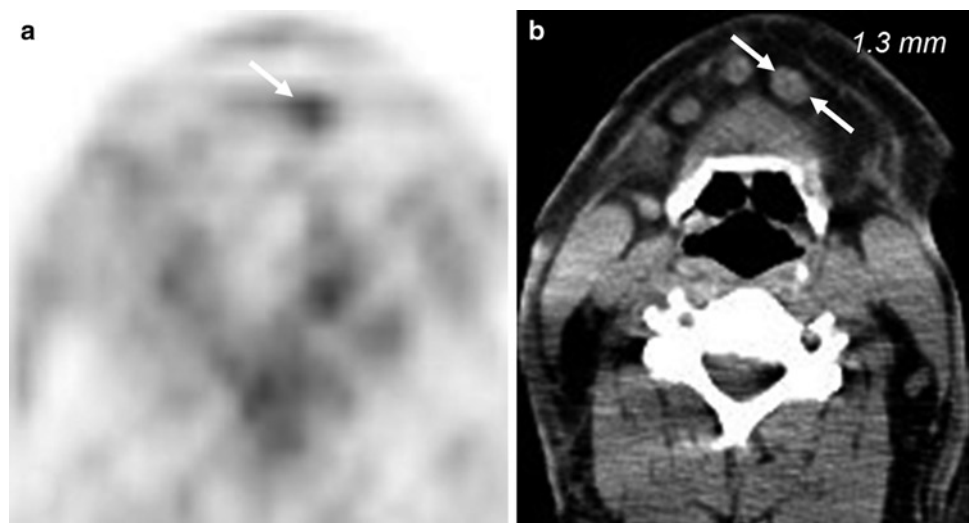


Fig. 13.6 Mantle cell lymphoma showing FDG avidity (a) in a nonenlarged left level 1 lymph node (arrows) in the neck (b)

seen on ^{18}F FDG-PET images [91]. In some situations, such as very small disseminated pulmonary metastases, addition of CT is able to increase the specificity and also the sensitivity of PET/CT examination [80].

PET/CT can detect unknown primary tumors of the upper aerodigestive tract [92, 93]. PET/CT can detect primary squamous cell carcinoma in 30–50% of patients presenting with an unknown primary tumor. PET/CT is generally performed after confirming the presence of metastatic squamous cell carcinoma. It is usually performed before endoscopic biopsies to improve the tissue yield. This diagnostic yield can increase with PET/CT because as it improves the anatomic localization of areas of abnormal FDG uptake [94, 95]. PET/CT is also utilized for determining response to chemotherapy and/or radiation. Comparison of pretreatment standard uptake values (SUVs) to SUVs 2 weeks into treatment can allow measurement of the speed of response and also the sensitivity of the tumor to the treatment technique [96]. Poorly responsive tumors can then be treated to higher effective tumor doses of radiation, or surgery can be performed. Initial results suggest that PET/CT can be used to assist in defining primary site and nodal tumor targets for radiation therapy approaches. PET/CT is useful adjuvant to clinical staging of squamous cell carcinoma and its utilization will increase with advancement of technology.

Local Tumor Detection and Staging

The most important information required before surgery for proper therapeutic planning is the accurate knowledge of location, size, extent, the depth of invasion of the primary tumor, and its relation to the surrounding structures [68, 97]. Large primary tumors of the oral cavity or the oropharynx can be detected easily by clinical examination. The sensitivity of FDG-PET was considered even higher than CT or MRI for detection of primary tumors [98]. The sensitivity of FDG-PET for detection of primary carcinoma ranged from 88 to 100% [60, 62, 99, 100]. Both MRI and CT can provide additional information about tumor extension into the deep spaces, the relationship to adjacent structures, and bone infiltration needed for treatment planning. Sensitivity of MRI earlier was thought to be less than that of CT [61, 99]. However, with increased technical improvements, it is thought to be comparable to CT [3]. Scattering of focal uptake in primary oropharyngeal tumors can lead to overestimation of the extent of primary disease and physiologic uptake in oropharynx may obscure small primary tumors in oropharynx [101]. Thus FDG-PET alone cannot provide the detailed information needed for planning of tumor resection, but fusion of FDG-PET data with CT data in PET/CT can overcome this limitation.

Sensitivity of CT, especially in oropharynx can be compromised by streak artifacts from dental hardware, especially if the size of the tumor is small [3]. However, high metabolism on FDG-PET would indicate the possibility of an underlying mass (Fig. 13.7). Earlier, the sensitivity of MRI was thought to be less than that of CT [61, 99], but with increased technical improvements, it is thought to be comparable to CT [3]. Some of the earlier reports showed that FDG-PET was more accurate than CT or MRI for local detection of smaller tumors [61, 99, 100]. But some more recent studies have shown that CT and FDG-PET are equivalent in local staging [60, 102].

CT detects lytic foci of cortical mandibular invasion, which are best accomplished with a dedicated dental protocol. The reported sensitivity and specificity for standard neck CT in the detection of mandibular involvement are 96 and 87%, respectively (Fig. 13.8) [103]. However, a later study demonstrated a 93% accuracy of MRI in detecting mandibular involvement in patients with oral and oropharyngeal cancer [104], indicating that CT may not be necessary to evaluate for cortical invasion. MRI with contrast-enhanced T1-weighted fat-sat images, provides satisfactory accuracy of tumor thickness. Presence of malignant neoplasm adjacent to the neurovascular bundle is highly concerning for invasion. Tumors larger than 2 cm with aggressive margins and deep sublingual extension probably involve the neurovascular bundle [30]. Oral malignancies, especially of buccal spaces and retromolar trigone are better visualized using the “puffed cheek” CT technique, in which the patients perform a modified Valsalva maneuver during the scan distending the oral cavity by air [105].

Deep extension of nasopharyngeal cancer including the presence of skull base invasion and intracranial spread is better evaluated with MRI than CT [106, 107]. Skull base invasion may occur through the neural foramina by perineural tumor spread, which primarily occurs after invasion of the pterygopalatine fossa, foramen ovale, and hypoglossal canal [108] (Fig. 13.9). Nonenhanced T1-weighted images are very well suited to evaluate perineural extension, revealing homogeneous gray mass of tumor that against natural tissue contrast of T1 bright fat planes and bone marrow. Pre- and postcontrast T1-weighted MRI is very accurate in the detection of subtle perineural tumor extension. Evaluation of possible perineural spread should be performed in all patients with facial paralysis and facial pain or numbness, because these symptoms may be the initial presentation of a head and neck malignancy [109, 110] (Fig. 13.10). Complementary direct coronal CT images with bone algorithm are recommended to evaluate subtle bone erosion which may escape detection by MRI.

Cartilage invasion by laryngeal and hypopharyngeal tumors is an important imaging finding because it automatically leads to a T4 stage [9]. The overall sensitivity is 82%,

overall specificity is 79%, and overall negative predictive value of cartilage erosion on CT overall is 91% [111]. Cartilage invasion on MRI shows high T2 signal intensity, a low to intermediate T1 signal, and postcontrast enhancement. However, due to frequent reactive inflammation, edema, and fibrosis, the MRI findings of cartilage invasion may frequently be false-positive, resulting in a positive predictive value of only 68–71% [112]. However, the advantages of MRI over CT for soft tissue differentiation may be outweighed by motion artifacts. CT remains a valuable and

frequently used screening modality for the larynx as it is fast and readily available.

Imaging studies cannot reliably distinguish benign from malignant salivary gland masses. MRI is the modality of choice for evaluation of parotid masses [20]. The real advantage of cross-sectional imaging is the ability to accurately reveal the location and extension of a tumor and to assess for perineural tumor spread. Magnetization transfer, dynamic imaging, and especially, diffusion imaging have shown promising results in the detection of parotid malignancies [113].

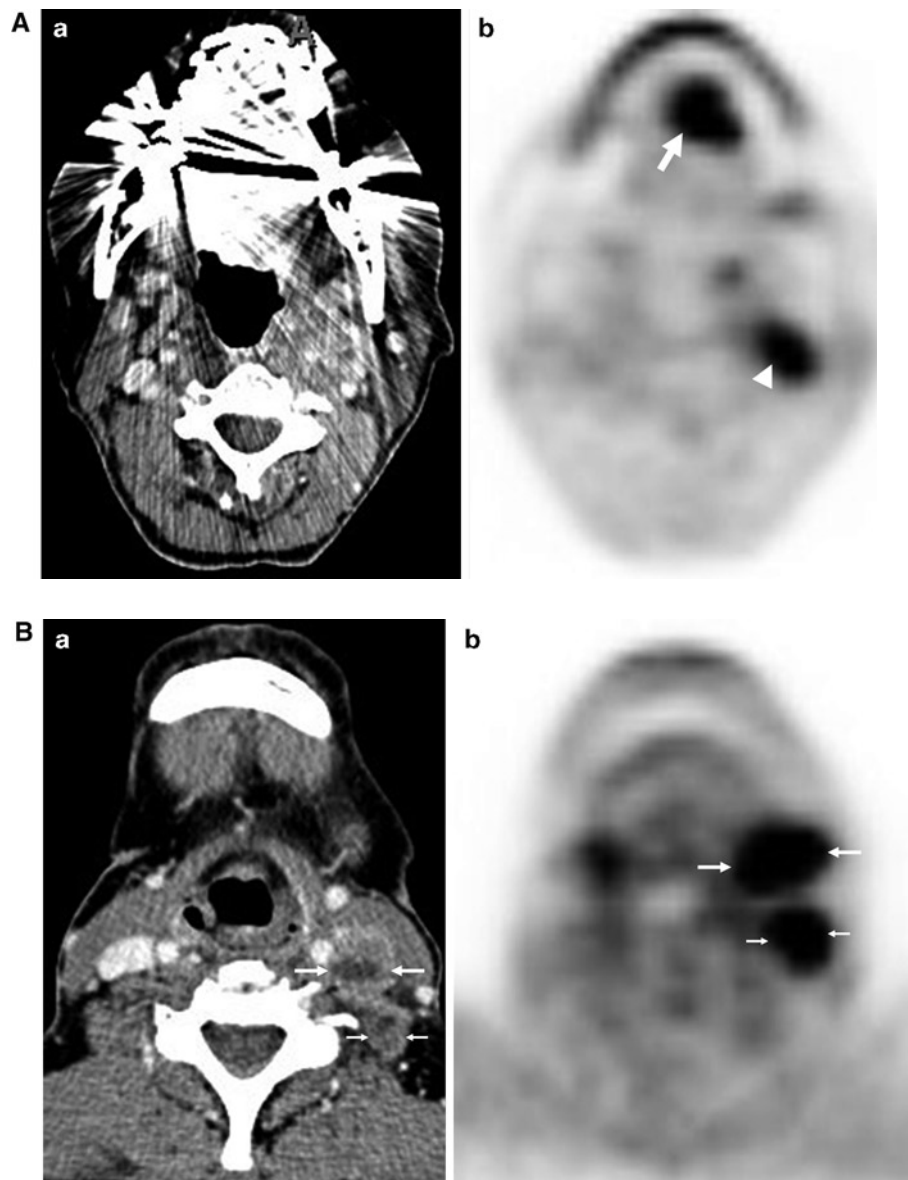


Fig. 13.7 (A) a, b: Axial postcontrast CT scan (a) showing dense streak artifacts from unmovable dental hardware obscuring FDG-avid squamous cell cancer in the oral tongue (arrow) with metastatic left level 2 lymph node (arrow head) as seen on PET scan (b). (B) a, b: Axial postcontrast CT scan (a) showing large necrotic left level 2 lymph node (large arrow) and necrotic left level 5 lymph node (small arrow), with FDG avidity on the corresponding PET scan (b). (C) a, b, c: CT thorax in mediastinal windows (a), and lung windows (b) showing a metachronous lung cancer (arrow) with increased FDG uptake on PET scan (c)

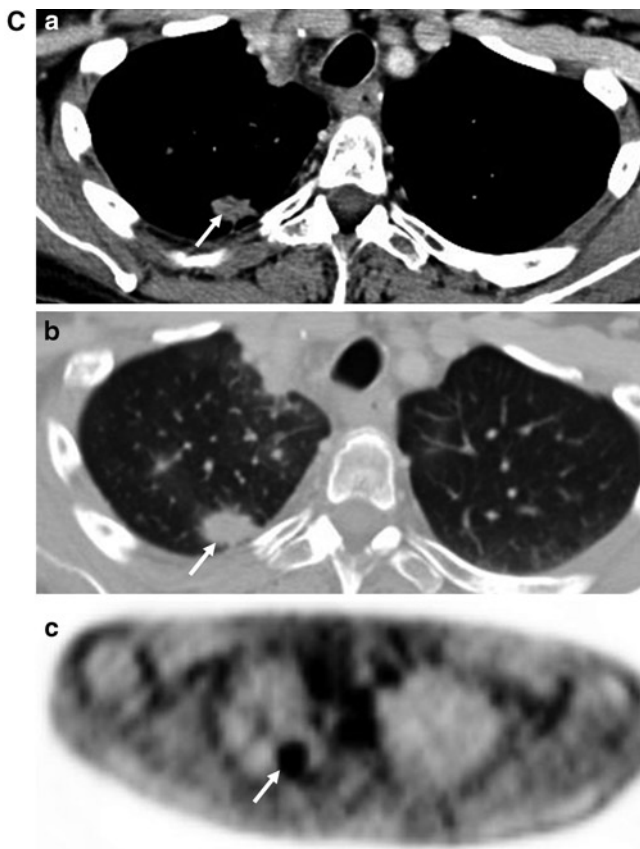

Fig. 13.7 (continued)

The relationship of a tumor to the facial nerve is difficult to determine on MRI. However, the lateral margin of the retromandibular vein on cross-sectional imaging as a marker for the facial nerve has an accuracy of approximately 90% [114]. A careful search for perineural tumor spread along the facial, auriculotemporal, and mandibular (V3) nerves should be undertaken on MRI scans in all patients with parotid masses [115].

Multiple series have been reported evaluating FDG-PET or PET/CT for patient with newly diagnosed HNSCC in the preoperative setting [59, 62, 116]. Sensitivity of FDG-PET was reported to be 98% and of PET/CT 97% for the detection of primary tumors in patients with newly diagnosed HNSCC in a large series with 167 patients [68], higher than sensitivity of CT (86%) and MRI (88%) in the same patient set. Similar results were reported in numerous previous studies [58, 59, 62, 81, 84, 85, 116]. Even as sensitivity of PET/CT is considered higher than any morphological imaging for primary detection of HNSCC, the detailed anatomic information such as depth of invasion and relationship of tumor to surrounding structures could not be provided only by the CT data of PET/CT. This may be due to inherent technical limitations of CT data set. With the availability of multislice and multidetector scanner capability in future with PET/CT, this situation may improve.

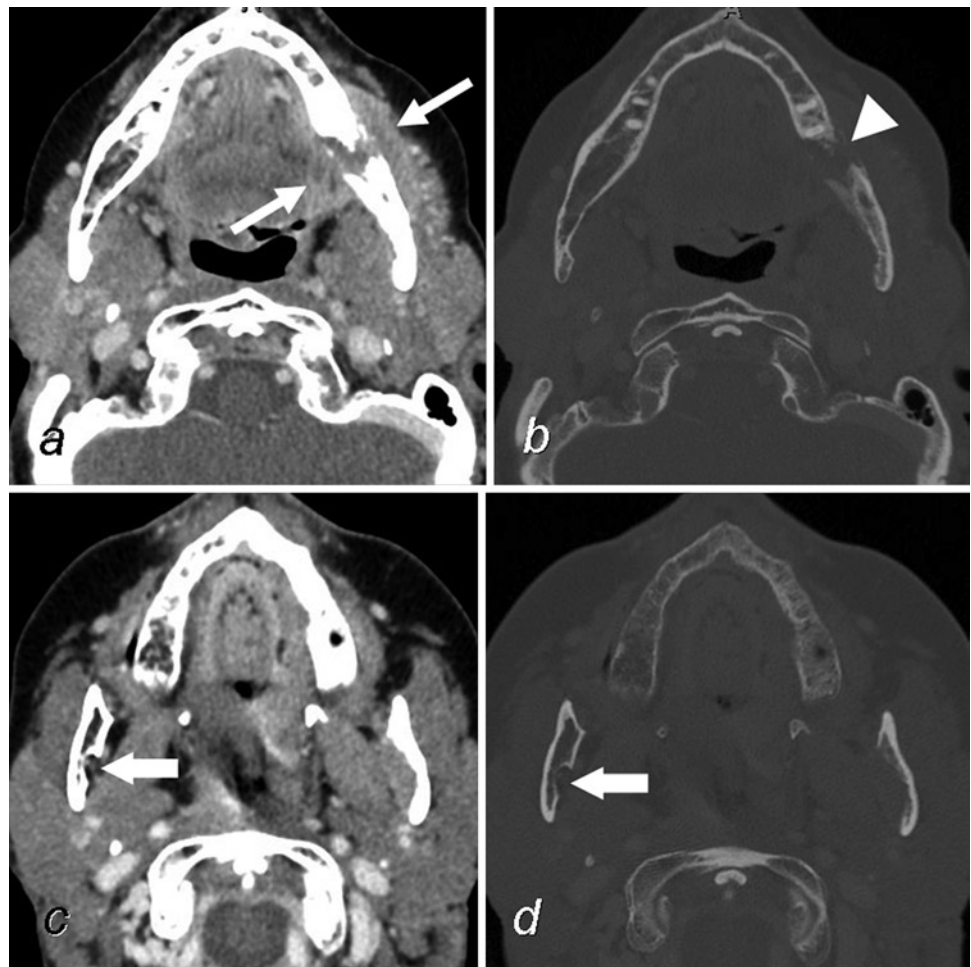
Lymph Node Staging

As most primary head and neck malignant neoplasm have a relatively high incidence of nodal metastasis, the staging of neck is most important before a therapeutic plan is evolved. Staging can be done by a combination of clinical palpation and anatomic imaging. Nearly 40% of all lymph nodes in the body are located above the clavicles. Lymph nodes are usually embedded within the fat planes that surround the vessels and separate major cervical muscles. Therefore, the fat of the neck provides an excellent natural contrast with the nodes on T1-weighted MR images [11]. Lymph nodes are divided into ten major groups [117] named for the structures in proximity to nodal location.

Patients with limited nodal spread of HNC are often treated surgical with radical neck dissection; while more extensive disease may additionally require adjuvant radiation therapy. Complete removal of all metastases lymph nodes is essential for curative treatment. Lymph node metastases are common in patients with HNCs. In up to 20–30% of patients, lymph nodal spread of the disease is found, even though it may not be apparent on physical exam [118, 119]. The prognosis for these patients is strongly influenced by the presence of lymph node metastases [99]. Metastatic lymph node disease was found in approximately 50% of the patients at the time of diagnosis [3, 70].

The imaging recommendations are mixed regarding an appropriate modality for evaluating lymphadenopathy [5, 120, 121]. CT is preferred because of its availability, speed, and excellent spatial resolution. Lymph nodes are usually embedded within fat, and fat is well portrayed by CT (see Fig. 13.6). MRI has superior soft-tissue contrast and multiplanar capabilities. CT and MRI, have a high rate of false-negative diagnoses, which can be explained by micro-metastases within otherwise normal lymph nodes [31, 122]. The reported sensitivity for CT in the detection of metastatic lymph nodes is from 67 to 90% [31, 70, 122–124] and for MRI is from 71 to 91% [3, 31, 64, 70, 99, 122]. The reported sensitivities of PET for nodal disease range from 67 to 91% [3, 61, 64, 70, 71, 100, 102, 123, 124]. Both FDG-PET and PET/CT have technical resolution limitations of 4–5 mm and were unable to detect lymph metastases smaller than 4–5 mm, contributing to false-negative results [125–127]. The reported specificity of FDG-PET ranges from 88 to 100% [64, 70, 71, 83, 100, 123]. The specificity value for CT is 38–97% and for MRI is 48–94% [31, 70, 123, 128]. False-positive FDG-PET findings may be primarily due to its inability to discriminate between inflammatory process and tumor infiltration [98]. This is because FDG is not tumor specific tracer but a metabolic marker and hence various inflammatory processes can lead to increased FDG uptake, potentially returning false-positive results [129]. However, a practical benefit of employing PET/CT in presurgical evaluation for

Fig. 13.8 Axial postcontrast CT scan (a) showing stage T4 left retromolar trigone cancer (arrow) with the destruction of left mandibular ramus (arrow head) on bone windows (b). Perineural spread along left inferior alveolar nerve with loss of normal fat in the alveolar foramen on the left (d), compare with normal right side (c) (arrowhead)



lymph node staging in patient with HNSCC is improved imaging staging for the expert and also a nonexpert interpreter [83]. PET/CT imaging is also reported to reduce equivocal head and neck image interpretations and increase evaluator confidence [130]. Combining structural information with morphological imaging such as CT and metabolic information with functional imaging such as FDG-PET with coregistered PET/CT is a method of choice for lymph node imaging in the future.

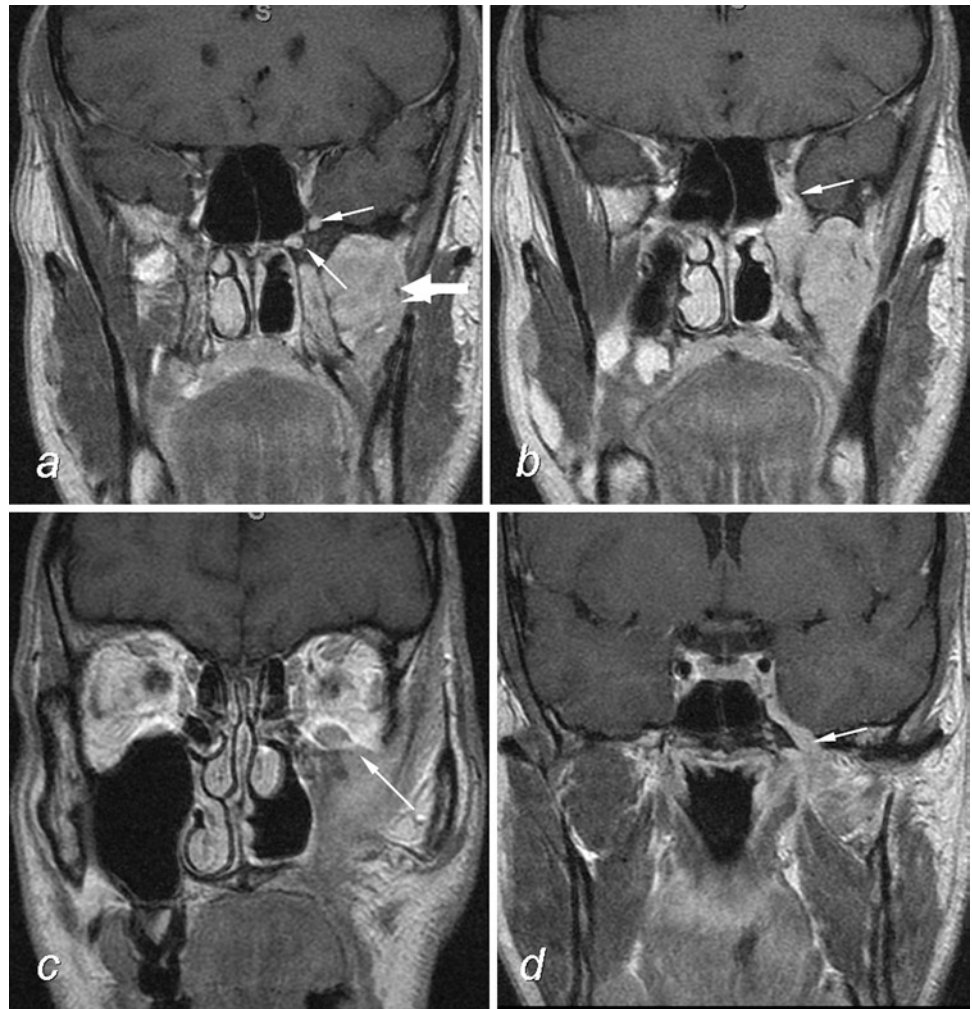
Distant Metastases

Distant metastasis to other organs and distant lymph nodes from HNSCC is generally a late event and usually represents an incurable disease [131]. Lung is the most common site of distant spread; however, distant bone metastasis can also occur in case of other widespread metastatic disease [132, 133]

and can cause severe local morbidity at the metastatic site [134]. The reported incidence for distant bone metastases in HNSCC ranges from 17 to 31% [135–137]. Apart from lungs, screening for distant metastases is routinely not performed in initial staging of patients with HNSCC [132, 138]. However, some studies have shown FDG-PET to be valuable in detecting distant metastasis in advanced HNSCC, suggesting a role for whole body FDG-PET scanning, including lungs and bones for initial staging [139–141].

PET-CT may be performed in squamous cell carcinoma to evaluate for possible occult distant metastases to the lungs or bones [123] (see Fig. 13.7). The presence of pulmonary metastases upstages a patient from M0 to M1 and alters treatment regimen. Routine imaging work-up for patient with squamous cell carcinoma pulmonary includes conventional radiography of the chest at most institutions. Chest CT is performed in patients with advanced stage disease. A solitary nodule on CT scan may represent a metastasis or

Fig. 13.9 Coronal fat suppressed postcontrast T1-W images showing large infiltrating soft tissue attenuation mass in the left masticator space (*bold arrow*) extending into the pterygopalatine fossa (**a**). There is associated abnormal enhancement along the second and third divisions of the left trigeminal nerves and left vidian canal (*small arrows*) (**a, b, d**). There is infiltration of the left orbital floor with enhancing soft tissue and thickening of the left inferior rectus muscle (*small arrow*) (**c**)



a granuloma. PET would be helpful in this evaluation as a FDG-positive nodule would likely be metastatic and may require biopsy. An FDG-negative nodule may likely indicate a granuloma.

Unknown Primary Tumor

The incidence of unknown primary tumors in the head and neck region ranges overall from 3 to 7% of all HNC including HNSCC [63, 66, 128, 142–148]. Apart from the routine physical examination, the evaluation includes fiberoptic laryngoscopy/nasopharyngoscopy, panendoscopy, and morphological imaging, including CT and MRI and directed biopsy [142, 146, 147]. The areas most likely to harbor an occult primary, such as tonsil, tongue, base, piriform fossa, and

postnasal space should be thoroughly evaluated with physical examination and office-based endoscopies [147]. Focused morphological imaging with CT and MRI looking for evidence of primary as well as additional areas of lymphadenopathy are also performed. Further management is often a combination of surgery and radiotherapy; however, this depends on the primary site of the disease as well as the treating center [149, 150]. In spite of thorough clinical, endoscopic and morphological imaging, 1–2% of HNC patients will not have a primary site detected [151, 152].

An important application of PET imaging may be in patients with nodal disease and unknown primary tumor – the primary site has been found in 10–60% of cases when conventional imaging and clinical investigations have failed [9]. FDG-PET is generally more sensitive than morphologic imaging in patients with unknown sites of the primary carcinoma [153, 154]. However, it is also associated with

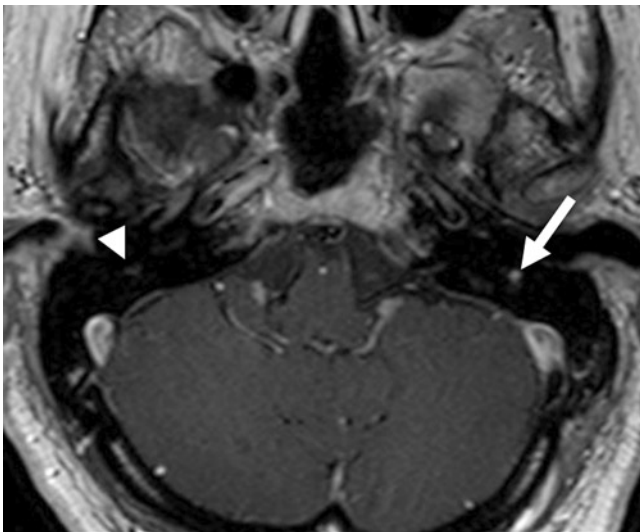


Fig. 13.10 Postradiotherapy “Facial Neuritis.” Axial (3-mm section) postcontrast, fat suppressed T1W image showing increased enhancement of the tympanic segment of the left facial nerve (*arrow*), compared to normal right-sided facial nerve (*arrow head*)

false-positive findings in up to 11% of these cases [153, 155]. Tumors of oral cavity account for a majority of cases with unknown primary and can generally be detected by clinical examination. However, in head and neck regions with lower sensitivity for clinical examinations and morphological imaging, the role of FDG-PET and PET/CT becomes more evident [3].

Tumor detection rate of about 31% of primary tumors is reported in patients presenting with unknown primary [148]. A few retrospective studies suggest FDG-PET detection rates of 24–27% for an occult head and neck primary carcinoma [63, 156]. Another study reported a low rate of true positive scan (33%) but a high rate of true negative scans (88%) [157], suggesting that negative FDG-PET or PET/CT helps to rule out a primary site (Fig. 13.11). This is complicated by the fact that false-positive reports are reported in large lymph nodes up to 20 mm in size [122, 123] or in necrotic lymph nodes. PET/CT serves as a valuable clinical tool for occult metastatic disease of head and neck, most commonly HNSCC and synchronous primary tumors.

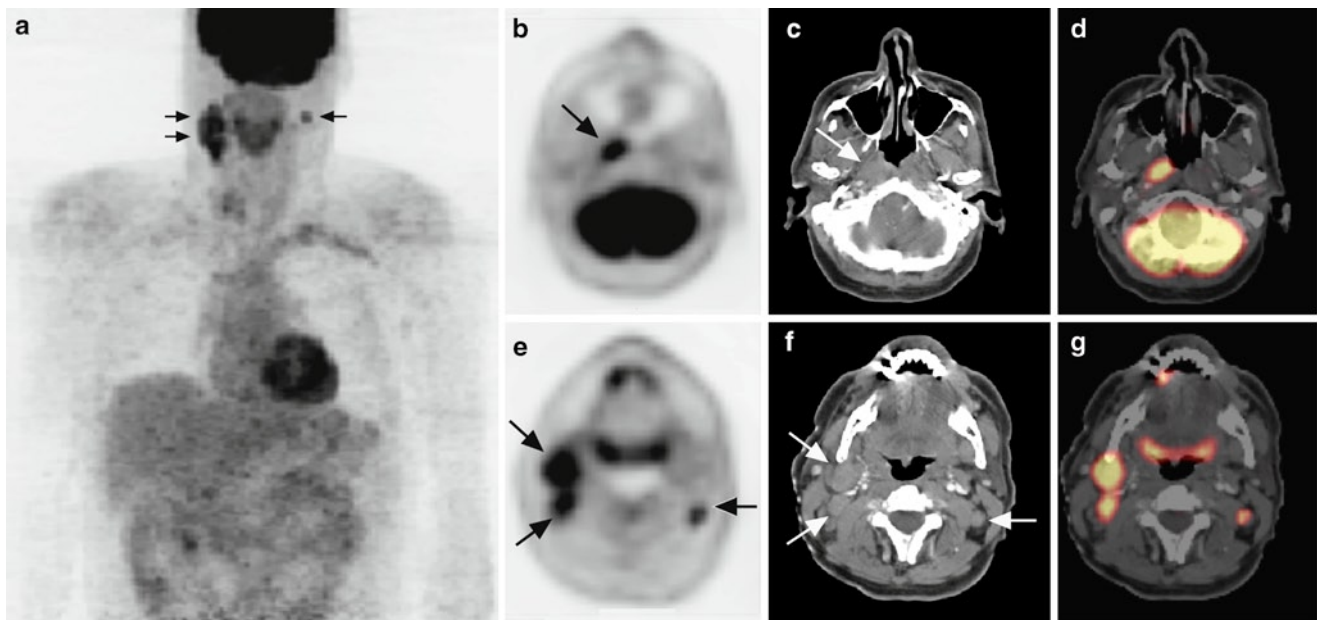


Fig. 13.11 Patient presented with bilateral lymph nodal neck masses. PET/CT reveals unknown primary neoplasm of nasopharyngeal squamous cell carcinoma. (a) MIP PET image demonstrates bilateral increased abnormal FDG uptake in the neck (*black arrows*). (b) Axial PET in the region of nasopharynx shows focal abnormal FDG uptake in the region of the right torus tubarius (*black arrow*). (c) Axial CT of nasopharynx shows mild soft tissue fullness in the same region (*white arrow*). (d) Axial PET/CT demonstrates increased abnormal FDG uptake in the region of mild soft tissue fullness representing primary

unsuspected squamous cell carcinoma of nasopharynx. (e) Axial PET of neck at the level of mandibular angle demonstrates FDG uptake in bilateral level II cervical lymph nodes (*black arrows*). (f) Axial CT shows enlarged bilateral level II lymph nodes (*white arrows*). (g) Axial PET/CT demonstrates fusion imaging signifying malignant nature of enlarged lymph nodes (from Shah GV, Wong KK, Gandhi D, Parmar H, Mukherji SK. Squamous cell carcinoma: initial diagnosis and staging with PET/CT. *PET Clin.* 2007;2(4):469–80, reprinted with permission from Elsevier)

Synchronous Second Tumor

Patients with head and neck tumors also have a high incidence of secondary tumors of the aerodigestive tract (estimated at approximately 8%), and PET identifies synchronous primary neoplasms that are missed on conventional imaging. The incidence for metastatic spread to lungs in patients with HNSCC is low but there is also a high incidence of second primary tumor in a patients with HNC, with detectable lung lesion [158]. A few previous studies have shown a high sensitivity of 100% and positive predictive value of 85% for FDG-PET to differentiate a malignant from a benign pulmonary lesion [139, 159]. Due to its ability to conduct whole body imaging, PET/CT can be useful for the detection of distant metastases and second primary cancer (see Fig. 13.7) [160, 161]. PET/CT can serve as an excellent screening tool for distant metastatic disease or a synchronous primary tumor in the lungs [148].

In conclusion, morphologic imaging techniques are crucial for therapy planning in head and neck neoplasm. The highest sensitivity and optimal anatomic information of the local tumor site for local staging are provided by MRI. MRI, CT, and PET are similar for the detection of abnormal and pathologic lymph nodes. However, in case of equivocal findings by MRI or CT, PET provides relevant information for determining the extent of surgical neck dissection. FDG-PET and CT compliment each of the strengths, providing additional accuracy for staging HNC and make a notable impact on clinical decision making.

References

1. Sankaranarayanan R, Masuyer E, Swaminathan R, Ferlay J, Whelan S. Head and neck cancer: a global perspective on epidemiology and prognosis. *Anticancer Res.* 1998;18(6B):4779–86.
2. American Cancer Society. Cancer facts and figures 2009, American Cancer Society surveillance research. <http://www.cancer.org>. Accessed 14 Jan, 2010
3. Dammann F, Horger M, Mueller-Berg M, et al. Rational diagnosis of squamous cell carcinoma of the head and neck region: comparative evaluation of CT, MRI, and 18FDG PET. *AJR Am J Roentgenol.* 2005;184(4):1326–31.
4. Som PM. Detection of metastasis in cervical lymph nodes: CT and MR criteria and differential diagnosis. *AJR Am J Roentgenol.* 1992;158(5):961–9.
5. Madison MT, Remley KB, Latchaw RE, Mitchell SL. Radiologic diagnosis and staging of head and neck squamous cell carcinoma. *Radiol Clin North Am.* 1994;32(1):163–81.
6. Close LG, Merkel M, Vuitch MF, Reisch J, Schaefer SD. Computed tomographic evaluation of regional lymph node involvement in cancer of the oral cavity and oropharynx. *Head Neck.* 1989;11(4):309–17.
7. Stark DD, Moss AA, Gamsu G, Clark OH, Gooding GA, Webb WR. Magnetic resonance imaging of the neck. Part II: Pathologic findings. *Radiology.* 1984;150(2):455–61.
8. Gatenby RA, Mulhern Jr CB, Strawitz J, Moldofsky PJ. Comparison of clinical and computed tomographic staging of head and neck tumors. *AJNR Am J Neuroradiol.* 1985;6(3):399–401.
9. Rumboldt Z, Gordon L, Bonsall R, Ackermann S. Imaging in head and neck cancer. *Curr Treat Options Oncol.* 2006;7(1):23–34.
10. Gordin A, Golz A, Keidar Z, Daitzchman M, Bar-Shalom R, Israel O. The role of FDG-PET/CT imaging in head and neck malignant conditions: impact on diagnostic accuracy and patient care. *Otolaryngol Head Neck Surg.* 2007;137(1):130–7.
11. Wippold 2nd FJ. Head and neck imaging: the role of CT and MRI. *J Magn Reson Imaging.* 2007;25(3):453–65.
12. Hu H, He HD, Foley WD, Fox SH. Four multidetector-row helical CT: image quality and volume coverage speed. *Radiology.* 2000;215(1):55–62.
13. Miles KA. Tumour angiogenesis and its relation to contrast enhancement on computed tomography: a review. *Eur J Radiol.* 1999;30(3):198–205.
14. Faggioni L, Neri E, Bartolozzi C. CT perfusion of head and neck tumors: how we do it. *AJR Am J Roentgenol.* 2010;194(1):62–9.
15. Gandhi D, Chepeha DB, Miller T, et al. Correlation between initial and early follow-up CT perfusion parameters with endoscopic tumor response in patients with advanced squamous cell carcinomas of the oropharynx treated with organ-preservation therapy. *AJNR Am J Neuroradiol.* 2006;27(1):101–6.
16. Zima A, Carlos R, Gandhi D, Case I, Teknos T, Mukherji SK. Can pretreatment CT perfusion predict response of advanced squamous cell carcinoma of the upper aerodigestive tract treated with induction chemotherapy? *AJNR Am J Neuroradiol.* 2007;28(2):328–34.
17. Rumboldt Z, Al-Okaili R, Deveikis JP. Perfusion CT for head and neck tumors: pilot study. *AJNR Am J Neuroradiol.* 2005;26(5):1178–85.
18. Ash L, Teknos TN, Gandhi D, Patel S, Mukherji SK. Head and neck squamous cell carcinoma: CT perfusion can help noninvasively predict intratumoral microvessel density. *Radiology.* 2009;251(2):422–8.
19. Weber AL, Romo L, Hashmi S. Malignant tumors of the oral cavity and oropharynx: clinical, pathologic, and radiologic evaluation. *Neuroimaging Clin N Am.* 2003;13(3):443–64.
20. Shah GV. MR imaging of salivary glands. *Neuroimaging Clin N Am.* 2004;14(4):777–808.
21. Rasch C, Keus R, Pameijer FA, et al. The potential impact of CT-MRI matching on tumor volume delineation in advanced head and neck cancer. *Int J Radiat Oncol Biol Phys.* 1997;39(4):841–8.
22. van den Brekel MW, Castelijns JA, Croll GA, et al. Magnetic resonance imaging vs palpation of cervical lymph node metastasis. *Arch Otolaryngol Head Neck Surg.* 1991;117(6):663–73.
23. van Dijke CF, van Waas PF. Head and neck tumors. MRI versus CT: a technology assessment pilot study. *Eur J Radiol.* 1992;14(3):235–9.
24. McCabe KJ, Rubinstein D. Advances in head and neck imaging. *Otolaryngol Clin North Am.* 2005;38(2):307–19. vii.
25. Baba Y, Furusawa M, Murakami R, et al. Role of dynamic MRI in the evaluation of head and neck cancers treated with radiation therapy. *Int J Radiat Oncol Biol Phys.* 1997;37(4):783–7.
26. Hudgins PA, Gussack GS. MR imaging in the management of extracranial malignant tumors of the head and neck. *AJR Am J Roentgenol.* 1992;159(1):161–9.
27. Jabour BA, Lufkin RB, Hanafee WN. Magnetic resonance imaging of the larynx. *Top Magn Reson Imaging.* 1990;2(4):60–8.
28. Glazer HS, Lee JK, Levitt RG, et al. Radiation fibrosis: differentiation from recurrent tumor by MR imaging. *Radiology.* 1985;156(3):721–6.
29. Hasso AN, Brown KD. Use of gadolinium chelates in MR imaging of lesions of the extracranial head and neck. *J Magn Reson Imaging.* 1993;3(1):247–63.
30. Lam P, Au-Yeung KM, Cheng PW, et al. Correlating MRI and histologic tumor thickness in the assessment of oral tongue cancer. *AJR Am J Roentgenol.* 2004;182(3):803–8.

31. Curtin HD, Ishwaran H, Mancuso AA, Dalley RW, Caudry DJ, McNeil BJ. Comparison of CT and MR imaging in staging of neck metastases. *Radiology*. 1998;207(1):123–30.
32. Yousem DM. Dashed hopes for MR imaging of the head and neck: the power of the needle. *Radiology*. 1992;184(1):25–6.
33. Shah GV, Wesolowski JR, Ansari SA, Mukherji SK. New directions in head and neck imaging. *J Surg Oncol*. 2008;97(8):644–8.
34. Chenevert TL, Meyer CR, Moffat BA, et al. Diffusion MRI: a new strategy for assessment of cancer therapeutic efficacy. *Mol Imaging*. 2002;1(4):336–43.
35. Ross BD, Moffat BA, Lawrence TS, et al. Evaluation of cancer therapy using diffusion magnetic resonance imaging. *Mol Cancer Ther*. 2003;2(6):581–7.
36. Abdel Razeq AA, Soliman NY, Elkhamary S, Alsharaway MK, Tawfik A. Role of diffusion-weighted MR imaging in cervical lymphadenopathy. *Eur Radiol*. 2006;16(7):1468–77.
37. Sumi M, Sakihama N, Sumi T, et al. Discrimination of metastatic cervical lymph nodes with diffusion-weighted MR imaging in patients with head and neck cancer. *AJNR Am J Neuroradiol*. 2003;24(8):1627–34.
38. Hermans R, Vandecaveye V. Diffusion-weighted MRI in head and neck cancer. *Cancer Imaging*. 2007;7:126–7.
39. Vandecaveye V, De Keyzer F, Vander Poorten V, et al. Head and neck squamous cell carcinoma: value of diffusion-weighted MR imaging for nodal staging. *Radiology*. 2009;251(1):134–46.
40. Schaefer PW, Ozsunar Y, He J, et al. Assessing tissue viability with MR diffusion and perfusion imaging. *AJNR Am J Neuroradiol*. 2003;24(3):436–43.
41. Bisdas S, Baghi M, Smolarz A, et al. Quantitative measurements of perfusion and permeability of oropharyngeal and oral cavity cancer, recurrent disease, and associated lymph nodes using first-pass contrast-enhanced computed tomography studies. *Invest Radiol*. 2007;42(3):172–9.
42. Schmitt P, Kotas M, Tobermann A, Haase A, Flentje M. Quantitative tissue perfusion measurements in head and neck carcinoma patients before and during radiation therapy with a non-invasive MR imaging spin-labeling technique. *Radiother Oncol*. 2003;67(1):27–34.
43. Niemi PT, Komu ME, Koskinen SK. Tissue specificity of low-field-strength magnetization transfer contrast imaging. *J Magn Reson Imaging*. 1992;2(2):197–201.
44. Gillams AR, Fuleihan N, Grillone G, Carter AP. Magnetization transfer contrast MR in lesions of the head and neck. *AJNR Am J Neuroradiol*. 1996;17(2):355–60.
45. Shah GV, Fischbein NJ, Patel R, Mukherji SK. Newer MR imaging techniques for head and neck. *Magn Reson Imaging Clin N Am*. 2003;11(3):449–69. vi.
46. Shah GV, Gandhi D, Mukherji SK. Magnetic resonance spectroscopy of head and neck neoplasms. *Top Magn Reson Imaging*. 2004;15(2):87–94.
47. Mukherji SK, Schiro S, Castillo M, Kwock L, Muller KE, Blackstock W. Proton MR spectroscopy of squamous cell carcinoma of the extracranial head and neck: in vitro and in vivo studies. *AJNR Am J Neuroradiol*. 1997;18(6):1057–72.
48. Mukherji SK, Schiro S, Castillo M, et al. Proton MR spectroscopy of squamous cell carcinoma of the upper aerodigestive tract: in vitro characteristics. *AJNR Am J Neuroradiol*. 1996;17(8):1485–90.
49. Castillo M, Kwock L, Mukherji SK. Clinical applications of proton MR spectroscopy. *AJNR Am J Neuroradiol*. 1996;17(1):1–15.
50. King AD, Yeung DK, Ahuja AT, Leung SF, Tse GM, van Hasselt AC. In vivo proton MR spectroscopy of primary and nodal nasopharyngeal carcinoma. *AJNR Am J Neuroradiol*. 2004;25(3):484–90.
51. El-Sayed S, Bezabeh T, Odlum O, et al. An ex vivo study exploring the diagnostic potential of 1H magnetic resonance spectroscopy in squamous cell carcinoma of the head and neck region. *Head Neck*. 2002;24(8):766–72.
52. Bezabeh T, Odlum O, Nason R, et al. Prediction of treatment response in head and neck cancer by magnetic resonance spectroscopy. *AJNR Am J Neuroradiol*. 2005;26(8):2108–13.
53. Nordmark M, Bentzen SM, Rudat V, et al. Prognostic value of tumor oxygenation in 397 head and neck tumors after primary radiation therapy. An international multi-center study. *Radiother Oncol*. 2005;77(1):18–24.
54. Le QT, Giaccia AJ. Therapeutic exploitation of the physiological and molecular genetic alterations in head and neck cancer. *Clin Cancer Res*. 2003;9(12):4287–95.
55. Rudat V, Vanselow B, Wollensack P, et al. Repeatability and prognostic impact of the pretreatment pO₂ histography in patients with advanced head and neck cancer. *Radiother Oncol*. 2000;57(1):31–7.
56. Star-Lack JM, Adalsteinsson E, Adam MF, et al. In vivo 1H MR spectroscopy of human head and neck lymph node metastasis and comparison with oxygen tension measurements. *AJNR Am J Neuroradiol*. 2000;21(1):183–93.
57. Le QT, Koong A, Lieskovsky YY, et al. In vivo 1H magnetic resonance spectroscopy of lactate in patients with stage IV head and neck squamous cell carcinoma. *Int J Radiat Oncol Biol Phys*. 2008;71(4):1151–7.
58. Schmid DT, Stoeckli SJ, Bandhauer F, et al. Impact of positron emission tomography on the initial staging and therapy in locoregional advanced squamous cell carcinoma of the head and neck. *Laryngoscope*. 2003;113(5):888–91.
59. Stokkel MP, ten Broek FW, Hordijk GJ, Koole R, van Rijk PP. Preoperative evaluation of patients with primary head and neck cancer using dual-head 18fluorodeoxyglucose positron emission tomography. *Ann Surg*. 2000;231(2):229–34.
60. Paulus P, Sambon A, Vivegnis D, et al. 18FDG-PET for the assessment of primary head and neck tumors: clinical, computed tomography, and histopathological correlation in 38 patients. *Laryngoscope*. 1998;108(10):1578–83.
61. Baillet JW, Abemayor E, Jabour BA, Hawkins RA, Ho C, Ward PH. Positron emission tomography: a new, precise imaging modality for detection of primary head and neck tumors and assessment of cervical adenopathy. *Laryngoscope*. 1992;102(3):281–8.
62. Hannah A, Scott AM, Tochon-Danguy H, et al. Evaluation of 18 F-fluorodeoxyglucose positron emission tomography and computed tomography with histopathologic correlation in the initial staging of head and neck cancer. *Ann Surg*. 2002;236(2):208–17.
63. Jungehulsing M, Scheidhauer K, Damm M, et al. 2[F]-fluoro-2-deoxy-D-glucose positron emission tomography is a sensitive tool for the detection of occult primary cancer (carcinoma of unknown primary syndrome) with head and neck lymph node manifestation. *Otolaryngol Head Neck Surg*. 2000;123(3):294–301.
64. Laubenbacher C, Saumweber D, Wagner-Manslau C, et al. Comparison of fluorine-18-fluorodeoxyglucose PET, MRI and endoscopy for staging head and neck squamous-cell carcinomas. *J Nucl Med*. 1995;36(10):1747–57.
65. Hafidh MA, Lacy PD, Hughes JP, Duffy G, Timon CV. Evaluation of the impact of addition of PET to CT and MR scanning in the staging of patients with head and neck carcinomas. *Eur Arch Otorhinolaryngol*. 2006;263(9):853–9.
66. Keyes Jr JW, Watson Jr NE, Williams 3rd DW, Greven KM, McQuirt WF. FDG PET in head and neck cancer. *AJR Am J Roentgenol*. 1997;169(6):1663–9.
67. Macapinlac HA, Yeung HW, Larson SM. Defining the role of FDG PET in head and neck cancer. *Clin Positron Imaging*. 1999;2(6):311–6.
68. Roh JL, Yeo NK, Kim JS, et al. Utility of 2-[18F] fluoro-2-deoxy-D-glucose positron emission tomography and positron emission tomography/computed tomography imaging in the preoperative staging of head and neck squamous cell carcinoma. *Oral Oncol*. 2007;43(9):887–93.

69. Gambhir SS, Czernin J, Schwimmer J, Silverman DH, Coleman RE, Phelps ME. A tabulated summary of the FDG PET literature. *J Nucl Med*. 2001;42(5 Suppl):1S-93.
70. Adams S, Baum RP, Stuckensen T, Bitter K, Hor G. Prospective comparison of 18F-FDG PET with conventional imaging modalities (CT, MRI, US) in lymph node staging of head and neck cancer. *Eur J Nucl Med*. 1998;25(9):1255-60.
71. Braams JW, Pruijm J, Freling NJ, et al. Detection of lymph node metastases of squamous-cell cancer of the head and neck with FDG-PET and MRI. *J Nucl Med*. 1995;36(2):211-6.
72. Lowe VJ, Boyd JH, Dunphy FR, et al. Surveillance for recurrent head and neck cancer using positron emission tomography. *J Clin Oncol*. 2000;18(3):651-8.
73. Wong RJ, Lin DT, Schoder H, et al. Diagnostic and prognostic value of [(18)F]fluorodeoxyglucose positron emission tomography for recurrent head and neck squamous cell carcinoma. *J Clin Oncol*. 2002;20(20):4199-208.
74. Mukherji SK, Bradford CR. Controversies: is there a role for positron-emission tomographic CT in the initial staging of head and neck squamous cell carcinoma? *AJNR Am J Neuroradiol*. 2006;27(2):243-5.
75. Gil Z, Even-Sapir E, Margalit N, Fliss DM. Integrated PET/CT system for staging and surveillance of skull base tumors. *Head Neck*. 2007;29(6):537-45.
76. Beyer T, Townsend DW, Brun T, et al. A combined PET/CT scanner for clinical oncology. *J Nucl Med*. 2000;41(8):1369-79.
77. Townsend DW, Carney JP, Yap JT, Hall NC. PET/CT today and tomorrow. *J Nucl Med*. 2004;45 Suppl 1:4S-14.
78. Ha PK, Hdeib A, Goldenberg D, et al. The role of positron emission tomography and computed tomography fusion in the management of early-stage and advanced-stage primary head and neck squamous cell carcinoma. *Arch Otolaryngol Head Neck Surg*. 2006;132(1):12-6.
79. Hany TF, Steinert HC, Goerres GW, Buck A, von Schulthess GK. PET diagnostic accuracy: improvement with in-line PET-CT system: initial results. *Radiology*. 2002;225(2):575-81.
80. von Schulthess GK, Steinert HC, Hany TF. Integrated PET/CT: current applications and future directions. *Radiology*. 2006;238(2):405-22.
81. Branstetter BF, Blodgett TM, Zimmer LA, et al. Head and neck malignancy: is PET/CT more accurate than PET or CT alone? *Radiology*. 2005;235(2):580-6.
82. Antoch G, Saoudi N, Kuehl H, et al. Accuracy of whole-body dual-modality fluorine-18-2-fluoro-2-deoxy-D-glucose positron emission tomography and computed tomography (FDG-PET/CT) for tumor staging in solid tumors: comparison with CT and PET. *J Clin Oncol*. 2004;22(21):4357-68.
83. Schwartz DL, Ford E, Rajendran J, et al. FDG-PET/CT imaging for preradiotherapy staging of head-and-neck squamous cell carcinoma. *Int J Radiat Oncol Biol Phys*. 2005;61(1):129-36.
84. Schoder H, Yeung HW, Gonen M, Kraus D, Larson SM. Head and neck cancer: clinical usefulness and accuracy of PET/CT image fusion. *Radiology*. 2004;231(1):65-72.
85. Syed R, Bomanji JB, Nagabhushan N, et al. Impact of combined (18)F-FDG PET/CT in head and neck tumours. *Br J Cancer*. 2005;92(6):1046-50.
86. Fakhry N, Lussato D, Jacob T, Giorgi R, Giovanni A, Zanaret M. Comparison between PET and PET/CT in recurrent head and neck cancer and clinical implications. *Eur Arch Otorhinolaryngol*. 2007;264(5):531-8.
87. Keidar Z, Haim N, Guralnik L, et al. PET/CT using 18F-FDG in suspected lung cancer recurrence: diagnostic value and impact on patient management. *J Nucl Med*. 2004;45(10):1640-6.
88. Kamel IR, Cohade C, Neyman E, Fishman EK, Wahl RL. Incremental value of CT in PET/CT of patients with colorectal carcinoma. *Abdom Imaging*. 2004;29(6):663-8.
89. Lardinois D, Weder W, Hany TF, et al. Staging of non-small-cell lung cancer with integrated positron-emission tomography and computed tomography. *N Engl J Med*. 2003;348(25):2500-7.
90. Zimmer LA, Branstetter BF, Nayak JV, Johnson JT. Current use of 18F-fluorodeoxyglucose positron emission tomography and combined positron emission tomography and computed tomography in squamous cell carcinoma of the head and neck. *Laryngoscope*. 2005;115(11):2029-34.
91. Reinartz P, Wieres FJ, Schneider W, Schur A, Buell U. Side-by-side reading of PET and CT scans in oncology: which patients might profit from integrated PET/CT? *Eur J Nucl Med Mol Imaging*. 2004;31(11):1456-61.
92. Mukherji SK, Drane WE, Mancuso AA, Parsons JT, Mendenhall WM, Stringer S. Occult primary tumors of the head and neck: detection with 2-[F-18] fluoro-2-deoxy-D-glucose SPECT. *Radiology*. 1996;199(3):761-6.
93. Kole AC, Nieweg OE, Pruijm J, et al. Detection of unknown occult primary tumors using positron emission tomography. *Cancer*. 1998;82(6):1160-6.
94. Sheikholeslam-zadeh R, Choufani G, Goldman S, Hassid S. Unknown primary detected by FDG-PET. A review of the present indications of FDG-PET in head and neck cancers. *Acta Otorhinolaryngol Belg*. 2002;56(1):77-82.
95. Gutzeit A, Antoch G, Kuhl H, et al. Unknown primary tumors: detection with dual-modality PET/CT-initial experience. *Radiology*. 2005;234(1):227-34.
96. Lowe VJ, Dunphy FR, Varvares M, et al. Evaluation of chemotherapy response in patients with advanced head and neck cancer using [F-18]fluorodeoxyglucose positron emission tomography. *Head Neck*. 1997;19(8):666-74.
97. Rohren EM, Turkington TG, Coleman RE. Clinical applications of PET in oncology. *Radiology*. 2004;231(2):305-32.
98. Kim MR, Roh JL, Kim JS, et al. Utility of 18F-fluorodeoxyglucose positron emission tomography in the preoperative staging of squamous cell carcinoma of the oropharynx. *Eur J Surg Oncol*. 2007;33(5):633-8.
99. Rege S, Maass A, Chaiken L, et al. Use of positron emission tomography with fluorodeoxyglucose in patients with extracranial head and neck cancers. *Cancer*. 1994;73(12):3047-58.
100. Wong WL, Chevretton EB, McGurk M, et al. A prospective study of PET-FDG imaging for the assessment of head and neck squamous cell carcinoma. *Clin Otolaryngol Allied Sci*. 1997;22(3):209-14.
101. Blodgett TM, Fukui MB, Snyderman CH, et al. Combined PET-CT in the head and neck: part 1. Physiologic, altered physiologic, and artifactual FDG uptake. *Radiographics*. 2005;25(4):897-912.
102. Popperl G, Lang S, Dagdelen O, et al. Correlation of FDG-PET and MRI/CT with histopathology in primary diagnosis, lymph node staging and diagnosis of recurrence of head and neck cancer. *Rofo*. 2002;174(6):714-20.
103. Mukherji SK, Isaacs DL, Creager A, Shockley W, Weissler M, Armao D. CT detection of mandibular invasion by squamous cell carcinoma of the oral cavity. *AJR Am J Roentgenol*. 2001;177(1):237-43.
104. Bolzoni A, Cappiello J, Piazza C, et al. Diagnostic accuracy of magnetic resonance imaging in the assessment of mandibular involvement in oral-oropharyngeal squamous cell carcinoma: a prospective study. *Arch Otolaryngol Head Neck Surg*. 2004;130(7):837-43.
105. Weissman JL, Carrara RL. "Puffed-cheek" CT improves evaluation of the oral cavity. *AJNR Am J Neuroradiol*. 2001;22(4):741-4.
106. Chong VF, Mukherji SK, Ng SH, et al. Nasopharyngeal carcinoma: review of how imaging affects staging. *J Comput Assist Tomogr*. 1999;23(6):984-93.
107. Sakata K, Hareyama M, Tamakawa M, et al. Prognostic factors of nasopharynx tumors investigated by MR imaging and the value of MR imaging in the newly published TNM staging. *Int J Radiat Oncol Biol Phys*. 1999;43(2):273-8.

108. Rumboldt Z, Castillo M, Smith JK. The palatovaginal canal: can it be identified on routine CT and MR imaging? *AJR Am J Roentgenol.* 2002;179(1):267–72.
109. Curtin HD. Detection of perineural spread: fat suppression versus no fat suppression. *AJNR Am J Neuroradiol.* 2004;25(1):1–3.
110. Ginsberg LE. MR imaging of perineural tumor spread. *Neuroimaging Clin N Am.* 2004;14(4):663–77.
111. Becker M, Zbaren P, Delavelle J, et al. Neoplastic invasion of the laryngeal cartilage: reassessment of criteria for diagnosis at CT. *Radiology.* 1997;203(2):521–32.
112. Zbaren P, Becker M, Lang H. Pretherapeutic staging of laryngeal carcinoma. Clinical findings, computed tomography, and magnetic resonance imaging compared with histopathology. *Cancer.* 1996;77(7):1263–73.
113. Habermann CR, Gossrau P, Graessner J, et al. Diffusion-weighted echo-planar MRI: a valuable tool for differentiating primary parotid gland tumors? *Rofo.* 2005;177(7):940–5.
114. Divi V, Fatt MA, Teknos TN, Mukherji SK. Use of cross-sectional imaging in predicting surgical location of parotid neoplasms. *J Comput Assist Tomogr.* 2005;29(3):315–9.
115. Schmalfuss IM, Tart RP, Mukherji S, Mancuso AA. Perineural tumor spread along the auriculotemporal nerve. *AJNR Am J Neuroradiol.* 2002;23(2):303–11.
116. Ng SH, Yen TC, Liao CT, et al. 18F-FDG PET and CT/MRI in oral cavity squamous cell carcinoma: a prospective study of 124 patients with histologic correlation. *J Nucl Med.* 2005;46(7):1136–43.
117. Williams 3rd DW. An imager's guide to normal neck anatomy. *Semin Ultrasound CT MR.* 1997;18(3):157–81.
118. Byers RM, Wolf PF, Ballantyne AJ. Rationale for elective modified neck dissection. *Head Neck Surg.* 1988;10(3):160–7.
119. Giacomarra V, Tirelli G, Papanikolla L, Bussani R. Predictive factors of nodal metastases in oral cavity and oropharynx carcinomas. *Laryngoscope.* 1999;109(5):795–9.
120. Yousem DM, Som PM, Hackney DB, Schwaibold F, Hendrix RA. Central nodal necrosis and extracapsular neoplastic spread in cervical lymph nodes: MR imaging versus CT. *Radiology.* 1992;182(3):753–9.
121. Takashima S, Noguchi Y, Takeuchi N, et al. Head and neck carcinoma: detection of extraorgan spread with MR imaging and CT. *Eur J Radiol.* 1992;14(3):228–34.
122. Jabour BA, Choi Y, Hoh CK, et al. Extracranial head and neck: PET imaging with 2-[F-18]fluoro-2-deoxy-D-glucose and MR imaging correlation. *Radiology.* 1993;186(1):27–35.
123. Benchaou M, Lehmann W, Slosman DO, et al. The role of FDG-PET in the preoperative assessment of N-staging in head and neck cancer. *Acta Otolaryngol.* 1996;116(2):332–5.
124. McGuirt WF, Williams 3rd DW, Keyes Jr JW, et al. A comparative diagnostic study of head and neck nodal metastases using positron emission tomography. *Laryngoscope.* 1995;105(4 Pt 1):373–5.
125. Fukui MB, Blodgett TM, Snyderman CH, et al. Combined PET-CT in the head and neck: part 2. Diagnostic uses and pitfalls of oncologic imaging. *Radiographics.* 2005;25(4):913–30.
126. Hyde NC, Prvulovich E, Newman L, Waddington WA, Visvikis D, Ell P. A new approach to pre-treatment assessment of the N0 neck in oral squamous cell carcinoma: the role of sentinel node biopsy and positron emission tomography. *Oral Oncol.* 2003;39(4):350–60.
127. Stoeckli SJ, Steinert H, Pfaltz M, Schmid S. Is there a role for positron emission tomography with 18F-fluorodeoxyglucose in the initial staging of nodal negative oral and oropharyngeal squamous cell carcinoma. *Head Neck.* 2002;24(4):345–9.
128. van den Brekel MW. Lymph node metastases: CT and MRI. *Eur J Radiol.* 2000;33(3):230–8.
129. Murakami R, Uozumi H, Hirai T, et al. Impact of FDG-PET/CT imaging on nodal staging for head-and-neck squamous cell carcinoma. *Int J Radiat Oncol Biol Phys.* 2007;68(2):377–82.
130. Schoder H, Erdi YE, Larson SM, Yeung HW. PET/CT: a new imaging technology in nuclear medicine. *Eur J Nucl Med Mol Imaging.* 2003;30(10):1419–37.
131. Basu D, Siegel BA, McDonald DJ, Nussenbaum B. Detection of occult bone metastases from head and neck squamous cell carcinoma: impact of positron emission tomography computed tomography with fluorodeoxyglucose F 18. *Arch Otolaryngol Head Neck Surg.* 2007;133(8):801–5.
132. de Bree R, Deurloo EE, Snow GB, Leemans CR. Screening for distant metastases in patients with head and neck cancer. *Laryngoscope.* 2000;110(3 Pt 1):397–401.
133. Brouwer J, Bree R, Hoekstra OS, Langendijk JA, Castelijns JA, Leemans CR. Screening for distant metastases in patients with head and neck cancer: what is the current clinical practice? *Clin Otolaryngol.* 2005;30(5):438–43.
134. Preciado DA, Sebring LA, Adams GL. Treatment of patients with spinal metastases from head and neck neoplasms. *Arch Otolaryngol Head Neck Surg.* 2002;128(5):539–43.
135. Merino OR, Lindberg RD, Fletcher GH. An analysis of distant metastases from squamous cell carcinoma of the upper respiratory and digestive tracts. *Cancer.* 1977;40(1):145–51.
136. Calhoun KH, Fulmer P, Weiss R, Hokanson JA. Distant metastases from head and neck squamous cell carcinomas. *Laryngoscope.* 1994;104(10):1199–205.
137. Al-Othman MO, Morris CG, Hinerman RW, Amdur RJ, Mendenhall WM. Distant metastases after definitive radiotherapy for squamous cell carcinoma of the head and neck. *Head Neck.* 2003;25(8):629–33.
138. Ferlito A, Saha AR, Silver CE, Rinaldo A, Mondin V. Incidence and sites of distant metastases from head and neck cancer. *ORL J Otorhinolaryngol Relat Spec.* 2001;63(4):202–7.
139. Wax MK, Myers LL, Gabalski EC, Husain S, Gona JM, Nabi H. Positron emission tomography in the evaluation of synchronous lung lesions in patients with untreated head and neck cancer. *Arch Otolaryngol Head Neck Surg.* 2002;128(6):703–7.
140. Perlow A, Bui C, Shreve P, Sundgren PC, Teknos TN, Mukherji SK. High incidence of chest malignancy detected by FDG PET in patients suspected of recurrent squamous cell carcinoma of the upper aerodigestive tract. *J Comput Assist Tomogr.* 2004;28(5):704–9.
141. Teknos TN, Rosenthal EL, Lee D, Taylor R, Marn CS. Positron emission tomography in the evaluation of stage III and IV head and neck cancer. *Head Neck.* 2001;23(12):1056–60.
142. van Veen SA, Balm AJ, Valdes Olmos RA, et al. Occult primary tumors of the head and neck: accuracy of thallium 201 single-photon emission computed tomography and computed tomography and/or magnetic resonance imaging. *Arch Otolaryngol Head Neck Surg.* 2001;127(4):406–11.
143. Nguyen C, Shenouda G, Black MJ, Vuong T, Donath D, Yassa M. Metastatic squamous cell carcinoma to cervical lymph nodes from unknown primary mucosal sites. *Head Neck.* 1994;16(1):58–63.
144. Maulard C, Housset M, Brunel P, et al. Postoperative radiation therapy for cervical lymph node metastases from an occult squamous cell carcinoma. *Laryngoscope.* 1992;102(8):884–90.
145. Harper CS, Mendenhall WM, Parsons JT, Stringer SP, Cassisi NJ, Million RR. Cancer in neck nodes with unknown primary site: role of mucosal radiotherapy. *Head Neck.* 1990;12(6):463–9.
146. Koch WM, Bhatti N, Williams MF, Eisele DW. Oncologic rationale for bilateral tonsillectomy in head and neck squamous cell carcinoma of unknown primary source. *Otolaryngol Head Neck Surg.* 2001;124(3):331–3.
147. Mendenhall WM, Mancuso AA, Parsons JT, Stringer SP, Cassisi NJ. Diagnostic evaluation of squamous cell carcinoma metastatic to cervical lymph nodes from an unknown head and neck primary site. *Head Neck.* 1998;20(8):739–44.
148. Miller FR, Hussey D, Beeram M, Eng T, McGuff HS, Otto RA. Positron emission tomography in the management of unknown

- primary head and neck carcinoma. *Arch Otolaryngol Head Neck Surg.* 2005;131(7):626–9.
149. Davidson BJ, Spiro RH, Patel S, Patel K, Shah JP. Cervical metastases of occult origin: the impact of combined modality therapy. *Am J Surg.* 1994;168(5):395–9.
150. Talmi YP, Wolf GT, Hazuka M, Krause CJ. Unknown primary of the head and neck. *J Laryngol Otol.* 1996;110(4):353–6.
151. Nieder C, Gregoire V, Ang KK. Cervical lymph node metastases from occult squamous cell carcinoma: cut down a tree to get an apple? *Int J Radiat Oncol Biol Phys.* 2001;50(3):727–33.
152. Grau C, Johansen LV, Jakobsen J, Geertsen P, Andersen E, Jensen BB. Cervical lymph node metastases from unknown primary tumours. Results from a national survey by the Danish Society for Head and Neck Oncology. *Radiother Oncol.* 2000;55(2):121–9.
153. AAssar OS, Fischbein NJ, Caputo GR, et al. Metastatic head and neck cancer: role and usefulness of FDG PET in locating occult primary tumors. *Radiology.* 1999;210(1):177–81.
154. Braams JW, Pruijm J, Kole AC, et al. Detection of unknown primary head and neck tumors by positron emission tomography. *Int J Oral Maxillofac Surg.* 1997;26(2):112–5.
155. Bohuslavizki KH, Klutmann S, Kroger S, et al. FDG PET detection of unknown primary tumors. *J Nucl Med.* 2000;41(5):816–22.
156. Johansen J, Eigtved A, Buchwald C, Theilgaard SA, Hansen HS. Implication of 18F-fluoro-2-deoxy-D-glucose positron emission tomography on management of carcinoma of unknown primary in the head and neck: a Danish cohort study. *Laryngoscope.* 2002;112(11):2009–14.
157. Silva P, Hulse P, Sykes AJ, et al. Should FDG-PET scanning be routinely used for patients with an unknown head and neck squamous primary? *J Laryngol Otol.* 2007;121(2):149–53.
158. Tepperman BS, Fitzpatrick PJ. Second respiratory and upper digestive tract cancers after oral cancer. *Lancet.* 1981;2(8246):547–9.
159. Wax MK, Myers LL, Gona JM, Husain SS, Nabi HA. The role of positron emission tomography in the evaluation of the N-positive neck. *Otolaryngol Head Neck Surg.* 2003;129(3):163–7.
160. Choi JY, Lee KS, Kwon OJ, et al. Improved detection of second primary cancer using integrated [18F] fluorodeoxyglucose positron emission tomography and computed tomography for initial tumor staging. *J Clin Oncol.* 2005;23(30):7654–9.
161. Kamel EM, Thumshirn M, Truninger K, et al. Significance of incidental 18F-FDG accumulations in the gastrointestinal tract in PET/CT: correlation with endoscopic and histopathologic results. *J Nucl Med.* 2004;45(11):1804–10.

Chapter 14

Ultrasound Investigations in Head and Neck Cancer Patients

Yolanda Y.P. Lee, K.T. Wong, Ann D. King, and Anil T. Ahuja

Abstract The wide availability, inexpensiveness, and its nonionizing nature make ultrasound an ideal initial imaging investigation in patients with head and neck cancer. Its high sensitivity and specificity (when combined with a guided FNAC) makes it a useful tool for cervical lymph node staging and investigating thyroid and salivary gland tumors. Gray scale ultrasound evaluates the internal architecture and local extent of superficially located head and neck cancers and color Doppler examines the tumor vascularity. Advances in elastography and contrast ultrasound further enhance the diagnostic capability of ultrasound. In addition, following treatment of head and neck cancer, ultrasound is a useful and safe tool for disease surveillance and assessment of treatment response.

Keywords Ultrasound • Head and neck cancer • Lymph node

Introduction

Ultrasound (US) has a well-recognized role in imaging of patients with head and neck cancer. Its nonionizing nature, high sensitivity, and specificity (when combined with a guided FNAC) make it a useful tool for cervical lymph node staging and investigating thyroid and salivary gland tumors. In addition, US is superior to CT or MR in the resolution of superficial structures and provides detailed information of the internal architecture, vascular pattern, and local extent of superficially located tumors (thyroid, superficial salivary glands, and lymph nodes). Therefore, the major applications for ultrasound in the head and neck cancer include characterization of neck masses, guide FNAC/biopsy, evaluate nodal status to accurately stage cancer, and

follow-up patients postoperatively to exclude local or regional tumor recurrence [1].

Detailed sonographic appearance of all thyroid, salivary gland cancers, malignant lymph nodes, and their benign mimics in the head and neck is beyond the scope of this chapter. The following paragraphs discuss the principles and practical application of US (+FNAC) in evaluating these sites in the head and neck.

Role of Ultrasound in Thyroid Cancer

Thyroid nodules pose a treatment dilemma as the prevalence of palpable nodules is 1–5% in iodine-sufficient parts of the world [2, 3]. The increasing use of high-resolution US in the head and neck detects thyroid nodules in 19–67% of randomly selected individuals [4]. The spectrum of these thyroid nodules ranges from the common multinodular change to malignant thyroid tumors that occur in 5–10% depending on age, gender, previous radiation history, and other factors [5, 6]. It is therefore necessary to identify the small group of patients with malignant thyroid disease so that prompt and appropriate treatment can be instituted; while avoiding unnecessary imaging and treatment in the vast majority with benign nodules.

The management guidelines for patients with thyroid nodules and differentiated thyroid cancer is well established [7]. The mainstay of initial investigations include US (gray scale [GS], and power Doppler [PDS]), FNAC, and radionuclide thyroid scan. In patients with thyroid nodule >1–1.5 cm, an initial TSH level is obtained. If the TSH is subnormal a radionuclide scan is indicated to document whether the nodule is functioning. However, if the TSH is not suppressed a thyroid ultrasound is indicated. This is often combined with a FNAC and nodules FNAed based on their sonographic appearance rather than their size, as the US characteristics, such as echogenicity, microcalcifications, vascularity, are better than nodule size in predicting malignancy [8, 9].

A.T. Ahuja (✉)
Department of Diagnostic Radiology and Organ Imaging,
The Chinese University of Hong Kong, Hong Kong, China
e-mail: aniltahuja@cuhk.edu.hk

Sonographic Features that Help to Differentiate Malignant from Benign Tumors

- *Echogenicity* (Figs. 14.1–14.3): Hypoechoic thyroid nodules have an increased risk of malignancy. It represents microfollicular structure on histology, compared to macrofollicular lesions which tend to be iso/hyperechoic [10]. The risk of malignancy is 4% when the nodule is hyperechoic and this increases to 26% with hypoechoic nodules. However, echogenicity alone is a poor predictor of malignancy, specificity 49% and positive predictive value 40% [11].
- *Margins* (Fig. 14.4): Malignant nodules are invasive by nature and tend to have irregular margins.
- *Halo* (Fig. 14.3): Benign hyperplastic nodules are slow growing, lack a true capsule, and displace adjacent vascularity.
- Therefore, they demonstrate a “vascular halo” on color Doppler. Thyroid cancer may demonstrate an “avascular halo” on Doppler which represents the fibrous capsule around the tumor [12]. The absence of a halo has a specificity of 77% and sensitivity of 67% in predicting malignancy [13].
- *Multinodularity*: High-resolution US is far more sensitive than palpation in picking up small thyroid nodules. However, multinodularity does not bestow benignity on a thyroid nodule as patients with multiple thyroid nodules have the same risk of malignancy as those with solitary thyroid nodules [8, 14].
- *Cystic change* (Figs. 14.5 and 14.6): True cysts of the thyroid gland are rare, and most “cystic” nodules seen on US are complex thyroid nodules with hemorrhage and necrosis. These complex nodules are predominantly cystic with

Fig. 14.1 Transverse GS US (a) shows a solid, ill-defined, hypoechoic thyroid nodule (arrow). The corresponding PDS (b) shows marked intranodular vascularity (arrows). The overall appearances are suspicious of malignancy. Histology confirmed a follicular carcinoma. Open arrow: CCA

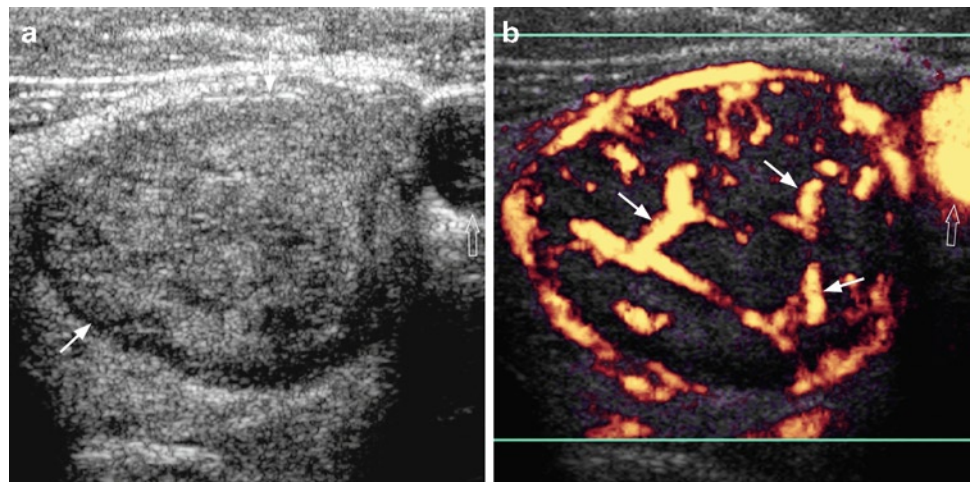
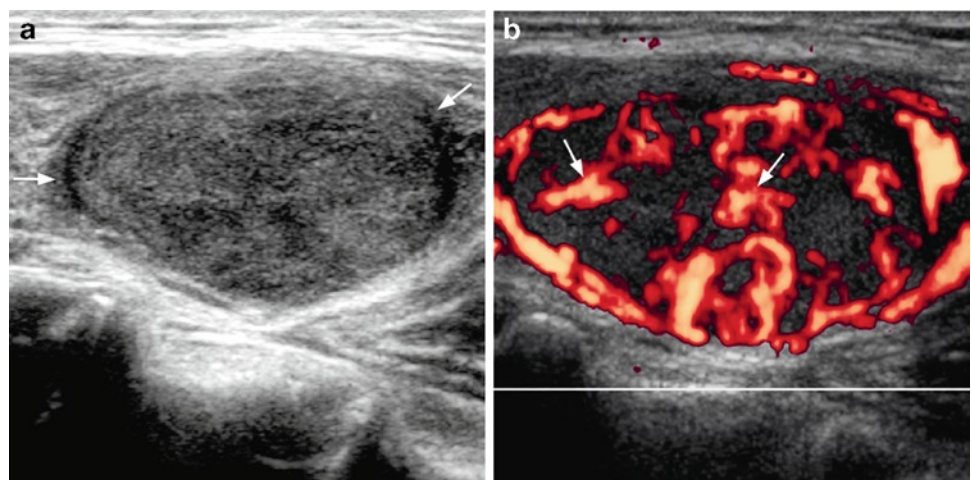


Fig. 14.2 Longitudinal GS US (a) shows a solid, fairly well-defined, hypoechoic, noncalcified thyroid nodule (arrows). Corresponding PDS (b) shows marked intratumoral vascularity (arrows). The combination of GS US and PDS suggests a malignant lesion which was confirmed at surgery



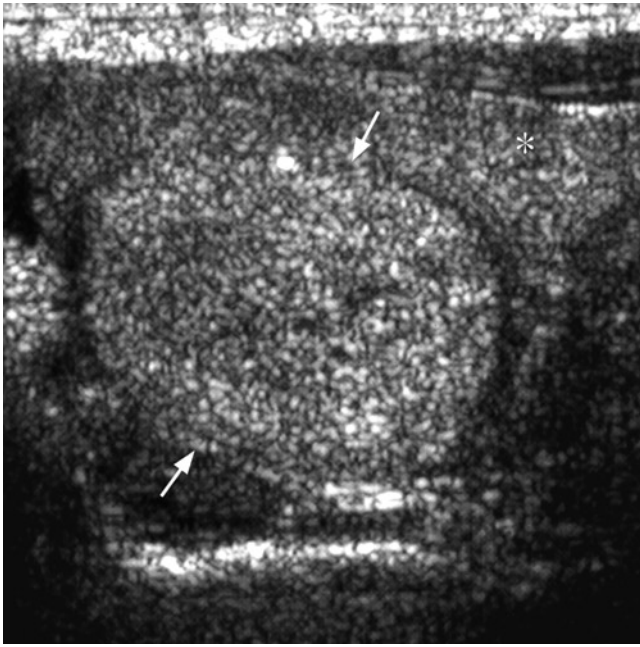


Fig. 14.3 Transverse GS US shows a well-defined, partially haloed, solid, homogeneous, noncalcified thyroid nodule (*arrows*). Note its echogenicity is similar to the adjacent thyroid (*asterisk*). Hypoechoic solid nodules are suspicious for malignancy. The incidence of malignancy decreases as the echogenicity increases

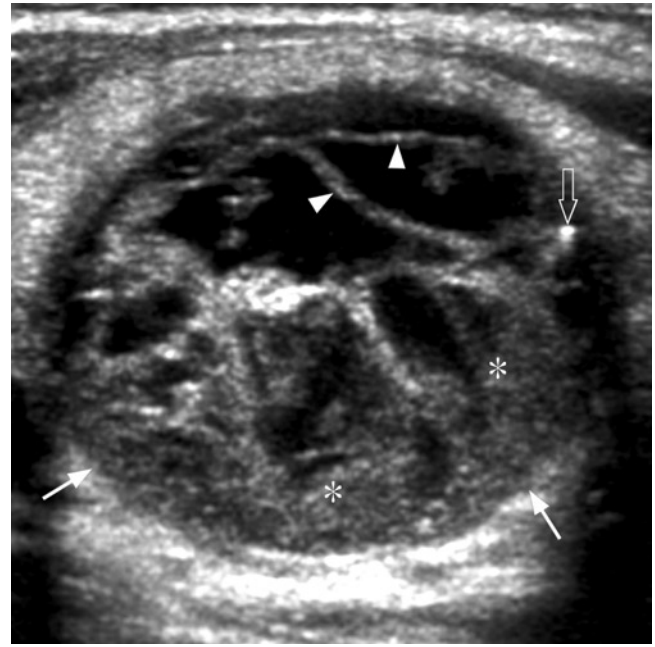


Fig. 14.5 Transverse GS US shows a heterogenous cystic nodule (*arrows*) with intranodular septa (*arrowheads*), debris (*asterisks*), and comet tail artifact (*open arrow*) suggestive of colloid nodule. The debris is usually avascular on Doppler and is suggests of intranodular hemorrhage

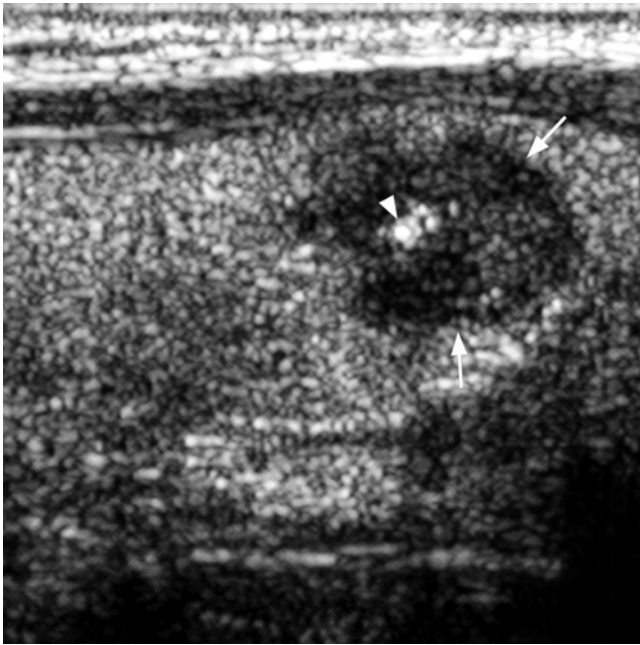


Fig. 14.4 Longitudinal GS US shows a solid, ill-defined, hypoechoic thyroid nodule (*arrows*) with focal intranodular punctate calcification/microcalcification (*arrowhead*). Typical appearances of a papillary carcinoma

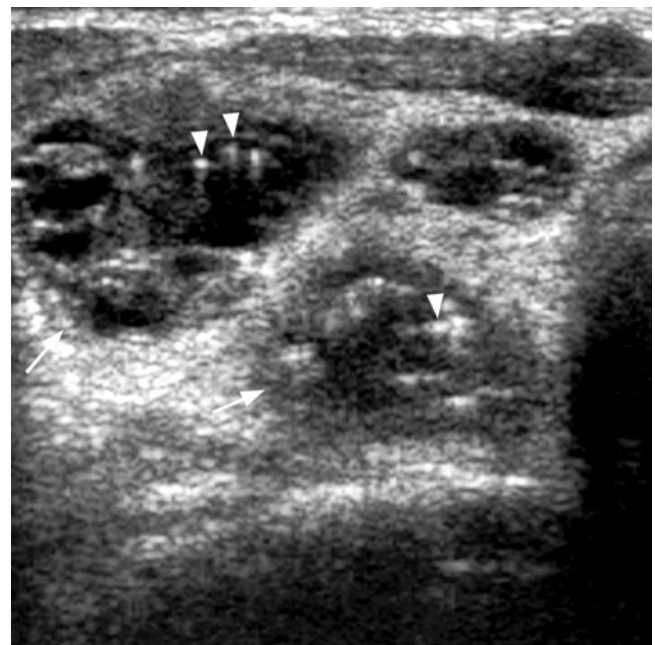

Fig. 14.6 Transverse GS US shows multiple, septated, heterogeneous nodules (*arrows*) with cystic change and comet tail artifacts (*arrowheads*) suggestive of colloid nodules in multinodular thyroid

internal septa, and a “solid” component/debris which is often avascular and possibly represent blood clots. Pure cystic nodules have no risk of malignancy and complex, non-calcified nodules harbor a 3% risk of malignancy [15]. The

presence of a comet tail artifact is a good indicator of benignity and reflects condensed colloid within the nodule [16].
– *Calcification* (Figs. 14.4 and 14.7): *Fine punctuate calcification* (microcalcifications, <1 mm) which represent

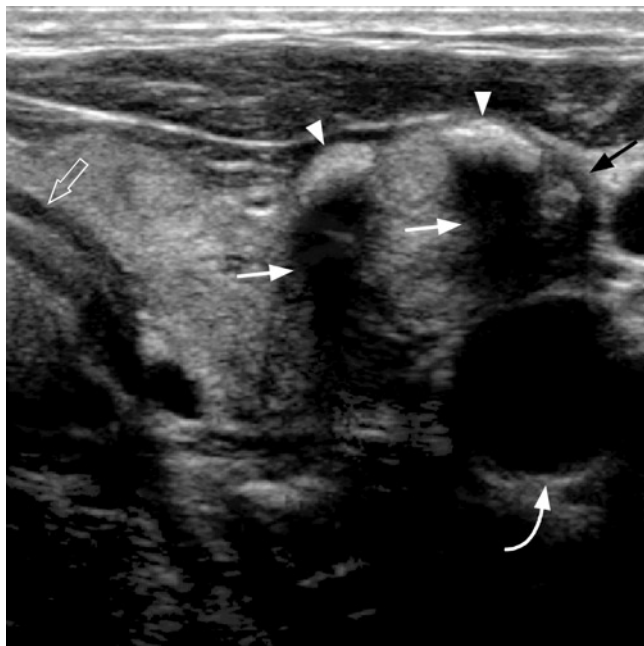

Fig. 14.7 Transverse GS US show a thyroid nodule (black arrow) with focal areas of dense calcifications (arrowheads) with posterior shadowing (white arrows) suggesting benignity. Curved arrow: CCA, open arrow: trachea

aggregates of psammoma bodies are seen in 25–40% of patients with papillary carcinoma [17]. As a sole predictor of malignancy it has an accuracy of 76%, specificity of 93%, positive predictive value of 70% [11], and also has good interobserver variability [18]. *Coarse, dense shadowing calcifications* are a reflection of fibrosis, necrosis, and tissue degeneration. Although often seen with benign nodules their presence with/without microcalcifications, in the center of a hypoechoic nodule are worrisome for malignancy [15, 19]. *Curvilinear or “egg-shell” calcification* was once considered as benign calcifications. However, interrupted rim calcification raises the possibility of malignancy [20].

- **Vascularity** (Figs. 14.1b and 14.2b): Most benign nodules have absent intranodular vascularity and most malignancies have intranodular flow [8, 21]. However, as the negative predictive value is 88% a negative study does not eliminate the need for a biopsy [21, 22]. It has been reported that follicular nodules with no intranodular flow have a 3% probability of being malignant, compared to 15–20% likelihood in unselected follicular nodules. Vascular follicular nodules have a 50% probability of being malignant [23].
- **Shape**: It has been reported anterior–posterior to transverse diameter (A/T ratio) ≥ 1 (taller than wide nodule) has a sensitivity of 84% and specificity of 82% in the detection of a malignant nodule.
- **Elastography**: Is a technique that is beginning to be routinely used in the evaluation of thyroid nodules. It estimates the tissue stiffness on application of external force. Malignant nodules tend to be stiffer than benign nodules

with increased tissue stiffness seen in malignant nodules compared to benign nodules [24, 25]. Recent reports have indicated that high elasticity scores were highly predictive of malignancy with a sensitivity of 97%, specificity 100%, positive predictive value of 100%, and negative predictive value of 98% [25].

- **Associated lymphadenopathy**: US examination for thyroid nodules must include a detailed examination of the neck for lymph nodes as they are frequently seen in thyroid cancers and may alter management. Although most patient with thyroid cancer present with a thyroid nodule, 15–30% present clinically with an enlarged palpable node [26]. Thirty to forty percent of patients with papillary carcinoma have nodal metastases at presentation [27–29]. Follicular carcinomas show a lower incidence of cervical nodal metastases in the range of 10–15% [30]. Patients with medullary carcinoma, anaplastic carcinoma, lymphoma, and thyroid metastases also have a high incidence of adjacent nodal involvement [17, 31]. Nodes from thyroid cancers commonly involve the pretracheal, paratracheal, nodes, and those along the internal jugular vein. Metastatic nodes from papillary carcinoma have characteristic US appearances [32]: hyperechoic to adjacent muscle (80%), intranodal cystic necrosis (25%), and 50% show punctuate calcification (reflecting psammoma bodies). The metastatic nodes often resemble the primary thyroid tumor. Metastatic nodes from medullary cancer may also show intranodal calcification, but the nodes are usually hypoechoic and the calcification dense shadowing in type (reflecting amyloid deposition).
- **Extrathyroid invasion**: Although US is able to evaluate extrathyroid invasion, CT and MR better evaluate the spread of thyroid cancer to the larynx, trachea, and involvement of adjacent vessels [33]. Shadowing from the trachea makes US suboptimal in the evaluation of pretracheal, paratracheal, laryngeal, and tracheal involvement. The above limitation also applies to sonographic evaluation of malignant nodes at these sites.

In evaluating the above sonographic features of thyroid nodules one must note that none of them alone are accurate in predicting malignancy. It is well accepted that US is a reliable predictor when multiple signs are present in the same nodule [13]. However, as the predictive value increases its sensitivity decreases [13]. The useful combinations to predict malignancy include:

- Microcalcifications and solid nature of the nodule [11] showed the highest accuracy (77%), specificity (96%), positive predictive value (75%) but a low specificity (30%).
- Absent halo combined with microcalcifications had a specificity of 93% but a sensitivity of 27% [13].
- A combination of absent halo, intranodular flow, and microcalcifications had a specificity of 97% and a sensitivity of 16% [13].

Role of Ultrasound in Recurrent Thyroid Disease

The evaluation of a patient for recurrent tumor includes clinical examination, biochemical parameters, and imaging findings. The imaging modalities include US, CT, MR, and PET/CT. The postoperative distortion of anatomy makes US difficult but the superficial location of the recurrent tumors makes US (+FNAC) a useful examination as it clearly evaluates the thyroid bed and the neck for lymphadenopathy. Postoperative suture granulomas must not be mistaken for recurrent tumors in the thyroid bed. The granulomas are usually solid, hypoechoic, avascular/hypovascular, and may show dense shadowing foci within (sutures). A guided FNAC quickly establishes the nature of the lesion.

CT and MR are easier to perform and have the added advantage that it is able to evaluate regional recurrence and any disease in the chest/mediastinum.

Role of Ultrasound in Salivary Gland Cancer

Imaging plays an important role in the evaluation of these tumors and the various modalities have complementary roles. In many cases, US may suffice, in others it may be necessary to follow it with a CT/MR, and in some the role of US may be restricted to guiding a biopsy. Irrespective of the modality used imaging appearances are not a substitute for tissue diagnosis.

The following *limitations of US* must be borne in mind when evaluating salivary gland cancers [34]:

- US does not adequately visualize the deep lobe of the parotid gland and the minor salivary glands. It is therefore unable to evaluate tumors in the deep lobe of the parotid gland, and minor salivary gland tumors in the oral cavity, pharynx, and tracheo-bronchial tree.
- US does not evaluate deep tissue involvement, perineural spread, bone invasion, and presence of nodes in the oro/retropharyngeal regions.
- US cannot identify the course of the intraparotid portion of the facial nerve. However, its location can be inferred by identifying the intraparotid portion of the external carotid artery and the retromandibular vein which run alongside the facial nerve.

Despite the above limitations, in our experience:

US is the ideal initial investigation for:

- Salivary gland mass with no obvious signs and symptoms suggestive of malignancy.
- Masses in the superficial lobe of the parotid gland (where most parotid tumors are located and are benign) and sub-mandibular and sublingual tumors.

In this group of patients, the high resolution of US helps to characterize tumors, evaluate associated lymphadenopathy,

and establish the diagnosis by a guided FNAC (sensitivity 88–93%, specificity 75–99%) [35–37]. If the tissue diagnosis suggests a malignancy, an MR helps to evaluate deep extension of the tumor, perineural spread, bone infiltration, and the presence of deep seated nodes.

MR is the initial investigation of choice for:

- Salivary gland mass with signs and symptoms suggestive of a malignant salivary gland tumor (short duration history, rapid enlargement of tumor, progressive facial paralysis, pain, trismus, or cranial nerve palsies associated with a salivary mass).
- Tumors arising from deep lobe of parotid gland, or large tumors bulging into the oral cavity.

In this group of patients, the use of US is restricted to its assistance in image-guided biopsy. Compared to CT, MRI better delineates perineural spread, skull base involvement, parapharyngeal involvement, and minor salivary gland cancers [38]. However, in centers with no access to MR, CT may be used as it appears to have the same diagnostic value for salivary gland tumors [39].

Sonographic Features that Help to Differentiate Malignant from Benign Tumors

- *Edge* (Figs. 14.8 and 14.9): Malignant tumors have ill-defined edges, are irregular in outline compared to benign salivary gland tumors.

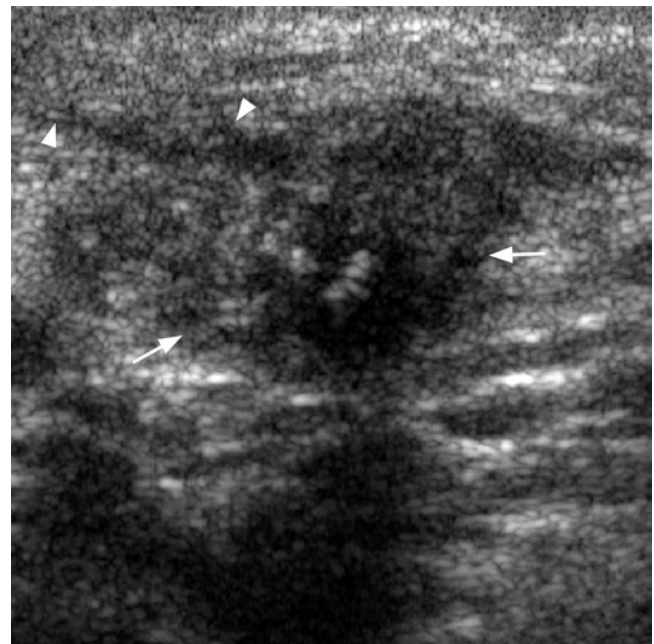


Fig. 14.8 Transverse GS US shows a solid, hypoechoic, ill-defined malignant submandibular tumor (*arrows*). Note the extra-capsular extension into subcutaneous soft tissues (*arrowheads*)

Fig. 14.9 Transverse GS US (a) shows typical features of a malignant tumor (arrows). Note its ill-defined edges and heterogenous internal architecture. Corresponding PDS (b) shows marked intratumoral vascularity (arrows)

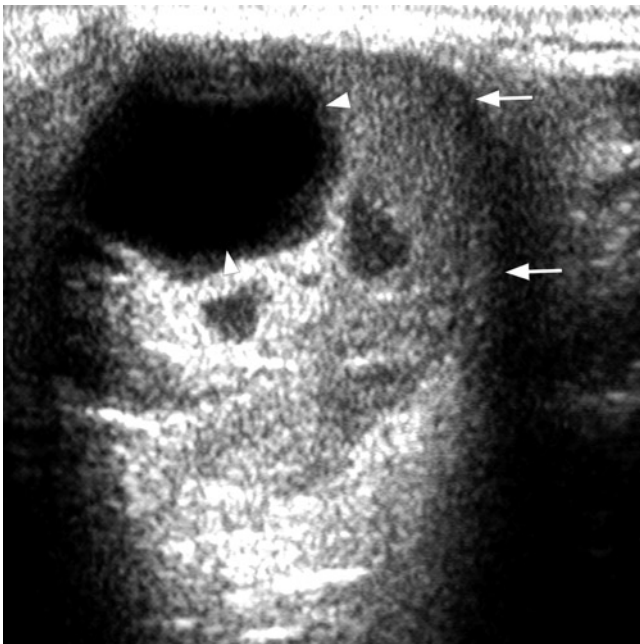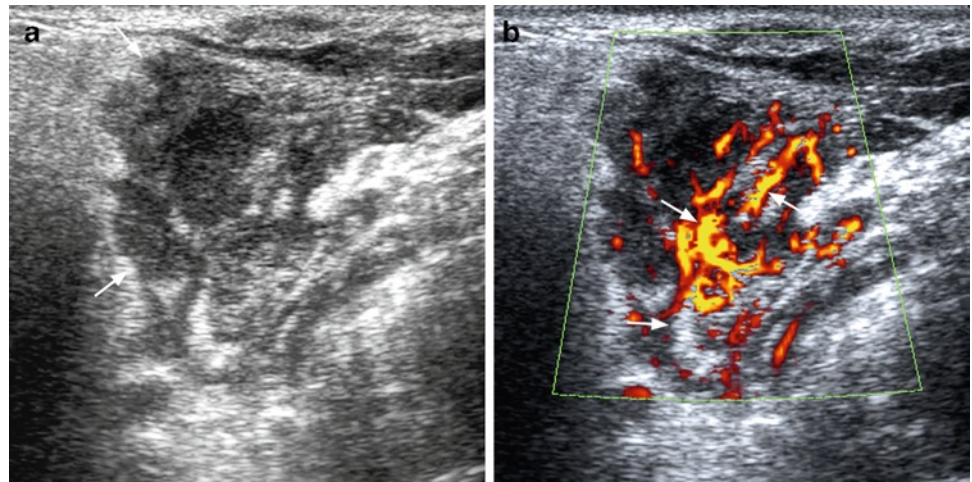


Fig. 14.10 Transverse GS US shows an ill-defined, heterogeneous parotid mass (arrows) with intratumoral necrosis (arrowheads). The US appearances are suspicious of a malignant tumor, muco-epidermoid carcinoma confirmed at surgery

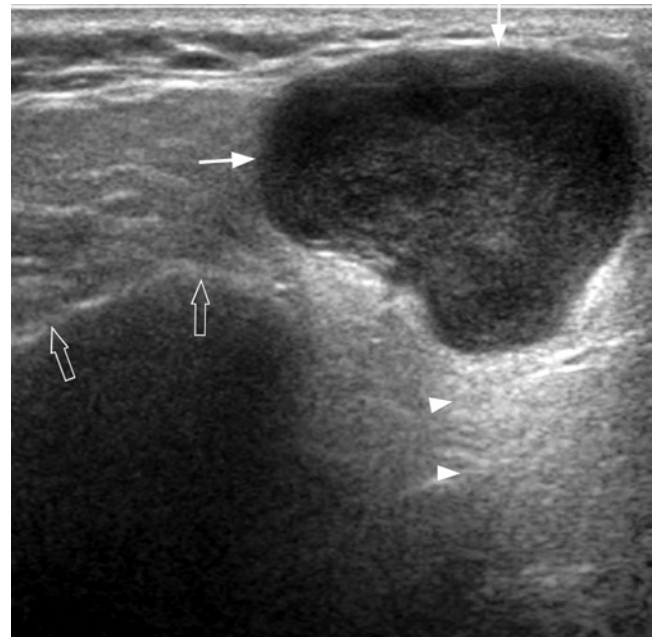


Fig. 14.11 Transverse GS US shows a well-defined, solid, lobulated, hypoechoic nodule (arrows) with posterior enhancement (arrowheads). The US appearances are typical of a pleomorphic adenoma. Open arrows: mandible

– *Internal architecture*: Malignant tumors have a heterogeneous internal architecture with focal areas of hemorrhage and necrosis (Fig. 14.10). Benign tumors such as pleomorphic adenomas (Fig. 14.11) tend to be more homogeneous and show posterior enhancement, whereas Warthin’s tumor (Fig. 14.12) may be heterogeneous with areas of septation and cystic change. Large (>3 cm) pleomorphic adenomas may also demonstrate hemorrhage and cystic change. The presence of calcification (Fig. 14.13) within benign mixed tumors indicates chronicity of the lesion.

9.5% of malignant transformations are seen in patients where the tumor has been present over 15 years [40].

- *Tumor extent*: Malignant tumors may be associated with extraglandular spread and invasion of the overlying muscle, subcutaneous tissues, and skin.
- *Tumor vascularity* (Fig. 14.9b): Malignant tumors are more vascular with a resistive index (RI) > 0.8, pulsatility index (PI) > 1.8 [41], and may demonstrate a hilar vascular pattern compared to pleomorphic adenoma which have peripheral vascularity [42].

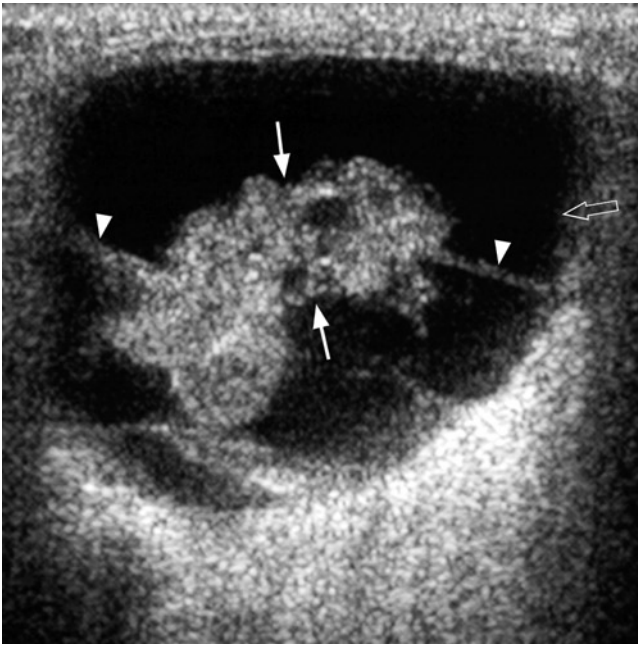


Fig. 14.12 Transverse GS US shows a predominantly cystic tumor (open arrow) with internal septa (arrowheads) and a “solid” component (arrows) in the superficial parotid. A similar smaller tumor was seen in the contralateral parotid. FNAC confirmed Warthins tumor

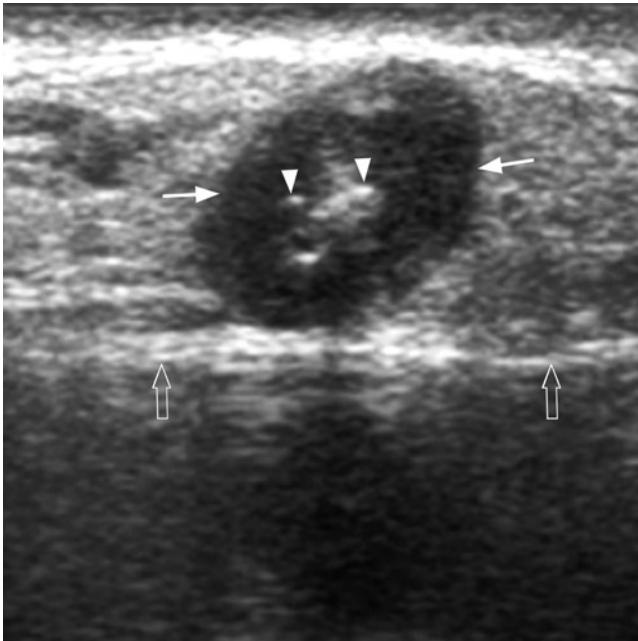


Fig. 14.13 Longitudinal GS US shows a well-defined, solid, hypochoic, parotid pleomorphic adenoma (arrows). Note intratumoral calcification (arrowheads), suggesting a long-standing lesion. Open arrows: mandible

- **Lymphadenopathy:** The presence of associated malignant looking nodes in the known draining sites of salivary gland cancer is another clue toward the malignant nature of a salivary mass.

However one must note that:

- Although US may help to differentiate benign from malignant lesions it is unable to distinguish between the various types of malignant tumors.
- Sonographic appearances of low-grade malignant tumors simulate benign salivary gland lesions and guided FNAC may be indicated for some benign looking salivary tumors to rule out a low-grade carcinoma.

Role of Ultrasound in Recurrent Salivary Gland Tumors

Distortion of anatomy and scarring often makes ultrasound difficult in the postoperative state. However, due to the superficial location of these recurrent lesions US again is an ideal investigation, and when combined with FNAC it provides the information necessary for treatment planning.

Benign tumors: Pleomorphic adenomas may recur following surgery with a recurrence rate between 1 and 50% [43]. The recurrences are frequently localized to the site of surgery and may be multiple. US readily evaluates these tumors, and the recurrent “nodules” are well-defined, homogeneous with posterior enhancement and peripheral vascularity.

Malignant tumors: MR is the investigation of choice for evaluating recurrent disease as in such cases the previous surgery may have been extensive with significant distortion of anatomy. MR clearly evaluates the operative site and extent of invasion of any recurrent tumor. The role of ultrasound is often restricted to guiding a confirmatory biopsy.

Role of Ultrasound in Neck Node Evaluation

The presence of metastatic nodes in the neck in a patient with HN cancer affects prognosis and treatment options [44, 45]. High-resolution ultrasound, with its excellent spatial resolution, ease of dynamic multiplanar imaging, wide availability, and lack of ionizing radiation, is a recognized modality for the assessment of cervical lymph node metastasis [46–48]. It is superior to CT and MR in its resolution, ability to show vascular characteristics, and the ease to combine with FNAC. The use of Doppler has clearly improved the specificity of ultrasound [49–51] and US + FNAC has a sensitivity of 97% and specificity of 93% [52].

In routine clinical ultrasound of neck nodes, the sonographic features assessed are divided into gray scale features and Doppler parameters. The gray scale features include nodal size, shape, border, internal architecture (echogenicity, nodal hilus, calcification, intranodal necrosis, and intranodal

reticulation), nodal matting, and associated soft tissue edema. The Doppler parameters include the presence and distribution of intranodal vessels and intranodal vascular resistance.

Sonographic Features (Gray Scale and Doppler) that Help to Differentiate Malignant from Benign Nodes

- *Size*: Nodal size alone cannot differentiate malignant from benign nodes. Nodal size is relevant in (a) increase in nodal size on serial examination in a patient with known HN carcinoma is suspicious for metastasis and (b) serial reduction in size is useful in evaluating patients response to treatment [53].
- *Shape* (Figs. 14.14 and 14.15): Normal/benign nodes are elliptical whereas metastatic nodes tend to be round [45, 46, 54]. Similarly, eccentric cortical hypertrophy (due to focal tumor infiltration) is another useful sign to identify nodal metastasis [46].
- *Nodal border* (Figs. 14.14–14.16): Malignant nodes are associated with sharp borders, whereas benign nodes have unsharp borders [55]. However, ill-defined border in a metastatic node indicates extracapsular spread [56]. Nodes that have previously received radiotherapy may also have ill-defined borders (Fig. 14.17).
- *Echogenicity*: Metastatic nodes are usually hypoechoic in relation to adjacent muscle [47, 54] except metastatic nodes from papillary thyroid carcinoma which are often hyperechoic relevant to muscle [32].
- *Nodal Hilus*: In a normal neck, most nodes >5 mm will demonstrate the presence of an echogenic hilus [57]. The presence of such an echogenic hilus (Fig. 14.14a) was thought to indicate benignity [45]. However, other studies have shown that the echogenic hilus may also be seen in metastatic nodes [58].
- *Calcification* (Fig. 14.18): Metastatic nodes from papillary carcinoma tend to show punctuate calcification, with faint shadowing on high-resolution ultrasound [32]. Calcification is also seen in a small proportion of metastatic nodes from medullary carcinoma, and nodes treated with chemotherapy or radiotherapy [32, 59].
- *Intranodal necrosis* (Fig. 14.19): Irrespective of nodal size the presence of intranodal necrosis indicates abnormality [59]. It is seen in metastatic and tuberculous nodes in the neck [54, 59].
- *Intranodal reticulation* (Fig. 14.20): It was previously reported that lymphomatous nodes have a pseudocystic appearance, i.e., solid, hypoechoic with posterior enhancement, especially in non-Hodgkin's lymphoma [60, 61]. However, with the advent of newer high-resolution ultrasound this pseudocystic appearance in non-Hodgkin's lymphoma is not often seen and an intranodal micronodular reticulated pattern is commonly found in lymphomatous nodes [62].
- *Nodal matting and soft tissue edema*: These are commonly seen in tuberculous neck nodes [54]. However, these features may also be seen in metastatic nodes with adjacent soft tissue infiltration and in patients who have received radiation therapy of the neck [63, 64].
- *Intranodal vascular distribution*: Evaluation of the vascular pattern within nodes is a reliable predictor of abnormality [65]. On Doppler, most normal nodes >5 mm will demonstrate the presence of hilar vascularity [57]. Normal or reactive nodes may be apparently avascular or demonstrate hilar vessels (Fig. 14.14b) [49, 66, 67]. However, metastatic nodes demonstrate peripheral or hilar and peripheral (mixed) vascularity (Figs. 14.16, 14.18b, and 14.21)

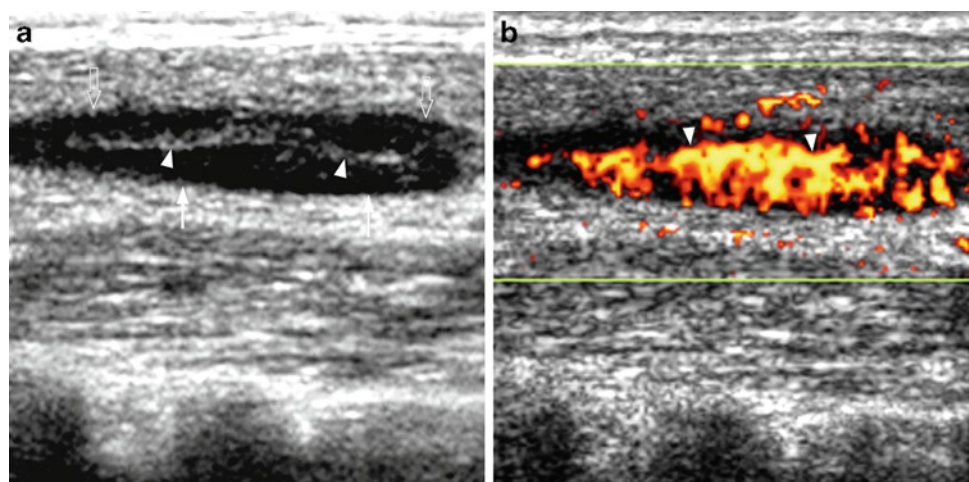


Fig. 14.14 Longitudinal GS US (a) shows a elliptical hypoechoic reactive lymph node (arrows). Note the ill-defined border (open arrows) and the linear echogenic hilus (arrowheads). Corresponding PDS (b) shows prominent hilar vascularity (arrowheads)

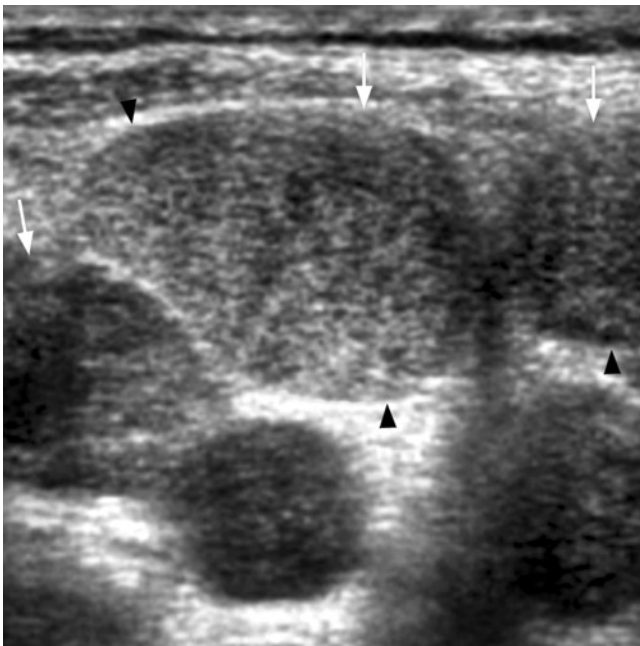


Fig. 14.15 Transverse GS US shows multiple, solid, hypoechoic metastatic nodes (*arrows*). Note their sharp borders (*arrowheads*) and the absence of the echogenic hilus

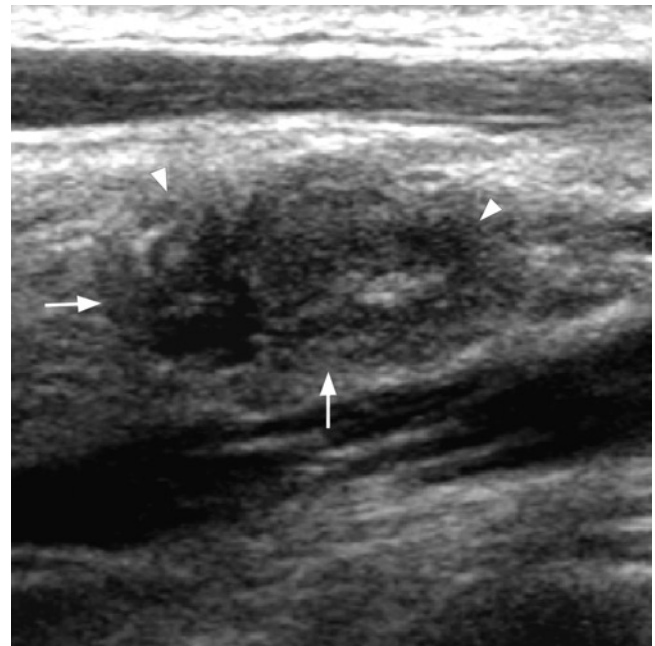


Fig. 14.17 Longitudinal GS US of a metastatic node (*arrows*) previously treated with radiotherapy. Note the diffuse, ill-defined borders (*arrowheads*) of the lymph node. The presence of such ill-defined borders in a metastatic node with no previous history of radiotherapy would indicate extracapsular spread

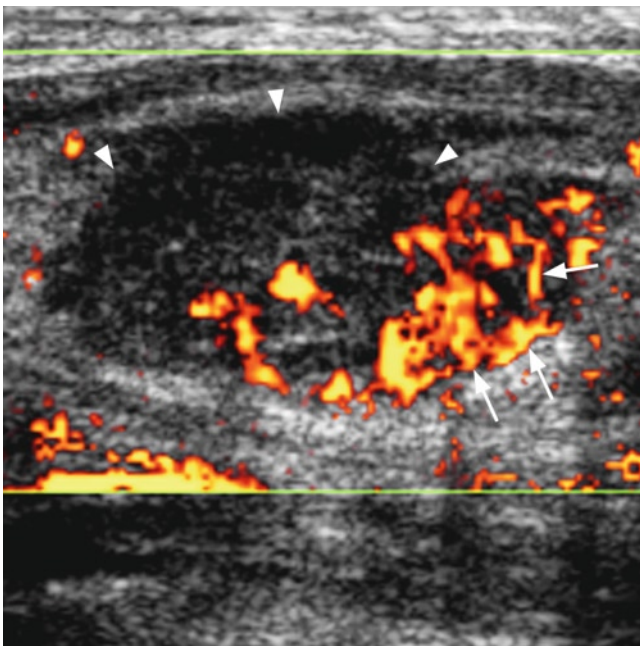


Fig. 14.16 PDS of a metastatic node shows abnormal peripheral vascularity (*arrows*). Note the ill-defined edges anteriorly (*arrowheads*) suggesting extracapsular spread

[68, 69]. Therefore, the presence of peripheral intranodal vessels should strongly raise the possibility of metastasis in a patient with known HN carcinoma. This abnormal vascularity is related to angiogenesis within metastatic nodes [66].

- *Intranodal vascular resistance*: Using spectral Doppler one can estimate intravascular resistance within small

vessels in the node. This is measured as resistive index (RI) and pulsatility index (PI). However, in routine clinical practice such measurements take a lot of time (guided FNAC is much quicker) and their overall values in differentiating benign from malignant nodes is unclear. In our experience, the optimum cut off values for RI and PI are 0.7 and 1.4 with a sensitivity of 86 and 80% and specificity of 70 and 86% respectively [69].

In addition to the above criteria, the *number of nodes* in the known draining site of the tumor may also help in predicting their nature. It has been suggested that one should have a high degree of suspicion if there are >3 equivocal/suspicious nodes in the draining site of the tumor, with specific measurements for minimal axial diameter of the nodes at these sites [70, 71].

One must note that for sonographic evaluation of neck nodes the operator must be familiar with anatomy and pay meticulous attention to detail as many of the nodes and vessels are small. None of the criterion used alone may accurately reflect the nature of the node, and it is a combination of sonographic features that helps in predicting the pathology. In clinical practice, the easiest criteria to evaluate are nodal shape, intranodal necrosis, presence/absence of echogenic hilum, punctuate calcification, and abnormal vascularity. These signs in summation are fairly accurate in predicting the nature of the node and at the same time repeatable and not time-consuming.

Fig. 14.18 Transverse GS US (a) shows a small, hyperechoic, solid node (*arrowheads*) with focal punctate calcification (*arrow*); adjacent to the common carotid artery (*open arrow*). The sonographic appearances are typical for metastatic lymph node from papillary carcinoma. Corresponding PDS (b) shows profuse, abnormal peripheral vascularity (*arrows*); typical of a metastatic node

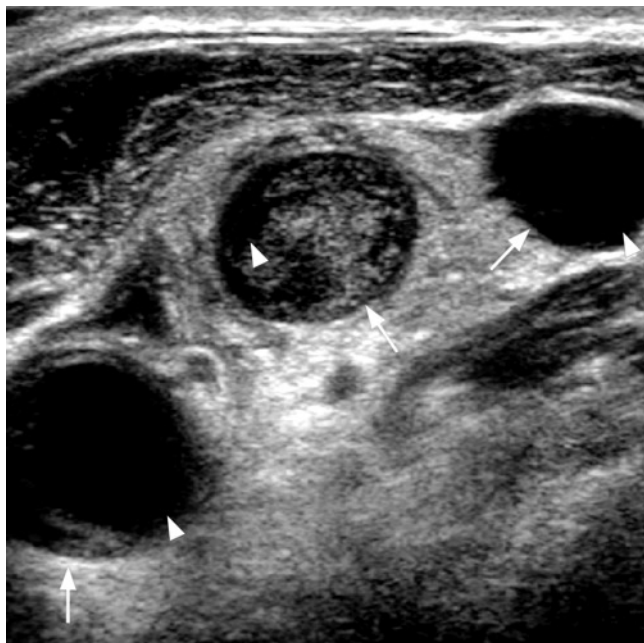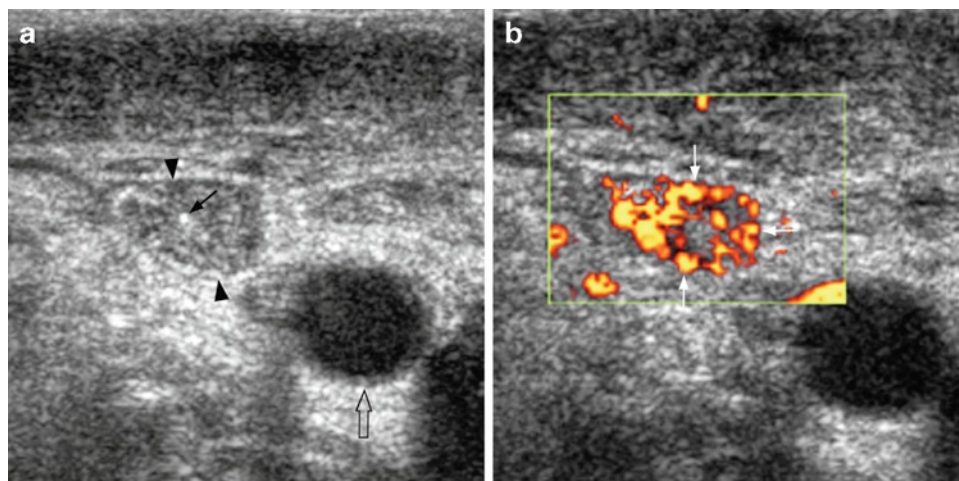


Fig. 14.19 Transverse GS US shows multiple, round metastatic nodes (*arrows*) from HN SCCa. Note the cystic change (*arrowheads*) within the nodes. Cystic change within a node, irrespective of nodal size indicates abnormality

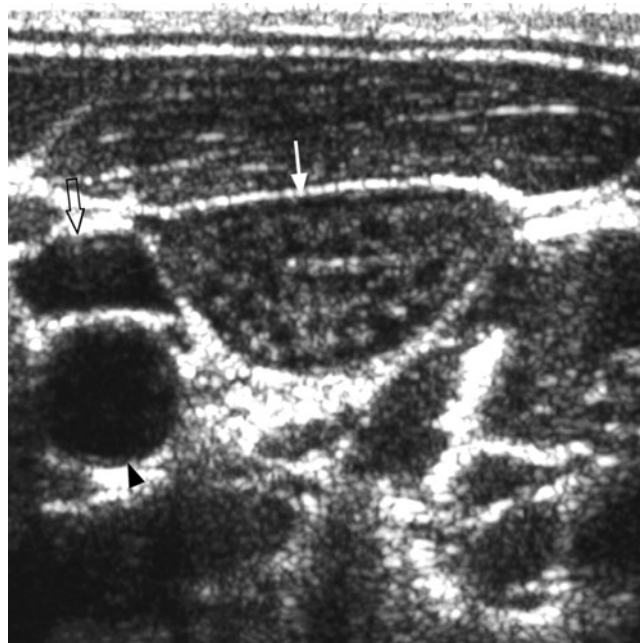


Fig. 14.20 Transverse GS US shows a lymphomatous (*arrow*) node with a typical reticulated/micronodular echopattern. *Arrowhead* identifies CCA and *open arrow* the IJV

Contrast-Enhanced Ultrasound of Lymph Nodes

Contrast-enhanced ultrasound demonstrates more intranodal vessels allowing for better visualization and characterization of these vessels [72, 73]. In addition, it provides an objective time-dependent enhancement curves which help to identify the nature of the nodes and better evaluate nodal

parenchymal perfusion [73]. We have used contrast to evaluate treatment response to patients with lymphoma, and showed a delay to peak enhancement following treatment [74, 75]. However, the change in the magnitude of peak enhancement was variable after treatment with some posttreatment nodes enhancing more than the others. Its use in routine clinical practice is still under consideration.

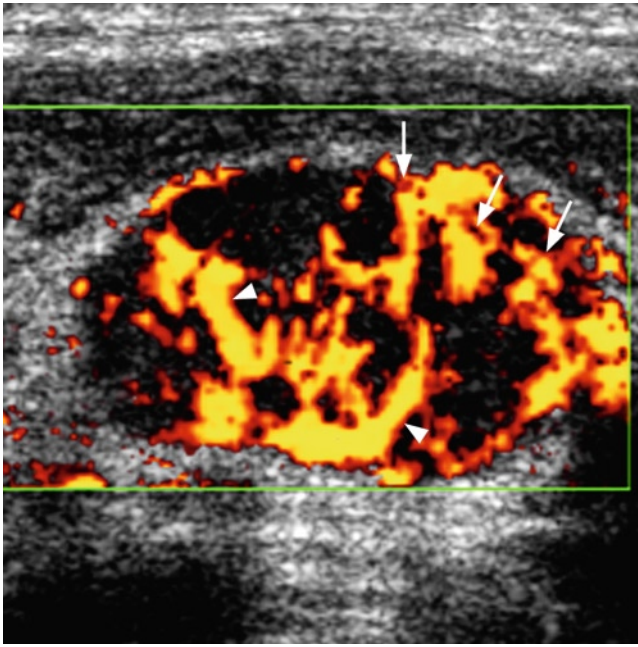


Fig. 14.21 PDS of a metastatic node shows abnormal mixed intranodal vascularity, hilar (*arrowhead*) and peripheral (*arrows*)

Role of Ultrasound in Evaluating Posttreatment Nodes

Following chemotherapy or radiation therapy it may not always be possible to predict the nature of residual nodes using US. However, in our experience some features that predict good response to treatment are:

- Serial reduction in size of node on treatment
- Serial change in shape of node from round to elliptical
- Reappearance of the echogenic hilum in nodes with absent hilum prior to treatment
- Prompt reduction in intranodal vascularity [76]

Conclusion

Despite its limitation in assessing deep seated lesions, ultrasound, combined with FNAC plays an important role in imaging patients with thyroid, salivary gland cancer, and metastatic neck nodes. It is quick, noninvasive, office-based procedure (with a short learning curve), and provides the clinician with key information (diagnosis, extent of local and distant disease [77]) necessary to comprehensively manage a patient with head and neck cancer.

References

1. Wong KT, Ahuja AT. Ultrasound of thyroid cancer. *Cancer Imaging*. 2005;5:157–66.
2. Tunbridge WM, Evered DC, Hall R, et al. The spectrum of thyroid disease in a community: the Wickham survey. *Clin Endocrinol (Oxf)*. 1977;7:481–93.
3. Vander JB, Gaston EA, Dawber TR. The significance of nontoxic thyroid nodules. Final report of a 15-year study of the incidence of thyroid malignancy. *Ann Intern Med*. 1968;69:537–40.
4. Tan GH, Gharib H. Thyroid incidentalomas: management approaches to nonpalpable nodules discovered incidentally on thyroid imaging. *Ann Intern Med*. 1997;126:226–31.
5. Hegedüs L. Clinical practice. The thyroid nodule. *N Engl J Med*. 2004;351:1764–71.
6. Mandel SJ. A 64-year-old woman with a thyroid nodule. *JAMA*. 2004;292:2632–42.
7. Cooper DS, Doherty GM, Haugen BR, The American Thyroid Association Guidelines Taskforce, et al. Management guidelines for patients with thyroid nodules and differentiated thyroid cancer. *Thyroid*. 2006;16:109–42.
8. Papini E, Guglielmi R, Bianchini A, et al. Risk of malignancy in nonpalpable thyroid nodules: predictive value of ultrasound and color-Doppler features. *J Clin Endocrinol Metab*. 2002;87:1941–6.
9. Leenhardt L, Hejblum G, Franc B, et al. Indications and limits of ultrasound-guided cytology in the management of nonpalpable thyroid nodules. *J Clin Endocrinol Metab*. 1999;84:24–8.
10. Brkljacić B, Cuk V, Tomić-Brzac H, Bence-Zigman Z, Delić-Brkljacić D, Drinković I. Ultrasonic evaluation of benign and malignant nodules in echographically multinodular thyroids. *J Clin Ultrasound*. 1994;22:71–6.
11. Takashima S, Fukuda H, Nomura N, Kishimoto H, Kim T, Kobayashi T. Thyroid nodules: re-evaluation with ultrasound. *J Clin Ultrasound*. 1995;23:179–84.
12. Cerbone G, Spiezia S, Colao A, et al. Power Doppler improves the diagnostic accuracy of color Doppler ultrasonography in cold thyroid nodules: follow-up results. *Horm Res*. 1999;52:19–24.
13. Rago T, Vitti P, Chiovato L, et al. Role of conventional ultrasonography and color flow Doppler sonography in predicting malignancy in ‘cold’ thyroid nodules. *Eur J Endocrinol*. 1998;138:41–6.
14. Marqusee E, Benson CB, Frates MC, Doubilet PM, et al. Usefulness of ultrasonography in the management of nodular thyroid disease. *Ann Intern Med*. 2000;133:696–700.
15. Frates MC, Benson CB, Doubilet PM, et al. Prevalence and distribution of carcinoma in patients with solitary and multiple thyroid nodules on sonography. *J Clin Endocrinol Metab*. 2006;91:3411–7.
16. Ahuja A, Chick W, King W, Metreweli C. Clinical significance of the comet-tail artifact in thyroid ultrasound. *J Clin Ultrasound*. 1996;24:129–33.
17. Yousem DM, Scheff AM. Thyroid and parathyroid. In: Som PM, Curtin HD, editors. *Head and neck imaging*. 3rd ed. St Louis: Mosby; 1996. p. 953–75.
18. Wienke JR, Chong WK, Fielding JR, Zou KH, Mittelstaedt CA. Sonographic features of benign thyroid nodules: interobserver reliability and overlap with malignancy. *J Ultrasound Med*. 2003;22:1027–31.
19. Reading CC, Charboneau JW, Hay ID, Sebo TJ. Sonography of thyroid nodules: a “classic pattern” diagnostic approach. *Ultrasound Q*. 2005;21:157–65.
20. Taki S, Terahata S, Yamashita R, et al. Thyroid calcifications: sonographic patterns and incidence of cancer. *Clin Imaging*. 2004;28:368–71.
21. Berni A, Tromba L, Falvo L, Marchesi M, Grilli P, Peparini N. Malignant thyroid nodules: comparison between color Doppler

- diagnosis and histological examination of surgical samples. *Chir Ital.* 2002;54:643–7.
22. Frates MC, Benson CB, Doubilet PM, Cibas ES, Marqusee E. Can color Doppler sonography aid in the prediction of malignancy of thyroid nodules? *J Ultrasound Med.* 2003;22:127–31.
 23. Levine RA. Value of Doppler ultrasonography in management of patients with follicular thyroid biopsy specimens. *Endocr Pract.* 2006;12:270–4.
 24. Lyshchik A, Higashi T, Asato R, et al. Thyroid gland tumor diagnosis at US elastography. *Radiology.* 2005;237:202–11.
 25. Rago T, Santini F, Scutari M, Pinchera A, Vitti P. Elastography: new developments in ultrasound for predicting malignancy in thyroid nodules. *J Clin Endocrinol Metab.* 2007;92:2917–22.
 26. McQuone SJ, Eisele DW. Cervical lymph node metastases in well-differentiated thyroid carcinoma. Proceedings 4th international conference on head and neck cancer. Arlington: Society of Head and Neck Surgeons; 1996. p. 967–71.
 27. Noguchi M, Yamada H, Ohta N, et al. Regional lymph node metastases in well-differentiated thyroid carcinoma. *Int Surg.* 1987;72:100–3.
 28. Mazzaferri EL, Young RL. Papillary thyroid carcinoma: a 10 year follow up report of the impact of therapy in 576 patients. *Am J Med.* 1981;70:511–8.
 29. Carcangiu ML, Zampi G, Pupi A, Castagnoli A, Rosai J. Papillary carcinoma of the thyroid. A clinicopathologic study of 241 cases treated at the University of Florence, Italy. *Cancer.* 1985;55:805–28.
 30. Harness JK, Thompson NW, McLeod MK, Eckhauser FE, Lloyd RV. Follicular carcinoma of the thyroid gland: trends and treatment. *Surgery.* 1984;96:972–80.
 31. LiVolsi VA. Pathology of thyroid disease. In: Falk SA, editor. *Thyroid disease: endocrinology, surgery, nuclear medicine and radiotherapy.* Philadelphia: Lippincott-Raven; 1997. p. 65–104.
 32. Ahuja AT, Chow L, Chick W, King W, Metreweli C. Metastatic cervical nodes in papillary carcinoma of the thyroid: ultrasound and histological correlation. *Clin Radiol.* 1995;50:229–31.
 33. King AD, Ahuja AT, To EW, Tse GM, Metreweli C. Staging papillary carcinoma of the thyroid: magnetic resonance imaging vs ultrasound of the neck. *Clin Radiol.* 2000;55:222–6.
 34. Ahuja AT, Evan RM, Valantis AC. Salivary gland cancer. In: *Imaging in head and neck cancer.* London: Greenwich Medical Media Limited; 2003. p. 115–41.
 35. Frable MA, Frable WJ. Fine-needle aspiration biopsy of salivary glands. *Laryngoscope.* 1991;101:245–9.
 36. Cohen MB, Reznicek MJ, Miller TR. Fine-needle aspiration biopsy of the salivary glands. *Pathol Annu.* 1992;27:213–45.
 37. Jayaram G, Verma AK, Sood N, Khurana N. Fine needle aspiration cytology of salivary gland lesions. *J Oral Pathol Med.* 1994;23:256–61.
 38. Snyderman NI, Suen JY. Neoplasms. In: Cummings CW, Fredrickson JM, Harker LA, et al., editors. *Otolaryngology – head and neck surgery.* 2nd ed. St Louis: Mosby Year Book; 1986. p. 1027–69. Chapter 58.
 39. Choi DS, Na DG, Byun HS, et al. Salivary gland tumors: evaluation with two-phase helical CT. *Radiology.* 2000;214:231–6.
 40. Silvers AR, Som PM. Salivary glands. *Radiol Clin North Am.* 1998;36:941–66.
 41. Bradley MJ, Durham LH, Lancer JM. The role of colour flow Doppler in the investigation of the salivary gland tumour. *Clin Radiol.* 2000;55:759–62.
 42. Martinoli C, Derchi LE, Solbiati L, Rizzato G, Silvestri E, Giannoni M. Color Doppler sonography of salivary glands. *AJR Am J Roentgenol.* 1994;163:933–41.
 43. Som PM, Brandwein M. Salivary glands. In: Som PM, Curtin HD, editors. *Head and neck imaging.* 3rd ed. St Louis: Mosby; 1996. p. 823–914.
 44. Ishii J, Amagasa T, Tachibana T, Shinozuka K, Shioda S. US and CT evaluation of cervical lymph node metastasis from oral cancer. *J Craniomaxillofac Surg.* 1991;19:123–7.
 45. Vassallo P, Edel G, Roos N, Naguib A, Peters PE. In-vitro high-resolution ultrasonography of benign and malignant lymph nodes. A sonographic-pathologic correlation. *Invest Radiol.* 1993;28:698–705.
 46. Vassallo P, Wernecke K, Roos N, Peters PE. Differentiation of benign from malignant superficial lymphadenopathy: the role of high-resolution US. *Radiology.* 1992;183:215–20.
 47. van den Brekel MW, Stel HV, Castelijns JA, et al. Cervical lymph node metastasis: assessment of radiologic criteria. *Radiology.* 1990;177:379–84.
 48. Ahuja A, Ying M, King W, Metreweli C. A practical approach to ultrasound of cervical lymph nodes. *J Laryngol Otol.* 1997;111:245–56.
 49. Arijji Y, Kimura Y, Hayashi N, et al. Power Doppler sonography of cervical lymph nodes in patients with head and neck cancer. *AJNR Am J Neuroradiol.* 1998;19:303–7.
 50. Wu CH, Hsu MM, Chang YL, Hsieh FJ. Vascular pathology of malignant cervical lymphadenopathy: qualitative and quantitative assessment with power Doppler ultrasound. *Cancer.* 1998;83:1189–96.
 51. Steinkamp HJ, Mueffelmann M, Böck JC, Thiel T, Kenzel P, Felix R. Differential diagnosis of lymph node lesions: a semiquantitative approach with colour Doppler ultrasound. *Br J Radiol.* 1998;71:828–33.
 52. de Baatenburg JRJ, Rongen RJ, Laméris JS, Harthoorn M, Verwoerd CD, Knegt P. Metastatic neck disease. Palpation vs ultrasound examination. *Arch Otolaryngol Head Neck Surg.* 1989;115:689–90.
 53. Ahuja A, Leung SF, Ying M, Metreweli C. Echography of metastatic nodes treated by radiotherapy. *J Laryngol Otol.* 1999;113:993–8.
 54. Ahuja A, Ying M, Evans R, King W, Metreweli C. The application of ultrasound criteria for malignancy in differentiating tuberculous cervical adenitis from metastatic nasopharyngeal carcinoma. *Clin Radiol.* 1995;50:391–5.
 55. Shozushima M, Suzuki M, Nakasima T, Yanagisawa Y, Sakamaki K, Takeda Y. Ultrasound diagnosis of lymph node metastasis in head and neck cancer. *Dentomaxillofac Radiol.* 1990;19:165–70.
 56. Johnson JT. A surgeon looks at cervical lymph nodes. *Radiology.* 1990;175:607–10.
 57. Ying M, Ahuja A, Brook F, Metreweli C. Vascularity and grey-scale sonographic features of normal cervical lymph nodes: variations with nodal size. *Clin Radiol.* 2001;56:416–9.
 58. Evans RM, Ahuja A, Metreweli C. The linear echogenic hilus in cervical lymphadenopathy – a sign of benignity or malignancy? *Clin Radiol.* 1993;47:262–4.
 59. Som PM. Lymph nodes of the neck. *Radiology.* 1987;165:593–600.
 60. Ishii J, Fujii E, Suzuki H, Shinozuka K, Kawase N, Amagasa T. Ultrasonic diagnosis of oral and neck malignant lymphoma. *Bull Tokyo Med Dent Univ.* 1992;39:63–9.
 61. Bruneton JN, Normand F, Balu-Maestro C, et al. Lymphomatous superficial lymph nodes: US detection. *Radiology.* 1987;165:233–5.
 62. Ahuja AT, Ying M, Yuen HY, Metreweli C. ‘Pseudocystic’ appearance of non-Hodgkin’s lymphomatous nodes: an infrequent finding with high resolution transducers. *Clin Radiol.* 2001;56:111–5.
 63. Swartz JD, Yussen PS, Popky GL. Imaging of the neck: nodal disease. *Crit Rev Diagn Imaging.* 1991;31:413–69.
 64. Ahuja A, Ying M, Leung SF, Metreweli C. The sonographic appearance and significance of cervical metastatic nodes following radiotherapy for nasopharyngeal carcinoma. *Clin Radiol.* 1996;51:698–701.
 65. Ying M, Ahuja A, Brook F. Repeatability of power Doppler sonography of cervical lymph nodes. *Ultrasound Med Biol.* 2002;28:737–44.
 66. Na DG, Lim HK, Byun HS, Kim HD, Ko YH, Baek JH. Differential diagnosis of cervical lymphadenopathy: usefulness of color Doppler sonography. *AJR Am J Roentgenol.* 1997;168:1311–6.
 67. Ying M, Ahuja A, Brook F, Metreweli C. Power Doppler sonography of normal cervical lymph nodes. *J Ultrasound Med.* 2000;19:511–7.
 68. Steinkamp HJ, Mäurer J, Cornehl M, Knöbber D, Hettwer H, Felix R. Recurrent cervical lymphadenopathy: differential diagnosis with color duplex sonography. *Eur Arch Otorhinolaryngol.* 1994;251:404–9.

69. Ahuja AT, Ying M, Ho SS, Metreweli C. Distribution of intranodal vessels in differentiating benign from metastatic neck nodes. *Clin Radiol*. 2001;56:197–201.
70. van den Brekel MW, Stel HV, Castelijns JA, Croll GJ, Snow GB. Lymph node staging in patients with clinically negative neck examinations by ultrasound and ultrasound-guided aspiration cytology. *Am J Surg*. 1991;162:362–6.
71. van den Brekel MW, Castelijns JA, Stel HV, et al. Occult metastatic neck disease: detection with US and US-guided fine-needle aspiration cytology. *Radiology*. 1991;180:457–61.
72. Moritz JD, Ludwig A, Oestmann JW. Contrast-enhanced color Doppler sonography for evaluation of enlarged cervical lymph nodes in head and neck tumors. *AJR Am J Roentgenol*. 2000;174:1279–84.
73. Rubaltelli L, Khadivi Y, Tregnaghi A, et al. Evaluation of lymph node perfusion using continuous mode harmonic ultrasonography with a second-generation contrast agent. *J Ultrasound Med*. 2004;23:829–36.
74. Lee YY, Antonio GE, Ho SSY, et al. Serial dynamic sonographic contrast enhancement changes in cervical lymph nodes: before and after treatment for lymphoma. International & 9th national head and neck cancer conference. Urumqi, China; 7–11 September 2007.
75. Ahuja AT, Ying M, Ho SY, et al. Ultrasound of malignant cervical lymph nodes. *Cancer Imaging*. 2008;8:48–56.
76. Ho SS, Ahuja AT, Yeo W, Chan TC, Kew J, Metreweli C. Longitudinal colour Doppler study of superficial lymph nodes in non-Hodgkin's lymphoma patients on chemotherapy. *Clin Radiol*. 2000;55:110–3.
77. Lee YYP, Wong KT, King AD, Ahuja AT. Imaging of salivary gland tumours. *Eur J Radiol*. 2008;66:419–36.

Chapter 15

Functional Imaging

Ludwig G. Strauss and Antonia Dimitrakopoulou-Strauss

Abstract Functional imaging has found widespread use within the last years due to the increasing availability of PET and PET/CT systems worldwide. The most frequently used tracer for PET examinations is F-18-deoxyglucose, which is transported like glucose into the cells and phosphorylated, but then trapped. Dynamic PET examinations provide detailed information about the kinetics of the tracer and facilitate the detection and delineation of lesions by parametric imaging techniques. However, even static images 1 h after tracer injection are helpful to assess malignant lesions. Tumor diagnostics is improved by the combination of PET and CT or MRI by the use of image fusion techniques. Radiotherapy planning is improved by the inclusion of functional images and the better delineation of a tumor. Other tracers like F-18-FLT provide information about the proliferation, and tracers like F-18-misonidazole can be used to assess hypoxia in tumors. Especially, hypoxia imaging is helpful for the radiotherapy of patients.

Keywords Positron emission tomography • PET • FDG • FLT • Misonidazole • Staging • Therapy management • Parametric imaging

Tumor Diagnostics

Morphological Imaging

Tumors of the oral cavity and oropharynx are within the most common cancer types in Germany. Like in other tumors, accurate methods are needed for diagnostics and staging to guide the individual patient to the appropriate therapy. Besides clinical methods including endoscopy and the histological assessment of suspicious lesions, morphological

methods are applied to assess a mass according to size, location, and infiltration of the surrounding region. Furthermore, the detection of metastases is important for staging and therapy planning. Within the last 10 years, MRI has gained increasing interest due to the possibility to obtain noninvasively high contrast images of morphological structures. Leslie et al. evaluated CT and MRI for T- and N-staging of squamous cell carcinoma of the oral cavity and oropharynx in patients with primary or recurrent disease [1]. Interestingly, the accuracy for the staging of primary tumors was 77% for MRI and 67% for CT. In contrast to the staging results, the detection of recurrent tumors was improved with an accuracy of 89% for MRI and 100% for CT [1]. The main problem with both imaging modalities was the N-staging, because the procedures failed to identify small lymph node metastases. Furthermore, changes in cell function may not necessarily be detected with morphological methods alone. The data demonstrate that other methods are needed to improve the staging accuracy, especially for N-staging.

Functional Imaging

Functional methods are primarily based on nuclear medicine procedures. Basically, radiopharmaceutical is used to generate functional images. A radiopharmaceutical is generally built from two major parts: the isotope and the pharmaceutical. The isotope is needed to obtain a signal outside the body. Labeling with a positron emitting isotope facilitates imaging with positron emission tomography (PET). Based on the physical properties of positron emitting isotopes, two high energy gamma rays are emitted during decay (511 keV) in an angle of about 180°. This enables the so-called coincidence imaging, which is the base for the superior resolution of PET as compared to conventional nuclear medicine methods. The isotope is linked to a pharmaceutical, which determines what functional information is achieved with an examination. Most of the current PET systems are actually PET/CT systems, which combine the advantages of functional PET imaging with the morphological information obtained by CT.

L.G. Strauss (✉)
CCU Nuclear Medicine, German Cancer Research Center,
Im Neuenheimer Feld 280, BW 69120, Heidelberg, Germany
e-mail: lgs@ads-lgs.de

PET: F-18-Deoxyglucose

One of the most common radiopharmaceuticals for PET is F-18-labeled deoxyglucose (FDG), which has found widespread use for oncological studies [2]. FDG is transported like glucose via the glucose transporters into the cells, also phosphorylated by the hexokinases, but then not further metabolized. In contrast to glucose, FDG is usually not a substrate for the sodium-dependent transport system. The dephosphorylation rate of the metabolized FDG is generally low in most of the malignant tumors for at least 1 h. Most of the PET examinations are done as static studies. For this purpose, images are acquired usually 1 h after tracer injection. In contrast to this protocol, at our center we prefer to combine dynamic and static imaging. Therefore, first a 60-min dynamic PET (dPET) study is acquired for the target region, usually the head and neck area. Then after the dPET acquisition additional static images are acquired to obtain partial or whole body images. Based on the dPET acquisition very accurate quantitative data can be obtained about the kinetics of FDG. For quantification purposes we introduced the term "standardized uptake value" (SUV) [2]. The SUV helps to compare different patient studies and follow-up examinations by standardizing the tracer concentration for the injected dose and body weight [2]. The SUV has no dimension and reflects the relative distribution of the tracer in the body. If the tracer would be equally distributed in the whole body an SUV of one would be measured. Based on the FDG transport and phosphorylation in tissue the uptake is usually greater than one. If dPET studies are used, compartment and non-compartment models can be applied to the data to gain detailed information about the tracer kinetics.

One of the initial PET studies was done from Minn et al., who compared the FDG data with flow cytometry in head and neck tumors [3]. The authors found no correlation with the histologic grade of the tumors, but a correlation was noted for the FDG uptake ratio and the proliferating cells as measured by flow cytometry [3]. We compared the tumor perfusion using O-15-water and FDG uptake with flow cytometry data in 35 patients with head and neck tumors [4]. Interestingly, the tissue perfusion data did not correlate neither to the FDG uptake nor to the flow cytometry results. The FDG data revealed two subgroups with a significant correlation of the FDG SUVs in each subgroup with the proliferative index [4]. The data demonstrate that functional methods such as PET FDG are closely related to molecular biological processes and may therefore be helpful to assess a malignant lesion in more detail.

Several studies have focused on the aspect of diagnostic accuracy of PET in head and neck tumors. Gambhir et al. performed a meta-analysis of data about the use of PET in oncology [5]. Their evaluation of studies concerning head and neck tumors comprise 298 patients and 580 lesions

assessed for tumor diagnostics and 591 patients with 2,113 lesions evaluated for tumor staging [5]. PET and CT results were compared and an average sensitivity and specificity of 93% and 70% for PET and 66% and 56% for CT were calculated from the literature data for primary tumor diagnostics, respectively. The data were comparable for tumor staging except for a higher specificity of PET and CT as compared to the diagnostic studies (PET: sensitivity 87%, specificity 89%; CT: sensitivity 62%, specificity 72%). The clinical situation, however, is usually associated with a certain prevalence of disease prior to any diagnostic procedure. Diagnostic methods are then applied and it is usually expected that the gain in information enhances the probability or absence of a disease. This is the application of the Bayesian statistics [6]. The data from Gambhir et al. can be analyzed using the Bayesian approach. Overall, PET provides a higher gain in information as compared to CT. Especially, the rate of false-negative results with PET is significantly lower as compared to CT. The advantage of combining a morphological method with a functional procedure is also assessed using the literature data and the predicted gain in information is calculated. Especially in patients with a low prior probability of disease the combination of PET and CT will be helpful. This directs to the preferential use of both, morphological and functional methods to achieve the most accurate tumor diagnosis and staging information in individual patients.

Hybrid Systems: PET/CT

The recent development of hybrid systems, combining PET and CT, is a major step forward to achieve the most accurate correlation between morphology and function. Due to the sequential acquisition of CT and PET data the misalignment between CT and PET is kept to a minimum and the images can be reviewed side by side or as fusion images. The combined assessment of both, CT and PET, as well as the fusion of images are especially helpful to delineate and locate the viable tumor tissue most accurately. Branstetter et al. compared PET/CT with PET and CT as individual modalities in patients with head and neck tumors [7]. Again, the lowest accuracy was noted for CT (74%), while PET (90%) and PET/CT (94%) were significantly more accurate. When Bayesian statistics is applied to the data, the highest gain in information is obtained with PET/CT. The advantages of PET/CT are also reported by Goerres et al. [8]. The authors are among the first who have used PET/CT in patients and they emphasize that PET and CT are matching with a few millimeters difference. Therefore, the combined use of the imaging modalities improves the presurgical staging by providing both, the anatomical location based on CT and the high lesion detectability of PET with FDG.

FDG: Sources of Error

The metabolically active tracer FDG provides generally a high sensitivity for the detection of abnormalities. Therefore, generally false-negative results are less likely than false-positive results when FDG is used for tumor diagnostics. However, little is reported about false-positive results. Ng et al. assessed the clinical usefulness of FDG PET in recurrent nasopharyngeal carcinomas and compared the results with MRI [9]. The overall sensitivity of PET, comprising the primary tumor site and the lymph node metastases, was 89.5%, while the specificity was only 55.6% [9]. One limitation of PET with FDG was the number of false-positive results obtained in these patients. However, in this study the patients have had received radiotherapy and also chemotherapy had been given to most of the patients. Therefore, there may be a higher likelihood for an enhanced, reactive metabolic activity in tissue according to treatment reflected by an enhanced FDG accumulation.

PET: Non-FDG Tracers

The problem of FDG uptake in both, malignant tumors as well as in inflammatory tissue, is already known for PET. False-positive results are mainly based on the enhanced FDG transport into leucocytes. To limit false-positive results, generally two approaches are possible: the use of more sophisticated quantification methods to assess the FDG kinetics in a target volume in detail, or the application of a second radiopharmaceutical to achieve additional biological information

about the lesions. Besides tumor metabolism the assessment of tumor proliferation is another important topic in oncology. The first tracer used to assess tumor proliferation noninvasively with PET was C-11-labeled thymidine. Shields et al. used C-11-thymidine and kinetic modeling to quantify the DNA synthesis rate [10]. In the following years, C-11-thymidine was replaced by 3'-deoxy-3'-18F-fluorothymidine (FLT). This tracer is also a substrate for the thymidine kinase and associated with the proliferation rate of tumors. In contrast to thymidine, FLT is not incorporated into the DNA, it can only act as a chain terminator. Initial results demonstrate that FLT has limited accuracy regarding the differentiation between reactive and metastatic lymph node metastases [11]. One reason discussed by the authors may be the B-lymphocyte proliferation in reactive lymph nodes. Another reason may be the dependency of FLT kinetics on the extracellular ATP concentration, which has an impact on the structure and performance of the thymidine kinase. Primary tumors usually demonstrate an increased FLT uptake. In some cases, the uptake of FLT may be significantly higher as compared to FDG (Fig. 15.1).

Another new tracer is 18F-Galacto-RGD, which binds preferentially to the $\alpha V\beta 3$ receptor [12]. Integrins are an important group of genes related to tumor growth, invasiveness, and likelihood of metastases. Initial studies suggest the use of these tracers in patients with head and neck tumors, however, further studies must be performed to assess the value of this tracer for the diagnostics or therapy management. Other tracers like F-18-labeled tyrosine or the SSTR2-binding Ga-68-DOTATOC have found limited use. Boer et al. report about a high accuracy of dynamic F-18-tyrosine examinations for the detection of recurrent laryngeal tumors [13].

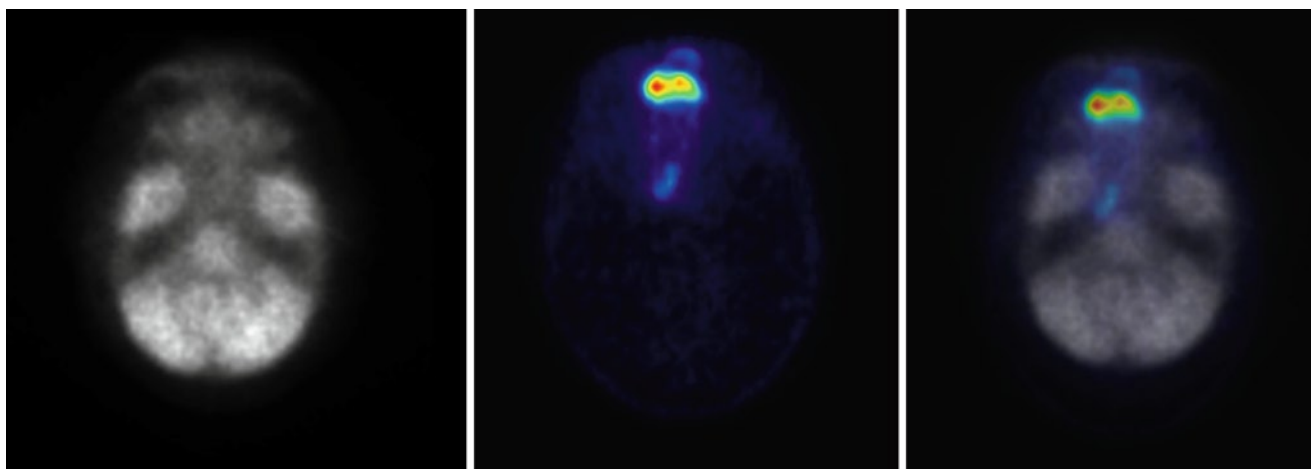


Fig. 15.1 *Left:* FDG image 60 min after tracer application in a patient with a malignant histiocytoma. Low FDG accumulation due to a low tumor metabolism. *Middle:* Image 60 min following FLT injection.

Preferential accumulation of the tracer in the tumor, indicating proliferative activity in the lesion. *Right:* Fusion image of FDG and FLT

Therapy Management

Diagnostics of Tumor Recurrence

One major aim of new diagnostic methods is besides improvements of tumor diagnostics the individualization and optimization of therapy. PET with FDG is an established procedure for the follow-up of patients for tumor recurrence since several years now [2]. In head and neck tumors, one important topic for follow-up is the improved detection of a recurrent tumor. Based on the data from Gambhir et al., who included 426 patients in the meta-analysis, the sensitivity of FDG PET on a patient-based analysis is 93% and the specificity is 83% (CT: 54% sensitivity, 74% specificity) for the detection of recurrent head and neck tumors [5]. These data are comparable to those obtained for tumor diagnostics. PET FDG studies are usually performed for therapy monitoring to assess changes in tumor metabolism following treatment. The evaluation of 169 patients demonstrated a sensitivity of 84% and specificity of 95% for the assessment of therapy-related changes in the tumor [5]. Again, PET was superior to CT (60% sensitivity, 39% specificity), because usually functional changes precede changes in tumor volume. Gambhir et al. noted a correlation of tracer kinetics and growth rates and report about a 33% change in treatment management due to PET results [5]. The combination of PET and CT is currently the state-of-the-art technique. The PET/CT systems used for FDG studies in patients with head and neck cancer provide easy access to both morphology and function. Some systems provide the possibility to perform the scans with localizer devices for radiotherapy. We use, additionally,

parametric images of the global metabolic rate and also fusion of the parametric images with CT and MRI in patients with recurrent head and neck cancer (Fig. 15.2).

Prognostic Aspects of PET

The prognostic value of PET with FDG was investigated in a few studies. Based on the results obtained by Minn et al. [3] and Haberkorn et al. [4], it can be expected that the quantitative evaluation of the FDG uptake may be helpful to assess the proliferative aspect of tumors. Halfpenny et al. evaluated the association of FDG uptake, as measured by the SUV, and therapy outcome [14]. The authors performed FDG studies in 73 patients prior to treatment (surgery and radiotherapy). An SUV of 10 was used for Kaplan Meier analysis and revealed a highly significant difference in survival [14]. Therefore, the quantitative data of the initial FDG uptake prior to treatment are predictive for therapy outcome. We investigated the correlation of changes in FDG uptake and tumor growth rates in patients with head and neck tumors, receiving a cisplatin-based chemotherapy [15]. Dynamic PET studies were performed prior and after one chemotherapeutic cycle, the changes in tracer uptake were compared to the changes in tumor volume. The growth rates and the changes in FDG uptake (SUV) were correlated for both tumors ($r=0.98$) and lymph node metastases ($r=0.94$). Interestingly, the growth rates were different for the same changes in the FDG uptake. Overall, tumors were more sensitive to treatment than lymph node metastases [15].

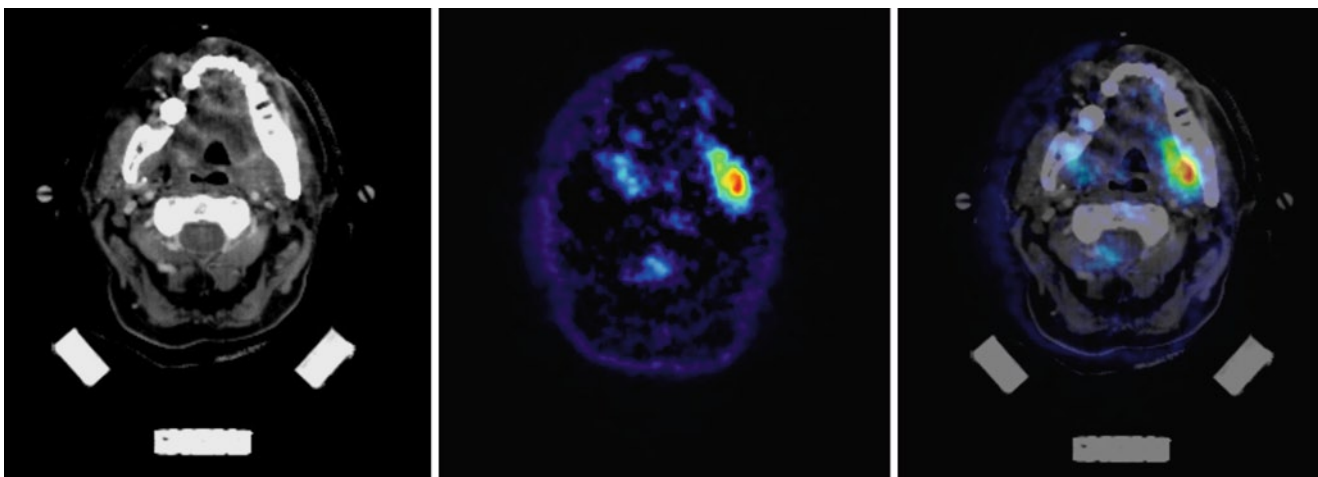


Fig. 15.2 CT (left) and dPET study with FDG (middle) of a patient with a recurrent squamous cell carcinoma. Parametric images of the FDG metabolic rate were calculated from the dPET data and fused with CT (right)

Assessment of Hypoxia

One problem in patients undergoing radiotherapy is the impact of hypoxia on treatment. Tumor resistance can be induced, e.g., by the hypoxia-inducible factor α (HIF-1 α). Furthermore, the von Hippel–Lindau (VHL) gene is involved in the mechanisms of hypoxia, angiogenesis, and radioresistance. Several studies have shown that these genes are important for the biological effects of radiotherapy and that the inhibition, e.g., of HIF-1 α may result in an either enhanced or decreased therapeutic effect, dependent on the timing when the inhibitor is applied during radiation therapy [16, 17]. Hypoxia is closely related to other biological factors such as angiogenesis, metabolism, and proliferation. Interestingly, even hypoxia and FDG metabolism are not independent parameters and hypoxia is affecting glucose metabolism. We noted an association of HIF-1 α expression and the pharmacokinetics of FDG in colorectal tumors [18]. In particular, the expression of HIF-1 α correlated with the SUV, FDG influx (global metabolic rate), k_3 (intracellular phosphorylation), and the fractal dimension (heterogeneity) of the tracer kinetics. In giant cell tumors, a correlation of HIF-1 α and k_3 was found, giving evidence for a modulation of the FDG kinetics by hypoxia-related gene expression [19]. The results direct to an impact of hypoxia on the FDG kinetics. If the impact of hypoxia on the FDG kinetics is known, the amount of hypoxia may be predicted from the dPET data using dedicated regression functions. However, data are reported only for colorectal tumors and giant cell tumors, results are missing for head and neck tumors.

The best approach to assess hypoxia in tumors is to use a tracer with close dependency on tissue oxygen pressure. Several approaches were already made to use a hypoxia-specific tracer for PET studies. One of the most common radiopharmaceuticals for hypoxia imaging is F-18-fluoromisonidazole (FMISO), which accumulates in tissues with oxygen concentrations of less than 3 mmHg. Studies have shown that FMISO can be used to detect and quantify local tissue hypoxia. One of the first reports is a study from Mathias et al. about the use of F-18-Misonidazole for the imaging of hypoxia in ischemic myocardium and brain [20]. One limitation of FMISO is the slow pharmacokinetics, demanding imaging either dynamically for more than 1 h or late images at least 90 min after tracer application. Several studies were performed in different tumor types. Koh et al. used F-18-misonidazole in patients with locally advanced nonsmall cell lung cancer prior to radiotherapy [21]. Furthermore, in some patients early treatment follow-up studies were also performed. The results gave evidence for a general tendency toward improved oxygenation during radiotherapy. However, patients with more radioresistant hypoxic tumors could be selected by a single pretreatment evaluation with PET and F-18-misonidazole [21]. Tumor hypoxia was

evaluated in head and neck tumors by Rajendran et al. in 73 patients prior to treatment and they compared the PET results to therapy outcome [22]. The tumor-to-blood ratios were helpful for the classification of the patients according to overall survival using a cut off value of 1.5: lower ratios were associated with a longer overall survival [22]. The range of the ratios was 1.0–3.5, reflecting a moderate retention of the tracer in hypoxic tumors. However, a more delayed imaging protocol may be helpful in order to achieve higher ratios.

One limitation of F-18-misonidazole is the long delay for tumor imaging of 90–120 min following tracer injection. Therefore, other tracers were evaluated as hypoxic markers. Besides FMISO, nitroimidazole analogs and tracers based on thiosemicarbazones (e.g., Cu-60-ATSM) have found increasing attention due to the shorter time interval required for the assessment of tissue hypoxia. Postema et al. used the substance 1- α -D: -(5-deoxy-5-[(18)F]-fluoroarabinofuranosyl)-2-nitroimidazole (F-18-FAZA) as a hypoxic marker in 50 patients with head and neck cancer, small cell as well as nonsmall cell lung cancer, malignant lymphoma, and high-grade gliomas [23]. The uptake ratios ranged from 1.9 to 15.6 and were higher as compared to the results reported for F-18-misonidazole. However, the delay needed for scanning was comparable for both tracers, therefore the major advantage of F-18-FAZA are the higher retention ratios as compared to F-18-misonidazole.

Other tracers have been investigated in order to shorten the delay time required for imaging. Holland et al. report in a detailed review about the properties of one of the most promising new tracers, the copper(II) complex of diacetyl-2,3-bis(N^4 -methyl-3-thiosemicarbazonato) ligand (Cu-ATSM) [24]. ATSM can be labeled with Cu-60 or Cu-64 and is useful for PET. Cu-ATSM is trapped in hypoxic cells and reflects the amount of hypoxia in tissue. In most studies, a delay of about 30 min following tracer injection is used for PET imaging [24]. Kinetic studies demonstrated that even 10 min after tracer application, constant activity levels may be achieved. Cu-60 labeling has the advantage of a short half-life ($t_{1/2}$ =32.7 min) and is therefore helpful to perform double tracer studies. Cu-64 ($t_{1/2}$ =12.7 h) may be helpful to achieve a somewhat higher contrast. Dence et al. compared F-18-misonidazole, Cu-64-ATSM, FDG, and FLT in a rodent model of cancer [25]. The results demonstrated an excellent correlation for F-18-misonidazole and Cu-64-ATSM, either at 10 min postinjection (R^2 =0.84) or 24 h (R^2 =0.86) [25]. Interestingly, also a significant correlation was noted for Cu-64-ATSM and FLT (R^2 =0.829), directing to an association of hypoxia and tumor proliferation rate.

The current results show that FDG is helpful to achieve functional data about a tumor in the head and neck region. Dependent on the planned treatment, other tracers may be used, e.g., to detect and quantify hypoxia in tumors, which is important for radiotherapy and provides prognostic information.

References

1. Leslie A, Fyfe E, Guest P, Goddard P, Kabala JE. Staging of squamous cell carcinoma of the oral cavity and oropharynx: a comparison of MRI and CT in T- and N-staging. *J Comput Assist Tomogr.* 1999;23:43–9.
2. Strauss LG, Conti PS. The applications of PET in clinical oncology. *J Nucl Med.* 1991;32:623–48. discussion 649–50.
3. Minn H, Joensuu H, Ahonen A, Klemi P. Fluorodeoxyglucose imaging: a method to assess the proliferative activity of human cancer in vivo comparison with DNA flow cytometry in head and neck tumors. *Cancer.* 1988;61:1776–81.
4. Haberkorn U, Strauss LG, Reisser C, et al. Glucose uptake, perfusion, and cell proliferation in head and neck tumors: relation of positron emission tomography to flow cytometry. *J Nucl Med.* 1991;32:1548–55.
5. Gambhir SS, Czernin J, Schwimmer J, Silverman DH, Coleman RE, Phelps ME. A tabulated summary of the FDG PET literature. *J Nucl Med.* 2001;42:1S–93S.
6. Strauss L, Bostel F, Clorius JH, Raptou E, Wellman H, Georgi P. Single-photon emission computed tomography (SPECT) for assessment of hepatic lesions. *J Nucl Med.* 1982;23:1059–65.
7. Branstetter Bf, Blodgett TM, Zimmer LA, et al. Head and neck malignancy: is PET/CT more accurate than PET or CT alone? *Radiology.* 2005;235:580–6.
8. Goerres GW, von Schulthess GK, Steinert HC. Why most PET of lung and head-and-neck cancer will be PET/CT. *J Nucl Med.* 2004;45 Suppl 1:66S–71S.
9. Ng SH, Joseph CT, Chan SC, et al. Clinical usefulness of 18F-FDG PET in nasopharyngeal carcinoma patients with questionable MRI findings for recurrence. *J Nucl Med.* 2004;45:1669–76.
10. Shields AF, Lim K, Grierson J, Link J, Krohn KA. Utilization of labeled thymidine in DNA synthesis: studies for PET. *J Nucl Med.* 1990;31:337–42.
11. Troost EG, Vogel WV, Merx MA, et al. 18F-FLT PET does not discriminate between reactive and metastatic lymph nodes in primary head and neck cancer patients. *J Nucl Med.* 2007;48:726–35.
12. Beer AJ, Haubner R, Wolf I, et al. PET-based human dosimetry of 18F-galacto-RGD, a new radiotracer for imaging alpha v beta3 expression. *J Nucl Med.* 2006;47:763–9.
13. De Boer JR, Pruim J, Burlage F, et al. Therapy evaluation of laryngeal carcinomas by tyrosine-pet. *Head Neck.* 2003;25:634–44.
14. Halfpenny W, Hain SF, Biassoni L, Maisey MN, Sherman JA, McGurk M. FDG-PET. A possible prognostic factor in head and neck cancer. *Br J Cancer.* 2002;86:512–6.
15. Haberkorn U, Strauss LG, Dimitrakopoulou A, et al. Fluorodeoxyglucose imaging of advanced head and neck cancer after chemotherapy. *J Nucl Med.* 1993;34:12–7.
16. Harada H, Kizaka-Kondoh S, Li G, et al. Significance of HIF-1-active cells in angiogenesis and radioresistance. *Oncogene.* 2007;26:7508–16.
17. Harada H, Itasaka S, Zhu Y, et al. Treatment regimen determines whether an HIF-1 inhibitor enhances or inhibits the effect of radiation therapy. *Br J Cancer.* 2009;100:747–57.
18. Strauss LG, Klippel S, Koczan D, et al. Correlation of hypoxia associated genes with FDG uptake and kinetics [abstract]. *J Nucl Med.* 2008;49(Suppl):346P.
19. Strauss LG, Dimitrakopoulou-Strauss A, Koczan D, et al. 18F-FDG kinetics and gene expression in giant cell tumors. *J Nucl Med.* 2004;45:1528–35.
20. Mathias CJ, Welch MJ, Kilbourn MR, et al. Radiolabeled hypoxic cell sensitizers: tracers for assessment of ischemia. *Life Sci.* 1987;41:199–206.
21. Koh WJ, Bergman KS, Rasey JS, et al. Evaluation of oxygenation status during fractionated radiotherapy in human nonsmall cell lung cancers using [F-18]fluoromisonidazole positron emission tomography. *Int J Radiat Oncol Biol Phys.* 1995;33:391–8.
22. Rajendran JG, Schwartz DL, O'Sullivan J, et al. Tumor hypoxia imaging with [F-18] fluoromisonidazole positron emission tomography in head and neck cancer. *Clin Cancer Res.* 2006;12:5435–41.
23. Postema EJ, McEwan AJ, Riauka TA, et al. Initial results of hypoxia imaging using 1-alpha-D:-(5-deoxy-5-[(18)F]-fluoroarabinofuranosyl)-2-nitroimidazole ((18)F-FAZA). *Eur J Nucl Med Mol Imaging.* 2009;36(10):1565–73.
24. Holland JP, Lewis JS, Dehdashti F. Assessing tumor hypoxia by positron emission tomography with Cu-ATSM. *Q J Nucl Med Mol Imaging.* 2009;53:193–200.
25. Dence CS, Ponde DE, Welch MJ, Lewis JS. Autoradiographic and small-animal PET comparisons between (18)F-FMISO, (18)F-FDG, (18)F-FLT and the hypoxic selective (64)Cu-ATSM in a rodent model of cancer. *Nucl Med Biol.* 2008;35:713–20.

Chapter 16

Sentinel Node Biopsy for Head and Neck Cancer

Lee Alkureishi and Gary L. Ross

Abstract The presence of cervical lymph node metastases remains one of the most important prognostic factors for various solid tumors of the head and neck, including melanoma, squamous cell carcinoma (SCC), and Merkel cell carcinoma (MCC). In patients with clinically evident neck involvement, the regional lymphatics clearly require directed treatment, and this may involve therapeutic neck dissection or radiotherapy. However, the decision whether or not to electively treat patients with clinically uninvolved cervical lymphatics is usually less clear-cut. On the one hand, elective neck dissection simultaneously allows for accurate pathological neck staging and definitive surgical management of patients found to harbor occult metastatic disease. On the other hand, the majority of patients with clinically negative (cN0) necks do not harbor occult disease and would therefore be overtreated by an elective neck dissection. The significant morbidity associated with neck dissection means that this is a real concern, and efforts to minimize the extent of surgical intervention while maintaining oncologic safety are ongoing.

The radical en bloc cervical lymph node dissections introduced at the start of the twentieth century have largely been surpassed by more focused surgical procedures, including the modified radical neck dissection (MRND) and more recently, selective neck dissection (SND). The operative morbidity of MRND and SND procedures compares favorably with more extensive dissections, though it remains significant. Sentinel lymph node biopsy (SLNB) represents an extension of this principle; by super-selecting the small subset of lymph nodes most likely to harbor disease, the extent of surgical intervention can be further minimized without adversely affecting diagnostic accuracy. The sentinel node concept states that tumor spread occurs in a stepwise progression from the primary tumor to the first-echelon lymph nodes, before progression to the remainder of the lymphatic basin.

G.L. Ross (✉)
Plastic Surgery Department, The Christie, Wilmslow Road,
Manchester, M20 4BX, UK
e-mail: gross@gmail.com

These first-echelon lymph nodes, known as the sentinel nodes, can be harvested, examined for the presence of tumor, and used to predict the disease status of the entire basin. In the head and neck region, considerable variability exists in the patterns of lymphatic drainage from each primary tumor site, and the exact location of the sentinel nodes therefore varies between patients. In order to accurately locate the SLNs, a number of techniques may be employed. Preoperatively, radio-labeled tracer is injected in a peritumoral fashion, traveling via the lymphatics to the first-echelon nodes, where it may be detected by gamma camera during lymphoscintigraphy (LSG). A handheld gamma probe is utilized intraoperatively to afford more precise radiolocalization, and some surgeons choose also to inject peritumoral blue dye, easing visual identification of the lymphatics. These comprise the sentinel lymph node biopsy technique, which has been applied to a variety of solid tumors, including breast cancer, malignant melanoma (MM), and penile cancer.

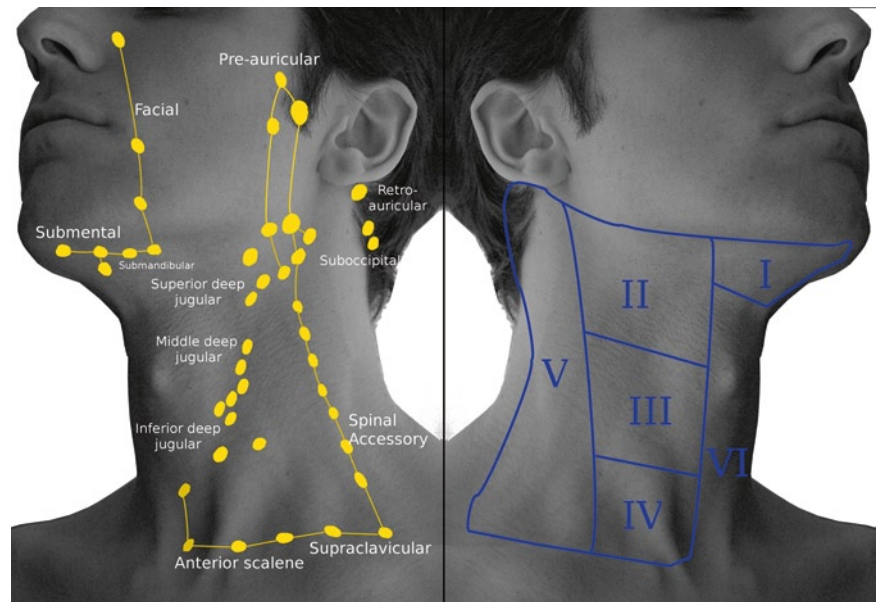
This chapter describes SLNB as it relates to the management of solid tumors in the head and neck region, particularly malignant melanoma, SCC, and MCC. A brief history of the development of the technique and its reported accuracy are presented, and the advantages and disadvantages of this relatively new application are discussed. Finally, this chapter explores the possible roles that SLNB may play in the future management of head and neck cancer.

Keywords Head and neck cancer • Oral cancer • Squamous cell carcinoma • Sentinel node biopsy

Introduction

Head and neck cancers comprise a diverse group of tumors arising from the epidermis, with significant differences in tumor biology, disease characteristics, and prognosis. The three most common types of head and neck cancer are malignant melanoma (MM), arising from melanocytes; squamous cell carcinoma (SCC), arising from keratinocytes;

Fig. 16.1 (a) Individual lymph node groups in the head and neck, grouped into superficial and deep jugular chains. (b) Robbins' Classification of cervical lymph node levels



and Merkel cell carcinoma (MCC), a rare aggressive skin tumor arising from neuroendocrine cells.

Despite their differences in many regards, these cancer types share one important characteristic; their prognosis is heavily dependent on the presence or absence of lymph node metastases. Patients with malignant melanoma and nodal involvement demonstrate less than 50% 5-year survival [1], and similar figures have been reported for patients with SCC [2]. In MCC, the presence of nodal disease has been shown to be the most important prognostic indicator by multivariate analysis [3], with a further study demonstrating a drop from 40 to 13 months median survival with nodal involvement [4].

Virchow [5] was the first to postulate that lymph nodes act as a barrier to particulate matter, and in particular cancer cells. The contention that cancer progression followed a sequential route from the primary site to the regional lymphatics before distant metastasis laid the way for the development of regional surgical treatments for a variety of cancers; first, Halsted radical mastectomy for breast cancer [6]; and in the case of the head and neck, the radical neck dissection (RND) as described by Crile [7].

Anatomy of the Cervical Lymph Node Basin

The lymphatic anatomy of the head and neck is complex, comprising approximately 250–350 lymph nodes and demonstrating great variability in the patterns of lymph flow observed [8]. The cervical lymph nodes may be divided into superficial and deep chains. The superficial chain lies between the skin and the superficial fascia of the face and scalp, following the anatomy of the major veins, and eventually

drains into the deep chain. The deep chain lies along the course of the internal jugular vein under the sternocleidomastoid muscle, draining inferiorly from the base of the skull to the brachiocephalic junction, where lymph is returned to the venous system. The most popular system of classification for cervical lymphatic anatomy was developed at the Memorial Sloan-Kettering Cancer Center [9], and forms the basis for describing the various types of neck dissection in current usage [10]. In this system, the cervical lymph nodes are divided into levels I through VI. The anatomy and classification system are illustrated in Fig. 16.1.

Neck Dissection

The introduction of the RND in 1906 [7] represented an important step for both staging and treatment of patients with head and neck cancer. However, the morbidity associated with such an extensive dissection was considerable. Complications included shoulder stiffness, pain, muscle atrophy, facial swelling, and cosmetic defects while the mortality rate following bilateral RND was reported as high as 10% [11]. A number of “modified radical” neck dissections were developed as a means of minimizing associated morbidity, being designated MRND I–III depending on the structures preserved (accessory nerve, sternocleidomastoid and/or internal jugular vein) [12]. Studies demonstrating the oncologic safety of the MRND led to its adoption as the standard of care, and the RND fell out of favor [13].

The goal of reducing morbidity continues to push the development of more conservative surgical management techniques, however, and this is particularly true for patients

with clinically uninvolved necks. Improved understanding of the lymphatic anatomy of the head and neck has facilitated the development of more selective lymphadenectomies, concentrating on the groups of lymph nodes most likely to be involved [14–16]. These selective neck dissections (SNDs) require less extensive dissection, leaving more of the normal lymphatic anatomy intact and have been shown to cause less morbidity when compared with MRND [17]. The various types of neck dissection are outlined in Table 16.1.

Despite these recent advances, neck dissection remains an invasive procedure with appreciable morbidity [18] and, while its use in clinically node-positive patients is well established, elective neck dissection for patients with clinically negative (cN0) necks remains controversial. Traditionally considered the gold standard, END provides tissue for accurate pathologic staging while also treating the neck by removing lymph nodes at risk for involvement [19]. However, the majority of cN0 patients do not in fact harbor occult nodal metastases, and may be unnecessarily subjected to the morbidity associated with the procedure.

As a result, selection of patients who would benefit most from neck dissection becomes increasingly important. Clinical staging of the cervical lymph nodes is unreliable, with poor reported sensitivities for both palpation and clinical imaging, and it is generally accepted that an occult nodal metastasis rate of 20–30% persists despite meticulous clinical staging [20–22]. For SCC, elective neck dissection is currently recommended for patients with a greater than 20% risk of occult nodal metastases based on primary tumor characteristics, such as site and T-stage [23]. The role of END for cN0 head and neck melanoma patients is unclear, with no consistent survival benefit demonstrated [24]. It has been suggested that END may be most beneficial for patients with primary tumors between 1.5 and 3.99 mm in thickness [25].

Table 16.1 Neck dissection classification

1991 Classification	2001 Classification
1. Radical neck dissection	1. Radical neck dissection
2. Modified radical neck dissection	2. Modified radical neck dissection
3. Selective neck dissection	3. Selective neck dissection
a. Supraomohyoid	Each variation is depicted by
b. Lateral	“SND”
c. Posterolateral	And the use of parentheses
d. Anterior	to denote
	The levels or sublevels
	removed
4. Extended neck dissection	4. Extended neck dissection

From Robbins KT, Clayman G, Levine PA, Medina J, Sessions R, Shaha A, Som P, Wolf GT. Neck dissection classification update: revisions proposed by the American Head and Neck Society and the American Academy of Otolaryngology-Head and Neck Surgery. *Arch Otolaryngol Head Neck Surg.* 2002;128(7):751–8. Reprinted with permission. Copyright © 2002 American Medical Association. All rights reserved

Sentinel Node Biopsy

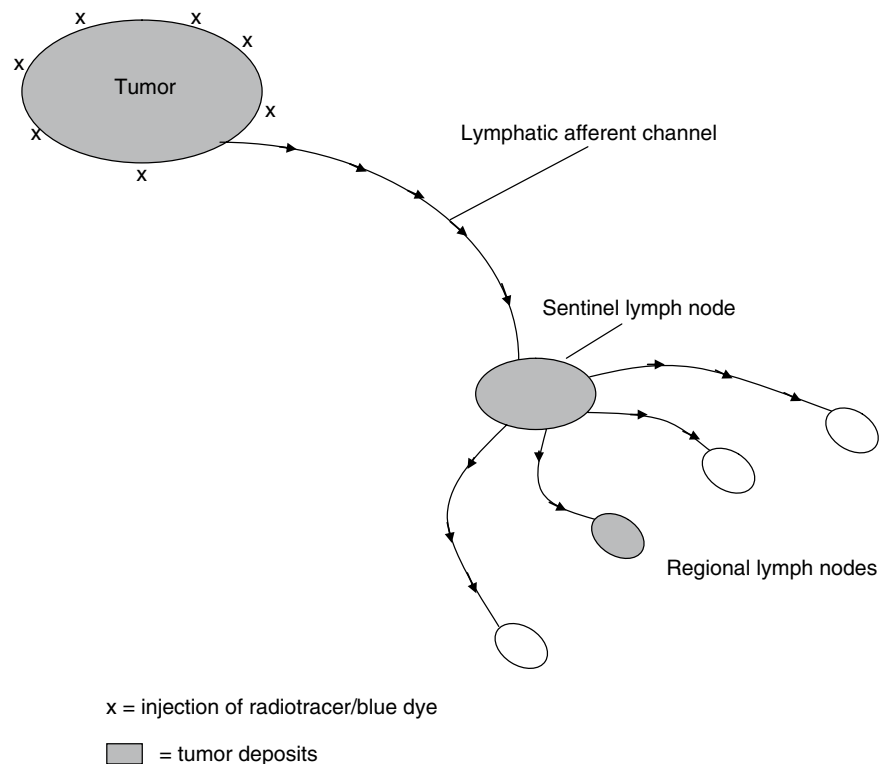
Sentinel node biopsy (SNB) represents a means of super-selecting the group of lymph nodes most at risk for disease involvement, allowing histopathologic staging of the neck while minimizing the extent of surgical intervention for patients without nodal involvement. The sentinel node concept is based on the assumption that spread from the primary tumor occurs to a single node (or group of nodes) before progressing to the remaining nodal basin and systemic metastasis (Fig. 16.2). Identification of these sentinel nodes allows for selective biopsy and pathologic evaluation of the nodes most likely to represent the disease status of the remaining nodal basin [26]. The results of SNB can then be used to guide further management, with SNB-positive patients going on to receive definitive (therapeutic) neck dissection and/or parotidectomy while SNB-negative patients may be followed clinically. These SNB-negative patients may therefore avoid some of the morbidity associated with neck dissection [27].

The potential advantages of SNB over neck dissection are many-fold, including its minimally invasive nature, a lower per-patient cost compared with comprehensive neck dissection [28, 29], and a drastic reduction in the number of lymph nodes submitted for pathologic evaluation. In turn, this allows a more in-depth search for micrometastatic deposits utilizing techniques, such as step-serial sectioning (SSS) and immunohistochemistry [30, 31]. However, SNB can be a technically challenging technique with a steep learning curve [26, 32] and as such, investigators wishing to begin using the technique for SCC are recommended to do so within the context of SNB-assisted END [33]. As with any biopsy technique, there exists the potential for sampling error and the reported false-negative rate ranges from 0 to 10.5% in most studies for both SCC and melanoma [33–39]. Finally, the usefulness of SNB is currently restricted to cN0 patients, since distortion of the normal lymphatic anatomy by extensive tumor infiltration may lead to unexpected drainage patterns and increase the likelihood of false-negative results [40].

Development of the Sentinel Node Concept

The first description of a “sentinel” lymph node dates back to 1960 with a total parotidectomy reported by Gould et al., during which frozen section examination of a single facial lymph node was used to guide the decision for neck dissection [41]. Subsequently, Cabanas et al. reported direct drainage from the penis to the lymph nodes associated with the superficial epigastric vein in a series of 46 patients with penile SCC and described 90% survival for sentinel node-negative patients [42]. Similarly, Weissbach and Boedefeld suggested a limited retroperitoneal lymph node dissection in

Fig. 16.2 The sentinel node concept



patients with testicular cancer, in order to detect lymphatic involvement while minimizing operative intervention [43]. Holmes et al. introduced the use of colloidal gold injections to demonstrate the actual patterns of lymph drainage for ambiguous areas, such as the midline [44], and followed this in 1992 with the description of intraoperative vital dye injection, providing a means of visually tracing dye-stained lymphatics to the first-echelon nodes [26]. In 1993, Alex and Krag described the intraoperative use of a handheld gamma probe, easing detection of the sentinel nodes and improving identification rates [45]. Since these early studies, SNB has gone on to become increasingly important as a staging tool for patients with early-stage melanoma [46], and work is underway to fully elucidate its utility in SCC management [33, 47]. The role played by SNB in the management of these and other head and neck cancers is described later in this chapter.

Technique of Sentinel Node Biopsy

In general, SNB comprises three parts: preoperative lymphoscintigraphy (LSG), intraoperative identification and harvest, and pathological evaluation of sentinel nodes. These components are described in detail in this section, with reference to the minor differences in protocol for each of the major head and neck cancer types.

Preoperative Lymphoscintigraphy

The lymphatic anatomy of the head and neck is complex and variable, with discordance between predicted and actual lymphatic drainage in up to 67% of patients [8]. Aberrant drainage patterns can lead to inaccurate placement of the initial access incision, and may contribute to the failure of sentinel node identification [15]. The goal of preoperative LSG is to demonstrate the location of sentinel nodes prior to incision. This begins with injection of a radio-labeled colloid solution at the site of the primary tumor. The radiocolloid may then track along the same afferent lymphatics draining the tumor, accumulating in the first-echelon lymph nodes where the resultant radioactivity may be detected by gamma camera. LSG may be carried out up to 24 h before surgery, or on the day of surgery, and this should be coordinated between the nuclear medicine physician and the surgeon.

The technique of radiocolloid injection varies according to the type of cancer being studied. For melanoma and other cutaneous tumors, multiple intradermal injections should be employed to completely encircle the tumor or site of previous excision biopsy. There has been considerable debate regarding the accuracy of LSG, and SNB in general, in cases where wide local excision (WLE) has previously been carried out. While it is strongly preferred that SNB be performed prior to excision, there is some evidence to suggest that previous WLE is not an absolute contraindication [48]. For intraoral lesions, the majority of which are SCC, multiple mucosal/

submucosal injections should be performed around the periphery of the tumor or scar margin, and deeper injections may be employed according to the depth of the lesion [49]. Ideally, the operating surgeon should be present for the injections to ensure consistency with injection of blue dye if used. The volume injected varies according to the location and size of the lesion, and ranges from two to four aliquots. A mouth-wash should be employed following intraoral injections, to prevent sumping or swallowing of radiotracer.

The ideal radiotracer should emit only gamma rays, be cleared rapidly from the injection site, have a uniform particle size, and should persist in the lymph nodes until imaging can be performed [50, 51]. A variety of Technetium-99m (^{99m}Tc)-labeled colloids are available, including ^{99m}Tc human serum albumin, ^{99m}Tc colloidal albumin, ^{99m}Tc antimony sulfur colloid, and ^{99m}Tc sulfur colloid, although regional licensing issues may restrict the available choices. In Europe and parts of the USA, AlburesTM and NanocollTM (Nycomed Amersham, Buckinghamshire, UK) are the most commonly available colloidal albumin preparations. The larger particle size of AlburesTM (500 nm) limits its use to primary tumor sites with high lymphatic density, such as the anterior tongue or floor of the mouth, while the 50 nm particle size of NanocollTM allows its use in other sites [33, 51]. For regions where human albumin-based colloids have not been approved, sulfur colloid preparations are available in both unfiltered (300–340 nm) and filtered (<200 nm) forms [52]. There is little consensus on the optimum activity for injection, which varies from 15 to 120 MBq between studies with higher doses or repeat injections being employed for the 2-day protocol [53–55]. However, it has been suggested that much lower doses (0.37–2.2 MBq) may be used in the setting of head and neck melanoma [56].

Planar lymphoscintigraphic imaging may be static or dynamic, or a combination of the two. The addition of dynamic imaging for melanoma patients improves the detection of “in-transit” nodes, which are reported to occur in 5–8% of the population and should also be considered sentinel nodes [57, 58]. To date, there have been no reports of in transit nodes in patients with SCC. There is currently no evidence favoring either technique in these patients, and the exact timing of static image acquisition varies between centers. Images should be obtained in two planes: anterior and lateral or lateral-oblique. A gamma camera fitted with a low energy, high resolution (LEHR) collimator is used to image the patient, whose silhouette can be delineated by a flood source of ^{57}Co or ^{99m}Tc placed behind the patient or by tracing his/her outline with a ^{57}Co -labeled marker pen. At this point, it may be helpful to mark the skin overlying visualized sentinel nodes with indelible marker pen [33, 49, 51]. However, this practice has not been universally accepted due to concerns that the change in positioning between LSG and surgery may misguide the placement of initial access incision [59].

Recent studies have reported potential improvements in preoperative sentinel node identification through the use of Single Photon Emission Computed Tomography (SPECT/CT) imaging [60, 61]. This hybrid anatomical/functional imaging modality affords better topographical orientation and separation of SLNs from adjacent structures, compared with planar LSG alone. In the melanoma literature, it appears that SPECT/CT can lead to more accurate incision placement and improvements in SLN detection rates [61, 62]. However, these advantages of SPECT/CT imaging have not been consistently demonstrated in the SCC population [63].

Surgical Technique

Within 24 h of LSG, patients may undergo the operative portion of SNB. Although SNB of cervical lymph nodes under local anesthesia has been reported [64], most surgeons prefer to employ general anesthesia for this technique. The patient is prepared and draped as for a standard excision and neck dissection. Preoperative LSG images should be available for reference in the operating suite, in electronic or hard copy form, and these may be used to guide the placement of the initial access incision. If skin markings have been placed in the nuclear medicine suite, underlying radioactivity levels should be verified using a handheld gamma probe prior to making the incision. The orientation of the incision should be such that it may be easily excised in the event of a future neck dissection.

If injection of vital (blue) dye is desired, this may be carried out prior to preparing and draping. Injections should be undertaken by the same operator as the radiotracer injection in order to ensure consistency, and the pattern and depth of injection should mirror that of the radiotracer. The brand of dye used varies according to geographical region, with Patent Blue V Dye (Laboratoire Guerbet, Aulnay-Sous-Bois, France) available in Europe and LymphazurinTM (Tyco Healthcare Group LP, Norwalk, CT, USA) in the USA. The technique of blue dye injection, introduced by Morton et al., provides a means of visually identifying the small lymphatic vessels intraoperatively, allowing them to be traced to the first-echelon nodes [26]. However, the success rate of identification of SLNs by blue dye injection is less than that of radiolocalization by gamma-probe, and the technique has a steeper learning curve [65]. In a study of 55 patients with head and neck melanoma, Wells et al. reported a 67% identification rate by blue-dye mapping and 95% utilizing a combined approach [38].

While most blue dye-stained SLNs are also found to be radioactive or “hot,” a small minority of SLNs are “cold,” and proponents of blue dye injection report the facilitation of intraoperative identification [33, 49, 66]. The major perceived

disadvantages to blue dye are related to persistent cutaneous staining and masking of true surgical margins; however, rare cases of anaphylactic reactions have also been reported [67]. As a result, the use of blue dye is considered optional, though many authors employ a combined approach.

Guided by the preoperative LSG images, skin markings (if present) and the handheld gamma probe, a small skin incision (2–4 cm) is made and limited skin flaps elevated. Dissection is carried through the superficial fascia, and is guided by the handheld gamma probe. If blue-stained lymphatics are visualized, these may be followed to the draining lymph node(s); if no staining is present (or dye was not used), the dissection may be guided solely by the gamma probe, which is fitted with a 14 mm diameter straight collimated probe. The angle of the probe may be gradually altered while watching or listening for a change in the counts-per-second (cps). In cases where the primary tumor site lies in close proximity to the regional lymph nodes, radioactive “shine-through” from the primary tumor site may mask the true position of the sentinel node. In these patients, the use of malleable lead plates between the injection site and the nodal basin may address this issue [26, 45, 49, 51]. All radioactive and/or blue-stained nodes are clipped and excised, and radioactivity is confirmed ex-vivo. Following excision, the remaining basin is examined with the gamma probe and no further SLNs are considered present when the residual count-rate is less than 10% that of the “hottest” excised SLN [68]. Patients undergoing SNB-assisted END may then proceed to completion neck dissection.

Pathologic Evaluation of Sentinel Nodes

Detection of metastatic disease in sentinel nodes by pathologic examination is intrinsic to the success of the procedure, and offers a number of advantages over traditional elective

neck dissection. Principally, the absolute number of lymph nodes examined is far fewer during SNB, allowing the pathologist to perform a more thorough search for micro-metastatic deposits.

Metastases, Micrometastases, and Isolated Tumor Cells

Occult metastases may be defined as those found in patients with cN0 necks, and may be subdivided into metastases (greater than 2 mm), micrometastases (≥ 0.2 mm and ≤ 2 mm), and isolated tumor cells (ITC; < 0.2 mm, single cells or small clusters, with no stromal reaction and no contact with vessel wall) according to the most recent International Union Against Cancer (UICC) classification. The relationship of this classification to the most recent AJCC Tumor-Node-Metastasis (TNM) classification of malignant tumors is illustrated in Table 16.2 [69].

In order to compare results across studies, uniform reporting standards for pathologic staging are critical. When SNB is undertaken, the designation (sn) should be added after the N category. The finding of ITCs does not upstage the cN0 neck, and should be reported as pN0 (i+)(sn) while micrometastatic disease results in upstaging and is reported as pN1 (mi)(sn). For each of the head and neck cancer types, the sequence of pathologic examination is broadly similar, and involves gross examination, bivalving of the lymph node, sectioning at predefined intervals and staining with a variety of histopathologic techniques. However, there are a number of minor differences in protocol according to the type of tumor being studied, and exact sectioning/staining protocols vary between centers. In some cases, additional techniques, such as real-time polymerase chain reaction (RT-PCR), may also be employed; these differences are briefly outlined below [70, 71].

Table 16.2 Comparison of UICC and TNM classifications of micrometastases and isolated tumor cells

Generic TNM coding for sentinel nodes	
pNX (sn)	Sentinel lymph node could not be assessed
pN0 (sn)	No sentinel node metastasis
pN1 (sn)	Sentinel node metastasis
Sentinel nodes with micrometastasis only are identified by (mi)	
pN1 (sn)(mi)	Single ipsilateral node with micrometastasis
pN2 (sn)(mi)	Multiple ipsilateral nodes with micrometastasis
SLNs with ITC are coded separately for morphological and nonmorphological techniques	
pN0 (i-)(sn)	No SLN metastasis histologically, negative morphological findings for ITC
pN0 (i+)(sn)	No SLN metastasis histologically, positive morphological findings for ITC
pN0 (mol-)(sn)	No SLN metastasis histologically, negative nonmorphological findings for ITC
pN0 (mol+)(sn)	No SLN metastasis histologically, positive nonmorphological findings for ITC

From Alkureishi LWT, Alvarez JA, Britten AJ, Gray HW, et al. Joint practice guidelines for radionuclide lymphoscintigraphy for sentinel node localization in oral/oropharyngeal squamous cell carcinoma. *Eur J Nucl Med Mol Imaging*. 2009;36(11):1915–1936. Reprinted with permission from Springer

Melanoma

The addition of immunohistochemical (IHC) techniques to standard H&E examination has been shown to increase melanoma detection rates by at least 10% [72], and a number of sectioning/staining protocols have been described in an effort to maximize detection rates while minimizing unnecessary workload. Some authors have advocated examination of only the central portion of the lymph node, based on the suggestion by Cochran et al. that the vast majority of micro-metastases occur centrally [73], while other suggested protocols have included sectioning of the entire node into 1 mm slices [74], or examination of one half of the SLN using a combination of histology and immunohistochemistry, and the other half using RT-PCR with a variety of probes [75].

RT-PCR detection of occult metastatic deposits is an attractive technique, potentially reducing the cost and labor associated with SLN evaluation. However, disadvantages include its destructive nature, and positivity rates of up to 70% in some studies [76]. False positives may be due to capsular or trabecular nevus cells, nerves, or macrophages. In a recent report by Cook et al., utilizing an extended stepwise study of bivalved nodes with immunohistochemistry, the discrepancy between detection rates using histology/IHC and RT-PCR was found to be only 3–5%. Nevertheless, the exact role of RT-PCR remains to be fully elucidated and the authors therefore recommend the routine use of their extended histology/IHC protocol, which sections deeper into the periphery of the node, until further data become available [70]. This protocol is currently recommended by the EORTC, and is illustrated in Fig. 16.3. Briefly, the sequence involves bivalving the formalin-fixed SLN, embedding in paraffin, and sectioning at 50 μm intervals to a total depth of 250 μm . Several sections are taken at each interval, and are alternately stained with H&E, S100 and/or HMB45 for IHC. Sections found positive by IHC are compared with adjacent H&E-stained sections in order to confirm the presence of viable tumor cells. “Spare” sections were stored for future use or stained with additional investigational antibodies, such as Pan Melanoma Plus (Biocarta). The use of this extended sectioning protocol results in thorough evaluation of the central 700–800 μm of each SLN, and is thought to represent the best balance between sensitivity, cost-effectiveness and pathologist workload [70].

For SCC, there remains considerable debate regarding the optimal method for sectioning SLNs. Current recommendations were formulated during the Second International Conference on Sentinel Node Biopsy in Mucosal Head and Neck Cancer in 2003, and are included in the recent joint guideline published by the European Association of Nuclear Medicine (EANM) and European Sentinel Node Trial (SENT) committee [54, 71].

Pathologist Dissection

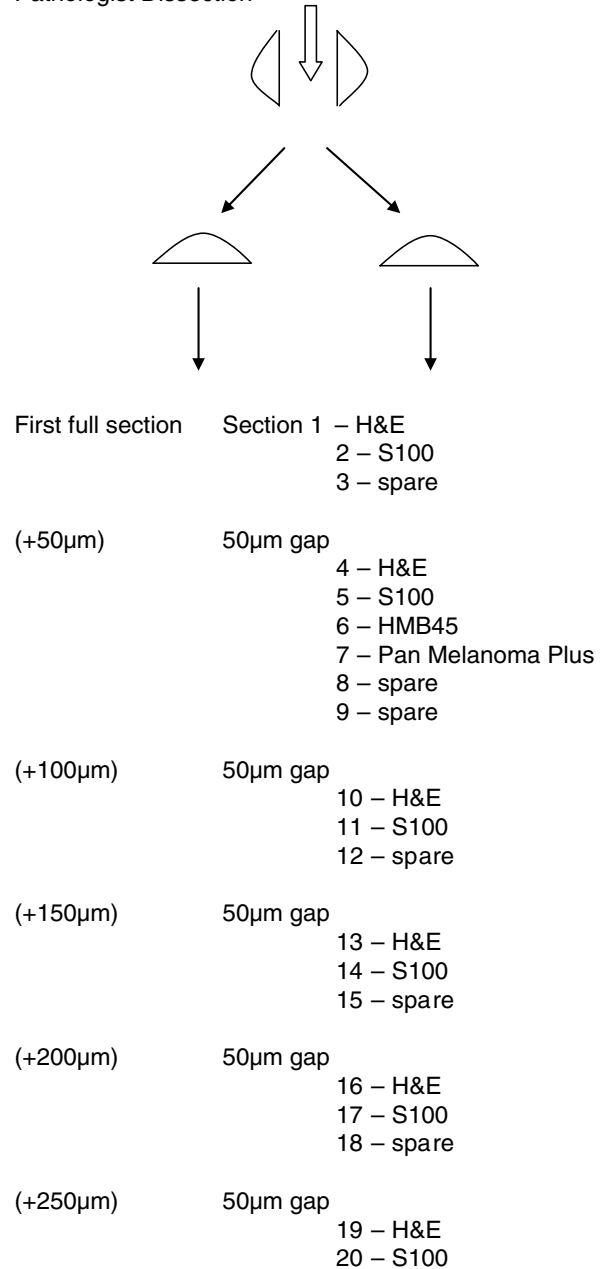


Fig. 16.3 Extended stepwise examination of bivalved SLNs with immunohistochemistry using S100 and HMB45 stains

SLNs less than 2 mm in longest dimension are processed whole while those measuring 2–5 mm should be bivalved and both halves processed en face. Nodes greater than 5 mm are cut into 2 mm slices, and each slice processed en face. A section from each slice is stained with H&E, and positive nodes/slices result in upstaging of the patient. Step-serial sectioning (SSS) at finer intervals of 150 μm (six sections per interval) should be carried out for SLNs found negative after initial sectioning, and these are H&E stained and examined as before. Finally, SLNs that remain negative are

subjected to immunohistochemical (IHC) staining with pancytokeratin antibody (AE1/AE3 or MNF116). The combination of SSS and IHC has previously been shown to detect an additional 10% of occult/micrometastatic deposits compared with H&E alone [33]. If no disease is found following H&E and IHC staining, the lymph node is considered free of tumor. For SLNs with positive IHC staining, the positive section must be compared with the immediately adjacent serial section in order to avoid false-positives due to nonviable tumor cells, artifacts and/or inclusion of other cell types [54].

The use of intraoperative frozen section analysis of SLNs offers the potential advantage of avoiding a second anesthetic for SNB-positive patients, but has traditionally been avoided due to concerns regarding freezing artifacts and loss of tissue. More recently, these views have been challenged by a number of authors who report excellent results using the technique, with only 10–17% of SNB-positive patients requiring a second procedure [35, 77, 78]. However, the technique has not yet gained universal acceptance. Novel techniques, such as imprint cytology [79] and intraoperative real-time genetic evaluation, [80] currently remain under investigation.

Merkel Cell Carcinoma

Pathologic evaluation of the sentinel nodes in MCC is similar to that of melanoma, though no standardized protocol has yet been adopted. The differences lie mainly in the type of step-serial sectioning, which varies from 2–3 mm slices [81] to 1 mm slices with multiple 200 μ m sections per slice [82], and the use of anti-CK-20 staining (Dako Corp, Carpinteria, Calif.) in place of S100/HMB-45 for immunohistochemistry. CK-20 is well established as the most sensitive and specific marker currently available for the detection of MCC [83].

The Role of SNB in Current Practice

Melanoma

Following the initial reports of SNB for cutaneous melanoma using blue dye only, technical difficulties and the significant learning curve associated with the procedure led to variable technical success rates ranging from 60 to 80% [46]. Subsequently, the introduction of radio-labeled tracer injection, preoperative LSG and intraoperative gamma-probe guidance led to significant improvements in identification rates to greater than 90%, and the use of both blue dye and radiotracers quickly gained acceptance [36, 59, 84].

Since then, the technique of SNB has been demonstrated to accurately predict the disease status of the remaining nodal basin in a number of landmark studies of cutaneous melanoma (all sites) [48, 85, 86].

The presence of metastases within SLNs has been demonstrated to be the most accurate predictor of outcome in melanoma patients without clinical lymph node involvement [87], and there is now some evidence to suggest that early lymphadenectomy following a positive SNB may confer a small but significant survival benefit over lymphadenectomy for nodal recurrence, albeit based on subgroup analysis (data from all sites) [88, 89].

As a result, SNB is now widely regarded as the gold standard for staging the lymphatic basins of intermediate-thickness melanoma patients without clinical evidence of nodal involvement [46]. The primary indication for lymph node staging in this population is a primary tumor greater than 1 mm in Breslow thickness, though SNB should also be considered for thinner tumors in the presence of high-risk features, such as ulceration, high mitotic rate, or Clark level IV/V [46, 87].

In the head and neck, the prognostic significance of sentinel node status is less clear, with SLN-negative patients demonstrating a 5-year disease-free survival rate of only 55% in one report. In their review of the existing head and neck melanoma literature, the authors noted false-negative rates in excess of 10% in 12 of 21 studies, and suggested that this high false-negative rate may contribute to the poor survival they observed in their series [90]. Similar results were described in the large Sunbelt Melanoma Trial, where false-negative rates were 12% for the head and neck, compared with 2–3% for other sites [37]. However, this view has been challenged by Civantos et al., who contended that surgeons with a subspecialty focus on the head and neck may achieve negative predictive values comparable to the 98.2% for cutaneous malignancies and 92% for oral cancer described in their series of 106 patients with head and neck malignancy [91].

Concluding their review, Tanis et al. stated that there is currently no conclusive survival advantage for either elective lymph node dissection or SNB in patients with intermediate thickness melanoma of the head and neck; however, the benefits of SNB may potentially justify its use in this patient population. These benefits include early prognostic information for patient and physician, reduced tumor load due to earlier lymphadenectomy, and the possibility of a survival advantage based on subgroup analysis [90].

A variety of micromorphometrical parameters of SN tumor deposits have been used in an attempt to determine the likelihood of further disease in the remaining nodal basin, such as tumor penetrative depth from the central plane, location within the node, and size. The potential applications for these measurements would include guidance of the decision to proceed with formal lymphadenectomy and prediction of survival.

For example, the knowledge that only 10–30% of patients with positive SLNs are found to have additional positive “non-SLN” nodes following lymphadenectomy has led some authors to suggest that formal lymphadenectomy may not be required in patients with SLN deposits <0.1 mm in size [92]. However, the promising results reported in some series have not been universally reproduced in other studies, and as a result the prognostic significance of tumor burden in the sentinel nodes has not yet been fully elucidated. In the meantime, it is recommended that all patients with detectable disease in the sentinel nodes be treated as SN-positive and offered formal lymphadenectomy [46, 75].

Future Application of SNB for Melanoma of the Head and Neck

For melanoma, SNB is well established as a staging tool for patients with intermediate thickness primary tumors, and for selected patients in other groups. The main questions now focus on the optimal management of SNB-positive patients, and this is currently unclear. The MSLT-2 trial is a prospective randomized controlled trial, comparing the outcomes of completion lymphadenectomy and observation alone for SNB-positive patients [48] while further upcoming studies aim to randomize SNB-positive patients to receive completion lymphadenectomy or therapeutic irradiation [93], and interferon-alpha alone or interferon-alpha and completion lymphadenectomy [94]. Until the results of these studies become available, the recommended management of all SLN-positive patients is completion lymphadenectomy. In addition, the differences in technical success and false negative rates for SNB in the head and neck compared with other sites suggests that the results of large-scale prospective RCTs reporting all-sites melanoma data may not be immediately applicable to the head and neck population. Therefore, similar prospective trials tailored specifically to this patient group are required before definitive conclusions regarding optimal management can be reached.

Oral/Oropharyngeal Squamous Cell Carcinoma

Validation of the SNB technique for patients with early oral/oropharyngeal SCC has, until recently, involved staging patients with SNB, followed by immediate elective neck dissection [34, 49, 95]. From these studies, it has been demonstrated that SNB may be safely and successfully applied to patients with T1 or T2 disease and cN0 necks [33, 54]. The vast majority of the tumors studied to date are located in

the oral cavity or accessible oropharynx and, while some reports do exist of SNB for other locations, such as the hypopharynx and supraglottic larynx [96], the status of the technique should remain “investigational” in these sites until further data becomes available. Furthermore, the use of SNB may be limited in patients with larger tumors which may be difficult to completely surround with tracer injections and which may ultimately require a neck dissection for tumor access or reconstruction purposes [51].

The promising results of these validation studies, demonstrating false negative rates of approximately 5%, have led some centers to over SNB as the sole staging tool for selected patients with early OSCC, with only those patients found SNB-positive going on to receive completion lymphadenectomy [33, 35].

The applications for SNB in early OSCC include staging of the ipsilateral cN0 neck, staging bilateral cN0 necks for tumors with ambiguous drainage (i.e., midline), and staging the contralateral cN0 neck for a midline tumor with an ipsilateral cN+ neck. Other applications, including the use of SNB for patients with recurrent primary tumors or following prior treatment to the neck, remain under investigation.

At the time of writing, there have been two large prospective clinical trials reported, examining SNB in this patient population [33, 35]. The interim results of a European multi-center trial involving patients from six centers were published in 2004, and demonstrated a 93% SN identification rate and 93% sensitivity in 134 patients undergoing SNB-assisted-END or SNB-alone for cT1/2 cN0 OSCC [33]. The 5-year follow-up for this population revealed one further nodal recurrence, giving an overall sensitivity of 91% at 5 years [97]. The identification rate and sensitivity were found to be significantly lower for patients with floor-of-mouth tumors, which the authors attribute to the technically challenging access to these tumors and close proximity to the first echelon lymph nodes. The authors concluded that SNB can safely be used as the sole staging tool for the majority of patients with early OSCC, but advise caution when evaluating floor-of-mouth tumors [33, 97].

Similar outcomes were reported by Stoeckli et al. in the largest single-institution series reported to date [35]. The authors reported a 98% identification rate and 94% negative predictive value in a series of 51 patients undergoing SNB alone for cT1/2, cN0 OSCC. The SENT is a large prospective study, incorporating the data from these two previous studies and several additional European centers. An interim analysis of this dataset, focusing on SLN-positive patients, was reported at 27 months of follow-up [98].

Of 72 patients (86 neck sides) undergoing completion lymphadenectomy for a positive SNB, 42% were found to harbor additional disease in the neck dissection specimen. Fifty-two percent of these additional positive nodes were located in the same neck level as the positive SLN, and only

4% were located out with the two adjacent neck levels. The authors conclude that it may be reasonable to limit therapeutic lymphadenectomies following positive SNB to three levels – one above and one below the positive SLN – potentially further reducing the morbidity associated with treatment of the neck.

Cutaneous SCC of the Head and Neck

For patients with cutaneous SCC, the rate of nodal metastasis is much lower, ranging from 0.3 to 16% [99, 100]. As a result, SNB has not been well studied in this patient group. As part of a larger series of multiple tumor types, Civantos et al. undertook SNB in a series of ten patients with “high-risk” cutaneous SCC, and detected occult nodal disease in only one patient. The authors concluded that further study is required to determine the most appropriate management strategy for these patients [91].

The Future of SNB in Oral/Oropharyngeal SCC

SNB provides the means for accurate and minimally invasive pathologic staging of the cN0 neck in patients with early OSCC. However, the exact role of SNB in the management of this patient group has yet to be fully elucidated and as a result, the technique has not yet gained universal acceptance. It is hoped that the upcoming results of the SENT trial and American College of Surgeons’ Oncology Group (ACOSOG) Z0360 validation study [101] will provide the foundations for randomized phase III studies comparing SNB-alone with elective neck dissection, which currently remains the gold standard in most centers [101].

Merkel Cell Carcinoma

MCC is a rare, highly aggressive neuroendocrine tumor arising from the Merkel mechanoreceptor of the skin. It is associated with an overall 5-year survival of 30–64%, with a high incidence of local recurrence, regional lymph node involvement, and distant metastasis [102, 103].

In part due to the rarity of this tumor, there is no consensus on the current standard of care for management. Excision of the primary tumor may require wide margins for elective local control [104], or the addition of adjuvant radiotherapy if smaller margins are used [105]. In some series, radiotherapy alone has been shown to achieve similar local control rates to primary excision [106]. Elective treatment of the lymph

nodes should be strongly considered due to reported nodal recurrence rates of up to 76% of stage I MCC patients in some series [107]. Prophylactic lymph node dissection appears to improve regional control, but does not lead to improved survival [108]. As a result, there is some disagreement regarding the utility of prophylactic node dissection in this population [82, 109].

Similarly, the utility of SNB in patients with early stage MCC is a topic of considerable debate. Advocates of the technique contend that SNB can help identify patients with occult nodal disease, demonstrate aberrant drainage patterns, and may prevent unnecessary neck dissection, parotidectomy and/or irradiation [81, 82]. In an exhaustive review of the existing literature, Mehrany et al. considered 60 patients undergoing SNB for MCC, and reported that SNB-positive patients were 18.9 times more likely to have nodal recurrence compared with SNB-negative patients after a median follow-up of 7 months [110]. Schmalbach et al. subsequently described a series of ten patients, eight of whom were found SNB-negative. After median follow-up of 34 months, nodal recurrence was observed in only one patient (12%), leading the authors to conclude that SNB is a safe and reliable technique for staging MCC [81].

However, these findings are at odd with a subsequent report by Warner et al., who found that SLN status is not an accurate predictor of locoregional recurrence in a series of 17 patients with MCC and a median follow-up of 16 months. The authors instead advocate the use of local and regional radiotherapy as a means of obtaining elective infield disease control [111]. Similarly, in a series of 23 patients undergoing SNB after previous excision of MCC, a nodal recurrence rate of 33% was noted in the SNB-negative group, leading the authors to question the prognostic value of SNB for MCC [112].

A smaller series of ten patients was recently reported by Schnayder et al., with six patients found SNB-negative. Of these, one patient developed nodal recurrence during the follow-up period (median 24 months). The authors concluded that, in this patient population with very high rates of occult micrometastatic lymph node involvement, the true utility of SNB may be ensuring that all at-risk nodes are adequately addressed, even in cases of “aberrant” drainage, e.g., to intra-parotid lymph nodes or the contralateral lymphatic basin. Furthermore, SNB may allow for accurate staging in patients who are reluctant to undergo formal lymphadenectomy [82].

As with melanoma and SCC, the true prognostic significance of submicroscopic lymph node metastases, which are reported to occur in up to 100% of MCC patients, remains unclear [113]. Further study will be required to clarify the exact role of SNB in this population.

In the USA, the National Comprehensive Cancer Network (NCCN) currently recommends SNB for all patients presenting with previously untreated, localized stage I disease (NCCN Clinical Practice Guidelines in Oncology, v.1.2004).

Complications of Sentinel Node Biopsy

The steep learning curve, technical difficulty and minimally invasive approach of SNB may potentially lead to a higher risk of complications compared with formal lymphadenectomy; principally, damage to the facial or spinal accessory nerve. In addition, the requirement for a completion lymphadenectomy in SLN-positive patients represents a second procedure in an inflamed, recently operated surgical field, theoretically contributing to the risk of iatrogenic injury [91]. However, in experienced hands the incidence of complications following SNB is reported to be as low as 1% [37, 114].

For SLNs located in the region of the parotid gland, some authors advocate careful dissection and enucleation of the sentinel nodes. However, high rates of facial nerve paresis in selected studies have led some authors to recommend superficial parotidectomy over biopsy alone [37, 115].

Summary

SNB represents a useful tool for staging the cN0 lymphatic basins in patients with selected head and neck malignancies. For patients with melanoma, SNB is widely accepted as the gold standard staging tool for patients with intermediate thickness tumors, and may also be useful for patients in other groups. However, questions remain with regards to the optimal management of SNB-positive patients and the prognostic significance of very small tumor deposits. For the management of patients with early OSCC, SNB has not yet gained universal acceptance as a sole staging tool, and the results of ongoing large prospective trials are awaited in order to better understand its true role. Finally, the prognostic value of SNB for MCC has been questioned, and its utility may ultimately be limited to improvements in staging. Sentinel node biopsy has improved staging and has led to a more appropriate selection of oncological therapies. It is essential that sentinel node biopsy be performed in oncological centers by validated teams of surgeons, pathologists and nuclear medicine physician's with rapid access to oncologists and clinical trials on site.

References

- Balch CM, Buzaid AC, Soong SJ, Atkins MB, Cascinelli N, Coit DG, et al. Final version of the American Joint Committee on Cancer staging system for cutaneous melanoma. *J Clin Oncol.* 2001;19:3635–48.
- Alvi A, Johnson JT. Extracapsular spread in the clinically negative neck (N0): implications and outcome. *Otolaryngol Head Neck Surg.* 1996;114(1):65–70.
- Poulsen M, Rischin D, Walpole E, Harvey J, Mackintosh J, Ainslie J, et al. High-risk Merkel cell carcinoma of the skin treated with synchronous carboplatin/etoposide and radiation: a trans-tasman radiation oncology group study-trog 96:07. *J Clin Oncol.* 2003;21(23):4371–6.
- Morrison WH, Peters LJ, Silva EG, Wendt CD, Ang KK, Goepfert H. The essential role of radiation therapy in securing locoregional control of Merkel cell carcinoma. *Int J Radiat Oncol Biol Phys.* 1990;19(3):583–91.
- Virchow R. *Die krankhaften Geschwülste* (3rd lesson, November 22, 1862). Berlin: August Hirschwald; 1863.
- Halsted WS. I. The results of operations for the cure of cancer of the breast performed at the Johns Hopkins Hospital from June, 1889, to January, 1894. *Ann Surg.* 1894;20(5):497–555.
- Crile G. Excision of cancer of the head and neck with special reference to the plan of dissection based on one hundred and thirty-two operations. *JAMA.* 1987;258(22):3286–93.
- Norman J, Cruse CW, Espinosa C, Cox C, Berman C, Clark R, et al. Redefinition of cutaneous lymphatic drainage with the use of lymphoscintigraphy for malignant melanoma. *Am J Surg.* 1991;162(5):432–7.
- Shah JP, Strong E, Spiro RH, Vikram B. Surgical grand rounds. Neck dissection: current status and future possibilities. *Clin Bull.* 1981;11(1):25–33.
- Robbins KT, Clayman G, Levine PA, Medina J, Sessions R, Shaha A, et al. Neck dissection classification update: revisions proposed by the American Head and Neck Society and the American Academy of Otolaryngology-Head and Neck Surgery. *Arch Otolaryngol Head Neck Surg.* 2002;128(7):751–8.
- Razaack MS, Baffi R, Sako K. Bilateral radical neck dissection. *Cancer.* 1981;47(1):197–9.
- Suarez O. El problema de las metastasis linfaticas y alejadas del cancer de laringe e hipofaringe. *Rev Otorinolaringol.* 1963;23:83–99.
- Bocca E, Pignataro O, Oldini C, Cappa C. Functional neck dissection: an evaluation and review of 843 cases. *Laryngoscope.* 1984;94(7):942–5.
- Fisch UP, Sigel ME. Cervical lymphatic system as visualized by lymphography. *Ann Otol Rhinol Laryngol.* 1964;73:870–82.
- Werner JA, Dunne A, Myers JN. Functional anatomy of the lymphatic drainage system of the upper aerodigestive tract and its role in metastasis of squamous cell carcinoma. *Head Neck.* 2003;25(4):322–32.
- Shah JP, Andersen PE. The impact of patterns of nodal metastasis on modifications of neck dissection. *Ann Surg Oncol.* 1994;1(6):521–32.
- Chepeha DB, Hoff PT, Taylor RJ, Bradford CR, Teknos T, Esclamado RM. Selective neck dissection for the treatment of neck metastasis from squamous cell carcinoma of the head and neck. *Laryngoscope.* 2002;112(3):434–8.
- Sobol S, Jensen C, Sawyer W, Costiloe P, Thong N. Objective comparison of physical dysfunction after neck dissection. *Am J Surg.* 1985;150(4):503–9.
- Pitman KT, Johnson JT, Myers EN. Effectiveness of selective neck dissection for management of the clinically negative neck. *Arch Otolaryngol Head Neck Surg.* 1997;123(9):917–22.
- Alkureishi LWT, Ross GL, MacDonald DG, Shoab T, Gray HW, Robertson AG, et al. Sentinel node in head and neck cancer: use of size criterion to upstage the N0 neck in head and neck squamous cell carcinoma. *Head Neck.* 2007;29(2):95–103.
- O'Brien CJ, Traynor SJ, McNeil E, McMahon JD, Chaplin JM. The use of clinical criteria alone in the management of the clinically negative neck among patients with squamous cell carcinoma of the oral cavity and oropharynx. *Arch Otolaryngol Head Neck Surg.* 2000;126(3):360–5.
- Rossi CR, Scagnet B, Vecchiato A, Mocellini S, Pilati P, Foletto M, et al. Sentinel node biopsy and ultrasound scanning in cutaneous melanoma: clinical and technical considerations. *Eur J Cancer.* 2000;36(7):895–900.

23. Yuen AP, Lam KY, Chan AC, Wei WI, Lam LK, Ho WK, et al. Clinicopathological analysis of elective neck dissection for N0 neck of early oral tongue carcinoma. *Am J Surg*. 1999;177(1):90–2.
24. Fisher SR. Elective, therapeutic, and delayed lymph node dissection for malignant melanoma of the head and neck: analysis of 1444 patients from 1970 to 1998. *Laryngoscope*. 2002;112(1):99–110.
25. Medina JE. Malignant melanoma of the head and neck. *Otolaryngol Clin North Am*. 1993;26(1):73–85.
26. Morton DL, Wen DR, Wong JH, Economou JS, Cagle LA, Storm FK, et al. Technical details of intraoperative lymphatic mapping for early stage melanoma. *Arch Surg*. 1992;127(4):392–9.
27. Wrightson WR, Wong SL, Edwards MJ, Chao C, Reintgen DS, Ross MI, et al. Complications associated with sentinel lymph node biopsy for melanoma. *Ann Surg Oncol*. 2003;10(6):676–80.
28. Kosuda S, Kusano S, Kohno N, Ohno Y, Tanabe T, Kitahara S, et al. Feasibility and cost-effectiveness of sentinel lymph node radiolocalization in stage N0 head and neck cancer. *Arch Otolaryngol Head Neck Surg*. 2003;129(10):1105–9.
29. Brobeil A, Cruse CW, Messina JL, Glass LF, Haddad FF, Berman CG, et al. Cost analysis of sentinel lymph node biopsy as an alternative to elective lymph node dissection in patients with malignant melanoma. *Surg Oncol Clin N Am*. 1999;8(3):435–45. viii.
30. van den Brekel MW, Stel HV, van der Valk P, van der Waal I, Meyer CJ, Snow GB. Micrometastases from squamous cell carcinoma in neck dissection specimens. *Eur Arch Otorhinolaryngol*. 1992;249(6):349–53.
31. Gershenwald JE, Colome MI, Lee JE, Mansfield PF, Tseng C, Lee JJ, et al. Patterns of recurrence following a negative sentinel lymph node biopsy in 243 patients with stage I or II melanoma. *J Clin Oncol*. 1998;16(6):2253–60.
32. van der Veen H, Hoekstra OS, Paul MA, Cuesta MA, Meijer S. Gamma probe-guided sentinel node biopsy to select patients with melanoma for lymphadenectomy. *Br J Surg*. 1994;81(12):1769–70.
33. Ross GL, Soutar DS, MacDonald DG, Shoaib T, Camilleri IG, Robertson AG, et al. Sentinel node biopsy in head and neck cancer: preliminary results of a multicenter trial. *Ann Surg Oncol*. 2004;11(7):690–6.
34. Civantos FJ, Moffat FL, Goodwin WJ. Lymphatic mapping and sentinel lymphadenectomy for 106 head and neck lesions: contrasts between oral cavity and cutaneous malignancy. *Laryngoscope*. 2006;112(3 Pt 2 Suppl 109):1–15.
35. Stoeckli SJ. Sentinel node biopsy for oral and oropharyngeal squamous cell carcinoma of the head and neck. *Laryngoscope*. 2007;117(9):1539–51.
36. Bostick P, Essner R, Sarantou T, Kelley M, Glass E, Foshag L, et al. Intraoperative lymphatic mapping for early-stage melanoma of the head and neck. *Am J Surg*. 1997;174(5):536–9.
37. Chao C, Wong SL, Edwards MJ, Ross MI, Reintgen DS, Noyes RD, et al. Sentinel lymph node biopsy for head and neck melanomas. *Ann Surg Oncol*. 2003;10(1):21–6.
38. Wells KE, Rapaport DP, Cruse CW, Payne W, Albertini J, Berman C, et al. Sentinel lymph node biopsy in melanoma of the head and neck. *Plast Reconstr Surg*. 1997;100(3):591–4.
39. Jansen L, Koops HS, Nieweg OE, Doting MH, Kapteijn BA, Balm AJ, et al. Sentinel node biopsy for melanoma in the head and neck region. *Head Neck*. 2000;22(1):27–33.
40. Dunne AA, Kulkens C, Ramaswamy A, Folz BJ, Brandt D, Lippert BM, et al. Value of sentinel lymphadenectomy in head and neck cancer patients without evidence of lymphogenic metastatic disease. *Auris Nasus Larynx*. 2001;28(4):339–44.
41. Gould EA, Winship T, Philbin PH, Kerr HH. Observations on a "sentinel node" in cancer of the parotid. *Cancer*. 1960;13:77–8.
42. Cabanas RM. An approach for the treatment of penile carcinoma. *Cancer*. 1977;39(2):456–66.
43. Weissbach L, Boedefeld EA. Localization of solitary and multiple metastases in Stage II non-seminomatous testis tumor as basis for a modified staging lymph node dissection in Stage I. *J Urol*. 1987;138(1):77–82.
44. Holmes EC, Moseley HS, Morton DL, Clark W, Robinson D, Urist MM. A rational approach to the surgical management of melanoma. *Ann Surg*. 1977;186(4):481–90.
45. Alex JC, Krag DN. Gamma-probe guided localization of lymph nodes. *Surg Oncol*. 1993;2(3):137–43.
46. Balch CM, Morton DL, Gershenwald JE, McMasters KM, Nieweg OE, Powell B, et al. Sentinel node biopsy and standard of care for melanoma. *J Am Acad Dermatol*. 2009;60(5):872–5.
47. Civantos FJ, Zitsch R, Bared A, Amin A. Sentinel node biopsy for squamous cell carcinoma of the head and neck. *J Surg Oncol*. 2008;97(8):683–90.
48. Morton DL, Cochran AJ, Thompson JF, Elashoff R, Essner R, Glass EC, et al. Sentinel node biopsy for early-stage melanoma: accuracy and morbidity in MSLT-I, an international multicenter trial. *Ann Surg*. 2005;242(3):302–11. discussion 311–3.
49. Shoaib T, Soutar DS, Prosser JE, Dunaway DJ, Gray HW, McCurrach GM, et al. A suggested method for sentinel node biopsy in squamous cell carcinoma of the head and neck. *Head Neck*. 1999;21(8):728–33.
50. Cody HS. Sentinel lymph node mapping in breast cancer. *Breast Cancer*. 1999;6(1):13–22.
51. Ross GL, Shoaib T, Soutar DS, MacDonald DG, Camilleri IG, Bessent RG, et al. The first international conference on sentinel node biopsy in mucosal head and neck cancer and adoption of a multicenter trial protocol. *Ann Surg Oncol*. 2002;9(4):406–10.
52. Tafra L, Chua AN, Ng PC, Aycock D, Swanson M, Lannin D. Filtered versus unfiltered technetium sulfur colloid in lymphatic mapping: a significant variable in a pig model. *Ann Surg Oncol*. 1999;6(1):83–7.
53. De Cicco C, Trifirò G, Calabrese L, Bruschini R, Ferrari ME, Travaini LL, et al. Lymphatic mapping to tailor selective lymphadenectomy in cN0 tongue carcinoma: beyond the sentinel node concept. *Eur J Nucl Med Mol Imaging*. 2006;33(8):900–5.
54. Stoeckli SJ, Pfaltz M, Ross GL, Steinert HC, MacDonald DG, Wittekind C, et al. The second international conference on sentinel node biopsy in mucosal head and neck cancer. *Ann Surg Oncol*. 2005;12(11):919–24.
55. Gershenwald JE, Thompson W, Mansfield PF, Lee JE, Colome MI, Tseng CH, et al. Multi-institutional melanoma lymphatic mapping experience: the prognostic value of sentinel lymph node status in 612 stage I or II melanoma patients. *J Clin Oncol*. 1999;17(3):976–83.
56. Rasgon BM. Use of low-dose technetium Tc 99m sulfur colloid to locate sentinel lymph nodes in melanoma of the head and neck: preliminary study. *Laryngoscope*. 2001;111(8):1366–72.
57. Uren RF, Howman-Giles R, Thompson JF, McCarthy WH, Quinn MJ, Roberts JM, et al. Interval nodes: the forgotten sentinel nodes in patients with melanoma. *Arch Surg*. 2000;135(10):1168–72. Chicago, IL: 1960.
58. Vidal-Sicart S, Pons F, Piulachs J, Castel T, Palou J, Herranz R. Mid-arm sentinel lymph nodes showing surprising drainage from a malignant melanoma in the forearm. *Clin Nucl Med*. 1998;23(5):273–4.
59. Alex JC. The application of sentinel node radiolocalization to solid tumors of the head and neck: a 10-year experience. *Laryngoscope*. 2004;114(1):2–19.
60. Bilde A, Von Buchwald C, Mortensen J, Marving J, Therkildsen MH, Kirkegaard J, et al. The role of SPECT-CT in the lymphoscintigraphic identification of sentinel nodes in patients with oral cancer. *Acta Otolaryngol*. 2006;126(10):1096–103.
61. Even-Sapir E, Lerman H, Lievshitz G, Khaff A, Fliss DM, Schwartz A, et al. Lymphoscintigraphy for sentinel node mapping using a hybrid SPECT/CT system. *J Nucl Med*. 2003;44(9):1413–20.
62. van der Ploeg IMC, Valdés Olmos RA, Kroon BBR, van den Brekel MW, Vogel WV, Hoefnagel CA, et al. The yield of SPECT/CT for anatomical lymphatic mapping in patients with melanoma. *Ann Surg Oncol*. 2009;16(6):1537–42.
63. Sidler SK, Stoeckli SJ, Haerle SK, Hany TF. Is there an additional value of SPECT/CT over lymphoscintigraphy for sentinel node

- mapping in oral/oropharyngeal squamous cell carcinoma? *Ann Surg Oncol.* 2009;16(11):3118–24.
64. Koljonen V, Suominen S. Sentinel node biopsy in local anaesthesia in patients with head and neck Merkel cell carcinoma. *Eur J Plast Surg.* 2007;5(30):205–10.
 65. Habib FA, Lodish ME, Mittal VK, Young SC. Sentinel lymph node dissection for primary cutaneous melanoma: a community hospital's initial experience. *Am Surg.* 2000;66(3):291–5.
 66. Shoaib T, Soutar D, MacDonald DG, Camilleri IG, Dunaway DJ, Gray HW, et al. The accuracy of head and neck carcinoma sentinel lymph node biopsy in the clinically N0 neck. *Cancer.* 2001;91(11):2077–83.
 67. Leong SP, Donegan E, Heffernon W, Dean S, Katz JA. Adverse reactions to isosulfan blue during selective sentinel lymph node dissection in melanoma. *Ann Surg Oncol.* 2000;7(5):361–6.
 68. McMasters KM, Noyes RD, Reintgen DS, Goydos JS, Beitsch PD, Davidson BS, et al. Lessons learned from the sunbelt melanoma trial. *J Surg Oncol.* 2004;86(4):212–23.
 69. Wittekind Ch, Sobin LH. *TNM classification of malignant tumours.* 6th ed. New York: Wiley; 2002.
 70. Cook MG, Green MA, Anderson B, Eggermont AMM, Ruiters DJ, Spatz A, et al. The development of optimal pathological assessment of sentinel lymph nodes for melanoma. *J Pathol.* 2003;200(3):314–9.
 71. Alkureishi LWT, Alvarez JA, Ballinger J, Bilde A, Britten AJ, Calabrese L, et al. Joint practice guidelines for radionuclide lymphoscintigraphy for sentinel node localisation in oral/oropharyngeal squamous cell carcinoma. *Eur J Nucl Med Mol Imaging.* 2009;36:1915–36.
 72. Messina JL, Glass LF, Cruse CW, Berman C, Ku NK, Reintgen DS. Pathologic examination of the sentinel lymph node in malignant melanoma. *Am J Surg Pathol.* 1999;23(6):686–90.
 73. Cochran AJ. Surgical pathology remains pivotal in the evaluation of "sentinel" lymph nodes. *Am J Surg Pathol.* 1999;23(10):1169–72.
 74. Starz H, Balda BR, Krämer KU, Büchels H, Wang H. A micromorphometry-based concept for routine classification of sentinel lymph node metastases and its clinical relevance for patients with melanoma. *Cancer.* 2001;91(11):2110–21.
 75. Scolyer RA, Murali R, McCarthy SW, Thompson JF. Pathologic examination of sentinel lymph nodes from melanoma patients. *Semin Diagn Pathol.* 2008;25(2):100–11.
 76. Bieligg SC, Ghossein R, Bhattacharya S, Coit DG. Detection of tyrosinase mRNA by reverse transcription-polymerase chain reaction in melanoma sentinel nodes. *Ann Surg Oncol.* 1999;6(3):232–40.
 77. Terada A, Hasegawa Y, Yatabe Y, Hyodo I, Ogawa T, Hanai N, et al. Intraoperative diagnosis of cancer metastasis in sentinel lymph node of oral cancer patients. *Oral Oncol.* 2008;44(9):838–43.
 78. Tschopp L, Nuyens M, Stauffer E, Krause T, Zbären P. The value of frozen section analysis of the sentinel lymph node in clinically N0 squamous cell carcinoma of the oral cavity and oropharynx. *Otolaryngol Head Neck Surg.* 2005;132(1):99–102.
 79. Asthana S, Deo SV, Shukla NK, Jain P, Anand M, Kumar R. Intraoperative neck staging using sentinel node biopsy and imprint cytology in oral cancer. *Head Neck.* 2003;25(5):368–72.
 80. Hamakawa H, Onishi A, Sumida T, Terakado N, Hino S, Nakashiro KI, et al. Intraoperative real-time genetic diagnosis for sentinel node navigation surgery. *Int J Oral Maxillofac Surg.* 2004;33(7):670–5.
 81. Schmalbach CE, Lowe L, Teknos TN, Johnson TM, Bradford CR. Reliability of sentinel lymph node biopsy for regional staging of head and neck Merkel cell carcinoma. *Arch Otolaryngol Head Neck Surg.* 2005;131(7):610–4.
 82. Shnyder Y, Weed DT, Arnold DJ, Gomez-Fernandez C, Bared A, Goodwin WJ, et al. Management of the neck in Merkel cell carcinoma of the head and neck: University of Miami experience. *Head Neck.* 2008;30(12):1559–65.
 83. Sian SU, Wagner JD, Sood R, Park HM, Havlik R, Coleman JJ. Lymphoscintigraphy with sentinel lymph node biopsy in cutaneous Merkel cell carcinoma. *Ann Plast Surg.* 1999;42(6):679–82.
 84. Albertini JJ, Cruse CW, Rapaport D, Wells K, Ross M, DeConti R, et al. Intraoperative radio-lympho-scintigraphy improves sentinel lymph node identification for patients with melanoma. *Ann Surg.* 1996;223(2):217–24.
 85. Wagner JD, Corbett L, Park HM, Davidson D, Coleman JJ, Havlik RJ, et al. Sentinel lymph node biopsy for melanoma: experience with 234 consecutive procedures. *Plast Reconstr Surg.* 2000;105(6):1956–66.
 86. Yee VSK, Thompson JF, McKinnon JG, Scolyer RA, Li LL, McCarthy WH, et al. Outcome in 846 cutaneous melanoma patients from a single center after a negative sentinel node biopsy. *Ann Surg Oncol.* 2005;12(6):429–39.
 87. Amersi F, Morton DL. The role of sentinel lymph node biopsy in the management of melanoma. *Adv Surg.* 2007;41:241–56.
 88. Morton DL, Thompson JF, Cochran AJ, Mozzillo N, Elashoff R, Essner R, et al. Sentinel-node biopsy or nodal observation in melanoma. *N Engl J Med.* 2006;355(13):1307–17.
 89. Hammond R, Rosenbaum P, Guerry D, Gimotty PA, Yoon F. Sentinel lymph node biopsy (slnb) improves survival among seer patients with melanoma. *J Clin Oncol.* 2008;26(May 20 Supplement):(abstract 9005).
 90. Tanis PJ, Nieweg OE, van den Brekel MW, Balm AJM. Dilemma of clinically node-negative head and neck melanoma: outcome of "watch and wait" policy, elective lymph node dissection, and sentinel node biopsy – a systematic review. *Head Neck.* 2008;30(3):380–9.
 91. Civantos FJ, Zitsch R, Bared A. Sentinel node biopsy in oral squamous cell carcinoma. *J Surg Oncol.* 2007;96(4):330–6.
 92. van Akkooi ACJ, de Wilt JHW, Verhoef C, Schmitz PI, van Geel AN, Eggermont AMM, et al. Clinical relevance of melanoma micrometastases (<0.1 mm) in sentinel nodes: are these nodes to be considered negative? *Ann Oncol.* 2006;17(10):1578–85.
 93. Bonnen MD, Ballo MT, Myers JN, Garden AS, Diaz EM, Gershenwald JE, et al. Elective radiotherapy provides regional control for patients with cutaneous melanoma of the head and neck. *Cancer.* 2004;100(2):383–9.
 94. Pu LLQ, Wells KE, Cruse CW, Shons AR, Reintgen DS. Prevalence of additional positive lymph nodes in complete lymphadenectomy specimens after positive sentinel lymphadenectomy findings for early-stage melanoma of the head and neck. *Plast Reconstr Surg.* 2003;112(1):43–9.
 95. Stoeckli SJ, Steinert H, Pfaltz M, Schmid S. Sentinel lymph node evaluation in squamous cell carcinoma of the head and neck. *Otolaryngol Head Neck Surg.* 2001;125(3):221–6.
 96. Werner JA, Dünne AA, Ramaswamy A, Dalchow C, Behr T, Moll R, et al. The sentinel node concept in head and neck cancer: solution for the controversies in the N0 neck? *Head Neck.* 2004;26(7):603–11.
 97. Alkureishi LW, Shoaib T, Soutar DS, Robertson AG, Sorensen JA, Thomsen J, et al. Sentinel node biopsy for head and neck cancer: 5 year follow up of a multicentre trial. Presented at the 3rd international conference on sentinel node biopsy in head and neck cancer, Miami, 2008.
 98. Ross GL, on behalf of the Sentinel European Node Trial organizing committee. Sentinel node biopsy for squamous cell carcinoma of the oral cavity: preliminary results of the sent trial. Presented at the annual meeting of the American Head and Neck Society (AHNS), San Francisco, 2008.
 99. Kraus DH, Carew DF, Harrison LB. Regional lymph node metastasis from cutaneous squamous cell carcinoma. *Arch Otolaryngol Head Neck Surg.* 1998;124(5):582–7.
 100. Dinehart SM, Pollack SV. Metastases from squamous cell carcinoma of the skin and lip. An analysis of twenty-seven cases. *J Am Acad Dermatol.* 1989;21(2 Pt 1):241–8.
 101. Bared A, Civantos FJ, Werner JA. Sentinel node biopsy in cancer of the oral cavity. *Oper Tech Otol Head Neck Surg.* 2005;16(4):275–85.

102. Wasserberg N, Feinmesser M, Schachter J, Fenig E, Gutman H. Sentinel-node guided lymph-node dissection for Merkel cell carcinoma. *Eur J Surg Oncol*. 1999;25(4):444–6.
103. Dancy AL, Rayatt SS, Soon C, Ilchshyn A, Brown I, Srivastava S. Merkel cell carcinoma: a report of 34 cases and literature review. *J Plast Reconstr Aesthet Surg*. 2006;59(12):1294–9.
104. Yiengpruksawan A, Coit DG, Thaler HT, Urmacher C, Knapper WK. Merkel cell carcinoma, prognosis and management. *Arch Surg*. 1991;126(12):1514–9. Chicago, IL: 1960.
105. Shaw JH, Rumball E. Merkel cell tumour: clinical behaviour and treatment. *Br J Surg*. 1991;78(2):138–42.
106. Mortier L, Mirabel X, Fournier C, Piette F, Lartigau E. Radiotherapy alone for primary Merkel cell carcinoma. *Arch Dermatol*. 2003;139(12):1587–90.
107. Suntharalingam M, Rudoltz MS, Mendenhall MN, Parsons JT, Stringer JP, Million RR. Radiotherapy for Merkel cell carcinoma of the skin of the head and neck. *Head Neck*. 1995;17(2):96–101.
108. Gillenwater AM, Hessel AC, Morrison WH, Burgess M, Silva EG, Roberts D, et al. Merkel cell carcinoma of the head and neck: effect of surgical excision and radiation on recurrence and survival. *Arch Otolaryngol Head Neck Surg*. 2001;127(2):149–54.
109. Poulsen M. Merkel-cell carcinoma of the skin. *Lancet Oncol*. 2004;5(10):593–9.
110. Mehrany K, Otley KC, Weenig RH, Phillips PK, Roenigk RK, Nguyen TH. A meta-analysis of the prognostic significance of sentinel lymph node status in Merkel cell carcinoma. *Dermatol Surg*. 2002;28(2):113–7.
111. Warner RE, Quinn MJ, Hruby G, Scolyer RA, Uren RF, Thompson JF. Management of Merkel cell carcinoma: the roles of lymphoscintigraphy, sentinel lymph node biopsy and adjuvant radiotherapy. *Ann Surg Oncol*. 2008;15(9):2509–18.
112. Maza S, Trefzer U, Hofmann M, Schneider S, Voit C, Krössin T, et al. Impact of sentinel lymph node biopsy in patients with Merkel cell carcinoma: results of a prospective study and review of the literature. *Eur J Nucl Med Mol Imaging*. 2006;33(4):433–40.
113. Victor NS, Morton B, Smith JW. Merkel cell cancer: is prophylactic lymph node dissection indicated? *Am Surg*. 1996;62(11):879–82.
114. Ross GL, Shoab T, Scott J, Soutar DS, Gray HW, MacKie R. The learning curve for sentinel node biopsy in malignant melanoma. *Br J Plast Surg*. 2002;55(4):298–301.
115. Eicher SA, Clayman GL, Myers JN, Gillenwater AM. A prospective study of intraoperative lymphatic mapping for head and neck cutaneous melanoma. *Arch Otolaryngol Head Neck Surg*. 2002;128(3):241–6.

Chapter 17

Approaches to Supportive Care

Barbara A. Murphy

Abstract Head and neck cancer is associated with substantial symptom and function loss. It is critical to understand the depth and breadth of issues face by patients in order to maximize quality of life. Symptoms and functional deficits may be secondary to either the cancer or its treatment. The mechanism of toxicity varies depending on the extent of tumor involvement, the site of tumor, treatment modality, and host factors. Toxicity is usually categorized as acute (occurring within 3 months of therapy) or late (occurring 3 months or after therapy). In addition, it is also important to distinguish local versus systemic toxicities. Although head and neck cancer therapy is associated with significant system effects, data pertaining to these toxicities are lacking. Thus, this chapter reviews the selected critical supportive care issues localized to the head and neck region. This includes: mucositis, nutrition, dysphagia, xerostomia and hyposalivation, oral health issues, and radiation dermatitis.

Keywords Head and neck cancer • Symptoms • Function • Pain • Mucositis • Nutrition • Dysphagia • Xerostomia • Trismus • Dental • Sialorrhea • Dermatitis

Introduction

Head and neck cancer and its treatment are associated with clinically significant symptom burden, alterations in function, and decrease in quality of life [1]. Due to the frequent compromise of structures which are critical for functions such as speech, swallowing, and breathing, supportive care has always been a critical albeit underappreciated component of head and neck cancer therapy. More recently, the role of supportive care has been highlighted due to a number of

issues, including: the increased use of aggressive combined modality therapies which are associated with an increase in acute and late effects, the increasing numbers of survivors who are living with the late effects of therapy, and the recognition that without appropriate management, the cost of acute and late effects to both the patient and society can be staggering.

Mechanism of Toxicity

Acute Tissue Damage

Normal tissues may be damaged by either cancer or its treatment. Surgical damage results from removal of the cancer and a surrounding rim of normal tissue. The degree to which surgical resection causes morbidity is related to the amount of tissue removed, the site of the tissue removed, and the ability to use reconstructive techniques to ameliorate the effect of normal tissue loss. Vascular and neurologic damage may contribute to surgical morbidity. Radiation therapy results in DNA and non-DNA damage to tissues within the radiation therapy port. The tissue damage initiates a sequence of biologic pathways that are involved in wound healing and tissue repair. In addition, both surgery and radiation may be associated with systemic effects [2] such as fatigue, deconditioning, pain, and altered mental status. These systemic effects of therapy are in part the result of: (1) proinflammatory cytokines and chemokines released as a component of acute tissue inflammation, (2) the humoral and neurologic stress response, and (3) drug-related toxicities.

Late Tissue Damage

Tissues damage by surgery or radiation must undergo repair. During the repair process, damaged tissue may be replaced by normal functioning tissue. Alternatively, tissue repair

B.A. Murphy (✉)
Pain and Symptom Management Program, Internal Medicine,
Vanderbilt Ingram Cancer Center, 777 Preston Research Blvd,
Nashville, TN 37215, USA
e-mail: barbara.murphy@vanderbilt.edu

mechanisms may cause replacement of normal tissue with fibrotic tissue. Fibrosis results from a chronic inflammatory process that involves growth factors, proteolytic enzymes, angiogenic factors, and fibrogenic cytokines [3]. It is manifested by excessive deposits of extracellular matrix by fibroblasts with resultant abnormal tissue architecture. There are three histopathologic phases of fibrosis: (1) chronic inflammation without fibrosis, (2) active fibrosis with dense myofibroblasts, and (3) late fibrosis with associated atrophy and decrease in parenchymal cells [4]. Tissues become noncompliant, contracted, and atrophic resulting in altered function and significant symptom burden. Thus, fibrosis plays a critical role in the development and manifestations of late tissue damage in the head and neck cancer population.

Specific Acute and Late Effects of Therapy

Mucositis

Mucositis is a process that results from chemotherapy and radiation-induced damage to the mucosa and underlying soft tissue. Recent studies have helped to elucidate the complex biologic mechanism underlying the tissue repair response and its associated manifestations [5, 6]. The clinical hallmarks of mucositis are erythema and ulceration of the mucous membranes. In addition, the underlying soft tissue may become swollen and edematous. There are a number of systems that have been used to grade mucositis (Table 17.1), the most frequently used systems are the Common Toxicity Criteria and the World Health Organization (WHO) Toxicity Criteria. The Common Terminology for Adverse Events 3.0

contains two separate criteria for grading mucositis: (1) direct visualization of lesions and (2) assessment of the functional impact of mucositis. The WHO criteria combine symptoms, function, and mucosal pathology into one single measure. Thus, it should be noted that there may be differences in how patients' mucositis is graded based on the toxicity criteria used. Unfortunately, underreporting of the frequency and severity of mucositis by health care providers is common. To avoid some of the pitfalls associated with health care provider for mucositis assessment, a number of tools have been developed which use patient-reported outcomes to measure mucositis severity and symptom burden. The most commonly used tool is the Oral Mucositis Questionnaire Head and Neck (Daily and Weekly versions). Originally developed for use in the transplant setting, the OMQ-HN has been demonstrated to be a valid and reliable tool for assessment of mucositis-related symptom burden [7]. The questionnaire focuses on mucositis-related pain and function loss.

The risk for the development of mucositis is highly variable and is based on a number of predictive factors. It has long been known that primary site, radiation dose, radiation schedule, and port size correlate with the extent and severity of mucositis [8, 9]. Although radiation parameters are clearly important, the most powerful predictor for the development of severe mucositis is the use of concurrent chemotherapy. In a retrospective review of 33 clinical treatment trials, Trotti reported that the incidence of grade 3 and 4 mucositis rose from 25 to 40% with radiation therapy alone to 60–100% in patients treated with chemoradiation [10]. In addition to an increase in the incidence of oral mucositis, the use of concurrent chemoradiation has been noted to increase the duration of mucositis [9]. Although tumor and treatment-related factors clearly predict mucositis outcomes, the role of patient

Table 17.1 Mucositis scoring systems

	1	2	3	4	5
WHO [110]	Erythema and soreness; no ulcers	Ulcers; able to eat a solid diet	Ulcers; requires a liquid diet	Ulcers; not able to tolerate a solid or liquid diet; requires IV of tube feeding	NA
CTCAE v 3.0 [111] (clinical exam)	Erythema	Patchy ulcerations or pseudomembranes	Confluent ulcerations or pseudomembranes	Tissue necrosis; significant spontaneous bleeding, life-threatening	Death
CTCAE v 3.0 (functional-symptomatic)	Minimal symptoms; normal diet; minimal respiratory symptoms but not interfering with function	Symptomatic but can eat and swallow modified diet; respiratory symptoms interfering with function but not with ADL	Symptomatic and unable to adequately aliment or hydrate orally; respiratory symptoms interfering with ADL	Symptoms associated with life-threatening consequences	Death

WHO World Health Organization, CTCAE 3.0 Common Terminology Criteria for Adverse Events

characteristics remains unclear. Numerous patient-related factors have been studied, yet epidemiologic data is lacking to clearly link mucositis outcomes with specific demographic factors [11]. The contribution of genetics factors is unknown at this time.

Mucositis-related symptoms usually begin to manifest themselves within 2–3 weeks after radiation therapy is initiated. Initial complaints include throat irritation and pain on swallowing. By week 5 of radiation, mucosal lesions have worsened substantially leading to moderate-to-severe pain. Unfortunately, mucositis-related pain is often refractory to opioid analgesics. Physical exam findings and symptoms usually peak within 2–3 weeks of completing therapy and gradually subsides thereafter. It is not uncommon for symptoms and ulcerative lesions to persist for 2–3 months after radiation therapy is completed. Occasionally, patients with developed ulcerative lesions fail to heal or heal over a protracted period of time. In this population, hyperbaric oxygen therapy or treatment with pentoxifylline may be attempted, however, data confirming efficacy is lacking.

Mucositis results in a number of adverse outcomes [12]. First and foremost, severe mucositis results in treatment breaks that may compromise disease control and survival [9, 10]. Second, mucositis is associated with significant symptom burden and alterations in function. The most common mucositis-related symptom is pain. Pain results in decreased speaking, swallowing, eating, and oral care [7]. Pain is worse on swallowing, thus leading to decreased oral intake [13]. For many patients, the pain becomes severe enough that adequate oral alimentation is not possible and a feeding tube is required. Data from the Longitudinal Oncology Registry for Head and Neck Cancer indicated that feeding tubes were placed in 59% of patients at academic centers and 48% of patients at community centers within the USA ($p=0.001$) [14]. Finally, mucositis results in an increase in the use of health care resources and associated increased cost of care [15]. The cost differential between patients with and without radiation-induced mucositis is variable based on the patient population and the severity of the mucositis. For patients with severe mucositis, the cost increment has been reported between \$6,000 [9] and \$18,000 [16].

Due to the high cost, investigators have attempted to identify effective preventive and treatment strategies for radiation-induced oral mucositis. A wide array of treatment interventions has been tested. To date, none have clearly demonstrated a marked impact on the incidence or duration of grade 3 and 4 mucositis. The Multinational Association for Supportive Care in Cancer has a standing committee that has developed and updated an evidence-based guideline for the treatment, prevention, and palliation of mucositis. Their recommendations include the following: oral care

protocols, adequate use of pain medications, and the use of conformation radiation techniques to minimize mucosal injury. Updated recommendations can be found on their Web site at www.mascc.org.

Swallowing Abnormalities

Dysphagia is one of the most common and concerning sequelae of head and neck cancer and its therapy. The normal swallowing mechanism is complex, requiring coordination of over 25 pairs of muscles [17], as well as an intact nervous system that mediates both voluntary and involuntary swallowing maneuvers [18]. The four phases of swallowing are: (1) the oral preparatory phase (food bolus formation), (2) the oral phase (bolus transported to the pharynx), (3) the pharyngeal phase (reflex closure of the larynx to prevent aspiration, coordinated contraction of the pharyngeal constrictors, and relaxation of the cricopharyngeus muscles) [19, 20], and (4) the esophageal phase (peristalsis of bolus into the stomach). Abnormalities in any of the above functions may result in clinically meaningful dysphagia.

Symptoms that indicate the presence of dysphagia are listed in Table 17.2. When dysphagia is suspected, a formal functional assessment is indicated. The clinical evaluation of swallowing (CES), which should be performed by an experienced Speech-Language Pathologists (SLP) [21], includes the following components: (1) identification of swallowing abnormalities, (2) recommendations for additional testing, (3) development of a treatment plan when indicated, (4) consultation with dietitians to develop a nutritional plan that is safe, and (5) assessment of aspiration risk. The SLP may recommend instrumental studies to assess swallowing function. The modified barium swallow study (MBSS) is a video-fluoroscopic exam of the oral and pharyngeal function that identifies swallowing impairments and aspiration [22]. Food boluses of differing sizes and consistencies are assessed

Table 17.2 Triggers for dysphagia evaluation [112, 113]

-
- Inability to control food, liquids, or saliva in the oral cavity
 - Pocketing of food in cheek
 - Excessive chewing
 - Drooling
 - Coughing, choking, or throat clearing before, during, or after swallowing
 - Abnormal vocal quality after swallowing – “wet” or “gurgly” voice
 - Build-up or congestion after a meal
 - Complaint of difficulty swallowing
 - Complaint of food “sticking” in throat
 - Nasal regurgitation
 - Weight loss
-

leading to appropriate dietary recommendations as well as testing of compensatory measures that may enhance swallow efficacy and safety. Standard compensatory measures include postural techniques, increased sensory input, and voluntary swallowing maneuvers. In addition, direct visualization of the structures and functioning of the pharynx and larynx can be done using the Flexible Endoscopic Evaluation (FEES) [23] allowing identification of issues such as: (1) premature spillage, (2) pooling, (3) laryngeal penetration, (4) aspiration, and (5) laryngopharyngeal reflux [24].

Dysphagia related to physiologic damage by an infiltrative cancer may be present at the time of diagnosis; however, it is more commonly due to the acute and late effects of surgery and radiation therapy. Resection of structures that are critical for normal swallowing function or surgically induced neurologic damage may result in postoperative dysphagia. Studies have demonstrated that the extent of dysfunction correlates with the site and extent of tissue resected [25, 26]. Acutely, postoperative dysphagia may be exacerbated by tissue edema and pain, while long-term tissue fibrosis and scar may contribute to persistent or deteriorating swallow function over time.

Acute dysphagia secondary to radiation therapy induced tissue damage manifested by painful mucositis, soft tissue edema, and thick mucous production. As the soft tissues and mucosa heal, scarring may take place resulting in the formation of fibrotic, noncompliant tissues [3]. Fibrosis may result in altered function including abnormal swallowing. Eisbruch identified “dysphagia/aspiration-related structures” (DARS) [27]. When these structures sustain acute and chronic damaged secondary to radiation, patients are at high risk for dysphasia and aspiration. Minimizing radiation to these structures using radiation techniques such as intensity modulated radiation therapy (IMRT) has been shown to improve swallowing outcomes [28, 29]. It should be noted that the use of concurrent chemotherapy with radiation therapy is associated with an increase of acute mucosal and soft tissue damage [30]. Although the relationship remains difficult to prove [31], increased acute toxicities are postulated to result in increased late effects; thus, explaining the clinical observation that patients receiving aggressive CCR regimens have a higher incidence of late effect dysphagia and long-term feeding tube dependence.

Stricture formation is an extreme fibrotic process which is generally noted in the upper esophagus. It may contribute to or be wholly responsible for a patient’s dysphagia. The majority of patients with upper esophageal stricture formation received high doses (>60 Gy) of radiation to the involved structures [32]. The use of concurrent chemoradiation does appear to increase the risk for strictures [33]. Usually identified on MBSSs, strictures may be treated with endoscopic balloon dilatation. Data would indicate that this technique is

successful in a high percentage of patients; however, repeat dilation is often required [34].

There are numerous sequelae of dysphagia, of which aspiration is the most concerning. Acutely, aspiration may result in pneumonia. In the head and neck population, particularly those receiving particularly myelosuppressive chemotherapy, pneumonia has been associated with significant morbidity and mortality [35]. Long-term chronic aspiration can result in pulmonary fibrosis and permanent lung damage [36]. Moderate dysphagia may result in altered dietary intake. In some patients, this may lead to poor diet quality and dietary inadequacies [37, 38]. Patients with severe dysphagia and/or aspiration may require a permanent feeding tube in order to ensure adequate and safe nutritional intake [31]. Predictive factors for long-term feeding tube dependence includes: oro/hypopharyngeal primaries, stage III/IV disease, flap reconstruction, current tracheotomy, chemotherapy or increased age [39].

Nutrition

Nutrient intake is often compromised in head and neck cancer patients’ either due to symptoms from their cancer or its treatment. Factors that may contribute to malnutrition include: (1) alimentary track obstruction or dysfunction, (2) radiation-induced acute effects such as mucositis, mucous production, and tissue edema, (3) chemotherapy side effects such as anorexia, nausea, and vomiting, (4) a history of substance abuse with associated nutrient deficiencies, (5) socioeconomic factors that inhibit patients from obtaining nutritionally replete diet or supplements, and (6) cancer cachexia syndrome with associated metabolic abnormalities that favor proteolysis. Overall, malnutrition is seen in 30 and 50% [40, 41] of head and neck patients; however, the numbers are substantially higher in patients with locally advanced disease [42, 43]. Weight loss is associated with numerous adverse outcome measures including: surgical complications [40], immune function [40], survival [41, 44, 45], and quality of life [45]. Thus, ongoing nutritional assessment is critical in all patients with head and neck cancer.

At diagnosis, a baseline nutritional assessment is vital for all head and neck cancer patients [46, 47]. This should include an accurate weight, weight loss history, and identification of barriers to adequate nutritional intake. Patients with a stable weight and adequate oral intake may be monitored prospectively. Patients with critical weight loss (see Table 17.3) should be seen by a dietician in order to generate an appropriate nutritional plan. Basal energy expenditure (BEE) can be calculated using the Harris Benedict equation [48] which takes weight, height, and age into consideration.

Table 17.3 Definition of critical weight loss [114]

Cumulative weight loss and time course		
Time course	Significant weight loss (%)	Severe weight loss (%)
1 week	≤2	>2
1 month	≤5	>5
3 months	≤7.5	>7.5
6 months	≤10	>10

Of note, the physiologic stress of therapy may substantially increase a patient's caloric requirement. This should be taken into account when counseling patient regarding caloric and protein goals.

$$\text{Men: BEE} = 66.5 + (13.75 \text{ kg}) + (5.003 \text{ cm}) - (6.775 \times \text{age}),$$

$$\text{Women: BEE} = 655.1 + (9.563 \text{ kg}) + (1.850 \text{ cm}) - (4.676 \times \text{age}).$$

The placement of a feeding tube may be necessary in order to ensure adequate nutritional intake. In the postoperative population, a nasogastric tube may be used in patients who are expected to have dysphagia of limited duration. For those patients who are expected to have protracted or permanent dysphagia, a percutaneous endoscopic gastrostomy (PEG) tube is usually placed [49, 50]. The role of feeding tubes in patients undergoing radiation therapy remains controversial. It is clear that radiation therapy results in painful mucositis, edema, and mucous, which decreases intake and contributes to treatment-associated weight loss. Reports indicate that the weight loss associated with radiation therapy is as high as 10% [51]. Data clearly demonstrate that the use of prophylactic feedings tubes reduces weight loss during and immediately after radiation therapy has been completed [52, 53]. Furthermore, the complication rate is low and most complications are generally minor [54]. However, there is concern that feeding tubes result in disuse atrophy and late effect dysphagia [31, 50]. Regardless of when a feeding tube is placed, posttube placement patients should be encouraged to continue to swallow as tolerated, to comply with swallowing exercises, and to wean off the feeding tube as quickly posttreatment as is feasible.

Once placed, the health care team work with the patient and caregiver to ensure that an appropriate nutritional plan is established and followed. It is important to recognize that the placement of a feeding tube does not in and of itself guarantee adequate caloric intake. The proper use and maintenance of a PEG or NG tube is complex and requires proper education and training. The patient's ability to master the use of feeding tube may be diminished by mental status changes, generalized weakness, and debility. Caregivers frequently spend considerable time helping in the care of head and neck cancer patients with feeding tubes [55].

Feeding tubes are associated with a number of management challenges. One of the most common issues difficult to

achieve is the intake of the desired amount of formula. This is often secondary to gastrointestinal dysmotility. Dysmotility may result from medications (such as opioids), electrolyte imbalance, decrease in activity level, dehydration, and the physiologic stress response. Symptoms of dysmotility include: nausea and vomiting, early satiety, and bloating. Prokinetic agents such as metaclopramide can increase gastric motility and ameliorate symptoms. Tubes must be inspected routinely to evaluate for infection, dermal irritation, leakage around the tube, and damage to the tube which requires repair or replacement.

Upon completing therapy, patients should be encouraged to transition to oral nutrition as quickly as possible. That being said, many patients experience late effect dysphagia. For some patients, dysphagia is of sufficient severity that oral alimentation is not feasible; thus leading to long term or permanent feeding tube dependence. For others, dysphagia may be less severe, resulting in altered food choices. The dietary adaptations that patients make in order to maintain an oral diet may be adaptive or maladaptive depending on the resulting nutrient intake. When dietary adaptations result in dietary inadequacies, supplementation is indicated. It should be noted that dysphagia associated with nutritional deficiencies may persist long term; thus, ongoing and periodic assessment by a dietician should be included in routine follow-up for head and neck cancer patients [37, 56].

Cachexia refers to a hypermetabolic state that is associated with proinflammatory cytokines [57]. It is associated with a number of symptoms including: anemia, weight loss, weakness, muscle, and fat wasting [58, 59]. Anorexia, which results from the loss of balance in the peripheral and central orexigenic and anorexigenic hormonal and neuropeptide signals, commonly occurs in patients undergoing active treatment and those with advanced disease [60]. To date, there is no convincing evidence for efficacy of any pharmacologic intervention for the treatment of cachexia. The French National Federation of Cancer Centers [61] has recommended the use of megestrol acetate, corticosteroids, and medroxyprogesterone for the treatment of anorexia. Data on the use of these agents in head and neck cancer are limited. In one randomized trial in patients treated with chemoradiation, the use of megace is increased appetite ($p=0.0001$) and resulted in decrease of weight loss [62].

Xerostomia and Hyposalivation

Xerostomia is the patient-reported symptom of dry mouth; hyposalivation is defined as a decrease in stimulated and/or unstimulated salivary flow. The normal unstimulated salivary flow is 0.3–0.5 ml/min and the normal stimulated flow rates

are 1–2 ml/min. CTCAE 3.0 criteria for xerostomia and hyposalivation are as follows: grade 1 – symptomatic (dry or thick saliva) without significant dietary alterations or unstimulated flow rate of >0.2 ml/min; grade 2 – symptomatic and significant oral intake alterations (e.g., copious water, other lubricants, diet limited to purees and/or soft, and moist foods) or unstimulated flow rate of 0.1–0.2 ml/min; Grade 3 symptoms lead to inability to adequately aliment orally, IV fluids, tube feedings, or TPN indicated or unstimulated flow rate of <0.1 ml/min. While xerostomia is associated with discomfort and decreased quality of life [63–65], hyposalivation has been associated with a number of adverse oral health outcomes. Of note, the correlation between the subjective symptom of xerostomia and the objective measure of hyposalivation may be poor; thus, it is important to assess both outcome parameters.

Saliva is a complex fluid of electrolytes, secretory proteins, and organic molecules [66]. It serves numerous physiologic functions that are integral to oral health including the following: lubrication of the mucous membranes, maintenance of the mucous membranes, aids in soft tissue repair, direct antibacterial effects, antiviral and antifungal effects, maintenance of pH, and maintenance of dental integrity [67]. Hyposalivation may result in increased symptom burden and functional loss (voice, swallowing, and sleep disturbance) as well as diminished oral health [68–72].

Although xerostomia and hyposalivation may be caused by a number of etiologic factors in the head and neck cancer population, the leading cause is radiation therapy induced damage to the salivary glands. Most patients note the development of symptoms within 2–3 weeks of initiating therapy [73]. Once therapy is completed, salivary gland function may return slowly over time. The severity of symptoms is related to the volume of salivary gland radiated [74]. Studies have shown that salivary gland damage is at least partially reversible when the total dose is 2,500–3,000 cGy. Above that dose, xerostomia may be permanent. Thus, considerable research has been conducted to identify methods to prevent or limit radiation-induced xerostomia and hyposalivation.

Approaches for the prevention of salivary gland damage from radiation therapy include: (1) surgical transplantation of the salivary glands out of the radiation port, (2) radiation techniques to minimize radiation-induced damage, and (3) pharmacologic techniques to prevent tissue damage. Salivary gland transfer is a technique during which the parotid gland is surgically transplanted to the submental space where it is shielded from radiation. Although numerous studies have demonstrated that this is a feasible and effective technique [75], it has not been broadly adopted. This may be due to the rapid increase in the use of IMRT as an alternative tissue sparing approach. Several pharmacologic agents have been investigated to determine their

capacity as cytoprotective agents in patient receiving radiation therapy to the salivary glands. The most extensively studied agent is amifostine, a free radical scavenger. In a meta-analysis conducted by Sasse, amifostine was shown to modestly decrease acute and late effect xerostomia [76]. Furthermore, several small studies demonstrated that the use of amifostine resulted in improved dental outcomes [77, 78]. Use of IV amifostine was limited due to toxicity including nausea, vomiting, and hypotension. This led to the evaluation of subcutaneous administration which proved to be equally effective to IV administration but substantially less toxic [79]. Pilocarpine has also been evaluated as a potential cytoprotective agent to prevent radiation-induced xerostomia [80]. RTOG 97-09 randomized 245 patients with a planned radiation dose of ≥ 50 Gy to the oral cavity/pharynx to either pilocarpine or placebo. Patients receiving pilocarpine had a significant increase in unstimulated salivary flow post treatment and at week 13. No improvement was noted in stimulated salivary flow rates or QOL measures [81]. No oral health outcomes were reported.

Finally, intensity modulated radiotherapy (IMRT) is a technique that allows radiation to be directed at the tumor while minimizing the dose to normal tissue. While randomized control trials are limited [82], cumulative evidence supports the hypothesis that IMRT allows sparing of salivary tissue and decrease in late effect xerostomia without compromising the radiation dose to the tumor [83–85].

Once xerostomia develops, the clinician must direct attention to (1) assessment and minimization of long-term oral health implications of hyposalivation (see section on “Oral Health Issues” below), (2) maximizing residual salivary flow, and (3) maximizing patient comfort. Gustatory and pharmacologic stimulants may increase salivary flow. Commonly patients will use sugar-free lozenges or gum with some relief of symptoms. Pharmacologic agents include pilocarpine and cevimeline. Pilocarpine is a parasympathomimetic agent that functions as a nonselective muscarinic agonist. In a randomized trial of 207 patients with radiation-induced xerostomia, pilocarpine was associated with an increase in salivary flow, improved comfort, and improved speech [86]. A second agent, cevimeline, acts as a selective M3 muscarinic receptor agonist. Two large randomized trials demonstrated that cevimeline results in increased salivary flow rates; however, the effect on patient-reported symptoms was mixed [87]. A number of topical agents have been developed that are generally classified as “salivary substitutes” [88]. The efficacy of these agents is variable and patient specific. Patients should be encouraged to try several agents in appropriate dose and schedules to determine whether they receive benefit. For those patients who do not receive benefit from salivary substitutes, carrying a water bottle for frequent oral rinsing can provide temporary relief. The use of a humidifier, particularly at night, may diminish discomfort [89].

Oral Health Issues

Dental

The major constituent of the dental enamel is calcium phosphate. Like bone, the enamel is constantly remodeling. Ideally, demineralization of the enamel surface is balanced by re-mineralization. However, if the balance sways toward demineralization, dental carries may develop. A number of factors predispose to demineralization, including an acidic milieu, lack of enamel substrates (calcium and phosphate), and cariogenic bacteria (streptococcus and lactobacillus species). Protective factors include fluoride treatment, calcium-phosphate paste/rinse, certain foods, and routine dental care.

Radiation induces hyposalivation which in turn results in loss of salivary buffering capacity and a decrease in enamel substrates for re-mineralization. This predisposes to the development of carries. Postradiation dental carries can develop shortly after the completion of radiation and may progress very rapidly. Manifestations include demineralization, fracture of the enamel with chipping, and auto-amputation of the tooth at the root. Even with aggressive dental intervention, it may not be possible to salvage dentition that manifests severe and rapidly progressing radiation carries. Thus, it is clear that oral health must be addressed aggressively throughout the trajectory of a patient's treatment course and long term for survivors.

Prior to the initiation of radiation therapy patients should undergo a thorough dental evaluation [90]. Nonviable teeth should be extracted 10–14 days prior to radiation to allow adequate healing. Patients must be educated extensively about oral health measures and compliance monitored on a routine basis. Patients should be instructed to brush after every meal. Oral rinses, such as baking soda gargles, may be used to buffer an acid pH. Patients should avoid acidic or sugar containing candy, drinks, or medications. Fluoride treatment should be utilized to enhance re-mineralization [91]. Chlorhexidine rinse may be used to minimize colonization with cariogenic bacteria. In small studies, posttreatment stimulation of residual salivary function with sialogogues has decreased late dental carries.

Sialorrhea

Patients commonly complain of "excess" mucous production. In a cohort of patients, salivary production may be normal but physiologic abnormalities such as dysphagia and obstruction prevent normal handling of secretions. In this group, treatment should be directed at maximizing control over secretions. On the other hand, patients may actually have an increase in salivary production or altered salivary

texture leading to difficulty in managing secretions. Commonly, patients undergoing radiation therapy will complain of copious, thick sputum that is difficult to expectorate or swallow. Clearing secretions is hampered by painful mucositis, dysphagia, and pharyngeal edema. Treatment is directed at suppression of mucous production with pharmacologic agents such as scopolamine or atropine, thinning of mucous by the use of mucolytics, night time postural techniques to prevent mucous pooling, and hydrating techniques such as a humidifier to keep mucous from hardening. Radiation-induced sialorrhea may result in difficulty swallowing, gagging with reflex vomiting, and altered sleep patterns. Generally, sialorrhea abates within 1–3 months treatment. Of note, patients undergoing radiation therapy may experience both xerostomia and sialorrhea. Unfortunately, treatment approaches that improve one symptom may exacerbate the other. Thus, treatment must be tailored to the individual to maximize symptom control. Chronic sialorrhea is more common in the postoperative setting and has been approached using a number of treatment techniques including anticholinergics, botulinum toxin, and salivary gland excision [92].

Trismus

Abnormalities in jaw motion resulting in either mal-occlusion or trismus are a common but frequently overlooked complication of head and neck cancer therapy. Normal occlusion requires the following structures: mandible, maxilla, muscles of mastication (including the pterygoids, masseter, and temporalis), dentition, an intact neurologic supply, and an adequate vascular supply. When the structures function normally, the mandible has six degrees of motion: depression, elevation, protrusion, retraction, and right and left lateral movement. Damage to any of these structures either by tumor or treatment may result in abnormal occlusion and/or decreased range of motion in the jaw.

Trismus is defined as a restriction in range of motion of the jaw. While differing criteria have been used to assess and report trismus, most studies report the maximal inter-incisor opening (MIO) measured in millimeter. Although the criteria for mild, moderate, and severe trismus varies, general guidelines are as follows: greater than 40 mm – normal, between 30 and 40 mm – mild trismus, 15–30 mm – moderate trismus, and <15 mm – severe trismus [93].

Radiation-induced trismus is secondary to fibrosis of the muscles of mastication. There is a strong correlation between the radiation dose to the muscles of mastication and subsequent development of alterations in jaw range of motion [94]. The incidence of radiation-induced trismus has not been well established. This is largely due to the variability in measurement techniques and the heterogenous populations

studied [95]. Rates as high as 45% have been reported in patients receiving curative doses of radiation therapy involving the muscles of mastication and/or the ligaments of the temporomandibular joint [96]. Current data do not demonstrate an increase in the incidence or severity of symptoms with the use of concurrent chemotherapy.

Trismus usually begins to develop 1–9 months after the completion of radiation therapy, however, late-onset trismus has been reported [97]. Trismus is usually permanent and may be progressive; thus, once it develops, ongoing supportive measures are required. Trismus is associated with a number of clinically important sequelae that merit close scrutiny. Decrease range of motion in the jaw may lead to alterations in oral intake, and when severe, patients may be limited to a liquid diet. Rigorous oral care, which is vital in patients with radiation-induced xerostomia, may be difficult or impossible. Speaking may be harder and patients may have trouble being understood. It is important to note that oral intubation or dental procedures may not be feasible in patients with severe decrease in jaw range of motion.

Treatment options for trismus are limited. Hyperbaric oxygen therapy, pentoxifylline [98], and botulinum toxin [99] have been investigated as potential therapeutic interventions, however, data is lacking to support any of these methodologies. Physical therapy with stretching of the muscles is commonly recommended. Although patients with cancer-related trismus do not experience dramatic improvement in jaw range of motion with physical therapy, deterioration may be prevented [100]. Appliances have been developed to maximize stretching of muscles and soft tissues [95].

Mucosal Sensitivity

Radiation therapy is associated with a unique posttreatment pain syndrome—Post Radiation Mucosal Sensitivity (PRMS). Characteristically, patients will complain of burning oral or pharyngeal pain that persists after resolution of the visible ulcerative lesions of mucositis. Symptoms are often exacerbated by spicy or hot food, xerostomia, and dry air. Although symptoms may lessen over time, sensitivity may persist long term. PRMS is a neuropathic pain which may be related to peripheral nerve sensitization and up regulations of Na⁺ channels by mucositis-associated inflammatory [101]. The cornerstone of treatment for PRMS is to avoid foods or environmental conditions that provoke pain. For patients with oral symptoms requiring intervention, topical anesthetics such as lidocaine (Na⁺ channel blockers) or ketamine (NMDA inhibitors) may be highly effective. If these agents fail or if patients have pharyngeal pain at sites that preclude administration of topical agents, systemic agents may be needed. Opioids may partially alleviate symptoms in some patients, however, PRMS is a neuropathic pain, thus it tends

to be opioid resistant. When indicated, adjunctive pain medication such as clonazepam, gabapentin, and other antidepressants may be tried.

Dermatitis

Radiation therapy damages radiosensitive keratinocytes found in the basal layer of the epidermis preventing normal maturation and repopulation. As progenitor cells die during radiation, few cells are left in the germinal layer to replenish the normally desquamating upper epithelium. This results in sloughing of the epidermis, exposing the underlying dermal tissue. Reactions are often worse in skin folds and areas of decreased tissue thickness such as around the pinna or at the laryngeal prominence. The administration of concurrent chemotherapy agents (such as cetuximab [102, 103], doxorubicin, actinomycin D, bleomycin, hydroxyurea, 5-fluorouracil, methotrexate, and taxanes) may increase the incidence and severity of symptoms. Other risk factors for the development of radiation dermatitis include: age, nutritional status, diabetes, and concurrent medications [104, 105].

A number of systems have been used to grade acute radiation dermatitis. The CTCAE 3.0 criteria are as follows: grade 1 – faint erythema or dry desquamation; grade 2 – moderate to brisk erythema or patchy moist desquamation, mostly confined to the skin folds and creases with moderate edema; grade 3 – confluent moist desquamation, ≥ 1.5 cm diameter, not confined to skin folds, with pitting edema; and grade 4 – skin necrosis or ulceration of full thickness dermis, may include bleeding not induced by minor trauma or abrasion. Acute radiation dermatitis usually begins within 2–3 weeks of initiating therapy and worsens over time. Once radiation has completed, the skin lesions resolve rapidly (over 2–3 weeks). Long-term patients may experience hypopigmentation, hyperpigmentation, textural changes, loss of hair follicles, and loss of sebaceous glands [106]. In addition, patient may experience fibrosis of the dermis and subcutaneous tissue leading tissue retraction and decreased range of motion or atrophy with increased skin fragility [106, 107]. Patients must be educated regarding the care of acute and late dermal effects of radiation therapy. The reader is referred to a number of manuscripts that provide thorough recommendations for the management of acute and late dermatitis [106, 108, 109].

Conclusions

Head and neck cancer is associated with a number of symptom control and functional issues. Although much attention has been directed at the acute effects of therapy, there is

increasing recognition of the importance of late effects. The acute and late effects of therapy span a wide range of clinical issues; thus, they require the expertise of a wide array of practitioners. In order to maximize symptom and functional outcomes, a coordinated multidisciplinary approach is needed. Bringing together a team that is able to care for patients in a holistic and proactive manner is challenging at best. Nonetheless, it is necessary.

References

- Murphy BA, Ridner S, Wells N, Dietrich M. Quality of life research in head and neck cancer: a review of the current state of the science. *Crit Rev Oncol Hematol*. 2007;62:251–67.
- Murphy BA, Gilbert J, Ridner SH. Systemic and global toxicities of head and neck treatment. *Expert Rev Anticancer Ther*. 2007;7:1043–53.
- Wynn TA. Cellular and molecular mechanisms of fibrosis. *J Pathol*. 2008;214(2):199–210.
- Delanian S, Lefaix JL. Current management for late normal tissue injury: radiation-induced fibrosis and necrosis. *Semin Radiat Oncol*. 2007;19:99–108.
- Sonis S. The pathobiology of mucositis. *Nat Rev*. 2004;4:277–84.
- Sonis S. Pathobiology of oral mucositis: novel insights and opportunities. *J Support Oncol*. 2007;5(9):3–11.
- Epstein JB et al. Longitudinal evaluation of the oral mucositis weekly questionnaire-head and neck cancer, a patient-reported outcomes questionnaire. *Cancer*. 2007;109(9):1914–22.
- Vera-Llonch M, Oster G, Hagiwara M, et al. Oral mucositis in patients undergoing radiation treatment for head and neck carcinoma. *Cancer*. 2006;106:329–36.
- Elting LS, Cooksley CD, Chambers MS, Garden A. Risk, outcomes, and costs of radiation-induced oral mucositis among patients with head-and-neck malignancies. *Int J Radiat Oncol Biol Phys*. 2007;68:1110–20.
- Trotti A et al. Mucositis incidence, severity and associated outcomes in patients with head and neck cancer receiving radiotherapy with or without chemotherapy: a systematic literature review. *Radiother Oncol*. 2003;66(3):253–62.
- Barasch A, Peterson DE. Risk factors for ulcerative oral mucositis in cancer patients: unanswered questions. *Oral Oncol*. 2003;39:91–100.
- Murphy B. Clinical and economic consequences of mucositis induced by chemotherapy and/or radiation therapy. *J Support Oncol*. 2007;5(9):13–21.
- Wong PC, Dodd MJ, Miaskowski C, et al. Mucositis pain induced by radiation therapy: prevalence, severity, and use of self-care behaviors. *J Pain Symptom Manage*. 2006;32(1):27–37.
- Murphy BA, Chen A, Curran WJ, Garden AS, Harari PM, Wong SJ, et al. Longitudinal oncology registry of head and neck carcinoma (LORHAN): initial supportive care findings. *Support Care Cancer*. 2009;17(11):1393–401.
- Peterman A, Cella D, Glandon G, Dobrez D, Yount S. Mucositis in head and neck cancer: economic and quality-of-life outcomes. *J Natl Cancer Inst*. 2001;29:45–51.
- Nonzee N, Dandade NA, Markossian T, Agulnik M, Argiris A, Patel J, et al. Evaluating the supportive care costs of severe radiochemotherapy-induced mucositis and pharyngitis. *Cancer*. 2008;113:1446–52.
- Kendall K. Anatomy and physiology of deglutition. In: Kendall LA, editor. *Dysphagia assessment and treatment planning*. San Diego, CA: Plural Publishing; 2008. p. 27–34.
- Murray T, Carrau RL, editors. Anatomy and function of the swallowing mechanism. In: *Clinical management of swallowing disorders*. San Diego, CA: Plural Publishing; 2006. p. 15–33.
- Aviv J. The normal swallow. In: Murry CA, editor. *Comprehensive management of swallowing disorders*. San Diego, CA: Plural Publishing; 2006. p. 23–9.
- Kendall K. Anatomy and physiology of deglutition. 2nd Edition. In: Kendall LA, editor. *Dysphagia assessment and treatment planning*. San Diego, CA: Plural Publishing; 2008. p. 1–26.
- Goodrich SJ, Walker AI. Clinical swallow evaluation. In: Leonard R, Kendall K, editors. *Dysphagia assessment and treatment planning*. San Diego, CA: Plural Publishing; 2008. p. 103–14.
- Murry T, Carrau RL, editors. Evaluation of dysphagia. In: *Clinical management of swallowing disorders*. San Diego, CA: Plural Publishing; 2006. p. 95–135.
- Aviv JE, Murry T, Zschommler A, Cohen M, Gartner C. Flexible endoscopic evaluation of swallowing with sensory testing: patient characteristics and analysis of safety in 1,340 consecutive examinations. *Ann Otol Rhinol Laryngeal*. 2005;114:173–6.
- Cohen MA, Setzen M, Perlman PW, Ditkoff M, Mattucci K, Guss J. The safety of flexible endoscopic evaluation of swallowing with sensory testing in an outpatient otolaryngology setting. *Laryngoscope*. 2003;113:21–4.
- Logemann J, Bytell D. Swallowing disorders in three types of head and neck surgical patients. *Cancer*. 1979;44:1095–105.
- Logemann JA, Pauloski BR, Rademaker AW, et al. Speech and swallow function after tonsil/base of tongue resection. *J Speech Hear Res*. 1993;36:918–26.
- Feng FY, Kim HM, Lyden TH, Haxer MJ, Feng M, Worden FP, et al. Intensity-modulated radiotherapy of head and neck cancer aiming to reduce dysphagia: early dose-effect relationships for swallowing structures. *Int J Radiat Oncol Biol Phys*. 2007;68(5):1289–98.
- Eisbruch A, Schwartz M, Rasch C, et al. Dysphagia and aspiration after chemoradiotherapy for head and neck cancer: which anatomic structures are affected and can they be spared by IMRT? *Int J Radiat Oncol Biol Phys*. 2004;60(5):1425–39.
- Fua TF et al. Intensity-modulated radiotherapy for nasopharyngeal carcinoma: clinical correlation of dose to the pharyngo-esophageal axis and dysphagia. *Int J Radiat Oncol Biol Phys*. 2007;67(4):976–81.
- Trotti A, Bellm LA, Epstein JB, Frame D, Fuchs HJ, Gwede CK, et al. Mucositis incidence, severity and associated outcomes in patients with head and neck cancer receiving radiotherapy with or without chemotherapy: a systematic literature review. *Radiother Oncol*. 2003;66:253–62.
- Rosenthal DI, Lewin JS, Eisbruch A. Prevention and treatment of dysphagia and aspiration after chemoradiation for head and neck cancer. *J Clin Oncol*. 2006;24:2636–43.
- Laurell G et al. Stricture of the proximal esophagus in head and neck carcinoma patients after radiotherapy. *Cancer*. 2003;97(7):1693–700.
- Lawson JD, Otto K, Grist W, Johnstone P. Frequency of esophageal stenosis after simultaneous modulated accelerated radiation therapy and chemotherapy for head and neck cancer. *Am J Otolaryngol*. 2008;29:13–9.
- Ahlawate SK, Al-Kawas FH. Endoscopic management of upper esophageal strictures after treatment of head and neck malignancy. *Gastrointest Endosc*. 2008;68:19–24.
- Nguyen NP, Moltz CC, Frank C, Vos P, Smith HJ, Karlsson U, et al. Dysphagia following chemoradiation for locally advanced head and neck cancer. *Ann Oncol*. 2004;15:383–8.
- Murry T, Carrau RL, editors. The abnormal swallow: conditions and diseases. In: *Clinical management of swallowing disorders*. San Diego, CA: Plural Publishing; 2006. p. 38–40.

37. Murphy BA, Friedman J, Dowling E, Cheatham R, Cmela A. Dietary intake and adaptations in head and neck cancer patients treated with chemoradiation. *Proc Am Soc Clin Oncol*. 2002; 21:abstract # 932.
38. Pauloski BR et al. Swallow function and perception of dysphagia in patients with head and neck cancer. *Head Neck*. 2002;24(6):555–65.
39. Cheng S, Terrell JE, Bradford CR, Ronis DL, Fowler KE, Prince ME, et al. Variables associated with feeding tube placement in head and neck cancer. *Arch Otolaryngol Head Neck Surg*. 2006;132:655–61.
40. Schuere, M.v.B.-d.v.d. Differences in immune status between well nourished and malnourished head and neck cancer patients. *Clin Nutr* 1998;17(3):107–11.
41. Brookes GB. Nutritional status—a prognostic indicator in head and neck cancer. *Otolaryngol Head Neck Surg*. 1985;93:69–74.
42. Schuere, M.v.B.-d.v.d. The impact of nutritional status on the prognoses of patients with advanced head and neck cancer. *Cancer*. 1999;86:519–27.
43. Newman LA et al. Eating and weight changes following chemoradiation therapy for advanced head and neck cancer. *Arch Otolaryngol Head Neck Surg*. 1998;124:589–92.
44. Schuere, M.v.B.-d.v.d. The impact of nutritional status on the prognosis of patients with head and neck cancer. *Cancer*. 1999;86:519–27.
45. Hammerlid E et al. Malnutrition and food intake in relation to quality of life in head and neck cancer patients. *Head Neck*. 1998;20:540–8.
46. Colasanto JM, Prasad P, Nash MA, Decker RH, Wilson LD. Nutritional support of patients undergoing radiation therapy for head and neck cancer. *Oncology*. 2005;19(3):371–87.
47. Minasian A, Dwyer JT. Nutritional implications of dental and swallowing issues in head and neck cancer. *Oncology*. 1998;12(8):1155–62.
48. Harris JA, Benedict FG. A biometric study of basal metabolism in man. Publication 279. Washington, DC: Carnegie Institution; 1919. p. 40–4.
49. Gibson S, Wenig B. Percutaneous endoscopic gastrostomy in the management of head and neck carcinoma. *Laryngoscope*. 1992;102:977–81.
50. Mekhail TM et al. Enteral nutrition during the treatment of head and neck carcinoma: is a percutaneous endoscopic gastrostomy tube preferable to a nasogastric tube? *Cancer*. 2001;91(9): 1785–90.
51. Lin A, Jabbari S, Worden FP, Bradford CR, Chepeha DB, Teknos T, et al. Metabolic abnormalities associated with weight loss during chemoradiation of head and neck cancer. *Int J Radiat Biol Phys*. 2005;63:1413–8.
52. Tyldesley S et al. The use of radiologically placed gastrostomy tubes in head and neck cancer patients receiving radiotherapy. *Int J Radiat Oncol Biol Phys*. 1996;36(5):1205–9.
53. Beer KT, Krause KB, Zuercher T, Stanga Z. Early percutaneous endoscopic gastrostomy insertion maintains nutritional state in patients with aerodigestive tract cancer. *Nutr Cancer*. 2005;52(1): 29–34.
54. Bergstrom LR, Larson D, Zinsmeister AR, Sarr MG, Silverstein MD. Utilization and outcomes of surgical gastrostomies and jejunostomies in an era of percutaneous endoscopic gastrostomy: a population-based study. *Mayo Clin Proc*. 1995;70:829–36.
55. Silver HJ, Wellman NS, Arnold DJ, Livingstone AS, Byers PM. Older adults on home enteral nutrition: enteral regimen, provider involvement, and health care outcomes. *J Parenter Enteral Nutr*. 2004;28:92–8.
56. Beecken L, Calaman F. A return to “Normal Eating” after curative treatment for oral cancer. *Eur J Cancer B Oral Oncol*. 1994; 30B:387–92.
57. Morley JE, Thomas DR, Wilson MMG. Cachexia: pathophysiology and clinical relevance. *Am J Clin Nutr*. 2006;83:735–43.
58. Innui A. Cancer anorexia-cachexia syndrome: current issues in research and management. *CA Cancer J Clin*. 2002;52:72–91.
59. Tisdale M. Metabolic alterations in cachexia and anorexia. *Nutrition*. 2000;16:1013–4.
60. Davis MP, Dreicer R, Walsh D, Lagman R, LeGrand SB. Appetite and cancer-associated anorexia: a review. *J Clin Oncol*. 2004;22(8):1510–7.
61. Desport JD, Gory-Delabaere G, Blanc-Vincent MP, et al. Standards, options and recommendations for the use of appetite stimulants in oncology 2000. *Br J Cancer*. 2003;89:S98–100.
62. Chen H. Effect of megestrol acetate and prepuisid on nutritional improvement in patients with head and neck cancers undergoing radiotherapy. *Radiother Oncol*. 1997;43(1):75–9.
63. Duncan GG, Epstein JB, Tu D, et al. Quality of life, mucositis, and xerostomia from radiotherapy for head and neck cancers: a report from the NCIC CTG HN2 randomized trial of an antimicrobial lozenge to prevent mucositis. *Head Neck*. 2005;27(5):421–8.
64. Henson BS, Inglehart MR, Eisbruch A, Ship JA. Preserved salivary output and xerostomia-related quality-of-life in head and neck cancer patients receiving parotid-sparing radiotherapy. *Oral Oncol*. 2001;37(1):84–93.
65. Lin A, Kim HM, Terrell JE, Dawson LA, Ship JA, Eisbruch A. Quality of life after parotid-sparing IMRT for head and neck cancer: a prospective longitudinal study. *Int J Radiat Oncol Biol Phys*. 2003;57(12):61–70.
66. Hand A. Salivary glands. In: Cate T, editor. *Oral histology*. Montreal: Mosby Elsevier; 2008. p. 290–1.
67. Mandel DD. The role of saliva in maintaining oral homeostasis. *JADA*. 1989;119:298–304.
68. Backstrom I, Funegard U, Andersson I, Franzen L, Johansson I. Dietary intake in head and neck irradiated patients with permanent dry mouth symptoms. *Eur J Cancer B Oral Oncol*. 1995; 31B(4):253–7.
69. Rhodus NL, Moller K, Colby S, Bereuter J. Articulatory speech performance in patients with salivary gland dysfunction: a pilot study. *Quintessence Int*. 1995;26:805–10.
70. Rho GJ et al. Influence of in vitro oxygen concentrations on pre-implantation embryo development, gene expression and production of Hanwoo calves following embryo transfer. *Mol Reprod Dev*. 2007;74(4):486–96.
71. Logemann J et al. Effects of xerostomia on perception and performance of swallow function. *Head Neck*. 2001;23:317–21.
72. Hamlet S et al. Mastication and swallowing in patients with postirradiation xerostomia. *Int J Radiation Biol Phys*. 1997;37:789–96.
73. Frazen L et al. Parotid gland function during and following radiotherapy of malignancies in the head and neck. *Br J Cancer*. 1992;28:457–62.
74. Eisbruch A, TenHaken RK, Kin HM, March LH, Ship JA. Dose, volume, and function relationships in parotid salivary glands following conformal and intensity-modulated irradiation of the head and neck cancer. *Int J Radiation Biol Phys*. 1999;45:577–87.
75. Jha N et al. Prevention of radiation induced xerostomia by surgical transfer of submandibular salivary gland into the submental space. *Radiother Oncol*. 2003;66(3):283–9.
76. Sasse AD, Clark LG, Sasse EC, Alark ACC. Amifostine reduces side effects and improves complete response rate during radiotherapy: results of a meta-analysis. *Int J Radiat Oncol Biol Phys*. 2005;64(1):784–91.
77. Rudat V, Meyer J, Momm F, Bendel M, Henke M, Strnad V, et al. Protective effect of amifostine on dental health after radiotherapy of the head and neck. *Int J Radiat Oncol Biol Phys*. 2000;48(5):1339–43.
78. Wasserman T, Mackowiak JI, Brizel DM, Oster W, Zhang J, Peoples PJ, et al. Effect of amifostine on patient assessed clinical

- benefit in irradiated head and neck cancer. *Int J Radiat Oncol Biol Phys.* 2000;48(4):1035–9.
79. Bardet E, Martin L, Calais G, Alfonsi M, Feham N, Tuchais C, et al. Subcutaneous versus intravenous administration of amifostine for head and neck cancer patients receiving radiotherapy: preliminary results of the GORTEC 2000-02 randomized trial. *Int J Radiat Oncol Biol Phys.* 2005;63(2):S127.
80. Brosky M. The role of saliva in oral health: strategies for prevention and management of xerostomia. *J Support Oncol.* 2007; 5:215–25.
81. Scarantino C et al. Effect of pilocarpine during radiation therapy: results of RTOG 97-09, a phase III randomized study in head and neck cancer patients. *J Support Oncol.* 2006;4(5):252–8.
82. Kam MKM, Leung SF, Zee B, Chau R, Suen JJS, Mo F, et al. Prospective randomized study of intensity-modulated radiotherapy on salivary gland function in early-stage nasopharyngeal carcinoma patients. *J Clin Oncol.* 2007;25(31):4873–9.
83. Chao KS et al. Intensity-modulated radiation therapy reduces late salivary toxicity without compromising tumor control in patients with oropharyngeal carcinoma: a comparison with conventional techniques. *Radiother Oncol.* 2001;61(3):275–80.
84. Daly ME, Lieskovsky Y, Pawlicki T, Yau J, Pinto H, Kaplan M, et al. Evaluation of patterns of failure and subjective salivary function in patients treated with intensity modulated radiotherapy for squamous cell head and neck cancer. *Head Neck.* 2007;29: 211–20.
85. Saarilahti K, Kouri M, Collan J, Kangasmaki A, Atula T, Joensuu H, et al. Sparing of the submandibular glands by intensity modulated radiotherapy in the treatment of head and neck cancer. *Radiat Oncol.* 2006;73:320–5.
86. Johnson JT et al. Oral pilocarpine for post-irradiation xerostomia in patients with head and neck cancer. *N Engl J Med.* 1993; 329:390–5.
87. Chambers MS et al. Cevimeline for the treatment of postirradiation xerostomia in patients with head and neck cancer. *Int J Radiat Oncol Biol Phys.* 2007;68(4):1102–9.
88. Oral health in cancer therapy: a guide for health care professionals. www.doep.org
89. Keck T, Rozsasi A, Leiacker R, Scheithauer MO. Lower airway humidification in spontaneously breathing tracheostomized patients: comparative study of trachea spray versus heated humidification. *Head Neck.* 2008;30:582–8.
90. Dreizen S, Brown LR, Daly TE, Drane BE. Prevention of xerostomia-related dental caries in irradiated cancer patients. *J Dent Res.* 1977;56(2):99–104.
91. Papas A et al. Caries clinical trial of a remineralising toothpaste in radiation patients. *Gerodontology.* 2008;25(2):76–88.
92. Bomeli SR, Desai S, Johnson JT. Management of salivary flow in head and neck patients. *Oral Oncol.* 2008;44:1000–8.
93. Dijkstra PU, Huisman PM, Roodenburg JLN. Criteria for trismus in head and neck oncology. *Int J Oral Maxillofac Surg.* 2006;35:337–42.
94. Teguh DN, Levendag PC, Voet P, van der Est H, Noever I, de Kruijf W, et al. Trismus in patients with oropharyngeal cancer: relationship with dose in structures of mastication apparatus. *Head Neck.* 2008;30:622–30.
95. Dijkstra PU, Kalk WWI, Roodenburg JLN. Trismus in head and neck oncology: a systematic review. *Oral Oncol.* 2004;40(9): 879–89.
96. Kent ML, Bennan MT, Noll JL, Fox PC, Burri SH, Hunter JC, et al. Radiation-induced trismus in head and neck cancer patients. *Support Care Cancer.* 2008;16:305–9.
97. Wang CJ, Huang EY, Hsu HC, Chen HC, Fang FM, Hsiung CY. The degree and time-course assessment of radiation-induced trismus occurring after radiotherapy for nasopharyngeal cancer. *Laryngoscope.* 2005;115:1458–60.
98. Chua D, Lo C, Yuen J, Foo YC. A pilot study of pentoxifylline in the treatment of radiation-induced trismus. *Am J Clin Oncol.* 2001;24(4):366–9.
99. Hartl DM, Cohen M, Julieron M, Marandas P, Janot F, Bourhis J. Botulinum toxin for radiation-induced facial pain and trismus. *Otolaryngol Head Neck Surg.* 2008;138:459–63.
100. Dijkstra PU, Sterken MW, Pater R, Spijkervet FKL, Roodenburg JLN. Exercise therapy for trismus in head and neck cancer. *Oral Oncol.* 2007;43:389–94.
101. Finnerup NB, Jensen TS. Mechanisms of disease: mechanism-based classification of neuropathic pain – a critical analysis. *Nat Clin Pract Neurol.* 2006;2(2):107–15.
102. Bonner JA, Ang K. More on severe cutaneous reaction with radiotherapy and cetuximab. *N Engl J Med.* 2007;357:1872–3.
103. Budach W, Bölke E, Horney B. Severe cutaneous reaction during radiation therapy with concurrent cetuximab. *N Engl J Med.* 2007;367(21):514–5.
104. Sitton E. Early and late radiation-induced skin alterations part 1: mechanism of skin changes. *Oncology Nursing Forum.* 1992;19(5):801.
105. Blackmar A. Radiation-induced skin alterations. *Medsurg Nursing.* 1997;6(3):172–5.
106. Hymes SR, Strom EA, Fife C. Radiation dermatitis: clinical presentation, pathophysiology, and treatment 2006. *J Am Acad Dermatol.* 2006;54(1):28–46.
107. Stohl R. The nursing role in radiation oncology: symptom management of acute and chronic reactions. *Oncol Nurs Forum.* 1988;15(4):429–34.
108. D'haessse S, Bate T, Claes S, Boone A, Vanvoorden V, Efficace F. Management of skin reactions during radiotherapy: a study of nursing practice. *Eur J Cancer Care.* 2005;14:28–42.
109. Bernier J et al. Consensus guidelines for the management of radiation dermatitis and coexisting acne-like rash in patients receiving radiotherapy plus EGFR inhibitors for the treatment of squamous cell carcinoma of the head and neck. *Ann Oncol.* 2008; 19:142–9.
110. World Health Organization. A handbook for reporting results of cancer treatment. Geneva: World Health Organization; 1979.
111. Trotti A et al. CTCAE v3.0: development of a comprehensive grading system for the adverse effects of cancer treatment. *Semin Radiat Oncol.* 2003;13(3):176–81.
112. American Speech-Language-Hearing Association. Roles of speech-language pathologists in swallowing and feeding disorders: technical report [Technical Report]. 2001. Available from www.asha.org.
113. Molseed L. Clinical evaluation of swallowing: the nutritionist's perspective. In: Murry CA, editor. *Comprehensive management of swallowing disorders*. San Diego, CA: Plural Publishing; 2006. p. 59.
114. Blackburn GL, Bistran BR, Miani BS, Schlamm HT, Smith MF. Nutritional and metabolic assessment of the hospitalized patient. *J Parenter Enteral Nutr.* 1977;1:11–22.

Chapter 18

Intensity-Modulated Radiation Therapy for Head and Neck Cancer

Nancy Lee, Daniel Gomez, Edward J. Shin, and K.S. Clifford Chao

Abstract Intensity-modulated radiation therapy (IMRT) has revolutionized the treatment of head and neck cancer. A general overview of IMRT in the treatment of head and neck cancer is provided, focusing on guidelines for target determination and delineation for the different subsites within the head and neck. General facts, general management, target delineation, and IMRT results of specific anatomic subsites are outlined, including the nasopharynx, the oropharynx, the hypopharynx, the larynx, the oral cavity, and the thyroid are discussed, along with cancer of unknown primary.

Keywords Intensity-modulated radiation therapy • Head and neck cancer • Target determination • Target delineation • Subsites

Introduction

Intensity-modulated radiation therapy (IMRT) has revolutionized the treatment of head and neck cancer. Compared with conventional opposed lateral fields that were used to treat these tumors, IMRT has provided comparable, if not better, local control with significantly improved long-term toxicities associated with high doses of radiation therapy. The ability to tightly conform to irregularly shaped tumors while limiting the dose delivered to the surrounding critical structures is the hallmark of IMRT. This advantage is especially seen when tumors are located near critical structures, i.e., the brainstem and optic structures, where there are great limitations in delivering effective therapeutic doses of radiation using conventional radiotherapy techniques. In addition,

because there is minimal organ motion in the head and neck, with the use of proper immobilization the planned dose distribution can be delivered with great assurance. The theoretical dosimetric advantage of IMRT has translated clinically into improvement in patient quality of life. Several Phase III trials have now demonstrated the beneficial effects of IMRT when compared with conventional radiotherapy in terms of minimizing late toxicities, and in particular xerostomia. The purpose of this chapter is to provide a general overview of IMRT in the treatment of head and neck cancer, focusing on guidelines for target determination and delineation for the different subsites within the head and neck. Clinical updates will also be presented.

Target Determination and Delineation for Head and Neck Cancer

The complexity of the head and neck anatomy requires the treating radiation oncologist to carefully and accurately delineate the target volume prior to initiating IMRT. One must have an understanding of the relationship of the various structures to one another and the patterns of spread from the primary tumor site as well as the nodal drainage. To date, no consensus delineation guidelines other than the N0 nonsurgically violated neck have been published. A guideline regarding the different neck lymph node levels can be found in Table 18.1 [1]. It is important not to use the N0 guideline for node-positive or postoperative cases in which the nodal planes are not as well defined either due to the presence of nodes or surgical violation of tissue planes. A proposal, though not a consensus guideline, for the node-positive neck has been published by Gregoire et al. [2]. The probability of nodal drainage to a specific ipsilateral lymph node level is directly related to the location and stage of the primary tumor. Table 18.2 specifies the likelihood of pathologic lymph node involvement in both the clinically positive and negative neck, by anatomic subsites.

N. Lee (✉)
Radiation Oncology, Memorial Sloan-Kettering Cancer Center,
1275 York Ave, Box 22, New York, NY 10021, USA
e-mail: leen2@MSKCC.ORG

Table 18.1 Lymph node levels

Robbins classification level	Terminology	Definition
Ia	Submental	Contains submental/submandibular triangles
Ib	Submandibular	Bounded by the posterior belly of digastric muscle, hyoid bone and the body of mandible
II	Upper jugular	Contains upper internal jugular lymph nodes. Extends from level of hyoid bone to skull base
III	Middle jugular	Contains middle internal jugular lymph nodes from hyoid bone to cricothyroid membrane
IV	Lower jugular	Contains lower internal jugular lymph nodes from cricothyroid membrane to clavicle
V	Spinal accessory	Posterior triangle lymph nodes bounded by trapezius, sternocleidomastoid, clavicle
VI	Anterior compartment	From hyoid bone to suprasternal notch bounded laterally by the carotid sheath
VII	Upper mediastinal	Lymph nodes inferior to suprasternal notch in the upper mediastinum

Table 18.2 Incidence and distribution of lymph nodes in N0 and N+ neck

Clinical presentation	Radiologically enlarged retropharyngeal nodes (%)		Pathologic nodal metastasis(%)										
	N-	N+	Level I		Level II		Level III		Level IV		Level V		
			N-	N+	N-	N+	N-	N+	N-	N+	N-	N+	
Nasopharynx	40	86	-	-	-	-	-	-	-	-	-	-	-
<i>Oral cavity</i>													
Oral tongue	-	-	14	39	19	73	16	27	3	11	0	0	0
Floor of mouth	-	-	16	72	12	51	7	29	2	11	0	5	5
Aveolar ridge and RMT	-	-	25	38	19	84	6	25	5	10	1	4	4
<i>Oropharynx</i>													
Base of tongue	0	6	4	19	30	89	22	22	7	10	0	18	18
Tonsil	4	12	0	8	19	74	14	31	9	14	5	12	12
<i>Hypopharynx</i>													
Pharyngeal wall	16	21	0	11	9	84	18	72	0	40	0	20	20
Pyramidal sinus	0	9	0	2	15	77	8	57	0	23	0	22	22
<i>Larynx</i>													
Supraglottic larynx	0	4	6	2	18	70	18	48	9	17	2	16	16
Glottic larynx	-	-	0	9	21	42	29	71	7	24	7	2	2

From Chao KSC, Wippold FJ, Ozyigit G, Tran BN, Dempsey JF. Determination and delineation of nodal target volumes for head and neck cancer based on patterns of failure in patients receiving definitive and postoperative IMRT. 2002;53:11. Reprinted with kind permission from Elsevier

General Delineation Guidelines

- An excellent reference in the delineation of nodal levels as visualized on computed tomography (CT) slices has been published by the Radiation Therapy Oncology Group (RTOG) (<http://www.rtog.org/atlas/hnatlas/main.html>) and the European Organization for Research and Treatment of Cancer (<http://groups.eortc.be/radio/ATLAS.html>).
- Gregoire et al. [2] has published recommendations for the treatment of the node-positive or postoperative neck. Selected recommendations are as follows:
 - Target delineation should include the retrostyloid space up to the skull base when level II is involved.
 - Supraclavicular fossa would be included when level IV or Vb is involved.
 - The entire muscle should be included in the target when there is clear extracapsular extension.
 - The entire surgical field (“surgical bed”) should be included in the target in postoperative cases.
- Extracapsular extension is a significant independent risk factor for local recurrence and distant metastasis. The clinical target volume (CTV) should be extended to the skin to account for microscopic spread.
- An “all in one” IMRT technique where all treated regions are being included in the IMRT fields is preferred over “split-field” IMRT when the low neck contains involved lymph nodes, or if the primary tumor is located in the larynx, hypopharynx, and thyroid. A “split-field” technique is preferred in all other scenarios in an attempt to minimize the dose delivered to the normal larynx. A low anterior neck field is then matched to the IMRT fields. The common match point is just above the arytenoids cartilages, which

will ensure adequate dosimetric coverage to the level II lymph nodal regions.

- A “cheater” spinal cord block is placed at the match point, approximately 2×2 cm, to add an extra layer of protection over the spinal cord in the region of the match line.
- The size of the lymph node denotes whether it should be included in the gross target volume (GTV). Lymph nodes with a minimal axial diameter of more than 1.1 cm in the subdiaphragmatic region and more than 1.0 cm in other nodal regions is considered suspicious for metastasis. Lymph nodes with a necrotic center should also be considered within the GTV.
- Communication between the operating surgeon and the radiation oncologist is crucial to ensure adequate delineation of the postoperative case.
- Imaging studies that are helpful to accurately define the gross extent of disease include CT with contrast, magnetic imaging resonance (MRI) with gadolinium, and positron emission tomography (PET) scans. Nodes that are smaller than 1 cm but are PET avid should be included in the target volume as GTV.
- PET and MRI fusion treatment planning is being used at an increasing number of institutions. While the treating physician should exercise caution in strictly defining the GTV and CTV in correlation with areas of increased fluorodeoxyglucose (FDG) uptake, these more sensitive imaging studies can provide useful information in target delineation.
- Different CTVs are established for all targets within one plan along with suggested dosing.
 - CTV1: highest dose region, margin given to GTV or the postoperative surgical bed. Definitive cases: 70 Gy, postoperative dose: 60–66 Gy.
 - CTV2: intermediate dose region, which is at high-risk but clinically uninvolved regions. Definitive cases: 59.4–63 Gy; postoperative dose: 54–60 Gy.
 - CTV3: low-dose region including regions at a lower risk for microscopic disease. Definitive cases: 54–56 Gy; Postoperative dose: 54 Gy

Treatment of Specific Anatomic Subsites

Nasopharynx

General Facts

- Anterior border: posterior choanae
- Posterior border: at the level of the first two cervical vertebrae and clivus
- Superior border: basisphenoid, basiocciput
- Inferior border: soft palate
- Lateral border: pharyngeal fascia including the eustachian tube.
- Approximately 85–90% of patients with nasopharyngeal cancer have lymph node involvement and 50% have bilateral lymph node involvement. Nodal drainage can be direct to level V, through the lateral pharyngeal walls to the retropharyngeal and subdiaphragmatic nodes. Therefore, levels I–V are all at risk for involvement.
- Anatomic knowledge of the skull base is important as nasopharyngeal tumors can involve multiple cranial nerves including II–VI and IX–XII.
- The World Health Organization divides nasopharyngeal carcinoma (NPC) into the following: keratinizing squamous cell carcinoma; nonkeratinizing carcinoma, which subdivides into differentiated and undifferentiated; and basaloid squamous cell carcinoma. Lymphoepithelial carcinoma is a further subtype that represents nonkeratinizing and undifferentiated carcinomas with an abundance of lymphocytes.

General Management

- Treatment consists of definitive radiation therapy ± cisplatin followed by adjuvant chemotherapy, though there are debates regarding the added benefit of adjuvant chemotherapy.
- The 5-year overall survival rates range from 35 to 60%.
- In the Phase III trial (Al-Sarraf et al. [3]), patients with stage III–IV NPC were randomized to radiotherapy alone (70 Gy) or radiotherapy with concurrent cisplatin (100 mg/m²) every 3 weeks during treatment, followed by cisplatin (80 mg/m²) and fluorouracil (1,000 mg/m²/day), 4 days every 4 weeks after the completion of radiation therapy. At 5 years, overall survival was 37% vs. 67% in the radiotherapy alone vs. chemoradiation arms, respectively, and progression-free survival was 29% vs. 58% in the radiotherapy alone vs. chemotherapy arms, respectively.
- A more recent Phase III study from Singapore [4] randomized 221 patients to radiation alone (70 Gy in 7 weeks) or concurrent cisplatin (weeks 1, 4, and 7 of radiation, 25 mg/m²), followed by adjuvant cisplatin (20 mg/m²) and fluorouracil (1,000 mg/m²) every 4 weeks for three cycles after the completion of radiation therapy. This trial has a design nearly identical to the US Intergroup Trial. The 3-year overall survival rate was 80% vs. 65% for the chemoradiation vs. the radiation-alone arm, respectively, with a hazard ratio for overall survival of 0.51 ($p=0.0061$). This trial confirmed the findings of the Intergroup Trial.

Table 18.3 Suggested target delineation guidelines for nasopharyngeal cancer

Stage	CTV1	CTV2
T1–T4N0	GTV + 5–10 mm	Entire nasopharynx, clivus, skull base, pterygoid fossae, parapharyngeal space, sphenoid sinus, posterior 1/4 to 1/3 of maxillary sinus and nasal cavity, bilateral retropharyngeal regions, bilateral levels II–V
T1–T4N1–3	GTV + 5–10 mm	As above and include bilateral level I

At the discretion of the treating physician, the CTV margin can be as small as 1 mm in regions near critical normal tissues, i.e., brain stem

- Several meta-analyses demonstrated that the addition of chemotherapy to radiation therapy increased both progression-free and overall survival.

Target Delineation for IMRT

- Table 18.3 contains the suggested guidelines for target delineation in NPC. The GTV includes the primary tumor and involved lymph nodes.
- Due to the high probability of lymph node metastases, levels IB–V and the retropharyngeal lymph nodes should be included in the CTV bilaterally. Level I can be omitted in N0 cases. CTV also includes areas where NPC is likely to spread: the entire nasopharynx, posterior 1/3 of the nasal cavity and maxillary sinuses, parapharyngeal fat, clivus, and skull base.
- Figure 18.1 depicts a sample target volume for a patient with locally advanced NPC. The planning target volume (PTV) represents the final treatment volume, and is the CTV with an “adequate” margin at the physician’s discretion, to account for patient day to day set-up errors as well as organ motion.

IMRT Results

- Two randomized studies on early-stage NPC have demonstrated an advantage of IMRT over conventional techniques in terms of salivary preservation [5, 6].
- Lee et al. [7] reviewed 67 patients who underwent IMRT for NPC at the University of California-San Francisco between 1995 and 2000. At a median follow-up of 31 months, the 4-year locoregional progression-free rate was 98%. Sixteen patients experienced distant metastases. At 24 months, only one of the 41 evaluable patients had Grade 2 xerostomia, with the remaining having Grade 0 or 1 toxicity. Several other single institutions also published similar results.

- Due to the encouraging locoregional control as well as improved salivary function with IMRT for NPC, the RTOG conducted a Phase II multi-institution trial and the results reproduced the excellent locoregional control rates reported by single institutions, with control rates on the order of 90% [8].
- The predominant failure pattern in patients treated with IMRT for NPC is distant metastasis. Therefore, the RTOG is conducting a Phase II trial (RTOG 0615) in which patients with loco-regionally advanced NPC are being treated with the current standard chemotherapy and IMRT with the addition of the study drug, bevacizumab, a targeted agent directed against the vascular endothelial growth factor, to test whether this addition will further decrease the rate of distant metastasis with the ultimate goal of improving overall survival. The trial is closed to patient accrual and results are pending.

Oropharynx

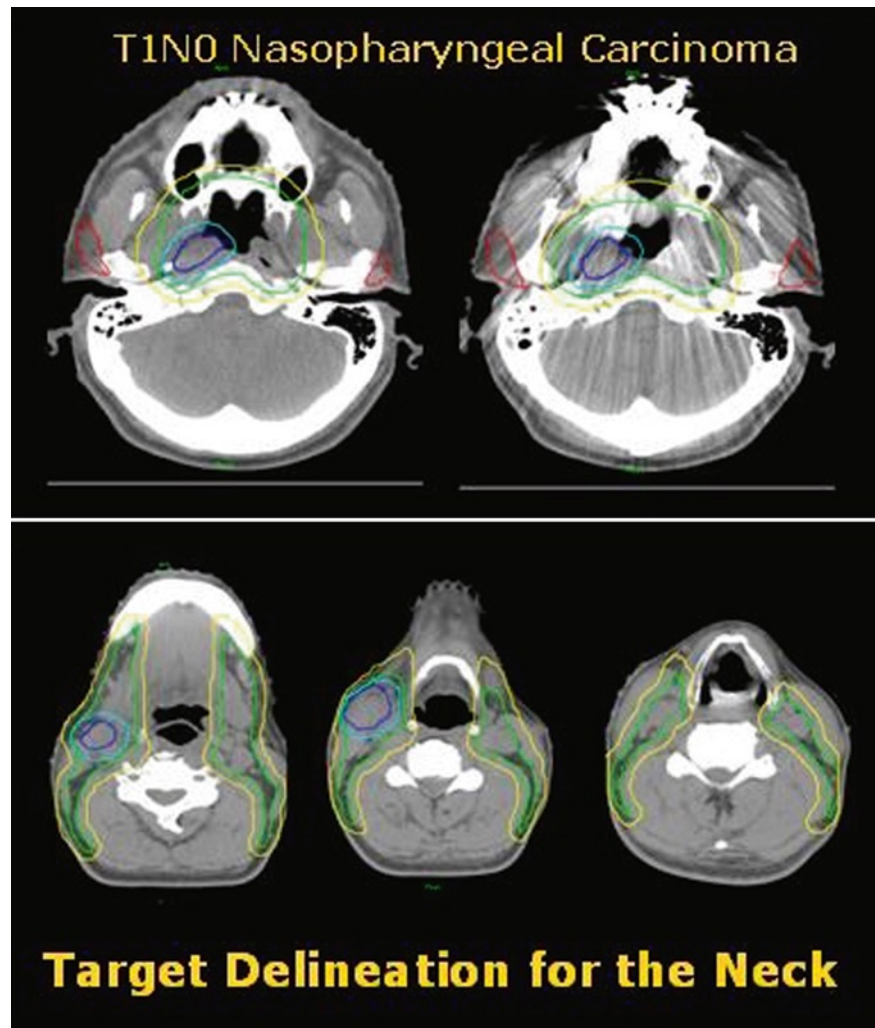
General Facts

- The oropharynx consists of four subsites: soft palate, palatine tonsillar region (fossa and pillars), lingual tonsil or base of tongue, and posterior and lateral pharyngeal walls.
- The oropharynx has a rich lymphatic network, and primarily drains into the subdigastric, upper cervical (II and III), and parapharyngeal lymph nodes (in proximity to cranial nerves IX–XII). Progression of nodal metastases is usually orderly, starting at level II and proceeding inferiorly to levels III and IV. Skip nodal metastases are relatively rare.
- The vast majority of tumors of the oropharynx are squamous cell carcinomas.

General Management

- Surgery and adjuvant radiation ± chemotherapy was previously the treatment paradigm.
- The study RTOG 73-03 (Kramer et al. [9]) was the first to suggest that surgery was not necessary as a component of treatment. This study randomized patients to either surgery, preoperative or postoperative radiation therapy or to definitive radiation therapy, reserving surgery for salvage treatment. There was no difference in locoregional control or overall survival, and complications were higher in the surgical arms.
- Parsons et al. [10] compiled results from 11 institutions from 1970 to 2000 using a MEDLINE search, to determine

Fig. 18.1 Axial slices of representative slices of a nasopharyngeal carcinoma patient undergoing IMRT



if there was a difference in outcomes for patients treated with surgery \pm adjuvant radiation vs. definitive radiation \pm neck dissection. While rates of local-regional control, 5-year overall survival, and 5-year cause-specific survival were similar in the two groups, the rate of significant complications was higher in patients who underwent upfront surgery.

- Fu et al. [11] performed a randomized trial of over 1,000 patients with locally advanced head and neck cancer, randomizing them to (a) standard fractionation at 2 Gy once daily to 70 Gy, (b) accelerated fractionation, 1.2 Gy BID to 81.6 Gy, (c) accelerated fractionation with a split-course, 1.6 Gy BID to 38.4 Gy, 2-week break, then to 67.2 Gy, or (d) accelerated fractionation with a concomitant boost, 1.8 Gy daily to 72 Gy, with a boost of 1.5 Gy as a second daily treatment for the last 12 fractions. Arms (b) and (d) had better local-regional control than arms (a) and (c).
- Denis et al. [12], randomized 226 patients with stage III or IV oropharyngeal carcinoma to either (a) radiation alone (70 Gy in 2 Gy fractions) or (b) concomitant chemoradiation with the regimen above and carboplatin (70 mg/m²) with fluorouracil (600 mg/m²). Five-year overall survival (22% vs. 16%), disease-free survival (27% vs. 15%), and locoregional control (48% vs. 25%) all favored the chemoradiation arm.
- Pignon et al. [13] performed a meta-analysis that included trials between 1965 and 2000 of patients with carcinoma of the oropharynx, oral cavity, larynx, or hypopharynx; there was an overall survival benefit of approximately 6.5% in 5 years in favor of concomitant chemoradiotherapy.

Target Delineation

- Table 18.4 depicts suggested guidelines for target delineation in oropharyngeal carcinoma.
- Note that the bilateral neck is covered in all oropharyngeal lesions other than T1N0 and small well-lateralized

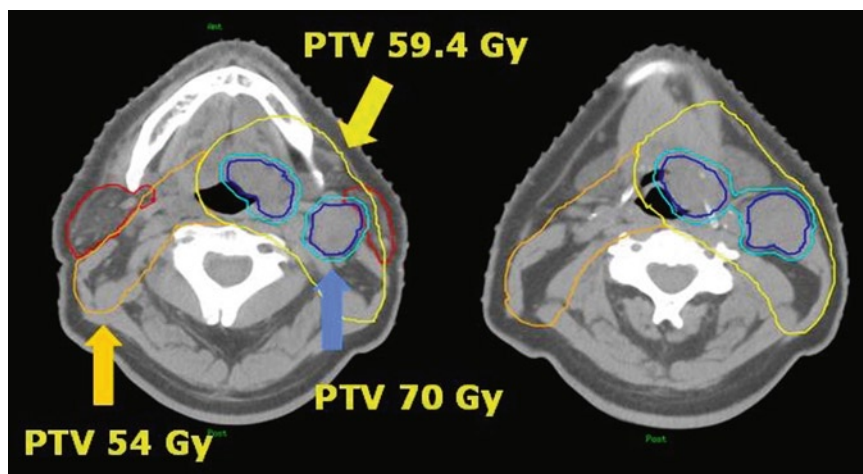
Table 18.4 Suggested target delineation guidelines for oropharyngeal cancer

Site/stage	CTV1	CTV2	CTV3
Tonsil/T1N0	GTV+5–10 mm	Ipsilateral levels IB-V ^a , RP	
Tonsil/T2–T4N0	GTV+5–10 mm	Bilateral levels IB-V ^a RP	
Tonsil/T1–T4N+	GTV+5–10 mm	Ipsilateral IB-V RP	Contralateral Ib-V, RP
Base of Tongue Soft Palate T1–T4N0	GTV+5–10 mm	Bilateral IB-V ^a , RP	
Base of Tongue Soft Palate T1–T4N+	GTV+ 5–10 mm	Ipsilateral Ib-V, RP	Contralateral Ib-V ^a , RP

Note: For all dosing, the treating physician can also decide on whether the N0 nodal CTVs are treated with the CTV2 or CTV3 dose

RP retropharyngeal nodes

^a At the discretion of the treating physician, can treat levels II–IV in N0 neck

Fig. 18.2 Axial slices of representative slices of a oropharyngeal carcinoma patient undergoing IMRT

T2N0 tonsillar lesions without soft palate or base of tongue involvement.

- Figure 18.2 depicts the delineation of a representative patient from Memorial Sloan-Kettering Cancer Center (MSKCC).

IMRT Results

- Chao et al. [14] reviewed 74 patients with squamous cell carcinoma of the oropharynx (all stages) treated with IMRT. Thirty-one received definitive IMRT and the remaining were treated postoperatively. Four-year overall survival and disease-free survival were 87 and 81%, respectively. Fifteen patients experienced Grade 3 or higher skin toxicity, while 32 experienced Grade 3 or higher mucosal toxicity (28 with Grade 3). There were no Grade 3 or higher late toxicities. The most common late toxicity was xerostomia; there were 32 patients with Grade 1 and nine patients with Grade 2 late toxicity.
- In a study by de Arruda et al. [15] at MSKCC, 50 patients with oropharyngeal carcinoma treated with IMRT between

1998 and 2004 were analyzed (78% stage IV disease, 96% with definitive treatment). Two-year local control and overall survival were both 98%. Thirty-one patients had Grade 3 acute toxicities, none had Grade 4 acute toxicities. 67% had Grade 0–1 late toxicities, and the remainder had Grade 2 late toxicities. Of the 42 patients that had a percutaneous endoscopic gastrostomy (PEG) tube placed at the beginning of treatment, 36 had the PEG tube removed at the time of analysis.

Hypopharynx

General Facts

- The anatomical boundaries of the hypopharynx are as follows: superior, hyoid bone; inferior, inferior edge of cricoid cartilage. The pyriform sinuses are lateral to the vocal cords, but the apices of the pyriform sinuses extend inferiorly to the vocal cords.

- Superior to the hypopharynx is the oropharynx, and inferiorly lies the most superior portion of the esophagus (the cervical esophagus).
- There is significant lymphatic drainage to the hypopharynx. Three main pathways exist: (1) through the internal branch of the superior laryngeal artery to levels II and III, (2) through the paratracheal lymph nodes into level IV and the mediastinal lymph nodes, and (3) to the retropharyngeal lymph nodes.
- The most common site of lymph node metastasis is to level II.
- Almost all hypopharyngeal tumors are squamous cell carcinomas.

General Management

- T1–T2N0 disease can be treated with either definitive radiation or surgery.
- Conservative surgery for early-stage disease entails a partial laryngopharyngectomy with ipsilateral neck dissection. Patients with N2C disease undergo a bilateral neck dissection.
- The following are contraindications for conservation surgery: vocal cord paralysis, pyriform sinus apex invasion, cartilage invasion, extralaryngeal extension, and/or arytenoid involvement.
- For locally advanced disease, including T3–T4 or node-positive tumors, surgery with adjuvant radiation ± chemotherapy or concurrent chemoradiotherapy is the treatment of choice.
- The surgery for locally advanced disease is a total laryngectomy and partial pharyngectomy with neck dissection.
- Multiple retrospective studies have demonstrated the efficacy of postoperative radiation therapy for advanced tumors [16–18].
- Randomized studies have shown the added benefit of chemotherapy given concurrently with postoperative radiation therapy in patients with high-risk features, i.e., positive margins or extracapsular extension [19–21].
- In a Phase III trial by Lefebvre et al. [22], patients with T2–T4N0–N2b disease were assigned to either: (a) immediate laryngectomy with postoperative radiotherapy (50–70 Gy) or (b) induction chemotherapy with cisplatin (100 mg/m²) and fluorouracil infusion (1,000 mg/m²), followed by either radiation (70 Gy) in the responders or laryngectomy followed by postoperative radiation (50–70 Gy) in the nonresponders. While local failures were approximately the same in the two arms (12% vs. 17%), there were fewer distant failures in arm b (25% vs. 36%), and the median overall survival was also greater (44 months vs. 25 months). The authors concluded that laryngeal

preservation is a feasible approach in patients with locally advanced hypopharyngeal cancer.

- Several randomized trials comparing chemoradiotherapy to radiotherapy alone included hypopharyngeal carcinoma and have shown improved locoregional control, disease-free survival, and overall survival in the combined-modality arm.

Target Delineation

- Table 18.5 depicts suggested target volumes for patients with hypopharyngeal tumors. GTV includes all gross disease and any clinically involved lymph nodes.
- Due to the high likelihood of lymphatic spread, levels II–V should be included in the field along with retropharyngeal nodal regions. Please see Table 18.5 for further details.
- Figure 18.3 depicts representative CT slices from a patient with locally advanced hypopharyngeal carcinoma.

IMRT Results

- Lee et al. [23] analyzed 20 patients with laryngeal cancer and 11 patients with hypopharyngeal cancer treated with IMRT and concurrent platinum-based chemotherapy at MSKCC, most of whom had stage IV disease. Two-year locoregional control for the patients with hypopharyngeal tumors was 73%, and 2-year overall survival was 53%. Four of the eleven patients were PEG-tube dependent at the time of the analysis, and the 2-year PEG-tube dependency rate was 31%.

Larynx

General Facts

- The larynx is divided into three subsites: the supraglottis, the glottis, and the subglottis.
- The supraglottis contains the following: epiglottis, aryepiglottic folds, arytenoids, and false vocal cords.

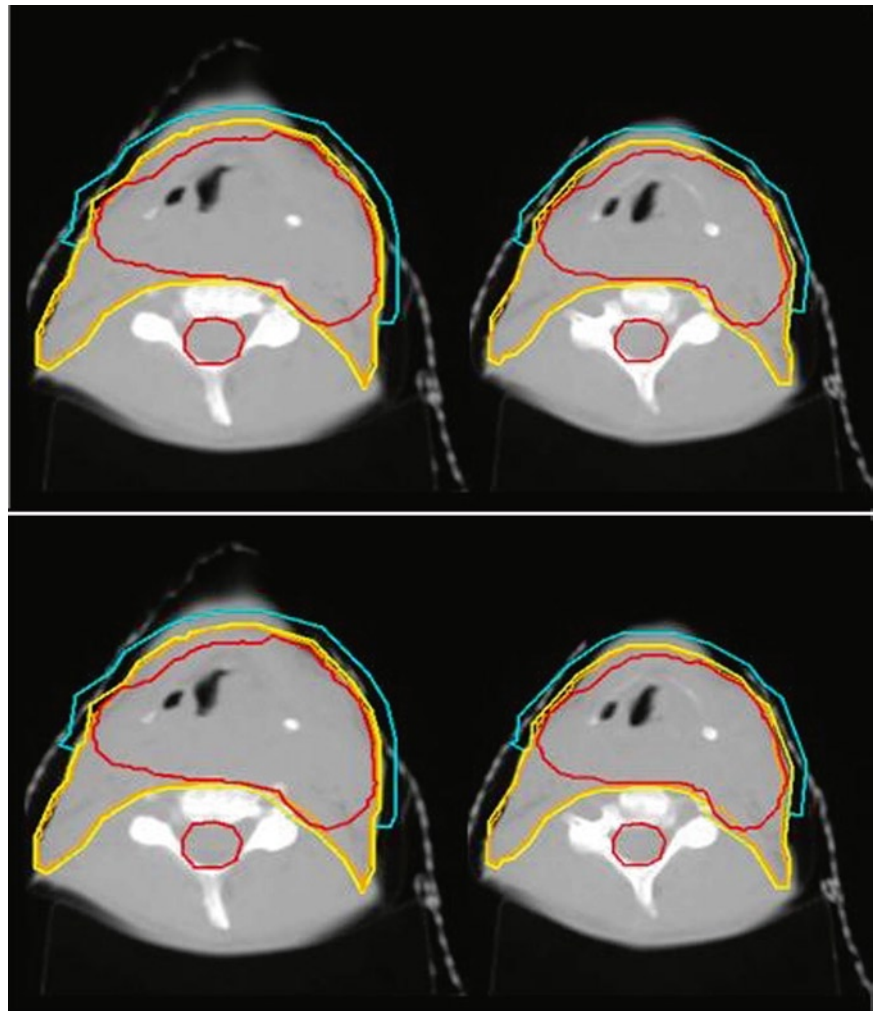
Table 18.5 Suggested target delineation guidelines for hypopharyngeal cancer

Site/stage	CTV1	CTV2	CTV3
T1–T4N0	GTV + 5–10 mm	Bilateral levels II–V ^a , RP	
T1–T4N+	GTV + 5–10 mm	Ipsilateral levels I–V, RP	Contralateral levels II–V, RP

RP retropharyngeal nodes

^aAt the discretion of the treating physician, can treat levels II–IV in N0 neck

Fig. 18.3 Axial slices of representative slices of a hypopharyngeal carcinoma patient undergoing IMRT



The supraglottis has a significant amount of lymphatic drainage. Through the thyrohyoid membrane, the lymphatic drainage proceeds to levels II–IV.

- The glottis contains the true vocal cords and the anterior and posterior commissures. There are no lymph nodes that drain from the true vocal cords. Lymph node metastases from tumors of the true vocal cords occur with extension of the tumor to the subglottis or supraglottis.
- The subglottis extends from the lower boundary of the glottis to the inferior aspect of the cricoid cartilage. The subglottis drains to prelaryngeal, lower jugular, pretracheal, and upper mediastinal lymph nodes.
- Greater than 95% of laryngeal tumors are squamous cell carcinomas.
- One distinct entity of squamous cell carcinoma in laryngeal cancer is verrucous carcinoma, which is well differentiated and exophytic. It has been cited in the past that these tumors undergo transformation to an aggressive phenotype after radiation, but whether or not this truly occurs remains unclear.

General Management

- Carcinoma in situ of the vocal cord can be managed by either radiation therapy, local excision, or laser therapy. With vocal cord “stripping” or laser excision, tumors often recur, and such patients should be referred for radiation therapy. Control rates are above 95% with radiation.
- For early-stage carcinoma of the vocal cord (T1–T2N0M0), surgical excision and radiation therapy have been shown to have comparable results. However, voice quality is generally better preserved with radiation therapy. The typical dose is 2.25 Gy to a total dose of 63 Gy for T1 and 65.25 Gy for T2 lesions.
- To study locally advanced laryngeal cancer, RTOG 9111 [24] randomized 547 patients with stage III or IV laryngeal carcinoma (T1 tumors and large-volume stage IV excluded) to either (a) induction chemotherapy with cisplatin (100 mg/m²) and fluorouracil (1,000 mg/m²) followed by radiation therapy (70 Gy in 2 Gy fractions), (b) concurrent radiation (70 Gy in 2 Gy fractions) and

cisplatin (100 mg/m² on days 1, 22, and 43), or (c) radiation alone (70 Gy in 2 Gy fractions). The study found that concurrent chemoradiation provided an increased rate of larynx preservation at 2 years (88% vs. 75% and 70% in arms b vs. arms a and c, respectively), as well as improved disease-free survival.

- Early exophytic lesions of the supraglottis (T1N0) can be treated with either definitive radiation or hemilaryngectomy (supraglottic laryngectomy), which provides voice preservation.
- For intermediate disease (T2NX), definitive chemoradiation and supraglottic laryngectomy offer similar rates of local control. The following are contraindications to supraglottic laryngectomy: bilateral arytenoid involvement, arytenoid fixation, base of tongue involvement, invasion of the thyroid or cricoid cartilage, involvement of the postcricoid region, impaired vocal cord mobility, glottic extension, and/or patients at increased risk of aspiration (elderly, patients with lung disease).
- For extensive lesions (T3–T4), either voice preservation with chemoradiation or surgery and postoperative radiation ± chemotherapy are utilized. Note that patients with significant thyroid cartilage invasion are usually referred for surgery. Postoperative chemotherapy should be considered in patients with a positive margin or extracapsular extension.
- Subglottic tumors are rare and are usually diagnosed at an advanced stage. The treatment of choice is typically surgery followed by radiation ± chemotherapy. Alternative treatment consists of concurrent chemoradiotherapy.

Target Delineation

- Table 18.6 demonstrates the suggested target delineation for a patient with supraglottic cancer. As noted above, subglottic tumors are rare and treatment should be individualized depending on the clinical situation.
- Laryngeal cancer (other than T1–T2N0 glottic tumors) is generally treated using an “all-in-one” technique. No low anterior neck field is utilized.
- As noted above, in T1–T2N0 tumors the neck is generally not treated. However, in T2N0 tumors that are bulky, or with subglottic extension, the physician can consider treating the bilateral neck, as described for T3–T4N0 tumors.

IMRT Results

- In the Lee et al. [23] study cited above, 20 patients with laryngeal cancer (and mainly stage IV disease) were treated with IMRT and concurrent platinum-based chemotherapy. The 2-year rates of locoregional control and overall survival

Table 18.6 Suggested target delineation guidelines for laryngeal cancer

Site/stage	CTV1	CTV2	CTV3
<i>Supraglottic</i>			
T1–T4N0	GTV + 5–10 mm	Bilateral levels II–V ^a , RP	
T1–T4N+	GTV + 5–10 mm	Ipsilateral levels I–V, RP	Contralateral levels II–V, RP
<i>Glottic</i>			
T3–T4N0	GTV + 5–10 mm	Bilateral levels II–V ^a	
T1–T4N+	GTV + 5–10 mm	Ipsilateral levels I–V	Contralateral levels II–V ^a , RP

Note: RP nodal regions should be covered if there is involvement of the hypopharynx or there are involved cervical lymph nodes
RP retropharyngeal nodes

^a At the discretion of the treating physician, can treat levels II–IV in N0 neck

were 90 and 69%, respectively, for the patients with laryngeal cancer. One patient developed laryngeal necrosis and one patient had an unusual complication of necrotizing fasciitis. The 2-year PEG-tube dependency rate was 15%.

Oral Cavity

General Facts

- The oral cavity is made up of the lips, buccal mucosa, the floor of the mouth, the upper and lower gingiva, the anterior two-thirds of the oral tongue, the hard palate, and the retromolar trigone.
- The upper lips are drained primarily by level IB (submandibular) lymph nodes, and less commonly by the periauricular and parotid lymph nodes.
- The lymphatic drainage to the buccal mucosa is primarily to levels IB and II.
- The primary lymphatic drainage of the floor of mouth is to levels IA and II.
- The primary lymphatic drainage of the upper gingival is to levels IB and II.
- The muscles of the oral tongue are innervated by the hypoglossal nerve, and sensory innervation is through the lingual nerve, which is part of the mandibular branch of the trigeminal nerve (V). Taste sensation is provided by cranial nerve VII. The three most common routes of lymphatic drainage are to levels IB, II, and, less commonly, IA. However, there is also a direct route to level III, and occasionally isolated metastases are found in this region.
- The most common lymphatic metastases of the hard palate are to levels IB and II.

- The retromolar trigone primarily drains to levels IB and II.
- Squamous cell carcinoma accounts for the vast majority of cases.

General Management

- Definitive surgery is the preferred treatment of choice for all oral cavity cancers unless there is a contraindication. Postoperative radiation therapy is given to those at high risk for recurrence.
- Chemotherapy has been shown to benefit patients with positive margins or extracapsular extension, as detailed above in the Cooper et al. and Bernier et al. studies [19–21].

Target Delineation

- Due to the higher propensity for oral cavity tumors (and in particular floor of mouth and oral tongue cancer) to invade lymph node level I, these lymph nodes should be included in the neck volumes. Therefore, in the positive neck, levels I–V should be included. In the node negative contralateral neck, levels I–IV should be included.
- Coverage for the postoperative bed should be generous as this anatomic site has been surgically violated. This volume should at least include the preoperative GTV.

- One can consider sparing the contralateral neck in early-stage lesions of the buccal mucosa, retromolar trigone, and gingiva; for lesions that are not well lateralized the bilateral neck should be treated.
- The risk of metastasis to retropharyngeal lymph nodes is low, but these lymph nodes can be treated in locally advanced or midline lesions at the physician's discretion.
- Figure 18.4 demonstrates representative CT slices from a patient with oral tongue cancer treated at MSKCC.

IMRT Results

- Yao et al. [25] recently reported on 55 patients with squamous cell carcinoma of the oral cavity, 91% of whom had stage III or IV disease. At a median follow-up of 17 months, 2-year disease-free and overall survival rates were 82 and 68%, respectively. When examining prognostic factors for locoregional control, the study found that anatomic subsite was predictive, with 2-year rates of locoregional control being 69% in oral tongue cancer, 100% for floor of mouth cancer, and 83% for all other groups together. Extracapsular extension was also found to significantly affect locoregional control.
- Studer et al. [26] analyzed 58 patients with oral cavity cancer treated at the University of Zurich. Twenty-eight of these patients were referred for postoperative treatment, and the remainder for definitive treatment. Forty

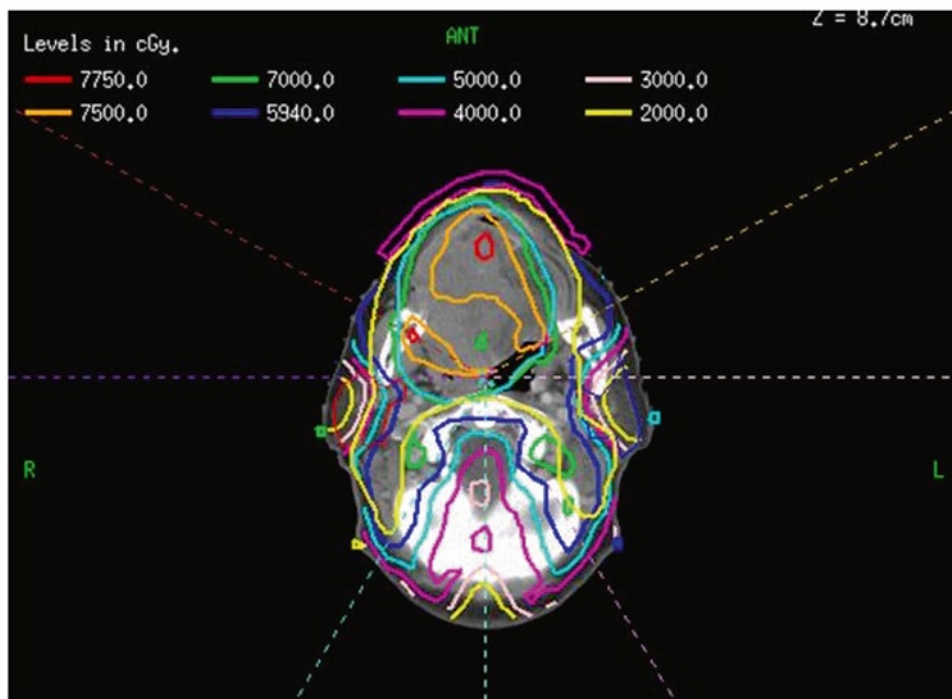


Fig. 18.4 Axial slices of representative slices of an oral cavity patient undergoing IMRT

patients had T3 or T4 lesions. Patients treated postoperatively had a 92% rate of local control at 2 years, while those treated with radiation alone had a local control rate of 30–40%.

- Gomez et al. [27] reported a series of 35 oral cavity patients treated with IMRT ± chemotherapy after definitive surgical resection. All patients had stage III–IV disease. With a median follow-up of 28.1 months, the 2 and 3 year estimates of locoregional progression-free survival were 84 and 77%, respectively. The overall survival was 74%. Late complications included trismus (17%) and osteoradionecrosis (5%).

Thyroid

General Facts

- The thyroid gland is made up of two lobes. They are joined by the thyroid isthmus. The gland lies posterior to the strap muscles and anterior to the prevertebral muscles, inferior to the thyroid cartilage and with the isthmus overlying the second and third tracheal rings.
- The thyroid gland has a rich vascular and lymphatic supply. The lymphatic drainage is primarily to the surrounding lymph nodes of the trachea and esophagus (level VI), with a secondary route being to the cervical lymph nodes, levels I–V. There is also lymphatic drainage to level VII.

General Management

- The mainstay of management for thyroid carcinoma is surgery. Depending on the extent of disease, this resection can entail a near-total thyroidectomy, total thyroidectomy, or wide composite resection to include the surrounding infiltrated tissue.
- External beam radiotherapy is given in select cases where patients are at high risk for local recurrence due to their locally aggressive nature, aggressive histology, or unsatisfactory surgery.

Target Delineation

- The CTV includes the thyroid bed, tracheo-esophageal groove, central compartment, levels II–VII, and the upper mediastinum to the level of the carina.
- Figure 18.5 demonstrates representative CT slices from a patient with thyroid cancer treated with IMRT.

IMRT Results

- Rosenbluth et al. [28] examined 20 patients with nonanaplastic thyroid carcinoma treated with IMRT. Seventeen of these patients had T4 disease and 16 patients had N1 disease. The median total radiation dose was 63 Gy

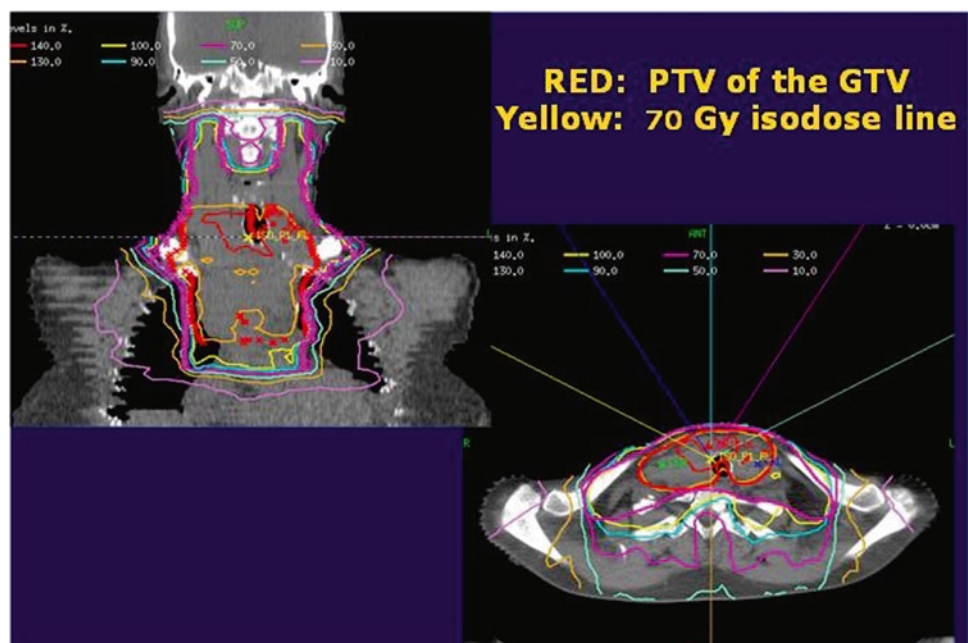


Fig. 18.5 Axial slices of representative slices of a thyroid cancer patient undergoing IMRT

(“high-risk” PTV with a total dose of 59.4–63 Gy, positive margins treated to 63–66 Gy). The 2-year local control rate was 85% and the 2-year overall survival rate was 60%. Four of the six deaths were due to metastatic disease.

- In terms of toxicity, 7 of 20 patients had Grade 3 acute mucositis, 3 of 20 patients developed Grade 3 pharyngitis, and 2 of 20 patients had Grade 3 skin toxicity. There was no Grade 3 or higher xerostomia.

Cancer of Unknown Primary

General Facts

- The most commonly involved lymph nodes in cancer of unknown primary (CUP) of the head and neck are levels II and III. Levels I, IV, and V are less commonly involved.
- The most common primary site for CUP is the oropharynx, which accounts for approximately 80% of tumors.
- The most common histology of CUP is squamous cell carcinoma, with lymphoma, adenocarcinoma, and poorly differentiated tumors being less common.
- Multiple studies have examined the role of PET scan in detecting the primary tumor, particularly when conventional techniques have not elucidated the origin of disease.

General Management

- Patients with N1 disease can be treated with a neck dissection alone if there is no extracapsular extension. However, a review by the Danish Society for Head and Neck Oncology, showed that patients treated with surgery alone had an emerging primary rate of 54% at 5 years and a neck control rate of 58% [29].
- Radiation therapy alone is also an option for patients in lieu of neck dissection. In the same study by the Danish Society, the mucosal control rate was 84% in patients receiving radiation alone and the neck control rate was 50%.
- Surgery in combination with radiation therapy has appeared to produce the lowest rates of mucosal primary emergence and neck control. The emerging primary rate in the study above for patients receiving surgery with radiation therapy was 15%.
- Patients are usually treated with a field that encompasses the bilateral cervical lymph nodes, the retropharyngeal lymph nodes, and the comprehensive mucosal membranes. However, studies have also been done that utilized ipsilateral neck radiation, particularly for patients with poorer performance status.

Target Delineation

- In addition to lymph node coverage, the mucosal surfaces throughout the head and neck should also be targeted, including the nasopharynx, oropharynx, larynx, and hypopharynx, while the oral cavity is excluded.
- The dosing of the different mucosal sites can differ depending on the likelihood of emergence of primary in that site. For example, a patient with Asian descent should receive a higher total radiation dose to the nasopharynx while a Caucasian is more likely to have disease involving the oropharynx and hence a higher total dose should be delivered to that site.
- There are situations at the discretion of the treating physician where only the involved neck needs to be treated.

IMRT Results

- Klem et al. [30] examined 21 patients treated with IMRT. Fourteen were treated with chemoradiation, and five patients received radiation with definitive intent (rather than in the adjuvant setting). Two-year rates of locoregional survival, distant-metastasis-free survival, and overall survival were 90, 90, and 85%, respectively.
- In terms of toxicity, at 6 months posttreatment one patient had greater than Grade 1 xerostomia, and Grade 3 acute skin and mucosal toxicity were 5 and 14%, respectively. PEG tube placement was required in 13 patients, but at last follow-up only one patient was PEG-tube dependent. Three patients experienced esophageal strictures, and all had improvement with dilation.

Conclusions

IMRT has resulted in clinical improvement quality of life for patients with head and neck cancer. Yet target delineation remains a challenge, due to the complexity of the head and neck anatomy. Improved imaging promises to help improve the delineation of the extent gross disease, but understanding the patterns of spread of disease from the primary tumor site and the nodal drainage is required.

References

1. Gregoire V, Levendag P, Ang KK, Bernier J, et al. CT-based delineation of lymph node levels and related CTVs in the node-negative neck: DAHANCA, EORTC, GORTEC, NCIC, RTOG consensus guidelines. *Radiother Oncol.* 2003;69:227–36.

2. Gregoire V, Eisbruch A, Hamoir M, Levendag P. Proposal for the delineation of the nodal CTV in the node-positive and the post-operative neck. *Radiother Oncol.* 2006;79:15–20.
3. Al-Sarraf M, LeBlanc M, Giri PG, Fu KK, et al. Chemoradiotherapy versus radiotherapy in patients with advanced nasopharyngeal cancer: phase III randomized Intergroup study 0099. *J Clin Oncol.* 1998;16:1310–7.
4. Wee J, Tan EH, Tai BC, Wong HB, et al. Randomized trial of radiotherapy versus concurrent chemoradiotherapy followed by adjuvant chemotherapy in patients with American Joint Committee on Cancer/International Union against cancer stage III and IV nasopharyngeal cancer of the endemic variety. *J Clin Oncol.* 2005;23:6730–8.
5. Kam MK, Leung SF, Zee B, Chau RM, et al. Prospective randomized study of intensity-modulated radiotherapy on salivary gland function in early-stage nasopharyngeal carcinoma patients. *J Clin Oncol.* 2007;25:4873–9.
6. Pow EH, Kwong DL, McMillan AS, Wong MC, Sham JS, Leung LH, et al. Xerostomia and quality of life after intensity-modulated radiotherapy vs. conventional radiotherapy for early-stage nasopharyngeal carcinoma: initial report on a randomized controlled clinical trial. *Int J Radiat Oncol Biol Phys.* 2006;66:981–91.
7. Lee N, Xia P, Quivey JM, Sultanem K, et al. Intensity-modulated radiotherapy in the treatment of nasopharyngeal carcinoma: an update of the UCSF experience. *Int J Radiat Oncol Biol Phys.* 2002;53:12–22.
8. Lee N, Harris J, Garden AS, Straube W, et al. Intensity-modulated radiation therapy with or without chemotherapy for nasopharyngeal carcinoma: radiation therapy oncology group phase II trial 0225. *J Clin Oncol.* 2009;27:3684–90.
9. Kramer S, Gelber RD, Snow JB, Marcial VA, Lowry LD, Davis LW, et al. Combined radiation therapy and surgery in the management of advanced head and neck cancer: final report of study 73-03 of the Radiation Therapy Oncology Group. *Head Neck Surg.* 1987;10:19–30.
10. Parsons JT, Mendenhall WM, Stringer SP, Amdur RJ, et al. Squamous cell carcinoma of the oropharynx: surgery, radiation therapy, or both. *Cancer.* 2002;94:2967–80.
11. Fu KK, Pajak TF, Trotti A, Jones CU, et al. A Radiation Therapy Oncology Group (RTOG) phase III randomized study to compare hyperfractionation and two variants of accelerated fractionation to standard fractionation radiotherapy for head and neck squamous cell carcinomas: first report of RTOG 9003. *Int J Radiat Oncol Biol Phys.* 2000;48:7–16.
12. Denis F, Garaud P, Bardet E, Alfonsi M, et al. Final results of the 94-01 French Head and Neck Oncology and Radiotherapy Group randomized trial comparing radiotherapy alone with concomitant radiochemotherapy in advanced-stage oropharynx carcinoma. *J Clin Oncol.* 2004;22:69–76.
13. Pignon JP, le Maitre A, Maillard E, Bourhis J. Meta-analysis of chemotherapy in head and neck cancer (MACH-NC): an update on 93 randomized trials and 17,346 patients. *Radiother Oncol.* 2009;92:4–14.
14. Chao KS, Ozyigit G, Blanco AI, Thorstad WL, Deasy JO, Haughey BH, et al. Intensity-modulated radiation therapy for oropharyngeal carcinoma: impact of tumor volume. *Int J Radiat Oncol Biol Phys.* 2004;59:43–50.
15. de Arruda FF, Puri DR, Zhung J, Narayana A, et al. Intensity-modulated radiation therapy for the treatment of oropharyngeal carcinoma: the Memorial Sloan-Kettering Cancer Center experience. *Int J Radiat Oncol Biol Phys.* 2006;64:363–73.
16. Driscoll WG, Nagorsky MJ, Cantrell RW, Johns ME. Carcinoma of the pyriform sinus: analysis of 102 cases. *Laryngoscope.* 1983;93:556–60.
17. Frank JL, Garb JL, Kay S, McClish DK, et al. Postoperative radiotherapy improves survival in squamous cell carcinoma of the hypopharynx. *Am J Surg.* 1994;168:476–80.
18. Slotman BJ, Kralendonk JH, Snow GB, Tiwari RM, Karim AB. Surgery and postoperative radiotherapy and radiotherapy alone in T3-T4 cancers of the pyriform sinus. Treatment results and patterns of failure. *Acta Oncol.* 1994;33:55–60.
19. Bernier J, Cooper JS, Pajak TF, van Glabbeke M, et al. Defining risk levels in locally advanced head and neck cancers: a comparative analysis of concurrent postoperative radiation plus chemotherapy trials of the EORTC (#22931) and RTOG (# 9501). *Head Neck.* 2005;27:843–50.
20. Bernier J, Dommange C, Ozsahin M, Matuszewska K, et al. Postoperative irradiation with or without concomitant chemotherapy for locally advanced head and neck cancer. *N Engl J Med.* 2004;350:1945–52.
21. Cooper JS, Pajak TF, Forastiere AA, Jacobs J, et al. Postoperative concurrent radiotherapy and chemotherapy for high-risk squamous-cell carcinoma of the head and neck. *N Engl J Med.* 2004;350:1937–44.
22. Lefebvre JL, Chevalier D, Lubinski B, Kirkpatrick A, Collette L, Sahnoud T. Larynx preservation in pyriform sinus cancer: preliminary results of a European Organization for Research and Treatment of Cancer phase III trial. EORTC Head and Neck Cancer Cooperative Group. *J Natl Cancer Inst.* 1996;88:890–9.
23. Lee NY, O'Meara W, Chan K, Della-Bianca C, et al. Concurrent chemotherapy and intensity-modulated radiotherapy for locoregionally advanced laryngeal and hypopharyngeal cancers. *Int J Radiat Oncol Biol Phys.* 2007;69:459–68.
24. Forastiere AA, Goepfert H, Maor M, Pajak TF, et al. Concurrent chemotherapy and radiotherapy for organ preservation in advanced laryngeal cancer. *N Engl J Med.* 2003;349:2091–8.
25. Yao M, Chang K, Funk GF, Lu H, Tan H, Wacha J, et al. The failure patterns of oral cavity squamous cell carcinoma after intensity-modulated radiotherapy—the University of Iowa experience. *Int J Radiat Oncol Biol Phys.* 2007;67:1332–41.
26. Studer G, Zwahlen RA, Graetz KW, Davis BJ, Glanzmann C. IMRT in oral cavity cancer. *Radiat Oncol.* 2007;2:16.
27. Gomez DR, Zhung JE, Gomez J, Chan K, et al. Intensity-modulated radiotherapy in postoperative treatment of oral cavity cancers. *Int J Radiat Oncol Biol Phys.* 2009;73:1096–103.
28. Rosenbluth BD, Serrano V, Happersett L, Shaha AR, et al. Intensity-modulated radiation therapy for the treatment of nonanaplastic thyroid cancer. *Int J Radiat Oncol Biol Phys.* 2005;63:1419–26.
29. Grau C, Johansen LV, Jakobsen J, Geertsen P, Andersen E, Jensen BB. Cervical lymph node metastases from unknown primary tumours. Results from a national survey by the Danish Society for Head and Neck Oncology. *Radiother Oncol.* 2000;55:121–9.
30. Klem ML, Mechalakos JG, Wolden SL, Zelefsky MJ, et al. Intensity-modulated radiotherapy for head and neck cancer of unknown primary: toxicity and preliminary efficacy. *Int J Radiat Oncol Biol Phys.* 2008;70:1100–7.

Chapter 19

Principles of Systemic Chemotherapy for Squamous Cell Head and Neck Cancer

Cristina P. Rodriguez and David J. Adelstein

Abstract Head and neck squamous cell carcinomas are a group of malignancies that are sensitive to systemic therapy, in part due to the complexity of the molecular aberrations in these malignancies that impair DNA repair mechanisms. Administration of chemotherapy in the treatment of head and neck cancers is guided by treatment goals and patient factors unique to this patient population. The known radiation sensitizing properties of chemotherapy and its ability to impact rates of distant failure have established concurrent chemoradiation as a standard definitive and adjuvant therapy for locally advanced disease. Although known to produce tumor responses, chemotherapy given in the metastatic setting has not been consistently demonstrated to improve overall survival. The combination of chemotherapy with targeted monoclonal antibodies has shown promising results. Future investigation of the role of nonoperative treatments in this disease will likely focus on efforts to decrease late treatment-induced morbidity, exploration of reirradiation with concurrent chemotherapy as a salvage therapy, and further integration of chemotherapy, radiation and targeted therapies in both definitive and palliative management.

Keywords Systemic chemotherapy • Multimodality therapy • Concurrent chemoradiation • Palliative chemotherapy

Introduction

Historically, the use of systemic treatments in squamous cell head and neck cancer has required an entirely different approach that taken by the radiation therapist and surgeon. For the medical oncologist, the anatomic distinctions so critical for locoregional disease management are of considerably

less importance than the commonalities that head and neck cancers share. These include the common risk factors of tobacco and alcohol abuse, and the associated comorbidity. In addition, these tumors are histologically similar and tend to be locoregionally aggressive with only a limited metastatic potential. The most important similarity, however, has been the relatively uniform response of head and neck cancers to systemic chemotherapy. Indeed, previously untreated squamous cell head and neck cancer is remarkably sensitive to systemic treatments, particularly when compared to most other common solid tumors [1].

Oncogenesis and the Progression from Benign to Malignant Epithelium

The complex process that transforms normal epithelium to invasive squamous cell carcinoma is incompletely understood, and the intense scientific inquiry focused on these events has paved the way for development of effective systemic agents for this disease. Malignant transformation is a multistep process that is thought to involve an accumulation of genetic defects and interplay between carcinogen exposure, genetic predisposition, and more recently, viral infection.

Tobacco and alcohol are well-established risk factors for head and neck cancer. “Field cancerization” is used to describe the predisposition to malignant transformation along the entire upper aerodigestive tract epithelium as a result of carcinogen exposure [2]. Molecular abnormalities known to occur early in oncogenesis are often observed not only in the premalignant lesions themselves, but the surrounding normal epithelium. Synchronous premalignant and malignant lesions in different areas of the aerodigestive tract have been noted to harbor similar molecular abnormalities. This process is felt to be responsible for the clinical observation of second or third primary upper aerodigestive tract malignancies in patients with heavy alcohol and tobacco exposure successfully treated for their index head and neck squamous cell cancer [3].

D.J. Adelstein (✉)
Department of Solid Tumor Oncology, Cleveland Clinic Taussig Cancer Center, Cleveland Clinic Lerner College of Medicine of Case Western Reserve University, Desk R-35, 9500 Euclid Avenue, Cleveland, OH 44195, USA
e-mail: adelstd@ccf.org

The stepwise progression to malignancy is somewhat similar to the colon cancer model of carcinogenesis. One of the first observations supporting this was the reproducible cytogenetic abnormalities identified in hyperplasia, dysplasia, carcinoma in situ, and invasive malignancy [4, 5]. For instance, loss of heterozygosity at the 3p and 9p loci have been frequently observed in early premalignant hyperplastic head and neck mucosal lesions. The transition from hyperplastic to dysplastic epithelium is often characterized by loss of heterozygosity at 17p, and gains in the 11q23 region. With more sophisticated molecular techniques, these chromosomal changes have been found to correspond to genes that play critical roles in cell cycle regulation, specifically the tumor suppressor genes p53, Rb, p16, and cyclin D1.

It is becoming increasingly apparent that neoplastic transformation is mediated by a far more complex interaction of factors than genetic mutations in proteins regulating the cell cycle. Gene silencing through epigenetic phenomena, such as hypermethylation of promoter regions of tumor suppressor genes, has been observed [6]. The role of overexpressed cell surface receptors such as EGFR and its downstream signaling cascade mediating cellular immortalization and invasion has been recognized [7]. The influence of genes and proteins responsible for cellular adhesion, such as E-cadherin [8], and matrix metalloproteinases [9], has also been implicated. These more recently identified pathways represent therapeutic targets and avenues for drug development [10].

The role of viral infection in carcinogenesis in head and neck cancer was first recognized in nasopharyngeal cancer. Virtually all cases of endemic undifferentiated nasopharyngeal carcinoma are found to harbor the Epstein–Barr virus. The viral proteins LMP1 and LMP2a are thought to exert transforming effects through intracellular signaling cascades promoting cellular immortalization [11]. These cancers behave differently from head and neck cancer of other subsites, with a predilection for early distant spread but otherwise superior treatment outcomes after therapy for local disease.

There has also been increasing recent awareness of a distinct patient population with oropharyngeal cancer harboring high-risk human papillomavirus (HPV) subtypes [12]. These patients may not have a prior exposure to tobacco and alcohol, an observation that has challenged the applicability of the field cancerization theory and the multistep carcinogenesis model to all head and neck cancers. These HPV-associated tumors often contain wild-type p53 and Rb, which are functionally inactivated by viral proteins [13]. Not only are these HPV-positive tumors molecularly distinct, but they also appear to have clinically distinct behavior, and a significantly better prognosis after treatment. Investigation into the optimal therapeutic approach for this unique subset is ongoing.

Treatment Goals and Efficacy Endpoints

When defining the management for any patient with cancer, it is critical that a clear treatment goal be identified. If the treatment goal is cure, considerable short- and long-term treatment-induced morbidity may be considered acceptable. Aggressive treatment approaches may still be justified when survival prolongation is possible, even if the disease cannot be cured. When the patient can only be palliated, however, considerable discretion must be exercised in the choice of treatment, and the toxicity considered acceptable. Thus the risk/benefit ratio varies considerably depending on the goal of the treatment and the anticipated outcome. What might be considered to be acceptable risk and toxicity for a potentially curable patient may be entirely unacceptable for a patient treated with palliative intent.

Multiple efficacy endpoints are used in assessing the success of any cancer treatment [14]. The gold standard endpoint, and the endpoint which is easiest to measure in a clinical trial, has always been overall survival. In patients with head and neck cancer, however, survival is not only impacted by the disease itself, but by the frequent underlying cardiopulmonary comorbidity, and by the significant incidence of second primary malignancy.

In patients with advanced disease, an improvement in survival may be difficult to demonstrate, and may not be a prerequisite for symptomatic palliation. Tumor response, i.e., a measurable shrinkage in tumor volume, has always been considered to be an accurate reflection of antineoplastic activity [14]. Clear definitions of what actually constitutes a meaningful response are critically important in determining which chemotherapeutic agents might be of value in drug combinations, or in definitive multimodality treatment. These definitions have evolved over time but have been recently standardized as the Response Evaluation Criteria in Solid Tumors (RECIST) [15]. Although these criteria are important in allowing investigators to assess the efficacy of chemotherapy drugs and combinations, it should also be recognized that achievement of a formal response may not be necessary for a patient to achieve symptomatic benefit.

There has been recent discussion about the value of “stable disease” as an endpoint of palliative systemic therapy [16]. Historically, if a chemotherapeutic drug was unable to produce actual tumor shrinkage, it was considered inactive, and the toxicity produced was not felt to be justified. With the recent proliferation of newer and better tolerated targeted therapies this has been called into question [17]. Many patients treated with these agents achieve disease stability without significant tumor shrinkage; and appear to benefit from continued treatment with a possible impact on survival. Thus the concept of “clinical benefit” (i.e., disease response and disease stability after treatment) has been legitimized as a meaningful endpoint in palliative management.

For patients being treated with curative intent, additional, more sophisticated endpoints are often chosen, including progression-free survival, disease-free survival, event-free survival, or disease-specific survival [18, 19]. Although these functions may be more reflective of the effect of treatment than the overall survival, they are often variably defined and difficult to interpret. Standard definitions have been proposed. When reporting the efficacy of local or regional treatment modalities, investigators have often chosen such endpoints as local or locoregional control [19]. While somewhat reflective of overall outcome, such assessments ignore the relationship between local, regional and distant disease, and do not fully address the overall impact of the disease on the patient. When measuring the effect of a systemic treatment, distant disease control is also a common endpoint. Once again, however, this function is not independent of locoregional control. Furthermore, distant metastases are a relatively infrequent cause of treatment failure in head and neck cancer.

Even these endpoints may not be the most important outcome from the patient's perspective. Cancers in the head and neck and their treatments may significantly compromise several major human functions including speech, swallowing, and nonstomal breathing. Preservation of these functions may be more important to a patient than survival. While organ preservation, i.e., the avoidance of surgical resection of the organ, is easy to measure, it is only a crude estimate of functional preservation, a more difficult endpoint to assess, particularly for any given patient [20].

Moreover, the acceptability of functional compromise will vary between patients, and functional restoration is often possible even after organ removal. Nonlaryngeal speech with preservation of swallowing, may or may not be a preferable outcome to speech preservation with feeding tube dependence for any given patient.

List and colleagues from the University of Chicago have explored these kinds of patient-defined goals after head and neck cancer treatment in some detail [21]. When patients were asked to rank the relative importance of several treatment outcomes, cure and longer survival were consistently most important. There was considerable variability in the relative importance of other functional and cosmetic treatment priorities, including those goals related to pain, energy, voice, swallowing, and appearance. This is a message that we, as physicians, must remember when discussing treatments with our patients.

A number of validated quality of life instruments have also been developed in an attempt to better assess the impact of treatment and disease from the patient's perspective. Several of these tools have been widely employed including the Performance Status Scale for Head and Neck Cancer [22], the Functional Assessment of Cancer Therapy (FACT) scale [23], the EORTC quality of life questionnaire [24], and

the University of Washington scale [25]. Thus far, however, the results and importance of these measurements are not entirely clear.

When using chemotherapy as palliative treatment in patients with incurable disease, the acceptability of the acute toxicities is the major determinant of the risk/benefit ratio of the treatment. However, when chemotherapy is being used as part of a curative multimodality treatment approach, the acute toxicities, while important, are of less concern than any late or long-term morbidity. Fortunately, except for a small risk of sterility or of a second malignancy, late morbidity from chemotherapy is uncommon. It is clear, however, that the combination of chemotherapy and radiation increases the likelihood and severity of the long-term morbidities commonly associated with radiation, an interaction which must also be considered when choosing treatments [26].

General Considerations in the Use of Chemotherapy

Most drugs used for systemic therapy in malignant disease exploit cancer cells' innate inability to repair genetic damage. Because normal cells in various tissues are vulnerable to these drug effects, chemotherapeutic agents are a class with a narrow therapeutic window. Preclinical models have demonstrated the steep dose–response curves after the administration of chemotherapy [27]. With any dose reduction of therapy, there is a consequent significant decrement in the degree of cancer cell kill and a resultant compromise in the ability to eliminate the malignant clone. The challenge in the delivery of chemotherapy is remaining within the therapeutic window, that is, being able to administer maximal drug doses while avoiding lethal injury to normal tissues.

Chemotherapy is usually administered intermittently, but at regular time intervals so as to allow normal tissue (usually bone marrow) recovery from drug-related toxicity, and enable administration of adequate drug dose over time. As many chemotherapeutic agents are cell cycle specific, at any given time, a certain proportion of cancer cells are not in the chemotherapy-sensitive phase of the cell cycle. Apart from limiting toxicity, repeated drug exposure over time allows for surviving cancer cells to enter the specific cell cycle phase during which an agent exerts its antitumor effects.

Due to consequences of the lifestyle that predisposes to head and neck cancer, cardiac, pulmonary and renal comorbidity, in addition to suboptimal compliance, complicate treatment planning in this subset of patients. Tailoring the choice of drug and treatment modality to patient factors is critical to optimizing treatment outcomes. The considerable acute toxicity of chemotherapy can result in significant

morbidity and even mortality in patients who are poor candidates for aggressive therapy.

Pharmacokinetic considerations for this patient population also have to be taken into account when selecting the appropriate chemotherapeutic regimen. The oral route is often compromised in patients with advanced tumors of the head and neck, and the delivery and absorption of active orally administered drugs such as hydroxyurea may be impaired. Most chemotherapeutic drugs active in this disease are metabolized in the liver, and excreted through the biliary or renal route. Renal dysfunction, hepatic impairment, pre-existing cardiovascular disease, and the frequency of considerable alcohol exposure, are all important considerations in the choice of chemotherapy.

It is well recognized that previously untreated malignancies are more responsive to therapy than is persistent or recurrent local, regional, or distant disease after initial therapy. Certain molecular characteristics have been reported to predict for relapse after chemotherapy and radiation [28–30]. In addition to intrinsic variations in gene expression, persistent or recurrent head and neck cancers often acquire molecular aberrations from prior exposure to pharmacologic agents that render them more resistant to chemotherapy compared to treatment-naïve tumors [31, 32]. Changes in tumor vasculature from previous surgery or radiation, and increased expression of genes that promote hypoxic tumor growth are thought to contribute to radiation insensitivity [33]. These, in addition to the significant symptom burden of recurrent disease and prior therapy, magnify the difficulty of administering effective systemic therapy in this compromised patient population.

Single Agents: Mechanisms of Action, Toxicities, Metabolism

The most frequently used agents in the treatment of both locally advanced and metastatic squamous cell head and neck cancer have been the platinum compounds, methotrexate,

5-fluorouracil, and the taxanes. All four drug classes have single agent activity, have differing mechanisms of action and toxicity, and can be administered concurrent with radiation as radiation sensitizers. Although many other antineoplastic drugs have known activity, the following section will focus on these four classes (Table 19.1).

Cisplatin was the first platinum compound noted to have antitumor activity in head and neck cancer [34]. The mechanism of action is believed to be drug incorporation into DNA, forming DNA adducts which distort the normal DNA helical structure. This triggers cellular recognition of DNA damage and subsequent apoptosis. Increased intracellular cisplatin doses are noted when the drug is given with radiation. The systemic toxicity of cisplatin can be significant and involves multiple organ systems. It is highly emetogenic compound, which can cause both early and delayed chemotherapy-induced nausea and vomiting, now more easily controlled with modern effective antiemetic regimens. Nephrotoxicity through glomerular and renal tubular damage with resultant salt wasting can be a consequence of treatment. This can often be prevented and ameliorated by aggressive hydration. Peripheral neuropathy and irreversible ototoxicity (in the form of high frequency hearing loss) can also result from cumulative drug exposure. Carboplatin is an analogue of cisplatin, whose properties render it less nephro- and neurotoxic, but more myelotoxic than cisplatin. The chemical structure of carboplatin results in delayed drug conversion and excretion, resulting in a longer half-life than cisplatin. Both of these drugs are excreted primarily through the kidney [35].

The antifolates, like methotrexate, exert antitumor effects by impairing the cancer cell's ability to generate precursors for DNA synthesis [36]. Methotrexate was approved for head and squamous cell cancer treatment in 1953. This drug inhibits dihydrofolate reductase, which maintains the intracellular supply of reduced folate essential for purine synthesis. Methotrexate has a wide range of systemic side effects, the most commonly observed are myelosuppression and gastrointestinal toxicity. Interstitial pneumonitis, hepatic transaminase elevation, and renal dysfunction from drug precipitation

Table 19.1 Commonly used chemotherapeutic agents in the management of head and neck cancer

Class	Agents	Mechanism of action	Clearance	Toxicity
Platinum agents	Cisplatin Carboplatin	DNA adduct formation	Renal	Nausea Nephro- and neurotoxicity Myelosuppression
Antifolates	Methotrexate	Depletes precursors for purine synthesis	Renal	Myelosuppression Gastrointestinal toxicity
Antimetabolites	5-Fluorouracil	Depletion of precursors for DNA synthesis	Renal (inactive drug)	Gastrointestinal toxicity Myelosuppression
Taxanes	Paclitaxel Docetaxel	Incorporation into RNA Mitotic arrest by microtubule stabilization	Hepatobiliary	Hypersensitivity Myelosuppression Peripheral neuropathy

in the renal tubules are also recognized side effects. The majority of this drug is eliminated through the kidneys, with a small proportion, about 10%, excreted through the bile.

5-Fluorouracil is a uracil analog that impairs both DNA and RNA synthesis [37]. It is intracellularly converted to its active form, 5FdUMP, which inhibits the enzyme thymidylate synthetase, depleting thymidylate and arresting DNA synthesis. The drug can also be intracellularly converted into 5FUTP which, when incorporated into RNA, results in cell death. The drug has a short half-life lasting minutes, and can be administered as a bolus or infusion. Like methotrexate, 5-fluorouracil results in myelosuppression and gastrointestinal toxicity. Nausea, stomatitis, mucositis, and diarrhea are common manifestations. Coronary vasospasm resulting in myocardial infarction is a rare but reported side effect. This drug is degraded by the enzyme dihydropyrimidine dehydrogenase, which is present in most tissues. The inactive metabolites are excreted in the urine [38].

The taxanes, paclitaxel and docetaxel, are pharmacologic class of agents that induce cell death by stabilizing microtubule formation [39]. Subsequent metaphase arrest results in apoptosis. Both paclitaxel and docetaxel are primarily metabolized by the liver and excreted in the bile, thus appropriate dosage adjustments may be necessary in the setting of hepatic dysfunction [40]. Hypersensitivity reactions to paclitaxel are the most common acute toxicity, myalgias and arthralgias after drug administration are also common. Peripheral neuropathy is a cumulative side effect of both drugs. Docetaxel can result in fluid retention or skin toxicity.

Combination Chemotherapy: Rationale and Principles

When single agents prove active in the management of a malignancy, the next step has always been an attempt to use these drugs in combination. The use of combination chemotherapy, however, is based on several clear principles [41] (Table 19.2).

The first is that for a drug to be useful in a combination chemotherapy regimen, it must have single agent antineoplastic activity. It makes little sense to include an ineffective chemotherapeutic agent in a drug combination, with the hope that it will suddenly prove to kill cancer cells. It should be noted, however, that recent experience using some of the

targeted agents, most notably bevacizumab, has suggested that this caveat does not always hold true. Bevacizumab, a vascular endothelial growth factor (VEGF) inhibitor is a relatively ineffective antineoplastic agent when used alone. When used in combination with other chemotherapeutic drugs, however, it has a demonstrated benefit in several disease sites [42, 43]. The second general principle in the use of combination chemotherapy is the importance of using drugs in full therapeutic doses. There has been general recognition of a dose–response curve for most systemic chemotherapeutic agents. Larger doses tend to produce larger, if not exponentially larger, responses, and suboptimal dosing of multiple agents would be unlikely to produce a better result than the full therapeutic dose of a single drug.

Third, drugs used in combination should have nonoverlapping mechanisms of action. There are a number of defined classes of chemotherapeutic agents, often with several different, but similar members. Rarely has the use of two drugs from the same class (e.g., two alkylating agents or two vinca alkaloids) been of any benefit. Finally, drugs, when used in combination should not have overlapping toxicities. In view of the steep dose–response curve for most chemotherapeutic agents, the optimal dosing for each drug is usually defined by its dose-limiting toxicity. Two drugs, with the same dose-limiting toxicity (e.g., myelosuppression), if used at their maximally tolerated dose, will undoubtedly produce significant and perhaps intolerable toxicity and would be a poor combination.

Despite the soundness of the rationale for combining chemotherapeutic agents, many of the common drug combinations used in this disease and others, violate one or several of these principles. Thus careful phase I and II testing for both toxicity and efficacy is important before widespread adoption of any chemotherapy combination.

Systemic Chemotherapy in Palliative Management

Patients with persistent or recurrent disease not amenable to local therapy such as radiation or salvage surgery, or patients who develop or present with systemic metastasis are incurable. The prognosis for patients in this situation is dismal and there is little evidence suggesting that chemotherapy is superior to best supportive care. Survival in this patient group, even when palliative chemotherapy is administered, uniformly ranges from 6 to 9 months. In this situation, when cure and survival prolongation are not possible, the treatment goal is to palliate symptoms and improve quality of life.

Quality of life can be adversely impacted by the local effects of tumors at both the primary site and the sites of metastasis. Local effects of the primary site tumor include

Table 19.2 Principles of combination chemotherapy

1. Drugs used in combination should have single agent activity
2. Drugs used in combination should be used in full therapeutic doses
3. Drugs used in combination should have nonoverlapping mechanisms of action
4. Drugs used in combination should have nonoverlapping toxicities

pain, and impairment or loss of important functions such as speech, swallowing, smell, hearing, and even vision. Cosmetic deformity in addition to functional compromise can cause significant body image issues and depression. Distant disease most often involves the lung, and less commonly bone. This can result in cough, hemoptysis, painful bone lesions, pathologic fractures, and nerve or spinal cord impingement. Palliative care to address these symptoms should be carried out by a multidisciplinary team. Modalities such as radiation therapy to painful sites, and adequate pain control contribute to palliation in the metastatic setting.

Systemic chemotherapy is a widely used tool for reducing tumor burden, with the assumption that this leads to alleviation of tumor-related symptoms [44]. Active chemotherapy drugs when given as single agents often result in modest response rates ranging from 10 to 30% depending on previous treatment [45–47]. Several well-designed clinical trials have been done to compare various single and multiple drug regimens [48–50]. Although multiagent chemotherapy does produce a consistent increase in response rates, with only one exception, no significant prolongation of median survival has been observed. One of the more important observations has been the reproducible increase in treatment-related toxicity that accompanies combination drug therapy.

This observation introduces a significant conflict with the palliative goals of care in a patient population with incurable disease and significant comorbidity. Certainly, the toxicity of chemotherapy would only be acceptable if it ultimately resulted in some alleviation of tumor-related symptoms. With little convincing evidence of a survival advantage with chemotherapy combinations, great care must be taken to appropriately select patients who are good candidates for combination treatment. In a patient with a compromised performance status, for example, combination chemotherapy may adversely impact quality of life rather than palliate symptoms.

Phase III clinical trials using chemotherapy for patients with incurable disease carried out in the last two decades have focused on examining the endpoints of toxicity, survival and response rates. Little has been done to incorporate validated measurements of quality of life in these studies. The recognition that response rates may not accurately translate to improved symptom control, along with the introduction of a new class of “targeted agents” believed to have a more tolerable side effect profile, have led to the integration of more accurate quality of life measurements in the design of clinical trials.

In general, among most solid tumors, the integration of new pharmacologic agents into curative intent therapy is initiated by observed drug activity in patients with recurrent, pretreated or metastatic disease. Some examples of these emerging drugs showing antitumor effects in the metastatic setting are newer generation nucleoside analogs, antifolates,

and topoisomerase inhibitors. Gemcitabine is a novel synthetic pyrimidine analog which is activated through intracellular phosphorylation. In its activated form, it is incorporated into DNA and RNA and arrests their synthesis, it also inhibits its own inactivating enzyme, increasing intracellular concentrations [51]. The new generation antifolate pemetrexed inhibits several enzymes involved in the maintenance of reduced folate pools essential for the production of DNA precursors. Its property of rapid entry into the cellular environment through several transport mechanisms is known to overcome cellular resistance that often hampers the efficacy of older generation antifolates [52]. Irinotecan is a partly synthetic camptothecin, which inhibits topoisomerase I, causing supercoiling of DNA during replication and growth arrest [53]. These drugs have been shown to possess radiation-sensitizing properties and their assimilation into curative treatment strategies awaits further investigation.

The epidermal growth factor receptor and its demonstrated synergistic activity with both chemotherapy and radiation resulted in studies using the EGFR inhibitors in the metastatic setting. When compared to single agent methotrexate, EGFR inhibitors used alone have had disappointing response rates and no demonstrable impact on survival [54]. However, recently published data on the combination of platinum-based chemotherapy and EGFR inhibition has shown an unprecedented albeit modest improvement in survival [55]. The combination of chemotherapy with targeted agents has demonstrated a similar survival advantage in other epithelial malignancies and may represent the future paradigm for investigating and treating metastatic disease.

Systemic Chemotherapy in Definitive Management

In the curative management of solid tumors, single modality chemotherapy is rarely sufficient. For most neoplasms, and in particular head and neck cancers, chemotherapy is only effective when used in combination with definitive radiation therapy and/or surgery. Chemotherapy must be considered adjunctive not curative, and its use in multimodality treatment regimens must not compromise the delivery of the definitive locoregional treatment. While considerable morbidity may be acceptable from aggressive curative treatment regimens, the toxicity produced by the addition of chemotherapy cannot be allowed to interfere with the required radiation or surgery.

A number of multimodality treatment approaches have been explored (Table 19.3). All have been based on the recognized chemosensitivity of head and neck cancer. Previously untreated patients with squamous cell head and neck cancer can be expected to respond to systemic

Table 19.3 Multimodality treatment approaches using chemotherapy

Induction chemotherapy	The use of chemotherapy prior to definitive locoregional management
Adjuvant chemotherapy	The use of chemotherapy after definitive locoregional management
Concurrent chemoradiotherapy	
Definitive chemoradiotherapy	The use of concomitant chemotherapy and radiation as definitive management
Adjuvant chemoradiotherapy	The use of concomitant chemotherapy and radiation after definitive locoregional management
Sequential treatment	The use of induction chemotherapy followed by definitive concomitant chemotherapy and radiation

combination chemotherapy up to 90% of the time, with complete responses described in between 30 and 50% of patients. These excellent responses are rarely durable, however, and disease regrowth is the rule. The question then becomes how best to exploit this antineoplastic activity in conjunction with definitive radiation and surgery.

Induction chemotherapy was the first treatment strategy developed. The rationale for induction chemotherapy was that given the increased chemotherapy responsiveness in the previously untreated patient, the optimal time to use chemotherapy would be prior to any locoregional intervention. It was reasoned that if significant tumor shrinkage could be achieved, there might, as well, be an improvement in locoregional control, a decrease in distant metastasis, and an overall survival improvement. The potential for surgical modification or organ preservation after chemotherapy-induced tumor shrinkage was also suggested.

An alternative strategy is the use of adjuvant, or postoperative chemotherapy. Adjuvant chemotherapy strategies are meant to address concern about disease recurrence, and are optimal for those patients likely to develop distant metastasis even after achieving locoregional control. Thus a patient identified as being at high risk for distant disease recurrence after definitive surgery and or radiation might be appropriate for further systemic chemotherapy. Not surprisingly, given the limited risk for distant metastases in this disease, single modality adjuvant chemotherapy has not been of major benefit.

Several observations emerged from these kinds of sequential treatment approaches, however. The first was the recognition that chemotherapy responsiveness was predictive for responsiveness to radiation therapy [56]. This suggested the potential that chemotherapy might serve as a selection tool to identify those patients most likely to benefit from radiotherapeutic (i.e., nonoperative) intervention [57]. Chemotherapy was also found to decrease the risk of distant metastases, an achievement with a limited survival impact in a disease with such a small risk for distant disease [58–60]. Unfortunately, it was also recognized that treatment compliance could be

compromised by successful induction chemotherapy. The dramatic response to systemic chemotherapy often experienced by these patients on occasion led to a motivational interference with completion of definitive treatment.

The observation was also made that those patients who respond to systemic chemotherapy live longer than those patients who do not. This has been suggested by some as a justification for the use of systemic chemotherapy. It must be recognized however, that a response to chemotherapy is more common in those patients with a better performance status and smaller disease burden. These are also the patients with a better prognosis irrespective of the treatment utilized [61].

An alternative to the sequential use of single treatment modalities has been the concurrent use of chemotherapy and radiation. The rationale for this approach has been the recognition that both chemotherapy and radiation therapy are independently active treatment modalities and that chemotherapy may potentiate radiation, improve locoregional control, and decrease the impact of distant micrometastatic disease. In addition, the use of these two treatment modalities together, rather than sequentially, will shorten the overall treatment duration and in theory improve compliance. Preclinical data support a synergistic role of chemotherapy and radiation therapy through various postulated mechanisms. The enhanced cell kill from simultaneous exposure to systemic chemotherapy and radiation has been attributed to increased cellular cytotoxic drug uptake during radiation, chemotherapy-induced impairment of DNA repair mechanisms in response to radiation-induced damage, and chemotherapy-induced cell cycle shift resulting in increased radiation sensitivity.

There are also several disadvantages to the concomitant use of chemotherapy and radiation. Clearly, the concurrent use of two treatment modalities will produce greater toxicity than the use of either treatment modality alone. This toxicity may then result in a compromise of dose intensity and efficacy, such as single agent rather than combination chemotherapy, split rather than continuous course radiation, or a reduction of the chemotherapy doses used. Nonetheless, the concurrent use of chemotherapy and radiation has been intensively explored in this disease both as definitive management, and as a postoperative adjuvant. Both locoregional control and survival have been improved with this approach although the treatment has been associated with significant acute and late toxicity [62].

Along with this improvement in locoregional control has been the recognition of a relative increase in the frequency of distant metastases, a change in the natural history of this disease [63, 64]. Given the apparent benefit achieved by induction chemotherapy in reducing the risk of distant metastasis, it has been recently suggested that a sequential treatment approach of induction chemotherapy followed by concurrent chemoradiotherapy might be advantageous [65].

The induction chemotherapy would address the risk of distant metastasis and the concurrent chemoradiotherapy would deal with the locoregional disease. Randomized studies of this treatment schedule are currently underway.

Critical to the use of systemic chemotherapy, both with and without radiation, has been the integration with surgery. Optimal management of the primary site and of the neck requires the definition of careful treatment algorithms. Patients with persistent or recurrent primary site disease after chemoradiotherapy will require some kind of surgical salvage. Patients presenting with large neck nodes at diagnosis, or with neck nodes that only incompletely respond to nonoperative intervention, will require subsequent neck dissection with curative intent [66]. Given the potential for cure after such surgical salvage, it would seem important that we be able to identify those patients likely to fail in the neck or at the primary site after nonoperative intervention.

The development of organ preservation strategies has been somewhat unique to this field. The rationale for organ preservation is the hope that the substitution of radiation, with or without chemotherapy, for surgery might not compromise survival and yet preserve organ integrity and function. The goal of treatment is no longer one of an improved survival. Instead, it is the hope that survival will not be compromised, but that there will be more organ (usually larynx) preservation. Again it is important to point out the difference between organ preservation and organ function preservation [20]. Preservation of a nonfunctional larynx is of little benefit to a patient despite maintenance of its anatomic integrity. Studies of both induction and concurrent chemotherapy and radiation schedules have been conducted with some success. However, recent data has raised the possibility that current organ preservation practices may have compromised overall survival in larynx cancer [67]. Thus, for any given patient, the debate about the relative importance of organ preservation vs. survival continues.

Emerging Issues

Increasing understanding of the molecular processes underlying head and neck squamous cell cancers, the discovery of new therapeutic targets, and the changing disease epidemiology has had a great impact on current scientific inquiry into the role of chemotherapy in improving patient outcomes.

The decreasing popularity of tobacco use has resulted in a plateau and decline of most tobacco-related malignancies of the upper aerodigestive tract [68]. Among head and neck cancers, a distinct clinical entity of high-risk HPV-positive oropharyngeal head and neck cancers in a patient population without exposure to tobacco or alcohol has surfaced. These tumors have a different molecular profile and have improved

prognosis compared to non-HPV-related squamous cell malignancies of the head and neck [69]. These patients are younger with less comorbid conditions, and respond to definitive therapy with excellent local and distant control rates. The applicability of previously established therapies for head and neck cancer to this previously unrecognized clinical entity has been called into question, and a reduction of the intensity of therapy to spare patients from the attendant toxicity of chemotherapy and radiation combinations has been proposed for this patient population. Contemporary clinical studies are now moving toward studying HPV-positive and negative head and neck cancers separately, to further define the appropriate therapy for these two distinct subsets of patients.

Since the discovery that inhibiting the bcr-abl tyrosine kinase results in dramatic responses in patients with CML, numerous molecular markers have been identified as therapeutic targets in head and neck cancer. Inhibiting the epidermal growth factor receptor has been shown to result in synergistic cell kill when used with radiation and chemotherapy [70]. The combination of the monoclonal antibody cetuximab with definitive radiation in locally advanced head and neck squamous cell carcinomas have been shown to be superior to radiation alone in a large phase III clinical trial, with no significant increase in treatment-related toxicity [71]. Another phase III trial comparing combination chemotherapy to the same chemotherapy with cetuximab in patients with recurrent metastatic head and neck cancer demonstrated a modest survival advantage; an observation never before made in clinical trials using chemotherapy combinations alone [55]. The generally more favorable toxicity profile of these agents make them attractive prospects for integration into definitive and palliative therapy, and they are currently under study.

Another emerging role for systemic therapy is in salvage treatment for recurrent or persistent disease. Historically, when a patient experiences locoregional failure after definitive chemotherapy and radiation, surgery, when possible, was the only potentially curative option for salvage therapy. With the advent of more sophisticated radiation therapy techniques, reirradiation has been shown to be a feasible and successful in a highly select group of patients. Because of the dose and field limitations imposed by prior radiation therapy, reirradiation with the addition of systemic therapy for radiation sensitization is an attractive prospect. Several phase II studies have demonstrated the tolerability and efficacy of this approach [72, 73].

Sensitivity to chemotherapy is generally thought to identify disease with a more favorable disease biology. Complete responses to systemic therapy in most solid tumor malignancies are almost always associated with improved outcomes. Because the acute and long-term toxicities of surgery and chemoradiation are substantial, the possibility of using chemotherapy alone

to select and cure local disease is being investigated. Single institution clinical studies have explored the use of chemotherapy alone for nonmetastatic laryngeal carcinoma and demonstrated long-term disease remission in a subset of patients [74, 75]. Results of further studies are awaited before this strategy becomes applicable to clinical practice.

Conclusion

The current role of chemotherapy in the definitive management of head and neck cancer has been established by extensive scientific investigation over many decades. The benefits and toxicities of these agents have been well defined. The identification of molecular therapeutic targets, the development of novel active agents, and the changing epidemiology and treatment failure patterns of head and neck cancer are providing avenues for expanding the application of systemic therapy to improve outcomes in both local and metastatic disease.

References

- Adelstein DJ, Tan EH, Lavertu P. Treatment of head and neck cancer: The role of chemotherapy. *Crit Rev Oncol Hematol*. 1996; 24:97–116.
- Slaughter DP, Southwick HW, Smejkal W. Field cancerization in oral stratified squamous epithelium; clinical implications of multicentric origin. *Cancer*. 1953;6:963–8.
- Chuang SC, Scelo G, Tonita JM, et al. Risk of second primary cancer among patients with head and neck cancers: A pooled analysis of 13 cancer registries. *Int J Cancer*. 2008;123:2390–6.
- Cowan JM, Beckett MA, Ahmed-Swan S, et al. Cytogenetic evidence of the multistep origin of head and neck squamous cell carcinomas. *J Natl Cancer Inst*. 1992;84:793–7.
- el-Naggar AK, Hurr K, Batsakis JG, et al. Sequential loss of heterozygosity at microsatellite motifs in preinvasive and invasive head and neck squamous carcinoma. *Cancer Res*. 1995;55:2656–9.
- Maruya S, Issa JP, Weber RS, et al. Differential methylation status of tumor-associated genes in head and neck squamous carcinoma: Incidence and potential implications. *Clin Cancer Res*. 2004;10: 3825–30.
- Rubin Grandis J, Tweardy DJ, Melhem MF. Asynchronous modulation of transforming growth factor alpha and epidermal growth factor receptor protein expression in progression of premalignant lesions to head and neck squamous cell carcinoma. *Clin Cancer Res*. 1998;4:13–20.
- Schipper JH, Frixen UH, Behrens J, et al. E-cadherin expression in squamous cell carcinomas of head and neck: Inverse correlation with tumor dedifferentiation and lymph node metastasis. *Cancer Res*. 1991;51:6328–37.
- O-Charoenrat P, Rhys-Evans P, Modjtahedi H, et al. Overexpression of epidermal growth factor receptor in human head and neck squamous carcinoma cell lines correlates with matrix metalloproteinase-9 expression and in vitro invasion. *Int J Cancer*. 2000;86: 307–17.
- Dy GK, Adjei AA. Systemic cancer therapy: Evolution over the last 60 years. *Cancer*. 2008;113:1857–87.
- Liu JP, Cassar L, Pinto A, et al. Mechanisms of cell immortalization mediated by EB viral activation of telomerase in nasopharyngeal carcinoma. *Cell Res*. 2006;16:809–17.
- D'Souza G, Kreimer AR, Viscidi R, et al. Case-control study of human papillomavirus and oropharyngeal cancer. *N Engl J Med*. 2007;356:1944–56.
- Vidal L, Gillison ML. Human papillomavirus in HNSCC: Recognition of a distinct disease type. *Hematol Oncol Clin North Am*. 2008;22:1125–42. vii.
- Pazdur R. Endpoints for assessing drug activity in clinical trials. *Oncologist*. 2008;13 Suppl 2:19–21.
- Therasse P, Arbuck SG, Eisenhauer EA, et al. New guidelines to evaluate the response to treatment in solid tumors. european organization for research and treatment of cancer, national cancer institute of the united states, national cancer institute of canada. *J Natl Cancer Inst*. 2000;92:205–16.
- Kurata T, Matsuo K, Takada M, et al. Is the importance of achieving stable disease different between epidermal growth factor receptor tyrosine kinase inhibitors and cytotoxic agents in the second-line setting for advanced non-small cell lung cancer? *J Thorac Oncol*. 2006;1:684–91.
- El-Maraghi RH, Eisenhauer EA. Review of phase II trial designs used in studies of molecular targeted agents: Outcomes and predictors of success in phase III. *J Clin Oncol*. 2008;26:1346–54.
- Mathoulin-Pelissier S, Gourgou-Bourgade S, Bonnetain F, et al. Survival end point reporting in randomized cancer clinical trials: A review of major journals. *J Clin Oncol*. 2008;26:3721–6.
- Michiels S, Le Maitre A, Buyse M, et al. Surrogate endpoints for overall survival in locally advanced head and neck cancer: Meta-analyses of individual patient data. *Lancet Oncol*. 2009;10:341–50.
- Adelstein DJ. Oropharyngeal cancer: The role of the medical oncologist in organ-function conservation. In: Perry MC, editor. *American Society of Clinical Oncology Education Book*. Alexandria, VA: American Society of Clinical Oncology; 1999. p. 544–50.
- List MA, Stracks J. Evaluation of quality of life in patients definitively treated for squamous carcinoma of the head and neck. *Curr Opin Oncol*. 2000;12:215–20.
- List MA, Ritter-Sterr C, Lansky SB. A performance status scale for head and neck cancer patients. *Cancer*. 1990;66:564–9.
- Cella DF, Tulsky DS, Gray G, et al. The functional assessment of cancer therapy scale: Development and validation of the general measure. *J Clin Oncol*. 1993;11:570–9.
- Bjordal K, Kaasa S. Psychometric validation of the EORTC core quality of life questionnaire, 30-item version and a diagnosis-specific module for head and neck cancer patients. *Acta Oncol*. 1992;31:311–21.
- Hassan SJ, Weymuller Jr EA. Assessment of quality of life in head and neck cancer patients. *Head Neck*. 1993;15:485–96.
- Denis F, Garaud P, Bardet E, et al. Final results of the 94-01 french head and neck oncology and radiotherapy group randomized trial comparing radiotherapy alone with concomitant radiochemotherapy in advanced-stage oropharynx carcinoma. *J Clin Oncol*. 2004;22:69–76.
- Levasseur LM, Slocum HK, Rustum YM, et al. Modeling of the time-dependency of in vitro drug cytotoxicity and resistance. *Cancer Res*. 1998;58:5749–61.
- Michaud WA, Nichols AC, Mroz EA, et al. Bcl-2 blocks cisplatin-induced apoptosis and predicts poor outcome following chemoradiation treatment in advanced oropharyngeal squamous cell carcinoma. *Clin Cancer Res*. 2009;15:1645–54.
- Chung CH, Ely K, McGavran L, et al. Increased epidermal growth factor receptor gene copy number is associated with poor prognosis in head and neck squamous cell carcinomas. *J Clin Oncol*. 2006;24:4170–6.

30. Riva C, Lavieille JP, Reyt E, et al. Differential c-myc, c-jun, c-raf and p53 expression in squamous cell carcinoma of the head and neck: Implication in drug and radioresistance. *Eur J Cancer B Oral Oncol.* 1995;31B:384-91.
31. van der Laan BF, Jansen G, Kathmann I, et al. Mechanisms of acquired resistance to methotrexate in a human squamous carcinoma cell line of the head and neck, exposed to different treatment schedules. *Eur J Cancer.* 1991;27:1274-8.
32. Yoshizawa K, Nozaki S, Kitahara H, et al. Copper efflux transporter (ATP7B) contributes to the acquisition of cisplatin-resistance in human oral squamous cell lines. *Oncol Rep.* 2007;18:987-91.
33. Koukourakis MI, Giatromanolaki A, Danielidis V, et al. Hypoxia inducible factor (HIF1alpha and HIF2alpha) and carbonic anhydrase 9 (CA9) expression and response of head-neck cancer to hypofractionated and accelerated radiotherapy. *Int J Radiat Biol.* 2008;84:47-52.
34. Rozenzweig M, von Hoff DD, Slavik M, et al. Cis-diamminedichloroplatinum (II) A new anticancer drug. *Ann Intern Med.* 1977;86:803-12.
35. Ribaud P, Gouveia J, Bonnay M, et al. Clinical pharmacology and pharmacokinetics of cis-platinum and analogs. *Cancer Treat Rep.* 1981;65 Suppl 3:97-105.
36. Bertino JR. The mechanism of action of the folate antagonists in man. *Cancer Res.* 1963;23:1286-306.
37. Mandel HG. The target cell determinants of the antitumor actions of 5-FU: Does FU incorporation into RNA play a role? *Cancer Treat Rep.* 1981;65 Suppl 3:63-71.
38. Diasio RB, Harris BE. Clinical pharmacology of 5-fluorouracil. *Clin Pharmacokinet.* 1989;16:215-37.
39. Rowinsky EK, Cazenave LA, Donehower RC. Taxol: A novel investigational antimicrotubule agent. *J Natl Cancer Inst.* 1990;82:1247-59.
40. Guchelaar HJ, ten Napel CH, de Vries EG, et al. Clinical, toxicological and pharmaceutical aspects of the antineoplastic drug taxol: A review. *Clin Oncol (R Coll Radiol).* 1994;6:40-8.
41. DeVita VT, Schein PS. The use of drugs in combination for the treatment of cancer: Rationale and results. *N Engl J Med.* 1973;288:998-1006.
42. Sandler A, Gray R, Perry MC, et al. Paclitaxel-carboplatin alone or with bevacizumab for non-small-cell lung cancer. *N Engl J Med.* 2006;355:2542-50.
43. Hurwitz H, Fehrenbacher L, Novotny W, et al. Bevacizumab plus irinotecan, fluorouracil, and leucovorin for metastatic colorectal cancer. *N Engl J Med.* 2004;350:2335-42.
44. Constenla DO, Hill ME, A'Hern RP, et al. Chemotherapy for symptom control in recurrent squamous cell carcinoma of the head and neck. *Ann Oncol.* 1997;8:445-9.
45. Wittes RE, Cvitkovic E, Shah J, et al. CIS-dichlorodiammine platinum(II) in the treatment of epidermoid carcinoma of the head and neck. *Cancer Treat Rep.* 1977;61:359-66.
46. Eisenberger M, Hornedo J, Silva H, et al. Carboplatin (NSC-241-240): An active platinum analog for the treatment of squamous-cell carcinoma of the head and neck. *J Clin Oncol.* 1986;4:1506-9.
47. Forastiere AA, Shank D, Neuberg D, et al. Final report of a phase II evaluation of paclitaxel in patients with advanced squamous cell carcinoma of the head and neck: An eastern cooperative oncology group trial (PA390). *Cancer.* 1998;82:2270-4.
48. Jacobs C, Lyman G, Velez-Garcia E, et al. A phase III randomized study comparing cisplatin and fluorouracil as single agents and in combination for advanced squamous cell carcinoma of the head and neck. *J Clin Oncol.* 1992;10:257-63.
49. Gibson MK, Li Y, Murphy B, et al. Randomized phase III evaluation of cisplatin plus fluorouracil versus cisplatin plus paclitaxel in advanced head and neck cancer (E1395): An intergroup trial of the eastern cooperative oncology group. *J Clin Oncol.* 2005;23:3562-7.
50. Forastiere AA, Metch B, Schuller DE, et al. Randomized comparison of cisplatin plus fluorouracil and carboplatin plus fluorouracil versus methotrexate in advanced squamous-cell carcinoma of the head and neck: A southwest oncology group study. *J Clin Oncol.* 1992;10:1245-51.
51. Raguse JD, Gath HJ, Bier J, et al. Gemcitabine in the treatment of advanced head and neck cancer. *Clin Oncol (R Coll Radiol).* 2005;17:425-9.
52. Pivrot X, Raymond E, Laguerre B, et al. Pemetrexed disodium in recurrent locally advanced or metastatic squamous cell carcinoma of the head and neck. *Br J Cancer.* 2001;85:649-55.
53. Murphy BA. Topoisomerases in the treatment of metastatic or recurrent squamous carcinoma of the head and neck. *Expert Opin Pharmacother.* 2005;6:85-92.
54. Stewart JS, Cohen EE, Licitra L, et al. Phase III study of gefitinib 250 compared with intravenous methotrexate for recurrent squamous cell carcinoma of the head and neck. *J Clin Oncol.* 2009;27:1864-71.
55. Vermorken JB, Mesia R, Rivera F, et al. Platinum-based chemotherapy plus cetuximab in head and neck cancer. *N Engl J Med.* 2008;359:1116-27.
56. Ensley JF, Jacobs JR, Weaver A, et al. Correlation between response to cisplatin-combination chemotherapy and subsequent radiotherapy in previously untreated patients with advanced squamous cell cancers of the head and neck. *Cancer.* 1984;54:811-4.
57. Urba S, Wolf G, Eisbruch A, et al. Single-cycle induction chemotherapy selects patients with advanced laryngeal cancer for combined chemoradiation: A new treatment paradigm. *J Clin Oncol.* 2006;24:593-8.
58. Paccagnella A, Orlando A, Marchiori C, et al. Phase III trial of initial chemotherapy in stage III or IV head and neck cancers: A study by the gruppo di studio sui tumori della testa e del collo. *J Natl Cancer Inst.* 1994;86:265-72.
59. Wolf GT, Hong WK, Fisher SG, et al. Induction chemotherapy plus radiation compared with surgery plus radiation in patients with advanced laryngeal cancer. the department of veterans affairs laryngeal cancer study group. *N Engl J Med* 1991;324:1685-1690.
60. Pignon JP, Bourhis J, Domenge C, et al. Chemotherapy added to locoregional treatment for head and neck squamous-cell carcinoma: Three meta-analyses of updated individual data. MACH-NC collaborative group. meta-analysis of chemotherapy on head and neck cancer. *Lancet.* 2000;355:949-55.
61. Anderson JR, Cain KC, Gelber RD. Analysis of survival by tumor response. *J Clin Oncol.* 1983;1:710-9.
62. Adelstein DJ, Rodriguez CP. Current and emerging standards of concomitant chemoradiotherapy. *Semin Oncol.* 2008;35:211-20.
63. Adelstein DJ, Saxton JP, Lavertu P, et al. Maximizing local control and organ preservation in stage IV squamous cell head and neck cancer with hyperfractionated radiation and concurrent chemotherapy. *J Clin Oncol.* 2002;20:1405-10.
64. Vokes EE, Kies MS, Haraf DJ, et al. Concomitant chemoradiotherapy as primary therapy for locoregionally advanced head and neck cancer. *J Clin Oncol.* 2000;18:1652-61.
65. Posner MR, Wirth L, Tishler RB, et al. The evolution of induction chemotherapy in locally advanced squamous cell cancer of the head and neck. In: Adelstein DJ, editor. *Current clinical oncology: squamous cell head and neck cancer.* Humana Press Inc.: Totowa, NJ; 2005. p. 171-85.
66. McHam SA, Adelstein DJ, Rybicki LA, et al. Who merits a neck dissection after definitive chemoradiotherapy for N2-N3 squamous cell head and neck cancer? *Head Neck.* 2003;25:791-8.
67. Hoffman HT, Porter K, Karnell LH, et al. Laryngeal cancer in the united states: Changes in demographics, patterns of care, and survival. *Laryngoscope.* 2006;116:1-13.
68. Chaturvedi AK, Engels EA, Anderson WF, et al. Incidence trends for human papillomavirus-related and -unrelated oral squamous cell carcinomas in the united states. *J Clin Oncol.* 2008;26:612-9.

69. Fakhry C, Westra WH, Li S, et al. Improved survival of patients with human papillomavirus-positive head and neck squamous cell carcinoma in a prospective clinical trial. *J Natl Cancer Inst.* 2008;100:261–9.
70. Holsinger FC, Doan DD, Jasser SA, et al. Epidermal growth factor receptor blockade potentiates apoptosis mediated by paclitaxel and leads to prolonged survival in a murine model of oral cancer. *Clin Cancer Res.* 2003;9:3183–9.
71. Bonner JA, Harari PM, Giralt J, et al. Radiotherapy plus cetuximab for squamous-cell carcinoma of the head and neck. *N Engl J Med.* 2006;354:567–78.
72. Langer CJ, Harris J, Horwitz EM, et al. Phase II study of low-dose paclitaxel and cisplatin in combination with split-course concomitant twice-daily reirradiation in recurrent squamous cell carcinoma of the head and neck: Results of radiation therapy oncology group protocol 9911. *J Clin Oncol.* 2007;25:4800–5.
73. Spencer SA, Harris J, Wheeler RH, et al. Final report of RTOG 9610, a multi-institutional trial of reirradiation and chemotherapy for unresectable recurrent squamous cell carcinoma of the head and neck. *Head Neck.* 2008;30:281–8.
74. Holsinger FC, Kies MS, Diaz Jr EM, et al. Durable long-term remission with chemotherapy alone for stage II to IV laryngeal cancer. *J Clin Oncol.* 2009;27:1976–82.
75. Laccourreye O, Brasnu D, Bassot V, et al. Cisplatin-fluorouracil exclusive chemotherapy for T1-T3N0 glottic squamous cell carcinoma complete clinical responders: Five-year results. *J Clin Oncol.* 1996;14:2331–6.

Chapter 20

Molecular Targeted Therapies in Head and Neck Cancer

Vinai Gondi, Anne M. Traynor, and Paul M. Harari

Abstract Molecular targeted therapies for head and neck cancer offer promising opportunities to improve upon clinical outcomes of conventional treatments. The toxicity profiles of these agents are unique, reflecting their distinct mechanisms of action, and generally do not appear to directly overlap or amplify the toxicities of conventional treatment modalities. Herein, we discuss strategies for targeting the epidermal growth factor receptor (EGFR) and angiogenesis (VEGF) as models for the development and clinical evaluation of molecular targeted agents. We explore phase III clinical data demonstrating measurable survival benefits with the use of cetuximab in the locally advanced and recurrent/metastatic head and neck cancer settings. In addition, we review EGFR tyrosine kinase inhibitors and angiogenesis inhibitors, both of which have shown activity in head and neck cancer. Finally, we review promising new agents and future directions for the incorporation of molecular targeted therapies in head and neck cancer.

Keywords Targeted therapies • EGFR • Angiogenesis • Head and neck cancer • Bevacizumab • Cetuximab • Tyrosine kinase inhibitors • Erlotinib • Gefitinib

Introduction

Conventional treatment of head and neck squamous cell carcinoma (HNSCC) frequently involves a combination of surgery, radiotherapy, and/or chemotherapy. However, the degree to which these treatments can be successfully implemented is commonly limited by toxicity. Targeted therapies, due to their specificity for molecular tumor targets, offer the potential to improve upon outcomes of conventional treatments without significantly amplifying treatment-limiting toxicity profiles.

Herein, we discuss strategies for targeting the epidermal growth factor receptor (EGFR) and angiogenesis (VEGFR) as models for the development and clinical evaluation of molecular targeted agents and briefly explore future directions of targeted therapies in head and neck cancer.

Targeting the Epidermal Growth Factor Receptor

The epidermal growth factor receptor (EGFR) is a member of the ErbB family of receptor tyrosine kinases and has been recognized as an important therapeutic target for a broad spectrum of epithelial tumors [1, 2]. The importance of epidermal growth factor receptor (EGFR) in head and neck squamous cell carcinoma is supported by its overexpression in the vast majority of head and neck tumors [3–12] and the predictive and prognostic value of EGFR expression level [13–16]. In the early 1980s, EGFR signaling blockade was postulated as a potential anticancer treatment strategy [17], and a series of EGFR inhibitors were subsequently developed with translational and clinical testing of lead agents in recent years [18, 19]. Cetuximab, a chimeric human: murine monoclonal antibody that prevents the binding of endogenous EGFR ligand to the extracellular domain of EGFR, represents one such class of EGFR inhibitor. The other primary class of EGFR inhibitor, tyrosine kinase inhibitors such as erlotinib and gefitinib, reversibly inhibit the catalytic activity of EGFR by binding the adenosine triphosphate (ATP) binding site of the EGFR kinase domain (Fig. 20.1).

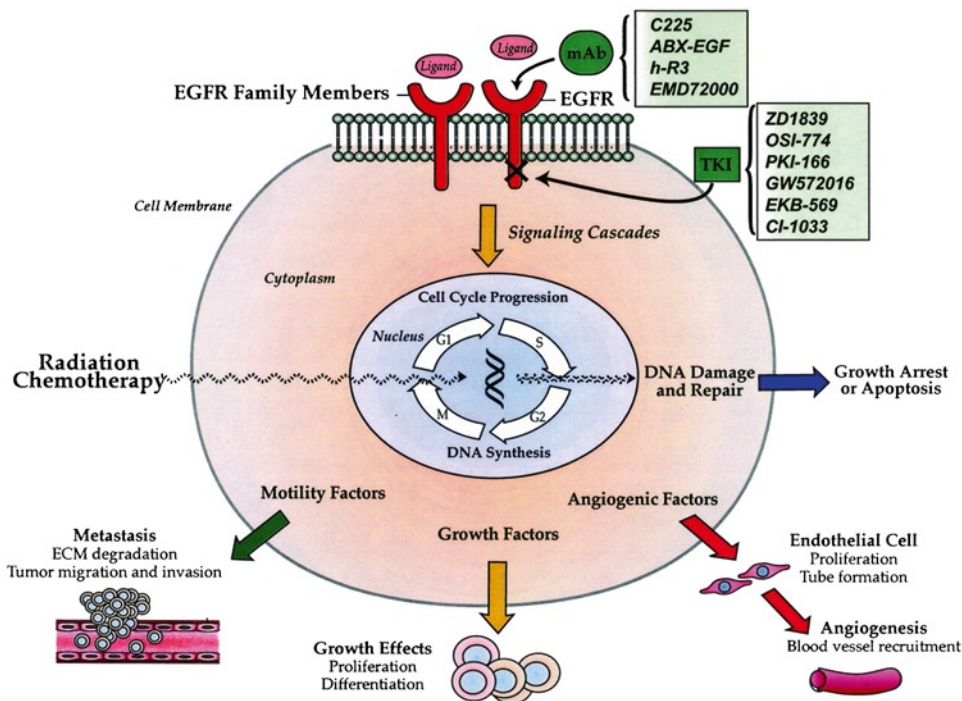
Cetuximab

Preclinical Data

Preclinical HNSCC models have demonstrated important cellular effects of cetuximab, including downregulation and internalization of EGFR, enhanced apoptosis, and inhibition

P.M. Harari (✉)
Department of Human Oncology, University of Wisconsin
Comprehensive Cancer Center, Madison, WI, USA
e-mail: harari@humonc.wisc.edu

Fig. 20.1 EGFR targeting with monoclonal antibodies (mAb) or tyrosine kinase inhibitors (TKI) and subsequent cellular and tissue effects. From Harari, Huang. *Clinical Cancer Research*, Online. Copyright 2004 by American Association for Cancer Research. Reproduced with permission of American Association for Cancer Research



of cell cycle proliferation, cell migration, and tumor angiogenesis [18, 19]. Furthermore, cetuximab has demonstrated important chemo- and radio-sensitization effects [20–23], highlighting the potential value of EGFR signal modulation in tumor response to conventional cancer treatments. The chemo- and radio-sensitizing properties of cetuximab have been clinically validated in recent phase III clinical trials in both the definitive and metastatic/recurrent settings.

Locoregionally Advanced HNSCC

In the curative treatment setting, a recent phase III international trial compared radiotherapy plus cetuximab to radiotherapy alone in patients with stage III–IV nonmetastatic HNSCC of the oropharynx, hypopharynx, or larynx [24]. Other eligibility criteria included medical suitability for definitive radiotherapy, Karnofsky performance score ≥ 60 , and normal hematopoietic, hepatic, and renal function. A total of 424 eligible patients were enrolled and randomized to either radiotherapy alone or concurrently with cetuximab. Given the global variance in preference for radiation fractionation at the time of trial design, investigators were permitted to employ conventional fractionation, hyperfractionation, or concomitant boost radiotherapy schedules. Cetuximab was initiated 1 week before radiotherapy at a loading dose of

400 mg/m², followed by weekly infusions of 250 mg/m². Patients were stratified according to Karnofsky performance status, nodal involvement, tumor stage, and radiation fractionation regimen. The primary endpoint was locoregional control, with secondary points including overall survival, progression-free survival, overall response rate, and toxicities.

After median follow-up of 54 months, the addition of cetuximab improved locoregional control (median duration of locoregional control 24.4 vs. 14.9 months, $p < 0.01$), progression-free survival ($p = 0.006$) and overall survival (median survival 49.0 months vs. 29.3 months, $p = 0.03$) (Fig. 20.2). Importantly, this therapeutic benefit was achieved without exacerbation of radiotherapy-related toxicities, such as mucositis, xerostomia, pain, weight loss, or performance status deterioration (Table 20.1a). The addition of cetuximab did increase the rate of Grade ≥ 3 acneiform rash or infusion reaction, both cetuximab-related toxicities, but notably did not adversely alter quality of life [25]. Long-term data from this trial with 5-year median follow-up confirms stability of the locoregional control and overall survival benefit with the addition of cetuximab to radiotherapy [26]. This study was the first to provide proof of principle that a molecular targeted agent could improve survival outcome without amplifying treatment-limiting toxicities in HNSCC.

Interestingly, the benefit of cetuximab combined with radiotherapy manifested most strongly with the use of

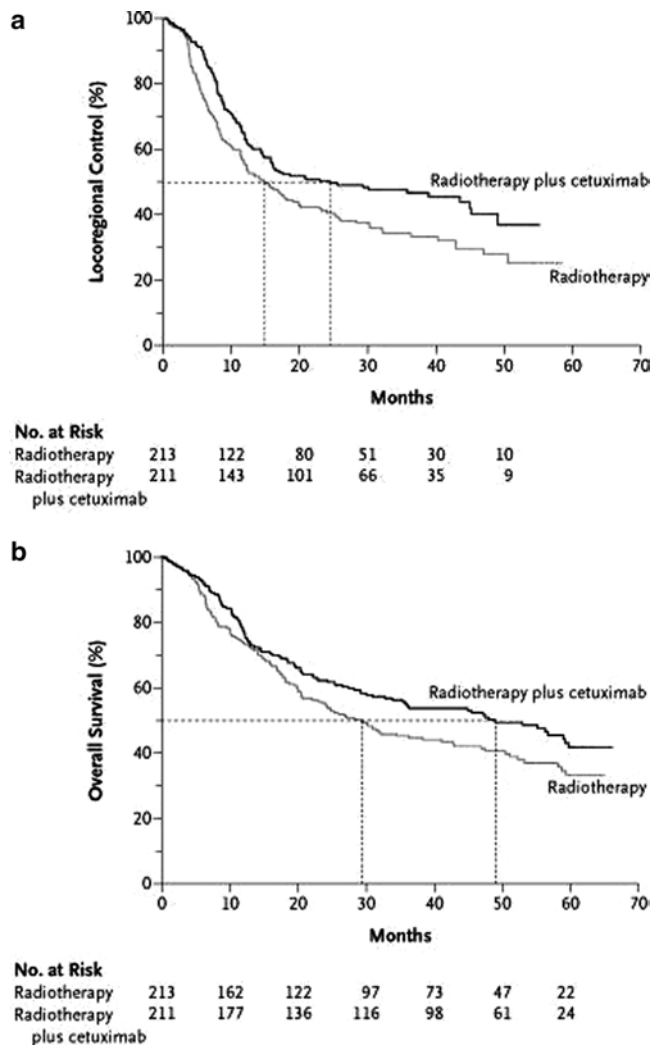


Fig. 20.2 Kaplan–Meier estimates of locoregional control (a) and overall survival (b) in the phase III international trial of radiotherapy with or without cetuximab for patients with stage III–IV HNSCC. The dotted lines indicate median duration of locoregional control (A; 24.4 months vs. 14.9 months, $p < 0.01$) and median survival (B; 49.0 months vs. 29.3 months, $p = 0.03$). From Bonner JA, Harari PM, Giralt J, et al. Radiotherapy plus cetuximab for squamous-cell carcinoma of the head and neck. *N Engl J Med.* 2006;354:567–578. Copyright © 2006 Massachusetts Medical Society. All rights reserved

concomitant boost radiotherapy ($n = 120$, $HR = 0.62$) or hyperfractionation technique ($n = 37$, $HR = 0.74$), but not with conventional fractionation ($n = 55$, $HR = 1.01$). There are data to suggest that HNSCC tumors with high EGFR expression may derive greater benefit with accelerated radiotherapy [27], pointing toward a relationship between EGFR signaling and altered radiation fractionation. However, caution is advised in interpreting clinical observations that derive from subset analyses. Further advances in our understanding

Table 20.1 Comparison of grade ≥ 3 toxicities in (a) phase III international trial of radiotherapy (RT) with or without cetuximab for patients with stage III–IV HNSCC, and (b) the EXTREME phase III trial of platinum-based doublet chemotherapy with or without cetuximab as first-line treatment for recurrent or metastatic HNSCC

(a)

Adverse event	RT alone ($N = 212$)	RT + Cetuximab ($N = 208$)	<i>P</i> value
Percent of patients			
Mucositis	52	56	0.44
Xerostomia	3	5	0.32
Dysphagia	30	26	0.45
RT dermatitis	18	23	0.27
Weight loss	7	11	0.12
Asthenia	5	4	0.64
Acneiform rash	1	17	<0.001
Infusion reaction	0	3	0.01

From Bonner JA, Harari PM, Giralt J, et al. Radiotherapy plus cetuximab for squamous-cell carcinoma of the head and neck. *N Engl J Med.* 2006;354:567–578. Copyright © 2006 Massachusetts Medical Society. All rights reserved

(b)

Adverse event	Chemo ($N = 215$)	Chemo + Cetuximab ($N = 219$)	<i>P</i> value
Percent of patients			
Neutropenia	23	22	0.91
Anemia	19	13	0.12
Thrombocytopenia	11	11	1.00
Leukopenia	9	9	1.00
Skin reaction	<1	9	<0.001
Sepsis	<1	4	0.02

From Vermorken JB, Mesia R, Rivera F, et al. Platinum-based chemotherapy plus cetuximab in head and neck cancer. *N Engl J Med.* 2008;359:1116–1127. Copyright © 2008 Massachusetts Medical Society. All rights reserved

of the survival benefits of altered radiation fractionation [28–30] and concurrent chemoradiotherapy [28, 31–33], contributed to the development of phase II trials [34, 35] and a subsequent ongoing phase III trial (RTOG 0522) combining cetuximab with concurrent cisplatin and accelerated radiotherapy. In this trial, patients with stage III–IV nonmetastatic HNSCC of the oropharynx, hypopharynx, or larynx are randomized to cisplatin-based chemoradiotherapy with or without cetuximab. Radiation therapy is delivered in an accelerated fashion, with patients stratified according to whether three-dimensional conformal radiotherapy or intensity-modulated radiotherapy is utilized. The primary endpoint is progression-free survival, and secondary endpoints include overall survival, locoregional control, acute and late toxicities, and quality of life and health economic endpoints. Additional phase II trials combining cetuximab with chemoradiotherapy are also ongoing in the postoperative (RTOG 0234) and unresectable (ECOG 3303) settings.

Metastatic/Recurrent HNSCC

The role of cetuximab in platinum-refractory metastatic/recurrent HNSCC has been investigated in three multicenter phase II trials. In one phase II trial, a total of 103 patients with platinum-refractory metastatic/recurrent HNSCC received cetuximab weekly until disease progression. The overall response rate was 13%, with all responders manifesting partial responses [36]. This response rate was similar to the response rate observed in other phase II trials of metastatic/recurrent HNSCC, in which cetuximab was added to the platinum-based chemotherapy regimen on which patients were failing [37, 38]. The similar response rates between cetuximab alone and cetuximab with chemotherapy in platinum-refractory HNSCC contrasted with prior observations in irinotecan-refractory metastatic colorectal cancer, in which cetuximab added to irinotecan showed improved activity compared to cetuximab alone [39].

In the first-line treatment of metastatic/recurrent HNSCC, an ECOG phase III study randomized 117 patients to cisplatin alone (100 mg/m² every 4 weeks) or with cetuximab (400 mg/m² cycle 1, followed by 250 mg/m² weekly) [40]. After a median follow-up of 31 months, the addition of cetuximab to cisplatin significantly improved response rate (26% vs. 10%, $p=0.03$), but did not significantly alter progression-free survival (primary study endpoint) or overall survival. The better than anticipated survival of patients in the cisplatin arm rendered this study underpowered to uncover a statistically significant improvement in progression-free survival despite the strong improvement in tumor response with the addition of cetuximab. During the accrual of this trial, phase II studies involving cetuximab therapy in colon cancer [41] and other EGFR inhibitors in head and neck cancer [42], observed an intriguing correlation between the development of skin toxicity and biologic activity to EGFR inhibition. Such a correlation was also investigated in this ECOG study. Consistent with prior literature, the development of a cetuximab-related skin reaction was correlated with an improvement in overall survival (HR 0.42, $p=0.01$).

After phase II data demonstrated activity combining 5-fluorouracil with cetuximab and cisplatin [43], the EXTREME phase III trial was designed to investigate the efficacy of this regimen as first-line therapy for metastatic/recurrent head and neck cancer [44]. Patients were included if their disease was considered unsuitable for local therapy and excluded if they received prior systemic chemotherapy less than 6 months, or surgery or radiotherapy less than 4 weeks, prior to study entry. A total of 442 patients underwent randomization at 81 centers in 17 European countries. Platinum-based chemotherapy involved a maximum of 6 cycles of either cisplatin (100 mg/m² on day 1) or carboplatin (area under the curve of 5 mg/ml on day 1) plus 5-fluorouracil (1,000 mg/m² per day for 4 days), delivered every

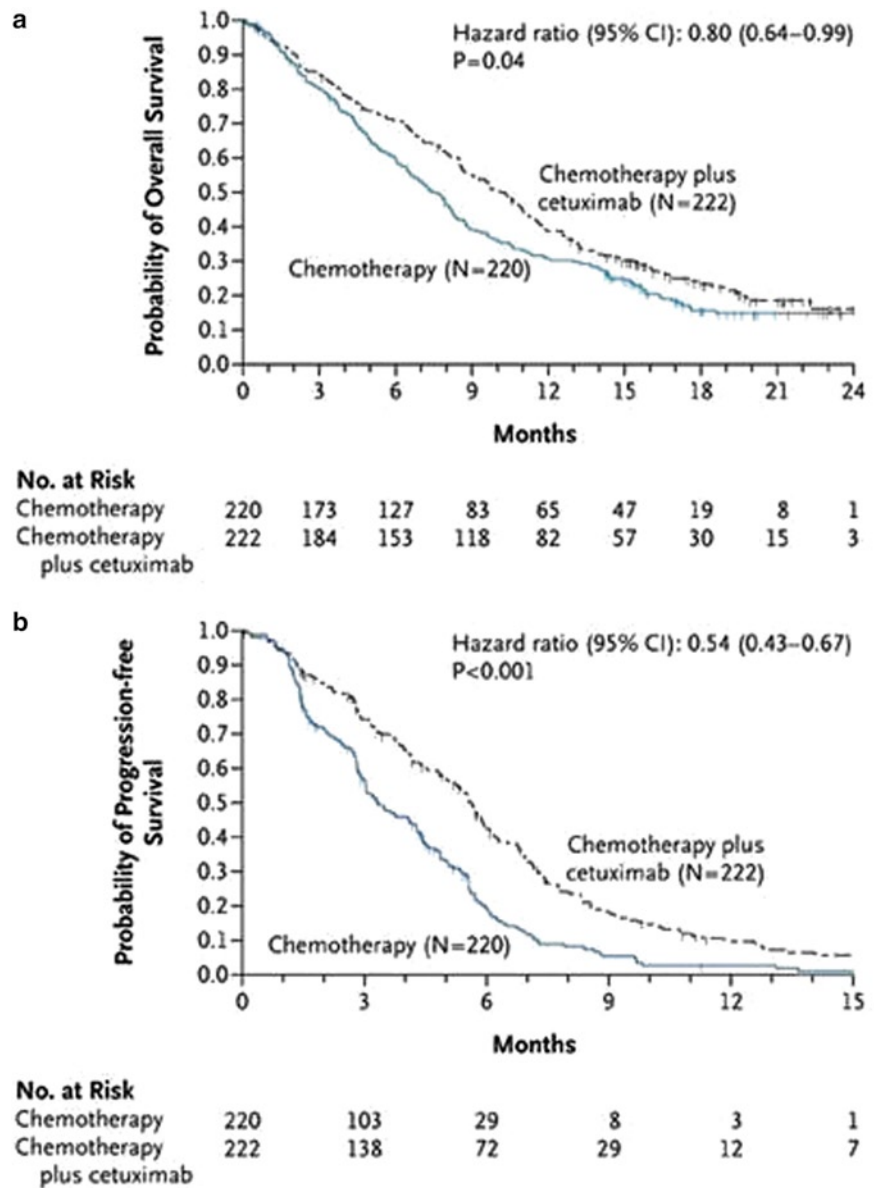
3 weeks. Cetuximab was administered at a dose of 400 mg/m² initially, followed by weekly infusions of 250 mg/m². In the cetuximab arm, patients with stable disease continued to receive cetuximab until disease progression or unacceptable toxicities, whichever occurred first. Patients in the chemotherapy-alone group received no further active treatment. Of the 413 tumors tested by immunohistochemical analysis, 98% had detectable EGFR, with 40% or more EGFR-positive cells observed in 80% of tested tumors. The addition of cetuximab to the platinum-based doublet regimen improved response rate (35.6% vs. 19.5%, $p=0.0001$) and prolonged median progression-free survival (5.6 months vs. 3.3 months, $p<0.001$) and median overall survival (10.1 months vs. 7.4 months, $p=0.04$) (Fig. 20.3) without exacerbation of chemotherapy-related hematologic toxicities or quality of life (Table 20.1b). Preliminary analysis of EGFR gene copy number, assayed by fluorescent in-situ hybridization (FISH), was not predictive of cetuximab efficacy [45].

Toxicities

A greater understanding of cetuximab-related toxicities has emerged in recent years, as its clinical use has become more widespread. Cetuximab-related toxicities generally involve skin and allergic reactions. Encompassing multiple different manifestations, the skin rash associated with cetuximab is most frequently acneiform in appearance and generally distributed in skin areas rich in sebaceous glands, such as the face, neck, shoulders, upper trunk, and scalp (Fig. 20.4). The development of the rash is largely attributed to high levels of EGFR expression in the epidermis and hair follicle. Approximately 70% cetuximab-related skin reactions are grade 1 or 2 [24] and resolve without the need for pharmacologic intervention. Both in head and neck cancer [40] and other tumor sites [46], the development of a cetuximab-related rash appears to correlate with improved activity.

As a chimeric mouse-human IgG₁ monoclonal antibody, cetuximab is associated with allergic and occasional anaphylactic reactions. Though the product label indicates that severe hypersensitivity reactions occur in approximately 3% of patients, higher rates have been reported in a few distinct geographic regions including the southeast USA and in Sydney, Australia, as compared to other areas [39, 47–49]. Many of these reactions occur within minutes after a patient's first exposure to the drug, compatible with IgE-mediated reaction. Recent data has observed an association between cetuximab-related reactions and the presence of IgE antibodies directed against galactose- α (alpha)-1,3-galactose prior to the first infusion with cetuximab (Fig. 20.5). Prior exposure to galactose- α (alpha)-1,3-galactose may induce the generation of galactose- α (alpha)-1,3-galactose-specific IgE antibodies

Fig. 20.3 Kaplan–Meier estimates of overall survival (a) and progression-free survival (b) in the EXTREME phase III trial of platinum-based doublet chemotherapy with or without cetuximab in the first-line treatment of recurrent or metastatic HNSCC. The addition of cetuximab to the platinum-based doublet regimen prolonged median progression-free survival (5.6 months vs. 3.3 months, $p < 0.001$) and median overall survival (10.1 months vs. 7.4 months, $p = 0.04$). From Vermorken JB, Mesia R, Rivera F, et al. Platinum-based chemotherapy plus cetuximab in head and neck cancer. *N Engl J Med.* 2008;359:1116-1127. Copyright © 2008 Massachusetts Medical Society. All rights reserved



in some patients, placing these patients at increased risk for cetuximab-related anaphylactic reactions [50]. In contrast to cetuximab, two other anti-EGFR monoclonal antibodies, panitumumab and zalutumumab, are fully human and therefore carry less theoretical risk for allergic reactions. Preclinical studies have shown augmentation of radiation response using panitumumab in HNSCC [51]. Phase II/III trials using panitumumab in the locally advanced and metastatic/recurrent settings, and phase III trials using zalutumumab in the locally advanced and platinum-refractory settings, are ongoing [52].

EGFR Tyrosine Kinase Inhibitors

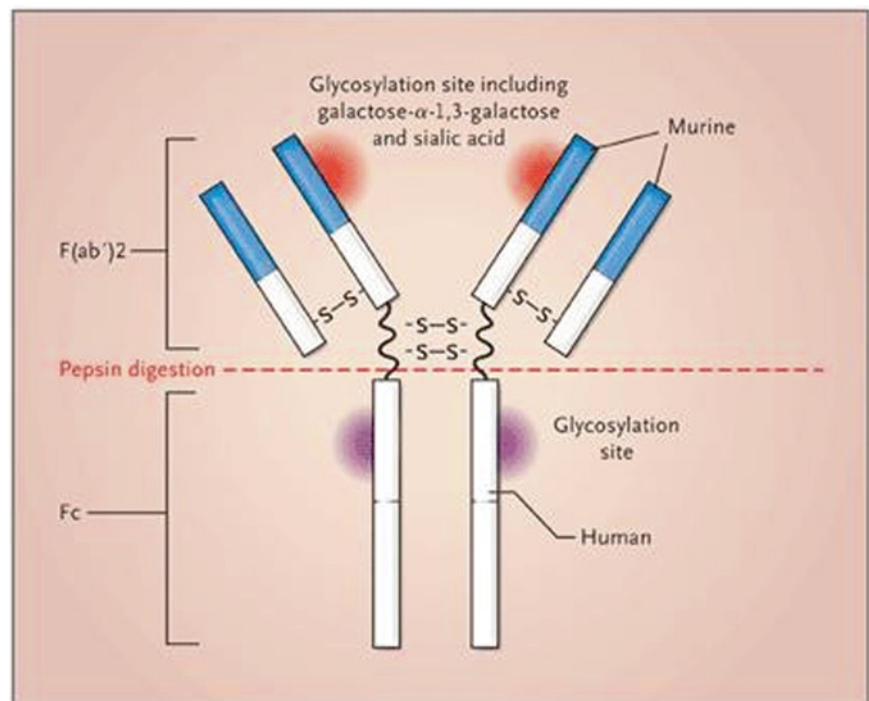
Small-molecule tyrosine kinase inhibitors (TKIs) bind to the intracellular tyrosine kinase domain of EGFR and inhibit phosphorylation, thereby blocking downstream signal transduction (see Fig. 20.1). These agents have demonstrated antitumor activity in multiple preclinical models [53–61]. Of the anti-EGFR TKIs, gefitinib, and erlotinib are the furthest along in their clinical development and, unlike monoclonal antibodies, can be administered orally, most commonly on a once daily basis. The phase III Iressa vs. Methotrexate or

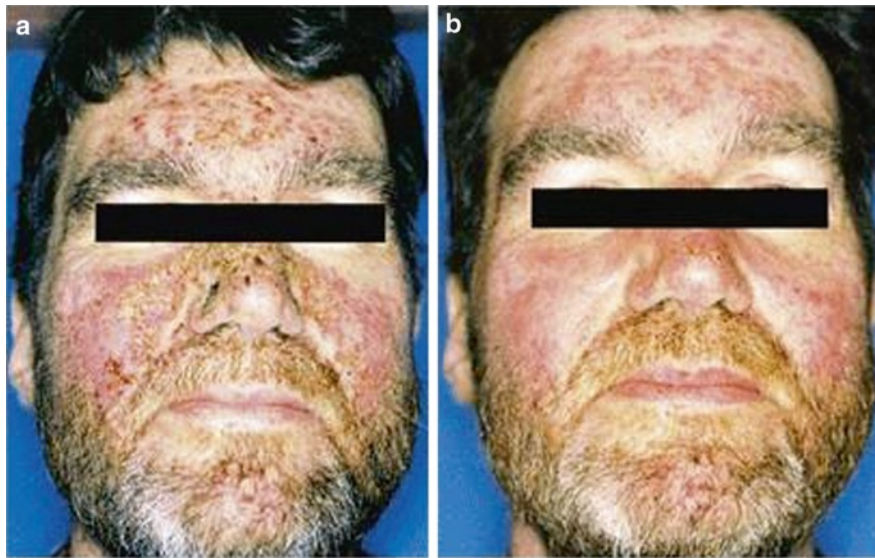

Fig. 20.4 Cetuximab-related acneiform rash. A 48-year-old man with metastatic colon cancer was treated with fluorouracil, leucovorin, oxaliplatin, and cetuximab. An acneiform eruption developed on his face, chest, and back (*Panel A*). After gentle débridement, the right half of his face was treated with 0.2% hydrocortisone valerate and the left treated with 0.1% tazarotene. One week later, there was greater

improvement on the right side (*Panel B*), suggesting that anti-inflammatory agents may prove effective for the skin toxicity associated with this class of agent. Adapted from Moss JE and Burtneß B. Cetuximab-associated Acneiform Eruption. *N Engl J Med.* 2005; 353 (19). Copyright © 2005 Massachusetts Medical Society. All rights reserved

Fig. 20.5 Structure of cetuximab. Galactose- α (alpha)-1,3-galactose oligopolysaccharides are located on the murine Fab portion, and not the human Fc portion. IgE antibodies directed at this antigen on cetuximab may predispose patients to cetuximab-related anaphylactic reactions. S-S denotes a disulfide bond. Adapted from Chung CH, Mirakhor B, Chan E, et al. Cetuximab-induced anaphylaxis and IgE specific for galactose- α -1,3-galactose. *N Engl J Med.* 2008;358: 1109-1117. Copyright © 2008 Massachusetts Medical Society. All rights reserved



“IMEX” trial randomized 486 patients with recurrent/metastatic HNSCC to gefitinib 250 or 500 mg/day or methotrexate [62]. No benefit was observed in objective response rate (2.7%, 7.6%, 3.9%, respectively), quality of life (13.4%, 18.0%, 6.0%, respectively), or the primary endpoint of overall survival (median overall survival, 5.6, 6.0, 6.7 months, respectively). A phase III ECOG study was designed to randomize 330 patients with recurrent/metastatic HNSCC to docetaxel with or without gefitinib. The study was terminated early after an interim analysis demonstrated a low likelihood of reaching an overall survival benefit, the primary endpoint. Preliminary analysis of the 270 enrolled patients demonstrated prolongation of time to progression with the addition of gefitinib (median, 3.5 and 2.0 months with and without gefitinib, respectively), but no improvement in overall or progression-free survival [63].

Targeting Angiogenesis

In 1971 Folkman described the ability of tumors to form new blood vessels, termed angiogenesis, and implicated the importance of this process for tumor growth and progression [64]. Initial preclinical data demonstrated the inability of solid tumors to grow larger than 2–3 mm or to generate metastases in the absence of new blood vessels [65–67]. Without angiogenesis, tumor cells reach equilibrium between the rate of proliferation and death [68]. To recruit their own blood supply, tumor cells must activate the “angiogenic switch,” a term coined to describe a shift in the peri-tumoral homeostasis between pro- and antiangiogenic factors (Fig. 20.6) [67, 69]. Preclinical data has demonstrated that this process occurs early in cancer development and represents a rate-limiting step in tumor progression [70].

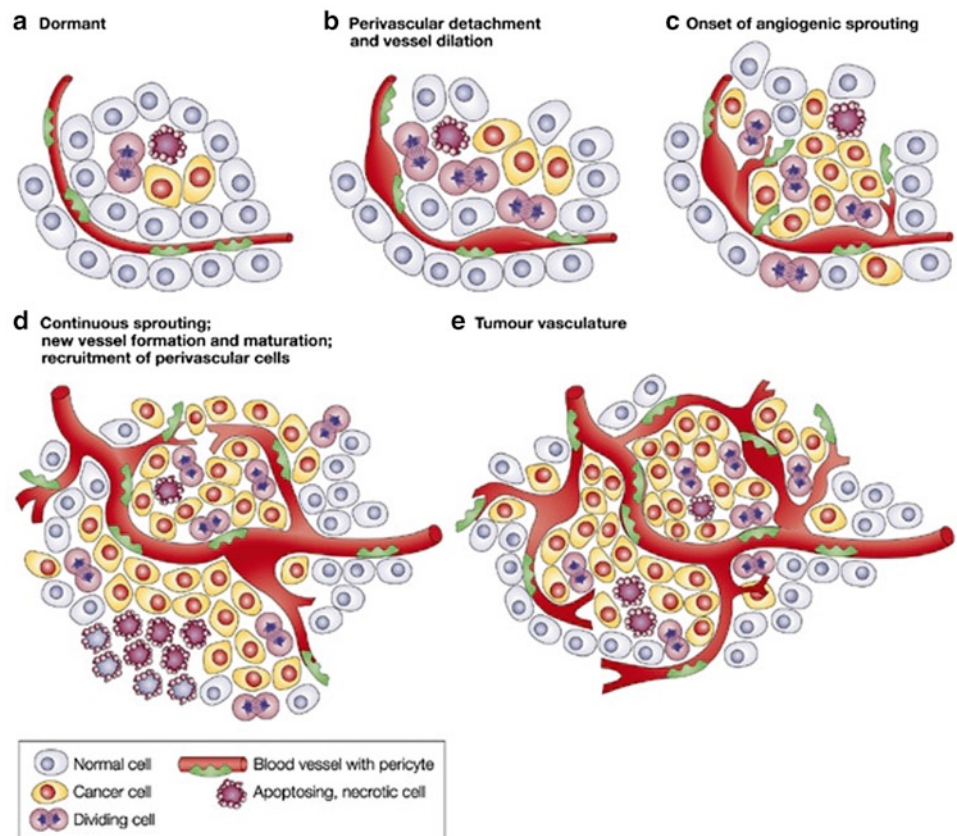


Fig. 20.6 Angiogenic switch. Most tumors start as avascular nodules (dormant) (a) until equilibrium is reached between rate of proliferation and apoptosis. The “angiogenic switch,” once activated, leads to perivascular detachment and vessel dilation (b), angiogenic sprouting (c), new vessel formation and maturation (d), and ultimately mature tumor vasculature (e). Adapted from Bergers G, Benjamin LE. Tumorigenesis and the angiogenic switch. *Nat Rev Cancer*. 2003;3:401–10. With permission from Nature Publishing Group

Triggers of the “angiogenesis switch” include hypoxia, which manifests as the tumor cell outgrows its existing blood supply. The net product of angiogenesis is the generation of new tumor vessels that are structurally abnormal, rendering the vessels “leaky” and inefficient in their ability to deliver blood, oxygen, and nutrients. This, in turn, results in further hypoxia, creating a feedback loop of perpetually activated angiogenesis [71].

One of the prime angiogenic targets, vascular endothelial growth factor (VEGF), is thought to play a central proangiogenic role in HNSCC [72–74]. VEGF binds to its transmembrane tyrosine kinase receptor VEGFR-2 to activate signal transduction, which ultimately stimulates vascular endothelial cell proliferation and survival and secretes proteolytic enzymes to break down extracellular matrix [67, 75]. The ubiquity of VEGF and VEGFR in HNSCC, expressed in 90% of HNSCC tumor samples [76, 77], renders the VEGF signaling pathway an attractive biologic target. In an analysis of HNSCC tumor samples from 1,002 patients in 12 studies, VEGF immunohistochemical staining was associated with a 1.88-fold higher risk of death at 2 years [78]. In addition, increased VEGF levels in HNSCC tumor samples and patient serum have been associated with tumor growth, metastasis, and treatment failure [79–82]. In preclinical HNSCC models, inhibition of the VEGF signaling pathway has markedly decreased angiogenesis, inhibited tumor growth, and augmented radiation response [83–85]. The latter effect is thought to be due, in part, to the ability of VEGF inhibition to prevent the development of structurally abnormal blood vessels. By normalizing tumor vasculature in this way, VEGF inhibition is thought to mitigate tumor hypoxia, a known marker of radioresistance [86].

Bevacizumab

Bevacizumab is a fully humanized monoclonal antibody specific to all isoforms of the VEGFA ligand. Approved by the FDA for use in metastatic colorectal cancer and non-small-cell lung cancer. Bevacizumab is the most mature agent in clinical testing of antiangiogenic therapies for HNSCC. In an ongoing phase III trial conducted by the Eastern Cooperative Oncology Group (ECOG), 400 patients with treatment-naïve recurrent/metastatic HNSCC are being randomized to docetaxel/cisplatin/5-FU with or without bevacizumab with overall survival as the primary endpoint [52]. Several phase I trials are underway examining the feasibility of incorporating bevacizumab into concurrent chemoradiation regimens for curative HNSCC patients.

Combining Anti-VEGF and Anti-EGFR Therapies

Based on preclinical data demonstrating a favorable interaction between anti-VEGF and anti-EGFR therapies [87] and the potential for anti-VEGF therapies to reverse EGFR resistance [88, 89], a phase I/II trial of combining bevacizumab with erlotinib in the recurrent/metastatic HNSCC setting was conducted [71]. In the phase I component, ten patients were enrolled in three successive cohorts with no dose-limiting toxicities. In the phase II component, 46 patients were enrolled on the highest dose of bevacizumab (15 mg/kg every 3 weeks). Median overall survival and progression-free survival were 7.1 and 4.1 months, respectively. The overall response rate was 14.6%, with 4 patients demonstrating a complete response. Common toxicities included rash and diarrhea from erlotinib. Three patients had severe bleeding events of grade 3 or higher. In the locally advanced setting, a phase II trial of induction chemotherapy of paclitaxel, carboplatin, 5-FU, and bevacizumab for two cycles, followed by concurrent chemoradiotherapy involving paclitaxel, bevacizumab, and erlotinib, enrolled 60 patients. Preliminary analysis demonstrated an 18-month progression-free survival and overall survival of 85 and 87%, respectively, after a median follow-up of 16 months [90]. In the locally advanced setting, the benefit of adding bevacizumab to chemoradiotherapy involving pemetrexed and cetuximab is being studied in a phase II trial, with progression-free survival as the primary endpoint [52].

Multikinase Inhibitors

By blocking multiple biologic targets, multikinase inhibitors have the potential to inhibit multiple signaling pathways as a single oral agent. Sorafenib, sunitinib, and vandetanib are furthest in their clinical testing in HNSCC. Sorafenib inhibits the activity of VEGFR, platelet-derived growth factor receptor (PDGFR), and the RAF/MEK/ERK signaling pathways, all of which are associated with tumor angiogenesis and tumor growth and proliferation. Sorafenib monotherapy in treatment-naïve recurrent/metastatic HNSCC was associated with median overall survival and time to progression of 8 and 4 months, respectively [91]. Sunitinib, FDA-approved for renal cell carcinoma, also inhibits multiple kinases, including VEGFR, PDGFR, c-kit, FLT3, to simultaneously inhibit angiogenesis and tumor proliferation. Preliminary results from GORTEC 2006-01, a phase II study of sunitinib monotherapy in

Table 20.2 Common toxicities associated with antiangiogenic agents

Toxicity	Frequency	Possible underlying mechanism	Treatment
Hypertension	15–60%	↓ NO and PGI release ↑ Vascular stiffness ↓ Vessel density	Antihypertensives
Hemorrhage	Minor: 26–60% Severe: <3%	Impaired platelet function ↓ tissue factor on endothelial cells	Severe: hemostasis via pressure, embolization, surgical repair
Thromboembolic events	5–15%	↓ endothelial cell renewal with exposure of prothrombotic ECM Platelet activation ↓ tissue factor on endothelial cells	Anticoagulation Recommend discontinuation of most agents
Proteinuria/edema	Up to 30%	Podocyte dysfunction	Hold treatment
Hypothyroidism	Up to 36%	Thyroid cell dysfunction ↓ Vascular density	Thyroid hormone replacement
Leukopenia/immune modulation	Unknown Usually asymptomatic	Impaired bone marrow production and cell function	None Consider stopping if severe
Skin toxicity/hand–foot syndrome	Up to 42% for sorafenib Less for other agents	Apoptosis of epidermal cells	Avoid cold or physical activity Gloves Skin care Antibiotics for open lesions

From Seiwert TY, Cohen EE. Targeting angiogenesis in head and neck cancer. *Sem Oncol.* 2008;35(3):274–85. Copyright Elsevier 2008

37 evaluable patients with recurrent/metastatic HNSCC, demonstrated a partial response in 1 patient, stable disease in 18 patients, and progressive disease in 19 patients, by RECIST criteria. Grade ≥ 3 tumor bleeding occurred in 6 patients, with 2 of those patients demonstrated fatal bleeding [92]. In contrast to sorafenib and sunitinib, vandetanib is a selective dual inhibitor of EGFR and VEGF signaling. RTOG 0619, an ongoing phase II trial, randomizes 170 patients with resected locally advanced HNSCC with high-risk features to chemoradiotherapy with or without vandetanib [52].

Toxicities

Under normal physiological circumstances, more than 99% of endothelial cells are quiescent [93, 94]. During early development, antiangiogenic therapies were anticipated to carry minimal toxicity, given the selectiveness of these agents for proliferating endothelial and perivascular cells [95, 96]. Clinical experience to date, however, has changed these expectations, with a characteristic toxicity profile now better understood. Underlying these toxicities are targeted signaling pathways critical for not just angiogenesis but other physiological processes as well. In addition, the possibility for “off-target” effects exerted by angiogenesis inhibitors on other signaling pathways complicates the picture. The most typical side effects of antiangiogenic agents involve hypertension, hemorrhagic complications, thromboembolic

events, wound healing, perforation, hypothyroidism, immunosuppression, proteinuria, edema, and hand–foot syndrome (Table 20.2) [97, 98].

Other Biologic Targets

SRC Family Kinases

Src family kinases consist of 8 family members, with c-Src most often overexpressed and/or aberrantly activated in epithelial and nonepithelial cancers [99]. Src kinases are associated with tumorigenesis, tumor progression, and/or metastases [100, 101]. In HNSCC, Src kinase activation follows EGFR stimulation and can be inhibited with EGFR targeting in pre-clinical HNSCC models [54, 102]. Dasatinib, a small-molecule inhibitor of Src family kinases, BCR-abl, c-Kit, and PDGFR, has been FDA-approved for chronic myeloid leukemia due to its ability to inhibit BCR-abl. Preclinical data has demonstrated the ability of dasatinib to overcome HNSCC tumor resistance to EGFR inhibition by cetuximab and to potentially resensitize resistant HNSCC cells to EGFR inhibition [103]. This has contributed to the clinical testing of dasatinib in ongoing phase II trials for recurrent/metastatic HNSCC. Preliminary results from a phase II study of dasatinib, dosed at 100 mg twice daily, in recurrent or metastatic HNSCC demonstrated fairly high rates of hospitalization (4 of 15 patients) and discontinuation (5 of 15 patients). Pharmacokinetic evaluation in this study is ongoing [104].

The Insulin-Like Growth Factor-1 Receptor (IGF-1R)

Overexpressed in multiple human epithelial tumors, the insulin-like growth factor-1 receptor (IGF-1R) binds ligand IGF to stimulate a multitude of signaling cascades. Preclinical studies have shown that IGF-1R inhibition attenuates tumorigenesis and tumor invasion and metastasis [105]. In addition, the heterodimerization of IGF-1R with EGFR may promote resistance to EGFR inhibition [106, 107]. Thus, combined targeting of IGF-1R and EGFR may be effective in enhancing antitumor activity. To address this potential, an ongoing randomized phase II trial is evaluating a monoclonal antibody of IGF-1R, IMC-A12, alone or in combination with cetuximab in patients with recurrent/metastatic HNSCC [52].

p53

The tumor suppressor gene *p53* has been implicated in HNSCC, with 43% of invasive HNSCC's harboring *p53* mutations and an increased frequency of *p53* mutations observed in patients with a history of tobacco use [108, 109]. A novel approach to targeted therapy, INGN 201 is a gene therapy in which a replication-defective adenovirus serotype 5 vector with a *p53* combinatorial DNA insertion is administered directly into the tumor to replace mutated *p53* genes with wild-type (normal) *p53* genes. A phase III trial of INGN 201 compared to methotrexate in HNSCC refractory to surgery, radiotherapy, and platinum or taxane-based chemotherapy is ongoing, with the primary endpoint of overall survival. A phase II feasibility study of surgery with perioperative INGN201 gene therapy followed by chemoradiotherapy for locally advanced resectable HNSCC has recently completed accrual [52].

Summary

Molecular targeted therapies for head and neck cancer offer promising opportunities to improve upon clinical outcomes of conventional treatments. Phase III clinical data demonstrate measurable survival benefits with the use of cetuximab in the locally advanced and recurrent/metastatic settings. EGFR tyrosine kinase inhibitors, erlotinib and gefitinib, and VEGF inhibitors, bevacizumab and multikinase inhibitors, have shown activity against HNSCC in a variety of settings. The toxicities of these agents are unique to their signaling cascades and, importantly, do not appear to directly overlap or amplify the toxicities of conventional treatments. The future

impact of targeted therapies in HNSCC relies on rigorous preclinical and clinical evaluation of promising new agents and advances in our ability to predict those patients most likely to benefit.

References

- Herbst RS, Onn A, Mendelsohn J. The role of growth factor signaling in malignancy. *Cancer Treat Res.* 2003;115:19–72.
- Mendelsohn J, Baselga J. The EGF receptor family as targets for cancer therapy. *Oncogene.* 2000;19:6550–65.
- Christensen ME, Therkildsen MH, Hansen BL, et al. Epidermal growth factor receptor expression on oral mucosa dysplastic epithelia and squamous cell carcinomas. *Eur Arch Otorhinolaryngol.* 1992;249:243–7.
- Grandis JR, Tweardy DJ. Elevated levels of transforming growth factor and epidermal growth factor receptor messenger RNA are early markers of carcinogenesis in head and neck cancer. *Cancer Res.* 1993;53:3579–84.
- Kalyankrishna S, Grandis JR. Epidermal growth factor receptor biology in head and neck cancer. *J Clin Oncol.* 2006;24:2666–72.
- Almadori G, Cadoni G, Galli J, et al. Epidermal growth factor receptor expression in primary laryngeal cancer: an independent prognostic factor of neck node relapse. *Int J Cancer.* 1999;84:188–91.
- Chung CH, Ely K, McGavran L, et al. Increased epidermal growth factor receptor gene copy number is associated with poor prognosis in head and neck squamous cell carcinomas. *J Clin Oncol.* 2006;24:4170–6.
- Dassonville O, Formento JL, Francoual M, et al. Expression of epidermal growth factor receptor and survival in upper aerodigestive tract cancer. *J Clin Oncol.* 1993;11:1873–8.
- Lee CS, Redshaw A, Boag G. Epidermal growth factor receptor immunoreactivity in human laryngeal squamous cell carcinoma. *Pathology.* 1997;29:251–4.
- Maurizi M, Almadori G, Ferrandina G, et al. Prognostic significance of epidermal growth factor receptor in laryngeal squamous cell carcinoma. *Br J Cancer.* 1996;74:1253–7.
- Storkel S, Reichert T, Reiffen KA, et al. EGFR and PCNA expression in oral squamous cell carcinomas—a valuable tool in estimating the patient's prognosis. *Eur J Cancer B Oral Oncol.* 1993;29B:273–7.
- Temam S, Kawaguchi H, El-Naggar AK, et al. Epidermal growth factor receptor copy number alterations correlate with poor clinical outcome in patients with head and neck squamous cancer. *J Clin Oncol.* 2007;25:2164–70.
- Ang KK, Berkey BA, Tu X, et al. Impact of epidermal growth factor receptor expression on survival and pattern of relapse in patients with advanced head and neck carcinoma. *Cancer Res.* 2002;62:7350–6.
- Hitt R, Ciruelos E, Amador ML, et al. Prognostic value of the epidermal growth factor receptor (EGFR) and p53 in advanced head and neck squamous cell carcinoma patients treated with induction therapy. *Eur J Cancer.* 2005;41:453–60.
- Liang K, Ang KK, Milas L, et al. The epidermal growth factor receptor mediates radioresistance. *Int J Radiat Oncol Biol Phys.* 2003;57:246–54.
- Pivot X, Magne N, Guardiola E, et al. Prognostic impact of the epidermal growth factor receptor levels for patients with larynx and hypopharynx cancer. *Oral Oncol.* 2005;41:320–7.
- Masui H, Kawamoto T, Sato J, et al. Growth inhibition of human tumor cells in athymic mice by anti-epidermal growth factor receptor monoclonal antibodies. *Cancer Res.* 1984;44:1002–7.

18. Arteaga C. Targeting HER1/EGFR: A molecular approach to cancer therapy. *Semin Oncol.* 2003;30:3–14.
19. Mendelsohn J, Baselga J. Status of epidermal growth factor receptor antagonists in the biology and treatment of cancer. *J Clin Oncol.* 2003;21:2787–99.
20. Huang SM, Bock JM, Harari PM. Epidermal growth factor receptor blockade with C225 modulates proliferation, apoptosis, and radiosensitivity in squamous cell carcinomas of the head and neck. *Cancer Res.* 1999;59:1935–40.
21. Huang SM, Harari PM. Modulation of radiation response after epidermal growth factor receptor blockade in squamous cell carcinomas: inhibition of damage repair, cell cycle kinetics, and tumor angiogenesis. *Clin Cancer Res.* 2000;6:2166–74.
22. Ciardiello F, Bianco R, Damiano V, et al. Antitumor activity of sequential treatment with topotecan and anti-epidermal growth factor receptor monoclonal antibody C225. *Clin Cancer Res.* 1999;5:909–16.
23. Fan Z, Baselga J, Masui H, et al. Antitumor effect of anti-epidermal growth factor receptor monoclonal antibodies plus cis-diamminedichloroplatinum on well established A431 cell xenografts. *Cancer Res.* 1993;53:4637–42.
24. Bonner JA, Harari PM, Giralt J, et al. Radiotherapy plus cetuximab for squamous-cell carcinoma of the head and neck. *N Engl J Med.* 2006;354:567–78.
25. Curran D, Giralt J, Harari PM, et al. Quality of life in head and neck cancer patients after treatment with high-dose radiotherapy alone or in combination with cetuximab. *J Clin Oncol.* 2007;25:2191–7.
26. Bonner JA, Harari PM, et al. Radiotherapy plus cetuximab for squamous-cell carcinoma of the head and neck. *J Clin Oncol.* 2009;Manuscript submitted.
27. Bentzen SM, Atasoy BM, Daley FM, et al. Epidermal growth factor receptor expression in pretreatment biopsies from head and neck squamous cell carcinoma as a predictive factor for a benefit from accelerated radiation therapy in a randomized controlled trial. *J Clin Oncol.* 2005;23:5560–7.
28. Brizel DM, Albers ME, Fisher SR, et al. Hyperfractionated irradiation with or without concurrent chemotherapy for locally advanced head and neck cancer. *N Engl J Med.* 1998;338:1798–804.
29. Fu KK, Pajak TF, Trotti A, et al. A Radiation Therapy Oncology Group (RTOG) phase III randomized study to compare hyperfractionation and two variants of accelerated fractionation to standard fractionation radiotherapy for head and neck squamous cell carcinomas: first report of RTOG 9003. *Int J Radiat Oncol Biol Phys.* 2000;48:7–16.
30. Bourhis J, Overgaard J, Audry H, et al. Hyperfractionated or accelerated radiotherapy in head and neck cancer: a meta-analysis. *Lancet.* 2006;368:843–54.
31. Adelstein DJ, Li Y, Adams GL, et al. An intergroup phase III comparison of standard radiation therapy and two schedules of concurrent chemoradiotherapy in patients with unresectable squamous cell head and neck cancer. *J Clin Oncol.* 2003;21:92–8.
32. Denis F, Garaud P, Bardet E, et al. Final results of the 94-01 French Head and Neck Oncology and Radiotherapy Group randomized trial comparing radiotherapy alone with concomitant radiochemotherapy in advanced-stage oropharynx carcinoma. *J Clin Oncol.* 2004;22:69–76.
33. Forastiere AA, Goepfert H, Maor M, et al. Concurrent chemotherapy and radiotherapy for organ preservation in advanced laryngeal cancer. *N Engl J Med.* 2003;349:2091–8.
34. Pfister DG, Su YB, Kraus DH, et al. Concurrent cetuximab, cisplatin, and concomitant boost radiotherapy for locoregionally advanced, squamous cell head and neck cancer: a pilot phase II study of a new combined-modality paradigm. *J Clin Oncol.* 2006;24:1072–8.
35. Suntharalingam M, Taylor R, Wolf J, et al. Initial report of phase II trial of weekly cetuximab, CBDCA, paclitaxel and daily RT in patients with locally advanced SCCHN [abstract]. Multidisciplinary Head and Neck Cancer Symposium, cosponsored by the American Society for Therapeutic Radiology and Oncology and the American Society of Clinical Oncology. California: Rancho Mirage; 2007.
36. Vermorken JB, Trigo J, Hitt R, et al. Open-label, uncontrolled, multicenter phase II study to evaluate the efficacy and toxicity of cetuximab as a single agent in patients with recurrent and/or metastatic squamous cell carcinoma of the head and neck who failed to respond to platinum-based therapy. *J Clin Oncol.* 2007;25:2171–7.
37. Baselga J, Trigo JM, Bourhis J, et al. Phase II multicenter study of the anti-epidermal growth factor receptor monoclonal antibody cetuximab in combination with platinum-based chemotherapy in patients with platinum-refractory metastatic and/or recurrent squamous cell carcinoma of the head and neck. *J Clin Oncol.* 2005;23:5568–77.
38. Herbst RS, Arquette M, Shin DM, et al. Phase II multicenter study of the epidermal growth factor receptor antibody cetuximab and cisplatin for recurrent and refractory squamous cell carcinoma of the head and neck. *J Clin Oncol.* 2005;23:5578–87.
39. Cunningham D, Humblet Y, Siena S, et al. Cetuximab monotherapy and cetuximab plus irinotecan in irinotecan-refractory metastatic colorectal cancer. *N Engl J Med.* 2004;351:337–45.
40. Burtneß B, Goldwasser MA, Flood W, et al. Phase III randomized trial of cisplatin plus placebo compared with cisplatin plus cetuximab in metastatic/recurrent head and neck cancer: an Eastern Cooperative Oncology Group study. *J Clin Oncol.* 2005;23:8646–54.
41. Saltz LB, Meropol NJ, Loehrer Sr PJ, et al. Phase II trial of cetuximab in patients with refractory colorectal cancer that expresses the epidermal growth factor receptor. *J Clin Oncol.* 2004;22:1201–8.
42. Cohen EE, Rosen F, Stadler WM, et al. Phase II trial of ZD1839 in recurrent or metastatic squamous cell carcinoma of the head and neck. *J Clin Oncol.* 2003;21:1980–7.
43. Bourhis J, Rivera F, Mesia R, et al. Phase I/II study of cetuximab in combination with cisplatin or carboplatin and fluorouracil in patients with recurrent or metastatic squamous cell carcinoma of the head and neck. *J Clin Oncol.* 2006;24:2866–72.
44. Vermorken JB, Mesia R, Rivera F, et al. Platinum-based chemotherapy plus cetuximab in head and neck cancer. *N Engl J Med.* 2008;359:1116–27.
45. Licitra L, Rolland F, Bokemeyer C, et al. Biomarker potential of EGFR gene copy number by FISH in the phase III EXTREME study: Platinum-based chemotherapy plus cetuximab in the first-line R/M SCCHN. *J Clin Oncol.* 2009;27:suppl; abstr 6005.
46. Perez-Soler R, Saltz L. Cutaneous adverse effects with HER1/EGFR-targeted agents: is there a silver lining? *J Clin Oncol.* 2005;23:5235–46.
47. Pryor DI, Porceddu SV, Burmeister BH, et al. Enhanced toxicity with concurrent cetuximab and radiotherapy in head and neck cancer. *Radiother Oncol.* 2009;90:172–6.
48. Chung KY, Shia J, Kemeny NE, et al. Cetuximab shows activity in colorectal cancer patients with tumors that do not express the epidermal growth factor receptor by immunohistochemistry. *J Clin Oncol.* 2005;23:1803–10.
49. O'Neil BH, Allen R, Spigel DR, et al. High incidence of cetuximab-related infusion reactions in Tennessee and North Carolina and the association with atopic history. *J Clin Oncol.* 2007;25:3644–8.
50. Chung CH, Mirakhor B, Chan E, et al. Cetuximab-induced anaphylaxis and IgE specific for galactose-alpha-1, 3-galactose. *N Engl J Med.* 2008;358:1109–17.
51. Kruser TJ, Armstrong EA, Ghia AJ, et al. Augmentation of radiation response by panitumumab in models of upper aerodigestive tract cancer. *Int J Radiat Oncol Biol Phys.* 2008;72:534–42.
52. National Institutes of Health. Clinical trials registry; 2009.

53. Sano D, Kawakami M, Fujita K, et al. Antitumor effects of ZD6474 on head and neck squamous cell carcinoma. *Oncol Rep.* 2007;17:289–95.
54. Yang Z, Bagheri-Yarmand R, Wang RA, et al. The epidermal growth factor receptor tyrosine kinase inhibitor ZD1839 (Iressa) suppresses c-Src and Pak1 pathways and invasiveness of human cancer cells. *Clin Cancer Res.* 2004;10:658–67.
55. Shintani S, Kiyota A, Mihara M, et al. Enhancement of radiosensitivity in head and neck cancer cells by ZD1839 (“Iressa”), a selective epidermal growth factor receptor tyrosine kinase inhibitor. *Am J Clin Oncol.* 2003;26:e150–156.
56. Magne N, Fischel JL, Tiffon C, et al. Molecular mechanisms underlying the interaction between ZD1839 (“Iressa”) and cisplatin/5-fluorouracil. *Br J Cancer.* 2003;89:585–92.
57. Modjtahedi H, Affleck K, Stubberfield C, et al. EGFR blockade by tyrosine kinase inhibitor or monoclonal antibody inhibits growth, directs terminal differentiation and induces apoptosis in the human squamous cell carcinoma HN5. *Int J Oncol.* 1998;13:335–42.
58. Rubin Grandis J, Chakraborty A, Melhem MF, et al. Inhibition of epidermal growth factor receptor gene expression and function decreases proliferation of head and neck squamous carcinoma but not normal mucosal epithelial cells. *Oncogene.* 1997;15:409–16.
59. Fry DW. Inhibition of the epidermal growth factor receptor family of tyrosine kinases as an approach to cancer chemotherapy: progression from reversible to irreversible inhibitors. *Pharmacol Ther.* 1999;82:207–18.
60. Magne N, Fischel JL, Dubreuil A, et al. Influence of epidermal growth factor receptor (EGFR), p53 and intrinsic MAP kinase pathway status of tumour cells on the antiproliferative effect of ZD1839 (“Iressa”). *Br J Cancer.* 2002;86:1518–23.
61. Shintani S, Li C, Mihara M, et al. Enhancement of tumor radioreponse by combined treatment with gefitinib (Iressa, ZD1839), an epidermal growth factor receptor tyrosine kinase inhibitor, is accompanied by inhibition of DNA damage repair and cell growth in oral cancer. *Int J Cancer.* 2003;107:1030–7.
62. Stewart JS, Cohen EE, Licitra L, et al. Phase III study of gefitinib 250 compared with intravenous methotrexate for recurrent squamous cell carcinoma of the head and neck. *J Clin Oncol.* 2009;27:1864–71.
63. Argiris A, Ghebremichael M, Gilbert J, et al. A phase III randomized, placebo-controlled trial of docetaxel with or without gefitinib in recurrent or metastatic squamous cell carcinoma of the head and neck: A trial of the Eastern Cooperative Oncology Group (ECOG). *J Clin Oncol.* 2009;27:suppl; abstr 6011.
64. Folkman J. Tumor angiogenesis: therapeutic implications. *N Engl J Med.* 1971;285:1182–6.
65. Folkman J. What is the evidence that tumors are angiogenesis dependent? *J Natl Cancer Inst.* 1990;82:4–6.
66. Folkman J. Angiogenesis in cancer, vascular, rheumatoid and other disease. *Nat Med.* 1995;1:27–31.
67. Folkman J. Seminars in Medicine of the Beth Israel Hospital, Boston. Clinical applications of research on angiogenesis. *N Engl J Med.* 1995;333:1757–63.
68. Holmgren L, O’Reilly MS, Folkman J. Dormancy of micrometastases: balanced proliferation and apoptosis in the presence of angiogenesis suppression. *Nat Med.* 1995;1:149–53.
69. Bergers G, Benjamin LE. Tumorigenesis and the angiogenic switch. *Nat Rev Cancer.* 2003;3:401–10.
70. Hanahan D, Christofori G, Naik P, et al. Transgenic mouse models of tumour angiogenesis: the angiogenic switch, its molecular controls, and prospects for preclinical therapeutic models. *Eur J Cancer.* 1996;32A:2386–93.
71. Cohen EE, Davis DW, Karrison TG, et al. Erlotinib and bevacizumab in patients with recurrent or metastatic squamous-cell carcinoma of the head and neck: a phase I/II study. *Lancet Oncol.* 2009;10:247–57.
72. Moriyama M, Kumagai S, Kawashiri S, et al. Immunohistochemical study of tumour angiogenesis in oral squamous cell carcinoma. *Oral Oncol.* 1997;33:369–74.
73. Denhart BC, Guidi AJ, Tognazzi K, et al. Vascular permeability factor/vascular endothelial growth factor and its receptors in oral and laryngeal squamous cell carcinoma and dysplasia. *Lab Invest.* 1997;77:659–64.
74. Petruzzelli GJ, Benefield J, Taitz AD, et al. Heparin-binding growth factor(s) derived from head and neck squamous cell carcinomas induce endothelial cell proliferations. *Head Neck.* 1997;19:576–82.
75. Ferrara N, Gerber HP, LeCouter J. The biology of VEGF and its receptors. *Nat Med.* 2003;9:669–76.
76. Neuchrist C, Erovic BM, Handisurya A, et al. Vascular endothelial growth factor receptor 2 (VEGFR2) expression in squamous cell carcinomas of the head and neck. *Laryngoscope.* 2001;111:1834–41.
77. Neuchrist C, Erovic BM, Handisurya A, et al. Vascular endothelial growth factor C and vascular endothelial growth factor receptor 3 expression in squamous cell carcinomas of the head and neck. *Head Neck.* 2003;25:464–74.
78. Kyzas PA, Cunha IW, Ioannidis JP. Prognostic significance of vascular endothelial growth factor immunohistochemical expression in head and neck squamous cell carcinoma: a meta-analysis. *Clin Cancer Res.* 2005;11:1434–40.
79. Kyzas PA, Stefanou D, Batistatou A, et al. Prognostic significance of VEGF immunohistochemical expression and tumor angiogenesis in head and neck squamous cell carcinoma. *J Cancer Res Clin Oncol.* 2005;131:624–30.
80. Kyzas PA, Geleff S, Batistatou A, et al. Evidence for lymphangiogenesis and its prognostic implications in head and neck squamous cell carcinoma. *J Pathol.* 2005;206:170–7.
81. Kyzas PA, Stefanou D, Agnantis NJ. Immunohistochemical expression of vascular endothelial growth factor correlates with positive surgical margins and recurrence in T1 and T2 squamous cell carcinoma (SCC) of the lower lip. *Oral Oncol.* 2004;40:941–7.
82. Lentsch EJ, Goudy S, Sosnowski J, et al. Microvessel density in head and neck squamous cell carcinoma primary tumors and its correlation with clinical staging parameters. *Laryngoscope.* 2006;116:397–400.
83. Riedel F, Gotte K, Li M, et al. Abrogation of VEGF expression in human head and neck squamous cell carcinoma decreases angiogenic activity in vitro and in vivo. *Int J Oncol.* 2003;23:577–83.
84. Kim KJ, Li B, Winer J, et al. Inhibition of vascular endothelial growth factor-induced angiogenesis suppresses tumour growth in vivo. *Nature.* 1993;362:841–4.
85. Hoang T, Huang S, Armstrong E, et al. Augmentation of radiation response with the vascular targeting agent ZD6126. *Int J Radiat Oncol Biol Phys.* 2006;64:1458–65.
86. Wachsberger P, Burd R, Dicker AP. Tumor response to ionizing radiation combined with antiangiogenesis or vascular targeting agents: exploring mechanisms of interaction. *Clin Cancer Res.* 2003;9:1957–71.
87. Yigitbasi OG, Younes MN, Doan D, et al. Tumor cell and endothelial cell therapy of oral cancer by dual tyrosine kinase receptor blockade. *Cancer Res.* 2004;64:7977–84.
88. Vilorio-Petit A, Crombet T, Jothy S, et al. Acquired resistance to the antitumor effect of epidermal growth factor receptor-blocking antibodies in vivo: a role for altered tumor angiogenesis. *Cancer Res.* 2001;61:5090–101.
89. Tuccillo C, Romano M, Troiani T, et al. Antitumor activity of ZD6474, a vascular endothelial growth factor-2 and epidermal growth factor receptor small molecule tyrosine kinase inhibitor, in combination with SC-236, a cyclooxygenase-2 inhibitor. *Clin Cancer Res.* 2005;11:1268–76.
90. Meluch AA, Spigel D, Burris HA, et al. Combined modality therapy with radiation therapy, chemotherapy, bevacizumab, and erlotinib in

- the treatment of patients with locally advanced squamous carcinoma of the head and neck. *J Clin Oncol*. 2009;27:suppl; abstr 6012
91. Williamson SK MJ, Huang CH, et al. A phase II trial of sorafenib in patients with recurrent and/or metastatic head and neck squamous cell carcinoma (HNSCC): A Southwest Oncology Group (SWOG) trial [abstract]. *Proc Am Soc Clin Oncol*. 2007;23; abstract 9649.
 92. Machiels JH, Henry S, Zanetta S, et al. Phase II study of sunitinib in patients with recurrent and/or metastatic squamous head and neck carcinoma: The GORTEC 2006-01 study. *J Clin Oncol*. 2009;27:suppl; abstr 6024.
 93. Augustin HG, Kozian DH, Johnson RC. Differentiation of endothelial cells: analysis of the constitutive and activated endothelial cell phenotypes. *Bioassays*. 1994;16:901–6.
 94. Denekamp J. Vascular endothelium as the vulnerable element in tumours. *Acta Radiol Oncol*. 1984;23:217–25.
 95. Folkman J. Fundamental concepts of the angiogenic process. *Curr Mol Med*. 2003;3:643–51.
 96. Folkman J, Kalluri R. Cancer without disease. *Nature*. 2004;427:787.
 97. Verheul HM, Pinedo HM. Possible molecular mechanisms involved in the toxicity of angiogenesis inhibition. *Nat Rev Cancer*. 2007;7:475–85.
 98. Seiwert TY, Cohen EE. Targeting angiogenesis in head and neck cancer. *Semin Oncol*. 2008;35:274–85.
 99. Irby RB, Yeatman TJ. Role of Src expression and activation in human cancer. *Oncogene*. 2000;19:5636–42.
 100. Thomas SM, Brugge JS. Cellular functions regulated by Src family kinases. *Annu Rev Cell Dev Biol*. 1997;13:513–609.
 101. Summy JM, Gallick GE. Src family kinases in tumor progression and metastasis. *Cancer Metastasis Rev*. 2003;22:337–58.
 102. Xi S, Zhang Q, Dyer KF, et al. Src kinases mediate STAT growth pathways in squamous cell carcinoma of the head and neck. *J Biol Chem*. 2003;278:31574–83.
 103. Wheeler DL, Iida M, Kruser TJ, et al. Epidermal growth factor receptor cooperates with Src family kinases in acquired resistance to cetuximab. *Cancer Biol Ther*. 2009;8:696–703.
 104. Brooks HD, Blisson B, Lu C, et al. Phase II study of dasatinib in the treatment of head and neck squamous cell carcinoma. *J Clin Oncol*. 2009;27:suppl; abstract 6022.
 105. Baserga R, Peruzzi F, Reiss K. The IGF-1 receptor in cancer biology. *Int J Cancer*. 2003;107:873–7.
 106. Morgillo F, Woo JK, Kim ES, et al. Heterodimerization of insulin-like growth factor receptor/epidermal growth factor receptor and induction of survivin expression counteract the antitumor action of erlotinib. *Cancer Res*. 2006;66:10100–11.
 107. Morgillo F, Kim WY, Kim ES, et al. Implication of the insulin-like growth factor-IR pathway in the resistance of non-small cell lung cancer cells to treatment with gefitinib. *Clin Cancer Res*. 2007;13:2795–803.
 108. Boyle JO, Hakim J, Koch W, et al. The incidence of p53 mutations increases with progression of head and neck cancer. *Cancer Res*. 1993;53:4477–80.
 109. Brennan JA, Boyle JO, Koch WM, et al. Association between cigarette smoking and mutation of the p53 gene in squamous-cell carcinoma of the head and neck. *N Engl J Med*. 1995;332:712–7.

Chapter 21

Phase I Study Methodology in Head and Neck Oncology

Christophe Le Tourneau and Lillian L. Siu

Abstract Phase I trials evaluating the combination of radiotherapy (RT) with anticancer agents in locally advanced head and neck squamous cell carcinomas (HNSCC) require disease-specific considerations. Given that these trials are often being conducted in patients with a curative diagnosis, both safety and efficacy are relevant factors in their design and conduct. Preclinical evidence of safety, as well as appropriate biological justification of antitumor activity, should be available to rationalize the incorporation of new agents in the combination treatment regime. Anticancer agents are typically given in combination with RT for a limited amount of time and their toxicity profile has usually been well described when used without RT. However, late toxicities can occur with RT, thus the risk of exacerbating such toxicities with the addition of a systemic agent needs to be considered. For this reason, the duration of time allocated for assessment and clearance of dose-limiting toxicities typically differs from phase I trials of systemic agents without RT. A balance must be struck to optimize patient safety while maintaining a feasible timeframe for trial completion. Innovative clinical trial designs, as well as the identification of valid predictive biomarkers of toxicity and antitumor activity, are urgently needed to expedite the development of safe and effective combination regimens in locally advanced HNSCC.

Keywords Phase I trial • Dose escalation • Dose-limiting toxicity • Novel agents • Radiotherapy

Introduction

Phase I clinical trials aim to establish the recommended dose or schedule of a new intervention. In oncology, these trials have primarily been designed to evaluate the safety of new

cytotoxic anticancer agents in successive cohorts of cancer patients treated with increasing doses until dose-limiting toxicity is observed in a prespecified proportion of accrued subjects. The design and methodology of phase I trials comprise of many components, including the choice of the starting dose, target toxicity level, number of patients per dose level, dose escalation method, specification of dose-limiting toxicity, and definition of the maximum tolerated dose and recommended phase II dose.

As efficacy is usually not the primary endpoint of phase I cancer clinical trials, these studies are often performed in unselected tumor types. However, phase I trials specific for patients with head and neck squamous cell carcinomas (HNSCC) have emerged in the 1990s, and several reasons might explain this shift. First, HNSCC treatment in the current era involves complex multidisciplinary strategies including surgery, radiotherapy (RT), chemotherapy, and molecularly targeted agents. These strategies may therefore produce unexpected treatment-related toxicities due to interactive effects and need to be exclusively assessed in the HNSCC population, as extrapolation from other tumor types may not be appropriate. Second, RT alone, or in combination with drugs, is a definitive treatment modality delivered with a curative intent in localized or locally advanced nonmetastatic HNSCC. As such, the evaluation of efficacy in addition to toxicity is of relevance when combining RT with new drugs. Third, molecularly targeted agents that propose to modulate specific targets in tumor cells are assumed to exert disease-specific anticancer activity. For instance, the epidermal growth factor receptor (EGFR) pathway plays a more critical biological role in HNSCC than in certain other solid tumors. Fourth, the prevalence of comorbidities in some HNSCC patients may hamper the delivery of a new intervention using dosing schedules defined for other malignancies. Fifth, adverse effects on mucosa and skin rendered by new interventions may be unacceptably exacerbated in patients suffering from locoregional recurrence of HNSCC due to potential prior therapy with surgery and/or RT. Lastly, late and delayed toxicities are important in HNSCC as they are frequently associated with functional impairment of vital organs.

L.L. Siu (✉)
Division of Medical Oncology and Hematology,
Princess Margaret Hospital, Toronto, ON, Canada
e-mail: lillian.siu@uhn.on.ca

The development of combination strategies in HNSCC that utilize multiple therapeutic modalities continues to evolve and needs to be evaluated for safety and tolerability in phase I trials before being compared against existent standard treatments for efficacy. As phase I trial methodology involving chemotherapy and/or molecularly targeted agents without a RT component is similar across advanced solid tumors, this chapter thereby focuses on the design of phase I trials for combining RT with anticancer agents in locally advanced HNSCC (Table 21.1 and Fig. 21.1). In clinical trials enrolling this curable patient population, efficacy

considerations are as critical as safety issues. Trials investigating multiple-drug combinations as well as those involving a neoadjuvant chemotherapy component raise specific methodological concerns and thus will also be discussed in this chapter.

Methodologic Considerations

Dose Escalation Methods in Phase I Trials Combining Radiation with Anticancer Agents

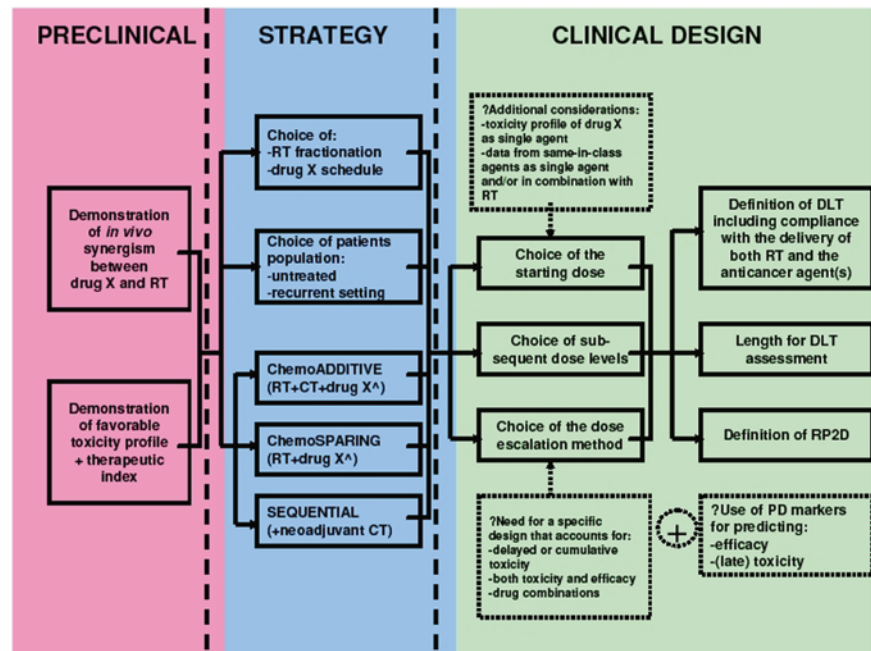
Most phase I dose escalation methods in oncology have been designed under the assumption that both efficacy and toxicity increase monotonically with dose. As such, the recommended phase II dose has traditionally been established as the highest safe dose, based on a prespecified acceptable level of dose-limiting toxicity. The most commonly used dose escalation method for phase I trials remains the traditional 3+3 dose escalation method, for which dose levels are prespecified, and dose increments often become smaller as the dose increases. The 3+3 method is a rule-based method that proceeds as follows: if none of the first three patients enrolled in a cohort experiences a dose-limiting toxicity, then another three patients will be treated at the next higher dose level. However, if one of the first three patients encounters a dose-limiting toxicity, then up to three more patients will be added to the same dose level. If the target toxicity level has been preset at 33% or less, then dose escalation would stop if two or more patients among a cohort of three to six patients experience dose-limiting toxicity. Besides the 3+3 method, other dose escalation methods such as Bayesian designs (e.g., modified continual reassessment method) which are model-based, have been developed but under-utilized for trials involving anticancer agents without RT [1]. Bayesian models require an initial estimate of the prior distribution of the dose-toxicity relationship, and then toxicity data obtained from patients enrolled in each dose level provide additional information for the statistical model to produce the posterior distribution. The latter is then used to help identify the dose closest to the target toxicity level.

No specific dose escalation methods have been proposed for trials of anticancer agents given in combination with RT, but the traditional 3+3 method or its variations are the most widely employed. Although the dose of an anticancer agent to be combined with RT would usually be escalated if tolerable to its full monotherapy recommended phase II dose, the optimal dose to combine with RT remains elusive, especially for some molecularly targeted agents which do not exhibit dose-dependent antitumor activity.

Table 21.1 Considerations for phase I trials combining radiation with anticancer agents in locally advanced SCCHN

Specific considerations	Issues
Methodologic considerations	Dose escalation methods: rule-based (e.g., standard 3+3 design) or model-based (e.g., Bayesian design) “Dose-intensity escalation” with escalation of dose of drug and/or number of drug administrations
Safety considerations	Use of preclinical models to predict safety; limitations such as the availability of appropriate models, cross-species specificity; extent to which these evaluations need to be completed prior to initiation of human phase I trial Choice of starting dose of anticancer agent to be combined with radiation Optimal length for observation for dose-limiting toxicity including acute and late toxicity Novel phase I trial designs to enable late toxicity assessment without causing delay in dose escalation Predictive markers of late toxicity
Efficacy considerations	Use of preclinical models to predict efficacy; limitations such as the availability of appropriate models, cross-species specificity; extent to which these evaluations need to be completed prior to initiation of human phase I trial Efficacy of anticancer agent to be combined with radiation Maintenance of radiation dose intensity in phase I trial Compliance of anticancer agent and of radiation therapy Novel phase I trial designs to account for efficacy in addition to toxicity Identification of surrogate markers of efficacy
Special considerations	Challenges for drug combinations to add to definitive radiation therapy Possibility of development of platinum-free radiation combinations with new drugs Phase I trials with a neoadjuvant chemotherapy component to add to chemoradiation as sequential therapy

Fig. 21.1 Selected key considerations for the design of a phase I clinical trial of drug X in combination with RT in head and neck cancer. *CT* chemotherapy, *RT* radiotherapy, *DLT* dose-limiting toxicity, *RP2D* recommended phase II dose, *PD* pharmacodynamic, ^ if drug X is noncytotoxic



Concept of “Dose-Intensity Escalation”

One unique feature of trials involving chemoradiation is that the anticancer agent is administered for a limited period of time, primarily during RT. The total dose of the anticancer agent administered to patients during this limited period of time can be increased by (1) escalating the dose of the drug with a fixed number of drug administrations, (2) escalating the number of drug administrations with a fixed dose of the drug, and (3) escalating both the dose and the number of drug administrations. In this context, the term “dose-intensity escalation” rather than “dose escalation” would more accurately reflect the different ways to increase the total administered dose of the drug. For example, a phase I trial of paclitaxel and concurrent hyperfractionated RT used a fixed dose of paclitaxel with a planned escalation of the number of administrations during RT from 3 to 6 [2]. In another phase I trial evaluating the farnesyltransferase inhibitor L-778,123 in combination with standard RT, the first dose level administered L-778,123 at the dose of 280 mg/m²/day during weeks 1, 2, 4, and 5, while the dose and the number of administrations were escalated in the second dose level to 560 mg/m²/day during weeks 1, 2, 4, 5, and 7 [3]. In this trial, dose level 2 was found to be too toxic. As such, dose level 1 was recommended for phase II evaluation, although intermediate dose levels with the escalation of either the dose or the number of drug administrations might have allowed the safe administration of a higher total dose beyond dose level 1.

Safety Considerations

Safety Issues in Phase I Trials Combining Radiation with Anticancer Agents

RT and anticancer agents are combined to optimize the therapeutic index in locally advanced HNSCC. Therapeutic index is a ratio that takes into account treatment efficacy and toxicity. Efficacy in the treatment of locally advanced HNSCC is measured by the prevention of locoregional recurrence and of distant metastasis. From the perspective of toxicity, combining RT with anticancer agents not only increases acute toxicity compared to RT alone, but may also produce chronic toxicity due to delayed or cumulative adverse effects on normal tissues. Therefore, specific safety issues that warrant careful consideration in these trials include maintenance of the standard RT dose, the choice of a safe starting dose and of subsequent dose levels for the anticancer agent, and the assessment for delayed or cumulative toxicity for the combined modality therapy.

Use of Preclinical Models to Predict Safety

No specific recommendations have been published on preclinical *in vitro* and *in vivo* models that reliably predict the safety of combination of RT and anticancer agents in humans. Preclinical studies may provide some useful safety data to

guide dosing, such as therapeutic index of the RT-anticancer agent combination. However, preclinical data must be interpreted with caution due to their limited cross-species predictability. Radiation in-field toxicity in the head and neck region that may be exacerbated by the addition of a new anticancer agent is of particular significance in HNSCC. Therefore, it would seem prudent to perform preclinical toxicity evaluations of RT and new drug combinations on mucosal, salivary gland, and neural tissues [4]. The extent to which these preclinical evaluations should be completed prior to the initiation of human phase I trials remains unclear.

Choice of the Starting Dose of Anticancer Agent to Combine with RT and Dose of RT in Phase I Trials

Once a new RT-anticancer agent combination is thought to be safe to enter human testing, based on properly conducted preclinical studies, the choice of the starting dose of the anticancer agent and subsequent dose escalation are key elements of the phase I trial design. While there is guidance on the choice of the starting dose of a novel anticancer agent entering phase I evaluation as monotherapy [5], no recommendations have been established to determine the starting dose of an anticancer agent to be combined with RT. Generally, the toxicity profiles of anticancer agents intended to be combined with RT would already have been described as single agents. The therapeutic index of a new combination evaluated in preclinical models should help identify a safe starting dose and schedule, along with subsequent dose escalation for phase I trials. If preclinical data indicated a wide therapeutic index for the combination, it is reasonable to use a higher starting dose along with greater dose increments between dose levels for the anticancer agent, whereas a narrow therapeutic index would stipulate a more conservative strategy. Nevertheless, the translation of available preclinical data to the clinic may not be straightforward. This was illustrated in a phase I trial that combined RT with weekly gemcitabine in locally advanced HNSCC [6]. Although the starting dose was selected based on preclinical data showing safe and potent radiosensitization at concentrations well below cytotoxic levels, only 1/30 of the initial starting dose of gemcitabine was ultimately deemed to be safe without causing excessive early as well as delayed toxicities.

Optimal Length for Dose-Limiting Toxicity Assessment

A safe dose for an anticancer agent to be combined with RT is a dose that does not produce excessive acute, delayed, and cumulative toxicity. Normal tissue recovery from RT is the

main determinant of delayed or cumulative toxicity. Delayed or cumulative toxicities are of concern in situations where patients are treated with a curative intent and many survive to suffer from such adverse effects in the long term. Preclinical studies may help identify delayed or cumulative toxicities from RT by observing the animal hosts for a sufficient time to assess for expected or unexpected adverse effects. However, the risk of toxicity exacerbation by the addition of a systemic agent may not be reliably predicted by preclinical models and needs to be carefully considered in the design of phase I trials [4]. In clinical practice, the duration of time allocated for assessment and clearance of dose-limiting toxicities to enable dose escalation or de-escalation decisions differs between phase I trials of systemic agents with or without RT. The Cancer Therapy Evaluation Program (CTEP) and the Radiation Research Program (RRP) of the National Cancer Institute suggested that toxicity assessment for dose-limiting events spans the entire RT period and up to 30 days after the completion of RT [7]. Although toxicities may still occur after 30 days from RT completion, a longer assessment period would be impractical by unreasonably lengthening the trial duration. Furthermore, it is expected that at the end of a phase I trial of novel agent and RT, all adverse events including those that occurred outside of the assessment window for dose-limiting toxicity will be reviewed, to derive at a safe recommended phase II dose for subsequent evaluation.

Accounting for Delayed or Cumulative Toxicity in the Dose Escalation

The suggested assessment period for toxicity of 30 days after the completion of RT in phase I trials combining RT with anticancer agents results in prolonged delays between cohort openings and closures. To avoid this limitation, several model-based dose escalation designs have been proposed that do not mandate trial suspension while patients are being observed. These designs use time-to-event endpoints. Cheung and Chappell developed a Bayesian-based method, known as the time-to-event continual reassessment method or TITE-CRM, which incorporates the time to the event (the event being toxicity) for each patient [8]. Simulations suggest that for treatments with late-onset toxicity, the TITE-CRM is more efficient than the traditional 3+3 design or the standard continual reassessment method for determining the maximum tolerated dose and leads to shorter trial durations [9]. Nevertheless, in two clinical trials combining RT with an anticancer agent in pancreatic cancer, this design led to the accrual of more patients to dose levels below the recommended phase II dose than was expected with the traditional 3+3 design [10, 11]. A variation of the TITE-CRM has been

proposed in which accrual is temporarily suspended if the risk of toxicity at proposed doses for future patients is unacceptably high [12]. Although these methods may theoretically shorten trial duration in case of delayed or cumulative toxicities, they need to be optimized for successful practical application in phase I clinical trials combining RT with anticancer agents.

Recently, a “rolling trials” strategy has been proposed to expedite the investigation of novel agent-RT combinations while allowing sufficient time to observe for potential delayed or cumulative toxicity. This strategy simultaneously activates several novel agent-RT combination trials such that while one trial is undergoing its mandatory waiting period to clear dose-limiting toxicity, another trial can actively recruit to fill its next cohort. This approach is particularly attractive if multiple anticancer agents are available to be combined with RT and can be evaluated by the same group of experienced investigators in the disease site of interest.

Predictive Markers of Late Toxicity

The identification of clinical and laboratory predictive markers for delayed or cumulative toxicity may help prevent or reduce the risk of delayed or cumulative toxicity in patients receiving RT in combination with an anticancer agent. A retrospective analysis of three chemoradiation trials performed by the Radiation Therapy Oncology Group (RTOG) found that older age, advanced T stage, larynx or hypopharynx primary site, and neck dissection were associated with an increased risk of late toxicities defined as chronic grade 3 or 4 pharyngeal/laryngeal toxicity, and/or requirement for a feeding tube >2 years after study registration, and/or treatment-related death within 3 years [13]. Besides these clinical predictive markers of chronic toxicity, there are also research efforts in progress aiming to identify laboratory-based predictive biomarkers for late adverse events [14]. For example, Li et al. showed that high levels of pretreatment circulating transforming growth factor beta (TGF- β), a potent fibrogenic cytokine, are associated with an increased risk of adverse effects after postoperative RT for breast cancer [15]. Similar results were observed in patients receiving thoracic RT [16]. Yuan et al. also showed that specific genotypes of the TGF- β gene were associated with lower risk of radiation pneumonitis in patients with non-small cell lung cancer treated with definitive radio(chemo)therapy [17]. However, none of these clinical or biological factors are being used in clinical practice for therapeutic decisions to select patients or to change treatment regimen, probably because of their low specificity. No predictive markers specific for late toxicity in HNSCC have been reported in the literature so far.

Efficacy Considerations

Efficacy Issues in Phase I Trials Combining Radiation with Anticancer Agents

Historically, the rationale for combining RT with anticancer agents has mainly been driven by pragmatic approaches rather than based on preclinical scientific evidence [18]. For most drugs given in combination with RT for HNSCC, synergism in preclinical models has usually been observed [19–21]. An example of consistency between preclinical and clinical studies includes EGFR inhibitors that have shown in both preclinical and clinical studies to produce greater activity when combined with accelerated over standard fractionation RT [20, 22]. However, some preclinical data have not been validated in the clinical setting. For example, although some preclinical studies have shown that lower doses of cisplatin tend to produce increased radiosensitization than higher doses [21, 23], the FDA-approved regimen in locally advanced HNSCC involves high dose cisplatin because of the lack of randomized trial comparing low versus high doses of cisplatin in combination with RT. As patients are often being treated with a curative intent, it is essential to minimize the likelihood of compromising their outcome while evaluating new chemoradiation combinations. The pragmatic approach is certainly not optimal, and preclinical results are now expected before launching a new RT-anticancer agent combination in the clinic.

Use of Preclinical Models to Predict Efficacy

In order to maximize safe and efficient investigations of new drugs in combination with RT, the CTEP and the RRP of the National Cancer Institute have provided guidelines regarding required preclinical studies before launching new chemoradiation combinations in the clinic [7]. They recommend the demonstration of *in vivo* synergy with fractionated RT, with little or no radiosensitization of normal tissues in two different tumor models. Additivity or synergy between RT and anticancer agents may be achieved by the modulation of the classical 5 Rs, which comprise Radiosensitivity, DNA damage Repair, cellular Repopulation and proliferation, Reoxygenation of hypoxic tumor cells, and Redistribution from more resistant to more sensitive phases of the cell cycle. Three decades ago, Steel and Peckham proposed a method to study drug-RT interactions based on the isoeffect concept reflected via the construction of isobolograms [24]. The central concept in the isobologram method is the determination of the envelope of additivity delineated by boundaries within which all responses are deemed to be purely additive.

These boundaries are determined by the addition of responses to each agent applied alone. Preclinical studies to evaluate tumor control or growth delay at biologically relevant doses of the anticancer agent and fractionated RT should be performed under controlled conditions (i.e., using RT alone and drug alone) [4]. The testing of multiple dosing schedules of drug and RT administration can help bring the most optimal schedules of combination to clinical trials.

Efficacy of Anticancer Agent to be Combined with RT

It is unclear whether new drugs should display a minimum threshold of clinical efficacy as a single agent in recurrent and/or metastatic HNSCC before being tested in combination with RT for locally advanced disease. Anticancer agents commonly used in combination with RT for locally advanced HNSCC, including cisplatin, carboplatin, 5-FU, and cetuximab, have demonstrated single agent efficacy in HNSCC patients. However, some new drugs are being studied in combination with RT despite lacking single agent activity. For instance, raltitrexed, an antimetabolite agent, was studied in combination with RT [25], although it was shown to display minimal antitumor activity as single agent in the inoperable setting [26]. Similarly, lapatinib, a dual EGFR and HER-2 inhibitor, was studied in combination with RT and cisplatin [27], even though no clinical activity had been observed as a single agent in recurrent and/or metastatic HNSCC [28]. These two agents have only been tested in single arm phase II trials in combination with RT. To demonstrate the relevance of this strategy, randomized controlled trials would be needed to determine whether these agents can improve patient outcome when combined with RT despite minimal single agent activity in the recurrent and/or metastatic setting.

Regardless of the properties of the anticancer agent to be combined, it is imperative that the dose of RT is not compromised to allow greater tolerance of the drug. Given that locally advanced HNSCC is a curative disease, the delivery of definitive dosages of RT is critical to ensure that the therapeutic efficacy is not affected by the systemic agent being added as an adjunct. Hence, compliance with the delivery of both RT and of the anticancer agent needs to be considered in the definition of dose-limiting toxicities of a combination regimen.

Accounting for Efficacy in the Dose Escalation

In phase I cancer clinical trials of novel anticancer agents, efficacy is generally not the primary endpoint. However, in trials where patients are treated with a curative intent, the evaluation of efficacy in addition to safety is relevant.

Novel trial designs have therefore emerged attempting to define a safe recommended phase II dose while simultaneously taking into consideration antitumor activity. Bayesian-based methods have been developed that incorporate both toxicity and efficacy in their designs. These methods have been originally designed for anticancer drugs used without RT, but can readily be applied to drugs in combination with RT. The EffTox method defines an acceptable dose combination based on trade-offs between the probabilities of treatment efficacy and toxicity [29]. The TriCRM is another Bayesian-based method that considers three categories (no efficacy and no toxicity, efficacy only, and toxicity only) [30]. Some investigators have proposed methods for drug combination studies that use both toxicity and efficacy as endpoints. In the design proposed by Yin et al., patients are randomly assigned among several combinations that are selected by a statistical model to determine the most effective and least toxic combination [31]. The main issue with these methods is that they assume response that can be accurately and rapidly assessed with standard response criteria or with surrogate endpoints in order to maintain a short assessment period. For instance, the use of time-to-event endpoints such as progression-free survival at 6 months would obviously lead to unacceptably long trial delays and closures. On the other hand, the use of objective response according to RECIST criteria after the completion of chemoradiation may not be relevant, as most of patients usually respond to treatment. The use of complete response is not a valid marker of overall survival in locally advanced HNSCC, since the absence of radiological complete response does not necessarily implicate the presence of residual disease but may due to treatment effects or scar tissues. The search for validated markers or endpoints of efficacy in this patient population is therefore of paramount importance before implementing these methods in clinical practice.

Special Considerations

Clinical Development Challenges

In the past, locally advanced HNSCC was managed primarily with RT and/or surgery. Chemotherapy has only been used in the metastatic setting or if recurrences were not amenable to surgery or re-irradiation. Since the publication of the MACH-NC meta-analysis, the benefit of concomitant platinum-based chemoradiation over RT alone has been established in this patient population [32]. Recently, the anti-EGFR monoclonal antibody cetuximab was approved in combination with RT in locally advanced HNSCC [22], based on a large randomized trial that compared this strategy against RT alone, which represented standard of care at the time the trial

was designed. With the shift of platinum-based chemoradiation as the current standard of care, three potential strategies can be perceived to further improve therapeutic index and clinical outcome. The first is a chemo-additive strategy by adding another drug to cisplatin. However, this strategy might lead to unacceptable toxicity even when drugs without overlapping toxicities are combined with cisplatin, as illustrated in a phase II trial combining concomitant boost RT with high dose cisplatin and cetuximab [33]. The second strategy is a chemo-sparing strategy which investigates platinum-free RT combinations with new drugs. The last strategy involves the addition of a neoadjuvant component prior to the delivery of chemoradiation.

Challenges for Drug Combinations

In situations where multiple systemic agents are combined with RT, the dose escalation can be challenging and raises specific issues in the design of phase I trials. If full doses of all agents cannot be delivered safely, the selection of appropriate dose combinations and schedules of systemic agents to combine with RT is not always straightforward. Most phase I trials evaluating several anticancer agents in combination with RT escalate the dose of only one agent, keeping fixed the doses of the other(s). However, it may not be always possible to administer all drugs at their recommended phase II doses as single agents. For example, while the weekly recommended phase II doses for cisplatin and docetaxel given as single agents in combination with RT are 40 and 15 mg/m², respectively [34], the combination of the two drugs with hyperfractionated RT showed that they could only be administered at the doses of 15 and 10 mg/m², respectively [35]. Hence, the decision of which drug to be administered at its full dose can be challenging. Several Bayesian-based designs specific for combination trials have been developed in an attempt to minimize this uncertainty [31, 36–39]. These designs do not require any prior assumption about the best dose combination, and aim to guide the dose escalation of the agents based on all toxicities observed. The ultimate goal is to determine the most active drug combination among those deemed to be safe. These methods may determine several maximum tolerated doses, and the investigator may then choose the one with the best therapeutic index as the recommended phase II dose.

Development of Platinum-Free RT Combinations with New Drugs

The investigation of platinum-free combinations with RT in locally advanced HNSCC is appealing since the platins are associated with substantial acute and long-term toxicity.

However, since platinum-based regimens remain the standard of care in this curative setting, the aim to develop non platinum-based regimens to combine with RT can be challenging. Three approaches may be taken to develop new platinum-free chemoradiation combinations without compromising efficacy.

The first approach involves the initial evaluation of new agents in combination with RT in the recurrent setting where therapeutic options remain limited. One drawback might be the difficulty to reliably extrapolate the safety profile of the investigational drug(s) from an advanced to a localized disease setting, as the latter group of patients are generally in better physical condition. This was illustrated in a phase I trial evaluating concomitant chemoradiation with bevacizumab, a monoclonal antibody targeting the vascular endothelial growth factor, in previously irradiated patients with locoregionally recurrent disease [40]. Five of 26 patients treated in the expansion cohort died, two of them from stroke and hemorrhage possibly related to bevacizumab. In contrast, chemoradiation with bevacizumab seemed to be well tolerated when used in untreated patients [41]. Furthermore, the potentially higher rate of adverse events in a heavily pretreated patient population may lead to a lower recommended phase II dose of the new agent than one that could be safely administered in untreated patients. This issue was highlighted in a phase I trial that evaluated concomitant pemetrexed and cetuximab in combination with RT in two different cohorts, depending on whether patients had received previous RT or not [42]. The recommended phase II dose for pemetrexed differed in the two cohorts, suggesting that previously irradiated patients may not tolerate the same dose intensity of concomitant systemic therapy than treatment-naïve patients.

The second approach utilizes the delivery of platinum-free regimens with a curative intent concomitantly with altered fractionation instead of standard fractionation RT. This approach assumes that the incorporation of a more intensified RT schedule would compensate for any potential loss of benefit due to the administration of a platinum-free regimen. Evidence in support of this approach includes the MARCH meta-analysis which reported a survival benefit with the use of altered fractionation RT schemes compared to standard fractionation RT [43]. Furthermore, a subgroup analysis of the trial by Bonner et al. showed that the addition of cetuximab was more effective when combined with altered fractionation than standard fractionation RT [22]. In another trial, the small molecule EGFR tyrosine kinase inhibitor gefitinib was designed to combine with altered fractionation RT using a concomitant boost scheme [44].

The third approach evaluates platinum-free combinations in the context of intolerance or contraindication to platinum compounds, such as in patients over 70 years of age who do not appear to derive benefit from the addition of concomitant

platinum to definitive RT [45]. However, the accrual of these selected patient populations to complete large randomized trials may be difficult due to their relative infrequent incidences in clinical practice. As well, the incorporation of new agents may be compromised in patients with renal dysfunction. Lastly, the results that can be generated by these trials would guide management for these subgroups but are not generalizable to patients who can tolerate platinum-based regimens.

Phase I Trials with a Neoadjuvant Chemotherapy Component

A survival benefit has been shown by the addition of a taxane to neoadjuvant chemotherapy with cisplatin and 5-FU, compared to cisplatin and 5-FU alone, before delivering definitive RT-based treatment for locally advanced HNSCC [46, 47]. Phase I clinical trials evaluating these so-called sequential strategies, which consist of neoadjuvant chemotherapy plus concurrent chemoradiotherapy, have become prevalent. Such trials can theoretically proceed with the dose escalation of one or several anticancer agents in either the neoadjuvant chemotherapy component, or the concurrent chemoradiotherapy component, or both.

In addition to the safety issues described above when RT is combined with anticancer agents without a neoadjuvant component, phase I trials incorporating an additional neoadjuvant chemotherapy component may further influence patients safety. First, there may be potential cumulative toxicities of drugs when used in both the neoadjuvant and concurrent components. For instance, administering cisplatin in both the neoadjuvant and concurrent components may increase the risk of ototoxicity, neurotoxicity, and nephrotoxicity. Combinations with cisplatin and/or a taxane in the neoadjuvant setting may also lead to cumulative peripheral neuropathy. Docetaxel is thought to enhance radiation activity by inducing an accumulation of tumor cells in the more radiosensitive G2/M phase of the cell cycle [48], supporting its role in the neoadjuvant setting. However, myelotoxicity is a major toxicity of docetaxel, which may not only delay the delivery of concurrent chemoradiotherapy, but may also lead to a higher risk of myelosuppression during concurrent chemoradiotherapy by affecting the bone marrow reserve. Similarly, the use of drugs such as 5-FU in the neoadjuvant component may induce mucositis, and therefore may delay the start of concurrent chemoradiotherapy or lead to more frequent RT interruptions because of preexisting mucositis. Furthermore, it was recently reported that only 45% of patients could complete concomitant chemoradiation with high dose cisplatin after three cycles of neoadjuvant chemotherapy with cisplatin, docetaxel, and 5-FU [49]. The dose-intensity of chemotherapy during chemoradiotherapy might

be decreased in comparison to what patients could have received if no neoadjuvant component was added. As such, even if dose escalation is applied only to one component of sequential therapy, dose-limiting toxicity should be defined based on both the neoadjuvant and concurrent components, including the maintenance of RT dose intensity, in order to assess the safety and tolerability of the entire multistep treatment regimen.

Conclusions

The addition of novel anticancer agents to RT-based treatment in locally advanced HNSCC aims to optimize the therapeutic index. While preclinical studies may contribute important data for the evaluation of new combinations, phase I clinical trials in locally advanced HNSCC represent a critical step during which both safety and efficacy endpoints are measured in this curative patient population. The unique aspects of these phase I trials, such as the potential for chronic toxicities related to RT and the relevance of preserving therapeutic efficacy, as well as the challenge in determining the optimal anticancer agent dose and/or schedule to be combined with RT, provide a strong impetus for the development and implementation of novel phase I trials designs in this setting.

References

1. Le Tourneau C, Lee JJ, Siu LL. Dose escalation methods in phase I cancer clinical trials. *J Natl Cancer Inst.* 2009;101:708–20.
2. Amrein PC, Clark JR, Supko JG, et al. Phase I trial and pharmacokinetics of escalating doses of paclitaxel and concurrent hyperfractionated radiotherapy with or without amifostine in patients with advanced head and neck carcinoma. *Cancer.* 2005;104:1418–27.
3. Hahn SM, Bernhard EJ, Regine W, et al. A Phase I trial of the farnesyltransferase inhibitor L-778, 123 and radiotherapy for locally advanced lung and head and neck cancer. *Clin Cancer Res.* 2002;8:1065–72.
4. Ma BB, Bristow RG, Kim J, et al. Combined-modality treatment of solid tumors using radiotherapy and molecular targeted agents. *J Clin Oncol.* 2003;21:2760–76.
5. Tomaszewski JE. Multi-species toxicology approaches for oncology drugs: the US perspective. *Eur J Cancer.* 2004;40:907–13.
6. Eisbruch A, Shewach DS, Bradford CR, et al. Radiation concurrent with gemcitabine for locally advanced head and neck cancer: a phase I trial and intracellular drug incorporation study. *J Clin Oncol.* 2001;19:792–9.
7. Colevas AD, Brown JM, Hahn S, et al. Development of investigational radiation modifiers. *J Natl Cancer Inst.* 2003;95:646–51.
8. Cheung YK, Chappell R. Sequential designs for phase I clinical trials with late-onset toxicities. *Biometrics.* 2000;56:1177–82.
9. Normolle D, Lawrence T. Designing dose-escalation trials with late-onset toxicities using the time-to-event continual reassessment method. *J Clin Oncol.* 2006;24:4426–33.

10. Muler JH, McGinn CJ, Normolle D, et al. Phase I trial using a time-to-event continual reassessment strategy for dose escalation of cisplatin combined with gemcitabine and radiation therapy in pancreatic cancer. *J Clin Oncol.* 2004;22:238–43.
11. Desai SP, Ben-Josef E, Normolle DP, et al. Phase I study of oxaliplatin, full-dose gemcitabine, and concurrent radiation therapy in pancreatic cancer. *J Clin Oncol.* 2007;25:4587–92.
12. Bekele BN, Ji Y, Shen Y, et al. Monitoring late-onset toxicities in phase I trials using predicted risks. *Biostatistics.* 2008;9:442–57.
13. Machtay M, Moughan J, Trotti A, et al. Factors associated with severe late toxicity after concurrent chemoradiation for locally advanced head and neck cancer: an RTOG analysis. *J Clin Oncol.* 2008;26:3582–9.
14. Alsner J, Andreassen CN, Overgaard J. Genetic markers for prediction of normal tissue toxicity after radiotherapy. *Semin Radiat Oncol.* 2008;18:126–35.
15. Li C, Wilson PB, Levine E, et al. TGF-beta1 levels in pre-treatment plasma identify breast cancer patients at risk of developing post-radiotherapy fibrosis. *Int J Cancer.* 1999;84:155–9.
16. Anscher MS, Marks LB, Shafman TD, et al. Using plasma transforming growth factor beta-1 during radiotherapy to select patients for dose escalation. *J Clin Oncol.* 2001;19:3758–65.
17. Yuan X, Liao Z, Liu Z, et al. Single Nucleotide Polymorphism at rs1982073:T869C of the TGF{beta}1 gene is associated with the risk of radiation Pneumonitis in patients with non-small-cell lung cancer treated with definitive radiotherapy. *J Clin Oncol.* 2009;27(20):3370–8.
18. Hennequin C, Favaudon V. Biological basis for chemo-radiotherapy interactions. *Eur J Cancer.* 2002;38:223–30.
19. Vokes EE, Beckett M, Karrison T, et al. The interaction of 5-fluorouracil, hydroxyurea, and radiation in two human head and neck cancer cell lines. *Oncology.* 1992;49:454–60.
20. Bonner JA, Maihle NJ, Folven BR, et al. The interaction of epidermal growth factor and radiation in human head and neck squamous cell carcinoma cell lines with vastly different radiosensitivities. *Int J Radiat Oncol Biol Phys.* 1994;29:243–7.
21. Gorodetsky R, Levy-Agababa F, Mou X, et al. Combination of cisplatin and radiation in cell culture: effect of duration of exposure to drug and timing of irradiation. *Int J Cancer.* 1998;75:635–42.
22. Bonner JA, Harari PM, Giralt J, et al. Radiotherapy plus cetuximab for squamous-cell carcinoma of the head and neck. *N Engl J Med.* 2006;354:567–78.
23. Myint WK, Ng C, Raaphorst GP. Examining the non-homologous repair process following cisplatin and radiation treatments. *Int J Radiat Biol.* 2002;78:417–24.
24. Steel GG, Peckham MJ. Exploitable mechanisms in combined radiotherapy-chemotherapy: the concept of additivity. *Int J Radiat Oncol Biol Phys.* 1979;5:85–91.
25. Planting AS, De Jonge M, Jansen P, et al. Phase I study of concomitant raltitrexed with radiotherapy in locally advanced head and neck cancer. *Eur J Cancer.* 2005;41(1):93–7.
26. Clarke SJ, Zalcberg J, Oliver I, et al. Open label, multi-centre phase II study of raltitrexed ('Tomudex') in patients with inoperable squamous-cell carcinoma of head and neck. *Ann Oncol.* 2000;11:239–41.
27. Harrington KJ, El-Hariry IA, Holford CS, et al. Phase I study of lapatinib in combination with chemoradiation in patients with locally advanced squamous cell carcinoma of the head and neck. *J Clin Oncol.* 2009;27:1100–7.
28. Abidoye OO, Cohen EE, Wong SJ. A phase II study of lapatinib (GW572016) in recurrent/metastatic (R/M) squamous cell carcinoma of the head and neck (SCCHN). *J Clin Oncol.* 2006;24(Suppl):297s.
29. Thall PF, Cook JD. Dose-finding based on efficacy-toxicity trade-offs. *Biometrics.* 2004;60:684–93.
30. Zhang W, Sargent DJ, Mandrekar S. An adaptive dose-finding design incorporating both toxicity and efficacy. *Stat Med.* 2006;25:2365–83.
31. Yin G, Li Y, Ji Y. Bayesian dose-finding in phase I/II clinical trials using toxicity and efficacy odds ratios. *Biometrics.* 2006;62:777–84.
32. Pignon JP, Bourhis J, Domenge C, et al. Chemotherapy added to locoregional treatment for head and neck squamous-cell carcinoma: three meta-analyses of updated individual data. MACH-NC Collaborative Group. Meta-analysis of chemotherapy on head and neck cancer. *Lancet.* 2000;355:949–55.
33. Pfister DG, Su YB, Kraus DH, et al. Concurrent cetuximab, cisplatin, and concomitant boost radiotherapy for locoregionally advanced, squamous cell head and neck cancer: a pilot phase II study of a new combined-modality paradigm. *J Clin Oncol.* 2006;24:1072–8.
34. Suzuki M, Nishimura Y, Nakamatsu K, et al. Phase I study of weekly docetaxel infusion and concurrent radiation therapy for head and neck cancer. *Jpn J Clin Oncol.* 2003;33(6):297–301.
35. Allal AS, Zwahlen D, Becker M, et al. Phase I trial of concomitant hyperfractionated radiotherapy with docetaxel and cisplatin for locally advanced head and neck cancer. *Cancer J.* 2006;12:63–8.
36. Thall PF, Millikan RE, Mueller P, et al. Dose-finding with two agents in Phase I oncology trials. *Biometrics.* 2003;59:487–96.
37. Huang X, Biswas S, Oki Y, et al. A parallel phase I/II clinical trial design for combination therapies. *Biometrics.* 2007;63:429–36.
38. Yuan Y, Yin G. Sequential continual reassessment method for two-dimensional dose finding. *Stat Med.* 2008;27:5664–78.
39. Yin G, Yuan Y. A latent contingency table approach to dose finding for combinations of two agents. *Biometrics.* 2009;65(3):866–75.
40. Seiwert TY, Haraf DJ, Cohen EE, et al. Phase I study of bevacizumab added to fluorouracil- and hydroxyurea-based concomitant chemoradiotherapy for poor-prognosis head and neck cancer. *J Clin Oncol.* 2008;26:1732–41.
41. Pfister DG, Lee NY, Sherman E, et al. Phase II study of bevacizumab (B) plus cisplatin (C) plus intensity-modulated radiation therapy (IMRT) for locoregionally advanced head and neck squamous cell cancer (HNSCC): Preliminary results. *Proc Am Soc Clin Oncol.* 2009;27:6013.
42. Gibson MK, Smith RP, Heron DE, et al. Phase I trial of pemetrexed, cetuximab, and concurrent radiotherapy (RT) in head and neck cancer (HNC). *Proc Am Soc Clin Oncol.* 2008;26:2540.
43. Bourhis J, Overgaard J, Audry H, et al. Hyperfractionated or accelerated radiotherapy in head and neck cancer: a meta-analysis. *Lancet.* 2006;368:843–54.
44. Chen C, Kane M, Song J, et al. Phase I trial of gefitinib in combination with radiation or chemoradiation for patients with locally advanced squamous cell head and neck cancer. *J Clin Oncol.* 2007;25:4880–6.
45. Pignon JP, le Maître A, Maillard E, et al. Meta-analysis of chemotherapy in head and neck cancer (MACH-NC): an update on 93 randomised trials and 17, 346 patients. *Radiother Oncol.* 2009;92:4–14.
46. Posner MR, Hershock DM, Blajman CR, et al. Cisplatin and fluorouracil alone or with docetaxel in head and neck cancer. *N Engl J Med.* 2007;357:1705–15.
47. Vermorken JB, Remenar E, van Herpen C, et al. Cisplatin, fluorouracil, and docetaxel in unresectable head and neck cancer. *N Engl J Med.* 2007;357:1695–704.
48. Dunne AL, Mothersill C, Robson T, et al. Radiosensitization of colon cancer cell lines by docetaxel: mechanisms of action. *Oncol Res.* 2004;14:447–54.
49. Lefebvre JL, Pointreau Y, Rolland F, et al. Sequential chemoradiotherapy (SCRT) for larynx preservation (LP): Preliminary results of the randomized phase II TREMPIN study. *Proc Am Soc Clin Oncol.* 2009;27:15s.

Chapter 22

Evidence-Based Head and Neck Oncology: Principles and Pitfalls

Søren M. Bentzen

Abstract Evidence-based Head and Neck Oncology is the implementation of, or the move toward, Evidence-based medicine (EBM) in the care of individual patients with head and neck squamous cell carcinoma. While the general principles and pitfalls of EBM apply in this subfield as well as in medicine in general, this chapter maintains a head and neck focus. A number of recent issues in head and neck oncology exemplify the wider challenges of introducing EBM in a diverse population of patients across a range of health care systems. Among the issues reviewed are early clinical trials of radiation therapy alone or combined with other modalities, randomized phase II trials, meta-analysis, efficacy endpoints in head and neck oncology, and patient reported outcomes. The likely prevalence of false-positive trial findings in the literature is discussed. This problem is partly caused by multiple comparisons and is aggravated by discordance between planned analyses according to trial protocols and those published in the literature. Finally, challenges related to incorporation of biomarkers in clinical trials are briefly summarized.

Keywords Head and neck oncology • Biostatistics • Trial design • Endpoints • Evidence-based medicine • Clinical research methodology

Evidence-Based Medicine: A Short Introduction

Following Sackett [1], Evidence-based Medicine (EBM) is the “conscientious, explicit and judicious use of the current best evidence in making decisions about the care of individual patients.”

S.M. Bentzen (✉)
Department of Human Oncology, Medical Physics, and Biostatistics and Medical Informatics, University of Wisconsin – Madison, School of Medicine and Public Health, K4/316 Clinical Science Center, 600 Highland Avenue, Madison, WI 53792, USA
e-mail: bentzen@humonc.wisc.edu

Eddy has argued that this definition is centered on the physician as the sole, or at least the *main*, provider of care and that the definition in fact focuses on Evidence-based Individual Decision making (EBID). He suggests that the development of Evidence-Based Guidelines (EBG), also known as Evidence-based Health Care, should be considered an equally worthy but separate branch of EBM. While Eddy’s distinction makes sense, it still appears that EBG is a means to an end, namely the use of current best evidence in decision making at the individual patient level. In this chapter, Sackett’s definition will be used in a broad sense, encompassing all decisions involved in caring for an individual patient, whether or not these are supported by EBG.

Evidence-based medicine is a compelling concept: the idea is that all medical interventions should be supported by evidence for a net benefit for the patient over that of other therapies. The overall aims of EBM are to improve treatment efficacy and safety, to optimize health-related quality of life (QoL) for the individual patient and to reduce health care costs. In the early 1990s, an expert committee of the US Institute of Medicine estimated that only 4% of all medical services were supported by strong evidence and more than 50% had very weak or no evidence. More recent estimates are not available and whether these figures have substantially changed in the last 15 years is anybody’s guess. Several ambitious EBM initiatives have been launched in the meantime. A major driver of EBM has been the not-for-profit Cochrane Collaboration, a large network of academic collaborators committed to preparing and disseminating systematic reviews of health care [2]. In addition, Cochrane collaborators have conducted and published a number of very helpful studies on research methodology and critical reviews of the quality of the literature underlying EBM. Comparisons have shown that Cochrane reviews have greater methodological rigor and are more frequently updated than other systematic reviews and meta-analyses [3]. A critic would point out that the methodological aspects on which Cochrane reviews score highly are exactly those that, although admittedly quite reasonable, are prioritized by the Cochrane collaborators! Independent “reviews of reviews”

have found that even if Cochrane reviews tend to follow more rigorous quality criteria, there is still room for improvement: a comparison of systematic reviews of critical care topics [4] found that adequate discussion of the quality of the included trials was missing in 44 and 79% of the Cochrane versus other systematic reviews, respectively.

Several countries have national bodies aiming to advance EBM. In the US, the Agency for Healthcare Research and Quality under the Department of Health and Human Services has established an Evidence-based Practice Center program with the aim of performing systematic reviews of best available evidence for clinical and health care policy decision making [5]. In the UK, the National Institute for Clinical Excellence [6] was founded in 1999 by the National Health Service (NHS). The name was changed in 2005 after a merger with the Health Development Agency to the National Institute for Health and Clinical Excellence, although the acronym NICE was maintained. NICE recommendations are legally binding for the individual NHS trust. This has been the cause of much controversy when individual patients or various patient interest groups have felt that NICE recommendations have been unreasonably restrictive regarding access to novel therapies [6]. While some of the criticism has related directly to how NICE functions, other criticism seems to be misguided and should more properly have been aimed at the health policy makers.

Evidence-based Head and Neck Oncology (EBHNO) is the implementation of, or the move towards, EBM in the care of individual patients with head and neck squamous cell carcinoma (HNSCC). While the general principles and pitfalls of EBM apply in this subfield as well as in medicine in general, the current chapter will attempt to maintain a head and neck focus. A number of recent issues in head and neck oncology exemplify the wider challenges of introducing EBM in a diverse population of patients across a range of health care systems.

Levels of Evidence

The first hurdle in implementing EBM is that not all published trials of a specific intervention will reach the same conclusion regarding its risk: benefit ratio. There are two aspects to be considered: Quantity and Quality. Quantity refers to the numerical outcome estimates. Trials typically report several efficacy endpoints such as time to progression, and disease-free and overall survival. Reports on phase III trials may – in addition to significance tests for an observed difference in outcome – often include the estimated ratio of hazard rates, or hazard ratio, between trial arms. The point is that all of these effect measures are *estimates* derived from the observed trial outcome; they have a magnitude as well as

an associated confidence interval. The *magnitude* of the effect estimate does not in itself provide an indication of how strong the *evidence* for a benefit from one of the trial arms is. It is necessary also to consider the width of the 95% confidence interval. Multiple effect estimates can be pooled in a meta-analysis, providing an overall best estimate, see also Meta-Analysis and EBHNO Section.

The other “Q” is equally important but unfortunately slightly more elusive: Trial Quality is difficult to assess objectively and even more difficult to rank on a grading scale. Different quality grading instruments have been shown to give discordant ranking of trials. It is possible to use quality as a weighting factor for example in a meta-analysis, i.e., giving relatively more weight to high-quality trials; while this is conceptually attractive it is clearly counter-indicated by the lack of an evidence-supported quality instrument. For an introductory discussion of these issues, see Bentzen [7].

Sample Size and Statistical Power

A quick MEDLINE search for phase III trials in “head and neck” + “cancer” published between 2006 and 2008 produces 67 hits of which 31 are primary trial reports. Figure 22.1 shows the cumulative distribution function of sample sizes in these 31 trials. The median sample size was 163 patients, or 82 per trial arm in a 2-arm study. Using standard statistical design parameters, significance level $\alpha=0.05$ and power $1-\beta=0.9$, and assuming the baseline success rate to be 40%, the resolvable improvement in outcome is estimated using the *arcsine* approximation to be 65%, or in other words, a

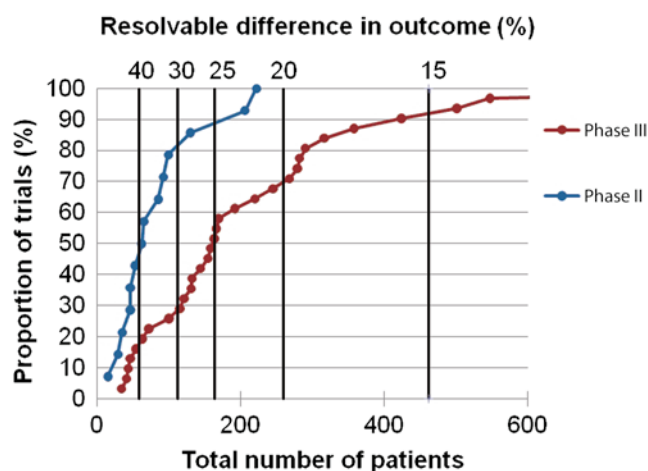


Fig. 22.1 Cumulative frequency distribution of the total sample size of HNSCC phase II and III trials registered in Medline 2006–2008. The upper horizontal scale indicates the minimum improvement in outcome that a trial of a given size can resolve with a significance level of 5 and 90% power. The baseline success rate is assumed to be 40%

25% points improvement in the outcome parameter of interest. Such an improvement would be a major treatment breakthrough and it appears that most HNSCC phase III trials are under-powered to detect less spectacular but more realistic improvements of clinical outcome.

Under-powered trials may lead to false-negative findings, that is, trials that on the surface seems to contradict the findings of other trials. This again leads to a lack of consistency in the clinical development of new therapies.

A similar search for randomized phase II trials in head and neck cancer published 2006–2008 produced 33 hits of which 14 were primary trial reports. Figure 22.1 shows the cumulative distribution of sample sizes in these trials as well. Interestingly, two of these trials are larger than the median sample size for reported phase III HNSCC trials in the same period. However, the median sample size of the randomized phase II trials was 62 patients, which under the same assumptions as above would allow detection of an improvement in success rate from 40 to 79%, which would be nothing short of a miracle in terms of therapeutic improvement. Randomized phase II trials were originally proposed by Simon and colleagues [8] as a strategy to pick the likely best treatment out of two or more alternatives. They were not, and are not, meant to be powered for comparative effect assessment. The problem is, however, that many investigators feel that the randomization in itself justifies a formal comparison of the efficacy of treatment arms [9]. Thus, all except one of the 14 randomized phase II trial reports surveyed here included at least one *P*-value relating to a comparison of efficacy in the two arms of the trial. And in 8 of these 13 reports, at least one of the reported *P*-values comparing treatment effect was significant at the 5% level!

False-Positive Results

If false-negative outcomes of under-powered trials are a concern, how can the high prevalence of trials reporting significant *P*-values be explained? This apparent paradox is likely explained by observing that many significant *P*-values are in fact false positive. Analysis of multiple endpoints, subgroup analyses, multiple looks at the data in the form of unplanned interim analyses, and early stopping of trials showing a significant benefit of one of the trial arms, all lead to a high risk of false-positive findings. Tannock [10] conducted a literature review of the actual and inferred number of significance tests comparing treatments in clinical trial reports and found that the median number of reported tests for major outcome parameters was six and estimated that the median number of reported plus implied tests was 13. If subgroup analyses were counted as well, the number of significance tests comparing treatments rose to 20. Conducting a test at the 5% significance

level means that there is a 5% chance of reporting a significant difference even if in reality there is no difference between treatments. This nominal 5% false-positive rate will increase to 26, 49, and 64% in the case of 6, 13, or 20 significance tests even if the null hypothesis is true.

The Prevalence of False-Positive Trial Results

Among all the published *P*-values in the literature that are significant at the 5% level, a large number are false positive. This is the background for the attention-catching title, “Why Most Published Research Findings Are False,” of John Ioannidis’ 2005 essay in *PLoS Medicine* [11]. The proportion of false-positive trials depends on the prevalence of true-positive treatment strategies that are tested in these. It is impossible to assess the true-positive rate, but it is likely to be quite low. In a 2005 analysis of 57 randomized controlled trials in various disease sites conducted by the Radiation Therapy Oncology Group (RTOG) between 1968 and 2002, the odds ratio for survival was 1.01 (99% CI 0.96–1.07; *P*=0.5) suggesting that *on average* experimental and control arm therapies were equally successful [12].

If the true prevalence of improved therapies tested in trials is, say, 10%, and if the trial is designed to have the fairly standard 90% power, then 9 out of a hundred trials will come out true positive. Based on Tannock’s estimates for the number of therapy comparisons per trial (see False-Positive Results section), this translates into 72, 83, and 86% of all significant *P*-values being false positive in the case of 6, 13, or 20 significance tests. And remember that Tannock estimated the *median* number of significance tests, the total body of trial reports with significant *P*-values will be enriched with papers conducting more than the median number of tests. These are disturbing numbers. It is useful to look at other assumptions for the true positive proportion to see just how big a problem this is – it is BIG!

Repeating “successful” trials is the remedy against false-positive findings. This is especially effective if the real significance level is 5%, the likelihood of an ineffective therapy coming out significantly twice by chance is only 1:400. Unfortunately, in practice, both trials will typically be subject to the “false-positive” problem, in which case repeatability becomes much less of a reassurance.

Trial Registration and Public Access to Trial Protocols

A balanced assessment of the efficacy of an intervention on the basis of reports in the literature is further complicated by publication bias, the well-documented fact that trials with a

significant P -value (true or false positive) are more likely to be published than trials without a significant P -value [13, 14]. In 2005, the International Committee of Medical Journal Editors (ICMJE) initiated a policy requiring investigators to register design details of new trials into an accepted clinical trials registry before opening the trial. This was nearly 20 years after Simes had convincingly argued the case for such a register [15]. ClinicalTrials.gov, the largest trial registry in 2005, contained 13,153 trials at the time. In April 2007, the registry contained over 40,000 trials [16]. The idea is that a complete picture of the “negative” studies can only be obtained if all trials are prospectively registered before any trial outcome data become available. While the existence of these trial registries is definitely a step forward, it is also clear that registration in itself is not enough. Registered trials with a statistically significant finding are still more likely to be published than other trials and a recent review found that trials sponsored by clinical collaborative groups published 59% of registered studies, compared to a meager 5.9% of studies sponsored by industry [17].

Even when trials *are* published and even if the trial report concentrates on a single primary endpoint, thereby apparently minimizing the issues with multiple comparisons discussed above, there is another source of biased reporting: discrepancies between trial reports and trial protocols. Chan et al. [18] found discordance between the published primary analysis and that specified in the protocol in 25 of 42 pairs (60%) of protocols/publications. Chan also found discrepancies between protocols and publications with respect to sample size calculations (18/34 trials), methods of handling protocol deviations (19/43), missing data (39/49), subgroup analyses (25/25), and adjusted analyses (23/28). Thirteen protocols described planned interim analyses, but any such analysis was mentioned in only five of the resulting publications. It seems that the remedy against this problem is prospective registration of the full protocol and making this available for peer reviewers of the final trial publication.

Endpoints for Outcome Assessment

Traditionally, HNSCC has been viewed predominantly as a locoregional disease and the main efficacy endpoint has been locoregional tumor control. Local control has been shown to be a surrogate endpoint for overall survival in trials of altered radiation dose fractionation [19]. Treatment intensity limiting toxicities have historically been localized to the high-dose region as well. With a flurry of new cytotoxic or molecular targeted agents in the pipeline and new biological rationales for combining drugs with radiation also in head and neck oncology [20, 21], both efficacy and toxicity endpoints have come under scrutiny. Empirically, combinations

of chemotherapy and radiation therapy are gaining wide acceptance as the standard of care in many patients with HNSCC. Bentzen et al. [22] identified five primary exploitable mechanisms for the rational combination of drugs with fractionated radiation therapy: spatial cooperation, cytotoxic enhancement, biological cooperation, temporal modulation, and normal tissue protection. The specific rationale exploited by a drug-radiation combination will guide the selection of optimal efficacy endpoints, facilitating a test of the underlying hypothesis for the combination.

Efficacy Endpoints

The time-honored local therapy-specific efficacy endpoint in HNSCC is local, or locoregional, tumor control. At least three current trends have put a question mark over local control as the default primary endpoint in HNSCC (1) As intensified multimodality therapeutic approaches have succeeded in improving locoregional outcome, distant disease progression has become a relatively more important competing cause of treatment failure; (2) Patients having persistent locoregional disease at the end of primary treatment have local failure at time zero, but may in fact have a therapeutic benefit in terms of a prolonged time to progression from local or systemic therapies; (3) Local control is a “non-event,” namely the absence of local failure. In some cases, there is a differential diagnostic problem in distinguishing persistent local disease from radiation sequelae. All of these considerations have turned the interest more in the direction of disease-progression based efficacy endpoints. Table 22.1 shows a proposed set of definitions for efficacy endpoints in HNSCC trials. The exact criteria for calling a progression (e.g., RECIST [23–25]) and the diagnostic procedures used to screen for progression should be defined in each case. For endpoints involving survival, death from any cause should be treated as an event. In all other cases, death will censor the observation. For a specific type of failure, say, local progression, nodal and distant progression will be ignored, i.e., the patient will still be at risk for failing locally. The exception is when patients are not followed beyond the time of the first disease progression, in which case progression outside the site of interest is a censoring event. For time to progression endpoints this author suggested to refer to the progression-free estimate at a specific follow-up time, typically 2 or 5 years, as the progression-free rate [26]. This is not an optimal terminology as “rate” normally refers to events per unit time. Instead the term “local-progression free estimate at x years” is preferable. In randomized trials, the date of randomization is the starting time, in other types of study the first day of active therapy is generally chosen as the starting time for calculating time to failure.

Table 22.1 Suggested definitions of clinical endpoints in HNSCC

Endpoint	Abbreviation	Local progression	Nodal progression	Distant progression	Death of any cause
Time to progression	TTP	E	E	E	C
Progression-free survival	PFS	E	E	E	E
Time to local progression	TTLP	E	I	I	C
Local-progression-free survival	LPFS	E	I	I	E
Time to locoregional progression	TTLRP	E	E	I	C
Locoregional progression-free survival	LRPFS	E	E	I	E
Time to distant progression	TTDP	I	I	E	C
Distant-progression-free survival	DPFS	I	I	E	E

E Event; *C* Censor; *I* Ignore. Loss to follow up is censored in all cases

Toxicity

The incidence and severity of toxicity in nonsurgically managed HNSCC patients have increased substantially over the last two decades [27, 28]. Disturbingly, there are reasons to believe that toxicity is generally under-recorded in clinical trials and under-reported in the published literature [29–32]. Even with high-quality evidence from clinical trials, issues remain regarding the generalizability of toxicity experienced in trials to unselected patient populations treated in routine practice. New therapies are most often tested in specific populations using strict inclusion and exclusion criteria. Exclusion criteria typically comprise various types of comorbidity or lab test values outside a defined range. It has been documented that tumor outcomes in trials may overestimate the benefit from introducing experimental therapies in routine care [7]. Although less well-documented, there are good reasons to believe that trial populations may experience less toxicity than unselected clinical cases [33]. This may in part be a result of more comorbidity and a higher proportion of vulnerable patients such as the elderly and because supportive care and surveillance is more intensive in the trial setting. The incidence of events reported in clinical trials could therefore be considered the *minimum* estimates of risk. As clinical trials are often not powered to provide precise risk estimates, 95% confidence intervals around the estimates should be reported. This is especially an issue with late effects incidence estimates, where competing risks and incomplete follow-up may lead to an overall low number of events that again may limit the precision of these.

Patient Reported Outcomes (PRO)

A strong case has been made that appropriate evaluation of new treatment strategies should incorporate the patient's perspective [34]. Patient self-reporting has long been accepted as the preferred method for collecting QoL data and for assessing pain relief in palliative studies [35, 36].

Patient Reported Normal Tissue Outcomes (PROs) comprise subjective symptoms and Quality Life (QoL). Generally speaking, there is rather poor concordance between physician and patient reported normal tissue outcomes [37–39]. Depending on the point of view, this can be interpreted either as an indication that physicians are not very good at assessing what really matters to the patient, or, alternatively, that patients are not very good at assessing their own side-effects of therapy. A more fruitful way to look at these discrepancies is to see these outcomes as complementary and at least partly independent domains of toxicity. Two recent studies provide relevant data for this discussion from slightly different perspectives.

Ataman et al. [40] conducted a large study of the value of routine follow-up of cancer patients after therapy in 15 European centers, matching questionnaires filled out by physicians and patients in 2,303 cases. One of the motivations for this study was to find out if patient-initiated could replace routine follow-up visits. As part of the study, the investigators determined the proportion of patients who had a treatment-related symptom that was associated with a positive finding on clinical examination. Reanalyzing the data from the paper shows that the sensitivity of symptoms as a screen for objective clinical side-effects was 80% and the specificity was 50%. The low specificity reflects a high proportion of false positives, i.e., patients reporting symptoms but with no objective clinical signs of side-effects.

In an interesting study, Basch et al. [41] used a CTCAE 3.0-based questionnaire “translated” into layman's terms [42] and compared self- with clinician-assessment of 11 common symptoms in 400 patients and concluded that “... patients with cancer and their clinicians generally agree on the severity of symptom grades for 11 common CTCAE items.” Again, this conclusion depends on the perspective taken. Basch et al. compared discrepancies between paired patient and clinician grading, where one of the two was G0–2 and the other G3+, often regarded the threshold for a “...clinically meaningful change in management” [41] and concluded that this was seen in “fewer than 10% of all pairs.” However, 10% would correspond to some 400 pairs, or approximately one toxicity-item pair per patient in the study.

These authors found perfect agreement in scores for between 41 and 96% of the patient–clinician pairs, depending on the item considered. However, interpretation of these frequencies is hampered by the fact that the proportion of patients with G0 score for a given item (i.e., no symptom at all), where a perfect agreement would seem more likely, is not stated in the paper.

One philosophical issue is that an individual patient is an “N of 1” trial, the patient’s experience of symptoms and how they affect QoL is unique to that individual and most patients will not have an accurate impression of the spectrum of severities of side effects experienced by their fellow patients after identical treatments. While there is no discussion that the patient’s perspective needs to be further emphasized, physician assessed outcome remains an important component of recording toxicity.

How to Quantify “Therapeutic Ratio” in Oncology?

Although the terms “therapeutic ratio” or “risk-benefit ratio” are widely used, there is still no consensus on how or even if, these can be meaningfully quantified [43]. Most of the methods explored in the literature require a more or less direct trade-off between toxicity and efficacy events. While this may be relatively uncontroversial in case of treatment-related mortality, the problem arises with toxicities that are not fatal or generally regarded “unacceptable.” At the individual patient level, this trade-off should clearly involve the patient’s priorities as well as a medical evaluation of risks and benefits. Informing this process requires reliable efficacy and toxicity estimates and a detailed knowledge of the toxicity profile of the therapy in question. At the societal or EBM level, there is currently no satisfactory way of quantifying the therapeutic ratio.

Specific Trial Designs

Clinical trials for drug development have traditionally been conducted in three phases. A phase I trial aims to establish the recommended dose for phase II trials of a new agent or combination of agents in humans based on the occurrence of unacceptable or dose-limiting toxicity as the dose is escalated in predefined steps. Phase II trials screen a new drug for activity in a specific tumor type. Historically, phase II trials were designed to reject drugs for further consideration if they did not show a minimum clinical efficacy, typically assessed by radiological tumor regression. Drugs that show promising activity in phase II are then taken into a randomized

controlled phase III trial, where the aim is to compare the new treatment with the current standard therapy. Investigators conducting radiation therapy trials have tried hard to apply the phase I, II, III model also to clinical radiation research [44]; however, local therapies and in particular radiation therapy do not fit comfortably under this research strategy.

Early Clinical Trials Involving Radiation Therapy

In phase I studies, the problem is that the dose-limiting toxicities after radiation therapy are typically late effects. This is because most radiation effects are seen locally, in the high-dose volume, and even relatively severe early reactions are often not dose limiting provided that the volume can be minimized. Late effects require prolonged observation of the patient and this effectively precludes rapid dose titration designs in early radiation therapy trials. Although methods have been devised [45] for pro-rating late effects according to the number of person-years at risk, which in principle will allow an early estimation of the level of late effects, these still require a sufficient number of patients with extended follow-up to be convincing. Also the standard phase II trial design is problematic; in radiation therapy, the main clinical endpoint is persistent local tumor control, whereas volume regression is not a very useful indicator of biological activity, simply because most solid malignancies regress after curative radiation doses.

Most early trials of combined drug and radiation therapy do not escalate the radiotherapy component. Drug doses will be escalated using the standard 3+3 design or rapid inpatient escalation designs [46] and the stopping rules will be defined in terms of early toxicity only. Often, there are phase I data for the drug as a sole agent or in combination with other drugs, and they are useful starting points for generating a relatively rapid escalation scheme when adding this to radiation. Due to the differences in toxicity between various organs and tissues, phase I trials of the combination must be conducted in the relevant tumor type. While phase I drug trials are often conducted in patients with a mix of tumor histologies and with no curative therapy options left, combined chemotherapy and radiation therapy phase I studies need to be conducted in patients treated with curative radiation dose schedules. Once the MTD is established, the traditional phase II study is often modified into a “feasibility study,” treating an expanded cohort of patients, perhaps 50–80, with the full therapeutic package, and the aim is to obtain more detailed toxicology – ideally also a beginning indication of late toxicity – and early efficacy data. A more complete characterization of efficacy and toxicity in combined modalities including radiation will have to come from

a phase III trial with mature follow-up data, often meaning 5 years at least for a fair proportion of the patients.

Phase III Trials

Randomized controlled trials of combination therapies involving radiation are not too different from other phase III trials. Typical primary phase III endpoints, like cause-specific and overall survival, in a disease with a relatively favorable prognosis such as HNSCC requires long-term follow-up of patients in any case. Thereby, the available observation time becomes sufficient also to provide estimates of radiotherapy-specific endpoints such as time to local progression and late side effects.

There are good statistical reasons why the primary analysis of a trial should be conducted according to the intention-to-treat principle. There is, however, an issue with relatively poor compliance in many intensified radiation fractionation [47] and combined modality regimens [48]. While poor compliance may be seen as a surrogate for toxicity in itself, this creates difficulties in interpreting both efficacy and toxicity outcomes of experimental therapies and generalizing these to routine practice.

Stratification and Predictive Biomarkers

Stratified randomization, aimed at ensuring that the most important prognostic factors are balanced between trial arms, has been used extensively for several decades also in HNSCC. Stratified analyses of trial outcomes have also been used, but not to a great extent. With an improved understanding of molecular and etiological characteristics of head and neck cancers, it is safe to predict that future trials will be conducted in highly selected populations. At the time of writing, the relatively favorable prognosis in HPV-related oral and oropharyngeal HNSCC has become well established [49–51]. In view of the considerable severity of late side-effects after current chemoradiation schedules, the idea that patients with HPV-related disease may be overtreated by standard multimodality therapies is gaining wider support. At the time of writing HNSCC trials with HPV positivity – often in combination with other prognostic factors – as an eligibility criterion are under development by the RTOG and other cooperative research groups. From an EBM perspective, this introduces a new degree of freedom as both the therapy and the exact definition of the trial population are being varied.

A separate potentially important stratification of patients into different treatment options would be according to the

risk of various failure types. Multiplexed immunohistochemical marker signatures may be of value in this respect [52, 53]. Novel high-throughput assays, like single nucleotide polymorphism (SNP) or DNA microarrays, hold enormous promise both in terms of assessing the risk of side effects and tumor recurrence, but so far none of these are near routine clinical use. One problem is the lack of definitive, large validation studies of interesting candidate biomarkers that will definitively prove (or disprove) the value of specific markers. This leads down false tracks and hinders rational progress in the field [53].

Meta-Analysis and EBHNO

Two high-profile, comprehensive meta-analyses of randomized controlled trials in HNSCC have been published in the last 10 years: one concerned with the possible benefit of adding cytotoxic chemotherapy to locoregional treatment [54], the other concerned with the benefit of altered radiation therapy dose-fractionation [55]. While successfully conducting this kind of large individual-patient level analyses is a major achievement in itself, the two studies illustrate brilliantly the strengths and weaknesses of this research methodology. The strength of course is the ability to weigh evidence for or against the benefit of an intervention based on – often apparently divergent – results of a large number of trials, for example the chemotherapy analysis included data from 93 randomized trials comprising 17,346 patients [56]. Both analyses showed a small but highly statistically significant benefit from the experimental relative to standard therapy. In case of chemotherapy there was a 4.5% absolute increase in survival at 5 years ($P < 0.0001$), a slightly higher 5-year benefit, 6.5% was seen after concurrent chemo-radiation therapy ($P < 0.0001$). However, at the same time the test for heterogeneity was highly significant ($P < 0.0001$) both among all trials as well as among concurrent chemo-radiation trials [56]. A significant heterogeneity test indicates that trial outcome varies beyond what can be expected by chance if the experimental therapies had all been associated with the same therapeutic gain. In other words, the very basic assumption of the meta-analysis must be rejected. Or, put differently, there seems to be information in the variation in outcome among studies. While proponents may interpret this as an indication that there is a real benefit from chemo-radiation, the question is: “Which chemo-radiation schedule?” And if the therapeutic gains vary according to the exact therapy it becomes difficult to interpret what the pooled effect estimate really means. The pooling of multiple quite variable therapies in a meta-analysis is associated with a loss of information, and may erroneously lead to an impression that ineffective therapies are effective or, conversely, that the benefit from the most potent therapies

is less than what it really is. A similar limitation affects the meta-analysis of altered radiotherapy dose-fractionation in HNSCC [55] where different strategies for accelerated and/or hyperfractionated radiation therapy were grouped into broad categories, such as “accelerated with dose-reduction” or “accelerated without dose-reduction.” The problem again is that the strategies within each category cannot be assumed to be biologically equivalent, which yet again causes problems when trying to interpret the effect estimates of the meta-analysis. Furthermore, both meta-analyses could not compile sufficient data to allow an analysis of late toxicity which evidently is an important part of selecting a therapy [29, 30]. It is conceivable that some of the therapies associated with a gain in efficacy were also associated with unacceptable or stronger than usual side effects.

Concluding Remarks: Towards EBHO

Head and neck oncology is increasingly evidence based. Yet, as discussed in this chapter, a number of issues affect the quality of published evidence. The randomized controlled trial remains the gold standard for comparative effectiveness research. There are, however, areas where the randomized trial has important limitations as a research methodology. One is health technology assessment both in the diagnostic and interventional setting [57] where the sensitivity and specificity of standard clinical effect measures in most cases is too low to allow a direct test in a reasonably sized trial [58]. Another is the integration of biomarkers into stratification of patients to various therapies. While the benefit of such a strategy can easily be tested in a randomized trial, it may in practice be difficult to conduct a straightforward comparative effectiveness trial once the stratification biomarkers are convincingly validated. Meta-analysis of evidence from randomized controlled trials is a powerful tool and the outcome of these analyses is hugely influential in shaping the evidence-based best practice, but again it is important to be aware of its shortcomings and pitfalls. Finally, there is the huge issue of increasing toxicity in nonsurgical management of HNSCC and the general lack of adequate documentation of this toxicity even in well-conducted clinical trials. All of these issues are challenges to be met in the coming decade.

References

- Sackett DL, Rosenberg WM, Gray JA, Haynes RB, Richardson WS. Evidence based medicine: what it is and what isn't. *Br Med J*. 1996;312(7023):71–2.
- Chalmers I, Haynes B. Reporting, updating, and correcting systematic reviews of the effects of health care. *BMJ*. 1994;309(6958):862–5.
- Jadad AR, Cook DJ, Jones A, et al. Methodology and reports of systematic reviews and meta-analyses: a comparison of Cochrane reviews with articles published in paper-based journals. *JAMA*. 1998;280(3):278–80.
- Delaney A, Bagshaw SM, Ferland A, Laupland K, Manns B, Doig C. The quality of reports of critical care meta-analyses in the Cochrane Database of Systematic Reviews: an independent appraisal. *Crit Care Med*. 2007;35(2):589–94.
- Atkins D, Fink K, Slutsky J. Better information for better health care: the Evidence-based Practice Center program and the Agency for Healthcare Research and Quality. *Ann Intern Med*. 2005;142(12 Pt 2):1035–41.
- Littlejohns P, Garner S, Doyle N, Macbeth F, Barnett D, Longson C. 10 years of NICE: still growing and still controversial. *Lancet Oncol*. 2009;10(4):417–24.
- Bentzen SM. A user's guide to evidence-based oncology. *Eur J Cancer Suppl*. 2003;1(S6):77–91.
- Simon R, Wittes RE, Ellenberg SS. Randomized phase II clinical trials. *Cancer Treat Rep*. 1985;69(12):1375–81.
- Liu PY, LeBlanc M, Desai M. False positive rates of randomized phase II designs. *Control Clin Trials*. 1999;20(4):343–52.
- Tannock IF. False-positive results in clinical trials: multiple significance tests and the problem of unreported comparisons. *J Natl Cancer Inst*. 1996;88:206–7.
- Ioannidis JP. Why most published research findings are false: author's reply to Goodman and Greenland. *PLoS Med*. 2007;4(6):e215.
- Soares HP, Kumar A, Daniels S, et al. Evaluation of new treatments in radiation oncology: are they better than standard treatments? *JAMA*. 2005;293(8):970–8.
- Dwan K, Altman DG, Arnaiz JA, et al. Systematic review of the empirical evidence of study publication bias and outcome reporting bias. *PLoS ONE*. 2008;3(8):e3081.
- Easterbrook PJ, Berlin JA, Gopalan R, Matthews DR. Publication bias in clinical research. *Lancet*. 1991;337:867–72.
- Simes RJ. Publication bias: the case for an international registry of clinical trials. *J Clin Oncol*. 1986;4(10):1529–41.
- Laine C, Horton R, DeAngelis CD, et al. Clinical trial registration: looking back and moving ahead. *Lancet*. 2007;369(9577):1909–11.
- Ramsey S, Scoggins J. Commentary: practicing on the tip of an information iceberg? Evidence of underpublication of registered clinical trials in oncology. *Oncologist*. 2008;13(9):925–9.
- Chan AW, Hrobjartsson A, Jorgensen KJ, Gotzsche PC, Altman DG. Discrepancies in sample size calculations and data analyses reported in randomised trials: comparison of publications with protocols. *BMJ*. 2008;337:a2299. doi:10.1136/bmj.a2299.a2299.
- Wadsley JC, Bentzen SM. Investigation of relationship between change in locoregional control and change in overall survival in randomized controlled trials of modified radiotherapy in head-and-neck cancer. *Int J Radiat Oncol Biol Phys*. 2004;60(5):1405–9.
- Bernier J, Bentzen SM, Vermorken JB. Molecular therapy in head and neck oncology. *Nat Rev Clin Oncol*. 2009;6(5):266–77.
- Wilson GD, Bentzen SM, Harari PM. Biologic basis for combining drugs with radiation. *Semin Radiat Oncol*. 2006;16(1):2–9.
- Bentzen SM, Harari PM, Bernier J. Exploitable mechanisms for combining drugs with radiation: concepts, achievements and future directions. *Nat Clin Pract Oncol*. 2007;4(3):172–80.
- Eisenhauer EA, Therasse P, Bogaerts J, et al. New response evaluation criteria in solid tumours: revised RECIST guideline (version 1.1). *Eur J Cancer*. 2009;45(2):228–47.
- Schwartz LH, Bogaerts J, Ford R, et al. Evaluation of lymph nodes with RECIST 1.1. *Eur J Cancer*. 2009;45(2):261–7.
- Therasse P, Arbuck SG, Eisenhauer EA, et al. New guidelines to evaluate the response to treatment in solid tumors. European Organization for Research and Treatment of Cancer, National Cancer Institute of the United States, National Cancer Institute of Canada. *J Natl Cancer Inst*. 2000;92(3):205–16.

26. Bentzen SM. Towards evidence based radiation oncology: improving the design, analysis, and reporting of clinical outcome studies in radiotherapy. *Radiother Oncol.* 1998;46:5–18.
27. Bentzen SM, Rosenthal DI, Weymuller EA, Trotti A. Increasing toxicity in nonoperative head and neck cancer treatment: investigations and interventions. *Int J Radiat Oncol Biol Phys.* 2007;69 (2 Suppl):S79–82.
28. Trotti A. Toxicity in head and neck cancer: a review of trends and issues. *Int J Radiat Oncol Biol Phys.* 2000;47(1):1–12.
29. Bentzen SM, Trotti A. Evaluation of early and late toxicities in chemoradiation trials. *J Clin Oncol.* 2007;25(26):4096–103.
30. Trotti A, Bentzen SM. The need for adverse effects reporting standards in oncology clinical trials. *J Clin Oncol.* 2004;22(1):19–22.
31. Ioannidis JP, Lau J. Completeness of safety reporting in randomized trials: an evaluation of 7 medical areas. *JAMA.* 2001;285(4):437–43.
32. Ioannidis JP. Adverse events in randomized trials: neglected, restricted, distorted, and silenced. *Arch Intern Med.* 2009;169(19):1737–9.
33. Hassett MJ, O'Malley AJ, Pakes JR, Newhouse JP, Earle CC. Frequency and cost of chemotherapy-related serious adverse effects in a population sample of women with breast cancer. *J Natl Cancer Inst.* 2006;98(16):1108–17.
34. Acquadro C, Berzon R, Dubois D, et al. Incorporating the patient's perspective into drug development and communication: an ad hoc task force report of the Patient-Reported Outcomes (PRO) Harmonization Group meeting at the Food and Drug Administration, February 16, 2001. *Value Health.* 2003;6(5):522–31.
35. Chow E, Wu JS, Hoskin P, Coia LR, Bentzen SM, Blitzer PH. International consensus on palliative radiotherapy endpoints for future clinical trials in bone metastases. *Radiother Oncol.* 2002;64(3):275–80.
36. Madsen EL. Painful bone metastasis: efficacy of radiotherapy assessed by the patients: a randomized trial comparing 4 Gy X 6 versus 10 Gy X 2. *Int J Radiat Oncol Biol Phys.* 1983;9(12):1775–9.
37. Davidson SE, Burns MP, Routledge JA, Swindell R, Bentzen SM, West CM. Assessment of morbidity in carcinoma of the cervix: a comparison of the LENT SOMA scales and the Franco-Italian glossary. *Radiother Oncol.* 2003;69(2):195–200.
38. Jensen K, Bonde JA, Grau C. The relationship between observer-based toxicity scoring and patient assessed symptom severity after treatment for head and neck cancer. A correlative cross sectional study of the DAHANCA toxicity scoring system and the EORTC quality of life questionnaires. *Radiother Oncol.* 2006;78(3):298–305.
39. Fromme EK, Eilers KM, Mori M, Hsieh YC, Beer TM. How accurate is clinician reporting of chemotherapy adverse effects? A comparison with patient-reported symptoms from the Quality-of-Life Questionnaire C30. *J Clin Oncol.* 2004;22(17):3485–90.
40. Ataman OU, Barrett A, Davidson S, et al. Audit of effectiveness of routine follow-up clinics after radiotherapy for cancer: a report of the REACT working group of ESTRO. *Radiother Oncol.* 2004;73(2):237–49.
41. Basch E, Iasonos A, McDonough T, et al. Patient versus clinician symptom reporting using the National Cancer Institute Common Terminology Criteria for Adverse Events: results of a questionnaire-based study. *Lancet Oncol.* 2006;7(11):903–9.
42. Basch E, Artz D, Dulko D, et al. Patient online self-reporting of toxicity symptoms during chemotherapy. *J Clin Oncol.* 2005;23(15):3552–61.
43. Bentzen SM. Design of clinical trials in radiation oncology: saving lives, not Grays. In: Dale RG, Jones B, editors. *Modelling in radiation oncology.* London: British Institute of Radiology, 2007; 196–211.
44. Bentzen SM, Dorr W, Anscher MS, et al. Normal tissue effects: reporting and analysis. *Semin Radiat Oncol.* 2003;13(3):189–202.
45. Cheung YK, Chappell R. Sequential designs for phase I clinical trials with late-onset toxicities. *Biometrics.* 2000;56(4):1177–82.
46. Simon R, Freidlin B, Rubinstein L, Arbusk SG, Collins J, Christian MC. Accelerated titration designs for phase I clinical trials in oncology. *J Natl Cancer Inst.* 1997;89(15):1138–47.
47. Khalil AA, Bentzen SM, Bernier J, et al. Compliance to the prescribed dose and overall treatment time in five randomized clinical trials of altered fractionation in radiotherapy for head-and-neck carcinomas. *Int J Radiat Oncol Biol Phys.* 2003;55(3):568–75.
48. Bernier J, Bentzen SM. Altered fractionation and combined radiochemotherapy approaches. Pioneering new opportunities in head and neck oncology. *Eur J Cancer.* 2003;39(5):560–71.
49. Dahlstrand H, Dahlgren L, Lindquist D, Munck-Wikland E, Dalianis T. Presence of human papillomavirus in tonsillar cancer is a favourable prognostic factor for clinical outcome. *Anticancer Res.* 2004;24(3b):1829–35.
50. Ragin CC, Taioli E. Survival of squamous cell carcinoma of the head and neck in relation to human papillomavirus infection: review and meta-analysis. *Int J Cancer.* 2007;121(8):1813–20.
51. Lassen P, Eriksen JG, Hamilton-Dutoit S, Tramm T, Alsner J, Overgaard J. Effect of HPV-associated p16INK4A expression on response to radiotherapy and survival in squamous cell carcinoma of the head and neck. *J Clin Oncol.* 2009;27(12):1992–8.
52. Ataman OU, Bentzen SM, Wilson GD, et al. Molecular biomarkers and site of first recurrence after radiotherapy for head and neck cancer. *Eur J Cancer.* 2004;40(18):2734–41.
53. Bentzen SM. From cellular to high-throughput predictive assays in radiation oncology: challenges and opportunities. *Semin Radiat Oncol.* 2008;18(2):75–88.
54. Pignon JP, Bourhis J, Domenge C, Designe L. Chemotherapy added to locoregional treatment for head and neck squamous-cell carcinoma: three meta-analyses of updated individual data. MACH-NC Collaborative Group. *Meta-Analysis of Chemotherapy on Head and Neck Cancer.* *Lancet.* 2000;355(9208):949–55.
55. Bourhis J, Overgaard J, Audry H, et al. Hyperfractionated or accelerated radiotherapy in head and neck cancer: a meta-analysis. *Lancet.* 2006;368(9538):843–54.
56. Pignon JP, Le MA, Maillard E, Bourhis J. Meta-analysis of chemotherapy in head and neck cancer (MACH-NC): an update on 93 randomised trials and 17, 346 patients. *Radiother Oncol.* 2009;92(1):4–14.
57. Bentzen SM. Randomized controlled trials in health technology assessment: overkill or overdue? *Radiother Oncol.* 2008;86(2):142–7.
58. Bentzen SM. Radiation oncology health technology assessment: the best is the enemy of the good. *Nat Clin Pract Oncol.* 2008;5(10):563.

Chapter 23

Programs of Organ and Function Preservation

Jean-Louis Lefebvre

Abstract An intensive clinical research has been carried out over the past three decades aiming to avoid performing a total laryngectomy. Large partial open procedures or endoscopic laser CO₂ surgery may be an alternative to total laryngectomy in very highly selected cases. Altered fractionated radiotherapy has proved to be more efficient than conventional radiotherapy. However, most of the research has been done by combining chemotherapy and radiotherapy. The first programs used induction chemotherapy (cisplatin and 5-fluorouracil with or without docetaxel) followed by radiotherapy in good responders. Toxicity was acceptable, neither disease control nor survivals were compromised and larynx could be preserved in at least two thirds of the cases. The second programs used concomitant chemoradiotherapy. Concurrent chemoradiotherapy provided higher larynx preservation rates but at the price of a substantial acute and late toxicity potentially compromising the larynx function. Alternating chemoradiotherapy did not increase toxicity but larynx preservation was similar to induction chemotherapy. Whether concurrent or alternating, there was no improvement of survival. The on-going third programs are assessing induction chemotherapy followed by radiotherapy with either concurrent chemotherapy or concurrent biotherapy.

Keywords Larynx • Hypopharynx • Chemotherapy • Biotherapy • Radiotherapy • Surgery

Introduction

Surgery has been the first treatment of larynx and hypopharynx cancers. This surgery was initiated at the end of the nineteenth century for larynx cancer and quite simultaneously consisted of either partial or total laryngectomy. At the very beginning of the twentieth century radiotherapy was also

used for the treatment of laryngeal malignancies. As a result, from the start there were two major options: surgery or radiotherapy. All along the twentieth century an intensive surgical research has allowed fine-tuning the indications and techniques of the various partial surgery procedures. With time some large partial procedures have been validated for cases that were until then only amenable to a total laryngectomy. That is the case, for example, of the supracricoid partial laryngectomies. Endoscopic laser surgery has also been a major advance. But open and endoscopic partial surgeries are indicated most often for quite limited tumors. Radiotherapy techniques have also been improved (better conformation of irradiated fields to the tumor volume, modification of the fractionation).

Larynx preservation has been a major advance in head and neck cancer management over the past three decades. The goal of larynx preservation is to control the disease and to maintain in place a functioning larynx. This definition of larynx preservation is only meaningful if indicated for advanced larynx and hypopharynx cancers that are, if surgery is considered, only resectable by a total laryngectomy. These cases have been until the 1980s treated by either total laryngectomy with postoperative radiotherapy if indicated or by definitive radiotherapy with surgery in reserve in case of failure. These two options have never been compared in a randomized trial that should have been the first larynx preservation program. Each option was indicated according to institutional policies. The appearance of active chemotherapy regimen in the early 1980s has had a definite impact on this discussion.

Programs with Partial Surgery

Some teams have explored the reliability of supracricoid laryngectomy in selected T3 and T4 larynx cancers [1, 2]. Some other teams have extended the indications of endoscopic laser surgery to T3 or T4 larynx or hypopharynx cancers [3–7]. Both have got undisputable satisfactory results but on quite limited series. Clearly, there is a room for these indications but for highly selected cases and for very

J.-L. Lefebvre (✉)
Head and Neck Department, Centre Oscar Lambret,
3 Rue Combemale, Lille 59020, France
e-mail: jl-lefebvre@o-lambret.fr

experienced surgical teams and are not on a large scale a real alternative to total laryngectomy. Transoral robotic surgery is under evaluation but again for early diseases.

Programs with Definitive Radiotherapy

Many reports have shown the improvement of radiotherapy results thanks to a modification of the fractionation. The goal is either to increase the total dose by the means of delivering more than one fraction per day (hyperfractionated radiotherapy) or to decrease the overall treatment time (reducing the ability of tumor cell repair and repopulation). A recent meta-analysis [8] has assessed the impact of altered fractionated radiotherapy on survival. A total of 6,515 patients enrolled in 15 randomized trials were included in the analysis. There was a significant 3.4% benefit in survival at 5 years as well as there was a significant better local control. The major improvement in 5-year survival was found for hyperfractionated radiotherapy (8%). The effect of altered fractionated radiotherapy on tumor control did not differ according to the primary site. However, the impact of altered fractionation on larynx preservation is probably limited. The acute toxicity of these treatments may be a limit due to the cartilaginous structure of the larynx, due to the impact of mucositis on larynx function and due to the vulnerability of the cricoarytenoid joints.

Programs Based on Chemotherapy and Radiotherapy

Programs with Induction Chemotherapy

In the early 1980s, the Wayne State University team reported their experience with platinum-based induction chemotherapy and in particular with the cisplatin and 5-fluorouracil regimen. Previously, untreated patients demonstrated impressive response rates at the primary tumor site. When subsequently treated with radiotherapy good responders to induction chemotherapy appeared to be also good responders to irradiation while poor responders to induction chemotherapy were also poor responders to the subsequent irradiation [9, 10].

These reports had a tremendous impact on the daily practice and induction chemotherapy was widely used for head and neck cancer. But a large meta-analysis [11] failed to find a significant advantage of induction chemotherapy in terms of survival. However, it must be stressed that when induction

chemotherapy consisted of cisplatin and 5-fluorouracil, there was a significant 5% improvement of the 5-year survival.

But the undisputable merit of induction chemotherapy has been to reopen the discussion on larynx preservation. If the discussion on a randomized comparison of radical larynx surgery versus definitive irradiation had not get the consensus between surgeons and radiation, on the contrary comparing radical surgery versus definitive irradiation in good responding patients after induction chemotherapy appeared acceptable. The first program on larynx preservation could really start.

Programs with Cisplatin and 5-Fluorouracil (PF) Induction Chemotherapy

The goal was to compare total laryngectomy with neck dissection with or without postoperative irradiation versus PF induction chemotherapy followed by irradiation (keeping total laryngectomy in reserve for salvage if necessary) in good responders or by total laryngectomy with or without postoperative irradiation in poor responders.

The Department of Veterans Affairs Laryngeal Cancer Study Group reported in 1991 the first randomized trial on larynx cancers [12]. Three hundred and thirty-two patients were randomly assigned to be treated by total laryngectomy or to receive two cycles of PF followed in responders (partial or complete responders) by a third cycle and irradiation or by total laryngectomy in nonresponders. In this trial 63% of the patients had a supraglottic tumor and 37% had a glottic cancer, and 57% had larynx fixity. There was no significant difference in survival between both arms (68% at 2 years). At 4 years, two thirds of the survivors in the chemotherapy arm had retained their larynx. These data were updated regularly in various meetings and these results did not vary with time. A quality of life study has been carried out on 46 survivors of this trial (25 in the surgery arm and 21 in the chemo arm). Better scores were found in the chemotherapy arm patients as regards more freedom of pain, better emotional well-being, and lower levels of depression. But surprisingly there was no correlation between quality of life scores and preservation of the speech function.

The European Organization for Research and Treatment of Cancer (EORTC) published in 1996 a similar trial on hypopharynx (78%) and lateral epilarynx (22%) tumors only eligible for a total laryngectomy with partial pharyngectomy [13]. Two hundred and two patients were enrolled in this study comparing the standard treatment (surgery and postoperative irradiation) versus two or three cycles of PF followed in clinically complete responders at the primary site by irradiation or, for other patients, by the conventional treatment.

For the 194 evaluable patients, there was no significant difference in survival, despite a notable difference in median survival favoring the experimental arm (44 months) when compared with the surgery arm (25 months). Finally, at 3 and 5 years half the survivors in the chemotherapy arm had retained a functional larynx. This trial was updated with a 10-year follow-up and these results were confirmed [14]. Of note in this trial there was a specific analysis of the impact of induction chemotherapy on tolerance and quality of the subsequent treatments. Radiation therapy was not compromised by the previous chemotherapy as well there was no unforeseen treatment interruption due to acute toxicity. Salvage surgery in poor responders had similar postoperative courses and similar quality of surgical margins when compared with patients treated in the surgical arm.

The French group (GETTEC) published also in 1998 a randomized trial on larynx cancer. Patients were randomized to receive either the standard treatment (total laryngectomy) or three cycles of PF followed by irradiation in case of clinical response over 80% or by total laryngectomy in the other cases [15]. In this trial, the selection was more restrictive than in the North-American study since all tumors were classified T3 and all patients had larynx fixity while only 31% had a supraglottic tumor while 69% had glottic or transglottic tumor and all had larynx fixity. The trial was prematurely closed due to a poor accrual. The 2-year survival was significantly higher in the surgery arm (84 vs. 69%) but 15 of the 36 patients (42%) enrolled in the chemotherapy arm avoided surgery.

These three trials were pooled in a subset analysis of the above-mentioned large meta-analysis [11]. It appeared that there was a nonsignificant 6% decrease in survival in the chemotherapy arms when analyzed together that was balanced by a 56% larynx preservation rate.

Programs with Docetaxel, Cisplatin, and 5-Fluorouracil (TPF) Induction Chemotherapy

In 2007, two randomized trials comparing the PF induction regimen with the TPF one were simultaneously published. The TAX 323 [16] trial assessed this comparison for nonresectable tumors to be treated after the induction phase with radiotherapy alone. The TAX 324 trial [17] assessed this comparison for either resectable or nonresectable tumors to be treated thereafter with radiotherapy and concurrent weekly carboplatin. Both trials concluded that the overall survival and locoregional control were significantly higher in the TPF

arm with a reduction as high as 30% in risk of death. This superiority of the TPF regimen was also supported by another specific meta-analysis. The TPF regimen is considered as the new standard for induction chemotherapy.

The French group GORTEC published in 2009 a randomized trial comparing PF and TPF as induction chemotherapy followed by irradiation in case of response of at least 50% in larynx and hypopharynx cancers [18]. A total of 213 patients were enrolled in this study. With a median follow-up of 3 years there was no difference in terms of survival but the 3-year actuarial larynx preservation rate was 70.3% with TPF versus 57.5% with PF ($p=0.03$).

Conclusions for the Programs with Induction Chemotherapy Followed by Irradiation in Good Responders

- The addition of induction chemotherapy for larynx preservation did not compromise the survival when compared with upfront surgery.
- Induction chemotherapy did not compromise subsequent treatment (either salvage surgery or definitive irradiation) in terms of tolerance or of efficacy.
- None of the different induction chemotherapy regimens (PF or TPF) has been able to improve survival in larynx preservation programs.

Programs with Concomitant Chemoradiotherapy

Concomitant chemoradiotherapy may be delivered with two different schedules.

Chemotherapy may be given either during irradiation without interruption in radiotherapy (concurrent chemoradiotherapy) or alternatively with radiotherapy during the radiation protocol (alternating chemoradiotherapy).

The advantage of concurrent chemoradiotherapy has been demonstrated by the meta-analysis and the administration of cisplatin at the dose of 100 mg/m² on days 1, 22, and 43 of a conventional 70 Gy irradiation has been shown as the highest advantage [11, 19].

Alternating chemoradiotherapy delivering four cycles of PF (on weeks 1, 4, 7, and 10) and three courses of radiotherapy at the dose of 20 Gy in 2 weeks (weeks 2–3, 5–6 and 8–9) for a total of 60 Gy has been reported as feasible and able to improve survival and disease control [20, 21].

Programs with Concurrent Chemoradiotherapy

The RTOG published in 2003 a large three-arm randomized trial [22]. In this trial, 547 patients were randomized to receive in one arm PF induction chemotherapy followed in responders by irradiation in another arm concurrent chemoradiotherapy (with cisplatin) or in the third arm radiotherapy alone. With a median follow-up of 3.8 years the highest 2-year larynx preservation rate was found in the concurrent arm (88%) while there was no difference in 5-year overall survival between the three arms. As regards acute toxicity, the grade 3–4 mucositis was twice higher in the concurrent arm when compared with the two others. The complication rate after salvage laryngectomy did not differ between the three arms. This trial was updated in 2006 [23] and confirmed the laryngeal preservation was of 83.6% in the concurrent arm versus 70.5% in the induction arm ($p=0.0029$) and versus 65.7% in the radiotherapy arm ($p=0.0017$) but again without any difference in overall or disease-free survivals. Of note there were twice as many noncancer-related deaths in the concurrent arm when compared with the two other arms.

There was no increase in late toxicity reported for this trial. However, the RTOG reported a combined study [24] of three concurrent chemoradiotherapy arms from three randomized trials conducted by this group (RTOG 91-11, RTOG 97-03, and RTOG 99-14). The aim of this study was to assess severe toxicity that occurred in 43% of patients. Severe late toxicity was found in particular for larynx and hypopharynx cancer.

Programs with Alternating Chemoradiotherapy

The EORTC published in 2009 a randomized trial comparing induction chemotherapy and alternating chemoradiotherapy in patients with advanced tumor of the larynx or hypopharynx candidates for a total laryngectomy [25]. In the induction arm, patients with a 50% or more reduction in primary tumor size after two cycles of PF received another two cycles, followed by radiotherapy (70 Gy total). In the alternating arm, a total of four cycles of PF (in weeks 1, 4, 7, and 10) were alternated with radiotherapy with 20 Gy during the three 2-week intervals between chemotherapy cycles (60 Gy total). A total of 450 patients were enrolled in this trial. With a median follow-up of 6.5 years, survival with a functional larynx was similar in sequential and alternating arms as were similar larynx preservation rates and overall or progression-free survivals. The acute toxicity was slightly lower in the alternating arm but there was no difference in late toxicity.

Conclusions for the Programs with Concomitant Chemoradiotherapy

- Concurrent chemoradiotherapy provides the highest larynx preservation defined as the larynx in place.
- Concurrent chemoradiotherapy generates a substantial acute toxicity.
- Late toxicity after concurrent chemoradiotherapy may compromise the laryngeal function. It is important to stress that for quality of life only the preservation of a functioning larynx is meaningful.
- Neither concurrent nor alternating chemoradiotherapy improves survival.

Programs with Sequential Chemoradiotherapy (I.E. Induction Chemotherapy Followed by Concurrent Chemoradiotherapy)

The TAX 324 trial (PF vs. TPF before radiotherapy and concurrent weekly carboplatin) showed the feasibility of sequential chemoradiotherapy [17]. Meanwhile a randomized trial on biotherapy comparing radiotherapy alone and radiotherapy with concurrent administration of a monoclonal antibody targeting the EGFR (cetuximab) showed that this combined treatment provided a significantly higher overall survival and locoregional control than radiotherapy alone, this improvement being in the range of that observed with concurrent chemoradiotherapy but without an increased acute mucosal toxicity [26].

Programs with Sequential Chemoradiotherapy

A subset analysis of the TAX 324 trial was carried out on 166 patients with larynx or hypopharynx cancer [27]. The same improvement in overall survival and progression-free survival in the TPF arm was found for this subgroup of patients as for the overall population. Among the 123 operable patients, the laryngectomy-free survival was also significantly greater.

The Ann Arbor group explored larynx preservation in 36 patients with T4 larynx cancers [28]. Usually these tumors are excluded from larynx preservation trials. Patients received one cycle of PF. In case of response of at least 50% the patients received thereafter chemoradiotherapy with adjuvant PF in case of clinically complete response. The larynx preservation rate was of 58%.

Programs with Sequential Biotherapy

The GORTEC group reported in 2009 the preliminary results of a randomized phase II trial in patients with larynx or hypopharynx tumor [29]. One hundred and fifty-three eligible patients were enrolled to receive three cycles of TPF. In case of response of at least 50% they were randomized to receive either concurrent chemoradiotherapy with cisplatin or concurrent radiotherapy and cetuximab. Only 74% of patients could receive the planned induction chemotherapy protocol. After induction chemotherapy 85% of patients were theoretically fulfilled the criteria for randomization but only 115 patients could be actually randomized (mainly due to toxicity induced by induction chemotherapy). Only 45% of patient randomized in the cisplatin arm could receive the planned three cycles of cisplatin while 71% of patients randomized in the cetuximab arm could receive the full protocol. Three months after treatment there was no significant difference in larynx preservation.

Conclusions for the Programs with Sequential Chemoradiotherapy

- Sequential chemoradiotherapy is potentially a new option but delivering the standard induction chemotherapy followed by the standard concurrent chemoradiotherapy generates a substantial overall toxicity.
- The integration of biotherapies may overcome this concern but clearly sequential chemoradiotherapy (either with cisplatin or a biotherapy such as cetuximab) remains to be evaluated on a large phase III trial specifically designed for larynx preservation.

Discussion

Larynx preservation is an important new concept that has been developed for tumors of the larynx and of the hypopharynx that can be removed only by a total laryngectomy. Extensive tumors (T4) and very infiltrative transglottic tumors are at least for the moment better controlled by an upfront total laryngectomy.

If the concept of larynx preservation is nowadays considered as a validated option, the best larynx preservation protocol remains to be defined. It is noticeable that all these trials even if they were conducted with the goal of larynx preservation had different definitions of larynx preservation: from the simplest one (larynx preservation=larynx in place) to the most

complex one (survival with a larynx free of tumor and without tracheotomy or feeding tube). A detailed quality of the function of the preserved larynx is often missing. A consensus should be reached in designing future trials [30] [31].

None of the larynx preservation protocols has had an impact on survival. This means that none provided a better survival than an upfront total laryngectomy. Whatever the protocol, distant metastases remain a concern.

It must be underscored that these larynx preserving protocols did not compromise disease local control and survival because the surgeons performed salvage surgery. It must be kept in mind that surgery plays an important role in this research. To this extent much attention must be paid to acute and late toxicity not only for the quality of the function of the larynx but also for the feasibility and reliability of salvage surgery.

Larynx preservation is a challenging approach that is permanently moving. Induction chemotherapy has the advantage of allowing adapting the subsequent treatment quite early in the treatment program. Concurrent chemoradiotherapy provides high local control but at the price of a substantial acute and late toxicity. Both has advantages and disadvantages, combining both is a logical new step in this clinical research but the balance between the induction and the concurrent phases remains to be defined. Finally, biotherapies have a role to play in this research. More than ever a multinational–multidisciplinary collaboration is requested.

References

1. Chevalier D, Laccourreye O, Brasnu D, Laccourreye H, Piquet JJ. Cricohyoidoepiglottopexy for glottic carcinoma with fixation or impaired motion of the true vocal cord: 5-year oncologic results with 112 patients. *Ann Otol Rhinol Laryngol.* 1997;106:364–9.
2. Lima RA, Freitas EQ, Kligerman J, et al. Near-total laryngectomy for treatment of advanced laryngeal cancer. *Am J Surg.* 1997;174:490–1.
3. Iro H, Waldfahrer F, Altendorf-Hofmann A, Weidenbecher M, Sauer R, Steiner W. Transoral laser surgery of supraglottic cancer: follow-up of 141 patients. *Arch Otolaryngol Head Neck Surg.* 1998;124(11):1245–50.
4. Motta G, Esposito E, Motta S, Tartaro G, Testa D. CO₂ laser surgery in the treatment of glottic cancer. *Head Neck.* 2005;27:566–74.
5. Vilaseca-Gonzalez I, Bernal-Sprekelsen M, Blanch-Alejandro JL, Moragas-Lluis M. Complications in transoral CO₂ laser surgery for carcinoma of the larynx and hypopharynx. *Head Neck.* 2003;25:382–8.
6. Martin A, Jäckel MC, Christiansen H, Mahmoodzadeh M, Kron M, Steiner W. *Laryngoscope.* 2008;118:398–402.
7. Rudert HH, Hoft S. Transoral carbon-dioxide laser resection of hypopharyngeal carcinoma. *Eur Arch Otorhinolaryngol.* 2003;260:198–206.
8. Bourhis J, Overgaard J, Audry H, et al. Hyperfractionated or accelerated radiotherapy in head and neck cancer: a meta-analysis. *Lancet.* 2006;368:843–54.
9. Decker DA, Drelichman A, Jacobs J, et al. Adjuvant chemotherapy with *cis*-diamminodichloroplatinum II and 120-hour infusion

- 5-fluorouracil in stage III and IV squamous cell carcinoma of the head and neck. *Cancer*. 1983;51:1353–5.
10. Ensley JF, Jacobs JR, Weaver A, et al. Correlation between response to *cis*-platinum-combination chemotherapy and subsequent radiotherapy in previously untreated patients with advanced squamous cell cancers of the head and neck. *Cancer*. 1984;54(5):811–4.
 11. Pignon JP, Bourhis J, Domenge C, Designe L. Chemotherapy added to locoregional treatment for head and neck squamous-cell carcinoma: three meta-analyses of updated individual data. MACH-NC Collaborative Group. Meta-analysis of chemotherapy on head and neck cancer. *Lancet*. 2000;355:949–55.
 12. The Department of Veterans Affairs Laryngeal Cancer Study Group. Induction chemotherapy plus radiation compared with surgery plus radiation in patients with advanced laryngeal cancer. *N Engl J Med*. 1991;324:1685–90.
 13. Lefebvre JL, Chevalier D, Luboinski B, Kirkpatrick A, Collette L, Sahmoud T. Larynx preservation in pyriform sinus cancer: preliminary results of a European Organization for Research and Treatment of Cancer phase III trial. EORTC Head and Neck Cancer Cooperative Group. *J Natl Cancer Inst*. 1996;88:890–9.
 14. Lefebvre J-L, Chevalier D, Luboinski B, et al. Is laryngeal preservation (LP) with induction chemotherapy (ICT) safe in the treatment of hypopharyngeal SCC? Final results of the EORTC 24891 trial. *J Clin Oncol*. 2004 ASCO Annual Meeting Proc. 2004; 22:abstract 5531.
 15. Richard JM, Sancho-Garnier H, Pessey JJ, et al. Randomized trial of induction chemotherapy in larynx carcinoma. *Oral Oncol*. 1998;34:224–8.
 16. Vermorken JB, Remenar E, van Herpen C, et al. Cisplatin, fluorouracil, and docetaxel in unresectable head and neck cancer. *N Engl J Med*. 2007;357:1695–705.
 17. Posner MR, Hershock DM, Bijman CR, et al. Cisplatin and fluorouracil alone or with docetaxel in head and neck cancer. *N Engl J Med*. 2007;357:1705–15.
 18. Pointreau Y, Garaud P, Chapet S, et al. Randomized trial of induction chemotherapy with cisplatin and 5-fluorouracil with or without docetaxel for larynx preservation. *J Natl Cancer Inst*. 2009; 101:498–506.
 19. Pignon JP, le Maitre A, Maillard E, et al. Meta-analysis of chemotherapy in head and neck cancer (MACH-NC): an update on 93 randomised trials and 17, 346 patients. *Radiother Oncol*. 2009; 92:4–14.
 20. Merlano M, Vitale V, Rosso R, et al. Treatment of advanced squamous-cell carcinoma of the head and neck with alternating chemotherapy and radiotherapy. *N Engl J Med*. 1992;327:1115–21.
 21. Merlano M. Alternating chemotherapy and radiotherapy in locally advanced head and neck cancer: an alternative? *Oncologist*. 2006;11:146–51.
 22. Forastiere AA, Goepfert H, Maor M, et al. Concurrent chemotherapy and radiotherapy for organ preservation in advanced laryngeal cancer. *N Engl J Med*. 2003;349:2091–8.
 23. Forastiere AA, Maor M, Weber RS, et al. Long-term results of Intergroup RTOG 91-11: a phase III trial to preserve the larynx-induction cisplatin/5-FU and radiation therapy versus concurrent cisplatin and radiation therapy versus radiation therapy. *J Clin Oncol*. 2006 ASCO Annual Meeting Proc. 2006;24:abstract 5517.
 24. Machtay M, Moughan J, Trotti A, et al. Factors associated with severe late toxicity after concurrent chemoradiation for locally advanced head and neck cancer: a RTOG analysis. *J Clin Oncol*. 2008;26:3582–9.
 25. Lefebvre JL, Rolland F, Tesselaaar M, et al. Phase 3 randomized trial on larynx preservation comparing sequential vs alternating chemotherapy and radiotherapy. *J Natl Cancer Inst*. 2009;101:142–52.
 26. Bonner JA, Harari PM, Giralt J, et al. Radiotherapy plus cetuximab for squamous-cell carcinoma of the head and Neck. *N Engl J Med*. 2006;354:567–78.
 27. Posner MR, Norris CM, Wirth LJ, et al. Sequential therapy for locally advanced larynx and hypopharynx cancer subgroup in TAX 324: survival, surgery, and organ preservation. *Ann Oncol*. 2009;20:921–7.
 28. Worden FP, Moyer J, Lee JS, et al. Chemosselection as a strategy for organ preservation in patients with T4 laryngeal squamous cell carcinoma with cartilage invasion. *Laryngoscope*. 2009;119:1510–7.
 29. Lefebvre JL, Pointreay Y, Rolland F, et al. Sequential chemoradiotherapy (SCRT) for larynx preservation (LP): preliminary results of the randomized phase II TREMPIN study. *PASCO Annual Meeting Proc*. 2009:abstract 6010.
 30. Lefebvre JL, Ang KK. Larynx preservation clinical trial design: key issues and recommendations – a consensus panel summary. *Int J Radiat Oncol Biol Phys*. 2009;73:1293–303.
 31. Lefebvre JL, Ang KK. Larynx preservation clinical trial design: key issues and recommendations – a consensus panel summary. *Head Neck*. 2009;31:429–41.

Chapter 24

Multidisciplinary Approach of Unresectable Head and Neck Cancer

Ricardo Hitt, Blanca Homet, and Robert I. Haddad

Abstract The management of locally advanced head and neck cancer has seen the emergence of different combined modality therapies in recent years, and new treatment types, such as chemoradiation, new induction chemotherapy schemes, and salvage surgery.

Keywords Unresectable head and neck cancer • Induction chemotherapy • Chemoradiation • Taxanes

Introduction

The management of locally advanced head and neck cancer (LAHNC) has seen the emergence of different combined modality therapies in recent years. These include surgery, chemoradiotherapy (CRT), induction chemotherapy (IC), sequential chemoradiotherapy (ST), and biologic therapy [1].

The management of this complex disease requires a multidisciplinary team including medical and radiation oncologists, head and neck and oral surgeons, speech and swallow therapists, psychiatrists, and dentists. The multi-D clinic role is valuable in determining the optimal staging, treatment and potential for rehabilitation after therapy. One of the more important factors in LAHNC patients is between resectable and unresectable disease. This is due to the differences in survival rates, locoregional control, and treatment in the two groups. Recently, this distinction has been taken into account in the design of clinical trials. It is clear based on randomized phase III studies that patients with unresectable disease have a worse prognosis with a high rate of both local and distant recurrence [2, 3].

There is no “consensus” on how to define unresectable disease. To improve the therapeutic approach in patients with nonsurgical disease, the term “Unresectable” will need to be

better defined. Herein, we present some guidelines with respect to unresectability criteria, though these criteria may vary depending on the specialist.

Unresectable Disease: Definition

The American Joint Commission on Cancer (AJCC) has recently revised its TNM classification to clearly separate T4 disease into two categories: Resectable or T4a and unresectable or T4b. The following is the official definition of unresectable or T4b disease per AJCC.

1. Oral cavity: Tumor invades masticator space, pterygoid plates, or skull base and/or encases internal carotid artery. The lesion must be so extensive that a functional reconstruction is not possible.
2. Oropharynx: Invasion of the lateral pterygoid muscle, pterygoid plates, lateral nasopharynx, or skull base or encases carotid artery.
3. Hypopharynx: Tumor invades prevertebral fascia, encases carotid artery, or involves mediastinal structures.
4. Larynx: Tumor invades prevertebral space, encases carotid artery, or involves mediastinal structures.

The following is also important in further establishing resectable or unresectable disease:

1. For vascular encasement, involvement of 270° or more of the circumference of the carotid artery is accurate in predicting the surgeons’ inability to peel the tumor off the carotid artery in 100% of the cases [4, 5]. This criterion is often used to determine whether a tumor is unresectable. MR is the preferred imaging modality.
2. Involvement of the prevertebral fascia means the fixation of the tumor to the prevertebral musculature. The presence of a high-signal-intensity fat stripe on sagittal or axial T1-weighted scans by MRI shows the absence of infiltration of the prevertebral musculature with an accuracy of 91% [6].

R.I. Haddad (✉)
Department of Medical Oncology, Dana–Farber Cancer Institute,
44 Binney Street, Boston, MA 02115, USA
e-mail: robert_haddad@dfci.harvard.edu

3. Mediastinal invasion, which is more typical in infrahyoid tumors, is the infiltration of the mediastinal fat, vascular invasion of the supra-aortic vessels, or infiltration of the trachea and esophagus [5].

It is important to note that patient inoperability is often determined using three criteria:

1. Technical unresectability as previously detailed for T4b disease.
2. Low surgical curability such as seen in many patients with T4a disease and large and fixed neck adenopathy.
3. Medical contraindication to surgery.

Concurrent Chemoradiotherapy

The use of concurrent chemoradiotherapy is considered by many to represent a standard of care in the management of patients with locally advanced and unresectable disease (Table 24.1). Studies have shown that combining chemotherapy with radiation improves local control and survival. Bolus cisplatin at 100 mg/m² every 3 weeks is the drug of choice for patients with a good performance status [2].

The American Head and Neck Intergroup conducted a phase III randomized trial to study the benefit of adding chemotherapy to radiation in patients with unresectable squamous cell carcinoma of the head and neck [2]. Patients were randomly assigned between arm A, single daily fractionated radiation (70 Gy at 2 Gy/day); arm B, identical radiation therapy with concurrent bolus cisplatin at 100 mg/m², given on days 1, 22, and 43; and arm C, a split course of single daily fractionated radiation and three cycles of concurrent infusional FU and bolus cisplatin chemotherapy, 30 Gy given with the first cycle and 30–40 Gy given with the third cycle. Surgical resection was encouraged if possible after the second chemotherapy cycle on arm C and, if necessary, as salvage therapy on all three treatment arms. The extent of midcourse surgery for arm C patients was defined on the basis of the residual disease present, not the original tumor. Two hundred and ninety-five patients were entered on this trial. Median age is 56 and half the patients had oropharynx primary. With a median follow-up of 41 months, the 3-year

overall survival for patients enrolled in arm A is 23%, compared with 37% for arm B ($p=0.014$) and 27% for arm C (p =not significant). Chemotherapy did not affect the likelihood of distant recurrence when compared with radiation therapy alone. Distant metastases were the first site of recurrence in 17.9% of arm A patients, 21.8% of arm B patients, and 19.1% of arm C patients; the differences were statistically insignificant. When surgical results were analyzed, little difference in the rate of surgical resection was observed among the three treatment arms. Ultimately, 21% of all patients underwent surgery; neck dissection alone was performed in 56% of the surgical cases. Grade 3 or worse toxicity occurred in 52% of patients enrolled in arm A, compared with 89% enrolled in arm B ($p<0.0001$) and 77% enrolled in arm C ($p<0.001$). Major toxicities encountered were mucositis and feeding tube dependency and toxicity was worse in arm B. The authors concluded that the addition of concurrent high-dose, single-agent cisplatin to conventional single daily fractionated radiation significantly improves survival, although it also increases toxicity.

Weekly low dose cisplatin has been tried and it does not appear to be as beneficial as high dose cisplatin with one study showing it to be equivalent to XRT alone [7].

Given the toxicity of high dose cisplatin, other regimens have been explored. Weekly carboplatin and paclitaxel is another regimen that can be used for those patients who cannot tolerate high dose cisplatin and phase II data suggest that the treatment can be effective. This regimen was explored in a single institution study with 55 patients [8]. Fifty-two patients (95%) had stage IV and 51 (93%) had technically unresectable disease; 62% had an oropharyngeal primary site. Grade 3 or 4 mucositis occurred in 30% of patients. Forty of 50 assessable patients (80%) had an objective response, with a complete response rate of 52%. With a median follow-up of 69 months for surviving patients, the 5-year progression-free survival was 36% and the 5-year overall survival was 35%. Another study from the University of Maryland group explored the same regimen of carboplatin/paclitaxel and standard daily radiation [9]. Sixty-two patients were treated with 70.2 Gy of RT at 1.8 Gy/fraction/day to the primary site. Weekly chemotherapy was given during RT consisting of paclitaxel (45 mg/m²/week) and carboplatin (100 mg/m²/week). All patients presented with

Table 24.1 Summary of clinical trials in unresectable head and neck cancer

	Type	Number	Treatment	Chemotherapy used	OS (%)
Intergroup study [2]	Phase III	295	RT/CRT/split	Bolus cisplatin (With 5-FU for split regimen)	23/37/27
Agarwala et al. [8]	Phase II	55	CRT	Weekly carboplatin and paclitaxel	35
University of Maryland [9]	Phase II	62	CRT	Weekly carboplatin/paclitaxel	48
Medina et al. [10]	Phase II	94	CRT	Weekly cisplatin	41
ECOG [12]	Phase II	60	CRT	Cisplatin q 3 weeks and cetuximab weekly	67

RT radiotherapy, CRT chemoradiotherapy

locally advanced disease; 77% had T4 disease and 21% had T3 disease. Fifty-eight percent had N2b–N3 disease. Ninety-eight percent of patients completed prescribed therapy. A clinical complete response at the primary site was obtained in 82%, with a total (primary site and neck) complete response rate of 75%. The median survival for the entire cohort is 33 months. Response to therapy and status of the neck at presentation were the only prognostic factors found to influence survival. The median survival for patients who attained a CR is 49 months versus 9 months in those who did not attain a CR. The 2- and 3-year overall survival for complete responders is 79 and 61%. The regimen was well tolerated with over 90% of patients completing prescribed therapy. With 48% 3-year overall survival for the entire group, this regimen is an acceptable choice for this group of patients with a historically poor prognosis.

Given the poor outcome encountered in patients with unresectable disease other radiation modalities have been tried. Concomitant boost radiation which applies a second daily radiation treatment can result in decreased tumor repopulation, a major factor in local regional failure. A phase II study exploring weekly cisplatin with concomitant boost radiation has been recently reported [10]. In this study, a total of 94 patients (median age, 58 years) with cancers of the oropharynx, larynx, hypopharynx, and oral cavity were included. Patients received radiotherapy with a concomitant boost scheme (1.8 Gy on days 1–40 and 1.5 Gy boost on days 25–40 with a total dose of 72 Gy) and concurrent cisplatin, 40 mg/m² weekly, for the first 4 weeks only. Most patients (95%) received both radiation and chemotherapy according to protocol. Toxicity was manageable. With a median follow-up of 41 months, median overall survival and time to progression were 27 and 25 months, respectively. The estimated overall survival at 4 years was 41%.

The poor results encountered with standard chemotherapy regimens have also prompted studies of novel agents. EGFR inhibitors appear to be the most promising class of drugs [11]. Recently, investigators from the Eastern Cooperative Oncology Group (ECOG) reported their first study of CRT with cetuximab in unresectable head and neck cancer [12]. In this study, patients with unresectable, newly diagnosed head and neck cancer received cetuximab, an EGFR inhibitor,

400 mg/m² on day 1, then 250 mg/m² weekly, in combination with definitive radiation therapy (70 Gy/2 Gy/day × 7 weeks) starting day 15 and cisplatin 75 mg/m² every 3 weeks. In the absence of disease progression or untoward toxicity, patients could continue cetuximab weekly for up to 1 year. In this trial, 60 patients were treated; median age was 56 and 98% were stage IV. Most common primary sites included base of tongue (34%), tonsil (21%), and other oropharynx (13%). One-year survival is 76% and projected 2-year survival is 67%. Median survival is 33 months. Unique toxicities include acneiform rash and an increase in severe mucositis. These early results are promising and do represent a significant improvement over cisplatin/radiation regimens. Further trials are underway to further study this regimen.

Sequential Treatment

As mentioned above, with CRT or radiation treatment alone, locoregional control (LRC) and survival rates in patients with unresectable LAHNC is quite poor. The use of new induction chemotherapy regimens with taxanes added to platinum–5-FU (PF) results in a high response rate and better survival compared to the traditional PF schedule. Taxane-based chemotherapy was not analyzed in the MACH meta-analyses, where patients included received different modality treatments with induction chemotherapy and CRT, and stratification according to resectable or unresectable tumors did not take place [13]. There are many studies that have examined the addition of taxanes to PF and these combinations do represent a significant improvement over PF in term of efficacy and toxicity (Table 24.2).

The safety and efficacy of docetaxel with PF (TPF) as induction chemotherapy for patients with SCCHN were evaluated in a multicenter, open-label, randomized trial (Tax 323) [3]. In this European study, 358 patients with SCCHN with previously untreated inoperable, locally advanced stages III and IV, and good performance status, received either docetaxel 75 mg/m² followed by cisplatin 75 mg/m² on day 1, followed by 5-FU 750 mg/m²/day as a continuous intravenous infusion on days 1–5 (TPF), or cisplatin 100 mg/m² on

Table 24.2 Summary of phase III induction chemotherapy trials in unresectable head and neck cancer

Study	Regimen	Number	Endpoint	Results
TAX 324 [14]	TPF vs. PF followed CRT	501	Overall survival (months)	71 vs. 30 ($p=0.006$)
TAX 323 [3]	TPF vs. PF followed CRT or RT	358	Progression-free survival (months)	11.0 vs. 8.2 ($p=0.007$)
Spanish Intergroup [16]	PF or TPF followed CRT vs. CRT	439	Time to treatment failure (months)	Induction chemotherapy plus CRT = 12.5 (median) vs. CRT = 5 (median) $p=0.0001$
Spanish Intergroup [15]	PCF vs. PF followed CRT	382	Complete response (CR)	33 vs. 14% ($p=0.001$)

TPF docetaxel, cisplatin, and 5-FU, PF cisplatin and 5-FU, PCF paclitaxel, cisplatin, and 5-FU, CRT chemoradiotherapy

day 1, followed by 5-FU 1,000 mg/m²/day as a continuous intravenous infusion on days 1–5 (PF). These regimens were administered every 3 weeks for four cycles. Four to 7 weeks after chemotherapy, patients whose disease had not progressed received radiotherapy. Radiation was delivered either with a conventional or an accelerated/hyperfractionated regimen (i.e., more than one fraction per day). Surgical resection was allowed following chemotherapy, before or after radiotherapy. The trial's primary endpoint was progression-free survival (PFS) that was defined as time from randomization to disease progression or death from any cause, whichever occurred first. Median PFS was significantly longer in the TPF arm (11.4 months) than in the PF arm (8.3 months). Median overall survival was significantly longer in the TPF arm (18.6 months) than in the PF arm (14.2 months). The FDA approved this regimen for patients with inoperable SCCHN on October 17, 2006.

Tax 324 [14] took a different approach from TAX 323. Patients included in this study had both operable and inoperable disease. The clinical observations of the last three decades that concurrent chemoradiotherapy is crucial in SCCHN were taken into account when this study was designed, and instead of giving radiation therapy only after IC, all patients received concurrent chemoradiotherapy. The goal is to combine both models of therapy in one study: IC and concurrent chemoradiotherapy.

This is an international multicenter, open-label, randomized phase III trial. In this study, 501 patients with previously untreated locally advanced SCCHN, and good performance status, received either docetaxel 75 mg/m² followed by cisplatin 100 mg/m² on day 1, followed by 5-FU 1,000 mg/m²/day as a continuous intravenous infusion on days 1–4 (TPF) or cisplatin 100 mg/m² on day 1, followed by 5-FU 1,000 mg/m²/day as a continuous infusion on days 1–5 (PF). These regimens were administered every 3 weeks for three cycles. All patients in both treatment arms who did not have progressive disease following induction chemotherapy (close to 80%) received 7 weeks of CRT. During radiotherapy, carboplatin, area under the curve (AUC) of 1.5 was administered weekly as a 1-h infusion for a maximum of seven doses. Surgery could be considered at any time following the completion of CRT. The majority of patients had locally advanced stage IV disease (84%). Overall survival was significantly prolonged with TPF compared to PF regimen (log-rank test, $p=0.0058$). The median survival was 70.6 months in the TPF group compared to 30.1 months in the PF group.

There is an increase in the incidence of neutropenia and febrile neutropenia with TPF and more stomatitis/diarrhea with PF likely reflecting the higher dose of 5-FU dose used.

In TAX 324, close to 70% of patients completed the concurrent chemoradiotherapy regimen as defined per protocol. The major reasons for not completing CRT are disease

progression and adverse events. Two treatment-related deaths related to induction chemotherapy occurred in TAX 324.

In TAX 323, close to 70% of patients completed radiotherapy per protocol, with disease progression as the main reason for not completing the protocol. Five treatment-related deaths related to induction chemotherapy occurred in this study.

The Spanish group examined the addition of Paclitaxel to PF in a randomized phase III study [15]. The primary objective is to compare the activity and toxicity of the two induction chemotherapy treatments of paclitaxel, cisplatin, and FU (PPF) versus standard cisplatin and FU (PF), both followed by CRT, in locally advanced and unresectable head and neck cancer. Both regimens were administered for three cycles every 21 days. Patients with complete response (CR) or partial response of greater than 80% in primary tumor received additional CRT (cisplatin 100 mg/m² on days 1, 22, and 43 plus 70 Gy). A total of 382 eligible patients were randomly assigned to PF ($n=193$) or PPF ($n=189$). The CR rate was 14% in the PF arm versus 33% in the PPF arm ($p<0.001$). Median time to treatment failure (TTF) was 12 months in the PF arm compared with 20 months in the PPF arm ($p=0.006$). PPF patients had a trend to longer overall survival that was not statistically significant. This difference was more evident in patients with unresectable disease. PF patients had a higher occurrence of grade 2–4 mucositis than PPF patients (53 vs. 16%, respectively; $p<0.001$). However, the induction chemotherapy plus CRT approach was limited to a select group of patients because of the significant toxicity produced by such treatment. Six cycles of cisplatin (induction plus chemoradiation) is possible only in patients with excellent performance status, adequate organ function, and intensive medical support. This significantly limits the use of this regimen.

Finally, the same Spanish group recently presented the data of a randomized phase III trial [16], where induction chemotherapy (With TPF or PF) plus CRT was compared with standard CRT as front line treatment in patients with unresectable locally advanced head and neck cancer. The primary end point of this study was TTF for induction versus no induction chemotherapy; secondary endpoints included LRC. In evaluable patients, the median TTF was 12.5 months with induction plus CRT versus 4.9 months with CRT alone ($p<0.001$). LRC was 60% with induction chemotherapy plus CRT versus 44.5% with CRT alone ($p=0.003$).

Further analysis of this trial is ongoing and the results should be viewed as preliminary at this point.

Discussion

The management of patients with LAHNC requires a multidisciplinary evaluation. Differentiation between resectable and unresectable disease is important and carries significant

prognostic implications. Patients with unresectable head and neck cancer have a worse prognosis and novel therapies are needed for this patient population. A multidisciplinary approach for these patients is crucial and helps with staging, treatment decision, and management of the acute and long-term complication of therapy. A better definition for unresectable disease is needed.

Currently, there are two acceptable standards for these patients: concurrent chemoradiotherapy and induction chemotherapy followed by CRT. Each approach has its own advantages and disadvantages. We would recommend induction chemotherapy for the following patients:

1. Symptomatic patients in need for immediate therapy or patients with impending local problems such as locally advanced larynx cancer where airway compromise is imminent.
2. Patients with high risk of distant metastasis such as nodal disease N2b, N2c, and N3 patients.
3. Patients with possible or proven distant metastasis at presentation.

For these patients, induction chemotherapy with TPF is our choice for therapy followed by concurrent chemoradiotherapy with weekly carboplatin and radiation based on the results of TAX 324. All other patients with unresectable disease can be treated with concurrent chemoradiotherapy upfront with either bolus cisplatin every 3 weeks or weekly carboplatin/paclitaxel.

Given the overall poor outcome for these patients, novel approaches are urgently needed. Two such approaches have shown early promise: accelerated radiotherapy and the addition of novel targeted agents. Early results appear to show some improvement over standard therapy and further studies are ongoing to define the optimal strategy for these patients.

References

1. Haddad RI, Shin DM. Recent advances in head and neck cancer. *N Engl J Med.* 2008;359:1143–54.
2. Adelstein DJ, Li Y, Adams GL, Wagner Jr H, Kish JA, Ensley JF, et al. An intergroup phase III comparison of standard radiation therapy and two schedules of concurrent chemoradiotherapy in patients with unresectable squamous cell head and neck cancer. *J Clin Oncol.* 2003;21:92–8.
3. Vermorken JB, Remenar E, van Herpen C, Gorlia T, Mesia R, Degardin M, et al. Cisplatin, fluorouracil, and docetaxel in unresectable head and neck cancer. *N Engl J Med.* 2007;357:1695–704.
4. Yousem DM, Hatabu H, Hurst RW, Seigerman HM, Montone KT, Weinstein GS, et al. Carotid artery invasion by head and neck masses: prediction with MR imaging. *Radiology.* 1995;195:715–20.
5. Yousem DM, Gad K, Tufano RP. Resectability issues with head and neck cancer. *AJNR Am J Neuroradiol.* 2006;27:2024–36.
6. Hsu WC, Loevner LA, Karpati R, Ahmed T, Mong A, Battineni ML, et al. Accuracy of magnetic resonance imaging in predicting absence of fixation of head and neck cancer to the prevertebral space. *Head Neck.* 2005;27:95–100.
7. Haselow R, Warshaw M, Oken M, et al. Radiation alone versus radiation with weekly low dose cis-platinum in unresectable cancer of the head and neck. In: Fee Jr WE, Goepfert H, Johns ME, et al., editors. *Head and neck cancer, vol. II.* Philadelphia, PA: Lippincott; 1990. p. 279–81.
8. Agarwala SS, Cano E, Heron DE, Johnson J, Myers E, Sandulache V, et al. Long-term outcomes with concurrent carboplatin, paclitaxel and radiation therapy for locally advanced, inoperable head and neck cancer. *Ann Oncol.* 2007;18:1224–9.
9. Sutharalingum M, Haas M, Conley B, Egorin M, Levy S, Sivasailam S, et al. The use of carboplatinum and paclitaxel with daily radiotherapy in patients with locally advanced squamous cell carcinomas of the head and neck. *Int J Radiat Biol Oncol Phys.* 2000;47:49–56.
10. Medina JA, Rueda A, de Pasos AS, Contreras J, Cobo M, Moreno P, et al. A phase II study of concomitant boost radiation plus concurrent weekly cisplatin for locally advanced unresectable head and neck carcinomas. *Radiother Oncol.* 2006;79:34–8.
11. Bonner JA, Harari PM, Giralt J, Azarnia N, Shin DM, Cohen RB, et al. Radiotherapy plus cetuximab for squamous-cell carcinoma of the head and neck. *N Engl J Med.* 2006;354:567–78.
12. Langer C, Lee J, Patel U, Shin D, Argiris A, Quon H et al. Preliminary analysis of ECOG 3303: concurrent radiation (RT), cisplatin (DDP) and cetuximab (C) in unresectable, locally advanced (LA) squamous cell carcinoma of the head and neck (SCCHN). *J Clin Oncol* 2008;26:(May 20 suppl; abstr 6006).
13. Pignon JP, Bourhis J, Domenge C, Designe L. Chemotherapy added to locoregional treatment for head and neck squamous-cell carcinoma: three meta-analyses of updated individual data. MACH-NC Collaborative Group. *Meta-Analysis of Chemotherapy on Head and Neck Cancer.* *Lancet.* 2000;355:949–55.
14. Posner MR, Hershock DM, Blajman CR, Mickiewicz E, Winquist E, Gorbounova V, et al. Cisplatin and fluorouracil alone or with docetaxel in head and neck cancer. *N Engl J Med.* 2007;357:1705–15.
15. Hitt R, Lopez-Pousa A, Martinez-Trufero J, Escrig V, Carles J, Rizo A, et al. Phase III study comparing cisplatin plus fluorouracil to paclitaxel, cisplatin, and fluorouracil induction chemotherapy followed by chemoradiotherapy in locally advanced head and neck cancer. *J Clin Oncol.* 2005;23:8636–45.
16. Hitt R, Grau J, Lopez-Pousa A, Berrocal A, Garcia Giron C, Irigoyen A et al. Final results of a randomized phase III trial comparing induction chemotherapy with cisplatin/5-FU or docetaxel/cisplatin/5-FU followed by chemoradiotherapy (CRT) versus CRT alone as first-line treatment of unresectable locally advanced head and neck cancer (LAHNC). *J Clin Oncol* 2009;27:15S, (suppl; abstr 6009).

Chapter 25

Laser Endoscopic Treatment

Pierre R. Moreau and Pierre H. Demez

Abstract After a review of CO₂ laser technique in the treatment of head and neck cancers, the results of the literature are presented for each localization. For early glottic cancers T1–T2, the specific survival rate at 5 years is around 100%, with a local recurrence rate of 10% and an incidence of total laryngectomy limited to 2–3%, lower than after radiotherapy. For supraglottic cancers, the expertise is important; techniques, indications, and results differ depending on the authors. One observes 10% of local recurrence for T1–T2 and 20% for T3–T4, with a specific survival rate of 80% at 5 years. This disparity is stronger for pharyngeal cancers. For precancerous lesions, laser gives a local recurrence rate around 10%, which can be salvaged without total laryngectomy –contrary to postradiation salvage –with a specific survival rate near 100%. Laser debulking of obstructing tumors can be performed in order to avoid tracheotomy. Postradiation recurrence can be salvaged by laser only for a few parts, with an important rate of new recurrences and total laryngectomies.

Keywords CO₂ laser • Endoscopic surgery • Transoral laser surgery • Glottic • Supraglottic • Pharyngeal carcinoma • Laryngeal carcinoma in situ • Glottic dysplasia • Airway obstruction • Recurrent laryngeal carcinoma

Introduction

Endoscopic removal of early laryngeal cancers was reported as early as 1915 [1]. The development of direct suspension laryngoscopy and subsequent use of microscopic examination was pioneered by Chevalier Jackson in the 1930s and Oskar Kleinsasser in the 1960s. The electric bistoury was introduced to surgery by Cushing in 1926, following the work of Bovie [2]. Einstein developed the theoretical design of the laser in 1917. The first pulsed ruby laser was described by Maiman

in 1960, then used a few months later to treat a retinal tumor [3]. The carbon dioxide laser (CO₂ laser), coupled with use of the microscope in direct suspension laryngoscopy, was first used by Jako and Strong in the early 1970s, and subsequently by other members of the Boston University group [4]. Used principally for benign lesions, in 1975, Strong reported three cases of laryngeal cancer excision using the CO₂ laser [5]. In the early 1980s, Wolfgang Steiner was responsible for the development and growth of CO₂ laser in the treatment of head and neck cancers. Table 25.1 presents an historical synopsis.

The term “laser” is an acronym for “light amplification by stimulated emission of radiation.” It consists of a spatially and temporally coherent beam of light produced by amplifying a stimulated emission beam, enabling a large amount of energy to be concentrated upon a small surface. Following production of the first ruby laser in 1960, various types of medical lasers were developed, differing in terms of their physical characteristics. The argon laser has coagulative properties, the Nd:YAG laser has absorptive properties, and the CO₂ laser has cutting properties. Because the CO₂ laser beam is invisible, a red-colored coaxial helium–neon beam is used to enable localization. A micromanipulator mounted on a mirror allows maneuvering of the beam. The length of a CO₂ laser wave results in it having a high capacity to absorb water, and thus tissue, resulting in heating and destruction of tissue. The first CO₂ lasers had a spot of approximately 1 mm in size. As a result of subsequent progress, the size of the spot has been reduced to around 200 μm, for example with the Acuspot. In contrast to the electric bistoury, which is active when in contact with tissue, the laser is used at a distance, allowing it to be used on the larynx and hypopharynx. The CO₂ laser is the principle laser used in the treatment of head and neck cancers, and this chapter will be devoted to discussions of this tool.

Laser Techniques

Precautions are required when using a CO₂ laser, as it is capable of being reflected and the resulting heat is liable to ignite. All operating theater staff must wear eye protection.

P.R. Moreau (✉)
Department of Otorhinolaryngology, University Hospital
of Liege, Liege, Belgium
e-mail: orl@ulg.ac.be

Table 25.1 Historical synopsis

1915	Lynch [1]	Endoscopic resection of nine early glottic cancers
1917	Einstein	Theoretical design of laser
1960	Maiman [3]	Ruby laser for retinal tumor
1970	Jako-Strong [4]	CO ₂ laser for benign laryngeal lesions
1975	Jako-Strong [5]	CO ₂ laser for three laryngeal cancers
1980	Steiner [6]	CO ₂ laser for head and neck cancers
1992	Eckel [7]	67 T1–T2 glottic cancers
1993	Steiner [8]	130 T1–T2a glottic cancers
1998	Iro [9]	141 supraglottic cancers
2001	Steiner [10]	129 pyriform sinus cancers
2005	Motta [11]	719 T1–T3 glottic cancers
2008	Martin [12]	172 hypopharyngeal cancers

The patient's eyes are closed and a cloth covers the patient's face around the laryngoscope. The endotracheal ventilation tube should be a Mallinckrodt, Xomed, or other specific laser tube designed such that it will not catch fire when touched by the laser beam. A moist cotton pad must protect the inflated cuff. Another ventilation solution consists of using a supra- or subglottic ventilation jet, which has the inconvenience of moving the laryngeal structures with each insufflation. Whether a ventilation tube or ventilation jet is used, it is recommended that the oxygen level be limited to 30% of the ventilation gas.

Various methods and techniques facilitate the use of the laser. As with diagnosis using a direct microlaryngoscopy, the use of a head clamp, a remote-controlled operating table, a height-adjustable chair, direct and lateral viewing optics via the laryngoscope, and palpation by microforceps are required. A direct view of the anterior part of the larynx is always more difficult to attain. A tooth guard, possibly made of a thermoplastic material for making Kerr type dental molds, is useful. Manual pressure by a nurse on the patient's neck is guided by a screen, allowing direction of the pressure to improve visibility. The loose movement of the epiglottis within the larynx can distort the anterior view. This can be remedied by passing a stitch through the epiglottis, holding it to the side of the laryngoscope while it is reinserted. A large suction tube is fixed to the laryngoscope to extract smoke produced by tissue vaporization. The laser beam is always used at the highest magnification possible while cutting, in order to destroy the least amount of tissue possible and allow for greater reliability of histological margins. The Acuspot allows the width of the section line to be reduced to, at best, 200 μm . The laser beam coagulates small vessels, while bleeding from larger vessels is stemmed using a monopolar suction-coagulator.

The resected specimen is always spread out and oriented upon a support such as a corkboard, in such a way as to enable precise histological analysis of the margins. So, adequate laser re-resections are feasible in case of involvement. After removal of the specimen, tissue remaining at the level

of the vocal cord is adjusted to improve voice result. In the event that a large amount of cartilage is exposed, it is standard procedure to prescribe antibiotic therapy to prevent chondritis. Postintervention scarring often lasts 2–3 months or more; granulomas may form and can be mistaken for an early recurrence. Some surgeons recommend a second look under general anaesthesia at 2 or 3 months postoperatively, and some even perform a third look [13].

Glottic Cancers

Before the creation of CO₂ lasers, early laryngeal cancers were treated endoscopically. In 1915, Lynch reported nine cases of endoscopic resection [1]. In 1973, Lillie and De Santo obtained excellent results in a series of 57 patients [14]. Nevertheless, it wasn't until the 1972 description by Strong and Jako of the use of the CO₂ laser, coupled with direct suspension microlaryngoscopy, that endoscopic resection really gained popularity [4]. The first publications reported between 1985 and 1990 included a limited number of patients and had only a short oncologic follow-up. Following Steiner, German teams were the first to publish a series of 100 patients with survival rate calculation, between 1990 and 1995 (Eckel and Thumfart [7], Steiner [8], Rudert and Werner [15]). Subsequently, other teams published their oncologic and functional results, although points of controversy still remained (see Table 25.1).

In the English-speaking world, radiation coupled with salvage surgery is a common approach in the treatment of early glottic cancers. Radiation is accompanied by a high rate of recurrence, approximately 10% for T1 and 30% for T2 tumors, according to various authors and publications [16]. Partial open surgery results in a recurrence rate of around 5% [17, 18].

The use of laser technique and its indications are controversial. Minimalists limit its use to small cancers of the medial third of the vocal cord while maximalists treat even advanced T4 laryngeal cancers, involving endoscopic resection of cartilaginous segments. Depending upon the indications, the technique and the results are highly variable. For small tumors, the majority of surgeons advise en bloc resection. For larger tumors, some surgeons apply the same principle while others, following Steiner, recommend piecemeal resection, using Moh's technique [6]. The European Laryngological Society's classification system is widely used in Europe [19]. Cordectomy is classified as superficial, transmuscular, or radical, possibly extending to the anterior commissure, the arytenoid, the ventricular fold, or subglottis [20]. Anterior commissure extension is the subject of much debate, due to the possible risk of tumoral extension along the Broyle ligament. For some surgeons, even a superficial

extension of the anterior commissure is a contraindication against endoscopy. For many others, it is not a contraindication as long as the extension is superficial. And for yet other surgeons, even significant extension does not constitute a contraindication [21, 22]. A superficial supraglottic or subglottic extension does not constitute a real contraindication for many authors. Decreased mobility (T2b) requires care and necessitates a radical cordectomy with removal of the entire muscular thickness [23]. Extension of the contralateral vocal cord leads to a synechia and strongly alters the vocal result, rendering this procedure controversial. Finally, only a few authors advise piecemeal cartilaginous excision for T3 or T4 lesions [8, 24]. Most authors attach crucial significance to the histological examination of superficial and deep margins, but this is not always the case. Some recommend a second examination a month or two after initial surgery to confirm that there has been no recurrence [13]. We do not see the need for this if the histological specimen removed en bloc has been analysed with care and shows no tumor at the surgical margins. Our only indication for revision under general anaesthesia is that of a granuloma that lasts more than 4 or 5 months or which alters vocal quality.

Large series with sufficient oncologic follow-up are now available. Table 25.2 summarises the most significant publications. Several series include 200–300 patients, with Motta publishing results for 400 cases. For T1–T2 and excluding T3 lesions, the adjusted survival rate at 5 years is close to 100%. Patients do not die as a result of their glottic tumor. Motta alone reported less favorable results. The local recurrence rate is around 10%, varying from 0% to 20%. Treatment of these recurrences is effective. A total laryngectomy rate of approximately 2–3% is reported, ranging from 0% to 10%, and higher in the case of T2 and T3 tumors. The overall survival rate at 5 years is around 80%. Numerous studies

demonstrate that failures are more frequent in the event of involvement of the anterior commissure, in the presence of decreased mobility, and even more so in the event of glottic fixation or when cartilage is affected [11, 22, 23]. Usually, laser treatment is not followed by radiation. Some surgeons recommend postoperative radiotherapy when compounding factors exist, such as involvement of the anterior commissure or decreased mobility [23].

In light of this literature, it has become clear that laser resection gives better results than radiation or partial open surgery for the majority of T1 and T2 glottic tumors. This superiority should be qualified in light of the significant expertise required to carry out laser resection. Less favorable results are reported in certain limited series [31]. Moreover, series with the worst outcomes are not even published. The problem of anterior commissure involvement and decreased mobility remain, with both laser resection and radiation therapy producing less favorable results. As far as we are concerned, laser resection does not rule out the possibility of partial open surgery in T1 and T2 glottic cancers found to have significant anterior commissure involvement, or found to be immovable with microinstruments. Few authors advise endoscopic treatment of T3 and T4 glottic cancers [8, 24].

When we consider the treatment of glottic cancers, we should also consider the resulting vocal quality. Studies attempt to compare three treatment methods: radiotherapy, laser surgery, and open surgery [27]. The occurrence of salvage total laryngectomies is higher after radiation than after laser resection (see Table 25.2), reducing the quality of vocal results obtained by radiotherapy. When laser resection is extended to the contralateral cord, synechia alter vocal quality. Radical cordectomy up to the cricoid only results in a compensatory voice being produced via the supraglottis.

Table 25.2 Literature review concerning laser of glottic carcinomas

Authors	Year	Number of patients	Classification	Local recurrence %	Salvage total laryngectomy %	5-year specific survival %	5-year overall survival %
Eckel [7]	1992	67	T1–T2	9	9	100	–
Steiner [8]	1993	130	T1–T2a	8	1	100	86
Rudert [15]	1995	108	T1–T2	9	3	100	–
Eckel [25]	2000	285	Tis–T2	14	6	99	71
Moreau [20]	2000	97	T1–T2	0	0	97	78
Gallo [26]	2002	139	T1	6	0	100	–
Brøndbo [27]	2004	118	T1a	10	2	99	–
Mortuaire [28]	2004	110	Tis–T1–T2	20	8	97	87
Peretti [29]	2004	322	Tis–T1–T2	9	3	99	88
Steiner [21]	2004	263	T1–T2a	13	3	–	–
Motta [11]	2005	432	T1	15	3	97	85
		236	T2	34	18	87	77
		51	T3	37	20	72	64
Peretti [23]	2005	55	T2	23	15	100	76
Ledda [30]	2006	103	Tis–T1–T2	3	0	–	92

Supraglottic Cancers

Endoscopic resection of limited supraglottic cancers was reported by Jackson and Jackson in 1939 [32]. After Jako and Strong, in 1978 Vaughan was the first to describe the use of resection using a CO₂ laser for neoplasms of the suprahoid epiglottis [4, 33]. Following his example, Zeitels and Davis used the CO₂ laser for small cancers and to remove obstruction of tumors causing dyspnea, routinely following the endoscopic operation with radiation treatment [34]. It was in Europe, with Steiner in 1979 followed by Rudert, Motta, and Eckel, that CO₂ laser endoscopic resection of supraglottic cancers really developed, without the use of systematic post-operative radiation treatment [15, 35–37].

A rise in the number of glottic cancers in the 1990s allowed the oncologic efficacy of endoscopic resection using the CO₂ laser to be demonstrated on several series of hundreds of patients. In contrast, supraglottic cancers are more rare and treatment indications are more controversial, hence the current literature includes primarily reports of only 30–40 patients with short oncologic follow-up. Currently, only a few authors have published series of a 100 or more patients. The surgeon-dependent nature of this type of exercise calls for care in interpreting results and does not enable generalizations to be made.

Steiner was the real pioneer in developing the technique of piecemeal resection for the removal of large supraglottic

cancers, extending its indication even to T4. Others remain loyal to en bloc resection, with more limited indications for laser use. The use of the bivalve laryngoscope as well as thicker forceps and suction tubes is indispensable for this type of resection. For small, limited tumors classed as T1, which are rare, all authors recommend en bloc resection. As soon as tumors become larger, Steiner recommends his piecemeal approach. Resection is carried out craniocaudally and layer by layer, using Moh's technique (Fig. 25.1a, b). The first lateral incision cuts across the tumor on the median sagittal plane, allowing the surgeon to evaluate tumoral depth and thus the amount of tissue requiring removal. If the tumor is bulky, additional sections are carried out across the tumor. Where required, the thyroid cartilage or anterior glottal commissure is resected, thus an endolaryngeal evisceration is carried out. As far as we are concerned, we remain convinced that en bloc resection enables greater certainty in the analysis of histological margins than piecemeal resection (Fig. 25.1c). Where the preepiglottic space is involved this is not a contraindication if the involvement is minor, that is to say, if it remains far from the hyoid bone. It may reach close to the thyroid cartilage without affecting it. Extension of the anterior commissure is, for us, a contraindication to CO₂ laser resection.

The classically quoted risk of lymph node involvement is around 30% for supraglottic tumors and higher for tumors of

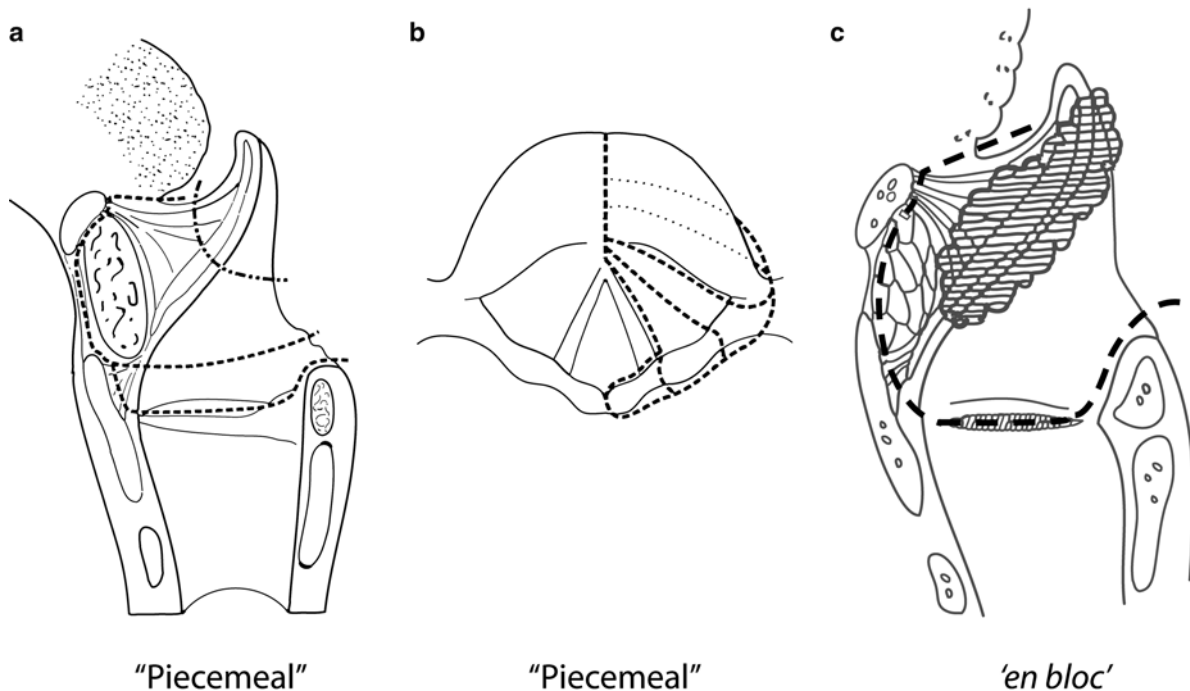


Fig. 25.1 Piecemeal (a, b) or en bloc (c) supraglottic resection. (a, b) From Rudert HH, Werner JA, Höft S. Transoral carbon dioxide laser resection of supraglottic carcinoma. *Ann Otol Rhinol Laryngol* 1999;108:819–827. Reprinted with permission from John Wiley

& Sons. (c) From Moreau P. Treatment of laryngeal carcinomas by laser endoscopic microsurgery. *Laryngoscope* 2000;110:1000–1006. Reprinted and modified with permission from John Wiley & Sons

Table 25.3 Literature review concerning laser of supraglottic carcinomas

Authors	Year	Number of patients	Classification	Local recurrence %	5-year specific survival %	5-year overall survival %
Eckel [7]	1992	15	T1–T2	0		
Zeitels [34]	1994	19	T1–T2	0		
Eckel [37]	1997	46	T1–T2	9	72	59
Ambrosch [35]	1998	48	T1–T2	8	83 ^a	76
Iro [9]	1998	141	T1–T4	16	66 ^a	
Rudert [39]	1999	34	T1–T4	29	80 ^b	62 ^b
Moreau [20]	2000	18	Tis–T3	0	100	63
Motta [36]	2004	124	T1–T2–T3	18-33-23	97-94-81	82-59-51
Davis [38]	2004	46	T2	3		63 ^c
Cabanillas [40]	2008	26	T1–T3	8	80	–

^aRecurrence-free survival

^b3-year survival

^cNon actuarial survival

the aditus. The majority of authors recommend carrying out a bilateral neck dissection; unilateral dissection is appropriate when the tumor is highly lateralised. In the event of a very superficial microinvasive tumor, the indication for neck dissection remains controversial. Postoperative radiation is indicated in the event of lymph node involvement, particularly significant involvement, and in cases where tumor margins are not resectable endoscopically. For some surgeons, such as Davis, postoperative radiation is routine [38].

Table 25.3 presents the most significant published series. Among the 517 patients identified in this literature compilation, only two authors report a group of more than 100 patients. For T1 and T2 tumors, the local recurrence rate varies between 0% and 10%, with the exception of Motta. When T3 and T4 are included in the series, the local recurrence rate rises to 0–30%. The compilation found 76 recurrences in 517 patients, for a rate of 15%. A large part of these recurrences improved with effective salvage treatment. The adjusted survival rate at 5 years varies between 70% and 100%, dependent primarily upon lymph node involvement and distal metastases. The overall survival rate at 5 years is on the order of 60–70%.

The unanimously recognised advantages of this approach include the avoidance of tracheotomy, simpler postoperative course than with open supraglottic laryngectomy, and more rapid removal of nasogastric tubes [41]. Salvage treatment after recurrence with an endoscopic resection is clearly more effective than after radiation or open surgery.

Pharyngeal Cancers

While the CO₂ laser is increasingly used for the treatment of glottic laryngeal cancers, its use to treat the pharynx remains completely marginal, and few publications exist.

The overall survival rate of cancers of the pharynx is not favorable, with a survival rate at 5 years of 50% for oropharyngeal cancers and of 30% for hypopharyngeal cancers. Wolfgang Steiner pioneered the use of CO₂ laser to treat cancers in different regions of the head and neck, notably of the pharynx, at the beginning of the 1980s. He replaced the use of the electric bistoury with the CO₂ laser for all transoral resections, whether in the oral cavity itself, the oropharynx, or the hypopharynx. Others, including us, have reserved the use of the CO₂ laser to regions that are inaccessible for transoral resection using an electric bistoury.

The material used for laser resection of pharyngeal lesions is comparable to that used for supraglottic cancers, requiring the use of a bivalve Weerda-type laryngoscope and thicker and more rigid forceps and suction tubes.

The indications for laser resection vary widely depending upon the author. Some surgeons use this technique only in a minority of the pharyngeal cancers they treat, limiting its indication to small early tumors, which are resectable en bloc with healthy superficial and deep histological limits [42, 43]. Scanner data and mobilisation of the tumor with the help of microforceps allow the depth of the extension to be evaluated and more precise evaluation to determine the appropriateness of laser resection. In contrast, Steiner and others use it to treat T3 and T4 tumors. He collated 31 pT3-T4 cancers from 129 laser resections [10]. As soon as the tumor reaches more than 1 cm in diameter, he recommends sectioning through the tumor and removing it piecemeal craniocaudally and layer by layer, according to Moh's technique (Fig. 25.2) [6]. All the authors agree that histological analysis of the tumor margins is crucial and requires the correct orientation of the specimen and a meticulous analysis of the superficial and deep margins, whether the resection is carried out en bloc or piecemeal [44, 45]. Steiner claims that transectioning the tumor in this way enables him to better evaluate the

Fig. 25.2 Piecemeal (a) or en bloc (b) pharyngeal resection

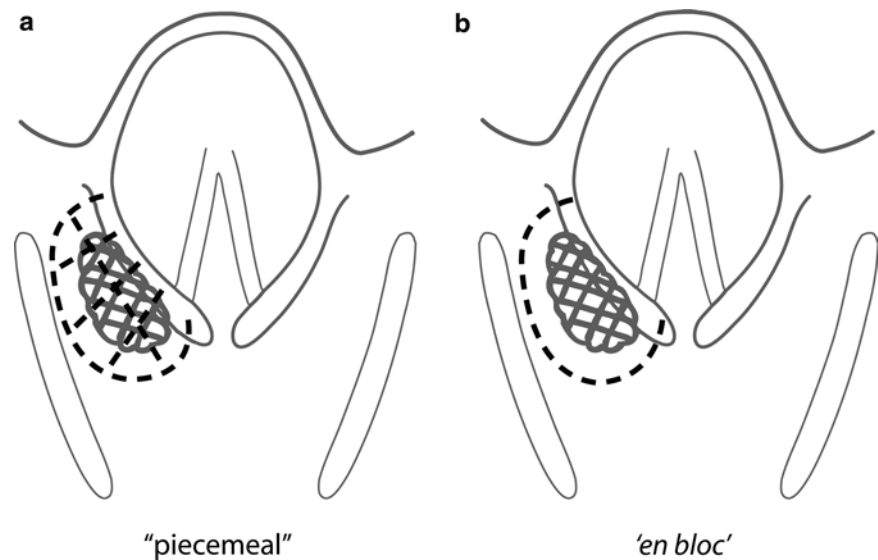


Table 25.4 Literature review concerning laser of pharyngeal carcinomas

Authors	Year	Number of patients	Localization	Local recurrence %	5-year specific* or rec. free** survival %	5-year overall survival %
Steiner et al. [10]	2001	129	Pyriiform sinus	13	76**	53
Steiner et al. [46]	2003	48	Base of tongue	15	73**	52
Rudert and Höft [42]	2003	29	Hypopharynx	28	58*	48
Vilaseca et al. [47]	2004	28	Hypopharynx	18	59*	43
Martin et al. [12]	2008	172	Hypopharynx	26	72*	52
Moreau et al. [43]	2008	74	Oro-hypopharynx	9	91*	49

N.B. The study of Steiner 2001 is included in Martin 2008. The survival of Vilaseca is at 4, and not 5-year

* 5-year specific survival

** 5-year recurrence free survival

depth of the infiltration and prevents hindrance by the tumoral volume. Others claim that histological analysis of all limits is more accurate with en bloc resection.

Unilateral or bilateral neck dissection is carried out depending upon the location of the tumor, either during the same operation or a few weeks later. This delay is required when there is a risk of communication between the two fields. For Rudert, postoperative radiation is routine [42]. For others, it is routine only in the event of lymph node involvement [43]. For Steiner, it is systematic in the event of advanced lymph node involvement, extracapsular spread, or carcinomatous lymphangitis [12].

Table 25.4 presents the results of the largest published series. In terms of the oropharynx, only the Steiner series, with 48 cases of localisation at the level of the base of the tongue, and Moreau, with 38 cases of various oropharyngeal localisations, exist [43, 46]. For the hypopharynx, the 172 Martin cases including the 129 cases published by Steiner are the only significant series [10, 12]. The remaining publications are limited to around 30 patients. For early stage T1 and T2N0, Steiner, Martin, and Moreau find an adjusted survival rate at 5 years of 90–100%. For all stages, the adjusted survival rate at 5 years is around 70%, while the overall survival

rate is around 50%. This difference is linked to second primaries, which are particularly common.

The local recurrence rate ranges between 10% and 30%. Effective treatment of these recurrences is possible, whether by repeated laser resection, radiation therapy, or open surgery.

One big advantage results from the simplicity of post-operative courses, with a reduction in the length of hospitalization, the avoidance of tracheotomy, and recovery of swallowing function and phonation. Bleeding is an immediate postoperative complication in around 5% of cases, and can be fatal [12, 43, 47].

Precancerous Lesions

In 1923, Jackson introduced the concept of pre-cancerous lesions of the larynx [48]. In 1952, Altman reported the first studies of in situ laryngeal carcinomas, analogous to those of the cervix [49]. In 1974, Strong described the use of the CO₂ laser for the treatment of premalignant lesions [50].

These precancerous stages have been classified by the World Health Organization [51]. Severe dysplasias are usually grouped with in situ carcinomas in a group called “high-level

precancerous” lesions, reflecting their significant tendency to become invasive. Classic treatments used for severe dysplasias and in situ carcinomas are stripping, external radiation, and laser resection.

When work with the CO₂ laser first began, some surgeons would use it to vaporize the mucous membrane, while others would perform a resection with histological margin examination. The first lasers had a spot that was around a millimeter in diameter, which did not allow for dissection of Reinke’s space. Resection inevitably took place in the superficial part of the vocal ligament, or even the musculature. Technological progress has enabled the spot to be reduced to 100 or 200 μm, allowing us to pass into Reinke’s space while retaining the vocal ligament. Supra- or subglottic extension requires correct visualization, with resection of the false cord in the event of extension towards the ventricle or a transversal section of the glottic musculature in the event of inferior extension. Contralateral or bilateral extension causes problems of anterior glottic synechia, altering the vocal quality. As with stripping, a resection carried out in stages can resolve this difficulty. Initially, we tend to treat the side which has been most affected, going up to the median line on the anterior commissure and 2 or 3 months later carry out resection of the contralateral side, slightly overlapping the median line.

Table 25.5 presents the results of the three main treatment techniques: stripping, radiotherapy, and laser resection. The rate of recurrence after stripping is very variable, ranging from 10% to 60% according to different authors. It is higher than that seen with the two other techniques. After radiation, the local recurrence rate varies between 0% and 20%. Sadri compiled 605 patients who had undergone radiotherapy and reported a 12% recurrence rate [62]. Radiotherapy however, gives a specific survival rate of close to 100%, but a total laryngectomy rate of 10%. With the CO₂ laser, the local recurrence rate is between 5% and 15%, averaging approximately 10%. The major advantage of the CO₂ laser is that

these recurrences can be treated in a nonmutilating way, either by repeating the laser resection or by radiation, with a rate of conservation of the larynx close to 100% and a specific survival rate also close to 100%. The surgeon-dependent nature of laser treatment is similar to that seen with invasive cancers. Small published series often show higher rates of recurrence, testimony to the importance of the surgeon’s skill [57, 63].

One of the major advantages of the laser is the ability to precisely classify the tumor. Patients receive radiotherapy on the basis of a biopsy which has shown a pre-cancerous stage while the lesion may in fact be microinvasive elsewhere. Laser resection enables classification of certain precancerous stages to be modified, based on analysis of the specimen, thus allowing for appropriate treatment following determination of the true extension of the tumor.

An argument often advanced in favor of radiotherapy is that of vocal quality. The rate of salvage total laryngectomy after radiation renders this argument null and void. While laser resection is limited to the superficial part of Reinke’s space, the mucosal wave in stroboscopy is salvaged, with no consequences for the voice. However, minor vocal consequences often occur for various reasons: Reinke’s space cannot be detached, for example in case of hypertrophic laryngitis, deep biopsy resulting scarring, or in the event of subglottic, supraglottic, or contralateral extension.

Debulking of Airway Obstruction

Pharyngeal or laryngeal cancers causing dyspnea require immediate restoration of a sufficient respiratory channel. The classic solution is a tracheotomy, carried out where required under local anaesthesia, prior to a total laryngectomy. The risk of recurrence around the orifice of the tracheotomy

Table 25.5 Literature review concerning laser of “in situ”

Technique	Authors	Year	Number of patients	Local recurrence %	Total laryngectomy %	5-year specific survival %	5-year overall survival %
Stripping	Miller [52]	1971	100	25	–	–	–
	Hintz [53]	1981	27	63	19	93 ^a	–
	Stenersen [54]	1988	41	46	–	–	–
Radiotherapy	Pene [55]	1976	79	15	10	–	–
	Elman [56]	1979	69	17	14	–	–
	Le [57]	2000	54	18	13	98	–
	Spayne [58]	2001	67	1	1	100	84
	Garcia-Serra [59]	2002	30	10	10	100	80
Laser	Steiner [8]	1993	29	9	0	100	–
	Moreau [20]	2000	26	4	0	100	83
	Eckel [25]	2000	31	6	0	100	86
	Damm [60]	2000	29	14	0	100	–
	Roedel [61]	2009	34	12	0	100	82

^aSalvage –augmented local control rate

is estimated at between 3% and 40%, particularly where the tracheotomy cuts across the tumoral tissue, but also as a result of neoplastic seeding [64]. Peristomal recurrences constitute an extremely unfavorable factor with a mortality rate of 80% to 90% [64, 65]. To avoid the need for tracheotomy, radical treatment can be proposed in the form of an emergency total laryngectomy [66]. The absence of an earlier assessment and practical contingencies, however, do not always permit this. A third possibility is the restoration of a sufficient airway passage by tumoral debulking using laser endoscopy [67]. The concept is simple; performing it is less so. Tumoral transection often results in hemorrhage, which is difficult to control. The remaining tumor has a crumbly texture which can obstruct the airways again immediately. Subglottic extension, which is often dyspneal, makes this difficult to carry out and is further hindered by the presence of the ventilation tube. The ventilation jet is no simpler as an airway return has to be restored to avoid pulmonary complications. In the event of localization at the level of the laryngeal aditus, laser resection can result in aspiration. It is not rare to have to repeat endoscopic disobstruction. An endoscopic resection on the side which is not affected by the tumor occasionally helps.

Debulking, however, most often enables a sufficient airway channel to be restored for a few weeks, allowing for the usual extended assessment to be carried out and for the curative procedure to be scheduled under the best conditions [6, 67]. Other types of laser techniques and different methodologies have been used with success, including the microdebrider [68].

Salvage After Glottic Radiation Failure

Postirradiation salvage surgery is difficult. The majority of T1–T2 glottic cancers are salvaged by total laryngectomy, with a failure rate of 20–50% [69]. In a minority of cases, open partial surgery is used, with a local recurrence rate of between 5% and 25% [70, 71]. Series published on salvage with laser resection are presented in Table 25.6. They are limited to a few dozen patients, demonstrating the small proportion of cases in which this laser surgery is possible. New recurrences can be seen in 25–60% of cases. Laser resection

can be repeated in the event of recurrence. The rate of total laryngectomy is between 20% and 50%. Some of these patients die from their cancer in the event of recurrence, but it is difficult to determine the exact proportion. All authors underline the technical difficulties of this laser resection in radiated areas as a result of imprecise margins.

Discussion

Steiner uses the CO₂ laser to carry out transoral resection of oral cavity cancers and those of the upper oropharynx, soft palate, or tonsillar area [6]. Other authors remain attached to conventional transoral instruments, such as the electric bistoury and “cold” instruments. They avoid the inconveniences of laser: coagulation necrosis at the margins, which renders scarring more difficult and increases the risk of stitches failing, and axial radiation complicating resection of the deepest part of the specimen.

Histologic analysis of margins is more difficult with CO₂ laser resection than with traditional means. A tissue thickness of 0.5 mm is destroyed by the laser section, reduced at best to 200 μm with Acuspot. The margins are subject to coagulation necrosis, which further complicates the analysis. When the laser was initially used, some authors advised the destruction of the tumor by vaporization without histological control of the margins. No significant series supports this concept. Formal or possible involvement of the resection margins of the specimen often occurs, in about 25–30% of cases [44, 45]. Re-resection for an inadequate margin uncovers residual tumor in only 20% of cases [45]. True histological involvement of the margins is associated with a higher rate of locoregional recurrence, an increased rate of distal metastases and a reduced specific survival rate [44, 45, 74]. Here we begin to appreciate all the difficulties of interpreting the histological involvement of the margins and the need to meticulously analyse them. Could a focal spread upon a margin be considered as insignificant following tissue destruction? Is an infra millimetric deep limit sufficient? Does the piecemeal resectioning technique enable as relevant an analysis of the margins as en bloc resection?

Lymph node involvement in supraglottic and pharyngeal tumors often occurs. Bilateral neck dissection is indicated in the event of median or near-median tumor, and unilateral dissection in the event of a lateralized tumor. In the event of a microinvasive tumor, with less than 2 mm infiltration, the indication is more subtle. For the supraglottis, where lymph node involvement is rarer, a microinvasive tumor prompts simple monitoring. For the pharynx, the discussion remains open. If the tumor is clearly invasive, neck surgery can be carried out during the same operation, but can also be deferred. In the event of laser resection adjoining the cervical

Table 25.6 Literature review concerning laser of recurrent glottic carcinomas after radiotherapy

Authors	Year	Number of patients	Local recurrence %	Total laryngectomy %
Quer [72]	2000	24	25	25
de Gier [70]	2001	40	58	50
Steiner [73]	2004	34	59	21
Ansarin [71]	2007	37	35	30

region, it is preferable to delay neck surgery in order to avoid communication between the two operating areas and the risk of fistula formation.

Mastering resection with the help of the CO₂ laser is not easy. Most of the large series published have been carried out by a single surgeon, who has progressively enlarged the indications and who has acquired an optimal technique. Large published series give better results than the smaller ones. Teaching appears more difficult than with open surgery. This surgeon-dependent nature of the endoscopic approach limits its growth and results in a disparity of results.

The term “laser” evokes new technology, which gives rise to great enthusiasm. In oncology, prudence imposes itself. In the past, various technologies such as color lasers and photosensitisers were tested with lukewarm results [75, 76]. The CO₂ laser is only one methodology used in surgical section. Recent literature proposes the use of diode lasers, the KTP laser, and pulsed dye lasers [77, 78]. Coupling the CO₂ laser with a robot appears to be a promising concept, which would facilitate the action of resection at the level of the base of the tongue and the supraglottis [79].

Conclusions

Over the course of 30 years, driven by Wolfgang Steiner, the CO₂ laser has become one of the means of treating early cancers of the upper aerodigestive tract. For dysplasias and in situ carcinomas, its results are better than those of radiation treatment, by decreasing the need for salvage total laryngectomy. For early glottic T1 and T2 cancers, removable endoscopically, it gives a specific survival rate of close to 100% with a total laryngectomy rate of around 2–3%, a rate less than that seen following radiotherapy. In the event of decreased mobility and fixation, the results are less favorable. Many authors prefer to perform open partial laryngectomy in these cases. For supraglottic cancers, the use of CO₂ lasers requires significant expertise. No consensus exists on the indications. A local recurrence rate of approximately 10% is seen in T1 and T2 tumors and 20% for T3 and T4 tumors. These can most often be salvaged. The specific survival rate at 5 years is 80%, depending mainly upon the extent of distal and lymph node metastases. For pharyngeal cancers, indications also vary depending upon the authors. The role of metastasis and of second primaries is of clear dominance in determining outcome. The rate of local recurrence is 20% with a specific survival rate of 70% and an overall survival rate of 50%.

Beyond simple morbidity, the fact that a tracheotomy can be avoided and that the postoperative course is simpler, the major advantage of laser resection remains the absence of locoregional dissemination. This allows for effective salvage

Table 25.7 Advantages and limitations of laser

	Advantages	Limitations
Global	More precise classification of T Avoid local dissemination Excellent salvage in case of local recurrence Postoperative course very simple Low cost	Required expertise Surgeon-dependent nature Inadequate endoscopic exposition
Glottic	For T1–T2a Local recurrence 10% Salvage total laryngectomy 2–3%	Involvement of anterior commissure Glottic fixation Low vocal quality in case of radical or bilateral cordectomy
Supraglottic	Avoid tracheotomy Local recurrence 15%	Disparity of contraindications T4, a part of T3 Extension near hyoid bone and to glottic area
Pharyngeal	Local recurrence 20% Very useful in case of multiple tumors	Controversy of indications and techniques Overall survival ~50%
Precancerous	Local recurrence 10% Specific survival ~100% Avoid salvage total laryngectomy	2 stages in case of bilateral glottic extension

treatment to be carried out, whether by repeated laser resection, open surgery, or radiation. One inconvenience is the difficulty of learning this technique and hence its surgeon-dependent nature. Table 25.7 summarizes the advantages and the limitations of CO₂ laser use.

References

1. Lynch RC. Suspension laryngoscopy and its accomplishments. *Ann Otol Rhinol Laryngol* 1915;24:429–478.
2. O’connor JL, Bloom DA. William T. Bovie and electrosurgery. *Surgery* 1996;119:390–396.
3. Maiman TH. Stimulated optical radiation in ruby. *Nature* 1960;187:493–494.
4. Strong MS, Jako GJ. Laser surgery in the larynx. *Ann Otol Rhinol Laryngol* 1972;81:791–798.
5. Strong MS. Laser excision of carcinoma of the larynx. *Laryngoscope* 1975;85:1286–1289.
6. Steiner W, Ambrosch P. Endoscopic laser surgery of the upper aerodigestive tract. New York: Thieme Stuttgart 2000.
7. Eckel HE, Thumfart WF. Laser surgery for the treatment of larynx carcinomas: indications, techniques, and preliminary results. *Ann Otol Rhinol Laryngol* 1992;101:113–118.
8. Steiner W. Results of curative laser microsurgery of laryngeal carcinomas. *Am J Otolaryngol* 1993;4:116–121.
9. Iro H, Waldfahrer F, Altendorf-Hofmann A, Weidenbecher M, Sauer R, Steiner W. Transoral laser surgery of supraglottic cancer: follow-up

- of 141 patients. *Arch Otolaryngol Head Neck Surg* 1998;124:1245–1250.
10. Steiner W, Ambrosch P, Hess CF, Kron M. Organ preservation by transoral laser microsurgery in piriform sinus carcinoma. *Otolaryngol Head Neck Surg* 2001;124:58–67.
 11. Motta G, Esposito E, Motta S, Tartaro G, Testa D. CO2 laser surgery in the treatment of glottic cancer. *Head Neck* 2005;27:566–574.
 12. Martin A, Jäckel MC, Christiansen H, Mahmoodzada M, Kron M, Steiner W. Organ preserving transoral laser microsurgery for cancer of the hypopharynx. *Laryngoscope* 2008;118:398–402.
 13. Preuss SF, Cramer K, Drebber U, Klussmann JP, Eckel HE, Guntinas-Lichius O. Second-look microlaryngoscopy to detect residual carcinoma in patients after laser surgery for T1 and T2 laryngeal cancer. *Acta Otolaryngol* 2008;16:1–5.
 14. Lillie JC, De Santo LW. Transoral surgery of early cordal carcinoma. *Trans Am Acad Ophthalmol Otolaryngol* 1973;77:92–96.
 15. Rudert HH, Werner JA. Endoscopic resections of glottic and supraglottic carcinomas with the CO2 laser. *Eur Arch Otorhinolaryngol* 1995;252:146–148.
 16. Sinha PP. Radiation therapy in early carcinoma of the true vocal cords (Stage I and II). *Int J Radiation Oncology Biol Phys* 1987;13:1635–1640.
 17. Thomas JV, Olsen KD, Neel III B, De Santo LW, Suman VJ. Early glottic carcinoma treated with open laryngeal procedures. *Arch Otolaryngol Head Neck Surg* 1994;120:264–268.
 18. Piquet JJ, Chevalier D. Subtotal laryngectomy with crico-hyoido-pexy for the treatment of extended glottic carcinomas. *Am J Surg* 1991;162:357–361.
 19. Remacle M, Eckel HE, Antonelli A, et al. Endoscopic cordectomy. A proposal for a classification by the Working Committee, European Laryngological Society. *Eur Arch Otorhinolaryngol* 2000;257:227–231.
 20. Moreau P. Treatment of laryngeal carcinomas by laser endoscopic microsurgery. *Laryngoscope* 2000;110:1000–1006.
 21. Steiner W, Ambrosch P, Rödel RM, Kron M. Impact of anterior commissure involvement on local control of early glottic carcinoma treated by laser microresection. *Laryngoscope* 2004;114:1485–1491.
 22. Sachse F, Stoll W, Rudack C. Evaluation of treatment results with regard to initial anterior commissure involvement in early glottic carcinoma treated by external partial surgery or transoral laser microresection. *Head Neck* 2009;31:531–537.
 23. Peretti G, Piazza C, Mensi MC, Magnoni L, Bolzoni A. Endoscopic treatment of cT2 glottic carcinoma: prognostic impact of different pT subcategories. *Ann Otol Rhinol Laryngol* 2005;114:579–586.
 24. Hinni ML, Salassa JR, Grant DG, Pearson BW, Hayden RE, et al. Transoral laser microsurgery for advanced laryngeal cancer. *Arch Otolaryngol Head Neck Surg* 2007;133:1198–1204.
 25. Eckel EH, Thumfart W, Jungehülsing M, Sittel C, Stennert E. Transoral laser surgery for early glottic carcinoma. *Eur Arch Otorhinolaryngol* 2000;257:221–226.
 26. Gallo A, de Vincentiis M, Manciooco V, Simonelli M, Fiorella ML, Shah JP. CO2 laser cordectomy for early-stage glottic carcinoma: a long-term follow-up of 156 cases. *Laryngoscope* 2002;112:370–374.
 27. Brøndbo K, Benninger MS. Laser resection of T1a glottic carcinomas: results and postoperative voice quality. *Acta Otolaryngol* 2004;124:976–979.
 28. Mortuaire G, Francois J, Wiel E, Chevalier D. Local recurrence after CO2 laser cordectomy for early glottic carcinoma. *Laryngoscope* 2006;116:101–105.
 29. Peretti G, Piazza C, Bolzoni A, Mensi MC, Rossini M, et al. Analysis of recurrences in 322 T1S, T1, or T2 glottic carcinomas treated by carbon dioxide laser. *Ann Otol Rhinol Laryngol* 2004;113:853–858.
 30. Ledda GP, Puxeddu R. Carbon dioxide laser microsurgery for early glottic carcinoma. *Otolaryngol Head Neck Surg* 2006;134:911–915.
 31. Sjögren EV, Langeveld TP, Baatenburg de Jong RJ. Clinical outcome of T1 glottic carcinoma since the introduction of endoscopic CO2 laser surgery as treatment option. *Head Neck* 2008;30:1167–1174.
 32. Jackson C and Jackson CL. Endoscopic removal of cancer of the epiglottis. In: *Cancer of the larynx*. Saunders, Philadelphia 1939:52.
 33. Vaughan CW. Transoral laryngeal surgery using the CO2 laser: laboratory experiments and clinical experience. *Laryngoscope* 1978;88:1399–1420.
 34. Zeitels SM, Koufman JA, Davis RK, Vaughan CW. Endoscopic treatment of supraglottic and hypopharynx cancer. *Laryngoscope* 1994;104:71–78.
 35. Ambrosch P, Kron M, Steiner W. Carbon dioxide laser microsurgery for early supraglottic carcinoma. *Ann Otol Rhinol Laryngol* 1998;107:680–688.
 36. Motta G, Esposito E, Testa D, Iovine R, Motta S. CO2 laser treatment of supraglottic cancer. *Head Neck* 2004;26:442–446.
 37. Eckel HE. Endoscopic laser resection of supraglottic carcinoma. *Otolaryngol Head Neck Surg* 1997;117:681–687.
 38. Davis RK, Kriskovich MD, Galloway EB 3rd, Buntin CS, Jepsen MC. Endoscopic supraglottic laryngectomy with postoperative irradiation. *Ann Otol Rhinol Laryngol* 2004;113:132–138.
 39. Rudert HH, Werner JA, Höft S. Transoral carbon dioxide laser resection of supraglottic carcinoma. *Ann Otol Rhinol Laryngol* 1999;108:819–827.
 40. Cabanillas R, Rodrigo JP, Llorente JL, Suárez C. Oncologic outcomes of transoral laser surgery of supraglottic carcinoma compared with a transcervical approach. *Head Neck* 2008;30:750–755.
 41. Rodrigo JP, Suárez C, Silver CE, Rinaldo A, Ambrosch P, Fagan JJ, Genden EM, Ferlito A. Transoral laser surgery for supraglottic cancer. *Head Neck* 2008;30:658–666.
 42. Rudert HH, Höft S. Transoral carbon-dioxide laser resection of hypopharyngeal carcinoma. *Eur Arch Otorhinolaryngol* 2003;260:198–206.
 43. Moreau PR, Bouchain OF, Demez PH. Exérèse laser des cancers pharyngés. In: Reyt E, Righini C, eds. *Les cancers du plancher buccal. La chirurgie minimale invasive* [in French]. Sèvres, EDK 2008: 125–131.
 44. Blanch JL, Vilaseca I, Bernal-Sprekelsen M, Grau JJ, Moragas M, et al. Prognostic significance of surgical margins in transoral CO2 laser microsurgery for T1-T4 pharyngolaryngeal cancers. *Eur Arch Otorhinolaryngol* 2007;264:1045–1051.
 45. Jäckel MC, Ambrosch P, Martin A, Steiner W. Impact of re-resection for inadequate margins on the prognosis of upper aerodigestive tract cancer treated by laser microsurgery. *Laryngoscope* 2007;117:350–356.
 46. Steiner W, Fierek O, Ambrosch P, Hommerich CP, Kron M. Transoral laser microsurgery for squamous cell carcinoma of the base of the tongue. *Arch Otolaryngol Head Neck Surg* 2003;129:36–43.
 47. Vilaseca I, Blanch JL, Bernal-Sprekelsen M, Moragas M. CO2 laser surgery: a larynx preservation alternative for selected hypopharyngeal carcinomas. *Head Neck* 2004;26:953–959.
 48. Jackson C. Cancer of the larynx: is it preceded by a recognizable precancerous condition? *Ann Surg* 1923;77:1–14.
 49. Altman F, Ginsberg I, Stout AF. Intraepithelial carcinoma (cancer in situ) of the larynx. *Arch Otolaryngol* 1952;56:121–133.
 50. Strong MS. Laser management of premalignant lesions of the larynx. *Can J Otolaryngol* 1974;3:560–563.
 51. Shanmugaratnam K, Sobin LH. Histological typing of tumours of the upper respiratory tract and ear. WHO international classification of tumours. 2nd edn. Springer, Berlin Heidelberg New York 1991.
 52. Miller AH, Fischer HR. Clues to the life history of carcinoma in situ of the larynx. *Laryngoscope* 1971;81:1475–1480.
 53. Hintz BL, Kagan A, Nussbaum H, Rao AR, Chan PY, Miles J. A 'watchful waiting' policy for in situ carcinoma of the vocal cords. *Arch Otolaryngol* 1981;107:746–751.

54. Stenersen TC, Hoel PS, Boysen M. Carcinoma in situ of the larynx. Results with different methods of treatment. *Acta Otolaryngol (Stockh)* 1988;449:131–133.
55. Pène F, Fletcher GH. Results in irradiation of the in situ carcinomas of the vocal cords. *Cancer* 1976;37:2586–2590.
56. Elman AJ, Goodman M, Wang CC, Pilch B, Busse J. In situ carcinoma of the vocal cords. *Cancer* 1979;43:2422–2428.
57. Le QT, Takamiyar R, Shu HK, Smitt M, Singer M, Terris DJ, et al. Treatment results of carcinoma in situ of the glottis. An analysis of 82 cases. *Arch Otolaryngol Head Neck Surg* 2000;126:1305–1312.
58. Spayne JA, Warde P, O'Sullivan B, et al. Carcinoma in situ of the glottic larynx: results of treatment with radiation therapy. *Int J Radiat Oncol Biol Phys* 2001;49:1235–1238.
59. Garcia-Serra A, Hinerman RW, Amdur RJ, Morris CG, Mendenhall WM. Radiotherapy for carcinoma in situ of the true vocal cords. *Head Neck* 2002;24:390–394.
60. Damm M, Sittel C, Streppel M, Eckel HE. Transoral CO2 laser for surgical management of glottic carcinoma in situ. *Laryngoscope* 2000;110:1215–1221.
61. Roedel RM, Christiansen H, Mueller RM, Matthias C. Transoral laser microsurgery for carcinoma in situ of the glottic larynx. A retrospective follow-up study. *ORL J Otorhinolaryngol Relat Spec* 2009;71:45–49.
62. Sadri M, McMahon J, Parker A. Management of laryngeal dysplasia: a review. *Eur Arch Otorhinolaryngol* 2006;263:843–852.
63. McGuirt WF, Browne JD. Management decisions in laryngeal carcinoma in situ. *Laryngoscope* 1991;101:125–129.
64. Carrillo JF, Frías-Mendivil M, Lopez-Graniel C, Beitia AI, Ochoa-Carrillo FJ. The impact of preoperative tracheotomy on T3 transglottic carcinomas of the larynx. *Eur Arch Otorhinolaryngol* 1999;256:78–82.
65. Davis RK, Shapshay SM. Peristomal recurrence: pathophysiology, prevention, treatment. *Otolaryngol Clin North Am* 1980;13:499–508.
66. McCombe A, Stell PM. Emergency laryngectomy. *J Laryngol Otol* 1991;105:463–465.
67. Davis RK, Shapshay SM, Vaughan CW, Strong MS. Pretreatment airway management in obstructing carcinoma of the larynx. *Otolaryngol Head Neck Surg* 1981;89:209–214.
68. Simoni P, Peters GE, Magnuson JS, Carroll WR. Use of the endoscopic microdebrider in the management of airway obstruction from laryngotracheal carcinoma. *Ann Otol Rhinol Laryngol* 2003;112:11–13.
69. McLaughlin MP, Parsons JT, Fein DA, Stringer SP, Cassisi NJ, et al. Salvage surgery after radiotherapy failure in T1-T2 squamous cell carcinoma of the glottic larynx. *Head Neck* 1996;18:229–235.
70. de Gier HH, Knegt PP, de Boer MF, Meeuwis CA, van der Velden LA, Kerrebijn JD. CO2-laser treatment of recurrent glottic carcinoma. *Head Neck* 2001;23:177–180.
71. Ansarin M, Planicka M, Rotundo S, Santoro L, Zurlo V, et al. Endoscopic carbon dioxide laser surgery for glottic cancer recurrence after radiotherapy. Oncological results. *Arch Otolaryngol Head Neck Surg* 2007;133:1193–1197.
72. Quer M, León X, Orús C, Venegas P, López M, Burgués J. Endoscopic laser surgery in the treatment of radiation failure of early laryngeal carcinoma. *Head Neck* 2000;22:520–523.
73. Steiner W, Vogt P, Ambrosch P, Kron M. Transoral carbon dioxide laser microsurgery for recurrent glottic carcinoma after radiotherapy. *Head Neck* 2004;26:477–484.
74. Caballero M, Vilaseca I, Bernal-Sprekelsen M, Guilemany JM, Moragas M, Blanch JL. Distant metastases after transoral laser microsurgery for laryngeal and hypopharyngeal squamous cell carcinoma. *Head Neck* 2008;30:1599–1606.
75. Delbove H, de Corbière S, Fugain C, Freche C, Chabolle F. Photochemotherapy in the treatment of carcinoma of the vocal cords of early stage (Tis, T1). *Ann Otolaryngol Chir Cervicofac* 1996;113:155–161.
76. Schweitzer VG. Photofrin-mediated photodynamic therapy for treatment of early stage oral cavity and laryngeal malignancies. *Lasers Surg Med* 2001;29:305–313.
77. Ferri E, Armato E. Diode laser microsurgery for treatment of Tis and T1 glottic carcinomas. *Am J Otolaryngol* 2008;29:101–105.
78. Zeitels SM, Burns JA, Lopez-Guerra G, Anderson RR, Hillman RE. Photoangiolytic laser treatment of early glottic cancer: a new management strategy. *Ann Otol Rhinol Laryngol Suppl* 2008;199:3–24.
79. Solares CA, Strome M. Transoral robot-assisted CO2 laser supra-glottic laryngectomy: experimental and clinical data. *Laryngoscope* 2007;117:817–820.

Chapter 26

Multidisciplinary Management of Skull Base and Superstructure Tumors

Giulio Cantù, Carlo L. Solero, Stefano Riccio, Sarah Colombo, and Madia Pompilio

Abstract Malignant tumors of the paranasal sinuses are rare, accounting for only 3% of all the head and neck malignancies. As a consequence, no report of a randomized clinical trial about different treatments has been published, and the chance to perform such a trial is remote. However, the combination of surgery and (chemo)-radiotherapy seems to offer better local control than radiotherapy alone.

The treatment of skull base tumors is, by definition, a multidisciplinary work. Even in cases where surgery may be the only treatment, at least a neurosurgeon and a head and neck surgeon must collaborate to reach good results avoiding complications. Plastic and reconstructive surgeons, radiologists, anesthesiologists, critical care and rehabilitations experts, and nurses are also indispensable. Moreover, the quite steady indication for pre- or postoperative (chemo)-radiotherapy involves the involvement of medical oncologists and radiotherapists in the therapeutic team.

This chapter will demonstrate in details the above-mentioned principles, mentioning the more recent papers on this topic and my own large experience in the treatment of malignant skull base tumors. Moreover, I will take into consideration the most frequent histologic types and their different etiology and standard or experimental treatment.

Keywords Sinonasal cancer • Skull base • Paranasal sinus • Reconstructive surgery

Introduction

Malignant tumors of the paranasal sinuses account for only 2–3% of the head and neck carcinomas and about 0.5% of all malignancies [1]. The low incidence and great variety of histologic types means that there are no large studies on

management of these tumors. No randomized clinical trials about different treatments have been published, and the chance to perform such a trial is remote.

Etiology

A possible occupational etiology of sinonasal cancers was first hypothesized in 1890, when a maxillary tumor was detected in a worker exposed to chrome [2]. An increased risk of sinonasal cancer has been demonstrated among workers exposed to formaldehyde, nickel, and chrome. Tobacco and alcohol are not considered major risk factors, even though heavy smokers have an increased risk of squamous cell carcinoma (SCC) [3].

The most interesting paranasal sinus tumor, for which there is an indisputable occupational etiology, is ethmoid adenocarcinoma, mainly Intestinal Type Adenocarcinoma (ITAC). Wood dust exposure as a risk factor for sinonasal cancers was recognized in 1968 by Acheson et al. [4]. Several papers have since been published on the occupational etiology of these tumors [5–9], including leather dust as a major risk factor [8]. These papers have a possible bias for properly classifying the histology and site of tumor. Some of the studies use the generic terms “nasal cancer” [4, 8], “nasal and sinonasal cancer” [9], and “sinonasal cancer” [3, 7]. Only one paper correctly stated in the title both the histology (adenocarcinoma) and location of the tumor (ethmoid sinus) [6]. Hadfield [5], who analyzed 92 patients with sinonasal cancer (34 SCC, 35 adenocarcinomas, and 23 anaplastic carcinomas), found that the tumor appeared to originate in the ethmoid sinus in all 35 patients with adenocarcinoma. This fact was confirmed in a later paper [10].

We carefully assessed the histology and tumor origin of 499 patients with sinonasal malignant tumors treated at the Istituto Nazionale dei Tumori of Milan between 1987 and 2001 [11]. Of the 249 patients with ethmoidal tumors, 124 (49.8%) had adenocarcinoma, and 90.4% of the adenocarcinoma patients had a history of wood or leather dust exposure. Of the remaining 125 patients with ethmoidal tumors

G. Cantù (✉)
Department of Cranio-Maxillo-Facial Surgery, Fondazione IRCCS
Istituto Nazionale dei Tumori, National Cancer Institute,
Via Venezian 1, Milano 20133, Italy
e-mail: gcantu43@gmail.com

other than adenocarcinoma, only 2 (1.6%) had been exposed to these dusts. The remaining 250 patients had non-ethmoidal sinonasal tumors, 17 of which (6.8%) were adenocarcinomas. No wood or leather dust exposure was reported in any of these patients.

The different role of hardwoods and softwoods in tumor development remains largely unknown. Some authors [9, 12] in Northern Europe (where furniture industries employ mainly softwoods) highlighted a minor and different carcinogenetic power of softwoods compared to the hardwoods that are more often employed in Southern Europe. The authors found an association between hardwood dust exposure and adenocarcinoma, while softwood dust exposure alone was associated with epidermoid and anaplastic carcinomas. However, there is a general consensus about the danger posed by a working environment with over 5 mg/m³ of wood dust, while some [13] suggest a lower dust level of 1 mg/m³.

Sinonasal tumors treated with an anterior craniofacial resection had different histological compositions in Europe compared to North America. The rate of adenocarcinomas in European countries is very high: Roux [14] (France) 74%, Suarez [15] (Spain) 53%, Cantu [16] (Italy) 49%, Cheesman [17] (United Kingdom) 27%. Conversely, the rates are much lower in American studies: McCutcheon [18] (USA) 17%, Bentz [19] (USA) 12%, Donald [20] (USA) 6%, and Irish [21] (Canada) 5%. Bridger [22] (Australia) reports 37% of sinonasal tumors were adenocarcinoma, consistent with the UK study. While no definitive explanation for these discrepancies exists, Blot et al. [23] hypothesizes the following:

- While the commonly accepted threshold for the level of wood dust in the air is 5 mg/m³, many European artisan furniture factories and joinery may have exceeded that threshold.
- Hardwoods, which are more dangerous than softwoods, are probably more widespread in Europe than in America.
- America adopted safety measures, such as masks and aspiration devices, earlier than Europe. Given that these tumors have a latent period of about 30–40 years between the beginning of exposure and clinical presentation [24], there will probably be a reduction in the incidence of this disease in Europe over the next decades resulting from the improved factory conditions.

Polymorphisms in xenobiotic metabolizing enzymes play an important role in the gene–environment interaction and may contribute to a high degree of variance in the individual susceptibility to cancer development. The Experimental Molecular Pathology Unit of our Institution investigated the role of polymorphisms in the CYP1A1 and GSTM1 genes in 30 ethmoid ITAC patients and 79 healthy blood donors [25]. The results revealed that patients with the CYP1A1 codon 461 polymorphism may be at an increased risk of developing ITAC, and that this risk increases in the presence of both the

polymorphism at this CYP1A1 codon and the GSTM1-null genotype. Our study strongly suggests that these genotype investigations may be useful in determining the exposed individuals who are at risk for developing ethmoid ITAC.

Pathology and Natural History

Excluding the nasal cavity, the maxillary sinus is the most frequent site of tumor origin (70–75%), followed by the ethmoid sinus (20–25%). Primary tumors in the frontal or sphenoid sinus are unusual, even though these sinuses are sometimes involved in large neoplasms.

The most common histologic type in maxillary sinus is SCC, more or less differentiated, followed by tumors affecting minor salivary glands: adenocarcinoma (ADE), adenoid cystic carcinoma (ACC), and mucoepidermoid carcinoma (MEC). Sarcomas (malignant fibrous histiocytoma, malignant peripheral nerve sheath tumors, chondro-, osteo-, fibro-, leiomyo-, and angiosarcomas) are rare. Rhabdomyosarcomas are more frequent, particularly during childhood [26]. In the ethmoid sinus, in addition to SCC and ITAC, other common histologies include sinonasal undifferentiated carcinomas (SNUC), melanomas, and sinonasal neuroendocrine tumors: esthesioneuroblastomas (ENB), neuroendocrine carcinomas (NEC), and small cell carcinoma neuroendocrine type (SCCNET) [26].

These tumors often grow silently, meaning that patients often present with advanced-stage disease. The air-filled sinus cavities do not offer resistance to tumor growth, and the tumor becomes symptomatic only after it erodes the bony walls. A tumor of the maxillary sinus may affect the hard palate and alveolar ridge inferiorly, the orbit superiorly, the cheek anteriorly, or the pterygoid plates posteriorly. These tumors may also invade the pterygopalatine and infratemporal fossa, the greater wing of the sphenoid and the middle cranial fossa. A tumor of the ethmoid may spread inferiorly into the nasal cavity, laterally into the orbit, posteriorly into the sphenoid sinus and nasopharynx, or superiorly into the anterior cranial fossa (after eroding the cribriform plate). The medial periorbital provides an effective barrier against tumor invasion, but the natural holes in this structure (lacrimal duct, anterior and posterior ethmoidal arteries) are roads for tumor invasion into the orbital contents. Although the dura is resistant to tumor growth, the olfactory nerves allow for the tumor to spread intradurally.

The lymphatics from the anterior part of maxillary sinus drain through the facial lymphatic vessel into the nodes at level I and II. Lymphatics from the ethmoid and posterior part of maxillary sinus drain into the lateral retropharyngeal nodes, which lead to the deep cervical chain.

Neck metastases are an unfavorable prognostic factor [27–33], although the incidence of neck metastases at

presentation is low. The meta-analysis by Dulguerov et al. [27] reported about 12% of patients presented with neck metastases, although the incidence of nodal metastases during the follow-up period was around 13%.

In a previous paper [34], we reviewed the medical records of 704 consecutive patients surgically treated for paranasal sinuses malignant tumors (305 ethmoid sinus tumors and 399 maxillary sinus tumors). Nodal metastases from ethmoid tumors were very rare, both at presentation (1.6%) and during follow-up (4.3%). Moreover, the majority of subsequent neck metastases appeared with a recurrence of the primary tumor. Only patients with SNUC, NEC, or SCCNET had a high rate of regional recurrence (25%), and these tumors probably behave similarly to nasopharyngeal undifferentiated carcinoma in this regard. In the maxillary sinus, the rate of neck metastases for non-squamous cell carcinomas was very low at presentation (6%). Subsequent nodal metastases were rare, except in SNUC (13%) and ADE (22.2%). Actually, ADE of maxillary sinus originates in the minor salivary glands and acts like ADE of the major salivary glands. This type of cancer is very different from ITAC of the ethmoid sinus, which rarely metastasized regionally.

Only 16 of the 156 patients with SCC of the maxillary sinuses presented with nodal lesions (10.3%), of which eleven patients were staged as T2, one was as T3, three were considered T4a and one was stage T4b. All five of the patients with T3–T4 tumors had involvement of the oral mucosa as well. Four of the 26 (15.4%) patients with SNUC presented with nodal lesions, as did 13 of the 217 (6%) patients with other histologic types. These data strongly suggest that a higher percentage of stage T2 tumors present with cervical metastases than stage T3–T4 tumors. By definition, a T2 tumor involves the floor of maxillary sinus (with possible mucosal invasion of the hard palate and upper gum) and/or the inferior nasal cavity, both of which have a more expansive lymphatic network than the mucosa of paranasal sinuses. Therefore, in terms of lymph node metastases, these tumors have a behavior more similar to oral cancers than paranasal cancers. The fact that paranasal sinus carcinoma behaves differently than other head and neck carcinomas was first recognized in 1937 by del Regato [35] and has been confirmed by numerous authors [27, 32].

Symptoms

While tumors affecting the hard palate or nasal cavity may cause symptoms early, superstructure tumors are asymptomatic for a long time, making an early diagnosis difficult. When the tumor is located in the ethmoid sinus or the upper part of the nasal cavity, patients may present with only unilateral nasal obstruction. Epistaxis generally

occurs only in vascular tumors (hemangiopericytoma and esthesioneuroblastoma), with the patient often complaining of blood-stained secretions. More advanced tumors that have invaded the nasolacrimal duct and orbit may cause epiphora, proptosis, and diplopia. The tumor may also invade the orbital apex posteriorly, causing ophthalmoplegia and visual loss, the sphenoid sinus and the nasopharynx. Anterior involvement of the nasal bones produces a characteristic broadening of the upper nasal region. Although few patients report anosmia as a first symptom, almost all patients remember some loss of smell when specifically asked. Incredibly, tumor invasion of the anterior cranial fossa is generally silent. Invasion of the infraorbital nerve, leading to dysesthesia and pain at the level of the cheek and upper lip, is often misdiagnosed as trigeminal neuralgia. A tumor invading the infratemporal fossa may infiltrate the third branch of the fifth cranial nerve at the foramen ovale, causing dysesthesia, pain and anesthesia of the chin, inferior teeth (mandibular nerve), and omolateral tongue (lingual nerve). In our series, some patients had these symptoms for over a year prior to diagnosis, particularly with slow-growing tumors like adenoid cystic carcinoma. A tumor can infiltrate the pterygoid muscles, causing trismus, and it may also erode the greater wing of the sphenoid, spreading into the middle cranial fossa.

Staging

Establishing a consistent prognostic staging system for each extension of paranasal sinus carcinoma has proven difficult, as demonstrated by the numerous classification schemes previously published [36–41]. All systems only considered tumors of the maxillary sinus and assigned a higher stage for tumors with posterosuperior extension. In 1906, Sebileau [42] realized that the prognosis of tumors differed depending on their location, either inferiorly or superiorly in the paranasal sinuses. He divided the upper jaw with two horizontal parallel “imaginary lines” into “*infrastructure, mesostructure and suprastructure*”. In 1933, Öhngren [43] recognized that Sebileau’s system did not address posterior extension of the tumor and proposed a classification system based upon a hypothetical plane passing through the inner canthus and the mandibular angle. The “*malignancy plane*” divided the upper jaw into an infrastructure (“*topographically more benign tumors*”) and a suprastructure (“*tumors of more malignant character*”). Öhngren’s line was the basis for the division between T1–T2 and T3–T4 maxillary sinus carcinomas in the first four versions of the American Joint Committee on Cancer (AJCC) classifications [44–47]. According to these guidelines, the maxillary sinus was “the only site to which the following classification applies. The ethmoid sinus and nasal cavity may ultimately be defined similarly with further study.”

While the AJCC partially staged paranasal sinus carcinoma from the beginning, the International Union Against Cancer (UICC) did not stage paranasal sinus tumors in the first three editions of its manuals. A classification of maxillary sinus carcinoma, similar to that of the AJCC, appeared only in the fourth edition in 1987 [48].

Several studies of the AJCC-UICC classification of maxillary sinus carcinoma have demonstrated its prognostic value, with a progressive worsening of the prognosis from T1 to T4. The absence of a universally accepted classification of ethmoid cancer led to an obvious lack of disease staging in the literature. Sisson [49] wrote: “The ethmoid cancers were not staged because there is no generally accepted staging system for this site.” Similarly, after having staged tumors of the maxillary sinus, Spiro [50] wrote: “As there is no widely accepted staging system for the remaining sinuses or the nasal cavity, no attempt was made to stage tumors arising in these sites.” In fact, some authors have tried to stage nasoethmoid tumors. Kadish [51], Biller [52], and Dulguerov [53] proposed a classification for esthesioneuroblastomas. Ellingwood [54] and Roux [55] published a classification for tumors of the nasal cavity and ethmoid–sphenoid sinuses. Despite of their historical significance, these classification systems were never tested in large-scale studies to determine their prognostic value. In 1997, the fifth edition of both the AJCC and UICC guidelines contained an unambiguous staging system for cancers of the maxillary sinus, nasal cavity and ethmoid sinus. Even if the terms “*infrastructure*” and “*superstructure*” formally disappeared, the concept of tumors divided by Öhngren’s line having differing prognosis was present in the fifth and sixth edition of the AJCC-UICC guidelines.

In the absence of a universally accepted staging system, we presented in 1997 an original classification for malignant ethmoid tumors [56] based on the most commonly accepted prognostic factors, including involvement of dura mater, intradural extension, involvement of the orbit (particularly the apex), invasion of maxillary, frontal and/or sphenoidal sinus, and invasion of the infratemporal fossa and skin (Table 26.1). In 2005, we tested our original classification for ethmoid tumors (*INT* – Istituto Nazionale Tumori) in terms of prognostic performance versus the fifth and sixth AJCC-UICC classifications [57–60] (Table 26.2). Both the 1997 and 2002 AJCC-UICC classification systems seemed to have limited prognostic value. In contrast, our *INT* classification demonstrated the progressive worsening of prognosis with different tumor classes for the overall series, when applied separately to untreated and recurring cases, and when applied only to adenocarcinomas, the most frequent histologic type in our series [61].

We agree with Dulguerov et al. [62], who stated in a recent review that “while the evolution of TNM staging is a work in continuous progress, the T staging of ethmoid and nasal primaries needs an urgent revision.”

Table 26.1 *INT* classification of ethmoid tumors

T1	Tumor involving the ethmoid and nasal cavity but sparing the most superior ethmoidal cells
T2	Tumor with extension to, or erosion of, the cribriform plate, with or without erosion of the lamina papyracea and without extension into the orbit
T3	Tumor extending into the anterior cranial fossa extradurally and/or into the anterior two-thirds of the orbit, with or without erosion of the anteroinferior wall of the sphenoid sinus, and/or involvement of the maxillary and frontal sinus
T4	Tumor with intradural extension, or involving the orbital apex, the sphenoid sinus, the pterygoid plate, the infratemporal fossa or the skin

Table 26.2 AJCC-UICC-2010 classification of nasal cavity and ethmoid sinus

T1	Tumor restricted to any one subsite, with or without bony invasion
T2	Tumor invading two subsites in a single region or extending to involve an adjacent region within the nasoethmoidal complex, with or without bony invasion
T3	Tumor extends to invade the medial wall or floor of the orbit, maxillary sinus, palate, or cribriform plate
T4a	Moderately advanced local disease. Tumor invades any of the following: anterior orbital contents, skin of nose or cheek, minimal extension to anterior cranial fossa, pterygoid plates, sphenoid or frontal sinuses
T4b	Very advanced local disease. Tumor invades any of the following: orbital apex, dura, brain, middle cranial fossa, cranial nerves other than (V ₂), nasopharynx, or clivus

Used with the permission of the American Joint Committee on Cancer (AJCC), Chicago, IL. The original source for this material is the AJCC Cancer Staging Manual, Seventh Edition (2010) published by Springer Science and Business Media LLC, www.springer.com

Imaging

All patients with a malignant tumor of the superstructure must undergo a high-resolution contrast-enhanced computer tomography (CT) in axial and coronal planes, and/or a multiplanar magnetic resonance imaging (MRI) enhanced with gadolinium. CT is helpful in determining the erosion of the bones surrounding the paranasal cavities and the involvement of the skull base. Although CT soft tissue windows are essential to evaluate intracranial or intraorbital extension of the tumor, MRI allows a better distinction of tumor from the adjacent soft tissue (orbital contents, dura, brain, cavernous sinus, infratemporal fossa, and carotid artery). Although neck nodes metastases are unlikely for these tumors, CT or MRI must be extended to the neck, and chest CT or positron emission tomography (PET scan) may be useful to exclude distant metastases.

Histologic Diagnosis

A biopsy is mandatory for a histologic diagnosis. The biopsy must be made in representative tissue, avoiding necrotic vegetations. An endoscopic approach, sometimes in the operating room, is almost always sufficient for a proper biopsy. An open procedure should be avoided, except in cases where an endoscopic approach is impossible.

We recommend all histologic slides be read separately by two experienced pathologists. Cohen et al. [63] report a high rate of misdiagnosis of olfactory neuroblastoma, as the diagnosis was changed by the pathologists at the M.D. Anderson Cancer Center in 10 out of 12 cases. In our experience, the rate of changing diagnosis is not as high, with our pathologist changing the previous diagnosis in about 20% of cases. Because the treatment regimens and prognosis of tumor types are often significantly different, the correct diagnosis should be confirmed before initiating treatment.

Prognostic Factors

Significant prognostic factors include the histologic findings of the primary tumor, the presence of neck nodes metastases, the status of surgical margins, and the extent of intracranial and intraorbital involvement. Tumor histology is statistically related to outcome. Patients with mucosal melanoma and undifferentiated carcinoma (SNUC, NEC, and SCCNET) have the worse outcome, whereas those with minor salivary gland tumors, esthesioneuroblastomas, and low-grade sarcomas have the best outcomes [27, 64]. However, one must remember that tumors like adenoid cystic carcinoma and esthesioneuroblastoma may recur after a long period of time, so the common reported 5-year survival may be misleading. Patients with ITAC have a better disease-specific survival than those with squamous cell carcinoma [34, 64, 65].

Although neck metastases are rare, their presence, whether upon presentation or later, worsens the prognosis for patients with ethmoid and maxillary sinus tumors. In the ethmoid sinus group of our series, 5-year survival rates were 45.3% in patients with N0 tumors versus 0% in those with N+ (N1, N2, or N3) tumors. In the maxillary sinus group, the corresponding 5-year survival rates were 50.6% and 16.8% [34]. No patients with ethmoid malignant tumors and nodal metastases, either at presentation or during follow-up, survived. For patients with maxillary sinus tumors, the situation was similar, although slightly less dramatic.

Because local failure is the most common cause of death, the status of surgical margins is an important prognostic factor [64, 66, 67]. As tumors of the superstructure often involve

the skull base and orbit, patients with these extensions have a worse prognosis. Therefore, craniofacial surgical techniques are mandatory to try to reach negative surgical margins.

Treatment

The treatment of tumors of the superstructure is by definition a multidisciplinary field. A wide variety of management approaches have been advocated and practiced in the past, and there is currently no standard treatment. The most common approaches involve some combination of surgery, radiation, and chemotherapy. The timing and combination of these three therapeutic means is dictated by the histology, locations, and extensions of the tumor. As surgery often entails a craniofacial resection, this treatment may also be dictated by the expertise of the surgical team.

Given the rarity of malignant tumors of paranasal sinuses, particularly tumors of the superstructure, the retrospective studies published by individual institutions are often based on a small number of patients with a diversity of histologic findings and tumor extension. Most studies also have selection bias, as higher proportions of patients with favorable lesions are found mainly in the surgery groups, whereas most patients with advanced disease, unfavorable histology, and/or unresectable tumors are found in the (chemo) radiation groups.

Nevertheless, the combination of surgery and (chemo)radiotherapy seems to offer better local control than radiotherapy alone, as "the meta-analysis confirmed that surgery and combined surgery and radiation offer better local control and cure rates than radiotherapy alone" [27]. Another study concluded that "surgery and postoperative radiation therapy may result in improved local control, absolute survival, and complications when compared with radiation therapy alone" [28]. Surgery and postoperative (chemo)-radiotherapy is considered the treatment of choice in most centers, even if some continue to prefer primary radiotherapy [68].

Surgery

For many years, surgical treatment of paranasal sinus cancers remained little more than a piecemeal resection. Lizars of Edinburgh, in 1826, proposed entirely removing the superior maxillary bone, and performed the first resection in 1829. He accurately described the procedure, although he could not remove the posterior portion of the tumor around the pterygoid process [69]. The goal of surgery is complete, en bloc resection of the malignant tumor with negative margins. Unfortunately, given the frequent extensions of these

tumors into the orbit, infratemporal fossa, middle and/or anterior cranial fossa, tumors involving the superstructure were considered unsuitable for a radical resection until the 1960s. Innovative surgical approaches into the pterygomaxillary and infratemporal fossa for tumors with posterior extension were introduced by pioneers such as Conley [70] and Crockett [71]. In 1970, Dingman and Conley [72] wrote, “In the standard maxillectomy, the posterior chisel cut is made in the pterygomaxillary sulcus, thus freeing the maxilla from the lateral process of the pterygoid lamina. Examination of a skull shows that this margin is inconsistent with good tumor management for many maxillary cancers with posterior extensions. Failure at this margin is often responsible for failure to effect local control of the maxillary cancers, and has led many clinicians away from surgery as a method of primary treatment. The obvious extension of the maxillectomy operation is the inclusion of the pterygoid plates and muscles to form the posterior margin of the specimen. When the surgeon attempts this by the anterior, or Weber-Fergusson approach, he finds that he must develop this critical margin in a cavity filled with blood, within several mm of the internal carotid artery”. After this publication, the anterolateral approach became the standard treatment for tumors involving the pterygomaxillary fossa.

Similarly, paranasal sinus tumors invading the skull base (middle or anterior cranial fossa) continued to be considered unresectable. Some isolated reports in the 1950s discussed a craniofacial approach to tumors of the frontal sinus [73, 74]. However, in 1963, Ketcham [75] was the first to report a remarkable series of patients with tumors involving the anterior skull base who were treated with a combined transcranial and transfacial approach. Today, anterior craniofacial resection is the standard treatment for these tumors, and the prognostic factors have been quite well established [76, 77]. Ketcham, a head and neck surgeon, began his enterprise with Van Buren (a neurosurgeon) and they published articles [78] stressing the importance of this collaboration: “Although some may consider a neurosurgeon helpful but not necessary for this surgical undertaking, his preoperative evaluation and intraoperative handling of the skull, dura, and sometimes the brain contributes to a lower rate of complications and a greater cure rate.”

Given the concept of a double approach (Fig. 26.1), surgical resection must be tailored to the tumor’s specific extension. For an ethmoid tumor involving the anterior cranial fossa but sparing the maxillary sinus and the orbit, a total ethmoidectomy with medial maxillectomy is the standard treatment. The anterior and inferior walls of the sphenoid sinus and the lamina papyracea must always be removed to allow for a radical resection (Fig. 26.2). For tumors with intracranial extension, the dura should always be resected and reconstructed, especially when infiltrated. Intradural invasion is usually a contraindication for surgery. In our series of anterior craniofacial resections for superstructure

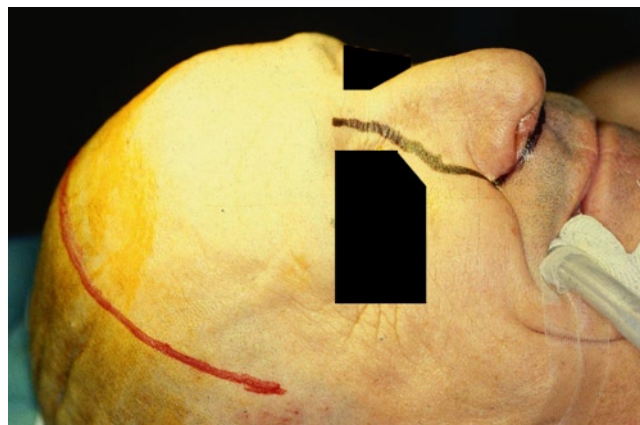


Fig. 26.1 Our standard coronal and lateral rhinotomy incisions for an anterior cranio-facial resection. The lateral rhinotomy incision without lip-splitting provides adequate exposure for total ethmoidectomy and medial maxillectomy

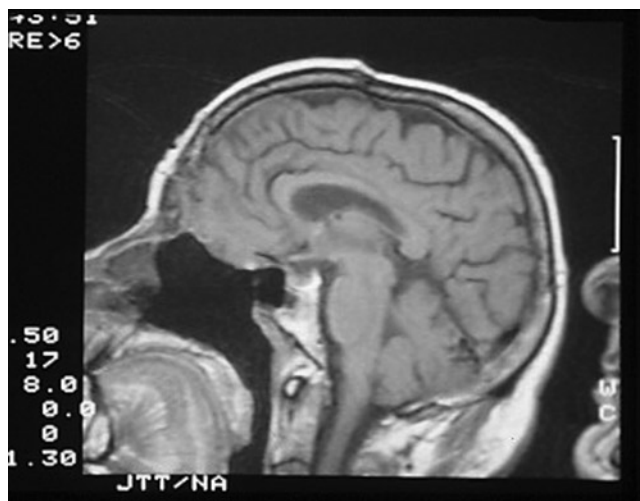


Fig. 26.2 Sagittal postoperative MR image showing total ethmoidectomy with resection of the anterior wall of the sphenoid sinus

malignant tumors, only some patients with esthesioneuroblastomas and intradural extension survived [61].

When the tumor has invaded the lamina papyracea, the medial periorbital layer should be resected, even if it is uninvolved. An orbital exenteration is required if the tumor has invaded the orbit deeply. Sometimes the orbital contents may be preserved, but the medial and inferior walls of the orbit must be removed. In these cases, alloplastic materials and free bone grafts are not a good choice for reconstruction as most of these patients will undergo postoperative radiotherapy, with probable extrusion of these materials. In spite of reconstruction with vascularized flaps, patients may complain of possible dysfunction of the eye, especially if postoperative radiotherapy is used [79].

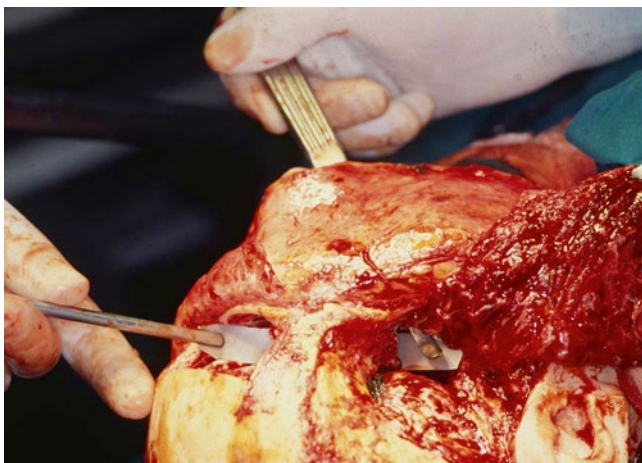


Fig. 26.3 Anterolateral craniofacial resection for a superstructure tumor involving both anterior and middle cranial fossa. After the resection of the tumor, the surgical instruments, introduced through the transfacial and anterior transcranial approaches, cross in the infratemporal fossa where the temporal lobe is exposed

For tumors involving the anterior cranial fossa, the posterior wall of the maxillary sinus, and the infratemporal fossa, a combined anterior craniofacial and infratemporal approach is mandatory, as the pterygoid plates and muscles must be removed. Sometimes the greater wing of the sphenoid may also be infiltrated requiring an anterolateral craniofacial resection [80] (Fig. 26.3). Following these resections, especially orbital exenterations, a vascularized free flap is required for a good functional and cosmetic reconstruction.

In the last decade, a number of papers have discussed endoscopic resection of malignant tumors involving the anterior skull base. While most include a small number of patients with brief follow-up, one paper from two Italian university hospitals report a number of purely endoscopic resections for T1–T2 ethmoid adenocarcinoma (12 cases) and squamous cell carcinoma (4 cases), with a median follow-up of 47 months. The 5-year disease-specific survival of these patients was 93% [81]. In a following paper from the same institutions, 134 patients were treated with an endoscopic approach alone while 50 cases used a combined craniotomoscopic approach [82]. The 5-year disease-specific survival was 91% for patients treated with endoscopic approach and 58% for those who underwent craniotomoscopic resection. Tumor size differed between the two groups, with the larger tumors requiring the craniotomoscopic approach. Nevertheless, the authors conclude that when properly planned and completed by an experienced surgeon, endoscopic surgery is a valid alternative to standard surgical approaches for the management of selected malignancies of the sinonasal tract.

We believe that regardless of method, resection of the sinonasal component of the tumor must be radical, especially

with intestinal type adenocarcinomas. As mentioned above, ITAC is a professional disease involving the whole ethmoid sinus. As the metaplastic transformation of ethmoidal mucosa to enteric-type epithelium precedes the development of enteric adenocarcinoma [83, 84], pre-neoplastic or neoplastic foci may be present in macroscopically uninvolved sites of ethmoid. In some cases, we found small tumor localizations in the contralateral ethmoid. These foci were separate from the apparent primary tumor and undetected by CT, MRI, and PET. As ITAC is a locally aggressive tumor that easily infiltrates the underlying bone [85], we believe that a total ethmoidectomy must always be performed. If this can be achieved endoscopically, we welcome such an approach.

Radiotherapy

There are few large-scale studies of patients with paranasal sinus malignant tumors treated with radiotherapy alone, and especially superstructure tumors. The majority of papers looked at a small number of patients, and included those who received postoperative radiotherapy and those treated with radiotherapy alone, but received surgery if radiotherapy failed. Almost all these papers reported combined surgery and radiotherapy worked better than RT alone. Katz et al. [86], discussing their experience in treating malignant tumors of the nasal cavity, and paranasal sinuses (excluding the nasal vestibule and the maxillary sinus), state that “until approximately 17 years ago, most nasal cavity and paranasal sinus tumors were treated with high-dose irradiation alone at the University of Florida. On the basis of our experience, a change in treatment philosophy has occurred such that most patients undergo resection followed by postoperative irradiation. Surgery alone may be acceptable for very early cancers of the nasal cavity. Radiation therapy alone is used in patients with unresectable disease.” Another paper on sinonasal undifferentiated carcinoma from the same institution makes a similar statement: “Our current guidelines are to treat patients with apparently resectable tumor with craniofacial resection and postoperative RT” [87]. Guntinas-Lichius et al. [88] report on 229 patients with nasal and paranasal sinuses cancer treated at a single institution. Although the study suffers from selection bias, patients treated surgically had higher overall survival rates than patients who only received radiotherapy. The multivariate analysis for overall survival revealed that the type of therapy was an independent risk factor. Surgery combined with radio(chemo)therapy achieved better results in comparison to radio(chemo)therapy alone.

Tanzler et al. also wrote that “one advantage associated with combined surgery and RT is that it may be possible to reduce the RT dose and thus reduce the risk of RT-induced optic neuropathy” [87]. Regarding the use of modern

radiotherapy techniques in the postoperative setting, the same authors wrote “Hyperfractionated RT is employed to further reduce the risk of injury to the visual apparatus. Intensity modulated radiotherapy (IMRT) and/or proton beam therapy may be useful to produce a more conformal dose distribution to reduce the dose to normal tissues and, thus, late toxicity” [87]. A paper from the Memorial Sloan-Kettering Cancer Center draws a similar conclusion: “Complete surgical resection followed by adjuvant RT is an effective and safe approach in the treatment of paranasal sinus cancer. Emerging tools, such as three-dimensional conformal treatment and, in particular, intensity-modulated RT for paranasal sinus tumors, may minimize the occurrence of late complications associated with conventional RT techniques” [89].

Regarding neutron radiotherapy, Douglas et al. [90] report a 5-year actuarial local-regional control of 59% of tumors that do not involve the cavernous sinus, base of skull, or nasopharynx. The local-regional control was significantly lower for patients with tumors involving these sites (15%). In a following paper [91], the same authors stated that “variables associated with decreased local-regional control in the patients with gross residual disease as determined by multivariate analysis included base of skull involvement and biopsy only versus an attempted surgical resection prior to treatment.” For proton beam radiation, Pommier et al. [92] concluded that tumor involvement of the sphenoid sinus and clivus are adverse prognostic factors. In a review on proton therapy in clinical practice, Brada et al. [93] concluded that “the lack of available evidence in favor of protons does not mean that protons may not be useful in selected tumors. It should be a stimulus for more research, particularly in the form of appropriately designed and powered prospective studies.”

Chemotherapy

Chemotherapy alone is normally reserved for cancers of the superstructure that are too advanced to be treated by surgery or radiotherapy, patients presenting with metastatic disease, or recurrent disease. However, chemotherapy may have a role into complex multimodal treatment plans along with surgery and radiotherapy.

Beginning in 1970, some Japanese authors reported high cure rates with a combination of intra-arterial chemotherapy with 5-fluorouracil (5-FU), necrotomy, and radiotherapy. Using these treatment combinations, Sato et al. [94] and Sakai et al. [95] achieved a 5-year cumulative survival rate of 67% and 54%, respectively. Other Japanese authors were unable to reproduce these results, concluding that the addition of intra-arterial chemotherapeutic agents to either surgery

[96] or radiotherapy [97] did not improve survival. Shibuya et al. [98] ascribed these contradictory results to the fact that the maxillary tumors receive blood from not only the internal maxillary artery, but also the facial and ethmoidal arteries. These latter arteries arise from the internal carotid artery and are the main feeding vessels of tumor of the ethmoid. This diverse blood flow may cause an irregular distribution of the intra-arterially infused antimetabolites, leading to decreased effectiveness. In order to prevent this situation, physicians have combined superselective intra-arterial chemotherapy with radiotherapy and surgery in the last decade. Studies of this treatment method have reported a 5-year survival of 75% and 53% [99, 100].

Knegt et al. reported an interesting experience using surgical debulking, low dose of irradiation, topically applied cytostatic drug (5-FU), and necrotomy [101]. The actuarial 5-year survival rate for squamous cell carcinoma and undifferentiated carcinoma of the maxillary sinus was 52%, and 100% for patients with adenocarcinoma of the ethmoid sinus. A subsequent paper by the same authors reported their experience in treating 62 patients with ethmoid adenocarcinoma. They performed surgical debulking via an extended anterior maxillary anastomy followed by a combination of repeated topical chemotherapy (fluorouracil) and necrotomy. Eight patients (13%) required additional radiotherapy for local recurrence, while one patient required surgery for regional lymph node metastases. Adjusted disease-free survival at 10 years was 74% [102]. However, we only know of one other reported on this approach to ethmoid adenocarcinoma [103].

There are few reports on the use of systemic chemotherapy in paranasal sinus carcinoma, and sinus squamous cell cancer is not included in many head and neck prospective randomized trials on chemotherapy and/or radiotherapy. The most often applied schedules were platinum-based, with a response rate ranging from 36% to 84% [104]. The combination of primary chemotherapy, surgery, and postoperative (chemo)radiotherapy achieved very high cure rates [105], particularly in cases with pathologic complete remission (pCR) after neoadjuvant chemotherapy [106, 107].

The ability to predict complete response to primary chemotherapy by analyzing predictive biomarkers, such as TP53, is critical to determining the usefulness of chemotherapy. In our institution, 30 patients with ethmoidal ITAC have been enrolled in a phase II study using cisplatin, fluorouracil, and leucovorin (PFL) followed by craniofacial resection and radiation. On surgical specimens, absence of viable tumor cells was defined as pCR. The TP53 status and p53 function, analyzed on pretreatment biopsies, were retrospectively correlated with pathologic results and patient outcome. In patients with wild-type (wt) TP53 or functional p53 protein, pCRs were seen in 83% and 80% of patients, respectively. However, only 11% of patients with mutated TP53 achieved

pCR, whereas no patients (0%) with an impaired p53 protein had pCR. At a median 55-month follow-up, all pCR patients were disease-free, while 44% of nonresponsive patients experienced relapse. These results indicate that differences in TP53 mutational status or protein functionality strongly influence pathologic response to primary chemotherapy and ultimately prognosis. PFL seems to be highly effective in patients with a functional p53 protein, even when encoded by a mutated TP53 gene. However, ITAC patients carrying a dysfunctional p53 protein will not respond to PFL [108]. The fact that only 40% of ITAC patients have a functional p53 protein diminishes our enthusiasm over these results.

Conclusions

The actual prognosis for malignant tumors of the superstructure is still difficult to determine. The reported 5-year local control and survival rates are somewhat unreliable, as these studies include patients with different histologies, localizations, extensions, and treatment strategies. In spite of the best modern treatments available, the prognosis of these tumors continues to be disappointing. Many patients present with advanced-stage tumors and with intracranial and intradural extension. In our study of ethmoid tumors [65], the prognosis of adenocarcinomas and esthesioneuroblastomas was better than for the other histologic types. In particular, the prognosis was very unfavorable for melanomas. Epidermoid carcinomas also had a poor prognosis due to a large number of undifferentiated types. Patients with adenoid cystic carcinomas had a good overall survival, but only a short disease-free survival, as these patients may survive for a long time after local recurrence or lung metastases. Untreated patients had better results compared to patients with relapses after previous treatment, suggesting that for these tumors, the first treatment is often the only treatment. The cure rates of patients with a tumor involving the middle cranial fossa are very low. For these patients, we may only perform surgery to improve the quality of their remaining life [80].

In conclusion, we must employ multidisciplinary treatments for these tumors, and translational research must continue to help improve how and when such treatments are used.

References

- Muir CS, Nectoux J. Descriptive epidemiology of malignant neoplasms of nose, nasal cavities, middle ear and accessory sinuses. *Clin Otolaryngol Allied Sci*. 1980;5:195–211.
- Newman DA. A case of adeno-carcinoma of the left inferior turbinate body, and perforation of the nasal septum, in the person of a worker in chrome pigments. *Glasgow Med J*. 1890;33:469–70.
- Manette A, Kogevinas M, Luce D, et al. Sinonasal cancer, occupation, and tobacco smoking in European women and men. *Am J Ind Med*. 1999;36(1):101–7.
- Acheson ED, Cowdell RH, Hadfield E, Macbeth RG. Nasal cancer in woodworkers in the furniture industry. *Br Med J*. 1968;2:587–96.
- Hadfield EH. A study of adenocarcinoma of the paranasal sinuses in woodworkers in the furniture industry. *Ann R Coll Surg Engl*. 1970;46(6):301–19.
- Klintonberg C, Olofsson J, Hellquist H, et al. Adenocarcinoma of the ethmoid sinuses. A review of 28 cases with special reference to wood dust exposure. *Cancer*. 1984;54(3):482–8.
- Luce D, Leclerc A, Morcet JF, et al. Occupational risk factors for sinonasal cancer: a case-control study in France. *Am J Ind Med*. 1992;21(2):163–75.
- Acheson ED. Nasal cancer in the furniture and boot and shoe manufacturing industries. *Prev Med*. 1976;5(2):295–315.
- Hernberg S, Westerholm P, Shultz-Larsen K, et al. Nasal and sinonasal cancer. Connection with occupational exposures in Denmark, Finland and Sweden. *Scand J Work Environ Health*. 1983;9(4):315–26.
- Hadfield EH, Macbeth RG. Adenocarcinoma of the ethmoids in furniture workers. *Ann Otol Rhinol Laryngol*. 1971;80(5):699–703.
- Bimbi G, Saraceno MS, Riccio S, et al. Adenocarcinoma of the ethmoid sinus: an occupational disease. *Acta Otorhinolaryngol Ital*. 2004;24(4):199–203.
- Voss R, Stenersen T, Roald Hoppedal B, et al. Sinonasal cancer and exposure to softwood. *Acta Otolaryngol*. 1985;99(1–2):172–88.
- Carton M, Goldberg M, Luce D. Occupational exposure to wood dust. Health effects and exposure limit values. *Rev Epidemiol Sante Publique*. 2002;50(2):159–78.
- Roux FX, Pages JC, Nataf F, et al. Malignant ethmoid-sphenoidal tumors. 130 cases. Retrospective study. *Neurochirurgie*. 1997;43(2):100–10.
- Suarez C, Suarez C, Llorente JL, Fernandez De Leon R, et al. Prognostic factors in sinonasal tumors involving the anterior skull base. *Head Neck*. 2004;26(2):136–44.
- Cantu G, Solero CL, Miceli R, et al. Which classification for ethmoid malignant tumors involving the anterior skull base? *Head Neck*. 2005;27(3):224–31.
- Cheesman AD. Craniofacial resection for tumors of the nasal cavity and paranasal sinuses. *Head Neck Surg*. 1986;8(6):429–35.
- McCutcheon IE, Blacklock JB, Weber RS, et al. Anterior transcranial (craniofacial) resection of tumors of the paranasal sinuses: surgical technique and results. *Neurosurgery*. 1996;38(3):471–9. discussion 479–80.
- Bentz BG, Bilsky MH, Shah JP, et al. Anterior skull base surgery for malignant tumors: a multivariate analysis of 27 years of experience. *Head Neck*. 2003;25(7):515–20.
- Donald PJ. Complications in skull base surgery for malignancy. *Laryngoscope*. 1999;109(12):1959–66.
- Irish JC, Gullane PJ, Gentili F, et al. Tumors of the skull base: outcome and survival analysis of 77 cases. *Head Neck*. 1994;16(1):3–10.
- Bridger GP, Kvok B, Baldwin M, et al. Craniofacial resection for paranasal sinus cancers. *Head Neck*. 2000;22(8):772–80.
- Blot WJ, Chow WH, McLaughlin JK. Wood dust and nasal cancer risk. A review of the evidence from North America. *J Occup Environ Med*. 1997;39(2):148–56.
- Nylander LA, Dement JD. Carcinogenetics effects of wood dust: review and discussion. *Am J Ind Med*. 1993;24(5):619–47.
- Pastore E, Perrone F, Orsenigo M, et al. Polymorphisms of metabolizing enzymes and susceptibility to ethmoid intestinal-type adenocarcinoma in professionally exposed patients. *Transl Oncol*. 2009;2(2):84–8.
- Barnes L, Everson JW, Reichart P, et al. World Health Organization classification of tumours: pathology & genetics-head and neck tumours. Lyon, France: IARC Press; 2005.

27. Dulguerov P, Jacobsen MS, Allal AS, et al. Nasal and paranasal sinus carcinoma: are we making progress? *Cancer*. 2001;92(12):3012–29.
28. Katz TS, Mendenhall WM, Morris CG, et al. Malignant tumors of the nasal cavity and paranasal sinuses. *Head Neck*. 2002;24(9):821–9.
29. Schantz SP, Harrison LB, Forastiere AA. Tumors of the nasal cavity and paranasal sinuses. In: De Vita Jr VT, Hellman S, Rosenberg SA, editors. *Cancer. Principles & practice of oncology*. 6th ed. Philadelphia: Lippincott Williams & Wilkins; 2001. p. 819–24.
30. Le QT, Fu KK, Kaplan MJ, Terris DJ, et al. Lymph node metastasis in maxillary sinus carcinoma. *Int J Radiat Oncol Biol Phys*. 2000;46(3):541–9.
31. Paulino AC, Fisher SG, Marks JE. Is prophylactic neck irradiation indicated in patients with squamous cell carcinoma of the maxillary sinus? *Int J Radiat Oncol Biol Phys*. 1997;39(2):283–9.
32. Kim GE, Chung EJ, Lim JJ, et al. Clinical significance of neck node metastasis in squamous cell carcinoma of the maxillary antrum. *Am J Otolaryngol*. 1999;20(6):383–90.
33. Bhattacharyya N. Factor affecting survival in maxillary sinus cancer. *J Oral Maxillofac Surg*. 2003;61(9):10016–1021.
34. Cantù G, Bimbi G, Miceli R, et al. Lymph node metastases in paranasal sinuses malignant tumors: prognostic value and treatment. *Arch Otolaryngol Head Neck Surg*. 2008;134(2):170–7.
35. del Regato JA. Roentgentherapy in epitheliomas of the maxillary sinus. *Surg Gynecol Obstet*. 1937;65:657–65.
36. Sisson GA, Johnson NE, Amiri CS. Cancer of the maxillary sinus. Clinical classification and management. *Ann Otol Rhinol Laryngol*. 1963;72(12):1050–9.
37. Sakai S, Hamasaki Y. Proposal for the classification of carcinoma of the paranasal sinuses. *Acta Otolaryngol (Stockolm)*. 1967;63(1):42–8.
38. Lederman M. Cancer of the upper jaw and nasal chambers. *Proc R Soc Med*. 1969;62(1):65–72.
39. Rubin P. Cancer of the head and neck: nose, paranasal sinuses. *JAMA*. 1972;219(3):336–8.
40. Chandler JR, Guillaumondegui OM, Sisson GA, et al. Clinical staging of cancer of the head and neck: a new “new” system. *Am J Surg*. 1976;132(4):525–8.
41. Harrison DF. Critical look at the classification of maxillary sinus carcinomata. *Ann Otol Rhinol Laryngol*. 1978;87(1pt1):3–9.
42. Sebileau P. Les formes cliniques du cancer du sinus maxillaire. *Annales malades d’oreille, du larynx, nez et pharynx*. 1906;32:430–50.
43. Öhngren LG. Malignant tumors of the maxillary-ethmoidal region. *Acta Otolaryngol (Stockolm)*. 1933;19:1–476.
44. AJCC. Manual for staging of cancer 1977. Chicago, IL: American Joint Committee; 1977. p. 45–8.
45. Beahrs OH, Myers MH. AJCC manual for staging of cancer. 2nd ed. Philadelphia, PA: J.B. Lippincott Company; 1983. p. 43–8.
46. Beahrs OH, Henson DE, Hutter RVP, et al. AJCC manual for staging of cancer. 3rd ed. Philadelphia, PA: J.B. Lippincott Company; 1988. p. 45–50.
47. Beahrs OH, Henson DE, Hutter RVP, et al. AJCC manual for staging of cancer. 4th ed. Philadelphia, PA: J.B. Lippincott Company; 1992. p. 45–8.
48. Hermanek P, Sobin LH. UICC TNM classification of malignant tumours. Berlin: Springer; 1987. p. 27–9.
49. Sisson GA, Toriumi DM, Atiyah RA. Paranasal sinus malignancy: a comprehensive update. *Laryngoscope*. 1989;99(2):143–50.
50. Spiro JD, Soo KC, Spiro RH. Nonsquamous cell malignant neoplasms of the nasal cavities and paranasal sinuses. *Head Neck*. 1995;17(2):114–8.
51. Kadish S, Goodman M, Wang CC. Olfactory neuroblastoma. A clinical analysis of 17 cases. *Cancer*. 1976;37(3):1571–6.
52. Biller HF, Lawson W, Sachdev VP, et al. Esthesioneuroblastoma: surgical treatment without radiation. *Laryngoscope*. 1990;100(11):1199–201.
53. Dulguerov P, Calcaterra T. Esthesioneuroblastoma: the UCLA experience 1970–1990. *Laryngoscope*. 1992;102(8):843–9.
54. Ellingwood KE, Million RR. Cancer of the nasal cavity and ethmoid/sphenoid sinuses. *Cancer*. 1979;43(4):1517–26.
55. Roux FX, Brasnu D, Menard M, et al. Combined approach to malignant tumors of the ethmoid and other paranasal sinuses. Principles and results. *Ann Otolaryngol Chir Cervicofac*. 1991;108(5):292–7.
56. Cantù G, Solero CL, Salvatori P, et al. A new classification of malignant ethmoid tumors. 3rd European Skull Base Congress. London, 9–11 April 1997. *Skull Base Surg*. 1997;7 Suppl 2:33.
57. American Joint Committee on Cancer. AJCC cancer staging manual. 5th ed. Philadelphia, PA: Lippincott-Raven; 1997.
58. Sobin LH, Wetteland C, editors. TNM classification of malignant tumours. 5th ed. New York, NY: John Wiley & Sons Inc; 1997.
59. American Joint Committee on Cancer. AJCC cancer staging manual. 6th ed. New York, NY: Springer-Verlag; 2002.
60. UICC. TNM classification of malignant tumours. 6th ed. New York, NY: Wiley-Liss; 2002.
61. Cantù G, Solero CL, Miceli R, et al. Which classification for ethmoid malignant tumors involving the anterior skull base? *Head Neck*. 2005;27(3):224–31.
62. Dulguerov P, Allal AS. Nasal and paranasal sinus carcinoma: how can we continue to make progress? *Curr Opin Otolaryngol Head Neck Surg*. 2006;14(2):67–72.
63. Cohen ZR, Marmor WE, Fuller GN, et al. Misdiagnosis of olfactory neuroblastoma. *Neurosurg Focus Neurosurg Focus*. 2002;12(5):e3.
64. Ganly I, Patel SG, Singh B, et al. Craniofacial resection for malignant paranasal sinus tumors: report of an International Collaborative Study. *Head Neck*. 2005;27(7):575–84.
65. Cantù G, Solero CL, Mariani L, et al. Anterior craniofacial resection for malignant ethmoid tumors – a series of 91 patients. *Head Neck*. 1999;21(3):185–91.
66. Patel SG, Singh B, Polluri A, et al. Craniofacial surgery for malignant skull base tumors: report of an international collaborative study. *Cancer*. 2003;98(6):1179–87.
67. Waldron J, Witterick I. Paranasal sinus cancer: caveats and controversies. *World J Surg*. 2003;27(7):849–55.
68. Waldron JN, O’Sullivan B, Warde P, et al. Ethmoid sinus cancer: twenty-nine cases managed with primary radiation therapy. *Int J Radiat Oncol Biol Phys*. 1998;41(2):361–9.
69. Stell PM. History of surgery of the upper jaw. In: Harrison D, Lund VJ, editors. *Tumours of the upper jaw*. Edinburgh: Ed Churchill Livingstone; 1993. p. 1–15.
70. Conley JJ. The surgical approach to the pterygoid area. *Ann Surg*. 1956;144(1):39–43.
71. Crockett DJ. Surgical approach to the back of the maxilla. *Br J Surg*. 1963;50:819–21.
72. Dingman DL, Conley JJ. Lateral approach to the pterygomaxillary region. *Ann Otol Rhinol Laryngol*. 1970;79(5):967–9.
73. Smith RR, Klopp CT, Williams JM. Surgical treatment of cancer of the frontal sinus and adjacent areas. *Cancer*. 1954;7(5):991–4.
74. Malecki J. New trends in frontal sinus surgery. *Acta Otolaryngol*. 1959;50(2):137–40.
75. Ketcham AS, Wilkins RH, Van Buren JM, et al. A combined intracranial facial approach to the paranasal sinuses. *Am J Surg*. 1963;106:698–703.
76. Patel SG, Singh B, Polluri A, et al. Craniofacial surgery for malignant skull base tumors. Report of an International Collaborative Study. *Cancer*. 2003;98(6):1179–87.
77. Ganly I, Patel SG, Singh B, et al. Craniofacial resection for malignant paranasal sinus tumors: report of an International Collaborative Study. *Head Neck*. 2005;27(7):575–84.
78. Ketcham AS, Van Buren JM. Tumors of the paranasal sinuses: a therapeutic challenge. *Am J Surg*. 1985;150(4):406–13.

79. Stern SJ, Goepfert H, Clayman G, et al. Orbital preservation in maxillectomy. *Otolaryngol Head Neck Surg.* 1993;109(1):111–5.
80. Cantu G, Solero CL, Riccio S, et al. Surgery for malignant maxillary tumors involving the middle cranial fossa. *Skull Base.* 2010;20(2):55–60.
81. Nicolai P, Castelnovo P, Lombardi D, et al. Role of endoscopic surgery in the management of selected malignant epithelial neoplasms of the naso-ethmoidal complex. *Head Neck.* 2007;29(12):1075–82.
82. Nicolai P, Battaglia P, Bignami M, et al. Endoscopic surgery for malignant tumors of the sinonasal tract and adjacent skull base: a 10-year experience. *Am J Rhinol.* 2008;22(3):308–16.
83. Choi HR, Sturgis EM, Rashid A, et al. Sinonasal adenocarcinoma: evidence for histogenetic divergence of the enteric and nonenteric phenotypes. *Hum Pathol.* 2003;34(11):1101–7.
84. Kennedy MT, Jordan RCK, Berean KW, et al. Expression pattern of CK7, CK20, CDX-2, and villin in intestinal-type sinonasal adenocarcinoma. *J Clin Pathol.* 2004;57(9):932–7.
85. Batsakis JG. Mucous gland tumors of the nose and paranasal sinuses. *Ann Otol Rhinol Laryngol.* 1970;79(3):557–62.
86. Katz TS, Mendenhall WM, Morris CG, et al. Malignant tumors of the nasal cavity and paranasal sinuses. *Head Neck.* 2002;24(9):821–9.
87. Tanzler ED, Morris CG, Orlando CA, et al. Management of sinonasal undifferentiated carcinoma. *Head Neck.* 2008;30(5):595–9.
88. Guntinas-Lichius O, Kreppel MP, Stuetzer H, et al. Single modality and multimodality treatment of nasal and paranasal sinuses cancer: a single institution experience of 229 patients. *Eur J Surg Oncol.* 2007;33(2):222–8.
89. Hoppe BS, Stegman LD, Zelefsky MJ, et al. Treatment of nasal cavity and paranasal sinus cancer with modern radiotherapy techniques in the postoperative setting – the MSKCC experience. *Int J Radiat Oncol Biol Phys.* 2007;67(3):691–702.
90. Douglas JC, Laramore GE, Austin-Seymour M, et al. Neutron radiotherapy for adenoid cystic carcinoma of the minor salivary gland. *Int J Radiat Oncol Biol Phys.* 1996;36:87–93.
91. Douglas JG, Laramore GE, Austin-Seymour M, et al. Treatment of locally advanced adenoid cystic carcinoma of the head and neck with neutron radiotherapy. *Int J Radiat Oncol Biol Phys.* 2000;46(3):551–7.
92. Pommier P, Liebsch NJ, Deschler DG, et al. Proton beam radiation therapy for skull base adenoid cystic carcinoma. *Arch Otolaryngol Head Neck Surg.* 2006;132(11):1242–9.
93. Brada M, Pijls-Johannesma M, De Ruyscher D. Proton therapy in clinical practice: current clinical evidence. *J Clin Oncol.* 2007;25(8):965–70.
94. Sato Y, Morita M, Takahashi HO, et al. Combined surgery, radiotherapy, and regional chemotherapy in carcinoma of the paranasal sinuses. *Cancer.* 1970;25(3):571–9.
95. Sakai S, Hohki A, Fuchihata H, et al. Multidisciplinary treatment of maxillary sinus carcinoma. *Cancer.* 1983;52(8):1360–4.
96. Kondo M, Ogawa K, Inuyama Y, et al. Prognostic factors influencing relapse of squamous cell carcinoma of the maxillary sinus. *Cancer.* 1985;55(1):190–6.
97. Tsujii H, Kamada T, Arimoto T, et al. The role of radiotherapy in the management of maxillary sinus carcinoma. *Cancer.* 1986;57(12):2261–6.
98. Shibuya H, Suzuki S, Horiuchi J, et al. Reappraisal of trimodal combination therapy for maxillary sinus carcinoma. *Cancer.* 1982;50(12):2790–4.
99. Konno A, Ishikawa K, Terada N, et al. Analysis of long-term results of our combination therapy for squamous cell cancer of the maxillary sinus. *Acta Otolaryngol Suppl.* 1998;537:57–66.
100. Samant S, Robbins KT, Vang M, et al. Intra-arterial cisplatin and concomitant radiation therapy followed by surgery for advanced paranasal sinus cancer. *Arch Otolaryngol Head Neck Surg.* 2004;130(8):948–55.
101. Kneigt PP, de Jong PC, van Andel JG, et al. Carcinoma of the paranasal sinuses. Results of a prospective pilot study. *Cancer.* 1985;56(1):57–62.
102. Kneigt PP, Ah-See KW, vd Velden LA LA, et al. Adenocarcinoma of the ethmoidal sinus complex: surgical debulking and topical fluorouracil may be the optimal treatment. *Arch Otolaryngol Head Neck Surg.* 2001;127(2):141–6.
103. Almeyda R, Capper J. Is surgical debridement and topical 5 fluorouracil the optimum treatment for woodworkers' adenocarcinoma of the ethmoid sinuses? A case-controlled study of a 20-year experience. *Clin Otolaryngol.* 2008;33(5):435–41.
104. Licitra L, Locati LD, Bossi P, et al. Head and neck tumors other than squamous cell carcinoma. *Curr Opin Oncol.* 2004;16(3):236–41.
105. Rosen A, Vokes EE, Scher N, et al. Locoregionally advanced paranasal sinus carcinoma. Favorable survival with multimodality therapy. *Arch Otolaryngol Head Neck Surg.* 1993;119(7):743–6.
106. Björk-Eriksson T, Mercke C, Petruson B, et al. Potential impact on tumor control and organ preservation with cisplatin and 5-fluorouracil for patients with advanced tumors of the paranasal sinuses and nasal fossa. A prospective pilot study. *Cancer.* 1992;70(11):2615–20.
107. Licitra L, Locati LD, Cavina R, et al. Primary chemotherapy followed by anterior craniofacial resection and radiotherapy for paranasal cancer. *Ann Oncol.* 2003;14(3):367–72.
108. Licitra L, Suardi S, Bossi P, et al. Prediction of TP53 status for primary cisplatin, fluorouracil, and leucovorin chemotherapy in ethmoid sinus intestinal-type adenocarcinoma. *J Clin Oncol.* 2004;22(24):4901–6.

Chapter 27

Multidisciplinary Management of Oral Cavity and Maxillary Sinus Cancers

Alexander D. Rapidis

Abstract During the last 30 years the belief that oral/head and neck cancer management is based on team work has been established. The functions of tumor boards and combined clinics is a common contemporary practice with an exceedingly large number of medical, surgical, and other specialties being part of comprehensive, multidisciplinary therapeutic head and neck teams. The basic treatment modalities remain surgery, radiotherapy, and chemotherapy.

Basic surgical techniques have not changed dramatically over the last 30 years. Among the major changes are the variations in the surgical management of the neck of both clinically negative and clinically positive neck patients, as well as the management of the mandible especially in the early invasion of oral squamous cell carcinoma in the mandibular bone. The revolution in the surgical treatment of oral/head and neck cancer is the introduction of reconstructive techniques with both pedicled locoregional flaps and free tissue transfer. These reconstructive techniques allowed for safer and wider resections with adequate disease-free margins and functional reconstruction of the created surgical defects.

Contemporary radiotherapeutic treatment has very little similarities with that of the late 1970s. Modern technology with the institution of new forms of radiation and the application of sophisticated computerized methods have enhanced the therapeutic effectiveness of irradiation with an equal important reduction in the sparing in irradiation of normal surrounding tissues. This has led to an increased therapeutic dose in the tumorous site and a decreased severity of radiation-induced injuries. Alterations in the fractionations have also shown to produce better therapeutic results in selected cases.

The era of methotrexate, the leading chemotherapeutic agent of the 1970s, was followed by the institution of platinum-based chemotherapies with or without the addition of 5 Fu.

A.D. Rapidis (✉)
Eastman Dental Institute, University College London, London, UK
and
Department of Head and Neck/Maxillofacial Surgery,
Greek Anticancer Institute, Sant Savvas Hospital, Athens, Greece
e-mail: rapidis@usa.net

Adjuvant and neoadjuvant schemes coupled with pre- or postoperative radiotherapy started in the late 1980s and showed a distinct survival benefit over radiotherapy alone. This major breakthrough was followed by the institution of various and diverse chemoradiation regimes tested over a large time period for their survival benefits. The introduction of taxanes and the development of molecular targeted therapies during the last 5 years have revolutionized the concept of chemoradiation. Induction chemotherapy and chemoradiation coupled with epidermal growth factor receptor antagonists proved to have a survival benefit in patients with locally advanced or recurrent squamous cell carcinoma of the head and neck. Other biological agents against tumor angiogenesis or restoring cell apoptosis are being tested in various phase I or II trials.

Perhaps the most promising noninvasive therapeutic method for squamous cell carcinoma of the oral mucosa is immunotherapy. The clinical applications so far are very limited but the research into these pathways is vast and extended.

Keywords Oral squamous cell carcinoma • Head and neck tumors • Oral cavity cancer • Head and neck cancer • Treatment of the oral cavity cancer • Maxillary carcinoma • Chemoradiation • Induction chemotherapy • Targeted therapies • Combined treatments

Introduction

Cancer of the oral cavity comprises nearly 30% of all malignant tumors of the head and neck. Squamous cell carcinoma represents approximately 90% of the cases [1] while the remaining 10% represents rare malignancies (unusual forms of squamous cell carcinoma, minor salivary gland tumors, melanomas, lymphomas, sarcomas), and a variety of malignant tumors of odontogenic origin. Lifestyle, habits, and demographic, as well as genetic factors, influence geographic variations in the incidence of disease. In North America, common risk factors for the development of cancer of the

oral cavity include tobacco and alcohol use. Outside of North America, dietary habits like chewing beetle, areca nut, and tobacco, represent additional risks for the development of oral cancer. Beyond these risks, there is little evidence linking dietary factors or nutritional deficiencies to the development of oral cavity cancer especially low fruit and vegetable consumption and high fat and/or sugar intake. The highest rates of incidence of cancer of oral cavity are observed in Pakistan, Brazil, India, and France [2]. While the use of alcohol and tobacco independently represent risk factors for the development of oral cavity cancer, the synergistic effect of these risk factors has been well documented. It has been suggested that the use of alcohol suppresses DNA repair following exposure to nitrosamine compounds; however, the exact mechanism of the observed synergy remains poorly defined. Human papillomavirus (HPV) is strongly associated with the development of oropharyngeal cancer and a small percentage of oral cavity cancers [3]. Over the past 30 years, the proportion of potentially HPV-related oral cancer in the USA has increased, possibly due to changing sexual behaviors especially in the young population. This probably explains the increasing number of patients with oral carcinoma who had never been exposed in tobacco or alcohol.

During the last 30 years there has been an explosion of accumulated knowledge and evidence in our understanding of the biological phenomenon of oral carcinogenesis as well as in the technological advances in the diagnosis of the disease in both the histopathological and clinical levels. An equal abundance of knowledge has been achieved in the therapeutic management of the disease from the combined uses of surgery, radiotherapy, and chemotherapy. Despite all these developments the 5 year overall survival of the disease has remained in the range of 50–60%. The quality of life though of the patients, which has become a major issue, has undoubtedly improved during these 30 years [4].

Principles of Oral Cavity Cancer Management

The treatment of primary tumors from different head and neck subsites often overlaps. Treatment for oral cavity cancer in general, is highly complex, not only because of the variety of tumor subsites, but also because of the anatomic constraints of the head and neck region, and the importance of maintaining organ function after treatment.

The factors that influence the choice of initial treatment are those related to the characteristics of the primary tumor, those related to the patient and those related to the therapeutic team (Tables 27.1–27.6) [5]. They are therefore classified under tumor, patient, and treatment factors. In the selection of optimal therapy for oral carcinoma, one should consider these three sets of parameters in primary treatment

planning. The ultimate goal of treatment of cancer of the oral cavity is to eradicate disease, preserve or restore form and function, minimize the sequelae of treatment and finally prevent the development of any subsequent new primary cancers.

Table 27.1 Staging for Tumors of the Lip and Oral Cavity (According to Patel and Shah [5])

T (primary tumor size)

TX Primary tumor cannot be assessed

T0 No evidence of primary tumor

Tis Carcinoma in situ

T1 Tumor 2 cm or less in greatest dimension

T2 Tumor more than 2 cm but not more than 4 cm in greatest dimension

T3 Tumor more than 4 cm in greatest dimension

T4a Lip Tumor invades through cortical bone, inferior alveolar nerve, floor of mouth, or skin of face (i.e., chin or nose)^a

Oral Cavity Tumor invades through cortical bone, into deep extrinsic muscle of tongue (genioglossus, hyoglossus, palatoglossus, and styloglossus), maxillary sinus, or skin of face

T4b Tumor involves masticator space, pterygoid plates, or skull base and/or encases internal carotid artery

^aSuperficial erosion alone of bone/tooth socket by gingival primary is not sufficient to classify as T4

Table 27.2 Staging for tumors of the nasal cavity and paranasal sinuses (according to Patel and Shah [5])

T (primary tumor size)

TX Primary tumor cannot be assessed

T0 No evidence of primary tumor

Tis Carcinoma in situ

Maxillary sinus

T1 Tumor limited to the maxillary sinus mucosa with no erosion or destruction of bone

T2 Tumor causing bone erosion or destruction including extension into the hard palate and/or middle nasal meatus, except extension to posterior wall of maxillary sinus, subcutaneous tissues, floor or medial wall of orbit, pterygoid fossa, ethmoid sinuses

T3 Tumor invades any of the following: bone of the posterior wall of maxillary sinus, subcutaneous tissues, floor or medial wall of orbit, pterygoid fossa, ethmoid sinuses

T4a Tumor invades anterior orbital contents, skin of cheek, pterygoid plates, infratemporal fossa, cribriform plate, sphenoid, or frontal sinuses

T4b Tumor invades any of the following: orbital apex, dura, brain, middle cranial fossa, cranial nerves other than maxillary division of trigeminal nerve V2, nasopharynx, or clivus

Nasal cavity and ethmoid sinus

T1 Tumor restricted to any one subsite, with or without bony invasion

T2 Tumor invading two subsites in a single region or extending to involve an adjacent region within the nasoethmoidal complex, with or without bony invasion

T3 Tumor extends to invade the medial wall or floor of the orbit, maxillary sinus, palate, or cribriform plate

T4a Tumor invades any of the following: anterior orbital contents, skin of nose or cheek, minimal extension to anterior cranial fossa, pterygoid plates, sphenoid, or frontal sinuses

T4b Tumor invades any of the following: orbital apex, brain, middle cranial fossa, cranial nerves other than V2, nasopharynx, or clivus

Table 27.3 Staging for all head and neck sites except the nasopharynx and thyroid (according to Patel and Shah [5])

<i>N (regional nodal status)</i>	
Nx	Regional lymph nodes cannot be assessed
N0	No regional lymph node metastasis
N1	Metastasis in a single ipsilateral lymph node, 3 cm or less in greatest dimension
N2	Metastasis in a single ipsilateral lymph node, more than 3 cm but not more than 6 cm in greatest dimension; or in multiple ipsilateral lymph nodes, none more than 6 cm in greatest dimension; or in bilateral or contralateral lymph nodes, none more than 6 cm in greatest dimension
N2a	Metastasis in a single ipsilateral lymph node more than 3 cm but not more than 6 cm in greatest dimension
N2b	Metastasis in multiple ipsilateral lymph nodes, none more than 6 cm in greatest dimension
N2c	Metastasis in bilateral or contralateral lymph nodes, none more than 6 cm in greatest dimension
N3	Metastasis in a lymph more than 6 cm in greatest dimension

Table 27.4 Staging for head and neck tumors (according to Patel and Shah [5])

<i>M (distant metastasis)</i>	
Mx	Distant metastasis cannot be assessed
M0	No distant metastasis
M1	Distant metastasis

Table 27.5 Stage grouping for all head and neck sites except the nasopharynx and thyroid (according to Patel and Shah [5])

Stage group	T stage	N stage	M stage
0	Tis	N0	M0
I	T1	N0	M0
II	T2	N0	M0
III	T3	N0	M0
	T1	N1	M0
	T2	N1	M0
IVA	T3	N1	M0
	T4a	N0	M0
	T4a	N1	M0
	T1	N2	M0
	T2	N2	M0
IVB	T3	N2	M0
	T4a	N2	M0
	T4b	Any N	M0
IVC	Any T	N3	M0
	Any T	Any N	M1

Table 27.6 Algorithm of stage status in cancer of the oral cavity

Staging of oral cavity cancer		N ₀	N ₁	N ₂	N ₃
T _{1s}	Stage 0				
T ₁	Stage I				
T ₂	Stage II				
T ₃			Stage III		
T _{4a}				Stage IVA	
T _{4b}					Stage IVB
Stage IVC any T any N when M1					

The tumor factors that affect the choice of initial treatment of oral cancer represent the clinical and histopathological characteristics of the tumor and more specifically, the anatomical site, size (T Stage), location (anterior versus posterior), proximity to bone (mandible or maxilla), status of regional cervical lymph nodes, previous treatment, and histology (type, grade, and depth of invasion). The ability of the patient to tolerate an optimal therapeutic scheme is similarly an important factor influencing the choice of initial treatment. The patient’s acceptance of and compliance with the proposed treatment are similarly important considerations in designing an optimal treatment strategy. Additionally, the performance status, the previous medical history and the presence of additional comorbidities should also be taken in consideration. The factors related to the therapeutic team are also important and are related with the experience, dexterity, ability, and availability of technical support of the surgical team and its environment. Expertise in various disciplines including surgery, radiotherapy, chemotherapy, rehabilitation services, dental, and psycho-social support are all crucial in bringing about a successful outcome of the therapeutic program.

For the purpose of providing an overview of treatment strategies in oral cancer patients, it is mandatory to group the oral squamous cell cancers into: Early-stage disease (stage I and II; no apparent lymph node involvement); and advanced disease which includes cancer metastatic to cervical lymph nodes (regionally advanced) and locally advanced primary tumors (stages T3 and T4).

Early-Stage Disease

Approximately 30–40% of patients with oral cavity cancer present with early (stage I and II) disease. In general, these patients are treated with curative intent using either Surgery or Radiotherapy (RT). Because both modalities result in similar rates of local control and survival, the choice is usually based upon an assessment of competing morbidities, functional outcomes, and accessibility. One advantage of RT over surgery is the ability to electively encompass areas at high risk for sub-clinical involvement (i.e., cervical lymph nodes). Prophylactic treatment of the clinically negative neck (i.e., no evidence of pathologic lymphadenopathy either by clinical examination or radiographic study) is somewhat controversial. However, in general, prophylactic neck irradiation or lymph node dissection is recommended if the likelihood of neck recurrence at a specific site exceeds 15 %. Generally in tongue cancer the incidence of nodal metastasis depends upon the stage of the tumor. T1, T2, and T3 tongue cancers are associated with 30, 50, and 70% respective incidence of microscopic nodal metastasis. Selective neck dissection can be used to effectively treat clinically positive nodal disease in selected patients [6, 7].

As surgical cures can often be achieved rapidly and with minimal morbidity, surgery has become the gold standard for management of early cancers of the oral cavity. Tumors involving the oral tongue can usually be managed through a transoral approach. While radiotherapy is equally effective for the treatment of early disease, the rates of long-term sequelae including xerostomia, dysphagia, and osteoradionecrosis are unacceptably high. Other advantages of surgery include the duration of treatment. Surgical therapy requires a single intervention while RT requires daily therapy over a period of several weeks in addition to possible catheter implants and the use of chemotherapy. Therefore, in resectable patients RT is usually reserved for those patients who are unable to undergo surgery [8].

Advanced-Stage Disease

Advanced disease (Stage III and IV) of the oral cavity is best managed with multimodality therapy. Surgery coupled with preoperative or postoperative RT is often utilized for advanced disease. Although preoperative radiation has been proposed to decrease the tumor mass and therefore increase the “resectability” of the tumor, it is common practice to surgically resect the tumor based on the pre-radiation margins because islands of viable tumor may persist in the initial peripheral margins. Additionally, preoperative radiation is associated with a higher rate of postoperative complications. For these reasons, most centers perform surgery followed by postoperative radiation [9, 10].

The Role of Radiotherapy and Chemoradiotherapy as Treatment Modalities in Oral Cancer

The current standard technique for delivery of radiotherapy (RT) to tumors involving the oral cavity is three-dimensional conformal RT (3D-cRT). As opposed to the historically two-dimensional planning which relied on simulation X-ray films, treatment planning with 3D-cRT is based upon three-dimensional information that is obtained on simulation CT scans. The radiation dose distribution is shown in three dimensions and doses to the treatment target as well as various organs are more accurately calculated. Modification of beam properties can be performed if needed to produce a conformal dose distribution to the treatment target [11].

Although primary surgical management has been advocated for advanced (T4) oral cavity cancers, recent evidence suggested that primary chemoradiotherapy (CRT) may be an

effective treatment approach for selected patients with T4 lesions, with comparable rates of locoregional control, survival, and complications associated with primary surgical management and postoperative RT [12].

Over the last few years, intensity-modulated RT (IMRT) has been implemented in most radiation oncology centers and is becoming a dominant treatment technique for head and neck cancer (HNC). With the assistance of advanced computer technology, IMRT is capable of delivering radiation doses that are highly conformal to the target, with rapid dose falloff outside of target volumes. This technique permits high doses of RT to be delivered to tumors which lie in close proximity to critical normal organs [13]. The newest technology, image-guided radiation therapy (IGRT) is being introduced into radiation therapy practice. A CT scanner is incorporated into the linear accelerator, allowing target position verification in the treatment position. The capacity for near real-time imaging during treatment permits tumors to be treated with greater precision and accuracy than is possible with conventional IMRT, further reducing toxicity to normal tissues.

For conventional fractionation RT, the dose for all gross disease (primary and nodal) is 70 to 72 Gy in 2 Gy fractions over 7 weeks. Subclinical regions of the neck are electively treated to 50 Gy in 25 fractions, while nodal regions with adjacent gross disease may receive 60 Gy in 30 fractions. IMRT also allows for the delivery of smaller radiation doses to the major salivary glands, thus reducing the risk of permanent post irradiation xerostomia.

Most oral cavity tumors as with the majority of head and neck cancer, typically present with advanced-stage locoregional disease (stages III or IV) for which local and regional control with surgery and/or radiation has been the mainstay treatment. After the publication of the trials on larynx preservation strategies in both Europe and the USA [14, 15], there was a rapid proliferation of non-site-specific trials to further investigate organ preservation protocols in the treatment of advanced head and neck squamous cell carcinoma. Over 70 divergent randomized trials compared traditional locoregional treatments of surgery and radiation vs. locoregional treatment plus chemotherapy. Unfortunately, this enthusiasm was plagued by small sample sizes and a lack of statistical power to confidently detect even modest effects on survival, leading to mixed results and an obscured clinical picture [16–18].

Concomitant CRT may represent an acceptable alternative in selected advanced stage of oral cancer patients. In addition to the optimal combination of drugs, the role of altered fractionation RT schedules are also under active study [19]. Two main strategies of altered fractionation have been explored in order to increase the effective dose of RT delivered without magnifying toxicity. Hyperfractionation that delivers smaller doses of RT twice daily (1.1 to 1.2 Gy fractions

compared to conventional daily 1.8 to 2.0 Gy fractions), allowing higher doses of RT to be administered (thereby improving local control) without a significantly higher risk of late complications [20].

Because delayed long-term toxicity of normal tissues is dependent on the size of the individual fractional dose, decreasing the size of each radiation fraction should permit utilization of a higher total doses without increasing late morbidity [21]. In practice, multiple daily treatments with smaller-than conventional fraction sizes are given over approximately the same treatment duration. Typically 1.1 to 1.2 Gy/fraction, two fractions per day, to total doses of 74 to 80 Gy have been employed. Accelerated fractionation RT schedules deliver the total dose of RT in shorter treatment duration. This seems to reduce the rapid tumor repopulation that is thought to occur during treatment interruptions [20].

A benefit for hyperfractionated compared to conventional fractionation RT in patients with locally advanced HNC has been shown in at least three prospective, randomized trials [21–23], and in meta-analyses of these trial data [14, 20].

Even in the absence of chemotherapy, significantly higher local control rates have been documented with both strategies compared to conventional fractionation RT alone, although demonstrating a survival benefit from either approach has been more difficult [24]. Taken together, these data support the view that accelerated treatments using split-course RT schedules or reduced total doses do not improve locoregional tumor control or overall survival. Accelerated treatments that employ continuous (rather than split-course) RT schedules, without compromising the total dose, improve local control. [21]. However, whether the added mucosal toxicity is justified by meaningful gains in survival remains an open question. Altered fractionation RT is considered by some to represent a standard approach for patients who are receiving RT alone as definitive treatment for oral cancer.

However, it is important to clarify that the indications for postoperative RT directed to the primary site are different from the indications for postoperative radiation directed at the neck. The goal of a surgical excision is to achieve a complete resection of the tumor with tumor-free margins. In cases where there are positive or close margins (tumor within 5 mm of the surgical margin), surgical re-resection is usually recommended. In cases where a re-resection is performed, if there remains evidence of microscopically positive margins, radiation directed at the primary site should be considered. In cases where there is neck disease that is N2 or greater, or the histopathological characteristics of the primary tumor demonstrate an aggressive behavior [25], radiation therapy to the neck is warranted, usually administered with concurrent chemotherapy [26, 27].

Definitive RT, usually administered with cisplatin-based chemotherapy, is the treatment of choice for patients with potentially resectable locoregionally advanced oral cancer

who desire organ preservation, for those who have surgically unresectable disease, or who are medically inoperable. Although direct comparative data are lacking, combined chemotherapy and RT appears to produce similar locoregional control and survival rates as does surgery, while providing the opportunity for function preservation [24].

Chemotherapy can be administered before, at the same time or after locoregional treatment corresponding to induction, concomitant, or adjuvant chemotherapy. There are several other potential advantages to giving neoadjuvant rather than postoperative (adjuvant) chemotherapy. These include the delivery of chemotherapeutic drugs through an intact vasculature which is optimal to enhance its therapeutic effectiveness before surgery or radiation. The neoadjuvant treatment is more likely to treat micrometastases, thus diminishing the chances of developing gross metastatic disease. Finally, the reduction in tumor size and healing prior to definitive RT may improve functional outcomes.

The response to chemotherapy may be an important predictor of survival, as various studies have shown that patients with a good response to induction chemotherapy have a better overall survival [4, 28, 29].

A greater benefit (8%) was observed in trials that gave CT concomitantly to RT. Effect of concomitant CT on survival did not differ significantly between the group of trials with postoperative RT, or curative RT with conventional or altered fractionation. No significant difference was also seen between mono- and poly-chemotherapy. In the poly-chemotherapy group, the effect of chemotherapy was not significantly different between the different subgroups: with cisplatin or carboplatin (platin) and 5-fluorouracil (5-FU), with either platin or 5-FU or with neither [30, 31]. As might be expected, the proportion of deaths not due to head and neck cancer increases progressively with age from 15% in patients less than 50 to an impressive 39% in patients 71 and over. The survival benefit resulting from the addition of CT to RT is confirmed to be around 4%. This benefit is larger for concomitant CT, whereas there was no clear evidence of a benefit for induction and adjuvant CTs. Another important issue is that the benefit of concomitant CT appears to be similar irrespective of whether the RT is given conventionally or using altered fractionation. Finally, the magnitude of the benefit of concomitant CT is less in older patients, a feature that has also been observed with altered fractionation compared to conventional RT in head and neck cancer [20] and also when combining anti-EGFR agents (cetuximab) with radiotherapy [32–34]. In a recent meta-analysis the comparison of the benefit associated with concomitant vs. induction CT was examined. It is interesting that both the indirect and the direct comparisons were consistent on survival, event-free survival and locoregional failure, showing a clear advantage in favor of concomitant CT [35, 36].

Postoperative RT with or without concomitant chemotherapy is reserved for those cases in which the risk of recurrence is high. Defining the “high-risk” patient has been the topic of controversy. This decision is made after a careful evaluation of the various patient and disease factors. The findings can be summarized as follows: Extracapsular extension and/or microscopically involved surgical margins are the only risk factors for which the impact on survival of adding chemotherapy to RT is statistically significant. There is a trend toward improved survival in favor of CRT in patients who had stage III–IV disease, perineural infiltration, vascular embolisms, and/or clinically enlarged levels IV–V lymph nodes secondary to tumors arising in the oral cavity or oropharynx. The differences though were not statistically significant. Patients with two or more histopathologically involved lymph nodes without extracapsular extension did not seem to benefit from the addition of CT. The problem with CRT in head and neck cancer is that the schedules are often rather toxic and associated with a substantial morbidity which in turn influences the compliance with treatment. Obviously, this morbidity is to some extent outnumbered by the benefit of the combined treatment, resulting in an improved survival; but we must not forget that many patients do not comply with treatment, and patients who do not fulfill a planned course of RT due to morbidity with the interacting drug, are in fact in a worse situation condition than the ones who are treated with RT alone.

Site-Specific Treatment

The anatomic boundaries of the oral cavity extend from the skin–vermillion junction of the lips to the junction of the hard and soft palate above, and to the line of circumvallate papilla of the tongue below. Specific sites of tumor origin include the lips, floor of the mouth, oral tongue, lower alveolar ridge and retromolar trigone, upper alveolar ridge and hard palate, and the buccal mucosa [37]. The maxillary sinus carcinomas will also be included.

Lip Cancer

The lip is the most common primary site within the oral cavity, accounting for approximately 25% of cancers at this site. The majority of lesions occur on the lower lip and 95 % occur in males [38]. Basal cell carcinomas (BCCs) may arise from the skin and cross the vermillion border to invade the lip, while squamous cell cancers (SCCs) most frequently develop at the vermillion margin. BCCs are more common on the upper lip. The similar local control and cure rates that can

be achieved with surgery or RT in stage I lower lip tumors make either treatment acceptable. Surgery is the treatment of choice for early-stage lesions and is preferred because of better cosmetic results and lower morbidity rates compared to RT. Defects that involve less than two-thirds of the lip usually can be closed primarily. Defects involving two-thirds of the lip can be reconstructed with full thickness pedicled flaps (“Abbe or Estlander”) from the upper or lower lip [39]. Many reconstructive options are available for defects larger than two-thirds of the lip, ranging from local nasolabial flaps to hair-bearing free flaps. The facial artery musculomucosal flap has shown application and success in upper and lower lip reconstruction [40]. Radiation therapy is generally reserved for recurrent tumors, nodal disease, and for patients who cannot tolerate surgery.

Maximum tumor thickness is a predictor of metastatic spread to the regional nodes, and is therefore important for treatment planning and assessment of prognosis in patients with squamous cell carcinoma [41, 42]. Among patients who have a clinically negative neck, those with T2 or larger tumors that are treated surgically should undergo ipsilateral neck dissection [42]. Upper lip and commissure tumors are more aggressive, tend to grow more rapidly, ulcerate sooner and metastasize earlier than those of the lower lip. Carcinomas in these sites may give regional metastases to preauricular and submandibular nodes.

Oral Tongue Cancer

The incidence of tongue cancer exceeds all other sites in the oral cavity, excluding lip cancer, accounting for almost 30% of oral cancer patients. The median age for patients with SCC of the tongue is 60 and, similar to other disease sites, the male to female ratio is 3:1. Cancers of the mobile tongue have a high incidence of occult and clinical cervical lymph node metastases.

Tongue cancer has been considered to have a more aggressive course in younger patients. However, more recent studies have found no difference in staging or survival among patients under the age of 40 as compared to a group of patients aged 60 to 70 [43, 44]. Those receiving neck dissection for prognostic or therapeutic purposes have significantly better 5-year survival rates than those who do not receive a neck dissection as part of their primary treatment. Surgery is recommended for small, anterior, and well-lateralized lesions. Radiation therapy is preferred for large T1 lesions and for T2 tumors where resection would result in impairment of normal speech and/or swallowing (Fig. 27.1).

Most stage I and II lesions can be resected via an intraoral approach with ample surgical margins. Due to the small size

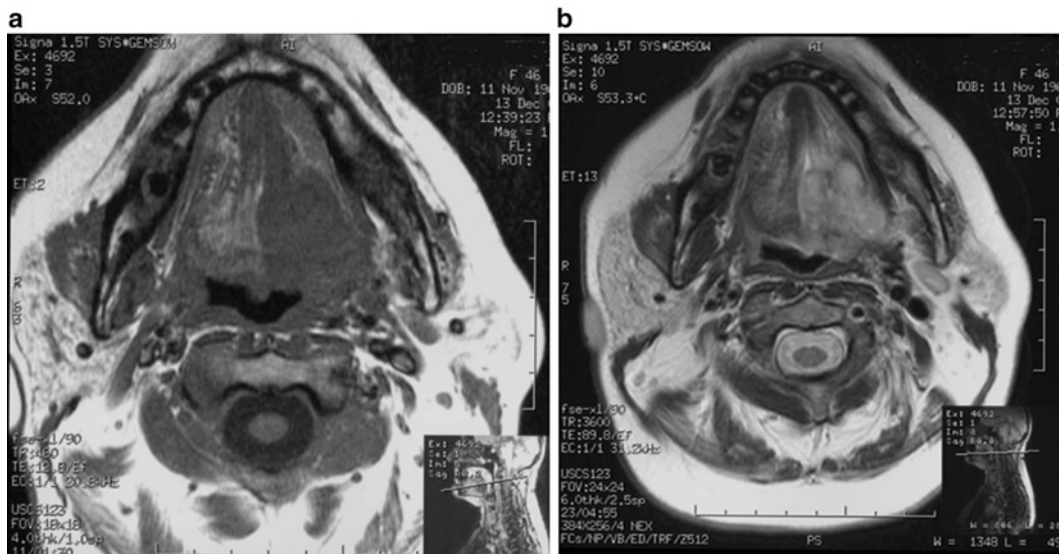


Fig. 27.1 Squamous cell carcinoma of the tongue in a 48-years old female patient. The MRI shows the lesion extending and occupying the right side of the tongue. T1 weighting (a) and T2 weighting (b)

of these early tumors in relationship to the usual bulky mass of the tongue, most T1 and T2 cancers of the oral tongue can be excised without permanent speech or swallowing deficits. Excision usually entails a partial glossectomy.

Adequate margins (>1 cm) and elective treatment of the clinically negative neck are extremely important in the treatment of early tongue cancer. The 5-year survival rate, in patients with stage I or II disease, after appropriate surgical treatment, approaches 90%.

Elective neck dissection is recommended in patients with T2-4 tumors and a clinically negative neck because of the high incidence of occult cervical nodal disease [45–47]. More than 25% of patients undergoing elective neck dissection will be found with pathologically node positive (N+) [46]. The staging information provided by the neck dissection is crucial for defining necessity for and type of postoperative additional treatment.

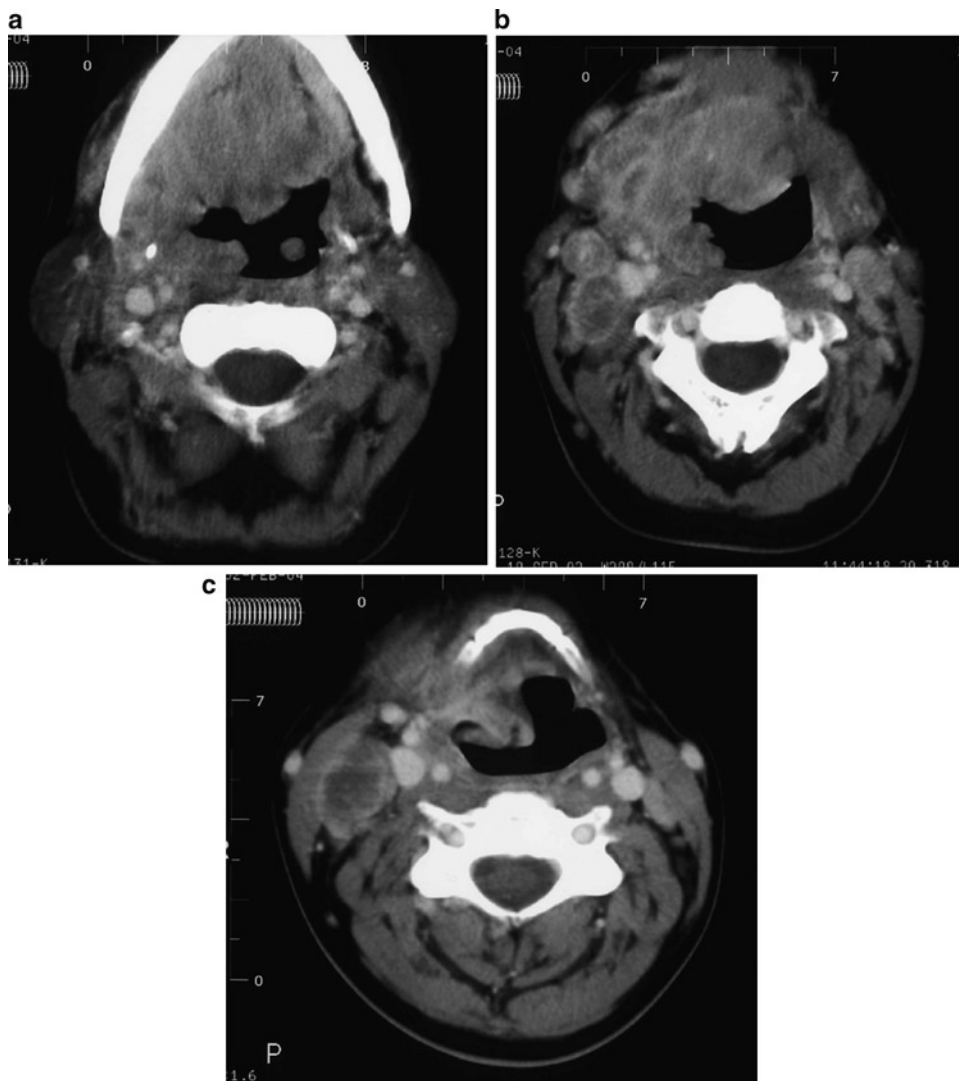
It is more difficult to define the role of elective neck dissection in patients with T1 disease and a clinically negative neck. There are no randomized trials examining this issue. The 5-year survival rates for patients undergoing synchronous (prophylactic) neck dissection, no dissection, or a metachronous dissection (at the time of clinical neck recurrence) are 81, 60, and 45%, respectively. This finding supports the concept that prophylactic neck dissections offer improved survival compared to the “wait and see” policy, and emphasizes the need for a more aggressive approach to the neck at primary tumor presentation [48]. The best pathologic predictors for the presence of occult neck metastases are depth of invasion above 5 mm, depth of muscle invasion, double DNA aneuploidy, and poor histologic differentiation.

It is therefore recommended that elective neck dissection must be considered in patients with T1N0 cancer undergoing surgical treatment of the primary who have aneuploid tumors, depth of muscle invasion >4 mm, or a poorly differentiated cancer [48].

As oral cavity cancer rarely metastasizes to neck level V, a radical or modified radical neck dissection of all five nodal levels is not necessary for patients with N0 neck. Selective neck dissection of levels I–III (“supraomohyoid neck dissection”) is the procedure of choice for elective neck dissection of the neck. Most of the relatively small numbers of isolated metastasis to level IV are from primary tumors of the tongue, which are known to produce “skip metastases.” Thus an “extended supraomohyoid neck dissection” of levels I–IV is recommended for elective treatment of the neck in tongue cancer in patients with T2 and above and N0 necks [49]. A number of recent prospective multi-institutional studies have demonstrated that sublevel IIB is rarely involved with isolated metastasis from oral cavity primary tumors, except from some tongue cancers [50–54]. Thus, it is justifiable to omit dissection of sublevel IIB in elective treatment of most cases of oral cavity cancers. In this way injury to the spinal accessory nerve is avoided [55].

It is recommended that elective neck dissection is performed for all patients with T2 or larger tumors if surgery is used to treat the primary tumor [47]. Ipsilateral neck dissection is generally sufficient for most T1/T2 tumors. However, bilateral node dissection should be considered for patients with anterior or midline lesions, as well as for those with more advanced stage disease (Fig. 27.2).

Fig. 27.2 Squamous cell carcinoma of the tongue in a 55-years old male patient. The CT shows the lesion occupying the entire musculature of the left side of the tongue. Regional node metastases are also present: (a) at the level of the floor of the mouth; (b) AT the level of the base of the tongue. Multiple nodal metastases with central necrosis can be seen; (c) at the level of the hyoid bone. A large nodal block can be seen under the sternocleidomastoid muscle



Floor of Mouth Cancer

The floor of the mouth is rich in neural and vascular structures including the lingual and hypoglossal nerves, the submandibular duct, and the sublingual glands. SCC of the floor of the mouth are aggressive oral cavity neoplasms. They typically present as painful infiltrative ulcerative lesions that may bleed. The lack of any substantial fascial barrier means that early tumors of the floor of mouth can quickly invade in to the underlying structures and metastasize to the first echelon lymph node basin (neck levels I and II). They have a high incidence of cervical nodal metastases which are detectable clinically in 30–60% of patients at presentation. The incidence of occult cervical metastases is also high [56].

Treatment approaches include surgery and RT. Due to the risk of radiation-induced bone necrosis, surgery is usually the preferred treatment approach in operable patients. Local control of these tumors can be difficult because of their proximity to the mandible and the lack of a good mechanical barrier to

tumor spread at this site. Surgery is generally preferred with an emphasis on negative margins, which can be technically difficult without rim mandibulectomy due to the proximity of and/or occult invasion into the mandible. The outcome of surgical treatment for patients with cancer of the floor of the mouth varies directly with tumor size and the status of the surgical margins. In early-stage T1 and T2 disease, the 5-year survival can be higher than 80% [56, 57].

Due to the high incidence of occult nodal disease in all but the earliest superficial carcinomas (i.e., those limited to less than 5 mm invasion) of the floor of the mouth, prophylactic neck dissection is recommended at these sites [45, 56]. For T1 or T2 lesions, an ipsilateral supraohyoid (level I to III), dissection is generally advocated as the surgical procedure of choice; bilateral selective dissections are indicated for more anterior/midline lesions [58]. Because of the density of neurovascular structures in the floor of the mouth, frequent metastasis occurs to the sublingual, submandibular, and level II lymph node basins.

Postoperative radiation (in some cases, with concomitant chemotherapy) is indicated for patients who have positive resection margins (if not re-resected), mandibular bone erosion, or pathologically positive lymph nodes after elective neck dissection. Postoperative RT should also be considered if there is vascular or perineural invasion in the primary tumor [59]. For resectable tumors in nonsurgical candidates, RT (usually a combination of external beam RT and brachytherapy) achieves similar local control rates [59].

Tumors Invading the Mandible

Tumors within the oral cavity may invade the mandible and gain entrance into the mandibular canal through several routes. Not uncommonly, SCC of the oral epithelium will travel along the surface mucosa until it approaches the attached gingiva where the tumor cells may come into contact with the periosteum of the mandible. This can be done in both dentate and edentulous patients. In the dentate patient tumor cells demonstrate a tendency to migrate into the dental sockets because this area represents a pathway of minimal

resistance. In edentulous patient, tumor cells will migrate onto the occlusal surface of the alveolus and enter the mandible through dental pits, which are cortical bone defects at the location of prior dentition. SCCs of the floor of the mouth may also extend to invade the neighboring mandibular bone. Less commonly, tumor may enter the mandible through mental or mandibular canals. Finally, adjacent tumor may erode through the cortical bone directly into the mandibular canal.

Plain radiography has been used in the past for the diagnosis of tumor invasion of the mandible. The introduction of orthopantomogram or panoramic radiography, CT, and MRI scans have increased the accuracy of preoperative imaging and staging (Fig. 27.3). Significant debate still exists regarding the optimal modality or combination of modalities recommended for preoperative assessment of mandibular invasion by oral SCC. While CT is a very accurate method for identifying gross bone invasion, prior work has suggested that bone invasion may be missed in as many as 27% of patients with preoperative CT scans [60]. The CT scan renders an excellent view of both the soft tissue and bone of the mandible; however, it has several limitations, the most significant being artifacts caused by dental amalgams and prosthetic metal bridgework. Dental amalgams commonly create

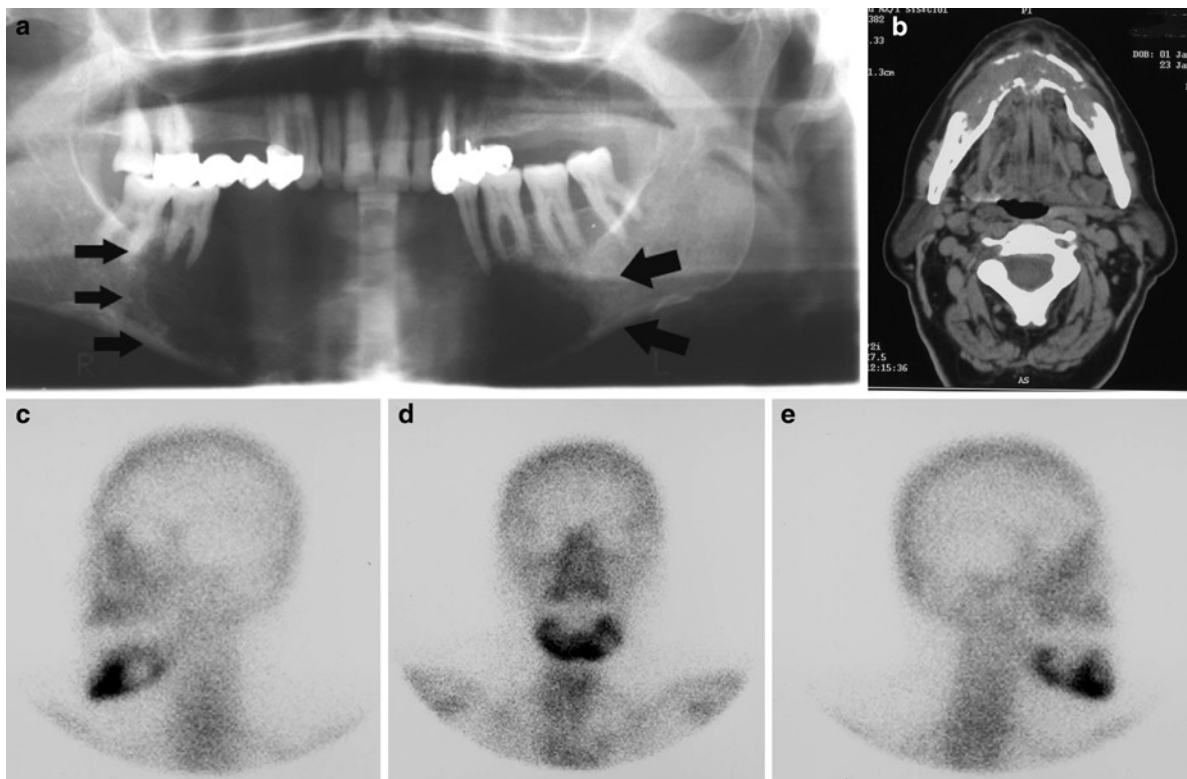


Fig. 27.3 Squamous cell carcinoma of the anterior part of the mandible in a 60-year old female (a). Orthopantomogram showing the lesion to extend from the right premolars area of the mandible to the left one (arrows) (b). CT of the mandible shows the extensive distraction of the

osseous architecture of the mandible extending to the buccal and lingual cortical bone (c–e). Bone Scan with Tc 99 m shows a pathological uptake of the radionuclide in the anterior part of the mandible. The uptake corresponds to the extend of the lesion

a shadow leading to artifact that can obscure invasion of the mandibular cortex. Additionally, the CT scan may misleadingly detect defects in the cortex secondary to irregular tooth sockets or periapical lesions of inflammatory origin.

In light of these shortcomings, several investigators have reported on the use of a Dentascan. The Dentascan was introduced in the early 1980s to assist oral maxillofacial surgeons in planning for osseointegrated implants. The Dentascan images are derived by reformatting standard axial CT scans in two views, panelliptical and parasagittal. This reformatting permits assessment of the buccal and lingual cortices. The diagnostic accuracy of the Dentascan is high, yielding a sensitivity of 95% and a specificity of 79% with a positive predictive value of 87% and a negative predictive value of 92% [61]. The Dentascan is therefore an accurate method for preoperative evaluation of mandibular invasion in patients with SCC of the oral cavity (Fig. 27.4).

While the CT scan and Dentascan may offer excellent methods for assessing bone, MRI offers the advantage of imaging soft tissue and potentially the medullary bone space. Several studies have examined the use of MRI in assessing mandibular invasion and it has been concluded that MRI is superior for evaluating the medullary space of the mandible [62] but inadequate for assessing mandibular invasion. Shaha [63] examined the value of various studies including panoramic X-rays, dental films, routine mandible films, bone scans, CT scans, and MRI and found that CT scanning was

not very helpful mainly because of the presence of irregular dental sockets and artifacts. Many suggest that clinical evaluation is the most accurate in determining the presence of bone invasion and the optimal method of resection, marginal vs. segmental [64].

Most centers consider the combination of a CT scan and a panoramic X-ray acceptable for preoperative imaging of the mandible and maxilla; however, the most accurate measure of bony invasion is determined clinically at the time of surgery. Unless there is frank invasion of the bony cortex, periosteal stripping followed by frozen section examination at the time of surgery is often the most reliable measure of bone invasion. Recent studies have shown that technetium (Tc) 99m bone scintigraphy in the form of planar views or as SPECT provide a high diagnostic accuracy for mandibular invasion by oral SCC of the alveolous in both edentulous and dentate patients [65, 66].

Among all investigations and evaluations of the extent of disease in the oral cavity in relation to involvement of the mandible, the best investigation continues to be routine clinical evaluation and intraoperative evaluation of the proximity of the tumor to the inner border of the mandible. Even though the tumor may not involve the mandible directly, a marginal mandibulectomy may be necessary for appropriate oncologic margins and resection of part of the mandible due to close proximity. This decision is best made using clinical judgment.

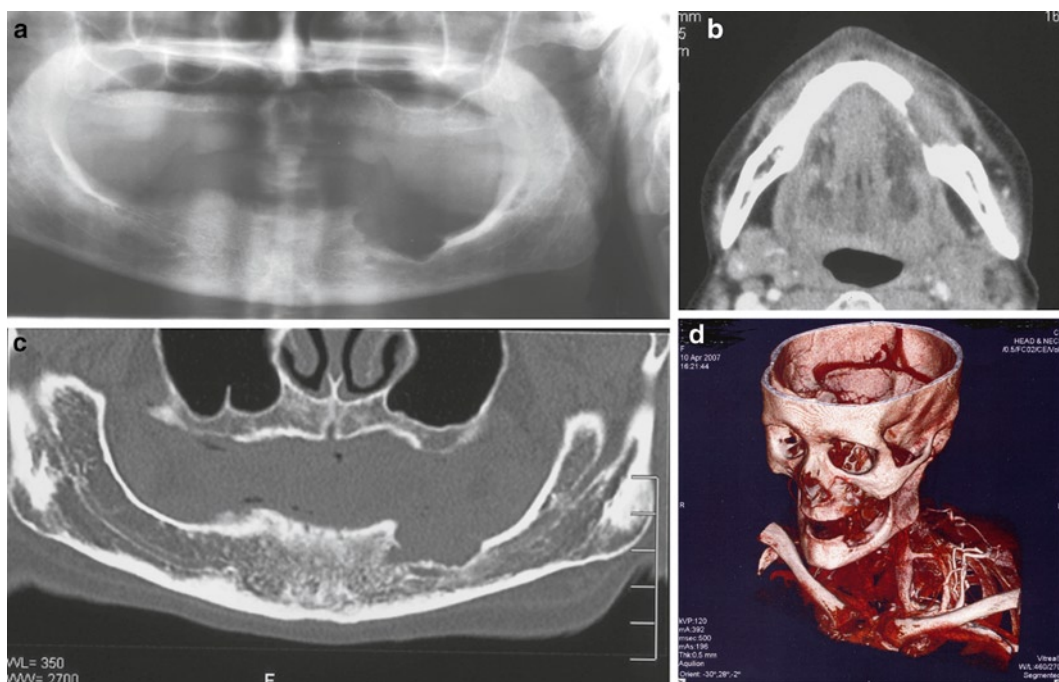


Fig. 27.4 Squamous cell carcinoma of the left body of the mandible in a 68-years old male patient (a). The orthopantomogram shows a lytic lesion in the left body of the mandible extending to the inferior dental canal (b). The CT shows complete destruction of the entire width of the

mandibular body (c). The Denta Scan CT depicts the erosion of the cortical bone and the extension of the tumor to the medullary part of the mandible (d). Three-dimensional reconstruction of the CT of the

Tumors invading the mandible can be managed either with a marginal resection or a segmental resection. The decision regarding the optimal method of tumor resection is largely dependent on the degree of invasion. It has been suggested that tumor invasion of the periosteum or cortical bone, without invasion of the medullary cortex, can be appropriately managed with a marginal resection. Tumors that erode into the medullary canal, however, require a segmental resection. It has been shown that once a tumor gains access to the medullary canal, tumor may travel through the canal via the neurovascular bundle. The inability to obtain frozen section assessment of the mandible intraoperatively represents a management dilemma because decalcification of the mandible specimen in preparation for definitive histopathological analysis can take as long as 2 weeks.

The periosteum is relatively resistant to cancer invasion. With the exception of the tooth sockets, the periosteum acts as a dense barrier to the invasion of adjacent tumor. In spite of the protective periosteum, aggressive and longstanding tumors erode the periosteum and invade the adjacent mandible through a variety of pathways. Two distinct histological patterns of tumor invasion have been identified. The first pattern is referred to as *infiltrative* and is characterized by finger-like projections of tumor which advance independently and invade the cancellous spaces without the intervening connective tissue layer and possess very little osteoclastic activity. The second pattern is referred to as *erosive*. In contrast to the infiltrative pattern, the erosive pattern is characterized by a broad front with a connective tissue layer and active osteoclast activity. The significance of the erosive and infiltrative patterns has been demonstrated in several reports, and it has been demonstrated that patient survival is significantly impacted by the pattern of invasion [67]. It has been suggested that the pattern of invasion is a reflection of the biologic aggressiveness of the tumor and may impact the approach to ablative therapy. While most tumors that invade the mandible mandate postoperative external beam radiation, some have suggested that superficially invading tumors may not benefit from postoperative radiation. Given the aggressive behavior of the infiltrative pattern of invasion, we recommend postoperative RT for all patients with this pattern of bone invasion.

While the superficial invasion of the periosteum or cortical bone may be managed with a marginal mandibulectomy, once the tumor has eroded into the medullary cavity and mandibular canal most advocate a segmental resection. Determining the presence of bone erosion and the extent of bone erosion represents an ongoing clinical dilemma. The poor predictability associated with preoperative imaging has led many to rely on preoperative clinical assessment as the primary method for determining the presence of mandibular invasion. Several groups have studied this issue and found that clinical evaluation of mandibular bone erosion is more

sensitive than radiographic evaluation; however, radiographic assessment may be more specific and provide a higher reliability index [68].

There are a few studies reviewing the impact of clinical assessment alone in determining the extent of mandibular invasion. This likely represents the difficulty in quantifying a clinical exam. However, most agree that clinical assessment for invasion is paramount. Several studies have evaluated the role of periosteal stripping as an indicator for tumor invasion of the mandible and found that periosteal stripping at the time of resection represented an accurate predictor of the presence of mandibular invasion [69]. Without clear preoperative evidence of mandibular invasion, a marginal resection followed by periosteal stripping and inspection is an adequate approach. In the event that microscopic evidence of invasion at the rim is discovered, the marginal mandibulectomy is converted into a segmental mandibulectomy.

Lower Alveolar Ridge and Retromolar Trigone Cancer

The retromolar trigone is a small mucosal space that begins at the third molar of the mandible and extends cranially to the maxillary tuberosity. It is directly continuous with the buccal mucosa, upper and lower gingiva, maxillary tuberosity, anterior tonsillar pillar, soft palate, and the floor of the mouth. Squamous cell cancers arising in the retromolar trigone and lower alveolar ridge comprise approximately 10% of all oral cancers and exhibit the same 3 or 4:1 male predominance of other head and neck cancers. The presenting symptom is typically pain, which is exacerbated by chewing.

Treatment options include RT and surgery. The local recurrence rate is higher with these tumors than for other sites in the oral cavity due to microscopic extension to the mandible and maxilla (for retromolar trigone tumors). In addition, the probability of occult regional lymph node metastases is higher than with most other oral cavity tumors, with the exception of tongue cancer and floor of mouth cancer [62]. Thus, elective neck dissection is usually recommended for patients with a clinically negative neck.

Surgical treatment involves wide local excision. Marginal or horizontal "rim" mandibulectomy may be required in order to achieve tumor-free margins. Due to the normally thin overlying mucosa and the close proximity to the mandible, alveolar ridge and retromolar sites have a propensity for early invasion of this bone, as well as the maxilla for retromolar trigone lesions [70, 71]. Consequently, lesions that are clinically staged T1/T2 and treated with rim mandibulectomy may become pathologic stage T4 after histologic

confirmation of bony invasion. Segmental or composite resection is reserved for those tumors that are deeply invasive or that wrap around the mandible [60]. In addition, segmental mandibulectomy may be necessary for early-stage lesions in the thin, edentulous mandible in order to achieve negative margins.

It is extremely important to determine the true invasive margin, which may extend grossly or microscopically beyond the tumor front [62]. Determining this invasive margin is challenging. For oral cavity lesions in general, computed tomography (CT) scans may be helpful for identifying bone invasion. The sensitivity of CT scan for bone involvement of the retromolar trigone is approximately 50% with a negative predictive value of 60%; however, the positive predictive value is approximately 90%. It has been concluded that while the CT scan is accurate when bone erosion is clearly identified, its negative predictive value is unacceptably low and therefore an inaccurate indicator of bone invasion at the retromolar trigone. In one report of 127 patients with oral cavity or oropharyngeal carcinoma treated with composite (segmental) resections, CT scan findings suspicious for bone invasion and primary tumor location (alveolus, retromolar trigone, tonsil, and sulcus) were the only independent variables that predicted for the presence of bony invasion [65, 70, 72]. However, in one report, preoperative CT scan failed to identify bone invasion in one-half of retromolar trigone lesions that histologically invaded bone [73]. Potential reasons for this low sensitivity include the thickness of CT sections, the lack of bone windows and coronal imaging, and the presence of distortion from dental artifact.

A resection margin of at least 1 cm in all directions is recommended [74]. At least for tumors involving the retromolar trigone, the optimal extent of surgery is controversial [56, 75]. In addition to stage, outcomes are dependent on the presence of bone invasion, deep infiltration of the masticator space, nodal involvement, and treatment modality [71, 76, 77].

Among the patients with stage I and II disease, survival exceeds 75% at 5 years. In a later series of 99 patients treated with definitive RT or surgery followed by RT, local control rates were better in surgically treated patients (approximately 71% vs. 48%) [76, 78]. Among all patients treated for stage I to III disease (RT or surgery plus RT), 5-year rates of cause-specific and overall survival were 70 and 58%, compared to 57 and 42% for those treated for stage IV disease. Notably, in multivariate analysis, both cause-specific and overall survival were significantly better in the group undergoing RT in addition to surgery.

For early lesions of the lower alveolar ridge and retromolar trigone, selective neck dissection in levels I–III is recommended as tumors are characterized by early invasion of the mandible and high rates of regional metastases.

Tumors Invading the Buccal Mucosa

Buccal cancer comprises less than 10% of oral cavity cancers and when it occurs, it commonly arises from a preexisting leukoplakia [79, 80]. SCCs arising within the buccal mucosa are notable for their locoregional aggressiveness. For early-stage disease, treatment with either surgery or definitive RT is reasonable, although in most circumstances surgery is favored. Surgical treatment can be compromised by anatomic difficulties in obtaining adequate margins. For locally advanced but resectable tumors, surgery followed by postoperative RT is the treatment of choice.

The principals of management of buccal cancer are no different than those of other subsites within the oral cavity. Surgical therapy is the preferred method of management. In early disease, surgical excision can usually be accomplished transorally. The buccal space has poor anatomic boundaries and it is difficult to obtain a clear surgical margin. Even patients with early-stage disease have potential microscopic invasion through the buccinator muscle into the buccal fat and buccal space.

Although more aggressive surgery including exenteration of the buccal space and parotidectomy may improve surgical results, the resulting disfigurement and morbidity of these procedures may be considerable. Tumors that invade the buccinator muscle and tumors that present with nodal disease or with poor prognostic features should be managed with postoperative radiation therapy. Negative surgical margins are paramount and in an effort to achieve this goal, careful preoperative planning is essential to determine the extent of the tumor. While early tumors of the buccal mucosa commonly present as an irregular mucosal mass, more than half of buccal tumors will present as deeply invasive tumors that may track along the parotid duct, masseter muscle or into the palate. The proximity of the buccal mucosa to the parotid duct requires that the duct be traced retrograde and sampled to ensure a negative margin.

Deeply invasive lesions may break into the buccal fat pad. When this occurs, it is advisable to resect the entire fat pad because negative surgical margins in this area are difficult to confirm. The rich lymphatic network, characteristic of the buccal region, and the high rate of lymph node metastasis, mandate that the neck be carefully evaluated and, in most cases, treated. Smaller tumors can usually be managed through a transoral approach; however, more advanced tumors may require a midline labiotomy incision.

Cancer of the buccal mucosa is a highly aggressive form of oral cavity cancer that is associated with a high rate of locoregional recurrence and poor survival.

Surgery is generally preferred for managing small lesions. The tumor can usually be excised using a transoral approach. Five-year survival rates are approximately 75% for patients with stage I disease and 65% for patients with stage II

lesions [81–83]. However, local recurrence rates with surgery alone are high, particularly with surgical margins less than 2 mm [81, 82, 84].

Treatment of the clinically negative neck is controversial. Elective neck dissection is not routinely recommended in all patients. For those with small (T1) lesions, cervical lymph node metastases occur in less than 10% and the neck can be observed. Selective neck dissection of levels I to III should be considered for larger lesions [82].

Upper Alveolar Ridge and Hard Palate Cancer

Malignant neoplasms of the upper alveolar ridge and hard palate comprise approximately 5% of oral cavity malignancies and have a male to female ratio of 8:1. Only about two-thirds of hard palate malignant neoplasms are SCCs; the remainders are minor salivary gland carcinomas and other rare malignancies. Unlike other areas of the oral cavity where SCC makes up the overwhelming majority of pathology, the palate is rich in minor salivary glands and therefore is the site of both benign and malignant salivary gland tumors.

Most upper alveolar ridge and hard palate SCCs are managed with primary surgery. RT can be used for small, superficial lesions, or tumors with extensive involvement of the hard and/or soft palate. Combined modality therapy provides better locoregional disease control than single modality therapy [76, 77]. Postoperative RT (in some cases with concomitant chemotherapy) is indicated for patients with positive resection margins, bone erosion, or pathologically positive lymph nodes after elective neck dissection [76, 77]. Others recommend that postoperative RT also be considered if there is vascular or perineural invasion in the primary tumor [59].

The principals of management of tumors of the palate are similar to those of mandible; obtaining tumor-free margins is essential to achieving a good outcome. Lateral tumors may represent a risk to invasion and perineural spread via the palatine or trigeminal neurovascular bundle. The depth of invasion will dictate the extent of the surgical resection. Superficial lesions of the palatal mucosa are best managed with a wide surgical resection including the underlying palatal periosteum. The periosteum serves as an early barrier to spread; however, as tumors become more invasive, tumors can vertically invade the nasal vault or maxillary sinus.

Tumors of the hard palate rarely metastasize to the neck and therefore a neck dissection is rarely warranted in the absence of demonstrable regional disease. One exception is when there is tumor erosion through the posterior or posterior lateral maxillary sinus into the pterygopalatine fossa.

Most lesions of the upper alveolar ridge and hard palate are managed with primary surgery. Lesions with extensive involvement of the hard and/or soft palate can also be

initially treated with primary RT. In patients initially treated with surgical resection, the 5-year survival rates are 70 and 45% for patients with stage I and II disease [85].

Selective neck dissection with removal of levels I–III nodal groups is adequate for early disease of the hard palate in patients with clinical positive nodes at presentation. If disease extends beyond the hard palate, however, elective treatment of the neck is indicated even in No neck patients.

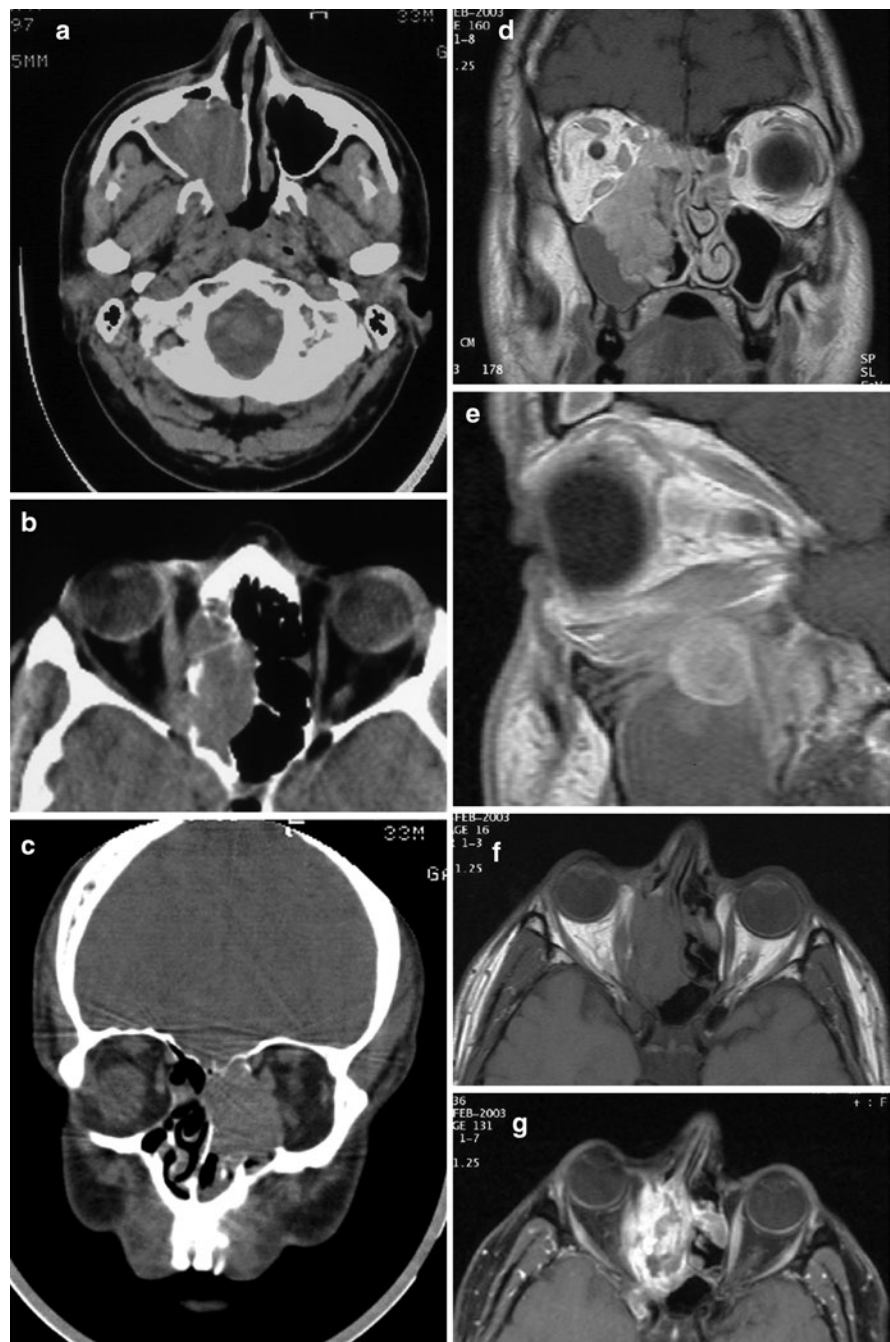
Maxillary Sinus Cancer

Paranasal sinus cancer is rare, accounting for just 3% of upper aerodigestive tract malignancies [86]. The incidence is higher in males than in females (2:1) with a peak incidence at 50–59 years of age. Lesions of the maxillary sinus are most common, followed by the ethmoid, sphenoid, and frontal sinuses. These tumors are generally slow-growing and tend to remain asymptomatic until late in the course. As a result, most patients present with locally advanced disease. SCCs constitute the majority of paranasal malignancies (45–80% of cases). This is followed by malignancies of salivary gland origin, of which adenoid cystic carcinomas predominate [87–89], followed by adenocarcinomas and mucoepidermoid carcinomas. The most common symptoms in patients with paranasal sinus cancer include facial or dental pain, nasal obstruction, and epistaxis [90]. Oral symptoms (e.g., ill-fitting dentures) occur in 25–30% of patients. Pain with unilateral nasal obstruction or ocular symptoms can be seen in 50 and 25% of patients with antral-ethmoidal disease, respectively. A classic triad of facial asymmetry, palpable/visible tumor in the oral cavity, and visible intranasal tumor occurs in 40–60% of patients with advanced disease. At least one of these signs is present in 90% of cases [91].

As disease progresses, symptoms and signs depend upon the involved site. The bony structures between the nasal cavity, sinuses, orbits, and cranial vaults are thin and offer little resistance to cancer spread (Fig. 27.5). Regional nodal metastases are uncommon, occurring in less than 20% of patients, lower if they have adenoid cystic tumors [87, 92–95]. The incidence of lymph node involvement increases as tumors extend locally to adjacent sites, especially with extension into the oral cavity. The retropharyngeal nodes comprise the first echelon lymphatic drainage for sinus malignancies. Other regional nodes that may be involved with lymphatic spread are the periparotid and level Ib nodes

There is no consensus as to optimal treatment for early-stage tumors. Traditionally, surgery has been the primary treatment modality for paranasal sinus cancers involving the maxillary or ethmoid sinuses. However, the limitations of surgery alone are obvious given the frequent presentation of advanced disease [96].

Fig. 27.5 Squamous cell carcinoma of the right maxillary antrum extending in the homolateral orbital cavity, the anterior ethmoids and the nasal cavity in a 72-years old male (a). CT shows the lesion occupying the right maxillary sinus. The lesion is confined within the maxillary sinus cavity and does not erode the wings of the sphenoid bone (b). The lesion occupies the anterior ethmoids and erodes the thin lateral orbital wall (c). Coronal section showing the extension of the tumor into the right orbital cavity (d). In the MRI (coronal T1 weight imaging) the tumor extends to the entire right middle third of the face (e). Sagittal T1 weighting image showing the tumor eroding the right orbital floor and extending into the content of the orbital cavity (f, g). T1 and T2 weighting images of the tumor invading the anterior ethmoids



Both, surgical technique and the overall approach to management have evolved to incorporate into the decision making process the histology and tumor size as well as location in relation to the adjacent critical structures. In many cases of maxillary and ethmoid sinus SCC, for example, aggressive local therapy includes en bloc craniofacial resection with or without orbital exenteration, followed by reconstruction and adjuvant RT.

RT may be used, particularly for T1 tumors of the ethmoid, sphenoid and frontal sinuses, with acceptable results

[97, 98]. However, in practice, RT is rarely used as the sole modality of treatment except for cancers of the frontal and sphenoid sinuses, which are unsuitable for en bloc surgical resection.

Elective neck treatment is not generally recommended given the low incidence of cervical metastases, unless there is significant soft tissue or skin involvement. Regardless of the surgical margin status, adjuvant postoperative RT optimizes local control. However, even with aggressive surgery and adjuvant RT, the results of treatment for most paranasal

sinus cancers is poor with local control rates from 50 to 60%, and 5-year survival rates ranging from 30 to 60% [97–105].

Preoperative RT has been explored as a means of making these lesions more amenable to surgical resection [92, 106]. However, given the inherent bias in these nonrandomized studies, it is unclear whether preoperative is superior to postoperative RT in enhancing local control and improving outcome.

The use of postoperative RT and concomitant chemotherapy should be considered in patients with pathologically positive lymph nodes, particularly in cases with adverse prognostic factors such as multiple metastatic lymph nodes or any node with extracapsular spread.

Conclusions

If one wants to summarize the most notable developments of the last 30 years in the therapeutic management of oral squamous cell carcinomas that have been incorporated into everyday clinical practice, he should definitely point out the following key issues.

During the last 30 years the belief that oral cancer management is based on team work has been established. The functions of tumor boards and combined clinics is a common contemporary practice with an exceedingly large number of medical, surgical and other specialties being part of comprehensive, multidisciplinary therapeutic head and neck teams.

The Basic Treatment Modalities Remain Surgery, Radiotherapy, and Chemotherapy

Basic surgical techniques have not changed dramatically over the last 30 years. Among the major changes are the variations in the surgical management of the neck of both clinically negative and clinically positive neck patients, as well as the management of the mandible especially in the early invasion of oral squamous cell carcinoma in the mandibular bone. The revolution in the surgical treatment of oral cancer is the introduction of reconstructive techniques with both pedicled locoregional flaps and free tissue transfer. These reconstructive techniques allowed for safer and wider resections with adequate disease-free margins and functional reconstruction of the created surgical defects.

Contemporary radiotherapeutic treatment has very little similarities with that of the late 1970s. Modern technology with the institution of new forms of radiation and the application of sophisticated computerized methods have enhanced the therapeutic effectiveness of irradiation with an equal important reduction in the sparing in irradiation of normal surrounding

tissues. This has led to an increased therapeutic dose in the tumorous bed and a decreased severity of radiation-induced injuries in the neighboring, unaffected by the disease, normal tissues. Alterations in the fractionations have also shown to produce better therapeutic results in selected cases.

The era of methotrexate, the leading chemotherapeutic agent of the 1970s, was followed by the institution of platinum-based chemotherapies with or without the addition of 5 Fu. Adjuvant and neoadjuvant schemes coupled with pre- or postoperative radiotherapy started in the late 1980s and showed a distinct survival benefit over radiotherapy alone. This major breakthrough was followed by the institution of various and diverse chemoradiation regimes tested over a large time period for their survival benefits. The introduction of taxanes and the development of molecular targeted therapies during the last 5 years have revolutionized the concept of chemoradiation. Induction chemotherapy and chemoradiation coupled with epidermal growth factor receptor antagonists proved to have a survival benefit in patients with locally advanced or recurrent squamous cell carcinoma of the head and neck. Other biological agents against tumor angiogenesis or resulting in the restoration of cell apoptosis are being tested in various phase I or II trials with promising results.

- In the course of the next decade: oral cancer in non-smoker non-drinkers will increase.
- The differences in the ratios between males and females will tend to equalize.
- Surgery will remain the prime modality in early (stage I and II) disease.
- Molecular prognosticators will be used to determine optimal treatment.
- Postoperative chemoradiation will remain the treatment of choice for “aggressive” early (stage I and II) disease.
- Organ preservation treatments will prevail in advanced (stage III and IV) disease.
- Surgery will remain the treatment of choice for locoregional salvage surgery.
- The use of stem cells and biomechanical engineering will compliment reconstructive surgery.

References

1. Cooper JS, Porter K, Mallin K, et al. National Cancer Database report on cancer of the head and neck: 10-year update. *Head Neck*. 2009;31:748–58.
2. de Camargo Cancela M, Voti L, Guerra-Yi M, Chapuis F, Mazuir M, Curado MP. Oral cavity cancer in developed and in developing countries: population-based incidence. *Head Neck*. 2010;32(3):357–67.

3. Hennessey PT, Westra WH, Califano JA. Human papillomavirus and head and neck squamous cell carcinoma: recent evidence and clinical implications. *J Dent Res*. 2009;88:300–6.
4. Ravidis AD, Gullane P, Langdon JD, Lefebvre JL, Scully C, Shah JP. Major advances in the knowledge and understanding of the epidemiology, aetiopathogenesis, diagnosis, management and prognosis of oral cancer. *Oral Oncol*. 2009;45:299–300.
5. Patel SG, Shah JP. TNM staging of cancers of the head and neck: striving for uniformity among diversity. *CA Cancer J Clin*. 2005;55:242–58. quiz 261–2, 264.
6. Ferlito A, Rinaldo A, Silver CE, et al. Elective and therapeutic selective neck dissection. *Oral Oncol*. 2006;42:14–25.
7. Patel RS, Clark JR, Gao K, O'Brien CJ. Effectiveness of selective neck dissection in the treatment of the clinically positive neck. *Head Neck*. 2008;30:1231–6.
8. Shah JP, Singh B. Keynote comment: why the lack of progress for oral cancer? *Lancet Oncol*. 2006;7:356–7.
9. Klug C, Berzaczy D, Voracek M, Millesi W. Preoperative chemoradiotherapy in the management of oral cancer: a review. *J Craniomaxillofac Surg*. 2008;36:75–88.
10. Robbins KT, Samant S, Vieira F, Kumar P. Presurgical cytoreduction of oral cancer using intra-arterial cisplatin and limited concomitant radiation therapy (Neo-RADPLAT). *Arch Otolaryngol Head Neck Surg*. 2004;130:28–32.
11. Bentzen SM, Harari PM, Bernier J. Exploitable mechanisms for combining drugs with radiation: concepts, achievements and future directions. *Nat Clin Pract Oncol*. 2007;4:172–80.
12. Cohen EE, Baru J, Huo D, et al. Efficacy and safety of treating T4 oral cavity tumors with primary chemoradiotherapy. *Head Neck*. 2009;31:1013–21.
13. Bernier J. Head and neck oncology: what the past decade has taught us. *Expert Rev Anticancer Ther*. 2006;6:1133–6.
14. Forastiere AA, Goepfert H, Maor M, et al. Concurrent chemotherapy and radiotherapy for organ preservation in advanced laryngeal cancer. *N Engl J Med*. 2003;349:2091–8.
15. Lefebvre JL, Chevalier D, Luboinski B, Kirkpatrick A, Collette L, Sahnoud T. Larynx preservation in pyriform sinus cancer: preliminary results of a European Organization for Research and Treatment of Cancer phase III trial. *EORTC Head and Neck Cancer Cooperative Group*. *J Natl Cancer Inst*. 1996;88:890–9.
16. Lefebvre JL, Rolland F, Tessler M, et al. Phase 3 randomized trial on larynx preservation comparing sequential vs alternating chemotherapy and radiotherapy. *J Natl Cancer Inst*. 2009;101:142–52.
17. Lefebvre JL, Ang KK. Larynx preservation clinical trial design: key issues and recommendations—a consensus panel summary. *Int J Radiat Oncol Biol Phys*. 2009;73:1293–303.
18. Lefebvre JL, Ang KK. Larynx preservation clinical trial design: key issues and recommendations – a consensus panel summary. *Head Neck*. 2009;31:429–41.
19. Bernier J. A multidisciplinary approach to squamous cell carcinomas of the head and neck: an update. *Curr Opin Oncol*. 2008;20:249–55.
20. Bourhis J, Overgaard J, Audry H, et al. Hyperfractionated or accelerated radiotherapy in head and neck cancer: a meta-analysis. *Lancet*. 2006;368:843–54.
21. Fu KK, Pajak TF, Trotti A, et al. A Radiation Therapy Oncology Group (RTOG) phase III randomized study to compare hyperfractionation and two variants of accelerated fractionation to standard fractionation radiotherapy for head and neck squamous cell carcinomas: first report of RTOG 9003. *Int J Radiat Oncol Biol Phys*. 2000;48:7–16.
22. Horiot JC, Le Fur R, N'Guyen T, et al. Hyperfractionation versus conventional fractionation in oropharyngeal carcinoma: final analysis of a randomized trial of the EORTC cooperative group of radiotherapy. *Radiother Oncol*. 1992;25:231–41.
23. Pinto LH, Canary PC, Araujo CM, Bacelar SC, Souhami L. Prospective randomized trial comparing hyperfractionated versus conventional radiotherapy in stages III and IV oropharyngeal carcinoma. *Int J Radiat Oncol Biol Phys*. 1991;21:557–62.
24. Bernier J. Current state-of-the-art for concurrent chemoradiation. *Semin Radiat Oncol*. 2009;19:3–10.
25. Brown JS, Rogers SN, McNally DN, Boyle M. A modified classification for the maxillectomy defect. *Head Neck*. 2000;22:17–26.
26. Cooper JS, Pajak TF, Forastiere AA, et al. Postoperative concurrent radiotherapy and chemotherapy for high-risk squamous-cell carcinoma of the head and neck. *N Engl J Med*. 2004;350:1937–44.
27. Bernier J, Dommene C, Ozsahin M, et al. Postoperative irradiation with or without concomitant chemotherapy for locally advanced head and neck cancer. *N Engl J Med*. 2004;350:1945–52.
28. Overgaard J. Chemoradiotherapy of head and neck cancer—can the bumble bee fly? *Radiother Oncol*. 2009;92:1–3.
29. Ravidis A, Sarlis N, Lefebvre JL, Kies M. Docetaxel in the treatment of squamous cell carcinoma of the head and neck. *Ther Clin Risk Manag*. 2008;4:865–86.
30. Pignon JP, le Maitre A, Maillard E, Bourhis J. Meta-analysis of chemotherapy in head and neck cancer (MACH-NC): an update on 93 randomised trials and 17, 346 patients. *Radiother Oncol*. 2009;92:4–14.
31. Pignon JP, Bourhis J, Dommene C, Designe L. Chemotherapy added to locoregional treatment for head and neck squamous-cell carcinoma: three meta-analyses of updated individual data. MACH-NC Collaborative Group. *Meta-Analysis of Chemotherapy on Head and Neck Cancer*. *Lancet*. 2000;355:949–55.
32. Bonner JA, Harari PM, Giralt J, et al. Radiotherapy plus cetuximab for squamous-cell carcinoma of the head and neck. *N Engl J Med*. 2006;354:567–78.
33. Vermorken JB, Mesia R, Rivera F, et al. Platinum-based chemotherapy plus cetuximab in head and neck cancer. *N Engl J Med*. 2008;359:1116–27.
34. Ravidis AD, Vermorken JB, Bourhis J. Targeted therapies in head and neck cancer: past, present and future. *Rev Recent Clin Trials*. 2008;3:156–66.
35. Posner MR, Herschock DM, Blajman CR, et al. Cisplatin and fluorouracil alone or with docetaxel in head and neck cancer. *N Engl J Med*. 2007;357:1705–15.
36. Vermorken JB, Remenar E, van Herpen C, et al. Cisplatin, fluorouracil, and docetaxel in unresectable head and neck cancer. *N Engl J Med*. 2007;357:1695–704.
37. Shah JP. Surgical approaches to the oral cavity primary and neck. *Int J Radiat Oncol Biol Phys*. 2007;69:S15–8.
38. Zitsch 3rd RP, Park CW, Renner GJ, Rea JL. Outcome analysis for lip carcinoma. *Otolaryngol Head Neck Surg*. 1995;113:589–96.
39. Baker SR, Krause CJ. Pedicle flaps in reconstruction of the lip. *Facial Plast Surg*. 1984;1:61–8.
40. Pribaz JJ, Meara JG, Wright S, Smith JD, Stephens W, Breuing KH. Lip and vermilion reconstruction with the facial artery musculomucosal flap. *Plast Reconstr Surg*. 2000;105:864–72.
41. de Visscher JG, Schaapveld M, Grond AJ, van der Waal I. Relationship of tumor thickness in punch biopsy and subsequent surgical specimens in stage I squamous cell carcinoma of the lower lip. *Oral Surg Oral Med Oral Pathol Oral Radiol Endod*. 1999;88:141–4.
42. Onercl M, Yilmaz T, Gedikoglu G. Tumor thickness as a predictor of cervical lymph node metastasis in squamous cell carcinoma of the lower lip. *Otolaryngol Head Neck Surg*. 2000;122:139–42.
43. Friedlander PL, Schantz SP, Shaha AR, Yu G, Shah JP. Squamous cell carcinoma of the tongue in young patients: a matched-pair analysis. *Head Neck*. 1998;20:363–8.
44. Yoshida K, Koizumi M, Inoue T, et al. Radiotherapy of early tongue cancer in patients less than 40 years old. *Int J Radiat Oncol Biol Phys*. 1999;45:367–71.

45. Hinerman RW, Mendenhall WM, Morris CG, Amdur RJ, Werning JW, Villaret DB. Postoperative irradiation for squamous cell carcinoma of the oral cavity: 35-year experience. *Head Neck*. 2004;26:984-94.
46. Yang TL, Wang CP, Ko JY, Lin CF, Lou PJ. Association of tumor satellite distance with prognosis and contralateral neck recurrence of tongue squamous cell carcinoma. *Head Neck*. 2008;30:631-8.
47. Greenberg JS, El Naggar AK, Mo V, Roberts D, Myers JN. Disparity in pathologic and clinical lymph node staging in oral tongue carcinoma. Implication for therapeutic decision making. *Cancer*. 2003;98:508-15.
48. Lim YC, Lee JS, Koo BS, Kim SH, Kim YH, Choi EC. Treatment of contralateral NO neck in early squamous cell carcinoma of the oral tongue: elective neck dissection versus observation. *Laryngoscope*. 2006;116:461-5.
49. Byers RM, Weber RS, Andrews T, McGill D, Kare R, Wolf P. Frequency and therapeutic implications of "skip metastases" in the neck from squamous carcinoma of the oral tongue. *Head Neck*. 1997;19:14-9.
50. Lim YC, Song MH, Kim SC, Kim KM, Choi EC. Preserving level IIb lymph nodes in elective supraomohyoid neck dissection for oral cavity squamous cell carcinoma. *Arch Otolaryngol Head Neck Surg*. 2004;130:1088-91.
51. Elsheikh MN, Mahfouz ME, Elsheikh E. Level IIb lymph nodes metastasis in elective supraomohyoid neck dissection for oral cavity squamous cell carcinoma: a molecular-based study. *Laryngoscope*. 2005;115:1636-40.
52. Villaret AB, Piazza C, Peretti G, et al. Multicentric prospective study on the prevalence of sublevel IIb metastases in head and neck cancer. *Arch Otolaryngol Head Neck Surg*. 2007;133:897-903.
53. Paleri V, Kumar Subramaniam S, Oozeer N, Rees G, Krishnan S. Dissection of the submuscular recess (sublevel IIb) in squamous cell cancer of the upper aerodigestive tract: prospective study and systematic review of the literature. *Head Neck*. 2008;30:194-200.
54. Ferlito A, Silver CE, Suarez C, Rinaldo A. Preliminary multi-institutional prospective pathologic and molecular studies support preservation of sublevel IIB and level IV for laryngeal squamous carcinoma with clinically negative neck. *Eur Arch Otorhinolaryngol*. 2007;264:111-4. discussion 109.
55. Hicks Jr WL, Loree TR, Garcia RI, et al. Squamous cell carcinoma of the floor of mouth: a 20-year review. *Head Neck*. 1997;19:400-5.
56. Duvvuri U, Simental Jr AA, D'Angelo G, et al. Elective neck dissection and survival in patients with squamous cell carcinoma of the oral cavity and oropharynx. *Laryngoscope*. 2004;114:2228-34.
57. Dias FL, Lima RA, Kligerman J, et al. Relevance of skip metastases for squamous cell carcinoma of the oral tongue and the floor of the mouth. *Otolaryngol Head Neck Surg*. 2006;134:460-5.
58. Chu A, Fletcher GH. Incidence and causes of failures to control by irradiation the primary lesions in squamous cell carcinomas of the anterior two-thirds of the tongue and floor of mouth. *Am J Roentgenol Radium Ther Nucl Med*. 1973;117:502-8.
59. Fu KK, Lichter A, Galante M. Carcinoma of the floor of mouth: an analysis of treatment results and the sites and causes of failures. *Int J Radiat Oncol Biol Phys*. 1976;1:829-37.
60. Lane AP, Buckmire RA, Mukherji SK, Pillsbury 3rd HC, Meredith SD. Use of computed tomography in the assessment of mandibular invasion in carcinoma of the retromolar trigone. *Otolaryngol Head Neck Surg*. 2000;122:673-7.
61. Brockenbrough JM, Petruzzelli GJ, Lomasney L. DentaScan as an accurate method of predicting mandibular invasion in patients with squamous cell carcinoma of the oral cavity. *Arch Otolaryngol Head Neck Surg*. 2003;129:113-7.
62. Tsue TT, McCulloch TM, Girod DA, Couper DJ, Weymuller Jr EA, Glenn MG. Predictors of carcinomatous invasion of the mandible. *Head Neck*. 1994;16:116-26.
63. Shaha AR. Preoperative evaluation of the mandible in patients with carcinoma of the floor of mouth. *Head Neck*. 1991;13:398-402.
64. Pandey M, Rao LP, Das SR. Predictors of mandibular involvement in cancers of the oromandibular region. *J Oral Maxillofac Surg*. 2009;67:1069-73.
65. Shaw RJ, Brown JS, Woolgar JA, Lowe D, Rogers SN, Vaughan ED. The influence of the pattern of mandibular invasion on recurrence and survival in oral squamous cell carcinoma. *Head Neck*. 2004;26:861-9.
66. Brown JS, Lowe D, Kalavrezos N, D'Souza J, Magennis P, Woolgar J. Patterns of invasion and routes of tumor entry into the mandible by oral squamous cell carcinoma. *Head Neck*. 2002;24:370-83.
67. Wong RJ, Keel SB, Glynn RJ, Varvares MA. Histological pattern of mandibular invasion by oral squamous cell carcinoma. *Laryngoscope*. 2000;110:65-72.
68. Werning JW, Byers RM, Novas MA, Roberts D. Preoperative assessment for and outcomes of mandibular conservation surgery. *Head Neck*. 2001;23:1024-30.
69. Brown JS, Griffith JF, Phelps PD, Browne RM. A comparison of different imaging modalities and direct inspection after periosteal stripping in predicting the invasion of the mandible by oral squamous cell carcinoma. *Br J Oral Maxillofac Surg*. 1994;32:347-59.
70. Hao SP, Tsang NM, Chang KP, Chen CK, Huang SS. Treatment of squamous cell carcinoma of the retromolar trigone. *Laryngoscope*. 2006;116:916-20.
71. Dubner S, Heller KS. Local control of squamous cell carcinoma following marginal and segmental mandibulectomy. *Head Neck*. 1993;15:29-32.
72. O'Brien CJ, Adams JR, McNeil EB, et al. Influence of bone invasion and extent of mandibular resection on local control of cancers of the oral cavity and oropharynx. *Int J Oral Maxillofac Surg*. 2003;32:492-7.
73. Lam KH, Lam LK, Ho CM, Wei WI. Mandibular invasion in carcinoma of the lower alveolus. *Am J Otolaryngol*. 1999;20:267-72.
74. Kowalski LP, Hashimoto I, Magrin J. End results of 114 extended "commando" operations for retromolar trigone carcinoma. *Am J Surg*. 1993;166:374-9.
75. Mendenhall WM, Morris CG, Amdur RJ, Werning JW, Villaret DB. Retromolar trigone squamous cell carcinoma treated with radiotherapy alone or combined with surgery. *Cancer*. 2005;103:2320-5.
76. Huang CJ, Chao KS, Tsai J, et al. Cancer of retromolar trigone: long-term radiation therapy outcome. *Head Neck*. 2001;23:758-63.
77. Byers RM, Newman R, Russell N, Yue A. Results of treatment for squamous carcinoma of the lower gum. *Cancer*. 1981;47:2236-8.
78. Lo K, Fletcher GH, Byers RM, Fields RS, Peters LJ, Oswald MJ. Results of irradiation in the squamous cell carcinomas of the anterior faucial pillar-retromolar trigone. *Int J Radiat Oncol Biol Phys*. 1987;13:969-74.
79. Holmstrup P, Thorn JJ, Rindum J, Pindborg JJ. Malignant development of lichen planus-affected oral mucosa. *J Oral Pathol*. 1988;17:219-25.
80. Vegers JW, Snow GB, van der Waal I. Squamous cell carcinoma of the buccal mucosa. A review of 85 cases. *Arch Otolaryngol*. 1979;105:192-5.
81. Diaz Jr EM, Holsinger FC, Zuniga ER, Roberts DB, Sorensen DM. Squamous cell carcinoma of the buccal mucosa: one institution's experience with 119 previously untreated patients. *Head Neck*. 2003;25:267-73.
82. Iyer SG, Pradhan SA, Pai PS, Patil S. Surgical treatment outcomes of localized squamous carcinoma of buccal mucosa. *Head Neck*. 2004;26:897-902.

83. Strome SE, To W, Strawderman M, et al. Squamous cell carcinoma of the buccal mucosa. *Otolaryngol Head Neck Surg.* 1999;120:375–9.
84. Nair MK, Sankaranarayanan R, Padmanabhan TK. Evaluation of the role of radiotherapy in the management of carcinoma of the buccal mucosa. *Cancer.* 1988;61:1326–31.
85. Delclos L. Afterloading interstitial irradiation techniques In: Levit SH, Khan FM, Potish RA, editors. *Technological basis of radiation therapy.* Philadelphia: Lea & Febiger; 1992.
86. What Are The Key Statistics About Nasal Cavity and Paranasal Sinus Cancers? In: http://www.cancer.org/docroot/CRI/content/CRI_2_4_1X_What_are_the_key_statistics_for_nasal_cavity_and_paranasal_cancer.asp?sitearea; Accessed on March 25, 2008.
87. Blanco AI, Chao KS, Ozyigit G, et al. Carcinoma of paranasal sinuses: long-term outcomes with radiotherapy. *Int J Radiat Oncol Biol Phys.* 2004;59:51–8.
88. Harbo G, Grau C, Bundgaard T, et al. Cancer of the nasal cavity and paranasal sinuses. A clinico-pathological study of 277 patients. *Acta Oncol.* 1997;36:45–50.
89. Chen AM, Daly ME, Bucci MK, et al. Carcinomas of the paranasal sinuses and nasal cavity treated with radiotherapy at a single institution over five decades: are we making improvement? *Int J Radiat Oncol Biol Phys.* 2007;69:141–7.
90. Jansen EP, Keus RB, Hilgers FJ, Haas RL, Tan IB, Bartelink H. Does the combination of radiotherapy and debulking surgery favor survival in paranasal sinus carcinoma? *Int J Radiat Oncol Biol Phys.* 2000;48:27–35.
91. Howard DJ, Lund VJ, Wei WI. Craniofacial resection for tumors of the nasal cavity and paranasal sinuses: a 25-year experience. *Head Neck.* 2006;28:867–73.
92. Vrionis FD, Kienstra MA, Rivera M, Padhya TA. Malignant tumors of the anterior skull base. *Cancer Control.* 2004;11:144–51.
93. Ganly I, Patel SG, Singh B, et al. Craniofacial resection for malignant paranasal sinus tumors: Report of an International Collaborative Study. *Head Neck.* 2005;27:575–84.
94. Porceddu S, Martin J, Shanker G, et al. Paranasal sinus tumors: Peter MacCallum Cancer Institute experience. *Head Neck.* 2004;26:322–30.
95. Kellman RM, Marentette L. The transglabellar/subcranial approach to the anterior skull base: a review of 72 cases. *Arch Otolaryngol Head Neck Surg.* 2001;127:687–90.
96. Shah JP, Gil Z. Current concepts in management of oral cancer—surgery. *Oral Oncol.* 2009;45:394–401.
97. Parsons JT, Mendenhall WM, Mancuso AA, Cassisi NJ, Million RR. Malignant tumors of the nasal cavity and ethmoid and sphenoid sinuses. *Int J Radiat Oncol Biol Phys.* 1988;14:11–22.
98. Waldron JN, O'Sullivan B, Warde P, et al. Ethmoid sinus cancer: twenty-nine cases managed with primary radiation therapy. *Int J Radiat Oncol Biol Phys.* 1998;41:361–9.
99. Tiwari R, van der Wal J, van der Waal I, Snow G. Studies of the anatomy and pathology of the orbit in carcinoma of the maxillary sinus and their impact on preservation of the eye in maxillectomy. *Head Neck.* 1998;20:193–6.
100. Vedrine PO, Thariat J, Merrot O, et al. Primary cancer of the sphenoid sinus – a GETTEC study. *Head Neck.* 2009;31:388–97.
101. Katz TS, Mendenhall WM, Morris CG, Amdur RJ, Hinerman RW, Villaret DB. Malignant tumors of the nasal cavity and paranasal sinuses. *Head Neck.* 2002;24:821–9.
102. Parsons JT, Kimsey FC, Mendenhall WM, Million RR, Cassisi NJ, Stringer SP. Radiation therapy for sinus malignancies. *Otolaryngol Clin North Am.* 1995;28:1259–68.
103. Brizel DM, Light K, Zhou SM, Marks LB. Conformal radiation therapy treatment planning reduces the dose to the optic structures for patients with tumors of the paranasal sinuses. *Radiother Oncol.* 1999;51:215–8.
104. Hoppe BS, Nelson CJ, Gomez DR, et al. Unresectable carcinoma of the paranasal sinuses: outcomes and toxicities. *Int J Radiat Oncol Biol Phys.* 2008;72:763–9.
105. National Comprehensive Cancer Network (NCCN) guidelines available online at http://www.nccn.org/professionals/physician_gls/f_guidelines.asp. In; Accessed May 12, 2009.
106. Hoppe BS, Stegman LD, Zelefsky MJ, et al. Treatment of nasal cavity and paranasal sinus cancer with modern radiotherapy techniques in the postoperative setting – the MSKCC experience. *Int J Radiat Oncol Biol Phys.* 2007;67:691–702.

Chapter 28

Management of Nasopharyngeal Carcinoma

Anne W.M. Lee, Wai-Tong Ng, Tsz-Kok Yau, Stephen C.K. Law, and William I. Wei

Abstract Nasopharyngeal carcinoma (NPC) is a distinctly radiosensitive and chemosensitive tumor. Best quality radiotherapy is demanded to build up the complex concave high-dose zone for this critical location. Intensity-modulated (IMRT) technique is advocated, image guidance to ensure setup precision and adaptive re-planning if major deviations from intended dose distribution occur during the treatment course are useful improvements if resources allow. Stringent dose constraint to organs at risk should be attempted to minimize late toxicities. Addition of cisplatin-based concurrent-adjuvant chemotherapy is recommended for patients with stages III–IVB and high-risk stage IIB diseases. More contemporary series using IMRT together with extensive use of chemotherapy and acceleration reported very encouraging early results with locoregional control in excess of 90% at 2–4 years; the key remaining problem is distant failure. Further improvement of efficacy by changing chemotherapy sequence to induction-concurrent is being explored.

The plasma level of Epstein–Barr Viral Deoxyribonucleic Acid is an additional tool for nonkeratinizing carcinoma for prognostication and monitoring disease progress. Integrated fluorodeoxyglucose positron emission tomography and computed tomography is useful for excluding distant metastases and posttreatment persistent/recurrent disease. Early detection of failure is critical for increasing the chance of salvage; aggressive treatment should be attempted as far as possible, long survival can be achieved for patients with limited failure or metastasis. Different salvage methods and reported results are summarized.

Keywords Nasopharyngeal carcinoma • Radiotherapy • Concurrent chemotherapy • Salvage treatment • Late toxicity

Nasopharyngeal carcinoma (NPC), particularly the classical non keratinizing type, is different from other head and neck cancers for its distinctly skewed geographic and ethnic distri-

bution, association with Epstein–Barr virus (EBV), and aggressive natural behavior with especially high predilection for distant metastases. Because of its deep-seated location and anatomical proximity to critical structures, radical surgical resection is very difficult. The role of surgery is mainly biopsy for histological confirmation and salvage of persistent or recurrent disease. This cancer is highly radiosensitive and chemosensitive; but the therapeutic margin is notoriously narrow, thorough knowledge of its complex anatomy and natural behavior (Fig. 28.1) is crucial in managing this great challenge.

Investigations and Staging

Evaluation of locoregional extent should include complete physical examination (particularly on involvement of cranial nerves and cervical nodes), endoscopy, and cross-sectional imaging. Magnetic resonance imaging (MRI) is preferred over computed tomography (CT) because of its superior sensitivity. A study by Liao et al. [1] on 420 patients showed that MRI was significantly superior to CT for detecting involvement of intracranial area, skull base, paranasal sinuses, oropharynx, parapharyngeal space, prevertebral muscle, and retropharyngeal node, resulting in changes of T-category in 50%, N-category 11%, and stage group in 39% of patients. In addition to more accurate delineation of gross tumor volume (GTV), this affected the decision on addition of chemotherapy in 20% of patients.

Comprehensive search for distant metastases is indicated for patients with advanced locoregional disease, and those with suspicious clinical or laboratory abnormalities. Comparison of 4 modalities by Chua et al. [2] showed that integrated fluorodeoxyglucose positron emission tomography (FDG-PET) and CT was the most sensitive and specific modality for detecting distant metastases when compared with PET alone, CT thorax-abdomen plus skeletal scintigraphy, and conventional workup (chest X-ray, abdominal ultrasound plus skeletal scintigraphy): the corresponding sensitivity varied from 83 to 33%, and specificity from 97 to 90%. Ng et al. [3] showed that the total incidence of distant metastases

A.W.M. Lee (✉)
Clinical Oncology, Pamela Youde Nethersole Eastern Hospital,
Chai Wan, Hong Kong, China
e-mail: awmlee@ha.org.hk

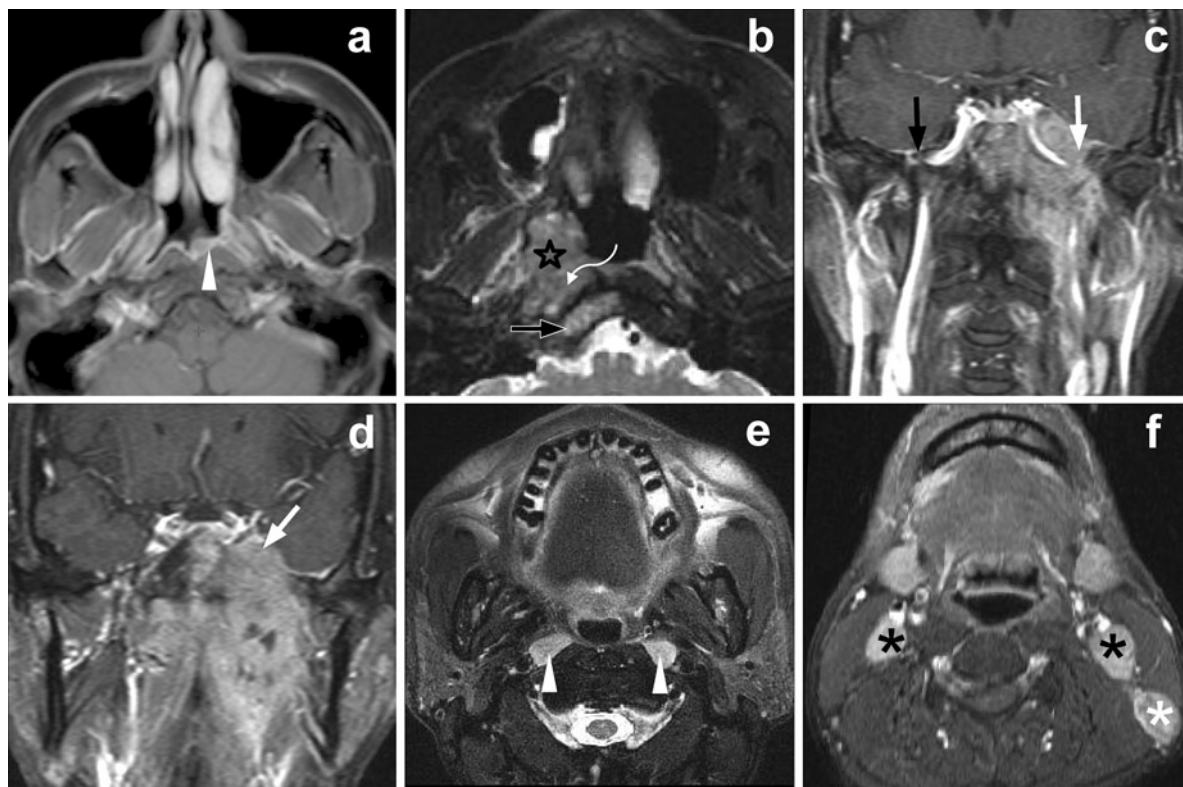


Fig. 28.1 MRI showing different patterns of local and lymphatic involvement by nasopharyngeal carcinoma: (a) small primary tumor (white arrowhead); (b) extension into parapharyngeal space (star), prevertebral muscle (curved arrow), and clivus (black arrow); (c) the infiltrated foramen ovale (white arrow) as compared to the normal

opposite side (black arrow); (d) infiltration of cavernous sinus (white arrow) through foramen lacerum and direct skull base extension; (e) metastases in retropharyngeal nodes (white arrowheads); (f) metastases in Level II (black asterisks) and Level V cervical nodes (white asterisk)

detected by PET/CT was up to 14% among newly diagnosed patients, the treatment strategy was altered in 9% of patients (with correct modification of M-category and detection of second malignancy); PET/CT was also more accurate for detecting cervical nodes in 7% of patients; but it was inferior to MRI for delineating local infiltration and retropharyngeal nodes.

Table 28.1 shows the staging criteria and groupings of the current staging system jointly used by American Joint Committee on Cancer [4] and International Union Against Cancer [5] (AJCC/UICC). It should be noted that the masticator space (one of the staging criteria for T4) is defined as a synonym of infratemporal fossa “extension of tumor beyond the anterior surface of the lateral pterygoid muscle, or lateral extension beyond the posterolateral wall of the maxillary antrum, and the pterygo-maxillary fissure” [4]. Unfortunately, different definitions are used in radiological textbook [6], inclusion of the medial and lateral pterygoid muscles as part of the masticator space will lead to unnecessary confusion and overtreatment.

The TNM staging is the most important prognostic factor and the key factor in deciding treatment strategy, continual refinement to maximize predictive accuracy is needed. For further improvement of current AJCC/UICC system, the most

widely supported suggestion was down-staging of T2a to T1 and correspondingly subgroup T2N0 to Stage I [7–10].

One ambiguity in the current staging system is the categorization of retropharyngeal node(s). Detailed analyses of 924 MRI-staged patients by Tang et al. [11] showed that retropharyngeal node involvement was an independent factor for distant failure ($p=0.04$), but there were no significant difference between unilateral and bilateral involvement ($p=0.73$). The data thus suggested that retropharyngeal node involvement should be classified as N1, regardless of laterality.

One additional investigation that helps to predict distant metastases and survival for non keratinizing cancer is the circulating Epstein–Barr Viral Deoxyribonucleic Acid (EBV-DNA). Studies from endemic countries showed that high pretreatment copies of *BamHI-W* were associated with poor prognosis [12–15]. Leung et al. [12, 13] further showed that this could identify the high-risk subgroup among patients presenting with apparently early disease: 37% of Stage IIB with high copies developed distant metastases compared with none among those with low copies. This thus helps in identifying the poor risk subgroup for addition of chemotherapy. However, the methods for measuring circulating EBV-DNA have yet to be standardized and the cut off level for portending a worse prognosis have yet to be defined [16].

Table 28.1 The Nasopharynx staging system by AJCC/UICC (7th edition)

<i>Primary tumor (T)</i>			
TX	Primary tumor cannot be assessed		
T0	No evidence of primary tumor		
Tis	Carcinoma in situ		
T1	Tumor confined to the nasopharynx, or tumor extends to oropharynx and/or nasal cavity without parapharyngeal extension ^a		
T2	Tumor with parapharyngeal extension ^a		
T3	Tumor involves bony structures of skull base and/or paranasal sinuses		
T4	Tumor with intracranial extension and/or involvement of cranial nerves, hypopharynx, orbit, or with extension to the infratemporal fossa/masticator space		
<i>Regional lymph nodes (N): Nasopharynx</i>			
The distribution and the prognostic impact of regional lymph node spread from nasopharynx cancer, particularly of the undifferentiated type, are different from those of other head and neck mucosal cancers and justify the use of a different N classification scheme			
NX	Regional lymph nodes cannot be assessed		
N0	No regional lymph node metastasis		
N1	Unilateral metastasis in cervical lymph node(s), 6 cm or less in greatest dimension, above the supraclavicular fossa, and/or unilateral or bilateral, retropharyngeal lymph nodes, 6 cm or less, in greatest dimension ^b		
N2	Bilateral metastasis in cervical lymph node(s), 6 cm or less in greatest dimension, above the supraclavicular fossa ^b		
N3	Metastasis in a lymph node(s) ^b >6 cm and/or to supraclavicular fossa ^b		
N3a	Greater than 6 cm in dimension		
N3b	Extension to the supraclavicular fossa ^c		
<i>Distant metastasis (M)</i>			
M0	No distant metastasis		
M1	Distant metastasis		
<i>Anatomic stage/prognostic groups: Nasopharynx</i>			
Stage 0	Tis	N0	M0
Stage I	T1	N0	M0
Stage II	T1	N1	M0
	T2	N0	M0
	T2	N1	M0
Stage III	T1	N2	M0
	T2	N2	M0
	T3	N0	M0
	T3	N1	M0
Stage IVA	T3	N2	M0
	T4	N0	M0
	T4	N1	M0
Stage IVB	T4	N2	M0
	Any T	N3	M0
Stage IVC	Any T	Any N	M1

Used with the permission of the American Joint Committee on Cancer (AJCC), Chicago, Illinois. The original source for this material is the AJCC Cancer Staging Manual, Seventh Edition (2010) published by Springer Science and Business Media LLC, <http://www.springer.com>

^aParapharyngeal extension denotes posterolateral infiltration of tumor.

^bMidline nodes are considered ipsilateral nodes

^cSupraclavicular zone or fossa is relevant to the staging of nasopharyngeal carcinoma and is the triangular region originally described by Ho. It is defined by three points: (1) The superior margin of the sternal end of the clavicle. (2) The superior margin of the lateral end of the clavicle. (3) The point where the neck meets the shoulder. Note that this would include caudal portions of levels IV and VB. All cases with lymph nodes (whole or part) in the fossa are considered N3b

Primary Treatment

Megavoltage radiation therapy (RT) has been the primary treatment modality. While excellent control can be achieved for patients with early disease, further improvement are needed for the majority of patients presenting with advanced locoregional diseases. The current recommendation is to treat patients with Stage I–IIA disease with RT alone, and those with Stage III–IVB (±IIB) disease with chemoradiotherapy (CRT).

Radiation Therapy

Dose, Time, and Fractionation

Although NPC is a radiosensitive tumor, high dose is needed for complete eradication. Retrospective studies showed a significant dose–response effect [17–19]; total dose ≥ 70 Gy is needed even for T1–2 tumors. Fractional dose did not affect local control, but it was a significant risk factor for temporal

lobe necrosis [20–22]. The general recommendation is to give 2 Gy per daily fraction to a total dose ≥ 70 Gy to gross tumor, and 50–60 Gy for elective treatment of potential risk sites.

Leung et al. [23] showed that for patients with T1–2b tumors, an additional boost by high-dose-rate (HDR) brachytherapy of 10–12 Gy in 2 weekly fractions following 66 Gy by 2-dimensional (2D) RT could achieve significantly better 5-year L-FFR (96% vs. 88%) and overall survival (OS) (91% vs. 80%) without excessive late toxicity (10% vs. 14%) when compared with historic controls. Study by Hara et al. [24] on 82 patients (52% with T3–4 tumor) showed that a single-fraction of 7–15 Gy by stereotactic RT following an external course of 66 Gy together with extensive use of concurrent-adjuvant chemotherapy in advanced cases, could achieve excellent 5-year L-FFR of 98%. However, relatively high incidences of late damage (including temporal lobe 12%, retina 4%, and carotid artery 1%) had been observed. The therapeutic risk and benefit of dose escalation, particularly for patients treated with CRT, have to be cautiously balanced.

Retrospective study showed that prolongation of treatment significantly jeopardized local control [25, 26], the hazard of local failure increasing by 3% per additional day even for non keratinizing tumor. However, the benefit of accelerated fractionation (AF) was uncertain. Teo et al. [27] randomized 159 patients (38% T3–4) to 2.5 Gy/fraction daily (QD) for 8 fractions followed by 1.6 Gy twice-daily (BID) for another 32 fractions vs. 2.5 Gy/fraction daily (QD) for 24 fractions, the 5-year L-FFR was 89% vs. 85%, but excessive neurological toxicities were incurred (49% vs. 23%). Daoud et al. [28] randomized 154 patients (45% T3–4) to 1.6 Gy/fraction BID to 70.4 Gy/6 weeks vs. 2 Gy/fraction QD to 70 Gy/7 weeks; the 5-year locoregional control (LR-FFR) was 81% vs. 78%; no major excessive toxicities were observed. The preliminary results of NPC-9902 Trial by Lee et al. [29] on 198 patients with T3–4N0–1M0 diseases comparing 5 vs. 6 fractions per week at 2 Gy per fraction also showed that AF per se was disappointing, but AF combined with concurrent-adjuvant chemotherapy achieved significantly

better event-free survival (EFS) than RT at conventional fractionation (CF) alone (94% vs. 70% at 3-year; $p=0.008$); further confirmation is warranted.

Tumor Targets and Technique

The delineation of gross tumor volume (GTV) should be based on all clinical, endoscopic, and imaging findings. Fusion of diagnostic MRI and PET (if available) with planning CT is valuable for accurate delineation of tumor targets, but setting of most accurate segmentation for PET can be difficult [30, 31], close collaboration with diagnostic radiologist and nuclear physician is important. The clinical target volume (CTV) covers the GTV and microscopic infiltration, including anatomical structures at risk.

There is little controversy that intensity-modulated technique (IMRT) is recommended if resources permit, dosimetric studies showed clear improvement in conformity of dose distribution for the complex concave tumor targets and better protection of the adjacent organs [32–35].

Different centers have different practices regarding the delineation of CTV, prescription of dose fractionation, priorities in dose constraints, acceptance criteria, and beam arrangements. Many use simultaneous boost to deliver AF: the dose/fraction to the GTV ranged from 2.12 Gy [36, 37] to 2.34 Gy [38]. Together with additional chemotherapy and/or enhanced RT with boosts or AF, all series using IMRT reported most encouraging early results with local control in excess of 90% at 2–4 years (Table 28.2).

Randomized trials on patients with early stages showed significant sparing of parotid glands [39, 40]. However, it should be cautioned that overenthusiasm in protecting the parotids might result in marginal miss. Furthermore, late toxicities at other sites still developed (see Section on Late Toxicities), stringent dose constraint to organs at risk (OAR) is needed. Caution on the risk of high doses to the larynx [41], mandible

Table 28.2 Treatment parameters and outcome by intensity-modulated radiotherapy

Author (reference)	Lee [36]	Kwong [155]	Kam [142]	Wolden [38]	Kwong [140]	Lin [156]	Tham [157]	Lee [37]	PYNEH
No. of patients	67	50	63	74	50	326	195	68	193
T3–4 category (%)	43	0	51	51	100	61	NS	34	93
Total dose (Gy)	65–70	68–70	66	70.2	76	66–69.75	70	70	70
Dose/fraction (Gy)	2.12–2.25	2–2.06	2	2.34	2.17	2.2–2.25	2.12	2.12	2
Acceleration (%)	0	0	0	80	0	0	0	0	62
Additional boost (%)	39	0	56	0	0	20	10	0	0
Chemotherapy (%)	75	0	30	93	68	90	57	84	84
Tumor control									
Time (years)	4	2	3	3	2	3	3	2	2
Local control (%)	97	100	92	91	96	95	90	93	95
Nodal control (%)	98	94	98	93	98	98	–	91	96
Distant control (%)	66	94	79	78	94	90	89	85	90
Overall survival (%)	88	–	90	83	92	90	94	80	93

[42], pharyngo-esophageal axis [43], brachial plexus [44], and the carotid arteries [45] should be noted. Depending on the disease extent, sparing of other normal structures such as the submandibular gland, soft palate, middle, and inferior constrictor muscles should also be attempted if feasible in order to reduce xerostomia, acute odynophagia/velopalatine insufficiency, and dysphagia, respectively,

Treatment Precision

Image guidance to ensure precision in treatment delivery is a major advance. Electronic treatment position verification devices allow daily imaging and online correction of positional errors prior to treatment. Orthogonal kV images to verify position of bony landmarks and recent development of online cone-beam CT-guided IMRT [46] further improve the accuracy of treatment delivery.

Interfractional anatomic changes due to tumor shrinkage and weight loss could adversely affect the ultimate doses delivered [47, 48], these changes could significantly increase the daily maximum dose to the neighboring critical structures including brain stem, spinal cord, and optic chiasm. Although the maximum dose point might not fall into the same part of the critical structures to cause damage, close

monitoring is needed; re-planning should be considered if marked deviation in dose distribution occurs.

Example of Planning and Treatment Practice

The current practice at the Pamela Youde Nethersole Eastern Hospital (Hong Kong) is described as an example. The patient is set up in a supine position with head extended, and immobilized by a customized thermoplastic mask covering the head to shoulder regions. A contrast CT is taken in treatment position covering from skull vertex to 2 cm below clavicles, with 3 mm slice thickness at gross tumor regions is performed. The diagnostic MRI and PET (if available) are co-registered with planning CT for delineation of tumor targets and OAR. The whole-volume is irradiated by 9–11 (mostly coplanar) 6-MV photon beams using IMRT technique with dynamic multileaf collimator (MLC).

Figure 28.2 illustrates the targets for patients with different locoregional involvement. A total dose of 70 Gy at 2 Gy/fraction is prescribed to CTV₁ that aims to include the primary tumor with a 2–5 mm margin, the whole nasopharynx, and gross lymph nodes with a 5–10 mm margin. Instead of using simultaneous boost, patients with T3–4 tumors are treated with a moderate AF schedule of 6 daily fractions per

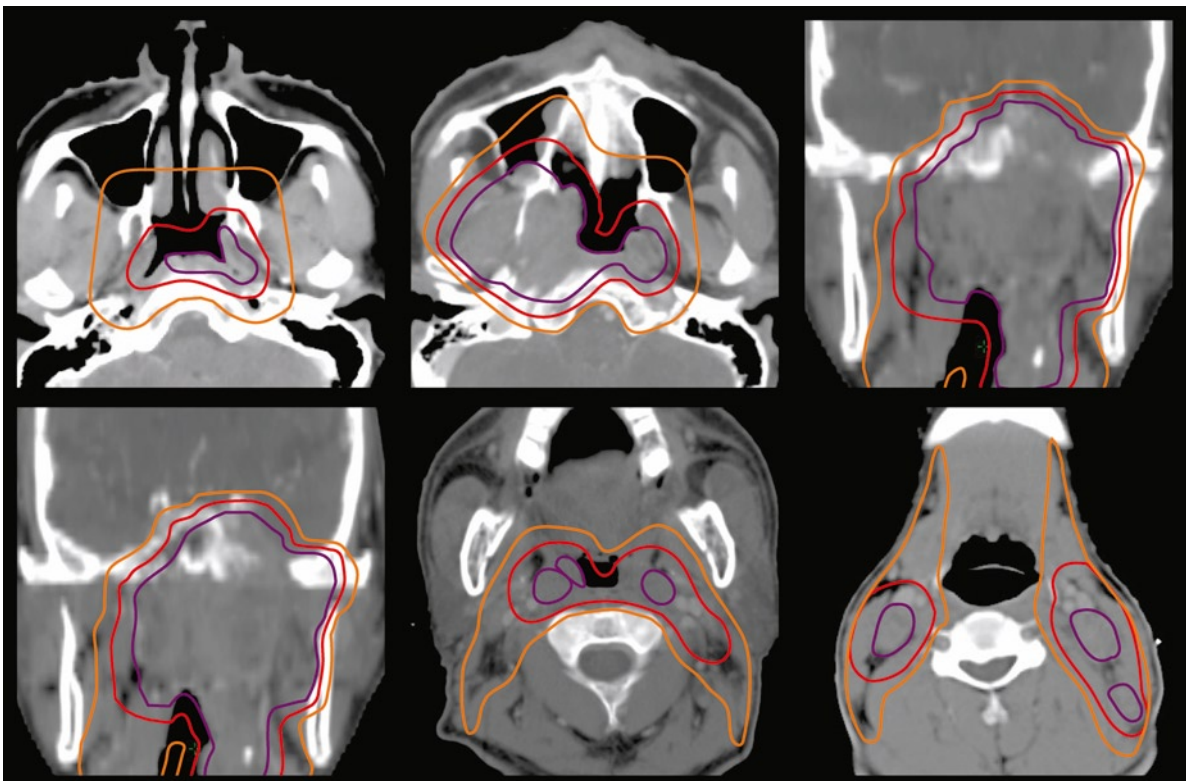


Fig. 28.2 Delineation of tumor targets for different locoregional involvement as listed above: the purple line for the gross tumor volume (GTV), the red line for the clinical target volume (CTV) aimed at 70 Gy, and the orange line for the CTV aimed at 61.25 Gy

week. The CTV₂ that aims to cover high-risk structures (including parapharyngeal spaces, posterior third of nasal cavities and maxillary sinuses, pterygoid processes, base of skull, lower half of sphenoid sinus, anterior half of the clivus, petrous tips, bilateral retropharyngeal nodes, Levels II, III, and upper VA lymphatic regions) receive 61.25 Gy at 1.75 Gy/fraction. By reducing the field borders for the last 5 fractions, the CTV₃ that covers low-risk structures including the remaining lymphatic Levels IV–VB and upper half of sphenoid sinus (if T3–4 tumor) receive 52.5 Gy also at 1.75 Gy/fraction. Selective sparing of level IB is considered in N0 patients. The CTV are expanded by 3 mm to constitute the planning target volume (PTV) for systemic and random set up variation.

With such a tight margin, image guidance to ensure setup accuracy (Fig. 28.3) is indicated particularly for patients with T4 tumors. Daily orthogonal kV images are taken to verify position of bony landmarks and correction applied for deviations ≥ 2 mm. Weekly fusions of cone-beam CT with deformable registration is currently under studied to assess the dosimetric variation due to anatomical changes during the RT course. Treatment is re-planned if the dose distribution deviates significantly from the intended plan.

Table 28.3 shows the acceptance criteria for Inverse Planning. Top priority is given to critical neurological structures, followed by tumor targets, organs with intermediate importance, and finally those with lower importance. Optimization to achieve the ideal criteria is attempted as far as possible; best possible balance between tumor control and toxicity is discussed with individual patient if it is technically difficult to fulfill even the minimal requirement.

From 2005 to 2007, 193 patients (93% with stage III–IVB disease) had been treated with the above described technique in our center. Accelerated fractionation was used in 62%, and additional chemotherapy was given to 84% of patients. The median follow-up was 30 months (range, 4–45 months). The 2-year L-FFR, nodal failure-free rate (R-FFR), D-FFR, and OS were 95, 96, 90, and 93%, respectively. Review of doses given to the locoregional failure sites showed that 4 failures were marginal miss: failure occurred at bilateral cavernous sinus (1%), maxillary and ethmoid sinuses (0.5%), and submental node (0.5%). Longer follow-up is needed to assess the ultimate efficacy and late toxicities.

Technological Developments

Development of helical tomography (HT) capable of calculating MLC position every 7 degrees of rotation opened a new opportunity for achieving more uniform target dose. Dosimetric comparisons showed that HT was superior to coplanar 5-fields IMRT delivered by dynamic MLC [49] and 7-fields step-and-shoot IMRT [50] in the homogeneity of

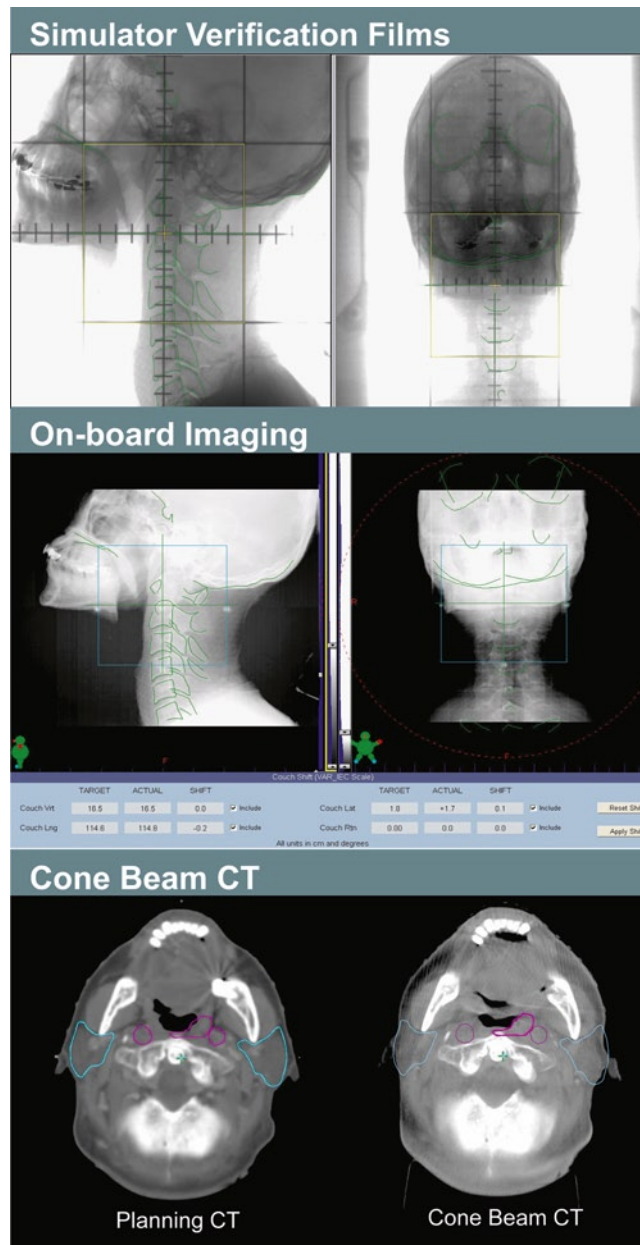


Fig. 28.3 Verification of setup accuracy: (upper) simulator check-films; (mid) checking of bony landmarks using On Board Imager™; and (lower) cone-beam computed tomography to ensure no major deviation

dose distribution within the PTV; significant improvement ratios of 129% in conformity index and 9% in homogeneity index was shown by Lee et al. [50]. In addition, significant reduction of mean/maximal doses to most of the OAR was achieved, but it should be noted that negative result was observed for optic chiasm, particularly for patients with T1–2 tumor, due to less sharp fall-off in craniocaudal dose. It is hoped that recent development of volumetric arc technique using linear accelerator can achieve improvement in dose distribution with greater efficiency in delivery.

Particle beam RT (hadrontherapy) with physical advantages of better spatial selectivity and/or higher biological

Table 28.3 Intensity-modulated radiation therapy for nasopharyngeal carcinoma: specification on dose constraints and acceptance criteria (current guideline at Pamela Youde Nethersole Eastern Hospital, Hong Kong)

	First criteria – ideal	Second criteria – acceptable
Priority 1: critical organ at risk		
Brainstem	Point <54 Gy	Point & 1% volume <60 Gy
Spinal cord	Point <45 Gy	Point & 1cc volume <50 Gy
Optic chiasma	Point <54 Gy	Point & 1% volume <60 Gy
Optic nerve	Point <54 Gy	Point & 1% volume <60 Gy
Temporal lobes	Point <65 Gy & 1% volume <60 Gy	Point <70 Gy & 1% volume <65 Gy
Priority 2: tumor targets		
GTV	≥68.6 Gy (98% dose) to 100% PTV ₁	<1% GTV <66.5 Gy (95% dose)
PTV	≥95% dose to 100% PTV	<5% PTV <100% dose
	<10% PTV ₁ ≥75 Gy (107% dose)	<1% PTV <93% dose
		<20% PTV ₁ ≥77 Gy (110% dose)
Priority 3: organ at risk with intermediate importance		
Pituitary	Point <60 Gy	1% volume <65 Gy
Mandible/T-M joint	1% volume <70 Gy	1% volume <75 Gy
Lens	Point <6 Gy	Point & 1% volume <10 Gy
Eyeball	Point <50 Gy	Mean <35 Gy
Priority 4: organ at risk with low importance		
Parotid glands	Mean <26 Gy (at least 1 gland)	50% volume <30 Gy (at least 1 gland)
Cochlea	Mean <50 Gy	–
Tongue	1% volume <70 Gy	Mean dose <55 Gy
Larynx	Mean <30 Gy	Mean <45 Gy
Nonspecified	<1% volume ≥75 Gy	<5% volume ≥70 Gy

GTV gross tumor volume, PTV planning target volume, PTV₁ aimed at 70 Gy

efficacy than photons is an attractive technological advance for NPC with its critical location. Dosimetric comparisons showed that 3D spot-scanned coplanar 3-fields intensity-modulated proton therapy (IMPT) was superior to coplanar 9-fields step-and-shoot IMRT by photon [51] in coverage and conformity for the GTV, as well as reduction of mean dose to most OAR and medium dose volumes by a factor of 2–3. The latter improvement might be important for minimizing late damages and carcinogenic effect of ionizing radiation.

Further comparative study by Widesott et al. [52] showed that both IMPT and HT could achieve similar coverage and homogeneity for PTV; the most remarkable superiority of IMPT was reduction in total body volume receiving ≥30–10 Gy by 15–23%. Selective use of this expensive treatment for extensive locoregional disease infiltrating/abutting critical OAR and re-irradiation of recurrent tumor, particularly for pediatric patients, is worth exploring.

Chemotherapy

Current Recommendations

The meta-analysis by Baujat et al. [53], based on 1,753 patients from trials on induction chemotherapy [54–57], adjuvant chemotherapy [58], and concurrent±adjuvant chemotherapy [59–61], confirmed that significant survival benefit could be achieved by adding chemotherapy: The absolute gain for 5-year

EFS was 10% (52% vs. 42%) and OS was 6% (62% vs. 56%). Concurrent chemotherapy was the most potent combination, and the only sequence that achieved significant benefit in OS: hazard ratio (HR)=0.71; 95% confidence interval (CI), 0.53–0.94. Induction chemotherapy per se could significantly reduce the risk of locoregional failures by 24% and distant failures by 35%; this resulted in significant improvement in EFS (HR=0.82; 95% CI, 0.68–0.97), but the benefit in OS was nonsignificant (HR=0.99; 95% CI, 0.80–1.21). Adjuvant chemotherapy per se failed to achieve significant benefit in any endpoints.

Table 28.4 summarizes the trials on concurrent±adjuvant chemotherapy published in the English literature. The first trial that achieved significant survival benefit was the Intergroup-0099 Study [59] using cisplatin (CDDP) (100 mg/m²) on days 1, 22, and 43 in concurrence with RT at conventional fractionation (70 Gy in 35 fractions) followed by combination of CDDP (80 mg/m²) and fluorouracil (FU) (1,000 mg/m²/day for 96 h) on days 71, 99, and 127 during the post-RT phase. Subsequent confirmatory trials by Lee et al. [62], Wee et al. [63], and Chen et al. [64], consistently supported that the Intergroup-0099 regimen could significantly improve tumor control; the latter two trials also showed significant survival benefit. In addition, the NPC-9902 Trial (on patients with T3–4N0–1 disease) by Lee et al. [29], showed that the concurrent-adjuvant chemotherapy was a significant independent factor for reducing relapse (HR=0.52; 95% CI, 0.28–0.97; *p*=0.039); furthermore, the preliminary results suggested that combining this regimen with accelerated fractionation could achieve substantially greater benefit.

Table 28.4 Randomized trials comparing concurrent chemoradiotherapy vs. radiotherapy alone for nasopharyngeal carcinoma

Author (reference)	Al-Sarraf [59, 74]	Wee [63]	Lee [62]	Lee [29]	Chen [64]	Kwong [60]	Lin [65]	Chan [61]	Zhang [67]
Patient characteristics									
Number enrolled	193	221	348	189	316	222	284	350	115
Stage (AJCC/UICC 6 th)	II-IVB	III-IVB	III-IVB	III-IVA	III-IVB	II-IVB	II-IVB	II-IVB	III-IVB
Radiotherapy									
Total dose (Gy)	70	70	mean 68	mean 69	70	62.5-68	70-74	66	70-74
Fractionation	C	C	C	C	C	C	C	C	C
Chemotherapy									
Concurrent	P	P	P	P	P	U	PF	P	O
Adjuvant	PF	PF	PF	PF	PF	±PF/VBM	-	-	-
Tumor control (%): CRT vs. RT									
Time point (year)	5	3	3	3	2	3	5	5	2
Locoregional control	S	-	92 vs. 82 <i>p</i> =0.01	81 vs. 85 NS	98 vs. 92 <i>p</i> =0.01	80 vs. 72 NS	L: 89 vs. 73 <i>p</i> <0.01	NS	L: 96 vs. 88 NS
Distant control	S	87 vs. 70 ^a <i>p</i> <0.01	76 vs. 73 NS	89 vs. 81 NS	87 vs. 79 <i>p</i> =0.02	85 vs. 71 <i>p</i> =0.03	79 vs. 70 <i>p</i> =0.06	NS	92 vs. 80 <i>p</i> =0.02
Progression-free survival	58 vs. 29 <i>p</i> <0.01	72 vs. 53 <i>p</i> =0.01	70 vs. 61 NS	73 vs. 68 NS	-	-	-	-	96 vs. 83 <i>p</i> =0.09
Failure-free survival	-	-	72 vs. 62 <i>p</i> =0.03	74 vs. 70 NS	85 vs. 73 <i>p</i> <0.01	69 vs. 58 NS	72 vs. 53 <i>p</i> =0.01	60 vs. 52 NS	-
Overall survival	67 vs. 37 <i>p</i> <0.01	80 vs. 65 <i>p</i> =0.01	78 vs. 78 NS	87 vs. 83 NS	90 vs. 80 <i>p</i> <0.01	87 vs. 77 <i>p</i> =0.06	72 vs. 54 <i>p</i> <0.01	70 vs. 59 <i>p</i> =0.07	100 vs. 77 <i>p</i> =0.01

^a2-year incidence of freedom from distant failure as the first site of failure

AJCC/UICC 6th, American Joint Committee on Cancer/International Union Against Cancer 6th Edition; C, conventional; A, accelerated; P, cisplatin; F, fluorouracil; U, uracil-tegafur; V, vincristine; B, bleomycin; M, methotrexate; O, oxaliplatin; L, local; S, significant but no detailed data; NS, no statistical significance (*p*>0.1); Progression-free survival: defining events included both failures and death; Failure-free survival: defining events included failures only

The trials using concurrent chemotherapy alone showed less consistent conclusions. Lin et al. [65] using concurrent CDDP/FU reported significant benefit in both EFS and OS. However, subsequent re-analysis [66] with retrospective re-staging of the accrued patients into different risk groups showed that the benefit was significant for low-risk patients only. The trial by Chan et al. [61] using concurrent weekly CDDP and that by Kwong et al. [60] using concurrent uracil-tegafur with or without adjuvant CDDP-based combination only showed borderline improvement in OS ($p>0.06$) and no significant improvement in failure rate ($p>0.14$). A trial by Zhang et al. [67] using concurrent oxaliplatin showed significant improvement in both EFS and OS at 2-year, longer results are awaited.

A randomized trial by Chitapanarux et al. [68] on 206 patients showed that replacing CDDP in the Intergroup-0099 regimen with carboplatin could lead to better tolerability (proportion of patients who could complete 6 cycles was 62% vs. 26%) with similar efficacy (3-year OS was 78% vs. 79%). However, it should be noted that the completion rate in the CDDP-group was very low. Our retrospective study comparing patients who completed two cycles of concurrent chemotherapy [69] showed that those with both cycles replaced by carboplatin had significantly inferior 3-year LR-FFR (56% vs. 86%, $p=0.014$) and OS (61% vs. 87%, $p=0.046$).

Retrospective comparison of concurrent-adjuvant chemotherapy vs. concurrent chemotherapy alone in stage I–III patients by Cheng et al. [70] showed that the former could achieve significantly better EFS (77% vs. 53% at 5-year, $p=0.01$), the adjuvant phase was beneficial particularly for patients with T2b–3 N0–2 diseases. Hence, basing on currently available data, the Intergroup-0099 regimen remains

the standard chemotherapy recommended for patients with advanced locoregional disease outside clinical trials.

However, there are concerns about the efficacy of the Intergroup-0099 regimen for distant control. Preliminary results of the NPC-9901 Trial [62] showed little improvement in distant control for patients with N2–3 disease (76% vs. 73% at 3-year; $p=0.47$). Reports from Stanford University [24] and University of California, San Francisco also showed that the incidence of distant failure remained high (>30%) despite achievement of excellent locoregional control by new technologies and extensive use of the Intergroup-0099 regimen (>75% of the series). Exploration for a more potent strategy is needed.

New Strategies Under Investigation

One logical strategy is to change the sequence of the Intergroup-0099 regimen from concurrent-adjuvant to induction-concurrent because the induction sequence is more potent for reducing failures and substantially better tolerated. Theoretically, early use of potent combination of cytotoxic drugs at full dose would be more effective for eradicating micrometastases. Another possible advantage is that this could shrink the primary tumor to give wider margin for irradiation, an advantage that is particularly needed for patients with extensive locoregional infiltration infiltrating/abutting critical neurological structures.

Table 28.5 summarizes the reported Phase II studies on induction-concurrent CRT. The first study on 35 patients

Table 28.5 Phase II studies on induction-concurrent chemoradiotherapy

Author (reference)	Rischin [71]	Oh [158]	Johnson [161]	Al-Amro [160]	Chan [79]	Hui [76]	Lee [72]	Yau [73]	
Patient characteristics									
Number studied	35	27	44	110	31	34	31	49	37
Stage IV (%)	40	NR	NR	74	39	44	39	100	100
Radiotherapy									
Total dose (Gy)	60	70	70	66	66	66	70	70	
Overall time (weeks)	6	14 ^a	7	6.5	6.5	6.5	6	6	
Chemotherapy									
Induction	PEF	PFI	PF	PE	TJ	DP	–	PF	PG
Concurrent	P	HF	PF	P	P	P	P	P	P
Tumor control (%)									
Time point (year)	4	5	5	3	2	3	3	3	
Locoregional control	L: 97	93	75 ^b	68	90 ^b	–	77	78	
Distant control	94	92	89 ^b	74	81 ^b	–	75	76	
Event-free survival	81	86	55	53	79	88 vs. 64 NS	61	63	
Overall survival	90	77	66	71	92	94 vs. 68 $p=0.01$	71	76	

^aSplit fractionation (2 Gy/fraction daily × 5 fraction, q 2 week)

^bCrude incidence

L, local failure-free rate alone; P, cisplatin; D, docetaxel; F, fluorouracil; E, epirubicin; I, interferon- α ; H, hydroxyurea, T, paclitaxel; J, carboplatin; G, gemcitabine

(40% with stage IV disease) by Rischin et al. [71] achieved excellent 4-year LR-FFR 97%, D-FFR 94%, and OS of 90%. All studies except that by Rischin et al. [71] aimed at a total radiation dose of 66–70 Gy. Additional enhancement by accelerated fractionation was attempted in our two studies that focused on patients with stage IVA–B disease [72, 73]. Different chemotherapy regimens have been tested; cross-series comparison is not possible because of marked variation in patient characteristics.

Experience from our center [72] on changing the sequence of the Intergroup-0099 regimen to three cycles of CDDP/FU as induction chemotherapy followed by two cycles of CDDP in concurrence with accelerated RT showed that patients did indeed have substantially better tolerance and compliance to induction chemotherapy: 98% of patients could complete three cycles of induction chemotherapy, even with a scheduled 20% increase in the dose intensity of CDDP and FU, whereas only 55% of patients in the Intergroup-0099 Trial [59] completed three cycles of adjuvant chemotherapy. Only 2% of patients had early termination of induction chemotherapy because of poor response. The induction treatment did not substantially jeopardize the tolerance during the concurrent phase, 96% of patients could complete the whole course of RT with a median overall treatment time of 41 days, only 7% failed to complete two cycles of concurrent chemotherapy. Using this chemotherapy sequence and accelerated 3D conformal RT for patients with stage IVA–B disease, our first study showed encouraging results of LR-FFR 77% and OS 71% at 3 years.

In a subsequent study [75] using IMRT technique, we further showed that induction chemotherapy using the CDDP/FU regimen could achieve significant down-staging of T-category ($p=0.016$): 25% of T3–4 tumors became T1–2 and another 10% decreased from T4 to T3. Furthermore, this could significantly reduce the GTV_P (primary tumor volume) by an average of 61%, leading to increase in minimum dose from 62.3 to 64.5 Gy ($p<0.020$), decrease in volume within GTV_P that failed to reach 70 Gy from 10.2 to 3.8%, and consequent improvement in the estimated tumor control probability (mean value) from 0.83 to 0.89 ($p=0.002$). With a median follow-up of 14 months, only 1/20 patient died of distant failure, while the remaining 95% were alive without locoregional failure; longer follow-up is needed to confirm the long-term treatment efficacy.

Although this strategy using CDDP/FU is effective and the treatment toxicity is acceptable, continuous infusion of FU for 120 h is very inconvenient, requiring frequent hospitalization or central access with insertion of infusion pump for administration. An effective regimen that is more convenient and less toxic will be desirable. Hence, we have also tried to replace FU with gemcitabine as induction chemotherapy [69, 73], retrospective comparison of the two induction regimens (CDDP/gemcitabine vs. CDDP/FU) in 75

patients with stage IVA–B disease treated with the same accelerated CRT schedule showed no significant differences in all tumor control endpoints: the 3-year EFS were almost identical (61% vs. 66%, $p=0.997$); although the LR-FFR was slightly higher in the CDDP/gemcitabine Group (85% vs. 76%, $p=0.310$), no improvements in D-FFR (78% vs. 83%, $p=0.310$) and OS (70% vs. 85%, $p=0.310$) were achieved. It seemed that this regimen is likely to be equally effective, but not superior to the CDDP/FU regimen.

A randomized Phase II trial [76] on 65 patients with stage III–IVB disease showed that those treated by induction chemotherapy using CDDP/docetaxel followed by concurrent CRT using weekly CDDP achieved significantly higher OS (94% vs. 68% at 2-year; $p=0.012$) than those treated by concurrent CRT alone, though the improvement in EFS did not reach statistical significance (88% vs. 60%; $p=0.12$). It should be cautioned that this induction regimen incurred Grade 3–4 neutropenia in 97% of patients, with 12% neutropenic fever.

Induction-concurrent CRT is hence a promising strategy for improving tumor control and there are two on-going randomized trials to evaluate this strategy. The GORTEC-NPC2006 Trial by Groupe Oncologie Radiothérapie Tête et Cou focuses on patients with stage II–IVB disease: the standard arm is weekly CDDP in concurrence with RT at conventional fractionation; the aim is to evaluate the benefits achieved by adding Docetaxel/CDDP/FU as induction chemotherapy. The NPC-0501 Trial by the Hong Kong Nasopharyngeal Cancer Study Group focuses on patients with stage III–IVB disease: the standard arm is the Intergroup-0099 regimen using concurrent CDDP plus adjuvant CDDP/FU with RT at conventional fractionation. The aims are to compare the therapeutic benefits achieved by changing the chemotherapy sequence from concurrent-adjuvant to induction-concurrent and changing the RT schedule from conventional to accelerated fractionation. In addition, this trial attempts to study the possibility of replacing FU with the oral pro-drug capecitabine.

Monitoring of Progress

Early detection of treatment failure is crucial for better chance of salvage; both endoscopic and imaging examinations are needed. A systemic review of 1,813 patients from published literature [77] showed that FDG-PET is the best modality for diagnosis of persistent/recurrent locoregional disease. Both the sensitivity and specificity estimates for PET (95 and 90%) were significantly superior to MRI and CT ($p<0.001$); the sensitivity of MRI and CT were similar (78 and 76%, respectively), but the specificity for MRI was significantly better than CT (76% vs. 59%, $p<0.001$).

Another useful investigation for monitoring disease is the circulating plasma EBV-DNA, patients with persistently elevated posttreatment levels had a significantly higher risk of relapse and death than those without [15, 16, 78–80]. Chan et al. [78] showed that the relative risk for recurrence was 11.9-fold for patients with persistently raised plasma EBV-DNA at 6–8 weeks posttreatment. Longitudinal follow-up showed that in 89% (8/9) of patients who developed treatment failure, the EBV-DNA level started to increase 2–16 months before clinical evidence of disease progression [79].

Treatment of Persistent/Recurrent Tumors

As it takes time for tumors to regress following RT, one difficult decision is when to consider residual tumors as genuine persistence and proceed with salvage treatment. Kwong et al. [81] showed that the incidence of positive histology decreased spontaneously from 29% in the first week after completion of RT to 12% by the ninth week and then rose again. The 5-year L-FFR was 82% for patients who achieved early histological remission (<5 weeks), 77% for those with delayed remission (5 to <12 weeks), but only 54% for those with persistent tumors at 12 weeks despite subsequent salvage treatment. The optimal time for intervention remains uncertain; avoidance of unnecessary overtreatment and excessive delay in treatment are both important considerations, treatment decision basing on findings between 8 and 12 weeks is a reasonable balance [82–84]; but some studies were based on biopsies taken between 3 to 8 weeks [85, 86], the time of intervention of “persistent disease” has to be taken into account in interpreting the treatment results.

Because the therapeutic considerations and prognosis are different, distinction should be made between persistent disease (tumors that do not completely regress following primary treatment) and recurrent disease (tumors that re-emerge after initial complete regression). Patients with persistent disease had better outcome than those with recurrent disease. Wu et al. [87] showed that the timing and the volume of tumor detected were independent prognostic factors, the 3-year disease-specific survival (DSS) was significantly higher for the persistent group (patients who failed within 6 months from completion of RT) than the recurrent group: 81% vs. 46% ($p=0.037$).

Nonsurgical Salvage

Table 28.6 summarizes the recent reports on different RT methods and the outcome for the two groups. Brachytherapy,

using intracavitary and interstitial methods, has been widely used for superficial persistent diseases. Excellent results with 5-year L-FFR of 90% and above have been reported for patients with initial T1–2 tumors [82, 83, 85, 86].

To ensure adequate coverage of more bulky tumor and precise delivery, stereotactic RT is increasingly used. Various dose prescriptions have been used, ranging from 7–35 Gy by single fraction radiosurgery (SRS) [88, 89] to 10–24 Gy by multiple fractions have been employed [84, 87]. Yau et al. [84] showed that 7% of 755 consecutive patients had positive biopsies 8 weeks after completion of primary RT: those treated with fractionated stereotactic RT (FSRT) to a median dose of 15 Gy achieved a 3-year L-FFR of 82%, a result that was very close to corresponding 86% in the contemporary cohort with complete remission, and was substantially better than corresponding L-FFR of 71% in those treated with HDR-brachytherapy to a median dose of 20 Gy. Wu et al. [87] also reported 3-year L-FFR of 89% with FSRT, and they further showed that severe late toxicity rate (9%) was substantially lower than SRS series.

For patients with local recurrence, the TNM stage of the recurrent tumor is one of the most important prognostic factors. Thorough re-staging workup is needed as 54% of patients also had synchronous regional and/or distant failures [90]. For the majority with recurrence infiltrating beyond the nasopharynx, re-irradiation with or without chemotherapy is the only option. Aggressive treatment should be attempted as far as possible because long-term survival might be achieved [91]; but doses ≥ 60 Gy are needed for effective salvage [92–94], significant morbidities are often incurred.

Re-irradiation poses a therapeutic challenge, it is crucial to restrict the irradiation of normal tissue to a minimum. A retrospective study by Lee et al. [95] comparing the late toxicity rate in 487 patients with two courses of external RT vs. 3,635 patients with one course suggested that there was partial recovery of normal tissues following the primary course: the summated total biological dose tolerated (BED- Σ (sigma)) was higher than that expected with a single course treatment (BED-1). Assuming an α (alpha)/ β (beta) ratio of 3 Gy, the BED- Σ (sigma) that incurred 20% toxicity at 5-years was 129% that of BED-1.

Brachytherapy has been widely used for treatment of superficial recurrent disease. Using interstitial implants with radioactive gold grains, Kwong et al. [82] reported a 5-year L-FFR of 63%; complications included headache (28%), palatal fistula (19%), and mucosal necrosis (16%). Using iridium mold, Law et al. [83] achieved excellent local salvage of 89%, but the complication rate was 53%. For more advanced recurrent tumors, addition of brachytherapy boost to external RT with 2D technique could achieve higher salvage rate [92–94, 96].

Table 28.6 Radiotherapy for salvage of persistent/recurrent nasopharyngeal carcinoma

Author	Treatment	Treatment outcome (Actuarial rate %)			Major late toxicity (Cumulative %)	
		Year	L-FFR	Survival	Overall	TLN
Persistence						
Kwong et al. [82]	Interstitial gold grain	5	T1: 87	79	28	NR
Law et al. [83]	Iridium mold	5	T1–2a: 90	65	14	NR
Leung et al. [85]	HDR-ICB	5	T1: 95	NR	NR	0
			T2: 88			
Zheng et al. [86]	HDR-ICB	5	T1: 100	NR	21	2
			T2: 90			
Yau et al. [84]	FSRT	3	T1–4: 82	82	27	NR
Wu et al. [87]	FSRT	3	T1–4: 89	NR	9	0
Recurrence						
Kwong et al. [82]	Interstitial gold grain	5	rT1: 63	54	19	NR
Law et al. [83]	Iridium mould	5	rT1–2a: 89	65	53	NR
Leung et al. [96]	2D-RT+HDR-ICB	3	rT1–2: 72	NR	NR	33
Chang et al. [102]	81% 2D, 19% 3D	3	NR	rT1: 39	2D: 23	2D: 14
				rT2: 24	3D: 9	3D: 0
				rT3: 28		
				rT4: 4		
Poon et al [108]	Concurrent-adjuvant chemo + RT	5	15	26	24	3
Zheng et al. [104]	All 3D	5	rT1: 92	rT1: 70	49	16
			rT2: 81	rT2: 52		
			rT3: 68	rT3: 32		
			rT4: 41	rT4: 10		
Chua et al. [106]	IMRT	1	rT1–3: 100	63	19	7
			rT4: 35			
Chua et al. [107]	Induction chemo + IMRT/SRS	1	rT2–3: 100	88	24	12
			rT4: 52			
Chua [101]	SRS	3	rT1–3: 68	78	22	14
Leung et al [100]	FSRT	5	57	40	57	20

L-FFR local failure-free rate, *TLN* temporal lobe necrosis, *HDR-ICB* high-dose-rate intracavitary brachytherapy, *RT* radiotherapy, *FSRT* fractionated stereotactic radiotherapy, *SRS* stereotactic radiosurgery, *2D* 2-dimensional, *3D* 3-dimensional conformal, *IMRT* intensity-modulated radiotherapy

Stereotactic RT is increasingly used; local salvage rates ranging from 53 to 86% have been reported [88, 97–100]. Leung et al. [100] showed that the total equivalent dose (TED) by FSRT was a significant factor, TED \geq 55 Gy was recommended. For patients with limited local failure, both SRS and gold grain implantation yielded comparable high tumor control rates [101]. A higher salvage rate by adding stereotactic RT as a boost after external RT has been reported [98, 102, 103]. Although, most series reported a low risk of complications, torrential hemorrhage with potential fatal outcome has been reported [98]; radiosurgery should be avoided in patients with tumor encasing the carotid artery or previous high cumulative dose.

Past series using 2D technique achieved 5-year survival rates in the range of 21–41%, while the incidence of temporal lobe necrosis (TLN) ranged from 2 to 27%. The use of 3D conformal radiotherapy showed improving results. Chang et al. [102] showed that none of the patients re-irradiated by

3D technique developed TLN compared to 14% in those by 2D technique. Zheng et al. [104] reported a very encouraging 5-year local salvage rate of 71%, but grade 4 late toxicity rate was still as high as 49%.

Preliminary reports using IMRT for re-irradiation show encouraging preliminary results. Using IMRT to deliver 68–70 Gy, Lu et al. [105] reported 100% salvage rate without any severe late complications in a series of 49 patients with a median follow-up of 9 months. Using IMRT to a median dose of 54 Gy in 31 patients (with or without induction chemotherapy and stereotactic boost), Chua et al. [106] reported a locoregional salvage rate of 56% and late grade 3 complications of 25% at 1-year. Longer follow-up is clearly needed.

Chemoradiotherapy may also improve treatment outcome for recurrent NPC. Using CDDP/gemcitabine as induction chemotherapy followed by re-irradiation with IMRT in 20 patients (95% rT3–4), Chua et al. [107] reported a 1-year

local salvage rate of 75%. Using concurrent CDDP followed by adjuvant chemotherapy with CDDP/FU in 35 patients (66% rT3–4), Poon et al. [108] reported a 1-year EFS of 42%.

Surgical Salvage

For patients who develop locoregional failure despite aggressive primary treatment, surgical salvage is one of the options to be considered. In patients with nodal failure, the extent of involvement is often extensive; radical neck dissection should be carried out as the salvage procedure, 5-year nodal salvage of 66% and EFS of 37% could be achieved. For those with extranodal infiltration, addition of after-loading brachytherapy to the tumor bed following radical neck dissection could achieve similar results [109–111].

For patients with local failure, nasopharyngectomy is an option for selected patients with localized disease. Different approaches have been employed to expose the nasopharynx for oncological extirpation of the tumor [112–115]. At the University of Hong Kong Medical Centre, we employ the anterolateral approach or the maxillary swing procedure: following facial incisions and osteotomies, the maxilla bone is swung laterally while attached to the anterior cheek flap as one osteocutaneous unit (Fig. 28.4). The nasopharynx and its vicinity including the parapharyngeal space could hence be widely exposed to enable adequate resection of the persistent/recurrent tumor; the maxilla is returned and fixed to the rest of the facial skeleton with mini-plates at completion of the nasopharyngectomy.

From 1989 to 2008, we have performed this salvage nasopharyngectomy with curative intent for 161 patients

with recurrent T1 disease. During resection, negative tumor resection margins with frozen section were achieved in 78% of patients, while the remaining had microscopic residual tumor beyond the scope of further resections. All patients recovered from the operation and were discharged. Associated morbidities included a varying degree of trismus in 60% and palatal fistula in 25% of patients; they were managed by passive stretching and dental plates, respectively. The palatal fistula problem has been further eliminated by recent modification of palatal incision; analyses on their quality of life showed satisfactory results [116, 117]. In concurrence with other reports [118], satisfactory long-term results with 5-year local salvage of 65% and EFS of 54% could be achieved [119].

Treatment of Metastatic Disease

Treatment should be individualized as there is marked heterogeneity in prognosis among patients with distant metastases. Toh et al. [120] proposed a prognostic index score basing on metastasis at diagnosis, disease-free interval, performance status, and hemoglobin level. The median OS ranged from 8 for the poor to 20 months for the good prognostic group. Hui et al. [121] showed that patients with lung metastasis alone had a relatively favorable prognosis, a more aggressive approach should be considered. In addition to chemotherapy, surgical resection and/or high-dose RT may be considered in selected patients with limited metastases.

Cisplatin-based chemotherapy is the mainstay of treatment for majority of distant failures, the most common regimen CDDP/FU [122] achieved an overall response rate (ORR) of 66% and median time to progression (TTP) of 8 months.

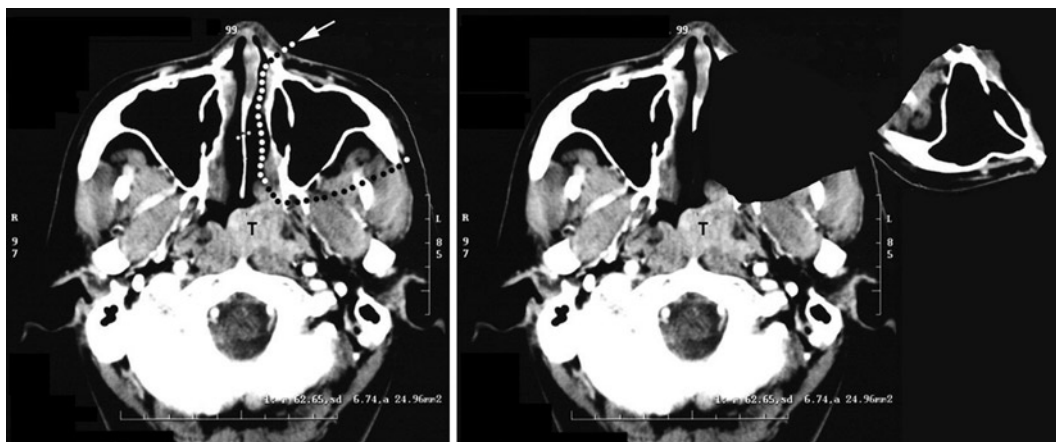


Fig. 28.4 Schematic computed tomography showing on (left): the recurrent tumor marked by (T) and the osteotomies by the dotted line; (right): the maxilla attached to the anterior cheek flap swung laterally to expose the recurrent tumor (T) for salvage nasopharyngectomy

Addition of different drugs like bleomycin, epirubicin, mitomycin, methotrexate to CDDP (with or without FU) failed to achieve substantial benefits, but incurred a high incidence of hematologic toxicities and even mortality [123–126].

Table 28.7 summarizes the response and major toxicities of different regimens; cross-series comparison is impossible because of difference in patient characteristics and previous treatment. Among the modern cytotoxic drugs, studies on combination of CDDP/docetaxel [127], CDDP/capecitabine [128], and CDDP/Gemcitabine [129] reported ORR of 63–73% and median TTP 6–11 months. The latter two combinations are particularly attractive because of moderate toxicity and easy administration; docetaxel should be used with caution because of very high incidence of neutropenic toxicity [127, 130]. Using a triplet combination of gemcitabine, paclitaxel, and carboplatin for 6 cycles followed by weekly FU and folinic acid for 48 weeks, Leong et al. [131] reported an ORR of 86%, the median TTP was 8 months and the OS was up to 22 months; but hematological toxicities occurred in >79% of patients.

The efficacy of molecular-targeted therapy for NPC remains uncertain. Although overexpression of epidermal growth factor receptor (EGFR) was found in more than 80% of NPC patients and this was associated with poor prognosis [132], a phase II study on combination of cetuximab (a monoclonal antibody against the extracellular domain of EGFR) with carboplatin on refractory patients only achieved an ORR of 12% and TTP of 3 months [133]. Other targeted agents including Gefitinib (a tyrosine kinase inhibitor against the intracellular EGFR signaling pathway) [134] and

sorafenib (a multitargeted kinase inhibitor) [135] showed very poor response (0–4%).

Management of Late Toxicities

The therapeutic margin for NPC is notoriously narrow, late toxicities following conventional 2D and 3D conformal RT have been extensively reported [136–138]. The problem of xerostomia has decreased substantially in modern IMRT era [39, 40, 71]. However, late toxicities at other sites remain a concern, especially with increasing use of concurrent CRT; swallowing problems and damage to carotid vessels become increasingly recognized.

Torrential epistaxis from ruptured pseudoaneurysm at the petrous portion of the internal carotid arteries is one of the most serious toxicities [139, 140], urgent endovascular occlusion or stenting is needed for life saving. Another potentially fatal complication is stenosis of the extracranial portion of carotid arteries; Cheng et al. [141] detected severe stenosis with $\geq 70\%$ occlusion in 16% of long survivors, ultrasound screening was advocated for elderly patients (especially those with cardiac/cerebrovascular symptoms), carotid endarterectomy or percutaneous transluminal endoplasty may be indicated.

Temporal lobe necrosis (TLN) is reported even with IMRT [140, 142, 143]. The risk increases with dose escalation [24], hypofractionation or rapid acceleration [22], and re-irradiation [100–104, 106–108]. Treatment includes anti-convulsants for temporal lobe epilepsy and steroid for gross

Table 28.7 Chemotherapy/molecular-targeted therapy for metastatic/recurrent nasopharyngeal carcinoma

Author	No.	Cytotoxic/targeted drugs	ORR % (complete)	Median TTP months	Toxicity % (grade ≥ 3)
Au et al. [122]	24	CDDP+FU	66 (12)	8	Neutropenia 42
Su et al. [123]	25	CDDP+FU+Bleomycin	40 (4)	NR	Neutropenia 36 Infections 32 Treatment death 12
Yeo et al. [161]	27	Carbo+paclitaxel	59 (11)	NR	Neutropenia 32 (with fever 3)
Chua et al. [127]	19	CDDP+docetaxel	62 (6)	6	Neutropenia >79 (with fever 42)
Ngan et al. [129]	44	CDDP+gemcitabine	73 (21)	11	Granulocytopenia 37
Wang et al. [159]	39	vinorelbine+gemcitabine	36 (3)	5	Neutropenia 44 Thrombocytopenia 18
Leong et al. [131]		Carbo+gemcitabine+paclitaxel	86 (11)	8	Neutropenia 79 Anemia 32 Thrombocytopenia 29
Li et al. [128]	48	CDDP+Capecitabine	62 (6)	8	Neutropenia 15 HFS 4
Chan et al. [133]	59	Carbo+cetuximab	12 (0)	3	Overall 52
Elser et al. [135]	26	Sorafenib	4 (0)	2	Lymphopenia 17 Fatigue 7

ORR overall response rate, TTP time to progression, CDDP Cisplatin, FU Fluorouracil, Carbo carboplatin, HFS hand-foot syndrome, NR not reported

increase in intracranial pressure; surgery is often reserved for severely symptomatic patients [144, 145].

Palsy of the last four cranial nerves (especially the twelfth) has been reported following 2D RT [136] especially among those with additional parapharyngeal boost. This could lead to swallowing difficulties and aspiration pneumonia. Damage to the pharyngo-oesophageal axis is another cause for dysphagia following IMRT [43].

The most common toxicity is hearing impairment. High tone sensorineural deafness is related to the dose to the inner ear, use of concurrent CDDP and age [138]. The mean dose to cochlea should preferably be ≤ 47 Gy especially for patients treated by CRT [146]. It should be noted that sudden deafness in long survivors might be a different problem related to vascular insufficiency and treatment with vascular expander like Dextran 40 was suggested [147]. Another problem is otitis media with effusion caused by Eustachian tube dysfunction, repeated myringotomy and aspiration can temporarily reduce the inflammation of the middle ear, prophylactic grommet insertion is not recommended as this would invite ascending infection [148].

Endocrine dysfunction remains a common toxicity following IMRT [142]. Regular endocrine assessment is indicated as hormonal replacement, mostly thyroxine or cortisol, might be required. Other complications include osteoradionecrosis [149], and radiation-induced malignancies [150, 151] with poor prognosis despite surgery.




Fig. 28.5 Exploring the possibility of further improvement by volumetric arc technique

Conclusion

Medical progress in the battle against NPC is one of the most gratifying successes. This peculiar cancer was invariably lethal before the advent of megavoltage RT. With improving knowledge and technology, representative series from Hong Kong showed that the 5-year DSS steadily increased from 50% for patients treated from 1976 to 1985 [152] to 80% for those treated from 1996 to 2000 [153]. Together with decreasing incidence, our age-standardized mortality rate has steadily decreased from the peak of 14.1 in 1983 to 5.8 per 100,000 male populations in 2006.

Continuous search for more potent systemic therapies, refinement of RT technique and precision are still demanded. Technological advances bring exciting opportunities; it is highly hopeful that these progresses can enable efficient delivery of high quality RT (Fig. 28.5). Novel therapies, for instance, recombinant adenovirus-p53 in concurrence with RT [154], open new frontiers for exploration. Furthermore, early detection and more accurate prognostication for personalized medicine are crucial for future improvement; concerted efforts in translational researches will become increasingly important.

References

1. Liao XB, Mao YP, Liu LZ, et al. How does magnetic resonance imaging influence staging according to AJCC Staging System for nasopharyngeal carcinoma compared with computed tomography? *Int J Radiat Oncol Biol Phys.* 2008;72:1368–77.
2. Chua ML, Ong SC, Wee JT, et al. Comparison of 4 modalities for distant metastasis staging in endemic nasopharyngeal carcinoma. *Head Neck.* 2009;31:346–54.
3. Ng SH, Chan SC, Yen TC, et al. Staging of untreated nasopharyngeal carcinoma with PET/CT: comparison with conventional imaging work-up. *Eur J Nucl Med Mol Imaging.* 2009;36:12–22.
4. Edge SB, Byrd DR, Compton CA, editors. *AJCC Cancer Staging Manual.* 7th ed. New York, NY: Springer; 2010.
5. Sobin L. *International Union Against Cancer (UICC): TNM classification of malignant tumors.* 7th ed. Oxford UK, Wiley-Blackwell; 2009.
6. Som PM, Curtin HD. *Head and neck imaging.* 3rd ed. St Louis: Mosby; 1999.
7. Lee AW, Au JS, Teo PM, et al. Staging of nasopharyngeal carcinoma: suggestions for improving the current UICC/AJCC Staging System. *Clin Oncol.* 2004;16:269–76.
8. Low JS, Heng DM, Wee JT. The question of T2a and N3a in the UICC/AJCC (1997) staging system for nasopharyngeal carcinoma. *Clin Oncol.* 2004;16:581–3.
9. Liu MZ, Tang LL, Zong JF, et al. Evaluation of the sixth edition of AJCC Staging System for nasopharyngeal carcinoma and proposed improvement. *Int J Rad Oncol Biol Phys.* 2008;70:1115–23.
10. Mao YP, Xie FY, Liu LZ, et al. Re-Evaluation of 6th Edition of AJCC Staging System for nasopharyngeal carcinoma and proposed improvement based on magnetic resonance imaging. *Int J Radiat Oncol Biol Phys.* 2009;73:1326–34.
11. Tang LL, Li L, Mao Y, et al. Retropharyngeal lymph node metastasis in nasopharyngeal carcinoma detected by magnetic resonance imaging. *Cancer.* 2008;113:347–54.

12. Leung SF, Chan AT, Zee B, et al. Pretherapy quantitative measurement of circulating Epstein-Barr virus DNA is predictive of posttherapy distant failure in patients with early-stage nasopharyngeal carcinoma of undifferentiated type. *Cancer*. 2003;98:288–91.
13. Leung SF, Zee B, Ma B, et al. Plasma Epstein-Barr Viral Deoxyribonucleic Acid quantitation complements tumor node-metastasis staging prognostication in nasopharyngeal carcinoma. *J Clin Oncol*. 2006;24:5414–8.
14. Lin JC, Wang WY, Chen KY, et al. Quantification of plasma Epstein-Barr virus DNA in patients with advanced nasopharyngeal carcinoma. *N Engl J Med*. 2004;350:2461–70.
15. Twu CW, Wang WY, Liang WM, et al. Comparison of the prognostic impact of serum anti-EBV antibody and plasma EBV DNA assays in nasopharyngeal carcinoma. *Int J Radiat Oncol Biol Phys*. 2007;67:130–7.
16. Le QT, Jones CD, Yau TK, et al. A comparison study of different PCR assays in measuring circulating plasma Epstein-Barr virus DNA levels in patients with nasopharyngeal carcinoma. *Clin Cancer Res*. 2005;11:5700–7.
17. Mesic JB, Fletcher GH, Goepfert H. Megavoltage irradiation of epithelial tumors of the nasopharynx. *Int J Radiat Oncol Biol Phys*. 1981;7:447–53.
18. Perez CA, Devineni VR, Marcial-Vega V, et al. Carcinoma of the nasopharynx: factors affecting prognosis. *Int J Radiat Oncol Biol Phys*. 1992;23:271–80.
19. Teo PML, Leung SF, Tung SY. Dose-response relationship of nasopharyngeal carcinoma above conventional tumoricidal level: A study by the Hong Kong nasopharyngeal carcinoma study group (HKNPCSG). *Radiother Oncol*. 2006;79:27–33.
20. Lee AW, Chan DK, Fowler JF, et al. Effect of time, dose and fractionation on local control of nasopharyngeal carcinoma. *Radiother Oncol*. 1995;36:24–31.
21. Lee AW, Foo W, Chappell R, et al. Effect of time, dose, and fractionation on temporal lobe necrosis following radiotherapy for nasopharyngeal carcinoma. *Int J Radiat Oncol Biol Phys*. 1998;40:35–42.
22. Lee AW, Kwong DL, Leung SF, et al. Factors affecting risk of symptomatic temporal lobe necrosis: significance of fractional dose and treatment time. *Int J Radiat Oncol Biol Phys*. 2002;53:75–85.
23. Leung TW, Wong VY, Sze WK, et al. High dose-rate brachytherapy boost for early T stage nasopharyngeal carcinoma. *Int J Radiat Oncol Biol Phys*. 2008;70:361–7.
24. Hara W, Loo BW, Goffinet DR, et al. Excellent local control with stereotactic radiotherapy boost after external beam radiotherapy in patients with nasopharyngeal carcinoma. *Int J Radiat Oncol Biol Phys*. 2008;71:393–400.
25. Vikram B, Mishra UB, Strong EW, et al. Patterns of failure in carcinoma of the nasopharynx: I Failure at the primary site. *Int J Radiat Oncol Biol Phys*. 1985;11:1455–9.
26. Kwong DL, Sham JS, Chua DT, et al. The effect of interruptions and prolonged treatment time in radiotherapy for nasopharyngeal carcinoma. *Int J Radiat Oncol Biol Phys*. 1997;39:703–10.
27. Teo ML, Leung SF, Chan TK, et al. Final report of a randomized trial on altered-fractionated radiotherapy in nasopharyngeal carcinoma prematurely terminated by significant increase in neurologic complications. *Int J Radiat Oncol Biol Phys*. 2000;48:1311–22.
28. Daoud J, Toumi N, Siala W, et al. Results of a prospective randomized trial comparing conventional radiotherapy to split course bifractionated radiation therapy in patients with nasopharyngeal carcinoma. *Radiother Oncol*. 2007;85:17–23.
29. Lee AW, Tung SY, Chan AT, et al. Preliminary results of a randomized study (NPC-9902 Trial) on therapeutic gain by concurrent chemotherapy and/or accelerated fractionation for locally-advanced nasopharyngeal carcinoma. *Int J Radiat Oncol Biol Phys*. 2006;66:142–51.
30. Daisne JF, Duprez T, Weynand B, et al. Tumor volume in pharyngolaryngeal squamous cell carcinoma: comparison at CT, MR imaging, and FDG PET and validation with surgical specimen. *Radiology*. 2004;233:93–100.
31. Schinagl DA, Vogel WV, Hoffmann AL, et al. Comparison of five segmentation tools for 18F-fluoro-deoxy-glucose positron emission tomography-based target volume definition in head and neck cancer. *Int J Radiat Oncol Biol Phys*. 2007;69:1282–9.
32. Xia P, Fu KK, Wong GW, et al. Comparison of treatment plans involving intensity-modulated radiotherapy for nasopharyngeal carcinoma. *Int J Radiat Oncol Biol Phys*. 2000;48:329–937.
33. Cheng JC, Chao KS, Low D. Comparison of intensity modulated radiation therapy (IMRT) treatment techniques for nasopharyngeal carcinoma. *Int J Cancer*. 2001;96:126–32.
34. Hunt MA, Zelefsky MJ, Wolden S, et al. Treatment planning and delivery of intensity-modulated radiation therapy for primary nasopharynx cancer. *Int J Radiat Oncol Biol Phys*. 2001;49:623–32.
35. Kam MK, Chau RM, Suen J, et al. Intensity-modulated radiotherapy in nasopharyngeal carcinoma: dosimetric advantage over conventional plans and feasibility of dose escalation. *Int J Radiat Oncol Biol Phys*. 2003;56:145–57.
36. Lee N, Xia P, Quivey JM, et al. Intensity-modulated radiotherapy in the treatment of nasopharyngeal carcinoma: an update of the UCSF experience. *Int J Radiat Oncol Biol Phys*. 2002;53:12–22.
37. Lee N, Harris J, Garden AS, et al. Intensity-modulated radiation therapy with or without chemotherapy for nasopharyngeal carcinoma: Radiation Therapy Oncology Group Phase II Trial 0225. *J Clin Oncol*. 2009;27:3684–90.
38. Wolden SL, Chen WC, Pfister DG, et al. Intensity-modulated radiation therapy (IMRT) for nasopharynx cancer: Update of the Memorial Sloan-Kettering experience. *Int J Radiat Oncol Biol Phys*. 2006;64:57–62.
39. Pow HN, Kwong LW, McMillan S, et al. Xerostomia and quality of life after intensity-modulated radiotherapy vs. conventional radiotherapy for early-stage nasopharyngeal carcinoma: initial report on a randomized controlled clinical trial. *Int J Radiat Oncol Biol Phys*. 2006;66:981–91.
40. Kam MK, Leung SF, Zee B, et al. Prospective randomized study of intensity-modulated radiotherapy on salivary gland function in early-stage nasopharyngeal carcinoma patients. *J Clin Oncol*. 2007;25:4873–9.
41. Amdur RJ, Li JG, Liu C, et al. Unnecessary laryngeal irradiation in the IMRT era. *Head Neck*. 2004;26:257–64.
42. Parliament M, Alidrisi M, Munroe M, et al. Implications of radiation dosimetry of the mandible in patients with carcinomas of the oral cavity and nasopharynx treated with intensity modulated radiation therapy. *Int J Oral Maxillofac Surg*. 2005;34:114–21.
43. Fua TF, Corry J, Milner AD, et al. Intensity-modulated radiotherapy for nasopharyngeal carcinoma: clinical correlation of dose to the pharyngo-esophageal axis and dysphagia. *Int J Radiat Oncol Biol Phys*. 2007;67:976–81.
44. Hall WH, Guiou M, Lee NY, et al. Development and validation of a standardized method for contouring the brachial plexus: preliminary dosimetric analysis among patients treated with IMRT for head-and-neck cancer. *Int J Radiat Oncol Biol Phys*. 2008;72:1362–7.
45. Vitolo V, Millender LE, Quivey JM, et al. Assessment of carotid artery dose in the treatment of nasopharyngeal cancer with IMRT versus conventional radiotherapy. *Radiother Oncol*. 2009;90:213–20.
46. Wang J, Bai S, Chen N, et al. The clinical feasibility and effect of online cone beam computer tomography-guided intensity-modulated radiotherapy for nasopharyngeal cancer. *Radiother Oncol*. 2009;90:221–7.
47. Barker Jr JL, Garden AS, Ang KK, et al. Quantification of volumetric and geometric changes occurring during fractionated radiotherapy for head-and-neck cancer using an integrated CT/linear accelerator system. *Int J Radiat Oncol Biol Phys*. 2004;59:960–70.

48. Hansen EK, Bucci MK, Quivey JM, et al. Repeat CT imaging and replanning during the course of IMRT for head-and-neck cancer. *Int J Radiat Oncol Biol Phys.* 2006;64:355–62.
49. Fiorino C, Dell'Oca I, Pierelli A, et al. Simultaneous accelerated boost (SIB) for nasopharynx cancer with helical tomotherapy. *Strahlentherapie und Onkologie.* 2007;183:497–505.
50. Lee TF, Fang FM, Chao PJ, et al. Dosimetric comparisons of helical tomotherapy and step-and-shoot intensity-modulated radiotherapy in nasopharyngeal carcinoma. *Radiother Oncol.* 2008;89:89–96.
51. Taheri-Kadkhoda Z, Björk-Eriksson T, Nill S et al. Intensity-modulated radiotherapy of nasopharyngeal carcinoma: a comparative treatment planning study of photons and protons. *Rad Oncol.* 2008;3:4 (<http://www.ro-journal.com/content/3/1/4>)
52. Widesott L, Pierelli A, Fiorino C, et al. Intensity-modulated proton therapy versus helical tomotherapy in nasopharynx cancer: planning comparison and NTCP evaluation. *Int J Radiat Oncol Biol Phys.* 2008;72:589–96.
53. Baujat B, Audry H, Bourhis J, et al. Chemotherapy in locally advanced nasopharyngeal carcinoma: An individual patient data meta-analysis of eight randomized trials and 1753 patients. *Int J Radiat Oncol Biol Phys.* 2006;64:47–56.
54. Chan AT, Teo PM, Leung TW, et al. A prospective randomized study of chemotherapy adjunctive to definitive radiotherapy in advanced nasopharyngeal carcinoma. *Int J Radiat Oncol Biol Phys.* 1995;33:569–77.
55. Chua DT, Sham JS, Choy D, et al. Preliminary report of the Asian-Oceanian Clinical Oncology Association randomized trial comparing cisplatin and epirubicin followed by radiotherapy versus radiotherapy alone in the treatment of patients with locoregionally advanced nasopharyngeal carcinoma. Asian-Oceanian Clinical Oncology Association Nasopharynx Cancer Study Group. *Cancer.* 1998;83:2270–83.
56. Cvitkovic E, Eschwege F, Rahal M, et al. Preliminary results of trial comparing neoadjuvant chemotherapy (cisplatin, epirubicin, bleomycin) plus radiotherapy vs. radiotherapy alone in stage IV (>N2, M0) undifferentiated nasopharyngeal carcinoma: a positive effect on progression free survival. *Int J Radiat Oncol Biol Phys.* 1996;35:463–9.
57. Hareyama M, Sakata K, Shirato H, et al. A prospective, randomized trial comparing neoadjuvant chemotherapy with radiotherapy alone in patients with advanced nasopharyngeal carcinoma. *Cancer.* 2002;94:2217–23.
58. Chi KH, Chang YC, Guo WY, et al. A phase III study of adjuvant chemotherapy in advanced nasopharyngeal carcinoma patients. *Int J Radiat Oncol Biol Phys.* 2002;52:1238–44.
59. Al-Sarraf M, LeBlanc M, Giri PG, et al. Chemoradiotherapy versus radiotherapy in patients with advanced nasopharyngeal cancer: phase III randomized Intergroup study 0099. *J Clin Oncol.* 1998;16:1310–7.
60. Kwong DL, Sham JS, Au GK, et al. Concurrent and adjuvant chemotherapy for nasopharyngeal carcinoma: a factorial study. *J Clin Oncol.* 2004;22:2643–53.
61. Chan AT, Leung SF, Ngan RK, et al. Overall survival after concurrent cisplatin-radiotherapy compared with radiotherapy alone in locoregionally advanced nasopharyngeal carcinoma. *J Natl Cancer Inst.* 2005;97:536–9.
62. Lee AW, Lau WH, Tung SY, et al. Preliminary results of a randomized study on therapeutic gain by concurrent chemotherapy for regionally-advanced nasopharyngeal carcinoma: NPC-9901 Trial by the Hong Kong Nasopharyngeal Cancer Study Group. *J Clin Oncol.* 2005;23:6966–75.
63. Wee J, Tan EH, Tai BC, et al. Randomized trial of radiotherapy versus concurrent chemoradiotherapy followed by adjuvant chemotherapy in patients with American Joint Committee on Cancer/International Union Against Cancer Stage III and IV nasopharyngeal cancer of the endemic variety. *J Clin Oncol.* 2005;23:6730–8.
64. Chen Y, Liu MZ, Liang SB, et al. Preliminary results of a prospective randomized trial comparing concurrent chemoradiotherapy plus adjuvant chemotherapy with radiotherapy alone in patients with locoregionally advanced nasopharyngeal carcinoma in endemic regions of China. *Int J Radiat Oncol Biol Phys.* 2008;71:1356–64.
65. Lin JC, Jan JS, Hsu CY, et al. Concurrent chemoradiotherapy versus radiotherapy alone for advanced nasopharyngeal carcinoma: positive effect on overall and progression-free survival. *J Clin Oncol.* 2003;21:631–7.
66. Lin JC, Liang WM, Jan JS, et al. Another way to estimate outcome of advanced nasopharyngeal carcinoma – is concurrent chemoradiotherapy adequate. *Int J Radiat Oncol Biol Phys.* 2004;60:156–64.
67. Zhang L, Zhao C, Peng PJ, et al. Phase III study comparing standard radiotherapy with or without weekly oxaliplatin in treatment of locoregionally advanced nasopharyngeal carcinoma: preliminary results. *J Clin Oncol.* 2005;23:8461–8.
68. Chitapanarux I, Lorvidhaya V, Kamnerdsupaphon P, et al. Chemoradiation comparing cisplatin versus carboplatin in locally advanced nasopharyngeal cancer: randomised, non-inferiority, open trial. *Eur J Cancer.* 2007;43:1399–406.
69. Yau TK, Lee AW, Wong DH, et al. Treatment of stage IV(A-B) nasopharyngeal carcinoma by induction-concurrent chemoradiotherapy and accelerated fractionation: Impact of chemotherapy schemes. *Int J Radiat Oncol Biol Phys.* 2006;66:1004–10.
70. Cheng SH, Tsai YC, Yen KL, et al. Prognostic significance of parapharyngeal space venous plexus and marrow involvement: Potential landmarks of dissemination for stage I-III nasopharyngeal carcinoma. *Int J Radiat Oncol Biol Phys.* 2005;61:456–65.
71. Rischin D, Corry J, Smith J, et al. Excellent disease control and survival in patients with advanced nasopharyngeal cancer treated with chemoradiation. *J Clin Oncol.* 2002;20:1845–52.
72. Lee AW, Yau TK, Wong HM, et al. Treatment of stage IV(A-B) Nasopharyngeal Carcinoma by induction-concurrent chemoradiotherapy and accelerated fractionation. *Int J Radiat Oncol Biol Phys.* 2005;63:1331–8.
73. Yau TK, Lee AW, Wong HM, et al. Induction chemotherapy with Cisplatin and Gemcitabine followed by accelerated radiotherapy and concurrent Cisplatin in patients with stage IV(A-B) Nasopharyngeal Carcinoma. *Head Neck.* 2006;28:880–7.
74. Al-Sarraf M, LeBlanc M, Giri PGS et al. Chemo-radiotherapy (CT-RT) vs. radiotherapy (RT) in patients (PTS) with advanced nasopharyngeal cancer (NPC). Intergroup (0099) (SWOG 8892, RTOG 8817, ECOG 2388) Phase III Study: progress report. *J Clin Oncol.* 1998b;17:385a [abstract]
75. Lee AW, Lau KY, Hung WM, et al. Potential improvement of tumor control probability by induction chemotherapy for advanced nasopharyngeal carcinoma. *Radiother Oncol.* 2008;87:204–10.
76. Hui EP, Ma BB, Leung SF, et al. Randomized phase II trial of cisplatin-radiotherapy with and without neoadjuvant docetaxel and cisplatin in advanced nasopharyngeal carcinoma. *J Clin Oncol.* 2009;27:242–9.
77. Liu T, Xu W, Yan WL, et al. FDG-PET, CT, MRI for diagnosis of local residual or recurrent nasopharyngeal carcinoma, which one is the best? A systematic review. *Radiother Oncol.* 2007;85:327–35.
78. Chan AT, Lo DY, Zee B, et al. Plasma Epstein-Barr virus DNA and residual disease after radiotherapy for undifferentiated nasopharyngeal carcinoma. *J Natl Cancer Inst.* 2002;94:1614–9.
79. Chan AT, Ma BY, Lo YM, et al. Phase II study of neoadjuvant carboplatin and paclitaxel followed by radiotherapy and concurrent cisplatin in patients with locoregionally advanced nasopharyngeal carcinoma: therapeutic monitoring with plasma Epstein-Barr Virus DNA. *J Clin Oncol.* 2004;22:3053–60.
80. Lin JC, Wang WY, Liang WM, et al. Long-term prognostic effects of plasma Epstein-Barr Virus DNA by minor groove binder-probe real-time quantitative PCR on nasopharyngeal carcinoma patients

- receiving concurrent chemoradiotherapy. *Int J Radiat Oncol Biol Phys.* 2007;68:1342–8.
81. Kwong DL, Nicholls J, Wei WI, et al. The time course of histologic remission after treatment of patients with nasopharyngeal carcinoma. *Cancer.* 1999;85:1446–53.
 82. Kwong DL, Wei WI, Cheng AC, et al. Long term results of radioactive gold grain implantation for the treatment of persistent and recurrent nasopharyngeal carcinoma. *Cancer.* 2001;91:1105–13.
 83. Law SC, Lam WK, Ng MF, et al. Reirradiation of nasopharyngeal carcinoma with intracavitary mold brachytherapy: an effective means of local salvage. *Int J Radiat Oncol Biol Phys.* 2002;54:1095–13.
 84. Yau TK, Sze WM, Lee WM, et al. Effectiveness of brachytherapy and fractionated stereotactic radiotherapy boost for persistent nasopharyngeal carcinoma. *Head Neck.* 2004;26:1024–30.
 85. Leung TW, Tung SY, Sze WK, et al. Salvage brachytherapy for patients with locally persistent nasopharyngeal carcinoma. *Int J Radiat Oncol Biol Phys.* 2000;47:405–12.
 86. Zheng XK, Chen LH, Chen YQ, et al. Three-dimensional conformal radiotherapy versus intracavitary brachytherapy for salvage treatment of locally persistent nasopharyngeal carcinoma. *Int J Radiat Oncol Biol Phys.* 2004;60:165–70.
 87. Wu SX, Chua DT, Deng ML, et al. Outcome of fractionated stereotactic radiotherapy for 90 patients with locally persistent and recurrent nasopharyngeal carcinoma. *Int J Radiat Oncol Biol Phys.* 2007;69:761–9.
 88. Cmelak AJ, Cox RS, Adler JR, et al. Radiosurgery for skull base malignancies and nasopharyngeal carcinoma. *Int J Radiat Oncol Biol Phys.* 1997;37:997–1003.
 89. Chua DT, Sham JS, Hung KN, et al. Salvage treatment for persistent and recurrent T1-2 nasopharyngeal carcinoma by stereotactic radiosurgery. *Head Neck.* 2001;23:791–8.
 90. Lee AW, Law SC, Foo W, et al. Retrospective analysis of patients with nasopharyngeal carcinoma treated during 1976-1985: survival after local recurrence. *Int J Radiat Oncol Biol Phys.* 1993;26:773–82.
 91. Yu KH, Leung SF, Tung SY, et al. Survival outcome of patients with nasopharyngeal carcinoma with first local failure: a study by the Hong Kong Nasopharyngeal Carcinoma Study Group. *Head Neck.* 2005;27:397–405.
 92. Wang CC. Re-irradiation of recurrent nasopharyngeal carcinoma-treatment techniques and results. *Int J Radiat Oncol Biol Phys.* 1987;13:953–6.
 93. Pryzant RM, Wendt CD, Delclos L, et al. Re-treatment of nasopharyngeal carcinoma in 53 patients. *Int J Radiat Oncol Biol Phys.* 1992;22:941–7.
 94. Lee AW, Foo W, Law SC, et al. Reirradiation for recurrent nasopharyngeal carcinoma: factors affecting the therapeutic ratio and ways for improvement. *Int J Radiat Oncol Biol Phys.* 1997;38:43–52.
 95. Lee AW, Foo W, Law SC, et al. Total biological effect on late reactive tissues following reirradiation for recurrent nasopharyngeal carcinoma. *Int J Radiat Oncol Biol Phys.* 2000;46:865–72.
 96. Leung TW, Tung SY, Sze WK, et al. Salvage radiation therapy for locally recurrent nasopharyngeal carcinoma. *Int J Radiat Oncol Biol Phys.* 2000;48:1331–8.
 97. Chen HJ, Leung SW, et al. Linear accelerator based radiosurgery as a salvage treatment for skull base and intracranial invasion of recurrent nasopharyngeal carcinomas. *Am J Clin Oncol.* 2001;24:255–8.
 98. Chua DT, Sham JS, Hung KN, et al. Stereotactic radiosurgery as a salvage treatment for locally persistent and recurrent nasopharyngeal carcinoma. *Head Neck.* 1999;21:620–6.
 99. Pai PC, Chuang CC, Wei KC, et al. Stereotactic radiosurgery for locally recurrent nasopharyngeal carcinoma. *Head Neck.* 2002;24:748–53.
 100. Leung TW, Wong VY, Tung SY (2009) Stereotactic radiotherapy for locally recurrent nasopharyngeal carcinoma. *Int J Radiat Oncol Biol Phys.* 2009;75:734–41.
 101. Chua DT, Wei WI, Sham JS, et al. Stereotactic radiosurgery versus gold grain implantation in salvaging local failures of nasopharyngeal carcinoma. *Int J Radiat Oncol Biol Phys.* 2007;69:469–74.
 102. Chang JT, See LC, Liao CT, et al. Locally recurrent nasopharyngeal carcinoma. *Radiother Oncol.* 2000;54:135–42.
 103. Xiao J, Xu G, Miao Y. Fractionated stereotactic radiosurgery for 50 patients with recurrent or residual nasopharyngeal carcinoma. *Int J Radiat Oncol Biol Phys.* 2001;51:164–70.
 104. Zheng XK, Ma J, Chen LH, et al. Dosimetric and clinical results of three-dimensional conformal radiotherapy for locally recurrent nasopharyngeal carcinoma. *Radiother Oncol.* 2005;75:197–203.
 105. Lu TX, Mai WY, Teh BS, et al. Initial experience using intensity-modulated radiotherapy for recurrent nasopharyngeal carcinoma. *Int J Radiat Oncol Biol Phys.* 2004;58:682–7.
 106. Chua DT, Sham JS, Leung LH, et al. Re-irradiation of nasopharyngeal carcinoma with intensity-modulated radiotherapy. *Radiother Oncol.* 2005;77:290–4.
 107. Chua DT, Sham JS, Au GK. Induction chemotherapy with cisplatin and gemcitabine followed by reirradiation for locally recurrent nasopharyngeal carcinoma. *Am J Clin Oncol.* 2005;28:464–71.
 108. Poon D, Yap SP, Wong ZW, et al. Concurrent chemoradiotherapy in locoregionally recurrent nasopharyngeal carcinoma. *Int J Radiat Oncol Biol Phys.* 2004;59:1312–8.
 109. Wei WI, Lam KH, Ho CM, et al. Efficacy of radical neck dissection for the control of cervical metastasis after radiotherapy for nasopharyngeal carcinoma. *Am J Surg.* 1990;160:439–42.
 110. Wei WI, Ho CM, Wong MP, et al. Pathological basis of surgery in the management of postradiotherapy cervical metastasis in nasopharyngeal carcinoma. *Arch Otolaryngol Head Neck Surg.* 1992;118:923–9.
 111. Wei WI, Ho WK, Cheng AC, et al. Management of extensive cervical nodal metastasis in nasopharyngeal carcinoma after radiotherapy: a clinicopathological study. *Arch Otolaryngol Head Neck Surg.* 2001;127:1457–62.
 112. Fisch U. The infratemporal fossa approach for nasopharyngeal tumors. *Laryngoscope.* 1983;93:36–44.
 113. Fee Jr WE, Roberson Jr JB, Goffinet DR. Long-term survival after surgical resection for recurrent nasopharyngeal cancer after radiotherapy failure. *Arch Otolaryngol Head Neck Surg.* 1991;117:1233–6.
 114. Wei WI, Lam KH, Sham JS. New approach to the nasopharynx: the maxillary swing approach. *Head Neck.* 1991;13:200–7.
 115. Morton RP, Liavaag PG, Mclean M, et al. Transcervico-mandibulo-palatal approach for surgical salvage of recurrent nasopharyngeal cancer. *Head Neck.* 1996;18:352–8.
 116. Ng RW, Wei WI. Elimination of palatal fistula after the maxillary swing procedure. *Head Neck.* 2005;27:608–12.
 117. Ng RW, Wei WI. Quality of life of patients with recurrent nasopharyngeal carcinoma treated with nasopharyngectomy using the maxillary swing approach. *Arch Otolaryngol Head Neck Surg.* 2006;132:309–16.
 118. Fee Jr WE, Moir MS, Choi EC, et al. Nasopharyngectomy for recurrent nasopharyngeal cancer: a 2- to 17-year follow-up. *Arch Otolaryngol Head Neck Surg.* 2002;128:280–4.
 119. Wei WI. Nasopharyngeal cancer: current status of management. *Arch Otolaryngol Head Neck Surg.* 2001;127:766–9.
 120. Toh CK, Heng D, Ong YK, et al. Validation of a new prognostic index score for disseminated nasopharyngeal carcinoma. *Br J Cancer.* 2005;92:1382–7.
 121. Hui EP, Leung SF, Au JS, et al. Lung metastasis alone in nasopharyngeal carcinoma: a relatively favorable prognostic group. A study by the Hong Kong Nasopharyngeal Carcinoma Study Group. *Cancer.* 2004;101:300–6.

122. Au E, Ang PT. A phase II trial of 5-fluorouracil and cisplatin in recurrent or metastatic nasopharyngeal carcinoma. *Ann Oncol*. 1994;94:87–9.
123. Su WC, Chen TY, Kao RH, et al. Chemotherapy with cisplatin and continuous infusion of 5-fluorouracil and bleomycin for recurrent and metastatic nasopharyngeal carcinoma in Taiwan. *Oncology*. 1993;50:205–8.
124. Siu LL, Czaykowski PM, Tannock IF. Phase I/II study of the CAPABLE regimen for patients with poorly differentiated carcinoma of the nasopharynx. *J Clin Oncol*. 1998;16:2514–21.
125. Hasbini A, Mahjoubi R, Fandi A, et al. Phase II trial combining mitomycin with 5-fluorouracil, epirubicin, and cisplatin in recurrent and metastatic undifferentiated carcinoma of nasopharyngeal type. *Ann Oncol*. 1999;10:421–5.
126. Taamma A, Fandi A, Azli N, et al. Phase II trial of chemotherapy with 5-fluorouracil, bleomycin, epirubicin, and cisplatin for patients with locally advanced, metastatic, or recurrent undifferentiated carcinoma of the nasopharyngeal type. *Cancer*. 1999;86:1101–8.
127. Chua DT, Sham JS, Au GK. A phase II study of docetaxel and cisplatin as first-line chemotherapy in patients with metastatic nasopharyngeal carcinoma. *Oral Oncol*. 2005;41:589–95.
128. Li YH, Wang FH, Jiang WQ, et al. Phase II study of capecitabine and cisplatin combination as first-line chemotherapy in Chinese patients with metastatic nasopharyngeal carcinoma. *Cancer Chemother Pharmacol*. 2008;62:539–44.
129. Ngan RK, Yiu HH, Lau WH, et al. Combination gemcitabine and cisplatin chemotherapy for metastatic or recurrent nasopharyngeal carcinoma: report of a phase II study. *Ann Oncol*. 2002;13:1252–8.
130. McCarthy JS, Tannock IF, Degendorfer P, et al. A Phase II trial of docetaxel and cisplatin in patients with recurrent or metastatic nasopharyngeal carcinoma. *Oral Oncol*. 2002;38:686–90.
131. Leong SS, Wee J, Rajan S, et al. Triplet combination of gemcitabine, paclitaxel, and carboplatin followed by maintenance 5-fluorouracil and folinic acid in patients with metastatic nasopharyngeal carcinoma. *Cancer*. 2008;113:1332–7.
132. Chua DT, Nicholls JM, Sham JS, et al. Prognostic value of epidermal growth factor receptor expression in patients with advanced stage nasopharyngeal carcinoma treated with induction chemotherapy and radiotherapy. *Int J Radiat Oncol Biol Phys*. 2004;59:11–20.
133. Chan AT, Hsu MM, Goh BC, et al. Multicenter, phase II study of cetuximab in combination with carboplatin in patients with recurrent or metastatic nasopharyngeal carcinoma. *J Clin Oncol*. 2005;23:3568–76.
134. Chua DT, Wei WI, Wong MP, et al. Phase II study of gefitinib for the treatment of recurrent and metastatic nasopharyngeal carcinoma. *Head Neck*. 2008;30:863–7.
135. Elser C, Siu LL, Winquist E, et al. Phase II trial of sorafenib in patients with recurrent or metastatic squamous cell carcinoma of the head and neck or nasopharyngeal carcinoma. *J Clin Oncol*. 2007;25:3766–73.
136. Lee AW, Law SC, Ng SH, et al. Retrospective analysis of nasopharyngeal carcinoma treated during 1976–1985: late complications following megavoltage irradiation. *Br J Radiol*. 1992;65:918–28.
137. Lee AW, Perez CA, Law CK et al. *Nasopharynx*. In: Halperin EC, Perez CA, Brady LW, editors. *Principles and practice of radiation oncology*, 5th edn. Philadelphia: Lippincott Williams & Wilkins; 2008b. p. 820–857
138. Lee AW, Ng WT, Hung WM, et al. Major Late toxicities following conformal radiotherapy for Nasopharyngeal Carcinoma – patient and treatment related risk factors. *Int J Radiat Oncol Biol Phys*. 2009;73:1121–8.
139. Cheng KM, Chan CM, Cheung YL, et al. Endovascular treatment of radiation-induced petrous internal carotid artery aneurysm presenting with acute haemorrhage. A report of two cases. *Acta Neurochir (Wien)*. 2001;143:351–6.
140. Kwong DL, Sham JS, Leung LH, et al. Preliminary results of radiation dose escalation for locally advanced nasopharyngeal carcinoma. *Int J Radiat Oncol Biol Phys*. 2006;64:374–81.
141. Cheng SW, Ting AC, Lam LK, et al. Carotid stenosis after radiotherapy for nasopharyngeal carcinoma. *Arch Otolaryngol Head Neck Surg*. 2000;126:517–21.
142. Kam MK, Teo PM, Chau RM, et al. Treatment of nasopharyngeal carcinoma with intensity-modulated radiotherapy: the Hong Kong experience. *Int J Radiat Oncol Biol Phys*. 2004;60:1440–50.
143. Bucci M, Xia P, Lee N, et al. Intensity modulated radiation therapy for carcinoma of the nasopharynx: an update of the UCSF experience. *Int J Radiat Oncol Biol Phys*. 2004;60:S317–318.
144. Cheng KM, Chan CM, Fu YT, et al. Brain abscess formation in radiation necrosis of the temporal lobe following radiation therapy for nasopharyngeal carcinoma. *Acta Neurochir (Wien)*. 2000;142:435–41.
145. Cheng KM, Chan CM, Fu YT, et al. Acute hemorrhage in late radiation necrosis of the temporal lobe: report of five cases and review of the literature. *J Neurooncol*. 2001;51:143–50.
146. Young YH, Lou PJ. Post-irradiation sudden deafness. *J Laryngol Otol*. 1999;113:815–7.
147. Chen CY, Young YH, Hsu WC, et al. Failure of grommet insertion in post-irradiation otitis media with effusion. *Ann Otol Rhinol Laryngol*. 2001;110:746–8.
148. Cheng SJ, Lee JJ, Ting LL, et al. A clinical staging system and treatment guidelines for maxillary osteoradionecrosis in irradiated nasopharyngeal carcinoma patients. *Int J Radiat Oncol Biol Phys*. 2006;64:90–7.
149. Dickens P, Wei WI, Sham JS. Osteosarcoma of the maxilla in Hong Kong Chinese postirradiation for nasopharyngeal carcinoma. A report of four cases. *Cancer*. 1990;66:1924–6.
150. King AD, Ahuja AT, Teo P, et al. Radiation induced sarcomas of the head and neck following radiotherapy for nasopharyngeal carcinoma. *Clin Radiol*. 2000;55:684–9.
151. Lee AW, Poon YF, Foo W, et al. Retrospective analysis of 5,037 patients with nasopharyngeal carcinoma treated during 1976–1985: overall survival and patterns of failure. *Int J Radiat Oncol Biol Phys*. 1992;23:261–70.
152. Lee AW, Sze WM, Au SK, et al. Treatment results for nasopharyngeal carcinoma in the modern era: the Hong Kong experience. *Int J Radiat Oncol Biol Phys*. 2005;61:1107–16.
153. Pan JJ, Zhang SW, Chen CB, et al. Effect of recombinant adenovirus-p53 combined with radiotherapy on long-term prognosis of advanced nasopharyngeal carcinoma. *J Clin Oncol*. 2009;27:799–804.
154. Kwong DL, Pow EH, Sham JS, et al. Intensity-modulated radiotherapy for early-stage nasopharyngeal carcinoma: a prospective study on disease control and preservation of salivary function. *Cancer*. 2004;101:1584–93.
155. Lin S, Pan J, Han L, et al. Nasopharyngeal carcinoma treated with reduced-volume intensity-modulated radiation therapy: Report on the 3-year outcome of a prospective series. *Int J Radiat Oncol Biol Phys*. 2009;75:1071–78.
156. Tham IW, Hee SW, Yeo RM, et al. Treatment of nasopharyngeal carcinoma using intensity-modulated radiotherapy – The National Cancer Centre Singapore experience. *Int J Radiat Oncol Biol Phys*. 2009;75:1481–86.
157. Oh JL, Vokes EE, Kies MS, et al. Induction chemotherapy followed by concomitant chemoradiotherapy in the treatment of locoregionally advanced nasopharyngeal cancer. *Ann Oncol*. 2003;14:564–9.
158. Wang CC, Chang JY, Liu TW, et al. Phase II study of gemcitabine plus vinorelbine in the treatment of cisplatin-resistant nasopharyngeal carcinoma. *Head Neck*. 2006;28:74–80.

159. Al-Amro A, Al-Rajhi N, Khafaga Y, et al. Neoadjuvant chemotherapy followed by concurrent chemo-radiation therapy in locally advanced nasopharyngeal carcinoma. *Int J Radiat Oncol Biol Phys.* 2005;62:508–13.
160. Johnson FM, Garden AS, Palmer JL, et al. A phase I/II study of neoadjuvant chemotherapy followed by radiation with boost chemotherapy for advanced T-stage nasopharyngeal carcinoma. *Int J Radiat Oncol Biol Phys.* 2005;63:717–24.
161. Yeo W, Leung TW, Chan AT, et al. A phase II study of combination paclitaxel and carboplatin in advanced nasopharyngeal carcinoma. *Eur J Cancer.* 1998;34:2027–31.

Chapter 29

Multidisciplinary Management of Oropharynx Carcinomas

Beth M. Beadle and David I. Rosenthal

Abstract The demographics, evaluation, and treatment of patients with oropharynx cancers have changed dramatically in the last decade. Compared to other head and neck malignancies, which are declining, oropharynx cancers are increasing in numbers, younger patients are being diagnosed, and more women are developing the disease; human papilloma virus (HPV) has been implicated as a likely causative factor in these notable changes. As the nature of the disease itself changes, so does the evaluation and treatment. The integration of detailed imaging modalities, including MRI and PET scans, has helped delineate the extent of disease and guide therapy, and the molecular analysis of tumor tissue for HPV infection has helped predict the outcomes for these patients. As late as the 1990s, the standard therapy for oropharynx cancer at most institutions was surgery with postoperative radiation therapy; during this time, the majority of oropharynx carcinomas were thought to be related to tobacco use. Now, advances in radiation therapy, chemotherapy, and our understanding of a potential viral etiology of these tumors that portends a better prognosis, have caused definitive radiation therapy and chemoradiation therapy to become the standard of care. As our understanding of this disease has improved, the integration of novel targeted therapies, including the anti-epidermal growth factor receptor inhibitors such as cetuximab, has been another milestone in the treatment for these patients. Overall, our understanding of the pathogenesis and methods of treatment has undergone a significant evolution, and the integration of multidisciplinary collaboration has improved outcomes and reduced treatment toxicities for patients with oropharynx carcinomas.

Keywords Oropharynx cancers • Human papilloma virus • Chemoradiation • Radiation

B.M. Beadle (✉)
The University of Texas M. D. Anderson Cancer Center,
Radiation Oncology Department, 1515 Holcombe Blvd.,
Unit 97, Houston, TX 77030, USA
e-mail: bbeadle@mdanderson.org

Introduction

In the last decade, the evaluation and management of carcinomas of the oropharynx have undergone perhaps the most radical change of all of the head and neck malignancies. The incidence is increasing, the patient age and gender disparities are decreasing, and the prognoses are improving as human papilloma virus (HPV) infection is recognized as another major causative factor. As late as the 1990s, the standard therapy for oropharynx cancer at most institutions was surgery with postoperative radiation therapy; during this time, the majority of oropharynx carcinomas were thought to be related to tobacco use. Now, advances in radiation therapy, chemotherapy, and our understanding of a potential viral etiology of these tumors that portends a better prognosis, have caused definitive radiation therapy and chemoradiation therapy to become the de facto standard of care. As our understanding of this disease has improved, the integration of novel targeted therapies, including the anti-epidermal growth factor receptor (EGFR) inhibitors such as cetuximab, has been another milestone in the treatment for these patients. Overall, our understanding of the pathogenesis and methods of treatment has undergone a significant evolution, and the integration of multidisciplinary collaboration has improved outcomes and reduced treatment toxicities for patients with oropharynx carcinomas.

Anatomy and Lymphatic Drainage

The oropharynx is situated approximately in the middle of the upper aerodigestive tract. It is directly in communication with the other sites of the head and neck, superiorly with the nasopharynx, anteriorly with the oral cavity, and posteroinferiorly with the supraglottic larynx and hypopharynx (Fig. 29.1). Anatomically, it is bounded by the junction of the posterior extent of the hard palate superiorly, the circumvallate papillae of the tongue anteriorly, the hyoid bone inferiorly, and the pharyngeal walls in the posterolateral directions.

The oropharynx is divided into four distinct subsites for the purposes of diagnosis and treatment planning. These are: (1) the base of tongue, (2) the tonsillar complex, (3) the soft palate, and (4) the oropharyngeal walls (Fig. 29.2).

Base of Tongue

The base of tongue is a muscular structure of the posterior tongue that is covered in squamous epithelium and contains numerous submucosal lymphoid nests; it is part of Waldeyer's

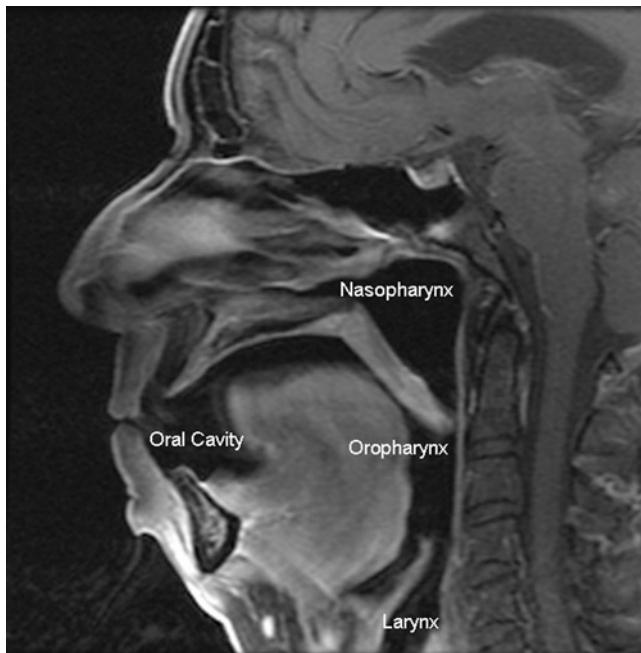


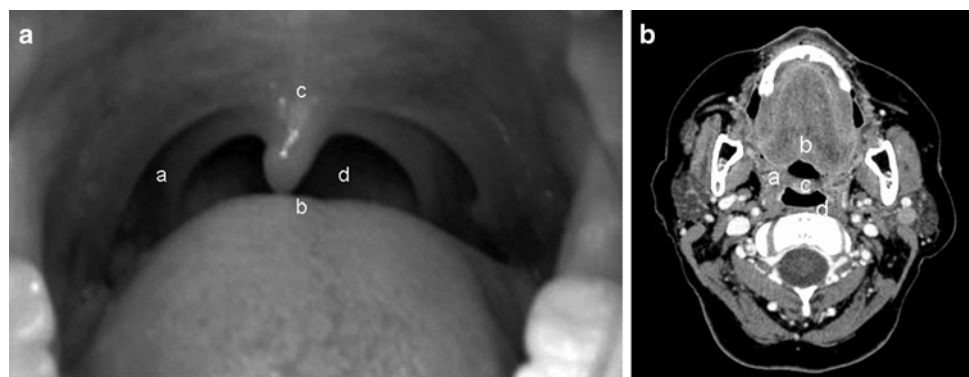
Fig. 29.1 Location of the oropharynx within the head and neck and its relationship with other sites, as shown on a sagittal MRI

ring. The base of tongue extends from the circumvallate papillae anteriorly to the base of the epiglottis inferiorly (including the valleculae) and to the glossopharyngeal sulci bilaterally. The base of tongue musculature is comprised of the genioglossus, styloglossus, palatoglossus, and hyoglossus muscles. The sensory innervation of the base of tongue is from the lingual branch of cranial nerve IX (glossopharyngeal), and the motor innervation is from cranial nerve XII (hypoglossal).

Primary tumors of the base of tongue can grow either in an infiltrative, submucosal pattern that invade the intrinsic muscles of the tongue or in an exophytic pattern across the mucosa and into the lumen of the upper aerodigestive tract. As the tumors become larger, they may go deeply through the intrinsic muscles of the tongue and affect the extrinsic musculature, inferiorly into the structures of the hypopharynx and larynx, or laterally to the glossopharyngeal sulci and tonsils; they may also cause oral tongue immobility and deviation. Tumors of the base of tongue tend to present with advanced stages since the tongue base is largely devoid of pain fibers, and lesions are frequently asymptomatic until quite large. However, due to the innervation of the base of tongue, tumors in this region can present with referred otalgia via cranial nerve IX (glossopharyngeal) as it joins the tympanic nerve (Jacobson's) and the two traverse the jugular foramen; this referred pain is typically deep in the ear canal.

Tumors of the base of tongue frequently present with nodal metastases. The base of tongue drains to levels II, III, and IV of the neck, as well as the retropharyngeal lymph nodes. The base of tongue is a midline structure, so lymph node drainage is bilateral. Prior studies at The University of Texas M. D. Anderson Cancer Center have shown that approximately 70% of patients with base of tongue tumors will present with unilateral lymph node metastases and approximately 10–20% will present with bilateral nodal disease [1].

Fig. 29.2 Subsites of the oropharynx on (a) oral examination (b) CT scan. The subsites of the oropharynx are: a – Tonsillar complex, b – Base of tongue, c – Soft palate, and d – Oropharyngeal walls. (a) from Veasey S. Obstructive Sleep Apnea. In: Binder MD, Hirokawa N, Windhorst U eds. *Encyclopedia of neuroscience*. Berlin:Springer;2009. Reprinted with permission from Springer



Tonsillar Complex

The tonsillar fossa is located between the palatoglossus and palatopharyngeus muscles, which when covered by their mucosa make up the anterior and posterior tonsillar pillars, respectively. The tonsils are a conglomeration of largely lymphoid tissue encased in a fibrous capsule, which rest within the tonsillar fossae. The entire region is covered in a squamous epithelium that serves as the nidus for the majority of tonsillar tumors. Tonsillar anatomy involves surface involutions, such that only a minority of the total mucosal area is visible on inspection of the surface; for this reason, a tonsillectomy is necessary for diagnosis of a potential primary tumor when no surface lesion is observed. The sensory innervation of the tonsils is branches of cranial nerve V2 (maxillary).

Primary tumors of the tonsillar fossae and tonsillar pillars can either grow as exophytic lesions along the mucosal surface, spreading onto adjacent subsites, such as the soft palate, tongue base, and pharyngeal walls, or as deeply invasive lesions into the stroma in an ulcerative or endophytic pattern. Advanced tumors are capable of significant submucosal spread, including invasion into the underlying pterygoid muscles and into adjacent regions of the head and neck, including the nasopharynx, hypopharynx, and larynx. Primary tumors may arise from the tonsillar pillars, the tonsillar fossae, or the tonsils themselves; even following a tonsillectomy, tonsil tissue typically remains that may serve as the nidus for malignancy. Lesions of the tonsillar fossae and tonsils tend to present with more advanced primary disease than do those that develop in the tonsillar pillars due to the later development of overt symptoms, including pain, odynophagia, and a globus sensation.

Tumors of the tonsillar region frequently present with nodal metastases. The tonsillar region primarily drains to level II of the neck, but lymph nodes in level I and the retropharyngeal nodes may also be involved. Tumors that arise from the tonsillar fossa are more likely to involve lymph nodes than those from the tonsillar pillars. In a study by Lindberg et al., lymph node metastases were noted in 71% of patients with T1 tonsillar fossa tumors, 68% of T2 lesions, 70% of T3 lesions, and 90% of T4 lesions [1]. Another study describing patients with tonsillar tumors treated at The University of Texas M. D. Anderson Cancer Center between 1968 and 1979 demonstrated 69% of patients having lymph node metastases at presentation [2]. Since the tonsil is a lateral structure, bilateral lymphadenopathy is less common than other sites of the oropharynx. For tumors confined to the tonsillar fossa and posterior pillar, contralateral lymph node positivity is reported in up to 22% of cases; for tumors of the anterior pillar, this is only 6% [3].

Soft Palate

The soft palate is a muscular structure largely covered in stratified squamous epithelium that separates the oropharynx from the nasopharynx superiorly and the oral cavity anteriorly. The soft palate musculature includes the levator veli palatine, tensor veli palatine, uvula, palatoglossus, and palatopharyngeus muscles. Anatomically, the soft palate attaches to the hard palate anteriorly and is contiguous with the tonsillar fossae on the lateral sides. Functionally, the soft palate is crucial in speech and swallowing. The motor innervation of the muscles of the soft palate include cranial nerve V3 (mandibular nerve) and X (vagus), which function to elevate the palate and close off the nasopharynx during swallowing and speech, preventing reflux of a food bolus superiorly and preventing breathiness and nasality of phonation, respectively termed velopharyngeal incompetence (VPI).

Primary tumors of the soft palate typically arise from the squamous mucosa of the oral aspect of the soft palate. Lesions that arise from the nasopharyngeal portion are much less common. Typically, lesions grow along the mucosal surfaces and tend to be superficial. As the lesions increase in size, they may extend to the adjacent tonsillar fossae, pharyngeal walls, or the anterior palatoglossal arches. Compared to other sites of the oropharynx, lesions tend to be more symptomatic and present at earlier stages.

Tumors of the soft palate predominantly drain to the lymph nodes in levels II and III, as well as the retropharyngeal nodes. In a study by Lindberg et al., clinically evident lymph nodes were present in 8% of T1 tumors, 37% of T2 tumors, 65% of T3 tumors, and 67% of T4 tumors; the overall rate of nodal metastases was 40% [1]. Given the centrality of the soft palate, bilateral lymphatic drainage is common, and bilateral nodal disease is not unusual.

Oropharyngeal Walls

The oropharyngeal walls are comprised of the mucosa of the lateral and posterior aspects of the upper aerodigestive tract within the confines of the oropharynx; specifically, the posterior pharyngeal wall extends from the inferior aspect of the nasopharynx to the level of the epiglottis and the lateral pharyngeal wall extends in the same longitudinal region on the right and left aspects of the oropharynx. The oropharyngeal walls consist of a squamous mucosal epithelium that overlies the pharyngeal constrictor musculature. In turn, the pharyngeal constrictors are anterior to the retropharyngeal space, the longus capitis and colli muscles, the prevertebral fascia, and finally the vertebral bodies. The oropharyngeal walls typically are situated adjacent to the second and third cervical

vertebrae, and this region is innervated by cranial nerves IX (glossopharyngeal) and X (vagus).

Primary tumors of the oropharyngeal walls typically arise from the squamous mucosa and grow toward the lumen of the aerodigestive tract and submucosally to other sites within the oropharynx. However, it is possible for lesions of the posterior pharyngeal wall to grow into the prevertebral musculature and bony involvement of the vertebral bodies, although rare, is possible. Lesions of the lateral pharyngeal wall may also grow directly into the structures of the neck and become confluent with the lymph node basins of that region. In many cases, lesions present at an advanced stage, due to the relative paucity of early symptoms until a critical size is reached.

Tumors of both the posterior and lateral pharyngeal walls primarily drain to the lymph nodes in levels II and III, as well as the retropharyngeal nodes. In a study by Lindberg et al., clinically evident lymph nodes were present in 25% of patients with T1 tumors, 30% of T2 tumors, 68% of T3 tumors, and 76% of T4 tumors [1]. An additional series, spanning 1954–1975 at The University of Texas M. D. Anderson Cancer Center, described an overall incidence of nodal disease of 57% in patients with oropharyngeal wall tumors [4]. Bilateral nodal drainage, both to the retropharyngeal and cervical nodes, is common.

Epidemiology

Incidence and Mortality

Tumors of the oropharynx are one of the most common types of head and neck cancer. Globally, oropharynx and hypopharynx cancer, combined, are estimated to affect over 130,000 individuals and result in over 50,000 deaths [5]. The diagnosis and outcomes of patients with these cancers, however, does significantly differ throughout the world. In men who live in developed nations, there is an estimate of 41,000 new cases per year with a mortality of 20,000, compared to an incidence of 65,000 new cases annually with a mortality of 48,000 in the developing world [5]. This discrepancy highlights the different propensities for disease development based on underlying lifestyle choices (for instance, tobacco and HPV), genetic dispositions, and preventive health measures, as well as the different standards of care throughout the world.

In the United States, oral cavity and oropharynx tumors affect approximately 35,000 new patients a year and cause approximately 7,500 deaths [6]. Oropharynx tumors alone are expected to occur in approximately 5,000 patients [7]. Current statistics in the USA suggest that the incidence of

oropharyngeal cancers has continued to increase (approximately 4% per year for tonsil cancers and 2% per year for base of tongue cancers) [8]; concurrently, however, there are decreasing death rates from oral cavity and oropharynx cancers. In 1990, the estimated cancer death rate per 100,000 was 5.61; this decreased to 3.84 in 2005 [6]. This represents an absolute decrease of 1.77 per 100,000 and a percentage decrease of 31.55%. The underlying reasons for the reduced death rate are ultimately unknown, but may be due to improved screening and diagnosis, improved treatment of these malignancies, or possibly improved prognosis of virally-related tumors.

In 2009, it is estimated that the patients with oropharynx and oral cavity cancers will present with largely locoregional disease. Overall, 33% of patients present with localized disease, 51% with regional disease, and only 10% with metastatic disease [6]. This highlights the opportunities for intervention for these patients, for whom locoregional disease is the common presentation and presents a unique opportunity for cure.

Changing Demographics and Risk Factors

Historically, oropharyngeal carcinoma has predominantly affected older men, with 70–80% of patients being male and an average age of 50–70 years at presentation [6]. In recent years, however, the demographics of oropharyngeal cancers have changed. Multiple studies from Western Europe and the USA have suggested less gender disparity and decreased average age of presentation, with more and more patients presenting under 45 years of age [9]. These observations prompted a variety of investigations, and even though the specific trends varied from country to country, similar changes were seen worldwide in both oral cavity [10–12] and oropharynx cancers [13–15].

One of the strongest associations in carcinogenesis is the link between the development of oropharyngeal carcinomas and the use of tobacco and alcohol products. Primary studies have suggested that smoking increases the risk of head and neck squamous cell carcinomas by 12 times in women and 5 times in men [8]. Furthermore, a synergistic effect has been seen between tobacco and alcohol use [16, 17]. A pooled analyses of 17 European and American case-control studies suggested there was a greater than multiplicative effect between tobacco and alcohol use, with a population attributable risk for head and neck cancers of 35% for tobacco and alcohol combined [18].

In addition to alcohol and tobacco consumption, other lifestyle factors and sexual habits have been implicated in the pathogenesis of oropharyngeal carcinomas. The use of marijuana [19–21], dietary intake of fruits and vegetables

[22, 23], body mass index [24, 25], and oral hygiene [26, 27] have all been studied with relation to the development of oropharynx carcinoma. Although the data have been somewhat mixed, patients who have a low dietary intake of fruits and vegetables and poor oral hygiene seem to have higher rates of oropharynx carcinomas.

One of the most interesting developments in the field of head and neck cancers has been the link between oropharyngeal carcinomas and HPV infection. Although this has been well-established in the cervical cancer literature, the possible etiologic contribution of viral infection to oropharyngeal carcinomas is a more recent realization [28]. In one review of 60 individual studies, the average rate of HPV-DNA positivity was 35.6% for oropharyngeal carcinomas; this is compared to approximately 20% in other oral cavity and larynx tumors [29]. In addition, oropharyngeal cancers tend to be associated with high-risk HPV subtype 16 (87%) in contrast to cancers of the uterine cervix, which tend to be associated approximately equally with subtypes 16 and 18 [30]. Further studies have shown that patients who developed oropharyngeal cancers below 55 years of age were found to have higher risk sexual behaviors and more HPV-positive tumors than those who developed cancers at a more advanced age [30]. Oral HPV infection itself, like anogenital infection, has been found to correlate with sexual behavior, for instance the number of oral sex partners [31, 32], number of lifetime sexual partners, young age at first coitus, and a history of genital warts [33]; all these factors have been shown to correlate with an increased risk of oropharyngeal cancer in individual studies. Larger case-control studies have not demonstrated significant associations between sexual behavior and oropharynx cancers; however, these are likely rendered insignificant by the more traditional patients with oropharyngeal carcinomas, attributable to alcohol and tobacco, and a minority of patients with HPV-related tumors [34, 35].

In addition to noting an association between HPV infection and the development of oropharynx carcinomas, patients with HPV-related tumors appear to have a better prognosis than those with non-HPV-related tumors. Fakhry and colleagues reported the outcomes of patients with HPV-related oropharynx tumors compared to non-HPV-related tumors as part of an Eastern Cooperative Oncology Group (ECOG) phase II prospective clinical trial (E2399) [36]. In this population, 40% of patients had genomic DNA of oncogenic HPV in the nuclei of the tumor cells. Patients with HPV-positive tumors had improved response after induction chemotherapy (82% vs. 55%, $p=0.01$) and after chemoradiation (84% vs. 57%, $p=0.007$) as well as improved overall survival at 2 years (95% vs. 62%, $p=0.005$). An analysis of the HPV-positivity in tumors of patients treated on RTOG H-0129, a phase III randomized trial of chemoradiation with either standard or altered fractionation, demonstrated HPV-16 positivity in 60.6% of oropharynx tumors [37]. Similar to the

ECOG study, patients with HPV-positive oropharynx tumors had improved 2-year overall survival (87.5% vs. 67.2%). These studies have been pivotal in establishing the role of HPV-positivity in both pathogenesis and prognosis for patients with oropharynx cancer.

The scientific link between oropharyngeal cancers and HPV is now well-recognized, and the data suggesting improved responsiveness to both chemotherapy and radiation in HPV-positive tumors are compelling. Indeed, future clinical trials addressing treatment for these malignancies are being designed separately for patients with HPV-positive and HPV-negative tumors. The philosophical approach being developed is to intensify treatment for those patients with HPV-negative tumors, and therefore poorer prognoses, and to evaluate patterns of failure and minimize overall toxicity for those with HPV-positive tumors, and therefore better prognoses.

Pathology and Pathogenesis

The large majority of tumors that arise in the oropharynx are squamous cell carcinomas; less than 10% of tumors are of a different histology, with minor salivary gland adenocarcinomas, lymphomas, melanomas, sarcomas, and undifferentiated cancers making up this group [38, 39]. In addition, benign conditions, including papillomas, fibromas, hemangiomas, neuromas, and cysts, may occur in the oropharynx and must be considered in the differential diagnosis. Finally, metastases to the oropharynx, although rare, have been described [40, 41]. Given the preponderance of squamous cell carcinomas, the remainder of this chapter concentrates on their diagnosis and management.

Role of Pathological Assessment

Tissue diagnosis and adequate pathologic assessment are crucial to the diagnosis of head and neck squamous carcinomas. Tissue can be obtained through core needle biopsies, excisional, or incisional biopsies. Conventional hematoxylin and eosin staining remains key to the diagnostic evaluation. A variety of features can be described in squamous carcinomas diagnosed through this analysis; however, the relative importance of other features of the tumor has been the subject of significant debate. Perineural invasion [42, 43], basaloid features [44], and keratinization [45] have all been investigated as potentially important prognostic features. More recently, studies suggest that basaloid features and nonkeratinizing tumors may reflect HPV status and confer their improved prognosis [46].

In addition to traditional histologic appearance, the tissue from oropharynx squamous cell carcinomas also can be analyzed for characteristic molecular markers. In situ hybridization analysis for high-risk HPV subtypes is increasingly used as part of the pathologic assessment of squamous cell carcinomas of the oropharynx (Fig. 29.3a); this, however, is a technique that requires specific training and expertise. Immunohistochemical analysis (IHC) for p16 overexpression has also proven useful; studies begun in HPV-positive cervical cancer specimens demonstrated a correlation between HPV-infection and p16 overexpression [47]. Now, viral infection with HPV is correlated with expression of p16 in carcinomas of the head and neck. Some studies suggest that p16 overexpression is indicative of better prognosis, similar to HPV-positivity [48]; in contrast, p16 is downregulated in tobacco-related cancers. IHC analysis for p16 often demonstrates diffuse positive staining in HPV-positive tumors (Fig. 29.3b); this is a relatively inexpensive and efficient test. Since HPV-associated tumors have been shown to have a better prognosis than non-HPV-associated tumors, this testing may have a significant impact on treatment decisions.

Pathogenesis of Oropharyngeal Carcinoma

Squamous cell carcinomas of the oropharynx are considered the result of multiple events at the molecular level; each of these events may reflect a change due to a genetic predisposition or an exposure to an exogenous environmental agent [49]. Multiple independent events that cause the loss or inactivation of tumor suppressor genes and activation of oncogenes appear crucial to the development of oropharyngeal carcinomas; environmental agents can cause specific damage or trigger cascades that contribute to these pathways.

Elegant studies of genetic alterations in squamous cell tumor specimens from the head and neck by Califano and colleagues have suggested a model of genetic progression in these lesions (Fig. 29.4). The most common alteration is the loss of chromosomal region 9p21, a region that encodes two suppressors p16 and p14^{ARF}; this abnormality is present in over 70% of dysplastic lesions, suggesting that its loss is an early event in the carcinogenic pathway [49–51]. Another early genetic abnormality is loss of a region of chromosome 3p, which encodes two suppressor genes *FHIT* and *RASSF1A* [51–53]. Later genetic events appear to include loss of

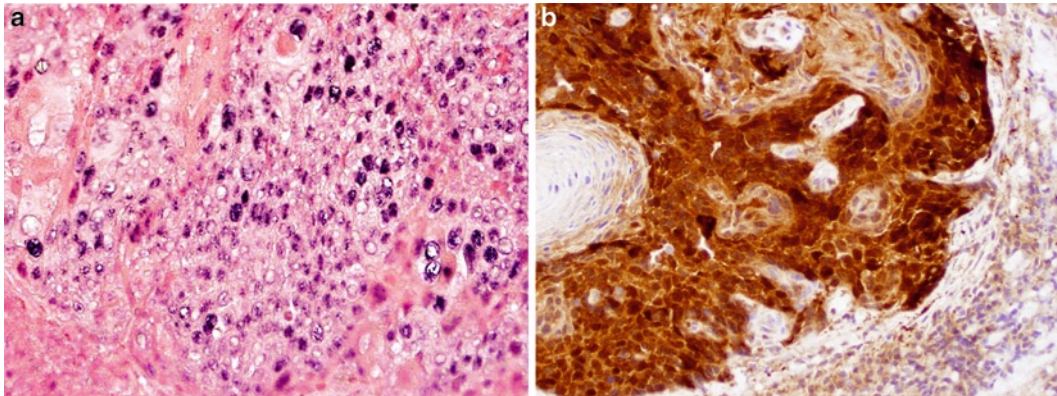


Fig. 29.3 Specialized pathologic assessment of oropharynx tumors. (a) HPV in situ hybridization demonstrating nuclear staining in a tonsil squamous cell carcinoma (b) p16 immunohistochemical analysis showing diffuse staining of a base of tongue squamous cell carcinoma

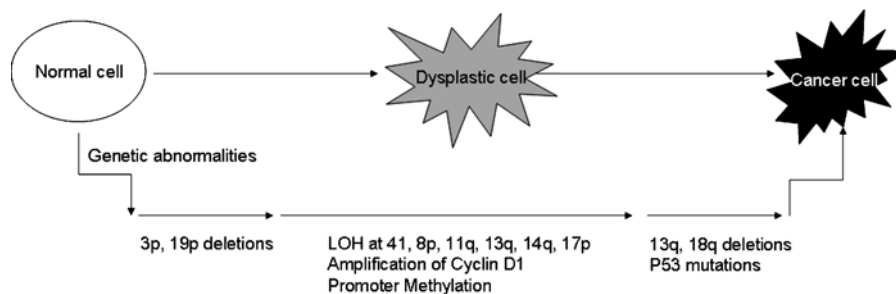


Fig. 29.4 Schematic of genetic alterations contributing to the development of squamous cell carcinoma

heterozygosity (LOH) of chromosome region 17p and p53 mutation [54]. In aggregate, these genetic events contribute to genomic instability and the development of aneuploidy; this progression has been shown to be crucial in the progression of normal mucosa to dysplasia and finally to invasive carcinoma.

Exogenous environmental factors appear to contribute to this cascade in a variety of ways. Carcinogen exposure, such as use of tobacco and alcohol, can cause direct genetic insult or act indirectly through mucosal damage. Damage of the mucosa may trigger inflammatory cascades that involve COX-2 and EGFR activation, Cyclin D1 activation, and increased proliferation; this compensatory mechanism to the acute injury increases proliferation and puts the mucosa at increased risk of mutation [55].

Viral infection with high-risk HPV subtypes exerts direct influence on the pathways of carcinogenesis in oropharyngeal carcinomas. Most HPV-related cancers carry the viral DNA integrated into the cellular chromosomes at one or more loci [56, 57]. It is believed that expression of two early genes in the viral genome, E6 and E7, are crucial to viral mediated cancer development. The E6 protein, mediated by a cellular protein called E6-associated protein (E6AP), forms a complex with the tumor suppressor p53, causing degradation of p53 via ubiquitin-mediated proteolysis [58]. The ability to inhibit the tumor suppressor activity of p53 has been shown to reduce the ability of the cell to respond to genotoxic stress [59] and genetic instability [60]. The E7 protein interferes with the activity of the protein product of the retinoblastoma gene, which is a tumor suppressor that is involved in cell-cycle control and progression; in this way, the E7 protein can disrupt signals that would normally stop DNA synthesis and cell-cycle progression [61–63]. The molecular effects of both E6 and E7 in HPV-associated cells are believed to contribute to the transformation of infected cells to carcinoma.

Multidisciplinary Initial Assessment and Staging

The Role of History and Physical Examination

The primary evaluation of a patient with oropharyngeal cancer is a comprehensive history and physical examination. On history, the patient's symptoms depend highly on the location and extent of the tumor. Patients with early stage oropharyngeal carcinomas may present with few symptoms; the tumors may have been found incidentally on scans for other indications or dental evaluations.

One common presenting symptom of oropharynx cancer is a painless neck mass, representing lymph node metastasis;

in many cases, only after a full examination is a primary identified. When patients do develop symptoms due to local disease, pain is often the earliest to develop. This may be pain at the site of the primary or referred pain to the middle ear. The latter occurs via the pharyngeal and tonsillar branches of cranial nerve IX, which traverse the petrosal ganglion and then synapse with the tympanic nerve of Jacobson, which innervate the middle ear. As tumors progress, odynophagia, dysphagia, dysarthria, and trismus may develop and cause the patient to seek medical attention.

The physical examination is a crucial part of the evaluation for oropharyngeal cancer patients, and it highly affects treatment decisions and planning. The head and neck examination should evaluate the local extent of the primary tumor and the presence and location of lymph nodes. Inspection of the oropharynx can be performed by direct or indirect laryngoscopy or fiberoptic nasopharyngolaryngoscopy; there should be a complete evaluation of all mucosal surfaces to ensure there are no other lesions and to fully appreciate the extent of the primary tumor. In addition, digital examination is crucial to the estimate of the primary disease size. Often, there can be infiltrative processes that are underappreciated by both inspection of the mucosal surface and segmental imaging. A full evaluation of the adjacent oral cavity should be performed to understand whether the tumor invades these areas. Attempts should be made to estimate the size of the primary lesion, its limits of spread, and associated lymphadenopathy, since all of these contribute to the ultimate staging and treatment recommendations. Depending on the subsite of the primary tumor, 45–78% of patients may present with cervical adenopathy at the time of diagnosis [1]; assessment of the lymph nodes is crucial to an accurate understanding of the extent of disease. While level II is the most common lymph node station affected, the other cervical nodal areas, as well as the supraclavicular fossae, should be assessed. Finally, associated symptoms, such as tongue deviation, tongue fixation, trismus, and sensory impairment, should be evaluated; these suggest further extension of the tumor that will influence stage and treatment recommendations. Cranial nerves V, VII, XI, X, and XII are especially at risk for compromise due to invasion by oropharyngeal cancers, and these should be specifically assessed during the physical examination. In the case of an inadequate physical examination, the patient may require an examination under anesthesia (coupled with biopsy) to fully appreciate the extent of disease and establish a diagnosis.

Pretreatment dental evaluation is also crucial to the ultimate management of patients with oropharyngeal carcinoma. Treatment of oropharyngeal cancer with radiation has several short- and long-term effects on dentition and oral health, and an evaluation of the baseline dentition is crucial to effective management. Patients who develop xerostomia are at greater risk for dental caries and demineralization. The decrement in

perfusion following radiation therapy leads to greater difficulty in healing from dental procedures. A clinical dental evaluation and radiographic studies should be done to assess the status of the teeth. Prior to radiation therapy, any non-restorable teeth should be extracted. In addition, the patient will benefit from lifetime dental fluoride prophylaxis. Long-term dental care by a dentist familiar with the effects of radiation therapy should be undertaken following treatment [64].

Finally, patients with oropharyngeal cancer should be assessed for the status of their general health, in a comprehensive manner, by the team of treating physicians; in many cases, an evaluation by an internist may be beneficial. Many of these patients have medical comorbidities, such as diabetes or hypertension, and many are at risk for secondary malignancies. In addition, patients are at risk for chemical hypothyroidism after treatment with radiation therapy to the neck; baseline thyroid function should be evaluated prior to treatment and then monitored appropriately in follow-up. A chest radiograph, complete blood count, and serum chemistry evaluation, in addition to a review of their past history, will provide a better understanding of their disease and baseline health status. Finally, lifestyle interventions, such as smoking cessation, are crucial for long-term success.

The Role of Imaging

Advanced imaging techniques are standard in the evaluation and staging of oropharyngeal tumors. The goal of imaging is to establish the extent and size of the primary tumor, evaluate nodal disease, and identify perineural spread and bony destruction. The optimal type of imaging for head and neck cancers depends on the site of disease and goals of the evaluation. Computed tomography (CT), magnetic resonance imaging (MRI), positron emission tomography (PET), and ultrasound

(US) are all complementary modalities and can be used to evaluate different aspects of the disease (Fig. 29.5).

Standard imaging evaluation for an oropharynx tumor includes CT or MR imaging of the head and neck, with intravenous contrast (unless medically contraindicated), to evaluate the primary tumor and nodal disease. CT is considered by many to be preferable to MRI for the imaging of oropharynx tumors because it is less affected by breathing and swallowing artifacts [65], although some centers prefer MRI due to their expertise with this modality. The imaging of oropharyngeal tumors on CT or MRI is quite variable, and enhancement may or may not reflect the full extent of disease. It is important to correlate the mass and enhancement observed on imaging with the clinical examination in order to fully appreciate the extent of disease. Bone invasion and destruction is well-delineated on CT scan, and hence CT may indicate more extensive disease than previously appreciated. Despite the benefits of CT, it is limited by artifacts caused by metallic dental implants and fillings; angled cuts may be helpful in providing more useful images through important areas. If these maneuvers are not sufficient, MRI may be used, since it is not affected by metallic artifact.

Imaging of nodal disease can be accomplished with CT, MRI, PET, or US. Clinical evaluation and cross-sectional imaging is estimated to be negative in 15–25% of patients with true nodal metastases from head and neck cancers [66]. However, patients with head and neck cancers often can have reactive adenopathy that does not reflect metastatic disease; hence, false positives and false negatives are clinically relevant.

With modern techniques, CT and MRI are considered equivalent in the detection of nodal disease from head and neck cancers [67]; CT is typically the primary modality used for staging of oropharynx tumors as it can effectively evaluate both the primary and nodal disease. The size criteria for suspicious nodes has been the subject of significant discussion;

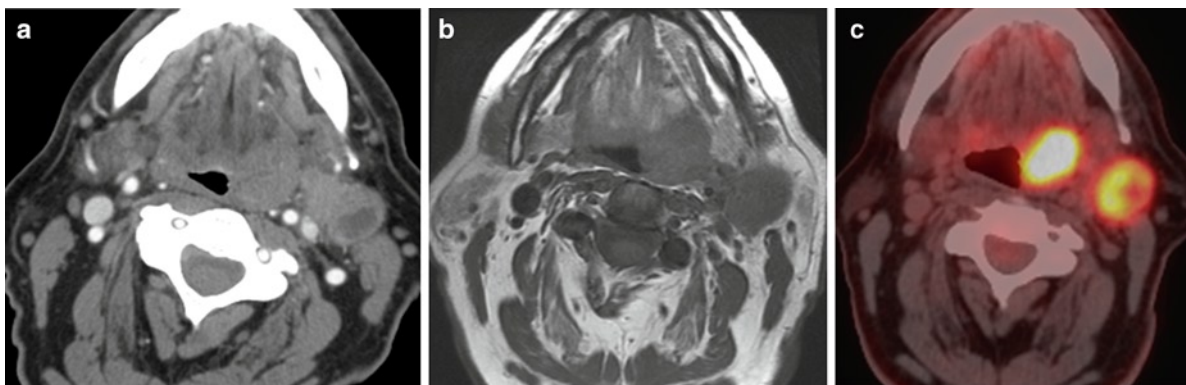


Fig. 29.5 Imaging evaluation of a T2 N2b left base of tongue squamous cell carcinoma by various modalities: (a) CT with iodinated contrast (b) MRI (c) PET/CT

currently, it is accepted that level I and II nodes greater than 15 mm in longest diameter and other nodal stations greater than 10 mm should be considered suspicious [65]. In addition, the characteristics of the nodes may shed light on their metastatic burden. Regardless of size, lymph nodes with central hypodensity and peripheral enhancement as well as round nodes are concerning [65]. Finally, extranodal extension may be identified on CT as irregular nodal margins, the loss of the fat cleavage plane around the node, thickening of fascia, or frank invasion of adjacent structures [65]. Ultrasound is an effective modality to identify and characterize lymph nodes if CT or MRI is contraindicated, and it has been especially useful when coupled with image-guided biopsy for suspicious lymph nodes for which involvement would affect a treatment plan [68]. PET is very sensitive for the identification of lymph nodes harboring metastatic disease that are at least 8 mm in size. A landmark study established a sensitivity of 90% and specificity of 94% for PET in the determination of histologically proven lymph node metastases, where CT and MRI had values of approximately 80% and US of 72% [69]. The integration of PET with CT has given even more utility to this modality, and it is now considered one of the best ways to establish the nodal status at the time of initial diagnosis.

Staging

The current system for staging oropharyngeal carcinomas is the American Joint Committee on Cancer (AJCC) system, which concentrates on the size and distribution of the primary, nodal disease, and metastatic disease (Table 29.1). All diagnostic modalities can be used to assess the stage, including CT, MRI, and PET imaging. In addition, clinical evaluation is crucial and may strongly affect the underlying stage. For instance, although imaging may not suggest involvement, limitations in tongue movement or tongue fixation can be assumed to indicate deep tongue muscle invasion, rendering a tumor T4. The primary source for this information is the AJCC Cancer Staging Manual, 7th Edition (2010).

Multidisciplinary Treatment for Locoregional Disease: Overview and by Subsite

The optimal management and outcomes of carcinomas of the oropharynx are highly dependent on the subsite of origin and extent of disease. Hence, recommendations should always account for the intricate details of the individual tumor.

Overview

Role of surgery

Surgical resection can be curative therapy in selected cases of oropharyngeal carcinomas in specific subsites. For early stage lesions (T1, N0-1 disease and limited T2, N0-1 disease) of the soft palate, tonsil, base of tongue, or oropharyngeal wall, surgical resection of well-delineated lesions can be curative with relatively minimal toxicity and cosmetic deformity. This is a reasonable approach in selected cases in which surgery can stand alone as local therapy, and the patients will not require both surgery and postoperative radiation therapy due to high-risk factors on pathologic assessment. However, since oropharyngeal tumors tend to present at more advanced stages, and there is a significant risk for lateral and retropharyngeal nodal metastases that are not readily amenable to dissection, the majority of these patients will require postoperative radiation therapy. For intermediate stage tumors (more substantial T2 lesions, T3 lesions, or any primary tumor with N2-3 nodal disease), surgical resection is not favored due to the potential magnitude of functional debilitation resulting from a curative resection and necessary reconstruction, as well as the requirement for postoperative radiation therapy, as compared to equivalent local control and overall survival with a nonsurgical approach [70, 71]. Finally, for advanced tumors (infiltrative T3 and T4 lesions), composite surgical resection with postoperative radiation therapy was traditionally standard therapy. However, the functional consequences of this treatment are significant. Newer studies have investigated the use of chemotherapy and radiation as curative treatment as part of an organ preservation approach; at this time, for patients with residual function of the oropharynx, surgical resection may not be the most favored treatment approach since equivalent local control and overall survival can be achieved with a nonsurgical approach. For these reasons, oropharynx cancer has become a primarily nonsurgical disease.

Patients with oropharyngeal cancer often present with nodal metastases, and management of the neck is often a subject of debate. The decision is based on the extent of nodal disease, primary treatment, and philosophy of the treating physician [72]. There are several approaches to treating the neck. First, the neck may be dissected as part of a definitive surgery for the primary disease; radiation therapy may be added adjuvantly, if indicated, based on pathologic risk factors. Second, the neck may be treated definitively with radiation therapy and standard neck dissection. Finally, the neck may be treated definitively with radiation therapy concurrent with primary tumor treatment with a neck dissection only in the case of persistent nodal disease. The management of the neck is somewhat controversial and dependent highly on the treatment philosophy of the institution; all have been shown to be effective strategies for management.

Table 29.1 Staging of oropharyngeal carcinomas

<i>Primary tumor (T)</i>			
TX	Primary tumor cannot be assessed		
T0	No evidence of primary tumor		
Tis	Carcinoma in situ		
T1	Tumor 2 cm or less in greatest dimension		
T2	Tumor more than 2 cm but not more than 4 cm in greatest dimension		
T3	Tumor more than 4 cm in greatest dimension		
T4a	Moderately advanced local disease. Tumor invades the larynx, extrinsic muscle of tongue, medial pterygoid, hard palate, or mandible ^a		
T4b	Very advanced local disease. Tumor invades lateral pterygoid muscle, pterygoid plates, lateral nasopharynx, or skull base or encases carotid artery		
<i>Regional lymph nodes (N)^b</i>			
NX	Regional lymph nodes cannot be assessed		
N0	No regional lymph node metastases		
N1	Metastasis in a single ipsilateral lymph node, 3 cm or less in greatest dimension		
N2	Metastasis in a single ipsilateral lymph node, more than 3 cm but not more than 6 cm in greatest dimension, or in multiple ipsilateral lymph nodes, none more than 6 cm in greatest dimension, or in bilateral or contralateral lymph nodes, none more than 6 cm in greatest dimension		
N2a	Metastasis in a single ipsilateral lymph node, more than 3 cm but not more than 6 cm in greatest dimension		
N2b	Metastasis in multiple ipsilateral lymph nodes, none more than 6 cm in greatest dimension		
N2c	Metastasis in bilateral or contralateral lymph nodes, none more than 6 cm in greatest dimension		
N3	Metastasis in a lymph node more than 6 cm in greatest dimension		
<i>Distant metastasis (M)</i>			
M0	No distant metastasis		
M1	Distant metastasis		
<i>Anatomic stage/prognostic groups: oropharynx, hypopharynx</i>			
Stage 0	Tis	N0	M0
Stage I	T1	N0	M0
Stage II	T2	N0	M0
Stage III	T3	N0	M0
	T1	N1	M0
	T2	N1	M0
Stage IVA	T3	N1	M0
	T4a	N0	M0
	T4a	N1	M0
	T1	N2	M0
Stage IVB	T2	N2	M0
	T3	N2	M0
	T4a	N2	M0
	T4b	Any N	M0
Stage IVC	Any T	N3	M0
	Any T	Any N	M1

^aMucosal extension to lingual surface of epiglottis from primary tumors of the base of the tongue and vallecula does not constitute invasion of larynx

^bMetastases at level VII are considered regional lymph node metastases

Used with the permission of the American Joint Committee on Cancer (AJCC), Chicago, Illinois. The original source for this material is the AJCC Cancer Staging Manual, Seventh Edition (2010) published by Springer Science and Business Media LLC, www.springer.com

Role of Radiation Therapy

As a single modality or with concurrent chemotherapy, radiation therapy is considered the standard of care for definitive treatment of oropharyngeal carcinomas [73]. The choice of technique, dose, and fractionation has been extensively studied.

Conventional Treatment

Historically, oropharynx cancers were treated with conventional radiation therapy using 2-dimensional simulation to delineate standard treatment fields based on bony landmarks. Patients were typically positioned supine, with the neck extended on a fixed headrest, and immobilized with a thermoplastic

mask device. The shoulders were displaced in the caudal direction, to lengthen the neck, using a pull-strap device. In cases where separation was needed in the oropharynx or to more accurately target the tumor, a bite block, intra-oral stent, or traditional cork and tongue blade was used to open the mouth in a reproducible way. After optimal positioning, orthogonal films were obtained for simulation and field delineation.

Typically, the field arrangement involved a mono-isocentric technique in which two opposed lateral fields treating the upper neck were matched with a lower anterior neck AP field (the “3-field technique”), with conedown and boosts delivered to respect normal tissue tolerance (Fig. 29.6). Typically, low energy megavoltage (4 MV or 6 MV photons) or Cobalt-60 irradiation was used to ensure adequate coverage.

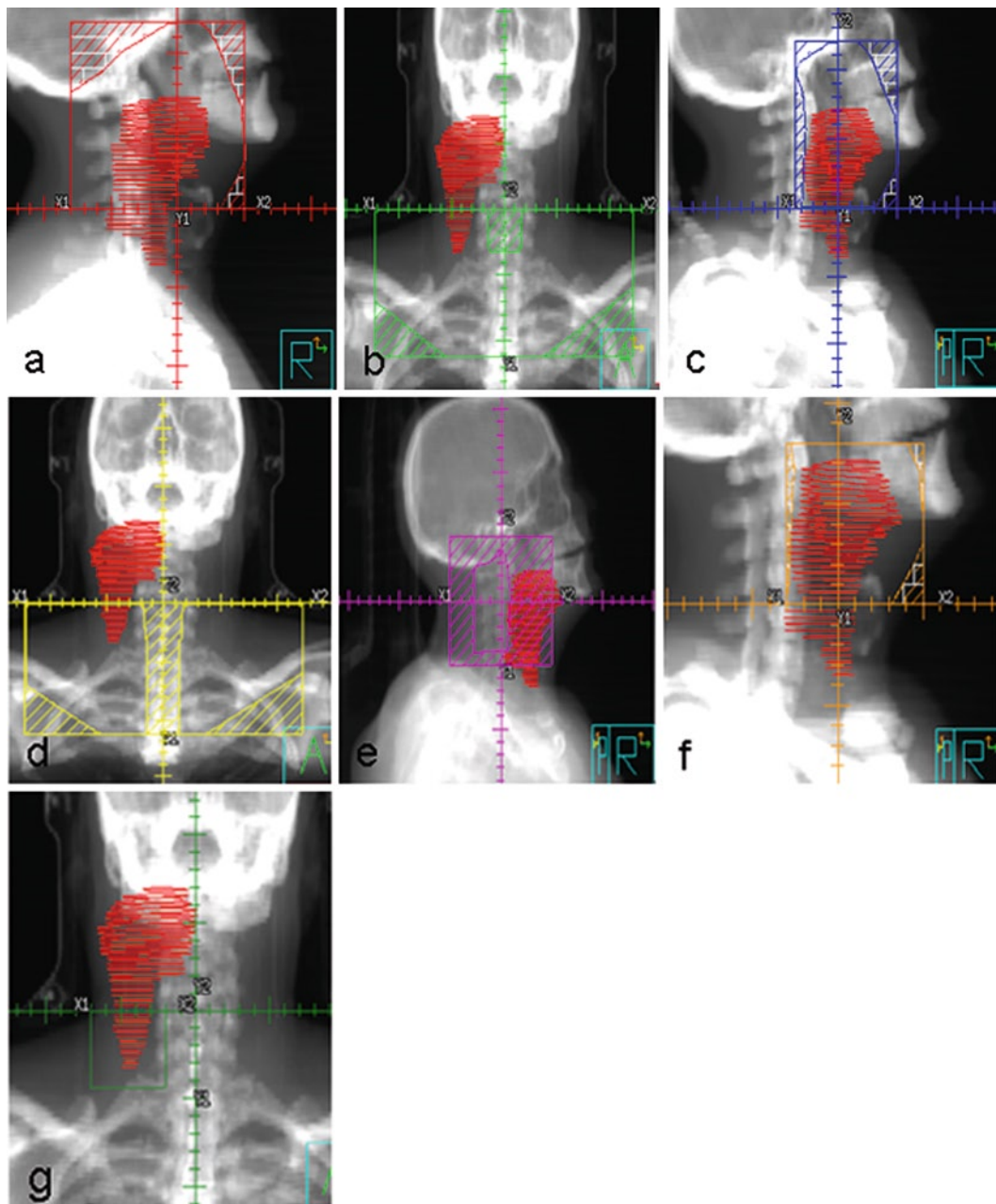


Fig. 29.6 Conventional treatment fields for a T2 N3 right tonsil cancer cancer. Initial fields are (a) opposed laterals and (b) AP:PA low neck fields to a total of 41.4 Gy. Secondary fields are (c) off-cord fields, (d) low neck fields with a midline block, and (e) posterior cord strip electron

fields are taken to an additional 12.6 Gy (total of 54 Gy). Finally, concomitant boost fields are given as a second daily fraction during the final weeks of therapy, consisting of conedown fields to the (f) primary and (g) nodal disease for an additional 18 Gy

For conventional treatment, targeting was based on understanding of the location of the primary tumor and neck disease with regard to bony landmarks. Care was taken to include all at-risk lymph node basins, based on the extent of disease, including the Levels II–IV lymph nodes, retropharyngeal nodes, Level IA nodes if the floor of mouth was involved, Level IB nodes if the upper jugular nodes were involved, and Level V nodes if the ipsilateral jugular nodes were involved. As mentioned above, tolerance of normal tissues, most notably the spinal cord, required field adjustments; typically, conedown fields that were off-cord were used after a dose of approximately 40–42 Gy, and posterior neck electron fields were used to treat tissues overlying the spinal cord at higher risk.

Several studies have carefully investigated the role of dose escalation and altered fractionation in the conventional treatment of oropharynx cancers. Withers and colleagues analyzed the outcomes of patients treated with different fractionation schema from a variety of centers; this study suggested that improved local control was related to total radiation dose and treatment time [74]. The EORTC investigated the clinical benefit of altered fractionation in trial EORTC 22791, which compared hyperfractionation (80.5 Gy total dose using 1.15 Gy/fraction twice daily radiation) to conventional radiation (70 Gy total dose using 1.8–2.0 Gy/fraction once daily radiation) [75]. In this study, patients treated with hyperfractionation had a significant improvement in locoregional control over conventional fractionation (59 vs. 40%, $p=0.02$) with a trend toward improved overall survival. Based on similar findings, the RTOG began the 90-03 trial, which investigated 4 different altered fractionation schemes: (1) conventional fractionation of 70 Gy total dose with 2 Gy/fraction delivered once daily, (2) split course accelerated fractionation of 67.2 Gy total dose with 1.6 Gy/fraction delivered twice daily with a 2 week break after 38.4 Gy, (3) concomitant boost fractionation of 72 Gy total dose delivered with a once daily 1.8 Gy/fraction treatment in the morning and a 1.5 Gy/fraction second daily fraction in the afternoon during the last 12 days of treatment, and (4) hyperfractionation of 81.6 Gy total dose delivered with a twice daily 1.2 Gy/fraction treatment [76]. Overall, 1,073 patients were enrolled and 60% had oropharynx cancers. This study suggested that patients treated with pure hyperfractionation and concomitant boost techniques had significantly better locoregional control and a trend toward improved disease-free survival compared to standard or split-course radiation. There was no difference in overall survival. In another investigation of altered fractionation, the Danish Head and Neck Cancer Study Group (DAHANCA) performed a randomized prospective trial (DAHANCA 6) comparing use of 5 (standard) vs. 6 (accelerated) fractions per week in treatment of head and neck squamous cell carcinomas to a total dose of 66–68 Gy at 2 Gy/fraction; 28%

of patients had pharyngeal tumors [76]. For all patients, the overall 5-year primary tumor control rates showed a benefit to 6 fractions/week (76% vs. 54%; $p=0.0005$) as well as disease-specific survival (73% vs. 66%; $p=0.01$). There was no demonstrable benefit to 6 fractions/week in terms of neck control or overall survival. These served as the seminal trials supporting altered fractionation for improved local control of intermediate primary oropharynx cancers, while recognizing that there was little benefit for nodal or advanced primary control.

IMRT

At this time, advanced techniques with 3-D planning, using CT or MRI based simulations, with treatment using intensity-modulated radiation therapy (IMRT) is largely considered as the standard treatment for oropharyngeal cancers. Simulations are performed similarly to conventional treatments; patients are supine with the neck extended, shoulders displaced in the caudal direction, and immobilized with a custom-made thermoplastic mask (Fig. 29.7). Immobilization is even more important with the use of IMRT due to the precise delineation of treatment volumes. In general, multiple fields are used (7–9 beams of 6 MV photons) to treat the primary tumor and, at least, the upper neck. The lower neck can be treated with IMRT (as a single field with the primary and upper neck) or matched to an anterior low neck field, similar to the conventional techniques.

Delineation of treatment volumes and treatment planning is of paramount importance in the definitive treatment of oropharyngeal carcinoma with radiation therapy in general, and especially IMRT. Understanding the full extent of disease requires integration of clinical examination and imaging findings, and the typical patterns of local and regional spread should be factored into delineated treatment volumes. For IMRT, the gross tumor volume (GTV) should encompass the primary and nodal volumes of gross tumor. If the patient received induction chemotherapy or some type of resection/biopsy, attempts should be made to recapitulate the tumor volume at the start of treatment and cover this area. The clinical target volume (CTV) for treatment planning is typically divided into three regions (Fig. 29.8). CTV1 comprises the volume of the GTV with a margin of 7–10 mm, respecting anatomic boundaries; this volume is typically taken to a dose of 66 Gy in 30 fractions (2.12 Gy/fraction) for T1-2 tumors treated with radiation alone or 69.96 Gy in 33 fractions (2.2 Gy/fraction) for T3-4 tumors if radiation is used with concurrent chemotherapy. CTV2 comprises adjacent high-risk nodal areas including a margin around CTV1 and the nodal spaces near the primary tumor; this volume is typically taken to a dose of 60 Gy in 30 fractions (2 Gy/fraction) if radiation is used alone or 63 Gy in 33 fractions (1.91 Gy/fraction)

Fig. 29.7 Patient positioning for radiation therapy treatment for oropharyngeal cancer using IMRT. The patient is supine with a box and strap device to displace the shoulders in the caudal direction; the patient's head and neck are immobilized with a custom-made thermoplastic mask

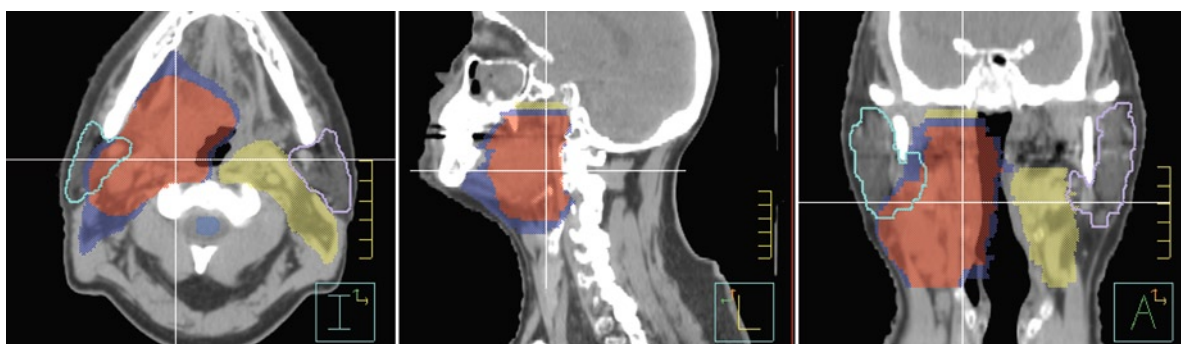
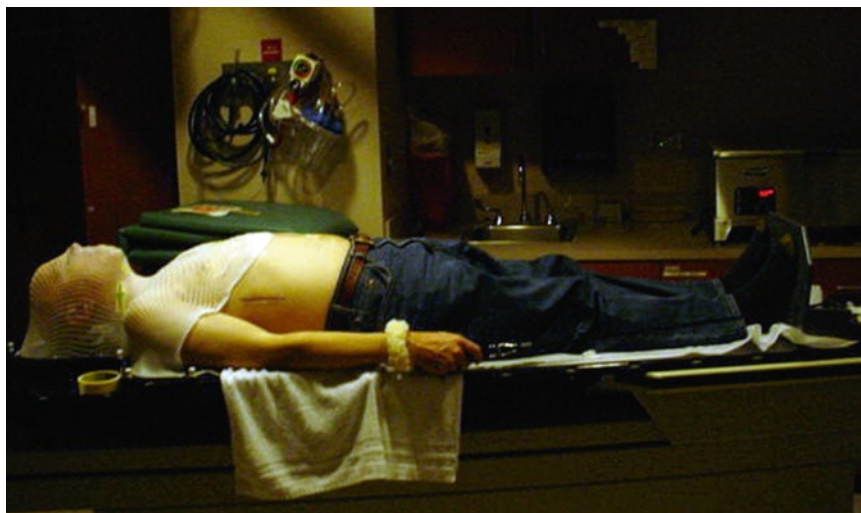
Fig. 29.8 Basic treatment volumes for IMRT for a T2 N2b squamous cell carcinoma of the right tonsil, showing CTV1 (red), CTV2 (blue), and CTV3 (yellow)

if radiation is used with concurrent chemotherapy. Finally, CTV3 comprises low-risk nodal disease, such as contralateral cervical nodal basins, and is typically taken to a dose of 54 Gy in 30 fractions (1.8 Gy/fraction) if radiation is used alone and 57 Gy in 33 fractions (1.73 Gy/fraction) if radiation is used with chemotherapy. We recommend that IMRT treatment to the primary oropharyngeal tumor and upper neck be matched with a conventional low neck field to treat the supraclavicular fossa bilaterally to a dose of 40 Gy in 20 fractions with an AP field with a larynx block followed by an additional 10 Gy in 5 fractions with a full midline block. Dosimetric analysis has shown that this technique promotes better larynx-sparing than full neck IMRT plans [77]. For patients with low nodal disease, additional boosts can be added with appositional electron fields or photon fields to augment the dose in the low neck, while respecting the accepted tolerance of the brachial plexus. Bulky lower neck nodal disease may require a planned neck dissection if the required radiation dose would exceed brachial plexus tolerance. This treatment algorithm is generalizable to the

majority of oropharyngeal cancers, even in the setting of prior chemotherapy or surgical resection.

The outcomes and toxicity of patients with oropharyngeal cancers treated with IMRT are now emerging. The RTOG completed a phase II trial, RTOG 00-22, to assess the use of IMRT for treatment of early stage oropharynx cancers, specifically assessing feasibility of treatment delivery (target coverage and parotid sparing), determine the patterns of failure, and assess early and late toxicities [78]. A total of 69 patients with clinical stage T1-2 N0-1 oropharynx cancers were treated with IMRT alone (no chemotherapy) to a dose of 66 Gy in 30 fractions. With a median follow-up of 2.8 years for living patients, the 2-year rate of locoregional failure was 9%. The rates of grade 2 or more toxicity were: 12% skin, 24% mucosa, 67% salivary, 19% esophagus, and 6% osteoradionecrosis. The authors concluded that moderately accelerated hypofractionated IMRT was feasible with high rates of locoregional control and lesser toxicity when applied to small high-dose volumes, such as T1-2 primary tumors (compared to historical

RTOG controls). Other single institution studies also indicate high rates of locoregional control and reduced toxicity with IMRT for oropharyngeal cancer [79–81].

Role of Chemotherapy

The role of chemotherapy in the management of head and neck cancers has been the subject of significant debate. The Meta-Analysis of Chemotherapy in Head and Neck Cancer (MACH-NC) database has collected data from 87 randomized trials comprising more than 16,000 patients treated from 1965 to 2000, in attempt to enumerate the added benefit of chemotherapy in the treatment of these patients [82]. The individual patient data was analyzed and patients treated with locoregional treatment alone were compared with those treated with locoregional treatment and chemotherapy (induction, concurrent, or adjuvant). Oropharynx carcinoma was the most common primary site of disease, occurring in 37% of patients. In the latest update of the MACH-NC, the benefit of chemotherapy, specifically concurrent chemotherapy, was sizable. The hazard ratio of death was 0.88 ($p < 0.0001$) with an absolute benefit of chemotherapy of 4.5% at 5 years and a significant interaction between the timing of chemotherapy and outcome. Both head-to-head and indirect comparisons supported the finding that concurrent chemotherapy was superior to either induction or adjuvant regimens. For 50 individual trials that involved concurrent chemotherapy, the hazard ratio of death was 0.81 ($p < 0.0001$) and the absolute benefit was 6.5% at 5 years [82]. Patients treated with concurrent cisplatin, alone or in combination with other agents, had the most benefit from chemotherapy. In addition, the benefit of concomitant chemotherapy was similar regardless of the fractionation schema of the radiation therapy.

The French Head and Neck Oncology and Radiotherapy Group (GORTEC) has also investigated the use of chemotherapy in patients with oropharyngeal cancer [83]. In this trial, 222 patients with stage III or IV oropharynx cancers were randomized to radiation alone (70 Gy in 7 weeks) or radiation with 3 cycles of concurrent carboplatin and 5-fluorouracil. There was a statistically significant improvement in locoregional control in the group that received concurrent treatment (48% vs. 25%; $p = 0.002$), as well as an improvement in overall survival at 5 years (22% vs. 16%; $p = 0.05$) [83]. Although it did not reach statistical significance, this improvement also resulted in increased rates of grade 3 and 4 complications at 5 years (56% vs. 30%; $p = 0.12$). This study strongly supports the use of concurrent chemotherapy in patients with Stage III and IV oropharyngeal cancer. In fact, these data prompted an editorial in the *Journal of the National Cancer Institute* in 1999 with the historic call for

combined chemoradiation to become an accepted standard of care for locally advanced oropharyngeal cancers; this data has supported a paradigm shift in the management of these patients, who were often treated surgically previously [73].

Concurrent chemoradiation has largely been accepted as standard of care for locally advanced primary tumors of the oropharynx [84, 85], but the role of induction chemotherapy continues to be controversial. Several individual trials have exhibited promising results with the use of induction chemotherapy, especially those regimens containing cisplatin [86–88]; other trials have shown promising results with the use of combined taxane induction therapy [89]. Most recently, the EORTC has investigated the role of induction chemotherapy as part of the EORTC 24971/TAX323 trial comparing induction TPF (docetaxel, cisplatin, and 5-fluorouracil) with PF alone (cisplatin and 5-fluorouracil) followed by definitive radiation therapy [90]; approximately 46% of patients on each treatment arm had oropharyngeal cancer. With a median follow-up of 32.5 months, treatment with TPF resulted in a statistically significant improvement in response to chemotherapy (68% vs. 54%, $p = 0.006$), progression-free survival (11.0 vs. 8.2 months, $p = 0.007$) and overall survival (18.8 vs. 14.5 months, $p = 0.02$). In addition, the TAX 324 study compared the same induction regimens (TPF vs. PF) followed by definitive chemoradiation therapy [91]. In this trial of 501 patients, approximately 52% were diagnosed with oropharynx cancers. With a median follow-up of 42 months, treatment with TPF resulted in improved overall survival at 3 years (62% vs. 48%; $p = 0.006$), progression-free survival (49% vs. 37%, $p = 0.004$), and locoregional control (38% vs. 30%; $p = 0.04$). These studies have largely been used to the use of TPF as induction therapy when it is to be used prior to definitive radiation or chemoradiation therapy.

The use of chemotherapy, in the induction setting, remains an area of significant controversy and active study. Results of phase III trials comparing concurrent chemoradiation alone to induction chemotherapy followed by chemoradiation are currently lacking; hence, there is no prospective phase III evidence to validate the use of an induction approach and define its absolute benefits. There is interest in designing and executing appropriate randomized trials that may provide further data and establish the true benefit of induction chemotherapy over definitive chemoradiation.

Role of Molecularly Targeted Agents

The explosion of genomic and proteomic analyses in head and neck cancers has provided an exciting opportunity for the development and integration of molecularly targeted agents in the treatment of oropharyngeal cancers.

Cetuximab, an anti-EGFR receptor antibody, is the most well-studied and successful molecularly targeted agent to be integrated into the treatment of head and neck cancers. In a phase III study, Bonner and coworkers investigated the outcomes of patients treated with radiation alone compared to those treated with radiation and concurrent cetuximab [92]. A total of 434 patients were enrolled, and 60% of these patients had oropharynx cancers. For all patients, the addition of concurrent cetuximab provided a statistically significant improvement in a 3-year overall survival (55% vs. 45%; $p=0.05$) with a hazard ratio for locoregional progression or death of 0.68 (95% confidence interval, 0.52–0.89, $p=0.005$). The patients in the experimental arm suffered no increase in high-grade mucositis or dysphagia requiring feeding tube placement, which is common with concurrent chemotherapy, as compared to those patients treated with radiation alone. However, patients treated with concurrent cetuximab did have a higher incidence of drug-related maculopapular skin reaction, which largely resolved when the drug was completed and a 2–3% incidence of high-grade infusion reactions. The results of this trial were promising and have spawned a variety of new investigations into the use of cetuximab for head and neck cancers and its integration with chemotherapy.

Base of Tongue Cancer

Tumors of the base of tongue tend to be locoregionally aggressive, with the majority being poorly differentiated and showing a propensity of local, regional, and distant spread. As a result, initial staging is crucial to determining the best definitive management, as the risk of metastatic disease is higher than other subsites of the oropharynx. There is some controversy in the optimal management of tumors of the base of tongue; institutional biases are significant, and the data reflect varying penchants for treating these tumors.

Role of Surgery

Previously, surgical resection was used often as definitive treatment of tumors of the base of tongue, but management decisions depend significantly on the stage of disease. Although resection had been standard for very small and very large primary lesions, surgery has become less common in recent years.

For early stage tumors, there is published data on the efficacy of surgical resection alone. Foote et al. reported the outcomes of 55 patients treated with surgery alone, typically a partial glossectomy and in some cases a subtotal or total laryngectomy (11 patients) [93]. The crude rates of local

control were 77% for T1, 83% for T2, and 75% for T3 tumors with a disease control rate of 49%. In this population, 16 patients required surgery to manage surgical complications, and 5 patients required permanent feeding tubes. Currently, surgical resection may be considered for small, especially exophytic lesions, in which a limited surgery may be performed with a minimum of morbidity, adhere to principles of oncologic resection, and avoid the need for postoperative radiation therapy. However, more infiltrative lesions do have the potential to require more extensive resections, which result in more functional debilitation and may have inferior outcomes compared to nonsurgical approaches.

Historically, advanced primary tumors, such as T4 lesions, have been treated with surgical resection followed by postoperative radiation therapy. The surgery of choice for these lesions is typically laryngectomy since a large resection of the tongue base will result in severe dysphagia and put the patient at risk for aspiration. Zelefsky and colleagues reported on a series of patients with advanced base of tongue and tonsil cancers treated with surgical resection and postoperative radiation therapy [94]. Overall, there was an 81% 7-year local control rate for patients with base of tongue tumors with 94% for T3 and 75% for T4 tumors. In another study, de los Santos and colleagues reported on 51 patients treated with advanced base of tongue tumors treated with surgery and postoperative radiation therapy at The University of Texas M. D. Anderson Cancer Center; 90% of patients had T3 or T4 primary tumors [95]. The 5-year locoregional control rate was 74%. Although toxicity was not reported explicitly, 21 patients were reported to have swallowing dysfunction.

Although surgical resection may be performed with adequate local control in early stage tumors as well as late stage tumors (when combined with postoperative radiation), approaches using definitive radiation therapy, with or without chemotherapy, have been widely accepted due to the reduced toxicity of treatment with equivalent outcomes [73, 83].

Role of Definitive Radiation Therapy: Radiation Therapy Alone or with Chemotherapy or Molecularly Targeted Therapy

Radiation therapy, alone or in combination with systemic therapy, has emerged as the standard of care for the majority of tumors of the base of tongue. The use of a nonsurgical approach, even for small lesions, has improved outcomes and minimized toxicity for these patients. At this time, definitive radiation therapy using IMRT is typically the treatment of choice for T1 and T2 primary tumors. For T3 lesions, concurrent chemoradiation is often the optimal treatment.

For T4 tumors, surgery with postoperative radiation has historically been the treatment of choice; however, a nonsurgical approach with concurrent chemoradiation has now emerged as standard treatment for these lesions. Due to the midline nature of the base of tongue, all patients should have lymph nodes treated bilaterally. In selected cases, boosts to the primary tumor directly or via a submental approach may be performed with brachytherapy; however, the use of dose escalation, with 3-D conformal techniques or IMRT, has largely supplanted brachytherapy.

External beam radiation has been used for definitive treatment of base of tongue cancer with excellent results. Historically, these studies have used conventional planning for treatment with daily fractions of 2 Gy, although current practice largely employs IMRT. Primary radiation therapy has an excellent local control rate for T1 and T2 tumors, typically in the range of 80–90+% across various institutions and treatment algorithms (Table 29.2). The reported outcomes for T3 lesions are more variable, likely due to the heterogeneity in this stage. Complications from definitive radiation alone have been well-documented. Rates of bone and soft tissue necrosis have reached 5–7% in multiple studies [93, 96].

The use of brachytherapy in conjunction with external beam radiation has been widely studied. Harrison and colleagues reported on a group of patients treated with 50–54 Gy external beam radiation followed by a boost of 20–30Gy with an Iridium-192 implant [97]. The 5-year actuarial local control rate was 87% for T1, 93% for T2, and 82% for T3 lesions. The rates of soft tissue or bone necrosis, bleeding, or ulceration were 19%. Similar outcomes have been reported on the combination of external beam radiation and brachytherapy at other institutions (see Table 29.2). Although the combination of external beam and brachytherapy has proven effective, it has largely fallen out of favor due to the emergence of altered fractionation, chemoradiation, and IMRT in standard practice; these methods of treatment intensification provide at least equivalent outcomes using solely external techniques.

At this time, standard practice in treatment of base of tongue carcinomas employs definitive radiation therapy with or without systemic therapy (Fig. 29.9). Using the same principles

outlined for general treatment of oropharynx cancers, small primary tumors are typically treated with radiation alone and those that are locally advanced (T3 or T4) are typically managed with altered fractionation or concurrent chemoradiation. For patients with positive nodes, extensive neck disease may be managed with concurrent chemoradiation.

Tonsillar Cancer

Tumors of the tonsillar complex are the most common of the oropharyngeal tumors, comprising 70–80% of the total cases. Like tumors of the base of tongue, these lesions commonly metastasize to the cervical lymph nodes, with greater than 50% of patients presenting with nodal metastases; however, contralateral nodal disease is more limited. Consideration can be made for unilateral treatment, unlike the majority of oropharynx cancers; however, this decision must be made carefully. For lesions that cross the midline, involve a midline structure (such as the base of tongue), or have advanced neck disease, bilateral treatment is warranted.

There is excellent data documenting the outcomes of patients treated with surgery and with radiation therapy for tonsillar cancers. The management philosophies employed with tonsil cancer are often extrapolated to other sites.

Role of Surgery

Surgical resection has been shown to be effective treatment for certain tonsillar cancers at the very early and late stages of disease. For early stage disease confined to the tonsillar fossa, single modality therapy has provided excellent results. Surgery alone has provided excellent local control rates, in the range of 80–90% [98]. However, for tumors with extension to the lateral pharyngeal wall or base of tongue, local control drops precipitously [99, 100]. New surgical techniques, including transoral robotic surgery (TORS) and transoral laser microsurgery (TLM), are now being utilized

Table 29.2 Outcomes of patients treated for tumors of the base of tongue with radiation therapy

Author	Reference	Institution	# Patients	Median FU (mo)	Local control (%)				Comments
					T1	T2	T3	T4	
Spanos	[96]	M. D. Anderson	174	100 (extrapolated)	91	71	78	52	Once daily fx
Foote	[93]	University of Florida	84	96	89	88	77	36	Once daily fx
Weber	[162]	M. D. Anderson	173	22	100	86	59	44	8% with interstitial boost; once daily fx
Mak	[163]	M. D. Anderson	54	41	100	98	76	9	Concomitant boost
Mendenhall	[71]	University of Florida	217	(All over 48 mo)	96	91	81	38	69% hyperfractionated
Harrison	[97]	Memorial Sloan-Kettering	68	36	87	93	82	100	EBRT +/- brachy

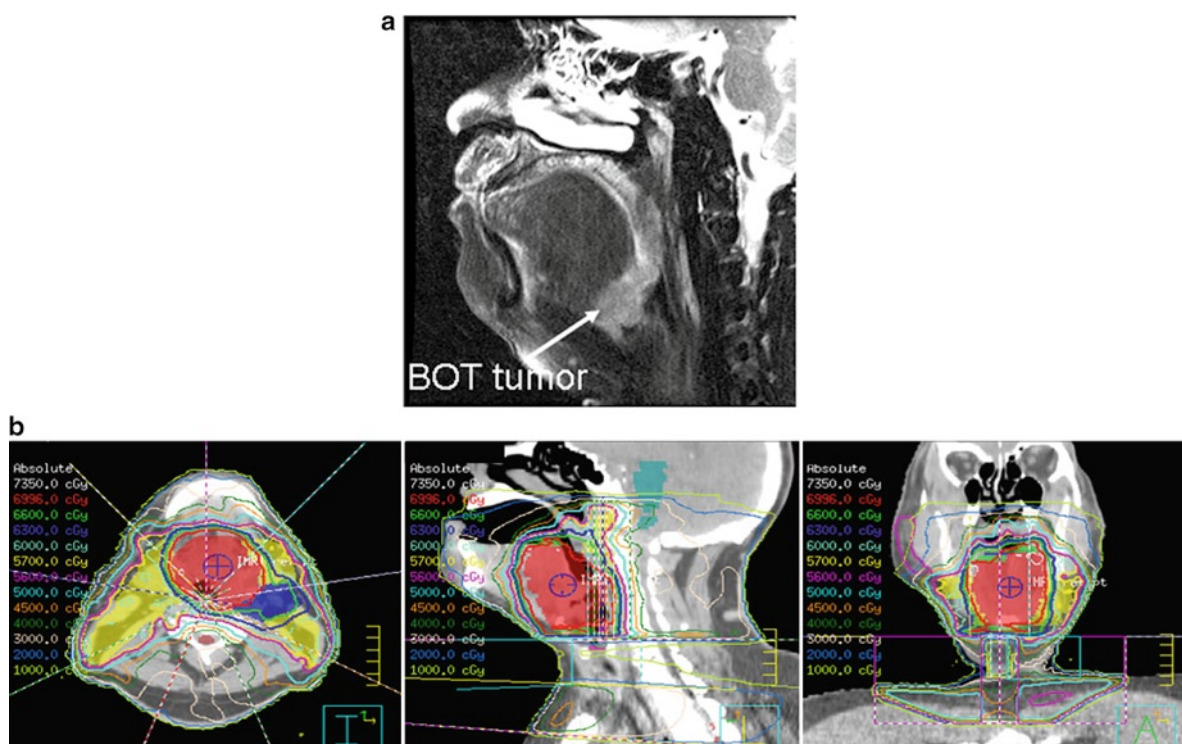


Fig. 29.9 Base of tongue tumor (a) Initial T2-weighted MRI appearance of a T3 N1 base of tongue squamous cell carcinoma (b) IMRT treatment plan for definitive chemoradiation of this lesion to a dose of 70 Gy in 33 fractions

in early stage tonsillar cancers with promising results [101–103]. These studies show that resections using these methods can provide excellent local control with acceptable morbidity, although VPI remains a potential problem. Regardless of the technique used for primary treatment, due to the potential for nodal metastases in patients with tonsil cancer, the neck must be addressed.

For locally advanced tonsil cancers, management has evolved from surgery with postoperative radiation, which was historically the standard treatment for advanced lesions, to nonsurgical approaches. In order to achieve negative margins, a complete resection adhering to oncologic principles required large volume composite resections and flap reconstructions; often, multiple positive lymph nodes were found. The use of adjuvant radiation therapy in these cases improved outcomes for patients with advanced disease. Foote and colleagues reviewed the results of patients with advanced tonsil cancers with surgery with or without adjuvant radiation [98]. In this series, 39% of patients treated with surgery alone had locoregional failure, compared to 31% undergoing surgery and radiotherapy; the latter group had more advanced neck disease than the former. For patients with Stage III disease, the 5-year overall survival was 100% for those treated with surgery and radiation, compared to 56% for those treated with surgery. For patients

with Stage IV disease, the 5-year overall survival rates were 78% for those treated with surgery and radiation and 43% (Stage IVA) and 50% (Stage IVB) for those treated with surgery alone.

Zelevsky and colleagues reported the results of patients with advanced oropharyngeal cancers treated with surgery and postoperative radiation; 20 of these patients had tonsil cancer [94]. For this subset, the 7-year actuarial local control rate was 83%. For patients who had close or positive margins and received a postoperative radiation dose of 60 Gy or more, the long-term control rate was 93%.

Overall, there is data to support the use of robotic or laser surgery alone in early stage cancers, when it can be used as a single modality and lead to acceptable functional outcomes (for instance, without the development of VPI or the need for an obturator). There are no randomized studies that have compared the outcomes of surgery and radiation therapy; comparisons between individual non-randomized studies have shown no compelling differences in their results. For advanced stage therapy, the use of surgery and postoperative radiation is effective; however, the improved outcomes of chemoradiation has led to similar rates of locoregional control in a population that would require major resections, reconstructions, and postoperative radiation therapy regardless.

Role of Definitive Radiation Therapy: Radiation Therapy Alone or with Chemotherapy or Molecularly Targeted Therapy

External beam radiation has been an effective modality for the treatment of tumors of the tonsil (Table 29.3). For early stage disease, several individual institutions have reported their results. Mendenhall and colleagues reviewed the experience of the University of Florida using definitive radiation treatment for tonsil cancer as an institutional policy [104]. In this series of 503 patients treated with either continuous conventional or hyperfractionated radiation therapy, the 5-year rates of local control were 88% for T1 tumors, 84% for T2 tumors, 78% for T3 tumors, and 61% for T4 tumors. In this population, 57 patients received chemotherapy and 198 patients underwent planned neck dissection. Overall, there were no severe acute radiation complications; however, 9% of patients developed long-term sequelae of radiation, including osteonecrosis requiring surgery, dysphagia requiring feeding tube, bone exposure, fistula, and fatal aspiration. Another series documented the experience of 465 patients treated with radiation therapy for early tonsillar cancers at the Institut Curie [105]. In this series, the local control rates were 89% for T1, 84% for T2, 63% for T3, and 43% for T4 tumors. The authors further noted that patients with tumors confined to the tonsillar fossa had higher local control rates than those from other sites.

The ipsilateral treatment of tonsillar cancers has been an area of active investigation, with the intention of sparing normal tissue toxicity for patients with well-lateralized tumors. O'Sullivan and colleagues documented the experience at Princess Margaret Hospital, in which they treated 228 patients with largely T1 or T2 N0 tonsillar cancers [106]. Overall, 191 patients had T1/2 tumors, 30 patients had T3 tumors, and 7 patients had T4 tumors with 133 patients having N0 disease, 35 patients have N1 disease, and 27 patients having N2/3 disease. Radiation was delivered using wedged-pair Cobalt-60 treatment matched to an ipsilateral low neck field. The 3-year local control rate for all patients was 77%, regional control was 80%, and cause-specific survival 76%. For the subset of patients with T1 or N0 disease, there was 100% control of the contralateral neck; for all patients, there was 97% control of

the contralateral neck. The authors identified a group of patients with greater than 10% risk of contralateral neck failure; this included patients with T3 lesions, lesions involving the medial third of the soft palate, lesions involving the middle third of the base of tongue, and patients with N1 disease. The latter, counterintuitive, association of N1 disease with an increased risk of contralateral neck failure was explained by the fact that those patients with N1 disease had a high proportion of advanced T-stage; of the 64 patients with T2-4, node-positive disease, 73% were N1. In another series, the University of Florida review of patients treated with definitive radiation for tonsillar cancer included 58 patients treated with ipsilateral primary and neck radiation therapy; of these, only 2 patients (3%) developed failure in the contralateral neck [104]. Another review by Jackson and colleagues documented the experience of 178 patients treated with ipsilateral definitive radiation therapy for tonsil cancers [107]. In this series, locoregional control was 91% for Stage I, 74% for Stage II, 51% for Stage III, and 53% for Stage IV disease. The contralateral nodal failure rates were less than 4% for all stages. Overall, the rate of local control was 84% for T1/2 tumors. These data suggest that ipsilateral treatment is appropriate for selected cases of well-lateralized tonsillar tumors, especially T1-2 and lower N-stage lesions with no invasion of central structures.

There is a well-documented prior experience in the use of external beam radiation with an interstitial brachytherapy boost for tonsillar cancer. Pernot and colleagues documented their experience treating 343 patients with this approach [108]. Local control rates were 89% for T1, 85% for T2, and 67% for T3 tumors. Mazeron and colleagues also described a similar experience using external beam radiation to a dose of 45 Gy with a 30 Gy interstitial boost; only 2 out of 69 patients experienced locoregional recurrence at a median follow-up of 5 years [109]. Although it has been shown effective, the use of interstitial brachytherapy as a boost for tonsillar cancers has largely been supplanted by the ability to deliver high doses using conformal methods of external beam therapy, including IMRT, or treatment intensification with concurrent chemotherapy.

External beam radiation therapy with IMRT has emerged as an effective technique for treatment of tonsillar cancers of all stages. As with other oropharynx subsites, understanding the full extent of the disease at the onset of treatment is crucial to determine appropriate volumes (Fig. 29.10).

Table 29.3 Outcomes of patients treated for tonsillar tumors with radiation therapy

Author	Reference	Institution	# Patients	Median FU (mo)	Local control (%)				Comments
					T1	T2	T3	T4	
Mendenhall	[104]	University of Florida	503	(All over 48)	88	84	78	61	3% contralateral failure in pts treated unilaterally
Bataini	[105]	Institut Curie	465	60	89	84	63	43	
Mazeron	[109]	Henry Mondor Hospital	165	60	100	94	–	–	

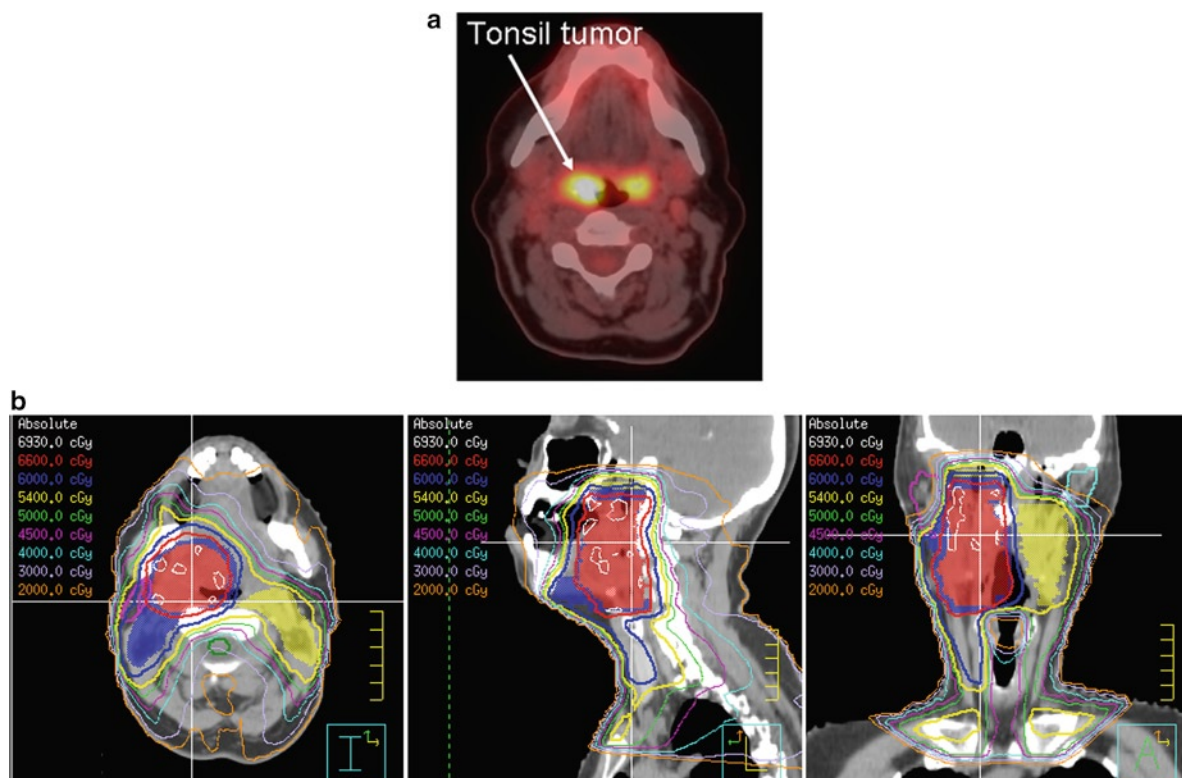


Fig. 29.10 Tonsillar tumor (a) Initial PET/CT appearance of a T2 N2b right tonsil squamous cell carcinoma (b) IMRT treatment plan for definitive radiation of this lesion to a dose of 66 Gy in 30 fractions with concurrent cetuximab

For lesions that extend onto midline structures, including the soft palate or base of tongue, bilateral treatment is warranted. For well-lateralized T1/2 N0 tumors with no invasion of midline structures (including the palate or base of tongue), ipsilateral treatment can be entertained.

Soft Palate Cancer

Soft palate carcinomas are relatively rare compared to other tumors of the oropharynx; however, they tend to present at earlier stages due to early symptom development and easy inspection and palpation of this region. Despite these features, these tumors are often highly infiltrative with indistinct margins and, as a result, are often more extensive than initially anticipated [39].

Since the soft palate is a midline structure, with no anatomic barriers either medially or laterally, tumors often extend to the tonsillar region or cross midline. Imaging is often helpful at delineating the submucosal extent of these lesions; however, careful consideration for broad coverage is necessary for definitive treatment by any modality. Soft palate carcinomas often present with ipsilateral lymph node metastases, but bilateral disease reaches 50% in some series of T3 and T4 primary tumors [3].

Role of Surgery

Surgical resection of soft palate carcinomas presents challenges due to the infiltrative nature of these lesions. In addition, surgical excision of the soft palate, except in the most limited of cases, result in VPI. These effects may be amenable to correction with prosthetic devices. More recent advances in laser surgery, new prosthetic technology, and microvascular free flap reconstruction may offer improved outcomes in patients with surgical resection of these tumors [110].

Role of Definitive Radiation Therapy: Radiation Therapy Alone or with Chemotherapy or Molecularly Targeted Therapy

External beam radiation therapy alone, or in combination with brachytherapy, has been established as a highly effective treatment of carcinoma of the soft palate (Table 29.4). Lindberg and colleagues described a series of patients treated with definitive external beam radiation therapy and noted local control rates of 100% for T1, 88% for T2, 77% for T3, and 83% for T4 tumors [111]. A study from the Netherlands

Table 29.4 Outcomes of patients treated for tumors of the soft palate with radiation therapy

Author	Reference	Institution	# Patients	Minimum FU (mo)	Local control (%)				Comments
					T1	T2	T3	T4	
Keus	[112]	Netherlands Cancer Institute	235	60	92	67	58	37	
Lindberg	[111]	M. D. Anderson	Not given	48	100	88	77	83	Once daily fx
Fein	[164]	University of Florida	45	48	81	65	50	25	Once daily fx
Fein	[164]	University of Florida	24	48	100	100	60	0	Twice daily fx
Mazon	[115]	Henry Mondor Hospital	59	48	93	87	–	–	+/- EBRT +/- brachy

noted a local control rate of 93% for T1, 67% for T2, 58% for T3, and 37% for T4 lesions treated with external beam radiation [112]. In the latter study, the mean total dose was 68 Gy. Patients who received a boost with an intraoral cone (29% of the patients included in the study) had fewer complications than those that received high dose as a result of external beam delivery alone.

The use of brachytherapy for the treatment of soft palate carcinomas is also the subject of extensive experience. Pioneered largely in France, excellent local control has been achieved with brachytherapy, often following external beam radiation. Esche and collaborators reported a series of 43 patients who were treated with 50 Gy of external beam radiation therapy to the oropharynx and bilateral necks followed by 20–35 Gy with an Iridium-192 low dose rate brachytherapy implant [113]. This regimen yielded a local control rate of 92% and cause-specific survival at 3 years of 81%. In a similar analysis, Mazon and colleagues reported on a subset of patients who received external beam radiation to a dose of 45 Gy followed by a 30 Gy boost with Iridium-192 brachytherapy [114, 115]. Local control was reported to be 85% for soft palate tumors. These reports suggest decreased toxicity, namely xerostomia, with the use of a low dose rate implant, presumably due to less scattered dose to the parotid glands. Small series have also reported excellent local control rates with combinations of external beam radiation and both high dose rate and pulse dose rate brachytherapy; however, these have yet to be well-established in routine practice [116]. Indeed, newer techniques, like chemoradiation and IMRT, have allowed a sufficient increase in treatment intensity with reduced dose to normal tissues, thereby making brachytherapy less popular.

External beam radiation therapy with IMRT has emerged as an effective technique for treatment of soft palate carcinomas. As with other oropharynx subsites, understanding the full extent of the disease at the onset of treatment is crucial to determine appropriate volumes (Fig. 29.11). Since the soft palate is a midline structure, the bilateral necks should be treated in all cases.

Oropharyngeal Wall Cancer

Tumors of the oropharyngeal wall are a rare subtype of oropharyngeal carcinomas. Because of the few early symptoms and the considerable amount of potential space in the posterior pharynx, these lesions are often not identified until they are quite large. As a result, the majority of patients present at advanced stages. Historically, the prognosis for tumors of the oropharyngeal wall was less favorable than other subsites of the oropharynx [111].

The pharyngeal wall is a midline structure with no anatomic boundaries to tumor spread. These lesions tend to invade the retropharyngeal and prevertebral spaces and only rarely spread in the lateral direction. Initial imaging with MRI is often helpful at delineating the full extent of the primary tumor and elucidating the extent of any vertebral extension [3]. Due to the midline nature of the pharyngeal wall, these lesions can metastasize to lymph nodes bilaterally.

Role of Surgery

The posterior pharyngeal wall is in close proximity to the prevertebral musculature and fascia, and lesions in this area often invade these structures. In selected cases of very small, superficial lesions, surgery is an appropriate therapy. In these cases, resections may be performed with negative margins and little functional debilitation. However, the majority of cases present at advanced stages. For these cases of technically resectable, locally advanced tumors, the postoperative morbidity is often significant and reconstructive options are often limited. In addition, for lesions that cannot be resected without compromising clear margins, postoperative radiation therapy may be indicated, thereby adding to the potential toxicity of definitive treatment. Finally, locally advanced tumors often are accompanied by early invasion of prevertebral musculature, rendering these tumors unresectable.

Small series have reported outcomes for definitive surgical resection for selected cases of oropharyngeal wall carcinoma.

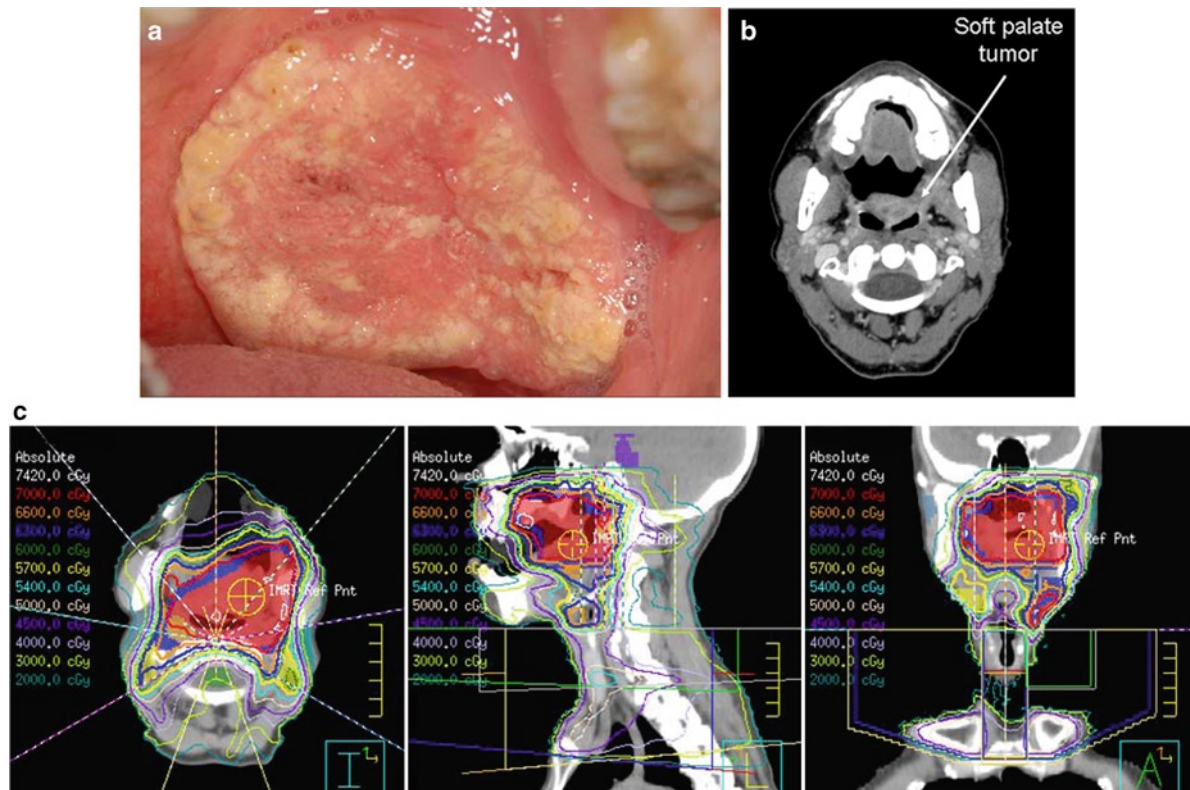


Fig. 29.11 Soft palate tumor (a) Initial clinical presentation of a T4 N1 squamous cell carcinoma (b) Initial contrast-enhanced CT appearance of the same T4 N1 squamous cell carcinoma

of the soft palate on (c) IMRT treatment plan for definitive chemoradiation of this lesion to a dose of 70 Gy in 33 fractions

Guillamondegui and colleagues reported the outcomes of 94 patients with pharyngeal wall tumors following surgery; 67 of these patients had primary tumors in the oropharynx and 27 in the hypopharynx [117]. For the entire group, they noted a 28% locoregional recurrence rate after resection. Salvage treatment with radiation or surgery was successful in less than 30% of patients.

Role of Definitive Radiation Therapy: Radiation Therapy Alone or with Chemotherapy or Molecularly Targeted Therapy

In recent years, radiation therapy has become widely used as definitive therapy for carcinomas of the oropharyngeal wall. Historically, the definitive treatment of oropharyngeal wall tumors with radiation therapy was a technical challenge; the curvature of the mucosa around the vertebral body was in close proximity to the typical spinal cord block in conventional radiation treatment fields. In an attempt to deliver curative dose and respect the tolerance of the adjacent spinal cord, oblique fields

and other special techniques were utilized; however, it is widely believed that these techniques resulted in geographic misses of the tumor in some cases. The development of IMRT has been crucial to the curative treatment of oropharyngeal carcinomas with radiation therapy; the ability to deliver curative dose to the curved target, while respecting the tolerance of the spinal cord, has revolutionized treatment of this disease.

The radiation treatment of patients with oropharyngeal wall carcinomas has been the subject of several small studies due to the relative rarity of the tumors; however, oropharyngeal wall tumors are often included as small subsets in larger head and neck trials. In a dedicated pharyngeal wall series by Hull and colleagues, 148 patients were treated for carcinoma of the pharyngeal wall; tumors were in the oropharynx in 63% of patients and hypopharynx for 37% [118]. The majority of patients were treated with hyperfractionation to a total dose of 76.8 Gy; local control rates were 93% for T1, 82% for T2, 59% for T3, and 50% for T4 lesions. On multivariate analysis, locoregional control rates were superior for those patients treated with hyperfractionation ($p=0.0009$). The use of concomitant boost therapy has also been successful for tumors of the oropharyngeal wall. Data from The University of Texas M. D. Anderson Cancer Center suggests local control

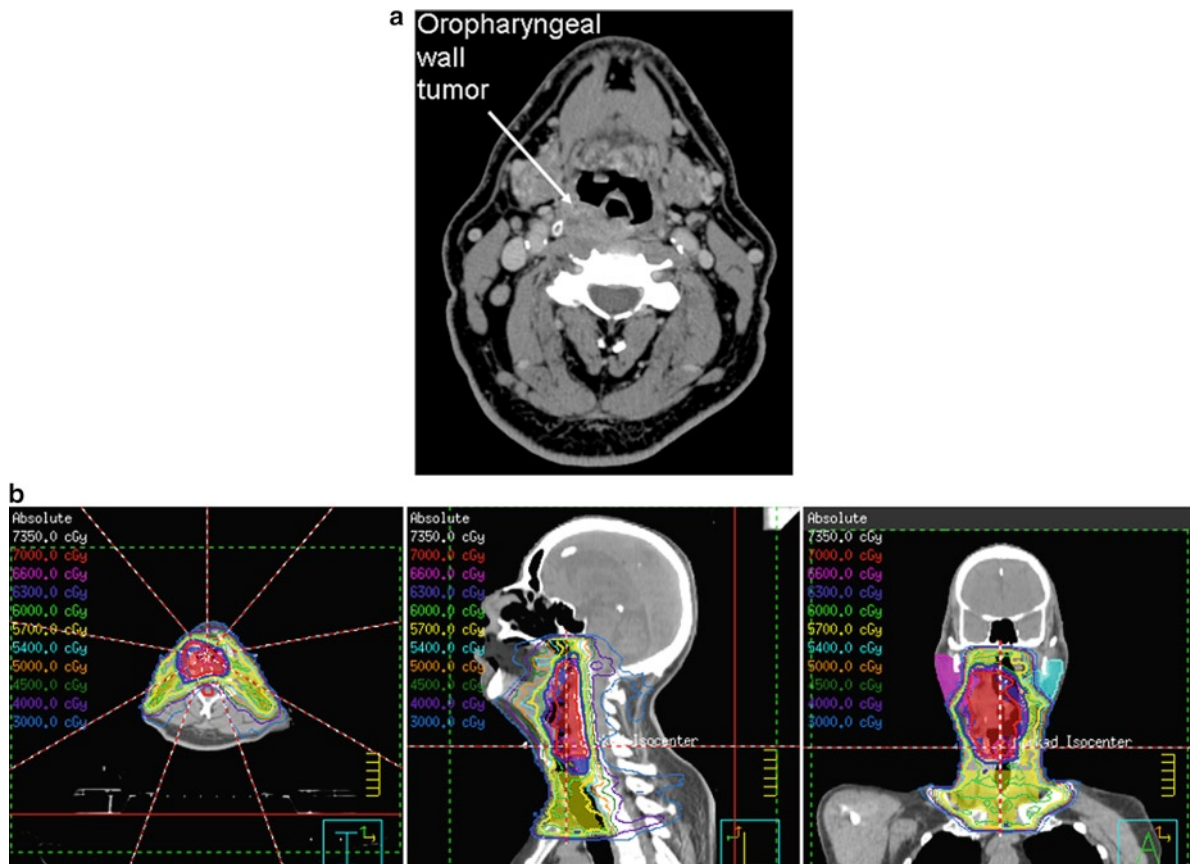


Fig. 29.12 Oropharyngeal wall tumor (a) Initial contrast-enhanced CT appearance of a T3 N1 squamous cell carcinoma of the right oropharyngeal wall (b) IMRT treatment plan for definitive chemoradiation of this lesion to a dose of 70 Gy in 33 fractions

rates of 93% for T2 tumors and 82% for T3 tumors using this fractionation schedule [119] (Personal Communication).

Similar to other subsites, external beam radiation therapy with IMRT has largely emerged as a standard of care for carcinomas of the oropharyngeal wall. The full extent of disease, including involvement or invasion of the vertebral region, must be delineated and used to design treatment volumes (Fig. 29.12). Given the midline nature of the oropharyngeal wall, the bilateral neck should be treated in all cases.

Multidisciplinary Follow-up and Surveillance

Surveillance following definitive treatment of oropharyngeal carcinomas with either surgery or radiation therapy is complex. As a result, complementary modalities of expert physical examination and imaging are helpful for surveillance. Treatment-related toxicities are also important metrics to assess, with an emphasis on quality of life and opportunities for improvement. Finally, patients require careful screening for second primary tumors, due to the high rate of second malignancies in this patient population.

Role of Clinical Evaluation

A history and physical examination are considered the mainstay of surveillance for patients with oropharyngeal cancer. Symptoms such as nonhealing ulcers, pain, trismus, nerve deficits, or swelling should be fully evaluated as potential recurrence or treatment-related toxicity. Patients with head and neck cancers are at high risk for second primary tumors, so the evaluations should be comprehensive. Recurrence and treatment effects can be subtle, and stability over time and correlation with imaging is crucial.

In addition to second primary head and neck cancers, patients with oropharyngeal carcinoma are at increased risk for the development of other second primaries [120]. Patients with diseases linked to alcohol and tobacco use are at risk for second primaries of the lung and esophagus, among others. Patients with diseases linked to HPV may also be at risk for other HPV-associated primary tumors [121]. Comprehensive follow-up protocols should include screening for these tumors, as well as attempts to prevent development of these lesions through education and screening, as well as continued support for cessation programs.

Patients treated for oropharyngeal cancers are at risk for hypothyroidism if radiation was used to treat the low neck [122]. Physicians should be attuned to the signs and symptoms of hypothyroidism, and patients should be evaluated with a blood test for thyroid stimulating hormone (TSH) at appropriate intervals.

Finally, patients with oropharyngeal carcinomas treated with radiation are at high risk for dental disease. A full dental evaluation should be performed prior to the onset of radiation; in addition, comprehensive follow-up with a dental specialist skilled in the evaluation and treatment of patients who have had head and neck radiation therapy is crucial for long-term oral health. The use of fluoride application trays is important, and a skilled dentist should evaluate the patient at regular intervals to assess dental health and any necessary interventions [123, 124].

Role of Imaging

Imaging studies in patients treated with radiation therapy and surgery for oropharyngeal carcinomas are often challenging to interpret. Baseline post-treatment studies are necessary to establish the new normal anatomy and judge subsequent changes; these are typically performed between 6 weeks and 6 months following the conclusion of definitive therapy. Both CT scans with contrast and MRI scans provide key information to differentiate post-treatment changes from recurrent disease, especially when used in conjunction with physical examination. In addition, PET has been shown to have a sensitivity over 88% and specificity over 75% in the detection of residual or recurrent tumor [125, 126].

Complete resolution of a lesion on CT or MRI studies often correlates with control at the primary site. Tumors that shrink by more than 50%, but less than fully resolve, require serial examination to distinguish the development of scar tissue from persistent disease; consideration may be given for biopsy of these areas for further investigation. For patients evaluated with PET scan, an FDG-avid lesion in the follow-up period should be evaluated with a biopsy. Even patients with a negative biopsy may benefit from rigorous surveillance with short interval physical examination and repeat imaging.

Optimal Follow-up Schedule

It is recommended that comprehensive head and neck physical examinations be completed every 1–3 months for the first year, every 2–4 months for the second year, and every 4–6 months for years 3–5; at that time, follow-up examinations

can be spaced to annually. In addition, post-treatment imaging is recommended to provide a baseline within 6 months of the completion of treatment; this should be deferred until at least 6 weeks following therapy, however, to ensure resolution of the acute effects of either surgery or radiation. Reimaging is recommended if indicated through changes in the physical examination.

Multidisciplinary Treatment for Recurrent Disease

The treatment of recurrent disease in the oropharynx is complex. An analysis from the National Cancer Database noted that, from 1985 to 2001, rates of definitive chemoradiation increased from 15 to 30% [127]; these rates have increased even more since 2001. Although our outcomes have improved significantly, locoregional recurrence [128] and secondary cancers [129] remain a challenge. Given that many patients are now treated with definitive chemoradiation, optimal management of persistent/recurrent disease, either in the treated field or marginal to it, is difficult secondary to the prior administration of high doses of radiation to adjacent critical structures. This has been the subject of extensive debate [130]. The management of these cases is highly individualized, based on the details of the initial treatment, extent and timing of the recurrence, and baseline performance status of the patient.

Role of Surgery

Surgical resection is a standard therapy for post-radiation recurrent or persistent disease in the oropharynx [131]. However, even in the best cases, salvage rates are relatively low; the failure to eradicate disease with chemoradiation portends a poor prognosis [132–134]. Many patients with recurrent disease are not candidates for surgical resection due to the extent of their disease at the time of presentation.

Surgical salvage may be performed through a transoral, transmandibular, or cervical approach. However, operating in a previously irradiated field does pose significant challenges. Postoperative complications following salvage surgery, after radiotherapy, have been reported as high as 42% [135, 136]. The use of reconstructions with vascularized regional pedicled myocutaneous and microvascular free flaps may improve the healing of these patients by providing fresh tissues and blood supply, as well as allowing larger resections [137].

There are several small series of reports documenting the outcomes of patients treated with surgical salvage for recurrent

oropharyngeal carcinoma. Agra et al. noted that patients with Stage I and II disease at recurrence had a 5-year overall survival rate of 43.6% compared to 24.1% for those with Stage III and IV disease at recurrence ($p=0.027$); the authors also noted that patients with a disease-free interval of greater than 1 year prior to recurrence had a significantly better 5-year survival than those with recurrence in less time (26.7% vs. 42.1%; $p=0.023$) [136]. Kim et al. also noted that patients with T1 or T2 tumors at the time of recurrence had a statistically significant improvement in outcomes with surgical salvage and microvascular flap reconstruction than did those with T3 and T4 tumors and those patients who continued to smoke after diagnosis [137].

Overall, salvage surgery is considered the primary therapy for patients with recurrent oropharyngeal cancer after definitive chemoradiation. However, the extent of disease at the time of recurrence considerably impacts whether the patient is a candidate for resection and the outcome if resection, is possible. Hence, early detection of recurrent disease with careful surveillance is crucial.

Role of Radiation Therapy

In recent years, reirradiation has become more common as an acceptable, although high-risk, means of attempted salvage for selected patients with recurrent oropharyngeal carcinoma or second primary tumors. For patients who present with recurrent disease that is not amenable to surgical resection, optimal therapy is left to radiation and chemotherapy. Reirradiation does pose a significant risk for severe life-threatening complications, and it should only be used judiciously in selected patients with recurrent disease.

One of the longest experiences of reirradiation in head and neck cancer is from the University of Chicago, in which a regimen of concomitant chemotherapy and reirradiation has been used as salvage therapy for almost 20 years [138, 139]. The regimen utilized in these studies employs a combination of 5-fluorouracil, hydroxyurea, and week-on/week-off radiation therapy. Further reports utilizing similar regimens from the Institute Gustave Roussy and University of Alabama-Birmingham have reported similar results [140–142]. Although the median survival for these patients remains limited, these series have demonstrated a durable disease response and survival in a subset of patients (approximately 15–25%).

Collaborative group trials have also explored the implementation of reirradiation in the setting of recurrent disease. The RTOG tested a similar regimen of chemotherapy and reirradiation in a phase II multiinstitutional trial (RTOG 96–10) [143, 144]. Eighty-six patients were treated with 60 Gy of radiation to the volume of recurrent disease in a week-on/week-off regimen with 5-fluorouracil and hydroxyurea; 34% of patients had primary disease in the oropharynx. The

radiation was delivered with conventional techniques with twice-daily fractionation (1.5 Gy per fraction twice daily for 5 days, followed by 9 days off, repeated for 4 cycles). The overall survival rate at 2 years was 15.2% and 5 years was 3.8% [143, 144]. Although toxicity was considered “acceptable”, there was 17.7% grade 4 and 7.6% grade 5 toxicities reported [144]. A follow-up phase II trial replaced the prior chemotherapy regimen with cisplatin and paclitaxel while employing a similar radiation schema (RTOG 99-11) [145]. This study enrolled 105 patients, with 40% having primary tumors in the oropharynx. The 2-year overall survival rate was 50.2%, which compared favorably to the prior study. The toxicity, however, remained relatively high; 8% of patients suffered grade 5 toxicities and 28% with grade 4 or 5. A subsequent phase III RTOG trial was designed to test the use of chemotherapy alone with the chemotherapy reirradiation regimen of protocol RTOG 99–11; however, this trial closed prematurely due to inadequate accrual. In aggregate, these studies have been interpreted as promising, with a subset of patients achieving significant long-term locoregional control and survival with reirradiation; this is tempered, however, by a subset of patients that experience severe toxicity, including death.

Additional series are now being published that document similarly promising results in selected patients treated with reirradiation (Table 29.5). There are emerging reports of using IMRT for reirradiation. Lee and colleagues reported on the outcomes of 69 patients treated for unresectable recurrent disease with 60 Gy (median dose); 70% of these patients were treated with IMRT [146]. The 2-year overall survival rate was 12%. Looking at the entire cohort, which did include patients who also received surgical resection as well as reirradiation, there was an improvement in locoregional-progression free survival in those patients treated with IMRT. In addition, for the entire cohort, there were acute grade 3 and 4 complications in 23% of patients and late in 15% of patients. Sulman and colleagues reported on the outcomes of a series of 54 patients all of whom were treated with IMRT for unresectable recurrent disease [147]. The 2-year overall survival was noted to be 58% with a locoregional control of 54%. In this series, 32% of patients experienced grade 3 and 4 toxicities; there were no deaths.

Overall, the reports on reirradiation for recurrent or second primary tumors suggest that it is a feasible approach in highly selected patients; it is imperative for the patients to understand, however, the risks of potential toxicity, including the very real risk for major edema, tissue necrosis, stroke, and death. Patient selection is crucial to the judicious use of reirradiation; patients who require reirradiation more than 2 years following definitive treatment for their first primary tumor, and those who have a second primary (rather than recurrent disease), do tend to have improved outcomes. In terms of treatment, the targets in recurrent disease are limited to the tumor or tumor bed with a small margin. Doses in

Table 29.5 Summary of selected clinical reports of the treatment of unresectable disease with reirradiation

Author	Reference	# Patients	% Oropharynx ^a	% Chemo	% IMRT	MS	2yr OS	2yr LRC	Grade 4± toxicity
De Crevoisier	[141]	169	60%	84%	0%	10 mo	21%	11% (PFS)	13% acute, 12% chronic, 3% carotid hemorrhage
Dawson	[165]	40	10%	35%	0%	12.5 mo	32.6%	19.5%	10% acute, 20% chronic, 3% carotid hemorrhage
Spencer	[166]	52	21%	100%	0%	9.4 mo	15%	Not reported	2% acute, 8% chronic
Kramer	[167]	38	11%	100%	0%	12.4 mo	35%	37%	16% acute, 29% chronic, 5% carotid hemorrhage
Salama	[139]	66	27%	100%	0%	11 mo ^b	11%	36%	13% chronic ^b 5% carotid hemorrhage ^b
Lee	[146]	69	15% ^c	71%	70%	15 mo ^b	12%	19%	4% chronic ^b
Sulman	[147]	54	41%	66%	100%	25.3 mo	54%	58%	32% grade 4 0% grade 5
RTOG 96-10	[144]	81	34%	100%	0%	8.2 mo	16.2%	Not reported	23% grade 4 7% grade 5
RTOG 99-11	[145]	99	40%	100%	0%	12.1 mo	25.9%	Not reported	28% acute 9% grade 5 2% carotid hemorrhage

MS median survival, OS overall survival, LRC locoregional control

^aPercentage of patients with oropharyngeal primary at the time of initial diagnosis

^bDescribes full series of patients, including those who received surgery

^cPercentage of patients with oropharyngeal primary at the time of recurrence; initial diagnosis was not reported

the range of 60–66 Gy at 2 Gy daily fractionation or 1.5 Gy twice-daily with or without chemotherapy appear to provide a sustained benefit in those patients that respond; patients treated with chemoradiation historically have better overall survival in this setting. Highly conformal techniques, such as IMRT, appear to be beneficial, presumably by sparing more normal tissues previously treated with radiation; however, the data on this is limited. One advantage to IMRT is the ability to limit the dose to the carotid arteries in patients in which the disease is located in a discrete location. Further studies are necessary to elucidate the optimal selection and management of these patients; however, reirradiation is a viable option in selected cases of recurrent disease.

Role of Chemotherapy

If recurrent oropharyngeal cancer is not amenable to treatment with surgical salvage or reirradiation, chemotherapy is often used for palliation. Systemic chemotherapy has been shown to have only a modest impact on overall survival in patients with recurrent disease; median survival in phase III trials has been 6–9 months [148–153].

Multiple studies have established platinum-based chemotherapy as the standard treatment for recurrent oropharyngeal carcinomas. Higher response rates have been observed in combination regimens, including platinum/5-fluorouracil [150, 151] and platinum/cetuximab [152]; however, survival was not improved with these regimens over platinum alone. Recently, Vermorken and colleagues reported a survival benefit to the use of platinum, 5-fluorouracil, and cetuximab compared to platinum and 5-fluorouracil alone with a median survival

of 10.1 vs. 7.4 months ($p=0.0362$) for patients with newly diagnosed recurrent or metastatic oropharyngeal carcinoma [154]. This is the first study to demonstrate improved survival over platinum-based chemotherapy alone.

For patients with recurrent disease that have failed platinum-based regimens, second-line agents are much less successful, and median survival falls dramatically to approximately 3.5 months [155]. For patients with good performance status, active therapies such as taxane- and vinorelbine-containing regimens may be utilized [156–158]. More recently, cetuximab has been employed in patients who have progressed on first-line therapy with some promising results. In a pooled analysis of three prospective studies investigating the use of cetuximab (with or without platinum) in the second-line setting, overall response rates from 10 to 13% and disease control rates from 46 to 56% were observed along with a median survival of approximately 6 months [159].

Overall, chemotherapy is the mainstay of treatment for patients with recurrent oropharyngeal carcinoma who are not candidates for surgical resection or reirradiation. Although overall survival is limited, palliation is achieved for some duration of time. Following the exhaustion of active regimens, best supportive care is the recommendation for treatment for these patients.

Multidisciplinary Treatment for Metastatic Disease

Although many patients present with Stage IV disease, this is typically due to advanced locoregional disease (Stages IVA and B) and rarely due to the concomitant diagnosis of distant

metastases (Stage IVC). In fact, metastatic disease is relatively uncommon as a first site of relapse for cancers of the oropharynx, but it may be more of a problem for patients with small primaries and more advanced nodal disease. Lindberg and colleagues found that distant metastasis was the first site of relapse for oropharyngeal carcinoma in only 7.7% of patients treated definitively with radiation therapy from 1960 to 1974 [160]. In a more recent review of patients with Stage III and IV oropharyngeal carcinomas treated with definitive radiation therapy with or without chemotherapy at The University of Texas M. D. Anderson Cancer Center, the 5-year actuarial distant failure rate was 11% for patients with N1/2a disease and 28% for patients with more advanced nodal disease (N2b/N2c/N3) ($p < 0.001$). For patients with locoregional control, the rate of distant failure at 5 years was 17% [161].

Despite the relative rarity of distant metastases in oropharyngeal carcinoma, its management does pose complex treatment questions. Largely, metastatic disease is managed with systemic treatment, as used in the recurrent setting (see above section for detailed review). Systemic chemotherapy has had a modest impact on overall survival in patients with metastatic disease; median survival is typically 6–9 months [148–153]. Like the treatment of locoregionally recurrent disease, platinum-based chemotherapy is typically considered as the first-line therapy in the metastatic setting.

Radiation therapy and surgical resection are typically employed in the metastatic setting for rare cases of solitary metastases with long-term control goals, but more generally for palliation of impending neurologic or musculoskeletal compromise. Radiation therapy can be used palliatively for sites of painful lesions, impending spinal cord compression, or for brain metastases. Surgical resection of isolated lesions may be beneficial in the setting of no other detectable disease. Overall, patients with metastatic oropharyngeal carcinoma are best managed in a multidisciplinary forum with consideration of systemic control, palliation, and end of life issues.

Future Directions

Although enormous strides have been made in the treatment of oropharyngeal carcinomas, further advances are needed to optimize the outcomes for these patients. Multidisciplinary management has improved the survival and local control for these patients, while minimizing toxicity and improving functionality, but patients do still fail, both locally and distantly, and they do suffer long-term toxicities from their definitive therapy.

The field is growing rapidly, and there are exciting developments in multidisciplinary management of these patients. Advances in imaging technologies have provided important

new understanding of the extent of oropharyngeal disease and the ability to tailor treatment and monitor for recurrence accordingly. Advances in robotic and laser surgery continue to optimize outcomes and minimize toxicities in patients treated with resection, and these techniques provide more patients options for surgical treatment. New basic science investigations into the molecular mechanisms of pathogenesis in oropharyngeal cancers provide exciting areas for further research and development of novel treatments, including targeted agents. Finally, the optimal integration of chemotherapy, biologically targeted therapy, radiation, and surgery is still an area of vigorous investigation. The development of new chemotherapy combinations and utilization of biologically targeted agents has promise for the prevention of metastatic disease and intensification of radiation therapy. Improvements in conformality and dose delivery with IMRT have reduced toxicity in patients treated with definitive or postoperative radiation therapy. Understanding the natural history of individual tumors, based on their location, stage, and molecular features, may allow us to further adjust treatment recommendations.

Overall, oropharyngeal cancer is a complex disease that requires the integration of almost every medical field. Attempts to improve outcomes, while minimizing toxicity, are active areas of research, and the field continues to evolve at an impressive pace.

Acknowledgements We would like to thank Michelle Williams, M. D., for the histological and immunohistochemical images of oropharynx cancers.

References

1. Lindberg R. Distribution of cervical lymph node metastases from squamous cell carcinoma of the upper respiratory and digestive tracts. *Cancer*. 1972;29:1446–9.
2. Remmler D, Medina JE, Byers RM, et al. Treatment of choice for squamous carcinoma of the tonsillar fossa. *Head Neck Surg*. 1985;7:206–11.
3. Weber AL, Romo L, Hashmi S. Malignant tumors of the oral cavity and oropharynx: clinical, pathologic, and radiologic evaluation. *Neuroimaging Clin N Am*. 2003;13:443–64.
4. Meoz-Mendez RT, Fletcher GH, Guillaumondegui OM, et al. Analysis of the results of irradiation in the treatment of squamous cell carcinomas of the pharyngeal walls. *Int J Radiat Oncol Biol Phys*. 1978;4:579–85.
5. Parkin DM, Bray F, Ferlay J, et al. Global cancer statistics, 2002. *CA Cancer J Clin*. 2005;55:74–108.
6. Jemal A, Siegel R, Ward E, et al. Cancer statistics, 2009. *CA Cancer J Clin*. 2009;59:225–49.
7. Lin DT, Cohen SM, Coppit GL, et al. Squamous cell carcinoma of the oropharynx and hypopharynx. *Otolaryngol Clin North Am*. 2005;38:59–74. viii.
8. Shiboski CH, Schmidt BL, Jordan RC. Tongue and tonsil carcinoma: increasing trends in the U.S. population ages 20–44 years. *Cancer*. 2005;103:1843–9.

9. Gillison ML. Current topics in the epidemiology of oral cavity and oropharyngeal cancers. *Head Neck*. 2007;29:779–92.
10. Davis S, Severson RK. Increasing incidence of cancer of the tongue in the United States among young adults. *Lancet*. 1987;2:910–1.
11. Annertz K, Anderson H, Björklund A, et al. Incidence and survival of squamous cell carcinoma of the tongue in Scandinavia, with special reference to young adults. *Int J Cancer*. 2002;101:95–9.
12. Kari S, Alho OP, Jokinen K, et al. Carcinoma of the oral tongue in northern Finland: trends in overall incidence and patient and tumour characteristics. *J Oral Pathol Med*. 1997;26:480–3.
13. Macfarlane GJ, Boyle P, Evstifeeva TV, et al. Rising trends of oral cancer mortality among males worldwide: the return of an old public health problem. *Cancer Causes Control*. 1994;5:259–65.
14. Hindle I, Downer MC, Speight PM. The epidemiology of oral cancer. *Br J Oral Maxillofac Surg*. 1996;34:471–6.
15. Franceschi S, Bidoli E, Herrero R, et al. Comparison of cancers of the oral cavity and pharynx worldwide: etiological clues. *Oral Oncol*. 2000;36:106–15.
16. Schildt EB, Eriksson M, Hardell L, et al. Oral snuff, smoking habits and alcohol consumption in relation to oral cancer in a Swedish case-control study. *Int J Cancer*. 1998;77:341–6.
17. Rodu B, Cole P. Smokeless tobacco use and cancer of the upper respiratory tract. *Oral Surg Oral Med Oral Pathol Oral Radiol Endod*. 2002;93:511–5.
18. Hashibe M, Brennan P, Chuang SC, et al. Interaction between tobacco and alcohol use and the risk of head and neck cancer: pooled analysis in the International Head and Neck Cancer Epidemiology Consortium. *Cancer Epidemiol Biomarkers Prev*. 2009;18:541–50.
19. Rosenblatt KA, Daling JR, Chen C, et al. Marijuana use and risk of oral squamous cell carcinoma. *Cancer Res*. 2004;64:4049–54.
20. Hashibe M, Straif K, Tashkin DP, et al. Epidemiologic review of marijuana use and cancer risk. *Alcohol*. 2005;35:265–75.
21. Zhang ZF, Morgenstern H, Spitz MR, et al. Marijuana use and increased risk of squamous cell carcinoma of the head and neck. *Cancer Epidemiol Biomarkers Prev*. 1999;8:1071–8.
22. Marshall JR, Boyle P. Nutrition and oral cancer. *Cancer Causes Control*. 1996;7:101–11.
23. McLaughlin JK, Gridley G, Block G, et al. Dietary factors in oral and pharyngeal cancer. *J Natl Cancer Inst*. 1988;80:1237–43.
24. Sanchez MJ, Martinez C, Nieto A, et al. Oral and oropharyngeal cancer in Spain: influence of dietary patterns. *Eur J Cancer Prev*. 2003;12:49–56.
25. Franceschi S, Dal Maso L, Levi F, et al. Leanness as early marker of cancer of the oral cavity and pharynx. *Ann Oncol*. 2001;12:331–6.
26. Moreno-Lopez LA, Esparza-Gomez GC, Gonzalez-Navarro A, et al. Risk of oral cancer associated with tobacco smoking, alcohol consumption and oral hygiene: a case-control study in Madrid, Spain. *Oral Oncol*. 2000;36:170–4.
27. Balaram P, Sridhar H, Rajkumar T, et al. Oral cancer in southern India: the influence of smoking, drinking, paan-chewing and oral hygiene. *Int J Cancer*. 2002;98:440–5.
28. Gillison ML, Lowy DR. A causal role for human papillomavirus in head and neck cancer. *Lancet*. 2004;363:1488–9.
29. Kreimer AR, Clifford GM, Boyle P, et al. Human papillomavirus types in head and neck squamous cell carcinomas worldwide: a systematic review. *Cancer Epidemiol Biomarkers Prev*. 2005;14:467–75.
30. Smith EM, Ritchie JM, Summersgill KF, et al. Age, sexual behavior and human papillomavirus infection in oral cavity and oropharyngeal cancers. *Int J Cancer*. 2004;108:766–72.
31. Rosenquist K, Wennerberg J, Schildt EB, et al. Oral status, oral infections and some lifestyle factors as risk factors for oral and oropharyngeal squamous cell carcinoma. A population-based case-control study in southern Sweden. *Acta Otolaryngol*. 2005;125:1327–36.
32. Kreimer AR, Alberg AJ, Daniel R, et al. Oral human papillomavirus infection in adults is associated with sexual behavior and HIV serostatus. *J Infect Dis*. 2004;189:686–98.
33. Schwartz SM, Daling JR, Doody DR, et al. Oral cancer risk in relation to sexual history and evidence of human papillomavirus infection. *J Natl Cancer Inst*. 1998;90:1626–36.
34. Talamini R, Vaccarella S, Barbone F, et al. Oral hygiene, dentition, sexual habits and risk of oral cancer. *Br J Cancer*. 2000;83:1238–42.
35. Lissowska J, Pilarska A, Pilarski P, et al. Smoking, alcohol, diet, dentition and sexual practices in the epidemiology of oral cancer in Poland. *Eur J Cancer Prev*. 2003;12:25–33.
36. Fakhry C, Westra WH, Li S, et al. Improved survival of patients with human papillomavirus-positive head and neck squamous cell carcinoma in a prospective clinical trial. *J Natl Cancer Inst*. 2008;100:261–9.
37. Gillison M, Harris J, Westra W, et al. Survival outcomes by tumor human papillomavirus (HPV) status in stage III-IV oropharyngeal cancer (OPC) in RTOG 0129. 2009 ASCO Annual Meeting. Vol 27. Chicago, IL: J Clin Oncol; 2009. p. Abstract 6003.
38. Crawford BE, Callihan MD, Corio RL, et al. Oral pathology. *Otolaryngol Clin North Am*. 1979;12:29–43.
39. Osborne RF, Brown JJ. Carcinoma of the oral pharynx: an analysis of subsite treatment heterogeneity. *Surg Oncol Clin N Am*. 2004;13:71–80.
40. Mochimatsu I, Tsukuda M, Furukawa S, et al. Tumours metastasizing to the head and neck—a report of seven cases. *J Laryngol Otol*. 1993;107:1171–3.
41. Aydogan LB, Myers JN, Myers EN, et al. Malignant melanoma metastatic to the tonsil. *Laryngoscope*. 1996;106:313–6.
42. Rahima B, Shingaki S, Nagata M, et al. Prognostic significance of perineural invasion in oral and oropharyngeal carcinoma. *Oral Surg Oral Med Oral Pathol Oral Radiol Endod*. 2004;97:423–31.
43. Fagan JJ, Collins B, Barnes L, et al. Perineural invasion in squamous cell carcinoma of the head and neck. *Arch Otolaryngol Head Neck Surg*. 1998;124:637–40.
44. Kleist B, Bankau A, Lorenz G, et al. Different risk factors in basaloid and common squamous head and neck cancer. *Laryngoscope*. 2004;114:1063–8.
45. El-Mofty SK, Patil S. Human papillomavirus (HPV)-related oropharyngeal nonkeratinizing squamous cell carcinoma: characterization of a distinct phenotype. *Oral Surg Oral Med Oral Pathol Oral Radiol Endod*. 2006;101:339–45.
46. Zhang MQ, El-Mofty SK, Davila RM. Detection of human papillomavirus-related squamous cell carcinoma cytologically and by in situ hybridization in fine-needle aspiration biopsies of cervical metastasis: a tool for identifying the site of an occult head and neck primary. *Cancer*. 2008;114:118–23.
47. von Knebel Doeberitz M. New markers for cervical dysplasia to visualise the genomic chaos created by aberrant oncogenic papillomavirus infections. *Eur J Cancer*. 2002;38:2229–2242.
48. Lassen P, Eriksen JG, Hamilton-Dutoit S, et al. Effect of HPV-associated p16INK4A expression on response to radiotherapy and survival in squamous cell carcinoma of the head and neck. *J Clin Oncol*. 2009;27:1992–8.
49. Califano J, van der Riet P, Westra W, et al. Genetic progression model for head and neck cancer: implications for field cancerization. *Cancer Res*. 1996;56:2488–92.
50. van der Riet P, Nawroz H, Hruban RH, et al. Frequent loss of chromosome 9p21-22 early in head and neck cancer progression. *Cancer Res*. 1994;54:1156–8.
51. Mao L, Lee JS, Fan YH, et al. Frequent microsatellite alterations at chromosomes 9p21 and 3p14 in oral premalignant lesions and their value in cancer risk assessment. *Nat Med*. 1996;2:682–5.
52. Kisielewski AE, Xiao GH, Liu SC, et al. Analysis of the FHIT gene and its product in squamous cell carcinomas of the head and neck. *Oncogene*. 1998;17:83–91.

53. Dong SM, Sun DI, Benoit NE, et al. Epigenetic inactivation of RASSF1A in head and neck cancer. *Clin Cancer Res.* 2003;9:3635–40.
54. Choi S, Myers JN. Molecular pathogenesis of oral squamous cell carcinoma: implications for therapy. *J Dent Res.* 2008;87:14–32.
55. Lippman SM, Sudbo J, Hong WK. Oral cancer prevention and the evolution of molecular-targeted drug development. *J Clin Oncol.* 2005;23:346–56.
56. Gillison ML, Koch WM, Capone RB, et al. Evidence for a causal association between human papillomavirus and a subset of head and neck cancers. *J Natl Cancer Inst.* 2000;92:709–20.
57. Koskinen WJ, Chen RW, Leivo I, et al. Prevalence and physical status of human papillomavirus in squamous cell carcinomas of the head and neck. *Int J Cancer.* 2003;107:401–6.
58. Scheffner M, Werness BA, Huibregtse JM, et al. The E6 oncoprotein encoded by human papillomavirus types 16 and 18 promotes the degradation of p53. *Cell.* 1990;63:1129–36.
59. Kessis TD, Slebos RJ, Nelson WG, et al. Human papillomavirus 16 E6 expression disrupts the p53-mediated cellular response to DNA damage. *Proc Natl Acad Sci USA.* 1993;90:3988–92.
60. White AE, Livanos EM, Tlsty TD. Differential disruption of genomic integrity and cell cycle regulation in normal human fibroblasts by the HPV oncoproteins. *Genes Dev.* 1994;8:666–77.
61. Funk JO, Waga S, Harry JB, et al. Inhibition of CDK activity and PCNA-dependent DNA replication by p21 is blocked by interaction with the HPV-16 E7 oncoprotein. *Genes Dev.* 1997;11:2090–100.
62. Jones DL, Alani RM, Munger K. The human papillomavirus E7 oncoprotein can uncouple cellular differentiation and proliferation in human keratinocytes by abrogating p21Cip1-mediated inhibition of cdk2. *Genes Dev.* 1997;11:2101–11.
63. Cheng S, Schmidt-Grimminger DC, Murrant T, et al. Differentiation-dependent up-regulation of the human papillomavirus E7 gene reactivates cellular DNA replication in suprabasal differentiated keratinocytes. *Genes Dev.* 1995;9:2335–49.
64. Chambers MS, Toth BB, Martin JW, et al. Oral and dental management of the cancer patient: prevention and treatment of complications. *Support Care Cancer.* 1995;3:168–75.
65. Rumboldt Z, Gordon L, Gordon L, et al. Imaging in head and neck cancer. *Curr Treat Options Oncol.* 2006;7:23–34.
66. Hao SP, Ng SH. Magnetic resonance imaging versus clinical palpation in evaluating cervical metastasis from head and neck cancer. *Otolaryngol Head Neck Surg.* 2000;123:324–7.
67. King AD, Tse GM, Ahuja AT, et al. Necrosis in metastatic neck nodes: diagnostic accuracy of CT, MR imaging, and US. *Radiology.* 2004;230:720–6.
68. Sreanion NJ, Berman LH, Grant JW. Head and neck lymphadenopathy: evaluation with US-guided cutting-needle biopsy. *Radiology.* 2002;224:75–81.
69. Adams S, Baum RP, Stuckensen T, et al. Prospective comparison of 18F-FDG PET with conventional imaging modalities (CT, MRI, US) in lymph node staging of head and neck cancer. *Eur J Nucl Med.* 1998;25:1255–60.
70. Mendenhall WM, Amdur RJ, Stringer SP, et al. Radiation therapy for squamous cell carcinoma of the tonsillar region: a preferred alternative to surgery? *J Clin Oncol.* 2000;18:2219–25.
71. Mendenhall WM, Stringer SP, Amdur RJ, et al. Is radiation therapy a preferred alternative to surgery for squamous cell carcinoma of the base of tongue? *J Clin Oncol.* 2000;18:35–42.
72. Rigual NR, Wiseman SM. Neck dissection: current concepts and future directions. *Surg Oncol Clin N Am.* 2004;13:151–66.
73. Forastiere AA, Trotti A. Radiotherapy and concurrent chemotherapy: a strategy that improves locoregional control and survival in oropharyngeal cancer. *J Natl Cancer Inst.* 1999;91:2065–6.
74. Withers HR, Peters LJ, Taylor JM, et al. Local control of carcinoma of the tonsil by radiation therapy: an analysis of patterns of fractionation in nine institutions. *Int J Radiat Oncol Biol Phys.* 1995;33:549–62.
75. Horiot JC, Le Fur R, N’Guyen T, et al. Hyperfractionation versus conventional fractionation in oropharyngeal carcinoma: final analysis of a randomized trial of the EORTC cooperative group of radiotherapy. *Radiother Oncol.* 1992;25:231–41.
76. Fu KK, Pajak TF, Trotti A, et al. A Radiation Therapy Oncology Group (RTOG) phase III randomized study to compare hyperfractionation and two variants of accelerated fractionation to standard fractionation radiotherapy for head and neck squamous cell carcinomas: first report of RTOG 9003. *Int J Radiat Oncol Biol Phys.* 2000;48:7–16.
77. Dabaja B, Salehpour MR, Rosen I, et al. Intensity-modulated radiation therapy (IMRT) of cancers of the head and neck: comparison of split-field and whole-field techniques. *Int J Radiat Oncol Biol Phys.* 2005;63:1000–5.
78. Eisbruch A, Harris J, Garden AS, et al. Multi-institutional trial of accelerated hypofractionated intensity-modulated radiation therapy for early-stage oropharyngeal cancer (RTOG 00–22). *Int J Radiat Oncol Biol Phys.* 2010;76:1333–8.
79. Garden AS, Morrison WH, Wong PF, et al. Disease-control rates following intensity-modulated radiation therapy for small primary oropharyngeal carcinoma. *Int J Radiat Oncol Biol Phys.* 2007;67:438–44.
80. de Arruda FF, Puri DR, Zhung J, et al. Intensity-modulated radiation therapy for the treatment of oropharyngeal carcinoma: the Memorial Sloan-Kettering Cancer Center experience. *Int J Radiat Oncol Biol Phys.* 2006;64:363–73.
81. Huang K, Xia P, Chuang C, et al. Intensity-modulated chemoradiation for treatment of stage III and IV oropharyngeal carcinoma: the University of California-San Francisco experience. *Cancer.* 2008;113:497–507.
82. Pignon JP, le Maitre A, Maillard E, et al. Meta-analysis of chemotherapy in head and neck cancer (MACH-NC): an update on 93 randomised trials and 17, 346 patients. *Radiother Oncol.* 2009;92:4–14.
83. Denis F, Garaud P, Bardet E, et al. Final results of the 94-01 French Head and Neck Oncology and Radiotherapy Group randomized trial comparing radiotherapy alone with concomitant radiochemotherapy in advanced-stage oropharynx carcinoma. *J Clin Oncol.* 2004;22:69–76.
84. Lefebvre JL. Current clinical outcomes demand new treatment options for SCCHN. *Ann Oncol.* 2005;16 Suppl 6:vi7–vi12.
85. Adelstein DJ, Li Y, Adams GL, et al. An intergroup phase III comparison of standard radiation therapy and two schedules of concurrent chemoradiotherapy in patients with unresectable squamous cell head and neck cancer. *J Clin Oncol.* 2003;21:92–8.
86. Paccagnella A, Orlando A, Marchiori C, et al. Phase III trial of initial chemotherapy in stage III or IV head and neck cancers: a study by the Gruppo di Studio sui Tumori della Testa e del Collo. *J Natl Cancer Inst.* 1994;86:265–72.
87. Zorat PL, Paccagnella A, Cavaniglia G, et al. Randomized phase III trial of neoadjuvant chemotherapy in head and neck cancer: 10-year follow-up. *J Natl Cancer Inst.* 2004;96:1714–7.
88. Dommenege C, Hill C, Lefebvre JL, et al. Randomized trial of neoadjuvant chemotherapy in oropharyngeal carcinoma. French Groupe d’Etude des Tumeurs de la Tete et du Cou (GETTEC). *Br J Cancer.* 2000;83:1594–8.
89. Pignon JP, Syz N, Posner M, et al. Adjusting for patient selection suggests the addition of docetaxel to 5-fluorouracil-cisplatin induction therapy may offer survival benefit in squamous cell cancer of the head and neck. *Anticancer Drugs.* 2004;15:331–40.
90. Vermorken JB, Remenar E, van Herpen C, et al. Cisplatin, fluorouracil, and docetaxel in unresectable head and neck cancer. *N Engl J Med.* 2007;357:1695–704.

91. Posner MR, Hershock DM, Blajman CR, et al. Cisplatin and fluorouracil alone or with docetaxel in head and neck cancer. *N Engl J Med.* 2007;357:1705–15.
92. Bonner JA, Harari PM, Giralt J, et al. Radiotherapy plus cetuximab for squamous-cell carcinoma of the head and neck. *N Engl J Med.* 2006;354:567–78.
93. Foote RL, Olsen KD, Davis DL, et al. Base of tongue carcinoma: patterns of failure and predictors of recurrence after surgery alone. *Head Neck.* 1993;15:300–7.
94. Zelefsky MJ, Harrison LB, Armstrong JG. Long-term treatment results of postoperative radiation therapy for advanced stage oropharyngeal carcinoma. *Cancer.* 1992;70:2388–95.
95. De los Santos JF, Morrison WH, Garden AS. Surgery and postoperative radiation therapy for advanced squamous cell carcinoma of the base of tongue. *Cancer J.* 2000;6:411.
96. Spanos Jr WJ, Shukovsky J, Fletcher GH. Time, dose, and tumor volume relationships in irradiation of squamous cell carcinomas of the base of the tongue. *Cancer.* 1976;37:2591–9.
97. Harrison LB, Lee HJ, Pfister DG, et al. Long term results of primary radiotherapy with/without neck dissection for squamous cell cancer of the base of tongue. *Head Neck.* 1998;20:668–73.
98. Foote RL, Schild SE, Thompson WM, et al. Tonsil cancer. Patterns of failure after surgery alone and surgery combined with postoperative radiation therapy. *Cancer.* 1994;73:2638–47.
99. Weichert KA, Aron B, Maltz R, et al. Carcinoma of the tonsil: treatment by a planned combination of radiation and surgery. *Int J Radiat Oncol Biol Phys.* 1976;1:505–8.
100. Gehanno P, Depondt J, Guedon C, et al. Primary and salvage surgery for cancer of the tonsillar region: a retrospective study of 120 patients. *Head Neck.* 1993;15:185–9.
101. Holsinger FC, McWhorter AJ, Menard M, et al. Transoral lateral oropharyngectomy for squamous cell carcinoma of the tonsillar region: I. Technique, complications, and functional results. *Arch Otolaryngol Head Neck Surg.* 2005;131:583–91.
102. Laccourreye O, Hans S, Menard M, et al. Transoral lateral oropharyngectomy for squamous cell carcinoma of the tonsillar region: II. An analysis of the incidence, related variables, and consequences of local recurrence. *Arch Otolaryngol Head Neck Surg.* 2005;131:592–9.
103. Weinstein GS, O'Malley Jr BW, Snyder W, et al. Transoral robotic surgery: radical tonsillectomy. *Arch Otolaryngol Head Neck Surg.* 2007;133:1220–6.
104. Mendenhall WM, Morris CG, Amdur RJ, et al. Definitive radiotherapy for tonsillar squamous cell carcinoma. *Am J Clin Oncol.* 2006;29:290–7.
105. Bataini JP, Asselain B, Jaulerry C, et al. A multivariate primary tumour control analysis in 465 patients treated by radical radiotherapy for cancer of the tonsillar region: clinical and treatment parameters as prognostic factors. *Radiother Oncol.* 1989;14:265–77.
106. O'Sullivan B, Warde P, Grice B, et al. The benefits and pitfalls of ipsilateral radiotherapy in carcinoma of the tonsillar region. *Int J Radiat Oncol Biol Phys.* 2001;51:332–43.
107. Jackson SM, Hay JH, Flores AD, et al. Cancer of the tonsil: the results of ipsilateral radiation treatment. *Radiother Oncol.* 1999;51:123–8.
108. Pernot M, Malissard L, Taghian A, et al. Velotonsillar squamous cell carcinoma: 277 cases treated by combined external irradiation and brachytherapy—results according to extension, localization, and dose rate. *Int J Radiat Oncol Biol Phys.* 1992;23:715–23.
109. Mazon JJ, Lusinchi A, Marinello G, et al. Interstitial radiation therapy for squamous cell carcinoma of the tonsillar region: the Creteil experience (1971–1981). *Int J Radiat Oncol Biol Phys.* 1986;12:895–900.
110. Scully C, Bagan JV. Recent advances in Oral Oncology 2007: imaging, treatment and treatment outcomes. *Oral Oncol.* 2008;44:211–5.
111. Lindberg RD, Fletcher GH. The role of irradiation in the management of head and neck cancer: analysis of results and causes of failure. *Tumori.* 1978;64:313–25.
112. Keus RB, Pontvert D, Brunin F, et al. Results of irradiation in squamous cell carcinoma of the soft palate and uvula. *Radiother Oncol.* 1988;11:311–7.
113. Esche BA, Haie CM, Gerbaulet AP, et al. Interstitial and external radiotherapy in carcinoma of the soft palate and uvula. *Int J Radiat Oncol Biol Phys.* 1988;15:619–25.
114. Mazon JJ, Crook J, Martin M, et al. Iridium 192 implantation of squamous cell carcinomas of the oropharynx. *Am J Otolaryngol.* 1989;10:317–21.
115. Mazon JJ, Marinello G, Crook J, et al. Definitive radiation treatment for early stage carcinoma of the soft palate and uvula: the indications for iridium 192 implantation. *Int J Radiat Oncol Biol Phys.* 1987;13:1829–37.
116. Levendag PC, Schmitz PI, Jansen PP, et al. Fractionated high-dose-rate and pulsed-dose-rate brachytherapy: first clinical experience in squamous cell carcinoma of the tonsillar fossa and soft palate. *Int J Radiat Oncol Biol Phys.* 1997;38:497–506.
117. Guillaumondegui OM, Meoz R, Jesse RH. Surgical treatment of squamous cell carcinoma of the pharyngeal walls. *Am J Surg.* 1978;136:474–6.
118. Hull MC, Morris CG, Tannehill SP, et al. Definitive radiotherapy alone or combined with a planned neck dissection for squamous cell carcinoma of the pharyngeal wall. *Cancer.* 2003;98:2224–31.
119. Morrison WH. Locoregional control for oropharyngeal wall carcinomas; 2009 (Personal Communication).
120. van der Haring IS, Schaapveld MS, Roodenburg JL, et al. Second primary tumours after a squamous cell carcinoma of the oral cavity or oropharynx using the cumulative incidence method. *Int J Oral Maxillofac Surg.* 2009;38:332–8.
121. Guiliano AR, Tortolero-Luna G, Ferrer E, et al. Epidemiology of human papillomavirus infection in men, cancers other than cervical and benign conditions. *Vaccine.* 2008;26:K17–28.
122. Garcia-Serra A, Amdur RJ, Morris CG, et al. Thyroid function should be monitored following radiotherapy to the low neck. *Am J Clin Oncol.* 2005;28:255–8.
123. Chambers MS, Mellberg JR, Keene HJ, et al. Clinical evaluation of the intraoral fluoride releasing system in radiation-induced xerostomic subjects. Part 1: Fluorides. *Oral Oncol.* 2006;42:934–45.
124. Chambers MS, Mellberg JR, Keene HJ, et al. Clinical evaluation of the intraoral fluoride releasing system in radiation-induced xerostomic subjects. Part 2: Phase I study. *Oral Oncol.* 2006;42:946–53.
125. Schoder H, Yeung HW, Gonen M, et al. Head and neck cancer: clinical usefulness and accuracy of PET/CT image fusion. *Radiology.* 2004;231:65–72.
126. Branstetter BFT, Blodgett TM, Zimmer LA, et al. Head and neck malignancy: is PET/CT more accurate than PET or CT alone? *Radiology.* 2005;235:580–6.
127. Chen AY, Schrag N, Hao Y, et al. Changes in treatment of advanced oropharyngeal cancer, 1985–2001. *Laryngoscope.* 2007;117:16–21.
128. Brockstein B, Haraf DJ, Rademaker AW, et al. Patterns of failure, prognostic factors and survival in locoregionally advanced head and neck cancer treated with concomitant chemoradiotherapy: a 9-year, 337-patient, multi-institutional experience. *Ann Oncol.* 2004;15:1179–86.
129. Mellott A, Vokes E. Chemoprevention in head and neck cancer. *Cancer Treat Res.* 2001;106:221–35.
130. Wong SJ, Machtay M, Li Y. Locally recurrent, previously irradiated head and neck cancer: concurrent re-irradiation and chemotherapy, or chemotherapy alone? *J Clin Oncol.* 2006;24:2653–8.
131. Bumpous JM. Surgical salvage of cancer of the oropharynx after chemoradiation. *Curr Oncol Rep.* 2009;11:151–5.
132. Cmelak AJ, Li S, Goldwasser MA, et al. Phase II trial of chemoradiation for organ preservation in resectable stage III or IV

- squamous cell carcinomas of the larynx or oropharynx: results of Eastern Cooperative Oncology Group Study E2399. *J Clin Oncol.* 2007;25:3971–7.
133. Kumar B, Cordell KG, Lee JS, et al. EGFR, p16, HPV Titer, Bcl-xL and p53, sex, and smoking as indicators of response to therapy and survival in oropharyngeal cancer. *J Clin Oncol.* 2008;26:3128–37.
 134. Worden FP, Kumar B, Lee JS, et al. Chemoselection as a strategy for organ preservation in advanced oropharynx cancer: response and survival positively associated with HPV16 copy number. *J Clin Oncol.* 2008;26:3138–46.
 135. Agra IM, Carvalho AL, Pontes E, et al. Postoperative complications after en bloc salvage surgery for head and neck cancer. *Arch Otolaryngol Head Neck Surg.* 2003;129:1317–21.
 136. Agra IM, Carvalho AL, Ulbrich FS, et al. Prognostic factors in salvage surgery for recurrent oral and oropharyngeal cancer. *Head Neck.* 2006;28:107–13.
 137. Kim AJ, Suh JD, Sercarz JA, et al. Salvage surgery with free flap reconstruction: factors affecting outcome after treatment of recurrent head and neck squamous carcinoma. *Laryngoscope.* 2007;117:1019–23.
 138. Vokes EE, Panje WR, Schilsky RL, et al. Hydroxyurea, fluorouracil, and concomitant radiotherapy in poor-prognosis head and neck cancer: a phase I-II study. *J Clin Oncol.* 1989;7:761–8.
 139. Salama JK, Vokes EE, Chmura SJ, et al. Long-term outcome of concurrent chemotherapy and reirradiation for recurrent and second primary head-and-neck squamous cell carcinoma. *Int J Radiat Oncol Biol Phys.* 2006;64:382–91.
 140. De Crevoisier R, Domenge C, Wibault P, et al. Full dose reirradiation combined with chemotherapy after salvage surgery in head and neck carcinoma. *Cancer.* 2001;91:2071–6.
 141. De Crevoisier R, Bourhis J, Domenge C, et al. Full-dose reirradiation for unresectable head and neck carcinoma: experience at the Gustave-Roussy Institute in a series of 169 patients. *J Clin Oncol.* 1998;16:3556–62.
 142. Spencer SA, Wheeler RH, Peters GE, et al. Concomitant chemotherapy and reirradiation as management for recurrent cancer of the head and neck. *Am J Clin Oncol.* 1999;22:1–5.
 143. Spencer SA, Harris J, Wheeler RH, et al. RTOG 96–10: reirradiation with concurrent hydroxyurea and 5-fluorouracil in patients with squamous cell cancer of the head and neck. *Int J Radiat Oncol Biol Phys.* 2001;51:1299–304.
 144. Spencer SA, Harris J, Wheeler RH, et al. Final report of RTOG 9610, a multi-institutional trial of reirradiation and chemotherapy for unresectable recurrent squamous cell carcinoma of the head and neck. *Head Neck.* 2008;30:281–8.
 145. Langer CJ, Harris J, Horwitz EM, et al. Phase II study of low-dose paclitaxel and cisplatin in combination with split-course concomitant twice-daily reirradiation in recurrent squamous cell carcinoma of the head and neck: results of Radiation Therapy Oncology Group Protocol 9911. *J Clin Oncol.* 2007;25:4800–5.
 146. Lee N, Chan K, Bekelman JE, et al. Salvage re-irradiation for recurrent head and neck cancer. *Int J Radiat Oncol Biol Phys.* 2007;68:731–40.
 147. Sulman EP, Schwartz DL, Le TT, et al. IMRT reirradiation of head and neck cancer-disease control and morbidity outcomes. *Int J Radiat Oncol Biol Phys.* 2009;73:399–409.
 148. Morton RP, Rugman F, Dorman EB, et al. Cisplatin and bleomycin for advanced or recurrent squamous cell carcinoma of the head and neck: a randomised factorial phase III controlled trial. *Cancer Chemother Pharmacol.* 1985;15:283–9.
 149. Grose WE, Lehane DE, Dixon DO, et al. Comparison of methotrexate and cisplatin for patients with advanced squamous cell carcinoma of the head and neck region: a Southwest Oncology Group Study. *Cancer Treat Rep.* 1985;69:577–81.
 150. Forastiere AA, Metch B, Schuller DE, et al. Randomized comparison of cisplatin plus fluorouracil and carboplatin plus fluorouracil versus methotrexate in advanced squamous-cell carcinoma of the head and neck: a Southwest Oncology Group study. *J Clin Oncol.* 1992;10:1245–51.
 151. Jacobs C, Lyman G, Velez-Garcia E, et al. A phase III randomized study comparing cisplatin and fluorouracil as single agents and in combination for advanced squamous cell carcinoma of the head and neck. *J Clin Oncol.* 1992;10:257–63.
 152. Burtness B, Goldwasser MA, Flood W, et al. Phase III randomized trial of cisplatin plus placebo compared with cisplatin plus cetuximab in metastatic/recurrent head and neck cancer: an Eastern Cooperative Oncology Group study. *J Clin Oncol.* 2005;23:8646–54.
 153. Gibson MK, Li Y, Murphy B, et al. Randomized phase III evaluation of cisplatin plus fluorouracil versus cisplatin plus paclitaxel in advanced head and neck cancer (E1395): an intergroup trial of the Eastern Cooperative Oncology Group. *J Clin Oncol.* 2005;23:3562–7.
 154. Vermorken JB, Mesia R, Rivera F, et al. Platinum-based chemotherapy plus cetuximab in head and neck cancer. *N Engl J Med.* 2008;359:1116–27.
 155. Leon X, Hitt R, Constenla M, et al. A retrospective analysis of the outcome of patients with recurrent and/or metastatic squamous cell carcinoma of the head and neck refractory to a platinum-based chemotherapy. *Clin Oncol (R Coll Radiol).* 2005;17:418–24.
 156. Numico G, Merlano M. Second-line treatment with docetaxel after failure of a platinum-based chemotherapy in squamous-cell head and neck cancer. *Ann Oncol.* 2002;13:331–3.
 157. Iop A, Cartei G, Isaia A. Vinorelbine, bleomycin and methotrexate as a salvage therapy for patients with head and neck squamous carcinoma in relapse after cisplatin/fluorouracil. *Ann Oncol.* 1998;9:225–7.
 158. Moroni M, Giannetta L, Gelosa G, et al. Second-line chemotherapy with bleomycin, methotrexate, and vinorelbine (BMV) for patients with squamous cell carcinoma of the head, neck and esophagus (SCC-HN&E) pretreated with a cisplatin-containing regimen: a phase II study. *J Chemother.* 2003;15:394–9.
 159. Vermorken JB, Herbst RS, Leon X, et al. Overview of the efficacy of cetuximab in recurrent and/or metastatic squamous cell carcinoma of the head and neck in patients who previously failed platinum-based therapies. *Cancer.* 2008;112:2710–9.
 160. Lindberg R. Sites of first failure in head and neck cancer. *Cancer Treat Symp.* 1983;2:21–31.
 161. Garden AS, Asper JA, Morrison WH, et al. Is concurrent chemoradiation the treatment of choice for all patients with Stage III or IV head and neck carcinoma? *Cancer.* 2004;100:1171–8.
 162. Weber RS, Gidley P, Morrison WH, et al. Treatment selection for carcinoma of the base of the tongue. *Am J Surg.* 1990;160:415–9.
 163. Mak AC, Morrison WH, Garden AS, et al. Base-of-tongue carcinoma: treatment results using concomitant boost radiotherapy. *Int J Radiat Oncol Biol Phys.* 1995;33:289–96.
 164. Fein DA, Lee WR, Amos WR, et al. Oropharyngeal carcinoma treated with radiotherapy: a 30-year experience. *Int J Radiat Oncol Biol Phys.* 1996;34:289–96.
 165. Dawson LA, Myers LL, Bradford CR, et al. Conformal re-irradiation of recurrent and new primary head-and-neck cancer. *Int J Radiat Oncol Biol Phys.* 2001;50:377–85.
 166. Spencer S, Wheeler R, Peters G, et al. Phase I trial of combined chemotherapy and reirradiation for recurrent unresectable head and neck cancer. *Head Neck.* 2003;25:118–22.
 167. Kramer NM, Horwitz EM, Cheng J, et al. Toxicity and outcome analysis of patients with recurrent head and neck cancer treated with hyperfractionated split-course reirradiation and concurrent cisplatin and paclitaxel chemotherapy from two prospective phase I and II studies. *Head Neck.* 2005;27:406–14.

Chapter 30

Multidisciplinary Management of Hypopharyngeal Carcinoma

Marc Hamoir, Jean-Pascal Machiels, Sandra Schmitz, and Vincent Gregoire

Abstract Despite advances in treatment modalities, the management of hypopharyngeal squamous cell carcinoma (SCC) remains difficult. Most patients have advanced locoregional disease at the time of diagnosis.

Treatment selection favor laryngeal preservation approaches either surgically or nonsurgically to improve the quality of life without compromising locoregional control and survival. For patients with early disease, conservation surgery and primary radiotherapy are equally effective therapeutic options. Patient with advanced locoregional disease, a conservative treatment combining chemotherapy and radiotherapy should be favored. Total laryngopharyngectomy (TLP) remains indicated in tumors not suitable for conservative nonsurgical approaches and for salvage. Despite a good locoregional control rate, most patients succumb to distant metastases, intercurrent diseases, or second primaries.

Future developments should be connected with treatments with a better toxicity profile than chemotherapy aimed to decrease the rate of late distant recurrences and the occurrence of second primaries. Targeted agents could be nicely incorporated into the standard regimen either to improve efficacy and/or decrease treatment toxicity. Ongoing studies investigating the combination of targeted agent administration during or after induction chemotherapy or with concomitant chemoradiation regimens will help to better define the respective role of chemotherapy and targeted agents in the multimodal treatment of this disease. In addition, efforts to identify predictive biomarkers that could help to better select the patients who will benefit of a specific treatment modality is of crucial importance.

Keywords Hypopharyngeal cancer • Head and neck squamous cell carcinoma • Conservation laryngopharyngectomy • Intensity modulated radiation therapy • Laryngeal preservation • Lymph node metastases • Neck dissection

Epidemiology, Etiology, and Molecular Biology

Hypopharyngeal cancer represents approximately 7–8% of all cancers of the upper aerodigestive tract. The estimated incidence in the USA is 2,500 cases per year [1]. In Belgium (ten million inhabitants), 192 hypopharyngeal cancers (8%) were diagnosed in 2005. Most of them (75%) are localized in the pyriform sinus, whereas the remaining 25% occurred in another hypopharyngeal site (posterior pharyngeal wall: 20%, postcricoid: 5%) [2, 3].

The male/female (M/F) ratio is 3/1 in USA for 5/1 in Belgium [1, 2]. Excessive alcohol and tobacco use remain the primary risk factors. Patients are typically 55–70-year-old men, heavy smokers and drinkers. Although earlier reports from northern Europe indicated a link between Plummer–Vinson syndrome and other nutritional deficiencies inducing postcricoid cancers in women, hypopharyngeal cancer in women is currently more likely to be associated with alcohol and tobacco abuse than with deficiency diseases [4–7]. Most hypopharyngeal cancers are diagnosed in people older than 40 years. The mean age at presentation is 65 years. Human papilloma virus (HPV) seems to be implicated in the physiopathology of hypopharynx cancers, but at a lower extent than in oropharynx and oral cancers.

The occurrence of multiple tumors is not uncommon and the risk of second primary tumor is estimated at 25% [8]. Many studies focused on molecular and genetic alterations do not make any distinction between different locations of head and neck squamous cell carcinoma (HNSCC). In hypopharynx SCC specifically, 11q13 amplification (encodes, i.e., for cyclin D1) was reported in 78% and loss of p53 heterozygosity in 70% [9]. Recently, it was prospectively

M. Hamoir (✉)
Head and Neck Surgery, Universite Catholique
de Louvain, St. Luc University Hospital and Cancer Center,
10, Avenue Hippocrate, 1200 Brussels, Belgium
e-mail: marc.hamoir@uclouvain.be

demonstrated that TP53 mutations, and particularly disruptive mutations of TP53, were associated with reduced survival. Mutations of TP53 were more frequent in hypopharynx SCC (75%) than in other sites [10].

Anatomy and Pathways of Spread

Primary Site

The pharynx is a continuous structure, extending from the base of the skull to the upper esophagus, divided into three segments: nasopharynx, oropharynx, and hypopharynx according to anatomic landmarks (Fig. 30.1). The hypopharynx is roughly a triangular space, wide superiorly, extending from the oropharynx above (at the tip of the epiglottis or the level of the hyoid bone) to the upper esophagus below (at the lower end of the cricoid cartilage). Although it is closely connected with the posterior part of the larynx, the hypopharynx must be considered as a separate structure embryologically

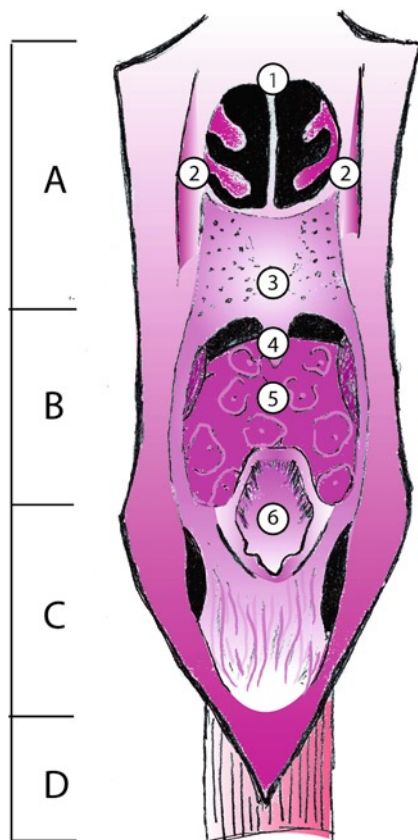


Fig. 30.1 Schematic view of the pharynx (1) nasal septum, (2) pharyngeal opening of Eustachian tube, (3) soft palate, (4) uvula, (5) base of tongue, (6) epiglottis. (A) Nasopharynx, (B) oropharynx, (C) hypopharynx, (D) esophagus

and anatomically. The hypopharynx is divided into three sites: the pyriform sinuses (right and left), the posterior hypopharyngeal wall, and the postcricoid region (Figs. 30.1 and 30.2).

The pyriform sinuses, so named for their pear shape, are paired and created by the invagination of the larynx into the hypopharynx. The medial wall is in close continuity with the lateral face of the larynx and superiorly, it becomes the aryepiglottic fold. The lateral wall is a prolongation of the lateral wall of the oropharynx. The anterior wall is the region where converge the medial and lateral walls. The apex is the most inferior extent where the three walls merge, below the level of the vocal cords. The superior extent is bordered by the pharyngoepiglottic fold that extends from the lateral pharyngeal wall to the epiglottis. The posterior hypopharyngeal wall is in continuation with the posterior pharyngeal wall. Arbitrary, the boundary between the oro and hypopharyngeal walls is the level of the hyoid bone. It extends down to the upper esophageal sphincter. The posterior hypopharyngeal wall is formed by the constrictor muscles and is in direct contact with the prevertebral fascia posteriorly. The postcricoid region, is the posterior surface of the larynx, extending from the arytenoids to the inferior edge of the cricoid cartilage and the upper esophagus. The pyriform sinus forms the posterior wall of the paraglottic space [11]. This close proximity with the posterior paraglottic space makes this a potential route for spread into the endolarynx, resulting often in fixation of the hemilarynx. Tumors of the medial wall of the pyriform sinus have a behavior very similar to supraglottic tumors arising

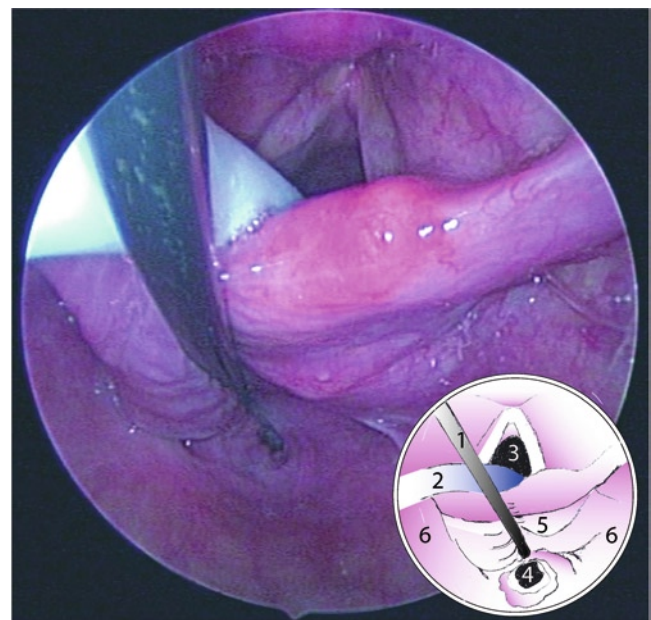


Fig. 30.2 Endoscopic view of the larynx and the hypopharynx (1) suction tube, (2) endotracheal tube, (3) larynx, (4) upper esophagus, (5) postcricoid area, (6) pyriform sinus

from the aryepiglottic fold and it is often difficult to identify the origin of some of these lesions. Posteriorly, there is no barrier to stand in the way of tumor extension to the postcricoid area or crossing from the ipsilateral arytenoid to the contralateral arytenoids (Fig. 30.3). Tumors of the lateral wall have also few barriers to growth. They can extend medially to involve the posterior hypopharyngeal wall or anteromedially to involve the anterior and medial walls. They can easily invade the apex inferiorly and extend frequently submucosally to involve the thyroid cartilage and cricoid cartilage or directly the thyroid gland or soft tissue into the neck (Fig. 30.4a, b). Besides, they can extend down to the cervical esophagus through submucosal spread, making an accurate delineation of tumor extension very difficult. Their behavior may be similar to esophageal tumors with extensive

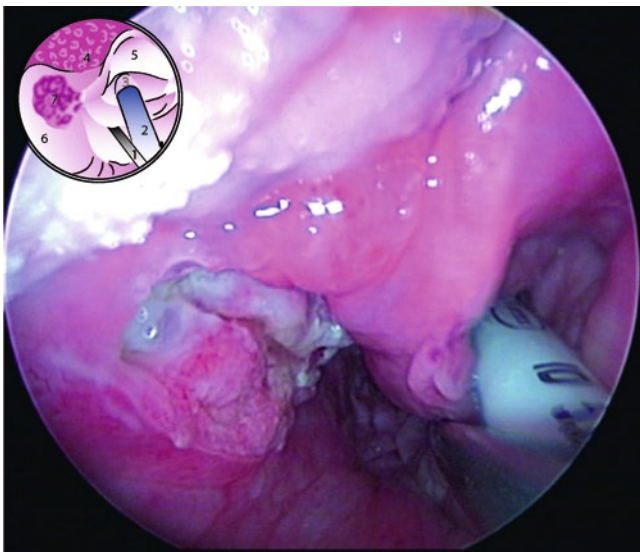


Fig. 30.3 Endoscopic view of a left pyriform sinus tumor (1) suction tube, (2) endotracheal tube, (3) larynx, (4) base of tongue, (5) epiglottis, (6) pyriform sinus, (7) tumor

spread along lymphatic spaces and skip lesions. Posterior hypopharyngeal wall tumors are infrequently diagnosed at early stage. They spread frequently along the mucosa to involve either the posterior or lateral oropharyngeal walls. At advanced stage, they can invade deeply the prevertebral tissue or even bone of the cervical spine (Fig. 30.5).

Regional Lymphatic Drainage

The head and neck region has a rich network of lymphatic vessels draining from the base of the skull through the jugular nodes, the spinal accessory nodes, and the transverse cervical nodes to the venous jugulo-subclavian confluent or the thoracic duct on the left side and the lymphatic duct on the right side [12, 13]. The whole lymphatic system of the neck is contained in the celluloadipose tissue delineated by aponeurosis enveloping the muscles, the vessels, and the nerves. Typically, the lymphatic drainage of the hypopharynx is bilateral; however, the lateral wall of the pyriform sinus only drains to the ipsilateral neck. Except level Ia (submental nodes), all nodes levels are at risk of harboring cells disseminating from hypopharyngeal primaries, but the highest incidence of nodal metastasis is observed in levels III and IV. In case of infiltration of the apex of the pyriform sinus and/or the pharyngo-esophageal junction, level VI is also at risk of nodal infiltration.

Distant Metastases

Patients with advanced hypopharynx cancer have a high incidence of distant metastases (60%) [14]. Among patients locoregionally controlled, the incidence of distant failure

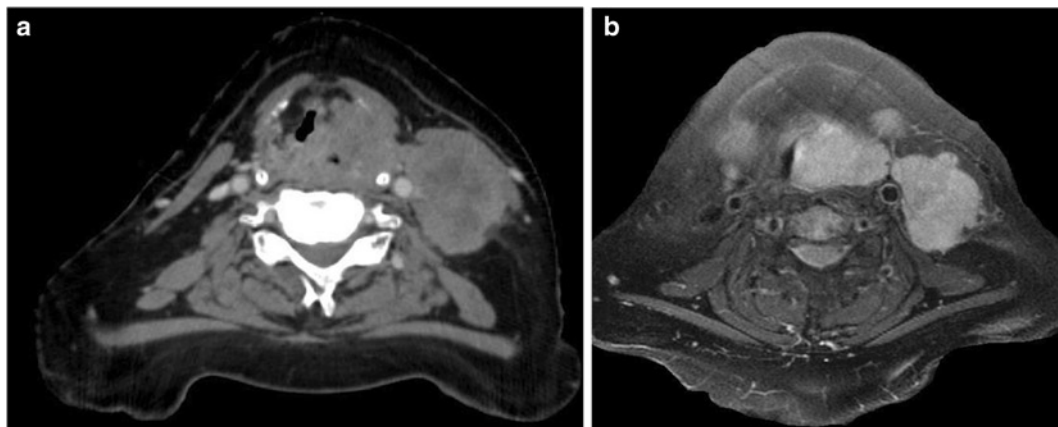


Fig. 30.4 Computed tomography (a) and magnetic resonance (T2-weighted) (b) images of an advanced pyriform sinus cancer invading the thyroid cartilage and directly extending to the soft tissues of the neck (T4a) with large lymph node metastasis (N3)

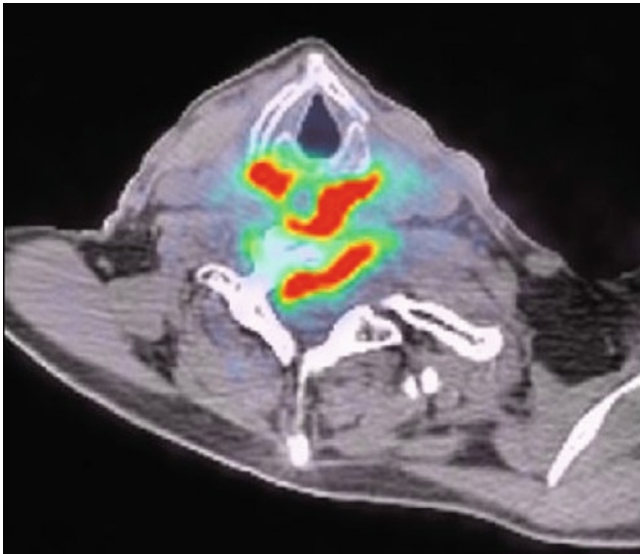


Fig. 30.5 PET-CT image of a posterior pharyngeal wall cancer with invasion of the prevertebral fascia and bone of the cervical spine

was reported as 23% [15, 16]. The lung is the most common site of distant metastases in 60–80% of patients, followed by bones, liver, and mediastinal lymph nodes [14].

Clinical Manifestation, Work-Up, Staging Evaluation

Clinical Manifestations

The time between initial symptoms and diagnosis is typically longer than that for other HNSCC. When symptomatic, most hypopharyngeal tumors are already advanced. The most common symptom is chronic sore throat. Typically, pain is unilateral and well localized with or without referred otalgia. Other symptoms include varying degree of dysphagia, from foreign body sensation in the throat to inability to swallow solid or even liquid food. Aspiration is occasionally seen. A unilateral asymptomatic mass in the neck is often the initial symptom. Typically, metastatic lymph node is located in level II or III. The incidence of clinically positive lymph nodes upon initial clinical examination is very high, even in early tumors: 63–68% for T1–T2 and 73–79% for T3–T4 [17, 18]. Other symptoms, reported in more advanced lesions, include weight loss, hemoptysis, and hoarseness induced by direct extension into the larynx or recurrent nerve involvement. Dyspnea is present in very advanced tumors growing into the larynx. Because many patients are diagnosed at advanced stage, weight loss and malnutrition are common at presentation.

Work-Up

Clinical Examination

Clinical evaluation includes complete history of the disease, physical examination including weight and weight loss. Performance status (Karnofsky, ECOG-WHO) should be carefully assessed. Flexible fiberoptic endoscopy is the examination of choice, allowing assessment of the tumor size and extension to adjacent structures. Visualization of the pyriform sinuses may be optimized with the Valsalva maneuver. All the upper aerodigestive tract must be meticulously assessed looking for synchronous second primaries. Lesions located in the apex of the pyriform sinus or postcricoid region are not always easy to see but may be suspected by either pooling of saliva or arytenoid edema [19]. Assessment of vocal cord mobility is paramount in medial wall tumors particularly. Neck palpation is required not only to detect enlarged lymph node but also for tumor evaluation. In advanced tumors, it is not infrequent to palpate the tumor by direct extension. A rigid endoscopy under general anesthesia remains a major step in the diagnosis. Tumor extension can be accurately delineated and biopsies of the tumor or any other suspicion of second primary can be performed. When required, teeth extraction is done simultaneously. In very advanced tumors with airway obstruction, tracheotomy can be also performed during the same procedure. The neck should be examined in a systematic fashion. Any lymph nodes should be assessed with regard to size, location, and mobility. On neck examination, loss of the grating sensation (laryngeal crepitus) of the laryngeal cartilages over the prevertebral tissues may indicate deep pharyngeal wall involvement.

Imaging for Locoregional Disease Evaluation

CT scan and/or MRI are essentials to assess the primary tumor and regional lymph nodes. Imaging work-up can provide information about submucous tumor extension and cartilage involvement, leading to upstaging in a significant number of cases. The contrast-enhanced CT scan is typically used as the initial imaging modality and is generally considered as more useful for staging hypopharyngeal cancers. MRI tends to be superior to CT in predicting tumor invasion and is particularly indicated in the selection of patients suitable for conservation surgery [20]. Recently, criteria for diagnosis of invasion of laryngeal cartilage were reassessed and MRI was found as more accurate than CT [21]. CT and MRI are considered as of comparable value in the radiological evaluation of the neck relative to clinical exam [22]. Diffusion-weighted MRI (DW-MRI) was recently reported as a better tool for regional staging of HNSCC [23, 24] and

the data suggest that DW-MRI should be used routinely in the initial imaging work-up of HNSCC [24].

The role of ^{18}F -fluorodeoxyglucose positron emission tomography (FDG-PET) is emerging in the initial assessment of HNSCC. Integrated PET-CT overcomes poor anatomic localization of PET together with the morphologic data revealed by CT. In a recent meta-analysis totaling 1,236 patients, it was however demonstrated that the accuracy of FDG-PET was only marginally superior to that of CT or MRI, thus questioning the routine value of FDG-PET for nodal staging [25]. A lot of work has been conducted on the use of PET for radiation treatment planning of HNSCC [26, 27], and it is likely that somehow metabolic imaging will affect the gross tumor volume (GTV), and hence the clinical (CTV) and planned target volumes (PTV).

Metastatic and Second Primary Evaluation

Despite a high specificity (94%), chest X-ray has a low sensitivity (50%) for the detection of pulmonary metastases [28]. Spiral chest CT is now routinely performed in the initial work. The sensitivity for the detection of distant metastases as well as for the detection of second primary in the lung is high. Use of FDG-PET was reported as detecting more distant metastases than conventional CT staging [29–31]. Recently, the results of a large prospective study demonstrated that FDG-PET significantly improves the staging of HNSCC. The greater impact is due to the detection of metastatic or additional disease [32].

The incidence of second primary tumors of the upper aerodigestive tract varies from 3 to 15%. The majority is detected within 2 years following diagnosis of the initial tumor [33]. Second primary cancers are common in patients with hypopharyngeal carcinoma. A high rate is reported for patients undergoing routine panendoscopy [33]. Routine esophago-gastroscopy in the initial work-up is justified, based not only on the detection of second primary but also because many patients have gastroesophageal reflux leading to more or less severe esophagitis requiring medical treatment. On the other hand, routine bronchoscopy is no longer necessary. Second primary tumors in the lung or distant metastases are now better ruled out using spiral chest CT or FDG-PET-CT.

Patient Evaluation

A full dental evaluation is required before the beginning of radiotherapy. This step is critical because of xerostomia caused by radiotherapy potentially leading to dental decay and osteoradionecrosis. In case of significant denutrition defined as weight loss more than 10% during the 6 months

before diagnosis, nutritional improvement via enteral and hyperalimentary routes through a feeding tube is highly recommended before starting the treatment. Percutaneous gastrostomy is generally preferred to nasogastric feeding tube for long-term enteral support.

A complete blood count is routinely asked. Hepatic enzymes assess the liver function. Many patients have an underlying hepatic disease due to alcohol abuse. Serum creatinine is asked to assess renal function for general tolerance to therapy. If the serum creatinine concentration is elevated and platin-based chemotherapy (CH) is under consideration, 24-h creatinine clearance must be measured. Serum albumin and prealbumin are good indicators of the nutritional status. Baseline TSH level should be routinely asked [34].

Staging Evaluation

T staging for hypopharynx carcinoma is based on size, sites of involvement, and vocal cord mobility (as an indirect way to measure tumor extension). As described for other HN sites, the last edition of the TNM staging system subdivided T4 into resectable tumor, T4a, and unresectable tumor, T4b [35]. Typically, T4a hypopharyngeal cancer can invade thyroid or cricoid cartilage, hyoid bone, thyroid gland, esophagus, or central compartment, while T4b invades prevertebral fascia, encases carotid artery, or involves mediastinal structures. There is in the literature confusion between “unresectable tumor” and “unresected” tumor. Some publications report results on medical treatments combining chemo and radiotherapy in the so-called unresectable disease including tumors staged from T1 to T4 [36, 37]. Unresectable tumor is clearly defined in the last edition of the staging system, meaning that the tumor is not resectable from an oncological point of view. This definition should not be amalgamated with an unresected tumor, which means that the tumor is theoretically resectable with free margins, but the multidisciplinary team, typically for functional reasons, decided to select a nonsurgical approach.

Regional staging (N) is uniform for all HN cancer sites with the exception of the nasopharynx. No changes were made in the sixth edition. Table 30.1 summarizes the details of T, N, and M stages for hypopharyngeal cancers.

Primary Therapy

Factors Affecting the Choice of Treatment

The management of hypopharyngeal cancer requires consideration of the tumor’s localization and extension, the patient’s age, performance status and patient’s preference, the presence

Table 30.1 TNM classification of hypopharyngeal cancer

Primary tumor (T)			
TX	The primary tumor cannot be assessed		
T0	No evidence of primary tumor is present		
Tis	The tumor is carcinoma in situ		
Hypopharynx			
T1	Tumor is limited to one subsite of the hypopharynx and/or 2 cm or less at its greatest dimension		
T2	Tumor invades more than one subsite of hypopharynx or an adjacent site, or measures more than 2 cm but not more than 4 cm in greatest dimension without fixation of the hemilarynx		
T3	Tumor more than 4 cm in greatest dimension or with fixation of the hemilarynx or extension to esophagus		
T4a	Moderately advanced local disease. Tumor invades thyroid/cricoid cartilage, hyoid bone, thyroid gland, or central compartment soft tissue ^a		
T4b	Very advanced local disease. Tumor invades prevertebral fascia, encases carotid artery, or involves mediastinal structures		
Regional lymph nodes (N) ^b			
NX	Regional lymph nodes cannot be assessed		
N0	No regional lymph node metastases		
N1	Metastasis in a single ipsilateral lymph node, 3 cm or less in greatest dimension		
N2	Metastasis in a single ipsilateral lymph node, more than 3 cm but not more than 6 cm in greatest dimension, or in multiple ipsilateral lymph nodes, none more than 6 cm in greatest dimension, or in bilateral or contralateral lymph nodes, none more than 6 cm in greatest dimension		
N2a	Metastasis in a single ipsilateral lymph node, more than 3 cm but not more than 6 cm in greatest dimension		
N2b	Metastasis in multiple ipsilateral lymph nodes, none more than 6 cm in greatest dimension		
N2c	Metastasis in bilateral or contralateral lymph nodes, none more than 6 cm in greatest dimension		
N3	Metastasis in a lymph node more than 6 cm in greatest dimension		
Distant Metastasis (M)			
M0	No distant metastasis		
M1	Distant metastasis		
Anatomic stage/prognostic groups: oropharynx, hypopharynx			
Stage 0	Tis	N0	M0
Stage I	T1	N0	M0
Stage II	T2	N0	M0
Stage III	T3	N0	M0
	T1	N1	M0
	T2	N1	M0
Stage IVA	T3	N1	M0
	T4a	N0	M0
	T4a	N1	M0
	T1	N2	M0
	T2	N2	M0
	T3	N2	M0
	T4a	N2	M0

Stage IVB	T4b	Any N	M0
	Any T	N3	M0
Stage IVC	Any T	Any N	M1

^aCentral compartment soft tissue includes prelaryngeal strap muscles and subcutaneous fat

^bMetastases at level VII are considered regional lymph node metastases Used with the permission of the American Joint Committee on Cancer (AJCC), Chicago, Illinois. The original source for this material is the AJCC Cancer Staging Manual, 7th Edition (2010) published by Springer Science and Business Media LLC, www.springer.com

and extent of lymph node metastasis and the anticipated functional outcome and long-term toxicity.

Age

In general, advanced age is not a contraindication to treatment. Survival rates for patients over 75 years of age are comparable to other age groups [38]. However, in hypopharyngeal cancer, 5-year site-specific survival for patients older than 75 years is not more than 10% with many patients eliminated from treatment consideration due to associated medical conditions [39]. In view of this poor prognosis, a palliative approach without surgery, whenever possible is recommended in many of these patients [38].

Medical Status

When surgery is planned, medical contraindication is based on the preoperative assessment of anesthetic risk. Patients with a poor pulmonary function are clearly not good candidates for conservation surgery because these patients are at greater risk of aspiration and recurrent pneumonia. Conservation surgery is indicated for early stage in patients who can tolerate some degree of chronic aspiration. Patients who are candidates for organ preservation protocols combining CH and radiotherapy (RT) should have an adequate performance status and good hematological, hepatic, renal, and cardiovascular functions.

Prior to RT in the head and neck for cancer located in another site requires a careful consideration of the dose and the volumes irradiated. In general, those patients are poor candidates for a full second dose of irradiation. Treatment combining surgery, concurrent CH, and reirradiation offers potential for long-term survival. Owing to the substantial toxicity and lack of an optimal regimen, reirradiation of recurrent head-and-neck cancer should be limited to clinical trials [40].

Lymph Node Status

In patients clinically N0, the volume that needs to be treated by neck dissection (ND) or RT should include levels II, III, and IV bilaterally, due to the high incidence of bilateral neck metastases [41].

Only patients with very early tumor of the lateral wall of the pyriform sinus are suitable for a unilateral treatment of the neck. In patients with advanced regional lymph node involvement, ND will be invariably followed by postoperative radiotherapy (PORT) or CH-RT with cumulated morbidity. For this reason, primary nonsurgical treatment seems preferable for those patients, with ND performed only for residual disease in the neck at completion of (CH) RT. Prior dissection or irradiation of the neck modified clearly the classic distribution of neck metastasis (levels II–IV). This concept must be kept in mind in patients with prior history of HN cancer.

Functional Outcome and Long-Term Morbidity

The functional deficit expected to result from a treatment is a useful parameter helping to the final decision when one or more options are supposed to produce equivalent locoregional control. For instance, either surgery or RT can be expected to control early lesions equally well. Surgery for an easy resectable lesion resulting in minimal functional deficit may be preferred over RT. Conversely, when surgery requires sacrifice such as larynx, due consideration must be given to organ-sparing nonsurgical approaches.

Patient's Preference

Finally, the patient's preference, his ability, and willingness to cope with the treatment and its functional consequences may also influence the decision. Logistic concerns and social factors must also be considered and the input of the social worker and the family is invaluable.

Treatment Modalities

Surgery

Partial Laryngopharyngectomy

Conservation surgery is rarely considered to be suitable because of either oncologic reasons or patient factors such as postoperative swallowing disorders [42, 43]. Early T1–T2

tumors show similar outcomes with RT or surgery. Operability needs to be determined by the possibility to perform voice-sparing surgery with clear margins and acceptable morbidity. Pathologic studies have shown that assessment of the extent of the disease based on endoscopic findings only was inaccurate [44]. Therefore, conservation surgery risks a high incidence of positive margins. Small lesions often discovered incidentally during a systematic work-up for a unilateral asymptomatic mass in the neck, may be amenable to conservation surgery. Lesions that do not extend into the apex of the pyriform fossa, the posterior wall, or the postcricoid area may be resected while preserving the larynx. Tumors limited to the lateral wall of the pyriform fossa may be treated with a partial pharyngectomy (PP). Extension to the medial wall of the pyriform fossa without vocal cord fixation may be managed with a partial pharyngolaryngectomy (PPL). Superficial well-localized tumors of the posterior hypopharyngeal may present an opportunity for wide excision through pharyngotomy or laser resection. On the other hand, submucosal spread and fixation to prevertebral structures complicate resection.

Conservation surgery may be precluded in favor of RT in individuals with poor underlying pulmonary function or poor overall functional status, which prevents them from tolerating minor aspiration in the postoperative period. The absence of functional outcome data comparing conservation surgery with nonsurgical approaches complicates the treatment decision.

Transoral CO₂ Laser Resection. This approach involves specialized transoral endoscopes with an operating microscope coupled to a CO₂ laser. Proponents of this approach claim that it can be used to resect any tumor suitable for open conservation surgery, provided that adequate transoral exposure can be obtained [45, 46]. Transoral laser surgery holds the theoretical advantages of not violating other normal anatomic structures of the anterior neck, as is required for the described open approaches and avoiding tracheotomy; thus, better functional outcome is suggested. Although an 87% local control rate has been described using laser procedures in a series of 129 pyriform sinus cancers [45], these techniques have not been widely adopted, in part because of their technical difficulty and absence of data that fully substantiate functional outcomes that are superior to those of open procedures or nonsurgical therapy. These tumors require wide mucosal and muscular margins not always easily achieved using this transoral approach. An open approach is still necessary to perform ND. Moreover, many patients are treated with adjuvant PORT.

Partial Lateral Pharyngectomy. Small tumors confined to the lateral wall of the pyriform sinus or posterolateral wall of the hypopharynx are amenable to conservative PP [47]. Only T1 of the posterior or posterolateral wall of the hypopharynx extending from above the level of the cricopharyngeal muscle

to the level of the tip of the epiglottis are suitable for the procedure. Technique of PP requires resection of the posterior third of the thyroid cartilage and the hyoid bone, the lateral wall of the pyriform sinus and as much of the posterior hypopharyngeal wall as required for an adequate resection margin. If the defect is too large for primary closure, closure with a myocutaneous flap or free flap is preferred [48, 49]. In recent series, the 3-year local control rate using this approach was 88.5%, but most of the patients had PORT [50]. Functional results are generally good with no aspiration or long-term dysphagia.

Partial Pharyngolaryngectomy. This procedure is essentially an extension of the traditional supraglottic laryngectomy to include the medial wall of the pyriform sinus [51]. A few decades back, PPL had been proposed for early staged pyriform sinus cancer with favorable oncologic results [52, 53]. More recently, high local control rates have been reported [54]. Selected patients with a tumor located in the medial wall of the pyriform sinus may be treated with this procedure. The ipsilateral arytenoid cartilage and the vocal cord must be mobile and free of tumor. Involvement of the apex of the pyriform sinus and extensive submucosal spread are contraindications for this procedure.

More extensive pyriform lesions are resectable sparing the larynx provided that reconstruction was achieved using free flaps. PPL associated with an extended pharyngectomy may be indicated for tumors of the medial wall extending to the lateral wall of the pyriform sinus with possible extension to the posterior hypopharyngeal wall, preserving laryngeal function (Fig. 30.6) [55]. In cases of hemilaryngeal fixation, or invasion of the apex, a technique of wide vertical hemilaryngopharyngectomy (HLP), including the hemicricoid and hemithyroid cartilages and resection of the ipsilateral thyroid lobe has been described. A free graft of costal cartilage was employed to restore laryngeal infrastructure in addition to

the rest of the reconstruction [56]. In our experience of 34 cases with a majority of stage III and IV lesions, the 5-year local control rate was 86 and 65% of the patients remained disease-free up to 5 years at 5 years [48].

Supracricoid Hemilaryngopharyngectomy. Supracricoid HLP can be performed for lesions involving the aryepiglottic fold, medial, anterior, and lateral wall of the pyriform sinus [57]. The procedure includes resection of the ipsilateral half of the hypopharynx, the entire hemithyroid ala, including the hemilarynx, the preepiglottic space, and one arytenoid. Contraindications are invasion of the apex or postcricoid region, invasion of the posterior hypopharyngeal wall, and fixation of the ipsilateral vocal cord. Early decannulation is usually possible, and rates of local control and laryngeal preservation of more than 90% have been recently reported in a series where almost all patients had induction CH and 50% of them had PORT [58]. Although the postoperative course is often marked by a gradual recovery of swallowing ability, more than 90% of patients no longer depended on gastrostomy tube at 1 year after surgery, in the largest published series [59].

Posterior Partial Pharyngectomy. Occasionally, limited midline posterior pharyngeal wall tumors are amenable to this approach, which involves creating a unilateral or bilateral lateral pharyngotomy opening up to the level of the lateral wall of the pyriform sinus. This approach may be combined with an anterior opening of the vallecula, above the hyoid bone. This allows direct exposure and resection of the posterior wall, typically to the depth of the prevertebral fascia.

Reconstruction requires use of a thin flap. Radial forearm flap or split jejunal transfer are used to reconstruct the pharyngeal wall [60].

Near-Total Laryngopharyngectomy. The procedure proposed by Pearson preserves one uninvolved arytenoid with a

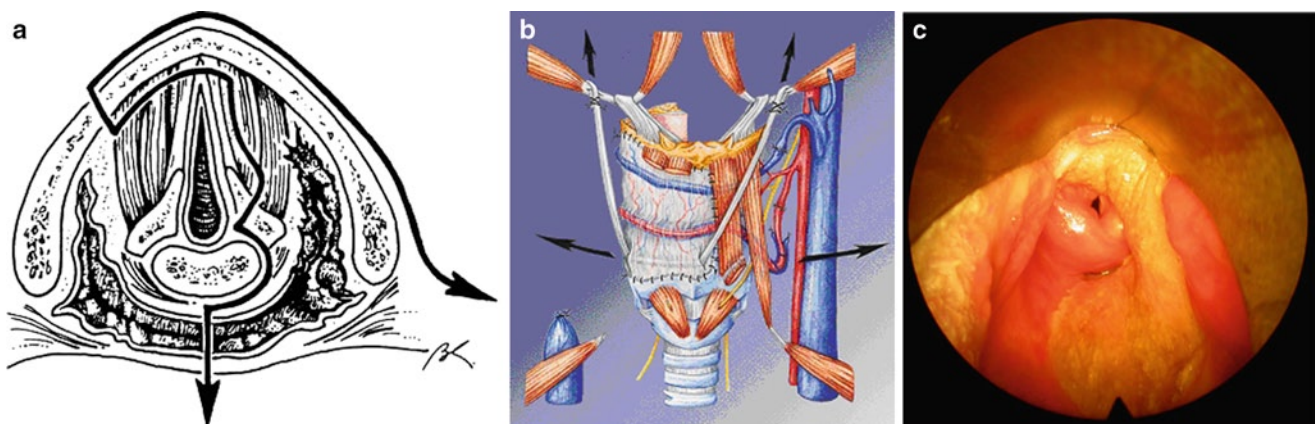


Fig. 30.6 Extended partial laryngopharyngectomy. Reconstruction using a stretched radial forearm free flap (a, b, c) [48, 55]

portion of the thyroid cartilage, recurrent laryngeal nerve, and a thyroarytenoid muscle to allow creation of a permanent tracheoesophageal shunt allowing lung-powered speech. However, the patients remain dependent of a permanent tracheostomy [61]. Near-total laryngopharyngectomy (NTLP) can be considered in patients with T2 and T3 lesions of the pyriform sinus in whom total laryngectomy is contemplated. Vocal cord fixation is not a contraindication. The resected specimen includes the entire hemilarynx from the base of the tongue to the trachea, the pyriform sinus, and part of the posterior pharyngeal wall, if indicated. The remaining contralateral posterior glottic tissues are reconstructed to form a semirigid tracheoesophageal shunt to allow phonation and effective swallowing. Reconstruction of the pharyngeal defect with a skin graft or myocutaneous flap is usually necessary to prevent pharyngeal stenosis [62].

NTLP has been used successfully by a limited number of surgeons with good locoregional control and minimal aspiration. In the Mayo Clinic experience, local control was reported as similar to that expected with TLP and conversational voice was achieved in 85% of patients [62]. This procedure is not recommended for salvage after radiation failure, postcricoid or interarytenoid tumors, bilateral vocal cord fixation, and tumors approaching the posterior midline.

Preoperative Details

Prior to treatment, the risks and benefits of treatment options should be frankly discussed with the patient. This should specifically address possible severe swallowing and speech dysfunction. Before treatment, a thorough speech therapy evaluation is necessary.

Total Laryngopharyngectomy ± Esophagectomy

Many patients are not suitable for conservation surgery and require total laryngectomy in combination with partial or total pharyngectomy and cervical esophagectomy. Total esophagectomy can be performed in combination with TLP if the tumor is extended below the cervical esophagus or in case of second primary [63].

Primary surgical procedures that do not spare the larynx are typically reserved for T4a tumors, as well as for some smaller tumors in which laryngeal function after primary CH-RT is expected to be poor. In contrast, T2–T3 lesions that involve the pyriform sinus apex or postcricoid region may require TLP for surgical cure and are thus deemed better candidates for organ preservation protocols.

Total Laryngopharyngectomy. Some hypopharyngeal cancers can be resected by total laryngectomy with partial

pharyngectomy. The pharyngeal defect is usually closed by primary closure. Because submucosal spread of hypopharyngeal tumors mandates wide margins, primary closure is sometimes not possible. If the pharyngeal defect is more extended or in a salvage situation after radiation failure, pedicled flap or free-tissue transfer is often required. Use of a pectoralis major myocutaneous flap usually allows a single stage closure [64, 65]. Most advanced tumors operated by TLP, including the cervical esophagus invariably require pedicled or free-tissue transfer for restoration of swallowing function.

Reconstruction of the hypopharynx and cervical esophagus is largely determined by the size of the defect, the availability of microvascular expertise, and the medical conditions of the patient. These defects can be reconstructed either by various tubular fasciocutaneous free flaps or pedicled myocutaneous flaps, but the preferred method of reconstruction is a free jejunal interposition [66, 67]. Free jejunal transfer has the advantages of fewer mucosal sutures, to be naturally tubular and to be harvested endoscopically. Longer segments of jejunum can be harvested for defects extending to the nasopharynx. Radial forearm flap has the advantages of ease of harvest and avoidance of intra-abdominal surgery. However, in salvage situation or in patients with poor general status, use of tubular pectoralis major myocutaneous flap has the cumulated advantages of a rapid reconstruction and the transfer of a large amount of well-vascularized muscle into the neck to protect the great vessels. A salivary by-pass is usually placed between the oropharynx and the esophagus to prevent stenosis and postoperative fistula. The by-pass is removed endoscopically a few weeks following surgery.

Surgery with curative intent is contraindicated in T4b patients with prevertebral musculature or cervical spine involvement, massive mediastinal nodal enlargement, and carotid artery involvement.

Total Laryngopharyngectomy with Total Esophagectomy. TLP with esophagectomy includes the resection of the larynx, circumferential hypopharynx, and varying lengths of the esophagus. When the lesion involves the esophagus, usually a total esophagectomy is recommended. Gastric transposition or gastric “pull-up” is indicated when total esophagectomy is necessary. Gastric transposition for esophageal replacement after laryngopharyngectomy was first reported in 1960 [68]. Elimination of the thoracotomy lessened the morbidity and mortality of the procedure and produced great improvements in results [69]. Further modifications and improvements were subsequently reported [70, 71]. Gastric transposition remains the most satisfactory one-stage method of reconstruction. However, the patient must be sufficiently healthy to withstand this extensive operation successfully. If the stomach is not suitable for use, the posterior mediastinal route can be used for left colon interposition [70, 72].

Neck Dissection: Indications and Types

Hypopharyngeal tumors have a high propensity for neck node metastases. At time of diagnosis, 70% of patients have clinically lymph node involvement [17, 18]. In addition, the incidence of patients with occult metastases is ranged between 17 and 56% [73–75]. This is most likely in pyriform sinus and posterior pharyngeal wall tumors and least likely in postcricoid tumors [73].

Consequently, for patients with SCC of the hypopharynx clinically N0, selective treatment of the neck is appropriate. Typically, levels II–IV should be treated. For tumors with invasion of the apex of the pyriform sinus or with esophageal extension, level VI nodes should also be included.

Similar guidelines could also be recommended for N1 patients without radiological evidence of extracapsular spread (ECS) [76]. For patients with multiple nodes (N2b), available data suggest that adequate treatment should include levels I–V. As for N0 patients, level VI should also be treated for tumors with esophageal extension. In tumors of the pharynx, the risk of contralateral neck metastases increased with involvement of the ipsilateral neck [77]. Bilateral neck metastasis may develop because of rich submucosal lymphatics, which cross the midline. One could recommend restricting the treatment to the ipsilateral neck for tumors of the lateral wall of the pyriform sinus only. In the other situations, prophylactic contralateral neck treatment is recommended. The selection of the node levels to be treated should follow similar rules to those for the ipsilateral neck.

Elective ND and elective neck irradiation are equally effective in controlling the N0 neck. The choice between these two procedures will thus generally depend on the treatment modality chosen for the primary tumor, which in turn mainly depends on the institutional policy. The basic rule that should guide the choice between surgery and RT is to favor the use of a single modality treatment to avoid over-treatment. For instance, for a T1N0 pyriform sinus carcinoma, conservation surgery plus selective neck dissection (SND) or primary RT on the hypopharynx and the neck are equally effective therapeutic options. For such stage disease, the need for PORT is indeed quite low.

Conversely, for a patient staged T1N2b, a conservative treatment with (CH) RT should be favored, because of the necessity of PORT in case of primary surgery and the non-superiority of the surgical approach.

SND were initially proposed for clinically node negative patients and, later on, extended to clinically node positive patients. Originally, SND was typically considered as a method to accurately stage the neck but without impact on regional control and survival. After SND, the rate of neck failure in undissected levels is low, typically below 10%. In our hands, the overall neck failure rate was 3% [78]. This low rate of neck failure is in accordance with most series

reporting neck failure rates ranged from 3.5 to 15% [73, 75, 79–81]. SND can be actually considered as the optimal procedure to manage surgically the N0 neck in patients with a high risk of occult lymph node metastasis.

The surgical management of the N1 neck is more controversial. Traditionally, radical neck dissection (RND) and modified radical neck dissection (MRND) have been the standards for patients presenting with neck disease. Andersen et al. reported that the rate of regional recurrences in the dissected neck following RND or MRND type I for N1 or N2 disease was similar [82]. Selective procedures have however gained popularity. We reported a regional failure rate of 8% in necks staged pN1 without better regional control in the necks treated with PORT, suggesting that PORT is not justified in pN1 necks without ECS [78]. Accordingly, it appears that SND for patients with limited neck disease is a safe procedure, providing that PORT is given in the presence of risk factors for regional relapse. In patients who were found to have more than one pathologically invaded lymph node following SND, PORT is clearly indicated. Patients with advanced metastatic neck disease still have poor prognosis because of high risk of regional failure and distant metastases [15].

However, the concept of less than radical procedure has gained acceptance during the last decade even in advanced regional disease. Khafif et al. reported the results of 118 patients with N2–N3 disease, treated with RND or MRND and was not able to find any difference in overall survival between the two groups [83]. In a study comparing RND and MRND (type I) in 212 patients with stages N2 and N3, the MSKCC group reported an overall 86% 5-year neck control rate and 61% 5-year actuarial survival rate [82]. No difference was found between the two groups.

PORT enhances regional control but does not seem to significantly improve survival [84]. Clark et al. reported the outcome of 181 patients who had 233 NDs for N2–N3 disease (163 extended RND, RND or MRND, and 70 SNDs) [85]. PORT to the neck was given in 82% of the patients. At 5 years, the control of disease in the treated neck was achieved in 86%. Adjuvant RT improved neck control but did not improve overall survival. The benefit of postoperative RT combined with CH was recently demonstrated in patients with ECS and is discussed further [86, 87].

Intensity Modulated Radiotherapy

Patient Set-Up

Typically, patients treated by RT for HNSCC will lie in supine position with the head and neck immobilized by some form of thermoplastic mask. They will undergo a planning CT-scan in treatment position. The use of intravenous

contrast medium and reconstruction in thin (e.g., 2.0–2.5 mm) slides is recommended.

With the use Intensity-Modulated Radiation Therapy (IMRT), there is no standard recipe anymore on how to set-up the field sizes and borders according to bony landmarks. Instead, the irradiation technique should be selected and adapted so that the entire PTV receives the prescribed dose within the adopted dose–volume constraints and in full respect of the ICRU recommendations. In that respect, it should be mentioned that a new ICRU report is in preparation aiming at updating the present recommendations on dose prescription, specification, and reporting for 3D-CRT and IMRT.

Selection and Delineation of Volumes

In collaboration with representatives of the major European and North American clinical cooperative groups, an international set of guidelines for the delineation of the neck node levels in the node-negative neck has been published [88]. Few amendments were later proposed to take into account the specific situation of the node-positive and the postoperative neck [89, 90].

The consensus guidelines for the delineation of levels I–VI and the retropharyngeal lymph nodes are presented in Fig. 30.7. It should be emphasized that the volumes delineated

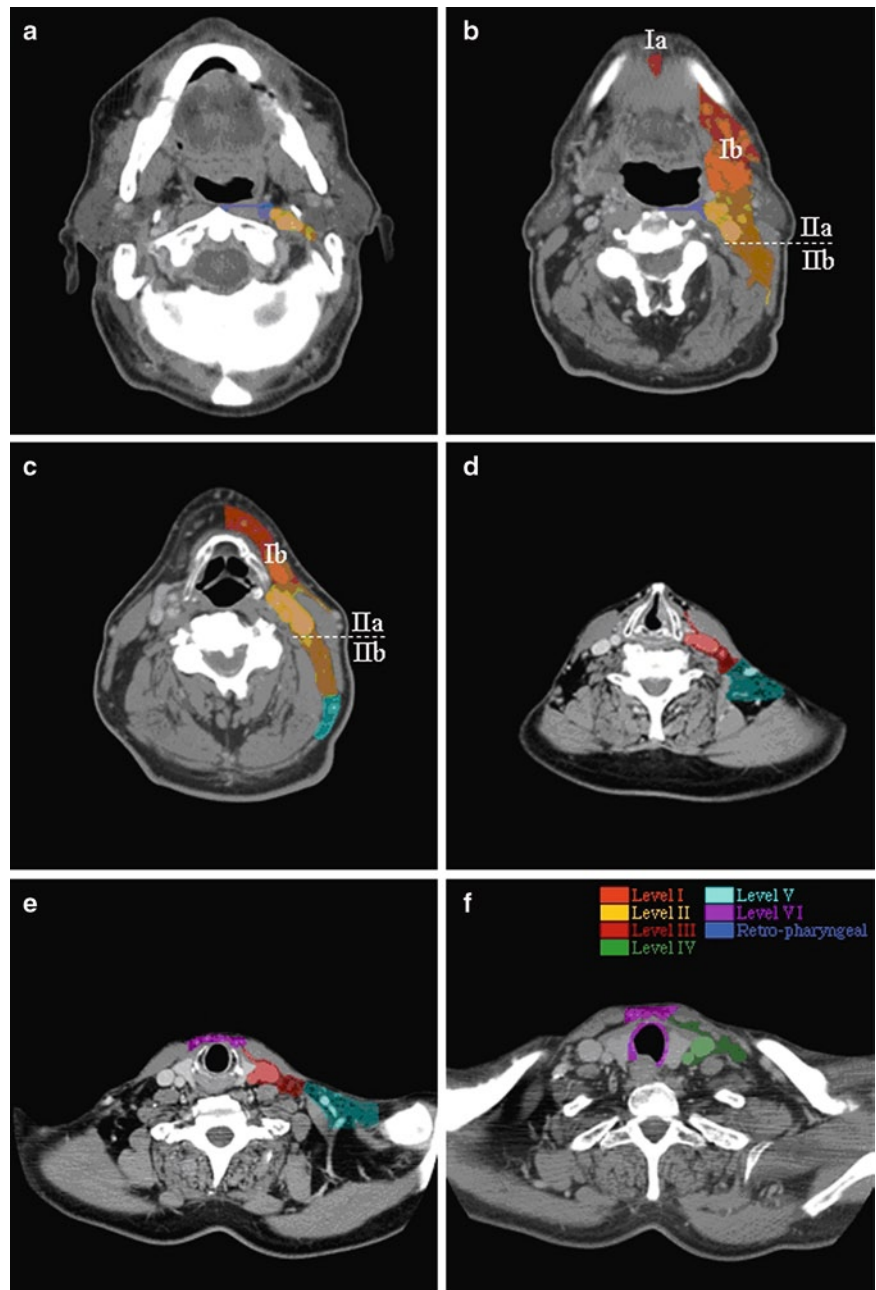


Fig. 30.7 Consensus guidelines for the delineation of levels I–VI and retropharyngeal LN. Each LN level corresponds to the clinical target volume and does not include any security margin for organ motion or set-up inaccuracy [88]

in this figure correspond to the CTV, and hence do not include margins for organ motion or set-up inaccuracy. The boundaries refer to a patient lying supine with the head in a “neutral” position. The terms “cranial” and “caudal” refer to structures closer to the cephalic and pedal ends, respectively. The terms “anterior” and “posterior” were chosen to be less confusing than the terms “ventral” and “dorsal,” respectively.

It is beyond the scope of this section to discuss in depth the various boundaries of all the node levels. The reader is referred to the original publication [88]. We however would like to draw the attention on few specific issues. The upper limit of level II was set at the caudal edge of the lateral process of the first vertebra, which is an easiest landmark than the insertion of the posterior belly of the digastric muscle to the mastoid, which is the surgical landmark. For the caudal limit of level IV, it was proposed to arbitrarily set the caudal limit of level IV 2 cm cranially to the cranial edge of the sternoclavicular joint, as the dissection of level IV typically does not go all the way down to the clavicle and definitely never reaches the medial portion of the clavicle at the level of the sternoclavicular joint. The cranial limit of level V (i.e., the base of skull) that was commonly accepted and depicted has been questioned. Hamoir has recently challenged the necessity to treat the uppermost part of level Va in mucosal HNSCC [91]. He proposed to divide the level Va into two sublevels; level Vas (superior) and level Vai (inferior), using the lower two thirds of the SAN as the cranial limit of level V. From a radiological point of view, a horizontal plane crossing the cranial edge of the body of the hyoid bone appears as a reliable landmark to separate level Vas and Vai. For the caudal limit of level V, it appears from critical examination of neck dissection procedure, that surgeons never dissect the neck further down than the cervical transverse vessels. It was thus agreed to set the caudal limit of level V at CT slices encompassing the cervical transverse vessels. Last, as the dissection of level V does not extend all the way to the anterior edge of the trapezius muscle, it was proposed to use a virtual line joining the anterolateral border of both trapezius muscles as the posterior limit of level V. The retropharyngeal space is bounded anteriorly by the pharyngeal constrictor muscles, and posteriorly by the prevertebral fascia. For the sake of simplicity and consistency, it was proposed to use the fascia below the pharyngeal mucosa as the anterior limit, and the prevertebral muscle (longus colli and longus capitis) as the posterior limit.

Retropharyngeal nodes are divided into a medial and a lateral group. The medial group is an inconsistent group which consists of one to two lymph nodes intercalated in or near the midline and it was recently proposed that it could be omitted from the delineation of the retropharyngeal CTV [92].

In some clinical situations, it was proposed to extend the delineation of the “standard” neck node levels to include the retrostyloid space and/or the subclavicular fossae [89]. In summary, the retrostyloid space should be included in the

neck CTV in case of infiltration of the upper level II, whereas the subclavicular fossae should be included in the nodal CTV in case of infiltration of level IV or Vb. Also, in case of suspicion of extracapsular extension, it was recently proposed to include the entire sterno-cleido-mastoid muscle in the target volume, at least in the entire invaded level. Another proposal was to adopt a 1-cm margin around the GTV to take into account the microscopic spread outside of the nodes [90]. This proposal would typically apply for the delineation of the therapeutic nodal CTV.

Dose Prescription, Fractionation, and Overall Treatment Time

The dose prescription depends on various factors, e.g., prophylactic versus therapeutic RT, the use of combined modality treatment, planned ND, PORT, etc., which is beyond the scope of this section for comprehensive review. Typically, for early tumor stage (e.g., T1 or small T2, node negative neck), a prophylactic dose in the order of 50 Gy in 2 Gy per fraction over 5 weeks, and a therapeutic dose in the order of 64–66 Gy in 2 Gy per fraction over 6.5 weeks will be prescribed.

For larger T stage (e.g., T3 and T4) and node positive neck, a therapeutic dose in the order of 70 Gy in 2 Gy per fraction over 7 weeks will be typically prescribed combined or not with concomitant chemotherapy or targeted agents such as EGFR inhibitor. In some clinical situations, hyperfractionation or accelerated fractionation may be proposed. Typically, hyperfractionation will deliver a therapeutic dose of 80.5 Gy in 70 fractions of 1.15 Gy delivered twice daily; a moderately accelerated regimen will deliver 70 Gy in 6 weeks using 2 Gy per fraction six times a week; very accelerated regimens will deliver a lower total dose in overall time that may range from 10 days to 3–4 weeks.

For PORT with or without concomitant CH, depending on the risk factors, doses will range from 60 to 64–66 Gy, in 2 Gy fraction over 6–6.5 weeks. There is still a debate whether a lower dose (e.g., 50 Gy) should be prescribed in low risk areas. Also should PORT always include both sides of the neck or only the side where the risk factors have been individualized? There is no firm answer to these questions, but there are some unpublished data to suggest that more selective irradiation could be safely delivered in a postoperative setting.

Chemotherapy

Platinum-based CH is the backbone of systemic treatment in HNSCC. Untreated HNSCC is a chemosensitive disease and therefore chemotherapy is frequently administered in combination with RT as a part of the multimodal curative treatment. Cytotoxic agents are often used in recurrent

and/or metastatic disease for palliation. In the curative indications, CH has been investigated either before (induction), after (adjuvant), or concomitantly to RT.

When part of the multidisciplinary approach, cisplatin, 5-fluorouracil (5-FU), and docetaxel (TPF) combination is currently the standard of care as induction CH. Three phase III trials in which induction therapy was followed by RT have demonstrated the superiority of TPF over cisplatin and 5-FU (PF) in unresectable disease, low surgical curability (stage 3 or 4) disease, or larynx preservation [37, 93, 94]. Objective response rate (ORR) after CH was 68–80% with TPF compared with 54–64% with PF [37, 93, 94]. The main clinically relevant adverse event is grade 3 and 4 neutropenia occurring in 76–83% of the patients. Antibiotic (ciprofloxacin 500 mg, orally twice daily, days 5–15) and/or granulocyte-colony stimulating factor (G-CSF) prophylaxis is recommended. The rate of febrile neutropenia despite the use of antibiotic prophylaxis, however, remains between 5 and 10%.

The most frequent regimen given concomitantly with radiation therapy is high-dose cisplatin (100 mg/m², three times during RT). Due to toxicities, only two thirds of the patients are able to receive the three planned injections of cisplatin in randomized clinical trials. Weekly cisplatin administration, with a cumulative dose beyond 200–240 mg/m², might be an alternative. However, no prospective randomized trials with enough power have compared three-weekly and weekly cisplatin administration and this invalidated regimen is not recommended on a routine basis. Cisplatin or carboplatin in combination with 5-FU and other polyCH regimens, including either platin or 5-FU were shown to be equally effective to high-dose cisplatin in a meta-analysis [95, 96].

Mono-CH regimens with another drug than cisplatin are inferior and should not be used in clinical routine. Adding CH to RT increases toxicity, mainly mucositis. Grade 3–4 mucositis occurs in more than 60% of the patients treated with CH-RT [97–99]. Nausea, vomiting, renal deficiency, and hematotoxicity are typical adverse events related to CT. To limit treatment interruption or delay, this acute morbidity requires intensive supportive care including feeding tubes when appropriate, adequate hydration (sometimes in hospitalization), and pain management.

CT has been studied in the palliative disease. The most frequently used regimens are cisplatin or carboplatin combined with 5-FU and weekly methotrexate.

Targeted Therapy

Epithelial Growth Factor Receptor Inhibitors

The epidermal growth factor receptor (EGFR) is a member of the HER tyrosine kinase growth factor receptor family. It is a transmembrane glycoprotein, which is commonly expressed

in many normal human tissues. The intracellular domain of EGFR is activated upon ligand fixation and triggers tyrosine kinase signal transduction pathways involved in tumor proliferation, apoptosis, angiogenesis, and cell migration/invasion [100]. Its expression is frequently dysregulated in many cancers including HNSCC. Preclinical studies as well as phase I and II trials have demonstrated that pharmacologic interventions that abrogate EGFR dysfunction have antitumor activity [101]. In addition, some inhibitors of EGFR have synergism with CH and RT in preclinical models [101, 102].

The most studied and investigated EGFR inhibitor is Cetuximab. Cetuximab is a chimeric IgG1 monoclonal antibody that specifically binds to the EGFR with high affinity, blocking ligand-induced EGFR phosphorylation [103]. The main side effects of Cetuximab monotherapy are acne-like skin reactions and rarely hypersensitivity. The recommended dose is a loading dose of 400–500 mg/m² and a maintenance weekly dose of 250 mg/m².

Panitumumab and Zalutumumab are two other monoclonal antibodies targeting EGFR under investigation in phase III trials for HNSCC. In contrast to Cetuximab, Panitumumab and Zalutumumab are fully human monoclonal antibodies limiting the risk of hypersensitivity.

EGFR tyrosine kinase inhibitors are orally available small molecules. The two main compounds are erlotinib and gefitinib. No significant activity has been detected in randomized trials in HN cancer [104]. Irreversible EGFR tyrosine kinase inhibitors are under development.

Other Targeted Agents

HNSCC is attractive for targeted therapies since different molecular pathways are frequently altered in this disease. However, except for EGFR inhibitors, these new drugs are not yet used in routine clinical practice, as their efficacy remains to be demonstrated in randomized trials.

The majority of HNSCC overexpress the vascular endothelial growth factor (VEGF) or the VEGF-2 and VEGF-3 receptors (VEGFR-2, -3). A meta-analysis involving 1,002 patients showed that VEGF tumor overexpression detected by immunohistochemistry was associated with decreased survival [105]. Type 1 insulin-like growth factor receptor overexpression or activation of the PI3K/AKT/mTOR pathways are also frequently observed [106]. Clinical trials with agents targeting these pathways are ongoing either in combination with radiation therapy or in the palliative setting [107].

Treatment Selection

Despite advances in treatment modalities, hypopharyngeal SCC remain the most lethal cancer of the upper aerodigestive tract.

Overall poor results are related to an anatomic disposition predisposing to silent evolution and the rich lymphatic network draining the hypopharynx, increasing the risk of regional metastasis [108]. Only 30% of patients have local disease at the time of diagnosis when 60% have locoregional disease and 10% present with distant metastases. More than 20% of patients locoregionally controlled will develop distant metastases [15, 16]. Whatever the therapeutic modality used, overall 5-year survival rates do not exceed 50% [108–110]. In selected patients with early lesions, the 5-year survival rate is about 60% [48], but in patients with advanced stage, overall survival ranges from 25 to 40% at 5 years [111–113]. It seems logical to favor laryngeal preservation approaches either surgically or non-surgically without compromising locoregional control and survival.

Early Tumors (T1-N0, N1, T2-N0, N1)

Surgery Versus Radiotherapy

The corner stone supporting guidelines for the selection of treatment in early tumors should favor the use of a single therapeutic modality. For patients with T1 or T2N0, conservation surgery plus SND and primary RT are equally effective therapeutic options. For such stage disease, the need for PORT is indeed quite low. Voice-sparing surgery is a reasonable option as patients may be cured with limited morbidity and no further treatment (Fig. 30.8a). For patients N1, surgery could be less an option owing the higher risk of PORT. For a patient staged N2, N3, a conservative treatment with (CH)RT should be favored, because of the necessity of PORT or PORT combined with CH in case of primary surgery and

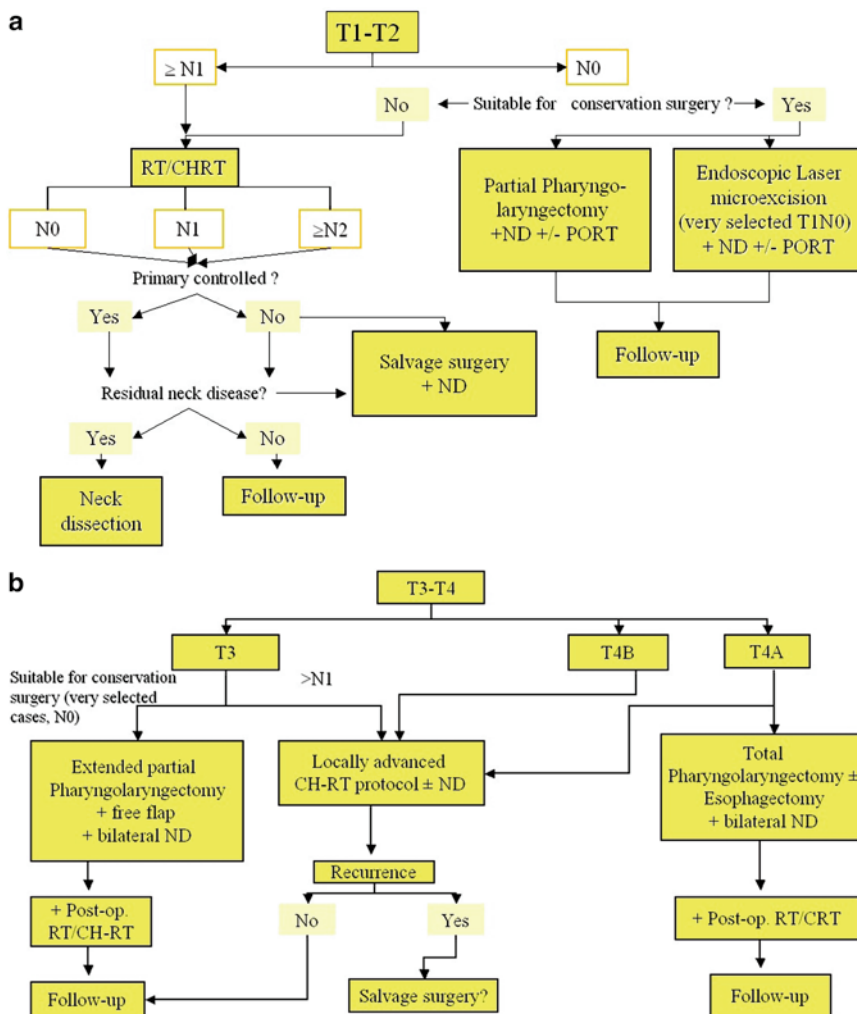


Fig. 30.8 Treatment algorithms for patients with cancer of the hypopharynx (a) early tumors (b) advanced tumors

the nonsuperiority of the surgical approach. RT is an option for nonoperable patients, patients refusing surgery and when conservation surgery is not indicated. For T1, 64–66 Gy standard fractionation is indicated when T2 should be treated with altered fractionation.

Locally Advanced Tumors (T3, T4-Any N)

Voice-Sparing Surgery

Typically, surgery should be considered as the treatment of choice for patients staged T4a. Adjuvant PORT has been demonstrated to improve locoregional control and overall survival [114, 115] (Fig. 30.8b).

Conservative surgery is rarely considered for advanced tumors because of either oncologic reasons or functional reasons. Reported series of voice-sparing surgery include a large majority of T1–T2 and less than 10% of T3–T4 [48, 52, 54, 110, 116, 117]. Selected T3–T4 of the pyriform sinus are operable using sophisticated voice-sparing procedures [56]. However, those procedures require considerable expertise and reported results are generally not reproducible in other institutions. NTLP can be considered in patients with T2 and T3 lesions of the pyriform sinus [62].

This operation has been used successfully by a limited number of surgeons with good results. But patients remain tracheostomy-dependent. Lecanu reported a series of T3–T4 treated by conservation surgery after induction chemotherapy [118]. The laryngeal functions were preserved in 54% of the patients who were alive at 3 years. This innovative concept of “therapeutic de-escalation” allowing a less morbid surgery for good responders to an induction therapy needs, however, to be validated in prospective trials.

Organ Preservation Strategy

Altered Fractionation

In the 1980s and early 1990s, several randomized studies have been conducted to validate the use of altered fractionation regimens, i.e., hyperfractionation and accelerated fractionation. A recent meta-analysis was performed and concluded that the use of altered fractionation was associated with an absolute increase in locoregional control by 6.4% at 5 years and an absolute increase in survival by 3.4% at 5 years [119]. The benefit was larger for hyperfractionation than for accelerated regimens, especially when comparing to those regimens with a reduction in total dose (very accelerated regimens). The benefit was larger for younger patients, most likely due to observation of extra-deaths in the elderly population due to intercurrent diseases.

All these regimens were associated with an increase acute mucosal toxicities, but no increase in late toxicities were reported providing that enough interfraction time was left [120–122]. Indeed, in an EORTC trial with only a 4-h interfraction time, a 50% risk of fibrosis was documented at 5 years after treatment [123].

In summary, altered fractionation regimens (especially hyperfractionation) can be recommended for moderately advanced stage tumors (e.g., T1-N1, T2-N0, T2-N1) as well as for locally advanced stage patients for whom there is a contraindication to the use of CH or EGFR inhibitors in association with RT.

Concomitant Chemoradiotherapy

Concomitant CH-RT with a platinum compound is the standard of care when a nonsurgical organ preservation approach is proposed. Most of the studies that compared concurrent CH-RT versus RT alone were generally multisites. These trials demonstrated that the addition of CH to RT improves local control and overall survival [98, 99, 124]. A meta-analysis including operable and nonoperable HNSC patients confirmed that survival was better when CH was given concomitantly to RT compared with the neoadjuvant or adjuvant approaches [95, 96]. However, it was reported that the benefit of concomitant CH-RT might be decreased in elderly patients [96].

The reason is unknown, but might be due to reduced dose intensity in elderly patients as a consequence of acute toxicity and/or to an increased in intercurrent death. Is concomitant CH-RT better than hyperfractionation or accelerated and is the combined approach (i.e., concomitant CH-altered fractionation RT) even better? A three-arm study was recently presented by the French cooperative group GORTEC comparing (1) concomitant CH-RT (70 Gy in 7 weeks and three courses of carbo-5-FU), (2) concomitant CH-accelerated RT (70 Gy in 6 weeks and two courses of carbo-5-FU), and (3) very accelerated RT (64.8 Gy in 3.5 weeks) [125]. No significant difference in survival was observed between the three arms, although there was a small advantage to concomitant chemo-RT over the two other arms.

All studies comparing RT to concomitant CH-RT were associated with a significant increase in acute locoregional toxicity. Typically, the percentage of grade 3 acute mucositis and pharyngitis reached values up to 80–90%, representing thus the upper limit of what is clinically tolerable by patients [97, 99, 125]. These studies were also associated with an increase in late toxicities [126, 127]. But it needs to be emphasized that all the mentioned studies were conducted in the pre-IMRT area, and that with the systematic use of highly conformal radiation techniques, a reduction of such toxicities is expected.

In summary, concomitant CH (3-weekly *cis*-platinum-based regimen) and RT represents the standard nonsurgical regimen for locally advanced HNSCC. It is associated with an increased acute toxicity requiring careful management and follow-up of patients during treatment.

Concomitant EGFR Inhibitors and Radiotherapy

RT plus Cetuximab also improves locoregional control and overall survival over RT alone: median duration of locoregional control 24.4 months versus 14.9 months and median overall survival 49 months versus 29.3 months, respectively [128]. There is however no study that directly compared concomitant CH-RT to concomitant Cetuximab-RT. Regarding acute toxicity, except infusion reactions and cutaneous rash, there was no increase of the typical radiation-induced laryngitis, mucositis, and pharyngitis in the combined modality arm [129]. There are however some reports on dramatic increase of skin toxicities in patients treated concomitantly with RT and Cetuximab [130, 131].

In summary, the concomitant use of Cetuximab and RT represent an alternative approach to concomitant CH-RT for patients with locally advanced SCC of the head and neck. However, as there is no confirmatory trial of the Cetuximab efficacy in combination with RT, this agent might be better used in case of contraindication to CH, e.g., impaired kidney function, poor performance status, and elderly patients.

Role of Induction Chemotherapy

Induction platinum-based therapy followed by RT in patients who responded to CH is an alternative to TLP for locally advanced operable hypopharynx cancers. For larynx preservation, in the RTOG 91-11 study, no difference for overall survival was detected between induction with cisplatin and 5-FU and concurrent chemo-RT, although local control and larynx preservation rates were greater with concomitant CH-RT. However, hypopharyngeal cancers were not included in this trial [97]. The EORTC 24891 study randomized 202 patients with locally advanced hypopharyngeal cancer between immediate TLP and postoperative RT versus induction CH with cisplatin and 5-FU (three cycles) followed by RT if a complete response was obtained after the three cycles of neoadjuvant CH [132, 133]. In the preservation arm, if macroscopic disease was still present after neoadjuvant CH, TLP was performed. There was no statistical difference between the arms regarding 5-year survival (preservation arm: 38% and surgery arm: 33%) and progression-free survival (preservation arm: 32% and surgery arm: 26%). The 5-year larynx preservation rate (alive with a functional larynx without local relapse or tracheotomy or feeding tube) was

22% in the induction CH group. More recently, the GORTEC compared TPF versus PF as induction CH for larynx preservation. A higher proportion of patients with advanced hypopharynx and larynx cancer achieved 3-year larynx preservation rate with TPF than with PF: 70.3% versus 57.5% [94].

Lefebvre and colleagues reported a phase II trial (TREMPLIN) investigating sequential CH-RT for larynx preservation to test the feasibility of combining the induction and concomitant approaches [134]. Larynx and hypopharynx cancer patients eligible for a total laryngectomy were included. TPF was given for three cycles. In case of response >50%, patients were randomized to receive either RT plus cisplatin or RT plus Cetuximab. TPF-induced toxicity precluded further cisplatin in seven patients. TPF followed by concurrent Cetuximab plus RT was better tolerated than TPF followed by concurrent cisplatin and RT with the same larynx preservation rate at 3 months (93 and 96% of the randomized patients in the cisplatin and Cetuximab groups, respectively). A planned transatlantic study should better define the role of induction and/or concomitant CH for larynx preservation. This trial will randomize patients between cisplatin-based concomitant CH-RT, TPF followed by RT, and TPF followed by RT and concomitant Cetuximab.

In summary, outside of clinical studies, the use of induction CH with TPF should remain investigational, and for organ preservation strategies, concomitant CH-RT should remain the treatment of choice.

Concomitant Chemoradiotherapy Versus Induction Chemotherapy

No study dedicated only to hypopharyngeal cancer subsite is currently available. Based on the Pignon meta-analysis and randomized trials, many consider concomitant CH-RT as the standard of care [95, 96]. Cetuximab can be used as radiosensitizer if the patients cannot tolerate platinum-based CH [128]. Two phase III trials have revisited the status of induction CH for patients with “unresectable” disease. TPF was followed by RT alone in EORTC 24971/TAX323 trial and by CH-RT (weekly carboplatin) in the TAX324 [37, 93]. Both studies demonstrated that TPF significantly improves median survival compared with PF as induction therapy: 18.8 months versus 14.5 months in TAX324 and 71 months versus 30 months in TAX323. Therefore, TPF is considered as the standard of care for induction.

There are important differences between these two trials. First, in the TAX 323, only patients considered unresectable were included. In contrast, inclusion criteria were larger in TAX324 with the inclusion, beside unresectable disease, of patients with low surgical curability on the basis of advanced tumor stage or regional-node stage, or who were candidates for organ preservation. Second, in the TAX323, TPF was

followed by RT only (70 Gy) and in the TAX 324 by concomitant weekly carboplatin (area under the curve 1.5) and RT. Of note, both studies included all HN sites. Hypopharynx cancer represented 29 and 16% of the patients in the TAX323 and TAX324, respectively.

There is a strong rationale to investigate if TPF induction followed by concomitant CH-RT is feasible and provides further benefit to patients with locally advanced HNSSC over CH-RT alone. Paccagnella and colleagues randomized 101 unresectable patients between TPF followed by CHRT with two cycles of cisplatin and 5-FU versus the same CH-RT regimen [135]. This small study suggested that TPF followed by CH-RT is feasible and that TPF does not compromise the subsequent delivery of CH-RT. Complete response was higher in the TPF group: 46% versus 19.6%. Hitt and colleagues recently reported data from a randomized study aiming at comparing concomitant CH (3-weekly platinum) with RT, induction CH with PF followed by CH-RT, or TPF followed by CH-RT [136]. Surprisingly, the data of the two induction CH arms were pooled and the analysis did not include all patients who were randomized. Because of this methodological concern, nothing can be concluded from this study and the issue on how to position the use of induction CH with TPF is still unresolved. Results of ongoing studies are awaited.

In addition, CH-RT is toxic and attempts to increase tolerability are important. In this context, targeted agents that have a better toxicity profile than CH could be nicely incorporated into the standard regimen either in combination with CH-RT or to replace CH as radiosensitizer.

Postradiotherapy Neck Dissection

Organ preservation strategy has led to controversial issues concerning the role of ND following (CH) RT for patients with advanced regional disease at initial diagnosis. Residual neck mass may be present in as much as 30–50% of patients after completion of RT. For those patients, irrespective of the neck stage, there is a consensus in the literature favoring an immediate ND, because of the very low probability of achieving a neck control with salvage surgery when recurrence develops [137]. Whether a ND should be systematically proposed to all patients initially staged N2–N3 regardless of the response [138–143] or only to those with clinical and/or radiological evidence of residual lymph node disease [144–147], is still a matter of debate.

Proponents of planned ND argue that the procedure reduces the regional failure rate, possibly improves the cause-specific survival and that salvage surgery in the event of neck recurrence is unlikely to succeed [137–139]. Proponents of a “wait and see” approach in case of clinical complete response argue that the probability of an isolated recurrence in the

neck is low and that a systematic planned ND strategy results in overtreatment with the risk of complications in a significant percentage of complete responders. The controversy is fueled by the difficulty of assessing the residual neck disease after organ-preservation protocol. In this respect, the use of PET-FDG has gained some interest [148–151]. Currently, multicenter prospective studies are ongoing, assessing the accuracy of PET-FDG in correctly predicting the pathological lymph node status after CH-RT. In the meantime, the role of ND will remain unresolved. However, ND should be recommended for patients with less than a complete response in the neck to optimize regional control.

Whatever are the opinions on to perform or not planned ND after CH-RT, little attention has been paid to the applicability of less than RND or MRND in this setting. The rationale for SND is based on the predictive patterns of lymphatic spread in cancer of the upper aerodigestive tract [74].

However, whereas the concept of SND is widely accepted for patients with limited regional disease when surgery is proposed as primary treatment, its applicability in advanced nodal disease remains oncologically unsound [78]. In the postCH-RT setting, one could, however, hypothesize that the preoperative treatment was effective to prophylactically treat all levels at risk for microscopic infiltration, and that only the levels in which residual disease is still anticipated require ND. In other words, when residual disease still persists in high-risk node levels following CH-RT, ND is clearly required, but the likelihood to find positive nodes in low-risk neck levels is very low despite the persistence of residual lymph node metastases in high-risk levels. Few data are available regarding the localization of residual invaded lymph nodes in patients with advanced nodal disease initially treated using a nonsurgical approach and SNDs. In limited series of 25 patients with clinically positive lymph nodes, Boyd et al. reported that level-specific locations of residual lymph nodes were predictable in all but one patient who had an initial N3 disease [138].

The use of SND was reported after CH-RT [141, 144]. In patients with advanced regional disease, Robbins et al. reported 35 neck dissections performed after CH-RT. Most procedures (33/35) were SNDs. In all cases, it was possible to completely excise all residual positive lymph nodes with negative margins on pathological examination of the whole specimen. There was only one neck recurrence [152]. Stenson et al. reported 69 patients who had ND after concomitant CH-RT. Most patients (56/69) underwent SNDs. Thirty five percent of patients had positive lymph nodes found in their specimens, while only one patient experienced recurrence in the neck after ND [153]. These results support the adequacy of SND after CH-RT even in patients with initially advanced regional disease [152–154]. SND II–IV is appropriate for the large majority of patients primarily treated by CH-RT who have residual regional disease. The rate of postoperative complications is low and

comparable to the rate of complications after primary surgery [153, 155]. Despite the absence of prospective study comparing SND with more comprehensive ND after organ preservation protocols, intuitively, one would expect less fibrosis, shoulder dysfunction, and neck deformity in patients who underwent limited neck surgery.

Postoperative Radiotherapy: Concomitant Chemoradiotherapy

The benefit of PORT in HNSCC has progressively emerged in the 1970s and 1980s as a standard of care for patients at high risk of locoregional relapse after surgery [156–159]. Prognostic indicators for locoregional relapse after surgery have been progressively identified, including the primary disease site, the surgical margins at the primary site, the presence of perineural invasion, the number of metastatic lymph nodes, and the presence of ECS [160, 161]. Based on the clustering of these pathologic factors, the MD Anderson Cancer Center proposed to stratify the patients into three risk categories conditioning the need for PORT [162]. In the absence of any risk factor, the need of PORT could not be demonstrated. Patients with extracapsular rupture or a combination of two or more risk factors were identified as being at high risk of locoregional relapse, and for those patients, a randomized study demonstrated the benefit of a radiation dose of 63 Gy (in 35 fractions) compared to 57.6 Gy (in 32 fractions). For patients with only one risk factor other than extracapsular rupture, a dose of 57.6 Gy was demonstrated as optimal. A subsequent study from the same group further validated the use of these categories of risk factors, and also individualized the time between surgery and the start of PORT as well as the total treatment time (from surgery to the end of RT) as additional risk factors [163]. In this study, it was also demonstrated that patients with high risk of relapse benefited from an accelerated treatment (63 Gy in 5 weeks versus 63 Gy in 7 weeks) both in term of locoregional control and survival.

With the need to further improve the locoregional control after surgery and PORT, few trials combining postoperative concomitant CH and RT have been reported in the 1990s [164, 165]. Although positive in favor of the combined approach, these studies did not really influence the pattern of care of patients primarily treated with surgery. More recently the EORTC and the RTOG conducted similarly designed studies aiming at assessing the benefit of PORT (60–66 Gy) combined with *cis*-platinum (100 mg/m²) given on days 1, 22, and 43 for patients with a variety of risk factors, but slightly different between the two trials [86, 87]. In the EORTC study, a highly statistically significant benefit in favor of the combined treatment was observed for both locoregional control and overall survival. In the RTOG study,

the benefit in locoregional control probability did not translate into a statistically significant difference in survival. Combined modality treatment did not decrease the incidence of distant metastasis in any of these studies. In both studies, the concomitant use of CH significantly enhanced the acute local toxicity of RT and only half the patients could actually receive the full treatment as planned. A meta-analysis of these two studies was recently performed and demonstrated a statistically significant benefit of combined CH-RT but only in patients presenting with positive surgical margins and/or ECS, i.e., patients with the highest risk of relapse after surgery [166]. For the other patients, RT alone can still be considered as a standard of care.

Recurrent Disease

Salvage Surgery

In a few highly selected cases of early tumors treated with primary RT, conservation surgery is feasible [48, 55]. Patients suitable for this approach should have a limited local recurrence without hemilarynx fixation and cartilaginous invasion. Most patients with local recurrence, candidate for salvage surgery require TLP. Salvage surgery for local recurrence is generally associated with high morbidity and poor oncological and functional outcome.

Investigators from Princess Margaret Hospital, Toronto, reviewed a series of 72 patients with salvage pharyngectomy for radiation failure. The 5-year overall survival, disease-specific survival, local and regional control rates were 31, 40, 71, and 70%, respectively [167]. ECS was the only independent prognostic variable on multivariable analysis. This study demonstrated that salvage surgery is a viable option with high locoregional control in experienced hands. These results contrast with those reported by others [168], reporting high rates of postoperative major complications, incomplete resections, and recurrences with only 10% of patients alive and tumor-free at 3 years [168]. Patients with regional recurrence in addition to local recurrence will be unlikely successfully salvaged by surgery and should be selected for adjuvant therapy.

Is PORT or concomitant CH-RT useful after salvage surgery? A randomized study has recently shown that for patients with adverse pathologic features on the pathologic specimen, the disease-free survival but not the survival was prolonged after concomitant CH-RT compared to RT alone [169]. The regimen was, however, not common and the toxicity was substantially increased. Whether such treatment should become a standard of care should be individually assessed.

For patients doomed unresectable or unfit for salvage surgery, salvage RT in previously irradiated sites (typically only directed to the recurrent area) has been reported, but

with modest or poor results depending on patient selection and extent of disease [170, 171]. Such reirradiation in previously irradiated sites has to be distinguished from a new irradiation in a previously unirradiated area that could be proposed for second primary tumor. In this latter situation, providing adequate dose could be delivered, cure rates similar to those expected in previously untreated patients are observed.

Palliative Disease

Systemic Treatment

Patients with distant metastases or locoregional relapse not amenable to surgery or RT are considered incurable. Pulmonary metastases accounts for two thirds of these metastases [16]. It is important to distinguish between head and neck metastasis and a primary lung cancer because the latest could be treated with a curative intention. Pathology is often required to orientate adequately the diagnosis. In case of a solitary SCC pulmonary nodule, the patient should be treated surgically as for a primary lung cancer.

In the presence of a palliative disease, the prognosis is dismal with a median survival ranging between 4.5 and 10 months. Patients with good performance status, locoregional relapse only or no previous exposure to CH have the best overall survival [172]. A small study suggested that cisplatin might improve overall survival over best supportive care although this trial did not have enough statistical power [173]. Patients who have symptoms to palliate and wish to try CH are often treated with a combination of cisplatin/carboplatin and 5-fluorouracil. Response rate ranges between 10 and 32% [174, 175]. Cisplatin/paclitaxel combination was compared with cisplatin/5-FU in a randomized phase III trial: ORR was 22 and 29% and median overall survival was 9 and 8 months, respectively. Methotrexate gives 10% ORR with a median survival around 6 months. Minimal activity has been also detected with other cytotoxics (docetaxel, paclitaxel, oxaliplatin, 5-FU, capecitabine, gemcitabine, vinorelbine, pemetrexed, ifosfamide, etc.) but large randomized trials are missing with these agents.

Targeted agents have been also tested in recurrent patients. The median progression-free survival (1.3–4.2 months) and overall survival (4.2–8.1 months) remain low when these agents are given as monotherapy, maybe also because they have been mainly studied in end-stage patients with progressive disease after platinum-based therapy [107]. The most promising targeted agents are inhibitors of the EGFR pathway. Cetuximab improves survival when added to the combination of cisplatin and 5-fluorouracil (5-FU) or carboplatin and 5-FU and this combination is the current standard of care for the first palliative line of HNSCC [176].

Role of Local Treatment

Half of the palliative patients never develop distant metastases but experience a noncurable locoregional relapse with frequent important functional comorbidities related to swallowing, speaking, and breathing. Cutaneous cancer ulceration can also be debilitating with pain, wound healing, infection, and esthetic problems. Therefore, it is of utmost importance to maintain a regular follow-up of these patients by the multidisciplinary team to adequately evaluate the local consequences of the recurrence and provide the best local supportive care. Systemic treatment can relieve temporally symptoms in case of response. Surgery is rarely useful and disfiguring. RT can be used to palliate symptoms such as pain and bleeding.

Follow-Up and Outcome

After the initial treatment, a comprehensive examination of all the upper aerodigestive tract including a flexible fiberoptic endoscopy and a neck examination is recommended every 2 months for 2 years after the initial treatment, every 4 months during the third year following treatment and two times per year thereafter. If PET-FDG was informative at initial diagnosis, posttreatment FDGPET should be repeated not sooner than 12 weeks after radiotherapy to optimize the accuracy of the reading [148–151]. Chest X-ray films for the detection of second primary lung cancer or distant metastases are routinely performed once per year. TSH level is checked once per year to detect occult hypothyroidism. Dental monitoring is important following RT, due to xerostomia and increased risk of tooth decay. Careful attention to cleaning, scaling, periodontal health, and lifelong topical fluoride treatment can reduce the risk of tooth loss and osteoradionecrosis.

Advanced hypopharyngeal SCC have still a dismal prognosis. The frequency of distant metastases is the highest of all HNSCC. During follow-up, 25% of patients locoregionally controlled will develop distant metastases, usually in the lungs, liver, and bones [15, 16, 19]. Despite a good local control rate, most patients succumb to distant metastases, intercurrent diseases, or second primaries. Not surprisingly, overall 5-year survival rates is approximately 30% [108–110]. When the 5-year survival rate with early lesions is about 50–60% [48, 177], in T3–T4 lesions or advanced regional disease, survival drops to 25–35% at 5 years [111–113, 132]. In 1997, a survey analyzed demographics and standards of care for the treatment of hypopharyngeal SCC in the USA. Of 2,939 cases, the 5-year disease-specific survival was 33.4%. The disease-specific survival based on stage was 63.1% for stage I disease, 57.5% for stage II, 41.8% for stage III, and 22% for stage IV [178].

Perspectives

Future directions are untimely connected with advances in the management of other HNSCC. This is essentially due to the difficulties of conducting large clinical trials in patients with cancers of only a single site. Several investigations have not improved survival but have improved the quality of life. In this frame, laryngeal preservation is a typical example. What is required is developing treatments with less toxicity, promoting protocols preserving the organ function more than the organ itself and individualizing therapy according to the molecular signature of the tumor.

The introduction of the EGFR inhibitors has demonstrated that targeted therapy combined to radiotherapy can be delivered to HNSCC without increasing mucositis. This last approach improves survival by increasing local control but did not affect the rate of distant metastases. In contrast, clinical trials have demonstrated that the addition of CH to RT decreases the risk of late distant recurrences, which is a particularly important pattern of failure in hypopharyngeal cancers.

However, CH-RT is toxic. Targeted agents have a better toxicity profile than CH and could be nicely incorporated into the standard regimen either to improve efficacy and/or decrease treatment toxicity. Ongoing studies investigating the combination of targeted agent administration during or after induction CH or with conventional CH-RT regimens will help to better define the respective role of CH and targeted agents in the multimodal treatment of this disease. In addition, efforts to identify predictive biomarker that could help to better select the patients who will benefit of a specific treatment modality is of crucial importance.

Continued improvements in conservative surgical techniques allow for the potential for further surgical resection to be performed with less swallowing morbidity. The incorporation of induction CH or targeted therapy to reduce tumor volume, allowing more oncologically sound conservative procedures, introduces an innovative concept of surgical de-escalation that should be validated in prospective trials.

Improvements in more conformal radiation techniques will continue to be limited by the need to define the extent of cancer spread. Traditional techniques have relied on alterations in the shape, size, and appearance of normal tissues. The increasing use of FDG-PET scans now allows smaller volumes of cancer spread, such as is found in normal-sized cervical lymph nodes, to be identified. This is particularly important for more conformal radiation techniques, in which underdosing areas of the neck that appear otherwise normal is possible.

Future developments in additional imaging agents that allow for more specific aspects of cancer to be detected offer the promise of smaller volumes of cancer spread to be

detected and greater confidence in the use of conformal irradiation. Even more exciting is the promise of newer imaging agents and techniques that can be used noninvasively to determine various biologic aspects of the cancer. Examples include the ongoing studies of various agents that bind to areas of tumor hypoxia, which has been shown to increase radiation resistance in head and neck cancers. The ability to tag such agents with radioactive markers allows them to be used as imaging agents such as has been achieved using an hypoxia marker which has been shown to be of prognostic significance in head and neck cancers.

References

1. Ries LAG, Eisner MP, Kosary CL, et al. SEER Cancer statistics review, 1997–2002. Bethesda: National Cancer Institute; 2005.
2. Cancer incidence in Belgium, 2004–2005, Belgian Cancer Registry, Brussels, Belgium.
3. Barnes L, Johnson JT. Pathologic and clinical considerations in the evaluation of head and neck specimens resected for cancer. Part 1. *Pathol Annu.* 1986;21(Pt 1):173–250.
4. Wynder EL, Hultberg S, Jacobson F, et al. Environmental factors in cancer of the upper alimentary tract; a Swedish study with special reference to Plummer-Vinson (Paterson-Kelly) syndrome. *Cancer.* 1957;10(3):470–87.
5. Ahlbom HE. Simple achlorhydric anaemia, Plummer-Vinson syndrome, and carcinoma of the mouth, pharynx, and oesophagus in women. *Br Med J.* 1936;2(3945):331–3.
6. Amos A. Women and smoking. *Br Med Bull.* 1996;52(1):74–89.
7. Ndiaye IC, Diom ES, Diop F, Tall A, Ndiaye M, Essalki I, et al. Squamous carcinoma of the hypopharynx in Senegal: between disarray and enigma. *Int J Pediatr Otorhinolaryngol.* 2009;73(3):357–61.
8. Raghavan U, Quraishi S, Bradley PJ. Multiple primary tumors in patients diagnosed with hypopharyngeal cancer. *Otolaryngol Head Neck Surg.* 2003;128(3):419–25.
9. Rodrigo JP, González MV, Lazo PS, et al. Genetic alterations in squamous cell carcinomas of the hypopharynx with correlations to clinicopathological features. *Oral Oncol.* 2002;38(4):357–63.
10. Poeta LM, Manola J, Goldwasser MA, et al. TP 53 mutations and survival in squamous cell carcinoma of the head and neck. *N Engl J Med.* 2007;357(25):2552–61.
11. Silver CE. Surgical anatomy of the larynx. In: Silver CE, editor. *Surgery for cancer of the larynx and related structures.* New York: Churchill Livingstone; 1981. p. 15–24.
12. Rouvière H. *Anatomie humaine descriptive et topographique.* 6th ed. Paris: Masson et Cie; 1948. p. 226–30.
13. Vidic B, Suarez-Quian C. Anatomy of the head and neck. In: Harrison LB, Sessions RB, Ki Hong W, editors. *Head and neck cancer. A multidisciplinary approach.* 1st ed. Philadelphia: Lippincott-Raven; 1998. p. 79–114.
14. Kotwall C, Sako K, Razack MS, et al. Metastatic patterns in squamous cell cancer of the head and neck. *Am J Surg.* 1987;154:439–42.
15. Merino OR, Lindberg RD, Fletcher GH. An analysis of distant metastases from squamous cell carcinoma of the upper respiratory and digestive tracts. *Cancer.* 1977;40:145–51.
16. Marks JE, Kurnik B, Powers WE, Ogura JH. Carcinoma of the pyriform sinus. An analysis of treatment results and patterns of failure. *Cancer.* 1978;41:1008–15.

17. Lindberg R. Distribution of cervical lymph node metastases from squamous cell carcinoma of the upper respiratory and digestive tract. *Cancer*. 1972;29:1446–9.
18. Houck JR, Medina JE. Management of cervical lymph nodes in squamous cell carcinomas of the head and neck. *Semin Surg Oncol*. 1995;11:228–39.
19. Garden AS, Morisson WH, Ang KK. Larynx and hypopharynx cancer. In: Gunderson LL, Tepper JE, editors. *Clinical radiation oncology*. 2nd ed. Philadelphia: Churchill Livingstone; 2007. p. 727–54.
20. Wenig BL, Ziffra KL, Mafee MF, Schild JA. MR imaging of squamous cell carcinoma of the larynx and hypopharynx. *Otolaryngol Clin North Am*. 1995;28:609–19.
21. Becker M, Zbären P, Casselman JW, et al. Neoplastic invasion of laryngeal cartilage: reassessment of criteria for diagnosis at MR imaging. *Radiology*. 2008;249:551–9.
22. Curtin HD, Ishwaran H, Mancuso AA, et al. Comparison of CT and MR imaging of neck metastases. *Radiology*. 1998;207:123–30.
23. King AD, Ahuja AT, Yeung DK, et al. Malignant cervical lymphadenopathy diagnostic accuracy of diffusion-weighted MR imaging. *Radiology*. 2007;245:806–13.
24. Vandecaveye V, De Keyzer F, Vander Poorten V, et al. Head and neck squamous cell carcinoma: value of diffusion-weighted MR imaging for nodal staging. *Radiology*. 2009;251:134–46.
25. Kyzas PA, Evangelou E, Denaxa-Kyza D, Ioannidis JPA. ¹⁸F-fluorodeoxyglucose positron emission tomography to evaluate cervical node metastases in patients with head and neck squamous cell carcinoma: a meta-analysis. *J Natl Cancer Inst*. 2008;100:71220.
26. Daisne JF, Duprez T, Weynand B, et al. Tumor volume in pharyngolaryngeal squamous cell carcinoma: comparison at CR, MR imaging, and FDG PET and validation with surgical specimen. *Radiology*. 2004;233:93–100.
27. Gregoire V, Haustermans K, Geets X, et al. PET-based treatment planning in radiotherapy: new standard? *J Nucl Med*. 2007;48 Suppl 1:68S–77.
28. Troel RJ, Terris DJ. Detection of metastases from head and neck cancers. *Laryngoscope*. 1995;105:247–50.
29. Basu D, Siegel BA, McDonald DJ, et al. Detection of occult bone metastases from head and neck squamous cell carcinoma: impact of positron emission tomography computed tomography with fluorodeoxyglucose F 18. *Arch Otolaryngol Head Neck Surg*. 2007;133:801–5.
30. Senft A, de Bree R, Hoekstra OS, et al. Screening for distant metastases in head and neck cancer patients by chest CT or whole body FDG-PET: a prospective multicenter trial. *Radiother Oncol*. 2008;87:221–9.
31. Gourin CG, Watts TL, Williams HT, et al. Identification of distant metastases with positron-emission tomography-computed tomography in patients with previously untreated head and neck cancer. *Laryngoscope*. 2008;118:671–5.
32. Lonnet M, Hamoir M, Reyckel H, et al. PET-FDG improves staging and patient management in head and neck squamous-cell carcinoma patients. A multi-center prospective study. *J Clin Oncol*. 2010;28:1190–5.
33. Haughey BH, Gates GA, Arfken CL, Harvey J. Meta-analysis of second malignant tumors in head and neck cancer: the case for an endoscopic screening protocol. *Ann Otol Rhinol Laryngol*. 1992;101:105–12.
34. de Bree R, Lips P, Leemans CR. The need for patient's endocrine function vigilance following treatment of head and neck cancer. *Curr Opin Otolaryngol Head Neck Surg*. 2008;16:154–7.
35. American Joint Committee on Cancer Staging. *American Joint Committee on Cancer Staging Manual*. 6th ed. Philadelphia: Lippincott-Raven; 2002.
36. Scrijvers D, Van Herpen C, Kerger J, et al. Docetaxel, cisplatin and 5-fluorouracil in patients with locally advanced unresectable head and neck cancer: a phase I-II feasibility study. *Ann Oncol*. 2004;15:638–45.
37. Vermorcken JB, Remenar E, van Herpen C, for the EORTC 24971/TAX323 Study Group, et al. Cisplatin, fluorouracil, and docetaxel in unresectable head and neck cancer. *N Engl J Med*. 2007;357:1695–704.
38. Thompson AC, Quraishi SM, Morgan DA, Bradley PJ. Carcinoma of the larynx and hypopharynx in the elderly. *Eur J Surg Oncol*. 1996;22:65–8.
39. Jones AS, Houghton DJ, Beasley NJ, Husband DJ. Improved survival in patients with head and neck cancer in the 1990s. *Clin Otolaryngol Allied Sci*. 1998;23:319–25.
40. Salama JK, Vokes EE, Chmura SJ, et al. Long term outcome of concurrent chemotherapy and reirradiation for recurrent and second primary head and neck squamous cell carcinoma. *Int J Radiat Oncol Biol Phys*. 2006;64:382–91.
41. Candela FC, Kothari K, Shah JP. Patterns of cervical node metastases from squamous carcinoma of the oropharynx and hypopharynx. *Head Neck*. 1990;12:197–203.
42. Mendenhall WM, Parsons JT, Devine JW, et al. Squamous cell carcinoma of the pyriform sinus treated with surgery and/or radiotherapy. *Head Neck Surg*. 1987;10:88–92.
43. Ho CM, Lam KH, Wei WJ, Yuen AP. Submucosal tumor extension in hypopharyngeal cancer. *Arch Otolaryngol Head Neck Surg*. 1997;123:959–65.
44. Hirano M, Kurita S, Tanaka H. Histopathologic study of carcinoma of the hypopharynx: implications for conservation surgery. *Ann Otol Rhinol Laryngol*. 1987;96:625–9.
45. Steiner W, Ambrosch P, Less CF, Kron M. Organ preservation by transoral laser microsurgery in pyriform sinus carcinoma. *Otolaryngol Head Neck Surg*. 2001;124:58–67.
46. Rudert HH, Höft S. Transoral carbon dioxide laser resection of hypopharyngeal carcinoma. *Eur Arch Otorhinolaryngol*. 2003;260:198–206.
47. Ogura JH, Watson RK, Jurema AA. Partial pharyngectomy and neck dissection for posterior hypopharyngeal cancer. Immediate reconstruction with preservation of voice. *Laryngoscope*. 1960;70:1523–34.
48. Plouin-Gaudon I, Lengelé B, Desuter G, et al. Conservation surgery for selected pyriform sinus cancer. *Eur J Surg Oncol*. 2004;30:1123–30.
49. Dolivet G, Gangloff P, Sarini J, et al. Modifications of the infrahyoid flap. *Eur J Surg Oncol*. 2005;31:294–8.
50. Holsinger FC, Motamed M, Garcia D, et al. Resection of selected invasive squamous cell carcinoma of the pyriform sinus by means of the lateral pharyngotomy approach: the partial lateral pharyngectomy. *Head Neck*. 2006;28:705–11.
51. Ogura JH, Jurema AA, Watson RK. Partial laryngopharyngectomy and neck dissection for pyriform sinus cancer. Conservation surgery with immediate reconstruction. *Laryngoscope*. 1960;70:1399–417.
52. Ogura JH, Marks JE, Freeman RB. Results of conservation surgery for cancers of the supraglottis and pyriform sinus. *Laryngoscope*. 1980;90:591–600.
53. Laccourreye H, Lacau St Guily J, Brasnu D, et al. Supracricoid hemilaryngopharyngectomy. Analysis of 240 cases. *Ann Otol Rhinol Laryngol*. 1987;96(2 Pt 1):217–21.
54. Chevalier D, Watelet JB, Darras JA, Piquet JJ. Supraglottic hemilaryngopharyngectomy plus radiation for the treatment of early lateral margin and pyriform sinus carcinoma. *Head Neck*. 1997;19:1–5.
55. Hamoir M, Lengelé B, Rombaux P, et al. Stretched radial forearm flap for reconstruction of the laryngopharynx: an alternative conservation procedure for radiation-failure carcinoma of the pyriform sinus. *Laryngoscope*. 1999;109:1339–43.
56. Urken ML, Blackwell K, Biller HF. Reconstruction of the laryngopharynx after hemispheric/hemithyroid cartilage resection.

- Preliminary functional results. *Arch Otolaryngol Head Neck Surg.* 1997;123:1213–22.
57. Laccourreye O, Mérite-Drancy A, Brasnu D, et al. Supracricoid hemilaryngopharyngectomy in selected pyriform sinus carcinoma staged as T2. *Laryngoscope.* 1993;103:1373–6.
 58. Kania R, Hans S, Garcia D, et al. Supracricoid hemilaryngopharyngectomy in patients with carcinoma of the pyriform sinus. Part II: Incidence and consequences of local recurrence. *Ann Otol Rhinol Laryngol.* 2005;114:95–104.
 59. Laccourreye O, Ishoo E, de Mones E, et al. Supracricoid hemilaryngopharyngectomy in patients with carcinoma of the pyriform sinus. Part I: Technique, complications and long term functional outcome. *Ann Otol Rhinol Laryngol.* 2005;114(1 Pt 1):25–34.
 60. Julieron M, Kolb F, Schwaab G, et al. Surgical management of posterior pharyngeal wall carcinomas: functional and oncologic results. *Head Neck.* 2001;23:80–6.
 61. Pearson BW. Subtotal laryngectomy. *Laryngoscope.* 1981;91:1904–12.
 62. Pearson BW, DeSanto LW, Olsen KD, Salassa JR. Results of near-total laryngectomy. *Ann Otol Rhinol Laryngol.* 1998;107:820–5.
 63. Morton KA, Karwande SV, Davis RK, et al. Gastric emptying after gastric interposition for cancer of the esophagus or hypopharynx. *Ann Thorac Surg.* 1991;51:759–63.
 64. Withers EH, Franklin JD, Madden Jr JJ, Lynch JB. Pectoralis major musculocutaneous flap: a new flap for head and neck reconstruction. *Am J Surg.* 1979;138:537–43.
 65. Baek S, Biller HF, Krespi YP, Lawson W. The pectoralis major myocutaneous flap for reconstruction of the head and neck. *Head Neck Surg.* 1979;1:293–300.
 66. Baudet J, Guimberteau JC, Traissac JL, et al. Reconstruction of the pharynx and cervical esophagus using free grafts from the intestine and stomach. *Chirurgie.* 1979;104:873–85.
 67. Temam S, Janot F, Germain M, et al. Functional results with advanced hypopharyngeal carcinoma treated with circular pharyngolaryngectomy and jejunal free-flap repair. *Head Neck.* 2006;28:8–14.
 68. Ong GB, Lee TC. Pharyngogastric anastomosis after oesophago-pharyngectomy for carcinoma of the hypopharynx and cervical esophagus. *Br J Surg.* 1960;48:193–200.
 69. Le Quesne LP, Ranger D. Pharyngolaryngectomy with immediate pharyngogastric anastomosis. *Br J Surg.* 1966;53:105–9.
 70. Akiyama H, Hyama M, Miyazono H. Total esophageal reconstruction after extraction of the esophagus. *Ann Surg.* 1975;182:547–52.
 71. Silver CE. Gastric pull up operation for replacement of the cervical portion of the esophagus. *Surg Gynecol Obstet.* 1976;142:243–5.
 72. Orringer MB, Sloan H. Esophagectomy without thoractomy. *J Thorac Cardiovasc Surg.* 1978;76:643–54.
 73. Byers RM, Wolf PF, Ballantyne AJ. The rationale for elective modified neck dissection. *Head Neck Surg.* 1988;10:160–7.
 74. Shah JP. Patterns of cervical lymph node metastasis from squamous carcinomas of the upper aerodigestive tract. *Am J Surg.* 1990;160:405–9.
 75. Pitman K, Johnson JT, Myers EN. Effectiveness of selective neck dissection in the management of the clinically negative neck. *Arch Otolaryngol Head Neck Surg.* 1997;123:917–22.
 76. Byers RM. Modified neck dissection. A study of 967 cases from 1970 to 1980. *Am J Surg.* 1985;150:414–21.
 77. Marks JE, Devineni VR, Harvey J, Sessions DG. The risk of contralateral lymphatic metastases for cancers of the larynx and pharynx. *Am J Otolaryngol.* 1992;13:34–9.
 78. Schmitz S, Machiels JP, Weynand B, et al. Results of selective neck dissection in the primary management of head and neck squamous cell carcinoma. *Eur Arch Otorhinolaryngol.* 2009;266:437–43.
 79. Spiro JD, Spiro RH, Shah JP, et al. Critical assessment of supraohyoideid neck dissection. *Am J Surg.* 1988;156:286–9.
 80. Pellitteri PK, Robbins KT, Neuman T. Expanded application of selective neck dissection with regard to nodal status. *Head Neck.* 1997;19:260–5.
 81. Byers RM, Clayman GL, McGill D, et al. Selective neck dissections for squamous cell carcinoma of the upper aerodigestive tract: patterns of regional failure. *Head Neck.* 1999;21:499–505.
 82. Andersen PE, Shah JP, Cambroner E, Spiro RH. The role of comprehensive neck dissection with preservation of the spinal accessory nerve in the clinically positive neck. *Am J Surg.* 1994;168:499–502.
 83. Khafif RA, Gelbfish GA, Asase DK, et al. Modified radial neck dissection in cancer of the mouth, pharynx and larynx. *Head Neck.* 1990;12:476–82.
 84. Shah JP. Cervical lymph node metastases—diagnostic, therapeutic and prognostic implications. *Oncology (Williston Park).* 1990;4:61–9.
 85. Clark J, Li W, Smith G, et al. Outcome of treatment for advanced cervical metastatic squamous cell carcinoma. *Head Neck.* 2005;27:87–94.
 86. Bernier J, Dommene C, Ozsahin M, et al. Postoperative irradiation with or without concomitant chemotherapy for locally advanced head and neck cancer. *N Engl J Med.* 2004;350:1945–52.
 87. Cooper JS, Pajak TF, Forastiere AA, et al. Postoperative concurrent radiotherapy and chemotherapy for high-risk squamous-cell carcinoma of the head and neck. *N Engl J Med.* 2004;350:1937–44.
 88. Grégoire V, Levendag P, Ang KK, et al. CT-based delineation of lymph node levels and related CTVs in the node-negative neck: DAHANCA, EORTC, GORTEC, NCIC, RTOG consensus guidelines. *Radiother Oncol.* 2003;69:227–33.
 89. Grégoire V, Eisbruch A, Hamoir M, Levendag P. Proposal for the delineation of the nodal CTV in the node-positive and the post-operative neck. *Radiother Oncol.* 2006;79:15–20.
 90. Apisarnthanarax S, Elliott DD, El-Naggar AK, Asper JA, Blanco A, Ang KK, et al. Determining optimal clinical target volume margins in head-and-neck cancer based on microscopic extracapsular extension of metastatic neck nodes. *Int J Radiat Oncol Biol Phys.* 2006;64:678–83.
 91. Hamoir M, Desuter G, Gregoire V, et al. A proposal for redefining the boundaries of level V. Is dissection of the apex of level V necessary in mucosal cell carcinoma of the head and neck. *Arch Otolaryngol Head Neck Surg.* 2002;128:1381–3.
 92. Bussels B, Hermans R, Reijnders A, Dirix P, Nuyts S, Van den Bogaert W. Retropharyngeal nodes in squamous cell carcinoma of oropharynx: incidence, localization, and implications for target volume. *Int J Radiat Oncol Biol Phys.* 2006;65(3):733–8.
 93. Posner MR, Herschock DM, Blajman CR, for the TAX 324 Study Group. Cisplatin and fluorouracil alone or with docetaxel in head and neck cancer. *N Engl J Med.* 2007;357:1705–15.
 94. Pointreau Y, Garaud P, Chapet S, et al. Randomized trial of induction chemotherapy with cisplatin and 5-fluorouracil with or without docetaxel for larynx preservation. *J Natl Cancer Inst.* 2009;101:498–506.
 95. Pignon JP, Bourhis J, Dommene C, Designé L. Chemotherapy added to locoregional treatment for head and neck squamous-cell carcinoma: three meta-analyses of updated individual data. MACH-NC Collaborative group. Meta-Analysis of chemotherapy on head and neck cancer. *Lancet.* 2000;355:949–55.
 96. Pignon JP, le Maître A, Maillard E, Bourhis J. Meta-analysis of chemotherapy in head and neck cancer (MACH-NC): an update on 93 randomised trials and 17,346 patients. *Radiother Oncol.* 2009;92:4–14.
 97. Forastiere AA, Goepfert H, Maor M, et al. Concurrent chemotherapy and radiotherapy for organ preservation in advanced laryngeal cancer. *N Engl J Med.* 2003;349:2091–8.
 98. Adelstein DJ, Li Y, Adams GL, et al. An intergroup phase III comparison of standard radiation therapy and two schedules of concurrent

- chemoradiotherapy in patients with unresectable squamous cell head and neck cancer. *J Clin Oncol.* 2003;21:92–8.
99. Calais G, Alfonsi M, Bardet E, et al. Randomized trial of radiation therapy versus concomitant chemotherapy and radiation therapy for advanced-stage oropharynx carcinoma. *J Natl Cancer Inst.* 1999;91:2081–6.
100. Yarden Y. The EGFR family and its ligand in human cancer: signalling mechanisms and therapeutic opportunities. *Eur J Cancer.* 2001;37:3–8.
101. Grünwald V, Hidalgo M. Developing inhibitors of the epidermal growth factor receptor for cancer treatment. *J Natl Cancer Inst.* 2003;18:851–67.
102. Milas L, Mason K, Hunter N, et al. In vivo enhancement of tumor radioresponse by C225 anti-epidermal growth factor receptor antibody. *Clin Cancer Res.* 2000;6:701–8.
103. Baselga J. The EGFR as a target for anticancer therapy—focus on cetuximab. *Eur J Cancer.* 2001;37 Suppl 4:16–22.
104. Stewart JS, Cohen EE, Licitra L, et al. Phase III study of gefitinib 250 compared with intravenous methotrexate for recurrent squamous cell carcinoma of the head and neck. *J Clin Oncol.* 2009;11:1864–71.
105. Kyzas PA, Cunha IW, Ioannidis JP. Prognostic significance of vascular endothelial growth factor immunohistochemical expression in head and neck squamous cell carcinoma: a meta-analysis. *Clin Cancer Res.* 2005;11:1434–40.
106. Bernier J, Bentzen SM, Vermorken J. Molecular therapy in head and neck oncology. *Nat Rev Clin Oncol.* 2009;6:266–77.
107. Machiels JP, Henry S, Zanetta S, et al. Sunitinib in recurrent and/or metastatic squamous carcinoma of the head and neck: the GORTEC 2006–01 phase II study. *J Clin Oncol.* 2010;28(1):21–8.
108. Shah JP, Shaha AR, Spiro RH, Strong EW. Carcinoma of the hypopharynx. *Am J Surg.* 1976;132(4):439–43.
109. Kramer S, Gelber RD, Snow JB, et al. Combined radiation therapy and surgery in the management of advanced head and neck cancer: final report of the Radiation Therapy Oncology Group. *Head Neck Surg.* 1987;10:19–30.
110. Kraus DH, Zelefsky MJ, Brock HA, et al. Combined surgery and radiation therapy for squamous cell carcinoma of the hypopharynx. *Otolaryngol Head Neck Surg.* 1997;116:637–41.
111. Driscoll WG, Nagorsky MJ, Cantrell RW, Johns ME. Carcinoma of the pyriform sinus: analysis of 102 cases. *Laryngoscope.* 1983;93:556–60.
112. Kajanti M, Mäntylä M. Carcinoma of the hypopharynx. A retrospective analysis of the treatment results over a 25-year period. *Acta Oncol.* 1990;29:903–7.
113. Kraus DH, Pfister DG, Harrison LB, et al. Larynx preservation with combined chemotherapy and radiation therapy in advanced hypopharynx cancer. *Otolaryngol Head Neck Surg.* 1994;111:31–7.
114. Vandenbrouck C, Sancho H, Le Fur R, et al. Results of a randomized trial of preoperative irradiation versus postoperative irradiation in treatment of tumors of the hypopharynx. *Cancer.* 1977;39:1445–9.
115. El Badawi SA, Goepfert H, Fletcher GH, et al. Squamous cell carcinoma of the pyriform sinus. *Laryngoscope.* 1982;92:357–64.
116. Vandenbrouck C, Eschwege F, De la Rochefordiere A, et al. Squamous cell carcinoma of the pyriform sinus: retrospective study of 351 cases treated at the Institut Gustave Roussy. *Head Neck Surg.* 1987;10:4–13.
117. Eckel HE, Staar S, Volling P, et al. Surgical treatment of hypopharynx carcinoma: feasibility, mortality and results. *Otolaryngol Head Neck Surg.* 2001;124:561–9.
118. Lecanu JB, Monceaux G, Périé S, et al. Conservative surgery in T3-T4 pharyngolaryngeal squamous cell carcinoma: an alternative to radiation therapy and to total laryngectomy for good responders to induction chemotherapy. *Laryngoscope.* 2000;110:412–6.
119. Bourhis J, Overgaard J, Audry H, et al. Hyperfractionated or accelerated radiotherapy in head and neck cancer: a meta-analysis. *Lancet.* 2006;368:843–54.
120. Fu KK, Pajak TF, Trotti A, et al. A Radiation Therapy Oncology Group (RTOG) phase III randomized study to compare hyperfractionation and two variants of accelerated fractionation to standard fractionation radiotherapy for head and neck squamous cell carcinomas: first report of RTOG 9003. *Int J Radiat Oncol Biol Phys.* 2000;48:7–16.
121. Horiot JC, Le Fur R, N'Guyen T, et al. Hyperfractionation versus conventional fractionation in oropharyngeal carcinoma: final analysis of a randomized trial of the EORTC cooperative group of radiotherapy. *Radiother Oncol.* 1992;25:231–41.
122. Overgaard J, Hansen HS, Specht L, et al. Five compared with six fractions per week of conventional radiotherapy of squamous-cell carcinoma of head and neck: DAHANCA 6 and 7 randomised controlled trial. *Lancet.* 2003;362(88):933–40.
123. Horiot JC, Bontemps P, van den Bogaert W, et al. Accelerated fractionation (AF) compared to conventional fractionation (CF) improves loco-regional control in the radiotherapy of advanced head and neck cancers: results of the EORTC 22851 randomized trial. *Radiother Oncol.* 1997;44:111–21.
124. Jeremic B, Milicic B, Dagovic A, et al. Radiation therapy with or without concurrent low-dose daily chemotherapy in locally advanced, nonmetastatic squamous cell carcinoma of the head and neck. *J Clin Oncol.* 2004;22:3540–8.
125. Bourhis J, Sire C, Lapeyre M, Grégoire V, Maingon P, Calais G, et al. Accelerated versus conventional radiotherapy with concomitant chemotherapy in locally advanced head and neck carcinomas: results of a phase III randomized trial. *Int J Radiat Oncol Biol Phys.* 2008;72(Suppl):S31–2.
126. Denis F, Garaud P, Bardet E, et al. Final results of the 94–01 French Head and Neck Oncology and Radiotherapy Group randomized trial comparing radiotherapy alone with concomitant radiochemotherapy in advanced-stage oropharynx carcinoma. *J Clin Oncol.* 2004;22:69–76.
127. Bourhis J, Calais G, Lapeyre M, et al. Concomitant radiochemotherapy or accelerated radiotherapy: analysis of two randomized trials of the French Head and Neck Cancer Group (GORTEC). *Semin Oncol.* 2004;31:822–6.
128. Bonner JA, Harari PM, Giralt J, et al. Radiotherapy plus cetuximab for squamous cell carcinoma of the head and neck. *N Engl J Med.* 2006;354:567–78.
129. Bonner JA, Raisch KP, Trummel HQ, et al. Enhanced apoptosis with combination C225/radiation treatment serves as the impetus for clinical investigation in head and neck cancers. *J Clin Oncol.* 2000;18:47–53.
130. Budach W, Bölke E, Homey B. Severe cutaneous reaction during radiation therapy with concurrent cetuximab. *N Engl J Med.* 2007;357:514–5.
131. Bernier J, Bonner J, Vermorken JB, et al. Consensus guidelines for the management of radiation dermatitis and coexisting acne-like rash in patients receiving radiotherapy plus EGFR inhibitors for the treatment of squamous cell carcinoma of the head and neck. *Ann Oncol.* 2008;19:142–9.
132. Lefebvre JL, Chevalier D, Luboinski B, et al. Larynx preservation in pyriform sinus cancer: preliminary results of a European Organization for Research and Treatment of Cancer phase III trial. EORTC Head and Neck Cancer Cooperative Group. *J Natl Cancer Inst.* 1996;88:890–9.
133. Lefebvre JL, Chevalier D, Luboinski B, et al. Is laryngeal preservation (LP) with induction chemotherapy (ICT) safe in the treatment of hypopharyngeal SCC? Final results of the EORTC 24891 trial. *J Clin Oncol (ASCO Annual meeting Proceedings).* 2004;22(Suppl):abstract 5531.

134. Lefebvre JL, Pointreau Y, Rolland F, et al. Sequential chemoradiotherapy (SCRT) for larynx preservation (LP): preliminary results of the randomized phase II TREMPIN study. *J Clin Oncol* (ASCO Annual meeting Proceedings). 2009;27(Suppl): abstract 6010.
135. Paccagnella A, Buffoli A, Koussis H, et al. Concomitant chemoradiotherapy (CT/RT) vs neoadjuvant chemotherapy with docetaxel/cisplatin/5-fluorouracil (TPF) followed by CT/RT in locally advanced head and neck cancer. Final results of a phase II randomized study. *ASCO Annual meeting Proceedings*. 2008;26(Suppl): abstract 6000.
136. Hitt R, Grau JJ, Lopez-Pousa A, et al. Final results of a randomized phase III trial comparing induction chemotherapy with cisplatin/5-FU follow by chemoradiotherapy (CRT) versus CRT alone as first-line treatment of unresectable locally advanced head and neck cancer (LAHNC). *ASCO Annual meeting Proceedings*. 2009;27(Suppl):abstract 6009.
137. Mendenhall W, Villaret DB, Amdur RJ, et al. Planned neck dissection after definitive radiotherapy for squamous cell carcinoma of the head and neck. *Head Neck*. 2002;24:1012–8.
138. Boyd TS, Harari PM, Tannehill SP, et al. Planned postradiotherapy neck dissection in patients with advanced head and neck cancer. *Head Neck*. 1998;20:132–7.
139. Mabanta SR, Mandenhall WM, Stringer SP, Cassisi NJ. Salvage treatment for neck recurrence after irradiation alone for head and neck squamous cell carcinoma with clinically positive neck nodes. *Head Neck*. 1999;21:591–4.
140. Brizel DM, Prosnitz RG, Hunter S, et al. Necessity for adjuvant neck dissection in setting of concurrent chemoradiation for advanced head-and-neck cancer. *Int J Radiat Oncol Biol Phys*. 2004;58:1418–23.
141. Lavertu P, Adelstein DJ, Saxton JP, et al. Management of the neck in a randomized trial comparing concurrent chemotherapy and radiotherapy with radiotherapy alone in resectable stage III and IV squamous cell head and neck cancer. *Head Neck*. 1997;19:559–66.
142. McHam SA, Adelstein DJ, Rybicki LA, et al. Who merits a neck dissection after definitive chemoradiotherapy for N2-N3 squamous cell head and neck cancer? *Head Neck*. 2003;25:791–8.
143. Stenson KM, Haraf DJ, Pelzer H, et al. The role of cervical lymphadenectomy after aggressive concomitant chemoradiotherapy: the feasibility of selective neck dissection. *Arch Otolaryngol Head Neck Surg*. 2000;126:950–6.
144. Clayman GL, Johnson 2nd CJ, Morrison W, et al. The role of neck dissection after chemoradiotherapy for oropharyngeal cancer with advanced nodal disease. *Arch Otolaryngol Head Neck Surg*. 2001;127:135–9.
145. Argiris A, Stenson KM, Brockstein BE, et al. Neck dissection in the combined-modality therapy of patients with locoregionally advanced head and neck cancer. *Head Neck*. 2004;26:447–55.
146. Goguen LA, Posner MR, Tishler RB, et al. Examining the need for neck dissection in the era of chemoradiation therapy for advanced head and neck cancer. *Arch Otolaryngol Head Neck Surg*. 2006;132:526–31.
147. Forest VI, Nguyen-Tan PF, Tabet JC, et al. Role of neck dissection following concurrent chemoradiation for advanced head and neck carcinoma. *Head Neck*. 2006;28:1099–105.
148. Yao M, Graham MM, Hoffman HT, et al. The role of post-radiation therapy FDG PET in prediction of necessity for post-radiation therapy neck dissection in locally advanced head and-neck squamous cell carcinoma. *Int J Radiat Oncol Biol Phys*. 2004;59:1001–10.
149. Yao M, Buatti JM, Dornfeld KJ, et al. Can post-RT FDG PET accurately predict the pathologic status in neck dissection after radiation for locally advanced head and neck cancer? In regard to Rogers et al. (*Int J Radiat Oncol Biol Phys* 2004;58:694–697). *Int J Radiat Oncol Biol Phys* 2005;61:306–7; author reply 307.
150. Yao M, Hoffman HT, Chang K, et al. Is planned neck dissection necessary for head and neck cancer after intensity-modulated radiotherapy? *Int J Radiat Oncol Biol Phys*. 2007;68:707–13.
151. Porceddu SV, Jarmolowski E, Hicks RJ, et al. Utility of positron emission tomography for the detection of disease in residual neck nodes after (chemo)radiotherapy in head and neck cancer. *Head Neck*. 2005;27:175–81.
152. Robbins KT, Wong FS, Kumar P, et al. Efficacy of targeted chemoradiation and planned selective neck dissection to control bulky nodal disease in advanced head and neck cancer. *Arch Otolaryngol Head Neck Surg*. 1999;125:670–5.
153. Stenson KM, Huo D, Blair E, et al. Planned post-chemoradiation neck dissection: significance of radiation dose. *Laryngoscope*. 2006;116:33–6.
154. Doweck I, Robbins KT, Mendenhall WM, et al. Neck level-specific nodal metastases in oropharyngeal cancer: is there a role for selective neck dissection after definitive radiation therapy? *Head Neck*. 2003;25:960–7.
155. Proctor E, Robbins KT, Vieira F, et al. Postoperative complications after chemoradiation for advanced head and neck cancer. *Head Neck*. 2004;26:272–7.
156. Vikram B, Strong EW, Shah JP, et al. Failure in the neck following multimodality treatment for advanced head and neck cancer. *Head Neck Surg*. 1984;6:724–9.
157. Nisi KW, Foote RL, Bonner JA, et al. Adjuvant radiotherapy for squamous cell carcinoma of the tongue base: improved local-regional disease control compared with surgery alone. *Int J Radiat Oncol Biol Phys*. 1998;41:371–7.
158. Dixit S, Vyas RK, Toparani RB, et al. Surgery versus surgery and postoperative radiotherapy in squamous cell carcinoma of the buccal mucosa: a comparative study. *Ann Surg Oncol*. 1998;5:502–10.
159. Lundahl RE, Foote RL, Bonner JA, et al. Combined neck dissection and postoperative radiation therapy in the management of the high-risk neck: a matched-pair analysis. *Int J Radiat Oncol Biol Phys*. 1998;40:529–34.
160. Amdur RJ, Parsons JT, Mendenhall WM, et al. Postoperative irradiation for squamous cell carcinoma of the head and neck: an analysis of treatment results and complications. *Int J Radiat Oncol Biol Phys*. 1989;16:25–36.
161. Parsons JT, Mendenhall WM, Stringer SP, et al. An analysis of factors influencing the outcome of postoperative irradiation for squamous cell carcinoma of the oral cavity. *Int J Radiat Oncol Biol Phys*. 1997;39:137–48.
162. Peters LJ, Goepfert H, Ang KK, et al. Evaluation of the dose for postoperative radiation therapy of head and neck cancer: first report of a prospective randomized trial. *Int J Radiat Oncol Biol Phys*. 1993;26:3–11.
163. Ang KK, Trotti A, Brown BW, et al. Randomized trial addressing risk features and time factors of surgery plus radiotherapy in advanced head-and-neck cancer. *Int J Radiat Oncol Biol Phys*. 2001;51:571–8.
164. Haffty BG, Son YH, Sasaki CT, et al. Mitomycin C as an adjunct to postoperative radiation therapy in squamous cell carcinoma of the head and neck: results from two randomized clinical trials. *Int J Radiat Oncol Biol Phys*. 1993;27:241–50.
165. Bachaud JM, Cohen-Jonathan E, Alzieu C, et al. Combined postoperative radiotherapy and weekly cisplatin infusion for locally advanced head and neck carcinoma: final report of a randomized trial. *Int J Radiat Oncol Biol Phys*. 1996;36:999–1004.
166. Bernier J, Cooper JS, Pajak TF, et al. Defining risk levels in locally advanced head and neck cancers: a comparative analysis of concurrent postoperative radiation plus chemotherapy trials of the EORTC (.22931) and RTOG (. 9501). *Head Neck*. 2005;27:843–50.
167. Clark JR, de Almeida J, Gilbert R, et al. Primary and salvage (hypo)pharyngectomy: analysis of outcome. *Head Neck*. 2006;28:671–7.

168. Relic A, Scheich M, Stäpf J, et al. Salvage surgery after induction chemotherapy with paclitaxel/cisplatin and primary radiotherapy for advanced laryngeal and hypopharyngeal carcinomas. *Eur Arch Otorhinolaryngol.* 2009;266:1799–805.
169. Janot F, de Raucourt D, Benhamou E, et al. Randomized trial of postoperative reirradiation combined with chemotherapy after salvage surgery compared with salvage surgery alone in head and neck carcinoma. *J Clin Oncol.* 2008;26:5518–23.
170. Bourhis J, Temam S, Wibault P, et al. Locoregional recurrences of HNSCC: place of re-Irradiations. *Bull Cancer.* 2004;91:871–3.
171. Langendijk JA, Kasperts N, Leemans CR, et al. A phase II study of primary reirradiation in squamous cell carcinoma of head and neck. *Radiother Oncol.* 2006;78:306–12.
172. Pivot X, Niyikiza C, Poissonnet G, et al. Clinical prognostic factors for patients with recurrent head and neck cancer: implications for randomized trials. *Oncology.* 2001;61:197–204.
173. Morton RP, Stell PM. Cytotoxic chemotherapy for patients with terminal squamous carcinoma – does it influence survival? *Clin Otolaryngol Allied Sci.* 1984;9:175–80.
174. Gibson MK, Li Y, Murphy B, et al. Randomized phase III evaluation of cisplatin plus fluorouracil versus cisplatin plus paclitaxel in advanced head and neck cancer (E1395): an intergroup trial of the Eastern Cooperative Oncology Group. *J Clin Oncol.* 2005;15:3562–7.
175. Forastiere AA, Metch B, Schuller DE, et al. Randomized comparison of cisplatin plus fluorouracil and carboplatin plus fluorouracil versus methotrexate in advanced squamous – cell carcinoma of the head and neck: a Southwest Oncology Group study. *J Clin Oncol.* 1992;10:1245–51.
176. Vermorken JB, Mesia R, Rivera F, et al. Platinum-based chemotherapy plus cetuximab in head and neck cancer. *N Engl J Med.* 2008;11(359):1116–27.
177. Garden AS, Morrisson WH, Clayman GL, et al. Early squamous cell carcinoma of the hypopharynx: outcomes of treatment with radiation alone to the primary disease. *Head Neck.* 1996; 18:317–22.
178. Hoffman HT, Karnell LH, Shah JP, et al. Hypopharynx cancer patient care evaluation. *Laryngoscope.* 1997;107:1974–81.

Chapter 31

Cancers of the Larynx: Tis, T1, T2 Evaluation and Management

Carol M. Lewis, Ollivier Laccourreye, Randal S. Weber, and F. Christopher Holsinger

Abstract In the USA, larynx cancer affects an estimated 1 in 250 people. Current treatment modalities emphasize obtaining a cure while maximizing the preservation of function and the quality of life. For early larynx cancers (Tis, T1, T2), these treatment options include primary radiotherapy, transoral endoscopic resection, and conservation laryngeal surgery. Current literature reports similar rates of local control and survival among these modalities, such that management decisions should incorporate the stage, extent of disease, and the anticipated functional outcomes within the context of patient social and medical factors. This chapter discusses the epidemiology, presentation, evaluation, and management of early larynx cancers, with a focus on treatment options and functional considerations.

Keywords Larynx cancer • Conservation laryngeal surgery • Radiotherapy • Transoral endoscopic resection

Introduction

It is estimated that cancers affecting the larynx, the organ of speech, affect 1 in 250 Americans. Worldwide, the public health impact of larynx cancer is much greater, ranking as the fourteenth most common cancer among men and the second most common malignancy among head and neck cancers. In 2009, there were estimated 12,290 new cases of and 3,660 deaths from larynx cancer [1]. Of these cases, roughly half originate at the level of the glottis [2]. Despite improvements in diagnostic and therapeutic techniques, the overall survival has not improved over the past 25 years [3]. In fact, there was a decline in 5-year survival for early stage supraglottic cancer from 66.7–67.5% in the mid-1980s to 61.2–60% in the mid-1990s. The 5-year survival for early stage glottic cancer also decreased, although to a milder degree [2]. Such trends

are important to consider and reevaluate as new treatment modalities evolve and management options expand.

Both larynx cancer and its treatment heavily impact three of the major functions of this organ: phonation, respiration, and airway protection during deglutition [4]. While this facilitates earlier presentation and diagnosis of glottic tumors, it also highlights the delicate balance between sound oncologic treatment and preservation of function. The American Society of Clinical Oncology (ASCO) recently recommended that early stage larynx cancer (T1 or T2) be treated initially with larynx-preserving modalities [5]. Given the numerous possibilities for the treatment of larynx cancer [6], management decisions must incorporate the preservation of organ function and the anticipated patient quality of life into the goal of curing this disease. As the overwhelming majority of larynx cancers are squamous cell carcinoma [7], this chapter addresses the above considerations as they relate to the management of early stage (Tis, T1, or T2) larynx squamous cell carcinoma.

Anatomy

The larynx is divided into the supraglottis, the glottis, and subglottis. Each level has distinct vascularization and lymphatics, as demonstrated by dye and histologic studies [8, 9], attributable to their different embryologic origins. The supraglottis encompasses the epiglottis superiorly, extending to the apices of the ventricles. Subsites within the supraglottis, which are important from a staging perspective, include the suprahyoid and infrahyoid epiglottis, aryepiglottic folds, arytenoids, and false vocal folds. The supraglottis develops from the buccopharyngeal anlage of the third and fourth branchial arches with a robust lymphatic supply both ipsi- and contralaterally. Consequently, supraglottic malignancies have a high incidence of both unilateral and bilateral cervical metastases, occurring in 25–75% of patients across all T stages [10], with 30% of clinically N0 necks harboring occult disease [11].

F.C. Holsinger (✉)
Department of Head and Neck Surgery, The University of Texas M.D.
Anderson Cancer Center, Houston, TX, USA
e-mail: holsinger@mdanderson.org

In contrast, the glottis and subglottis develop from the tracheobronchial anlage of the fifth and sixth branchial arches with relatively sparse lymphatic drainage. The glottis extends from the apices of the ventricles superiorly to 1 cm inferior to the free edge of the true vocal fold. The incidence of cervical metastases in early glottic cancer is 5–10% and increases to up to 40% for T4 tumors [12, 13]. The subglottis encompasses the area between the inferior limit of the glottis and the inferior border of the cricoid cartilage. The incidence of cervical metastases in subglottic cancer ranges from 4.3 to 25%, with up to 50% incidence of paratracheal lymph node metastases [14]. These reports may be skewed by the tendency for subglottic cancers to present in advanced stages.

The larynx contains natural boundaries to tumor spread, which tend to confine neoplasms until more advanced stages [15, 16]. These structures include the thyroid and cricoid cartilages and associated perichondrium, the conus elasticus, the quadrangular membrane, and the hyoepiglottic ligament. One area of weakness is at the anterior commissure, where the thyroid perichondrium is deficient. Another such area is the laryngeal ventricle, which is not reinforced by the quadrangular membrane. Clinically relevant spaces include the preepiglottic space, where the superior laryngeal neurovascular bundle creates dehiscence in the thyrohyoid membrane and allows for cervical extension of tumors. Additionally, the paraglottic space, once invaded, allows tumor access to all three regions of the larynx [17].

Etiology

More than 85% of larynx cancer can be attributed to tobacco use and alcohol consumption, with smoking being the predominant etiology and alcohol being an independent and synergistic factor [18]. The male:female ratio, once as high as 15:1, is now less than 5:1 [3], likely due to increased rates of smoking in women. Current smokers have a 10–20-fold increased risk of developing larynx cancer when compared to nonsmokers [19, 20]; those that stop smoking have a 60% reduction in relative risk 10–15 years after cessation [21].

Other risk factors include environmental exposure to asbestos, nickel compounds, wood dust, leather products, paint, diesel fumes, and glass-wool [22]. Gastroesophageal reflux has also been identified as a risk factor for larynx cancer [23], with alkaline reflux as the causative factor [24]. Although human papillomavirus (HPV) infection (particularly types 16 and 18) may play a role in the development of larynx cancer, there does not appear to be as strong a causal association as in oropharynx cancer [25, 26]. Three to seven percent of respiratory papillomatosis cases undergo malignant degeneration to squamous cell carcinoma [27], and, interestingly, HPV types 6 and 11 prevail in these cases [28].

Clinical Presentation

In the USA, 59% of larynx cancers arise in the glottis, 40% develop in the supraglottis, and 1% occur in the subglottis [29]. Tumors arising in the different regions of the larynx have varying presentations, with glottic lesions becoming symptomatic at a smaller size than supraglottic tumors. Symptoms of early larynx cancer include dysphonia, hoarseness, referred otalgia, dyspnea, neck mass and, in larger T2 supraglottic cancers, even dysphagia and odynophagia. Regardless of tumor site, dysphonia and hoarseness are the most common symptoms with sore throat being the second most common complaint for supraglottic masses [30]. Patients with reflux laryngitis and a history of heavy smoking may not notice subtle changes and may therefore present later [17]. The duration of symptoms has not been found to have prognostic significance, perhaps because of recall bias on the part of the patient, inaccurate charting, or the aggressive nature of the malignancy. However, the number of symptoms with which a patient presents has been found to correlate with tumor stage [30].

Evaluation

A thorough history includes not only a discussion of current symptoms, but also an assessment of potential risk factors, family history, and comorbidities, with particular attention to respiratory pathology if partial laryngeal surgery may be planned. In addition, nutritional status and constitutional symptoms should be addressed.

A complete physical exam should be performed, including inspection and, if possible, palpation of the mucosal surfaces of the upper aerodigestive tract. Cervical palpation should evaluate the presence of cervical lymphadenopathy and the integrity of the laryngeal framework. Tenderness of the thyroid cartilage, cricothyroid or thyrohyoid membranes, or the loss of laryngeal crepitus with horizontal movement may indicate extralaryngeal spread. Fixation of the larynx is suggestive of prevertebral fascia involvement. If indirect mirror laryngoscopy does not provide an adequate exam, fiberoptic transnasal endoscopy should be undertaken to complete the examination of mucosal surfaces and assess vocal fold and arytenoid cartilage mobility. If the appropriate equipment is available, transnasal endoscopy may also be used to obtain a biopsy; in a prospective cohort, this technique has been demonstrated to provide diagnoses congruent with biopsies obtained in the operating room [31].

Preoperative laryngeal videostroboscopy reveals abnormalities of the true vocal fold mucosal wave, which may be the earliest finding for an invasive glottic cancer. If the mucosal wave is largely normal, extensive vocal ligament

invasion is improbable and a reasonable postmicrosurgical resection voice quality is more likely [32].

In a patient with a larynx tumor, an exam under general anesthesia is necessary to evaluate tumor extent, take a biopsy, assess candidacy for conservation laryngeal surgery (CLS), and to exclude the presence of a second primary tumor. This is best executed using 0, 30, and 70° telescopes which can evaluate the anterior commissure, ventricles, and subglottis. Performing rigid endoscopy prior to intubation allows for an unobstructed view of the all mucosal surfaces in the larynx, as well as the evaluation of cricoarytenoid mobility without the impediment of an endotracheal tube. With very superficial lesions, excisional biopsy can be both diagnostic and therapeutic [33, 34].

The patient should be assessed by a speech pathologist for preoperatively to review and arrange potential treatment rehabilitation for both speech and swallowing. If radiotherapy is being considered, the patient should undergo a dental evaluation with the management of dental problems as indicated. Pulmonary function tests are sometimes indicated if CLS is planned, although functional assessment by simply walking a flight of stairs has been shown to be equally effective in the thoracic surgery literature [35].

Imaging

Imaging is a useful adjunct to physical examination; the combination of clinical examination and computed tomography (CT) has been shown to have a higher staging accuracy than either evaluation alone [36]. Both CT and magnetic resonance imaging (MRI) provide information on potential lymphadenopathy and the extent of the primary tumor within and beyond the larynx, thereby assisting with the determination of resectability and with surgical planning [37].

CT staging of the neck has a reported 87–93% accuracy with comparable results with MRI [17]. Thyroid cartilage invasion is difficult to assess on imaging because it often has areas of contiguous areas of chondrification and ossification [37]. Although Becker et al. identified several CT findings suggestive of cartilage invasion, no single indicator had both a sensitivity and a specificity higher than 70%, despite several criteria having either a high sensitivity or a high specificity [38]. Although both modalities have a similar accuracy, CT has a higher specificity but lower sensitivity than MRI for thyroid cartilage invasion [39]. More recently, revised criteria to evaluate thyroid cartilage invasion on MRI significantly increase specificity [40].

For small T1 larynx cancers, imaging may not be indicated. In a small cohort of patients, Dullerud et al. reported that imaging did not alter the staging of T1 or T2 glottic cancers [41]. In a larger study, Barbera et al. found that 54% of T1 larynx cancers showed no abnormality on CT,

whereas only 20% of T2 lesions appeared normal. Although only 6% of T1 supraglottic cancers were upstaged because of CT findings, 25% of T1 glottic carcinomas, 14% of T2 glottic carcinomas, and 36% of T2 supraglottic carcinomas were upstaged [42]. This indicates that imaging may not be warranted for a select group of patients with early T1 larynx cancers, although this patient population needs to be better defined.

A metastatic work-up is necessary, although distant metastases are unlikely in early stage disease. Chest X-ray can evaluate nonneoplastic pulmonary disease, synchronous tumors, or lung metastases. If done for a metastatic work-up, a chest X-ray should be accompanied by liver function tests with possible liver ultrasonography. Suspicious findings on preliminary imaging or a high suspicion for distant metastases should lead to CT imaging. Alternatively, positron emission tomography (PET)/CT may be used. Recently, pretreatment PET/CT has been found to alter management in 18–31% of head and neck cancer patients [43–45] and the availability of this technology is increasingly more widespread.

In addition, if CLS is being considered, a modified barium swallow is indicated to assess the risk of aspiration and dysphagia.

Staging

The current staging system for larynx cancer is set forth by the 2010 American Joint Committee on Cancer (AJCC) Staging Manual, seventh edition [46] (Table 31.1). This system is based on tumor, node, and metastasis (TNM) criteria and, as opposed to the prior criteria, differentiates between resectable and unresectable T4 tumors (T4a and T4b, respectively). Hence, stage IV disease is divided into IVA, IVB, and IVC; the latter denotes the presence of distant metastases. For the this chapter, focusing on T1–T2 cancers, a crucial aspect of staging is for the invasion of the paraglottic space noted on the CT scan, which would classify the tumor as T3. This leads to upstaging tumors that clinically appear as T2 (some T2 with impaired motion of the true vocal cord for instance or T2 with anterior invasion of the floor of the ventricle) [47].

This staging system begins to address important prognostic factors by recognizing differences among tumors of varying sizes and prognoses which were grouped together by previous criteria. However, limitations still exist. Prognostic factors, such as nodal extracapsular spread, perineural or lymphovascular invasion, and histologic grade, have yet to be incorporated [13]. Another consideration includes molecular characterization [48]; for example, the overexpression of p53 as identified on immunohistochemistry lowers the rate of 5-year local control for a T1 glottic tumor from 94 to 48% [49]. Other potential improvements include a more objective definition of vocal fold immobility, in order to

Table 31.1 AJCC staging for larynx cancer

<i>Primary tumor (T)</i>	
TX	Primary tumor cannot be assessed
T0	No evidence of primary tumor
Tis	Carcinoma in situ
<i>Supraglottis</i>	
T1	Tumor limited to one subsite of supraglottis with normal vocal cord mobility
T2	Tumor invades mucosa of more than one adjacent subsite of supraglottis or glottis or region outside the supraglottis (e.g., mucosa of base of tongue, vallecula, medial wall of pyriform sinus) without fixation of the larynx
T3	Tumor limited to larynx with vocal cord fixation and/or invades any of the following: postcricoid area, preepiglottic space, paraglottic space, and/or inner cortex of thyroid cartilage
T4a	Moderately advanced local disease Tumor invades through the thyroid cartilage and/or invades tissues beyond the larynx (e.g., trachea, soft tissues of neck, including deep extrinsic muscle of the tongue, strap muscles, thyroid, or esophagus)
T4b	Very advanced local disease Tumor invades prevertebral space, encases carotid artery, or invades mediastinal structures
<i>Glottis</i>	
T1	Tumor limited to the vocal cord(s) (may involve anterior or posterior commissure) with normal mobility
T1a	Tumor limited to one vocal cord
T1b	Tumor involves both vocal cords
T2	Tumor extends to supraglottis and/or subglottis, and/or with impaired vocal cord mobility
T3	Tumor limited to the larynx with vocal cord fixation and/or invasion of paraglottic space, and/or inner cortex of the thyroid cartilage
T4a	Moderately advanced local disease Tumor invades through the outer cortex of the thyroid cartilage and/or invades tissues beyond the larynx (e.g., trachea, soft tissues of neck, including deep extrinsic muscle of the tongue, strap muscles, thyroid, or esophagus)
T4b	Very advanced local disease Tumor invades prevertebral space, encases carotid artery, or invades mediastinal structures
<i>Subglottis</i>	
T1	Tumor limited to the subglottis
T2	Tumor extends to vocal cord(s) with normal or impaired mobility
T3	Tumor limited to larynx with vocal cord fixation
T4a	Moderately advanced local disease Tumor invades cricoid or thyroid cartilage and/or invades tissues beyond the larynx (e.g., trachea, soft tissues of neck, including deep extrinsic muscles of the tongue, strap muscles, thyroid, or esophagus)
T4b	Very advanced local disease Tumor invades prevertebral space, encases carotid artery, or invades mediastinal structures
<i>Regional lymph nodes (N)^a</i>	
NX	Regional lymph nodes cannot be assessed
N1	Metastasis in a single ipsilateral lymph node, 3 cm or less in greatest dimension
N2	Metastasis in a single ipsilateral lymph node, more than 3 cm but not more than 6 cm in greatest dimension, or in multiple ipsilateral lymph nodes, none more than 6 cm in greatest dimension, or in bilateral or contralateral lymph nodes, none more than 6 cm in greatest dimension
N2a	Metastasis in a single ipsilateral lymph node, more than 3 cm but not more than 6 cm in greatest dimension
N2b	Metastasis in multiple ipsilateral lymph nodes, none more than 6 cm in greatest dimension
N2c	Metastasis in bilateral or contralateral lymph nodes, none more than 6 cm in greatest dimension
N3	Metastasis in a lymph node, more than 6 cm in greatest dimension
<i>Distant metastasis (M)</i>	
M0	No distant metastasis
M1	Distant metastasis

(continued)

Table 31.1 (continued)

<i>Anatomic stage/prognostic groups</i>			
Stage 0	Tis	N0	M0
Stage I	T1	N0	M0
Stage II	T2	N0	M0
Stage III	T3	N0	M0
	T1	N1	M0
	T2	N1	M0
	T3	N1	M0
Stage IVA	T4a	N0	M0
	T4a	N1	M0
	T1	N2	M0
	T2	N2	M0
	T3	N2	M0
	T4a	N2	M0
Stage IVB	T4b	Any N	M0
	Any T	N3	M0
Stage IVC	Any T	Any N	M1

^aMetastases at level VII are considered regional lymph node metastases

Used with the permission of the American Joint Committee on Cancer (AJCC), Chicago, Illinois. The original source for this material is the AJCC Cancer Staging Manual, Seventh Edition (2010) published by Springer Science and Business Media LLC, www.springer.com

differentiate among mucosal, vocal fold, and arytenoid immobility, as well as grouping severe dysplasia and carcinoma in situ (Cis) together, since these are similar in terms of histology and prognosis [48].

Management

The treatment goal for larynx cancer is the judicious use of available treatment modalities to achieve a cure while maximizing the preservation of function. The importance of maintaining function from a patient's perspective is highlighted by an oft-cited study by McNeil et al. in which one out of five patients in a cohort of firefighters and upper management executives with advanced larynx cancer would accept a 20–30% decrease in survival in order to preserve voice [50]. Additionally, despite the paucity of randomized, controlled studies comparing treatment modalities [5, 51], guidelines designed by ASCO recommend larynx-preserving treatment options as the initial approach for T1 or T2 larynx cancers [5]. Appropriate treatment modalities are best decided by the multidisciplinary approach, in which a head and neck surgeon, radiologist, pathologist, radiation oncologist, medical oncologist, and speech pathologist convene to determine the best management strategy for an individual patient.

Radiotherapy

Radiotherapy alone and CLS are accepted as effective single modality treatments in the management of T1 larynx cancer. Although there are several large cohort studies evaluating

each modality individually, there are no randomized, controlled trials comparing the two and not enough evidence to declare one superior to the other [51]. However, for T2 cancers, there is much less clinical equipoise, both in terms of local control, which is the key for laryngeal preservation, and long-term survival.

In general, early T1-2N0 glottic tumors are treated using narrow-field irradiation, extending superiorly to the thyroid notch and inferiorly to the inferior border of the cricoid cartilage. Local control rates for T1 glottic tumors range from 82 to 94%; after surgical salvage, the ultimate local control rate ranges from 90 to 96%, with an 83–95% rate of larynx preservation. The 5-year cause-specific survival ranges from 95 to 98% [52–60]. For T2 glottic cancer, local control rates range from 61 to 80%, with ultimate local control after salvage ranging from 80 to 91% and a 60–82% larynx preservation rate. Rates of 5-year disease-specific survival range from 86 to 95% [52–54, 56–58, 61, 62]. For this reason, the use of altered fractionation for T2 cancers is strongly recommended [58].

The outcomes of early supraglottic tumors treated with radiotherapy vary widely; those studies addressing tumor grades separately note a local control rate of 84–100% for T1 lesions and 74–86% for T2 tumors [63–66]. Studies evaluating these groups collectively report local control rates of 77–100% [52], with 5-year disease-specific survival ranging from 76 to 100% [64, 67, 68]. Studies comparing surgery with radiotherapy for early supraglottic cancer generally report better rates of local control after surgery [52, 67], although these findings may be confounded by adjuvant radiotherapy given to select surgery patients and by the selection of healthier patients who can tolerate postoperative aspiration as surgical candidates. Regardless, management of the

T2 laryngeal cancer is challenging. In fact, these local control rates are the justification for including T2 laryngeal cancer in the RTOG 91-11 study [69].

Traditionally, radiation doses have ranged from 60 to 70 Gy; T1 lesions receive 66–68 Gy and T2 tumors receive a total of 70 Gy. Total doses less than 65 Gy have been associated with lower rates of local control [54, 59, 62, 70, 71]. In addition, accelerated regimens, characterized by higher daily fractions and shorter duration of treatment, have been associated with improved outcomes. Daily fraction size impacts 5-year local control rates: the local control rate for fractions of 2.25 Gy or more is 84–100%; for 2 Gy fractions, it is 77%; and for 1.8 Gy fractions, it drops below 50% [53, 54, 72, 73]. The length of treatment is also an independent factor affecting local control [74]; rates of local control range from 95 to 100% for treatment lasting fewer than 40 days and 79–84% for treatment lasting longer than 40 days [54, 75].

Other factors portending a worse prognosis in early larynx cancer patients treated initially with radiotherapy may include a larger number of involved subsites [54, 55, 62, 63], involvement of the anterior commissure [54, 56, 59], reduced vocal fold mobility [59, 62], and whether patients continued to smoke through treatment [63]. However, none of these is a clear prognosticator; there are contrasting studies showing no association between these factors and local control for each of these considerations.

Complications from radiotherapy include early and late subgroups. Early complications include edema, mucositis, hoarseness, and dysphagia, while late complications include fibrosis, xerostomia, stenosis, and hypothyroidism. The growing use of intensity-modulated radiation therapy (IMRT) has been found to reduce the incidence of xerostomia and dysphagia while preserving survival outcomes [52, 76]. Xerostomia, which may affect as many as 80% of patients receiving radiotherapy [77], may be ameliorated by agents such as pilocarpine and amifostine. The incidence of hypothyroidism, reported to be as high as 48% [78], highlights the importance of close follow-up.

Although compelling intellectually, the efficacy of IMRT has yet to be demonstrated in a randomized prospective trial [79].

For recurrence after primary radiotherapy, surgical options range from CLS to total laryngectomy [80–84]. Recurrence has been correlated with T stage, degree of histologic differentiation, and patients' overall health. The rate of recurrence after primary radiotherapy for T1 tumors is 5% and for T2 tumors, it is 17%. Unfortunately, roughly three-quarters of patients who recur ultimately require total laryngectomy [85]. Holsinger et al. compared outcomes of salvage CLS with those of salvage laryngectomy, demonstrating no significant differences in recurrence rates or disease-free interval between the two approaches, but a lower rate of survival in patients undergoing salvage laryngectomy [86]. The latter finding may reflect more extensive disease or degree of comorbidities in the salvage laryngectomy group.

Nonetheless, surgical salvage enhances local control rates; for example, the local control rate for T1 glottic lesions is 82–94% with primary radiotherapy and 90–96% after surgical salvage. Additionally, Steiner et al. reported that 71% of early stage recurrences were cured after salvage CLS (although some patients required multiple surgeries), citing a 5-year disease-specific survival of 86% for those treated with CLS or total laryngectomy. In its review of the literature, this article cites a 50–100% cure rate [84]. However, local control through salvage surgery often necessitates a total laryngectomy; for this reason, primary surgery is encouraged for early stage laryngeal cancer.

Chemotherapy

Chemotherapy has been evaluated as a monotherapy and in combination with either surgery or radiotherapy. While not currently the standard of care, chemotherapy has been investigated as a single agent modality for larynx cancer. Laccourreye et al. examined the curative effects of chemotherapy in N0 patients with all tumor grades of squamous cell carcinoma of the pharyngolarynx who had undergone induction chemotherapy with complete response. Patients presenting with glottic cancer had a local control rate of 66% (100% after salvage treatment), larynx preservation rate of 100%, and a 5-year survival rate of 85%. Those with cancer of the pharyngolarynx fared worse with a local control rate of 38% (83% after salvage treatment), a larynx preservation rate of 64%, and a 5-year survival rate of 55% [87].

The combination of neoadjuvant chemotherapy and CLS was evaluated by Laccourreye et al. They retrospectively evaluated the use of cisplatin-fluorouracil induction chemotherapy in combination with CLS for patients having T2 glottic cancer, reporting a 5-year survival rate of 92% and a local recurrence rate of 6% [88]. Compared with previous management with CLS without neoadjuvant chemotherapy at their institution, they demonstrated a 22% increase in local recurrence together with a significant increase in overall laryngeal preservation and long-term survival [89].

There is no role for chemoradiotherapy for T1 larynx cancer. However, in the Radiation Therapy Oncology Group (RTOG) randomized, controlled trial 91-11, patients with T2 tumors comprised 11–16% of each study population. Although there was no significant difference in overall survival among these treatment strategies, concurrent chemoradiotherapy had significantly better rates of both locoregional control and larynx preservation [69].

Groups in Japan have investigated the use of chemoradiotherapy specifically for early larynx cancer. Nagahashi et al. demonstrated similar 5-year survival rates for patients with stage II supraglottic cancer treated either with radiotherapy

alone or with chemoradiotherapy using carboplatin, but found a significant increase in the rate of larynx preservation in the latter group [90]. More recently, Nishimura et al. reported analogous findings in patients with T1 or T2 larynx cancer treated either with radiotherapy alone or with chemoradiotherapy using uracil-tegafur with or without carboplatin; they reported similar 5-year survival rates among the groups, and an organ preservation rate of 93% in the chemoradiotherapy group versus 67% in the radiotherapy alone group [91].

Despite the promising findings of these studies, further study is needed to determine the role of chemotherapy in the management of early stage larynx cancer and to identify the patient population that would most benefit.

Surgery

Options for surgical extirpation of early larynx cancer include transoral endoscopic resection, with cold steel technique or transoral laser microsurgery (TLM), and open CLS procedures.

Endoscopic Resection

As mentioned earlier, excisional biopsies may be performed for very superficial, minimally invasive lesions of the larynx [33, 34]. These cases, however, must be carefully selected; as many as 20% of T1 glottic lesions with invasion of the vocal ligament may display normal mobility [92].

In 1972, Jako and Strong described the utilization of the carbon dioxide (CO₂) laser during microlaryngeal surgery to remove larynx cancer [93]. As the use of TLM has become more widespread [94], its application has been expanded both to other regions of the upper aerodigestive tract and to larger tumors [95]. TLM entails piecemeal excision of the tumor which, advocates argue, enables a better appreciation of the interface between tumor and healthy tissue, as determined by tissue-specific properties encountered during dissection with the CO₂ laser [96, 97] (Fig. 31.1a, b). This piecemeal approach, however, requires very close follow-up. Jackel et al. reported a 30% revision rate for T1–T4 lesions of the upper aerodigestive tract treated with TLM, mostly for inadequate margins on final histopathology. 82% of the

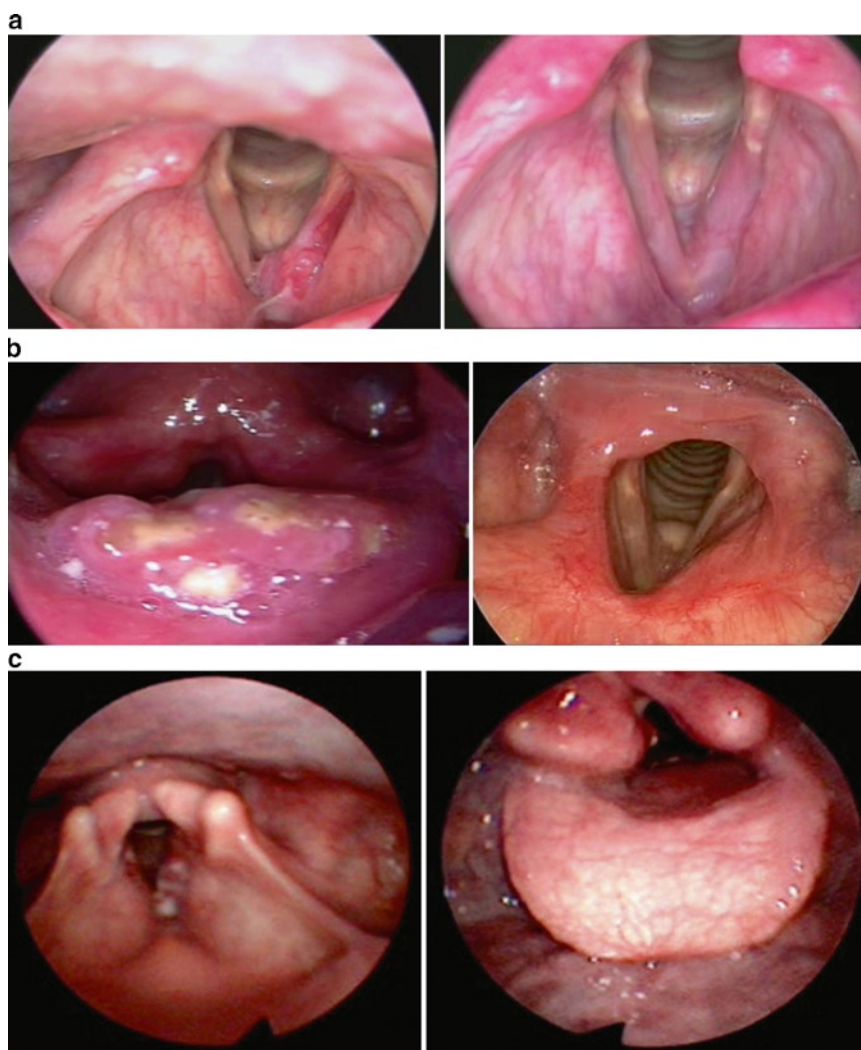


Fig. 31.1 Surgical approaches for early larynx cancer. Laryngoscopy preoperatively (*left*) revealing a laryngeal cancers arising in the anterior third of the left vocal cord and involving the anterior commissure and postoperatively (*right*) demonstrating preservation of both arytenoids and nearyepiglottic folds, which have formed from the arytenoids to the epiglottis, permitting normal swallowing function and voice without tracheostomy. (**a** and **b**) After TLM extirpation. (**c**) After SCL for tumor ablation with CHEP reconstruction. From Holsinger FC, et al. Current concepts and new horizons in conservation laryngeal surgery: an important part of multidisciplinary care. Head Neck. In press. Reprinted with permission from John Wiley & Sons, Inc

re-resection specimens were negative for residual tumor, and these cases had similar rates of local control as those patients in whom revision was not necessary. Residual tumor on revision surgery specimens correlated with worse locoregional control and larynx preservation rates but did not significantly alter the duration of survival [98].

For the management of T1–T2 glottic cancer, TLM has outcomes comparable to other organ-preserving treatment modalities. Rates of local control range from 77 to 92% for T1 lesions and 61 to 88% for T2 tumors, with a local control rate after salvage of 97–98% and a 5-year disease-specific survival of 86–98% [71, 99–104]. Larynx preservation rates in many studies range from 90 to 99% [71, 99–101, 103, 104], although one group reported a larynx preservation rate of 97% for T1 tumors and 82.5% for T2 lesions [102]. In general, TLM for the treatment of early larynx cancer has local control and larynx preservation rates on par with open approaches [94].

Since each endoscopic surgery is tailored for the tumor being excised, it is difficult to delineate distinct procedures. The European Laryngological Society (ELS) developed a classification system pertaining to the endoscopic removal of glottic cancer. In this schema, endoscopic cordectomy is categorized into four types, ranging from subepithelial to anterior commissurectomy with bilateral anterior cordectomy, and four subtypes of extended cordectomy, inclusive of such subsites as the contralateral vocal fold, the false vocal fold, the arytenoids, and the subglottis [105, 106] (Table 31.2). More recently, ELS has proposed a classification system for endoscopic supraglottic laryngectomy (SGL) with four main types, ranging from limited excision to a lateral supraglottic laryngectomy [107] (Table 31.3).

The limitations of endoscopic resection include inadequate endoscopic exposure, caused by factors such as micrognathia, macroglossia, or arthrosis; the potential for poor functional outcomes, as determined by such findings as gross infiltration of the tongue base and circumferential infiltration of the hypopharynx or esophageal inlet; and extralaryngeal spread [94, 108].

Short-term benefits of an endoscopic approach include the avoidance of a tracheotomy and early return to oral intake, which is reflected by short hospital stays. In most

Table 31.2 Classification of endoscopic cordectomy

I	Subepithelial cordectomy
II	Subligamental cordectomy
III	Transmuscular cordectomy
IV	Total cordectomy
V	Extended cordectomy
	Va including contralateral vocal fold
	Vb including the arytenoids
	Vc including the ventricular fold
	Vd including the subglottis
VI	Anterior commissurectomy with bilateral anterior cordectomy

Table 31.3 Classification of endoscopic supraglottic laryngectomy

I	Excision of small, superficial lesions confined to a single subsite within the supraglottis
II	Medial supraglottic laryngectomy with preservation of the preepiglottic space
	IIa with superior hemi-epiglottectomy
	IIb with total epiglottectomy
III	Medial supraglottic laryngectomy including the preepiglottic space
	IIIa with preservation of the ventricular fold
	IIIb with resection of the ventricular fold
IV	Lateral supraglottic laryngectomy
	IVa with resection of the ventricular fold
	IVa with resection of the arytenoid

cases, endoscopic surgery broadens the management possibilities for persistent or recurrent disease; salvage can be approached with endoscopic or open surgical procedures or with radiotherapy [34, 97].

Complications of endoscopic resection include infection, bleeding, granuloma formation, cutaneous fistula, cervical emphysema, dyspnea requiring tracheotomy, dysphagia, aspiration, and perichondritis. For early stage larynx cancer, the complication rate is 0.3–6% [109, 110].

Conservation Laryngeal Surgery

CLS ranges from laryngofissure with cordectomy to supracricoid laryngectomies (SCLs). There are four fundamental tenets of CLS that determine patient eligibility in order to optimize both oncologic and functional outcomes: (1) maintain satisfactory rates of local control, (2) accurately predict the extent of the tumor, (3) respect the cricoarytenoid unit (defined as 1 arytenoid, cricoid cartilage, associated muscles, and corresponding innervation by the superior and recurrent laryngeal nerves) as the basic functional unit of the larynx, and (4) understand that the resection of normal tissue is necessary to achieve consistent functional outcomes [111].

Laryngofissure with cordectomy is best-suited for small, mid-vocal fold lesions with no impairment of vocal fold mobility in patients in whom endoscopic exposure is inadequate [48, 112]. This approach involves splitting of the thyroid cartilage to gain access to the endolarynx and excise the affected vocal fold. Although this procedure was previously characterized by the need for a perioperative tracheotomy [112], Laccourreye et al. reported a series of 33 cases in which no tracheotomies were needed. In this cohort, the local control rate was 100% and the 5-year survival rate was 97% [113].

Vertical partial laryngectomy (VPL), or vertical hemilaryngectomy, entails extending a laryngofissure with cordectomy to include resection of the corresponding thyroid ala with the

affected vocal fold, sparing the ipsilateral arytenoid. If the lesion approaches or involves the anterior commissure or the anterior one-third of the contralateral vocal fold, a VPL may be extended to a frontolateral vertical hemilaryngectomy. Similarly, the ipsilateral arytenoid may be included in the resection in a posterolateral vertical hemilaryngectomy. For T1 lesions treated with VPL, local control rates are 89–100% [114–117]. Involvement of the anterior commissure decreases local control; one study reported that anterior commissure involvement decreased local control from 93 to 75%. In addition, the same study found that local recurrence decreased the 10-year survival rate from 63 to 31% [116]. T2 tumors treated with VPL have local control rates of 74–86% [114–116, 118]. Studies reporting better rates of local control select patient without impairment of vocal fold immobility or significant extension to the subglottis or supraglottis [119].

In a supraglottic laryngectomy (SGL), or horizontal partial laryngectomy, the laryngectomy is resected between the preepiglottic space and the ventricles, with the preservation of both true vocal folds, both arytenoids, and the hyoid bone. Extended procedures may include resection of the tongue base, arytenoids, aryepiglottic fold, or superior medial pyriform wall. Contraindications to SGL are involvement of the glottis, thyroid or cricoid cartilage invasion, tongue base involvement within 1 cm of the circumvallate papillae, and deep musculature involvement in the tongue base [119]. Local control rates after SGL are 92–100% for T1 lesions and 85–100% for T2 tumors [120–123].

Supracricoid laryngectomy (SCL) involve the resection of both true and false vocal folds, the entire thyroid cartilage, both paraglottic spaces, and one partial or full arytenoids (Fig. 31.1c). The epiglottis may or may not be included. This procedure is reconstructed with either a cricothyroidopexy (CHEP) or a cricothyroidopexy (CHP), depending

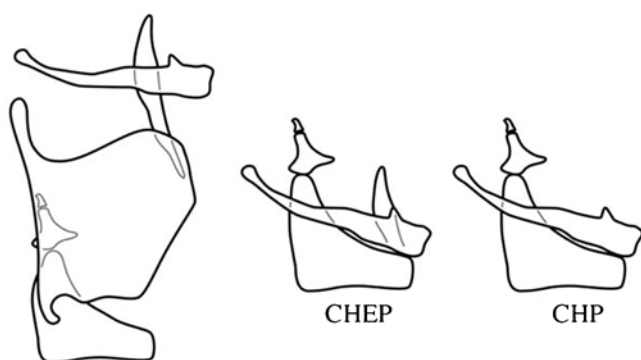


Fig. 31.2 Schematic for SCL with CHEP and CHP reconstruction. A diagram indicating the extent of resection with SCL and the optimal mechanical cricothyroid impaction for reconstruction using CHEP or CHP. From Holsinger FC, et al. Technical refinements in the supracricoid partial laryngectomy to optimize functional outcomes. *J Am Coll Surg*. 2005;201(5):809–820. Reprinted with permission from Elsevier Ltd

on whether the epiglottis is resected (Fig. 31.2). In early larynx cancer, SCL is used for T1b and T2 carcinomas. Contraindications to SCL include: cricoarytenoid joint fixation, invasion of the cricoid or posterior commissure, subglottic extension to level of the cricoid, and extension beyond the outer perichondrium of the thyroid cartilage [119]. For T1 and T2 lesions, the 5-year actuarial estimate of local control is as high as 98% [124]; another study reported rates of 96% and 91% for T1 and T2 tumors, respectively [125]. Overall, local control rates range from 87 to 98% [124–128] and overall 5-year actuarial estimates of survival range from 73 to 79% [126–128], with disease-specific survival estimated at 94% [127]. The mortality rate for SCL is 1–3.7%, with a 9.6–11% postoperative morbidity rate [124, 129].

Complications of CLS include infection, bleeding, adhesions, cutaneous fistulae, stenosis, aspiration pneumonia, feeding tube or tracheotomy dependence, granulation tissue, and tracheocutaneous fistulae [97, 119]. The incidence of postoperative morbidity correlates with a previous history of irradiation, especially in the instances of local wound healing complications and laryngocutaneous fistulae [130].

Management of the Neck

As discussed earlier, supraglottic cancers present with a higher incidence of cervical metastasis; up to 30% of N0 patients have occult lymph node metastases [11]. It is therefore recommended that the levels II–IV of the neck be addressed bilaterally for all supraglottic tumors, either surgically or with radiotherapy [131, 132]. On the other hand, only 5–10% of early glottic tumors present with nodal metastases [13] and a retrospective review reported a 0% incidence of occult cervical metastases with T1 and T2 glottic cancer [133]. Therefore, treatment of the neck is not indicated for early glottic cancer with N0 disease.

Management guidelines from ASCO state that patients with N1 disease who have a complete response to definitive radiotherapy or chemoradiotherapy do not need elective neck dissection. Patients with N2 or N3 disease, however, require surgical management of the neck regardless of response to radiotherapy or chemoradiotherapy [5].

Functional Outcomes

Larynx preservation does not guarantee functional status. Whether voice quality is superior after surgery or after primary radiotherapy remains controversial. There are currently no randomized trials comparing posttreatment voice quality

after transoral endoscopic resection, open CLS, or radiotherapy; most studies are retrospective series that report conflicting findings. In general, open CLS is thought to have worse voice outcomes, with the main controversy between which of radiotherapy and endoscopic procedures results in better voice quality [97]. Recently, Sjogren et al. compared two cohorts of patients with T1a mid-cord glottic cancer treated either with laser excision or radiotherapy. They reported no significant difference in posttreatment findings of both groups with respect to the voice handicap index scores and perceptual, acoustic, aerodynamic, and stroboscopic analyses [134]. Hirano et al. evaluated similar cohorts, reporting no significant difference between the two modalities with regard to functional conversational speech, despite that TLM resulted in a higher incidence of hoarseness, incomplete glottal closure, and altered vocal fold vibration [135]. Other reports support this finding of similar voice outcomes after either radiotherapy or laser surgery [136, 137], including a meta-analysis evaluating voice handicap index scores for patients with T1 glottic cancer [137].

Factors that worsen voice outcomes after radiotherapy may include the continuation of tobacco use through treatment, as well as extensive surgical manipulation (e.g., vocal cord stripping and multiple biopsies) [52, 138]. With regard to endoscopic procedures, resections extending to or into the vocalis muscle are associated with worse postoperative voice quality [136, 139]. Likewise, greater postoperative changes in stroboscopic, objective, and perceptual analyses correspond with more extensive cordectomies [140].

Swallowing is another measure of organ function that greatly impacts a patient's posttreatment quality of life. In a study evaluating swallowing outcomes after radiotherapy for larynx cancer, Hutcheson et al. reported that 78% of patients required feeding tubes during treatment, although of these, 52% were eventually removed. This group found aspiration in 84%, with nearly half of these cases having silent aspiration. They determined a significant association between pre- and posttreatment degrees of feeding tube dependence and a significant correlation between whether a patient could safely swallow liquids at initial assessment and the ability for oral intake at final evaluation. Although only 25% of the evaluated patients had early stage disease, there was no significant correlation between T stage and these findings [141]. Recommendations for optimizing swallowing recovery after radiotherapy include avoiding unnecessary mucosal irradiation or using the minimal required dose; minimizing xerostomia through the use of IMRT, cytoprotective agents, and sialogogues; encouraging the largest tolerated bolus size, delaying feeding tube placement as long as is safely possible; and using a nasogastric tube instead of a gastrostomy tube whenever possible [142].

After TLM, nasogastric tubes are usually removed within 3 weeks [4]. Bernal-Sprekelsen et al. found that 28% of their

postoperative patients had a temporary cough with oral intake. While that statistic included patients of all T stages, only 23.2% of early stage tumors had postoperative nasogastric tube feeding for an average of 2.5 days. 3.8% of all patients had a tracheotomy, with 75% of these being permanent. 6.2% of all patients required gastrostomy tubes for dysphagia, with 38% of these being permanent. The need for a gastrostomy tube correlated with higher T stage, radiotherapy, and the location of the primary tumor [143]. The association of irradiation with postoperative dysphagia has been reported by others [144].

In general, endoscopic procedures are associated with a more rapid return to swallowing than open CLS, and return to swallowing is dependent on the extent of the surgery [4, 119]. Endoscopic SGL is associated with a lower incidence of dysphagia with a more rapid return to normal swallowing, likely because laryngeal innervation is not as at risk in endoscopic approaches [4]. Sasaki et al. found that the glottic closure reflex returned within 72 h after endoscopic SGL, as opposed to more than 3 weeks with an open SGL in historical controls [145]. The average time to regain swallowing after VPL is 28 days, as compared to 91 days for nonextended SGL and greater than 335 days for SGL including tongue-base resection [146]. After SCL, 75–100% of patients achieve full oral diets, with the duration of feeding tube dependence ranging from 19 to 210 days [129, 147–150]. Within the first postoperative month, 65% of patients attain normal swallowing [129], with 81–92% of patients having oral intake within 1 year [129, 150].

Conclusion

Current multidisciplinary guidelines for early larynx cancer emphasize both oncologic and functional outcomes [5, 6]. These organ preservation treatment modalities include primary radiotherapy, transoral endoscopic resection, and open CLS. There are currently no well-designed randomized, controlled trials comparing surgery with radiotherapy to guide treatment decisions [51], however, current literature reports similar rates of local control and survival among these modalities. Treatment decisions should consider the stage and extent of disease and the likelihood of good functional outcomes within the context of patient social and medical factors.

References

1. Jemal A, Siegel R, Ward E, Hao Y, Xu J, Thun MJ. Cancer statistics, 2009. *CA Cancer J Clin.* 2009;59:225–49.

2. Hoffman HT, Porter K, Karnell LH, et al. Laryngeal cancer in the United States: changes in demographics, patterns of care, and survival. *Laryngoscope*. 2006;116(9 Pt 2 Suppl 111):1–13.
3. Jemal A, Siegel R, Ward E, et al. Cancer statistics, 2008. *CA Cancer J Clin*. 2008;58(2):71–96.
4. Starmer HM, Tippett DC, Webster KT. Effects of laryngeal cancer on voice and swallowing. *Otolaryngol Clin North Am*. 2008;41(4):793–818. vii.
5. Pfister DG, Laurie SA, Weinstein GS, et al. American Society of Clinical Oncology clinical practice guideline for the use of larynx-preservation strategies in the treatment of laryngeal cancer. *J Clin Oncol*. 2006;24(22):3693–704.
6. National Comprehensive Cancer Network I. NCCN clinical practice guidelines in oncology: head and neck cancers. 2007 <http://www.nccn.org>. To view the most recent and complete version of the guideline. www.nccn.org. Accessed 2007.
7. Mendenhall WM, Riggs CE, Cassisi NJ. Treatment of head and neck cancer. In: DeVita VT, Hellman S, Rosenberg SA, ed. *Cancer: Principles and Practice of Oncology*. 7th ed. Philadelphia, PA: Lippincott Williams and Wilkins;2005.
8. Beitler JJ, Mahadevia PS, Silver CE, et al. New barriers to ventricular invasion in paraglottic laryngeal cancer. *Cancer*. 1994;73(10):2648–52.
9. Pressman JJ. Submucosal compartmentation of the larynx. *Ann Otol Rhinol Laryngol*. 1956;65(3):766–71.
10. Marioni G, Marchese-Ragona R, Cartei G, Marchese F, Staffieri A. Current opinion in diagnosis and treatment of laryngeal carcinoma. *Cancer Treat Rev*. 2006;32(7):504–15.
11. Hicks Jr WL, Kollmorgen DR, Kuriakose MA, et al. Patterns of nodal metastasis and surgical management of the neck in supraglottic laryngeal carcinoma. *Otolaryngol Head Neck Surg*. 1999;121(1):57–61.
12. Breau RL, Suen JY. Management of the N(0) neck. *Otolaryngol Clin North Am*. 1998;31(4):657–69.
13. Concus AP, Tran TP, Sanfilippo NJ, DeLacure MD. Malignant Laryngeal Lesions. In: Lalwani AK, ed. *Current Diagnosis and Treatment: Otolaryngology Head and Neck Surgery*. 2nd ed. New York: McGraw Hill Companies, Inc.; 2008.
14. Ferlito A, Rinaldo A. The pathology and management of subglottic cancer. *Eur Arch Otorhinolaryngol*. 2000;257(3):168–73.
15. Buckley JG, MacLennan K. Cancer spread in the larynx: a pathologic basis for conservation surgery. *Head Neck*. 2000;22(3):265–74.
16. Kirchner JA, Carter D. Intralaryngeal barriers to the spread of cancer. *Acta Otolaryngol*. 1987;103(5–6):503–13.
17. Chu EA, Kim YJ. Laryngeal cancer: diagnosis and preoperative work-up. *Otolaryngol Clin North Am*. 2008;41(4):673–95. v.
18. Sadri M, McMahan J, Parker A. Laryngeal dysplasia: aetiology and molecular biology. *J Laryngol Otol*. 2006;120(3):170–7.
19. Tuyns AJ, Esteve J, Raymond L, et al. Cancer of the larynx/hypopharynx, tobacco and alcohol: IARC international case-control study in Turin and Varese (Italy), Zaragoza and Navarra (Spain), Geneva (Switzerland) and Calvados (France). *Int J Cancer*. 1988;41(4):483–91.
20. Talamini R, Bosetti C, La Vecchia C, et al. Combined effect of tobacco and alcohol on laryngeal cancer risk: a case-control study. *Cancer Causes Control*. 2002;13(10):957–64.
21. Bosetti C, Garavello W, Gallus S, La Vecchia C. Effects of smoking cessation on the risk of laryngeal cancer: an overview of published studies. *Oral Oncol*. 2006;42(9):866–72.
22. Muscat JE, Wynder EL. Tobacco, alcohol, asbestos, and occupational risk factors for laryngeal cancer. *Cancer*. 1992;69(9):2244–51.
23. El-Serag HB, Hepworth EJ, Lee P, Sonnenberg A. Gastroesophageal reflux disease is a risk factor for laryngeal and pharyngeal cancer. *Am J Gastroenterol*. 2001;96(7):2013–8.
24. Galli J, Cammarota G, Calo L, et al. The role of acid and alkaline reflux in laryngeal squamous cell carcinoma. *Laryngoscope*. 2002;112(10):1861–5.
25. Gillison ML, Koch WM, Capone RB, et al. Evidence for a causal association between human papillomavirus and a subset of head and neck cancers. *J Natl Cancer Inst*. 2000;92(9):709–20.
26. Smith EM, Summersgill KF, Allen J, et al. Human papillomavirus and risk of laryngeal cancer. *Ann Otol Rhinol Laryngol*. 2000;109(11):1069–76.
27. Gallagher TQ, Derkay CS. Recurrent respiratory papillomatosis: update 2008. *Curr Opin Otolaryngol Head Neck Surg*. 2008;16(6):536–42.
28. Jeong WJ, Park SW, Shin M, et al. Presence of HPV type 6 in dysplasia and carcinoma arising from recurrent respiratory papillomatosis. *Head Neck*. 2009;31(8):1095–101.
29. Thekdi AA, Ferris RL. Diagnostic assessment of laryngeal cancer. *Otolaryngol Clin North Am*. 2002;35(5):953–69. v.
30. Raitiola H, Pukander J. Symptoms of laryngeal carcinoma and their prognostic significance. *Acta Oncol*. 2000;39(2):213–6.
31. Postma GN, Bach KK, Belafsky PC, Koufman JA. The role of transnasal esophagoscopy in head and neck oncology. *Laryngoscope*. 2002;112(12):2242–3.
32. Colden D, Zeitels SM, Hillman RE, Jarboe J, Bunting G, Spanou K. Stroboscopic assessment of vocal fold keratosis and glottic cancer. *Ann Otol Rhinol Laryngol*. 2001;110(4):293–8.
33. Ansarin M, Zabrodsky M, Bianchi L, et al. Endoscopic CO₂ laser surgery for early glottic cancer in patients who are candidates for radiotherapy: results of a prospective nonrandomized study. *Head Neck*. 2006;28(2):121–5.
34. Moreau PR. Treatment of laryngeal carcinomas by laser endoscopic microsurgery. *Laryngoscope*. 2000;110(6):1000–6.
35. Brunelli A, Al-Refai M, Monteverde M, Borri A, Salati M, Fianchini A. Stair climbing test predicts cardiopulmonary complications after lung resection. *Chest*. 2002;121(4):1106–10.
36. Thabet HM, Sessions DG, Gado MH, Gnepp DA, Harvey JE, Talaat M. Comparison of clinical evaluation and computed tomographic diagnostic accuracy for tumors of the larynx and hypopharynx. *Laryngoscope*. 1996;106(5 Pt 1):589–94.
37. Yousem DM, Gad K, Tufano RP. Resectability issues with head and neck cancer. *AJNR Am J Neuroradiol*. 2006;27(10):2024–36.
38. Becker M, Zbaren P, Laeng H, Stoupis C, Porcellini B, Vock P. Neoplastic invasion of the laryngeal cartilage: comparison of MR imaging and CT with histopathologic correlation. *Radiology*. 1995;194(3):661–9.
39. Zbaren P, Becker M, Lang H. Pretherapeutic staging of hypopharyngeal carcinoma. Clinical findings, computed tomography, and magnetic resonance imaging compared with histopathologic evaluation. *Arch Otolaryngol Head Neck Surg*. 1997;123(9):908–13.
40. Becker M, Zbaren P, Casselman JW, Kohler R, Dulguerov P, Becker CD. Neoplastic invasion of laryngeal cartilage: reassessment of criteria for diagnosis at MR imaging. *Radiology*. 2008;249(2):551–9.
41. Dullerud R, Johansen JG, Dahl T, Faye-Lund H. Influence of CT on tumor classification of laryngeal carcinomas. *Acta Radiol*. 1992;33(4):314–8.
42. Barbera L, Groome PA, Mackillop WJ, et al. The role of computed tomography in the T classification of laryngeal carcinoma. *Cancer*. 2001;91(2):394–407.
43. Fleming Jr AJ, Smith Jr SP, Paul CM, et al. Impact of [18F]-2-fluorodeoxyglucose-positron emission tomography/computed tomography on previously untreated head and neck cancer patients. *Laryngoscope*. 2007;117(7):1173–9.
44. Schoder H, Yeung HW, Gonen M, Kraus D, Larson SM. Head and neck cancer: clinical usefulness and accuracy of PET/CT image fusion. *Radiology*. 2004;231(1):65–72.

45. Zanation AM, Sutton DK, Couch ME, Weissler MC, Shockley WW, Shores CG. Use, accuracy, and implications for patient management of [18F]-2-fluorodeoxyglucose-positron emission/computerized tomography for head and neck tumors. *Laryngoscope*. 2005;115(7):1186–90.
46. Edge SB, Byrd DR, Compton CA, editors. *AJCC cancer staging manual*. 78th ed. New York, NY: Springer; 2010.
47. Holsinger FC, Diaz Jr EM. Laryngeal preservation in the era of chemoradiation: limitations of the current AJCC staging system. *Head Neck*. 2006;28(12):1058–60.
48. Flint PW. Minimally invasive techniques for management of early glottic cancer. *Otolaryngol Clin North Am*. 2002;35(5):1055–66. vi–vii.
49. Narayana A, Vaughan AT, Kathuria S, Fisher SG, Walter SA, Reddy SP. P53 overexpression is associated with bulky tumor and poor local control in T1 glottic cancer. *Int J Radiat Oncol Biol Phys*. 2000;46(1):21–6.
50. McNeil BJ, Weichselbaum R, Pauker SG. Speech and survival: tradeoffs between quality and quantity of life in laryngeal cancer. *N Engl J Med*. 1981;305(17):982–7.
51. Dey P, Arnold D, Wight R, MacKenzie K, Kelly C, Wilson J. Radiotherapy versus open surgery versus endolaryngeal surgery (with or without laser) for early laryngeal squamous cell cancer. *Cochrane Database Syst Rev*. 2002(2):CD002027.
52. Hristov B, Bajaj GK. Radiotherapeutic management of laryngeal carcinoma. *Otolaryngol Clin North Am*. 2008;41(4):715–40. vi.
53. Mendenhall WM, Parsons JT, Million RR, Fletcher GH. T1-T2 squamous cell carcinoma of the glottic larynx treated with radiation therapy: relationship of dose-fractionation factors to local control and complications. *Int J Radiat Oncol Biol Phys*. 1988;15(6):1267–73.
54. Le QT, Fu KK, Kroll S, et al. Influence of fraction size, total dose, and overall time on local control of T1-T2 glottic carcinoma. *Int J Radiat Oncol Biol Phys*. 1997;39(1):115–26.
55. Warde P, O'Sullivan B, Bristow RG, et al. T1/T2 glottic cancer managed by external beam radiotherapy: the influence of pretreatment hemoglobin on local control. *Int J Radiat Oncol Biol Phys*. 1998;41(2):347–53.
56. Marshak G, Brenner B, Shvero J, et al. Prognostic factors for local control of early glottic cancer: the Rabin Medical Center retrospective study on 207 patients. *Int J Radiat Oncol Biol Phys*. 1999;43(5):1009–13.
57. Mendenhall WM, Amdur RJ, Morris CG, Hinerman RW. T1-T2N0 squamous cell carcinoma of the glottic larynx treated with radiation therapy. *J Clin Oncol*. 2001;19(20):4029–36.
58. Johansen LV, Grau C, Overgaard J. Glottic carcinoma – patterns of failure and salvage treatment after curative radiotherapy in 861 consecutive patients. *Radiother Oncol*. 2002;63(3):257–67.
59. Cellai E, Frata P, Magrini SM, et al. Radical radiotherapy for early glottic cancer: results in a series of 1087 patients from two Italian radiation oncology centers. I. The case of T1N0 disease. *Int J Radiat Oncol Biol Phys*. 2005;63(5):1378–86.
60. Cheah NL, Lupton S, Marshall A, Hartley A, Glaholm J. Outcome of T1N0M0 squamous cell carcinoma of the larynx treated with short-course radiotherapy to a total dose of 50 Gy in 16 fractions: the Birmingham experience. *Clin Oncol (R Coll Radiol)*. 2009;21(6):494–501.
61. Garden AS, Forster K, Wong PF, Morrison WH, Schechter NR, Ang KK. Results of radiotherapy for T2N0 glottic carcinoma: does the “2” stand for twice-daily treatment? *Int J Radiat Oncol Biol Phys*. 2003;55(2):322–8.
62. Frata P, Cellai E, Magrini SM, et al. Radical radiotherapy for early glottic cancer: results in a series of 1087 patients from two Italian radiation oncology centers. II. The case of T2N0 disease. *Int J Radiat Oncol Biol Phys*. 2005;63(5):1387–94.
63. Terhaard CH, Snippe K, Ravasz LA, van der Tweel I, Hordijk GJ. Radiotherapy in T1 laryngeal cancer: prognostic factors for locoregional control and survival, uni- and multivariate analysis. *Int J Radiat Oncol Biol Phys*. 1991;21(5):1179–86.
64. Mendenhall WM, Parsons JT, Mancuso AA, Stringer SP, Cassisi NJ. Radiotherapy for squamous cell carcinoma of the supraglottic larynx: an alternative to surgery. *Head Neck*. 1996;18(1):24–35.
65. Hinerman RW, Mendenhall WM, Amdur RJ, Stringer SP, Villaret DB, Robbins KT. Carcinoma of the supraglottic larynx: treatment results with radiotherapy alone or with planned neck dissection. *Head Neck*. 2002;24(5):456–67.
66. Wall TJ, Peters LJ, Brown BW, Oswald MJ, Milas L. Relationship between lymph nodal status and primary tumor control probability in tumors of the supraglottic larynx. *Int J Radiat Oncol Biol Phys*. 1985;11(11):1895–902.
67. Spriano G, Antognoni P, Piantanida R, et al. Conservative management of T1-T2N0 supraglottic cancer: a retrospective study. *Am J Otolaryngol*. 1997;18(5):299–305.
68. Jones AS, Fish B, Fenton JE, Husband DJ. The treatment of early laryngeal cancers (T1–T2N0): surgery or irradiation? *Head Neck*. 2004;26(2):127–35.
69. Forastiere AA, Goepfert H, Maor M, et al. Concurrent chemotherapy and radiotherapy for organ preservation in advanced laryngeal cancer. *N Engl J Med*. 2003;349(22):2091–8.
70. Spector JG, Sessions DG, Chao KS, Hanson JM, Simpson JR, Perez CA. Management of stage II (T2N0M0) glottic carcinoma by radiotherapy and conservation surgery. *Head Neck*. 1999;21(2):116–23.
71. Spector JG, Sessions DG, Chao KS, et al. Stage I (T1N0M0) squamous cell carcinoma of the laryngeal glottis: therapeutic results and voice preservation. *Head Neck*. 1999;21(8):707–17.
72. Schwaibold F, Scariato A, Nunno M, et al. The effect of fraction size on control of early glottic cancer. *Int J Radiat Oncol Biol Phys*. 1988;14(3):451–4.
73. Yamazaki H, Nishiyama K, Tanaka E, Koizumi M, Chatani M. Radiotherapy for early glottic carcinoma (T1N0M0): results of prospective randomized study of radiation fraction size and overall treatment time. *Int J Radiat Oncol Biol Phys*. 2006;64(1):77–82.
74. Rudoltz MS, Benammar A, Mohiuddin M. Prognostic factors for local control and survival in T1 squamous cell carcinoma of the glottis. *Int J Radiat Oncol Biol Phys*. 1993;26(5):767–72.
75. van der Voet JC, Keus RB, Hart AA, Hilgers FJ, Bartelink H. The impact of treatment time and smoking on local control and complications in T1 glottic cancer. *Int J Radiat Oncol Biol Phys*. 1998;42(2):247–55.
76. Eisbruch A, Schwartz M, Rasch C, et al. Dysphagia and aspiration after chemoradiotherapy for head-and-neck cancer: which anatomic structures are affected and can they be spared by IMRT? *Int J Radiat Oncol Biol Phys*. 2004;60(5):1425–39.
77. Dische S, Saunders M, Barrett A, Harvey A, Gibson D, Parmar M. A randomised multicentre trial of CHART versus conventional radiotherapy in head and neck cancer. *Radiother Oncol*. 1997;44(2):123–36.
78. Mercado G, Adelstein DJ, Saxton JP, Secic M, Larto MA, Lavertu P. Hypothyroidism: a frequent event after radiotherapy and after radiotherapy with chemotherapy for patients with head and neck carcinoma. *Cancer*. 2001;92(11):2892–7.
79. Glatstein E, Glick J, Kaiser L, Hahn SM. Should randomized clinical trials be required for proton radiotherapy? An alternative view. *J Clin Oncol*. 2008;26(15):2438–9.
80. Ganly I, Patel SG, Matsuo J, et al. Results of surgical salvage after failure of definitive radiation therapy for early-stage squamous cell carcinoma of the glottic larynx. *Arch Otolaryngol Head Neck Surg*. 2006;132(1):59–66.
81. Pellini R, Pichi B, Ruscito P, et al. Supracricoid partial laryngectomies after radiation failure: a multi-institutional series. *Head Neck*. 2008;30(3):372–9.

82. Rodriguez-Cuevas S, Labastida S, Gonzalez D, Briseno N, Cortes H. Partial laryngectomy as salvage surgery for radiation failures in T1-T2 laryngeal cancer. *Head Neck*. 1998;20(7):630-3.
83. Schwaab G, Mamelle G, Lartigau E, Parise Jr O, Wibault P, Luboinski B. Surgical salvage treatment of T1/T2 glottic carcinoma after failure of radiotherapy. *Am J Surg*. 1994;168(5):474-5.
84. Steiner W, Vogt P, Ambrosch P, Kron M. Transoral carbon dioxide laser microsurgery for recurrent glottic carcinoma after radiotherapy. *Head Neck*. 2004;26(6):477-84.
85. Viani L, Stell PM, Dalby JE. Recurrence after radiotherapy for glottic carcinoma. *Cancer*. 1991;67(3):577-84.
86. Holsinger FC, Funk E, Roberts DB, Diaz Jr EM. Conservation laryngeal surgery versus total laryngectomy for radiation failure in laryngeal cancer. *Head Neck*. 2006;28(9):779-84.
87. Laccourreye O, Veivers D, Hans S, Menard M, Brasnu D, Laccourreye H. Chemotherapy alone with curative intent in patients with invasive squamous cell carcinoma of the pharyngolarynx classified as T1-T4N0M0 complete clinical responders. *Cancer*. 2001;92(6):1504-11.
88. Laccourreye O, Weinstein G, Brasnu D, et al. A clinical trial of continuous cisplatin-fluorouracil induction chemotherapy and supracricoid partial laryngectomy for glottic carcinoma classified as T2. *Cancer*. 1994;74(10):2781-90.
89. Laccourreye O, Bassot V, Brasnu D, Laccourreye H. Chemotherapy combined with conservation surgery in the treatment of early larynx cancer. *Curr Opin Oncol*. 1999;11(3):200-3.
90. Nagahashi T, Fukuda S, Homma A, Yagi K, Furuta Y, Inuyama Y. Concurrent chemotherapy and radiotherapy as initial treatment for stage II supraglottic squamous cell carcinoma. *Auris Nasus Larynx*. 2001;28(Suppl):S95-8.
91. Nishimura G, Tsukuda M, Mikami Y, et al. Efficacy of concurrent chemoradiotherapy for T1 and T2 laryngeal squamous cell carcinoma regarding organ preservation. *Anticancer Res*. 2009;29(2):661-6.
92. DeSanto LW, Olsen KD. Early glottic cancer. *Am J Otolaryngol*. 1994;15(4):242-9.
93. Strong MS, Jako GJ. Laser surgery in the larynx. Early clinical experience with continuous CO₂ laser. *Ann Otol Rhinol Laryngol*. 1972;81(6):791-8.
94. Jackel MC, Martin A, Steiner W. Twenty-five years experience with laser surgery for head and neck tumors: report of an international symposium, Göttingen, Germany, 2005. *Eur Arch Otorhinolaryngol*. 2007;264(6):577-85.
95. Genden EM, Ferlito A, Silver CE, et al. Evolution of the management of laryngeal cancer. *Oral Oncol*. 2007;43(5):431-9.
96. Steiner W. Results of curative laser microsurgery of laryngeal carcinomas. *Am J Otolaryngol*. 1993;14(2):116-21.
97. Agrawal N, Ha PK. Management of early-stage laryngeal cancer. *Otolaryngol Clin North Am*. 2008;41(4):757-69. vi-vii.
98. Jackel MC, Ambrosch P, Martin A, Steiner W. Impact of re-resection for inadequate margins on the prognosis of upper aerodigestive tract cancer treated by laser microsurgery. *Laryngoscope*. 2007;117(2):350-6.
99. Eckel HE, Thumfart W, Jungehulsing M, Sittel C, Stennert E. Transoral laser surgery for early glottic carcinoma. *Eur Arch Otorhinolaryngol*. 2000;257(4):221-6.
100. Pradhan SA, Pai PS, Neeli SI, D'Cruz AK. Transoral laser surgery for early glottic cancers. *Arch Otolaryngol Head Neck Surg*. 2003;129(6):623-5.
101. Motta G, Esposito E, Cassiano B, Motta S. T1-T2-T3 glottic tumors: fifteen years experience with CO₂ laser. *Acta Otolaryngol Suppl*. 1997;527:155-9.
102. Motta G, Esposito E, Motta S, Tartaro G, Testa D. CO₂ laser surgery in the treatment of glottic cancer. *Head Neck*. 2005;27(7):566-73. discussion 573-4.
103. Peretti G, Nicolai P, Redaelli De Zinis LO, et al. Endoscopic CO₂ laser excision for Tis, T1, and T2 glottic carcinomas: cure rate and prognostic factors. *Otolaryngol Head Neck Surg*. 2000;123(1 Pt 1):124-31.
104. Rudert HH, Werner JA. Endoscopic resections of glottic and supraglottic carcinomas with the CO₂ laser. *Eur Arch Otorhinolaryngol*. 1995;252(3):146-8.
105. Remacle M, Eckel HE, Antonelli A, et al. Endoscopic cordectomy. A proposal for a classification by the Working Committee, European Laryngological Society. *Eur Arch Otorhinolaryngol*. 2000;257(4):227-31.
106. Remacle M, Van Haverbeke C, Eckel H, et al. Proposal for revision of the European Laryngological Society classification of endoscopic cordectomies. *Eur Arch Otorhinolaryngol*. 2007;264(5):499-504.
107. Remacle M, Hantzakos A, Eckel H, et al. Endoscopic supraglottic laryngectomy: a proposal for a classification by the working committee on nomenclature, European Laryngological Society. *Eur Arch Otorhinolaryngol*. 2009;266(7):993-8.
108. Peretti G, Piazza C, Bolzoni A. Endoscopic treatment for early glottic cancer: indications and oncologic outcome. *Otolaryngol Clin North Am*. 2006;39(1):173-89.
109. Ellies M, Steiner W. Peri- and postoperative complications after laser surgery of tumors of the upper aerodigestive tract. *Am J Otolaryngol*. 2007;28(3):168-72.
110. Vilaseca-Gonzalez I, Bernal-Sprekelsen M, Blanch-Alejandro JL, Moragas-Lluis M. Complications in transoral CO₂ laser surgery for carcinoma of the larynx and hypopharynx. *Head Neck*. 2003;25(5):382-8.
111. Tufano RP, Laccourreye O, Rassekh C, Weinstein GS. Conservation laryngeal surgery. In: Cummings CW, Flint PW, Harker LA, Haughey BH, Richardson MA, Robbins KT, Schuller DE, Thomas JR, ed. *Cummings: Otolaryngology Head and Neck Surgery*. vol 3. 4th ed. Philadelphia: Elsevier Mosby; 2005.
112. Hoffman HT, Karnell LH, McCulloch TM, Bulatti J, Funk G. Management of early glottic cancer. In: Cummings CW, Harker LA, Haughey BH, Richardson MA, Robbins KT, Schuller DE, Thomas JR, ed. *Cummings: Otolaryngology Head and Neck Surgery*. vol 3. 4th ed. Philadelphia: Elsevier Mosby; 2005.
113. Muscatello L, Laccourreye O, Biacabe B, Hans S, Menard M, Brasnu D. Laryngofissure and cordectomy for glottic carcinoma limited to the mid third of the mobile true vocal cord. *Laryngoscope*. 1997;107(11 Pt 1):1507-10.
114. Liu C, Ward PH, Pleet L. Imbrication reconstruction following partial laryngectomy. *Ann Otol Rhinol Laryngol*. 1986;95(6 Pt 1):567-71.
115. Bailey BJ, Calcaterra TC. Vertical, subtotal laryngectomy and laryngoplasty. Review of experience. *Arch Otolaryngol*. 1971;93(3):232-7.
116. Laccourreye O, Weinstein G, Brasnu D, Trotoux J, Laccourreye H. Vertical partial laryngectomy: a critical analysis of local recurrence. *Ann Otol Rhinol Laryngol*. 1991;100(1):68-71.
117. Rothfield RE, Johnson JT, Myers EN, Wagner RL. The role of hemilaryngectomy in the management of T1 vocal cord cancer. *Arch Otolaryngol Head Neck Surg*. 1989;115(6):677-80.
118. Johnson JT, Myers EN, Hao SP, Wagner RL. Outcome of open surgical therapy for glottic carcinoma. *Ann Otol Rhinol Laryngol*. 1993;102(10):752-5.
119. Tufano RP, Stafford EM. Organ preservation surgery for laryngeal cancer. *Otolaryngol Clin North Am*. 2008;41(4):741-55. vi.
120. Spaulding CA, Constable WC, Levine PA, Cantrell RW. Partial laryngectomy and radiotherapy for supraglottic cancer: a conservative approach. *Ann Otol Rhinol Laryngol*. 1989;98(2):125-9.
121. Lee NK, Goepfert H, Wendt CD. Supraglottic laryngectomy for intermediate-stage cancer: U.T. M.D. Anderson Cancer Center

- experience with combined therapy. *Laryngoscope*. 1990;100(8):831–6.
122. Burstein FD, Calcaterra TC. Supraglottic laryngectomy: series report and analysis of results. *Laryngoscope*. 1985;95(7 Pt 1):833–6.
 123. Herranz-Gonzalez J, Gavilan J, Martinez-Vidal J, Gavilan C. Supraglottic laryngectomy: functional and oncologic results. *Ann Otol Rhinol Laryngol*. 1996;105(1):18–22.
 124. Laccourreye O, Muscatello L, Laccourreye L, Naudo P, Brasnu D, Weinstein G. Supracricoid partial laryngectomy with cricothyroidopexy for “early” glottic carcinoma classified as T1-T2N0 invading the anterior commissure. *Am J Otolaryngol*. 1997;18(6):385–90.
 125. Kania R, Hans S, Garcia D, Brasnu D, De Mones E, Laccourreye O. Supracricoid hemilaryngopharyngectomy in patients with invasive squamous cell carcinoma of the pyriform sinus. Part II: incidence and consequences of local recurrence. *Ann Otol Rhinol Laryngol*. 2005;114(2):95–104.
 126. Gallo A, Manciooco V, Simonelli M, Pagliuca G, D’Arcangelo E, de Vincentiis M. Supracricoid partial laryngectomy in the treatment of laryngeal cancer: univariate and multivariate analysis of prognostic factors. *Arch Otolaryngol Head Neck Surg*. 2005;131(7):620–5.
 127. Karasalioglu AR, Yagiz R, Tas A, Uzun C, Adali MK, Koten M. Supracricoid partial laryngectomy with cricothyroidopexy and cricothyroidopexy: functional and oncological results. *J Laryngol Otol*. 2004;118(9):671–5.
 128. Sun DI, Cho KJ, Cho JH, Joo YH, Jung CK, Kim MS. Pathological validation of supracricoid partial laryngectomy in laryngeal cancer. *Clin Otolaryngol*. 2009;34(2):132–9.
 129. Laccourreye O, Ishoo E, de Mones E, Garcia D, Kania R, Hans S. Supracricoid hemilaryngopharyngectomy in patients with invasive squamous cell carcinoma of the pyriform sinus. Part I: technique, complications, and long-term functional outcome. *Ann Otol Rhinol Laryngol*. 2005;114(1 Pt 1):25–34.
 130. Ganly I, Patel SG, Matsuo J, et al. Analysis of postoperative complications of open partial laryngectomy. *Head Neck*. 2009;31(3):338–45.
 131. Byers RM. Modified neck dissection. A study of 967 cases from 1970 to 1980. *Am J Surg*. 1985;150(4):414–21.
 132. Shah JP. Patterns of cervical lymph node metastasis from squamous carcinomas of the upper aerodigestive tract. *Am J Surg*. 1990;160(4):405–9.
 133. Yang CY, Andersen PE, Everts EC, Cohen JI. Nodal disease in purely glottic carcinoma: is elective neck treatment worthwhile? *Laryngoscope*. 1998;108(7):1006–8.
 134. Sjogren EV, van Rossum MA, Langeveld TP, et al. Voice outcome in T1a midcord glottic carcinoma: laser surgery vs radiotherapy. *Arch Otolaryngol Head Neck Surg*. 2008;134(9):965–72.
 135. Hirano M, Hirade Y, Kawasaki H. Vocal function following carbon dioxide laser surgery for glottic carcinoma. *Ann Otol Rhinol Laryngol*. 1985;94(3):232–5.
 136. McGuirt WF, Blalock D, Koufman JA, et al. Comparative voice results after laser resection or irradiation of T1 vocal cord carcinoma. *Arch Otolaryngol Head Neck Surg*. 1994;120(9):951–5.
 137. Cohen SM, Garrett CG, Dupont WD, Ossoff RH, Courey MS. Voice-related quality of life in T1 glottic cancer: irradiation versus transoral endoscopic resection. *Ann Otol Rhinol Laryngol*. 2006;115(8):581–6.
 138. Benninger MS, Gillen J, Thieme P, Jacobson B, Dragovich J. Factors associated with recurrence and voice quality following radiation therapy for T1 and T2 glottic carcinomas. *Laryngoscope*. 1994;104(3 Pt 1):294–8.
 139. Zeitels SM. Phonosurgical treatment of early glottic cancer and carcinoma in situ. *Am J Surg*. 1996;172(6):704–9.
 140. Ledda GP, Grover N, Pundir V, Masala E, Puxeddu R. Functional outcomes after CO₂ laser treatment of early glottic carcinoma. *Laryngoscope*. 2006;116(6):1007–11.
 141. Hutcheson KA, Barringer DA, Rosenthal DI, May AH, Roberts DB, Lewin JS. Swallowing outcomes after radiotherapy for laryngeal carcinoma. *Arch Otolaryngol Head Neck Surg*. 2008;134(2):178–83.
 142. Rosenthal DI, Lewin JS, Eisbruch A. Prevention and treatment of dysphagia and aspiration after chemoradiation for head and neck cancer. *J Clin Oncol*. 2006;24(17):2636–43.
 143. Bernal-Sprekelsen M, Vilaseca-Gonzalez I, Blanch-Alejandro JL. Predictive values for aspiration after endoscopic laser resections of malignant tumors of the hypopharynx and larynx. *Head Neck*. 2004;26(2):103–10.
 144. Jepsen MC, Gurushanthaiah D, Roy N, Smith ME, Gray SD, Davis RK. Voice, speech, and swallowing outcomes in laser-treated laryngeal cancer. *Laryngoscope*. 2003;113(6):923–8.
 145. Sasaki CT, Leder SB, Acton LM, Maune S. Comparison of the glottic closure reflex in traditional “open” versus endoscopic laser supraglottic laryngectomy. *Ann Otol Rhinol Laryngol*. 2006;115(2):93–6.
 146. Rademaker AW, Logemann JA, Pauloski BR, et al. Recovery of postoperative swallowing in patients undergoing partial laryngectomy. *Head Neck*. 1993;15(4):325–34.
 147. Farrag TY, Koch WM, Cummings CW, et al. Supracricoid laryngectomy outcomes: the Johns Hopkins experience. *Laryngoscope*. 2007;117(1):129–32.
 148. Lallemand JG, Bonnin P, el-Sioufi I, Bousquet J. Cricothyroidopexy: long-term results in 55 patients. *J Laryngol Otol*. 1999;113(6):532–7.
 149. Zacharek MA, Pasha R, Meleca RJ, et al. Functional outcomes after supracricoid laryngectomy. *Laryngoscope*. 2001;111(9):1558–64.
 150. Lewin JS, Hutcheson KA, Barringer DA, et al. Functional analysis of swallowing outcomes after supracricoid partial laryngectomy. *Head Neck*. 2008;30(5):559–66.

Chapter 32

Diagnosis and Multidisciplinary Treatment of Laryngeal Cancers

Nabil F. Saba, J. Trad Wadsworth, Jonathan J. Beitler, and Fadlo R. Khuri

Abstract Laryngeal cancer is the second most common respiratory cancer after lung cancer. Most laryngeal squamous cell carcinomas result from prolonged exposure to carcinogens that stimulate mucosal hyperplasia and lead ultimately to carcinoma. The treatment of laryngeal cancer has evolved through several phases, initially with surgical resection, and evolving to multimodality nonsurgical approaches. Several novel nonsurgical approaches have emerged over the past decade. In this chapter, we will be discussing in depth the sequencing of nonsurgical therapies for advanced disease, the role of systemic therapy in general, and the development and approval of novel anticancer agents such as epidermal growth factor receptor and their use in combination with radiation or chemotherapy. In addition, we will touch on novel truly investigational approaches for highly selected patients and cover aspects related to staging and diagnosis, radiation and surgical techniques, as well as supportive care issues.

Keywords Larynx • Head and neck cancer • Larynx cancer • Carcinoma of the larynx

Epidemiology and Etiology

Laryngeal cancer is the second most common respiratory cancer after lung cancer. Its incidence is increasing in much of the world and this increase is generally accepted to be related to changes in tobacco and alcohol consumption [1]. Other implicated risk factors include occupational hazards, such as asbestos [2], inorganic acids, cement dust, and free crystalline silica [3, 4]. Dietary factors seem to play a role, as

salted meat and total fat intake have been linked to elevated risk of laryngeal cancer [5, 6], whereas intake of raw leafy vegetables and legumes may have a protective effect [7]. Gastroesophageal reflux is also an established risk factor [8, 9]. Some genetic polymorphisms, such as of genes that code for glutathione S-transferase, have been linked to risk for laryngeal cancer [10, 11]. Human papilloma virus has not been associated with laryngeal cancer [12].

Most laryngeal squamous cell carcinomas (SCCs) result from prolonged exposure to carcinogens that stimulate mucosal hyperplasia. The risk of developing malignancy appears to correlate with the severity of dysplasia present on initial biopsy [13]. Laryngopharyngeal reflux (LPR) as a causative irritating factor in the development of laryngeal carcinoma has been suggested. However, the association between LPR and laryngeal carcinoma remains unclear [14].

The treatment of advanced laryngeal cancer has evolved through several phases, initially with wide surgical resection, and evolving to multimodality nonsurgical treatment. Several novel nonsurgical approaches have emerged over the past decade, including a focus on the sequencing of nonsurgical therapies, the development and approval of novel anticancer agents such as epidermal growth factor receptor (EGFR) inhibitors used in combination with radiation or chemotherapy for advanced disease, and even definitive chemotherapy for highly selected patients, a truly investigational strategy. Advances in radiation therapy have also been noted and have focused mainly on fractionation schedules or novel techniques such as the now widely used intensity-modulated radiation therapy (IMRT) [15]. Advances in surgical techniques include endoscopic laryngeal surgery, use of laser resection for early and late tumors, and use of robotic technology in the resection of these tumors.

Sixty-two percent of laryngeal cancer presents as stage III or IV disease require multimodality therapy [16]. In this chapter, we discuss therapeutic approaches for laryngeal carcinoma in general and focus our discussion on multimodal therapy for locally advanced and metastatic disease.

F.R. Khuri (✉)
Department of Hematology and Medical Oncology,
Emory University, Atlanta, GA, USA
e-mail: fkhuri@emory.edu

Pathology and Patterns of Spread

Anatomy

The larynx (Fig. 32.1) is situated anterior to the fourth to sixth cervical vertebrae in adults, and is composed of a framework of cartilages held in position by a series of intrinsic and extrinsic musculature and is lined by an epithelial layer that is arranged in different folds [17]. For the purpose of assessment and treatment of neoplastic diseases, the larynx is clinically divided into three areas: the supraglottis, the glottis, and the subglottis. The supraglottis is derived from the buccopharyngeal anlage, and the glottis and subglottis organize around the pulmonary diverticulum [18]. The supraglottis extends from the vallecula of the base of tongue to the apex of the ventricle. Its different components include the arytenoid cartilages, the aryepiglottic folds, the false vocal folds, the ventricles, and the infrahyoid and suprahyoid epiglottis. The glottis is composed of the true vocal cords, the posterior commissure between the two cords, and the anterior commissure. The subglottis extends from the undersurface of the true cords at the respiratory and squamous epithelial juncture to the inferior border of the cricoid cartilage [19]. Definitions vary, however, and the AJCC manual [20] describes the glottis as a 1-cm horizontal plane extending inferiorly from the lateral apex of the ventricle. Practically, this puts the glottic–subglottic junction 5 mm inferior to the true vocal cords. The majority of laryngeal tumors arise from the surface epithelium and are therefore SCCs. The thyroid cartilage opposes the inferior larynx anteriorly and laterally. The hyoid bone is connected to the thyroid cartilage by a thyrohyoid membrane. The hyoid bone serves as a point of attachment for laryngeal muscles and is the upper boundary of the laryngeal framework.

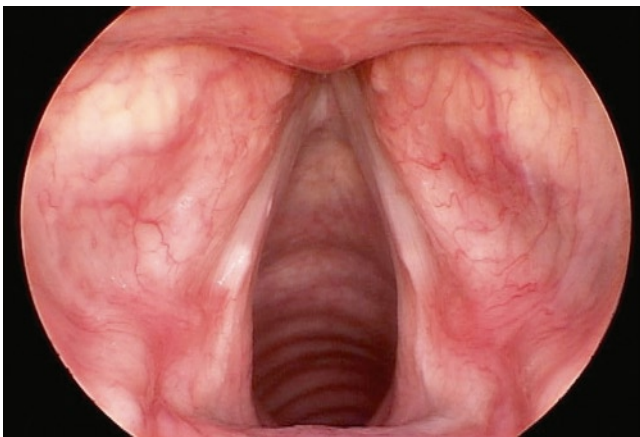


Fig. 32.1 Picture of a normal larynx

Unlike the rest of the larynx which is lined by respiratory epithelium, the vocal cords are covered by pseudostratified epithelium. Because of the sparse lymphatic supply to the glottis, true vocal cord lesions rarely present with cervical nodal metastases. On the other hand, supraglottic tumors metastasize to neck nodes in about 50% of cases [21, 22], dependent on T stage. In stage I and II tumors with clinically negative neck nodes, there is a 32% reported rate of cervical nodal involvement. With radiation therapy to both sides of the neck, the rate of relapse in nodal areas is reduced from 38 to 19% [21, 23]. Patterns of growth and spread of cancer within the larynx were found to be influenced by fibro-elastic ligaments and membranes which confine the tumor to anatomic compartments, and which provide margins of safety when performing a partial laryngectomy [24]. Two barriers to periventricular extension contiguous with the quadrangular membrane superiorly and the conus elasticus membrane inferiorly have been described [25]. Consequently, a high rate of local control can be obtained by surgeons performing horizontal supraglottic laryngectomy [26].

Supraglottic Cancer

Lesions of the supraglottis tend to spread locally. The majority of these lesions arise from the epiglottis. Lesions arising from the lower portion of the epiglottis tend to have an endophytic pattern which may spread to the preepiglottic space, whereas lesions from the upper portion of the epiglottis tend to be exophytic [24]. Modern imaging technologies, such as CT, have provided increased ability to recognize tumors that have spread to the preepiglottic space and unenhanced T1-weighted magnetic resonance (MR) images are highly sensitive for the detection of neoplastic infiltration of the preepiglottic space [27]. When the preepiglottic fold is uninvolved, patients may be treated conservatively with radiation therapy or local surgery, whereas deep invasion into the preepiglottic space may necessitate a supraglottic or total laryngectomy [28].

It has been reported that the contralateral undissected neck is a common site of failure in patients treated for SCC of the supraglottic larynx [23]. Routine bilateral neck dissection decreases cervical recurrence and appears to improve survival in the management of supraglottic cancer [23, 29].

Glottic Cancer

Glottic or true vocal cord carcinomas often demonstrate infiltrative growth patterns, and about two thirds are confined to the vocal folds (glottis), with the majority of these

confined to the anterior two thirds of that structure. About 34% of glottic tumors involve the anterior commissure, and close to 11% involve the posterior commissure [30–32]. The anterior commissure influences growth spread of the tumor, initially retarding invasion of tumors and possibly causing diversion into the epiglottis [26]. When vocal cord lesions progress, they may invade the subglottic region or penetrate through the thyroid cartilage, penetrate the thyrohyoid membrane or just expand superiorly to involve the base of tongue. Early glottis carcinomas may be treated with external radiation or endoscopic laser techniques. For larger glottis tumors with unilateral ventricle extension or involvement of the vocal process, a vertical laryngectomy may be used [33]. A supracricoid partial laryngectomy with cricothyroidopiglottopexy (SCPL-CHEP) is a partial horizontal laryngectomy for selected patients with glottis cancers. It offers an alternative to TL and has a single method of reconstruction [34]. A low recurrence rate of 10% has been reported for patients with T3 lesions following induction chemotherapy and SCPL-CHEP [35]. However, few surgeons are skilled in this technique, and the functional consequences are unpredictable.

Subglottic Cancer

Tumors arising in the subglottic area of the larynx tend to be poorly differentiated and often are readily infiltrative. They are rare tumors and do not exceed 1–7% of all laryngeal carcinomas [36, 37]. As discussed above, the subglottis is practically considered to begin 5 mm below the free margin of the vocal cords and extends to the inferior border of the cricoid cartilage. The incidence of nodal metastasis from subglottic cancers is estimated to be close to 16%, however, this may be an underestimation as the primary drainage pattern of these lesions is to the para- and pretracheal lymph nodes which are more difficult to detect [37]. Surgeons should, however, be aware of the relatively high incidence of micrometastases in patients with laryngeal cancer. Just as elective neck treatment is recommended for supraglottic tumors staged T2 or higher, and T3 or higher glottic cancer, subglottic cancers of stage T3 or higher merit elective regional treatment [38].

Diagnosis and Staging

Accurate staging is imperative for laryngeal carcinomas, as minute differences in tumor size and location may have a significant impact on overall stage, prognosis, and therefore choice of treatment. Staging is initiated clinically with

thorough examination, usually with the aid of a flexible fiberoptic nasopharyngoscope. Further clinical examination under anesthesia with direct laryngoscopy may be necessary. In addition to the clinical examination and endoscopy, imaging techniques, including CT, Magnetic resonance imaging (MRI), and PET scans play a crucial role in pretherapeutic and posttherapeutic diagnostics [28]. MRI is useful in determining submucosal transglottic spread, and is also very sensitive in detecting cartilage and preepiglottic space invasion [39]. Interpretation of CT and MR images requires a thorough knowledge of the patterns of submucosal spread and familiarity with recognizing signs of invasion. CT imaging of advanced laryngeal cancer is surprisingly inaccurate [40]. In the past, MRI has also been unreliable, but new MRI interpretation techniques which help differentiate peritumor edema from tumor invasion are promising [41]. Both CT and MR imaging are highly sensitive for the detection of neoplastic invasion of the preepiglottic and paraglottic spaces, as well as cartilage invasion [42]. Even though there is a good negative predictive value of both modalities allowing exclusion of cartilage invasion, recent evidence exists to support the use of new diagnostic criteria that help distinguish cartilage invasion from reactive inflammatory processes [43].

The staging of laryngeal cancer follows the current AJCC guidelines using standard TNM stratification (see Table 31.1) [20]. T staging is performed differently for each subsite and is therefore separated into supraglottic, glottic, and subglottic sections.

A T1 designation is reserved for small, localized tumors in each respective subsite (Fig. 32.2). Transition to T2 indicates

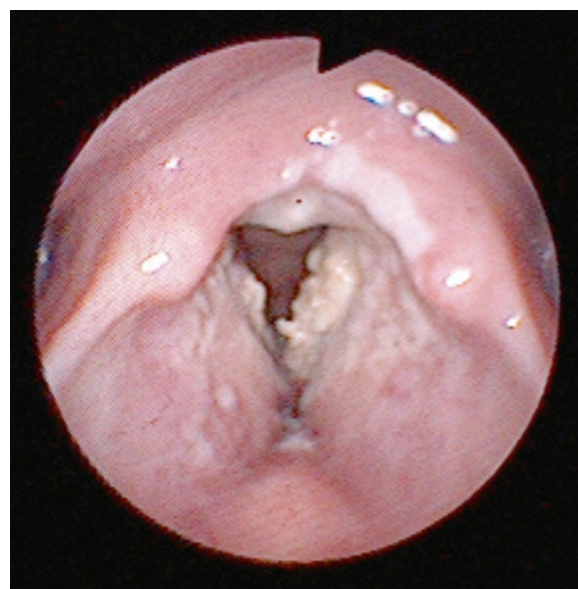


Fig. 32.2 A T1b glottic tumor

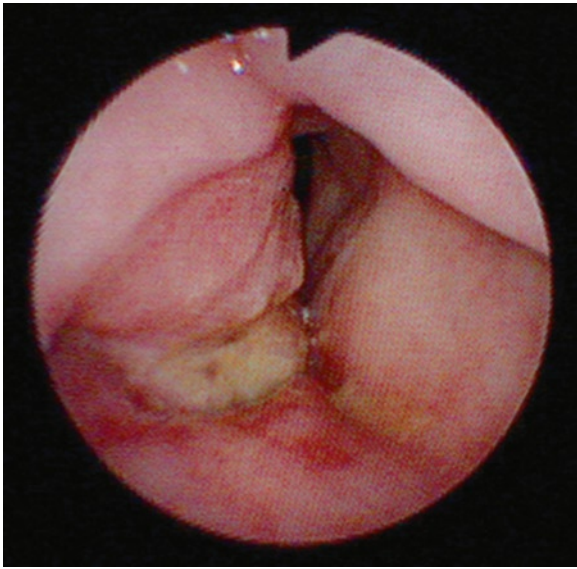


Fig. 32.3 A T3 glottic tumor

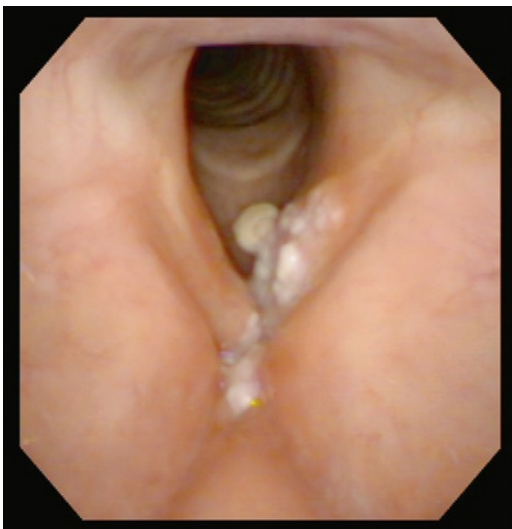

Fig. 32.4 A T2 glottic tumor with extension to the supraglottic area

involvement of another laryngeal subsite (Fig. 32.4). Similarly, a T3 tumor exhibits vocal cord fixation and/or involvement of one or more of the potential spaces within the laryngeal framework (Fig. 32.3). This is particularly important when evaluating the larynx radiographically as involvement of the preepiglottic and paraglottic spaces is often difficult to detect clinically, yet has significant bearing on the stage and therefore treatment of the disease. T4 tumors are noted by involvement of extralaryngeal structures or other organs within the visceral compartment, with T4b tumors being considered “unresectable.”

An excellent discussion on the role of imaging for staging of advanced larynx cancer was recently published by Becker et al. [28]. The N and M stages are similar to those of other head and neck subsites.

Treatment and Outcome for Advanced Stage Disease

Supraglottic Cancers

Advanced Stage

The success of supraglottic laryngectomy for T3 and T4 lesions has been variable with poor predictability for recurrence. However, a local control rate of 70–85% has been reported [44]. A supraglottic laryngectomy can be successfully done for T3 with preepiglottic space invasion since the preepiglottic space is removed during the procedure. The poor predictability for recurrence may be a result of poor appreciation of tumor extent preoperatively. As a result, caution and selectivity should be exerted when treating T3 and T4 lesions with supraglottic laryngectomies. In an attempt to spare the patient postoperative radiation therapy, elective bilateral neck dissections should be considered in the T3N0 setting. A near total laryngectomy is another less commonly performed surgery for supraglottic tumors with cord fixation or glottis tumors with subglottic extension [45]. A local control rate similar to that reported with TL or laryngopharyngectomy with conversational voice was achieved in 85% of patients surviving beyond 1 year [45]. In this procedure, there is preservation of the posterior half of the hemilarynx with a long-term tracheotomy, with the major advantage being maintaining the voice and avoiding synthetic prostheses. A local recurrence rate of 7% was noted [45].

A supraglottic laryngectomy is usually not recommended in patients who have had a prior radiation therapy course because of associated wound healing or in patients whose pulmonary function cannot tolerate some aspiration.

Glottic and Subglottic Cancers

Advanced Stage

Advanced stage glottic tumors tend to present with nodal involvement with a probability of cure of 60%. Whenever possible, the goal should be laryngeal preservation. However, if there is evidence of aspiration or a need for a tracheostomy because of airway compromise, TL is often required. There is a lack of randomized studies comparing surgery with

radiation therapy alone for T3–T4 lesions. A subtotal laryngectomy with the advantage of maintaining the airway may be achieved with a subtotal laryngectomy and cricothyroidopexy or cricothyroidoepiglottopexy [34, 46, 47]. Radiation therapy as a single modality is not usually given for curative intent. Combined modality therapy is the nonsurgical approach of choice as discussed in the following section.

Treatment of Locally Advanced Disease

Trials of Laryngeal Preservation

Primary chemoradiotherapy in patients with advanced laryngeal cancer can achieve high rates of organ preservation without sacrificing survival compared with radiation alone or conventional laryngectomy. Appropriate selection of patients for organ preservation approaches could enhance overall treatment outcome and quality of life.

A major shift in treatment for patients with advanced laryngeal cancer occurred with the publication of results indicating that successful organ preservation, with survival rates similar to those with primary laryngectomy, could be achieved with definitive radiation therapy in patients responding to neoadjuvant chemotherapy [48, 49]. The landmark Veterans Affairs' (VA) laryngeal cancer study, initially published in 1991, provided the best initial evidence to support cisplatin-based, induction chemotherapy as part of a larynx-preserving treatment approach. In the VA laryngeal study, 332 patients were randomly assigned to receive either three cycles of chemotherapy (cisplatin and fluorouracil) and radiation therapy or surgery and radiation therapy. The clinical tumor response was assessed after two cycles of chemotherapy, and patients with a response received a third cycle followed by definitive radiation therapy (6,600–7,600 cGy). Patients in whom there was no tumor response or who had locally recurrent cancers after chemotherapy and radiation therapy underwent salvage laryngectomy. After a median follow-up of 33 months, the estimated 2-year survival was 68% (95% confidence interval, 60–76%) for both treatment groups ($p=0.9846$). Patterns of recurrence differed significantly between the two groups, with more local recurrences ($p=0.001$) and fewer distant metastases, 11% versus 17% ($p=0.016$) in the chemotherapy group than in the surgery group. The 66% rate of laryngeal preservation in the chemotherapy group suggested that a treatment strategy involving induction chemotherapy and definitive radiation therapy can be effective in preserving the larynx in a high percentage of patients, without compromising overall survival [48].

The similarly designed European Organization for Research and Treatment of Cancer (EORTC) larynx preservation study, which focused on patients with advanced cancer

of the hypopharynx, further supported the principles of the VA trial. Induction chemotherapy followed by radiation with surgery reserved for salvage came to be considered a new standard treatment for patients with locally advanced cancer of the larynx [49].

The Radiation Therapy Oncology Group and the Head and Neck Intergroup conducted a randomized trial (RTOG 91-11) to investigate three radiation-based treatments for nonbulky advanced laryngeal cancers: induction cisplatin plus fluorouracil followed by radiotherapy if there was a response to the chemotherapy (a regimen identical to that given in the VA laryngeal trial), radiotherapy with concurrent administration of cisplatin, and radiotherapy alone. The purpose was to determine the contributions of chemotherapy and radiotherapy to larynx-preserving treatment. Patients were eligible if they had biopsy-proven, previously untreated stage III or IV SCC of the glottic or supraglottic larynx that would otherwise require a total laryngectomy. Patients were excluded if they had a T1 primary tumor or large-volume stage T4 disease (defined as a tumor penetrating through the cartilage or extending more than 1 cm into the base of the tongue). A total of 547 patients were randomly assigned to one of the three study groups. The median follow-up period was 3.8 years. At 2 years, the proportion of patients who had an intact larynx after radiotherapy with concurrent cisplatin was significantly improved compared with the groups given induction chemotherapy followed by radiotherapy (88% versus 75%, $p=0.005$) or radiotherapy alone (70%, $p<0.001$) suggesting that cisplatin was an active radiosensitizer [50]. Concurrent chemoradiation became the new standard of care for advanced laryngeal cancer without massive base of tongue involvement.

Chemotherapy: Induction Chemotherapy

It has been shown that outcome for patients with locally advanced SCC of the head and neck (SCCHN) may differ according to the type of induction therapy they receive. As compared with induction chemotherapy using cisplatin and fluorouracil, induction chemotherapy with the addition of docetaxel significantly improved progression-free and overall survival in patients with unresectable SCCHN, as shown in the TAX 324 study [51]. Outcomes were analyzed in the subgroup of assessable laryngeal and hypopharyngeal cancer patients enrolled in TAX 324, a phase III trial of sequential therapy comparing docetaxel plus cisplatin and fluorouracil (TPF) against cisplatin and fluorouracil (PF), followed by chemoradiotherapy. Among operable patients (TPF, $n=67$; PF, $n=56$), laryngectomy-free survival (LFS) was significantly greater with TPF (HR: 0.59; 95% CI: 0.37–0.95; $p=0.030$). Three-year LFS with TPF was 52% versus 32% for PF, and fewer TPF patients had surgery (22% versus 42%;

$p=0.030$) supporting the use of sequential TPF followed by carboplatin-based weekly chemoradiotherapy [52].

In another study originating in Europe, TPF was compared to PF as induction chemotherapy in patients with locoregionally advanced, unresectable SCCHN. A total of 358 patients underwent randomization, with 177 assigned to the TPF group and 181 to the PF group. At a median follow-up of 32.5 months, the median progression-free survival was 11.0 months in the TPF group and 8.2 months in the PF group (hazard ratio for disease progression or death in the TPF group, 0.72; $p=0.007$). Treatment with TPF resulted in a reduction in the risk of death of 27% ($p=0.02$), with a median overall survival of 18.8 months, as compared with 14.5 months in the PF group, showing that the addition of docetaxel significantly improved progression-free and overall survival in patients with unresectable SCCHN [53]. The Gortec (TREMPLIN) study looked at three cycles of TPF chemotherapy followed by either concurrent cisplatin or cetuximab with radiation therapy in responders, or TL in nonresponders with a primary endpoint being laryngeal preservation 3 months after therapy. A total of 116 patients (79% of those enrolled) were randomized between the two concurrent arms. Due to a better overall toxicity profile, TPF followed by RT-cetuximab improved compliance to treatment and was more manageable (unpublished data presented at ASCO 2009).

In an effort to select patients for organ preservation based on response to a single cycle of induction chemotherapy, patients with stage III and IV larynx cancer were treated depending on their response to chemotherapy with surgical or nonsurgical approaches. The overall survival rate at 3 years was 85%. The cause-specific survival rate was 87%. Larynx preservation was achieved in 69 patients (70%), indicating that excellent survival results achieved with a targeted approach to patient selection may be a result of the early selection for laryngectomy of patients likely to fail chemoradiotherapy. No solid conclusions could however be reached from phase II studies [54].

Definitive Chemotherapy

An exciting but as yet investigational concept is the use of definitive chemotherapy for laryngeal cancer [55]. A total of 31 previously untreated patients with laryngeal cancer (stages T2–4, N0–1, M0), who were deemed resectable with conservation laryngeal surgery (CLS), received four cycles of paclitaxel, ifosfamide, and cisplatin (TIP) chemotherapy with or without CLS. Response was assessed histologically. With TIP chemotherapy alone, 11 patients (37%) achieved a pathologic CR, ten of whom (33%) remain alive with durable disease remission and no evidence of recurrence over a median follow-up time of 5 years. Nineteen patients (63%) treated with TIP alone achieved PR. The overall laryngeal

preservation (LP) rate was 83%, and only five patients (16%) required postoperative RT. It is of note however that this patient group was carefully selected, with predominantly stage II disease, and which was suitable for CLS from the outset. Also, a supracricoid laryngectomy was performed which is not a widely performed procedure. This raises the question of the generalizability of this approach for T3 and T4 lesions. For these lesions the acceptable standards of care remain to be concurrent chemo and radiation therapy or a total laryngectomy.

Recurrent Disease

Surgical Management

Despite many surgical options, the standard of care for surgical management of recurrent disease and/or persistent disease after attempted organ preservation treatment remains a TL [56]. Some of the best data available are those from the VA Study and follow-up studies, in which the survival rates of patients treated with organ preservation radiation and chemotherapy were not significantly different than those patients treated with primary surgery, specifically because treatment failures were still able to undergo the gold standard of TL for salvage [48]. Indeed, most organ preservation protocols involve radiation and chemotherapy for advanced stage III or IV laryngeal disease, the recurrences of which are often not amenable to less than total laryngectomy, either from tumor size, inability to differentiate tumor from treatment effect on the tissues, or a nonfunctional organ.

Lessons learned from the VA Study also include the necessity of evaluating the neck separately from evaluation of the primary site. Early neck salvage after induction chemotherapy followed by radiation failures was recommended [57].

However, more studies are emerging with preliminary data indicating that less than TL may be oncologically feasible in select patients with early stage disease who have failed initial nonsurgical treatment and are still amenable to a conservation surgery attempt. In one recent study, 55 patients with laryngeal cancer that were previously treated underwent transoral laser surgery salvage with comparable outcomes to traditional TL [58]. Similarly, in 2006, Holsinger, et al. reviewed 105 cases undergoing salvage surgery with TL ($n=73$) versus partial laryngectomy ($n=32$) and found no statistically significant difference in oncologic outcome [59]. Finally, in a large study of 662 patients with T1 or T2 initial disease who failed radiation therapy and underwent either salvage total or partial laryngectomy, up to 50% of patients undergoing partial laryngectomy had to be yet again salvaged by TL due to disease progression [60]. Thus, current data are promising that select patients may be able to be salvaged surgically without a total

laryngectomy; but, the surgeon and patient must both be aware that although salvage partial laryngectomy may sometimes be feasible, a TL may yet be necessary due to disease recurrence or aspiration.

The current NCCN guidelines do not delineate which surgical intervention is suggested for salvage after primary nonsurgical treatment for laryngeal cancer. The choice, therefore, is made on an individual basis predicated by the initial stage, the amount of residual disease, the functional status of the larynx, and the performance status of the patient [61].

Systemic Therapy

Most of the information in this section applies to recurrent metastatic SCCHN in general. Several phase II trials combining cetuximab with a platinum agent in patients who were refractory to the platinum-based combination have reached an objective response rate of 10–13% [62]. As a result of these trials, cetuximab has been approved by the FDA for treatment of platinum-resistant disease as well as in combination with radiation for the treatment of locally advanced disease. In the EXTREME trial, adding cetuximab to platinum-based chemotherapy for recurrent or metastatic SCCHN significantly prolonged median overall survival from 7.4 to 10.1 months (HR=0.8, $p=0.04$), with a prolongation of median progression-free survival from 3.3 to 5.6 months (HR=0.54, $p<0.001$). This study showed for the first time an improvement in overall survival with the addition of cetuximab to platinum-based therapy, and resulted in the longest reported survival ever seen in a phase III study, resulting in a practice-shifting change toward the use of the cetuximab combination [63]. Other targeted agents under development include newer anti-EGFR agents such as the fully humanized antibody panitumumab [64], novel anti-angiogenic therapies [65], dual EGFR and ErbB2 inhibitors [66], mTOR inhibitors [67], and inhibitors of insulin-like growth factor-1R [67], as well as c-MET inhibitors.

Radiation Therapy Techniques for Laryngeal Cancer

Early glottic cancer is best treated with simple fields, usually parallel opposed. The use of CT-guided treatment planning as well as wedges (virtual or physical) brings the inhomogeneity of the field to 3–4% for most patients. Schwaibold first demonstrated that fraction sizes of <2 Gy/day are associated with inferior results. For T1 disease, 63 Gy in 2.25 Gy daily fractions is a standard dosing schedule. For T2 disease, the RTOG has investigated hyperfractionation, and while the

final results remain unpublished, an oral presentation suggested that there may be some benefit in local control with hyperfractionation [68].

For more advanced laryngeal cancer, being treated definitively with external radiation and chemotherapy IMRT allows salivary sparing for most patients. Involved necks should be covered from levels 2–6 and the lateral retropharyngeal nodes. Bulky disease may dictate that level IB may need to be covered in selected cases. Contralateral coverage of the clinically negative neck may begin superiorly at the transverse process of C1 or where the posterior belly of the digastrics crosses the jugular vein. Coverage of the medial retropharyngeal nodes may not be necessary and sparing this region may be functionally important [69, 70].

For patients treated postoperatively it is important to boost the dose to the laryngeal stoma, as tolerated, and this is conventionally done with bolus. A tracheostomy tube or aquaplast may be an effective bolus [71].

After supraglottic laryngectomy, postoperative radiation may impair the functional results. Because local failures on the glottic side are particularly uncommon, if neck dissection has not been performed, nodal irradiation with sparing of at least the laryngeal anastomosis may be the best treatment technique.

Fractionation has been an area that radiation oncologists have investigated with good results [72–75]. RTOG 9003 [72] randomized patients with locally advanced head and neck cancer to (1) standard fractionation at 2 Gy/fraction/day, 5 days/week, to 70 Gy/35 fractions/7 weeks; (2) hyperfractionation at 1.2 Gy/fraction, twice daily, 5 days/week to 81.6 Gy/68 fractions/7 weeks; (3) accelerated fractionation with split at 1.6 Gy/fraction, twice daily, 5 days/week, to 67.2 Gy/42 fractions/6 weeks including a 2-week rest after 38.4 Gy; or (4) accelerated fractionation with concomitant boost at 1.8 Gy/fraction/day, 5 days/week and 1.5 Gy/fraction/day to a boost field as a second daily treatment for the last 12 treatment days to 72 Gy/42 fractions/6 weeks. Later follow-up [76] showed that for the 1,073 analyzable patients, hyperfractionation and accelerated fractionation with a concomitant boost both had significantly better 5-year local–regional control ($p=0.037$ and $p=0.042$, respectively) as well as improved disease-free survival ($p=0.013$ and $p=0.042$, respectively). A trend toward improved overall survival was seen for patients randomized to the hyperfractionation arm ($p=0.063$). The incidence of late grade 3+ toxicities in the hyperfractionation arm was similar to the standard fractionation arm.

RTOG 9003 was performed in the era before IMRT. IMRT allows radiation oncologists to increase the dose per fraction to gross disease while keeping dose per fraction to clinical target volumes smaller. Simultaneous in-field boosts have thus become the present day result of some of the lessons regarding fractionation.

Most oncologists believe that concurrent chemoradiation is more effective than hyperfractionation alone for advanced disease. Data are available showing that hyperfractionation plus concurrent cisplatin improved overall survival compared to hyperfractionation alone, and that hyperfractionation with concurrent docetaxel, cisplatin, and 5-fluorouracil produced significantly better local–regional control than standard fractionation and the same chemotherapy [77, 78]. RTOG 0522 assessed the addition of cetuximab to IMRT radiation plus concurrent cisplatin, and those results are pending. Since RTOG 0522 required years to complete, and toxicity data were monitored by a data safety monitoring committee, it is reasonable to conclude that both regimens were tolerated.

Specific to laryngeal cancer patients, DAHANCA 6 and 7 [79] showed that six compared to five fractions per week improved voice preservation among patients with laryngeal cancer (80% versus 68%, $p=0.007$).

Surgical Technique

A traditional laryngectomy approach involves a U-shaped, or “apron” incision in the anterior neck from mastoid tip to contralateral mastoid tip, encompassing a planned stoma just above the sternal notch. This allows exposure to the visceral compartment of the neck while also allowing both neck nodal basins to be approachable via a single incision. The visceral compartment is then separated from the rest of each neck by dividing the blood vessels and nerves entering the larynx from the hyoid bone to the trachea. The suprahyoid musculature is then dissected free from the hyoid bone superiorly, while the trachea is entered inferiorly with care taken to be well below the inferior-most extent of tumor. The stoma is then created in an appropriate position. The aerodigestive tract is then usually entered at the vallecula, depending on the superior limit of the tumor. This allows retraction of the larynx anteriorly for direct visualization of the tumor and facilitates further mucosal cuts around the tumor with adequate margins. The thyroid lobe ipsilateral to the tumor is often left in continuity with the larynx. The last mucosal cuts along the postcricoid region fully deliver the specimen from the patient. Once negative margins are reached, the mucosal defect can usually be closed primarily, traditionally by hand sewing the defect, or sometimes with an automatic linear stapler [80].

Neck dissection is performed concurrently if there are clinically known positive nodes, or if there is a high probability of occult nodal metastases. In advanced disease, a selective neck dissection of levels II–IV is likely adequate for N0 necks, with formal modified neck dissections likely reserved for clinically N+ necks [81].

On the near horizon, a promising adjunct to traditional surgical treatment of laryngeal cancer is emerging in the form of transoral robotic surgery with carbon dioxide laser (TORS). The use of laser with transoral approach has been established as a viable method for treating select laryngeal tumors for many years and even in some advanced disease [82]. However, with the addition of robotic technology, the application of the transoral approach is broadened due to the finer control and more advantageous angle of dissection than is possible with traditional transoral exposure. Although not currently FDA-approved at the time of this writing, several institutions have shown feasibility and potential benefits in experimental use [83, 84]. Whether this technique eventually replaces the traditional external approach, much like laparoscopic surgery and robotic urologic surgery have in their respective specialties, remains to be seen.

Voice and Swallowing Changes

Total laryngectomy is one of the surgical procedures most feared by patients. Body image reintegration is critical to subsequent quality of life after head and neck cancer surgery. When disfigurement and dysfunction is associated with treatment, quality of life may be profoundly and adversely affected [85, 86]. To determine how head and neck cancer patients prioritize potential treatment effects in relationship to each other, 131 patients were assessed pretreatment using standardized quality of life (QOL) measures (Functional Assessment of Cancer Therapy-Head and Neck) and performance (Performance Status Scale for Head and Neck Cancer). Patients were also asked to rank a series of 12 potential head and neck cancer treatment effects. The data suggest that, at least in the pretreatment period, survival is of primary importance to patients. Patients might be more willing than nonpatients to undergo aggressive treatments and endure acute distress in the interest of potential long-term gains [87].

Effective treatment for laryngeal cancer concerns the preservation of voice. Supracricoid partial laryngectomy can have a significant social and professional impact. Patients may find themselves withdrawing from society and the work force in which vocal involvement is essential. The potential postsurgical social voice impact should be taken into consideration before proposing surgery, and it is essential to estimate the possible impacts of the vocal handicap according to the patient’s professional or other activities. Progress has been made in treatment, rehabilitation, restoration of the airway, and nonsurgical treatments. With the introduction of tracheo-esophageal speech and voice prosthesis, many treated patients acquire socially acceptable speech after TL and maintain satisfactory quality of life [88].

Successful voice restoration can be attained with any of three speech options, namely esophageal speech, electro-larynx, and tracheo-esophageal (TO) speech using an artificial valve. Although no single method is considered the best for every patient, the tracheo-esophageal puncture has become the preferred method in the past decade [88].

All patients with advanced laryngeal cancer should undergo a swallowing assessment, even in the absence of symptoms, to detect possible aspiration and initiate therapeutic maneuvers and swallowing precautions. Pretreatment swallowing assessment results in measurable improvements in posttreatment swallowing in patients undergoing concomitant radiation and chemotherapy [89, 90].

References

- Cattaruzza MS, Maisonneuve P, Boyle P. Epidemiology of laryngeal cancer. *Eur J Cancer*. 1996;32(5):293–305.
- Stell PM, McGill T. Asbestos and laryngeal carcinoma. *Lancet*. 1973;2(7826):416–7.
- Dietz A, Ramroth H, Urban T, Ahrens W, Becher H. Exposure to cement dust, related occupational groups and laryngeal cancer risk: results of a population based case-control study. *Int J Cancer*. 2004;108(6):907–11.
- Flanders WD, Rothman RK. Occupational risk for laryngeal cancer. *Am J Public Health*. 1982;72(4):369–72.
- De Stefani E, Oreggia F, Rivero S, Ronco A, Fierro L. Salted meat consumption and the risk of laryngeal cancer. *Eur J Epidemiol*. 1995;11(2):177–80.
- Oreggia F, De Stefani E, Boffetta P, Brennan P, Deneo-Pellegrini H, Ronco AL. Meat, fat and risk of laryngeal cancer: a case-control study in Uruguay. *Oral Oncol*. 2001;37(2):141–5.
- Bosetti C, La Vecchia C, Talamini R. Food groups and laryngeal cancer risk: a case-control study from Italy and Switzerland. *Int J Cancer*. 2002;100(3):355–60.
- Galli J, Cammarota G, Calò L. The role of acid and alkaline reflux in laryngeal squamous cell carcinoma. *Laryngoscope*. 2002;112(10):1861–5.
- El-Serag HB, Hepworth EJ, Lee P, Sonnenberg A. Gastroesophageal reflux disease is a risk factor for laryngeal and pharyngeal cancer. *Am J Gastroenterol*. 2001;96(7):2013–8.
- Jahnke V, Matthias C, Fryer A, Strange R. Glutathione S-transferase and cytochrome-P-450 polymorphism as risk factors for squamous cell carcinoma of the larynx. *Am J Surg*. 1996;172(6):671–3.
- Jourenkova-Mironova N, Voho A, Bouchardy C, et al. Glutathione S-transferase GSTM3 and GSTP1 genotypes and larynx cancer risk. *Cancer Epidemiol Biomarkers Prev*. 1999;8(2):185–9.
- Smith EM, Summersgill KF, Allen J, Hoffman HT, McCulloch T, Turek LP, et al. Human papillomavirus and risk of laryngeal cancer. *Ann Otol Rhinol Laryngol*. 2000;109(11):1069–76.
- Isenberg JS, Crozier DL, Dailey SH. Institutional and comprehensive review of laryngeal leukoplakia. *Ann Otol Rhinol Laryngol*. 2008;117(1):74–9.
- Ozlugedik S, Yorulmaz I, Gokcan K. Is laryngopharyngeal reflux an important risk factor in the development of laryngeal carcinoma? *Eur Arch Otolaryngol*. 2006;263(4):339–43.
- Haddad RI, Shin DM. Recent advances in head and neck cancer. *N Engl J Med*. 2008;359:1143–54.
- Groome PA, O'Sullivan B, Irish JC, Rothwell DM, Schulze K, Warde PR, et al. Management and outcome differences in supraglottic cancer between Ontario, Canada, and the Surveillance, Epidemiology, and End Results areas of the United States. *J Clin Oncol*. 2003;21(3):496–505.
- Fried MP. *The larynx-A multidisciplinary approach*. 2nd ed. St Louis: Mosby; 1996.
- Tucker HM. *Developmental anatomy*. In: Tucker HM, editor. *The larynx*. New York: Thieme; 1987. p. 18.
- Lippert BM, Teymoortash A, Folz BJ, Werner JA. Wound healing after laser treatment of oral and oropharyngeal cancer. *Lasers Med Sci*. 2003;18:36–42.
- Edge SB, Byrd DR, Compton CA, editors. *AJCC cancer staging manual*. 7th ed. New York: Springer; 2010.
- Kirchner JA, Owen JR. Five hundred cancers of the larynx and pyriform sinus: results of treatment by radiation and surgery. *Laryngoscope*. 1977;87:1288–303.
- Suárez C, Llorente JL, Nuñez F, Diaz C, Gomez J. Neck dissection with or without postoperative radiotherapy in supraglottic carcinomas. *Otolaryngol head Neck Surg*. 1993;109(1):3–9.
- Levendag P, Vikram B. The problem of neck relapse in early stage supraglottic cancer – results of different treatment modalities for the clinically negative neck. *Int J Rad Oncol Biol Phys*. 1987;13(11):1621–4.
- Krischner JA, Carter D. Intralaryngeal barriers to the spread of cancer. *Acta Otolaryngol*. 1987;103(5–6):503–13.
- Beitler JJ, Mahadevia PS, Silver CE, Wadler S, Rubin JS, Bello JA, et al. New barriers to ventricular invasion in paraglottic laryngeal cancer. *Cancer*. 1994;73:2648–52.
- Krischner JA. Glottic-supraglottic barrier: fact or fantasy? *Ann Otol Rhinol Laryngol*. 1997;106–8:700–4.
- Loevner LA, Yousem DM, Montone KT, Weber R, Chalian AA, Weinstein GS. Can radiologists accurately predict preepiglottic space invasion with MR imaging? *AJR Am J Roentgenol*. 1997;169(6):1681–7.
- Becker M, Burkhardt K, Dulguerov P, Allal A. Imaging of the larynx and hypopharynx. *Eur J Radiol*. 2008;66(3):460–79.
- Chiu RJ, Myers EN, Johnson JT. Efficacy of routine bilateral neck dissection in the management of supraglottic cancer. *Otolaryngol Head Neck Surg*. 2004;131(4):485–8.
- Rucci L, Bocciolini C, Romagnoli P, Olofsson J. Risk factors and prognosis of anterior commissure versus posterior commissure T1-T2 glottic cancer. *Ann Otol Rhinol Laryngol*. 2003;112(3):223–9.
- Rödel RM, Steiner W, Müller RM, Kron M, Matthias C. Endoscopic laser surgery of early glottic cancer: involvement of the anterior commissure. *Head Neck*. 2009;31(5):583–92.
- Lawson W, Biller H, Suen J. *Cancer of the larynx*. In: Myers G, Suen J, editors. *Cancer of the head and neck*. 2nd ed. New York: Churchill Livingstone; 1989. p. 533.
- Bailey BJ, Calcaterra TC. Vertical, subtotal laryngectomy and laryngoplasty. Review of experience. *Arch Otolaryngol*. 1971;93(3):232–7.
- Laccourreye H, Laccourreye O, Weinstein G, Menard M, Brasnu D. Supracricoid laryngectomy with cricohyoidopexy: a partial laryngeal procedure for selected supraglottic and transglottic carcinomas. *Laryngoscope*. 1990;100(7):735–41.
- Laccourreye O, Salzer SJ, Brasnu D, Shen W, Laccourreye H, Weinstein GS. Glottic carcinoma with a fixed true vocal cord: outcomes after neoadjuvant chemotherapy and supracricoid partial laryngectomy with cricohyoidopexy. *Otolaryngol Head Neck Surg*. 1996;114(3):400–6.
- Smee RI, Williams JR, Bridger GP. The management dilemmas of invasive subglottic carcinoma. *Clin Oncol (R Coll Radiol)*. 2008;20(10):751–6.
- Stell PM, Tobin KE. The behavior of cancer affecting the subglottic space. *Can J Otolaryngol*. 1975;4(4):612–7.
- Ferlito A, Silver CE, Rinaldo A, Smith RV. Surgical treatment of the neck in cancer of the larynx. *ORL J Otorhinolaryngol Relat Spec*. 2000;62(4):217–25.

39. Kikinis R, Wolfensberger M, Boesch C, Martin E. Larynx: MR imaging at 2.35 T. *Radiology*. 1989;171(1):165–9.
40. Beitler JJ, Muller S, Chen AY, Grist WJ, Klein AM, Johns MM, et al. Arytenoid, cricoid and thyroid sclerosis and CT imaging as predictors for extralaryngeal spread. *Oncology*. 2009;23(Suppl):7–8.
41. Becker M, Zbaren P, Casselman JW, Kohler R, Dulguerov P, Becker CD. Neoplastic invasion of laryngeal cartilage: reassessment of criteria for diagnosis at MR imaging. *Radiology*. 2008;249(2):551–9.
42. Loevner LA, Yousem DM, Montone KT, Weber R, Chalian AA, Weinstein GS. Can radiologists accurately predict preepiglottic space invasion with MR imaging? *AJR Roentgenol*. 1997;169–6:1681–7.
43. Becker M, Burkhardt K, Allal AS, Dulguerov P, Ratib O, Becker CD. Pretherapeutic and posttherapeutic laryngeal imaging. *Radiologe*. 2009;49(1):43–58.
44. De Santo LW. Cancer of the supraglottic larynx: a review of 260 patients. *Otolaryngol Head Neck Surg*. 1985;114:400.
45. Pearson BW, DeSanto LW, Olsen KD, Salassa JR. Results of near-total laryngectomy. *Ann Otol Rhinol Laryngol*. 1988;107(10 pt 1):820–5.
46. Piquet JJ, Chevalier D. Subtotal laryngectomy with crico-hyoido-epiglottopexy for the treatment of extended glottic carcinomas. *Ann Otolaryngol Chir Cervicofac*. 1991;162(4):681–6.
47. Schwaab G, Kolb F, Julieron M, Janot F, Le Ridant AM, Mamelle G, et al. Subtotal laryngectomy with cricohyoidopexy as first treatment procedure for supraglottic carcinoma: Institut Gustave-Roussy experience (146 cases, 1974–1997). *Eur Arch Otorhinolaryngol*. 2001;258(5):246–9.
48. The Department of Veterans Affairs' Laryngeal Cancer Study Group: induction chemotherapy plus radiation compared with surgery plus radiation in patients with advanced laryngeal cancer. *N Engl J Med*. 1991;324:1685–90.
49. Lefebvre JL, Chevalier D, Luboinski B, Kirkpatrick A, Collette L, Sahnoud T. Larynx preservation in pyriform sinus cancer: preliminary results of a European Organization for Research and Treatment of Cancer Phase III Trial. *J Natl Cancer Inst*. 1996;88(13):890–9.
50. Forastiere AA, Maor M, Pajak TF, Weber R, Morrison M, Glisson B, et al. Concurrent chemotherapy and radiotherapy for organ preservation in advanced laryngeal cancer. *N Engl J Med*. 2003;349:2091–8.
51. Posner MR, Herschock DM, Blajman CR, Mickiewicz E, Winquist E, Gorbounova V, et al. Cisplatin and fluorouracil alone or with docetaxel in head and neck cancer. *N Engl J Med*. 2007;357(17):1705–15.
52. Posner MR, Norris CM, Wirth LJ, Shin DM, Cullen KJ, Winquist EW, et al. Sequential therapy for the locally advanced larynx and hypopharynx cancer subgroup in TAX 324: survival, surgery, and organ preservation. *Ann Oncol*. 2009;20(5):921–7.
53. Vermorken JB, Remenar E, van Herpen C, Gorlia T, Mesia R, Degardin M, et al. Cisplatin, fluorouracil, and docetaxel in unresectable head and neck cancer. *N Engl J Med*. 2007;357(17):1695–704.
54. Urba S, Wolf G, Eisbruch A, Worden F, Lee J, Bradford C, et al. Single-cycle induction chemotherapy selects patients with advanced laryngeal cancer for combined chemoradiation: a new treatment paradigm. *J Clin Oncol*. 2006;24(4):593–8.
55. Holsinger FC, Kies MS, Diaz Jr EM, Gillenwater AM, Lewin JS, Ginsberg LE, et al. Durable long-term remission with chemotherapy alone for stage II to IV laryngeal cancer. *J Clin Oncol*. 2009;27(12):1933–40.
56. Silver CE, Beitler JJ, Shaha AR. Current trends in initial management of laryngeal cancer: the declining use of open surgery. *Eur Arch Otorhinolaryngol*. 2009;266(9):1332–52.
57. Wolf GT, Fisher SG. Effectiveness of salvage neck dissection for advanced regional metastases when induction chemotherapy and radiation are used for organ preservation. *Laryngoscope*. 1992;102(8):934–9.
58. Grant DG, Salassa JR, Hinni ML. Transoral laser microsurgery for recurrent laryngeal and pharyngeal cancer. *Otolaryngol Head Neck Surg*. 2008;138(5):606–13.
59. Holsinger FC, Funk E, Roberts DB, Diaz Jr EM. Conservation laryngeal surgery versus total laryngectomy for radiation failure in laryngeal cancer. *Head Neck*. 2006;28(9):779–84.
60. Ganly I, Patel SG, Matsuo J, et al. Results of surgical salvage after failure of definitive radiation therapy for early-stage squamous cell carcinoma of the glottic larynx. *Arch Otolaryngol Head Neck Surg*. 2006;132(1):59–66.
61. NCCN: National Comprehensive Cancer Network. http://www.nccn.org/professionals/physician_gls/f_guidelines.asp. Accessed on 29 April, 2011 version #2–2011.
62. Herbst RS, Arquette M, Shin DM. Phase II multicenter study of the epidermal growth factor receptor antibody cetuximab and cisplatin for recurrent and refractory squamous cell carcinoma of the head and neck. *J Clin Oncol*. 2005;23(24):5440–2.
63. Vermorken JB, Mesia R, Rivera F, Remenar E, Kaweckki A, Rottey S, et al. Platinum-based chemotherapy plus cetuximab in head and neck cancer. *N Engl J Med*. 2008;359:1116–27.
64. Ciardiello F, Tortora G. EGFR antagonists in cancer treatment. *N Engl J Med*. 2008;358:1160–74.
65. Saba N, Shin DM, Khuri FR. Targeting angiogenesis in head and neck cancer. *Curr Cancer Drug Target*. 2007;7:325–34.
66. Agulnik M, Cohen EE, Cohen RB, Chen EX, Hotte SJ, Winquist E, et al. A phase II study of lapatinib in recurrent or metastatic EGFR and/or ErbB2 expressing adenoid cystic (ACC) and non-ACC malignant tumors of the salivary glands (MSGT). *J Clin Oncol 2006 ASCO Annu Meet Proc*. 2006;24(18S):5566. Part I.
67. Le Tourneau C, Siu LL. Molecular-targeted therapies in the treatment of squamous cell carcinomas of the head and neck. *Curr Opin Oncol*. 2008;20(3):256–63.
68. Fu KK, Pajak TF, Trotti A, Jones CU, Spencer SA, Phillips TL, et al. A Radiation Therapy Oncology Group (RTOG) phase III randomized study to compare hyperfractionation and two variants of accelerated fractionation to standard fractionation radiotherapy for head and neck squamous cell carcinomas: first report of RTOG 9003. *Int J Rad Oncol Biol Phys*. 2000;48(1):7–16.
69. Ozyigit G, Sele U, Cengiz M, Yildiz F. Comment on “Cranial location of level II lymph nodes in laryngeal cancer: implications for elective nodal target volume delineation”: in regard to Braam et al. (*Int J Radiat Oncol Biol Phys* 2007;67:462–468). *Int J Rad Oncol Biol Phys*. 2007;68(5):1582–3.
70. Braam PM, Raaijmakers CP, Terhaard CH. Cranial location of level II lymph nodes in laryngeal cancer: implications for elective nodal target volume delineation. *Int J Rad Oncol Biol Phys*. 2007;67(2):462–8.
71. Beitler JJ, Yarpalvi R, Della Bianca C, Fontenla DP. Methods of bolusing the tracheostomy stoma. *Int J Radiat Oncol Biol Phys*. 2001;50(1):69–74.
72. Fu KK, Pajak TF, Trotti A, Jones CU, Spencer SA, Phillips TL, et al. A Radiation Therapy Oncology Group (RTOG) phase III randomized study to compare hyperfractionation and two variants of accelerated fractionation to standard fractionation radiotherapy for head and neck squamous cell carcinomas: first report of RTOG 9003. *Int J Radiat Oncol Biol Phys*. 2000;48(1):7–16.
73. Horiot JC, Le-Fur R, Nguyen T, Chenal C, Schraub S, Alfonsi S, et al. Hyperfractionation vs. conventional fractionation in oropharyngeal carcinoma: final analysis of a randomized trial of EORTC cooperative group of radiotherapy. *Radiother Oncol*. 1992;25:231–41.
74. Marcial VA, Pajak TF, Chang C, Tupchong L, Stetz J. Hyperfractionated photon radiation in the treatment of advanced squamous cell carcinoma of the oral cavity, pharynx, larynx, and sinuses, using radiation therapy as the only planned modality: (Preliminary report) by the Radiation Therapy Oncology Group (RTOG). *Int J Radiat Oncol Biol Phys*. 1987;13:41–7.

75. Pinto LHJ, Canary PCV, Araujo CMM, Bacelar SC, Souhami L. Prospective randomized trial comparing hyperfractionated versus conventional radiotherapy in Stages III and IV oropharyngeal carcinoma. *Int J Radiat Oncol Biol Phys.* 1991;21:557–62.
76. Trotti A, Fu KK, Pajak TF, Jones CU, Spencer SA, Phillips TL, et al. Long term outcomes of RTOG 90-03: a comparison of hyperfractionation and two variants of accelerated fractionation to standard fractionation radiotherapy for head and neck squamous cell carcinoma. *Int J Radiat Oncol Biol Phys.* 2005;63(Suppl):S70–1.
77. Jeremic B, Shibamoto Y, Milicic B, Nikolic N, Dagovic A, Aleksandrovic J, et al. Hyperfractionated radiation therapy with or without concurrent low-dose daily cisplatin in locally advanced squamous cell carcinoma of the head and neck: a prospective randomized trial. *J Clin Oncol.* 2000;18(7):1458–64.
78. Katori H, Tsukuda M, Watai K. Comparison of hyperfractionation and conventional fractionation radiotherapy with concurrent docetaxel, cisplatin and 5-fluorouracil (TPF) chemotherapy in patients with locally advanced squamous cell carcinoma of the head and neck (SCCHN). *Cancer Chemother Pharmacol.* 2007;60(3):399–406.
79. Overgaard J, Hansen HS, Specht L, Overgaard M, Grau C, Andersen E, et al. Five compared with six fractions per week of conventional radiotherapy of squamous-cell carcinoma of head and neck: DAHANCA 6 and 7 randomised controlled trial. *Lancet.* 2003;362(9388):933–40.
80. Bedrin L, Ginsburg G, Horowitz Z, Talmi YP. 25-year experience of using a linear stapler in laryngectomy. *Head Neck.* 2005;27(12):1073–9.
81. Dias FL, Lima RA, Manfro G. Management of the N0 neck in moderately advanced squamous carcinoma of the larynx. *Otolaryngol Head Neck Surg.* 2009;141(1):59–65.
82. Hinni ML, Salassa JR, Grant DG, et al. Transoral laser microsurgery for advanced laryngeal cancer. *Arch Otolaryngol Head Neck Surg.* 2007;133(12):1198–2004.
83. Iseli TA, Kulbersh BD, Iseli CE, et al. Functional outcomes after transoral robotic surgery for head and neck cancer. *Otolaryngol Head Neck Surg.* 2009;141(2):166–71.
84. Desai SC, Sung CK, Jang DW, Genden EM. Transoral robotic surgery using a carbon dioxide flexible laser for tumors of the upper aerodigestive tract. *Laryngoscope.* 2008;118(12):2187–9.
85. Dropkin MJ. Body image and quality of life after head and neck cancer surgery. *Cancer Pract.* 1999;7(6):309–13.
86. Beitler JJ, Chen AY, Jacobson K, Owens A, Edwards M, Johnstone PAS. Health literacy and health care in an inner-city, total laryngectomy population. *Int J Radiat Oncol Biol Phys.* 2009;75:734–41.
87. List MA, Rutherford JL, Stracks J, Pauloski BR, Logemann JA, Lundy D, et al. Prioritizing treatment outcomes: head and neck cancer patients versus nonpatients. *Head Neck.* 2004;26(2):163–70.
88. Pawar PV, Sayed SI, Kazi R, Jagade MV. Current status and future prospects in prosthetic voice rehabilitation following laryngectomy. *J Cancer Res Ther.* 2008;4(4):186–91.
89. Langerman A, Maccracken E, Kasza K, Haraf DJ, Vokes EE, Stenson KM. Aspiration in chemoradiated patients with head and neck cancer. *Arch Otolaryngol Head Neck Surg.* 2007;133(12):1289–95.
90. Carroll WR, Locher JL, Canon CL, Bohannon IA, McColloch NL, Magnuson JS. Pretreatment swallowing exercises improve swallow function after chemoradiation. *Laryngoscope.* 2008;118(1):39–43.

Chapter 33

Principles and New Approaches in Surgical Reconstruction

Christina Kenney Magill and Bruce H. Haughey

Abstract The reconstruction of oncologic defects remains a critical element in the surgical treatment of head and neck cancer. Goals of reconstruction are wound healing, vital structure protection, function, and cosmesis. In this chapter, we discuss the reconstructive ladder as it applies to defects of the oral cavity, oropharynx, nose, orbit, midface, hypopharynx, larynx, and cervical esophagus. Patient cases are shown to illustrate outlined principles. New approaches in surgical reconstruction are discussed, including salvage surgery after failed chemoradiotherapy, the use of perforator flaps, and the frontier of transoral laser microsurgery defects that require flap reconstruction.

Keywords Transoral laser microsurgery • Tongue reconstruction • Facial reconstruction • Radial forearm free flap • Laryngeal organ preservation • Hypopharynx reconstruction • Oral cavity defect

Reconstruction of Surgical Defects: Principles and Goals

The reconstruction of a surgical defect follows a generalized set of principles applied to the patient's anatomic and functional deficit(s). These principles allow the surgeon to reconstruct a wide variety of defects to achieve optimal functional and aesthetic outcomes for patients. Before a patient is ever taken to the operating room, the potential defect and postoperative functional and cosmetic results should be known and accepted by both the patient and the surgeon. In addition, an oncologically sound resection must be performed, meaning the surgeon must not compromise the complete excision of neoplastic disease, even if a larger or more challenging reconstructive defect may result.

C.K. Magill (✉)
Department of Otolaryngology, Head and Neck Surgery,
Washington University School of Medicine, 3819 Juniata St.,
St. Louis, MO 63116, USA
e-mail: magillc@ent.wustl.edu

The first and most basic principle in reconstructive surgery applies to the creation of a defect. When planning to make incisions, these should be made in areas of low tension to facilitate optimal wound healing. If incisions are made in a cosmetic area, such as the face, this is especially important. The facial relaxed skin tension lines, such as the melolabial crease, are often diagrammed in textbooks to convey this point. Further, the creation of surgical defects should be mindful of aesthetic and functional subunits (Fig. 33.1). Incisions should not cross subunits if this can be prevented, and in surgeries involving facial or neck tissue, the excision of an entire subunit often allows for better reconstructive results. In the creation of a surgical defect, the surgeon should be mindful of its functional, aesthetic, and psychological impact upon the patient. A reconstructive plan should be made before a resection ever takes place.

The second principle in reconstructive surgery applies to the repair of a defect and follows a sequence often referred to as the “reconstructive ladder.” As this analogy suggests, wound management should begin with the most simple technique first, and then progress to more complex rearrangement and transfers as needed. The strategy ultimately chosen should provide the best functional and cosmetic outcome for patients, yet pose the least surgical risk. The dense anatomical structures in the head and neck, coupled with limited soft tissue redundancy, must be allowed for in surgical planning.

The lowest rung of the ladder, and therefore the simplest option for defect closure, is to allow a wound to heal on its own with no intervention, so-called “secondary intention.” In the head and neck, some limited mucosal and superficial cutaneous or scalp defects will heal well by secondary intention. The next option is to reapproximate wound edges in a primary closure, although when tissue is missing, this method effectively becomes repair by local advancement flaps. When tension or tissue loss negates this type of repair, skin grafting or tissue expansion techniques may be used. Alternately, local or regional tissue can be inset into a wound bed by creating transposition, advancement, or rotation flaps. If wounds involve multiple tissue layers, such as skin, subcutaneous fat, muscle, and mucosa, the use of a skin graft or local flap may lack adequate volume, strength, or function; in these cases,

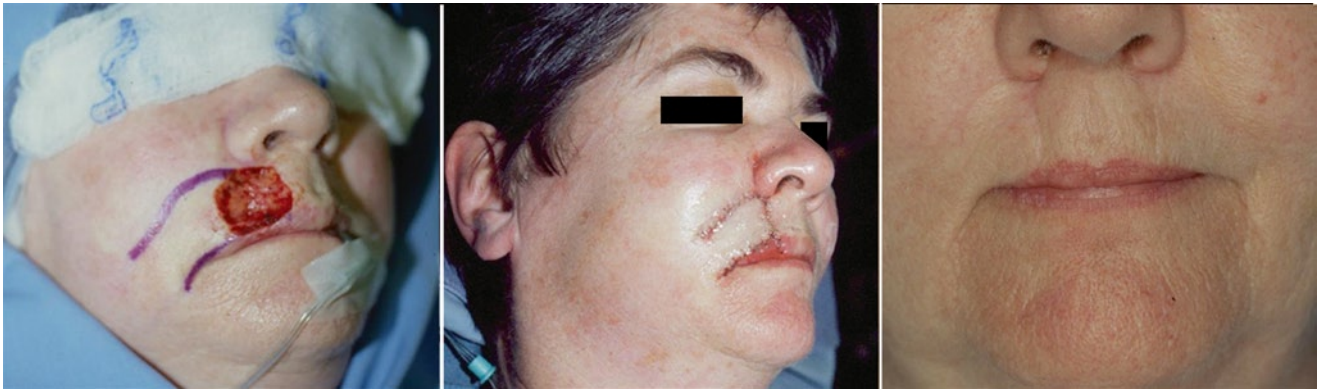

Fig. 33.1 The principle of subunits in facial reconstruction. A right upper lip defect is shown following the excision of a skin cancer. A local tissue advancement flap was designed along relaxed skin tension lines,

and used to reconstruct the upper lateral lip subunit. The medial suture line was placed along the philtral ridge. The resulting scars are camouflaged

the use of composite grafts, composite local flaps (e.g., the Gilles fan flap), pedicled flaps, or microvascular free flaps must be considered.

A “flap” refers to tissue that is moved from a donor to recipient site and carries its own blood supply. Although there are multiple classification schemes for flaps, the two main types that will be discussed here are pedicled flaps and microvascular free flaps. These two flaps differ from each other in that pedicled free flaps remain connected to their native blood supply, either random or axial, while microvascular free flaps are tissue units with axial vessels, completely separated from their donor site and then connected to a recipient vein and artery at the defect.

A pedicled flap offers some advantages in head and neck reconstruction. As exemplified by the pectoralis major myocutaneous flap popularized in 1979, pedicled flaps can be inset into a wound in a single stage and bring with them a robust and reliable blood supply [1]. Pedicled flaps are best suited for defects requiring tissue bulk for a multilayer tissue closure in which minimal tissue folding is required. They are also potentially a good choice for reconstruction when a patient has vascular disease or donor site morbidity that would preclude the use of a microvascular free flap. However, the arc of rotation for a pedicled flap is limited, and the pedicled nature of the blood supply limits tissue molding, sculpting, and tubing. The bulk of pedicled flaps also limits their functional use when used in the oral cavity or alimentary tract. Other pedicled flaps used in head and neck reconstruction include the latissimus dorsi flap, trapezius flap, deltopectoral flap, temporoparietal flap, and scapular flap [2–6].

Microvascular free tissue transfers offer distinct advantages in head and neck reconstruction for use in scalp, facial, oral cavity, osteocutaneous defects, and pharyngeal defects. The ability to mold and sculpt microvascular free flaps to three-dimensional forms allows them to be used in a multitude of settings. Although first described in case reports, such

as the use of a free jejunal segment for cervical esophageal reconstruction in 1959 [7], subsequent angiosome mapping has inspired many different free flaps for reconstructive use [8]. By understanding angiosomes as discrete subunits of vascularized tissue with identifiable and reasonably predictable zones of blood supply, free flaps with both bone and soft tissue from all over the body can be designed and tailored to suit a specific defect. High-utility flaps in head and neck reconstruction have been the radial forearm and anterolateral thigh free flaps, which afford low donor site morbidity, and vascular pedicles with good length and vessel caliber [9, 10]. For defects requiring bony and soft tissue reconstruction, a fibular osteocutaneous free flap can be used to bridge large or mandibular defects, and provide a skin paddle for intra-, extraoral, or combined use [11, 12]. For shallow defects requiring tissue coverage without excess bulk, the thinned anterolateral thigh flap is ideal [13].

Although free-flap success has been the rule due to advances in microsurgical techniques and technologies, flap “salvage” is necessary if arterial or venous flow is compromised [14–16]. Impairment of the flap macrocirculation can be addressed by exploring and revising vascular anastomoses, with the removal of any occluding thrombi. Damage to the microcirculation or interstitial areas of the flap can be more difficult to remedy, with techniques ranging from thrombolytic agents, hyperbaric oxygen, and leeching of the flap [17–19].

As transferred tissue heals and inosculates, revising the flap may be necessary to improve function and contour. Bulky flaps may need to be thinned in order to improve functional results, and tethered tissues may need to be released. Flap revision is especially important for reconstructions of the tongue for speech, or to afford swallowing if tissue transfer has caused dysphagia and obstruction from excess bulk in the pharynx [20].

Ultimately, the choice of reconstructive technique must afford patients with the best functional outcome that poses

the least surgical risk, and these factors must be carefully weighed for each individual. By applying basic principles and carefully negotiating the reconstructive ladder, patients can have restored aesthetics and function after the resection of disease.

Goals of Reconstruction: Wound Healing, Vital Structure Protection, Function, and Cosmesis

The overarching goal of reconstructive surgery is to create new tissue arrangements that serve in place of native structures, allowing for form to follow function. Because of the enormous complexity and inter-relatedness of the deep tissue function, surgery of the head and neck poses unique challenges in achieving reconstructive results that go beyond simple wound healing. The reconstructive surgeon must devise strategies that preserve a patient's ability to eat, speak, swallow, and breathe, in addition to yielding an acceptable aesthetic outcome and quality of life. A site of defect-based approach to reconstruction will be discussed here, and will incorporate general principles and techniques in treating defects of the oral cavity, oropharynx, hypopharynx, esophagus, larynx, midface, and orbit.

Oral Cavity

The mouth or oral cavity, encompasses the lips, alveolar ridges, floor of mouth, retromolar trigone, buccal regions/cheeks, and hard palate. These structures rest on the foundation of the mandible. The primary functions of the oral cavity include mastication, speech, facial expression, and early deglutition. The oral preparatory stage and oral phase of swallowing take place in the mouth. Oral cavity malignancy can leave a patient with a postsurgical defect that impairs any one of these essential functions. Reconstructive efforts should focus on maintaining oral competence, tongue bulk and mobility, and the ability to initiate a swallow.

Beginning with defects of the lip or oral soft tissue, the surgeon needs to consider the wound in terms of location, size, and thickness. Due to the highly cosmetic impact of lip reconstruction, few areas should be left to heal by secondary intention, but include superficial vermillion, cutaneous and inner mucosa lip defects, especially those that are in close proximity to the alar–cheek junction. A local advancement design with linear repair may be considered when the defect occupies less than 30–35% of the lip. Limitations to primary closure include potential for microstomia as well as cosmesis.

Full thickness skin grafts can be used for superficial cutaneous defects, but often do not provide a cosmetically favorable result compared to local flap options. A wide variety of local flap options exists for lip reconstruction, and are designed based on the involvement of the mucosal, vermillion, or cutaneous lip, in addition to involved lip subunits (see Fig. 33.1). These include the Abbe or Estlander flaps for redistributing full thickness tissue from the unaffected lip to the operated lip [21, 22], cheek rotation or advancement flaps (e.g., Gilles flap, Johansen flap) [23], and the Karpanzic flap which acts as a circumferential rotation/advancement flap with partially preserved muscle function and sensation for large full thickness defects [24]. If a cancer resection results in a loss of >40% of the total lip area, or >80% of either lip, any local reconstructive technique will result in undesirable microstoma, which is especially problematic for those with dentures. In these cases, total or subtotal lip reconstruction must be undertaken, and is best accomplished with a microvascular tissue transfer, such as the radial forearm free flap [25].

In addition to lip reconstruction, tongue reconstruction must be carefully planned in order to preserve a patient's ability to eat, speak, and swallow. Defects of the oral tongue often include a lateral or anterior floor of mouth wound, a hemiglossectomy defect, or a total/subtotal oral glossectomy defect in which complete reconstruction is necessary to restore optimal function. For small superficial mucosal defects, healing by secondary intention is often possible. Occasionally, a skin graft may be used. In partial tongue resections which create a small anterior or a longitudinal defect, primary closure can provide excellent results. However, in considering primary closure, or advancement of limited local tissue, the surgeon needs to be cautious about creating a lateral or anterior tethering effect on the tongue that would impair speech or swallowing. Pedicled myocutaneous flaps may play little or no role in tongue reconstruction. However, for patients who have undergone a total or hemiglossectomy, or will have an unacceptable functional deficit from remaining tissue, a microvascular tissue transfer usually affords the best results (see Fig. 33.2a). The reconstruction of the oral tongue is a prime example of where a free flap bestows a distinct functional advantage compared to other choices on the reconstructive ladder. In using a free flap, the surgeon is able to mold the tissue to form a tubed or rolled structure that can ultimately approximate with the palate, lips, or teeth to allow speech, and facilitate a functional swallow [26–30] (Fig. 33.2b). Reconstructive options include fasciocutaneous flaps, such as the radial forearm free flap, and the fasciocutaneous version of the anterolateral thigh flap [31]. If a concomitant mandibular defect is being reconstructed, a fibular free flap can also be employed in the reconstructive effort [32] (Fig. 33.3). For defects of bone reconstruction, the readers are referred elsewhere [33].

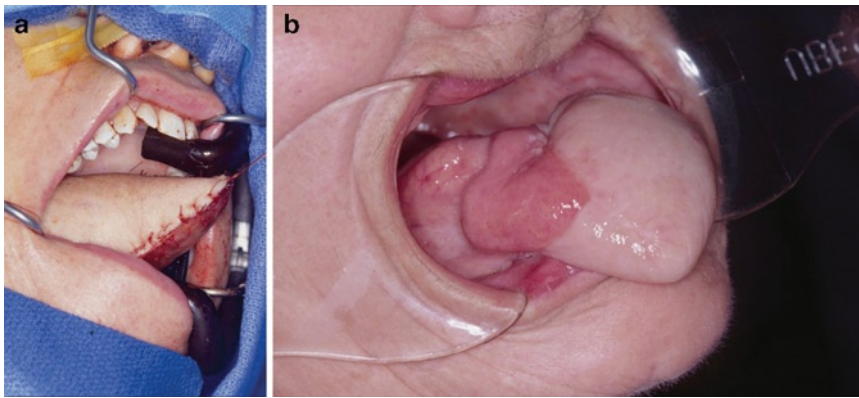


Fig. 33.2 (a) Functional tongue reconstruction. Fifty-three-year-old patient with a T2N0M0 squamous cell carcinoma of the right lateral tongue. He underwent a two-thirds anterior glossectomy and floor of mouth resection, followed by a radial forearm free flap reconstruction with a neuroorrhaphy between the lingual nerve and the lateral

antebrachial cutaneous nerve. (b) “Fold-and-roll” tongue reconstruction. Final healed result of the fold-and-roll technique at 8 months postoperatively (preoperative radiation therapy only). The native tongue remnant is atrophied from a previous anastomosis of cranial nerves XII to VII

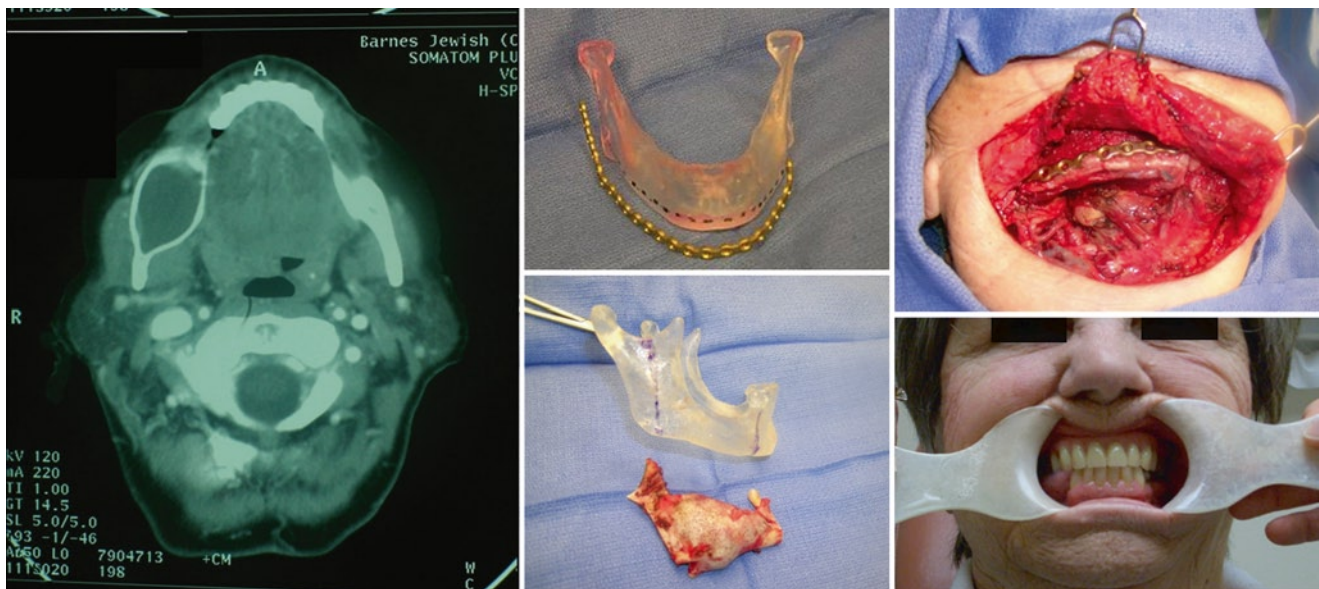


Fig. 33.3 Medical models for reconstruction. Advances in three-dimensional imaging and technologies allow precise models to be created for preoperative reconstruction planning. An axial CT image reveals an expansile cystic lesion (*left image*). Surgical planning to remove this dentigerous cyst includes a generated mandibular model for

precise reconstruction bar fitting (*upper middle image*) and planning of segmental mandibulectomy (*lower middle image*, tumor specimen shown). Fibular free flap reconstruction is then performed followed by successful postoperative placement of dental implants (*right sided images*)

Oropharynx

The oropharynx, similar to the oral cavity, plays an essential role in swallowing and also maintains velopharyngeal competence. The oropharynx extends from the plane of the posterior hard palate to the horizontal plane of the pharyngoepiglottic folds, and contains the soft palate, base of tongue, and the lateral oropharyngeal walls, including the tonsils and their arches. Contact of the soft palate to the posterior pharyngeal wall effectively separates the oropharynx

from the nasopharynx superiorly, and allows food and air propulsion to occur without nasal regurgitation. The palate also aids in controlling airflow during speech and respiration. A surgical defect of the soft palate or pharyngeal walls can cause a patient to reflux food into the nasal cavity during swallowing efforts, and can also make speech unintelligible. Reconstructive goals in this zone are designed around maintaining the separation of the nasopharynx from the oropharynx and preserving velopharyngeal competence with speech and deglutination. Base of tongue reconstruction is designed

to protect the airway against aspiration, promote swallowing, and avoid oral tongue tethering. As such, a well-tailored fasciocutaneous flap is the best options if more than 2/3 of the tongue base is missing [26].

The small volume of the oropharynx and limited tissue redundancy restrict reconstructive options. Healing by secondary intention may cause unwanted scarring, contracture, and stenosis if a very large or circumferential raw surface area is exposed. An open wound may pose risk to surrounding structures if a communication exists between the oropharynx and deep neck. Primary closure may be possible if there is limited tension and narrowing from reapproximated wound edges. Skin grafts can be used to restore superficial tissue loss. More involved defects of the oropharynx or soft palate are best treated with a regional flap, free flap, or prosthesis. There are some limited local flaps for soft palate reconstruction, such as the superior constrictor advancement rotation flap (SCARF) [34]. The SCARF reconstruction is a myomucosal advancement flap that aims to restore the sphincter function of the nasopharynx. Another local flap option is the palatal island flap, in which hard palate mucoperiosteum pedicled on the greater palatine artery is rotated postero-medially into the defect [35]. For larger defects, a thin free tissue transfer of fasciocutaneous tissue can be performed, and the donor tissue should be carefully designed and inset. To avoid velor nasopharyngeal stenosis with resultant nasal obstruction, sleep apnea, and rhinolalia clausa, the surgeon should aim to imbricate the flap tissue for soft palate reconstruction such that both dorsal and central lining of the neo-soft palate is provided, but without obstructive bulk. Free flap options for the soft palate and base of tongue include the radial forearm free flap [36], other fasciocutaneous flaps, and a thinned rectus abdominus flap [37] (Fig. 33.4). The use of free flaps can also be combined with local flaps as necessary [38–40].

Hypopharynx

The hypopharynx represents a functional junction between the passage of air from the pharynx to the larynx anteriorly, and the routing of food into the cervical esophagus posteriorly. The final pharyngeal phase of swallowing occurs in the hypopharynx, as the tongue propels food posteriorly, and local peristalsis combined with distal muscle relaxation allows food to pass inferiorly into the alimentary tract. The regions of the hypopharynx include its posterior wall, continuous above with the posterior oropharyngeal wall, the floor of the vallecula superiorly, the postcricoid area anteriorly, and the pyriform sinuses laterally.

The function of the hypopharynx relies on the circumferential movement of muscles in order to facilitate a swallow, and any reconstructive efforts must maintain this form. Creating a functional funnel or U-shaped reconstruction can pose a significant challenge in patients who have failed organ preservation therapy for hypopharyngeal cancer, or who have undergone a combined pharyngolaryngectomy for advanced stage disease. If the larynx is present, the prognosis for swallowing must remain cautious [41]. Most defects of the hypopharynx should not be left to heal by secondary intention due to risk of fistulization or contamination of deep tissue spaces with saliva. In defects that have sacrificed minimal hypopharyngeal mucosa, a primary repair may be possible. The superior hypopharynx is often more amenable to a primary repair than defects that approach the cervical esophagus and the surgeon must be especially careful to eschew an area of dysfunctional stenosis. Historically, repairs of hypopharyngeal defects have relied on a multitude of different grafting techniques in attempts to avoid narrowing or stricture. These have included shaping skin grafts around mesh [42] or a tube [43], but were unfortunately related to high rates of fistulization

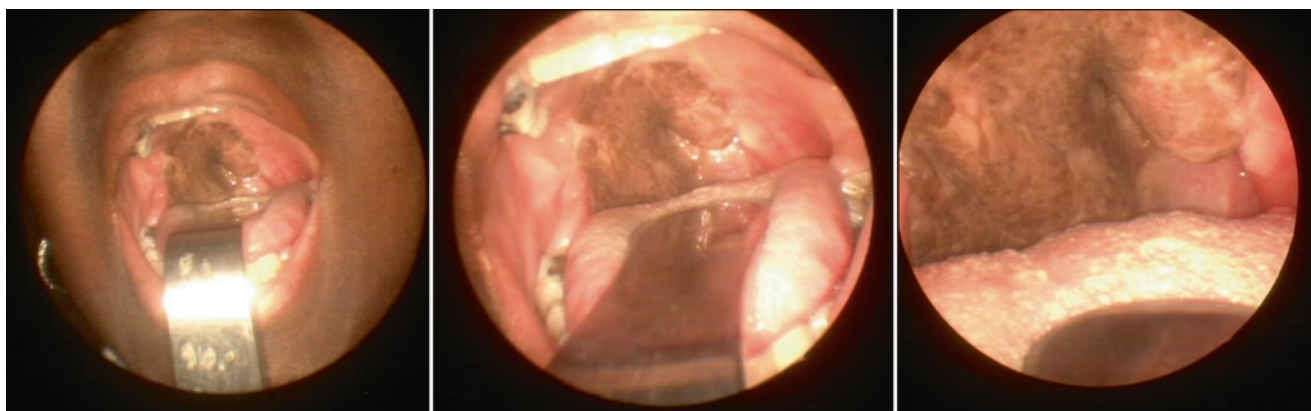

Fig. 33.4 Transoral inset of a free flap. Sixty-five-year-old woman s/p radial forearm free flap for reconstruction following resection of a T3N1M0 squamous cell carcinoma of the right tonsil and soft palate. The patient's resection included a transoral CO₂ laser partial pharyngectomy, parapharyngeal space resection, base of tongue glossectomy,

and wide soft palate resection. A widefield view of her skin paddle inset is shown on the *left*, with *middle* and *right* images demonstrating the neo-uvula junction with the soft palate, in addition to volume recreation in her right tonsillar fossa and excellent pharyngeal wall coverage

and stricture. Currently, skin grafts are best used for partial, noncircumferential defects, and larger reconstructions are best repaired with pedicled or free flaps.

For circumferential defects, e.g., from a total laryngopharyngectomy, the use of a local, broadly based cervical flap was introduced by Wookey in 1942, and resulted in the first series of patients with reliable functional results following extensive pharyngeal repair [44]. Subsequently, the robust pectoralis major flap was used in pharyngeal reconstruction, and excelled in importing well-vascularized muscle to aid in wound closure, even in contaminated or previously radiated fields [1]. However, the functional result and inset of the pectoralis flap is limited by its bulk, which makes tubing and circumferential shaping of the flap difficult [45].

The thin, reliable fasciocutaneous free flap has largely replaced pedicled flap reconstruction of pharyngoesophageal defects. The anatomy of the fasciocutaneous tissue lends itself to three-dimensional molding and inset, characteristics that can be used to restore function and create a circumferential repair [46–48]. These features are shared by the anterolateral thigh (ATLF) and the radial forearm flaps, which can provide a larger skin paddle, in addition to muscle tissue [48–51]. However, the ALTF is often limited by the course of its perforators (intramuscular versus intermuscular, and fascial) and its degree of thickness, dependent on a patient's body habitus. However, the ALTF can be thinned peripherally.

Occasionally, defects of the hypopharynx require a long segment of circumferential tissue for reconstruction that cannot be accomplished with a fasciocutaneous flap. Historically, this has been accomplished with the use of either a jejunal free flap or a tubed gastric pull-up. Both of these options have the increased morbidity of intrathoracic or intraabdominal surgery for flap harvest and inset. The jejunal flap is harvested via a laparotomy, and the defect is reanastomosed end-to-end. The use of this flap was first described in the early 1900s [52], and later became the first free tissue transfer described in humans [7]. Functionally, the jejunal flap provides a tube of mucosal peristaltic tissue and has been used in large numbers of patients [53–58]; however, in addition to functional problems and risks associated with the pharyngeal reconstruction such as fistula and stricture [59], patients are at risk for small bowel obstruction, peritonitis, and intraabdominal adhesions from the donor site [60]. Similarly, the transposition of proximal stomach tissue to reach the edge of a pharyngeal defect in a gastric pull-up requires exposure in the abdomen, thorax, and neck, posing increased donor site morbidity to patients. The use of a gastric transposition was described in the 1960s [61, 62], and has evolved to incorporate laparoscopic techniques to reduce complications from open abdominal or thoracic surgery. Functionally and technically, the advantages of a gastric pull-up for hypopharyngeal or esophageal reconstruction include a decreased rate of stricture, a single anastomosis,

fairly although not totally reliable bloody supply, and in-continuity mucosal surface in the alimentary tract. The main disadvantage is the failure to reach the pharynx without tension and the high rate of perioperative morbidity [63].

Cervical Esophagus

The cervical esophagus extends from the cricopharyngeus inlet and is a tubular striated muscle and tubed segment of mucosal, stratified squamous epithelium. Functionally, the cervical esophagus transmits food and secretions from the hypopharynx to the distal esophagus via peristalsis coordinated with cricopharyngeus muscle relaxation. Any surgical defect of the cervical esophagus will impair a patient's ability to swallow, and also puts the patient at risk for fistula and mediastinitis. Reconstructive goals include restoration of swallowing coupled with maintenance of laryngeal airway and voice production. Tissue for reconstruction should be thin and cylindrical to afford swallowing, and should be sufficient diameter to avoid stricture or dysphagia. For incomplete or partial defects (less than 50% of circumference), reconstructive options include the use of a "patch on" flap, such as the pliable radial forearm free flap [64, 65]. For longer segment defects above the thoracic inlet, tubed fasciocutaneous flap options or the jejunal free flap may be used as discussed above [66, 67]. For defects extending below the brachiocephalic vessels, a gastric transposition flap may be used [68].

Larynx

Surgery of pharyngoesophageal tumors often necessitates surgery of the larynx, as disease may be isolated or confluent in these closely related structures. The larynx has a range of critical functions, including the generation of speech, regulation of airflow into the trachea and lungs, and airway protection during eating and swallowing. Defects and malfunction of the larynx can impair a patient's ability to breathe, eat, and phonate. Anatomically, the larynx has three main subunits that extend from the tip of the epiglottis to the inferior border of the cricoid cartilage. The supraglottic larynx encompasses the epiglottis, the false vocal cords, ventricles, aryepiglottic folds, and arytenoids. The glottic larynx encompasses the true vocal cords and anterior commissure, and extends inferiorly by 5 mm below the free margin of the cords. The subglottic larynx is the airway segment between the vocal cords and the trachea, and extends inferiorly to the distal cricoid cartilage. After surgery involving any one of these structures, goals of laryngeal reconstruction are to maintain a protected

airway, preserve airway patency with avoidance of long-term tracheostomy, and to allow for speech generation.

There has been a tremendous effort in the treatment of head and neck cancer to preserve the larynx and its functionality. Historically, and in chronological order, laryngeal organ preservation techniques have included modified surgical techniques that remove only part of the laryngeal framework involved by disease, radiation therapy, and chemoradiotherapy (CRT) [69–71]. Partial laryngectomies are accomplished by transoral endoscopic laser microsurgery (TLM), resulting in a vertical hemilaryngectomy or a supra-glottic laryngectomy [72–74]. Historically, these procedures have been performed by the open techniques and more frequently committed a patient to a tracheostomy due to aspiration or upper airway obstruction. However, the TLM approach, the only minimally invasive technique available on a routine basis for larynx cancer, results in a low (<5%) tracheostomy rate and rapid functional recovery, even for advanced disease [74]. In the context of well-trained modern surgical personnel and services, a total laryngectomy, by contrast, is an infrequent event [75].

Following treatment for laryngeal cancer, reconstruction is largely confined to two populations of patients: (1) patients who are undergoing surgery as a primary treatment modality and (2) patients who require a partial laryngectomy after failing CRT. The first subset of patients may require advancement of distal laryngeal structures to approximate the edges of the defect, or recruitment and transposition of extralaryngeal musculature [76–82]. These types of local reconstructive options are more limited for the second subset of patients, whose local tissues are more likely to have radiation damage, including fibrosis and impaired vasculature. In these patients, pedicled myocutaneous flaps can be used to aid in wound healing, but are limited by their bulk and pedicle reach in functional reconstruction. In a radiated field, free tissue transfer may offer the best functional results in reconstructive efforts [83].

The radial forearm free flap may be used to aid in reconstruction following primary laryngeal surgery as well as in salvage efforts. The tissue can be inset into hemilaryngectomy defects, including those with concomitant pharyngeal involvement [84–86]. In addition to the radial forearm free flap, the temporoparietal flap may be utilized as a “vascular carrier” in various reconstructive efforts, meaning that it provides a blood supply to otherwise avascular graft materials, such as cartilage [83, 87–90]. A reconstructive method for patients who have undergone a standard hemilaryngectomy after radiation failure includes using the temporoparietal flap as a vascular supply in a technique described by Ralph Gilbert [83]. In this technique, a layered reconstruction is created with a buccal mucosa graft on the deep laryngeal surface, followed by the temporoparietal tissue enveloping an avascular cartilage graft superficially, effectively mimicking the native laryngeal tissue structure of mucosa, perichondrium,

and cartilage [83]. A study of functional outcomes in 21 patients included 90% resuming a normal diet within 6 weeks after surgery, and 85% of patients being discharged without a tracheostomy. No patients were reported as being tracheostomy dependent at 3 months after surgery [83].

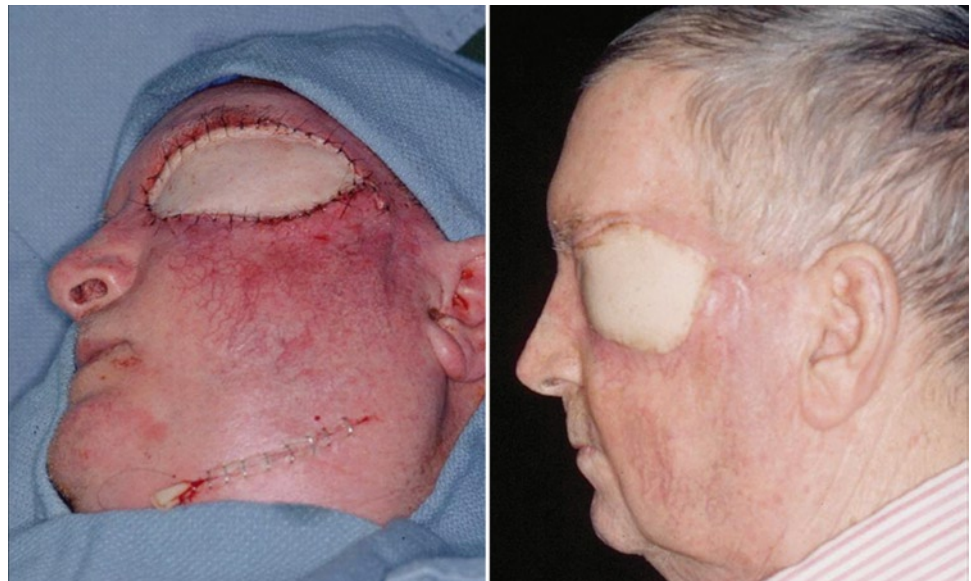In summary, there are multiple surgical options for laryngeal organ preservation, many of which offer patients an oncologically sound and functionally restorative outcome, without progressive inexorable long-term tissue degeneration, which results in high late “toxicity” (i.e., swallowing failure) rates [91].

Orbit, Nose, and Midface

Tumors of the head and neck may involve the orbit, nose, or midface, and create significant reconstructive defects that greatly impact a patient’s appearance and functional capacity. The orbits are bony compartments that include the globe, periorbital fat, and extraocular muscles, bordered by 16 named maxillofacial bones. The zygomatic, frontal, sphenoid, maxillary, palatine, ethmoid, and lacrimal bones comprise the bony orbit, which is situated lateral to the ethmoid sinuses, superior to the maxillary sinus, inferior to the frontal sinus, and anterior and inferior to the cranial vault. The shape of the orbital space approximates a quadrangular pyramid with an apex at the deep surface, near the optic nerve in its bony foramen. Functionally, the orbit houses the visual organ system, and provides bony support and protection of the eye. Reconstruction may follow an orbital exenteration, in which a significant volume deficit may be present along with exposed bone. An empty orbital space can be reconstructed with a split thickness skin graft to line the orbital cavity and permits the use of an ocular prosthetic. Alternately, a local (e.g., forehead, temporalis) or free flap can be used to restore volume. The rectus abdominus muscle or other myocutaneous flaps can be used to restore contour to the orbit and obliterate dead space after extensive surgical resection, although the volume requirement is surprisingly small [92–94] (Fig. 33.5). Sometimes a thick fasciocutaneous flap will suffice.

In any reconstruction of the orbit or midface, the separation of anatomical compartments, especially the subarachnoid space, must be recreated. The skull base, bony orbit, sinuses, and oral cavity need reliable tissue or bony barriers to permit function and also restore facial form. Anatomically, the midface can be conceptualized as consisting of three subunits: lower, upper, and central [95]. The lower subunit supports the maxillary dentition and effects a separation between the midface and oral cavity, allowing for functional speech and eating. The upper subunit provides facial contour, separates the midface and maxillary sinus from the cranial vault, and supports the orbital contents. The central subunit provides

Fig. 33.5 Orbital reconstruction with a rectus abdominis free flap. Sixty-six-year-old gentleman initially presented with a history of major skin cancer, including a massive basal cell carcinoma invading the orbit and the frontal bone. This necessitated a wide excision of the frontal bone, orbital exenteration, partial excision of the maxilla, and repair with a rectus abdominis free flap. This lesion had arisen from the left lower lid



structural support to counteract forces of mastication and dictates the proportions of vertical facial height. The central subunit additionally provides the scaffolding for midface soft tissue and projection. Priority in reconstruction should begin with establishing the most important barrier or functional subunit first, with meticulous care given to defects involving the skull base.

The evolution of midface reconstruction has progressed slowly due to a multitude of factors, including interval use of prosthetics, poor prognosis in advanced disease, and a wide variety of surgical paradigms. Wound healing, facial contour, and palatal competence are the basic requirements of any midfacial reconstruction. Options for reconstruction must offer appropriate bulk for facial symmetry and orbital support. Similar to other defects of the head and neck, this was initially attempted using locoregional pedicled flaps [96–99]. As techniques have progressed, midfacial reconstruction may now utilize multiple components of the reconstructive ladder to offer a comprehensive result (Fig. 33.6). A single reconstruction may employ a free tissue transfer from the radial forearm, scapula, rectus, or fibula depending on tissue bulk and bony defects [100, 101]. These may be combined with local or pedicled flaps, free bone grafts, or prosthetics to ultimately restore function. Details of skull base reconstruction are specifically excluded in this chapter, the reader being directed to other sources [102].

New Approaches

Evolving treatment strategies for head and neck cancer have created new surgical defects and considerations after oncological resections. Specifically, a new variety of surgical defects have been introduced by the practice of surgical

salvage after failed CRT, in addition to the use of TLM for organ preservation. New reconstructive options and flaps have also emerged in the surgical armamentarium for these and other previously described defects.

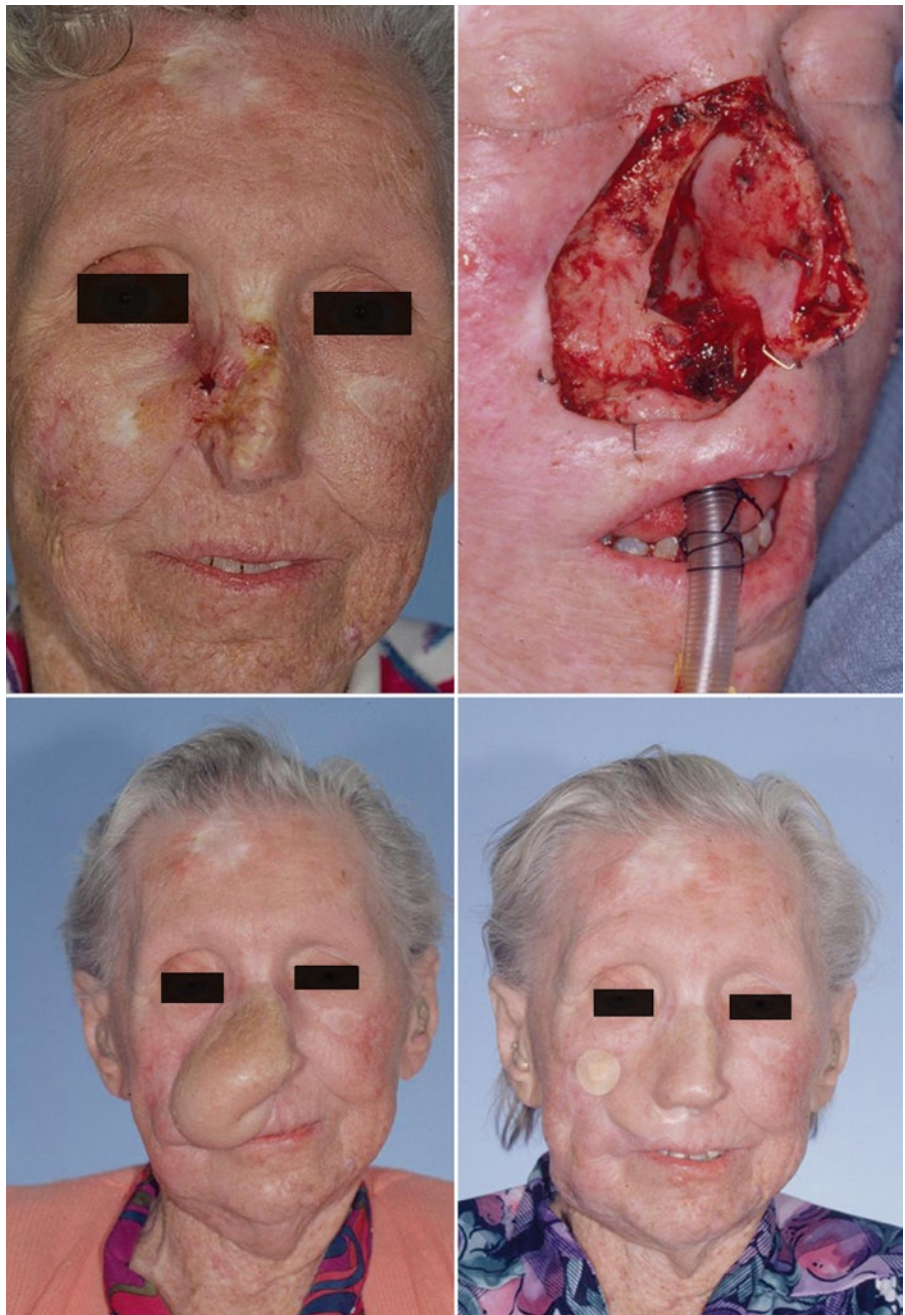Surgical Salvage

Historically, surgical salvage after failed primary radiotherapy treatment was primarily limited by what reconstructive options were available. Today, advances in microsurgical techniques enable more candidates to undergo resection and reconstruction, but the effects of radiation are still a major consideration before undertaking surgical salvage, in addition to what functional status and quality of life a patient may have postoperatively [103].

Radiation alters the quality of tissue at the primary site, in addition to the surrounding tissue available for reconstructive efforts. The effects of radiation on vital tissue include fibrosis, desiccation, and altered vascularity. Subsequently, patients with recurrent cancer after failed CRT or radiotherapy can have disrupted tissue planes and poor wound healing [104]. These factors must be considered in planning surgical salvage.

Local flaps and skin grafts are limited and often contraindicated in postradiated patients, but free flaps have provided reasonable success in reconstructive efforts after salvage surgery [105]. Defects can be reconstructed in a similar manner as previously outlined in this chapter, with goals of functional restoration as well as protection of vital structures. Technical advances in microsurgery have enabled more patients to undergo salvage surgery, although they have not changed the poor prognosis of patients with advanced recurrent disease [103, 106].

Fig. 33.6 Subtotal nasal reconstruction with radial forearm free flap and second stage debulking. Patient is an elderly woman with a history of invasive basal cell carcinoma of the right lateral nasal sidewall and ala (*top left*) who underwent Mohs excision resulting in a subtotal nasal defect, right cheek defect, and right upper lip defect (*top right*). A reconstruction for soft tissue coverage and bulk was performed using a radial forearm free flap, followed by a second stage revision of the flap, including adjacent tissue transfer, debulking, and inseting (*lower left and right images*). A conchal cartilage graft for alar reconstruction was also performed



Perforator Flaps

A notable technical advance in microsurgery has been the introduction of perforator flaps [107, 108]. Research and development of the use of perforator flaps is based on the observation that a free flap of skin can be transferred without any underlying fascial plexus vessels or muscle carrier tissue if the musculocutaneous perforator vessels are carefully

dissected and preserved [109]. The advantages of perforator flaps are decreased donor site morbidity, increased pliability of the flap, decreased necessity for flap revision, and improved aesthetic outcome [110]. Disadvantages are increased operative time depending on a surgeon's experience and variability in the anatomy of the perforator vessels. Perforator flaps are indicated in certain defects requiring thin, easily molded tissue, but are contraindicated in patients with perforators

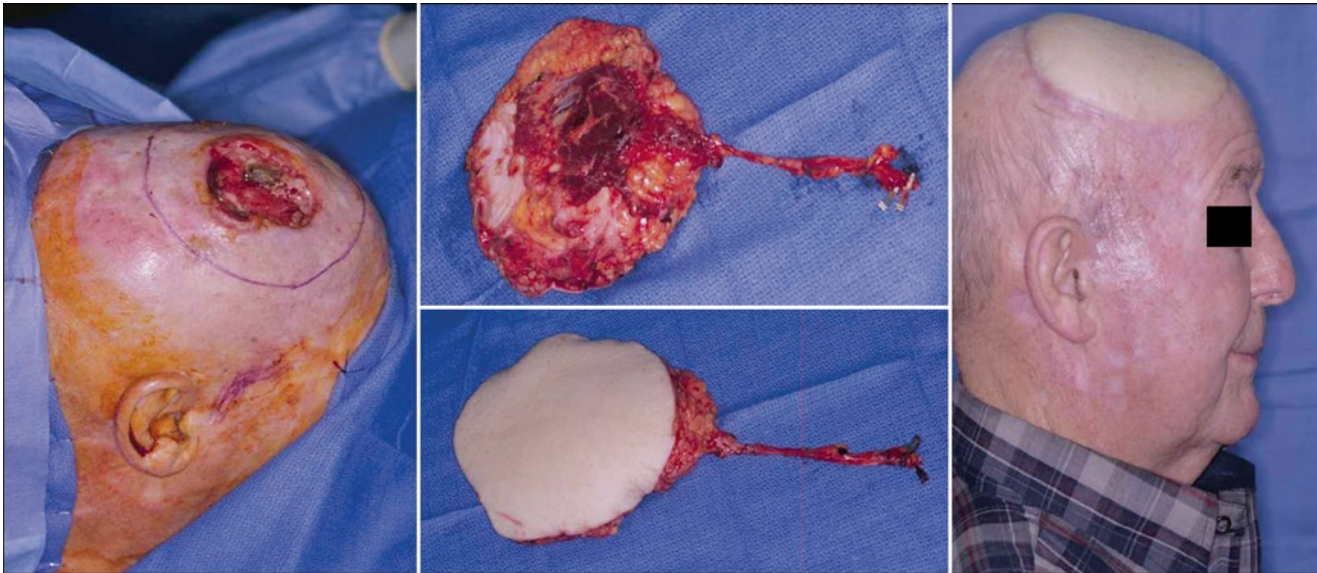


Fig. 33.7 Perforator flap for scalp reconstruction. Seventy-eight-year-old gentleman who underwent resection of a squamous cell carcinoma of the scalp followed by reconstruction with a left rectus abdominus perforator free flap, in addition to an acrylic implant placed

for cranial reconstruction. The preoperative view is seen on the *left*, and the dorsal and ventral surfaces of the flap in addition to the vascular pedicle are seen in the *middle images*. A postoperative view is seen on the *right*

that are too small to safely dissect, or patients who have wound healing problems or vascular disease.

Two applicable perforator flaps in head and neck reconstruction include the anterolateral thigh flap harvested as a septocutaneous flap, and the large, versatile deep inferior epigastric artery perforator (DIEAP) flap harvested from the abdomen. The septocutaneous anterolateral thigh flap can be harvested with <5 mm thickness and is based off of a lateral circumflex artery perforator. It can be used for skin defects, including the auricle and neck soft tissue, in addition to other sites [111, 112]. The DIEAP flap has been described for use in the repair of glossectomy, floor of mouth, scalp, and lateral facial defects and provides soft tissue bulk [113] (Fig. 33.7). The use of both of these, in addition to other perforator flaps, broadens reconstructive options in the head and neck, and new technologies are continuing to expand the delineation of perforator anatomy, i.e., “perforasomes,” that provide individual maps to potential flaps throughout the body [114].

Transoral Laser Microsurgery

The most recent development in head and neck resectional surgery is the minimally invasive approach through natural orifices viz. the mouth and nostrils. Various tools for resection using this approach have included retractors, endoscopes and cutting instruments have included bovie, laser,

and cold steel. Robotic manipulation of these tools has been described for small tumors.

The operative procedures to routinely remove large tumors of the upper aerodigestive tract are currently restricted to the transoral laser microsurgical (TLM) method, in which the tumor can be taken out in pieces, with precise visualization and control of the margin at many areas around the tumor’s perimeter [115]. When the volume or surface area of the defect left behind is large, tissue reconstruction will accelerate wound healing and minimize functional loss. Various local advancement flaps, such as the SCARF approach [34], have been reported. Limited advancement at the pharyngeal wall and for graft inset can also be accomplished transorally (Fig. 33.8). Free flaps are also suitable under specific circumstances. The conditions where I have used free tissue transfer for reconstructions are (a) soft palate defects, full thickness, half or greater, (b) oral tongue defects, greater than hemiglossectomy, or total deep base of tongue, and (c) full thickness pharyngeal wall and parapharyngeal space defects with exposure of the internal carotid artery

In brief, the free flap needs to be thin, so that the radial forearm donor site has proven the best available, although the ALT flap has been used successfully on patients with appropriate habitus (see Fig. 33.4). Vessel access and anastomosis is accomplished via the neck dissection and a small pharyngotomy, if not already present from the resection, is created to pass the pedicle through from the oral cavity or pharynx to the neck. Sometimes, this is enlarged slightly for posteroinferior suture placement. Most of the inset, however,

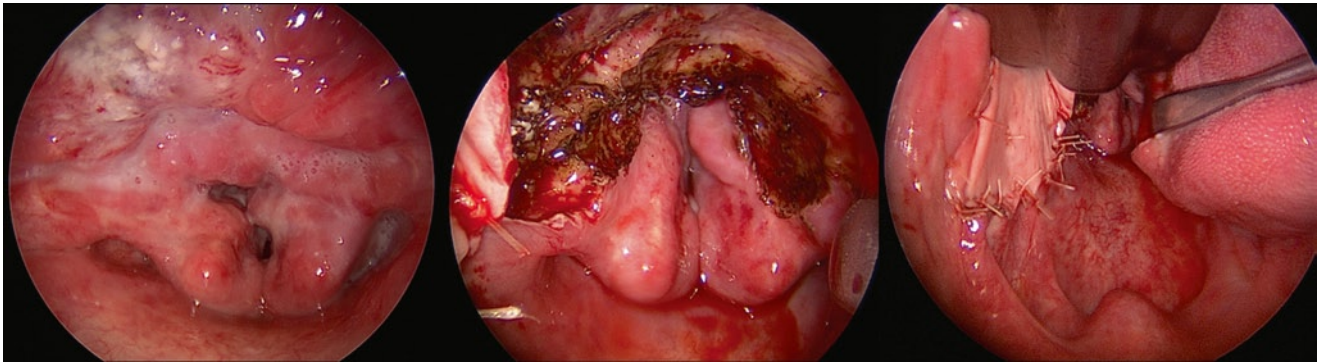


Fig. 33.8 Transoral laser microsurgery. Patient with history of radiotherapy for supraglottic squamous cell cancer presented with a second primary involving the base of tongue and pharyngeal wall (*top left*). The

patient subsequently underwent transoral laser microsurgery (*middle*), with pharyngeal flap and alloderm graft (*top right*)

is accomplished by transoral suturing using the same retractor systems (Dingman, Feyh-Katzenbauer) as were used for the resection. Although not technically simple, the functional advantages for extensive defects are obvious, especially in the reduction of severe velopharyngeal incompetence for soft palate resections. The indications for and techniques of reconstruction following minimally invasive resections continue to evolve.

References

1. Ariyan S. The pectoralis major myocutaneous flap. A versatile flap for reconstruction in the head and neck. *Plast Reconstr Surg.* 1979;63:73–81.
2. Chaikhouni A, Dyas CLJ, Robinson JH, Kelleher JC. Latissimus dorsi free myocutaneous flap. *J Trauma.* 1981;21(5):398–402.
3. Bakamjian VY. A two-stage method for pharyngoesophageal reconstruction with a primary pectoral flap. *Plast Reconstr Surg.* 1965;36:173.
4. Mantero R, Rossi F. Reconstruction of hemi-eyebrow with a temporoparietal flap. *Int Surg.* 1974;59(6–7):369–70.
5. Shapiro MJ. Use of trapezius myocutaneous flaps in the reconstruction of head and neck defects. *Arch Otolaryngol Head Neck Surg.* 1981;107(6):333–6.
6. Shapiro MJ. Composite myocutaneous flaps. *Otolaryngol Head Neck Surg.* 1981;89(6):969–73.
7. Seidenberg B, Rosenak SS, Hurwitt ES, Som ML. Immediate reconstruction of the cervical esophagus by a revascularized isolated jejunal segment. *Ann Surg.* 1959;149:162–71.
8. Taylor GI, Palmer JH. The vascular territories (angiosomes) of the body: experimental study and clinical applications. *Br J Plast Surg.* 1987;40:113–41.
9. Harii K, Ebihara S, Ono I, Saito H, Terui S, Takato T. Pharyngoesophageal reconstruction using a fabricated forearm free flap. *Plast Reconstr Surg.* 1985;75:463–76.
10. Yang G, Chen B, Gao Y, et al. Forearm free skin flap transplantation. *Natl Med J China.* 1981;61:139.
11. Taylor GI, Miller GD, Ham FJ. The free vascularized bone graft. A clinical extension of microvascular techniques. *Plast Reconstr Surg.* 1975;55:533–44.
12. Hidalgo DA. Fibula free flap: a new method of mandible reconstruction. *Plast Reconstr Surg.* 1989;84:71–9.
13. Song YG, Chen GZ, Song YL. The free thigh flap: a new free flap concept based on the septocutaneous artery. *Br J Plast Surg.* 1984;37:149–59.
14. Kutchai HC. Cellular membranes and transmembrane transport of solutes and water. In: Berne RM, Levy MN, editors. *Physiology.* St. Louis: Mosby; 1988.
15. Hayden RE, Paniello RC, Yeung CS, Bello SL, Dawson SM. The effect of glutathione and vitamins A, C, and E on acute skin flap survival. *Laryngoscope.* 1987;97:1176.
16. Uhl E, Rösken F, Curri SB, Menger MD, Messmer K. Reduction of skin flap necrosis by transdermal application of bupivacaine bound to liposomes. *Plast Reconstr Surg.* 1998;102(5):1598–604.
17. Kerrigan C, Daniel R. Critical ischemia time and the failing skin flap. *Plast Reconstr Surg.* 1982;69:986.
18. Zhao X, Higgins KM, Enepekides D, Farwell G. Medicinal leech therapy for venous congested flaps: case series and review of the literature. *J Otolaryngol Head Neck Surg.* 2009;38(2):E61–4.
19. Kernahan D, Zingg W, Kay C. The effects of hyperbaric oxygen on the survival of experimental skin flaps. *Plast Reconstr Surg.* 1965;36:19.
20. Neligan P, Gullane P, Gilbert R. Functional reconstruction of the oral cavity. *World J Surgery.* 2003;27(7):856–62.
21. Abbe R. A new operation for the relief of deformity due to double harelip. *Med Res Rev.* 1888;53:477.
22. Estlander JA. Eine methode auf der einen lippe substanzverluste der anderen zu erstegen. *Arch Klin Chir.* 1872;14:622.
23. Gillies HD. *Plastic surgery of the face.* London: Oxford University Press; 1980.
24. Karapandzic M. Reconstruction of lip defects by local arterial flaps. *Br J Plast Surg.* 1974;27(1):93–7.
25. Daya M, Nair V. Free radial forearm flap lip reconstruction: a clinical series and case reports of technical refinements. *Ann Plast Surg.* 2009;62(4):361–7.
26. Haughey BH, Taylor SM, Fuller D. Fasciocutaneous flap reconstruction of the tongue and floor of mouth: outcomes and techniques. *Arch Otolaryngol Head Neck Surg.* 2002;128(12):1388–95.
27. Haughey BH. Tongue reconstruction: concepts and practice. *Laryngoscope.* 1993;103(10):1132–41.
28. Loewen IJ, Boliek CA, Harris J, Seikaly H, Rieger JM. Oral sensation and function: a comparison of patients with innervated radial forearm free flap reconstruction to healthy matched controls. *Head Neck.* 2010;32(1):85–95.
29. Matsui Y, Shiota T, Yamashita Y, Ohno K. Analyses of speech intelligibility in patients after glossectomy and reconstruction with fasciocutaneous/myocutaneous flaps. *Int J Oral Maxillofac Surg.* 2009;38(4):339–45.

30. Khariwala SS, Vivek PP, Lorenz RR, et al. Swallowing outcomes after microvascular head and neck reconstruction: a prospective review of 191 cases. *Laryngoscope*. 2007;117(8):1359–63.
31. de Vicente JC, de Villalán L, Torre A, Peña I. Microvascular free tissue transfer for tongue reconstruction after hemiglossectomy: a functional assessment of radial forearm versus anterolateral thigh flap. *J Oral Maxillofac Surg*. 2008;66(11):2240–5.
32. Coleman Jr J, Wooden WA. Mandibular reconstruction with composite microvascular tissue transfer. *Am J Surg*. 1990;160(4):390–5.
33. Urken ML, Buchbinder D, Genden EM. Reconstruction of the mandible and maxilla. In: Cummings C, editor. *Cummings: otolaryngology: head and neck surgery*. 4th ed. St. Louis: Mosby; 2005.
34. Zeitels SM, Kim J. Soft-palate reconstruction with a “SCARF” superior-constrictor advancement-rotation flap. *Laryngoscope*. 1998;108(8 Pt 1):1136–40.
35. Gullane P, Arena S. Palatal island flap for reconstruction of oral defects. *Arch Otolaryngol Head Neck Surg*. 1977;103:598.
36. Marques FJC, Rodrigues ML, Scopel GP, Kowalski LP, Ferreira MC. The versatility of the free lateral arm flap in head and neck soft tissue reconstruction: clinical experience of 210 cases. *J Plast Reconstr Aesthet Surg*. 2008;61(2):172–9.
37. Meland NB, Fisher J, Irons GB, Wood MB, Cooney WP. Experience with 80 rectus abdominis free-tissue transfers. *Plast Reconstr Surg*. 1989;83(3):481–7.
38. Brown JS, Zuydam AC, Jones DC, Rogers SN, Vaughan ED. Functional outcome in soft palate reconstruction using a radial forearm free flap in conjunction with a superiorly based pharyngeal flap. *Head Neck*. 1997;19(6):524–34.
39. Penfold CN, Brown AE, Lavery KM, Venn PJ. Combined radial forearm and pharyngeal flap for soft palate reconstruction. *Br J Oral Maxillofac Surg*. 1996;34(4):322–4.
40. Ducic Y, Herford AS. The use of palatal island flaps as an adjunct to microvascular free tissue transfer for reconstruction of complex oromandibular defects. *Laryngoscope*. 2001;111(9):1666–9.
41. Sumer BD, Gastman BR, Nussenbaum B, Gao F, Haughey BH. Microvascular flap reconstruction of major pharyngeal resections with the intent of laryngeal preservation. *Arch Otolaryngol Head Neck Surg*. 2009;135(8):801–6.
42. Conley JJ. One-stage radical resection of cervical esophagus, larynx, pharynx, and lateral neck. *Arch Otolaryngol Head Neck Surg*. 1953;58:645–54.
43. Negus VE. Reconstruction of pharynx after pharyngoesophageal laryngectomy. *Br J Plast Surg*. 1953;6(2):99–101.
44. Wookey H. Surgical treatment of carcinoma of the pharynx and upper esophagus. *Surg Gynecol Obstet*. 1942;75:499–500.
45. Patel RS, Goldstein DP, Brown D, Irish J, Gullane PJ, Gilbert RW. Circumferential pharyngeal reconstruction: history, critical analysis of techniques, and current therapeutic recommendations. *Head Neck*. 2010;32(1):109–20.
46. Anthony JP, Singer MI, Deschler DG, Dougherty ET, Reed CG, Kaplan MJ. Long-term functional results after pharyngoesophageal reconstruction with the radial forearm free flap. *Am J Surg*. 1994;168:441–5.
47. Azizzadeh B, Yafai S, Rawnsley JD, et al. Radial forearm free flap pharyngoesophageal reconstruction. *Laryngoscope*. 2001;111:807–10.
48. Scharpf J, Esclamado RM. Reconstruction with radial forearm flaps after ablative surgery for hypopharyngeal cancer. *Head Neck*. 2003;25:261–6.
49. Lewin JS, Barringer DA, May AH, et al. Functional outcomes after laryngopharyngectomy with anterolateral thigh flap reconstruction. *Head Neck*. 2006;28:142–9.
50. Murray DJ, Gilbert RW, Vesely MJ, et al. Functional outcomes and donor site morbidity following circumferential pharyngoesophageal reconstruction using an anterolateral thigh flap and salivary bypass tube. *Head Neck*. 2007;29:147–54.
51. Genden EM, Jacobson AS. The role of the anterolateral thigh flap for pharyngoesophageal reconstruction. *Arch Otolaryngol Head Neck Surg*. 2005;131:796–9.
52. Willstein L. Ueber antethorakale oesophago-jejunosomie und operationen nach gleichem prinzipio. *Dtsch Med Wochenschr*. 1904;31:734.
53. Disa JJ, Pusic AL, Hidalgo DA, Cordeiro PG. Microvascular reconstruction of the hypopharynx: defect classification, treatment algorithm, and functional outcome based on 165 consecutive cases. *Plast Reconstr Surg*. 2003;111:652–60.
54. Theile DR, Robinson DW, Theile DE, Coman WB. Free jejunal interposition reconstruction after pharyngolaryngectomy: 201 consecutive cases. *Head Neck*. 1995;17:83–8.
55. Bova R, Goh R, Poulson M, Coman WB. Total pharyngolaryngectomy for squamous cell carcinoma of the hypopharynx: a review. *Laryngoscope*. 2005;115:864–9.
56. Sarukawa S, Asato H, Okazaki M, Nakatsuka T, Takushima A, Harii K. Clinical evaluation and morbidity of 201 free jejunal transfers for oesophagopharyngeal reconstruction during the 20 years 1984–2003. *Scand J Plast Reconstr Surg Hand Surg*. 2006;40(3):148–52.
57. Peters CR, McKee DM, Berry BE. Pharyngoesophageal reconstruction with revascularized jejunal transplants. *Am J Surg*. 1971;121:675–8.
58. Julieron M, Germain MA, Schwaab G, et al. Reconstruction with free jejunal autograft after circumferential pharyngolaryngectomy: eighty-three cases. *Ann Otol Rhinol Laryngol*. 1998;107:581–7.
59. Haughey BH, Forsen JW. Free jejunal graft: effects of longitudinal myotomy. *Ann Otol Rhinol Laryngol*. 1992;101(4):333–8.
60. Reece GP, Schusterman MA, Miller MJ, et al. Morbidity and functional outcome of free jejunal transfer reconstruction for circumferential defects of the pharynx and cervical esophagus. *Plast Reconstr Surg*. 1995;96:1307–16.
61. Ong GB, Lee TC. Pharyngogastric anastomosis after oesophagopharyngectomy for carcinoma of the hypopharynx and cervical oesophagus. *Br J Surg*. 1960;48:193–200.
62. Le Quesne LP, Ranger D. Pharyngolaryngectomy, with immediate pharyngogastric anastomosis. *Br J Surg*. 1966;53:105–9.
63. Clark JR, Gilbert R, Irish J, Brown D, Neligan P, Gullane PJ. Morbidity after flap reconstruction of hypopharyngeal defects. *Laryngoscope*. 2006;116(2):173–81.
64. Disa JJ, Cordeiro PG. Reconstruction of the hypopharynx and cervical esophagus. *Clin Plast Surg*. 2001;28(2):349–60.
65. Anthony JP, Singer MI, Mathes SJ. Pharyngoesophageal reconstruction using the tubed free radial forearm flap. *Clin Plast Surg*. 1994;21(1):137–47.
66. Ott K, Lordick F, Molls M, Bartels H, Biemer E, Siewert JR. Limited resection and free jejunal graft interposition for squamous cell carcinoma of the cervical oesophagus. *Br J Surg*. 2009;96(3):258–66.
67. Wadsworth JT, Futran N, Eubanks TR. Laparoscopic harvest of the jejunal free flap for reconstruction of hypopharyngeal and cervical esophageal defects. *Arch Otolaryngol Head Neck Surg*. 2002;128(12):1384–7.
68. Daiko H, Hayashi R, Saikawa M, et al. Surgical management of carcinoma of the cervical esophagus. *J Surg Oncol*. 2007;96(2):166–72.
69. Wolf G, Hong K, Fisher S, et al. Induction chemotherapy plus radiation compared with surgery plus radiation in patients with advanced laryngeal cancer: VA Laryngeal Cancer Study Group. *N Engl J Med*. 1991;324:1685–90.
70. Forastiere AA, Goepfert H, Maor M, et al. Concurrent chemotherapy and radiotherapy for organ preservation in advanced laryngeal cancer. *N Engl J Med*. 2003;349:2091–8.
71. Tufano RP, Stafford EM. Organ preservation surgery for laryngeal cancer. *Otolaryngol Clin North Am*. 2008;41(4):741–55.
72. Bailey BJ. Partial laryngectomy and laryngoplasty. *Laryngoscope*. 1971;81:1742–71.

73. Iro H, Waldfahrer F, Altendorf-Hofmann A, Weidenbecher M, Sauer R, Steiner W. Transoral laser surgery of supraglottic cancer: follow-up of 141 patients. *Arch Otolaryngol Head Neck Surg.* 1998;124(11):1245–50.
74. Hinni ML, Salassa JR, Grant DG, et al. Transoral laser microsurgery for advanced laryngeal cancer. *Arch Otolaryngol Head Neck Surg.* 2007;133(12):1198–204.
75. Weir NF. Theodore Billroth: the first laryngectomy for cancer. *J Laryngol Otol.* 1973;87:1162–70.
76. Biacabe B, Crevier-Buchman L, Hans S, et al. Vocal function after vertical partial laryngectomy with glottic reconstruction by false vocal fold flap: durational and frequency measures. *Laryngoscope.* 1999;109(5):698–704.
77. Biller HF, Lucente FE. Reconstruction of the larynx following vertical partial laryngectomy. *Otolaryngol Clin North Am.* 1979;12(4):761–6.
78. Burgess LP. Laryngeal reconstruction following vertical partial laryngectomy. *Laryngoscope.* 1993;103(2):109–32.
79. Calcaterra TC. Bilateral omohyoid muscle flap reconstruction for anterior commissure cancer. *Laryngoscope.* 1987;97(7 Pt 1):810–3.
80. Eliachar I, Papay F, Tucker HM. Laryngotracheal reconstruction. Extended vertical partial laryngectomy: reconstruction combining epiglottoplasty and the rotary door flap. *Otolaryngol Clin North Am.* 1991;24(6):1367–83.
81. Zohar Y, Shvilli I, Laurian N. Laryngeal reconstruction by composite nasoseptal graft after extended partial laryngectomy. twelve-year followup. *Arch Otolaryngol Head Neck Surg.* 1988;114(8):868–71.
82. Pleet L, Ward PH, DeJager HJ, Berci G. Partial laryngectomy with imbrication reconstruction. *Trans Am Acad Ophthalmol Otolaryngol.* 1977;84:ORL882–9.
83. Gilbert RW, Neligan PC. Microsurgical laryngotracheal reconstruction. *Clin Plastic Surg.* 2005;32:293–301.
84. Chantrain G, Deraemaeker R, Andry G, et al. Wide vertical hemipharyngolaryngectomy with immediate glottic and pharyngeal reconstruction using a radial forearm free flap: preliminary results. *Laryngoscope.* 1991;101(8):869–75.
85. Chantrain G, Deraemaeker R, Andry G, et al. Vertical hemipharyngolaryngectomy: reconstruction with the radial forearm free flap. *Eur J Surg Oncol.* 1989;15(6):564–7.
86. Urken ML, Blackwell K, Biller HF. Reconstruction of the laryngopharynx after hemicricoid/hemithyroid cartilage resection. *Arch Otolaryngol Head Neck Surg.* 1997;123(11):1213–22.
87. Delaere PR, Liu Z, Pauwels P, et al. Experimental revascularization of airway segments. *Laryngoscope.* 1994;104(6 Pt 1):736–40.
88. Delaere PR, Van Damme B, Feenstra L. Vascularized fascia as a transferable bed for experimental laryngeal reconstruction. *Ann Otol Rhinol Laryngol.* 1994;103(3):215–21.
89. Golovine SS. Procédé de clôture plastique de l'orbite après l'exenteration. *Arch Ophthalmol.* 1889;18:16.
90. Smith RA. The free fascial scalp flap. *Plast Reconstr Surg.* 1980;66(2):204–9.
91. Machtay M, Moughan J, Trotti A, et al. Factors associated with severe late toxicity after concurrent chemoradiation for locally advanced head and neck cancer: an RTOG analysis. *J Clin Oncol.* 2008;26(21):3582–9.
92. Taylan G, Yildirim S, Akoz T. Reconstruction of large orbital exenteration defects after resection of periorbital tumors of advanced stage. *J Reconstr Microsurg.* 2006;22(8):583–9.
93. Moyer JS, Chepeha DB, Prince ME, Teknos TN. Microvascular reconstruction of the orbital complex. *Facial Plast Surg Clin North Am.* 2009;17(2):225–37.
94. Pryor SG, Moore EJ, Kasperbauer JL. Orbital exenteration reconstruction with rectus abdominis microvascular free flap. *Laryngoscope.* 2005;115(11):1912–6.
95. Archibald S, Jackson S, Thoma A. Paranasal sinus and midfacial reconstruction. *Clin Plastic Surg.* 2005;32:309–25.
96. Konno A, Togawa K, Iizuka K. Primary reconstruction after total or extended total maxillectomy for maxillary cancer. *Plast Reconstr Surg.* 1981;67(4):440–8.
97. Demergasso F, Piazza M. Trapezius myocutaneous flap in reconstructive surgery for head and neck cancer; an original technique. *Am J Surg.* 1979;138:533–6.
98. Sabatier RE, Bakamjian VY. Transaxillary latissimus dorsi flap reconstruction in head and neck cancer. Limitations and refinements in 56 cases. *Am J Surg.* 1985;150(4):427–34.
99. Shagets MJ, Panje WR, Shore CJ. Use of temporalis muscle flap in complicated defects of the head and face. *Arch Otolaryngol Head Neck Surg.* 1986;112:60–5.
100. Coleman III JJ. Osseous reconstruction of the midface and orbits. *Clin Plast Surg.* 1994;21(1):113–24.
101. Cordeiro PG, Santamaria E. A classification system and algorithm for reconstruction of maxillectomy and midfacial defects. *Plast Reconstr Surg Gynecol Obstet.* 2000;105(7):2331–46.
102. Snyderman CH, Janecka IP, Sekhar LN, Sen CN, Eibling DE. Anterior cranial base reconstruction: role of galeal and pericranial flaps. *Laryngoscope.* 1990;100(6):607–14.
103. Kim AJ, Suh JD, Sercarz JA, et al. Salvage surgery with free flap reconstruction. *Laryngoscope.* 2007;117:1019–23.
104. Suh JD, Abemayor EA, Sercarz JS, Calcaterra TC, Rawnsley JD, Blackwell KE. Analysis of outcome and complications in 400 cases of microvascular head and neck reconstruction. *Arch Otolaryngol Head Neck Surg.* 2004;130:962–6.
105. Head C, Sercarz JA, Abemayor E, Calcaterra TC, Rawnsley JD, Blackwell KE. Microvascular reconstruction after previous neck dissection. *Arch Otolaryngol Head Neck Surg.* 2002;128:328–31.
106. Schwartz GJ, Mehta RH, Wenig BL, Shaligram C, Portugal LG. Salvage treatment for recurrent squamous cell carcinoma of the oral cavity. *Head Neck.* 2000;22(1):34–41.
107. McCraw JB. Musculocutaneous flaps: principles. *Clin Plast Surg.* 1980;7:9–13.
108. Mathes SJ, Nahai F. Clinical atlas of muscle, musculocutaneous flaps. St. Louis: Mosby; 1979.
109. Koshima I, Soeda S. Inferior epigastric artery skin flaps without rectus abdominis muscle. *Br J Plast Surg.* 1989;42:645–8.
110. Geddes C, Morris S, Neligan P. Perforator flaps: evolution, classification, and applications. *Ann Plast Surg.* 2003;50(1):90–9.
111. Kimura N, Satoh K. Consideration of a thin flap as an entity and clinical applications of the thin anterolateral thigh flap. *Plast Reconstr Surg.* 1996;97:985–92.
112. Kimura N, Satoh K, Hasumi T, Ostuka T. Clinical application of the free thin anterolateral thigh flap in 31 consecutive patients. *Plast Reconstr Surg.* 2001;108(5):1197–208.
113. Beausang ES, McKay D, Brown DH, et al. Deep inferior epigastric artery perforator flaps in head and neck reconstruction. *Ann Plast Surg.* 2003;51(6):561–3.
114. Saint-Cyr M, Wong C, Schaverien M, Mojallal A, Rohrich R. The perforasome theory: vascular anatomy and clinical implications. *Plast Reconstr Surg.* 2009;124(5):1529–44.
115. Steiner W, Ambrosch P. Endoscopic laser surgery of the upper aerodigestive tract: with special emphasis on cancer surgery. New York: Thieme; 2000.

Chapter 34

Multidisciplinary Treatment of the Neck

Remco de Bree, Johannes A. Langendijk, and C. René Leemans

Abstract Because the degree of lymph nodes metastases is the most important prognostic factor and recurrence in the neck is generally incurable, management of the neck has become one of the most actively debated topics in the field of head and neck oncology. Treatment of the neck, i.e., surgical (neck dissection with or without postoperative (chemo)radiotherapy) or nonsurgical (irradiation with or without chemotherapy), is usually dependent on the treatment modality for the primary tumor.

Elective treatment of the neck is still one of the subjects still under debate. If the neck is primarily treated surgically, the extent of the neck dissection and the eventual adjuvant (chemo) radiotherapy should be discussed in the multidisciplinary team. If the neck is treated by (chemo)radiation planned and salvage neck dissection are the subject to discuss.

Keywords Lymph node metastases • Neck dissection • Adjuvant treatment • Radiotherapy • Chemoradiation • Salvage surgery • Elective treatment

Head and neck squamous cell carcinomas have a proclivity to metastasize through lymphatics to regional nodes rather than to spread hematogeneously. The degree of involvement of lymph nodes with tumor is the most important prognostic factor. Patients with multiple and contralateral or bilateral metastases have a markedly reduced survival. Because recurrence in the neck generally carries a fatal prognosis, optimal treatment planning is vital. Considering these factors, management of the neck has become one of the most actively debated topics in the field of head and neck oncology. Because squamous cell carcinoma is the most frequent primary tumor type within the head and neck, focus will be mainly on this tumor type.

The lymphatics of the head and neck form a rich plexus of vessels, of which the anatomy was first described by

Rouvière [1]. Current standardization of nomenclature recognizes five nodal levels in the lateral neck, of which several levels are further subdivided into two (Table 34.1 and Fig. 34.1). The central neck consists of a sixth level, which also includes the paratracheal nodes [2, 3]. Staging of cervical lymph node metastases is based on number, size, and side. In a N0 neck no lymph node metastases are diagnosed. A N1 neck means that only one enlarged ipsilateral lymph node less than 3 cm is detected. In N2 disease multiple or contralateral lymph node metastases or lymph nodes of 3 cm or more but smaller than 6 cm are found. If lymph node metastases of 6 cm or larger are present the neck is staged N3 (Table 34.2) [4].

Cervical lymphadenectomy, i.e., neck dissection, has for a long time been the principal treatment for nodal metastases from head and neck cancer. Currently, with advances in non-surgical management of head and neck squamous cell carcinoma, the role of surgery is changing. This has led to an altered approach to patients with nodal disease when treated by chemoradiation. Indeed, several aspects of the management of clinically detectable and occult neck disease in patients have become controversial [5].

Treatment of the neck, i.e., surgical (neck dissection with or without postoperative (chemo)radiotherapy) or nonsurgical (irradiation with or without chemotherapy), is usually dependent on the treatment modality for the primary tumor. Contrary to such accepted principles, however, in some circumstances there may be an indication to treat the neck surgically, leaving the primary tumor for subsequent (chemo)radiotherapy. In patients with advanced lymph node metastases and a primary tumor that can be treated well with nonsurgical means, the justification for such an approach is to minimize morbidity [6]. A different strategy is radiotherapy to the primary site and neck followed by a planned neck dissection in case one judges the chances for neck cure limited [7]. Both strategies may yield acceptable locoregional control and survival rates.

A number of strategies toward management of the neck in patients with head and neck squamous cell carcinoma currently exist. Whereas diagnostic work-up is discussed in other chapters, herein we discuss the different treatment options and strategies for the different stages of the neck.

C.R. Leemans (✉)
Otolaryngology/Head and Neck Surgery, VU University Medical
Center, De Boelelaan 1117, Amsterdam 1081HV, The Netherlands
e-mail: cr.leemans@vumc.nl

Table 34.1 Anatomical and radiological structures defining the boundaries of the neck levels and sublevels

Level	Anatomical boundary					Radiological boundary				
	Superior	Inferior	Anterior (medial)	Posterior (lateral)	Caudal	Anterior	Posterior	Lateral	Medial	
IA	Symphysis of mandible	Body of hyoid	Anterior belly of contralateral digastric muscle	Anterior belly of ipsilateral digastric muscle	Geniohyoid muscle, plane tangent to basilar edge of mandible	Symphysis ment, platysma	Body of hyoid bone	Medial edge of anterior belly of digastric muscle	Midline	
IB	Body of mandible	Posterior belly of digastric muscle	Anterior border of digastric muscle	Stylohyoid muscle	Mylohyoid muscle, cranial edge of submandibular gland	Symphysis ment, platysma	Posterior edge of submandibular gland	Basilar edge/ inner side of mandible, platysma, skin	Lateral edge of anterior belly of digastric muscle	
IIA	Skull base	Horizontal plane defined by inferior border of hyoid	Stylohyoid muscle	Vertical plane defined by spinal accessory nerve	Caudal edge of lateral process of C1	Posterior edge of submandibular gland; anterior edge of internal carotid artery; posterior edge of belly digastric muscle	Posterior border of internal jugular vein	Medial edge of sternocleidomastoid muscle	Medial edge of internal carotid artery, levator scapulae muscle	
IIB	Skull base	Horizontal plane defined by inferior border of hyoid	Vertical plane defined by spinal accessory nerve	Lateral border of sternocleidomastoid muscle	Caudal edge of lateral process of C1	Posterior border of internal jugular vein	Posterior border of sternocleidomastoid muscle	Medial edge of sternocleidomastoid muscle	Medial edge of internal carotid artery, levator scapulae muscle	
III	Horizontal plane defined by inferior border of hyoid	Horizontal plane defined by inferior border of cricoid cartilage	Lateral border of sternohyoid muscle	Lateral border of sternocleidomastoid muscle or sensory branches of cervical plexus	Caudal edge of body of hyoid bone	Posterolateral edge of sternohyoid muscle; anterior edge of sternocleidomastoid muscle	Posterior edge of sternocleidomastoid muscle	Medial edge of sternocleidomastoid muscle	Internal edge of internal carotid artery, scalenus muscle	

IV	Horizontal plane defined by inferior border of cricoid cartilage	Clavicle	Lateral border of sternohyoid muscle	Lateral border of sternocleidomastoid muscle or sensory branches of cervical plexus	Caudal edge of cricoid cartilage	2 cm cranial to sternoclavicular joint	Anteromedial edge of sternocleidomastoid muscle	Posterior edge of sternocleidomastoid muscle	Medial edge of sternocleidomastoid muscle	Medial edge of internal carotid artery, scalenus muscle
VA	Apex of convergence of sternocleidomastoid and trapezius muscles	Horizontal plane defined by lower border of the cricoid cartilage	Posterior border of sternocleidomastoid muscle or sensory branches of cervical plexus	Anterior border of trapezius muscle	Cranial edge of body of hyoid bone	CT slice encompassing the transverse cervical vessels	Posterior edge of sternocleidomastoid muscle	Anterolateral border of trapezius muscle	Platysma, skin	Levator scapulae, splenius capitis muscles
VB	Horizontal plane defined by inferior border of cricoid cartilage	Clavicle	Posterior border of sternocleidomastoid muscle or sensory branches of cervical plexus	Anterior border of trapezius muscle						
VI	Hyoid bone	Suprasternal	Common carotid artery	Common carotid artery	Cranial edge of body of thyroid cartilage	Sternal manubrium	Skin; platysma	Separation between trachea and esophagus	Medial edge of thyroid gland, skin and	n.a. anteromedial edge of sternocleidomastoid muscle

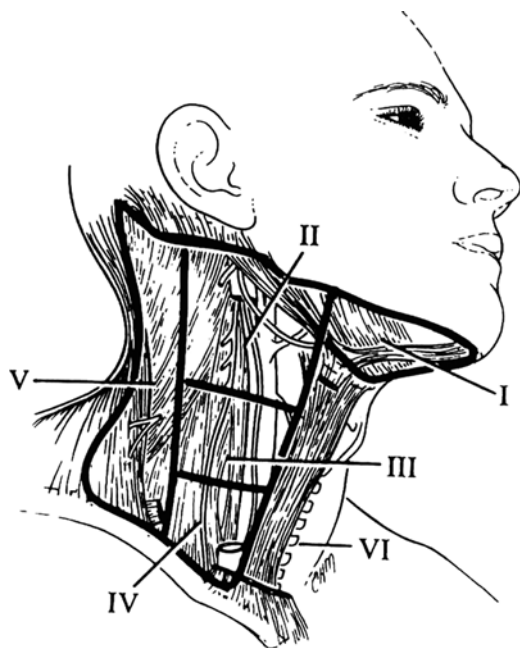


Fig. 34.1 Classification of neck node levels. From [9], Copyright 2002 American Medical Association. All rights reserved. Reprinted with permission from American Medical Association

Table 34.2 Classification of cervical lymph node metastases

<i>N stage</i>	
N0	No lymph node metastasis
N1	One lymph node metastasis <3 cm
N2a	One lymph node metastasis ≥3 cm
N2b	Multiple ipsilateral lymph node metastases
N2c	Multiple bilateral or contralateral lymph node metastases
N3	Lymph node metastasis ≥6 cm

Surgical Treatment

Neck dissection has proven to be an important procedure in the treatment of head and neck cancer. The neck dissection procedures performed today are the result of many years of refinements and modifications of the first description in the English language by Crile in 1906 [8]. The described procedure is a systematic en bloc dissection of the lymphatic tissue of the lateral neck and is presently known as the radical neck dissection (RND). In an effort to reduce the morbidity of the classic RND, various modifications have been proposed that preserve nonlymphatic structures that are normally sacrificed during this procedure but still remove all of the lymphatic tissue excised in RND. In these modified radical neck dissections (MRND), the spinal accessory nerve, the internal jugular vein, and/or the sternocleidomastoid muscle are preserved. Due to better insights into lymph drainage pathways and the assumption of predictable patterns

Table 34.3 Neck dissection classification

Type of neck dissection	Dissected levels	Sacrificed structures	Preserved structures
Radical	I–V	Spinal accessory nerve, internal jugular vein, and sternocleidomastoid muscle	
Modified radical	I–V		Spinal accessory nerve, internal jugular vein, and/or sternocleidomastoid muscle
Selective	Denote the (sub) levels removed		Spinal accessory nerve, internal jugular vein, and sternocleidomastoid muscle
Extended	I–V	Additional structures	

based on the location of the primary tumor, further modifications were developed such as the selective neck dissection (SND). In these techniques, only those lymph node groups that have the highest risk of containing metastases are removed. The main goal of these modifications is minimizing morbidity without diminishing tumor control in the neck. Due to the variety of surgical techniques, the American Academy of Otolaryngology-Head and Neck Surgery standardized the nomenclature of the different types of neck dissections in 1991. An update was published in 2002 [2, 9]. The update of 2002 brought further consensus in the description of the modified and selective neck dissections. In modified neck dissections, the structure(s) preserved are named and in SNDs the dissected levels or sublevels are specified between brackets (Table 34.3).

Recently further refinements in the selection of lymph nodes which should be included in a SND have been made. There is discussion about the inclusion of sublevel 1A (submental regions), sublevel IIB (submuscular recess), and level IV in SND in patients with certain primary tumor sites. Most authors agree that dissection of sublevel IIB is not necessarily in oral cancer, while it should be included in SND in oropharyngeal cancer [10]. A novel approach may be the sentinel node guided superselective neck dissection. In this approach, only the lymphatic structures (e.g., one level) surrounding the sentinel node, which is identified by scintigraphy or per-operative gamma-probe, are dissected [11].

Besides a therapeutic procedure, a neck dissection could also be considered as staging procedure. Neck dissections may, indeed, provide valuable additional information that helps in counseling the patients and planning adjuvant treatment, e.g., postoperative radiotherapy with or without chemotherapy.

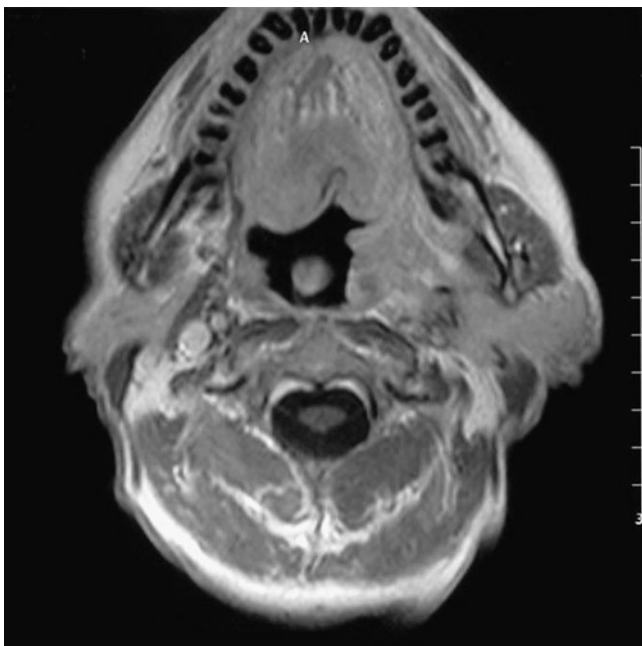


Fig. 34.2 MRI of a patient with a T3N3 oropharyngeal carcinoma and encasement of the carotid artery

The neck nodes may be fixed to adjacent structures, but are still resectable if the adjacent structures are dispensable, such as the jugular vein, the sternocleidomastoid muscle, and skin. Although the prognosis may be poor, these neck node metastases are considered operable if vertebrae, brachial plexus or common or internal carotid artery are not involved. Sacrificing both internal jugular veins harbors the risk of increased intracranial pressure with eventual blindness and therefore has to be avoided [12]. Although the carotid artery is resectable with either ligation or replacement with a graft, most surgeons consider neck masses that involve the common or internal carotid artery as unresectable. The most important criteria for vascular invasion are compression and deformation of the artery and partial fat or fascia deletion between the tumor and the artery on computed tomography (CT) [13]. Yousem et al. [14] found that the single criterion of involvement of 270° or more of the circumference of the carotid artery on magnetic resonance imaging (MRI) was accurate in predicting the surgeon's inability to peel the tumor off the carotid artery in all investigated 29 patients with clinical suspicion of carotid artery encasement (Fig. 34.2).

Paratracheal Lymph Node Metastases

Paratracheal lymph node metastases carry a high risk for subsequent metastases to the mediastinum and to distant sites [15]. Paratracheal lymph node metastases also have

been linked to stomal recurrence after total laryngectomy [15, 16]. Plaat et al. [17] evaluated the prognostic significance of paratracheal lymph node metastases with respect to tumor recurrence and survival in a group of patients with laryngeal or hypopharyngeal carcinoma treated with total laryngectomy. The presence of paratracheal lymph node metastases with extranodal growth appeared to be the most predicting factor of overall survival (OS) [17]. The reported incidence of paratracheal metastases varies according to primary site (larynx, hypopharynx, and proximal esophagus), stage, and extension of the primary tumor from 3 to 26% [15, 18–20]. Unfortunately, the indications for elective paratracheal dissection during laryngectomy are not well defined. As the reported incidence of paratracheal metastases is low in supraglottic and glottic carcinomas without subglottic extension, paratracheal lymph node dissections are not routinely performed for these tumors. Because of the high incidence of paratracheal metastases, paratracheal lymph node dissections are recommended in patients with hypopharyngeal and esophageal cancer and laryngeal tumors with subglottic extension beyond 1 cm caudally from the glottis [17].

Adjuvant Treatment

Patients with HNSCC with multiple metastatic lymph nodes or lymph node metastases with extranodal spread (ENS) have been shown to have better locoregional control and survival with the addition of postoperative radiotherapy [21–23]. Adjuvant treatment is given to reduce the risk of (locoregional) failure. In the past indications for adjuvant treatment included advanced T-stage (especially cartilage and bone invasion), perineural invasion, vasoinvasive growth, close or positive surgical margins, multiple lymph node metastases, and ENS. If adjuvant treatment is indicated by the primary tumor, this treatment is usually also given on the neck.

Langendijk et al. [24] performed a recursive partitioning analysis (RPA) to define risk groups of patients with HNSCC treated with surgery and postoperative radiotherapy. Patients were classified as intermediate risk had one or more of the aforementioned classical indications but had negative surgical margins and no ENS. Those with T1, T2, and T4 tumors with close or positive surgical margins and/or one lymph node metastasis without ENS were classified as high risk, while T3 tumors with close or positive margins, multiple lymph node metastases with ENS and/or N3 neck disease were classified as very high risk. This RPA classification system allows for a distinct stratification of patients with different outcome with regard to locoregional tumor control which was 92, 78, and 58% in class I, II, and III patients, respectively. The overall survival was 67, 50 and 37% in class I, II

and III respectively. The RPA classification system was a strong prognosticator for other endpoints as well, including disease-free survival and the occurrence of distant metastases, and has been validated among different study populations [25, 26].

Since the results of surgery and postoperative radiotherapy alone have been unsatisfactory in particular among high and very high-risk patients, the added value of concomitant chemotherapy to postoperative radiotherapy has also been investigated in a number of randomized trials. In the EORTC trial, 334 patients treated with primary surgery for HNSCC of the oral cavity, oropharynx, larynx, and hypopharynx, were randomly assigned to receive either radiotherapy alone (66 Gy in 33 fractions) or chemoradiation with the same radiation schedule combined with cisplatin 100 mg/m² every 3 weeks [27]. The progression-free survival, which was the primary endpoint, was 23 months in the radiotherapy group compared to 55 months in the chemoradiation group ($p=0.02$), which also translated into significant improvement of the 5-year overall survival after chemoradiotherapy compared to after postoperative radiotherapy alone (53% vs. 40%, $p=0.02$). Grade III/IV mucositis was more frequently observed in the chemoradiation arm of the study (41% vs. 21%, $p=0.001$). Severe late effects (\geq grade III) were not statistically different [27]. In the RTOG trial, 449 patients with high-risk HNSCC were randomly assigned after primary surgery to either receive radiotherapy alone (66 Gy in 33 fractions) or chemoradiation with the same radiation schedule combined with cisplatin 100 mg/m² every 3 weeks [28]. A significant improvement was observed in disease-free survival, which was 20 months in the radiotherapy group and 28 months in the chemoradiation group ($p=0.04$), which resulted in a nonsignificant improvement of the 5-year overall

survival in the chemoradiotherapy group (44% vs. 37%, $p=0.19$). Grade III/IV mucositis was more frequently observed in the chemoradiation arm of the study (30% vs. 18%, $p=0.003$). Severe late effects (\geq grade III) were observed in 17% in the radiotherapy arm and 21% in the chemoradiation arm of the study, but this difference did not reach the level of statistical significance ($p=0.3$) [28]. Similar results were found in a third large randomized trial conducted by a German Group (ARO) that have not been presented in a full paper yet. In this study, 440 high-risk patients were randomly assigned to receive either 64 Gy conventionally fractionated radiotherapy alone, or to the same radiotherapy in combination with two cycles of concurrent chemotherapy (cisplatin 20 mg/m² + 600 mg/m² 5FU CI; day 1–5 and 29–33). Also in this study, a significant improvement of locoregional control and overall survival was observed. In a meta-analysis of the EORTC and the RTOG trial, a statistically significant survival benefit of chemoradiation was observed in overall survival, but this difference was confined to the subset of patients with ENS and/or close surgical margins (<5 mm) (Fig. 34.3), i.e., the RPA class II and III patients (high and very high) risk patients [29]. However, HNSCC with other risk factors such as perineural disease, vascular embolism, and >2 involved lymph nodes did not benefit from chemoradiation (RPA class I: intermediate risk patients) [29]. The RPA classification system can thus be used to assess standard treatment strategies for HNSCC in the postoperative setting. In general, in case of intermediate risk RPA-class (RPA-class I), conventional postoperative radiotherapy alone is indicated, while postoperative chemoradiation is indicated in case of the high or very high-risk RPA-classes.

Recently, the results of a meta-analysis showed a significant improvement of survival after altered fractionation

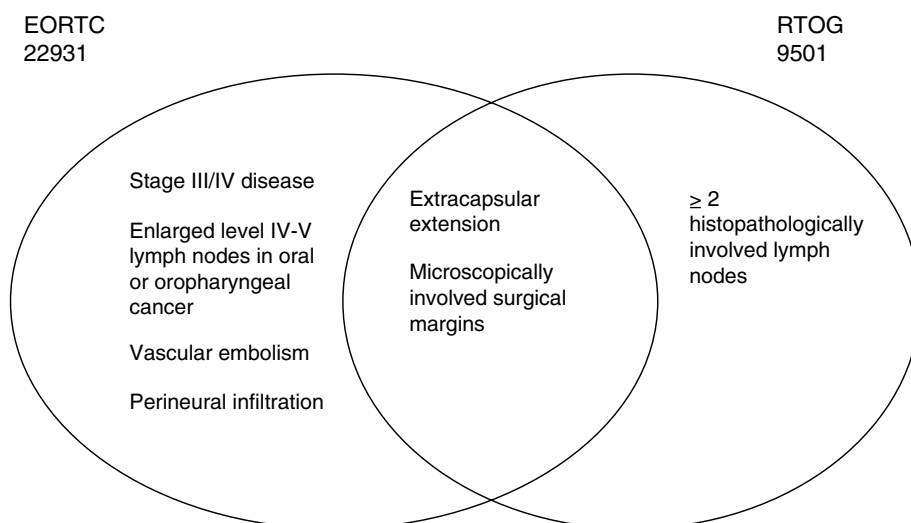


Fig. 34.3 Criteria for postoperative chemoradiation from RTOG and EORTC studies in stage III/IV head and neck cancer patients [28]

Table 34.4 Overview of studies regarding the prognostic significance of the interval between surgery and (postoperative) radiotherapy

Study	Design	Dose	Interval surgery – radiotherapy	Number of patients	5-year results		Comments
					Locoregional control	Overall survival	
Ang et al. [30]	Retrospective analysis from a prospective phase II study	63 Gy	0–31 days	76	80%; 72%	51%; 47%	No randomization for interval
			>31 days	75	65%; 48%	41%; 20%	
Bastit et al. [32]	Retrospective multivariate	45–74 Gy	0–30 days	219	$p=0.34$; 0.33	$p=0.50$; 0.01	No multivariate analysis
			>30 days	201	78%	35%	
Muriel et al. [33]	Retrospective multivariate	50–75 Gy	0–50 days	Total 214	73%	28%	Interval independent prognostic factor for locoregional control
			>50 days		ns	ns	
Parsons et al. [34]	Retrospective univariate	55–73 Gy	0–50 days	76	83%	NA	Interval independent prognostic factor for locoregional control
			>50 days	39	68%	NA	
Schiff et al. [35]	Retrospective univariate	32–76 Gy	0–6 weeks	61	$p=0.02$	NA	Interval independent prognostic factor for locoregional control
			>6 weeks	50	79%	NA	
					$p=0.02$		
					88%	NA	
					73%		
					$p=0.11$		

radiotherapy in the primary setting. The results suggested that the most benefit could be obtained by using hyperfractionated schedules. The benefit of altered fractionation in the postoperative setting is less clear. Ang et al. [30] reported on the results of a phase III study, in which patients following surgery were randomly assigned to receive conventionally fractionated postoperative radiotherapy (63 Gy in 7 weeks) versus accelerated radiation (63 Gy in 5 weeks). In that study, locoregional control (LRC) after 5 years improved from approximately 62% with conventional fractionation to 76% with accelerated fractionation which was also translated in higher rates in OS that improved from 30 to 48% after 5 years. However, these differences were not statistically significant possibly due to the relatively low number of patients included in that study. The 5-year LRC and OS rates among patients with intermediate risk (comparable with RPA class I) in that study was approximately 93 and 68% [30]. In another relatively small randomized study, shortening of the overall treatment time of postoperative radiotherapy by accelerated hyperfractionation provided a significant improvement of LRC without significantly improving the OS only in fast growing tumors [31]. It has to be stressed that the results of shortening the overall treatment of radiation is likely to be influenced by the interval between surgery and the start of radiation treatment [30, 31].

The total treatment package is defined as the period from the day of surgery to the last day of radiation and can be divided in the interval between surgery and radiotherapy and the total treatment time of radiation itself. In a number

of studies [30, 32–35], the prognostic significance of the interval between surgery and radiotherapy was investigated (Table 34.4).

In most studies, the univariate analysis showed that the interval between surgery and radiotherapy was significantly associated with LRC. However, this was confirmed in the multivariate analysis in just one study [33]. In another study, the interval was only associated with local–regional control and survival among patients who had been treated with conventionally fractionated radiation and not in those treated according to the accelerated fractionation schedule [30].

If single lymph node metastases without ENS are identified, adjuvant radiotherapy is usually not recommended. Controversy exists what to do in this latter situation when found in a SND: wait-and-see, adjuvant radiotherapy on the whole neck or complete the neck dissection. In most occasions, adjuvant radiotherapy will be given, increasing the morbidity to an extent probably higher than a MRND.

Nonsurgical Treatment

Primary radiotherapy alone can be considered in case of non-bulky nodal disease. In a retrospective study, regional control of nodal metastases among patients with HNSCC treated with radiotherapy alone was over 90% after 2 years in case of small nodal volumes (<3 cm), no presence of radiological central necrosis and no presence of radiological ENS [36].

In these cases, a planned neck dissection appears not to be indicated. However, in case of a larger volumes of more than 3 cm, central necrosis and/or radiological sign of ENS, the risk on regional recurrence turned out to be unacceptably high [36, 37]. In these cases, chemoradiation and/or planned neck dissection is indicated as the application of accelerated radiotherapy does not result in better regional control [38].

Treatment of bulky neck disease with radiation alone offers poor regional control. Modern definitive chemoradiation of N3 neck disease results in a 2-year locoregional control of 88% [39].

The decision to perform a neck dissection following (chemo)radiation is clear when patients have proven residual neck disease. However, distinguishing between residual metastasis and chemoradiation sequelae is difficult in most cases with a residual neck mass, since posttreatment induration and fibrosis obscure accurate clinical assessment. The difficulty in evaluating for recurrence has made salvage neck surgery less effective and late recurrences in the neck rarely surgically salvageable [40]. Therefore, in some institutes, planned neck dissections after curative (chemo)radiation are performed, as a reliable assessment of the pathological status after chemoradiation is often difficult [41, 42]. A negative predictive value of CT for the detection of residual or recurrent neck metastasis of 94–97% is reported, with a good sensitivity (75–97%) but with a specificity ranging from 24 to 93% [43–45]. Ojiri et al. [45] reported specific abnormal radiological measures for predicting residual tumor in metastatic nodes in patients with head and neck cancer treated with radiotherapy: If lymph nodes on CT after radiotherapy were ≤ 15 mm, free of significant internal focal low-attenuation or calcification, and without imaging evidence of ENS, the neck was positive in 1 (3.4%) side of the 29 surgical neck specimens.

Recently, some retrospective studies on the use of FDG-PET in the prediction of necessity for postradiation therapy neck dissection have been reported [46]. To avoid futile neck dissections a high-negative predictive value is needed. Negative predictive values between 14 and 100% are reported in these studies, probably depending on the timing of positron emission tomography (PET) scanning. PET imaging obtained too soon after radiation had been associated with high rate of false-positive findings due to postradiation soft tissue effects, and false-negative findings because of the residual viable cancer cells not having sufficient time to repopulate to a level that can be detected by PET. One month after radiation the negative predictive value was only of 14% [47]. When PET scanning was performed 4–12 weeks after chemoradiation this figure was 73% [48]. When the interval between PET and completion of chemoradiation was 8–12 weeks a negative predictive value of 92% was reported [49]. If the time interval between the end of therapy and PET scanning increases the negative predictive value improved to

97–100% [50, 51]. Also a high sensitivity is warranted to refrain patients from neck dissection. In these studies, the sensitivities from 45 to 100% are reported, depending on timing of the scanning. The reported specificity was 65–94%. A study of 43 HNSCC patients with N2 or N3 neck disease before chemoradiation, FDG-PET/CT 2–5 months after treatment reported a sensitivity of 88%, a specificity of 91%, a positive predictive value of 70%, and a negative predictive value of 97% [52]. These studies indicate that FDG-PET can predict residual neck disease after (chemo)radiation for HNSCC is reliable [53]. Although these data suggest that in patients with a negative FDG-PET scan neck dissection can be avoided, concern exists that delaying a neck dissection allows more time for both cancer progression as well as for radiation-induced fibrosis, which may hamper the feasibility of a neck dissection and increase surgical complications.

Diffusion-weighted MRI uses strong magnetic field gradients to make the MRI signal sensitive to the molecular motion of water and is able to characterize tissue and generate imaging contrast based on differences in diffusion motion of water protons in the tissues. In a pilot study of 26 patients, Vandecaveye et al. [54] found a sensitivity of 95%, a specificity of 96%, and accuracy of 96% for the detection of residual or recurrent head and neck tumors after radiotherapy with or without chemotherapy using diffusion-weighted MRI with apparent diffusion coefficient (ADC) measurements. When compared with CT, conventional MRI, and FDG-PET, diffusion-weighted MRI yielded fewer false-positive results for persistent nodal disease [54]. Although these results are promising, larger studies on diffusion-weighted MRI including patients with tumors at specific sites and treatments are needed.

Because no reliable clinical parameters are available to predict pathological status after (chemo)radiation, routine planned neck dissection are performed in some institutes. The integration of planned neck dissection into the multidisciplinary management of patients with locoregionally advanced head and neck cancer treated by concomitant chemoradiotherapy is highly effective in controlling residual cervical metastatic disease [55, 56]. However, in the majority of neck dissection specimens, no vital tumor cells are found [57–62]. Moreover, neck dissection after radiation bears a significant risk of wound healing problems. To prevent wound healing problems, pedicled pectoralis major muscle flaps should be used which may further increase treatment-related morbidity. In patients treated with a combination of chemotherapy and radiotherapy, this risk of wound healing problems is even higher. Extensive fibrosis is an untoward outcome observed in many patients who undergo surgery after (chemo)radiation therapy. These late and frequently progressive soft tissue side effects are more likely to occur after chemoradiation than after radiation alone. Delayed wound healing of surgical incision and potential

wound breakdown with flap necrosis and large vessel exposure may complicate surgery after chemoradiation. Complication rates for planned neck dissections after chemoradiation of 17–35% have been reported [41, 57, 63]. Postoperative complication rates of 53% have been reported after en bloc salvage surgery for HNSCC. The clinical stage of the recurrent tumor and the previous site treated are major factors associated with the occurrence of postoperative complications [64].

Taking into account the relatively high complication rate of planned neck dissections, the question arises if all patients actually need such an “elective” surgical treatment. If the neck was clinically staged N0 or N1 before (chemo)radiation, no planned neck dissection is needed [64, 65, 66]. In HNSCC patients with initial N2 or N3 neck disease or residual mass in the neck after (chemo)radiation, the perplexing decision remains whether to see the patient in clinical follow-up (watch-and-wait), looking for eventual growth of the mass, or performing a planned neck dissection regardless of whether the neck disease seems to regress completely [40, 62]. In some institutions, routine planned neck dissections are performed for pretreatment of N2/3 disease. Other institutes recommend neck dissection only for patients with no or partial clinical or radiological response [67]. In other institutes, neck dissections following chemoradiation are performed in all patients with clinically residual disease and/or N3 [68]. The advantage of limiting neck dissection to patients with residual neck disease 6–8 weeks posttreatment is that overtreatment is reduced. There is a tendency to perform neck dissections after chemoradiation only if indicated by posttreatment diagnostic (physical examination, imaging, and/or cytologic) evaluation of the neck [45, 49, 69–72]. Van der Putten et al. [73] reported on 129 patients with neck recurrence out of 540 HNSCC patients who underwent after chemoradiation. They found that 6% might have benefited from a planned neck dissection, while this planned neck dissection would have been unnecessary in 76% of the patients with N2–N3 disease. For patients with N0–N1 neck the number of unnecessary neck dissections was even higher (92.8%). Together with the relatively good regional control rate, they concluded that a watch and careful observational strategy has an acceptable outcome and that a planned neck dissection strategy results in a considerable overtreatment [73]. Due to improvements in imaging techniques and criteria routine planned neck dissection will probably be performed less often in the near future.

In the event of neck failure after (chemo)radiation, salvage surgery is indicated. Neck dissection as salvage procedure is also employed when initial response of tumor to nonsurgical treatment is only partial, and when these patients present with residual lymphadenopathy. Similar to what has been discussed for the planned neck dissection, wound healing after salvage surgery may be problematic as well. As the

possibilities of postoperative reirradiation are often limited, in particular when the interval is short, it is essential to carry out adequate dissection in order to remove all residual or recurrent cervical lymph nodes harboring malignancies while at the same time minimizing morbidity to the surgical procedure [74].

If the decision to perform a neck dissection following radiation or chemoradiation has been made, the next dilemma is determined by the extent of the neck dissection that needs to be performed. The potential scope of lymph node removal ranges from excision of the affected nodal level, through SND to (modified) RND [5]. Based on the assumption that any occult disease present before treatment will be sterilized by (chemo)radiation in low-risk levels, a (modified) RND is probably not always warranted. Robbins et al. [75] examined the histopathological results of 84 neck dissections performed because of residual mass after chemoradiation in 240 patients with advanced stage head and neck carcinoma. In 34(40%) of the neck dissection specimens, residual tumor was found of which 41% was confined to one level, 35% had positive nodes in two levels, and 24% had positive nodal disease in three or more levels. In the selected group of patients who underwent selective or super-selective (two or fewer levels) neck dissections, regional disease as the first site of failure was only 5 and 0%, respectively. They concluded that (super) selective neck dissections seems to be an effective procedure with potentially better preservation of function and less morbidity for patients with residual lymph adenopathy confined to one neck level after chemoradiation [75]. Stenson et al. [76] confirmed the feasibility and safety in 67 planned postchemoradiation SNDs. However, further prospective studies are needed to confirm these observations [75].

The Patient Presenting with N0 Disease

The management of the clinically negative (N0) neck is a controversial issue. There is general agreement that elective treatment of the neck is indicated when there is a high likelihood of occult, clinically undetectable, lymph node metastases and when the neck needs to be entered for surgical treatment of the primary tumor (excision and/or reconstruction), or when the patient will be unavailable for regular follow-up. If the primary tumor is treated by irradiation the adjacent lymph nodes are generally treated as well partly due to technical reasons.

Since lymph node metastases of T1 and T2 glottic laryngeal carcinoma are rare, the regional lymphatics are usually not treated electively. On the other hand, even in small oropharyngeal, hypopharyngeal, and supraglottic tumors the risk of occult metastases is high and the lymph node levels at

risk are treated electively. Since most of these tumors are treated by irradiation, the radiation field must be extended to include the neck. When there is intermediate likelihood of occult lymph node metastases, the choice is between elective treatment and watchful waiting. This question certainly arises in the smaller (T1 and T2) carcinomas of the oral cavity and oropharynx, because these usually can be excised adequately by the transoral route and the neck is not entered surgically.

The rationale for elective treatment is based on the following premises. First, occult metastases will inevitably develop into clinically manifest disease. Secondly, despite regular follow-up some patients will develop extensive or even inoperable disease in the neck with a wait-and-see policy. Finally, untreated disease in the neck may give rise to distant metastases, while the lymph node metastasis is growing to a clinically detectable size. The arguments against elective treatment of the neck are as follows. Firstly, a large proportion of patients are subjected to treatment that they do not require. Secondly, such treatment may remove or destroy a barrier to cancer spread in case of local recurrence or second primary tumor. Finally, elective treatment of the neck is associated with morbidity, i.e., shoulder morbidity.

A number of mostly retrospective studies have shown a better regional control by elective neck dissection or irradiation as compared to observation in oral cancer patients [76–83]. The results of surgery after “watchful waiting” (observation) are generally poor and often more extensive than elective treatment [76, 77, 84, 85]. However, most studies did not show improved survival for elective treatment of the neck [79, 86–91]. D’Cruz et al. [92] compared the results of 159 patients with T1-2N0 oral tongue carcinoma who underwent an elective neck dissection with 190 patients who had wait-and-watch follow-up of the neck for these tumors. The estimated 5-year disease-specific survival was 71 and 68% for these groups, respectively. Only a few studies found a survival benefit of elective neck dissection [78, 83]. In one study, an improved survival was found for elective neck dissection only in T2 oral tongue carcinoma [77]. It may be possible that the survival advantage offered by elective treatment is small and that the sample size of most studies does not afford sufficient power to adequately demonstrate this difference [90]. It seems likely, however, that if elective treatment of the neck is to improve survival, that it will be most benefit to those patients with a high risk of occult metastasis. In 1994, Weiss et al. [93] reported on a decision analysis based on the diagnostic techniques and the expert opinions in those days. Since this, it is generally accepted that the neck should be treated if the risk of lymph node metastases is greater than 20%. It is remarkable that this risk percentage is still accepted despite technical improvements in the last decades. In these days, an acceptable risk of not treating occult metastases is probably much lower. The risk of occult

metastases is dependent on site, stage, and other tumor characteristics. Histopathological features such as differentiation (in the deep portion), (invasive) growth pattern, thickness, depth of muscle invasion, vasoinvasive growth (angiolymphatic invasion), perineural invasion, and degree of inflammatory reaction surrounding the tumor may have some relevance in predicting nodal disease [92, 94–98]. In the near future it may be anticipated that molecular biological diagnostic techniques will be able to predict the presence of (occult) lymph node metastases more reliable.

If clinically negative neck is not treated electively, close follow-up with or without diagnostic techniques, e.g., ultrasound-guided fine needle aspiration cytology (USgFNAC), is an option in carefully selected patients to detect occult metastases in an early stage [99, 100]. In such strategies, futile elective neck dissections can be avoided in the majority of patients, and neck disease control and survival seem not to be compromised. However, in the few patients who need a (salvage) neck dissection for delayed metastases, treatment of the neck will probably be more extensive, e.g., MRND with or without radiotherapy than if they had undergone elective treatment.

If it is decided to treat the clinically N0 neck surgically, several types of operation are available: selective and (modified) RNDs. Rarely adjuvant radiotherapy is indicated. The reported regional recurrence rate after elective neck dissection is between 5 and 12% [77–91]. Elective radiation to a dose of 5,000 cGy yields a control rate of the neck exceeding 90% [101].

In the management of the clinically N0 neck, it is important to realize that the definition of the N0 neck is not uniform since different diagnostic techniques have been used in different studies. The risk of occult metastases is also dependent on the diagnostic techniques used. Modern imaging techniques, such as computed tomography (CT), MRI, PET, and ultrasound (US) are more reliable than palpation. The capability of all of these techniques to detect small tumor deposits (micrometastases) is limited. USgFNAC proved to be superior to the other current imaging techniques [102]. In the clinical negative neck FDG-PET was not superior to conventional imaging techniques [103–105]. In an attempt to select the lymph nodes potentially containing metastases more reliably the sentinel lymph node (SN) concept was introduced. Whereas, conventional USgFNAC uses above-mentioned criteria, the SN concept is fundamentally based on the theory of orderly spread of tumor cells within the lymphatic system. The first lymph node in a regional lymphatic basin that receives lymphatic flow from a tumor is considered to be the SN. The SN concept assumes that lymphatic metastases, if present, can always be found at least in the SN. A tumor-negative SN would thus preclude the presence of lymphatic malignant involvement elsewhere in the neck. Oral cancer is eminently suitable for sentinel node evaluation

as metastasis takes place through lymphatic corridors to specific areas of the neck, depending on the site of the primary tumor [106–110]. In a multi-institutional study by Ross et al. [111], the sensitivity of this technique in head and neck cancer has been estimated as 94%. A meta-analysis revealed a sensitivity of 93% for the detection of occult lymph node metastases in early oral cancer [112]. To confirm these findings larger multicenter studies are ongoing. In some institutes treating most pharyngeal and laryngeal cancers endoscopically sentinel node procedures have been performed for these sites as well [113].

The Patient Presenting with N1 Disease

In general management of N1 disease by MRND harbors an excellent oncological outcome. The role of SNDs in N1 disease is evolving. Adjuvant (chemo)radiation may be indicated by the results of the histopathological examination of the surgical specimen.

Almost all patients presenting with N1 disease receive nodal control from (chemo)radiation, provided that the primary site is cured. In only 0–8% of the neck dissection specimens after radiotherapy alone for N1 disease tumor is found [66]. In 30 patients presented with N1 disease who obtained local control after hyperfractionated radiotherapy and concurrent cisplatin and 5-fluorouracil chemotherapy, MRND showed pathologic complete response in 92% [114]. In general, patients with N1 disease do not need to undergo a neck dissection after (chemo)radiation unless there is a persistent mass in the neck. Neck dissections in patients with a residual mass in the N1 neck after (chemo)radiation yield viable tumor cells in 25% of cases [5].

The Patient Presenting with N2/3 Disease

The role of nonsurgical treatment of head and neck cancer with the aim of organ and function preservation is evolving. Also in advanced head and neck cancer, chemoradiation have been proven effective in achieving disease control at the primary site. The management of the neck in patients with N2/3 disease who undergo nonsurgical treatment for the primary tumor is debatable. Although the addition of neck dissection to radiation of N2 or N3 disease shows fewer regional recurrences, planned neck dissection following radiation for patients presented with N2/3 lesions reveals tumor in only 20–50% of the specimens. For patients treated with chemoradiation this figure is even lower [40]. Such findings provide rationale for withholding neck dissection for patients staged N2 with a complete clinical response. Since the probability

of complete pathologic response decreases with increasing pretreatment nodal size, some authors recommend a neck dissection for N3 patients, regardless of clinical response to nonsurgical therapy [66, 68, 69]. Because the salvage rate (if neck disease recurs clinically) is low, regional control is enhanced by planned neck dissection. However, an improvement in overall survival with the addition of a planned neck dissection to (chemo)radiation for N2/3 head and neck cancer is not demonstrated consistently. The improvement of regional control by planned neck dissections must be weighed against the complications and morbidity of neck dissections after (chemo)radiation. Recent studies show that a careful observational strategy is worthwhile and safe [73]. No generally accepted guidelines are available on this difficult subject.

Recurrence in the Neck

Recurrence of cancer in the neck following appropriate treatment is a poor prognostic sign. When considering treatment for recurrent neck disease examinations for local recurrence, distant metastases, and second primary tumors have to be performed. Treatment options depend on previous treatment and extent of the recurrence in the neck. If surgical treatment is not possible, radiation therapy or chemotherapy may be used with curative intent or as palliation. Even in case of distant metastases surgery may be considered as palliative option since uncontrolled tumor growth in the neck induces severe morbidity.

Shoulder Morbidity

It is well established that neck dissection procedures are associated with shoulder morbidity. This morbidity is characterized by shoulder pain, limitations of abduction, and scapular winging. Shoulder function is an important aspect of health-related quality of life as it is related to various activities of daily living, e.g., dressing, writing, driving, lifting objects, and reaching for things [115, 116]. Because of the impact of impaired shoulder function on social and leisure activities and work, several domains of quality of life may be affected [117].

Modifications of the RND were fashioned to limit the extent and frequency of shoulder dysfunction [118]. Spinal accessory nerve sparing neck dissections are associated with better preservation of shoulder function as compared to nerve-sacrificing neck dissections [119, 120]. Nevertheless, significant shoulder dysfunction continues to arise even when the spinal accessory nerve is spared during the neck

dissection procedure [121]. To diminish shoulder morbidity the concept of the SND was introduced in which only the levels at risk for (occult) lymph node metastases are dissected [122].

Also after nonsurgical treatment of the neck shoulder morbidity is often present but to a lesser extent compared to surgical treatment. Radiotherapy adds no morbidity to neck dissection and chemotherapy does not add extra morbidity to primary radiation [123].

Shoulder morbidity may be improved by physiotherapy and exercising programs. Physiotherapy has an important role in promoting function, improvement of scapular stability, and reducing pain by maintaining length of muscles, range of movement, and preventing frozen shoulder symptoms [117]. In the postoperative care, a specific rehabilitation program may be prescribed.

References

- Rouvière H. Anatomie des lymphatiques de l'homme. Paris: Masson et Cie; 1932.
- Robbins KT, Medina JE, Wolfe GT, et al. Standardizing neck dissection terminology. Official report of the Academy's Committee for head and neck surgery and oncology. *Arch Otolaryngol Head Neck Surg.* 1991;117:601–5.
- Grégoire V, Levendag P, Ang KK, et al. CT-based delineation of lymph node levels and related CTVs in the node-negative neck: DHANCA, EORTC, GORTEC, NCIC, RTOG consensus guidelines. *Radiother Oncol.* 2003;69:227–36.
- Sobin LH, Wittekind Ch, editors. TNM Classification of Malignant Tumours. 6th ed. New York: Wiley-Liss; 2002.
- Brown KM, Lango M, Ridge JA. The role of neck dissection in the combined modality therapy setting. *Semin Oncol.* 2008;35:229–35.
- Smeele LE, Leemans CR, Reid CBA, et al. Neck dissection for advanced lymph node metastasis before definitive radiotherapy for primary carcinoma of the head and neck. *Laryngoscope.* 2000;110:1210–1214.
- Wang SJ, Wang MB, Calcaterra TC. Radiotherapy followed by neck dissection for small head and neck cancer with advanced cervical metastases. *Ann Otol Rhinol Laryngol.* 1999;108:128–31.
- Crile GW. Excision of cancer in the head and neck. With special reference to the plan of dissection based on one hundred and thirty-two operations. *JAMA.* 1906;47:1780–6.
- Robbins KT, Clayman G, Levine PA, et al. Neck dissection classification update. Revisions proposed by the American Head and Neck Society and the American Academy of Otolaryngology-Head and Neck Surgery. *Arch Otolaryngol Head Neck Surg.* 2002;128:751–8.
- Paleri V, Kumar Subramaniam S, Ozeer N, et al. Dissection of the submuscular recess (sublevel IIb) in squamous cell carcinoma of the upper aerodigestive tract: prospective study and review of the literature. *Head Neck.* 2008;30:194–200.
- Werner JA. Selective sentinel lymphadenectomy for head and neck squamous cell carcinoma. *Cancer Treat Res.* 2005;127:187–206.
- Balm AJ, Brown DH, De Vries WA, et al. Blindness: a potential complication of bilateral neck dissection. *J Laryngol Otol.* 1990;104:154–6.
- Yu Q, Wang P, Shi H, et al. Carotid artery and jugular vein invasion of oralmaxillofacial and neck malignant tumors: diagnostic value of computed tomography. *Oral Surg Oral Med Oral Pathol Oral Radiol Endo.* 2003;96:368–72.
- Yousem DM, Hatabu H, Hurst RW, et al. Carotid artery invasion by head and neck masses: prediction with MR imaging. *Radiology.* 1995;195:715–20.
- Weber R, Marvel J, Smith P, et al. Paratracheal lymph node dissection for carcinoma of the larynx, hypopharynx and cervical oesophagus. *Otolaryngol Head Neck Surg.* 1993;108:11–7.
- Leon X, Quer M, Burgues J, et al. Prevention of stomal recurrence. *Head Neck.* 1996;18:54–9.
- Plaat RE, de Bree R, Kuik DJ, et al. Prognostic importance of paratracheal lymph node metastases. *Laryngoscope.* 2005;115:894–8.
- Timon CV, Toner M, Conlon BJ. Paratracheal lymph node involvement in advanced cancer of the larynx, hypopharynx, and cervical esophagus. *Laryngoscope.* 2003;113:1595–9.
- Petrovic Z, Djordjevic V. Stomal recurrence after primary total laryngectomy. *Clin Otolaryngol.* 2004;29:270–3.
- Shenoy AM, Nanjundappa A, Kumar P, et al. Interjugular neck dissection and post-operative irradiation for neck control in advanced glottic cancers- are we justified? *J Laryngol Otol.* 1994;108:26–29.
- Leemans CR, Tiwari R, van der Waal I, et al. The efficacy of comprehensive neck dissection with or without postoperative radiotherapy in nodal metastases of squamous cell carcinoma of the upper respiratory and digestive tracts. *Laryngoscope.* 1990;100:1194–8.
- Huang DT, Johnson CR, Schmidt-Ulrich R, et al. Postoperative radiotherapy in head and neck carcinoma with extracapsular lymph node extension and/or positive margins: a comparative study. *Int J Radiat Oncol Biol Phys.* 1992;23:737–42.
- Bartelink H, Breur K, Hart G, et al. The value of postoperative radiotherapy as an adjuvant to radical neck dissection. *Cancer.* 1983;52:1008–13.
- Langendijk JA, Slotman BJ, van der Waal I, et al. Risk-group definition by recursive partitioning analysis of patients with squamous cell carcinoma treated with surgery and postoperative radiotherapy. *Cancer.* 2005;104:1408–17.
- Jonkman A, Kaanders JHAM, Terhaard CHJ, et al. Multicenter validation of recursive partitioning analysis classification for patients with squamous cell head and neck carcinoma treated with surgery and postoperative radiotherapy. *Int J Radiat Oncol Biol Phys.* 2007;68:119–25.
- Leon X, Lopez M, Pineiro Z, et al. External validation of a risk group defined by recursive partitioning analysis in patients with head and neck carcinoma treated with surgery and postoperative radiotherapy. *Head Neck.* 2007;29:815–21.
- Bernier J, Dommene C, Ozsahin M, et al. Postoperative irradiation with or without concomitant chemotherapy for locally advanced head and neck cancer. *New Engl J Med.* 2004;350:1945–52.
- Cooper JS, Pajak TF, Forastiere AA, et al. Postoperative concurrent radiotherapy and chemotherapy for high-risk squamous-cell carcinoma of the head and neck. *New Engl J Med.* 2004;350:1937–44.
- Bernier J, Cooper JS, Pajak TF, et al. Ding risk levels in locally advanced head and neck cancers. A comparative analysis of concurrent postoperative radiation and chemotherapy trials of the EORTC (#22931) and RTOG (#9501). *Head Neck.* 2005;27:843–50.
- Ang KK, Trotti A, Brown BW, et al. Randomized trial addressing risk features and time factors of surgery plus radiotherapy in advanced head and neck cancer. *Int J Radiat Oncol Biol Phys.* 2001;51:571–8.
- Awwad HK, Lotayef M, Shouman T, et al. Accelerated hyperfractionation (AHF) compared to conventional fractionation (CF) in the postoperative radiotherapy of locally advanced head and neck cancer: influence of proliferation. *Br J Cancer.* 2002;86:517–23.

32. Bastit L, Blot E, Debourdeau P, et al. Influence of the delay of adjuvant postoperative radiation therapy on relapse and survival in oropharyngeal and hypopharyngeal cancers. *Int J Radiat Oncol Biol Phys.* 2001;49:139–46.
33. Muriel VP, Tejada MR, de Dios Luna del Castillo J. Time-dose-response relationships in postoperatively irradiated patients with head and neck squamous cell carcinomas. *Radiother Oncol.* 2001;60:137–45.
34. Parsons JT, Mendenhall WM, Stringer SP, et al. An analysis of factors influencing the outcome of postoperative irradiation for squamous cell carcinoma of the oral cavity. *Int J Radiat Oncol Biol Phys.* 1997;39:137–48.
35. Schiff PB, Harrison LB, Strong EW, et al. Impact of the time interval between surgery and postoperative radiation therapy on locoregional control in advanced head and neck cancer. *J Surg Oncol.* 1990;43:203–8.
36. Vergeer MR, Doornaert P, Leemans CR, et al. Control of nodal metastases in squamous head and neck cancer treated by radiation therapy or chemoradiation. *Radiother Oncol.* 2006;79:39–44.
37. Hermans R, Op de Beeck K, van den Bogaert W, et al. The relation of CT-determined tumor parameters and local and regional outcome of tonsillar cancer after definitive radiation treatment. *Int J Radiat Oncol Biol Phys.* 2001;50:37–45.
38. Ballonoff A, Raben D, Rusthoven KE, et al. Outcome of patients with N3 neck nodes treated with chemoradiation. *Laryngoscope.* 2008;118:995–8.
39. Overgaard J, Hansen HS, Specht L, et al. Five compared with six fractions per week of conventional radiotherapy of squamous-cell carcinoma of head and neck: DAHANCA 6 and 7 randomised controlled trial. *Lancet.* 2003;362:933–40.
40. McHam SA, Adelstein DJ, Rybicki LA, et al. Who merits a neck dissection after definitive chemoradiotherapy for N2-N3 squamous cell head and neck cancer? *Head Neck.* 2003;25:791–8.
41. Kutler DI, Patel SG, Shah JP. The role of neck dissection following definitive chemoradiation. *Oncology.* 2004;18:993–8.
42. Mukherji SK, Wolf GT. Evaluation of head and neck squamous cell carcinoma after treatment. *AJNR Am J Neuroradiol.* 2003;24:1743–6.
43. Farrag TY, Lin FR, Cummings CW, et al. Neck management in patients undergoing postradiotherapy salvage laryngeal surgery for recurrent/persistent laryngeal cancer. *Laryngoscope.* 2006;116:1864–6.
44. Liauw SL, Mancuso AA, Amdur RJ, et al. Postradiotherapy neck dissection for lymph node-positive head and neck cancer: the use of computed tomography to manage the neck. *J Clin Oncol.* 2006;24:1421–7.
45. Ojiri H, Mendenhall WM, Stringer SP, et al. Post-RT CT results as a predictive model for the necessity of planned post-RT neck dissection in patients with cervical metastatic disease from squamous cell carcinoma. *Int J Radiat Oncol Biol Phys.* 2002;52:420–8.
46. de Bree R, van der Putten L, Brouwer J, et al. Detection of locoregional recurrent head and neck cancer after (chemo) radiotherapy using modern imaging. *Oral Oncol.* 2009;45:386–93.
47. Rogers JW, Greven KM, McGuirt WF, et al. Can post-RT neck dissection be omitted for patients with head-and-neck cancer who have a negative PET scan after definitive radiation therapy? *Int J Radiat Oncol Biol Phys.* 2004;58:694–7.
48. McCollum AD, Burrell SC, Haddad RI, et al. Positron emission tomography with 18F-fluorodeoxyglucose to predict pathologic response after induction chemotherapy and definitive chemoradiotherapy in head and neck cancer. *Head Neck.* 2004;26:890–6.
49. Brkovich VS, Miller FR, Karnad AB, et al. The role of positron emission tomography scans in the management of the N-positive neck in head and neck squamous cell carcinoma after chemoradiotherapy. *Laryngoscope.* 2006;116:855–8.
50. Porceddu SV, Jarmolowski E, Hicks RJ, et al. Utility of positron emission tomography for the detection of disease in residual neck nodes after (chemo)radiotherapy in head and neck cancer. *Head Neck.* 2005;27:175–81.
51. Yao M, Smith RB, Graham MM, et al. The role of FDG PET in management of neck metastasis from head-and-neck cancer after definitive radiation treatment. *Int J Radiat Oncol Biol Phys.* 2005;63:991–9.
52. Nayak JY, Walvekar R, Andrade RS, et al. Deferring planned neck dissection following chemoradiation for stage IV head and neck cancer: the utility of PET-CT. *Laryngoscope.* 2007;117:2129–34.
53. Isles MG, McConkey C, Mehanna HM. A systematic review and meta-analysis of the role of positron emission tomography in the follow up of head and neck squamous cell carcinoma following radiotherapy or chemoradiotherapy. *Clin Otolaryngol.* 2008;33:210–22.
54. Vandecaveye V, de Keyser F, Nuyts S, et al. Detection of head and neck squamous cell carcinoma with diffusion weighted MRI after (chemo)radiotherapy: correlation between radiologic and histopathologic findings. *Int J Radiat Oncol Biol Phys.* 2007;67:960–71.
55. Frank DK, Hu KS, Culliney BE, et al. Planned neck dissection after concomitant radiochemotherapy for advanced head and neck cancer. *Laryngoscope.* 2005;115:1015–20.
56. Sewall GK, Palazzi-Churas KL, Richards GM, et al. Planned postradiotherapy neck dissection: rationale and clinical outcomes. *Laryngoscope.* 2007;117:121–8.
57. Narayan K, Crane CH, Kleid S, et al. Planned neck dissection as an adjunct to the management of patients with advanced neck disease treated with definitive radiotherapy: for some or for all? *Head Neck.* 1999;21:606–13.
58. Weisman RA, Robbins KT. Management of the neck in patients with head and neck cancer treated by concurrent chemotherapy and radiation. *Otolaryngol Clin North Am.* 1998;31:773–84.
59. Robbins KT, Wong FS, Kumar P, et al. Efficacy of targeted chemoradiation and planned selective neck dissection to control bulky nodal disease in advanced head and neck cancer. *Arch Otolaryngol Head Neck Surg.* 1999;125:670–5.
60. Corry J, Smith JG, Peters LJ. The concept of a planned neck dissection is obsolete. *Cancer J.* 2001;7:472–4.
61. Pellitteri PK, Ferlito A, Rinaldo A, et al. Planned neck dissection following chemoradiotherapy for advanced head and neck cancer: is it necessary for all? *Head Neck.* 2006;28:166–75.
62. Grabenbauer GG, Rodel C, Ernst-Stecken A, et al. Neck dissection following radiochemotherapy of advanced head and neck cancer—for selected cases only? *Radiother Oncol.* 2003;66:57–63.
63. Gokhale AS, Lavertu P. Surgical salvage after chemoradiation of head and neck cancer: complications and outcomes. *Curr Oncol Reports.* 2001;3:72–6.
64. Agra IM, Carvalho AL, Pontes E, et al. Postoperative complications after en bloc salvage surgery for head and neck cancer. *Arch Otolaryngol Head Neck Surg.* 2003;129:1317–21.
65. Mendenhall WM, Million RR, Cassisi NJ. Squamous cell carcinoma treated with radiation therapy: the role of neck dissection for clinically positive neck nodes. *Int J Radiat Oncol Biol Phys.* 1986;12:733–40.
66. Lavertu P, Adelstein DJ, Saxton JP, et al. Management of the neck in a randomized trial comparing concurrent chemotherapy and radiotherapy with radiotherapy alone in resectable stage III and IV squamous cell carcinoma head and neck cancer. *Head Neck.* 1997;19:559–66.
67. Clayman GL, Johnson II CJ, Morrison W, et al. The role of neck dissection after chemoradiotherapy for oropharyngeal cancer with advanced nodal disease. *Arch Otolaryngol Head Neck Surg.* 2001;127:135–9.
68. Argiris A, Stenson KM, Brockstein BE, et al. Neck dissection in the combined-modality therapy of patients with locoregionally advanced head and neck cancer. *Head Neck.* 2004;26:447–55.
69. Goguen LA, Posner MR, Tishler RB, et al. Examining the need for neck dissection in the era of chemoradiation therapy for advanced

- head and neck cancer. *Arch Otolaryngol Head Neck Surg.* 2006;132:526–31.
70. Sanguineti G, Corvo R, Benasso M, et al. Management of the neck after alternating chemoradiotherapy for advanced head and neck cancer. *Head Neck.* 1999;21:223–8.
 71. Wolf GT, Fisher SG. Effectiveness of salvage neck dissection for advanced regional metastases when induction chemotherapy and radiation are used for organ preservation. *Laryngoscope.* 1992;102:934–9.
 72. Ojiri H, Mancuso AA, Mendenhall WM, et al. Lymph nodes of patients with regional metastases from head and neck squamous cell carcinoma as a predictor of pathologic outcome: size changes at CT before and after radiation therapy. *AJNR Am J Neuroradiol.* 2002;23:1627–31.
 73. Putten L van der, Broek GB van den, Bree R de, et al. Effectiveness of salvage selective and modified radical neck dissection for regional pathological lymphadenopathy after chemoradiation. *Head Neck.* 2009 Jan 8. [Epub ahead of print].
 74. Wei WI. Salvage neck dissection after radiation and/or chemotherapy. *Oper Tech Otolaryngol.* 2004;15:269–72.
 75. Robbins KT, Doweck I, Samant S, Vieira F. Effectiveness of super-selective and selective neck dissection for advanced nodal metastases after chemoradiation. *Arch Otolaryngol Head Neck Surg.* 2005;131:965–9.
 76. Stenson KM, Huo D, Blair E, Cohen EE, Argiris A, Haraf DJ, et al. Planned post-chemoradiation neck dissection: significance of radiation dose. *Laryngoscope.* 2006;116:33–6.
 77. Dias FL, Kligerman J, Matos de Sã C, et al. Elective neck dissection versus observation in stage I squamous cell carcinoma of the tongue and floor of mouth. *Otolaryngol Head Neck Surg.* 2001;125:23–9.
 78. Capote A, Escorial V, Muñoz-Guerra MF, et al. Elective neck dissection in early-stage oral squamous cell carcinoma – does it influence recurrence and survival? *Head Neck.* 2007;29:3–11.
 79. Yuen APW, Wei WI, Wong YM, et al. Elective neck dissection versus observation in the treatment of early oral tongue carcinoma. *Head Neck.* 1997;19:583–8.
 80. Yip NW, Patel SG, Rhys-Evans PH, Breach NM. Management of the N0 neck in early cancer of the tongue. *Clin Otolaryngol.* 1999;24:75–9.
 81. August M, Gianetti K. Elective neck irradiation versus observation of the clinically negative neck of patients with oral cancer. *J Oral Maxillofac Surg.* 1996;54:1050–5.
 82. Keski-Säntti H, Atula T, Törnwall J, et al. Elective neck treatment versus observation in patients with T1/T2 N0 squamous cell carcinoma of the oral tongue. *Oral Oncol.* 2006;42:96–101.
 83. McGuirt WF, Johnson JT, Myers EN, et al. Floor of mouth carcinoma; management of the clinically negative neck. *Arch Otolaryngol Head Neck Surg.* 1995;121:278–82.
 84. Kligerman J, Lima RA, Soares JR, et al. Supraomohyoid neck dissection in the treatment of T1/T2 squamous cell carcinoma of oral cavity. *Am J Surg.* 1994;168:391–4.
 85. Kowalski LP. Results of salvage treatment of the neck in patients with oral cancer. *Arch Otolaryngol Head Neck Surg.* 2002;128:58–62.
 86. Fakih AR, Rao RS, Borges AM, et al. Elective versus therapeutic neck dissection in early carcinoma of the tongue. *Am J Surg.* 1989;158:309–13.
 87. Vandenbrouck C, Sancho-Garnier H, Chassagen D, et al. Elective versus therapeutic neck dissection in epidermoid carcinoma of the oral cavity: results of a randomized clinical trial. *Cancer.* 1980;46:386–90.
 88. Franceschi D, Gupta R, Spiro RH, et al. Improved survival in the treatment of squamous cell carcinoma of the oral tongue. *Am J Surg.* 1993;166:360–5.
 89. Khafif A, Lopez-Garza JR, Medina JE. Is dissection of level IV necessary in patients with T1-T3N0 tongue cancer? *Laryngoscope.* 2001;111:1088–90.
 90. Duvvuri U, Simental AA, D'Angelo G, et al. Elective neck dissection and survival in patients with squamous cell carcinoma of the oral cavity and oropharynx. *Laryngoscope.* 2004;114:2228–34.
 91. Yuen AP, Ho CM, Chow TL, et al. Prospective randomized study of selective neck dissection versus observation for N0 neck of early tongue carcinoma. *Head Neck.* 2009;31:765–72.
 92. D'Cruz AK, Siddachari RC, Walvekar RR, et al. Elective neck dissection for the management of the N0 neck in early cancer of the oral tongue: need for a randomized controlled trial. *Head Neck.* 2009;31:618–24.
 93. Weiss MH, Harrison LB, Isaacs RS. Use of decision analysis in planning a management strategy for the stage N0 neck. *Arch Otolaryngol Head Neck Surg.* 1994;120:699–702.
 94. Sparano A, Weinstein G, Chalian A, et al. Multivariate predictors of occult neck metastasis in early oral tongue cancer. *Otolaryngol Head Neck Surg.* 2004;131:472–6.
 95. Kurokawa H, Yamashita Y, Takeda S, et al. Risk factors for late cervical lymph node metastases in patients with stage I and II carcinoma of the tongue. *Head Neck.* 2002;24:731–6.
 96. Sheahan P, O'Keane C, Sheahan JN, et al. Effect of tumour thickness and other factors on the risk of regional disease and treatment of the N0 neck in early oral squamous cell carcinoma. *Clin Otolaryngol.* 2003;28:461–71.
 97. Lim SC, Zhang S, Ishii G, et al. Predictive markers for late cervical metastasis in stage I and II invasive squamous cell carcinoma of the oral tongue. *Clin Cancer Res.* 2004;10:166–72.
 98. Shingaki S, Suzuki I, Nakajima T, et al. Evaluation of histopathological parameters in predicting cervical lymph node metastasis of oral and oropharyngeal carcinomas. *Oral Surg Oral Med Oral Pathol.* 1988;66:683–8.
 99. Borgmeester MC, van den Brekel MWM, van Tinteren H, et al. Ultrasound-guided aspiration cytology for the assessment of the clinically N0 neck: factors influencing its accuracy. *Head Neck.* 2008;30:1505–13.
 100. Nieuwenhuis EJ, Castelijns JA, Pijpers R, et al. Wait-and-see policy for the N0 neck in early-stage oral and oropharyngeal squamous cell carcinoma using ultrasonography-guided cytology: is there a role for identification of the sentinel node? *Head Neck.* 2002;24:282–9.
 101. Mendenhall WM, Million RR, Cassisi NJ, et al. Elective neck irradiation in squamous-cell carcinoma of the head and neck. *Head Neck Surg.* 1980;3:15–20.
 102. de Bondt RBJ, Nelemans PJ, Hofman PAM, et al. Detection of lymph node metastases in head and neck cancer: a meta-analysis comparing US, USgFNAC, CT and MR imaging. *Eur J Radiol.* 2007;64:266–72.
 103. Kyrzas PA, Evangelou E, Denaxa-Kyza D, et al. 18F-Fluorodeoxyglucose positron emission tomography to evaluate cervical node metastases in patients with head and neck squamous cell carcinoma: a meta-analysis. *J Natl Cancer Inst.* 2008;100:712–20.
 104. Brouwer J, de Bree R, Comans EFI, et al. Positron emission tomography using [18F]fluorodeoxyglucose (FDG-PET) in the clinically negative neck; is it likely to be superior. *Eur Arch Otorhinolaryngol.* 2004;261:479–83.
 105. Wensing BM, Vogel WV, Marres HAM, et al. FDG-PET in the clinically negative neck in oral squamous cell carcinoma. *Laryngoscope.* 2006;116:809–13.
 106. Koch WM, Choti MA, Civelek C, et al. Gamma probe-directed biopsy of the sentinel lymph node in oral squamous cell carcinoma. *Arch Otolaryngol Head Neck Surg.* 1998;124:455–9.
 107. Alex JC, Sasaki CT, Krag DN, et al. Sentinel lymph node radiolocalization in head and neck squamous cell carcinoma. *Laryngoscope.* 2000;110:198–203.

108. Shoaib T, Soutar DS, MacDonald DG, et al. The accuracy of head and neck carcinoma sentinel lymph node biopsy in the clinically N0 neck. *Cancer*. 2001;91:2077–83.
109. Stoeckli SJ, Steinert H, Pfaltz M, et al. Sentinel node evaluation in squamous cell carcinoma of the head and neck. *Otolaryngol Head Neck Surg*. 2001;125:221–6.
110. Ross GL, Shoaib T, Soutar DS, et al. The First International Conference on Sentinel Node Biopsy in Mucosal Head and Neck Cancer and adoption of a multicenter trial protocol. *Ann Surg Oncol*. 2002;9:406–10.
111. Ross GL, Soutar DS, MacDonald DG, et al. Sentinel node biopsy in head and neck cancer: preliminary results of a multicenter trial. *Ann Surg Oncol*. 2004;11:690–6.
112. Paleri v, Rees G, Allurendran P, et al. Sentinel node biopsy in squamous cell cancer of the oral cavity and oral pharynx: a diagnostic meta-analysis. *Head Neck*. 2005;27:739–47.
113. Werner JA, Dünne AA, Ramaswamy A, et al. Sentinel node detection in N0 cancer of the pharynx and larynx. *Br J Cancer*. 2002;87:711–5.
114. Brizel DM, Prosnitz RG, Hunter S, et al. Necessity for adjuvant neck dissection in setting of concurrent chemotherapy for advanced head and neck cancer. *Int J Radiat Oncol Biol Phys*. 2004;58:1418–23.
115. Van Wilgen CP, Dijkstra PU, Van der Laan BFAM, et al. Shoulder and neck morbidity in quality of life after surgery for head and neck cancer. *Head Neck*. 2004;26:839–44.
116. Rogers SN, Ferlito A, Pellitteri PK, et al. Quality of life following neck dissections. *Acta Otolaryngol*. 2004;124:231–16.
117. Van Wilgen CP, Dijkstra PU, Van der Laan BFAM, et al. Morbidity of the neck after head and neck cancer therapy. *Head Neck*. 2004;26:785–91.
118. Boca E. Functional neck dissection: an evaluation and review of 843 cases. *Laryngoscope*. 1984;94:942–5.
119. Remmler D, Byers R, Scheetz J. A study of shoulder disability resulting from radical and modified neck dissections. *Head Neck Surg*. 1986;8:280–6.
120. El Ghani F, van den Brekel MWM, de Goede CJT, et al. Shoulder function and patient well-being after various types of neck dissections. *Clin Otolaryngol*. 2002;27:403–8.
121. Erisen L, Basel B, Irdesei J, et al. Shoulder function after accessory nerve-sparing neck dissections. *Head Neck*. 2004;26:967–71.
122. Medina J. Supraomohyoid neck dissection: rational, indications and surgical technique. *Head Neck*. 1989;11:111–22.
123. van Wouwe M, de Bree R, Kuik DJ, et al. Shoulder morbidity after non-surgical treatment of the neck. *Radiother Oncol*. 2009;90:296–01.

Chapter 35

Postoperative Management of High-Risk Resectable Head and Neck Cancer

Jay S. Cooper

Abstract Head and neck cancers are heterogeneous and require therapies of different intensities. Some “low risk” cancers require no additional treatment after surgery, some “medium risk” require additional radiation therapy and, we recently have come to learn, some “high risk” require postoperative concurrent chemotherapy-enhanced radiation therapy.

This chapter describes how risk currently is defined, how therapy can be adapted to match that risk, the improvements in outcome associated with intensified therapy and the related toxicity cost. It reviews both phase II and phase III data and describes trials that currently are maturing or being conducted that may provide clues to better risk-adapted strategies in the future.

Keywords Head and neck cancer • Surgery • Radiation therapy • Chemotherapy • Chemoradiotherapy • High risk • Risk-adapted therapy • RTOG • EORTC • Package time • Altered fractionation • Biologic agents

Introduction

Head and neck cancers traditionally have been treated by surgery, radiation therapy or, when more locally and/or regionally advanced, by a combination of surgery and radiation therapy. There has been a general appreciation of the factors that pose a higher risk of recurrence following surgery alone and these factors generally have allowed clinicians to apply postoperative irradiation selectively to appropriate cases. Cancers that are low stage, not involving the surgical margins, not invading regional lymph nodes and without perineural invasion generally are identified as tumors that can be treated successfully by surgery alone. But, what is the evidence-based proof that we can appropriately predict risk?

J.S. Cooper (✉)
Maimonides Cancer Center, 6300 8th Avenue,
Brooklyn, NY 11220, USA
e-mail: jcooper@maimonidesmed.org

Predicting Postoperative Risk

In 2001, Ang et al. [1] reported a prospective trial in which patients who had carcinomas of the head and neck that had all of the “low-risk” features described above (excluding tumors arising in the oral cavity as they were considered to be of higher risk) were treated solely by surgery. The 5-year actuarial locoregional control rate was 90% and the 5-year actuarial survival was 83%. Consequently, it is unlikely that adding more therapy to this group as a whole would improve outcome. Whether or not we will yet discover a means of identifying beforehand the 10% of patients in this group who currently are destined to suffer locoregional recurrence of their disease and whether or not we will be able to change their outcome by changing the manner in which they are treated is open to speculation.

However, for tumors that display features that suggest more aggressive behavior a combined modality approach generally is warranted, and precisely how much more aggressive the regimen should be is the subject of current investigation. In addition, the precise definition of high risk is evolving and likely will continue to do so as alternatives of therapy are investigated and better understood.

Traditionally, combined modality (surgery and radiation therapy) has consisted of definitive surgery followed by adjuvant radiation therapy. Between March 1973 and June 1979, the Radiation Therapy Oncology Group (RTOG) conducted a prospective randomized trial (RTOG 7303) that included patients who had advanced operable squamous cell carcinoma of the head and neck (oral cavity, oropharynx, supraglottic larynx, or hypopharynx) whose tumors were randomly allocated to receive either preoperative radiation therapy (5,000 cGy) or postoperative radiation therapy (6,000 cGy) [2, 3]. With follow-up ranging from 9 to 15 years (only 7.6% of patients were lost to follow-up before 7 years) locoregional control was significantly better for the patients treated with postoperative radiation therapy than for preoperative radiation therapy ($p=0.04$), but absolute survival was not ($p=0.15$). Rates of severe surgical and radiation therapy complications were similar overall. Within 2 years

of treatment, 31% of the patients who were treated with preoperative radiation therapy experienced local recurrence versus 18% of the patients who received postoperative radiation therapy. Although this data cannot discriminate between the effects of timing versus the greater dose given postoperatively, concerns about inducing more complications following 6,000 cGy delivered preoperatively effectively established 6,000 cGy postoperative irradiation as the gold standard of care for high-risk disease. Interestingly, once 2 years following treatment had passed, distant metastases and second primaries became the most common modes of treatment failure, particularly among the patients who were treated with postoperative radiation therapy. These late failures, plus an increased number of unrelated deaths, erased a potential advantage in absolute survival for postoperative radiation therapy that was suggested by early analyses of this trial. This prompted the authors to comment presciently that “additional therapeutic intervention is required beyond surgery and postoperative irradiation to impact significantly upon survival.”

As part of the above referenced trial by Ang et al. [1], patients who had some of the mentioned risk factors were further grouped into an intermediate risk group and a high-risk group. Intermediate risk was defined by the presence of any one (and only one) of the following factors: (1) microscopically involved surgical resection margins, (2) two or more involved lymph nodes, (3) a lymph node greater than 3 cm in diameter, (4) perineural invasion, or (5) cancer arising in the oral cavity. These patients uniformly were treated postoperatively with 5,760 cGy delivered in 32 fractions (of 180 cGy each) over 6.5 weeks. Their 5-year actuarial locoregional control rate was 94% and their 5-year actuarial overall survival rate was 66%. Although they presumably had more aggressive disease than did the patients triaged to the low-risk group, their local and regional control was just as good, presumably because of the added locoregional control from postoperative radiation therapy. On the other hand, their overall survival was considerably worse, suggesting that postoperative radiation therapy, as it was given in that trial, could not compensate totally for more aggressive phenotype tumors, thereby corroborating the investigators' ability to group tumors by differing levels of risk. However, the system employed in the MD Anderson trial clearly is not the only way to identify risk.

The identification of “high-risk” tumors can rely on a variety of systems ranging from the imprecise and impossible to test rigorously concept of “clinical experience” to rigidly defined mathematical operations, such as recursive partitioning analysis (RPA). And, like most models they are only approximations of reality, but to the degree that they provide new insights into the triage or therapy of malignancies are useful.

One such model comes from the “control arm” of Inter-group protocol 0034 in which all patients who had locally advanced, but clinically completely resected, squamous cell cancers of the oral cavity, oropharynx, hypopharynx, or larynx, which were prospectively treated with surgery and postoperative irradiation (and compared to an experimental arm including interdigitated, sequential chemotherapy) [4]. Retrospectively, the outcome data for the patients treated by surgery and postoperative radiation therapy (without chemotherapy) was sorted into three groups based on presumed markers of risk. Patients assigned to Group 1 had fewer than two involved lymph nodes, no extracapsular spread of tumor and histologically uninvolved surgical margins. Patients assigned to Group 2 had at least two involved nodes and/or extracapsular spread of tumor, but histologically uninvolved surgical margins. Patients assigned to Group 3 had histologically involved surgical margins. At 5 years, the locoregional control rate in Group 1 was 83%, in Group 2 was 70%, and in Group 3 was 38%. Similarly, at 5 years, the overall survival rate in Group 1 was 53%, in Group 2 was 32%, and in Group 3 was 26%.

Others have looked at institutional databases for similar models. Rosenthal et al. [5] performed a retrospective review of 208 consecutive patients who had squamous cell carcinomas of the head and neck that were treated with surgery and postoperative radiation therapy between 1992 and 1997 at the Hospital of the University of Pennsylvania. Patients whose tumors involved two or more regional lymph nodes, had extended outside a lymph node capsule and/or microscopically shown to be within 5 mm of the resection margins were considered high risk. Patients whose tumors had none of these features but did have T4 disease, perineural or perivascular disease, invasion of cartilage, bone, or soft tissues by the primary tumor, a 3-cm or greater involved lymph node, and/or required an emergency tracheostomy were considered intermediate risk. The 2-year overall survival rate of the high-risk group was 60% as compared to 86% in the intermediate-risk group. Similarly, the 2-year locoregional control rate of the high-risk group was 74% as compared to 91% in the intermediate-risk group.

Le Tourneau et al. [6] conducted a similar retrospective analysis of the overall survival of 621 consecutive patients who had squamous cell carcinomas arising in the oral cavity, oropharynx, larynx, or hypopharynx that were resected by one surgical team between 1990 and 1997 at the Sainte-Barbe Clinic in Strasbourg, France. They concluded that tumor volume, pT and pN classification, the number of involved lymph nodes, and the presence of extracapsular extension (ECE) were significantly associated with overall survival.

Others have approached the assignment of risk through predefined mathematical models. Langendijk et al. [7] used RPA to evaluate risk factors in 801 patients who had

squamous cell carcinomas of the head and neck that were treated by primary surgery and postoperative radiation therapy. RPA created three distinct groups. Class I (the authors deemed them intermediate risk) consisted of patients who had no N3 lymph nodes, free surgical margins (>5 mm), and no ECE of disease. RPA Class II (high risk) consisted of patients who had only one lymph node that had ECE or had T1, T2, or T4 tumors with close or positive surgical margins. RPA Class III (very high risk) consisted of patients who had a N3 nodal disease, at least two lymph nodes with ECE and/or a T3 tumor with close or positive surgical margins. The 5-year LRC rate was 92, 78, and 58% in RPA Class I, II, and III, respectively ($p < 0.0001$). Similarly, the 5-year overall survival rate was 67, 50, and 36%, in RPA Class I, II, and III, respectively ($p < 0.0001$). The authors then took their analysis one step further [8] by validating the RPA derived definitions of risk in a new patient population consisting of 780 head and neck cancer patients who were treated at eight Dutch centers. These results closely mirrored their previous analysis; the 5-year LRC rate was 82, 75, and 36% and the 5-year overall survival rate was 60, 50, and 36%, in RPA Class I, II, and III, respectively ($p < 0.0001$ for each comparison).

Risk-Adapted Strategies

The data discussed thus far suggest that the relative risk posed by individual head and neck tumors can be assessed, albeit imperfectly, by different methods that yield relatively similar results. This ability leads to the question, “can postoperative therapy be adapted to match the inherent nature of the tumor?” More specifically, can postoperative radiation therapy be intensified to counteract more aggressive tumors?

Because the biologic effect of radiation in a given tissue or tumor can be moderated by the total dose, the dose per fraction, and the total time over which the radiation is delivered, physicians at the University of Pennsylvania [5] sought to examine the influence of the “package time” (the time from surgery to the completion of radiation therapy) on outcome. In a retrospective analysis, using 100 days as their cut-point, they observed that locoregional control at 2 years dropped from 85 to 72% in patients who had shorter versus longer package times and that 2-year overall survival similarly dropped from 74 to 66%. Huang et al. [9] conducted a review of the literature to identify studies that described an association between delay in starting radiation therapy and the probability of local control and/or survival. They found data in seven studies that included a total of 851 head and neck cancers which demonstrated worse locoregional control when radiation therapy was started more than 6 weeks

after surgery. In contrast, they could not establish a connection between delay and an effect on the probability of metastasis or survival. Only two studies addressed the relationship between delay and survival: in one [10] delay was significantly associated with poorer survival, in the other [11] the trend was in the same direction but the outcomes were not significantly different.

So, is it possible to counteract the deleterious effect of increasing package time? At least to some degree, the answer is yes.

While the duration from surgery to the initiation of radiation therapy can be delayed by factors beyond the control of the treating physicians, such as infection, slow wound healing, etc., the duration of radiation therapy can be shortened at the potential price of increased toxicity. In the previously mentioned trial conducted by Ang et al. [1], patients who had high-risk tumors volunteered to be assigned randomly to postoperative radiation therapy of differing durations, but identical total doses. In one group, patients received 6,300 cGy in 35 fractions delivered once daily over a total of 7 weeks. In the other group, patients also received 6,300 cGy in 35 fractions but accelerated into only 5 weeks, delivered once daily for the first 3 weeks and then delivered twice daily (five times per week) for the final 2 weeks, thereby shortening the duration of radiation therapy and the total package time by 2 weeks. When the outcome of all participants was measured by local control or overall survival, the two groups were not significantly different. However, the authors also examined the outcome within each radiation regimen by separating patients into two subgroups based on the length of time from surgery to the start of radiation (defined as less than vs. equal to or greater than the median interval). In the group of patients who received accelerated postoperative radiation therapy over 5 weeks, there was no significant difference in either locoregional control or survival between the subgroups who started radiation therapy sooner versus later. In contrast, patients who were assigned to 7 weeks of treatment, experienced significantly worse locoregional control and significantly worse survival rates if they started radiation therapy later rather than sooner. These findings strongly imply that the accelerated 5-week regimen can compensate, at least to some degree, for the greater risk inherent in prolonged package times by shortening the package time by 2 weeks and/or by applying biologically more intense therapy (Table 35.1).

Biologically Intensified Radiation Therapy

Could the biologic effect of radiation therapy be augmented in some other manner? By the mid-1980s chemotherapy routinely was being used to treat metastases from head and

neck cancers and the possibility of using both chemotherapy and radiation therapy in the postoperative setting was ready to be tested. However, it was not clear initially if the augmentation of the biologic effect of radiation therapy by chemotherapy would be greater in the tumor or in the normal tissues. Consequently, sequential application of postoperative chemotherapy followed by radiation therapy was tested first in the hope that it would not be unacceptably toxic. Intergroup trial #0034 (also known as RTOG 8503) [12] was a prospective randomized comparison of surgery followed by postoperative irradiation versus surgery followed by chemotherapy (three cycles of *cis*-platinum and 5-FU) followed by radiation therapy for locally advanced, but operable, squamous cell carcinomas of the head and neck. Although tumors were categorized as high risk (treated with 60 Gy) or low risk (treated with 50–54 Gy) and the treatment volumes depended on the size of the surgical margin, the presence or absence of extracapsular nodal extension, and/or the presence or absence of carcinoma-in situ at the surgical margins, the radiation therapy design was identical in both arms of the trial; the major difference was the interposition of chemotherapy with its attendant delay of radiation therapy. With a total of 442 analyzable patients and median follow-

up of 45.7 months the locoregional failure rate was 29% for RT and 26% for chemotherapy followed by radiation therapy and the 4-year actuarial survival rate was 44% for RT and 48% for chemotherapy followed by radiation therapy, neither comparison being significantly different. On the other hand, chemotherapy did not prevent the subsequent delivery of radiotherapy raising the possibility of further intensification (Table 35.2).

Still looking to find a way to use drugs to intensify the biologic effect of radiation therapy and buoyed by the absence of unacceptable toxicity when chemotherapy was added in sequence, drugs were sought that might provide beneficial interactions with radiation therapy if administered concurrently. Based on the synergy seen in vitro [13–16], the RTOG created and conducted trial 88-24 [17], a single arm registry trial that tested the combination of concurrent cisplatin (100 mg/m² i.v. every 21 days) and 60 Gy (in 30 fractions over 6 weeks) for patients who had resected stage IV cancers of the head and neck or any stage cancer of the head and neck that microscopically involved the margins of resection. As this was a single arm trial, its results were compared to the control (surgery follow by radiation therapy) arm of the just described RTOG 8503 trial [18]. At 3 years of follow-up, the locoregional recurrence rate in patients who received surgery and radiation therapy (RTOG 8503) was 37%, but when concurrent chemotherapy was added the rate was 20% (RTOG 8824). This suggested that the concurrent administration of cisplatin with postoperative radiation therapy might decrease the locoregional recurrence rate for advanced resectable head and neck cancers. In turn, locoregional control might influence survival since the 3-year overall survival after surgery and radiation therapy was 42% versus 47% when concurrent chemotherapy was added.

Others tested other drugs and other delivery schedules. Haffty et al. [19] used mitomycin C as an adjunct to postoperative radiation therapy. In 113 patients followed for 93 months, the authors observed 12 local and 8 regional recurrences in patients treated by postoperative radiation therapy alone arm compared to 0 local and 5 regional recurrences in the postoperative radiation therapy plus mitomycin C group. However, overall survival was not significantly

Table 35.1 Simplified scheme of risk by author [and reference]; see text for details

	Ang et al. [1]	IGRP 0034 [4]	Rosenthal et al. [5]	LeTourneau et al. [6]	Langendijk et al. [7]
2+ Invaded nodes	I	I	H	H	
Extra-capsular extension	I	I	H	H	I
Involved margin	I	H	H		I
N3 disease				H	H
Node 3 cm+	I	I			
Oral cavity primary	I				
Perineural invasion	I		I		
Perivascular			I		
T4 disease			I	H	
Tumor volume				H	

If more than one intermediate risk feature is present, consider the tumor high risk

I intermediate risk, *H* high risk

Table 35.2 Attempts at biologically intensifying radiation therapy by author [and reference]

	Agent #1	Agent #2	Timing	Outcome
IGRP 0034 [12]	Cisplatin	5-FU	Sequential	No significant improvement
RTOG 88-24 [17]	Cisplatin		Concurrent	Possible increase in LR control
Haffty et al. [19]	Mitomycin C		Concurrent	Possible increase in LR control
Bachaud et al. [20]	Cisplatin		Concurrent	Significant increase in LR control and OS
Smid et al. [21]	Mitomycin C	Bleomycin	Concurrent	Significant increase in LR control and OS
Racadot et al. [22]	Carboplatin		Concurrent	No significant improvement
Cooper et al. [23]	Cisplatin		Concurrent	Significant increase in LR control
Bernier et al. [24]	Cisplatin		Concurrent	Significant increase in LR control and OS

LR locoregional, *OS* overall survival

different between the two groups. Bachaud et al. [20] tested concurrent cisplatin and postoperative radiation therapy in patients who had Stage III or IV squamous cell carcinoma of the head and neck, but used an intensifying daily dose of radiation (1.7 Gy for the first 54 Gy and 1.8–2 Gy until the completion of the treatment) and administered the cisplatin on a once weekly schedule (50 mg i.v.). Based on 44 patients treated by postoperative irradiation only and 39 treated by irradiation with chemotherapy the authors concluded that the concomitant use of weekly cisplatin and postoperative radiation (as was given in their trial) significantly improved locoregional control (59% vs. 77%) and overall survival (36% vs. 13% at 5 years). Smid et al. [21] randomly assigned 114 eligible patients who had Stage III or IV squamous cell head and neck carcinoma to receive postoperative radiation therapy alone (56–70 Gy) or the same regimen plus concurrent bleomycin (5 mg twice weekly for 7 weeks), mitomycin C (15 mg/m² given one time after 10 Gy), and nicotinamide (225 mg daily). At 2 years, patients treated with chemoradiotherapy had statistically significantly better locoregional control (86% vs. 69%) and overall survival (74% vs. 64%). Furthermore, subgroup analysis suggested that the benefit from concurrent chemotherapy occurred only in those patients whose tumors exhibited high-risk factors (extracapsular tumor spread, perineural, lymphatic and/or venous invasion, micro and/or macroscopic residual disease). Racadot et al. [22] performed a prospective randomized trial in 144 “node-positive” head and neck cancers consisting of surgery and postoperative radiation therapy versus the same treatment plus carboplatin (50 mg/m² administered by i.v. infusion twice weekly). At a median follow-up of 106 months, the 2-year locoregional control rate was 68% in the radiotherapy group versus 73% in the chemoradiotherapy group ($p=0.26$). The authors concluded that twice-weekly carboplatin concomitant to postoperative radiotherapy did not improve local control or overall survival. Thus the concurrent addition of a variety of chemotherapies to postoperative radiation therapy had shown some promise, but was not uniformly beneficial.

In 2004, the simultaneous publication [23, 24] of two [European Organization for Research and Treatment of Cancer (EORTC) and RTOG] relatively large, independent, multicenter, prospective randomized clinical trials testing postoperative radiation therapy (60–66 Gy) with or without concurrent cisplatin (100 mg/m² i.v. days 1, 22, and 43) more firmly established the potential benefit of concurrent therapy. Conducted on opposite sides of the Atlantic Ocean, the trials were remarkably similar in design and conclusions. Both trials [23, 24] included completely resected “high-risk” head and neck tumors and both demonstrated significantly improved local control and disease-free survival associated with the concurrent postoperative use of cisplatin and radia-

tion therapy. The EORTC trial also demonstrated significantly improved overall survival associated with chemoradiotherapy while the RTOG trial showed a trend in the same direction that was not statistically significant ($p=0.19$).

However, differences exist between the trials and it may be that the differences are as instructive as the similarities. In the EORTC trial, “high-risk” eligibility was defined as the presence of any of the following features: microscopically involved surgical margins, extranodal spread of disease, tumors arising in the oral cavity or oropharynx with spread to levels 4 and/or 5, perineural disease. In the RTOG trial, “high-risk” was also defined by the presence of microscopically involved surgical margins and/or extranodal spread of disease, and also was defined by the presence of tumor in two or more lymph nodes, but not by tumors arising in the oral cavity or oropharynx with spread to levels 4 and/or 5, or perineural disease. Could these differences account for the different overall survival outcomes?

To answer that question the data from both the trials were pooled and analyzed [25]. In essence, the data clearly indicated that the benefit of concurrent chemotherapy accrued only in those patients who would have been eligible for both trials (i.e., patients who had microscopically involved surgical margins and/or extranodal spread of disease) but not in those patients who were included in either trial based on other criteria.

While these two trials help define a group of patients who potentially could derive benefit from concurrent postoperative chemotherapy-enhanced radiotherapy as was administered in these trials, they also help clarify the price such patients pay in toxicity, mindful of the reality that only relatively fit patients were included. In the RTOG trial, grade 3 or greater acute adverse effects (mostly hematologic, mucous-membrane, and/or gastrointestinal) more than doubled [34% of patients who received radiotherapy alone vs. 77% who received concurrent combined therapy ($p<0.001$)]. Similarly, in the EORTC trial, the cumulative incidence of grade 3 or greater acute functional mucosal adverse effects doubled (21% for radiation alone vs. 41% for concurrent therapy, $p=0.001$).

And, the traditional method of adverse events reporting used in these trials may underestimate the true burden of toxicity since the maximum grade system that was used does not consider how often multiple, severe toxicities were seen in one patient. For example, if one patient experienced a grade 3 mucosal toxicity and another patient experienced grade 3 mucosal toxicity, grade 3 neurologic toxicity, and grade 3 hematologic toxicity, in these and most analyses they are both considered alike and reported as having grade 3 toxicity even though the second patient surely is suffering more. Trotti et al. [26] have calculated that of the 206 patients who received concurrent chemoradiotherapy as

part of RTOG 9501 and had 155 acute grade 3–4 events reported by the maximum grade methodology, another 173 events of the total burden of 328 events were overlooked. Similarly 31 of the 85 total late grade 3–4 events were overlooked. They therefore have proposed a new method for calculating and presenting the summary of adverse reactions that seeks not to overlook multiple toxicity events in the aggregation process. According to this methodology, when compared to the acute toxicity of postoperative radiation therapy alone (calculated as 100 U), the addition of concurrent cisplatin, as it was used in the EORTC and RTOG trials, increases the acute toxicity burden more than threefold to 320 U. Similarly, the late toxicity burden increases from 100 to 170 U. Thus it seems fair to conclude that the benefit of concurrent chemotherapy-enhanced radiation therapy comes at a price and, outside of a clinical study, should be offered only to those patients who have microscopically involved surgical margins and/or ECE of disease and are in sufficiently good general condition that they can tolerate the added toxicity burden. Whether this conclusion will hold true for other drugs/doses/radiation regimens tested in the future is an important question waiting to be answered.

Future Directions

One potential avenue for such progress is aimed at decreasing the burden of disease that postoperative chemoradiotherapy must combat. Because of the time required for wound healing, radiation therapy generally is deferred for 4–6 weeks after surgery. In patients who have complications of surgery, radiation therapy may need to be deferred for even longer. During this interval, the residual subclinical burden of tumor cells, now free of their prior competition for oxygen and nutrients with the tumor cells that were excised, presumably can grow at an accelerated rate and require postoperative therapy to try to cope with increasing volumes of subclinical disease as time passes. Any intervention that impaired this repopulation, leading to relatively smaller tumor burdens, might make subsequent therapy more effective.

As an example of one way this concept could be applied, RTOG 0024 investigated the administration of paclitaxel in the interval between surgery and the initiation of postoperative chemoradiation. In this nonrandomized, phase II trial, 70 patients received 80 mg/m² of paclitaxel once weekly during postoperative weeks 2, 3, and 4. [They also received paclitaxel (30 mg/m²) and cisplatin (20 mg/m²) once weekly during the last 3 weeks of subsequent chemoradiation therapy.] Mindful of the concerns that must apply to comparisons of phase II and phase III trials, the investigators [27] observed that the 2-year rates of locoregional control (88%), disease-free survival (59%), and overall survival (65%) exceeded

those seen in RTOG 9501 after adjustment for important prognostic variables (positive margins, ECE, primary site, performance status). Moreover, treatment reportedly was well-tolerated and toxicity was acceptable.

Conclusions

In recent years, it has become possible to subdivide the previous category of locoregionally advanced, but resectable, squamous cell carcinomas of the head and neck into cohorts having greater or lesser biologic aggressiveness. The science behind these allocations has yet to achieve rigorous precision; however, the presence of even microscopic-size tumor at the mucosal margin of a surgical specimen and/or the presence of ECE beyond an involved resected lymph node reliably correlate with worse prognosis. For this particularly high-risk group, it is now clear that the concurrent administration of three doses of 100 mg/m² of cisplatin with postoperative radiation therapy results in better tumor control (and probably improved survival) at the price of increased, although tolerable, toxicity. This proof of principle justifies testing other combinations of conventionally cytotoxic chemotherapy and/or targeted biologic drugs in combination with postoperative radiation therapy in the hope of finding still better regimens that have wider applicability, greater efficacy, and less toxicity.

References

1. Ang KK, Trotti A, Brown BW, Garden AS, Foote RL, Morrison WH, et al. Randomized trial addressing risk features and time factors of surgery plus radiotherapy in advanced head-and-neck cancer. *Int J Radiat Oncol Biol Phys.* 2001;51(3):571–8.
2. Kramer S, Gelber RD, Snow JB, Marcial VA, Lowry LD, Davis LW, et al. Combined radiation therapy and surgery in the management of advanced head and neck cancer: final report of study 73-03 of the Radiation Therapy Oncology Group. *Head Neck Surg.* 1987;10(1):19–30.
3. Tupchong L, Scott CB, Blitzer PH, Marcial VA, Lowry LD, Jacobs JR, et al. Randomized study of preoperative versus postoperative radiation therapy in advanced head and neck carcinoma: long-term follow-up of RTOG study 73-03. *Int J Radiat Oncol Biol Phys.* 1991;20(1):21–8.
4. Laramore GE, Scott CB, al-Sarraf M, Haselow RE, Ervin TJ, Wheeler R, et al. Adjuvant chemotherapy for resectable squamous cell carcinomas of the head and neck: report on Intergroup Study 0034. *Int J Radiat Oncol Biol Phys.* 1992;23(4):705–13.
5. Rosenthal DI, Liu L, Lee JH, Vapiwala N, Chalian AA, Weinstein GS, et al. Importance of the treatment package time in surgery and postoperative radiation therapy for squamous carcinoma of the head and neck. *Head Neck.* 2002;24(2):115–26.
6. Le Tourneau C, Velten M, Jung GM, Bronner G, Flesch H, Borel C. Prognostic indicators for survival in head and neck squamous cell

- carcinomas: analysis of a series of 621 cases. *Head Neck*. 2005;27(9):801–8.
7. Langendijk JA, Slotman BJ, van der Waal I, Doornaert P, Berkof J, Leemans CR. Risk-group definition by recursive partitioning analysis of patients with squamous cell head and neck carcinoma treated with surgery and postoperative radiotherapy. *Cancer*. 2005;104(7):1408–17.
 8. Jonkman A, Kaanders JH, Terhaard CH, Hoebers FJ, van den Ende PL, Wijers OB, et al. Multicenter validation of recursive partitioning analysis classification for patients with squamous cell head and neck carcinoma treated with surgery and postoperative radiotherapy. *Int J Radiat Oncol Biol Phys*. 2007;68(1):119–25.
 9. Huang J, Barbera L, Brouwers M, Browman G, Mackillop WJ. Does delay in starting treatment affect the outcomes of radiotherapy? A systematic review. *J Clin Oncol*. 2003;21(3):555–63.
 10. Kajanti M, Holsti LR, Holsti P. Radical surgery and postoperative split-course radiotherapy in squamous cell carcinoma of the mobile tongue: factors influencing local control and the time to recurrence. *Radiother Oncol*. 1991;22(3):174–9.
 11. Bastit L, Blot E, Debourdeau P, Menard J, Bastit P, Le Fur R. Influence of the delay of adjuvant postoperative radiation therapy on relapse and survival in oropharyngeal and hypopharyngeal cancers. *Int J Radiat Oncol Biol Phys*. 2001;49(1):139–46.
 12. Laramore GE, Scott CB, al-Sarraf M, Haselow RE, Ervin TJ, Wheeler R, et al. Adjuvant chemotherapy for resectable squamous cell carcinomas of the head and neck: report on Intergroup Study 0034. *Int J Radiat Oncol Biol Phys*. 1992;23(4):885–6.
 13. Richmond RC, Zimbrick JD, Hykes DL. Radiation induced DNA damage and lethality in *E. coli* as modified by the antitumor agent cis-dichlorodiammineplatinum (II). *Radiat Res*. 1977;71:447–60.
 14. Duple EB, Richmond RC, Logan ME. Therapeutic potentiation in a mouse mammary tumor and an intracerebral rat brain tumor by combined treatment with cis-dichlorodiammineplatinum (II) and radiation. *J Clin Hematol Oncol*. 1977;7:585–603.
 15. Soloway MS, Morris CR, Sudderth B. Radiation therapy and cis-diamminedichloroplatinum (II) in transplantable and primary murine bladder cancer. *Int J Radiat Oncol Biol Phys*. 1979;5:1355–60.
 16. Szumiel I, Nias AHW. The effect of combined treatment with a platinum complex and ionizing radiation on Chinese hamster ovary cells in vitro. *Br J Cancer*. 1976;33:450–8.
 17. al-Sarraf M, Pajak TF, Byhardt RW, Beitler JJ, Salter MM, Cooper JS. Postoperative radiotherapy with concurrent cisplatin appears to improve locoregional control of advanced, resectable head and neck cancers: RTOG 88-24. *Int J Radiat Oncol Biol Phys*. 1997;37(4):777–82.
 18. Cooper JS, Pajak TF, Forastiere A, Jacobs J, Fu KK, Ang KK, et al. Precisely defining high-risk operable head and neck tumors based on RTOG #85-03 and #88-24: targets for postoperative radiochemotherapy? *Head Neck*. 1998;20(7):588–94.
 19. Haffty B, Son Y, Sasaki C, et al. Mitomycin C as an adjunct to postoperative radiation therapy in squamous cell carcinoma of the head and neck: results from two randomized clinical trials. *Int J Radiat Oncol Biol Phys*. 1993;27:241–50.
 20. Bachaud JM, Cohen-Jonathan E, Alzieu C, et al. Combined postoperative radiotherapy and weekly cisplatin infusion for locally advanced head and neck carcinoma: final report of a randomized trial. *Int J Radiat Oncol Biol Phys*. 1996;36:999–1004.
 21. Smid L, Budihna M, Zakotnik B, et al. Postoperative concomitant irradiation and chemotherapy with mitomycin C and bleomycin for advanced head-and-neck carcinoma. *Int J Radiat Oncol Biol Phys*. 2003;56:1055–62.
 22. Racadot S, Mercier M, Dussart S, Dessard-Diana B, Bensadoun RJ, Martin M, et al. Randomized clinical trial of postoperative radiotherapy versus concomitant carboplatin and radiotherapy for head and neck cancers with lymph node involvement. *Radiother Oncol*. 2008;87(2):164–72.
 23. Cooper JS, Pajak TF, Forastiere AA, Jacobs J, Campbell BH, Saxman SB, et al. Radiation Therapy Oncology Group 9501/Intergroup. Postoperative concurrent radiotherapy and chemotherapy for high-risk squamous-cell carcinoma of the head and neck. *N Engl J Med*. 2004;350(19):1937–44.
 24. Bernier J, Domenge C, Ozsahin M, Matuszewska K, Lefèbvre JL, Greiner RH, et al. European organization for research and treatment of cancer trial 22931. Postoperative irradiation with or without concomitant chemotherapy for locally advanced head and neck cancer. *N Engl J Med*. 2004;350(19):1945–52.
 25. Bernier J, Cooper JS, Pajak TF, van Glabbeke M, Bourhis J, Forastiere A, et al. Defining risk levels in locally advanced head and neck cancers: a comparative analysis of concurrent postoperative radiation plus chemotherapy trials of the EORTC (#22931) and RTOG (# 9501). *Head Neck*. 2005;27(10):843–50.
 26. Trotti A, Pajak TF, Gwede CK, Paulus R, Cooper J, Forastiere A, et al. TAME: development of a new method for summarising adverse events of cancer treatment by the Radiation Therapy Oncology Group. *Lancet Oncol*. 2007;8(7):613–24.
 27. Rosenthal DI, Harris J, Forastiere AA, Weber RS, Ridge JA, Myers JN, et al. Early postoperative paclitaxel followed by concurrent paclitaxel–cisplatin with radiation therapy for patients with resected, high-risk head and neck squamous cell carcinoma: report of the phase II trial RTOG 0024. *J Clin Oncol*. 2009;27(28):4727–32.

Chapter 36

Management of Salivary Gland Cancer

Laura D. Locati, Marco Guzzo, Patrizia Olmi, and Lisa Licitra

Abstract Carcinomas of the salivary glands are uncommon representing only 2–6.5% of all head and neck cancer and less than 1% of all cancers. About 85% of salivary gland tumors arise in the parotid glands and approximately 75% of these are benign while about 75% of tumors arising from minor salivary glands are malignant. The latest WHO's histological classification (2005) includes both benign and more than 20 different types of malignant tumors. The morphological diversity between different tumor types and sometimes within the same tumor mass along with the relative rarity of some tumors can make diagnosis difficult and needs a skilled pathologist.

The American Joint Cancer Committee's (AJCC) tumor, node, metastasis (TNM) has defined a staging system for major salivary gland malignancies. Cancer from minor salivary gland scattered throughout all the head and neck mucosa are staged according to the AJCC system for the more common squamocellular cancer arising in the same location.

Surgery of primary tumor, whenever possible, is the treatment of choice both for major and minor salivary gland tumors. A clinically positive neck requires a neck dissection along with the resection of primary tumor. The treatment of N0 neck in patients with malignant salivary gland tumors is a matter of debate. High-grade tumors, high primary T stage, and the presence of facial paralysis are associated with high incidence of neck node metastasis.

Adjuvant radiotherapy improves locoregional control following surgery. Despite the absence of randomized trials, postoperative radiotherapy is recommended in high-grade tumors, advanced stage tumor (T4), "close" (≤ 5 mm) or microscopically positive surgical margins, and neck node metastases.

Radiotherapy can be the best treatment option in case of "technically" unresectable or "medically" inoperable tumor. The use of concomitant chemoradiotherapy in salivary gland cancer is still investigational.

Chemotherapy is delivered in case of relapsed and/or metastatic disease with a palliative aim. There is neither standard chemotherapy regimen nor data on whether polychemotherapy is more active than monochemotherapy. Although, a cisplatin-based chemotherapy for four to six courses is considered the best choice.

Targeted therapies, as tyrosine-kinase inhibitor or monoclonal antibodies, are under evaluation. Phase II studies are ongoing.

Keywords Salivary gland cancer • Surgery • Radiotherapy • Chemotherapy • Target therapy

Epidemiology

Malignant cancers of salivary glands are uncommon: the world annual incidence rates are comprised between <2 and <0.05 per 100,000 [1]. In the United States, incidence rates showed a significant increase in the period during 1974–1999, accounting for 6.3%, compared to 8.1% of all head and neck cancers in 1998–1999 ($p=0.002$) [2]. The causes of salivary gland cancer are still to be further investigated. Diet may effectively prevent salivary gland cancer, by increasing fruit and vegetables consumption, in particular those rich in vitamin C, and by limiting cholesterol intake [3, 4]. Irradiation may also favor the onset of malignant salivary gland tumors [5]. Many studies have indicated a possible association with a history of prior cancers, especially those caused by ultraviolet radiation, immunosuppression, and Epstein–Barr virus [6–9]. Workers employed in rubber manufacturing companies, in hair dresser's shops and beauty shops, as well as those exposed to nickel compounds, showed an increased risk to develop salivary gland carcinomas [10, 11]. Chronic inflammation of salivary glands is not clearly defined as a risk factor.

L. Licitra (✉)

Department of Medical Oncology, IRCCS Fondazione Istituto Nazionale Tumori Milan Italy, Via Venezian, 1, Milan 20133, Italy
e-mail: lisa.licitra@istitutotumori.mi.it

Anatomy

Salivary glands are exocrine organs responsible for the production and secretion of saliva. They comprise the three paired major salivary glands – the parotid, submandibular, and sublingual – and the minor salivary glands. The head and neck contains about 450–750 minor salivary glands. They are widely distributed throughout the mouth and oropharynx and similar glands are present in the upper respiratory and sinonasal tracts, and the paranasal sinuses. These latter are morphologically and functionally similar to many of the oral minor salivary glands but effectively they are not salivary glands since they do not contribute to saliva. However, they are often comprised in papers on salivary gland cancer as in this text, because some histotypes are similar or identical to tumors of the salivary glands.

Histology

Salivary gland tumors are classified according to the latest WHO's histological classification published in 2005 [12]. More than 20 different malignant histotypes are included in this classification, characterized by a range of various biological behaviors. Salivary gland cancers can be divided into histotypes originated from the intercalated ducts (including adenoid cystic carcinoma and adenocarcinoma, NOS) and those of secretory duct origin, as mucoepidermoid carcinoma and salivary duct cancer. Mucoepidermoid cancer, adenoid cystic carcinoma, and adenocarcinoma, NOS, are the most represented salivary gland cancer histotypes, although their frequency varies according to the site of origin (major versus minor salivary glands). Tumor grading does not seem to have any prognostic value. In this classification, only mucoepidermoid carcinomas are graded by a point score system, as low-grade type (well differentiated), intermediate, or high-grade type (poorly differentiated). Differences in tumor grade have been also suggested for adenocarcinoma NOS, salivary duct carcinoma, and acinic cell carcinoma. In these cases, prognosis correlates with grading: high-grade tumors are associated with a poor prognosis, whereas the prognosis of low-grade tumors is much more favorable.

The wide spectrum of morphological diversity among different tumor types and sometimes within the same tumor mass, together with the presence of hybrid tumors, may sometimes require a skilled pathologist to make the diagnosis.

Benign epithelial tumors	Pleomorphic adenoma (8940/0)
	Myoepithelioma (8982/0)
	Basal cell adenoma (8147/0)
	Warthin tumor (adenolymphoma) (8561/0)
	Oncocytoma (oncocytic adenoma) (8290/0)
	Canalicular adenoma (8149/0)
	Sebaceous adenoma (8410/0)
	Lymphadenoma (8410/0)
	Sebaceous
	Non-sebaceous
	Ductal papillomas
	Inverted ductal papilloma (8503/0)
	Intraductal papilloma (8503/0)
	Sialadenoma papilliferum (8406/0)
	Cystadenoma (8440/0)
Malignant epithelial tumors	Acinic cell carcinoma (8550/3)
	Mucoepidermoid carcinoma (8430/3)
	Adenoid cystic carcinoma (8200/3)
	Polymorphous low-grade adenocarcinoma
	Epithelial–myoepithelial carcinoma (8562/3)
	Clear cell carcinoma, not otherwise specified (8310/3)
	Basal cell adenocarcinoma (8147/3)
	Sebaceous carcinoma (8410/3)
	Sebaceous lymphadenocarcinoma (8410/3)
	Cystadenocarcinoma (8440/3)
	Low-grade cribriform cystadenocarcinoma
	Mucinous adenocarcinoma (8480/3)
	Oncocytic carcinoma (8290/3)
	Salivary duct carcinoma (8500/3)
	Adenocarcinoma, not otherwise specified (8140/3)
	Myoepithelial carcinoma (8982/3)
	Carcinoma ex pleomorphic adenoma (8941/3)
	Carcinosarcoma (8980/3)
	Metastasizing pleomorphic adenoma (8940/1)
	Squamous cell carcinoma (8070/3)
	Small cell carcinoma (8041/3)
	Large cell carcinoma (8012/3)
Lymphoepithelial carcinoma (8082/3)	
Sialoblastoma (8974/1)	
Soft tissue tumors	Haemangioma (9120/0)
Haematolymphoid tumors	Hodgkin lymphoma
	Diffuse large B-cell lymphoma (9680/3)
	Extranodal marginal zone B-cell lymphoma (9699/3)
Secondary tumors	

TNM Classification and Stage Grouping [13]

Tables 36.1 and 36.2 report the TNM classification and Stage Grouping, of the salivary gland cancer, according to the latest AJCC/UICC classification.

Table 36.1 Major salivary glands: definitions of TNM

<i>Primary tumor (T)</i>	
TX	Primary tumor cannot be assessed
T0	No evidence of primary tumor
T1	Tumor 2 cm or less in greatest dimension without extraparenchymal extension ^a
T2	Tumor more than 2 cm but not more than 4 cm in greatest dimension without extraparenchymal extension ^a
T3	Tumor more than 4 cm and/or tumor having extraparenchymal extension ^a
T4a	Tumor invades skin, mandible, ear canal, and/or facial nerve
T4b	Tumor invades skull base and/or pterygoid plates and/or encases carotid artery
<i>Regional lymph nodes (N)</i>	
NX	Regional lymph nodes cannot be assessed
N0	No regional lymph node metastasis
N1	Metastasis in a single ipsilateral lymph node, 3 cm or less in greatest dimension
N2	Metastasis as specified in N2a, 2b, 2c below:
N2a	Metastasis in a single ipsilateral lymph node, more than 3 cm but not more than 6 cm in greatest dimension
N2b	Metastasis in multiple ipsilateral lymph nodes, none more than 6 cm in greatest dimension
N2c	Metastasis in bilateral or contralateral lymph nodes, none more than 6 cm in greatest dimension
N3	Metastasis in a lymph node, more than 6 cm in greatest dimension
<i>Distant metastasis (M)</i>	
M0	No distant metastasis
M1	Distant metastasis

^aExtraparenchymal extension is clinical or macroscopic evidence of invasion of soft tissues or nerve, except those listed under T4a and 4b. Microscopic evidence alone does not constitute extraparenchymal extension for classification purposes.

Used with the permission of the American Joint Committee on Cancer (AJCC), Chicago, IL. The original source for this material is the AJCC Cancer Staging Manual, Seventh Edition (2010) published by Springer Science and Business Media LLC, www.springer.com

Table 36.2 Major salivary glands: anatomic stage/prognostic groups

Stage I	T1	N0	M0
Stage II	T2	N0	M0
Stage III	T3	N0	M0
	T1	N1	M0
	T2	N1	M0
Stage IV A	T3	N1	M0
	T4a	N0	M0
	T4a	N1	M0
Stage IV B	T1	N2	M0
	T2	N2	M0
	T3	N2	M0
	T4a	N2	M0
Stage IV C	T4b	Any N	M0
	Any T	N3	M0
Stage IV C	Any T	Any N	M1

Used with the permission of the American Joint Committee on Cancer (AJCC), Chicago, IL. The original source for this material is the AJCC Cancer Staging Manual, Seventh Edition (2010) published by Springer Science and Business Media LLC, www.springer.com

Clinical Presentation

Major Salivary Gland Tumors

Malignant neoplasms in these sites usually appear clinically indistinguishable from benign tumors. Consequently, every painless swelling of a salivary gland must be suspected, especially in the absence of further signs of inflammation. Pain is not typical but it is reported as intermittent in over a third of patients affected by acinic cell carcinoma [14]. Malignant tumors account for 15–32% in the parotid gland, 41–45% in the submandibular gland, and 70–90% in the sublingual gland. Malignant salivary tumors show a range of biological behaviors. In approximately 40% of cases, these tumors are indolent (especially in patients under the age of 40 years) and present as slow growing lumps and, if long lasting, they may be associated with pain or early nerve involvement. In about 40% of cases, moreover, such tumors are also aggressive (especially in elderly patients); facial palsy may be a presenting sign and soon an evolving mass is evident. Malignant neoplasms of the salivary glands are characterized by rapid growth rate, pain, facial nerve involvement, and cervical lymph nodes. Nodal metastases seem to depend on histologic type and grading more than primary tumor site (Table 36.3). A rapid growth and sometimes ulceration of a long stay parotid mass is seen in one third of patients suffering from carcinoma ex pleomorphic adenoma. Facial nerve palsy, either complete or partial, always indicates a locally infiltrating cancer of the parotid. Soft palatal fullness may also be present, in case of tumors invading the parapharyngeal space. Trismus, fixation of the tumor to overlying skin, ulceration, and fistulas are signs of very advanced stage disease.

Table 36.3 Occurrence of cervical lymphadenopathies in malignant tumors of the salivary glands

	Nodal metastases	References
<i>Site of primary</i>		
Parotid gland	12–25%	[15–18]
Submandibular gland	15–42%	[15, 19, 20]
Minor salivary gland	8–18%	[15, 21–23]
<i>Histotype – grade</i>		
Mucoepidermoid carcinoma low grade	3–8%	[24–26]
Mucoepidermoid carcinoma high grade	50–70%	[24–26]
Acinic cell carcinoma	1–47%	[27–31]
Acinic cell carcinoma high grade	56%	[32]
Adenoid cystic carcinoma	12–38%	[31, 33, 34]
Salivary duct carcinoma	43–58%	[35, 36]
Salivary duct carcinoma low grade	0	[37]

Minor Salivary Gland Tumors

A greater proportion of malignancies occur in the minor salivary glands than in the major counterpart. The incidence of malignancy depends on the site of occurrence, as well as signs and symptoms depend on tumor size and position and may vary according to tumor location. Survival rates for palate tumors are similar to those related to submandibular carcinomas, i.e., 40–60%. Incidence increases up to 90% from the tongue to the floor of the mouth and sublingual glands. Upper lip is affected twice as much by malignancies compared with lower lip, i.e., 60% vs. 30% respectively. In over 50% of cases, minor salivary gland tumors are intraoral: a painless submucosal swelling is usually present, sometimes accompanied by ulceration of the overlying mucosa. A painless lump may indicate tumors arising in the oropharyngeal area. In case of nasopharyngeal or the nasal cavity infiltration, facial pain, nasal obstruction, or bleeding may be present. Tumors occurring in the larynx or trachea may cause hoarseness, voice change, or dyspnoea.

Diagnosis

Physical examination represents the most important diagnostic tool for major salivary gland carcinomas. As approximately 80% of salivary gland tumors arise in the parotid and approximately 75% of them are benign, an initial differential diagnosis should be performed between cancer and other benign diseases, such as cysts, inflammatory status, and lymph node hyperplasia. In case of a suspected malignant lesion, a pathological diagnosis must be considered. Ultrasonography (US) is a highly sensitive (approximately 100% – similar to CT scan) and low cost modality. This is always recommended as a preoperative examination, since approximately 90% of tumors arise in the superficial lobe of the parotid gland. US is the most indicated tool to differentiate intraglandular from extraglandular lesions, although it is not feasible to visualize the deeper parotid lobe. MRI has a sensitivity of 87% with a specificity of 94% and it is particularly useful in visualizing the tumor interface and surrounding tissues for a correct surgical planning, especially in case of larger tumors (more than 4 cm), tumors arising in deep structures and/or involving them. Among the advantages of MRI, in comparison with CT, the elimination of dental artifacts and the ability to distinguish between a tumor and obstructed secretions should be mentioned. Since the full extent of minor salivary gland cancers arising in oral and nasal cavity, paranasal sinuses cannot be defined by clinical examination, MRI is, instead, recommended. In particular, MRI with contrast-enhanced and with fat-suppressed T1-weighted images results useful in case of perineural invasion.

Tissue biopsy is indicated in those cases when an evidence of malignancy has been assessed and demolitive surgery, such as neck dissection and total parotidectomy, is needed.

More controversial are those cases, in which an indolent cancer masquerades as a benign tumor. The clinician's experience can distinguish between the two in 90% of cases [38], while fine needle aspiration cytology (FNAC) may further support the best treatment choice. FNAC is highly sensitive and specific with an accuracy of 87–96% [39], although it is an operator-related modality. Sensitivity rates range between 73 and 86.6% both in malignant and in benign tumors, while specificity proved better in benign than in malignant tumors (97% vs. 85%) [40]. Inadequate sampling may lead to false-negative diagnoses, which is the most frequent error. In case of a periglandular nodule, FNAC is feasible to distinguish a primary salivary tumor from a pathological lymph node. A proper diagnosis allows to avoid unnecessary surgery [41]. Tumor with cystic degeneration, which is relatively frequent in mucoepidermoid carcinomas, may be recognized by repeating aspirations. The procedure accuracy may be improved by the combination of US and guided FNAC.

Open biopsy should be avoided because of the risk of seeding. In case small masses in minor salivary glands (palate, tongue) should be proved malignant, punch biopsy (dermatological punch) may be preferable to direct excision, unless the latter provides adequate margins. Frozen section diagnosis is still an issue of debate. False-positive rates account for 1.1%, false-negative rates are 2.6%. Accuracy is better for benign tumors than for malignant lesions (98.7% versus 85.9%) [42]. If malignancy is not confirmed by FNAC, frozen section should always be performed. Frozen section examination, including periglandular lymph nodes, is often performed in view of an immediate neck dissection. The difficulty to differentiate among various histotypes represents the major limit of this procedure.

Natural History and Prognosis

Initial spread of the major salivary gland cancer is local invasion. Parotid tumors present fixation to surrounding structures in about 20% of cases [43], skin invasion in 10% of cases [15], and facial nerve involvement in 25% of cases [43, 44].

Neck lymph node metastases are more common in submandibular gland than in the parotid gland, about 40% versus 25% [15, 45]. The frequency (Table 36.4) seems to be dependent on T stage, site of origin, and histological type.

Distant metastases at presentation are rare. At 10 years they account for about 30–40% mainly depending on the histological type (adenoid cystic, squamous cell, undifferentiated and salivary duct carcinoma). Lung and bone are the most common sites of distant metastases [15].

Table 36.4 Risk of positive neck nodes (%), according to summation of scores (T: T1=1; T2=2; T3–4=3, and histological type: acinic/adenoid cystic/carcinoma ex pleomorphic adenoma = 1, mucoepidermoid carcinoma = 2; squamous cell/undifferentiated carcinoma = 3) and site

T score + histological type score	Parotid gland (%)	Submandibular gland (%)	Oral cavity (%)	Other locations (%)
2	4	0	4	0
3	12	33	135	29
4	25	57	19	56
5	33	60	–	–
6	38	50	–	–

Reprinted from [45]. Copyright 2005, with permission from Elsevier

Table 36.5 Survival rates of the most common major salivary gland malignancies

Histology	5-year survival	References
Polymorphous low-grade adenocarcinoma	95–100%	[58, 59]
Acinic cell carcinoma	75–96%	[60, 61]
Mucoepidermoid carcinoma LG	75–89%	[26, 60, 62]
Myoepithelial carcinoma	67%	[63, 64]
Mucoepidermoid carcinoma HG	23–50%	[26, 60, 62]
Adenoid cystic carcinoma	35–70% (10-years DFS 10–20%)	[65, 66]
Carcinoma ex pleomorphic adenoma	40%–(30–96% correlated with histology)	[60, 67, 68]
Salivary duct carcinoma HG	4-years DFS 20–35%	[36, 69]

Reprinted from the article submitted to Critical Reviews in Oncology & Hematology, Guzzo M, Locati LD, Prott FJ, Gatta G, McGurk M, Licitra L. Major and minor salivary gland tumors

Survival is related to tumor stage, histologic type (Table 36.5), grading, facial nerve paralysis, extrasalivary gland tumor extension and cervical node involvement. All these predictors may influence treatment outcome: among them, stage seems to be more important than grading [46–49]. Besides the above-mentioned predictors of survival, patient's age and positive surgical margins are the most important factors predicting locoregional control in parotid gland cancer [50, 51]. Perineural invasion and solid histological features are additional prognostic factors in adenoid cystic carcinomas [52]. Moreover, it should be pointed out that Ki-67 tumor value is significantly higher in case of treatment failure and large tumors [53]. Margin status, angiolymphatic invasion, tumor necrosis, and myoepithelial anaplasia are the major predicting factors of recurrence in epithelial–myoepithelial carcinomas [54].

Patients with mucoepidermoid carcinoma of the parotid gland have a better prognosis than those with submandibular gland tumors [55, 56] but these figures were not confirmed for other histotypes. No data suggesting different prognosis between major and minor salivary gland tumors are available.

The site of occurrence is an effective predicting factor of prognosis in the small subset of minor salivary glands cancers [57].

Treatment

Surgery

Major Salivary Glands

Salivary gland cancer patients should receive an individualized treatment, more than any other cancer patients. For this reason, experienced clinicians are particularly important. Both benign and malignant salivary gland neoplasms may be approached by the similar surgical techniques and strategies. In general, tumor must be resected, together with right normal tissue margins surrounding the neoplasm. Treatment plan may be influenced by tumor location, extension, and histology.

In parotid neoplasms, the diagnostic procedure of choice is superficial parotidectomy with formal facial nerve dissection and preservation, which is also the treatment of choice for many malignant tumors of the superficial gland lobe. Enucleation may, instead, increase the risk of recurrence and facial nerve dysfunction. Local excision should only be performed in tumors arising in the tail of the gland (i.e., Warthin tumors). Partial superficial parotidectomy, as described by Leverstein, proved a safe and effective procedure in the treatment of benign tumors [70]. In the presence of a large tumor extension into the parapharyngeal space, superficial lobectomy is needed for the surgical exposure of the deep lobe, and it may be achieved also by cervical approach, which may be accompanied by submandibular gland displacement and/or mandibulotomy.

A cervical approach may be adopted to remove a deep parotid benign tumor, by avoiding superficial parotidectomy. In this case, the formal exposition of the seventh nerve is not always necessary but it should be pointed out that the nerve is still vulnerable. When approaching through the superficial lobe, whenever feasible, this tissue should be preserved, reflected anteriorly, and finally replaced to minimize cosmetic damage.

Histologic confirmation, also by means of intraoperative frozen sections, should be obtained before any deliberate surgical injury of the seventh nerve.

Partial or complete sacrifice of the facial nerve occurred in up to 40% of the patients treated for a parotid malignancy [48, 71, 72]. Tumor eradication must be balanced against facial nerve preservation. When the patient has a normal facial function preoperatively, the nerve preservation should always be attempted, particularly when dealing with benign neoplasms. In selected cases, the tumor may be peeled off of the nerve. In case of the tumor should be adherent or infiltrating other structures and the nerve encased (preoperative facial palsy, skin involvement), radical parotidectomy including the facial nerve, is the treatment of choice. Immediate nerve grafting should be performed in patients under 65 years. Older patients should, instead, be submitted to rehabilitative local procedures. Extraparotid tumor extensions

may need skin excision, mandibulectomy, or partial resection of maxilla and temporal bone.

For either benign or small submandibular tumors, well confined to the parenchyma and of low-grade histology, excision of the whole gland alone is indicated. An adequate resection should, instead, be performed in every other case, including the bed of the gland and any adjacent structure in contact with it, up to a real supra-omohyoid selective dissection (removal of level I, II, and III lymph nodes). This procedure allows to obtain the tissue needed for diagnosis and also remove the primary echelon lymph nodes at risk for metastasis [19].

The risk of lymph node metastasis from parotid cancer is generally low [31] and it increases in high grade and advanced T-stage tumors, as well as in the presence of extracapsular extension or facial paralysis, regardless of histology [17, 47, 73, 74]. In these cases, a selective prophylactic neck dissection, including levels IB, II, III, may be appropriate. The same procedure may also be offered to selected cases, in which lymphadenectomy may facilitate primary resection. Nodal involvement requires conventional neck dissection including levels IB, II, III, IV, and VA.

Selective prophylactic neck dissection should include levels I, II, III in the rare cancer of sublingual glands.

Minor Salivary Glands

A very high number of minor salivary glands are scattered throughout the head and neck. Most of them are located in the oral cavity. Surgery is the recommended treatment for patients with resectable tumors. The treatment of these tumors is usually similar to the one adopted for squamous cell carcinomas arising in the same sites. Low rates of cervical lymph node metastases have been reported [15, 23, 57]. Therefore, elective neck dissection seems not to be of much benefit for patients with small and low-grade minor salivary gland tumors. In general, if the primary tumor is accessed through the neck, then some form of neck dissection should follow.

Radiotherapy

Benign Tumors

Pleomorphic adenoma, mixed benign tumor, is the most frequent, accounting for about 60% of all epithelial tumors with an incidence of 2.4–3.05 per 100,000 [12]. It occurs in young people, mainly in the fifth decade with a slight predominance among females. In 80% of cases it arises from parotid gland and the standard therapy is represented by conservative parotidectomy. This tumor tends to recur and sometimes, as a malignant lesion. Some authors reported

recurrences rate of 3.4% at 5 years, 2.5–6.8% at 10 years, and 5% at 20 years [61, 75]. The risk of relapse seems to be higher in multinodular disease [76].

The indication to postoperative radiotherapy may include recurrences, positive margins (R1) after surgery or disease located in deep part with an operation that would require facial nerve damage. With conventional fractionation (2 Gy per day) the parotid area should receive a total dose ranging from 50 to 60 Gy.

Malignant Tumors

Major salivary gland tumors (parotid gland, submandibular gland, sublingual gland).

Postoperative Radiotherapy

Radiation therapy as adjuvant treatment depends on the extent of surgery, often less aggressive for the preservation.

There is a consensus in the literature to indicate postoperative radiotherapy on the base of T (T3 and T4), incomplete or close margins (R1 and R2), bone involvement, perineural invasion. The need to include ipsilateral neck nodes depends on their positivity at histological exam if dissected, on T stage, and on histologic type. The risk of positive nodes is reported in a score system elaborated by Terhaard et al. (Table 36.4) and based on T stage, histological type, and site of origin [45].

For elective nodes irradiation to the ipsilateral levels Ib, II, and III, can be included. If positive nodes are present at the pathologic report, levels I–V are to be also included. Submandibular tumors may require the irradiation of the contralateral neck nodes at least at level I.

The contour of the clinical target volume (CTV) will be customized on the basis of disease extent, with the cover of parapharyngeal space and temporal fossa in parotid gland tumor, and the surrounding structures in submandibular gland tumor. In case of perineural invasion, the radiotherapy plan has to cover the pathway of cranial nerve up to the skull base.

Three-dimensional conformal radiation therapy (3DCRT) or intensity modulated radiotherapy (IMRT) are the recommended techniques with the aim to spare the possibly involved organs at risk (Table 36.6) and to obtain an optimal dose distribution. The technical choice can be individualized for each patient also through the elaboration of comparison treatment plans.

The dose to CTV will range from at least 60 Gy for postoperative treatment to 66–70 Gy according to positive margins (R1 and R2) with conventional fractionation (2 Gy for each session).

Table 36.6 Organs at risk: constraints for head and neck tumors

Chiasma	D1% ≤55 Gy
Optical nerves	D1% ≤55 Gy
Brain stem	D1% ≤55 Gy
Eyeball	Dm ≤35 Gy
Lens	D1% ≤6 Gy
Temporal lobe	D1% ≤60 Gy
Cochlea	Dm ≤45 Gy; D1% <55 Gy
Spinal cord	D1% ≤45 Gy
Parotid	Dm ≤26 Gy or V30 Gy ≤50%
Masseter	Dm ≤50 Gy
PTV external mucosae	Dm ≤35–40 Gy
Mandible	D1% ≤70 Gy; Dm ≤60–65 Gy
Sop.glottic, glottic larynx	V60 Gy <45%/Dm <50 Gy
Pharynx constrictor muscles	V60 Gy <60%
Temporomandibular joint	D1% ≤70 Gy; Dm ≤60–65 Gy
Thyroid	V30 Gy <50%
Brachial plexus	D1% ≤60–63 Gy
Submand. gland	Dm <35 Gy

Courtesy of Prof. P. Olmi

Results obtained in different literature series combining surgery and radiotherapy in parotid tumor show a survival at 5 and 10 years of 65 and 51% [45, 77], 78 and 60% [78], 71 and 65% [79].

For submandibular tumors, two series contained in the literature [15, 80] reported survival at 5 and 10 years of 57 and 45%, respectively, and 60 and 53% as disease-free survival (DFS). Local control was 91% at 10 years for the first series and 88% for the second one.

Minor Salivary Glands

Most minor salivary gland tumors arise from oral cavity mainly from palate, cheek, lips, tongue, followed by paranasal sinuses and nasal fossa; less frequent are larynx, oropharynx, nasopharynx involved. The rule of radiation therapy depends on tumor site, on the possibility to perform a surgical approach, and on the histology. The criteria for surgery and postoperative treatment are similar to these for squamous cell carcinomas in the same sites and the indication for postoperative radiotherapy is related to T stage, status of margins, bone involvement, and perineural invasion.

When the histological exam shows an adenoid cystic carcinoma, the most frequent histologic type together with the mucoepidermoid carcinoma in minor salivary glands, the most complete surgical excision as possible is mandatory, followed by radiotherapy. When a branch of the cranial nerve is involved, all the nerve pathways to the base of the skull should electively be irradiated. It can be omitted when the focal perineural invasion is located only in a small unnamed nerve [81].

IMRT and 3DCRT represent the best radiotherapy techniques and the dose to CTV will range from at least 60 Gy for postoperative treatment to 66–70 Gy according to positive margins (R1 and R2) with conventional fractionation (2 Gy for each session).

Primary Radiotherapy

Irradiation alone must be reserved to inoperable patients (T4b) or some metastatic patients treated for palliation.

Photon beams only achieve poor results when radiotherapy is used with curative intent and local control is about 50% at 5 years. Better results have been obtained with neutron irradiation in a study conducted on patients with inoperable primary or recurrent disease. A study of RTOG-MRC (Radiation Therapy Oncology Group in the United States and Medical Research Council in Great Britain) [82] made a comparison among 32 patients, 17 randomized to receive neutrons and 15 to receive photon irradiation. The study was stopped after 2 years because of statistical differences between the two arms with patients treated with neutrons (55 Gy) and photons (70 Gy). After a minimum follow-up of 2 years the results on locoregional control were 67% for neutrons and 17% for photons. Borderline impact on survival without statistical significance was reported in a successive paper [83].

The authors reported higher late morbidity defined “severe,” as also reported in other studies of single institutions [84, 85] in which G3 and G4 late sequelae accounted for about 10–19%.

The use of neutrons has been important mainly in adenoid cystic carcinoma [86].

More recently, adenoid cystic carcinomas can be treated with hadron therapy with protons and in the literature there are encouraging results as local control rates in patient affected by inoperable tumor [87].

Chemotherapy and Other Therapies

In the management of salivary gland cancer, chemotherapy is employed almost exclusively with a palliative aim. Different chemotherapy regimens have been tested, although no randomized studies have been conducted to date to define the best therapeutic choice in this setting. A platinum-based chemotherapy seems to be associated with the best response rate, both as a monotherapy and as a combined regimen, although it is still not clear whether a combination

chemotherapy has any advantage over a single agent chemotherapy (Table 36.7). Chemotherapy activity seems to be histotype driven. Patients with adenocarcinoma, adenoid cystic carcinoma, acinar cell carcinoma, and malignant mixed tumors have been reported to be similarly sensitive to the CAP regimen. In patients with mucoepidermoid and undifferentiated tumors, however, a better response seems to be obtained, to those drugs, which are active against squamous cell carcinomas (e.g., cisplatin, 5-FU, methotrexate) [88]. The choice of the best chemotherapy regimen and whether polychemotherapy rather than monotherapy should be used considering the histotype to cure and the potentially high rate of toxicities expected in case of polychemotherapy, are all still issues of debate. No benefit, in terms of survival, has been observed in patients responding to chemotherapy over nonresponding. For this reason, chemotherapy could be reserved to symptomatic patients and/or those with a rapid progressive disease. A watchful waiting is, instead,

preferable, in cases of indolent disease or for patients with just a few symptoms.

Tailored therapies have been also investigated in case of advanced disease. Hormonal receptors (estrogen/progesterone receptors and androgen receptors) and tyrosine-kinase receptors, such as c-kit and epidermal growth factor receptors 1 (EGFR) and 2 (HER2), are the most investigated molecular targets (Table 36.8).

Phase II trials have been conducted (Table 36.9): one long-lasting partial response was reported with trastuzumab in a case of HER2 3+ mucoepidermoid cancer [112], while no activity has been recorded for imatinib, gefitinib, cetuximab, and lapatinib [89, 113–115]. Rare objective responses to imatinib were recorded favored in case of strong c-kit immunostaining [116]. Case reports on activity of antihormonal treatment in selected histotypes have also been reported [117–119]. The employment of target therapies is currently recommended only within clinical trials.

Table 36.7 Chemotherapy regimens and clinical activity

Treatment	Adenoid cystic		Mucoepidermoid	Mucoepidermoid	Adenocarcinoma	Adenocarcinoma
	Response rate %	Response rate %	cancer	cancer	Response rate %	Response rate %
Cisplatin	R	15	R	20	NR	0
Paclitaxel	NR	0	R	25	R	24
Vinorelbine	R	15	–	–	R	40
Epirubicin	R	10	–	–	–	–
Mitoxantrone	R	10	–	–	–	–
Methotrexate	–	–	R ^a	40	–	–
CAP (various) or CAP-5FU	R	28	R	83	R	62
Anthracyclin/cisplatin ± 5FU	R	32	R	25	R	57
Cisplatin/vinorelbine	R	44	–	–	R	20
Carboplatin/paclitaxel	R	20	–	–	R ^a	100
Cyclophosphamide/ doxorubicin	R	3	NR	0	R ^a	100
Gemcitabine	NR	0	–	–	–	–

Reprinted with permission. © 2008 American Society of Clinical Oncology. All rights reserved. Adapted from Laurie SA, Licitra L. Special Series (Head and Neck): Systemic therapy in the palliative management of advanced salivary gland cancers. *J Clin Oncol* 2006; 24: 2673–2378

R objective response, NR no response, CAP cyclophosphamide/doxorubicin/cisplatin, 5FU 5 Fluorouracil

^aData derived from case reports/retrospective series rather than prospectively performed clinical trials

Table 36.8 Frequency of expression of biological targets in salivary gland cancer

Histotype	c-kit %	EGFR %	HER2 %	Androgen	Estrogen	Estrogen receptor	Estrogen	Progesterone
	[89–95]	[89, 90, 96]	[89, 90, 97, 98]	receptor %	receptor %	alpha % [69, 89,	receptor beta %	receptor %
Adenoid cystic carcinoma	78–92	36–85	2–36	0	<10	99, 101–109]	17 [110]	<10
Mucoepidermoid carcinoma	0–40	53–100	0–38	0	<10	Not investigated	Not investigated	<10
Adenocarcinoma	9	59	14–21	21	<10	Not investigated	Not investigated	<10
Salivary duct cancer	0–8	9–41	44–83	43–100	<10	Not investigated	73 [111]	0

This table is adapted from Guzzo et al. [112]

Table 36.9 Phase II study with biological drugs

References	Drug	Target	Response rate (%)	SD \geq 6 months (%)
[113]	Imatinib	c-kit	0	12
[112]	Trastuzumab	HER2	7	n.r.
[114]	Gefitinib	EGFR	0	n.r.
[115]	Lapatinib	HER2/EGFR	0	47
[89]	Cetuximab	EGFR	0	50

This table is adapted from [112]

Conclusions

Surgery is currently the cornerstone of benign and malignant salivary gland tumors management. Radiation therapy is reserved in postoperative setting in malignant tumors according to the pathological report (e.g., positive surgical margins; high-grade histotype) and seldom in benign tumors. Radiotherapy alone must be recommended to unresectable neoplasms or to metastatic patients with a palliative aim. Promising results are coming from hadron therapy in selected cases. Chemotherapy has a palliative role; clinical trials with emerging tailored therapies are ongoing.

Acknowledgment The authors thank Maria Teresa Giannelli for her help in editing this chapter.

References

- Parkin DM, Whelan SL, Ferlay J, Teppo L, Thomas DB. Cancer incidence in five continents. Lyon: IARC Press; 2002. Vol. VIII IARC Scientific Publications No. 155.
- Carvalho AL, Nishimoto IN, Califano JA, Kowalski LP. Trends in incidence and prognosis for head and neck cancer in the United States: a site-specific analysis of the SEER database. *Int J Cancer*. 2005;114:806–16.
- Horn-Ross PL, Morrow M, Ljung BM. Diet and the risk of salivary gland cancer. *Am J Epidemiol*. 1997;146:171–6.
- Zheng W, Shu XO, Ji BT, Gao YT. Diet and other risk factors for cancer of the salivary glands: a population-based case-control study. *Int J Cancer*. 1996;67:194–8.
- Schneider AB, Lubin J, Ron E, et al. Salivary gland tumors after childhood radiation treatment for benign conditions of the head and neck: dose-response relationships. *Radiat Res*. 1998;149:625–30.
- Dong C, Hemminki K. Second primary neoplasms among 53 159 haematolymphoproliferative malignancy patients in Sweden, 1958–1996: a search for common mechanisms. *Br J Cancer*. 2001;85:997–1005.
- Goldstein AM, Yuen J, Tucker MA. Second cancers after medulloblastoma: population-based results from the United States and Sweden. *Cancer Causes Control*. 1997;8:865–71.
- Milan T, Pukkala E, Verkasalo PK, et al. Subsequent primary cancers after basal-cell carcinoma: A nationwide study in Finland from 1953 to 1995. *Int J Cancer*. 2000;87:283–8.
- Spitz MR, Tilley BC, Batsakis JG, Gibeau JM, Newell GR. Risk factors for major salivary gland carcinoma. A case-comparison study. *Cancer*. 1984;54:1854–9.
- Horn-Ross PL, Ljung BM, Morrow M. Environmental factors and the risk of salivary gland cancer. *Epidemiology*. 1997;8:414–9.
- Swanson GM, Burns PB. Cancers of the salivary gland: workplace risks among women and men. *Ann Epidemiol*. 1997;7:369–74.
- Barnes L, Eveson JW, Reichart P, Sidransky D. World Health Organization classification of tumours. Pathology and genetics of head and neck tumours. Lyon: IARC Press; 2005.
- UICC. UICC (International Union Against Cancer). In: TNM classification of malignant tumours. Sobin LH, Wittekind CH, editors. 6th ed. New York, Chichester, Weinheim, Brisbane, Singapore, Toronto: Wiley-Liss; 2002.
- Ellis GL, Corio RL. Acinic cell adenocarcinoma. A clinicopathologic analysis of 294 cases. *Cancer*. 1983;52:542–9.
- Terhaard CH, Lubsen H, Van der Tweel I, et al. Salivary gland carcinoma: independent prognostic factors for locoregional control, distant metastases, and overall survival: results of the Dutch head and neck oncology cooperative group. *Head Neck*. 2004;26:681–92.
- De Regis BSI, Kowalski LP, De Cavalcante AV, Flavia LA, Magrin J. Multivariate analysis of risk factors for neck metastases in surgically treated parotid carcinomas. *Arch Otolaryngol Head Neck Surg*. 2001;127:56–60.
- Armstrong JG, Harrison LB, Thaler HT, et al. The indications for elective treatment of the neck in cancer of the major salivary glands. *Cancer*. 1992;69:615–9.
- Gallo O, Franchi A, Bottai GV, et al. Risk factors for distant metastases from carcinoma of the parotid gland. *Cancer*. 1997;80:844–51.
- Weber RS, Byers RM, Petit B, et al. Submandibular gland tumors. Adverse histologic factors and therapeutic implications. *Arch Otolaryngol Head Neck Surg*. 1990;116:1055–60.
- McGuirt WF. Management of occult metastatic disease from salivary gland neoplasms. *Arch Otolaryngol Head Neck Surg*. 1989;115:322–5.
- Anderson JNJ, Beenken SW, Crowe R, et al. Prognostic factors in minor salivary gland cancer. *Head Neck*. 1995;17:480–6.
- Lopes MA, Santos GC, Kowalski LP. Multivariate survival analysis of 128 cases of oral cavity minor salivary gland carcinomas. *Head Neck*. 1998;20:699–706.
- Cianchetti M, Sandow PS, Scarborough LD, et al. Radiation therapy for minor salivary gland carcinoma. *Laryngoscope*. 2009;119:1334–8.
- Spiro RH, Huvos AG, Berk R, Strong EW. Mucoepidermoid carcinoma of salivary gland origin. A clinicopathologic study of 367 cases. *Am J Surg*. 1978;136:461–8.
- Evans HL. Mucoepidermoid carcinoma of salivary glands: a study of 69 cases with special attention to histologic grading. *Am J Clin Pathol*. 1984;81:696–701.
- Guzzo M, Andreola S, Sirizzotti G, Cantu G. Mucoepidermoid carcinoma of the salivary glands: clinicopathologic review of 108 patients treated at the National Cancer Institute of Milan. *Ann Surg Oncol*. 2002;9:688–95.
- Greig SR, Chaplin JM, McIvor NP, et al. Acinic cell carcinoma of the parotid gland: Auckland experience and literature review. *ANZ J Surg*. 2008;78:754–8.
- Gomez DR, Katabi N, Zhung J, et al. Clinical and pathologic prognostic features in acinic cell carcinoma of the parotid gland. *Cancer*. 2009;115:2128–37.
- Hoffman HT, Karnell LH, Robinson RA, Pinkston JA, Menck HR. National cancer data base report on cancer of the head and neck: acinic cell carcinoma. *Head Neck*. 1999;21:297–309.
- Laskawi R, Rodel R, Zirk A, Arglebe C. Retrospective analysis of 35 patients with acinic cell carcinoma of the parotid gland. *J Oral Maxillofac Surg*. 1998;56:440–3.

31. Stennert E, Kisner D, Jungehulsing M, et al. High incidence of lymph node metastasis in major salivary gland cancer. *Arch Otolaryngol Head Neck Surg.* 2003;129:720–3.
32. Skalova A, Sima R, Vanecek T, et al. Acinic cell carcinoma with high-grade transformation: a report of 9 cases with immunohistochemical study and analysis of TP53 and HER-2/neu genes. *Am J Surg Pathol.* 2009;33(8):1137–45.
33. Spiro RH, Huvos AG, Strong EW. Adenoid cystic carcinoma of salivary origin. A clinicopathologic study of 242 cases. *Am J Surg.* 1974;128:512–20.
34. Sur RK, Donde B, Levin V, et al. Adenoid cystic carcinoma of the salivary glands: a review of 10 years. *Laryngoscope.* 1997;107:1276–80.
35. Brandwein MS, Jagirdar J, Patil J, Biller H, Kaneko M. Salivary duct carcinoma (cribriform salivary carcinoma of excretory ducts). A clinicopathologic and immunohistochemical study of 12 cases. *Cancer.* 1990;65:2307–14.
36. Guzzo M, Di Palma S, Grandi C, Molinari R. Salivary duct carcinoma: clinical characteristics and treatment strategies. *Head Neck.* 1997;19:126–33.
37. Brandwein-Gensler M, Hille J, Wang BY, et al. Low-grade salivary duct carcinoma: description of 16 cases. *Am J Surg Pathol.* 2004;28:1040–4.
38. Renehan A, Gleave EN, Hancock BD, Smith P, McGurk M. Long-term follow-up of over 1,000 patients with salivary gland tumours treated in a single centre. *Br J Surg.* 1996;83:1750–4.
39. Gal R. Fine needle aspiration of the salivary glands: a review. *Oper Tech Otolaryngol Head Neck Surg.* 1996;7:323–6.
40. Riley N, Allison R, Stevenson S. Fine-needle aspiration cytology in parotid masses: our experience in Canterbury, New Zealand. *ANZ J Surg.* 2005;75:144–6.
41. Ellis GL, Auclair PL. Tumors of the salivary glands, atlas of tumor pathology, 3rd Series, Fascicle 17. Washington DC: Armed Forces Institute of Pathology. 1996; 135–6.
42. Gnepp DR, Brandwein MS, Henley JD. Salivary and lacrimal glands. In: Gnepp DR, editor. *Diagnostic surgical pathology of head and neck.* Philadelphia: Saunders; 2001. p. 408.
43. Pohar S, Gay H, Rosenbaum P, et al. Malignant parotid tumors: presentation, clinical/pathologic prognostic factors, and treatment outcomes. *Int J Radiat Oncol Biol Phys.* 2005;61:112–8.
44. Vander PV, Balm AJ, Hilgers FJ, et al. The development of a prognostic score for patients with parotid carcinoma. *Cancer.* 1999;85:2057–67.
45. Terhaard CH, Lubsen H, Rasch CR, et al. The role of radiotherapy in the treatment of malignant salivary gland tumors. *Int J Radiat Oncol Biol Phys.* 2005;61:103–11.
46. Hocwald E, Yoo GH, Adsay V, et al. Prognostic factors in major salivary gland cancer. *Laryngoscope.* 2001;111:1434–9.
47. Bhattacharyya N, Fried MP. Nodal metastasis in major salivary gland cancer: predictive factors and effects on survival. *Arch Otolaryngol Head Neck Surg.* 2002;128:904–8.
48. Frankenthaler RA, Luna MA, Lee SS, et al. Prognostic variables in parotid gland cancer. *Arch Otolaryngol Head Neck Surg.* 1991;117:1251–6.
49. Spiro RH, Huvos AG. Stage means more than grade in adenoid cystic carcinoma. *Am J Surg.* 1992;164:623–8.
50. Carrillo JF, Vazquez R, Ramirez-Ortega MC, et al. Multivariate prediction of the probability of recurrence in patients with carcinoma of the parotid gland. *Cancer.* 2007;109:2043–51.
51. Chen AM, Garcia J, Lee NY, Bucci MK, Eisele DW. Patterns of nodal relapse after surgery and postoperative radiation therapy for carcinomas of the major and minor salivary glands: what is the role of elective neck irradiation? *Int J Radiat Oncol Biol Phys.* 2007;67:988–94.
52. Fordice J, Kershaw C, El-Naggar A, Goepfert H. Adenoid cystic carcinoma of the head and neck: predictors of morbidity and mortality. *Arch Otolaryngol Head Neck Surg.* 1999;125:149–52.
53. Triantafyllidou K, Dimitrakopoulos J, Jordanidis F, Koufogiannis D. Management of adenoid cystic carcinoma of minor salivary glands. *J Oral Maxillofac Surg.* 2006;64:1114–20.
54. Seethala RR, Barnes EL, Hunt JL. Epithelial-myoepithelial carcinoma: a review of the clinicopathologic spectrum and immunophenotypic characteristics in 61 tumors of the salivary glands and upper aerodigestive tract. *Am J Surg Pathol.* 2007;31:44–57.
55. Wahlberg P, Anderson H, Biorklund A, Moller T, Perfekt R. Carcinoma of the parotid and submandibular glands – a study of survival in 2465 patients. *Oral Oncol.* 2002;38:706–13.
56. Goode RK, Auclair PL, Ellis GL. Mucoepidermoid carcinoma of the major salivary glands: clinical and histopathologic analysis of 234 cases with evaluation of grading criteria. *Cancer.* 1998;82:1217–24.
57. Strick MJ, Kelly C, Soames JV, McLean NR. Malignant tumours of the minor salivary glands – a 20 year review. *Br J Plast Surg.* 2004;57:624–31.
58. Castle JT, Thompson LD, Frommelt RA, Wenig BM, Kessler HP. Polymorphous low grade adenocarcinoma: a clinicopathologic study of 164 cases. *Cancer.* 1999;86:207–19.
59. Evans HL, Luna MA. Polymorphous low-grade adenocarcinoma: a study of 40 cases with long-term follow up and an evaluation of the importance of papillary areas. *Am J Surg Pathol.* 2000;24:1319–28.
60. Witt RL. Major salivary gland cancer. *Surg Oncol Clin N Am.* 2004;13:113–27.
61. Hickman RE, Cawson RA, Duffy SW. The prognosis of specific types of salivary gland tumors. *Cancer.* 1984;54:1620–4.
62. Clode AL, Fonseca I, Santos JR, Soares J. Mucoepidermoid carcinoma of the salivary glands: a reappraisal of the influence of tumor differentiation on prognosis. *J Surg Oncol.* 1991;46:100–6.
63. Nagao T, Sugano I, Ishida Y, et al. Salivary gland malignant myoepithelioma: a clinicopathologic and immunohistochemical study of ten cases. *Cancer.* 1998;83:1292–9.
64. Di Palma S, Guzzo M. Malignant myoepithelioma of salivary glands: clinicopathological features of ten cases. *Virchows Arch A Pathol Anat Histopathol.* 1993;423:389–96.
65. Hamper K, Lazar F, Dietel M, et al. Prognostic factors for adenoid cystic carcinoma of the head and neck: a retrospective evaluation of 96 cases. *J Oral Pathol Med.* 1990;19:101–7.
66. Perzin KH, Gullane P, Clairmont AC. Adenoid cystic carcinomas arising in salivary glands: a correlation of histologic features and clinical course. *Cancer.* 1978;42:265–82.
67. Tortoledo ME, Luna MA, Batsakis JG. Carcinomas ex pleomorphic adenoma and malignant mixed tumors. *Histomorphologic indexes.* *Arch Otolaryngol.* 1984;110:172–6.
68. Lewis JE, Olsen KD, Sebo TJ. Carcinoma ex pleomorphic adenoma: pathologic analysis of 73 cases. *Hum Pathol.* 2001;32:596–604.
69. Barnes L, Rao U, Krause J, et al. Salivary duct carcinoma. Part I. A clinicopathologic evaluation and DNA image analysis of 13 cases with review of the literature. *Oral Surg Oral Med Oral Pathol.* 1994;78:64–73.
70. Leverstein H, van der Wal JE, Tiwari RM, van der Wal JE, Snow GB. Surgical management of 246 previously untreated pleomorphic adenomas of the parotid gland. *Br J Surg.* 1997;84:399–403.
71. Spiro RH, Huvos AG, Strong EW. Cancer of the parotid gland. A clinicopathologic study of 288 primary cases. *Am J Surg.* 1975;130:452–9.
72. Hodgkinson DJ, Woods JE. The influence of facial-nerve sacrifice in surgery of malignant parotid tumors. *J Surg Oncol.* 1976;8:425–32.
73. Scianna JM, Petruzzelli GJ. Contemporary management of tumors of the salivary glands. *Curr Oncol Rep.* 2007;9:134–8.
74. Bell RB, Dierks EJ, Homer L, Potter BE. Management and outcome of patients with malignant salivary gland tumors. *J Oral Maxillofac Surg.* 2005;63:917–28.
75. Dawson AK, Orr JA. Long-term results of local excision and radiotherapy in pleomorphic adenoma of the parotid. *Int J Radiat Oncol Biol Phys.* 1985;11:451–5.

76. Renehan AG, Gleave EN, Slevin NJ, McGurk M. Clinico-pathological and treatment-related factors influencing survival in parotid cancer. *Br J Cancer*. 1999;80:1296–300.
77. Bhattacharyya N, Fried MP. Determinants of survival in parotid gland carcinoma: a population-based study. *Am J Otolaryngol*. 2005;26:39–44.
78. Garden AS, El-Naggar AK, Morrison WH, et al. Postoperative radiotherapy for malignant tumors of the parotid gland. *Int J Radiat Oncol Biol Phys*. 1997;37:79–85.
79. Poulsen MG, Pratt GR, Kynaston B, Tripcony LB. Prognostic variables in malignant epithelial tumors of the parotid. *Int J Radiat Oncol Biol Phys*. 1992;23:327–32.
80. Storey MR, Garden AS, Morrison WH, et al. Postoperative radiotherapy for malignant tumors of the submandibular gland. *Int J Radiat Oncol Biol Phys*. 2001;51:952–8.
81. Garden AS, Weber RS, Ang KK, et al. Postoperative radiation therapy for malignant tumors of minor salivary glands. Outcome and patterns of failure. *Cancer*. 1994;73:2563–9.
82. Griffin TW, Pajak TF, Laramore GE, et al. Neutron vs. photon irradiation of inoperable salivary gland tumors: results of an RTOG-MRC cooperative randomized study. *Int J Radiat Oncol Biol Phys*. 1988;15:1085–90.
83. Laramore GE, Krall JM, Griffin TW, et al. Neutron versus photon irradiation for unresectable salivary gland tumors: final report of an RTOG-MRC randomized clinical trial. Radiation therapy oncology group. Medical research council. *Int J Radiat Oncol Biol Phys*. 1993;27:235–40.
84. Douglas JG, Koh WJ, Ustin-Seymour M, Laramore GE. Treatment of salivary gland neoplasms with fast neutron radiotherapy. *Arch Otolaryngol Head Neck Surg*. 2003;129:944–8.
85. Huber PE, Debus J, Latz D, et al. Radiotherapy for advanced adenoid cystic carcinoma: neutrons, photons or mixed beam? *Radiother Oncol*. 2001;59:161–7.
86. Douglas JG, Laramore GE, Austin-Seymour M, et al. Neutron radiotherapy for adenoid cystic carcinoma of minor salivary glands. *Int J Radiat Oncol Biol Phys*. 1996;36:87–93.
87. Pommier P, Liebsch NJ, Deschler DG, et al. Proton beam radiation therapy for skull base adenoid cystic carcinoma. *Arch Otolaryngol Head Neck Surg*. 2006;132:1242–9.
88. Kaplan MJ, Johns ME, Cantrell RW. Chemotherapy for salivary gland cancer. *Otolaryngol Head Neck Surg*. 1986;95:165–70.
89. Locati LD, Perrone F, Losa M, et al. Treatment relevant target immunophenotyping of 139 salivary gland carcinomas (SGCs). *Oral Oncol*. 2009;45(11):986–90.
90. Ettl T, Schwarz S, Kleinsasser N, et al. Overexpression of EGFR and absence of C-KIT expression correlate with poor prognosis in salivary gland carcinomas. *Histopathology*. 2008;53:567–77.
91. Andreadis D, Epivatianos A, Pouloupoulos A, et al. Detection of C-KIT (CD117) molecule in benign and malignant salivary gland tumours. *Oral Oncol*. 2006;42:57–65.
92. Holst VA, Marshall CE, Moskaluk CA, Frierson Jr HF. KIT protein expression and analysis of c-kit gene mutation in adenoid cystic carcinoma. *Mod Pathol*. 1999;12:956–60.
93. Jeng YM, Lin CY, Hsu HC. Expression of the c-kit protein is associated with certain subtypes of salivary gland carcinoma. *Cancer Lett*. 2000;154:107–11.
94. Penner CR, Folpe AL, Budnick SD. C-kit expression distinguishes salivary gland adenoid cystic carcinoma from polymorphous low-grade adenocarcinoma. *Mod Pathol*. 2002;15:687–91.
95. Edwards PC, Bhuiya T, Kelsch RD. C-kit expression in the salivary gland neoplasms adenoid cystic carcinoma, polymorphous low-grade adenocarcinoma, and monomorphic adenoma. *Oral Surg Oral Med Oral Pathol Oral Radiol Endod*. 2003;95:586–93.
96. Vered M, Braunstein E, Buchner A. Immunohistochemical study of epidermal growth factor receptor in adenoid cystic carcinoma of salivary gland origin. *Head Neck*. 2002;24:632–6.
97. Press MF, Pike MC, Hung G, et al. Amplification and overexpression of HER-2/neu in carcinomas of the salivary gland: correlation with poor prognosis. *Cancer Res*. 1994;54:5675–82.
98. Glisson B, Colevas AD, Haddad R, et al. HER2 expression in salivary gland carcinomas: dependence on histological subtype. *Clin Cancer Res*. 2004;10:944–6.
99. Nasser SM, Faquin WC, Dayal Y. Expression of androgen, estrogen, and progesterone receptors in salivary gland tumors. Frequent expression of androgen receptor in a subset of malignant salivary gland tumors. *Am J Clin Pathol*. 2003;119:801–6.
100. Moriki T, Ueta S, Takahashi T, Mitani M, Ichien M. Salivary duct carcinoma: cytologic characteristics and application of androgen receptor immunostaining for diagnosis. *Cancer*. 2001;93:344–50.
101. Dori S, Trougouboff P, David R, Buchner A. Immunohistochemical evaluation of estrogen and progesterone receptors in adenoid cystic carcinoma of salivary gland origin. *Oral Oncol*. 2000;36:450–3.
102. Dimery IW, Jones LA, Verjan RP, et al. Estrogen receptors in normal salivary gland and salivary gland carcinoma. *Arch Otolaryngol Head Neck Surg*. 1987;113:1082–5.
103. Miller AS, Hartman GG, Chen SY, et al. Estrogen receptor assay in polymorphous low-grade adenocarcinoma and adenoid cystic carcinoma of salivary gland origin. An immunohistochemical study. *Oral Surg Oral Med Oral Pathol*. 1994;77:36–40.
104. Jeannon JP, Soames JV, Bell H, Wilson JA. Immunohistochemical detection of oestrogen and progesterone receptors in salivary tumours. *Clin Otolaryngol Allied Sci*. 1999;24:52–4.
105. Lewis JE, McKinney BC, Weiland LH, Ferreiro JA, Olsen KD. Salivary duct carcinoma. Clinicopathologic and immunohistochemical review of 26 cases. *Cancer*. 1996;77:223–30.
106. Hellquist HB, Karlsson MG, Nilsson C. Salivary duct carcinoma – a highly aggressive salivary gland tumour with overexpression of c-erbB-2. *J Pathol*. 1994;172:35–44.
107. Wick MR, Ockner DM, Mills SE, Ritter JH, Swanson PE. Homologous carcinomas of the breasts, skin, and salivary glands. A histologic and immunohistochemical comparison of ductal mammary carcinoma, ductal sweat gland carcinoma, and salivary duct carcinoma. *Am J Clin Pathol*. 1998;109:75–84.
108. Shick PC, Riordan GP, Foss RD. Estrogen and progesterone receptors in salivary gland adenoid cystic carcinoma. *Oral Surg Oral Med Oral Pathol Oral Radiol Endod*. 1995;80:440–4.
109. Pires FR, da Cruz Perez DE, de Almeida OP, Kowalski LP. Estrogen receptor expression in salivary gland mucoepidermoid carcinoma and adenoid cystic carcinoma. *Pathol Oncol Res*. 2004;10:166–8.
110. Luo SD, Su CY, Chuang HC, et al. Estrogen receptor overexpression in malignant minor salivary gland tumors of the sinonasal tract. *Otolaryngol Head Neck Surg*. 2009;141:108–13.
111. Williams MD, Roberts D, Blumenschein Jr GR, et al. Differential expression of hormonal and growth factor receptors in salivary duct carcinomas: biologic significance and potential role in therapeutic stratification of patients. *Am J Surg Pathol*. 2007;31:1645–52.
112. Guzzo M, Locati LD, Prott FJ et al. Major and minor salivary gland tumors. *Crit Rev Oncol Hematol*. 2010;74:134–48. Review.
113. Hotte SJ, Winkquist EW, Lamont E, et al. Imatinib mesylate in patients with adenoid cystic cancers of the salivary glands expressing c-kit: a Princess Margaret Hospital phase II consortium study. *J Clin Oncol*. 2005;23:585–90.
114. Glisson BS, Blumenschein G, Francisco M, et al. Phase II trial of gefitinib in patients with incurable salivary gland cancer. *ASCO Annual Meeting Proceedings* 2005;23:508s
115. Agulnik M, Cohen EW, Cohen RB, et al. Phase II study of lapatinib in recurrent or metastatic epidermal growth factor receptor and/or erbB2 expressing adenoid cystic carcinoma and non adenoid cystic carcinoma malignant tumors of the salivary glands. *J Clin Oncol*. 2007;25:3978–84.

116. Faivre S, Raymond E, Casiraghi O, Temam S, Berthaud P. Imatinib mesylate can induce objective response in progressing, highly expressing KIT adenoid cystic carcinoma of the salivary glands. *J Clin Oncol.* 2005;23:6271–3.
117. Shadaba A, Gaze MN, Grant HR. The response of adenoid cystic carcinoma to tamoxifen. *J Laryngol Otol.* 1997;111:1186–9.
118. Locati LD, Quattrone P, Bossi P, et al. A complete remission with androgen-deprivation therapy in a recurrent androgen receptor-expressing adenocarcinoma of the parotid gland. *Ann Oncol.* 2003;14:1327–8.
119. van der Hulst RW, van Krieken JH, van der Kwast TH, et al. Partial remission of parotid gland carcinoma after goserelin. *Lancet.* 1994;344:817.

Chapter 37

Head and Neck Melanoma

Genevieve A. Andrews and Jeffery N. Myers

Abstract The head and neck region, a sun-exposed area, is the site of up to one-third of all primary cutaneous melanomas. In addition, rare melanoma subtypes such as mucosal melanoma and desmoplastic variant occur more commonly in the head and neck than other regions of the body. Although the same general treatment principles that apply to melanoma at other body sites also apply to the management of melanoma of the head and neck, treatment in this region is complicated by the complexity of the regional lymphatic drainage pathways and the close proximity of lesions to structures of functional or esthetic significance. Early-stage melanoma of the head and neck can in many cases be effectively treated with surgery; however, the prognosis for patients with more advanced disease remains poor. In addition to complete excision of the primary tumor with adequate margins, for selected patients, radiotherapy, chemotherapy, and other adjuvant treatments can play a role in optimizing patient outcomes.

Keywords Cutaneous melanoma • Head and neck • Desmoplastic melanoma • Risk factors • Staging • Surgery • Immunotherapy • Sentinel lymph node biopsy • Neck dissection • Adjuvant radiation

Epidemiology, Risk Factors, and Etiology

Epidemiology

The incidence of cutaneous melanoma has increased dramatically worldwide over the last half century, with an estimated 160,177 new cases in 2008. For the USA there were an estimated 62,480 new cases [1, 2], and there has been an increase

J.N. Myers (✉)
Department of Head and Neck Surgery, UT MD Anderson Cancer Center, 1515 Holcombe Blvd, Unit 1445, Houston, TX 77030-4009, USA
e-mail: jmyers@mdanderson.org

in melanoma incidence since 1992 equal to 3.1% per year in the Caucasian population in the USA [3]. As of 2004, the lifetime risk of developing melanoma was 1 in 41 for men and 1 in 61 for women in America [4]. This can be compared with a 1 in 53 risk for men and a 1 in 78 risk for women just 2 years prior, a 1 in 250 lifetime risk for individuals in 1980, and a 1 in 1,500 risk for individuals in 1935 [5].

Although the incidence of melanoma has steadily increased, the mortality rate has improved, with the 5-year disease-specific survival rates among melanoma patients increasing over the last 3 decades from 82 to 92% [4]. Worldwide deaths from melanoma in 2008 were estimated at 40,781 [2], with an estimate of 8,420 deaths occurring in the USA [2]. Despite improved mortality rates, the number of total deaths from melanoma continues to increase somewhat among American men as a result of the increased incidence of the disease. However, among American women, the death rates are decreasing slightly. Several theories for the increasing incidence of melanoma have been proposed, including increased environmental risk factors, changes in sun exposure behavior, earlier identification of melanomas, and increased reporting of low-risk melanomas to cancer registries [6–9]. The explanation of earlier melanoma detection as the reason for the increased incidence is an attractive one given the improvement in melanoma-specific survival.

Risk Factors

The primary environmental risk factor for the development of melanoma is sun exposure, particularly intermittent and intense exposures in childhood that lead to blistering sunburns [10–12]. This in part explains the high incidence of melanoma in the head and neck region, which has substantial exposure to sunlight, leading to an increased melanocyte density [13]. Interestingly, inherited melanoma occurs less frequently on head and neck skin, which is consistent with its propensity for sites with intermittent sun exposure, such as the trunk [14].

Because the head and neck area tends to be continually exposed to the sun, the American Cancer Society recommends that this region should be protected with the combination of avoidance of sunlight during the peak hours from 10 AM to 4 PM, use of a hat, and generous and frequent application of sunscreen with an SPF of 15 or greater on uncovered areas. While there is some concern about the actual efficacy of sunscreens, and the potential misuse of sunscreens for the justification of even greater amounts of sun exposure, the recommendation for sunscreen usage stands, since most evidence suggests that sunscreens offer protection by blocking ultraviolet (UV) light in the UVA and UVB portions of the spectrum (310–400 and 290–320 nm, respectively). In fact, due to advancements in the development of sunscreens in the 1990s such as longer-lasting UV filters, and the development of better methods of assessing the UV protection of a formulation, sunscreens are currently about four times more effective at blocking UVA and UVB irradiation than the sunscreens of 10–20 years ago [15]. Other environmental risk factors, such as occupation and hobbies, geographic latitude, and tanning are surrogates for UV irradiation exposure.

Patient factors that contribute to the risk of melanoma include fair complexion, genetic predisposition, immune compromise, and the presence of pigmented nevi [16]. Whether pigmented nevi are precursors and not simply risk factors for the development of melanoma is controversial. The most convincing evidence supporting this precursor theory is the spatial association of nevi and melanoma histologically and clinically [17]. High nevus counts are strongly associated with melanoma of the trunk but less so in patients with melanoma of the head and neck [18]. The most important pigmented lesion associated with the development of melanoma is the dysplastic nevus, which is a variegated-colored lesion usually greater than 5 mm in diameter with an irregular border. Persons who have dysplastic nevi and no significant family history have a 6% lifetime risk of melanoma [19]. People who have both dysplastic nevi and a positive family history of melanoma have a 50% lifetime risk of melanoma [20]. However, the conversion of any single dysplastic nevus into melanoma is low [19]. In contrast to dysplastic nevi, the giant congenital nevus is associated with a 2–40% lifetime risk of transformation into melanoma and usually occurs before 5 years of age [21]. Lentigo maligna melanoma in situ is another premalignant melanocytic lesion that carries a 5–10% risk of progression to invasive disease [22]. The vast majority of these lesions occur on the head and neck, most commonly on the cheeks and nose [23].

Etiology

Although the overwhelming majority (90%) of cases of melanoma is sporadic, familial syndromes with a high risk of development of melanoma, such as dysplastic nevus

syndrome or xeroderma pigmentosa, have been studied and have provided some insights into the etiology of melanoma. Patients with familial melanoma have been found to have primary germ-line mutations, which include CDKN2A (cyclin-dependent kinase inhibitor 2A) on chromosome 9p21, CDK4 (cyclin-dependent kinase 4) on chromosome 12q14, and the MC1R (melanocortin-1 receptor) [16]. The CDKN2A gene encodes the p16^{INK4a} and p14^{ARF} tumor-suppressor genes, which induce G1 cell-cycle arrest and p53-dependent apoptosis, respectively. P16^{INK4a} exerts its effect by inhibiting CDK4/6-mediated phosphorylation of the Rb protein. When dephosphorylated, Rb associates with E2F, preventing E2F from inducing progression of the cell past the G1 checkpoint. P14^{ARF} exerts its effect by inhibiting HDM2-induced ubiquitination of p53, thus preventing p53 degradation, and allowing p53's DNA-damage sensing, cell-cycle pausing, and pro-apoptotic effects [24]. The MC1R protein is a G-protein-coupled receptor that is activated in response to MSH (melanocyte-stimulating hormone) to ultimately promote a switch of production from red/yellow-type melanin to a brown/black-type melanin by melanocytes. MCR1 mutants do not make the switch from the red/yellow type melanin to the brown/black type, and persons with such mutations are phenotypically Fitzpatrick grade I, that is, possessing extreme sun sensitivity that puts them at higher risk for development of melanoma [24]. Somatic mutations in CDKN2A and CDK4 have also been identified in some sporadic cases of melanoma [24]. Other genes frequently mutated in sporadic melanoma include the kinase BRAF; the tumor suppressor PTEN; and cKIT, the tyrosine kinase responsible for melanocyte differentiation. Several other proteins are upregulated in melanoma, including Bcl-2, AKT, and p53 [16].

Presently, neither GenoMEL (the Melanoma Genetic Consortium) nor the American Society of Clinical Oncology recommends using clinical genetic testing of CDKN2A, even though it is thought to be the highest-risk mutation associated with the development of melanoma. Reasons for the hesitation to use this genetic test include the fact that less than half (39%) of patients with a strong family history of melanoma will test positive for CDKN2A mutation, with the majority having germ-line mutations in other genes or independent sporadic events. Thus, the utility of directed screening of family members with a strong family history of melanoma for CDKN2A mutations is unclear [25, 26].

There is evidence to suggest that there are different etiologies of melanoma depending on the pattern of sun exposure and the area of skin on which the melanoma lesion arises. For instance, mutations in BRAF have been found to be significantly more common in melanomas occurring on skin subject to intermittent sun exposure, such as the trunk, compared with those occurring on areas chronically exposed to the sun, such as the extremities or face [27]. Patients with melanomas in areas of chronic sun exposure most commonly

have wild-type BRAF but frequently also have increased copy numbers of the CCND1 gene and the cKIT gene [28, 29]. Also expression of the tumor suppressor p53 has been found to be greater in patients with head and neck melanoma than in patients with melanoma on the trunk [30].

Diagnosis and Evaluation

Diagnosis

Patient history is the key to early diagnosis of melanoma. The majority of melanomas are suspected by the patient and his or her family members, with fewer than 25% detected by physicians during the course of examination [31]. Patients with melanoma frequently complain of color change, growth, or the development of itching, bleeding, pain, or ulceration in a lesion that was previously present. While obtaining the patient history, the physician should take particular note of current occupational and recreational risks for excessive sun exposure, and history of sunburns especially as a child, as well as a history of melanoma or other skin cancer in family members.

A thorough physical examination is focused on risk stratification of the suspicious lesion, to determine whether biopsy is indicated, and the identification of additional suspicious lesions. It is important not to miss a second lesion, since development of a pigmented lesion in one area is likely a marker for overall for excessive sun exposure. Patients with one melanoma lesion are known to have a significantly increased risk of synchronous melanomas and nonmelanoma skin cancers (e.g., basal cell and squamous cell carcinomas) compared with the general population [32–36]. Proper examination requires adequate light and magnification and should include all skin and mucosal surfaces of the head and neck, including the scalp. The ABCDE mnemonic describes a checklist that can be useful for physicians in assessing pigmented lesions: *A*symmetry in growth, *B*order irregularity, *C*olor abnormality (variation in color in a single mole), *D*iameter greater than 6 mm, and *E*levation or raised from the skin. Of these characteristics, border irregularity most strongly predicts malignancy [37, 38]. Evidence suggests that physician observation of a change, or evolution, in a lesion is very important in increasing physician-suspicion that a pigmented lesion is a melanoma [39]. The importance of lesion observation over time in predicting development of melanoma was reflected in the incorporation of an alternative E, for “evolving,” into the previously mentioned ABCD mnemonic for describing a changing pigmented lesion [40]. Other features to note on physical examination that have bearing on the stage of a melanoma include skin ulceration, satellite lesions, in-transit metastases,

and lymphadenopathy in draining nodal basins. Patients with suspicious lesions or photo-damage in the head and neck region should be referred to a dermatologist for full-body screening and long-term follow-up, as a dermatologist’s visual examination is 89–97% sensitive, with a 35–75% positive predictive value [41].

Suspicious pigmented lesions must be biopsied in a manner that allows pathologic examination of the point of maximum depth. Excisional biopsy with 1- to 3-mm margins is recommended for small lesions in favorable locations. Excisional biopsy (as opposed to wide local excision) has been shown to leave lymphatic drainage pathways unaltered including drainage to sentinel lymph nodes. In addition, patients who have had excisional biopsy for small lesions have improved survival compared with those who have not [42]. However, it is recommended that large lesions, or those that encroach on cosmetically unfavorable areas, be evaluated with incisional biopsy, such as via punch biopsy, ensuring that the thickest part of the lesion is included. Needle or shave biopsy in the evaluation of suspicious pigmented lesions is not recommended as they may miss the full depth of the lesion. The decision as to which pigmented lesions are suspicious enough to warrant biopsy is based on the ABCDE criteria and should take into account all the patient’s risk factors for melanoma, keeping in mind that most dysplastic nevi will never progress to melanoma [43]. Although supportive data are lacking, some recommend that dysplastic nevi in areas that are difficult to follow clinically, such as the hair-bearing scalp, be prophylactically excised [44].

Further Evaluation

Once the diagnosis of malignant melanoma is confirmed by biopsy, the focus of further workup is on identifying any regional or distant metastases, as these have a great impact on prognosis and further treatment planning. A multidisciplinary evaluation and a cooperative approach to disease management in this disease includes involvement of multiple specialties such as radiology, nuclear medicine, radiation therapy, medical oncology, plastic and reconstructive surgery, dermatology, and other specialists to guide an individual’s treatment plan.

In the absence of evidence on physical examination of regional or distant spread of melanoma, thickness of the primary cutaneous lesion is used to determine the need for additional diagnostic evaluation, since tumor thickness is known to strongly influence the risk of metastasis [45]. Thus, the stage of the melanoma, which is based on the thickness of the cutaneous melanoma, is the primary determining factor for the extent of the metastatic workup. According to the National Comprehensive Cancer Network

(NCCN) guidelines, the choice of diagnostic tests to determine extent of disease and possible regional spread varies greatly among institutions. This variation is likely due to the lack of prospective data demonstrating the most appropriate work-up of the patient with melanoma. For this reason, the NCCN makes suggestions for work-up but largely leaves the choice of diagnostic test to the discretion of the treating physician [46]. Most physicians who treat melanoma would agree that for patients with in situ disease, no additional testing is needed. At The University of Texas M.D. Anderson Cancer Center, all thin (≤ 1 mm) melanomas, require only a chest X-ray and measurement of serum lactate dehydrogenase (LDH) as a screen for distant disease. Intermediate-thickness melanomas (>1 to 4 mm) are at greater risk of regional spread of melanoma and are thus candidates for preoperative lymphoscintigraphy and subsequent intraoperative sentinel lymph node biopsy (SLNB) to aid with pathologic staging. Patients with thick (>4 mm) or recurrent disease are at very high risk for distant disease, and consideration should be given to a more extensive metastatic work-up including CT scan of the neck as well as CT of the chest, abdomen, and pelvis and a brain MRI. Patients with clinically evident regional disease or ulceration of the primary melanoma should have preoperative neck CT or ultrasound imaging to help in treatment planning. The role of PET scanning is unclear, with many studies reporting low yield and a significant false-positive rate in patients with early-stage melanoma [47]. There may be an emerging role for PET imaging in the work-up of patients with more advanced melanoma, especially when potentially mutilating surgery is planned. However, it is unclear if the diagnostic yield of PET is better than that of traditional imaging techniques [48, 49].

Melanoma in rare cases can be found in the cervical or parotid nodes in patients with no evidence of a primary melanoma (metastatic melanoma of unknown origin), leading to the possibility that the primary melanoma had spontaneously regressed. In this case, more extensive diagnostic testing than would normally be done should be undertaken in the search for a head and neck primary melanoma, including ocular and mucosal sites. Physical examination and endoscopy are the first steps in the search for a primary. If physical examination and endoscopy do not identify the primary lesion, a PET scan may be considered, although there is a paucity of evidence of its effectiveness in this case. If no primary is located, patients should be treated with regional lymphadenectomy (neck dissection) appropriate to the nodal level(s) involved, with or without parotidectomy, plus adjuvant radiotherapy with or without chemotherapy (more below). In general, the outcome for patients with melanoma of unknown primary is the same or better than that for patients with regional nodal metastases from a known primary lesion [50].

Staging

The current AJCC staging system was revised in 2009 to better reflect factors proven to worsen prognosis and decrease the chance of survival. The current staging system, which has been validated, is detailed in Table 37.1 [51]. This latest staging system incorporates several variables proven to influence survival of patients with melanoma. Thus survival

Table 37.1 Melanoma of the skin: TNM classification and anatomic stage/prognostic groups

Definitions of TNM		
<i>Primary tumor (T)</i>		
TX	Primary tumor cannot be assessed (e.g., curettaged or severely regressed melanoma)	
T0	No evidence of primary tumor	
Tis	Melanoma in situ	
T1	Melanomas 1.0 mm or less in thickness	
T2	Melanomas 1.01–2.0 mm	
T3	Melanomas 2.01–4.0 mm	
T4	Melanomas more than 4.0 mm	
<i>Note: a and b subcategories of T are assigned based on ulceration and number of mitoses per mm² as shown below:</i>		
T Classification	Thickness (mm)	Ulceration status/mitoses
T1	≤ 1.0	a: w/o ulceration and mitosis $<1/\text{mm}^2$ b: with ulceration or mitoses $\geq 1/\text{mm}^2$
T2	1.01–2.0	a: w/o ulceration b: with ulceration
T3	2.01–4.0	a: w/o ulceration b: with ulceration
T4	>4.0	a: w/o ulceration b: with ulceration
<i>Regional lymph nodes (N)</i>		
NX	Patients in whom the regional nodes cannot be assessed (e.g., previously removed for another reason)	
N0	No regional metastases detected	
N1-3	Regional metastases based upon the number of metastatic nodes and presence or absence of intralymphatic metastases (in-transit or satellite metastases)	
<i>Note: N1-3 and a–c subcategories assigned as shown below:</i>		
N classification	Number of metastatic nodes	Nodal metastatic mass
N1	1 node	a: micrometastasis ^a b: macrometastasis ^b
N2	2–3 nodes	a: micrometastasis ^a b: macrometastasis ^b c: in-transit met(s)/satellite (s) without metastatic nodes

(continued)

Table 37.1 (continued)

N3	4 or more metastatic nodes, or matted nodes, or in transit met(s)/satellite(s) with metastatic node(s)
----	--

^aMicrometastases are diagnosed after sentinel lymph node biopsy and completion lymphadenectomy (if performed)

^bMacrometastases are defined as clinically detectable nodal metastases confirmed by therapeutic lymphadenectomy or when nodal metastasis exhibits gross extracapsular extension

Distant metastasis (M)

M0	No detectable evidence of distant metastases
M1a	Metastases to skin, subcutaneous, or distant lymph nodes
M1b	Metastases to lung
M1c	Metastases to all other visceral sites or distant metastases to any site combined with an elevated serum LDH

Note: Serum LDH is incorporated into the M category as shown below:

M Classification	Site	Serum LDH
M1a	Distant skin, subcutaneous, or nodal mets	Normal
M1b	Lung metastases	Normal
M1c	All other visceral metastases	Normal
	Any distant metastasis	Elevated

Anatomic stage/prognostic groups

Clinical staging ^a				Pathologic staging ^b								
Stage 0	Tis	N0	M0	0	Tis	N0	M0					
Stage IA	T1a	N0	M0	1A	T1a	N0	M0					
Stage IB	T1b	N0	M0	1B	T1b	N0	M0					
	T2a	N0	M0		T2a	N0	M0					
Stage IIA	T2b	N0	M0	IIA	T2b	N0	M0					
	T3a	N0	M0		T3a	N0	M0					
Stage IIB	T3b	N0	M0	IIB	T3b	N0	M0					
	T4a	N0	M0		T4a	N0	M0					
Stage IIC	T4b	N0	M0	IIC	T4b	N0	M0					
Stage III	Any T	≥N1	M0	IIIA	T(1–4)a	N1a	M0					
					T(1–4)a	N2a	M0					
					IIIB	T(1–4)b	N1a	M0				
						T(1–4)b	N2a	M0				
					IIIC	T(1–4)a	N1b	M0				
						T(1–4)a	N2b	M0				
						T(1–4)a	N2c	M0				
						T(1–4)b	N1b	M0				
										T(1–4)b	N2b	M0
										T(1–4)b	N2c	M0
					Any T	N3	M0					
Stage IV	Any T	Any N	MI	IV	Any T	Any N	M1					

^aClinical staging includes micro staging of the primary melanoma and clinical/radiologic evaluation for metastases. By convention, it should be used after complete excision of the primary melanoma with clinical assessment for regional and distant metastases

^bPathologic staging includes microstaging of the primary melanoma and pathologic information about the regional lymph nodes after partial or complete lymphadenectomy. Pathologic Stage 0 or Stage IA patients are the exception; they do not require pathologic evaluation of their lymph nodes

Used with the permission of the American Joint Committee on Cancer (AJCC), Chicago, IL. The original source for this material is the AJCC Cancer Staging Manual, Seventh Edition (2010) published by Springer Science and Business Media LLC, <http://www.springer.com>

varies depending on the stage of disease (Fig. 37.1) [51]. Of note, the current staging system incorporates microscopic lymph node metastases, such as those found upon sentinel lymph node biopsy, into the definition of pathologic staging. One prognostic factor that was not included in the 2002 AJCC melanoma staging revisions was mitotic count of the primary tumor. This index reflects the proliferative potential of the melanoma at the time of resection. The importance in the mitotic index in predicting survival had been examined previously, and since then even more data has emerged pointing to its importance [52].

Management

General Principles

The treatment of malignant melanoma of the head and neck follows the same overall guidelines of melanoma treatment as for other sites of the body. In general, the treatment of cutaneous melanoma includes complete resection of the primary tumor with sufficient margins, with the decision to perform adjuvant treatment based on stage of disease. However, the complex anatomy of the head and neck requires consideration of the important esthetic and functional defects that may result from treatment, and requires that planning for appropriate reconstruction be incorporated into treatment planning. For these reasons, melanoma of the head and neck is more likely to necessitate multispecialty assessment and frequently multimodality therapy than melanoma at other sites of the body. A synopsis of treatment recommendations according to stage is given in Table 37.2 [53].

Treatment of the Primary

The keystone of treatment for nearly any resectable primary is the complete wide local excision (WLE) of the tumor complete with adequate margins. However, the definition of an “adequate” surgical margin is often controversial and a matter of compromise. On the basis of studies of melanoma of non-head-and-neck sites, 5-mm margins of excision have been recommended for in situ disease, 1-cm margins for thin melanomas (<1 mm), 1- to 2-cm margins for intermediate lesions (1–2 mm), and 2-cm margins for thick melanomas (>2 mm) [54]. Surgical margins greater than 2 cm have not been shown to improve overall survival or local-regional control [55]. In the head and neck, the surgeon is often unable to take a wide local margin of 1–2 cm without causing substantial esthetic or functional disability. Considering the potentially adverse effect on quality of life that may result

Fig. 37.1 Twenty-year survival curves for patients with localized melanoma (Stages I and II), regional metastases (Stage III), and distant metastases (Stage IV). The numbers in parentheses are the numbers of patients from the AJCC Melanoma Staging Database used to calculate the survival rates. The differences between the curves are highly significant ($p < 0.0001$). Used with the permission of the American Joint Committee on Cancer (AJCC), Chicago, IL. The original source for this material is the AJCC Cancer Staging Manual, Seventh Edition (2010) published by Springer Science and Business Media LLC, <http://www.springer.com>

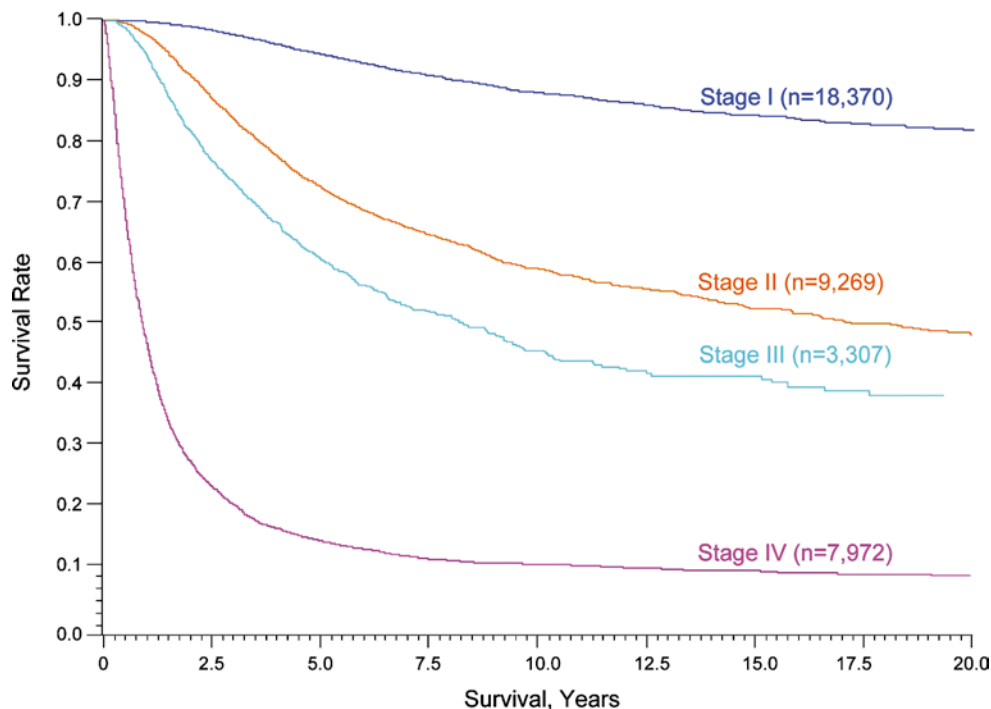


Table 37.2 Recommendations for treatment, on the basis of stage

Stage	Treatment
I	Primary tumor – WLE
II	Primary tumor – WLE
	Regional lymphatics – observation vs. END vs. SLNB vs. ENI
III	Primary tumor – WLE
	Regional lymphatics – neck dissection ± parotidectomy
	Consider postoperative radiotherapy
	Consider systemic adjuvant therapy trials
IV	Primary tumor – WLE
	Regional lymphatics – neck dissection ± parotidectomy if N+
	Metastasis – site-directed surgery or radiotherapy
	Consider systemic adjuvant therapy trials
	Supportive care

END elective neck dissection, ENI elective neck irradiation, N+, node positive, SLNB sentinel lymph node biopsy, WLE wide local excision
Used with permission from [53]. Copyright 2003 Elsevier Science. All rights reserved

from oncologic resection, it is best to discuss the treatment options with the patient before surgery and obtain his or her thoughts on how to best balance competing functional and oncological concerns.

Both superficial and deep margins need to be kept in mind in order for the surgeon to appropriately resect the primary tumor in all three dimensions. Adequate margins in the scalp most commonly extend to the galea and potentially include the periosteum or portions of the calvarium for more extensive disease. Facial melanoma often requires resection down

to the deep layer of the subcutaneous fat, and potentially up to and through the muscles of facial expression. Tumors overlying the parotid gland are excised down to the parotidomasseteric fascia. If the lesion extends into this fascial barrier, parotidectomy is recommended. Because the skin of the external ear is thin and adherent to the underlying cartilage, sufficient margins in this region often necessitate resection of the underlying cartilage or partial or complete auriclectomy. Extension medially into or beyond the external auditory canal requires a temporal bone resection [53]. Surgical extirpation of mucosal melanoma of the head and neck often resembles those surgeries performed for squamous cell carcinomas of the upper aerodigestive tract, and frequently require local, regional, or vascularized free flaps for reconstruction.

Frozen section control of resection margins may sometimes be helpful in minimizing unnecessary tissue loss if there is good communication between the surgeon and a pathologist who is comfortable with this technique in the setting of melanoma. Otherwise, there is a significant potential for false-negative results [56]. Therefore, our preferred practice in an area that will require complex reconstruction is to excise a lesion and then cover it with a bolster dressing, followed by expedited histopathologic review of the formalin-fixed, paraffin-embedded tissue with subsequent additional resection if necessary. In this scenario, margin status can be confirmed within 24 h, and definitive reconstruction is delayed until after adequate margins are ensured. Moh's

micrographic surgery is another technique utilized by specially trained dermatologic surgeons for sparing tissue in areas of functional or cosmetic significance. While Moh's surgery has been described in the literature, particularly in thin melanomas, long-term results are unclear, and it is not presently the standard of melanoma care [57].

While all primary melanomas should be surgically excised, there is evidence that postoperative radiotherapy can be employed to improve local-regional control in certain cases, such as when the adequacy of surgical margins is compromised by the proximity of key structures or there is extensive peri-neural invasion by tumor within the specimen. This is further addressed below.

Desmoplastic melanoma is an infrequent variant of cutaneous melanoma that is most often found in the head and neck, with about 50% of cases of desmoplastic melanoma arising above the clavicles. It tends to occur in older male patients and to present with greater depth of invasion at the primary site compared with nondesmoplastic melanoma. Importantly, desmoplastic melanoma has a propensity for perineural spread, with reported rates ranging from 17 to 94% [58, 59]. Desmoplastic melanoma also has a high rate of amelanosis, or lack of pigmentation (about 40–73%), compared with non-desmoplastic cutaneous melanoma (~7%), which may lead to a delay in clinical diagnosis of melanoma [60]. Additionally, desmoplastic melanoma can be a challenge to diagnose histologically by conventional hematoxylin and eosin staining. In fact, one study showed that patients with pure desmoplastic melanoma were incorrectly diagnosed on initial biopsy or excision in 28% of cases, with 10% of mixed desmoplastic melanoma cases being misdiagnosed initially on histopathology [61]. All of these factors have been implicated as contributing to desmoplastic melanoma's high rate of local recurrence (up to 56%) [62]. For this reason, adjuvant radiation is recommended for the desmoplastic variant of melanoma and has been shown in retrospective data to decrease local recurrence rate and improve recurrence-free survival [63, 64].

Treatment of the Neck

The neck should be treated surgically in patients with clinical evidence of spread of tumor to regional lymph nodes (stage III). For patients with positive lymphadenopathy by physical examination or imaging, a neck dissection is almost always performed. In most cases, a comprehensive neck dissection sparing all nonlymphatic structures is sufficient, with resection of all the most likely lymphatic drainage basins of the primary site including additional areas, such as the parotid gland, as well as the peri-facial, occipital, and peri-

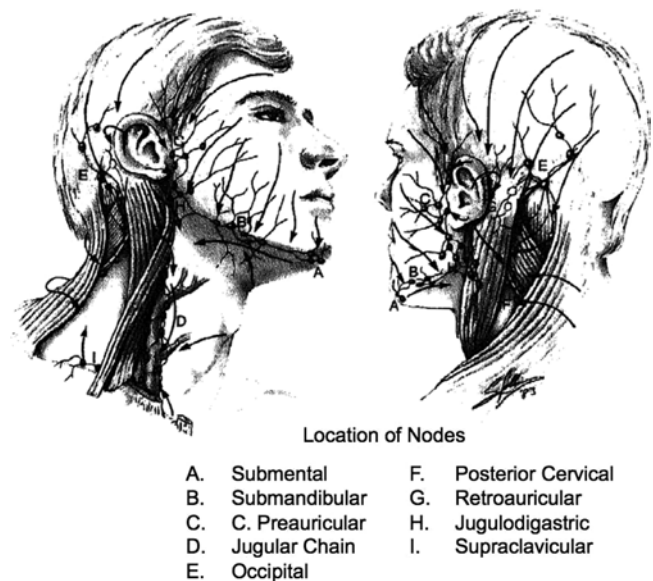


Fig. 37.2 Cutaneous lymphatic drainage of the head and neck. The usual patterns of lymphatic drainage from cutaneous regions of the head and neck are shown in this drawing, along with the major corresponding lymph node basins. In general, lymph node level I corresponds to the submental and submandibular nodes (A, B). Additionally levels II, III, IV, and V correspond to the jugulodigastric (H), jugular (D), supraclavicular (I), and posterior cervical (F) nodal areas, respectively. Used with permission from Balch CM, Houghton AN, Milton GW, et al., editors. *Cutaneous melanoma*. 2nd ed. Lippincott; 1992

auricular nodes as needed [65]. Figure 37.2 depicts the nodal regions, or “levels” of the neck.

While the role of neck dissection in treatment of macroscopic lymphadenopathy is well established, substantially more controversy surrounds the management of the N0 neck, in which there may be occult spread of melanoma to regional lymph nodes. Options for treatment of the neck include observation, elective neck dissection (END), sentinel lymph node biopsy (SLNB), and elective neck irradiation. An argument favoring observation of the N0 neck is that neither elective neck dissection nor SLNB has been shown to substantially improve overall survival [66]. Currently, patients with thin melanomas (T1a) are considered to be at minimal risk for regional lymph node metastasis, and as such are routinely treated with observation without any surgical intervention. However, patients with T1b or stage II disease are at substantial risk for nodal metastasis and have been traditionally considered candidates for END and more recently for SLNB.

Melanoma of the head and neck spreads to the neck along relatively predictable lymphatic pathways, and therefore the site of the primary has been used to determine the type of elective neck dissection performed in treatment of the neck. In general, patients with a neck or scalp primary melanoma posterior to a vertical line through the external auditory canal require postero-lateral neck dissection that encompasses levels II–V of the neck plus the retroauricular and suboccipital

lymph nodes [67]. Patients with a scalp or neck primary anterior to that vertical line through the external auditory canal typically undergo a lateral neck dissection (levels II–IV) and a parotidectomy. Melanoma primary lesions on the face are treated with a supraomohyoid neck dissection (levels I–III). Because cutaneous cancers may spread to nodal groups other than levels I–V, which are the nodal areas more commonly involved in mucosally derived head and neck tumors such as squamous cell carcinoma, it is important that the clinician have a high index of suspicion for involvement of the facial, peri-auricular, and especially parotid lymph nodes. The parotid is a frequent site of metastasis from the temple, peri-auricular, and anterior scalp areas. As a general rule, parotidectomy must be considered when the parotid lies between the primary melanoma lesion and the site of clinically evident nodal metastasis. For very anterior lesions occurring on the central face, chin, and neck, the parotid lymph nodes are usually not likely to be a site of melanoma metastasis [53].

The justification for elective neck dissection is that it removes the nodal groups at risk before the appearance of clinical evidence of metastases, theoretically reducing the risk of regional or distant spread. Although this reasoning seems sound, only limited prospective data support the use of END to improve local-regional control or overall survival. Even among the subsets of patients with intermediate-thickness and nonulcerated melanomas shown in prospective studies to have improved survival after END [51, 68], a significant number of patients would have never developed neck disease and yet are subjected to the morbidity of END when it is performed routinely. Sentinel lymph node biopsy addresses this dilemma. This technique is based on the principle that initial lymphatic spread from a given primary site is to a very limited subset of lymph nodes before wider dissemination occurs. Thus, by injecting the primary site of the melanoma with tracer substances, it is possible to use preoperative nuclear imaging, intraoperative blue dye localization, and intraoperative lymphoscintigraphy to find the sentinel node or nodes and perform a very limited lymphadenectomy with increased pathologic investigation of the sentinel nodes to determine the presence of nodal metastasis with greater sensitivity [70, 71].

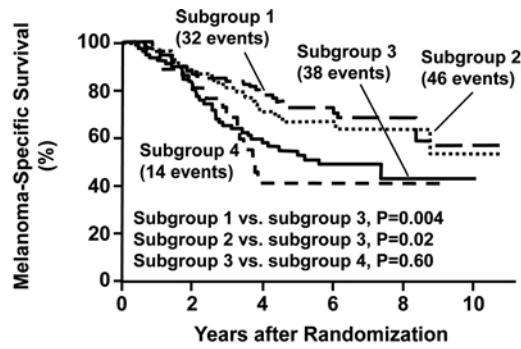
The validity of SLNB is well-established for melanoma on the trunk or extremities. However, its role in the treatment of cutaneous melanoma of the head and neck is still being refined. Identification and removal of sentinel lymph nodes in the head and neck can be difficult because (1) the primary and metastatic sites are often very close to each other, (2) routes of lymphatic drainage can be complex, (3) central lesions can potentially spread bilaterally, and (4) sentinel nodes can be found at several neck levels concurrently, or within the parotid gland. Despite this, numerous studies have shown that one or more sentinel nodes can be located in the vast majority of patients (>95%) if both vital dye staining and lymphoscintigraphy are

used [69, 72]. Considering the evidence that the lymphatic drainage patterns from cutaneous melanoma of the head and neck do not always occur in a predictable way, one could see how using SLNB initially to map out the first echelon lymph nodes most likely at risk would be an attractive alternative to the traditional staging END [73–75]. Approximately 2–3 sentinel nodes are usually identified, often in nonadjoining lymph node areas. Despite a very low average false-negative rate in trials where SLNB is followed by END, some of studies have found higher than expected rates of lymph node metastases in patients with negative SLNB [75].

The prognostic power of SLNB in head and neck melanoma is supported by several retrospective and prospective studies. Data from a retrospective study of SLNB performed on 113 patients at a large cancer center followed for a median of 34 months verified successful sentinel node identification in 96% of patients [76]. While the rate of regional recurrence in the 23% of patients with positive sentinel nodes was 13%, it was 5% in patients with negative sentinel nodes. The overall rate of all types of recurrences was 48% in patients with a positive sentinel node biopsy, and 23% in those with negative sentinel nodes. Despite the higher recurrence rate in patients with positive SLNB, sentinel node status was not significantly associated with survival on multivariate analysis; the only variables associated with decreased disease-free survival and overall 5-year survival were Breslow thickness, and age greater than or equal to 60 years, respectively.

Results from a Sentinel Lymph Node Working Group trial consisting of 614 patients accrued from 13 centers demonstrated significantly worse 5-year disease-free survival for patients with positive sentinel nodes (about 50%) compared with patients with negative sentinel nodes (about 80%) and found that sentinel lymph node status was the most significant predictor of disease-free survival by multivariate analysis [77].

The prognostic value of SLNB was quite convincingly demonstrated in the landmark prospective Multicenter Selective Lymphadenectomy Trial (MSLT I), the results of which were published in 2006 [66]. In this trial, 1,269 patients with intermediate-thickness melanomas from multiple sites including the head and neck, with no evidence of regional spread at presentation (N0), were randomly assigned to WLE with SLNB, or WLE alone with performance of a delayed lymph node dissection (LND) if nodal metastases became clinically apparent. Taking into account all patients in the study, there was an improvement in the 5-year disease-specific survival rate for the WLE–SLNB group (78%) compared with the WLE alone group (73%), although melanoma-specific and overall survivals showed no difference. In a subset analysis of only the patients who had micrometastases on SLNB or developed lymph node metastases, however, the 5-year melanoma-specific survival was significantly better in the WLE–SLNB–early LND group (72%) than in the WLE–delayed LND group (52%) (Fig. 37.3) [66].



No. at Risk						
Subgroup 1	122	100	65	38	15	2
Subgroup 2	148	120	73	43	18	2
Subgroup 3	78	63	37	23	5	1
Subgroup 4	26	20	8	5	3	0

Fig. 37.3 Melanoma-specific survival among patients with nodal metastases. Subgroup 1 is comprised of patients with a tumor-positive sentinel node. Subgroup 3 contains patients with nodal recurrence during observation who underwent delayed lymphadenectomy. Subgroup 4 is comprised of patients with nodal recurrence after a negative sentinel lymph node biopsy result. Subgroup 2 contains patients in subgroup 1 plus those in subgroup 4. The 5-year survival rate of subgroup 1 was significantly better than that of subgroup 3 at $72.3 \pm 4.6\%$ and $52.4 \pm 5.9\%$, respectively (hazard ratio for death, 0.51; CI, 0.31–0.81; $p=0.004$ by log-rank test and $p=0.007$ by the Cox model). Used with permission from [66]. Copyright 2006 Massachusetts Medical Society. All rights reserved

Additionally, the number of tumor-positive nodes in the delayed LND group was greater than twice that of the positive SLNB-early LND group (3.3 vs. 1.4, respectively). Given these observations, and other studies showing similar results, the use of SLNB with subsequent early lymph node dissection if positive, as opposed to delayed neck dissection when nodal involvement becomes clinically apparent, is recommended [78].

Considering the retrospective nature of available data, the role of SLNB in predicting the prognosis of clinically N0 patients with thick (>4 mm) primary melanomas is not clear. However, since several of these studies show that SLNB is predictive of either recurrence or survival, the routine use of SLNB is recommended for this group of N0 patients with thicker lesions [79–83].

A special situation in the management of the N0 neck arises when the histopathology is that of desmoplastic melanoma. A retrospective study examining a major cancer center's experience with desmoplastic melanoma over a 25-year period showed that the regional spread of this variant of melanoma depends upon the degree of desmoplasia within the tumor, with the pure form of desmoplastic melanoma being much less likely than the mixed form to metastasize to regional lymph nodes (1 vs. 18%, respectively) [61]. Additionally, the melanoma-specific mortality was

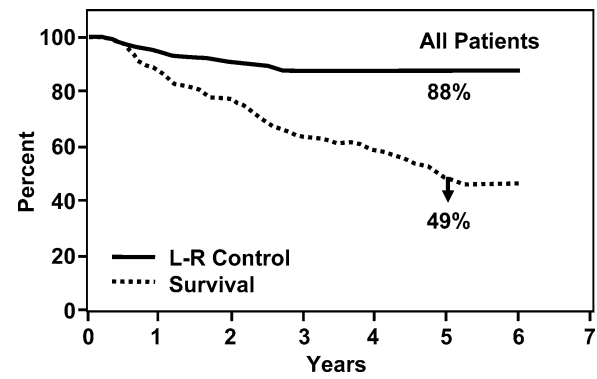


Fig. 37.4 Actuarial local-regional control and survival rates of 174 patients treated with hypofractionated postoperative radiotherapy for high-risk cutaneous melanoma. The adverse features evaluated in this study were thickness ≥ 1.5 mm or Clark level IV/V (79 patients), palpable lymphadenopathy (32 patients), and nodal relapse after previous excision of melanoma (63 patients). The local-regional control rate was 88% at 5 years following hypofractionated postoperative radiotherapy in high risk cutaneous melanoma patients. This is substantially improved compared to similar historical controls not treated with adjuvant radiotherapy. Used with permission from [86]. Copyright 1994 Elsevier

significantly greater for patients with the mixed form compared with the pure form of desmoplastic melanoma and conventional melanoma. Consequently, elective lymphadenectomy and sentinel lymph node biopsy are not recommended in patients with pure desmoplastic melanoma.

In approximately 80% of SLNB-positive patients, the removed sentinel nodes are the only tumor-containing nodes found at completion lymphadenectomy. Given this relatively high rate of a second positive lymph node, completion lymphadenectomy is currently the standard of care to ensure regional control in those patients with a positive SLN. However, this issue is being further investigated in the MSLT II trial that was designed to determine whether serial nodal ultrasound can be used to select for those SLNB-positive patients who will need completion lymphadenectomy [84]. The results of this ongoing trial may further help guide the use of sentinel lymph node dissection to maximize survival and minimize unnecessary morbidity.

Although melanoma was historically thought to be radio-resistant, some studies have shown that an enhancement in local-regional control of cutaneous melanoma with adverse features (≥ 1.5 -mm thickness, Clarks level IV/V, nodal metastases, or recurrence after excision) in the head and neck is possible using a hypofractionation regimen [85, 86]. This hypofractionation scheme consisted of large-dose fractions of 6 Gy delivered in five fractions, or 30 Gy total, to the primary site and regional lymph node basins. This regimen has been shown to achieve local-regional control rates of up to 88% when administered postoperatively, which is a definite improvement over historical control rates in this population (~50%) (Fig. 37.4) [86]. Although this percentage is based

on retrospective data with historical controls, the substantial degree of the benefit suggests that this altered fractionation radiotherapy regimen is appropriate as an adjuvant local-regional therapy. Although the hypofractionated scheme described is used most commonly, there is some evidence that conventional fractionation can be as efficacious as hypofractionation in the adjuvant treatment of cutaneous melanoma of the head and neck [87]. Additionally, adjuvant and primary radiotherapy have been suggested to improve local-regional control in both mucosal melanoma and desmoplastic melanoma of the head and neck, although overall survival is not improved [88, 89].

Prevention and Treatment of Distant Metastases

Patients with stage III melanoma are at elevated risk for development of distant metastatic melanoma, even when local-regional control is achieved. Stage IIB and IIC patients also have a considerable risk, albeit smaller than that for stage III patients, of developing distant metastases [90]. Several approaches have been developed to decrease the risk of distant metastases in high-risk patients. While many show promise, none have consistently reduced the risk of distant metastases in prospective studies.

The only FDA-approved adjuvant systemic therapy for melanoma patients at high risk for metastasis is interferon-alpha-2b (IFN-alpha-2b). However, the conflicting results of multiple randomized controlled trials evaluating adjuvant IFN-alpha-2b for melanoma patients at high risk for metastasis have created confusion regarding its usefulness in patients. To summarize these results, the data support a small increase in average disease-free survival for patients with stage III and high-risk stage II disease who take high-dose IFN-alpha-2b without a consistent benefit in overall survival [91]. IFN-alpha-2b therapy is administered for a 1-year period and can lead to considerable toxicity, such as nausea, fatigue, depression, and influenza-like illness. These disadvantages must be weighed against the mild benefit in disease-free survival when deciding whether or not to recommend IFN-alpha-2b to a patient. Other adjuvant therapies are considered experimental and include biochemotherapy (immunotherapy plus antimelanoma chemotherapy) and melanoma vaccines [90]. To date no prospective data support a consistent benefit for any of these therapies, nor for chemotherapy alone, and are thus best administered to a patient in the context of a clinical trial [92–94]. Our practice is to refer patients with stage III disease who have completed their local-regional therapy to a medical oncologist with experience in treatment of melanoma for a candid discussion of all available systemic adjuvant therapy options.

Patients with stage IV (distantly metastatic) disease have a poor prognosis that has not been shown to be substantially improved by any treatment. Dacarbazine (DTIC) is the only chemotherapeutic agent recommended for stage IV melanoma. In fact, no combination regimen has been shown to be significantly more efficacious than dacarbazine alone in increasing disease-free or overall survival, despite modest improvements in the <20% response rate seen with dacarbazine alone [95]. Temozolomide, an agent closely related to DTIC, has shown efficacy equivalent to that for DTIC and has the added benefit of greater blood–brain barrier penetration, which is important in patients with melanoma metastases to the brain [96]. Continued evaluation of new chemotherapeutic agents and immunotherapeutic approaches in the treatment of disseminated disease remains experimental, and thus far such approaches have not been reliably beneficial in most patients [95]. Some trials combining chemotherapeutic drugs such as vinblastine, cisplatin, tamoxifen, and dacarbazine with the biochemotherapeutic agents interferon-alpha-2a and interleukin-2 have shown increased response rates in the combination arms compared with chemotherapy alone [97–100]. Overall, however, the conclusion can be drawn that the results are conflicting and that these regimens are best used primarily in the setting of a clinical trial.

The combination of chemotherapy with various targeted therapies is being studied in metastatic melanoma more frequently given the lack of an effective treatment for this disease. Sorafenib is an agent that was designed to inhibit the ATP-binding site of the BRAF kinase. It has also been found to inhibit CRAF, VEGFR2, PDGF-beta, p38, flt-3, and c-KIT [101]. In the phase II trial setting, sorafenib has shown modest activity in refractory metastatic melanoma [102]. In a phase III trial looking at sorafenib combined with carboplatin and paclitaxol, given after failed treatment of advanced melanoma with dacarbazine or temozolomide regimens, there was no improvement in progression-free survival, overall survival or response rate with the addition of sorafenib to the chemotherapeutic regimen [103]. Thus in the second-line setting, sorafenib added to paclitaxol and carboplatin is not recommended. The trial evaluating the efficacy of this regimen as a first-line agent for advanced melanoma is ongoing [103]. Another targeted agent currently being studied is oblimersen sodium, which is an anti-Bcl-2 antisense oligonucleotide designed to induce apoptosis by inhibiting expression of the antiapoptotic product of the Bcl-2 gene. When combined with DTIC in a phase II trial in patients with metastatic melanoma, overall survival and progression-free survival were significantly improved compared with the use of DTIC alone [104]. Sorafenib and oblimersen sodium are just two of many promising targeted agents currently being tested in the clinical trial setting for the treatment of metastatic melanoma.

Table 37.3 Recommendations for follow-up, on the basis of stage

Stage	Physical examination	Radiology	Laboratory tests
Melanoma in situ	Every 6 months×4 years, then annually	None	None
Stage I or II (with ulceration, or thickness >1.0 mm)	Every 6 months×4 years, then annually	CXR	LDH
Stage I or II (with ulceration, or thickness >1.0 mm)	Every 4 months×2 years, then every 6 months×2 years then annually	CXR	LDH
Stage III, or recurrent primary	Every 3 months×2 years, then every 6 months×3 years, then annually	CXR	LDH, CBC
Stage IV	Individualize	Individualize	Individualize

CBC complete blood count, CXR chest X-ray, LDH lactate dehydrogenase

Used with permission from [53]. Copyright 2003 Elsevier Science. All rights reserved

Treatment of Recurrent Disease

Whether it is local, regional, or distant, recurrence of melanoma is a poor prognostic sign. Re-excision is the treatment of choice for local or regional recurrences, with strong consideration given to recommending adjuvant radiotherapy. Patients with local recurrences that cannot be excised may be evaluated for palliative systemic treatment with or without a subsequent attempt to resect the recurrence. In the case of isolated distant metastatic melanoma, particularly to the lung, it might be prudent to excise the distant recurrence, as aggressive treatment occasionally results in a long-term progression-free interval or even cure. Brain and liver metastases have a worse prognosis, which is reflected in the M3 categorization of such visceral distant metastases in the melanoma staging system delineated by the AJCC [51, 105]. Although the majority of patients with recurrence will die of their disease, quality of life can be preserved by maintaining local-regional control.

Posttreatment Follow-Up

Because melanoma tends to occur in relatively younger patients, extended periods of follow-up are the norm. It has been reported that 28–56% of melanoma recurrences are discovered by a physician, indicating that a schedule of routine physical examination is an important aspect of follow-up [106, 107]. The routine use of laboratory and radiographic tests in follow-up is controversial, with little reliable data to guide their use. A summary of a recommended follow-up protocol based on stage of disease is in Table 37.3 [53].

References

- Parkin DM, Bray F, Ferlay J, et al. Global cancer statistics, 2002. *CA Cancer J Clin.* 2005;55:74–108.
- American Cancer Society. *Cancer facts & figures 2008.* Atlanta, GA: American Cancer Society; 2008.
- Linos E, Swetter SM, Cockburn MG, Colditz GA, Clarke CA. Increasing burden of melanoma in the United States. *J Invest Dermatol.* 2009;129:1666–74.
- Jemal A, Siegel R, Ward E, et al. Cancer statistics, 2008. *CA Cancer J Clin.* 2008;58:71–96.
- Rigel DS, Carucci JA. Malignant melanoma: prevention, early detection, and treatment in the 21st century. *CA Cancer J Clin.* 2000;50:215–36.
- Diffey B. Climate change, ozone depletion and the impact on ultraviolet exposure of human skin. *Phys Med Biol.* 2004;49:R1–11.
- Welch HG, Wotoshin S, Schwartz LM. Skin biopsy rates and incidence of melanoma: population based ecological study. *BMJ.* 2005;331:481.
- Swerlick RA, Chen S. The melanoma epidemic: more apparent than real? *Mayo Clin Proc.* 1997;72:559–64.
- Hall HI, Jamison P, Fulton JP, Clutter G, Roffers S, Parrish P. Reporting cutaneous melanoma to cancer registries in the United States. *J Am Acad Dermatol.* 2003;49:624–30.
- Armstrong BK. Epidemiology of malignant melanoma: intermittent or total exposure to the sun? *J Dermatol Surg Oncol.* 1988;14(8):835–49.
- Whiteman DC, Whiteman CA, Green AC. Childhood sun exposure as a risk factor for melanoma: a systematic review of epidemiologic studies. *Cancer Causes Control.* 2001;12:69–82.
- Thomas NE, Edmiston SN, Alexander A, et al. Number of nevi and early-life ambient UV exposure are associated with BRAF-mutant melanoma. *Cancer Epidemiol Biomarkers Prev.* 2007;16(5):991–7.
- Hendi A, Brodland DG, Zitelli JA. Melanocytes in long-standing sun-exposed skin: quantitative analysis using the MART-1 immunostain. *Arch Dermatol.* 2006;142:871–6.
- Siskind V, Whiteman DC, Aitken JF, Martin NG, Green AC. An analysis of risk factors for cutaneous melanoma by anatomical site (Australia). *Cancer Causes Control.* 2005;16:193–9.
- Diffey BL. Sunscreens and melanoma: the future looks bright. *Br J Dermatol.* 2005;153:378–81.
- Ibrahim N, Haluska FG. Molecular pathogenesis of cutaneous melanocytic neoplasms. *Annu Rev Pathol.* 2009;4:551–79.
- Skender-Kalnenas TM, English DR, Heenan PJ. Benign melanocytic lesions: risk markers or precursors of cutaneous melanoma? *J Am Acad Dermatol.* 1995;33(6):1000–7.
- Olsen CM, Zens MS, Stukel TA, et al. Nevus density and melanoma risk in women: a pooled analysis to test the divergent pathway hypothesis. *Int J Cancer.* 2009;124(4):937–44.
- Kraemer KH, Tucker M, Tarone R, Elder DE, Clark Jr WH. Risk of cutaneous melanoma in dysplastic nevus syndromes types A and B. *N Engl J Med.* 1986;315:1615–6.
- Tucker MA, Fraser MC, Goldstein AM, Elder DE, Guerry 4th D, Organic SM. Risk of melanoma and other cancers in melanoma-prone families. *J Invest Dermatol.* 1993;100:350S–55S.

21. Lorentzen M, Pers M, Bretteville-Jensen G. The incidence of malignant transformation in giant pigmented nevi. *Scand J Plast Reconstr Surg*. 1977;11:163–7.
22. Weinstein MA, Sober AJ. The risk of progression of lentigo maligna to lentigo maligna melanoma. *Br J Dermatol*. 1987;116:303–10.
23. Koh HK, Michalik E, Sober AJ, et al. Lentigo maligna melanoma has no better prognosis than other types of melanoma. *J Clin Oncol*. 1984;2:994–1001.
24. Nelson AA, Tsao H. Melanoma and genetics. *Clin Dermatol*. 2009;27:46–52.
25. Kefford RF, Newton Bishop JA, Bergman W, Tucker MA. Counseling and DNA testing for individuals perceived to be genetically predisposed to melanoma: a consensus statement of the Melanoma Genetics Consortium. *J Clin Oncol*. 1999;17:3245–51.
26. Kefford R, Bishop JN, Tucker M, et al. Genetic testing for melanoma. *Lancet Oncol*. 2002;3(11):653–4.
27. Maldonado JL, Fridlyand J, Patel H, et al. Determinants of BRAF mutations in primary melanomas. *J Natl Cancer Inst*. 2003;95:1878–90.
28. Curtin JA, Fridlyand J, Kageshita T, et al. Distinct sets of genetic alterations in melanoma. *N Engl J Med*. 2005;353:2135–47.
29. Curtin JA, Busam K, Pinkel D, Bastian BC. Somatic activation of KIT in distinct subtypes of melanoma. *J Clin Oncol*. 2006;24:4340–6.
30. Whiteman DC, Parsons PG, Green AC. p53 expression and risk factors for cutaneous melanoma: a case control study. *Int J Cancer*. 1998;77:843–8.
31. Koh HK, Miller DR, Geller AC, Clapp RW, Mercer MB, Lew RA. Who discovers melanoma? Patterns from a population-based survey. *J Am Acad Dermatol*. 1992;26(6):914–9.
32. Kang S, Barnhill RL, Mihm Jr MC, Sober AJ. Multiple primary cutaneous melanomas. *Cancer*. 1992;70:1911–6.
33. Slingluff CL, Vollmer RT, Seigler HF. Multiple primary melanoma: incidence and risk factors in 283 patients. *Surgery*. 1993;113:330–9.
34. Marghoob AA, Slade J, Salopek TG, Kopf AW, Bart RS, Rigel DS. Basal cell and squamous cell carcinomas are important risk factors for cutaneous malignant melanoma: screening implications. *Cancer*. 1995;75 Suppl 2:707–14.
35. Bhatia S, Estrada-Batres L, Maryon T, Boque M, Chu D. Second primary tumors in patients with cutaneous malignant melanoma. *Cancer*. 1999;86(10):2014–20.
36. Goggins WB, Tsao H. A population-based analysis of risk factors for a second primary cutaneous melanoma among melanoma survivors. *Cancer*. 2003;97:639–43.
37. Friedman RJ, Rigel DS, Kopf AW. Early detection of malignant melanoma: the role of physician examination and self-examination of the skin. *CA Cancer J Clin*. 1985;35:130–350.
38. Mackie RM. Illustrated guide to recognition of early malignant melanoma. Edinburgh: Blackwood Pillans and Wilson Ltd; 1986.
39. Harris JM, Salasche SJ, Harris RB. Can internet-based continuing medical education improve physicians knowledge and skills? *J Gen Intern Med*. 2001;16:50–6.
40. Abbasi NR, Shaw HM, Rigel DS, et al. Early diagnosis of cutaneous melanoma: revisiting the ABCDE criteria. *JAMA*. 2004;292:2771–6.
41. McDonald CJ. Status of screening for skin cancer. *Cancer*. 1993;72(3s):1066–70.
42. Austin JR, Byers RM, Brown WD, Wolf P. Influence of biopsy on the prognosis of cutaneous melanoma of the head and neck. *Head Neck*. 1996;18:107–17.
43. Clark Jr WH, Elder DE, Guerry 4th D, Epstein MN, Greene MH, Van Horn M. A study of tumor progression: the precursor lesions of superficial spreading and nodular melanoma. *Hum Pathol*. 1984;15:1147–65.
44. Tsao H, Sober AJ. Atypical melanocytic nevi. In: Freedberg IM et al., editors. *Fitzpatrick's dermatology in general medicine*. 6th ed. New York: McGraw-Hill; 2003. p. 906–16.
45. Balch CM, Buzaid AC, Soong SJ, et al. Final version of the American Joint Committee on Cancer Staging system for cutaneous melanoma. *J Clin Oncol*. 2001;19:3635–45.
46. National Comprehensive Cancer Network. <http://www.nccn.org>. Accessed 28 June 2009.
47. Wagner JD, Schauwecker D, Davidson D, et al. Inefficacy of F-18 fluorodeoxy-D-glucose-positron emission tomography scans for initial evaluation in early-stage cutaneous melanoma. *Cancer*. 2005;104:570–9.
48. Clark PB, Soo V, Kraas J, Shen P, Levine EA, et al. Futility of fluorodeoxyglucose F18 positron emission tomography in initial evaluation of patients with T2 to T4 melanoma. *Ann Surg*. 2006;141:284–8.
49. Maubec E, Lumbroso J, Masson F, et al. F-18 fluorodeoxy-D-glucose positron emission tomography scan in the initial evaluation of patients with a primary melanoma thicker than 4 mm. *Melanoma Res*. 2007;17:147–54.
50. Santini H, Byers RM, Wolf PF. Melanoma metastatic to cervical and parotid nodes from an unknown primary site. *Am J Surg*. 1985;150:510–2.
51. Edge SB, Byrd DR, Compton CA, editors. *AJCC cancer staging manual*. 7th ed. New York, NY: Springer; 2010.
52. Azzola MF, Shaw HM, Thompson JF, et al. Tumor mitotic rate is a more powerful prognostic indicator than ulceration in patients with primary cutaneous melanoma: an analysis of 3661 patients from a single center. *Cancer*. 2003;97:1488–98.
53. Myers EN, Suen JY, Myers JN, Hanna EY. *Cancer of the head and neck*. 4th ed. Philadelphia, PA: Saunders; 2003. p. 133–53.
54. Yao K, Balch G, Winchester DJ. Multidisciplinary treatment of primary melanoma. *Surg Clin N Am*. 2009;89:267–81.
55. Balch CM, Urist MM, Karakousis CP, et al. Efficacy of 2-cm surgical margins for intermediate-thickness melanomas (1 to 4 mm). Results of a multi-institutional randomized surgical trial. *Ann Surg*. 1993;218:262–7. discussion 267–269.
56. Zitelli JA, Moy RL, Abell E. The reliability of frozen section in the evaluation of surgical margins for melanoma. *J Am Acad Dermatol*. 1991;24:102–6.
57. Zalla MJ, Lim KK, Dicando DJ, Gagnot MM. Mohs micrographic excision of melanoma using immunostains. *Dermatol Surg*. 2000;26:771–84.
58. Payne WG, Kearney R, Wells K, et al. Desmoplastic melanoma. *Am Surg*. 2001;67:1004–6.
59. Livestro DP, Muzikansky A, Kaine EM, et al. Biology of desmoplastic melanoma: a case-control comparison with other melanomas. *J Clin Oncol*. 2005;23:6739–46.
60. Quinn MJ, Crotty KA, Thompson JF, Coates AS, O'Brien CJ, McCarthy WH. Desmoplastic and desmoplastic neurotropic melanoma: experience with 280 patients. *Cancer*. 1998;83:1128–35.
61. Hawkins WG, Busam KJ, Ben-Porat L, et al. Desmoplastic melanoma: a pathologically and clinically distinct form of cutaneous melanoma. *Ann Surg Oncol*. 2005;12(3):207–13.
62. Anstey A, McKee P, Jones EW. Desmoplastic malignant melanoma: a clinicopathological study of 25 cases. *Br J Dermatol*. 1993;129:359–71.
63. Vongtama R, Safa A, Gallardo D, Calcaterra T. Efficacy of radiation therapy in the local control of desmoplastic malignant melanoma. *Head Neck*. 2003;25(6):423–8.
64. Foote MC, Burmeister B, Burmeister E, Bayley G, Smithers BM. Desmoplastic melanoma: the role of radiotherapy in improving local control. *ANZ J Surg*. 2008;78(4):273–6.
65. Byers RM. The role of modified neck dissection in the treatment of cutaneous melanoma of the head and neck. *Arch Surg*. 1986;121:1338–41.

66. Morton DL, Thompson JF, Cochran AJ, et al. Sentinel-node biopsy or nodal observation in melanoma. *N Engl J Med*. 2006;355:1307–17.
67. Goepfert H, Jesse RH, Ballantyne AJ. Posterolateral neck dissection. *Arch Otolaryngol*. 1980;106:618–20.
68. Balch CM, Soong SJ, Bartolucci AA, et al. Efficacy of an elective regional lymph node dissection of 1 to 4 mm thick melanomas for patients 60 years of age or younger. *Ann Surg*. 1996;224(3):255–63.
69. Bostick P, Essner R, Sarantou T, et al. Intraoperative lymphatic mapping for early-stage melanoma of the head and neck. *Am J Surg*. 1997;174:536–9.
70. Wells KE, Rapaport DP, Cruse CW, et al. Sentinel lymph node biopsy in melanoma of the head and neck. *Plast Reconstr Surg*. 1997;100(3):591–4.
71. Alex JC, Krag DN, Harlow SP, et al. Localization of regional lymph nodes in melanomas of the head and neck. *Arch Otolaryngol Head Neck Surg*. 1998;124:135–40.
72. Eicher SA, Clayman GL, Myers JN, Gillenwater AM. A prospective study of intraoperative lymphatic mapping for head and neck cutaneous melanoma. *Arch Otolaryngol Head Neck Surg*. 2002;128:241–5.
73. Shah JP, Kraus DH, Dubner S, Sarker S. Patterns of regional lymph node metastases from cutaneous melanomas of the head and neck. *Am J Surg*. 1991;162:320–3.
74. Norman J, Cruse CW, Espinosa C, et al. Redefinition of cutaneous lymphatic drainage with the use of lymphoscintigraphy for malignant melanoma. *Am J Surg*. 1991;162:432–7.
75. O'Brien CJ, Uren RF, Thompson JF, et al. Prediction of potential metastatic sites in cutaneous head and neck melanoma using lymphoscintigraphy. *Am J Surg*. 1995;170:461–6.
76. Gomez-Rivera F, Santillan A, McMurphey AB, et al. Sentinel node biopsy in patients with cutaneous melanoma of the head and neck: recurrence and survival study. *Head Neck*. 2008;30(10):1284–94.
77. Leong SP, Accortt NA, Essner R, et al. Impact of sentinel lymph node status and other risk factors on the clinical outcome of head and neck melanoma patients. *Arch Otolaryngol Head Neck Surg*. 2006;132:370–3.
78. Kretschmer L, Hilgers R, Mohrle M, et al. Patients with lymphatic metastases of cutaneous malignant melanoma benefit from sentinel lymphadenectomy and early excision of their nodal disease. *Eur J Cancer*. 2004;40:212–8.
79. Gershenwald JE, Mansfield PF, Lee JE, Ross MI. Role for lymphatic mapping and sentinel lymph node biopsy in patients with thick (>4 mm) primary melanoma. *Ann Surg Oncol*. 2000;7(2):160–5.
80. Essner R, Chung MH, Bleicher R, Hsueh E, Wanek L, Morton DL. Prognostic implications of thick (>4 mm) melanoma in the era of intraoperative lymphatic mapping and sentinel lymphadenectomy. *Ann Surg Oncol*. 2002;9(8):754–61.
81. Carlson GW, Murray DR, Hestley A, Staley CA, Lyles RH, Cohen C. Sentinel lymph node mapping for thick (> or =4 mm) melanoma: should we be doing it? *Ann Surg Oncol*. 2003;10(4):408–15.
82. Jacobs IA, Chang CK, Salti GI. Role of sentinel lymph node biopsy in patients with thick (>4 mm) primary melanoma. *Am J Surg*. 2004;41:531–8.
83. Cecchi R, Buralli L, Innocenti S, Seghieri G, De Gaudio C. Sentinel lymph node biopsy in patients with thick (≥4 mm) melanoma: a single-centre experience. *J Eur Acad Dermatol Venereol*. 2007;21(6):758–61.
84. Morton DL, Cochran AJ, Thompson JF, et al. Multicenter Selective Lymphadenectomy Trial Group. Sentinel node biopsy for early-stage melanoma: accuracy and morbidity in MSLT-I, an international multicenter trial. *Ann Surg* 2005; 242:302–311.
85. Ang KK, Byers RM, Peters LJ, et al. Regional radiotherapy as adjuvant treatment for head and neck melanoma. Preliminary results. *Arch Otolaryngol Head Neck Surg*. 1990;116:169–72.
86. Ang KK, Peters LJ, Weber RJ, et al. Postoperative radiotherapy for cutaneous melanoma of the head and neck region. *Int J Radiat Oncol Biol Phys*. 1994;30:795–8.
87. Chang DT, Amdur RJ, Morris CG, Mendenhall WM. Adjuvant radiotherapy for cutaneous melanoma: comparing hypofractionation to conventional fractionation. *Int J Radiat Oncol Biol Phys*. 2006;66(4):1051–5.
88. Beenken S, Byers RM, Smith JL, Goepfert H, Shallenberger R. Desmoplastic melanoma. Histologic correlation with behavior and treatment. *Arch Otolaryngol Head Neck Surg*. 1989;115:374–9.
89. Hicks MJ, Flaitz CM. Oral mucosal melanoma: epidemiology and pathobiology. *Oral Oncol*. 2000;36:152–69.
90. Verma S, Quirt I, McCready D, Bak K, Charette M, Iscoe N. Systematic review of systemic adjuvant therapy for patients at high risk for recurrent melanoma. *Cancer*. 2006;106(7):1431–42.
91. Kirkwood JM, Manola J, Ibrahim J, et al. A pooled analysis of Eastern Cooperative Oncology Group and Intergroup trials of adjuvant high-dose interferon for melanoma. *Clin Cancer Res*. 2004;10:1670–7.
92. Hill 2nd GJ, Moss SE, Golomb FM, et al. DTIC and combination therapy for melanoma: III. DTIC (NSC 45388) Surgical Adjuvant Study COG PROTOCOL 7040. *Cancer*. 1981;47:2556–62.
93. Veronesi U, Adamus J, Aubert C, et al. A randomized trial of adjuvant chemotherapy and immunotherapy in cutaneous melanoma. *N Engl J Med*. 1982;307:913–6.
94. Lejeune FJ, Lienard D, Leyvraz S, Mirimanoff RO, et al. Regional therapy of melanoma. *Eur J Cancer*. 1993;29A:606–12.
95. Gogas HJ, Kirkwood JM, Sondak VK. Chemotherapy for metastatic melanoma: time for a change? *Cancer*. 2007;109(3):455–64.
96. Middleton M, Grob JJ, Aaronson N, et al. Randomized phase III study of temozolomide versus dacarbazine in the treatment of patients with advanced metastatic malignant melanoma. *J Clin Oncol*. 2000;18(1):158–66. Erratum in: *J Clin Oncol*. 2000; 18(11):2351.
97. Keilholz U, Goey SH, Punt CJ, et al. Interferon alfa-2a and interleukin-2 with or without cisplatin in metastatic melanoma: a randomized trial of the European Organization for Research and Treatment of Cancer Melanoma Cooperative Group. *J Clin Oncol*. 1997;15:2579–88.
98. Rosenberg SA, Yang JC, Schwartzentruber DJ, et al. Prospective randomized trial of the treatment of patients with metastatic melanoma using chemotherapy with cisplatin, dacarbazine, and tamoxifen alone or in combination with interleukin-2 and interferon alfa-2a. *J Clin Oncol*. 1999;17(3):968–75.
99. Eton O, Legha SS, Bedikian AY, et al. Sequential biochemotherapy versus chemotherapy for metastatic melanoma: results from a phase III randomized trial. *J Clin Oncol*. 2002;20:2045–52.
100. Keilholz U, Punt CJ, Gore M, et al. Dacarbazine, cisplatin and interferon-alfa-2b with or without interleukin-2 in metastatic melanoma: a randomized phase III trial (18951) of the European Organization for Research and Treatment of Cancer Melanoma Group. *J Clin Oncol*. 2005;23:6747–55.
101. Wilhelm SM, Carter C, Tang L, et al. BAY-43-9006 exhibits broad spectrum oral antitumor activity and targets receptor tyrosine kinases involved in tumor progression and angiogenesis. *Cancer Res*. 2004;64(19):7099–109.
102. Eisen T, Ahmad T, Flaherty KT, et al. Sorafenib in advanced melanoma: a phase II randomized discontinuation trial analysis. *Br J Cancer*. 2006;95:581–6.

103. Hauschild A, Agarwala SS, Trefzer U, et al. Results of a phase III, randomized, placebo-controlled study of sorafenib in combination with carboplatin and paclitaxel as second-line treatment in patients with unresectable stage III or stage IV melanoma. *J Clin Oncol*. 2009;27(17):2823–30.
104. Bedikian AY, Milward M, Pehamberger H, et al. Bcl-2 antisense (oblimersen sodium) plus dacarbazine in patients with advanced melanoma: the Oblimersen Melanoma Study Group. *J Clin Oncol*. 2006;24:4738–45.
105. McLoughlin JM, Zager JS, Sondak VK, Berk LB. Treatment options for limited or symptomatic metastatic melanoma. *Cancer Control*. 2008;15(3):239–47.
106. Baughan CA, Hall VL, Leppard BJ, Perkins PJ. Follow-up in stage I cutaneous malignant melanoma: an audit. *Clin Oncol (R Coll Radiol)*. 1993;5:174–80.
107. Poo-Hwu WJ, Arivan S, Lamb L, et al. Follow-up recommendations for patients with American Joint Committee on Cancer stages I-III malignant melanoma. *Cancer*. 1999;86:2252–8.

Chapter 38

Cervical Lymph Node Metastases of Squamous Cell Carcinoma from an Unknown Primary Site

Nicholas Pavlidis and George Plataniotis

Abstract Metastases of squamous cell carcinoma from an unknown primary site involving the cervical lymph nodes represents the 5% of all head and neck cancers and belongs to the favorable subsets of unknown primaries. In this chapter, we describe the incidence, the natural history, the diagnostic approach in detecting the primary site, the therapeutic management, and the prognostic and predictive factors of these patients.

Keywords Cancer of unknown primary • Head and neck carcinoma • Metastatic squamous cell carcinoma • Diagnosis • Treatment

Introduction

Cancer of unknown primary (CUP) represents a heterogeneous group of malignancies presenting with distant metastases without an identified primary tumor at diagnosis. The nature of CUP remains unanswered. The primary tumor may either have a slow growth rate or it may possibly regress.

In a general medical oncology service, metastatic carcinoma of unknown primary site is not a rare diagnosis. CUP accounts for 3–5% of all tumors. Similarly, in a Head and Neck or Otolaryngology Department the proportion of patients presented with cervical lymph node metastatic disease of not known origin it follows more or less the same pattern.

Today, the definition of CUP includes patients who present with histologically confirmed metastatic cancer in whom a detailed medical history, complete physical examination, full blood count and biochemistry, urinalysis and stool occult blood testing, histopathological review of biopsy material with the use of immunohistochemistry, chest radiography, computed tomography (CT Scan) of the abdomen and pelvis

and in certain cases mammography, magnetic resonance imaging (MRI), or position emission tomography (PET-Scan) fail to identify the primary site. Recently, gene expression profiling platforms were shown to accurately assign CUP to a primary tissue of origin, with unknown, however, impact on patient outcome [1–3].

In general, CUP is associated with dismal prognosis with a median survival of 9–12 months. Nowadays, CUP patients are divided into various subsets of favorable or unfavorable prognosis. Patients with cervical lymph node metastases from an unknown primary site of squamous cell histology (SQ-CUP) belong to the favorable prognostic subsets of CUP [1, 2].

Every medical or surgical specialty could come across to a CUP patient and therefore they should be aware of the optimal diagnostic and therapeutic approach of these patients.

Incidence

In 1957, the first definition of cervical lymph node metastasis of an unknown primary site was reported by Comess et al. [4].

Cervical lymph node metastases from SQ-CUP constitute approximately 5% (range 1–10%) of all head and neck cancers [5]. The annual incidence of SQ-CUP tumors is 0.34 cases per 100,000 per year [6]. Median age is around 57–60 years (range 30–80 years) and almost 80% of the patients are males. They usually carry a history of chronic tobacco or alcohol use.

Squamous cell histology is the most common type representing the 75% of the cases, followed by undifferentiated carcinoma and adenocarcinoma [7]. Regarding the distribution of involved cervical lymph nodes jugulodigastric nodes are the most commonly affected (71%) followed by midjugular nodes (22%) [8].

In this chapter, only patients with squamous cell histotype are discussed, since patients with other histological types are managed differently and carry different prognosis.

N. Pavlidis (✉)
University of Ioannina, Av. S. Niarchos, Ioannina 45110, Greece
e-mail: npavlid@uoi.gr

Diagnostic Evaluation

The diagnostic approaches in patients with SQ-CUP refer first to the establishment of the histopathological type of the tumor and secondly to the detection of the primary tumor site.

Therefore, the diagnostic maneuvers include (a) physical examination, (b) FNA or biopsies (c) endoscopic examination, and (d) imaging studies.

Physical Examination

A cervical painless and unilateral mass is the most common clinical presentation. The site of palpable cervical lymph nodes could be useful in suggesting the possible primary tumor site. In patients with squamous cell histotype, the jugulodigastric and midjugular lymph nodes are most commonly involved, whereas metastatic adenocarcinoma is more frequently diagnosed in the low cervical or supraclavicular areas.

In addition, based on the metastatic lymph node level, several probable sites of the primary tumors can be predicted, i.e. (a) if submandibular nodes (level I) are involved the primary site could be in the floor of the mouth, lips, and anterior tongue, (b) if jugulodigastric or upper jugular nodes (level II) are affected search for a primary tumor in epipharynx, base of the tongue, tonsils, nasopharynx, and larynx, (c) if middle and lower jugular nodes (levels III and IV) are involved the most likely primaries are located in hypopharynx or larynx, and (d) if supraclavicular nodes (level V) are the metastatic sites, the possible primary tumors could be derived from the lungs, thyroid, breast, gastrointestinal, or genitourinary system (Table 38.1) [8, 9].

The most commonly involved level is level II (30–50%), followed by levels I and III (10–20%) and levels IV and V (5–10%).

Table 38.1 Location of neck nodes and possible site of primary tumor

Level	Neck nodes involved	Possible primaries
I	Submental, submandibular nodes	Mouth's floor, lips, anterior tongue
II	Jugulodigastric/upper jugular nodes	Epipharynx, base of tongue, tonsils, nasopharynx, larynx
III	Middle jugular nodes	Supraglottic larynx, inferior pyriform sinus, postcricoid region
IV	Inferior jugular nodes	Hypopharynx, subglottic larynx, thyroid, esophagus
V	Supraclavicular	Lungs, thyroid, breast, gastrointestinal system

Cytology and Histopathology

Fine needle aspiration (FNA) is most commonly used as a first step diagnostic procedure to establish malignancy. The diagnostic accuracy of FNA in these patients is closed to 95% [10].

Incisional biopsy of enlarged cervical nodes remains controversial since higher rates of local recurrence has been observed due to seeding of tumor cells along the tract [11, 12]. However, open biopsy is indicated if the mass is suspected to be lymphoma, sarcoma, melanoma, or adenocarcinoma.

While traditional histochemistry has been established as a useful technique in other tumor types, it has not proven particularly helpful in the diagnostic work-up of SQ-CUP. Advanced molecular techniques such as in situ hybridization or polymerase chain reaction could be useful in detecting Epstein–Barr virus (EBV) or human papillomavirus (HPV), differentiating a nasopharyngeal or oropharyngeal primary cancer, respectively [13, 14].

Endoscopic Examination

If history, physical examination, and imaging studies are unrevealing to identify a primary site, the patient should undergo a panendoscopy under anesthesia with the use of a flexible nasopharyngoscope. Blind biopsies from nasopharynx, tongue base, tonsil, and pyriform sinus are recommended. Esophagoscopy and bronchoscopy are also parts of panendoscopic examination [8, 15].

Imaging Studies

Imaging investigation in SQ-CUP patients include CT scan, MRI, and PET-scan. The goals of performing imaging studies in these patients include first, the detection of primary site in the head–neck region or in the lungs and second, the staging evaluation of lymph nodal status before any local–regional treatment.

Imaging should be performed prior to any invasive procedure or treatment in order to avoid any diagnostic misinterpretation.

CT scan is considered as the imaging study of choice, because it has a low cost and offers detailed anatomical information. Primary tumor detection rate is approximately 22% [16, 17].

MRI has a higher accuracy in identifying the primary site of 36%. Due to better soft-tissue definition comparing to CT scan it makes it more useful for investigating the area of nasopharynx and oropharynx [18, 19].

PET has also been used in patients with SQ-CUP. A review of 16 studies using [18] F-FDG PET showed a diagnostic accuracy in detecting the primary of 24.5%, while sensitivity and specificity were 88% and 75%, respectively [20].

A disadvantage of FDG-PET, however, is its lack of anatomic information with precise localization of FDG accumulation. Therefore, the application of combined FDG-PET/CT or MRI could offer a greater value for the detection of primary site.

Several studies with FDG-PET/CT demonstrated identification of primary tumor in 48–73% of the cases and modification of treatment plans in almost 30% of the patients [21–23].

Prognostic Factors

The prognostic outcome of patients with SQ-CUP is based on several endpoints such as the overall survival, disease-free survival, distant failure or local–regional control.

Numerous treatment, patient, or tumor-related variables have been implicated. However, the most prominent prognostic factors correlated with disease outcome are two tumor-related variables, the lymph nodal stage and the extracapsular spread [5]. Table 38.2 demonstrates the neck nodal staging.

Treatment

The optimal therapeutic management of patients with SQ-CUP remains controversial as a result of the absence of randomized studies comparing treatment options. Therefore, the treatment is mainly based on nonrandomized evidence as well as on institutional policies.

Surgery

Surgical therapy includes excisional biopsy, neck dissection (“radical,” “modified,” or “selective”), and tonsillectomy.

“Radical neck dissection” refers to the removal of the levels I–V neck nodes, which at the same time sacrifices the spinal

accessory nerve, internal jugular vein, and sternocleidomastoid muscle. “Modified radical neck dissection” removes the same nodal levels but spares the rest of the neck structures. It is important to notice that preservation of spinal accessory nerve saves shoulder mobility. “Selective neck dissection” targets specific nodal groups and it is considered as the safest operational procedure.

Patients with N1 or N2a limited disease without extracapsular extension could be treated with surgery alone. Local–regional control rates range from 80 to 90%, median nodal recurrence rate about 34% and 5-year overall survival rate up to 65% [24–27].

Therefore, neck dissection alone is advocated only for patients with N1 and N2a disease without extracapsular spread, whereas postoperative irradiation is indicated in cases with an incisional or excisional biopsy and in patients with extracapsular extension.

Tonsils are considered as one of the commonest site of a hidden primary site in patients with SQ-CUP. Although the true incidence is not known, it is estimated to be between 18 and 40% [28].

Various reports suggest that directed random biopsies or unilateral or even bilateral tonsillectomy should be part of the screening for detection of the occult primary tumor [28–32]. It is interesting that in 10% of the cases the primary tonsillar lesion is located in contralateral to the metastatic cervical nodes [28].

Nowadays, several specialized centers, recommend bilateral tonsillectomy (screening tonsillectomy) as standard procedure in the investigation of patients presented with subdigastric, mid-jugulocarotid, or submandibular nodal metastases.

Radiotherapy

The most frequently used therapeutic approach by the majority of centers consists of surgical removal of the neck disease followed by postoperative radiotherapy (or radiochemotherapy) either to the neck, or to both the neck and the potentially involved mucosa.

Indications for postoperative radiotherapy in SQ-CUP patients are:

- (a) Excisional or incisional biopsy of the neck before definitive treatment.
- (b) Extracapsular extension of the tumor.
- (c) Multiple positive lymph nodes (stage N2b or higher).

However, primary radiotherapy or chemoradiotherapy (in fit patients) may be given to the following situations:

- (a) Initial stage N2b or N3 as a sole treatment or followed 4–6 weeks after radiotherapy by neck dissection or removal of the remaining node.

Table 38.2 Nodal staging in patients with SQ-CUP

Nodal disease	Nodal characteristics
N1	Single ipsilateral node <3 cm
N2a	Single ipsilateral node 3–6 cm
N2b	Multiple ipsilateral nodes <6 cm
N2c	Bilateral or contralateral nodes <6 cm
N3	Lymph node >6 cm

- (b) Large nodes fixed to the adjacent structures (e.g., to the carotid sheath).
- (c) Patients with a low performance status and comorbidities, which make them unable to tolerate radical surgery.

Although the value of irradiation of the potentially (occult) primary sites has not been confirmed by randomized studies, many authors have observed that mucosal irradiation reduced both the emergence of primary tumor and regional recurrence [33], but without affecting overall survival [24, 34–40]. In a recent study, a higher 5-year overall survival rate has been reported for patients treated with extensive radiotherapy including neck nodes and the entire pharyngeal mucosa (Fig. 38.1)

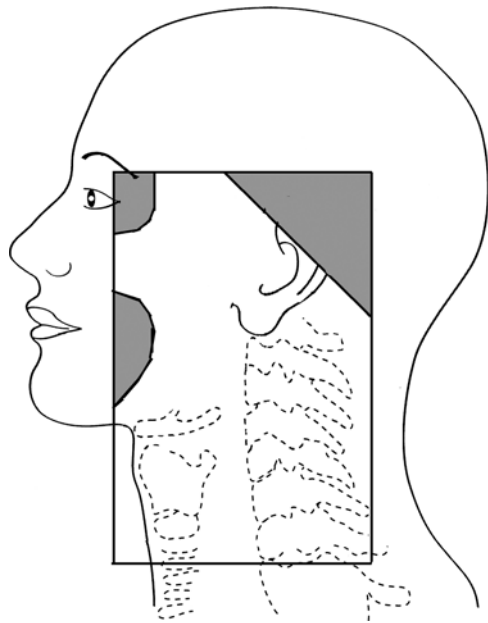


Fig. 38.1 An example of an extended field irradiation of the entire pharynx (naso-, oro-, and hypopharynx). Posterior border: tip of spinous process T2. Anterior: second molar tooth, or anterior masseter muscle. Superior: superior orbital margin and inferior: as low as possible, avoiding matching through nodal disease of the lower neck. Customized shielding is used to protect brain, orbit, and oral cavity

Table 38.3 Occult primary sites to be included in radiotherapy fields, according to the level of the enlarged lymph nodes

Levels of the neck	Sites to be irradiated
I	Oral cavity, Waldeyer’s ring, oropharynx, both sides of the neck. Protection of larynx
II, III, (upper) V	Nasopharynx, oropharynx, hypopharynx, larynx, both sides of the neck, to the level of the clavicles
IV only	Waldeyer’s ring, larynx, hypopharynx, both sides of the neck
Lower level V	Larynx, hypopharynx, both sides of the neck, generous regional portal to include adjacent apex of the axilla
Preauricular	Radiotherapy alone (or combined with parotidectomy). Squamous cell carcinoma is suggestive of skin cancer

relatively to those treated by more limited volumes (57.6 vs. 24% $p < 0.01$) [41].

Chemoradiotherapy has been mainly suggested for patients with extracapsular spread of the disease or with stages N2b–N3. In case of initially bulky neck disease, induction chemotherapy followed by chemoradiotherapy is sometimes given, although this is not supported by randomized studies.

Radiotherapy portals should encompass the sites shown in Table 38.3, according to the level of the neck affected (Fig. 38.2) [24, 25, 38–40, 42–44]. The dose usually given with standard fractionation (dose per fraction of 1.8–2 Gy) is for:

- (a) The neck, 65–70 Gy to the involved nodal stations and, 50 Gy for the uninvolved sites.
- (b) The mucosal sites usually 50–60 Gy. In case of clinically suspicious mucosal sites a dose of 60–64 Gy is recommended.

The use of three-dimensional (3D) radiotherapy techniques is suggested to have an impact on survival [41], although there may be a selection bias to this conclusion: most patients who received 2D radiotherapy were treated 20 or more years

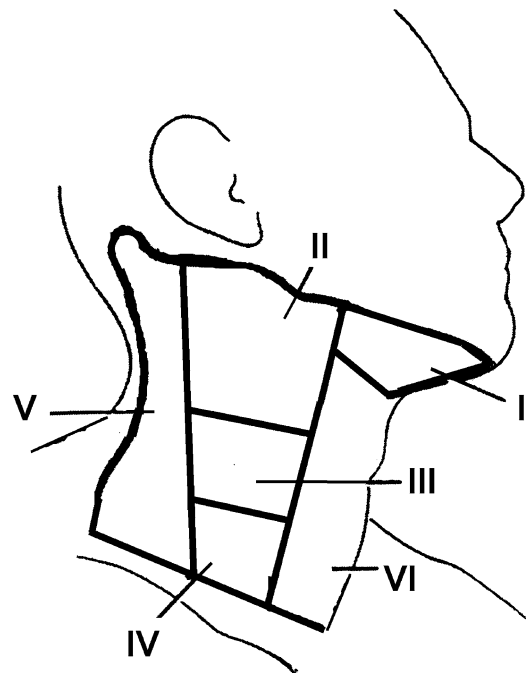


Fig. 38.2 The head and neck lymph node areas are currently classified into six levels (I–VI): I: submandibular and submental, II: jugulodigastric (base of skull to hyoid), III: deep cervical (hyoid to cricoid), IV: Virchow’s nodes (cricoid to clavicle), V: accessory spinal (superior and inferior posterior triangle), VI: anterior compartment group. The lymphatics of the head and neck follow several drainage pathways depending on their origin (see also Table 38.3). This is an important information for the design of radiotherapy portals in squamous-cell cancer of the neck, of unknown primary. The figure roughly illustrates the six levels. For detailed description see [44]

ago when diagnostic procedures were less sophisticated. Therefore, patients with distant metastases at the time of initial treatment were more frequently included in those studies.

Main acute radiation toxicity consists of dysphagia and mucositis especially in patients treated with combined chemoradiotherapy compared with those treated with radiotherapy alone. Xerostomia is the main late complication of radiotherapy. Other late effects are persisting edema of the larynx or skin, soft tissue fibrosis, necrosis, and osteoradionecrosis [24, 35, 40, 45]. Combined with postoperative complications and postchemotherapy toxicity, can potentially affect the quality of life especially of the long-term surviving patients. This underlines the significance of advanced radiotherapy techniques, such as 3D conformal and IMRT, regardless of any anticipated benefit on tumor control.

Chemotherapy

Concurrent chemoradiotherapy in patients with locally advanced squamous cell carcinoma of the head and neck significantly improves response rate and overall survival [46–48]. In addition, the combination of platinum-based chemotherapy with cetuximab increased efficacy as first-line treatment in patients with recurrent or metastatic head and neck cancer [49]. All these studies are large well conducted randomized studies published during the last few years.

Unfortunately, up to now there are no randomized reports on the efficacy of chemoradiotherapy in patients with SQ-CUP. To the best of our knowledge there are only four retrospective studies with approximately 100 patients treated with various cytotoxic drugs (platinum or nonplatinum). Chemotherapy was administered before, during, or after radiotherapy and results in some studies were compared with historical controls [41, 50–52].

In the oldest study, complete response rate to combined treatment was 81% and median survival was 24 months [50]. In the second study, the 5-year progression-free and overall survival rate was 87 and 75%, respectively [51]. In the third report, the local–regional control and overall survival rates were 95 and 89%, respectively [52]. In the last report published in 2007, chemotherapy was administered as neo-adjuvant or concomitantly to radiotherapy in 52 and 48% of the patients, respectively. Disease-free survival and 5-year overall survival were 17 and 26.5%, respectively [40]. It is worthwhile to notice also that acute or late toxicities following aggressive combined treatment were acceptable in these small studies.

Based on these encouraging preliminary results, prospective multicentric studies in a larger number of SQ-CUP patients will be warranted, in order to establish the efficacy of concurrent chemoradiotherapy in a cohort of patients with bulky neck disease.

Discovery of Primary Site

The incidence of the appearance of primary site is around 10% (ranging between 5 and 30%) and it usually occurs within the first 2 years of treatment. Several authors consider primary tumors arising later than 5 years after primary diagnosis, as second primaries [5, 15].

The most common sites of the appearance of primary tumors include nasopharynx, base of the tongue, tonsil, and pyriform sinus. Patients undergoing bilateral tonsillectomy have threefold increase chance to discover the primary site in the tonsils [53]. On the contrary, patients treated with radiotherapy bilaterally to the neck as well as to mucosa sites seem to decrease considerably the appearance of mucosal primary sites [54].

Conclusions

SQ-CUP most commonly affects middle-aged men and typically presented as a painless neck mass. More than 90% of these cases represent squamous cell carcinoma originating within Waldeyer's ring (nasopharynx, tonsil, and base of tongue). The other 10% comprised of other histologies, such as adenocarcinoma, undifferentiated carcinoma, or other variants. Following diagnosis of metastatic cervical disease, all patients require a thorough head and neck history and clinical examination, radiographic imaging including PET-scan, panendoscopy with directed biopsies of Waldeyer's ring, and possibly bilateral tonsillectomy.

Lymph nodal stage and extracapsular spread are considered as the most prominent prognostic factors.

The optimal treatment of SQ-CUP has not yet been defined. Randomized trials are lacking. Definitely, combined modality treatment is offering a better outcome. Surgery alone is indicated in early stages (N1 or N2a), whereas neck dissection followed by postoperative radiotherapy is indicated in more advanced disease. The extent of radiation portals coverage though, remains controversial. The role of chemotherapy as neo-adjuvant, concomitantly or adjuvant modality is waiting to be elucidated. Nevertheless, the 5-year survival rates are still encouraging.

References

1. Pavlidis N, Briasoulis E, Hainsworth J, Greco FA. Diagnostic and therapeutic management of cancer of an unknown primary. *Eur J Cancer*. 2003;39:1990–2005.
2. Pavlidis N, Fizazi K. Carcinoma of unknown primary (CUP). *Crit Rev Oncol Hematol*. 2000;69:271–8.

3. Pentheroudakis G, Golfopoulos V, Pavlidis N. Switching benchmarks in cancer of unknown primary: from autopsy to microarray. *Eur J Cancer*. 2007;43(14):2026–36.
4. Comess MS, Beahrs OH, Dockerty MB. Cervical metastasis from occult carcinoma. *Surg Gynecol Obstet*. 1957;104:607–17.
5. Jereczek-Fossa BA, Jassem J, Orecchia R. Cervical lymph node metastases of squamous cell carcinoma from an unknown primary. *Cancer Treat Rev*. 2004;30:153–64.
6. Grau C, Johansen LV, Jakobsen J, et al. Cervical lymph node metastases from unknown primary tumours. Results from a national survey by the Danish Society for Head and Neck Oncology. *Radiother Oncol*. 2000;55:121–9.
7. Haas I, Hoffmann KT, Enger R, Ganzer U. Diagnostic strategies in cervical carcinoma of an unknown primary (CUP). *Eur Arch Otorhinolaryngol*. 2002;259:325–33.
8. de Braud F, Al-Sarraf M. Diagnosis and management of squamous cell carcinoma of unknown primary tumor site of the neck. *Semin Oncol*. 1993;20(3):273–8.
9. Molinari R, Cantu G, Ghiesia F, et al. A statistical approach to detection of the primary cancer based on the site of neck lymph node metastases. *Tumori*. 1997;63:267–82.
10. Mui S, Li T, Rasgon M, et al. Efficacy and cost effectiveness of multihole fine-needle aspiration of squamous cell carcinoma of head and neck masses. *Laryngoscope*. 1997;107(6):759–64.
11. Pisharodi LR. False negative diagnosis in fine needle aspiration of squamous cell carcinoma of head and neck. *Diagn Cytopathol*. 1997;17:70–3.
12. Mendenhall W, Mancuso A, Parsons J, et al. Diagnostic evaluation of squamous cell carcinoma metastatic to cervical lymph nodes from an unknown head and neck primary site. *Head Neck*. 1998;20:739–44.
13. Lee WY, Hsiao JR, Jin YT, et al. Epstein-Barr virus detection in neck metastases by in situ hybridization in fine-needle aspiration cytologic studies: an aid differentiating the primary site. *Head Neck*. 2000;22:336–40.
14. Gillison ML, Koch WM, Capone RB, et al. Evidence for a casual association between human papillomavirus and a subset of head and neck cancers. *J Natl Cancer Inst*. 2000;92:709–20.
15. Adams JR, O'Brien CJ. Unknown primary squamous cell carcinoma of the head and neck: a review of diagnosis, treatment and outcomes. *Asian J Surg*. 2002;25(2):188–93.
16. Mancuso AA. Cervical lymph node metastases: oncologic imaging and diagnosis. *Int J Radiat Oncol Biol Phys*. 1984;10:411–23.
17. Muraki AS, Mancuso AA, Harnsberger HR. Metastatic cervical adenopathy from tumours of unknown origin: the role of CT. *Radiology*. 1984;152:749–53.
18. Tien RD, Hesselink JR, Chu PK, Jerzy S. Improved detection and delineation of head and neck lesions with fat suppression spin-echo MR imaging. *AJNR Am J Neuroradiol*. 1991;12:19–24.
19. Kassel EE, Keller MA, Kucharczyk W. MRI of the floor of the mouth, tongue and oropharynx. *Radiol Clin North Am*. 1989;2:331–51.
20. Rusthoven KE, Koshy M, Paulino AC. The role of fluorodeoxyglucose positron emission tomography in cervical lymph node metastases from an unknown primary tumor. *Cancer*. 2004;101(11):2641–9.
21. Johansen J, Eigtved A, Buchwald C, et al. Implication of 18F-fluoro-2-deoxy-D-glucose position emission tomography on management of carcinoma of unknown primary in the head and neck: a Danish cohort study. *Laryngoscope*. 2002;112(11):2009–14.
22. Fleming Jr AJ, Smith Jr SP, Paul CM, et al. Impact of [18F]-2-fluorodeoxyglucose-positron emission tomography/computed tomography on previously untreated head and neck cancer patients. *Laryngoscope*. 2007;117(7):1173–9.
23. Wartski M, Le Stanc E, Gontier E, et al. In search of an unknown primary tumour presenting with cervical metastases: performance of hybrid FDG-PET-CT. *Nucl Med Commun*. 2007;28(5):365–71.
24. Coker DD, Casterline PF, Chamber RG, Jaques DA. Metastases to lymph nodes of the head and neck from an unknown primary site. *Am J Surg*. 1977;134:517–22.
25. Coster JR, Foote RL, Olsen KD, et al. Cervical nodal metastasis of squamous cell carcinoma of unknown origin: indications for withholding radiation therapy. *Int J Radiat Oncol Biol Phys*. 1992;23:743–9.
26. Wang RC, Goepfert H, Barber AE, et al. Unknown primary squamous cell carcinoma metastatic to the neck. *Arch Otolaryngol Head Neck Surg*. 1990;116:1388–93.
27. Iganej S, Kagan R, Anderson P, et al. Metastatic squamous cell carcinoma of the neck from an unknown primary: management options and patterns of relapse. *Head Neck*. 2002;24(3):236–46.
28. Koch WM, Bhatti N, Williams MF, Eisele D. Oncologic rationale for bilateral tonsillectomy in head and neck squamous cell carcinoma of unknown primary source. *Otolaryngol Head Neck Surg*. 2001;124:331–3.
29. Kothari P, Randhawa P, Farrell R. Role of tonsillectomy in the search for a squamous cell carcinoma from an unknown primary in the head and neck. *Br J Oral Maxillof Surg*. 2008;46:283–7.
30. Lapeyre M, Malissard L, Peiffert D, et al. Cervical lymph node metastasis from an unknown primary: is a tonsillectomy necessary? *Int J Radiat Oncol Biol Phys*. 1997;39(2):291–6.
31. Righi PD, Sofferan RA. Screening unilateral tonsillectomy in the unknown primary. *Laryngoscope*. 1995;105:548–50.
32. Randall DA, Johnstone PAS, Foss RD, et al. Tonsillectomy in diagnosis of the unknown primary of the head and neck. *Otolaryngol Head Neck Surg*. 2000;122:52–5.
33. Nieder C, Gregoire V, Ang K. Cervical lymph node metastases from occult squamous cell carcinoma: cut down a tree to get an apple? *Int J Radiat Oncol Biol Phys*. 2001;50:727–33.
34. Colletier PJ, Garden AS, Morrison WH, et al. Postoperative radiation for squamous cell carcinoma metastatic to cervical lymph nodes from an unknown primary site: outcomes and patterns of failure. *Head Neck*. 1998;20:674–81.
35. Erkal HS, Mendenhall WM, Amdur RJ, et al. Squamous cell carcinomas metastatic to cervical lymph nodes from an unknown head-and-neck mucosal site treated with radiation therapy alone or in combination with neck dissection. *Int J Radiat Oncol Biol Phys*. 2001;50:55–63.
36. Erkal HS, Mendenhall WM, Amdur RJ, et al. Squamous cell carcinomas metastatic to cervical lymph nodes from an unknown head-and-neck mucosal site treated with radiation therapy with palliative intent. *Radiother Oncol*. 2001;59:319–21.
37. Klop WM, Balm AJ, Keus RB, et al. Diagnosis and treatment of 39 patients with cervical lymph node metastases of squamous cell carcinoma of unknown origin referred to Netherlands Cancer Institute/Antoni van Leeuwenhoek Hospital, 1979–1998. *Ned Tijdschr Geneesk*. 2000;144:1355–60.
38. Jesse RH, Perez CA, Fletcher GH. Cervical lymph node metastasis: unknown primary cancer. *Cancer*. 1973;31:854–9.
39. Bataini JP, Rodriguez J, Jaulerry C, et al. Treatment of metastatic neck nodes secondary to an occult epidermoid carcinoma of the head-and-neck. *Laryngoscope*. 1987;97:1080–4.
40. Maulard C, Housset M, Brunel P, et al. Postoperative radiation therapy for cervical lymph node metastases from an occult squamous cell carcinoma. *Laryngoscope*. 1992;102:884–90.
41. Beldi D, Jereczek-Fossa BA, D' Onofrio A, et al. Role of radiotherapy in the treatment of cervical lymph node metastases from an unknown primary site: retrospective analysis of 113 patients. *Int J Radiat Oncol Biol Phys*. 2007;69(4):1051–8.
42. Lefebvre JL, Coche-Dequeant B, Van JT, et al. Cervical lymph nodes from an unknown primary tumour in 190 patients. *Am J Surg*. 1990;160:443–6.
43. Million RR, Cassisi NJ, Mancuso AA. The unknown primary. In: Million RR, Cassisi NJ, editors. *Management of head and neck*

- cancer. A multidisciplinary approach. 2nd ed. Philadelphia: J.B Lippincott Company; 1994. p. 311–20.
44. Gregoire V, Scalliet P, Ang KK, editors. Clinical target volumes in conformal and intensity modulated radiation therapy. A clinical guide to cancer treatment. Berlin: Springer; 2004.
 45. Adelstein DJ, Li Y, Adams GI, et al. An intergroup phase III comparison of standard radiation therapy and two schedules of concurrent chemoradiotherapy in patients with unresectable squamous cell head and neck cancer. *J Clin Oncol.* 2003;21(1):92–8.
 46. Bernier J, Domez C, Ozsahin M, et al. Postoperative irradiation with or without concomitant chemotherapy for locally advanced head and neck cancer. *N Engl J Med.* 2004;350(19):1945–52.
 47. Cooper JS, Pajak TF, Forastiere AA, et al. Postoperative concurrent radiotherapy and chemotherapy for high-risk squamous-cell carcinoma of the head and neck. *N Engl J Med.* 2004;350(19):1937–44.
 48. Forastiere AA, Goepfert H, Maor M, et al. Concurrent chemotherapy and radiotherapy for organ preservation in advanced laryngeal cancer. *N Engl J Med.* 2003;349(22):2091–8.
 49. Vermorken JB, Mesia R, Rivera F, et al. Platinum-based chemotherapy plus cetuximab in head and neck cancer. *N Engl J Med.* 2008;359(11):1116–27.
 50. de Braud F, Heilbrun LK, Ahmed K, et al. Metastatic squamous cell carcinoma of an unknown primary localized to the neck. Advantages of an aggressive treatment. *Cancer.* 1989;64(2):510–5.
 51. Argiris A, Smith SM, Stenson K, et al. Concurrent chemoradiotherapy for N2 or N3 squamous cell carcinoma of the head and neck from an occult primary. *Ann Oncol.* 2003;14:1306–11.
 52. Shehadeh NJ, Ensley JF, Kucuk O, et al. Benefit of postoperative chemoradiotherapy for patients with unknown primary squamous cell carcinoma of the head and neck. *Head Neck.* 2006;28:1090–8.
 53. Mc Quone S, Eisele D, Lee D, et al. Occult tonsillar carcinoma in the unknown primary. *Laryngoscope.* 1998;108:1605–10.
 54. Tong C, Luk M, Chow S, et al. Cervical nodal metastases from occult primary: undifferentiated carcinoma versus squamous cell carcinoma. *Head Neck.* 2002;24:361–9.

Chapter 39

Management of Thyroid and Parathyroid Cancers

Ranee Mehra, Charu Aggarwal, and Roger B. Cohen

Abstract Thyroid and parathyroid cancers are both relatively rare malignancies, although the incidence of thyroid cancer is increasing at a rate of 3% per year. The mainstay of treatment of these endocrine malignancies has been surgical resection and radioactive iodine treatment for thyroid cancer. Differentiated thyroid cancers (DTCs) encompass papillary and follicular carcinomas and are responsive to radioactive iodine treatment and thyroid stimulating hormone suppression, in contrast to medullary thyroid cancer (MTC). There is now a greater understanding of the molecular pathogenesis of DTCs, poorly differentiated and anaplastic thyroid cancers, and MTC. This has prompted numerous phase studies utilizing oral biologically targeted agents that inhibit a variety of tyrosine kinase inhibitors, such as the vascular endothelial growth factor receptors, c-kit, ret, and platelet-derived growth factor receptor. This review discusses the epidemiology, histologies, pathogenesis, and issues in the management of thyroid and parathyroid cancers.

Keywords Thyroid cancer • Parathyroid cancer • Tyrosine kinase inhibitors

Introduction

Thyroid cancers constitute a heterogeneous group of malignancies of differing histologies. While they are relatively uncommon compared to other solid tumors, thyroid cancer is the most common endocrine malignancy. The annual incidence is 34,000 cases in the USA, and for undefined reasons this has been increasing at a rate of ~3% per year. Despite this, the mortality rate has remained stable over 30 years. The rise in incidence may be accounted in part for by the

increased detection of small papillary thyroid cancers (PTCs) [1–3]. Parathyroid cancers are rare as well and are discussed later in this chapter.

Epidemiology

Risk factors for the development of differentiated thyroid cancer (DTC) include prior radiation exposure, reduced dietary iodine intake, lymphocytic thyroiditis, and a family history of thyroid cancer. In addition, exposure to radiation from nuclear disasters is known to increase the risk of PTC [4–7]. There also have been reports of an association between thyroid cancer and hepatitis C virus infection, possibly due to increased thyroid autoimmunity [8]. Recently, two genetic variants, 9q22.33 and 14q13.3, are apparently associated with an increased risk of papillary and follicular thyroid cancers in a European population. Those individuals who are homozygous for both alleles have a 5.7-fold higher risk of developing thyroid cancer [9].

The incidence of thyroid cancer is higher in women, although male gender is associated with a worse prognosis [10]. The elderly also are more prone to develop thyroid cancers and these are often the more aggressive histologies, such as anaplastic and follicular cancer [11]. Reasons for this are unknown, but one hypothesis is that the elderly have a greater rate of autoimmune phenomena with end-organ effects on thyroid tissue. It is well documented that the prognosis of DTCs among patients over the age of 45 is worse than in a younger population. For instance, the 10-year survival of patients over the age of 45 who had a lymph node recurrence is 41% versus 100% in the younger group [12].

Histological Classification and Prognosis

Thyroid cancers originate from two different cell types. Papillary, follicular, and anaplastic thyroid cancers (ATCs) arise from the follicular cells [papillary and follicular cancers

R.B. Cohen (✉)
Medical Oncology, Fox Chase Cancer Center, 333 Cottman Ave,
Philadelphia, PA 19111, USA
e-mail: rb_cohen@fccc.edu

are commonly referred to as DTCs], while medullary cancers arise from the parafollicular C-cells. The majority of thyroid cancers are DTCs, with PTC being the most common (80%) histology. Follicular cancer/Hurthle cell variant (FTC) accounts for 15% and is associated with male gender, older age, larger tumor size, multifocal carcinoma, and distant metastases compared to PTC [13]. The 20-year tumor-specific survival is worse in FTC (74%) than PTC (90%). Tall cell variant is a histological subtype of PTC that is associated with more aggressive biological behavior, with an increased rate of nodal and distant metastases [14]. It is thought that an initial well-differentiated thyroid cancer de-differentiates over time and may eventually progress to the more aggressive ATC, which accounts for 2% of diagnoses. An intermediate stage in this process is a variant of thyroid cancer known as poorly differentiated or insular thyroid cancer, which also carries a poor prognosis [15].

Prognosis

Overall, DTCs carry a good long-term prognosis, although a small subset of patients are not cured and require ongoing follow-up and treatment. Features associated with a worse prognosis include distant metastases, extrathyroidal extension, age >45, and larger tumor size [13]. In addition, other risk factors for local persistent and recurrent local and systemic disease include male gender, >10 involved lymph nodes at the time of surgery, extracapsular nodal extension, and tumors >4 cm [16].

Many of these characteristics are components of various staging methods. However, there is no clear consensus regarding the use of one system over another. One classification is the MACIS (metastasis, age, completeness of resection, invasion, and size) prognostic score, which has been validated to correlate with survival [17]. Another simple method is the AMES system (age, metastasis, extent, and size) which divides patients into high- and low-risk groups [18]. The low-risk group includes younger patients, those without distant metastases, papillary cancers confined to the thyroid, or a primary tumor <5 cm. The National Thyroid Cancer Treatment Cooperative Study (NTCTCS) prospectively studied a staging approach that was based on patient age, tumor histology, size, multifocality, metastases, and extra glandular invasion [19]. When this was applied across 14 institutions, 5-year survival was 100% for stage I and II disease, 92% for stage III disease, and 49% for stage IV disease. Finally, the TNM by the American Joint Committee on Cancer (AJCC) system is widely used among other solid tumors. Compared to the TNM system for other tumors, thyroid cancer is distinct in that age and is a component of the staging classification. Patients under the age of 45 can have either stage I disease or stage II if there is evidence of distant

metastatic disease [20]. As with other systems, stage IV disease is associated with a worse prognosis.

Papillary microcarcinomas, defined as tumors less than 1 cm, are usually cured by surgery alone. Given the low risk of recurrence and mortality from thyroid cancer, patients with microcarcinomas likely to derive little benefit from radioactive iodine remnant ablation (RAI). However, there is a small group of patients with a more aggressive disease course. In one series of 900 patients, those with microcarcinomas who were at slightly higher risk of recurrence were those with multifocal tumors and nodal disease [21]. In the analysis of 900 patients, a total thyroidectomy and radioactive iodine ablation were not associated with improved outcomes. Current recommendations from the American Thyroid Association (ATA) Guidelines state that a thyroid lobectomy alone may be appropriate for the treatment of small, low-risk papillary carcinomas without lymph node metastases [22]. For multifocal tumors, a total thyroidectomy is recommended. For stage I tumors (papillary microcarcinomas are not a separate entity in the AJCC classification system), the ATA only recommends RAI for selected tumors, such as those with multifocal disease, nodal metastases, extrathyroidal or vascular invasion, and more aggressive histologies. Thus, the final decision regarding RAI is likely individualized based on these factors.

In contrast, for those patients who do recur with distant metastatic disease, the clinical course is variable. Many patients have indolent, asymptomatic metastatic disease and remain relatively stable with levothyroxine therapy and thyroid stimulating hormone (TSH) suppression. However, in other patients, recurrent thyroid cancer is more aggressive and can be lethal. In one retrospective analysis, the 10-year disease-specific survival of patients with PTC was 45%. Markers of poor prognosis included older age at the time of detection of distant metastases, metastatic sites other than the lungs, metastatic sites over 2 cm in size, and a poorly differentiated histology [23].

Medullary thyroid cancers (MTCs) are not iodine avid and are not sensitive to the presence of TSH. After surgical resection, there is no standard adjuvant therapy for MTC. A greater understanding of the prognostic features of MTC is needed. Known adverse features of MTC include the presence of nodal and distant metastases at diagnosis [24]. In one series, somatic RET mutations in exons 15 and 16 in sporadic cancers were also associated with a worse prognosis [25].

Molecular Pathogenesis

Papillary Thyroid Cancers

A greater understanding of the pathogenesis of the various types of thyroid cancer has greatly facilitated the development and study of newer therapies for advanced disease. This

Table 39.1 Molecular events associated with thyroid cancer

<i>Primary molecular events</i>	
Papillary thyroid cancer	RET/PTC rearrangements BRAF mutations NTRK1 (neurotrophic tyrosine kinase receptor-1) rearrangements RAS mutations
Follicular thyroid cancer	RAS mutations PAX8-PPAR γ rearrangements
Medullary cancer	RET mutations
<i>Potential secondary molecular events</i>	
Transformation to poorly differentiated/anaplastic thyroid cancer	VEGF EGFR PI3K/Akt p53

is summarized further in Table 39.1. While the pathogenesis of sporadic and radiation-induced tumors differs, the primary molecular events associated with the development of PTC involve alterations of genes downstream of the MAPK pathway [26]. The initiating event consists of nonoverlapping activating mutations in one of the following four genes that are components of the MAPK signaling pathway and are detectable in 70% of PTCs: RET/PTC rearrangements, BRAF mutations (V600E), NTRK1 (neurotrophic tyrosine kinase receptor-1) rearrangements, or the less common RAS mutations [27–29].

RET and NTRK1 are proto-oncogenes that encode tyrosine kinase receptors. DNA damage causes the fusion of the RET oncogene with one of the ten partner genes, resulting in 15 characterized rearrangements. Numerous RET/PTC rearrangements have been identified in sporadic and especially in radiation exposure-related PTCs, with RET/PTC1 and RET/PTC3 being more common [30–32]. In contrast, Ras mutations are not commonly found in PTCs [33].

RAF encodes a serine/threonine kinase. The somatic mutation in BRAF (V600E) is one of the more common mutations identified (36–69%) in PTC. In an analysis of 320 thyroid tumors, BRAF mutations have been detected in 38% of papillary carcinomas, 13% of poorly differentiated carcinomas, and 10% of anaplastic carcinomas, but not in follicular or Hurthle cell malignancies [34]. Thus, BRAF mutations are restricted to PTC and poorly differentiated or anaplastic carcinomas arising from PTC. RAF mutations correlate with adverse clinical features, such as extrathyroidal invasion, lymph node metastases, advanced stage, risk of recurrence, loss of I-131 avidity, and increased risk of death [35–38]. In addition, BRAF mutation correlates with lower expression of the sodium iodide symporter (NIS), which could provide a molecular explanation for the de-differentiation process and loss of iodine avidity that occurs in the more aggressive BRAF-mutated thyroid cancers [39]. Given the role that mutated BRAF and RET/PTC-activating mutations play in

oncogenesis, inhibition of downstream effectors of the MAPK pathway becomes an obvious therapeutic target for advanced iodine refractory thyroid cancers [40]. Preclinical data from cell lines that harbor either BRAF, RAS, or RET mutations indicate that the presence of a BRAF mutation predicts for sensitivity to MEK inhibition with AZD6244 [41].

Follicular Thyroid Cancers

The primary molecular events that contribute to the development of FTC's include RAS mutations and PAX8-PPAR γ (gamma) rearrangements (t(2;3)(q13;p25)) [26]. The fusion of the thyroid transcription factor PAX8 and the steroid nuclear hormone receptor PPAR γ has been detected in up to 50% of FTC's, but not in follicular adenomas or PTCs [42]. A distinct genetic signature differentiating FTC tumors with the fusion gene from those without it has been characterized [43]. The rearrangement functions as a dominant negative inhibitor of the wild-type PPAR γ receptor, which is likely a tumor suppressor. In cell lines, this activated oncogene promotes accelerated cell growth, inhibition of apoptosis, and promotes anchorage independent and contact uninhibited growth [44]. In vitro, PPAR γ agonists led to reduced growth of follicular carcinoma tumor cells, and thus the clinical study in follicular cancers of PPAR γ modulators such as the thiazolidinediones (pioglitazone and rosiglitazone) is warranted [45].

RAS mutations and PAX8-PPAR γ rearrangements are rarely found in the same tumor, suggesting two distinct pathogenic pathways for follicular thyroid cancer [46]. Point mutations in H-RAS and N-RAS have been detected in FTCs, but it is not clear how these mutations relate to prognosis [33, 47].

Molecular Events Related to Progression/Transformation

While the genes discussed above are involved in the initial pathogenesis of thyroid cancers, other growth factor receptors likely play key roles in determining the progression and phenotype of thyroid carcinomas. The most extreme example of this evolution is the development of anaplastic and undifferentiated thyroid cancers that are aggressive malignancies which are not responsive to radioactive iodine, but are felt in many cases to arise from preexisting DTC. For instance, pathological series have described remnants of papillary or follicular thyroid cancer co-existing with ATCs, suggesting that clonal evolution has occurred [48–50]. Factors that may be involved in this transformation include

vascular endothelial growth factor (VEGF), epidermal growth factor receptor (EGFR), the PI3K signaling pathway, and p53. The VEGF is present at increased levels in papillary and follicular thyroid cancer cells compared with hyperplastic or benign thyroid tissue, and is associated with increased risk for recurrence and metastatic disease [51–54]. In addition, compared to benign tissue, thyroid cancers are noted to have increased levels of VEGF, VEGF-C, angiopoietin-2, and of the tyrosine kinase receptors KDR and Flt-4. VEGF and Flt-1 have also been associated with a larger-sized primary thyroid tumor [55]. Thus, increased angiogenesis is not specific to a particular histological subtype of thyroid cancer, but seems to be related to more aggressive tumors in general. Preclinical data have shown a reduction in tumor size in xenografts of PTC and ATC treated with a monoclonal antibody against VEGF [56, 57].

The EGFR is also a target of interest in thyroid cancers. Greater EGF binding has been noted in thyroid cancers versus normal thyroid tissue and is associated with a worse prognosis [58]. Also, EGFR is overexpressed in ATC cell lines, and treatment with a small molecule inhibitor of the EGFR resulted in decreased proliferation of ATC cells [59]. EGFR activation may also lead to activation of c-met and the RET/PTC oncogene [60, 61]. Inhibition of EGFR decreases RET autophosphorylation, and the two proteins likely complex as they co-immunoprecipitate from cell lysates. In vitro, a role for EGFR activation in thyroid cancer is also supported by the finding that the EGFR and multikinase inhibitors, gefitinib, PKI1166, and AEE788 had growth inhibitory effects in cell lines with the RET-activating mutation. ZD6474 (vandetanib), which targets RET, VEGFR, and EGFR, is another compound of interest in this setting, and in preclinical studies does limit the growth of thyroid cancer cells with the RET/PTC-activating rearrangement [62].

Patients with Cowden's syndrome, who have a loss of PTEN resulting in activation of the Akt pathway, are at increased risk of developing thyroid cancer, prompting further study of this pathway in thyroid cancer cells. Mutations in PTEN and PI3-K have been detected in ATC cells, and thus this pathway is thought to be critical to progression to the more aggressive thyroid cancers [63, 64]. In follicular and PTC cells, activation of Akt has also been observed, and inhibition of Akt decreased cell proliferation and increased apoptosis in thyroid carcinoma cell lines in vitro [65]. A mouse model of follicular thyroid adenoma has been generated by engineering a loss of PTEN in the thyroid follicular cells, but another genetic event is likely required for malignant transformation, such as mTOR activation [66, 67].

Alterations in p53 have also been detected in anaplastic carcinoma cell lines but not in the more differentiated histologies [68, 69]. In one series, evidence of p53 mutations

was noted in cells that also harbored BRAF mutations, suggesting that both events are important to malignant transformation and development of an aggressive phenotype. Finally, an emerging molecule that may be a marker of more aggressive thyroid cancers is MUC-1. Overexpression of MUC-1 has been seen in some thyroid cancer cell lines, and in these cells, an antibody against MUC-1 did decrease cell viability [70].

Medullary Thyroid Cancer

MTC harbors activating mutations in the RET proto-oncogene, a tyrosine kinase receptor. The majority (75%) of MTCs are sporadic, and mutations in RET are detected in up to 25–66% of this population [71]. Most somatic mutations are in exon 16. In contrast, the 25% of MTCs that are familial as part of the multiple endocrine neoplasia type 2 syndrome (MEN2) all carry RET mutations, often in exons 10 or 11 [72]. Ret inhibitors are currently being studied in patients with MTC.

Management of Thyroid Cancer

Radioactive Iodine

The primary treatment for DTC and MTC is surgical resection. For DTC's, it is important to utilize clinical and pathologic features in order to appropriately characterize a patient's prognosis, as this will guide further recommendations. Currently, the consensus is to treat patients with a higher risk of recurrence with postoperative radioactive iodine, as this has been shown in retrospective series to significantly reduce the rate of recurrence [73, 74]. Toxicities of I-131 therapy include acute effects, such as nausea, taste disturbance, salivary gland swelling, and neck edema. Late effects include xerostomia, ocular dryness, and secondary malignancies. Recently, there has been interest in using recombinant thyrotropin hormone, rather than hormone withdrawal, as the mechanism to obtain an elevated TSH in order to prime cancer cells for diagnostic iodine scans and I-131 treatment [75]. Recombinant thyrotropin (rhTSH) allows patients to be maintained in a euthyroid state and avoid potentially debilitating symptoms of hormone withdrawal. One randomized study compared both approaches prospectively, and at a follow-up period of 8 months after I-131 treatment, the primary end point of "no visible uptake in the thyroid bed, or if visible, fractional uptake less than 0.1%" was attained in 100% of patients in both groups [76]. In addition, patients who received rhTSH maintained a better quality of life and

had less radiation exposure in the blood. This approach seems promising and has already been adopted in many centers. However, it should be noted that given the long natural history of thyroid cancer, 8 months is not a long period of follow-up and thus long-term outcomes with the use of rhTSH are not fully known.

TSH Suppression

After thyroid remnant ablation postsurgery, the current standard in the management of DTC is lifelong administration of oral levothyroxine to suppress TSH, which is a known growth factor for thyroid cancers. Although this has never been validated in prospective, randomized trials, a meta-analysis has shown that suppressing TSH is associated with a decrease in disease-specific events [77]. TSH suppression may result in subclinical hyperthyroidism and can increase a patient's risk of osteoporosis, atrial fibrillation, resting tachycardia, and systolic/diastolic dysfunction.

External Beam Radiation Therapy

External beam radiation therapy (EBRT) is occasionally indicated in patients with DTC over the age of 45 who are at high risk of locoregional recurrence because of invasion of normal tissues (T4 primary) or who have a positive surgical margin [78]. Younger patients with iodine avid tumors are not felt to derive meaningful benefit from EBRT given the generally favorable prognosis of their disease. Thus, EBRT use is usually limited to elderly patients over the age of 60. At times though, EBRT may be indicated even in younger patients with noniodine avid disease for palliative purposes or to treat a solitary refractory site of disease. Data for EBRT for the treatment of MTC are lacking.

Similarly, EBRT is often considered for patients with ATC in order to prevent or delay the profound morbidity of uncontrolled locoregional disease. However, considering the dismal prognosis among this group of patients, especially those with metastatic disease, it is important to weigh the risks of therapy with the ultimate prognosis. In some cases though, there is a role for palliative radiation to aid in symptom management, even in patients with metastatic disease. For patients with resectable ATC confined to the thyroid, EBRT is indicated. It is usually given concurrently with chemotherapy (doxorubicin ± cisplatin) in this setting [79–81]. For patients with unresectable ATC, EBRT with or without chemotherapy may still be a reasonable treatment option, given the morbidity of untreated and uncontrolled locoregional disease.

Surveillance and Follow-Up

Given the indolent nature of DTC, recurrences often become evident many years after the initial diagnosis, and thus long-term follow-up is required. DTCs are sensitive to TSH and produce the tumor marker thyroglobulin. Thus, among patients who underwent a total thyroidectomy and radioactive iodine remnant ablation, a sensitive means to detect recurrent disease is to measure serum thyroglobulin after rhTSH stimulation [82]. This approach has a high negative predictive value (NPV) of 98%, and when combined with neck ultrasound the sensitivity and NPV of both procedures is 96 and 99.5%, respectively [83–85]. Due to the sensitivity of a TSH-stimulated thyroglobulin, a common clinical conundrum is the management of a rising thyroglobulin without clinical evidence of gross disease. In these situations, the neck ultrasound may be normal or equivocal. MRI of the neck is another means to detect otherwise clinically unapparent disease in the neck, a common site of recurrence [86].

Recurrent Disease

Recurrent locoregional disease can often be salvaged with resection and additional radioactive iodine treatment for iodine avid tumors. Given the indolent nature of DTCs, it may also be reasonable in certain situations to treat solitary sites of distant metastatic disease with local therapy, such as surgery or radiation. Recurrent, metastatic disease that is not surgically resectable or iodine avid has historically been very difficult to treat. Doxorubicin is currently the only FDA-approved systemic agent for the treatment of advanced, incurable thyroid cancer. Numerous small phase II studies of doxorubicin, with sample sizes ranging from 2 to 19 subjects, have yielded response rates ranging from 22 to 90% [87–94]. Although clinical experience with doxorubicin for thyroid cancer treatment has spanned for decades, in current practice it is rarely utilized as a first-line option. It is likely that the effectiveness of doxorubicin was over-estimated in these studies with small subject numbers and varying antiquated criteria for assessing response, especially among the older studies that predated spiral CT scans and consensus criteria for response assessment such as RECIST (response evaluation criteria in solid tumors) [95, 96]. Doxorubicin has been studied in two contemporary trials. First, 17 subjects were treated with doxorubicin in combination with interferon alpha [97]. One patient had a partial response and ten had stable disease, with a median time to progression of 5.9 months. In another study, patients received doxorubicin monotherapy (either given weekly or once every 3 weeks) [98]. Among the subjects with papillary or follicular cancer,

Table 39.2 Molecularly targeted agents in the treatment of medullary thyroid cancer (MTC) and differentiated thyroid cancer (DTC)

Drug	Target	Subtype	Toxicity
Axitinib	VEGFR-1, -2, -3; PDGFR- α , - β ; KIT	MTC, DTC	HTN
Motesanib	VEGF; PDGF; KIT; RET	DTC	Diarrhea; HTN; fatigue; weight loss
Sorafenib	VEGFR-2, VEGFR-3, PDGFR- β ; Flt-3; C-Kit; RET; RAF; FGFR-1	MTC, DTC	Diarrhea; palmar-plantar erythema; skin rash; HTN
Sunitinib	VEGFR; PDGFR; c-kit; RET	MTC, DTC	Diarrhea; fatigue; HTN; palmar-plantar erythema
Pazopanib	VEGF	DTC	Diarrhea; mucositis
Vandetanib	RET; VEGFR; EGFR	MTC	Rash; diarrhea; QTc prolongation
XL 184	RET; MET; VEGFR2	MTC	Diarrhea; hypopigmentation of hair
Gefitinib	EGFR	MTC, DTC	Skin rash; diarrhea
Imatinib	PDGFR	ATC	Rash
Thalidomide	Antiangiogenic; anti-TNF- α ; immunomodulator	MTC, DTC	Hematological
Lenalidomide	Antiangiogenic; anti-TNF- α ; immunomodulator	MTC, DTC	Hematological

there was a partial response (PR) rate of 5%, with 42% of patients showing SD. Among patients with MTC, the rates of PR and SD were both 11%. The Eastern Cooperative Oncology Group has studied etoposide for iodine refractory disease as well, and no sign of activity was noted [99].

The study of cytotoxic therapy for the treatment of metastatic ATC has been limited. In a study of doxorubicin monotherapy, a response was only noted in 1 patient out of 21 [92]. In the same study, there was a slight improvement in response (6 out of 18 patients) with the combination of cisplatin and doxorubicin. Additional studies of more intense combination regimens of cytotoxic therapy (cisplatin, doxorubicin, and bleomycin) have been studied in small numbers of patients with limited activity [100]. More recently, paclitaxel had antitumor activity, with a 53% response rate, in a small study composed of 20 patients with ATC [101]. Preclinical studies have also shown synergistic activity between paclitaxel and an oncolytic herpes simplex virus. Overall, though, the natural history and prognosis of this disease remains poor.

Molecularly Targeted Therapies

Recent advances in understanding the pathogenesis of thyroid cancer and development of various molecularly targeted therapies in medical oncology have dramatically transformed the field of clinical research in thyroid cancer. Over the last 5 years, great progress has been made in this field for the first time. Multiple phase I–III clinical trials have been conducted in patients with different subtypes of thyroid cancers with notable results.

A range of orally available kinase inhibitors have been studied that include axitinib, motesanib diphosphate, sorafenib, sunitinib, gefitinib, and imatinib. Most of these agents (except gefitinib and imatinib) have multiple targets, especially the vascular epithelial growth factor (VEGFR) that plays a central role in angiogenesis, tumor growth, and

progression. Other targets such as platelet-derived growth factor receptor (PDGFR), Kit, RET, and the EGFR are also relevant to the clinical activity of these kinase inhibitors (Table 39.2).

Differentiated Thyroid Cancers

Axitinib is an oral multikinase inhibitor that has shown promising early results. In a phase II trial, patients with advanced, incurable thyroid cancer not amenable to surgery or radioactive iodine therapy were enrolled to receive axitinib at 5 mg orally twice a day. The primary end point was response rate. Duration of response, progression-free survival (PFS), overall survival, safety, and modulation of soluble VEGFR were secondary end points. In this phase II trial, axitinib demonstrated selective inhibition of VEGFR with antitumor activity in all histological subtypes of advanced thyroid cancer. Of 60 patients, 45 had DTC with an overall response rate (ORR) of 31%. Stable disease (SD) lasting ≥ 16 weeks was reported in another 44% of patients. Median PFS in the entire cohort was 18.1 months. Axitinib was generally well tolerated, with the most common grade ≥ 3 treatment-related adverse event being hypertension ($n=7$; 12%) [102, 103].

Motesanib diphosphate (AMG 706) is a multitargeted oral inhibitor of VEGF receptors, platelet-derived growth-factor receptor, and Kit. In a phase I study, treatment with 125 mg of motesanib diphosphate once daily resulted in antitumor activity in patients with advanced solid cancers, including five patients with DTC [104]. A phase II study was designed to assess its efficacy and tolerability in progressive, locally advanced or metastatic DTC. ORR was 14%, 67% of the patients had SD and this was maintained for 24 weeks or longer in 35% of the patients. The most common adverse events were diarrhea, hypertension, fatigue, and weight loss [105].

Sorafenib is another multitargeted tyrosine kinase inhibitor that blocks the activities of BRAF, VEGF, c-kit, and Ret. Several studies have been designed to assess the activity and safety profile of sorafenib in advanced/metastatic thyroid cancer patients [106–109]. In one phase II study, 18 patients with medullary and DTCs were recruited. Preliminary results indicate that at 3 months, nine out of ten evaluable patients had SD and one patient had a PR. At 6 months, two out of two patients had SD. Biochemically, seven out of seven assessable patients had demonstrated PR. More than half of patients (78%) required a dose reduction from the starting dose of 400 mg bid [109]. In another more mature phase II study, a total of 55 patients with metastatic, iodine refractory, unresectable, or locally advanced thyroid cancer (DTC and MTC) were treated with sorafenib 400 mg orally BID. Data were initially reported at the completion of the first stage accrual with 30 patients. At that point, 90% of patients had DTC, with 25 patients evaluable for a response, 23% had a PR, and 53% had SD. Since, then enrollment has completed and 52 of 55 patients are evaluable for response at this time (83% with DTC). Among all evaluable patients, PR and SD rates were 36 and 46%, respectively. Sorafenib was generally well tolerated in this study, but grade 3 or higher treatment-related adverse events of note included rash (7%), diarrhea (7%), palmer-plantar erythema (PPE, 7%), hypertension (10%), and pruritis (7%). One MTC patient had grade 5 liver toxicity [107, 108]. Correlative studies included BRAF mutation analysis and measurements of changes in phospho-erk and phospho-akt levels. Sixteen patients' samples have been tested so far. Patients with wild-type BRAF had shorter PFS (54 weeks) compared to patients with the V600E mutation (84 weeks, $p=0.028$). These data are premature and require confirmation in a larger cohort of patients [110].

Targeted therapy against BRAF V600E mutant tumors is also being explored [111]. For instance, PLX4032 is an oral inhibitor of the BRAF V600E mutant kinase. A phase I study with this agent has been conducted. Only three patients with V600E mutant thyroid cancer were enrolled, but all had some degree of tumor response. Thus, this is an agent that warrants future study.

Sunitinib is another oral multitargeted kinase inhibitor with activity against RET, VEGFR, and PDGFR. It has been tested in a phase II trial in patients with refractory DTC or MTC. Forty-three patients were enrolled (37 DTC) and treated with 6-week cycles of sunitinib malate 50 mg daily on a 4-week on/2-week off schedule. Primary end points were response rate by RECIST and biochemical response. Stable disease was observed in 68% of 31 evaluable DTC patients who completed two cycles. Thirteen percent had a PR and 10% had PD. The most common drug-related adverse events included fatigue, diarrhea, PPE, neutropenia, and hypertension. In patients with iodine refractory DTC with evidence of progressive disease, sunitinib (50 mg daily in a

4 week on, 2 week off schedule) was able to induce responses or disease stabilization [112]. In a similar study, 17 patients with advanced refractory DTC (12 patients) and MTC (4 patients) were treated with sunitinib at similar doses (50 mg daily in a 4 week on, 2 week off schedule). Out of 15 patients who were evaluable for response, 1 had a PR, 12 had SD (with 1 patient have >90% decrease of thyroglobulin and 1 patient have a dramatic decrease of symptoms). Toxicities were mainly hypertension, asthenia, mucositis, hand foot syndrome, and thrombocytopenia. Grade 3/4 events were hypertension, asthenia, mucositis, and hand foot syndrome [113]. Four patients required dose reductions. Continuous dosing of sunitinib at a dose of 37.5 mg orally daily was evaluated in a phase II study in 35 patients with metastatic, refractory DTC (26 patients) or MTC (7 patients). The primary end point was response rate by RECIST. Secondary end points included FDG-PET response rate (defined as 20% reduction from baseline SUV) after 7 days of treatment, toxicity, overall survival, duration of response, and time to progression. To date, 33 patients have been enrolled and 29 patients have been evaluated for disease response with CR in 7% (2/29), PR in 25% (8/29), and SD in 48% (14/29). Continuous dosing of sunitinib is highly active (disease control rate 83%) in patients with high risk, metastatic thyroid cancer, as defined by FDG-PET [114, 115].

Pazopanib, an oral anti-VEGF tyrosine kinase inhibitor, has been studied in a phase II trial of 32 patients with advanced and progressive radioiodine-insensitive DTC. Measurement data are available for 26 patients; 5 patients had PR (19%). Two patients are alive with disease progression and another has died from disease progression. Pazopanib was overall well tolerated with diarrhea and mucositis being the dose-limiting toxicities. More data and longer follow-up are needed to validate response and efficacy for this agent [116].

Additional antiangiogenesis therapies have also been tested in advanced and iodine refractory thyroid cancer. Thalidomide offers modest therapeutic benefit in subsets of thyroid cancer patients with rapidly progressive metastatic disease. In a phase II trial, 36 patients with follicular, papillary, insular, or medullary thyroid carcinomas and distant, radioiodine-unresponsive metastases were treated with daily thalidomide (started at 200 mg orally and increased to 800 mg or maximum tolerated dose). Five patients had PR and nine patients had SD, for ORR of 50%. Median survival was 23.5 months for responders (PR+SD) and 11 months for nonresponders [117]. Fourteen percent of patients had grade 3/4 infections and 8% had grade 3/4 fatigue. Fatigue was the most significant toxicity overall with 69% of patients having some degree (grade 1/2) of fatigue related to therapy. A related drug, lenalidomide, has also been studied in a phase II trial in this patient population with a 67% ORR (44% SD+22% PR). Three patients continued to have a response

for greater than 12 months. Lenalidomide was relatively well tolerated; hematological toxicities were common (44% neutropenia, 22% thrombocytopenia) but responded to dose reductions. Full accrual and long-term data analysis are pending [118]. Overall, while these agents did have activity, the toxicities are a concern, especially in light of the long-term duration of therapy that is possible in responding patients.

Anaplastic Thyroid Cancer

Many of the trials studying antiangiogenesis agents included patients in ATC. For instance, in the phase II study of axitinib, 3% (2) of patients had ATC, with one of these patients having a documented PR [103]. Also, in the sorafenib study reported by Brose and colleagues, only two out of five patients with ATC who were treated with some degree of response [108]. In the sunitinib studies, the numbers of patients with ATC were small as well (one patient in the study reported by Ravaud et al.), thus it is difficult to form a conclusion regarding this agent's activity against ATC.

In p53-mutated/deficient ATC cell lines, c-Abl is overexpressed, and selective inhibition of c-Abl had a cytostatic effect. Thus, imatinib has been tested in a small patient population (11 patients) with ATC [119]. Of the eight evaluable patients, two (25%) had a PR and four (50%) had SD. Grade 3 toxicities included lymphopenia, edema, anemia, and hyponatremia. Thus, imatinib appeared to have activity in ATC, but unfortunately, this study was closed early due to poor accrual. Thus, larger studies, possibly involving multiple centers in order to improve access to this rare disease, are required for confirmation.

In preclinical studies, ATC cell lines were found to express the EGFR. Specific EGFR stimulation with epidermal growth factor showed significant phosphorylation of ERK1/2 and Akt, and resulted in marked growth stimulation. This EGFR-transmitted proliferation effect on the cancer cells was completely inhibited by gefitinib, an EGFR tyrosine kinase inhibitor [120]. Similar activation of EGFR was found in human tissue array of ATC and gefitinib blocked the activation of EGFR by EGF, inhibited cellular proliferation, and induced apoptosis *in vitro* [59]. Based on these preclinical data, a clinical trial was undertaken to determine the efficacy of gefitinib in patients with advanced thyroid cancer. Twenty-seven patients with radioiodine-refractory, locally advanced, or metastatic thyroid cancer were treated with 250 mg of daily gefitinib. The study was open to all refractory thyroid cancers, and histologic subtypes included papillary (41%), follicular (22%), anaplastic (19%), medullary (15%), and Hurthle cell carcinomas (4%). The primary end point was ORR. Toxicity, PFS, and OS were secondary end points. There were

no objective responses among the 25 patients evaluated. After 3, 6, and 12 months of treatment, SD was seen in 48, 24, and 12% of patients, respectively. Thirty-two percent of patients had some reductions in tumor volume that did not meet the formal criteria for PR [121]. Despite the promising preclinical data, the oral EGFR inhibitor monotherapy are not considered to be very active in thyroid cancer. It is possible that EGFR inhibitors do have a role in combination with other systemic therapies, for instance, the monoclonal antibody that targets EGFR, cetuximab, when combined with irinotecan inhibits the growth and progression on ATC xenografts [122]. Thus, this could be an avenue for future study.

Medullary Thyroid Cancer

MTC is the most common cause of death in patients with hereditary syndromes caused by activating mutations in the RET proto-oncogene. RET activation is the initial oncogenic event, with the activity of other receptor tyrosine kinases, including VEGFR and EGFR, likely to contribute to tumor growth and metastasis. Several targeted agents have been tested in phase I and II studies specific for MTC. The limited activity of EGFR inhibitors for MTC has been discussed in the previous section.

Vandetanib (ZD6474) is an oral multikinase inhibitor that targets Ret, VEGFR, and EGFR tyrosine kinases. It demonstrated efficacy in a phase II study in patients with unresectable, measurable, locally advanced or metastatic hereditary MTC, and a RET germline mutation. Patients received vandetanib 300 mg daily until disease progression or unacceptable toxicity. The primary objective was objective tumor response. Secondary assessments included disease control rate, biochemical response, safety, and tolerability. Twenty percent (6/30) of patients had a PR and another 30% (9/30) had SD (ORR of 50%). Vandetanib was overall well tolerated; grade 3 adverse effects were asymptomatic QTc prolongation, rash, and diarrhea, all of which were manageable [123]. In another study, vandetanib at a dose of 100 mg was evaluated in patients with unresectable, measurable, locally advanced, or metastatic hereditary MTC. Upon disease progression, eligible patients could enter postprogression treatment with vandetanib 300 mg. The primary objective was objective tumor response rate (RECIST). Secondary assessments included PFS and safety and tolerability. Nineteen patients (15 with a confirmed RET germline mutation) were accrued to the study and received initial treatment with vandetanib 100 mg. PR was observed in two patients, SD in six, and PD in two patients, yielding an objective response rate of 10.5% (2/19) and a disease control rate of 42.1% (8/19). These preliminary results suggest that vandetanib 100 mg also has activity in patients with hereditary MTC [124].

Sorafenib is an oral agent with documented efficacy in DTC. It was tested in five patients with symptomatic metastatic MTC with elevated calcitonin. All patients had prior thyroidectomy, four had prior octreotide therapy, and three had prior chemotherapy. Patients received 800 or 400 mg (weight < 50 kg) of sorafenib as a starting dose. After 2–3 months, calcitonin decreased to < 50% of baseline in all patients and to levels < 90% of baseline in two patients. In this small pilot study, one patient had CR and another patient had PR [125]. Several trials of multikinase inhibitors that were discussed above are also enrolled limited numbers of MTC patients. For instance, 12 patients with MTC were treated on the axitinib trial, with a resulting PR in 25% and SD in 33%. These data are especially interesting in light of the fact that axitinib is an antiangiogenesis agent and does not target Ret. Thus, illustrating that targeting angiogenesis is a potent mechanism in the treatment of this disease. As discussed previously, the sorafenib studies also included patients with MTC [108, 109]. In the study by Brose et al. that was updated at the 2009 American Society of Clinical Oncology Meeting, two patients with MTC were treated; one had SD and one had a PR. The phase II studies of sunitinib included patients with MTC, although in small numbers. In one study, six patients with MTC were enrolled. The best response in MTC patients was SD 83% and PD 17% [112].

Another promising agent is XL184, an oral inhibitor of Ret, Met, and VEGFR2. XL184 strongly inhibits cell proliferation in MTC cell lines harboring activated Ret, and pharmacodynamic studies have showed inhibition of Ret and Met phosphorylation in xenograft tumors. In a phase I study, 55 patients either received XL184 once a day on Days 1–5 of each 2 week cycle or continuous daily dosing. Response, pharmacokinetic, and pharmacodynamic parameters were assessed. Three patients with MTC had a confirmed PR and all evaluated patients with MTC had reductions in plasma calcitonin. The MTD cohort has been expanded to include 20 patients with MTC and results will likely be reported shortly [126].

Discussion and Future Directions

Significant advances have been made in our understanding of the biology of thyroid cancer, and the introduction of molecularly targeted agents is transforming the treatment paradigm for incurable metastatic thyroid cancer. With the use of oral agents, patients can avoid toxicities associated with conventional cytotoxic chemotherapy, and in studies presented to date appear to enjoy greater overall benefit than that historically seen with doxorubicin and other cytotoxic chemotherapies. Although sunitinib and sorafenib are potential off-trial options, as both are commercially available and approved for

other oncology indications, patients should be offered clinical trials whenever possible. Given the responses and clinical benefit that is possible with many of the agents discussed above, some key unanswered questions in the management of these patients include: (1) what is the best time to initiate therapy, (2) what is the best sequence of these newer agents, and (3) what are the mechanisms and patterns of resistance and cross-resistance to these agents? Although treatment with oral TKI's is fairly well tolerated, many patients develop grade 1 and 2 toxicities that do affect their quality of life especially with the very prolonged administration (years in some cases) that is required for a treatment which does not result in a sustained complete response or cure. Thus, for many patients with what is often an indolent, asymptomatic disease even when incurable and metastatic, a watchful waiting approach may be the most reasonable option. Also, it is not known which treatment to use once a patient has progressed on one of the available TKIs. It is worth noting that in patients with MTC, for example, XL184 did have activity in patients who had progressed on a prior oral tyrosine kinase inhibitor therapy. It is not known if this will also be true for other agents or if the same observation will be made in DTC.

As summarized above, there is a growing body of phase II data on the clinical activity of the new drugs in DTC and MTC. Larger randomized phase III studies are needed to confirm the benefits reported to date, and ideally result in FDA approval of some of these promising agents. Such a study is ongoing for sorafenib. Key considerations in the design of any phase III study are the choice of the control arm: should it be the current FDA standard of doxorubicin or placebo? If a placebo control is used, should cross-over be allowed? Patient selection is important as well. For many of the therapies discussed above, the most likely outcome is prolonged stable disease. In order to avoid confusing and clinically irrelevant results in studies of patients whose disease has a natural history that is often indolent without treatment, clear definitions of progressive disease upon study entry need to be incorporated in the eligibility criteria. It is also not practical to use a primary end point of overall survival in a disease that is relatively indolent, especially with the emerging option of potentially active second and third line treatments on or off study. Finally, with limited patient resources, any phase III effort will require involvement from many centers worldwide and will require a highly coordinated effort.

The goal for the future of cancer therapy overall is to utilize validated biomarkers in order to guide treatment selection and avoid the current practice of sequential, empiric therapy. As oncology moves closer toward the practice of personalized medicine, the hope is that the expected benefit for each treatment will increase, and patients can be spared the toxicity of treatment with little chance of benefit.

Given the growing knowledge of key pathways involved in the initial pathogenesis and progression of thyroid cancer, future studies of this disease should also focus on the development of biomarkers that can help guide the decision of which TKI is best for an individual patient. Also, defining prognostic markers would allow physicians to select patients with the more aggressive tumors who should initiate treatment sooner or receive more aggressive combination regimens of TKI's.

Parathyroid Cancer

Parathyroid cancer is a very rare cancer, with an estimated incidence of 0.015 per 100,000 population and an estimated prevalence of 0.005% in the USA [127, 128]. Mean age at presentation is 44–54 years, with similar incidence in both males and females. These tumors generally have low malignant potential and parathyroid cancer typically runs an indolent course. The major clinical manifestations of parathyroid carcinoma are hypercalcemia (65–75%), neck mass (34–52%), bone and renal disease (34–73% each), and high serum parathyroid hormone (PTH) concentrations (five to ten times upper limit of normal). At initial presentation, very few patients with parathyroid carcinoma have metastases either to regional lymph nodes (<5%) or distant sites (<2%). A higher proportion of patients present with locally invasive disease (into surrounding soft tissue, muscles, and nerves) [129–131].

There is an increased risk of parathyroid cancer in patients with multiple endocrine neoplasia 1, a p53 mutation, radiation exposure, and autosomal dominant familial isolated hyperparathyroidism [132–135]. HRPT2 is a tumor suppressor gene that is located on chromosome 1 and encodes parafibromin, a protein involved in the regulation of gene expression and inhibition of cell proliferation. Mutation of this tumor gene plays a central role in the molecular pathogenesis of parathyroid carcinoma [136–139].

Parathyroidectomy with en bloc resection of involved adjacent lymph nodes remains the mainstay in the management of parathyroid cancer [140–142]. Both adjuvant chemotherapy and radiation therapy have generally given poor results. Use of either should be considered only when a patient is not a candidate for surgery and hypercalcemia cannot be controlled.

Approximately 40–60% of patients experience a postsurgical recurrence, typically between 2 and 5 years after the initial resection. Recurrence is usually local and hypercalcemia is one of the harbingers of disease recurrence. Repeat surgical exploration with resection may be employed in cases of local recurrence. Removal of isolated metastatic sites may also help in alleviating symptoms associated with hypercalcemia. Because parathyroid carcinoma can be slow-growing,

resection of local recurrences or distant metastases can provide effective palliation without curing the patient. When the tumor is no longer amenable to surgical intervention, treatment becomes limited to the control of hypercalcemia with hydration, a calcimimetic agent or intravenous bisphosphonates [143–146]. Given the rarity of this disease and its indolent course, there is a paucity of clinical trials of systemic therapy and many patients would likely be candidates for phase I studies.

References

1. Jemal A, Siegel R, Ward E, et al. Cancer statistics, 2008. *CA Cancer J Clin.* 2008;58(2):71–96.
2. Ries L, Eisner M, Kosary C, et al. SEER Cancer Statistics Review, 1975–2002. Bethesda, MD: National Cancer Institute, 1998. http://seer.cancer.gov/csr/1975_2002/.
3. Davies L, Welch HG. Increasing incidence of thyroid cancer in the United States, 1973–2002. *JAMA.* 2006;295(18):2164–7.
4. Mack WJ, Preston-Martin S. Epidemiology of thyroid cancer. In: Fagin JA, editor. *Thyroid cancer.* Kluwer Academic: Boston; 1998.
5. Kazakov VS, Demidchik EP, Astakhova LN. Thyroid cancer after Chernobyl. *Nature.* 1992;359(6390):21.
6. Sigurdson AJ, Land CE, Bhatti P, et al. Thyroid nodules, polymorphic variants in DNA repair and RET-related genes, and interaction with ionizing radiation exposure from nuclear tests in Kazakhstan. *Radiat Res.* 2009;171(1):77–88.
7. Giles Senyurek Y, Fatih T, Harika B, Yersu K, Tarik T, Serdar T. The risk factors for malignancy in surgically treated patients for Graves' disease, toxic multinodular goiter, and toxic adenoma. *Surgery.* 2008;144(6):1028–36. discussion 1036–1027.
8. Antonelli A, Ferri C, Fallahi P, et al. Thyroid cancer in HCV-related chronic hepatitis patients: a case-control study. *Thyroid.* 2007;17(5):447–51.
9. Gudmundsson J, Sulem P, Gudbjartsson DF, et al. Common variants on 9q22.33 and 14q13.3 predispose to thyroid cancer in European populations. *Nat Genet.* 2009;41(4):460–4.
10. Ward LS, Assumpcao LV. The impact of gender in differentiated thyroid cancer. *Clin Endocrinol (Oxf).* 2007;66(5):752. author reply 752–753.
11. Morganti S, Ceda GP, Sacconi M, et al. Thyroid disease in the elderly: sex-related differences in clinical expression. *J Endocrinol Invest.* 2005;28(11 Suppl Proceedings):101–4.
12. Voutilainen PE, Multanen MM, Leppaniemi AK, Haglund CH, Haapiainen RK, Franssila KO. Prognosis after lymph node recurrence in papillary thyroid carcinoma depends on age. *Thyroid.* 2001;11(10):953–7.
13. Verburg F, Maeder U, Luster M, Reiners C. Histology does not influence prognosis in differentiated thyroid carcinoma when accounting for age, tumour diameter, invasive growth and metastases. *Eur J Endocrinol.* 2009;160(4):619–24.
14. Ghossein RA, Leboeuf R, Patel KN, et al. Tall cell variant of papillary thyroid carcinoma without extrathyroid extension: biologic behavior and clinical implications. *Thyroid.* 2007;17(7):655–61.
15. Patel KN, Shaha AR. Poorly differentiated and anaplastic thyroid cancer. *Cancer Control.* 2006;13(2):119–28.
16. Lebouilleux S, Rubino C, Baudin E, et al. Prognostic factors for persistent or recurrent disease of papillary thyroid carcinoma with neck lymph node metastases and/or tumor extension beyond the thyroid capsule at initial diagnosis. *J Clin Endocrinol Metab.* 2005;90(10):5723–9.

17. Hay ID, Bergstralh EJ, Goellner JR, Ebersold JR, Grant CS. Predicting outcome in papillary thyroid carcinoma: development of a reliable prognostic scoring system in a cohort of 1779 patients surgically treated at one institution during 1940 through 1989. *Surgery*. 1993;114(6):1050–7. discussion 1057–1058.
18. Cady B, Rossi R. An expanded view of risk-group definition in differentiated thyroid carcinoma. *Surgery*. 1988;104(6):947–53.
19. Sherman SI, Brierley JD, Sperling M, et al. Prospective multicenter study of thyroid carcinoma treatment: initial analysis of staging and outcome. National Thyroid Cancer Treatment Cooperative Study Registry Group. *Cancer*. 1998;83(5):1012–21.
20. AJCC (American Joint Committee on Cancer). *Cancer Staging Manual*. 6th ed. New York: Springer; 2002.
21. Hay ID, Hutchinson ME, Gonzalez-Losada T, et al. Papillary thyroid microcarcinoma: a study of 900 cases observed in a 60-year period. *Surgery*. 2008;144(6):980–7. discussion 987–988.
22. Cooper DS, Doherty GM, Haugen BR, et al. Management guidelines for patients with thyroid nodules and differentiated thyroid cancer. *Thyroid*. 2006;16(2):109–42.
23. Sugitani I, Fujimoto Y, Yamamoto N. Papillary thyroid carcinoma with distant metastases: survival predictors and the importance of local control. *Surgery*. 2008;143(1):35–42.
24. Pelizzo MR, Boschin IM, Bernante P, et al. Natural history, diagnosis, treatment and outcome of medullary thyroid cancer: 37 years experience on 157 patients. *Eur J Surg Oncol*. 2007;33(4):493–7.
25. Moura MM, Cavaco BM, Pinto AE, et al. Correlation of RET somatic mutations with clinicopathological features in sporadic medullary thyroid carcinomas. *Br J Cancer*. 2009;100(11):1777–83.
26. Kondo T, Ezzat S, Asa SL. Pathogenetic mechanisms in thyroid follicular-cell neoplasia. *Nat Rev Cancer*. 2006;6(4):292–306.
27. Frattini M, Ferrario C, Bressan P, et al. Alternative mutations of BRAF, RET and NTRK1 are associated with similar but distinct gene expression patterns in papillary thyroid cancer. *Oncogene*. 2004;23(44):7436–40.
28. Soares P, Trovisco V, Rocha AS, et al. BRAF mutations and RET/PTC rearrangements are alternative events in the etiopathogenesis of PTC. *Oncogene*. 2003;22(29):4578–80.
29. Fagin JA. Genetics of papillary thyroid cancer initiation: implications for therapy. *Trans Am Clin Climatol Assoc*. 2005;116:259–69. discussion 269–271.
30. Sadetzki S, Calderon-Margalit R, Modan B, Srivastava S, Tuttle RM. Ret/PTC activation in benign and malignant thyroid tumors arising in a population exposed to low-dose external-beam irradiation in childhood. *J Clin Endocrinol Metab*. 2004;89(5):2281–9.
31. Tallini G, Asa SL. RET oncogene activation in papillary thyroid carcinoma. *Adv Anat Pathol*. 2001;8(6):345–54.
32. Fenton CL, Lukes Y, Nicholson D, Dinauer CA, Francis GL, Tuttle RM. The ret/PTC mutations are common in sporadic papillary thyroid carcinoma of children and young adults. *J Clin Endocrinol Metab*. 2000;85(3):1170–5.
33. Karga H, Lee JK, Vickery Jr AL, Thor A, Gaz RD, Jameson JL. Ras oncogene mutations in benign and malignant thyroid neoplasms. *J Clin Endocrinol Metab*. 1991;73(4):832–6.
34. Nikiforova MN, Kimura ET, Gandhi M, et al. BRAF mutations in thyroid tumors are restricted to papillary carcinomas and anaplastic or poorly differentiated carcinomas arising from papillary carcinomas. *J Clin Endocrinol Metab*. 2003;88(11):5399–404.
35. Oler G, Cerutti JM. High prevalence of BRAF mutation in a Brazilian cohort of patients with sporadic papillary thyroid carcinomas: correlation with more aggressive phenotype and decreased expression of iodide-metabolizing genes. *Cancer*. 2009;115(5):972–80.
36. Elisei R, Ugolini C, Viola D, et al. BRAF(V600E) mutation and outcome of patients with papillary thyroid carcinoma: a 15-year median follow-up study. *J Clin Endocrinol Metab*. 2008;93(10):3943–9.
37. Kimura ET, Nikiforova MN, Zhu Z, Knauf JA, Nikiforov YE, Fagin JA. High prevalence of BRAF mutations in thyroid cancer: genetic evidence for constitutive activation of the RET/PTC-RAS-BRAF signaling pathway in papillary thyroid carcinoma. *Cancer Res*. 2003;63(7):1454–7.
38. Xing M, Westra WH, Tufano RP, et al. BRAF mutation predicts a poorer clinical prognosis for papillary thyroid cancer. *J Clin Endocrinol Metab*. 2005;90(12):6373–9.
39. Romei C, Ciampi R, Faviana P, et al. BRAFV600E mutation, but not RET/PTC rearrangements, is correlated with a lower expression of both thyroperoxidase and sodium iodide symporter genes in papillary thyroid cancer. *Endocr Relat Cancer*. 2008;15(2):511–20.
40. Ouyang B, Knauf JA, Smith EP, et al. Inhibitors of Raf kinase activity block growth of thyroid cancer cells with RET/PTC or BRAF mutations in vitro and in vivo. *Clin Cancer Res*. 2006;12(6):1785–93.
41. Leboeuf R, Baumgartner JE, Benezra M, et al. BRAFV600E mutation is associated with preferential sensitivity to mitogen-activated protein kinase inhibition in thyroid cancer cell lines. *J Clin Endocrinol Metab*. 2008;93(6):2194–201.
42. Kroll TG, Sarraf P, Pecciarini L, et al. PAX8-PPARgamma1 fusion oncogene in human thyroid carcinoma [corrected]. *Science*. 2000;289(5483):1357–60.
43. Lui WO, Foukakis T, Liden J, et al. Expression profiling reveals a distinct transcription signature in follicular thyroid carcinomas with a PAX8-PPAR(gamma) fusion oncogene. *Oncogene*. 2005;24(8):1467–76.
44. McIver B, Grebe SK, Eberhardt NL. The PAX8/PPAR gamma fusion oncogene as a potential therapeutic target in follicular thyroid carcinoma. *Curr Drug Targets Immune Endocr Metabol Disord*. 2004;4(3):221–34.
45. Martelli ML, Iuliano R, Le Pera I, et al. Inhibitory effects of peroxisome proliferator-activated receptor gamma on thyroid carcinoma cell growth. *J Clin Endocrinol Metab*. 2002;87(10):4728–35.
46. Nikiforova MN, Lynch RA, Biddinger PW, et al. RAS point mutations and PAX8-PPAR gamma rearrangement in thyroid tumors: evidence for distinct molecular pathways in thyroid follicular carcinoma. *J Clin Endocrinol Metab*. 2003;88(5):2318–26.
47. Lemoine NR, Mayall ES, Wyllie FS, et al. High frequency of ras oncogene activation in all stages of human thyroid tumorigenesis. *Oncogene*. 1989;4(2):159–64.
48. Rapkiewicz A, Roses D, Goldenberg A, Levine P, Bannan M, Simsir A. Encapsulated anaplastic thyroid carcinoma transformed from follicular carcinoma: a case report. *Acta Cytol*. 2009;53(3):332–6.
49. Rosai J, Carcangiu M, DeLellis R. Undifferentiated (anaplastic) carcinoma. In: Rosai J, Sobin L, editors. *Atlas of tumor pathology: tumors of the thyroid gland*. Washington D.C.: Armed Forces Institute of Pathology; 1992. p. 154.
50. Spires JR, Schwartz MR, Miller RH. Anaplastic thyroid carcinoma. Association with differentiated thyroid cancer. *Arch Otolaryngol Head Neck Surg*. 1988;114(1):40–4.
51. Soh EY, Duh QY, Sobhi SA, et al. Vascular endothelial growth factor expression is higher in differentiated thyroid cancer than in normal or benign thyroid. *J Clin Endocrinol Metab*. 1997;82(11):3741–7.
52. Katoh R, Miyagi E, Kawaoi A, et al. Expression of vascular endothelial growth factor (VEGF) in human thyroid neoplasms. *Hum Pathol*. 1999;30(8):891–7.
53. Klein M, Picard E, Vignaud JM, et al. Vascular endothelial growth factor gene and protein: strong expression in thyroiditis and thyroid carcinoma. *J Endocrinol*. 1999;161(1):41–9.
54. Lennard CM, Patel A, Wilson J, et al. Intensity of vascular endothelial growth factor expression is associated with increased risk of recurrence and decreased disease-free survival in papillary thyroid cancer. *Surgery*. 2001;129(5):552–8.
55. Fenton C, Patel A, Dinauer C, Robie DK, Tuttle RM, Francis GL. The expression of vascular endothelial growth factor and the type 1 vascular endothelial growth factor receptor correlate with the size of papillary thyroid carcinoma in children and young adults. *Thyroid*. 2000;10(4):349–57.

56. Bauer AJ, Patel A, Terrell R, et al. Systemic administration of vascular endothelial growth factor monoclonal antibody reduces the growth of papillary thyroid carcinoma in a nude mouse model. *Ann Clin Lab Sci.* 2003;33(2):192–9.
57. Bauer AJ, Terrell R, Doniparthi NK, et al. Vascular endothelial growth factor monoclonal antibody inhibits growth of anaplastic thyroid cancer xenografts in nude mice. *Thyroid.* 2002;12(11):953–61.
58. Duh QY, Gum ET, Gerend PL, Raper SE, Clark OH. Epidermal growth factor receptors in normal and neoplastic thyroid tissue. *Surgery.* 1985;98(6):1000–7.
59. Schiff BA, McMurphy AB, Jasser SA, et al. Epidermal growth factor receptor (EGFR) is overexpressed in anaplastic thyroid cancer, and the EGFR inhibitor gefitinib inhibits the growth of anaplastic thyroid cancer. *Clin Cancer Res.* 2004;10(24):8594–602.
60. Bergstrom JD, Westermarck B, Heldin NE. Epidermal growth factor receptor signaling activates met in human anaplastic thyroid carcinoma cells. *Exp Cell Res.* 2000;259(1):293–9.
61. Croyle M, Akeno N, Knauf JA, et al. RET/PTC-induced cell growth is mediated in part by epidermal growth factor receptor (EGFR) activation: evidence for molecular and functional interactions between RET and EGFR. *Cancer Res.* 2008;68(11):4183–91.
62. Carlomagno F, Vitagliano D, Guida T, et al. ZD6474, an orally available inhibitor of KDR tyrosine kinase activity, efficiently blocks oncogenic RET kinases. *Cancer Res.* 2002;62(24):7284–90.
63. Santarpia L, El-Naggar AK, Cote GJ, Myers JN, Sherman SI. Phosphatidylinositol 3-kinase/akt and ras/raf-mitogen-activated protein kinase pathway mutations in anaplastic thyroid cancer. *J Clin Endocrinol Metab.* 2008;93(1):278–84.
64. Garcia-Rostan G, Costa AM, Pereira-Castro I, et al. Mutation of the PIK3CA gene in anaplastic thyroid cancer. *Cancer Res.* 2005;65(22):10199–207.
65. Mandal M, Kim S, Younes MN, et al. The Akt inhibitor KP372-1 suppresses Akt activity and cell proliferation and induces apoptosis in thyroid cancer cells. *Br J Cancer.* 2005;92(10):1899–905.
66. Yeager N, Klein-Szanto A, Kimura S, Di Cristofano A. Pten loss in the mouse thyroid causes goiter and follicular adenomas: insights into thyroid function and Cowden disease pathogenesis. *Cancer Res.* 2007;67(3):959–66.
67. Yeager N, Brewer C, Cai KQ, Xu XX, Di Cristofano A. Mammalian target of rapamycin is the key effector of phosphatidylinositol-3-OH-initiated proliferative signals in the thyroid follicular epithelium. *Cancer Res.* 2008;68(2):444–9.
68. Fagin JA, Matsuo K, Karmakar A, Chen DL, Tang SH, Koeffler HP. High prevalence of mutations of the p53 gene in poorly differentiated human thyroid carcinomas. *J Clin Invest.* 1993;91(1):179–84.
69. Quiros RM, Ding HG, Gattuso P, Prinz RA, Xu X. Evidence that one subset of anaplastic thyroid carcinomas are derived from papillary carcinomas due to BRAF and p53 mutations. *Cancer.* 2005;103(11):2261–8.
70. Patel KN, Maghami E, Wreesmann VB, et al. MUC1 plays a role in tumor maintenance in aggressive thyroid carcinomas. *Surgery.* 2005;138(6):994–1001. discussion 1001–1002.
71. Marsh DJ, Learoyd DL, Andrew SD, et al. Somatic mutations in the RET proto-oncogene in sporadic medullary thyroid carcinoma. *Clin Endocrinol (Oxf).* 1996;44(3):249–57.
72. Eng C, Mulligan LM, Smith DP, et al. Mutation of the RET proto-oncogene in sporadic medullary thyroid carcinoma. *Genes Chromosom Cancer.* 1995;12(3):209–12.
73. Pacini F, Schlumberger M, Harmer C, et al. Post-surgical use of radioiodine (¹³¹I) in patients with papillary and follicular thyroid cancer and the issue of remnant ablation: a consensus report. *Eur J Endocrinol.* 2005;153(5):651–9.
74. Mazzaferri EL, Jhiang SM. Long-term impact of initial surgical and medical therapy on papillary and follicular thyroid cancer. *Am J Med.* 1994;97(5):418–28.
75. Robbins RJ, Larson SM, Sinha N, et al. A retrospective review of the effectiveness of recombinant human TSH as a preparation for radioiodine thyroid remnant ablation. *J Nucl Med.* 2002;43(11):1482–8.
76. Pacini F, Ladenson PW, Schlumberger M, et al. Radioiodine ablation of thyroid remnants after preparation with recombinant human thyrotropin in differentiated thyroid carcinoma: results of an international, randomized, controlled study. *J Clin Endocrinol Metab.* 2006;91(3):926–32.
77. McGriff NJ, Csako G, Gourgoutis L, Lori CG, Pucino F, Sarlis NJ. Effects of thyroid hormone suppression therapy on adverse clinical outcomes in thyroid cancer. *Ann Med.* 2002;34(7–8):554–64.
78. Farahati J, Reiners C, Stuschke M, et al. Differentiated thyroid cancer. Impact of adjuvant external radiotherapy in patients with perithyroidal tumor infiltration (stage pT4). *Cancer.* 1996;77(1):172–80.
79. Kim JH, Leeper RD. Treatment of anaplastic giant and spindle cell carcinoma of the thyroid gland with combination Adriamycin and radiation therapy. A new approach. *Cancer.* 1983;52(6):954–7.
80. Tennvall J, Lundell G, Wahlberg P, et al. Anaplastic thyroid carcinoma: three protocols combining doxorubicin, hyperfractionated radiotherapy and surgery. *Br J Cancer.* 2002;86(12):1848–53.
81. Kim JH, Leeper RD. Treatment of locally advanced thyroid carcinoma with combination doxorubicin and radiation therapy. *Cancer.* 1987;60(10):2372–5.
82. Robbins RJ, Chon JT, Fleisher M, Larson SM, Tuttle RM. Is the serum thyroglobulin response to recombinant human thyrotropin sufficient, by itself, to monitor for residual thyroid carcinoma? *J Clin Endocrinol Metab.* 2002;87(7):3242–7.
83. Pacini F, Molinaro E, Castagna MG, et al. Recombinant human thyrotropin-stimulated serum thyroglobulin combined with neck ultrasonography has the highest sensitivity in monitoring differentiated thyroid carcinoma. *J Clin Endocrinol Metab.* 2003;88(8):3668–73.
84. Schlumberger M, Berg G, Cohen O, et al. Follow-up of low-risk patients with differentiated thyroid carcinoma: a European perspective. *Eur J Endocrinol.* 2004;150(2):105–12.
85. Fish SA, Langer JE, Mandel SJ. Sonographic imaging of thyroid nodules and cervical lymph nodes. *Endocrinol Metab Clin North Am.* 2008;37(2):401–17. ix.
86. Kaplan SL, Mandel SJ, Muller R, Baloch ZW, Thaler ER, Loevner LA. The role of MR imaging in detecting nodal disease in thyroidectomy patients with rising thyroglobulin levels. *AJNR Am J Neuroradiol.* 2009;30(3):608–12.
87. Droz JP, Rougier P, Goddefroy V, Schlumberger M, Gardet P, Parmentier C. Chemotherapy for medullary cancer of the thyroid. Phase II trials with adriamycin and cis-platinum administered as monochemotherapy. *Bull Cancer.* 1984;71(3):195–9.
88. Gottlieb JA, Hill Jr CS. Chemotherapy of thyroid cancer with adriamycin. Experience with 30 patients. *N Engl J Med.* 1974;290(4):193–7.
89. Gottlieb JA, Hill Jr CS, Ibanez ML, Clark RL. Chemotherapy of thyroid cancer. An evaluation of experience with 37 patients. *Cancer.* 1972;30(3):848–53.
90. Benker G, Reinwein D. Results of chemotherapy in thyroid cancer. *Dtsch Med Wochenschr.* 1983;108(11):403–6.
91. Kolaric K, Maricic Z, Nola P, Krusic J. Modified administration schedule of adriamycin in solid tumors. *Z Krebsforsch Klin Onkol Cancer Res Clin Oncol.* 1977;88(3):255–60.
92. Shimaoka K, Schoenfeld DA, DeWys WD, Creech RH, DeConti R. A randomized trial of doxorubicin versus doxorubicin plus cisplatin in patients with advanced thyroid carcinoma. *Cancer.* 1985;56(9):2155–60.
93. Porter AT, Ostrowski MJ. Medullary carcinoma of the thyroid treated by low-dose adriamycin. *Br J Clin Pract.* 1990;44(11):517–8.
94. Williams SD, Birch R, Einhorn LH. Phase II evaluation of doxorubicin plus cisplatin in advanced thyroid cancer: a Southeastern Cancer Study Group Trial. *Cancer Treat Rep.* 1986;70(3):405–7.

95. Eisenhauer EA, Therasse P, Bogaerts J, et al. New response evaluation criteria in solid tumours: revised RECIST guideline (version 1.1). *Eur J Cancer*. 2009;45(2):228–47.
96. Therasse P, Le Cesne A, Van Glabbeke M, Verweij J, Judson I. RECIST vs. WHO: prospective comparison of response criteria in an EORTC phase II clinical trial investigating ET-743 in advanced soft tissue sarcoma. *Eur J Cancer*. 2005;41(10):1426–30.
97. Argiris A, Agarwala SS, Karamouzis MV, Burmeister LA, Carty SE. A phase II trial of doxorubicin and interferon alpha 2b in advanced, non-medullary thyroid cancer. *Invest New Drugs*. 2008;26(2):183–8.
98. Matuszczyk A, Petersenn S, Bockisch A, et al. Chemotherapy with doxorubicin in progressive medullary and thyroid carcinoma of the follicular epithelium. *Horm Metab Res*. 2008;40(3):210–3.
99. Leaf AN, Wolf BC, Kirkwood JM, Haselow RE. Phase II study of etoposide (VP-16) in patients with thyroid cancer with no prior chemotherapy: an Eastern Cooperative Oncology Group Study (E1385). *Med Oncol*. 2000;17(1):47–51.
100. De Besi P, Busnardo B, Toso S, et al. Combined chemotherapy with bleomycin, adriamycin, and platinum in advanced thyroid cancer. *J Endocrinol Invest*. 1991;14(6):475–80.
101. Ain KB, Egorin MJ, DeSimone PA. Treatment of anaplastic thyroid carcinoma with paclitaxel: phase 2 trial using ninety-six-hour infusion. Collaborative Anaplastic Thyroid Cancer Health Intervention Trials (CATCHIT) Group. *Thyroid*. 2000;10(7):587–94.
102. Cohen E, Vokes E, Rosen L. A phase II study of axitinib (AG-013736 [AG]) in patients (pts) with advanced thyroid cancers. *J Clin Oncol (ASCO Annual Meeting Proceedings Part I)*. 2007;25(18S):abstract 6008.
103. Cohen EE, Rosen LS, Vokes EE, et al. Axitinib is an active treatment for all histologic subtypes of advanced thyroid cancer: results from a phase II study. *J Clin Oncol*. 2008;26(29):4708–13.
104. Rosen L, Kurzrock R, Mulay M. Safety, pharmacokinetics, and efficacy of AMG 706, an oral multikinase inhibitor, in patients with advanced solid tumors. *J Clin Oncol (ASCO Annual Meeting Proceedings)*. 2007;25:2369–76.
105. Sherman SI, Wirth LJ, Droz JP, et al. Motesanib diphosphate in progressive differentiated thyroid cancer. *N Engl J Med*. 2008;359(1):31–42.
106. Brose M, Nellore A, Paziana K. A phase II study of sorafenib in metastatic thyroid carcinoma. *J Clin Oncol*. 2008;26(Suppl):abstract 6026.
107. Gupta V, Puttaswamy K, Lassoued W. Sorafenib targets BRAF and VEGFR in metastatic thyroid carcinoma. *J Clin Oncol (ASCO Annual Meeting Proceedings Part I)*. 2007;25(18S):abstract 6019.
108. Gupta-Abramson V, Troxel AB, Nellore A, et al. Phase II trial of sorafenib in advanced thyroid cancer. *J Clin Oncol*. 2008;26(29):4714–9.
109. Ahmed M, Barbachano Y, Riddell AM, et al. Preliminary results of an open labelled phase 2 study evaluating the safety and efficacy of sorafenib in metastatic advanced thyroid cancer. Paper presented at: ASCO; 2008; Chicago, IL.
110. Brose M, Troxel A, Redlinger M. Effect of *BRAF*^{V600E} on response to sorafenib in advanced thyroid cancer patients. *J Clin Oncol (ASCO Annual Meeting Proceedings)*. 2009;27(15S):abstract 6002.
111. Flaherty K, Puzanov I, Sosman J. Phase I study of PLX4032: proof of concept for V600E BRAF mutation as a therapeutic target in human cancer. *J Clin Oncol (ASCO Annual Meeting Proceedings)*. 2009;27(15S):abstract 9000.
112. Cohen E, Needles B, Cullen K. Phase 2 study of sunitinib in refractory thyroid cancer. *J Clin Oncol*. 2008;26:abstract 6025.
113. Ravaud A, de la Fouchardière C, Courbon F. Sunitinib in patients with refractory advanced thyroid cancer: the THYSU phase II trial. *J Clin Oncol*. 2008;26:abstract 6058.
114. Goulart B, Carr L, Martins R, Eaton K. Phase II study of sunitinib in iodine refractory, well-differentiated thyroid cancer (WDTC) and metastatic medullary thyroid carcinoma (MTC). *J Clin Oncol*. 2008;26:abstract 6062.
115. Carr L, Goulart B, Martins R. Phase II trial of continuous dosing of sunitinib in advanced, FDG-PET avid, medullary thyroid carcinoma (MTC) and well-differentiated thyroid cancer (WDTC). *J Clin Oncol (ASCO Annual Meeting Proceedings)*. 2009;27(15S):abstract 6056.
116. Bible K, Smallridge R, Maples W. Phase II trial of pazopanib in progressive, metastatic, iodine-insensitive differentiated thyroid cancers. *J Clin Oncol (ASCO Annual Meeting Proceedings)*. 2009;27(15S):abstract 3521.
117. Ain KB, Lee C, Williams KD. Phase II trial of thalidomide for therapy of radioiodine-unresponsive and rapidly progressive thyroid carcinomas. *Thyroid*. 2007;17(7):663–70.
118. Ain K, Lee C, Holbrook K. Phase II study of lenalidomide in distantly metastatic, rapidly progressive, and radioiodine-unresponsive thyroid carcinomas: preliminary results. *J Clin Oncol*. 2008;26:abstract 6027.
119. Ha H, Lee J, Urba S. Phase II trial evaluating imatinib (I) in patients (pts) with anaplastic thyroid carcinoma (ATC). *J Clin Oncol (ASCO Annual Meeting Proceedings)*. 2009;27(15S):abstract 6057.
120. Nobuhara Y, Onoda N, Yamashita Y, et al. Efficacy of epidermal growth factor receptor-targeted molecular therapy in anaplastic thyroid cancer cell lines. *Br J Cancer*. 2005;92(6):1110–6.
121. Pennell NA, Daniels GH, Haddad RI, et al. A phase II study of gefitinib in patients with advanced thyroid cancer. *Thyroid*. 2008;18(3):317–23.
122. Kim S, Prichard CN, Younes MN, et al. Cetuximab and irinotecan interact synergistically to inhibit the growth of orthotopic anaplastic thyroid carcinoma xenografts in nude mice. *Clin Cancer Res*. 2006;12(2):600–7.
123. Wells S, You Y, Lakhani V. A phase II trial of ZD6474 in patients with hereditary metastatic medullary thyroid cancer. *J Clin Oncol (ASCO Annual Meeting Proceedings Part I)*. 2006;24(18S):abstract 5533.
124. Haddad R, Krebs A, Vasselli J. A phase II open-label study of vandetanib in patients with locally advanced or metastatic hereditary medullary thyroid cancer. *J Clin Oncol*. 2008;26:abstract 6024.
125. Kober F, Hermann M, Handler A. Effect of sorafenib in symptomatic metastatic medullary thyroid cancer. *J Clin Oncol (ASCO Annual Meeting Proceedings Part I)*. 2007;25(18S):abstract 14065.
126. Salgia R, Sherman S, Hong D. A phase I study of XL184, a RET, VEGFR2, and MET kinase inhibitor, in patients (pts) with advanced malignancies, including pts with medullary thyroid cancer (MTC). *J Clin Oncol*. 2008;26:abstract 3522.
127. Lee PK, Jarosek SL, Virnig BA, Evasovich M, Tuttle TM. Trends in the incidence and treatment of parathyroid cancer in the United States. *Cancer*. 2007;109(9):1736–41.
128. Jemal A, Siegel R, Ward E, Hao Y, Xu J, Thun MJ. Cancer statistics, 2009. *CA Cancer J Clin*. 2009;59(4):225–49.
129. Busaidy N, Jimenez C, Habra M. Two decades of experience with parathyroid carcinoma. *Proc Am Soc Clin Oncol*. 2003;22:abstract 2078.
130. Robert JH, Trombetti A, Garcia A, et al. Primary hyperparathyroidism: can parathyroid carcinoma be anticipated on clinical and biochemical grounds? Report of nine cases and review of the literature. *Ann Surg Oncol*. 2005;12(7):526–32.
131. Sandelin K, Auer G, Bondeson L, Grimelius L, Farnebo LO. Prognostic factors in parathyroid cancer: a review of 95 cases. *World J Surg*. 1992;16(4):724–31.
132. Marx S, Spiegel AM, Skarulis MC, Doppman JL, Collins FS, Liotta LA. Multiple endocrine neoplasia type 1: clinical and genetic topics. *Ann Intern Med*. 1998;129(6):484–94.

133. Marx SJ, Agarwal SK, Kester MB, et al. Germline and somatic mutation of the gene for multiple endocrine neoplasia type 1 (MEN1). *J Intern Med.* 1998;243(6):447–53.
134. Cryns VL, Rubio MP, Thor AD, Louis DN, Arnold A. p53 abnormalities in human parathyroid carcinoma. *J Clin Endocrinol Metab.* 1994;78(6):1320–4.
135. Cryns VL, Thor A, Xu HJ, et al. Loss of the retinoblastoma tumor-suppressor gene in parathyroid carcinoma. *N Engl J Med.* 1994;330(11):757–61.
136. Carpten JD, Robbins CM, Villablanca A, et al. HRPT2, encoding parafibromin, is mutated in hyperparathyroidism-jaw tumor syndrome. *Nat Genet.* 2002;32(4):676–80.
137. Cetani F, Pardi E, Borsari S, et al. Genetic analyses of the HRPT2 gene in primary hyperparathyroidism: germline and somatic mutations in familial and sporadic parathyroid tumors. *J Clin Endocrinol Metab.* 2004;89(11):5583–91.
138. Krebs LJ, Shattuck TM, Arnold A. HRPT2 mutational analysis of typical sporadic parathyroid adenomas. *J Clin Endocrinol Metab.* 2005;90(9):5015–7.
139. Shattuck TM, Valimaki S, Obara T, et al. Somatic and germ-line mutations of the HRPT2 gene in sporadic parathyroid carcinoma. *N Engl J Med.* 2003;349(18):1722–9.
140. Flye MW, Brennan MF. Surgical resection of metastatic parathyroid carcinoma. *Ann Surg.* 1981;193(4):425–35.
141. Hoelting T, Weber T, Werner J, Herfarth C. Surgical treatment of parathyroid carcinoma (Review). *Oncol Rep.* 2001;8(4):931–4.
142. Obara T, Okamoto T, Ito Y, et al. Surgical and medical management of patients with pulmonary metastasis from parathyroid carcinoma. *Surgery.* 1993;114(6):1040–8. discussion 1048–1049.
143. Collins MT, Skarulis MC, Bilezikian JP, Silverberg SJ, Spiegel AM, Marx SJ. Treatment of hypercalcemia secondary to parathyroid carcinoma with a novel calcimimetic agent. *J Clin Endocrinol Metab.* 1998;83(4):1083–8.
144. de Papp AE, Kinder B, LiVolsi V, Gupta SM, Stewart AF. Parathyroid carcinoma arising from parathyroid hyperplasia: auto-infarction following intravenous treatment with pamidronate. *Am J Med.* 1994;97(4):399–400.
145. Newrick PG, Braatvedt GD, Webb AJ, Sheffield E, Corral RJ. Prolonged remission of hypercalcaemia due to parathyroid carcinoma with pamidronate. *Postgrad Med J.* 1994;70(821):231–2.
146. Silverberg SJ, Rubin MR, Faiman C, et al. Cinacalcet hydrochloride reduces the serum calcium concentration in inoperable parathyroid carcinoma. *J Clin Endocrinol Metab.* 2007;92(10):3803–8.

Chapter 40

Head and Neck Paragangliomas

Matthew O. Old and James L. Netterville

Abstract Head and neck paragangliomas are rare vascular tumors of neural crest origin that arise from extra-adrenal paraganglia of the autonomic system. The nomenclature of these tumors has been confusing throughout the literature. Most are benign tumors and rarely display malignant features. A majority of paragangliomas are sporadic with 10–30% representing familial cases. Most present as an asymptomatic mass in the head or neck, and MRI with and without contrast is the best initial imaging modality. Surgical resection is the preferred treatment for isolated paragangliomas, but observation versus radiation therapy should be considered for high surgical risk patients or multiple paragangliomas. The potential morbidity of surgical treatment must be weighed with the patient-oriented factors to determine an appropriate course of action. Rehabilitation of the surgical patient is sometimes necessary to assist with voice and swallowing dysfunction, baroreflex failure, and first-bite syndrome.

Keywords Paragangliomas • Glomus tumors • Head and neck • Familial paragangliomas • Baroreflex failure • First-bite syndrome • Cranial nerve deficit • Therapy

Introduction

Head and neck paragangliomas are rare vascular tumors of neural crest origin that arise from extra-adrenal paraganglia of the autonomic system. The nomenclature of these tumors has been confusing throughout the literature. Most are benign tumors and rarely display malignant features. A majority of paragangliomas are sporadic with only 10–28% representing familial cases [1, 2]. Most present as an asymptomatic mass in the head or neck, and MRI with and without contrast is the best initial imaging modality. Surgical resection is

the preferred treatment for isolated paragangliomas, but observation versus radiation therapy should be considered for high surgical risk patients or multiple paragangliomas. The potential morbidity of surgical treatment must be weighed with the patient-oriented factors to determine an appropriate course of action. Rehabilitation of the surgical patient is sometimes necessary to assist with voice and swallowing dysfunction, baroreflex failure, and first-bite syndrome.

Nomenclature

The nomenclature of paragangliomas is confusing, and these tumors have various terminologies such as chemodectoma, nonchromaffin paragangliomas, carotid body tumors, and glomus tumors. Carotid body tumors are also known as chemodectomas due to the physiologic function of the carotid body as a chemoreceptor. The carotid and aortic bodies are the only paraganglia that act as chemoreceptors so the term chemodectomas is inappropriate for all paragangliomas. Nonchromaffin refers to the histologic staining which distinguishes these paragangliomas from the chromaffin-reacting tissue of the adrenal medulla. Glomus is the most frequently misused term in the literature, and it refers to the morphology of the tumors [3]. Glomus is technically a term for a histologically different benign cutaneous tumor [4]. The World Health Organization Classification of Tumours has designated these paragangliomas by their location (i.e., carotid, vagal, jugular, and tympanic paragangliomas) [5]. This is the most widely accepted and appropriate terminology for paragangliomas, and highlights the common nature and origin of these tumors.

Epidemiology and Genetics

These rare, highly vascular tumors demonstrate an incidence of 1:100,000 to 1:1,000,000, representing an estimated 0.01% of all human tumors [2]. Ninety percent of paragangliomas are pheochromocytomas arising in the adrenal glands.

M.O. Old (✉)

Department of Otolaryngology – Head and Neck Surgery, The James Cancer Hospital and Solove Research Institute at the Ohio State University Comprehensive Cancer Center, 456 W. 10th Ave., Suite 4a, Columbus, OH 43210, USA
e-mail: Matthew.Old@osumc.edu

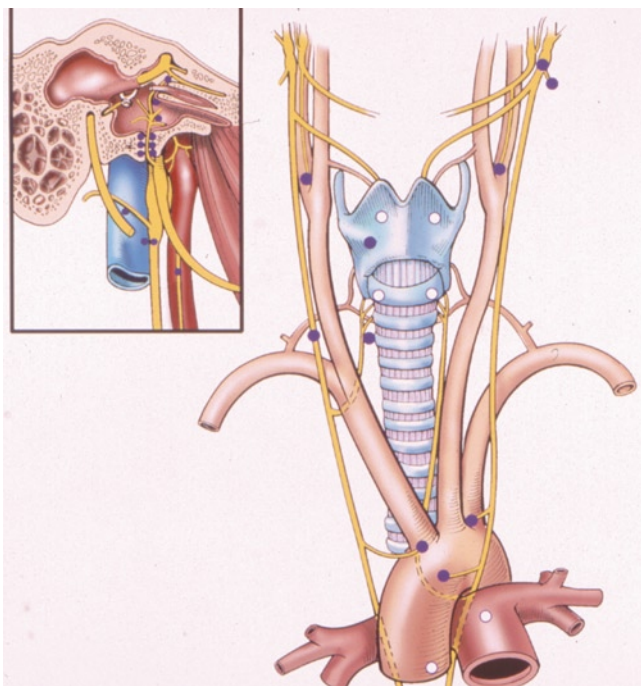


Fig. 40.1 Head and neck paraganglia and locations of paragangliomas

Abdominal (8.5%) and thoracic (1.2%) tumors are followed by head and neck tumors which comprise only 0.3% of paragangliomas. Paragangliomas arising outside the head and neck are more common in males. However, the head and neck subset of tumors are more prevalent in females [6]. There is evidence of a higher incidence of carotid body tumors at altitudes over 2,000 m which is discussed later in the chapter [7]. Paragangliomas typically present in mid-age adults. Over 60% of head and neck paragangliomas consist of carotid body tumors, followed by jugulotympanic and vagal paragangliomas [8]. The vagal tumors account for roughly 5% of all head and neck paragangliomas [9]. Paragangliomas can arise in the larynx, paranasal sinuses, nasopharynx, orbit, and the thyroid gland which all contain paraganglia (Fig. 40.1). Due to the rare nature of these sub-sites, they are not discussed in this chapter.

Paragangliomas are typically solitary but may present with multicentricity, particularly in familial syndromes such as Carney's syndrome (Carney's Triad) and multiple endocrine neoplasia syndromes (MEN), Types II A and II B. Carney's syndrome consists of the triad of gastric epithelioid leiomyosarcomas, pulmonary chondromas, and extra-adrenal paragangliomas [10]. Neurofibromatosis and von Hippel-Lindau are also associated with paragangliomas.

Familial paragangliomas constitute approximately 28% of paraganglioma cases. Eight to twenty-five percent of sporadic paraganglioma cases have germline succinate dehydrogenase (SDH) mutations leading to a probable

underestimation of the hereditary factor. Thus, the familial paraganglioma prevalence is likely much higher as genetic testing of every patient is not common [2]. The presentation is typically at younger ages and often involves multiple sites. Multicentricity is present 10% of the time in sporadic paragangliomas versus 30–40% in the familial version [11].

The primary gene (PGL1) has been identified at 11q23 locus, and other less common genes have been found [12]. The PGL genes code for the SDH complexes subunit D (SDHD, 11q23), B (SDHB, 1p36), and C (SDHC, 1q21) which are part of mitochondrial complex II. Mutations of these genes are hypothesized to lead to defective oxygen sensing and cellular proliferation, similar to conditions produced by chronic hypoxia. This may explain the higher incidence of paragangliomas at altitude. Of the familial cases, mutated SDHD, SDHB, and SDHC are found at rates of 51, 34, and 14.2% respectively [13]. The PGL1 (SDHD) gene is inherited in an autosomal dominant fashion with genomic imprinting, leading to "skipping" of generations. Males with the gene can produce children with a 50% chance of developing paragangliomas. Females can inherit the gene and pass it along but will not have affected children. Interestingly, the genes encoding for SHDB and SDHC are inherited in standard autosomal dominant fashion [1]. Multicentricity is found in about two-thirds of SDHD mutation patients. Malignant paragangliomas are more prevalent in SDHB patients (37.5%) than in SDHD (3.2%) and SDHC patients (0%) [14].

In addition to genomic imprinting, Knudson's two-hit hypothesis can help explain the higher rates of multicentricity in familial paraganglioma cases [15]. In sporadic cases, wild-type alleles of a tumor-suppressor gene must be mutated or inactivated by two independent mutations. In familial versions, one is already inactivated and one-hit events can lead to multiple tumor site development [16].

Anatomy, Physiology, and Histopathology

Paraganglia are neural-crest derived collection of cells that are critical in fetal development until the adrenal medulla takes over producing catecholamines [17]. Paraganglia are contained within vascular adventitia or intraneuronally releasing catecholamines and neurotransmitters [18]. Most of these structures degenerate after birth except for those along the autonomic nervous system and in a few other tissues [19]. Typical locations of head and neck paragangliomas include the carotid body, jugulotympanic, and vagal bodies (see Fig. 40.1). Rarely, paragangliomas can arise in the larynx, paranasal sinuses, nasopharynx, orbit, and the thyroid gland.

Paragangliomas generally have a slow rate of growth, and physiologic activity is rare. Intra-abdominal tumors have a higher rate of hormone production. Even though all paragangliomas contain neurosecretory granules in the cytoplasm, only 1–3% demonstrates physiologic activity [20]. If a patient exhibits symptoms of excess catecholamine production, they should be evaluated for a hyperfunctional paraganglioma and multiple tumors such as pheochromocytomas.

The histology of paragangliomas demonstrates three different elements: chief cells (Type I), sustentacular cells (Type II), and capillaries. The cells are arranged in a distinctive pattern with clusters of chief cells surrounded by fibrovascular stroma, sustentacular cells, and capillaries. The pattern has been termed Zellballen (Fig. 40.2). Paraganglia are highly vascular which provides the chief cells an excellent environment to sample the milieu and alter physiologic parameters via hormonal means or neurotransmitter release to alter afferent nerve firing. Chief cells are of neural crest origin and have many similarities to other neural crest cells and tumors. Due to this origin, many histopathologic stains used to identify these tumors are positive in other neural-crest tumors. Chromogranins, synaptophysin, serotonin, and neuron-specific enolase markers can be found in these and other neural-crest tumors [11]. Thus, other neural-crest tumors should be considered in the differential.

The carotid body is a chemoreceptor located on the medial surface of the common carotid bifurcation. Its normal size is approximately $5 \times 3 \times 1.5$ mm [21]. The carotid body is sensitive to changes in pH, blood flow, and the partial pressure oxygen. It acts to regulate respiration and maintain homeostasis of arterial gases by stimulating the cardiopulmonary

system. Chronic hypoxic states such as chronic obstructive pulmonary disease, high altitude, and heart disease can induce hyperplastic changes in the carotid body that are identical to paraganglioma development. This corroborates the increased incidence of these tumors at higher altitudes.

The baroreceptor function of the carotid body–sinus complex is well known and first described by Hering in 1927 [22]. The sinus is made up of stretch receptors and is in close proximity to the carotid body (Fig. 40.3). The stretch receptors are in the adventitia near the carotid body and are stimulated when stretched by increased intraluminal pressure [22].

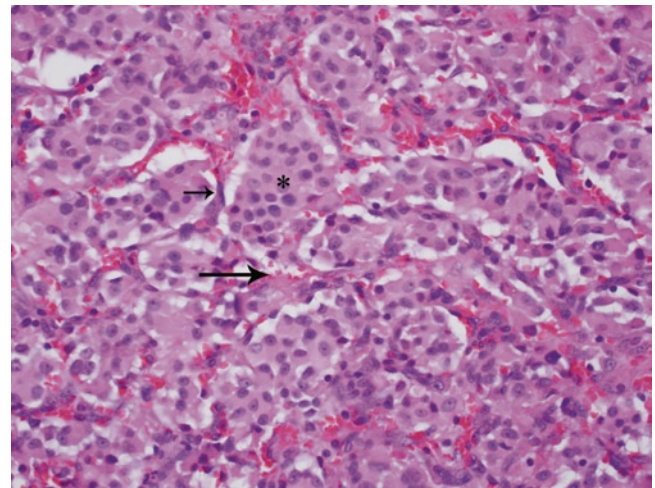


Fig. 40.2 Histopathology paraganglioma. Note Type I chief cells (asterisk) in clusters surrounded by sustentacular cells (short arrow) creating “Zellballen” pattern; capillaries are abundant throughout (long arrow). Courtesy of William Chopp, M.D. from Vanderbilt University Department of Pathology

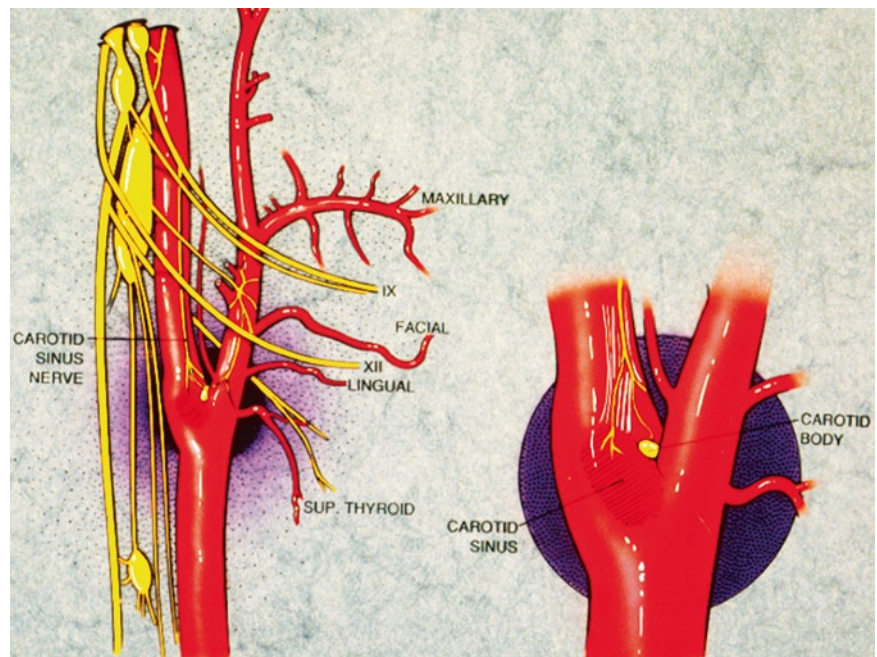


Fig. 40.3 Carotid system, carotid body–sinus complex, and associated cranial nerves. From Netterville JL, Reilly KM, Rovertson D, et al. Carotid body tumors. A review of 30 patients with 46 tumors. *Laryngoscope*. 1995;105:115–126. Reprinted with permission from John Wiley & Sons

The nerve supply to the carotid sinus and body is supplied mostly via Herring's nerve, a branch of the glossopharyngeal. Minor inputs come from the sympathetic chain and vagus nerves. Stretching of the carotid sinus increases the firing rate that is transmitted to the brainstem. This is relayed to the vagal center of the medulla to inhibit vasoconstriction, decrease the heart rate, and reduce blood pressure. This physiology is important, particularly in the surgical management of bilateral carotid body tumor patients which is discussed later in this chapter.

The vagus is the most important cranial nerve as it affects the ability to swallow, protect the airway, and speak. Vagal paragangliomas typically occur along the first 2 cm of the vagus nerve after it exits the skull base in the parapharyngeal space. It may involve the skull base or intracranial compartment (Fig. 40.4). There are three different vagal ganglia but these tumors typically arise from the inferior nodose ganglion [23]. The superior laryngeal nerve provides sensory feedback from the supraglottic larynx and passes deep to the external and internal carotid to join the vagus nerve approximately 1–2 cm below the jugular foramen at the level of the inferior ganglion. The hypoglossal nerve is at significant risk during surgery because it is frequently involved or associated with vagal and carotid body paragangliomas.

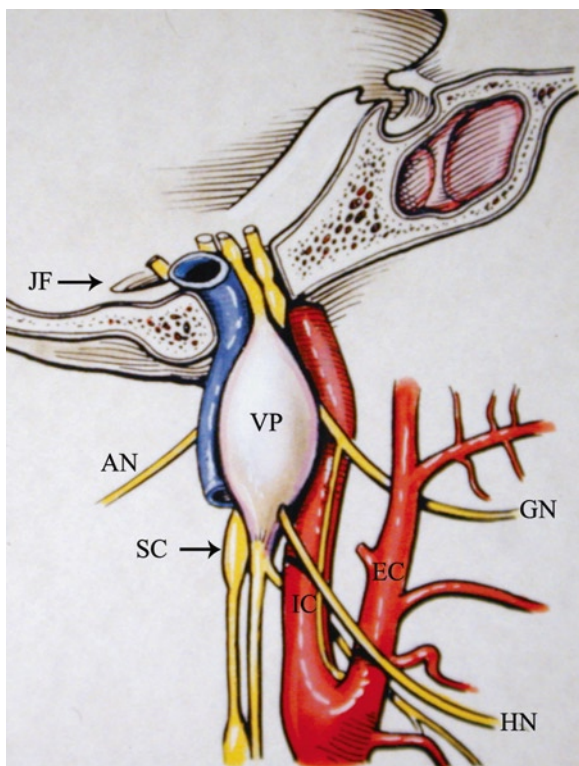


Fig. 40.4 Anatomy of vagal paragangliomas and proximity to skull base and other cranial nerves. VP vagal paraganglioma, IC internal carotid, EC external carotid, AN accessory nerve, SC sympathetic chain, GN glossopharyngeal nerve, HN hypoglossal nerve, JF jugular foramen

Jugular paragangliomas present in the base of skull and sometime extend intercranially, extracranially, and into the jugular vein. These tumors are intimately associated with the temporal bone. The facial nerve and hearing apparatus often play a major role in the management of these tumors. The anatomy of the skull base in this region is out of the scope of this chapter. Surgical treatment involves a team approach with the head and neck surgeon, neuro-otologist, and the neurosurgeon depending upon the extent of temporal bone and intracranial involvement.

Clinical Features and Evaluation

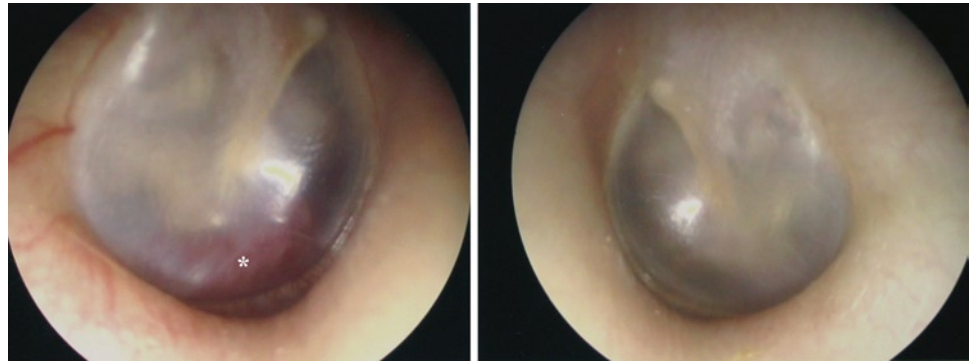
The typical presentation of a head and neck paraganglioma is an asymptomatic neck mass in a middle-aged patient. Familial versions may present in younger adults. Physical examination findings include a neck mass (carotid body tumors), unilateral oropharyngeal asymmetry from a parapharyngeal tumor (carotid body or vagal paragangliomas), and neurotologic symptoms (jugulotympanic tumors). A detailed cranial nerve examination and documentation must occur with every patient. A comprehensive history and physical examination is necessary and should include a family history of suspected relatives with paragangliomas or neck masses.

Carotid body tumors are described as mobile in the medial-lateral directions but not up and down. We have found this to be of little clinical utility. Palpable pulsation and/or a bruit may be heard over the mass. Parapharyngeal extension demonstrated by a medial bulge of the lateral oropharyngeal wall can be present in large carotid body tumors. Vagal tumors present with a variety of signs and symptoms depending upon the size of the tumor. Common presentations are an asymptomatic neck mass, pulsatile tinnitus, pharyngeal mass, hoarseness, and partial to complete loss of the lower cranial nerves 9 through 12 [24]. Jugulotympanic tumors present with otologic symptoms such as pulsatile tinnitus, hearing loss, ear fullness, and facial paralysis. Physical examination may demonstrate a red to bluish mass behind the tympanic membrane (Fig. 40.5).

Overall, paragangliomas grow slowly at approximately 0.5 cm per year. There is no reliable predictor of the growth rate other than following clinically and with serial imaging.

The majority of paragangliomas are benign. To date, histology is not able to determine malignant behavior of these tumors. The malignant potential is defined by spread to lymph nodes or distant metastases. It has been demonstrated to be highest in vagal tumors (16%), followed by carotid body (6%) and jugulotympanic (4%). The reported 5-year survival rate based on the National Cancer Data base is about 60% when regional metastases were found [14]. Frequently,

Fig. 40.5 Right jugular paraganglioma with middle ear extension. *Asterisk* – red hue of tumor behind the anterior-inferior quadrant of the tympanic membrane



lymph nodes around the tumors are removed to aid in the dissection. These should be sent for pathology to help stage the tumor and determine if it has malignant potential.

Diagnostic Testing

Patients with suspected neck masses often undergo a CAT scan of the neck with IV contrast. This is an appropriate diagnostic test, particularly in a middle-aged adult with a neck mass. This is the preferred initial modality for most head and neck cancers, which are significantly more common than paragangliomas. If a paraganglioma is suspected or revealed on CT, an MRI should be performed. MRI with and without contrast is the best imaging modality for initial evaluation and follow-up. Because of the vascular nature of these tumors, imaging with contrast is standard of care in paraganglioma patients. The classic picture is low signal voids among a background of heterogeneous signal or contrast enhancement (Fig. 40.6) [25]. With paragangliomas involving the skull base (jugulotympanic or vagal), CT is complimentary to MRI imaging. CT is superior to MRI for demonstrating bony integrity or destruction. The CT appearance of a paraganglioma typically reveals a homogenous enhancing mass in well-defined locations: carotid bifurcation (carotid body), posterior to great vessels (vagal), and jugular foramen (jugulotympanic) (Fig. 40.7). Central necrosis on imaging frequently represents an aggressive tumor in our experience. Many head and neck surgeons and neuro-otologists prefer CT for surgical planning.

MRI and MR angiography (MRA) compliment CT in the parapharyngeal and skull base regions, particularly in resolving the native enhancement of the great vessels and tumors in this region. MRA can demonstrate the position and integrity of the carotid lumen (Fig. 40.8). The most definitive method for determining vessel integrity is angiography. Angiography allows the opportunity to perform preoperative balloon-occlusion studies and embolization if deemed appropriate. Carotid body and vagal paragangliomas have classic features with angiography. The external and internal carotid arteries

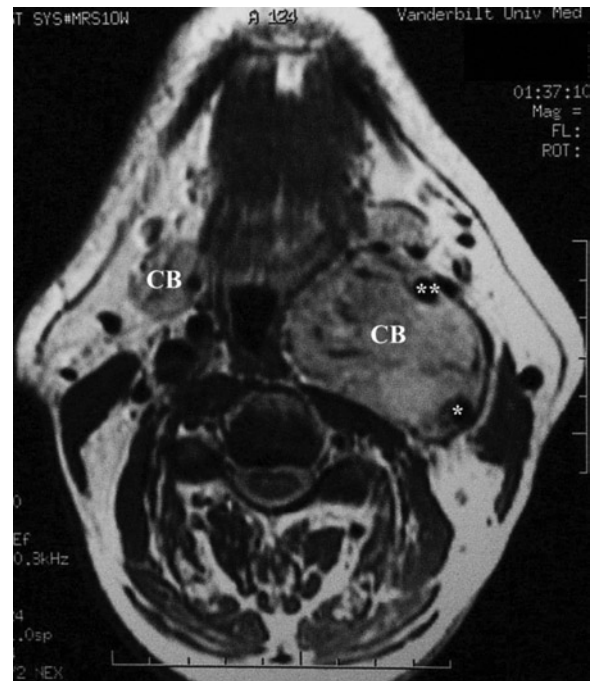


Fig. 40.6 MRI of bilateral carotid body tumors. Note heterogeneous appearance due to signal voids and vascularity. *CB* carotid body tumors, *asterisk* internal carotid artery, *double asterisk* external carotid artery

are played when a carotid body paraganglioma is present. This is referred to as the “Lyre sign” named after the shape of the ancient stringed instrument (Fig. 40.9). The great vessels are classically pushed forward with vagal tumors (Fig. 40.10). We prefer to use angiography with preoperative embolization only in circumstances in which the tumor is aggressive and significant blood loss is probable during surgical resection. Our experience is that large tumors with central necrosis tend to be the most aggressive ones requiring embolization prior surgery.

Radiographic evaluation of the multicentricity in familial paragangliomas may be supplemented with ¹¹¹Indium pentetreotide scanning which uses radiolabeled somatostatin [26]. Another alternative to consider is octreotide scintigraphy [27].

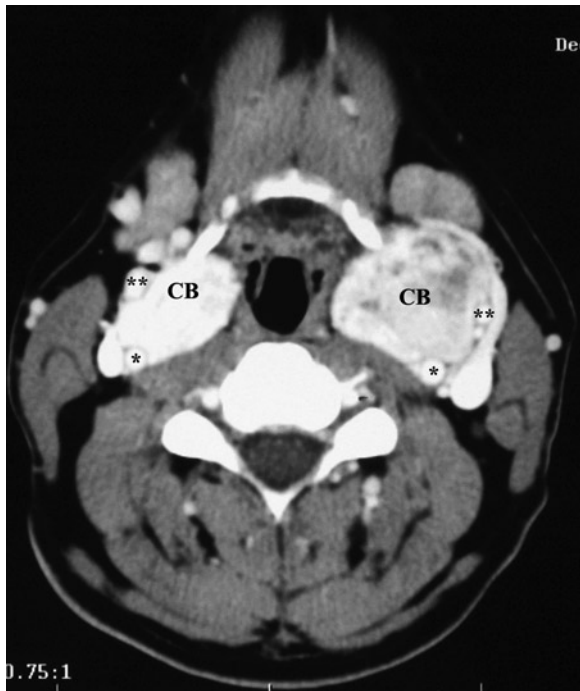


Fig. 40.7 CT of bilateral carotid body tumors. Note the intense enhancement and more homogenous appearance in comparison to the MRI in Fig. 40.6. *CB* carotid body tumors, *asterisk* internal carotid artery, *double asterisk* external carotid artery

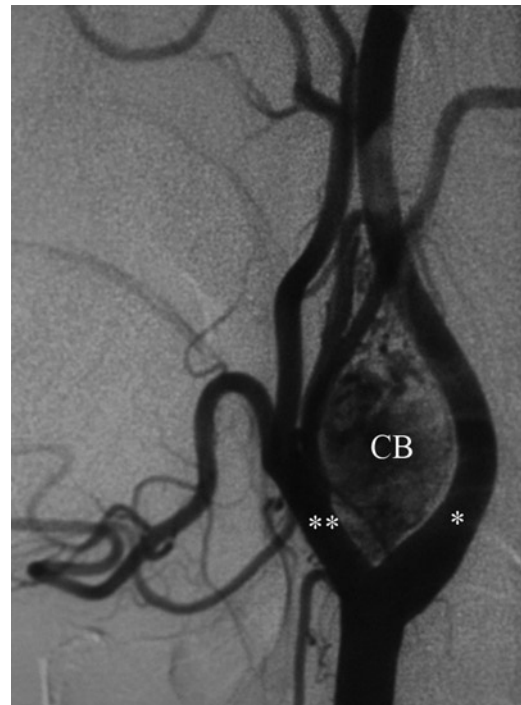

Fig. 40.9 Angiography of carotid body tumor. Notice the classic "Lyre sign" with the splayed internal (*asterisk*) and external carotids (*double asterisk*) by the tumor (*CB*)

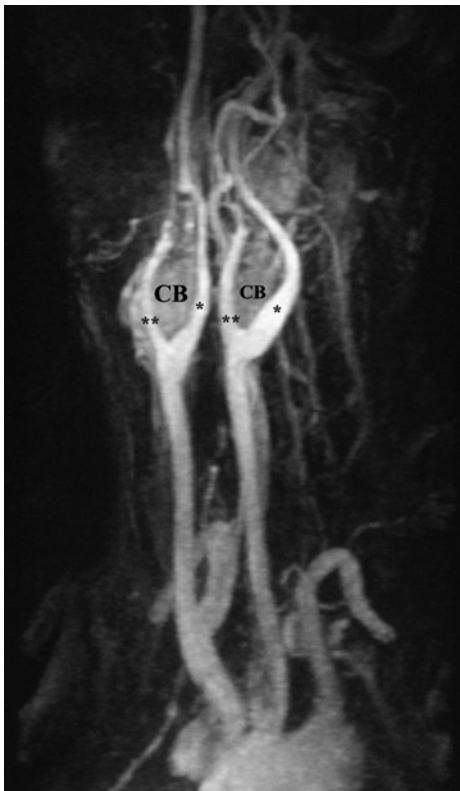

Fig. 40.8 MRA demonstrating bilateral carotid body tumors. *CB* carotid body tumors, *asterisk* internal carotid artery, *double asterisk* external carotid artery

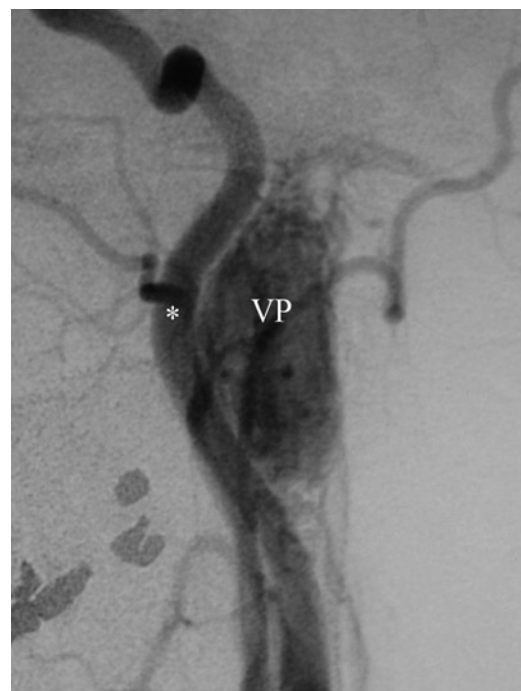

Fig. 40.10 Angiography of vagal paraganglioma. Notice the classic picture of the internal carotid (*asterisk*) being pushed forward by the vagal paraganglioma (*VP*)

These techniques will vary depending upon institutional resources.

Patient's with symptoms of a hyperfunctional tumor such as headaches, excessive sweating, and palpitations should be evaluated with a 24-h urine collection for norepinephrine and the metabolites metanephrine and vanillylmandelic acid. Serum catecholamines may be measured as well. This would be important to know preoperatively for proper anesthetic safety and appropriate alpha- and beta-blockade. Most patients do not have functional paragangliomas so testing is not routine for every paraganglioma patient. Endocrinology consultation is extremely valuable with suspected or confirmed active tumors. Genetic testing and counseling is appropriate in cases where a family history exists or multicentricity is present. These patients should be referred to genetics for the appropriate testing and counseling.

Surgery

Three different treatment modalities exist: surgery, radiation, and observation. These options must be weighed with the size, location, physiologic activity, and patient's overall health status to determine the appropriate treatment modality. Potential morbidity is associated with each of these modalities, and thus a frank discussion with the patient is necessary to obtain realistic treatment goals. The perspective of the treating physician and definition of cure versus local control must be balanced with the patient's overall health status, tumor details, and the patient's desire for treatment. This later factor can often be underestimated as each patient has a different expectation and tolerance for watching a tumor, undergoing a major surgery or radiation therapy. The role of the head and neck surgeon is to elucidate these factors from each patient to create an appropriate course of therapy or observation. Observation is an appropriate first modality in any head and neck paraganglioma patient to document the rate of growth and stability of the lesion, even when surgical resection is the probable treatment modality.

Traditional therapy for carotid body paragangliomas is surgical resection. Improvements in anesthesia and surgical techniques over the last 20 years have significantly improved the safety of surgical extirpation. The basic principles of the surgery involve locating and preserving the cranial nerves prior to dissecting the tumor. The hypoglossal, ansa cervicalis, vagus, superior laryngeal nerves are often embedded within the capsule of the paragangliomas (Fig. 40.11). Large tumors may involve the sympathetic chain and glossopharyngeal nerve. With the exception of the superior laryngeal nerve on the back side of the tumor, the nerves are located and mobilized prior to dissecting the tumor from the artery (Fig. 40.12). Following mobilization of the nerves, the tumor

is slowly dissected from the artery (Fig. 40.13). It is difficult to ascertain whether the carotid will need to be replaced with a reverse saphenous vein graft until intraoperative dissection

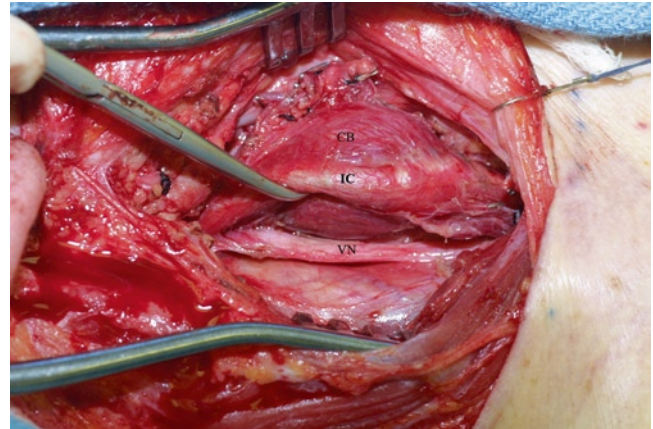


Fig. 40.11 Left carotid body paraganglioma. *CB* carotid body tumor, *IC* internal carotid, *VN* vagus nerve

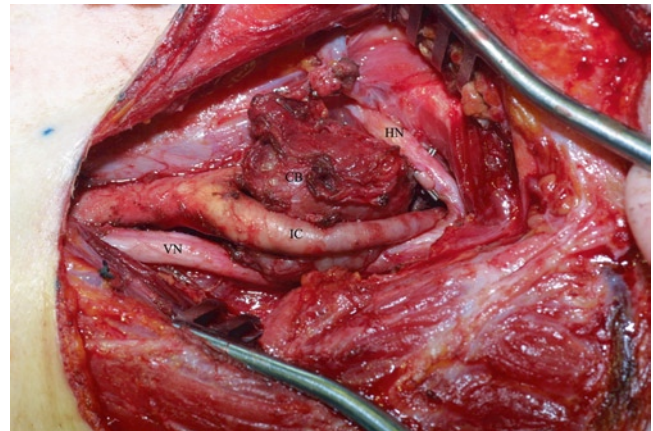

Fig. 40.12 Left carotid body paraganglioma after mobilization of nerves and tumor. *HN* hypoglossal nerve, *CB* carotid body tumor, *IC* internal carotid, *VN* vagus nerve

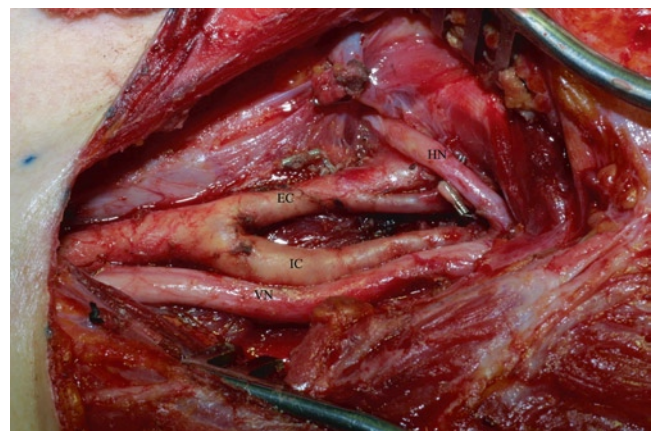

Fig. 40.13 Left carotid body paraganglioma after removal. *HN* hypoglossal nerve, *EC* external carotid, *IC* internal carotid, *VN* vagus nerve

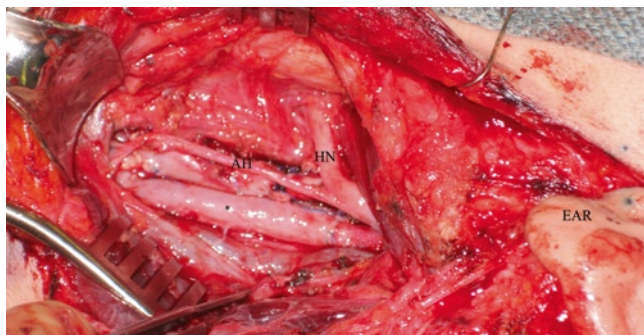


Fig. 40.14 Left carotid bypass following tumor removal. Saphenous vein graft (*asterisk*), *HN* hypoglossal nerve, *AH* ansa hypoglossal, *EAR* earlobe

of the tumor occurs. If we suspect an aggressive tumor, we will prepare both groins and thighs at the beginning to the case. If there is not a good separation between the tumor and artery, then 360° dissection of the tumor and artery are performed. The vascular surgeon then performs a vein graft of the internal carotid (Fig. 40.14). If bilateral tumor resections are planned, these will be performed in a staged fashion. If significant cranial nerve deficits occur with the first tumor removal (vagal or hypoglossal), then radiation or observation will be considered for the second side.

Vagal paragangliomas are approached in similar fashion as carotid body tumors although the location of these paragangliomas can vary from superior to inferior locations. Those with skull base involvement require a combine cervical and neuro-otologic approach. In lower tumors, a cervical parapharyngeal space approach that includes resection of the styloid process and retraction of the mandible anteriorly to assist with exposure and dissection is sufficient for resection of the tumor [28]. The associated nerves are dissected free and the great vessels retracted anteriorly to dissect the tumor (Fig. 40.15). The incidence of vagal paralysis in our practice is essentially 100%. Sacrifice of the nerve or significant paresis occurs in most cases of vagal tumor extirpations in the author's experience. Vagal tumors are often intimately associated or involved with other lower cranial nerves and the internal carotid artery. If vagal paralysis is combined with loss of other lower cranial nerves during surgery, significant morbidity may occur. Over the years, we have developed a more conservative approach to these tumors. If all of the cranial nerves are intact, we tend to observe these more often. If significant growth and cranial nerve involvement occurs, then we will consider surgical resection. In our practice, younger patients and those with preoperative nerve paralysis recover from surgical resection better than older individuals or those with no nerve paralysis preoperatively. We hypothesize that the slow nerve paralysis that occurs with the growing tumor allows the patient to compensate over time prior to surgery. Postoperative rehabilitation is important in

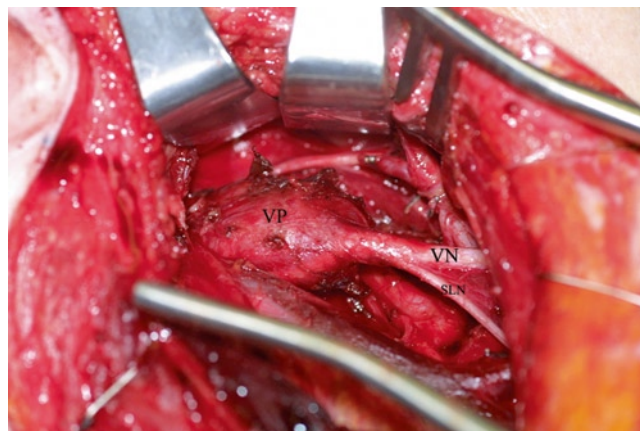


Fig. 40.15 Vagal paraganglioma: *VP* vagal paraganglioma, *VN* vagus nerve, *SLN* superior laryngeal nerve

these patients. Medialization laryngoplasty, speech and swallow therapy, and sometimes unilateral palatal adhesion are required to assist with recovery.

Radiotherapy

Radiotherapy may be successful in ceasing the growth of paragangliomas but complete regression of tumor with this modality is extremely rare. Surgical resection is the only method that will eliminate these tumors. However, local control defined as cessation or regression of growth is similar to the local control rates of surgical therapy. Proponents of surgery argue that the only chance of cure, if defined as eradication of tumor, is surgery. Advocates of radiation therapy argue that if the tumor does not grow over the patient's life following therapy, the patient is effectively cured. Local control for benign paragangliomas after radiotherapy or surgery is similar and approaches 90% [29, 30]. Radiation of paragangliomas may be delivered via stereotactic radiosurgery, stereotactic radiotherapy, or a conventional fractionated schedule. Stereotactic radiosurgery consists of a single high-dose fraction to a precise region. Stereotactic radiotherapy involves a fractionated scheme of the former protocol with the added benefits of reducing the dose of each fraction but with the same precision of radiosurgery. Standard fractionated radiotherapy protocols for benign paragangliomas require approximately 45 Gy in 25 fractions to achieve local control [31, 32]. Complication rates of radiotherapy are low but vary depending upon the dose and location of the tumor. Osteoradionecrosis, decreased wound healing with subsequent procedures, and radiation-induced tumors are possible but uncommon.

Complications and Rehabilitation of the Surgical Patient

Paraganglioma surgery can result in significant morbidity. In experienced hands and with proper patient selection and counseling, morbidity can be significantly reduced. A multidisciplinary team is necessary to manage these patients and often include a head and neck surgeon, neuro-otologist, laryngologist, vascular surgeon, neurosurgeon, speech pathologist, audiologist, physical therapist, and a variety of other ancillary staff.

Resection of unilateral carotid body paragangliomas is well tolerated by most patients. If bilateral resections are planned, the procedures should be staged as the vagus nerve is at risk on both sides. Bilateral vagal denervation can be devastating for a patient and result in severe breathing, swallowing, and airway protection issues. This could lead to tracheotomy and G-tube dependence if not planned appropriately. If vagal paralysis occurs with the first surgery, radiation or observation should be considered for the contralateral tumor.

In bilateral carotid body cases or multicentric cases with one carotid body and one vagal tumor, baroreflex dysfunction can be problematic. Baroreflex failure results when bilateral carotid body–sinus complexes are denervated, leading to loss of the parasympathetic drive of this system. Issues arise with the unopposed sympathetic tone resulting in severe labile hypertension, hypotension, headache, diaphoresis, and emotional problems. Stress can induce a hypertensive crisis and antianxiety medications play an important role in the prevention and treatment of these patients. Drugs that target the excess sympathetic tone are used. Sodium nitroprusside is used to control hypertension in the early postoperative period. Controlling hypertension postoperatively in these patients is critical, especially in those who underwent vascular repair or replacement [22]. Clonidine can be helpful as well as phenoxymethamine. The latter acts as an α_1 and α_2 -blocker and has a more rapid onset than clonidine, which is a selective α_2 -adrenergic agonist. Compensation does occur in these patients but is unpredictable and variable.

Surgical treatment of vagal paragangliomas can result in significant morbidity. Speech therapy and medialization of the paralyzed vocal fold are important tools to help the patients through the recovery process. We prefer to delay our medialization until after recovery from the procedure has occurred. This allows us to perform it in standard fashion under local anesthesia [33]. We feel this gives us the best control of obtaining a good outcome compared to coupling it with the initial procedure under general anesthesia. If significant velopharyngeal insufficiency persists in the postoperative patients, unilateral palatal adhesion can greatly benefit the patient [34].

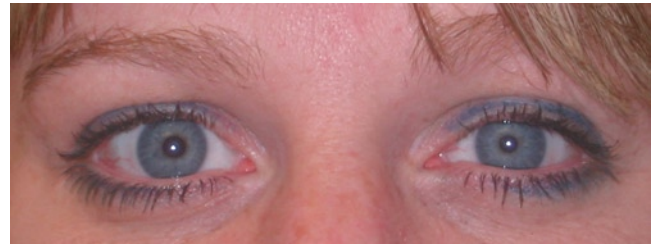


Fig. 40.16 Horner's syndrome – patient has mild left ptosis and miosis following surgical resection

Caution should be taken when considering therapy of vagal tumors in elderly or unhealthy patients. If the cranial nerves are already affected by the tumor, patients generally compensate. On the other hand, if there is a little to no cranial nerve dysfunction, acute denervation with surgery can cause significant morbidity in many individuals, particularly the elderly population. Radiation therapy or observation should be strongly considered in the patients.

Damage to the cervical sympathetic chain can lead to two different issues – Horner's syndrome and first-bite syndrome. Horner's leads to ptosis, miosis, and anhidrosis and is usually well tolerated (Fig. 40.16). This usually resolves if the sympathetic chain has been preserved. If ptosis is troubling and it does not resolve, Muller's muscle may be resected or a levator-shortening procedure can be performed. Losing sympathetic input to the parotid gland can lead to first-bite syndrome from unopposed parasympathetic stimulation of the myoepithelial cells. Patients complain of mild to severe pain with the first bite of food that abates throughout the meal. Strong sialogogues increase the severity of symptoms. The symptoms generally fade overtime but the timing is unpredictable. Thorough counseling should include dietary modifications. Eating bland foods at the start of a meal is the best treatment available at this time. Medications such as carbamazepine can be employed but we have not been encouraged with this treatment modality.

Follow-Up

Routine long-term follow-up is necessary in all paraganglioma patients due to the slow growth rate of these tumors. Once a surgical patient has recovered fully, we prefer to follow our patients annually in clinic with an MRI. In those that we are following conservatively without surgery, we initially scan them at two 6-month intervals to establish stability or a slow growth rate. If the tumor is not growing or if it is progressing slowly according to the 6-month interval MRI scans, we elect to see the patients on an annual basis. Patients with significant morbidity secondary to their tumor or treatment require shorter intervals depending upon the particular issues.

Conclusion

The treatment of head and neck paragangliomas has evolved over the last two decades. Improvements in anesthesia and surgical techniques during this time have significantly improved the safety of surgical extirpation of head and neck paragangliomas. Surgical excision is the preferred treatment for isolated paragangliomas, but observation versus radiation therapy should be considered for high surgical risk patients or multiple paragangliomas. Despite the advances in head and neck surgery, the nature of paragangliomas and their intimate relationship with cranial nerves still means cranial nerve deficits and morbidity can still occur. Based on this reality and our experience over the years, we have developed a more conservative approach to these tumors. If all of the cranial nerves are intact and surgical resection may result in significant cranial nerve deficits (vagal paragangliomas), we tend to observe these patients. However, if cranial nerve deficits are present preoperatively, then surgical resection is better tolerated. The potential morbidity of surgical treatment must be weighed with the patient-oriented factors to determine an appropriate course of action. If surgery is chosen, some patients may need rehabilitation. Rehabilitation of the surgical patient has improved over the years in the areas of voice and swallowing dysfunction, baroreflex failure, and first-bite syndrome. Most patients with postoperative deficits do well with time and rehabilitation.

If surgery is determined to be too risky or not an appropriate approach, radiation may be an option. The development of improved radiation techniques, particularly stereotactic radiation, has afforded patients a viable modality that can slow or cease the growth of these tumors in selected cases. The patient may avoid surgery altogether, but the main limitation to this approach is that tumor eradication is not possible. However, radiation may be a realistic approach in some patients who have underlying comorbidities or other factors that have a greater chance at causing morbidity or mortality.

References

- Martin TPC, Irving RM, Maher ER. The genetics of paragangliomas: a review. *Clin Otolaryngol*. 2007;32:7–11.
- Sevilla MA, Hermsen MA, Weiss MM, et al. Chromosomal changes in sporadic and familial head and neck paragangliomas. *Otolaryngol Head Neck Surg*. 2009;140:724–9.
- Martin TPC. What we call them: the nomenclature of head and neck paragangliomas. *Clin Otolaryngol*. 2006;31:185–6.
- Blume-Peytavi U, Adler YD, Geilen CC, et al. Multiple cutaneous glomangioma: a pedigree of four generations and critical analysis of histologic and genetic differences of glomus tumors. *J Am Acad Dermatol*. 2000;42:633–9.
- Barnes L, Everson J, Reichart P, Sidransky D, editors. World Health Organization Classification Of Tumours. Pathology and genetics of tumours of the head and neck. Lyon: IARC; 2005.
- Lack E. Tumors of the adrenal gland and extra-adrenal paraganglioma. In: Atlas of tumor pathology, series 3, fasc 19. Washington, DC: Armed Forces Institute of Pathology; 1997.
- Rodriguez-Cuevas S, Lau I, Rodriguez HP. High-altitude paragangliomas: diagnostic and therapeutic considerations. *Cancer*. 1986; 57:672–6.
- Pellitteri PK, Rinaldo A, Myssiorek D, Jascson CG, et al. Paragangliomas of the head and neck. *Oral Oncol*. 2004;40:563–75.
- Arts HA, Fagan PA. Vagal body tumors. *Otolaryngol Head Neck Surg*. 1991;105:78–85.
- Carney JA. The triad of gastric epithelioid leiomyosarcoma, functioning extra-adrenal paraganglioma, and pulmonary chondroma. *Cancer*. 1979;43:372–82.
- Myssiorek D. Head and neck paragangliomas: an overview. *Otolaryngol Clin North Am*. 2001;34(5):829–36.
- Baysal BE, van Schothorst EM, Farr JE, et al. Repositioning the hereditary paraganglioma critical region on chromosome band 11q23. *Hum Genet*. 1999;104:219–25.
- Neumann HP, Erlic Z, Boedeker CC, et al. Clinical predictors for germline mutations in head and neck paraganglioma patients: cost reduction strategy in genetic diagnostic process as fall-out. *Cancer Res*. 2009;69(8):3650–6.
- Burnichon N, Rohmer V, Amar L, et al. The succinate dehydrogenase genetic testing in a large prospective series of patients with paragangliomas. *J Clin Endocrinol Metab*. 2009;94:2817–27.
- Knudson Jr AG. Genetics of human cancer. *Annu Rev Genet*. 1986;20:231–51.
- Baysal BE. Genetics of familial paragangliomas: past, present, and future. *Otolaryngol Clin North Am*. 2001;34(5):863–79.
- Kovrishko NM. Postnatal development and structural characteristic of the principle paraganglia in man. *Fed Proc*. 1964;22(Suppl):740.
- Wasserman PG, Savargaonkar P. Paragangliomas: classification, pathology, and differential diagnosis. *Otolaryngol Clin North Am*. 2001;34(5):845–62.
- Coupland RE. Electron microscope observation on the structure of the rat adrenal medulla: the ultrastructure and organization of chromaffin cells in the normal adrenal medulla. Normal innervations. *J Anat*. 1965;99:231–54.
- Mandolis S, Shohet JA, Jackson CG, Glasscock III ME. Malignant glomus tumors. *Laryngoscope*. 1999;109:30–4.
- Patel YC. Somatostatin and its receptor family. *Front Neuroendocrinol*. 1999;20:157–98.
- Netteville JL, Reilly KM, Rovertson D, et al. Carotid body tumors. A review of 30 patients with 46 tumors. *Laryngoscope*. 1995;105:115–26.
- Lawson W. The neuroendocrine nature of the glomus cells: an experimental, ultrastructural, and histochemical tissue culture study. *Laryngoscope*. 1980;90:120–44.
- Netteville JL, Jackson CG, Miller FR, et al. Vagal paraganglioma: a review of 46 patients treated during a 20-year period. *Arch Otolaryngol Head Neck Surg*. 1998;124:1133–40.
- Weed DT, Netteville JL, O'Malley B. Paragangliomas of the head and neck. In: Harrison LB, Sessions RB, Hong WK, editors. Head and neck cancer: a multidisciplinary approach. Philadelphia, PA: Lippincott-Raven; 1999. p. 777–98.
- Myssiorek D, Palestro CJ. ¹¹¹Indium pentetreotide scanning detection of familial paragangliomas. *Laryngoscope*. 1998;108:228–31.
- Telisch FF, Bustillo A, Whiteman ML, et al. Octreotide scintigraphy for detection of paragangliomas. *Otolaryngol Head Neck Surg*. 2000;122:358–62.
- Cohen SM, Netteville JL. Surgical management of vagal paragangliomas. *Oper Tech Otolaryngol*. 2004;15:196–200.
- Mendenhall WM, Hinerman RW, Amdur RJ, et al. Treatment of paragangliomas with radiation therapy. *Otolaryngol Clin North Am*. 2001;34(5):1007–20.
- Chino JP, Sampson JH, Tucci DL, et al. Paraganglioma of the head and neck: long-term local control with radiotherapy. *Am J Clin Oncol*. 2009;32(3):304–7.

31. Evenson LJ, Mendenhall WM, Parsons JT, et al. Radiotherapy in the management of chemodectomas of the carotid body and glomus vagale. *Head Neck*. 1998;20:609–13.
32. Mendenhall WM, Parsons JT, Stringer SP, et al. Radiotherapy in the management of temporal bone chemodectoma. *Skull Base Surg*. 1995;5:83–91.
33. Netterville JL, Stone RE, Lukens LS, et al. Silastic medialization and arytenoid adduction: the Vanderbilt experience. A review of 116 phonosurgical procedures. *Ann Otol Rhinol Laryngol*. 1993; 102:413–24.
34. Netterville JL, Vrabec JT. Unilateral palatal adhesion for paralysis after high vagal injury. *Arch Otolaryngol Head Neck Surg*. 1994;120:218–21.

Chapter 41

Treatment of the Elderly Head and Neck Cancer Patient

Jean-Claude Horiot and Matti S. Apro

Abstract Elderly patients represent at least 40% of head and neck squamous cell carcinoma (HNSCC). These patients often receive inadequate treatment, either exceeding their tolerance capability or exposing them to a lesser chance of cure because of undertreatment. Customizing treatment to the individual patient is the key for avoiding such pitfalls. This paper analyses the literature on optimal management of elderly patients with HNSCC, from the diagnostic procedures with a comprehensive geriatric assessment (CGA) of co-morbidities to the specific recommendations for surgery, radiotherapy, and chemotherapy.

Keywords Head and neck • Cancer • Elderly • Geriatric • Diagnostic • Treatment • Surgery • Radiotherapy • Chemotherapy

Introduction

The concept of elderly patient is highly questionable and definitely not closely linked to civil age. The median age for the diagnosis of invasive head and neck cancers is of about 60 years. More than 40% of head and neck cancers occur in patients older than 65 years [1]. Hence, the management of so-called “elderly patients” with head and neck cancer represents a very common situation in our daily practice. This incidence of elderly people with head and neck cancer squamous cell carcinoma (HNSCC) will further grow in the next decade due to several independent parameters: the constant increase of life expectancy in most industrialized countries, the limited efficacy of tobacco and alcohol prevention campaigns and growing female incidence, and finally the medical awareness to provide a better quality of care to the geriatric population. Unfortunately, as for other cancer types, most research trials have been using an upper age limit

excluding patients over 65 or 70 years of age, thus leaving us with no evidence-based guidelines and a few often ill-defined recommendations for older patients’ age groups. This lack of evidence stresses the need for prospective studies with reliable assessment of patient’s co-morbidities aiming at well-defined treatment schedules including individually customized variations according to patient’s condition.

Several conflicting facts need some clarification: it seems logical to accept the statement that the number and severity of co-morbidities increase with age and interfere with the choice of treatment and disease outcome. However, every year, more reports claim that head and neck cancer patients should be treated regardless of age when their general condition is satisfactory. Unfortunately, there is an epidemiologic evidence that most elderly patients do not benefit of the same chance of access to proper oncologic management as younger patients.

The Specificity of the Elderly Head and Neck Cancer Patient

By definition, the elderly patient with HNSCC has been exposed for a longer time to the main epidemiological features of such diseases: heavy tobacco and/or alcohol addictions with resulting co-morbidities, chronic obstructive broncho-pneumonitis, infection with various degrees or cardio-respiratory insufficiencies, liver steatosis and cirrhosis, poor oral hygiene and dental condition, fungal infections, malnutrition, weight loss, frailty, low-performance status, Wernicke’s encephalopathy, and associated neurological disorders. However, the degree of severity and combinations of co-morbidities widely differ from a patient to another. They should not constitute a contra-indication to curative treatment unless they would expose the patient to a shorter life expectancy than the spontaneous evolution of the malignant tumor. Moreover, a number of these co-morbidities are either ignored or insufficiently controlled at the time of the diagnosis of cancer. The identification, systematic evaluation, and, whenever possible, correction of such conditions

J.-C. Horiot (✉)
Clinique de Genolier, Institut Multidisciplinaire d’Oncologie,
5 Route du Muids, Genolier CH-1272, Vaud, Switzerland
e-mail: JCHORIOT@genolier.net

should be done before starting the treatment of head and neck malignancies to give the patient the best chance for tolerance and ultimate benefit.

Sometimes, however, the elderly head and neck cancer patient may just present with a perfect general condition and be biologically younger than most people in the same age group. Such patients should also be clearly identified and offered the same management as for younger patients.

Upper Age and Outcome in Curatively Treated Head and Neck Cancer Patients

The more solid data come from prospective research trials including patients older than 65 years with reliable data on acute and late morbidity as well as disease outcome, compared per age group. Under those conditions, the eligible patient population presents with a similar range of patient's health conditions, disease stages, and management. In 1996, Pignon et al. [2] reported 1,589 patients with head and neck cancers enrolled in EORTC trials with follow-up on radiotherapy toxicity and survival. Patients over 65 years represented more than 20% of the sample. Survival and toxicity were examined in different age ranges from 50 to 75 years and over. There was no significant difference in survival between age groups. A trend test was performed to assess correlation between age and acute toxicity. There was no significant difference in acute objective mucosal reactions ($p=0.1$) and in weight loss $>10\%$ ($p=0.4$). In contrast, older patients had more severe (grade 3 and 4) functional acute toxicity ($p<0.001$) than younger patients. The probability of late toxicity occurrence in relation to time was evaluated with the Kaplan–Meier method and the logrank test. Eighteen percent of patients were free of late effects at 5 years, the logrank test showing no significant difference between ages ($p=0.9$). In conclusion, chronological age was considered irrelevant for therapeutic decisions. As a consequence, the recommendation was made to delete the upper age limit from the eligibility criteria in every EORTC on-going and new protocol of radiotherapy in head and neck cancer.

In 2004, a report on the compliance to this recommendation in subsequent protocols was made by Horiot [3] during the 2004 SIOG (International Society of Geriatric Oncology) meeting in San Francisco and later published [4]. Six EORTC head and neck trials (including 574 patients) were activated after 1996. Two had an upper limit at ≤ 75 years and four no upper age limit (EORTC protocols 22954, 24954, 22962, and 24001). Only 15% of these 574 patients were aged 65 or more: Unfortunately, only one patient was older than 75. Despite of a satisfactory compliance from protocol writers, the recruitment of older patients was disappointing. The reasons for that low recruitment are probably multifactorial:

resistance to change, insufficient information of doctors and patients, and need for specific protocol design for adequate selection of elderly patients. Another probably relates to the increasing number of treatment schedules involving concomitant radio-chemotherapy regimens, obviously more toxic than radiotherapy alone.

Literature reports on the outcome of treatment for head and neck cancer patients aged ≥ 80 years were very rare up until a few years ago. Several reports on this upper age group were recently published. Similar prognosis regardless of age after radiotherapy of head and neck cancers, including small subsets of patients over 80 years of age, has been reported by Metges [5], Schofield [6], and Zachariah [7]. Italiano [8] reports a series of 316 patients treated by surgery and/or radiotherapy and concludes that the outcome is similar to that of younger patients. However, this is an historical retrospective analysis of a regional database with selection biases and wide treatment variations. Ortholan [9] reports 260 patients over 80 years of age with oropharyngeal cancers. Two hundred patients received a locoregional treatment with a curative intent (surgery and/or radiotherapy), 29 with a palliative intent, and 31 did not receive a LR treatment. The median disease-specific survival (DSS) was 29 months. In multivariate analysis, the independent prognostic factors for DSS were stage (HR=0.42 [0.24–0.72]), age (HR=0.43 [0.24–0.75]), and performance status (HR=0.50 [0.27–0.95]). The median overall survival (OS) was 14 months. In multivariate analysis, the independent prognostic factors for OS were age (HR=0.52 [0.35–0.79]), stage (HR=0.56 [0.38–0.84]), tumor differentiation (HR=0.60 [0.33–0.93]), and performance status (HR=0.6 [0.37–0.97]). In patients treated with a curative intent, treatment adapted to age was not associated with a decreased overall survival or DSS as compared with the standard treatment. However, prophylactic lymph node treatment in stage I–II tumors decreased the rate of nodal recurrence from 38 to 6% ($p=0.01$).

Impact of age at diagnosis on prognosis and treatment in laryngeal cancer was recently reviewed in 945 patients with laryngeal cancer treated from 1978 to 2004 in the Uppsala-Orebro region in Sweden [10]: There were no significant differences in the clinical features between the age groups. Overall survival (OS) and DSS were worse among the oldest, although a significant proportion was cured. Relapse risk was lower among the oldest (12%) compared with the youngest (23%). However, the risk of never becoming tumor-free was 25% among the oldest versus 7% in the youngest. The authors conclude that although elderly patients with laryngeal carcinoma cope well with treatment, undertreatment may determine the outcome more than age.

Although specific prospective trials are still badly missing, recent literature reports all stress that older age groups are of increasing relevance in HNSCC and need reliable and comprehensive pretreatment evaluations. This patient

population also require the activation of prospective trials on adapted strategies and dose reductions whenever justified by risk factors induced by co-morbidities.

Multidisciplinary Diagnosis and Pretreatment Assessment in Geriatric Patients

Definitions, Geriatric Scales, and Geriatric Evaluation Focused on Head and Neck Cancer Patients. Selection of Patients for Radical Treatment

The inclusion of a specific geriatric assessment in the multidisciplinary work-up of the cancer patient is a pre-requisite to give the best chance to the well-fit patient to receive the same treatment as a younger patient and to plan the appropriate changes in treatment strategies for patients with co-morbidities. The comprehensive geriatric assessment (CGA) [11, 12] is a multidisciplinary evaluation of functional, cognitive and psychological status, co-morbidities, nutritional status and medications, family, relatives, and social support. Functional status explores patient's ability to fulfill usual daily activities. Objective performance measurements include the "timed up and go" test and the 6-min walk and grip test. Optimally, the geriatrician coordinates these evaluations and collect the data needed to complete the scoring scale. CGA is now a well-documented tool to predict morbidity and mortality in elderly patients with cancer [13–15]. Repeated measurements during treatment and follow-up can reliably quantify the changes of patient's condition with time.

Practical algorithms have been published to assist clinicians in selecting patients for standard treatment versus modified schemes [15]. The severity of a single co-morbidity is of more relevance than the number of co-morbidities. The weight of such combinations is taken into account in the Adult Comorbidity Evaluation 27 (ACE-27) [16].

Nutritional evaluation, ultrasound screening of carotid arteries, identification of tobacco and alcohol addictions and assistance for stopping it, detection and treatment of depression, assessment of renal function measured by isotopic clearance methods are part of the pretreatment assessment of elderly head and neck cancer patients. Fatigue is a very common symptom, often of multifactorial origin. Its causes must be understood and whenever possible corrected before the starting of treatment since the deterioration of general condition and exhaustion of patient resources are the major reasons for noncompliance and/or early treatment interruption in curative management of elderly cancer patients.

There are, however, practical obstacles to organize a full-scale multidisciplinary CGA: Sometimes because of insufficient expertise or availability of some of the involved disciplines (including the geriatrician!), but mostly because of the lack of coordination to ensure a smooth and timely planning of the consultations and specific work-up of each consultant. That situation may result in suboptimal coordination and customization of treatment strategy. Obviously, multidisciplinary hospitals and/or cancer institutes usually offer the best conditions to set-up this rather heavy multidisciplinary work-up and management of the elderly cancer patient.

Preparation of the Patient to Treatment

Denutrition or malnutrition is present in about 20% of cancer patients. This figure is probably underestimated in geriatric head and neck cancer patients due to a reduced oral intake because of pain, difficulty in swallowing, and inappetence. Moreover, elderly people often do not complain of loss of appetite. Fluid intake is frequently suboptimal resulting in various degrees of dehydration, electrolyte imbalance sometimes associated with impaired renal function. The nutritional status of elderly patients should be systematically evaluated [17] at the time of the initial work-up since rapid deterioration may occur early in the course of radiotherapy and is a common observation when delivering concomitant radiochemotherapy. Missing this point would expose the patient to a high risk of poor treatment tolerance, treatment interruption, and/or dose reduction with a loss of chance of cure. Minor denutrition conditions should be dealt with dietetic counseling, oral nutritional supplements, and regular follow-up of oral intake during and after treatment. Artificial nutrition should be planned before treatment when oral intake is of less than 60% of needs and/or when severe mucosal and general side effects of treatment are expected. Percutaneous endoscopic gastrostomy (PEG) should be preferred to naso-gastric feeding tubes which may become a cause of discomfort upon the appearance of severe acute mucosal reactions. With proper prospective management, the need for parenteral nutrition remains rare, except for situations of severe malnutrition with poor digestive function, preexisting to cancer diagnosis.

A systematic evaluation of the denture and periodontal tissues is mandatory in every head and neck cancer patient. It is even more important in the elderly patient in whom the probability of deterioration of dental condition is usually higher than in the younger patients. The clinical and radiological dental work-up should take place as early as possible to allow healing of dental extractions when needed without increasing the delay between diagnosis and treatment.

When radiation therapy is planned, teeth in good condition will be preserved. Daily fluoride topical applications and oral hygiene will prevent postradiation dental caries [18]. Customized dental gutters will be manufactured to enable lifetime daily topical fluoride gel applications. Oral hygiene recommendations and compliance to fluoride applications should be initiated and checked during radiotherapy. The use of very high fluoride toothpaste contents (about 1,300 ppm) is an alternative method when customized gutters are poorly tolerated, e.g., when acute mucosal reactions occur. Keeping good dental status and hygiene is an essential component of maintaining a good nutritional intake. Edentulous patients also need to be evaluated to detect the presence of hidden risks (sharp extraction edges, residual roots, impacted wisdom teeth, etc.) and to check the condition of removable dental prosthesis.

Elderly patients are often left alone to deal with the constraints of disease diagnostic and therapeutic procedures. This may sometimes result in inappropriate patient understanding and adherence to therapeutic recommendations, thus leading to refusal or poor compliance to treatment. Adequate management of the elderly cancer patient, including specific advice and support on head and neck cancer treatment, must be organized in the frame of the geriatric oncology team, with, whenever needed, the availability of psycho-social workers and psycho-oncologists. This includes the information of patients and relatives as well as the assistance for proper organization of patient venues (transportation and timing) for the duration of ambulatory treatments.

Management of the Elderly Cancer Patient

Curative Aim

Surgical Management of the Elderly Patient

Predictive factors for complications in surgically treated elderly patients with HNSCC have been analyzed by Sanabria [19] in 242 patients over 70 years of age. Co-morbidities were present in 87.6% of patients and 56.6% presented with complications (44.6% local and 28.5% systemic). Male sex, bilateral neck dissection, presence of two or more co-morbidities, reconstruction procedures, and clinical stage IV were associated with a high risk of postoperative complications. The authors propose a predictive index based upon preoperative variables which, in their series, shows a 84% sensitivity and 41% specificity.

As expected, the main limitation to surgical indications in the elderly cancer patients is the number and severities of

co-morbidities, interfering with the risks of general anesthesia, and perioperative period. In most cases, mild cardiovascular co-morbidities can be corrected and should not interfere with the treatment choice. Conservative surgical techniques should be preferred whenever possible. Reconstructive surgery with flaps is seldom considered in older patients since higher complications rates are reported in patients of more than 70 years of age [20]. Moreover, older patients are known to be less compliant to feeding and phonatory rehabilitation procedures than younger patients [21]. Radiotherapy alone or radio-chemotherapy when feasible should be preferred to mutilating surgery in moderately advanced and advanced laryngeal and hypopharyngeal carcinomas. Conservative surgical procedures either by cervicotomy or by transoral resections [22] can be considered in the management of limited carcinomas of oral cavity, oropharynx, and larynx especially when the need for postoperative radiotherapy is unlikely. Early vocal cord cancers can be either treated surgically (usually by microsurgical carbon dioxide laser techniques) or by radiotherapy alone although the quality of voice seems superior with radiotherapy. Difficult access to radiotherapy facilities and shorter treatment with surgery may be good arguments in favor of surgery. Functional neck node surgery, whenever indicated, can be usually performed regardless of age except for major medical contra-indications.

Recommendations on the surgical management of elderly patients with cancer have been issued by experts of the International Society of Geriatric Oncology [23].

In most cases, however, surgery will be combined to radiation therapy, mostly postoperatively. The quality of surgical techniques and pathology report are essential to optimal radiotherapy planning and to reduce the risk of late complications from combined treatment.

With modern radio-surgical techniques, the risk of carotid artery rupture has become very low. However, the risk of carotid stenosis and cerebrovascular stroke is not negligible after neck dissection and radiotherapy, reported sometimes as high as 30–40% [24, 25]. An effective prevention of such risk is made by identifying and treating patients with risk factors (tobacco addiction, hypertension, dyslipidemia, and ultrasound screening of carotid arteries before and after treatment). Modern radiotherapy techniques have almost eliminated the dose hot spots that could result, for instance, from overlapping the upper and lower neck nodal target volumes.

Radiotherapy

The consistency of geriatric assessment recommendations to patients receiving radiotherapy was discussed by Falandry [26]. However, although general statements apply to HNSCC patients, no comments is made regarding the specificity of

head and neck radiotherapy. By definition, radiotherapy to HNSCC is a local-regional treatment. Small tumors from almost any head and neck site, adequately irradiated with well-controlled target volumes to the primary site and first nodal level, produce moderate mucosal side effects and provide high cure rates. Hence, age should not interfere at all with the indication of curative radiotherapy. Larger primary tumors, usually associated with various degrees of nodal spread, will need a more aggressive treatment on larger tumor and nodal target volumes with more toxic mucosal acute side effects that will interfere with patient nutrition and treatment tolerance. The difficulties met with radiotherapy to elderly patients will be potentialized in these moderately advanced and advanced HNSCC.

Techniques of external megavoltage radiotherapy have considerably progressed over the past decade allowing high accuracy to conform target volumes to effectively irradiate volumes and enable a better sparing of normal tissues. Intensity-modulated radiotherapy technique (IMRT) is now the reference radiotherapy technique to treat head and neck cancers. Brachytherapy also benefited from imaging progress but remains less frequently used probably because it requires a more specific expertise and is performed under general anesthesia.

As a result, acute tolerance has markedly improved while the incidence and severity of late normal tissue damage decreased. The benefit from innovative radiotherapy techniques is essential to offer head and neck cancer geriatric patients, the best chance of a good tolerance to curative radiotherapy. Acute tolerance is improved by minimizing skin and mucosal reactions. The main benefit seems however arise from the reduction of the incidence and severity of late effects, mainly fibrosis (by multiplication of portals) and xerostomia by sparing whenever possible the contra-lateral salivary glands [27].

Unfortunately, IMRT is not available in every radiotherapy department. When present, not all patients can benefit of it for reasons of cost, availability, and experience. Even when novel techniques are available, the geriatric population may be excluded from their use, either by the absence of specific protocol recommendations or worst, as being considered as a low priority. Most of the literature on radiotherapy toxicity in elderly patients is gathered from the reports of series treated with “standard radiotherapy” which still provide a biased message to contraindicate radiotherapy or lower total doses, thus reducing the chance of cure of these patients.

Socioeconomic and psychological issues may interfere with the medical decision as well as the patient acceptance or refusal to radiotherapy. The distance between patient home and treatment site may not be consistent with a protracted ambulatory treatment. Access to local hosting facilities for elderly people for the duration of their treatment is rare and sometimes unaffordable. Hospital admission may be either

impossible because of priorities given to other patients or refused by the patient. Daily transportation for long distances may generate psychological lassitude and physical fatigue that may jeopardize treatment delivery and outcome by early stopping or increased overall treatment time. In some cases, a dose/fractionation compromise is proposed to patients, by reducing the number of fractions and increasing the dose per fraction. This concept called hypofractionation, when equivalent biologic tumor doses are delivered, always results in increased late normal tissue damage, sequelae, and complications. Head and neck hypofractionated radiotherapy with a lower biological tumor dose exposes the patient to a poorer outcome and should be reserved for palliation only.

Prevention of nutritional deterioration is essential when irradiating large volumes of oral cavity, oropharyngeal, and hypopharyngeal mucosa. As said earlier, a PEG should be performed before starting treatment and be progressively used to compensate reduced oral intake due to the progression of mucosal reactions. Oral hygiene recommendations, preventive treatment of bacterial and fungal infections, should almost systematically be activated.

Radiotherapy and Chemotherapy

Up until the advent of platinum compounds, there was no or little interest in combining radiotherapy and chemotherapy in head and neck cancers. The additional toxicity of chemotherapy was then a major argument to contra-indicate its use in frail and/or elderly patients. The results of randomized trials and meta analyses [28] then demonstrated that cisplatin-based schemes and radiotherapy could significantly improve the outcome compared to radiotherapy alone, the main benefit being observed after concomitant radio-chemotherapy at the cost of an increased (mostly acute) toxicity. Postoperative concomitant radio-chemotherapy has become standard management of moderately advanced and advanced head and neck cancers carrying a significant locoregional failure risk [29]. Of course, these randomized trials excluded almost all frail and elderly patients. The revival of the interest of induction chemotherapy was raised by trials on laryngeal preservations [30, 31] and more recently by the local-regional and survival benefit of neoadjuvant Taxanes [32]. Moreover, a noncytotoxic molecular-targeted therapy [anti-epidermal growth factor receptor (anti-EGFR) cetuximab] combined with radiotherapy also produced a significant locoregional and survival benefit in moderately advanced head and neck cancers. These progresses, although not applicable in all patients, have urged to reconsider the indications of chemotherapy in the elderly patients.

The main severe toxicities of cisplatin-based chemotherapy consist of renal failure with potassium and magnesium

losses, nausea and vomiting, peripheral neuropathies, and hearing impairment. Adequate hydration is not always feasible in older patients. Dose reductions based only on the patient's age should not be done when treatment is given with a curative aim. Attention should be given about the results provided by the Cockcroft–Gault method to calculate creatinine clearance which often underestimates renal function in elderly patients [33]. Combined platinum-based chemoradiotherapy regimens, used in healthy nonelderly patients, substantially increase the incidence of severe acute [34, 35] and late adverse events [36, 37]. Hence, they should be prescribed with care in fit elderly patients only. Cisplatin is the preferred platinum agent and is associated with higher tumor response rates than carboplatin [38], which because of a better toxicity profile is often reserved for patients unable to tolerate cisplatin.

The usefulness of the addition of 5-FU to platinum compounds is still debated in younger patients because its advantages are not obvious while inconveniences (cardiotoxicity and increased mucosal toxicity) are well documented. Hence, although it can be safely delivered to elderly patients in good general condition [39], it is preferable in most cases to prescribe a single platinum compound.

Taxanes (Paclitaxel and Docetaxel) metabolism can be affected in patients with impaired liver function, a significant decrease in total paclitaxel clearance being observed with increasing age [40]. This may contra-indicate the use of taxanes in patients with severe alcoholic-induced liver dysfunction. The sequential combinations of cisplatin and taxanes increase the incidence and severity of peripheral neuropathies. Combinations of cisplatin, fluorouracil, and taxanes, now widely used for induction chemotherapy, can produce a large range of acute severe toxicities: Grade 4 neutropenia and febrile agranulocytosis, sepsis, and severe mucositis. Thus, the combination of these three therapies must be avoided or prescribed only to elderly patients without any co-morbidity. Careful patient selection of elderly patients allows induction chemotherapy with cisplatin and docetaxel as shown in 44 patients over 65 years of age with stage III and IV head and neck cancers using a 3-week course [41]: The overall response rate was 88%, with grade 3–4 neutropenia in 75% and febrile neutropenia in 4%.

Radiotherapy and Molecular-Targeted Therapies

About 90% of head and neck cancer cells over-express the epidermal growth factor receptor (EGFR), which correlates to the malignant phenotype leading to reduced apoptosis, high proliferation rate, angiogenesis, and metastatic invasiveness. Agents blocking this malignant phenotype have a

lower toxicity than most cytotoxic drugs and seem an attractive alternative combination with radiotherapy in older and/or frail patients. The first randomized trial comparing radiotherapy and cetuximab to radiotherapy alone [42] concluded to a 30% reduction in the risk of disease progression and 11% increase in the 3-year PFS rate survival in favor of the experimental arm. There was no upper age limit in the eligibility criteria. Acute mucosal reactions were similar in both arms. The main acute cetuximab toxicity consists of acneiform rash (17%) occurring predominantly in the facial and cervical areas. Of interest, this rapidly reversible side effect seems to be associated with a better chance for improved survival; grade 2–4 acne/rash being associated with a 51% reduction in the risk of death compared to that of patients with a 0–1 grade of acne/rash [43]. This rather acceptable toxicity profile seems attractive for including cetuximab in the radiotherapy management of elderly head and neck cancer patients. In the original randomized trial, the median age is 57, suggesting a very low percentage of elderly patients entered in this study. Although not formally established on a nonselected elderly population, the addition of cetuximab to curative radiotherapy for elderly patients seems to be safe. Several trials are underway to evaluate the combination of cetuximab and radiotherapy in the management of other cancers, esophageal, and non-small cell lung cancers in elderly patients. Moreover, the addition of an intratumoral EGFR antisense oligonucleotide gene therapy (EGFR AS) is underway in untreated locally advanced HNSCC who either elderly (i.e., 70 years or older) or cisplatin ineligible [44].

Radiotherapy, Chemotherapy, and Molecular-Targeted Therapies

The EXTREME phase III trial [45, 46] undertaken in recurrent and/or metastatic head and neck cancers, adding cetuximab to standard first-line platinum-based chemotherapy, produced statistically and clinically significant benefits, in terms of prolonged survival, and improved tumor response, compared with the traditional approach of combination chemotherapy. Of interest, 77 patients (10% of the whole sample) were over 65 years of age. The next logical step in healthy patients is to investigate the role of cetuximab in combination with definitive chemoradiotherapy in locally advanced disease. The on-going phase III RTOG 0522 trial, comparing a chemoradiotherapy regimen of accelerated concurrent radiotherapy plus cisplatin with the same chemoradiotherapy regimen plus cetuximab, should provide the answer. Presently, it is premature to propose this combined scheme to elderly fit head and neck cancer patients outside of a research trial.

Recommendations

- Elderly head and neck cancer patients should benefit of the same diagnostic investigations and multidisciplinary decision process than younger patients.
- Elderly patients should access to a CGA (comprehensive geriatric assessment) to identify, quantify, and whenever possible treat co-morbidities.
- Elderly patients should be exposed to more aggressive management than they are currently receiving. This management should be closer to that currently received by younger patients.
- Patients should receive the most intensive and appropriate treatment thought to be safe and effective according to their biological age and co-morbidities.
- The aim should be to maximize the overall survival while minimizing the toxicity to achieve the greatest patient benefit.
- Socioeconomic and psychological issues should be dealt with to facilitate access, acceptance, and compliance to treatment.
- The maintenance of a proper dietetic input and balance should be planned and controlled before during and after treatment using preferably PEG whenever an insufficient oral intake is foreseen.
- Lighter radiotherapy (and chemotherapy) schedules should be preferred to supportive care only, unless survival expectancy is very short.
- The inclusion of fit elderly patients in research protocols should be encouraged regardless of age.
- Specific protocols should be designed for elderly patients with co-morbidities in order to collect evidence-based data on optimal management of these patients.
- CGA should be involved in trial design and clinical practice to document how to tailor treatment to a patient population of growing incidence.

References

1. Horner MJ, Ries LAG, Krapcho M, Neyman N, Aminou R, Howlander N, et al., editors. SEER Cancer Statistics Review, 1975–2006. Bethesda: National Cancer Institute; 2008.
2. Pignon T, Horiot JC, Van Den Bogaert W, Van Glabbeke M, Scalliet P. No age limit for radical radiotherapy in head and neck tumours. *Eur J Cancer*. 1996;32(12):2075–81.
3. Horiot JC. Revisiting the concept of age limit in radiotherapy research protocols. Proceedings of the 5th meeting of the International Society of Geriatric Oncology; San Francisco; 2004. p. 91–93.
4. Horiot JC. Radiation therapy and the geriatric oncology patient. *J Clin Oncol*. 2007;25(14):1930–5.
5. Metges JP, Eschwège F, de Crevoisier R, et al. Radiotherapy in head and neck cancer in the elderly: a challenge. *Crit Rev Oncol Hematol*. 2000;34:195–203.
6. Schofield CP, Sykes AJ, Slevin NJ, et al. Radiotherapy for head and neck cancer in elderly patients. *Radiother Oncol*. 2003;69:37–42.
7. Zachariah B, Balducci L, Verkattamanabalaaji GV, et al. Radiotherapy for cancers aged 80 and older. A study of effectiveness and side effects. *Int J Radiat Oncol Biol Phys*. 1997; 39:1125–9.
8. Italiano A, Ortholan C, Dassonville O, et al. Head and neck squamous cell carcinoma in patients aged > or = 80 years: patterns of care and survival. *Cancer*. 2008;113:3160–8.
9. Ortholan C, Lusinchi A, Italiano A, et al. Oral cavity squamous cell carcinoma in 260 patients aged 80 years or more. *Radiother Oncol*. 2009;93:516–23.
10. Reizenstein JA, Bergström SN, Holmberg L, et al. Impact of age at diagnosis on prognosis and treatment in laryngeal cancer. *Head Neck*. 2009;32:1062–8.
11. Extermann M. Studies of comprehensive geriatric assessment in patients with cancer. *Cancer Control*. 2003;10:463–8.
12. Extermann M, Hurria A. Comprehensive geriatric assessment for older patients with cancer. *J Clin Oncol*. 2007;25:1824–31.
13. Repetto L, Fratino L, Audisio RA, et al. Comprehensive geriatric assessment adds information to Eastern Cooperative Oncology Group performance status in elderly cancer patients: an Italian Group for Geriatric Oncology Study. *J Clin Oncol*. 2002;20: 494–502.
14. Extermann M, Aapro M, Bernabei R, et al. Use of comprehensive geriatric assessment in older cancer patients: recommendations from the task force on CGA of the International Society of Geriatric Oncology (SIOG). *Crit Rev Oncol Hematol*. 2005;55:241–52.
15. Rodin MB, Mobile SG. A practical approach to geriatric assessment in patients with cancer. *J Clin Oncol*. 2007;25:1936–44.
16. Sanabria A, Carvalho AL, Vartanian JG, et al. Comorbidity is a prognostic factor in elderly patients with head and neck cancer. *Ann Surg Oncol*. 2007;14:1449–57.
17. Tran M, Raynard B, Bataillard A, Duguet A, Garabige V, Lallemand Y, et al. Standards, Options and Recommendations 2005 for a good practice in enteral nutrition in oncology (summary report). *Bull Cancer*. 2006;93:715–22.
18. Horiot JC, Schraub S, Bone MC, et al. Dental preservation in patients irradiated for head and neck tumours: a 10 year experience with topical fluoride and a randomized trial between two fluoridation methods. *Radiother Oncol*. 1983;1:77–82.
19. Sanabria A, Carvalho AL, Melo R, et al. Predictive factors for complications in elderly patients who underwent oncologic surgery. *Head Neck*. 2008;30(2):170–7.
20. Pompei S, Tedesco M, Pozzi M, et al. Age as a risk factor in cervico-facial reconstruction. *J Exp Clin Cancer Res*. 1999;18: 209–12.
21. Ashley J, Duggan M, Sutcliffe N. Speech, language and swallowing disorders in older adult. *Clin Geriatr Med*. 2006;22:291–310.
22. Werner JA, Dunne AA, Folz BJ, et al. Transoral laser microsurgery in carcinomas of the oral cavity, pharynx and larynx. *Cancer Control*. 2002;9:379–86.
23. Audisio RA, Bozzetti F, Gennari R, et al. The surgical management of elderly cancer patients: recommendations of the SIOG surgical task force. *Eur J Cancer*. 2004;40:926–38.
24. Dubec JJ, Munk PL, Tsang V, et al. Carotid artery stenosis in patients who have undergone radiotherapy for head and neck malignancies. *Br J Radiol*. 1998;71:872–5.
25. Brown PD, Foote RL, McLaughlin MP, et al. A historical prospective cohort study of carotid artery stenosis after radiotherapy for

- head and neck malignancies. *Int J Radiat Oncol Biol Phys.* 2005;63:1361–7.
26. Falandry C, Tartouki K, Mornex F, et al. Is geriatric assessment adapted to radiotherapy? *Cancer Radiother.* 2008;12:541–7.
 27. van Rij CM, Oughlane-Heemsbergen WD, Ackerstaff AH, Lamers EA, Balm AJM, Rasch CRN. Parotid gland sparing IMRT for head and neck cancer improves xerostomia related quality of life. *Radiat Oncol.* 2008;3:41.
 28. Pignon JP, le Maître A, Bouhris J, et al. Meta-analysis of chemotherapy in head and neck cancer (MACH-NC): an update. *Int J Radiat Oncol Biol Phys.* 2007;69(2 Suppl):S112–4.
 29. Bernier J. Current state-of-the-art for concurrent chemo-radiation. *Semin Radiat Oncol.* 2009;19:3–10.
 30. Lefebvre JL, Chevalier D, Luboinski B, et al. Larynx preservation in pyriform sinus cancer: preliminary results of a European Organization for Research and Treatment of Cancer phase III trial. EORTC Head and Neck Cancer Cooperative Group. *J Natl Cancer Inst.* 1996;88(13):890–9.
 31. Lefebvre JL, Rolland F, Tesselaar M, et al. Phase 3 randomized trial on larynx preservation comparing sequential vs. alternating chemotherapy and radiotherapy. *J Natl Cancer Inst.* 2009;101(3):142–52.
 32. Vermorken JB, Remenar E, van Herpen C, et al. Cisplatin, fluorouracil, and docetaxel in unresectable head and neck cancer. *N Engl J Med.* 2007;357(17):1695–704.
 33. Fliser D. Assessment of renal function in elderly patients. *Curr Opin Nephrol Hypertens.* 2008;17:604–8.
 34. Adelstein DJ, Ly Y, Adams JL, et al. An intergroup phase III comparison of standard radiation therapy and two schedules of concurrent chemoradiotherapy in patients with resectable squamous cell head and neck cancer. *J Clin Oncol.* 2003;21:92–8.
 35. Cooper JS, Pajak TF, Forastiere AA, et al. Postoperative concurrent radiotherapy and chemotherapy for high risk squamous cell carcinoma of the head and neck. *N Engl J Med.* 2004;350:1937–44.
 36. Calais G, Alfonsi M, Bardet E, et al. Randomized trial of radiation therapy versus concomitant chemotherapy and radiation therapy for advanced-stage oropharynx carcinoma. *J Natl Cancer Inst.* 1999;91(24):2081–6.
 37. Machtay M, Moughan J, Trotti A, et al. Factors associated with severe late toxicity after concurrent chemoradiation for locally advanced head and neck cancer: an RTOG analysis. *J Clin Oncol.* 2008;26:3582–9.
 38. Lokich J, Anderson N. Carboplatin versus cisplatin in solid tumors: an analysis of the literature. *Ann Oncol.* 1998;9:13–21.
 39. Wildiers H. Mastering chemotherapy dose reductions in elderly cancer patients. *Eur J Cancer.* 2007;43:2235–41.
 40. Lichtman SM, Hollis D, Miller AA, et al. Prospective evaluation of the patient age and paclitaxel clinical pharmacology: cancer and leukemia group B (CALGB 9762). *J Clin Oncol.* 2006;24:1846–704.
 41. Choi YJ, Chung J, Shin HJ, Cho GJ, et al. Induction chemotherapy of docetaxel and Cisplatin for the elderly patients with squamous cell carcinoma of the head and neck. *Cancer Res Treat.* 2007;39(1):1–5.
 42. Bonner JA, Harari PM, Giralt J, et al. Radiotherapy plus cetuximab for squamous-cell carcinoma of the head and neck. *N Engl J Med.* 2006;354:567–78.
 43. Bonner JA, Harari PM, Giralt J, et al. Radiotherapy plus cetuximab for locoregionally advanced head and neck cancer: 5-year survival data from a phase 3 randomised trial, and relation between cetuximab-induced rash and survival. *Lancet Oncol.* 2010;11:21–8.
 44. Athanassios A. EGFR antisense DNA added to cetuximab and radiotherapy for head and neck cancer. Grant 1R21CA130241-01A1 from National Cancer Institute.
 45. Bernier J. Cetuximab: a standard approach to the first-line treatment of recurrent and/or metastatic and locally advanced squamous cell carcinoma of the head and neck. *Oncol Rev.* 2009;3:247–56.
 46. Vermorken JB, Mesia R, Rivera F, et al. Platinum-based chemotherapy plus cetuximab in head and neck cancer. *N Engl J Med.* 2008;359:1116–27.

Chapter 42

Interstitial Radiation Therapy in Cancer of the Oropharynx and Oral Cavity

Peter C. Levendag, David N. Teguh, and Paul I.M. Schmitz

Abstract

Background Interstitial brachytherapy (IBT) is a highly conformal radiation therapy technique for the treatment of head and neck cancer; it is used as a boost technique integrated in an organ function preservation protocol, with oropharynx being a site of preference.

Material and Methods The dose of radiation can be accurately delivered to the target by a radioactive source, dwelling in the implanted afterloading catheters connected to an afterloading machine. The prescribed dose (dwell times and source positions) is delivered after 3D dose calculation, using computerized (optimization) algorithms. Characteristics as steep dose fall-off and small margins make the dose distribution highly conformal and confine to the irradiated volume. Thus, it allows for delivering high doses of radiation to the target (with intrinsic dose escalation), while at the same time sparing the critical surrounding normal tissues. Moreover, being able at present to sum the dose of the external beam (46/2 Gy) and the dose of the IBT, biological treatment planning is within reach.

Results and Conclusions For oropharyngeal cancer boosted by IBT, at 10 years an excellent local control rate of 90% was observed. However, lack of training and clinical experience, only suitable for relatively small volume disease, invasiveness of the procedure, and difficult logistics (operating room) can be, albeit rarely, conditionally limiting. Late side effects (e.g., soft tissue necrosis) are not totally negligible either, but if present in the great majority of cases spontaneously healing will occur. When comparing IBT to other forms of conformal radiation, such as stereotactic radiation therapy, Cyberknife, and IMRT, the quality of life, as scored by the patient responses to the EORTC H&N35 questionnaires, in general speaks in favor of IBT.

Keywords Brachytherapy • Oropharynx • Oral cavity • Swallowing • Implant • Base of tongue • Tonsillar fossa • Soft palate • Quality of life • Side effects

P.C. Levendag (✉)
Department of Radiation Oncology,
Erasmus MC – Daniel den Hoed Cancer Center,
Groene Hilledijk 301, 3063AD, Rotterdam, The Netherlands
e-mail: p.levendag@erasmusmc.nl

Introduction

Although there have been major improvements in surgical- and radiation therapy (RT) techniques, overall survival (OS) showed little change. That is, typically patients with tumors of the head and neck present in more than 50% with locally advanced disease at the time of diagnosis, have local control rates of about 60–80%, and a 5-year OS of approximately 30–50%, due to high incidence of secondary tumors originating from the aerodigestive tract (second tumors actuarial increase 3% annually). Substantially enhanced morbidity during and immediately after treatment, in particular, in the fragile elderly, and less compliance due to excessive comorbidity because of alcohol and tobacco abuse might be reasons why some of these patients do not benefit (in terms of improvement of overall survival) from some of the proposed and promising new treatment approaches [1]. Also the late-occurring side effects, such as xerostomia, dysphagia, pain and fibrosis (e.g., trismus), gives rise for concern. That is, some of these (interrelated) side effects can have a significant impact on the quality of life (QoL) [2]. This again might be a reason for being somewhat reluctant in enrolling patients in aggressive but promising protocols. In trying to improve one's result, that is in order to investigate new treatment strategies, a proper balance must exist between tumor response and treatment-related acute- and late morbidity as opposed to the associated risk of noncompliance.

We have opted over many years for IMRT with moderate acceleration, a treatment strategy which, according to a large meta-analysis, is very beneficial. In fact, it can be given without any enhancement of (late) side effects and with only a minimally increased acute reaction [3]. For the external beam radiotherapy (EBRT) part (46/2 Gy) of the protocol, we have preferred, as of the year 2000, IMRT as the treatment technique. Boost doses to the primary tumor were given, if technically feasible, by means of high-dose-rate interstitial brachytherapy (IBT), similar to EBRT in an accelerated fashion. As with IBT, in general, only limited sized tumors (T1–3) are eligible for an IBT boost. If IBT is not feasible, then IMRT and (in case of T3, T4 disease) concomitant chemotherapy are applied. In conclusion, this chapter is

focused on dose acceleration (majority of patients receiving six fractions of IMRT per week; first series to a total dose of 46 Gy/2); dose escalation (majority treated by HDR-IBT), and on sparing (IMRT; HDR-IBT). It also focus on issues such as local and regional control, survival, early and late side effects, and QoL after primary radiation therapy by EBRT and IRT (boost) treatment. To note, BT can play a significant role in case of persistent disease [4] with regard to local control and overall survival (80% complete response to brachytherapy) after previous definitive EBRT or in case of a recurrence after previous RT [5–7]. Results are frequently reported dependent on volume of the (persistent and recurrent) disease, previously applied dose fractionation, and interval between treatment and site. For example, the most rewarding site seems to be cancer of the nasopharynx. Although it has been shown that BT can play a substantial role in these cases, we will not discuss the literature on this subject in detail. To summarize, in general variable response rates were observed (20–80%) with only limited or no survival benefit [5–7].

Historical Perspective Brachytherapy

In many of the classical handbooks on radiation therapy, as well as in the current literature, one can find excellent reviews on low- and high-dose-rate brachytherapy [8–24]. The history of BT dates back to the beginning of the twentieth century, with the first BT procedures being performed using radium-226 needles. Alexander Graham Bell, the inventor of the telephone, suggested in 1901 that a tumor can be destroyed “by inserting radioactive needles in the heart of the cancer,” a first example of interstitial radiation therapy. Brachytherapy (brachy=Greek for short) is a treatment modality in which the tumor is irradiated by positioning the radioactive sources very close to the target surface (surface mould type), in naturally existing cavities of the body (endocavitary type) or in afterloading catheters implanted in the irradiated tissue (interstitial type). In recent times, many artificial radionuclides such as I-125 and Ir-192 have become available and are used for example in the treatment of cancer of the head and neck. The French developed the so-called Paris system for LDR dosimetry purposes, that is, for parallel-equidistant sources the system recommends specifying the dose of the implant at 85% of the average dose in the basal dose points (local minima). Currently, a similar type of dose prescription is used for high-dose rate (HDR) volume implants, such as the implant of the base of tongue (BOT), even though the sources may not be totally equidistant. Also computerized afterloading devices are supported by sophisticated 3D treatment-planning software with optimization capabilities became available. Finally, the concept of HDR versus pulsed-dose rate (PDR; in principle mimicking LDR

Table 42.1 Dose rate categories, taken from the literature and from the Erasmus MC protocols (PDR, fr.HDR)

Dose rate	Specifications
LDR	0.4–2 Gy/h
MDR	2–12 Gy/h
HDR	>12 Gy/h
Fractionated HDR	Erasmus MC day-time schedule. First and last fraction 4 Gy, in between 4 fractions of 3 Gy, maximum 2 fractions per day, interval 6 h. No radiation in weekend
Pulsed-dose rate	Erasmus MC 24 h schedule. First and last fraction 2 Gy, in between 18 fractions of 1 Gy, maximum 2 fractions of 1 Gy, interval 3 h. Continuation of BT over the weekend

Fr.HDR: Fractionated HDR is given in fraction sizes of 3–4 Gy by connecting the afterloading tubes to microSelectron HDR (source strength 370 MBq). In case of PDR, fraction sizes of 1–2 Gy are being delivered by microSelectron PDR (source strength 37 MBq)

by using many small fractions at small intervals) was launched (Table 42.1). More recently, a renewed interest has emerged in being able to sum the doses delivered by EBRT and BT (an example is presented in this chapter). This way the biological treatment planning comes within reach.

Brachytherapy Protocol Evolution

From the beginning, it was realized that BT can be used routinely as a very conformal type of treatment, particularly for cancer located in the midline. Obvious examples are endocavitary boosts in cancers of the nasopharynx, IBT as a boost for cancer in the oropharynx, oral cavity, and in general for small volume disease in case of re-irradiation or in postoperative irradiation of the neck. In the Erasmus MC, we initiated a treatment protocol implementing the use of IBT in 1991. Over the years, a few changes were introduced because of important biological and/or technical developments at the time, such as the introduction of IMRT, accelerated RT (six fractions per week), and concomitant chemotherapy (for advanced T3, T4 tumors only) [25].

In the course of time, in the Erasmus MC, the preferred treatment for oral cavity tumors was argued to be surgery rather than IMRT [20, 26]. This is partly due to the ease of surgical access and/or feasibility of reconstruction after resection of these tumors. Also in favor of surgery are the facts that this treatment is frequently a one-time type of treatment procedure (surgery) and the notion that IBT in the oral cavity is being associated with a relatively high risk of serious complications (osteoradionecrosis) [27].

For oropharyngeal tumors, the principle therapy in the Erasmus MC is primary RT by IMRT to the neck and primary cancer to a dose of 46 Gy followed by a neck dissection in case of the neck containing positive lymph nodes and a boost to the primary by HDR-IBT. Finally, the principles underlying the BT protocol as designed in 1991 have been

strictly adhered to (see section on “Results of Cancer in the Oropharynx”), in general.

However, at the time, a number of patients were found to be noneligible for IBT, due to, e.g., medical reasons (medically unfit to undergo invasive procedures), or because of tumors with deep parapharyngeal extension, or (albeit rare) simply because of patient refusal. These patients would be offered surgery to the primary (and neck) or a boost to the primary tumor by IMRT. Currently, however, if brachytherapy is not feasible, they offered a Cyberknife (CBK) boost as a second-line

of boost treatment. The CBK, a noninvasive stereotactic – robotic – linear accelerator, was installed in 2005 in the department of RT in the Erasmus MC. The dose fractionation of the CBK boost protocol is three times 5.5 Gy, with the dose prescribed to the 80% isodose line. The boost volume is based on the original tumor mass, only with a PTV margin of 3 mm. Treatment policy regarding the neck remained the same, except that in N+ cases the proposed ND was planned after completion of the CBK boost (in order not to have too large split between the IMRT series and the CBK boost) (Fig. 42.1).

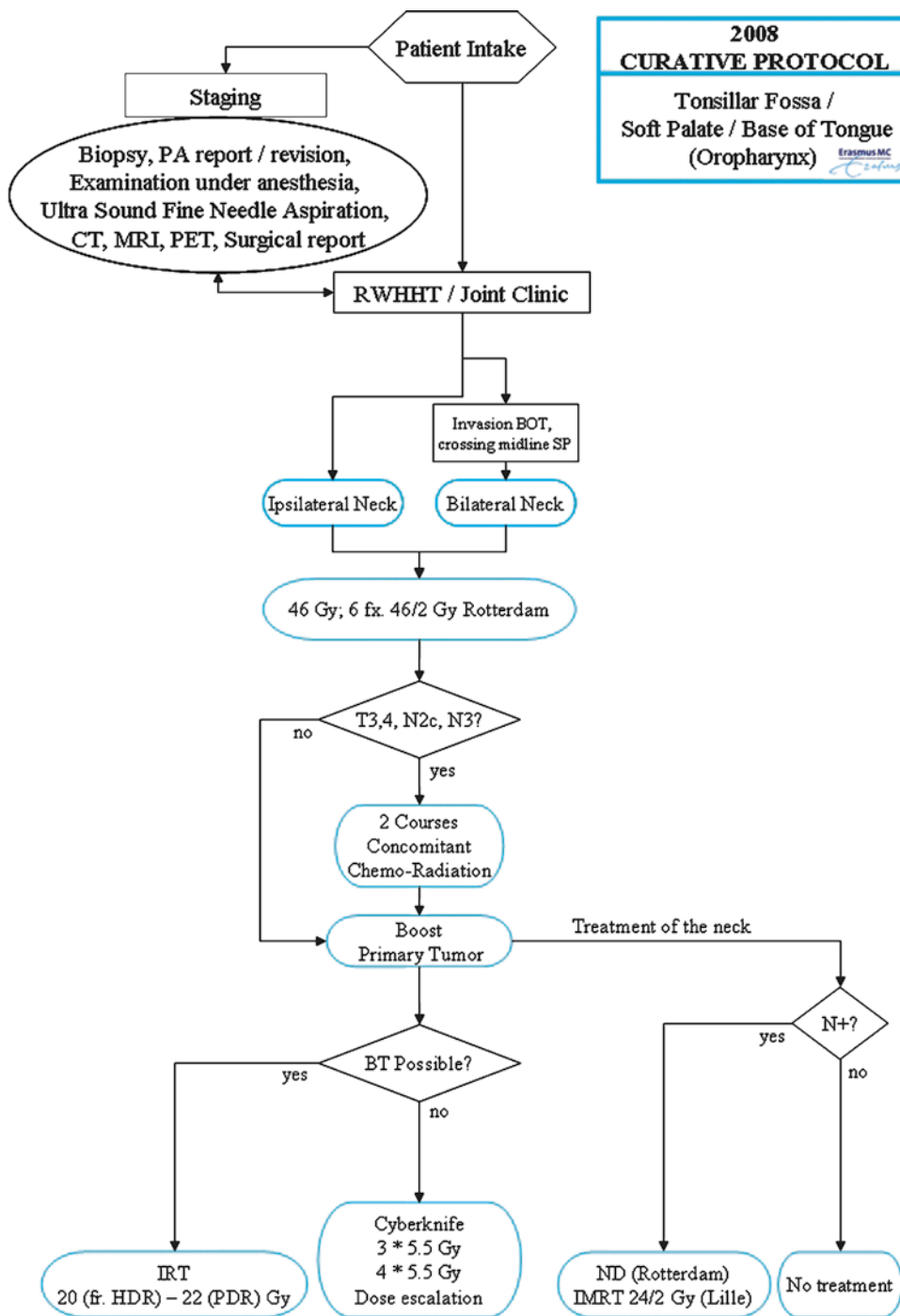


Fig. 42.1 In the course of time, changes have been introduced: First around 1996 accelerated fractionation to a total dose of 46 Gy was introduced (for details see the legend of Fig. 42.2). As of 2000, all primary cancers were treated by IMRT. In later years, for some of the very advanced T3/T4 cancers, concomitant chemotherapy was added. Treatment policy regarding neck dissection and implant primary tumor remained the same. In 2008, the Cyberknife was used for boosting the primary tumor in case IBT was not feasible (see text for further details)

Brachytherapy Techniques

All oropharyngeal tumors are jointly seen by the H&N surgeon and radiation oncologist with the patient under general anesthesia. Using clinical information, pan-endoscopy, CT/MRI of the primary and neck, biopsy from the primary tumor and fine needle aspiration cytology (FNAC) of the node(s), and placing the radiopaque markers, patients are staged [28, 29]. That is, at the time of examination, markers are placed at the boundaries of what we believe the microscopic extensions (CTV) of the primary tumor. With the clinical information of the marker positions and on the images of the tumor (CT/MRI) combined, the primary tumor is delineated on a treatment-planning CT. The BT techniques that are described in great detail in this section are the typical implants of primary cancers in the oropharynx, that is the single plane tonsillar fossa (TF) and/or soft palate (SP) implant, and the volume implant of the BOT or combinations of these. IBT of oral cavity tumors (e.g., mouth, cheek, oral tongue, etc.) is certainly feasible but in our institution (Erasmus MC) it is in “competition” with surgery, and as a consequence less often executed.

Brachytherapy Technique: Oral Cavity

For IBT of cancer of the oral cavity, in general, the Ir-192 source “lines” are introduced in parallel-opposed looping catheters covering the CTV of the primary tumor. Besides this arching technique, single plane in practice are frequently used. Basically simple, straightforward techniques. The preferred spacing between the source “lines” is approximately 0.5–0.7 cm. Care should be taken to maintain strict parallelism of the sources, and lead protection at the inner side mandible of at least one HVL (half value layer) should be provided at the time of the irradiation in order to prevent osteoradionecrosis (ORN) to occur. Because of easy access to surgery of these small oral cavity tumors, and still a relatively high risk of ORN when using IBT, implanting these cancers is not routinely being performed in Erasmus MC (anymore). Moreover, the necessary lead protection of the mandible per se leaves sometimes just too limited space for the afterloading catheters (sources) to be implanted. With regard to the oral cavity, the Results section of this chapter is mainly focused on and illustrate some of the results as reported in the literature.

Brachytherapy Technique: TF and/or SP

With regard to the TF and/or SP tumors: these sites are often difficult to accurately depict on CT or MRI images. At the

time of the brachytherapy procedure, the (residual) tumor as well as the boundaries of CTV can be clearly seen and thus accurately delineated. In general, the implant, as opposed to IMRT, is thus more “on target,” has smaller margins (no PTV margin), and as a consequence the irradiated volume is thus smaller and more conformal (see also Fig. 42.2) [16, 29]. With regard to the protocol; first, an IMRT treatment plan of the primary tumor and neck is generated (CTV margin 5 mm, PTV margin 5 mm) and applied using an accelerated fractionation scheme to a total dose of 46/2 Gy. Afterloading tubes (2–3) are then implanted in the TF and SP approximately 1 (–2) week(s) after completion of the IMRT. Markers are implanted at the boundary of the CTV (CTV can some-

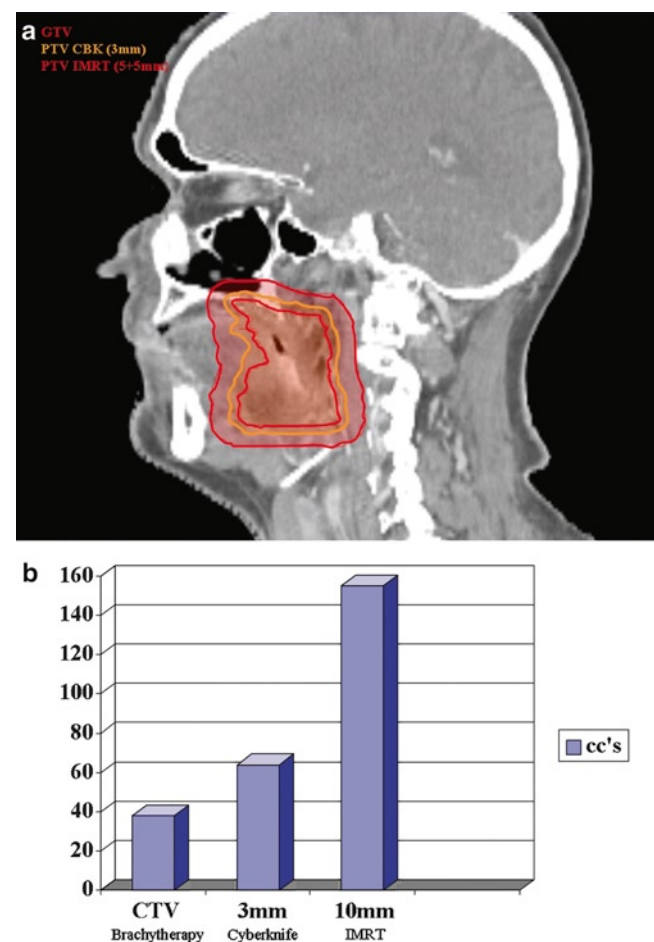


Fig. 42.2 The treated volume of a tonsillar fossa and soft palate tumor with a delineated PTV using a margin of 3 mm in case of a Cyberknife treatment. For a similar tumor treated by brachytherapy or the IMRT, the margin for PTV is 0 or 5 mm, respectively. Using the different margins as discussed in the text, the panel (b) displays the consequences for the irradiated volume of a tonsillar fossa tumor radiated either by brachytherapy (CTV), Cyberknife (PTV), or IMRT (PTV). From Levendag PC, Al-Mamgani A, Teguh DN. Contouring in head & neck cancer. München: Elsevier Professional Education; 2009. p. 17–25. Reprinted with kind permission from Elsevier

times be determined by the demarcating mucositis after the first series of IMRT [46 Gy] has been applied). No PTV margin is needed in case of IBT, since the tumor is moving with the catheters in situ. The dose is prescribed at a distance of 5 or 7.5 mm of the central plane. The 3D dose distribution plan is also generated using dose point optimization. A neck

dissection (ND) is performed in case of an N+ neck. Whether the contralateral neck is to be irradiated electively is still a subject to debate. Our data suggest that this should only be done in case of infiltration of the primary tumor in the BOT or in case the SP tumor infiltration extends over the midline 29 (Figs. 42.3–42.6).

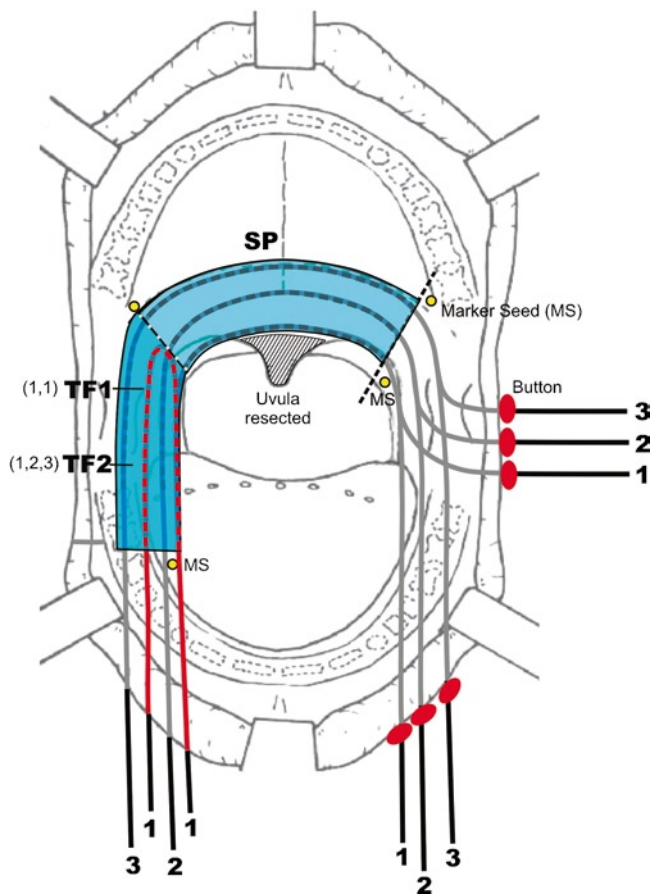


Fig. 42.3 Schematic diagram of implant techniques (routes for the after-loading catheters to cover the target) in case of tumors sitting in the TF, SP, or both. From Levendag PC, Al-Mamgani A, Teguh DN. Contouring in head & neck cancer. München: Elsevier Professional Education; 2009. p. 17–25. Reprinted with kind permission from Elsevier

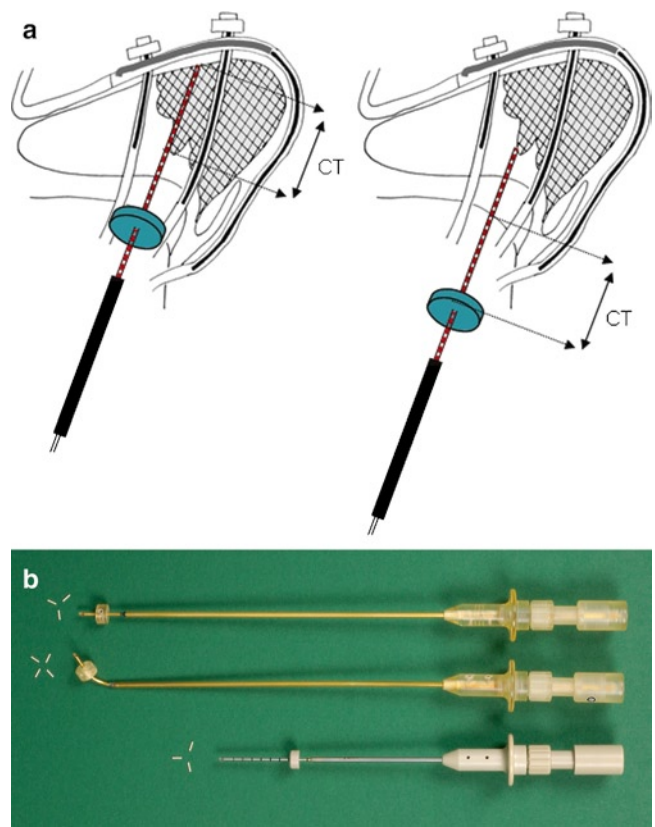


Fig. 42.4 Home made instruments to inject marker seeds to demarcate the clinical target volume. From Levendag PC, Al-Mamgani A, Teguh DN. Contouring in head & neck cancer. München: Elsevier Professional Education; 2009. p. 17–25. Reprinted with kind permission from Elsevier

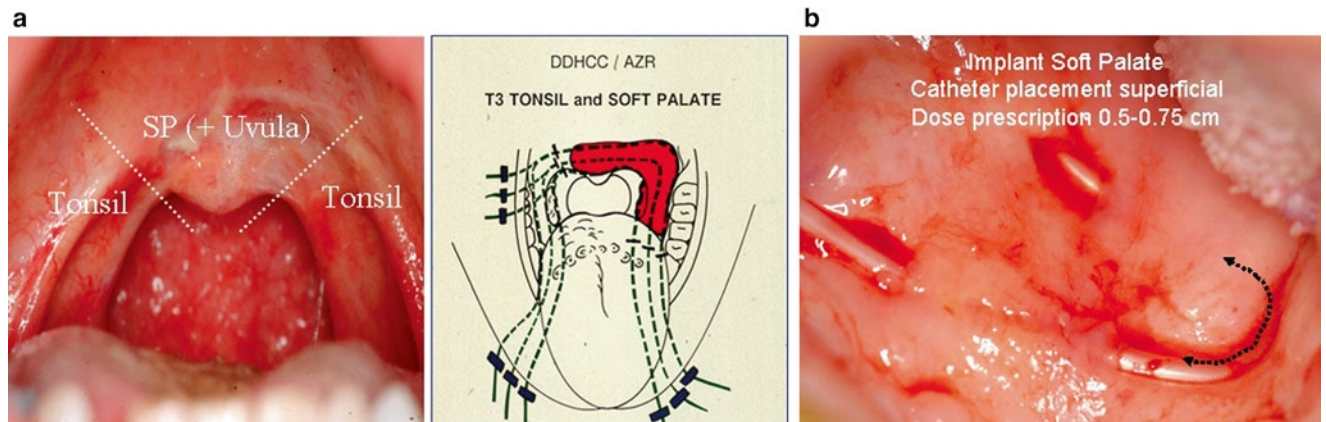


Fig. 42.5 Afterloading catheters running submucosally after having been implanted according to one of the techniques shown in Fig. 42.4

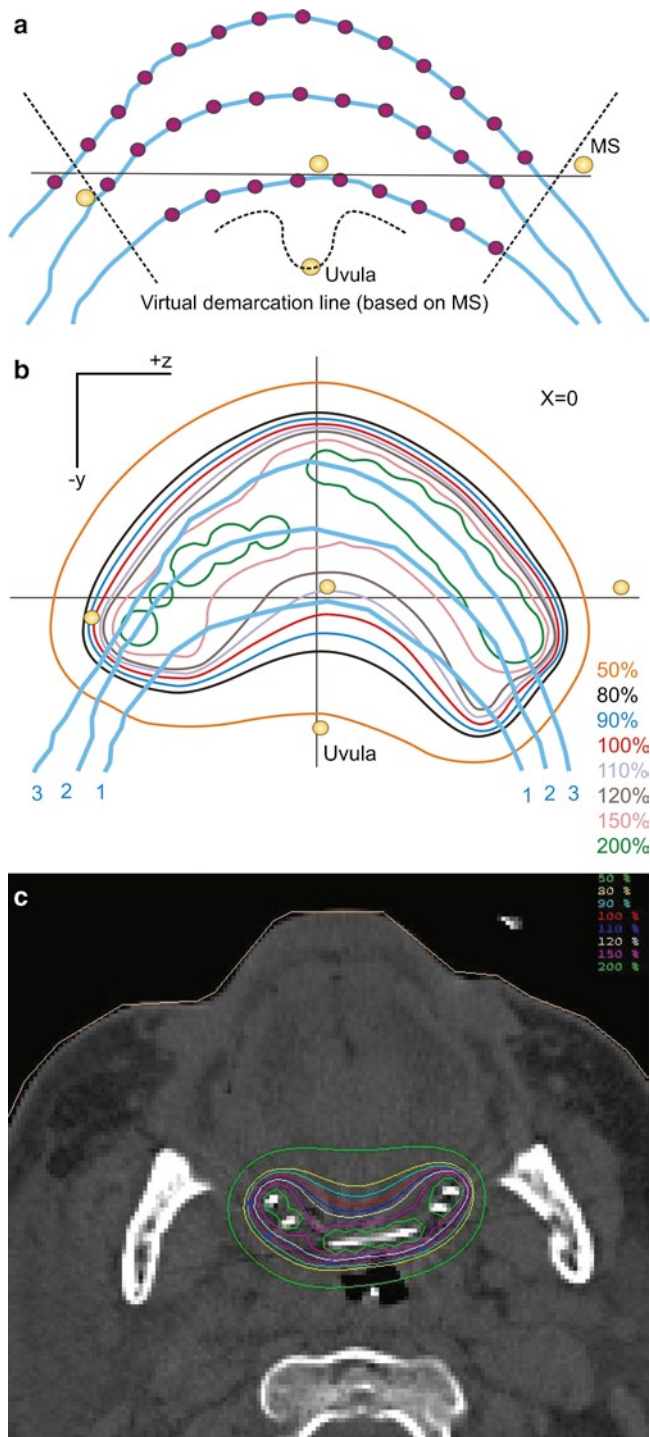


Fig. 42.6 Dose distribution TF tumor with extension into the SP. Note marker seed position demarcating the boundary of the CTV

Brachytherapy Technique: BOT

Another frequently performed implant technique is the volume implant of the BOT originally described and pioneered as a LDR technique by Vikram in 1981 [13, 15, 22, 23].

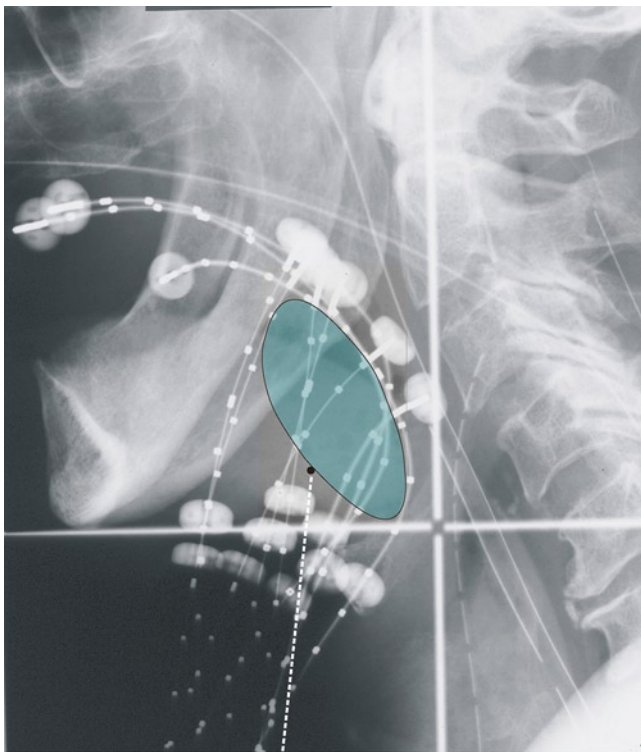
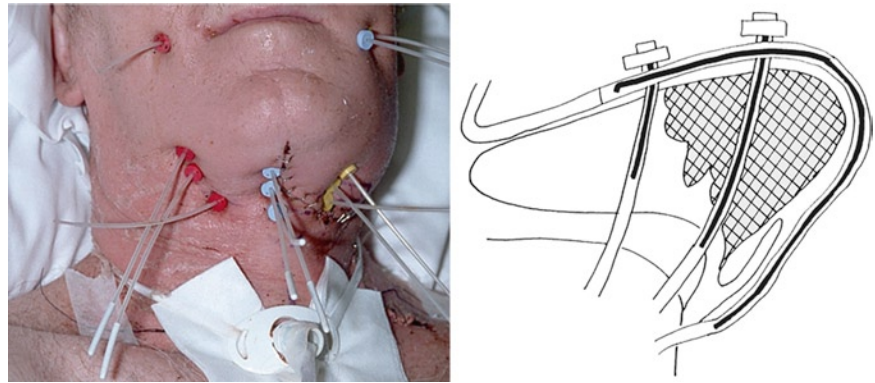
In general, three afterloading catheters are implanted by introducing the afterloading (slightly curved) needles just above or beneath the hyoid bone (depending on the location of the primary tumor), thereby entering the oropharyngeal air cavity just posteriorly/caudal to the primary BOT tumor. These catheters run over the dorsum of the tongue and exit through the cheek (Figs. 42.7 and 42.8). Another six catheters are introduced somewhat more ventrally; each dorsum running catheter is then connected with specially designed sliding buttons to two of these vertical/ventral catheters, with 1 cm spacing between the sliding buttons. This way, three planes are constructed, each consisting of three catheters; that is, one central plane and two lateral sagittal planes. After geometrical optimization, a 3D dose plan is generated. The dose of the implant is specified at 85% of the average dose in the basal dose points (local minima), quite similar to the Paris system. For safety precautions (e.g., bleed at the time of removal of the implant), a tracheotomy is sometimes performed. In case of small, lateralized tumors in the BOT, we sometimes refrain from implanting the whole of the BOT (as was routinely done in the past), but instead (boost) the residual or primary tumor mass only (CTV margin inclusive). Both necks are irradiated to 46/2 Gy in an accelerated fashion by means of IMRT. In case of N+ disease, a ND and an implant of the primary tumor are performed in the same session (Figs. 42.9 and 42.10).

Results

Results of Cancer in the Oral Cavity

Many papers have been published on IBT of primary cancers in the head and neck, the majority being classical papers from the LDR era on cancers in the oral cavity and oropharynx [19, 26, 30–37]. Some of the outcome data on local control have been summarized in Tables 42.2 (oral cavity tumors) and 42.3 (oropharyngeal tumors). Furthermore, the references provided in this chapter enables one to get an in-depth view on the good results about IBT in terms of local- and regional control, disease-free survival, and overall survival. Given the reasons presented before (see section on “Brachytherapy Techniques”), the oral cavity experience as presented in the literature can be summarized as follows: At 5 years, the LC varies between 36 and 93%, and the OS from 8 to 69% (see Table 42.2). Importantly, one of the few randomized studies in brachytherapy is on mobile tongue cancer and was published by the Japanese [34]; showed no significant difference for mobile tongue cancer treated with LDR versus fractionated HDR. This was true for LC (84% vs. 87%) and cause-specific survival (CSS) (86% vs. 88%) [34].

Fig. 42.7 View of patient with BOT implant. From Levendag PC, Al-Mamgani A, Teguh DN. Contouring in head & neck cancer. München: Elsevier Professional Education; 2009. p. 17–25. Reprinted with kind permission from Elsevier



Marker Seed deepest point

Fig. 42.8 Dorsum of the tongue running afterloading catheter connected to two more ventrally positioned afterloading catheters in the same sagittal plane. Note specially constructed sliding (connecting) button. From Levendag PC, Al-Mamgani A, Teguh DN. Contouring in head & neck cancer. München: Elsevier Professional Education; 2009. p. 17–25. Reprinted with kind permission from Elsevier

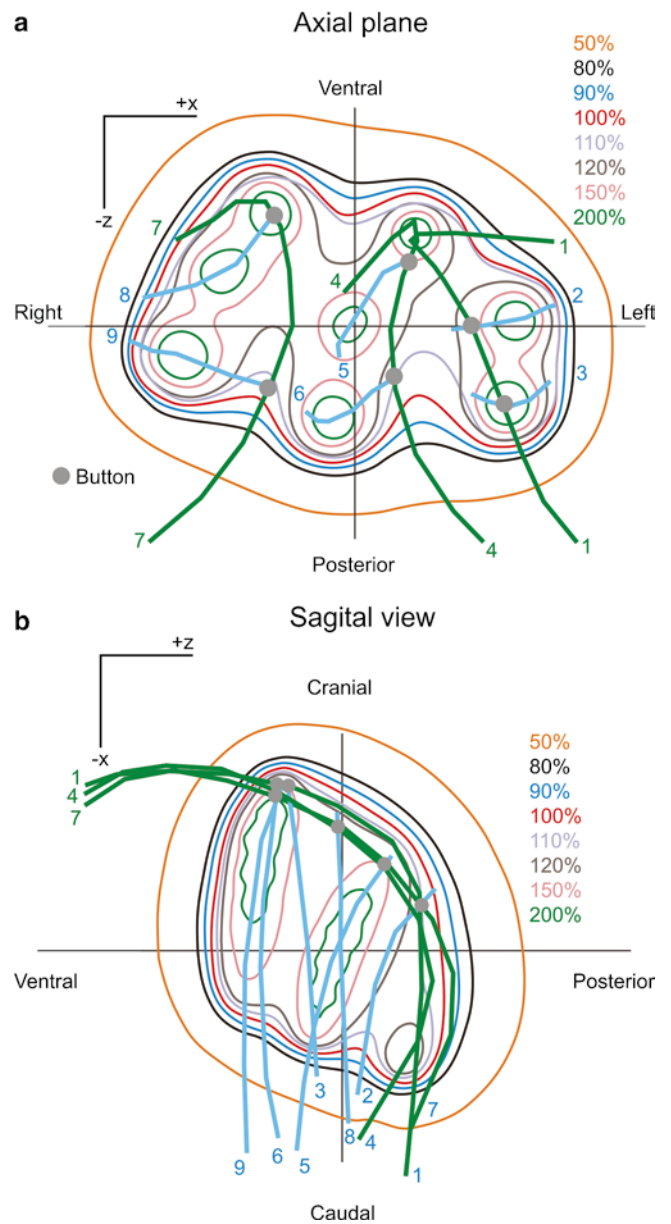


Fig. 42.9 Dose distribution of BOT implant after geometrical optimization. Note marker seeds

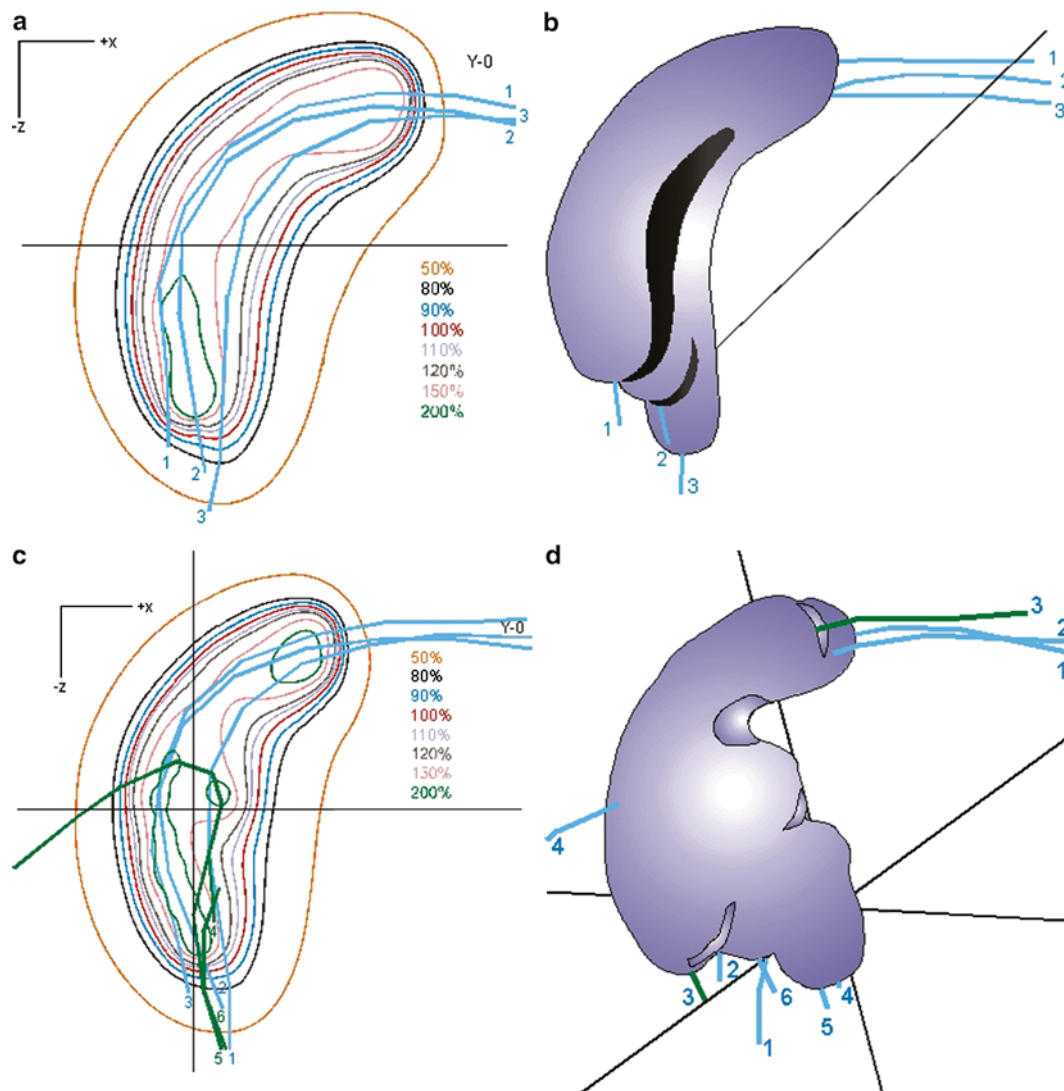


Fig. 42.10 Tumor in BOT with extensions into TF and partially in SP. Basically, it is a complex implant combining the dose distributions as shown in Figs. 42.6 and 42.9. This type of implant is preferably done under direct vision and would be difficult to perform by CT guidance

Table 42.2 Overview of some of the published data on local control (LC), disease-free survival (DFS), and overall survival (OS) for cancer in the oral cavity

First author	<i>N</i>	Primary, boost, or PO BT	LC (5 years %)	DFS (5 years %)	OS (5 years %)
Lefebvre [26]	429		53–91		
Wadsley [31]	24	Primary BT	76	91 (2 years)	81 (2 years)
Mazon [19]	117	Primary BT	50–86		8–52
Chu [67]			83–94		
Wendt (1990)	103	Primary BT and boost	65–92 (2 years)		
Mendenhall [33]	31	Primary BT and boost	40–75		
Inoue [34]	51	Primary BT	84–87		
Benk [36]	110	Primary BT and boost	36–88	24–42	
Baillet [37]	966		53–91		
Decroix [35]	602	Primary BT and boost	76	48	36
Pernot [32]	448	Primary BT and boost	49–93		25–69

Table 42.3 Overview of some of the published data on local control (LC), disease-free survival (DFS), and overall survival (OS) for cancer in the tonsillar fossa and soft palate (SP and/or SP), and cancer in the base of tongue (BOT)

A: Tonsillar fossa/soft palate								
First author	N	T1/T2 (%)	T3/T4 (%)	LC T1/T2 (5 years %)	LC T3/T4 (5 years %)	DFS (5 years %)	Overall survival (5 years %)	
Pernot [73]	277		57			76 (5 years)	51	
Puthawala [74]	80		24			84		
Pernot [32]	361		1	LRC Stage I: 3/3 LRC Stage II: 100 T1: 80, T2: 71	LRC Stage III: 85 LRC Stage IV: 56 T3: 65, T4: 58	CSS: 63	53	
Levendag [16]	104	77			LRC: 75 T1–T3: 88		67	
Esche [9]	43	T1: 34/43			92	CSS: 64	37	
Mazeron [71]	165	100		94		71	53	
Peiffert [72]	73	65/73	2/73	T: 80, T2: 67		CSS: 64	30	
B: Base of tongue								
First author	N	T1/T2 (%)	T3/T4 (%)	NO (%)	LC T1/T2 (5 years %)	LC T3/T4 (5 years %)	DFS (5 years %)	Overall survival (5 years %)
Harrison [47]	68		3 (T4)		T1: 87, T2: 93	T3: 82, T4: 100	T1: 88, T2: 93, T3: 82	87
Puthawala [75]	70		17 (T4)		T1: 100, T2: 88	T3: 75, T4: 67	67	35
Barrett [65]	20		35	10			33	
Takacsi-Nagy [76]	37		81	19	100	60	52	46
Karakoyun-Celik [69]	40		54	30		LC: T1–4: 78	54	62
Pol [21]	30		67 (T4)	30		LC 63	45	40
Gibbs [41]	41		49	32	14	20	79	66
Brunin [66]	216		61	30	T1: 93, T3: 66	T3: 45, T4: 18	CSS I–IV: 63–23	27
Crook [8]	48	100			T1: 85, T2: 71		50	
Hofstetter [68]	136	55/136		NO/N1 81	T1: 86, T2: 69	T3: 64		
Horwitz [14]	20	11/20	9/20		10/11	T4: 8/9		72
Housset [15]	29	100			T1: 6/6, T2: 74			30.5
Lusinchi [70]	108	57/108	T3: 51/108		T1: 85, T2: 50	T3: 69		26

Results of Cancer in the Oropharynx

To investigate the results of using a combination of EBRT or IMRT (46/2 Gy) and LDR- or HDR-IBT (boost), we first analyzed the data of our institution. From 1991 to 2005, 336 oropharyngeal cancer patients were treated nonsurgically for the primary cancer at the Erasmus MC, Rotterdam; at 5 years, an actuarial LC rate for BT vs. non-BT was 84% vs. 60% ($P < 0.05$), DFS of 59% vs. 43% ($P < 0.05$), and OS of 64% vs. 39% ($P < 0.05$) were found. Apparently, the use of IBT seems to be of benefit, when considering LC, RC, DFS, and OS [16]. From a multivariate analysis, it was found that

BT and the time period (i.e., before or after the year 2000) are of significant influence on local control.

Piccirillo and Vlahiotis [38] reported that the co-morbidity being of significant influence in the outcome of treatment and prognosis. Similar experiences have been reported by others. For example, Mazeron reported in 1988 and 1989 his LDR experience with IBT for T1, T2 cancers in the TF and/or SF; at 5 years a local control of 85% and regional control of 97% (88% for N1–3 disease) [39]. Also, Pernot et al. obtained 90% LC with T1T2N0 TF/SP tumors and 86% in case of T1T2N1–3 using an LDR-IBT boost [20]. Esche [9] reported on 43 patients with tumors in SP and

uvula. LC was again high (92%) with OS of only 64% at 5 years, emphasizing in his paper the force of mortality of aerodigestive secondary tumors. Harrison reported excellent LC rates using HDR-IBT volume implants, a technique first pioneered by Vikram [22, 23]. A 5-year LC, DFS, and OS of 89, 80, and 86% were published. Similar observations were made by van de Pol et al. [21]; data were published in 2004 describing the Rotterdam results of T3/T4 BOT cancer treated by IBT as opposed to BOT cancer treated with surgery and PORT (VUmc, Amsterdam). The local failure at 5 years was 37 and 9%, for the IBT-series as opposed to the surgical series. The BT cases were nonselected; in fact some of these patients would now even consider palliation. Thus, not unexpectedly, a lesser control for the IBT was found considering Rotterdam. However, analyzing the data in more detail, the overall survival was not significantly different (median 2.5 years vs. 2.9 years, respectively [$P=0.47$]). Moreover, the QoL was significantly better for the IBT patients (see section on “Acute Side Effects”) treated in Rotterdam.

Side Effects and Quality of Life

Acute Side Effects

It has been argued that many studies insufficiently address the enhanced toxicity and the compliance of patients during and immediately after treatment for some of the currently used aggressive treatment regimes. Although acute side effects in cancer of the oral cavity are certainly not negligible, it appears hard to produce reliable data on this issue with respect to this type of cancer if solely based on the literature. This section therefore deals only with the acute side effects of patients with cancer in the oropharynx based on our own (peer-reviewed) experience. It is evident from the charts that acute morbidity, leading to noncompliance, is extremely low. Obviously, this is due to the fact that the large irradiated volume is treated by a slightly accelerated fractionation schedule and only taken to a dose of 46/2 Gy. Moreover, the implant is done after 1–2 weeks at the time when the side effects, experienced from the external beam irradiation (IMRT) part of the treatment, are already partly subdued. The acute side effects typically seen in IBT patients are mucositis grade 3 (–4), maximally at the site of implant during the time of irradiation, and xerostomia; soft tissue necrosis (“ulceration,” grades 3 and 4) and pain, leading to swallowing problems, are typically in case of IBT experienced maximally between 3 and 6 months posttreatment. Most frequently, there is a good healing tendency, with spontaneous healing. If soft tissue necrosis and/or pain are persistent, patients are subjected to a course of hyperbaric oxygen (6 weeks; 30 sessions) with often good results [40].

Table 42.4 Late complications after oropharyngeal cancer radiation treatment, BT, and boost

N	First author	Site	Incidence	%	
104	Levendag [16]	All	Late effect: mucosa	41/104	39
			Late effect: salivary glands	6/104	6
			Late effect: dysphagia	21/104	20
			Late effect: pain	21/104	20
			Late effect: trismus	1/104	1
68	Harrison [13]	BOT	Fatal complications		3
41	Gibbs [77]	BOT	Soft tissue necrosis/ ulceration	3/41	7.3
			Osteoradionecrosis	2/41	4.8
			Gastrostomy	1/41	2.4
			Sarcoma	1/41	2.4

Late Side Effects

From the charts of 336 oropharyngeal cancer patients, we found that patients treated according to our IBT protocol do experience late side effects such as mucositis (32%), xerostomia (15%)¹, dysphagia (31%), pain (22%), and osteoradionecrosis (3%). Table 42.4 [13, 16, 41] summarizes some results published in the literature. Most of these typically radiation-induced late side effects, in particular, the soft tissue necrosis or ulceration, are self-limiting, that is heal spontaneously over a period of few months. As suggested by the literature, several of these late-occurring side effects might not only be dose-related, but also associated with the quality of the implant [42–46]. For that purpose, a number of physical parameters were analyzed in patients with large implants of the BOT; that is, 43 LDR and 32 optimized fr.HDR/PDR volume implants. These 75 patients were considered to be a representative sample taken from the database of the “oropharyngeal cancer patients” (see section on “Acute Side Effects”). The physical parameters, being defined in Table 42.5, were studied in these rather irregular large volume implants. Albeit may be somewhat preliminary, some conclusions can be drawn: (1) It seems relevant to study the maximum and minimum doses in the basal dose points. (2) The UI and QI are strongly correlated. (3) Probably due to the optimization of the 32 fr.HDR/PDR implants, only relatively small differences exist among the UI, QI, DNR, and the SD of the basal dose of the LDR – as opposed to the same parameters of the fr.HDR/PDR BOT implants. Most striking, no correlation was observed between the responses to the QoL questionnaires and any of the physical parameters (see section on “Quality of Life”). In conclusion, quality indices are not very useful in daily practice

¹Unfortunately, not systemically scored/reported in charts.

Table 42.5 Physical parameters studied in 32 LDR and 43 fr.HDR/PDR volume implants in a sample of patients with cancer in the oropharynx

Parameter	Definition
Dbase85	85% of the average dose in all basal dose points [44]
Db_min	Lowest dose in any of the basal dose points
Db_max	Highest dose in any of the basal dose points
Sd_dbas	Standard deviation in the doses of overall basal dose points; a measure of the (in)homogeneity of the dose of overall basal dose points (and thus the implant)
Vdis 100	Total volume (distributed, so not necessarily contiguous) receiving at least the prescribed dose; also called treated volume according to ICRU 58 [44]
Vdis 150	Total volume (distributed, so not necessarily contiguous) receiving at least 150% of the prescribed dose. The ratio Vdis150/Vdis100 is a measure of the dose inhomogeneity (=DNR) [44]
UI	Uniformity index derived from natural DVH (according to Anderson [42]); a measure of the dose homogeneity taking into account the choice of reference isodose in relation to the relatively homogeneously irradiated volume
QI	Quality index derived from natural DVH (according to Anderson [42] and modified by R. van der Laarse); a measure of the dose homogeneity only, without taking into account the choice of the reference isodose in relation to the relatively homogeneously irradiated volume [40]

DNR dose nonuniformity ratio, *DVH* dose-volume histogram, *ICRU* International Commission on Radiation Units and Measurements, *QI* quality index

Quality of Life

Harrison et al. [47] published one of the first reports on QoL for IBT treatment of the BOT. It was stated that “most patients achieved excellent functional status and QoL.” Moreover, patients in general had no problem with maintaining their employment status after primary radiation (fr.HDR boost) for advanced BOT cancer. According to Babin et al. [48], the “sociability” of individual patients has never been evaluated properly. He advocates studying QoL with emphasis in three domains: physical, psychological, and social symptom domains.

On the other hand, Pourel et al. [49] stated that although health-related QoL is significantly impaired in long-term survivors, the focus on treatment option comparisons should still be “survival” as being the most relevant endpoint. Pourel et al. found that no patient-, disease-, or treatment-related factors correlating with the swallowing scale and dry mouth items of the European Organization for Research and Treatment of Cancer EORTC – H&N35 questionnaire. Hammerlid et al. [50] reported on a prospective QoL study using the EORTC QLQ-C30 and EORTC H&N35 questionnaires for patients with oral and pharyngeal carcinoma treated with external beam irradiation with or without BT. Most symptoms were at

their peak 2 or 3 months after the start of treatment. Nutrition and pain were found to be the major problems, and, of special interest, as many as 19–40% reported psychiatric distress.

Quality of Life: Dysphagia

Dysphagia-related complaints have been the subject of a number of recent publications [51–58]. Poulsen et al. [56] found that a field length greater than 82 mm for the second phase of irradiation increased the probability of requiring intervention with percutaneous endoscopic gastrostomy or nasogastric tube feeding, that is, 36% (>82 mm) versus 16% (<82 mm). Manger et al. [55] showed that prophylactic enteral feeding during RT minimizes average weight loss compared with reactive feeding. Caudell et al. [51] found a prevalence of 38% for dysphagia; by univariate analysis, the primary site, concurrent chemotherapy, RT schedule, and increasing age were significantly associated with the development of long-term dysphagia. The use of concurrent chemotherapy, the primary site, and increasing age remained significant factors on multivariate analysis. The authors concluded that adding concurrent chemotherapy to RT for locally advanced head and neck cancer resulted in increased and long-time present dysphagia. Feng et al. [53], Jensen et al. [54], Teguh et al. [57, 58], and Levendag et al. [2], all were able to demonstrate the presence of significant relationships between the dose-volume parameters of structures and objective and subjective measurements of swallowing function and/or aspiration.

Between 1991 and 2005, 458 oropharyngeal cancer patients were treated in a single institution (Erasmus MC, Rotterdam) by RT (boost), 336 were available for analysis of side effects. Chart review revealed 31% (103 of 336) of patients with “severe” dysphagia (Research Therapy Oncology Group grade III and IV). Out of the 336 patients, 188 were treated with IBT as a boost. All patients are alive and at least 1 year NED received three types of questionnaires: (1) the EORTC QLQ-C30 and EORTC QLQ-H&N35, which include a swallowing scale with four items (problems with swallowing liquid, pureed food, or solid food, and aspiration when swallowing) [59]; (2) the Performance Status Scale of List et al. [60], which includes a Normalcy of Diet item; and (3) the M.D. Anderson Dysphagia Inventory [61], which consists of 20 questions with global, emotional, functional, and physical subscales. By the censor date (January 1, 2006), 155 patients had responded to the QoL questionnaires. Of these 155 patients, 91 were male and 64 were female, and the mean age was 56 years (range: 35–78 years). Primary treatment sites were TF/SP ($n=108$) and BOT ($n=47$). Seventy-seven percent (119 of 155) had stage III or IV disease. Of the 155 patients, 107 received a BT boost (TF/SP:

83; BOT: 24) and 48 received a boost by non-BT techniques (TF/SP: 25; BOT: 23) and 59 of 155 (38%) received chemotherapy in a concomitant fashion. We focused the data analysis in this review on the late side effects: “swallowing problems” and “xerostomia.”

Percentages of severe QoL scores for swallowing and dry mouth were lower for IBT patients than for non-BT patients (14–25% vs. 32–46% for H&N35 [swallowing] and 52% vs. 67% for H&N35 [xerostomia]); the outcome of the other questionnaires on “swallowing problems” (i.e., MDADI, List) are consistent for EORTC H&N 35 QoL questionnaires. For more detailed analyses, see also Tables 42.6 and 42.7. From the univariate analysis, one can conclude that the following factors are significant for swallowing-related problems: IBT, T stage, boost treatment, neck surgery, and neck irradiation.

In the multivariate analysis, IBT and the dose in the superior constrictor muscle remained the only two significant variables. Finally, xerostomia and dysphagia are strongly correlated ($P < 0.001$), as well as the mean dose in the superior and middle constrictor muscle with the dry mouth syndrome [58].

A steep dose–effect relationship was established (Fig. 42.11) [62]; for the way, the calculation was performed in order to arrive at this D–E curve, the reader is referred to previous publications by Levendag [2] and Teguh [58]. A 20% increase in complaints per 10 Gy was found after

60 Gy in the superior constrictor muscle. The tolerance of the swallowing muscles depends to some extent on the treatment modality used. In patients who receive BT as boost therapy, dysphagia is seen in 14% treated with an average dose of 53 Gy. In contrast, dysphagia was seen in 40% of patients treated with EBRT to a mean dose of 68 Gy (see Fig. 42.11). We speculate that the increase in dysphagia is related to the increase in irradiated volume and radiation dose. Apparently, the IBT side effects are not totally negligible; this could be due the high cumulative dose of radiation, that is the dose of IBT plus the dose of the first series of EBRT (IMRT) (46/2 Gy) being delivered to (a part of) the swallowing muscle and/or the combination with chemotherapy. However, from our data, it seems that patients treated with an IBT boost still have a better swallowing-related QoL than those receiving IMRT only. This is probably because of the steep dose fall-off in case of IBT in part of the swallowing-related structure(s). It would be of interest to do the same type of analysis in the future in a more precise way; that is, instead of roughly summing physical “numbers of Grays,” it would be more appropriate to add real dose distributions in the total volume of interest (biological treatment planning). Because of the work on this issue at our department by Vásquez Osorio [63], it will now possible to do so in clinic. We expect this type of dose summing in combination with a process called auto-contouring [64], will further increase the accuracy of the treatment-planning process, and thereby hopefully allows for a further improvement of the QoL of our patients.

Table 42.6 Quality of life and dysphagia (mean) scores compared by technique and boost type

QoL responses (mean scores)	C30 (QoL) ^a	H&N35 (swallowing) ^b
Brachytherapy (<i>n</i> = 111) boost		
IMRT/3DCRT (<i>n</i> = 52) first series	75	14
Par-Opp (<i>n</i> = 59) first series	72	25
Cyberknife (<i>n</i> = 12) boost		
IMRT/3DCRT (<i>n</i> = 12) first series	73	15
Non-RT (<i>n</i> = 49) boost		
IMRT/3DCRT (<i>n</i> = 23) first series	71	32
Par-Opp (<i>n</i> = 26) first series	60	46

^aFunction scale: high score = good functions

^bProblem scale: high score = severe problems

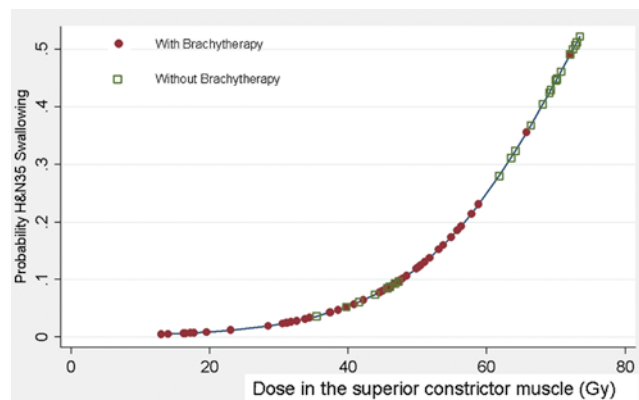


Fig. 42.11 Dose–effect relationship swallowing problems measured by the scores obtained through responses to QoL questionnaires and the dose received by the swallowing muscles (as an example, this dataset is relevant for the superior constrictor muscle)

Table 42.7 Quality of life and dysphagia (mean) scores compared by technique and boost type

Selected groups	C30 (H&N35)	H&N35 (swallowing)	MDADI (physical)	MDADI (functional)	MDADI (emotional)
All patients, CBK excl. (<i>n</i> = 160)					
BT (<i>n</i> = 111)	74	20	68	78	77
Vs. non-BT (<i>n</i> = 49)	66	40	50	60	60
<i>P</i> -values	n.s.	<0.001	<0.001	<0.001	<0.001

Conclusion

In conclusion, for oropharyngeal cancer boosted by IBT, at 10 years an excellent local control rate of 90% was observed. However lack of training, experience, small volume disease, invasiveness, and logistics (operating room) can all be, albeit rarely, conditionally limiting. (Late) Side effects (e.g., soft tissue necrosis) are not totally negligible, but if present, are in the great majority of cases spontaneously healing. When comparing IBT to other forms of conformal radiation, such as stereotactic radiation therapy, Cyberknife, and IMRT, the QoL, in particular, regarding the clinically significant problem of dysphagia, speaks in favor of IBT.

References

- Overgaard J. Chemoradiotherapy of head and neck cancer – can the bumble bee fly? *Radiother Oncol.* 2009;92:1–3.
- Levendag PC, Teguh DN, Voet P, Van der Est H, Noever I, de Kruijf WJ, et al. Dysphagia disorders in patients with cancer of the oropharynx are significantly affected by the radiation therapy dose to the superior and middle constrictor muscle: a dose-effect relationship. *Radiother Oncol.* 2007;85:64–73.
- Bourhis J, Overgaard J, Audry H, Ang KK, Saunders M, Bernier J, et al. Hyperfractionated or accelerated radiotherapy in head and neck cancer: a meta-analysis. *Lancet.* 2006;368:843–54.
- Grimard L, Esche B, Lamothe A, Spaans JN. Interstitial brachytherapy in the management of persistent head and neck disease after definitive external beam radiation therapy. *Brachytherapy.* 2009;8:284–9.
- Glatzel M, Buntzel J, Schroder D, Kuttner K, Frohlich D. High-dose-rate brachytherapy in the treatment of recurrent and residual head and neck cancer. *Laryngoscope.* 2002;112:1366–71.
- Grimard L, Esche B, Lamothe A, Cygler J, Spaans J. Interstitial low-dose-rate brachytherapy in the treatment of recurrent head and neck malignancies. *Head Neck.* 2006;28:888–95.
- Narayana A, Cohen GN, Zaider M, Chan K, Lee N, Wong RJ, et al. High-dose-rate interstitial brachytherapy in recurrent and previously irradiated head and neck cancers – preliminary results. *Brachytherapy.* 2007;6:157–63.
- Crook J, Mazon JJ, Marinello G. Combined external and interstitial implantation for T1 and T2 epidermoid carcinoma of base of tongue: the Creteil experience. *Int J Radiat Oncol Biol Phys.* 1988;15:105–14.
- Esche BA, Haie CM, Gerbaulet AP, Eschwege F, Richard JM, Chassagne D. Interstitial and external radiotherapy in carcinoma of the soft palate and uvula. *Int J Radiat Oncol Biol Phys.* 1988;15:619–25.
- Foot RL, Parsons JT, Mendenhall WM, Million RR, Cassisi NJ, Stringer SP. Is interstitial implantation essential for successful radiotherapeutic treatment of base of tongue carcinoma? *Int J Radiat Oncol Biol Phys.* 1990;18:1293–8.
- Gerbaulet A, Poetter R, Mazon JJ. The GEC ESTRO handbook of brachytherapy. Brussels, Belgium: ESTRO; 2002. ISBN 90-804532-6.
- Goffinet DR, Fee Jr WE, Wells J, Austin-Seymour M, Clarke D, Mariscal JM, et al. 192Ir pharyngoepiglottic fold interstitial implants. The key to successful treatment of base tongue carcinoma by radiation therapy. *Cancer.* 1985;55:941–8.
- Harrison LB, Lee HJ, Pfister DG, Kraus DH, White C, Raben A, et al. Long term results of primary radiotherapy with/without neck dissection for squamous cell cancer of the base of tongue. *Head Neck.* 1998;20:668–73.
- Horwitz EM, Frazier AJ, Martinez AA, Keidan RD, Clarke DH, Lacerna MD, et al. Excellent functional outcome in patients with squamous cell carcinoma of the base of tongue treated with external irradiation and interstitial iodine 125 boost. *Cancer.* 1996;78:948–57.
- Housset M, Baillet F, Dessard-Diana B, Martin D, Miglianico L. A retrospective study of three treatment techniques for T1-T2 base of tongue lesions: surgery plus postoperative radiation, external radiation plus interstitial implantation and external radiation alone. *Int J Radiat Oncol Biol Phys.* 1987;13:511–6.
- Levendag P, Nijdam W, Noever I, Schmitz P, van de Pol M, Sipkema D, et al. Brachytherapy versus surgery in carcinoma of tonsillar fossa and/or soft palate: late adverse sequelae and performance status: can we be more selective and obtain better tissue sparing? *Int J Radiat Oncol Biol Phys.* 2004;59:713–24.
- Levendag PC, Schmitz PI, Jansen PP, Senan S, Eijkenboom WM, Sipkema D, et al. Fractionated high-dose-rate and pulsed-dose-rate brachytherapy: first clinical experience in squamous cell carcinoma of the tonsillar fossa and soft palate. *Int J Radiat Oncol Biol Phys.* 1997;38:497–506.
- Mazon JJ, Marinello G, Crook J, Marin L, Mahot P, Raynal M, et al. Definitive radiation treatment for early stage carcinoma of the soft palate and uvula: the indications for iridium 192 implantation. *Int J Radiat Oncol Biol Phys.* 1987;13:1829–37.
- Mazon JJ, Crook JM, Benck V, Marinello G, Martin M, Raynal M, et al. Iridium 192 implantation of T1 and T2 carcinomas of the mobile tongue. *Int J Radiat Oncol Biol Phys.* 1990;19:1369–76.
- Pernot M, Hoffstetter S, Peiffert D, Aletti P, Lapeyre M, Marchal C, et al. Role of interstitial brachytherapy in oral and oropharyngeal carcinoma: reflection of a series of 1344 patients treated at the time of initial presentation. *Otolaryngol Head Neck Surg.* 1996;115:519–26.
- van de Pol M, Levendag PC, de Bree RR, Franssen JH, Smelee LE, Nijdam WM, et al. Radical radiotherapy compared with surgery for advanced squamous cell carcinoma of the base of tongue. *Brachytherapy.* 2004;3:78–86.
- Vikram B, Hilaris BS. A non-looping afterloading technique for interstitial implants of the base of the tongue. *Int J Radiat Oncol Biol Phys.* 1981;7:419–22.
- Vikram B, Strong E, Shah J, Spiro R, Gerold F, Sessions R, et al. A non-looping afterloading technique for base of tongue implants: results in the first 20 patients. *Int J Radiat Oncol Biol Phys.* 1985;11:1853–5.
- Halperin EC, Perez CA, Brady LW. Perez and Brady's principles and practice of radiation oncology. Philadelphia, PA: Lippincott Williams & Wilkins; 2009.
- Pignon JP, Bourhis J, Domenge C, Designe L. Chemotherapy added to locoregional treatment for head and neck squamous-cell carcinoma: three meta-analyses of updated individual data. MACH-NC Collaborative Group. Meta-analysis of chemotherapy on head and neck cancer. *Lancet.* 2000;355:949–55.
- Lefebvre JL, Coche-Dequeant B, Buisset E, Mirabel X, Van JT, Prevost B. Management of early oral cavity cancer. Experience of Centre Oscar Lambret. *Eur J Cancer B Oral Oncol.* 1994;30B:216–20.
- Lee IJ, Koom WS, Lee CG, Kim YB, Yoo SW, Keum KC, et al. Risk factors and dose-effect relationship for mandibular osteoradionecrosis in oral and oropharyngeal cancer patients. *Int J Radiat Oncol Biol Phys.* 2009;75(4):1084–91.
- Greene FL, Page DL, Fleming ID, et al. AJCC cancer staging manual. 6th ed. New York: Springer; 2006.
- Levendag PC, Al-Mamgani A, Teguh DN. Contouring in head & neck cancer. München: Elsevier Professional Education; 2009. p. 17–25.

30. Wendt CD, Peters LJ, Delclos L, Ang KK, Morrison WH, Maor MH, et al. Primary radiotherapy in the treatment of stage I and II oral tongue cancers: importance of the proportion of therapy delivered with interstitial therapy. *Int J Radiat Oncol Biol Phys.* 1990;18:1287–92.
31. Wadsley JC, Patel M, Tomlins CD, Gildersleve JQ. Iridium-192 implantation for T1 and T2a carcinoma of the tongue and floor of mouth: retrospective study of the results of treatment at the Royal Berkshire Hospital. *Br J Radiol.* 2003;76:414–7.
32. Pernot M, Malissard L, Hoffstetter S, Luporsi E, Peiffert D, Aletti P, et al. The study of tumoral, radiobiological, and general health factors that influence results and complications in a series of 448 oral tongue carcinomas treated exclusively by irradiation. *Int J Radiat Oncol Biol Phys.* 1994;29:673–9.
33. Mendenhall WM, Parsons JT, Stringer SP, Cassisi NJ, Million RR. T2 oral tongue carcinoma treated with radiotherapy: analysis of local control and complications. *Radiother Oncol.* 1989;16:275–81.
34. Inoue T, Inoue T, Yoshida K, Yoshioka Y, Shimamoto S, Tanaka E, et al. Phase III trial of high- vs. low-dose-rate interstitial radiotherapy for early mobile tongue cancer. *Int J Radiat Oncol Biol Phys.* 2001;51:171–5.
35. Decroix Y, Ghossein NA. Experience of the Curie Institute in treatment of cancer of the mobile tongue: I. Treatment policies and result. *Cancer.* 1981;47:496–502.
36. Benk V, Mazon JJ, Grimard L, Crook J, Haddad E, Piedbois P, et al. Comparison of curietherapy versus external irradiation combined with curietherapy in stage II squamous cell carcinomas of the mobile tongue. *Radiother Oncol.* 1990;18:339–47.
37. Baillet F, Delouche G, Bachelot F. Epithelioma of the floor of mouth: multicentre retrospective study of 908 cases. *J Eur Radiother.* 1982;3:147–52.
38. Piccirillo JF, Vlahiotis A. Comorbidity in patients with cancer of the head and neck: prevalence and impact on treatment and prognosis. *Curr Oncol Rep.* 2006;8:123–9.
39. Mazon JJ, Crook J, Martin M, Peynegre R, Pierquin B. Iridium 192 implantation of squamous cell carcinomas of the oropharynx. *Am J Otolaryngol.* 1989;10:317–21.
40. Teguh DN, Levendag PC, Noever I, Voet P, Van der Est H, van Rooij P, et al. Early hyperbaric oxygen therapy for reducing radiotherapy side effects: early results of a randomized trial in oropharyngeal and nasopharyngeal cancer. *Int J Radiat Oncol Biol Phys.* 2009;75:711–6.
41. Gibbs IC, Le QT, Shah RD, Terris DJ, Fee WE, Goffinet DR. Long-term outcomes after external beam irradiation and brachytherapy boost for base-of-tongue cancers. *Int J Radiat Oncol Biol Phys.* 2003;57:489–94.
42. Anderson LL. A “natural” volume-dose histogram for brachytherapy. *Med Phys.* 1986;13:898–903.
43. Das RK. ICRU 58 (dose and volume specification for reporting interstitial therapy), by International Commission on Radiation Units and Measurements. *Med Phys.* 1998;25(7):1225–2008.
44. Kolkman-Deurloo IK, Visser AG, Niel CG, Driver N, Levendag PC. Optimization of interstitial volume implants. *Radiother Oncol.* 1994;31:229–39.
45. Saw CB, Suntharalingam N. Quantitative assessment of interstitial implants. *Int J Radiat Oncol Biol Phys.* 1991;20:135–9.
46. Thomadsen BR, Houdek PV, van der Laarse R, Edmunson G, Kolkman-Deurloo IK, Visser AG. Treatment planning and optimization. In: Nag S, editor. *HDR brachytherapy: a textbook.* Armonk, NY: Futura; 1994. p. 79–145.
47. Harrison LB, Zelefsky MJ, Pfister DG, Carper E, Raben A, Kraus DH, et al. Detailed quality of life assessment in patients treated with primary radiotherapy for squamous cell cancer of the base of the tongue. *Head Neck.* 1997;19:169–75.
48. Babin E, Sigston E, Hitier M, Dehesdin D, Marie JP, Choussy O. Quality of life in head and neck cancers patients: predictive factors, functional and psychosocial outcome. *Eur Arch Otorhinolaryngol.* 2008;265:265–70.
49. Pourel N, Peiffert D, Lartigau E, Desandes E, Luporsi E, Conroy T. Quality of life in long-term survivors of oropharynx carcinoma. *Int J Radiat Oncol Biol Phys.* 2002;54:742–51.
50. Hammerlid E, Mercke C, Sullivan M, Westin T. A prospective quality of life study of patients with oral or pharyngeal carcinoma treated with external beam irradiation with or without brachytherapy. *Oral Oncol.* 1997;33:189–96.
51. Caudell JJ, Schaner PE, Meredith RF, Locher JL, Nabell LM, Carroll WR, et al. Factors associated with long-term dysphagia after definitive radiotherapy for locally advanced head-and-neck cancer. *Int J Radiat Oncol Biol Phys.* 2009;73:410–5.
52. Dornfeld K, Simmons JR, Karnell L, Karnell M, Funk G, Yao M, et al. Radiation doses to structures within and adjacent to the larynx are correlated with long-term diet- and speech-related quality of life. *Int J Radiat Oncol Biol Phys.* 2007;68:750–7.
53. Feng FY, Kim HM, Lyden TH, Haxer MJ, Feng M, Worden FP, et al. Intensity-modulated radiotherapy of head and neck cancer aiming to reduce dysphagia: early dose-effect relationships for the swallowing structures. *Int J Radiat Oncol Biol Phys.* 2007;8:1289.
54. Jensen K, Lambertsen K, Grau C. Late swallowing dysfunction and dysphagia after radiotherapy for pharynx cancer: frequency, intensity and correlation with dose and volume parameters. *Radiother Oncol.* 2007;85:74–82.
55. Mangar S, Slevin N, Mais K, Sykes A. Evaluating predictive factors for determining enteral nutrition in patients receiving radical radiotherapy for head and neck cancer: a retrospective review. *Radiother Oncol.* 2006;78:152–8.
56. Poulsen MG, Riddle B, Keller J, Porceddu SV, Tripcony L. Predictors of acute grade 4 swallowing toxicity in patients with stages III and IV squamous carcinoma of the head and neck treated with radiotherapy alone. *Radiother Oncol.* 2008;87:253–9.
57. Teguh DN, Levendag PC, Sewnaik A, Hakkesteeft MM, Noever I, Voet P. Results of fiberoptic endoscopic evaluation of swallowing vs. radiation dose in the swallowing muscles after radiotherapy of cancer in the oropharynx. *Radiother Oncol.* 2008;89:57–63.
58. Teguh DN, Levendag PC, Noever I, van Rooij P, Voet P, Van der Est H. Treatment techniques and site considerations regarding dysphagia-related quality of life in cancer of the oropharynx and nasopharynx. *Int J Radiat Oncol Biol Phys.* 2008;72:1119–27.
59. Bjordal K, de Graeff A, Fayers PM, Hammerlid E, van Pottelsberghe C, Curran D, et al. A 12 country field study of the EORTC QLQ-C30 (version 3.0) and the head and neck cancer specific module (EORTC QLQ-H&N35) in head and neck patients. *EORTC Quality of Life Group.* *Eur J Cancer.* 2000;36:1796–807.
60. List MA, D’Antonio LL, Cella DF, Siston A, Mumby P, Haraf D, et al. The performance status scale for head and neck cancer patients and the functional assessment of cancer therapy head and neck scale – A study of utility and validity. *Cancer.* 1996;77:2294–301.
61. Chen AY, Frankowski R, Bishop-Leone J, Hebert T, Leyk S, Lewin J, et al. The development and validation of a dysphagia-specific quality-of-life questionnaire for patients with head and neck cancer: the M. D. Anderson dysphagia inventory. *Arch Otolaryngol Head Neck Surg.* 2001;127:870–6.
62. Teguh DN, Levendag PC, Kolkman-Deurloo IK, van Rooij P, Schmitz PI. Quality of life of oropharyngeal cancer patients treated with brachytherapy. *Curr Oncol Rep.* 2009;11:143–50.
63. Vasquez Osorio EM, Hoogeman MS, Bondar L, Levendag PC, Heijmen BJ. A novel flexible framework with automatic feature correspondence optimization for nonrigid registration in radiotherapy. *Med Phys.* 2009;36:2848–59.
64. Han X, Hoogeman MS, Levendag PC, Hibbard LS, Teguh DN, Voet P, et al. Atlas-based auto-segmentation of head and neck CT images. *Med Image Comput Assist Interv.* 2008;11:434–41.

65. Barrett WL, Gluckman JL, Wilson KM, Gleich LL. A comparison of treatments of squamous cell carcinoma of the base of tongue: surgical resection combined with external radiation therapy, external radiation therapy alone, and external radiation therapy combined with interstitial radiation. *Brachytherapy*. 2004; 3:240–5.
66. Brunin F, Mosseri V, Jaulerry C, Point D, Cosset JM, Rodriguez J. Cancer of the base of the tongue: past and future. *Head Neck*. 1999;21:751–9.
67. Chu A, Fletcher GH. Incidence and causes of failures to control by irradiation the primary lesions in squamous cell carcinomas of the anterior two-thirds of the tongue and floor of mouth. *Am J Roentgenol Radium Ther Nucl Med*. 1973;117:502–8.
68. Hoffstetter S, Malissard L, Pernot M, Luporsi E, Peiffert D, Lapeyre M. Retrospective study of 136 cases of epidermoid carcinoma of the base of the tongue treated at the Alexis Vautrin Centre 1978–1992. *Bull Cancer Radiother*. 1996;83:90–6.
69. Karakoyun-Celik O, Norris CM, Jr., Tishler R, et al. Definitive radiotherapy with interstitial implant boost for squamous cell carcinoma of the tongue base. *Head Neck*. 2005;27:353–61.
70. Lusinchi A, Eskandari J, Son Y, et al. External irradiation plus curietherapy boost in 108 base of tongue carcinomas. *Int J Radiat Oncol Biol Phys*. 1989;17:1191–7.
71. Mazon JJ, Belkacemi Y, Simon JM, et al. Place of Iridium 192 implantation in definitive irradiation of faucial arch squamous cell carcinomas. *Int J Radiat Oncol Biol Phys*. 1993;27:251–7.
72. Peiffert D, Pernot M, Malissard L, et al. Salvage irradiation by brachytherapy of velotonsillar squamous cell carcinoma in a previously irradiated field: results in 73 cases. *Int J Radiat Oncol Biol Phys*. 1994;29:681–6.
73. Pernot M, Malissard L, Taghian A, et al. Velotonsillar squamous cell carcinoma: 277 cases treated by combined external irradiation and brachytherapy—results according to extension, localization, and dose rate. *Int J Radiat Oncol Biol Phys*. 1992;23:715–23.
74. Puthawala AA, Syed AM, Eads DL, Neblett D, Gillin L, Gates TC. Limited external irradiation and interstitial 192 iridium implant in the treatment of squamous cell carcinoma of the tonsillar region. *Int J Radiat Oncol Biol Phys*. 1985;11:1595–602.
75. Puthawala AA, Syed AM, Eads DL, Gillin L, Gates TC. Limited external beam and interstitial 192 iridium irradiation in the treatment of carcinoma of the base of the tongue: a ten year experience. *Int J Radiat Oncol Biol Phys*. 1988;14:839–48.
76. Takacs-Nagy Z, Polgar C, Oberna F, et al. Interstitial high-dose-rate brachytherapy in the treatment of base of tongue carcinoma. *Strahlenther Onkol*. 2004;180:768–75.
77. Gibbs IC, Le QT, Shah RD, Terris DJ, Fee WE, and Goffinet DR. Long-term outcomes after external beam irradiation and brachytherapy boost for base-of-tongue cancers. *Int J Radiat Oncol Biol Phys*. 2003;57:489–494.

Chapter 43

Proton Beam Therapy for Head and Neck Cancer

Danielle N. Margalit, Judy A. Adams, and Annie W. Chan

Abstract The goal of multimodality therapy for head and neck cancer is to improve the therapeutic ratio by increasing the tumor control probability and decreasing treatment-related toxicity. Due to the close spatial relationship of head and neck cancers to numerous normal anatomical structures, conventional photon radiation therapy can be associated with significant acute and long-term treatment-related toxicities. Superior dose localization properties of proton radiation therapy allow smaller volumes of normal tissues to be irradiated than is feasible with any photon technique. Initial clinical experience with proton radiation therapy in the treatment of head and neck cancers is promising. Prospective trials are underway to define the role of proton radiation therapy in the treatment of head and neck and skull base tumors.

Keywords Proton beam therapy • Head and neck cancers • Sinonasal malignancy • Paranasal sinus cancer • Nasopharyngeal cancer • Radiation therapy • Bragg peak • Intensity-modulated proton therapy • Intensity-modulated radiation therapy

Introduction

Rationale for Using Proton Beam Therapy for Head and Neck Cancers

The goal of multimodality therapy for head and neck cancer is to improve the therapeutic ratio by increasing the tumor control probability and decreasing treatment-related toxicity. Proton beam therapy is a valuable tool to achieve this goal. A proton beam has similar biological properties to that of photons (X-rays) yet has markedly different physical properties that account for its superior dose distribution. A proton

beam delivers most of its dose at a finite range with no dose beyond the target. In contrast, the dose from a photon beam decreases exponentially with depth in the irradiated tissues. Therefore, proton beam therapy irradiates a smaller volume of normal tissue both proximal and distal to the tumor than is feasible with any photon technique.

Cancers of the head and neck present unique challenges for which the benefits of proton beam therapy can be realized. Due to the anatomical location of head and neck and skull base tumors, multimodality therapy can cause significant treatment-related toxicity such as xerostomia, swallowing dysfunction, hearing loss, vision loss, and encephalopathy. By reducing the volume of normal tissue that is irradiated, proton therapy may reduce acute and late toxicities, and also improve local control by allowing for dose escalation. Initial clinical experiences from single institutions are promising and clinical trials are underway to define the role of proton radiotherapy in the treatment of head and neck cancers.

History of Proton Beam Therapy

The use of protons for medical therapy is not a recent proposal. The first published proposal for proton therapy was Robert Wilson's 1946 article, *Radiological use of fast protons* [1]. In 1954, shortly after construction of the cyclotron at Lawrence Berkeley Laboratory, the University of California at Berkeley began treating cancer patients. In 1974, investigators at the Massachusetts General Hospital (MGH)/Harvard Cyclotron Laboratory pioneered the use of fractionated proton beam therapy. Rather than deliver a single high-dose fraction, they treated patients with sarcomas of the skull base using 2 GyE per fraction to decrease the risk of normal tissue toxicity [2]. In 1990, Loma Linda University opened the first hospital-based proton therapy center with gantry systems. As of October 2010, there were 35 proton beam facilities in operation worldwide [3]. Smaller and less costly proton beam delivery units are currently under investigation and may further expand the clinical application of proton beam therapy.

A.W. Chan (✉)
Department of Radiation Oncology, Harvard Medical School,
55 Fruit St., Boston, MA 02114, USA
e-mail: awchan@partners.org

Physical Aspects of Proton Beam Therapy

Protons were first described by Ernest Rutherford in the early 1900s [4] and have a charge of +1 and a mass that is 1,800 times that of electrons. Equipment is required to accelerate protons because of their mass. The dose profile for a proton beam is markedly different from that of a photon beam, and is the key physical property that accounts for the superior dose distribution achieved with proton therapy. As the proton particles enter tissue, they slow down and deposit most of their energy just before stopping. This region of maximum dose deposition at the end of the proton range is called the Bragg Peak, named after William Henry Bragg who described the phenomenon for α (alpha) particles in 1903. The location of the Bragg Peak is a function of the proton energy and the electron density of the material through which it passes. By modulating the energy of the proton beam and density through which it passes, the precise location of maximum dose deposition (the Bragg Peak) can be specified within the tumor. There is no significant radiation dose beyond the Bragg Peak [5, 6]. In contrast, the dose from a photon beam decreases exponentially with depth in the irradiated tissues. The physical properties of the proton beam result in less irradiation of normal tissue both proximal and distal to the target compared with photon therapy (Fig. 43.1).

There are two general methods for delivering proton radiotherapy, passive scattering, and pencil beam scanning. Most patients have been treated with passively scattered systems. With this technique, a fixed monoenergetic beam is broadened and shaped by a system of scatterers and degraders that determine the desired range of the beam and the area required to cover the target. In order to cover the entire target volume, the depth of the monoenergetic beam is modulated by rotating wheels of different thickness in the beam line. The Bragg Peak is pulled closer to the source by the water equivalent thickness of the plastic wheel. This creates a

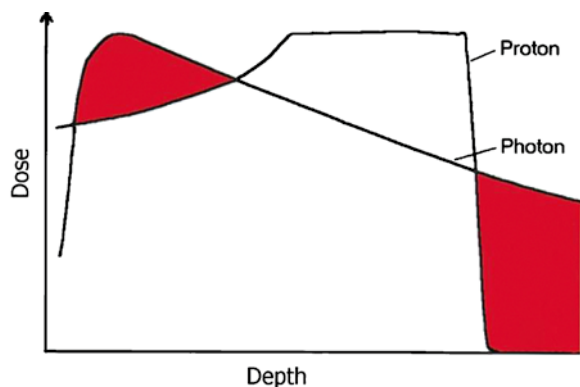


Fig. 43.1 This illustrates the central axis depth dose of a high-energy photon beam and a modulated proton energy beam. The red emphasizes the regions to which the photon beams delivers a higher dose than does the proton beam

“spread-out” Bragg Peak that covers the target volume. Patient-specific hardware must be made for each patient to define the lateral edges of the target and shape the distal edge of the spread-out Bragg Peak (SOBP).

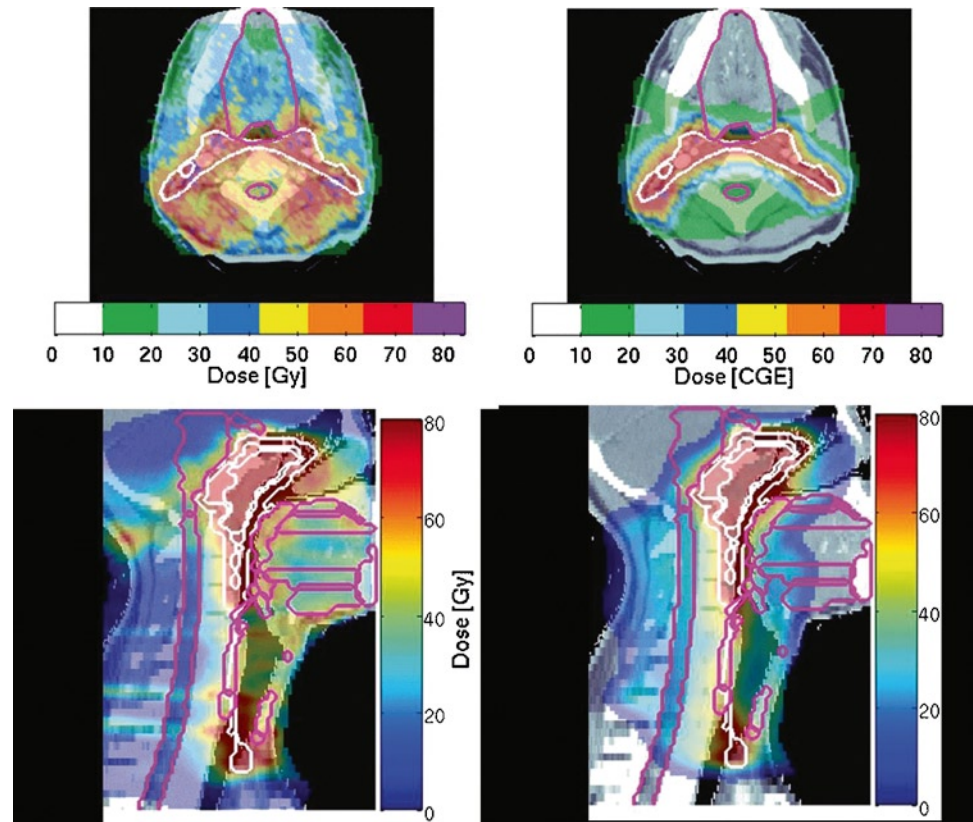
In pencil beam scanning, magnets are used to steer the positively charged proton beam. Pencil beam scanning was first described by Kanai et al. of Chiba, Japan [7] and was developed for medical use at the Paul Scherer Institute (PSI) in Switzerland. The technology required for beam scanning is more sophisticated and more sensitive to tissue inhomogeneity and organ motion [8, 9] than passive scattering systems. Yet, there are several advantages compared with passively scattered delivery. For pencil beam scanning, there is no patient-specific hardware needed to shape the beam which also results in less neutron contamination to the patient. Intensity-modulated proton therapy (IMPT) is enabled with beam scanning technology, and a steeper lateral dose gradient can be achieved. Despite the advantages of active pencil beam scanning compared with passive scattering systems, most facilities in existence and in construction use passive scattering systems.

The planning and delivery of proton radiotherapy is currently more complex than that of photon radiotherapy. The estimated tissue density from the planning CT-scan must be converted to proton stopping power to determine the range of the beam and the required compensator thickness to ensure that the beam covers the target without overshooting or undershooting. Protons are more sensitive to slight changes in tissue inhomogeneity than photons [10–12]. Therefore, daily error in patient set-up and immobilization are less tolerated in proton radiotherapy. Accurate delineation of the target volume is absolutely essential to avoid marginal misses, and appropriate margins must be placed on the target to ensure adequate target coverage. Proton beam delivery requires a high degree of specialized training and quality control for those facilities that deliver proton radiotherapy.

Intensity-Modulated Radiation Therapy Versus Intensity-Modulated Proton Therapy

Intensity-modulated radiation therapy (IMRT) is a technique in which the intensity of the photon (X-ray) radiation varies throughout the treatment field. Compared with traditional external beam therapy, IMRT can create a sharp dose gradient between the target and surrounding nontarget tissue. IMRT is increasingly used for the treatment of head and neck cancers in effort to decrease morbidity and improve tumor control. With IMRT, the dose is frequently spread among many beams that enter the patient from different angles. This results in a “dose bath” in which normal tissue receives a low-to-medium dose of unnecessary irradiation, which may result in unwanted acute and late side effects.

Fig. 43.2 Comparison of an intensity-modulated radiation therapy plan (IMRT, *left*) versus an intensity-modulated proton therapy plan (IMPT, *right*) in the treatment of locally advanced nasopharyngeal carcinoma. Note the significant sparing of the oral cavity and brain with IMPT



The intensity of the proton radiation can also be modulated to produce IMPT. This is achieved by a pencil beam scanning technique in which a small circular beam is scanned across the defined treatment field with the energy and intensity varying so that the dose in each voxel can be optimized. IMRT only achieves two-dimensional optimization with modulation of the fluence in the plane orthogonal to the beam direction. IMPT is a three-dimensional optimization technique [13] that allows modulation of the fluence and the position of the Bragg Peak. In a dosimetric comparison study, IMPT provided greater sparing of normal organs-at-risk compared with IMRT while preserving the dose homogeneity of the target [14].

Figure 43.2 demonstrates an optimized plan using IMRT and IMPT for the treatment of a patient with locally advanced nasopharyngeal carcinoma. With IMRT, the nontarget structures such as the oral cavity, optic nerves, optic chiasm, orbits, and the brain receive unnecessary low and moderate doses of radiation. This large “dose bath” created by IMRT is absent with the use of IMPT.

Radiobiology of Proton Beam Therapy

Even though the physical properties of protons differ substantially from photons, the biologic properties of

therapeutic protons are similar to that of photons. The density of ionizations produced by therapeutic radiation as it traverses the tissue is quantified by the linear energy transfer (LET) value. The LET is a calculation of the energy transferred by the radiation along a unit length within the biologic material and is related to the biologic effectiveness of the radiation. The LET value for therapeutic proton-beam ranges from 0.2 to 2.0 keV/ μM , much lower than carbon or neutron particles which are high-LET radiations.

The International Commission on Radiation Units and Measurements (ICRU) and the International Atomic Energy Agency (IAEA) established the unit of proton dose as “Gy (RBE)” [15]. Protons have a relative biologic effectiveness (RBE) comparable to that of 250 kV X-rays [16], and a generic RBE value of 1.1 [14]. That is, the ratio of the dose of ^{60}Co γ (gamma)-rays relative to that of protons required to produce a defined biologic response is 1.1. The RBE may vary depending on the dose and fractionation, proton energy utilized, and specific tissue irradiated, yet current evidence supports the use of an RBE of 1.1 in dose calculation for treatment planning [17]. There is an increase in RBE over the terminal few millimeters of the SOBP. The RBE at the terminal SOBP is estimated to be a maximum of 100 keV/ μm over a few microns as the particles come to rest [17, 18]. For high-energy protons, this region is so tiny that it is not thought to have any clinical consequence [16]. Therefore, dose adjustments based on variations in RBE in the SOBP are not made.

Due to physical and biologic uncertainties at the end of range, the proton beam is not aimed directly at a critical structure when it is located in close proximity to the distal edge of the target. Protons and photons have similar biologic effects; it is the difference in physical characteristics that account for the superiority of dose distributions with protons.

Clinical Experience

Proton Beam Therapy for Sinonasal Malignancies

For most sinonasal malignancies, a combination of radical surgery and postoperative radiation constitutes standard treatment. Despite aggressive therapy, the outcome is poor, with most institutions reporting a 5-year overall survival rate of less than 50% [19–25]. In advanced tumors that involve the skull base, survival is further reduced. Treatment failure at the primary site is the main pattern of failure for these tumors, ranging from 30 to 100% [26–29], and local failure is the primary cause of death. Alternative treatment strategies are clearly needed for sinonasal malignancies with skull base involvement.

Higher radiation doses are associated with improved local control [29, 30]. Yet dose escalation is limited because of the adjacent normal tissues of the skull base and optic apparatus. Radiation-induced late ocular and visual toxicity is common. At the University of Florida, 27% of patients developed unilateral blindness secondary to radiation retinopathy or optic neuropathy, and 5% developed bilateral blindness due to optic neuropathy [22]. Takeda et al. reported a similar incidence of radiation retinopathy in patients with malignancies of the nasal cavity and paranasal sinuses without tumor invasion of the eyes [31]. Waldron et al. reported visual outcomes in patients with ethmoid sinus cancer treated with primary radiation therapy. At a median follow-up of 4 years, 41% of patients developed unilateral or bilateral blindness and 24% developed visual impairment [32]. Other radiation-induced ocular/visual toxicities such as neovascular glaucoma, cataract, and dry-eye syndrome are also common after treatment with conventional radiation therapy in sinonasal malignancies [31, 33]. The rates of visual toxicity have declined over time with increased use of three-dimensional conformal radiation therapy and IMRT. But these new technologies have not resulted in gains in local control or survival [20, 23, 34].

At MGH, 99 patients with advanced sinonasal cancers received proton therapy between 1991 and 2002. There were 32 squamous cell carcinomas, 30 carcinomas with neuroendocrine differentiation, 20 adenoid cystic carcinomas,

11 soft-tissue sarcomas, and 6 adenocarcinomas. The median dose was 70.2 GyE and 21% of patients underwent complete resection before proton radiation therapy. With a median follow-up of 5.9 years, the 5-year actuarial local control was 87% [35, 36]. The improvement in local control also shifted the pattern of failure from local to distant. These results compare very favorably to that achieved by IMRT or three-dimensional conformal radiation therapy [20, 23, 34].

Management of locally advanced adenoid cystic carcinoma with combined modality therapy remains a challenge. For patients with inoperable tumors or gross residual disease, the local control rate ranges from 0 to 43% [26, 27, 29]. Neutron radiation therapy, though an accepted treatment option for adenoid cystic carcinoma, results in a locoregional control rate of 23% for patients with the base of skull involvement [37]. Pommier et al. [36] reported the results of 23 patients with adenoid cystic carcinoma involving the base of skull treated with combined proton and photon radiotherapy at MGH from 1991 to 2003. Only 3 patients had a gross total resection; 11 patients (48%) received a biopsy alone, and 9 (39%) had a partial resection. With a median dose of 76 GyE, the 5-year locoregional control rate was 93%. High-dose conformal proton beam radiation therapy results in encouraging local control in advanced adenoid cystic carcinoma with skull base involvement.

Treatment of sphenoid sinus cancer is technically challenging for both the radiation oncologist and surgeon because of the close proximity and relative radiosensitivity of adjacent critical structures including the orbit, cavernous sinus, and central nervous system. Investigators at MGH performed a retrospective analysis of oncologic and toxicity outcomes of locally advanced primary sphenoid sinus carcinoma treated with proton radiation therapy [38]. From 1991 to 2005, 20 patients received a median dose of 76 GyE. With a median follow-up of 27 months, the 2-year local control and regional control rates were each 86%, and the freedom from distant metastasis rate was 50%. None of the patients developed grade 3 or higher late ocular or visual toxicity after radiation. These data demonstrated that proton beam therapy can achieve local control and toxicity rates that compare favorably with previously published studies [22, 25].

The MGH also reported the long-term ocular and visual toxicity in a group of patients with advanced sinonasal cancers treated with accelerated hyperfractionated proton radiation therapy [39]. The median dose to the gross tumor target was 70 GyE. All patients had a baseline ophthalmology examination and every 6 months thereafter. At a median follow-up of 52 months, there were only two cases of LENT/CTC grade 3 toxicity. There was no vascular glaucoma, retinal detachment, or optic neuropathy. Proton beam therapy allowed the delivery of tumoricidal doses with minimal ocular/visual complications compared to historical series.

Proton Beam Therapy for Nasopharyngeal Carcinoma

Concurrent chemoradiation became the standard of care for patients with advanced nasopharyngeal carcinoma since the publication of the landmark Intergroup 0099 study [40]. The optimal radiation technique used alone or in combination with chemotherapy, however, still needs to be defined. The therapeutic margin for nasopharyngeal carcinoma is narrow due to the proximity of critical structures. Conformal radiation therapy is associated with ototoxicity, xerostomia, dysphagia, cranial neuropathies, temporal lobe necrosis, endocrinopathy, soft-tissue necrosis, and vision loss [41]. Despite improvements in survival and local control, multimodality therapy with the addition of chemotherapy is associated with increased late toxicity [41, 42]. Two randomized control trials compared parotid-sparing IMRT with two-dimensional radiation therapy in patients with early stage (T1-2b, N0-1) nasopharyngeal carcinoma [43, 44]. Both studies demonstrated significantly better objective measurements of salivary flow at 1 year after IMRT as determined by the stimulated parotid flow rate and stimulated whole saliva flow rate. One of the studies also showed a significant difference in subjective xerostomia-related symptoms at 1 year [44].

IMRT achieves increased tumor conformality and parotid-sparing compared with conventional radiation techniques by increasing the amount of dose delivered to the oral cavity and other structures. Figure 43.2 compares the dose distribution between IMRT and IMPT in a patient with nasopharyngeal carcinoma. The medium- and low-dose irradiation of the oral cavity that is routinely seen with the use of IMRT is absent in the IMPT plan, thus sparing the sublingual and minor salivary glands of the oral mucosa in addition to the parotid glands.

Prospective studies are needed to determine if health-related quality of life improves by reducing the amount of normal tissue receiving radiation. A phase II study is currently enrolling at the Francis Burr Proton Therapy Center at MGH investigating the use of three-dimensional (3D) proton beam therapy for the treatment of nasopharyngeal carcinoma. In addition to the assessment of recurrence and survival endpoints, the primary study aims to determine the health-related quality of life using both objective measurements and validated quality-of-life instruments.

Proton Beam Therapy for Oropharyngeal Carcinoma

Gains in tumor control for oropharyngeal carcinoma occurred with the addition of concurrent chemotherapy to

radiation therapy and with altered fractionation [45–48]. However, treatment intensification is also associated with increased rates of acute and long-term toxicity. Technological advances in radiation therapy including IMRT and proton therapy may be harnessed to decrease toxicity by increasing conformality of radiation and minimizing dose to normal structures, including the spinal cord, salivary glands, mandible, and pharyngeal muscles. The results of IMRT from single institutional series report local control rates and toxicity rates that compare favorably to historical rates using conventional external beam radiation [49–51]. The Radiation Therapy Oncology Group (RTOG) conducted the first multi-institutional prospective phase II study to assess the feasibility of using IMRT with standardized dose and target delineation procedures in patients with early stage (T1-2, N0-1) oropharyngeal carcinoma [52]. Sixty-nine patients received moderately accelerated hypofractionated IMRT to dose of 66 Gy in 2.2 Gy/fraction to the primary tumor and involved nodes and 54–50 Gy/fraction to subclinical target volumes. Patients did not receive concurrent chemotherapy. The study included centralized quality control and found a high rate of minor treatment variation (89% of evaluable cases) and an 11% rate of major deviations in target coverage. With a median follow-up time of 2.8 years for surviving patients, the 2-year estimated local-regional failure rate was 9% and xerostomia grade ≥ 2 was 55% at 6 months and decreased to 16% at 24 months. Both local control and salivary toxicity was improved compared with patients from prior RTOG studies.

There are limited published reports describing the use of proton therapy for the treatment of oropharyngeal carcinoma. Investigators at Loma Linda University Medical Center (LLUMC) conducted an accelerated hyperfractionation study for Stages II–IV oropharyngeal carcinoma using a technique similar to the MD Anderson concomitant boost technique [53]. The LLUMC trial differed from the concomitant boost trial in a number of factors including a higher total dose of 75.9 Gy that was delivered in a shorter overall time of 28 treatment days [46]. The majority of dose was delivered using the opposed lateral photon technique and protons were used to deliver the boost dose of 25.5 GyE. The study accrued 29 patients over more than 10 years. All patients completed the prescribed dose without any interruption. With a median follow-up of 28 months, the 2-year locoregional control and disease-free survival rates were 93% and 81%, respectively. The 2-year actuarial incidence of late RTOG Grade 3 toxicity was 16%. This small study was performed over a prolonged period of time without the use of chemotherapy and employed proton radiation therapy for only 35% of the total dose. Further prospective studies of proton beam therapy for oropharyngeal cancer are needed with detailed assessment of toxicity rates in addition to oncologic outcomes.

Proton Beam Therapy and Concerns Regarding Risks of Second Malignancy

Concerns have been raised regarding the risk of second malignancy from neutron contamination during proton delivery [54]. Low doses of neutrons are carcinogenic [55]. Proton collision with a heavy atomic nucleus can cause neutrons to be expelled. During proton radiotherapy, the major source of neutrons comes from proton interactions with the scattering components in the treatment nozzle [56] of which the largest source of neutrons is the final patient-specific brass aperture [57]. Neutrons are also generated internally, within the patient. Measuring neutron dose in tissue is challenging and most methods involve the use of Monte Carlo simulations. In addition, the biological effectiveness for carcinogenesis for low-dose high-energy neutrons is uncertain especially for very low doses such as during fractionated therapy [58]. Since most contamination comes from the treatment nozzle and patient-specific hardware, if inaccurate or outdated delivery parameters are incorporated into the model, neutron contamination can be overestimated by several orders of magnitude [54, 59, 60].

Protons result in a lower integral dose to nontarget tissue compared with intensity-modulated therapy, which may actually result in a reduction in the potential risk of secondary cancer. Miralbell et al. [61] estimated at least a twofold reduction in secondary cancers in pediatric patients treated with protons compared with photons (intensity modulated or passively scattered) due to a reduction in the integral dose to nontarget organs. Jarlskog and Paganetti [62] used a Monte Carlo approach to estimate the risk of second malignancy from neutron dose in patients treated for a brain tumor using passive scattered proton beams. The risk was highest in young patients and was comparable to the risk caused by scattered photon dose with IMRT. A matched retrospective analysis compared second malignancy rates of 503 children treated at the Harvard Cyclotron from 1974 to 2001 with 1,591 matched patients treated with photons identified via the Surveillance, Epidemiology, and End Results (SEER) cancer registry. There were 32 (6.4%) malignancies in the proton group compared with 66 (13.1%) in the photon group. There was a significantly higher risk of second malignancy in patients treated with photons even after adjustment for gender and age at treatment (adjusted HR 3.01, $P < .0001$) [63].

Due to the long latency of second malignancies, long-term follow-up is of utmost importance. The contribution of secondary neutron dose to second malignancy is “a charged issue” [57] and any potential risk of secondary cancer from externally generated neutrons can be lowered with the use of active scanning proton beams.

Prospective Studies on Proton Beam Therapy

There is debate regarding the necessity of randomized control trials to evaluate the efficacy of new technology, and proton beam therapy has received much attention [64–68]. There are no randomized control trials comparing proton and photon radiotherapy. Protons have unique physical characteristics that account for the superior dose distribution compared with photons. Those in favor of requiring randomized control trials state that dosimetric studies may not translate to clinical benefits. Others argue that there can be no benefit to irradiating normal tissue and question the presence of equipoise when considering such randomized control trials [64].

The cost of proton therapy is also a key issue when considering future prospective trials. Some argue that if it were not for the increased cost of proton therapy relative to standard photons and electrons, the necessity for randomized control trials would not be as fervently debated [64]. Others argue that clinical trials are needed to justify the high costs of therapy [69]. A cost analysis performed by Goitein and Jermann [70] estimated the cost of protons to be 2.4-fold greater than for X-ray therapy, largely due to the high initial investment in facility construction. If the operating costs did not need to repay the initial investment, they estimated a reduction in the cost ratio to approximately 1.6. Additional cost-effectiveness analyses are needed that take into account current costs of implementing and operating proton facilities as well as the costs associated with acute and late toxicity that may be spared with the use of protons.

Future Directions

Proton beam therapy results in decreased radiation dose to normal tissue. The potential benefits of proton therapy can be fully exploited with active beam scanning technology which also allows for IMPT, a powerful delivery technique with an improved dose distribution compared to that of IMRT. Proton beam therapy is less tolerant than photon radiotherapy of uncertainty in treatment planning and delivery, requiring a high degree of specialized training and quality control for those facilities that deliver proton radiotherapy. Accurate delineation of the target structures and careful avoidance planning of normal tissue is essential.

Currently, we recommend proton beam therapy for cancers of the head and neck that are in close proximity to critical structures of the central nervous system, spinal cord, optic apparatus, and base of skull, for which photon-based therapy will exceed the dose-limiting constraints of these critical structures. Cancers of the nasopharynx, paranasal sinuses, nasal cavity, and periorbital skin cancers with orbital

invasion are particularly suited to realizing the benefits of proton therapy. Well-designed studies are needed and are currently underway to determine if the well-demonstrated dosimetric benefits translate to decreased acute and long-term toxicity and improved local control in the context of multimodality therapy.

References

- Wilson RR. Radiological use of fast protons. *Radiology*. 1946;47:487–91.
- Suit H et al. Evaluation of the clinical applicability of proton beams in definitive fractionated radiation therapy. *Int J Radiat Oncol Biol Phys*. 1982;8(12):2199–205.
- October 28, 2010; Available from: <http://ptcog.web.psi.ch/ptcentres.html>.
- Rutherford E. Engineering. 1920;CX(2854).
- Suit HD. Protons to replace photons in external beam radiation therapy? *Clin Oncol (R Coll Radiol)*. 2003;15(1):S29–31.
- Suit H et al. Proton beams to replace photon beams in radical dose treatments. *Acta Oncol*. 2003;42(8):800–8.
- Kanai T et al. Spot scanning system for proton radiotherapy. *Med Phys*. 1980;7(4):365–9.
- Bortfeld T et al. Effects of intra-fraction motion on IMRT dose delivery: statistical analysis and simulation. *Phys Med Biol*. 2002;47(13):2203–20.
- Lambert J et al. Intrafractional motion during proton beam scanning. *Phys Med Biol*. 2005;50(20):4853–62.
- Goitein M. Magical protons? *Int J Radiat Oncol Biol Phys*. 2008;70(3):654–6.
- Urie M et al. Degradation of the Bragg peak due to inhomogeneities. *Phys Med Biol*. 1986;31(1):1–15.
- Goitein M. Calculation of the uncertainty in the dose delivered during radiation therapy. *Med Phys*. 1985;12(5):608–12.
- Lomax A. Intensity-modulated proton therapy. In: DeLaney T, Kooy H, editors. *Proton and charged particle radiotherapy*. Philadelphia: Lippincott Williams and Wilkins; 2008. p. 98–107.
- Steneker M, Lomax A, Schneider U. Intensity modulated photon and proton therapy for the treatment of head and neck tumors. *Radiother Oncol*. 2006;80(2):263–7.
- ICRU. Prescribing, recording, and reporting proton-beam therapy (ICRU Report 78). *J ICRU*. 2007;7(2):89–91.
- Hall EJ, Giaccia AJ. *Radiobiology for the radiologist*. 6th ed. Philadelphia: Lippincott Williams & Wilkins; 2006. p. ix, 546.
- Paganetti H et al. Relative biological effectiveness (RBE) values for proton beam therapy. *Int J Radiat Oncol Biol Phys*. 2002;53(2):407–21.
- Gerweck LE, Kozin SV. Relative biological effectiveness of proton beams in clinical therapy. *Radiother Oncol*. 1999;50(2):135–42.
- Blanco AI et al. Carcinoma of paranasal sinuses: long-term outcomes with radiotherapy. *Int J Radiat Oncol Biol Phys*. 2004;59(1):51–8.
- Chen AM et al. Carcinomas of the paranasal sinuses and nasal cavity treated with radiotherapy at a single institution over five decades: are we making improvement? *Int J Radiat Oncol Biol Phys*. 2007;69(1):141–7.
- Jansen EP et al. Does the combination of radiotherapy and debulking surgery favor survival in paranasal sinus carcinoma? *Int J Radiat Oncol Biol Phys*. 2000;48(1):27–35.
- Katz TS et al. Malignant tumors of the nasal cavity and paranasal sinuses. *Head Neck*. 2002;24(9):821–9.
- Daly ME et al. Intensity-modulated radiation therapy for malignancies of the nasal cavity and paranasal sinuses. *Int J Radiat Oncol Biol Phys*. 2007;67(1):151–7.
- Jiang GL et al. Maxillary sinus carcinomas: natural history and results of postoperative radiotherapy. *Radiother Oncol*. 1991;21(3):193–200.
- Dulguerov P et al. Nasal and paranasal sinus carcinoma: are we making progress? A series of 220 patients and a systematic review. *Cancer*. 2001;92(12):3012–29.
- Mendenhall WM et al. Radiotherapy alone or combined with surgery for adenoid cystic carcinoma of the head and neck. *Head Neck*. 2004;26(2):154–62.
- Kim GE et al. Adenoid cystic carcinoma of the maxillary antrum. *Am J Otolaryngol*. 1999;20(2):77–84.
- Lavertu P et al. Squamous cell carcinoma of the paranasal sinuses: the Cleveland Clinic experience 1977–1986. *Laryngoscope*. 1989;99(11):1130–6.
- Vikram B et al. Radiation therapy in adenoid-cystic carcinoma. *Int J Radiat Oncol Biol Phys*. 1984;10(2):221–3.
- Garden AS et al. The influence of positive margins and nerve invasion in adenoid cystic carcinoma of the head and neck treated with surgery and radiation. *Int J Radiat Oncol Biol Phys*. 1995;32(3):619–26.
- Takeda A et al. Late retinal complications of radiation therapy for nasal and paranasal malignancies: relationship between irradiated-dose area and severity. *Int J Radiat Oncol Biol Phys*. 1999;44(3):599–605.
- Waldron JN et al. Ethmoid sinus cancer: twenty-nine cases managed with primary radiation therapy. *Int J Radiat Oncol Biol Phys*. 1998;41(2):361–9.
- Parsons JT et al. Severe dry-eye syndrome following external beam irradiation. *Int J Radiat Oncol Biol Phys*. 1994;30(4):775–80.
- Hoppe BS et al. Treatment of nasal cavity and paranasal sinus cancer with modern radiotherapy techniques in the postoperative setting – the MSKCC experience. *Int J Radiat Oncol Biol Phys*. 2007;67(3):691–702.
- Cianchetti M et al. Long-term Outcome of Proton Beam Therapy for Advanced Sinonasal Malignancies. Chandler, AZ: Multidisciplinary Head and Neck Cancer Symposium Annual Meeting; 2010.
- Pommier P et al. Proton beam radiation therapy for skull base adenoid cystic carcinoma. *Arch Otolaryngol Head Neck Surg*. 2006;132(11):1242–9.
- Douglas JG et al. Treatment of locally advanced adenoid cystic carcinoma of the head and neck with neutron radiotherapy. *Int J Radiat Oncol Biol Phys*. 2000;46(3):551–7.
- Truong MT et al. Proton radiation therapy for primary sphenoid sinus malignancies: treatment outcome and prognostic factors. *Head Neck*. 2009;31(10):1297–308.
- Weber DC et al. Visual outcome of accelerated fractionated radiation for advanced sinonasal malignancies employing photons/protons. *Radiother Oncol*. 2006;81(3):243–9.
- Al-Sarraf M et al. Chemoradiotherapy versus radiotherapy in patients with advanced nasopharyngeal cancer: phase III randomized Intergroup study 0099. *J Clin Oncol*. 1998;16(4):1310–7.
- Lee AW et al. Major late toxicities after conformal radiotherapy for nasopharyngeal carcinoma-patient- and treatment-related risk factors. *Int J Radiat Oncol Biol Phys*. 2009;73(4):1121–8.
- Lee AW et al. Preliminary results of a randomized study on therapeutic gain by concurrent chemotherapy for regionally-advanced nasopharyngeal carcinoma: NPC-9901 Trial by the Hong Kong Nasopharyngeal Cancer Study Group. *J Clin Oncol*. 2005;23(28):6966–75.
- Kam MK et al. Prospective randomized study of intensity-modulated radiotherapy on salivary gland function in early-stage nasopharyngeal carcinoma patients. *J Clin Oncol*. 2007;25(31):4873–9.

44. Pow EH et al. Xerostomia and quality of life after intensity-modulated radiotherapy vs. conventional radiotherapy for early-stage nasopharyngeal carcinoma: initial report on a randomized-controlled clinical trial. *Int J Radiat Oncol Biol Phys.* 2006;66(4):981–91.
45. Denis F et al. Final results of the 94-01 French Head and Neck Oncology and Radiotherapy Group randomized trial comparing radiotherapy alone with concomitant radiochemotherapy in advanced-stage oropharynx carcinoma. *J Clin Oncol.* 2004;22(1):69–76.
46. Fu KK et al. A Radiation Therapy Oncology Group (RTOG) phase III randomized study to compare hyperfractionation and two variants of accelerated fractionation to standard fractionation radiotherapy for head and neck squamous cell carcinomas: first report of RTOG 9003. *Int J Radiat Oncol Biol Phys.* 2000;48(1):7–16.
47. Brizel DM et al. Hyperfractionated irradiation with or without concurrent chemotherapy for locally advanced head and neck cancer. *N Engl J Med.* 1998;338(25):1798–804.
48. Adelstein DJ et al. An intergroup phase III comparison of standard radiation therapy and two schedules of concurrent chemoradiotherapy in patients with unresectable squamous cell head and neck cancer. *J Clin Oncol.* 2003;21(1):92–8.
49. Chao KS et al. Intensity-modulated radiation therapy for oropharyngeal carcinoma: impact of tumor volume. *Int J Radiat Oncol Biol Phys.* 2004;59(1):43–50.
50. Garden AS et al. Disease-control rates following intensity-modulated radiation therapy for small primary oropharyngeal carcinoma. *Int J Radiat Oncol Biol Phys.* 2007;67(2):438–44.
51. Lee NY et al. A comparison of intensity-modulated radiation therapy and concomitant boost radiotherapy in the setting of concurrent chemotherapy for locally advanced oropharyngeal carcinoma. *Int J Radiat Oncol Biol Phys.* 2006;66(4):966–74.
52. Eisbruch A et al. Multi-institutional trial of accelerated hypofractionated intensity-modulated radiation therapy for early-stage oropharyngeal cancer (RTOG 00-22). *Int J Radiat Oncol Biol Phys.* 2010;76:1333–8.
53. Slater JD et al. Proton radiation for treatment of cancer of the oropharynx: early experience at Loma Linda University Medical Center using a concomitant boost technique. *Int J Radiat Oncol Biol Phys.* 2005;62(2):494–500.
54. Hall EJ. Intensity-modulated radiation therapy, protons, and the risk of second cancers. *Int J Radiat Oncol Biol Phys.* 2006;65(1):1–7.
55. National Council on Radiation Protection and Measurements. The relative biological effectiveness of radiations of different quality. NCRP Report 104. Bethesda, MD: NCRP; 1990.
56. Jiang H et al. Simulation of organ-specific patient effective dose due to secondary neutrons in proton radiation treatment. *Phys Med Biol.* 2005;50(18):4337–53.
57. Brenner DJ, Hall EJ. Secondary neutrons in clinical proton radiotherapy: a charged issue. *Radiother Oncol.* 2008;86(2):165–70.
58. Kocher DC, Apostoaiei AI, Hoffman FO. Radiation effectiveness factors for use in calculating probability of causation of radiogenic cancers. *Health Phys.* 2005;89(1):3–32.
59. Paganetti H, Bortfeld T, Delaney TF. Neutron dose in proton radiation therapy: in regard to Eric J. Hall (*Int J Radiat Oncol Biol Phys* 2006;65:1-7). *Int J Radiat Oncol Biol Phys.* 2006;66(5):1594–5. author reply 1595.
60. Gottschalk B. Neutron dose in scattered and scanned proton beams: in regard to Eric J. Hall (*Int J Radiat Oncol Biol Phys* 2006; 65:1-7). *Int J Radiat Oncol Biol Phys.* 2006;66(5):1594. author reply 1595.
61. Miralbell R et al. Potential reduction of the incidence of radiation-induced second cancers by using proton beams in the treatment of pediatric tumors. *Int J Radiat Oncol Biol Phys.* 2002;54(3):824–9.
62. Jarlskog CZ, Paganetti H. Sensitivity of different dose scoring methods on organ-specific neutron dose calculations in proton therapy. *Phys Med Biol.* 2008;53(17):4523–32.
63. Chung CS et al. Comparative analysis of second malignancy risk in patients treated with proton therapy versus conventional photon therapy. *Int J Radiat Oncol Biol Phys.* 2008;72(1):S8.
64. Goitein M, Cox JD. Should randomized clinical trials be required for proton radiotherapy? *J Clin Oncol.* 2008;26(2):175–6.
65. Glatstein E et al. Should randomized clinical trials be required for proton radiotherapy? An alternative view. *J Clin Oncol.* 2008;26(15):2438–9.
66. Bentzen SM. Randomized controlled trials in health technology assessment: overkill or overdue? *Radiother Oncol.* 2008; 86(2):142–7.
67. Suit H et al. Should positive phase III clinical trial data be required before proton beam therapy is more widely adopted? No. *Radiother Oncol.* 2008;86(2):148–53.
68. Tepper JE. Protons and parachutes. *J Clin Oncol.* 2008; 26(15):2436–7.
69. Schulz RJ, Kagan AR. Should proton-beam therapy be widely adopted? *Int J Radiat Oncol Biol Phys.* 2008;72(5):1307–9. discussion 1309–10.
70. Goitein M, Jermann M. The relative costs of proton and X-ray radiation therapy. *Clin Oncol (R Coll Radiol).* 2003;15(1):S37–50.

Chapter 44

Normal Tissue Complications and Protection in Head and Neck Cancer Patients

Andy Trotti, Nikhil Rao, Avraham Eisbruch, and David I. Rosenthal

Abstract It has been long recognized that radiotherapy, surgery, and chemotherapy for head and neck (H&N) cancer cause a wide range of acute and late morbidities. These effects impact general and H&N-specific symptoms, quality of life, and critical functions. The increasing use of altered fractionation and chemoradiation has led to a substantial increase in both acute and late toxicity. Countering this is the growing use of intensity modulated radiation which has lowered dry mouth-related issues, and targeted agents which are associated with less complex/lower burden toxicity profiles. In this chapter, we discuss issues in toxicity measures and reporting methods. We also discuss the management of mucositis, swallowing disorders, and osteonecrosis.

Keywords Toxicity • Morbidity • Complications • Side-effects • Adverse effects • Adverse events • Quality of life • CTCAE

Introduction

It has been long recognized that radiotherapy, surgery, and chemotherapy cause a wide range of acute and late morbidities. These effects impact general and H&N-specific quality of life (QOL) measures and functional outcomes. The increasing use of altered fractionation and chemoradiation has led to a substantial increase in both acute and late toxicity. Due to variations in data collection and reporting methods, it is difficult to quantify the magnitude of these changes, which in turn constrains efforts to reduce morbidity or interpret therapeutic gain. In this chapter, we discuss issues in toxicity measures, reporting methods, and interventions to reduce toxicity. There is no single gold standard for defining or

measuring the adverse effects of cancer treatment. The measures selected must be based on the specific focus of the trial or study objectives [1].

Toxicity, Adverse Events, QOL, and Function

Although often used interchangeably in everyday oncology vernacular, the terms toxicity, morbidity, QOL, and adverse events have specific definitions that arise from their focus or purpose. There is overlap and potentially complex interactions between these terms and concepts. For example, a mild degree of physiologic change or impairment may be noted on expert examination or specific testing (barium swallow), but may or may not create a clinical consequence (e.g., aspiration pneumonia), be perceived by the patient, or rated as problematic by some patients, and not others, thus having lesser impact on measured QOL. Social, environmental, or comorbidity factors as well as compensatory responses may be operative.

Toxicity may be applied broadly to changes in tissue or symptoms *related to cancer treatment*. Also, known as morbidity, these events are the focus of measurement efforts and interventions to reduce incidence or severity. On a practical level, use of the Common Terminology Criteria for Adverse Events (CTCAE) terms is considered “toxicity reporting” or adverse event reporting. In this respect, most, but not all, adverse events are generally viewed as a consequence of cancer treatment.

“Adverse event” is a regulatory term applied to any “unfavorable and unintended sign (including an abnormal laboratory finding), symptom, or disease temporally associated with the use of a medical treatment or procedure that may or may not be considered related to the medical treatment or procedure” [2]. This distinction is important since one may be unable to determine the underlying cause of an event: while most are from cancer therapy, some events are from comorbid illnesses, some are related to the cancer itself, and some are multifactorial in etiology.

A. Trotti (✉)
Radiation Oncology Department, H. Lee Moffitt Cancer Center
& Research Institute, 12902 Magnolia Drive, MCC-RAD ONC,
Tampa, FL 33612, USA
e-mail: andy.trotti@moffitt.org

“Quality of Life” is also used broadly to indicate changes in the state of health as related to the cancer diagnosis or treatment. More specifically, QOL is the patient’s perception of changes in symptoms and health state, and are thus determined by the patient alone, without interpretation or grading by a clinician or observer. More recently these endpoints have been referred to as “patient reported outcomes” or PROs. There is a current effort to develop CTCAE-based PRO tools, essentially converting a patient reported symptom or event into a CTCAE grading scale [1].

Function endpoints for the head and neck (H&N) patient refer to activities, such as speech, eating (oral and swallowing phases), vision, hearing, smell, and taste. This chapter focuses on the most bothersome and long-lasting issues affecting the QOL of H&N patients: eating/swallowing and dry mouth. QOL tools for these issues will be briefly reviewed. Objective testing of swallowing, salivary function, taste and smell are beyond the scope of this chapter.

Acute and Late Effects

Examples of acute adverse event rates from modern trials are listed in Table 44.1, comparing three cycles of concurrent cisplatin (from RTOG 0129 conducted between 2002 and 2005) and from radiation and concurrent cetuximab (conducted between 1999 and 2002) [3, 4]. Both trials utilized 2D radiotherapy. In general, there are significant pitfalls in comparing event rates between two trials. The specific rates of adverse events (or changes in QOL) must be considered in the context of a specific clinical trial and are dependent on the specific tools used, methods, frequency, and general rigor of data collection. However, the toxicity profiles of concurrent cisplatin versus concurrent cetuximab are strikingly different. Notably, cetuximab carries significantly lower acute toxicity than cisplatin: early death (0% vs. 3.3%); auditory (<10% vs. 21%); grades 3–4 febrile neutropenia (0% vs. 10%), pain (28% vs. 53%), and renal (0% vs. 4%). Rates of high-grade mucositis appear similar (33% vs. 26%). However, cetuximab carries high out-of-field dermatologic effects (acneform rash; 87% vs. 2%). The cetuximab trial did not separately score the combined effects of radiation and cetuximab on in-field dermatitis, which is generally more intense due to the presence of both the drug rash and radiation. The Bonner cetuximab trial did not report late effects.

Late effects from RTOG 0129 for three cycles of cisplatin and conventional radiation are shown in Table 44.2. The median follow-up was 4.8 years. For multiple reasons (e.g., competing risk of death, challenges in recognition and grading or late injuries which may be mostly subjective), the rates of late injuries may be considered as somewhat under-reported.

Table 44.1 Acute effects from conventional radiation and concurrent cisplatin versus concurrent cetuximab in 2D era

	RTOG 0129 cisplatin (%)	Bonner trial cetuximab (%)
Early or toxic death	3.3	0
Febrile neutropenia grades 3–4	10.0	0
Auditory grades 1–3	21	<10
Renal grades 3–4	3.6	0
Mucositis grades 3–4	33	26
Other GI/nausea	52	49
Skin grades 3–4 in-field	10	23
Skin out-field (grades 1–4)	2	87
Pain grades 1–3	53	28

Adapted from Refs. [3, 4]

Table 44.2 Late effects from conventional radiation and concurrent cisplatin in 2D era (from RTOG 0129)

Events	70 Gy plus cisplatin x3 (%)
Worst overall grades 1–2	64
Worst overall grades 3–4	21
Feeding tube at 1 year	29
Mucositis grades 3–4	1
Esophagus	4
Skin grades 3–4	1
Osteonecrosis	3
Subcutaneous fibrosis	3
Soft tissue or bone grades 1–3	10

Adapted from Ref. [4]

Predictors of Toxicity and Function

Several factors have been identified that may predict for worse QOL outcomes, including older age, advanced T-stage, and larynx/hypopharynx primary site and neck dissection [5]. Additional factors include the presence of a feeding tube, comorbid disease, tracheotomy, site, and stage. Data correlating QOL with functional outcome and symptom burden or specific CTCAE terms and grades are inconsistent. This may be due to methodological issues, patient adaptation, patient prioritization of symptoms in relation to other dimensions of QOL, or issues in study design.

Adverse Events Reporting

Evolution of Toxicity Reporting

The methods for reporting adverse events (AEs) in oncology have evolved in response to new treatments and the needs of end users [1, 2]. Previous terminology and grading systems include WHO (1979), CTC for chemotherapy (1983), RTOG for radiotherapy acute and late effects (1984), and the

LENT-SOMA late effects system (1995). While some of these systems are still in use, the NCI-CTC system was revised in 2003 (NCI-CTCAE) to provide a comprehensive grading system for all modalities and includes terminology to cover both acute and late effects. The CTCAE system is designed for broad capture of adverse events such as secondary endpoints in clinical trials. While the individual terms and descriptive language has evolved and has been used for many decades, the individual terms and grading parameters have not been validated for reliability or sensitivity, nor were they intended to be used as primary endpoints in clinical trials. Trials with a toxicity focus generally require multiple tools and morbidity endpoints including patient-reported outcome instruments (PROs), objective testing of function to more fully characterize the degree and impact of a given injury.

CTCAE Terminology and Grading System

In late 2009, the fourth revision of CTCAE was released [6]. The main purpose of the revision was to reconcile and map CTCAE terms to the Medical Dictionary for Regulatory Activities (MedDRA) dictionary, the official regulatory terminology standard used across all medical areas. CTCAE v 4.0 includes approximately 800 AE terms. Each AE term is associated with a five-point severity scale using specific language for each grade. The AE terms useful in H&N cancer are dispersed among many organ system categories (i.e., there is no “H&N” section of the CTCAE).

Table 44.3 (CTCAE v 4.0 Terms Relevant to H&N Cancer) provides a compilation of CTCAE 4.0 terms that are most commonly applied in H&N cancer trials. The shaded scales are useful for late effects reporting, but may also be applied as descriptors of earlier effects. As noted in 2003, a time-related designation sharply dividing acute from late effects no longer makes sense in an era of complex and protracted multimodality treatments. However, as a general rule, events developing or present 90 days after completion of cancer therapy (usually from the completion of radiotherapy) are generally considered late effects. The grading terms and descriptors should not be considered modality-specific since many injuries may be caused by more than one modality or are from the interaction of multiple modalities, cancer response, or comorbidities.

Adverse Event Reporting Methods

The analysis and publication of toxicity data from clinical trials is a key component of outcomes reporting. Enormous amounts of adverse event data collected on clinical trials

requires methods to condense this information into a digestible summaries. There are no regulatory or cooperative group standards for such analysis or presentation, resulting in wide variations in reporting, and hampering the comparison of trials outcomes [7]. The most common approach uses a tabular display showing the incidence of various terms commonly known as a “safety” or “toxicity profile” table. One method to summarize such data is the “worst grade summary method” (WGSM) [8]. The WGSM provides an overall incidence rate, summarized by severity grade, consolidating adverse event data among organ and tissue categories. However, patients receiving multimodality therapy often experience multiple coincident (and/or sequential) adverse events during or after the delivery of treatment. Since each patient may contribute only one event to the summary, the more events one tries to summarize using the worst grade method, the more data are excluded, resulting in systematic under-reporting of toxicity. An alternative method for summarizing complex toxicity data has been proposed, but requires further testing and is not considered a routine reporting method at this time [8].

Late Effects Reporting

Accurately recognizing, collecting, and reporting late effects have been a thorny issue haunting radiotherapy studies since late effects were first recognized. Challenges include the need for long-term follow-up, data loss due to competing risks, the need for reliable grading scales, difficulty in the clinical recognition of the features and variations of the injury, the overall small number of recorded events, and need for standardized methods of analysis and presentation.

Two common methods used to summarize late effects reporting have been reviewed [9]. Actuarial estimates using Kaplan–Meier calculations are designed to adjust for incomplete follow-up either because the patient was still alive and without the relevant adverse effect when last seen or because the patient died of cancer or unrelated causes without having expressed the adverse effect. Actuarial rates provide an estimate of the cumulative incidence of late events that become clinically manifest in long-term survivors, and thus may reflect the level of biologic injury. However, it is also informative to estimate prevalence as a function of time, since some late events are resolved by medical intervention or spontaneously improve with time. The latter aspect will become even more important with improved methods to mitigate or manage late injuries. Both actuarial and prevalence estimates are much more relevant than crude incidence rates (responders divided by number of patients), with each providing different information on the occurrence of late toxicity and its time evolution.

Table 44.3 CTCAE v 4.0 terms commonly applicable to H&N trials

Pain (select site) (pain)	Mild pain not interfering with function	Moderate pain; pain or analgesics interfering with function, but not interfering with ADL	Severe pain; pain or analgesics severely interfering with ADL	Disabling
Mucositis oral definition: a disorder characterized by inflammation of the oral mucosal	Asymptomatic or mild symptoms; intervention not indicated	Moderate pain; not interfering with oral intake; modified diet indicated	Severe pain; interfering with oral intake	Life-threatening consequences; urgent intervention indicated
Oral pain definition: a disorder characterized by a sensation of marked discomfort in the mouth, tongue, or lips	Mild pain	Moderate pain; limiting instrumental ADL	Severe pain; limiting self-care ADL	–
Facial pain definition: a disorder characterized by a sensation of marked discomfort in the face	Mild pain	Moderate pain; limiting instrumental ADL	Severe pain; limiting self-care ADL	–
Pain definition: a disorder characterized by the sensation of marked discomfort, distress, or agony	Mild pain	Moderate pain; limiting instrumental ADL	Severe pain; limiting self-care ADL	–
Fatigue definition: a disorder characterized by a state of generalized weakness with a pronounced inability to summon sufficient energy to accomplish daily activities	Fatigue relieved by rest	Fatigue not relieved by rest; limiting instrumental ADL	Fatigue not relieved by rest, limiting self-care ADL	–
Myelitis definition: a disorder characterized by inflammation involving the spinal cord. Symptoms include weakness, paresthesia, sensory loss, marked discomfort, and incontinence	Asymptomatic; mild signs (e.g., Babinski's reflex or Lhermitte's sign)	Moderate weakness or sensory loss; limiting instrumental ADL	Severe weakness or sensory loss; limiting self-care ADL	Life-threatening consequences; urgent intervention indicated
Peripheral motor neuropathy definition: a disorder characterized by inflammation or degeneration of the peripheral motor nerves	Asymptomatic; clinical or diagnostic observations only; intervention not indicated	Moderate symptoms; limiting instrumental ADL	Severe symptoms; limiting self-care ADL; assistive device indicated	Life-threatening consequences; urgent intervention indicated
Peripheral sensory neuropathy definition: a disorder characterized by inflammation or degeneration of the peripheral sensory nerves	Asymptomatic; loss of deep tendon reflexes or paresthesia	Moderate symptoms; limiting instrumental ADL	Severe symptoms; limiting self-care ADL	Life-threatening consequences; urgent intervention indicated
Hearing impaired definition: a disorder characterized by partial or complete loss of the ability to detect or understand sounds resulting from damage to ear structures	Adults enrolled on a monitoring program (a 1, 2, 3, 4, 6, and 8 kHz audiogram): threshold shift of 15–25 dB averaged at 2 contiguous test frequencies in at least one ear or subjective change in the absence of a Grade 1 threshold shift pediatrics (a 1, 2, 3, 4, 6, and 8 kHz audiogram): >20 dB at any frequency tested and does not meet criteria for >Grade 2	Adults enrolled in monitoring program (a 1, 2, 3, 4, 6, and 8 kHz audiogram): threshold shift of >25 dB averaged at 2 contiguous test frequencies in at least one ear Adult not enrolled in monitoring program: hearing loss but hearing aid or intervention not indicated; limiting instrumental ADL Pediatrics (a 1, 2, 3, 4, 6, and 8 kHz audiogram): >20 dB at >4 kHz	Adults enrolled in monitoring program (a 1, 2, 3, 4, 6, and 8 kHz audiogram): threshold shift of >25 dB averaged at 3 contiguous test frequencies in at least one ear; therapeutic intervention indicated Adults not enrolled in monitoring program: hearing loss with hearing aid or intervention indicated; limiting self-care ADL Pediatrics (a 1, 2, 3, 4, 6, and 8 kHz audiogram): hearing loss sufficient to indicate therapeutic intervention, including hearing aids; >20 dB at 3 kHz and above in one ear; additional speech-language related services indicated	Adults: profound bilateral hearing loss (>80 dB at 2 kHz and above); nonserviceable hearing Pediatric: audiologic indication for cochlear implant and additional speech-language related services indicated

Table 44.3 (continued)

Pain (select site) (pain)	Mild pain not interfering with function	Moderate pain; pain or analgesics interfering with ADL	Severe pain; pain or analgesics severely interfering with ADL	Disabling
Dental caries	One or more dental caries, not involving the root	Dental caries involving the root	Dental caries resulting in pulpitis or periapical abscess or resulting in tooth loss	
Periodontal disease	Gingival recession or gingivitis; limited bleeding on probing; mild local bone loss	Moderate gingival recession or gingivitis; multiple sites of bleeding on probing; moderate bone loss	Spontaneous bleeding; severe bone loss with or without tooth loss; osteonecrosis of maxilla or mandible	
Dysgeusia (taste alteration)	Altered taste but no change in diet	Altered taste with change in diet (e.g., oral supplements); noxious or unpleasant taste; loss of taste		
Salivary duct inflammation definition: a disorder characterized by inflammation of the salivary duct. <i>Formerly salivary gland changes/saliva (a common acute effect – thick mucus)</i>	Slightly thickened saliva; slightly altered taste (e.g., metallic)	Thick, ropy, sticky saliva; markedly altered taste; alteration in diet indicated; secretion-induced symptoms; limiting instrumental ADL	Acute salivary gland necrosis; severe secretion-induced symptoms (e.g., thick saliva/oral secretions or gagging); tube feeding or TPN indicated; limiting self-care ADL; disabling	Life-threatening consequences; urgent intervention indicated
Dry mouth	Symptomatic (e.g., dry or thick saliva) without significant dietary alteration; unstimulated saliva flow >0.2 ml/min	Moderate symptoms; oral intake alterations (e.g., copious water, other lubricants, diet limited to purees and/or soft, moist foods); unstimulated saliva 0.1–0.2 ml/min	Inability to adequately aliment orally; tube feeding or TPN indicated; unstimulated saliva <0.1 ml/min	
Dysphagia	Symptomatic, able to eat regular diet	Symptomatic and altered eating/swallowing	Severely altered eating/swallowing; tube feeding or TPN or hospitalization indicated	Life-threatening consequences; urgent intervention indicated
Mucositis laryngeal definition: a disorder characterized by an inflammation involving the mucous membrane of the larynx	Endoscopic findings only; mild discomfort with normal intake	Moderate discomfort; altered oral intake	Severe pain; severely altered eating/swallowing; medical intervention indicated	Life-threatening airway compromise; urgent intervention indicated (e.g., tracheotomy or intubation)
Mucositis oral definition: a disorder characterized by inflammation of the oral mucosal	Asymptomatic or mild symptoms; intervention not indicated	Moderate pain; not interfering with oral intake; modified diet indicated	Severe pain; interfering with oral intake	Life-threatening consequences; urgent intervention indicated
Pharyngeal mucositis definition: a disorder characterized by an inflammation involving the mucous membrane of the pharynx	Endoscopic findings only; minimal symptoms with normal oral intake; mild pain but analgesics not indicated	Moderate pain and analgesics indicated; altered oral intake; limiting instrumental ADL	Severe pain; unable to adequately aliment or hydrate orally; limiting self-care ADL	Life-threatening consequences; urgent intervention indicated
Tracheal mucositis definition: a disorder characterized by an inflammation involving the mucous membrane of the trachea	Endoscopic findings only; minimal hemoptysis, pain, or respiratory symptoms	Moderate symptoms; medical intervention indicated; limiting instrumental ADL	Severe pain; hemorrhage or respiratory symptoms; limiting self-care ADL	Life-threatening consequences; urgent intervention indicated

Dermatitis radiation	Faint erythema or dry desquamation	Moderate to brisk erythema; patchy moist desquamation, mostly confined to skin folds and creases; moderate edema	Moist desquamation in areas other than skin folds and creases; bleeding induced by minor trauma or abrasion	Life-threatening consequences; skin necrosis or ulceration of full thickness dermis; spontaneous bleeding from involved site; skin graft indicated
Radiation recall reaction (dermatologic)	Faint erythema or dry desquamation	Moderate to brisk erythema; patchy moist desquamation, mostly confined to skin folds and creases; moderate edema	Moist desquamation in areas other than skin folds and creases; bleeding induced by minor trauma or abrasion	Life-threatening consequences; skin necrosis or ulceration of full thickness dermis; spontaneous bleeding from involved site; skin graft indicated
Skin induration	Mild induration, able to move skin parallel to plane (sliding) and perpendicular to skin (pinching up)	Moderate induration, able to slide skin, unable to pinch skin; limiting instrumental ADL	Severe induration, unable to slide or pinch skin; limiting joint movement or orifice (e.g., mouth, anus); limiting self-care ADL	Generalized; associated with signs or symptoms of impaired breathing or feeding
Superficial soft tissue fibrosis	Mild induration, able to move skin parallel to plane (sliding) and perpendicular to skin (pinching up)	Moderate induration, able to slide skin, unable to pinch skin; limiting instrumental ADL	Severe induration; unable to slide or pinch skin; limiting joint or orifice movement (e.g., mouth, anus); limiting self-care ADL	Generalized; associated with signs or symptoms of impaired breathing or feeding
Fibrosis deep connective tissue	Mild induration, able to move skin parallel to plane (sliding) and perpendicular to skin (pinching up)	Moderate induration, able to slide skin, unable to pinch skin; limiting instrumental ADL	Severe induration; unable to slide or pinch skin; limiting joint or orifice movement (e.g., mouth, anus); limiting self-care ADL	Generalized; associated with signs or symptoms of impaired breathing or feeding
Trismus	Decreased ROM (range of motion) without impaired eating	Decreased ROM requiring small bites, soft foods, or purees	Decreased ROM with inability to adequately aliment or hydrate orally	Generalized; associated with signs or symptoms of impaired breathing or feeding
Head region soft tissue necrosis definition: a disorder characterized by a necrotic process occurring in the soft tissues of the head	–	Local wound care; medical intervention indicated (e.g., dressings or topical medications)	Operative debridement or other invasive intervention indicated (e.g., tissue reconstruction, flap, or grafting)	Life-threatening consequences; urgent intervention indicated
Neck region soft tissue necrosis definition: a disorder characterized by a necrotic process occurring in the soft tissues of the neck	–	Local wound care; medical intervention indicated (e.g., dressings or topical medications)	Operative debridement or other invasive intervention indicated (e.g., tissue reconstruction, flap, or grafting)	Life-threatening consequences; urgent intervention indicated
Esophageal (mucosal–submucosal) necrosis definition: a disorder characterized by a necrotic process occurring in the esophageal wall	–	–	Inability to aliment adequately by GI tract; radiologic, endoscopic, or operative intervention indicated	Life-threatening consequences; urgent operative intervention indicated
Pharyngeal (mucosal–submucosal) necrosis definition: a disorder characterized by a necrotic process occurring in the pharynx	–	–	Inability to aliment adequately by GI tract; tube feeding or TPN indicated; radiologic, endoscopic, or operative intervention indicated	Life-threatening consequences; urgent operative intervention indicated

(continued)

Table 44.3 (continued)

Pain (select site) (pain)	Mild pain not interfering with function	Moderate pain; pain or analgesics interfering with function, but not interfering with ADL	Severe pain; pain or analgesics severely interfering with ADL	Disabling
Skin ulceration definition: a disorder characterized by circumscribed, inflammatory and necrotic erosive lesion on the skin	Combined area of ulcers <1 cm; nonblanchable erythema of intact skin with associated warmth or edema	Combined area of ulcers 1–2 cm; partial thickness skin loss involving skin or subcutaneous fat	Combined area of ulcers >2 cm; full-thickness skin loss involving damage to or necrosis of subcutaneous tissue that may extend down to fascia	Any size ulcer with extensive destruction, tissue necrosis, or damage to muscle, bone, or supporting structures with or without full thickness skin loss
Periodontal disease	Gingival recession or gingivitis; limited bleeding on probing; mild local bone loss	Moderate gingival recession or gingivitis; multiple sites of bleeding on probing; moderate bone loss	Spontaneous bleeding; severe bone loss with or without tooth loss; osteonecrosis of maxilla or mandible	–
Osteonecrosis of jaw	Asymptomatic; clinical or diagnostic observations only; intervention not indicated	Symptomatic; medical intervention indicated (e.g., topical agents); limiting instrumental ADL	Severe symptoms; limiting self-care ADL; elective operative intervention indicated	Life-threatening consequences; urgent intervention indicated
Hypothyroidism definition: a disorder characterized by a decrease in production of thyroid hormone by the thyroid gland	Asymptomatic; clinical or diagnostic observations only; intervention not indicated	Symptomatic; thyroid replacement indicated; limiting instrumental ADL	Severe symptoms; limiting self-care ADL; hospitalization indicated	Life-threatening consequences; urgent intervention indicated

Yellow Shaded scales are useful for late effects (generally occurring >3 months after completion of treatment)

Table 44.4 QOL and PRO tools

Focus	Reference	Instrument	Items	Reporter	Other
QOL	[13]	EORTC QLQ-C30/HN37	65	Self	Modular
	[14]	UW-QOL	13	Self	Surgical focus
	[15]	FACT-H&N	37 ^a	Self	Modular
Performance status	[16]	PSS-HN	3	Clinician	Speech, diet, public eating
Symptoms	[17]	MDASI-HN	22	Self	Modular
Xerostomia	[18]	UM-XQ	8	Self	Interview; no formal validation
	[19]	LASA	6	Self	No formal validation
Voice	[20]	VHI	30	Self	
Swallowing	[21]	MDADI	20	Self	

^aTwo additional items are not scored.

“Quality of Life” Measures

QOL for H&N patients has become an increasingly important consideration in selecting cancer therapy and for clinical trials reporting. Strictly speaking, QOL is a global and multidimensional construct reported by patients without assistance or interpretation by others. A range of tools are available including broad measures of the health state as well as tools which measure specific areas of H&N function or injury, such as mucositis, swallowing, or xerostomia [10–12]. A number of well-developed QOL tools for use in H&N studies have been compiled by J. Ringash (Table 44.4).

In general, broad measures of QOL for a group will decline during therapy, and the average values return to baseline by 1 year. However, specific testing of individual symptoms (single item questions on dry mouth and swallowing) may persist for many years. Several factors have been identified that may predict for worse QOL outcomes including the presence of a feeding tube, comorbid disease, tracheotomy, site, and stage. Data correlating QOL with functional outcome and symptom burden or specific CTCAE terms and grades are inconsistent. This may be due to methodological issues, patient adaptation, patient prioritization of symptoms in relation to other dimensions of QOL, or issues in study design.

Protection of Normal Tissues

Medical Prevention of Mucosal Injury and Xerostomia

One of the most common toxicities noted during radiotherapy is mucositis or injury to the epithelial-lined mucosal surfaces of the H&N. With the increased use of concomitant chemotherapy and accelerated radiotherapy, mucositis may appear earlier in onset, be more severe, and of longer duration.

Ulceration lasting more than 3 months after treatment may be difficult to distinguish from soft tissue necrosis. Several medical strategies have been investigated to alter the onset and course of mucositis.

Fibroblast growth factor-7 is an epithelial specific growth factor. The recombinant human form is called keratinocyte growth factor (KGF). In 2005, the FDA approved KGF to reduce oral mucositis in the stem cell transplant setting based on the results of a phase III trial in patients with hematological malignancies undergoing total body irradiation with high-dose chemotherapy [22]. The incidence and duration of severe oral mucositis were significantly reduced.

In the H&N cancer setting, a randomized phase II study evaluated palifermin weekly for 10 doses with concurrent cisplatin/5-fluorouracil-based chemotherapy [23]. Although the drug was well tolerated, the results were inconclusive and the dose of KGF (60 µg/kg) was felt to be suboptimal. This has led to two large phase III industry-sponsored trials evaluating KGF at higher dose levels, one in the resected and one in the unresected setting. In 2008, the preliminary results of these trials have been reported [24]. Patients were treated with platinum based chemoradiation, and in both trials the incidence of severe mucositis was significantly reduced compared with placebo with no difference in survival. Long-term follow-up is needed to assess any differences in cancer control or long-term toxicity.

Amifostine (Ethyol) is a thioorganic compound originally developed as a radioprotector against radiation-induced toxicity in the event of nuclear war. The active metabolite, WR-1065 accumulates in many epithelial tissues, including the salivary glands. Once inside the cell, the agent scavenges radiation-induced reactive oxygen species which may confer radioprotection in normal tissue injuries.

A landmark clinical trial in the prevention of normal tissue injury involved the use of amifostine in H&N cancer. Patients were randomized to receive once daily radiation therapy for 5–7 weeks (total dose 50–70 Gy) or open label amifostine at 200 mg/m² i.v. 15–30 min before each fraction

of radiation [23]. Amifostine was associated with a reduced incidence of RTOG Grade ≥ 2 xerostomia over 2 years of follow-up, an increase in the proportion of patients with meaningful unstimulated saliva production at 24 months and reductions in mouth dryness scores on a patient benefit questionnaire at 24 months, leading to the FDA approval for use in postoperative radiotherapy.

Despite these results, the role of amifostine in the treatment of carcinomas of the H&N is not without controversy. Current data do not support the routine use of amifostine with chemoradiotherapy for H&N cancer. Data are also insufficient to recommend amifostine to prevent mucositis associated with radiation therapy for H&N cancer [24].

Intravenous amifostine administration carries substantial risks of acute side effects consisting of allergic reaction, hypotension, emesis, and fatigue. In an effort to decrease toxicity and improve convenient delivery of the drug, subcutaneous administration of amifostine has been studied. The preliminary results of Groupe Oncologie Radiotherapie Tête et Cou (GORTEC) 2000-02 were reported comparing amifostine delivery via subcutaneous versus i.v. administration [25]. Although compliance was better with delivery subcutaneously, the rate of compliance was still only 80%, and insufficient data on efficacy were reported.

The role amifostine in the current era of concurrent chemoradiation and intensity modulated radiation therapy (IMRT) is not clear. Technology which physically spares the parotid submandibular glands from higher dose radiation has been shown in several trials to reduce xerostomia, as described below. The potential benefit of amifostine in conjunction with IMRT and strict dose-volume constraints to critical organs is unknown. This coupled with concerns regarding amifostine-related toxicities may explain the far from universal use of amifostine in the treatment of H&N cancer in recent years.

Physical Protection of Normal Tissues

There is growing body of evidence demonstrating significant reductions in late toxicity through the use of IMRT in H&N cancer. Several single-institution trials have demonstrated a reduction in dose to the parotid glands and an associated reduction in xerostomia using IMRT technology

[11, 28, 29]. More recently, three phase III randomized trials have been reported, two from Hong Kong and one from the UK (Table 44.5).

Pow et al. compared conventional radiotherapy to treatment with IMRT in nasopharynx cancer [30]. There was a significant improvement in both salivary flow and in QOL parameters. The study by Kam et al. showed improved observer-rated xerostomia at 1 year but the subjective sensation of xerostomia showed no significant difference in patient-reported outcome between the two arms [31]. The relationship between salivary gland output and subjective sensation of dry mouth is complex, and may carry low correlation. The parotid glands generate the serous/watery component of saliva and function to supplement saliva volume during eating. Lack of parotid saliva may still leave one with a baseline sensation of dryness or sticky saliva. Current investigations are evaluating contributions from the submandibular and minor salivary glands that provide mucinous saliva and are thought to be important for lubrication and sensation of baseline oral moisture.

Preliminary findings of the PARSPORT phase III trial from the United Kingdom were reported at ASCO in 2009 for patients with oropharynx and hypopharynx cancers [32]. Randomization was to conventional 2D (two-dimensional) parallel opposed fields or parotid-sparing IMRT. Mean doses to ipsilateral parotid glands were 57–60 Gy with 2D versus 26–27 Gy with IMRT. The incidence of LENT-SOMA \geq grade 2 xerostomia 1 year after treatment was 74% in the 2D arm versus 40% of patients in the IMRT arm. QOL and salivary flow data are pending.

While the benefit of salivary gland sparing is widely accepted, there are no results yet reported on the potential of IMRT to improve cancer control through radiation dose escalation. The GORTEC is conducting a multicenter phase III trial comparing IMRT (75 Gy) with cisplatin versus conventional radiation (70 Gy) with cisplatin in stage III/IV H&N SCC of the oral cavity, oropharynx, or hypopharynx (personal communication J. Bourhis). The main endpoints are locoregional control and the rate of xerostomia at 2 years.

With the use of IMRT, there has been rising interest in sparing critical structures in addition to the parotid gland. The submandibular glands, larynx, oral cavity, cochlea, brachial plexus, trachea, esophagus, and pharyngeal constrictors are all subjects of ongoing research to determine the optimal dose volume constraints [33–37].

Table 44.5 Phase III trials of IMRT to reduce xerostomia

First author	Site	No. of patients	Primary endpoint	Outcome
Pow [30]	Nasopharynx	51	Stimulated whole salivary flow	50% vs. 4.8% at 1 year ($p < 0.05$)
Kam [31]	Nasopharynx	60	RTOG/EORTC xerostomia	39% vs. 82% at 1 year ($p < 0.001$)
Nutting [32]	Oropharynx/hypopharynx	94	LENT SOMA \geq Grade 2 xerostomia	39% vs. 74% at 1 year ($p = 0.004$)

Dysphagia and associated aspiration have emerged in recent years as major late sequelae of intensive chemo-RT [38]. Dysphagia represents a multiorgan dysfunction; however, clinical research in recent years demonstrated several major anatomical structures in which damage is the likely cause of dysphagia: the pharyngeal constrictors (Fig. 44.1), glottic and supraglottic larynx, and esophagus. Significant dose-volume–effect relationships between each of these organs, and various measures of dysphagia, have been published during the past 3 years and recently summarized [39]. These dose–effect relationships remain significant even after correcting for clinical factors such as tumor stage [39, 40].

In general, a mean dose of less than 50 Gy to at least some portion of the pharyngeal constrictors and less than 40 Gy to larynx serves as a general dosimetric guideline to minimize the risk of chronic dysphagia. Reducing the doses to the glottic larynx and part of the inferior constrictors may best be achieved by split-field IMRT, treating the low neck with an anterior field containing a laryngeal block [41], however, whole field IMRT in which sparing the glottis is given a high weight may achieve similar results [42]. The need for whole-field IMRT is common in oropharyngeal cancer patients with significant mid/low-neck lymphadenopathy or with gross involvement of the vallecula, where an anterior beam containing a laryngeal block may shield potential subclinical disease, and in which whole-field IMRT may provide better target dose distributions. Efforts to spare noninvolved pharyngeal constrictors and larynx by whole-field IMRT concurrent with full-dose chemotherapy resulted in no recurrences in the vicinity of these structures and only mild worsening of dysphagia compared with pretherapy [40].

Reducing the intensity of the concurrent chemotherapy regimen may also reduce the prevalence of late dysphagia. A study of MRI before and after chemo-RT demonstrated

both thickening and increase in T2 sequences in the pharyngeal constrictors (PCs) and larynx 3 months after therapy compared with pretherapy, suggesting that tissue edema is the most likely explanation to the changes occurring in the subacute posttherapy period [43]. These radiologic changes were dose-dependent and were most prominent in PCs and larynxes in which the mean dose given was >50 Gy. In contrast, similar changes were not noted in any other muscle, including those receiving high doses. The likely reason these edema-like changes were noted only in the PCs and larynx is the fact that these organs are submucosal and were affected by the acute inflammatory processes occurring during RT, while all other swallowing-related organs, which are not submucosal, were not affected by moderate RT doses. Thus, long-term dysphagia seems to be consequential to acute mucositis (notwithstanding the lack in most patients of the severe, nonhealing mucositis causing chronic ulcers, which underlies a common description of “consequential” late sequelae).

Importance of Peer Review to IMRT Plan Quality and Toxicity

The use of IMRT permits wider variations in targeting and dose distribution, suggesting that normal tissue contouring and cancer targeting may be extremely crucial to IMRT outcomes. Das et al. examined variations in IMRT planning and delivery at five different medical institutions to assess variability in patient care. They reviewed 803 patients who were treated with IMRT 2004–2006 treated for brain (12%), H&N (26%), or prostate (62%). Forty-six percent of the patients received a maximum dose that was more than 10% higher than the prescribed dose, and 63% of the patients received a dose that was more than 10% lower than the prescribed dose. H&N cancer cases had the largest variation. This study suggests the need for national and/or international guidelines for dose prescription, planning, and reporting in IMRT. More specific guidance in H&N cancer has recently become available from ASTRO [44].

The importance of careful patient examination and accurate disease localization in relation to selecting cancer targets has also become more critical with IMRT. Rosenthal et al. collected prospective data on 134 consecutive patients with preliminary radiation therapy (RT) plans. Peer review was performed that included H&N examination and imaging review to confirm target localization [45]. Peer review led to changes in treatment plans for 66% of patients. Most changes were minor, but 11% of changes were major and thought to be of a magnitude that could potentially affect therapeutic outcome or normal tissue toxicity. Most changes involved target delineation based on physical findings.

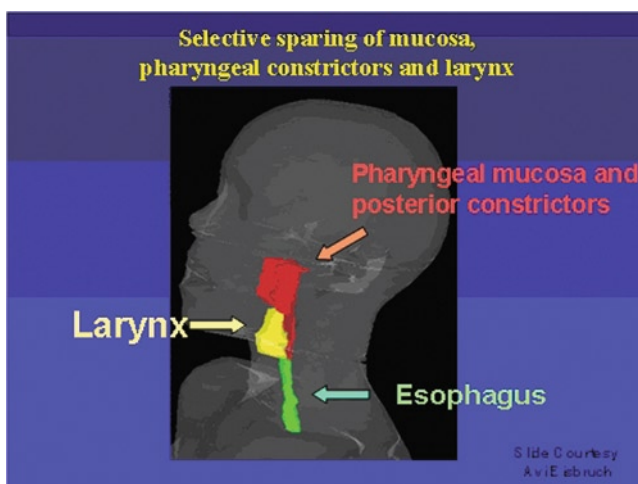


Fig. 44.1 Anatomic location of pharyngeal constrictors and larynx

IMRT beams traverse nontarget normal structures that were not traditionally exposed during 2D RT for H&N cancer. Dose-volume histograms (DVH) were used in one study to evaluate radiation dose to the lip, cochlea, brainstem, occipital scalp, and segments of the mandible [46]. One hundred and sixty patients were evaluated for toxicity. Thirty percent of IMRT patients had headaches and 40% had occipital scalp alopecia. A total of 76 and 38% of patients treated with IMRT alone had nausea and vomiting, compared with 99 and 68%, respectively, of those with concurrent cisplatin. IMRT had a markedly distinct toxicity profile from 2D or 3D cases. Scalp alopecia and anterior mucositis were associated with reconstructed mean brainstem dose >36 Gy, occipital scalp dose >30 Gy, and anterior mandible dose >34 Gy, respectively. Thus, dose reduction to specified structures (salivary glands) during IMRT implies an increased beam path dose to alternate nontarget structures that may result in clinical toxicities that were uncommon with previous, less conformal approaches.

While there are no current outcome data regarding the quality of targeting from the current IMRT era, a recent report from the 2D era is a sobering reminder of the importance of peer review in RT quality assurance. The Trans-Tasman Radiation Oncology Group (TROG) reported outcomes from a randomized phase III trial studying radiation and cisplatin with or without tirapazamine. The trial used traditional 2D radiation fields and techniques, was conducted under 89 centers in 16 countries, some with limited experience in radiotherapy clinical trials [47]. Noncompliant radiation planning occurred in 25% of cases; 47% of non-compliant cases (12% overall) had deficiencies expected to have a major adverse impact on tumor control. Major deficiencies were highly correlated with number of patients enrolled at the treating center ($p < 0.0001$), with poorer outcomes at less experienced centers. In patients who received at least 60 Gy, those cases with major deficiencies had a markedly inferior outcome compared to those whose treatment was protocol compliant (*Overall survival* 50% vs. 70%; $HR = 1.99$, $p < 0.001$).

Protons

Proton beam irradiation carries significant dosimetric advantages compared to photon irradiation in H&N cancer. Protons have the potential for therapeutic gain through superior conformality near critical structures (base of skull) and may permit cancer target dose escalation. However, with better conformality and steep dose gradients, target volume delineation becomes paramount to reduce the risk of a marginal miss. Additionally, physics quality assurance, beam modeling, and setup uncertainty play increasing roles.

The technology and delivery methods of proton beam irradiation have been relatively slow to evolve compared to photons. There are currently less than ten operating centers in the USA, but more are expected by 2010 [48–50]. Most centers currently use flat (unmodulated) protons associated with protracted treatment times, often limiting treatments to one field per day. A few centers can routinely deliver 3D proton plans. Figure 44.2 shows excellent conformality and normal tissue sparing using 3D protons. No US centers are routinely delivering intensity modulated protons (IMPT) at this time, although trials are expected to begin in near future.

Chan et al. have published their experience in the treatment of sino-nasal malignancies with proton irradiation. The main benefit of using protons in this location is to protect the optic structures. Between 1991 and 2002, 102 patients were treated to a median dose of 71.6 Gy. The 5-year local control was 86% [49].

Protons have also been utilized in the treatment of newly diagnosed or recurrent nasopharyngeal (NPX) carcinoma in an attempt to reduce the volume of irradiated normal tissue. Between 1990 and 2002, 17 patients with T4 tumors were treated at MGH with combined photon and proton irradiation. The median dose prescribed was 73.6 Gy and only one patient developed local recurrence. Loma Linda University Medical Center (LL) has reported their results of reirradiation of the NPX with doses between 50.4 and 70.2 Gy. The local control rates at 2 years have been promising at 50% [49].

There is less data for the use of protons in the treatment of oropharyngeal carcinoma. Loma Linda has conducted a trial of hyperfractionation in stages II–IV oropharyngeal carcinoma with mixed photon/proton beam irradiation [49]. 25.5 Gy was delivered with protons with the rest given with opposed lateral technique. The results of this trial show

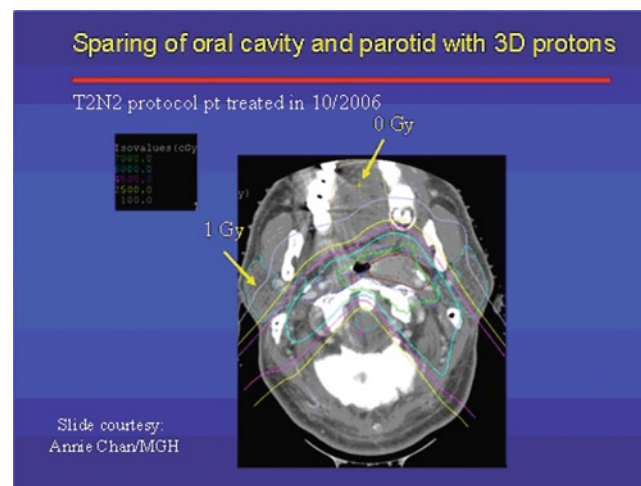


Fig. 44.2 3D protons in the treatment of pharyngeal tumor

locoregional control rates of 93% at 2 years and late RTOG grade 3 toxicity of 16%.

In summary, proton beam irradiation carries potentially important dosimetric advantages. This technology is rapidly evolving and more centers are coming on line. Multicenter trials using 3D protons or IMPT are needed in larger patient numbers and in more homogenous populations (e.g., oropharynx cancers) in order to better document the clinical outcomes of this technology.

Management of Adverse Effects

Management of Mucositis

The increased use of altered fractionation radiotherapy and concomitant chemotherapy, while resulting in significant improvements in survival and decreased progression rates, has also led to a marked increase in the rates of mucosal and skin reactions. Thus, strategies to prevent and manage mucositis have become more critical in recent years. Our methods are summarized in more detail in a recent publication and will be briefly covered here [51].

It is extremely important to appropriately match therapeutic options to the stage and risk of cancer failure. We support NCCN treatment guidelines which permit tailoring of treatment based on a patient's stage, comorbidities, and preferences of the patient and H&N care team [52]. Therapy can thus be individualized in order to maximize tumor control and minimize toxicity. For example, early carcinoma of the tonsil and base of tongue (T1-2, N0-N1) do not require multimodality therapy to achieve excellent outcomes [52].

MASCC and NCCN guidelines and a National Cancer Institute report recommend "basic oral care" as a standard practice to prevent infections and to alleviate mucosal symptoms. However, despite these recommendations there is little evidence that these interventions decrease the incidence or severity of mucositis.

Basic oral care during radiation involves brushing with a soft brush and nontraumatic way, frequent rinsing with normal saline sodium bicarbonate (1 l of water with 1/2 teaspoon baking soda, and 1/2 teaspoon salt), using moisturizing agents as necessary, periodic dental evaluations and cleanings and the lifelong use of daily dental fluoride prophylaxis.

Pain is the most important aspect of symptom control during radiation therapy to the H&N. Narcotic medications are needed in most patients and must be monitored frequently for total dose, route, frequency, and duration. Long acting narcotics or fentanyl patches may be used with short acting narcotics for breakthrough pain. These medications may cause constipation and thus prophylactic stool softeners or other bowel regimens should be considered. Additionally,

viscous lidocaine may provide topical relief in anticipation of meals.

"Magic Mouthwash" consisting of some combination of antacids, diphenhydramine, nystatin, viscous lidocaine, and steroids are frequently used in an attempt at analgesia and for antifungal properties. These agents are frequently used, however, they have never undergone formal testing to ascertain their utility.

MASCC and the Cochrane groups have not found sufficient evidence to support the use of oral sucralfate to prevent mucositis. The FDA currently supports the following swish and spit products to decrease mucositis symptoms: Gelclair, Mugar, Mucitol, and Caphsol. The latter product is currently the subject of a multicenter prospective trial to evaluate its symptom profiles and patient satisfaction in radiation-related mucositis.

Swallowing Disorders

The use of more aggressive chemoradiation treatments has resulted in higher rates of swallowing dysfunction [53]. This has prompted initiatives to prevent or rehabilitate swallowing dysfunction, including systematic use of IMRT, judicious use of feeding tube support, and swallowing exercises [38].

Radiation-induced xerostomia plays an important role in swallowing [54]. Single center results of IMRT for salivary gland sparing also report low rates of feeding tube dependence [55]. Eisbruch has published detailed methods for minimizing dose to pharyngeal constrictors with excellent results [56]. There no large multicenter trials with mature data from the "IMRT trials era" (~2005 forward) that have reported swallowing outcomes (check BC/SC tables). Thus, it is too early to know whether IMRT, which spares parotid function and employs smaller volume of high-dose tumor targets (compared with 2D), has had any broad impact on rates of swallowing dysfunction.

Swallowing ability after treatment represents a combination of pretreatment tumor-related dysfunction, treatment-related dysfunction, and the patient's ability to compensate spontaneously or with therapy. Patients' perceptions of their swallowing function may be inconsistent with objectively measured swallowing testing. These findings underscore the importance of swallowing evaluation before, during, and after treatment [57].

There is controversy about the potential benefits of prophylactic versus therapeutic feeding tube (FT) placement [58, 59]. Decision to place a feeding tube is dependent on the degree of pretreatment dysfunction and weight loss, location and target volume of the primary site tumor, use of IMRT and structure sparing techniques, clinician and patient preference, access to feeding tube procedures, and availability of swallowing

therapists. The once widespread use of prophylactic feeding tubes seems to be declining in recent years [60].

There are no large, multi-institution, prospective, controlled studies of early swallowing therapy or interventions. Rather, most data are from retrospective, single-institution series. Nonetheless, most larger centers perform baseline swallowing evaluation in at-risk patients, and often employ early prevention strategies including swallowing exercises during and after therapy. Nothing-by-mouth (NPO) intervals as short as 2 weeks have been shown to predict poor swallowing outcomes. Recovery of swallowing function may require between 6 months and 2 years in chemoradiation patients [12]. Since 6 month rates seem to predict longer term function, it seems reasonable to aim for maximal swallowing recovery by 6 months post-CRT.

Rosenthal and Lewin recommend that patients swallow as large a volume of maximally tolerated food viscosity as frequently as possible during and after treatment, even if they have a FT, for swallowing exercise. Patients who aspirate or who are at risk for aspiration can be taught to protect their airway. They also recommend specific swallowing exercises that have been demonstrated to improve swallowing ability [38]. There are no current prospective, randomized data to support the use of electrical stimulation of swallowing muscles.

Future directions to reduce swallowing dysfunction include judicious use of aggressive concurrent chemoradiation patients, systematic sparing of pharyngeal constrictors via IMRT, and reducing radiation dose in favorable risk HPV-related cancers.

Osteoradionecrosis

Osteoradionecrosis (ORN) is an uncommon event after standard dose and fractionation radiotherapy for H&N cancer with an incidence reported between 5 and 15% [61–66].

With the use of modern radiotherapy techniques, the rates of bone necrosis appear to be on the decline in part due to better homogeneity and high dose target volume reduction associated with IMRT. Eisbruch et al. reported no cases of ORN between 1996 and 2005 with strict prophylactic dental care and IMRT with a maximum mandible dose constraint <72 Gy [64].

The range of clinical ORN varies from small areas of exposed bone to large open wounds showing necrotic bone with purulence. Early disease may be managed with careful debridement, meticulous dental hygiene, and antibiotic therapy. For patients with more advanced/established ORN, hyperbaric oxygen (HBO) may be considered with or without surgical resection of necrotic bone. When HBO is used with resection, treatments are usually delivered pre and postoperatively.

Retrospective series have reported an advantage to the use of HBO for established ORN. However, a prospective trial with HBO alone in the management of ORN was inconclusive [67]. This study considered HBO to be a failure in any patient who subsequently required surgery. Another study reported promising results of HBO and surgery when conservative therapy has been ineffective [66]. It appears that a strict program of smoking cessation may also be important for durable healing. A Cochrane review of studies published between 1975 and 2007 concluded that current information was insufficient in establishing definitive guidelines in the management of ORN [65]. In practice, clinicians appear to utilize HBO in selected cases of advanced injury and in patients with wound healing risk factors (e.g., diabetes).

References

1. Trotti A, Colevas AD, et al. Patient-reported outcomes and the evolution of adverse event reporting in oncology. *J Clin Oncol*. 2007;25(32):5121–7.
2. Trotti A, Colevas AD, et al. CTCAE v3.0: development of a comprehensive grading system for the adverse effects of cancer treatment. *Semin Radiat Oncol*. 2003;13(3):176–81.
3. Bonner JA, Harari PM, Giralt J, Azarnia N, et al. Radiotherapy plus cetuximab for squamous-cell carcinoma of the head and neck. *N Engl J Med*. 2006;354(6):567–78.
4. Ang KK, Harris J, Wheeler R, Weber R, et al. Human papillomavirus and survival of patients with oropharyngeal cancer. *N Engl J Med*. 2010;363(1):24–35.
5. Machtay M, Moughan J, et al. Factors associated with severe late toxicity after concurrent chemoradiation for locally advanced head and neck cancer: an RTOG analysis. *J Clin Oncol*. 2008;26(21):3582–9.
6. CTEP (Cancer Therapy Evaluation Program). http://ctep.cancer.gov/protocolDevelopment/electronic_applications/ctc.htm. Accessed 9/20/2010.
7. Trotti A, Bentzen S. The need for adverse effects reporting standards in oncology. *J Clin Oncol*. 2004;22(1):19–22.
8. Trotti A, Pajak TF, et al. TAME: development of a new method for summarising adverse events of cancer treatment by the Radiation Therapy Oncology Group. *Lancet Oncol*. 2007;8(7):613–24.
9. Bentzen SM, Trotti A. Evaluation of early and late toxicities in chemoradiation trials. *J Clin Oncol*. 2007;25(26):4096–103.
10. Chen AY, Frankowski R, et al. The development and validation of a dysphagia-specific quality-of-life questionnaire for patients with head and neck cancer: the M. D. Anderson dysphagia inventory. *Arch Otolaryngol Head Neck Surg*. 2001;127(7):870–6.
11. Eisbruch A, Kim HM, et al. Xerostomia and its predictors following parotid-sparing irradiation of head-and-neck cancer. *Int J Radiat Oncol Biol Phys*. 2001;50(3):695–704.
12. Gillespie MB, Brodsky MB, et al. Swallowing-related quality of life after head and neck cancer treatment. *Laryngoscope*. 2004;114(8):1362–7.
13. Bjordal K, Ahlner-Elmqvist M, Tolleson E, et al. Development of a European Organization for Research and Treatment of Cancer (EORTC) questionnaire module to be used in quality of life assessments in head and neck cancer patients. EORTC Quality of Life Study Group. *Acta Oncol*. 1994;33(8):879–85.

14. Hassan SJ, Weymuller Jr EA. Assessment of quality of life in head and neck cancer patients. *Head Neck*. 1993;15(6):485–96.
15. List MA, D'Antonio LL, Cella DF, et al. The performance status scale for head and neck cancer patients and the functional assessment of cancer therapy-head and neck scale. A study of utility and validity. *Cancer*. 1996;77(11):2294–301.
16. List MA, Ritter-Sterr C, Lansky SB. A performance status scale for head and neck cancer patients. *Cancer*. 1990;66:564–9.
17. Rosenthal DI, Mendoza TR, Chambers MS, Asper JA, et al. Measuring head and neck cancer symptom burden: the development and validation of the M. D. Anderson symptom inventory, head and neck module. *Head Neck*. 2007;29(10):923–31.
18. Eisbruch A, Kim HM, Terrell JE, et al. Xerostomia and its predictors following parotid-sparing irradiation of head-and-neck cancer. *Int J Radiation Oncol Biol Phys*. 2001;50:695–704.
19. Johnson JT, Ferretti GA, Nethery WJ, et al. Oral pilocarpine for post-irradiation xerostomia in patients with head and neck cancer. *N Engl J Med*. 1993;329:390–5.
20. Benninger MS, Ahuja AS, Gardner G, Grywalski C. Assessing outcomes for dysphonic patients. *J Voice*. 1998;12(4):540–50.
21. Chen AY, Frankowski R, Bishop-Leone J, Hebert T, Leyk S, Lewin J, et al. The development and validation of a dysphagia-specific quality-of-life questionnaire for patients with head and neck cancer: the M. D. Anderson dysphagia inventory. *Arch Otolaryngol: Head Neck Surg*. 2001;127(7):870–6.
22. Spielberger R, Stiff P, et al. Palifermin for oral mucositis after intensive therapy for hematologic cancers. *N Engl J Med*. 2004;351(25):2590–8.
23. Brizel DM, Murphy BA, et al. Phase II study of palifermin and concurrent chemoradiation in head and neck squamous cell carcinoma. *J Clin Oncol*. 2008;26(15):2489–96.
24. Le Q, Kim H, et al. Palifermin reduces severe oral mucositis in subjects with locally advanced head and neck cancer undergoing chemoradiotherapy. *Int J Radiat Oncol Biol Phys*. 2008;72(1):S32.
25. Brizel DM, Wasserman TH, et al. Phase III randomized trial of amifostine as a radioprotector in head and neck cancer. *J Clin Oncol*. 2000;18(19):3339–45.
26. Hensley ML, Hagerty KL, et al. American Society of Clinical Oncology 2008 clinical practice guideline update: use of chemotherapy and radiation therapy protectants. *J Clin Oncol*. 2009;27(1):127–45.
27. Bardet E, Martin L, et al. Preliminary data of the GORTEC 2000-02 phase III trial comparing intravenous and subcutaneous administration of amifostine for head and neck tumors treated by external radiotherapy. *Semin Oncol*. 2002;29(6 Suppl 19):57–60.
28. Eisbruch A, Ten Haken RK, et al. Dose, volume, and function relationships in parotid salivary glands following conformal and intensity-modulated irradiation of head and neck cancer. *Int J Radiat Oncol Biol Phys*. 1999;45(3):577–87.
29. Blanco AI, Chao KS, et al. Dose-volume modeling of salivary function in patients with head-and-neck cancer receiving radiotherapy. *Int J Radiat Oncol Biol Phys*. 2005;62(4):1055–69.
30. Pow EH, Kwong DL, et al. Xerostomia and quality of life after intensity-modulated radiotherapy vs. conventional radiotherapy for early-stage nasopharyngeal carcinoma: initial report on a randomized controlled clinical trial. *Int J Radiat Oncol Biol Phys*. 2006;66(4):981–91.
31. Kam MK, Leung SF, et al. Prospective randomized study of intensity-modulated radiotherapy on salivary gland function in early-stage nasopharyngeal carcinoma patients. *J Clin Oncol*. 2007;25(31):4873–9.
32. Nutting CM, Morden JP, Harrington KJ, et al. On behalf of the PARSPORT trial management group. Parotid-sparing intensity modulated versus conventional radiotherapy in head and neck cancer (PARSPORT): a phase 3 multicentre randomised controlled trial. *Lancet Oncol*. 2011;12(2):110–1.
33. Honore HB, Bentzen SM, et al. Sensori-neural hearing loss after radiotherapy for nasopharyngeal carcinoma: individualized risk estimation. *Radiother Oncol*. 2002;65(1):9–16.
34. Pan CC, Eisbruch A, et al. Prospective study of inner ear radiation dose and hearing loss in head-and-neck cancer patients. *Int J Radiat Oncol Biol Phys*. 2005;61(5):1393–402.
35. Sanguineti G, Adapala P, et al. Dosimetric predictors of laryngeal edema. *Int J Radiat Oncol Biol Phys*. 2007;68(3):741–9.
36. Hall WH, Guiou M, et al. Development and validation of a standardized method for contouring the brachial plexus: preliminary dosimetric analysis among patients treated with IMRT for head-and-neck cancer. *Int J Radiat Oncol Biol Phys*. 2008;72(5):1362–7.
37. Murdoch-Kinch CA, Kim HM, et al. Dose-effect relationships for the submandibular salivary glands and implications for their sparing by intensity modulated radiotherapy. *Int J Radiat Oncol Biol Phys*. 2008;72(2):373–82.
38. Rosenthal DI, Lewin JS, et al. Prevention and treatment of dysphagia and aspiration after chemoradiation for head and neck cancer. *J Clin Oncol*. 2006;24(17):2636–43.
39. Caudell JJ, Schaner PE, Meredith RF, Locher JL, Nabell LM, Carroll WR, et al. Factors associated with long-term dysphagia after definitive radiotherapy for locally advanced head-and-neck cancer. *Int J Radiat Oncol Biol Phys*. 2009;73(2):410–5.
40. Feng FY, Kim HM, Lyden TH, Haxer MJ, Worden FP, Feng M, et al. Intensity-modulated chemoradiotherapy aiming to reduce dysphagia in patients with oropharyngeal cancer: clinical and functional results. *J Clin Oncol*. 2010;28(16):2732–8.
41. Amdur RJ, Liu C, Li J, Mendenhall W, Hinerman R. Matching intensity-modulated radiation therapy to an anterior low neck field. *Int J Radiat Oncol Biol Phys*. 2007;69(2 Suppl):S46–8.
42. Caudell JJ, Burnett 3rd OL, Schaner PE, Bonner JA, Duan J. Comparison of methods to reduce dose to swallowing-related structures in head and neck cancer. *Int J Radiat Oncol Biol Phys*. 2010;77(2):462–7.
43. Popovtzer A, Cao Y, Feng FY, Eisbruch A. Anatomical changes in the pharyngeal constrictors after chemo-irradiation of head and neck cancer and their dose-effect relationships: MRI-based study. *Radiother Oncol*. 2009;93(3):510–5.
44. Holmes T, Das R, et al. American Society of Radiation Oncology recommendations for documenting intensity-modulated radiation therapy treatments. *Int J Radiat Oncol Biol Phys*. 2009;74(5):1311–8.
45. Rosenthal DI, Asper JA, et al. Importance of patient examination to clinical quality assurance in head and neck radiation oncology. *Head Neck*. 2006;28(11):967–73.
46. Rosenthal DI, Chambers MS, et al. Beam path toxicities to non-target structures during intensity-modulated radiation therapy for head and neck cancer. *Int J Radiat Oncol Biol Phys*. 2008;72(3):747–55.
47. Peters LJ, O'Sullivan B, Giral J, Fitzgerald TJ, et al. Critical Impact of Radiotherapy Protocol Compliance and Quality in the Treatment of Advanced Head and Neck Cancer: Results From TROG 02.02. *J Clin Oncol* 2010; May 17. [Epub ahead of print] PMID: 20479390 [PubMed – as supplied by publisher]
48. Ask A, Bjork-Eriksson T, et al. The potential of proton beam radiation therapy in head and neck cancer. *Acta Oncol*. 2005;44(8):876–80.
49. Chan AW, Liebsch NJ. Proton radiation therapy for head and neck cancer. *J Surg Oncol*. 2008;97(8):697–700.
50. Truong MT, Kamat UR, et al. Proton radiation therapy for primary sphenoid sinus malignancies: treatment outcome and prognostic factors. *Head Neck*. 2009;31(10):1297–308.
51. Rosenthal DI, Trotti A. Strategies for managing radiation-induced mucositis in head and neck cancer. *Semin Radiat Oncol*. 2009;19(1):29–34.
52. National Comprehensive Cancer Network. http://www.nccn.org/professionals/physician_gls/f_guidelines.asp. Accessed 9/22/2010

53. Bentzen SM, Rosenthal DI, et al. Increasing toxicity in nonoperative head and neck cancer treatment: investigations and interventions. *Int J Radiat Oncol Biol Phys.* 2007;69(2 Suppl):S79–82.
54. Logemann JA, Pauloski BR, et al. Xerostomia: 12-month changes in saliva production and its relationship to perception and performance of swallow function, oral intake, and diet after chemoradiation. *Head Neck.* 2003;25(6):432–7.
55. Rusthoven KE, Raben D, et al. Effect of radiation techniques in treatment of oropharynx cancer. *Laryngoscope.* 2008;118(4):635–9.
56. Feng FY, Kim HM, et al. Intensity-modulated radiotherapy of head and neck cancer aiming to reduce dysphagia: early dose-effect relationships for the swallowing structures. *Int J Radiat Oncol Biol Phys.* 2007;68(5):1289–98.
57. Nguyen NP, Moltz CC, et al. Dysphagia following chemoradiation for locally advanced head and neck cancer. *Ann Oncol.* 2004;15(3):383–8.
58. Beaver ME, Myers JN, et al. Percutaneous fluoroscopic gastrostomy tube placement in patients with head and neck cancer. *Arch Otolaryngol Head Neck Surg.* 1998;124(10):1141–4.
59. Silas AM, Pearce LF, et al. Percutaneous radiologic gastrostomy versus percutaneous endoscopic gastrostomy: a comparison of indications, complications and outcomes in 370 patients. *Eur J Radiol.* 2005;56(1):84–90.
60. McLaughlin BT, Gokhale AS, et al. Management of patients treated with chemoradiotherapy for head and neck cancer without prophylactic feeding tubes: the University of Pittsburgh experience. *Laryngoscope.* 2010;120(1):71–5.
61. Kielbassa AM, Hinkelbein W, et al. Radiation-related damage to dentition. *Lancet Oncol.* 2006;7(4):326–35.
62. Sciubba JJ, Goldenberg D. Oral complications of radiotherapy. *Lancet Oncol.* 2006;7(2):175–83.
63. Wahl MJ. Osteoradionecrosis prevention myths. *Int J Radiat Oncol Biol Phys.* 2006;64(3):661–9.
64. Ben-David MA, Diamante M, et al. Lack of osteoradionecrosis of the mandible after intensity-modulated radiotherapy for head and neck cancer: likely contributions of both dental care and improved dose distributions. *Int J Radiat Oncol Biol Phys.* 2007;68(2):396–402.
65. Pitak-Arnop P, Sader R, et al. Management of osteoradionecrosis of the jaws: an analysis of evidence. *Eur J Surg Oncol.* 2008;34(10):1123–34.
66. Freiburger JJ, Yoo DS, et al. Multimodality surgical and hyperbaric management of mandibular osteoradionecrosis. *Int J Radiat Oncol Biol Phys.* 2009;75(3):717–24.
67. Annane D, Depondt J, et al. Hyperbaric oxygen therapy for radionecrosis of the jaw: a randomized, placebo-controlled, double-blind trial from the ORN96 study group. *J Clin Oncol.* 2004;22(24):4893–900.

Chapter 45

Rehabilitation of Heavily Treated Head and Neck Cancer Patients

Rachael E. Kammer and JoAnne Robbins

Abstract Head and neck cancer treatment may comprise several sequential or concurrent modalities, such as surgical resection and adjuvant radiation therapy or chemotherapy and radiation concurrently, known as chemoradiation. As the tumor grows larger or becomes more invasive, the patient is more likely to receive multimodality treatment, a combination of surgery with adjuvant chemoradiation. Often multimodality treatment produces greater changes in functional ability than single modality treatment, even if the patient receives two or three single modality treatments over a period of 5 or even more than 10 years.

Integrative relationships to better understand these curatively aimed interventions in terms of their cross-system interactions and how they can impact clinical, particularly functional, and quality of life outcomes related to the upper airway are emerging very slowly for patients undergoing the treatments. That is likely because the training of scientists focusing on basic biological research traditionally has been vastly different from the research training offered to those interested in and/or providing clinical care, including rehabilitation.

Various traditional interventions believed for decades to be safe are now questioned as risk factors for more disastrous consequences (e.g., feeding tube placement for enteral nutrition associated with increased risk of reflux and pneumonia in the elderly). Such problems emphasize the critical need for translation of new knowledge into patient-oriented research to address the underpinnings leading to diminished functioning in the upper aerodigestive tract. Elucidation of the underlying processes may facilitate treatments that minimize negative effects on function or that clarify better methods for rehabilitation. This chapter provides specific information, including different types of treatment and location,

in the heavily treated head/neck cancer patient, with initial focus on surgery followed by radiation and chemotherapy. Discussion of specific functions integral to survival and quality of life accompany each section with emphasis on rehabilitation.

Keywords Quality of life • Rehabilitation • Dysphagia • Multidisciplinary team • Speech–language pathologist • Compensatory strategies • Exercise • Articulation • Survivorship • Muscle strength

Over the latter part of the last century and with increased momentum in the first decade of this new millennium, medical science has forged paths of immense progress in important fields. Multidisciplinary approaches, resulting in multimodal therapies, are now providing effective interventions and even cures for numerous conditions that previously were fatal, such as a variety of cancers. However, in many circumstances, if survival is facilitated, the treatment provided may wreak havoc on bodily function, negatively affecting other aspects of health status and/or quality of life.

Head and neck cancer may be treated with a single treatment modality, such as surgery or radiation therapy. Or treatment may comprise several sequential or concurrent modalities, such as surgical resection and adjuvant radiation therapy or chemotherapy and radiation concurrently, known as chemoradiation. As the tumor grows larger or becomes more invasive, the patient is more likely to receive multimodality treatment, a combination of surgery with adjuvant chemoradiation. Often multimodality treatment produces greater changes in functional ability than single modality treatment, even if the patient receives two or three single modality treatments over a period of 5 or even more than 10 years.

Integrative relationships to better understand these curatively aimed interventions in terms of their cross-system interactions and how they can impact clinical, functional, and quality of life outcomes related to the upper airway are emerging very slowly for patients undergoing the treatments. That is likely because the training of scientists focusing on basic biological research traditionally has been vastly different

J. Robbins (✉)
Department of Medicine, University of Wisconsin,
Madison, WI 53726, USA
and
Geriatric Research Education and Clinical Center (GRECC),
William S. Middleton Memorial Veterans Hospital, Madison,
WI 53705, USA
e-mail: jrobbin2@wisc.edu

from the research training offered to those interested in and/or providing clinical care, including rehabilitation.

Traditionally, the effects of central nervous system damage on numerous conditions and their functional outcomes have long been studied. However, more recently, attention has been focused on peripheral mechanisms, such as changes in muscle strength, which may impact central control of endurance and coordination of bulbar-innervated mechanisms critical for vital functions [1, 2]. Changes in bulbar-innervated aerodigestive tract structure, musculature, and mechanisms are being documented across the lifespan [3, 4] and secondary to disorders following neurological injury or disease, such as stroke or postsurgical intervention. On the other hand, peripheral neuropathies and neuronal damage may occur as a result of postradiation and/or chemotherapy for head and neck cancers producing associated functional outcome deficits, including dysphagia, disorders affecting sleep, respiration, smell, taste, and voice and speech production [5].

Various traditional interventions believed for decades to be safe are now questioned as risk factors for more disastrous consequences (e.g., feeding tube placement for enteral nutrition associated with increased risk of reflux and pneumonia in the elderly) [6, 7]. Such problems emphasize the critical need for translation of new knowledge into patient-oriented research to address the underpinnings leading to diminished functioning in the upper aerodigestive tract. Elucidation of the underlying processes may facilitate treatments that minimize negative effects on function or that clarify better methods for rehabilitation.

The Rehabilitation Process: The current notion is that the process of rehabilitation of head and neck cancer patients is best begun when the patient is diagnosed and treatment choices are discussed in a multidisciplinary forum, such as a tumor board meeting, where representatives of all relevant disciplines can discuss alternative treatment modalities. The speech–language pathologist, the specialist who focuses on speech and voice production as well as swallowing, should be present at these sessions. Pretreatment counseling is critical to help the patient understand his/her role in the rehabilitation process. Most are not familiar with what rehabilitation requires and the responsibility of the patient in successful rehabilitation. The patient must be informed of the treatment suggested and told what is required of him/her to have a successful rehabilitation.

Rehabilitation requires the patient to be a very active participant in the process. None of us are taught how to be patients, nor our role in returning to best function after cancer treatment. Each tumor and each type of tumor treatment requires different rehabilitation strategies, as does the variability of site in treatment.

The following sections have specific information, including different types of treatment and location, in the heavily

treated head/neck cancer patient, with initial focus on surgery followed by radiation and chemotherapy. Discussion of specific functions integral to survival and quality of life accompanies each section with emphasis on rehabilitation.

Partial Laryngectomy

Tumors of the larynx are treated differently depending on size and location of tumor. Tumors that are classified as T1–T2 can be transorally resected with laser or treated with radiation while T3–T4 necessitates an open surgery [8]. If tumor has not invaded the entire larynx, a partial laryngectomy may be considered in order to preserve the voice. Hemilaryngectomy, supraglottic laryngectomy, or supracricoid laryngectomy are all types of partial laryngectomies and have varying functional outcomes.

Hemilaryngectomy

Surgery

Hemilaryngectomy is a vertical resection of the larynx. Traditionally, thyroid cartilage is divided medially, and resection includes one false vocal fold, ventricle, and one true vocal fold. A pedicled muscle flap may be used to rebuild the resection defect [9], and improve glottic closure. A variation is frontolateral laryngectomy, which includes anterior commissure and 1/3 of healthy vocal fold [10, 11]. If posterior extension needed, arytenoid will also be included in the resection [12]. Initially, patients require a tracheostomy for postoperative edema, but can usually be decannulated within a short period of time.

Swallowing

Given the resection of the larynx, patients experience decreased airway protection and resulting aspiration risk. Aspiration risk increases with the extent of resection. Instrumental evaluation with videofluoroscopy or Fiberoptic Endoscopic Evaluation of Swallowing (FEES) is necessary to determine the safety of oral intake. If aspiration occurs, compensatory strategies are often effective in improving airway protection. With the use of strategies, patients usually may return to oral intake quickly. However, extended resection may result in longer swallow rehabilitation, or less favorable results [12].

Compensatory Strategies

- Head rotation to right or left is utilized for unilateral pharyngeal impairment. This posture closes off one side (the impaired channel) of the pharynx, and forces bolus flow down the opposite side. It places extrinsic pressure on thyroid cartilage which increases adduction [13].
- The chin tuck may also be beneficial post-hemilaryngectomy. In this posture, the chin is tucked down to the chest during the swallow, which causes the epiglottis to move posteriorly, improving airway protection [14].
- The two postures may be combined.

Voice and Speech/Articulation

Although voice is preserved, it will likely be dysphonic. Degree of dysphonia is dependent on the ability of the remaining vocal fold to achieve glottic closure with the reconstructed tissue on the opposing side. Hirano described three criteria for optimal voice: adequate glottic closure, alignment of the reconstructed fold on the same plane as the remaining vocal fold, and a smooth surface of reconstruction [15]. If the remaining vocal fold is unable to achieve glottic closure, resulting voice quality is severely breathy [9]. New reconstruction techniques, like hemicricoidectomy with strap muscle reconstruction, are emerging in attempt to improve voice outcomes. Articulation should not be affected after hemilaryngectomy.

Supraglottic Laryngectomy

Surgery

Supraglottic laryngectomy is a horizontal, superior resection of the larynx. In this surgery, true vocal folds are spared, but false vocal folds, aryepiglottic folds, epiglottis, and superior third of thyroid cartilage with or without hyoid bone are resected. Superior laryngeal nerve also is involved [15]. Tracheostomy is initially required due to postoperative airway edema.

Swallowing

Given described resection, patients have significant decrease in airway protection, creating aspiration risk. They may aspirate during the swallow, or if there is residue in the pharynx or laryngeal vestibule, they may aspirate after the swallow [16–21]. Superior laryngeal nerve resection also results in decreased sensation and glottic closure reflex. Patients often

suffer prolonged or chronic dysphagia [16]. Therefore, careful patient selection is very important for successful rehabilitation after supraglottic laryngectomy. Preoperative work-up should include pulmonary function testing. Aspiration of secretions postoperatively is certain, and lifelong microaspiration of liquid is often unavoidable [16]. A frail patient may not be able to tolerate this aspiration and may develop numerous aspiration pneumonias. Another consideration is cognitive ability to complete swallow rehabilitation and perform complex compensatory strategies.

Swallow rehabilitation may be extensive. Initiation of safe oral intake of some consistency may take 14–40 days, with 30 days being an average [22]. Endoscopic resections often have shorter rehabilitation times, with oral intake achieved in 6–18 days, and an average of 11.5 days [22].

Compensatory Strategies

The traditional compensatory strategies are the supraglottic swallow or the super supraglottic swallow [23]. These strategies require training from a speech–language pathologist. The patient must be able to coordinate the sequence of steps carefully to perform the strategy with success. If patients have cognitive impairment, learning these strategies may not be realistic [20].

- The supraglottic swallow strategy employs volitional airway closure at the level of the vocal folds prior to swallowing, then the swallow is followed by a cough to expel any material on top of the vocal folds that has invaded the airway, and then a second swallow is completed to clear the pharyngeal residue [24].
- The super supraglottic swallow strategy utilizes the same steps, but uses a more effortful breath hold and swallow, and may result in even better airway protection [24].

Exercises

Beyond swallow strategies, oral, pharyngeal and/or range of motion exercises also play a role in rehabilitation. Analysis of swallow function in patients who have undergone supraglottic laryngectomy reveals decreased base of tongue retraction to posterior pharyngeal wall, and change in closure at airway entrance (between arytenoids and base of epiglottis) [25].

- Base of tongue retraction exercises [26].
 - Patient retracts base of tongue and holds tongue in retracted position 5 s.

- Patient yawns to achieve base of tongue retraction, holds tongue in position 5 s.
- Patient gargles or pretends to gargle to achieve base of tongue retraction, holds position 5 s.
- Anterior tilting of arytenoids with laryngeal rise exercises.
 - Shaker exercise, in which patient lays flat and lifts head, tucking chin down to chest. Three sustained lifts for 60 s, followed by 30 consecutive repetitions [27].
 - Mendelsohn exercise, in which patient swallows intentionally, holding larynx in elevated position at the end of swallow for 6 s [28, 29].

resection may affect swallow rehabilitation; the presence of a partial epiglottis results in faster return to oral intake [34].

Compensatory Strategies

- Chin tuck may help to position neoglottis under the tongue base to improve closure and decrease aspiration risk [35].
- Performing supraglottic swallow may help to eliminate aspiration [33]. (See compensatory strategies in previous section).

Voice and Speech/Articulation

Regarding voice, because true vocal folds and arytenoids are preserved, significant dysphonia is not expected after wound healing is complete [30]. Articulation should not be affected after supraglottic laryngectomy.

Exercises

Swallowing rehabilitation should initially focus on restoring mobility of arytenoid(s), with voice use and cough or throat clearing [34].

Supracricoid Laryngectomy

Surgery

Supracricoid laryngectomy is a horizontal resection of the larynx which includes the entire thyroid cartilage, both vocal folds and paralaryngeal spaces, leaving the cricoid cartilage and at least one arytenoid. Hyoid bone is preserved, and reconstruction is achieved by suturing cricoid cartilage to the hyoid bone. Variations are cricohyoidoepiglottopexy (CHEP), in which epiglottis is preserved, and cricohyoidopexy (CHP), in which epiglottis is resected [31]. Initially, patients require a tracheostomy for postoperative edema.

Voice and Speech/Articulation

Regarding voice quality, given that both vocal folds have been resected, patients speak with an aphonic voice. They are found to be able to communicate effectively in one-on-one conversation; however, they cannot raise volume of the voice to project in a group setting or noisy background [31]. This decline in voice quality may have a significant impact on patients' social and professional lives, and should be considered in patient selection [36]. Articulation should not be affected after supracricoid laryngectomy.

Swallowing

Supracricoid laryngectomy leaves patients with significantly decreased airway protection, given the resection of bilateral vocal folds. Patient selection criteria are important to define. As with the supraglottic laryngectomy, postoperative aspiration of secretions is certain, and therefore patients need adequate pulmonary reserve to tolerate the procedure [32]. In a review of 27 patients, Lewin et al. found 100% of patients aspirated on first evaluation, but 81% eventually returned to oral intake at a median of 9.4 weeks postsurgery, with the use of compensatory strategies [33]. Dysphagia was characterized by neoglottic incompetence, decreased hyolaryngeal excursion and decreased tongue base retraction. The amount of

Total Laryngectomy

Surgery

Total laryngectomy involves complete resection of the larynx, including all cartilages, intrinsic muscles, hyoid bone, and epiglottis superiorly [37]. The upper tracheal rings are resected, and the trachea is then brought out through the front of the neck, and patients breathe through a permanent stoma. As a result, there is a complete separation between pharynx and trachea. This surgery may be utilized as initial treatment for large T3 or T4 larynx tumors or as salvage treatment if chemoradiation fails. Given morbidity of the surgery, it may be reserved for salvage treatment. If tumor extends outside larynx, pharyngectomy may also be included. Reconstruction with laryngectomy may be necessary depending on the health

of tissue (prior radiotherapy), or the extent of resection. Reconstruction may be accomplished with rotated pectoral flap, or forearm free flap for pharyngoplasty.

Swallowing

Swallow function post-laryngectomy is significantly altered, though safer. Given separation of trachea and pharynx, aspiration is not possible. However, the resection of larynx results in weaker bolus propulsion. Normally, anterior and superior rise of larynx pulls open cricopharyngeus and helps to clear bolus from pharynx to esophagus. Without the larynx, bolus propulsion primarily is reliant on base of tongue retraction and pharyngeal wall constriction (in the absence of pharyngectomy). Pharyngeal phase time is longer, and there is more resistance to bolus clearance. Patients often report a “weak swallow,” and require multiple swallows to clear the bolus. McConnel et al. found laryngectomy patients compensate by utilizing increased lingual propulsion [38]. Postsurgically patients often do best with soft foods, but may progress to a general diet; however, they often report needing liquid wash. Depending on the extent of tumor, sometimes base of tongue is involved in resection, which results in even more significant dysphagia. In such cases, patients may be restricted to a puree or liquid diet. They may utilize liquid supplemental nutrition, orally or via gastrostomy tube.

Beyond expected swallow changes, there are swallowing problems that may emerge in total laryngectomy patients. One problem is a pseudoepiglottis, which is the development of a fold of tissue at the base of tongue [39]. Food and liquid can collect in the fold, and is difficult to clear. If pooling is severe enough, the resection of the pseudoepiglottis may be needed [20]. Another issue is narrowing of the neopharynx, due to scar tissue. As a result, patients have difficulty clearing food and liquid to the esophagus. Severe cases lead to nasal regurgitation of liquids. Serial dilation may provide significant relief to these patients [20], and if successful, they will often require periodic dilation for the rest of their lives. Another option is pharyngoesophageal myotomy [40].

Voice and Speech/Articulation

Alaryngeal voice is the most challenging part of post-laryngectomy rehabilitation. There are three options for communication: communication with electrolarynx, esophageal voice, and tracheoesophageal voice. The electrolarynx is a handheld device that creates sound when a piston strikes a fixed diaphragm at high speed [41]. Pitch and loudness may be adjusted. The device is held against the neck or cheek, and

then sound travels through the pharynx and oral cavity, and is articulated into speech. Electrolarynx is a very effective mode of communication. It does require a course of speech therapy to learn. Some patients master it quite quickly while others require extensive training. There is no invasiveness to utilize the electrolarynx, and training may be initiated within days postoperatively.

Some patients are put off by the mechanical sound of the voice when using the electrolarynx. Esophageal voice utilizes vibration of the pharyngoesophageal segment to create sound. The sound then travels through the pharynx and oral cavity, and is articulated into speech. The voice is more natural sounding, but is often lower pitch. Patients must learn to swallow air, using the tongue as a pumping mechanism in a process called glossopress [42]. This method of speech is difficult to learn, and unfortunately only produces a 24–26% success rate [43, 44].

From esophageal speech evolved tracheoesophageal speech [45–47]. This mode of communication also utilizes vibration of pharyngoesophageal segment to create voice; however, air is shunted from the lungs instead of being swallowed. A tract is created by the surgeon between trachea and esophagus. A trained speech–language pathologist then places a voice prosthesis into the tract. This device is a one-way valve which allows air to travel anterior–posterior, but does not allow food or liquid to travel posterior–anterior. Patients often achieve voice immediately after the voice prosthesis is placed. Speech therapy is still usually needed to learn efficient stoma occlusion and exhalation strategies. Patients choose this mode of communication because voice sounds more natural and it is fairly easy to learn. The prosthesis does require periodic replacement. Patients may learn to do this procedure independently, or it can be done by the speech–language pathologist. There are outer stoma attachments that allow hands-free speech, or provide filtration to the stoma.

Articulation is only affected if there is tongue base resection. With tongue base resection comes reduced tongue range of motion and resulting distorted articulation.

Glossectomy

Surgery

Primary treatment for a tumor of the oral tongue is surgical resection. Size of tumor determines the amount of resection and the need for reconstruction. If less than 1/3 of tongue is resected, primary closure of tongue can be accomplished. However, if 1/3–2/3 of tongue is resected, reconstruction is needed. Microvascular free tissue transfers, first described by Daniel and Taylor have increasingly been used for

reconstruction in oral cavity due to improved functional results [48]. It is most important that the oral tongue is not tethered to floor of mouth, to maximize articulation, bolus formation, and bolus transit ability. The radial forearm free flap is most often used for the reconstruction of the oral tongue because it is healthy thin tissue, and may be formed to the original shape of the tongue. This tissue bulk also allows for the coverage of floor of mouth [49]. If greater than 2/3 tongue is resected, or if total glossectomy is required, a rectus abdominus or latissimus dorsi flap will be used to reconstruct the defect [8].

Swallowing

Swallow results postglossectomy are determined by the extent of resection; a larger resection produces more swallow impairment [50–52]. Best results are achieved with primary closure; functional results are directly related to the amount of resection and reconstruction. Due to changes in shape and range of motion of tongue, the patient often cannot complete tongue to palate contact. This gap results in decreased bolus manipulation, poor oral transit, and oral stasis. Spillage to the pharynx prior to the initiation of the pharyngeal swallow response also is observed, again due to decreased bolus control and decreased sensation. A palatal lowering prosthesis, created by a prosthodontist, may improve tongue to palate contact, and therefore improve oral dysphagia [20, 39].

Compensatory Strategies

- Bolus presentation to unaffected side of oral cavity (with remaining native tongue) improves patient's ability to sense bolus and effectively manipulate it.
- Liquid wash is helpful to clear oral cavity stasis, which may occur due to decreased sensation and tongue range of motion.
- In larger resections in which premature spillage of the bolus to the pharynx occurs due to difficulty with oral containment, the supraglottic swallow or super supraglottic swallow can improve airway protection [24].

Exercises

- Tongue range of motion exercises may help to improve the range of motion and reduce fibrosis, improving bolus clearance [53].
- Tongue exercise with resistance, utilizing tongue blades or devices providing knowledge of performance, may increase tongue strength [54, 55].

Voice and Speech/Articulation

Voice quality should not be affected with glossectomy. However, speech and articulation almost always be altered. Changes to anatomy of tongue result in decreased articulatory preciseness. Again, the amount of resection is directly correlated with speech outcomes, and primary closure produces best results. In most cases, articulation is distorted, but still intelligible. As with swallowing, a palatal drop prosthesis could facilitate improved articulation if tongue to palate contact is improved [56, 57]. In the case of total glossectomy, when no articulation is possible, sometimes an augmentative communication device is necessary.

Compensatory Strategies

- Decreased rate of speech
- Exaggerated articulation

Exercises

- Articulation drills of affected phonemes
- Tongue range of motion and strengthening exercises [58]

Composite Resection

Surgery

A composite resection refers to surgery in which tumor, surrounding tissue, and bone need to be removed. Most common sites are in oral cavity: alveolar ridge, anterior or lateral floor of mouth, and retromolar trigone, and resection includes mandible. The defect requires reconstruction, and is best achieved by osteocutaneous free flaps, such as fibula, scapula, iliac crest, rib, and radius, with fibula being most common [8]. Fibula flaps are best for dental implants, which can be considered to improve mastication and oral transit. Surgeons must consider functional outcomes of speech and swallowing; poor resection and reconstruction result in tethering of the tongue to floor of mouth. With bone invasion of tumor, postoperative chemoradiation or radiation alone is usually recommended.

Swallowing

Degree of swallow impairment is determined by the amount of resection and reconstruction, and site of cancer [59].

Anterior resections can result in the loss of sensation and motor control to lower lip. Patients may have difficulty with oral incompetence and lip anesthesia. Lateral resections are less debilitating, though patients may report significant oral stasis on affected side. Posterior resections may cause decreased sensation and difficulty triggering pharyngeal swallow, and subsequent premature spillage of bolus to pharynx. Patients do usually return to general or soft diet [60] with the use of compensatory strategies.

Compensatory Strategies

- In lateral resection, bolus presentation to the unaffected side improves bolus transit and reduces oral stasis.
- Liquid wash helps clear oral stasis.
- In anterior resections, posterior bolus placement may reduce the loss of bolus.
- In posterior resections, chin tuck may help to compensate for delayed onset/trigger of the pharyngeal swallow response.

Exercises

If tongue tethering, tongue range of motion exercises may be helpful.

Radiotherapy and Chemotherapy

Radiotherapy

Radiation may be used as a primary or secondary treatment for head neck cancer. Delivery of radiotherapy has advanced considerably. Conventional radiotherapy utilized lateral beams that covered primary tumor and cervical lymph nodes. Unfortunately, this method often resulted in unnecessary radiation to surrounding normal tissue and structures. Patients suffered significant decreases in quality of life, including xerostomia and dysphagia [61]. Intensity Modulated Radiotherapy (IMRT) has since evolved. This method utilizes multiple beams of varying intensity to deliver a relatively uniform dose to the tumor, and avoids high dose to surrounding normal structures. Image-guided radiotherapy has also recently emerged, which allows for better precision of patient positioning [61]. With this technique, a CT scan is taken prior to initiation of each radiation treatment, to make sure patient and tumor are in proper position. It also allows for better tracking of tumor regression.

Chemotherapy

Chemotherapy has been used and evaluated as induction, concomitant, and/or adjuvant treatment. A meta-analysis of 87 trials revealed concomitant chemotherapy improves survival by 8% at 5 years [62], therefore concomitant chemoradiotherapy has become standard-of-care for stage III and IV squamous cell carcinomas of the head and neck [63]. Induction treatment involves initial chemotherapy followed by resection and/or radiotherapy; this technique is considered for unresectable tumors or organ preservation.

Concomitant chemoradiotherapy has been shown to have increased acute side effects of radiotherapy, including mucositis, dysphagia, aspiration, dysphonia, and dermatitis [64–66]. Xerostomia and dysgeusia are frequently both acute and chronic side effects [67]. Side effects are intensified due to the radiosensitization of chemotherapy.

Site-Specific Treatment

Generally, oral cavity tumors are treated with resection first, followed by concomitant chemoradiation or radiation alone. Surgery to oral cavity generally produces functional speech and swallowing, unless resection is greater than 2/3 of tongue. Oropharynx tumors and hypopharynx tumors, however, are usually treated with primary chemoradiation due to poor functional results with surgery [63]. If primary treatment fails, salvage resection can be offered; however, swallowing and speech will most likely be significantly altered. Treatment of larynx tumors depends on staging. Tumors staged at T1–T2 N0 may be treated with primary radiation or surgery [68]. Larger T3–T4 tumors necessitate open surgery, and may require adjuvant radiotherapy.

Swallowing

Dysphagia may be an acute and chronic side effect of radiotherapy and chemoradiotherapy [69–71]. A summary of research reveals changes in swallow are characterized by delayed onset/trigger of the pharyngeal swallow response, decreased laryngeal elevation, impaired tongue base retraction, impaired epiglottic inversion, and increased oral pharyngeal transit time. As a result, instrumental evaluations reveal poor bolus propulsion, pharyngeal residue, and laryngeal penetration and aspiration. It has also been documented that dysphagia is more significant in patients undergoing concomitant chemoradiotherapy than radiotherapy alone [72–74].

With the emergence of IMRT, it was hoped that patients would experience improved quality of life due to more precise treatment to the tumor, and sparing of surrounding structures. Preservation of contralateral salivary gland with IMRT has resulted in decreased xerostomia [75, 76]. However, improved dysphagia outcomes have not yet been reported.

Prophylactic feeding tubes are often placed due to acute toxicities and the challenge of oral intake while patients are going through treatment. However, swallow function may be better maintained if patients continue oral intake during treatment [65]. Therefore, it is recommended that patients continue oral intake throughout treatment, at the maximally tolerated diet, even if they are supplementing with tube feedings.

Exercises

Prophylactic pharyngeal range of motion exercises are recommended during radiotherapy or chemoradiotherapy to maintain swallow function [77].

- Shaker exercise: head lifts in supine position to increase hyolaryngeal rise and cricopharyngeal opening [27].
- Base of tongue: sustained retraction to increase range of motion [77].
- Tongue hold exercise (Masako maneuver): bite tip of tongue and swallow to pull posterior pharyngeal wall anteriorly [78].
- Effortful swallow: Volitional swallow with increased effort.

If dysphagia is identified before, during, or after treatment with instrumental evaluation, exercises may be targeted to specific abnormalities. Compensatory strategies may also be appropriate, and help to improve diet tolerance.

There is also increased esophageal toxicity with chemoradiation to head and neck [79, 80], and early dilation can improve dysphagia [81]. Appropriate interventions have been shown to improve swallow function in 75% of radiation patients [82].

Voice and Speech/Articulation

When the larynx has been irradiated, primary chemoradiation patients report dysphonia on patient-based questionnaires: Voice Handicap Index and the Voice Related Quality of Life [83]. Articulation also may be negatively affected, if tongue range of motion changes after radiation [84]. Finally, nasal resonance problems may develop due to velopharyngeal insufficiency, especially in patients treated for oropharynx cancer [85].

Survivorship and Rehabilitation

Ever more complex cancer therapies are leading to better outcomes with improved cure rates and prolonged survivals even for patients who may ultimately succumb to their disease. Advances in screening and treatment have contributed to lengthening the survival period for many individuals, and long-term survival is a growing possibility for many patients. The need for cancer care to more fully address survivorship issues has been increasingly a noted mission emerging in the literature [86] evidenced in sponsorship by such groups as the National Cancer Institute, the National Coalition for Cancer Survivorship and, most recently, the Institute of Medicine (IOM). The term “survivorship” has been added to cancer care [87, 88] and awareness of the importance of looking beyond cancer treatment to the survivorship phase of care is receiving increased attention.

An IOM report entitled, “From Cancer Patient to Cancer Survivor: Lost in Transition” identified cancer survivorship as a distinct phase of care that has been neglected in areas, such as advocacy, education, clinical practice, and research [87]. The report recognized four essential components of patient-centered survivorship care (Table 45.1), and ten recommendations for improving the care provided to survivors were made (Table 45.2) [87]. These recommendations are far-reaching and broad, requiring cooperation among health care providers, researchers, advocacy groups, professional organizations, government bodies, and policy makers [86].

Table 45.1 Essential components of survivorship care

1	Prevention of recurrent and new cancers, and other late effects
2	Surveillance for cancer spread, recurrence, or second cancers; assessment of medical and psychosocial late effects
3	Intervention for consequences of cancer and its treatment
4	Coordination between specialists and primary care providers to ensure that all of the survivor's health needs are met

From: Jacobs et al. [86]. Reprinted with permission from John Wiley & Sons

Table 45.2 IOM recommendations for survivorship care

1	Raise awareness of cancer survivorship
2	Provide a care plan for survivors
3	Develop clinical practice guidelines for cancer survivors
4	Define quality health care for cancer survivors
5	Overcome health care system challenges
6	Address survivorship as a public health concern
7	Provide survivorship education and training of health care professionals
8	Address employment concerns of cancer survivors of all ages
9	Improve access to adequate and affordable health insurance

From: Jacobs et al. [86]. Reprinted with permission from John Wiley & Sons

As head and neck cancer survivor numbers and longevity increase, the life and health sustaining functions of swallowing and speech production are relied upon for longer periods of time, requiring optimal long-term rehabilitation. Foci for the evolving field of adult survivorship must include clinical care, research and education, engaging the survivors, and cancer care providers alike to help guide clinicians in their clinical care of the cancer survivors. As models are developing for the care of adult cancer survivors, thoughtfully designed evaluative research that can truly inform clinical care and guide evolving models of care must be conducted.

It is not easy to change a paradigm in which providers have historically focused on cancer treatment and cure. The field of adult cancer survivorship is growing and may serve as a nexus for the talents and intellects of oncologists, other physician providers, including primary care physicians with other health professionals, and in the case of head and neck cancer, speech–language pathologists. It is the SLPs who have the daunting task to facilitate the maintenance of swallowing and speech function to sustain health maintenance and acceptable quality of life with a paucity of survivorship research. There is a need for specialists to address the myriad of late effects associated with cancer treatments rather than monitoring for a recurrence of the original cancer. Programs designed to educate and counsel survivors on the treatment they received and their potential late effects may serve as collection points for data related to head and neck rehabilitation and outcomes as much needed new information emerges in the years ahead.

In addition, as cancer survivors age, they face managing late effects of cancer therapies (e.g., accelerated cardiovascular-, pulmonary-, and bone-health decline) [89], as well as other ongoing comorbid illnesses (e.g., diabetes, arthritis, recurring pain, and distress) [90]. The complexity of the health issues faced by survivors requires coordinated, patient-centered care, and a paradigm shift from disease-focused to wellness-centered comprehensive care. Survivorship care focuses on restoring health and quality of life [91] and the care provided to survivors needs to be personalized, preventative, and participatory. Thus, an essential component of health care for cancer survivors is active involvement of primary and specialty care providers [86, 92]. The speech–language pathologist is poised to be at least a partner at best, a leader, in this regard, his/her role as a key member of the multidisciplinary team charged with rehabilitating (heavily) treated head and neck cancer patients.

Acknowledgment The authors wish to acknowledge Dr. Jerilyn Logemann's major and ongoing contributions to the field of swallowing and speech rehabilitation for head and neck cancer patients. Without Dr. Logemann's enduring focus, there would be little known and much less to offer our many heavily treated head and neck cancer patients we see in the clinic every day.

References

1. Kays S, Hind J, Gangnon R, Robbins J. Effects of dining on tongue endurance and swallowing-related outcomes. *J Speech Lang Hear Res.* 2010;53(4):898–907.
2. Nicosia MA, Hind JA, Roecker EB, Carnes M, Robbins JA. Age effects on the temporal evolution of isometric and swallowing pressure. *J Gerontol A Biol Sci Med Sci.* 2000;55A:M634–40.
3. Robbins J, Gangnon R, Theis S, Kays SA, Hind J. The effects of lingual exercise on swallowing in older adults. *J Am Geriatr Soc.* 2005;53:1483–9.
4. Tracy F, Logemann JA, Kahrilas PJ, Jacob P, Kobara M, Krugla C. Preliminary observations on the effects of age on oropharyngeal deglutition. *Dysphagia.* 1989;4:90–4.
5. El Sharkawi A, Ramig L, Logemann JA, et al. Swallowing and voice effects of Lee Silverman Voice Treatment (LSVT): a pilot study. *J Neurol Neurosurg Psychiatry.* 2002;72:31–6.
6. Marik PE. Aspiration pneumonia and aspiration pneumonia. *N Engl J Med.* 2001;344:665–71.
7. Johnston SD, Tham TC, Mason M. Death after PEG: results of the National Confidential Enquiry into Patient Outcome and Death. *Gastrointest Endosc.* 2008;68:223–7.
8. Hartig G, Chaiet G. Improving form and function through surgical care in head and neck squamous cell carcinoma. In: Harari P, Connor NP, Grau C, editors. *Functional preservation and quality of life in head and neck radiotherapy.* Berlin: Springer; 2009.
9. Amin MR, Koufman JA. Hemicoideotomy for voice rehabilitation following hemilaryngectomy with ipsilateral arytenoid removal. *Ann Otol Rhinol Laryngol.* 2001;110:514–8.
10. Som M. Surgery in premalignant lesions. *Can J Otolaryngol.* 1975;3:551.
11. Som ML, Silver CE. The anterior commissure technique of partial laryngectomy. *Arch Otolaryngol.* 1968;87:138–45.
12. Jenkins P, Logemann J, Lazarus C, Ossoff R. Functional changes after hemilaryngectomy. Paper presented at the American Speech Language Hearing Association annual meeting. Los Angeles, CA; 1981.
13. Logemann J, Kahrilas P, Kobara M, et al. The benefit of head rotation on pharyngeal dysphagia. *Arch Phys Med Rehabil.* 1989;70:767–71.
14. Welch MV, Logemann JA, Rademaker AW, Kahrilas PJ. Changes in pharyngeal dimensions effected by chin tuck. *Arch Phys Med Rehabil.* 1993;74:178–81.
15. Hirano M. Technique for glottic reconstruction following vertical partial laryngectomy: a preliminary report. *Ann Otol Rhinol Laryngol.* 1976;85:25–31.
16. Sasaki CT, Leder SB, Acton LM, Maune S. Comparison of the glottic closure reflex in traditional “open” versus endoscopic laser supraglottic laryngectomy. *Ann Otol Rhinol Laryngol.* 2006;115:93–6.
17. McConnel FM, Mendelsohn MS, Logemann JA. Manofluorography of deglutition after supraglottic laryngectomy. *Head Neck Surg.* 1987;9:142–50.
18. Flores TC, Wood BG, Levine HL, Koegel Jr L, Tucker HM. Factors in successful deglutition following supraglottic laryngeal surgery. *Ann Otol Rhinol Laryngol.* 1982;91:579–83.
19. Litton WB, Leonard JR. Aspiration after partial laryngectomy: cineradiographic studies. *Laryngoscope.* 1969;79:887–908.
20. Logemann J. Evaluation and treatment of swallowing disorders. 2nd ed. Austin, TX: Pro-Ed Inc.; 1998.
21. Staple TW, Ogura JH. Cineradiography of the swallowing mechanism following supraglottic subtotal laryngectomy. *Radiology.* 1966;87:226–30.
22. Bernal-Sprekelsen M, Vilaseca-Gonzalez I, Blanch-Alejandro JL. Predictive values for aspiration after endoscopic laser resections of malignant tumors of the hypopharynx and larynx. *Head Neck.* 2004;26:103–10.

23. Ohmae Y, Logemann JA, Kaiser P, Hanson DG, Kahrilas PJ. Effects of two breath-holding maneuvers on oropharyngeal swallow. *Ann Otol Rhinol Laryngol.* 1996;105:123–31.
24. Martin BJ, Schleicher MA, O'Connor A. Management of dysphagia following supraglottic laryngectomy. *Clin Commun Disord.* 1993;3:27–36.
25. Logemann JA, Gibbons P, Rademaker AW, et al. Mechanisms of recovery of swallow after supraglottic laryngectomy. *J Speech Hear Res.* 1994;37:965–74.
26. Veis S, Logemann JA, Colangelo L. Effects of three techniques on maximum posterior movement of the tongue base. *Dysphagia.* 2000;15:142–5.
27. Shaker R, Kern M, Bardan E, et al. Augmentation of deglutitive upper esophageal sphincter opening in the elderly by exercise. *Am J Physiol.* 1997;272:G1518–22.
28. Jacob P, Kahrilas PJ, Logemann JA, Shah V, Ha T. Upper esophageal sphincter opening and modulation during swallowing. *Gastroenterology.* 1989;97:1469–78.
29. Kahrilas PJ, Logemann JA, Krugler C, Flanagan E. Volitional augmentation of upper esophageal sphincter opening during swallowing. *Am J Physiol.* 1991;260:G450–6.
30. Roh JL, Kim DH, Park CI. Voice, swallowing and quality of life in patients after transoral laser surgery for supraglottic carcinoma. *J Surg Oncol.* 2008;98:184–9.
31. Bron L, Brossard E, Monnier P, Pasche P. Supracricoid partial laryngectomy with cricohyoideopiglottopexy and cricohyoidopexy for glottic and supraglottic carcinomas. *Laryngoscope.* 2000;110:627–34.
32. Tucker HM. Conservation laryngeal surgery in the elderly patient. *Laryngoscope.* 1977;87:1995–9.
33. Lewin JS, Hutcheson KA, Barringer DA, et al. Functional analysis of swallowing outcomes after supracricoid partial laryngectomy. *Head Neck.* 2008;30:559–66.
34. Holsinger FC, Laccourreye O, Weinstein GS, Diaz Jr EM, McWhorter AJ. Technical refinements in the supracricoid partial laryngectomy to optimize functional outcomes. *J Am Coll Surg.* 2005;201:809–20.
35. Holsinger FC, Weinstein GS, Laccourreye O. Supracricoid partial laryngectomy: an organ-preservation surgery for laryngeal malignancy. *Curr Probl Cancer.* 2005;29:190–200.
36. Makeieff M, de la Breteque A, Guerrier B, Giovanni A. Voice handicap evaluation after supracricoid partial laryngectomy. *Laryngoscope.* 2009;119:746–50.
37. Myers EN, Suen JY. *Cancer of the head and neck.* 2nd ed. New York: Churchill Livingstone; 1989.
38. McConnel FM, Mendelsohn MS, Logemann JA. Examination of swallowing after total laryngectomy using manofluorography. *Head Neck Surg.* 1986;9:3–12.
39. Davis RK, Vincent ME, Shapshay SM, Strong MS. The anatomy and complications of “T” versus vertical closure of the hypopharynx after laryngectomy. *Laryngoscope.* 1982;92:16–22.
40. Singer MI, Blom ED. Selective myotomy for voice restoration after total laryngectomy. *Arch Otolaryngol.* 1981;107:670–3.
41. Case JL. *Clinical management of voice disorders.* 2nd ed. Austin, TX: Pro-Ed; 1991.
42. Diedrich WM, Youngstrom KA. *Alaryngeal speech.* Springfield, IL: Thomas; 1996.
43. McIvor J, Evans PF, Perry A, Cheesman AD. Radiological assessment of post laryngectomy speech. *Clin Radiol.* 1990;41:312–6.
44. Blom ED, Singer MI, Hamaker RC. A prospective study of tracheoesophageal speech. *Arch Otolaryngol Head Neck Surg.* 1986;112:440–7.
45. Robbins J. Acoustic differentiation of laryngeal, esophageal, and tracheoesophageal speech. *J Speech Hear Res.* 1984;27:577–85.
46. Robbins J, Fisher HB, Blom EC, Singer MI. A comparative acoustic study of normal, esophageal, and tracheoesophageal speech production. *J Speech Hear Disord.* 1984;49:202–10.
47. Robbins J, Fisher HB, Blom ED, Singer MI. Selected acoustic features of tracheoesophageal, esophageal, and laryngeal speech. *Arch Otolaryngol.* 1984;110:670–2.
48. Daniel RK, Taylor GI. Distant transfer of an island flap by microvascular anastomoses. A clinical technique. *Plast Reconstr Surg.* 1973;52:111–7.
49. Urken ML, Biller HF. A new bilobed design for the sensate radial forearm flap to preserve tongue mobility following significant glossectomy. *Arch Otolaryngol Head Neck Surg.* 1994;120:26–31.
50. Skelly M. *Glossectomee speech rehabilitation.* Springfield, IL: Thomas; 1973.
51. McConnel FM, Logemann JA, Rademaker AW, et al. Surgical variables affecting postoperative swallowing efficiency in oral cancer patients: a pilot study. *Laryngoscope.* 1994;104:87–90.
52. Zimmerman J. *Speech production after glossectomy.* Paper presented at the American Speech Language Hearing Association annual meeting. New York; 1958.
53. Pauloski BR, Rademaker AW, Logemann JA, Colangelo LA. Speech and swallowing in irradiated and nonirradiated postsurgical oral cancer patients. *Otolaryngol Head Neck Surg.* 1998;118:616–24.
54. Robbins J, Kays SA, Gangnon R, Hewitt A, Hind J. The effects of lingual exercise in stroke patients with dysphagia. *Arch Phys Med Rehabil.* 2007;88:150–8.
55. Lazarus C, Logemann J, Huang C, Rademaker A. Effects of two types of tongue strengthening exercises in young normals. *Folia Phoniatrica et Logopedica.* 2003;55:199–205.
56. Logemann J, Kahrilas P, Hurst P, Davis J, Krugler C. Effects of intraoral prosthetics on swallowing in oral cancer patients. *Dysphagia.* 1989;4:118–20.
57. Davis JW, Lazarus C, Logemann J, Hurst P. Effect of a maxillary glossectomy prosthesis on articulation and swallowing. *J Prosthet Dent.* 1987;57:715–9.
58. Sullivan P, Hind J, Roecker E, et al. Lingual pressure exercise protocol for head and neck cancer: a case study. *Dysphagia.* 2001;16:154 (Abst).
59. Pauloski BR, Logemann JA, Rademaker AW, et al. Speech and swallowing function after anterior tongue and floor of mouth resection with distal flap reconstruction. *J Speech Hear Res.* 1993;36:267–76.
60. Cordeiro PG, Disa JJ, Hidalgo DA, Hu QY. Reconstruction of the mandible with osseous free flaps: a 10-year experience with 150 consecutive patients. *Plast Reconstr Surg.* 1999;104:1314–20.
61. Eisbruch A. Improving the quality of life of patients with head and neck cancer by highly conformal radiotherapy. In: Harari P, Connor NP, Grau C, editors. *Functional preservation and quality of life in head and neck radiotherapy.* Berlin: Springer; 2009.
62. Bourhis J, Amand C, Pignon J. Update of MACH-NC (meta-analysis of chemotherapy in head & neck cancer) database focused on concomitant chemoradiotherapy. *J Clin Oncol.* 2004;22:5505.
63. Argiris A, Karamouzis MV, Raben D, Ferris RL. Head and neck cancer. *Lancet.* 2008;371:1695–709.
64. Garcia-Peris P, Paron L, Velasco C, et al. Long-term prevalence of oropharyngeal dysphagia in head and neck cancer patients: Impact on quality of life. *Clin Nutr.* 2007;26:710–7.
65. Rosenthal DI, Lewin JS, Eisbruch A. Prevention and treatment of dysphagia and aspiration after chemoradiation for head and neck cancer. *J Clin Oncol.* 2006;24:2636–43.
66. Trotti A, Bellm LA, Epstein JB, et al. Mucositis incidence, severity and associated outcomes in patients with head and neck cancer receiving radiotherapy with or without chemotherapy: a systematic literature review. *Radiother Oncol.* 2003;66:253–62.
67. Ruo Redda MG, Allis S. Radiotherapy-induced taste impairment. *Cancer Treat Rev.* 2006;32:541–7.
68. Mendenhall WM, Werning JW, Hinerman RW, Amdur RJ, Villaret DB. Management of T1-T2 glottic carcinomas. *Cancer.* 2004;100:1786–92.

69. Carrara-de Angelis E, Feher O, Barros AP, Nishimoto IN, Kowalski LP. Voice and swallowing in patients enrolled in a larynx preservation trial. *Arch Otolaryngol Head Neck Surg.* 2003;129:733–8.
70. Lazarus CL. Management of swallowing disorders in head and neck cancer patients: optimal patterns of care. *Semin Speech Lang.* 2000;21:293–309.
71. Kotz T, Abraham S, Beitler JJ, Wadler S, Smith RV. Pharyngeal transport dysfunction consequent to an organ-sparing protocol. *Arch Otolaryngol Head Neck Surg.* 1999;125:410–3.
72. Bleier BS, Levine MS, Mick R, et al. Dysphagia after chemoradiation: analysis by modified barium swallow. *Ann Otol Rhinol Laryngol.* 2007;116:837–41.
73. Eisbruch A, Lyden T, Bradford CR, et al. Objective assessment of swallowing dysfunction and aspiration after radiation concurrent with chemotherapy for head-and-neck cancer. *Int J Radiat Oncol Biol Phys.* 2002;53:23–8.
74. Logemann JA, Pauloski BR, Rademaker AW, et al. Swallowing disorders in the first year after radiation and chemoradiation. *Head Neck.* 2008;30:148–58.
75. Chao KS, Deasy JO, Markman J, et al. A prospective study of salivary function sparing in patients with head-and-neck cancers receiving intensity-modulated or three-dimensional radiation therapy: initial results. *Int J Radiat Oncol Biol Phys.* 2001;49:907–16.
76. Eisbruch A, Ship JA, Martel MK, et al. Parotid gland sparing in patients undergoing bilateral head and neck irradiation: techniques and early results. *Int J Radiat Oncol Biol Phys.* 1996;36:469–80.
77. Logemann JA, Pauloski BR, Rademaker AW, Colangelo LA. Speech and swallowing rehabilitation for head and neck cancer patients. *Oncology (Williston Park).* 1997;11:651–6. 659; discussion 659, 663–654.
78. Fujiu M, Logemann J. Effects of a tongue-holding maneuver on posterior pharyngeal wall movement during deglutition. *Am J Speech Lang Pathol.* 1996;5:23–30.
79. Guadagnolo BA, Li S, Neuberg D, et al. Organ preservation and treatment toxicity with induction chemotherapy followed by radiation therapy or chemoradiation for advanced laryngeal cancer. *Am J Clin Oncol.* 2006;28:371–8.
80. Abdel-Wahab M, Abitbol A, Lewin A, Troner M, Hamilton K, Markoe A. Quality-of-life assessment after hyperfractionated radiation therapy and 5-fluorouracil, cisplatin, and paclitaxel (Taxol) in inoperable and/or unresectable head and neck squamous cell carcinoma. *Am J Clin Oncol.* 2005;28:359–66.
81. Lawson JD, Otto K, Grist W, Johnstone PA. Frequency of esophageal stenosis after simultaneous modulated accelerated radiation therapy and chemotherapy for head and neck cancer. *Am J Otolaryngol.* 2008;29:13–9.
82. Mittal BB, Pauloski BR, Haraf DJ, et al. Swallowing dysfunction – preventative and rehabilitation strategies in patients with head-and-neck cancers treated with surgery, radiotherapy, and chemotherapy: a critical review. *Int J Radiat Oncol Biol Phys.* 2003;57:1219–30.
83. Thomas L, Jones TM, Tandon S, Carding P, Lowe D, Rogers S. Speech and voice outcomes in oropharyngeal cancer and evaluation of the University of Washington quality of life speech domain. *Clin Otolaryngol.* 2009;34:34–42.
84. van der Molen L, van Rossum MA, Burkhead LM, Smeele LE, Hilgers FJ. Functional outcomes and rehabilitation strategies in patients treated with chemoradiotherapy for advanced head and neck cancer: a systematic review. *Eur Arch Otorhinolaryngol.* 2009;266:901–2.
85. de Buijn MJ, ten Bosch L, Kuik DJ, et al. Objective acoustic-phonetic speech analysis in patients treated for oral or oropharyngeal cancer. *Folia Phoniatr Logop.* 2009;61:180–7.
86. Jacobs LA, Palmer SC, Schwartz LA, et al. Adult cancer survivorship: evolution, research, and planning care. *CA Cancer J Clin.* 2009;59:391–410.
87. Hewitt M, Greenfield S, Stovall E. From cancer patient to cancer survivor: lost in transition. Washington, DC: National Academies Press; 2006.
88. Hoffman B, Stovall E. Survivorship perspectives and advocacy. *J Clin Oncol.* 2006;24:5154–9.
89. Carver JR, Shapiro CL, Ng A, et al. American Society of Clinical Oncology clinical evidence review on the ongoing care of adult cancer survivors: cardiac and pulmonary late effects. *J Clin Oncol.* 2007;25:3991–4008.
90. Mao JJ, Bowman MA, Stricker CT, et al. Delivery of survivorship care by primary care physicians: the perspective of breast cancer patients. *J Clin Oncol.* 2009;27:933–8.
91. Harari PM, Connor NP, Grau C, (eds). Functional preservation and quality of life in head and neck radiotherapy. (Medical Radiology Series/Radiation Oncology) Berlin: Springer-Verlag; 2009.
92. Grunfeld E. Primary care physicians and oncologists are players on the same team. *J Clin Oncol.* 2008;26:2246–7.

Chapter 46

Salvage Therapy in Head and Neck Cancer Patients

Saba Aftab, Rod Rezaee, and Pierre Lavertu

Abstract This chapter discusses the unique challenges in the diagnosis, workup, treatment and follow-up of patients who may have, or have failed chemoradiation protocols. The role of various imaging modalities, particularly PET scanning, is reviewed. Surgical salvage in this population is emphasized, addressing the extent of resection both at the primary site and the neck, and the surgical complications encountered in this population. Options for surgical reconstruction are discussed, including free tissue transfer.

While surgical salvage is the main focus of this chapter, other salvage modalities available to patients who have been previously chemoirradiated are examined. These include re-irradiation with or without chemotherapy, brachytherapy and photodynamic therapy. Finally, the treatment outcomes with respect to morbidity and mortality in this population are reviewed.

Keywords Salvage surgery • Chemoradiation • Head and neck reconstruction • Neck dissection • PET scanning • Re-irradiation

Introduction

The pattern of care for head and neck cancer patients has changed considerably since the landmark paper by the Department of Veterans Affairs Laryngeal Cancer Study Group in 1991. Organ preservation protocols involving chemotherapy and radiation have become standard at many institutions for not only the treatment of advanced laryngeal carcinomas, but also for advanced lesions of other head and neck sites. As more patients are treated with chemoradiation as a primary modality, the role of surgery is evolving. The head and neck cancer surgeon must now be familiar with the

unique diagnostic and therapeutic challenges presented by the patient who may have, or has failed chemoradiotherapy.

This chapter will discuss the challenges in diagnosis, workup, treatment and follow-up of patients with head and neck squamous cell carcinoma who present after chemoradiation protocols. The role of surgical salvage will be emphasized. In addition, the treatment of patients who present with *persistent* disease (an incomplete response to chemoradiation), vs. those with *recurrent* disease (complete initial clinical response to chemoradiation, with presence of tumor found >6 months after completion of treatment) will be highlighted. This chapter will focus mainly on tumors involving the oral cavity, oropharynx, hypopharynx and larynx. Carcinoma of the nasopharynx generally behaves differently than squamous cell carcinomas of the remainder of the head and neck, and therefore will not be discussed here.

Diagnosis

The clinical diagnosis of persistent or recurrent squamous cell carcinoma after chemoradiation is often challenging. Radiation and chemotherapy induced changes in mucosa and soft tissue can mimic many of the worrisome signs and symptoms of local recurrence. For example, treatment induced mucositis, pain, edema, dysphagia and hoarseness can be significant and prolonged. Tumor necrosis can leave residual ulceration that is difficult to distinguish from malignancy. Radionecrosis of the mandible and the larynx can occur late after treatment, and present with ulceration, pain and edema. This is often difficult to distinguish from tumor recurrence. Palpation of lymphadenopathy is often problematic because of postradiation neck fibrosis.

The best hope of a successful surgical salvage is if recurrent disease is found early. Most tumor recurrence occurs in the first 2 years after therapy. It is for this reason that clinical guidelines suggest frequent follow-up visits in the head and neck cancer population. Carefully elicited histories and physical examinations can sometimes detect subtle changes in signs and symptoms, which are often the only clue to the

P. Lavertu (✉)
Department of Otolaryngology, Head and Neck Surgery,
University Hospitals Case Medical Center, 11100 Euclid Ave,
Cleveland, OH 44106, USA
e-mail: Pierre.Lavertu@UHhospitals.org

presence of a tumor persistence or recurrence. Any suspicion of a tumor should prompt timely further evaluation. This involves endoscopy, biopsy and/or imaging, which will be discussed in detail in the following sections.

Imaging

Obtaining imaging studies is often the first step in evaluating the patient with suspected tumor persistence or recurrence. Comparison of these images with prior imaging is essential, so it is beneficial to ensure that these examinations are available both to the surgeon and the interpreting radiologist.

CT and MRI

Many patients undergo CT and/or MRI imaging with contrast to evaluate extent of tumor, bony involvement and the presence or absence of lymphadenopathy. However, it is difficult to suspect recurrence on the basis of imaging studies alone. Interpretation of CT and MRI is challenging in the presence of postradiation changes. Edema, tumor necrosis and inflammation can lead to MRI signal characteristics that are similar to tumor. A prospective study by Lell et al. followed patients with serial MRI scanning before and after undergoing concurrent chemoradiation, correlating suspicious MRI findings with biopsy. MRI led to false-positive results in 46% of patients in the first 3 months after completion of therapy, and 58% in the interval 3–6 months after therapy. In a similar analysis of CT scanning to detect recurrences, these authors also found that the presence of osteonecrosis, abscess and inflammation led to false-positive results [1].

In the case of biopsy proven disease, CT and/or MRI can be helpful to provide spatial detail in planning for salvage surgery. As will be discussed later, the surgeon must be cautioned, however, that true extent of tumor is often difficult to assess, and is often beyond what can be appreciated clinically and radiologically.

PET Scanning

^{18}F -FDG-PET and ^{18}F -FDG-PET-CT scanning are emerging as very useful tools to evaluate suspected persistent or recurrent head and neck cancer. Their utility as a screening tool is also being investigated. In a study by Salaun et al., PET scanning was performed on 30 patients considered free of their disease by routine negative physical exam, flexible endoscopy and lack of worrisome symptoms. A single scan was performed at an interval ranging from 6 to 35 months post-treatment. They were able to detect tumor recurrence in eight patients, with a sensitivity of 100%, specificity of 95%, and

overall accuracy of 97% [2]. A similar study by Abgral et al. prospectively followed 91 patients considered free of their disease by conventional surveillance with PET scanning done 7–15 months after the completion of therapy. The PET scan was positive in 39 patients, and 30 of those patients had proven recurrence, leading to a sensitivity of 100%, specificity of 85% and overall accuracy of 90% [3]. Neither of these studies addressed the cost-effectiveness of surveillance PET scanning to detect tumor recurrence, or whether surveillance PET scanning had any impact on survival. As of this writing, there are no long-term prospective studies to answer these questions, so the clinical utility of surveillance PET scanning is still unclear. Nonetheless, the ability of PET scanning to find recurrent disease before it is detected clinically is certainly intriguing, and may have significant implications for resectability of recurrent disease, the morbidity of treatment, and overall survival.

The benefit of PET scanning to detect persistent disease after chemoradiation has been better studied. If performed 10–12 weeks after the completion of chemoradiotherapy, PET scanning has been shown to be beneficial in evaluating for the presence of persistent disease both at the primary site and in the neck. A recent meta-analysis of 27 studies by Isles et al. showed the pooled mean positive and negative predictive values for the detection of residual/recurrent disease at the primary site were 75 and 95%. For the neck these numbers were 49 and 96%, respectively. The overall pooled sensitivity was 94% for the detection disease at the primary site. The same analysis revealed that the sensitivity of PET scanning improves if done 10 or more weeks after completion of treatment [4]. A meta-analysis by Wong showed similar promising results for the use of PET scan in detecting recurrent disease. The analysis of eight studies showed the sensitivity of PET scanning for detecting recurrent carcinoma as 84–100%, with specificities of 61–93%. The negative predictive value of PET scanning was 96%, similar to the high value in the analysis by Isles et al. [5].

The results of these meta-analyses, among other studies in the literature, have laid the foundation for the changing standard of care regarding post chemoradiation protocols. Previously it was standard of care that any patient with N2 or N3 disease should undergo routine planned neck dissection approximately 6 weeks after treatment, regardless of the clinical response to therapy. This was due to the high incidence of treatment failures with bulky adenopathy, the difficulty of following these patients for recurrence, and the devastating consequences of uncontrolled neck disease. PET scanning has now greatly improved our ability to detect persistent disease in this population. Due to the very high negative predictive value of PET scanning as quoted in the above studies, many centers now defer planned neck dissection after chemoradiation in favor of careful observation if the posttreatment PET scan is negative.

Imaging for Evaluation of Distant Disease

If clinical suspicion dictates, imaging should also be performed to evaluate for distant metastases when a patient presents with recurrent head and neck carcinoma. Patients with more advanced carcinomas are more likely to present with distant metastases, and the main site of metastasis is the lung. Currently there is no consensus regarding the best imaging modalities for detection of distant metastases. Many practitioners will order a routine CXR to look for pulmonary nodules, followed by a chest CT if the CXR is suspicious. Measurement of serum aminotransferases and radionuclide bone scintigraphy can be used to screen for liver or bone metastases, respectively, as clinical suspicion dictates.

The use of ^{18}F -FDG-PET scanning for evaluation of distant metastases is also being investigated. In a review by Wong, data from five studies with a total of 233 subjects was pooled. The overall true positive rate of PET scan to detect second primary or distant metastases was 73%, while the false-positive rate was 27%. The analyzed studies rarely reported the incidence of false-negative PET scans. Overall, he found no large clinical trials that showed the benefit of PET over other cross sectional imaging to detect distant metastases [5].

More recent work may suggest otherwise. A prospective study by Senft et al. suggests that PET scanning is superior to conventional chest CT to detect pulmonary metastases, with the best results obtained by combination PET-CT. The negative predictive value and accuracy of PET-CT to detect distant metastases was 84%, vs. 75% for chest CT alone [6]. Gourin et al. showed that PET-CT is superior to conventional screening modalities (defined as CXR and liver function tests in this study) to detect distant metastases in previously untreated patients with head and neck cancer [7]. The same authors have investigated the utility of PET-CT scanning to detect distant metastases in patients with suspected head and neck cancer recurrence. They retrospectively analyzed data of 64 consecutive patients with suspected recurrence. All patients had CXR and liver function tests in addition to whole

body PET-CT imaging. Ten patients had biopsy proven pulmonary malignancy, of which only two were suspected by CXR alone, and seven were detected by a positive PET-CT scan. Five patients had extra-thoracic metastases or second primary tumors detected by PET-CT scanning, and all of these patients were previously unsuspected to have metastases by both clinical suspicion and negative liver function testing. Overall, 23% of patients had distant metastases, and only 3% had distant disease suspected by conventional methods prior to PET-CT imaging [8]. This study highlights two important points with respect to patients with recurrent head and neck cancer. First, the absolute rate of distant metastases in this population is high, illustrating the importance of a thorough evaluation for distant disease prior to initiating any salvage therapy. Second, it appears combination PET-CT imaging may offer superior detection of this distant disease vs. other modalities (Table 46.1).

Biopsies

The use of ^{18}F -FDG-PET scanning approximately 10 weeks after the completion of chemoradiotherapy has decreased the need for planned posttreatment surveillance endoscopies with biopsies of suspicious areas due to its high negative predictive value in detecting recurrent or persistent carcinoma. In the face of clinical suspicion or a positive PET scan, biopsies of suspicious areas should be performed. It is important to remember that biopsies performed less than 10 weeks after the completion of treatment can be erroneously positive because tumor regression continues even after the completion of radiotherapy.

It is also important to remember that biopsy of recurrent disease can yield false-negative results. Recurrent head and neck carcinomas often display different growth patterns compared with primary carcinomas – they tend to be multifocal and submucosal [9]. Sampling tissue that is too

Table 46.1 Summary of the main considerations in imaging a suspected head and neck cancer recurrence or persistence

	Advantages	Disadvantages	Main indications
Key points: imaging			
CT	Excellent delineation of bony anatomy	Posttreatment changes difficult to distinguish from tumor	Good spatial detail of tumor and/or lymphadenopathy Surgical planning
MRI	Excellent delineation of soft tissue anatomy	Posttreatment changes difficult to distinguish from tumor	Good spatial detail of tumor and/or lymphadenopathy Surgical planning <i>Not used as frequently as CT scanning</i>
PET	High negative predictive value to detect persistent local or regional disease	False positives if done too early, or in presence of infection or inflammation	Monitor disease at primary site Screening for regional or distant metastases Screening for second primary tumor Helps determine the need for posttreatment neck dissection

superficial or is in between foci of tumor can lead to erroneous results. If the clinician maintains a high index of suspicion despite a negative biopsy, it is prudent to continue very close follow up with repeat biopsies of suspicious areas.

The use of fine-needle aspiration cytology for the evaluation of suspicious neck nodes has been shown to be efficacious in the setting of previously untreated neck disease. However, its use in the setting of a previously chemoirradiated neck has not been well studied. One of the few papers to address this question showed disappointing results, with an overall accuracy of FNA in detecting persistent or recurrent neck disease as only 57% [10].

Surgical Treatment

Management of the Primary Site

The extent of resection required to extirpate tumor in the case of persistent or recurrent head and neck carcinoma following chemoradiation is unclear. Some authors would advocate tailoring the extent of resection to pretreatment tumor size with appropriate margins, even if the posttreatment tumor is significantly smaller in size. Others would argue that the chemoradiation reduces tumor load, and thus resection margins should encompass only presently active disease, thereby reducing morbidity and the need for extensive reconstruction. This follows the concept that unresectable tumors can be “downstaged” with chemoradiation to make them operable.

To date, no prospective, randomized trials have been conducted to answer this question. In fact, a recent survey of members of the American Head and Neck Society showed that current surgical practice varies widely. Seventy percent of respondents stated they used pretreatment margins to tailor surgical resection, and 26% stated they used the margins of the recurrence only [11].

The argument against restaging the tumor after chemoradiation therapy is that even though the tumor may appear clinically, endoscopically and radiologically smaller in size, it may not be by histologic analysis. Recurrent tumor is often submucosal and difficult to detect on clinical examination, especially among surrounding radiation-induced edema, fibrosis and inflammation. A histologic analysis of whole organ slices in recurrent laryngeal carcinoma vs. primary laryngeal carcinoma showed that recurrent tumor is much more likely to have perineural spread, contralateral spread and cricoid cartilage invasion. The same authors showed that recurrent tumors tend to be multifocal rather than follow a concentric growth pattern. There is also a much greater incidence of dissociated, isolated tumor cells separate to tumor foci in the laryngectomy specimens of recurrent tumors [9].

As outlined earlier, radiologic studies in previously irradiated or chemoirradiated patients are difficult to interpret, and thus preoperative imaging is less reliable in planning the extent of dissection. Zbären et al. compared preoperative imaging and endoscopy results of patients with recurrent laryngeal cancer with their postoperative histopathologic specimens. Endoscopy was able to accurately evaluate tumor extension in only 52%. Radiologic examination of tumor extension was correct in only 24%, with the majority of incorrect interpretations underestimating tumor extension [12].

Thus, in discussing the concept of “restaging” tumors after chemoradiation to plan extent of resection, it is important to remember that preoperative endoscopy and imaging is not always reliable. Tumors do not always follow the concentric growth pattern, and resecting only visible disease (vs. tailoring to pretreatment tumor size) may leave behind microscopic nests of tumor cells. This emphasizes the need for strict frozen section control, even with wide margins of resection. In addition, it has implications in preoperative counseling for patients. Given the uncertainties involved, the accurate planning of surgery is difficult. The extirpative surgeon, reconstructive surgeon and the patient should always be prepared for a larger than anticipated resection.

Management of the Neck

N0 Neck

Traditionally, a neck dissection for recurrent head and neck carcinoma in the clinically N0 neck is advocated if there is a >20% likelihood of occult neck disease, based on site and size of the recurrent primary tumor. This follows similar principles to the need for elective neck dissection in any primary head and neck carcinoma. Some authors continue to follow this principle, arguing that the neck should be managed aggressively due to the devastating consequences of regional failure in this population, and the difficulty in clinically following these patients [13]. The disadvantage of this is the additional morbidity incurred in an already compromised population. There are other reports to suggest a more conservative approach should be taken. A retrospective review by Farrag et al. of patients treated with salvage laryngeal surgery after primary radiation therapy suggested that the management of the neck should be based on the presurgical CT scan of the neck, as opposed to the risk of occult metastasis. Even though 85% of their patients had T3 or T4 disease, which would normally have a high likelihood of occult metastasis, the majority of their patients had a pathologically N0 neck after neck dissection. Their analysis revealed that 97% of patients with a negative CT scan also had a pathologically negative neck dissection, concluding that a presurgical CT

scan of the neck had a high negative predictive value [14]. This suggests that previous (chemo)radiotherapy renders patients unlikely to harbor the same degree of occult metastases.

In patients with an N0 neck who require neck exploration, whether for access to the primary site, or for free-flap reconstruction, a selective neck dissection should be considered as it adds little morbidity or operative time.

N+ Neck

In patients with persistent neck disease, there is no doubt that the neck needs to be addressed surgically. The extent of neck dissection, however, is still under debate. A radical or modified radical neck dissection is certainly efficacious to eradicate persistent neck disease. Recent reports in the literature purport the feasibility of a more conservative approach. In this population, patients often have significant pre-existing problems with soft tissue fibrosis, dysphagia, and poor neck range of motion secondary to the effects of chemoradiation. A selective neck dissection may afford smaller incisions, less tissue dissection, as well as a shorter hospitalization [15]. It can decrease the significant morbidity of more radical procedures that may lead to chronic neck and shoulder pain, decreased range of motion, and chronic numbness. Stenson et al. report in their series of 58 patients who underwent selective (unilateral or bilateral) neck dissection after chemoradiation that only one patient developed disease recurrence in the neck [16]. Robbins et al. performed a prospective study to compare radical or modified radical neck dissection against more selective neck dissections in patients with persistent disease after chemoradiation. After a median follow up of 58 months, the rates of regional failure were low in the selective neck dissection group, and there was no difference in overall survival and distant metastases [17]. This study was not randomized and thus confounded by selection bias, but the results do suggest that selective neck dissections are a safe and feasible option in selected patients. Interestingly, in this paper, and in other published works, Robbins has suggested that a “superselective” neck dissection may also be a feasible option. Robbins et al. suggest that patients with residual post chemoradiation adenopathy confined to one single neck level can be salvaged with a neck dissection limited to only two contiguous neck levels. They analyzed a series of 54 patients undergoing complete neck dissection. Pathologic analysis of neck dissection specimens revealed that only one patient had disease outside of the two contiguous neck levels, and thus in this population it would have been safe to do a superselective neck dissection only [15].

The studies advocating the use of more selective neck dissections emphasize that this approach should be tailored to those with persistent disease who have nodal disease addressed as part of a “planned” neck dissection or an early

salvage neck dissection when chemoradiation has failed to fully eradicate neck disease. The data for more limited neck dissections is lacking when patients present with late recurrences in the neck. It is thus recommended that in this population with late recurrence, radical or modified radical neck dissections should be performed.

Surgical Reconstruction

Reconstruction of salvage surgical defects in general follows the same principles as for primary surgical defects. Options span the “reconstructive ladder,” from primary closure to the use of free tissue transfer. In the previously chemoirradiated population, the use of regional or free flaps is especially important, as it allows the transfer of abundant, healthy, non-irradiated tissue with good vascular supply. Regional flap reconstruction, particularly the pectoralis major myocutaneous flap, has been used successfully in salvage surgical reconstruction, especially for large defects involving the oral cavity and oropharynx [18, 19]. Myocutaneous flaps are useful to protect the carotid artery, which is at an increased risk of exposure in previously radiated patients. They are also used in combination with free flap reconstruction for larger defects to provide soft tissue bulk [20]. Regional flap reconstruction is an especially useful option in elderly or medically compromised patients who may not tolerate lengthy free-flap reconstructions.

Free flaps have been shown to be safe in patients previously treated with radiotherapy and/or chemotherapy, with complication rates similar to previously untreated patients [21]. The use of free flap reconstruction has expanded the realm of salvage surgery, allowing more aggressive extirpative procedures with decreased morbidity. Patients that were previously considered “unresectable” are now offered a chance of cure with acceptable outcomes with respect to speech, swallowing, and cosmesis.

As part of the multidisciplinary approach to managing these patients, the reconstructive surgeon should be involved early in the process. As mentioned earlier in this chapter, surgical defects can become much larger than anticipated intraoperatively, and careful planning and anticipation of this by the primary and reconstructive surgeon is imperative.

Surgical Complications

Salvage surgery has classically been associated with an increased rate of surgical complications. In particular, wound complications such as breakdown and fistula, pharyngoesophageal stenosis and carotid rupture have been reported with increased frequency. Ganly et al. showed a significant

increase in postoperative wound complications (45% vs. 25%) and pharyngocutaneous fistulas (32% vs. 12%) in their 38 patients who underwent salvage total laryngectomy after chemoradiation compared to their primary total laryngectomy patients. They showed that the overall complication rate and local complication rate was higher in the chemoradiation group compared to the primary group as well as to those patients previously treated with radiation only [22]. Other authors have also shown that prior chemoradiation leads to increased surgical complications vs. radiation alone or primary surgery [23, 24], but other reports do not demonstrate an increased surgical complication rate after chemoradiation vs. radiation therapy alone [23, 25]. Nonetheless, it is clear that prior therapy does predispose patients to an overall higher risk of surgical complications.

With the increased use of free flap reconstruction, however, the incidence of surgical complications in salvage surgical procedures may be decreasing. In fact, some studies have shown that the wound complication rate with the use of free flap reconstruction equals that of nonirradiated patients. Fung et al. showed that the use of free tissue transfer in the salvage total laryngectomy population did not reduce the overall incidence of pharyngocutaneous fistula, but did reduce the rate of major complications, defined as re-hospitalization, re-exploration or death [26]. Withrow and colleagues showed that prophylactic reconstruction with a vascularized free flap after salvage total laryngectomy was associated with a lower fistula rate of 18% vs. 50% for primary closure, although this was not statistically significant ($p=0.08$), likely due to small sample size ($N=37$) [27]. However, the use of free flap reconstruction in this study did lower the absolute rate of pharyngocutaneous fistula to that of previously nonirradiated tissues. The rates of pharyngocutaneous fistula in primary laryngectomy in nonirradiated patients have been reported to range from 10 to 21% [28–31].

Supplementing pharyngeal mucosa in the closure of a post-laryngectomy defect can also decrease the pharyngeal constriction and stenosis that previously chemoradiated patients are prone to develop. By utilizing vascularized free flap reconstruction after salvage total laryngectomy, Withrow et al. reduced the rate of esophageal strictures to 18% (vs. 25% for primary closure) and dependence on tube feeding to 23% (vs. 45%) [27].

In summary, salvage surgery after chemoradiation can lead to an increased risk of local wound complications, but many of these risks can be decreased with the use of free flap reconstruction of defects.

Adjuvant Therapy

Traditionally, head and neck radiation oncologists have been reluctant to offer re-irradiation as adjuvant therapy for fear of unacceptable toxicity and morbidity. Modern

treatment planning protocols, in particular IMRT, have allowed repeat courses of radiation to be delivered while minimizing lifetime doses to critical structures such as the spinal cord and brainstem [32]. Recent trials have shown adjuvant re-irradiation (with or without chemotherapy) to be both feasible and effective. Machtay et al. showed that adjuvant chemotherapy and re-irradiation in patients with stage III or IV recurrent carcinoma had promising results, offering 3 year locoregional control of 81% and overall survival of 63%. These outcomes are better than would be expected with surgical salvage treatment alone. However, the rate of severe and long-term toxicities was also higher in this group [33]. A randomized trial by Janot et al. comparing salvage surgery alone vs. salvage surgery with postoperative re-irradiation and chemotherapy showed a significant improved disease-free survival in the adjuvant therapy arm, but no improvement in overall survival. As in the previous study, the improved locoregional control in this group came at the expense of higher toxicities [34].

Although surgery remains the preferred primary treatment option for previously chemoradiated patients, there are certain patients who are considered unresectable based on size and location of tumor recurrence, or who cannot tolerate surgery due to other comorbidities. The use of re-irradiation with or without adjuvant chemotherapy is currently being studied as the sole treatment modality for this population, and in some scenarios, may even be curative. A review of this topic by Mendenhall et al. shows that external beam re-irradiation with or without chemotherapy for recurrent head and neck cancer results in 2 year overall survival rates of 16–35%, with a small fraction of patients achieving long-term survival [35]. Similar to postoperative re-irradiation therapy, primary re-irradiation protocols are associated with higher toxicities. A review by Salama et al. showed that chemotherapy and re-irradiation protocols do not carry an increased risk of acute toxicities such as mucositis or hematologic abnormalities compared to primary chemoradiation protocols, but treatment-related mortality and late toxicities appear to be higher [36].

Some patients are not good candidates for external beam re-irradiation, and for this population, other adjuvant treatment modalities can be considered. Brachytherapy and photodynamic therapy are currently under investigation as potential treatment options. Their use as a single treatment modality at this time is generally limited to palliation, although small numbers of patients have been cured of their disease. In a phase I–II study of patients referred for “last hope” treatment for recurrent head and neck cancer, interstitial photodynamic therapy offered significant palliation; long-term disease-free survival was observed in a small number of patients [37]. Both low-dose and high-dose interstitial brachytherapy can also be effective tools in providing durable

Table 46.2 Summary of the main treatment considerations in a patient with persistent or recurrent squamous cell carcinoma after chemoradiation therapy

	Advantages	Disadvantages	Main indications
Key points: Treatment of persistent or recurrent carcinoma after chemoradiation			
Surgery	Best chance for cure	High morbidity, especially with advanced stage disease Increased wound complications (decreased with regional or free flap reconstruction)	Persistent or recurrent resectable disease Absence of metastatic disease?
Re-irradiation (+/- chemotherapy)	Can offer cure in some number of patients with unresectable disease, good locoregional control	Higher incidence of late toxicities	Adjuvant therapy postoperatively [advanced stage disease, positive margins, multiple positive nodes, extranodal spread] Nonsurgical candidates [unresectable, medical co-morbidities, patient preference]
Chemotherapy alone	Relatively less morbid than XRT/surgery	Rarely curative Variable morbidity	Palliation, local control Nonsurgical, nonreirradiation candidates
Adjuvant therapies (brachytherapy, PDT)	Minimal morbidity	Rarely curative	Palliation, local control Non-surgical candidates

PDT photodynamic therapy, *XRT* radiation therapy

palliation and local control of disease with acceptable toxicities. In certain cases, patients receiving these therapies have shown prolonged disease-free survival [38, 39] (Table 46.2).

Outcomes

The prognosis of patients requiring surgical salvage for chemoradiation failure has not been well studied in long-term prospective studies. Nonetheless, some generalities can be made based on current data and extrapolating data from patients with radiation or other primary treatment failures. A meta-analysis by Goodwin of 1,080 patients undergoing salvage surgical therapy showed the 5-year survival to be 39% [40]. Certain characteristics of persistent or recurrent tumor correlate with prognosis. For example, patients with greater initial tumor burden in the neck (N3 disease), positive surgical margins, and extranodal extension of disease have poorer survival [41]. Stage of recurrent disease is important, and correlates strongly with disease-free survival. A prospective study by Goodwin illustrated median disease-free survival after surgical salvage was greater than the 22 month study for stage I recurrence, and only 5.5 months in stage IV recurrence [40].

Patients with recurrence in certain subsites of the head and neck fare better. In particular, the survival rates for patients with recurrent carcinoma of the larynx after chemoradiation failure are better than those with recurrent oropharyngeal or hypopharyngeal tumors. The cause for this is likely multifactorial. Patients treated with organ preservation protocols for the hypopharynx or oropharynx were more

likely to have advanced disease at the outset, and these subsites tend to have greater propensity for regional metastases. In addition, tumors of the oropharynx and hypopharynx can spread to involve unresectable areas such as the pterygoid plates and prevertebral muscles, whereas recurrent disease of the larynx tends to be more confined to resectable areas [42].

When one describes surgical success after salvage procedures, the morbidity of such interventions must also be considered. The ability to improve a patient's quality of life is an inherent part of defining surgical success. Patients who present with stage I or II recurrence have a better quality of life after surgical salvage compared with those with recurrent stage III or IV disease. In Goodwin's study, only 41 and 39% of patients with stage III and IV recurrence, respectively, reported an improved quality of life postsurgical salvage [40]. The poor quality of life and survival outcomes in advanced stage recurrence, coupled with the prolonged recovery time after free tissue transfer or other major extirpative procedures, have prompted some authors to advocate a careful, individualized risk/benefit analysis of the role of surgical salvage for therapeutic or palliative purposes in this group of patients [43].

Conclusion

Salvage surgical therapy is one of the most difficult challenges facing the head and neck cancer surgeon. It remains the best option for treatment in patients with persistent or recurrent disease after failed chemoradiotherapy. Advances in imaging techniques, surgical reconstruction and adjuvant

therapies have improved our ability to diagnose and manage patients with this difficult problem. Surgical salvage can be a very successful operation in select groups of patients, offering long-term survival with minimal morbidity. Nonetheless, the overall survival in this population remains poor, and thorough discussions must be held with the family and caregivers prior to treatment to establish reasonable expectations. The multidisciplinary management of these patients is essential, and all members of the head and neck cancer team must be involved early in the process.

References

- Lell M, Baum U, Greess H, et al. Head and neck tumors: imaging recurrent tumor and post-therapeutic changes with CT and MRI. *Eur J Radiol*. 2000;33:239–47.
- Salaun PY, Abgral R, Querellou S, et al. Does 18Fluoro-Fluorodeoxyglucose positron emission tomography improve recurrence detection in patients treated for head and neck squamous cell carcinoma with negative clinical follow up? *Head Neck*. 2007;29:1115–20.
- Abgral R, Querellou S, Potard G, et al. Does 18F-FDG PET/CT improve the detection of posttreatment recurrence of head and neck squamous cell carcinoma in patients negative for disease on clinical follow-up? *J Nucl Med*. 2009;50(1):24–9.
- Isles MG, McConkey C, Mehanna HM. A systematic review and meta-analysis of the role of positron emission tomography in the follow up of head and neck squamous cell carcinoma following radiotherapy or chemoradiotherapy. *Clin Otolaryngol*. 2008;33:210–22.
- Wong RJ. Current status of FDG-PET for head and neck cancer. *J Surg Oncol*. 2008;97:649–52.
- Senft A, de Bree R, Hoekstra OS, et al. Screening for distant metastases in head and neck cancer patients by chest CT or whole body FDG-PET: a prospective multicenter trial. *Radiother Oncol*. 2008;87:221–9.
- Gourin CG, Watts TL, Williams HT, Patel VS, Bilodeau PA, Coleman TA. Identification of distant metastases with positron-emission tomography-computed tomography in patients with previously untreated head and neck cancer. *Laryngoscope*. 2008;118:671–5.
- Gourin CG, Watts T, Williams HT, Patel VS, Bilodeau PA, Coleman TA. Identification of distant metastases with PET-CT in patients with suspected recurrent head and neck cancer. *Laryngoscope*. 2009;119(4):703–6.
- Zbären P, Christe A, Caversaccio MD, Stauffer E, Thoeny HC. Pretherapeutic staging of recurrent laryngeal carcinoma: clinical findings and imaging studies compared with histopathology. *Otolaryngol Head Neck Surg*. 2007;137:487–91.
- van der Putten L, van den Broek GB, de Bree R. Effectiveness of salvage selective and modified radical neck dissection for regional pathological lymphadenopathy after chemoradiation. *Head Neck*. 2009;31:593–603.
- Meier JD, Oliver DA, Varvares MA. Surgical margin determination in head and neck oncology: current clinical practice. The results of an international American Head and Neck Society member survey. *Head Neck*. 2005;27:952–8.
- Zbären P, Weidner S, Thoeny HC. Laryngeal and hypopharyngeal carcinomas after (chemo)radiotherapy: a diagnostic dilemma. *Curr Opin Otolaryngol Head Neck Surg*. 2008;16:147–53.
- Lee WT, Esclamado RM. Salvage surgery after chemoradiation therapy. In: Adelstein DJ, editor. *Squamous cell head and neck cancer: recent clinical progress and prospects for the future*. Totowa, NJ: Humana Press; 2005. p. 69–78.
- Farrag TY, Lin FR, Cummings CW. Neck management in patients undergoing post radiotherapy salvage laryngeal surgery for recurrent/persistent laryngeal cancer. *Laryngoscope*. 2006;116:1864–6.
- Robbins KT, Shannon K, Vieira F. Superselective neck dissection after chemoradiation. *Arch Otolaryngol Head Neck Surg*. 2007;133:486–9.
- Stenson KM, Recant DJ, Kies W, Kies MS, Weichselbaum RR, Vokes EE. The role of cervical lymphadenectomy after aggressive concomitant chemoradiotherapy: the feasibility of selective neck dissection. *Arch Otolaryngol Head Neck Surg*. 2000;126:950–6.
- Robbins KT, Doweck I, Samant S, Vieira F. Effectiveness of superselective and selective neck dissection for advanced nodal metastases after chemoradiation. *Arch Otolaryngol Head Neck Surg*. 2005;131:965–9.
- Zou H, Zhang W, Han Q, Zhao Y. Salvage reconstruction of extensive recurrent oral cancer defects with the pectoralis major myocutaneous flap. *J Oral Maxillofac Surg*. 2007;65:1935–9.
- Vartanian JG, Carvalho AL, Carvalho SM, Mizobe L, Magrin J, Kowalski LP. Pectoralis major and myofascial/myocutaneous flaps in head and neck cancer reconstruction: experience with 437 cases at a single institution. *Head Neck*. 2004;26(12):1018–23.
- Zbar RIS, Funk GF, McCulloch TM, Graham SM, Hoffman HT. Pectoralis major myofascial flap: a valuable tool in contemporary head and neck reconstruction. *Head Neck*. 1997;19:412–8.
- Suh JD, Sercarz JA, Abemayor E, et al. Analysis of outcome and complications in 400 cases of microvascular head and neck reconstruction. *Arch Otolaryngol Head Neck Surg*. 2004;130:962–6.
- Ganly I, Patel S, Matsuo J. Postoperative complications of salvage total laryngectomy. *Cancer*. 2005;103:2073–81.
- Weber RS, Berkey BA, Forastiere A, et al. Outcome of salvage total laryngectomy following organ preservation therapy: the Radiation Therapy Oncology Group trial 91-11. *Arch Otolaryngol Head Neck Surg*. 2003;129(1):44–9.
- Agra IM, Carvalho AL, Pontes E, et al. Postoperative complications after en bloc salvage surgery for head and neck cancer. *Arch Otolaryngol Head Neck Surg*. 2003;129:1317–21.
- Lavertu P, Bonafede JP, Adelstein DJ, et al. Comparison of surgical complications after organ-preservation therapy in patients with stage III or IV squamous cell head and neck cancer. *Arch Otolaryngol Head Neck Surg*. 1998;124:401–6.
- Fung K, Teknos TN, Vandenberg CD. Prevention of wound complications following salvage laryngectomy using free vascularized tissue. *Head Neck*. 2007;29:425–30.
- Withrow KP, Rosenthal EL, Gourin CG, et al. Free tissue transfer to manage salvage laryngectomy defects after organ preservation failure. *Laryngoscope*. 2007;117:781–4.
- Virtaniemi JA, Kumpulainen EJ, Hirvikoski PP, Johansson RT, Kosma VM. The incidence and etiology of postlaryngectomy pharyngocutaneous fistulae. *Head Neck*. 2001;23(1):29–33.
- Soylu L, Kiroglu M, Aydogan B, et al. Pharyngocutaneous fistula following laryngectomy. *Head Neck*. 1998;20:22–5.
- Redaelli de Zinis LO, Ferrari L, Tomenzoli D, Premoli G, Parrinello G, Nicolai P. Postlaryngectomy pharyngocutaneous fistula: incidence, predisposing factors, and therapy. *Head Neck*. 1999;21:131–8.
- Herranz J, Sarandeses A, Fernandez MF, Barro CV, Vidal JM, Gavilan J. Complications after total laryngectomy in nonradiated laryngeal and hypopharyngeal carcinomas. *Otolaryngol Head Neck Surg*. 2000;122(6):892–8.
- Machtay M. Selected topics in head and neck cancer. *Commun Oncol*. 2006;3(10):644–50.
- Machtay M, Rosenthal DI, Chalian AA, et al. Pilot study of postoperative reirradiation, chemotherapy and amifostine after surgical

- salvage for recurrent head-and-neck cancer. *Int J Radiat Oncol Biol Phys.* 2004;59(1):72–7.
34. Janot F, de Raucourt D, Benhamou E, et al. Randomized trial of postoperative reirradiation combined with chemotherapy after salvage surgery compared with salvage surgery alone in head and neck carcinoma. *J Clin Oncol.* 2008;26(34):5518–23.
 35. Mendenhall WM, Mendenhall CM, Malyapa RS, Palta JR, Mendenhall NP. Re-irradiation of head and neck carcinoma. *Am J Clin Oncol.* 2008;31(4):393–8.
 36. Salama JK, Vokes EE. Concurrent chemotherapy and re-irradiation for locoregionally recurrent head and neck cancer. *Semin Oncol.* 2008;35(3):251–61.
 37. Lou PJ, Jager HR, Jones L, Theodossy T, Bown SG, Hopper C. Interstitial photodynamic therapy as salvage treatment for recurrent head and neck cancer. *Br J Cancer.* 2004;91(3):441–6.
 38. Glatzel M, Büntzel J, Schröder D, Küttner K, Fröhlich D. High-dose-rate brachytherapy in the treatment of recurrent and residual head and neck cancer. *Laryngoscope.* 2002;112:1366–71.
 39. Puthawala A, Syed AMN, Gamie S, Chen Y, Londrc A, Nixon V. Interstitial low-dose-rate brachytherapy as a salvage treatment for recurrent head-and-neck cancers: long-term results. *Int J Radiat Oncol Biol Phys.* 2001;51(2):354–62.
 40. Goodwin WJ. Salvage surgery for patients with recurrent squamous cell carcinoma of the upper aerodigestive tract: when do the ends justify the means? *Laryngoscope.* 2000;110 Suppl 93:1–18.
 41. Richey LM, Shores CG, George J, et al. The effectiveness of salvage surgery after the failure of primary concomitant chemoradiation in head and neck cancer. *Otolaryngol Head Neck Surg.* 2007;136:98–103.
 42. Scher RL, Esclamado RM. Organ and function preservation: the role of surgery as the optimal primary modality or as salvage after chemoradiation failure. *Semin Radiat Oncol.* 2009;19:17–23.
 43. Kim AJ, Suh JD, Sercarz JA, et al. Salvage surgery with free flap reconstruction: factors affecting outcome after treatment of recurrent head and neck squamous carcinoma. *Laryngoscope.* 2007;117:1019–23.

Chapter 47

Systemic Treatment of Recurrent/Metastatic Squamous Cell Carcinoma of the Head and Neck

Jan B. Vermorcken

Abstract Most patients with recurrent or metastatic head and neck squamous cell cancers qualify for palliative treatment. The management of these patients includes supportive care only, mono- or multiagent chemotherapy, and more recently targeted therapies. While platinum-based combinations are superior to single-agent therapies in terms of response rate, they are more toxic and so far have not shown to lead to meaningful survival benefit. Attempts to improve on this by using other or additional cytotoxic drugs were unsuccessful in the last 30 years. It was therefore an urgent need to investigate the efficacy of novel anticancer therapies that specifically target the tumor cells in such patients. A recent randomized trial showed that adding cetuximab, an EGFR-directed monoclonal antibody, to a standard platinum-based chemotherapy regimen led to an important survival benefit. Despite the still dismal prognosis, the outcome of this latter trial has changed practice in this category of head and neck cancer patients. The next challenge will be to sort out how to incorporate the numerous targeted agents that are currently studied into the existing treatment strategies, also in consideration of an optimization of their therapeutic index.

Keywords Head and neck • Recurrent • Metastatic • Targeted therapies • Platinum • Monoclonal antibodies • Tyrosine kinase inhibitors

Introduction

Approximately 60–65% of patients with head and neck cancer can be cured with surgery and/or radiotherapy [1]. While a large proportion of patients presenting with stage I and II

squamous cell carcinoma of the head and neck (SCCHN) will remain disease free after single modality treatment (either surgery or radiotherapy), the majority of patients presenting in a more advanced disease stage, and treated with whatever combined modality approach, will eventually relapse either locoregionally and/or at distant sites. A few patients with a locoregional recurrence can be salvaged by surgery or reirradiation. However, most patients with recurrent or metastatic (R/M) disease only qualify for palliative treatment. Treatment options in these patients include supportive care only, or in addition single-agent chemotherapy, combination chemotherapy, or targeted therapies either alone or in combination with cytotoxic agents. Treatment choice should be based on factors such as performance status, comorbidity, prior treatment, symptoms, patient preference, and logistics [2]. Goals of treatments in these circumstances is mainly symptom control and prevention of new cancer-related symptoms, and improvement in quality of life (QoL), and if assessable, objective tumor response (OR), disease stabilization (SD), or both combined (disease control; DC), and in addition prolongation of overall survival (OS) and progression-free survival (PFS). Unfortunately, correlation between objective tumor reduction (or DC) and subjective benefit (symptom control and QoL) has not been adequately studied, underscoring the importance of clinical trials in this patient group [3].

Associated Problems

Patients with R/M-SCCHN can have specific problems related to their social habits such as ongoing heavy tobacco and alcohol use or the use of other carcinogens, which may lead to poor cognitive function, comorbid medical conditions (cardiovascular and/or pulmonary diseases) and malnutrition. Moreover, typically disease-related problems may be present, such as infections (local, aspiration pneumonia, systemic), hypercalcemia, local pain or bleeding (arterial,

J.B. Vermorcken (✉)
Medical Oncology Department, Antwerp University Hospital,
Wilrijkstraat 10, Edegem 2650, Belgium
e-mail: jan.b.vermorcken@uza.be

venous, capillary), which all can influence quality of life and overall survival and may necessitate active supportive care [4].

Prognostic Factors

Several clinical prognostic factors have been proposed to define patients who are most likely to benefit from palliative chemotherapy and these can be categorized as patient-related, tumor-related, or treatment-related. Already for a long time it is known that the performance status is one of the most important prognostic factors that not only influences the incidence of response to chemotherapy, but also effects the overall survival of these patients regardless of the response to the applied chemotherapeutic agents [4, 5]. Patients with only local recurrence with or without regional lymph node involvement and no bony erosion after definitive treatment have a better chance to respond to chemotherapy than do patients with systemic and visceral metastases. Other factors that have been reported to influence outcome are a good response to prior induction (adjuvant) chemotherapy or radiotherapy, a long interval between primary and recurrence, good organ functions, poorly differentiated histotype, and the response to palliative treatment [4, 6–8]. Data from two more recently conducted US trials in R/M-SCCHN (E1395 and E1393) were combined and analyzed for prognostic factors for response and survival. The median follow-up of the patients in these two trials was 4.7 years; survival rates at 1, 2, 3 and 5 years were 32, 12, 7, and 3.6%, respectively, and median overall survival was 7.8 months. The OR rate was 32%. On multivariate analysis, the investigators were able to identify one pathologic feature (tumor cell differentiation) and four clinical baseline characteristics (ECOG performance status, weight loss, location of the primary tumor and prior radiotherapy) as independent predictors of OS. They constructed a prognostic model for OS based on the presence of these five independent prognostic factors and were able to categorize the patients into two groups with significantly different outcome, i.e. one in which patients had only 0–2 adverse prognostic factors and another in which patients had ≥ 3 poor prognostic factors. The first group had a median survival that was nearly twice that of the second group (0.98 years vs. 0.52 years). In this study, 283 of the 399 patients included in the analysis had three or more adverse factors, explaining the median survival of only 7.8 months [9]. They also identified that the same variables and the presence of residual tumor at the primary site were independent predictors of response to chemotherapy. In fact, response to chemotherapy was found to be of prognostic significance. When the investigators added response to chemotherapy to the model, the location of the primary tumor lost its prognostic significance but all

other parameters, including tumor cell differentiation, retained their significance as independent predictors of survival. Predictors of 2-year survivorship were response to chemotherapy (complete or partial response vs. no response), white race (vs. others), ECOG performance status of 0 (vs. 1), poor cell differentiation (vs. well/moderate) and no prior radiotherapy. Interestingly, all long-term survivors had locally recurrent disease at study entry. The findings in this study suggested that (1) there is an urgent need of better therapy for this category of patients, (2) response to systemic therapy has a major impact on survival, (3) patients with locally recurrent disease, but not the patients with distant metastases, who are primarily treated with chemotherapy, rarely will be cured from their disease, and (4) future trials in patients with R/M-SCCHN should take the five adverse prognostic factors into consideration.

R/M-SCCHN patients who fail platinum-based first-line therapy do very poorly; they have a very low chance to respond to second-line chemotherapy and have an extremely poor survival [10, 11]. Leon et al., in a retrospective analysis of the outcome of patients with R/M SCCHN who were progressing while on platinum-based palliative chemotherapy reported no responses using traditional chemotherapeutic agents and a median OS of 3.4 months [10]. Specenier et al. very recently reported that in these unfavorable conditions a taxane (docetaxel) in a weekly dose regimen induced only response in 6.7% of patients and mentioned a median OS of 17.9 weeks [11]. This is a practical problem in evaluating the effectiveness of new agent(s) which very often are tested in previously treated patients.

The Chemotherapeutic Approach

Squamous cell carcinoma of the head and neck is one of the more chemosensitive human neoplasms. Recent reports on induction chemotherapy in locoregionally advanced SCCHN have indicated that OR rates and complete response (CR) rates approaching 90% and 60%, respectively, are achievable [3]. These data are far from what can be reached in the recurrent/metastatic disease setting in which a more unfavorable (resistant) phenotype has emerged. In fact, compiled results from 12 nonrandomized trials showed an OR rate of 50% and a CR rate of 16% [12]. Some investigators have indicated that reaching a CR, especially if confirmed histologically, is meaningful for survival benefit [4, 13, 14], while PRs might have much less impact on survival and merely indicate biologic effectiveness [4]. This may certainly be so for long-term survival. In the earlier mentioned prognostic factor analysis of the two ECOG studies, ten times more CRs were observed in those alive at 2 years and beyond vs. those with a survival <2 years (37% vs. 3%). For overall

response (CR+PR) these percentages were 78% vs. 25%, suggesting that CR might be a surrogate marker for survival.

Single-Agent Chemotherapy

The four most extensively studied single cytotoxic agents in advanced or recurrent disease are bleomycin (average OR 21%), methotrexate (average OR 31%), 5-fluorouracil (average OR 15%), and cisplatin (average OR 28%). Response rates with these agents, but also with several other conventional agents of different classes [the platinum analog carboplatin (25%), the alkylating agents ifosfamide (26%) and cyclophosphamide (36%), the anthracycline doxorubicin (24%) and the vinca alkaloid vinblastine (29%)], are generally in the 15–30% range, while response duration is generally between 3 and 5 months [7, 15–23]. Similar response rates, mostly observed in phase II studies, were observed with newer agents such as paclitaxel, docetaxel, vinorelbine, irinotecan, edatrexate, pemetrexed, capecitabine, orzel, and S-1 [24–33] (Table 47.1).

As evident from the table, the taxanes paclitaxel and docetaxel are among the highest in activity in this disease setting. At the same time, it is clear from the table that there is a wide range of activity in different studies, most likely

reflecting variations in patient characteristics. For most of the conventional agents, but also of the newer agents, no direct comparison has been made with the standard palliative agent methotrexate. The few exceptions to this are summarized in Table 47.2.

Grose et al. [34] randomized 100 patients to be treated either with methotrexate or cisplatin. Response rates were 16 and 8%, median durations of response were 18 and 8 weeks and median durations of survival were 20 and 18 weeks, with methotrexate and cisplatin, respectively. A similar but smaller study was conducted by Hong et al. [19]. They found neither a difference in OR rate nor in median overall survival. However, mucositis occurred more frequently in the methotrexate group (38% vs. 0%; $p=0.001$), while vomiting occurred more frequently in the cisplatin group (87% vs. 10%; $p<0.0001$). These two randomized studies demonstrated that in the treatment of recurrent SCCHN, methotrexate and cisplatin are equally effective, although methotrexate appears to be better tolerated. Schornagel et al. [30] reported on an adequately sized European Organization for the Research and Treatment of Cancer (EORTC) trial, in which edatrexate (an analog of methotrexate) was compared with methotrexate. The originally favorable outcome in the phase II part of this protocol could not be confirmed in the phase III final results. There was strikingly more toxicity with edatrexate than with methotrexate (90% vs. 45% high-grade toxicity) and similar efficacy. As mentioned above, nonrandomized trials suggested a high activity with the use of taxanes in R/M-SCCHN patients. Direct comparisons were therefore of major interest. Vermorken et al. [35] compared paclitaxel 175 mg/m² administered either as a 3- or a 24-h infusion, with standard-dose methotrexate (40–60 mg/m² weekly) in a randomized phase II study. The 24-h infusion regimen was considered too toxic due to a high incidence of febrile neutropenia. However, none of the regimens was superior with respect to response or survival. Weekly schedules of taxanes induce interesting response rates and may have a better therapeutic index than three weekly schedules. Guardiola et al. [36] randomized 57 patients between weekly docetaxel 40 mg/m² or weekly methotrexate 40 mg/m².

Table 47.1 New active^a agents in recurrent/metastatic SCCHN

Drug	Response rates (%)	First author, year (references)
Edatrexate	6–21	Schornagel, 1995 [30]
Pemetrexed	26	Pivot, 2001 [26]
Vinorelbine	6–22	Testolin, 1994 [27]
Irinotecan	21	Murphy, 2005 [29]
Capecitabine	8–22	Martinez-Trufero, 2009 [28]
Orzel	21	Colevas, 2001 [33]
S-1	27	Park, 2008 [31]
Paclitaxel	20–43	Schrijvers, 2005 [24]; Grau, 2008 [25]
Docetaxel	20–42	Schrijvers, 2005 [24]; Hitt 2006 [32]

^aActivity defined as $\geq 15\%$ responses

Table 47.2 Randomized single-agent trials in recurrent/metastatic SCCHN

Author (year)	No. of patients	Drugs randomized	Response rate (%)	Median OS (months)
Grose (1986)	100	Methotrexate	16	4.6
		Cisplatin	8	4.1
Hong (1983)	38	Methotrexate	23	6.1
		Cisplatin	29	6.3
Schornagel (1995)	264	Methotrexate	16	6.0
		Edatrexate	21	6.0
Vermorken (1999)	95	Methotrexate	16	6.8
		Paclitaxel 3 h (vs. 24 h)	11 (–23)	6.5
Guardiola (2004)	57	Methotrexate	15	3.9
		Docetaxel	27	3.7

The overall response rate in this phase II trial was significantly higher with docetaxel (27% vs. 15%). However, there was no indication that overall survival or time to progression was any different between the two treatment arms. It is currently unclear if any of the cytotoxic agents prolongs survival when compared with supportive care alone as an adequately powered randomized controlled trial has never been performed. Only one small study in the past was designed to demonstrate clinical benefit over best supportive care only using randomized controlled trial methodology. In that trial, 31 patients treated with single-agent cisplatin demonstrated prolonged survival compared with 26 patients treated with supportive measures only [37]. An interested aspect in this trial was the demonstration that patients who respond do so quickly. Of the 16 responders, 75% responded after the first cycle and the remaining 25% after the second cycle [3].

Combination Chemotherapy

Standard Platinum-Based Combinations

Combination chemotherapy is very often considered in patients who are young and in a good condition, in particular when favorable prognostic factors for response to chemotherapy are available [4]. The Wayne State University cisplatin/infusional 5-fluorouracil (5-FU) (PF) regimen gradually emerged as the most commonly used combination chemotherapy regimen in patients with SCCHN. With that regimen, nonrandomized trials suggested a better outcome than what was observed with single-agent treatment, at least with respect to OR rates and CR rates [12]. However, response rates were notably lower for the subsets of patients who had prior surgery and radiation and those who had metastatic disease [3]. In a number of adequately sized randomized trials performed in the 1990s, this PF regimen was shown to be superior to single-agent regimens, in terms of response rates but not in terms of meaningful survival advantage, and this gain in response rates was obtained at the cost of more toxicity [6, 7, 18] (Table 47.3).

Jacobs et al. [7] compared the PF regimen with either cisplatin alone or 5-fluorouracil alone in a randomized phase III trial which included 249 patients. The overall response rate to PF (32%) was superior to that of cisplatin (17%) or 5-fluorouracil (13%) ($p=0.035$). However, there was neither a difference in median time to progression nor in survival among the three groups. Forastiere et al. [6] randomized 277 patients to PF, carboplatin/5-fluorouracil (CF) or standard dosed methotrexate. Hematologic and nonhematologic toxicities were significantly worse with PF than with methotrexate ($p=0.001$). Toxicity with CF was intermediate between the

Table 47.3 Cisplatin/5-fluorouracil PF vs. single agents or other Pt-regimens: Randomized trials

Reference	No. of patients	Agents	RR (%)	MS (mo)
[7]	249	PF	32*	5.5
		P	17	5.0
		F	13	6.1
[6]	277	PF	32**	6.6
		CF	21	5.0
		M	10	5.6
[18]	382	CABO	34†	7.0
		PF	31‡	
		P	15	
[44]	218	PF	27	8.7
		PT	26	8.1

P cisplatin, C carboplatin, M methotrexate, B bleomycin, V vincristine, T paclitaxel, CABO=P+M+B+V

* $p=0.035$; ** $p<0.001$; † $p<0.001$; ‡ $p=0.003$

two other regimens. The response rates were 32% for PF, 21% for CF, and 10% for methotrexate, respectively. The comparison of PF to methotrexate was statistically significant ($p<0.001$), and the comparison of CF to methotrexate was of borderline statistical significance ($p=0.05$). Median response durations and median survival times were similar for all three treatment groups. The CF combination also induced fewer responses than the PF regimen in a randomized phase III trial in the neoadjuvant setting [38]. Moreover, there was no difference in response rate in a randomized comparison of carboplatin plus methotrexate vs. single-agent methotrexate [39]. Taken together, these data clearly suggest that carboplatin is less active than cisplatin in the treatment of SCCHN.

Clavel et al. [40] in a first prospective trial randomized 185 patients between CABO, which consisted of cisplatin, methotrexate, bleomycin and vincristine, and ABO (CABO without cisplatin). Although the overall response rate was higher with CABO (50% vs. 28%; $p=0.003$), this did not lead to a better survival. In a next phase III study Clavel et al. [18] compared PF with CABO and with cisplatin alone in 382 patients with metastatic or recurrent SCCHN. The overall response rate was 31% with PF, 34% with CABO, and 15% with cisplatin alone. The two combination regimens were significantly better in that respect than cisplatin alone ($p<0.001$ and 0.003, respectively). In addition, the complete response rate with CABO (9.5%) was higher than with cisplatin alone (2.5%) ($p=0.02$), or with PF (1.7%) ($p=0.01$). However, although perhaps expected differently, these higher response rates (and CR rates) did not translate into an improved median survival, which was 7.3 months in all three arms. The median time to progression (TTP) among the assessable patients was 19 weeks in the CABO arm, 17 weeks in the PF arm, and 12 weeks in the cisplatin arm (log rank $p=0.02$). Both combination regimens were associated with more toxicity.

Platinum–Taxane Combinations

Of the newer agents, the taxanes have been studied most extensively in combination chemotherapy regimens [24, 41–45]. More recently, the carboplatin/docetaxel combination was evaluated in a phase II study conducted by the Southwest Oncology Group [45]. Sixty-eight patients were treated with docetaxel 65 mg/m² and carboplatin AUC 6 every 21 days. The overall response rate was 25%. Sixty-one percent of the patients experienced grade 3/4 neutropenia. The median PFS was 3.8 months and the median overall survival 7.4 months.

The paclitaxel plus cisplatin (PP) combination was directly compared to the PF regimen in the Intergroup trial E1395 conducted by ECOG [44]. Patients received either paclitaxel 175 mg/m² (over 3 h) and cisplatin 75 mg/m², both on day 1, or the classical PF regimen. The objective response rate was 27% with PP and 26% with PF. The overall grade 3/4 toxicity rate was similar between the two groups. However, grade 3/4 mucositis (31%) was only observed in the PF arm, while the occurrence of neurotoxicity was similar in the two groups. Median overall survival was 8.7 months in the PF group and 8.1 month in the PP group. Considering the more favorable toxicity profile, PP may be a valuable alternative to PF.

Two-Drug and Three-Drug Platinum–Taxane Combinations

The response rates of two-drug or three-drug combinations with paclitaxel or docetaxel in nonrandomized trials are summarized in Table 47.4. With TPF (docetaxel 80 mg/m² day 1, cisplatin 40 mg/m² days 2 and 3, and 5-FU 1,000 mg/m² by continuous infusion days 1–3, repeated every 28 days), Janinis et al. [46] observed an overall response rate of 44%, a median TTP of 7.5 months and a median overall survival of 11 months. Despite the use of G-CSF, febrile

neutropenia occurred rather frequently (in 15% of the patients). Benasso et al. [47] treated 47 patients with PPF (paclitaxel 160 mg/m² on day 1 and cisplatin 25 mg/m²/day and 5-fluorouracil 250 mg/m²/day, both on days 1–3), every 3 weeks. The overall response rate was 31% with 13.3% complete responders. Median PFS and overall survival were 4.1 and 7.9 months, respectively. Forty-eight percent of the patients experienced grade 3/4 neutropenia. The TIP and TIC regimens were tested in R/M-SCCHN by Shin et al. [42, 43]. The TIP regimen consisted of paclitaxel 175 mg/m² on day 1, ifosfamide 1,000 mg/m² (by 2-h infusion) on days 1–3, mesna 600 mg/m² on days 1–3 and cisplatin 60 mg/m² on day 1, repeated on day 22 [42]. Ninety percent of the patients experienced grade 3 or 4 neutropenia and the rate of febrile neutropenia was unacceptably high (27%). The overall response rate was 58% with 17% complete responders. In the TIC regimen similar doses of paclitaxel and ifosfamide were used as in TIP, but cisplatin was replaced by carboplatin AUC 6 [43]. Also TIC was repeated every 3 weeks. TIC induced febrile neutropenia in 30% of the patients and one patient died of neutropenic sepsis. The overall response rate was 59% with 17% complete responders. The median duration of the responses was 3.7 months. Overall, it can be concluded that taxane containing triplets induce high response rates, also in the recurrent/metastatic disease setting. However, they are associated with substantial hematologic toxicity and a high complication rate. As these triplets have never been directly compared with PF in a randomized phase III study in this setting, they should not be recommended outside clinical trials. Moreover, as none of the combination chemotherapy regimens demonstrated an overall survival benefit when compared to single-agent methotrexate, cisplatin or 5-fluorouracil, the use of combination chemotherapy preferably is used in younger patients with a good performance status and with symptomatic disease who require prompt symptom relief.

Cytotoxic Chemotherapy in R/M-SCCHN: Summary

For patients who are not in the condition to be treated with the more aggressive platinum-based combination chemotherapy regimens, single-agent methotrexate is still a standard palliative therapy.

Platinum-based combinations are superior to single-agent therapies in terms of response rate (at the cost of more toxicity), but do not lead to meaningful survival benefit.

Once platinum-resistance occurs, the outlook is very poor. The reference arm for testing new single cytotoxic agents, preferably in a randomized trial design, is single-agent methotrexate.

Table 47.4 Platinum–taxane combinations in recurrent/metastatic SCCHN: two vs. three drugs

	Response rates (complete response rates) (%) with	
	Paclitaxel	Docetaxel
Two drugs		
Cisplatin	32–39 (0)	33–52 (9–11)
Carboplatin	33–33 (4–8)	25 (NR)
Three drugs		
Cisplatin/5-FU	31–38 (13)	44 (12)
Cisplatin/ifosfamide	58 (17)	–
Carboplatin/ifosfamide	59 (17)	–

Based on references [24, 41–43, 45]; NR not reported

There is thus clearly an urgent need of novel anticancer therapies that target the tumor cells specifically while minimizing the toxic side effects.

Targeted Therapies in R/M-SCCHN

Several biological therapies have been chosen in head and neck cancer patients because of their different mechanism of action, greater selectivity (target of action is overexpressed as compared to normal tissue), different toxicity profile or because they play a role in carcinogenesis [2, 48]. These include drugs that target growth factors and their receptors, signal transduction, cell cycle control, prostaglandin synthesis, protein degradation, hypoxia, and angiogenesis [49]. In this chapter, only those data will be highlighted that have presently some relevance for the treatment of patients with R/M-SCCHN.

Epidermal Growth Factor Receptor and ErbB2

The epidermal growth factor receptor (EGFR) inhibitors are of particular interest, because EGFR and its ligand TGF- α (alpha) are overexpressed in the vast majority of cases of SCCHN. In contrast, ErbB2 expression in SCCHN ranges between 40 and 60% [50]. EGFR overexpression and increased EGFR copy number have been related to poor prognosis in patients with SCCHN [51, 52]. Its prognostic role is more specifically related to the treatment received, such as radiotherapy [51, 53] and chemotherapy [54]. Recently, it was found, however, that both EGFR expression and FISH determination were not predictive for response to anti-EGFR therapy with cetuximab [55].

Two of the potential EGFR-targeting strategies are currently in clinical use: the monoclonal antibodies (MoAbs)

directed at the extracellular domain of the receptor and the small molecule and ATP-competitive tyrosine kinase inhibitors (TKIs). Table 47.5 is summarizing some important EGFR inhibitors under clinical investigation in R/M-SCCHN. EGFR-activated signaling pathways and the effect of activation on cell proliferation and survival are well documented [56]. Ligand binding to the EGFR is followed by stimulation of a number of different signal transduction cascades, including the mitogen-activated protein kinase (MAPK) pathway and the phosphatidylinositol 3-kinase (PI3K)-Akt pathway. The MoAbs and TKIs act at different points on the pathway to disrupt signaling. However, it is likely that the effects of these agents are not mediated by disruption of EGFR signaling pathways alone. Also, antibody-dependent cellular cytotoxicity (ADCC) is thought to be an important mechanism of action, but for a long time it was thought that this only referred to IgG1 MoAbs [57, 58]. However, very recently it was discovered that also human IgG2 MoAbs against EGFR effectively trigger ADCC but, in contrast to IgG1, only by cells of the myeloid lineage [59]. The ability of many EGFR inhibitors to enhance the effects of radiation and/or chemotherapy has been demonstrated both in vitro and in vivo [60]. In vitro and in vivo data suggest that the combined use of an EGFR-targeted MoAb and a TKI increases the impact of either agent alone on downstream signaling, apoptosis, proliferation and tumor (xenograft) growth [61, 62], and this may be of interest for the clinical situation, in particular for the recurrent/metastatic disease setting (see below).

Monoclonal Antibodies

Cetuximab

The best studied monoclonal antibody thus far is cetuximab, which is a human–murine chimeric immunoglobulin G₁ (IgG₁) monoclonal antibody, which competitively binds to

Table 47.5 Selection of relevant EGFR-targeting agents under clinical investigation in SCCHN

Monoclonal antibodies				Toxicity
Cetuximab	IMC225	Chimeric human/murine	IgG1	Skin
Matuzumab	EMD72000	Humanized mouse	IgG1	Skin
Nimotuzumab	h-R3	Humanized mouse	IgG1	Systemic/hemodynamic
Zalutumumab	2F8	Human	IgG1	Skin
Panitumumab	ABX-EGF	Human	IgG2	Skin
Tyrosine kinase inhibitors				
Gefitinib	ZD1839	Reversible	EGFR	Skin/gastrointestinal (GI)
Erlotinib	OSI-774	Reversible	EGFR	Skin/GI
	PKI-166	Reversible	EGFR/ErbB2	Skin/GI/systemic/hepatic
Lapatinib	GW-572016	Reversible	EGFR/ErbB2	Skin/GI/systemic
Canertinib	CI-0033	Irreversible	EGFR	Skin/oral/GI/systemic

From [48], reprinted with kind permission from Springer Science+Business Media

the extracellular domain of the EGFR. Cetuximab has been tested in R/M-SCCHN, either in second-line after failure of platin-based chemotherapy or in first-line in combination with platin-based chemotherapy. Moreover, it has been tested as part of the combined modality treatment for locoregionally advanced SCCHN. This latter application is beyond the scope of this chapter.

Cetuximab in Second-Line Therapy

Three phase II trials examined the role of cetuximab in platinum-refractory or platinum-resistant disease. All patients received cetuximab intravenously at an initial loading dose of 400 mg/m² followed by weekly 250 mg/m².

Baselga et al. [63] added weekly cetuximab to platinum-based chemotherapy in 96 patients with truly platinum-refractory SCCHN. The objective response rate (primary endpoint) was 10%. The disease control rate (CT + PR + SD) was 53%. The median time to progression and overall survival were 85 and 183 days, respectively.

Herbst et al. [64] studied the combination of cetuximab and chemotherapy in a rather heterogeneous population of 130 patients with recurrent and/or metastatic SCCHN. The patients had either stable disease after two cycles or had progressed under cisplatin-based chemotherapy. After cetuximab was added to the same regimen, 13% of the patients responded. The disease control rate in the patients with progressive disease at study entry was 55%. Median duration of response was about 4 months in the cohort of patients with progressive disease at study entry and 7.4 months in the cohort of patients with stable disease at study entry.

Vermorcken et al. [65] conducted an open-label, uncontrolled, multicenter phase II study, with a two-phase design. In the first phase, 103 patients with platin-refractory metastatic or recurrent SCCHN received single-agent cetuximab. A partial response was documented in 13% of the patients. The disease control rate was 46%. The median duration of response was 126 days. The median time to progression was 70 days. Fifty-three patients (51%) who experienced progression while receiving single-agent cetuximab continued treatment with cetuximab, but then again in combination with a platinum compound. No objective responses were

observed in this second phase. Responses in the latter three studies were remarkably similar, irrespective of whether the cetuximab was administered as a single-agent or added to a platinum-based regimen. This suggests that the observed responses were attributable to cetuximab alone rather than to the reversal of platinum-resistance by cetuximab.

Interestingly, the survival of around 6 months achieved with cetuximab in platinum-refractory disease was found similar to that seen with first-line therapy and represented an increase in survival of 2.5 months compared with platinum-refractory historical controls [10]. Based on these results and particularly considering the fact that about 50% of the patients showed disease control, cetuximab monotherapy seems to be a good option for patients with recurrent and/or metastatic SCCHN who have progressed on platinum-based chemotherapy.

Cetuximab in First-Line Therapy

The feasibility of the combination of cetuximab with cisplatin or carboplatin and 5-fluorouracil was demonstrated in a phase I/II study [66]. In addition, it was shown that cetuximab could be easily combined with weekly paclitaxel [67] and with the combination of a platinum and a taxane [68]. The second step was to evaluate whether the addition of cetuximab to platinum-based chemotherapy in first-line for recurrent/metastatic disease would benefit patients in terms of survival gain. Up to this moment, this has been studied only in two randomized multicenter phase III trials [69, 70] (Table 47.6).

Burtneß et al. [69] assigned 117 patients to cisplatin 100 mg/m² every 4 weeks either with weekly cetuximab or with weekly placebo. The primary endpoint of this study was progression-free survival. The study was designed to detect a difference in median PFS of 2 months, i.e., 2 months with cisplatin plus placebo and 4 months with the experimental arm. However, the observed median PFS in the control arm was longer than expected (2.7 months). The median PFS in the cetuximab arm was 4.2 months and that difference did not reach statistical significance ($p=0.09$). In fact, the actual power to detect a 2 months difference in this situation was only 50%. The objective response rate was 26% in the

Table 47.6 Completed randomized trials with EGFR inhibitors in recurrent/metastatic SCCHN

Study (reference)	N	Regimen	Population	RR (%)	OS (mo)
EXTREME [70]	442	PFE vs. PF	1st-line	36 vs. 20	10.1 vs. 7.4
ECOG 5397 [69]	117	PE vs. P+placebo	1st-line	26 vs. 10	9.2 vs. 8.0
IMEX [78]	486	Gefitinib (250 mg) vs. Gefitinib (500 mg) vs. methotrexate	2nd-line	2.7 vs. 7.6 vs. 3.9	5.6 vs. 6.0 vs. 6.7
ECOG 1302 [84]	270	D+Gefitinib vs. D	Any line	14 vs. 6	6.8 vs. 6.0

PF cisplatin or carboplatin plus 5-FU, E cetuximab (Erbix[®]), D docetaxel, RR response rate, OS overall survival, mo months

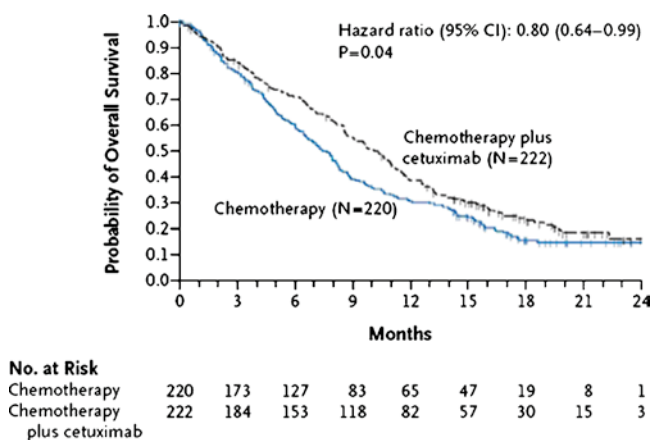


Fig. 47.1 Overall survival with platinum/5-FU combination chemotherapy with or without cetuximab. From [70], copyright 2008 Massachusetts Medical Society. All rights reserved

experimental arm vs. 10% in the control arm ($p=0.03$). Median overall survival was not significantly different (9.2 vs. 8 months, $p=0.21$). Development of cetuximab-related skin toxicity was associated with an improved overall survival (hazard ratio 0.42, $p=0.01$). In the EXTREME study [70] 442 patients were randomized to receive either chemotherapy alone (cisplatin 100 mg/m² or carboplatin AUC 5 mg/ml.min on day 1 followed by 5-fluorouracil 1,000 mg/m²/day for 4 days) or the same regimen combined with weekly cetuximab (initial loading dose of 400 mg/m² followed by weekly doses of 250 mg/m²). Cycles were repeated every 3 weeks for a maximum of six cycles. Thereafter, in the combined arm, cetuximab was continued as a single agent until disease progression or unacceptable toxicity whatever came first. No crossover was permitted in this study. Excluded were patients who had received prior chemotherapy except when this had been part of their primary treatment provided this chemotherapy was ended at least 6 months before inclusion in the study. The primary endpoint was overall survival. The addition of cetuximab to platinum–fluorouracil significantly prolonged the median overall survival from 7.4 months in the chemotherapy-alone group to 10.1 months in the group that received chemotherapy plus cetuximab (hazard ratio for death, 0.80; 95% confidence interval, 0.64–0.99; $p=0.04$) (Fig. 47.1).

The addition of cetuximab also prolonged the median progression-free survival time from 3.3 to 5.6 months (hazard ratio for progression, 0.54; $p<0.001$) and increased the response rate from 20 to 36% ($p<0.001$). The beneficial effect was evident both in the patients treated with cisplatin/5-FU and the patients treated with carboplatin/5-FU, although also in this study response rates with carboplatin/5-FU were below those obtained with cisplatin/5-FU independent from the treatment arm (Fig. 47.2). Moreover, protocol-defined subgroup analyses showed that the beneficial effects of adding cetuximab to platinum–fluorouracil chemotherapy on

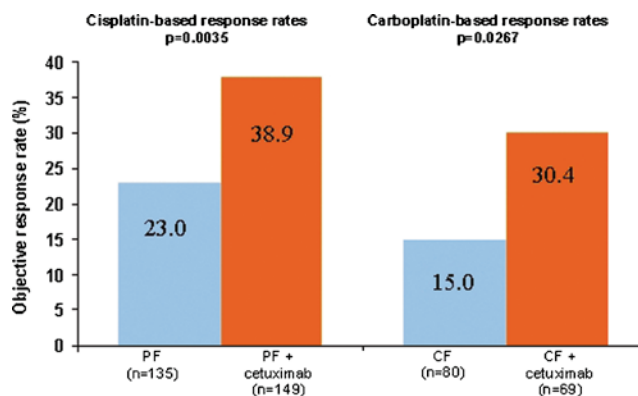


Fig. 47.2 Response rates: Cisplatin/5-FU (PF)-based therapy vs. Carboplatin/5-FU (CF)-based therapy

overall survival and progression-free survival were evident in nearly all subgroups analyzed. The most common grade 3 or 4 adverse events in the chemotherapy-alone and cetuximab groups were anemia (19 and 13%, respectively), neutropenia (23 and 22%), and thrombocytopenia (11% in both groups). Sepsis occurred in nine patients in the cetuximab group and in one patient in the chemotherapy-alone group ($p=0.02$). There were 11 cases of grade 3 or 4 hypomagnesemia in the cetuximab group, as compared with three cases in the chemotherapy-alone group ($p=0.05$). Of the 219 patients receiving cetuximab, 9% had grade 3 skin reactions and 3% had grade 3 or 4 infusion-related reactions. There were no cetuximab-related deaths.

This is the first time in over 30 years that superiority (in terms of survival) of a new regimen over standard platinum-based combination chemotherapy has been observed. Cetuximab and platinum-based chemotherapy is now considered as a new standard for the treatment of R/M-SCCHN for those who are able to tolerate platinum-based combination chemotherapy regimens [71].

Panitumumab

Panitumumab (ABX-EGF) is a fully human IgG2 antibody with a very strong binding to the receptor [48, 72]. It blocks ligand binding and induces internalization of the receptor but no receptor degradation. Side effects include pruritus, skin rash, dyspnea, fatigue, abdominal pain, asthenia, and diarrhea. Panitumumab at a weekly dose of 2.5 mg/kg has an acceptable tolerability and encouraging clinical activity in patients with a variety of tumor types. Its pharmacokinetic profile allows a more convenient three weekly administration (9 mg/kg). Three studies with panitumumab in the recurrent/metastatic disease setting are of interest, i.e. the PRISM study, the PARTNER study and the SPECTRUM study. The PRISM study is a phase II study with single-agent

panitumumab in second-line, the PARTNER study is a randomized phase II study in first-line studying docetaxel plus cisplatin with or without panitumumab and in the SPECTRUM trial, similar patients as in the EXTREME trial were randomized to receive cisplatin/5-fluorouracil with or without panitumumab. Enrolment in this latter trial has been completed. The combination was safe and efficacy data are awaited in 2010 [73].

Zalutumumab

Zalutumumab [48] is also a fully human IgG1 EGFR-directed monoclonal antibody. The frequency of acneiform rashes with this compound increases with dose. Zalutumumab is currently undergoing phase III testing in patients who failed standard platinum-based chemotherapy vs. best supportive care (BSC) alone. Patients in the BSC arm were allowed to receive single-agent methotrexate, if so wished by the investigator. Promising data were released in a company announcement in March 2010. It is expected that data of this trial will be reported at the annual meeting of ASCO in June 2010.

Matuzumab

Matuzumab is a humanized IgG1 monoclonal antibody that in a phase I dose escalation study in stage III/IV larynx and hypopharynx cancer showed that fever and transient elevations of liver enzymes were the most frequently observed treatment-related adverse events [74]. A weekly dose of 200 mg, based on pharmacokinetic findings, was selected for further studies. No data of randomized trials in R/M-SCCHN are available.

Nimotuzumab

Nimotuzumab [48] is also a humanized IgG1 mouse antibody. Preliminary data suggest that therapeutic levels of nimotuzumab can be achieved without eliciting skin toxicity, which is the most common side effect of the other anti-EGFR-directed antibodies. Nimotuzumab has a lower receptor affinity than, e.g., panitumumab, cetuximab, or matuzumab, and there seems to be a relationship between receptor affinities and incidence of acneiform rash for anti-EGFR MoAbs [75]. It has been hypothesized that higher binding and internalization of MoAbs in the tumor together with a lower level of internalization in noncancerous tissues is obtained with intermediate K_d values between 10^{-9} and

10^{-8} M, as is the case for nimotuzumab. Moreover, recent experimental observations have demonstrated that in contrast to other anti-EGFR antibodies, the intrinsic properties of nimotuzumab requires bivalent binding for stable attachment to cellular surfaces, which leads to a greater selectivity of nimotuzumab to bind to cells that express moderate to high EGFR levels, such as SCC. At present, there is no clinical evidence that higher affinity to the receptor leads to greater efficacy, though stronger binding clearly leads to higher toxicities. A phase IIB clinical study in Indian patients with SCCHN showed very few skin reactions, including urticaria and pruritus, but did show some headache, hypertension, and fluctuation in blood pressure [76]. Nimotuzumab is presently approved for use in SCCHN, glioma, and nasopharyngeal cancer in different countries and is granted orphan drug status for glioma in the USA and for glioma and pancreatic cancer in Europe.

Tyrosine Kinase Inhibitors

The tyrosine kinase inhibitors (TKIs) compete with ATP for the cytoplasmatic catalytic domain of EGFR. Gefitinib and erlotinib are reversible specific EGFR TKIs and belong to the group of quinazole TKIs. This group also comprises PD153035 and GW 572016 (lapatinib), which are reversible dual EGFR/HER-2 inhibitors; EKB-569, which irreversibly inhibits the EGFR and HER-2 tyrosine kinase; and the irreversible pan-ErbB TKI CI-1033 (canertinib) (see Table 47.5). PKI-166 (dual EGFR/ErbB-2) belongs to the pyrrolotriazine TKIs, which also include AEE788 (dual EGFR/ErbB-2) and BMS 599626. ARRY-334543 (dual EGFR/ErbB-2) and PD1578 belong to the pyridopyrimidine TKI [48].

Single-Agent Use

In general, the results with oral tyrosine kinase inhibitors have been disappointing. So far, there has been no randomized trial reported with a positive outcome. Single-arm trials with gefitinib and erlotinib showed response rates ranging from 0% (in chemotherapy-refractory disease) to 15% (in “untreated” recurrent/metastatic disease patients) and a median progression-free survival of approximately 3.5 months, summarized in [48, 61, 77]. Drug toxicity was generally mild, consisting of skin rash and diarrhea, more frequent at higher dosages. It has been suggested, based on some of these single-arm studies, that outcome might not only be related to the occurrence and severity of the skin reaction, but also related to the dose used. This latter aspect was tested in a large phase III trial (1839 IL/0704; IMEX)

in which 482 patients with recurrent and/or metastatic SCCHN, unresponsive to platinum or unfit for platinum, were randomized in a three-armed study to receive either gefitinib 250 or 500 mg/day or methotrexate 40 mg/m² IV weekly [78]. Neither gefitinib 250 nor 500 mg/day improved survival compared with single-agent methotrexate. Overall response rates were 2.7, 7.6, and 3.9%, respectively, and median overall survival was 5.6, 6, and 6.7 months, respectively (see also Table 47.6). Tumor bleeding was observed more frequently in patients treated with gefitinib than with methotrexate. Single-agent lapatinib (1,500 mg/day) was associated with disappointing activity (no objective responses) in a phase II study in 42 patients with recurrent and/or metastatic disease, 15 of whom had previously received treatment with an EGFR inhibitor [79]. Cohen et al. [80] reviewed individual patient data from five clinical trials of erlotinib, lapatinib, or gefitinib to determine if there are clinical characteristics that are associated with clinical benefit. Performance status (PS) ($p=0.04$), older age ($p=0.02$), and development of rash ($p<0.01$), diarrhea ($p=0.03$), or oral side effects ($p=0.02$) were independently associated with clinical benefit. Older age, better PS, and development of rash were associated with longer PFS and OS. EGFR mechanistic toxicities that developed during therapy were also highly associated with benefit and suggest a relationship between drug exposure and outcome [80].

Combinations with Chemotherapy

A phase I/II trial of erlotinib and cisplatin performed by the Princess Margaret Hospital phase II consortium and the National Cancer Institute of Canada Clinical Trials Group in a population of platinum-sensitive recurrent/metastatic SCCHN patients revealed a response rate of 21% and a median OS of 7.9 months [81]. These data are similar to those reported by Burtneess et al. [69] with the combination of cisplatin and cetuximab in similar patients, albeit that these latter data were obtained in a randomized trial setting. Combinations of the tyrosine kinase inhibitors with cisplatin plus docetaxel (in Europe with gefitinib; in the USA with erlotinib) have shown interesting results in small groups of patients and did not cause more hematologic toxicity than normally observed with cisplatin plus docetaxel alone [82, 83]. However, ECOG [84] conducted a randomized, placebo-controlled trial of docetaxel 35 mg/m² on days 1, 8, and 15 every 28 days, with or without gefitinib 250 mg/day in recurrent or metastatic SCCHN patients. Although the combination was well tolerated and improved the time to progression from 2.0 to 3.5 months ($p=0.03$), this did not translate into an improved overall survival (see Table 47.6). The ErbB2-directed antibody trastuzumab was added to paclitaxel and

carboplatin in a phase II study that included patients with metastatic or recurrent SCCHN [85]. The response rate (36%) was not higher than what could be expected with this chemotherapy regimen alone.

Vascular Endothelial Growth Factor and Vascular Endothelial Growth Factor Receptor

Activation of the vascular endothelial growth factor/vascular endothelial growth factor receptor (VEGF/VEGFR) axis triggers a cascade of signaling processes that promote tumor angiogenesis and lymphangiogenesis. The majority of the studies, although not all, examining the prognostic significance of VEGF expression did observe a worse outcome in patients with SCCHN expressing VEGF and VEGFR-2 [86, 87]. Anti-VEGF strategies include neutralizing antibodies to VEGF or VEGFR and VEGFR TKIs.

Bevacizumab

Bevacizumab is a humanized VEGF-A-directed antibody that is in clinical development in a wide variety of tumors including NSCLC, breast cancer, ovarian cancer, prostate cancer, and brain tumors. Seiwert et al. [88] integrated bevacizumab 10 mg/kg every 2 weeks into an alternating regimen of infusional 5-FU, hydroxyurea, and daily radiation as treatment for newly diagnosed or recurrent SCCHN requiring local control. Because of neutropenia, the originally planned chemotherapy doses (5-FU 800 mg/m², HU 1,000 mg/m²) needed to be decreased (5-FU 600 mg/m², HU 500 mg/m²). Three thrombotic events and two fatal bleedings as well as late complications including five patients with fistula formation (11.6%) and four with ulceration/tissue necrosis (9.3%) were observed, for which a relation to bevacizumab was suspected. A randomized phase II study in a better prognosis, treatment-naïve patient population is ongoing. An interim analysis of a phase II study demonstrated activity of a combination of bevacizumab and pemetrexed in first-line treatment of recurrent/metastatic SCCHN [89]. A response rate of 45% among 14 evaluable patients was reported. However, bleeding complications were relatively high, with two grade 3 and three grade 1–2 bleeding events.

Tyrosine Kinase Inhibitors

The complications mentioned above are regularly reported in different studies, not only with bevacizumab, but also with the TKIs [48]. Early data on semaxanib (a small molecule TKI that interferes with angiogenesis by selectively

inhibiting the VEGFR-2 receptor) and the multikinase inhibitor sorafenib [which is both an inhibitor of Raf-1 and B-Raf kinases and protein tyrosine kinases associated with VEGFR-2 and -3 as well as the platelet-derived growth factor receptor B (PDGFR-B)] are summarized in two recent reviews, showing only modest activity and a higher than expected thromboembolic events [48, 60]. Recently, a high incidence of fatal and nonfatal hemorrhagic complications and fistulization in R/M-SCCHN were reported with sunitinib, a multitargeted TKI of RET, VEGFR, PDGFR and c-KIT [77]. The severity of these complications highlights the importance of improved patient selection for future studies with these compounds in head and neck cancer. Use outside clinical trials is not recommended.

Combined Targeting of EGFR and VEGFR

Based on preclinical data combined targeting seems of interest and maybe particularly of interest for patients with recurrent/metastatic SCCHN when tolerance of such an approach proves to be good. Cohen et al. [90] combined erlotinib 150 mg/day and bevacizumab in patients with recurrent or metastatic squamous cell carcinoma of the head and neck. In the phase I portion of the study, no dose-limiting toxic effects were observed at the highest dose level of bevacizumab (15 mg/kg every 3 weeks). Forty-eight patients were treated at that dose level. The most common toxic effects were rash and diarrhea. Three patients had serious bleeding events of grade 3 or higher. The overall response rate was 14.6% with 8.3% complete responses. Median time of overall survival and progression-free survival were 7.1 months (95% CI 5.7–9.0) and 4.1 months (2.8–4.4), respectively. Gibson et al. [91] presented early data on the combined treatment with weekly cetuximab and bevacizumab 15 mg/kg every 3 weeks in patients with R/M-SCCHN. Best response in 25 evaluable patients was 20% PR, 56% SD, and 24% progressions. PFS was 2.8 months and median survival 8.1 months. Toxicity was manageable. Only rarely serious toxicities were observed.

Other Targets

Other targets such as those along the EGFR downstream pathways (the RAS-RAF mitogen-activated protein kinase pathway, the phosphatidylinositol 3-kinase-Akt, the signal transducer and activator of transcription (STAT) phosphorylation of tyrosine kinases in its intracellular domain, and the phospholipase-C gamma and protein kinase-C), Aurora A, insulin-like growth factor-1 receptor (IGF-1R), the proteasome, histone deacetylases (HDAC), and the

epithelial cellular adhesion molecule (Ep-CAM) and cyclooxygenase-2, are all of interest, but not being at the level of having relevance for daily practice, as yet.

Targeted Therapy in R/M-SCCHN: Summary

After decades without real progress, a recent randomized trial showed that adding cetuximab, the first clinically available EGFR-directed monoclonal antibody, to a standard chemotherapy regimen (platinum/5-fluorouracil) led to an important survival benefit in patients with R/M-SCCHN, and this has changed practice. So far, the data on the monoclonal antibodies against EGFR seem to be more promising in their interaction with cytotoxic agents than the small molecule TKIs. However, combined targeting either with different anti-EGFR approaches or with both anti-EGFR and anti-VEGF(R) approaches seems an interesting field of research. There is a plethora of targeted therapies in various stages of preclinical and clinical development. The next challenges will be to sort out which of those agents have clinically meaningful activity and to find out how to incorporate them into the existing treatment strategies for those suffering from this devastating disease.

References

1. Licitra L, Locati LD, Bossi P. Optimizing approaches to head and neck cancer. *Metastatic head and neck cancer: new options*. *Ann Oncol*. 2008;19 Suppl 7:vii200–3.
2. Vermorken JB. Medical treatment in head and neck cancer. *Ann Oncol*. 2005;16 Suppl 2:ii258–64.
3. Colevas AD. Chemotherapy options for patients with metastatic or recurrent squamous cell carcinoma of the head and neck. *J Clin Oncol*. 2006;24:2644–52.
4. Al-Sarraf M. Head and neck cancer: chemotherapy concepts. *Semin Oncol*. 1988;15(1):70–85.
5. Amer MH, Al-Sarraf M, Vaitkevicius VK. Factors that affect response to chemotherapy and survival of patients with advanced head and neck cancer. *Cancer*. 1979;42:2202–6.
6. Forastiere AA, Metch B, Schuller DE, et al. Randomized comparison of cisplatin plus fluorouracil and carboplatin plus fluorouracil versus methotrexate in advanced squamous-cell carcinoma of the head and neck: a Southwest Oncology Group study. *J Clin Oncol*. 1992;10(8):1245–51.
7. Jacobs C, Lyman G, Velez-García E, et al. A phase III randomized study comparing cisplatin and fluorouracil as single agents and in combination for advanced squamous cell carcinoma of the head and neck. *J Clin Oncol*. 1992;10(2):257–63.
8. Stell PM, McCormick MS. The design of phase III palliative chemotherapy trials in head and neck cancer. *Clin Otolaryngol Allied Sci*. 1986;11:21–9.
9. Argiris A, Li Y, Forastiere A. Prognostic factors and long-term survivorship in patients with recurrent or metastatic carcinoma of the head and neck. An analysis of two Eastern Cooperative Oncology Group randomized trials. *Cancer*. 2004;101:2222–9.

10. Leon X, Hitt R, Constenla M, et al. A retrospective analysis of the outcome of patients with recurrent and/or metastatic squamous cell carcinoma of the head and neck refractory to a platinum-based chemotherapy. *Clin Oncol.* 2005;17:418–24.
11. Specenier P, Rasschaert M, Vroman PH, et al. Weekly docetaxel in patients with recurrent and/or metastatic squamous cell carcinoma of the head and neck. *Am J Clin Oncol.* 2010; Oct 8 [Epub ahead of print].
12. Urba SG, Forastiere AA. Systemic therapy of head and neck cancer: most effective agents, areas of promise. *Oncology (Williston Park).* 1989;4:79–88.
13. Kish JA, Ensley JF, Jacobs J, Weaver A, Cummings G, Al-Sarraf M. A randomized trial of cisplatin (CACP) and 5-fluorouracil (5-FU) infusion and CACP+5-FU bolus for recurrent and advanced squamous cell carcinoma of the head and neck. *Cancer.* 1985;56:2740–4.
14. Amrein PC, Weitzman SA. Treatment of squamous cell carcinoma of the head and neck with cisplatin and 5-fluorouracil. *J Clin Oncol.* 1985;3:1632–9.
15. Tannock IF. Chemotherapy for head and neck cancer. *J Otolaryngol.* 1984;13:99–104.
16. Al-Sarraf M. Chemotherapy strategies in squamous cell carcinoma of the head and neck. *Crit Rev Oncol Hematol.* 1984;1:323–55.
17. Carter SK, Slavik M. Current investigational drugs of interest in the chemotherapy program of the National Cancer Institute. *Natl Cancer Inst Monogr.* 1977;45:101–21.
18. Clavel M, Vermorken JB, Cognetti F, et al. Randomized comparison of cisplatin, methotrexate, bleomycin and vincristine (CABO) versus cisplatin and 5-fluorouracil (CF) versus cisplatin (C) in recurrent or metastatic squamous cell carcinoma of the head and neck. A phase III study of the EORTC Head and Neck Cancer Cooperative Group. *Ann Oncol.* 1994;5(6):521–6.
19. Hong WK, Schaefer S, Issell B, et al. A prospective randomized trial of methotrexate versus cisplatin in the treatment of recurrent squamous cell carcinoma of the head and neck. *Cancer.* 1983;52:206–10.
20. Eisenberger M, Hornedo J, Silva H, et al. Carboplatin (NSC-241-240): an active platinum analog for the treatment of squamous-cell carcinoma of the head and neck. *J Clin Oncol.* 1986;4:1506–9.
21. Wittes RE. Chemotherapy of head and neck cancer. *Otolaryngol Clin North Am.* 1980;13:515–20.
22. Glick JH, Zehngbot LM, Taylor SG. Chemotherapy for squamous cell carcinoma of the head and neck: a progress report. *Am J Otolaryngol.* 1980;1:306–23.
23. Airoldi M, Cortesina G, Giordano C, et al. Ifosfamide in the treatment of head and neck cancer. *Oncology.* 2003;65(Suppl):237–43.
24. Schrijvers D, Vermorken JB. Taxanes in the treatment of head and neck cancer. *Curr Opin Oncol.* 2005;17:218–24.
25. Grau JJ, Caballero M, Verger E, Monzo M, Blanch JL. Weekly paclitaxel for platin/resistant stage IV head and neck cancer patients. *Acta Otolaryngol.* 2008;31:1–6.
26. Pivot X, Raymond E, Laguerre B, et al. Pemetrexed disodium in recurrent locally advanced or metastatic squamous cell carcinoma of the head and neck. *Br J Cancer.* 2001;85:649–55.
27. Testolin A, Recher G, Cristoferi V, et al. Vinorelbine in pre-treated advanced head and neck squamous cell carcinoma: a phase II study. *Invest New Drugs.* 1994;12:213–34.
28. Martinez-Trufero J, Isla D, Adansa JC, et al. Phase II study of capecitabine as palliative treatment for patients with squamous head and neck cancer with locoregional and/or metastatic relapse after previous platinum-based treatment: final results of Spanish Head and Neck Cancer Group. *J Clin Oncol.* 2009;27(15S):312s. Abstract 6047.
29. Murphy BA. Topoisomerases in the treatment of metastatic or recurrent squamous carcinoma of the head and neck. *Expert Opin Pharmacother.* 2005;6:85–92.
30. Schornagel JH, Verweij J, de Mulder PH, et al. Randomized phase III trial of edetrexate versus methotrexate in patients with metastatic and/or recurrent squamous cell carcinoma of the head and neck: a European Organization for Research and Treatment of Cancer Head and Neck Cancer Cooperative Group study. *J Clin Oncol.* 1995;13:1649–55.
31. Park S, Lee S, Park J, Cho E, Shin D, Lee J. Phase II study of oral S-1 in pretreated patients with recurrent or metastatic head and neck cancer. *J Clin Oncol.* 2008;26(15S):692s. Abstract 17007.
32. Hitt R, Amador ML, Quintela-Fandino M, et al. Weekly docetaxel in patients with recurrent and/or metastatic squamous cell carcinoma of the head and neck. *Cancer.* 2006;106:106–11.
33. Colevas AD, Amrein PC, Gomolin H, et al. A phase II study of combined oral uracil and ftorafur with leucovorin for patients with squamous cell carcinoma of the head and neck. *Cancer.* 2001;92:326–31.
34. Grose WE, Lehane DE, Dixon DO, Fletcher WS, Stuckey WJ. Comparison of methotrexate and cisplatin for patients with advanced squamous cell carcinoma of the head and neck region: a Southwest Oncology Group study. *Cancer Treat Rep.* 1985;69(6):577–81.
35. Vermorken JB, Catimel G, de Mulder P, et al. Randomized phase II trial of weekly methotrexate versus two schedules of three-weekly paclitaxel in patients with metastatic or recurrent squamous cell carcinoma of the head and neck. *Proc Am Soc Clin Oncol.* 1999;18:395a. Abstract 1527.
36. Guardiola E, Peyrade F, Chaigneau L, et al. Results of a randomised phase II study comparing docetaxel with methotrexate in patients with recurrent head and neck cancer. *Eur J Cancer.* 2004;40(14):2071–6.
37. Morton RP, Rugman F, Dorman EB, et al. Cisplatin and bleomycin for advanced or recurrent squamous cell carcinoma of the head and neck: a randomised factorial phase III controlled trial. *Cancer Chemother Pharmacol.* 1985;15:283–9.
38. De Andres L, Brunet J, Lopez-Pousa A, et al. Randomized trial of neoadjuvant cisplatin and fluorouracil versus carboplatin and fluorouracil in patients with stage IV-M0 head and neck cancer. *J Clin Oncol.* 1995;13(6):1493–500.
39. Eisenberger M, Krasnow S, Ellenberg S, et al. A comparison of carboplatin plus methotrexate versus methotrexate alone in patients with recurrent and metastatic head and neck cancer. *J Clin Oncol.* 1989;7(9):1341–5.
40. Clavel M, Cognetti F, Dodion P, et al. Combination chemotherapy with methotrexate, bleomycin, and vincristine with or without cisplatin in advanced squamous cell carcinoma of the head and neck. *Cancer.* 1987;60(6):1173–7.
41. Schantz SP, Harrison LB, Forastiere AA. Tumors of the nasal cavity and paranasal sinuses, nasopharynx, oral cavity, and oropharynx. In: DeVita VT, Hellman S, Rosenberg SA, editors. *Cancer: principles & practice of oncology.* 6th ed. Philadelphia: Lippincott-Raven; 2001. p. 797–860.
42. Shin DM, Glisson BS, Khuri FR, et al. Phase II trial of paclitaxel, ifosfamide, and cisplatin in patients with recurrent head and neck squamous cell carcinoma. *J Clin Oncol.* 1998;16(4):1325–30.
43. Shin DM, Khuri FR, Glisson BS, et al. Phase II study of paclitaxel, ifosfamide, and carboplatin in patients with recurrent or metastatic head and neck squamous cell carcinoma. *Cancer.* 2001;91(7):1316–23.
44. Gibson MK, Li Y, Murphy B, Hussain MH, et al. Randomized phase III evaluation of cisplatin plus fluorouracil versus cisplatin plus paclitaxel in advanced head and neck cancer (E1395): an Intergroup trial of the Eastern Cooperative Oncology Group. *J Clin Oncol.* 2005;23(15):3562–7.
45. Samlowski WE, Moon J, Kuebler JP, et al. Evaluation of the combination of docetaxel/carboplatin in patients with metastatic or recurrent squamous cell carcinoma of the head and neck (SCCHN): a Southwest Oncology Group phase II study. *Cancer Invest.* 2007;25(3):182–8.
46. Janinis J, Papadaku M, Xidakis E, et al. Combination chemotherapy with docetaxel, cisplatin, and 5-fluorouracil in previously

- treated patients with advanced/recurrent head and neck cancer: a phase II feasibility study. *Am J Clin Oncol.* 2000;23(2):128–31.
47. Benasso M, Ponzanelli A, Merlano M, et al. Paclitaxel, cisplatin and 5-fluorouracil in recurrent squamous cell carcinoma of the head and neck: a phase II trial from an Italian cooperative group. *Acta Oncol.* 2006;45(2):168–74.
 48. Specenier P, Vermorken JB. Targeted therapies in head and neck cancer. *Targeted Oncol.* 2007;2(2):73–8.
 49. Cohen EEW. Novel therapeutic targets in squamous cell carcinoma of the head and neck. *Semin Oncol.* 2004;31:755–68.
 50. Xia W, Lau YK, Zhang HZ, et al. Combination of EGFR, HER-2/neu, and HER-3 is a stronger predictor for the outcome of oral squamous cell carcinoma than any individual family members. *Clin Cancer Res.* 1999;5:4164–74.
 51. Ang KK, Berkey BA, Tu X, et al. Impact of epidermal growth factor receptor expression on survival and pattern of relapse in patients with advanced head and neck carcinoma. *Cancer Res.* 2002;62:7350–6.
 52. Chung CH, Ely K, McGavran L, et al. Increased epidermal growth factor receptor gene copy number is associated with poor prognosis in head and neck squamous cell carcinomas. *J Clin Oncol.* 2006;24:4170–6.
 53. Eriksen JG, Steiniche T, Askaa J, et al. The prognostic value of epidermal growth factor receptor is related to tumor differentiation and the overall treatment time of radiotherapy in squamous cell carcinomas of the head and neck. *Int J Radiat Oncol Biol Phys.* 2004;58:561–6.
 54. Santini J, Formento JL, Francoual M, et al. Characterization, quantification, and potential clinical value of the epidermal growth factor receptor in head and neck squamous cell carcinomas. *Head Neck.* 1991;13:132–9.
 55. Licitra L, Rolland F, Bokemeyer C, et al. Biomarker potential of EGFR gene copy number by FISH in the phase III EXXTREME study: platinum-based CT plus cetuximab in first-line R/M SCCHN. *J Clin Oncol.* 2009;27(15S):302s. Abstract 6005.
 56. Scaltriti M, Baselga J. The epidermal growth factor pathway: a model for targeted therapy. *Clin Cancer Res.* 2006;12:5268–72.
 57. Kimura H, Sakai K, Arao T, Shimoyama T, Tamura T, Nishio K. Antibody-dependent cellular cytotoxicity of cetuximab against tumor cells with wild-type or mutant epidermal growth factor receptor. *Cancer Sci.* 2007;98:1275–80.
 58. Bleeker WK, Lammerts van Bueren JJ, van Ojik HH, et al. Dual mode of action of a human anti-epidermal growth factor receptor monoclonal antibody for cancer therapy. *J Immunol.* 2004;173:4699–707.
 59. Schneider-Merck T, Lammerts van Bueren JJ, Berger S, et al. Human IgG2 antibodies against epidermal growth factor receptor effectively trigger antibody-dependent cellular cytotoxicity but, in contrast to IgG1, only by cells of myeloid lineage. *J Immunol.* 2010;184:512–20.
 60. Rapidis AD, Vermorken JB, Bourhis J. Targeted therapies in head and neck cancer: past, present and future. *Rev Recent Clin Trials.* 2008;3:156–66.
 61. Huang S, Armstrong EA, Benavente S, Chinnaiyan P, Harari PM. Dual-agent molecular targeting of the epidermal growth factor receptor (EGFR): combining anti-EGFR antibody with tyrosine kinase inhibitor. *Cancer Res.* 2004;64:5355–62.
 62. Matar P, Rojo F, Cassia R, et al. Combined epidermal growth factor receptor targeting with the tyrosine kinase inhibitor gefitinib (ZD1839) and the monoclonal antibody cetuximab (IMC-C225): superiority over single-agent receptor targeting. *Clin Cancer Res.* 2004;10:6487–501.
 63. Baselga J, Trigo JM, Bourhis J, et al. Phase II multicenter study of the anti-epidermal growth factor receptor monoclonal antibody cetuximab in combination with platinum-based chemotherapy in patients with platinum-refractory metastatic and/or recurrent squamous cell carcinoma of the head and neck. *J Clin Oncol.* 2005;23(24):5568–77.
 64. Herbst RS, Arquette M, Shin DM, et al. Phase II multicenter study of the epidermal growth factor receptor antibody cetuximab and cisplatin for recurrent and refractory squamous cell carcinoma of the head and neck. *J Clin Oncol.* 2005;23(24):5578–87.
 65. Vermorken JB, Trigo J, Hitt R, et al. Open-label, uncontrolled, multicenter phase II study to evaluate the efficacy and toxicity of cetuximab as a single agent in patients with recurrent and/or metastatic squamous cell carcinoma of the head and neck who failed to respond to platinum-based therapy. *J Clin Oncol.* 2007;25(16):2171–7.
 66. Bourhis J, Rivera F, Mesia R, et al. Phase I/II study of cetuximab in combination with cisplatin or carboplatin and fluorouracil in patients with recurrent or metastatic squamous cell carcinoma of the head and neck. *J Clin Oncol.* 2006;24(18):2866–72.
 67. Hitt R, Irigoyen A, Nuñez J, et al. Phase II study of combination cetuximab and weekly paclitaxel in patients with metastatic/recurrent squamous cell carcinoma of head and neck (SCCHN): Spanish Head and Neck cancer group (TTCC). *J Clin Oncol.* 2007;25(18S):302s. Abstract 6012.
 68. Buentzel J, de vries A, Micke O. Experience with cetuximab plus paclitaxel/carboplatinum in primary platinum-resistant recurrent head and neck cancer. *J Clin Oncol.* 2007;25(18S):318s. Abstract 6077.
 69. Burtneß B, Goldwasser MA, Flood W, Mattar B, Forastiere AA. Eastern Cooperative Oncology Group. Phase III randomized trial of cisplatin plus placebo compared with cisplatin plus cetuximab in metastatic/recurrent head and neck cancer: an Eastern Cooperative Oncology Group study. *J Clin Oncol.* 2005;23(34):8646–54.
 70. Vermorken JB, Mesia R, Rivera F, et al. Platinum-based chemotherapy plus cetuximab in head and neck cancer. *N Engl J Med.* 2008;359:1116–27.
 71. Petrelli NJ, Winer EP, Brahmer J, et al. Clinical cancer advances 2009 major research advances in cancer treatment, prevention, and screening – a report from the American Society of Clinical Oncology. *J Clin Oncol.* 2009;27(35):6052–69.
 72. Carteni G, Fiorentino R, Vecchione L, Chiurazzi B, Battista C. Panitumumab a novel drug in cancer treatment. *Ann Oncol.* 2007;18 Suppl 6:vi16–21.
 73. Vermorken JB, Stöhlmacher J, Davidenko I, et al. An analysis of safety in patients (pts) with recurrent and/or metastatic squamous cell carcinoma of the head and neck (R/M SCCHN) receiving chemotherapy (CT) with or without panitumumab (pmab) in a phase III clinical trial (SPECTRUM). *J Clin Oncol.* 2009;27(15S):313s. Abstract 6050.
 74. Bier H, Hoffman T, Hauser U, et al. Clinical trial with escalating doses of the anti-epidermal growth factor receptor humanized monoclonal antibody EMD72000 in patients with advanced squamous cell carcinoma of the larynx and hypopharynx. *Cancer Chemother Pharmacol.* 2001;47:519–24.
 75. Arteaga ME, Ledón N, Casacó A, et al. Systemic and skin toxicity in *Cercopithecus aethiops sabaues* monkeys treated during 26 weeks with a high intravenous dose of the anti-epidermal growth factor receptor monoclonal antibody nimotuzumab. *Cancer Biol Ther.* 2007;6:1390–5.
 76. Ramakrishnan MS, Eswaraiha A, Crombet T, et al. Nimotuzumab, a promising therapeutic monoclonal for treatment of tumors of epithelial origin. *mAbs.* 2009;1:41–8.
 77. Specenier P, Vermorken JB. Advances in the systemic treatment of head and neck cancers. *Curr Opin Oncol.* 2010;22(3):200–5.
 78. Stewart JS, Cohen EE, Licitra L, et al. Phase III study of gefitinib compared with intravenous methotrexate for recurrent squamous cell carcinoma of the head and neck. *J Clin Oncol.* 2009;27:1864–71.
 79. Abidoye OO, Cohen EE, Wong SJ, et al. A phase II study of lapatinib (GW572016) in recurrent/metastatic (R/M) squamous cell carcinoma of the head and neck (SCCHN). *J Clin Oncol.* 2006;24(18S):297s. Abstract 5568.
 80. Cohen EE, Halpern AB, Kasza K, et al. Factors associated with clinical benefit from epidermal growth factor receptor inhibitors in

- recurrent and metastatic squamous cell carcinoma of the head and neck. *Oral Oncol.* 2009;45:155–60.
81. Siu LL, Soulieres D, Chen EX, et al. Phase I/II trial of erlotinib and cisplatin in patients with recurrent or metastatic squamous cell carcinoma of the head and neck: a Princess Margaret Hospital phase II consortium and National Cancer Institute of Canada Clinical Trials Group study. *J Clin Oncol.* 2007;25:2178–83.
82. Belon J, Irigoyen A, Rodriguez I, et al. Preliminary results of a phase II study to evaluate gefitinib combined with docetaxel and cisplatin in patients with recurrent and/or metastatic squamous-cell carcinoma of the head and neck. *J Clin Oncol.* 2005;23(16S):515s. Abstract 5563.
83. Kim ES, Kies MS, Glisson BS, et al. Final results of a phase II study of erlotinib, docetaxel and cisplatin in patients with recurrent/metastatic head and neck cancer. *J Clin Oncol.* 2007;25(18S):302s. Abstract 5521.
84. Argiris A, Ghebremichael M, Gilbert J, et al. A phase III randomized, placebo-controlled trial of docetaxel with or without gefitinib in recurrent or metastatic squamous cell carcinoma of the head and neck: a trial of the Eastern Cooperative Oncology Group (ECOG). *J Clin Oncol.* 2009;27(15S):303s. Abstract 6011.
85. Gillison ML, Glisson BS, O’Leary E, et al. Phase II trial of trastuzumab (T), paclitaxel (P), and cisplatin (C) in metastatic (M) or recurrent (R) head and neck squamous cell carcinoma (HNSCC): response by tumor EGFR and HER2/neu status. *J Clin Oncol.* 2006;24(18S):282s. Abstract 5511.
86. Kyzas PA, Stefanou D, Batistatou A, Agnantis NJ. Prognostic significance of VEGF immunohistochemical expression and tumor angiogenesis in head and neck squamous cell carcinoma. *J Cancer Res Clin Oncol.* 2005;131:624–30.
87. Kyzas PA, Cunha IW, Ioannidis JP. Prognostic significance of vascular endothelial growth factor immunohistochemical expression in head and neck squamous cell carcinoma: a meta-analysis. *Clin Cancer Res.* 2005;11:1434–40.
88. Seiwert TY, Haraf DJ, Cohen EEW, et al. Phase I study of bevacizumab added to fluorouracil- and hydroxyurea-based concomitant chemoradiotherapy for poor-prognosis head and neck cancer. *J Clin Oncol.* 2008;26:1732–41.
89. Karamouzis MV, Friedland D, Johnson R, Rajasenan K, Branstetter B, Argiris A. Phase II trial of pemetrexed and bevacizumab in patients with recurrent or metastatic head and neck squamous cell carcinoma (HNSCC): an interim analysis. *J Clin Oncol.* 2007;25(18S):311s. Abstract 6049.
90. Cohen EE, Davis DW, Karrison TG, et al. Erlotinib and bevacizumab in patients with recurrent or metastatic squamous-cell carcinoma of the head and neck: a phase I/II study. *Lancet Oncol.* 2009;10:247–57.
91. Gibson MK, Kies M, Kim S, et al. Cetuximab and bevacizumab in patients with recurrent or metastatic head and neck squamous cell carcinoma: an updated report. *J Clin Oncol.* 2009;27(15S):313s. Abstract 6049.

Chapter 48

Best Supportive Care for Palliative Treatment

Michaela Salzwimmer

Abstract Head and neck cancer includes epithelial malignancies of the upper aerodigestive tract, including the skull base, paranasal sinuses, nasal cavity, oral cavity, naso-, oro- and hypopharynx, larynx and salivary glands, squamous-cell carcinoma being the most prevalent histopathological type. More than 2/3 of patients present at an advanced tumour-stage (III+IV UICC) at time of diagnosis. Although much effort has been done in the research of tumour-specific therapy (e.g. new chemotherapy protocols, induction chemotherapy, targeted therapy, intensity-modulated radiotherapy) the overall survival rates have unfortunately not improved. Learning of their cancer diagnosis and receiving tumour-specific treatment has a great impact on individuals living with the disease and their families. Supportive and palliative care is interdisciplinary care and provides support for the physical, emotional and psychological suffering of patients with any advanced illness, regardless of age, diagnosis or life expectancy. The goal is to prevent and relieve suffering and to improve the quality of life for patients. All patients with a cancer diagnosis need general supportive and palliative care, which represents a wide range of services to help the patients to live as actively as possible until death.

Keywords Supportive care • Palliative care • Tumour pain • Mucositis • Nausea • Dysphagia • Cancer cachexia • Quality of life • Psychosocial support

Introduction

Head and neck cancer includes epithelial malignancies of the upper aerodigestive tract, including the skull base, paranasal sinuses, nasal cavity, oral cavity, naso-, oro- and hypopharynx, larynx and salivary glands, squamous-cell carcinoma being the most prevalent histopathological type. Head and

neck cancer constitutes about 6% of most common cancer localizations worldwide [1]. More than 2/3 of patients present at an advanced tumour-stage (III+IV UICC) at time of diagnosis. There is a significant male-over-female predominance, the median age ranges between 50 and 60 years [2]. As co-carcinogenic factors, tobacco and alcohol play an important role. More recently, human papillomavirus (HPV) has been recognized as an additional risk factor. Approximately 25% of head and neck squamous cell carcinoma specimens contain HPV genomic DNA, primarily HPV type 16 and, less frequently, type 18 [3]. Although much effort has been focused in the research of tumour-specific therapy (e.g. new chemotherapy protocols, induction chemotherapy, targeted therapy, intensity-modulated radiotherapy), the overall survival rates have unfortunately not improved (Fig. 48.1).

The WHO has defined palliative care in 1990 as follows: “Palliative care is an approach that improves the quality of life of patients and their families facing the problems associated with life-threatening illness, through the prevention and relief of suffering by means of early identification and impeccable assessment and treatment of pain and other problems, physical, psychosocial and spiritual”.

The EORCT defined supportive care in 1998: “Supportive care for cancer patients includes a multiprofessional effort for the individual psychical, psycho-social, spiritual and cultural requirements, and should be available at every point in time of illness and for patients of all age and independent of the actual therapy intentions”.

Literature has shown that palliative care is associated with the end phase of life, and supportive care usually with an earlier stage of illness [4]. Although the meaning of both terms is nearly the same, palliative care has a negative image and evokes more negative emotions [5]. Supportive and palliative care are essential for cancer patients before, during and after therapy, so these terms should not be separated, but mentioned together.

Learning of their cancer diagnosis and receiving tumour-specific treatment has a great impact on individuals living with the disease and their families. Supportive and palliative care are interdisciplinary and provide support for the physical,

M. Salzwimmer (✉)
Department of General ORL, H&NS, Medical University of Graz,
Auenbruggerplatz 26-28, 8036 Graz, Austria
e-mail: michaela.salzwimmer@klinikum-graz.at

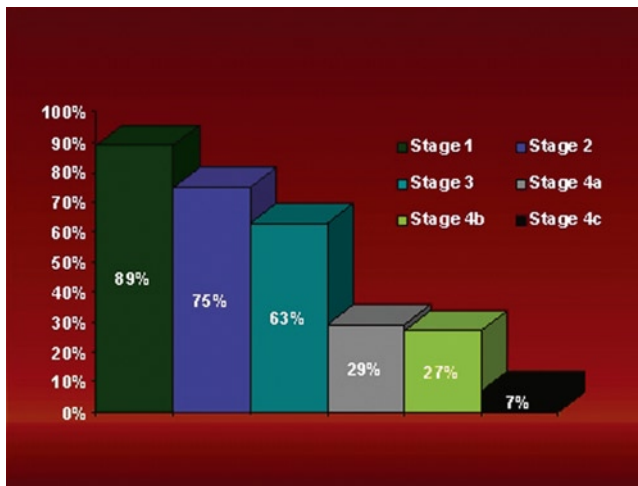


Fig. 48.1 Five-year survival rate

emotional and psychological suffering of patients with any advanced illness, regardless of age, diagnosis or life expectancy. The goal is to prevent and relieve suffering and to improve the quality of life for patients [6]. All patients with a cancer diagnosis need general supportive and palliative care, which represents a wide range of services to help the patients to live as actively as possible until death.

Supportive and palliative care includes the following special aspects:

- Pain therapy
- Oral complications due to radiotherapy: oral mucositis, damage to dentition, xerostomia
- Therapy for nausea and vomiting
- Dysphagia, cancer cachexia, feeding tube, diet counselling
- Quality of life, psychosocial support, end of life

Management of Cancer Pain

Pain is one of the most impacting burdens of a cancer disease. Pain has a great influence on physical functioning and social interaction and is strongly associated with elevated psychological distress [7].

Causes of Pain

Tumour Associated

- Bone invasion or metastatic disease
- Nerve compression and infiltration
- Infiltration of tissue and fascia

- Compression and occlusion of blood vessels with resulting lack of perfusion
- Tumour necrosis, ulceration

Cancer Treatment Associated

- Surgery (neck dissection, laser resection, ...)
- Chemotherapy (mucositis, neuropathy, ...)
- Radiotherapy (mucositis, dermatitis, fibrosis – xerostomia, ...)

Non-cancer-Related Pain

Pain resulting from the tumour itself can be nociceptive, related to tumour infiltration of tissue, such as the tongue or jaw, as well as neuropathic, related to nerves damaged by spreading tumours [8]. Documentation of patients suffering from cancer should routinely include inquiries about presence and severity of pain. The use of a validated quantitative pain assessment tool, such as a 10-point verbal scale, a visual analogue scale or instruments, such as a memorial pain card, are very useful for monitoring the adequacy of the therapy [9–11]. The evaluation of the pain intensity is very important for the therapeutic decision making, such as the selection of analgesic drugs, the rate of dose titration and the route of administration.

In analgesic treatment the following points for application should be considered [12]:

1. By the clock:
 - Medication should be given regularly before pain arrives (preventive)
 - Appropriate medication is necessary for breakthrough pain
 - Adequate access to medication is required
2. By the easiest way: medication given orally or transdermal
3. By the ladder: sequentially escalated according to pain intensity
4. For the individual patient:
 - Adapted to organ function and co-morbidities
 - Regular monitoring
 - Additional medication for side effects

Cancer pain treatment should follow the recommendations of the World Health Organization (Fig. 48.2). The three-step analgesic ladder provides a useful approach to drug selection and at present, is the gold standard of cancer pain therapy.

At step 1, patients with mild to moderate pain are treated with non-opioid analgesics. These analgesics provide additional analgesia when combined with opioids (steps 2 and 3) in the treatment of severe pain.

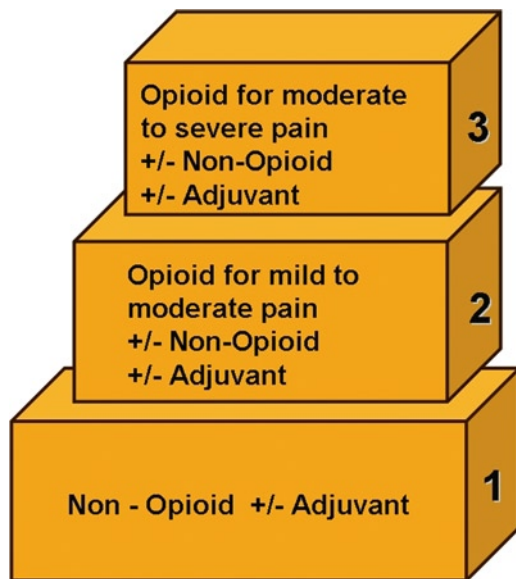


Fig. 48.2 WHO Pain Relief Ladder

Non-opioid analgesics comprise several subclasses:

- Paracetamol
- Diclofenac
- Ibuprofen
- Metamizol

Unlike opioids, non-opioid analgesics have a “ceiling” effect and produce neither tolerance nor physical dependence. For safe administration, it is also very important to know the potential side effects. Non-steroidal anti-inflammatory drugs in particular can cause bleeding disorders, renal failure and gastrointestinal problems.

At step 2, patients with moderate to severe pain should be treated with an opioid conventionally used for moderate pain (“weak opioids”). At step 3, patients who present with severe pain, an opioid drug of the “strong opioids” group is the choice of treatment.

Weak Opioids

- Codeine
- Tramadol

Strong Opioids

- Morphine
- Hydromorphone
- Fentanyl
- Oxycodone
- Methadon
- Buprenorphine

In general, opioids may also be combined with a non-opioid analgesic and/or an adjuvant drug. The route of administration should be least invasive and most convenient. The oral way is, when possible, most appropriate. For patients with swallowing disorders non-invasive alternatives are sublingual, transdermal and rectal. A limitation of the transdermal route is that a short-acting opioid is additionally required for breaking through pain.

Parenteral administration should be considered when a rapid onset of analgesia or high doses of analgesics, that cannot be otherwise given, is required. Another form is patient-controlled analgesia (PCA), where patients control titration of the analgesic according to their individual need. This technique of analgesia, common in the postoperative setting, gains increasing importance in cancer pain treatment. The route is mostly subcutaneous or intravenous using an ambulatory infusion device [13]. So this system offers the possibility of an outpatient therapy, which sometimes is very helpful in a palliative setting to keep patients as long as possible at home with their family, if desired.

Opioids also have side effects [12]:

1. General: physical dependence, tolerance, hyperalgesia, itching
2. Gastrointestinal: delayed gastric emptying, nausea, vomiting, constipation
3. Neurological: sedation, dizziness, confusion, respiratory depression, muscle rigidity, myoclonus
4. Immunologic and hormonal dysfunction

Constipation is such a common adverse reaction of opioids that laxative medications should be prescribed prophylactically [14]. The incidence of opioid-induced nausea is estimated to be 10–40% [15]. There is a direct effect on the chemoreceptor trigger zone, an enhanced vestibular sensitivity and delayed gastric emptying [13]. Metoclopramide is the choice of treatment in postprandial vomiting and early satiety. If nausea is induced by movement, an antiveriginous drug, such as scopolamine, will help [13]. Otherwise, neuroleptics, e.g. haloperidol, benzodiazepine, a steroid or a serotonin antagonist, are very effective to relieve nausea.

The group of the adjuvant analgesics plays an important role for patients who cannot attain an acceptable balance between relief of pain and opioid side effects.

Adjuvant drugs:

- Corticosteroids
- Neuroleptics
- Biphosphonates

Adjuvant analgesics have primary indications other than pain, but have analgesic effects in combination with opioids and non-opioid drugs.

Corticosteroids act as anti-inflammatory and anti-oedematous. Patients also profit by the stimulation of appetite

and mood stabilization. The benefit of *neuroleptics* is the sedative and dissociating effect. These drugs have also a high antiemetic potential. *Bisphosphonate drugs*, reducing osteoclast activity, are very helpful to relieve malignant bone pain. In general, parenteral administration monthly is well tolerated.

A very particular situation is the end-phase of life of cancer patients, suffering from intractable pain and other physical symptoms. With the use of systemic opioids, benzodiazepine or neuroleptics, sedation and adequate relief can be achieved [16, 17]. From an ethical side, this should be discussed before in a candid way with the person concerned (when possible) and the family.

Management of Oral Complications Due to Radiotherapy: Prevention and Therapy of Oral Mucositis, Damage to Dentition and Xerostomia

The oral cavity and oropharynx are very sensitive regions for side effects due to chemotherapy, radiation or combined forms. The oral mucosa has a high cellular turnover rate and a diverse and complex microflora. In 90–100% of patients with head and neck cancer undergoing radiotherapy, some degree of oral complication develops as result [18]. Acute effects develop during the first weeks of radiotherapy and continue until the post-treatment period. Chronic effects can manifest at any time after treatment, weeks and sometimes years afterwards [19]. Complications of radiotherapy are especially evident in head and neck region, where several different tissue structures like skin, mucosa, salivary glands, bone, teeth and the masticatory organ are located. Most head and neck cancer patients treated with radiotherapy in a curative intent, receive a dose of 2 Gy per fraction delivered five times a week, up to a total dose of 64–70 Gy [20]. The extent of adverse effects is related to the daily and total cumulative dose, the volume of irradiated tissue and use of concurrent radiation-sensitizing chemotherapeutic drugs [21].

Mucositis is not only a common side effect of radiation, but can also be caused by some chemotherapeutic drugs. Mucositis is inflammation of oral mucosa, and in literature, several classifications are mentioned, the WHO-Classification being most commonly applied (Fig. 48.3).

Pathogenesis

Radiation-induced mitotic death of basal keratinocytes is an adverse effect of radiotherapy. Within the first 2 weeks a measurable reduction of epithelial cells occurs. After 2–3 weeks, the destruction of the intact basement membrane follows

WHO ORAL MUCOSITIS SCALE					
Grade,	0	1	2	3	4
WHO	none	soreness ± erythema	erythema ulcers, swallow solid food	ulcers, extensive erythema cannot swallow solid food	mucositis to the extent that alimentation is not possible

Fig. 48.3 WHO Oral Mucositis Scale

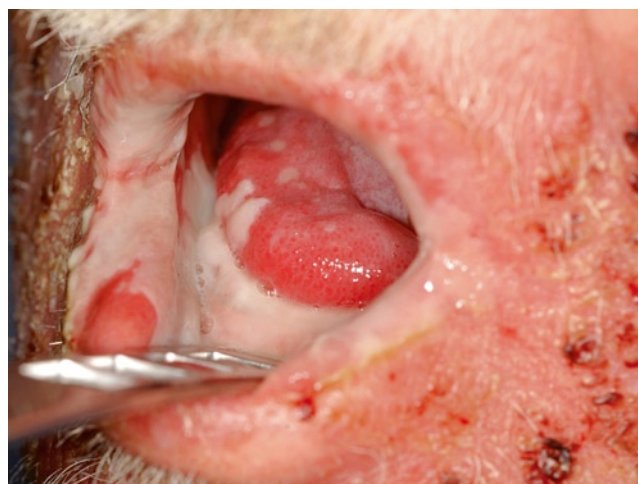

Fig. 48.4 Oral mucositis

(Fig. 48.4). The symptoms of radiation-induced mucositis include pain, speech problems, consecutive dysphagia and odynophagia. A significantly high number of patients suffer from pain to the extent that oral nutrition becomes nearly impossible [22]. To prevent weight loss and cachexia, the placement of a feeding tube (percutaneous oesophageal gastrostomy) should be considered before start of therapy (see: nutrition and feeding tube).

The treatment of radiation-induced mucositis includes mucosal-coating drugs (e.g. sucralfat), cleansing devices (e.g. chlorhexidin), lubricants and pain control. Several drugs have been investigated in the prevention of mucositis, unfortunately, their efficacy is still in question [22]. During the radiotherapy cycle, a periodic (weekly) plaque control and strict oral hygiene should be maintained. Radiotherapy damages healthy oral mucosal flora with the consequence of a shift in this flora. Cytoprotectants have been developed to protect normal tissue against the toxic effect of radiation

and/or chemotherapy. *Amifostine* acts as a free-radical scavenger, thus preventing damage to DNA. Outcomes of several clinical trials concerning the ability of amifostine to protect against mucositis and xerostomia are, however, controversial. In 1994, McDonald showed the benefit on salivary gland function giving amifostine concurrently with every fraction of radiotherapy for 6–7 weeks. On the other hand, no randomized controlled trial has proven the efficacy yet for this drug during concomitant radiochemotherapy [23].

Palifermin, a recombinant human keratinocyte growth factor, stimulates epithelial cell proliferation, migration and differentiation and has been shown to prevent severe oral mucositis in patients undergoing high dose chemotherapy and stem cell rescue for haematologic malignancies [24, 25]. This drug has been proven in a randomized controlled phase 3 trial, where palifermin significantly reduces the incidence of severe oral mucositis in patients with resected locally advanced head and neck cancer undergoing concomitant radiochemotherapy.

Xerostomia is a common, distressing side effect of radiotherapy, occurring to some degree in up to 100% of patients undergoing such treatment [26]. The acinar salivary gland cells are highly radiosensitive. Decrease of salivary flow starts within 1–2 weeks, and after 3 or 4 weeks basal flow reaches a nadir [27]. The electrolyte and immunoglobulin composition changes with increased viscosity and the saliva pH falls from 7.0 to 5.0, which is definitively cariogenic [28]. Patients complain about altered taste, dry mouth and difficulty in chewing and swallowing. Especially, dry food gets stuck in their mouth or throat. Functional impairment correlates with the total radiation dose and the volume of salivary gland parenchyma exposed in the radiation field. Doses greater than 30 Gy lead to permanent or semipermanent xerostomia [29, 30].

So patients may benefit from *sialogoga*, when a residual function of salivary glands is preserved. Salivary stimulants can be gustatory (acidic and bitter substances), tactile (chewing gum) and pharmacological. Sialogogues drugs are typically agonists of muscarinic M3 receptor, e.g. *pilocarpine* [31]. As a parasympathomimetic agent, it causes stimulation of cholinergic receptors on the surface of exocrine glands [32]. Contraindications are patients suffering from asthma, glaucoma, chronic obstructive pulmonary disease and cardiovascular disease. There are also products like saliva substitutes or artificial saliva providing lubrication, but as a matter of comfort, most patients prefer carrying a bottle of water with them all the times.

Other aspects in prevention of xerostomia are salivary-sparing radiation techniques, such as intensity-modulated radiotherapy. The goal of this three-dimensional planning is the increased dose to target tissue and reduced dose to adjacent healthy tissue.

Damage to dentition is a common side effect of radiotherapy. A very high percentage of head and neck cancer

patients present with a very poor dental situation. To avoid complications, a dental counselling before the beginning of radiotherapy is strongly recommended [28]. The restoration of caries lesions, root canal treatment, extractions and oral hygiene instructions should be started *before* cancer therapy so that a healing is terminated at the beginning of radio/chemotherapy. The late side effects of radiotherapy, like caries or periodontal infections, are due to the shift of oral microflora towards cariogenic bacteria, the reduced salivary flow (oral clearance) and the altered saliva composition (pH, immunoproteins) [28]. The close cooperation of ENT specialists, radiotherapists and dentists is of great importance to keep the adverse events as little as possible.

Management of Nausea and Vomiting

Nausea caused by chemotherapy is triggered at the postremal area on the floor of the fourth ventricle. The centre of vomiting, located within the formatio reticularis of the medulla oblongata, receives inputs from various afferent impulses. Also, the release of serotonin in the gastrointestinal tract causes activation of visceral afferent nerves, and the signals are transferred to postremal area.

Nausea and vomiting are the most distressing side effects reported by patients undergoing chemotherapy [33–35]. Depression, anxiety and a feeling of helplessness are consequences of chemotherapy-induced nausea and vomiting [36, 37]. If not properly controlled, patients sometimes decide to delay or even terminate chemotherapy because of fear of those side effects, often unaware of the oncological consequences of not receiving cancer treatment.

Chemotherapy-related emesis is classified as:

1. Acute nausea
2. Delayed nausea
3. Anticipatory nausea

Acute Nausea: Vomiting Occurring 0–24 h After Therapy

The gold standard of treatment is the combination of three agents: 5-HT₃ serotonin receptor antagonists, corticosteroids and the neurokinin-1-receptor antagonists.

5-HT₃ serotonin antagonists (dolasetron, granisetron, ondansetron, palonosetron, tropisetron). Several randomized controlled trials have proven the equivalent antiemetic efficacy and safety. Adverse effects include mild headache, asymptomatic elevation of serum aminotransferases, and constipation.

Corticosteroids (dexamethasone and methylprednisolone). Although efficacy has been reported with both agents, there

have been no comparison trials. Adverse effects are elevations of serum glucose levels, epigastric burning and sleep disorders.

Neurokinin-1-receptor antagonists (aprepitant). NK1 receptors are found in the brainstem emetic centre and in the gastrointestinal tract. By blocking this receptor subtype, aprepitant prevents emesis.

Current Recommendations for the Treatment of Acute Vomiting (ASCO Guidelines 2006)

The three-drug combination (5-HT₃ serotonin receptor antagonists, corticosteroids, neurokinin-1-receptor antagonists) is standard in high (>90%) emetic risk, mainly resulting from platin-based chemotherapy (e.g. cisplatin). In chemotherapy with moderate emetic risk (e.g. carboplatin), a two-drug combination (5-HT₃ serotonin receptor antagonists and corticosteroids) is recommended. No antiemetic treatment is routinely suggested in therapy with low emetic risk (e.g. palcitaxel, docetaxel, fluorouracil). The use of a preventive single dose of dexamethasone is appropriate.

Delayed Nausea: Vomiting Occurring 24 or More Hours After Chemotherapy

The two-drug combination of dexamethasone and aprepitant is recommended for the prevention of delayed emesis due to chemotherapy with a high emetic risk. Chemotherapy agents with moderate emetic risk are suggested to be treated either with dexamethasone or a 5-HT₃ serotonin receptor antagonist. Also in this group, no routine preventive antiemetics are indicated for agents with low risk.

Anticipatory Emesis

Anticipatory or conditioned emesis occurs when nausea and vomiting has not been controlled in the previous chemotherapy cycles. It is also known that patients with motion sickness are more likely to experience anticipatory vomiting. Patients have a conditioned response provoked by certain situations, such as the smell or sound of the clinic [38–41]. Emesis starts before or during the administration of chemotherapy, before the acute chemotherapy-related symptoms are expected to occur [42].

The current recommendations for therapy are the same antiemetic regimes as suggested for acute and delayed

vomiting. Because of their antianxiety effect, benzodiazepines (e.g. lorazepam) are used to prevent anticipatory symptoms.

As nowadays several agents and drug regimes are available, the best way to manage nausea and vomiting due to chemotherapy is to prevent it [43]!

Dysphagia, Cancer Cachexia, Feeding Tube, Diet Counselling

Cachexia is defined as weight loss of greater than 5% of the pre-morbid weight within the previous 6-month period [44]. Characteristics are weight loss, lipolysis, muscle wasting, anorexia, chronic nausea, changes in body image and psychological distress [45]. Nutrition plays a very important role in cancer treatment. A high percentage of head and neck cancer patients present at diagnosis in poor nutritional conditions. Many of them are addicted to alcohol and nicotine and have bad dietary habits. The tumour itself can also cause dysphagia by mechanical obstruction. Other reasons for malnutrition are treatment-related toxicities. Chemotherapy can cause nausea, vomiting or diarrhoea. The radiosensitization effect of chemotherapy leads to more severe mucositis, thus preventing the patient from oral intake and leading to severe weight loss [46].

Cancer and its treatment can have a great influence on patients' ability to eat. Besides dysphagia, the manifestation of aspiration may also have a great impact on tumour patients. After radiotherapy, the pharyngeal transit time is increased, and pharyngeal motility is affected, especially when the base of tongue and the larynx are included in the radiation field [47]. Physicians should be aware that patients often present aspiration with depressed cough reflex, with the great risk of coming down with pneumonia. In this case, the collaboration with speech therapists is very helpful. A speech therapist should always be involved in the assessment and management of dysphagia and possible aspiration before the beginning of cancer-specific treatment.

One therapeutic aim in cancer therapy should be the prevention of catabolic metabolism and consecutive weight loss. Several trials have shown that for patients receiving chemoradiotherapy, a tube feeding is often necessary for at least some weeks. Enteral alimentation is always superior to parenteral nutrition. It is also more cost-effective, and can be administered at home easier. As cancer treatment, especially radiotherapy, has a number of side effects limiting oral intake, tube feeding should always be considered before starting therapy. Tube feeding can be administered via gastrostomy or nasogastric tube. Although the percutaneous endoscopic gastrostomy (PEG) is an invasive procedure and bears risks, the great advantage to the nasogastric tube is the possibility of the longer retention time and no irritation of

the mucous membrane and altering of cosmetic aspect in the head and neck region. Gastroenterologists recommend prophylactic antibiotics started the day before the placement of the PEG and administered for 3 days total.

Every tumour patient should receive individual and personal advice for nutrition from a dietician. Nutritional status and weight should be controlled regularly, at least once weekly during cancer therapy. Tube feeding has to be started either when patients lose weight, or oral nutrition is insufficient. It is very important that oral food intake is attempted as long as it is possible.

Quality of Life, Psychosocial Support, End of Life

Patients confronted with the diagnosis of cancer often experience a painful reaction. The ominous implications and uncertainty of such an illness lead to intense emotions, usually including a sense of shock or initial disbelief, followed by a period of anxiety and sadness, irritability, sleep loss and disturbance of appetite. After a period of several weeks, most patients experience a certain degree of acceptance [48].

The head and neck region is a centre of many essential features (breathing, communication, nutrition), difficulty in this area has a great impact on the quality of life. Cancer, as a life-threatening disease, changes the physical, psychical, familial, social and professional well-being. The treatment of cancer patients is complex and a great challenge for physicians as well. Besides cancer-specific therapy (surgery, radiotherapy, chemotherapy, etc.) preservation of the quality of life gains more and more importance. In addition to eating, drinking, mobility, etc., quality of life includes psychic and social well-being. Psychotherapy has been shown to reduce psychological distress and depressive symptoms effectively, as well as improving the quality of life. Spiritual support is helpful for those with advanced disease facing the end of life. To achieve this spectrum of needs, the collaboration of psychiatrists, clinical psychologists, psychotherapists and social workers is required.

The goals of psycho-oncological interventions are:

- Improvement of communication between patients, their relatives and physicians
- Preservation of the quality of life
- Support in coping with the disease
- Crisis management with psychosocial conflicts (partnership, family, job, etc.)
- Psychotherapeutic help with psychic problems
- Medical treatment of psychic dysfunctions
- Reduction of tumour or therapy-related symptoms (pain, nausea, etc.)

As a matter of fact, it is impossible and may not be indicated individual cases that all cancer patients receive psycho-oncological support; however, every tumour patient should be informed about this possibility of therapy.

Palliative-care teams gain great importance in inpatient and outpatient care during the last phase of life. To become acquainted with each other, contact with the patients and their families should be made at an early stage of the tumour disease. The aim is to allow for the domestic care of a patient with advanced disease as long as possible by outpatient support.

Palliative care lays the groundwork to handle critical situations in an outpatient setting. As most patients wish to die at home, emergency admissions to hospital can be avoided in many cases in accordance with the patients' and relatives' wishes [49, 50].

It is a must that palliative-care teams work in close contact with the clinical physicians to get information about the diagnosis, the oncological treatment and the prognosis of the disease. The focus is not on "what can be done?" with diagnostic or therapeutic algorithms, but rather on "what is the appropriate treatment in a particular situation?" In some cases, e.g. aggressive resuscitation might be inappropriate towards the end of life [49].

In course of a cancer disease heading towards the end of life, the therapeutic priorities change gradually. A primary aim of palliative care is to prepare the patient and family for possible critical situations, also for the imminent death. As with all cancer patients, predicting when an individual is near the end of life can be difficult. At this point, clear communication with patients (when possible) and families is important. It is not the question whether or not to communicate the truth to a severely ill patient, but rather of timing and the proper measure of the truth to be communicated. This requires a high degree of sensitivity and readiness to reflect on the part of the attendant [51].

Conclusion

Treatment and care of head and neck cancer patients is very complex, so the expertise of many specialists is required (Fig. 48.5). More importantly, cooperation across these fields has created an integrated multidisciplinary approach that maximizes patient outcomes and facilitates the development of better treatment regimes [1].

Much research in the field of cancer therapy has been done during the past few years, new chemotherapy regimes and targeted agents have improved loco-regional control, but unfortunately, the 5-year overall survival rate has not improved for cancer patients in advanced stages. This group of patients has unique physical symptoms and emotional

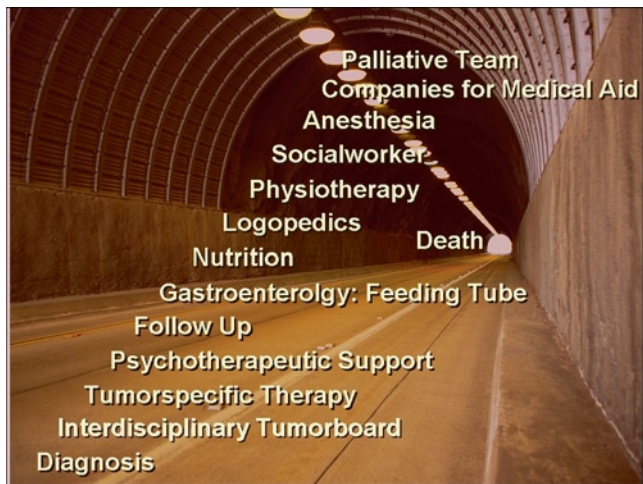

Fig. 48.5 Multidisciplinary treatment

needs relating to both the disease and its treatment. When reaching this “point of no return”, improving and preserving the quality of life is the main goal of therapy.

You matter, because you are you, and you matter to the last moment of your life. We will do all we can, not only to die peacefully, but to *live* until you die.

Cicely Saunders, the founder of Hospice

References

- Cognetti DM, Weber RS, Lai SY. Head and neck cancer, an evolving treatment paradigm. *Cancer*. 2008;113(7 Suppl):1911–32.
- Parkin DM, Bray F, Ferlay J, Pisani P. Global cancer statistics, 2002. *CA Cancer J Clin*. 2005;55:74–108.
- Kreimer AR, Clifford GM, Boyle P, Franceschi S. Human papillomavirus types in head and neck squamous cell carcinomas worldwide: a systemic review. *Cancer Epidemiol Biomarkers Prev*. 2005;14:467–75.
- Fadul N, Elsayem A, Palmer JL, Del Fabbro E, Swint K, Li Z, et al. Supportive versus palliative care: what’s in a name?: a survey of medical oncologists and midlevel providers at a comprehensive cancer center. *Cancer*. 2009;119(9):2013–21.
- Morstad Boldt A, Yusuf F, Himmelstein B. Perceptions of the term palliative care. *J Palliat Med*. 2006;5:1128–36.
- National Consensus Project for Quality Palliative Care. Clinical practice guidelines for quality palliative care. 2004. <http://www.nationalconsensusproject.org>. Accessed 30 March 2008.
- Portenoy RK, Miransky J, Thaler HT, et al. Pain in ambulatory patients with lung or colon cancer: Prevalence, characteristics, and effect. *Cancer*. 1992;70:1616–24.
- Payne R, Gonzales GR. Pathophysiology of pain in cancer and other terminal disease. In: Doyle D, Hanks G, Cherny N, et al., editors. *Oxford textbook of palliative medicine*. 3rd ed. New York: Oxford University Press; 2005. p. 288–98.
- Grossmann SA, Sheidler VR, Swedeen K, et al. Correlation of patient and caregiver ratings of cancer pain. *J Pain Symptom Manage*. 1991;6:53–7.
- Agency for Health Care Policy and Research. *Cancer Pain Management Panel: Management of Cancer Pain*. Washington, DC: U.S. Dept. of Health and Human Services; 1994. Clinical Practice Guidelines Number 9.
- Grossman SA, Sheidler VR, McGuire DB, et al. A comparison of the Hopkins pain rating instrument with standard visual analogue and verbal descriptor scales in patients with cancer pain. *J Pain Symptom Manage*. 1992;7(4):196–203.
- Schrijvers D. Management of Cancer Pain Professor Session. 2nd European perspectives in head and neck cancer. Prague: Marriott Hotel; 2009.
- Cherny NI, Portenoy RK. The management of cancer pain. *CA Cancer J Clin*. 1994;44:262–303.
- Sykes NP. Constipation and diarrhoea. In: Doyle D, Hanks GW, MacDonalld N, editors. *Oxford textbook of palliative medicine*. New York: Oxford University Press; 1993. p. 299–310.
- Campora E, Merlini L, Pace M, et al. The incidence of narcotic-induced emesis. *J Pain Symptom Manage*. 1991;6:428–30.
- Greene WR, Davis WH. Titrated intravenous barbiturates in the control of symptoms in patients with terminal cancer. *South Med J*. 1991;84:332–7.
- Truog RD, Berde CB, Mitchell C, Greir HE. Barbiturates in the care of the terminally ill. *N Engl J Med*. 1992;327:1678–82.
- Herrstedt J. Prevention and management of mucositis in patients with cancer. *Int J Antimicrob Agents*. 2000;16:161–3.
- Cox JD, Stetz J, Pajak TF. Toxicity criteria of the Radiation Therapy Research and Treatment of Cancer(EORTC). *Int J Radiat Oncol Biol Phys*. 1995;31:1341–6.
- Bourhis J, Etesami A, Lusinchi A. New trend in radiotherapy for head and neck cancer. *Ann Oncol*. 2005;16 Suppl 2:ii255–7.
- Archibald D, Lockhart PB, Sonis ST, et al. Oral complications of multimodality therapy for advanced squamous cell carcinoma of head and neck. *Oral Surg Oral Med Oral Pathol*. 1986;61:139–41.
- Sciubba JJ, Goldenber G. Oral complications of radiotherapy. *Lancet Oncol*. 2006;7:175–83.
- Brizel D, Overgaard J. Does amifostine have a role in chemoradiation treatment? *Lancet Oncol*. 2003;4:378–81.
- Spielberger R, Stiff P, Bensinger W, et al. Palifermin for oral mucositis after intensive therapy for hematologic cancers. *N Engl J Med*. 2004;351:2590–8.
- Stiff PJ, Emmanouilides C, Bensinger WI, et al. Palifermin reduces patient-reported mouth and throat soreness and improves patient functioning in the hematopoietic stem-cell transplantation setting. *J Clin Oncol*. 2006;24(33):5186–93.
- Chambers MS. Radiation-induced xerostomia. *Head Neck*. 2007; 29:58–63.
- Wescott WB. Alterations in whole saliva flow rate induced by fractionated radiotherapy. *AJR Am J Roentgenol*. 1978;130(1):145–9.
- Keilbasa AM, Hinkelbein W, Hellwig E, Meyer-Lückel H. Radiation-related damage to dentition. *Lancet Oncol*. 2006;7:326–35.
- Eisbruch A, Kim HM, Terrell JE, et al. Xerostomia and its predictors following parotid-sparing irradiation of head-and-neck cancer. *Int J Radiat Oncol Biol Phys*. 2001;50:695–704.
- Roesink JM, Konings AW, Terhaard CH, et al. Preservation of the rat parotid gland function after radiation by prophylactic pilocarpine treatment: radiation dose dependency and compensatory mechanisms. *Int J Radiat Oncol Biol Phys*. 1999;45:483–9.
- Vissink A, Johannes’s-Gravenmade E, Panders AK, Vermey A. Treatment of hyposalivation. *Ear Nose Throat J*. 1988;67:179–85.
- Dirix P, Nuyts S, Walter Van den Bogaert W. Radiation-induced xerostomia in patients with head and neck cancer. *Cancer*. 2006;107: 2525–34.
- Morrow SG. Mechanism and management of chemotherapy-induced nausea and vomiting. *Blood Rev*. 1987;1:50–7.
- Bakowski MT. Advances in anti-emetic therapy. *Cancer Treat Rev*. 1984;11:237–56.
- Kaye SB. How should nausea be assessed in patients receiving chemotherapy? *Cancer Treat Rev*. 1991;1:85–93.
- Wilcox PM, Fetting JH, Nettesheim KM, Abeloff MD. Anticipatory vomiting in women receiving cyclophosphamide, methotrexate, and

- 5-FU (CMF) adjuvant chemotherapy for breast carcinoma. *Cancer Treat Rep.* 1982;66:1601–4.
37. Dodds LJ. The control of cancer chemotherapy-induced nausea and vomiting. *J Clin Hosp Pharm.* 1985;10(2):143–66.
38. Wickham R. Managing chemotherapy-related nausea and vomiting: the state of the art. *Oncol Nurs Forum.* 1989;16:563–74.
39. Coons HL, Levanthal H, Nerenz DR, Love RR, Larson S. Anticipatory nausea and emotional distress in patients receiving cisplatin-based chemotherapy. *Oncol Nurs Forum.* 1987;14(4):31–5.
40. Morrow GR. Chemotherapy-related nausea and vomiting: etiology and management. *Cancer J Clin.* 1989;39:89–104.
41. Gralla RJ, Tyson LB, Kris MG, Clark RA. The management of chemotherapy-induced nausea and vomiting. *Med Clin North Am.* 1987;71(2):289–301.
42. Andrykowski MA. Definitional issues in the study of anticipatory nausea in cancer chemotherapy. *J Behav Med.* 1986;9:33–41.
43. ASCO Patient Guide. 2006 <http://www.asco.org/ASCOv2/Press+Center/Latest+News+Releases/ASCO+Releases+Updated+Clinical+Practice+Guideline+on+the+Use+of+Antiemetics+for+Cancer+Patients>. Accessed 20 July 2009.
44. Inui A. Cancer anorexia-cachexia syndrome. *CA Cancer J Clin.* 2002;52:72–91.
45. Bruera E, Sweeney C. Cachexia and asthenia in cancer patients. *Lancet Oncol.* 2000;1:138–47.
46. Newman LA, Vierra F, Schwiezer V, et al. Eating and weight changes following chemoradiation therapy for advanced head and neck cancer. *Arch Otolaryngol Head Neck Surg.* 1998;124:589–92.
47. Lazarus CL, Logemann JA, Pauloski BR, et al. Swallowing disorders in head and neck cancer patients treated with radiotherapy and adjuvant chemotherapy. *Laryngoscope.* 1996;106:1157–66.
48. Chonchinov HM. Depression in cancer patients. *Lancet Oncol.* 2001;2:499–505.
49. Nauck F, Al-Epping B. Crises in palliative care – a comprehensive approach. *Lancet Oncol.* 2008;9:1086–91.
50. Ciais JF, Pradier C, Ciais C, et al. Impact of a hospice home team on unwanted hospitalisation of terminally-ill patients at home in acute medical emergencies. *Presse Méd.* 2007;36:404–9.
51. Klocker JG, Klocker-Kaiser U, Schwaninger M. Truth in the relationship between cancer patient and physician. *Ann N Y Acad Sci.* 1997;809:56–65.

Chapter 49

Quality of Life in Head and Neck Cancer Patients

Jolie Ringash

Abstract While improving the survival outcomes of head and neck cancer (HNC) patients remains the primary goal of advances in therapy, the importance of the quality of life (QOL) impact of both tumor and the treatment to patients cannot be overemphasized. In cancer generally, baseline QOL is among the strongest available prognostic factors.

Broadly speaking, QOL is a measure of an individual's overall personal well-being. QOL instruments measure a subjective concept, but their measurement properties are based on sound scientific principles. Evidence of reliability, validity, and responsiveness should be required for instruments chosen for use in clinical research. Poor compliance with planned questionnaires (missing data) can threaten both internal and external validity (generalizability); study design should include strategies to maximize compliance.

QOL instruments may be general (applicable to the general population), disease-specific, symptom-specific, or treatment-specific. Disease site-specific QOL instruments are a subset of cancer-specific instruments designed for a specific cancer site, such as HNC, that address concerns, such as xerostomia, pain, dysphagia, and speech disruption. A number of HNC cancer-specific instruments are described.

Current evidence remains somewhat limited as the results of ongoing trials are anticipated. Future questions include the potential value of using QOL questionnaires in routine clinical care, the best strategies for translating QOL knowledge to clinicians, and the role of computer-adaptive administration of patient reported outcome measures.

Keywords Quality of life • Head and neck neoplasms • Questionnaires • Patient reported outcomes • Validity

J. Ringash (✉)
Department of Radiation Oncology, The Princess Margaret Hospital,
610 University Ave., Toronto, ON, Canada M5G 2M9
e-mail: jolie.ringash@rmp.uhn.on.ca

Introduction: What Is QOL?

Traditionally, the outcome of cancer care was assessed in terms of survival and/or tumor response. As early as 1948, Karnofsky recognized that other outcomes were important to patients. In his study, “subjective improvement was indicated by the patient’s feeling of well-being, his increased appetite and strength, and the relief of specific complaints...” [1], by applying a performance status scale (PSS) which is still in use. In the intervening 60 years, his initial concept of patient well-being has been expanded into our modern conception of quality of life (QOL). QOL is now recognized as an important outcome of cancer care.

Definition

Broadly speaking, QOL is a measure of an individual's overall personal well-being. Three aspects critical to the concept are subjectivity (only the individual truly knows his or her own internal state), multidimensionality, and sociocultural context.

QOL and “Health-Related” QOL

Overall QOL is impacted by issues, such as income and adequacy of housing, which cannot typically be influenced by the health care system. In the context of health care, QOL measures are often used to measure the effect of disease, illness, and treatment on the patient and family. For this purpose, issues which are not expected to change based on these effects become measurement “noise,” and reduce the ability of questionnaires to detect actual changes. For this reason, the more limited concept of “health-related” QOL is usually applied. The WHO has defined it as: “an individual’s perception of their position in life in the context of the culture and value systems in which they live and in relation to their goals, standards and concerns. It is a broad ranging concept affected

in a complex way by the person's physical health, psychosocial state, level of independence, social relationships, and their relationships to salient features of their environment [2].” When the term “quality of life” is used in the context of health care (and in the remainder of this chapter), it is usually health-related QOL which is meant.

Domains and Multidimensionality

Human beings are complex; the overall human experience reflects many underlying functions and roles. Under the stress of illness, that experience is influenced as well by specific symptoms. Such complexity may be addressed by two very different methods. The first method attempts to explicitly address the many dimensions of experience by constructing specific “domains” within a questionnaire, such as measures of particular symptoms, as well as cognitive, emotional, social, spiritual, role, and physical functioning. This approach results in long questionnaires with multiple items organized into separate subscales relating to each domain. The alternative method is to rely upon the respondent's ability to internally integrate his or her experience, and to report overall QOL as a single item index. One example would be the use of visual analog scales, such as the “feeling thermometer,” originally developed in 1964 by the United States National Election Services to allow voters to rate their feelings toward political candidates, but more recently adapted as a health utility instrument [3, 4]. Some instruments use a mixture of both methods; for example, “overall QOL” may be included as a single item, along with more specific domains. Typically, multi-item instruments are more reliable and more sensitive to change over time than single items; however, they require more time to complete.

Patient-Reported Outcomes

In 2006, the United States Food and Drug Administration issued a draft guidance document addressing the use of patient-reported outcomes (PROs) in support of drug-labeling claims [5]. This document was received as both a strong recognition of the importance of QOL research, and as a controversial perspective, especially due to several methodological recommendations. Nevertheless, although QOL research is conducted for many reasons beyond the development of new drugs, and although the document remains an unfinalized draft, it has been influential around the world. The term PRO, which has become increasingly popular as a result of the draft guidance, covers both QOL and other outcomes which may be solicited directly from the patient, such as adherence to therapy, satisfaction with treatment, and direct symptom ratings.

Health Utilities

Utility measures are intended to quantify not only health, but also its value to the individual. They are derived from utility theory to address preference under conditions of uncertainty [6]. Direct utility assessment uses one of the two methods: the standard gamble, in which the respondent must accept a risk of immediate death to gain QOL, or the time trade-off, in which he or she gives up time in order to gain QOL. Both methods use the concept of “perfect health,” defined by the World Health Organization (WHO) as, “a state of complete physical, mental and social well-being, not merely the absence of disease and infirmity [7].” Utilities have the advantage that they may be used directly as quality weights to determine “quality adjusted life years” (QALYs) for use in decision analyses, thus allowing integration of quality and quantity of life. Direct utility measurement requires abstract thinking and an understanding of probabilities, so can be cognitively challenging for some patients and cumbersome to use in busy clinical settings [8]. More feasible alternatives include rating scales, such as the feeling thermometer, or multi-attribute utility scales (questionnaires for which response options have known utility weights).

Dominant QOL Issues in Head and Neck Cancer Patients

Specific concerns, such as xerostomia, pain, dysphagia, and speech disruption, often dominate the posttreatment QOL experience of head and neck cancer (HNC) patients. Only a brief review can be provided below, however, more detail is available in a recent review article [9].

Pain

Pain in HNC patients arises as a result of many factors: tumor-related ulceration, pressure effect, or nerve infiltration; acute treatment-related pain due to radiation and/or chemotherapy mucositis and postoperative wounds, and late treatment-related effects, such as shoulder dysfunction, trismus, chronic edema, or osteoradionecrosis (bone necrosis due to radiotherapy). The quality and timing of pain can differ for each responsible mechanism so that a full characterization of pain may require detailed questioning. QOL instruments for HNC typically include two to three pain-related questions: one on general pain, one specific to pain in the mouth or throat, and perhaps one related to shoulder discomfort [10]. A PRO specifically focused on pain, such as the Brief

Pain Inventory (BPI), may complement QOL instruments when pain relief is a focus of treatment, such as in the palliative care setting [11]. International efforts to harmonize the classification of pain are ongoing [12].

Xerostomia

Xerostomia, or dry mouth, is a complex problem. Acute and late phases of xerostomia differ in both their pathophysiology and in their response to preventive strategies [13]. Salivary fraction from the parotid glands, submandibular/submental glands, and minor salivary glands may play different roles in baseline dryness and in eating-related difficulties. Similarly, swallowing and speech performance have been shown to be impaired in xerostomic patients [14, 15]. Evidence to link xerostomia prevention strategies to reduction in late complications, such as dental caries, osteoradionecrosis, and chronic malnutrition, is lacking.

The relationship between reduced salivary flow, patient-reported dry mouth, and overall QOL is complex. Reduction in salivary flow to $\leq 25\%$ of baseline has been arbitrarily classified as xerostomia [16]. Physician-rated outcomes include the Radiation Therapy Oncology Group (RTOG)/EORTC grading scale, the Late Effects Normal Tissue – Subjective, Objective, Management, Analytic (LENT-SOMA) and the National Cancer Institute Common Toxicity Criteria (CTC version 3) systems [17–19]. These measures have rarely been validated against salivary flow or PRO data. All common HNC-specific QOL instruments include at least one item related to xerostomia; however, non-QOL PROs specific to xerostomia have also been developed. Two popular instruments have been a 6-item linear analog scale (LAS) [20] and the 8-item University of Michigan XQ [21]. Though less rigorously developed and validated as most HNC QOL questionnaires, these instruments have performed well in research use.

Clinical strategies to reduce the risk of xerostomia for patients treated with radiotherapy (RT) have included the use of the drugs pilocarpine [22] and amifostine [23], intensity-modulated RT (IMRT) [24, 25], and surgical salivary gland transfer [26–28]. A recent review discusses the literature supporting each strategy, with the latter two approaches showing the most promise [9].

Speech

Of HNC patients who undergo surgical treatment, speech is affected in most patients immediately after surgery [29] and continues to be affected in over a third (37%) of patients at 3 months postsurgery [30]. Measures that target speech include

the Swedish Self-Evaluation of Communication Experiences after Laryngeal Cancer (S-SECEL) [31] and the Voice Handicap Index (VHI) [32]. A Linear Analog Self-Assessment (LASA) tool has also been developed [33].

Swallowing

Swallowing relies on complex coordination of function, and is frequently disrupted by both surgical treatment and RT. After head and neck surgery, short-term dysphagia is common, with about half of the patients experiencing dysphagia at 3 years [34]. Post-RT dysphagia may be worsened with concurrent chemotherapy [29] and may even increase in severity over the years [35]. There is good evidence that impairment of both swallowing and speech significantly reduce overall QOL [36]. Fortunately, more than 75% of selected patients with dysphagia may return to oral intake with swallowing rehabilitation [37].

The gold standard for the assessment of dysphagia is the videofluoroscopic (VFS) assessment. A popular physician-rated performance status measure, the Performance Status Scale for Head and Neck Cancer (PSS-HN) [38, 39], focuses on the impact of dysphagia. Patient-reported QOL measures targeting dysphagia include the MD Anderson Dysphagia Inventory (MDADI) [39, 40], the Swallowing Quality of Life (SWAL-QOL) [41–43] and the Swallowing Quality of Care (SWAL-CARE) [41–43]. Patients' perceptions of their swallowing problems are not always consistent with their physiological swallowing ability [44]. Some patients with normal VFS may perceive swallowing difficulties, whereas silent aspiration leading to pneumonia can occur in others [45].

Measurement of QOL: Basic Methodology

QOL instruments measure a subjective concept, but their measurement properties are based on sound scientific principles. Psychometrics, the science of indirect measurement through questionnaires and other related instruments, evolved in educational and psychology research over the course of the twentieth century, has been applied to health-related questionnaires and PROs for over 20 years [46]. Instruments chosen for use in clinical research should adhere to the principles outlined below.

Item generation should incorporate information about the issues of importance to patients from literature review, health professional expertise, and direct input from patients similar to the instrument's target population. Questions should be written at an appropriate educational level; grade 6 is often recommended [47]. Items should be formatted in a standard

way, including both positively- and negatively-worded items, and avoiding jargon, skip formats, and double-barreled questions. Utilization in other languages and cultural groups requires a formal process of cultural adaptation, including forward- and back-translation, pilot and field testing in the new language/culture [48].

Item reduction is often required to produce a questionnaire of practical length, but which remains sufficiently sensitive to change over time for *evaluative* (longitudinal) use. Direct testing in patients is typically carried out to identify the items most frequently endorsed by patients, and ranked as being of the greatest importance. Statistical methods may also be used to identify items which are most informative [49].

Questionnaire design includes principles of readability and clarity. Questionnaires should include a large proportion of white space, with font size and type which is easy to read. Special requirements for the target group need to be considered (e.g., the visually impaired, young children, low-literacy populations, etc.).

Indices and Profiles

Controversy exists regarding the relative preferability of *indices* or *profiles* for QOL measurement. Different individuals may apply personal weights to aspects of their QOL, so summation of scores over multiple domains, as is done for indices, may impose the developer's values inappropriately on the patient. Exploration of individual, patient-assigned weighting has proven cumbersome and is rarely used. Other instruments present scores separately for each domain (profiles), without summation. Popular questionnaires of both types are currently in use.

Reliability refers to the reproducibility of scores. It may be assessed by repeated administration of the instrument to a population with stable QOL (test-retest reliability), or by correlation of items within a questionnaire (internal consistency). Higher levels of reliability coefficients are conventionally required for *evaluative* use (to measure change in individuals over time) than in *discriminative* use (to measure difference between groups of patients); typically, 0.7 and 0.8, respectively, for internal consistency [50, 51].

Validity refers to the ability of a questionnaire score to reflect the actual concept of interest. It is important that a "QOL questionnaire" is actually related to the patient's overall well-being during a defined period (e.g., 1 week), and not his or her momentary comfort or passing mood. Questionnaire validation lacks a gold standard, so validity is defined by hypothesis testing with respect to convergence or divergence from other findings (concurrent validity). For example, QOL scores might be expected to be better in patients with better

performance status, and to improve over time in patients who were gaining weight posttreatment. A HNC-specific QOL questionnaire would also be expected to show a moderate correlation with other, more general, QOL or utility instruments. It is important that validation studies included patients similar to those for whom the instrument is used; a questionnaire validated exclusively in surgically treated patients may not exhibit the same measurement properties in chemoradiation patients.

Responsiveness is the sensitivity of the instrument to changes over time in an individual patient. Responsiveness is inversely correlated with instrument length and directly correlated with the specificity of items. A very detailed, HNC-specific QOL instrument would be highly responsive, whereas a short, general QOL instrument would be less responsive, to change in a HNC patient. Prospective evaluation is required to determine instrument responsiveness.

Minimal Clinically Important Difference (MID) is defined as the smallest change in value on a measurement instrument, which, from the point of view of the patient, represents an important rather than trivial change. In practice, it has been estimated for groups by the use of the minimal detectable difference, that is, the smallest difference which is detectable by the average patient [52]. It is important to differentiate this clinical concept from statistically significant differences, which reflect only the likelihood of observing a given difference, not what it may or may not mean to a patient. Ideally, MID should be determined for every new instrument; however, several studies suggest that a change of 5–10% of instrument range may represent the MID for many instruments [53, 54].

Types of QOL Questionnaires

General QOL Instruments can be applied to the general population, as well as to those suffering from various types of illness. Popular examples include the SF-36 [55, 56] and the EQ-5D [57].

Disease-specific QOL instruments have been developed in patients with specific types of illness, such as cardiac or respiratory disease, or of course cancer. Two of the most popular cancer-specific QOL instruments are the EORTC QLQ-C30 [58] and the FACT-G [59]. Their questions are better suited to the difficulties of cancer patients, resulting in better validity and responsiveness as compared to general instruments; however, the trade-off is increased difficulty in comparing results with those from healthy people.

Symptom-specific QOL instruments have been developed for several symptoms of importance to HNC patients, such as dysphagia (e.g., MD Anderson Dysphagia Index or MDADI) [40].

Table 49.1 Selected characteristics of HNC-specific QOL questionnaires

Instrument	Administration	Questions	Language(s)	Summary Score	Focus ^b
EORTC QLQ-C30/HN35	Self	65	Many	No	All HNC
FACT-H&N	Self	37 ^a	Many	Yes	All HNC
UW-QOL	Self	13	English	Yes	Surgical
HNQOLQ	Interview	21	English	No	All HNC
HNCI	Self	30	English		Surgical
QOL-RTI/H&N	Self	39	English	Yes	Radiation
HNRQ	Interview	22	English	Yes	RT/chemoRT

^aTwo additional items are not scored

^bDerived from initial development of the instrument and does not necessarily imply lack of validity for other patient types

Treatment-specific QOL instruments exist for many cancer treatments which are not specific to HNC (e.g., FACT-Taxane) [60]. The author has recently developed an instrument for HNC patients with prophylactic feeding tubes, the QOL-EF [61].

Oncology and disease site-specific QOL instruments are a subset of cancer-specific instruments designed for a specific cancer site, such as HNC. Two structured literature reviews have evaluated such instruments for HNC [10, 62]. Several of these instruments are modular, incorporating a cancer-specific instrument, and a disease-site specific module (e.g., EORTC, FACT, and QOL-RTI instruments). A selection of the more popular, well-validated questionnaires is mentioned below, with a summary of their characteristics in Table 49.1. Other PROs which are designed for HNC, but which focus on performance status, symptoms, specific treatments or functional issues (e.g., dysphagia, voice, disfigurement, xerostomia) may be complimentary to these HNC QOL instruments.

Popular H&N Cancer-Specific QOL Instruments

EORTC QLQ-C30/HN35 [63, 64] is the most commonly used instrument (unpublished data), as well as the longest. It has been translated and cross-culturally validated in many languages. *FACT-H&N* [59, 65] is another modular instrument which has been translated into many languages; it has been the most popular in North America. Several English-language instruments have been developed at American universities: the surgically oriented *UW-QOL* [66, 67] at the University of Washington; the *HNQOLQ* [68] at the University of Michigan, the *HNCI* [69] at the University of Iowa, and a modular instrument designed for RT patients, the *QOL-RTI* [70], at the University of South Florida. Finally, the *HNRQ* [71] was developed with the clearest focus on acute QOL in patients with advanced HNC receiving RT or chemoRT, but has been used infrequently.

Interpretation of QOL Results

Each individual conceptualizes QOL in a personal way. Life experience, optimism or pessimism, and psychological state all contribute to the perception of QOL. Consequently, cross-sectional comparisons among individuals are subject to measurement “noise” which should be less problematic when patient scores are self-controlled, by calculating one individual’s change in QOL over time in a longitudinal study. For this reason, if QOL is to be used as an outcome of a treatment in a clinical trial, prospective measurement at multiple timepoints is preferred. However, it is important to realize that the baseline administration usually occurs soon after a patient has received a cancer diagnosis, or has been found to have disease recurrence or progression. Thus, the “baseline QOL” does not reflect that person’s QOL when healthy. QOL scores that return to baseline over a period of time cannot be interpreted as indicating a resolution of tumor- and treatment-related effects; in many cases, the patient may, in fact, have exchanged tumor-related impairments for different problems induced by treatment.

Response Shift

An additional important consideration in the interpretation of longitudinal QOL data relates to response shift, or changing internal standards [72]. Over time, an individual confronted with critical illness may modify his or her values, or standards of measurement, and may also reconceptualize QOL entirely. Response shift may play a role in some initially unexpected findings, such as the fact that patients with serious illness routinely rate their own QOL as better than the ratings applied to them by surrogates (e.g., family members or health care professionals). Response shift may be viewed as a beneficial adaptive process; however, it also introduces an additional source of measurement error. Methods of quantifying response shift exist, but are labor-intensive. One approach to descriptive studies is to compare

QOL results with population norms drawn from healthy individuals [73]. Once again, the randomized trial design is favored for studies with QOL outcomes, since it is hoped that unmeasured covariates, such as response shift, should be balanced between the arms by chance.

Compliance and Missing Data

Results of any study must be assessed for two types of validity: internal validity (does the study measure what it says it does?) and external validity (generalizability). In QOL studies, compliance with planned questionnaires and missing data can threaten both types of validity. Patients self-select study participation, which influences external validity (i.e., study results are applicable only to the type of patients who agreed to participate). Once enrolled in the study, participants determine whether or not they complete requested evaluations. Certain questions or even pages of a given questionnaire may not be completed, or the entire questionnaire may have been missed, either because the patient did not attend a scheduled appointment, or because he or she attended but did not complete the QOL instrument. Missed questionnaires threaten both types of validity, since reported results do not really reflect the experience of ALL patients in the study. Specifically, it has been shown that healthier patients are more likely to comply with QOL assessments [74]. While statistical methods exist to attempt to correct for missing data, they require the assumption that data is missing at random, which is known to be unlikely in QOL studies. Consequently, every effort should be made to maximize compliance in QOL studies. Strategies to do so include adequate resources, education, and feedback for those administering the questionnaires, real-time monitoring of compliance, and back-up methods of administering questionnaires if an error is detected within an acceptable time window [75].

Mean Changes Versus Response Analyses

Longitudinal studies may report mean change in an overall group, however, this can overestimate long-term QOL due to “survivor effect”: data from all patients are included at baseline, but only patients who survive and continue to comply with assessments are included in follow-up. In comparison of two trial arms, it is even possible that the QOL may appear to be better in the arm with fewer survivors, since a more toxic treatment may selectively eliminate those with poorer QOL. One alternative is to prespecify the QOL hypothesis and MID, and analyze QOL response. Each participant is categorized according to “improved,” “stable,” or “worsened”

QOL, and arms are compared for proportion of patients with a QOL benefit [76]. This approach also allows calculation of a number needed to treat (NNT) statistic [77].

Knowledge Translation

The concept of knowledge translation refers to the gap between evidence and practice [78]. Awareness, agreement, adoption, and adherence that have been proposed as the necessary steps required before clinicians use new knowledge. A prerequisite of both awareness and agreement is that information must be presented in a manner which is interpretable and usable. This has been a challenge for QOL data [79]. Two User’s Guides have been published to assist the clinician with evaluating and interpreting QOL results [80, 81]. In addition, two papers have provided lists of study details which should be included in publications of QOL results [82, 83]. However, a recent review showed that in recent publications of oncology clinical trials, recommended information items were included 10–70% of cases; a trend to the improvement of most data points was seen over time [84]. Additional research is needed to help bridge the current gap between QOL researchers and oncologists in the clinical setting.

Research and Clinical Applications

Clinical Trials

The concept of levels of evidence for medical decision making applies to QOL research just as it does to studies with survival outcomes. However, the field of QOL research is newer and few phase III randomized controlled trials (RCTs) in HNC have yet reported QOL results. The author recently performed a Medline search for QOL in oral cavity cancer; of 45 articles found, only 17 actually reported QOL after the treatment on validated scales. No randomized trials, and only one controlled trial, were found; most publications were of cross-sectional studies or small, uncontrolled prospective trials. However, a few high-quality RCTs using valid instruments have begun to appear, and most current, large studies include a QOL component.

A few useful results have been reported for definitive therapy. QOL after RT for nasopharynx cancer was found to be superior after parotid sparing with IMRT than with conventional RT [25], and QOL was found to return to baseline 12 months after the treatment of locoregionally advanced HNC of the oropharynx, hypopharynx, and larynx, regardless of whether patients received RT or RT plus cetuximab [85]. A comparison of intravenous versus intra-arterial

cisplatin given with concurrent RT showed no differences in QOL at 1 year, although there was a transient worsening of nausea and vomiting reported in the intravenous group [86].

In the adjuvant setting, the addition of subcutaneous mistletoe extract to surgery +/- postoperative RT had no effect on QOL as compared to no further therapy [39].

In the palliative setting, injection of a cisplatin/epinephrine gel into HNC tumors, as compared to placebo, did not appear to alter QOL, although QOL compliance was poor [87]. No differences in QOL change from baseline were seen between methotrexate or gefitinib for recurrent/metastatic HNC [88].

Other RCTs have focused on supportive care for HNC patients. Two RCTs of pilocarpine showed no QOL benefit over placebo in patients with post-RT xerostomia [22, 89], and two others showed no QOL benefit from a lozenge intended to reduce mucositis [90], or from a cream intended to reduce dermatitis [45]. More such studies are needed and indeed, anticipated.

Prognostic Applications

In cancer generally, baseline QOL is among the strongest available prognostic factors. A *confounding variable* is defined as a covariate which is associated with both the predictor and the outcome; for baseline QOL and survival, there are many potential confounders. Less baseline comorbidity, lack of ongoing tobacco and alcohol use, higher socioeconomic status and education levels, better social supports, a more optimistic outlook, and less extensive disease have all been associated with both higher QOL and improved survival. Nonetheless, several studies have shown the independent value of baseline QOL in multivariable analyses. Figure 49.1 shows the overall survival by baseline global QOL on the EORTC QLQ-C30 in a study of RT versus RT and cetuximab; only Karnofsky performance status was a stronger predictor of survival [85].

A retrospective analysis of prospectively collected QOL data categorized HNC patients as short- (<1 year), intermediate- (1–3 years) or long- (>3 years) term survivors and found significant differences in QOL at all timepoints, including baseline [91]. The RTOG has published a combined analysis of two HNC randomized trials using FACT-H&N, which showed baseline QOL to be predictive of locoregional control, but not overall survival [92]. Finally, a recently completed study of concurrent chemoRT with or without the hypoxic cell sensitizer tirapazamine, has shown QOL to be a strong predictor of overall survival (unpublished data). These results suggest that baseline QOL may be useful as a future tool to assist in selecting patients for differing treatment intensities or for additional supportive care measures, but such a strategy has not yet been explored.

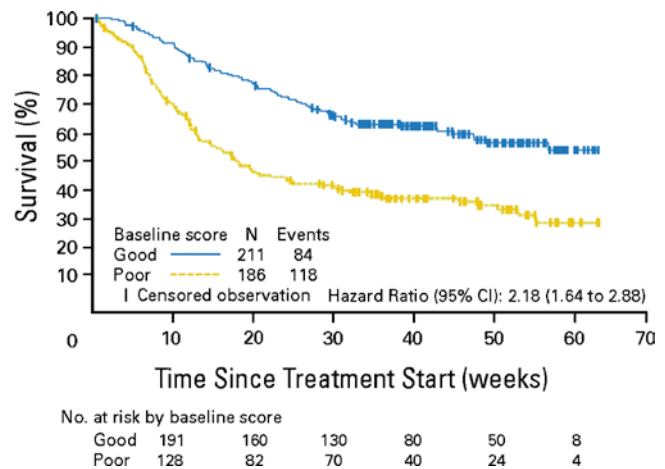


Fig. 49.1 Kaplan Meier survival curves stratified by baseline EORTC QLQ-C30 global health status/quality of life scores [85] (from Curran D, Giralt J, Harari P, et al. Quality of life in head and neck cancer patients after treatment with high-dose radiotherapy alone or in combination with cetuximab. *J Clin Oncol.* 2007;25:2191–7. Reprinted with permission. © 2008 American Society of Clinical Oncology. All rights reserved)

Routine Clinical Application

The use of QOL instruments in clinical trial protocols has become widely accepted, however, such questionnaires are not yet used in routine practice. An overview of RCTs allocating patients or physicians to use versus not use QOL data in routine practice showed mixed results, with some studies showing benefits in patient satisfaction or process of care, but others failing to show such benefits [93]. Two oncology RCTs have suggested positive effects: Velikova et al. found more frequent discussion of symptoms and improved emotional well-being in patients for whom QOL data was provided to the physician before a visit compared to those for whom it was not [94]. Detmar et al. found more frequent discussion of QOL issues by physicians who had been provided QOL data for patients receiving palliative chemotherapy [95]. However, neither of these studies demonstrated a change in patient management, and the routine use of QOL instruments is unlikely to be cost-effective. No published studies evaluating the use of QOL instruments in routine practice for HNC patients were identified.

Special Challenges (Compliance, Education, and Communication)

The incident population of HNC patients is undergoing a period of rapid change. The traditional risk factors of smoking and alcohol use translated into a patient population with

lower than average socioeconomic status and educational levels [38]. For QOL measurement, this led to special considerations, including the need for instruments that were short, easy to read, and not excessively intellectually complex. In many studies, compliance with questionnaire completion was low; moreover, lack of social support, alcohol abuse, and lower levels of education have all been shown to correlate with lower QOL [96]. More recently, however, 66% of oropharynx cancer patients in Toronto, Canada, were shown to have HPV/p16 associated cancers; such patients often lack the risk factors of smoking or alcohol use, and tend to be younger with higher socioeconomic status and education levels [97]. HPV-associated cancer appears to have an improved prognosis, and new clinical trials to test less toxic treatment approaches in such patients are anticipated; QOL is an important outcome in such trials. At this time, it is unknown exactly how this shift in HNC etiology affects QOL measurement or results, but strategies to maximize the compliance with QOL within any research protocol continue to be very important to assure the validity of results.

A Glimpse into the Future

Computer-Adaptive Tests (CATs) use technology to deliver questionnaires in a logical manner, and can significantly reduce respondent burden by producing high reliability and validity with far fewer questions. The approach combines the capability of computers to adapt using if/then algorithms, with the application of item response theory (IRT) to individual questions. IRT is a statistical method which uses mathematical modeling to characterize the ability of each individual item to discriminate differences depending on the level of a patient's problem. Together, this type of system allows the computer to present questions which are most likely to produce a reliable and valid characterization of the underlying trait of interest. For example, a CAT test might begin with an item, such as "do you have pain?" which does not make any assumptions about pain level. However, a respondent who answers "yes" would receive follow-up questions regarding pain severity, whereas one who answers "no" might have confirmatory question, such as "does discomfort interfere with your ability to participate in sports?"

PROMIS and CaPS

The Patient-Reported Outcomes Measurement Information System (PROMIS) is a large-scale project sponsored by the National Institute of Health (NIH) in the USA [98]. The goal of PROMIS is to develop a comprehensive bank of items

with known IRT characteristics, drawn from existing PRO instruments. These items may then be used for CAT or combined in new ways to create fixed-length PROs for specific purposes [49]. Significant progress has been made for the general health bank, and a prototype online CAT administration tool now exists [99]. Validation of the PROMIS instruments is ongoing. The Cancer PROMIS Supplement (CaPS) has been funded to insure that PROMIS adequately meets the needs of PRO measurement in cancer patients [100].

Summary

While improving the survival outcomes of HNC patients remains the primary goal of advances in therapy, the importance of the QOL impact of both tumor and treatment to patients cannot be overemphasized. The measurement science of QOL and other PRO tools is well developed, and these instruments have been increasingly incorporated into clinical trials. Available evidence remains somewhat limited as the results of ongoing trials are anticipated. Future questions include the potential value of using QOL questionnaires in routine clinical care, the best strategies for translating QOL knowledge to clinicians, and the role of CAT administration of PROs.

References

1. Karnofsky DA, Abelmann WH, Craver LF, et al. The use of nitrogen mustards in the palliative treatment of carcinoma. *Cancer*. 1948;1(4):634–56.
2. Rehabilitation after cardiovascular diseases, with special emphasis on developing countries. Report of a WHO Expert Committee. *World Health Organ Tech Rep Ser*. 1993;831:1–122.
3. National Election Studies, 1964: Pre/Post Election Study. In: Political Behavior Program tSRCotIoSR. Ann Arbor: University of Michigan, Center for Political Studies; 1999.
4. Bennet KJ, Torrance G. Measuring health state preferences and utilities: rating scale, time trade-off, and standard gamble techniques. In: Spilker B, editor. *Quality of life and pharmacoeconomics in clinical trials*. 2nd ed. Philadelphia, PA: Lippincott-Raven; 1996. p. 259.
5. FDA. Draft guidance for industry on patient-reported outcome measures: use in medicinal product development to support labeling claims. *Fed Regist*. 2006;71:5862–3.
6. Schoemaker PJH. The expected utility model: its variants, purposes and limitations. *J Econ Lit*. 1982;20:529–63.
7. Leppo NE. The first ten years of the World Health Organization. *Minn Med*. 1958;41(8):577–83.
8. Schwartz S, McDowell J, Yueh B. Numeracy and the shortcomings of utility assessment in head and neck cancer patients. *Head Neck*. 2004;26(5):401–7.
9. Martino R, Ringash J. Evaluation of quality of life and organ function in head and neck squamous cell carcinoma. *Hematol Oncol Clin North Am*. 2008;22(6):1239–56.

10. Pusic A, Liu J, Chen C, et al. A systematic review of patient-reported outcome measures in head and neck cancer surgery. *Otolaryngol Head Neck Surg.* 2007;136:525–35.
11. Daut RL, Cleeland CS, Flanery RC. Development of the Wisconsin Brief Pain Questionnaire to assess pain in cancer and other diseases. *Pain.* 1983;17(2):197–210.
12. Hjermstad MJ, Fainsinger RL, Kaasa S. Assessment and classification of cancer pain. *Curr Opin Support Pall Care.* 2009;3(1):24–30.
13. Dirix P, Nuyts S, Van den Bogaert W. Radiation-induced xerostomia in patients with head and neck cancer: a literature review. *Cancer.* 2006;107:2525–34.
14. Hamlet S, Faull J, Klein B, et al. Mastication and swallowing in patients with postirradiation xerostomia. *Int J Radiat Oncol Biol Phys.* 1997;37(4):789–96.
15. Rhodus N, Moller K, Colby S, et al. Articulatory speech performance in patients with salivary gland dysfunction: a pilot study. *Quintessence Int.* 1995;26:805–10.
16. Roesink JM, Schipper M, Busschers W, et al. A comparison of mean parotid gland dose with measures of parotid gland function after radiotherapy for head-and-neck cancer: implications for future trials. *Int J Radiat Oncol Biol Phys.* 2005;63(4):1006–9.
17. LENT SOMA tables. *Radiotherapy Oncol.* 1995;35:17–60.
18. Cox JD, Stetz J, Pajak TF. Toxicity criteria of the Radiation Therapy Oncology Group (RTOG) and the European Organization for Research and Treatment of Cancer (EORTC). *Int J Radiat Oncol Biol Phys.* 1995;31(5):1341–6.
19. Trotti A, Colevas AD, Setser A, et al. CTCAE v3.0: development of a comprehensive grading system for the adverse effects of cancer treatment. *Semin Radiat Oncol.* 2003;13(3):176–81.
20. Johnson J, Ferretti G, Nethery W, et al. Oral pilocarpine for post-irradiation xerostomia in patients with head and neck cancer. *N Engl J Med.* 1993;329:390–5.
21. Eisbruch A, Kim H, Terrell J, et al. Xerostomia and its predictors following parotid-sparing irradiation of head-and-neck cancer. *Int J Radiat Oncol Biol Phys.* 2001;50:695–704.
22. Ringash J, Warde P, Lockwood G, et al. Postradiotherapy quality of life for head-and-neck cancer patients is independent of xerostomia. *Int J Radiat Oncol Biol Phys.* 2005;61(5):1403–7.
23. Brizel D, Wasserman T, Henke M, et al. Phase III randomized trial of amifostine as a radioprotector in head and neck cancer. *J Clin Oncol.* 2000;18:3339–45.
24. Kam M, Leung S, Zee B, et al. Prospective randomized study of intensity-modulated radiotherapy on salivary gland function in early-stage nasopharyngeal carcinoma patients. *J Clin Oncol.* 2007;25:4873–9.
25. Pow EH, Kwong DL, McMillan AS, et al. Xerostomia and quality of life after intensity-modulated radiotherapy vs. conventional radiotherapy for early-stage nasopharyngeal carcinoma: initial report on a randomized controlled clinical trial. *Int J Radiat Oncol Biol Phys.* 2006;66(4):981–91.
26. Jha N, Seikaly H, McGaw T, et al. Submandibular salivary gland transfer prevents radiation-induced xerostomia. *Int J Radiat Oncol Biol Phys.* 2000;46:7–11.
27. Seikaly H, Jha N, Harris J, et al. Long-term outcomes of submandibular gland transfer for prevention of postirradiation xerostomia. *Arch Otolaryngol Head Neck Surg.* 2004;130:956–61.
28. Jha N, Seikaly H, Harris J, et al. Prevention of radiation induced xerostomia by surgical transfer of submandibular salivary gland into the submental space. *Radiother Oncol.* 2003;66:283–9.
29. Lewin JS. Dysphagia after chemoradiation: prevention and treatment. *Int J Radiat Oncol Biol Phys.* 2007;69(2 Suppl):S86–7.
30. Perry AR, Shaw MA. Evaluation of functional outcomes (speech, swallowing and voice) in patients attending speech pathology after head and neck cancer treatment(s): development of a multi-centre database. *J Laryngol Otol.* 2000;114(8):605–15.
31. Blood G. Development and assessment of a scale addressing communication needs of patients with laryngectomies. *Am J Speech Lang Pathol.* 1993;2(3):82–90.
32. Jacobson B, Johnson A, Grywalski C, et al. The voice handicap index (VHI): development and validation. *Am J Speech Lang Pathol.* 1997;6(3):66–70.
33. Llewellyn-Thomas HA, Sutherland HJ, Hogg SA, et al. Linear analogue self-assessment of voice quality in laryngeal cancer. *J Chronic Dis.* 1984;37(12):917–24.
34. Ward EC, Bishop B, Frisby J, et al. Swallowing outcomes following laryngectomy and pharyngolaryngectomy. *Arch Otolaryngol Head Neck Surg.* 2002;128(2):181–6.
35. Lewin J. Speech and swallowing following treatment for oral cancer. In: Werning J, editor. *Oral cancer.* New York: Thieme Medical Publishers; 2007. p. 304–8.
36. Karnell LH, Funk GF, Hoffman HT. Assessing head and neck cancer patient outcome domains. *Head Neck.* 2000;22(1):6–11.
37. Logemann JA, Pauloski BR, Rademaker AW, et al. Supersupraglottic swallow in irradiated head and neck cancer patients. *Head Neck.* 1997;19(6):535–40.
38. Hoffman HT, Karnell LH, Funk GF, et al. The National Cancer Data Base report on cancer of the head and neck. *Arch Otolaryngol Head Neck Surg.* 1998;124(9):951–62.
39. Steuer-Vogt MK, Bonkowsky V, Ambrosch P, et al. The effect of an adjuvant mistletoe treatment programme in resected head and neck cancer patients: a randomised controlled clinical trial. *Eur J Cancer.* 2001;37(1):23–31.
40. Chen AY, Frankowski R, Bishop-Leone J, et al. The development and validation of a dysphagia specific quality-of-life questionnaire for patients with head and neck cancer: The M. D. Anderson dysphagia inventory. *Arch Otolaryngol Head Neck Surg.* 2001;127(7):870–6.
41. McHorney CA, Bricker DE, Kramer AE, et al. The SWAL-QOL outcomes tool for oropharyngeal dysphagia in adults: I. Conceptual foundation and item development. *Dysphagia.* 2000;15(3):115–21.
42. McHorney CA, Bricker DE, Robbins J, et al. The SWAL-QOL outcomes tool for oropharyngeal dysphagia in adults: II. Item reduction and preliminary scaling. *Dysphagia.* 2000;15(3):122–33.
43. McHorney CA, Robbins J, Lomax K, et al. The SWAL-QOL and SWAL-CARE outcomes tool for oropharyngeal dysphagia in adults: III. Documentation of reliability and validity. *Dysphagia.* 2002;17(2):97–114.
44. Logemann JA, Pauloski BR, Rademaker AW, et al. Xerostomia: 12-month changes in saliva production and its relationship to perception and performance of swallow function, oral intake, and diet after chemoradiation. *Head Neck.* 2003;25(6):432–7.
45. Elliott EA, Wright JR, Swann RS, et al. Phase III Trial of an emulsion containing trolamine for the prevention of radiation dermatitis in patients with advanced squamous cell carcinoma of the head and neck: results of Radiation Therapy Oncology Group Trial 99-13. *J Clin Oncol.* 2006;24(13):2092–7.
46. Feinstein AR. *Clinimetrics.* New Haven, CT: Yale University Press; 1987.
47. Woodard CA, Chambers LW. *Guide to questionnaire construction and question writing.* 1st ed. Ottawa: Canadian Public Health Association; 1980.
48. Cull A, Sprangers M, Bjordal K, et al. on behalf of the EORTC Quality of Life Group. *EORTC Quality of Life Group Translation Procedure.* Brussels: EORTC; 2002.
49. Reeve B, Hays R, Bjorner J, et al. Psychometric evaluation and calibration of health-related quality of life item banks: plans for the Patient-Reported Outcomes Measurement Information System (PROMIS). *Med Care.* 2007;45(5 Suppl 1):S22–31.
50. Nunnally JC. *Psychometric theory.* New York: McGraw Hill; 1978. p. 245–6.

51. Weiner EA, Stewart BJ. Assessing individuals: psychological and educational tests and measurements. Boston, MA: Little Brown; 1984.
52. Wright JG. The minimal important difference: who's to say what is important? *J Clin Epidemiol*. 1996;49(11):1221–2.
53. Ringash J, O'Sullivan B, Bezjak A, et al. Interpreting clinically significant changes in patient-reported outcomes. *Cancer*. 2007;110:196–202.
54. Norman GR, Sloan JA, Wywich KW. Interpretation of changes in health-related quality of life: the remarkable universality of half a standard deviation. *Med Care*. 2003;41(5):582–92.
55. Ware Jr JE, Sherbourne CD. The MOS 36-item short-form health survey (SF-36). I. Conceptual framework and item selection. *Med Care*. 1992;30(6):473–83.
56. Schlenk EA, Erlen JA, Dunbar-Jacob J, et al. Health-related quality of life in chronic disorders: a comparison across studies using the MOS SF-36. *Qual Life Res*. 1998;7(1):57–65.
57. Johnson JA, Coons SJ. Comparison of the EQ-5D and SF-12 in an adult US sample. *Qual Life Res*. 1998;7(2):155–66.
58. Bjordal K, Kaasa S. Psychometric validation of the EORTC Core Quality of Life Questionnaire, 30-item version and a diagnosis-specific module for head and neck cancer patients. *Acta Oncol*. 1992;31(3):311–21.
59. Cella DF, Tulsky DS, Gray G, et al. The Functional Assessment of Cancer Therapy scale: development and validation of the general measure. *J Clin Oncol*. 1993;11(3):570–9.
60. Cella DF. F.A.C.I.T. manual, version 4. Evanston, NY: Centre on Outcomes, Research and Education; 1997.
61. Ringash J, Lemon B, Lockwood G, et al. Tu-be or not tu-be? The QOL-EF tool for measuring the impact of enteral feeding on QOL. *QLR J*. 2006;A-63.
62. Ringash J, Bezjak A. A structured review of quality of life instruments for head and neck cancer patients. *Head Neck*. 2001;23(3):201–13.
63. Aaronson NK, Ahmedzai S, Bullinger M. The EORTC core quality of life questionnaire: interim results of an international field study. In: Osoba D, editor. *Effect of cancer on quality of life*. Boston, MA: CRC; 1991.
64. Bjordal K, Ahlner-Elmqvist M, Tolleson E, et al. Development of a European Organization for Research and Treatment of Cancer (EORTC) questionnaire module to be used in quality of life assessments in head and neck cancer patients. EORTC Quality of Life Study Group. *Acta Oncol*. 1994;33(8):879–85.
65. List MA, D'Antonio LL, Cella DF, et al. The performance status scale for head and neck cancer patients and the functional assessment of cancer therapy-head and neck scale. A study of utility and validity. *Cancer*. 1996;77(11):2294–301.
66. Weymuller EA, Yueh B, Deleyiannis FW, et al. Quality of life in patients with head and neck cancer: lessons learned from 549 prospectively evaluated patients. *Arch Otolaryngol Head Neck Surg*. 2000;126(3):329–35. discussion 335–326.
67. Hassan SJ, Weymuller Jr EA. Assessment of quality of life in head and neck cancer patients. *Head Neck*. 1993;15(6):485–96.
68. Terrell JE, Nanavati KA, Esclamado RM, et al. Head and neck cancer-specific quality of life: instrument validation. *Arch Otolaryngol Head Neck Surg*. 1997;123(10):1125–32.
69. Funk G, Karnell L, Christensen A, et al. Comprehensive head and neck oncology health status assessment. *Head Neck*. 2003;25:561–75.
70. Trotti A, Johnson DJ, Gwede C, et al. Development of a head and neck companion module for the quality of life-radiation therapy instrument (QOL-RTI). *Int J Radiat Oncol Biol Phys*. 1998;42(2):257–61.
71. Browman GP, Levine MN, Hodson DI, et al. The head and neck radiotherapy questionnaire: a morbidity/quality-of-life instrument for clinical trials of radiation therapy in locally advanced head and neck cancer. *J Clin Oncol*. 1993;11(5):863–72.
72. Sprangers MAG, Schwartz CE. Integrating response shift into health-related quality of life research: a theoretical model. *Soc Sci Med*. 1999;48:1507–15.
73. Holzner B, Kemmler G, Cella D, et al. Normative data for functional assessment of cancer therapy – general scale and its use for the interpretation of quality of life scores in cancer survivors. *Acta Oncol*. 2004;43(2):153–60.
74. Guren MG, Dueland S, Skovlund E, et al. Quality of life during radiotherapy for rectal cancer. *Eur J Cancer*. 2003;39(5):587–94.
75. Osoba D, Zee B. Completion rates in health-related quality-of-life assessment: approach of the National Cancer Institute of Canada Clinical Trials Group. *Stat Med*. 1998;17(5–7):603–12.
76. Osoba D, Bezjak A, Brundage M, et al. Analysis and interpretation of health-related quality-of-life data from clinical trials: basic approach of The National Cancer Institute of Canada Clinical Trials Group. *Eur J Cancer*. 2005;41(2):280–7.
77. Laupacis A, Sackett DL, Roberts RS. An assessment of clinically useful measures of the consequences of treatment. *N Engl J Med*. 1988;318(26):1728–33.
78. Davis D, Evans M, Jadad A, et al. The case for knowledge translation: shortening the journey from evidence to effect. *BMJ*. 2003;327(7405):33–5.
79. Bezjak A, Ng P, Skeel R, et al. Oncologists' use of quality of life information: results of a survey of Eastern Cooperative Oncology Group physicians. *Qual Life Res*. 2001;10(1):1–13.
80. Guyatt GH, Naylor CD, Juniper E, et al. Users' guides to the medical literature. XII. How to use articles about health-related quality of life. Evidence-Based Medicine Working Group. *JAMA*. 1997;277(15):1232–7.
81. Sprangers MA, Moinpour CM, Moynihan TJ, et al. Assessing meaningful change in quality of life over time: a users' guide for clinicians. *Mayo Clin Proc*. 2002;77(6):561–71.
82. Lee CW, Chi KN. The standard of reporting of health-related quality of life in clinical cancer trials. *J Clin Epidemiol*. 2000;53(5):451–8.
83. Efficace F, Bottomley A, van Andel G. Health related quality of life in prostate carcinoma patients: a systematic review of randomized controlled trials. *Cancer*. 2003;97(2):377–88.
84. Brundage M, Bass B, Davidson J, et al. Patterns of reporting HRQL outcomes in randomized clinical trials of cancer therapies: implications for clinicians. International Society for Quality of Life Research meeting abstracts. *QLR J*. 2007;A-31.
85. Curran D, Giralt J, Harari P, et al. Quality of life in head and neck cancer patients after treatment with high-dose radiotherapy alone or in combination with cetuximab. *J Clin Oncol*. 2007;25:2191–7.
86. Ackerstaff AH, Balm AJ, Rasch CR, et al. First-year quality of life assessment of an intra-arterial (RADPLAT) versus intravenous chemoradiation phase III trial. *Head Neck*. 2009;31(1):77–84.
87. Castro DJ, Sridhar KS, Garewal HS, et al. Intratumoral cisplatin/epinephrine gel in advanced head and neck cancer: a multicenter, randomized, double-blind, phase III study in North America. *Head Neck*. 2003;25(9):717–31.
88. Stewart JS, Cohen EE, Licitra L, et al. Phase III study of gefitinib 250 compared with intravenous methotrexate for recurrent squamous cell carcinoma of the head and neck. *J Clin Oncol*. 2009;27(11):1864–71.
89. Fisher J, Scott C, Scarantino CW, et al. Phase III quality-of-life study results: impact on patients' quality of life to reducing xerostomia after radiotherapy for head-and-neck cancer – RTOG 97-09. *Int J Radiat Oncol Biol Phys*. 2003;56(3):832–6.
90. Duncan GG, Epstein JB, Tu D, et al. Quality of life, mucositis, and xerostomia from radiotherapy for head and neck cancers: a report

- from the NCIC CTG HN2 randomized trial of an antimicrobial lozenge to prevent mucositis. *Head Neck*. 2005;27(5):421–8.
91. Goldstein DP, Hynds Karnell L, Christensen AJ, et al. Health-related quality of life profiles based on survivorship status for head and neck cancer patients. *Head Neck*. 2007;29(3):221–9.
92. Siddiqui F, Pajak T, Watkins-Bruner D, et al. Pretreatment quality of life predicts for locoregional control in head and neck cancer patients: a radiation therapy oncology group analysis. *Int J Radiat Oncol Biol Phys*. 2008;70:353–60.
93. Guyatt GH, Ferrans CE, Halyard MY, et al. Exploration of the value of health-related quality-of-life information from clinical research and into clinical practice. *Mayo Clin Proc*. 2007;82(10):1229–39.
94. Velikova G, Booth L, Smith A, et al. Measuring quality of life in routine oncology practice improves communication and patient well-being: a randomized controlled trial. *J Clin Oncol*. 2004;22(4):714–24.
95. Detmar S, Muller M, Schornagel J, et al. Health-related quality-of-life assessments and patient-physician communication: a randomized controlled trial. *JAMA*. 2002;288(23):3027–34.
96. Sehlen S, Hollenhorst H, Lenk M, et al. Only sociodemographic variables predict quality of life after radiography in patients with head-and-neck cancer. *Int J Radiat Oncol Biol Phys*. 2002;52(3):779–83.
97. Shi W, Kato H, Perez-Ordonez B, et al. Comparative prognostic value of E6 mRNA vs. HPV16 in-situ hybridization for human oropharyngeal squamous carcinoma. *J Clin Oncol*. 2009;27(36):6213–21.
98. Ader DNS. Developing the Patient-Reported Outcomes Measurement Information System (PROMIS). *Med Care*. 2007;45(1):S1–2.
99. <http://www.assessmentcenter.net/ac1/>. Accessed 21 July 2009.
100. <http://www.dcri.duke.edu/ccge/projects/promis/caps/index.html>. Accessed 21 July 2009.

Chapter 50

Quality Assurance of Clinical Trials in the Management of Cancer in the Head and Neck

Thomas J. FitzGerald, Maryann Bishop-Jodoin, Marcia M. Urie, Kenneth Ulin, Geoffrey S. Ibbott, James A. Purdy, Joel H. Saltz, Lester J. Peters, M. Giulia Cicchetti, Mitchell Schnall, Joseph Deasy, Walter R. Bosch, Michael V. Knopp, Lawrence H. Schwartz, Keith S. White, Richard Hanusik, Sandra K. Kessel, Karen Morano, and Fran Laurie

Abstract Integrating tissue analysis and imaging strategies in clinical trial objectives is an important area of clinical translational research. Clinical trial designs that incorporate clear guidelines for clinical trial execution, definitions of data submission pathways and study deviations, and integration of real time and adaptive quality assurance will provide uniformity of study populations for clinical trial analysis. Essential to clinical trials management is a robust, validated informatics platform to display data and imaging in a uniform manner acquired from diverse platforms and re-presented for both on site and distributed review in a uniform file format.

The Quality Assurance Review Center (QARC) uses a robust informatics platform to provide protocol development, site credentialing, data acquisition, case management, capable of both real time and retrospective review of objects, data transfer to clinical trial sponsor and/or industry partner and data archiving. As a member of the Virtual Imaging Evaluation Workspace (VIEW) and the Advanced Technology Quality Assurance (QA) Consortium (ATC), QARC collaborates in the development, sharing and implementation of credentialing tools, digital acquisition and review tools and processes, a common platform for data storage for radiotherapy and imaging with emphasis on compliance to caBIG and 21 CFR Part 11. Recent evidence demonstrates that compliance to study guidelines may have significant influence on study and patient outcome. Head and neck cancer is a very good area to study biopharmacology of treatment response and the quality assurance process is a vehicle for adaptive clinical trial and patient management.

Keywords Compliance • Real-time review • Quality assurance • Informatics • Clinical trial • Credentialing • QA

T.J. FitzGerald (✉)

Department of Radiation Oncology, University of Massachusetts Medical School, UMass Memorial Medical Center, QARC, Suite 201, 640 George Washington Highway, Lincoln, RI 02865, USA
e-mail: TJFitzGerald@qarc.org

Introduction

With the expanding role of advanced technology imaging as a vehicle for target volume definition and as a biomarker for validating response to management, cancers of the head and neck have become an important area of clinical translational oncology research. Tools for tissue acquisition, even during therapy, have become more facile and readily available; therefore, strategies incorporating tissue analysis have become integrated into clinical protocol management as both primary and secondary clinical trial objectives. These cancers comprise 3% of all malignancies with 35 sites of origin. Most are squamous cell cancers in origin that share a similar morphology with the established environmental risks of oncogenesis, including both patient habit and occupational environment. Clinical trials with emphasis on validation of new therapies frequently select patients with locally advanced stage 3 and 4A disease at presentation as the study population. These trials include endpoints of patient survival, progression free survival, and local tumor control. There is an evolving field of clinical trials that focus on normal tissue outcome, including evaluation of mouth moisture, taste, salivary function, swallowing function, voice quality, and second malignancies. These trials include patients with less advanced disease at presentation with normal tissue function.

There are many important features to clinical trial design and the integration of quality assurance. The primary goal of quality assurance is to provide a uniform study population for analysis with all protocol required data available for review in both real time and retrospective evaluation. Protocol deviation should be limited to as low a figure as possible as lack of compliance to study guidelines may influence clinical trial outcome. Rapid and timely review of imaging and treatment planning objects prior to study entry and/or treatment execution can identify patients and treatment plans that are not eligible or compliant to study objectives. The increasing use of digital media for data acquisition in clinical trials provides an opportunity to distribute clinical trial data to study management teams. The protocol needs to provide a complete platform for clinical trial execution as well as clear

defined pathways for data submission. The protocol must include definitions of study deviation.

Imaging and clinical information are essential elements to defining staging and eligibility. Protocols are now using many advanced technology anatomic and metabolic imaging studies to validate both response and radiation therapy target volume definition. Pathology objects, including microarrays, are DICOM compatible; therefore, these objects can be stored in a computer database directly with images and radiation therapy data objects making them available for timely study analysis. Integrating these objects with outcome information, including images at the time of disease progression, can now be accomplished with a single demonstration platform and displayed via Web-based techniques for real-time review by on and off-site study investigators.

Informatics

Essential to the management of clinical trials is a robust informatics platform. The platform must include many features for successful clinical trial management. The epicenter to the informatics infrastructure is the database as it becomes the central feature for daily operation. Validation, regulatory compliance and integration with sponsor platforms are important features for the informatics platform.

The Quality Assurance Review Center (QARC) uses a robust informatics platform. Central to the informatics systems at QARC is the QARC database known as MAX. The database is a fully validated relational operating system central to all daily functions. Data for each case, including imaging, biopathology, radiation therapy planning, clinical demographics, as well as study-specific elements, are assembled in the database and linked archives. Reviewers have the ability to review, annotate the images and communicate their evaluations all within the database. Query functions and standard reports are incorporated into the database functionality allowing facile navigation through patient records.

Nimble and user friendly mechanisms for informatics data management are crucial for successful real-time evaluation of information for timely feedback to site investigators. Questions regarding staging and eligibility require rapid evaluation (often same day) in order to determine which trial may be better suited for the patient under review. Likewise, questions regarding therapy response and compatibility of radiation therapy treatment intent also require timely response from the central review center to the site investigator team. Mechanisms need to be in place to facilitate these interactions from remote locations, including international participation of clinical trial investigators.

The database is used by all QARC divisions. Established processes are in place for protocol development, site identification and credentialing (benchmarking), data acquisition,

case management, case review, data transfer, and data archiving. The database offers user-friendly extended query function for protocol analysis both during the study and in retrospect to answer secondary questions generated by the clinical trial. Internal to the database, data is indexed and tailored to database users. The database employs controls for 21 CFR Part 11 compliance and ICH-GCP adherence. One feature includes the automatically created audit trails of stored data through multiple pathways. The database monitors its own function through a code tracker utility that can identify and monitor highly trafficked areas as well as identify items that are obsolete. A separate audit is triggered every time a field of the database is changed. Another audit is initiated when a predetermined trip point is met, such as the time that a patient undergoes the final review process. The audit processes can be fully queried. In aggregate, the audit processes track each time an audit is fired, who fired it, identify and segregate original and changed data, and present the users explanation of why the data were changed. Each step is essential for data management and insures that all data transferred to cooperative group database systems are validated and uncorrupted.

Data Acquisition and Data Flow

Essential to a data acquisition system is the active communication between QARC CRA staff and participating institution CRA staff. These interactions facilitate information transfer and are of significant importance to the success of the clinical trial. Placing informatics systems, including image and radiation therapy treatment data transfer systems, at participating clinical trial sites facilitates data transfer. In situations where placement of object transfer devices cannot be accomplished, forwarding objects to QARC via compact disc (CD) is facile and achieves the objectives required for digital data submission. Once data arrives at QARC, CRA staff review the information for both quality and correctness for protocol objectives. It is assimilated into the database for review by QARC physician staff and study investigators. Data flow is depicted in Fig. 50.1.

Data Management

Data management is the next step after data acquisition. Once the information is acquired and placed in the appropriate format, quality assurance and study investigators review the data for study compliance in order to make certain the information meets study guidelines. Many of these review processes are performed in real time to make certain the study needs are met and deviations on study are kept to a

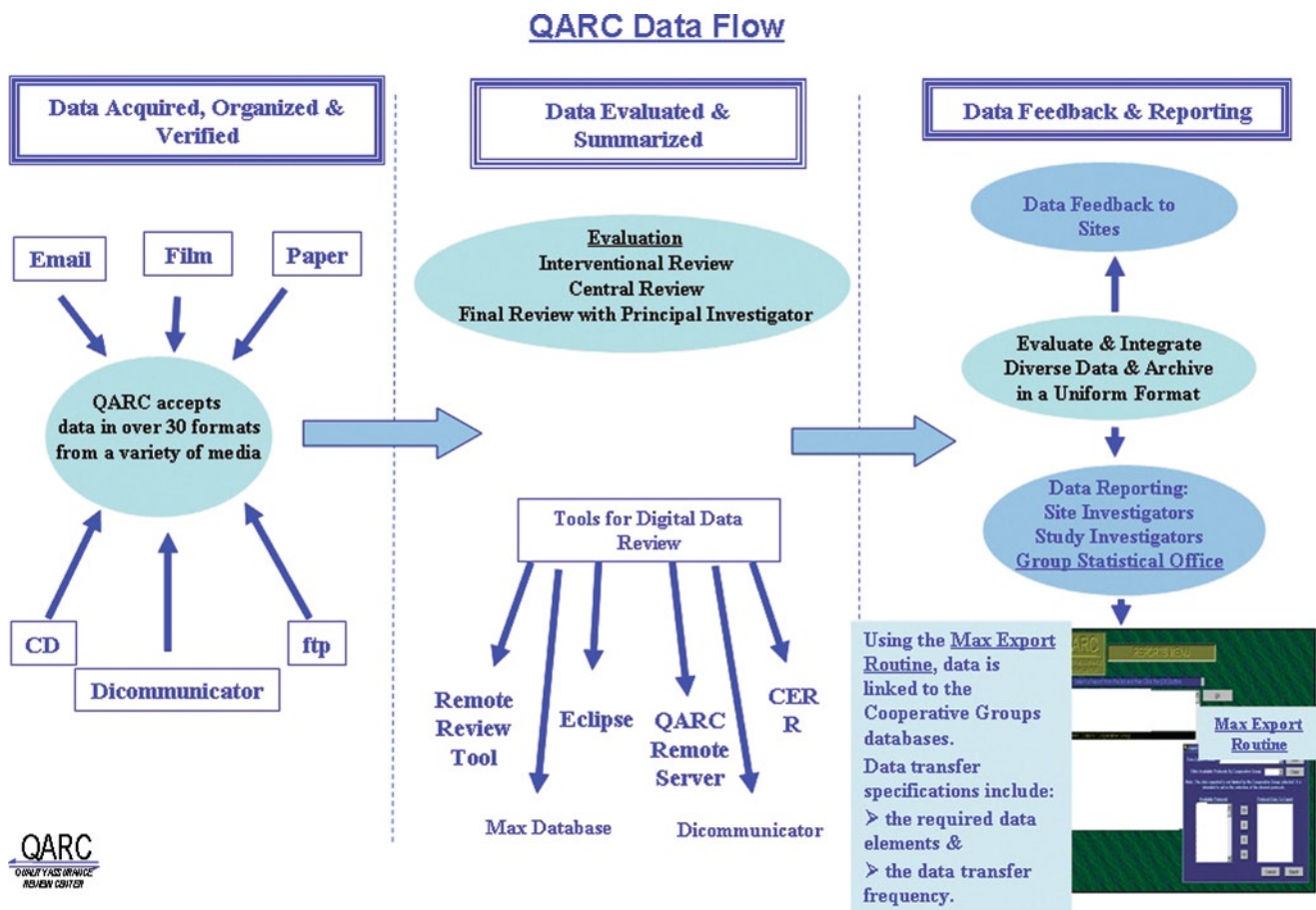


Fig. 50.1 QARC data flow. The Quality Assurance Review Center (QARC) data flow enables QARC to establish a diverse portfolio of digital imaging and radiotherapy objects to ensure study needs are met and study deviations are kept to a minimum

minimum. When data arrives at QARC, 50% of the time a portion of data is missing or noncompliant to the study. Interactions between QARC staff and the site investigator team occur to make the data complete. More than 99% of data at QARC is complete, largely due to the thorough interactions between QARC staff and site investigator teams.

Imaging

Anatomic and metabolic imaging has become an important biomarker for clinical trial validation. Imaging in clinical trials is essential for patient staging and eligibility. Imaging defines the response to targeted therapy/chemotherapy, defines the target volume for radiation therapy, and evaluates the outcome to treatment/defines patterns of failure.

For head and neck cancers, volumetric and metabolic imaging has become invaluable for patient care. Computer tomography with contrast has played a valuable role defining both the primary target and draining lymph nodes. Magnetic resonance imaging has the advantage of providing a more

clear definition between muscle and fat planes often providing improved definition of the primary target volume and lymph node draining regions. Positron emission tomography (PET) with FDG has also become invaluable in target definition for both the primary lesion and lymph node draining areas, including lymph nodes of borderline size that may harbor tumor. This has also become a valued biomarker for evaluating response to therapy in a more rapid manner than volumetric measurement using computer tomography, magnetic resonance imaging, or even clinical exam.

There are potential new applications for FDG that hold promise for the evaluation of patients and may serve to further validate staging and response. Thymidine imaging can now be performed with positron emission imaging infrastructure. Thymidine is incorporated during DNA synthesis, therefore may be more accurate than FDG in predicting tumor aggressiveness. Tumor hypoxia imaging is accomplished with several compounds, including misonidazole. These and other imaging vehicles, including molecular and receptor-based strategies, are important allies in the clinical trials process moving forward. As more of the metabolic imaging platforms become compliant to DICOM standards, fusing these

advanced technology images with radiation therapy planning images becomes more commonplace and available for integrated review by investigators for protocol compliance.

Because clinical trials have worldwide participation, it is important to have diverse strategies for both data and image acquisition in order to facilitate trial management. This permits participation and promotes study accrual. Of equal importance is the ability to display data acquired from many diverse platforms in a uniform manner in a single database. This is crucial for data management and review. QARC collects anatomic and metabolic images using several strategies and displays them in a common format in the QARC database. QARC uses several image acquisition strategies to achieve this objective. Our initial software system, Dicommunicator, was written by Dr. Keith White of Primary Children's Medical Center in Salt Lake City, Utah and is used by institutions worldwide to facilitate DICOM imaging to QARC. It has been further developed at QARC and fully integrated into the QARC database. Successful integration of the Dicommunicator system has been made with all major picture archiving and communication system (PACS) vendors. In addition to these features, other accomplishments include remote installation process utilizing WebEx internet conferencing tools. QARC has developed terminal server access for reviewers through the Web, therefore further facilitating remote review processes for clinical trials. The software has become of critical importance to managing digital data at QARC. In addition to the primary feature of direct digital transfer of images, the software is used to directly import images into the database sent to QARC via CD. CRA staff at QARC reviews the image data to make certain that it is the appropriate study at the correct time point (pre- and postoperative imaging, relapse imaging, etc.) and that the quality of the imaging is appropriate for completing both on site and distributed review of the objects by clinical trial investigators.

The Virtual Imaging Evaluation Workspace (VIEW) consortium consists of the American College of Radiology Imaging Network (ACRIN), the Cancer and Leukemia Group B (CALGB) imaging core science center at the Ohio State University, and QARC. The responsibility of this consortium is to facilitate the development of transparent and all-inclusive image acquisition and review platforms for use by the clinical cooperative groups and industry partners. It is expected that the groups share the tools of data management, including both anatomic and metabolic image review and annotation, as well as develop a common platform for data storage. The consortium emphasizes compliance to caBIG and 21 CFR Part 11 objectives and be a resource for the NCI clinical trials process. It is expected the consortium supports work performed by each member in credentialing institutions for participation in the imaging component of clinical trials, including metabolic imaging and image fusion.

Radiation Therapy Treatment Objects

Timely acquisition of radiation therapy treatment planning data objects is essential for clinical trial management. The data objects must be reviewed with relevant images to insure appropriate drawing of the radiation therapy target volume(s) of interest. This often includes both anatomic and metabolic imaging to validate the target specification, including regions receiving both macroscopic and microscopic X-ray dose. The data objects can be forwarded to QARC in multiple formats for review by physics staff as well as QARC and protocol investigators.

Digital review of radiation therapy treatment objects is accomplished through several mechanisms. The Advanced Technology Quality Assurance (QA) Consortium (ATC) is a consortium of QA Centers that includes QARC, the Image-Guided Therapy QA Center (ITC), the Radiation Therapy Oncology Group (RTOG), and the Radiological Physics Center (RPC) that share informatics development for the collection of digital radiation therapy treatment objects. QARC has integrated two review plan software packages, (a) Computational Environment for Radiotherapy Research (CERR) [1] and (b) the ATC Remote Review Tool [2] into the QARC database system, which allows remote review of both RTOG Data Exchange data objects and DICOM data object. These objects are integrated directly with images that are used to define the tumor target volume of interest as well as define the response to therapy. The use of the CERR platform has been an important development for head and neck clinical trials as the sagittal and coronal displays developed by CERR investigators, Deasy et al. [1] have been important for protocol review. The quality assurance program requires that institutions conform to physical accelerator measurements and use treatment planning algorithms in a uniform format. The medical team needs to conform to protocol definitions of target volume with uniform radiation dose delivery to target and normal tissues. The quality assurance program needs to address each of these issues for uniform clinical trial execution.

Credentialing for Clinical Trials

For cooperative group and industry-sponsored trials, it is important that the treatment team demonstrate protocol compliant treatment execution. This requires the ability to perform imaging per protocol and interpret the images for radiation target volume definition. Investigators are trained in varied institutions with different treatment techniques and internal protocols. Therefore compliance, both in target definition and radiation dose calibration are important to be

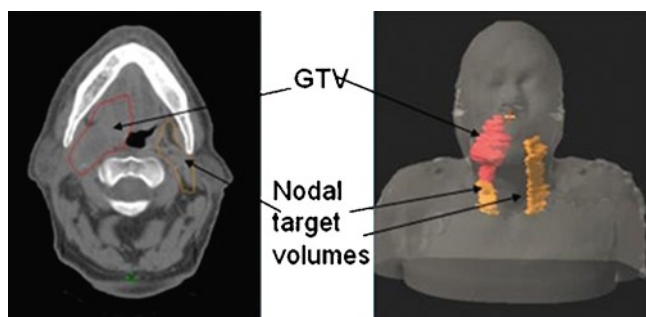


Fig. 50.2 Head and Neck benchmark. Method: A treatment planning scan of an anonymized patient with a T2N1 lesion of the larynx was uploaded (DICOM format) by each institution into its treatment planning system. A diagnostic scan with contrast was also provided to aid the institution's physicians who delineate the target volumes according to the guidelines of the protocol. These included the sites of macroscopic disease (GTV) to receive 70 Gy, small volume nodal disease which could electively be treated to 60 Gy, and sites of potential microscopic disease to receive 44–50 Gy. Lymphatic pathways were to include a minimum of two echelons of uninvolved nodes and patients with ipsilateral nodal disease were to have the entire opposite neck treated. At least 0.5 cm margin was to be added to the defined targets to create PTV2 (GTV + >0.5 cm), PTV1 (microscopic disease + GTV + >0.5 cm), and PTV3 (nodal disease + >0.5 cm)

performed in a uniform manner. Benchmarks, or test cases, are often used to validate this point as part of the clinical trial charter for protocol participation.

Radiation therapy has several credentialing methodologies for participation in the clinical trials process. For head and neck cancer, QARC has a benchmark test case that requires participating physicians to draw both tumor and normal tissue objects and the institutional planning team has to create a conformal treatment plan with defined tumor and normal tissue objectives (Fig. 50.2). Also reviewed is the physician and treatment planner team. QARC also uses the intensity modulation therapy benchmark for head and neck clinical trials process. Institutions must complete and pass the benchmark prior to being permitted to patients on study.

The RPC has significant experience in credentialing institutions for clinical trials for head and neck cancer using a postal phantom system. The phantom comes with dosimeters, as well as inserts containing tissue equivalent targets and critical structures that can be imaged. The phantoms are sent to an institution seeking credentialing. The phantom is CT scanned and planned according to protocol and then treated. The phantom with dosimeters is returned to RPC and the digital data are submitted to the ITC, where they are processed and reviewed by the RPC physicists/dosimetrists using the Web-based Remote Review Tool or CERR (Fig. 50.3). Thus far, approximately 34% of institutions have failed on their first attempt [3].

The most common TPSs used to plan the irradiations of the phantom were the Phillips Pinnacle and Varian Eclipse

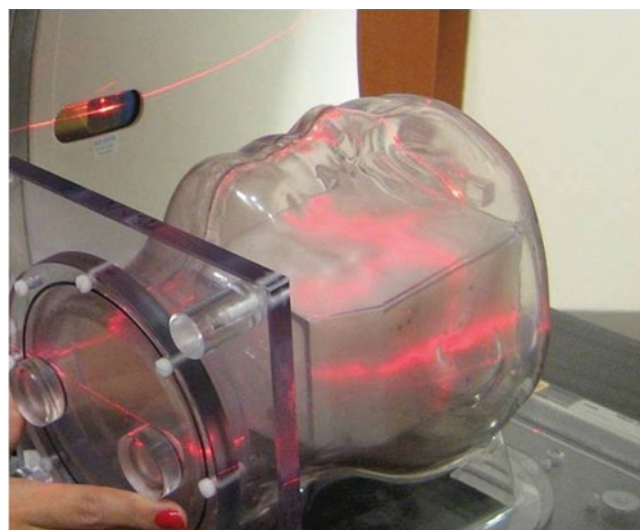

Fig. 50.3 RPC Head and Neck phantom. Positioning the RPC head and neck phantom for imaging, in preparation for treatment planning and treatment

systems. The pass rates for these two TPSs were approximately 73% and 85%, respectively. The difference is believed to be due to difficulties in modeling the penumbra at the ends of rounded MLC leaves [4].

The ITC has considerable experience in credentialing institutions for submission of full three-dimensional data sets in radiation treatment for cancers of the head and neck in RTOG protocols. The process for credentialing validates the ability of the institution to forward digital data, which is in turn reviewed through the Remote Review Tool for protocol compliance. For one particular head and neck protocol (RTOG 0522), in collaboration with ACRIN both radiation therapy treatment planning data and PET head and neck imaging (both pre- and post-therapy) are forwarded to the National Cancer Institute Archive (NCIA) for data archive and future secondary study analysis. Institutions must pass a “dry run” or ability to forward radiation therapy data in a digital format for uniform study review. In the RTOG 0522 head and neck protocol radiation therapy, objects are transferred to the ITC and image objects are collected and archived by ACRIN. Both are uploaded to the national archive for review and query for investigators.

These processes insure, as best as possible, uniform target volume definition and treatment execution coupled with the needed confidence that treatment is delivered daily in a protocol compliant manner. They are applied with different strengths and visibility based on the specific needs of each trial. In the initial development of quality assurance for radiation therapy, clinical trials did place emphasis on computational algorithms and machine calibration. As clinical trials have matured, there has been increasing emphasis on uniform definition of both tumor and normal tissue target definition.

The addition of diagnostic imaging to the review process validates the definition of the target volume and has become an integral component to the clinical trials processes.

Pathology/Microarray

As pathology objects become DICOM compliant, they can be stored in a computer database similar to an image or a radiation therapy treatment object. There has been significant work in this area in the fields of neuroblastoma and non-Hodgkin lymphoma with computer aided and grid compliant computer tools that are used to score and differentiate tumor stage and aggressiveness, including analysis of head and neck stroma with these tools. Recent efforts in digital pathology have evaluated these tools for cancer of the cervix in order to provide uniform review of pathology objects and share information concerning genomics and proteomics.

For cancers of the head and neck, the potential vision of this approach can be very robust. Molecular and receptor-based imaging tools are in development, and there is an evolving science between the integration of imaging with defined pathology expression products. These tools are under analysis to determine if specific biomarkers can be used to image and measure response. Validating the relationship between imaging and pathology is the next step in this process. This becomes an important area for the development of translational science.

Clinical Trial Imaging Charter

Minimizing data variability in the collection of heterogeneous imaging to answer study questions is established in the clinical trial imaging charter. Specifics for imaging acquisition, management, independent review, and transfer are documented to ensure uniformity and consistency, deliverables to the clinical trial sponsor while upholding Good Clinical Practice guidelines.

Real-Time Review of Study Objects

Review of protocol objects in real time has become an integral aspect of the clinical trials process. As clinical trials become more complex in both objective and scope, it is of increasing importance to involve primary study investigators in the data management process to make certain that the acquired data meets their vision defined in the protocol.

Improving Study Compliance

There is increasing evidence that early intervention in the clinical trial with pre or on treatment review of protocol objects by quality assurance staff and/or study investigators both improves compliance to the study and may improve patient outcome. The Pediatric Oncology Group (POG) protocol 8725 evaluated patients with intermediate to advanced stage Hodgkin disease. The protocol treated patients with eight cycles of chemotherapy with randomization to radiation therapy delivered to all sites of disease defined by pre-chemotherapy imaging as the study intent. The protocol patient objects were reviewed after completion of therapy for study compliance. The initial evaluation published in 1999 revealed no advantage to the addition of radiation therapy to patient outcome [5]. The data were re-reviewed at QARC. It was found that 31% of patients were not treated to protocol guidelines. In this patient group, there were different interpretations between site and central review as to the sites of disease requiring radiation therapy. If patients were treated to the areas of involvement at presentation defined in the protocol, there was a 10% survival advantage to the patients treated with radiation therapy that was statistically significant. If patients were treated with radiation therapy in a noncompliant manner, the survival for this group was identical to the group of patients treated with chemotherapy alone. The areas of noncompliance were essentially driven by varied interpretations of the regions of involvement at presentation between site and study investigators (unpublished data-personal communication). The next series of POG/Children's Cancer Study Group (CCG) integrated studies for Hodgkin disease required pretreatment review of radiation therapy treatment objects for study compliance and this was highly successful in improving compliance to study. However, these studies had response-driven chemotherapy treatment strategies imbedded into the protocol. In retrospective review of the diagnostic images at QARC, there was a 50% discrepancy between site and central reviewers scoring whether patients were rapid or slow early responders to chemotherapy. Current Hodgkin disease studies of the Children's Oncology Group (COG) now require real-time review of both image response and pretreatment review of intended radiation therapy treatment objects. This strategy has improved compliance to greater than 95% with discrepancies between site and study investigators resolved in a real-time format via WebEx with full involvement of the protocol investigators [6–8].

Recent evidence also demonstrates similar findings in clinical trials for head and neck cancer. In an industry sponsored clinical trial managed at QARC for radiation therapy quality assurance, head and neck cancer patients with locally advanced disease were treated with concurrent chemotherapy and radiation therapy with selected chemotherapy as the randomization strategy for the clinical trial. The radiation therapy treatment objects were reviewed in an on-treatment manner and requests

from QARC were directed to site investigators for study compliance. In 95 patients, requests for plan adjustment were made by QARC to site investigators and the adjustments were completed. All of these patients were deemed compliant during the final review process, and these patients had study outcome similar to those deemed compliant at the time of the on-treatment review. In 116 patients, adjustments were requested by QARC to site investigators and the site made the decision to maintain their original plan. These patients had a statistically significant decrease in local control as well as a survival disadvantage on study analysis. In further review, deviations were scored as being clinically significant or not judged on secondary analysis for consistency with standard clinical practice. If the deviations were found to be not clinically significant, patient local control and survival was very similar to patients whose initial plans were adjusted to meet study guidelines. Both of these groups had survival less than those patients that had compliant plans from the initiation of therapy. Patients with noncompliant plans with deviations of clinical significance had survival significantly less than the other three groups. Therefore, compliance to study guidelines may have significant influence on study and patient outcome [9].

There are many strategies to improve study compliance. Frequent interaction between study/site investigators and the quality assurance data management center facilitates dialog and familiarizes site investigators with study objectives. Compressing the time between patient treatment completion and final review of the therapy data also provides timely feedback to site investigators. Distributing information to both study and site investigators in a timely and uniform format is an essential feature to data management. QARC uses several mechanisms to achieve this objective. One mechanism is to download digital imaging and radiation therapy treatment objects through the Dicomcommunicator.net mechanism. This places digital images and radiation therapy treatment objects directly on the investigator PC for review of objects. This approach is not fully compliant to 21 CFR Part 11 as annotations need to be locked on site in a separate area to insure that they are not corrupted on return to the point of distribution. In order to provide a different approach more compliant with 21 CFR Part 11 objectives, QARC has developed a platform where images and objects to be reviewed by offsite investigators using a terminal server and remote desktop technologies. Through this innovation, remote users access review and annotate patient records through the functionality of the QARC database. This has the unique advantage of not moving the images from QARC, hence compliant with regulatory processes involved for object review and annotation. QARC works with study investigators and radiologists worldwide and tailors review strategies to the particular informatics platforms and needs of the reviewer. It is expected that Web-based review processes facilitate real-time review of objects by study investigators which further serve to improve study compliance.

Future Directions

One of the important objectives of the National Cancer Institute is to increase enrollment of adult patients into clinical trials. With the advent of targeted therapies and process improvements in biopharmacology, the clinical trials process is an important vehicle to validate potential improvements in therapeutic strategies. Historically, industry and the NCI clinical cooperative group trials program have not functioned in a symbiotic manner as each has developed clinical trials through segregate mechanisms with separate mission strategies. Industry and the clinical cooperative groups are now beginning to work in parallel, especially in cancers of the head and neck. In head and neck cancer, many of the new therapeutic strategies are validated through imaging with radiation therapy an integral part of the protocol. The clinical cooperative groups have strong administrative infrastructure in place and can draw upon institution participation to meet accrual objectives. Because imaging and radiation therapy increase both the complexity and cost of the clinical trial, industry may draw upon the imbedded strengths of the established quality assurance mechanisms in both imaging and radiation therapy and work synergistically with the cooperative groups in protocol development and execution. This would be especially helpful in phase 3 clinical trials that require large number of patients to validate study objectives. Often local control and patient survival are the study objectives and with this purpose studies require 800–1,000 study patients to meet planned objectives of the study. As imaging becomes fully integrated into the clinical trials process, the relationship between government sponsored cooperative groups and industry grows as both embrace the importance of imaging in the clinical trials process.

Head and neck cancer is a very good area to study biopharmacology of treatment response. With available tissue and imaging vehicles possibly predictive of response in the early phase of the clinical trial, integrating imaging and pathology objects as study points into a single common informatics platform is currently available. Therefore, imaging response validated by either metabolic or anatomic imaging platforms can be immediately integrated as a DICOM compatible profile for concurrent review and data analysis. Neoadjuvant chemotherapy with targeted therapy can be reviewed for response with pathology integration prior to radiation therapy. The metabolic profiles of expression products not responding to induction therapy could be identified pre-radiotherapy (Integrin, IGF-R, etc.) and therapies could be incorporated into a clinical trial during radiotherapy to improve patient outcome. We have demonstrated that review of objects can be performed on a real-time basis [6, 10]. The rapid review process can facilitate adjustments in patient care moving forward and serve to further improve the care we deliver to this group of patients.

The quality assurance process has proven valuable for retrospective chart review. For modern studies requiring real-time review of imaging and pathology objects, the quality assurance process can move forward and become a facile tool for adaptive patient management.

Acknowledgment This work was supported in part by NIH/NCI U10 Grant CA29511, NIH/NCI/RRP: CA81647-09 and GSA Federal Supply IT schedule – GS-35F-0306J.

References

1. Deasy JO, Blanco AI, Clark VH. CERR: a computational environment for radiotherapy research. *Med Phys.* 2003;30:979–85.
2. Bosch W, Matthews J, Ulin K, et al. Implementation of ATC method 1 for clinical trials data review at the Quality Assurance Review Center. *Med Phys.* 2006;33:2109.
3. Molineu A, Followill D, Balter P, et al. Design and implementation of an anthropomorphic quality assurance phantom for intensity-modulated radiation therapy for the Radiation Therapy Oncology Group. *Int J Radiat Oncol Biol Phys.* 2005;63:577–83.
4. Cadman P, Bassalow R, Sidhu N, et al. Dosimetric considerations for validation of a sequential IMRT process with a commercial treatment planning system. *Phys Med Biol.* 2002;47:3001–10.
5. Weiner MA, Leventhal B, Brecher ML, et al. Randomized study of intensive MOPP-ABVD with or without low-dose total-nodal radiation therapy in the treatment of stages IIB, IIIA2, IIIB, and IV Hodgkin's disease in pediatric patients: a Pediatric Oncology Group study. *J Clin Oncol.* 1997;15:2769–79.
6. Wolden S, Constine L, Schwartz CL. Real time diagnostic imaging central review and radiotherapy interventional review in multicenter cancer trials. Montreal, Quebec: PROS; 2009.
7. Mendenhall NP, Meyer J, Williams J, et al. The impact of central quality assurance review prior to radiation therapy on protocol compliance: POG 9426, a trial in pediatric Hodgkin's disease. *Blood.* 2005;106:753.
8. FitzGerald TJ, Urie M, Ulin K, et al. Processes for quality improvements in radiation oncology clinical trials. *Int J Radiat Oncol Biol Phys.* 2008;71(S1):S76–9.
9. Peters L, O'Sullivan B, Giralt J, et al. Critical impact of radiotherapy protocol compliance and plan quality in the treatment of advanced HNSCC: results from TROG 02.02. *J Clin Oncol.* 2010;28(18):2996–3001.
10. McCarten KM, Rosen N, Friedman D, et al. Feasibility of real time diagnostic imaging central review in multicenter cancer trials. Boston, MA: ARRS; 2009.

Index

A

Accelerated radiotherapy with carbogen and nicotinamide (ARCON), 173
Adjuvant drugs, role, 667
Aetiology
 air pollution, 28
 areca nut, 24–25
 betel leaf and inflorescence, 23–24
 betel quid, 16
 diet and nutrition, 27
 genetic predisposition, 27–28
 laryngeal leukoplakia, 30
 microorganisms, 28
 mouthwashes, 27
 salivary gland neoplasms, 31–32
 slake lime, 25
 solar radiation, 28
 tobacco
 chewing, 25
 smoking, 25
Alternating chemoradiotherapy, 330
Ameloblastoma, epidemiology, 34
American Joint Committee on Cancer (AJCC) system, 556
Amifostine, 260, 669
Analytical epidemiology, 3
Anaplastic thyroid carcinoma (ATC), 69
 molecularly targeted therapies, 562
 prognosis, 556
Anatomical boundary, 498–499
Anatomy, oropharynx carcinomas
 base of tongue, 402
 oropharyngeal walls, 403–404
 soft palate and tonsillar complex, 403
Angiogenesis
 angiogenic switch, 299–300
 anti-VEGF/anti-EGFR combination therapy, 300
 definition, 299–300
 multikinase inhibitors, 300–301
 toxicities, 301
 vascular endothelial growth factor (VEGF), 300
Ataxia telangiectasia (AT), 97
Axitinib, thyroid cancer, 560

B

Bacterial/viral vaccines, 114
Base of tongue cancer
 radiation therapy, 415–416
 surgical resection, 415

Bcl-2, 163–164
Bevacizumab, 300
Biologic prognostic markers, 145–149
Biomarkers
 Bcl-2, 163–164
 chemoprevention, 44–49
 cyclin D1, 163
 DNA damage repair, 164
 epidermal growth factor receptor (EGFR)
 definition, 159–161
 drugs classification, 159
 immunohistochemistry (IHC), 159
 polymorphisms, 160–161
 epigenetics, 102–103
 human papillomavirus (HPV)
 detection and risk factors, 162
 retrospective studies, 162
 types of, 161
 IGFR/AKT Pathway, 161
 methylation, 164
 molecular predictive markers identification, 157–158
 nuclear factor- κ B (NF- κ B), 163
 PI3 Kinase/AKT pathway, 161
 p53 role, 164
 Src/STAT pathway, 161
Bioreductive drugs, 174–175
Blooms syndrome (BS), 97
B lymphocytes, 108
Bonner's pivotal trial, 184
Buccal mucosa tumors, 374–375

C

Cachexia, supportive care, 259
Cancer biomarkers, 113
Cancer cachexia, 670–671
Cancer of unknown primary (CUP)
 definition, 547
 IMRT, 278
Cancer pain management
 bisphosphonate drugs, 668
 causes, 666
 corticosteroids, 667–668
 neuroleptics, 668
 non related pain, 666–667
 opioids, 667–668
Cancer registries, 2
Cancer stem cells, 113
Carcinoma of the larynx. *See* Laryngeal cancer

- Carney's syndrome, 570
- Carotid body paragangliomas, 571, 574, 575
- Cell therapy, 130
- Cellular and molecular pathology
- cellular concept, 60
 - DNA-based studies
 - LOH findings, 60
 - specific gene finding, 60–61
 - epigenetic alterations, 61
 - fibrous and vascular neoplasms, 72
 - genomic studies, 61
 - histopathology
 - clinical relevance, adverse pathologic features, 60
 - erythroplakia and leukoplakia, 58
 - oral premalignant lesions, 57–58
 - squamous carcinoma variants, 59
 - verrucous hyperplasia, 58
 - lymphoproliferative disorders, 73
 - melanoma, 72
 - neuroblastoma, 72
 - neuroendocrine carcinomas, 72
 - non-salivary type adenocarcinoma, 71
 - odontogenic tumors, 72
 - parathyroid lesions
 - adenoma and carcinoma, 70
 - derivation of, 70–71
 - hyperplasia and infiltrative neoplasm, 70
 - molecular analysis of, 70–71
 - salivary gland tumors
 - benign tumors, 64–65
 - canalicular adenoma, 65
 - in children, 63
 - classification of, 64
 - definition, 63
 - fine needle aspiration (FNA), 63–64
 - genomic and proteomics, 67
 - malignant tumors, 65–67
 - salivary type neoplasms, 71
 - schneiderian papillomas, 71
 - signal transduction pathways
 - epidermal growth factor (EGFR), 61–62
 - PI3k/AkT/mTOR inhibitors, 62
 - VEGF and FGF, 62
 - squamous carcinoma, 71–72
 - squamous mucosal carcinogenesis, 57
 - structural concept
 - biomarker applications, 63
 - mesenchymal epithelial transformation, 62–63
 - teratocarcinosarcoma, 72–73
 - thyroid tumors
 - definition, 67–69
 - etiology, 68
 - molecular analysis, 69–70
 - pathology, 68–69
 - undifferentiated sinonasal carcinoma (SNUC), 72
- Cervical esophagus, surgical reconstruction, 488
- Cervical lymphadenectomy. *See* Neck dissection
- Cervical lymph node basin anatomy, 242
- Cervical lymph node metastases
- classification, 500
 - diagnostic evaluation
 - cytology and histopathology, 548
 - imaging techniques, 548–549
 - physical and endoscopic examinations, 548
 - discovery of primary site, 551
 - incidence, 547
 - primary tumour site, 548
 - prognostic factors, 549
 - treatment
 - chemotherapy, 551
 - radiotherapy, 549–551
 - surgical therapy, 549
- Cetuximab
- locoregionally-advanced HNSCC, 294–295
 - mAb therapy, 114, 477
 - metastatic/recurrent HNSCC, 296
 - preclinical data, 293–294
 - systemic therapy, recurrent disease, 294–295
 - toxicities, 296–297
- Chemodectomas, 569
- Chemoprevention
- adjuvant, 45–47
 - description, 44
 - in high risk populations, 47–48
 - primary, 44–45
 - therapeutic regimens evaluation, 47–49
- Chemoradiation
- persistent/recurrent squamous cell carcinoma, 647
 - rehabilitation treatment, 632
 - salvage therapy, in patients, 642
- Chemotherapy
- cervical lymph node metastasis, 551
 - hypopharyngeal carcinoma, 442–443
 - meta-analysis, 184
 - nasopharyngeal carcinoma (NPC), 387–389
 - nausea, management
 - acute, 669–670
 - anticipatory and delayed, 670
 - salivary gland cancer, 527–528
 - skull base tumors, 358–359
 - squamous cell carcinoma treatment
 - combination therapy, 651, 654
 - cytotoxic therapy, 655–656
 - single agent therapy, 653–654
 - targeted therapy, 656, 661
 - treatment, in elderly patient, 585–586
- Cisplatin and 5-fluorouracil (PF) induction chemotherapy, 328–329
- Clinical trial, quality assurance
- credentialing, 690–692
 - data acquisition and data flow, 688
 - data management, 688–689
 - imaging, 689–690
 - improving study compliance, 692–693
 - informatics, 688
 - pathology/microarray, 692
 - real time review, 692
 - validation, 687–689
- Clinical vs. pathological staging, 140
- CO₂ laser technique
- advantage, 347
 - airway obstruction, debulking of, 345–346
 - direct microlaryngoscopy, 340
 - glottic cancers, 340–341
 - historical synopsis, 340
 - inconveniences of, 346
 - lymph node involvement, 346–347
 - pharyngeal cancers, 343–344
 - precancerous lesions, 344–345
 - precautions, 339–340
 - properties, 339

salvage after glottic radiation failure, 346
 supraglottic cancers, 342–343
 Common Terminology Criteria for Adverse Events (CTCAE),
 262, 613–615
 Comparative genomic hybridization (CGH),
 82, 99
 Comprehensive geriatric assessment (CGA), 583
 Concurrent chemoradiotherapy
 larynx preservation, 330
 unresectable disease
 clinical trials, 334
 median survival and patient outcome, 335
 radiation dose and toxicity, 334
 Conservation laryngeal surgery (CLS), larynx cancer,
 464–465
 Corticosteroids, acute nausea, 669–670
 Cowden's syndrome, 558
 CpG methylation pattern, 100–101
 Cricohyoidoepiglottopexy (CHEP), 465
 Cricohyoidopexy (CHP), 465
 CTLA-4, 114
 Cu-ATSM, 239
 CUP. *See* Cancer of unknown primary (CUP)
 Cutaneous melanoma. *See* Melanoma
 Cutaneous SCC, 250
 Cyclin D1, 163
 Cyclin-dependent kinase inhibitor 2A (CDKN2A), 534
 Cytogenetics, 98–99

D

Dacarbazine, 542–543
 DC. *See* Dendritic cells (DC)
 DCE-MRI. *See* dynamic contrast-enhanced MRI (DCE-MRI)
 Definitive management
 chemotherapy, 286, 287
 induction chemotherapy, 287
 organ preservation, 288
 Definitive radiotherapy, 328
 Dendritic cells (DC)
 cross presentation, antigen, 109
 vaccines, 114
 Descriptive epidemiology, 3
 Desmoplastic melanoma, 525, 541
 2D gel electrophoresis (2-DE), 83
 Differentiated thyroid cancer (DTC)
 molecularly targeted therapies, 560
 prognosis, 556
 Distant metastases, prevention and treatment, 542
 DNA-based studies
 LOH findings, 60
 specific gene finding, 60–61
 DNA damage repair, 164
 DNA methylation role, 100–101
 DNA microarray, 99
 DNA vaccines, 113–114
 Docetaxel, cisplatin, and 5-fluorouracil (TPF) induction
 chemotherapy, 329
 Dose-intensity escalation, 309
 Dynamic contrast-enhanced MRI (DCE-MRI), 184
 Dysmotility, supportive care, 259
 Dysphagia
 end of life, 671
 normal tissue complications, 623
 palliative treatment, 670–671
 psychosocial support, 671

quality of life, 599–600, 671
 swallowing, 677

E

EBER transcripts, 128–129
 EBM. *See* Evidence-based medicine (EBM)
 EGFR. *See* Epidermal growth factor receptor (EGFR)
 Electrode pO₂ measurements, 171
 Endogenous molecular markers, 171
 Endoscopic cordectomy, classification, 464
 Endoscopic resection, larynx cancer, 463–464
 Endoscopic supraglottic laryngectomy, classification, 464
 E6 oncoprotein, 162
 Epidemiology
 ameloblastoma, 34
 global scenario
 age distributions, 13–16
 alcohol, 26–27
 ethnic variations, 13
 incidence and mortality, females, 7
 incidence and mortality rates, 3
 laryngeal cancer, 8, 9, 12
 mortality rates, males, 6
 Mouth Cancer Deaths, 5
 nasopharyngeal cancer, 10–12
 oral cancer, 4, 12
 pie charts, 4
 sex differences, 12–13
 World standardised incidence rates, 5
 inequalities, 34
 Kaposi's sarcoma (KS), 32–33
 laryngeal leukoplakia, 30
 malignant melanoma, 32–33
 mortality rates
 age-standardised rates, 14, 17–20
 birth cohort curves, 15–16, 20–23
 SEER programme, oral and pharyngeal cancer, 15, 23
 osteosarcomas, 34
 primary neoplasms, jaws, 33–34
 salivary gland neoplasms, 30
 tumours metastatic, 34
 types, 3
 Epidermal growth factor receptor (EGFR)
 cetuximab, 293
 definition, 159–161
 drugs classification, 159
 ErbB2, 656
 immunohistochemistry (IHC), 159
 polymorphisms, 160–161
 roadblocks, translational research, 180
 SCCHN, 114
 thyroid cancer, 558
 Epigenetics
 aspects of, 100
 biomarkers, 102–103
 chromatin vs. DNA methylation, 100–101
 clinical application, 102
 CpG methylation pattern, 100–101
 definition, 100
 genetic paradigm, 101–102
 gliomas treatment, 103
 histones modifications, 101
 molecular assay of, 102
 nucleosome, 101
 role of DNA methylation, 100–101

Epithelial growth factor receptor inhibitors (EGFR), 443

Epstein-Barr virus (EBV)

- detection and diagnosis of, 128–129
- life cycle, 126
- mechanisms of, 126–127
- nasopharyngeal cancer, 128–129
- proteomics of, 130–131
- therapeutic treatment, 129–130
- tumorigenic activities, 127

Erbix in first-line treatment of recurrent or metastatic (EXTREME), 180

European Organization for Research and Treatment of Cancer (EORTC), 517

Evidence-based medicine (EBM)

- Cochrane reviews, 317–318
- concept of, 317
- definition, 317
- false-positive results, 319
- false-positive trial results, 319
- levels, 318
- meta-analysis and, 323–324
- patient outcome assessment
 - efficacy endpoints, 320–321
 - patient reported outcomes, 321–322
 - therapeutic ratio, 322
 - toxicity, 321
- sample size and statistical power, 318–319
- specific trial designs
 - early clinical trials with RT, 322–323
 - phase III trials, 323
 - stratification and predictive biomarkers, 323
 - trial registration and protocols, 319–320

EXTREME. *See* Erbix in first-line treatment of recurrent or metastatic (EXTREME)

F

Fanconi anaemia (FA), 97

¹⁸F-FDG-PET, 642

¹⁸F-FDG-PET-CT, 642

FDG PET sensitivity, 208–209

F–18-fluoromisonidazole (FMISO), 239

Fiberoptic Endoscopic Evaluation of Swallowing (FEES).
See Videofluoroscopy

Flap, 483

Fluorescent in situ hybridisation (FISH), 99

18 F-fluorothymidine (FLT), 237

Fluorouracil, leucovorin, and oxaliplatin (FOLFOX), 182

FMISO. *See* F–18-fluoromisonidazole (FMISO)

FOLFIRI, 184

FOLFOX. *See* fluorouracil, leucovorin, and oxaliplatin (FOLFOX)

Follicular thyroid cancer (FTC)

- molecular pathogenesis, 557–558
- prognosis, 556

Functional imaging

- therapy management, 238–239
- tumor diagnostics, 235–237

G

Generation sequencing, 99

Genetically engineered mouse models (GEMMs), 192

Genetic paradigm, 101–102

Genetics, carcinogenesis

- detection techniques, 98–99
- oncogenes, 94–95

- 17p loss, heterozygosity/p53 mutation, 96
- predisposition and mutagen sensitivity, 98
- 9p21 region loss, 95
- principles, 94
- progression model, 95
- somatic mitosis, 97–98
- tumour suppressor genes (TSG), 94–95

Genomic changes, oncogenomics

- malignant transformation
 - DNA microanalysis, 84–85
 - gene signature and biomarkers, 86
 - SCC lesions, 85–86
 - transcriptional progression model, 86
- metastases
 - detection of, 86
 - DNA microarray gene-expression profiling, 86–87
 - four gene model, 87
 - gene-expression, microarray analysis, 86
 - hypopharynx, 87
 - solid tumors analysis, 86
 - microarray analysis, 88
 - responses to treatment, 87
 - surrogate tissues, 87

Geriatric patient. *See* Treatment, in elderly patient

Gliomas treatment, 103

Glossectomy, 633–634

Glottic cancers

- laser technique, 340–341
- pathology, 472–473
- radiation therapy, 477
- treatment, 474–475

H

Hard palate cancer, 375

Hazard ratio (HR), 184

Head and neck reconstruction, 645

Head and neck squamous cell carcinoma (HNSCC), 581

Hemicricoidectomy, 631

Hemilaryngectomy, 630–631

Hemoglobin, erythropoietin manipulation, 173–174

Heterozygosity/p53 mutation, 17p loss, 96

History, 2

Horner's syndrome, 577

HPV. *See* Human papillomavirus (HPV)

5-HT3 serotonin antagonists, acute nausea, 669

Human papillomavirus (HPV)

- detection, 124–125, 162
- diagnosis of, 124–125
- distribution of, 123–124
- dysplastic lesions, 123
- E6 oncoprotein, 162
- infection
 - risk factors, 50
 - vaccination, prevention, 50
- life cycle, 121–122
- mechanisms of, 122–123
- proteomics of, 130–131
- retrospective studies, 162
- risk factors, 162
- role of, 122–123
- squamous cell carcinomas (SCCs), 123–124
- therapeutic treatment, 125–126
- types, 123–124
- types of, 161–162
- viral types, 131

- Hurthle cell variant, 556
- Hyperbaric oxygen treatment, 173
- Hyperfractionation radiotherapy (HFRT), 176
- Hypofractionation, melanoma, 541
- Hypopharyngeal carcinoma
- anatomy and pathways
 - distant metastases, 433–434
 - primary site, 432–433
 - regional lymphatic drainage, 433
 - clinical manifestation, 434
 - epidemiology and etiology, 431–432
 - factors affecting choice of treatment
 - age, 436
 - functional outcome and long-term morbidity, 437
 - lymph node status, 437
 - medical status, 436
 - patient's preference, 437
 - follow-up and outcome, 449
 - molecular biology, 431–432
 - staging evaluation, 435
 - TNM classification of, 436
 - treatment modalities
 - chemotherapy, 442–443
 - intensity modulated radiotherapy, 440–442
 - surgery, 437–440
 - targeted therapy, 443
 - treatment selection
 - early tumors, 444–445
 - locally advanced tumors, 445
 - organ preservation strategy, 445–448
 - palliative disease, 449
 - postoperative radiotherapy, 448
 - recurrent disease, 448–449
 - work-up
 - clinical examination, 434
 - evaluation, 435
 - locoregional disease evaluation, imaging for, 434–435
- Hypopharynx
- IMRT, 272–273
 - surgical reconstruction
 - circumferential defects, 488
 - function, 487–488
- Hyposalivation. *See* Xerostomia
- Hypoxia
- accelerated radiotherapy with carbogen and nicotinamide (ARCON), 173
 - bioreductive drugs, 174–175
 - clinical outcomes, 172–173
 - detecting tumor, 170–172
 - factors description, 169–170
 - hyperbaric oxygen treatment, 173
 - hyperfractionation radiotherapy (HFRT), 176
 - hypoxic cell radiosensitizers–nitroimidazoles, 174
 - improving hemoglobin, erythropoietin manipulation, 173–174
 - IMRT, 176
 - molecular pathways, 170
 - targeting HIF-1, 175
 - vascular normalization, 175
- Hypoxic cell radiosensitizers, 174
- I**
- IGFR/AKT pathway, 161
- Immune system, 108–109
- Immunohistochemistry (IHC), 159
- Immunology
- B lymphocytes, 108
 - cancer biomarkers, 113
 - cancer stem cells, 113
 - dendritic cells (DC), 109
 - immune system, 108–109
 - immunosuppression, 110–111
 - immunosurveillance and immunoediting, 109–110
 - immunotherapy, 113–114
 - inflammation vs. cancer, 112–113
 - monoclonal antibody (mAb) therapy, 114–116
 - myeloid derived suppressor cells (MDSC), 111
 - natural kill (NK) cells, 109
 - T lymphocytes, 108–109
 - T regulatory cells, 111–112
- Immunosuppression, 110–111
- Immunosurveillance, 109–110
- Immunotherapy
- treatment, HPV-positive HNSCC, 125–126
 - vaccines, 113–114
- IMPT. *See* Intensity-modulated proton therapy (IMPT)
- IMRT. *See* Intensity-modulated radiation therapy (IMRT)
- Incisional biopsy, cervical lymph node metastasis, 548
- Induction-concurrent chemoradiotherapy, NPC, 389–390
- Inflammation vs. cancer, 112–113
- Insulin-like growth factor–1 receptor (IGF-1R), 302
- Intensity-modulated proton therapy (IMPT), 606–607
- Intensity-modulated radiation therapy (IMRT)
- hypopharyngeal carcinoma, 440–442
 - vs. intensity-modulated proton therapy, 606–607
 - PET-based, 176
 - plan quality and toxicity, 623–624
 - proton beam therapy, 606–610
 - base of tongue cancer, 415–416
 - chemotherapy role, 414
 - CUP, 278
 - delineation, 412–413
 - hypopharynx
 - anatomy, 272–273
 - clinical management, 273
 - slices of, 274
 - target delineation, 273
 - larynx
 - anatomy, 273–274
 - clinical management, 274–275
 - target delineation, 275
 - molecularly targeted agents, role, 414–415
- nasopharynx
- anatomy, 269
 - clinical management, 269–270
 - slices of, 271
 - target delineation, 270
- optimal follow-up schedule, 423
- oral cavity
- anatomy, 275–276
 - clinical management, 276
 - slices of, 276
 - target delineation, 276
- oropharyngeal wall cancer, 420–422
- oropharynx
- anatomy, 270
 - clinical management, 270–271
 - slices of, 272
 - target delineation guidelines, 271–272
- soft palate cancer, 419–420
- supportive care, 258
- surveillance, 422–423

- Intensity-modulated radiation therapy (IMRT) (*Cont.*)
 target determination and delineation
 clinical target volume (CTV), 268–269
 gross target volume (GTV), 269
 incidence and distribution, lymph nodes, 268
 recommendations, 268
 thyroid gland
 anatomy, 277
 clinical management, 277
 target delineation, 277
 tonsillar cancer, 416–419
 treatment, in elderly patient, 585
 use of, 413–414
- Interferon-alpha-2b (IFN-alpha-2b)
 distant metastases, 542–543
 melanoma, 542
- Interstitial brachytherapy (IBT)
 cyberknife (CBK) boost, 591
 dysphagia, 599–600
 implant, types, 590–591
 oral cavity cancer, 594
 oropharynx cancer, 597–598
 quality of life, 599
 side effects
 acute, 598
 late, 598
 techniques
 base of tongue (BOT), 594
 oral cavity, 592
 TF and/or SP, 592–593
- Irradiation, 550
- Isolated tumour cells, 246
- J**
- Jugular paraganglioma, 573
- K**
- Kaposi's sarcoma (KS), 32–33
 Kinase inhibitors, thyroid cancer, 560
 KRAS gene, 184
- L**
- Laryngeal cancer
 anatomy, 472
 diagnosis, 473–474
 epidemiology, 471
 etiology, 471
 glottic cancer
 pathology, 472–473
 radiation therapy, 477
 treatment, 474–475
 radiation therapy techniques
 chemoradiation, 478
 fractionation, 477
 staging, 473–474
 subglottic cancer
 pathology, 473
 treatment, 474–475
 supraglottic cancer
 pathology, 472
 radiation therapy, 474
 treatment, 474
 surgical technique, 478
 swallowing assessment, 479
 treatment, advanced disease
 definitive chemotherapy, 476
 induction chemotherapy, 475–476
 organ preservation and radiation therapy, 475
 treatment, recurrent disease
 surgical management, 476–477
 systemic therapy, 477
 voice changes, 478–479
- Laryngeal leukoplakia
 aetiology, 30
 epidemiology, 30
- Laryngopharyngectomy, 488
- Larynx cancer
 AJCC Staging, 460–461
 anatomy, 457–458
 chemotherapy, 462–463
 clinical presentation, 458
 clinical staging, 459–461
 etiology, 458
 evaluation, 458–459
 functional outcomes, 465–466
 imaging, 459
 IMRT, 273–275
 leukoplakias, 43–44
 management, 461
 neck management, 465
 radiotherapy
 complications, 462
 control rate, 462
 narrow-field irradiation, 461
 recurrence, 462
 vs. surgery, 461–462
 surgery
 conservation laryngeal surgery, 464–465
 endoscopic resection, 463–464
 surgical reconstruction
 radial forearm free flap, 489
 temporoparietal flap, 489
 treatment, 489
 treatment, 44
- Larynx preservation, 327
- Laser endoscopic treatment
 airway obstruction, debulking of, 345–346
 CO₂ laser, 339
 glottic cancers, 340–341
 historical synopsis, 340
 pharyngeal cancers, 343–344
 precancerous lesions, 344–345
 salvage after glottic radiation failure, 346
 supraglottic cancers, 342–343
 techniques, 339–340
- Leukoplakias, treatment
 larynx, 43–44
 oral cavity, 43
- Li-Fraumeni syndrome, 98
- Lip cancer, 368
- Lip reconstruction, 485
- Local tumor detection
 cartilage invasion, 209–210
 cortical mandibular invasion, 209
 FDG PET sensitivity, 208–209
 nasopharyngeal cancer, 209
 oropharynx, 209
 relationship of, 211
- Locoregional disease, multidisciplinary treatment
 radiation therapy, 410–415
 surgical resection, 409

- Lower alveolar ridge cancer, 373–374
- Lymph node, 230
 - classification, 141, 550
 - dissection, melanoma, 540
 - staging, 211–212
- Lynch syndrome II, 98
- M**
- Magnetic resonance imaging (MRI)
 - diffusion, 203–204
 - perfusion, 204–205
 - spectroscopy, 206–208
 - standard, 203
- Magnetization transfer (MT), 205–206
- Malignant melanoma, 32–33
- Management
 - cancer pain, 666–667
 - nausea, 669–670
 - oral complications, radiotherapy, 668–669
 - vomiting, 669–670
- Mandible tumors
 - CT, 371–372
 - dentascans, 372
 - histological patterns, 373
 - marginal mandibulectomy, 373
 - SCC, 371
- Matrix-assisted laser desorption ionization (MALDI), 84
- Maxillary sinus cancer, 375–377
- Medullary thyroid cancer (MTC)
 - molecularly targeted therapies, 562–563
 - molecular pathogenesis, 558
 - prognosis, 556
- Melanoma
 - AJCC staging system, 536–537
 - diagnosis
 - pathologic examination, 535
 - patient history, 535
 - physical examination, 535
 - epidemiology, 533
 - etiology, 534–535
 - evaluation, 535–536
 - management
 - adequate margins, 537
 - distant metastases, 542–543
 - primary treatment, 537–539
 - primary tumor resection, 537
 - recurrent disease, 543
 - treatment of neck, 539–542
 - post-treatment follow up, 543
 - risk factor, 533–534
 - sentinel node biopsy, 247–248
- Merkel cell carcinoma, 247–248, 250
- Metastatic disease, 393–394
- Metastatic squamous cell carcinoma. *See* Squamous cell carcinoma
- Methylation, 164
- Microarray, 692
- 18-F misonidazole-PET, 186
- Moh's micrographic surgery, 538–539
- Molecular biology, development, 50
- Molecular targeted therapy
 - biologic targets
 - insulin-like growth factor-1 receptor (IGF-1R), 302
 - p53, 302
 - SRC family kinases, 301
 - cetuximab
 - locoregionally-advanced HNSCC, 294–295
 - metastatic/recurrent HNSCC, 296
 - preclinical data, 293–294
 - toxicities, 296–297
 - epidermal growth factor receptor (EGFR), 293
 - targeting angiogenesis
 - angiogenic switch, 299–300
 - anti-VEGF/anti-EGFR combination therapy, 300
 - bevacizumab, 300
 - definition, 299–300
 - multikinase inhibitors, 300–301
 - toxicities, 301
 - vascular endothelial growth factor (VEGF), 300
 - treatment, in elderly patient, 586
 - tyrosine kinase inhibitors (TKI), 297, 299
- Monoclonal antibody (mAb) therapy
 - cetuximab, 114
 - first-line therapy, 657–658
 - second-line therapy, 657
 - epidermal growth factor receptor (EGFR), 114
 - humoral immunity effector, 115
 - matuzumab and nimotuzumab, 659
 - mechanisms, 115
 - NK cell–DC cross-talk, 116
 - panitumumab, 658–659
 - T cell activation, 115
 - zalutumumab, 659
- Morphologic investigations
 - CT perfusion, 202–203
 - distant metastasis, 212–213
 - local tumor detection
 - cartilage invasion, 209–210
 - cortical mandibular invasion, 209
 - FDG PET sensitivity, 208–209
 - nasopharyngeal cancer, 209
 - oropharynx, 209
 - relationship of, 211
 - lymph node staging, 211–212
 - magnetic resonance (MR)
 - diffusion, 203–204
 - perfusion, 204–205
 - spectroscopy, 206–208
 - magnetic resonance imaging (MRI), 203
 - magnetization transfer (MT), 205–206
 - PET/CT, 208–209
 - secondary tumors, 215
 - standard CT, 202
 - unknown primary tumor, 213–214
- Motesanib diphosphate, thyroid cancer, 560
- Mouth cancer, 370
- Mucosal injury and xerostomia
 - amifostine (Ethyol), 621
 - fibroblast growth factor-7, 621
 - keratinocyte growth factor (KGF), 621
- Mucosal melanoma classification, 144
- Mucositis, normal tissue complications, 625
- Multidisciplinary treatment
 - initial assessment
 - history and physical examination, 407–408
 - imaging techniques, 408–409
 - staging, 409–410
 - locoregional disease
 - radiation therapy, 410–415
 - surgical resection, 409
 - metastatic disease, 425–426
- Multikinase inhibitors, 300–301
- Myeloid derived suppressor cells (MDSC), 111

- N**
- Nasopharyngeal carcinoma (NPC)
- chemotherapy/molecular-targeted therapy for, 394
 - concurrent chemoradiotherapy vs. radiotherapy, 388
 - definition, 128
 - IMRT dose specification, 385, 386
 - investigations and staging, 381–383
 - late toxicity management
 - cranial nerve palsy, 395
 - endocrine dysfunction, 395
 - hearing impairment, 395
 - temporal lobe necrosis (TLN), 394–395
 - torrential epistaxis, 394
 - metastatic disease, treatment of
 - cisplatin-based chemotherapy, 393–394
 - molecular-targeted therapy, 394
 - MRI, 381, 382
 - patient monitoring, 390–391
 - persistent/recurrent tumor treatment
 - nonsurgical salvage, 391–393
 - surgical salvage, 393
 - precancer, 127–128
 - primary treatment
 - CDDP/FU, 390
 - chemotherapy, 387–389
 - induction-concurrent chemoradiotherapy, 389–390
 - radiation therapy, 383–384
 - technological developments, 386–387
 - tumor targets and technique, 384–386
 - strain variation, 128
 - translational research, 182
 - type 3, 128
 - volumetric arc technique, 395
- Nasopharynx, 143, 269–270
- Natural history, 42–43
- Natural kill (NK) cells, 109
- Nausea and vomiting, palliative treatment, 669–670
- N classification, 143–144
- N1 disease treatment, 507
- N2/3 disease treatment, 507
- Near-total laryngopharyngectomy, 438–439
- Neck dissection
- classification, 500
 - N+ neck, 645
 - N0 neck, 644–645
 - non-surgical treatment, 505
 - PET scanning, 642
- Neck metastases, prevention, 49
- Negative (N0) neck disease treatment, 505–507
- Neoadjuvant chemotherapy, phase I study
- methodology in, 314
- Neurokinin-1-receptor antagonists, acute nausea, 670
- Nitroimidazoles. *See* Hypoxic cell radiosensitizers
- Nomograms, 152
- Nonchromaffin, 569
- Nonsurgical salvage, 391–393
- Non-surgical treatment
- chemoradiation, 504
 - FDG-PET imaging, 504
 - MRI, 504
 - neck dissection, 505
 - radiotherapy, 503–504
- Normal tissue complications
- acute effects, 614
 - adverse effects
 - mucositis, 625
 - osteoradionecrosis (ORN), 626
 - swallowing disorders, 625–626
- adverse events
- CTCAE terminology, 615
 - description for, 615
 - evolution, 615
 - evolution of toxicity, reporting, 614–615
 - grading system, 615
 - late effects, 615
 - quality of life (QOL), 621
 - reporting methods, 615
- function, 615
- late effects, 614, 615
- morbidity, 613, 614
- predictors, 614
- protection of
- IMRT plan quality and toxicity, 623–624
 - mucosal injury and xerostomia, 621–622
 - physical protection, 622–623
 - protons, 624–625
- quality of life (QOL), 614, 621
- NPC. *See* Nasopharyngeal carcinoma (NPC)
- Nuclear factor-kappa B (NF- κ B), 163
- Nucleosome, 101
- O**
- Oncogenomics. *See also* Proteomics
- biologic heterogeneity, 81
 - genomic changes under
 - malignant transformation, 84–86
 - metastases, 86–87
 - microarray analysis, 88
 - responses to treatment, 87
 - surrogate tissues, 87
 - goal, 82
 - histologic features and molecular changes, 82
 - technologies
 - bioinformatics, 82–83
 - comparative genomic hybridization (CGH), 82
 - cytogenetic analysis, 82
 - DNA microarray technology, 82
 - single nucleotide polymorphisms (SNP), 82–83
 - treatment, 81–82
- Opioids
- constipation and side effects, 667
 - weak and strong, 667–668
- OPMD. *See* Oral Potentially Malignant Disorders (OPMD)
- Oral cavity cancer
- IMRT, 275–277
 - interstitial brachytherapy (IBT), 594
 - leukoplakias, 43
 - management
 - advanced-stage disease, 366
 - buccal mucosa tumors, 374–375
 - common risk factors, 363–364
 - early-stage disease, 365–366
 - floor of mouth cancer, 370–371
 - lip cancer, 368
 - lower alveolar ridge and retromolar trigone cancer, 373–374
 - mandible tumors, 371–373
 - maxillary sinus cancer, 375–377
 - methotrexate, 377
 - oral tongue cancer, 368–370
 - principles of, 364–365
 - radiotherapy and chemoradiotherapy, 366–368

- site-specific treatment, 368
 - upper alveolar ridge and hard palate cancer, 375
 - surgical reconstruction
 - lip reconstruction, 485
 - tongue reconstruction, 485
 - wound location, 485
 - treatment, 43
 - Oral mucositis, 668–669
 - Oral Mucositis Questionnaire Head and Neck (OMQ-HN), 256
 - Oral/oropharyngeal squamous cell carcinoma, 249–251
 - Oral Potentially Malignant Disorders (OPMD)
 - age and gender distribution, 30
 - global prevalence, 29–30
 - malignant transformation, 30
 - Oral squamous cell carcinoma
 - of mandible, 371, 372
 - of right maxillary antrum, 376
 - of tongue, 369, 370
 - Oral tongue cancer, 368–370
 - Orbits, surgical reconstruction, 489
 - Organ and function preservation
 - chemotherapy and radiotherapy
 - alternating chemoradiotherapy, 330
 - cisplatin and 5-fluorouracil induction chemotherapy, 328–329
 - concomitant chemoradiotherapy, 329
 - concurrent chemoradiotherapy, 330
 - docetaxel, cisplatin, and 5-fluorouracil induction chemotherapy, 329
 - induction chemotherapy, 328
 - sequential biotherapy, 331
 - sequential chemoradiotherapy, 330
 - definitive radiotherapy, 328
 - larynx preservation, 327
 - partial surgery, 327–328
 - Organ preservation strategy
 - altered fractionation, 445
 - concomitant chemoradiotherapy, 445–446
 - concomitant chemoradiotherapy vs. induction chemotherapy, 446–447
 - concomitant EGFR inhibitors and radiotherapy, 446
 - induction chemotherapy, 446
 - postradiotherapy neck dissection, 447–448
 - Oropharyngeal carcinoma, 501
 - Oropharynx cancer
 - anatomy
 - base of tongue, 402
 - oropharyngeal walls, 403–404
 - soft palate, 403
 - tonsillar complex, 403
 - conventional treatment, 410–412
 - dysphagia, 599–600
 - epidemiology
 - demographics, 404–405
 - incidence and mortality, 404
 - future advances, 426
 - IMRT, 270–272
 - intensity-modulated radiation therapy (IMRT)
 - base of tongue cancer, 415–416
 - chemotherapy role, 414
 - delineation, 412–413
 - molecularly targeted agents, role, 414–415
 - optimal follow-up schedule, 423
 - oropharyngeal wall cancer, 420–422
 - soft palate cancer, 419–420
 - surveillance, 422–423
 - tonsillar cancer, 416–419
 - use of, 413–414
 - interstitial brachytherapy (IBT), 597–598
 - locoregional disease, multidisciplinary treatment
 - radiation therapy, 410–415
 - surgical resection, 409
 - metastatic disease, multidisciplinary treatment, 425–426
 - multidisciplinary initial assessment
 - history and physical examination, 407–408
 - imaging techniques, 408–409
 - staging, 409–410
 - pathogenesis
 - oropharyngeal carcinoma, 406–407
 - role of, 405–406
 - recurrent disease treatment, role of, 423–425
 - surgical reconstruction, 486–487
 - xerostomia, 600
 - Osteoradionecrosis, normal tissue complications, 626
 - Osteosarcomas, epidemiology, 34
 - Oxygen enhancement effect, 169–170
- P**
- Paclitaxel, 518
 - Palifermin, 669
 - Palliative treatment
 - cachexia, 670–671
 - cancer pain management, 666–667
 - chemotherapy, 285
 - definition, 665
 - diet counselling, 670–671
 - dysphagia, 670–671
 - end of life, 671
 - gemcitabine, 286
 - human papillomavirus (HPV), 665
 - nausea and vomiting management
 - anticipatory emesis, 670
 - chemotherapy-related emesis, 669–670
 - oral complications, radiotherapy, 668–669
 - pathogenesis, radiation-induced mitotic death, 668–669
 - role, 665
 - supportive care, defined, 665
 - targeted agents, 286
 - Papillary microcarcinomas, 556
 - Papillary thyroid cancer (PTC)
 - molecular pathogenesis, 556–557
 - prognosis, 556
 - Paragangliomas
 - anatomy, 570–572
 - carotid body, 571
 - clinical features and evaluation, 572
 - complications and rehabilitation, surgical patient, 577
 - diagnostic testing, 573–575
 - epidemiology, 569–570
 - follow up, 577
 - genetics, 569–570
 - histopathology, 570–572
 - nomenclature, 569
 - physiology, 570–572
 - radiotherapy, 576
 - surgery, 575–576
 - Parathyroid cancer, 564
 - Parathyroid lesions, 70–71
 - Parotid gland tumor. *See* Salivary gland cancer

- Partial laryngopharyngectomy, hypopharyngeal carcinoma
 - conservation surgery, 437
 - near-total laryngopharyngectomy, 438–439
 - partial lateral pharyngectomy, 437–438
 - partial pharyngolaryngectomy, 438
 - posterior partial pharyngectomy, 438
 - supracricoid hemilaryngopharyngectomy, 438
 - transoral CO₂ laser resection, 437
- Partial lateral pharyngectomy, 437–438
- Partial pharyngolaryngectomy, 438
- Pathology, thyroid tumors
 - cytology, 68
 - differentiated carcinomas, 68–69
 - follicular adenoma, 68
 - histology, 38
 - undifferentiated carcinomas, 68–69
- Patient-reported outcomes measurement information system (PROMIS), 676, 682
- Pazopanib, thyroid cancer, 561
- Pedicle flaps, 484
- Perforator flaps, surgical reconstruction, 491–192
- PET scanning, 642
- Pharyngeal cancers, 343–344
- Phase I study methodology
 - aim, 307
 - clinical development challenges, 312–313
 - considerations for, 308, 309
 - drug combinations, 313
 - efficacy considerations
 - of anticancer agents, 312
 - combining radiation with anticancer agents, 311
 - in dose escalation, 312
 - preclinical models, 311–312
 - methodologic considerations
 - dose escalation methods, radiation with anticancer agents, 308
 - dose-intensity escalation, 309
 - with neoadjuvant chemotherapy, 314
 - platinum-free RT combinations with new drugs, 313–314
 - safety considerations
 - delayed or cumulative toxicity, 310–311
 - dose-limiting toxicity assessment, 310
 - preclinical models, safety prediction by, 309–310
 - predictive markers of late toxicity, 311
 - safety issues, radiation with anticancer agents, 309
 - starting dose of anticancer agent, 310
- PI3 Kinase/AKT pathway, 161
- Pilocarpine, 260, 669
- Platinum-taxane combinations, 655
- Positron emission tomography (PET), 176, 235
- Posterior partial pharyngectomy, 438
- Postoperative management
 - high-risk, patients, 514
 - intermediate risk, patients, 514
 - radiation therapy
 - chemotherapy, 516
 - clinical trials testing, 517
 - cumulative incidence of grade 3, 517–518
 - drug testing, 516–517
 - Radiation Therapy Oncology Group (RTOG), 513
 - recursive partitioning analysis (RPA), 514–515
 - retrospective analysis, 514
 - risk adapted strategies, 515
- Post radiation mucosal sensitivity (PRMS), 262
- Precancerous lesions
 - larynx
 - leukoplakias, 43–44
 - treatment, 44
 - oral cavity
 - leukoplakias, 43
 - treatment, 43
 - treatment techniques, 344–345
- Preclinical models, squamous cell carcinoma
 - carcinogenesis pathways, 191
 - INK4a, 191
 - P53, 191
 - cell lines, 192–193
 - advantage, 192
 - chronic myelogenous leukemia (CML), 193
 - epidermal growth factor receptor (EGFR), 192
 - mouse tonsil epithelial cell lines (MTECs), 192
 - chemically induced carcinogens, 194–195
 - dimethylbenz(a)anthracene (DMBA), 195
 - genotoxic effects, 195
 - 4-nitroquinoline N-oxide (4-NQO), 195
 - clonogenic assay, 193
 - radioresistance, 193
 - radiosensitivity, 193
 - short term cultures, 193–194
 - targeting
 - BCL2, 191
 - insulin-like growth receptor, 191
 - (PI)–3-Kinase-AKT, 191
 - MET, 191
 - transgenic mouse models, 195–197
 - xenograft mouse models, 194
- Predictive biomarkers, 323
- Preoperative lymphoscintigraphy, 244–245
- Prevention
 - biomarker, 44–49
 - chemoprevention
 - adjuvant, 45–47
 - description, 44
 - in high risk populations, 47–48
 - primary, 44–45
 - therapeutic regimens evaluation, 47–49
 - HPV infection
 - risk factors, 50
 - vaccination, prevention, 50
 - levels of intervention, 42
 - molecular biology, development, 50
 - natural history, 42–43
 - neck metastases, prevention, 49
 - precancerous lesions
 - larynx, 43–44
 - oral cavity, 43
- Primary neoplasms, jaws, epidemiology, 33–34
- PRMS. *See* Post radiation mucosal sensitivity (PRMS)
- Prognostic model
 - group handling, 151
 - indexes, 151–152
 - nomograms, 152
 - validation and comparison of, 152–153
- p53 role, 164, 302
- Protein vaccines, 114
- Proteomics
 - biologic heterogeneity, 81
 - goal, 82
 - histologic features, 82
 - HPV-and EBV-associated cancers, 130–131
 - molecular changes, 82

- surrogate tissue studies, 89
 - technologies
 - 2D gel electrophoresis (2-DE), 8
 - mass spectrometry (MS), 8–9
 - matrix-assisted laser desorption ionization (MALDI), 83–84
 - reverse phase protein arrays (RPPA), 84
 - surface-enhanced laser desorption ionization (SELDI), 83–84
 - tissue microarray (TMA), 84
 - treatment, 81–82
 - tumor tissue studies, 88–89
 - Proton beam irradiation, normal tissue complications, 624–625
 - Proton beam therapy
 - Bragg peak, 606
 - future prospect, 610
 - literature review, 605
 - nasopharyngeal carcinoma, 609
 - oropharyngeal carcinoma, 609
 - physical aspects, 606
 - principle, 605
 - prospective studies, 609
 - radiotherapy
 - linear energy transfer (LET), 607
 - relative biologic effectiveness (RBE), 607
 - second malignancy, 610
 - sinonasal malignancies, 608
 - Psycho-oncological support, 671
- Q**
- Quality Assurance Review Center (QARC), 688, 690, 692–693
 - Quality of life (QOL), in patients
 - cancer-specific instruments, 679
 - clinical research applications
 - challenges, 681–682
 - clinical trials, 680–681
 - prognostic, 681
 - routine, 681
 - computer-adaptive tests (CATs), 682
 - definition, 675
 - description for, 675
 - domains and multi-dimensionality, 676
 - dominant issues in
 - pain, 676–677
 - speech, 677
 - swallowing, 677
 - xerostomia, 677
 - and health-related, 675–676
 - health utilities, 676
 - measurement of
 - indices, 678
 - item generation, 677–678
 - item reduction, 678
 - minimal clinically important difference (MID), 678
 - profiles, 678
 - psychometrics, 677
 - questionnaires, 678
 - reliability, 678
 - responsiveness, 678
 - validity, 678
 - patient-reported outcomes (PROs), 676
 - PROMIS and CaPS, 682
 - psychic, 671
 - questionnaires types, 678–679
 - result interpretation
 - compliance, 680
 - knowledge translation, 680
 - mean changes vs. response analyses, 680
 - missing data, 680
 - response shift, 679–680
 - social workers, 671
 - validity
 - definition, 678
 - types, 680
- R**
- Radiation therapy, 125, 690
 - nasopharyngeal carcinoma (NPC), 383–384
 - postoperative management
 - chemotherapy, 516
 - clinical trials testing, 517
 - cumulative incidence of grade 3, 517–518
 - drug testing, 516–517
 - skull base tumors, 357–358
 - Radiation Therapy Oncology Group (RTOG), 513
 - Radical neck dissection, cervical lymph node metastasis, 549
 - Radiobiology, proton beam therapy
 - linear energy transfer (LET), 607
 - relative biologic effectiveness (RBE), 607
 - Radiological boundary, 500
 - Radionecrosis, mandible and larynx, 641
 - Radioreistance, 193
 - Radiosensitivity, 193
 - Radiotherapy (RT)
 - cervical lymph node metastasis, 549–551
 - IMRT, supportive care, 258
 - post radiation mucosal sensitivity (PRMS), 262
 - salivary gland cancer, 526–527
 - treatment, in elderly patient, 584–585
 - xerostomia, QOL, 677, 680
 - RECIST. *See* response evaluation criteria in solid tumors (RECIST)
 - Reconstructive ladder, 483
 - Recurrence of cancer, 507
 - Recurrent disease treatment
 - chemotherapy, 425
 - radiation therapy, 424–425
 - surgery, 423–424
 - Recurrent squamous cell carcinoma. *See* Squamous cell carcinoma
 - Rehabilitation treatment, 630
 - chemoradiation, 632
 - composite resection
 - fibula flaps, 634
 - retromolar trigone, 634
 - dysphagia, 630
 - partial laryngectomy
 - composite resection, 634–635
 - glossectomy, 633–634
 - hemilaryngectomy, 630
 - radiotherapy and chemotherapy, 635–636
 - supracricoid laryngectomy, 632
 - supraglottic laryngectomy, 631–632
 - survivorship and rehabilitation, 636–637
 - total laryngectomy, 632–633
 - process of rehabilitation, 630
 - radiation therapy, 632
 - radiotherapy and chemotherapy
 - dysgeusia, 635
 - intensity modulated radiotherapy (IMRT), 635
 - radiosensitization, 635
 - xerostomia, 635

Response evaluation criteria in solid tumors (RECIST), 282
 Retromolar trigone cancer, 373–374
 Risk-benefit ratio. *See* Therapeutic ratio
 RT. *See* Radiotherapy (RT)

S

Salivary gland cancer

anatomic stage, 523
 anatomy, 522
 biological drugs, 529
 cervical lymphadenopathies, 523
 chemotherapy, 527–528
 clinical presentation
 malignant tumours, 523
 minor tumours, 524
 definitions, TNM, 522–523
 diagnosis, 524
 epidemiology, 521
 expression, biological targets, 528
 histological classification, 522
 history and prognosis, 524
 organs risk constraints, 527
 positive neck nodes, risk of, 525
 radiotherapy, 526–527
 surgical treatment, 525–526
 survival rate, 525
 TNM classification and Stage Grouping, 523

Salivary gland neoplasms

aetiology, 31
 epidemiology, 30
 incidence, 31
 site, age and sex, 30–31

Salivary gland tumors

benign tumors, 64–65
 canalicular adenoma, 65
 in children, 63
 classification of, 64
 definition, 63
 fine needle aspiration (FNA), 63–64
 genomic and proteomics, 67
 malignant tumors, 65–67

Salvage surgery, 448–449

Salvage therapy, in patients

adjuvant therapy, 646–647
 biopsies, 643–644
 clinical diagnosis of, 641–642
 complications of, 645–646
 CT and MRI imaging, 642
 distant disease evaluation, imaging for, 643
 PET scanning, 642
 prognosis of, 647
 surgical reconstruction, 645
 surgical treatment
 N+ neck management, 645
 N0 neck management, 644–645
 primary site management, 642

Sentinel lymph node biopsy (SLNB), melanoma, 539–541

Sentinel node biopsy

application, 249
 cervical lymph node basin anatomy, 242
 complications of, 251
 cutaneous SCC, 250
 description, 243
 development of, 243–244
 isolated tumour cells, 246
 melanoma, 247–248

metastases, 246
 micrometastases, 246
 oral/oropharyngeal squamous cell carcinoma,
 249–251
 pathologic examination, 246
 potential advantages, 243
 radical neck dissection (RND), 242–243
 role of, 248–249
 technique
 preoperative lymphoscintigraphy, 244–245
 surgical, 245–246

Sequential treatment

biotherapy, 331
 chemoradiotherapy, 330
 unresectable disease
 CRT, 336
 phase III induction chemotherapy trials, 335
 PPF vs. PF, activity and toxicity, 336
 TAX 323, 336
 Tax 324, 336
 TPF, safety and efficacy, 335–336

Serum markers, 147–148

Shoulder morbidity treatment, 507–508

Sialogoga, 669

Signal transduction pathways

epidermal growth factor (EGFR), 61–62
 PI3k/AkT/mTOR inhibitors, 62
 VEGF and FGF, 62

Single nucleotide polymorphisms (SNP), 82, 99

Sinonasal and skull base tumors, 71–73

Skull base tumors

ethmoid sinus classification, 354
 ethmoid tumor classification, 354
 etiology
 ethmoidal tumors, 351–352
 hardwood and softwood dust, 352
 paranasal sinus tumor, 351
 polymorphisms, 352
 sinonasal cancers, 351
 histologic diagnosis, 355
 imaging, 354
 pathology and natural history, 352–353
 prognostic factors, 355
 staging, 353–354
 symptoms, 353
 treatment
 chemotherapy, 358–359
 radiotherapy, 357–358
 surgery, 355–357

Soft palate cancer

radiation therapy, 419–420
 surgical resection, 419

Somatic mitosis

ataxia telangiectasia (AT), 97
 blooms syndrome (BS), 97
 fanconi anaemia (FA), 97
 Li-Fraumeni syndrome, 98
 lynch syndrome II, 98
 xeroderma pigmentosum (XP), 97

Sorafenib

distant metastases, 542–543
 thyroid cancer, 561

Squamous cell carcinoma

carcinogen problems, 651–652
 chemotherapy
 combination, 654
 cytotoxic, 655–656

- single agent, 653–654
- targeted therapy, 656, 661
- monoclonal antibodies
 - cetuximab, 657–658
 - matuzumab, 659
 - nimotuzumab, 659
 - panitumumab, 658–659
 - zalutumumab, 659
- prognostic factors, 652
- tyrosine kinase inhibitors
 - vs. chemotherapy, 660–661
 - single agent, use of, 659–660
- vascular endothelial growth factor (VEGF)
 - bevacizumab, 660
 - EGFR and VEGFR, combined targeting of, 660
 - tyrosine kinase inhibitors, 660–661
- Squamous cell carcinoma of the head and neck (SCCHN).
 - See Squamous cell carcinoma
- Src/STAT pathway, 161
- Staging and prognosis
 - anatomic staging, 136–137
 - environmental factor importance, 150–151
 - limitations and opportunities, 136
 - morphological imaging, 235
 - non-anatomic prognostic factors, 137–138
 - prognostic model
 - group handling, 151
 - indexes, 151–152
 - nomograms, 152–153
 - validation and comparison of, 152–153
 - tumor-node-metastasis (TNM)
 - designations and rules, 139–142
 - evolution, 137
 - future of, 144–149
 - modification, 138–139
- Standard radiotherapy, 585
- Structural concept
 - biomarker applications, 63
 - mesenchymal epithelial transformation, 62–63
- Subglottic cancer
 - pathology, 473
 - treatment, 474–475
- Sublingual gland tumor. *See* Salivary gland cancer
- Submandibular gland tumor. *See* Salivary gland cancer
- Sunitinib, thyroid cancer, 561
- Superstructure tumors. *See* Skull base tumors
- Supportive care. *See also* Palliative treatment
 - anorexia, 259
 - cachexia, 259
 - dysmotility, 259
 - dysphagia
 - clinical evaluation, 257
 - dysphagia/aspiration related structures (DARS), 258
 - extreme fibrotic process, 258
 - flexible endoscopic evaluation, 258
 - food boluses, 257
 - IMRT, 258
 - late effect, 259
 - sequelae of, 258
 - stricture formation, 258
 - symptoms, 257
 - hyposalivation, 260
 - mucositis, 256
 - nutrition, 258–259
 - oral health issues, 261–262
 - percutaneous endoscopic gastrostomy, 259
 - pharmacologic agents, 260
 - radiation therapy, approaches, 260
 - toxicity mechanism, 255–256
 - xerostomia, 259–260
- Supracricoid hemilaryngopharyngectomy, 438
- Supracricoid laryngectomy (SCL), 465–466, 632
 - cricohyoidoepiglottopexy (CHEP), 632
 - cricohyoidopexy (CHP), 632
 - horizontal resection, 632
 - neoglottic incompetence, 632
- Supraglottic cancers, 342–343
 - pathology, 472
 - radiation therapy, 474
 - treatment, 474
- Supraglottic laryngectomy
 - aspiration risk, 630
 - mendelsohn exercise, 632
 - superior resection, 631
- Surface-enhanced laser desorption ionization (SELDI), 84, 88
- Surgical reconstruction
 - cervical esophagus, 488
 - creation of surgical defects, 483
 - defect repair, 483
 - hypopharynx
 - circumferential defects, 488
 - function, 487–488
 - larynx
 - radial forearm free flap, 489
 - temporoparietal flap, 489
 - treatment, 489
 - midface reconstruction, 490
 - oral cavity
 - lip reconstruction, 485
 - tongue reconstruction, 485
 - wound location, 485
 - orbits, 489
 - oropharynx, 486–487
 - pedicle flaps, 484
 - perforator flaps, 491–492
 - surgical salvage, 490
 - tissue transfer, 484
 - transoral laser microsurgery, 492–493
- Surgical resection, carotid body paragangliomas, 575
- Surgical salvage, 393, 490
- Surgical treatment
 - adjuvant treatment, 501–503
 - neck dissection, 505
 - neck node dissection, 500–501
 - paratracheal lymph node metastases, 501–503
- Surrogate tissues, 87
- Swallowing abnormality. *See* Dysphagia
- Swallowing disorders, normal tissue complications, 625–626
- Systemic chemotherapy
 - combination chemotherapy, 285
 - definitive management, 286–288
 - emerging issues, 288–289
 - radiation, 288
 - salvage treatment, 288
 - mechanisms of action, single agents, 284–285
 - oncogenesis, malignant epithelium, 281–282
 - treatment goals
 - clinical benefit, 282
 - multiple efficacy endpoints, 282
 - quality of life instruments, 283
 - treatment goals and efficacy endpoints, 282–283
 - uses, 283–284

T

- Taxanes metabolism, 586
- TAX 323, unresectable disease, 336
- TAX 324, unresectable disease, 336
- Therapeutic index, 309
- Therapeutic ratio, 322
- Therapy management
 - diagnostics and tumor recurrence, 238
 - hypoxia assessment and radiotherapy, 239
 - prognostic aspect, PET, 238
 - von Hippel-Lindau (VHL), 239
- Thyroid cancer
 - epidemiology, 555
 - histological classification and prognosis, 555–556
 - kinase inhibitors, 560
 - management
 - external beam radiation therapy, 559
 - radioactive iodine, 558–559
 - recurrent disease, 559–560
 - surveillance and follow-up, 559
 - TSH suppression, 559
 - molecularly targeted therapies
 - anaplastic thyroid cancer, 562
 - differentiated thyroid cancers, 560–562
 - medullary thyroid cancer, 562–563
 - molecular pathogenesis
 - follicular thyroid cancers, 557–558
 - medullary thyroid cancer, 558
 - papillary thyroid cancers, 556–557
 - progression/transformation, 557–558
 - neoplasms, molecular analysis
 - genetics, 69–70
 - genomics, 70
 - tumors
 - definition, 67–69
 - etiology, 68
 - molecular analysis, 69–70
 - pathology, 68–69
- T lymphocytes, 108–109
- TNM classification, thyroid cancer, 556
- Tongue reconstruction, 485
- Tonsillar cancer
 - radiation therapy, 418–419
 - surgical resection, 416–417
- Tonsillectomy, cervical lymph node metastasis, 549
- Total laryngectomy, 632–633
- Total laryngopharyngectomy, 439
- Total laryngopharyngectomy with esophagectomy, 439
- Tracheostomy, 631
- Translational research, oncology
 - biologically underpowered, 186
 - definition, 179
 - efficacy, 182, 184
 - epidermal growth factor receptor (EGFR), 180
 - erythropoietin, darbepoietin alfa, 185
 - hazard ratio (HR), 184
 - health care system, 179
 - human papillomavirus (HPV), 182
 - hypoxia, 185, 186
 - mortality, 179
 - non-responding, 185
 - prognostic factors, 183
 - roadblocks, 180
 - tamoxifen, 181
 - targeted agents, 182
 - toxicity, 180, 184
- Transoral CO₂ laser resection, hypopharyngeal carcinoma, 437
- Transoral laser microsurgery (TLM), 492–493
- Treatment
 - in elderly patient
 - diagnosis and pre-treatment assessment, 583–584
 - management, 584–586
 - recommendations, 587
 - specificity of, 581–582
 - upper age and outcome, 582–583
 - N1 disease, 507
 - N2/3 disease, 507
 - Negative (N0) neck disease, 505–507
- T regulatory cells, 111–112
- Tube feeding, 671
- Tumor cell vaccines, 114
- Tumor diagnostics
 - cytometry, 236
 - F-18-Deoxyglucose (FDG), 236
 - functional imaging, 235
 - hybrid systems, 236
 - morphological, 235
 - non-FDG Tracers, 237
 - positron emission tomography (PET), 235
 - sources of error, 237
 - staging, 235
 - standardized uptake value (SUV), 236
- Tumor-node-metastasis (TNM)
 - additional descriptors usage, 140
 - biologic prognostic markers, 145–149
 - biology evolution, 148–149
 - biomarkers, 144
 - clinical vs. pathological staging, 140
 - domains, 145
 - evolution, 137
 - host factors, 149–150
 - lymph node classification, 141
 - modification, 138–139
 - AJCC approach, 138–139
 - elements, 138–139
 - mucosal melanoma classification, 144
 - nasopharynx, 143
 - N classification, 143–144
 - need for, 138
 - non-melanoma skin, 142
 - to T classification, 142
 - UICC approach, 138
 - rules, 140
 - serum markers, 147–148
 - stage grouping, 141–142
 - tumor volume, 148
- Tumor volume, 148
- Tyrosine kinase inhibitors (TKI), 297, 299
- Tyrosine kinase receptors, 557, 558

U

- Ultrasound (US) investigations, in patients
 - applications, 221
 - benign tumors, 227
 - echogenicity, 222, 228
 - lymph node, 230–231

- malignancy
 - edge, 225–226
 - extent, 226
 - internal architecture, 226
 - neck node evaluation
 - Doppler, gray scale, 227
 - necrosis, 227
 - reticulation and vascular distribution, 228
 - salivary gland
 - evaluation, 225
 - MR initial investigation, 225
 - sonographic features, 225–227
 - US initial investigation, 225
 - thyroid, 222–224
 - vascularity, 5
 - Unresectable disease
 - concurrent chemoradiotherapy
 - clinical trials, 334
 - median survival and patient outcome, 335
 - toxicity and radiation dose, 334
 - definition, 333–334
 - sequential treatment
 - CRT, 336
 - phase III induction chemotherapy trials, 335
 - PPF vs. PF, activity and toxicity, 336
 - TAX 323 and 324, 336
 - TPF, safety and efficacy, 335–336
 - Upper alveolar ridge cancer, 375
- V**
- Vaccination, prevention, 50
 - Vagal paraganglioma, 576
 - anatomy and physiology, 572
 - angiography, 574
 - surgical technique, 576
 - Vandetanib, thyroid cancer, 562
 - Vascular endothelial growth factor (VEGF), 300
 - Vascular normalization, 175
 - Videofluoroscopy, 630, 677
 - Voice-sparing surgery, 445
 - Vomiting
 - after chemotherapy, 670
 - after therapy, 669–670
- X**
- Xeroderma pigmentosum (XP), 97
 - Xerostomia
 - palliative treatment, 669
 - quality of life (QOL), in patients, 677