

2

Basics of Ultrasound Imaging

Vincent Chan and Anahi Perlas

Introduction.....	13
Basic Principles of B-Mode US.....	14
Generation of Ultrasound Pulses.....	14
Ultrasound Wavelength and Frequency.....	14
Ultrasound–Tissue Interaction.....	15
Recent Innovations in B-Mode Ultrasound.....	18
Conclusion.....	19
References.....	19

Introduction

Ultrasound has been used to image the human body for over half a century. Dr. Karl Theo Dussik, an Austrian neurologist, was the first to apply ultrasound as a medical diagnostic tool to image the brain.¹ Today, ultrasound (US) is one of the most widely used imaging technologies in medicine. It is portable, free of radiation risk, and relatively inexpensive when compared with other imaging modalities, such as magnetic resonance and computed tomography. Furthermore, US images are tomographic, i.e., offering a “cross-sectional” view of anatomical structures. The images can be acquired in “real time,” thus providing instantaneous visual guidance for many interventional procedures including those for regional anesthesia and pain management. In this chapter, we describe some of the fundamental principles and physics underlying US technology that are relevant to the pain practitioner.

V. Chan (✉)
Department of Anesthesia, University of Toronto, Toronto Western Hospital,
399 Bathurst Street MP 2-405, Toronto, ON, Canada M5T 2S8
e-mail: mail2vincechan@aol.com

Basic Principles of B-Mode US

Modern medical US is performed primarily using a pulse-echo approach with a brightness-mode (B-mode) display. The basic principles of B-mode imaging are much the same today as they were several decades ago. This involves transmitting small pulses of ultrasound into the body. As the ultrasound waves penetrate body tissues of different acoustic impedances along the path of transmission, some are reflected back to the transducer (echo signals) and some continue to penetrate deeper. The echo signals returned from many sequential coplanar pulses are processed and combined to generate an image. Thus, an ultrasound transducer works both as a speaker (generating sound waves) and a microphone (receiving sound waves). The ultrasound pulse is in fact quite short, but since it traverses in a straight path, it is often referred to as an ultrasound beam. The direction of ultrasound propagation along the beam line is called the axial direction, and the direction in the image plane perpendicular to axial is called the lateral direction.² Usually only a small fraction of the ultrasound pulse returns as a reflected echo after reaching a body tissue interface, while the remainder of the pulse continues along the beam line to greater tissue depths.

Generation of Ultrasound Pulses

Ultrasound transducers (or probes) contain multiple piezoelectric crystals which are interconnected electronically and vibrate in response to an applied electric current. This phenomenon called the piezoelectric effect was originally described by the Curie brothers in 1880 when they subjected a cut piece of quartz to mechanical stress generating an electric charge on the surface.³ Later, they also demonstrated the reverse piezoelectric effect, i.e., electricity application to the quartz resulting in quartz vibration.⁴ These vibrating mechanical sound waves create alternating areas of compression and rarefaction when propagating through body tissues. Sound waves can be described in terms of their frequency (measured in cycles per second or hertz), wavelength (measured in millimeter), and amplitude (measured in decibel).

Ultrasound Wavelength and Frequency

The wavelength and frequency of US are inversely related, i.e., ultrasound of high frequency has a short wavelength and vice versa. US waves have frequencies that exceed the upper limit for audible human hearing, i.e., greater than 20 kHz.³ Medical ultrasound devices use sound waves in the range of 1–20 MHz. Proper selection of transducer frequency is an important concept for providing optimal image resolution in diagnostic and procedural US. High-frequency ultrasound waves (short wavelength) generate images of high axial resolution. Increasing the number of waves of compression and rarefaction for a given distance can more accurately discriminate between two separate structures along the axial plane of wave propagation. However, high-frequency waves are more attenuated than lower frequency waves for a given distance; thus, they are suitable for imaging mainly superficial structures.⁵ Conversely, low-frequency waves (long wavelength) offer images of lower resolution but can penetrate to deeper structures due to a lower degree of attenuation (Figure 2.1). For this reason, it is best to use high-frequency transducers (up to 10–15 MHz range) to image superficial structures (such as for stellate ganglion blocks) and low-frequency transducers (typically 2–5 MHz) for imaging the lumbar neuraxial structures that are deep in most adults (Figure 2.2).

Ultrasound waves are generated in pulses (intermittent trains of pressure) that commonly consist of two or three sound cycles of the same frequency (Figure 2.3). The pulse

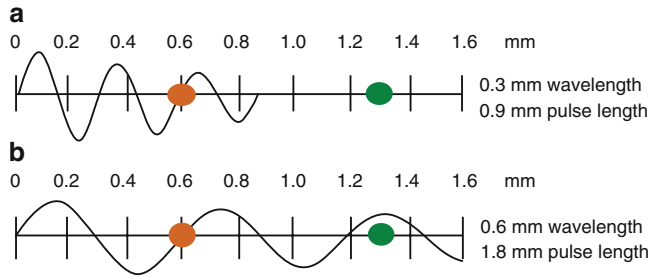


Figure 2.1. Attenuation of ultrasound waves and its relationship to wave frequency. Note that higher frequency waves are more highly attenuated than lower frequency waves for a given distance. Reproduced with permission from ref.⁶

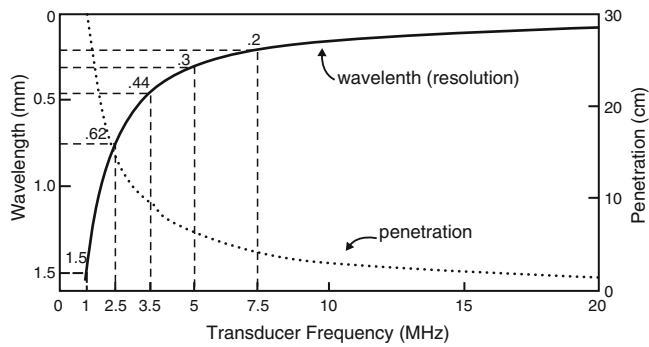


Figure 2.2. A comparison of the resolution and penetration of different ultrasound transducer frequencies. This figure was published in ref.³ Copyright Elsevier (2000).

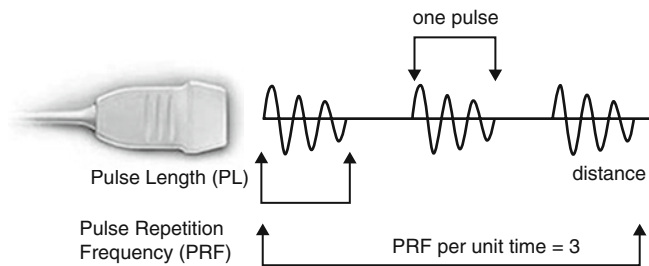


Figure 2.3. Schematic representation of ultrasound pulse generation. Reproduced with permission from ref.⁶

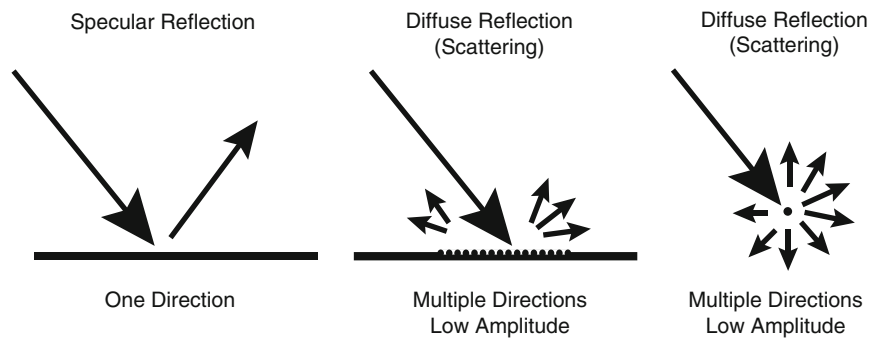
repetition frequency (PRF) is the number of pulses emitted by the transducer per unit of time. Ultrasound waves must be emitted in pulses with sufficient time in between to allow the signal to reach the target of interest and be reflected back to the transducer as echo before the next pulse is generated. The PRF for medical imaging devices ranges from 1 to 10 kHz.

Ultrasound–Tissue Interaction

As US waves travel through tissues, they are partly transmitted to deeper structures, partly reflected back to the transducer as echoes, partly scattered, and partly transformed to heat. For imaging purposes, we are mostly interested in the echoes reflected back to the transducer. The amount of echo returned after hitting a tissue interface is determined by a tissue property called acoustic impedance. This is an intrinsic physical property of a medium defined as the density of the medium times the velocity of US wave propagation in the

Table 2.1. Acoustic impedances of different body tissues and organs.

Body tissue	Acoustic impedance (10^6 Rayls)
Air	0.0004
Lung	0.18
Fat	1.34
Liver	1.65
Blood	1.65
Kidney	1.63
Muscle	1.71
Bone	7.8

Reproduced with permission from ref.⁶**Figure 2.4.** Different types of ultrasound wave–tissue interactions. Reproduced with permission from ref.⁶

medium. Air-containing organs (such as the lung) have the lowest acoustic impedance, while dense organs such as bone have very high-acoustic impedance (Table 2.1). The intensity of a reflected echo is proportional to the difference (or mismatch) in acoustic impedances between two mediums. If two tissues have identical acoustic impedance, no echo is generated. Interfaces between soft tissues of similar acoustic impedances usually generate low-intensity echoes. Conversely interfaces between soft tissue and bone or the lung generate very strong echoes due to a large acoustic impedance gradient.⁷

When an incident ultrasound pulse encounters a large, smooth interface of two body tissues with different acoustic impedances, the sound energy is reflected back to the transducer. This type of reflection is called specular reflection, and the echo intensity generated is proportional to the acoustic impedance gradient between the two mediums (Figure 2.4). A soft-tissue–needle interface when a needle is inserted “in-plane” is a good example of specular reflection. If the incident US beam reaches the linear interface at 90° , almost all of the generated echo will travel back to the transducer. However, if the angle of incidence with the specular boundary is less than 90° , the echo will not return to the transducer, but rather be reflected at an angle equal to the angle of incidence (just like visible light reflecting in a mirror). The returning echo will potentially miss the transducer and not be detected. This is of practical importance for the pain physician, and explains why it may be difficult to image a needle that is inserted at a very steep direction to reach deeply located structures.

Refraction refers to a change in the direction of sound transmission after hitting an interface of two tissues with different speeds of sound transmission. In this instance, because the sound frequency is constant, the wavelength has to change to accommodate the difference in the speed of sound transmission in the two tissues. This results in a redirection of the sound pulse as it passes through the interface. Refraction is one of the important causes of incorrect localization of a structure on an ultrasound image. Because the speed of sound is low in fat (approximately 1,450 m/s) and high in soft tissues (approximately 1,540 m/s), refraction artifacts are most prominent at fat/soft tissue interfaces.

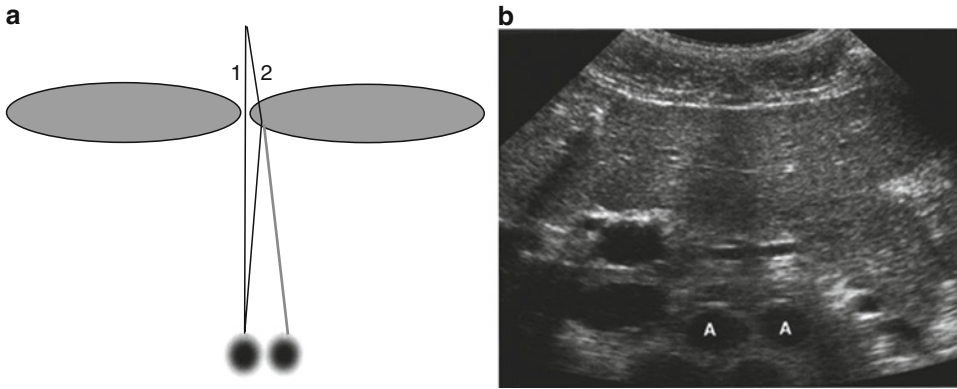


Figure 2.5. Refraction artifact. Diagram (a) shows how sound beam refraction results in duplication artifact. (b) is a transverse midline view of the upper abdomen showing duplication of the aorta (A) secondary to rectus muscle refraction. This figure was published in ref.⁸ Copyright Elsevier (2004).

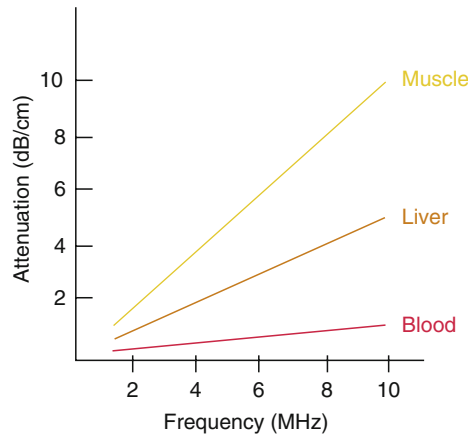


Figure 2.6. Degrees of attenuation of ultrasound beams as a function of the wave frequency in different body tissues. Reproduced with permission from ref.⁶

The most widely recognized refraction artifact occurs at the junction of the rectus abdominis muscle and abdominal wall fat. The end result is duplication of deep abdominal and pelvic structures seen when scanning through the abdominal midline (Figure 2.5). Duplication artifacts can also arise when scanning the kidney due to refraction of sound at the interface between the spleen (or liver) and adjacent fat.⁸

If the ultrasound pulse encounters reflectors whose dimensions are smaller than the ultrasound wavelength, or when the pulse encounters a rough, irregular tissue interface, scattering occurs. In this case, echoes reflected through a wide range of angles result in reduction in echo intensity. However, the positive result of scattering is the return of some echo to the transducer regardless of the angle of the incident pulse. Most biologic tissues appear in US images as though they are filled with tiny scattering structures. The speckle signal that provides the visible texture in organs like the liver or muscle is a result of interface between multiple scattered echoes produced within the volume of the incident ultrasound pulse.²

As US pulses travel through tissue, their intensity is reduced or attenuated. This attenuation is the result of reflection and scattering and also of friction-like losses. These losses result from the induced oscillatory tissue motion produced by the pulse, which causes conversion of energy from the original mechanical form into heat. This energy loss to localized heating is referred to as absorption and is the most important contributor to US attenuation. Longer path length and higher frequency waves result in greater attenuation. Attenuation also varies among body tissues, with the highest degree in bone, less in muscle and solid organs, and lowest in blood for any given frequency (Figure 2.6). All ultrasound

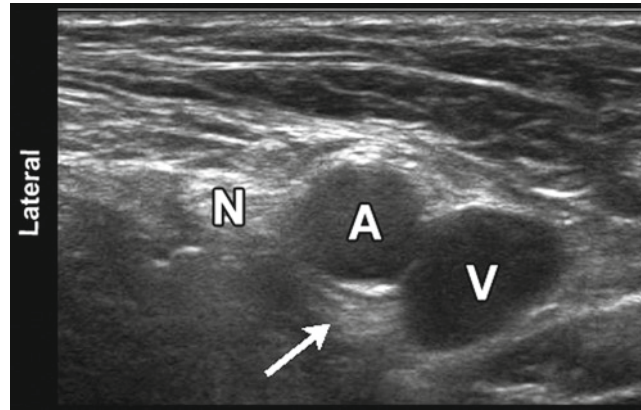


Figure 2.7. Sonographic image of the femoral neurovascular structures in the inguinal area. A hyperechoic area can be appreciated deep to the femoral artery (*arrowhead*). This well-known artifact (known as posterior acoustic enhancement) is typically seen deep to fluid-containing structures. *N* femoral nerve, *A* femoral artery, *V* femoral vein.

equipment intrinsically compensates for an expected average degree of attenuation by automatically increasing the gain (overall brightness or intensity of signals) in deeper areas of the screen. This is the cause for a very common artifact known as “posterior acoustic enhancement” that describes a relatively hyperechoic area posterior to large blood vessels or cysts (Figure 2.7). Fluid-containing structures attenuate sound much less than solid structures so that the strength of the sound pulse is greater after passing through fluid than through an equivalent amount of solid tissue.

Recent Innovations in B-Mode Ultrasound

Some recent innovations that have become available in most ultrasound units over the past decade or so have significantly improved image resolution. Two good examples of these are tissue harmonic imaging and spatial compound imaging.

The benefits of tissue harmonic imaging were first observed in work geared toward imaging of US contrast materials. The term harmonic refers to frequencies that are integral multiples of the frequency of the transmitted pulse (which is also called the fundamental frequency or first harmonic).⁹ The second harmonic has a frequency of twice the fundamental. As an ultrasound pulse travels through tissues, the shape of the original wave is distorted from a perfect sinusoid to a “sharper,” more peaked, sawtooth shape. This distorted wave in turn generates reflected echoes of several different frequencies, of many higher order harmonics. Modern ultrasound units use not only a fundamental frequency but also its second harmonic component. This often results in the reduction of artifacts and clutter in the near surface tissues. Harmonic imaging is considered to be most useful in “technically difficult” patients with thick and complicated body wall structures.

Spatial compound imaging (or multibeam imaging) refers to the electronic steering of ultrasound beams from an array transducer to image the same tissue multiple times by using parallel beams oriented along different directions.¹⁰ The echoes from these different directions are then averaged together (compounded) into a single composite image. The use of multiple beams results in an averaging out of speckles, making the image look less “grainy” and increasing the lateral resolution. Spatial compound images often show reduced levels of “noise” and “clutter” as well as improved contrast and margin definition. Because multiple ultrasound beams are used to interrogate the same tissue region, more time is required for data acquisition and the compound imaging frame rate is generally reduced compared with that of conventional B-mode imaging.

Conclusion

US is relatively inexpensive, portable, safe, and real time in nature. These characteristics, and continued improvements in image quality and resolution have expanded the use of US to many areas in medicine beyond traditional diagnostic imaging applications. In particular, its use to assist or guide interventional procedures is growing. Regional anesthesia and pain medicine procedures are some of the areas of current growth. Modern US equipment is based on many of the same fundamental principles employed in the initial devices used over 50 years ago. The understanding of these basic physical principles can help the anesthesiologist and pain practitioner better understand this new tool and use it to its full potential.

REFERENCES

1. Edler I, Lindstrom K. The history of echocardiography. *Ultrasound Med Biol.* 2004;30:1565–1644.
2. Hangiandreou N. AAPM/RSNA physics tutorial for residents: topics in US. B-mode US: basic concepts and new technology. *Radiographics.* 2003;23:1019–1033.
3. Otto CM. Principles of echocardiographic image acquisition and Doppler analysis. In: *Textbook of Clinical Ecocardiography*. 2nd ed. Philadelphia, PA: WB Saunders; 2000:1–29.
4. Weyman AE. Physical principles of ultrasound. In: Weyman AE, ed. *Principles and Practice of Echocardiography*. 2nd ed. Media, PA: Williams & Wilkins; 1994:3–28.
5. Lawrence JP. Physics and instrumentation of ultrasound. *Crit Care Med.* 2007;35:S314–S322.
6. Chan VWS. *Ultrasound Imaging for Regional Anesthesia*. 2nd ed. Toronto, ON: Toronto Printing Company; 2009.
7. Kossoff G. Basic physics and imaging characteristics of ultrasound. *World J Surg.* 2000;24:134–142.
8. Middleton W, Kurtz A, Hertzberg B. Practical physics. In: *Ultrasound, the Requisites*. 2nd ed. St Louis, MO: Mosby; 2004:3–27.
9. Fowlkes JB, Averkiou M. Contrast and tissue harmonic imaging. In: Goldman LW, Fowlkes JB, eds. *Categorical Courses in Diagnostic Radiology Physics: CT and US Cross-Sectional Imaging*. Oak Brook: Radiological Society of North America; 2000:77–95.
10. Jespersen SK, Wilhelm JE, Sillesen H. Multi-angle compound imaging. *Ultrasound Imaging.* 1998;20:81–102.