

Chapter 8

Frozen Section Techniques Used in Mohs Micrographic Surgery

Barbara Beck and Stephen R. Peters

Abstract The chapter offers a comprehensive discussion of the technical process of preparing frozen sections in the setting of Mohs dermatographic surgery. In Mohs surgery procedure, the surgeon removes a skin cancer which is immediately examined by frozen section to access the resection margin. Most critical to accurate specimen preparation is the proper *on face embedding* of tissues such that the epidermal edge, deep and lateral margins are embedded in a single flat plane. Techniques for relaxing the tissues are discussed and illustrated in detail. Techniques traditionally used by Mohs technologists including slide technique, heat extractor technique, and embedding in plastic molds are described. Technical advances in embedding using innovative apparatus include, techniques using the *Cryo-embedder*, the *Miami Special* and the *Precision Cryoembedding System*. The chapter covers aspects critical to the cutting and staining of tissue sections for Mohs surgery.

Keywords Parallel faces • Cryo-embedder • Fredrick E Mohs • Miami special • Mohs surgery • Notating the map • Plastic molds • Precision cryoembedding system • Relaxation • Slide technique

8.1 Mohs Surgery Procedure

Mohs surgery refers to a procedure in which a dermatologic surgeon removes a skin cancer which is immediately examined by frozen section to assess the resection margin. This procedure employs *on face embedding* of the entire resection margin including the skin edge. As we learned in Chap. 2, when we embed *on face*, we will

B. Beck
Mohs Technical Consulting, Inc

S.R. Peters (✉)
Department of Pathology University of Medicine and Dentistry of New Jersey
Pathology Innovations, LLC, 410 Old Mill Lane, Wyckoff, NJ 07481, USA
e-mail: petepath@yahoo.com

be examining the entire resection margin. In contrast, skin margins taken perpendicular to the margin in actuality, are examining only a relatively small sample of the entire margin see Chap. 2 p. 18. The procedure was first performed by Dr. Fredrick E Mohs in 1953 and reported in (1978). The procedure is performed in one or more layers or stages. After each stage, the resection margin is examined for tumor microscopically. The specimen is first oriented and marked with ink, so that the specific location of the involved margin can be determined. If tumor is present, an additional layer is removed from the specific location where the tumor was seen. When the resection margin no longer contains tumor, we have successfully removed the entire tumor and the patient is ready for repair. At times, this can be performed in one stage, other times it can take several stages.

The goal of Mohs surgery is to completely remove all tumor tissues with the minimal amount of tissue loss. By examining complete on face margins, the surgeon can be confident that the tumor is completely excised. By removing the tissue in multiple, very thin layers, the point at which no tumor remains will become obvious with the least amount of tissue excised.

Mohs surgery is performed as a team consisting of the Mohs surgeon who removes the tissue working closely in tandem with the Mohs technologist performing the gross and frozen sectioning of the specimens. In many cases, Mohs surgeons are trained to interpret the sections microscopically. In other settings, a pathologist will interpret the sections and represent a third member of the team.

First, the surgeon resects the tissue and immediately submits it to the technologist. All tissue submitted to the lab MUST be accompanied with a map or diagram showing the orientation of the specimen and how it coincides with the patients anatomy. It is up to the surgeon to decide how they are going to process the tissue. Depending on both clinical factors such as size and location, as well as the surgeon's own preferences, the specimen may be processed in one piece, bisected, or may require examination in several pieces. In either case, the tissues will be embedded on face, with all margins in a flat plane.

To begin a Mohs procedure the cryostat needs to be set at -20°C to -25°C . Adjust the section thickness setting to 5 or 6 microns which is most suitable for sectioning and interpreting skin sections. Following these simple procedures, one should be able to prepare high quality sections for the surgeon to interpret in less than 15 min.

8.2 Relaxing the Specimen

Our goal when embedding specimens for Mohs surgery, is to embed the tissue with the *entire skin edge, deep and lateral resection margins on face in a single flat plane*. In the first stage of the resection, nearly all of the specimens will require some degree of flattening by a process known as relaxation. Let's imagine the resected skin sample as having a shape like a pie. The crust of the pie represents the epidermis and the resected margin represents the entire bottom and slanting sides of the pie. The edge of the pie, typically showing the impressions of fork marks represents the edge of the epidermis. It is critical that the entire bottom, and

sides of the pie, and the forked edge of the pie crust are flattened into a single plane Fig. 8.1.

Relaxation of the specimen is accomplished by scoring the skin surface parallel to the skin edge, very close to the skin edge so the outside edges of the skin hinge down flat. This skin edge **MUST** be on the same level as the deep and lateral margin of the specimen. Thicker, more rigid samples may require additional scoring of the central portion of the epidermal surface for adequate relaxation. Our goal is to embed our tissue as in Figs. 8.2 and 8.3, which illustrate the process in three and

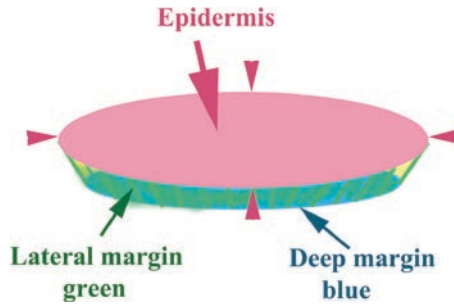


Fig. 8.1 A typical pie shaped portion of skin removed in the first stage of Mohs surgery. The *pink surface* represents the epidermis. The *pink arrow heads* indicate the epidermal edge which is present the entire 360° of the specimen. The *green arrow* indicates the lateral margin of the specimen. The *blue arrow* indicates the deep margin of the specimen. *Yellow areas* in this and later illustrations represent underlying dermal and subcutaneous tissues beneath the resection margins. These colors will be used in all of the illustrations to graphically designate these vital margins and do not represent dye applied to the tissue or map

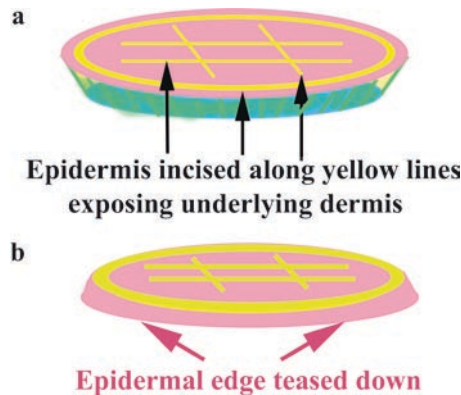


Fig. 8.2 The process of relaxing the specimen. *Yellow lines* represent incisions made partially into but not through the tissue. In figure (a) a circumferential incision has been made several millimeters from the epidermal edge to allow the epidermal edge to hinge down. Four lines have been made cross hatching the center of the tissue to add further relaxation. These incisions are only as deep as needed to relax the tissue and not through the tissue. Figure (b) illustrates the relaxed specimen. The epidermal edge is hinged down and the lateral margin (no longer visible) is now in the plane of the deep margin along with the epidermal edge

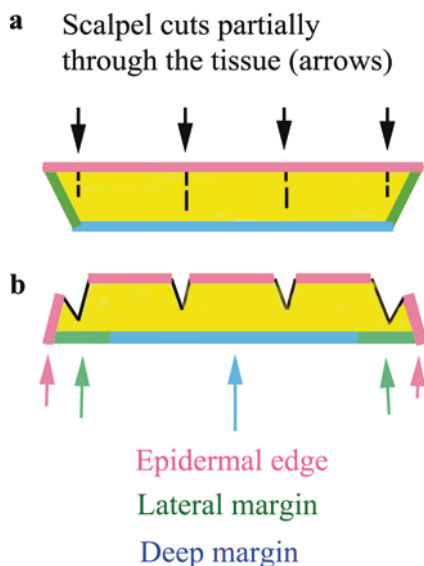


Fig. 8.3 A cross sectional view of the relaxation process in Fig. 8.2. In figure (a) the *black arrows* point to incisions (*dashed lines*) made through the epidermis partially into the *yellow* underlying dermis circumferentially near the edge and centrally. Figure (b) illustrates the tissue after it has been teased into position. The pink epidermal edge has been hinged down with the *green lateral margin* so that both are now in a flat plane with the *blue deep margin*

two dimensional drawings. The red skin edge, the green lateral margins and the blue deep margin are embedded in a single flat plane.

Figure 8.4 shows an example of a portion of a large specimen which required embedding in several parts. In this case, a well placed incision allows the tissue to relax flat as the incision opens up.

Figure 8.5 shows our final preparations in three dimensions and cross section. Our final preparation will be embedded with our tissue face now flipped over and face up on the chuck. Both examples show the pink epidermal edge, the green lateral margin, and the blue deep margin face up in a single flat plane.

In addition, we must embed the tissue so the plane of the face of the tissue is as parallel as possible to the plane of the chuck face. I refer to this as *parallel faces*. The illustration in Fig. 8.6a shows parallel black lines corresponding to these two planes. This will give us our best possible x-y orientation when cutting the section with the least amount to tissue wastage or cryostat adjustment. In contrast, Fig. 8.6b shows an example of a 5° angle between the chuck face and the tissue face. The dotted red line represents the path the blade would take if it were aligned with the plane of the chuck. It is clear from this illustration that the entire left side lateral margin, deep margin and epidermal edge, would be lost to examination

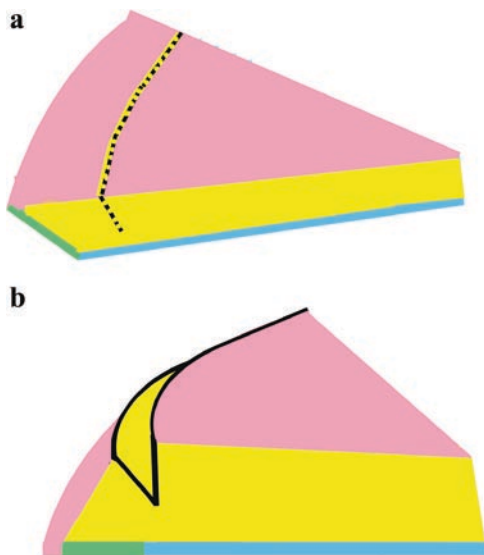


Fig. 8.4 Relaxation of a portion of a specimen which has been cut into four pieces. Figure (a) shows what now represents a slice of the pie. Relaxation is accomplished with a single incision parallel to the epidermal edge. Figure (b) shows the skin in the relaxed position. The *yellow skin* incision opens up to give freedom for the epidermal edge to hinge down along with the lateral margin resulting in all three margin elements in the same plane

before the right epidermal edge was available for examination. This would require a 5° adjustment of x-y orientation of the block to achieve a complete superficial section or result in disastrous wastage of the specimen. Figures 4.8 and 4.9 show additional examples of blocks trimmed in poor x-y orientation.

8.3 Notating the Map

The next step is to mark your map with the dye lines you wish to follow. The tissue is sectioned and carefully marked with dye to correlate with the map. This *must* correspond precisely with the tissue and patients anatomy, so the surgeon can identify where the residual tumor remains. Your surgeon may choose to mark the tissue with ink or dye. Here are some suggested dye markings:

The dotted blue line $\circ\circ\circ\circ$ designates blue dye; solid red line ————— designates red dye; the green xxx marking designates green dye; the black ++++ designates black dye and the yellow ^^^^^ designates the yellow dye.

After the tissue has been scored and marked with the dyes, notations of the specific ink markings will be added to the map. Figure 8.7 shows several examples of maps made for various sized tissues.

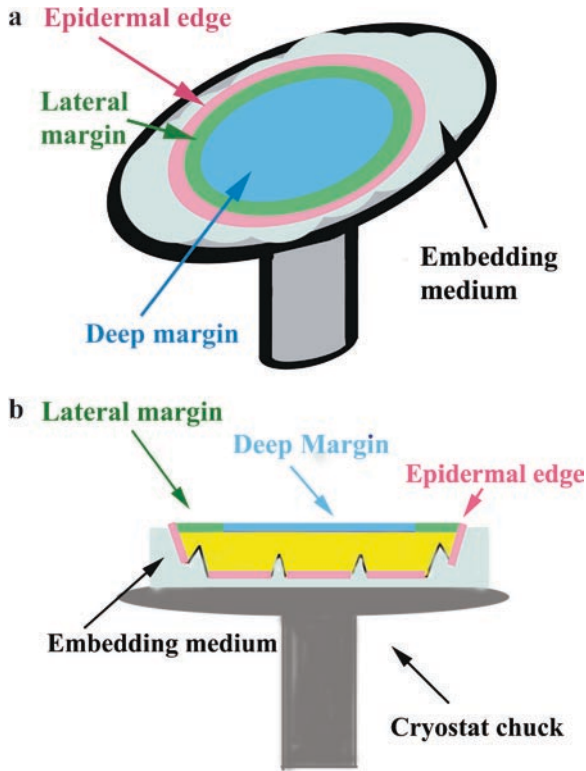


Fig. 8.5 The finished embedded specimen. Figure (a) shows our relaxed specimen from Fig. 8.2b now inverted onto a cryostat chuck frozen in position in light blue embedding medium. The *pink epidermal edge*, the *green lateral margin* and the *blue deep margin* are all in a single flat plane available to the first section of the cryostat blade. Figure (b) shows a cross sectional view of the embedded specimen. This is an inverted view of Fig. 8.3b. The *pink epidermal edge*, the *green lateral margin* and the *blue deep margin* are frozen into position in a flat plane embedded and frozen into position in the light blue embedding medium

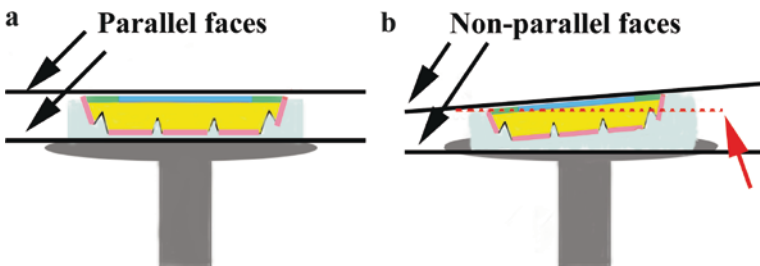


Fig. 8.6 Figure (a) shows a block prepared with parallel faces. The *black lines* indicated by arrows represent the parallel planes of the tissue face and chuck face. In figure (b), the tissue has been embedded with the tissue and chuck face at a 5° angle. The *dashed red line* indicated by the *red arrow* represents the plane the blade will pass if not adjusted for poor x-y orientation. In this example, the blade would cut across the most of the deep and both lateral margins before reaching the epidermal edge on the *left side*

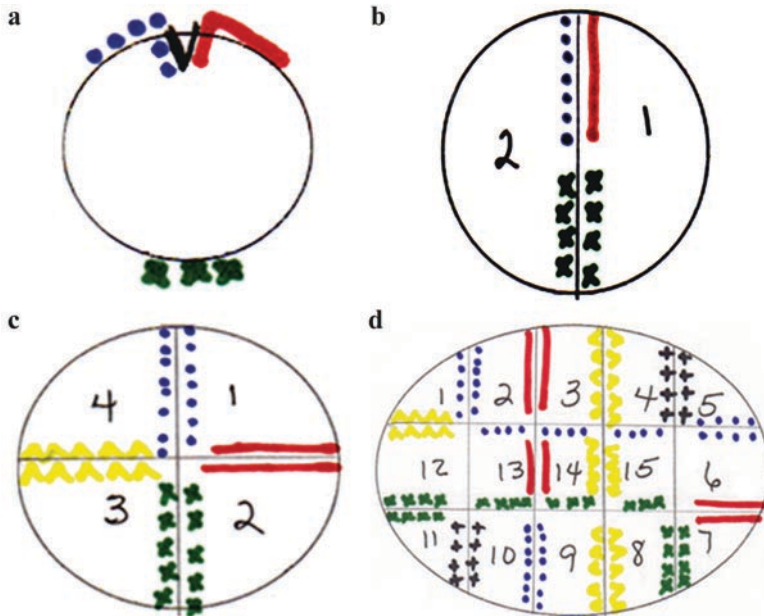


Fig. 8.7 Four examples of maps notated for specimens of varying size. The various markings described in the text represent *red, blue, green, and yellow ink* applied to the tissue to coincide with the orientation of the specimen in the map oriented and given by the surgeon to the technologist. Specimen (a) will be embedded in one piece; specimen (b) in two pieces; specimen (c) in four pieces; specimen (d) in 16 pieces

8.4 Embedding the Specimen

Now that our tissue is relaxed to the degree that our tissue can be embedded in a flat position, our next step is to embed the tissue. The topic of embedding was discussed in detail in Chap. 3. There are a number of techniques employed to embed Mohs surgery specimens. Essentially, these are a variety of methods of freezing the relaxed tissue into the position shown in Fig. 8.3 with the entire epidermal edge, deep and lateral resection margins in a flat plane. The Precision Cryoembedding system accomplishes this task in a single step, and easily prepares blocks with *parallel faces*, minimizing the need for x–y orientation and tissue wastage. Several of the other methods involve several steps with the pre-frozen tissue, frozen in place on a chuck as the last step. Extra care must be taken to achieve *parallel faces* when using these multistep methods.

We will discuss the glass slide technique, the Miami-special, the Cryo-embedder, the heat extractor method, the cryostat stage and direct embedding using the Precision Cryoembedding System and using plastic molds. In well trained hands, all of these methods will accomplish the desired tasks. Which method is used, is a matter of preference, and what is available to you. First, we will discuss embedding the specimens removed in the first stage of Mohs Surgery. These are typically elliptical or irregular portions of skin which contain what the surgeon hopes is the entire tumor Fig. 8.8.

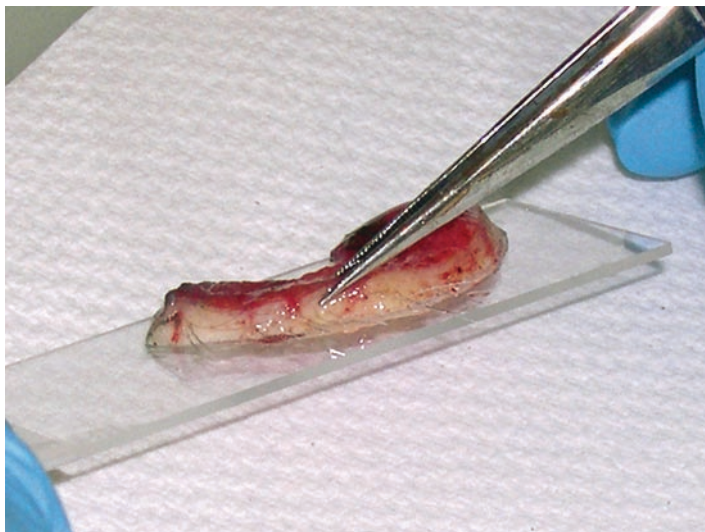


Fig. 8.8 A large portion of skin which has been relaxed placed on a glass slide with epidermal edges teased into position flat against the glass slide

8.5 Slide Technique

The relaxed tissue specimen is placed as flat as possible on a glass slide with the epidermis layer up and our deep and lateral margins flat down on the slide. The epidermal edge is pulled flat so the epidermal edge is in the same flat plane and available on the first section off of the block.

After teasing the epidermis out and the tissue is FLAT against the slide, place a small amount of embedding medium over the tissue on the slide, and dip the slide in LN2 (liquid nitrogen) to fast freeze in liquid nitrogen. This may be done by pouring a small amount of LN2 in a container and slowly dipping the slide in the container. Be careful not to leave the slide in the LN2 for more than 10 s, freeze just long enough until all the media has turned white and only a small center portion has a graying effect. Freezing sprays can also be used to freeze the tissue if liquid nitrogen is not available. While the “button” is still freezing on the glass slide, place your room temperature chuck in the cryostat on the fast freeze bar, and place a small amount of embedding medium on the chuck, and let it begin to freeze. While the button is frozen on your slide, slowly warm the bottom of the slide by pressing a gloved finger on the glass beneath the tissue to remove the button of embedding medium and tissue off the slide. Flip the button so the flattened deep aspect is up, and place the button on the partially frozen chuck in the cryostat. Make sure your chuck has enough liquid embedding medium to adhere the button in place. Make every effort to place the tissue on the chuck so the face of the tissue is parallel to the face of the chuck. The final step is to place your cryostat heat extractor over the tissue button on the chuck to flatten the surface and complete the freezing process Fig. 8.9.

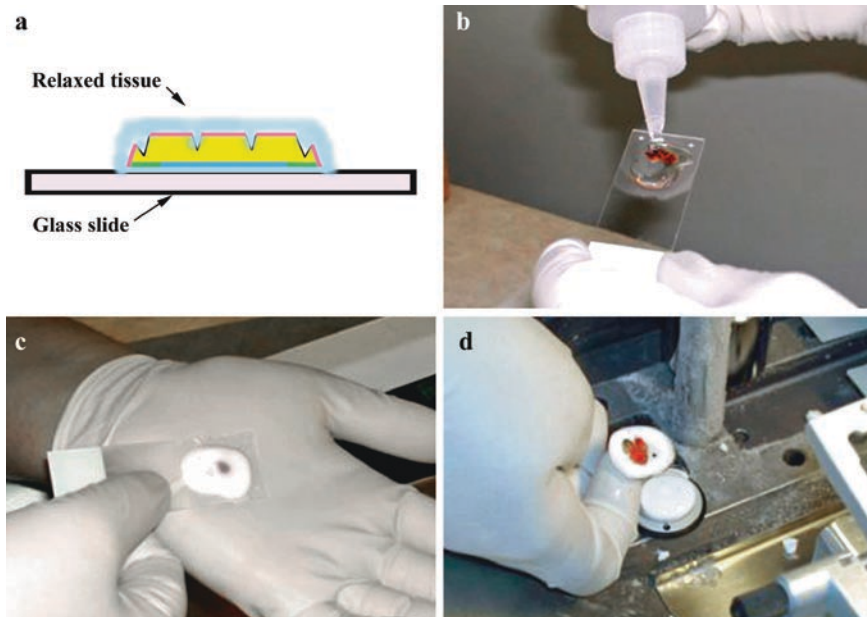


Fig. 8.9 Embedding using the slide technique. Figure (a) illustrates a specimen which has been relaxed and teased into position on a glass slide with the epidermal edge, lateral and deep margins in a flat plane down against the surface of a glass microscope slide. Figure (b) shows embedding medium being applied to relaxed tissue on a glass slide. Figure (c) shows the specimen on the slide after being frozen in liquid nitrogen or with a canned freezing spray. The specimen is being rewarmed with the gloved palm from underneath to remove the tissue from the glass slide. Figure (d) shows the frozen specimen which has been inverted and is being placed with the tissue face up onto a chuck with partially frozen embedding medium. Tissue should be frozen into position with parallel faces as illustrated in Fig. 8.6

8.6 Miami Special

The *Miami Special* is a hand held clamping device designed to hold a chuck and a portion of tissue together with *parallel faces* while being dipped in liquid nitrogen to rapidly freeze into a block Fig. 8.10.

Again, we start with the relaxed tissue placed as flat as possible with the epidermis layer up and the deep and lateral margins down on a glass slide. The epidermis is pulled out so that the epidermal edge, deep and lateral margins are in the same flat plane. Place a small amount of embedding medium over the tissue on the slide, and dip the slide in LN₂ to fast freeze in liquid nitrogen as with the slide technique above. Place the *Miami Special clamp* in the LN₂ to get it cold. Place a chuck from the cryostat on the Miami special and put a small amount of embedding medium on the chuck. Warm the bottom of the slide with a gloved finger just enough to pop off the frozen button from the slide. Place the button on the chuck with atop the embedding medium, with the flat tissue face UP. The process must be timed so that the



Fig. 8.10 Miami Special clamp. One of the two spatula shaped end portions is designed with a hole and grooves to accept a variety of common cryostat chucks and hold them in position (*left side* of illustration). The right side spatula holds the tissue in position atop the chuck. The chuck is clamped into fixed position like a common hemostat allowing the sandwiched tissue and chuck to be dipped into liquid nitrogen to complete the freezing process

tissue is placed on the chuck before there is significant freezing of the embedding medium. Clamp down with the Miami special and place return it to LN₂ for approximately 5 s. Your chuck is now ready for sectioning.

8.7 Cryo-embedder

The cryo-embedder is another innovative device designed to freeze tissue into position on the cryostat chuck while maintaining *parallel faces*. The relaxed tissue is placed with the deep and lateral margins down on the cryo-embedder's flat disc. This disc has been kept in the cryostat to remain as cold as possible. The epidermal edge is teased down against the disc so that it will be in the same plane as the deep and lateral margins, so all are available on the first cut. Next, place a small amount of embedding medium around the tissue and allow it to freeze. Place a chuck in the holder in the cryostat and place a small amount of embedding medium on the chuck. When the embedding medium on the chuck is partially frozen, add a little more embedding medium to the chuck and insert the chuck into the opposite side of the cryo-embedder. While holding on to the chuck, flip the cryo-embedder and the chuck upside down, and put it on top of the other side of the cryo-embedder with the tissue.

Once placed on top of one another, flip both pieces of the cryo-embedder and slightly spray them with the cryospray. Place the cryo-embedder inside the cryostat and allow the button to freeze. Your chuck is now ready for sectioning Fig. 8.11.

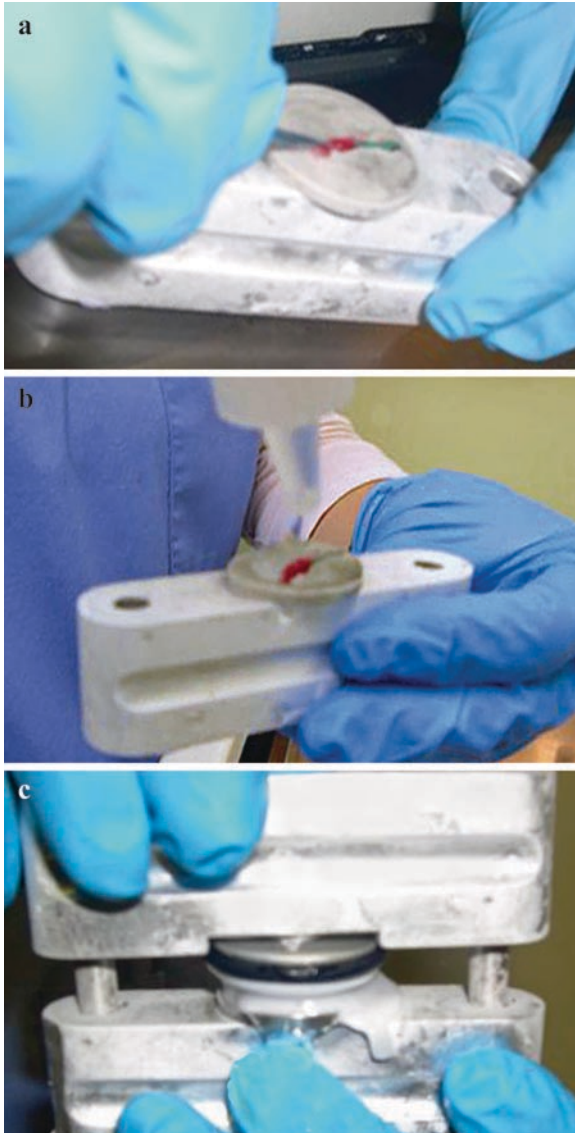


Fig. 8.11 Preparation of a specimen using the *cryo-embedder*. Figure (a) shows the specimen being teased into position on the freezing disk on the bottom half of the apparatus. Figure (b) shows embedding medium being applied to the surface of the tissue. Figure (c) shows the top half of the apparatus containing a cold chuck being sandwiched against the tissue to complete the freezing process

8.8 Heat Extractor/Cryostat Stage Method

Using this common method, the tissue is first frozen into position on a cryostat heat extractor or the cryostat stage. The relaxed tissue is placed with the deep and lateral margins down on a free standing heat extractor which has been kept in the cryostat to remain as cold as possible.

Most cryostats are equipped with some form of heat extractor. The stage of the cryostat can also be used as a heat extractor, or any substantial flat piece of metal or freezing temperature surface can be substituted. The epidermal edge is teased down against the heat extractor so that it will be in the same plane as the deep and lateral margins making all available on the first cut see Fig. 8.12. An advantage of this method is that tissue will adhere in place to the cold metal. After teasing the epidermis out and the tissue is FLAT on the bottom of the heat extractor, place a small amount of embedding medium around the tissue and allow it to freeze. Place a chuck in the holder in the cryostat and place a small amount of embedding medium on the chuck. As the embedding medium begins freezing, place your heat extractor on top of the chuck in the cryostat. The embedding medium on the heat sink and the chuck must be only partially frozen when sandwiched together so they will freeze together in a solid block. Try your best to achieve *parallel faces* when freezing the tissue in position on the chuck. The completed block is now ready for sectioning Fig. 8.13.

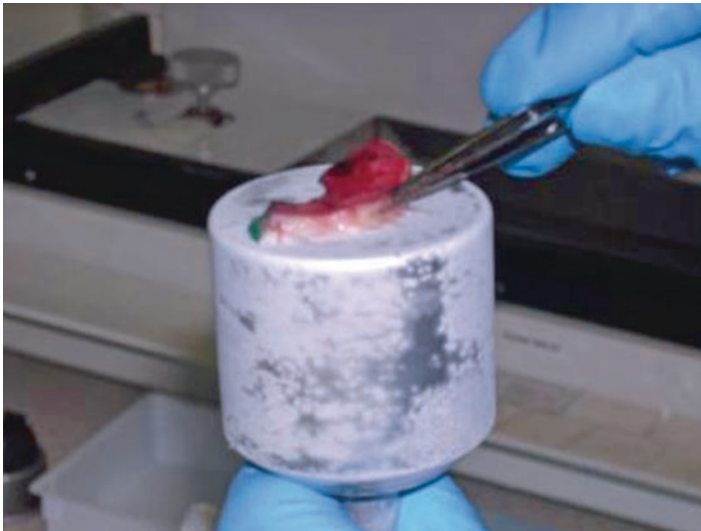


Fig. 8.12 A large portion of skin which has been relaxed placed on a heat extractor with epidermal edges teased into position flat against freezing metal surface

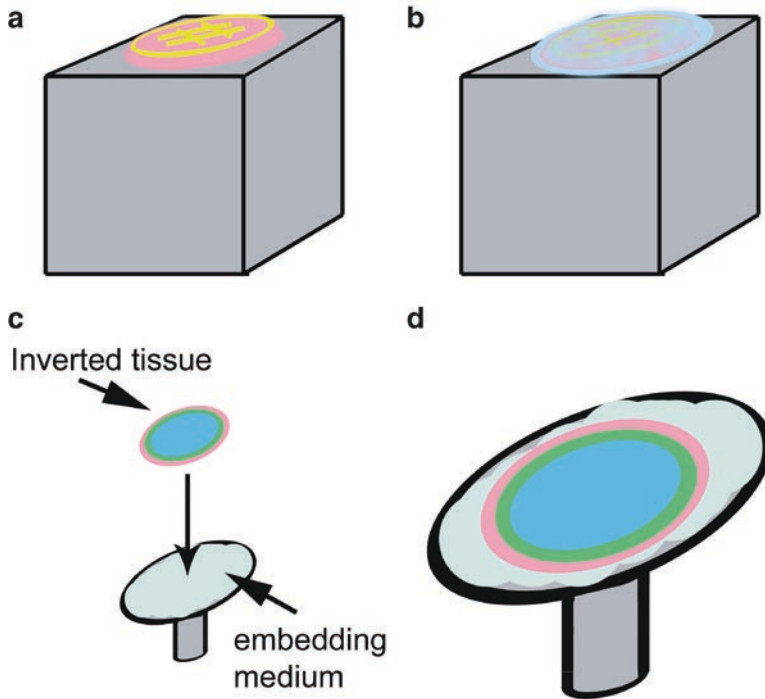


Fig. 8.13 Heat extractor method. Figure (a) shows the relaxed tissue teased into position on a cold heat extractor, cryostat stage or any freezing metal surface. Figure (b) shows the freezing tissue covered with embedding medium. Figure 8.3 illustrated the frozen tissue, now inverted, and to be placed face up on a layer of embedding medium on a cryostat chuck with faces as close to parallel as possible. Figure (d) represents the tissue frozen in position on the completed block with epidermal edge, lateral and deep margins in a flat plane

8.9 The Precision Cryoembedding System

The Precision Cryoembedding System discussed in detail in Chap. 3 allows precisely flat and rapid embedding of all tissues, and is particularly suitable for Mohs surgery specimens. It will also easily prepare blocks with *parallel faces*. After adequate tissue relaxation, the specimen is placed with the deep and lateral margins flat and down on the dispensing slide near the tip of the slide. See Fig. 8.14a. Looking at the tissue from beneath the clear dispensing slide, check that all of the margins and epidermal edge are visible in the flat plane of the slide. The leading edge of the tissue is pulled to the edge of the dispensing slide with a forceps and touched to the well floor. Be careful to guide the leading edge with a forceps to the floor, so it does not turn or flip on contacting the floor. Next, slowly pull the dispensing slide out from under the tissue while continuing to address the epidermal edges, so they are all flat against the well floor as in Fig. 8.14b.

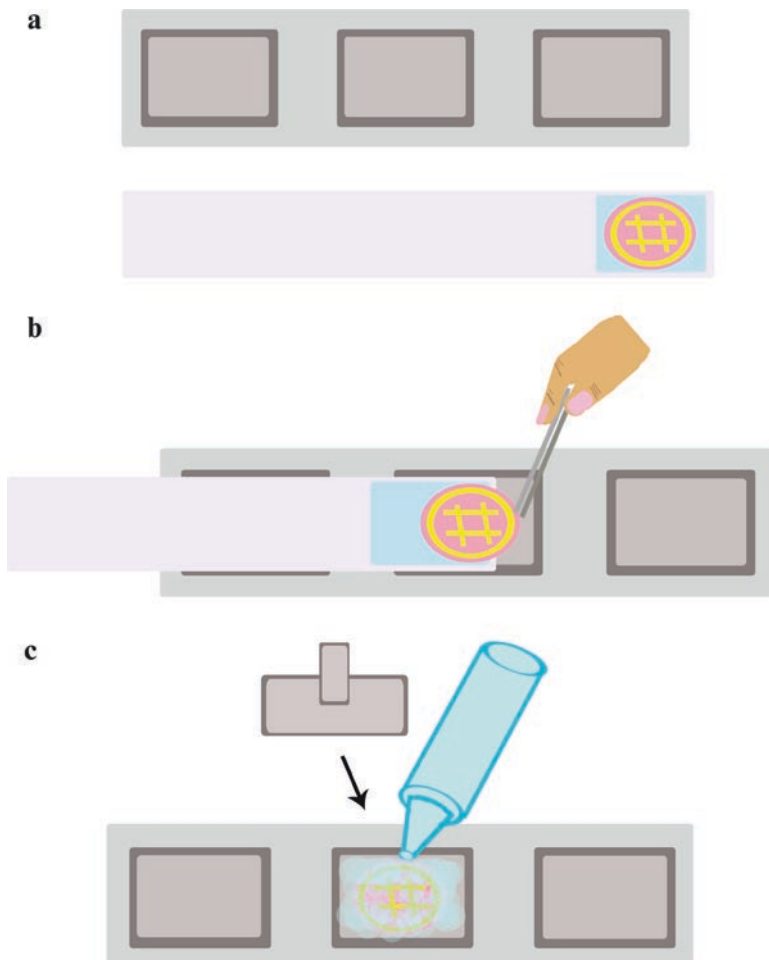


Fig. 8.14 Embedding using the Precision Cryoembedding System to embed a Mohs surgery specimen. Figure (a) shows our relaxed tissue from Fig. 8.2b on a thin film of embedding medium at the edge of a dispensing slide. The well bar is pictured above. Figure (b) shows the leading edge of the tissue being touched to adhere to the embedding well floor with a forceps. As the dispensing slide is slowly pulled out from under the tissue the tissue is pressed or ironed flat against the well floor while the epidermal edge is precisely teased to the floor through its circumference. Figure (c) illustrates the well being filled with embedding medium after which the chuck will be placed over the well. The block is finished when freezing is complete

The system comes with an L shaped flattening forceps that can be used to iron larger specimens flat as the tissue meets the well floor see Fig. 3.11. A great advantage to using the freezing steel well bars is that the tissue will adhere into position when touched to the well floor. As each portion of the tissue meets the well floor, the adhesive property of the cold metal allows the epidermal edge to be teased into

position in the plane with the deep and lateral margins. These precisely flat wells beautifully prepare a perfectly flat face, rapidly, in a single step. Next, simply fill the well with embedding medium and place on the chuck as in Fig. 8.14c. After a period of freezing, remove the block with a tap of the over-chuck freezing block. Complete the block with a thin layer of plastering. This simple one step freezing technique can be performed very quickly and precisely when compared to other multistage techniques in use.

Paper embedding technique, also discussed in Chap. 3, is an alternative method for embedding Mohs surgery specimens. It is particularly suitable for the very thin and flimsy specimens received in the later stages of the procedure. Using paper embedding, a dispensing slide is prepared with a piece of lens paper as in Chap. 3 p. 23. Tissue is placed with the desired surface face down on the lens paper. Check the tissue from under the slide, making sure that the tissue is flat and there is no flipping of the epidermal edge. The tab of paper overhanging the slide is touched and adhered to the well floor. As the slide is pulled out from under the paper, the paper and tissue falls flat to the well floor. Fill the well to complete the block. The paper will be trimmed away when sectioning the block. An alternative is to remove the paper by touching the block face to a warm metal surface for a few seconds, peeling away the paper and refreezing with a touch of plastering.

8.10 Embedding in Plastic Molds

The relaxed tissue is placed with the deep and lateral margins down in the plastic mold, making sure all of the skin edges are flat against the embedding mold. Embedding medium is placed in the mold and a chuck is placed on top of the mold. The specimen is then sprayed with cryo spray for approximately 10–15 s. The mold and specimen chuck is placed on the quick freeze bar of the cryostat. When the block is completely frozen, the mold is peeled off. The completed block is now ready for sectioning in the cryostat. Figure 3.4 shows an example of embedding in these plastic molds.

8.11 Embedding Samples from Secondary and Latter Stages of Mohs Surgery

If any portion of the resection margin contains tumor on microscopic interpretation, the surgeon will need to remove an additional layer or layers of tissue until the resection margin is negative. When embedding these tissues, we will follow the same basic principles. Our goal will be to embed these samples on face with the margin in a flat plane on the face of our prepared block. We will need to see the entire epidermal edge and margin face in a flat plane. Typically, these samples are taken in very thin layers, so relaxing the tissue takes less effort to get these thin samples

to lie flat. If the tissue is thicker or firm by nature, a few well places scalpel cuts partially through the tissue will relax the tissue as needed.

As these samples can sometimes be very thin, a new potential problem may arise. In very thin tissues, it is quite easy to cut entirely through the tissue if approached aggressively. It is imperative that the tissue be embedded in a flat plane which is in the best x-y orientation achievable. As I said in discussing, trimming the primary stage specimens, if adequate x-y orientation is not possible, sections should be taken as the tissue is first reached with additional sections picked up at various levels until the entire face has been reached. If not, the true margin of much of the sample will be shaved away before the entire face is reached. If orientation is poor and the specimen is very thin, some of the margin may be shaved away completely without any available for microscopic interpretation. This will require removal of more tissue, causing the patient to have more tissue excised unnecessarily.

All of the techniques discussed under embedding of primary stage samples can be used. When tissues are very thin, our best technique will be mandatory.

8.12 Sectioning the Block

All of the information offered in Chaps. 4 and 5 apply to the sectioning of tissues for Mohs surgery specimens as well. In this section, we will address sectioning issues pertinent to the proper sectioning of specimens common to our topic of Mohs surgery.

As we described earlier in this chapter, our goal is to embed our tissues so that the deep, lateral and skin edge margins are all in the same plane. Properly embedded, this entire plane should represent the face of our newly prepared block. If we could take the first 5 micron section directly off of the face of the block, this would represent the true resection margin of the specimen. It is unrealistic to imagine taking the section produced by the very first turn of the wheel, as all blocks will need some degree of trimming before our first complete section is produced. Our goal is to take our first section with the least amount of trimming. The deeper we need to trim the block, the further we will be from the actual margin, and the closer we will be to the tumor. What might have been, in reality, a true negative margin can appear as a false positive involved margin if we trim to deeply into the tissue.

For this reason, we want to approach the tissue very gradually with the least amount of trimming possible. As we learned in Chap. 4, in order to achieve a section of the full block face with the least amount of trimming, the x-y orientation of the block must be in the same plane as the blade. As sectioning begins, the blade should first meet the block in the center. If it begins by trimming any edge or corner, it will require adjustment of x-y orientation (*see* Chap. 4 p. 11).

Every section is important to be able to determine the depth of the tumor. Start by trimming just enough to pass any embedding medium covering the tissue and the first few sections off the block, until you achieve a complete full section which

include the epidermal edge with our flattened deep and lateral margins. It is helpful for the technologist to check for the skin edge microscopically, before placing the slide on the stainer to assure the skin edge is complete. This will save the technologist and the surgeon the time of having to repeat the initial sectioning and staining because the section is incomplete. If you find yourself in a situation where proper x–y orientation is not possible because of cryostat issues, it would be better to start by picking up partial sections to stain. This way, we will not have wasted the true margin tissue from the sides of the block that were reached first in the maloriented block. The block can then be further trimmed to the depth of a complete section.

While sectioning the tissue, it will help your surgeon to orient the sections so each section on the slide can match the map. It will be necessary at this step to check with your surgeon, how the slide is placed on the stage of the microscope for proper orientation. Find out when placing the slide on the microscope, if they hold the slide label in their right hand or left, while looking under the microscope. If your surgeon holds the slide in the left hand, and your map is showing the first quadrant on the left, you should pick up your frozen section in quadrant one so the epidermis is to the right of the slide. In quadrant two, the epidermis is to the left. If the epidermis is on the top, the epidermis should be picked up so the epidermis is closest to the bottom of the slide. The best way to remember this is whatever your map shows, pick up your section so the epidermis is opposite the map. If your surgeon holds the slide in the right hand while looking at sections under the microscope, then pick up just the opposite keeping in mind that the microscope will invert all objects.

When sectioning your blocks, place the first section closest to the labeled end of the slide, rotate your cryostat wheel three to four times, take your second section, rotate three to four times again and take your third section. Place each section evenly distributed on the slide. When you rotate three to four times between each section, this will give you 15 microns between sections; if there is positivity, your surgeon will be able to track the direction on the tumor; if it's clear, the surgeon will know it's clear all the way.

Normally, I suggest taking two slides per block and three to four sections per slide. Remember to check your slides microscopically before you stain them. Again, this will allow you to see if you have the complete epidermal edge, before wasting too much time in the stainer only to find recuts will be required, because the epidermal edge is not yet completely available microscopically. All slides should be checked before beginning to stain them. This procedure will work for all tissue specimens.

8.13 Staining the Sections

Hematoxylin and eosin stain is the stain of choice in most settings; however, some surgeons prefer to use the Toluidine blue for basal cells. Staining is discussed in detail in Chap. 6. Upon completion, slides are cover-slipped with permanent mounting medium. Your sections are now ready for the surgeon's desk. Place all slides with the correct map next to the microscope and notify your surgeon this case is ready for review.

8.14 Suggestions for Sectioning Specific Difficult to Handle Tissues

8.14.1 *Fatty Specimens*

Difficulties associated with fatty specimens are discussed in detail in Chap. 5 p. 9. In Mohs surgery, it is common to receive fatty subcutaneous tissue at the deep aspects of the specimen. If you have an extra fatty section, you will need a container holding a small quantity of liquid nitrogen, a stiff bristle brush (preferably camel hair) of about ½ inch in width. Align the block with the knife just as you are getting ready to cut, dip the brush in the liquid nitrogen, press the cold brush directly on the tissue, and concentrate on getting the liquid nitrogen directly on the fatty part of the block and away from the skin. Continue to dip the brush in the liquid nitrogen and press against the block approximately six to eight times. Rotate the wheel two times, section as usual and repeat as necessary until an adequate section is achieved. Using this method, one can produce a complete section containing a nice webbing of the fat and a complete epidermal edge. If liquid nitrogen is not available, an alternative is to use commercially available cans of freezing sprays Fig. 8.15.

8.14.2 *Cartilage*

Cartilage usually sections easily due to the consistency of the tissue. The challenge is keeping the cartilage from coming off the slide in the staining process. The best way to do this is to use charged slides which augment the adhesion of the tissue




Fig. 8.15 An operator using liquid nitrogen to aid in the cutting of fatty tissues. Figure (a) shows a metal container with a small amount of liquid nitrogen with a brush being dipped into it. Figure (b) shows the liquid nitrogen being painted on to the surface of the tissue face, in order to bring the fatty tissue to the ultra cold temperature required to harden fat enough to section

section. As discussed in Chap. 6, tissues prone to fall off slides should be stained with *very* gentle agitation. The thicker the tissue section, the thicker the section edge will be present. This thicker edge will offer more edge surface to receive the forces of the agitation of the solutions pulling the tissue from the slide. For this reason, by making the section a bit thinner, and using minimal agitation, there will be fewer forces pulling the tissue from the slide. If you use an auto stainer, lower the pressure of the water wash. Another hint is to warm the back of the slide after you place your sections on. Just adding slight heat will help to better adhere the section to the slide. Another method to help cartilage adhere is to first briefly dip the slide containing the section into acetone prior to fixing the slide in 95% ethanol see Chap. 6 p. 11.

8.14.3 *Mucosa and Soft Tissues*

When you have an eyelid lesion or lip lesion, it is best to embed the tissue in the same manner. These somewhat more watery tissues section best at a warmer temperature. This does not require lowering the cryostat temperature. Simply warm your specimen chuck with your thumb prior to sectioning. Just a few seconds of pressure with your gloved thumb will warm enough to make a nice section. Stain as usual. Effects of block temperature are discussed in detail in Chap. 5 p. 2.

Reference

Mohs F (1978) Chemosurgery, microscopically controlled surgery for skin cancer. Charles C. Thomas, Springfield, IL