

# Chapter 5

## Metastatic Orbital Tumors

Syed Mehdi Ahmad and Bitu Esmali

**Abstract** Orbital metastasis is uncommon, accounting for only 1–13% of all orbital tumors reported. The approach to metastatic orbital tumors has dramatically changed in recent decades. The improved life expectancy of patients with common cancers, such as breast cancer and prostate cancer, together with aging of the population and the resultant increase in the number of patients at risk for cancer, has led to a higher incidence of patients living with metastatic disease in unusual sites such as the orbit. Furthermore, vigilant surveillance and advances in diagnostic testing have led to increased detection of orbital metastases. Because of the poor prognosis for patients with metastatic orbital disease, treatment is usually palliative and may include radiotherapy, chemotherapy, hormonal therapy, surgery, or a combination of these modalities. The ophthalmologist may play a pivotal role in the detection and management of these lesions in patients with and without a primary cancer diagnosis.

### 5.1 Introduction

Orbital metastases were first documented by Horner in 1864 and Perl in 1872. Though many cases have been described in the literature, metastasis to the orbit is rare and occurs less frequently than metastasis to uveal tissue [1]. With emerging novel therapies, the longevity of cancer patients has risen and so has the frequency with which metastases in the orbit are detected [2–4]. Generally, orbital metastases reflect multisystem, end-stage cancer and patients with orbital metastases have a poor prognosis.

---

S.M. Ahmad (✉)

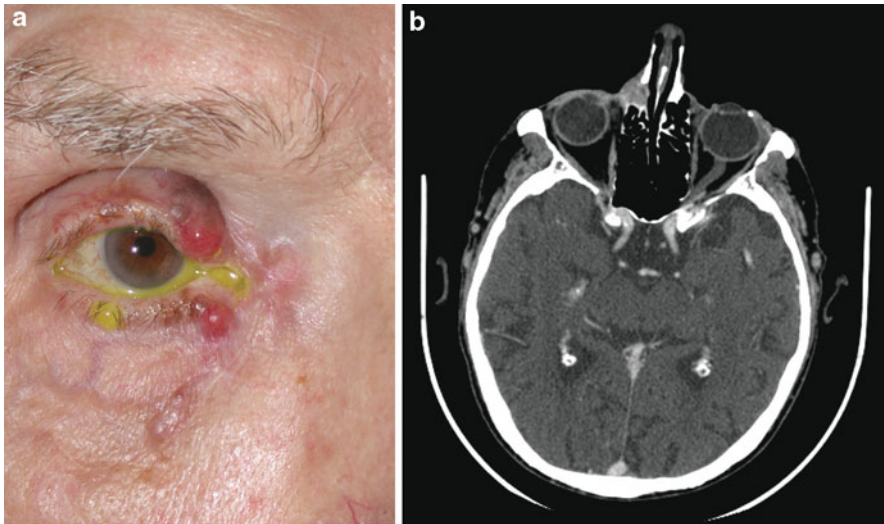
Department of Ophthalmology, Baylor University Medical Center at Dallas, Dallas, TX, USA  
e-mail: sma967@gmail.com

## 5.2 Incidence

Metastatic orbital lesions have been estimated to account for 1–13% of all orbital tumors reported, and the prevalence of these lesions in cancer patients is estimated to range from 2 to 4.7% [2–13]. With the increase in the median survival time of cancer patients, the true incidence of these metastatic lesions is likely to be higher than reported in the literature. Patients with small orbital lesions are more likely to remain asymptomatic and undiagnosed than patients with similarly sized ocular lesions [6]. For example, subclinical metastatic orbital lesions are estimated to be present in 10–30% of breast cancer patients [2–4, 8]. The presence of debilitating systemic symptoms may overshadow orbital symptoms, thus leading to a lower rate of referral to the ophthalmologist. Another factor suggesting that the true incidence of metastatic orbital lesions may be underestimated is that rates of orbital evaluation at autopsy are low [7].

## 5.3 Anatomical Considerations

Unilateral presentation is common; bilateral presentation is highly unusual. Some studies have suggested that metastatic disease is more common in the left orbit [10, 11], while other studies have shown no greater prevalence of metastasis to the left orbit [3, 8, 12]. Recent cumulative data have shown the following distribution of involvement: lateral quadrant, 39%; superior, 32%; medial, 20%; and inferior, 12% [3, 12]. Another report of 68 patients with orbital metastasis found that the main



**Fig. 5.1** (a) Melanoma metastatic to the lacrimal sac and periorbital soft tissue in a 90-year-old man with stage IV cutaneous melanoma. (b) Computed tomography scan in the same patient demonstrating the metastatic melanoma lesion in the lacrimal sac

component of the metastatic lesion lay in the anterior orbit in 41 cases and in the posterior orbit in 27 cases [8]. Although different tumor types have a propensity to metastasize to different tissues in the orbit, the overall distribution of metastases within the orbit seems to be in a bone to fat to muscle ratio of 2:2:1 [3].

Isolated metastasis to the eyelid and periocular skin is less common and has been reported mainly in single case reports, most describing cutaneous melanoma nodules [14, 15, 29] in the eyelid or eyelid metastasis in the background of widespread metastatic disease (Fig. 5.1) [16].

## 5.4 Presentation and Clinical Features

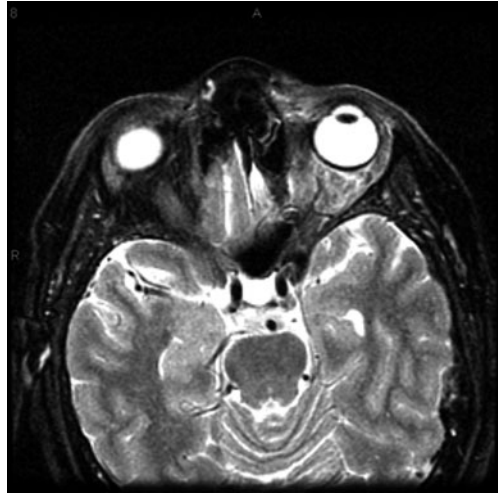
Orbital metastasis is predominantly a condition of adulthood and usually arises from carcinomas [4]. In children, the most common tumor metastatic to the orbit is neuroblastoma. Most orbital metastases present in patients with widespread cancer, although in 19–25% of cases there is no preexisting cancer [2–4]. Orbital metastases are usually associated with a rapid onset of symptoms that may be progressive over weeks to months. Typical manifestations of orbital metastases include mass effect, causing displacement or proptosis of the globe, pain, inflammation, bone involvement, chemosis, and eyelid swelling. Infiltration of soft tissue structures can lead to ptosis, diplopia, or enophthalmos. Because the signs and symptoms of orbital metastases are nonspecific and provide no clinical framework for categorization of lesions, Goldberg et al. [3, 9] suggested categorization into five generalized syndromes of presentation, frequencies of which were as follows: infiltrative (53%); mass (37%); inflammatory (5%); functional (3%); and silent (very rare) [3].

## 5.5 Diagnosis

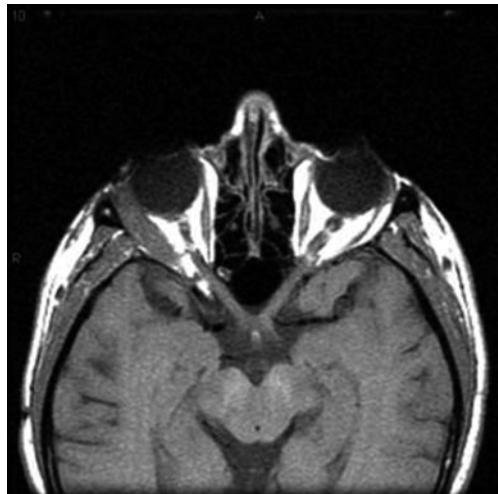
A thorough patient history and detailed examination are a must and should be done in conjunction with a prompt referral to an oncologist for a simultaneous evaluation for systemic disease. Computed tomography and magnetic resonance imaging are the primary imaging modalities in evaluating any suspected orbital lesion. Though computed tomography is usually the first choice in evaluating the orbit, magnetic resonance imaging provides the best resolution of orbital soft tissues. A computed tomography scan may be more appropriate for lesions that are known to metastasize to the orbital bony walls, such as metastatic prostate cancer.

Findings on imaging may range from a diffuse infiltrative pattern (Fig. 5.2) with obscuration of normal anatomical landmarks to a focal lesion in which a discrete, well-defined mass is seen; orbital metastatic lesions can be extraconal or intraconal. Enlargement of one or more of the extraocular muscles may be seen, particularly in patients with metastatic cutaneous melanoma (Fig. 5.3). Involvement of the bony orbital walls suggests that prostate cancer is the primary tumor. It is unusual to see cystic changes or calcification within metastatic lesions of the orbit.

**Fig. 5.2** Magnetic resonance imaging demonstrates left orbital infiltration from a metastatic breast carcinoma



**Fig. 5.3** Magnetic resonance imaging of the orbit shows a metastasis to the right lateral rectus muscle from cutaneous melanoma



The definitive diagnosis of an orbital lesion requires a tissue diagnosis. In patients with widespread metastatic disease and/or an established diagnosis of cancer, an orbital biopsy may be forgone and the inherent risks of biopsy—such as visual loss, bleeding, and diplopia—avoided. Fine-needle aspiration biopsy has been advocated by many authorities as an excellent diagnostic modality [3, 17–19]. However, there have been reports of dissemination of tumor cells and risk of globe injury with this procedure, although the probability of such problems is low. Other limitations of fine-needle aspiration biopsy for orbital lesions include lack of opportunity to assess

tissue architecture and limited volume of tissue, both of which may limit ability to make a diagnosis in some cases [17–19].

In the case of suspected but undiagnosed breast malignancy, estrogen receptor expression should be measured in the orbital biopsy specimen, not only to aid in diagnosis but also to determine the value of hormonal therapy.

## 5.6 Treatment

Treatment for orbital metastases is palliative in the sense that the presence of these lesions suggests a hematogenous spread of cancer even if no other metastases are identifiable. Various treatment modalities exist, including radiotherapy, chemotherapy, hormonal therapy, surgery, and combinations of these. The goals of treatment for orbital metastases are to maximize the patient's quality of life and maximize the patient's visual function. Each treatment modality should always be carefully considered in the context of the patient's general state of health, life expectancy, and anticipated effects of treatment.

Radiotherapy is the mainstay of treatment for orbital metastases and is usually administered to control tumor growth, preserve vision, decrease proptosis and exposure keratopathy, and/or improve patient comfort. The recommended dose is 20–40 Gy delivered in fractions over 1–2 weeks [3–9, 20]. Radiotherapy alleviates symptoms in 80% of cases and in some cases restores vision [5]. Shielding of the globe may lessen the risk of radiation-induced side effects, such as radiation retinopathy and cataract formation, in some situations [21].

Systemic chemotherapy may be helpful in the treatment of orbital metastases, especially for chemosensitive tumors, such as small-cell lung cancer and neuroblastoma [22]. Hormonal therapy plays an important role in the treatment of metastases from hormone-sensitive tumors, such as breast cancer and prostate cancer.

Generally, orbital surgery to remove the tumor mass is not curative and may be associated with significant ocular morbidity [2–5, 7–9]. However, in selected cases, partial resection may improve the patient's symptoms and help restore visual function. Orbital exenteration or other radical measures offer no advantage in terms of slowing disease progression or increasing survival time and should be used only in cases of intractable ocular pain or unmanageable local hygiene because of rapid tumor growth.

## 5.7 Types of Cancer Metastatic to the Orbit

### 5.7.1 *Breast Carcinoma*

Breast cancer is the most common primary source of orbital metastases, and the median age of patients with newly diagnosed breast cancer is in the fifth or sixth decade of life [23]. Various large studies show that a breast primary accounts for

28.5–58.8% of cases of orbital metastasis [4, 8, 13]. Most patients, 89% in one series, have an established diagnosis prior to presentation [4]. The mean interval from the diagnosis of breast cancer to the detection of orbital metastasis has been reported to range from 4.5 to 6.5 years [4].

The characteristic presentation of orbital metastases from breast cancer consists of infiltration of the extraocular muscles and surrounding orbital fat, causing motility deficits, proptosis, globe dystopia, and enophthalmos. The association between an enophthalmic presentation and scirrhous adenocarcinoma is well known, but it is important to recognize that breast cancer metastasis to orbit may also produce proptosis rather than enophthalmos.

The histologic features of adenocarcinoma of the breast differ, and the histology of orbital metastases may vary from that of the primary tumor. Orbital metastatic cells are usually undifferentiated anaplastic cells showing single-file infiltration of fat or dense lakes of cellular lobules [4]. In a report by Garrity et al. [4], 94.6% of cases (35/37) were anaplastic grade 3 or grade 4 tumors.

Regardless of the primary tumor, the presence of orbital metastases portends a poor prognosis; the mean survival after diagnosis of such metastases is 31 months (range, 1–116 months) [4, 24]. The only appropriate surgical intervention for breast carcinoma metastatic to the orbit is biopsy to establish the diagnosis, after which external-beam radiotherapy is the mainstay therapy used to stabilize the disease. Chemotherapy or hormonal therapy may also be administered, depending on the overall disease burden.

### **5.7.2 Lung Carcinoma**

Lung cancer remains the leading cause of cancer-related mortality in the Western world and is the second most common carcinoma to metastasize to the orbit. It accounts for 8–12% of cases of orbital metastasis. Patients have an aggressive presentation reflecting the degree of mass effect and extraocular muscle infiltration. Compared to breast carcinoma, lung carcinoma metastasizes to the orbit earlier after diagnosis and has a poorer prognosis, with a shorter median survival time (188 vs. 666 days) [4, 25].

Treatment is guided by cancer type and tumor histology. Though there are four principal variants, non-small-cell lung cancer accounts for 80% of thoracic malignancies. The types most likely to metastasize to the orbit are large-cell undifferentiated carcinoma and small-cell carcinoma; squamous cell carcinoma and adenocarcinoma have a low incidence of orbital metastasis [2, 4].

As the majority of patients with metastatic lung carcinoma succumb to disease within a relatively short period, palliative orbital radiotherapy is the only real therapeutic option for patients with orbital metastatic lesions. Debulking surgery or orbital exenteration is reserved for severe cases of intractable orbital pain and should be avoided if at all possible.

### 5.7.3 Prostate Carcinoma

Despite being the second most common malignant neoplasm in men, prostate carcinoma accounts for only 3–10% of all orbital metastases reported [4, 26]. Several studies report that prostate cancer is the third most common tumor to metastasize to the orbit [3, 4, 7, 9]; however, in some other series it is reported to metastasize to the orbit less frequently than melanoma [3, 8, 15].

Common symptoms include proptosis, diplopia, eyelid swelling, decreased vision, ptosis, and red eye. Because bone metastasis is common in prostate cancer, pain is also a more common symptom in patients with prostatic orbital metastases. Ninety percent of metastatic lesions are predominantly or entirely osteoblastic [27]. When an osteoblastic lesion presents, one must keep the differential diagnosis of meningioma in mind, especially if the sphenoid bone is affected. The rapid development of osteoblastic orbital lesions in an elderly man is highly suggestive of metastatic prostate carcinoma [4].

If metastatic prostate cancer is suspected, the clinician must also inquire about nocturia, weight loss, and pain. Most prostate cancers are adenocarcinomas and range from well to very poorly differentiated. When such tumors are poorly differentiated, the primary site may remain unknown; in such cases, immunohistochemical stains can be used as a diagnostic tool. Specifically, immunoperoxidase stains should be used for prostatic-specific acid phosphatase as these levels are abnormal in more than 80% of patients with metastatic prostate cancer. The prostate-specific antigen level will often be high. Prostate cancer metastatic to the orbit can be managed safely and effectively because it is a radiosensitive malignancy; treatment for orbital disease usually consists of radiotherapy combined with hormonal therapies.

### 5.7.4 Melanoma

Orbital metastases from cutaneous melanoma represent 5.3–15% of all metastatic tumors of the orbit [3, 8, 15]. These are usually seen in patients with a preexisting diagnosis and disseminated end-stage disease. The primary site of origin is usually the dermis but can also be a mucosal site or the uveal tract [4, 28].

The clinical signs of orbital metastatic melanoma are similar to those of other orbital metastases; however, metastasis to extraocular muscles was seen in more than half of patients [3, 15]. This affinity for muscle would be consistent with the main presenting symptom of diplopia. Imaging studies show smooth enlargement of the muscle rather than a pattern of infiltration into the orbit (Fig. 5.3).

The survival of patients with melanoma metastatic to the orbit depends on the extent of metastatic disease and overall disease burden but generally does not exceed 12 months. However, the mean survival in one series was 19.7 months, much longer than the 5.75 and 8.4 months reported in two other published series [9, 15].

In certain cases, surgical resection to debulk the mass, even incomplete resection, may be appropriate as a palliative measure. In the case of an isolated eyelid or orbital

soft tissue metastasis with no other detectable sites of metastasis, complete surgical resection of the mass followed by radiotherapy with doses of 30–60 Gy would be appropriate to achieve local control [25, 26, 29]. In patients with high disease burden and multiple metastatic sites with poor life expectancy, radical surgery is generally not indicated. Though melanoma has traditionally been considered a chemoresistant tumor, various trials of immunotherapy or standard chemotherapy for metastatic melanoma are available and should be considered for these patients.

### **5.7.5 Carcinoid Tumors**

Carcinoid tumors are unusual tumors that arise from enterochromaffin cells and account for 4–5% of all orbital metastases [3, 30, 31]. Two-thirds of carcinoid tumors originate from the gastrointestinal tract; other sites of origin include the lung, ovary, thymus, and breast [30]. The peak incidence of such metastases occurs in the sixth decade, and there is a slight female predominance.

Metastatic orbital lesions from carcinoid tumors are usually slow growing and may present with a mass causing proptosis, diplopia, or less commonly inflammatory symptoms. A search for coexisting disorders should be conducted as carcinoid tumors can be associated with multiple endocrine neoplasia (either type 1 or 2) and neurofibromatosis type 1.

Standard treatment is local radiotherapy with combination chemotherapy. External-beam radiotherapy has been reported to be helpful in palliative local control of solitary orbital carcinoids [31]. Novel targeted treatments may play a greater role as standard chemotherapy has a variable degree of efficacy. The 5-year survival rate for patients with orbital metastasis from carcinoid tumors is 72% [31]. Death is usually secondary to cardiac toxicity rather than the cancer itself.

### **5.7.6 Other Cancers**

Virtually any cancer that can metastasize through the hematogenous route can gain access to the orbit. Gastrointestinal cancers are a common cause of metastasis to the orbit in Japan [4, 13, 32]. Renal cell carcinoma is the most common urologic malignancy to metastasize to the orbit [4, 33]. In the pediatric population, neuroblastomas and rhabdomyosarcomas have been reported to metastasize to the orbit [4].

## **5.8 Conclusion**

Orbital metastasis is rare. An orbital metastatic lesion may be the initial presentation of cancer in up to 25% of patients. The leading causes of orbital metastasis are breast, lung, and prostate carcinomas and cutaneous melanoma. Clinical manifestations of orbital metastases include rapid onset of orbital symptoms, including



mass effect with displacement of the globe or proptosis, diplopia, orbital pain, inflammation, and bony destruction. Orbital metastasis from lung cancer tends to occur early in the disease course, whereas there is generally a long latency period between initial diagnosis and discovery of the orbital metastasis in patients with breast cancer or melanoma. Imaging studies may be helpful in diagnosing orbital metastases but are nonspecific. Fine-needle aspiration or open biopsies provide the best means to obtain a definitive diagnosis, but these procedures should be done only in patients with no known previous history of cancer, in whom the orbit is the only site of suspected metastasis, and for whom having a definitive diagnosis would change the overall management of the disease. The goal of treatment for orbital metastatic lesions is palliative, and the mainstay of treatment is external-beam radiotherapy, which is combined with chemotherapy or hormonal therapy when appropriate. Surgical resection of an orbital or an eyelid metastatic lesion is appropriate only in selected patients with metastatic cutaneous melanoma, in some patients with metastatic sarcoma for whom the ocular adnexa is the only site of detectable metastasis, and in patients with very slow-growing cancers with potential for prolonged survival, such as patients with carcinoid tumors in whom the orbital metastasis cause significant morbidity in the orbit.

## References

1. Shields CL, Shields JA, Gross N, et al. Survey of 520 uveal metastases. *Ophthalmology* 1997;104:1265–76.
2. Ahmad SM, Esmali B. Metastatic tumors of the orbit and ocular adnexa. *Curr Opin Ophthalmol* 2007;18:405–13.
3. Goldberg RA, Rootman J, Cline R. Tumors metastatic to the orbit: a changing picture. *Surv Ophthalmol* 1990;35:1–24.
4. Garrity JA, Henderson JW, Cameron JD, et al. Metastatic carcinomas. In: Henderson's *Orbital Tumors*, fourth edition. New York, NY: Raven Press, 2007:313–26.
5. Char DH, Miller T, Kroll S. Orbital metastasis: diagnosis and course. *Br J Ophthalmol* 1997;81:386–90.
6. Fenton S, Kemp SE, Harnett AN. Screening for ophthalmic involvement in asymptomatic patients with metastatic breast carcinoma. *Eye* 2004;18:38–40.
7. Ferry AP. Tumors metastatic to the eye and ocular adnexa. In: Jakobiec FA, editor. *Ocular and Adnexal Tumors*. Birmingham, AL: Aesculapius, 1978:862–92.
8. Shields JA, Shields CL, Brotman HK, et al. Cancer metastatic to the orbit: the 2000 Robert M. Curtis lecture. *Ophthalm Plast Reconstr Surg* 2001;17:346–54.
9. Goldberg RA, Rootman J. Clinical characteristics of metastatic orbital tumors. *Ophthalmology* 1990;97:620–4.
10. Hart WM. Metastatic carcinoma to the eye and orbit. *Int Ophthalmol Clin* 1962;2:465–82.
11. Castro PA, Albert DM, Wang WJ, et al. Tumors metastatic to the eye and adnexa. *Int Ophthalmol Clin* 1982;22:189–223.
12. Font RL, Ferry AP. Carcinoma metastatic to the eye and orbit. III. A clinicopathologic case of 28 cases metastatic to the orbit. *Cancer* 1976;38:1326–35.
13. Gunalp I, Gunduz K. Metastatic orbital tumors. *Jpn J Ophthalmol* 1995;39:65–70.
14. Hartstein ME, Beisman B, Kincaid MC. Cutaneous malignant melanoma metastatic to the eyelid. *Ophthalmic Surg Lasers Imaging* 1998;29:993–5.

15. Zografos L, Ducrey N, Beati D, et al. Metastatic melanoma in the eye and orbit. *Ophthalmology* 2003;110:2245–56.
16. Esmaeli B, Cleary KL, Ho L, et al. Leiomyosarcoma of the esophagus metastatic to the eyelid: a clinicopathologic report. *Ophthal Plast Reconstr Surg* 2002;18:159–61.
17. Liu D. Complications of fine needle aspiration biopsy of the orbit. *Ophthalmology* 1985;92:1768–71.
18. Arora R, Rewari R, Betharia SM. Fine needle aspiration cytology of orbital and adnexal masses. *Acta Cytol* 1992;36:483–91.
19. Kennerdell JS, Dekker A, Johnson SL, et al. Fine needle aspiration: its use in orbital tumors. *Arch Ophthalmol* 1979;97:1315–17.
20. Capone A Jr, Slamovits TL. Discrete metastases of solid tumors to extraocular muscles. *Arch Ophthalmol* 1990;108:237–43.
21. Glassburn JR, Klionsky M, Brady LW. Radiation therapy for metastatic disease involving the orbit. *Am J Clin Oncol* 1984;7:145–8.
22. Ahmed S, Goel S, Khandwala M, et al. Neuroblastoma with orbital metastasis: ophthalmic presentation and role of ophthalmologists. *Eye* 2006;20:466–70.
23. Dieing A, Schulz CO, Schmid P, et al. Orbital metastases in breast cancer: report of two cases and review of the literature. *J Cancer Res Clin Oncol* 2004;130:745–48.
24. Torres JJ, Medel R, Alonso T. Orbital metastases from male breast cancer in two cases. *Ophthal Plast Reconstr Surg* 2007;23:154–6.
25. Macedo JE, Machado M, Araujo A, et al. Orbital metastasis as a rare form of clinical presentation of non-small cell lung cancer. *J Thorac Oncol* 2007;2:166–7.
26. Boldt HC, Nerad JA. Orbital metastases from prostate carcinoma. *Arch Ophthalmol* 1988;106:1403–8.
27. Carriere VM, Karcioğlu ZA, Apple DJ, et al. A review of prostate carcinoma with bilateral metastasis and a review of the literature. *Ophthalmology* 1982;89:402–6.
28. Hutchison BM, Damato BE, Kyle PM, et al. Choroidal melanoma metastatic to the contralateral orbit. *Orbit* 1994;13:85–9.
29. Ramirez R, Ivan D, Prieto VG, et al. Cutaneous melanoma metastatic to the eyelid and periocular skin. *Ophthal Plast Reconstr Surg*. 2010;26:88–94.
30. Modlin IM, Lye KD, Kidd M. A 5-decade analysis of 13,715 carcinoid tumors. *Cancer* 2003;97:934–59.
31. Mehta JS, Abou-Rayyah Y, Rose GE. Orbital carcinoid metastases. *Ophthalmology* 2006;113:466–72.
32. Amemiya T, Hayashida H, Dake Y. Metastatic orbital tumors in Japan: a review of the literature. *Ophthalmic Epidemiol* 2002;9:35–47.
33. Shome D, Honavar SG, Gupta P, et al. Metastasis to the eye and orbit from renal cell carcinoma: a report of three cases and review of literature. *Surv Ophthalmol* 2007;52:213–23.