

Derek C. Allen, R. Iain Cameron,
and Maurice B. Loughrey

2.1 Anatomy

The esophagus is a tubular structure, approximately 25 cm long, extending from the laryngeal part of the pharynx at the level of the sixth cervical vertebra, passing through the diaphragm at the level of the tenth thoracic vertebra to join the stomach at the esophagogastric (EG) junction (Fig. 2.1). For purposes of practicality during endoscopic procedures, the site of a lesion in the esophagus is given as the distance from the upper incisor teeth. As it is approximately 16 cm from the upper incisor teeth to the proximal esophageal limit, the EG junction is at approximately 40–41 cm. The esophagus traverses the neck, thorax, and enters the abdominal cavity and so can be anatomically divided into three subsites:

1. Cervical esophagus – 2–3 cm long and extends from the proximal esophageal limit (C6) to the thoracic inlet, which is marked by the surface landmark of the suprasternal notch of the sternum (breast bone).
2. Intrathoracic esophagus – approximately 21 cm long and extends from the thoracic inlet to the esophageal hiatus in the diaphragm. At 25 cm from the upper incisor teeth, the esophagus is constricted by the aortic arch and the left main bronchus crossing its anterior surface.
3. Abdominal esophagus – 1–1.5 cm long and extends from the esophageal hiatus in the diaphragm to the right side of the stomach. It is covered anterolaterally by the peritoneum and comes into close relationship with the left lobe of liver.

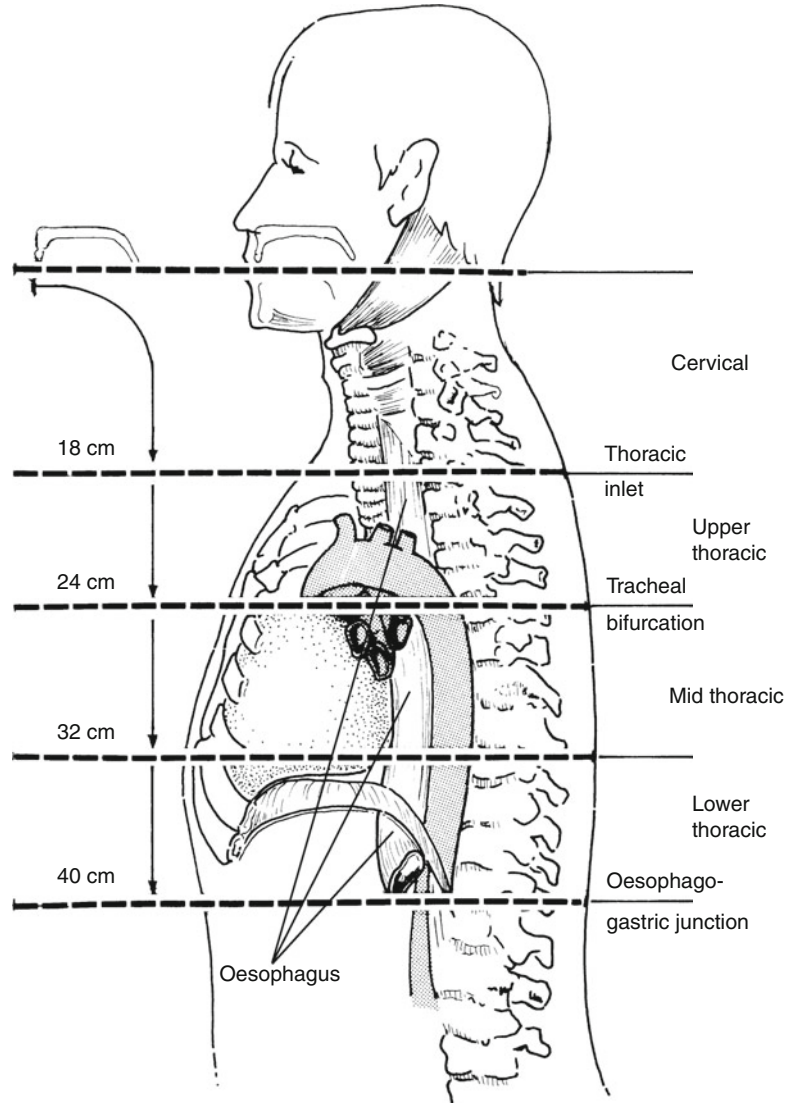
An internal landmark of relevance to determining the site of origin of an EG tumor is the EG junction where the pale esophageal squamous mucosa meets the glandular mucosa of the gastric cardia. The EG junction can be somewhat irregular in outline (the Z line) and does not necessarily correspond to the lower physiological valve or sphincter. External landmarks are distal esophagus orientated to adventitial fat while the junctional area and proximal stomach relate to a covering of serosa or peritoneum. Thus, a tumor of the distal esophagus or EG junction can spread through the wall either to adventitial fat of the mediastinum or the abdominal peritoneum. Adventitial fat is disposed laterally, but absent anteriorly and posteriorly where the esophagus is adjacent to the heart

D.C. Allen (✉)
Histopathology Laboratory, Belfast City Hospital,
Belfast Health and Social Care Trust,
Belfast, UK
e-mail: derek.allen@belfasttrust.hscni.net

R.I. Cameron
Histopathology Laboratory, Altnagelvin Hospital,
Western Health and Social Care Trust,
Londonderry, UK
e-mail: iain.cameron@westerntrust.hscni.net

M.B. Loughrey
Histopathology Laboratory, Institute of Pathology,
Royal Victoria Hospital,
Belfast Health and Social Care Trust,
Belfast, UK
e-mail: maurice.loughrey@belfasttrust.hscni.net

Fig. 2.1 Esophagus (Used with the permission of the Union for International Cancer Control (UICC), Geneva, Switzerland. The original source for this material is from Wittekind et al. (2005))



and vertebral column, respectively. Note that the adventitia of the mid-esophagus may also relate to a serosal surface – that of resected mediastinal pleura.

As well as determining the position of the lesion within the esophagus by its anatomical site, it can also be defined by its relative position in the upper, middle, or lower third of the esophagus. This is of relevance clinically as the lymphovascular drainage is considered in these terms and is therefore important in cancer surgery.

Lymphovascular drainage (Fig. 2.2):

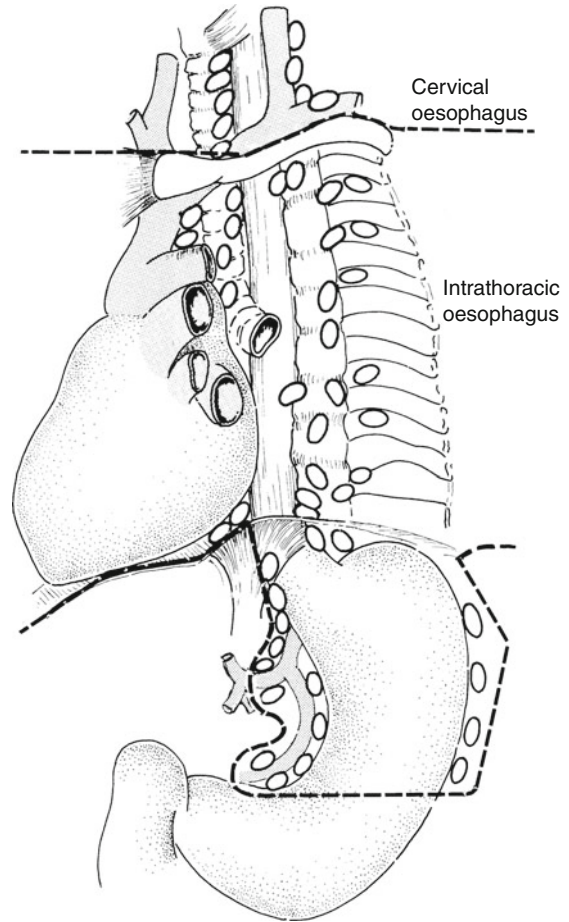
Upper third – deep cervical nodes

Middle third – superior and posterior mediastinal nodes

Lower third – nodes along the left gastric blood vessels and the celiac nodes

Venous drainage from the middle third (azygos vein) into the lower third (gastric vein) leads to the formation of a porto-systemic anastomosis and, with raised portal venous pressure (e.g., as in liver cirrhosis), the possibility of the

Fig. 2.2 The regional lymph nodes, irrespective of the site of the primary tumor, are those in the esophageal drainage area including celiac axis nodes and paraesophageal nodes in the neck, but not supraclavicular nodes (Used with the permission of the Union for International Cancer Control (UICC), Geneva, Switzerland. The original source for this material is from Wittekind et al. (2005))



formation of esophageal varices (dilatation of esophageal veins).

2.2 Clinical Presentation

Patients with esophageal disease may be asymptomatic, but usually experience one or more of the following: chest pain, heartburn (a retrosternal burning sensation), reflux of acid/food, and dysphagia (difficulty swallowing). Dysphagia can be painful (odynophagia) and progressive due to benign or malignant strictures, i.e., initially for solid foods, e.g., meat, then soft foods, and ultimately liquids. Patient localization of the site of obstruction can be poor. Occult bleeding can lead to iron-deficiency anemia, while hemorrhage

(hematemesis) can be potentially life threatening (varices) or self-limiting due to linear tears of the EG junction mucous membrane after prolonged vomiting (Mallory-Weiss syndrome).

2.3 Clinical Investigations

- Endoscopy and biopsy.
- CXR to detect any enlargement of the heart, mediastinal lymph nodes, or pulmonary hilum that might extrinsically press on the esophagus. Barium swallow to outline the contour of the esophageal lumen and wall, and assess motility/swallowing.
- For biopsy-proven cancer – ELUS and PET CT scan chest and abdomen to determine the

pretreatment tumor stage directed toward pT/pN and pM disease, respectively.

- Laparoscopy with peritoneal washings for EG junctional and select distal esophageal adenocarcinoma cases.
- Twenty-four hour pH monitoring – has a high diagnostic sensitivity for reflux esophagitis.
- Esophageal manometry can assess the effectiveness of motility, e.g., achalasia, scleroderma.

Miscellaneous: Other causes of esophagitis, ulceration, and/or stricture are drugs (e.g., NSAIDs, aspirin), mediastinal radiotherapy, motility disorders (e.g., achalasia), Crohn's disease and direct injury (foreign body, prolonged nasogastric intubation, corrosive ingestion).

Incidental endoscopic findings are inflammatory or fibrovascular polyps of the EG junction.

2.4 Pathological Conditions

2.4.1 Non-neoplastic Conditions

Reflux esophagitis: usually due to hiatus hernia (slippage of the EG junction into the thorax) resulting in gastro-esophageal reflux (GER) of acid and bile; there is poor correlation with symptoms, endoscopy and biopsy being normal in 20–30% of cases. Otherwise well-orientated biopsies show basal zone hyperplasia and prominent vascularized connective tissue papillae. This is superseded by inflammatory infiltrates of neutrophils and eosinophils, surface erosion, full thickness ulceration, and, ultimately, fibrous stricture formation (10% of cases). It may require operative dilatation (often repeatedly) to relieve dysphagia and, although it usually has a smooth outline, it may be difficult to distinguish endoscopically from a malignant growth. Prior to this, treatment of GER is either medical (weight loss, antacids) or occasionally surgical. This is usually done laparoscopically by wrapping the fundus of the stomach around the distal esophagus (Nissen fundoplication) to maintain lower esophageal tone and retain it in the abdominal cavity.

Infective esophagitis: may be seen in otherwise healthy individuals but is more commonly encountered where there is alteration of either local or systemic immunity (e.g., AIDS). Underlying ulceration, broad-spectrum antibiotics, diabetes, corticosteroid therapy, and immunosuppressive drugs can all alter the local gut flora resulting in superimposed infection. Causative agents are candidal fungus, herpes simplex virus (HSV 1 and 2), cytomegalovirus (CMV), and atypical mycobacteria.

2.4.2 Neoplastic Conditions

Benign tumors: These are rare in surgical material, e.g., squamous papilloma, leiomyoma, or granular cell tumor.

Esophageal carcinoma: Predisposing conditions to esophageal cancer include GER, obesity, diverticula, achalasia, and Plummer–Vinson syndrome (elderly females, iron-deficiency anemia, upper esophageal web). Predisposing lesions to esophageal cancer are squamous cell dysplasia and Barrett's metaplasia/dysplasia.

Squamous cell dysplasia/carcinoma in situ: Macroscopically often inapparent but seen histologically adjacent to, overlying or distant from squamous cell carcinoma.

Barrett's metaplasia or columnar epithelium lined lower esophagus (CLO): Seen in about 10% of patients with hiatus hernia and/or GER. It arises from erosion with differentiation of multipotential stem cells to metaplastic small intestinal or gastric glandular epithelia. The Barrett's segment appears as a velvety area proximal to the EG junction surrounded by pale squamous mucosa. It can be multifocal or continuous. The segment is either classical/long (≥ 3 cm) or short (< 3 cm). About 10% of Barrett's cases develop mucosal dysplasia and/or adenocarcinoma, representing an increased risk of $\times 20$ – 30 that of the general population. Barrett's metaplasia positive for mucosal dysplasia is classified as either low grade or high grade. The latter has a strong (20–30%) association with concurrent or subsequent adenocarcinoma, indicating the need for immediate clinicopathological reassessment and, if a tumor is identified, consideration of surgery. In the absence of tumor or in a medically unfit

patient with an early lesion, local ablative therapy can be used, e.g., EMR, HALO (high-radiofrequency ablation) or laser eradication. The appearances of Barrett's metaplasia can also be altered by its treatment with antacid medication, ablative techniques, or photodynamic therapy.

Squamous cell carcinoma: Forms 30–40% of esophageal cancers and is typically seen in the mid-esophagus of elderly patients. It is usually moderately differentiated and keratinizing, ulcerates or strictures with rolled, irregular margins, involves a long segment of esophagus, and has spread through the full thickness of the wall at presentation. Palliation can be achieved by chemoradiation, ablative laser therapy, or the insertion of an expanding metal stent or tube to relieve obstruction. Primary treatment of choice in a medically fit patient with a locally confined lesion <5 cm in length is chemoradiotherapy alone or in combination with subsequent surgery. Preoperative chemoradiotherapy produces signs of tumor regression (degeneration, necrosis, fibrosis, keratin granulomas) in some 50–60% of cases, but often makes identification of tumor on gross inspection of the specimen difficult. Perforation with potentially fatal mediastinitis is a possible complication of preoperative therapy and endoscopy of malignant strictures. Depending on the CT chest findings, bronchoscopy is sometimes done to exclude the possibility of a primary lung cancer invading esophagus, which would preclude primary resection as do hematogenous and distant nodal metastases or invasion of mediastinal vessels and main structures.

Variants of squamous carcinoma are verrucous carcinoma (warty, slow growth), basaloid carcinoma (aggressive), and spindle cell/polypoid carcinoma (carcinosarcoma – intermediate prognosis).

Adenocarcinoma: Forms 50–60% of esophageal cancers and arises in the distal esophagus/EG junction, often secondary to intestinal-type Barrett's metaplasia and dysplasia. The incidence of this tumor has greatly increased in the last 20 years due in part to antibiotic eradication of helicobacter pylori with loss of its gastric acid suppressor effect, resulting in more GER disease. As well as extensive radial spread through the

wall out to the CRM, it can spread upward, undermining the esophageal squamous mucosa and downward to the proximal stomach where clear distinction from a primary gastric carcinoma can be difficult. Clues as to site of origin are both anatomical and histological in the adjacent mucosa (esophagus – Barrett's metaplasia/dysplasia; stomach – gastric mucosal dysplasia). TNM 7 includes as an esophageal cancer any tumor of the proximal stomach where its epicenter is within 5 cm of the EG junction and involves the esophagus (Siewert 3). Adenocarcinoma is usually ulcerated with irregular rolled margins or polypoid, and histologically tubular or papillary with an intestinal glandular pattern but sometimes of diffuse signet ring cell type. Treatment of choice for locally confined disease is preoperative chemotherapy combined with surgical resection. This is supplemented by postoperative chemotherapy if indicated by subsequent pathological staging of the resection specimen.

Other features: Esophageal cancer tends to show multifocality (15–20%). Examination of specimen proximal and distal surgical margins is therefore important. "Early" or superficial squamous carcinoma is confined to the mucosa or submucosa with or without regional lymph node involvement and is of better prognosis than "advanced" or deep muscle invasive carcinoma. Involvement of the periesophageal CRM is partly dependent on individual patient anatomy but is also an indicator of extent of tumor spread, adequacy of surgical resection, and potential local recurrence due to residual mediastinal disease.

Other cancers: Rare but can include small cell carcinoma, malignant melanoma, leukemia/malignant lymphoma, metastatic cancer (e.g., lung or breast), leiomyosarcoma, and Kaposi's sarcoma (AIDS).

Prognosis: Prognosis of esophageal cancer is poor (5-year survival 5–15%) relating mainly to depth of spread and lymph node involvement, i.e., tumor stage, and involvement of longitudinal and circumferential excision margins. Early or superficial carcinoma does significantly better – 55% → 88% 5-year survival depending on the depth of mucous membrane invasion.

2.5 Surgical Pathology Specimens: Clinical Aspects

2.5.1 Biopsy Specimens

Two main types of esophageal endoscopy exist, namely rigid and flexible. Rigid esophagoscopy is only occasionally used to provide larger biopsies when previous flexible endoscopy (EGD – esophagogastroduodenoscopy) samples have proven non-diagnostic. Specific lesions such as polyps or ulcers necessitate multiple targeted biopsies that may be supplemented by brush cytology of the mucosal surface. Mapping and annual/biennial surveillance of flat mucosa for Barrett’s metaplasia and dysplasia is achieved by multiple segmental (every 2 cm) and quadrantic biopsies. The clinical extent of the Barrett’s is described according to its length of circumferential disposition (cm) and total length (cm) of the metaplastic segment respectively, e.g., C2M6. The basis of an esophageal stricture may be easier to demonstrate if malignant in nature because of carcinoma ulcerating the squamous epithelium, whereas a benign peptic stricture due to submucosal or mural fibrosis is often not accessible to mucosal biopsy. Endoscopic biopsy of achalasia or esophageal webs is often unrewarding as it provides intact surface mucosa only. EMR (“big biopsy”) specimens can be both diagnostic, staging and therapeutic, e.g., in dysplastic Barrett’s to diagnose and remove any “early” nodular areas of carcinoma confined to the mucosa.

2.5.2 Resection Specimens

The surgical techniques for resecting esophageal tumors fall into two broad categories – those which employ a chest incision (thoracotomy) and those which do not (transdiaphragmatic hiatal procedures). The type of procedure used depends on the general level of health of the patient, any previous operations, the preference of the operating surgeon, the size and position of the tumor in the esophagus (see Table 2.1), and the choice of esophageal substitute, i.e., stomach, jejunum, or colonic interposition. Ideally the surgeon should

Table 2.1 Choice of surgical procedure in esophageal neoplasia

Proximal 1/3 tumors	Pharyngo-esophagectomy
Middle 1/3 tumors	Ivor Lewis technique Thoracoabdominal esophagectomy Two-field transhiatal esophagectomy
Lower 1/3 tumors	Ivor Lewis technique Thoracoabdominal esophagectomy Transhiatal esophagectomy
Barrett’s	Transhiatal esophagectomy

strive for a 5 cm longitudinal margin of clearance with adenocarcinoma and 10 cm for squamous carcinoma, with an appropriate lymphadenectomy. There is currently no evidence-based favored method of resection.

2.5.2.1 Procedures employing a thoracotomy:

- (a) *Ivor Lewis technique* – in this operation, upper abdominal and right thoracotomy incisions are made. The proximal stomach is divided and the esophagus is transected proximal to the tumor. The distal stomach is then raised into the chest and an EG anastomosis is fashioned.
- (b) *Thoracoabdominal esophagectomy* – a continuous incision extending from the midline of the upper abdomen running obliquely across the rib margin and posterolateral aspect of the chest wall. The left diaphragm is divided and this gives access for potential en bloc resection of the esophagus, stomach, gastric nodes and, if required, the spleen and distal pancreas. An esophagojejunal or EG anastomosis is fashioned in the neck.

2.5.2.2 Transhiatal esophagectomy:

Depending on whether a total or distal esophagectomy is to be performed, two variations of this procedure are used.

- (a) “Two-field approach” – the entire esophagus and stomach is mobilized via upper abdominal and oblique neck incisions. The cervical esophagus is divided and anastomosed to stomach which had been mobilized and raised high into the posterior mediastinum.

- (b) Distal esophagectomy with proximal gastrectomy (for distal esophageal/junctional tumors) – only an upper abdominal incision is used, with the distal esophagus being mobilized and an EG anastomosis fashioned in the chest.

Although transhiatal resection for diseases of the thoracic esophagus used to be uncommon, it is now more commonly used, reducing the physiological insult experienced with a thoracotomy. Minimally invasive esophagectomy (MIE) procedures are being developed using combined laparoscopic and thoracoscopic techniques.

Whenever possible the stomach should be used in the anastomosis and with appropriate mobilization the stomach will reach the neck in virtually all patients. If the tumor is limited to the EG junction, the entire greater curvature of the gastric fundus (shaded area in Fig. 2.3), including the point which usually reaches most cephalad to the neck (*in Fig. 2.3), may be preserved while still obtaining a 4–6 cm gastric margin distal to the malignancy.

There are several benefits in performing a total thoracic esophagectomy with cervical anastomosis: maximum clearance of surgical margins is

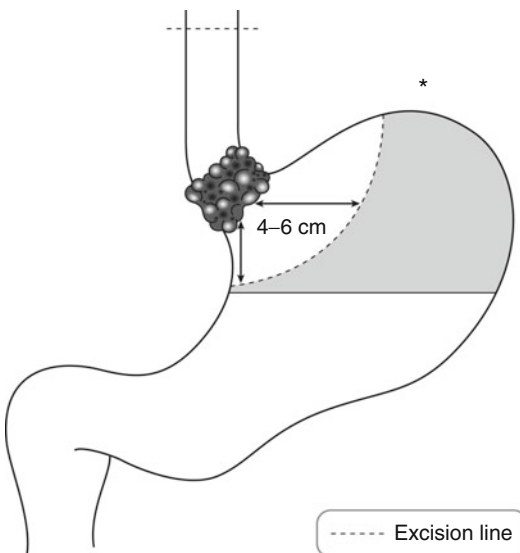


Fig. 2.3 Transhiatal esophagectomy with limited proximal gastrectomy (Reproduced, with permission, from Allen and Cameron (2004))

obtained while the risk of mediastinitis, sepsis, and GER that can be seen with an intrathoracic anastomosis is diminished.

2.6 Surgical Pathology Specimens: Laboratory Protocols

2.6.1 Biopsy Specimens

See Chap. 1.

2.6.2 Resection Specimens

Specimen:

- Most esophageal resections are for neoplastic conditions: partial esophagectomy, total thoracic esophagectomy (TTE), esophagectomy with limited gastrectomy, esophagogastrectomy

Initial procedure:

- By palpation and with the index finger locate the luminal position of the tumor.
- Paint the overlying external CRM comprising adventitial fatty connective tissue and any related serosa.
- Open longitudinally with blunt-ended scissors, cutting on the opposite side of the tumor. Open proximal stomach along the greater curvature continuous with the esophageal cut. Alternatively some pathologists prefer to leave the tumor segment unopened for fixation and subsequent transverse slicing.
- Measurements:
 - Esophagus – length (cm), width (cm)
 - Proximal stomach – lengths (cm) along lesser and greater curvatures
 - Tumor – length × width × depth (cm) or maximum dimension (cm)
 - Distances (cm) to the proximal and distal limits of resection
 - Distance (cm) to the EG junction if the tumor is mid-esophageal in location
 - Relationship to the EG junction: distal esophageal tumor involving the junction (Siewert 1), tumor straddling the junction (Siewert 2), proximal gastric tumor involving the junction (Siewert 3).

- Note that the junction may be obscured by tumor, and external landmarks (esophagus – adventitia; stomach – serosa) should also be used in determining the location.
 - Barrett’s mucosa – location/length (cm).
 - Photograph.
 - Fixation by immersion in 10% formalin for 48 h preferably pinned out on a corkboard in the opened position but not placed under tension (to avoid splitting).
- Description:*
- Tumor
 - Polypoid: spindle cell carcinoma/carcinoma
 - Warty/verrucous: verrucous carcinoma
 - Nodular/plaque: superficial carcinoma
 - Fungating/strictured/ulcerated/infiltrative edge: usual carcinoma
 - Multifocal
 - Regression and scarring
 - Mucosa
 - Barrett’s mucosa (velvety appearance)
 - Wall
 - Tumor confined to mucous membrane, in the wall or through the wall
 - Other
 - Achalasia, diverticulum, mucosal web, perforation.

Blocks for histology (Fig. 2.4):

- Sample the proximal and distal limits of surgical resection – complete circumferential transverse section (esophagus) or multiple circumferential blocks (proximal stomach).
- Alternatively, if separate anastomotic doughnuts are submitted, take one complete circumferential transverse section of each.
- Serially section the bulk of the tumor transversely at 3–4 mm intervals.
- Lay the slices out in sequence and photograph.
- Sample a minimum of four blocks of tumor and wall to show the deepest point of circumferential invasion.
- Sample two longitudinal blocks of tumor and adjacent mucosa, proximal and distal to the gross lesion, respectively.
- Sample one block of esophagus proximal to the tumor and one block of esophagus (or proximal stomach) distal to the tumor.

- Sample any abnormal background mucosa, e.g., multiple sequential blocks may be required to map the extent of Barrett’s metaplasia.
- If tumor is not seen grossly, sequentially sample and correspondingly label unremarkable and abnormal areas of mucosa.
- Count and sample all lymph nodes.
- Sample the midpoint and proximal surgical limit (as marked by the surgeon) of any separate proximal segment of normal esophagus excised to facilitate pull-through of the EG anastomosis to the neck.

Histopathology report:

- Tumor type – adenocarcinoma/squamous carcinoma/other
- Tumor differentiation

	Adenocarcinoma	Squamous carcinoma
Well	>95% glands	Keratinization/intercellular bridges
Moderate	50–95% glands	
Poor	<50% glands	No keratinization/intercellular bridges

- Tumor edge – pushing/infiltrative/lymphoid response
- Extent of local tumor spread

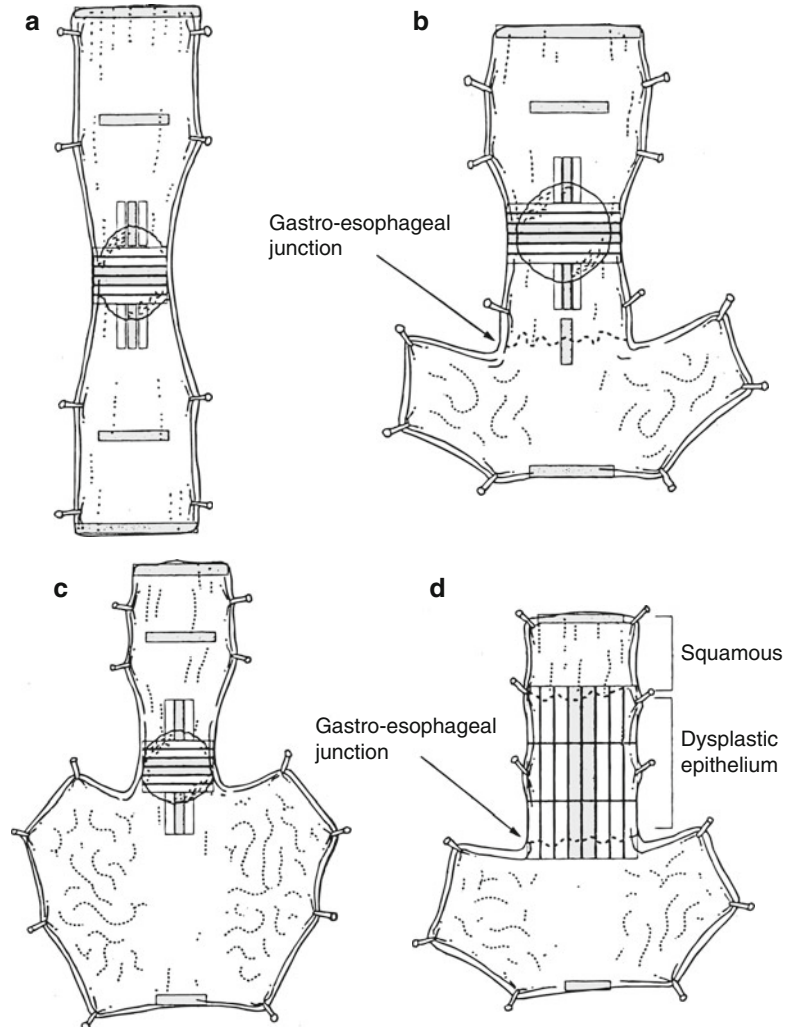
pTis	Carcinoma in situ/high-grade dysplasia
pT1	Tumor invades lamina propria or submucosa
pT2	Tumor invades muscularis propria
pT3	Tumor invades adventitia
pT4	Tumor invades adjacent structures (4a: pleura/pericardium/diaphragm. 4b: aorta/vertebral body /trachea)

Note also any invasion of the proximal gastric serosa.

Siewert 1–3 tumors are staged as esophageal under TNM 7.

- Lymphovascular invasion – present/not present. Note perineural invasion.
- Regional lymph nodes
- Periesophageal, including celiac axis nodes and paraesophageal nodes in the neck, but not

Fig. 2.4 Recommended blocks for histology in resected esophageal neoplasms (a) esophagectomy specimen (b) esophago-gastrectomy specimen containing tumor above the gastro-esophageal junction (c) esophago-gastrectomy specimen containing tumor at the gastro-esophageal junction (d) resected specimen for high-grade dysplasia/in situ carcinoma (Shaded blocks represent the recommended minimum number to be sampled) (Reproduced, with permission, from Ibrahim (2000))



supraclavicular nodes. A regional lymphadenectomy will ordinarily include six or more lymph nodes.

pN0	No regional lymph node metastasis
pN1	Metastasis in 1–2 regional lymph node(s)
pN2	Metastasis in 3–6 regional lymph nodes
pN3	Metastasis in 7 or more regional lymph nodes

- Excision margins
Proximal and distal limits of tumor clearance (cm)

Separate proximal esophageal and distal gastric anastomotic doughnuts – involved/not involved

Deep CRM of clearance (mm)

- Other pathology:
- Squamous dysplasia, Barrett's metaplasia/dysplasia, radio-/chemotherapy necrosis and tumor regression grade (Mandard score), perforation, achalasia, esophageal web, diverticulum

Bibliography

Allen DC, Cameron RI. Histopathology specimens: clinical, pathological and laboratory aspects. 1st ed. Berlin/Heidelberg: Springer; 2004.

- Allum WH, Blazeby JM, Griffin SM, Cunningham D, Jankowski JA, Wong R, On behalf of the Association of Upper Gastrointestinal Surgeons of Great Britain and Northern Ireland, the British Society of Gastroenterology and the British Association of Surgical Oncology. Guidelines for the management of oesophageal and gastric cancer. *Gut*. 2011;60:1449–72.
- Bosman FT, Carneiro F. WHO classification of tumours of the digestive system. 4th ed. Lyon: IARC Press; 2010.
- Cotton P, Williams C. Practical gastrointestinal endoscopy. 4th ed. London: Blackwell Science; 1996.
- Day DW, Jass JR, Price AB, Shepherd NA, Sloan JM, Talbot IC, Warren BF, Williams GT. Morson and Dawson's gastrointestinal pathology. 4th ed. Oxford: Blackwell Science; 2003.
- Ibrahim NBN. Guidelines for handling oesophageal biopsies and resection specimens and their reporting. *J Clin Pathol*. 2000;53:89–94.
- Lewin KJ, Appelman HD. Tumors of the esophagus and stomach, Atlas of tumor pathology, vol. 3rd series. Fascicle 18. Washington: AFIP; 1996.
- Logan RPH, Harris A, Misciewicz JJ, Baron JH, editors. ABC of the upper gastrointestinal tract. London: BMJ Books; 2002.
- Odze RD, Goldblum JR. Surgical pathology of the GI tract, liver, biliary tract and pancreas. 2nd ed. Philadelphia: Saunders/Elsevier; 2009.
- Schlemper RJ, Riddell RH, Kato Y. The Vienna classification of gastrointestinal epithelial neoplasia. *Gut*. 2000;47:251–5.
- The Royal College of Pathologists. Cancer datasets (oesophageal carcinoma, gastric carcinoma, carcinomas of the pancreas, ampulla of Vater and common bile duct, colorectal cancer, gastrointestinal stromal tumours (GISTs), liver resection specimens and liver biopsies for primary and metastatic carcinoma, endocrine tumours of the gastrointestinal tract including pancreas) and tissue pathways (gastrointestinal and pancreatobiliary pathology, liver biopsies for the investigation of medical disease and for focal liver lesions). <http://www.rcpath.org/index.asp?PageID=254>. Accessed on Dec 2011.
- Wittekind C, Greene L, Hutter RVP, Klimfänger M, Sobin LH. TNM atlas: illustrated guide to the TNM/pTNM classification of malignant tumours. 5th ed. Berlin/Heidelberg: Springer; 2005.