

Chapter 46

Prospects for Lymphatic Reconstructive Surgery

Victor S. Krylov

To get a better prospect of reconstructive microlymphatic surgery we need further improvement of the diagnosis and use of the appropriate classification. The most useful practical classification allows us to divide all lymphatic disorders into primary and secondary.

Primary lymphatic insufficiency, which is of hereditary origin, cannot be successfully cured with reconstructive microsurgery. The creation of the new lymphatic vessels in congenital cases is a matter for the future. Genetic research in this field will hopefully yield valuable information for future practical use.¹

Secondary lymphatic insufficiency assumes that before the damage or disease occurred, the patient had a normal lymphatic system. In many cases the damage can be corrected with the help of modern reconstructive microsurgery.

We also have to keep in mind that contemporary conservative treatment, when properly indicated and carried out, such as well-organized and systematized manual lymphatic drainage,² must be tried first, before the patient is offered any reconstructive surgery. Today, only 20–25% of patients with secondary lymphedema can benefit from modern reconstructive microsurgery of the lymphatic system. The remaining 75–80% of the patients are candidates for conservative palliation, which, if carried out thoroughly enough and with the cooperation of the patient, can offer a quite tolerable quality of life.^{3,4}

The lack of a system in manual lymphatic drainage considerably discredits the conservative treatment, which is sometimes the only hope for the patient.

Lymphatico-venous anastomosis – the microsurgical operation of the direct junction of the lymphatic vessel to the adjacent systemic vein – has been in practice since the late 1970s⁵ and now can offer up to 83–87%⁶ of properly selected patients stable benefit through reduction, or full elimination, of the edema or cessation of the erysipelas (cellulitis).

V.S. Krylov

Vascular Research Laboratory, Department of Surgery, University of Tennessee, Graduate School of Medicine, Knoxville, TN, USA

Sometimes the situation during surgery does not allow the creation of the direct anastomosis between the lymphatic vessel and the systemic vein. In these case such maneuvers like interposition of the auto-vein graft is a very important innovation, which will to improve results considerably. The auto-vein interposition technique provides a connection between the afferent lymphatic vessels, bringing the lymph from the extremity with the outflow tract – either the adjacent vein or the efferent lymphatic vessels, or the lymph node.⁷ Using this technique today can improve remote results by offering subjective improvement in 87% of the patients and objective improvement in 83%. Reduction of 67% of the excess volume in the extremity was achieved with this technique. In 87% of the patients there were no new episodes of erysipelas. This perspective of technical innovation, interposition of the vein between two lymphatic vessels, or connection of the lymph vessel with the vein, makes it possible to overcome technical difficulties in many cases. Both microsurgical techniques are prospective and progress is only limited by organizational difficulties.

Microsurgery is one of the highly specialized parts of today's surgery and we cannot expect the required facilities to be available everywhere. Because microsurgical technique requires the surgeon to maintain an appropriate level of training – so-called technical optimum – it is not currently used as widely as it deserves. Future development and refinement of this technique can be accomplished in the centers where these operations are performed often. This can significantly improve the results, even at the present level of the diagnostic and surgical technique.

The most common reason for secondary lymphedema is the treatment of breast cancer. One promising technique to prevent secondary lymphedema after treatment for breast cancer has been suggested. This suggested technique consists of not blocking the lymph outflow after axillary dissection and performing prophylactic creation of the lymphovenous anastomosis using the afferent lymphatic vessels in the axillary area during the primary cancer operation.⁸

This direction in reconstructive microlymphatic surgery is very significant, considering the number of patients suffering with breast cancer.

The situation after treatment of breast cancer is characterized not only by the lesion of the lymphatic vessels and lymph nodes, but often by the involvement of the venous system. This may be characterized by stenosis and/or occlusion of the axillary vein with corresponding venous hypertension and also by involvement of the brachial plexus (radiation plexitis). Sometimes there is also radiation dermatitis in a region of the clavicle. The lesion is called “postmastectomy syndrome”⁹ and correction of the lymphatic insufficiency in such a case is indicated only after correction of the venous hypertension.

In some cases, intervention on the brachial plexus (microsurgical endoneurolysis)¹⁰ and excision of damaged skin and radiation ulcers with subsequent free flap transfer could also be indicated. In this area, the composite free flap is often the best solution. For instance, after the brachial plexus neurolysis combined with the excision of the skin (radiation dermatitis), the nerve trunks can be successfully covered with the greater omentum free flap, and the flap itself is covered with the split skin graft (Fig. 46.1).

One important question remains unsolved in the literature – how stable are the remote results of the lymphatico-venous reconstruction? To get the stable and

Fig. 46.1 Lymphogram with contrast media showing the transport of the lymph through the free flap with the lymph node (original picture)

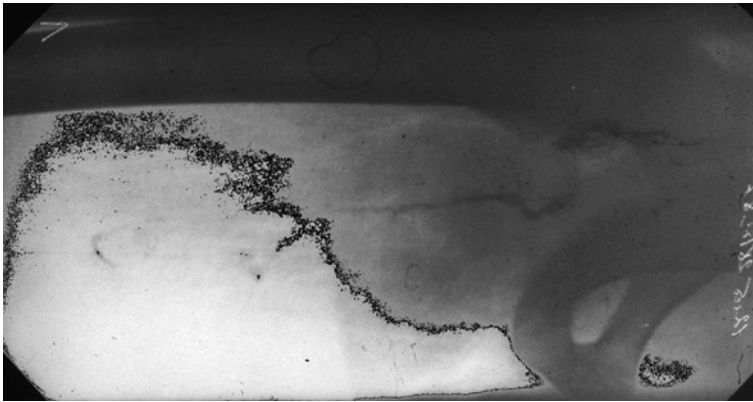
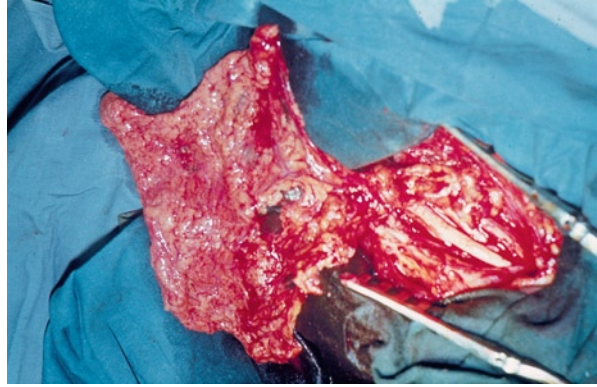


Fig. 46.2 Greater omentum free flap is vascularized in the axillary area to cover the trunks of the brachial plexus after microsurgical endoneurolysis (personal observation)

long-lasting function of the LVA there must be a pressure gradient between the lymphatic vessel and the adjacent vein. When there is successful functioning of the anastomosis, the pressure gradient is decreased and theoretically we must assume that when the gradient falls to zero the flux of the lymph from the lymph vessel into the vein will stop.

There is also another possible outcome, which is the reverse flow of the blood from the vein into the lymph vessel followed by thrombosis of the anastomosis.

Research must be continued in order to study the remote results of the lympho-venous reconstructive microsurgery.

Microsurgical reconstructive operations on the lymph nodes, a very prospective direction in the reconstructive lymphatic microsurgery, has its own history. The first attempts to transfer the lymphatic nodes were made in the hope of helping patients with primary lymphedema of the lower extremity and the lymph nodes were taken as part of the free flap of the greater omentum (Fig. 46.2).⁵

Later, a free transplantation of the lymph node was successfully reported by a few authors.¹¹ The transplantation of the lymphatic nodes is best accomplished by forming the flap of the tissue with the incorporation of one or several lymphatic nodes. The greater omentum can be considered the most reliable and safe. The laparotomy in this case can be minimal with a very low postoperative complication rate.

In conclusion, as conservative treatment of lymphedema offers only temporary palliation, there is no alternative to the radical approach, namely, reconstructive microsurgical intervention, which already helps more than 80% of the patients with secondary lymphedema with good remote results. Preventive microsurgical operations can significantly improve the remote results.

References

1. Bellini C, Witte MH, Campisi C, Bonioli E, Boccardo F. Congenital lymphatic dysplasias: genetics review and resources for the lymphologist. *Lymphology*. 2009;42(1):36-41.
2. Foldi M. *Foldi's "Textbook of Lymphology"*. 2nd ed. Munchen: Elsevier; 2006.
3. Boccardo FM, Ansaldi F, Bellini C, et al. Prospective evaluation of a prevention protocol for lymphedema following surgery for breast cancer. *Lymphology*. 2009;42(1):1-9.
4. Campisi C, Davini D, Bellini C, et al. Is there a role for microsurgery in the prevention of arm lymphedema secondary to breast cancer treatment? *Microsurgery*. 2006;26(1):70-72.
5. Abalmasov KG. *Microsurgery and plastic surgery* (point of view). In: *Microsurgery in Russia* ed. Krylov VS. Geotar Moscow, 2005;189-263.
6. Campisi C, Eretta C, Pertile D, et al. Microsurgery for treatment of peripheral lymphedema: long-term outcome and future perspectives. *Microsurgery*. 2007;27(4):333-338.
7. Campisi C, Davini D, Bellini C, et al. Lymphatic microsurgery for the treatment of lymphedema. *Microsurgery*. 2006;26(1):65-69.
8. Boccardo F, Casabona F, De Cian F, et al. Lymphedema microsurgical preventive healing approach: a new technique for primary prevention of arm lymphedema after mastectomy. *Ann Surg Oncol*. 2009;16(3):703-708.
9. Milanov NO. *Postmastectomy Syndrome and Its Surgical Correction* [doctoral dissertation]. Moscow; 1984. In: *Microsurgery in Russia* CD disc. Moscow Geotar, 2005.
10. Becker C, Pham DN, Assouad J, Badia A, Foucault C, Riquet M. Postmastectomy neuropathic pain: results of microsurgical lymph nodes transplantation. *Breast*. 2008;17(5):472-476.
11. Becker C, Assouad J, Riquet M, Hidden G. Postmastectomy lymphedema: long-term results following microsurgical lymph node transplantation. *Ann Surg*. 2006;243(3):313-315.