Offprint from
Advances and Technical Standards in Neurosurgery, Vol. 31
Edited by J.D. Pickard

Endoscopic Third Ventriculostomy in the Treatment of Hydrocephalus in Pediatric Patients

C. Di Rocco[1], G. Cinalli[2], L. Massimi[1], P. Spennato[2], E. Cianciulli[3], and G. Tamburrini[1]

[1]Pediatric Neurosurgical Unit, Catholic University Medical School, Rome, Italy
[2]Neuroendoscopy Unit, Department of Pediatric Neurosurgery, Santobono-Pausilipon Children's Hospital, Naples, Italy
[3]Department of Pediatric Neuroradiology, Santobono-Pausilipon Children's Hospital, Naples, Italy

With 28 Figures

Contents

Abstract

Advances in surgical instrumentation and technique have lead to an extensive use of endoscopic third ventriculostomy in the management of pediatric hydrocephalus. The aim of this work was to point out the leading aspects related to this technique. After a review of the history, which is now almost one century last, the analysis of the endoscopic ventricular anatomy is aimed to detail normal findings and possible anatomic variations which might influence the correct conclusion of the procedure. The overview of modern endoscopic instrumentation helps to understand the technical improvements that have contributed to significantly reduce the operative invasiveness. Indications are analysed from a pathogenetic standpoint with the intent to better understand the results reported in the literature. A further part of the paper is dedicated to the neuroradiological and clinical means of outcome evaluation, which are still a matter of debate. Finally a review of transient and permanent surgical complications is performed looking at their occurrence in different hydrocephalus etiologies.

Keywords: Hydrocephalus; endoscopic third ventriculostomy; pediatric age.

Historical Background

The increasing diffusion of endoscopy in the surgical practice is one of the most impressive results of the continuous search of methodologies aimed at decreasing patient's discomfort while maintaining a therapeutic efficacy comparable to that of traditional approaches requiring more invasive procedures. Its progressive wider use is supported by a constantly developing technology. Actually, endoscopic third-ventriculostomy (ETV) has become the routine treatment for obstructive hydrocephalus in many neurosurgical centers and neuroendoscopic procedures are more and more employed for both diagnostic and therapeutic purposes in various pathological conditions. In spite of its wide diffusion in recent years, neuroendoscopy is, however, an old technique.

The concept of internal visualization of the human cavities through natural orifices or small wounds was introduced by Bozzini in 1806 (Bozzini 1806). He carried out the first endoscopic procedure with directed light by using candlelight and a series of mirrors placed at an angle of 45°. Bozzini applied the methodology to the study of the urethra and the rectum. His experience was inherited by other authors during the century who attempted to improve the technique, especially the quality of the light source. The year 1879 was fundamental for endoscopy: Thomas Edison invented the electricity bulb and Nitze created a cystoscope to remove bladder stones (Nitze 1879). This last instrument was widely used and modified for the different human cavities and, thanks to the advances in anesthesiology and in the medical care, actually opened the era of endoscopy. The development of the computer chip TV camera during the Eighties finally ratified the beginning of the modern endoscopic surgery (Stellato 1992).

Neuroendoscopy originated during the first years of the last century with the aim to find an effective treatment for hydrocephalus. Its history started in 1910 when Lespinasse, an urologist, used a cystoscope to explore the lateral ventricles of two hydrocephalic children in order to coagulate their choroid plexus (Lespinasse 1910). After a few years, Dandy (Dandy 1918) reported the avulsion of the choroid plexus in five hydrocephalic children (four of them died during the operation) under direct cystoscopic visualization. He made use of rigid Kelly's cystoscope and alligator forceps, besides headlight and transillumination of the heads of his patients as light source; he called his instrumentation "ventriculoscope". In 1922 he proposed also a subfrontal approach to open the floor of the third ventricle by sacrificing an optic nerve (Dandy 1922). One year later, Mixter (Mixter 1923) synthesized the ideas of Dandy in a single procedure and performed a third-ventriculo-cisternostomy using an urethroscope introduced through the anterior fontanel and a flexible probe in a 9-months-old child with non-communicating hydrocephalus. The presence of contrast dye (previously injected in the lateral ventricle) in the lumbar subarachnoid space, demonstrated the success of the first ETV ever realized. In the same year, Fay and Grant (Fay and Grante 1923) were able to take the first endoscopic photographs of the cerebral ventricles. In the following years the efforts of the scientists were addressed towards the improvement of the endoscopic techniques (Putnan 1943). In fact, although the procedures were correctly carried out and based on a sound theory, the long-term results were not rewarding yet and the morbidity and mortality rate unacceptable. Poorly design of the instruments and optical apparatus were the main causes of the disappointing outcomes. For such a reason, Dandy, the "father of neuroendoscopy", was compelled to abandon ventriculoscopy after his first attempts and devoted himself to the development of ventriculographic techniques and direct craniotomic approaches. Other authors, on the other hand, looked for different surgical approaches (for example, stereotaxy) for the treatment of hydrocephalus, so that endoscopic neurosurgery never achieved a widespread popularity. The interest in neuroendoscopy further declined during the second half of the 20th century after the introduction of low morbidity/mortality procedures for the implantation of CSF shunting devices.

Several factors have contributed to the renaissance of the neuroendoscopy in the last two decades. Among them, the pioneer work of Bosma, who applied a 8-mm film registration in his interventions, and the introduction by Harold Hopkins of a solid-rod lens system during 1960s. The system, which still represents the base of the current nonflexible endoscopes, was further enhanced by Guiot who introduced the solid quartz rod lenses, with their internal reflective properties. These innovations were the base for the following development of modern instruments, as, for example, the ductile Fukishima's ventriculofiberscope introduced in 1973 (Fukushima *et al.* 1973). The advent of microsurgery initially diverted neurosurgeons' interest from endoscopic neurosurgery, but afterwards made the neurosurgeons more confident with the neuro-microanatomy and more conscious about the potential applications of the neuroendoscopy. The development of the computerized technology, either for diagnostic or therapeutic purposes, stimulated a renewed interest towards a technique which could represent a valid alternative to the CSF shunt devices and their excessively high risk of infective complications and mechanical malfunctions. The first modern and important clinical experience with ETV in the management of hydrocephalus was reported by Vries in 1978 (Vries 1978). In 1990, Jones *et al.* (Jones *et al.* 1990) reported about the possibility to manage different types of noncommunicating hydrocephalus. Their work became a milestone for the indications and the evaluation of the results after ETV. An increasing number of reports on large series of hydrocephalic patients treated by ETV, which appeared in the literature in recent years, justifies the increasingly wider use of the technique throughout the world. Many innovative clinical and experimental studies concerning the procedure itself, the instrumentation and the possible integration with other techniques represents the last steps in the diffusion of ETV (Burtscher *et al.* 2002, Broggi *et al.* 2000, Decq *et al.* 2000, Foroutan *et al.* 1998, Horowitz *et al.* 2003, Vandertop *et al.* 1998).

Thanks to the improvement in the video imaging and in the endoscopic instrumentation, the current use of the neuroendoscope is not limited only to the treatment of hydrocephalus. Though intraventricular surgery still remains its main field of application (third-ventriculostomy, aqueductal plasty, septostomy of the septum pellucidum, choroid plexectomy, tumor biopsy, arachnoid or colloid cysts marsupialization,...), endoscopy or the endoscopic-assisted microsurgery is more and more used in the management of intra-axial lesions and for skull base, spinal and peripheral nerves surgery. It is likely that neuroendoscopy will be further enriched by the advances of three-dimensional imaging, image fusion, surgical armamentarium, and telepresence surgery in the very near future (Frazee and Shah 1998).

Ventricular Anatomy

A correct preoperative study of individual ventricular anatomy and the endoscopic recognition of ventricular structures is mandatory to increase the success rate of ETV and to decrease the percentage of operative complications. Anatomic anomalies and morphological variants of the cerebral ventricular system have been indeed extensively described, most of them in relation with the etiology of the hydrocephalus and the patient's age; their potentially adverse effects on the surgical procedure have been pointed out (Rohde and Gilsbach 2000, Rohde *et al.* 2001). Preoperatively, modern Magnetic Resonance (MR) apparatuses allow the 3D anatomic reconstruction and measurement of linear distances in any chosen image plane, with the possibility to evaluate anatomical characteristics in the single patient (Duffner *et al.* 2003, Rohde *et al.* 2001). Virtual neuroendoscopic planning, based on MR, 3D ultrasonography and neuronavigation systems have been also recently claimed to improve the safety of the endoscopic procedures (Duffner *et al.* 2003, Riegel *et al.* 2001). Furthermore a wealth of information comes from the improvement of intraoperative digital imaging (Decq 2004, Grant 1998, Kamikawa *et al.* 2001c, Lang 1992, Longatti 2003, Oka *et al.* 1993a, Pavez Salinas 2004, Riegel *et al.* 2001, Rohde and Gilsbach 2000, van Aalst *et al.* 2002). More precise endoscopic view reports are indeed extremely helpful, as they increase our knowledge of the anatomical variations that can be found in hydrocephalus of different etiologies.

Preoperative Evaluation of Ventricular Anatomy

It is almost universally accepted that whenever an ETV procedure is planned a MR study of the brain should be performed. Basic MR studies allow to obtain an overall view of ventricular structures and their anatomical relationships, width of the cerebral mantle, size of the basal subarachnoid spaces, and basilar artery position. Three-D reconstructions and distances measurements can be subsequently obtained and used in the preoperative planning.

In such a regard, the recently published study of Duffner *et al.* (Duffner *et al.* 2003) is of particular importance. The authors compared preoperative MR findings of thirty patients with a diagnosis of obstructive hydrocephalus and thirty healthy volunteers. After acquisition the images were analyzed with a software that enabled the visualization of the three scanning planes (sagittal, axial and coronal) through any free chosen point in the image volume, the definition of oblique planes displaying two structures of interest a time, and the measurement of angles and distances within each of the selected planes. Significant anatomic differences were found between the two groups; in particular lateral ventricles height was 2.08 times higher in the hydrocephalic patients so as third ventricle width (4.39 times larger in the hydrocephalic group). The mean distance between anterior and posterior commissures was 1.19 times longer in patients than in volunteers and the distance between the ventricular system and the cortical surface was significantly higher in this latter group; moreover the mean size of the Monro foramina was about 20 times the size in hydrocephalic patients if compared with normal individuals and it was larger than 5 × 5 mm in 24 of them. The position of an optimally located burr hole for third ventriculostomy was also calculated and was found to vary significantly between different patients. In an anterior-posterior direction it varied between 16.1 mm in front of and 46.5 mm behind the coronal suture, with a mean value of 8.2 mm behind the coronal suture, that is about 2 cm posterior to the point suggested by most authors (1 cm anterior to the coronal suture). The study provided two further interesting conclusions: the first is that a rigid endoscope used for ETV should not exceed an external diameter of 5 mm and the second is that they should be longer than 120 mm to allow a safe access to the floor of the third ventricle.

Another useful application of 3D MR reconstructions is related with virtual neuroendoscopic procedures. Virtual MR neuroendoscopy has been introduced in the clinical practice in late '90s. Brutscher and coworkers (Brutscher *et al.* 1999) produced virtual endoscopic images of 5 non-hydrocephalic brain specimens and compared the obtained images with intraventricular endoscopic views. The foramen of Monro, fornix, choroid plexus, clivus, mammillary bodies and basilar artery could be virtually visualized and the images obtained were comparable to the actual views. Similar results were obtained by Auer and Auer (Auer and Auer 1998), who simulated several approaches to the ventricular system by virtual MR endoscopy in healthy volunteers as well as in patients with hydrocephalus. Rohde *et al.* (Rohde *et al.* 2001) analyzed the sensitivity of virtual MRI endoscopy in detecting anatomic variations that could be found at surgery. Seven anomalies of the normal ventricular anatomy were encountered during ETV in 5 of 18 patients; five of the seven anomalies had been already identified by virtual MR with an overall sensitivity of 71%. All the missed information concerned anatomical variations of the third ventricular floor. This anatomic structure invariably appeared as a defect when it was translucent so as when it was thick and opaque or steeply inclined. According to the authors, the advantage of this virtual endoscopy of the third ventricle region is that the surgeon can "look through" the third ventricular floor onto the first segment of the posterior cerebral arteries and onto the basilar artery tip and relate these data with the planned surgical approach. However, other authors have underlined the difficulties to study the anatomic relationships of the basilar bifurcation with the designated site of ventriculostomy due to the lack of segmentation between cerebral vessels and brain tissue (Jodicke *et al.* 2003). On these grounds alternative devices for virtual neuroendoscopy have been proposed such as, for example, 3D ultrasonography (3D-US). This examination has the advantage of an high resolution for ventricular pathologies and can be performed on a routine basis without the need of sedation. Jodicke *et al.* (Jodicke *et al.* 2003) recently evaluated the sensitivity of 3D US-based virtual neuroendoscopy in the identification of parenchymal and vascular anatomical landmarks of the third ventricle. A software able to reconstruct sequential 2D images in a 3D mathematical model was used and a power-doppler mode was employed to depict vessels in relation to ventricular walls. In the authors experience, the definition of ventricular and vascular structures position was comparable to virtual MR neuroendoscopy. One main advantage of 3D US-based over MR virtual neuroendoscopy was the co-registration of parenchymal ventricular and vascular anatomy with one single image acquisition due to flow detection and coding using the sensitive Doppler properties of ultrasonography. On the other side, the non vascular anatomical arrangement of the basal cisterns cannot be studied on ultrasonography images, due to reflexion artifacts from the bony clivus and the narrow space of the basal cisterns with multiple anatomical borders; for this reason the same authors maintained as essential a preoperative MR study.

Neuroendoscopic Ventricular Anatomy

The majority of ETV procedures are performed in patients with noticeable dilatation of the ventricular system. It should be therefore considered that the endoscopic anatomic views correspond to this kind of situation, the anatomic structures being often displaced and separated from each other. Regarding the cranial surface parameters most of the authors agree that the burr hole for ETV should be placed immediately (up to 1 cm) anterior to the coronal suture, 2–3 cm. from the midline, on the mid-pupillary line (Decq 2004). The distance between the cortical surface and the frontal horn of the lateral ventricle is extremely variable and should be individually calculated. In the previously quoted paper by Duffner *et al.* (Duffner *et al.* 2003), this distance varied from 5.4 to 34.6 mm.

Anatomy of the Frontal Horn of the Lateral Ventricles and of the Foramen of Monro; Key-Points for Endoscopic Orientation

The frontal horn of the lateral ventricle is delimited by a medial wall, formed by the septum pellucidum, an anterior wall and roof, formed by the genu of the corpus callosum, a lateral wall, composed of the head of the caudate nucleus, and a narrow floor formed by the rostrum of the corpus callosum (Rhoton 2002). Most of the endoscopic orientation inside the frontal horn is based on the visualization of the Monro foramen (MF). This structure is bound anteriorly and superiorly by the column of the fornix and medially by the interventricular septum. The anterior septal vein is visible along the septum and crosses the fornix column. The thalamus appears as a bulging on the posterolateral margin of the MF. The thalamostriate vein passes backward at its boundary with the caudate nucleus, turns medially and empties into the internal cerebral vein. The choroid plexus constitutes the posterior wall of the MF; it is attached medially to the fornix by the tenia fornix and laterally to the thalamus by the tenia thalami. It travels over the superior surface of the thalamus, either in a straight line or with a sinuous course. Reflecting posteriorly it contributes to the formation of the roof of the third ventricle. The posterior and medial margin of the MF is also composed of the angle of anastomosis of the anterior septal vein, choroidal veins (rarely visible within the choroid plexus) and thalamostriatal veins (Rhoton 2002). The Y-shaped angle between these veins may be extremely variable, usually being 80–90°. The veins usually have the same diameter, but in some case either the thalamostriatal vein, or the anterior septal vein is much larger. Looking laterally to the thalamostriate vein several affluent venous branches may be recognized, draining the anterior part of the caudate nucleus. The consequent striped appearance has lead to the name of "striatum" for this anatomic structure (Decq 2004).

Anatomy and Endoscopic View of the Third Ventricle

Once separated from cerebral hemispheres and viewed from inside the lateral ventricles, the third ventricle has nearly a prismatic shape in which we can distinguish a roof, a floor, an anterior, a posterior and two lateral walls. The roof forms a gentle upward arch, extending from the foramen of Monro anteriorly to the suprapineal recess posteriorly. It is composed by four layers: one neural layer formed by the fornix, two thin membranous layers of tela choroidea and a layer of blood vessels between the sheets of tela choroidea. During endoscopic procedures the roof of the third ventricle can almost only be seen from above when there is a partial or complete agenesia of the septum pellucidum; it appears as a thin vascularized triangular membrane peripherically bounded by the two columns of the fornix (Decq 2004, Grant 1998, Rhoton 2002). The floor of the third ventricle extends from the optic chiasm anteriorly to the orifice of the aqueduct of Sylvius posteriorly. When viewed from inferiorly, the structures forming the floor include, from anterior to posterior the optic chiasm, the infundibulum of the hypothalamus, the tuber cinereum, the mammillary bodies, the posterior perforated substance and most posteriorly the part of the tegmentum of the midbrain located above the medial aspect of the cerebral peduncles. The optic chiasm is located at the junction of the floor and the anterior wall of the third ventricle, the inferior surface forming the anterior part of the floor, the superior surface constituting the lower part of the anterior wall. During endoscopic procedures the optic chiasm is viewed as a prominence at the anterior margin of the floor. Immediately behind it and inferiorly a graysh hole, circumscribed by a pink anular ring represent the infundibular recess. The thin whitish parenchimatous structure which can be visible at the base of the infundibulum is the tuber cinereum (Vinas *et al.* 1996). One of the most important reference points inside the third ventricle are the mammillary bodies, which form paired prominences on the inner surface of the floor. Commonly, they form a narrow angle, but they can be widely separated from each other and occasionally they are not clearly recognizable (Decq 2004). Just anteriorly to the mammillary bodies and behind the tuber cinereum lies the premammillary recess, which appears as an almost constantly translucent area; it can sometimes be very small or, on the contrary appear very large and even deep. Its anterior margin is considered as the safest area to perform the orifice for third ventriculostomy (Vinas *et al.* 1996). The termination of the basilar artery and its branches, posterior cerebral arteries, or even the superior cerebellar arteries may be visible through under this recess, particularly in case of extreme hydrocephalus. The part of the third ventricular floor between the mammillary bodies and the aqueduct of Sylvius has a smooth surface and is concave from side to side. This smooth surface lies above the anterior perforated substance, a triangular area of gray matter which has a punctated appearence due to multiple branches of the posterior cerebral arteries passing through it and directed to the brainstem. The subarachnoid space under the floor of the third ventricle is the interpeduncular cistern. It has a conic shape and is bound posteriorly by the cerebral peduncles and anteriorly by the Liliequist's membrane. Laterally, the interpeduncular cistern is surrounded by the oculomotor, crural and ambient cisterns. A membrane arising from the posterior edge of Liliequist's membrane separates this cistern into two compartments: anterior and posterior. The anterior compartment contains the bifurcation of the basilar artery, the origin of both posterior cerebral arteries and both medial and lateral posterior choroidal arteries. The posterior compartment contains posterior thalamo-perforating branches, arising from the basilar and posterior cerebral arteries.

The anterior wall of the third ventricle extends from above the foramina of Monro to the optic chiasm below. During endoscopic procedures only its lower two-thirds can be seen; indeed, the upper third is hidden posterior to the rostrum of the corpus callosum. The part of the anterior wall that can be endoscopically viewed is formed by the optic chiasm and the lamina terminalis. This last appears as a thin sheet of gray matter and pia mater that attaches to the upper surface of the chiasm and stretches upward to fill the interval between the optic chiasm and the rostrum of the corpus callosum (Rhoton 2002). Two arachnoid cisterns can be found underneath the anterior third ventricle: the chiasmatic cistern and the lamina terminalis cistern. The first one is bordered by the superior surface of the optic nerves, chiasm, lamina terminalis cistern and Liliequist's membrane. It commonly has extensions through the diafragma sellae and optic foramen and contains the optic nerves, pituitary stalk, branches of the internal carotid artery and ophtalmic artery. The lamina terminalis cistern lies above the chiasmatic cistern. It is delimited by the superior surface of the optic chiasm, the lamina terminalis, the rostrum of the corpus callosum, gyrus cinguli, interhemispheric fissure and gyrus recti; laterally it is bordered by the olfactory gyrus and the anterior cerebral membrane. The lamina terminalis cistern contains both anterior cerebral artery and veins, the recurrent artery of Heubner, the anterior communicating arteries and veins, the fronto-orbital arteries and the most proximal A2 segments of the anterior cerebral arteries (Lang 1992, Oka *et al.* 1993a, Vinas *et al.* 1994, Vinas *et al.* 1996). The lateral walls of the third ventricle are formed by the hypothalamus inferiorly and the thalamus superiorly. Endoscopically they have an outline like the lateral silhouette of a bird's head with an open beak. The head is formed by the oval medial surface of the thalamus and the two beaks are respectively formed: the upper by the optic recess and the inferior by the infundibular recess. The columns of the fornix form distinct prominences in the lateral walls of the third ventricle, just below the foramina of Monro, but inferiorly they disappear under the surface of the floor (Kamikawa *et al.* 2001c, Oka *et al.* 1993a, Rhoton 2002).

Endoscopic Ventricular Anatomy Variations

Variations in the anatomy of the lateral and third ventricles can be found in more than one third of the cases (Decq 2004, Vinas *et al.* 1996). Some of them might hamper the correct conclusion of the endoscopic procedures, be responsible of a longer operating time and increase the complications rate. The most frequent anatomic variations regard the thickness of the floor of the third ventricle and its position. In cases of acute hydrocephalus (shunt malfunction; hydrocephalus associated with posterior fossa tumors) the floor may be undistended and extremely thick, with the mammillary bodies hardly recognizable. On the contrary, in children with long-standing hydrocephalus (i.e. hydrocephalus associated with aqueductal stenosis) the floor of the third ventricle can be extremely distended and bulge downward into the interpeduncular cistern because of the pressure gradient between the third ventricle and the subarachnoid space. According to van Aalst *et al.* (van Aalst *et al.* 2002) this finding may complicate ETV procedures. In a recent paper these authors reported four cases of triventricular hydrocephalus with deeply located third ventricular floor. The stretching of the floor in front of the basilar artery increased the risks of damaging this vascular structure; moreover in all four cases an immediate upward ballooning of the third ventricular floor was observed soon after the performance of the stoma, completely filling the third ventricle, obscuring the vision of the fenestration site with consequent problems of orientation.

Two other common findings in cases of extreme and long-standing hydrocephalus are the “loss” of the posterior margin of the MF and the partial or complete absence of the septum pellucidum, which may appear as a spiderweb structure; the only recognizable structure in the lateral ventricles may be the choroid plexus, which appears adherent to the outline of the thalamus laterally; through the dehiscence of the septum pellucidum the controlateral anatomic ventricular structures may be seen (Decq 2004).

Rohde and Gilsbach (Rohde and Gilsbach 2000) recently compared the above mentioned anatomical variations with a critical review of their personal experience. The video recordings, operative reports and preoperative MR images of 25 patients who underwent third ventriculostomy at their institution were analyzed. All the patients were affected by long standing hydrocephalus due to aqueductal stenosis in 18 cases, to obstruction of the fourth ventricle outlets in 4 patients and to presumed CSF malresorption mechanisms in the last three patients. Overall 10 anatomic variants were identified in 9 cases. Six anatomic variants were identified at the floor of the third ventricle. In four patients the floor of the third ventricle was not a thin transparent membrane, as could be expected in long-standing hydrocephalus, but a firm opaque structure. Blunt perforation was more time-consuming and the stretching of the hypothalamic structures seemed to be higher than usual. The identification of the basilar artery was not possible in two of these patients and repeated minor bleeding occurred in three of them, leading to the abandoning of the surgical procedure in one case. The lack of sufficient third ventricle dilatation lead to the abandoning of the surgical procedure in a further case. In two children the floor of the third ventricle atypically inclined steeply from the mammillary bodies to the infundibular recess. This finding increased the operative time, because of the slipping off of the tip of the perforation catheter and lead to a functionally insufficient stoma in one case. The other anatomic variations described by Rohde *et al.* regarded the Monro foramen; it was reduced in size in spite of chronic hydrocephalus in two cases with an associated agenesia of the corpus callosum and septum and division of the body of the fornix in one case. Differently from what occurred for the third ventricle anatomic variations the ones related to the MF did not lengthened the operative time nor influenced the correct conclusion of the surgical procedure.

Different anatomic variations have been described in hydrocephalus of different etiologies. Kamikawa *et al.* (Kamikawa *et al.* 2001c) analyzed the ventriculoscopic findings of four neonates with posthemorrhagic hydrocephalus who underwent ETV. The choroid plexus was atrophic with hematoma clots attached to it as well as at the orifice of the aqueduct of Sylvius in all cases. The septum pellucidum was widely fenestrated with a number of small varices at the level of the septal veins in two cases. In all patients fragments of old hematomas were scattered on the ventricular walls and on the floor of the third ventricle, appearing brown because of the presence of hemosiderin, an aspect defined by the authors as "leopard-like" (Fig. 1). At time distance from the hemorrhage thickening of the ventricular walls, due to fibrous scarring is common and septations can be found in the ventricular cavities as well as at the inlet of the aqueduct of Sylvius (Fig. 2). This could explain the occurrence of an acquired aqueductal stenosis in some of these patients (Scavarda *et al.* 2003). Septations as well as a thickened ventricular floor are common findings also in children with previous CSF infections. An extensive arachnoid sepimentation under the third ventricular floor might further complicate the correct conclusion of an ETV procedure in this subset of patients (Riegel *et al.* 2001).

Hydrocephalus associated with spinal dysraphism is another clinical condition that is frequently associated with ventricular anatomic anomalies. In a review of ten personally performed endoscopic procedures, Pavez Salinas (Pavez Salinas 2004) described significant anatomic variations in this kind of patients if compared with other hydrocephalus etiologies. In particular: a small Monro foramen and unrecognizable infundibulum, mammillary bodies and basilar artery occurred in 40% of the cases; septations inside the third ventricle and third ventricular floor umbilications occurred in 50% of the patients; 60% of the children presented atypical veins inside the third ventricle and 70% of them arachnoid adherences under the floor of the third ventricle (Figs. 3, 4). Most of these alterations are consistent with previous histopathological findings. In particular the presence of septations, and abnormal veins inside the third ventricle, or a

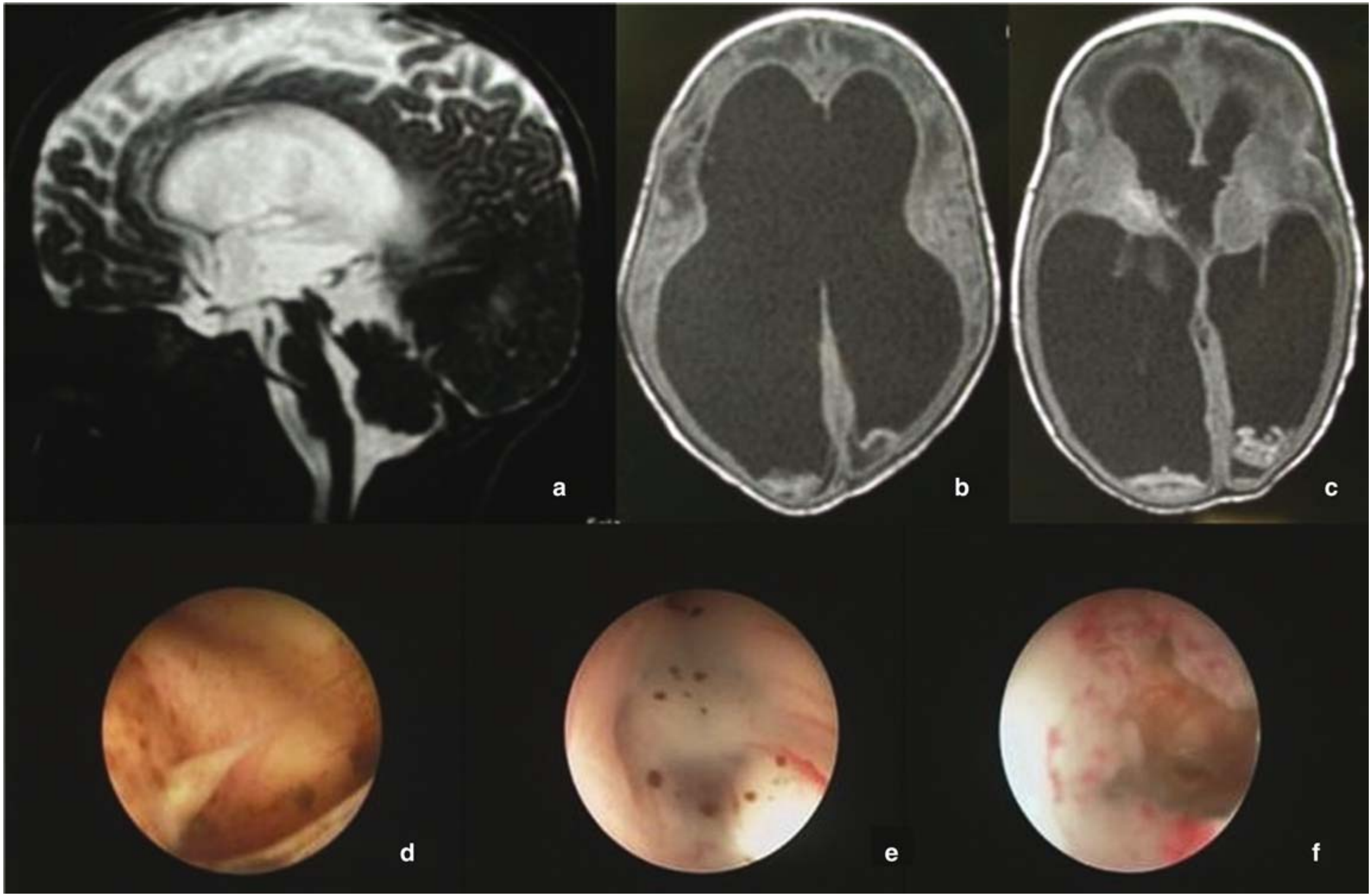
a
b
c
d
e
f

second arachnoidal membrane under the floor of the third ventricle, might be in relation with embryonic development alterations with abnormal degrees of hypothalamus fusion.

Table 1 summarizes the possible variations of ventricular anatomy in different types of hydrocephalus.

Modern Neuroendoscopic Instrumentation

Optic Devices

The neuroendoscope is the only instrument that allows access to deep anatomic structures in a minimally invasive way. Pre-requisites are the ability to bring the illumination and the subsequent ability to transmit the images accurately, clearly, and brightly to the eyes of the neurosurgeon.

To understand the functioning of an endoscope, one should know some principles of optical physics. These, focused on the neuroendoscope, have been recently reviewed by Liu *et al.* (Liu *et al.* 2004). More detailed treatments of principles of physics can be found in the optical engineering literature (Fisher and Biljana 2000, Laikin 2001).

The endoscopes specifically designed for neuroendoscopy can be classified into four types:

- Flexible fiberscopes
- Steerable fiberscopes
- Rigid fiberscopes
- Rigid rod lens endoscopes

These endoscopes varies for diameter, optical quality and number, and diameter of working channels.

Flexible Fiberscopes

These endoscopes are not useful for third ventriculostomy. They have a very small diameter (<2 mm), which allow their use inside the lumen of ventricular catheters for optimal ventricular catheter positioning during ventriculoperitoneal shunting. Their limitations are poor quality of vision and the absence of a working channel.

Fig. 1. Ventricular anatomy variations in children with posthemorrhagic hydrocephalus. (a, b, c) T2 sagittal (a) and T1 axial (b, c) MRI images showing an irregular ventricular walls signal (a) and the appearance of intraventricular clots at long distance from the hemorrhage (b, c). (d, e, f) endoscopic views of the same patient documenting a "leopard-like" appearance of the lateral ventricle walls (d) and of the floor of the third ventricle (e). After the endoscopic opening of the third ventricle floor extensive arachnoid adhesions in the interpeduncular cistern are detected (f)

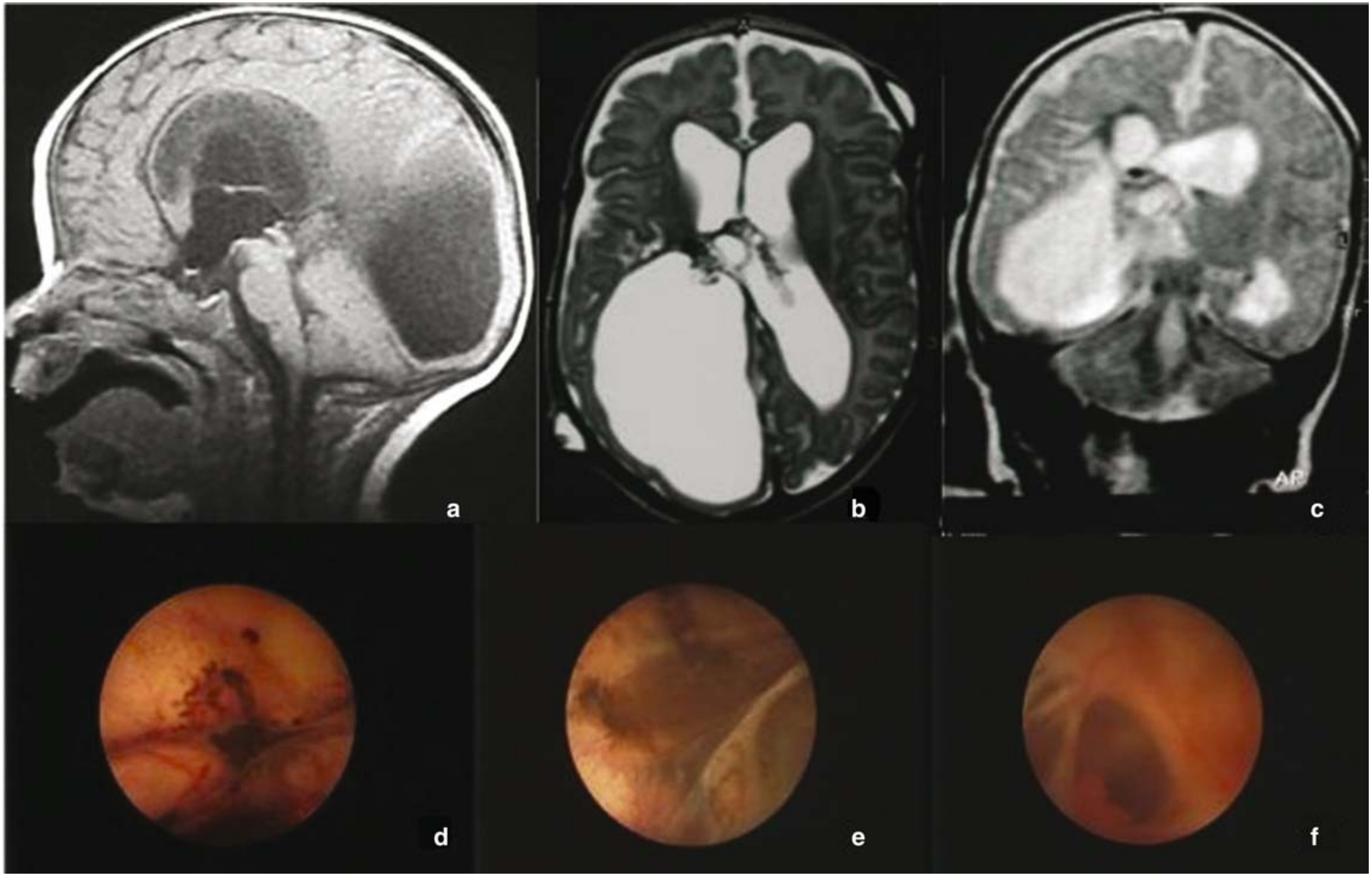
a
b
c
AP
d
e
f

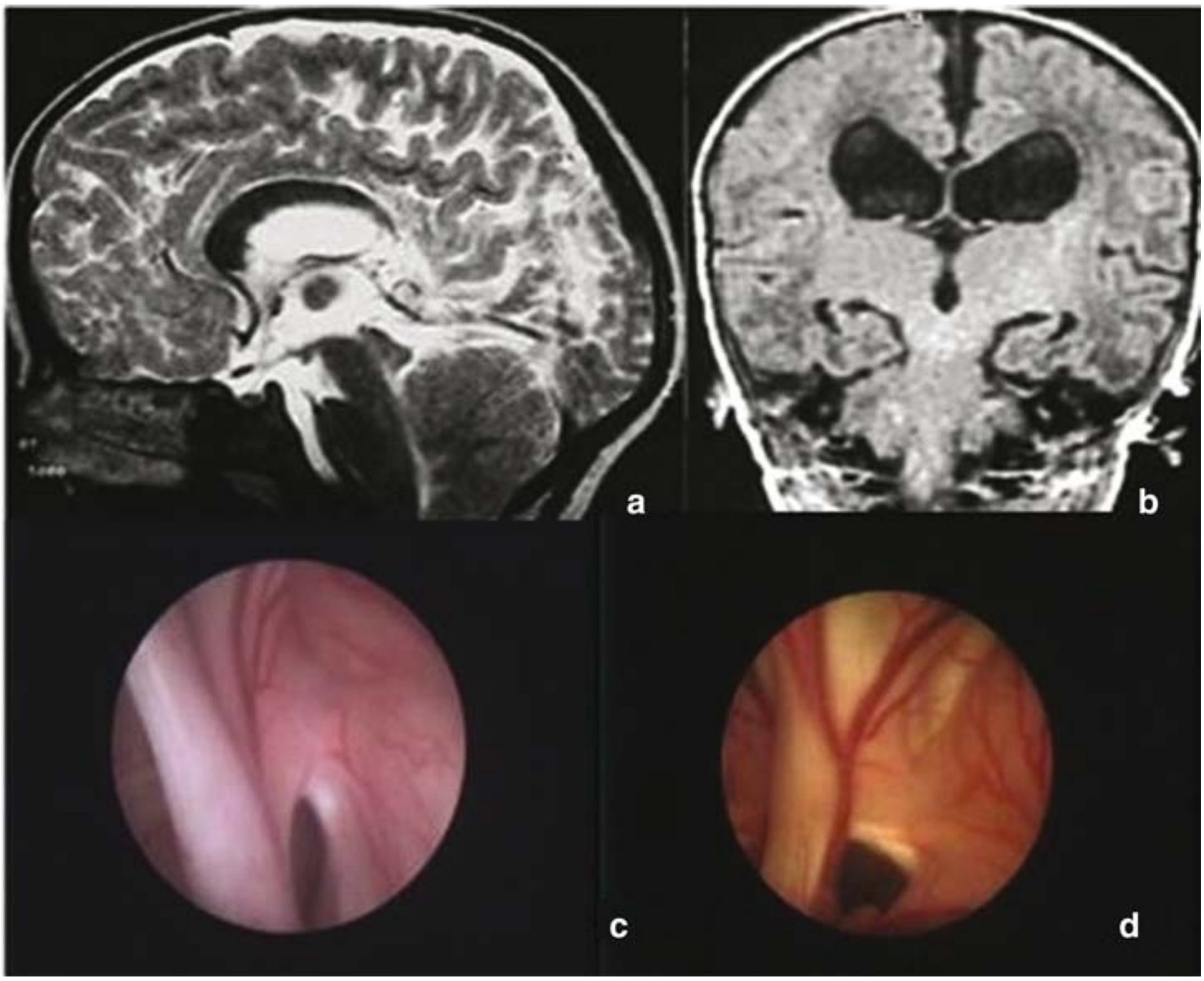

Fig. 3. Ventricular anatomy variations in children with hydrocephalus and myelomeningocele. (a, b) T2 sagittal (a) and proton density coronal (b) MRI images of a 2 years old child: the foramen of Monro is narrow and steeply oriented; the interventricular septum is apparently preserved. (c, d) endoscopic views of the same patient confirming the reduced size and the oblique orientation of the foramen of Monro; differently from what documented by the MRI images the inteventricular septum is widely opened

Steerable Fiberscopes

Flexible-Steerable endoscopes became a reality with the development of fiber optic technology (Fukushima *et al.* 1973, Hecht 1999). They are constructed of silica glass (which can be flexed without breaking) (Nobles

◀

Fig. 2. Ventricular anatomy variations in children with posthemorrhagic hydrocephalus. (a, b, c) T1 sagittal (a) and T2 axial (b) and coronal (c) images of an infant with posthemorrhagic hydrocephalus. Intraventricular septa (a, b, c) and clots (b, c) lead to a compartimentalization of the right lateral ventricle. The interventricular septum seems to be preserved. (d, e, f) endoscopic views of the same patient showing the aspect of intraventricular clots (d) and of the right ventricle cella media septation (e); the interventricular septum is opened and has a "spider-web" appearance (f)

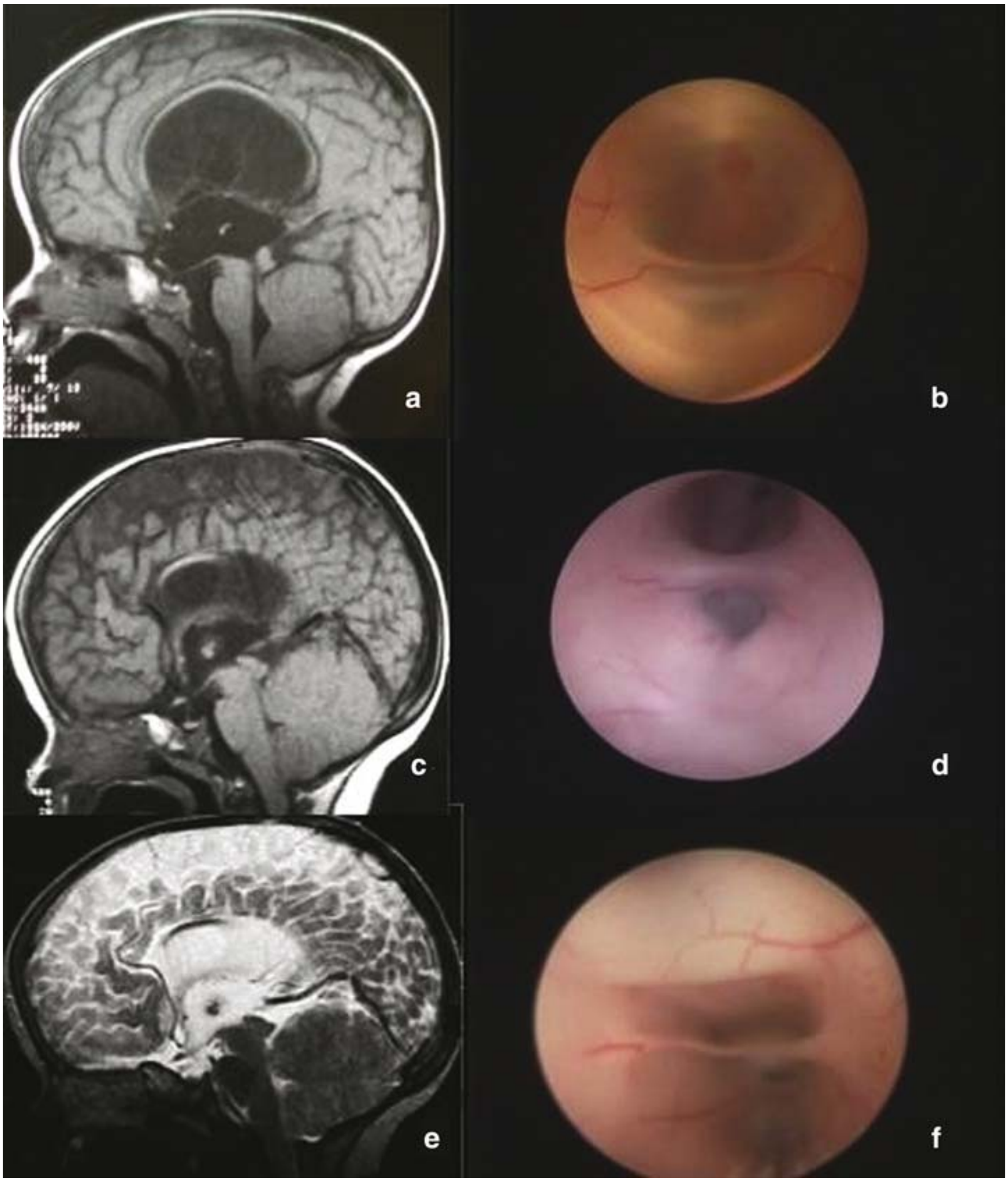

Fig. 4. Ventricular anatomy variations in children with hydrocephalus and myelomeningocele. (a, c, e) T1 (a, c) and T2 (e) sagittal images of three different patients. The third ventricle does not seem to have significant anatomic variations, as in the patient of Fig. 1 it appears oblique and steeply oriented. (b, d, f) endoscopic views of the same patients showing different third ventricle anatomic variations which were not detected by the MRI. (b) the mammillary bodies are not recognizable; the premammillary recess is crossed by a septum and an overlapping vein. (d, f) the route to the premammillary recess is crossed by and interthalamic adhesion, which can be found at different distances from the floor of the third ventricle

Table 1. *Possible Variations of Ventricular Endoscopic Anatomy in Different Types of Hydrocephalus*

Diagnosis	Foramen of Monro	Ventricular walls	III ventricle floor	Various	Associated risk
Aqueductal stenosis	loss of the posterior margin	absence of the septum pellucidum	1 – distended and bulging downward 2 – more rarely thick and opaque		1 – basilar artery damage 2 – stretching of the hypothalamus
Posterior cranial fossa tumors			1 – undistended, thick and opaque	2 – mammillary bodies hardly recognizable	1 – stretching of the hypothalamus 2 – orientation
Post-hemorrhagic	1 – atrophic choroid plexus, with attached clots	fenestrated septum pellucidum; hemosiderin deposition (“leopard like” appearance)	2 – (at long distance) thickened, with fibrous scarring		1 – orientation 2 – stretching of the hypothalamus
Myelomeningocele			unrecognizable infundibulum, basilar artery and mammillary bodies; septations and umbilications; atypical veins; arachnoid adherences under the floor		orientation; intraoperative hemorrhage; insufficient CSF flow through the soma (arachnoid adherences)

Table 2. *List of main steerable neuroendoscopes with fiberoptic system suitable for endoscopic third ventriculostomy*

Manifacturer	Model	Outer diameter	Channels*	Working channel diameter	Bending
Aesculap[1]	flexible – steerable endoscope	4.3 mm	1 W, 1 I/A	1.4 mm	280°
Codman & Shurtleff[2]	steerable neuroendoscope	4.0 mm	1 W	1.0 mm	260°
Olympus	flexible – steerable endoscope	4.2 mm	1 W + 2 I/A	2.0 mm	180°
Storz[3]	neurofiberscope	2.9 mm 3.7 mm	1 W + 2 I/A 1 W + 2 I/A	1.2 mm 1.5 mm	290°

[1] Aesculap – Tuttlingen, Germany; Wolf, Knittlingen, Germany.
[2] Codman & Shurtleff (Johnson & Johnson) New Brunswick, NJ.
[3] Karl Storz GmbH & Co., Tuttlingen, Germany.
* *W* Working channel; *I/A* Irrigation/Aspiration channel.

1998). The image formed by the objective lens is relayed to the eye lens by multiple fibers contained in a very small package. Image fibers are formed in a coherent bundle that allows the image to be properly reconstructed on the proximal end of the fiber. By contrast, light fibers are not constructed in a coherent fashion.

The main characteristic of the flexible and steerable fiberscope is that the last 4 cm can be oriented 100° upward and 160° downward. This is the only system that makes looking and working around a corner possible. The diameter of the scope ranges from 2.3 to 4.6 mm (Table 2) allowing to work also in small ventricles and through a small foramen of Monro. The size of the device usually determines the number of individual fibers, consequently the number of pixels: the smaller the size, the fewer the number of pixels. For each endoscope, designated fiberoptic cables and lighting equipment are used in combination with a standard camera and television monitor. The diameter of the working channel ranges from 1.0 mm to 1.5 mm, allowing the introduction of 3-French (1 mm) flexible instruments (micro scissors, micro grasping forceps, micro biopsy forceps, monopolar electrodes, Fogarty balloon). Distinct irrigation channel and the outflow channel are usually available. Access to the ventricle is possible using a dedicated peel-away sheath. Some steerable scopes with only one working channel present the limit of very slow irrigation when the instrument occupies the channel. For this reason it is impossible to work under continuous irriga-

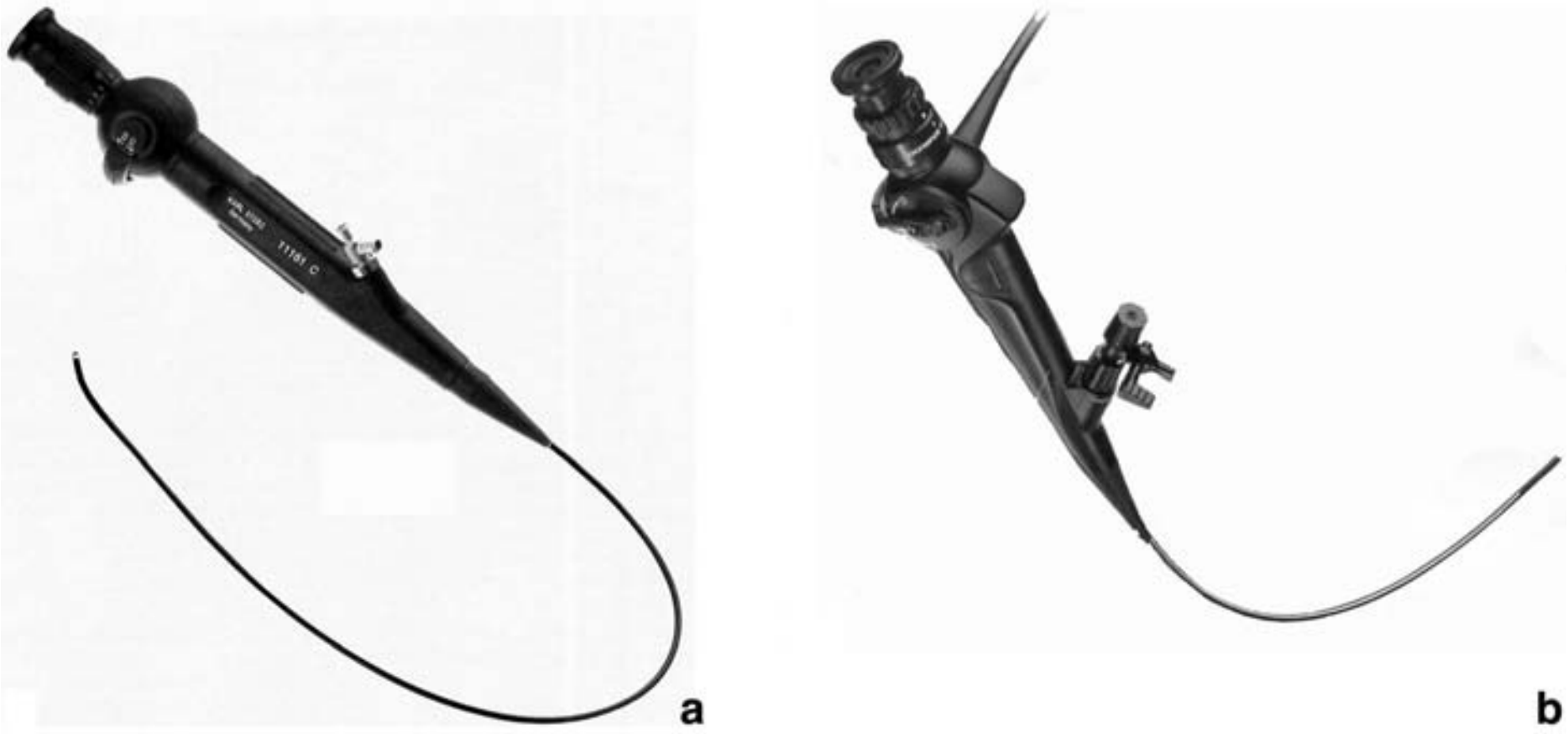

Fig. 5. (a) Storz steerable neuroendoscope. The largest part is usually kept by a holder, the proximal steerable tip is inserted into the ventricle through a peel-away sheath and oriented with the left hand, while the right hand manipulates the instruments (image courtesy of Karl Storz GmbH & Co., Tuttlingen, Germany). (b) Olympus steerable endoscope. A short fiberscope, easier to manipulate for neuroendoscopic procedures (Courtesy of Olympus opt, Tokyo, Japan)

tion and this makes more complex operations (tumor biopsies or removal) more complicated. When an instrument is introduced into the working channel, the steering properties are decreased, sometimes significantly, according to the stiffness of the instrument introduced. The steerable scope modifies the orientation of the optical fibers but also of the working channel, allowing the instruments to reach all the structures visualized. A holder is necessary to maintain the rigid part of the scope (Fig. 5a,b). The distance from the target should be carefully and precisely evaluated. Being too close to the target obliges the surgeon to work with a curved endoscope, while being too far obliges the surgeon to release the holder, with possible rough movements in the proximity of potentially delicate anatomical structures. When the endoscope is in the position of maximum flexion, the flexible instruments can have some problems in progressing through the working channel. Finally, the scope must be in the neutral position before backing out the ventricular system, to avoid the risk of damage to the fornices and other intraventricular structures. Some steerable scopes cannot be sterilized according to the protocols used in some countries (i.e. France) in order to prevent prion transmission. These protocols include decontamination with alkaline medium and sterilization for 20 minutes at 134°C. Therefore, these devices should be considered as disposable, that makes their use prohibitive in these countries.

Rigid Fiberscopes

These fiberscopes are formed by a main rigid body of variable length (13–27 cm) with a diameter of 3–4 mm. This contains the end of the optic fiber tract, a working channel (1–2 mm), and the irrigation-aspiration channel (Fig. 6a–c). Separate inflow and outflow channels avoid excessive increase of ICP balancing irrigation with outflow. Access to the ventricle is possible using a dedicated peel-away sheath. The major advantage is that this endoscope is extremely light and short, and can be handled like a pencil, so that it is easier to manipulate. This is made possible by the fiberoptic technology, which allows remote placement of the camera and the light source: they can be placed 40 cm away on the operating table. One single soft, fiberoptic cable is the only link to the fiberscope itself. The small diameter of the scope allows its use in neonates and in case of small ventricles –

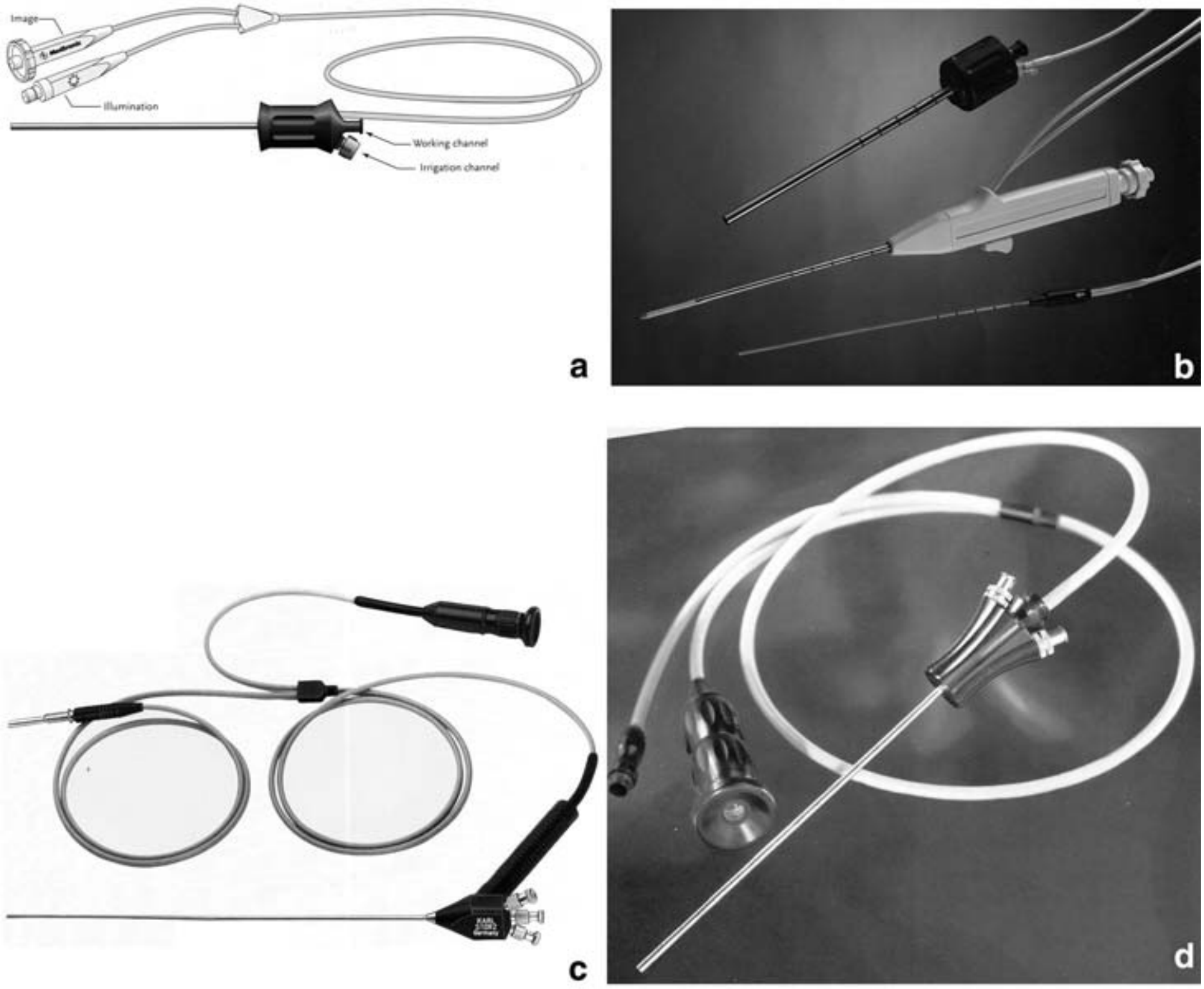

Fig. 6. Extremely light and easy to handle, their quality of vision is higher than steerable fiberscopes but lower than rod lenses endoscopes. They can be disposable like the Medtronic (a) or the Integra Neuroview (b) or re-sterilizable for a limited number of operations like the Storz (c) or the Paediscope Aesculap (d) (images courtesy of manufacturers)

Table 3. *List of main rigid straight neuroendoscopes with fiberoptic system suitable for endoscopic third ventriculostomy*

Manifacturer	Model	Outer diameter	Channels*	Working channel diameter
Aesculap	paediscope (autoclavable)	3 mm	1 W, 2 I/A	1.2 mm
Medtronic	channel neuroendoscope (disposable)	3.5 mm (10000 pixel fibers) 4.2 mm (30000 pixel fibers) 4.5 mm (10000 pixel fibers)	1 W, 1 I/A 1 W, 1 I/A 1 W, 1 I/A	2.13 mm 2.13 mm 3.12 mm
Integra neuroview	neuroview disposable rigid/semirigid scope	2.3 mm 4.6 mm	1 W 1 W + 1 I/A	1.0 mm 2.4 mm
Storz	Gaab miniature neuroscope (autoclavable)	3.2 mm	1 W, 2 I/A^{+}	1.3 mm

* *W* Working channel; *I/A* Irrigation/Aspiration channel.

$^{+}$ Lateral irrigation channel allows use of additional instruments with a diameter of 1 mm parallel to the instrument channel.

small foramen of Monro (Table 3). The absence of a rigid rod lens system allows a very wide working channel and a wide irrigating channel, making it possible to use virtually all endoscopically designed surgical instruments, of any length. However, the fiberscopes with smaller diameter have smaller working channel as well, allowing the use of 1 mm diameter instruments.

Vision is superior to that with the steerable fiberscopes because the number of optic fibers can be higher since there is no need for tip orientation. More modern fiberscopes provide higher quality images, thanks to the presence of as high as 30000 pixel fibers (Medtronic, Aesculap). Nevertheless, the quality of vision cannot be compared to that offered by rigid rod lens endoscopes.

Rigid Rod Lens Endoscopes

The quality of vision is the main advantage that makes the rigid rod lens scope an indispensable item in the armamentarium of any neuroendoscopist. In the sixties, Hopkins described a series of glass rods with small air gaps, which is the exact opposite of the design since then used which was

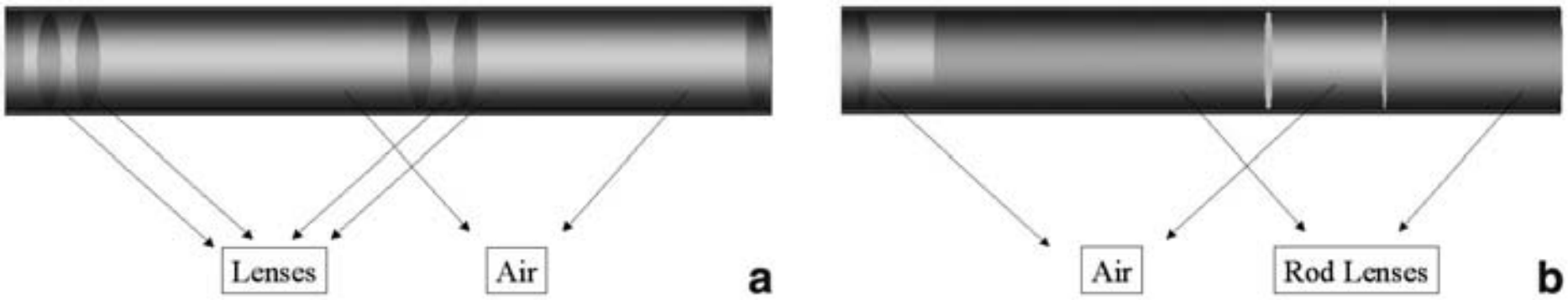

Fig. 7. Traditional (a) and Rod lenses optic systems (b). In the rod lenses optical system the air gap between lenses is significantly reduced, decreasing light dispersion and increasing the stability of the system

composed by a series of small glass lenses interspersed with large air spaces (Fig. 7a,b). This technique forms the basis of most modern endoscopic systems and bear his name (Nobles 1998, Siomin and Constantini 2004). Further reduction in light loss is achieved through the coating of the glass surfaces with an ultrathin layer of magnesium fluoride. This layer markedly decreases the reflection and improves the optic characteristics of endoscopes and cameras (Nobles 1998, Shiau and King 1998, Siomin and Constantini 2004). With this technology the quality of vision is extremely sharp, and allows easier and more precise identification of the anatomical structures encountered, with an excellent visual definition of details. The rod lens system requires the presence of the camera and of the fiberoptic cable for the cold light attached to the proximal extremity of the endoscope (Figs. 8–11). The whole system requires good surgical training to be manipulated freehand during navigation and throughout the whole surgical procedure. A holder may be useful. The rigid lens system only allows targets to be reached that are located on a straight line from the burr

Fig. 8. Wolf Neuroendoscope (image courtesy of Richard Wolf, Henke-Sass, Tuttlingen, Germany)

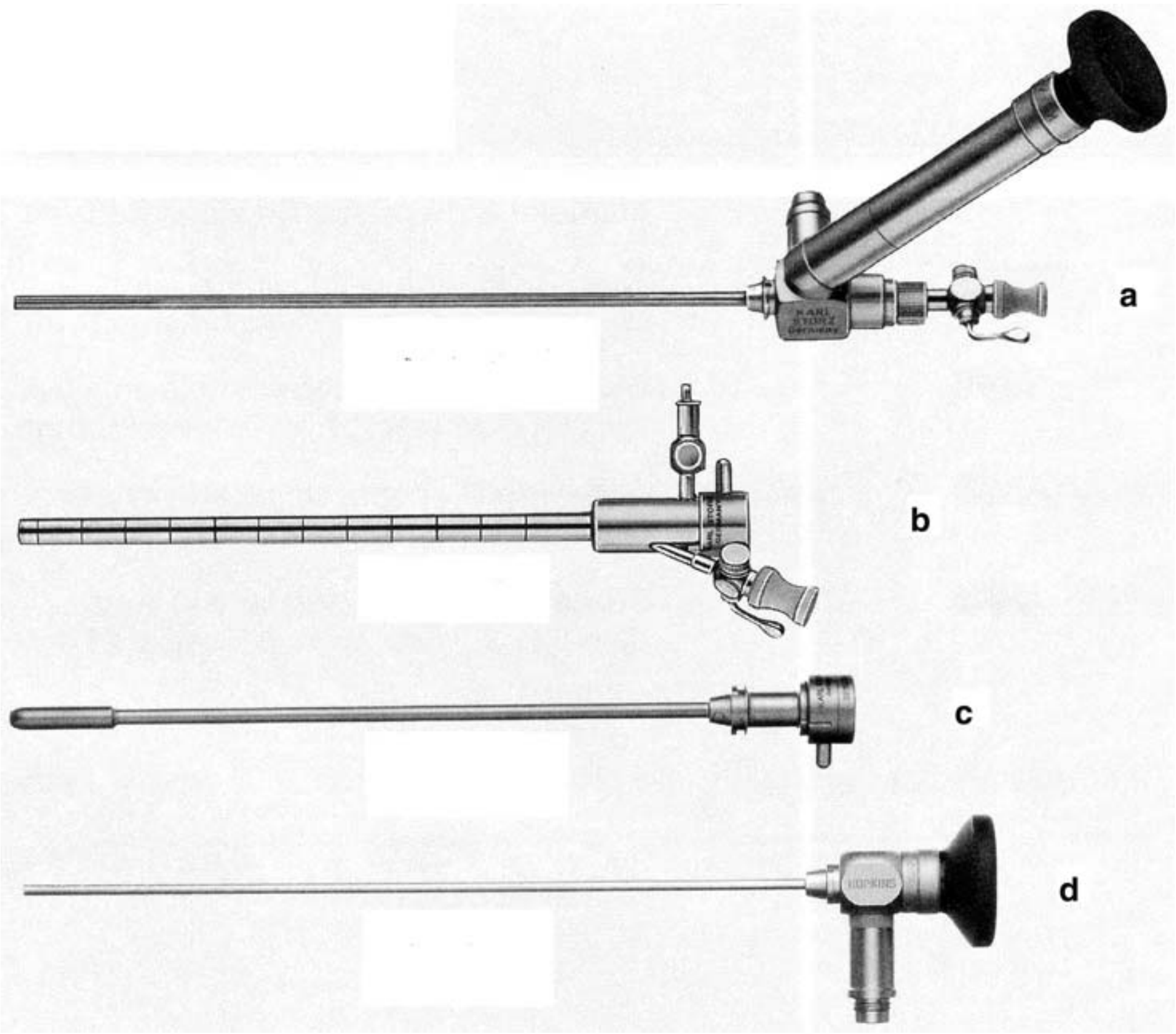

Fig. 9. Elements of the Gaab endoscope: (A) optic, (B) trochar, (C) stylet (D) optic (image courtesy of Karl Storz GmbH & Co., Tuttlingen, Germany)

hole. Unlike rigid fiberscope, that incorporates an instrument channel and two separate channels for irrigation in- and outflow, the rigid lens system requires the presence of an endoscope trochar with multiple parallel operative channels: the optic is inserted in the "optic channel" while the instruments are inserted in different operating channels. The operating sheath allows one to change scopes intraoperatively without reinserting them through brain tissue, thus avoiding unnecessary damage to the surrounding brain.

The trochars are of different diameters, according to the number of channels available (Table 4). For third ventriculostomy 4 channels should be available: an optic channel (in which the optic is inserted), a working channel for surgical instruments, an irrigation channel and an overflow channel. The diameter of the whole system ranges from 3.2 to 6 mm, the



Fig. 10. Elements of the Decq endoscope (image courtesy of Karl Storz GmbH & Co., Tuttlingen, Germany). When used with a holder, two hands work is possible through the two symmetric working channels (image courtesy of Dr. Philippe Decq, Hopital Henri Mondor, Paris, France)

working channel allows the use of 2 mm instruments. However, also "miniature endoscope" (3.2-mm outer diameter) has been developed for use in pediatric patients (4.0-mm Gaab II miniature system, Karl Storz GmbH & Co., Tuttlingen, Germany). In some endoscopes (Minop System, Aesculap, Tuttlingen, Germany), 1 mm instruments can be introduced short term through the irrigation channel for bi-instrumental operation. Decq endoscope (Karl Storz GmbH & Co., Tuttlingen, Germany), is the only system provided by 2 working channels of 2 mm. To allow the presence of the two working channels, the section of the endoscope is oval-shaped with the two diameters ranging from 3.5 and 4.0 mm × 5.2 and 7.0 mm. This is specifically designed for tumor or cyst surgery allowing simultaneous grasping and fenestration (or aspiration). However it is also a useful tool in third ventriculostomy in case of large, redundant, highly pulsating third ventricle floor (as occur in long standing hydrocephalus). The endoscope trochars are available in "short version" (150–160 mm) for "freehand" use (or with the aid of a holder) or "long version" (250 mm) to be used with stereotactic frame.

Angle of view of the endoscope can range from 0° to 120°, according to the objective lens used. The most used are 0° and 30°. The 0° objective portray only what it is viewing head-on, minimizing the risk of disorientation (Siomin and Constantini 2004). The 30° objective offers some advantages:

Fig. 11. The Minop endoscope (image courtesy of Aesculap – Tuttlingen, Germany)

by simple rotation it provides an angle of view with a surface area twice as large as that obtained with 0° objective and it allows a better control of the instruments because with the 30° objective the instruments introduced in the working channel (parallel to the endoscope) converge towards the center of the image (directed at 30°), while with the 0° objective the instruments remain in the periphery of the image. Major disadvantage of angled scopes is that the indirect image may cause the surgeon to become disoriented. More than 30° angled objective are useful only to "look around the corner" (Decq 2004).

The Future: The Videoscope

The future development of the technology of the endoscopes will allow the wide diffusion of the group of Videoscopes. A videoscope is characterized by a 1 CCD chip camera positioned at the proximal tip of the endoscope.

Table 4. *List of main rod lenses neuroendoscopes suitable for endoscopic third ventriculostomy*

Manifacturer	Model	Outer diameter of the trochar	Channels*	Working channel diameter	Optic tip orientation
Aesculap[1]	neuroendoscope	6.2 mm	1 O, 1 W, 2 I/A	2.2 mm	0°, 30°
Aesculap[1]	Minop system	3.2 mm 4.6 mm 6.0 mm	1 O/W 1 O/W, 2 I/A 1 O, 1 W, 2 I/A	2.8 mm (optic/work) 2.8 mm (optic/work) 2.2 mm	0°, 30°
Codman[2]	Gaab neuroendoscope system	5.8 mm	1 O, 1 W, 2 I/A	1.6 mm	0°, 30°, 70°, 120°
Integra neuroscience[3]	neuroview 700R	5.6 mm	1 O, 1 W, 2 I/A	2.0 mm	0°, 30°, 70°
Storz[4]	Gaab neuroendoscope	6.5 mm	1 O, 1 W, 2 I/A	3.0 mm	0°, 30°, 70°, 120°
Storz[4]	Decq	Oval 3.5 mm × 5.2 mm Oval 4.0 mm × 7.0 mm	1 O, 2 W, 2 I/A 1 O, 2 W, 2 I/A	1.7 mm 3.0 mm	30°
Storz[4]	Oi-Samii Handy Pro®	Oval 3.5 × 2.5	Single space lumen	1.3 mm	0°–12°
Wolf[5]	pediatric neuroendoscope system	3.3 mm × 4.5 mm 4.8 mm × 5.8 mm	1 O, 1 or 2 W, 2 I/A	1.6 mm	0°, 25°, 70°

[1] Aesculap – Tuttlingen, Germany; Wolf, Knittlingen, Germany.

[2] Codman & Shurtleff (Johnson & Johnson) New Brunswick, NJ.

[3] NeuroNavigational (Integra NeuroSciences) Plainsboro, NJ.

[4] Karl Storz GmbH & Co., Tuttlingen, Germany.

[5] Richard Wolf, Henke-Sass, Tuttlingen, Germany.

* *O* Optic channel; *W* Working channel; *O*/*W* Optic and Work channel; *I*/*A* Irrigation/Aspiration channel.

This allows for the extreme simplification of the optical system, without the need for complex and long rod lenses systems improving at the same time significatively the quality of vision if compared to the fiberscopes. Although the 1 CCD camera is somehow less performant than the 3 CCD camera (see below) that can be used with rigid rod lenses systems and fiberscopes, the proximity of the camera to the target of vision allows for excellent magnification and sharpness of the image. Moreover, the steerable properties of the device are preserved because of the lack of rigid lens systems. Some videoscope are already commercially available for ENT use in some countries, with an outer diameter of 6–8 mm; prototypes with smaller outer diameter for neuroendoscopic use are under clinical validation studies and should be available commercially in the next 2–3 years (Kamikawa *et al.* 2001a, Kamikawa *et al.* 2001b). The real, significant advantage of this device is the excellent quality of vision (1 CCD camera like), comparable to the 1 CCD rod lens systems, associated with the steerable properties, allowing for perfect fusion of rigid and steerable systems (Fig. 12a–d).

Camera and Monitor

Two basic cameras are available: a single chip charged coupled device (CCD) and a three chip CCD. A good resolution for neuroendoscopy is available with 0.5 inches single chip cameras (resolution of 500 lines) (Schroeder *et al.* 2001). If the resolution is poor, the image needs computer-enhancement. The three chip CCD produces images of better quality (more than 800 horizontal lines) but is more expensive and heavier. So, most endoscopic system use single chip cameras. Some manifacturers produce both the type of digital cameras (David 1 and David 3, Aesculap, Tuttlingen, Germany; Image1 and Image3, Karl Storz GmbH & Co., Tuttlingen, Germany). In some models all the function can be controlled by the surgeon in the operative field. Zoom endo-lens is useful to enlarge the image section.

To achieve good quality images, a monitor with the highest possible resolution should be selected. However, the resolution of the monitor should not greatly exceed that of the camera. The size of the screen is limited by the loss of quality when an image is enlarged. In fact, one should remember that the images of the camera are displayed over an area larger than cross section of the optic cable. In monitor larger than 13 inches, the picture is enlarged too much and decreases in quality. This is especially true in case of fiberoptic endoscopes, where the spaces among the pixels may become evident. Larger monitors (19 or 20 inches) are useful for displaying multiple images (Cinalli 2004, Nobles 1998, Schroeder and Gaab 1999, Siomin and Constantini 2004).

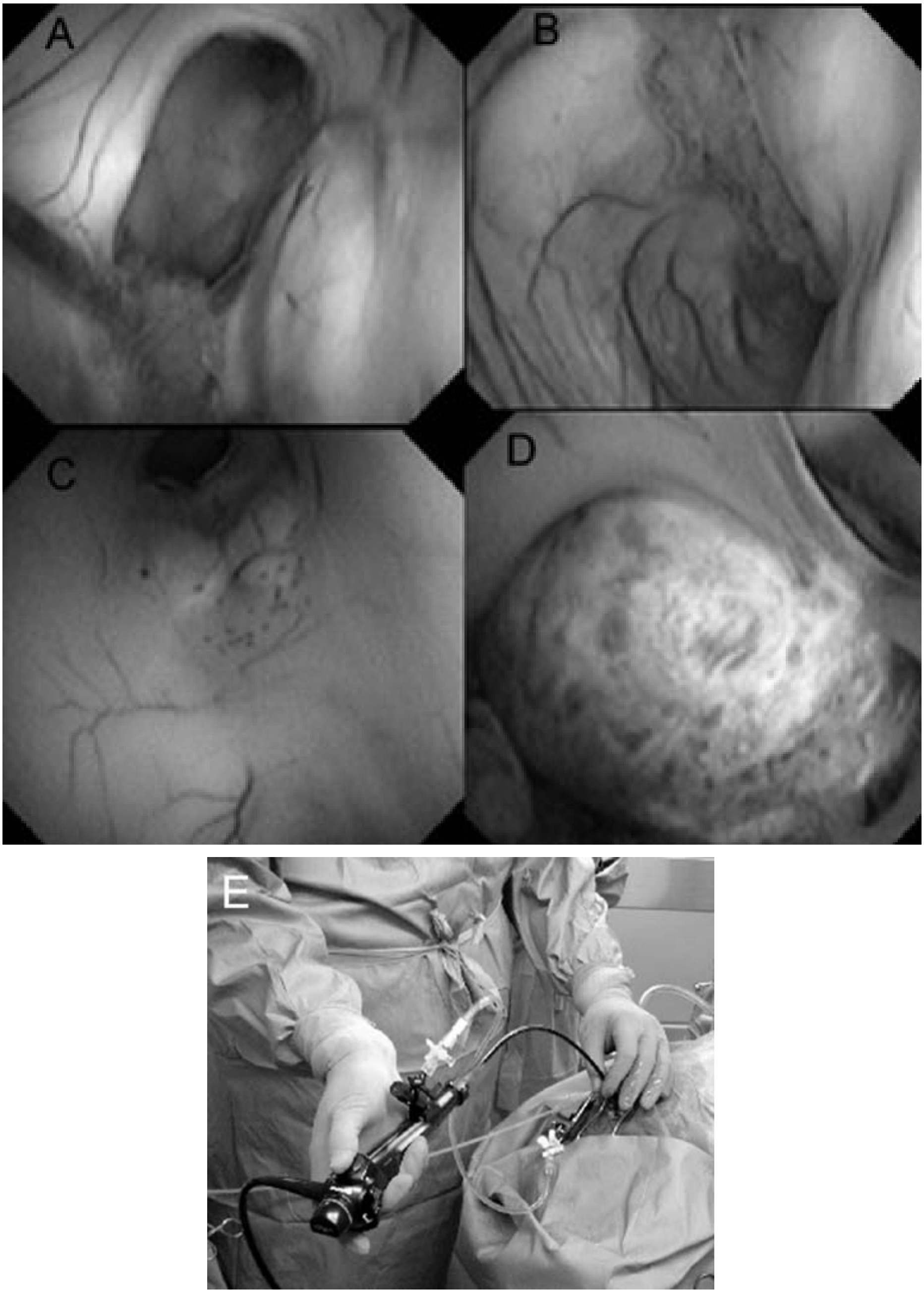
A
B
C
D
E

Illumination

Xenon light sources provide the best illumination for neuroendoscopic procedures. The light is transmitted via fiber bundles from the light fountain to the endoscope. Setting the light source to between 300 and 500 W provides a superior picture quality. Other types of light source, such as halogen, are not able to generate a light bright enough for neuroendoscopy. Siomin and Constantini (Siomin and Constantini 2004) have calculated that, due to the significant light loss in the fiberoptic system, only 30% of the light generated within the light source reaches the distal tip of the endoscope.

Accessories (Irrigation, Holders)

Imaging with an endoscope requires the clearest possible medium for optimum light with the lowest diffraction. So, irrigation is important to assure good visualization. It should be balanced by the egress of fluid. Care should be given to avoid entrapment of fluid inside the ventricle: it may lead to disastrous sequels (Cinalli 2004, Teo 2004). Irrigation can be performed simply by hand with a catheter connected to the irrigation channel of the endoscope. It can be also provided with the use of a pump irrigator for which the flow is easily controlled using a foot switch (The Malis CMS-II Irrigation Module, Codman and Shurtleff, Inc., Randolph, MA; Endoscopy Pump, Medtronic, Minneapolis, USA).

The use of a holder is sometimes advised when using a rigid rod lens endoscope. During these procedures it allows the surgeon to use both hands and two instruments through two different working channels (Fig. 13). The disadvantages of use of holders is the minor freedom of movements, especially when configuration needs to be frequently changed. However, holders with pneumatic (Fig. 14a) or electromagnetic (Fig. 14b) brakes offer a significant improvement over the mechanical systems, combining the advantages of freehand movements with the possibility of very secure and firm positioning, and are certainly the gold standard for both beginners and expert surgeons (Fig. 14c). With traditional holding devices, a precise steering of the neuroendoscope is not possible, but only a rough positioning. A new device has been developed (NeuroPilot, Aesculap, Tuttlingen, Germany) that used in combination with a pneumatic holder

◄

Fig. 12. Images of a Neuroendoscopic third ventriculostomy and pineal tumor biopsy obtained with a prototype of videoscope (Olympus opt, Tokyo, Japan). (a) foramen of Monro. (b) ventricular trigone with choroids plexus. (c) from up to down, stoma of the ETV, mammillary bodies, mesencephalic roof. (d) pineal tumor. (e) prototype of videoscope during manipulation (images courtesy of Professor Shuji Kamikawa, Isesaki Sawa Medical Association Hospital, Japan)

Fig. 13. The use of a holder allows working with both hands if two working channels are available (image courtesy of Dr. Philippe Decq, Hopital Henri Mondor, Paris, France)

(Unitrac, Aesculap, Tuttlingen, Germany) allows, after positioning of the neuroendoscope, fine, sub-millimetric adjustment in the three dimensional space by three screws.

Neuronavigation and Stereotaxy

Stereotactic guidance was used before the advent of neuroendoscopy to perform third ventriculostomy (Hoffman *et al.* 1980, Kelly 1991) and was used in association with neuroendoscopy by several authors at the beginning of their experience (Grunert *et al.* 1994, Hellwig *et al.* 1998b, Hopf 1999a). In fact, stereotactic guidance can be of some value only in choosing the correct entry point and entering the lateral ventricle in a small-sized ventricular system. The limit of the technique is that the stereotactic frames are bulky and sometimes interfere with the endoscopic procedures and most importantly, frame-based stereotactic systems do not provide an ongoing intraoperative feedback to the surgeon about anatomical structures encountered in the surgical field (Tirakotai *et al.* 2004).

A good alternative to traditional stereotactic frames can be the combination with frameless neuronavigation (Alberti *et al.* 2001, Broggi *et al.* 2000, Hopf *et al.* 1999a, Riegel *et al.* 2000, Riegel *et al.* 2002, Schroeder *et al.* 2001, Tirakotai *et al.* 2004). Unlike based stereotaxis, frame-less navigation is still useful for intraoperative orientation, especially in cases of impaired visualization, distorted anatomy or narrowed ventricles. In endoscopic third ventriculostomy, the use of neuronavigation may not be

Fig. 14. (a) Holder Unitrac Aesculap: Pneumatically assisted holder (image courtesy of Aesculap – Tuttlingen, Germany). (b) the Storz-Mitaka arm. (c) the Endo-Arm from Olympus

necessary (Schroeder *et al.* 2001); however, in cases with thickened, non-translucent third ventricular floors, neuronavigation is useful for anatomical orientation (Alberti *et al.* 2001, Tirakotai *et al.* 2004). Brain shift can be a major factor in influencing the accuracy of the target localization. This problem occurs less often if some precautions are taken to prevent the abrupt change of CSF compartments or cystic lesion. The position of the burr hole should be at the highest point in order to minimize CSF loss. Moreover, brain distortion occurs rarely in midline structures and most endoscopic procedures use midline structures as anatomical landmarks.

Neuronavigation requires a rigid three-pin head fixation, difficult to obtain in case of younger babies. Moreover the neuronavigation can be coupled only with rigid endoscopes.

Equipment for neuronavigation coupled with neuroendoscopy has been discussed in a recent paper by Tirakotai *et al.* (Tirakotai *et al.* 2004).

Operative Instruments

Operative instruments for neuroendoscopy include sharp micro scissor, blunt micro scissor, biopsy forceps, grasping forceps, monopolar and bipolar electrodes.

Floor Perforation

The perforation of the floor can be achieved mechanically (by either a sharp instrument or, in combination with more force, a blunt instrument), electrically or with the aid of a laser.

Perforation With the Endoscope Itself

The endoscope can be gently pushed through the floor behind the clivus, stretching the fibers of the floor progressively until complete perforation is achieved and entry into the subarachnoid spaces is ensured by the sudden, direct visualization of the anatomical structures of the interpeduncular cistern (El-Dawlatly *et al.* 1999, El-Dawlatly *et al.* 2000, Teo and Jones 1996). This technique has several inconveniences: the traction on the floor can be significant and it is directly transmitted to the hypothalamic structures situated above. Until perforation is achieved this is a blind procedure, with no visual control of the depth reached by the endoscope or of the space remaining behind the membrane to be perforated.

Monopolar or Bipolar Coagulation

It is the most widely used technique (Cinalli 2004, Hellwig *et al.* 1999, Sainte-Rose and Chumas 1996). The advantages are evident. The point at which to perforate can be precisely chosen: if the floor is translucent, the tip of the coagulating wire can be positioned where the interpeduncular cistern is wider, as far as possible from the basilar bifurcation. Without applying cautery current, the tip of the wire can be used as a probe to "palpate" the floor of the third ventricle or to pierce it (Siomin and Constantini 2004). The coagulation is especially useful when the floor is very large and floating in the lumen of the ventricle: it allows the catheter tip to adhere to the chosen point, avoiding the natural tendency of the tip to slide. Coagulation should be used at the lowest effective energy to bring about coagulation of the floor. In most cases it is not necessary to maintain the coagulation until the perforation is achieved. A very short coagulation (<1 s) is usually sufficient to weaken the floor enough to allow perforation easily and atraumatically with the inactive probe, avoiding the risk of entering the interpeduncular cistern with an electric device on.

Both monopolar and bipolar coagulation are useful in this regard. Coagulation is also useful to achieve hemostasis. Most bleedings are venous with a slow flow, and can be managed only with irrigation. Sometimes a Fogarty balloon can be used to tamponade a bleeding vessel or the margins of a cutting (i.e. the stoma in the floor of the third ventricle). However, in some instances, neurosurgeon must appeal to coagulation to achieve hemostasis. Monopolar cautery can be used in both cutting and coagulation modes to achieve fenestration, dissection or cauterisation. The use of electrical current can be associated with some problems (Vandertop *et al.* 1998). The pathway of the currents flowing out of a tip cannot be controlled because the fluid in the ventricles is conductive and the current flows along the way of least resistance. Moreover energy losses caused by resistance in the leads makes them less efficient, so that very high currents could be necessary. Thus, tissue adherence and thermal damage of surrounding neural tissue are the major limitations of these instruments. However, the thermal damage to the hypothalamic region following coagulation has never been accurately studied. It may perhaps explain the fever sometimes observed after third ventriculostomy (Decq *et al.* 2000, Decq 2004, Sainte-Rose and Chumas 1996). Because of these problems, Heilman and Cohen (Heilman and Cohen 1991) invented a "saline torch": a device that sends a jet of saline past a monopolar wire. The saline acts as a conductor and coagulation can be achieved without direct contact with the probe (Shiau and King 1998).

Bipolar cautery may represent a more controlled method of coagulation: it has demonstrated minimal current spread; it permits sharply demarcated coagulation fields and precise cuts; damage to lateral or underlying structures is kept to a minimum. Therefore, bipolar coagulator should be preferred (Shiau and King 1998). The simplest way to achieve bipolar coagulation is through a fork electrode (Aesculap 2.1-mm fork electrode). The use of grasping bipolar forceps (2.5 mm – Codman & Shurtleff, Johnson & Johnson, Raynham, MA) allows the surgeon to pick up tissue for dissection and fenestration, and to coagulate vessels of more than 2 mm in diameter. Riegel *et al.* (Riegel *et al.* 2002) developed a new microbipolar forceps (ERBE Elektromedizin GmbH, Tübingen, Germany) that can be used for grasping, dissection, dilation, shrinkage of tissue, and precise coagulation even of larger vessels. The branches of the forceps are moved via elastic deformation of the metal without the use of a mechanical joint of

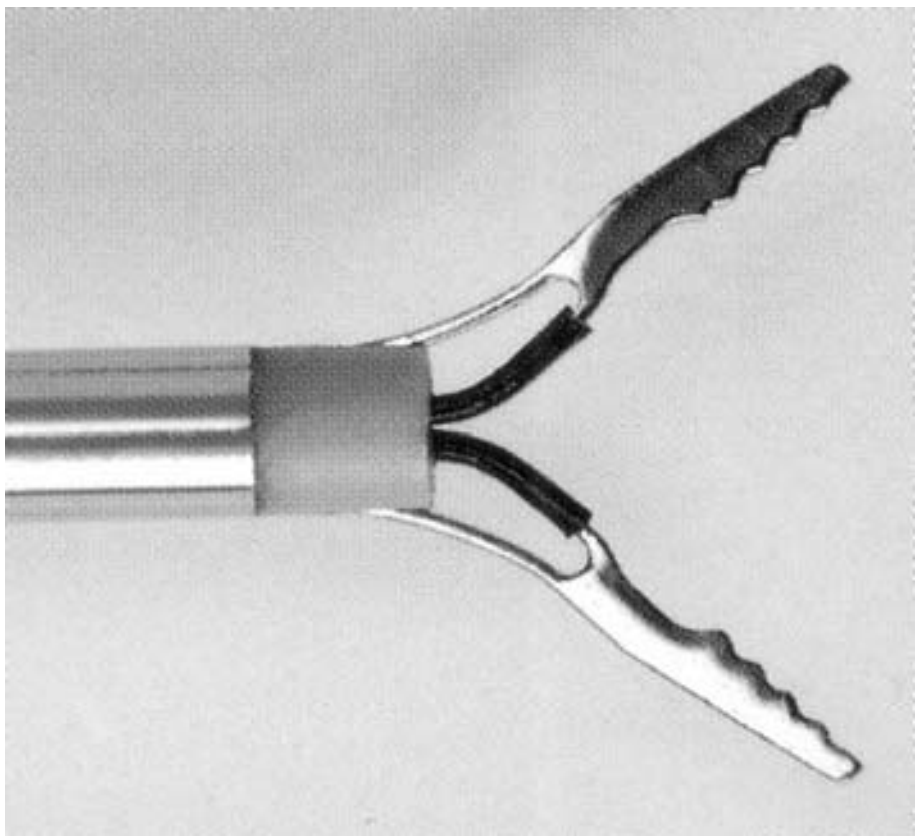

Fig. 15. The lack of mechanical joint allows very slow and delicate movements in this bipolar forceps produced by ERBE (Courtesy of ERBE Elektromedizin GmbH, Tübingen, Germany)

any kind (Fig. 15). The instrument has a outer diameter of 1.5 mm along its entire length and is compatible with most working channels of neuroendoscopes. It can be opened up to a width of 6 mm. So, it can be used either to perforate or to enlarge the stoma. Bipolar electrodes of different shape are also available and are extremely effective for coagulation and perforation (Fig. 16).

Decq Forceps

Also this instrument can perforate the floor and enlarge the stoma (Decq *et al.* 2000). It is a modified endoscopic flexible grasping forcep with an outer diameter less than 1 mm, allowing it to be used with working channels of virtually all endoscopes. The tip is thin enough to allow easy perforation of the floor of the ventricle by the application of gentle pressure, while its pointed but blunt shape do not damage structures like vessels as a needle could.

The peculiarity of this forcep is that the inner surface is smooth whereas the outer surface presents indentations: this avoids accidental catching of vessels during closure and slipping of the edges of the stoma during opening, allowing easy dilatation with one single movement and avoiding the repeated manoeuvers that are often necessary to enlarge the first opening and that are potentially hazardous (Fig. 17a–c). The opening is approximately 4 mm in diameter. The advantage of this forcep is that it combines a thin, almost pointed tip with the potential for performing a gentle dissection by opening the jaws, especially when the floor is thick and difficult to puncture (Cinalli 2004, Decq *et al.* 2000).

Fig. 16. Single, smooth tip bipolar electrodes allow atraumatic and small coagulation and perforation (Courtesy of ERBE Elektromedizin GmbH, Tübingen, Germany)

Laser

The physics of lasers in medicine has been reviewed by Nobles (Nobles 1998) and Siomin and Constantini (Siomin and Constantini 2004). Application of laser to tissue causes an instantaneous increase in temperature, leading to vaporization of the cells. Most lasers cannot be used in neuroendosopy, because they are not able to work through water and transmit through a miniature fiberoptic cables (600 μm and 400 μm). The only lasers suitable for neuroendoscopy are the neodymium:yttrium aluminum garnet (Nd:YAG) laser, the argon laser and the potassium-tetanyl-phosphate (KTP) laser (Nobles 1998, Shiau and King 1998, Siomin and Constantini 2004, Wharen *et al.* 1984, Wong and Lee 1996). A sharper-edge tip maximizes the cutting ability, but diminishes its coagulative properties (Shiau and King 1998). The lasers can be used in a contact or non-contact mode. Free laser light would be rapidly absorbed by the CSF with scattering and possible thermal injury to the surrounding structures (Vandertop *et al.* 1998). The contact probe offers more controlled tissue vaporization and requires less energy (Shiau and King 1998). In this case, the tip of the probe can become heat. The tip may remain hot even when the laser is off, so that care should be given to do not inadvertently damage neural tissue. Some authors have proposed the use of contact tipped Nd:YAG laser (1064 nm) (Miller 1992, Oka and Tomonaga 1992, Ymakawa 1995), although this only offers a partial solution to the problem. Vandertop *et al.* (Vandertop *et al.* 1998) propose the use of specially designed laser probes with atraumatic ball-shaped fiber tips coated with a layer of carbon particles. This allows 90% absorption of the laser light that is converted into heat,

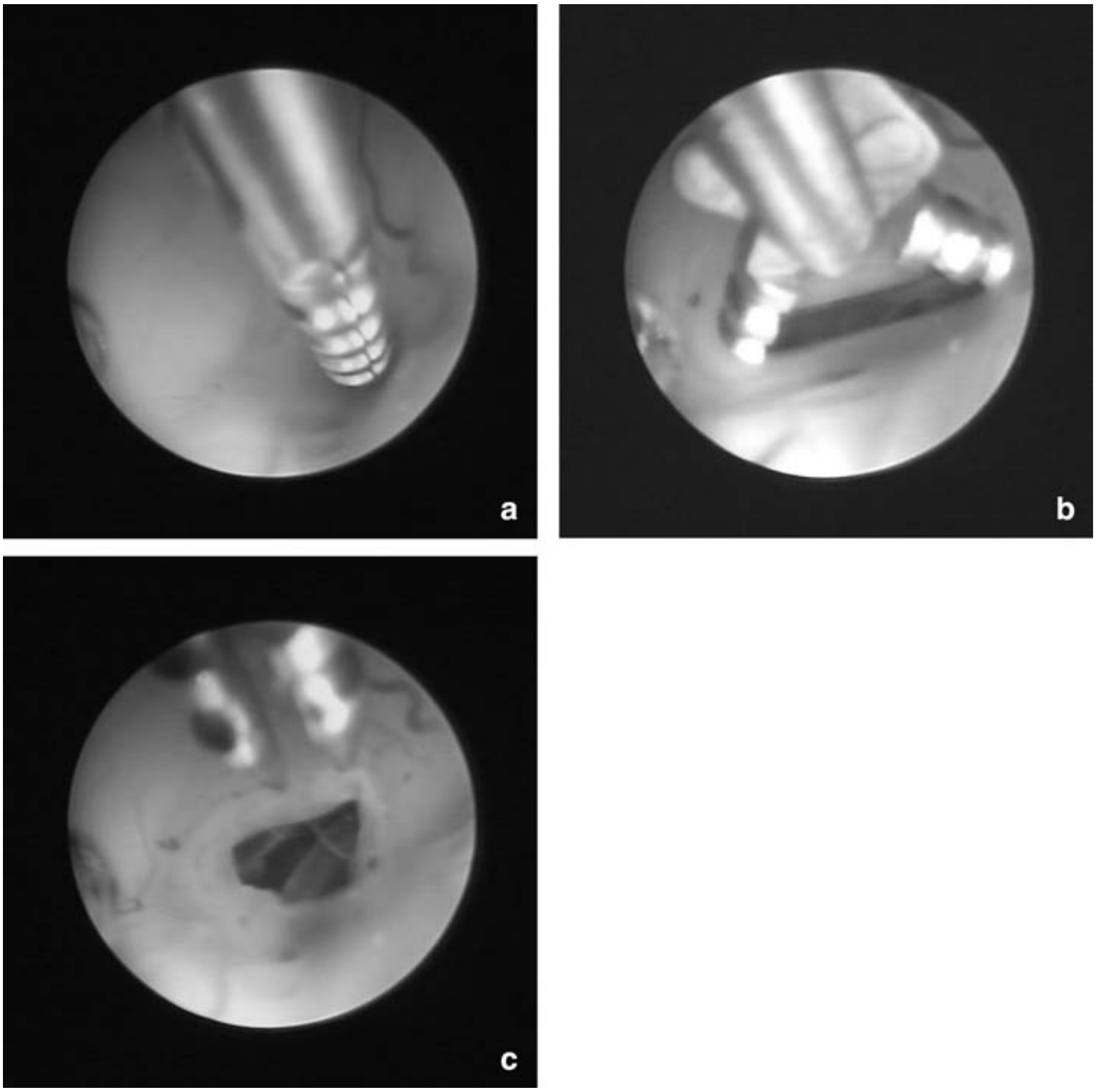

Fig. 17. The forceps described by Decq (Karl Storz GmbH & Co., Tuttlingen, Germany) present a smooth tip when closed, suitable for floor perforation (a), and indentation on the outer surface, allowing opening of the perforation (b) to a satisfying diameter (c) with one single movement (image courtesy of Dr. Philippe Decq, Hopital Henri Mondor, Creteil, France)

allowing both the amount of laser light used and the length of exposure to be reduced (Willems *et al.* 2001). Other authors (Büki *et al.* 1999) have proposed combined pulsed holmium (Ho)-Nd-YAG laser and claim that it is superior to mechanical cutting of the tissues, both for third ventriculostomy and for cyst fenestration. According to Siomin and Constantini (Siomin and Constantini 2004), the KTP laser offers some advantages on Nd: YAG laser: the emission of a visible light, that makes it easier to manipulate; an inferior tissue penetration, that makes it safer, and less dependency on tissue pigmentation, that makes it more versatile.

Nd: YAG laser and KTP laser are more useful in case of tumor removal and cyst fenestration than in case of third ventriculostomy. In fact, great care should be given when using a laser to perform a third ventriculostomy, since a case of injury of the vessels of the interpeduncolar cistern has been reported (McLaughlin *et al.* 1997).

Suction-Cutting (Grotenhuis) Device

The suction-cutting device (Synergetics), developed recently by Grotenhuis, is composed of a thin suction cannula that can be introduced through an operative channel at least 2 mm in diameter. The outer surface and the edges of the inlet of the cannula are smooth, whereas small blades are inserted into the lumen of the cannula. When the tip of the cannula comes into contact with the floor of the third ventricle, the suction hole on the handle is closed and the membrane is sucked into the lumen of the cannula. Rotation of the cannula allows section of only the tissue aspirated into the lumen, limiting the risk of accidental injury to vascular structures.

"Semisharp" Instruments

The cautious blunt perforation is usually safe, but in case of more resistant floor of the third ventricle a forceful pushing of the instruments is necessary and might be dangerous. Surgical tools specifically designed for safe perforation of a resistant and/or thick floor have a semisharp, slightly angulated tip that, directed anteriorly and pushed inferiorly along the clivus, would allow safe perforation minimizing the risk of injury of the basilar artery (Kehler *et al.* 1998).

Ultrasound Microprobes

Ultrasound microprobes have been specifically designed for use through the working channel of the endoscope (6 French) or paraendoscopically (8 French). These probes offer the major advantage of direct visualization of the anatomical structures of the interpeduncolar and prepontine cisterns and can be used for blunt perforation of the floor. This allows safer perforation under the double control of the floor of the third ventricle (endoscopic) and of the anatomical and vascular structures hidden behind the floor membrane (ultrasonographic) (Paladino *et al.* 2000, Resch and Reisch 1997, Resch and Perneczky 1998, Resch 2003) (Fig. 18a–c).

Forceps and Scissors

Instruments of various design are commercially available, suitable for rigid or flexible endoscopes. These include: grasping forceps, biopsy forceps

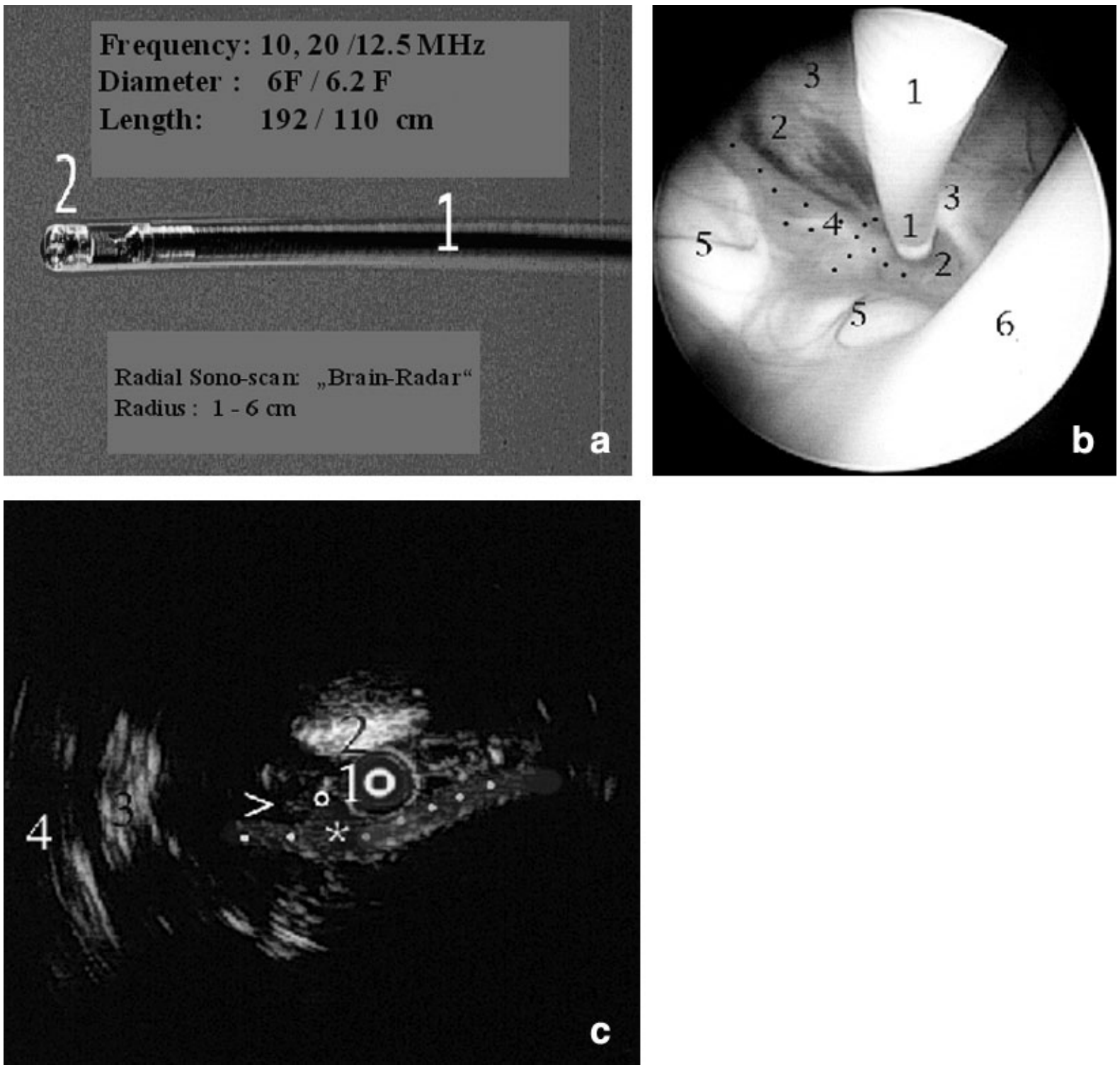

Fig. 18. (a) Probe for endosonography (*1* Sono-catheter, *2* Sono-Mini-Probe). (b) anatomic view of the third ventricle during neuroendosonography (*1* Sono-Mini-Probe, *2* Cinereum (premammillar membrane), *3* Dorsum of Sellae, *4* Basilar Head (beneath floor of 3. ventricle), *5* Mammillary Bodies, *6* Hypothalamus. (c) *1* Sono-Mini-Probe, *2* Dorsum of Sellae, *3* Oculomotor Nerve, *4* Tentorial Notch, * Basilar Artery, .. Right and Left P1

and straight or curved microscissors. Their use is finalized chiefly for tissue biopsy and fenestration of membranes. Flexible instruments for flexible-steerable fiberscope may have the disadvantage that they do not open gradually. They snap, with a short delay between the action of the hand and the effect at the tip of the instrument (Hellwig *et al.* 1998b).

Dilatation of the Stoma

After perforation of the floor, the hole obtained is usually no larger than the outer diameter of the instrument used (<2 mm). If left like this, it is bound to close rapidly because of the inflammatory reaction induced by the thermal or mechanical injury inflicted for perforation and the consequent formation of glial scar tissue.

Grasping or Biopsy Forceps

Dilatation can be achieved by introducing a grasping or biopsy forceps into the hole closed, then carefully opening it. This technique is usually relatively safe, but has several drawbacks. The dorsal surface of the forceps is smooth, so that the edges of the hole slip on this surface during opening: this necessitates several manoeuvres of opening and closing the forceps to obtain a satisfactory result, especially in the case of a thick, nontranslucent floor. These repeated manoeuvres can result in accidental grasping of a perforating vessel in the interpeduncular cistern.

Fogarty Balloon

Dilatation with a Fogarty balloon (usually 3 or 4 French) is much safer, since both the tip of the catheter and the surface of the balloon are smooth. For the same reason, the edges of the stoma slip very easily on this surface, requiring repeated inflations before the stoma is dilated to the largest diameter allowed by the balloon (4–5 mm). Fogarty catheter is the cheapest and most common used device; the balloon must be inflated with saline. This allows the balloon to inflate very gradually, without the sudden inflation that is quite traumatic and is usually observed when only air is used for inflation or too much air remains trapped within the balloon when saline is used.

Double Balloon Catheter

A balloon specifically designed for third ventriculostomy (Lighttouch balloon, Integra Neuroscience, Biot, France) offers the ideal solution since the inflatable part is a dumbbell-shaped silicone membrane. The narrowest part is marked with a black dot when the balloon is deflated. The catheter is introduced deflated into the stoma and advanced until the black dot is at the level of the floor. Unlike Fogarthy balloon, the double balloon catheter must be inflated with air. The proximal part inflates first, then the distal one (Fig. 19). The floor membrane remains trapped between the two balloons and the stoma is gently dilated with further air inflation to the largest extent allowed with one single maneuver. This technique remains by far the simplest, safest, and fastest and should be recommended. However, the outer diameter of the available double balloon catheter is larger than 1 mm and cannot be used in small instrument channels.

The "Urological" Device

A variant of the balloon technique has been proposed using instruments designed for stone extraction in urological endoscopic surgery (Wong and

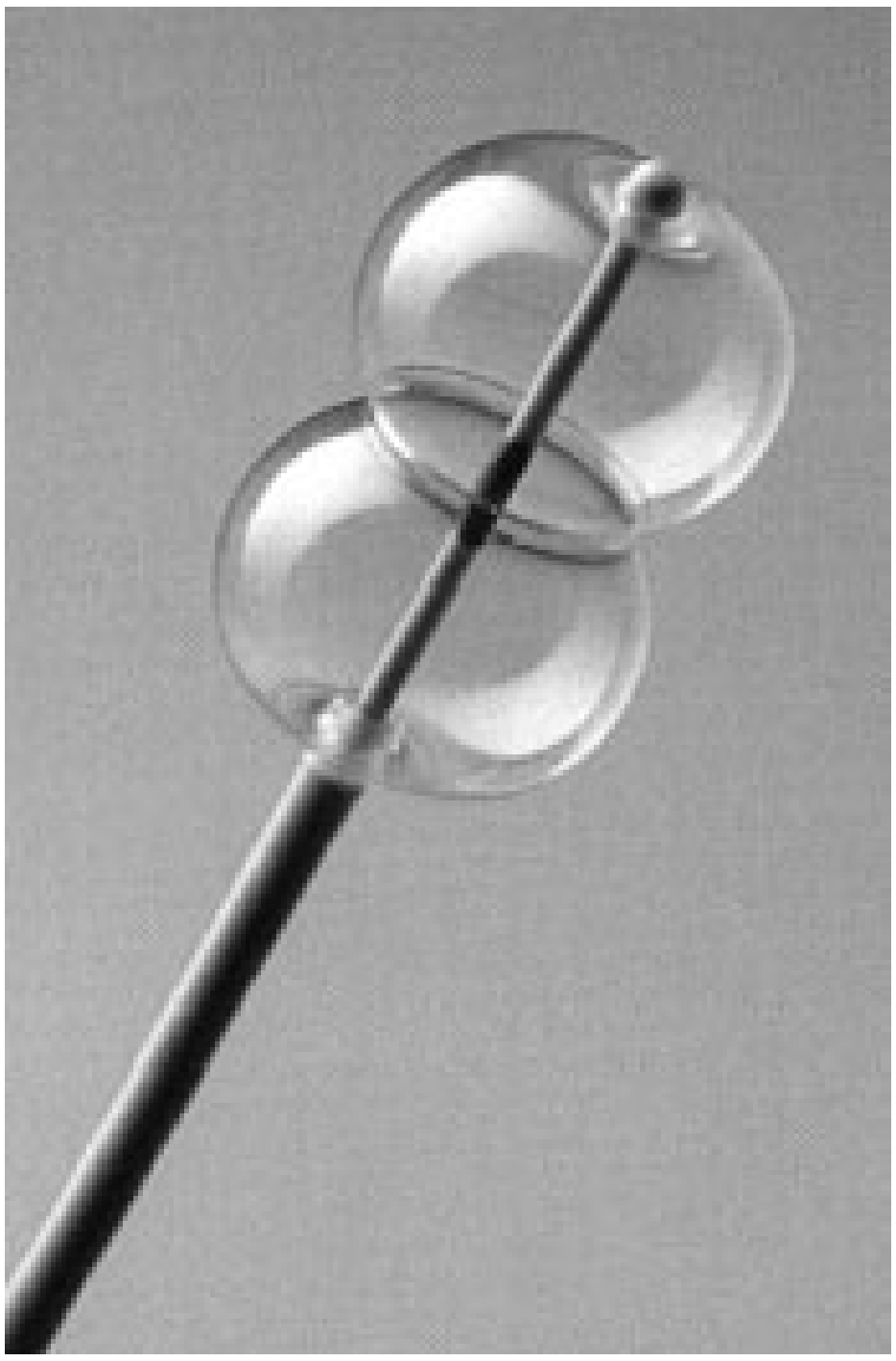

Fig. 19. The light-touch balloon is dumbbell shaped, in order to allow the floor membrane not to slide over the smooth surface of a normal Fogharty balloon. With this shape one single inflation is possible to obtain the largest dilatation (image courtesy of Integra Neuroscience, Plainsboro, NJ)

Lee 1996). The device is composed by a four-flat-wire basket tip that has a 1-mm outer diameter when closed. When opened it has a basket-like shape that enlarges the stoma by tearing the edges. The risk of catching a small vessel within the wires of the basket during closure reduces the advantages of this device compared to a Fogarty balloon.

Decq Forceps

As already discussed this is an useful tool to both perforate and dilate the floor. The inner surface of the forceps is smooth avoiding accidental catching of vessels during closure, while the outer surface presents indentations, avoiding the slipping of the edges of the stoma during opening, allowing dilatation with one single movement.

Opening of Liliequist's Membrane

The opening of Liliequist's membrane requires delicate surgical manipulation, since it can be more difficult to perforate than the floor of the third ventricle itself. Bipolar coagulation should be preferred; monopolar coagulation should be avoided because of the proximity of the basilar artery. In any case, only smooth instruments should be used at this level and the grasping forceps should also be avoided.

Disclosures: The authors have no financial interest in the material presented and discussed in this chapter.

Indications

A correct clinical indication is the most important factor influencing the success rate of ETV. Advances in MR imaging have improved the understanding of the specific physiopathologic mechanism at the base of the different forms of hydrocephalus consequently representing an essential adjunct for the correct patient selection. A more accurate preoperative diagnosis of mixed types of communicating hydrocephalus, where obstructive factors may still play a role, has lead to extend the indications for ETV to patients once excluded, namely subjects with posthemorrhagic hydrocephalus, postinfectious hydrocephalus and hydrocephalus in myelomeningocele. However, several points are still under discussion. The first is the role of age. In past years, many authors reported low success rates in infants independently from hydrocephalus etiology (Buxton *et al.* 1998a, Buxton *et al.* 1998b, Hopf *et al.* 1999b, Kim *et al.* 2000). Actually an increasing number of papers have challenged this assumption recently. In fact, when infants with pure obstructive hydrocephalus are considered, success rates up to 85% were reported (Beems and Grotenhuis, 2002, Javadpour *et al.* 2001). A second important point that has merged in recent years is that the primary hydrocephalus features may change in time in some patients; for example, "reopening" of subarachnoid spaces may occur in cases of posthemorrhagic or postinfectious hydrocephalus in children who initially presented with purely communicating forms of hydrocephalus; an acquired aqueductal stenosis is propounded as the long term main etiological factor accounting for the hydrocephalus persistence (Cinalli *et al.* 1998, Smyth *et al.* 2003).

Pure Obstructive Hydrocephalus

Aqueductal Stenosis

Aqueductal stenosis (AS) is responsible for 6–66% of cases of hydrocephalus in children and 5–49% in adults (Hirsch *et al.* 1986). Many classifications of this clinical condition were proposed; the first and most important distinction is between primary stenosis, due to intrinsic pathology of the aqueduct itself and secondary stenosis, which follows a compression of the aqueduct from mass lesions (i.e. tectal tumors, pineal region tumors, Galen vein region vascular malformations) or in patients with communicating hydrocephalus from excessive dilatation of the occipital horns.

Primary Aqueductal Stenosis

Although pure primarily aqueductal stenosis is considered as a congenital condition, hydrocephalus secondary to AS is frequently diagnosed during adolescence or in adulthood. Different "evolution theories" have been proposed to explain this phenomenon. Head trauma, a small subarachnoid hemorrhage or a viral infection with benign meningitis have all been claimed as anatomic causes of aqueductal stenosis decompensation (Cinalli *et al.* 2004a, Jellinger, 1986, Lapras *et al.* 1986). A functional mechanism might also contribute: progressive enlargement of the lateral and third ventricles would lead to a distortion of the brainstem and kinking of the aqueduct (Nugent *et al.* 1979, Raimondi *et al.* 1976).

Secondary Aqueductal Stenosis

CSF flow obstruction in pure obstructive hydrocephalus may be the consequence of aqueductal compression by lesions arising within or around the Sylvian aqueduct. Tectal gliomas and hamartomas are actually considered one of the most frequent causes of this kind of condition. Unlike the majority of other diffuse brainstem tumors tectal tumors usually have an indolent clinical course, often remaining stable in size for several years (Chapman, 1990, Pollack *et al.* 1994).

Hydrocephalus in children with tectal plate tumors commonly becomes symptomatic when the tumor is small in size; indeed a circular restriction of the aqueduct occurs due to supependymal tumor growth. Brainstem clinical signs are often lacking; in most of the patients the management of hydrocephalus warrants a favorable long-term outcome (Cinalli *et al.* 2004a).

Differently from what occurs with tectal plate tumors, pineal region tumors are usually larger in size when hydrocephalus becomes clinically manifest. In these cases, Sylvian aqueduct obstruction is generally the result of a distortion of the whole mesencephalon from outside by part of the tumor (Rieger *et al.* 2000). Vascular malformations are a rare cause of secondary Sylvian aqueduct obstruction; abnormal draining veins of midbrain arteriovenous malformations may obstruct the CSF flow crossing the aqueduct so as large fusiform aneurysms of the basilar artery. Hydrocephalus in children with vein of Galen aneurysms has a multifactorial origin; beside venous hypertension a tectal plate compression and tonsillar herniation may contribute to the development of hydrocephalus (Russell, 1940). On these grounds, ETV may be considered in children with persistent hydrocephalus after aneurysm/AVM endovascular treatment according to Cinalli *et al.* (Cinalli *et al.* 2004a).

Pathogenesis of Hydrocephalus in Patients With Aqueductal Stenosis

It is actually accepted that CSF flow through the aqueduct is not unidirectional but has a systolic and a dyastolic cycle. According to recent MRI studies, a downward displacement of CSF would occur during systole. The decrease of blood volume and the recoil of CSF displaced in the lumbar sac during the dyastolic phase of the cardiac cycle would lead to a partial upward reversal of CSF flow. A net downward movement of CSF will result, corrisponding to CSF production (0.0067 ml × s) (Enzmann and Pelec, 1991, Quencer *et al.* 1990). Changes in aqueductal size and shape alter this volume flow rate and pattern. In aqueductal stenosis a decrease of CSF flow and an increase up to ten times of its normal velocity occurs, with a consequent increase of wall shear stresses (Jacobson *et al.* 1999). Increasing pressure within the aqueduct may be responsible for secondary gliosis and for a progressive narrowing; in the "forking form", CSF flow turbulence and stasis further contribute to CSF accumulation. The consequent increase of CSF pulsations during systole lead to periventricular edema, partial displacement of blood from parenchymal vessels and further accumulation of CSF in the lateral and third ventricles (Cinalli *et al.*, 2004a).

The role of CSF pulsations in the pathogenesis of ventricular dilatation in this kind of hydrocephalus is confirmed by a previous experimental work done at our institution. In this experience, the effects of increasing the amplitude of the intraventricular CSF pulse pressure in lambs was studied. Intraventricular pulse pressure was artificially modified by inserting a pulsating balloon inside the lateral ventricles; modifications of ICP waves, mean CSF pressure and ventricular anatomic structures were recorded. No significant changes in mean CSF pressure were observed. On the contrary, ICP waves were significantly modified, with maximal changes when the mechanical pulses were in phase with the physiological (arterial) ones. Moreover, an increase of ventricular volume, with the pathological evidence of stretching of the ependymal layers and periventricular white matter spongiosis was already obtained when the amplitude of the pulse intraventricular pressure was increased three times the basal value. In the animals, in which the intraventricular pulse pressure was mechanically increased as much as six times the control value, a necrotic lesion of the periventricular structures, associated with the ventricular dilatation, occurred (Pettorossi *et al.* 1978).

An alternative pathophysiological mechanism has been proposed in infants in order to explain the relatively less satisfactory results of ETV in this specific subset of patients. Oi *et al.* (Oi *et al.* 2004) prospectively analyzed 12 infantile cases of aqueductal stenosis with CT ventriculocisternography. Nine of them revealed to have a predominant transependymal intraparenchymal CSF outflow, with a minor involvement of the aqueduct pathway. On these grounds, the authors proposed that CSF dynamics undergo an evolutionary mechanism: a transependymal CSF absorption (also defined as minor pathway) would be favored in neonates and infants due to the incomplete development of Pacchionian bodies; once ended, the maturation process of subarachnoid spaces the CSF flow through the aqueduct (major pathway) and to the cranial vault would prevail.

Analysis of Results of ETV in Patients With Primary and Secondary Aqueductal Stenosis

Aqueductal stenosis is considered the ideal indication for third ventriculostomy. When patients with an exclusively obstructive triventricular hydrocephalus are selected, the success rate is quite homogeneous and stable, being between 63% and 92% in most series (Böschert *et al.* 2003). The influence of age on the final result has been long discussed. Jones *et al.* (Jones *et al.* 1994) reported a 40% success rate of ventriculostomy in children with triventricular hydrocephalus operated on within the age of two years. For the same pathology with a clinical onset within the age of two years, but operated on later in childhood and adolescence the success rate increased to 71%. Kim *et al.* (Kim *et al.* 2000) reported age as a significant predictor of outcome. Of the six patients younger than one year of age, only two (33.3%) had good outcomes, whereas 19 out of 23 patients older than one year of age (82.6%) were successfully treated with ETV. Similar results were reported by Grunert *et al.* (Grunert *et al.* 2003): in their personal experience a statistically worse success rate was found in infants (22.3%) if compared with children aged over one year (71.4%) and adults (81.6%). Incomplete development of the subarachnoid spaces and consequent impairment of CSF absorption are the main factors which are claimed to explain why ETV fails more frequently in infants (Buxton *et al.* 1998a, Buxton *et al.* 1998b, Hopf *et al.* 1999b, Kim *et al.* 2000). However, considering exclusively children with pure obstructive hydrocephalus, other factors might have influenced the reported ETV failure rate in infants. First of all, in most of these series a second endoscopic view was never or not always performed, in order to estabilish ventriculostomy patency and this factor might further have negatively influenced the overall outcome. In a multicenter study Siomin *et al.* (Siomin *et al.* 2001) reported repeat ETV as effective as primary procedures with an overall 65% success rate. Javadpour *et al.* (Javadpour *et al.* 2001) analyzed the ETV success rate in a series of 21 infants with obstructive hydrocephalus. The success rate in 7 infants with congenital aqueductal stenosis was 71%; a redo third ventriculostomy was performed with success in one of the two initial failures with a final success rate of 86%. In a recent personal communication, Wagner *et al.* (Wagner and Koch, 2004) confirmed this finding, reporting the occlusion of the ventriculostomy site as the most frequent factor causing ETV failure in infants. The lower ICP with slowing of CSF flow through the stoma might explain ventriculostomy obstruction in this subset of patients (Böschert *et al.* 2003).

Another important point to consider is the time for defining ETV failure. According to Beems and Grotenhuis (Beems and Grotenhuis, 2002), infants have a longer adaptation time if compared with their older counterpart. Fourty-five percent of the 35 patients, aged less than two years, who underwent successful ETV at their institution required a relatively long adaptation time (mean adaptation time: 1 week). This is important to recognize, because it means that these young patients should not be treated too soon using a shunting device if the ETV does not lead to immediate relief of the symptoms.

Finally, concerning older series, a further factor which may have lead to a lower success of ETV in infants is the adopted surgical technique. In their earliest experience Cinalli *et al.* (Cinalli *et al.* 1999) reported a higher failure rate in infants (<6 months of age) operated on under ventriculographic guidance. In a subsequent series of 119 cases with triventricular hydrocephalus who underwent endoscopic third ventriculostomy, no significant difference was found between the two groups with an overall success rate of 79% (<6 months) and 71% (>6 months) respectively. Direct visualization of the ventricle floor and the anatomical landmarks of the interpeduncular cistern under magnified conditions allow a greater safety and efficacy of the procedure. Moreover, the larger size and more precise location of the stoma in the floor of the third ventricle might play a role in young patients, in whom the risk of secondary obstruction may be high.

A further discussed point is the influence of AS etiology on the success rate of ETV procedures. Most authors report ETV as effective in primary as in secondary forms of aqueductal stenosis (Boschert *et al.* 2003, Fukuhara *et al.* 2000, Hopf *et al.*, 1999b, Rieger *et al.* 2000). Pople *et al.* (Pople *et al.* 2001) reported ETV to be effective in the control of the hydrocephalus in 17 out of 18 cases with pineal region tumors. Macarthur *et al.* (Macarthur *et al.* 2001) referred a long-term (median follow-up: 12 months) control of the hydrocephalus in 39 out of 47 pediatric patients (82.9%) with secondary neoplastic AS. Similar results were reported by Rieger *et al.* (Rieger *et al.* 2000) in a series of 7 patients with pineal region tumors. A successful control of the hydrocephalus was obtained in all cases; however six of the seven children also underwent tumor removal few days after the neuroendoscopic procedure, this factor possibly contributing to the long term results. In contrast with what previously said, Goh and Abbott (Goh and Abbott, 2000) recently reported a 49% failure rate of ETV in 63 patients with tumoral AS (mean follow-up: 11.4 months). This result compared unfavorably with their 65% success rate obtained in children with primary aqueductal stenosis. An analysis of the different series does not seem to show differences in the prevalence of tumor location. Neverthless none of the reported authors details histological types nor the presence or absence of subarachnoid tumor seeding, a factor which might specifically influence the success of ventriculocisternostomy. This is particularly true for some pineal region tumors (i.e. germinal cell tumors) and it is confirmed by the fact that when exclusively benign lesions are selected (i.e. tectal plate gliomas) the success rates of ETV are almost homogeneous (ranging between 65% and 100%) and comparable with those obtained in patients with primary AS (Grunert *et al.* 2003, Macarthur *et al.* 2001). Moreover, as part of the therapeutic protocol, endoscopic tumor biopsy was combined with ETV in selected cases of some of these series; either minor intraoperative bleeding and/or increase in CSF proteins which can follow the bioptic step of endoscopic surgical procedures may condition the functional patency of the ventriculostomy site.

Another point that has been investigated in recent years is the role of ETV as secondary procedure in children with AS and previously implanted malfunctioning or infected shunt. Most series report results comparable to those obtained in primary procedures with overall success rates ranging from 62.9 to 82.3% (Böschert *et al.* 2003, Cinalli *et al.* 2004). The relative variability of these results can again be ascribed to different selection criteria and different methods in the evaluation of results. Böschert *et al.* (Böschert *et al.* 2003) found that two of the three failures in their seventeen patients series occurred in children with shunt malfunction and a previous history of shunt infection, suggesting a concurrent CSF absorption impairment in the pathogenesis of the hydrocephalus for these cases. However, other authors have pointed out that previous shunt infections or infected shunt malfunctions do not influence outcome. Jones *et al.* (Jones *et al.* 1990) reported on 4 patients having ETV for AS and infected shunt malfunction having a 75% success rate. Buxton *et al.* (Buxton *et al.* 2003) referred that 33% of their 88 patients had previously suffered one or more shunt infection, but they did not observe significant differences in their outcome if compared with those who did not have a history of an infected shunt.

Regarding evaluation of results Cinalli *et al.* (Cinalli *et al.* 1998) reported 30 patients, having a 76.7% ETV success rate, but many patients in their series were left with a potentially patent shunt in situ; only seven patients were left in the initial stages to rely on the NTV alone (6 with their shunts removed and one with it clipped). More stringent criteria were used by Buxton *et al.* (Buxton *et al.*, 2003) who retrospectively analyzed a personal series of 27 children with AS who underwent secondary third ventriculostomy at their institution. The shunt was removed or tied off in the neck in all cases; the final success rate was 62.9%.

Hydrocephalus in Posterior Cranial Fossa Tumors

The incidence of preoperative hydrocephalus in children with posterior fossa tumors is around 60–80%; however only 15–25% of these patients require a permanent "shunting" procedure. Younger age, the severity of hydrocephalus at diagnosis, midline tumor localization, degree of tumor removal and the use of substitute dural grafts are all factors considered to increase this risk (Sainte-Rose *et al.* 2001).

Pathogenesis

The development of hydrocephalus in children with posterior fossa tumors is directly related at diagnosis with the nature and localization of the tumor. Tumors arising or secondarily filling the IV ventricle primarily obstruct the ventricular cavity and its foraminal outlets. On the other hand, cerebellar hemisphere tumors induce an anatomical distortion of the fourth ventricle with a secondary occlusion of CSF pathways. In patients with malignant tumors, subarachnoid seeding may contribute, impairing CSF absorption. Though, logically, tumor removal should re-estabilish the communication between the fourth ventricle cavity and the subarachnoid spaces one-fourth to one third of these patients remain hydrocephalic (Sainte-Rose 2004). In the immediate postoperative period the surgical subarachnoid hemorrhage and the presence of cerebellar swelling may contribute to increase the resistance in CSF circulation. Subsequently the development of adhesions at the level of the fourth ventricle outlets and the adjacent cisterns may permanently alter CSF dynamics.

Management Strategies: The Role of ETV

Different protocols have been proposed for the management of hydrocephalus in children with posterior fossa tumors. Actually, most pediatric neurosurgeons use a combination of corticosteroids, early tumor surgery and external ventricular drainage where needed (Fritsch *et al.* 2004, Sainte-Rose 2004). Children with persistent postoperative hydrocephalus can be alternatively treated with ETV or shunt implantation. An important drawback of this protocol is the risk of CSF infections which is related with external ventricular drainage positioning (10% in the series of Rappaport and Shalit; 4.9% in the series of Schmid) (Rappaport and Shalit, 1989, Schmid and Seiler, 1986); upward brainstem herniation and intracranial hemorrhages have been also described.

Due to its relatively recent employment there is a noticeable lack of information about the role of ETV in the management of persistent hydrocephalus after posterior fossa tumor surgery. The reported successes vary from 50% (Jones *et al.* 1990, Ruggiero *et al.* 2004) to 100% (Sainte-Rose *et al.* 2001).

An alternative management strategy has been proposed by Sainte-Rose *et al.* (Sainte-Rose *et al.* 2001). Sixty-seven patients affected by posterior fossa tumors and hydrocephalus underwent endoscopic third ventriculostomy prior to tumor removal; postoperatively four of them (6%) required a second shunting procedure. A comparable group of 82 children underwent tumor removal as first surgical step; the rate of postoperative hydrocephalus in this subset of patients was 26.8%, significantly higher than in the first group ($p = 0.001$). However, the same authors acknowledge that the routine application of preoperative third ventriculostomy results in a proportion of patients undergoing an "unnecessary" procedure. The overall "shunting" rate in their preoperative ventriculostomy group was 106%. A further possible factor against preoperative ETV is the risk that surgical subarachnoid hemorrhage may induce the occlusion of the stoma within the floor of the third ventricle. Indeed, the role of preoperative ETV in "preventing" postoperative hydrocephalus has not been confirmed in more recent series. Ruggiero *et al.* (Ruggiero *et al.* 2004), performed ETV in 20 children with posterior fossa tumors preoperatively. One of the procedures was complicated by intraventricular bleeding requiring an external ventricular drainage and subsequent VP shunt implantation. Three of the remaining 19 patients developed postoperative hydrocephalus with a final 20% postoperative shunting rate. This percentage was comparable in their experience with the 15% rate of persistent hydrocephalus in children who underwent tumor removal as first surgical step.

Hydrocephalus With Possible Subarachnoid Spaces Impairment

Posthemorrhagic Hydrocephalus of Premature Infants

Between twenty and seventy-four percent of infants suffering an intraventricular haemorrhage (IVH) will go on to develop posthemorrhagic hydrocephalus (Boop 2004). It is important to remember that progressive ventricular dilatation in these patients does not represent always a pressure-related phenomenon. It may indeed represent an ex vacuo manifestation related to loss of brain substance as a result of venous infarction or periventricular white matter ischemia; this kind of evolution is more frequent when an hypoxic-ischemic encephalopathy is associated. In some other instances, a combination of volume loss and slowly progressive hydrocephalus occurs, making it difficult to determine whether to treat or follow the infant conservatively (Siomin *et al.* 2002). These factors may help to explain the variability of reported posthemorrhagic hydrocephalus rates and the differences in the surgical indications that may be found in the literature.

Pathogenesis

Posthemorrhagic hydrocephalus is presumed to develop as a consequence of the breakdown of blood products and cellular debris within the ventricular system. These blood products in turn cause chemical arachnoiditis and a fibrotic reaction within the ventricles and the arachnoid granulations, leading to granular ependymitis and adhesive arachnoiditis (Hill and Volpe, 1981). CSF flow studies seem to confirm this hypothesis, suggesting that it is an impairment of CSF circulation over the cerebellum and up to the cerebral vault subarachnoid spaces which is implicated in the pathogenesis of hydrocephalus in premature infants. This would explain why, in most cases, the increased intracranial pressure and full fontanel can be ameliorated with lumbar punctures temporarily (Roland and Hill, 1997). However, in some instances, infants with IVH develop a purely triventricular hydrocephalus. Kreusser *et al.* (Kreusser *et al.* 1985) attempted serial lumbar punctures as temporary management of hydrocephalus in 16 infants; this procedure was unsuccessful in four of them who all presented a triventricular hydrocephalus at neuroradiological investigations. On these grounds, the authors suggested that, in selected cases, a blood debris may alter CSF circulation by obstructing the posterior third ventricle and/or the Sylvian aqueduct selectively. This hypothesis seems to be confirmed by the recent description of infants with an apparently pure aqueductal stenosis that had suffered a fetal IVH, documented by prenatal MRI and/or by neonatal endoscopic findings previously (Beni-Adani *et al.* 2004). An evolutionary mechanism has also been suggested for cases initially presenting with an apparently communicating hydrocephalus, and hence primarily shunted, who underwent a successful third ventriculostomy at the time of shunt malfunction. In these specific cases, a reopening of subarachnoid spaces may occur as a consequence of the reabsorption of subarachnoid blood debris (Siomin *et al.* 2002, Smyth *et al.* 2003); moreover, the CSF produced by the choroid plexus of the fourth ventricle, during the shunting period, may maintain the absorptive function of the arachnoid granulations, furtherly improved by the persisting reduction of intraventricular pressure. Consequently, at the time ETV is performed, the access to previously impaired CSF absorption spaces can be obtained, by-passing a persistent obstruction at the level of the Sylvian aqueduct and/or the IV ventricle outlets (Siomin *et al.* 2002).

Results of ETV in Infants and Children With Posthemorrhagic Hydrocephalus

In the past, a history of hemorrhage was considered as a contraindication for ETV, because most patients were considered to suffer a communicating form of hydrocephalus. With the extension of the indications, an increasing number of patients with hydrocephalus and a history of ventricular hemorrhage has been included in ETV management protocols. Actually, the most relevant paper that can be found in the literature is the one of Siomin *et al.* (Siomin *et al.* 2002) reporting the results of a multicentric retrospective study on the role of ETV in children with posthemorrhagic and postinfectious hydrocephalus. Overall 36 children suffered a history of hemorrhage with an ETV success rate of 55.6%. A striking difference was documented between primary and secondary ETV procedures. At a mean follow-up of 1.87 ± 1.6 years, the 13 posthemorrhagic patients who had primarily received a VP shunt had a 100% ETV success rate. On the other hand, all the premature infants in whom ETV was performed as first line of treatment subsequently required a shunt. This result is confirmed by other authors. Buxton *et al.* (Buxton *et al.* 1998b) reported on 16 infants (mean corrected age: 8.9 months) with posthemorrhagic hydrocephalus who all underwent ETV as primary treatment for their hydrocephalus with a success rate of 30%. More recently Smyth *et al.* (Smyth *et al.* 2003) described a 71.4% success rate in 7 children (mean age: 9.2), all the successes being documented after secondary ETV procedures.

Javadpour *et al.* (Javadpour *et al.* 2001) suggested that a further mechanism which may negatively influence the results of ETV in infants with posthemorrhagic hydrocephalus is their low intracranial pressure; ICP compensating mechanisms due to expanding opened sutures may impair to build up a sufficient pressure gradient across the stoma and the arachnoid granulations, with secondary insufficient CSF reabsorption and ventriculostomy closure. In their experience only three out of ten infants were successfully treated with ETV, two of them requiring two endoscopic procedures, because of first closure of the ventriculostomy.

Two further factors that influenced the outcome of infants who had undergone ETV in the multicentric study of Siomin *et al.* (Siomin *et al.* 2002) were a history of associated CSF infection (the overall ETV success rate in this specific subset of patients was 10%) and the time interval between the onset of hydrocephalus and ETV (mean temporal gap of 6.34 ± 8.31 years successful results versus 3.15 ± 5.16 years for treatment failures). The latter factor probably influenced the results obtained by Beems and Grotenhuis too (Beems and Grotenhuis 2002). In contrast with previous reports, these authors did not find significant difference between the results of primary (44.4%) and secondary (50%) ETV procedures; however the time interval from the hydrocephalus clinical appearance and the surgical operation was less than two years in the children who required a second procedure subsequently.

Postinfectious Hydrocephalus

In the past, postinfectious hydrocephalus was commonly considered as a communicating form of hydrocephalus, the predominant pathogenetic factor being the inflammatory obstruction of the basal cisterns and cerebral vault subarachnoid spaces. The progressing knowledge of pathophysiology in different CNS infectious diseases has lead to a reevaluation of this clinical entity that should actually be regarded as a complex disease.

Pathogenesis

The consequences of a CNS infectious disease on CSF dynamics depend on the age of the child at the time of the primary infection (prenatal, neonatal, postnatal) as well as on the infectious agent (bacterial, viral, parasitic).

Prenatal Infections. Toxoplasmosis is one of the most frequent prenatal infections involving the CNS. In this condition, the parasites invade and destroy the ependymal lining of the ventricles. In acute cases extensive necrosis of the cerebral hemispheres can be observed with associated significant cerebral tissue loss, which contributes to the ventricular enlargement. Most authors consider post-toxoplasmosis hydrocephalus a consequence of severe leptomeningeal inflammation blocking the subarachnoid spaces (Kaiser 1985, Ciurea *et al.* 2004). However, a significant percentage of these children present with purely triventricular hydrocephalus. According to the experimental model of Stahl (Stahl *et al.* 1997), the inflammatory debris may selectively obstruct, in these cases, the Sylvian aqueduct. Moreover, ventricular enlargement would lead to a compression of the midbrain further limiting CSF flow to the IV ventricle.

Another prenatal infection which is commonly related to CNS diseases is Cytomegalovirus infection. However, the occurrence rate of hydrocephalus in these children is relatively low (10–15%) (Ciurea *et al.* 2004). In most cases an extensive involvement of the cerebral structures takes place leading to a diffuse encephalomalacia and consequent ex vacuo ventricular dilatation. Patients with an active hydrocephalus usually present with a diffuse involvement of the leptomeninges, revealed by an extensive contrast enhancement on CT scans. Obstruction of the Sylvian aqueduct with consequent triventricular hydrocephalus was only occasionally described (Perlman and Argyle, 1992).

Neonatal Infections. The majority of CSF infections in the neonatal period are due to bacterial agents. A recent study on very low birth weight neonates with meningitis identified coagulase-negative staphylococci as the most common cause (43% of episodes), followed by other gram-positive bacteria (19%) and gram-negative bacteria (17%) (Doctor *et al.* 2001). The incidence of postinfective hydrocephalus in this specific subset of patients ranges between 50% and 75% (Ciurea *et al.* 2004). It usually occurs within 2–3 weeks following the initial diagnosis, but it may develop months or years after the acute phase of the disease. If hydrocephalus develops soon after the resolution of the infection it is more frequently of the communicating type with tetraventricular dilatation; obstructive forms have more commonly been described in patients developing late hydrocephalus. As in the posthemorrhagic cases, the hypothesis is that the sequence of fibrosis, thickening of the leptomeninges and consequent obliteration of the subarachnoid spaces may be reversible, with, however, the possible persistence of an impaired CSF flow at the level of the Sylvian aqueduct or the basal cisterns (Siomin *et al.* 2002). In some cases the inflammatory reaction may lead to a loculation of the CSF spaces and the formation of multiple intraventricular septations. This process is more frequent after gram-negative and mycotic infections which are associated with a more severe subependymal inflammatory reaction.

Postneonatal Infections. About 60–75% of postneonatal bacterial meningitis in children are caused by Haemophilus influenzae type B. However, hydrocephalus in these patients is uncommon occurring in less than 10% of the cases (Daoud *et al.* 1998). One of the hypothesis for this low rate is that Haemophilus B ventriculitis usually causes choroid plexuses atrophy, with consequently reduced CSF production (Ciurea *et al.* 2004). In contrast with Gram negative CSF infections, viral ventriculitis are frequently followed by the development of hydrocephalus. Viruses inclusions cause granular ependymitis and ependimal cell loss or fusion; this process frequently involves the Sylvian aqueduct leading to secondary aqueductal stenosis; however, some authors have pointed out that the damaged ependyma itself may contribute to this process because of the secondarily induced reduction in CSF transportation and replacement (Ciurea *et al.* 2004). In non endemic countries hydrocephalus, secondary to tuberculous meningitis is a rare occurrence.

It is more frequently of the communicating type and secondary to extensive meningeal involvement of the basal cisterns; in rare cases the mass effect of an intracranial tuberculoma may lead to direct or secondary aqueductal stenosis (Shoeman *et al.* 2000).

Results of ETV in Infants and Children With Postinfectious Hydrocephalus

A relatively low number of cases of infants and children with post-infectious hydrocephalus treated with ETV was reported in literature, mostly as a subgroup of combined series. In the multicentric study of Siomin *et al.* (Siomin *et al.* 2002), children with a history of meningitis, ventriculitis or shunt infection represented only 2.1% (27 cases) of all third ventriculostomies performed in seven international neurosurgical centers; at a mean follow-up of 1.87 ± 1.6 years the rate of success was 55.6% (15 cases). The severity of the infection, the number of episodes (less or more than 2), location of the inflammatory process (meninges, ventricular system, CSF shunt device) or the type of the agent (bacterial, yeast, unknown culture) did not appear to affect outcome with statistical significance. On the contrary, a history of associated hemorrhage had a negative predictive impact (ETV success rate: 10%); actually, at a review of endoscopic video recordings in this last subgroup of patients demonstrated a high incidence (53.8%) of interpeduncular fossa adhesions, a factor which might have accounted for the failure of the procedure at least in some patients.

Age was a significant factor with regards to the outcome, younger patients showing a greater rate of treatment failures. This observation was confirmed in other series and has a particular significance in infants; when patients under 2 years of age are selectively considered the reported ETV success rate ranges between 0% and 44.4% (Fukuhara *et al.*, 2000, Siomin *et al.* 2002, Smyth *et al.* 2003). The role of the age factor is further supported by the relatively high success rate reported, on the contrary, for secondary ETV procedures. For example, Smyth *et al.* (Smyth *et al.* 2003) obtained a 60% success rate in five cases of postinfective hydrocephalus, three of them primarily shunted and then treated by ETV at the time of shunt malfunction. Similarly to what propounded in cases of posthemorrhagic hydrocephalus, also in post-infectious hydrocephalus the resolution of the acute inflammatory reaction and the temporary control of CSF dynamics assured by the presence of an extrathecal CSF shunt may allow an improvement of CSF absorption mechanisms with time. ETV would then enhance the CSF access to the subarachnoid spaces by-passing a possible persistent obstruction at the level of the aqueduct or fourth ventricle outlets.

Hydrocephalus Associated with Dandy-Walker Syndrome

According to the original definition of Dandy and Blackfan, the term Dandy-Walker syndrome (DWS) indicate the association of: 1) cystic dilatation of the fourth ventricle; 2) partial or complete absence of the cerebellar vermis and 3) hydrocephalus. The remarkable variability of the pathological features of the disease has posed some problems in distinguishing this entity from other types of posterior fossa cysts, such as persistent Blake's pouch, retrocerebellar cyst, megacisterna magna and arachnoid cysts. Further difficulties were determined by the consistent controversy in the meaning of the terminology adopted by the various authors. Actually the differential diagnosis is done on radiological criteria; according to Barkovich (Barkovich *et al.* 1989), the main distinguishing factor between these different pathologies is the extension of the communication between the cystic cavity and the fourth ventricle: 1) a wide communication is documented in Dandy-Walker and Dandy Walker variant syndromes which are also characterized by a more or less extended dysgenesis of the cerebellar vermis; 2) a limited communication via the vallecula can be found in patients with mega cisterna magna; 3) a complete absence of communication occurs in posterior fossa arachnoid cysts. Hydrocephalus is typical only of children with DWS; however it is not always, in fact, associated with the disease. Hirsch (Hirsch *et al.* 1984) reported a 90% incidence of an associated hydrocephalus in their clinical series, but they argued that it could be an overestimation, since children are referred to neurosurgeons only when they develop active hydrocephalus and require surgical treatment.

Pathogenesis

The relevance of IV ventricle outlets atresia as a pathogenetic factor of hydrocephalus in children with DWS is debated; indeed the foramina of Lushcka and Magendie have occasionally been found to be patent in these patients. It has also to be considered that more than 80% of Dandy-Walker infants are not hydrocephalic at birth (Cinalli *et al.* 2004b). Shaw *et al.* (Shaw *et al.* 1995) described atresia of one or both foramina of Lushcka in 20% of autoptic normal brains. Barr (Barr, 1948) observed nonpatency of the foramina of Magendie in 1% of autopsies. On these grounds other factors have been claimed to contribute to the development of hydrocephalus in these patients. Aqueductal stenosis, due to a primary development defect or secondary to herniation of the vermis may be important in some specific cases (Cinalli *et al.* 2004b). Furthermore, the obstruction of CSF flow can also be distal to the outlets of the fourth ventricle. Glasauer (Glasauer, 1975) noted at isotope cisternography that occasionally the subarachnoid space anterior to the medulla and basal cisterns was not patent. Other authors have confirmed that the subarachnoid spaces can be abnormally developed in children with DWS (Hirsch *et al.* 1984). Finally, the severe malformation of the posterior fossa with elevation of the tentorium, the torcular Herophili and the transverse sinuses can lead to a lenghtening of the venous sinuses and to their direct compression from the posterior fossa cyst (Cinalli *et al.* 2004b). Subsequently, the possible role of venous hypertension should not be underestimated.

Results of ETV in Children With Hydrocephalus and Dandy-Walker Syndrome

Due to the relative rarity of the disease the papers that can be found in the literature on this subject are essentially limited to case reports or description of very limited series of patients. Hirsch *et al.* (Hirsch *et al.* 1984) and Hoffman *et al.* (Hoffman *et al.* 1980) reported a 50% success rate (2 out of four patients joining the two series). All the endoscopic procedures were performed under an exclusively radioscopic control, a factor which might have influenced the correct conclusion of the procedure. More recently, a higher success rate was reported by Cinalli (Cinalli, 1999) who described three long term outcomes out of four personal cases.

In children with secondary aqueductal stenosis a combined ETV and aqueductal stenting placement has been suggested. Mohanty (Mohanty, 2003) successfully performed this kind of procedure in two out of three patients (66.6%). Intraoperative endoscopic confirmation of aqueduct patency might be useful in order to select the appropriate surgical procedure (Jodicke *et al.* 2003).

One of the conditions that seems to negatively influence the results of ETV in patients with Dandy-Walker syndrome is the presence of associated CNS malformations, such as agenesis of the corpus callosum which might preoperatively allow the escape of CSF into the convexity subarachnoid spaces. Contrast dynamic CT scans, MRI with flow studies and flow-sensitive phase-contrast cine MRI images might help to make the correct patient's selection (Cinalli *et al.* 2004b). Anatomic modifications of the interpeduncular cistern, the orientation of the third ventricular floor, the higher position of the tip of the basilar artery and the displacement of the brainstem against the clivus are the conditions which usually make the endoscopic procedure difficult to perform. Endoneurosonography and transendoscopic Doppler ultrasound were proposed as technical adjuncts in order to identify intraoperatively parenchimal and vascular landmarks (Jodicke *et al.* 2003). Controlled CSF leak through the endoscope may allow a slow decompression of the cyst, which in turn may reduce the mass effect on the brainstem and recreate the space for a safe ETV.

Constrictive Hydrocephalus

Hydrocephalus Patients with Myelomeningocele

The exact incidence of hydrocephalus in myelomeningocele patients is not known. In most cases it is not present at birth but it develops in the first few weeks or months of life. Postnatal neuroimaging studies, obtained before closure of the spinal defect, have documented the presence of hydrocephalus in 15.25% of the cases; however, the proportion of patients who subsequently require shunting reaches up to 80–90% in most surgical series. No correlation has been shown between the level of the lesion and the presence of hydrocephalus (Teo and Jones, 1996).

Pathogenesis

A variety of factors are implicated in the pathogenesis of hydrocephalus in children with myelomeningocele which characteristically may combine the features of the communicating and obstructive forms of hydrocephalus. The Chiari type II malformation, aqueduct stenosis, anomalous venous drainage, and the closure of an open myelomeningocele all contribute to the development of hydrocephalus. In particular, the hypoplasic posterior cranial fossa and the hindbrain anomalies, typical of the Chiari II malformation, usually result in an overcrowing of the nervous and vascular structures and reduction of the CSF spaces, with secondary caudal dislocation of the IV ventricle and cerebellar tonsils with the upper cervical canal (Sgouros 2004). The consequent increased resistance to venous outflow and venous hypertension, may account for the development of a "communicating" form of hydrocephalus. On the other side, the mechanical distortion and deformation of the brain stem can secondarily lead to a functional aqueductal stenosis. Furthermore the tonsillar herniation may also contribute to the obstructive component of this type of hydrocephalus, impairing CSF flow at the level of the fourth ventricle outlets. The relevant role of CSF obstruction in the pathogenesis of hydrocephalus in myelomeningocele patients seems to be confirmed by recent series reporting on intrauterine repair of opened spina bifida and the possible correlation between the severity of Chiari type II malformation and the occurrence of hydrocephalus. Tulipan *et al.* (Tulipan *et al.* 1998) and Sutton *et al.* (Sutton *et al.* 1999) described a significant reduction of the hindbrain herniation occurrence in children who underwent intrauterine closure of myelomeningocele if compared with historical controls. The incidence of associated hydrocephalus was reduced from 91% to 59% in the series of Tulipan. Only one of the nine survivors in the series of Sutton required ventriculoperitoneal shunting. Hence these authors postulated that the lower incidence of hydrocephalus in their series had to be related to the absence of the obstructing effect of the hindbrain herniation at the level of the foramen magnum. However other authors have claimed this assumption to be oversimplistic as the intrauterine procedure had induced significant changes in volume of the posterior fossa, with consequent improved flow through the aqueduct, improved compliance of CSF flow around the brain stem and the tentorial hiatus, and lower venous outflow pressure. Some authors claimed that the predominant features of hydrocephalus in children with myelomeningocele may change in time. In infants, the subarachnoid spaces deformation and immaturity combined with the increased venous outflow resistance would prevail, consequently justifying the placement of an extrathecal CSF shunt device. However, the venous hypertension would not be corrected by the procedure, subsequently leading to an accumulation of interstitial fluid which in turn would worsen the aqueductal stenosis and change the hydrocephalus form, mainly communicating, in a mainly obstructive type (Sgouros 2004).

Results of ETV in Myelomeningocele Patients

Third ventriculostomy has been proposed in the management of hydrocephalus in children with MMC since mid 90's but its role remains controversial. Actually the most relevant series is still the one of Teo and Jones (Teo and Jones, 1996) who reported on 69 patients with an overall success rate of 72%. At a mean follow-up of 28 months (min 12 months; max 17 years), a significant worse outcome was found in patients aged less than six month (12.5% success rate) if compared with their older counterpart (80% success rate). The authors also described significant differences in success rates if ETV was performed as first line of treatment or secondary procedure (29% vs. 84% success rate). Though not reaching statistical significance, other factors that predicted a favorable result were the presence of a triventricular hydrocephalus, a diameter of the third ventricle > than 4 mm, the evidence of normal or slightly reduced subarachnoid spaces. On the other hand, the previous cerebrospinal fluid infection and/or of an intraventricular hemorrhage were negative predictive factors. Mori *et al.* (Mori *et al.* 2003) also observed differences in the outcome in patients aged less than one year as compared with their older counterpart (25% vs. 90% success rate). Other papers in the literature, though based on single case reports or series with limited numbers of patients, have challenged the just mentioned results, in particular the role of age and the lower success rate of primary versus secondary ETV. Fritsch *et al.* (Fritsch *et al.*, 2003) reported a 50% success rate which was independent from children's age at surgery. Similar results were reported in the multicenter study of Portillo *et al.* (Portillo *et al.* 2004) who referred an overall success rate of 21% in a series of 19 myelomeningocele patients, a rate which was not related with age or time when ETV was performed. In a recent series, Tamburrini *et al.* (Tamburrini *et al.* 2004) were not able to found significant differences between infants (<six months) undergoing primary ETV (overall success rate: 70%) and older patients who underwent third ventriculostomy as secondary procedure at the time of malfunction of a previously inserted CSF

shunt device (overall success rate: 60%). Such discordant results suggest that particular caution should be paid in these type of hydrocephalus, when planning ETV.

On the other hand, the slow and insidious progression which characterizes the evolution of this specific form of hydrocephalus in a large portion of subjects, might lead to a wrong claiming of a successful result after the surgical operation in patients who actually continue to have hydrocephalus. Subsequently, strict neuroradiological, ophtalmological and neuropsychological follow-up control is mandatory.

Analysis of Outcome

ETV, by forming a communication between the third ventricle and the subarachnoid spaces, restores an almost "physiological" CSF circulation in case of obstructive hydrocephalus. The recent views on the pathophysiology of hydrocephalus (Greitz 2004) enhance the importance of the intracranial compliance, that is widely dependent on the free movement of the CSF between the cranial and the spinal subarachnoid spaces. Despite of the accuracy of patients selection, several reports show that in a significant number of cases the symptoms and signs of increasing intracranial pressure related to hydrocephalus are however not controlled by the procedure (Cinalli *et al.* 1999, Hirsh *et al.* 1986). The phenomenon is more frequently observed in the immediate post-operative period (early failures), being only sporadically observed in a later phase, usually within 5–6 years from the operation (late failures). Recurrence of hydrocephalus beyond this period has been reported exceptionally (Beems and Grotenhuis 2004, Tuli *et al.* 1999). Pre-requisite of a successful ventriculostomy is the patency of the distal subarachnoid pathways: the difficulty to detect pre-operatively the presence of coexisting obstruction in the basilar cisterns or in the subarachnoid space of the surface may account for the 25–40% failure rate still reported in literature (Cinalli *et al.* 1999, Fritsch and Mehdorn 2002, Javadpour *et al.* 2001). A reliable non-invasive pre-operative test is not available yet; invasive tests have been proposed, but they are difficult to propose on a routine basis, especially in children (Bech *et al.* 1999, Czosnyka *et al.* 1996, Magnaes 1982, Magnaes 1989). Therefore, generally failures continue to be detected post-operatively on the basis of clinical, instrumental and radiological data.

The evaluation of the results immediately following the procedure may be sometimes difficult. After the opening of the third ventriculostomy, the increased amount of circulating CSF may require a so-called "adaptation period" (Bellotti *et al.* 2001, Cinalli 2004, Hopf *et al.* 1999b) to circulate or to be re-absorbed. This could explain the persistence of symptoms and increasing ventriculomegaly at CT scan examination, that can be erroneously interpreted as failure of the procedure and indication to perform a VP shunt.

Unfortunately, a widely accepted method to accurately detect early failures is not available and management of post-operative intracranial hypertension is controversial. Accurate pressure measurements associated, when necessary, to CSF withdrawal may allow the patients to reach an equilibrium in CSF dynamics in safe condition.

The persistence of dilatation of the ventricular system can be often observed following ETV also in the late post-operative phase in otherwise asymptomatic subjects. Such a ventricular dilation raises the question of its possible influence on intellectual outcome, especially when ETV is performed in very young children. Even though the findings seem not to be correlated with adverse effects, the absence of long-term follow-up observation in large series suggests the opportunity of prospective, multicentric, randomized studies for the direct comparison with he already available long-term outcomes of extrathecal CSF shunting procedures.

Early Results

Clinical Signs and Symptoms

Symptoms and signs of intracranial hypertension resolve immediately following a successful procedure in the great majority of the operated on patients. In particular, Parinaud's sign, if present preoperatively, is expected to disappear from the earliest post-operative moment; persistence of this sign should be taken as a potential predictor of failure (Cinalli 2004, Schijns and Beuls 2002). Papilledema disappears within 2–3 weeks. Feng *et al.* (Feng *et al.* 2004) found that an early satisfactory clinical response (within two weeks after the surgical operation) provided a high correlation with the overall ETV success.

The possible persistence of clinical symptoms using high ICP can be a major pitfall in the evaluation of the patient and can lead to the wrong, premature conclusion of a failure of the technique, with consequent decision to implant or re-implant the CSF shunt device. Symptoms and signs of persistently high ICP are relatively rare in patients operated on primarily for primitive aqueductal stenosis or obstructive triventricular hydrocephalus of any nature. In these patients, the most frequent sign of increased ICP are swelling at the level of the coronal incision due to subcutaneous accumulation of CSF or, in some cases, CSF leaks. In our experience of ICP monitoring post-operatively, patients operated on primarily can tolerate very high levels of ICP without complaining of any symptom. The situation is different when ETV is performed on patients operated on for shunt malfunction or for slit ventricle syndrome. These patients may have signifi-

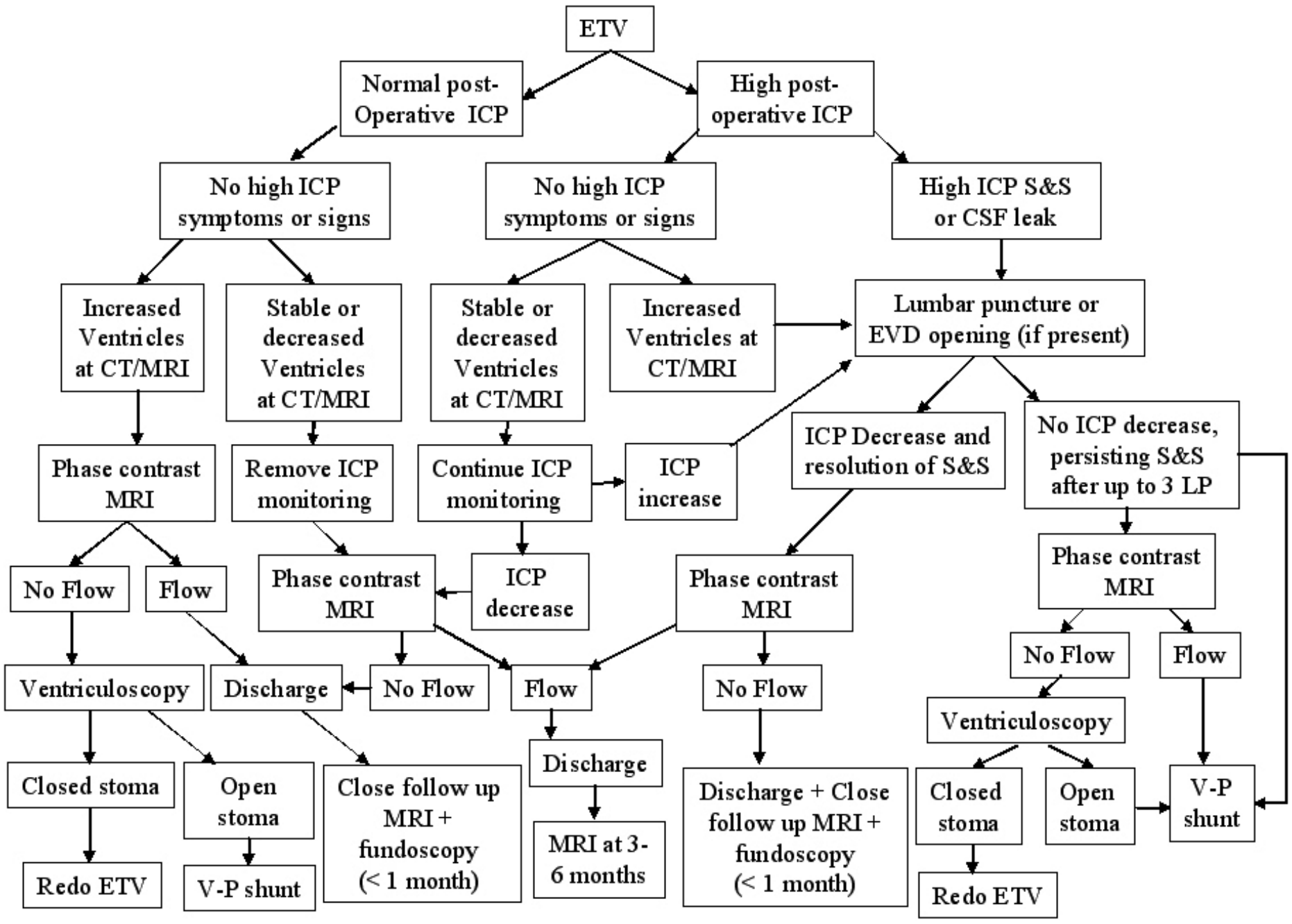

Fig. 20. Algorythm of evaluation of the early post-operative days following ETV and management of high ICP with or without symptoms and signs of increased intracranial pressure

cantly lowered intracranial compliance due to cephalocranial disproportion induced by the shunt, and may exhibit a progressive clinical deterioration as their ICP may tend to increase in the first 7–10 days after surgery. Consequently, ICP monitoring and safety external ventricular catheter (EVC) to be placed into the same corticotomy track produced by the endoscope should be considered as mandatory in these patients. In case of symptoms of high ICP seriated lumbar punctures should be performed according to the algorithm reported in Fig. 20. EVC should be kept closed and open only if lumbar punctures cannot manage the situation.

ICP Monitoring

The persistence of high ICP in the post-operative period following ventriculo-cisternostomy, is a well known phenomenon which was reported in the literature since the earliest descriptions of Matson's ventriculo-subarachnoid shunt (Matson 1969, Cinalli 2004). The explanations proposed so far are not conclusive, varying from the hypothesis of the progressive dilatation of the subarachnoid spaces not used to receive the circulation of the whole amount of CSF produced to that of the progressive adaptation of the compliance of the intracranial system, due to the "stiffness" of the brain. The last evenience would be frequent especially in patients shunted around birth and who had their shunt removed. Whatever the reason anyway, as a matter of fact ICP is usually higher than normal in the immediate post-operative period in several cases. In some patients, the average ICP levels can remain below 20 mmHg with, however, frequent spikes above this value. The values may then rapidly fall to even lower-than-normal level in very few days: these patients usually remain asymptomatic following ETV and lumbar punctures. EVC (if present) opening is rare if ever necessary. In other patients, mostly those who had their shunt removed and exhibit signs and symptoms of intracranial hypertension, the average ICP levels can be significantly higher. The transitory nature of the phenomenon in most instances may explain why some patients with EVC maintained at the same hydrostatic level show a high CSF output in the early post-operative days, followed by a gradual decreasing within the first two post-operatively weeks (Nishiyama *et al.* 2003).

Management of high ICP (see below) leads to resolution of symptoms in most cases, without the need of an extrathecal shunt. Thus, presence of symptoms of increased ICP in the post-operative period not always means that the procedure had failed (Bellotti *et al.* 2001, Cinalli 2004).

Neuroradiological Evaluation

Compared to the implant of an extrathecal CSF shunt device, the most important difference is the effect on the volume of the cerebral ventricles as demonstrated by the neuroimaging investigations. The ventricular size usually decreases rapidly and significantly following the shunt implantation. The volume decrease is much slower and smaller in scale after third ventriculostomy. A transient "adaptation period" (Bellotti *et al.* 2001, Hopf *et al.* 1999b) in which the CSF "finds its way" through the subarachnoid spaces could account for the persistence of the ventricular dilation in the early post-operative phase, whereas the lack of communication with a lower pressure cavity (e.g., right atrium, peritoneal cavity), and the nature of the ventricular dilation in case of hydrocephalus related to aqueductal stenosis, which often evolves over several years before becoming symptomatic (Fukuhara *et al.* 2000), might account for the persistent ventriculomegaly in later phases of the post-operative clinical course.

In spite of such a limitation, some radiological criteria that must be fulfilled for definition of success have been established (Cinalli 2004).

1. Reduction in ventricular size ranging from 10% to 50% must be observed from the first week (Schwartz *et al.* 1999), even if the ventricles remain large.

2. Periventricular lucency, if present before operation, must disappear.
3. CSF flow artifact must be visible on sagittal median T2-weighted fast spin-echo MRI sequences (Fukuhara *et al.* 2002, Kulkarni *et al.* 2000). CSF flow has been described in newborns with color Doppler ultrasonography (Wilcock *et al.* 1996).
4. The floor of the third ventricle, if bulging downward in the preoperative images, must be straight on postoperative images.
5. Atrial diverticula and pseudocystic dilatation of the suprapineal recess, if present preoperatively, must disappear or decrease significantly.
6. Pericerebral sulci, if not visible before operation, must reappear or increase in size.

When considering different neuroradiological indices, it has been shown that the width of the third ventricle is the quickest to decrease; such a volumetric modification remains stationary in time. A more than 15% decrease in size of the third ventricle within 1 month is considered the most reliable indicator of favorable outcome following third ventriculostomy (Buxton *et al.* 2002, Schwartz *et al.* 1996, Schwartz *et al.* 1999, Tisel *et al.* 2000).

The greater decrease of both the third ventricle (30%–40%) and the lateral ventricles (30%–32%) is already visible from the first postoperative week. The extent of ventricular volume decrease is in inverse correlation with the preoperative duration and magnitude of clinical symptoms (Figs. 21–23). A decrease in volume of less than 10% may be observed in

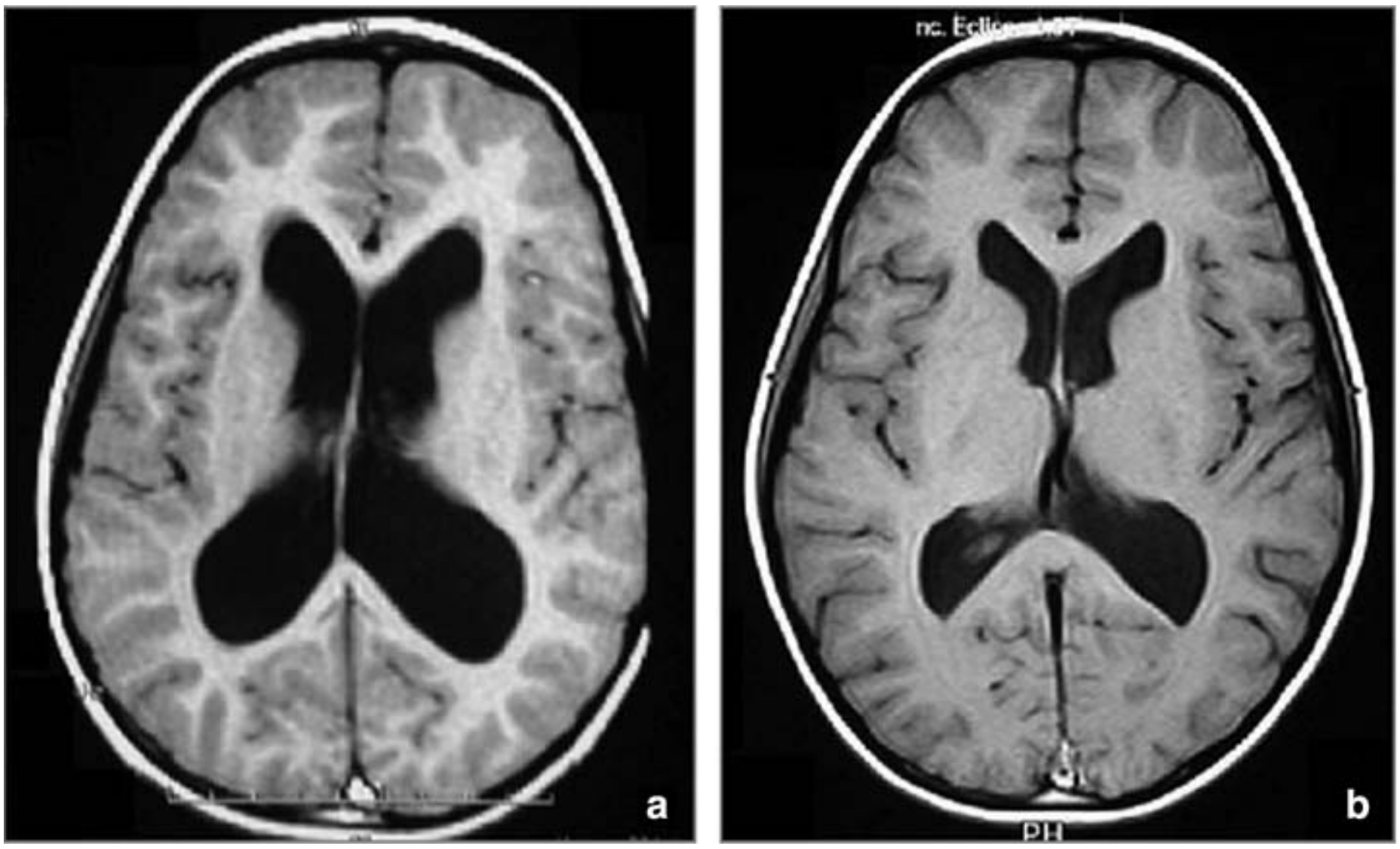

Fig. 21. Nine year old boy presenting with acute symptoms of intracranial hypertension (a) lasting for 1 week. After ETV, the ventricles return to near-normal size (b)

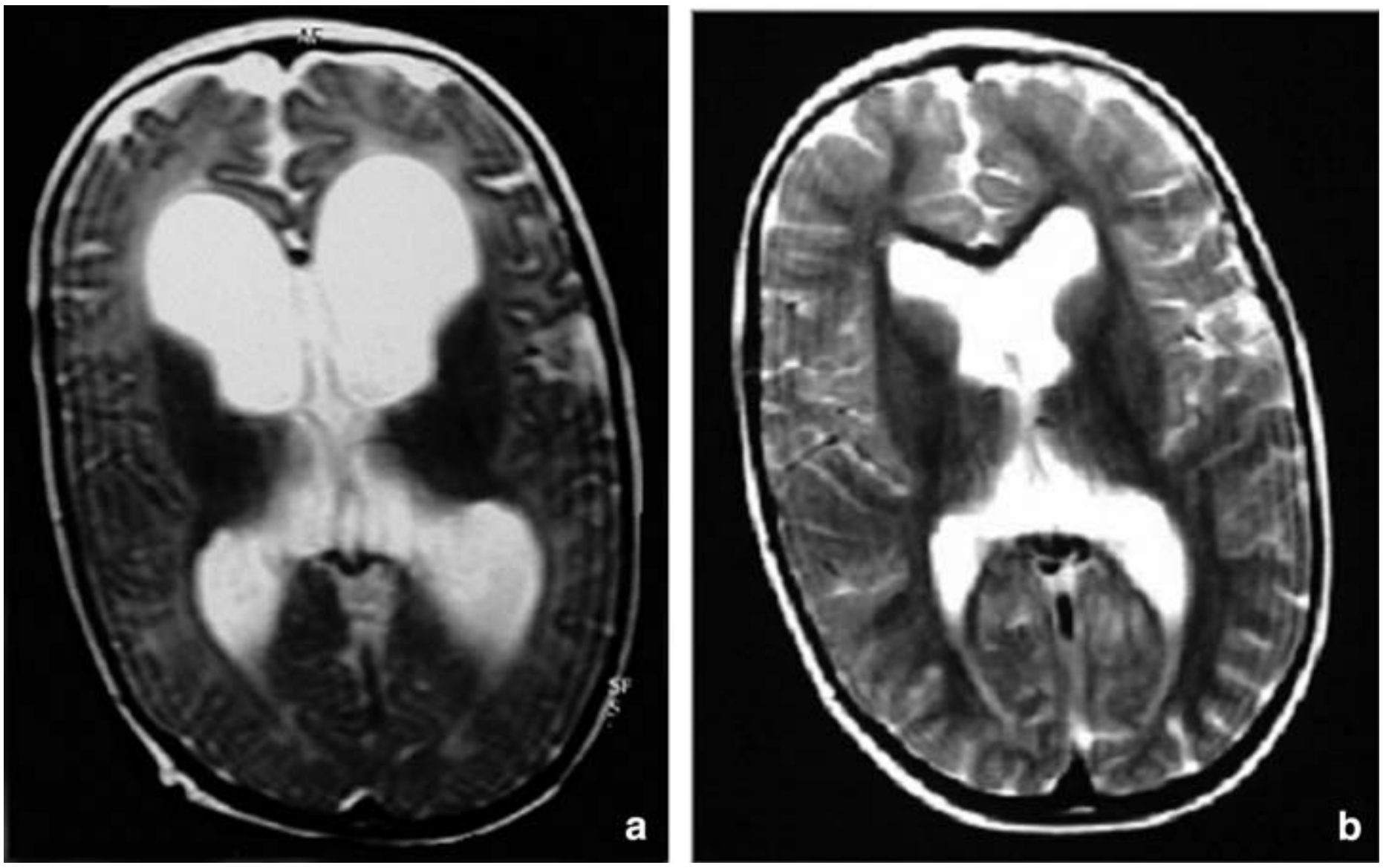

Fig. 22. Six month old boy presenting with a 4-month history of progressive macrocrania and vomiting. Pre-operative MRI shows significant ventricular dilatation (a), that regressed only partially after ETV (b)

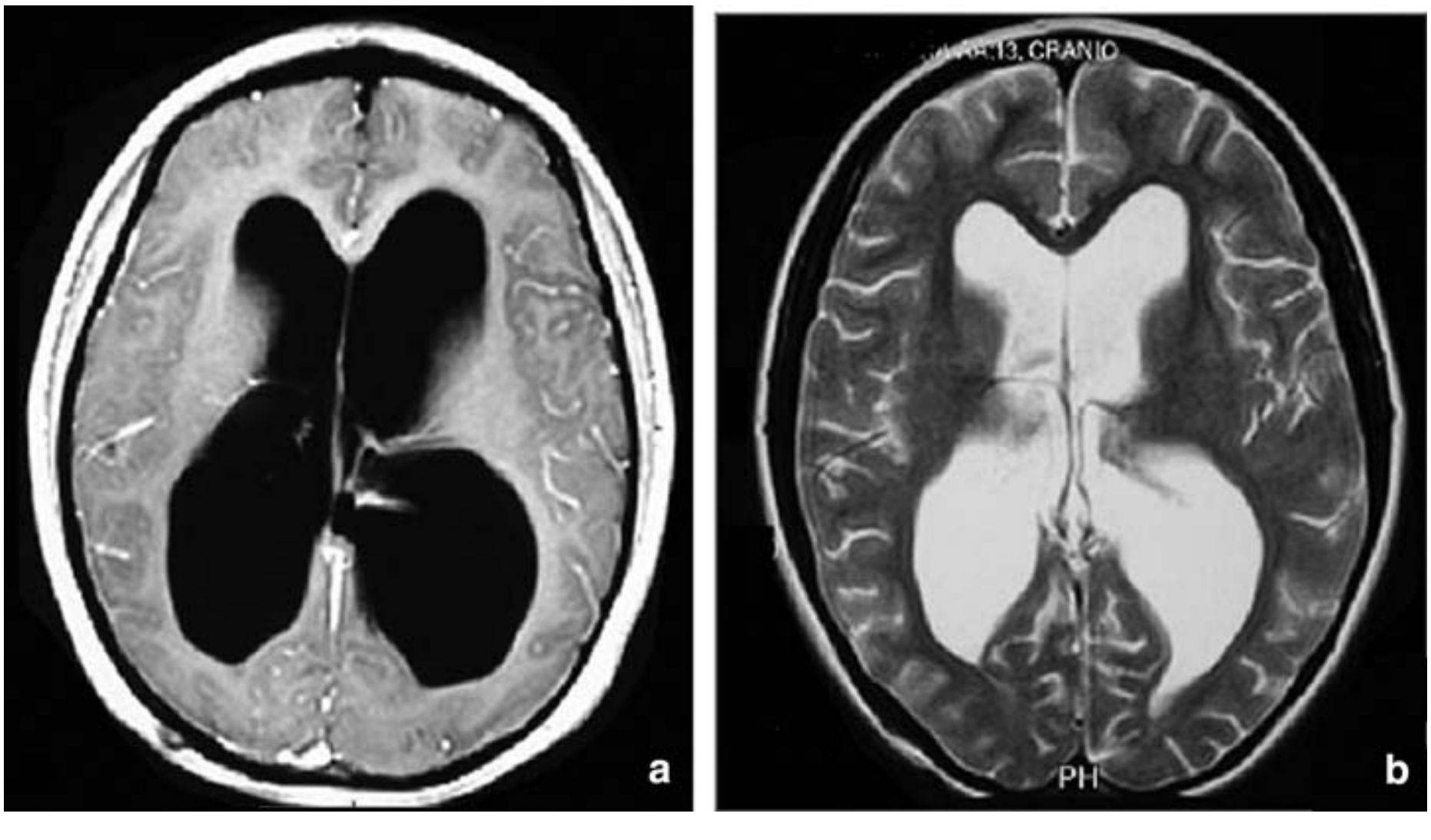

Fig. 23. Eleven year old girl, presenting with a 4-year history of intermittent headache, decreasing school performance and finally blurred vision and papilledema (a). After ETV there is almost no modification of the ventricular volume (b) in spite of an excellent clinical result

patients with long-standing chronic symptoms (Schwartz *et al.* 1999). The downward deviation and flattening of the brainstem reverts within 1 year, whereas the width and height of the lateral ventricles continue to decrease steadily for at least 2 years (Oka *et al.* 1993b).

Nevertheless radiographic evaluation in the immediate post-operative period is challenging. CT scan during the adaptation period may not reveal any modification or even serial scans may show re-enlargement of the ventricles following initial reduction in size, leading to the misdiagnosis of failure. Feng *et al.* (Feng *et al.* 2004) reported satisfactory results in 5 of 10 patients in which a persistent increase of the ventricular size was observed after surgery and they concluded that the size of the ventricles is not a good predictor in the evaluation of the outcome within 3 months following surgery. The same paradoxical re-enlargement of ventricular volume after an initial decrease has been described by other authors (Saint George *et al.* 2004).

Cine-phase contrast MRI, showing directly the patency of the stoma, could be useful as a prognostic factor for a successful ETV. However, the data of the literature are controversial: Kulkarni *et al.* (Kulkarni *et al.* 2000) demonstrated a statistically significant relation between evidence of postoperative aqueductal CSF on MRI and clinical success. Feng *et al.* (Feng *et al.* 2004) in a recent paper found a good correlation between the finding of a patent stoma and outcome. They documented that 12 of 16 patients (75%) in whom a positive flow void was observed on post-operative (within two weeks) cine MRI had a successful ETV, even if 4 patients, in whom a positive flow void was shown, experienced treatment failure. Other reports (Cinalli *et al.* 1999, Goumnerova and Frim 1997) had shown that cine MRI has not high sensibility and specificity in predicting outcome. The exam is more useful as an element of comparison to a previous similar exam in the same patient than evaluated independently. For this reason, we perform a cine PC MRI in the first post-operative week before discharge in order to have a baseline exam when the stoma is certainly patent to compare with similar studies carried out in the late post-operative period (Fig. 20). Early post-operative MRI is also useful in order to detect modifications of the profile of the third ventricle and of the lateral ventricle: in cases where cine PC is not conclusive and flow void artifact is not well visible on sagittal or coronal T2 turbo spin echo. The morphological analysis of the profile of the third ventricle is probably the most reliable evidence of occlusion of the stoma (Fig. 24a–g). The anatomical details can be visible well before symptoms and signs of increased intracranial pressure occur, and should prompt the surgeon to re-operate the patient even if asymptomatic in order to avoid situations of extreme emergency with possible fatal complications (Hader *et al.* 2002).

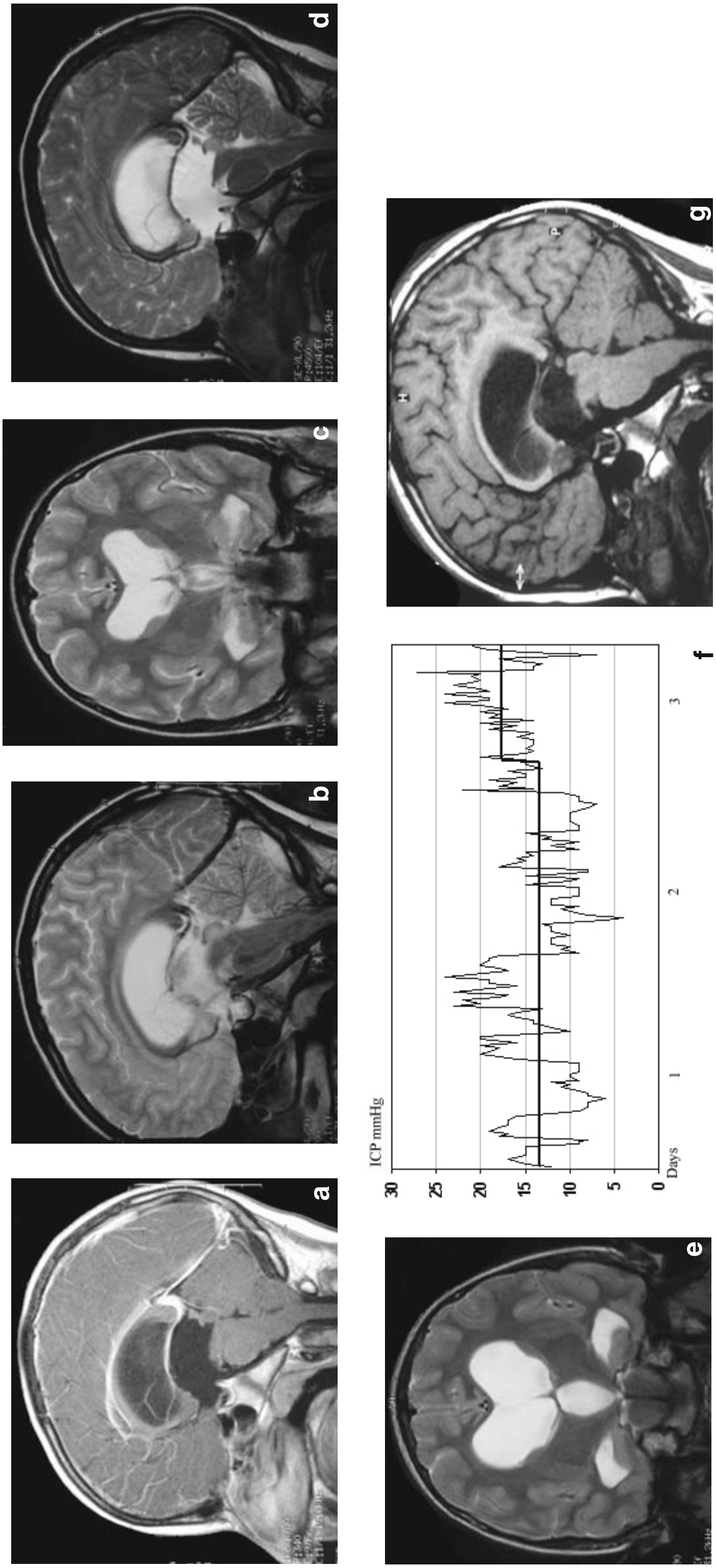

Fig. 24. Eleven year old boy presenting with headache and papilledema: MRI reveals aqueductal stenosis due to a small tectal mass (a). Nine days following ETV, note the decreased third ventricular dilatation with decreased flattening of the mesencephalon and downward ballooning of the third ventricular floor (b, c). One year following ETV, third ventricle has returned to pre-operative shape and size, both in the sagittal (d) and coronal (e) view. ICP monitoring showed increased intracranial pressure with "plateau" waves (f). Patient was re-operated, ETV was found closed and re-opened. MRI performed one month after the second ETV (g) shows a large defect in the third ventricle floor and decreased volume of the third ventricle

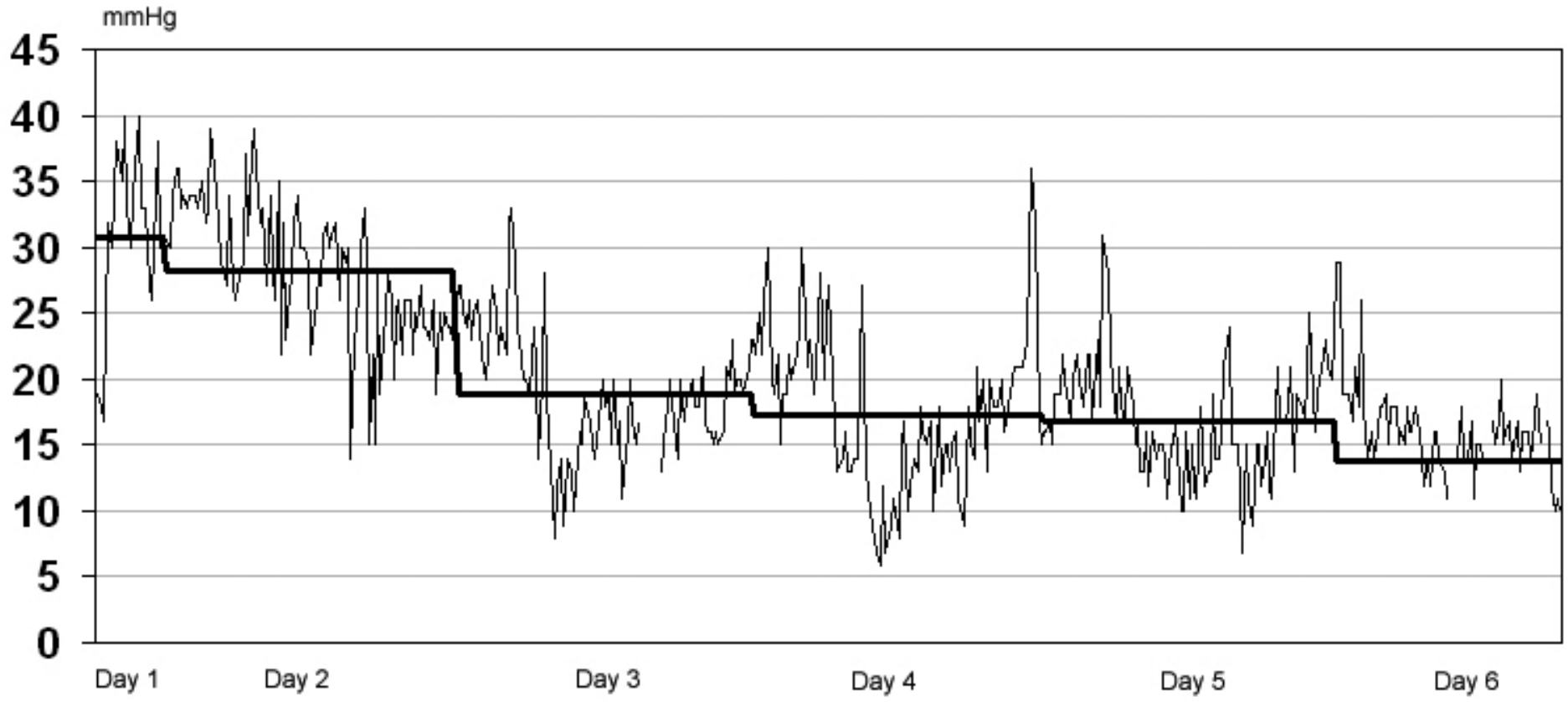

Fig. 25. Twelve year old girl affected by aqueductal stenosis. ICP monitoring following ETV shows very high values, asymptomatic, in the first 3–4 days with progressive, spontaneous normalization

ICP Monitoring and Management of Increased ICP During the "Adaptation Period"

On the base of the continuous monitoring of ICP in the first two weeks following ETV in a personal series of 56 children affected by non-communicating hydrocephalus, we were able to distinguish two patterns in the ICP behavior during the "adaptation period". In a first subgroup of subjects, ICP returned immediately to the normal levels (<20 mmHg), and remained normal for all the length of the monitoring: about half of all our patients belonged to this group. In a second subgroup, ICP remained or became high until the second post-operative day, to decrease in the subsequent days slowly (Fig. 25). In some cases, elevated values of ICP were recorded until the 9th post-operative day, often associated with headache and vomiting. In some children, the symptoms were so impressive to induce a suspect of failure. CT scan performed in this period demonstrated an increasing dilatation of the ventricular system in some cases, adding further evidence to the suspicion of failure (Fig. 26a–e). However, such high values of ICP in the first post-operative days, in our and in other series

→

Fig. 26. Eleven year old girl shunted at birth for neonatal hydrocephalus. Admitted for shunt malfunction (a). After ETV and shunt removal, ventricles are smaller (b). Four days after ETV the patient is severely symptomatic with high ICP values and increased ventricular dilatation at CT scan (c). After lumbar puncture, ventricles progressively decrease in size 6 days (d) and 9 days (e) after ETV

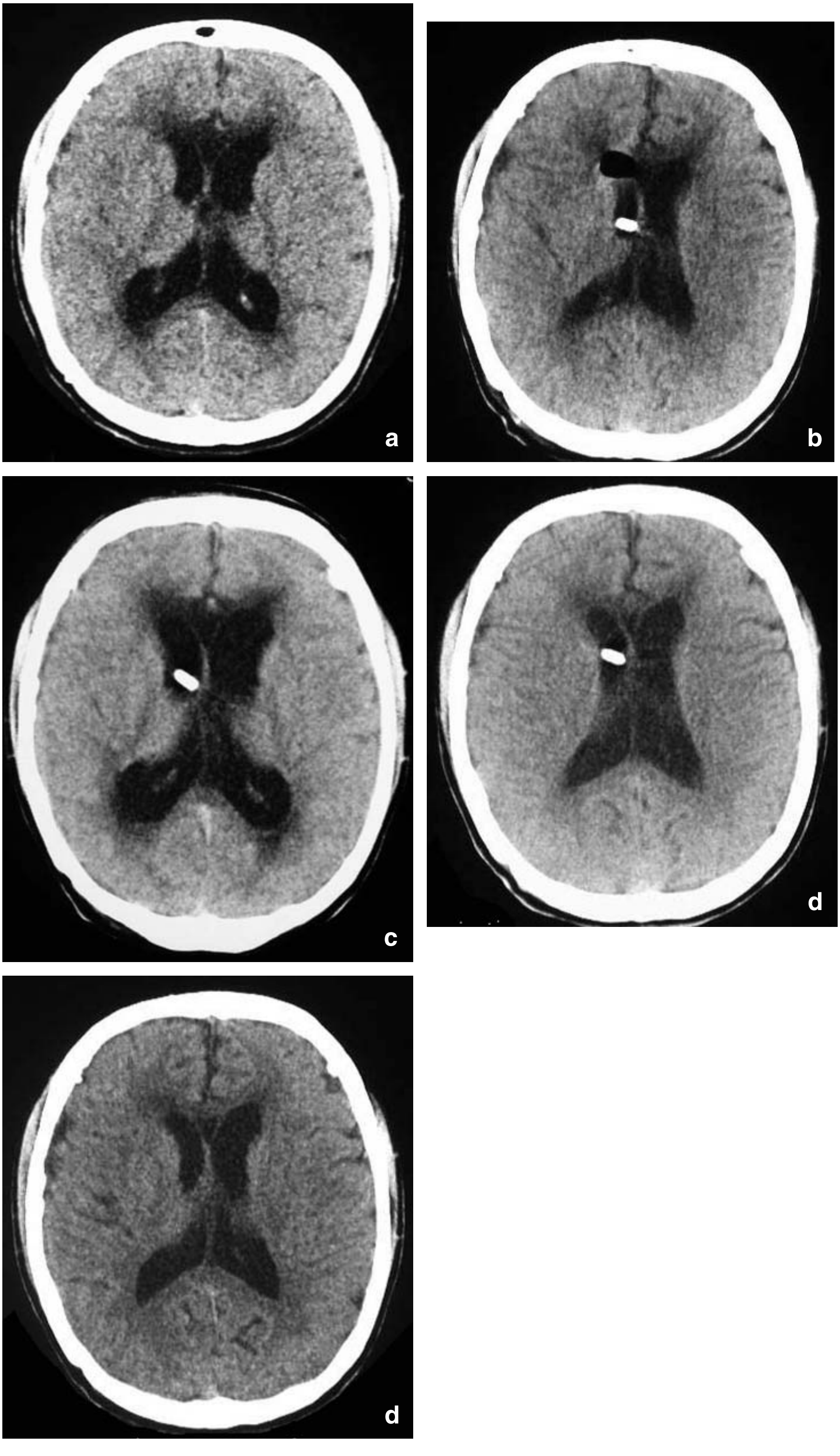
a
b
c
d
d

(Bellotti *et al.* 2001, Hopf *et al.* 1999b), were not necessarily associated with late failure. Actually, their incidence was not statistically significant when compared to that observed in cases of true failure. In the only 4 cases in which the procedure failed in the first 15 days (early failure), the ICP, after an initial decrease that lasted for 2–4 days, rapidly rose again between the 5th and 8th day to reach high values unaccettable for the patient, consequently suggesting the need for a further surgical procedure (second ETV or CSF shunt implant).

ICP monitoring is very useful to detect intracranial hypertension. However, how to adequately manage high ICP is still under debate. Some authors (Bellotti *et al.* 2001, Böschert *et al.* 2003, Hopf *et al.* 1999b, Nishiyama *et al.* 2003, Oi *et al.* 2000), have proposed leaving an external ventricular drainage in place during the procedure, to allow intermittent CSF drainage during the periods of pathological ICP elevation. According to these authors, this would allow transient drop in intraventricular pressure, allowing re-expansion of the intracranial subarachnoid spaces and facilitating CSF circulation toward the convexity. The same result can be obtained by performing CSF evacuation by lumbar taps under ICP monitoring (Cinalli 2004). Post-operative withdrawl CSF to restore a normal ICP was already suggested by Matson in 1969 (Matson 1969) and by others later (Hoffman *et al.* 1980, Jaksche and Loew 1986, Oka *et al.* 1995). In some cases lumbar tapping had been repeated 24–48 hours later; a third tap had been rarely necessary (Fig. 27). The positive effects on the ICP last longer than can be explained by the simple subtraction of the small

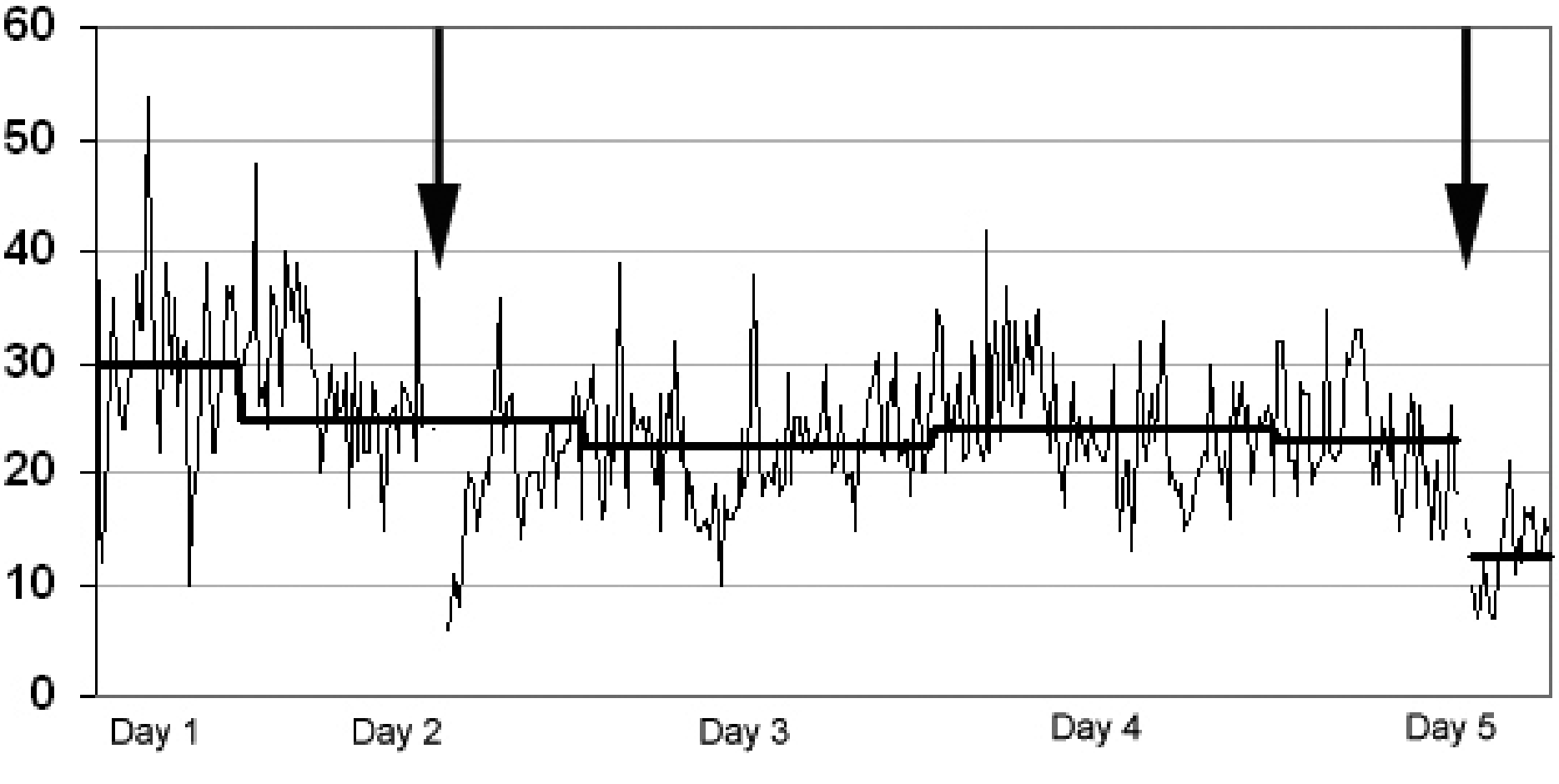

Fig. 27. Three year old boy shunted at birth for hydrocephalus and aqueductal stenosis. At the time of shunt malfunction, ETV was performed and shunt was removed. Post-operative ICP monitoring shows high ICP values. Lumbar punctures were performed (arrows) because of persisting symptoms and signs of increased ICP

amount of CSF, usually limited to 5–10 ml. One possible explanation is the increased compliance of the spinal subarachnoid spaces (SAS) and the increased pressure gradient between third ventricle and the SAS of the posterior cranial fossa induced by the CSF subtraction. This would facilitate CSF flow through the third ventriculostomy and, in turn, the reduction of the ventricular volume, so allowing the re-expansion of the intracranial subarachnoid spaces. In patients with intracranial mass lesions, in which ETV was performed before tumor removal, we refrained from using lumbar tapping, for the risk of tonsillar herniation and preferred to implant an external drainage in the ventricle to be utilized to remove CSF when necessary.

In conclusion ICP must return to normal values within 10 days after ETV. Should ICP remain elevated with persistent symptoms of intracranial hypertension, we suggest to perform at least two lumbar taps before concluding that the procedure failed (Fig. 27).

The algorythm of post-operative patient's evaluation we utilized in the first weeks after ETV is shown in Figure 4. A central role is attributed to ICP monitoring in subjects above one year of age. In newborns, ICP monitoring is very effectively replaced by fontanel examination.

Late Results

Review of the Literature

As shown on Table 5, different authors describe various definitions of failure by taking into account several factors, such as the need of an external CSF shunt, the clinical symptomatology, or the changes of the ventricular volume. According to this variability, outcome evaluation can differ as much as 30% in the same group of patients depending on the criteria used for definition of success. Moreover, in the same group of patients, different criteria of success have been reasonably used according to the different procedures. Most authors include neuroradiological criteria to confirm the clinical success (Beems and Grotenhuis 2004, Brockmeyer *et al.* 1998, Cinalli *et al.* 1999, Gorayeb *et al.* 2004, Teo 1998). According to these authors, the ventricular system must decrease in size or at least remain stable and radiographic signs of active hydrocephalus must disappear. In case of progressive dilatation of the ventricles (despite the absence of symptomatology) a further surgical procedure (ETV re-do or VP shunt insertion, according to the criteria discussed below) is warranted. Only Feng *et al.* (Feng *et al.* 2004) considered successful 5 cases in which clinical improvement occurred despite of the progressive dilatation of the ventricular system, and did not implant a shunt. Actually long-term effect of persistent ventriculomegaly (present in about 30% of patients) (Goumnerova and

Table 5. *Third ventriculostomy studies*

Author	N	Etiology		Patients <1 year	Previous shunt	History of hem./ infec.	Techn. failures	Definition of success/failure	Success, %	Follow up
Jones, 1990	24	AS MMC Tumor	14 5 5	5	NA	0	4	successful: not shunt insertion, normal head growth, no evidence of high ICP improved: no high ICP, but not normal head growth. failure: no improvement, shunt insertion	successful: 50% improved: 21% failed: 12% shunt free: 66.7%	13–121 mo (mean 68)
Kelly, 1991	16	AS	16	0	11	5	0	shunt freedom	94%	12–60 mo (mean 42)
Goumnerova, 1997	23	AS tectal abn. Other	12 7 4	NA	4	1	0	resolution of symptoms, no shunt	73%	7–44 mo (mean 17)
Brockmeyer, 1998	97	MMC AS tumors tectal abn post hem. other/comm. hydroc.	24 19 10 9 7 28	NA	NA	7	26	complete shunt avoidance or removal. relief of symptoms. reduction or maintenance of ventricular size.	49% (34% including technical failures)	15–69 mo (mean 24)

Hellwig, 1998	14	AS	14	NA	8	0	0	decline of clinical symptoms. No shunt	93%	1–43 mo
Teo, 1998	121 + 8[1]	MMC AS tumor post hem. post inf. other	55 38 17 5 4 2	NA	NA	9	8[1]	1. resolution of clinical s/s and decrease of ventricular size on CT. or 2. resolution of clinical symptoms and signs and no change in ventricular size but improvement on psychometric testing.	73% (68% including technical failures)	6–72 mo (mean 22)
Cinalli, 1998	30[2]	AS tumor post men post hem. other	10 7 5 4 4	NA	30	13	3	shunt definitely removed. Resolution of signs and symptoms of high ICP without revision	76.7%	6–186 mo (mean 24)
Buxton, 1998	27	commun. hydroc. non-com. hydroc.	21 9	27	0	10	0	absence of any subsequent procedure for the hydrocephalus	23%	6–42 mo

Table 5 (*Continued*)

Author	N	Etiology		Patients <1 year	Previous shunt	History of hem./ infec.	Techn. failures	Definition of success/failure	Success, %	Follow up
Choi, 1999	71	AS tumor other	33 33 5	0	6	0	0	improvement in clinical status. No need of a shunt	91.5%	NA
Tuli, 1999	32	AS tumor	17 15	NA	0	0	0	failure defined according to the guidelines established in the shunt designed trial	56%	12–120 mo
Cinalli, 1999	119 + 94[3]	AS toxo pineal t. other	126 23 15 49	NA	NA	0	7 + 12[3]	resolution of clinical s/s. disappearance of all radiographic signs of active hydrocephalus	72% 65%[3]	0.2–108 mo (mean 25) 1–209 mo[3] (mean 76)[3]
Hopf, 1999	95	tumor AS hem/inf. other	42 40 9 4	4	25	9	2	improvement: partial or complete relief of symptoms	76%[4]	3–71 mo (mean 26)

Fukuhara, 2000	89	AS tumor hem. other	37 32 8 12	NA (<7)	32	22	0	failure: any condition requiring surgical intervention because residual or recurrent symptoms	67.4%	3–63 mo
Tisell, 2000	18	AS	16	0	3	0	0	unsatisfactory results: persistence or relapsing of symptoms compatible with hydrocephalus	50%	14–66 mo (mean 37)
Buxton, 2001	63	tumor AS other	22 18 23	0	24	6	0	absence of any subsequent procedure for the hydrocephalus	75%	0–84 mo (mean 37)
Helseth, 2002	58	prim AS seco AS tumors	22 22 14	NA	NA	0	NA	resolution of ICP s/s no shunt in the follow up	72%	30 mo
Siomin, 2002	101	post haem post inf. AS other	46 41 10 4	NA	56	101	0	resolution of ICP s/s no shunt in the follow up	57.4%	6–120 mo (mean 22)

Table 5 (*Continued*)

Author	N	Etiology		Patients <1 year	Previous shunt	History of hem./infec.	Techn. failures	Definition of success/failure	Success, %	Follow up
Feng, 2004	58	tumor AS cyst hem/inf.	21 18 11 8	0	5	8	NA	partial or complete relief of symptoms. no shunt implantation	77.6%	3–41 mo (mean 24)
Gorayeb, 2004	36	AS chiari II other	11 11 14	36	NA	1	0	resolution of s/s of high ICP; normal head growth; no untoward finding on neuroimaging	64%	22–69 mo (mean 47)
Beems, 2004	380	NA		NA	NA	NA	4	definitive CSF shunt not implanted	77.1%	>6 mo

AS Aqueductal stenosis, *MMC* Myelomeningocele, *Hem* Hemorrhage, *Inf*. infection, *Comm. hydroc*. Communicating hydrocephalus, *S/s* Symptoms and signs.

[1] Technical failures.

[2] Seven of these procedures have been performed under ventriculographic guidance.

[3] Procedures performed under ventriculographic guidance.

[4] Including 6 patients requiring second ETV.

Frim 1997) on neuropsychological developmental is not fully known. Teo (Teo 1998) highlights the importance of maintaining a close vigilance on the patients whose ventricles remain large, by the means of neuropsychological testing. He recommended to shunt those individuals in which a neuropsychological deterioration is documented during the follow up, despite the absence of symptoms and signs of acute intracranial hypertension (see below).

Iantosca *et al.* (Iantosca *et al.* 2004), reviewing the influence of hydrocephalus etiology on outcome, found three groups with different rates of success: a group with high success rates (>75%), that included patients affected by acquired aqueductal stenosis, tumor, cyst or infectious lesions obstructing third ventricular outflow, tectal, pineal, thalamic or intraventricular tumor, shunt malfunction; a group of intermediate success rates (about 50%) that included patients affected by myelomeningocele (previously shunted), tumor obstructing fourth ventricle outflow, congenital aqueductal stenosis, Dandy-Walker malformation, slit ventricles syndrome, recurrent or intractable shunt infection/malfunction; and a group with a low success rate (<50%) that included patients affected by myelomeningocele (previously unshunted) and posthaemorrhagic/postmeningitc hydrocephalus. These authors, on the basis of their experience (Drake 1993, Iantosca *et al.* 2004) and that of others (Jones 1990), discourage the use of ETV in patients who have undergone prior radiation therapy, because poor success rates, altered anatomy (in particular thickness of the third ventricle floor) and increased risk of bleeding.

Thereafter, the best results are achieved in series in which only hydrocephalus secondary to aqueductal stenosis or benign mass lesions is considered (Choi *et al.* 1999, Cinalli *et al.* 1999, Hellwig *et al.* 1998a, Helseth *et al.* 2002, Kelly 1991). However, when only patients affected by obstructive tri-ventricular hydrocephalus are selected the success rate is actually quite homogeneous and stable, being above 60–70% at any age (Fritsch and Mehdorn 2002, Gorayeb *et al.* 2004, Javadpour *et al.* 2001), even if a history of haemorrhage or infection is present (Siomin *et al.* 2002). All the series studied with actuarial method (Buxton *et al.* 2001, Cinalli *et al.* 1999, Elbabaa *et al.* 2001, Feng *et al.* 2004, Fukuhara *et al.* 2000, Helseth *et al.* 2002, Tuli *et al.* 1999) show a long term success rate above 70% with follow-up ranging from 4 years to 9 years (Fig. 28). Only Tuli *et al.* (Tuli *et al.* 1999) reported a 44% failure rate in a group of pediatric patients affected by obstructive tri-ventricular hydrocephalus. This may be secondary to the different definition of failure used in the different papers (Table 5). While most authors define failure as the need of extracranial shunt (table 1), Tuli *et al.* defined failure in a manner similar to the guidelines established in the shunt design trial (Drake *et al.* 1998), accounting for an unusually high rate of failure in selected patients. However, all long-term studies seem to

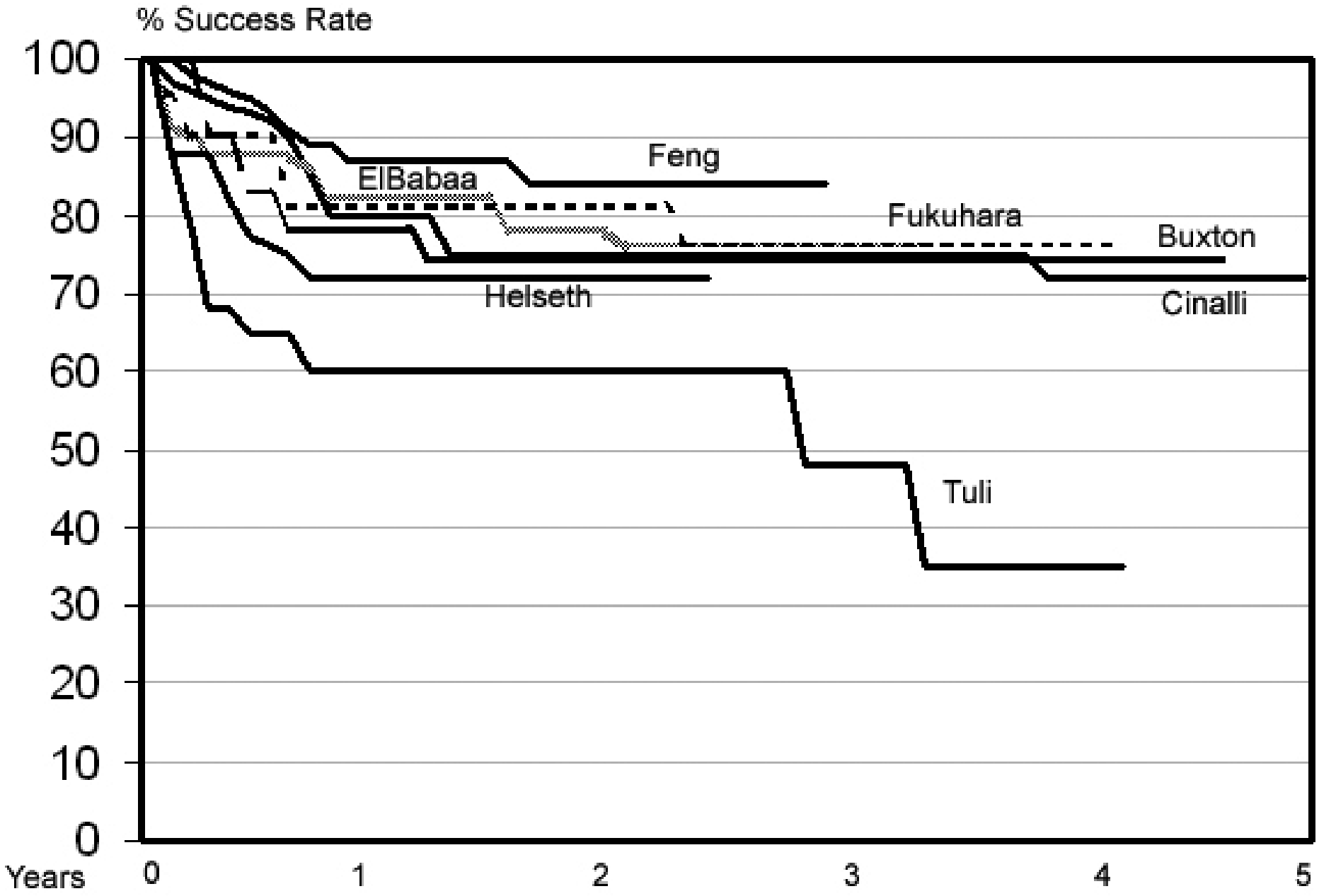

Fig. 28. Comparison of the seven actuarial studies available in the literature showing long term success rate studied with actuarial method following ETV in obstructive hydrocephalus. All the studies, except Tuli, remain between 70 and 85% at 5 years, no failures being observed beyond that date

show that most of the failures occur during the first year after surgery, and only sporadically after; basically no late failure has been described after the 5th year from ETV. Thus, close follow-up is mandatory in the first 5–6 years, and parents must be informed that immediate neurosurgical assessment is required if symptoms and signs of intracranial hypertension appear. Such failures can manifest with a very acute clinical onset, and if not recognized early may have dramatic consequences, leading to sudden death (Hader *et al.* 2002). As argued by Iantosca *et al.* (Iantosca *et al.* 2004), "education and regular follow up are important to counteract the false sense of security that may arise in the absence of a shunt".

Re-Obstruction of the Stoma

The lack of multicentric, prospective, randomized studies account for the current lack of reliable figures about the long term outcome of the children treated with ETV. However, Feng *et al.* (Feng *et al.* 2004) calculated a proportion of 75–80% functioning ETV at 1 year, Cinalli *et al.* (Cinalli *et al.* 1999) a functioning rate of 72% at 15 years, excluding technical failures.

Most failures of ETV occur in the first year following surgery; however, late failures have been reported, usually secondary to obstruction of the stoma by the growth of gliotic ependymal scarring tissue (Cinalli *et al.* 1999, Elbabaa *et al.* 2001, Hader *et al.* 2002, Hayashi *et al.* 2000, Koch *et al.* 2002, Mohanty *et al.* 2002, Siomin *et al.* 2001, Tuli *et al.* 1999).

If the patient is readmitted with recurrent signs of intracranial hypertension and increased ventricular dilatation on CT scan or MRI, the most likely diagnosis is obstruction or severe narrowing of the third ventriculostomy. This must be immediately confirmed by sagittal median T2-weighted fast spin-echo MRI sequences, which will show disappearance of the flow artifact and recurrence of the indirect signs of occlusion of the stoma (Elbabaa *et al.* 2001, Koch *et al.* 2002, Siomin *et al.* 2002). The treatment for obstruction can be reopening or enlargement of the stoma; this procedure carries the same success rate as the primary treatment (>65%) and should be preferred in a first instance to shunt implantation. If MRI at this stage shows good flow through the stoma, then a ventriculo-peritoneal shunt should be inserted.

The "delayed open-stoma" failure can rarely be observed also in children, especially in patients who have multiple potential etiological factors for hydrocephalus (e.g., hemorrhage, meningitis). This is the most insidious form of failure because of the difficulties in diagnosing it. Patients can present mild developmental delay that is sometimes difficult to diagnose without appropriate psychomotor testing. Radiology reveals large ventricles (stable at follow-up) and open stoma at MRI with clearly visible pericerebral CSF and no transependymal resorption. Clinically, papilledema is usually absent and only mild hyperreflexia can be observed, but progressive macrocrania in the first 2–3 years of life is almost the rule. ICP monitoring in these patients reveals abnormal baseline ICP values and B waves. After ventriculo-peritoneal shunting, patients usually show significant improvements in psychomotor testing.

Intellectual Outcome

Only a few studies focusing on neuropsychological outcome are available. Burtscher *et al.* (Burtscher *et al.* 2003) in a prospective study evaluated six patients affected by late onset aqueductal stenosis using standardized psychometric testing pre- and postoperatively. They found improvement of pre-operative deficits (usually combined deficits of memory and frontal-executive function) in all patients (full recovery in two, good recovery in three and moderate recovery in one). Ventricular size diminished in all these cases but never reached normal size. When comparable series of patients with aqueductal stenosis treated by insertion of VP shunt or ETV at the same Institution were analysed, no significant differences in the post-operative IQ or in the neurological, endocrinologic, social and behavioral status could be detected (Hirsch *et al.* 1986, Sainte-Rose 1992, Tuli *et al.* 1999). A controlled randomized study comparing neuroendoscopic versus non neuroendoscopic treatment of hydrocephalus in children seems to show that the outcome of the patients treated initially with a neuroendoscopic procedure is significantly better than that of the patients initially treated with extrathecal CSF shunt implantation, but this observation requires further investigation in multicentric studies (Kamikawa *et al.* 2001b).

Complications

Although indications, surgical technique and technological advances regarding ETV have been largely reported, the complications of the technique have been the subject of a surprisingly scarce interest (Teo *et al.* 1996, Schroeder *et al.* 2002). Furthermore, only a few papers discuss the quality of the complications in term of cost-effectiveness among ETV and traditional treatments (Garton *et al.* 2002, Richard *et al.* 2000). Such a phenomenon depends on the low rate of complications itself but also reflects the bias of a recently "re-introduced" technique with the obvious limitations in the evaluation of the long-term outcomes Anyway, the data so far cumulated may allow a sufficiently reliable analysis and the comparison with those related to the traditional treatment of hydrocephalus, based on the placement of an extrathecal CSF shunt device.

The overall morbidity rate related to the shunting procedures is estimated to be about 40–50% in the patients operated on before the second year of age and near 30% in those ones treated afterwards (Drake *et al.* 2000). Mechanical malfunctions (60% of the cases), infections (1–40%, mean 8.5%), over/underdrainage (10%) and post-inflammation intraventricular septa (6%) are the most frequent causes of complication of the CSF shunt devices (Di Rocco *et al.* 1994, Drake *et al.* 2000). The reported overall complication rate associated with ETV is lower, ranging from 6 to 20% (Buxton and Jonathan 2000, Hopf *et al.* 1999b, Teo and Jones 1996). The experience of the neuroendoscopic team is one of the most influencing factor (Schroeder *et al.* 2002). Some authors report even a nil rate of complications (Boschert *et al.* 2003).

The complications of ETV may be divided into "significant" and "nonsignificant". Significant complications such as hemorrhages, post-operative neurological deficits, hypothalamic dysfunction, severe bradycardia, epilepsy, infections, CSF leak are more frequently observed after ETV than after shunt placement. On the other hand, infections are more commonly associated to the placement of CSF shunt devices.

In most cases, the significant complications of ETV are only transient. The rate of significant complications ranges around 7% of the cases with only one sixth of them leading to permanent neurological damages (Broggi *et al.* 2000, Cinalli *et al.* 1998, Fukuhara *et al.* 2000, Sainte-Rose and Chumas 1996, Schroeder *et al.* 2002, Teo *et al.* 1991, Teo *et al.* 1996). Many of these complications, often the most severe ones, occur during the opening of the floor of the third ventricle, a phenomenon which accounts for a large number of techniques and instruments proposed so far to carry out the ventriculocisternostomy (Decq *et al.* 2004, Guiot 1973, Kehler *et al.* 1998, Kunz *et al.* 1994, Lewis and Crone 1994, Oka *et al.* 1993b, Paladino *et al.* 2000, Rieger *et al.* 1996, Vandertop *et al.* 1998, Vries 1978, Wellons *et al.* 1999). On the other hand, non-significant complications are linked up to transient intra-operative accidents (small bleeding, least contusions of the ventricular wall or the brain, short episodes of bradycardia) that do not affect the success of the operation and do not cause any significant damages. Their rate ranges from 5 to 13% in the largest series (Schroeder *et al.* 2002, Teo *et al.* 1996) even if their exact occurrence is difficult to establish because they are not always reported or perhaps misunderstood. The loss of substance due to the introduction of the endoscopic instrumentation and its movements inside the brain parenchyma might be one of them (Aschoff 2002).

Data about the mortality rate for ETV show an incidence meanly lower than 1%, often equal to 0% in many series (Abtin *et al.* 1998, Hopf *et al.* 1999b, Javadpour *et al.* 2001, Schroeder *et al.* 2002, Siomin *et al.* 2001). This incidence is comparable to the very low one observed for extrathecal shunts (0.1%) (Di Rocco *et al.* 1994) and it confirms ETV is a safe surgical procedure. In fact, death usually occurs after catastrophic bleedings from large vessels or, less frequently, because of severe secondary complications (infections) in patients with poor clinical conditions (Schroeder *et al.* 2002, Singh *et al.* 2003). Nevertheless, deaths after late closure of the fenestrated floor of the third ventricle have been recently reported (Abtin *et al.* 1998, Hader *et al.* 2002, Javadpour *et al.* 2003, Jones *et al.* 1996). This is the most insidious complication of ETV, mainly because sudden, unexpected and potentially fatal. Nonetheless, a potential and simple solution, as placing a ventricular catheter and a subcutaneous reservoir, has been successfully used (Mobbs *et al.* 2003).

Hemorrhages

The control of the intraoperative bleeding during ETV may be challenging since the minimally invasive procedures often do not give the surgeon enough space to arrest it. Moreover, the chances to arrest a blood loss are reduced by a poor three-dimensional vision. Currently, however, the risk of severe hemorrhage during ETV is rather low (Abtin *et al.* 1998, Buxton and Jonathan 2000, Schroeder *et al.* 1999).

The damage to the vessels is brought through a mechanical (endoscope, balloon, forceps) or a thermal injury (electrocoagulation, lasers) (Abtin *et al.* 1998, Buxton and Jonathan 2000, McLaughlin *et al.* 1997, Schroeder *et al.* 1999). The risk of vascular damage is higher when monopolar/bipolar or laser probe are used as their thermal effect is not much predictable and it may add itself to the mechanical one (Vandertop *et al.* 1998). Correct instruments in expert hands and continuous irrigation are the only tools available to decrease this risk.

Intraventricular bleeding from the small subependymal vessels, due to the traumatic rhexis of these delicate vascular structures caused by the impact with the endoscopic instrumentation, is the most frequent hemorrhagic complication happening during ETV (Choi *et al.* 1999, Cinalli *et al.* 1999, Fukuhara *et al.* 2000, Gangemi *et al.* 1999, Sainte-Rose and Chumas 1996). The reported incidence ranges from 1 to 3% (Beems and Grotenhuis 2004, Fukuhara *et al.* 2000, Gangemi *et al.* 1999) but higher figures can be hypothesized (Koch and Wagner 2004, Schroeder *et al.* 2004). Usually, it is a non-significant complication that can be easily managed and stopped by (extensive) irrigation with lactate Ringer's solution or, less frequently, through a prudent coagulation of the bleeding vessel. On the contrary, mild hemorrhages (hypothalamic, thalamostriate, septal veins) sometimes make the irrigation ineffective, so affecting the operative visibility and the possibility to perform a safe electrocoagulation. In these cases, the procedure has to be abandoned and an extracranial CSF drainage is placed (Buxton *et al.* 1998b, Cinalli *et al.* 1999). This "technical" failure does not prevent the possibility to try again the ETV after the clearing of the CSF, with a risk of closure of the stoma following the aseptic ventriculitis just a little increased (Cinalli *et al.* 1999, Fukuhara *et al.* 2000, Hopf *et al.* 1999b). In some instances, the venous bleeding results in a subependymal clot that may clear up spontaneously without the need to abort the surgical procedure, as reported by Schönauer *et al.* (Schönauer *et al.* 2000). Otherwise, the management of the hematoma requires a microsurgical approach (Hopf *et al.* 1999b).

Cerebral hemorrhagic contusion, due to the damage toward the pial vessels at the introduction of the endoscope (Schroeder *et al.* 2002, Vandertop *et al.* 1998), and extradural hematoma (Choi *et al.* 1999, Cinalli *et al.* 1998) are uncommon.

The damage of large vascular structures is equally rare, occurring in about 1% of ETVs (Abtin *et al.* 1998, Cinalli *et al.* 1998, McLaughlin *et al.* 1997, Schroeder *et al.* 1999, Schroeder *et al.* 2002). The basilar artery and its branches (P1 segment of the posterior cerebral artery, perforating vessels) are usually involved but also the injury to the anterior cerebral artery or to the pericallosal branch has been described (Buxton and Jonathan 2000, Cohen 1993). The surgeon's prudence and her/his anatomical knowledge, besides her/his skill to succeed in "seeing" the arteries or their pulsations through the ventricular floor, can explain this low rate. It is recommended to perforate the floor of the third ventricle halfway between the infundibular recess and the mammillary bodies, in the midline, in order to minimize the risk of vascular as well as neurological and hypothalamic damage (Schroeder *et al.* 1999). The use of ultrasonic or neuronavigation guidance to reduce the incidence of vascular complications has been recommended (Broggi *et al.* 2000, Strowitzki *et al.* 2002). An unfavorable anatomy (small or too thick or excessively elastic floor of the third ventricle) and a poor intraoperative visibility are important risk factors. Basilar artery perforation appears as a intraventricular bloody flooding that suddenly obscures the operating field. The management consists of quick removal of the endoscope and placement of an external ventricular drain through which a copious irrigation must be performed till the bleeding is arrested. After that, the drainage can be use to infuse thrombin in order to achieve the lysis of the intraventricular clot (Abtin *et al.* 1998). Also blood replacement may be necessary and an adequate neuroanesthesiologic monitoring is mandatory. The preventive placement of a peelaway sheath in the third ventricle has been proved to be very helpful to avoid the blood accumulation, so preventing an herniation syndrome and saving the patient's life (Abtin *et al.* 1998). The radiological findings of post-operative vascular complications include the demonstration of more or less extensive subarachnoid hemorrhage, intraventricular clots, persistent hydrocephalus and possible pseudoaneurysm formation (McLaughlin *et al.* 1997, Schroeder *et al.* 1999). The hydrocephalus is usually treated by ventriculoperitoneal shunt but the traumatic aneurysm could need a craniotomy to be excluded (Abtin *et al.* 1998, McLaughlin *et al.* 1997). In spite of the reported successful management, the injury to the basilar artery remains a dramatic event, potentially fatal (Schroeder *et al.* 1999). Sometimes, fatal major intraventricular bleedings occur without the possibility to establish their source (Husain *et al.* 2003).

Neurological Disorders

Also the damage to the nervous structures resulting in both diffuse or focal nervous functional impairment are caused by mechanical and/or thermal injury, either directly or indirectly. The incidence of such a type of complication is, however, lower than that of vascular complications (Beems and Grotenhuis 2004, Schroeder *et al.* 2004). Indirect injuries derive from vascular ischemic impairment, sometimes as the consequence of one of the significant hemorrhagic complications seen before. Whatever the mechanism, the result is often limited to a transient morbidity (non-permanent significant complication). In most cases the damage involve the fornix, the thalami or the mammillary bodies (Schroeder *et al.* 2002). Actually, long term neurological complications are very rare as demonstrated by only anedoctical reports (two cases of hemiparesis and one case of midbrain damage (Jones *et al.* 1994), one case of confusion after herniation syndrome and one case of oculomotor palsy (Schroeder *et al.* 2002), one case of ankle clonus and speech delay (McLaughlin *et al.* 1997). Nevertheless, it is possible that some of the complications remain unreported (Schroeder *et al.* 2004).

Among the complications leading to diffuse impairment of cerebral function, the decrease in level of consciousness and confusion are the most common, mainly depending on focal diencephalic/brain stem lesions or extensive SAH (Brockmeyer *et al.* 1998, Buxton and Jonathan 2000, Fukuhara *et al.* 2000, Schroeder *et al.* 2002), and seldom resulting from post-herniation syndrome (Beems and Grotenhuis 2004). Transient memory disfunctions seem to share a similar pathogenesis (Baskin *et al.* 1998, Choi *et al.* 1999, Ferrer *et al.* 1997, Handler *et al.* 1994). The fornix and the mammillary bodies, thanks to their neural connections to the hippocampus, exert an important role in the acquisition and consolidation of newly learned information. The contusions of these two endoscopic landmark during the surgical procedure may result in impairment of immediate memory, though rarely (Benabarre *et al.* 2001). Psychiatric complications of ETV (disinhibition, aggressive behavior) are exceptional and usually related to primary or secondary lesions of the frontal lobe (Benabarre *et al.* 2001, Buxton and Jonathan 2000). Also epilepsy is rare after ETV, in most cases resulting from an impaired general clinical condition (Siomin *et al.* 2001), from a previous extensive brain damage (Handler *et al.* 1994) or from associated metabolic disfunction (Vaicys and Fried 2000). Some authors even assert that ETV minimizes the risk of late seizures, compared to traditional shunts, thanks to the lack of a permanent irritating foreign body (ventricular drain) (Kramer *et al.* 2001).

Focal neurological deficits result from localized lesions, more often ischemic than mechanical, affecting the long neural pathways (internal capsule, brain stem), with consequent side motor impairment (hemiparesis) (Brockmeyer *et al.* 1998, Buxton and Jonathan 2000, Cinalli *et al.* 1999, Sainte-Rose and Chumas 1996, Teo *et al.* 1991), the III–VI cranial nerves and/or their nuclei, with consequent oculomotion palsy (Buxton and Jonathan 2000, Gangemi *et al.* 1999, Siomin *et al.* 2001), or the optic chiasm (hemianopia) (Beems and Grotenhuis 2004). The case of Horner's syndrome due to a probable hypothalamic suffering, reported by Fukuhara *et al.* (Fukuhara *et al.* 2000), and the case of peduncular hallucinosis (visual hallucinations resulting from midbrain, pontine or diencephalic lesions), described by Kumar *et al.* (Kumar *et al.* 1999), are still unique as complications of ETV.

Although uncommonly, focal and generalized neurological deficits, as consequence of both direct and indirect mechanism, can occur simultaneously. The case of a young patient, who underwent ETV because of a ventriculoperitoneal shunt twice complicated by subdural hematoma, is emblematic (Buxton and Jonathan 2000): the opening of the ventricular floor caused a bleeding from a perforating branch of the left anterior cerebral artery, with ESA and consequent vasospasm with bilateral cerebral infarction, and a lesion of the right III cranial nerve. The patient initially developed a right oculomotor palsy and drowsiness, both transient; afterwards, a left hemiparesis and behavior disfunction, both transient; finally, a late hyperphagia.

Brain herniation syndrome is unusual but potentially dangerous neurological complication of ETV, though only transient morbidity has been attributed to it so far. It can result from intraventricular overirrigation (Brockmeyer *et al.* 1998, Schroeder *et al.* 2002) or from sudden hydrocephalus resolution in case of posterior fossa tumor (upward herniation) (Sainte-Rose *et al.* 2001).

Hypothalamic and Neurovegetative Disfunction

As expected, the anatomy of the third ventricle makes the hypothalamus vulnerable during ETV. Besides all the other mechanisms seen before, the injuries to the hypothalamus can arise from the distortion of its nuclei caused by the strain of the ventricular floor or by overirrigation. This mechanism might be liable of one of the most frequent and less studied complications of ETV, the bradycardia. In fact, it has been found that the incidence of the phenomenon at the opening of the stoma may exceed a rate of 40%, because of the distortion of the hypothalamic autonomic nuclei (El-Dawlatly *et al.* 2000). However, this complication is clinically non-significant in most cases, rarely requiring a temporary interruption of the procedure. Seldom it leads to cardiac asystole and transient cardiac arrest (Fukuhara *et al.* 2000, Teo *et al.* 1996).

Ventricular tachycardia, followed by ventricular fibrillation and near-fatal cardiac arrest, reported in 14-years-old girl, was explained on the base of a similar mechanism (rapid and/or excessive distension of the third ventricle due to the irrigation) (Handler *et al.* 1994).

A few cases of transient respiratory arrest following ETV were laso described and attributed to the patient's general clinical condition after extubation rather than to the procedure itself (Enya *et al.* 1997, Siomin *et al.* 2001).

Diabetes insipidus is a common complication among the hypothalamic imbalances due to ETV but, since it is basically transient, its actual incidence is not well known (Schroeder *et al.* 2002, Teo and Jones 1996, Teo *et al.* 1996). The damage concerns the supraoptic and paraventricular nuclei or, more probably, their connections to the hypophyseal median eminence (Coulbois *et al.* 2001). It usually affects the patient for a few days after the operation and regresses spontaneously or after a short treatment by vasopressin (Coulbois *et al.* 2001, Teo and Jones 1996). To date, only three cases of persistent diabetes insipidus have been described (Di Roio *et al.* 1999, Schroeder *et al.* 2002, Beems and Grotenhuis 2004).

Other possible hypothalamic endocrinologic or metabolic disfunctions are uncommon. They include secondary amenorrhea (Teo *et al.* 1996), inappropriate secretion of antidiuretic hormone/hyponatriemia (Javadpour *et al.* 2001, Vaicys and Fried 2000), hyperphagia (Buxton and Jonathan 2000, Teo *et al.* 1996), and loss of thirst (Schroeder *et al.* 2002, Teo *et al.* 1996).

Transient hyperthermia is reported as possible result of hypothalamic manipulation, though it is often difficult to exclude a concomitant aseptic irritation of the ependyma (Sainte-Rose 1992, Sainte-Rose and Chumas 1996). In all the cases, however, it is mandatory to rule out a secondary infective complication when the fever persists after the first 24–48 postoperative hours. On the other hand, hypothermia, plausibly due to excessively cold irrigating fluid, is a not rare finding during the early recovery after ETV (Singh *et al.* 2003).

Other Complications

Infections account for the majority of non-specific complications of ETV. They are facilitated by the presence of a previous infected shunt or an external drainage more than depending on the endoscopic procedure itself (Fukuhara *et al.* 2000, Hopf *et al.* 1999b, Schroeder *et al.* 2002). According to the literature, the approximate overall rate ranges from 1 to 5% (Beems and Grotenhuis 2004, Schroeder *et al.* 2004, Teo *et al.* 1996) and includes wound infections (Jones *et al.* 1994, Siomin *et al.* 2001, Teo *et al.* 1991), ventriculitis (Abtin *et al.* 1998, Brockmeyer *et al.* 1998, Buxton *et al.* 1998b, Jones *et al.* 1994, Teo *et al.* 1991), and meningitis (Gangemi *et al.* 1999, Hopf *et al.* 1999b, Schroeder *et al.* 2002). This low incidence rate accounts for the current favor of ETV, especially when the data related to extrathecal CSF shunts (range 1–40%, mean 8.5%) (Whitehead and Kestle 2001) are taken into consideration. In spite of their generally benign course and the effectiveness of the antibiotic drugs (Schroeder *et al.* 2004), CSF infections following ETV are a very feared complication of the procedure because of the risk of arachnoiditis and consequent obliteration of the CSF pathways. Actually, postoperative meningitis resulted as an independent risk factor of failure of ETV from the multivariate analysis of Fukuhara *et al.* (Fukuhara *et al.* 2000).

CSF leak is a characteristic complication of ETV (Buxton *et al.* 1998b, Gangemi *et al.* 1999, Schroeder *et al.* 2002, Siomin *et al.* 2001, Tamburrini *et al.* 2004, Teo *et al.* 1996), especially in infants (thin skin, immature subarachnoid spaces) (Teo 2004). Though in many cases it can be successfully managed by intermittent tapping from lumbar or ventricular drainage (Cinalli 2004, Husain *et al.* 2003, Siomin *et al.* 2001), revealing the possibility of a gradual adaptation of the CSF hydrodynamics to the ETV (Nishiyama *et al.* 2003), this type of complication represents a risk factor for infections and, in particular, it may be the early sign of a failure of the procedure and the need of a shunt placement.

Subdural fluid collections (hematomas or hygromas) are reported as the second frequent complication involving the vascular structures after the intraventricular blood hemorrhages (Oka *et al.* 1993b, Fukuhara *et al.* 2000, Jones *et al.* 1994, Sainte-Rose and Chumas 1996, Teo *et al.* 1991). Their incidence, however, is relatively low, being less than 2% in large series (Genitori *et al.* 2004, Schroeder *et al.* 2002, Schroeder *et al.* 2004). These extracerebral collections are likely related to the quick drop of the intracranial pressure following the opening of the stoma (Sgaramella *et al.* 2004) and/or, more probably, to the possible acute CSF leak at the beginning or at the end of the procedure (Teo 2004). The phenomenon is especially common in children with a very thin brain cortex and massive hydrocephalus (Schönauer *et al.* 2000). They are quite often asymptomatic and do not require any further surgical procedure (Fukuhara *et al.* 2000, Schroeder *et al.* 2002). Only in a few cases, they need to be evacuated, producing a transient morbidity (Jones *et al.* 1990, Sgaramella *et al.* 2004). The case of a 3-months-old child, who developed a cardiorespiratory arrest because of a massive subdural collection after ETV and who was successfully treated by resuscitation and urgent aspiration of the fluid collection, is exceptional (Mohanty *et al.* 1997).

Finally, tension pneumocephalus is a rarely reported (Hamada *et al.* 2004) but dangerous complication of ETV, likely depending on the CSF leak during the procedure.

References

1. Abtin K, Thompson BG, Walker ML (1998) Basilar artery perforation as a complication of endoscopic third ventriculostomy. Pediatr Neurosurg 28: 35–41
2. Alberti O, Riegel T, Hellwig D, Bertalanffy H (2001) Frameless navigation and endoscopy. J Neurosurg 95: 541–543

3. Aschoff A (2002) III Ventriculostomy. EANS Winter Meeting, Rome, March 19th
4. Auer LA, Auer DP (1998) Virtual endoscopy for planning and simulation of minimally invasive neurosurgery. Neurosurgery 43: 529–548
5. Barkovich AJ, Kjos BO, Norman D, Edwards MS (1989) Revised classification of posterior fossa cysts and cyst-like malformations based on the results of multiplanar MR imaging. AJNR 10: 977–988
6. Barr (1948) Observations on the foramen of Magendie in a series of human brains. Brain 71: 281
7. Baskin JJ, Manwaring KH, Rekate HL (1998) Ventricular shunt removal: the ultimate treatment of the slit ventricle syndrome. J Neurosurg 88: 478–484
8. Bech RA, Bogeskov L, Borgesen SE, Juhler M (1999) Indications for shunt insertion or 3rd ventriculostomy in hydrocephalic children, guided by lumbar and intraventricular infusion tests. Child's Brain 15: 213–218
9. Beems T, Grotenhuis JA (2002) Is the success rate of endoscopic third ventriculostomy age dependent? An analysis of the results of third ventriculostomy in young children. Child's Nerv Sist 18: 605–608
10. Beems T, Grotenhuis JA (2004) Long term complications and definition of failures of neuroendoscopic procedures. Child's Nerv Syst 20: 868–877
11. Bellotti A, Rapana A, Iaccarino C, Schonauer (2001) Intracranial pressure monitoring after endoscopic third ventriculostomy: an effective method to manage the 'adaptation period'. Clin Neurol Neurosurg 103: 223–227
12. Benabarre A, Ibáñez J, Boget T, Obiols J, Martínez-Aran A, Vieta E (2001) Neuropsychological and psychiatric complications in endoscopic third ventriculostomy: a clinical case report. J Neurol Neurosurg Psychiatry 71: 268–271
13. Beni-Adani L, Bental Y, Ben-Sira L (2004) Does aqueductal stenosis really exist as an independent diagnosis or does it represent an old fetal hemorrhage misdiagnosed on real time fetal US? Child's Nerv Syst 20: 663
14. Boop FA (2004) Post-hemorrhagic hydrocephalus of prematurity. In: Cinalli G, Meixner W, Sainte-Rose C (eds) Pediatric hydrocephalus, Springer-Verlag, Milan, pp 121–132
15. Böschert J, Hellwig D, Krauss JK (2003) Endoscopic third ventriculostomy for shunt dysfunction in occlusive hydrocephalus: long-term follow up and review. J Neurosurg 98: 1032–1039
16. Bozzini P (1806) Lichtleiter; eine Erfindung zur Ashauung innerer Theile und Krankheiten nebst der Abbildung. In: Hufeland CW (ed) J der practischen Arzneykunde und Wundarrzneykunst, Berlin, 24: 107–124
17. Brockmeyer D, Abtin K, Carey L, Walker M (1998) Endoscopic third ventriculostomy: an outcome analysis. Pediatr Neurosurg 28: 236–240
18. Broggi G, Dones I, Ferroli P, Franzini A, Servello D, Duca S (2000) Image guided neuroendoscopy for third ventriculostomy. Acta Neurochir (Wien) 142: 893–899
19. Büki A, Doczi T, Veto F, Horvath Z, Gallyas F (1999) Initial clinical experience with a combined pulsed holmiumneodymium-YAG laser in minimally invasive neurosurgery. Minim Invasive Neurosurg 42: 35–40

20. Burtscher J, Bale R, Dessl A, Eisner W, Twerdy K, Sweeney RA, Felber S (2002) Virtual endoscopy for planning neuro-endoscopic intraventricular surgery. Minim Invasive Neurosurg 45: 24–31
21. Burtscher J, Bartha L, Twerdy K, Eisner W, Benke T (2003) Effect of endoscopic third ventriculostomy on neuropsychological outcome in late onset idiopathic aqueductal stenosis: a prospective study. J Neurol Neurosurg Psychiatry 74: 222–225
22. Burtscher J, Dessl A, Maurer H, Seiwald M, Felber S (1999) Virtual neuroendoscopy, a comparative magnetic resonance and anatomical study. Minim Invas Neurosurg 42: 113–117
23. Buxton N, Jonathan P (2000) Cerebral infarction after neuroendoscopic third ventriculostomy: case report. Neurosurgery 46: 999–1002
24. Buxton N, Macarthur D, Mallucci C, Punt J, Vloeberghs M (1998a) Neuroendoscopy in the premature population. Child's Nerv Syst 14: 649–652
25. Buxton N, Macarthur D, Mallucci C, Punt J, Vloeberghts M (1998b) Neuroendoscopic third ventriculostomy in patients less than 1 year old. Pediatr Neurosurg 29: 73–76
26. Buxton N, Macarthur D, Robertson I, Punt J (2003) Neuroendoscopic third ventriculostomy for failed shunts. Surg Neurol 60: 193–200
27. Buxton N, Turner B, Ramli N, Vloeberghs M (2002) Changes in third ventricular size with neuroendoscopic third ventriculostomy: a blinded study. J Neurol Neurosurg Psychiatry 72: 385–387
28. Chapman PH (1990) Indolent gliomas of the midbrain tectum. Concepts Pediatr Neurosurg 10: 97–107
29. Choi JU, Kim DS, Kim SH (1999) Endoscopic surgery for obstructive hydrocephalus. Yonsei Med J 40: 600–607
30. Cinalli G (1999) Alternatives to shunting. Child's Nerv Syst 15: 718–731
31. Cinalli G (2004) Endoscopic third ventriculostomy. In: Cinalli G, Maixner WJ, Sainte-Rose C (eds) Pediatric Hydrocephalus, Springer, Milan, pp 361–388
32. Cinalli G, Sainte-Rose C, Chumas P, Zerah M, Brunelle F, Lot G, Pierre-Khan A, Renier D (1999) Failure of third ventriculostomy in the treatment of aqueductal stenosis in children. J Neurosurg 90: 448–454
33. Cinalli G, Salazar C, Mallucci C, Yada JZ, Zerah M, Sainte-Rose C (1998) The role of endoscopic third ventriculostomy in the management of shunt malfunction. Neurosurgery 43: 1323–1329
34. Cinalli G, Spennato P, Cianciulli E, D'Armiento M (2004a) Hydrocephalus and aqueductal stenosis. In: Cinalli G, Meixner W, Sainte-Rose C (eds) Pediatric Hydrocephalus, Springer-Verlag, Milan, pp 279–294
35. Cinalli G, Spennato P, Del Basso De Caro ML, Buonocore MC (2004b) Hydrocephalus and the Dandy-Walker malformation. In: Cinalli G, Meixner W, Sainte-Rose C (eds) Pediatric Hydrocephalus, Springer-Verlag, Milan, pp 279–294
36. Ciurea AV, Coman TC, Mircea D (2004) Postinfectious hydrocephalus in children. In: Cinalli G, Meixner W, Sainte-Rose C (eds) Pediatric Hydrocephalus, Springer-Verlag, Milan, pp 201–218

37. Cohen AR (1993) Endoscopic ventricular surgery. Pediatr Neurosurg 19: 127–134
38. Coulbois S, Boch A-L, Philippon J (2001) Diabète insipide après ventriculocisternostomie par voie endoscopique. A propos d'un cas et revue de la littérature. Neurochirurgie 47: 435–438
39. Czosnyka M, Whitehouse M, Smielewski P, Simac S, Pickard JD (1996) Testing of cerebrospinal compensatory reserve in shunted and non-shunted patients: a guide to interpretation based on an observational study. J Neurol Neurosurg Psychiatry 60: 549–558
40. Dandy WE (1918) Extirpation of the choroid plexuses of the lateral and fourth ventricle in communicating hydrocephalus. Ann Surg 68: 569–579
41. Dandy WE (1922) An operative procedure for hydrocephalus. Bull Johns Hopkins Hosp 33: 189–190
42. Daoud AS, Omari H, al-Sheyyab M, Abuekteish F (1998) Indications and benefits of computer tomography in childhood bacterial meningitis. J Trop Pediatr 44: 167–169
43. Decq P (2004) Endoscopic anatomy of the ventricles. In: Cinalli G, Maixner WJ, Saint-Rose C (eds) Pediatric Hydrocephalus, Springer, Milan, pp 351–359
44. Decq P, Le Guerinel C, Palfi S, Djindjian M, Kéravel Y, Nguyen J (2000) A new device for endoscopic third ventriculostomy. J Neurosurg 93: 509–512
45. Di Rocco C, Marchese E, Velardi F (1994) A survey of the first complication of newly implanted CSF shunt devices for the treatment of nontumoral hydrocephalus. Cooperative survey of the 1991–1992 Education Committee of the ISPN. Child's Nerv Syst 10: 312–327
46. Di Roio C, Mottolese C, Cayrel V, Berlier P, Artru F (1999) Ventriculostomie du troisième ventricule et diabète insipide. Ann Fr Anesth Reanim 18: 776–778
47. Doctor BA, Newman N, Minich NM, Taylor HG, Fanaroff AA, Hack M (2001) Clinical outcomes of neonatal meningitis in very-low birth-weight infant. Clin Pediatr 40: 473–480
48. Drake JM (1993) Ventriculostomy for treatment of hydrocephalus. Neurosurg Clin North Am 4: 657–666
49. Drake JM, Kestle JRW, Milner R, Cinalli G, Boop F, Piatt J Jr, Hainess S, Schiff SJ, Cochrane DD, Steinbok P, McNeil N (1998) Randomized trial of cerebrospinal fluid shunt valve design in pediatric hydrocephalus. Neurosurgery 43: 294–303
50. Drake JM, Kestle JRW, Tuli S (2000) CSF shunts 50 years on – past, present and future. Child's Nerv Syst 16: 800–804
51. Duffner F, Shiffbauer H, Glenser D, Skalej M, Freudenstein D (2003) Anatomy of the cerebral ventricular system for endoscopic neurosurgery: a magnetic resonance study. Acta Neurochir 145: 359–368
52. Elbabaa SK, Steinmetz M, Ross J, Moon D, Luciano M (2001) Endoscopic third ventriculostomy for obstructive hydrocephalus in the pediatric population: evaluation of outcome. Eur J Pediatr Surg 11 (suppl. 1): 552–554

53. El-Dawlatly AA, Murshid WR, El-Khwsky F (1999) Endoscopic third ventriculostomy: a study of intracranial pressure vs heamodynamic changes. Minim Invas Neurosurg 42: 198–200
54. El-Dawlatly AA, Murshid WR, Elshimy A, Magboul MA, Samarkandi A, Takrouri MS (2000) The incidence of bradycardia during endoscopic third ventriculostomy. Anesth Analg 91: 1142–1144
55. Enya S, Masuda Y, Terui K (1997) Respiratory arrest after a ventriculoscopic surgery in infants: two case reports. Masui 46: 416–420 [Japanese]
56. Enzmann DR, Pelec NJ (1991) Normal flow pattern in intracranial and spinal cerebrospinal fluid defined with phase-contrast cine-MR imaging. Radiol 178: 467–474
57. Fay T, Grant FC (1923) Ventriculoscopy and intraventricular photography in internal hydrocephalus. JAMA 80: 461–463
58. Feng H, Huang G, Liao X, Fu K, Tab H, Pu H, Cheng Y, Liu W, Zhao D (2004) Endoscopic third ventriculostomy in the management of obstructive hydrocephalus: an outcome analysis. J Neurosurg 100: 626–633
59. Ferrer E, Santamarta D, Garcia-Fructuoso G, Caral L, Rumia J (1997) Neuroendoscopic management of pineal region tumors. Acta Neurochir 139: 12–21
60. Fischer RE, Biljana T (2000) Optical system design, McGraw Hill, New York
61. Foroutan M, Mafee MF, Dujovny M (1998) Third ventriculostomy, phase-contrast cine MRI and endoscopic techniques. Neurol Res 20: 443–448
62. Frazee JG, Shah AS (1998) Interactive surgery and telepresence. In: King W, Frazee J, De Salles A (eds) Endoscopy of the Central and Peripheral Nervous System, Thieme, New York, 1998, pp 243–251
63. Fritsch MJ, Mehdorn M (2002) Endoscopic intraventricular surgery for treatment of hydrocephalus and loculated CSF space in children less than one year of age. Pediatr Neurosurg 36: 183–188
64. Fritsch MJ, Mehdorn HM (2003) Indication and controversies for endoscopic third ventriculostomy in children. Child's Nerv Syst 19: 706–707
65. Fritsch MJ, Dorner L, Kienke S, Claviez A, Mehdorn HM (2004) Indication for endoscopic third ventriculostomy in children with posterior fossa tumors. Child's Nerv Syst 20: 668
66. Fukuhara T, Luciano MG, Kowalski RJ (2002) Clinical features of third ventriculostomy failures classified by fenestration patency. Surg Neurol 58: 102–110
67. Fukuhara T, Vorster SJ, Luciano MG (2000) Risk factors for failure of endoscopic third ventriculostomy for obstructive hydrocephalus. Neurosurgery 46: 1100–1111
68. Fukushima T, Ishijima B, Hirakaw K, Nakamura N, Samo K (1973) Ventriculofiberscope: a new technique for endoscopic diagnosis and operation. J Neurosurg 38: 251–256
69. Gangemi M, Donati P, Maiuri F, Longatti P, Godano U, Mascari C (1999) Endoscopic third ventriculostomy for hydrocephalus. Minim Invasive Neurosurg 42: 128–132

70. Garton HJL, Kestle JRW, Cochrane DD, Steinbok P (2002) A cost-effectiveness analysis of endoscopic third ventriculostomy. Neurosurgery 51: 69–78
71. Genitori L, Peretta P, Mussa F, Giordano F (2004) Endoscopic third ventriculostomy in children: are age and etiology of hydrocephalus predictive factors influencing the outcome in primary and secondary treated patients? A series of 328 patients and 353 procedures. II CURAC Congress, Munich, October 8th
72. Glasauer FE (1975) Isotope cisternography and ventriculography in congenital anomalies of the central nervous system. J Neurosurg 43: 18–26
73. Goh KYC, Abbott R (2000) Is endoscopic third ventriculostomy of benefit in tumour related aqueductal stenosis? Child's Nerv Syst 16: 127–128
74. Gorayeb RP, Cavalheiro S, Zymberg SY (2004) Endoscopic third ventriculostomy in children younger than 1 year of age. J Neurosurg (Pediatrics 5) 100: 427–429
75. Goumnerova LC, Frim D (1997) Treatment of hydrocephalus with third ventriculostomy: outcome and CSF flow patterns. Pediatr Neurosurg 27: 149–152
76. Grant JA (1998) An endoscopic view of the anterior commissure. Pediatr Neurosurg 28: 42
77. Greitz D (2004) Radiological assessment of hydrocephalus: new theories and implications for therapy. Neurosurg Rev 27: 145–165
78. Grunert P, Perneczki A, Resch K (1994) Endoscopic procedures through the foramen of Monro under stereotactic conditions. Mim Invasive Neurosurg 37: 2–8
79. Grunert P, Charalampaki P, Hopf N, Filippi R (2003) The role of third ventriculostomy in the management of obstructive hydrocephalus. Minim Invasive Neurosurg 46: 16–21
80. Guiot G (1973) Ventriculo-cisternostomy for stenosis of aqueduct of Silvius. Puncture of the floor of the third ventricle with a leucotome under television control. Acta Neurochir 28: 275–289
81. Hader WJ, Drake J, Cochrane D, Sparrow O, Johnson ES, Kestle J (2002) Death after late failure of third ventriculostomy in children. Report of three cases. J Neurosurg 97: 211–215
82. Hamada H, Hayashi N, Kurimoto M, Umemura K, Hirashima Y, Nogami K, Endo S (2004) Tension pneumocephalus after neuroendoscopic procedure – case report. Neurol Med Chir (Tokyo) 44: 205–208
83. Handler MH, Abbott R, Lee M (1994) A near-fatal complication of endoscopic third ventriculostomy: case report. Neurosurgery 35: 525–528
84. Hayashi N, Hamada H, Hirashima Y, Kurimoto M, Takaku A, Endo S (2000) Clinical features in patients requiring reoperation after failed endoscopic procedures for hydrocephalus. Minim Invasive Neurosurg 43: 181–186
85. Hecht J (1999) City of light: the story of fiber optics, Oxford University Press, New York
86. Heilman CB, Cohen AR (1991) Endoscopic ventricular fenestration using "saline torch". J Neurosurg 74: 224–229

87. Hellwig D, Haag R, Bartel V, Riegel T, Eggers F, Becker R, Bertalanffy H (1999) Application of new electrosurgical devices and probes in endoscopic neurosurgery. Neurol Res 21: 67–72
88. Hellwig D, Heinemann A, Riegel T (1998a) Endoscopic third ventriculostomy in treatment of obstructive hydrocephalus caused by primary aqueductal stenosis. In: Hellwig D, Bauer B (eds) Minimally Invasive Techniques for Neurosurgery, Springer, Berlin, pp 65–72
89. Hellwig D, Riegel T, Bertalanffy H (1998b) Neuroendoscopic techniques in treatment of intracranial lesions. Minim Invasive Ther Allied Technol 7: 123–135
90. Helseth E, Due-Tonnessen B, Egge A, Eide PK, Meling T, Lundar T, Froslie KF (2002) Behandling av Hydrocephalus med endoskopisk tredjeventrikkelstomi. Tidsskr Nor Loegeforen 122: 994–998
91. Hill A, Volpe J (1981) Seizures, hypoxic-ischemic brain injury, and intraventricular hemorrhage in the newborn. Ann Neurol 10: 109–121
92. Hirsch JF, Pierre-Kahn A, Renier D, Sainte-Rose C, Hoppe-Hirsch E (1984) The Dandy-Walker malformation. A review of forty cases. J Neurosurg 61: 512–522
93. Hirsch JF, Hirsch E, Sainte-Rose C, Renier D, Pierre-Kahn A (1986) Stenosis of the aqueduct of Sylvius. Etiology and treatment. J Neurosurg Sci 30: 29–36
94. Hoffman HJ, Harwood-Nash D, Gilday DL, Craven MA (1980) Percutaneous third ventriculostomy in the management of non-communicating hydrocephalus. Neurosurgery 7: 313–321
95. Hopf NJ, Grunert P, Darabi K, Busert C, Bettag (1999a) Frameless neuronavigation applied to endoscopic neurosurgery. Minim Invasive Neurosurg 42: 187–193
96. Hopf NJ, Grunert P, Fries G, Resch KDM, Perneczky A (1999b) Endoscopic third ventriculostomy: outcome analysis of 100 consecutive procedures. Neurosurgery 44: 795–806
97. Horowitz M, Ramzipoor K, Mair A, Miller S, Rappard G, Spiro R, Purdy P (2003) Experimental third ventriculostomy performed using endovascular surgical techniques and their adaptation to percutaneous intradural neuronavigation: proof of concept cadaver study. Neurosurgery 53: 387–392
98. Husain M, Jha D, Vatsal DK, Thaman D, Gupta A, Husain N, Gupta RK (2003) Neuroendoscopy surgery – experience and outcome analysis of 102 consecutive procedure in a busy neurosurgical center of India. Acta Neurochir 145: 369–376
99. Iantosca MR, Hader WJ, Drake JM (2004) Results of endoscopic third ventriculostomy. Neurosurg Clin N Am 15: 67–75
100. Jacobson EE, Fletcher DF, Morgan MK, Johnston IH (1999) Computer modelling of the CSF flow dynamics of aqueductal stenosis. Med Biol Eng Comput 37: 59–63
101. Jaksche H, Loew F: Burr hole third ventriculostomy (1986) An unpopular but effective procedure for treatment of certain forms of occlusive hydrocephalus. Acta Neurochir 79: 48–51

102. Javadpour M, Mallucci C, Brodbelt A, Golash A, May P (2001) The impact of endoscopic third ventriculostomy on the management of newly diagnosed hydrocephalus in infants. Pediatr Neurosurg 35: 131–135
103. Javadpour M, May P, Mallucci C (2003) Sudden death secondary to delayed closure of endoscopc third ventriculostomy. Br J Neurosurg 17: 266–269
104. Jellinger G (1986) Anatomomorphology of nontumoral aqueductal stenosis. J Neurosurg Sci 30: 1–16
105. Jodicke A, Berthold LD, Scharbrodt W, Schroth I, Reiss I, Neubauer BA, Boker DK (2003) Endoscopic surgical anatomy of the paediatric third ventricle studied using virtual neuroendoscopy based on 3-D ultrasonography. Child's Nerv Syst 19: 325–331
106. Jones FRC, Stening WA, Brydon M (1990) Endoscopic third ventriculostomy. Neurosurgery 26: 86–92
107. Jones RFC, Kwok BCT, Stening WA (1996) Endoscopic III ventriculostomy. How long does it last? Child's Nerv Syst 12: 364–365
108. Jones RFC, Kwok BCT, Stening WA, Vonau M (1994) The current status of endoscopic third ventriculostomy in the management of non-communicating hydrocephalus. Minim Invasive Neurosurg 37: 28–36
109. Kaiser G (1985) Hydrocephalus following toxoplasmosis. Z Kinderkir 40 (Suppl. 1): 10–11
110. Kamikawa S, Inui A, Kobayashi N, Kuwamura K, Kasuga M, Yamadori T, Tamaki N (2001b) Endoscopic treatment of hydrocephalus in children: a controlled study using newly developed Yamadori-type ventriculoscopes. Minim Invasive Neurosurg 44: 25–30
111. Kamikawa S, Inui A, Kobayashi N, Tamaki N, Yamadori T (2001c) Intraventricular hemorrhage in neonates: endoscopic findings and treatment by the use of our newly developed Yamadori-type 8 ventriculoscope. Min Invas Neurosurg 44: 74–78
112. Kamikawa S, Inui A, Tamaki N, Kobayashi N, Yamadori T (2001a) Application of flexible neuroendoscope to intracerebroventricular arachnoid cyst in children – Use of videoscope. Minim Invas Neurosurg 44: 186–189
113. Kehler U, Gliemroth J, Knopp U, Arnold H (1998) How to perforate safely a resistant floor of the third ventricle? Technical note. Minin Invasive Neurosurg 41: 198–199
114. Kelly PJ (1991) Stereotactic third ventriculostomy in patients with nontumoral adolescent/adult onset aqueductal stenosis and symptomatic hydrocephalus. J Neurosurg 75: 865–873
115. Kim SK, Wang KC, Cho BK (2000) Surgical outcome of pediatric hydrocephalus treated by endoscopic III ventriculostomy: prognostic factors and interpretation of postoperative neuroimaging. Child's Nerv Syst 16: 161–169
116. Koch D, Grunert P, Filippi R, Hopf N (2002) Re-ventriculostomy for treatment of obstructive hydrocephalus in cases of stoma dysfunction. Minim Invasive Neurosurg 45: 158–163
117. Koch D, Wagner W (2004) Endoscopic third ventriculostomy in infants of less than 1 year of age: which factors influence the outcome? Child's Nerv Syst 20: 405–411

118. Kramer U, Kanner AA, Siomin V, Harel S, Constantini S (2001) No evidence of epilepsy following endoscopic third ventriculostomy: a short-term follow up. Pediatr Neurosurg 34: 121–123
119. Kreusser K, Tarby T, Kovnar E, Taylor DA, Hill A, Volpe JJ (1985) Serial lumbar punctures for at least temporary amelioration of neonatal posthemorrhagic hydrocephalus. Pediatrics 75: 719–724
120. Kulkarni AV, Drake JM, Armstrong DC, Dirks PB (2000) Imaging correlates of successful endoscopic third ventriculostomy. J Neurosurg 92: 915–919
121. Kumar R, Behari S, Wahi J, Banerji D, Sharma K (1999) Peduncular hallucinosis: an unusual sequel to surgical intervention in the suprasellar region. Br J Neurosurg 13: 500–503
122. Kunz U, Goldman A, Bader C, Waldbaur H, Oldenkott P (1994) Endoscopic fenestration of the 3rd ventricular floor in aqueductal stenosis. Minim Invasive Neurosurg 37: 42–47
123. Laikin M (2001) Method of lens design, Dekker, New York
124. Lang J (1992) Topographic anatomy of preformed intracranial spaces. Acta Neurochir (Wien) (suppl.) 54: 1–10
125. Lapras C, Bret P, Patet JD, Huppert J (1986) Hydrocephalus and aqueductal stenosis. Direct surgical treatment by interventriculostomy (aqueduct cannulation). J Neurosurg Sci 30: 47–53
126. Lespinasse VL (1910) In: Davis L (ed) Neurological Surgery, Lea & Febinger, Philadelphia, 1936, p 405
127. Lewis AI, Crone KR (1994) Advances in neuroendoscopy. Contemp Neurosurg 16: 1–6
128. Liu CY, Wang MY, Apuzzo MLJ (2004) The physics of image formation in the neuroendoscope. Childs Nerv Syst 20: 777–782
129. Longatti P, Martinuzzi A, Fiorindi A, Malobabic S, Carteri A (2003) Endoscopic anatomic features of the triangular recess. Neurosurgery 52: 1491–1494
130. Macarthur DC, Buxton N, Vloeberghs M, Punt J (2001). The effectiveness of neuroendoscopic interventions in children with brain tumors. Child's Nerv Syst 17: 589–594
131. Magnaes B (1982) Cerebrospinal fluid hydrodynamics in adult patients with benign non-communicating hydrocephalus: one-hour test shunting and balanced cerebrospinal fluid infusion test to select patients for intracranial bypass operation. Neurosurgery 11: 769–775
132. Magnaes B (1989) Hydromechanical testing in non-communicating hydrocephalus to select patients for microsurgical third ventriculostomy. Br J Neurosurg 3: 443–450
133. Matson DD (1969) Neurosurgery of Infancy and Childhood, 2nd edition, Charles C Thomas, Springfield, Illinois
134. McLaughlin MR, Wahlig JB, Kaufmann AM, Albright AL (1997) Traumatic basilar aneurysm after endoscopic third ventriculostomy: case report. Neurosurgery 41: 1400–1404
135. Miller MN (1992) Organisation of the neuroendoscopy suite. In: Manwaring KH, Crone KR (eds) Neuroendoscopy, vol 1, Mary Ann Liebert, New York, pp 9–15

136. Mixter WJ (1923) Ventriculoscopy and puncture of the floor of the third floor. Preliminary report of a case. Boston Med Surg J 1: 277–278
137. Mobbs RJ, Vonau M, Davies MA (2003) Death after late failure of endoscopic third ventriculostomy: a potential solution. Neurosurgery 53: 384–386
138. Mohanty A, Anandt B, Reddy MS, Sastry KVR (1997) Contralateral massive acute subdural collection after endoscopic third ventriculostomy – a case report. Minim Invasive Neurosurg 37: 28–36
139. Mohanty A, Vasudev MK, Sampath S, Radhesh S, Sastry, Kolluri VR (2002) Failed endoscopic third ventriculostomy in children: management options. Pediatr Neurosurg 37: 304–309
140. Mohanty A (2003) Endoscopic third ventriculostomy with cystoventricular stent placement in the management of Dandy-Walker malformation: technical case report of three patients. Neurosurgery 53: 1223–1229
141. Mori H, Nishiyama K, Tanaka R (2003) Endoscopic third ventriculostomy in shunt malfunction and slit-ventricle syndrome. Child's Nerv Syst 19: 690
142. Murshid WR (2000) Endoscopic third ventriculostomy: towards more indications for the treatment of non-communicating hydrocephalus. Minim Invas Neurosurg 43: 75–82
143. Nishiyama K, Mori H, Tanaka R (2003) Changes in cerebrospinal fluid hydrodynamics following endoscopic third ventriculostomy for shunt-dependent noncommunicating hydrocephalus. J Neurosurg 98: 1027–1031
144. Nitze M (1879) Eine neue Beobachtungs und Untersuchungs Methode für Harnröhre, Harnblse und Rectum. Wien Med Wochenschr 24: 649–652
145. Nobles A (1998) The physics of neuroendoscopic systems and the instrumentation. In: Jimenez DF (ed) Intracranial Endoscopic Neurosurgery, Park Ridge, IL: American Association of Neurological Surgeons, pp 1–12
146. Nugent GR, Al-Mefty O, Chou S (1979) Communicating hydrocephalus as a cause of aqueductal stenosis. J Neurosurg 51: 812–818
147. Oi S, Shibata M, Tominaga J, Honda Y, Shinoda M, Takei F, Tsugane R, Matsuzawa K, Sato O (2000) Efficacy of neuroendoscopic procedures in minimally invasive preferential management of pineal region tumors: a prospective study. J Neurosurg 93: 245–253
148. Oi S, Hamada H, Nonaka Y, Kusaka Y, Samii A, Samii M (2004) Proposal of a "evolution theory in CSF dynamics": a significant factor affecting the failure of neuroendoscopic ventriculostomy in treatment of hydrocephalus. Child's Nerv Syst 20: 662
149. Oka K, Go Y, Kin Y, Tomonaga M (1993a) An observation of the third ventricle under flexible fiberoptic ventriculoscope: normal structure. Surg Neurol 40: 273–277
150. Oka K, Go Y, Kin Y, Utsunomiya H, Tomonaga M (1995) The radiographic restoration of the ventricular system after third ventriculostomy. Minim Invasive Neurosurg 38: 158–162
151. Oka K, Tomonaga M (1992) Instruments for flexible endoneurosurgery. In: Manwaring KH, Crone KR (eds) Neuroendoscopy, vol 1, Mary Ann Liebert, New York, pp 17–28

152. Oka K, Yamamoto M, Ikeda K, Tomonaga M (1993b) Flexible endoneurosurgical therapy for aqueductal stenosis. Neurosurgery 33: 236–243
153. Paladino J, Rotim K, Stimac D, Pirker N, Stimac A (2000) Endoscopic third ventriculostomy with ultrasonic contact microprobe. Minim Invasive Neurosurg 43: 132–134
154. Pavez Salinas A (2004) Description of endoscopic ventricular anatomy in meningomyelocele. Child's Nerv Syst (in press)
155. Perlman JM, Argyl C (1992) Lethal cytomegalovirus infection in preterm infants: clinical, radiological, and neuropathological findings. Ann Neurol 31: 64–68
156. Pettorossi VE, Di Rocco C, Mancinelli R, Caldarelli M, Velardi F (1978) Communicating hydrocephalus induced by mechanically increased amplitude of the intraventricular cerebrospinal fluid pulse pressure: rationale and method. Exp Neurol 59: 30–39
157. Pollack JK, Pang D, Albright AL (1994) The long term outcome in children with late-onset aqueductal stenosis resulting from benign intrinsic tectal tumors. J Neurosurg 80: 681–688
158. Pople IK, Athanasiou TC, Sandeman DR, Coakham HB (2001) The role of endoscopic biopsy and third ventriculostomy in the management of pineal region tumours. Br J Neurosurg 15: 305–311
159. Portillo S, Zuccaro G, Fernandez-Molina A, Houssay A, Sosa F, Konsol O, Jaimovich R, Olivella E, Ledesma J, Guevara M, Ajler G, Picco P (2004) Endoscopic third ventriculostomy in the treatment of pediatric hydrocephalus. A multicentric study. Child's Nerv Syst 20: 666–667
160. Putnan TJ (1943) The surgical treatment of infantile hydrocephalus. Surg Gynecol Obst 76: 171–182
161. Quencher RM, Donovan Post MJ, Hinks RS (1990) Cine MR in the evaluation of normal and abnormal CSF flow: intracranial and intraspinal studies. Neuroradiology 32: 371–391
162. Raimondi AJ, Clark SJ, McLone DG (1976) Pathogenesis of aqueductal occlusion in congenital murine hydrocephalus. J Neurosurg 45: 66–77
163. Rappaport ZH, Shalit MN (1989) Perioperative external ventricular drainage in obstructive hydrocephalus secondary to infratentorial brain tumours. Acta Neurochir 96: 118–121
164. Resch KDM (2003) Endo-neuro-sonography: first clinical series (52 cases). Childs Nerv Syst 19: 137–144
165. Resch KDM, Perneczky A (1998) Endo-neuro-sonography: basics and current use. In: Hellwig D, Bauer BL (eds) Minimally Invasive Techniques for Neurosurgery, Springer, Berlin Heidelberg New York, pp 21–31
166. Resch KDM, Reisch R (1997) Endo-neuro-sonography: anatomical aspects of the ventricles. Minim Invasive Neurosurg 1: 2–7
167. Rhoton AL Jr (2002) The lateral and third ventricles. Neurosurgery 51 (suppl. 1): 207–270
168. Richard HK, Seeley HM, Okane C, Pickard JD (2000) ICP 11, Cambridge, July 22–26th

169. Riegel T, Alberti O, Hellwig D, Bertalanffy H (2001) Operative management of third ventriculostomy in cases of thickened, non-translucent third ventricular floor: technical note. Minim Invas Neurosurg 44: 65–69
170. Riegel T, Alberti O, Retsch R, Shiratori V, Hellwig D, Bertalanffy H (2000) Relationships of virtual reality neuroendoscopic simulations to actual imaging. Minim Invasive Neurosurg 43: 176–180
171. Riegel T, Freudenstein D, Alberti O, Duffner F, Hellwig D, Bartel V, Bertalanffy H (2002) Novel multipurpose bipolar instrument for endoscopic neurosurgery. Neurosurgery 51: 270–274
172. Rieger A, Rainov NG, Sanchin L, Schoop G, Burkert W (1996) Ultrasound-guided endoscopic fenestration of the third ventricular floor for non-communicating hydrocephalus. Minim Invasive Neurosurg 39: 17–20
173. Rieger A, Rainov NG, Brucke M, Marx T, Holz C (2000) Endoscopic third ventriculostomy is the treatment of choice for obstructive hydrocephalus due to pediatric pineal tumors. Minim Invas Neurosurg 43: 83–86
174. Rohde V, Gilsbach JM (2000) Anomalies and variants of the endoscopic anatomy for third ventriculostomy. Min Invas Neurosurg 43: 111–117
175. Rohde V, Krombach GA, Struffert T, Gilsbach JM (2001) Virtual MRI endoscopy: detection of anomalies of the ventricular anatomy and its possible role as a presurgical planning tool for endoscopic third ventriculostomy. Acta Neurochir 143: 1085–1091
176. Roland E, Hill A (1997) Intraventricular hemorrhage and posthemorrhagic hydrocephalus: current and potential future interventions. Clin Perinatol 1: 589–605
177. Ruggiero C, Cinalli G, Spennato P, Aliberti F, Cianciulli E, Trischitta V, Maggi G (2004) Endoscopic third ventriculostomy in the treatment of hydrocephalus in posterior fossa tumors in children. Child's Nerv Syst 20: 828–833
178. Russel DS, Nevin S (1940) Aneurysm of the great vein of Galen causing internal hydrocephalus: report of two cases. J Pathol Bacteriol 51: 447–448
179. Saint George E, Natarajan K, Sgouros S (2004) Changes in ventricular volume in hydrocephalic children following successful endoscopic third ventriculostomy. Childs Nerv Syst 20: 834–838
180. Sainte-Rose C (1992) Third ventriculostomy. In: Manwaring KH, Crone K (eds) Neuroendoscopy, Mary Ann Libert, New York, pp 47–62
181. Sainte-Rose C, Chumas P (1996) Endoscopic third ventriculostomy. Tech Neurosurg 1: 176–184
182. Sainte-Rose C, Cinalli G, Roux FE, Maixner V, Chumas PD, Mansour M, Carpentier A, Bourgeois M, Zerah M, Pierre-Kahn A, Renier D (2001) Management of hydrocephalus in pediatric patients with posterior fossa tumors: the role of endoscopic third ventriculostomy. J Neurosurg 95: 791–797
183. Sainte-Rose C (2004) Hydrocephalus in pediatric patients with posterior fossa tumours. In: Cinalli G, Meixner W, Sainte-Rose C (eds) Pediatric Hydrocephalus, Springer-Verlag, Milan, pp 155–162
184. Scavarda D, Bednarek N, Litre F, Koch C, Lena G, Morville P, Rousseaux P (2003) Acquired aqueductal stenosis in preterm infants: an indication for neuroendoscopic third ventriculostomy. Child's Nerv Syst 19: 756–759

185. Schijns OE, Beuls EA (2002) Parinaud's syndrome as a sign of acute obstructive hydrocephalus: recovery after acute ventriculostomy. Ned Tijdschr Geneeskd 46: 1136–1140
186. Schmid UD, Seiler RW (1986) Management of obstructive hydrocephalus secondary to posterior fossa tumours by steroids and subcutaneous ventricular catheter reservoir. J Neurosurg 65: 649–653
187. Schoeman JF, Honey EM, Loock DB (1996) Raised ICP in a child with cryptococal meningitis: CT evidence of a distal CSF block. Child's Nerv Syst 12: 568–571
188. Schönauer C, Bellotti A, Tessitore E, Parlato C, Moraci A (2000) Traumatic subependymal hematoma during endoscopic third ventriculostomy in a patient with a third ventricle tumor: case report. Minim Invasive Neurosurg 43: 135–137
189. Schroeder HWS, Gaab MR (1999) Intracranial neuroendoscopy. Neurosurg Focus 6 (4): Article 1
190. Schroeder HWS, Niendorf W-R, Gaab MR (2002) Complications of endoscopic third ventriculostomy. J Neurosurg 96: 1032–1040
191. Schroeder HWS, Oertel J, Gaab MR (2004) Incidence of complications in neuroendoscopic surgery. Child's Nerv Syst 20: 878–883
192. Schroeder HWS, Wagner W, Tschiltschke W, Gaab MR (2001) Frameless neuronavigation in intracranial endoscopic neurosurgery. J Neurosurg 94: 72–79
193. Schroeder HWS, Warzok RW, Assaf JA, Gaab MR (1999) Fatal subarachnoid hemorrhage after endoscopic third ventriculostomy. Case report. J Neurosurg 90: 153–155
194. Schwartz TH, Ho B, Prestigiacomo CJ, Bruce JN, Feldstein NA, Goodman RR (1999) Ventricular volume following third ventriculostomy. J Neurosurg 91: 20–25
195. Schwartz TH, Yoon SS, Cutruzzola FW, Goodman RR (1996) Third ventriculostomy: post-operative ventricular size and outcome. Minim Invasive Neurosurg 39: 122–129
196. Sgaramella E, Castelli G, Sotgiu S (2004) Chronic subdural collection after endoscopic third ventriculostomy. Acta Neurochir 146: 529–530
197. Sgouros S (2004) Hydrocephalus with myelomeningocele. In: Cinalli G, Meixner W, Sainte-Rose C (eds) Pediatric Hydrocephalus, Springer-Verlag, Milan, pp 133–144
198. Shaw CM, Alvord EC (1995) Hydrocephalus. In: Duckett S (ed) Pediatric Neuropathology, Williams and Wilkins, Baltimore pp 149–211
199. Shiau JSC, King WA (1998) Neuroendoscopes and instruments. In: Jimenez DF (ed) Intracranial Endoscopic Neurosurgery, Park Ridge, IL: American Association of Neurological Surgeons, pp 13–27
200. Singh D, Gupta V, Goyal A, Singh H, Sinha S, Singh AK, Kumar S (2003) Endoscopic third ventriculostomy in obstructed hydrocephalus. Neurology India 51: 39–42
201. Siomin V, Weiner H, Wisoff J, Cinalli G, Pierre-Khan A, Sainte-Rose C, Abbott R, Elran H, Beni-Adani L, Ouaknine G, Constantini S (2001) Re-

peat endoscopic third ventriculostomy: is it worth trying? Child's Nerv Syst 17: 551–555

202. Siomin V, Cinalli G, Grotenhuis A, Golash A, Oi S, Kothbauer K, Weiner H, Roth J, Beni-Adani L, Pierre-Kahn A, Takahashi M, Mallucci C, Abbott R, Wisoff J, Constantini S (2002) Endoscopic third ventriculostomy for patients with cerebrospinal fluid infections and/or hemorrhage. J Neurosurg 97: 519–524
203. Siomin V, Constantini S (2004) Basic principles and equipment in neuroendoscopy. Neurosurg Clin N Am 15: 19–31
204. Smyth MD, Tubbs RS, Wellons JC 3rd, Oakes WJ, Blount JP, Grabb PA (2003) Endoscopic third ventriculostomy for hydrocephalus secondary to central nervous system infection or intraventricular hemorrhage in children. Pediatr Neurosurg 39: 258–263
205. Stahl W, Kaneda Y (1997) Pathogenesis of murine toxoplasmic hydrocephalus. Parasitology 114: 219–229
206. Stellato TA (1992) History of laparoscopic surgery. Surg Clin North Am 72: 997–1002
207. Strowitzki M, Kiefer M, Steudel W-I (2002) A new method of ultrasonic guidance of neuroendoscopic procedures. J Neurosurg 96: 628–632
208. Sutton LM, Adzick NS, Bilaniuk LT, Johnson MP, Crombleholme TM, Flake AW (1999) Improvement in hindbrain herniation demonstrated by serial fetal magnetic resonance imaging following fetal surgery for myelomeningocele. JAMA 282: 1826–1831
209. Tamburrini G, Caldarelli M, Massimi L, Ramirez-Reyes G, Di Rocco C (2004) Primary and secondary third ventriculostomy in children with hydrocephalus and myelomeningocele. Child's Nerv Syst 20: 666
210. Teo C, Jones RFC, Stening WA (1991) Neuroendoscopic third ventriculostomy. In: Matsumoto S (ed) Hydrocephalus: pathogenesis and treatment. Springer, Berlin Heidelberg New York Tokyo, pp 65–78
211. Teo C, Jones R (1996) Management of hydrocephalus by endoscopic third ventriculostomy in patients with myelomeningocele. Pediatr Neurosurg 25: 57–63
212. Teo C, Rahman S, Boop FA, Cherny B (1996) Complications of endoscopic neurosurgery. Child's Nerv Syst 12: 248–253
213. Teo C (1998) Third ventriculostomy in the treatment of hydrocephalus: Experience with more than 120 cases. In: Hellwig D, Bauer B (eds) Minimally Invasive Techniques for Neurosurgery. Springer, Berlin Heidelberg New York Tokyo, pp 73–76
214. Teo C (2004) Complications of endoscopic third ventriculostomy. In: Cinalli G, Maixner J, Saint-Rose C (eds) Pediatric Hydrocephalus, Springer, Milan, pp 411–420
215. Tirakotai W, Bozinov O, Sure U, Riegel T, Bertalanffy H, Hellwig D (2004) The evolution of stereotactic guidance in neuroendoscopy. Child's Nerv Syst 20: 790–795
216. Tisell M, Almstrom O, Stephensen H, Tullberg M, Wikkelso C (2000) How effective is endoscopic third ventriculostomy in treating adult hydrocephalus caused by primary aqueductal stenosis? Neurosurgery 46: 104–110

217. Tuli S, Alshail E, Drake JM (1999) Third ventriculostomy versus cerebrospinal fluid shunt as a first procedure in pediatric hydrocephalus. Pediatr Neurosurg 30: 11–15
218. Tulipan M, Hernanz-Schulman M, Bruner JP (1998) Reduced hindbrain herniation after intrauterine myelomeningocele repair: a report of four cases. Pediatr Neurosurg 29: 274–278
219. Vaicys C, Fried A (2000) Transient hyponatriemia complicated by seizures after endoscopic third ventriculostomy. Minim Invasive Neurosurg 43: 190–191
220. van Aalst J, Beuls EAM, van Nie FA, Vles JSH, Cornips EMJ (2002) Acute distortion of the anatomy of the third ventricle during third ventriculostomy. J Neurosurg 96: 597–599
221. Vandertop WP, Verdaasdonk RM, Van Swol CFP (1998) Laser assisted neuroendoscopy using a neodymium-yttrium aluminium garnet or diode contact laser with pretreated fiber tips. J Neurosurg 88: 82–92
222. Vinas FC, Dujovny N, Dujovny M (1996) Microanatomical basis for the third ventriculostomy. Minim Invas Neurosurg 39: 116–121
223. Vinas FC, Fandino R, Dujovny M, Chavez V (1994) Microsurgical anatomy of the supratentorial arachnoidal trabecular membranes and cisterns. Neurol Res 16: 417–424
224. Vries J (1978) An endoscopic technique for third ventriculostomy. Surg Neurol 9: 165–168
225. Wagner W, Koch D (2004) Why does third ventriculostomy fail more often in infants? Child's Nerv Syst 20: 666
226. Wellons JC III, Bagley CA, George TM (1999) A simple and safe techniques for endoscopic third ventriculocisternostomy. Pediatr Neurosurg 30: 219–223
227. Wharen REJ, Anderson RE, Scheithauer B, Sundt TM (1984) The Nd:YAG laser in neurosurgery: Part 1. Laboratory investigations: dose-related biological response of neural tissue. J Neurosurg 60: 531–539
228. Whitehead WE, Kestle JRW (2001) The treatment of cerebrospinal fluid shunt infections. Pediatr Neurosurg 35: 205–210
229. Wilcock DJ, Jaspan T, Punt J (1996) CSF flow through third ventriculostomy demonstrated with colour Doppler ultrasonography. Clin Radiol 51: 127–129
230. Willems PW, Vandertop WP, Verdaasdonk RM, van Swol CF, Jansen GH (2001) Contact laser-assisted neuroendoscopy can be performed safely by using pretreated 'black' fibre tips: experimental data. Lasers Surg Med 28: 324–329
231. Wong TT, Lee LS (1996) A method of enlarging the opening of the third ventricular floor for flexible endoscopic third ventriculostomy. Child's Nerv Syst 12: 396–398
232. Yamakawa K (1995) Instrumentation for neuroendoscopy. In: Cohen AR, Haines SJ (eds) Minimally invasive techniques in neurosurgery. Williams & Wilkins, Baltimore, pp 6–13