

# 5

## Patient Evaluation and Selection

M.J.B. Stallmeyer and Gregg H. Zoarski

Vertebral compression fractures (VCFs) can occur as a result of osteoporosis, malignant primary bone tumors, osteolytic metastases, and some benign bone tumors such as vertebral hemangiomas. Percutaneous vertebroplasty (PV) has emerged as an effective technique for treatment of painful VCFs. At present, the safety and effectiveness of PV in treating asymptomatic but abnormal vertebral bodies remains unproven and controversial (1). When considering whether a patient is an appropriate candidate for PV, it is important to distinguish the pain caused by VCFs from numerous other causes of back pain. Careful adherence to clinical and imaging selection criteria is crucial to procedural success; when patients are properly selected, PV may provide substantial pain relief and/or improved mobility in 75% to 92.4% of patients with osteoporotic fractures (1–9) and in 50% to 86% of patients with pathologic VCFs secondary to neoplasm (1,3,5,10–15).

### **Disease Processes Causing Vertebral Compression Fractures**

#### **Osteoporosis**

The most common cause of VCF is osteoporosis, which may be related to aging (primary osteoporosis) or result from chronic steroid use or androgen deprivation therapy (secondary osteoporosis). It is estimated that 10 million Americans over age 50 years have osteoporosis, with another 34 million at risk on the basis of low bone mass (16). Direct care costs for osteoporotic fractures range from \$12.2 to \$17.9 billion each year (17). More than 700,000 symptomatic VCFs come to medical attention in the United States each year. These result in 150,000 hospital admissions and 161,000 physician office visits (18). More than 4% of patients with osteoporotic spine fractures due to minimal trauma become functionally dependent, and 1.9% require nursing home placement (19,20). With aging of the population, the

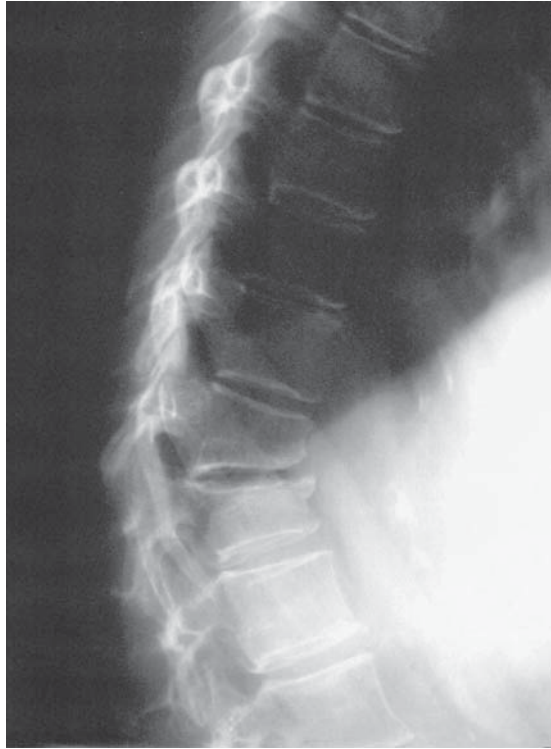burden of osteoporosis on the health care system is expected to increase substantially.

Primary osteoporosis is characterized by diminished bone mass involving both cortical and trabecular bone, with increased susceptibility to microfracture and thus gross insufficiency fracture. The axial skeleton, femoral neck, and wrist are most commonly affected. The majority of VCFs due to primary osteoporosis occur in postmenopausal women (21,22). The radiographic prevalence of thoracic or lumbar vertebral compression deformity has been reported to be as high as 26% in women over age 50 years when defined as a loss of more than 15% of vertebral body height (22). The frequency of vertebral compression deformity, which may or may not be symptomatic, increases with age in postmenopausal women, from 500 per 100,000 person-years in women 50–54 years of age to 2,960 per 100,000 person-years in women older than 85 (22). The age-adjusted prevalence of osteoporosis in Hispanic and Asian women is similar to that found in Caucasian women, while that of African-American women is lower (23); nevertheless, the rate of bone loss in all ethnic groups increases with age. The incidence of primary osteoporosis in elderly men is also significant: Cooper et al. (24) found an age-adjusted incidence of VCFs in men of 81 per 100,000 person-years, slightly more than half that of women (153 per 100,000) in the same study population.

About 20% of women and more than 50% of men with osteoporosis have a secondary cause of bone loss (25–27). One of the most frequent causes is long-term corticosteroid use, which decreases bone formation and accelerates bone resorption by osteoclasts (28). Patient populations at risk for steroid-induced insufficiency fracture include patients with asthma or chronic obstructive pulmonary disease (COPD), rheumatoid arthritis, malignancies such as lymphoma and multiple myeloma, transplant patients (26), and patients with inflammatory bowel disease (29,30). Osteoporosis is also an important side effect of androgen deprivation therapy for prostate cancer (31).

Vertebral compression fractures, which are the most frequently occurring type of osteoporosis-related fracture, are associated with significant morbidity and mortality. They have been associated with difficulty in performing activities of daily living and impaired psychosocial performance; patients may curtail their activity level due to fear of additional fractures and become unable to care for themselves (20,32–38). Furthermore, there is increased mortality in patients who have had osteoporotic VCFs compared with age-matched controls, with mortality increasing with both the number of fractures (39) and the duration of follow-up (40). The kyphotic deformities caused by VCFs are associated with pulmonary dysfunction, including significantly decreased vital capacity and forced expiratory volume (32), constipation, and alterations in balance.

Although osteoporosis is a systemic disease, most osteoporotic VCFs are located at or near the thoracolumbar junction (Figure 5.1). Most occur “spontaneously” (46%) or after only minimal trauma (36%).



**Figure 5.1.** Lateral radiograph of the lumbar spine showing adjacent osteoporotic thoracolumbar VCFs that occurred when this patient lifted a bag of groceries. (From J.M. Mathis, H. Deramond, and S.M. Belkoff [eds], *Percutaneous Vertebroplasty*. New York: Springer, 2002, with permission.)

Because a history of clear antecedent trauma is often lacking, a correct diagnosis is made in only 43% of first visits to a health care provider (41). Patients typically present with acute pain and tenderness over the spine at or near the level of radiographic compression deformity. Radiculopathy is rare but has been reported (42); severe neurologic deficit or spinal cord compression is even more unusual but does occur (43).

Magnetic resonance imaging (MRI) is extremely useful in the evaluation of osteoporotic VCFs, especially when fractures of different ages are present. Magnetic resonance imaging demonstrates characteristic changes in marrow signal that vary with the age of the fracture (44–46). Acute and subacute fractures less than 30 days old typically demonstrate signal changes consistent with bone marrow edema: the marrow is hypointense in signal on T1-weighted images and hyperintense on T2-weighted and short tau inversion recovery (STIR) sequences (Figure 5.2). About 1 month following fracture, the majority of osteoporotic VCFs become isointense to normal bone marrow on T1- and T2-

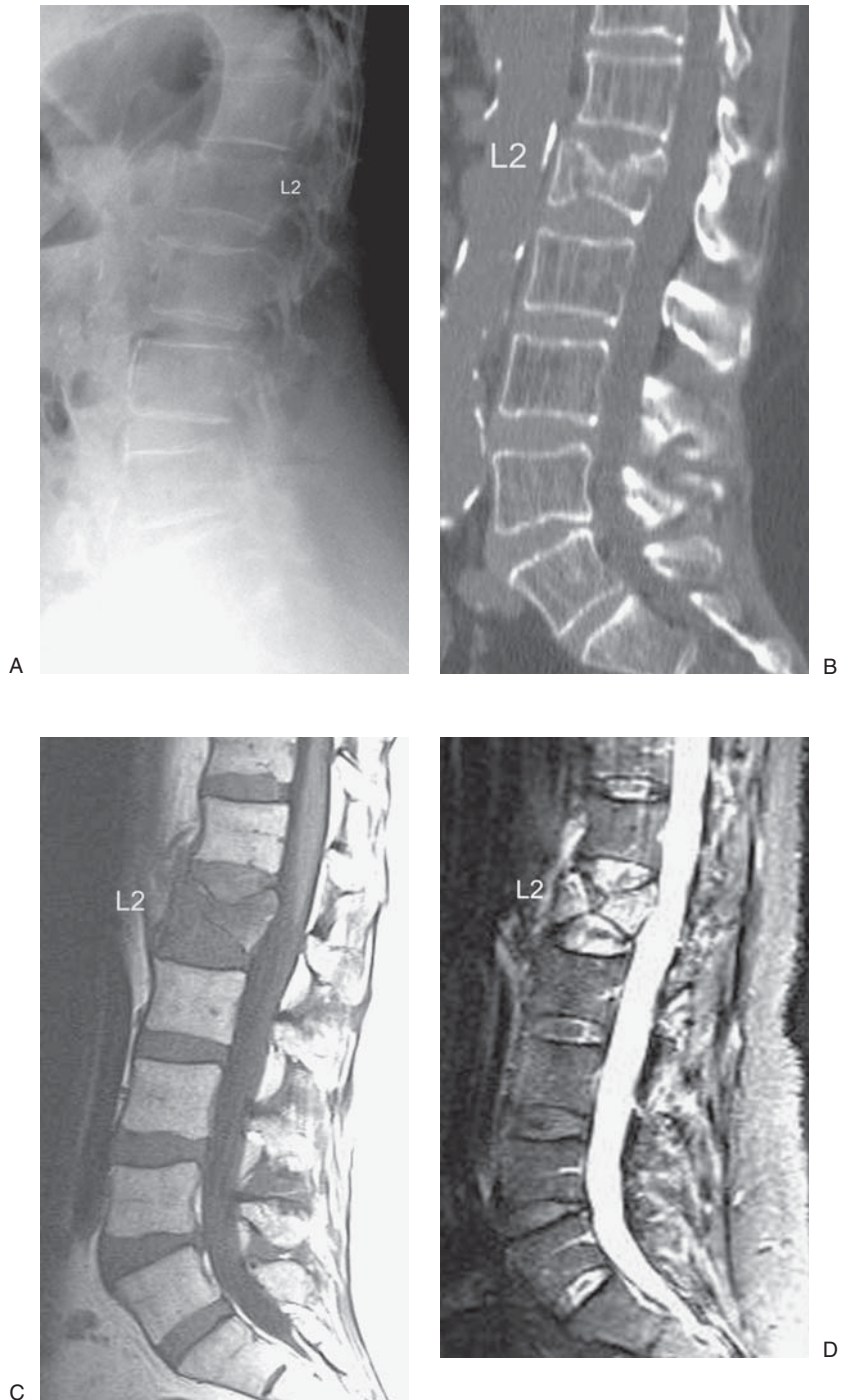
weighted sequences (Figure 5.2). Fully healed compression fractures may demonstrate a return of normal marrow signal (Figure 5.3) or may appear hypointense on both T1- and T2-weighted sequences when there is significant sclerosis. Cuenod et al. (47) described a band of T2-hyperintense signal subjacent to the fractured endplate in 48% of acute osteoporotic VCFs (Figure 5.3). Additionally, subacute blood products may be found beneath the endplates of the affected vertebra. Acute and subacute fractures may become isointense to normal vertebrae following administration of gadolinium contrast.

The finding of bone marrow edema on MRI is extremely helpful in predicting which patients are most likely to respond favorably to treatment. In a retrospective review of a large series of patients treated with PV for osteoporotic VCFs, Alvarez et al. (9) demonstrated marked to complete pain relief in 68.4% and moderate pain relief in 27.6% of patients demonstrating typical T1-hypointense, T2-hyperintense changes on MRI. They found no significant pain relief in 78.6% of patients in whom these findings were absent. When MRI signal changes suggestive of healing with sclerosis are seen, a confirmatory computed tomography (CT) scan should be obtained; in such cases needle placement and injection of polymethylmethacrylate (PMMA) cement may be impossible or may yield suboptimal clinical and radiographic results (Figure 5.4).

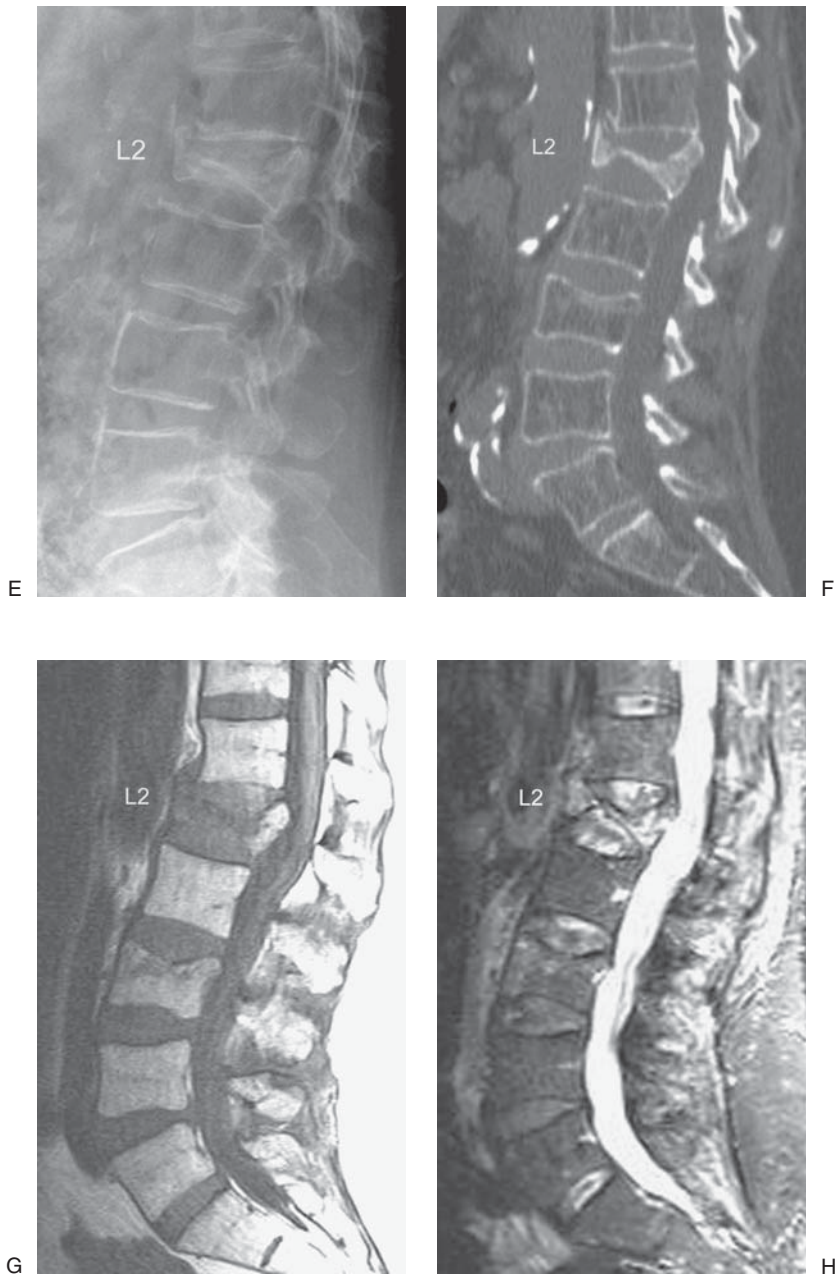
In some cases of benign osteoporotic VCF there may be retropulsion of bone into the spinal canal; this usually occurs at the level of the superior endplate but may also occur along the inferior endplate (47) (Figures 5.2 and 5.3). In Kummell's disease, thought to be a result of avascular necrosis, a fluid collection forms along the superior endplate following osteoporotic VCF (48–50) (Figure 5.5). Magnetic resonance imaging of patients with Kummell's disease demonstrates a fluid collection that borders the superior endplate and that is hypointense on T1-weighted images and markedly hyperintense on T2-weighted sequences. Adjacent inflammatory changes in the vertebral body that would be expected in osteomyelitis are absent (44).

Plain radiographs, often the first study obtained when an osteoporotic VCF is suspected, will demonstrate diffuse osteopenia and may reveal more than one vertebral compression deformity. This makes exact localization of symptomatic levels by plain films alone unreliable, except perhaps when sequential films have been obtained (Figure 5.2). Thin-section (3 mm or less) CT with sagittal reconstructions is the best modality for determining whether a fracture line extends through the endplates or posterior wall of the vertebral body (Figure 5.2). These are important findings when PV is considered, as it may increase the risk of cement extrusion into the disc or spinal canal.

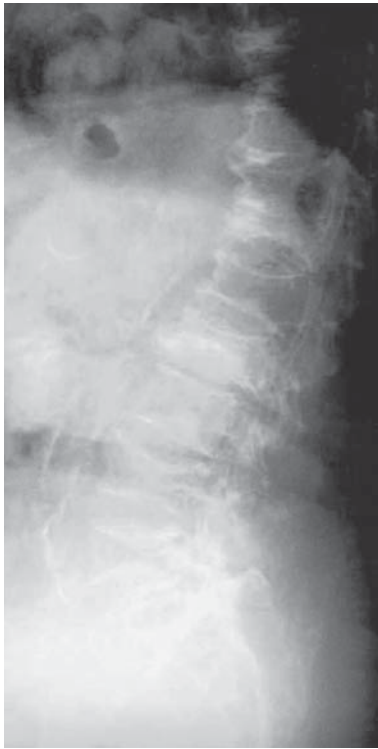
Bone scintigraphy may also aid in differentiating acute from chronic fractures and should be considered for patients unable to undergo MRI. A study by Maynard et al. (51) suggested that increased tracer uptake at the level of a vertebral compression fracture is highly predictive of a positive clinical response following PV; these authors achieved subjective pain relief in 26 out of 28 (93%) patients in their series. Of 44 patients with positive bone scan findings in the series of Alvarez et al.



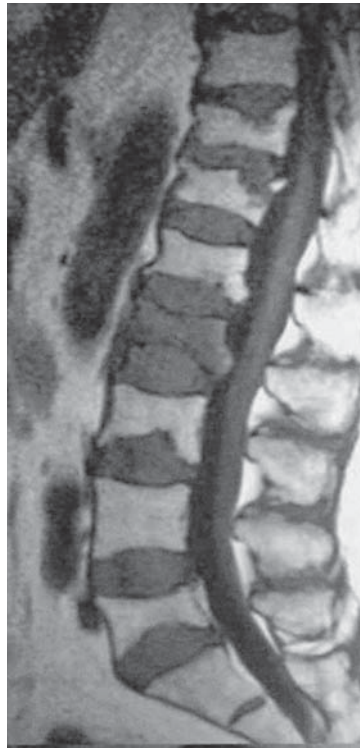**Figure 5.2.** This 70-year-old woman with primary osteoporosis presented with severe focal back pain and urinary retention. (A) Lateral spine radiograph demonstrates a mild compression deformity at L2. (B) CT sagittal reconstruction shows a compression fracture at L2 with fracture lines extending through the posterior wall and inferior endplate. (C) Sagittal T1-weighted and (D) STIR MR images show edema signal in the L2 vertebral body, consistent with acute fracture. Note retropulsion of the superior endplate of L2. Remaining vertebral bodies show normal signal on MRI.



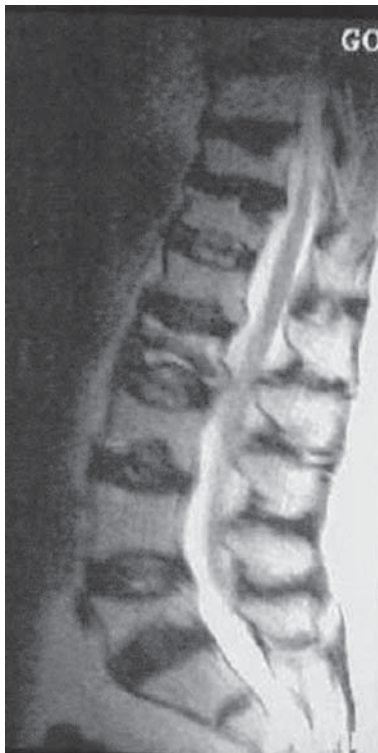**Figure 5.2.** *Continued* Three months later, (E) lateral spine radiograph, (F) CT sagittal reconstruction, (G) sagittal T1-weighted MR image, and (H) STIR sagittal image show progression of the L1 vertebral body fracture to vertebra plana. Note persistent edema signal in L1 and worsening local kyphotic deformity. T1-weighted and STIR sagittal MR images demonstrate new edema signal and within L3, representing a new compression fracture.



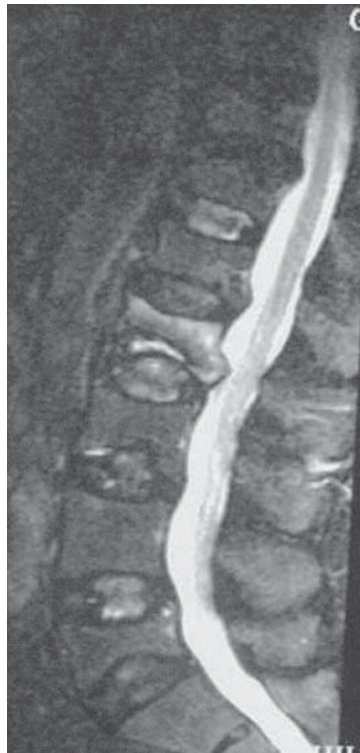A



B

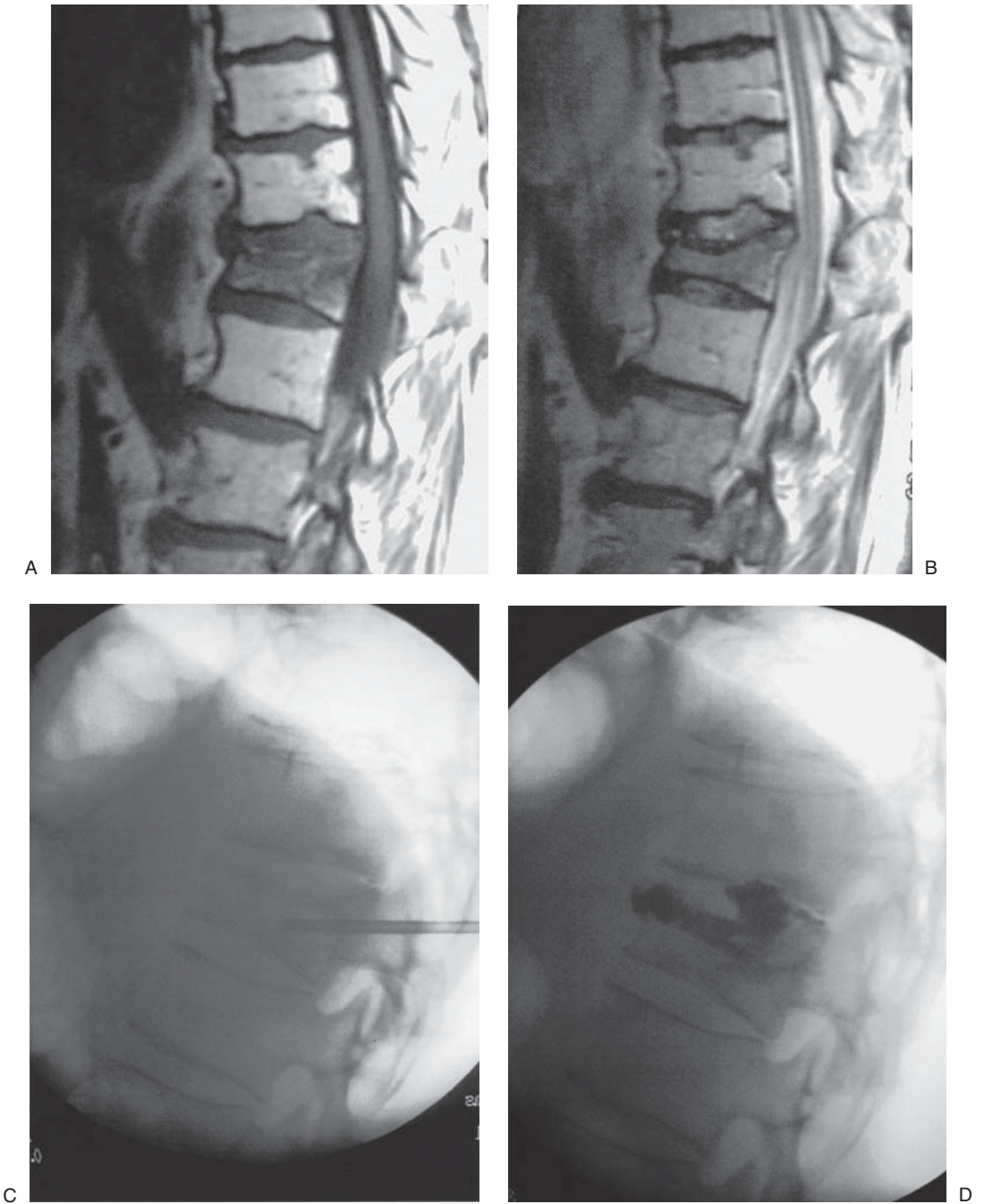


C



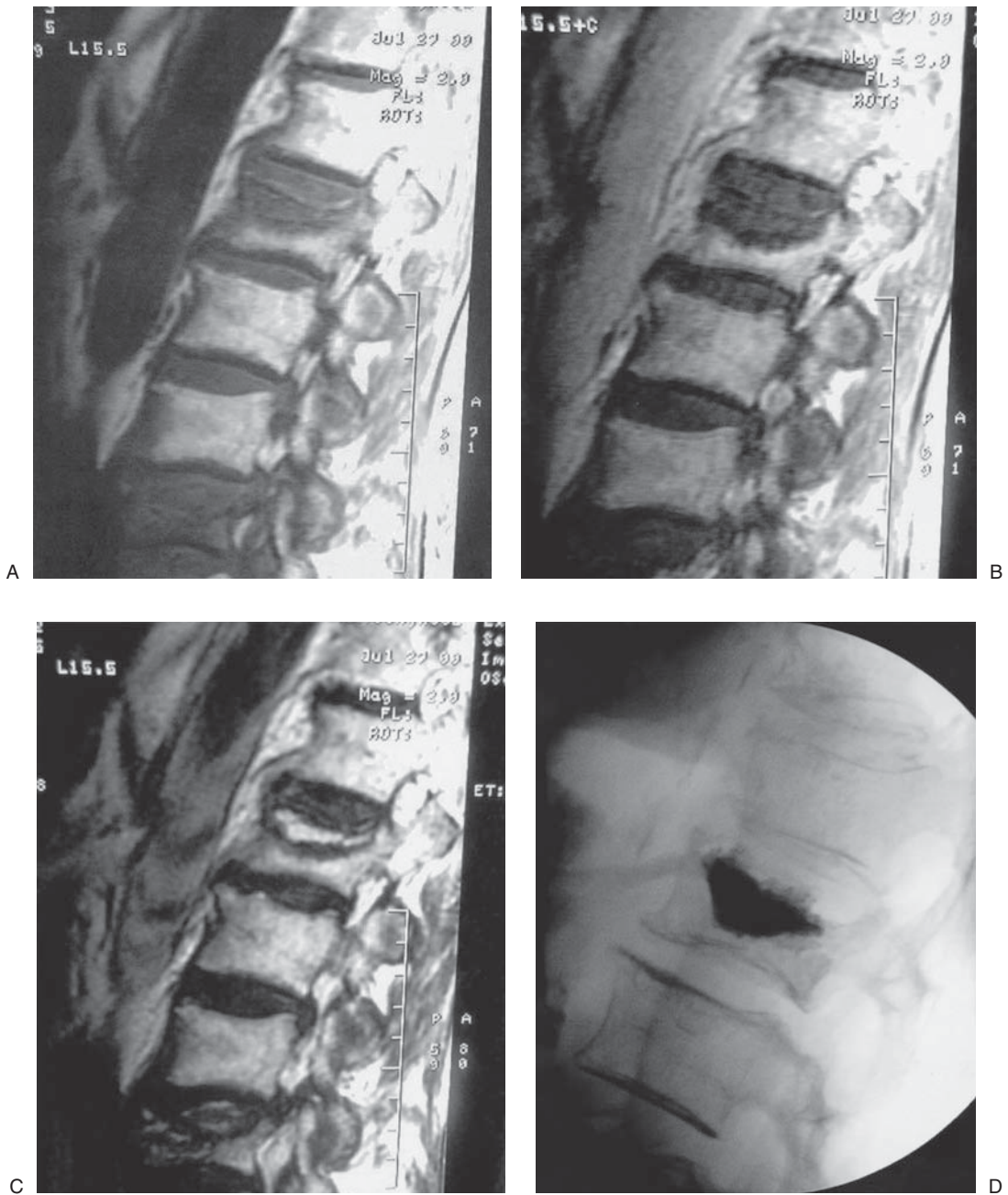
D

**Figure 5.3.** This patient with osteoporosis and multiple lower thoracic and lumbar vertebral compression deformities complained of focal pain and tenderness. (A) Lateral spine radiograph. (B) Sagittal T1-weighted MR image showing acute and chronic osteoporotic compression fractures. The acutely compressed L2 vertebra showed hypointense marrow signal. Other compressed vertebrae showed normal marrow signal, indicating old, healed fractures. (C) T2-weighted MR image showing heterogeneously increased signal in the L2 vertebral body, representing fracture edema. (D) Sagittal STIR MR image showing prominent hyperintense signal in L2 with characteristic location to the upper portion of the vertebral body. On examination under fluoroscopy, L2 was the most painful level. (From J.M. Mathis, H. Deramond, and S.M. Belkoff [eds], *Percutaneous Vertebroplasty*. New York: Springer, 2002, with permission.)

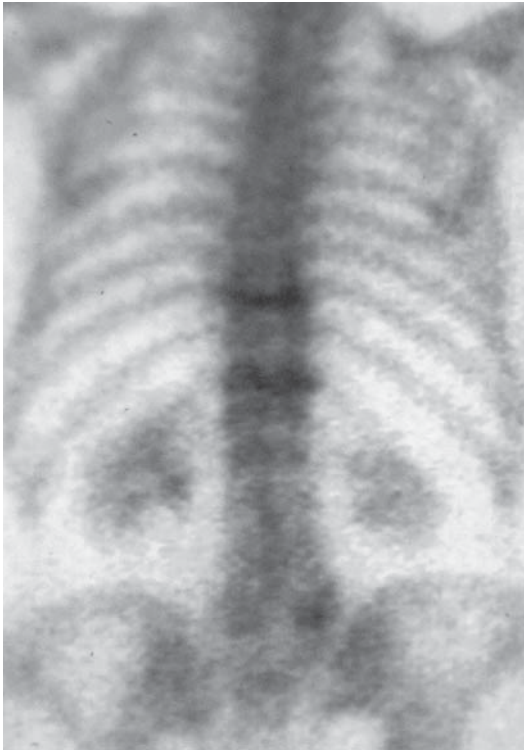

**Figure 5.4.** This 68-year-old man had long-standing thoracolumbar compression fracture and back pain. Sagittal T1-weighted (A) and T2-weighted (B) images show hypointense signal in the fractured T12 vertebral body, indicating sclerosis rather than edema. (C) Lateral radiograph shows increased density of T12 compared with neighboring vertebral bodies. Placement of needles for cement injection was very difficult because of increased bone density. (D) Lateral view after PV shows relatively little intraosseous deposition of cement and minor extrusion into the disc space. (From J.M. Mathis, H. Deramond, and S.M. Belkoff [eds], *Percutaneous Vertebroplasty*. New York: Springer, 2002, with permission.)





**Figure 5.5.** Kummell's disease (avascular necrosis of the superior endplate). This 95-year-old woman had a painful L1 compression fracture. (A) T1-weighted MR image showing markedly diminished signal along upper vertebral endplate. (B) Postcontrast T1-weighted MR image showing no enhancement within the abnormal region of the vertebra. (C) T2-weighted MR image showing compression fracture of L1 with fluid along the superior endplate and subjacent sclerotic bone. (D) Lateral image after PV showing deposition of cement in the region of avascular necrosis and fluid accumulation. The patient reported substantial pain relief. (From J.M. Mathis, H. Deramond, and S.M. Belkoff [eds], *Percutaneous Vertebroplasty*. New York: Springer, 2002, with permission.)



**Figure 5.6.** Tc-99m-labeled MDP radionuclide bone scan image, posterior view, showing increased uptake at the levels of acute T10 and T12 osteoporotic VCFs. (From J.M. Mathis, H. Deramond, and S.M. Belkoff [eds], *Percutaneous Vertebroplasty*. New York: Springer, 2002, with permission.)

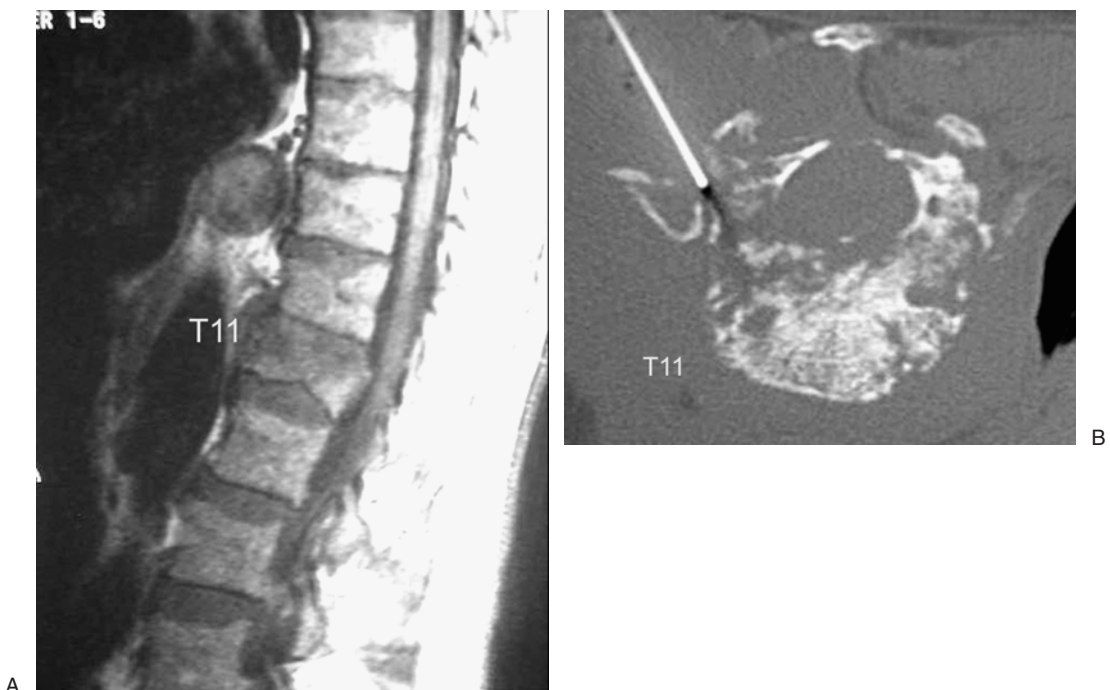
(9), 28 described marked to complete pain relief, while 16 reported partial pain relief. Of note, the majority of patients in this series also had abnormal findings on MRI. Although this study did not explicitly compare the predictive value of MRI and scintigraphy, of the four patients with increased uptake on bone scan but normal bone marrow signal on MRI, only one patient was considered a treatment success. This is consistent with the finding that a bone scan may show elevated tracer uptake for up to 12 months following fracture; bone scintigraphy should be interpreted with this fact in mind (Figure 5.6).

### **Malignant Compression Fractures**

Common causes of malignant VCFs include osteolytic metastases and multiple myeloma. As with osteoporotic compression fractures, patients usually present with acute pain and tenderness over the spine at or very near the level of radiographic deformity. An antecedent history of malignancy is often known at the time of presentation, and these lesions tend to have certain imaging features that distinguish them from benign VCFs.

Plain film and CT imaging of malignant bone lesions often reveals focal lytic lesions within the affected vertebral body, with destruction or focal rarefaction of bony trabeculae. Expansion of the contours of the bone and the presence of additional lesions at other levels favor a malignant etiology. If a potentially malignant lesion is located in the posterior aspect of the vertebral body, thin-section (1-mm) CT images are usually helpful in evaluating the integrity of the posterior wall of the vertebral body and pedicles prior to performing vertebroplasty (Figure 5.7). Posterior wall involvement or pedicle destruction is not an absolute contraindication to PV; in one early series by Deramond et al. (5), partial or complete destruction of the posterior vertebral body wall was present in over 50% of patients with malignant lesions treated with PV, and successful treatment of lytic lesions involving the pedicles has been reported (52,53). Where tumor mass has destroyed the usual bony landmarks of the posterior vertebral body wall or pedicles, intrathecal injection of myelographic contrast prior to performing vertebroplasty may help in visualizing any tumor displacement into the spinal canal as cement is injected (54).

Bone scintigraphy may demonstrate increased uptake, but may be normal or equivocal, particularly in multiple myeloma. Foci of increased uptake within the spine on F-18 fluorodeoxyglucose (FDG) positron emission tomography (PET) is highly suggestive of spinal metastatic disease, even when lesions are single (55).



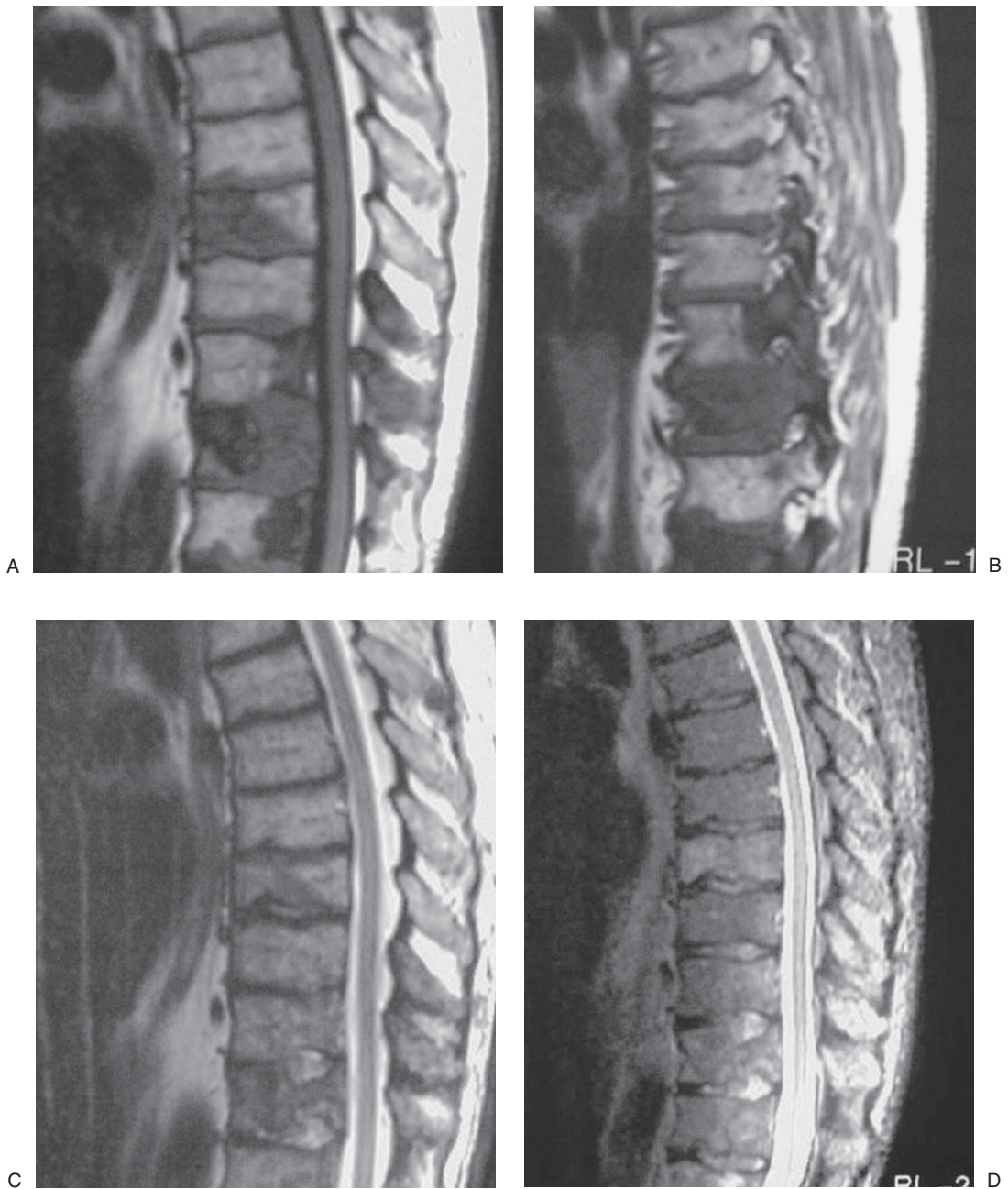
**Figure 5.7.** Malignant compression fracture. (A) Sagittal T1-weighted image and (B) thin-section axial CT image demonstrate diffuse tumor infiltration of T11 with destruction of the posterior wall of the vertebral body.

Magnetic resonance imaging findings suggestive of malignant compression fracture include heterogeneous marrow signal or bright enhancement (Figure 5.8). Short tau inversion recovery sequences with fat suppression are particularly helpful in identifying edema within malignant VCFs; heterogeneous or diffuse vertebral hyperintensity on STIR and T2-weighted sequences is typical of malignant disease (46). While some authors have reported that malignant compression fractures demonstrate hypointense or isointense signal compared with adjacent vertebrae on diffusion-weighted MR sequences (56–58), other authors have disputed this finding (59). Other findings that favor the diagnosis of malignant VCF include abnormal signal in the posterior elements, expansion of the contour of the vertebral body or posterior elements, and an associated epidural or extravertebral soft tissue mass (46,47). In some patients, however, imaging findings remain equivocal, particularly in patients with hematopoietic malignancies, who often demonstrate a diffuse pattern of bone marrow infiltration (60). In patients with multiple myeloma, distinguishing VCFs due to tumor infiltration versus those caused by steroid treatment (secondary osteoporosis) can be difficult. While the distribution of lesions in myeloma is often similar to that seen in benign osteoporotic fracture, upper thoracic involvement has been suggested to favor the diagnosis of myeloma (61). In cases where the etiology of a compression fracture is in question, biopsy can easily be performed coaxially through the vertebroplasty needle prior to injection of cement.

Symptomatic spinal cord compression at the level of a VCF is a clear contraindication to PV; even a small amount of cement extravasation or displacement of tumor into the spinal canal as cement is injected could worsen symptoms or could make decompressive surgery technically more difficult. Percutaneous vertebroplasty may be considered after the stenotic canal has been decompressed. Radiculopathy without cord compression is not a contraindication to PV; in these patients, however, tumor infiltration of the pedicle may make needle placement more difficult or could increase the risk of cement extravasation as the needle is withdrawn.

### **Vertebral Hemangiomas**

Vertebral hemangiomas (VHs) are common benign vascular lesions of the spine found in 5%–11% of patients at autopsy. Approximately two-thirds are solitary and about one-third are multiple (62); the majority (about 60%) are found in the thoracic region (63,64). Most VHs are asymptomatic and only come to attention when discovered incidentally during a radiologic examination. Rarely, VHs become painful either with or without an associated compression fracture. Some exhibit aggressive characteristics such as expansion of the contours of the vertebral body and extension of tumor outside the vertebrae and into the epidural space. Either of these features may produce nerve root impingement or spinal cord compression (64–66). Cement injection in these cases may be performed for pain relief, strengthening of the bone, and devascularization of the hemangioma (67–69).



**Figure 5.8.** This 51-year-old man had metastatic adenocarcinoma. (A) Sagittal T1-weighted MR image showing multiple hypointense foci of marrow replacement within lower thoracic vertebrae. (B) T1-weighted MR image showing foci of marrow replacement within multiple pedicles. (C) T2-weighted MR image showing intermediate but heterogeneous signal throughout the vertebral bodies. (D) Sagittal STIR MR image showing increased signal intensity within metastatic foci. The more homogeneous high signal represented edema from a partial pathologic compression fracture of a mid-thoracic vertebra. (From J.M. Mathis, H. Deramond, and S.M. Belkoff [eds], *Percutaneous Vertebroplasty*. New York: Springer, 2002, with permission.)

Plain films of VHs reveal a coarse, thickened, vertically striated trabecular pattern within the vertebral body, sometimes with bulging of the posterior cortical margin. Extension of tumor into the pedicles may occur. Thin-section (1-mm) CT imaging is useful in evaluating for involvement of the pedicles (which may modify needle trajectory), in determining the integrity of the posterior wall of the vertebral body, and in identifying encroachment upon the spinal canal (70,71) (Figure 5.9).

Magnetic resonance imaging of VHs typically demonstrates a circumscribed, mottled lesion that is predominantly hyperintense to normal bone marrow on both T1- and T2-weighted sequences (72,73). Histologically, hyperintense signal within the lesion corresponds to fat tissue and not to a hemorrhagic component, while more hypointense striations correspond to thickened bony trabeculae. Aggressive hemangiomas, however, may appear hypointense on T1- and T2-weighted MR sequences when vascular channels predominate (74); these will also tend to enhance more densely than normal bone marrow (Figure 5.9).

Injection of PMMA cement or the acrylic cement n-butyl cyanoacrylate into VHs has been performed for analgesia and reduction of intraoperative blood loss (75–77). In particular, preoperative injection of PMMA into VHs has been found to reduce the risk of massive hemorrhage associated with decompressive laminectomy and resection of VHs bulging into the epidural space (75–77). Percutaneous vertebroplasty can be performed safely in this setting (77), as long as frank spinal cord compression is not present.

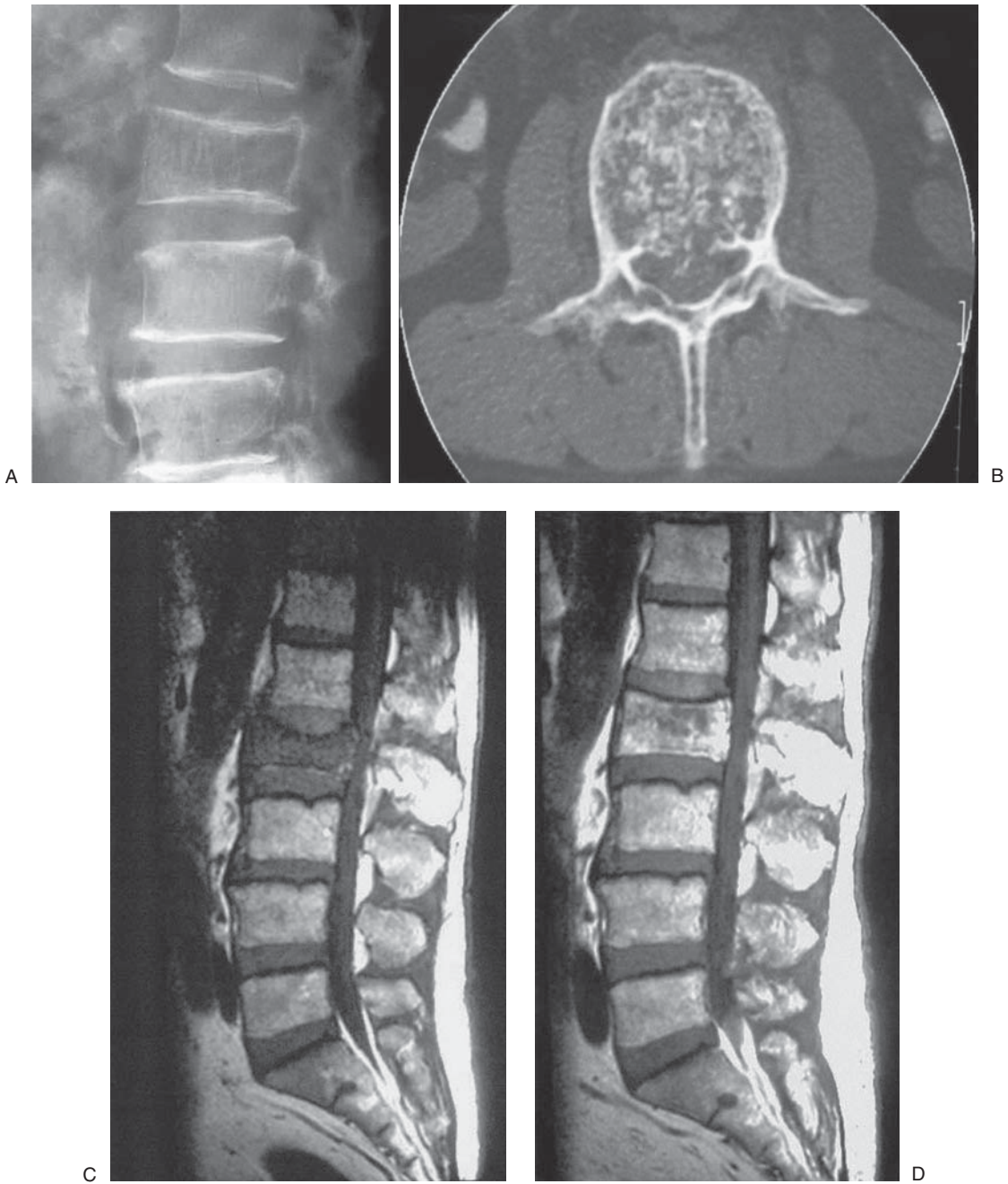
## Patient Selection

Appropriate patient selection is essential to achieving clinical success with PV. Because more than 80% of the population will suffer from back pain at some point in life (78–80), practitioners of PV commonly receive inquiries regarding patients with other etiologies of back pain such as degenerative disc disease, spinal stenosis, facet arthropathy, and sacroiliac joint dysfunction. Physicians practicing PV need an efficient screening mechanism to avoid being overwhelmed by requests to see patients for whom treatment is not indicated.

## Indications

The primary indication for PV is alleviation of pain associated with VCFs caused by osteoporosis, hemangioma, or tumor invasion. Best clinical success is generally achieved in patients with pain and tenderness on palpation that is localized to the level of radiographic compression deformity or vertebral marrow infiltration.

The timing of treatment has liberalized as clinical experience with PV has broadened. In early published and unpublished treatment series, most patients had been allowed to fail conventional medical therapy (analgesics, bracing, and bed rest) for at least several months



**Figure 5.9.** Vertebral hemangioma. This patient had focal back pain and tenderness. **(A)** Lateral radiograph showing coarse vertical trabecular striations characteristic of VH. **(B)** Axial CT through L2 confirmed trabecular thickening typical of VH. Expansion of posterior cortex resulted in narrowing of the spinal canal. **(C)** Sagittal T1-weighted MR image showing deformity and hypointense signal within L2. **(D)** Postcontrast T1-weighted image showing enhancement of L2 VH. Again, note expansion of posterior cortical margin. (From J.M. Mathis, H. Deramond, and S.M. Belkoff [eds], *Percutaneous Vertebroplasty*. New York: Springer, 2002, with permission.)

prior to vertebroplasty (4,8). More recent series have advocated treatment as early as a few weeks (2) or even within days of the occurrence of a painful VCF if pain is so severe as to require parenteral narcotics and hospitalization. Late treatment (after 6 months) is less likely to be successful in completely relieving pain; however, investigators have reported symptomatic improvement with PV performed even years after the initial injury (9,81).

At present, there is no definable role for prophylactic treatment of osteoporotic vertebrae thought to be at high risk for collapse (1). Current data suggest that even patients with severe kyphosis and pulmonary compromise due to prior osteoporotic compression fractures are unlikely to benefit significantly from the procedure in the absence of local pain and tenderness. Although some have advocated a role for prophylactic PV in patients with sentinel pain or signal changes on MRI suggestive of microfracture, these indications are neither widely accepted nor approved as an indication, and no studies have been undertaken to substantiate the utility of performing vertebroplasty for prophylaxis. This indication may change in the future as additional research is performed.

Treatment of painful tumor infiltration without fracture seems more reasonable; however, the increased risk of cement leakage, particularly where cortical breakthrough of tumor is present, should be considered. At this time, there is likely insufficient data to evaluate the efficacy of vertebroplasty for this particular indication. For patients with malignant infiltration, it is not clear whether PV should be performed prior to radiation therapy or reserved for patients who have already received maximal doses of therapeutic radiation. In our experience, vertebroplasty does not adversely impact upon the effects of radiation given subsequent to PMMA injection, and irradiation has not been shown to alter the integrity of cured PMMA (82). Percutaneous vertebroplasty likely dislodges some marrow elements into the bloodstream as PMMA is injected (83). This has raised a concern that PV may promote the dissemination of metastases. While only theoretical, these concerns suggest that vertebroplasty should probably be performed after rather than before an effective dose of radiation therapy.

Younger patients with normal bone mineral density and traumatic VCFs are generally not considered candidates for PV, as it is expected they will heal well without intervention. However, PV has been performed successfully in some patients with burst fracture and disabling back pain refractory to bracing and analgesics; for these patients, successful pain relief was obtained by injection of cement into the clefts of the burst fracture (84). Percutaneous vertebroplasty should certainly be considered for young patients with irreversible underlying metabolic abnormality, such as those with secondary osteoporosis receiving steroid treatment for inflammatory bowel disease, asthma, or COPD and those who have received a transplant. Multiple vertebral fractures have been successfully and appropriately treated in a 36-year-old woman with systemic lupus erythematosus, eliminating debilitating pain and the need for narcotic analgesics (85). Percutaneous vertebroplasty also resulted in rapid relief of pain for a 25-year-old man with



collapse of L2 due to previously radiated Langerhans cell histiocytosis (86).

Kyphoplasty, a modification of the standard vertebroplasty procedure, utilizes a balloon bone tamp to attempt to elevate the fractured endplates and restore vertebral body height, thus reducing kyphotic deformity. Height restoration has been demonstrated *ex vivo* (87), but was often incomplete under conditions simulating physiologic axial loads (88). Recent reports (88–91) describe success in partially restoring vertebral body height in clinical use in both benign and malignant compression fractures. Average height restoration with kyphoplasty has been reported as approximately 3 mm, with a trend (at least anecdotally) toward better height restoration in patients with more recent fractures (90,92). At least 8 mm of residual vertebral height is required for introduction of the required cannulas, which may limit treatment of vertebra plana and other severe compression fractures by this technique. Remarkable height restoration, up to 106% of expected normal vertebral height, has also been observed in many patients undergoing PV alone for dynamically mobile fractures (93,94).

## Contraindications

The role of this PV in stabilizing VCFs in the absence of local pain and tenderness, that is, asymptomatic VCFs, and in prophylactic treatment of patients with osteoporotic vertebrae thought to be at high risk for collapse remains unproven.

Active infection is a contraindication to PV; osteomyelitis, discitis, and epidural abscess are absolute contraindications. Emergent performance of PV is rarely, if ever, required, and treatment of patients with fever or sepsis should be postponed until they are afebrile and leukocytosis has resolved. It is also necessary to correct any significant coagulopathy prior to placement of a large-bore bone needle in the vicinity of the spinal canal.

Fractures with greater than 70% loss of vertebral height are technically difficult to treat: the operator may find it challenging or impossible to achieve a satisfactory needle placement within the remaining vertebral body. However, even in severe collapse, vertebral body height is typically better preserved along the lateral aspects of the vertebral body than centrally. Preprocedure evaluation with CT scanning including sagittal and coronal reconstructions may help in selecting a region of the vertebra with adequate residual height to permit treatment by PV. Successful treatment of a small series of patients with greater than 65% to 70% loss of vertebral body height in low thoracic or lumbar vertebrae has been reported (95); the operators used a bilateral transpedicular approach and positioned bone needles in the lateral aspects of the vertebral bodies. Another report described successful PV in a series of 37 patients with 48 severe osteoporotic compression fractures, also with less than one-third of original vertebral body height remaining (96). Complete pain relief was obtained in 47% of patients, while partial pain

relief was obtained in 50%. In these series there was a significant incidence of cement leakage into the adjacent disc (35%) or paravertebral soft tissues (8%), but these were asymptomatic. Despite these encouraging results, treating a true vertebra plana may be technically impossible.

Percutaneous vertebroplasty above the level of T5 or T6 is technically difficult: pedicles are typically small, and the orientation of the pedicles may be unfavorable for transpedicular needle placement. Vertebral access can often be obtained using smaller needles (typically 13 gauge or 16 gauge) or a parapedicular trajectory. Computed tomography, or combined fluoroscopic and CT guidance, may be used to plan a reasonably safe approach to these lesions. If appropriate precautions are taken, the risk of complications such as pedicle fracture, cement extravasation, or pneumothorax can be minimized (97).

Cervical vertebral lesions such as hemangiomas (98,99) and metastases may be treated by using smaller needles and a lateral or an anterolateral approach. An anterior trans-oral approach under general anesthesia with biplane fluoroscopic guidance was recently reported in the treatment of upper cervical pain due to myelomatous infiltration of the C2 vertebra; the patient was discharged pain free at 24 hours after the procedure and continued to be pain free at 6 month follow up (100).

At the present time, PV of traumatic compression fractures in young, otherwise healthy patients is not recommended, as the long term effects of vertebral PMMA injection are unknown. The majority of these patients have normal capability to heal the fracture within 4 to 6 weeks; in the interim, symptomatic relief can be obtained with oral analgesics, bed rest, and bracing.

Radiculopathy is not a contraindication to PV; however, the procedure may not improve these symptoms and may in some cases worsen them (101). As previously noted, significant spinal canal stenosis at the level of the compression fracture is at least a relative contraindication to PV. In such cases, preprocedure CT scan supplemented by sagittal and coronal reformatted images can aid in determining whether treatment is possible or advisable. In the case of osteoporotic VCFs, CT will usually reveal that the posterior vertebral body wall is intact. In some cases, however, a fracture line may extend into the posterior vertebral body wall (see Figure 5.2); this likely increases the risk for symptomatic extravasation; however, this has never been studied in a formal fashion. If the degree of retropulsion is so severe as to cause myelopathy, vertebroplasty should not be performed without prior surgical decompression (1).

In malignant compression fractures, the posterior wall of the vertebral body may be destroyed by tumor; it is generally accepted by most practitioners of vertebroplasty that this finding increases the risk of extravasation of cement or tumor displacement into the ventral epidural space and neural foramina (4,5,102–104). However, as long as tumor protrusion into the epidural space is not so severe as to produce cord compression or myelopathy, and appropriate needle

placement can be obtained, PV can be performed safely in such patients (103).

In treatment of osteoporotic compression fractures, the risk of complication requiring surgical intervention ranges from 0% to 3% (2–5). Of patients treated with PV for neoplasm (e.g., lytic metastases), multiple myeloma, or lymphoma, surgical intervention for complications such as cord compression or unremitting radiculopathy has been required in 2.7% to 5.4% (11). Less significant complications that do not require surgery have been reported in up to 10% of patients treated for malignant etiologies (5). In one large series of 258 patients with various etiologies of VCF (113 tumors, 78 hemangiomas, 67 osteoporotic collapse), there was only a single case of spinal cord compression requiring surgery (0.38%), and this occurred in a patient with tumor. Radicular pain occurred in 13 patients (5%), but only 3 required surgery (104). These results are encouraging and suggest the value of operator experience.

### **Screening of the Physician-Referred Patient**

An appropriate clinical history, physical examination, and relevant imaging studies should be obtained as the first step in evaluation of the vertebroplasty candidate. This information is sought in order to differentiate the pain of compression fracture from other etiologies such as disc herniation, spinal cord or nerve root compression, discogenic back pain, facet arthropathy, or spinal stenosis. In our practice, all patients who have no contraindication are studied with MRI obtained just prior to treatment with PV.

Clinical history should include a discussion of the precipitating event leading to compression fracture. Commonly, the patient will report acute onset of pain following minimal trauma. Pain generally worsens with weight bearing and is often at least partially relieved by recumbency. Physical examination should demonstrate pain and tenderness corresponding closely to the level of radiographic fracture deformity. If multiple levels of VCF are present, successful identification of the target level(s) can often only be accomplished after thoughtful analysis of physical examination combined with MRI.

It is important to determine whether the etiology of a VCF might be due to underlying malignancy. Referring physicians' office notes aid considerably in deciding in advance whether a biopsy should be performed prior to cement injection.

### **Screening of the Self-Referred Patient**

Initial evaluation of the self-referred patient is often more difficult, as this population tends to include not only patients for whom PV may be indicated, but also patients with other causes of subacute and chronic back pain. It is important to stress that disease processes such as disc herniation, spinal stenosis, or facet and sacroiliac joint arthropathy will not be helped by PV.

## Preprocedure Consultation

Once imaging and clinical findings have been reviewed, and it has been determined that the patient may be an appropriate candidate for PV, a preprocedure consultation with the patient and interested family members may be arranged. Meeting with the family members involved in the patient's care is particularly important for elderly or debilitated patients. Alternatively, and especially in cases where patients must travel a long distance for treatment, telephone consultation with the patient and family prior to the day of the procedure is suggested to screen for allergies, anticoagulant medications, sleep apnea, or medical problems (e.g., COPD, congestive heart failure) that could lead to procedural difficulties. An MRI is performed prior to consultation, but on the same day. Often, PV is performed on the same day when appropriate.

It is helpful to begin by reviewing the history and clinical findings with the patient. Important points to discuss include the time of onset of symptoms, precipitating factors such as trauma, the premorbid status of the patient, impact on activities of daily living, and analgesic use. It is also helpful to know whether prior similar episodes of pain have occurred and, if so, how they resolved. A brief clinical examination can help identify the approximate location of pain and tenderness for correlation with imaging findings. This examination will also serve as an opportunity to evaluate the patient's overall condition and readiness to undergo PV, identify potential difficulties in prone positioning and unique sedation requirements, and allow discovery of contraindicated medications such as coumadin.

Most patients and families will be somewhat familiar with PV through the popular press or Internet searches. The consultation should nevertheless include a brief discussion of how the procedure is performed at your institution, as well as specific instructions about whether current medications should be taken on the day of the procedure, diet instructions, what to expect during the procedure, and information on postprocedure care, transport back to home or to a health care facility, and the expected course of recovery.

The preprocedure consultation is also a time to discuss potential treatment complications. If the procedure is performed by a trained operator with adequate fluoroscopic imaging and appropriate opacification of cement, serious clinical complications should be extremely rare. The most commonly encountered complication is localized pain and tenderness at the needle sites in the first 72 hours following the procedure, usually due to local bruising or hematoma. Minor bruising will resolve with only mild analgesics such as ibuprofen or acetaminophen, and bruising can be minimized with 5 minutes of manual compression over the dermatotomy incision following trocar removal. Dermatomal pain can sometimes occur, more commonly when PV is being performed for treatment of a malignant lesion, but will also often resolve without specific treatment. Patients with significant postoperative radicular pain may require a brief course of nonsteroidal anti-inflammatory drugs, oral steroids, or local steroid injections at

the affected area (2,13). Serious potential complications include significant cement extravasation into epidural veins or into the spinal canal, with subsequent spinal cord or nerve root compression, and possible radiculopathy or paraplegia. Excessive cement extrusion into paravertebral veins may cause symptomatic pulmonary embolism (105,106), and a single case of paradoxical cerebral arterial embolism has been reported (107). Puncture of the lung with resultant pneumothorax may occur during inaccurate needle placement for an intended thoracic vertebroplasty. Infection complicating PV is rare, but has been reported (104).

Adequate visualization of cement during injection is a crucial factor for safe performance of PV. Several newer methacrylate preparations are packaged with premeasured amounts of radio-opacifying agents such as barium, tungsten, or tantalum to provide adequate visibility. Some operators, however, may still prefer to add radio-opacifying agents to one of the commercially available bone cements. With their addition, however, the cement injected is no longer the same medical device approved by the Food and Drug Administration. The operator should address this fact with the patient at the time of consultation.

### **Patient and Family Expectations**

It is important to consider patient and family expectations during the consultation. If the patient is a good candidate for PV and the fracture is subacute, a good response can be expected; 80% to 90% of patients typically report significant pain relief. If, however, the fracture has been present for many months or years, the likelihood of substantial pain relief will be diminished (9,44). If a patient has multiple symptomatic VCFs, staging options should focus on treating the most painful compression fractures first. A thorough discussion of staging strategy may also prevent disappointment should the patient's pain not be significantly alleviated during the first treatment session.

No more than two, or perhaps three, levels should be treated at a single session in order to minimize the incidence of symptomatic complications related to venous extravasation of cement (105,106) or fat (83). Fat embolization, in particular, has been implicated as a cause of fatal pulmonary embolization in patients undergoing cemented hip arthroplasty (108); it should be noted, however, that much larger volumes of cement are utilized in hip arthroplasty than in PV.

Another concern in treating multiple levels in a single session is the potential cardiotoxic effect of free methylmethacrylate monomer. Injection of free monomer in concentrations similar to those for surgical patients undergoing cemented hip arthroplasty has been shown to produce hypotension, bradycardia, and depression of myocardial function in isolated perfused rabbit hearts (109) and in anesthetized dogs (110). A few cases of transient arterial hypotension have been reported in patients undergoing PV (111,112). A recent study of the cardiac effects of cement injection, however, found no significant association

between PMMA injection during PV and systemic cardiovascular instability (113).

### **Patient Instructions**

For vertebroplasty procedures performed during the morning, the patient should have had nothing by mouth (NPO) after midnight except for medications. If the procedure is scheduled for the afternoon, the patient should be NPO for a sufficient time (at least 4 hours in most institutions) to permit safe administration of medication for conscious sedation.

In general, patients are advised to take their usual medications with sips of water on the day of the procedure. Diabetics who will be NPO after midnight should be instructed to adjust their insulin dosage appropriately. Patients taking anticoagulants should discontinue their use at an appropriate interval before the procedure, but only following consultation with the primary care or prescribing physician.

### **Preprocedure Laboratory Studies**

Routine examinations that should be performed before percutaneous vertebroplasty include a complete blood count, prothrombin time/partial thromboplastin time/International Normalized Ratio or activated clotting time, and platelet count. If intraosseous venography is contemplated, laboratory evaluation of blood urea nitrogen and creatinine levels may also be ordered.

### **Examination Under Fluoroscopy**

Although in many cases it is possible to make a reasonable correlation between the general area of pain described by the patient and the level of VCF on imaging studies, it is always a good idea to localize painful vertebrae by examining the patient under fluoroscopy immediately prior to performing PV. This is especially true for patients with multi-level disease, who often have difficulty precisely localizing discomfort, and for patients reporting diffuse pain and tenderness.

Careful palpation over the posterior elements is performed to identify the most painful vertebral levels. Thumb pressure over each spinous process, or side-to-side movement of a spinous process, will often elicit tenderness in the setting of an acute VCF. Pressure and palpation over paravertebral muscles (i.e., parasagittal palpation) may also help to identify whether or not muscle spasm constitutes an additional component of the patient's pain.

### **Conclusions**

Numerous studies have documented the safety and efficacy of PV. Technical skill alone will not guarantee consistently good outcomes; adherence to rigid patient selection criteria suggested by previous publications will help to ensure clinical success.

## References

1. McGraw JK, Cardella J, Barr JD, Mathis JM, Sanchez O, Schwartzberg MS, Swan TL, Sacks MD, for the Society of Interventional Radiology Standards of Practice Committee. Society of Interventional Radiology quality improvement guidelines for percutaneous vertebroplasty. *J Vasc Intervent Radiol* 2003; 14(9):S311–S315.
2. Cyteval C, Sarrabere MP, Roux JO, Thomas E, Jorgensen C, Blotman F, Sany J, Taourel P. Acute osteoporotic vertebral collapse: open study on percutaneous injection of acrylic surgical cement in 20 patients. *Am J Roentgenol* 1999; 173(6):1685–1690.
3. Gangi A, Dietemann JL, Mortazavi R, Pflieger D, Kauff C, Roy C. CT-guided interventional procedures for pain management in the lumbosacral spine. *RadioGraphics* 1998; 18(3):621–633.
4. Jensen ME, Evans AJ, Mathis JM, Kallmes DF, Cloft HJ, Dion JE. Percutaneous polymethylmethacrylate vertebroplasty in the treatment of osteoporotic vertebral body compression fractures: technical aspects. *Am J Neuroradiol* 1997; 18(10):1897–1904.
5. Deramond H, Depriester C, Galibert P, Le Gars D. Percutaneous vertebroplasty with polymethylmethacrylate. Technique, indications, and results. *Radiol Clin North Am* 1998; 36(3):533–546.
6. McGraw JK, Lippert JA, Minkus KD, Rami PM, Davis TM, Budzik RF. Prospective evaluation of pain relief in 100 patients undergoing percutaneous vertebroplasty: results and follow-up. *J Vasc Intervent Radiol* 2002; 13(9 Pt 1):883–886.
7. Zoarski GH, Snow P, Olan WJ, Stallmeyer MJ, Dick BW, Hebel JR, De Deyne M. Percutaneous vertebroplasty for osteoporotic compression fractures: quantitative prospective evaluation of long-term outcomes. *J Vasc Intervent Radiol* 2002; 13(2 Pt 1):139–148.
8. Cortet B, Cotten A, Boutry N, Flipo RM, Duquesnoy B, Chastanet P, Delcambre B. Percutaneous vertebroplasty in the treatment of osteoporotic vertebral compression fractures: an open prospective study. *J Rheumatol* 1999; 26(10):2222–2228.
9. Alvarez L, Perez-Higueras A, Granizo JJ, deMiguel I, Quinones D, Rossi RE. Predictors of outcomes of percutaneous vertebroplasty for osteoporotic vertebral fractures. *Spine* 2004; 30(1):87–92.
10. Jensen ME, Kallmes DE. Percutaneous vertebroplasty in the treatment of malignant spine disease. *Cancer J* 2002; 8(2):194–206.
11. Cortet B, Cotten A, Boutry N, Dewatre F, Flipo RM, Duquesnoy B, Chastanet P, Delcambre B. Percutaneous vertebroplasty in patients with osteolytic metastases or multiple myeloma. *Rev Rhum Engl Ed* 1997; 64(3):177–183.
12. Cotten A, Dewatre F, Cortet B, Assaker R, Leblond D, Duquesnoy B, Chastanet P, Clarisse J. Percutaneous vertebroplasty for osteolytic metastases and myeloma: effects of the percentage of lesion filling and the leakage of methyl methacrylate at clinical follow-up. *Radiology* 1996; 200(2):525–530.
13. Weill A, Chiras J, Simon JM, Rose M, Sola-Martinez T, Enkaoua E. Spinal metastases: indications for and results of percutaneous injection of acrylic surgical cement. *Radiology* 1996; 199(1):241–247.
14. Kaemmerlen P, Thiesse P, Bouvard H, Biron P, Mornex F, Jonas P. [Percutaneous vertebroplasty in the treatment of metastases. Technique and results.] *J Radiol* 1989; 70(10):557–562.

15. Kaemmerlen P, Thiesse P, Jonas P, Bascoulegue Y, Lapras C, Duquesnel J. Percutaneous injection of orthopedic cement in metastatic vertebral lesions [letter]. *N Engl J Med* 1989; 321(2):121.
16. National Osteoporosis Foundation. America's Bone Health: The State of Osteoporosis and Low Bone Mass in Our Nation. Washington, DC: National Osteoporosis Foundation, 2002.
17. Tosteson AN, Hammond CS. Quality of life assessment in osteoporosis: health status and preference based measures. *Pharmacoeconomics* 2002; 20(5):289–303.
18. Riggs BL, Melton LJ 3rd. The worldwide problem of osteoporosis: insights afforded by epidemiology. *Bone* 1995; 17(Suppl 5):505S–511S.
19. U.S. Dept. of Health and Human Services, Public Health Service, Office of the Surgeon General. Report of the Surgeon General's Workshop on Osteoporosis and Bone Health, December 12–13, 2002. Washington, DC: U.S. Department of Health and Human Services, 2002.
20. Greendale GA, Barrett-Connor E, Ingles S, Haile R. Late physical and functional effects of osteoporotic fracture in women: the Rancho Bernardo study. *J Am Geriatr Soc* 1995; 43(9):955–961.
21. Melton LJ 3rd. How many women have osteoporosis now? *J Bone Miner Res* 1995; 10(2):175–177.
22. Melton LJ 3rd, Kan SH, Frye MA, Wahner HW, O'Fallon WM, Riggs BL. Epidemiology of vertebral fractures in women. *Am J Epidemiol* 1989; 129(5):1000–1011.
23. U.S. Dept. of Health and Human Services, Public Health Service, Office of the Surgeon General. Bone Health and Osteoporosis: A Report of the Surgeon General: Executive Summary. Washington, DC: U.S. Department of Health and Human Services, 2004.
24. Cooper C, Atkinson EJ, O'Fallon WM, Melton LJ 3rd. Incidence of clinically diagnosed vertebral fractures: a population-based study in Rochester, Minnesota, 1985–1989. *J Bone Miner Res* 1992; 7(2):221–227.
25. Fitzpatrick LA. Secondary causes of osteoporosis. *Mayo Clin Proc* 2002; 77(5):453–468.
26. Nolla JM, Gomez-Vaquero C, Romera M, Roig-Vilaseca D, Rozadilla A, Mateo L, Fiter J, Juanola X, Rodriguez-Moreno J, Valverde J, Roig-Escofet D. Osteoporotic vertebral fracture in clinical practice. 669 Patients diagnosed over a 10 year period. *J Rheumatol* 2001; 28(10):2289–2293.
27. Stein E, Shane E. Secondary osteoporosis. *Endocrinol Metab Clin North Am* 2003; 32(1):115–134.
28. Rehman Q, Lane NE. Effect of glucocorticoids on bone density. *Med Pediatr Oncol* 2003; 41(3):212–216.
29. Schulte CM. Review article: bone disease in inflammatory bowel disease. *Aliment Pharmacol Ther* 2004 (Suppl 20); 4:43–49.
30. Reinshagen M, von Tirpitz C. Osteoporosis and other extraintestinal symptoms and complications of inflammatory bowel diseases. *Dig Dis* 2003; 21(2):138–145.
31. Ross RW, Small EJ. Osteoporosis in men treated with androgen deprivation therapy for prostate cancer. *J Urol* 2002; 167(5):1952–1956.
32. Schlaich C, Minne HW, Bruckner T, Wagner G, Gebest HJ, Grunze M, Ziegler R, Leidig-Bruckner G. Reduced pulmonary function in patients with spinal osteoporotic fractures. *Osteoporos Int* 1998; 8(3):261–267.
33. Gold DT, Shipp KM, Lyles KW. Managing patients with complications of osteoporosis. *Endocrinol Metab Clin North Am* 1998; 27(2):485–496.
34. Leidig-Bruckner G, Minne HW, Schlaich C, Wagner G, Scheidt-Nave C, Bruckner T, Gebest HJ, Ziegler R. Clinical grading of spinal osteoporosis:



- quality of life components and spinal deformity in women with chronic low back pain and women with vertebral osteoporosis. *J Bone Miner Res* 1997; 12(4):663–675.
35. Lyles KW, Gold DT, Shipp KM, Pieper CF, Martinez S, Mulhausen PL. Association of osteoporotic vertebral compression fractures with impaired functional status. *Am J Med* 1993; 94(6):595–601.
  36. Huang C, Ross PD, Wasnich RD. Vertebral fracture and other predictors of physical impairment and health care utilization. *Arch Intern Med* 1996; 156(21):2469–2475
  37. Nevitt MC, Ettinger B, Black DM, Stone K, Jamal SA, Ensrud K, Segal M, Genant HK, Cummings SR. The association of radiographically detected vertebral fractures with back pain and function: a prospective study. *Ann Intern Med* 1998; 128(10):793–800.
  38. Lindsay R, Silverman SL, Cooper C, Hanley DA, Barton I, Broy SB, Licata A, Benhamou L, Geusens P, Flowers K, Stracke H, Seeman E. Risk of new vertebral fracture in the year following a fracture. *JAMA* 2001; 285(3):320–323.
  39. Kado DM, Browner WS, Palermo L, Nevitt MC, Genant HK, Cummings SR. Vertebral fractures and mortality in older women: a prospective study. Study of Osteoporotic Fractures Research Group. *Arch Intern Med* 1999; 159(11):1215–1220.
  40. Cooper C, Atkinson EJ, Jacobsen SJ, O'Fallon WM, Melton LJ 3rd. Population-based study of survival after osteoporotic fractures. *Am J Epidemiol* 1993; 137(9):1001–1005.
  41. Patel U, Skingle S, Campbell GA, Crisp AJ, Boyle IT. Clinical profile of acute vertebral compression fractures in osteoporosis. *Br J Rheumatol* 1991; 30(6):418–421.
  42. Heggeness MH. Spine fracture with neurological deficit in osteoporosis. *Osteoporos Int* 1993; 3(4):215–221.
  43. Salomon C, Chopin D, Benoist M. Spinal cord compression: an exceptional complication of spinal osteoporosis. *Spine* 1988; 13(2):222–224.
  44. Do HM. Magnetic resonance imaging in the evaluation of patients for percutaneous vertebroplasty. *Top Magn Reson Imaging* 2000; 11(4):235–244.
  45. Yamato M, Nishimura G, Kuramochi E, Saiki N, Fujioka M. MR appearance at different ages of osteoporotic compression fractures of the vertebrae. *Radiat Med* 1998; 16(5):329–334.
  46. Baker LL, Goodman SB, Perkash I, Lane B, Enzmann DR. Benign versus pathologic compression fractures of vertebral bodies: assessment with conventional spin-echo, chemical-shift, and STIR MR imaging. *Radiology* 1990; 174(2):495–502.
  47. Cuenod CA, Laredo JD, Chevret S, Hamze B, Naouri JF, Chapaux X, Bondeville JM, Tubiana JM. Acute vertebral collapse due to osteoporosis or malignancy: appearance on unenhanced and gadolinium-enhanced MR images. *Radiology* 1996; 199(2):541–549.
  48. Kummell H. Ueber traumatische ezkrankungen der wirbelsault. *Dtsch Med Wochenschr* 1895; 21:180–181.
  49. Brower AC, Downey EF Jr. Kummell disease: report of a case with serial radiographs. *Radiology* 1981; 141(2):363–364.
  50. Dupuy DE, Palmer WE, Rosenthal DI. Vertebral fluid collection associated with vertebral collapse. *Am J Roentgenol* 1996; 167(6):1535–1538.
  51. Maynard AS, Jensen ME, Schweickert PA, Marx WF, Short JG, Kallmes DF. Value of bone scan imaging in predicting pain relief from percuta-

- neous vertebroplasty in osteoporotic vertebral fractures. *Am J Neuroradiol* 2000; 21(10):1807–1812.
52. Gailloud P, Beauchamp NJ, Martin JB, Murphy KJ. Percutaneous pediculoplasty: polymethylmethacrylate injection into lytic vertebral pedicle lesions. *J Vasc Intervent Radiol* 2002; 13(5):517–521.
  53. Martin JB, Wetzel SG, Seium Y, Dietrich PY, Somon T, Gailloud P, Payer M, Kelekis A, Ruefenacht DA. Percutaneous vertebroplasty in metastatic disease: transpedicular access and treatment of lysed pedicles—initial experience. *Radiology*. 2003; 229(2):593–597.
  54. Sarzier JS, Evans AJ. Intrathecal injection of contrast medium to prevent polymethylmethacrylate leakage during percutaneous vertebroplasty. *Am J Neuroradiol* 2003; 24(5):1001–1002.
  55. Bohdiewicz PJ, Wong CY, Kondas D, Gaskill M, Dworkin HJ. High predictive value of F-18 FDG PET patterns of the spine for metastases or benign lesions with good agreement between readers. *Clin Nucl Med* 2003; 28(12):966–970.
  56. Chan JH, Peh WC, Tsui EY, Chau LF, Cheung KK, Chan KB, Yuen MK, Wong ET, Wong KP. Acute vertebral body compression fractures: discrimination between benign and malignant causes using apparent diffusion coefficients. *Br J Radiol* 2002; 75(891):207–214.
  57. Baur A, Stabler A, Bruning R, Bartl R, Krodell A, Reiser M, Deimling M. Diffusion-weighted MR imaging of bone marrow: differentiation of benign versus pathologic compression fractures. *Radiology* 1998; 207(2):349–356.
  58. Park SW, Lee JH, Ehara S, Park YB, Sung SO, Choi JA, Joo YE. Single shot fast spin echo diffusion-weighted MR imaging of the spine; is it useful in differentiating malignant metastatic tumor infiltration from benign fracture edema? *Clin Imaging* 2004; 28(2):102–108.
  59. Castillo M, Arbelaez A, Smith JK, Fisher LL. Diffusion-weighted MR imaging offers no advantage over routine noncontrast MR imaging in the detection of vertebral metastases. *Am J Neuroradiol* 2000; 21(5):948–953.
  60. Kim HJ, Ryu KN, Choi WS, Choi BK, Choi JM, Yoon Y. Spinal involvement of hematopoietic malignancies and metastasis: differentiation using MR imaging. *Clin Imaging* 1999; 23(2):125–133.
  61. Lecouvet FE, Vande Berg BC, Maldague BE, Michaux L, Laterre E, Michaux JL, Ferrant A, Malghem J. Vertebral compression fractures in multiple myeloma. Part I. Distribution and appearance at MR imaging. *Radiology* 1997; 204(1):195–199.
  62. Schmorl G, Junghanns H. *The Human Spine in Health and Disease*, 2nd Ed. New York: Grune and Stratton, 1971:325.
  63. Laredo JD, Reizine D, Bard M, Merland JJ. Vertebral hemangiomas: radiographic evaluation. *Radiology* 1986; 161(1):183–189.
  64. Krueger EG, Sobel GL, Weinstein C. Vertebral hemangioma with compression of the spinal cord. *J Neurosurg* 1961; 18:331–338.
  65. McAllister VL, Kendall BE, Bull JW. Symptomatic vertebral haemangiomas. *Brain* 1975; 98(1):71–80.
  66. Ghormley RK, Adson AW. Hemangioma of the vertebrae. *J Bone Joint Surg* 1941; 23:887–895.
  67. Galibert P, Deramond H, Rosat P, LeGars D. Note preliminaire sur le traitement des angiomes vertebraux par vertebroplastie acrylique percutanee. [Preliminary note on the treatment of vertebral angioma by percutaneous acrylic vertebroplasty.] *Neurochirurgie (France)* 1987; 33(2): 166–168.
  68. Galibert P, Deramond H. La vertebroplastie percutanee comme traitement des angiomes vertebraux et des affections dorigenes et fragilisantes du

- rachis. [Percutaneous acrylic vertebroplasty as a treatment of vertebral angioma as well as painful and debilitating diseases.] *Chirurgie* 1990; 116(3):326–334; discussion, 335.
69. Deramond H, Darrasson R, Galibert P. Percutaneous vertebroplasty with acrylic cement in the treatment of aggressive spinal angiomas. *Rachis* 1989; 1:143–153.
  70. Schnyder P, Fankhauser H, Mansouri B. Computed tomography in spinal hemangioma with cord compression. Report of two cases. *Skel Radiol* 1986; 15(5):372–375.
  71. Yu R, Brunner DR, Rao KC. Role of computed tomography in symptomatic vertebral hemangiomas. *J Comput Tomogr* 1984; 8(4):311–315.
  72. Friedman DP. Symptomatic vertebral hemangiomas: MR findings. *Am J Roentgenol* 1996; 167(2):359–364.
  73. Ross JS, Masaryk TJ, Modic MT, Carter JR, Mapstone T, Dengel FH. Vertebral hemangiomas: MR imaging. *Radiology* 1987; 165(1):165–169.
  74. Laredo JD, Assouline E, Gelbert F, Wybier M, Merland JJ, Tubiana JM. Vertebral hemangiomas: fat content as a sign of aggressiveness. *Radiology* 1990; 177(2):467–472.
  75. Ng VW, Clifton A, Moore AJ. Preoperative endovascular embolisation of a vertebral haemangioma. *J Bone Joint Surg Br* 1997; 79(5):808–811.
  76. Ide C, Gangi A, Rimmelin A, Beaujeux R, Maitrot D, Buchheit F, Sellal F, Dietemann JL. Vertebral haemangiomas with spinal cord compression: the place of preoperative percutaneous vertebroplasty with methyl methacrylate. *Neuroradiology* 1996; 38(6):585–589.
  77. Cotten A, Deramond H, Cortet B, Lejeune JP, Leclerc X, Chastanet P, Clarisse J. Preoperative percutaneous injection of methyl methacrylate and N-butyl cyanoacrylate in vertebral hemangiomas. *Am J Neuroradiol* 1996; 17(1):137–142.
  78. Lee P, Helewa A, Goldsmith CH, Smythe HA, Stitt LW. Low back pain: prevalence and risk factors in an industrial setting. *J Rheumatol* 2001; 28(2):346–351.
  79. Wells N. *Studies of Current Health Problems: Back Pain*. London: Office of Health Economics, 1985:4–25.
  80. Roland MO, Morrell DC, Morris RW. Can general practitioners predict the outcome of episodes of back pain? *BMJ (Clin Res Ed)* 1983; 286(6364):523–525.
  81. Kaufmann TJ, Jensen ME, Schweickert PA, Marx WF, Kallmes DF. Age of fracture and clinical outcomes of percutaneous vertebroplasty. *Am J Neuroradiol* 2001; 22(10):1860–1863.
  82. Murray JA, Bruels MC, Lindberg RD. Irradiation of polymethylmethacrylate: in vitro gamma radiation effect. *J Bone Joint Surg Am* 1974; 56(2):311–312.
  83. Aebli N, Krebs J, Davis G, Walton M, Williams MJ, Theis JC. Fat embolism and acute hypotension during vertebroplasty: an experimental study in sheep. *Spine* 2002; 27(5):460–466.
  84. Chen JF, Lee ST. Percutaneous vertebroplasty for treatment of thoracolumbar spine bursting fracture. *Surg Neurol* 2004; 62(6):494–500.
  85. Mathis JM, Petri M, Naff N. Percutaneous vertebroplasty treatment of steroid-induced osteoporotic compression fractures. *Arthritis Rheum* 1998; 41(1):171–175.
  86. Cardon T, Hachulla E, Flipo RM, Chastanet P, Rose C, Deprez X, Duquesnoy B, Delcambre B, Devulder B. Percutaneous vertebroplasty with acrylic cement in the treatment of a Langerhans cell vertebral histiocytosis. *Clin Rheumatol* 1994; 13(3):518–521.

87. Belkoff SM, Mathis JM, Fenton DC, Scribner RM, Reiley ME, Talmadge K. An ex vivo biomechanical evaluation of an inflatable bone tamp used in the treatment of compression fracture. *Spine* 2001; 26(2):151–156.
88. Belkoff SM, Jasper LE, Stevens SS. An ex vivo evaluation of an inflatable bone tamp used to reduce fractures within vertebral bodies under load. *Spine* 2002; 27(15):1640–1643.
89. Dudeney S, Lieberman IH, Reinhardt MK, Hussein M. Kyphoplasty in the treatment of osteolytic vertebral compression fractures as a result of multiple myeloma. *J Clin Oncol* 2002; 20(9):2382–2387.
90. Lieberman IH, Dudeney S, Reinhardt MK, Bell G. Initial outcome and efficacy of “kyphoplasty” in the treatment of painful osteoporotic vertebral compression fractures. *Spine* 2001; 26(14):1631–1638.
91. Theodorou DJ, Theodorou SJ, Duncan TD, Garfin SR, Wong WH. Percutaneous balloon kyphoplasty for the correction of spinal deformity in painful vertebral body compression fractures. *Clin Imaging* 2002; 26(1): 1–5.
92. Garfin SR, Yuan HA, Reiley MA. New technologies in spine: kyphoplasty and vertebroplasty for the treatment of painful osteoporotic compression fractures. *Spine* 2001; 26(14):1511–1515.
93. Hiwatashi A, Moritani T, Numaguchi Y, Westesson PL. Increase in vertebral body height after vertebroplasty. *Am J Neuroradiol* 2003; 24(2): 185–189.
94. McKiernan F, Jensen R, Faciszewski T. The dynamic mobility of vertebral compression fractures. *J Bone Miner Res* 2003; 18(1):24–29.
95. O’Brien JP, Sims JT, Evans AJ. Vertebroplasty in patients with severe vertebral compression fractures: a technical report. *Am J Neuroradiol* 2000; 21(8):1555–1558.
96. Peh WC, Gilula LA, Peck DD. Percutaneous vertebroplasty for severe osteoporotic vertebral body compression fractures. *Radiology* 2002; 223(1):121–126.
97. Kallmes DF, Schweickert PA, Marx WF, Jensen ME. Vertebroplasty in the mid- and upper thoracic spine. *Am J Neuroradiol* 2002; 23(7):1117–1120.
98. Feydy A, Cognard C, Miaux Y, Sola Martinez MT, Weill A, Rose M, Chiras J. Acrylic vertebroplasty in symptomatic cervical vertebral haemangiomas: report of 2 cases. *Neuroradiology* 1996; 38(4):389–391.
99. Dousset V, Mousselard H, de Monck d’User L, Bouvet R, Bernard P, Vital JM, Senegas J, Caille JM. Asymptomatic cervical haemangioma treated by percutaneous vertebroplasty. *Neuroradiology* 1996; 38(4):392–394.
100. Tong FC, Cloft HJ, Joseph GJ, Rodts GR, Dion JE. Transoral approach to cervical vertebroplasty for multiple myeloma. *Am J Roentgenol* 2000; 175(5):1322–1324.
101. Ratliff J, Nguyen T, Heiss J. Root and spinal cord compression from methylmethacrylate vertebroplasty. *Spine* 2001; 26(13):E300–E302.
102. Cotten A, Boutry N, Cortet B, Assaker R, Demondion X, Leblond D, Chastanet P, Duquesnoy B, Deramond H. Percutaneous vertebroplasty: state of the art. *RadioGraphics* 1998; 18(2):311–320; discussion, 320–323.
103. Shimony JS, Gilula LA, Zeller AJ, Brown DB. Percutaneous vertebroplasty for malignant compression fractures with epidural involvement. *Radiology* 2004; 232(3):846–853. Epub 2004 Jul 23.
104. Chiras J, Deramond H. Complications des vertebroplasties. In *Echecs et Complications de la Chirurgie du Rachis: Chirurgie de Reprise*. G Saillant, C Laville (eds). Paris, France: Sauramps Medical, 1995:149–153.

105. Jang JS, Lee SH, Jung SK. Pulmonary embolism of polymethylmethacrylate after percutaneous vertebroplasty: a report of three cases. *Spine* 2002; 27(19):E416–E418.
106. Padovani B, Kasriel O, Brunner P, Peretti-Viton P. Pulmonary embolism caused by acrylic cement: a rare complication of percutaneous vertebroplasty. *Am J Neuroradiol* 1999; 20(3):375–357.
107. Scroop R, Eskridge J, Britz GW. Paradoxical cerebral arterial embolization of cement during intraoperative vertebroplasty: case report. *Am J Neuro-radiol* 2002; 23(5):868–870.
108. Parvizi, J. Holiday AD, Ereth MH, Lewallen DG. The Frank Stinchfield Award. Sudden death during primary hip arthroplasty. *Clin Orthop* 1999; 369:39–48.
109. Wong KC, Martin WE, Kennedy WF, Akamatsu TJ, Convery RF, Shaw CL. Cardiovascular effects of total hip placement in man. With observations on the effects of methylmethacrylate on the isolated rabbit heart. *Clin Pharmacol Ther* 1977; 21(6):709–714.
110. Wade Waters IW, Baran KP, Schlosser MJ, Mack JE, Davis WM. Acute cardiovascular effects of methyl methacrylate monomer: characterization and modification by cholinergic blockade, adrenergic stimulation and calcium chloride infusion. *Gen Pharmacol* 1992; 23(3):497–502.
111. Marx WF, Schweikert P, Jensen ME, Kallmes DF. Short Term Clinical Complication Rate of Percutaneous Vertebroplasty for Osteoporotic Compression Fractures: Analysis of 462 Treated Levels. Proceedings of the 40th Annual Meeting of the American Society of Neuroradiology, May 13–17, 2002, Vancouver, BC, Presentation 85, p 76.
112. Vasconcelos C, Gailloud P, Martin JB, Murphy KJ. Transient arterial hypotension induced by polymethylmethacrylate injection during percutaneous vertebroplasty. *J Vasc Intervent Radiol* 2001; 12(8):1001–1002.
113. Kaufmann TJ, Jensen ME, Ford G, Gill LL, Marx WF, Kallmes DF. Cardiovascular effects of polymethylmethacrylate use in percutaneous vertebroplasty. *Am J Neuroradiol* 2002; 23(4):601–604.