



Dental management of patients with substance use disorder

Mara Cuberos¹ · Elias M. Chatah¹ · Hugo Zegarra Baquerizo¹ · Geraldine Weinstein¹

Received: 7 April 2020 / Accepted: 14 May 2020 / Published online: 15 June 2020

© This is a U.S. government work and not under copyright protection in the U.S.; foreign copyright protection may apply 2020

Abstract

Substance use disorder (SUD) is a relapsing brain disorder characterized by compulsion and chronicity. SUD has detrimental effects on oral health. Drugs and alcohol negatively impact oral health by inducing a myriad of orofacial conditions including xerostomia, dental caries, periodontal disease, bruxism, pre-cancer and cancer, to name a few. Limited recommendations are available for dental professionals on how best to manage patients afflicted with SUD. The aim of this article is to review the oral health consequences of alcohol and commonly abused drugs to provide guidelines for the public health community and dental professionals. The United Nations estimates that a quarter billion people, representing five per cent of the global adult population, used drugs at least once in 2015. Developing public health interventions that include the participation of dental professionals and access to dental services for persons afflicted with SUD could play a critical role in improving their quality of life, their recovery, and their reintroduction into society.

Keywords Substance use disorder (SUD) · Oral health · Drug abuse · Meth mouth · Xerostomia

Quick reference/description

The American Psychiatric Association's "Diagnostic and Statistical Manual of Mental Disorders (DSM-5)" states that "The essential feature of substance use disorder is a cluster of cognitive, behavioral, and physiological symptoms indication that the individual continues using the substance despite significant substance-related problems." A diagnosis of SUD "is based on evidence of impaired control, social impairment, risky use, and pharmacological criteria".

✉ Geraldine Weinstein
gweinstein@uchc.edu

¹ University of Connecticut School of Dental Medicine, Farmington, CT, USA

The ICD-11 describes substance abuse disorders under chapter 6 (mental, behavioral, or neurodevelopmental disorders). This block contains a wide variety of substance use disorders that differ in severity—they include use disorders pertaining to problematic use of alcohol, cannabinoids, opioids, cocaine, sedative hypnotics, hallucinogens, tobacco and other stimulants.

Overview

Oral manifestations of SUD

Substance abuse affects all body systems negatively: it impacts appetite, heart rate and blood pressure, it induces psychosis through structural and chemical brain changes and it can lead to serious blood-borne infections such as HIV/AIDS, Hepatitis C. etc. ... Baghaie et al. identified an association between poor oral health and substance abuse. Oral conditions in patients with SUDs such as poor oral hygiene, changes in salivary pH and cariogenic diets can lead to progressive caries and maxillofacial infections (Table 1).

The complexity of the oral condition of patients with SUD presents a challenge for dental professionals. Patients are commonly difficult to manage due to their lack of compliance with treatment and instructions. A number of patients tend to be apprehensive about dental care resulting in non-compliance with appointments and avoidance in seeking dental care. The literature reports that SUD patients self-medicate for painful medical and dental conditions.

A clinical examination and a detailed medical history are vital for identifying patients with substance misuse/abuse problems. Many patients do not report the misuse of drugs, prescribed or otherwise. It is essential to practice non-confrontational medical history taking with “judgement-free” questioning of possible drug use and alcohol consumption. Soft tissue examination should be performed frequently due to the increased risk of oral cancer in patients who consume alcohol in large amounts. Periodontitis in young adults may suggest chronic marijuana use. Poor oral hygiene and a sugar-based diet are likely to present in the majority of patients with SUD who consequently develop extensive caries. A comprehensive evaluation is recommended to determine the extent the patient can actively participate in the dental treatment and treatment plans should be simple and feasible (Fig. 1). Dental management should prioritize pain and the prevention of orofacial infections over esthetic concerns.

A multidisciplinary approach is essential for the coordination of dental treatment whenever pain control is necessary. Regular communication with the patient’s physician and pharmacist should be maintained and pain management is best coordinated with the patient’s physician to prevent poly-pharmacy, drug interactions and overdosing. Documentation is essential, as is careful treatment planning and patient engagement.

Table 1 Effects of long-term substance abuse on systemic and oral health

Abused substance	Systemic manifestations	Oral manifestations
Alcohol	Liver toxicity, impairment of immune system	Predisposition to oropharyngeal cancer Predisposition to periodontal disease
Cannabis (marijuana)	Immuno-suppressive effect	Smoked without a filter, it increases inhaled smoke which causes cannabis stomatitis, leukoedema of the buccal mucosa and hyperkeratosis Periodontitis can be present in young adults due to frequent marijuana use
Methamphetamine	Stimulates sympathetic system Highly addictive Mode of ingestion: smoking, snorting, swallowing or injecting	Xerostomia (dry mouth) leads to the loss of protective function of saliva thus resulting in high caries and periodontal disease rates, often referred to as "meth mouth". More common in individuals who inject the drug rather than those who use it intranasally or through smoking Due to its sympathomimetic effect, it induces clenching and bruxism Osteonecrosis of mandible
Opioids (heroin, opioid prescription pain killers)	Psychoactive drugs that bind to opioid receptors: Mu-opiate receptor is activated which leads to changes in glucose intake and glycemic control	Use leads to salivary hypofunction causing xerostomia, caries, burning mouth and taste impairment The literature reports opioids to induce a preference for sweet foods Duration of drug use, poor oral hygiene and nutritional habits contribute to oral health complications
Cocaine	Inhaled intranasally, smoked form (crack) or rubbed on gingival tissue	Long-term intranasal use can lead to perforations of the hard palate and nasal septum. Recurrent maxillary sinusitis, burns, blisters and sores are often associated with cocaine use
Tobacco	Long term use increases the risk of cancer and respiratory tract diseases like Chronic Obstructive Pulmonary Disease (COPD) Vaping may predispose otherwise healthy individuals to viral infections like Covid-19	Use of the powder form introrally causes a substantial decrease in saliva pH creating an opportunity for caries-causing bacteria Chronic use increases the risk for periodontitis, staining of teeth It also increases the risk of oro-pharyngeal cancers

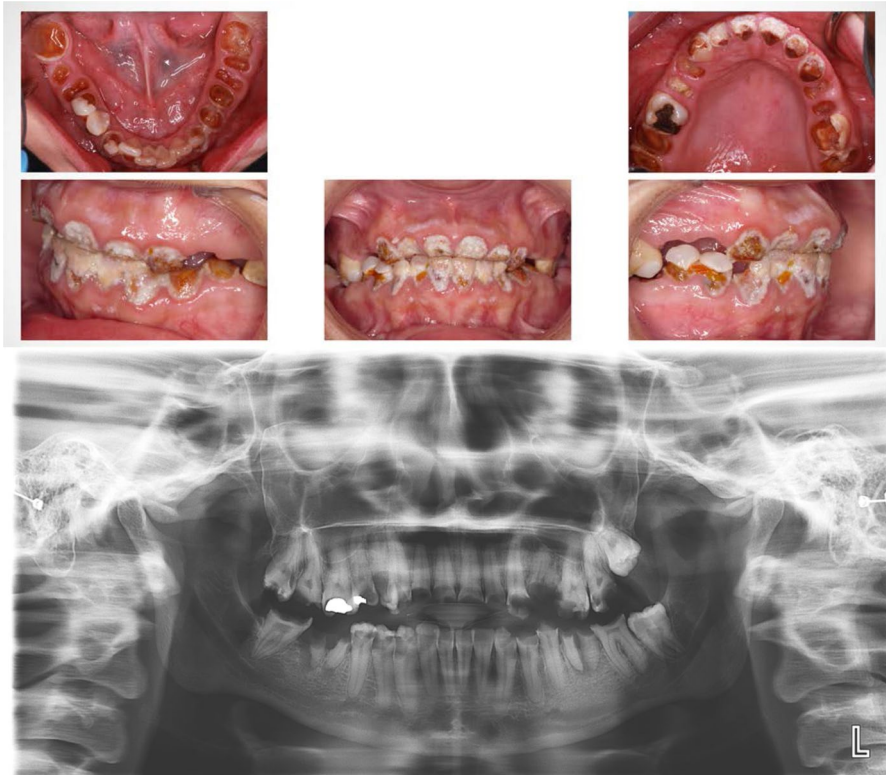


Fig. 1 Clinical photos and a panoramic radiograph of a 27-year-old patient with a history of methamphetamine use for a number of years. Prevention and early intervention are necessary in SUD to prevent irreversible damage to oral structures as seen in the photos below

It is important for the clinician to remember that SUD is a chronic disorder like other chronic disorders including diabetes mellitus, hypertension and cardiovascular disease—successful dental treatment is only possible in a patient who is stable, treatment-compliant and is in the remission phase of the disease.

Materials/instruments

- Medical history questionnaire that inquires about drug and alcohol use
- Basic dental examination instruments
- Dental radiographs

Table 2 The following precautions are recommended when treating patients with SUD

Drug	Precaution(s)
Alcohol	Alcoholism likely results in liver disease. Prior to dental surgery, a medical consult is recommended to establish the ability of the patient to control bleeding
Cocaine, ecstasy and methamphetamines	Use of anesthetics containing epinephrine should be avoided due to a systemic increase in blood pressure that usually follows us
Cannabis (Marijuana)	Use of local anesthetic containing epinephrine can cause prolonged tachycardi
Opioids	Do not prescribe opioids analgesics in suspected abusers of any drug. Consult with the patient's medical provider re. pain management PRIOR to treating pain-producing procedures

Procedure

Prior to commencing treatment on patients with SUD, practitioners should be familiar with a number of precautions (Table 2).

Early medical intervention in patients with SUD is crucial for the prevention of permanent damage to systemic and oral health. Once a patient is in the recovery/remission phase, disease prevention and patient education are critical to maintaining good oral health and preventing further oro-dental deterioration. The importance of oral hygiene needs to be emphasized and basic oral hygiene steps should be regularly reviewed with the patient. Preventive measures including fluoride supplementation, prescription toothpaste and chlorhexidine use should be encouraged. Sugarless products like xylitol could potentially help substance abuse patients. Recommending the use of xylitol-containing gum or candies has shown good results in the prevention of caries helping regulate saliva pH. Furthermore, in patients who are not in SUD remission or not successful in their SUD therapy, Silver Diamine Fluoride (SDF) for caries control should be considered. SDF has been used outside the United States for many years for caries control and in 2014 it was cleared by FDA as a desensitizing agent. SDF arrests active carious lesions without local anesthetic in a noninvasive way, avoiding or delaying traditional mechanical removal of caries. SDF is indicated in treating caries in people who are unable to access dental treatment or tolerate conventional dental care.

Patients on buprenorphine/naloxone or methadone therapy (treatment for SUD) should be instructed to rinse their mouths with water immediately following tablet or liquid dissolution and consumption, respectively (Table 3). Patients should be advised to drink eight to ten glasses of water each day and avoid consumption of caffeine, tobacco and alcoholic beverages. Other recommendations include chewing sugar-free gum and drinking methadone through a straw.

Managing xerostomia in patients with SUD should be an integral part of the treatment plan: adequate hydration and the reduction of sugar consumption must be prioritized. Salivary substitutes, oral moisturizers and artificial saliva are recommended for patients with recurring xerostomia. For severe xerostomia and suspected salivary gland dysfunction, muscarinic-cholinergic agonist drugs such as pilocarpine stimulate salivary flow and may be prescribed in the absence of contraindications and

Table 3 Treatment for substance use disorder

Drugs use to treat addiction	Oral effects
Methadone	Synthetic opioid used to treat patients addicted to opioids e.g. heroin, morphine, fentanyl: administered orally and usually has a high sugar content. Request that only methadone formulations made with sorbitol be dispensed by the methadone clinic Concomitant use of methadone with antidepressants can lead to xerostomia Like other opioids, methadone can increase sugar cravings Bruxism
Buprenorphine	Semisynthetic opioid with partial agonist activity at the mu receptor. Used for the treatment of opioid dependence Administered sublingually. Due to its acidic nature, studies suggest it increases caries risk It induces xerostomia and thus increases caries risk

drug interactions. There is limited information in the literature related to the treatment of bruxism and temporomandibular disorders as a consequence of SUD; fabrication and the regular use of bite splints or mouth guards is recommended on a case-by-case basis though patient compliance may be a limiting factor!

Pitfalls and complications

- Only palliative and emergency treatment should be performed on SUD patients who are not in the remission/recovery phase. Multidisciplinary systemic and psychological management are essential prior to definitive dental treatment.
- Definitive treatment is given to recovering patients and those in remission must include preventive measures to improve oral hygiene and reduce the risk and burden of oral disease.

The management of oral health consequences of SUD is complex. It is necessary to have collaborative efforts amongst health professionals during the recovery/remission phase. Oral health providers must be in communication with the patient's medical providers when coordinating the delivery of dental treatment for the safety and well-being of the patient. Sequencing and re-evaluation of dental treatment are essential in patients who have not recovered from SUD. Dental professionals hold a unique position in the early identification of drug abuse and mitigating the associated risks of adverse oral effects.

Further reading

1. Bader JD et al (2013) Results from the xylitol for adult caries trial (X-ACT). *J Am Dent Assoc* 144(1):21–30. <https://doi.org/10.14219/jada.archive.2013.0010>
2. Bahdila D et al (2020) Cocaine, polysubstance abuse, and oral health outcomes, NHANES 2009 to 2014. *J Periodontol*. <https://doi.org/10.1002/jper.19-0509>
3. Baghaie H et al (2017) A systematic review and meta-analysis of the association between poor oral health and substance abuse. *Addiction* 112(5):765–779. <https://doi.org/10.1111/add.13754>
4. Brand HS, Gonggrijp S, Blanksma CJ (2008) Cocaine and oral health. *Br Dent J* 204(7):365–369. <https://doi.org/10.1038/sj.bdj.2008.244>
5. Cocco F et al (2017) The caries preventive effect of 1-year use of low-dose xylitol chewing gum. A randomized placebo-controlled clinical trial in high-caries-risk adults. *Clin Oral Investig* 21(9):2733–2740. <https://doi.org/10.1007/s00784-017-2075-5>
6. American Psychiatric Association (2013) Diagnostic and statistical manual of mental disorders, 5th edn. Washington, DC
7. Evans SC, Roberts MC (2015) International classification of diseases (ICD), mental and behavioural disorders section. The encyclopedia of clinical psychology. Wiley, Hoboken, pp 1–10. <https://doi.org/10.1002/9781118625392.wbecp257>
8. Qiao HH, Zhu LN, Wang Y et al (2019) Implications of alpha-synuclein nitration at tyrosine 39 in methamphetamine-induced neurotoxicity in vitro and in vivo. *Neural Regen Res*. 14(2):319–327. <https://doi.org/10.4103/1673-5374.244795>
9. Mysels DJ, Sullivan MA (2010) The relationship between opioid and sugar intake: review of evidence and clinical applications. *J Opioid Manag* 6(6):445–452
10. Riemer L, Holmes R (2014) Under the influence: informing oral health care providers about substance abuse. *J Evid Based Dent Pract* 14:127–135.e1. <https://doi.org/10.1016/j.jebdp.2014.04.007>
11. Rommel N et al (2016) Sympathomimetic effects of chronic methamphetamine abuse on oral health: a cross-sectional study. *BMC Oral Health* 16(1):1–8. <https://doi.org/10.1186/s12903-016-0218-8>
12. Rustemeyer J et al (2014) Osteonecrosis of the maxilla related to long-standing methamphetamine abuse: a possible new aspect in the etiology of osteonecrosis of the jaw. *Oral Maxillofac Surg* 18(2):237–241. <https://doi.org/10.1007/s10006-014-0449-2>
13. Shetty V et al (2016) Methamphetamine users have increased dental disease: a propensity score analysis. *J Dent Res* 95(7):814–821. <https://doi.org/10.1177/0022034516640478>
14. Smit DA, Naidoo S (2015) Oral health effects, brushing habits and management of methamphetamine users for the general dental practitioner. *Br Dent J* 218(9):531–536. <https://doi.org/10.1038/sj.bdj.2015.341>
15. Sordi MB et al (2017) Oral health assessment for users of marijuana and cocaine/crack substances. *Brazil Oral Res Sociedade Brasileira de Pesquisa Odontológica*. <https://doi.org/10.1590/1807-3107bor-2017.vol31.0102>
16. Suzuki J, Mittal L, Woo S-B (2013) Sublingual buprenorphine and dental problems: a case series. *Prim Care Companion CNS Disord*. <https://doi.org/10.4088/PCC.13101533>
17. Tezal M et al (2004) Alcohol consumption and periodontal disease: the third national health and nutrition examination survey. *J Clin Periodontol* 31(7):484–488. <https://doi.org/10.1111/j.1600-051X.2004.00503.x>
18. Titsas A, Ferguson MM (2002) Impact of opioid use on dentistry. *Aust Dent J* 47(2):94–98. <https://doi.org/10.1080/09205071.2013.811040>
19. Tripathy S et al (2012) The relationship between sugar-containing methadone and dental caries: a systematic review. *Health Educ J* 72(4):469–485. <https://doi.org/10.1177/0017896912450247>
20. Turati F et al (2010) A meta-analysis of alcohol drinking and oral and pharyngeal cancers. Part 2: results by subsites. *Oral Oncol* 46(10):720–726. <https://doi.org/10.1016/j.oraloncology.2010.07.010>
21. United Nations Office on Drugs and Crime (2017) World Drug Report 2017: executive summary conclusions and policy implications. World Drug Report 2017, p. 34. https://www.unodc.org/wdr2017/field/Booklet_1_EXSUM.pdf
22. Horst JA et al (2016) UCSF protocol for caries arrest using silver diamine fluoride: rationale, indications, and consent. *J Calif Dent Assoc* 44(1):16

23. Wang P et al (2014) Comprehensive dental treatment for “meth mouth”: a case report and literature review. *J Formosan Med Assoc* 113(11):867–871. <https://doi.org/10.1016/j.jfma.2012.01.016>
24. World Health Organization (2011) Global status report on alcohol and health. World Health Organization. doi: /entity/substance_abuse/publications/global_alcohol_report/en/index.html
25. World Health Organization (2017) WHO | Substance abuse, WHO. World Health Organization. https://www.who.int/topics/substance_abuse/en/. Accessed 2 Jul 2018

Publisher’s Note Springer Nature remains neutral with regard to jurisdictional claims in published maps and institutional affiliations.